

THIEME FLEXIBOOK

Sotirios A. Tsementzis

Differential Diagnosis in Neurology and Neurosurgery

A Clinician's Pocket Guide



Thieme

Differential Diagnosis in Neurology and Neurosurgery

A Clinician's Pocket Guide

Sotirios A. Tsementzis, M.D., Ph.D.

Professor and Chairman of Neurosurgery

Director of the Neurosurgical Institute

University of Ioannina Medical School

Ioannina, Greece

16 Illustrations



Thieme
Stuttgart · New York 2000

Library of Congress Cataloging-in-Publication Data

Tsementzis, S. A.

Differential diagnosis in neurosurgery / Sotirios A. Tsementzis.
p. cm.

Includes bibliographical references and index.

ISBN 3-13-116151-5. – ISBN 0-86577-830-2

1. Nervous system—Surgery—Diagnosis Handbooks, manuals, etc.

2. Diagnosis, Differential Handbooks, manuals, etc. I. Title.

[DNLM: 1. Nervous System Diseases—diagnosis. 2. Diagnosis, Differential.

3. Neurologic Examination. 4. Signs and Symptoms.

WL 141 T881d 1999]

RC348.T84 1999

616.8'0475—dc21

DNLM/DLC

for Library of Congress

99-23138

CIP

Cover drawing by Cyclus, Stuttgart

Any reference to or mention of manufacturers or specific brand names should not be interpreted as an endorsement or advertisement for any company or product.

Some of the product names, patents, and registered designs referred to in this book are in fact registered trademarks or proprietary names even though specific reference to this fact is not always made in the text. Therefore, the appearance of a name without designation as proprietary is not to be construed as a representation by the publisher that it is in the public domain.

This book, including all parts thereof, is legally protected by copyright. Any use, exploitation, or commercialization outside the narrow limits set by copyright legislation, without the publisher's consent, is illegal and liable to prosecution. This applies in particular to photostat reproduction, copying, mimeographing or duplication of any kind, translating, preparation of microfilms, and electronic data processing and storage.

© 2000 Georg Thieme Verlag,
Rüdigerstraße 14, D-70469 Stuttgart
Thieme New York, 333 Seventh Avenue,
New York, N.Y. 10001 USA

Typesetting by Druckhaus Götz GmbH,
D-71636 Ludwigsburg
Printed in Germany by Offizin Andersen
Nexö, Leipzig

ISBN 3-13-116151-5 (GTV)

ISBN 0-86577-830-2 (TNY) 1 2 3 4 5 6

Important Note: Medicine is an ever-changing science undergoing continual development. Research and clinical experience are continually expanding our knowledge, in particular our knowledge of proper treatment and drug therapy. Insofar as this book mentions any dosage or application, readers may rest assured that the authors, editors, and publishers have made every effort to ensure that such references are in accordance with **the state of knowledge at the time of production of the book.**

Nevertheless this does not involve, imply, or express any guarantee or responsibility on the part of the publishers in respect of any dosage instructions and forms of application stated in the book. **Every user is requested to examine carefully** the manufacturers' leaflets accompanying each drug and to check, if necessary in consultation with a physician or specialist, whether the dosage schedules mentioned therein or the contraindications stated by the manufacturers differ from the statements made in the present book. Such examination is particularly important with drugs that are either rarely used or have been newly released on the market. Every dosage schedule or every form of application used is entirely at the user's own risk and responsibility. The authors and publishers request every user to report to the publishers any discrepancies or inaccuracies noticed.

This book is dedicated to the Greek national benefactress
Mrs Theoula Carouta
for generously supporting to the department of neurosurgery,
to my university professors
N. Matsaniotis, S. Mouloupoulos, Gr. Skalkeas, K. Stefanis
and to my neurosurgical instructors
F. J. Gillingham, E. R. Hitchcock, M. Salcman, G. Slougher,
H. J. Hoffman, C. Tator, and J. T. Hoff
who have greatly influenced my professional career

Preface

A wealth of neurological textbooks, journals, and papers are available today. The student of clinical neuroscience is therefore faced with a large number of unrelated facts that can be very difficult to remember and apply. In neurology, one of the most difficult tasks is knowing how to reach the correct diagnosis by differentiating it from the other possibilities, so that the patient can receive the appropriate treatment for the disease concerned.

Physicians frequently encounter clinical symptoms and signs, as well as other data, that require interpretation. Establishing a differential diagnosis list is essential to allow correct interpretation of clinical and laboratory data, and it provides the basis for appropriate therapy. But it is difficult for the physician, who is unable to remember everything on the spot, to compile a complete differential diagnosis list. Despite a firm intention to “check it,” the physician does not always do so, because the information is located in multiple reference sources at the library or at home, but not at the bedside or prior to taking final examinations. Lists of differential diagnoses of neurological signs provide information that can be used logically when analyzing a neurological problem. But time-consuming searches in massive textbooks, trying to memorize lists, or—even worse—trying to construct them oneself, all involve time and effort that could be put to better use elsewhere. I felt that if this information could be brought together in a single source and made available in paperback format, it would be a valuable aid to medical students, house staff, emergency room physicians, and specialist clinicians.

This book of differential diagnosis provides a guide to the differentiation of over 230 symptoms, physical and radiological signs, and other abnormal findings. The lists of differential diagnoses for the major disease categories are organized into a familiar pattern, so that completely different clinical problems can be approached using a common algorithm. The template is arranged under 15 major headings in neurology and neurosurgery, typically beginning with the most general and prevalent, to allow the physician to proceed, in as much detail as may be required, to the most rarely encountered disorders.

The aim of this book is to provide assistance with differential diagnosis in neurological and neurosurgical disease. It is not intended for use on its own, as it is not a complete textbook of neurology and neurosurgery.

I should like to express my thanks to the colleagues, trainees, and students who encouraged me to write this book. In particular, I am grateful to my patients who taught me how to look and how to differentiate. I am indebted to Dr. P. Toulas for providing several personal X-ray cases for the book. I am also grateful to Dr. Clifford Bergman, medical editor at Thieme, for excellent advice and collaboration in preparing this book.

Sotirios A. Tsementzis

Contents

Epidemiological Characteristics of Neurological Diseases	1
Prevalence of Neurological Diseases	1
Incidence of Common Neurological Diseases	2
Disorders and Incidence of First Seizure, Based on Age Distribution	2
Incidence of Brain Tumors	3
Epidemiology of Spinal Cord Injury	4
Incidence	4
Prevalence	5
Age at Injury	5
Ethnic Groups and Spinal Cord Injury	5
Etiology	6
Associated Injuries	6
Neurological Level of Injury (at Discharge)	6
Neuroradiology	7
Solitary Radiolucent Skull Lesion without Sclerotic Margins in Adults	7
Solitary Radiolucent Skull Lesion without Sclerotic Margins in Children	8
Solitary Radiolucent Skull Lesion with Sclerotic Margins	9
Multiple Radiolucent Skull Lesions	10
Localized Increased Density or Hyperostosis of the Skull Vault . . .	11
Diseases Affecting the Temporal Bone	12
Destructive (Lucencies with Irregular Margins)	12
Erosive (Lucencies with Well-Defined Margins, with or without Sclerosis)	14
Abnormalities of the Craniovertebral Junction	18
Congenital Anomalies and Malformations	18
Developmental and Acquired Abnormalities	19
Craniosynostosis	21
Types	21
Associated Craniofacial Syndromes	21
Associated Congenital Syndromes	22
Associated Disorders	23
Macrocephaly or Macrocrania	23

Microcephaly or Microcrania	24
Pneumocephalus	25
Small Pituitary Fossa	25
Enlarged Pituitary Fossa	26
Suprasellar and Parasellar Lesions	27
Neoplastic Lesions	27
Nonneoplastic Lesions	32
Intracranial Calcifications	35
Calcifications of the Basal Ganglia	37
Parasellar Calcification	38
Posterior Fossa Tumors	39
Postoperative Brain Scar Versus Residual Brain Tumor	41
Stages and Estimation of Age of Hemorrhage on MRI	43
Normal Pressure Hydrocephalus Versus Brain Atrophy	44
Meningeal Enhancement	45
Gyriform Enhancement	46
Corpus Callosum Lesions	46
Ring Enhancing Lesions	47

Developmental and Acquired Anomalies and Pediatric Disorders	50
Movements Resembling Neonatal Seizures	50
Neonatal Seizures by Time of Onset	51
First Nonfebrile Tonic–Clonic Seizure after Two Years of Age	53
Causes of Confusion and Restlessness	54
Causes of Coma	55
Papilledema	56
Hypotonic Infant	56
Precocious Puberty	59
Arthrogyposis	59
Progressive Proximal Weakness	59
Progressive Distal Weakness	61
Acute Generalized Weakness	62
Sensory and Autonomic Disturbances	63
Ataxia	63
Acute Hemiplegia	65
Progressive Hemiplegia	66
Acute Monoplegia	66
Agenesis of the Corpus Callosum	67
Megalencephaly	67
Unilateral Cranial Enlargement	68

Cranial Nerve Disorders	69
Anosmia	69
Oculomotor Nerve Palsy	70
Trochlear Nerve Palsy	72
Trigeminal Neuropathy	73
Abducens Nerve Palsy	75
Facial Nerve Palsy	77
Neuropathy in the Glossopharyngeal, Vagus, and Accessory Nerves	78
Hypoglossal Neuropathy	80
Multiple Cranial Nerve Palsies	82
 Neuro-Ophthalmology	 85
Causes of Horner's Syndrome	85
Pupillary Syndromes	86
Argyll Robertson pupil	86
Horner's Syndrome	87
Holmes–Adie or Tonic Pupil	88
Afferent Pupillary Defect or Marcus Gunn Pupil	88
Posttraumatic Mydriasis or Iridoplegia	89
Hippus	89
Unilateral Pupillary Dilatation (Mydriasis)	89
Bilateral Pupillary Dilatation (Mydriasis)	90
Unilateral Pupillary Constriction (Miosis)	91
Bilateral Pupillary Constriction (Miosis)	91
Diplopia	92
Monocular Diplopia	92
Binocular Diplopia	92
Vertical Binocular Diplopia	94
Horizontal Binocular Diplopia	94
Ptosis	95
Acute Ophthalmoplegia	96
Internuclear Ophthalmoplegia	98
Vertical Gaze Palsy	99
Unilateral Sudden Visual Loss	99
Bilateral Sudden Visual Loss	100
Slowly Progressing Visual Loss	102
Transient Monocular Blindness	103
Transient Visual Loss	104
Swollen Optic Disks (Papilledema)	107
Optic Nerve Enlargement	108

Intracranial Tumors	111
Cerebral Hemispheres	111
Intraventricular	112
Pineal Gland	115
Cerebellopontine Angle	116
Internal Auditory Meatus	119
Foramen Magnum	119
Skull Base	123
Choroid Plexus Disease	130
Gliomatosis Cerebri	131
Tolosa–Hunt Syndrome	132
Recurrence of Malignant Gliomas	132
Congenital Posterior Fossa Cysts and Anomalies	133
Posterior Fossa Cysts	134
Enhancing Lesions in Children and Young Adults	136
Tumoral Hemorrhage	136
Brain Metastases	137
Subarachnoid Space Metastases	140
Hyperprolactinemia	142
Demyelinating Disease and Brain Atrophy	143
Multifocal White Matter Lesions	143
Multiple Sclerosis–Like Lesions	144
Cerebellar Atrophy	147
Cerebral Atrophy	147
Dementia	148
Cerebrovascular Disease	151
Cerebral Infarction in Young Adults	151
Causes of Infarction in Young Adults	154
Stroke Risk Factors	155
Common Cardiac Disorders Associated with Cerebral Infarction ..	159
Transient Ischemic Attack	161
Incidence	161
Differential Diagnosis	161
Cervical Bruit	162
Cerebral Arteritis	162
Stroke	163
Clinical Grading Scales in Subarachnoid Hemorrhage	165
Cerebral Salt-Losing Syndrome and Syndrome of Inappropriate Secretion of Antidiuretic Hormone after Subarachnoid Hemorrhage	166

Syndrome of Inappropriate Secretion of Antidiuretic Hormone and Diabetes Insipidus	167
Syndromes of Cerebral Ischemia	168
Brain Stem Vascular Syndromes	170
Midbrain	170
Pons	176
Medulla	178
Differentiation of the Various Types of Cerebral Ischemic Vascular Lesion	179
Predisposing Factors and Associated Disorders of Cerebral Veins and Sinuses Thrombosis	181
Venous Thrombosis	182
Spontaneous Intracerebral Hemorrhage	183
Spinal Disorders	186
Failed Back Syndrome	186
Diffuse Thickening of the Nerve Root	187
Scar Versus Residual Disk	187
Multiple Lumbar Spine Surgery (Failed Back Syndromes)	188
Causes of Failed Back Syndromes	189
Differential Diagnosis	189
Low Back Pain	193
Acute and Subacute Low Back Pain	193
Chronic Low Back Pain	195
Thoracic Pain	197
Radiculopathy of the Lower Extremities	200
Spinal Cord Lesions	201
Complete Transection	201
Hemisection (Brown–Sequard Syndrome)	206
Central Cord Syndrome	207
Posterolateral Column Disease	208
Posterior Column Disease	208
Anterior Horn Cell Syndromes	208
Combined Anterior Horn Cell and Pyramidal Tract Disease	209
Vascular Syndromes	209
Cauda Equina Mass Lesions	210
Clinical Differentiation of Cauda Equina and Conus Medullaris Syndromes	211
Differential Diagnosis of Extramedullary and Intramedullary Spinal Cord Tumors	212
Cervical Spondylotic Myelopathy	212
Spinal Hematoma	214

Spinal Cord Compression	215
Epidural Spinal Cord Compression	217
Intradural and Extramedullary Tumors	218
Intramedullary Tumors	218
Leptomeningeal Metastases	218
Radiation Myelopathy	219
Transverse and Ascending Myelopathy	219
Epidural Hematoma	220
Epidural Abscess	221
Herniated Disk	222
Pediatric Intraspinial Cysts	222
Spinal Intradural Cysts	222
Spinal Extradural Cysts	224
Myelopathy in Cancer Patients	225
Lumbar Disk Protrusion	226
Disorders of the Spinal Nerve Roots	227
Foot Drop	227
Lumbar Root Syndrome Versus Hip Pain	229
Sciatica	229
Juvenile Idiopathic Scoliosis	231
Cervicocephalic Syndrome Versus Migraine Versus Ménière's Disease	232
Differentiation between Spasticity and Rigidity	233
Peripheral Nerve Disorders	234
Carpal Tunnel Syndrome	234
Ulnar Neuropathy	238
Ulnar Entrapment at the Elbow (Cubital Tunnel)	238
Radial Nerve Palsy	239
Compression in the Axilla	240
Compression within the Spiral Groove of the Humerus	240
Compression at the Elbow	241
Radial Nerve Injury at the Wrist	242
Differential Diagnosis of Radial Palsies	243
Meralgia Paresthetica (Bernhardt–Roth syndrome)	243
Femoral Neuropathy	244
Peroneal Neuropathy	245
Tarsal Tunnel Syndrome	245
Anterior Tarsal Tunnel Syndrome	245
Posterior Tarsal Tunnel Syndrome	245
Plantar Digital Nerve Entrapment (Morton's Metatarsalgia)	246

Movement Disorders	247
Chorea	247
Dystonia	247
Blepharospasm	248
Torticollis (Head Tilt)	248
Parkinsonian Syndromes (Hypokinetic Movement Disorders) ...	249
Classification of Parkinsonism	249
Differential Diagnosis of Parkinsonism	250
Progressive Supranuclear Palsy	251
Multiple System Atrophy	252
Corticobasal Ganglionic Degeneration	253
Diffuse Lewy Body Disease	254
Parkinsonism–Dementia–Amyotrophic Lateral Sclerosis Complex of Guam	255
Cervical Dystonia	256
Myoclonus	257
Chorea	258
Tic Disorders	259
Tremor	260
Disorders Associated with Blepharospasm	261
Gait Disorders	262
Neurological Disorders of Stance and Gait	263
Types of Stance and Gait	264
Neurotrauma	269
Glasgow Coma Scale	269
Pediatric Coma Scale	269
The Unconscious Patient	270
Metabolic and Psychogenic Coma	272
Metabolic and Structural Coma	273
Comatose Patients with Metabolic Disease	273
Comatose Patients with Gross Structural Disease	274
Coma-Like States	275
Trauma Score	279
Respiratory Patterns in Comatose Patients	281
Pupillary Changes in Comatose Patients	282
Spontaneous Eye Movements in Comatose Patients	283
Abnormal Motor Responses in Comatose Patients	284

Infections of the Central Nervous System	285
Bacterial Infections	285
Viral Infections	286
RNA Viruses	286
DNA Viruses	287
Slow Viruses	289
Human Immunodeficiency Virus (HIV)	289
Fungal Infections	290
Parasitic and Rickettsial Infections	291
Protozoa	291
Cestodes	293
Nematodes	293
Trematodes (Flukes)	294
Rocky Mountain Spotted Fever	295
Cat-Scratch Disease	295
Central Nervous System Infections in AIDS	295
Acute Bacterial Meningitis	296
Most Frequent Pathogens by Age Group	296
Most Frequent Pathogens by Predisposing Conditions	296
Chronic Meningitis	300
Recurrent Meningitis	301
Conditions Predisposing to Recurrent Bacterial Meningitis	303
Conditions Predisposing to Polymicrobial Meningitis	303
Spinal Epidural Bacterial Abscess	303
Neurological Complications of Meningitis	304
Acute Complications	304
Intermediate Complications	305
Long-Term Complications	306
Pain	307
Myofascial Pain Syndrome	307
Diagnostic Clinical Criteria	307
Associated Neurological Disorders	307
Differential Diagnosis	308
Postherpetic Neuralgia	308
Atypical Facial Pain	309
Cephalic Pain	310
Face and Head Neuralgias	312
Headache: World Health Organization Classification	314
Pseudospine Pain	318
Back Pain in Children and Adolescents	322
Low Back Pain during Pregnancy	324
Back Pain in Elderly Patients	324

Neurorehabilitation	326
Measures (Scales) of Disability	326
Glasgow Outcome Scale	326
Rankin Disability Scale	326
Barthel Index	327
Mini-Mental State Examination	328
Neuropsychological Evaluation and Differential Diagnosis of Mental Status Disturbances	329
Karnofsky Scale	330
 Index	 331

Epidemiological Characteristics of Neurological Diseases

Prevalence of Neurological Diseases

Disorder	Rate (per 100 000 population)	Disorder	Rate (per 100 000 population)
Epilepsy	6500	Cervical disk herniation	50
Migraine	2000	Spinal cord injury	50
Other types of severe headache	1500	Transient postconcussive syndrome	50
Brain injury	800	Trigeminal neuralgia	40
Acute cerebrovascular disease	600	Mononeuropathy/poly- neuropathy	40 / 40
Low back pain	500	Peripheral nerve trauma	30
Alcoholism	500	Metastatic brain tumor	15
Sleep disorders	300	Other demyelinating dis- ease	12
Ménière's disease	300	Benign cord tumor	10
Lumbosacral disk hernia- tion	300	Encephalitides	10
Cerebral palsy	250	Syrinx	7
Dementia	250	Motor neuron disease	6
Parkinsonism	200	Malignant primary brain tumor	5
Transient ischemic attacks	150	Metastatic cord tumor	5
Febrile seizures	100	Meningitides	5
Persistent postconcussive syndrome	80	Bell's palsy	5
Congenital malformations of the CNS	70	Myasthenia gravis	4
Multiple sclerosis	60	Intracerebral abscess	2
Benign brain tumors	60	Cranial nerve trauma	2
Cervical pain syndromes	60	Guillain-Barré syndrome	1
Down's syndrome	50	Vascular disease of the spinal cord	1
Subarachnoid hemor- rhage	50	Acute transverse myelitis	1

Adapted from: Kurtzke JF. The current neurological burden of illness in the United States. *Neurology* 1982; 32: 1207 – 14. CNS: central nervous system.

Incidence of Common Neurological Diseases

Disorder	Rate (per 100 000 population)	Disorder	Rate (per 100 000 population)
Herpes zoster	400	Mononeuropathies/poly- neuropathies	40 / 40
Migraine	250	Transient ischemic attacks	30
Brain trauma	200	Bell's palsy	25
Other types of severe headache	200	Parkinsonism	20
Acute cerebrovascular dis- ease	150	Persistent postconcussive syndrome	20
Other head injury	150	Cervical pain syndrome	20
Transient postconcussive syndrome	150	Meningitides	15
Lumbosacral disk hernia- tion	150	Encephalitides	15
Low back pain	150	Sleep disorders	15
Epilepsy	50	Subarachnoid hemor- rhage	15
Febrile seizures	50	Cervical disk herniation	15
Dementia	50	Metastatic brain tumor	15
Ménière's disease	50	Peripheral nerve trauma	15
		Benign brain tumor	10

Adapted from: Kurtzke JF. The current neurological burden of illness in the United States. *Neurology* 1982; 32: 1207–14.

Disorders and Incidence of First Seizure, Based on Age Distribution

The incidence of epilepsy associated with brain tumors is approximately 35% when all locations and histological types are taken into account. Age increases the risk of epilepsy being caused by a tumor, particularly in those over 45 years of age.

Disorder	Incidence of first seizure			
	< 45 y		> 45 y	
	n	%	n	%
Idiopathic	18	45.0	9	15.5
Cerebral infarction	1	2.5	22	37.9
Alcohol-related	6	15.0	5	8.6
CNS infection	7	17.5	2	3.4

Disorder	Incidence of first seizure			
	< 45 y		> 45 y	
	n	%	n	%
Tumor	1	2.5	7	12.0
Vascular malformation	3	7.5	3	5.2
Trauma	3	7.5	1	1.7
Drug toxicity	0	0	3	5.2
Subdural hematoma	0	0	2	3.4
Hyperglycemia	0	0	2	3.4
Uremia	0	0	1	1.7
Hyponatremia	1	2.5	0	0
Cerebral malformation	0	0	1	1.7

Adapted from: Berger MS, Keles E. Epilepsy associated with brain tumors. In: Kaye AH, Laws ER, editors. Brain tumors. Edinburgh: Churchill Livingstone, 1995: 239–46. CNS: central nervous system.

Incidence of Brain Tumors

Classification	Incidence (%)	
	Walker	Lane et al.
Glioblastoma multiforme	23.0	25.0
Meningioma	16.0	14.0
Astrocytoma (low grade)	13.0	9.0
Metastatic*	13.0	–
Pituitary adenoma	8.2	11.0
Neurilemoma (esp. acoustic)	5.7	7.0
Craniopharyngioma	2.8	3.0
Hemangioblastoma	2.7	–
Sarcoma	2.5	–
Mixed and other gliomas	1.9	3.0
Ependymoma	1.8	3.0
Oligodendroglioma	1.6	2.0
Medulloblastoma (PNET)	1.5	3.0
Pineal tumor	1.1	1.0
Other rare tumors (dermoid, epidermoid, colloid cyst, choroid plexus papilloma)	7.0	3.0

* The true incidence of metastatic tumors is certainly higher, since complete metastatic work-up with computed tomography (CT) and magnetic resonance imaging (MRI) is not routinely done.

Walker: Walker M. Malignant brain tumors: a synopsis. *Cancer J Clin* 1975; 25: 114–20.

Lane et al.: Lane BA, Mosely IF, Theron J. Intracranial tumors. In: Grainger RG, Allison DJ, editors. *Diagnostic radiology*, vol 3. Edinburgh: Churchill Livingstone, 1992: 1935.

PNET: primitive neuroectodermal tumor.

Epidemiology of Spinal Cord Injury

Incidence

The incidence in different American states varies, due to a combination of differences in reporting procedures, differences in underlying population characteristics such as age, sex, ethnic groups, and educational levels; and differences in geographical and interrelated social factors such as climate, degree of urbanization, driving patterns, road conditions, gun ownership, and alcohol consumption.

State	Period of study	Incidence (%)	Mortality (cases per million population)
Northern California	1970–71	32.2	21.3
Minnesota (Olmsted County)	1975–81	49.6	21.2
Houston/Galveston, Texas	1981	60.0	–
Alabama	1973–77	29.4	–
National (247 hospitals)	1974	50.0	–
National	1970–77	40.1	–
Florida (pooled data)	1980	40.3	–
	1984	33.1	–
Virginia	1979	33.1	–
	1984	29.5	–
	1990–92	29.6	–
Arkansas	1980	32.4	–
	1989	26.6	–
New York	1982–88	43.0	–
Louisiana	1990	37.7	–
	1991	46.0	–
Georgia	1991–92	46.1	–
Colorado	1989–92	37.7	–
Utah	1989–91	35.0	8.0
Oklahoma	1988–92	41.0	6.0
Delaware	1990	30.0	–
United States		30.0–40.0	–

Prevalence

State	Period of study	Prevalence (cases per million population)
Statewide (USA)	1974	130.0
Statewide (USA)	1975	525.0
Minnesota (Olmsted County)	1980	473.0
– With net population migration		583.0
Area sampling of the USA	1988	721.0

Age at Injury

Age (y)	Cases (%)
0–15	4.5
16–30	58.5
31–45	21.1
46–60	9.7
61–75	4.9
76–95	1.3

Ethnic Groups and Spinal Cord Injury

Ethnic group	Cases (%)
White	70.1
African-American	19.6
American Indian	1.3
Asian	1.2
Other	7.8

Etiology

Type of injury	Cases (%)
Motor vehicle	44.5
Falls	18.1
Acts of violence	16.6
Sports	12.7
Other	8.1

Associated Injuries

Associated injuries	Etiology (%)					Total
	Motor vehicle	Falls	Acts of violence	Sports	Other	
Fractures	39.7	30.5	16.0	5.7	35.4	29.3
Loss of consciousness	42.5	24.0	8.1	22.4	26.2	28.2
Head injury	18.4	10.3	2.5	4.2	11.4	11.5
Brachial plexus injury	1.2	0.8	1.8	0.2	2.8	1.3
Peripheral nerve injury	1.1	0.8	2.2	0.2	1.6	1.2
Traumatic						
– pneumothorax	16.6	10.1	35.9	2.7	16.6	17.8
– hemothorax						
Other	34.4	49.5	50.4	69.4	54.5	45.9

Neurological Level of Injury (at Discharge)

Cervical		Thoracic		Lumbar		Sacral	
Nerve	%	Nerve	%	Nerve	%	Nerve	%
C1	0.7	T1	1.2	L1	4.6	S	0.3
C2	1.0	T2	1.6	L2	2.0		
C3	2.2	T3	2.0	L3	1.8		
C4	12.8	T4	4.1	L4	1.0		
C5	16.0	T5	3.1	L5	0.5		
C6	12.9	T6	3.3				
C7	6.7	T7	2.3				
		T8	3.4				
		T9	1.8				
		T10	3.7				
		T11	3.0				
		T12	7.4				

Neuroradiology

Solitary Radiolucent Skull Lesion without Sclerotic Margins in Adults

Normal

Foramina, canals and unfused sutures

Vascular markings and emissary channels

Arachnoid granulations (near midline or superior sagittal sinus)

Variants

Parietal thinning

Involves only the outer table in elderly individuals

Sinus pericranii

Anomalous venous diploic channel between the extracranial and intracranial venous system, most commonly seen in the frontal bones. Clinically, it appears as a soft mass under the scalp that changes in size with alterations in the intracranial blood volume

Congenital and developmental defects

Encephaloceles

Extracranial protrusions of brain and/or meninges through skull defects; occipital in 70% and frontal in 15%

Dermoid cyst

Midline orbital in 80%; lesion originating from ectodermal inclusions

Neurofibroma

May cause a lucent defect in the occipital bone, usually adjacent to the left lambdoid suture

Intradiploic arachnoid cyst

Expansion of the diploic space and thinning of the outer table

Traumatic and iatrogenic defects

Linear skull fracture

Suture diastasis

Burr hole, craniectomy (very well defined)

Leptomeningeal cyst or "growing fracture"

Solitary Radiolucent Skull Lesion without Sclerotic Margins in Children

Normal

Parietal foramina

Fontanelle

Venous lakes and emissary channels

Arachnoid granulations (near midline or superior sagittal sinus)

Trauma

Burr hole, craniectomy

Leptomeningeal cyst or “growing fracture” Under a skull fracture. If the dura is torn, the arachnoid membrane can prolapse, and the CSF pulsations can, over several weeks, cause a progressive widening and scalloping of the fracture line

Intraosseous hematoma

Congenital and developmental defects

Cranium bifidum, meningocele, encephalocele, dermal sinus

Epidermoid or dermoid cyst Midline orbital in 80%; lesion originating from ectodermal inclusions

Intradiploic arachnoid cyst Expansion of diploic space and thinning of the outer table

Neurofibromatosis

Infection

Osteomyelitis E.g., bacterial or fungal

Hydatid cyst

Tuberculosis

Syphilis

Neoplasia

Metastasis Commonly from a neuroblastoma and leukemia

Histiocytosis X

- Eosinophilic granuloma: a solitary lesion which causes only local pain. Only has sclerotic margins if it is in the healing process
- Hand-Schüller-Christian disease. “Geographic” as well as multiple lytic lesions are common, associated with systemic symptoms such as exophthalmos, diabetes insipidus, chronic otitis media, and “honeycombing”

Sarcoma	E.g., Ewing's brown tumor, osteosarcoma
Solitary plasmacytoma	
Miscellaneous	
Aneurysmal bone cyst	
Hemangioma	
Arteriovenous malformation	

CSF: cerebrospinal fluid.

Solitary Radiolucent Skull Lesion with Sclerotic Margins

Congenital and developmental

Epidermoid	Arises from the diploic region, and so it can expand both the inner and the outer tables. Most common location is the squamous portion of the occipital bone; less commonly the frontal and temporal. It is the commonest erosive lesion of the cranial vault
Meningocele	Midline skull defect with a smooth sclerotic margin and an overlying soft tissue mass. In 70% of the cases it appears in the occipital bone; in 15% occurs in the frontal and less commonly in the basal or parietal bones

Neoplastic

Histiocytosis X	Only has a sclerotic margin if it is in the healing process
Hemangioma	Originates in the diploic area and rarely has a sclerotic margin

Infectious

Frontal sinus mucocele	Secondary to chronic sinusitis
Chronic osteomyelitis	Most commonly pyogenic, but may be fungal, syphilitic, or tubercular. Reactive sclerosis dominates, particularly with fungal infections such as actinomycosis, with only a few lytic areas

Miscellaneous

Fibrous dysplasia	The normal medullary space is replaced by fibro-osseous tissue. It involves the craniofacial bones in 20% of cases. It appears as solitary or multiple lytic lesions, with or without sclerotic regions on MRI
-------------------	--

MRI: magnetic resonance imaging.

Multiple Radiolucent Skull Lesions

Normal

Fissures, parietal foramina, and channels

Pacchionian depressions from arachnoidal granulations (near midline or superior sagittal sinus)

Venous lakes and diploic channels

Metabolic

Hyperparathyroidism Multiple punctate lytic changes in the cranium cause the so-called “pepperpot” appearance. The focal lucencies consist of fibrous tissue and giant cells known as brown tumors, as indicated by the old term “osteitis fibrosa cystica”

Renal osteodystrophy Excessive excretion or loss of calcium due to kidney disease results in calcium mobilization and a skull appearance identical to that of primary hyperthyroidism

Osteoporosis Loss of the protein matrix results in lytic areas in the diploic and inner table of the skull in elderly and in patients with endocrine diseases, such as Cushing’s disease

Neoplasm

Metastatic tumors The most frequent neoplastic involvement of the skull is by hematogenous metastases from the breast, lung, prostate, kidney, and thyroid, or by invasion from adjacent primary neoplasms with osteolytic metastases, such as medulloblastoma

Multiple myeloma Produces small, discrete round holes of variable size, also referred to as “punched-out lesions”

Leukemia and lymphoma Produce small, poorly defined, or separate multiple lesions, which tend to coalesce

Neuroblastoma In infants, this is the most common metastatic tumor of the skull

Ewing’s sarcoma May rarely metastasize to the skull

Miscellaneous

Radiation necrosis Focal irradiation results in multiple small areas of bone destruction localized to the area treated

Avascular necrosis A few months after local ischemia due to trauma, destructive changes occur in the outer and diploic region of the cranium

Hand-Schüller-Christian disease	Multiple large areas of bone destruction with irregular edges and without marginal sclerosis; the latter feature differentiates this form of histiocytosis X from eosinophilic granuloma, which is believed to be the more benign form of the two
Osteoporosis circumscripta	Represents the first stage of an idiopathic decalcification/ossification condition, which results in areas of lucency sharply separated from normal bone. The second stage is characterized by an abnormal recalcification and ossification, suggesting an initial insult followed by disordered repair. The coexistence of these two stages of bone destruction and sclerosis are characteristic of the pathological changes seen in Paget's disease

Localized Increased Density or Hyperostosis of the Skull Vault

Traumatic

Depressed skull fracture Due to overlapping bone fragments

Cephalhematoma Old calcified hematoma under elevated periosteum. It is commonly found in the parietal area; may be bilateral

Miscellaneous

Calcified sebaceous cyst

Paget's disease Involves all skull layers, and characteristically has an appearance of both lytic (osteogenesis circumscripta) and sclerotic phases

Fibrous dysplasia Affects the craniofacial bones in approximately 20%, and may be monostotic or polyostotic and diffuse. It consists of abundant myxofibromatous tissue mixed with dysplastic, nonmaturing or atypical bone. The CT shows thickened, sclerotic bone with a "ground-glass" appearance, with cystic components found in the early stages of the disease. On MRI, the expanded, thickened bone typically has a low to intermediate signal intensity on both the T1-weighted and T2-weighted images, although scattered hyperintensity areas may be present. After gadolinium injection, variable enhancement occurs

Hyperostosis frontalis interna This idiopathic condition refers to the thickening of the inner table. It is commonly found in the frontal bone of sexually active women, indicating a true endocrine relationship

Neoplasia

Osteoblastic metastases Metastatic prostatic carcinoma is most frequently osteoblastic, and it is the most common cause of osteoblastic metastasis in males. Medulloblastoma is a rare example of blastic metastasis

Neuroblastoma

Primary skull tumors

- **Benign skull tumors**
 - Osteoid osteoma. When arising from the dura, it stimulates a calvarial lesion. To reveal it, the neurosurgeon needs to open the dura
 - Osteoblastoma
- **Malignant skull tumors**
 - Chondrosarcoma, osteosarcoma, fibrosarcoma, and angiosarcoma

Meningioma Focal hyperostosis and enlargement of meningeal arterial grooves are the classic findings in a plain skull radiograph

CT: computed tomography; MRI: magnetic resonance imaging.

Diseases Affecting the Temporal Bone

Destructive (Lucencies with Irregular Margins)

Petrous ridge or apex

Inflammatory

Acute petrositis is a nondestructive inflammatory condition, affecting only 30–50% of patients with an aerated petrous apex, and is characterized by irregular spotty opacifications scattered throughout the petrous pyramid. Spread of the inflammation may lead to osteomyelitis and abscess formation in the petrous pyramid. The involvement of the surrounding tissues causes irritation of cranial nerve V, with periorbital pain, and sixth nerve palsy, causing diplopia and otorrhea, e.g., Gradenigo's syndrome. On MRI, the conditions present typically with a low signal intensity on T1-weighted images and a high intensity on T2-weighted images. In chronic petrositis, the lesion's high protein content and viscosity causes a high signal intensity on T1-weighted images and/or a lower signal intensity on T2-weighted images

Malignant neoplasms

- Nasopharyngeal carcinoma
Usually, a large area of destruction in the floor of the middle cranial fossa is also seen
- Metastatic tumors
Any site in the petrous pyramid; particularly from lung, breast, and kidney carcinoma
- Parotid gland neoplasia
- Chordoma
Arises from a notochordal remnant, usually in the midline at the spheno-occipital synchondrosis. The origin is the clivus in 35% of cases, sacrococcygeal in 50% and spinal in 15%. The presence of dense retrosellar calcification with bone destruction of the clivus, dorsum sellae, and petrous bones is characteristic of clivus chordoma. The tumor frequently calcifies, shows lytic destruction of bone, and has mild enhancement. On T1-weighted imaging, the lesions are usually isointense (75%) or hypointense (25%), but nearly all are hyperintense on T2-weighted images

Benign tumors

- Glomus jugulare, ganglioglioma, or chemodectoma
Arises from chemoreceptor organs on the promontory in the jugular fossa in the superior portion of the jugular bulb. These tumors usually spread superiorly and laterally through the inferior surface of the petrous pyramids. At this stage, they show irregular enlargement of the jugular foramen and irregular destruction of the inferior aspect of the petrous pyramid. As the tumor grows, it causes further destruction involving the ossicular system, the internal jugular vein, the posterior margin of the carotid canal, and the posterior fossa. On CT images, this mass is seen to erode the jugular foramen of the temporal bone. The mass may grow inferiorly into the jugular vein, or may grow from the jugular bulb region into the sigmoid and transverse sinuses or the vein. A mass within the vessel plexus can be distinguished from thrombosis by the presence of enhancement in the former. On MRI, the glomus jugulare has a typical “salt-and-pepper” appearance. Characteristically, undulating channel-like voids are seen, especially on T2-weighted images. After gadolinium injection, there is moderate enhancement. Angiography used to be needed for definitive diagnosis of these lesions, but now the location of the lesion at or extending into the jugular bulb plus the vascularity and the “salt-and-pepper” appearance on MRI makes this an easy diagnosis

Miscellaneous

- Histiocytosis X (Langerehans granulomatosis)

Middle ear and mastoid

Infection

- Acute or chronic bacterial Chronic mastoiditis was commonly associated with benign intracranial hypertension, due to the extension of the inflammation to the neighboring sigmoid and lateral sinuses
- Tuberculosis Very rare; causes bone destruction without sclerosis

Malignant neoplasm

- Squamous-cell carcinoma The most common malignant tumor of the middle ear. Lucent defects with irregular margins, with no evidence of sclerosis
- Adenocarcinoma Less common than squamous-cell carcinoma
- Sarcoma Rare

Benign neoplasm

- Glomus hypotympanicum tumor—chemodectoma The most common benign tumor of the middle ear. Arises from the receptor organs on the promontory in the hypotympanum. These are locally invasive, extremely vascular tumors

Miscellaneous

- Histiocytosis X (Langerhans granulomatosis) This disease has a propensity for the mastoid portion of the temporal bone in children and young adults. It presents as a lytic process, and clinically involves loss of hearing without pain or tenderness. The patients are afebrile, otherwise healthy children. The lesion is hypointense on T1-weighted images and hyperintense with enhancement on T2-weighted images

CT: computed tomography; MRI: magnetic resonance imaging.

Erosive (Lucencies with Well-Defined Margins, with or without Sclerosis)

Petrous pyramid or apex

Acoustic neurinoma

Bone neoplasm, benign or malignant E.g., hemangioma, osteoblastoma, chordoma, chondroma, metastasis

Epidermoid In the cerebellopontine angle cistern

Aneurysm of the intracavernous or intrapetrous internal carotid artery

Meningioma of Meckel's cavity

Subarachnoid cyst

Neurinoma of nerves
V, IX, or X

Histiocytosis X

Internal auditory canal

Acoustic neuroma

Represents about 8% of all intracranial tumors. It arises from the Schwann cells which invest the eighth nerve as it enters the internal auditory canal. Ninety-five percent of these lesions originate within the auditory canal, and the other 5% arise from the nerve at its cerebellopontine angle course, proximal to the canal. Often bilateral in neurofibromatosis. Most acoustic neuromas arise from the superior vestibular branch of the eighth cranial nerve. The most noticeable radiographic change caused by these tumors is erosion of the superior and posterior lips of the porus acusticus.

Acoustic schwannomas are isodense or slightly hypodense to the adjacent brain on CT scans. Calcification and hemorrhage are uncommon.

On MRI, acoustic neurinomas are usually isointense to slightly hypointense compared with the pontine tissue on all pulse sequences. Enhancement is always evident, and is homogeneous in approximately 70% of patients.

Peritumoral edema can be seen in 30–35% of cases with larger lesions, and less frequently calcification, cystic change, and hemorrhage

Facial nerve neuroma

Very rare tumors, but may cause radiographic changes similar to those seen with acoustic neuroma

Meningioma of the
Gasserian cavity

Meningiomas of the auditory canal may cause erosion of the canal, and usually extend to involve the posterior surface of the petrous apex

Chordomas

Vascular lesions

- Aneurysm of the intracavernous or intrapetrous carotid artery
- Arteriovenous malformation or occlusive disease of the anterior inferior cerebellar artery may cause erosion of the internal auditory canal, giving it a funnel-shaped appearance
- Aneurysm at the origin of the internal auditory artery may cause erosion of the canal

Miscellaneous

- Epidermoid adjacent to the apex
- Leptomeningeal cyst
- Histiocytosis X
- Metastasis
- Glioma of the brain stem
- Neurofibromatosis

Middle ear or mastoid

Infection

- Acute or chronic bacterial Chronic mastoiditis was commonly associated with benign intracranial hypertension due to the contiguous extension of the inflammation to the neighboring sigmoid and lateral sinuses
- Tuberculosis Very rare; causes bone destruction without sclerosis

Trauma (postoperative changes)

Cholesteatoma

Primary cholesteatomas are developmental in origin, and less common than the secondary ones, which result from inflammatory ear disease; the radiographic findings are identical. The earliest radiographic sign is partial to complete destruction of the bony ridge or drum spur of the innermost portion of the roof of the external auditory canal in 80% of cases. More than 95% of cholesteatomas are visible on autoscopic examination.

The mastoid antrum is enlarged, and may often be sclerotic due to the associated chronic infection. A soft-tissue mass within the tympanic cavity, with destruction or demineralization of the ossicular chain may also be seen. The latter radiographic changes may also be seen after involvement of the tympanic cavity by granulation tissue due to chronic inflammation, in which case the two are indistinguishable using radiography. On CT scans, cholesteatomas appear as noninvasive, erosive, well-circumscribed lesions in the temporal bone, with scalloped margins. On MRI, they are usually hypointense on T1-weighted images and hyperintense on T2-weighted images

Neoplasm

- Metastases Hematogenous from the breast, lung, prostate, kidney, and other primary neoplasms with osteolytic metastases

- Carcinoma of the middle ear This is associated with chronic otitis media in 30% of cases; pain and bleeding appear late. Bone destruction is seen in 12%, particularly in the temporal fossa of the temporomandibular joint
- Glomus jugulare tumor The jugular foramen is enlarged and destroyed; a very vascular lesion
- Nasopharyngeal tumor invasion
- Rhabdomyosarcoma This is a tumor of children and young adults, and it has a predilection for the nasopharynx. May be very vascular, and may displace the posterior antral wall forward, thus stimulating angiofibroma. Imaging studies show a bulky soft-tissue mass, with areas of bone destruction. The signal intensity is similar to that of muscle on T1-weighted images, but becomes hyperintense on T2-weighted images. Some contrast enhancement is usual

Dermoid cyst

Granuloma

Histiocytosis X

Tuberculosis

Rare; may be present without evidence of tuberculosis elsewhere. Lytic lesions, with no sclerotic margins

Sphenoid wing

Meningioma (CT, MRI)

Benign bone neoplasm E.g., chondroma, giant-cell tumor

Chordoma

Craniopharyngioma

Glioma E.g., optic

Metastasis

Parasellar aneurysm

Pituitary tumor E.g., chromophobe adenoma

Histiocytosis X

Plexiform neurofibroma

CT: computed tomography; MRI: magnetic resonance imaging.

Abnormalities of the Craniovertebral Junction

These abnormalities may involve either the bones and joints, the meninges and the nervous system, or all of the above.

Congenital Anomalies and Malformations

Malformations of the occipital bone

Manifestations of occipital vertebrae These are ridges and outgrowths around the bony margins of the foramen magnum. Although the bony anomaly occurs extracranially at the anterior margin, it is often associated with an abnormal angulation of the craniovertebral junction, resulting in a ventral compression of the cervicomedullary junction. This particular anomaly is frequently associated with primary syringomyelia and Chiari malformation

- Basilar invagination
- The term “basilar invagination” refers to the primary form of invagination of the margins of the foramen magnum upward into the skull. The radiographic diagnosis is based on pathological features seen on plain films, CT, and MRI. Basilar invagination is often associated with anomalies of the notochord of the cervical spine, such as atlanto-occipital fusion, stenosis of the foramen magnum and Klippel–Feil syndrome; and with maldevelopments of the epichordal neuraxis such as Chiari malformation, syringobulbia, and syringomyelia.
 - The term “basilar impression” refers to the secondary, acquired form of basilar invagination, which is due to softening of the bone secondary to diseases such as Paget’s disease, osteomalacia, hyperparathyroidism, osteogenesis imperfecta, renal rickets, and achondroplasia.
 - The term “platybasia” applies to a condition in which the basal angle formed by joining the planes of the clivus and the anterior cranial fossa is greater than 140°. It does not cause any symptoms or signs by itself, but if it is associated with basilar invagination, then obstructive hydrocephalus may occur

Condylar hypoplasia The elevated position of the atlas and axis can lead to vertebral artery compression, with compensatory scoliotic changes and lateral medullary compression

Malformations of the atlas

Assimilation or occipitalization of the atlas	Occurs in 0.25% of the population; it only causes neurological symptoms and signs in one-quarter or one-third of this number
Atlantoaxial fusion	Very rare, except when associated with Klippel–Feil syndrome

Aplasia of atlas arches

Malformations of the axis

Irregular atlantoaxial segmentation

Dens dysplasias

- Ossiculum terminale Results from the persistence of the summit ossification center; seldom appears before the age of five years
- Os odontoideum Results from nonfusion of the epiphyseal plate and separation of the deformed odontoid process from the axial centrum. There is an increased incidence in patients with Down's syndrome, spondyloepiphysial dysplasia, and Morquio's syndrome
- Hypoplasia/aplasia

Segmentation failure of C2–C3

CT: computed tomography; MRI: magnetic resonance imaging.

Developmental and Acquired Abnormalities

These lesions may be misdiagnosed as: multiple sclerosis (31%), syringomyelia or syringobulbia (18%), tumor of the brain stem or posterior fossa (16%), lesions of the foramen magnum or Arnold–Chiari malformation (13%), cervical fracture or dislocation or cervical disk prolapse (9%), degenerate disease of the spinal cord (6%), cerebellar degeneration (4%), hysteria (3%), or chronic lead poisoning (1%).

The chief complaints of patients with symptomatic bony anomalies at the craniovertebral junction are: weakness of one or both legs (32%), occipital or suboccipital pain (26%), neck pain or paresthesias (13%), numbness or tingling of fingers (12%), and ataxic gait (9%). The average age of onset of symptoms in such patients is 28 years.

Abnormalities at the foramen magnum

Secondary basilar invagination	E.g., Paget's disease, osteomalacia, rheumatoid cranial setting
Foraminal stenosis	E.g., achondroplasia, occipital dysplasia, rickets

Atlantoaxial instability

Down's syndrome	The high incidence of craniovertebral anomalies and increased incidence of general ligament laxity may lead to instability in 30–40% of such patients. The usual onset of neurological symptoms is between seven and 12 years
-----------------	---

Inflammatory

– Rheumatoid arthritis (96%)	The cervical spine is variably affected in 44–88% of patients, with conditions ranging from minor asymptomatic atlantoaxial subluxation to total incapacity due to severe and progressive myelopathy. Autopsies have shown that severe atlantoaxial dislocation and high spinal cord compression is the commonest cause of sudden death in patients with rheumatoid arthritis
– Postinfectious (2.5%)	E.g., upper respiratory tract infections, mastoiditis, parotitis, tuberculosis
– Gout (1.5%)	

Traumatic lesions in the craniovertebral junction

– Occipitoatlantal dislocation	Excessive hyperflexion of the skull with distraction, which is usually fatal
– Atlantoaxial luxations	The anterior predental space is greater than 5 mm, indicating that the transverse and alar ligaments are incompetent

Tumors

E.g., meningiomas, neurinomas, chordomas, dermoids, epidermoids, lipomas, primary bone tumors, metastases, and multiple myeloma

Inborn errors of metabolism

E.g., dysplasia or absence of teeth is characteristic of the various types of dwarfism, such as Morquio's syndrome, pseudoachondroplastic dysplasia, Scott's syndrome, and spondyloepimetaphyseal dysplasia

Miscellaneous syndromes

E.g., Marfan's syndrome, Hurler's syndrome, neurofibromatosis, and the fetal warfarin syndrome

Craniosynostosis

Types

Scaphocephaly, or dolichocephaly	Elongated skull from front to back, with the biparietal diameter the narrowest part of the skull; e.g., boat or keel-shaped head due to premature closure of the sagittal suture
Trigonocephaly	Triangular head; angular and pointed forehead with a prominent midline bony ridge, due to premature closure of the metopic suture
Frontal plagiocephaly	Ipsilateral flattened frontal region with contralateral outward bulging and marked facial asymmetry—"harlequin eye"—due to unilateral coronal suture synostosis
Occipital plagiocephaly	Flattening of the involved occipital region with prominence in the ipsilateral frontal region due to unilateral lambdoid suture synostosis
Oxycephaly, turri- cephaly, or acrocephaly	Tall and pointed head with overgrowth of bregma and flat, underdeveloped posterior fossa, due to premature closure of the coronal and lambdoid sutures
Brachycephaly	Short, wide, slightly high head due to bilateral coronal suture synostosis
Triphyllocephaly, clover- leaf head, or "kleeblatt- schädel"	Trilobular skull with temporal and frontal bulges due to intrauterine closure of the sagittal, coronal, and lambdoid sutures

Associated Craniofacial Syndromes

Crouzon's syndrome	Coronal synostosis, maxillary hypoplasia, shallow orbits with exophthalmos, hypertelorism and often strabismus. Hydrocephalus, mental retardation, seizures, conductive deafness, and optic atrophy may be present
Apert syndrome or acrocephalosyndactyly	Craniosynostosis most commonly coronal, midfacial hypoplasia, hypertelorism, down-slanting of the palpebral features, and strabismus. Associated anomalies include osseous or cutaneous syndactyly, pyloric stenosis, ectopic anus, and pyloric aplasia

Carpenter's syndrome	Brachycephaly, lateral displacement of the inner canthi, brachydactyly of the hands, syndactyly of the feet, and hypogenitalism
Kleeblattschädel syndrome	Trilobular skull, low-set ears, and facial deformities. Dwarfism, aqueductal stenosis, and hydrocephalus may be seen
Pfeiffer's syndrome	Brachycephaly, hypertelorism, up-slanting palpebral fissures, a narrow maxilla, and broad thumbs and toes. Mental retardation, Chiari malformation, and hydrocephalus are often present
Saethre–Chotzen syndrome	Brachycephaly, maxillary hypoplasia, prominent ear crus, syndactyly, and often mental retardation
Baller–Gerold syndrome	Craniosynostosis, dysplastic ears, and radial aplasia–hypoplasia. Optic atrophy, conductive deafness, and spina bifida occulta may be present
Summitt's syndrome	Craniosynostosis, syndactyly, and gynecomastia
Herrmann–Opitz syndrome	Craniosynostosis, brachysyndactyly, syndactyly of the hands, and absent toes
Herrmann–Pallister–Opitz syndrome	Craniosynostosis, microcrania, cleft lip and palate, symmetrically malformed limbs, and radial aplasia

Associated Congenital Syndromes

Achondroplasia (base of skull)
Asphyxiating thoracic dysplasia
Hypophosphatasia (late)
Mucopolysaccharidoses (Hurler's syndrome); mucopolidosis III; fucosidosis
Rubella syndrome
Trisomy 21 or Down's syndrome
Trisomy 18 syndrome
Chromosomal syndromes (5 p–, 7 q+, 13)
Adrenogenital syndrome
Fetal hydantoin syndrome
Idiopathic hypercalcemia or Williams syndrome
Meckel's syndrome
Metaphyseal chondrodysplasia or Jansen syndrome
Oculomandibulofacial or Hallermann–Streiff syndrome

Associated Disorders

Rickets
 Hyperthyroidism
 Hypocalcemia
 Polycythemia
 Thalassemia

Macrocephaly or Macrocrania

“Macrocephaly” refers to large cranial vault.

Thickened skull

- Thalassemia or anemias with increased marrow activity
- Rickets
- Osteopetrosis
- Osteogenesis imperfecta
- Epiphyseal dysplasia

Hydrocephalus

- Noncommunicating, congenital
 - Aqueduct stenosis, stenosis of the foramen of Monro causing asymmetrical enlargement, Dandy–Walker cyst, Chiari malformation
- Communicating, acquired
 - Meningeal fibrosis (postinflammatory, posthemorrhagic, posttraumatic)
 - Malformation, destructive lesions (hydranencephaly, holoprosencephaly, porencephaly)
 - Choroid plexus papilloma

Extra-axial fluid collection

- Subdural effusion/hygroma
- Subdural hematoma

Brain edema

- Toxic E.g., lead encephalopathy
- Endocrine E.g., hypoparathyroidism, galactosemia

Megalencephaly Refers to a large brain

Familial macrocephaly

Congenital syndromes

- Chondrodystrophies E.g., achondroplasia, achondrogenesis, thanatophoric dwarfism and metaphoric dwarfism, cleidocranial dysplasia, Sotos syndrome
 - Mucopolysaccharidoses E.g., Hurler, Hunter, Morquio, gangliosidosis G_M
 - Neurocutaneous syndrome E.g., neurofibromatosis, tuberous sclerosis
-

Microcephaly or Microcrania

Perinatal damage E.g., cortical atrophy from hypoxia or ischemia

Craniosynostosis

Encephalocele

Genetic abnormalities

- Familial microcephaly Autosomal recessive and X-linked
- Hereditary nonchromosomal syndromes E.g., Fanconi syndrome, Prader-Willi syndrome, Seckel syndrome, Rubinstein-Taybi syndrome

Metabolic abnormalities

- Neonatal hypoglycemia
- Phenylketonuria
- Aminoaciduria
- Homocystinuria

Chromosomal abnormalities

- Trisomy 21 (Down's syndrome)
- Trisomy 18
- Trisomy 13-15
- Cat cry syndrome (5p-)

Intrauterine injury or infection (TORCH)*

- Radiation
- Infection E.g., toxoplasmosis, rubella, cytomegalic inclusion disease, herpes simplex
- Diabetes
- Uremia
- Malnutrition

- Fetal alcohol syndrome
- Maternal phenytoin use

Miscellaneous

- Chronic cardiopulmonary disease
- Chronic renal disease
- Xeroderma pigmentosa

* TORCH: toxoplasmosis, other, rubella, cytomegalovirus, and herpes simplex virus.

Pneumocephalus

Trauma	E.g., penetrating injury or fracture of the ethmoid bone, frontal bone, or of the mastoid sinuses is most common
Iatrogenic	E.g., postoperative, pneumoencephalography, ventriculography
Brain abscess	Infection with gas-forming organisms
Neoplasm of skull base	
– Osteoma	If it is eroding the cribriform plate
– Nasopharyngeal/ethmoid	

Small Pituitary Fossa

Normal variant

Hypopituitarism;
growth hormone deficiency

Decreased intracranial pressure E.g., brain atrophy, shunted hydrocephalus

Fibrous dysplasia

Radiotherapy during childhood

Dystrophia myotonica Hereditary, affecting early adult life and being associated with cataracts, testicular atrophy, frontal baldness, thick skull, and large frontal sinus

Deprivational dwarfism

Trisomy 21 (Down's syndrome)

Enlarged Pituitary Fossa

Intrasellar, parasellar, or juxtasellar masses

Neoplastic disorders

- Pituitary adenoma E.g., chromophobe, eosinophilic; the basophilic form virtually never expands
- Craniopharyngioma
- Meningioma
- Hypothalamic/chiasmatic gliomas
- Clival lesions E.g., metastases, chordomas
- Teratomas, including dysgerminoma
- Epidermoid and dermoid cysts

Nonneoplastic disorders

- Nonneoplastic cysts E.g., Rathke's cleft cyst, mucocele, arachnoid cyst
- Vascular lesions E.g., aneurysm or ectasia of the cavernous or suprasellar segment of the ICA and caroticocavernous fistula
- Inflammatory disorders E.g., abscesses, sarcoidosis, histiocytosis, lymphoid adenohypophysitis

Empty sella

Primary syndrome

Due to a deficiency in the diaphragma sella and associated herniation of the subarachnoid space into the sella turcica, which allows pulsating CSF to expand the sella. Associated with benign intracranial hypertension

Secondary

The result of prior surgery or radiation therapy, usually for a pituitary tumor

Raised intracranial pressure, chronic

E.g., obstructive hydrocephalus, dilated third ventricle, neoplasm, craniosynostosis

Suprasellar and Parasellar Lesions

The most frequent suprasellar masses are: suprasellar extension of pituitary adenoma, meningioma, craniopharyngioma, hypothalamic/chiasmatic glioma, and aneurysm. These five entities account for more than three-quarters of all sellar and juxtaseellar masses. Metastases, meningitis, and granulomatous disease account for a further 10%. Other suprasellar masses are uncommon; each is seen in less than 1–2% of cases.

Neoplastic Lesions

The most common suprasellar tumor masses are suprasellar extension of pituitary adenoma and meningioma in adults, and craniopharyngioma and hypothalamic/chiasmatic glioma in children (Fig. 1).

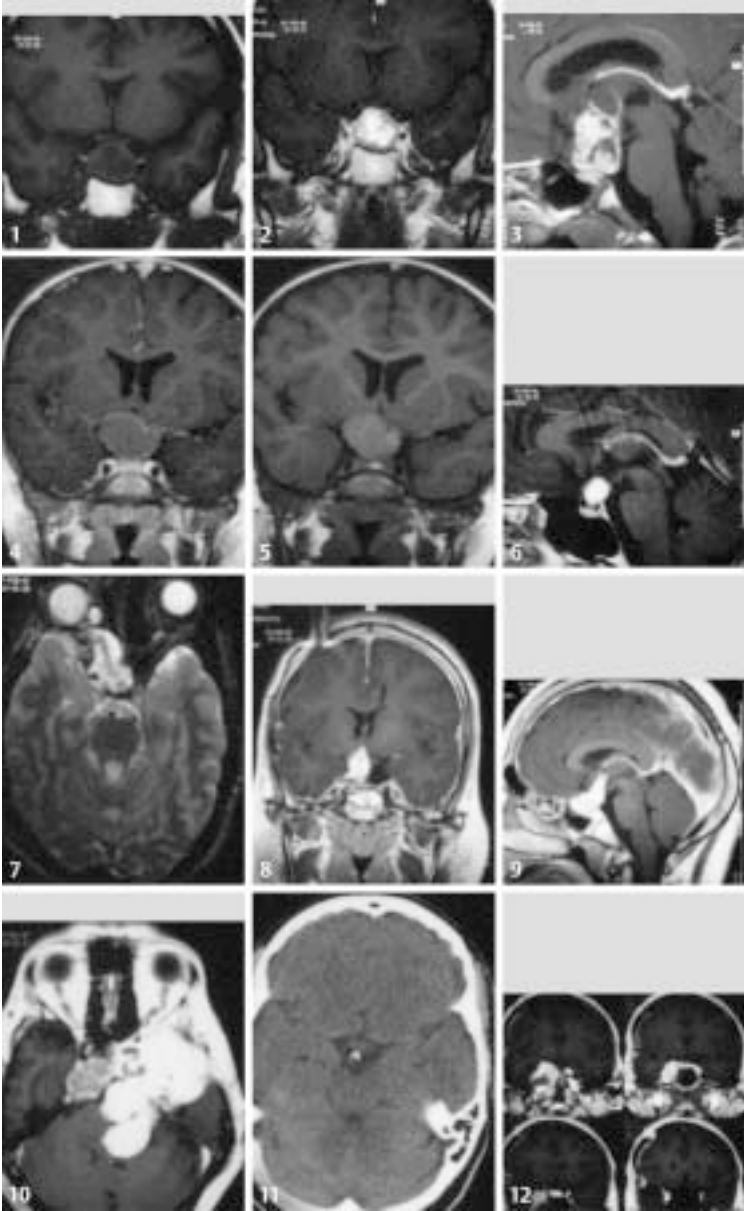
Pituitary tumor

– Pituitary adenoma

Autopsy series indicate that asymptomatic microadenomas account for 14–27% of cases, pars intermedia cysts 13–22%, and occult metastatic lesions 5% of patients with known malignancy. In descending order of frequency, the primary sources of pituitary metastases are:

- In women: breast cancer is by far the most common, accounting for over half of all secondary pituitary tumors; followed by lung, stomach, and uterus
- In men: the most frequent primary tumors are neoplasms of the lung, followed by prostate, bladder, stomach, and pancreas. Suprasellar extension accounts for 30–50% of suprasellar masses, e.g., chromophobe or eosinophilic; the basophilic form virtually never expands. On CT, the microadenoma (< 10 mm) is of low density compared with the normal gland, with or without enhancement. On MRI, microadenomas are generally hypointense in comparison with the normal gland on T1-weighted images, and display a variable intensity on T2-weighted images.

Macroadenomas have roughly the same signal characteristics as microadenomas, although they have a propensity for hemorrhage and infarction due to their poor blood supply. Cystic areas produce low intensity signals on T1-weighted images and high intensity sig-



nals on T2-weighted images. MRI now has a major role in the evaluation of adenomas of the pituitary. It can locate deformations of the optic tracks, chiasm, and optic nerves, and can demonstrate invasion of the cavernous sinuses or the surrounding structures by neoplasms. MRI is particularly helpful in outlining blood vessels and ruling out aneurysms

- Pituitary carcinoma, or carcinosarcoma
- Granular-cell tumor of the pituitary or choristoma

Craniopharyngiomas

These account for 20% of tumors in adults and 54% in children. Three neuroimaging hallmarks have been identified, which may be present in individual lesions: calcification, observed in 80% of cases; cyst formation, observed in 85% of cases; and solid or nodular enhancement. MRI is relatively insensitive to calcification, shows varying intensities for cystic fluid, and is not as specific as CT for the diagnosis of calcification and the low-density appearance of cyst formation

◀ Fig. 1 Suprasellar lesions (neoplastic)

- 1, 2. Pituitary macroadenoma. Coronal T1 WI with a pituitary macroadenoma in close relationship with the optic chiasm presenting a heterogeneous, post-contrast high intensity signal.
3. Pituitary macroadenoma. Sagittal T1 WI shows a pituitary tumor with a heterogeneous postcontrast high intensity signal with cystic and/or necrotic features in its posterior section filling the suprasellar cisterns and exerting compression on the optic chiasm.
- 4, 5. Craniopharyngioma. A suprasellar space-occupying mass with no postcontrast enhancement on coronal T1 WI.
6. Meningioma. Sagittal T1 WI shows a suprasellar space-occupying neoplastic lesion with a postcontrast high intensity signal showing an unusual development alongside the pituitary stalk.
7. Optic nerve glioma. Axial T2 WI shows a right optic nerve glioma with widening of the optic foramen in a patient with neurofibromatosis type I.
- 8, 9. Pilocytic astrocytoma. A highly enhanced mass, occupying part of the sella and the suprasellar cisterns and extending behind the optic chiasm, is seen on coronal and sagittal T1 WI respectively.
10. Chordoma. Axial T1 WI demonstrates a multilobular space-occupying neoplastic lesion, which is heterogeneously and highly enhanced, developing into the left parasellar region and ipsilateral temporal and posterior fossae along the ridge of the petrous bone.
11. Dermoid tumor. Calcification with elements of fat in the retrochiasmatic suprasellar cisterns.
12. Meningioma. Coronal T1 WI shows a postcontrast highly enhancing neoplastic lesion of the right cavernous sinus.

Meningiomas	These represent 15–20% of primary intracranial tumors, and are the second most frequent suprasellar neoplasm in adults. Rarely, meningiomas may arise from the parasellar lateral wall of the cavernous sinus, and they may extend posteriorly along the tentorial margin, with a dovetail appearance. The extra-axial mass is noncystic and heterogeneous in texture, and on CT imaging reveals hyperostosis, blistering of the tuberculum and erosion of the dorsum sellae; on T1-weighted images, the lesions are isointense and on T2-weighted images isointense to slightly hypertense to brain, enhancing dramatically
Hypothalamic and optic nerve/chiasm gliomas	These are the second most common form of pediatric suprasellar tumor, accounting for 25–30% of such cases. Bilateral optic nerve gliomas are associated with neurofibromatosis type I in 20–50% of these patients. On CT, the lesions are isodense to hypodense, and frequently enhance following contrast injection. On MRI, the lesions are hypointense on T1-weighted images and hyperintense on T2-weighted images. The MRI may show no contrast enhancement, variable enhancement, or intense uniform enhancement. The contrast pattern does not correlate with the pathological grade of the tumors
Dermoid tumors	These are midline tumors, found most commonly in the posterior fossa and only rarely in the suprasellar region. Imaging reflects the high fat content of these lesions. Calcification is relatively common. CT shows a hypodense lesion. The signals on MRI reflect a higher fat content than that of the brain. These tumors with the lipomas are two uncommon causes of suprasellar “bright spots”
Epidermoid tumors (“pearly tumors”)	These are located along the cisterns in the cerebellopontine angle, or in the parasellar area and elsewhere as in the fourth ventricle, lateral ventricles, cerebrum, cerebellum, and brain stem. On CT, epidermoids appear as low-density lesions that do not enhance with contrast. The MRI appearance is hypointense compared to brain on T1-weighted images and hyperintense on the T2-weighted images
Teratomas and teratoid tumors, including dysgerminomas	Found in the pineal region, intrasellar or suprasellar, and in the sacrococcygeal region. Teratomas include tissue from all three germ-cell layers. MRI demonstrates an infiltrating mass that is isointense to brain on T1-weighted images, moderately hyperintense on proton density and T2-weighted images. Homogeneous enhancement is common in both CT and MRI studies

Lipomas	Most intracranial lipomas are considered as congenital abnormalities rather than neoplasms. The most common sites are the interhemispheric fissure (50%), the quadrigeminal cistern and pineal region, the suprasellar cistern and cerebellopontine angle cistern. CT imaging shows attenuation values that are in the negative range, usually -30 to -100 HU, and are isodense to subcutaneous fat. MRI demonstrates lipomas high in intensity on T1-weighted images and intermediate to low on T2-weighted images.
Metastases	Represent approximately 1% of sellar and parasellar masses.
– Hematogenous spread	The most frequent metastatic lesions in this region from systemic primary cancer come from lung, breast, and prostate.
– Perineural spread	<ul style="list-style-type: none"> • Head and neck tumors may demonstrate perineural spread through the foramen at the skull base into the brain; e.g., basal-cell carcinoma, melanoma, adenoid cystic carcinoma, schwannoma, lymphoma. • Infections; e.g., actinomycosis, Lyme disease, herpes zoster. Metastases are typically isointense on T1-weighted images and moderately hyperintense on T2-weighted images. Moderate enhancement occurs after gadolinium injection
Chondrosarcoma	Rare tumor arising from embryonal residues, endochondral bone, or cartilage and located at the skull base, parasellar region, in the meninges, or in the brain. CT demonstrates a mass (calcified in 60% of cases) and enhancing neoplastic tissue. MRI shows the enhanced mass. The CT is probably more specific for this tumor, because of its sensitivity to calcium
Lymphoproliferative disorders	
– Lymphoma	Intrasellar and suprasellar component. May involve the pituitary gland, hypothalamus, infundibular stalk in older adults
– Granulocytic sarcoma or chloroma	Primitive myeloid cell tumor; rarely involving the CNS
Olfactory neuroblastoma	

Trigeminal schwannoma	Rare tumors (0.4% of brain tumors), arising most commonly from the parasellar region of the Gasserian ganglion or the posterior fossa. On CT imaging, particularly with bone windows, erosion can be demonstrated at the petrous apex. On MRI, the lesions are smooth masses, isointense on T1-weighted images and with high intensity on T2-weighted images, with avid enhancement and intratumoral “cystic” changes observed within the enhancing mass
-----------------------	--

CNS: central nervous system; CT: computed tomography; HU: Hounsfield unit; MRI: magnetic resonance imaging.

Nonneoplastic Lesions (Fig. 2)

Nonneoplastic cysts

Rathke's cleft cyst	Benign cysts containing mucous protein, arising from Rathke's pouch and located in the anterior sellar and/or anterior suprasellar region. They resemble craniopharyngiomas, which calcify. CT is useful here because of its sensitivity to calcification as compared to MRI. MRI of these lesions demonstrates a variable intensity depending on the cyst contents, and the lesions enhance much less than craniopharyngiomas
Sphenoid sinus mucoceles	Mucoceles are most common in the frontal and ethmoidal sinuses, with sphenoid sinus mucoceles the least common. CT demonstrates an isodense smooth mass (with an enhancing ring). MRI shows varying intensities, depending on the protein concentration and viscosity, but most mucoceles are hyperintense on T1-weighted images and T2-weighted images, with peripheral enhancement (not solid, as in neoplasms)
Arachnoid or leptomeningeal cysts	Approximately 15% of arachnoid cysts occur in the suprasellar region. They enlarge and produce mass effects on adjacent structures. The CT density and MRI intensities of these cysts are those of CSF; they are not associated with enhancement or calcification. Cisternography can be helpful in differentiating these cysts from an ependymal cyst of the third ventricle or an enlarged third ventricle due to aqueduct stenosis

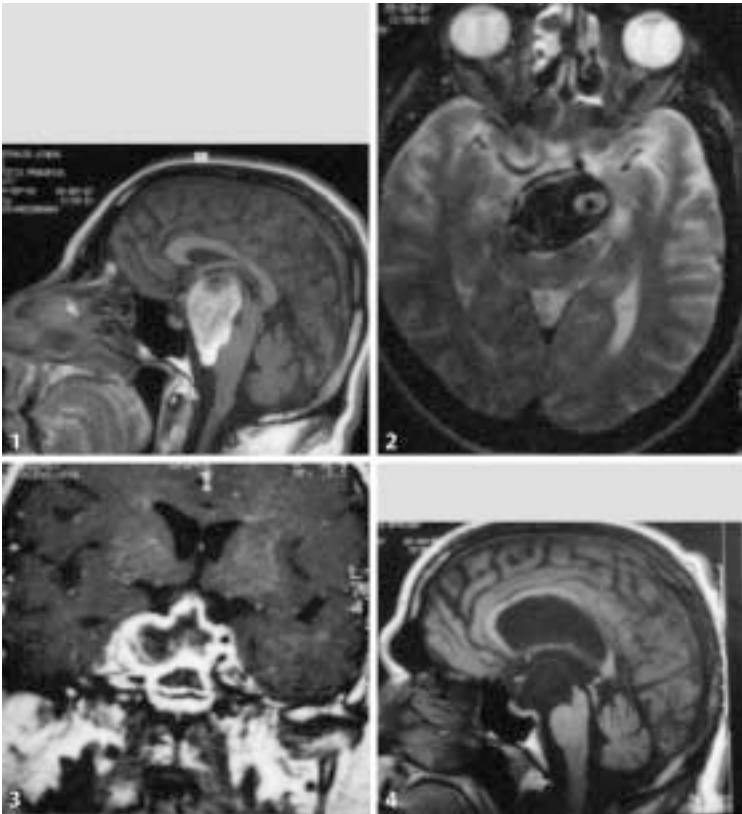


Fig. 2 Suprasellar lesions (non-neoplastic)

- 1, 2. Basilar aneurysm. Sagittal T1 WI shows a partially thrombosed (flow void appearance) giant aneurysm of the tip of the basilar artery extending retrochiasmatically into the suprasellar cisterns compressing the brain stem.
3. Pituitary bacterial abscess. Coronal T1 WI demonstrates a sellar/suprasellar ring enhancing lesion containing necrotic fluid.
4. Arachnoid cyst. Sagittal T1 WI with a retrochiasmatic cyst extending into the suprasellar cisterns with an intensity signal identical to that of cerebrospinal fluid.

Vascular lesions

Aneurysms of the cavernous or suprasellar portion of the ICA or ACoA

MR imaging is variable, depending on the presence and age of the thrombus

- The typical patent aneurysm lumen with rapid flow is seen as a well-delineated suprasellar mass that shows high-velocity signal loss (flow void) on T1-weighted images and T2-weighted images
- Completely thrombosed aneurysms may show variable MRI findings. Subacute thrombus is predominantly hyperintense on T1-weighted and T2-weighted images. Multilayered clots can be seen in thrombosed aneurysms that have undergone repeated episodes of intramural hemorrhage. Acutely thrombosed aneurysms may be isointense with brain parenchyma, and difficult to differentiate from other intracranial masses

Vascular ectasias

Cavernous hemangiomas

Located in Meckel's cavity and in the cavernous sinus. Due to lack of a hemosiderin rim, central large hemorrhage and calcification is extremely difficult to diagnose with MRI

Caroticocavernous fistula or dural malformation

Cavernous sinus thrombosis

May occur after a septic process, after an interventional procedure or after surgery. CT shows an irregular filling defect in an irregularly enhancing sinus. MRI without enhancement demonstrates a high intensity in the occluded sinus; enhancement is not helpful, because unthrombosed regions of the sinus enhance, and blood clot also has a high intensity

Infectious/inflammatory lesions

Parasitic infections

Cysticercosis and echinococcus parasitic cysts in this region are usually inhomogeneous, and may be calcified

Abscesses

These can occur after surgery, but also in situations that predispose to bacterial infection, including sinusitis. Exudative bacterial meningitis and tuberculous meningitis have a predilection for the basal sub-arachnoid spaces

Granulomatous disease

Giant-cell granuloma, sarcoidosis and syphilis can affect the pituitary and suprasellar region, often causing hypopituitarism and rarely diabetes insipidus

Histiocytosis X	E.g., Hand–Schüller–Christian and Letterer–Siwe diseases. Cranial involvement occurs in over 90% of patients, who present with diabetes insipidus and a thickened and enhancing infundibular stalk with or without a hypothalamic mass
Lymphoid adenohypophysitis or lymphocytic hypophysitis	A rare inflammatory process affecting the anterior pituitary gland, causing hypopituitarism and an expanding suprasellar mass. Affects women during late pregnancy or in the postpartum period. Imaging findings are nonspecific and resemble macroadenoma

ACoA: anterior communicating artery; CSF: cerebrospinal fluid; CT: computed tomography; ICA: internal carotid artery; MRI: magnetic resonance imaging.

Intracranial Calcifications

Physiological

Physiological calcification is extremely rare below the age of 9 years old. For example, physiological calcification in the pineal gland and choroid plexuses happens in only 2% of children below 9 years of age, but increases fivefold by 15 years, and is common in adults

Pineal gland	In about 60% of all persons over 20 years of age
Habenula	About 30% of all persons
Choroid plexus	It is usually seen in the glomus and is bilateral
Dura	E.g., falx, superior sagittal sinus, tentorium, petroclinoid ligaments, and diaphragma sellae

Familial, congenital, or metabolic

Sturge–Weber syndrome	“Railroad track” type of calcification
Tuberous sclerosis	Calcification is seen most commonly centrally or near the lateral ventricles in nearly 50% of patients
Basal ganglion and dentate nucleus calcification	
Lissencephaly	Calcification in a small nodule in the roof of the cavum septi pellucidi, just behind the foramen of Monro
Pseudoxanthoma elasticum	Calcification of the dura, thickening of the cranial vault and platybasia
Congenital cerebral granuloma	

Inflammatory disorders

Bacterial infections

- Tuberculosis Tuberculous granuloma, healed meningitis
- Pyogenic infections Calcification occurs late following a healed brain abscess, purulent meningitis, or other pyogenic intracranial infection
- Syphilitic granuloma or gumma

Parasitic infestations

- Cysticercosis Cysts of *Taenia solium* form in the basal cisterns or brain in 5% of infections. Only dead cysts can calcify
- Hydatid cysts Only 2% of infections produce cysts in the brain, and these rarely calcify
- Paragonimiasis Cysts of the oriental lung fluke occur commonly in the posterior parts of the cerebral hemispheres. Massive regions of calcification may be seen

Fungal disease

Cryptococcosis, coccidioidomycosis

Vascular

Arterial aneurysms

- Giant aneurysms Show curvilinear calcification outlining part of the aneurysmal sac in 50% of cases
- Dilatation of the vein of Galen In older children or adults, a ringlike calcification may be seen in the region of the pineal gland

Arteriovenous malformation

Curvilinear, amorphous and patchy, or nodular calcifications are seen in 6–29% of cases

Intracranial hemorrhage

- Chronic subdural hematoma 1–5% calcify
- Extradural hematoma Calcification rarely occurs

Arteriosclerotic vascular disease

Especially at the carotid siphon

Neoplasm

Glioma

Overall 9–10% calcify; 6% of astrocytomas and 47% of oligodendrogliomas. Grade I gliomas show a 25% incidence of calcification and grade IV a 2% incidence. Ependymomas show calcification in 15% of cases. Calcification is seen only in 1% of medulloblastomas

Craniopharyngioma

The incidence of calcification in most series varies between 55% and 94%. Calcification is less likely in older patients

Chordoma

About 15% show some amorphous or nodular calcification

Chondroma and osteochondroma	Dense and nodular calcification in the ethmoid or sphenoid air cells or the cerebellopontine angle
Meningioma	In most series, calcification with various appearances has been reported in 6–9% of cases
Pituitary adenoma	Approximately 6% show calcification, commonly on the posteroinferior surface of the tumor
Brain metastasis	Calcification is found in about 2% of patients with brain metastasis
– Mucinous adenocarcinoma	Colon, stomach, ovary, breast
– Osteocarcinoma	
– Chondrosarcoma	
Pinealoma	About 50% of pinealomas show a dense and homogeneous or scattered calcification
Choroid plexus papilloma	About 20% show calcification; the most common site is the fourth ventricle in children and the temporal horn in adults
Dermoid and epidermoid tumors and teratoma	Calcification is rare in dermoid and epidermoid tumors, but common in teratomas
Lipoma of the corpus callosum	Characteristically, two curvilinear bands of calcification, one on each side of the corpus callosum
Hamartoma	Usually in the temporal lobe
Neoplasms after radiotherapy	

Calcifications of the Basal Ganglia

Basal ganglia calcifications are seen in 0.6% of CT scans. They usually affect the globus pallidus, and are bilateral and symmetrical, but can be unilateral. These lesions are mainly idiopathic and are often associated with dentate nuclei calcification.

Idiopathic	These account for over 50% of cases, and can be familial
Disorders of calcium metabolism	Hyperparathyroidism, hypoparathyroidism, and pseudohypoparathyroidism

Fahr's disease	Also known as familial cerebrovascular ferrococalcinos and characterized by microcephaly, spasticity, epilepsy, progressive neural deterioration and fine iron and calcium deposits in the basal ganglia, dentate nuclei and periventricular areas
Parasitic disease	Toxoplasmosis, cysticercosis. About half the cases of congenital toxoplasmosis result in intracranial calcification, e.g., in the caudate nucleus, choroid plexus, ependyma
Radiation therapy	Mineralization microangiography
Tuberous sclerosis	
Trisomy 21	Down's syndrome
Encephalitis	E.g., rubella, measles, chickenpox
Birth anoxia	
Carbon monoxide intoxication	
Methotrexate therapy	
Lead toxicity	
Addison's disease	
Leigh's disease	
Neurofibromatosis	
Cockayne syndrome	

Parasellar Calcification

Neoplastic

- Craniopharyngioma
- Meningioma
- Pituitary adenoma (Chromophobe)
- Chordoma
- Optic chiasm glioma
- Cholesteatoma

Vascular

- Aneurysm Circle of Willis or basilar artery
- Atheroma Carotid siphon

Infectious

- Tuberculous meningitis Calcification in the basal meninges
-

Posterior Fossa Tumors

Differentiation between medulloblastoma, ependymoma, and astrocytoma based on their radiological characteristics (Fig. 3).

Radiological characteristic	Astrocytoma	Ependymoma	Medulloblastoma
CT scan (enhancement)	Hypodense (nodule enhances; cyst does not)	Isodense (minimal)	Hyperdense (moderate)
T1-weighted images	Hypointense	Hypointense	Hypointense
T2-weighted images	Hyperintense	Isointense	Isointense
Location	Eccentric	Midline	Midline
Origin	Cerebellar hemisphere	4th ventricle, ependymoma	4th ventricle, superior medullary velum
Calcification	Uncommon (< 10%)	Common (40–50%)	Uncommon (> 10–15%)
Cystic degeneration	Typical	Common	Rare
Hemorrhage	Uncommon	Common (> 10%)	Uncommon
Subarachnoid seeding	Very rare	Common	Very common (25–50%)
Hydrocephalus	Unusual	Common	Very common
4th ventricle appearance	Unaffected	Enlargement (shape unaffected)	Distortion (posteroinferiorly)
Age (years)	10–12	2–10 & 40	5–12

CT: computed tomography.

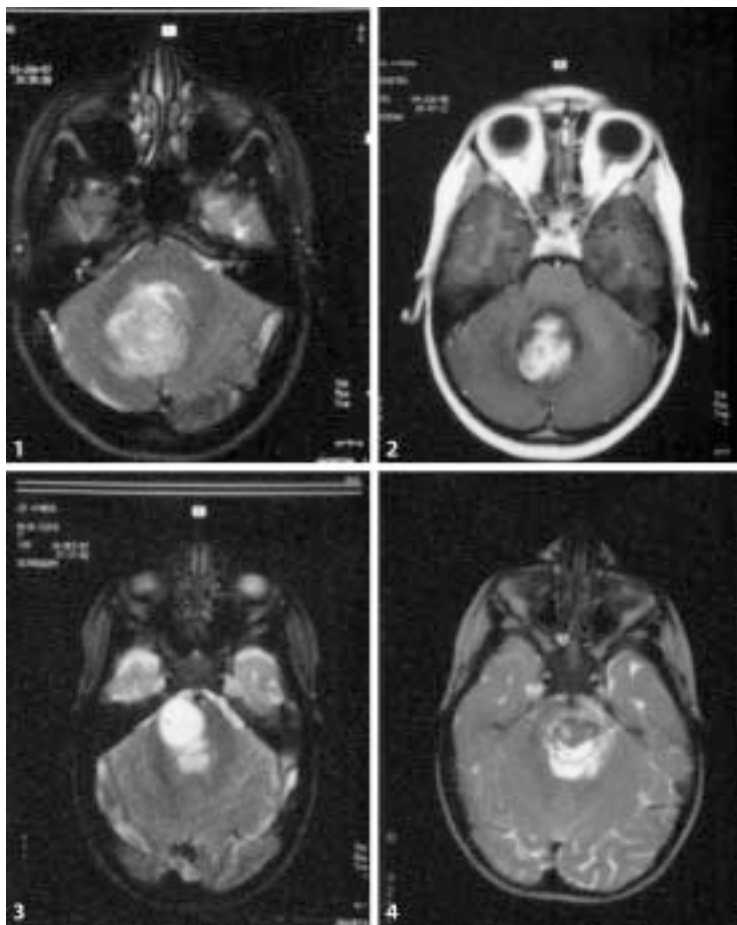


Fig. 3 Posterior fossa lesions

1. Medulloblastoma. Axial MRI T1 WI shows a solid space-occupying lesion with a moderate signal intensity on T2 WI which occupies the area behind the 4th ventricle exerting pressure on it.
2. Ependymoma. Axial MRI T1 WI shows a multilobular space-occupying lesion with solid features, which are enhanced without homogeneity, and cystic features in the periphery and focal calcifications.
3. Pilocytic astrocytoma of the brain stem on axial MRI T1 WI with well-delineated margins and a highly pathological signal; mild compression on the 4th ventricle.
4. Chronic hematoma within a ruptured cavernous hemangioma of the pons in a child. Axial T2 WI with a heterogeneous signal of a parenchymal lesion within the pons. This lesion displaces the 4th ventricle and is characterized by low and high intensity and surrounding edema.

Postoperative Brain Scar Versus Residual Brain Tumor

There is nothing more frustrating for the neurosurgeon than a postoperative CT scan or MRI showing residual tumor after a supposedly “complete” resection.

Granulation tissue, which enhances on CT and MRI due to its fibrovascular nature, develops 72 hours after surgery. After that time, it is consequently difficult to distinguish between enhancing surgical bed tissue and marginal residual tumor, assuming that there was preoperative tumor enhancement. The scan enhancement may persist for several months postoperatively, and neurosurgeons therefore scan patients within 48 hours after the operation. Scan enhancement at the surgical site within 48 hours should be compatible with a residual tumor.

Radiological characteristic	Postoperative scar	Residual tumor
Contrast enhancement		
– Within 48–72 hours	No	Yes
– After 48–72 hours	Yes	Yes
Type of enhancement	Linear (at the periphery of the preoperative tumor bed area)	Solid and nodular (within the tumor bed area)
Peritumoral edema (with time)	Decreases	Increases
Change in size (with time)	Stays the same or decreases	Increases
Blood (in the tumor bed area)	Resolves while the granulation tissue stays the same or decreases	May be present while the residual tumor mass increases

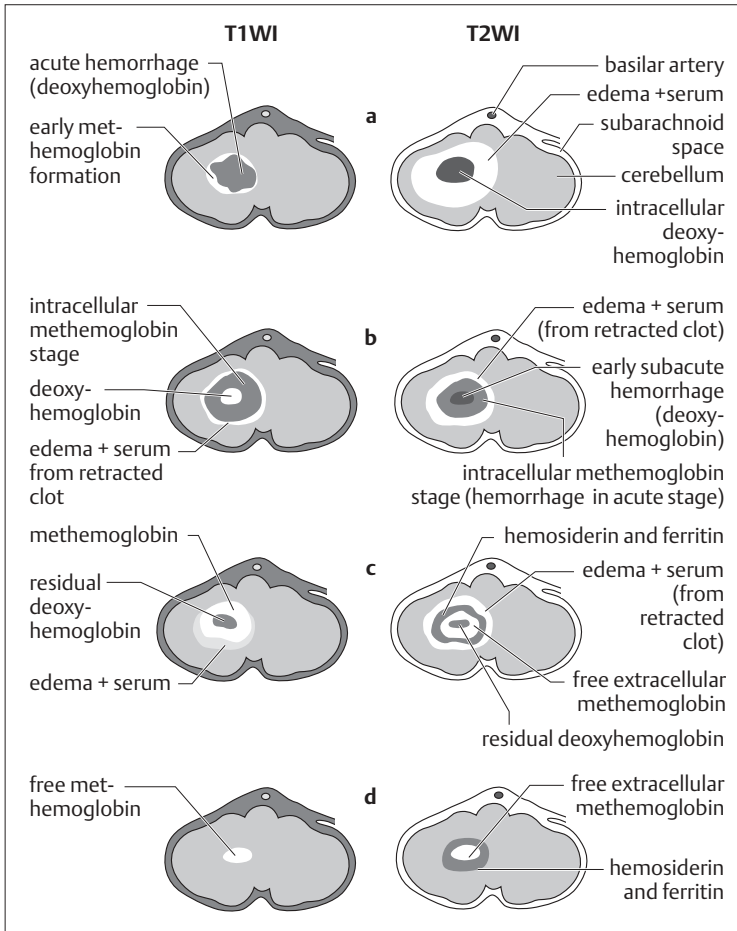


Fig. 4 Stages and estimation of age of hemorrhage on MRI. MRI scenarios of posterior fossa (right cerebellar) hemorrhage during:
a the acute stage, i.e., within 48 hours of ictus. On the T1WI hemorrhage appears slightly hypodense to cerebellar parenchyma, due to the T2 effect of deoxyhemoglobin. There is a small amount of peripheral high density due to early intracellular methemoglobin formation. The T2WI demonstrates marked hypointensity caused by intracellular deoxyhemoglobin in intact red blood cells.
b Early subacute stage, i.e., within 3 to 7 days from ictus, during the time in which there is oxidation of the deoxyhemoglobin to methemoglobin inside the red blood cells at the periphery of the clot. On the T1WI the central hemorrhage shows a high signal due to intracellular deoxyhemoglobin, whereas on the T2WI

there is a marked hypointensity. The peripheral area of the hemorrhage, which represents the intracellular methemoglobin stage is isointense on the T1WI, and on the T2WI appears hypointense. Furthermore, surrounding this hemorrhage is a high-intensity area composed of edema and serum from the retracted blood clot.

c Late subacute stage, i. e., within 7 to 10 days, during which time the heme-free molecule of the methemoglobin and/or other exogenous compounds including peroxide and superoxide can produce red blood cells lysis and accumulation of extracellular methemoglobin within the hematoma cavity. Methemoglobin in free solution is very hyperintense on T1- and T2WI. Inside this high signal rim of metHb a hypointense area appears, representing residual deoxyhemoglobin. Around the hematoma on the T2WI there is a hypointense rim (hemosiderin and ferritin) and peripherally, surrounding this rim there is a high signal intensity, representing vasogenic edema.

d Chronic stage, i. e., more than 14 days, during which there is a pool of dilute-free metHb surrounded by the ferritin and hemosiderin, containing vascularized wall. These iron cores produce a thin hypo- or isointense rim on the T1WI and a very hypointense rim on the T2WI.

Stages and Estimation of Age of Hemorrhage on MRI

Recognizing cerebral hemorrhage is critically important, and a knowledge of the complex parameters that influence the MRI appearance of an evolving hematoma is therefore essential. The MRI of a hematoma depends on whether T1-shortening proton electron dipole–dipole (PEDD) interactions or T2-shortening preferential T2 proton relaxation enhancement (PT2-PRE) occur. The interaction that predominates thereafter depends on the particular heme moiety present (e.g., oxyhemoglobin, deoxyhemoglobin, methemoglobin, or hemosiderin), and on whether it is in free solution or compartmentalized into red blood cells or macrophages (Fig. 4).

Stage	Time	Compartment	Hemoglobin	T1 signal intensity	T2 signal intensity
Hyperacute	< 24 h	Intracellular	Oxyhemoglobin	Medium (isointense)	Medium (hyperintense)
Acute	1–3 days	Intracellular	Deoxyhemoglobin	Long (= ↓) (isointense low intensity)	to short (↓ ↓) (low intensity)
Subacute – Early	3+ days	Intracellular	Methemoglobin	Short (↑) (high intensity)	Short (↓ ↓) (low intensity)
– Late	7+ days	Extracellular	Methemoglobin	Short (↑) (high intensity)	Long (↑) (high intensity with rim of low intensity)
Chronic – Center	14+ days	Extracellular	Hemochromes	Medium (isointense to low intensity)	Medium (isointense to low intensity)
– Rim		Intracellular	Hemosiderin	Medium (↓) (isointense)	Short (↓ ↓) (very hypointense)

Normal Pressure Hydrocephalus Versus Brain Atrophy

Although brain atrophy and normal pressure hydrocephalus (NPH) often share the finding of dilation of the ventricular system, the prognostic and therapeutic implications of the two entities are markedly different. Atrophy reflects the loss of brain tissue, whether it is cortical cell bodies, axonal subcortical degeneration, or demyelination. Generally, there is no treatment for atrophy, whereas hydrocephalus can often be treated with ventricular or subarachnoid space shunts and/or removal of the obstructive or overproducing lesion.

The diagnosis of NPH requires very close correlation between the clinical findings and the imaging results, and the best diagnostic test for NPH is still clinical improvement after ventricular shunting. It is difficult to distinguish NPH from atrophic ventriculomegaly on a single examination. Follow-up with serial CT or MR imaging is therefore necessary, and may show that the dilated ventricles have returned to normal size, remain enlarged, or, most importantly, that there has been no further interval enlargement.

Differentiation based on radiological features

Radiological characteristic	Hydrocephalus	Brain atrophy
Ventricular system		
Temporal horns	Enlarged	Normal (except in Alzheimer's disease)
Frontal horns (ventricular angle)	More acute	More obtuse
3rd ventricle	Convex	Concave
4th ventricle	Normal or enlarged	Normal (except in cerebellar atrophy)
Periventricular edema	Present (transependymal migration of CSF, especially to the frontal and occipital horns. Edema resolves quickly after ventricular decompression by shunting, within 24 hours)	Absent (rule out ischemia)
Aqueduct flow void	Accentuated (in normotensive hydrocephalus)	Normal
Corpus callosum	Thin, distended, rounded elevation. Increased fornico-callosal distance	Normal or atrophied Normal fornico-callosal distance
Sulci	Flattened	Enlarged disproportionately to age
Fissures (choroidal, hippocampal)	Normal to mildly enlarged	Markedly enlarged (in Alzheimer's disease)

CSF: cerebrospinal fluid.

Meningeal Enhancement

Postcraniotomy meningeal enhancement	In 80% of patients indicating inflammatory or chemical arachnoiditis from blood
Meningitis	Bacterial, viral, syphilitic, and granulomatous
Meningioma en plaque	
Meningeal carcinoma-tosis	

Meningeal fibrosis from:	<ul style="list-style-type: none">- Aneurysmal subarachnoid hemorrhage- CSF leaks, CSF shunting and intracranial hypotension- Dural sinus thrombosis
Nonneoplastic meningeal disorders	<ul style="list-style-type: none">- Histiocytosis- Sarcoidosis- Rheumatoid disease- Idiopathic pachymeningitis
Lymphoma, leukemia	
Extraskelletal mesenchymal osteocartilaginous tumors	<ul style="list-style-type: none">- Osteochondroma- Chondrosarcoma
Miscellaneous and rare causes of dural enhancement	<ul style="list-style-type: none">- Amyloid- Mucopolysaccharidoses (e.g., Gaucher disease)- Glioblastoma multiforme- Wegener's granulomatosis- Glioneuronal heterotopias

CSF: cerebrospinal fluid.

Gyriform Enhancement

Cerebral infarction
Encephalitis
Infiltrating primary or subpial metastatic neoplasm
Cortical contusion
Postepilepsy (e.g., transient blood-brain barrier disruption)
Cortical hamartomas in tuberous sclerosis

Corpus Callosum Lesions

Neoplasms	Near the top of the list of lesions involving the corpus callosum are: <ul style="list-style-type: none">- Glioblastoma multiforme- Lymphoma- Metastases- Lipoma
Trauma	There is a propensity for shearing injuries in this location, because of its relatively fixed location spanning the interhemispheric fissure

White matter lesions

- Multiple sclerosis The frequent localization of acute and chronic MS lesions in the corpus callosum is thought to be due to tracking of these lesions along the ependymal veins from the ventricular surface into the adjacent white matter. T2 lesions of the corpus callosum have recently become important in diagnosing MS, because they improve the sensitivity and specificity of MRI for the disease
- Leukodystrophies The hallmark of the leukodystrophies is demyelination of the cerebral white matter; they are due to disorders of the peroxisomes, as in ADL, or of the lysosomal enzymes, as in Krabbe's disease
 - Adrenal leukodystrophy (ADL)
 - Krabbe disease (globoid cell leukodystrophy)
- Marchiafava–Bignami syndrome This is a rare disorder of demyelination or necrosis of the corpus callosum and adjacent subcortical white matter, which occurs in malnourished alcoholics

Severe hydrocephalus, and after ventricular shunting

Infection

- Lyme disease (borreliosis)
- Progressive multifocal leukoencephalopathy

Radiation damage

Infarction

Rare, as the blood supply is bilateral through the anterior cerebral arteries

ADL: adrenal leukodystrophy; MRI: magnetic resonance imaging; MS: multiple sclerosis.

Ring Enhancing Lesions

The triad tumor, pus, or blood accounts for most cases in adults (Fig. 5).

Tumor

Primary brain tumors E.g., anaplastic astrocytoma, glioblastoma multiforme

Metastatic brain tumors Especially from the lung

Abscess

Pyogenic brain abscess Common organisms causing pyogenic cerebral abscess:

Aerobic bacteria: *Staphylococcus aureus*, *Streptococcus*, Gram-negative organisms (*Escherichia coli*, *Klebsiella*, *Proteus*, *Pseudomonas*, *Haemophilus influenzae*)

Anaerobic bacteria: *Streptococcus*, *Bacteroides*, *Peptostreptococcus*

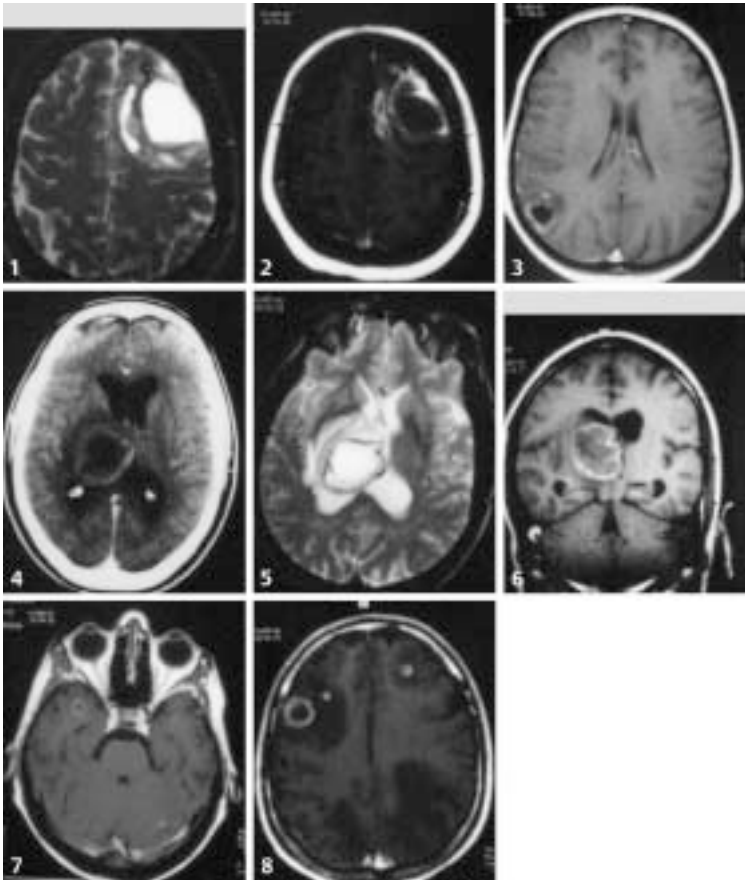


Fig. 5 Ring enhancing lesions

1. Oligodendroglioma. Axial T2 WI shows a space-occupying lesion with a high intensity heterogeneous signal with solid and cystic features.
2. Oligodendroglioma. Axial T1 WI of the same case demonstrates an irregular postcontrast ring enhancement.
3. Astrocytoma grade III. Axial T1 WI shows a space-occupying lesion with a post-contrast ring enhancement, central necrosis, and peritumoral edema.
4. Bacterial abscess. A postcontrast axial CT with a space-occupying lesion in the right basal ganglia with an irregular ring enhancement and marked surrounding edema.
5. Bacterial abscess. Axial T2 WI of the same case with a space-occupying lesion in the right basal ganglia with a thick capsule and marked perifocal edema.
6. Bacterial abscess. Coronal T1 WI of the same case.

Fungal abscess

- Cryptococcosis *Cryptococcus* ranks third behind HIV and toxoplasmosis as a cause of CNS infection in AIDS
- Coccidioidomycosis
- Mucormycosis
- Nocardiosis *Nocardia* lesions show a well-formed enhancing capsule containing multiple loculations
- Aspergillosis In contrast to *Nocardia* infection, intracranial aspergillosis rarely presents with ring enhancement
- Candidiasis *Candida* is the most common cause of autopsy-proved non-AIDS cerebral mycosis

Parasitic abscess

- Toxoplasmosis (*Toxoplasma gondii* infects the CNS in 10% of patients with AIDS and also immunocompromised adults)
- Cysticercosis

Subacute resolving hematoma with capsule**Infarct****Miscellaneous**

Tuberculosis

Granuloma

Demyelinating disease E.g., multiple sclerosis

Radiation necrosis

Lymphoma E.g., primary CNS lymphoma in AIDS or secondary systemic lymphoma

Trauma

Thrombosed vascular malformation or aneurysm

AIDS: acquired immune deficiency syndrome; CNS: central nervous system; HIV: human immunodeficiency virus.

7. Toxoplasmosis. Axial T1 WI shows a small subcortical postcontrast ring enhancing toxoplasmosis brain abscess within the right temporal lobe.
8. Cerebral metastases. Axial T1 WI with multiple secondary focal lesions demonstrating postcontrast ring enhancement and an extensive infiltrating edema disproportionate to the size of the lesions.

Developmental and Acquired Anomalies and Pediatric Disorders

Movements Resembling Neonatal Seizures

Benign nocturnal myoclonus	Sudden jerking movements of the limbs during sleep occur in normal people, and require no treatment
Jitteriness or tremulousness	Low-frequency, high-amplitude shaking of the limbs and jaw in response to stimulation. Occurs in newborns with perinatal asphyxia, some of whom have seizures and require EEG monitoring for differential diagnosis
Nonconvulsive apnea	Irregular respiratory patterns of 3–6 seconds, followed by 10–15 seconds of hyperpnea without significant changes in heart rate, blood pressure, temperature, or skin color. This condition affects premature infants, and is caused by immaturity of the respiratory centers in the brain stem and not by a pathological condition
Opisthotonos	A prolonged arching of the back, probably caused by meningeal irritation. It is observed in the infantile Gaucher's disease and kernicterus, and has to be differentiated from tonic seizures and decerebrate posturing
Benign myoclonus	Spasms in clusters increasing in frequency and intensity over weeks, which then after three months usually stop, with the exception of a few episodes; no spasms occur after two years of age. The infants are neurologically normal, and their EEG and CT scans of the head are normal

CT: computed tomography; EEG: electroencephalography

Neonatal Seizures by Time of Onset

Seizures in the first 24 h

(In order of frequency, especially during the first 12 hours)

Hypoxic – ischemic encephalopathy
Sepsis and bacterial meningitis
Subarachnoid hemorrhage
Intrauterine infection
Trauma (laceration of tentorium or falx)
Direct drug effects
Intraventricular hemorrhage at term
Pyridoxine dependency

Seizures from 24 h to 72 h

(In order of frequency and importance)

Intraventricular hemorrhage in premature infants
Subarachnoid hemorrhage
Cerebral contusion with subdural hemorrhage
Sepsis and bacterial meningitis
Cerebral infarction or intracerebral hemorrhage
Cerebral dysgenesis
Drug withdrawal
Metabolic disorders

- Glycine encephalopathy
- Glycogen synthetase deficiency
- Hypoparathyroidism – hypocalcemia
- Pyridoxine encephalopathy
- Urea cycle disturbances

Seizures from 72 h to 1 week*(In order of frequency and importance)*

Inborn errors of metabolism, especially organic acid disorders

- Hypoglycemia Fructose dysmetabolism, maple syrup urine disease
- Hypocalcemia Hypoparathyroidism
- Hyperammonemia Propionic acidemia, methylmalonic acidemia, etc.
- Hyperlactacidemia Glycogen storage disease, mitochondrial disease, etc.
- Metabolic acidosis Maple syrup urine disease, fructose dysmetabolism, multiple carboxylase deficiency
- No rapid screening test Neonatal adrenoleukodystrophy, glycine encephalopathy, infantile gangliosidosis G_M, Gaucher type 2

Cerebral dysgenesis

Cerebral infarction

Intracerebral hemorrhage

Familial neonatal seizures

Kernicterus

Tuberous sclerosis

Seizures from 1 to 4 weeks

Inborn errors of metabolism, especially organic acid disorders

- Hypoglycemia Fructose dysmetabolism, maple syrup urine disease
- Hypocalcemia Hypoparathyroidism
- Hyperammonemia Propionic acidemia, methylmalonic acidemia, etc.
- Hyperlactacidemia Glycogen storage disease, mitochondrial disease, etc.
- Metabolic acidosis Maple syrup urine disease, fructose dysmetabolism, multiple carboxylase deficiency
- No rapid screening test Neonatal adrenoleukodystrophy, glycine encephalopathy, infantile gangliosidosis G_M, Gaucher type 2

Herpes simplex encephalitis

Cerebral dysgenesis

Familial neonatal seizures

Tuberous sclerosis

First Nonfebrile Tonic–Clonic Seizure after Two Years of Age

Viral encephalitis

- Herpes simplex encephalitis
- Arboviral encephalitis
 - St. Louis encephalitis
 - Western and Eastern equine encephalitis
 - Japanese B encephalitis
 - California–La Crosse encephalitis
- Retrovirus encephalitis E.g., AIDS encephalitis
- Rhabdovirus encephalitis E.g., rabies encephalitis

Idiopathic isolated seizure

Partial complex seizures with secondary generalization Any seizure originating in the cortex may discharge into the brain stem

- Benign Rolandic epilepsy of childhood
- Benign occipital epilepsy of childhood
- Epilepsia partialis continua

Progressive encephalopathy

- Infectious diseases E.g., subacute sclerosing panencephalitis
- Lysosomal enzyme disorders
 - Glycoprotein disorders
 - Mucopolysaccharidoses types II and VII
 - Sphingolipidoses

Genetic disorders of gray matter

- Huntington's disease
- Mitochondrial disorders
- Xeroderma pigmentosum

Genetic disorders of white matter

- Alexander's disease
- Adrenoleukodystrophy

AIDS: acquired immune deficiency syndrome.

Causes of Confusion and Restlessness

Epileptic	E.g., partial complex seizures, absence-type seizures
Metabolic and systemic disorders	
– Osmolality disorders	E.g., hyponatremia, hypoglycemia
– Endocrine disorders	E.g., adrenal insufficiency, parathyroid and thyroid disorders
– Hepatic encephalopathy	
– Metabolic disorders	E.g., carnitine deficiency, urea cycle and pyruvate disorders
– Renal disease	E.g., hypertensive and uremic encephalopathy
Infectious disorders	
– Bacterial infections	E.g., meningitis, cat scratch disease
– Rickettsial infections	E.g., Lyme disease
– Viral infections	E.g., herpes simplex, arboviruses, measles and postinfectious encephalitis, Reye's syndrome
Vascular	
– Congestive heart failure	
– Subarachnoid hemorrhage	
– Embolic infarction	
– Vasculitis and connective tissue disorders	
– Migraine	
Toxic	
– Substance abuse	
– Prescription drugs	
– Toxins	
Psychogenic	E.g., panic disorder, schizophrenia

Causes of Coma

Epilepsy	E.g., status epilepticus, postictal state
Trauma	
– Contusion	
– Intracranial hemorrhage	E.g., epidural and subdural, intracerebral
Raised intracranial pressure	
– Brain edema	
– Brain tumor	
– Brain abscess	
– Intracranial hemorrhage	E.g., spontaneous, traumatic
– Hydrocephalus	
Hypoxic – ischemic damage	
– Cardiac arrest	
– Congestive heart failure	
– Hypotension and hypoperfusion	
– Near-drowning	
Infectious diseases	
– Bacterial infections	
– Rickettsial infections	
– Viral infections	
– Postimmunization encephalopathy	
Metabolic and systemic disorders	
– Osmolality disorders	E.g., hyperglycemia, hypoglycemia, hyponatremia, hypernatremia
– Endocrine disorders	E.g., adrenal insufficiency, thyroid disorders
– Metabolic disorders	E.g., pyruvate and urea cycle disorders, glycogen storage disease, carnitine deficiency
– Renal disorders	E.g., uremic, dialysis, and hypertensive encephalopathy
– Toxic	E.g., drug abuse, toxins

Papilledema

Congenital disk elevation (drusen)
 Elevated intracranial pressure
 Papillitis
 Optic glioma
 Ischemic neuropathy
 Juvenile diabetes
 Retinitis, uveitis
 Retrobulbar mass lesion (unilateral papilledema)

Hypotonic Infant

Cerebral hypotonia

Clues to diagnosis

Other brain dysfunction; dysmorphic features; fisting of the hands; malformations of other organs; movement through postural reflexes; normal or brisk tendon reflexes; scissoring on vertical suspension

Benign congenital hypotonia

Hypotonic at birth, but later on have normal tone and increased incidence of cerebral abnormalities, e.g., retardation, learning difficulties, and other disabilities

Chromosomal disorders

- Trisomy
- Prader-Willi syndrome

E.g., deletion of the long arm of chromosome 15 causing hypotonia, mental retardation, obesity, short stature, and hypogonadism

Cerebral dysgenesis

This is suspected when hypotonia is associated with malformations in other organs, or abnormalities in the size and shape of the head

Peroxisomal dysfunctions

- Cerebrohepatorenal syndrome (Zellweger's syndrome)
- Neonatal ADL
- Infantile Refsum's disease

Severe hypotonia, arthrogryposis, dysmorphic features, seizures. Death from aspiration, gastrointestinal bleeding, or liver failure within one year

X-linked, characterized by hypotonia, dysmorphia, failure to thrive, seizures, retardation, and spasticity. Death in early childhood

Genetic disorders

- Familial dysautonomia (Riley–Day syndrome) Autosomal recessive hypotonia from disturbances in the brain, dorsal root ganglia, and peripheral nerves
- Oculocerebrorenal syndrome (Lowe syndrome) X-linked recessive hypotonia, hyporeflexia, cataracts, and glaucoma. Normal lifespan

Spinal cord disorders

- Hypoxic–ischemic myelopathy In severe perinatal asphyxia causing hypotonia and areflexia
- Spinal cord injury Cervical spinal cord injury occurs exclusively during vaginal delivery; approximately 75% with breech presentation and 25% with cephalic presentation. Sphincter dysfunction and a sensory level at the mid-chest suggest myelopathy

Motor unit disordersClues to diagnosis

Absent or depressed tendon reflexes; failure of movement on postural reflexes; fasciculations; muscle atrophy; no abnormalities in other organs

- Spinal muscular atrophies Genetic degeneration of anterior horn cells in the spinal cord and motor nuclei of the brain stem
 - Acute infantile spinal muscular dystrophy Werdnig–Hoffmann disease
 - Chronic infantile spinal muscular dystrophy
 - Infantile neuronal degeneration
 - Neurogenic arthrogryposis

Polyneuropathies

- Axonal
 - Familial dysautonomia
 - Hereditary motor-sensory neuropathy type II
 - Idiopathic with encephalopathy
 - Infantile neuronal degeneration
- Demyelinating
 - Acute inflammatory (Guillain–Barré syndrome)
 - Congenital hypomyelinating neuropathy
 - Hereditary motor-sensory neuropathies, type I and type III
 - Metachromatic leukodystrophy

Disorders of neuromuscular transmission

- Infantile botulism
- Familial infantile myasthenia

- Transitory neonatal myasthenia

Congenital myopathies

- Central core disease Fiber-type disproportion
Tightly packed myofibrils in the center of all type I fibers undergo degeneration
- Fiber-type disproportion myopathy Predominance of type I fibers and hypotrophy
- Myotubular myopathy Predominance of type I fiber and hypotrophy, many internal nuclei and a central core of increased oxidative enzyme and decreased myosin ATPase activity
- Nemaline myopathy Multiple rod-like particles are present in most or all muscle fibers

Muscular dystrophies

- Congenital muscular dystrophy Various sizes of fibers present nucleation, extensive fibrosis and proliferation of adipose tissue, regeneration and degeneration, and thickening of the muscle spindle capsule
 - Fukuyama type
 - Leukodystrophy
 - Cerebro-ocular dysplasia
- Neonatal myopathic dystrophy Maturation arrest in muscles surrounding a fixed joint, and predominance of type II fibers

Metabolic myopathies

- Acid maltase deficiency (Pompe's disease)
- Carnitine deficiency
- Cytochrome-c oxidase deficiency
- Phosphofructokinase deficiency
- Phosphorylase deficiency

Infantile myositis

Diffuse inflammation and proliferation of connective tissue, and muscle fiber degeneration

Endocrine myopathies

- Hyperthyroidism, hypothyroidism
- Hyperparathyroidism, hypoparathyroidism
- Hyperadrenalism, hypoadrenalism

ADL: adrenoleukodystrophy.

Precocious Puberty

The differential diagnosis in a child presenting with precocious puberty includes the following conditions.

Hypothalamic astrocytoma
Optic nerve/chiasmal glioma
Germinoma
Craniopharyngioma
Suprasellar cyst
Hypothalamic hamartomas
Hypothalamic gangliogliomas
Hypothalamic gangliocytomas

Arthrogryposis

This condition varies in severity from the most common feature, club foot, to symmetric flexion deformities of all limb joints.

Cerebrohepatorenal syndrome
Cerebral malformations
Chromosomal disorders
Motor unit disorders
Nonfetal causes

Progressive Proximal Weakness

This condition is most commonly due to myopathy, usually muscular dystrophy.

Myopathies

Muscular dystrophies

- Duchenne and Becker muscular dystrophy
- Facioscapulohumeral syndrome
- Limb-girdle dystrophy

Inflammatory myopathies

- Dermatomyositis
- Polymyositis

Metabolic myopathies

- Acid maltase deficiency
- Carbohydrate myopathies (McArdle disease)
- Muscle carnitine deficiency
- Lipid myopathies

Endocrine myopathies

- Hyperthyroidism, hypothyroidism
- Hyperparathyroidism, hypoparathyroidism
- Hyperadrenalism, hypoadrenalism

Juvenile spinal muscular atrophies

(Wohlfart–Kugelberg–Welander disease)

- Autosomal recessive form
- Autosomal dominant form
- Gangliosidosis G_{M2} (Tay–Sachs disease)

Myasthenic syndromes

- Familial limb-girdle myasthenia
- Slow-channel syndrome

Spinal cord disorders**Congenital malformations**

- Arteriovenous malformations
- Myelomeningocele
- Chiari malformation (Type I and II)
- Tethered spinal cord
- Atlantoaxial dislocation (Aplasia of odontoid process, Morquio syndrome, Klippel–Feil syndrome)

Familial spastic paraplegia**Trauma**

- Spinal cord concussion
- Compressed vertebral body fractures
- Fracture dislocation and spinal cord transection
- Spinal epidural hematoma

Tumors of the spinal cord

- Astrocytoma
- Ependymoma
- Neuroblastoma
- Other tumors (Sarcoma, neurofibroma, dermoid/epidermoid, meningioma, teratoma)

Transverse myelitis**Neonatal cord infarction****Infections**

- Diskitis
 - Epidural abscess
 - Tuberculous osteomyelitis
-

Progressive Distal Weakness

This condition is most commonly due to myopathies; the next most frequent cause is neuropathy.

Myopathies

Hereditary distal myopathies

- Infantile or adult-onset dominant type
- Autosomal recessive type (Miyoshi myopathy)

Myotonic dystrophy

Scapulohumeral peroneal syndromes

- Bethlehem myopathy
- Emery–Dreifuss muscular dystrophy
- Scapulohumeral syndrome with dementia
- Scapulo-peroneal syndrome

Neuropathies

Idiopathic chronic neuropathy

- Axonal form
- Demyelinating form

Hereditary motor and sensory neuropathy

- Type I: Charcot–Marie–Tooth disease
- Type II: Charcot–Marie–Tooth disease, neuronal type
- Type III: Dejerine–Sottas disease
- Type IV: Refsum disease

Other genetic neuropathies

- Giant axonal neuropathy
- Metachromatic leukodystrophy

Neuropathies with systemic disease

- Drug-induced neuropathy (e.g., isoniazid, nitrofurantoin, vincristine, zidovudine)
- Toxins (e.g., heavy metals, inorganic chemicals, insecticides)
- Uremia
- Systemic vasculitis and vasculopathy

Motor neuron disease

Juvenile amyotrophic lateral sclerosis

Spinal muscular atrophy

Spinal cord disorders

Congenital malformations

- Arteriovenous malformations
- Myelomeningocele
- Chiari malformation (type I and II)
- Tethered spinal cord

- Atlantoaxial dislocation (Aplasia of odontoid process, Morquio syndrome, Klippel–Feil syndrome)

Familial spastic paraplegia

Trauma

- Spinal cord concussion
- Compressed vertebral body fractures
- Fracture dislocation and spinal cord transection
- Spinal epidural hematoma

Tumors of the spinal cord

- Astrocytoma
- Ependymoma
- Neuroblastoma
- Other tumors (e.g. sarcoma, neurofibroma, dermoid/epidermoid, meningioma, teratoma)

Transverse myelitis

Neonatal cord infarction

Infections

- Diskitis
 - Epidural abscess
 - Tuberculous osteomyelitis
-

Acute Generalized Weakness

The sudden onset of flaccid weakness in the absence of encephalopathy is always due to motor unit disorders. Of all the disorders listed, Guillain–Barré syndrome is the most common cause.

Infectious diseases

Guillain–Barré syndrome (acute inflammatory demyelinating polyradiculoneuropathy)

Acute infectious myositis

Enterovirus infections (e.g., poliovirus, coxsackievirus, echovirus)

Neuromuscular blockade

Botulism

Tick paralysis

Periodic paralysis

Familial hyperkalemic periodic paralysis

Familial hypokalemic periodic paralysis

Familial normokalemic periodic paralysis

Sensory and Autonomic Disturbances

These conditions present with pain, dysesthesias, and loss of sensitivity.

Brachial neuritis

- Acute idiopathic brachial neuritis
- Familial recurrent brachial neuritis
- Reflex sympathetic dystrophy

Congenital insensitivity to pain There is no sensory neuropathy; pain indifference is due to severe mental retardation, e.g., Lesch-Nyhan syndrome

Hereditary sensory and autonomic neuropathy

Hereditary metabolic neuropathy

Foramen magnum tumors E.g., neurofibroma

Syringomyelia

Multiple sclerosis

Thalamic syndromes of Dejerine and Roussy E.g., ischemia of the thalamus or of the primary sensory cortex and in thalamic gliomas

Lumbar disk herniation

Ataxia

Acute ataxia

The most common causes in otherwise healthy children are drug ingestion, postinfectious cerebellitis, and migraine

Drug ingestion

E.g., psychoactive drugs, anticonvulsants, anti-histamines

Postinfectious neuro-immune

- Acute postinfectious cerebellitis
- Multiple sclerosis
- Miller-Fisher syndrome E.g., ataxia, ophthalmoplegia, areflexia

Migraine	E.g., basilar migraine, benign paroxysmal vertigo
Brain stem encephalitis	Echoviruses, coxsackieviruses, adenoviruses are the implicated etiological agents
Brain tumor	Acute complication of existing neuroblastoma, e.g., bleeding, sudden foraminal shift
Conversion reaction	Especially in girls aged 10–15 years
Trauma	E.g., postconcussion syndrome, vertebrobasilar occlusion

Vascular disorders

- Cerebellar hemorrhage Commonly due to an arteriovenous malformation
- Vasculitis E.g., lupus erythematosus, Kawasaki disease

Genetic disorders causing metabolic deficiencies

- Hartnup disease
- Maple syrup urine disease
- Carnitine acetyltransferase deficiency
- Pyruvate decarboxylase deficiency

Chronic ataxia

Progressive ataxia in a previously healthy child is most commonly due to a posterior fossa brain tumor

Brain tumors

- Medulloblastoma
- Cerebellar astrocytoma
- Ependymoma
- Cerebellar hemangioblastoma
- Brain stem glioma
- Supratentorial tumors

Congenital malformations

- Basilar impression
- Cerebellar malformations E.g., hemispheric vermian aplasia, Dandy–Walker cyst

Hereditary disorders

- Ramsay–Hunt syndrome
- Olivopontocerebellar degeneration
- Ataxia–telangiectasia
- Friedreich’s ataxia
- Hartnup disease

- Abetalipoproteinemia, hypolipoproteinemia
- Maple syrup urine disease
- Pyruvate dysmetabolism
- Adrenoleukodystrophy

Acute Hemiplegia

The acute onset suggests either a vascular or an epileptic etiology.

Stroke

- Arteriovenous malformation
- Brain tumors and systemic cancer
- Carotid disorders E.g., fibromuscular dysplasia, cervical infection, trauma
- Drug abuse E.g., cocaine, amphetamine
- Heart disease Congenital, rheumatic
- Moyamoya disease
- Vasculopathies E.g., lupus, Kawasaki's disease, Takayasu arteritis
- Sickle-cell anemia

Migraine

- Complicated migraine Causing hemiplegia or ophthalmoplegia
- Familial hemiplegic migraine

Epilepsy

- Absence status
- Hemiparetic seizures (Todd paralysis)

Diabetes mellitus

Insulin-dependent diabetes causing a complicated migraine as a pathophysiological mechanism

Infections

Bacterial or viral infections causing hemiplegia preceded by prolonged and persistent focal seizures, resulting from vasculitis or venous thrombosis

Trauma

- Hematomas E.g., epidural, subdural, intracerebral
- Brain edema

Tumors

After complications such as hemorrhage, epilepsy

Progressive Hemiplegia

Brain tumor	
Brain abscess	
Arteriovenous malformation	
Demyelinating disease	
Phakomatosis	E.g., Sturge–Weber disease

Acute Monoplegia

A child's failure to use a limb indicates that there is pain, weakness, or both in the limb. Pain is usually caused by injury, infection, or tumor. Complicated migraine may cause weakness. Pain and weakness together are signs of plexopathy, syringomyelia, and tumors of the cervical cord or brachial plexus. The leading causes of monoplegia are plexopathies and mononeuropathies.

Plexopathies	
– Acute idiopathic plexitis	A demyelinating disorder of the brachial and lumbar plexuses
– Osteomyelitis, neuritis	Ischemic nerve damage due to vasculitis
– Hopkins syndrome	Postasthmatic viral spinal paralysis due to infection of the anterior horn cells
– Injuries	<ul style="list-style-type: none"> • Neonatal brachial neuropathy (e.g., upper and lower plexus injuries) • Motor vehicle and sports-related postnatal plexopathies
– Tumors of the brachial plexus	<ul style="list-style-type: none"> • Malignant schwannoma • Neuroblastoma
Mononeuropathies	E.g., lacerations, pressure and traction injuries to the radial, ulnar, and peroneal nerves
Spinal muscular atrophy	E.g., hereditary degeneration of the anterior horn cells
Stroke	
Syringomyelia	
Congenital malformations of the spinal cord	
Tumor of the spinal cord	

Agenesis of the Corpus Callosum

Agenesis of the corpus callosum is one of the more common congenital abnormalities, occurring in 0.7% of births and presenting clinically with intractable seizures and mental retardation. Various degrees of corpus callosum agenesis can occur (e.g., complete agenesis, loss of splenium). Associated midline abnormalities include the following.

Interhemispheric
arachnoid cyst

Interhemispheric lipoma

Agyria or lissencephaly

Pachygyria

Schizencephaly

Heterotopias

Dandy–Walker syndrome

Holoprosencephaly

Septo-optic dysplasia

Chiari malformation,
types I and II

Trisomy 13 – 15 and 18

Aicardi's syndrome Agenesis of the corpus callosum, epilepsy, and
choroidal abnormalities

Megalencephaly

Metabolic and toxic causes

Cerebral edema

- Benign intracranial hypertension
- Intoxication E.g., lead, vitamin A, tetracycline
- Galactosemia
- Endocrine E.g., hypoparathyroidism, hypoadrenocorticism

Leukodystrophy E.g., Alexander's disease, Canavan's disease

Lysosomal diseases E.g., Tay–Sachs disease, metachromatic leukodystrophy

Mucopolysaccharidoses E.g., Hurler's disease, Hunter's disease, Morquio's syndrome, Maroteaux–Lamy syndrome

Structural causes

Cerebral gigantism Sotos syndrome

Familial megalencephaly Dominant and recessive

Neurocutaneous syndromes E.g., neurofibromatosis, tuberous sclerosis, multiple hemangiomas

Fragile X syndrome

Congenital neuronal migrational anomaly

Unilateral Cranial Enlargement

Dyke–Davidoff–Masson syndrome

Hemimegalencephaly E.g., neuronal migrational anomaly

Neurofibromatosis

Klippel–Trenaunay syndrome

Proteus syndrome

Cranial Nerve Disorders

Anosmia

Trauma	E.g., severe head injury, cranial surgery. This is the most common cause. Only one-third of the cases are reversible
Changes in the mucous membrane	
– Infections	E.g., influenza, viral hepatitis, syphilis
– Atrophic rhinitis (leprosy)	
– Chronic rhinitis and sinusitis	
– Osteomyelitis of frontal and ethmoidal sinuses	
Aplasia of the olfactory bulbs	E.g., Kallmann syndrome: hypogonadism with eunuchoid gigantism, absence of puberty, and occasionally color blindness
Generalized diseases	
– Diabetes mellitus	
– Hypothyroidism	
– Scleroderma	
– Sheehan's syndrome	
– Paget's disease	
Toxins	
– Cocaine	
– Amphetamine	
– Lead	
– Calcium	
Local radiation therapy	
Tumors of the olfactory epithelium	
Frontal lobe masses	
– Tumor	E.g., olfactory groove meningioma
– Abscess	
Heavy smoking	

Subarachnoid hemorrhage

Meningitis

Albinism

Oculomotor Nerve Palsy

(Cranial nerve III)

Intra-axial (midbrain)

- Ischemia E.g., paramedian/basal midbrain infarction; Benedikt's/Weber's syndromes
- Tumor E.g., glioma, metastasis
- Inflammation/demyelination E.g., herpes zoster encephalitis, poliomyelitis, multiple sclerosis
- Hemorrhage E.g., intracranial hematoma, subarachnoid hemorrhage
- Tuberculoma
- Congenital hypoplasia of third cranial nerve nucleus

Basilar subarachnoid space

- Aneurysm E.g., posterior communicating; less commonly, posterior cerebral, basilar tip, or superior cerebellar
- Temporal lobe herniation
- Meningeal disease processes E.g., tuberculous, fungal, bacterial, and carcinomatous meningitis, meningovascular syphilis

Cavernous sinus and superior orbital fissure

- Aneurysm (internal carotid)
- Tumor E.g., meningioma, pituitary adenoma, nasopharyngeal and other metastases
- Tolosa-Hunt syndrome
- Cavernous sinus thrombosis
- Pituitary apoplexy

Carotid–cavernous
fistula

Dural arteriovenous
malformation

Diabetic infarction of
the nerve trunk

Pupil spared in 80% of cases; classically described as painful, although it can be painless; reversible within three months

Fungal infection

E.g., mucormycosis, usually found in diabetics

Ophthalmic herpes
zoster

Orbit

Orbital pseudotumor

Orbital blowout fracture

Orbital tumors

E.g., meningioma 40%, hemangioma 10%, carcinoma of the lacrimal duct, neurofibroma, lipoma, epidermoid, fibrous dysplasia, sarcoma, melanoma 35%

Miscellaneous

Ophthalmoplegic mi-
graine

Arteritis

Guillain–Barré syn-
drome

Fisher's syndrome of isolated polyradiculitis

Sarcoidosis

Infectious mononucleo-
sis and other viral infec-
tions

After immunization

Conditions simulating oculomotor nerve lesion

Thyrotoxicosis

Weakness of the superior and lateral rectus muscles due to an inflammatory myopathic process

Myasthenia gravis

Diplopia, ptosis, varying eye signs or fatigability of eye movements should always raise this possibility

Internuclear ophthal-
moplegia

Diplopia without weakness of any eye movement—disruption of the conjugate eye movements, e.g., multiple sclerosis, brain stem infarction

Latent strabismus

Diplopia under conditions of fatigue or drowsiness

Progressive ocular my-
opathy

Familial ptosis variant; a rare form of muscular dystrophy affecting the extraocular muscles

Trochlear Nerve Palsy

(Cranial nerve IV)

Intra-axial (brain stem)

Infarction

Hemorrhage

Trauma

Demyelination

Iatrogenic (neurosurgical complication)

Congenital aplasia of fourth cranial nerve nucleus

Subarachnoid space

Trauma

Mastoiditis

Meningitis (infectious and neoplastic)

Tumor

E.g., tentorial meningioma, germinoma, teratoma, gliomas, choriocarcinoma, trochlear schwannoma, metastases

Iatrogenic

Neurosurgical complication

Cavernous sinus and superior orbital fissure

Diabetic infarction

Most common cause; reversible within three months

Aneurysm

E.g., congenital, aneurysmal dilatation of the intracavernous portion of the internal carotid artery usually occurring in elderly hypertensive women

Caroticocavernous fistula

E.g., traumatic, spontaneous

Cavernous sinus thrombosis

Serious complication from sepsis of the skin over the upper face, or in the paranasal sinuses

Tumor

E.g., pituitary adenoma, parasellar, tuberculum or diaphragm sella meningioma, teratoma, dysgerminoma, metastases

Tolosa–Hunt syndrome

Herpes zoster

Conditions simulating trochlear nerve palsy

Thyrotoxicosis	Myopathy of the extraocular muscles
Myasthenia gravis	
Latent strabismus	
Brown's syndrome	Mechanical impediment of the tendons of the superior oblique muscle in the trochlea characterized by sudden onset, transient and recurrent inability to move the eye upward and inward

Trigeminal Neuropathy

(Cranial nerve V)

Intra-axial (pons)

Infarction	Distal pontine dorsolateral infarction may cause ipsilateral facial anesthesia, because the lesion damages the entering and descending fibers of the fifth nerve
Neoplastic	E.g., pontine glioma, metastases
Demyelination	E.g., multiple sclerosis; an attack of numbness of one side of the face in a young person, occasionally after local anesthesia for dental work, is quite a common symptom of multiple sclerosis
Syringobulbia	<ul style="list-style-type: none"> – Congenital, e.g., Chiari malformations – Secondary, e.g., trauma, ischemic necrosis, high cervical intramedullary tumor

Cerebellopontine angle

Acoustic neurinoma	
Meningioma	Usually associated with bony hyperostosis and/or calcification within the lesion
Ectodermal inclusions	E.g., epidermoid, dermoid
Metastases	
Trigeminal neurinoma	
Aneurysm	

Lesions at the petrous tip

Petrositis	E.g., diffuse inflammation of the petrous bone from mastoiditis or middle ear infection. This causes severe ear pain and a combination of lesions in nerves VI, VII, VIII, and V, and is known as Gradenigo's syndrome
------------	--

Cavernous sinus/orbital fissure

Severe trauma

Metastatic carcinomas E.g., carcinomas of the nasopharynx or the paranasal sinuses

Cavernous sinus thrombosis

Aneurysm Dilatation of the intracavernous portion of the carotid artery at the posterior end of the sinus may irritate the ophthalmic division of the fifth nerve

Tumors arising in the orbit and optic foramina E.g., meningioma 40%; hemangiomas 10%; pseudotumor 5%; glioma 5%; carcinoma of the lacrimal duct, neurofibroma, epidermoid, fibrous dysplasia of bone, sarcoma, melanoma, lipoma, Tolosa-Hunt syndrome, Hand-Schüller-Christian disease 40%

Miscellaneous

Diabetic vascular neuropathy

Trigeminal neuralgia

Acute herpes zoster In the elderly, the virus has a predilection for the first division of the seventh nerve

Systemic lupus erythematosus Vasculitic trigeminal neuropathy

Scleroderma Isolated trigeminal neuropathy may be the presenting sign in 10% of patients with neurological manifestations of scleroderma and occurs in 4–5% of all patients with scleroderma

Progressive systemic sclerosis Fibrosis with nerve entrapment is the likely cause of trigeminal and other cranial neuropathies

Sjögren's syndrome Vasculitic trigeminal neuropathy

Amyloidosis Peripheral neuropathy with involvement of the fifth cranial nerve

Arsenic neuropathy Peripheral and trigeminal neuropathy

Trigeminal sensory neuropathy A slowly progressing unilateral or bilateral facial numbness or paresthesia, thought to be caused by vasculitis or fibrosis of the gasserian ganglion; most frequently leads to the diagnosis of an underlying connective tissue disease, e.g., Sjögren's syndrome, systemic lupus erythematosus, and dermatomyositis

Abducens Nerve Palsy

(Cranial nerve VI)

Intra-axial (pons)

Infarction	Paramedian and basal pontine infarction; e.g., Foville syndrome, Gasperini syndrome, Millard–Gubler syndrome
Wernicke’s encephalopathy	Serious complication of alcoholism and severe malnutrition; reversible following intravenous therapy with vitamin B ₁
Möbius syndrome	Congenital absence of facial nerve nuclei and associated absence of the abducens nuclei
Pontine glioma	Many of these tumors start in the region of the abducens nerve nucleus; any combination of sixth and seventh nerve palsy in a young child or a patient with neurofibromatosis should be regarded with suspicion
Demyelination	E.g., multiple sclerosis; internuclear ophthalmoplegia or isolated sixth nerve palsy is a common manifestation

Basal subarachnoid space

Trauma	16–17%; e.g., severe head injury and movement of the brain stem
Raised intracranial pressure	Causing downward displacement of the brain stem and stretching of the abducens nerve over the petrous tip, leading to paresis of the nerve
Basal meningeal process	E.g., tuberculous, fungal, bacterial and carcinomatous meningitis, meningovascular syphilis
Subarachnoid hemorrhage	Obstruction of the CSF at the aqueduct level, causing obstructive hydrocephalus and possibly raised ICP
Clival tumors	E.g., chordoma, chondroma, sarcoma, metastases, Paget’s disease
Large cerebellopontine angle tumors	E.g., acoustic neuroma, meningioma, epidermoid, metastases, giant aneurysm (AICA or basilar artery aneurysm), arachnoid cyst
Gradenigo’s syndrome	Diffuse inflammation of the petrous bone and thrombosis of the petrosal sinus, causing severe ear pain and a combination of lesions of cranial nerves VI, VII, VIII, and occasionally V
Infiltration	E.g., carcinomas of the nasopharynx or the paranasal sinuses, leukemias, CNS lymphoma

Sarcoidosis

Iatrogenic Neurosurgical complication

Cavernous sinus and superior orbital fissure

Aneurysm E.g., congenital, aneurysmal dilatation of the intracavernous portion of the internal carotid artery, usually occurring in elderly hypertensive women

Carotico-cavernous fistula E.g., traumatic, spontaneous

Cavernous sinus thrombosis Serious complication from sepsis of the skin over the upper face, or in the paranasal sinuses

Tumor E.g., pituitary adenoma, parasellar, tuberculum or diaphragm sella meningioma, metastases, nasopharyngeal carcinoma

Tolosa–Hunt syndrome

Herpes zoster

Diabetic infarction

Miscellaneous

Nonspecific febrile illness Benign transient sixth nerve palsy, particularly in children

Infectious, parainfectious diseases E.g., diphtheria, botulism intoxication. Spontaneous recovery of the sixth nerve palsy is usual

Lumbar puncture Differential pressure gradients between the supratentorial and infratentorial compartments causes downward herniation, resulting in a reversible sixth nerve palsy

Conditions simulating abducens nerve palsy

Thyrotoxicosis Myopathy of the extraocular muscles

Myasthenia gravis

Congenital esotropia

Convergence spasm

Migraine

AICA: anterior inferior cerebellar artery; CNS: central nervous system; CSF: cerebrospinal fluid; ICP: intracranial pressure.

Facial Nerve Palsy

(Cranial nerve VII)

Intra-axial 1%

Supranuclear

- Contralateral central motor neuron lesions Either in the region of the precentral gyrus or its efferent pathways; e.g., vascular insults, trauma, tumor
- Progressive supranuclear palsy Marked neuronal loss in subcortical structures, such as the basal nucleus of Meynert, the pallidum, subthalamic nucleus, substantia nigra, locus ceruleus, and superior colliculi; patients have ophthalmoparesis of downward gaze, Parkinsonism, pseudobulbar palsy, and frontal lobe signs

Nuclear (pontine tegmentum)

- Vascular insults Paramedian and basal infarction; e.g., Millard–Gubler syndrome, Gasperini’s syndrome, and Foville’s syndrome
- Pontine tumors E.g., gliomas, metastases; many of the pontine gliomas start in the region of the sixth and seventh nerve nuclei
- Multiple sclerosis
- Syringobulbia Progression of the disease is marked by symptoms of long-track involvement, and eventually by dissociated sensory loss in the face
- Poliomyelitis Acute facial paralysis always associated with paralysis and atrophy of other nuclear muscles

Cerebellopontine angle

E.g., tumors = 6%. Slowly progressing facial paralysis in combination with other cranial nerve involvement, particularly the statoacoustic and eventually with CNS dysfunction

Acoustic neurinoma

Meningioma

Usually associated with bony hyperostosis and/or calcification within the lesion

Ectodermal inclusions

E.g., epidermoid, dermoid

Metastases

Trigeminal, facial, or other cranial nerve neurinoma

Aneurysm

Dolichoectasia of the basilar artery

Peripheral lesions

Bell's palsy	57%
Head trauma with basal fracture	17%. A fracture across the pyramid will also involve the statoacoustic nerve, whereas a longitudinal fracture usually does not involve it
Infections	4%. E.g., herpes zoster virus, varicella zoster virus, cytomegalovirus, mumps, rubella, Epstein–Barr virus, Lyme disease, syphilis, HIV
Ramsey–Hunt syndrome	Herpes zoster involving the seventh and eighth cranial nerves; very severe ear pain may precede the facial weakness and ipsilateral hearing loss, and the later eruption of vesicles in or around the external auditory canal, or over the mastoid process
Melkersson–Rosenthal syndrome	Patients present with recurrent episodes of facial weakness associated with facial edema and a fissured tongue
Heerfordt's syndrome	Facial diplegia associated with sarcoidosis, swelling of the parotid glands, and involvement of the optic apparatus
Otitis media and middle ear tumors	E.g., cholesteatoma, glomus tumor
Mechanical lesions of the mandibular branch of the facial nerve	Pressure, facial trauma, or surgical trauma from procedures in the submandibular area, e.g., high cervical fusions, carotid endarterectomy, parotid surgery
Guillain–Barré syndrome	Proximal motor neuropathy with frequent involvement of the sixth and seventh cranial nerves
Porphyria	Peripheral neuropathies with involvement most commonly of the seventh and tenth cranial nerves

CNS: central nervous system; HIV: human immunodeficiency virus.

Neuropathy in the Glossopharyngeal, Vagus, and Accessory Nerves

(Cranial nerves IX, X, and XI)

Intra-axial (medulla)

Dorsolateral infarction	Lateral medullary or Wallenberg's syndrome
Hemorrhage	Hypertensive, arteriovenous malformation
Multiple sclerosis	

Central pontine myelinolysis	Demyelinating disease occurring in malnourished or alcoholic patients, complicated by hyponatremia; rapid correction of the hyponatremia is implicated as a cause of the demyelination, which presents with tetraparesis and lower cranial nerve involvement
Tumor	E.g., gliomas, metastases
Jugular foramen	
Infection	E.g., meningitis, malignant external otitis media: a destructive soft-tissue mass in the temporal bone, which can mimic neoplasm
Vascular lesions	E.g., vertebral artery ectasia, vertebral artery aneurysm
Tumor	
– Paranglioma	Glomus jugulare or carotid body tumors
– Neural sheath	E.g., schwannoma, neurofibroma
– Nasopharyngeal carcinomas	80% squamous cell, 18% adenocarcinoma; the latter are often from minor salivary glands
– Metastases	The most common tumors affecting skull base. Sources: lung, breast, prostate, or nasopharyngeal tumors
– Miscellaneous neoplasms	E.g., non-Hodgkin's lymphoma, rhabdomyosarcoma; in children
– Meningiomas	
– Epidermoid tumors	Cholesteatomas
Trauma	
– Extensive skull base fractures	
– Penetrating wounds	
– Surgical wounds	E.g., radical dissection of the neck
Other causes	
Polyneuritis cranialis	Idiopathic entity consisting of multiple transient cranial nerve palsies; predilection in patients suffering from diabetes or syphilis. Rule out metastatic carcinoma. Irradiation without tissue diagnosis is not justified, particularly since the prognosis is very good
Glossopharyngeal neuralgia	Exploration often reveals aberrant vessels coursing across the nerve, or unsuspected neurofibromas, leptomeningeal metastases, jugular foramen syndrome
Extracranial neuropathy (vagus nerve only)	
Infection	E.g., mediastinum, carotid space
Vascular	E.g., jugular vein thrombosis, left aortic arch aneurysm

Surgical trauma	E.g., intubation, thyroidectomy, carotid endarterectomy, cardiovascular surgery, esophageal resection for carcinoma
Tumor	
– Paranglioma	Glomus jugulare
– Neural sheath	E.g., schwannoma, neurofibroma
– Primary or nodular squamous-cell carcinoma; other metastases	
– Non-Hodgkin's lymphoma	
– Thyroid malignancies	
– Lung carcinoma	
– Mediastinal masses on the left	

Hypoglossal Neuropathy

(Cranial nerve XII)

Intra-axial (medulla)

Paramedian/basal medullary infarction Dejerine's anterior bulbar syndrome

Brain stem hemorrhage

Multiple sclerosis With lesions affecting the intramedullary parts of the lower cranial nerves

Glioma

Syringobulbia

Bulbar-type poliomyelitis

Botulism, diphtheria Bilateral paralysis of the caudal cranial nerves

Degenerative process E.g., true bulbar paralysis in association with amyotrophic lateral sclerosis; Shy-Drager: orthostatic hypotension of multiple system atrophy

Subarachnoid space/ base of skull

Chiari malformation

Basilar invagination

Chronic meningitis or carcinomatous meningitis

Sarcoidosis May affect any cranial nerve either unilaterally or bilaterally

Vascular lesions E.g., vertebrobasilar dolichoectasia, aneurysm, subarachnoid hemorrhage

Skull base neoplasms

- Meningioma
- Neural sheath tumors E.g., schwannoma, neurofibroma
- Metastases E.g., lung, breast, prostate, nasopharyngeal carcinomas
- Primary osteocartilaginous tumors E.g., chordoma, osteoma, sarcoma
- Glomus jugulare or chemodectoma

Trauma

- Extensive skull base fractures
- Penetrating wounds
- Surgical wounds E.g., radical dissection of the neck, carotid endarterectomy

Infection E.g., malignant external otitis media, mucormycosis, aspergillosis

Distal (nasopharynx/carotid space)

Neoplasms E.g., squamous-cell carcinoma, metastases, non-Hodgkin's lymphoma, glomus jugulare

Trauma E.g., penetrating, surgical wounds

Infection E.g., bacterial abscess, "cold" abscess

Vascular thrombosis

Miscellaneous

Benign recurrent cranial nerve paralyzes Predominantly affecting nerves V, VII, VIII, and XII

Isolated benign unilateral palatal palsy Predominantly in boys, preceded by a viral illness with spontaneous recovery

Multiple Cranial Nerve Palsies

These conditions involve weakness in multiple ocular and faciobulbar muscles.

Intra-axial (brain stem)

Intrinsic tumors

Large infarcts

Motor neuron disease

Leigh's disease

Subacute necrotizing encephalomyelopathy

Subarachnoid

Severe head trauma

E.g., sphenoid fractures—orbital apex fractures affect the orbital motor nerves, temporal bone fractures affect the sixth and seventh cranial nerves, and uncus herniation affects the third cranial nerve

Meningeal infection

E.g., tuberculosis

Base of brain inflammation

E.g., sarcoidosis

Basal meningeal carcinomatosis

Leukemic meningitis

Tumor

E.g., clivus tumor or nasopharyngeal tumor invading the intracranial cavity

Giant ICA aneurysms

Iatrogenic

Posterior fossa and cerebellopontine angle explorations

Cavernous sinus and orbital processes

Tumor

E.g., meningioma, pituitary adenoma with apoplexy, and metastases such as nasopharyngeal tumor spreading into the intracranial cavity or maxillary antral carcinoma invading the floor of the orbit, and multiple myeloma

Aneurysm

Giant ICA aneurysm

Cavernous sinus thrombosis

Caroticocavernous fistula

Iatrogenic postsurgical complication

Orbital trauma with entrapment of connective tissue and muscles

Fungal infections E.g., actinomycosis, mucormycosis, especially in elderly diabetic and immunosuppressed patients

Pseudotumor Myositis

Tolosa–Hunt syndrome

Thyroid orbitopathy An autoimmune disorder in which the extraocular muscles are enlarged and infiltrated with inflammatory elements, eventually leading to a restrictive oculomyopathy and motility disorder. The onset of the ensuing painful exophthalmos and chemosis, diplopia and lid retraction is rapid. The clinical picture needs to be differentiated: in adults the condition results from idiopathic orbital inflammation, and in children it is caused by rhabdomyosarcoma or orbital cellulitis

Miscellaneous

Specific viral infection E.g., Epstein–Barr virus or herpes zoster. This disorder has autoimmune features, and seems to cause symptoms by demyelination

Myasthenia gravis

Diabetes mellitus

Lambert–Eaton syndrome

Chronic progressive external ophthalmoplegia

Miller–Fisher syndrome Postinflammatory neuropathy, a variant of the Guillain–Barré syndrome

Toxic

- Botulism
- Diphtheria

Metabolic

- Wernicke’s encephalopathy
- Leigh’s syndrome

Rare disorders

- Trichinosis
- Amyloid
- Arteritis Especially temporal arteritis
- Tumor infiltration of the muscles

Paraproteinemia Bing–Neel syndrome

Vasculitides

- Polyarteritis nodosa
 - Cogan’s syndrome
 - Wegener’s granulomatosis
-

ICA: internal carotid artery.

Neuro-Ophthalmology

Causes of Horner's Syndrome

Horner's syndrome is an interruption of the sympathetic supply to the eye, resulting in the classic triad of ptosis, miosis, and anhidrosis.

First-order neuron	<i>(Hypothalamus to upper thoracic cord)</i>
Cerebral hemispheric lesions	E.g., hemispherectomy; massive infarction may cause ipsilateral Horner's syndrome
Brain stem lesions	The sympathetic and spinothalamic pathways in the brain stem lie throughout their course next to each other. Horner's syndrome here is therefore frequently associated with contralateral pain and temperature loss
– Infarction	E.g., dorsolateral pontine; lateral medullary or Wallenberg's syndrome
– Demyelinating diseases	E.g., multiple sclerosis
– Pontine gliomas	
– Syringobulbia	
– Bulbar poliomyelitis	
– Encephalitis	E.g., herpes zoster
Cervical cord lesions	These usually cause loss of pain and deep tendon reflexes in the arms, and frequently a bilateral Horner's syndrome; ptosis usually draws attention to the condition
– Trauma	Particularly causing a central cord lesion
– Gliomas or ependymomas	
– Syringomyelia	
– Bulbar-type polio	
– Amyotrophic lateral sclerosis or Lou Gehrig disease	
Second-order neuron	<i>(Mediolateral column in the upper cord to superior cervical ganglion)</i>
Trauma to the lower brachial plexus	E.g., T1 and C8 root avulsion, known as Klumpke's paralysis

Lesions of the lower trunk of the brachial plexus	E.g., carcinoma of the lung apex extending through the apical pleura, also known as Pancoast's tumor; metastatic disease in the axillary glands, from malignant disease from the breast or elsewhere; radiation injury to the lower plexus
Iatrogenic	E.g., surgical procedures in the thyroid, larynx, pharynx, anterior cervical decompression and fusion
Neck and paravertebral masses	Impingement on the paravertebral sympathetic chain; e.g., thyroid tumor, lymphoma, bacterial or tubercular abscess, tumors of the posterior mediastinum, prevertebral hematoma
Neural sheath tumors	E.g., neurofibroma affecting the T1 nerve root
Cervical rib syndrome	Usually in young women
Cervical disk	Very rare; less than 2%
Third-order neuron	<i>(Superior cervical ganglion via carotid tree to orbit)</i>
Cluster headaches	12% of cases; postganglionic oculosympathetic palsy
Carotid artery lesions	E.g., trauma, dissection; associated with persistent facial pain, and is an indication for further evaluation
Cavernous sinus lesions	Lesions in this area usually damage both the sympathetic and the parasympathetic nerves, leading to a semi-dilated and fixed pupil, associated with other extraocular nerve palsies
Superior orbital fissure lesions	Ipsilateral partial dilatation and pupillary fixation with extraocular nerve palsies

Pupillary Syndromes

Argyll Robertson pupil

Loss of light reflex	The pupil does not contract when a bright light is shone into the eye. Artificial light is better for testing than strong daylight. The test is best performed in a darkened room
Retained ability to accommodate	Strong and tonic contractions
Miosis is usually present	
Imperfect dilatation of pupil after instillation of atropine	

Failure of ciliospinal reflex When the neck is irritated or when cocaine is instilled into the eye, the pupil will dilate on the contralateral side

Usually bilateral

Significance: Argyll Robertson pupil is traditionally ascribed to injury to the central parasympathetic pathway in the periaqueductal area. It is a classical sign of meningovascular syphilis (e.g., neurosyphilis, tabes, and general paresis). It is also occasionally seen in epidemic brain stem encephalitis, alcoholism, pinealomas, and advanced diabetes.

Horner's Syndrome

Ptosis of varying degrees in the upper and lower eyelids In the worst form, the lid may reach to the edge of the pupil, whereas in mild cases the ptosis is barely detectable; isolated ptosis of the lower lid may occur, and is known as "upside-down ptosis"

Narrowing of the palpebral fissure Due to ptosis of the upper eyelid and slight elevation of the lower lid: paresis of Müller's muscle

Miosis The affected pupil is slightly smaller than the contralateral one. The resulting anisocoria is minimal in bright light, and exaggerated in darkness. Occasionally, pupillary involvement can only be demonstrated on pharmacological testing

Transient increase in accommodation

Anhidrosis Occurs in 5%, with preganglionic lesions; sudomotor and vasoconstrictor fibers pass to the face along with branches of the external carotid artery

Transient vascular dilatation of face and conjunctiva The conjunctiva may be slightly bloodshot due to the loss of vasoconstrictor activity

Enophthalmos This is not an easily detected sign; it is not a feature of oculosympathetic palsy

Change in tear viscosity

Iris heterochromia In congenital Horner's syndrome, the iris on the affected side fails to become pigmented and remains a blue-gray color

Significance: Horner's syndrome results from an interruption of the sympathetic supply to the eye. The pathway has three neurons. *First-order fibers* descend from the ipsilateral hypothalamus through the brain stem and cervical cord to T1–T2, and C8 (the ciliospinal center of Budge). They synapse on ipsilateral preganglionic sympathetic fibers, exit the cord through the first and second anterior dorsal roots, ascend in the cervical sympathetic chain as *second-order neurons* to the superior cervical ganglion, and then synapse on postganglionic sympathetic fibers. The *third-order neurons* travel via the internal carotid artery, pass to the Gasserian ganglion and through the first division of the trigeminal nerve to the orbit, and innervate the radial smooth muscle of the pupil. The sudomotor and vasoconstrictor fibers pass to the face separately, with the external carotid artery branches.

Holmes–Adie or Tonic Pupil

Widely dilated, circular pupil

Does not react to light. Pupil may react very slowly and after prolonged exposure to very bright light

Tonic accommodation

Strong and tonic contraction to near effort

Usually unilateral (80%) and more frequently found in females

Often associated with loss of knee tendon reflexes and impairment of sweating

Significance: The Holmes–Adie or tonic pupil is due to the degeneration of the nerve cells in the ciliary ganglion. The cause of the condition is unknown. The dissociation between the poor or absent light reaction and the more definite response to accommodation are thought to be produced by slow inhibition of sympathetic activity, and not by any residual parasympathetic activity.

Afferent Pupillary Defect or Marcus Gunn Pupil

Shining a light into the normal eye causes brisk pupillary contraction (the affected pupil also contracts consensually). When the light is shone into the affected eye in turn, the reaction is slower and less complete, and the pupil is therefore slow to dilate again (the pupillary escape phenomenon). The reaction is best seen if the light is moved rapidly from the normal to the affected eye and vice versa, with each stimulus lasting approximately one second and two to three seconds being left in be-

tween. The affected pupil is therefore dilating when the moving light touches it.

Significance: The Marcus Gunn pupillary reaction is thought to be due to a reduction in the number of the fibers serving the light reflex on the affected side. The lesion must be prechiasmal, and almost always involves the optic nerve, often due to multiple sclerosis.

Posttraumatic Mydriasis or Iridoplegia

Irregular pupillary dilatation
Poor or absent reaction to light

Significance: Disruption of the fine short ciliary nerve filaments in the sclera by blunt trauma results in a usually transient paralysis of the iris, causing an irregularly dilated pupil with impairment of the light reaction. A history of trauma and findings of local periorbital or orbital injury, or both, in a conscious and mentally unaffected patient are diagnostic.

Hippus

Spontaneous, sometimes rhythmic and alternating contractions and dilations of the pupil under uniform, constant illumination. The pupils show wide excursions visible to the naked eye, gradually decreasing. This phenomenon is called hippus. Both pupils normally exhibit fine movements (known as “pupillary unrest”), particularly under high magnification. An absence of pupillary unrest suggests organic disease.

Significance: The condition is seen in normal individuals; in cases of hysteria; and is associated with incipient cataracts, multiple sclerosis, meningitis, contralateral cerebrovascular insults, and recovery from oculomotor paralysis.

Unilateral Pupillary Dilatation (Mydriasis)

Local mydriatic and cycloplegic drug agents

Phenylephrine, epinephrine
Cocaine
Hydroxyamphetamine
Atropine, homatropine, eucatropine
Scopolamine
Cyclopentolate

Migraine

Cluster headaches often lead to miosis with Horner’s syndrome

Holmes–Adie pupil	
Oculomotor nerve paralysis	
– Aneurysm	E.g., posterior communicating artery, posterior cerebral artery, superior cerebellar artery
– Temporal lobe (uncal) herniation	
Acute ciliary ganglionitis	A large pupil not reacting to light or convergence and initially to accommodation develops suddenly, several days after an infection or trauma
Ciliospinal reflex	When the neck is irritated or when cocaine is instilled into the eye, the pupil will dilate on the ipsilateral side
Pseudodilation	Contralateral pupillary constriction, e.g., in Horner’s syndrome

Significance: Unilateral pupillary dilatation is the most important physical sign in the unconscious patient, and until proved otherwise a dilated pupil indicates that a herniated temporal lobe is compressing the ipsilateral oculomotor nerve, and that immediate surgical action is required.

Bilateral Pupillary Dilatation (Mydriasis)

Rostricaudal deterioration	From supratentorial masses, leading to almost irreversible cerebral damage and coma
Systemic drug poisoning	
– Anticholinergics	E.g., atropine, scopolamine, belladonna, propantheline
– Tricyclic antidepressants	
– Antihistamines	E.g., diphenhydramine, chlorpheniramine
– Phenothiazines	
– Amphetamines	
– Cocaine	
– Epinephrine, norepinephrine	
– LSD	
– Thiopental	
Postictal	E.g., major seizures
Bilateral optic nerve damage and blindness	

Parinaud's syndrome	Lesions within the tectum will interfere with the decussating light reflex fibers in the periaqueductal area, resulting in dilated and nonreacting pupils and paralysis of the upward gaze
Thyrotoxicosis	
Emotional state	Sympathetic overdrive, e.g., fear, pain

LSD: lysergic acid diethylamide.

Unilateral Pupillary Constriction (Miosis)

Horner's syndrome

Local miotic drugs

- Pilocarpine
- Neostigmine, physostigmine
- Carbachol
- Methacholine

Local affection of the anterior chamber of the eye

Bilateral Pupillary Constriction (Miosis)

Systemic drug poisoning

- Narcotics E.g., morphine and opiates, meperidine, methadone, propoxyphene
- Barbiturates
- Phentolamine
- Meprobamate
- Cholinergics E.g., neostigmine, edrophonium, physostigmine, pyridostigmine
- Marijuana
- Guanethidine
- MAO inhibitors, reserpine

Pontine lesions

A massive intrapontine hemorrhage is usually associated with pin-point pupils, loss of consciousness, and spastic tetraparesis with brisk reflexes

Argyll Robertson pupils

Neurosyphilis Very rarely, may cause unilateral miosis

Advanced age

MAO: monoamine oxidase.

Diplopia

Monocular Diplopia

This condition may be psychogenic, or may be due to a refractive disturbance in the eye.

Astigmatism or opacity of the cornea or lens

Corneal dystrophy

Iridodialysis

Foreign body (e.g., air bubbles, glass, parasites)

Large retinal tear

Retinal macular cyst

Occipital lobe lesions

Tonic conjugate gaze deviation

Lack of correspondence between the frontal eye fields and occipital associative areas

Palinopsia

Binocular Diplopia

If double vision is relieved by occlusion of either eye, it is due to malalignment of the visual axes.

Extraocular muscle disorders

Myasthenia gravis

Thyroid orbitopathy

Orbital apex trauma
with connective tissue
and muscle entrapment

Orbital myositis

Tumors E.g., pituitary adenoma and growth hormone – secreting adenoma. The tumors cause enlargement of the extraocular muscles

Oculomotor nerve disorders

Severe head trauma E.g., sphenoid fractures (orbital apex) affect the oculomotor nerves, temporal bone fractures affect cranial nerves VI and VII

Microvascular ischemia Associated with diabetes mellitus

Compression

– Tumor Meningioma, pituitary adenoma with apoplexy, metastases (particularly from nasopharyngeal carcinoma)

– Giant intracranial aneurysm

Increased intracranial pressure E.g., uncal and tonsillar herniation affecting cranial nerves III and VI

Meningeal infection, basal inflammation and carcinomatosis

Central pathway disorders

Internuclear ophthalmoplegia A lesion of the medial longitudinal fasciculus (MLF) between cranial nerves III and VI produces disconjugate eye movements and diplopia on lateral gaze

Skew deviation This is thought to represent damaged otolithic inputs. It occurs frequently with unilateral MLF lesions, but may also occur in many brain stem lesions. Usually, the higher eye is on the side of the lesion

Divergence insufficiency E.g., bilateral sixth cranial nerve palsies, increased intracranial pressure

Convergence insufficiency E.g., convergence spasm suggested by associated miosis due to the near response

Decompensated strabismus Usually of no pathological importance

Optical system disorders

Nuclear lens sclerosis

Uncorrected refractory error

Corneal disease

– Keratoconus E.g., Gorlin–Goltz syndrome or focal dermal hypoplasia, Crouzon's disease

– Megalocornea E.g., Marfan's syndrome, Pierre Robin's syndrome

– Microcornea E.g., Bardet–Biedl syndrome

Peripheral iridectomy

Disorders of the lens

- Dislocated lens E.g., Alport's syndrome, Marfan's disease
- Spherophakia E.g., hyperlysinemia, sulfite oxidase deficiency

Unclear or combined disorders

Chronic progressive external ophthalmoplegia

Toxic ophthalmoplegia E.g., botulism and diphtheria

Miller–Fisher syndrome, E.g., postviral neuropathy

Guillain–Barré syndrome

Metabolic E.g., Wernicke's encephalopathy

Eaton–Lambert myasthenic syndrome

Myotonic dystrophy

MLF: medial longitudinal fasciculus.

Vertical Binocular Diplopia

Blowout fracture of orbital floor with entrapment of the inferior rectus muscle

Thyroid orbitopathy with tight inferior rectus muscle

Ocular myasthenia

Cranial nerve III (oculomotor) palsy

Cranial nerve IV (trochlear) palsy

Skew deviation

Horizontal Binocular Diplopia

Blowout fracture of medial orbital wall and entrapment of the medial rectus muscle

Thyroid orbitopathy with tight medial rectus muscle

Ocular myasthenia

Internuclear ophthalmoplegia

Convergence insufficiency

Decompensated strabismus

Cranial nerve III (oculomotor) palsy

Cranial nerve VI (abducens) palsy

Ptosis

Congenital

Isolated	Drooping is unilateral in 70% of congenital ptosis cases
Familial	Very rare, bilateral
Sympathetic denervation	Congenital Horner's syndrome
Anomalous synkinesis between cranial nerves III and V	Marcus Gunn phenomenon, jaw winking
Blepharophemosis syndromes	
Neonatal myasthenia	

Neurogenic

Nuclear lesions	E.g., due to third nerve lesions Severe bilateral ptosis, medial rectus weakness, upward gaze paresis and pupillary dilation if the lesion is complete
Peripheral lesions	Unilateral ptosis, mydriasis, and ophthalmoplegia

Myopathy

Myasthenia gravis	
Oculopharyngeal muscular dystrophy	
Chronic progressive external ophthalmoplegia	
Polymyositis	
Chronic use of topical steroid eye drops/ointment	

Orbit

Inflammatory disease	
– Thyroid orbitopathy	
– Idiopathic orbital inflammatory disease	Orbital pseudotumor
– Tolosa–Hunt syndrome	
– Orbital apex syndrome	Painful ophthalmoplegia

Tumors	Infantile rhabdomyosarcoma, dermoid cyst, hemangioma, metastatic neuroblastoma, optic glioma
--------	--

Trauma Iatrogenic, especially after surgery for strabismus, retinal detachment, and cataract

Pseudoptosis

Secondary to ocular irritations, foreign body (e.g., protective)

Blepharospasm

Enophthalmos

Pathological contralateral lid retraction

Contralateral exophthalmos

Huntington's chorea (lid-opening apraxia)

Hysterical

Acute Ophthalmoplegia

Unilateral

Aneurysm or anomalous vessels	The nerve palsy is considered to be due to hemorrhage, either within the aneurysmal sac to which the nerve is adherent, or directly into the nerve
– Oculomotor nerve palsy	Aneurysms at the junction of the posterior communicating and internal carotid arteries
– Abducens nerve palsy	Aneurysm of the anterior inferior cerebellar artery and basilar artery
Small brain stem hemorrhages	E.g., emboli, leukemia, blood coagulopathies
Ophthalmoplegic migraine	Transitory palsy affecting the oculomotor nerve in 85% of cases, and the abducens and trochlear nerves in only 15%
Cavernous sinus thrombosis	Originating almost exclusively from spread of infection from the mouth, nose, or face
Inferior petrosal sinus thrombosis (Gradenigo syndrome)	Originating from infections of the middle ear and affecting the abducens nerve, facial nerve, and trigeminal ganglion
Cavernous sinus fistula	Traumatic in origin

Brain tumors	Brain stem glioma, craniopharyngioma, pituitary adenoma, nasopharyngeal carcinoma, lymphoma, pineal region tumors
Idiopathic cranial nerve palsy	Transitory nerve palsy, attributed to a viral infection and affecting the abducens nerve more often than the oculomotor or trochlear nerves
Myasthenia gravis	And other pharmacological or toxic causes of neuromuscular blockade
Orbital	
– Tumors	Dermoid cyst, hemangioma, metastatic neuroblastoma, optic glioma, rhabdomyosarcoma
– Inflammatory disease	Tolosa–Hunt syndrome, orbital pseudotumor, sarcoid
Trauma	E.g., blowout fracture of the orbit with entrapment myopathy
Increased intracranial pressure	E.g., uncal herniation, pseudotumor cerebri
Demyelination	E.g., fascicular, affecting all three nerves
Bilateral	Most of the conditions causing unilateral acute ophthalmoplegia may also produce bilateral ophthalmoplegia
Botulism	
Intoxication	Ocular motility may be impaired by drugs such as anti-convulsants, tricyclic antidepressants, and other psychotropic medications at toxic serum concentrations
Encephalitis of the brain stem	Caused by echovirus, coxsackievirus, and adenovirus
Diphtheria	
Cavernous sinus thrombosis	
Caroticocavernous fistula	
Myasthenia gravis, thyrotoxicosis	

Internuclear Ophthalmoplegia

This is a disorder of horizontal eye movements due to a lesion of the medial longitudinal fasciculus (MLF) in the mid-pons, between the third and sixth cranial nerves. The MLF lesion produces disconjugate eye movements and diplopia on lateral gaze, since impulses to the lateral rectus travel abnormally, whereas those to the medial rectus are intact.

Brain stem infarction	Most common in the older population; the syndrome is unilateral, and is caused by occlusion of the basilar artery or its paramedian branches
Multiple sclerosis	Most common in the young adults, especially when the syndrome is bilateral
Intrinsic and extra-axial brain stem and fourth ventricular tumors	E.g., glioma, metastasis
Brain stem encephalitis	E.g., viral or other forms of infection
Drug intoxication	E.g., tricyclic antidepressants, phenothiazines, barbiturates, phenytoin
Metabolic encephalopathy	E.g., hepatic encephalopathy, maple syrup urine disease
Lupus erythematosus	
Head trauma	
Degenerative conditions	E.g., progressive supranuclear palsy
Syphilis	
Chiari types II and III malformation and associated syringobulbia	
Pseudointernuclear ophthalmoplegia	As a feature of myasthenia gravis, Wernicke's encephalopathy, Guillain-Barré syndrome, exotropia, Fisher's syndrome

Vertical Gaze Palsy

Tumors

- Pineal area
- Midbrain
- Third ventricle

Aqueduct stenosis and hydrocephalus

Infarction or hemorrhage of the dorsal midbrain

Head trauma

Multiple sclerosis

Miller–Fisher syndrome

Vitamin B₁₂ or B₁ deficiency

Neurovisceral lipid storage diseases

- Gaucher's disease
- Niemann–Pick disease, type C

Congenital vertical oculomotor apraxia

The syndrome can be mimicked by:

- Progressive supranuclear palsy
- Thyroid ophthalmopathy
- Myasthenia gravis
- Guillain–Barré syndrome
- Congenital upward gaze limitation

Unilateral Sudden Visual Loss

Vascular disturbances

Ischemic optic atrophy due to arteriosclerosis Pallor of the optic nerve head, pale retinas, pseudo-papilledema and incomplete blindness are the prominent diagnostic features

Transient monocular blindness or amaurosis fugax Stenosis of the internal carotid artery or cardiogenic emboli are mainly responsible

Temporal arteritis Affects elderly individuals, and frequently leads to complete blindness; patients complain of headaches, and the ESR is usually raised

Acute retrobulbar neuritis

Acute inflammatory reaction of the optic nerve in response to:

- Multiple sclerosis
- Metabolic and toxic insults
- Birth control pill

Up to 50% of cases have other manifestations of multiple sclerosis

Patients complain of impairment of central vision (e.g., “puff of smoke,” “fluffy ball”). The examination reveals impaired visual acuity (20/200), a central scotoma, and occasionally papilledema (when the inflammation is just behind the nerve head)

Differential diagnosis

- Papilledema (due to the severe visual loss, since vision remains normal in papilledema unless there is hemorrhage or exudate into the macula retinal area, which leads into rapid central visual loss)
- Optic chiasmal compression (central vision is served by the papillomacular bundle, which is more sensitive to external compression than the rest of the optic nerve fibers. The presence of optic atrophy and bitemporal field defects are the clues to the diagnosis)
- Trauma (fracture of the anterior cranial fossa extending into the optic foramen)
- Amblyopia with papilledema (transient attacks associated with raised intracranial pressure, e.g., benign intracranial hypertension)

ESR: erythrocyte sedimentation rate.

Bilateral Sudden Visual Loss

Cortical blindness	Loss of vision with preservation of the pupillary light reflex and normal ophthalmoscopic examination
Transient blindness	Mild head trauma, migraine, hypoglycemia, hypotension

Permanent blindness

- Anoxia
 - Infarction
 - Sudden and marked impairment of the basilar artery flow, usually in elderly individuals
 - Posttraumatic intracranial hypertension, leading to tentorial herniation and causing compression of the posterior cerebral arteries
 - Hemorrhage
 - E.g., traumatic, or rarely spontaneous
- Multifocal metastatic tumors in the occipital lobes
- Multifocal primary tumors
 - E.g., malignant gliomas
- Multifocal abscess in the occipital lobes

Optic neuropathy

Ischemic neuropathy E.g., infarction of the anterior portion of the optic nerve due to systemic vascular disease or hypotension

Traumatic neuropathy E.g., severe head trauma with indirect optic neuropathy from nerve swelling, tear, or hemorrhage

Toxic nutritional neuropathy

- Drugs
 - E.g., barbiturates, streptomycin, chloramphenicol, isoniazid, sulfonamides
- Alcohol
 - E.g., methyl alcohol: overnight visual loss; tobacco and ethyl alcohol: progressive visual loss
- Vitamin B₁, B₁₂, folic acid deficiencies
 - Progressive visual loss over weeks

Demyelinating neuropathy Binocular visual loss in more than 50% of children, whereas in adults it is usually monocular

Retinal disease

- Retinal ischemia E.g., central retinal artery occlusion
- Hemodynamic
 - Usually with aortic arch syndrome, after a sudden change from the recumbent to the upright position in elderly individuals
 - Retinal migraine
 - In one-third of cases in children and young adults
 - Coagulopathies
 - E.g., increased platelet activity, and increased factor VIII
 - Miscellaneous risk factors
 - E.g., congenital heart disease, sickle-cell disease, vasculitis, and pregnancy

Blind trauma E.g., retinal contusion, tear, or detachment

Trauma to carotid or vertebral arteries

Symptoms develop over several hours, or sometimes days

Pituitary apoplexy

E.g., hemorrhagic infarction of the pituitary gland occurring usually in preexisting pituitary tumor

Psychogenic blindness The pupillary reaction to light is normal, and funduscopy is unremarkable; the patient is not alarmed by the sudden blindness, and has not suffered any of the known causes of blindness

Slowly Progressing Visual Loss

Compressive optic nerve atrophy Mostly unilateral

– Aneurysm of the carotid artery

– Tumors Pituitary adenoma, meningioma, optic nerve and hypothalamic glioma in children, craniopharyngioma, dermoid

Hereditary optic atrophy

– Macular degeneration

– Leber's familial optic atrophy

– Wolfram's syndrome Juvenile diabetes mellitus, optic atrophy, and bilateral hearing loss

– Infantile Refsum disease Blindness, deafness, dementia, ataxia

Prolonged elevation of the intracranial pressure

– Pseudotumor cerebri

– Obstructive hydrocephalus

Intraocular tumors E.g., retinoblastoma

Toxic agents E.g., industrial solvents

Tapetoretinal degeneration

– Aminoacidopathy

– Abnormal lipid metabolism

– Abnormal carbohydrate metabolism

– Cockayne syndrome Primary pigmentary degeneration of the retina, ataxia, spasticity, deafness, peripheral neuropathy

Transient Monocular Blindness

Embolic

3–5 minutes in duration; quadrantic, altitudinal, or total visual loss, corresponding in distribution of retinal arterioles; associated with contralateral hemiplegia with or without hemihypoesthesia. The most common type of embolus is cholesterol embolus, manifesting as a glistening, shiny, slightly irregular object with the narrowed retinal vessel, corresponding to a field defect, and in other retinal areas, since the cholesterol emboli are often multiple. Fibrin platelet emboli manifest as creamy white molding on the arterial tree, resembling an amorphous plug; they may coexist with cholesterol emboli. Calcific emboli are the rarest, and appear as jagged, bright white spots within the vessels, originating exclusively from the heart valves

The most frequent source

Carotid bifurcation thromboembolism

Cardiogenic emboli

Valve, mural thrombus, intracardial tumor

Great vessel or distal internal carotid atheroembolism

Drug abuse-related intravascular emboli

Hemodynamic

Binocular attacks of visual loss, predominantly in the elderly, lasting a few seconds to minutes, and described as a graying-out or dimming-out of vision. They are related to posture and/or cardiac arrhythmias. They may be associated with occasional tinnitus, diplopia, vertigo, and perioral paresthesias

Extensive atheromatous occlusive disease

Inflammatory arteritis
Hypoperfusion

Takayasu's disease
E.g., cardiac failure, acute hypovolemia, coagulopathy, blood viscosity

Ocular

Anterior ischemic optic neuropathy

Central or branch retinal artery occlusion (often embolic)

Central retinal vein occlusion

Nonvascular causes

E.g., hemorrhage, pressure, tumor, congenital

Neurological	Extremely brief and secondary episodes of visual dimming affecting both eyes simultaneously, or either eye alternately; these episodes occur in association with papilledema
Brain stem, vestibular, or oculomotor	
Optic neuritis	Compression of optic nerve or chiasm
Papilledema	
Multiple sclerosis	
Migraine	
Psychogenic	
Idiopathic	

Adapted from: Amaurosis Fugax Study Group. Current management of amaurosis fugax. Stroke 1990; 21: 201–8.

Transient Visual Loss

Embolic	Usually monocular, lasting 3–10 minutes. Most frequently, the source is an ulcerated plaque at the carotid bifurcation, but it can also be cardiac valves, mural thrombi, and atrial myxomas. Clinically, there is a quadrantic, altitudinal, or total pattern of visual loss, corresponding to the distribution of the retinal arterioles. In the case of a central TIA, the condition is associated with contralateral hemiplegia, with or without hemihypoesthesia
Cholesterol embolus or carotid bifurcation thromboembolism	50%. The most common type is cholesterol embolus, most often from the ipsilateral carotid bifurcation and less frequently from the distal internal carotid and the great vessels. At funduscopy, it is seen as a glistening, shiny, slightly irregular object within the vessel and sometimes at a bifurcation
Fibrin platelet emboli or cardiogenic emboli	4%. These emboli may come from thrombotic changes in ulcerated plaques, mural thrombi in the heart, abnormalities of the valves, or drug abuse–related intravascular emboli and intracranial tumor. At funduscopy, they have a soft and creamy appearance, and mold themselves to the arterial tree like an amorphous plug; they may coexist with cholesterol emboli (79%)
Calcific emboli	9%. Very rare, appearing as bright white spots within the vascular tree, and originating almost exclusively from heart valves

Other	Rarer emboli include cardiac myxomas, fat (Purtscher's retinopathy and pancreatitis), air, amniotic fluid, and particles injected by intravenous drug abusers
Hemodynamic	Unioocular or binocular attacks of blindness, usually described as a total and rarely as an altitudinal graying-out or dimming-out of vision. The elderly patients who are predominantly affected may describe a flickering of the field like "snow" on a television screen, or may have attacks without complaining. The attacks last from a few seconds to minutes, and are occasionally associated with tinnitus, diplopia, vertigo, and rarely perioral paresthesias

The attacks of blindness are related to:

- Hypoperfusion E.g., cardiac failure, cardiac arrhythmia, compression of the vertebral artery, postural hypotension, acute hypovolemia, coagulopathy, blood viscosity
- Extensive vascular occlusive disease E.g., of the orbit or carotid distribution, making the orbital circulation susceptible to slight decreases in perfusion that would not normally affect visual function
- Inflammatory arteritis Takayasu's disease ("pulseless disease")

Ocular

Anterior ischemic optic neuropathy (AION)	Presents with a sudden unioocular decrease in visual acuity and color vision on awakening, with swelling of the optic head cup, an afferent pupillary defect, and microhemorrhages within the nerve fibers. AION occurs with increased incidence in those with systemic diseases (e.g., diabetes mellitus, atherosclerosis, hypertension, hypotension, hypoxia, migraine, carotid occlusive disease), vasculitides (e.g., temporal arteritis, SLE, postviral vasculitis, radiation necrosis, postimmunization), hematological conditions (e.g., polycythemia vera, hyperviscosity, increased antiphospholipid antibodies, protein C deficiency, sickle-cell disease), and infectious and inflammatory diseases (e.g., sarcoidosis, syphilis, Lyme disease, cytomegalovirus, herpes)
Central or branch retinal artery occlusion (often embolic)	About 20% of central artery occlusions are due to emboli; most others are arteriosclerotic and inflammatory in nature. Contributing processes include hypertension, diabetes mellitus, sarcoidosis, fungi, temporal arteritis, hypercoagulable states. Clinically, there is a sudden severe visual loss, and funduscopy would show an opaque posterior retina and cherry-red macula, whereas the fovea and peripheral retina maintain a normal color.

Central retinal vein occlusion After a few hours or days of fluctuating visual acuity, this finally leads to very poor vision (20/200) and photopsias, with funduscopy showing a massive retinal hemorrhage, tortuous and dark distended veins, and papilledema. Spontaneous recovery of visual acuity often occurs 6–12 months later (up to 20/50 in half of the cases). Important factors in the pathogenesis of venous occlusions are: atherosclerosis and hypertension (75%), glaucoma (15%), diabetes, and hyperviscosity states

Nonvascular causes E.g., hemorrhage, pressure, tumor, congenital

Neurological

“Classic” migraine

By far the most frequent cause of transient visual loss is “classic” migraine, manifesting in a bilateral homonymous visual field loss, often followed by a scotoma. This is considered to be due to vascular spasm or arteriovenous shunting, which rarely leads to infarction, usually clears within 10–20 minutes, and is almost invariably followed by headache, which lasts for hours to more than a day and may be associated with nausea and photophobia

Optic neuritis, multiple sclerosis

Optic neuritis is the most frequent cause of neurogenic blindness in patients under the age of 50. Optic neuritis is often a manifestation of demyelination (e.g., idiopathic multiple sclerosis, Schilder’s disease, or other leukodystrophy), and it is the first symptom in 20–75% of MS patients. Demyelination is the most frequent cause of optic neuritis, and MS is the most frequent cause of demyelination

Brain stem, vestibular, or oculomotor

Papilledema

The only symptom with true papilledema may be obscurations or momentary episodes of visual blurring—usually unilateral at each occurrence, but either eye can be affected. True papilledema with equivocal disk swelling from generalized increased ICP is not associated with visual loss until the disk swelling has become chronic, and atrophy begins. Visual loss can occur in association with papilledema secondary to compression of the optic nerve or chiasma by intracranial tumors (e.g., craniopharyngioma, pituitary adenoma)

Psychogenic

AION: anterior ischemic optic neuropathy; ICP: intracranial pressure; MS: multiple sclerosis; SLE: systemic lupus erythematosus; TIA: transient ischemic attack.

Swollen Optic Disks (Papilledema)

The term “papilledema” is usually reserved for bilateral swelling of the optic disk, associated with increased intracranial pressure. All other types should be described as a “swollen disk” or “disk swelling” and the majority are unilateral. True papilledema with raised intracranial pressure is not associated with visual loss unless the disk swelling becomes chronic and atrophy sets in.

Pseudopapilledema

Congenital disk elevation

A false impression of papilledema, usually caused by hyaline bodies (drusen) within the nerve head. Found in 4% of adults; children below the age of 10 years do not have optic nerve head drusen

“Small full disk”

Slightly indistinct disk margins, late-branching central vessels, and no central cup; a true normal variant

True papilledema

Increased intracranial pressure

Almost always bilateral

- Intracranial mass lesion
- Diffuse brain swelling
- Acute obstructive hydrocephalus
- Pseudotumor cerebri

E.g., tumor, abscess, hematoma
E.g., posttraumatic, infectious

Perineuritis, neuritis, neuroretinitis

Syphilitic; sarcoid; viral meningoencephalitis; Lyme disease

Unilateral disk swelling

Without visual loss

- The large blind spot syndrome
- Juvenile diabetes

Possibly a viral form of optical meningitis

With visual loss

- Papillitis
- Anterior ischemic optic neuropathy
- Foster–Kennedy syndrome

E.g., papilledema, central scotoma, profound decrease in color vision, afferent pupillary defect, pain on movement

E.g., sudden decrease in visual acuity, optic nerve head swelling, afferent pupillary reflex, decrease in color vision, altitudinal field defect

Optic atrophy in one eye and a swollen disk in the other, associated with anosmia

- Pseudo-Foster-Kennedy syndrome More common: a swollen disk due to acute anterior ischemic optic neuropathy (AION) and atrophy of the other eye from a previous AION. May be due to cocaine abuse or orbital groove meningioma
- Other ischemic optic neuropathies
 - Infectious and inflammatory diseases (e.g., sarcoidosis, syphilis, Lyme disease, cytomegalovirus, Epstein-Barr virus, and herpes virus infections can give rise to an ischemic appearance)
 - Systemic arteritis (e.g., lupus erythematosus)
 - Tumor invasion of the optic nerve head: *primary* (e.g., hemangioma, hemangioblastoma, melanocytomas); *metastatic* (e.g., leukemia, reticulum cell sarcoma, meningeal carcinomatosis, breast cancer, lung cancer)
 - Tumors compressing the optic nerve in the orbit

AION: anterior ischemic optic neuropathy

Optic Nerve Enlargement

MRI scanning is able to differentiate between most of the vascular lesions and can help to reduce the large numbers of confusing lesions within the orbit.

Tumors

Optic nerve gliomas

- Astrocytic tumors of the anterior visual pathway These occur predominantly in prepubertal children, and one-third of the tumors are associated with neurofibromatosis. Clinically, they present with unilateral visual loss, proptosis, disk pallor and/or swelling, and strabismus. Half of childhood gliomas have a stable clinical course, particularly those associated with neurofibromatosis; the other half of these tumors undergo continuing progressive enlargement. Neuroimaging work-up with CT and MRI demonstrates a characteristic fusiform shape of the glioma, optic canal enlargement if the tumor extends out of the orbit, and associated abnormalities of the sphenoid ridge
- Malignant glioma or glioblastoma Rare, affecting adults; may present as optic neuritis with unilateral visual loss. The contralateral optic nerve becomes involved rapidly, and the disease progresses within a few months to total blindness and finally to death within a year

Meningiomas

- Primary meningiomas of the optic nerve sheaths
Classically in middle-aged women, with insidious and minor visual loss and with time proptosis. Neuroimaging usually shows a “railroad-track” enlargement of the optic nerve shadow, sometimes associated with calcification on both CT and MRI
- Meningiomas originating intracranially
These may involve the optic nerve, either by invasion along its sheaths or by compression. Intracranial meningiomas arise from the sphenoid ridge, the planum sphenoidale and areas of the tuberculum sellae. En plaque meningiomas originate from the outer third of the sphenoid wing, form a thin layer of tumor, spread medially, and infiltrate the optic nerve. They produce massive hyperostosis, significant proptosis with chemosis, vascular engorgement, and enlargement of the extraocular muscles

Other tumors of neurogenic origin

E.g., plexiform neuroma causing massive enlargement of nerves within the orbit, often coexistent with enlargement of nerves within the cavernous sinus and associated with neurofibromatosis

Metastases

- In children
The most common are as follows.
 - Neuroblastoma
 - Ewing’s sarcoma
 - Breast cancer
 - Lung cancer
 - Prostate cancer
- In women
- In men

Leukemic infiltration**Idiopathic inflammatory pseudotumor**

An inflammation that acts like a tumor and resembles one histologically, with orbital lymphomas

Central retinal vein occlusion**Optic neuritis**

Inflammation of the optic nerve, causing an acute or subacute decrease in central vision, which ranges from 20/15 to no light perception over hours to days, with contrast sensitivity in 98% and photopsia in 30%, diminution of color vision, pain on eye movement, and an afferent pupillary defect. There is an excellent prognosis for visual recovery over a period of months

Idiopathic**Demyelination**

- Multiple sclerosis
This is the most common cause of optic neuritis
The most frequent cause of demyelination, and the first symptom in 20–75% of MS patients
- Devic’s disease
Schilder’s disease
- Adrenoleukodystrophy

Viral	Measles, mumps, rubella, polio, coxsackie, viral encephalitis, herpes zoster, infectious mononucleosis
Special infections	Toxoplasmosis, cryptococcus, histoplasmosis, Lyme disease, syphilis, tuberculosis
Inflammatory	E.g., sarcoidosis may involve chiasmal, sellar and parasellar structures, and is usually associated with meningeal thickening on contrast-enhanced CT or MRI
Associated with systemic disease	Crohn's disease, ulcerative colitis, Whipple's disease, Reiter's syndrome, autoimmune disorders

CT: computed tomography; MRI: magnetic resonance imaging; MS: multiple sclerosis

Intracranial Tumors

Cerebral Hemispheres

Adults

Astrocytoma

- Anaplastic astrocytoma (10–30% of gliomas)
- Glioblastoma multiforme (45–50% of gliomas)

Meningioma

Metastases

Pituitary adenoma

Oligodendroglioma

Primary CNS lymphoma

Ependymoma

Ganglioglioma

Sarcoma

Young adults and children

Glioblastoma

Ganglioglioma

Gangliosarcoma

Malignant astrocytoma

Meningioma

Meningiosarcoma

Oligodendroglioma

Juvenile pilocytic astrocytoma

Solitary metastasis

Pleomorphic xanthoastrocytoma

Fibrous histiocytoma

Fibrous xanthomas

Infants

Primitive neuroectodermal tumor (PNET)

Supratentorial ependymomas

Astrocytoma

Desmoplastic infantile gangliogliomas

Dysembryoplastic neuroepithelial tumors

CNS: central nervous system.

Intraventricular

Lateral ventricles	Favored sites
Astrocytoma	Anaplastic, glioblastoma
Subependymal giant cell astrocytoma	Foramen of Monro
Ependymoma	Fourth ventricle
Subependymoma	Fourth ventricle
Oligodendroglioma (neurocytoma)	Septum pellucidum, lateral ventricle
Choroid plexus cysts, xanthogranulomas	Atrium of lateral ventricle
Meningioma	Atrium of lateral ventricle
Metastases	All sites
Choroid plexus papilloma, carcinoma	Atrium of lateral ventricle
Epidermoid, dermoid	
Primary cerebral neuroblastoma	
Hamartomas	Ependyma of lateral ventricle
Cerebral hemangiomas	All sites
Spongioblastomas	
Neurinomas	
Cysticercosis	All sites
Ependymal cyst	
Choroidal xanthoma	Foramen of Monro
Third ventricle	
Colloid cyst	
Pilocytic astrocytoma, astrocytoma	
Oligodendroglioma	
Ependymoma	
Metastases	
Lymphoma	

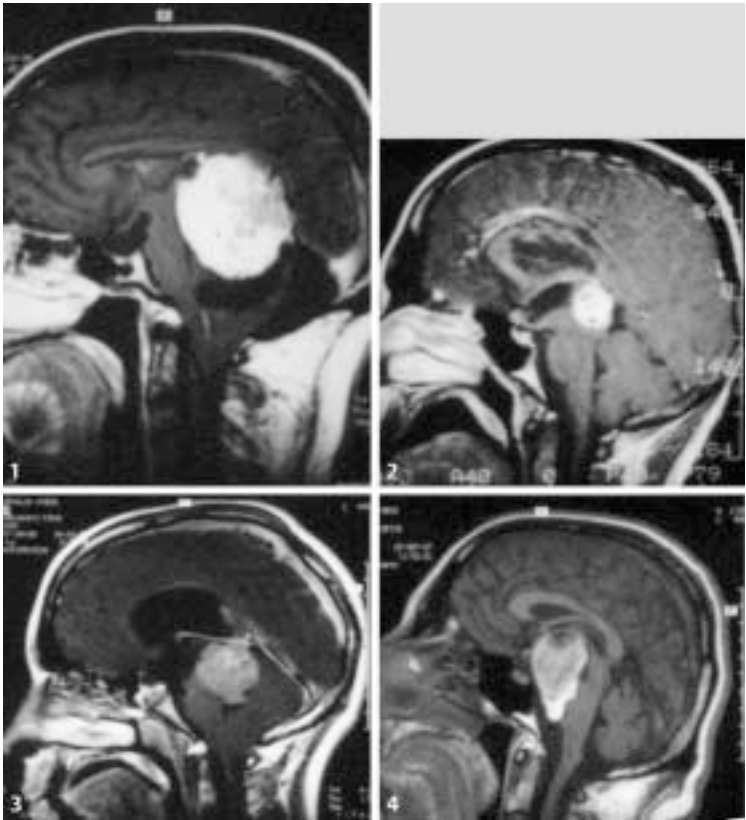


Fig. 6 Pineal lesions

1. Germinoma. Sagittal T1 WI with a large, solid space-occupying lesion originating from the pineal gland and a high postcontrast signal intensity causing compression of the brain stem and cerebellum with distortion of the 4th ventricle. There is also descent of the cerebellar tonsils.
2. Astrocytoma and suprasellar metastasis. Sagittal T1 WI shows a postcontrast enhancing mass in the pineal region producing compression of the quadrigeminal plate. A second suprasellar mass compresses the pituitary stalk. The patient presented clinical signs of diabetes insipidus.
3. Medulloblastoma. Sagittal T1 WI with a solid, multilobular space-occupying lesion, which presents an intermediate, heterogenous postcontrast enhancement and is housed in the upper region of the cerebellum and 4th ventricle.
4. Basilar aneurysm. Sagittal T1 WI demonstrates a partially thrombosed giant aneurysm of the basilar artery, which acts as a space-occupying mass and thus compresses the pons, the cerebral peduncles, and the 3rd ventricle, extending retrochiasmatically into the suprasellar cisterns.

Pineal Gland

(Fig. 6)

Germ-cell tumors

- Pure germinoma The most common variant of germ-cell neoplasm in this area, accounting for 50% of pineal neoplasms
- Embryonal cell carcinoma
- Choriocarcinoma
- Teratoma
- Mixed germ-cell tumor
- Yolk sac tumor Endodermal sinus

Pineal parenchymal (cell origin) tumors

- Pineoblastoma
- Pineocytoma

Tumors of supportive tissues and adjacent structures

- Astrocytoma
- Ependymoma
- Meningioma
- Hemangiopericytoma
- Ganglioneuroma
- Ganglioglioma
- Chemodectoma
- Craniopharyngioma
- Lipoma (quadrigeminal cistern)

Metastatic tumors of the pineal gland

Extremely rare; 75 reported cases in total

- Lung
- Breast
- Stomach
- Kidney

Nonneoplastic tumor-like conditions

- Pineal cysts Degenerative cysts lined with fibrillary astrocytes
- Arachnoid cysts
- Cysticercus cysts
- Vascular lesions

Aneurysmal dilation of the vein of Galen, vertebrobasilar dolichoectasia, basilar tip aneurysm

Cerebellopontine Angle

(Figs. 7 and 8)

Acoustic schwannoma	Most common mass, up to 75% of cases
Meningioma	Second most common lesion, up to 10% of cases
Ectodermal inclusion tumors	
– Epidermoid	Also known as “congenital cholesteatoma” or “pearly tumor”; 5–7%
– Dermoid	
Metastases	
Paraganglioma	Also known as “glomus jugulare tumor”; a chemodectoma arising from the jugular foramen and extending into the CPA; 2–10%
Other schwannomas	2–5%. The trigeminal and facial nerves are probably the most common sites of nonacoustic schwannomas. Other cranial nerves involved are: VI, IX, X, XI, and rarely XII
Vascular	2–5%
– Dolichobasilar ectasia	3–5%
– Aneurysm	1–2%
– Vascular malformation	1%
Choroid plexus papilloma	1%; primary in the CPA or extension via the lateral foramina of Luschka
Ependymoma	1%; extension from the fourth ventricle
Rare lesions	Incidence < 1%
– Arachnoid cyst	
– Lipoma	
– Exophytic brain stem or cerebellar astrocytoma	
– Chordoma	
– Osteocartilaginous tumors	
– Cysticercosis	

CPA: cerebellopontine angle.

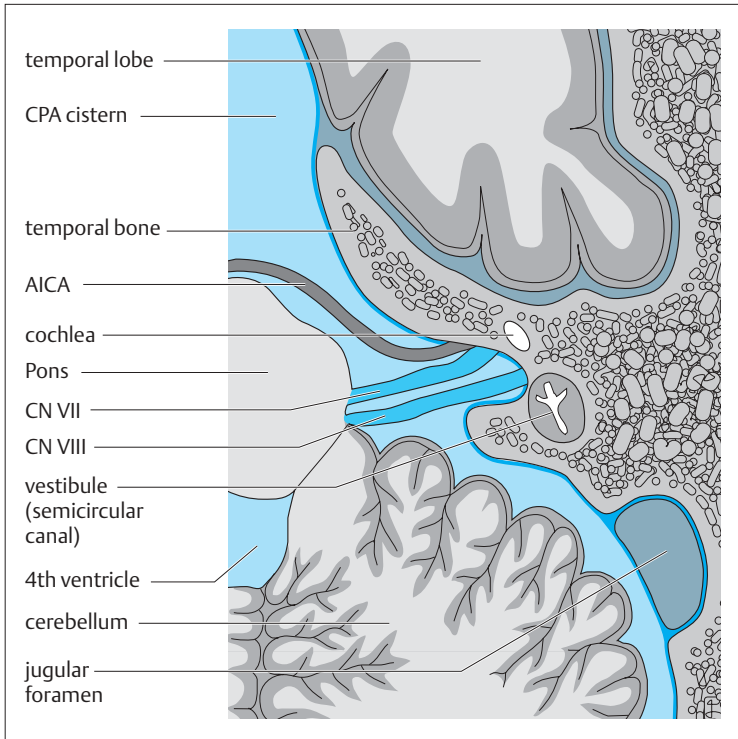


Fig. 7 Cerebellopontine angle. Diagram of the cerebellopontine angle anatomy

Fig. 8 Cerebellopontine angle lesions

1. Acoustic neurinoma. Axial CT with right acoustic neurinoma and erosion of the internal auditory meatus with a small protrusion of the tumor in the cerebellopontine angle.
2. Erosion of the auditory meatus. Bone windows of an axial CT of the same patient with an abnormal erosion of the right internal auditory meatus.
3. Acoustic neurinoma. A solid space-occupying mass with mild postcontrast enhancement producing erosion of the right acoustic meatus, protrusion into the right CP angle, and compression of the pons and cerebellar peduncles.
4. Chordoma. Axial T1 WI shows a solid, space-occupying lesion with postcontrast enhancement occupying the left middle temporal fossa and ipsilateral CP angle as well as erosion of the apex of the petrous and sphenoid bone.

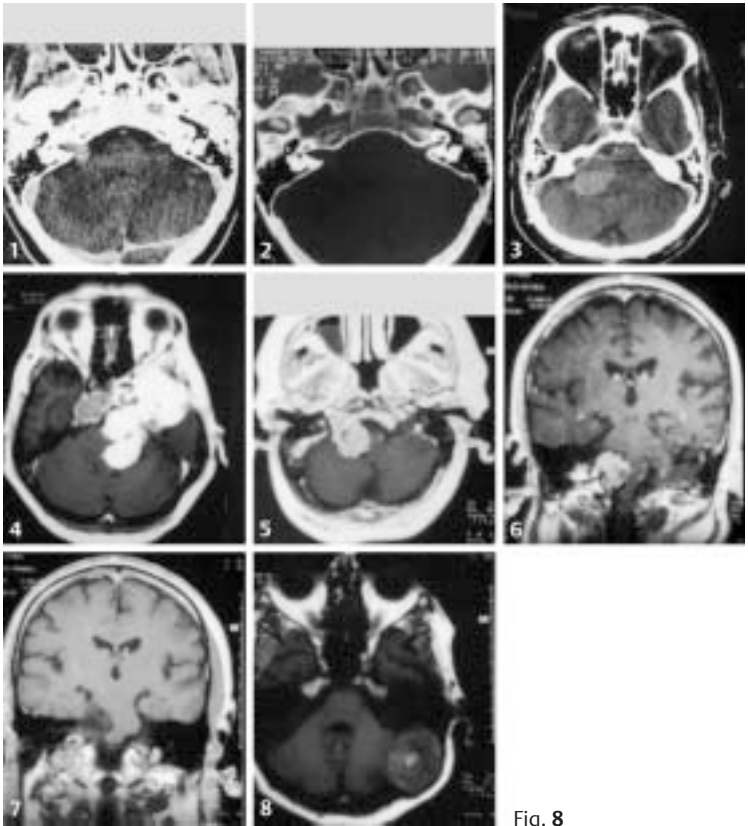


Fig. 8

- 5, 6. Meningioma. Axial and coronal T1 WI with a postcontrast enhancing meningioma of the right CP angle that extends into the right jugular foramen causing compression of the medulla oblongata and the right cerebellar hemisphere.
7. Epidermoid tumor. Coronal T1 WI with a cystic space-occupying, nonenhancing lesion in the right CP angle with compression signs of the pons.
8. Epidermoid tumor. A solid and heterogeneous mass with smooth margins eroding the left occipital bone and compressing the left cerebellar hemisphere is seen on axial T1 WI.

Internal Auditory Meatus

Neoplastic masses

- Intracanalicular acoustic Schwannoma
- Facial schwannoma
- Lipoma
- Meningioma
- Hemangioma
- Lymphoma

Nonneoplastic masses

- Postoperative reactive dural fibrosis The second most common cause of enlargement of the internal auditory meatus
- Neuritis Bell's palsy, Ramsay Hunt syndrome or herpes zoster otitis, and viral infections are benign conditions that can cause cranial nerve enlargement
- Meningitis
- Sarcoidosis
- Vascular Hemorrhage, vascular loop of AICA, AVM or aneurysm

AICA: anterior inferior cerebellar artery; AVM: arteriovenous malformation.

Foramen Magnum

(Figs. 9 and 10)

Intra-axial cervicomedullary masses

Nonneoplastic

- Syringomyelia In 25% of Chiari I patients; secondary syrinxes due to trauma can be seen
- Demyelinating diseases
 - Multiple sclerosis
 - Acute transverse myelopathy
 - Miscellaneous (e.g., radiation, AIDS, vascular AVM)

Neoplastic

- Gliomas, astrocytomas Commonly of low grade, 50% occurring in the cervicomedullary junction. Extension of spinal cord gliomas into this area is also common. Other types of gliomas, however, such as anaplastic astrocytoma, ganglioglioma, ependymoma are also found here
- Nonglial neoplasms Inferior extensions of medulloblastomas in children and hemangioblastomas in adults are common in this area
- Metastases Rare

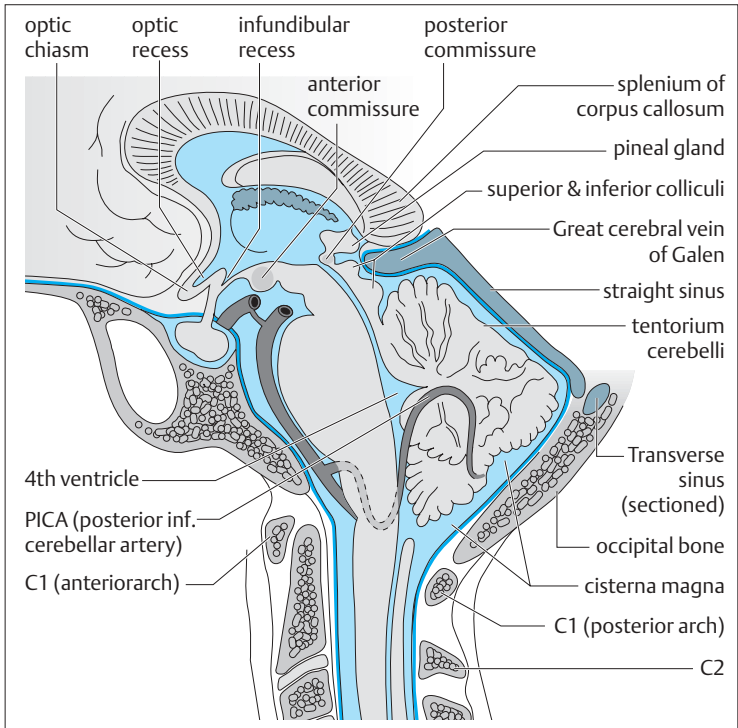
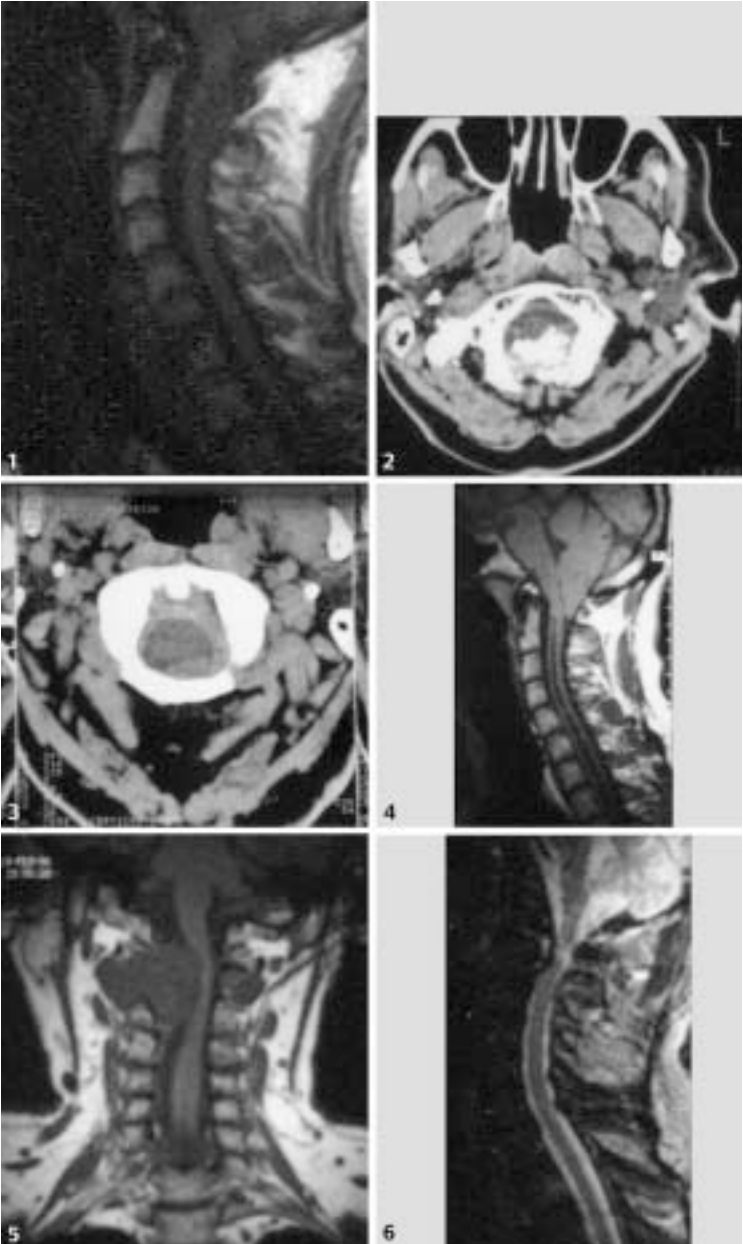


Fig. 9 Intracranial tumors. Midsagittal anatomic diagram of the pineal and foramen magnum regions

Fig. 10 Foramen magnum

1. Glioma of the high cervical spinal cord (C2), producing a focal expansion of the spinal cord, is seen on this midsagittal T1 WI.
2. Meningioma. Axial CT demonstrates a calcified meningioma of the posterior part of the foramen magnum compressing the medulla oblongata.
3. Epidermoid cyst. Axial CT with a cystic lesion of the foramen magnum causing compression of the medulla oblongata.
4. Chiari II malformation. Sagittal T1 WI shows a descent of the cerebellar tonsils and compression of the medulla oblongata and associated syringomyelia.
5. Osteolysis of C2 and a mass of soft tissues producing compression and displacement of the spinal cord is seen on coronal T1 WI.
6. Atlantoaxial subluxation. Sagittal T2 WI shows atlantoaxial subluxation with the development of inflammatory tissue around the dens of C2. This pathology causes stenosis of the foramen magnum and compression of the spinal cord and lower medulla. Focal myelinolysis is indicated by a high intensity signal.



Anterior extramedullary intradural masses

Ectatic vessel, aneurysm	The most common mass anterior to the medulla is a tortuous, ectatic vertebral artery. Occasionally, aneurysms of the vertebral artery or PICA are seen
Meningioma	The most common primary neoplasm in this area
Schwannoma	From cranial nerves IX and XI. Neurofibromas from existing spinal nerve segments occur laterally
Epidermoid tumors	
Metastases	Cisternal, perineural, and skull base
Paragangliomas	
Arachnoid, inflammatory and neurenteric cysts	
Chordomas, rheumatoid nodules	Extraosseous intradural

Posterior extramedullary intradural masses

Congenital or acquired tonsillar herniation	Represents 5 – 10% of all foramen magnum masses
Ependymoma, medulloblastoma	Intra-axial caudal extension of posterior fossa neoplastic masses

Extradural masses

Trauma	Odontoid fractures
Arthropathies	
– Rheumatoid arthritis	Affects 80% of cervical spine in these patients, causing severe cord compression
– Osteoarthritis	
– Paget's disease	
– Osteomyelitis	
Congenital anomalies	
– Os odontoideum	
– Vertebralization of occipital condyles	
– Odontoid hypoplasia	
– Arch hypoplasias or aplasias	
Neoplasms	
– Primary	<ul style="list-style-type: none"> • Chordoma • Osteocartilaginous tumors chondroma and chondrosarcoma
– Metastases	Hematogenous or local extensions from nasopharyngeal or skull base tumors

AIDS: acquired immune deficiency syndrome; AVM: arteriovenous malformation; PICA: posterior inferior cerebellar artery.

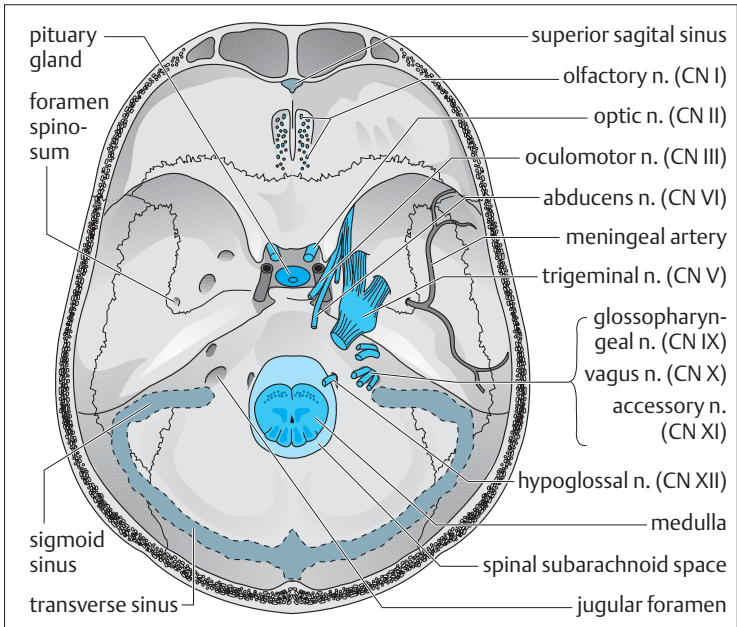


Fig. 11 **Intracranial tumors.** Anatomic drawing depicting the endocranial aspect of the skull base

Skull Base

(Figs. 11 and 12)

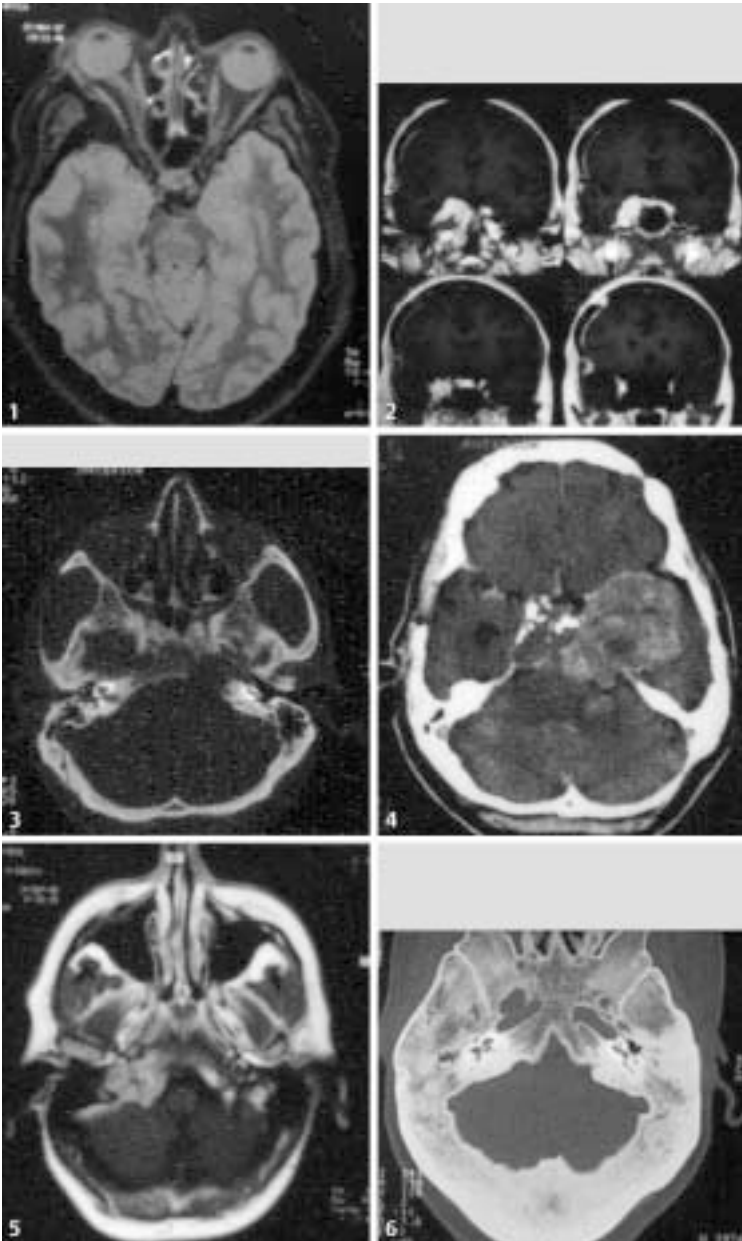
Anterior skull base

Orbital plates, frontal bones, cribriform plate, planum sphenoidale

Extracranial lesions
– Nasal, paranasal sinus malignant tumors

Occur in up to 30% of anterior skull base cases. Carcinomas represent 98% of adult nasopharyngeal tumors

- Squamous cell carcinomas (80%), adenocarcinomas (18%)
- Rhabdomyosarcoma (the most common soft tissue sarcoma in children—up to 35% of these lesions occur here)
- Esthesioneuroblastoma, or olfactory neuroblastoma (arises from the bipolar sensory cells and is histologically similar to adrenal or sympathetic ganglionic neuroblastomas or retinoblastomas)



<ul style="list-style-type: none"> – Bacterial or fungal sinusitis – Sarcoidosis – Lymphoma – Granulomatoses 	Cocaine abuse, Wegener's
Intrinsic lesions	
<ul style="list-style-type: none"> – Fibrous dysplasia – Paget's disease – Osteopetrosis 	
Intracranial lesions	
<ul style="list-style-type: none"> – Meningioma 	Planum sphenoidale and olfactory groove meningiomas account for 10–15% of all meningiomas
<ul style="list-style-type: none"> – Nasoethmoidal encephalocele 	The most common anterior skull base lesion that originates from the brain; 15% of basal encephaloceles occur here
<ul style="list-style-type: none"> – Dermoid sinuses – Cerebral heterotopias – Primary brain neoplasms 	Rare lesions; may cause dural invasion or calvarial destruction <ul style="list-style-type: none"> • Ganglioglioma • Anaplastic glioma or glioblastoma multiforme
Central skull base	Upper clivus, sella turcica, cavernous sinuses, sphenoid alae
Metastases	Arise from regional extension of head and neck malignancies or hematogenous spread from extracranial sites, e.g., prostate, lung, and breast carcinomas

◀ Fig. 12 Skull base lesions

1. Fibrous dysplasia. Axial proton density MRI with thickening of the right sphenoid bone and reduction of the size of the orbit and associated exophthalmos.
2. Meningioma of the right cavernous sinus. Coronal T1 WI shows expansion of the right cavernous sinus and a very high signal intensity following contrast enhancement.
3. Metastasis. Axial CT demonstrating an osteolytic lesion of the sphenoid tip of the petrous bone.
4. Chordoma. Axial CT with a high-density space-occupying lesion of the left temporal fossa and the parasellar region. The mass is eroding the apex of the petrous bone and is extending to the cerebellopontine angle of the same side.
5. Paraganglioma or glomus jugulare. Axial CT shows a space-occupying lesion of the right CP angle that occupies the right jugular foramen and demonstrates intense, heterogeneous postcontrast enhancement.
6. Paget's disease. Axial CT shows a marked thickening of all bones of the skull base with reduction of the size of the posterior fossa.

Infection and inflammatory disease

- Osteomyelitis Immunocompromised states, diabetes, chronic mastoiditis, paranasal sinus infection, trauma or necrotizing otitis externa
- Bacterial sinusitis From ethmoid or sphenoid sinuses, or intracranially via emissary veins and the cavernous sinus, resulting in cerebral infarction, meningitis, subdural empyema, and brain abscess
- Fungal sinusitis Candidiasis, aspergillosis, histoplasmosis, rhinocormycosis, resulting in multiple cranial nerve palsies, internal carotid artery thrombosis, cavernous sinus thrombosis, cerebral infarction, and brain abscess in immunocompromised patients
 - Wegener's granuloma
 - Sarcoidosis
 - Leprosy
 - Syphilis
 - Rhinoscleroma
 - Cocaine abuse granulomatosis
 - Lethal midline granuloma (variant of T-cell lymphoma)
 - Eosinophilic granuloma
- Nonfungal granulomas

Primary benign neoplasms

- Pituitary adenoma May extend superiorly through the diaphragma sellae and laterally into the cavernous sinus
- Meningioma Located alongside the sphenoid wing, diaphragma sellae, clivus, and cavernous sinus
- Nerve sheath tumors
 - Plexiform neurofibromas Diffusely infiltrating masses originating primarily along the ophthalmic and the maxillary and mandibular divisions of the trigeminal nerve
 - Schwannomas Cause one-third of primary trigeminal nerve and Meckel's cavity tumors. Neurinomas of the third, fourth and sixth cranial nerves are rare
- Juvenile angiofibroma The most common benign nasopharyngeal tumor; highly vascular
- Chordoma
- Enchondroma The most common benign osteocartilaginous tumor in this area
- Epidermoid tumors
- Lipomas
- Cavernous hemangiomas

Primary malignant neoplasms

- Nasopharyngeal carcinoma
- Rhabdomyosarcoma
- Multiple myeloma

The most common primary bone tumor originating in the central skull base

- Solitary plasmacytoma

- Osteosarcoma

The second most common primary bone tumor after multiple myeloma

- Chondrosarcomas

Posterior skull base, clivus

Includes the clivus below the spheno-occipital synchondrosis, the petrous temporal bone, the pars lateralis and squamae of the occipital bones, and surrounds the foramen magnum

Lesions in the temporal bone

Lesions in the foramen magnum

Clival and paraclival lesions

- Chordoma

Chordomas or chondrosarcomas usually originate from the sacrococcygeal region, the spheno-occipital region (40%), or the vertebrae. Both these tumors represent 6–7% of primitive skull base lesions, and they are very rare, representing only 0.2% of intracranial tumors. *Differential diagnosis* of intracranial chordomas vs. invasive and calcified tumors includes:

- Chromophobe adenoma
- Mucinous adenocarcinoma
- Meningioma
- Craniopharyngioma
- Schwannoma
- Nasopharyngeal carcinoma
- Salivary gland tumors

- Chondrosarcomas

- Metastasis

- Regional extension

E.g., nasopharyngeal squamous-cell carcinoma

- Hematogenous extracranial sites

E.g., lung, prostate, breast

- Meningioma

- Osteomyelitis

Including Gradenigo's syndrome

- Multiple myeloma

- Plasmacytoma

- Histiocytosis

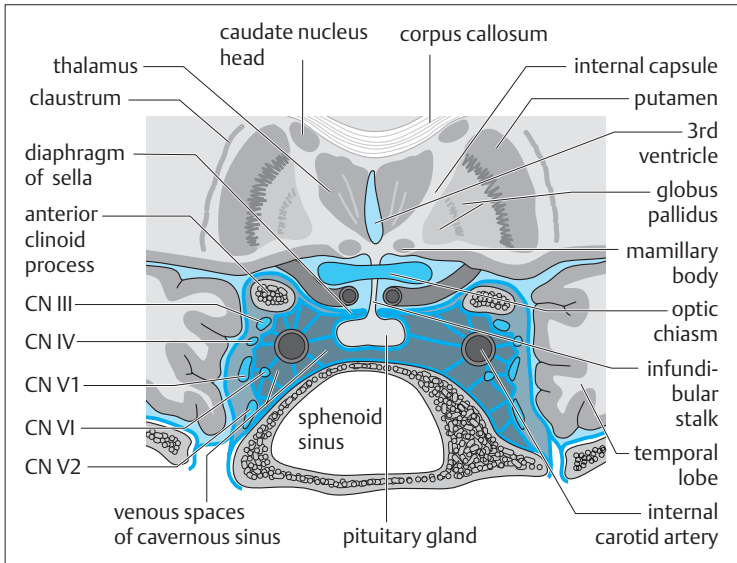


Fig. 13 **Suprasellar and parasellar lesions.** Diagram of the cavernous sinus and its contents; the sellar, suprasellar, and parasellar structures

Jugular foramen lesions

- Neoplastic masses
 - Parangliomas Chemodectomas or glomus tumors; parasympathetic paraganglia located in the jugular bulb adventitia and in various sites of the head and neck, especially the carotid body, glomus jugulare, and glomus tympanicum
 - Metastases
 - Regional extension (e.g., nasopharyngeal carcinoma, lymph node metastatic disease)
 - Hematogenous extracranial sites (e.g., lung, prostate, breast)
 - Nerve sheath tumors Uncommon location
 - Schwannomas of cranial nerves IX and XI
 - Neurofibromas
- Epidermoid tumor
- Chondroid, chordoma lesions
 - Meningioma

Nonneoplastic masses

- Prominent jugular bulb “Pseudomass”—normal variant
- Jugular vein thrombosis
- Osteomyelitis

Diffuse skull base lesions

Neoplastic masses

- Metastases
- Multiple myeloma, plasmacytoma
- Meningioma
- Lymphoma

Primary or secondary; uncommon, but increasing in incidence, causing leptomeningeal disease and multiple cranial nerve palsies

Nonneoplastic masses

- Fibrous dysplasia
- Paget’s disease
- Eosinophilic granuloma

The most common benign skeletal disorder in adolescents and young adults. In the most common monostotic type, 25% of skull and facial bones are involved, compared with 40–60% in the polyostotic type, causing facial deformities and cranial nerve palsies

Cavernous sinus lesions

(Fig. 13)

Unilateral

- Schwannoma Cranial nerves III, IV, V, and VI
- Meningioma These tend to follow the lateral margin of the cavernous sinus, and may extend posteriorly along the tentorial margin, with a dovetail appearance on MRI. May encase or distort the cavernous portion of the ICA
- Metastasis E.g., adenoid cystic carcinoma, basal-cell carcinoma, lymphoma, mucoepidermoid carcinoma, melanoma, and schwannoma, showing perineural spread through the basal skull foramen and into the brain
- Vascular lesions E.g., ectatic carotids, caroticocavernous fistula, cavernous carotid aneurysm, cavernous hemangioma, and cavernous sinus thrombosis
- Chordoma
- Lymphoma
- Chondrosarcoma
- Lipoma
- Infection E.g., actinomycosis, Lyme disease, and herpes zoster can also demonstrate perineural involvement

- Idiopathic inflammatory disease Tolosa–Hunt syndrome: characterized by recurrent attacks of retro-orbital pain, defects in cranial nerves III, IV, Va, and VI, with spontaneous remission and prompt response to steroid therapy

 - Bilateral
 - Extensive and aggressive pituitary adenoma
 - Meningioma
 - Metastases
 - Thrombosis of the cavernous sinus May occur as part of a septic process associated with spontaneous dural malformations, or may result from an interventional or surgical procedure
-

ICA: internal carotid artery; MRI: magnetic resonance imaging.

Choroid Plexus Disease

Differential diagnosis:

Tumors

Choroid plexus papilloma

Choroid plexus carcinoma

Meningioma

Ependymoma, subependymoma

Neurofibroma

Glioblastoma, astrocytoma

Oligodendroglioma

Tuberous sclerosis, subependymal giant-cell astrocytoma

CNS lymphoma

PNET

E.g., medulloblastomas, ependyoblastomas, pineoblastomas, cerebral neuroblastomas, medulloepitheliomas, melanotic vermian PNET of infancy

Metastases

Nonneoplastic tumor-like lesions

Epidermoid tumor

Dermoid tumor

Nonneoplastic cysts

Colloid cyst

Rathke's cleft cyst

Neuroglial (neuroepithelial) cyst

Vascular malformations

Choroid plexus angiomas

Phakomatosis E.g., Sturge-Weber syndrome

InfectionChoroid plexitis Pathogens include *Cryptococcus* and *Nocardia*

Other

Inflammation

Sarcoidosis

Xanthogranuloma

CNS: central nervous system; PNET: primitive neuroectodermal tumor.

Gliomatosis Cerebri

This is a diffusely infiltrative neoplasm, with variably undifferentiated astrocytes and without a necrotic center. Gliomatosis cerebri presents as a diffuse involvement of the cerebral hemispheres, leading to progressive changes in personality, headaches, and impaired mental status. Positron-emission tomography (PET) scanning with methionine shows isotope accumulation in the diffusely infiltrative tumorous area, with greater accuracy than computed tomography or magnetic resonance imaging. The definitive diagnosis is at autopsy. The prognosis is variable, with survival measured in months to years.

Differential diagnosis:

Low-grade glioma

Oligodendroglioma

Gliomatosis cerebri

Leptomeningeal gliomatosis

Encephalitis

Diffuse and demyelinating disease

Pseudotumor cerebri

Tolosa–Hunt Syndrome

Idiopathic inflammatory disease of the cavernous sinus.

Sarcoidosis

Meningioma

Lymphoma

Metastatic and neurotropic spread of tumor into the cavernous sinus

Infections (e.g., actinomycosis, mucormycosis, aspergillosis)

Recurrence of Malignant Gliomas

An enlarging lesion at the site of a previously treated glioma most probably represents a regrowth of an incompletely treated initial tumor, and is less likely to be the development of a new pathological entity. In the differential diagnosis of an enlarging lesion at the site of a previously eradicated malignant glioma, the clinician should consider the following possibilities.

Development of a distinct new tumor	In cases of genetic predisposition to tumor development shared by cells in the area: <ul style="list-style-type: none"> – Multiple gliomas in patients with tuberous sclerosis – Multiple neurofibromas developing along the same nerve root in patients with neurofibromatosis
Growth of a tumor with related pathology	A tumor with related histopathology may supplant the original tumor. <ul style="list-style-type: none"> – The astrocytic component of a mixed glioma replacing its previously treated oligodendrocytic component – A gliosarcoma can arise from a previously treated glioblastoma
Growth of a secondary tumor	The initial treatment may induce a secondary tumor of a different type: <ul style="list-style-type: none"> – A parasellar sarcoma after irradiation for a pituitary adenoma – A glioblastoma in the radiation field of a meningioma
Metastatic tumor at the original tumor site	E.g., a breast metastasis within a pituitary adenoma

Nonneoplastic lesions	Nonneoplastic lesions can mimic tumor growth: <ul style="list-style-type: none"> – Radiation necrosis after focal high-dose irradiation – Abscess formation at the site of the tumor resection
-----------------------	--

Congenital Posterior Fossa Cysts and Anomalies

Dandy–Walker complex	In 70% of cases, the syndrome has a number of associated anomalies, such as hydrocephalus, agenesis of the corpus callosum, nuclear dysplasia of the brain stem, and other cerebrocerebellar heterotopias
Dandy–Walker malformation	Large posterior fossa and CSF cyst, high transverse sinuses and tentorial insertion, vermian, cerebellar hemispheric and brain stem hypoplasia in 25% of cases
Dandy–Walker variant	Mild vermian hypoplasia, moderately enlarged fourth ventricle although the posterior fossa is typically of normal size, the brain stem is normal, and there is a variable degree of vermian hypoplasia

Other posterior fossa cysts

Arachnoid and neuroepithelial cysts	Arachnoid cysts are formed by a splitting of the arachnoid membrane with layers of thickened fibrous connective tissue, whereas neuroepithelial or gliopendymal cysts are lined with a low cuboidal-columnar epithelium
Megacisterna magna	The fourth ventricle appears normal and the vermis and cerebellar hemispheres are normal, but occasionally the posterior fossa can be enlarged, with prominent scalloping of the occipital bones
Isolated fourth ventricle	After ventriculoperitoneal shunt, leading to secondary aqueductal stenosis, but in addition the CSF outflow from the fourth ventricle is prevented, or its absorption is prevented, e.g., in patients in whom the hydrocephalus is due to or associated with an inflammatory meningeal process, such as infection or hemorrhage
Pulsion diverticulum	In advanced hydrocephalus, the thin ventricular wall may dehisce into the adjacent subarachnoid space, forming diverticula commonly in the inferomedial wall of the atria, the suprapineal recess, and through the incisure, causing downward displacement of the cerebellum

3. Arachnoid cyst of the 4th ventricle. Sagittal T1 WI showing dilatation of the 4th ventricle and isodense signal with the cerebrospinal fluid.
4. Hemangioblastoma. Coronal T1 WI demonstrates a cystic space-occupying lesion with a small postcontrast enhancing mural nodule.
5. Epidermoid cyst. Axial T1 WI with a solid extrinsic space-occupying mass with smooth margins and a relative heterogeneity, which causes smooth erosion of the occipital bone and exerts mild compression on the left cerebellar hemisphere.
6. Epidermoid cyst. Coronal T1 WI shows a solid extrinsic space-occupying mass with well-defined margins, it is non-contrast enhancing and causes erosion of the occipital bone.

Miscellaneous cerebellar hypoplasias

Chiari type IV malformation	Absent or severely hypoplastic cerebellum and small brain stem
Joubert’s syndrome	Split or segmented vermis, transmitted by autosomal recessive genes
Rhombencephalosynapsis	Agenesis of the vermis and midline fusion of the cerebellar hemispheres and peduncles
Tectocerebellar dysraphia	Vermian hypoplasia, occipito-encephalocele, and dorsal brain stem traction
Lhermitte–Duclos disease or dysplastic cerebellar gangliocytoma	Gross thickening of the cerebellar folia, hypertrophy of the granular cell layer, and axonal hypermyelination of the molecular cell layer

CSF: cerebrospinal fluid.

Posterior Fossa Cysts

(Fig. 14)

- Dandy–Walker complex
- Megacisterna magna
- Arachnoid cyst
- Nonneoplastic cysts
 - Inflammatory
 - Enterogenous
- Neoplastic cysts
 - Hemangioblastoma
 - Pilocytic astrocytoma
- Cyst-like tumors
 - Dermoid
 - Epidermoid

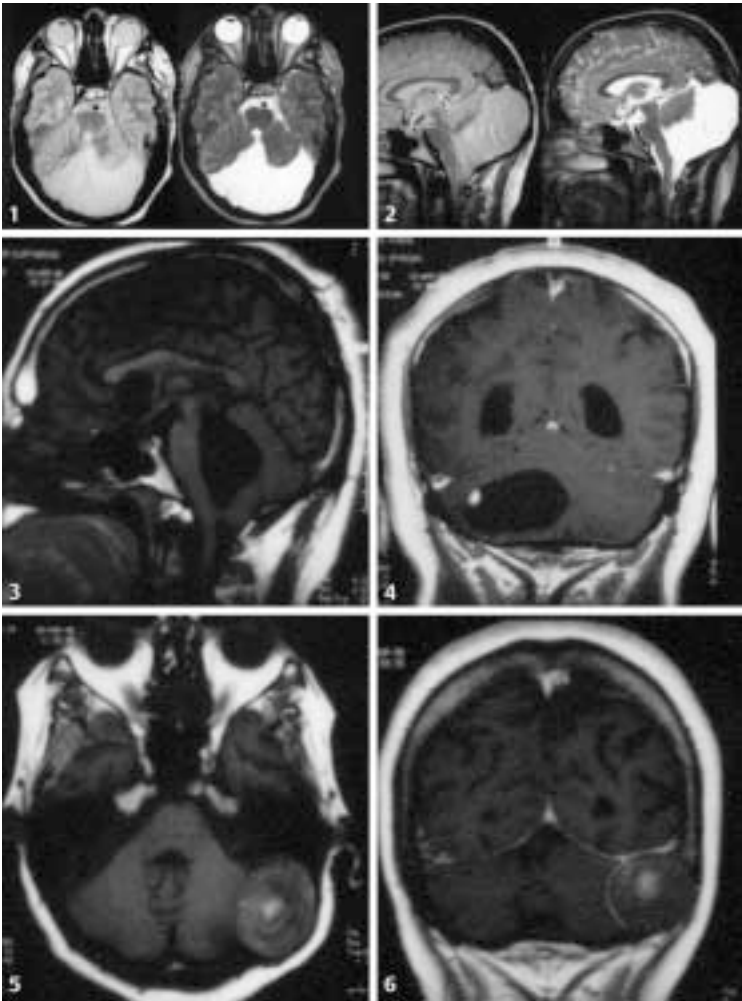


Fig. 14 Posterior fossa cysts

1. Dandy-Walker cyst. Proton density axial MRI T2 WI presenting a cystic dilatation of the cisterna magna that communicates with the 4th ventricle. There is an associated atrophy of the cerebellar vermis and a smooth erosion of the occipital bone.
2. Dandy-Walker cyst. Proton density sagittal T2 WI (same case). The communication of the cyst with the 4th ventricle and the significant vermian atrophy are noted. There is also elevation of the confluence of sinuses and of the tentorium cerebelli.

Enhancing Lesions in Children and Young Adults

Imaging differential diagnoses for a peripheral enhancing lesion in a child or young adult include the following.

- Glioblastoma
- Ganglioglioma
- Gangliosarcoma
- Malignant astrocytoma
- Meningioma
- Meningiosarcoma
- Oligodendroglioma
- Juvenile pilocytic astrocytoma
- Solitary metastasis
- Pleomorphic xanthoastrocytoma
- Fibrous histiocytoma
- Fibrous xanthomas

Tumoral Hemorrhage

Intratumoral hemorrhage may be suspected in the appropriate clinical circumstances, for example in patients with known malignancy, in elderly nonhypertensive persons, and in patients who had progressive symptoms before the hemorrhage ictus. Hemorrhage has been noted in about 1% of brain tumors, whereas underlying tumors have been reported in up to 10% of cases with intracranial hemorrhage.

Metastatic lesions are usually seen as well-defined, round masses located around the gray-white junction, and they show contrast enhancement and moderate edema. Hemorrhagic metastases are usually seen as areas of high signal intensity on T1-weighted images and T2-weighted images, with a relative absence of hemosiderin deposition.

Brain tumors associated with hemorrhage include the following.

Primary brain tumors

Malignant astrocytoma

- Anaplastic astrocytoma
- Glioblastoma multiforme

Of the adult gliomas, glioblastoma multiforme (GBM) is the one most often associated with intratumoral hemorrhage and subarachnoid seeding

Oligodendroglioma (neurocytoma)	Although intraventricular neurocytomas have a more benign course, they are more often subject to hemorrhage than oligodendrogliomas, which may suggest the diagnosis
Meningioma	
Pituitary adenoma	
Hemangioblastoma	
Acoustic neurinoma	
Lymphomas	Hemorrhage is rare in lymphomas
Metastatic brain tumors	
Lung cancer	Bronchial carcinomas spread to the CNS in 30% of cases; oat-cell carcinoma is the most frequent, whereas squamous-cell carcinoma is the least frequent subtype to metastasize to the brain
Breast cancer	It is estimated that 18–30% of patients with breast cancer will develop brain metastases
Malignant melanoma	Third most common neoplasm, with a propensity for metastatic spread to the brain, after the lung and breast
Renal-cell carcinoma	
Thyroid cancer	
Gastrointestinal primary tumors	
Choriocarcinoma	
Retinoblastoma	

CNS: central nervous system.

Brain Metastases

A known history of systemic cancer and the presence of multiple lesions on magnetic resonance imaging (MRI) make the diagnosis of metastatic brain tumor probable. Even a typical scan only suggests, but does not prove, that the lesion is a brain metastasis and not another lesion, such as a primary brain tumor or a cerebral abscess. Stereotactic needle biopsy is required for definitive diagnosis.

*Differential diagnosis:***Primary brain tumors**

Meningioma

- Meningiomas show homogeneous contrast enhancement, a relative lack of peritumoral edema, and attachment to the dura. Metastatic cancers may also arise from the dura, and can even be supplied by the external carotid artery, making the distinction between metastasis and meningioma impossible except by biopsy.
- If the neurological symptoms have developed very slowly, or if the MRI suggests a lesion neighboring the falx or the inner skull table, the diagnosis is in favor of a meningioma
- It should also be borne in mind that breast cancer may metastasize to a meningioma

Astrocytoma

Brain metastasis presents as a spherical mass, whereas primary gliomas are usually irregular, and present finger-like extensions of contrast enhancing tumor running along the white matter tracts and bundles

Primary brain lymphoma

These lesions often present as uniform, multiple, periventricular lesions on MRI, with irregular margins that are not discrete

Acoustic neurinoma and pituitary adenoma

Almost impossible to distinguish from metastatic brain tumors in the same areas

Vascular disorders

Cerebral infarction

- Acute infarctions do not enhance, and the MRI findings may be entirely normal for 24–48 hours after the event
- Contrast enhancement of the pial surface of the overlying cortical gyri develops 1–3 weeks after the ictus, unlike the ring-like enhancing lesion of a brain metastasis
- Several weeks postictally, the contrast enhancement in an infarct diminishes and gradually disappears, and the ischemic area becomes hypointense

Cerebral hemorrhage

- Acute hemorrhage is hyperdense on a noncontrast CT scan, but may have a normal appearance on MRI
- Contrast enhancement 3–6 weeks postictally demonstrates an isodense clot with a ring enhancement, resembling a metastasis or an abscess. Early enhancement suggests tumoral hemorrhage

Infections	Cerebral abscess usually occurs in patients with reduced immunity, and particularly in those suffering from Hodgkin's disease and other lymphomas, conditions in which brain abscesses are more common than metastatic brain tumors
Toxoplasma abscess	This is the most common parasitic CNS infection, and has a predilection to lodge in the basal ganglia as a single mass
Multiple nocardia abscesses	These develop in 50% of immunosuppressed patients with <i>Nocardia</i> pulmonary infection.
Progressive multifocal leukoencephalopathy (PML)	An infection of the oligodendrocytes caused by the JC polyomavirus, affecting patients with depressed cellular immunity due to lymphoma or chronic lymphocytic leukemia, or after prolonged chemotherapy
	<i>Differential features</i>
	<ul style="list-style-type: none"> - CT and MRI help identify brain abscesses. The enhancing ring of an abscess is generally thinner and more uniform than the ring of a tumor. The capsule of an abscess is characteristically thicker near the cortex, where oxygenation is better, and somewhat thinner near the ventricular surface. - With suspected <i>Toxoplasma</i> abscesses, a therapeutic trial with sulfadiazine and pyrimethamine has a rapid response, and this can establish the diagnosis without the need for a biopsy. With other suspected abscesses, stereotactically directed needle biopsy performed early in the diagnostic work-up both establishes the diagnosis and reveals the involved organism for the appropriate antibiotic therapy - CT and MRI in PML reveal multifocal, punched-out lesions of the white matter, with no mass effect and usually no contrast enhancement. Nonenhancing lymphomas may be similar. A definitive diagnosis is secured only by biopsy
Radiation necrosis	CT and MRI reveal a hypodense or isodense ring-enhancing brain lesion, surrounded by edema. Differentiating between radiation necrosis and recurrent brain metastases in a patient previously irradiated for a brain metastasis may be impossible without needle biopsy
Methotrexate leukoencephalopathy	Causes bilateral white matter lesions and ventricular enlargement. The lesions show a reduced density on CT scanning and appear hyperintense on T2-weighted MRI without enhancement, a feature that distinguishes the condition from a brain metastasis

Multiple sclerosis MS lesions may be single or multiple, and contrast-enhancing, which makes them indistinguishable from brain tumors. However, MS lesions do not enhance after 6–8 weeks, and other new nonenhancing lesions may be present, which is unlikely with brain metastases

Miscellaneous Transient changes in CT or MRI sometimes follow focal or generalized epilepsy in the absence of underlying primary or metastatic brain tumor. These lesions disappear within a few weeks after control of the seizures

CNS: central nervous system; CT: computed tomography; MRI: magnetic resonance imaging; MS: multiple sclerosis; PML: progressive multifocal leukoencephalopathy.

Subarachnoid Space Metastases

Between 6% and 18% of central nervous system (CNS) metastases involve the arachnoid and subarachnoid space, or the pia, or both. The subarachnoid space can be diffusely or focally involved by spread from a primary CNS tumor, or by an extraneural malignancy. The typical locations for metastatic seeding are at the basal cisterns, the cerebellopontine angle cistern, the suprasellar cisterns, along the course of the cranial nerves, and over the convexities. Subtle leptomeningeal and subarachnoid space metastatic disease is identified in up to 45% of cases using contrast-enhanced magnetic resonance imaging (MRI) scans. Cerebrospinal fluid (CSF) cytology provides definitive diagnosis of leptomeningeal carcinomatosis, with abnormal CSF noted in up to 55% of cases after the first spinal tap and in up to 90% after the third. If lumbar puncture is contraindicated or the CSF cytology is equivocal, gadolinium-enhanced MRI is a useful diagnostic tool.

Sources of subarachnoid metastases

Children

Primary brain tumors

- Primary neuroectodermal tumors (PNETs)
 - Medulloblastoma
 - Ependymoblastoma
- Pineal tumors Germinoma, pineoblastoma
- Choroid plexus carcinoma

Primary extracranial tumors

- Neuroblastoma

- Lymphoma
- Leukemia

Adults

Primary brain tumors

- Glioblastoma multiforme, anaplastic astrocytoma
- Oligodendroglioma
- Primary lymphoma

Primary extracranial tumors

- Lung cancer
- Breast cancer
- Malignant melanoma
- Gastrointestinal carcinoma
- Ovary
- Lymphoma
- Leukemia

Differential diagnosis:

Cranial meningeal carcinomatosis

Meningitis

- Acute bacterial meningitis
- Chronic meningitis

Fungal and granulomatous meningitis. Chronic meningitides have a predilection to invade the basal cisterns

- Tuberculous meningitis
- *Coccidioidomycosis imitans* meningitis
- *Cryptococcus neoformans* meningitis
- Neurocysticercosis

Noninfectious inflammatory diseases

- Sarcoidosis

Lymphoma

Leukemia

Posttraumatic basal cranial adhesions

Intrathecal chemotherapy, radiation

Idiopathic pachymeningitis

Hyperprolactinemia

Hyperprolactinemia in women leads to amenorrhea, galactorrhea, and osteoporosis, while in men it may result in diminished sexual drive and impotence, or may be asymptomatic. The degree of hyperprolactinemia is directly related to the functionality of the prolactin-secreting tumor. Serum prolactin levels over 200 ng/mL correlate well with the presence of a prolactinoma. Normal prolactin levels are in the ranges of 1–20 ng/mL in men, and 1–25 ng/mL in women.

Differential diagnosis:

Nonpathological causes

Pregnancy
Early nursing periods
Nipple stimulation
Coitus
Sleep
Stress
Exercise

Diseases

True prolactinomas
Pituitary traumatic stalk section
Pituitary stalk compression from chromophobe macroadenomas
Empty sella syndrome
Hypothalamic disorders
– Tumors (e.g., craniopharyngiomas)
– Histiocytosis X
– Sarcoidosis
Primary hypothyroidism
Chiari–Frommel syndrome
Renal failure
Liver cirrhosis

Drugs

Dopamine antagonists (e.g., phenothiazine-like drugs)
Reserpine
– α -methyl
– Dopa
Opiate derivatives (e.g., morphine)
Prostaglandin F_{2 α}
Thyrotropin-releasing hormone
Estrogens

Demyelinating Disease and Brain Atrophy

Multifocal White Matter Lesions

Multiple sclerosis

Hypertension and ischemic white matter lesions (leukokraurosis) Increases with age, and has also been seen with chronic hypertension. There are two types of ischemic white matter lesions:

- Lesions involving the watershed distribution of the major brain arteries
- Lesions caused by intrinsic disease of the small penetrating medullary arteries (arteriolar sclerosis)

Perivascular (Virchow–Robin) spaces Enlargement of these perivascular spaces with age and hypertension, associated with thinning, pallor and atrophy of the adjacent myelin, is called *état criblé*

Metastases

Trauma, nonvascular white matter injury Diffuse axonal shearing caused by acceleration, deceleration, and rotation forces on the brain

Inflammatory E.g., Lyme disease, cysticercosis

Vasculitides

- Systemic lupus erythematosus
- Sjögren’s syndrome
- Behçet’s disease
- Moyamoya disease
- Amyloid angiopathy
- Polyarteritis nodosa

Primary CNS lymphoma

Migraine Mysterious lesions of the frontal lobe, centrum semi-ovale, and basal ganglia, possibly due to microemboli from increased platelet aggregation during migraine attacks

Inherited leukoencephalopathy

Secondary leukoencephalopathy

- Acute disseminated encephalomyelitis (ADEM)

- Progressive multifocal encephalopathy (PML)
- Binswanger's disease Subcortical arteriosclerotic encephalopathy
- Postanoxic encephalopathy
- Osmotic demyelination, or central pontine myelolysis
- Alcoholism (Marchiafava-Bignami syndrome)
- Drugs Methamphetamine, cocaine, heroin
- Toxins Hexachlorophene, lead, isoniazid, chemotherapeutic agents, eclampsia
- Radiation changes

Dysmyelinating diseases

- Metachromatic leukodystrophy (MLD) The most common type, resulting from a deficiency of the enzyme arylsulfatase A
- Adrenoleukodystrophy E.g., associated with adrenal cortical insufficiency and the accumulation of very long chain fatty acids in the white matter, adrenal cortex, and plasma due to impairment in peroxisomes of β -oxidation
- Alexander's disease
- Canavan's disease Deficiency of the enzyme aspartoacyclase
- Krabbe's disease Deficiency of β -galactosidase

CNS: central nervous system.

Multiple Sclerosis–Like Lesions

Multiple sclerosis (MS) is a clinical diagnosis that should never be made using neuroimaging alone. In 78–95% of clinically diagnosed MS patients, gadolinium-enhanced magnetic resonance imaging (MRI) features include ovoid periventricular, infratentorial, temporal lobe, and corpus callosum white matter lesions that are isointense to hypointense on T1-weighted images, and show high intensity on proton density and T2-weighted images. Many conditions have to be taken into account in the differential diagnosis of multiple white matter high-signal abnormalities on proton density and T2-weighted images. Other conditions may produce lesions with or without enhancement, and can occur in a patient population similar to that with MS. The list of diseases with clinical and neuroimaging features similar to those of multiple sclerosis includes the following.

Neurosarcoidosis	The granulomatous process invades and thromboses affected blood vessels, and produces a granulomatous angiitis similar to primary angiitis of the CNS. High-intensity white matter in sarcoid may be indistinguishable from MS
Lyme disease	Neuroborreliosis. Approximately 10–15% of patients with Lyme disease have CNS involvement. High-signal contrast-enhancing subcortical abnormalities on proton density and T2-weighted images on MRI in the frontal and parietal lobes, the basal ganglia and pons, cranial nerves (facial nerve)
Vasculitides	Multisystem immune-related vasculitis, with CNS involvement in 10–49% of cases, e.g. systemic lupus erythematosus, Behçet’s disease. May resemble MS clinically and due to a white matter lesion pattern in the brain and spinal cord
Neurosyphilis	Contrast-enhanced MRI shows patchy enhancement involving the basal ganglia or the middle cerebral artery territories
Tuberculosis	Single or multiple lesions located in the cerebral hemisphere and basal ganglia in adults, and in the cerebellum in children. On MRI with gadolinium injection, a hypodense rim may separate the hyperintense center from the peripheral hyperintense edema on T2-weighted images, and T1-weighted images often show nodular enhancement
Viral infection	
Devic’s disease, or neuromyelitis optica	
Diffuse sclerosis (Schilder’s disease)	An acute, rapidly progressing form of MS with bilateral, relatively symmetric and large areas of demyelination, often involving the centrum semiovale and the occipital lobes; seen usually in childhood, and rarely in those over 40
Myelopathy	
Acute disseminated encephalomyelitis	Acute monophasic inflammatory demyelination, distinguished from MS by its clinical course—a single acute episode including fever and headache. The locations and characteristics of the lesions on the MRI may be indistinguishable from MS

Baló's disease (concentric sclerosis)	Represents a histological MS lesion with alternating concentric regions of demyelination and normal brain
Hypertension and ischemic white matter lesions	In elderly patients with malignant hypertension, high-signal patchy or diffuse bilateral periventricular white matter abnormalities, most likely representing small-vessel disease manifesting as lacunar, deep white matter infarctions
Virchow–Robin spaces	Dilated perivascular spaces enlarge with age and hypertension and occur in characteristic locations, typically in the basal ganglia, around the ventricular atria, centrum semiovale, brain stem. The perivascular spaces remain isodense to CSF, whereas lesions are hypodense on the proton density–weighted MRI sequence
Lesions associated with migraine	High-intensity abnormalities in the centrum semiovale and frontal white matter in young patients under 40. The lesions appear to be a diffuse process, possibly resulting from platelet microemboli or primary neuronal damage related to the pathophysiology of migraine
Multi-infarct dementia, leukoencephalopathy, and Binswanger's disease	Affects the elderly population, and the predominant clinical manifestations are cognitive and behavioral disorders. The MRI shows periventricular white matter and centrum ovale watershed infarcts, similar in appearance to the demyelinating lesions of MS; however, in contrast to the MS lesions, there are no associated lesions in the basal ganglia, brain stem, or occipital horns, and there is sparing of the subcortical U fibers
Normal aging	In healthy individuals of 52–72 years of age, atrophic periventricular demyelination has been found in 53.4% and white matter infarcts are seen in 13.4%. Incidental white matter T2 hyperintensities occur frequently in elderly people
Metastases and brain abscesses	Rarely produce lesional patterns quite similar to MS. The presence of a mass effect and a clinical history suggesting a remote source for the lesions is important
Motor neuron disease	
Intracranial tumor	Especially brain stem, cerebellum
Vitamin B ₁₂ deficiency	Gastrectomy, gastric carcinoma, malabsorption syndromes

CSF: cerebrospinal fluid; CNS: central nervous system; MRI: magnetic resonance imaging; MS: multiple sclerosis.

Creutzfeldt–Jakob disease	Frontal predominance atrophy, abnormal intensity of the basal ganglia
Multi-infarct dementia	White matter and deep gray lacunae, central pontine infarcts and strokes of different ages
Dyke–Davidoff–Masson syndrome	E.g., hemiatrophy of one hemisphere
Porencephaly	E.g., from trauma, infection, and perinatal ischemia
Miscellaneous causes	
– Previous infections	
– Long-standing multiple sclerosis	
– Extensive traumatic brain injury	
– Chronic use of steroids	
– Radiation injury	
– Intrathecal chemotherapy	
– Starvation, anorexia	
– Dehydration	

Dementia

Dementia is very common, and is the most disabling psychiatric disorder in the adult population. The incidence increases exponentially with age, from 0.5% at age 40 years up to 20% of the population aged 80 years and over. Over 80% of patients with dementia suffer from a small number of conditions, associated with characteristic types of pathology and different etiologies.

Etiology	% of dementia cases
Alzheimer's disease	45
Cerebrovascular disease	15
Cortical Lewy body disease	10
Head trauma	3
Parkinson's disease	3
Motor neuron disease	2
Other	5
AIDS dementia (prion disease)	> 1
Unknown	15

AIDS: acquired immune deficiency syndrome.

 Differential diagnosis

Degenerative disorders

Presenile dementia

- Alzheimer's disease
- Pick's disease
- Cortical Lewy body disease
- Prion disease
- Huntington's chorea

Senile dementia

Cerebrovascular disease

Multi-infarct dementia

A series of relatively large infarcts damaging a sufficient volume of brain results in dementia. Neuro-pathological calculations indicate that infarct volumes that total over 50 mL are often associated with dementia, and that a total infarct volume over 100 mL is always associated with dementia. Vascular dementia may coexist with Alzheimer's disease in 20% of cases, and smaller volumes of infarct could therefore contribute significantly to the dementia symptoms

Cerebral embolism

Cerebral hemorrhage

Subarachnoid hemorrhage

Disseminated lupus erythematosus

Transient ischemic attacks

Head injury

Acute head injury

Subdural hematoma

Posttraumatic dementia

Hypoxia

Post-cardiac arrest

- Heart failure
- Myocardial infarction

Respiratory disorders

Carbon monoxide poisoning

Intracranial tumors

Infections

Intracranial

- Encephalitis
- Meningitis
- Meningoencephalitis E.g., general paresis
- AIDS dementia

General

E.g., Urinary tract, bronchopneumonia, topical infection

Epilepsy

Toxic disorders

Drugs

E.g., Alcohol, barbiturates, opiates, amphetamines, LSD, cocaine, tricyclic antidepressants, steroids, lithium, l-dopa, cycloserine, digoxin, MAOIs, cycloserine, isoniazid

Heavy metals

E.g., Lead, mercury, manganese

Metabolic disorders

Acute

- Electrolyte disturbance
- Uremia
- Hepatic encephalopathy
- Hypoglycemia
- Porphyria
- Endocrine diseases E.g., thyrotoxicosis, diabetes mellitus, Addison's disease, parathyroid disorder, hypopituitarism
- Vitamin deficiencies E.g., thiamine, B₁₂, nicotinic acid

Chronic

- Chronic alcoholic dementia
- Heavy metals
- Myxedema, hypoglycemia, hypopituitarism
- Vitamin deficiency E.g., thiamine—Korsakoff's psychosis; nicotinic acid—pellagra; vitamin B₁₂ and folic acid

Other disorders affecting the CNS

Multiple sclerosis

Parkinson's disease

Normal pressure hydrocephalus

AIDS: acquired immune deficiency syndrome; CNS: central nervous system; LSD: lysergic acid diethylamide; MAOI: monoamine oxidase inhibitor.

Cerebrovascular Disease

Cerebral Infarction in Young Adults

Cerebrovascular atherosclerosis

Thrombotic or embolic

Embolism

Cardiac source

- Valvular
 - Mitral stenosis, prosthetic valve, infective endocarditis, marantic endocarditis, Libman–Sacks endocarditis, mitral annulus calcification, mitral valve prolapse, calcific aortic stenosis
- Atrial fibrillation and sick sinus syndrome
- Acute myocardial infarction and/or left ventricular aneurysm
- Left atrial myxoma
- Cardiomyopathy

Paradoxical embolism or pulmonary source

- Pulmonary AVM
 - Including Osler–Weber–Rendu disease
- Atrial and ventricular septal defects with right-to-left shunt
- Patent foramen ovale with shunt
- Pulmonary vein thrombosis
- Pulmonary and mediastinal tumors

Other

- Aortic cholesterol embolism
- Transient embolic aortitis
- Emboli distal to unruptured aneurysm
- Fat embolism syndrome

Arteriopathy

Inflammatory

See also the vasculitis classification

- Takayasu's disease
- Allergic Churg–Strauss syndrome, granulomatous
- Specific infection Syphilis, mucormycosis, ophthalmic zoster, tuberculosis, malaria
- Nonspecific infection Severe tonsillitis or lymphadenitis
- Associated with drug use E.g., amphetamine, cocaine, phenylpropanolamine
- Associated with systemic disease Lupus, Wegener's granulomatosis, polyarteritis nodosa, rheumatoid arthritis, Sjögren's syndrome, scleroderma, Degos disease, Behçet's syndrome, acute rheumatic fever, inflammatory bowel disease

Noninflammatory

- Spontaneous dissection
- Posttherapeutic irradiation
- Fibromuscular hyperplasia
- Moyamoya disease and progressive arterial occlusion syndrome
- Congophilic (amyloid) angiopathy
- Thromboangiitis obliterans
- Familial Homocystinuria, Fabry's disease, pseudoxanthoma elasticum

Vasospasm associated with:

Migraine

Subarachnoid hemorrhage

Hypertensive encephalopathy

Cerebral arteriography

Hematological disease and coagulopathy

Hyperviscosity

- Polycythemia and myeloproliferative dysproteinemia Myeloma, Waldenström's macroglobulinemia, cryoglobulinemia

Coagulopathy

- Thrombotic thrombocytopenic purpura
- Chronic diffuse intravascular coagulation
- Paroxysmal nocturnal hemoglobinuria
- Oral contraceptive use, peripartum, pregnancy
- Thrombocythemia
- Sickle-cell and hemoglobin C disease
- Lupus anticoagulant
- Nephrotic syndrome
- C₂ complement deficiency (familial)
- Protein C deficiency (familial)

Controversial associations

- Platelet hyperaggregability
- Fibrinolytic insufficiency
- Increased factor VIII
- Antithrombin III deficiency
- Vitamin K and antifibrinolytic therapy
- Acute alcohol intoxication

Miscellaneous

Trauma	Direct, indirect, rotation, and extension injuries
Mechanical	Cervical rib, atlantoaxial subluxation
Related to systemic hypotension	
Iatrogenic	Perioperative and periprocedural, including air and foreign particle embolism
Cortical sinus or vein thrombosis	

From: Hart RG, Miller VT. Cerebral infarcts in young adults: a practical approach. Stroke 1983; 14: 110–4.

AVM: arteriovenous malformation.

Causes of Infarction in Young Adults

Cause	Total (%)
Cerebrovascular atherosclerosis	18
Cerebral embolism	31
– Previously known cardiac disease (23%)	
– Rheumatic heart disease	
– Valve prosthesis	
– Previously unrecognized source (8%)	
– Left atrial myxoma	
– Pulmonary arteriovenous malformation	
– Atrial septal defect	
– Occult mitral stenosis	
– Idiopathic cardiomyopathy	
Nonatherosclerotic cerebral vasculopathy (angiographic diagnosis)	10
– Spontaneous carotid dissection	
– Following neck irradiation	
– Idiopathic venous sinus thrombosis	
– Cerebral vasculitis	
– Vertebral artery injury secondary to neck turning	
Coagulopathy and systemic inflammation (serological diagnosis)	9
– SLE with/without lupus anticoagulant	
– Lupus anticoagulant without SLE	
– Homocystinuria	
– Systemic vasculitis	
– Coagulopathy with thrombocytopenia	
– Severe Crohn's disease	
Peripartum	5
Uncertain etiology	27
– Idiopathic (no association)	
– Migraine and oral contraceptive use	
– Associated with migraine only	
– Mitral valve prolapse	
– Associated with oral contraceptive use only	

From: Hart RG, Miller VT. Cerebral infarcts in young adults: a practical approach. *Stroke* 1983; 14: 110–4.

SLE: systemic lupus erythematosus.

Stroke Risk Factors

Age	Age is the most powerful single stroke risk factor. About 30% of strokes occur before the age of 65; 70% occur in those 65 and over. The risk of stroke approximately doubles for every decade of age over 55 years
Hypertension	The risk of stroke is related to the level of systolic hypertension. This applies to both sexes, all ages, and to the risk for hemorrhagic, atherothrombotic, and lacunar stroke. Interestingly, the risk of stroke at a given level of systolic hypertension is less with advancing age, so that it becomes a less powerful, although still important and treatable, risk factor in the elderly
Sex	Brain infarcts and stroke occur about 30% more frequently in men than women; the sex differential is even higher before age 65
Family history	A fivefold increase in the prevalence of stroke among monozygotic compared to dizygotic male twin pairs suggests a genetic predisposition to stroke. The 1913 Swedish birth cohort study demonstrated a threefold increase in the incidence of stroke in men whose mothers died of stroke, compared with men without such a maternal history. Family history also seems to play a role in stroke mortality among the upper middle-class Caucasian population in California
Diabetes mellitus	After other stroke risk factors have been controlled for, diabetes increases the risk of thromboembolic stroke by approximately twofold to threefold relative to persons without diabetes. Diabetes may predispose an individual to cerebral ischemia via acceleration of atherosclerosis of the large vessels, such as the coronary artery or carotid tree, or by local effects on the cerebral microcirculation
Cardiac disease	Individuals with heart disease of any type have more than twice the risk of stroke compared to those with normal cardiac function
– Coronary artery disease	Both a strong indicator of the presence of diffuse atherosclerotic vascular disease and a potential source of emboli from mural thrombi due to myocardial infarction
– Congestive heart failure, hypertensive heart disease	Associated with increased stroke

- Atrial fibrillation	Strongly associated with embolic stroke and atrial fibrillation due to rheumatic valvular disease; substantially increases the stroke risk by 17 times
- Other	Various other cardiac lesions have been associated with stroke, such as mitral valve prolapse, patent foramen ovale, atrial septal defect, atrial septal aneurysm, and atherosclerotic and thrombotic lesions of the ascending aorta
Carotid bruits	A carotid bruit does indicate an increased risk of a future stroke, although the risk is for stroke in general, and not for stroke specifically in the distribution of the artery with the bruit
Smoking	Several reports, including a meta-analysis of a number of studies, have shown that cigarette smoking clearly confers an increased risk for stroke in all ages and both sexes; that the degree of risk correlates with the number of cigarettes smoked; and that cessation of smoking reduces the risk, with the risk reverting to that of nonsmokers by five years after cessation
Increased hematocrit	Heightened viscosity causes stroke symptoms when hematocrit exceeds 55%. The major determinant of whole blood viscosity is the red blood cell content; plasma proteins, particularly fibrinogen, play a contributing role. When heightened viscosity results from polycythemia, hyperfibrinogenemia, or paraproteinemia, it usually causes generalized symptoms, such as headache, lethargy, tinnitus, and blurred vision. Focal cerebral infarction and retinal vein occlusion is much less common, and may follow platelet dysfunction due to thrombocytosis. Intracerebral and subarachnoid hemorrhages may occur occasionally
Elevated fibrinogen level and other clotting system abnormalities	An elevated fibrinogen level constitutes a risk factor for thrombotic stroke. Rare abnormalities of the blood clotting system have also been noted, such as antithrombin III deficiency, and deficiencies of protein C and protein S and are associated with venous thrombotic events
Hemoglobinopathy	
- Sickle-cell disease	Can cause ischemic or hemorrhagic infarction, intracerebral and subarachnoid hemorrhages, venous sinus and cortical vein thrombosis. The overall incidence of stroke in sickle-cell disease is 6–15%.
- Paroxysmal nocturnal hemoglobinuria	May result in cerebral venous thrombosis

Drug abuse	Drugs that have been associated with stroke include methamphetamines, norepinephrine, LSD, heroin, and cocaine. Amphetamines induce a necrotizing vasculitis that may result in diffuse petechial hemorrhages, or focal areas of ischemia and infarction. Heroin can produce an allergic vascular hypersensitivity leading to infarction. Subarachnoid hemorrhage and cerebral infarction have been reported after the use of cocaine
Hyperlipidemia	Although elevated cholesterol levels have been clearly related to coronary heart disease, their relation to stroke is less clear. Elevated cholesterol does appear to be a risk factor for carotid atherosclerosis, especially in males under 55 years. The significance of hypercholesterolemia declines with increasing age. Cholesterol below 160 is related to intracerebral hemorrhage or subarachnoid hemorrhage. There is no apparent relationship between cholesterol level and lacunar infarction
Oral contraceptives	Early high-estrogen oral contraceptives were reported to increase the risk of stroke in young women. Reducing the estrogen content has decreased this problem, but not eliminated it altogether. This risk factor is strongest in women over 35 years who are also smokers. The presumed mechanism is increased coagulation, due to estrogen stimulation of liver protein production, or rarely an autoimmune cause
Diet	
Alcohol consumption	There is an increased risk of cerebral infarction, and subarachnoid hemorrhage has been associated with alcohol abuse in young adults. Mechanisms by which ethanol can produce stroke include effects on blood pressure, platelets, plasma osmolality, hematocrit, and red blood cells. In addition, alcohol can induce myocardiopathy, arrhythmias, and changes in cerebral blood flow and autoregulation
Obesity	Measured using relative weight or the body mass index, obesity has consistently predicted subsequent strokes. Its association with stroke could be explained partly by the presence of hypertension and diabetes. A relative weight more than 30% above average was an independent contributor to a subsequent atherosclerotic brain infarction
Peripheral vascular disease	

Infection	Meningeal infection can result in cerebral infarction through the development of inflammatory changes in vessel walls. Meningovascular syphilis and mucormycosis can cause cerebral arteritis and infarction
Homocystinemia or homocystinuria (homozygous form)	Predisposes to cerebral arterial or venous thromboses. The estimated risk of stroke at a young age is 10–16%
Migraine	
Ethnic group	African-Americans have disproportionately higher rates of stroke than other groups
Geographic location	In the United States and most European countries, stroke is the third most frequent cause of death, after heart disease and cancer. Most often, strokes are caused by atherosclerotic changes rather than by hemorrhage. An exception is middle-aged black women, in whom hemorrhage tops the list. In Japan, stroke is the leading cause of death in adults, and hemorrhage is more common than atherosclerosis
Circadian and seasonal factors	The circadian variation of ischemic strokes, peaking between 10 a.m. and noon, has led to the hypothesis that diurnal changes in platelet function and fibrinolysis may be relevant to stroke. A relationship between seasonal climatic variation and ischemic stroke occurrence has been postulated. An increase in referrals for cerebral infarction was observed during the warmer months in Iowa. The mean ambient temperature showed a negative correlation with the incidence of cerebral infarction in Japan. Seasonal temperature variation has been correlated with a higher risk of cerebral infarction in 40–64-year-olds who are nonhypertensive, and in individuals with a serum cholesterol below 160 mg/dL

LSD: lysergic acid diethylamide.

Common Cardiac Disorders Associated with Cerebral Infarction

Cerebral embolism arising from the heart and leading to infarction may be the presenting symptom for previously unidentified cardiac disease. Most cerebral emboli, including those of cardiac origin, lodge in the branches of the middle cerebral artery; no more than 6.8% affect the anterior cerebral artery, and 10% of emboli occlude the vertebral or basilar arteries and their branches.

Arrhythmia

Chronic nonvalvular atrial fibrillation

This is recognized as a frequent cause of embolic cerebral ischemia, and is associated with some 15% of all ischemic strokes. Patients with nonvalvular atrial fibrillation (NVAf) have a fivefold risk of ischemic stroke compared with age-matched individuals, facing a 35% lifetime risk of ischemic stroke and a yearly stroke risk of 5%. NVAf with comorbid states can further increase the risk of embolic stroke. The risk of cerebral embolism in thyrotoxic NVAf averages 12% yearly, while associated congestive heart failure or coronary heart disease will increase the stroke risk slightly above the baseline. Other cardiac arrhythmias carry a higher stroke rate than NVAf, but are less common and do not pose the same challenge to population-based disease management. Patients with NVAf associated with rheumatic heart disease have a 17-fold increase in the risk of stroke compared with age-matched controls, but constitute no more than 25% of the entire population suffering from atrial fibrillation

- Associated with rheumatic fever
- Without rheumatic fever

Sick sinus syndrome

Prolonged Q–T intervals

Valvular defects

Mitral valve prolapse

A common disorder, observed in 6–8% of the general population; may be associated with embolic infarction involving the brain or the retina. The incidence of cerebral infarction associated with this disorder is low—approximately one in 6000 known cases

Prosthetic heart valves

Infection

The most common neurological complication of infective endocarditis is cerebral embolism, occurring in 17% of patients. Cerebral embolism is associated with a high mortality rate, causing death in 30 of 37 in one study; brain abscess was discovered in 4.09%, and mycotic aneurysm was detected in 1.8%

– Bacterial

- *Streptococcus viridans* (acute or subacute bacterial endocarditis). Typically seen in elderly individuals who have had rheumatic heart disease and are infected with *Streptococcus viridans*
- *Staphylococcus aureus*. Patients are more typically younger individuals, most frequently intravenous drug abusers, and this organism is more virulent

– Fungal

Thrombotic endocarditis

This is a clinical disorder consisting of aseptic cardiac valvular vegetations that may cause cerebral or systemic emboli. Abnormal coagulation profiles in cancer patients with cerebral ischemia should prompt consideration not only of embolic arterial occlusion observed in thrombotic endocarditis, but also of microvascular thrombosis associated with disseminated intravascular coagulation (DIC)

– Associated with chronic systemic illnesses

– Associated with mucin-secreting tumors (7.4%)

- Adenocarcinoma of the lung
- Gastrointestinal cancer
- Breast cancer
- Lymphoma
- Leukemia
- Miscellaneous solid tumors

Myxomatous degeneration

Caused by Libman–Sacks endocarditis

Abnormalities of the myocardial wall

Atrial myxoma

Mural thrombi

Associated with cardiac wall dyskinesia or aneurysm. Some 45% (range 17–83%) of lethal myocardial infarctions are associated with mural thrombi. These patients have an overall stroke rate of 4.7%

DIC: disseminated intravascular coagulation; NVAf: nonvalvular atrial fibrillation.

Transient Ischemic Attack

Incidence

Disorder	Incidence (%)
Postural hypotension	14.6
Seizure disorder	14.6
Syncope	13.1
Dizziness	11.4
Anxiety	11.4
Cardiac arrhythmia and myocardial infarction	7.3
Mental confusion	5.7
Migraine headache	4.0
Brain tumor	4.0
Visual disturbances	3.3
Miscellaneous conditions	10.6

Differential Diagnosis

The “three Bs.”

Brain

Brain tumor

Seizures

Subdural hematoma

Blood vessels

Atherosclerotic disease Extracranial, intracranial, aorta

Arteritides Giant-cell arteritis, CNS angiitis, polyarteritis nodosa, etc.

Migraine

Dissection

Fibromuscular dysplasia

Moyamoya disease

Hypercalcemia

Arterial kinking

Neck extension, rotation

Venous occlusive disease

Blood constituents

Erythrocyte disorders	Polycythemia vera, sickle-cell disease
Platelet dysfunction	Thrombocytosis
Protein abnormalities	Anticardiolipin/antiphospholipid antibodies, protein C and S deficiency, lupus anticoagulant
Emboli	Cardiogenic sources, infective endocarditis, atrial myxoma, mitral valve prolapse, lupus, paradoxical emboli, etc.

CNS: central nervous system.

Cervical Bruit

Internal carotid artery stenosis
External carotid artery stenosis
Internal carotid artery dissection
Internal carotid artery kink
Fibromuscular dysplasia
Subclavian or Innominate artery stenosis
Radiated cardiac murmur
High flow state

- Intracranial arteriovenous malformations
- Caroticocavernous fistula
- Hyperthyroidism

Venous hum

Cerebral Arteritis

Conditions associated with arteritis probably account for some portion of the approximately 25% of strokes that are of undetermined etiology.

Infection

Syphilis
AIDS
Lyme disease (borreliosis)
Tuberculous meningitis
Mycoplasma angiitis
Sarcoid

Drug abuse

Amphetamines
Heroin
LSD
Cocaine
Phenylephrine (Neo-Synephrine)

Diseases of altered immunity (including hypersensitive states)

Hodgkin's disease with CNS vasculitis
Non-Hodgkin's lymphoma with CNS vasculitis
Serum sickness

Systemic necrotizing vasculitides

Giant-cell arteritis
Polyarteritis nodosa
Takayasu's arteritis
Wegener's granulomatosis
Henoch-Schönlein purpura

Connective-tissue diseases

Sjögren's syndrome
Progressive systemic sclerosis
Polymyositis, dermatomyositis
Systemic lupus erythematosus
Rheumatoid disease
Behçet's syndrome
Cryoglobulinemia

AIDS: acquired immune deficiency syndrome; CNS: central nervous system; LSD: lysergic acid diethylamide.

Stroke

Determining whether a stroke is hemorrhagic or ischemic has important implications for the patient's prognosis and for decisions concerning surgery or anticoagulant treatment. The suddenness of onset and the focal neurological signs give these syndromes the popular term "stroke," and help to distinguish cerebrovascular disease from other neurological disorders. Hypertension, atherosclerosis, or other evidence of vascular disease are commonly present. The disappearance of symptoms within minutes or hours allows transient ischemic attacks (TIAs) to be distinguished from stroke.

Cerebral embolism	This is suggested by a sudden onset and a focal neurological deficit attributable to brain surface ischemia, e.g., pure aphasia, pure hemianopia
Cerebral thrombosis	A more complex and extensive neurological deficit suggests a thrombosis, particularly when the stroke has been preceded by transient ischemic attacks. When the deficits are of sudden onset, thrombus is clinically indistinguishable from embolus. The two mechanisms of thrombosis are difficult to distinguish on clinical grounds
Cerebral hemorrhage	The neurological symptoms have a characteristically smooth onset and evolution. However, if the syndrome advances within minutes, or is halted at an early stage with only minor signs, the clinical picture may then become indistinguishable from that of infarction
Trauma	Sudden onset also characterizes trauma, subsequent to which epidural and subdural hematomas may occur, possibly mimicking stroke. Although the trauma itself is sudden, the accumulation of the hematoma takes time: minutes or hours for epidural hemorrhage, and as long as week for subdural hemorrhage
Seizures	Seizures may be a sign of lobar hemorrhage. The immediate postictal deficit mimics that caused by major stroke. A small percentage of seizures develop months or years after a stroke. A proper history may help rule out a new stroke
Migraine	This represents a major source of difficulty in the diagnosis of TIA. Migraine affects young people and involves repeated attacks, with the patients experiencing classic visual migraine auras at other times. Symptoms include a pounding headache contralateral to the sensory or motor symptoms hours after the attack
Cerebral neoplasia	The focal cerebral disturbance evolves gradually over days or weeks, which is a longer period than stroke. CT in tumors demonstrates an enhancing mass, but in ischemic stroke, by contrast, the CT is often negative
Cerebral abscess	Clinical and CT findings similar to those of a brain tumor

- Metabolic disturbances In comatose patients, consideration should be given to other conditions causing focal neurological signs, which often remit when the cause is removed
- Metabolic glucose disturbances
 - Renal failure
 - Severe disturbances of electrolyte balance
 - Alcohol intoxication
 - Barbiturate intoxication

CT: computed tomography; TIA: transient ischemic attack.

Clinical Grading Scales in Subarachnoid Hemorrhage

Botterell scale	Grade
Conscious, with or without signs of bleeding in the subarachnoid space	I
Drowsy, without significant neurological deficit	II
Drowsy, with significant neurological deficit	III
Major neurological deficit, deteriorating, or older with preexisting cerebrovascular disease	IV
Moribund or near-moribund, failing vital centers, extensor rigidity	V

Hunt–Hess scale	Grade
Asymptomatic or mild headache	I
Moderate to severe headache, nuchal rigidity, may have oculomotor palsy	II
Confusion, drowsiness, or mild focal signs	III
Stupor or hemiparesis	IV
Coma, moribund appearance, and/or extensor posture	V

World Federation of Neurologic Surgeons (WFNS) scale	Grade
Glasgow Coma Scale score 15: – no headache or focal signs	I
Glasgow Coma Scale score 15: – headache, nuchal rigidity, no focal signs	II
Glasgow Coma Scale score 13–14: – may have headache, nuchal rigidity, no focal signs	III
Glasgow Coma Scale score 13–14: – may have headache, nuchal rigidity, or focal signs	IVa
Glasgow Coma Scale score 9–12: – may have headache, nuchal rigidity, or focal signs	IVb
Glasgow Coma Scale score 8 or less: – may have headaches, nuchal rigidity, or focal signs	V

Cooperative Aneurysm Study scale	Grade
Symptom-free	I
Mildly ill, alert and responsive, headache present	II
Moderately ill – Lethargic, headache, no focal signs – Alert, focal signs present	III
Severely ill – Stuporous, no focal signs – Drowsy, major focal signs present	IV

Cerebral Salt-Losing Syndrome and Syndrome of Inappropriate Secretion of Antidiuretic Hormone after Subarachnoid Hemorrhage

Clinical parameter	SIADH	Cerebral salt-losing syndrome
Blood pressure	Normal	Low or postural hypotension
Heart rate	Slow or normal	Resting or postural tachycardia

Clinical parameter	SIADH	Cerebral salt-losing syndrome
Blood volume	Normal or increased	Decreased
Hematocrit	Normal or low	Elevated
Hydration	Well hydrated	Dehydrated
Body weight	Normal or increased	Decreased
Glomerular filtration rate	Increased	Decreased
Blood urea nitrogen/creatinine	Normal or low	Normal or high
Urine volume	Normal or low	Normal or low
Urine concentration	High	High
Hyponatremia	Dilutional (false)	True
Hypo-osmolality	Dilutional (false)	True
Mean day of appearance	8 (range 3 – 15)	4 – 5 (range 2 – 10)
Treatment	Fluid restriction	Sodium and volume expansion

SIADH: syndrome of inappropriate secretion of antidiuretic hormone.

Syndrome of Inappropriate Secretion of Antidiuretic Hormone and Diabetes Insipidus

The syndrome of inappropriate secretion of antidiuretic hormone (SIADH) involves the release of antidiuretic hormone (ADH) at levels inappropriate for a low serum osmolality. Due to continued water ingestion, the elevated ADH results in water retention, hyponatremia, and hypo-osmolality. SIADH results from partial damage to the supraoptic and paraventricular nuclei or neighboring areas, or from production of ADH by tumor or inflammatory tissue outside the hypothalamus.

The laboratory criteria for the diagnosis of SIADH are as follows.

- Low serum sodium (< 135 mEq/L)
- Low serum osmolality (< 280 mOsm/Kg)
- Elevated urinary sodium level (25 mEq/L)
- Urine osmolality that is inappropriately high compared to the serum osmolality
- Absence of clinical evidence of volume depletion or diuretic use and normal thyroid, renal, and adrenal function. Symptoms of hyponatremia include confusion, muscle weakness, seizures, anorexia, nausea and vomiting, and stupor, when the serum sodium falls below 110 mEq/L

Diabetes insipidus involves a lack of free water due to a partial or complete deficiency in ADH. The clinical symptoms include polyuria (urine output greater than 300 mL/h or 500 mL/2 h), thirst, dehydration, hypovolemia, and polydipsia. Diabetes insipidus results from the destruction of at least 90% of the large neurons in the supraoptic and paraventricular nuclei. The lesion often involves the supraoptic and hypothalamic tract rather than the neuronal bodies themselves.

The laboratory criteria for the diagnosis of diabetes insipidus are as follows.

- Urine specific gravity of less than 1.005
- Urine osmolality between 50 and 150 mOsm/Kg
- Serum sodium greater than 150 mEq/L, unaccompanied by a corresponding fluid deficiency. Sodium levels reaching 170 mEq/L are accompanied by muscle cramping, tenderness and weakness, fever, anorexia, paranoia, and lethargy

Syndromes of Cerebral Ischemia

Occluded artery	Signs and symptoms
Common carotid artery	<ul style="list-style-type: none">– May be asymptomatic– Ipsilateral blindness
Middle cerebral artery	<ul style="list-style-type: none">– Contralateral hemiplegia (face and arm greater than leg)– Contralateral hemisensory deficit (face and arm greater than leg)– Homonymous hemianopsia– Horizontal gaze palsy– Language and cognitive deficits in the left hemisphere: aphasia (motor, sensory, global); apraxia (ideomotor and ideational); Gerstmann syndrome (agraphia, acalculia, left–right confusion, and finger agnosia)– Language and cognitive deficits in the right hemisphere: constructional/spatial defects (constructional apraxia, or apractognosia, dressing apraxia); agnosias (atopognosia, prosopagnosia, anosognosia, asomatognosia); left-sided unilateral neglect; amusia

Occluded artery	Signs and symptoms
Anterior cerebral artery	<ul style="list-style-type: none"> - Contralateral hemiparesis (distal leg more than arm) - Contralateral sensory loss (distal leg more than arm) - Urinary incontinence - Left-sided ideomotor apraxia or tactile anomia - Severe behavior disturbance (apathy or “abulia,” motor inertia, akinetic mutism, suck and grasp reflexes, and diffuse rigidity—“gegenhalten”) - Eye deviation toward side of infarction - Reduction in spontaneous speech, perseveration
Posterior cerebral artery	<ul style="list-style-type: none"> - Contralateral homonymous hemianopia or quadrantanopia - Memory disturbance with bilateral inferior temporal lobe involvement - Optokinetic nystagmus, visual perseveration (palinopsia), hallucinations in the blind field - There may be alexia (without aphasia or agraphia), and anomia for colors, in dominant hemisphere involvement - Cortical blindness, with patient not recognizing or admitting the loss of vision (Anton’s syndrome), with or without macular sparing, poor eye–hand coordination, metamorphopsia, and visual agnosia when cortical infarction is bilateral - Pure sensory stroke: may leave anesthesia dolorosa with “spontaneous pain,” in cortical and thalamic ischemia - Contralateral hemiballism and choreoathetosis in subthalamic nucleus involvement - Oculomotor palsy, internuclear ophthalmoplegia, loss of vertical gaze, convergence spasm, lid retraction (Collier’s sign), corectopia (eccentrically positioned pupils), and some times lethargy and coma with midbrain involvement
Anterior choroidal artery	<p>May cause varying combinations of:</p> <ul style="list-style-type: none"> - Contralateral hemiplegia - Sensory loss - Homonymous hemianopia (sometimes with a striking sparing of a beak-like zone horizontally)

Brain Stem Vascular Syndromes

Midbrain (Fig. 15 a)

Syndrome	Structures involved	Manifestations
Weber's syndrome	<ul style="list-style-type: none"> • Ventral midbrain • CN III corticospinal track 	<ul style="list-style-type: none"> • Ipsilateral CN III palsy, including parasympathetic paresis (i.e., dilated pupil) • Contralateral hemiplegia
Benedikt's syndrome	<ul style="list-style-type: none"> • Midbrain tegmentum • Red nucleus • CN III brachium conjunctivum 	<ul style="list-style-type: none"> • Ipsilateral CN III palsy, usually with a dilated pupil • Contralateral involuntary movements (intention tremor, hemichorea, or hemiathetosis)
Claude's syndrome	<ul style="list-style-type: none"> • Dorsal mesencephalic tegmentum • Dorsal red nucleus • Brachium conjunctivum • CN III 	<ul style="list-style-type: none"> • Ipsilateral CN III palsy, usually with a dilated pupil • Prominent cerebellar signs • Contralateral involuntary movements (nucleus ruber tremor, hemiataxia, and no hemiballismus)
Parinaud's syndrome	<ul style="list-style-type: none"> • Dorsal rostral midbrain • Pretectal area • Posterior commissure 	<ul style="list-style-type: none"> • Paralysis of conjugate upward (and occasionally downward) gaze • Pupillary abnormalities (dissociation of pupil response close to light) • Convergence – retraction nystagmus on upward gaze • Pathological lid retraction (Collier's sign) • Lid lag • Pseudo-abducens palsy

CN: cranial nerve.

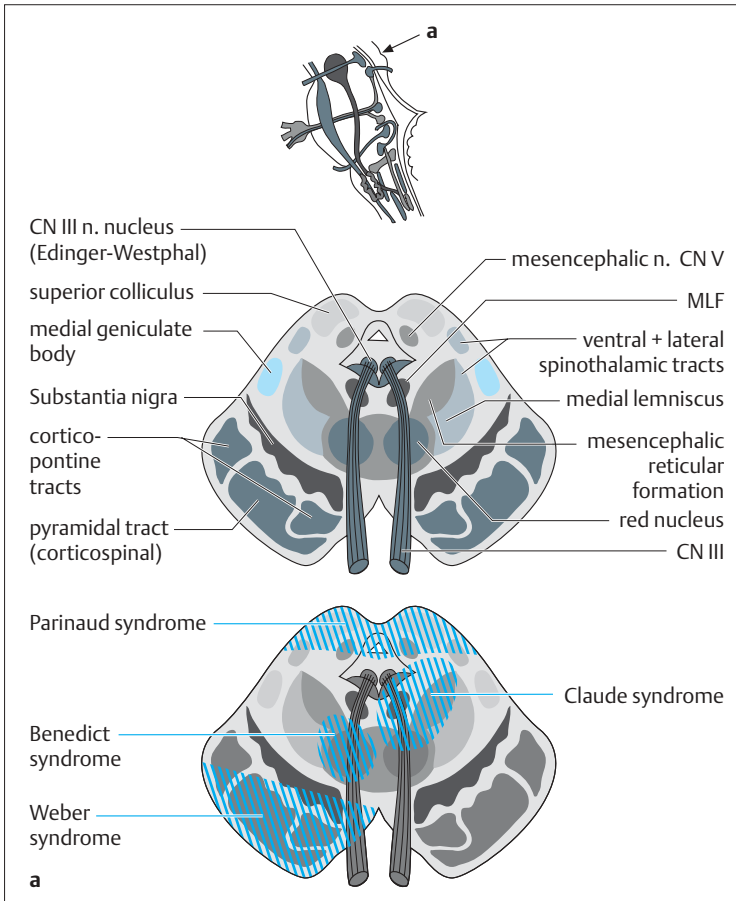


Fig. 15a

Fig. 15 Brain stem vascular syndromes:

a Midbrain (superior colliculus): Weber syndromes: a) corticospinal and corticopontine tracts (contralateral hemiplegia including the face); b) parasympathetic root fibres of CN III (ipsilateral oculomotor nerve paresis with fixed and dilated pupil); c) substantia nigra (Parkinsonian akinesia). **Benedict syndrome:** a) red nucleus (contralateral involuntary movements, including intention tremor, hemichorea, and hemiathetosis); b) brachium conjunctivum (ipsilateral ataxia); c) parasympathetic root fibres of CN III (ipsilateral oculomotor paresis with fixed and dilated pupil). **Claude syndrome:** a) dorsal red nucleus (contralateral involuntary movements, including intention tremor, hemichorea, and hemiathetosis); b)

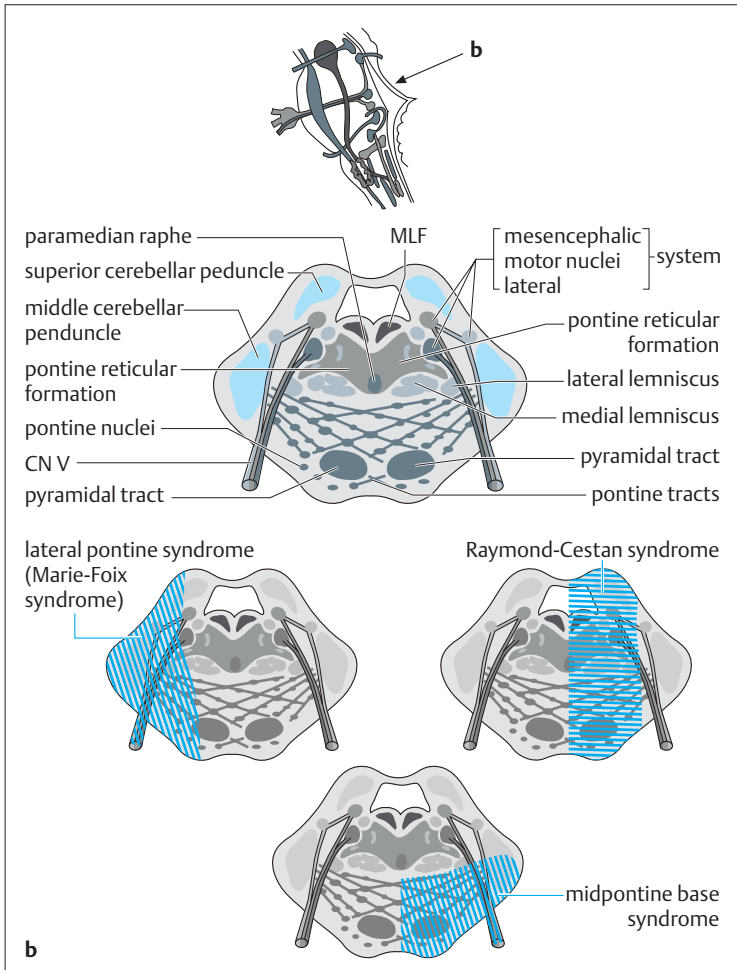


Fig. 15b

brachium conjunctivum (prominent cerebellar signs and no hemiballismus); c) dorsal midbrain tegmentum. **Parinaud syndrome:** a) superior colliculi (conjugated gaze paralysis upward); b) medial longitudinal fasciculus (nystagmus and internal ophthalmoplegia); c) eventual paresis of the CNs III and IV; d) cerebral aqueduct stenosis/obstruction (hydrocephalus). Involvement of the inferior colliculi produces hearing loss.

b Pons (rostral): Raymond-Cestan syndrome: a) superior cerebellar peduncle (cerebellar ataxia with a coarse “rubral” tremor); b) medial lemniscus and

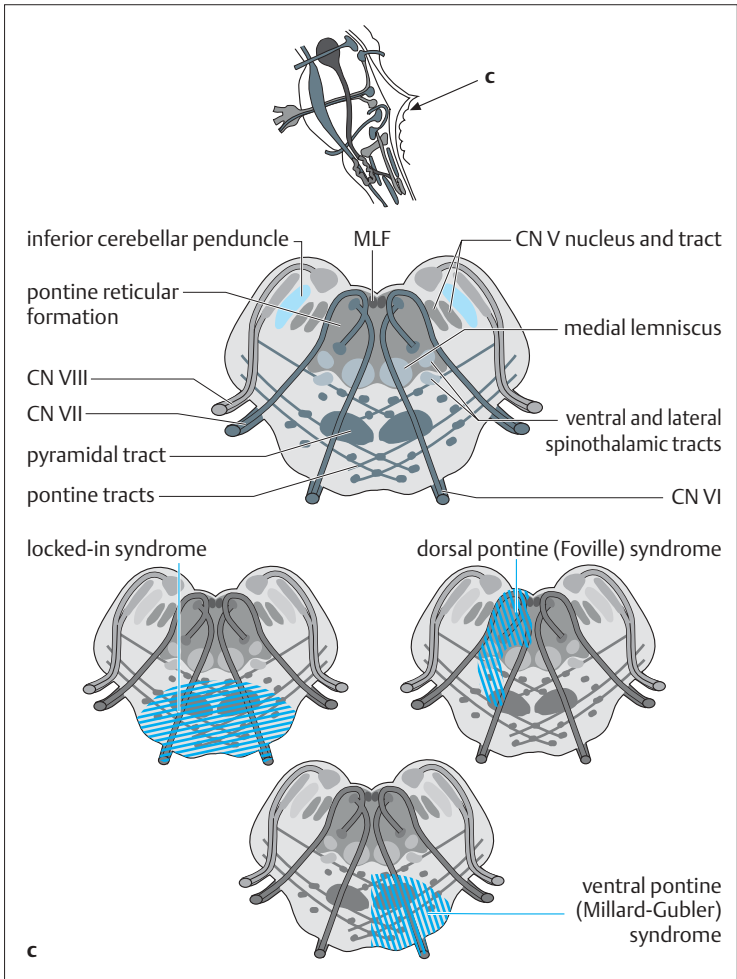


Fig. 15c

spinothalamic tract (contralateral decrease in all sensory modalities, involving face and extremities). Ventral extension of the lesion involves additionally; c) corticospinal tract (contralateral hemiparesis), d) paramedian pontine reticular formation (paralysis of the conjugate gaze towards the side of the lesion). **Marie-Foix syndrome:** a) superior and middle cerebellar peduncles (ipsilateral cerebellar ataxia); b) corticospinal tract (contralateral hemiparesis); c) spinothalamic tract (variable contralateral hemihyphesthesia for pain and temperature). **Midpon-**

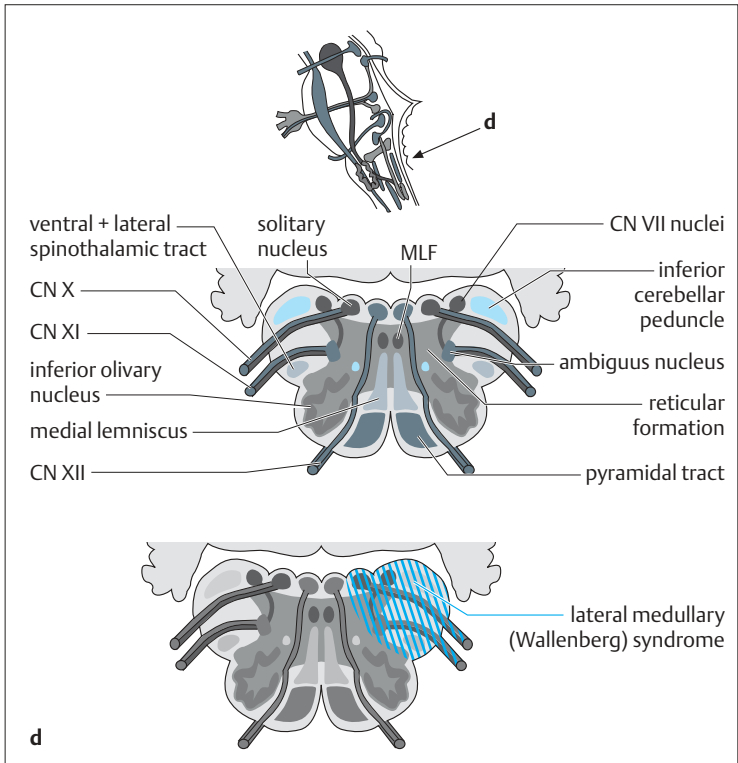


Fig. 15d

tine base syndrome: a) middle cerebellar peduncle (ipsilateral ataxia and asynergy); b) corticospinal tract (contralateral hemiparesis); c) corticopontine fibres (ipsilateral dystaxia); d) root fibres of CN V (ipsilateral hemianesthesia of all modalities and flaccid paralysis of chewing muscles).

c Pons (caudal): Foville syndrome: a) nucleus and fascicles of CN VII (ipsilateral peripheral type facial palsy), b) nucleus of CN VI (gaze is “away from” the lesion), c) corticospinal tract (contralateral hemiplegia with sparing of the face), d) paramedian pontine reticular formation. **Millard–Gubler syndrome:** a) pyramidal tract (contralateral hemiplegia sparing the face); b) CN VI (diplopia accentuated when the patient “looks towards” the lesion); c) CN VII (ipsilateral peripheral facial nerve paresis). **Locked-in syndrome:** a) bilateral corticospinal tracts in the basis pontis (tetraplegia); b) corticobulbar fibres of the lower CNs (aphonia); c) occasionally bilateral fascicles of the CN VI (impairment of horizontal eye movements).

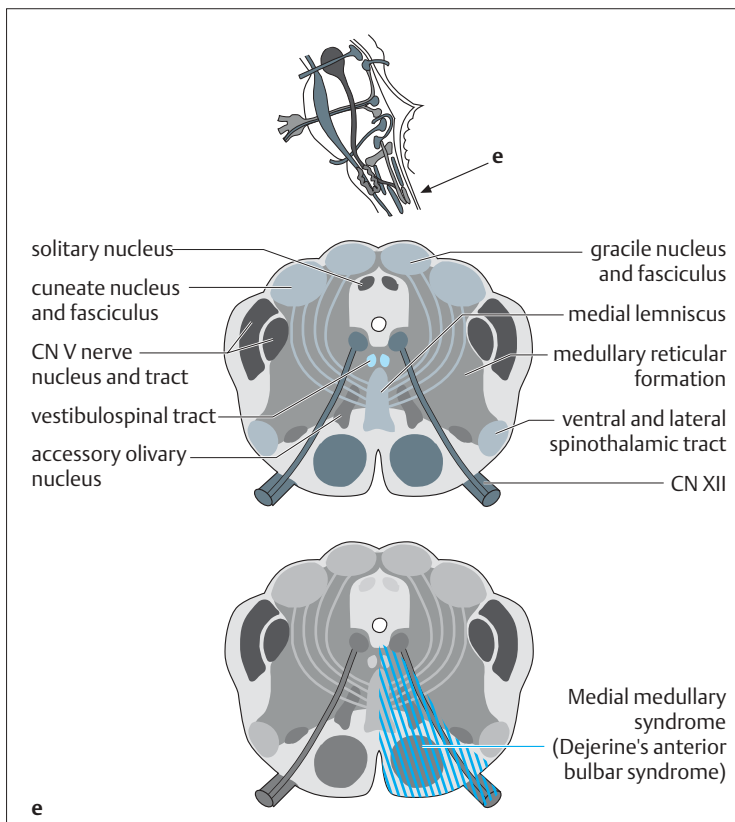


Fig. 15e

d Medulla (rostral): Lateral medullary (Wallenberg) syndrome: a) nucleus and tract of CN V (ipsilateral facial pain and hypalgesia and thermoanesthesia); b) spinothalamic tract (contralateral trunk and extremity hypalgesia and thermoanesthesia); c) nucleus ambiguus (ipsilateral palatal, pharyngeal, and vocal cord paralysis with dysphagia and dysarthria); d) vestibular nuclei (vertigo, nausea, and vomiting); e) descending sympathetic fibers (ipsilateral Horner's syndrome); f) inferior cerebellar peduncle and cerebellum (ipsilateral cerebellar signs and symptoms); g) medullary respiratory centers (hiccups); h) lower pons (diplopia).

e Medulla (caudal): Medial medullary (Dejerine) syndrome: a) CN XII (ipsilateral paresis atrophy, and fibrillation of the tongue); b) pyramidal tract (contralateral hemiplegia with sparing of the face); c) medial lemniscus (contralateral loss of position sense and vibration occasionally); d) medial longitudinal nystagmus (upbeat nystagmus).

Pons (Figs. 15 b and 15 c)

Syndrome	Structures involved	Manifestations
Millard–Gubler syndrome	<ul style="list-style-type: none"> • Ventral paramedian pons • CN VI and VII fascicles • Corticospinal tract 	<ul style="list-style-type: none"> • Contralateral hemiplegia (sparing the face) • Ipsilateral lateral rectus palsy with diplopia • Ipsilateral peripheral facial paresis
Dysarthria–clumsy hand syndrome	<ul style="list-style-type: none"> • Basis pontis (lacunar infarction) at junction of upper one-third and lower two-thirds of pons • CN VII 	<ul style="list-style-type: none"> • Clumsiness and paresis of the hand, ipsilateral hyperreflexia, and Babinski sign • Facial weakness • Severe dysarthria and dysphagia
<i>Differential diagnosis:</i> this syndrome has also been described with lesions in a) the genu of the internal capsule or b) with small deep cerebellar hemorrhages.		
Pure motor hemiparesis	<ul style="list-style-type: none"> • Lacunar infarction involving the corticospinal tracts in the basis pontis 	<ul style="list-style-type: none"> • Pure motor hemiplegia • With or without facial involvement
Ataxic hemiparesis	<ul style="list-style-type: none"> • Lacunar infarction involving the basis pontis at the junction of the upper third and lower two-thirds of the pons 	<ul style="list-style-type: none"> • Hemiparesis more severe in the lower extremity • Ipsilateral hemiataxia • Occasional dysarthria, nystagmus, and paresthesias
<i>Differential diagnosis:</i> this syndrome has also been described with lesions in a) the contralateral thalamocapsular area, b) the contralateral posterior limb of the internal capsule, and c) the contralateral red nucleus		
Locked-in syndrome (deafferentation)	<ul style="list-style-type: none"> • Bilateral ventral pontine lesions (infarction, tumor, hemorrhage, trauma, central pontine myelinolysis) 	<ul style="list-style-type: none"> • Tetraplegia due to bilateral corticospinal tract involvement • Aphonia due to involvement of the corticobulbar fibers destined for the lower cranial nerves • Occasionally, impairment of horizontal eye movements due to bilateral involvement of the fascicles of CN VI

Syndrome	Structures involved	Manifestations
Primary pontine hemorrhage syndromes	<ul style="list-style-type: none"> • Classic type (60%): severe pontine destruction • Hemipontine type (20%) • Dorsolateral tegmental type (20%) 	<ul style="list-style-type: none"> • Tetraparesis, coma, and death • Hemiparesis, skew deviation, dysarthria, unilateral absent corneal reflex, CN VII palsy, ipsilateral facial sensory changes, survival with functional recovery • Gaze paresis and/or ipsilateral CN VI palsy, unilateral CN VII palsy, contralateral extremity and ipsilateral facial sensory loss, dysarthria, preserved consciousness, motor sparing, occasional gait or limb ataxia
Foville's syndrome	<ul style="list-style-type: none"> • Dorsal pontine tegmentum in the caudal third of the pons, PPRF 	<ul style="list-style-type: none"> • Contralateral hemiplegia (with facial sparing) • Ipsilateral peripheral-type facial palsy (involvement of CN VII fascicles) • Gaze palsy to side of lesion
Raymond–Cestan syndrome	<ul style="list-style-type: none"> • Rostral lesions of the dorsal pons 	<ul style="list-style-type: none"> • Cerebellar signs (ataxia) • Contralateral reduction of all sensory modalities (face and extremities) • Contralateral hemiparesis • Paralysis of conjugate gaze in PPRF involvement
Marie–Foix syndrome	<ul style="list-style-type: none"> • Lateral pontine lesions (especially brachium pontis) 	<ul style="list-style-type: none"> • Ipsilateral cerebellar ataxia • Contralateral hemiparesis • Variable contralateral hemihypesthesia for pain and temperature

CN: cranial nerve; PPRF: paramedian pontine reticular formation.

Medulla (Figs. 15 d and 15 e)

Syndrome	Structures involved	Manifestations
Dejerine anterior bulbar syndrome	<ul style="list-style-type: none"> • Medial medulla oblongata (corticospinal tract, medial lemniscus, CN XII) 	<ul style="list-style-type: none"> • Ipsilateral paresis, atrophy (tongue deviates toward the lesion) • Contralateral hemiplegia with sparing of the face • Contralateral loss of position and vibratory sensation. Pain and temperature sensation are spared
Wallenberg's syndrome	<ul style="list-style-type: none"> • Lateral medulla • Inferior cerebellum (inferior cerebellar peduncle, descending sympathetic tract, spinothalamic tract, CN V nucleus) 	<ul style="list-style-type: none"> • Ipsilateral facial hypalgesia and thermoanesthesia • Contralateral trunk and extremity hypalgesia and thermoanesthesia • Ipsilateral palatal, pharyngeal, and vocal cord paralysis with dysphagia and dysarthria • Ipsilateral Horner's syndrome • Vertigo, nausea, and vomiting • Ipsilateral cerebellar signs and symptoms • Occasionally, hiccups and diplopia
Lateral pontomedullary syndrome	<ul style="list-style-type: none"> • Lateral medulla • Inferior cerebellum • Lower pons (to the region of exit of CNs VII and VIII) 	<ul style="list-style-type: none"> • All clinical findings seen in the lateral medullary syndrome • Ipsilateral facial weakness • Ipsilateral tinnitus and occasionally hearing disturbance

CN: cranial nerve.

Differentiation of the Various Types of Cerebral Ischemic Vascular Lesion

Ischemic vascular lesions		Clinical and radiological characteristics			
	Risk factors	Onset/cause	Anatomical characteristics	Associated signs	Imaging characteristics
Systemic hypoperfusion	Heart disease, trauma, GI bleeding, hypotension	Systemic disease present (cardiac arrest, bleeding)	Border zone regions between ACA, MCA, PCA and SCAs, PICA, AICA	Pallor, sweating, hypotension	Located in watershed CT: low density (dark) MRI: hypointensity (dark) in T1-weighted images and hyperintensity (white) in T2-weighted images
Embolism	Heart/coronary disease, peripheral vascular disease in white men, smoking hyperlipidemia	Sudden onset in 80% of cases during first 24 h; progressive in 20%	Middle cerebral artery region most frequently, followed by PCA or PICA distribution	Headache during and after the onset of cerebral embolism is prominent in 25% of cases	Superficial or deep wedge-shaped areas CT: low density (dark) MRI: hypointensity (dark) in T1-weighted images and hyperintensity (white) in T2-weighted images

Cont. ▲

Clinical and radiological characteristics

Ischemic vascular lesions

	Risk factors	Onset/cause	Anatomical characteristics	Associated signs	Imaging characteristics
Large artery thrombosis	Heart/coronary disease, peripheral vascular disease in white men, smoking hyperlipidemia	Fluctuating, progressive and remitting, manifested by a TIA in approx. 40% of cases	Middle cerebral artery region most frequently, followed by PCA or PICA distribution	Headache during and after the onset of cerebral embolism is prominent in 25% of patients	Located in watershed areas or center of arterial supply CT: low density (dark) MRI: hypointensity (dark) in T1-weighted images and hyperintensity (white) in T2-weighted images
Small artery thrombosis	Systemic hypertension, diabetes, polycythemia	Fluctuating, progressive and remitting, manifested by a TIA in approx. 25% of patients	Small perforating arteries of deep brain structures, basal ganglia, thalamus, pons, cerebellum, cerebral white matter	Usually none	Small, deep lesions (lacunar infarcts) CT: low density (dark) MRI: hypointensity (dark) in T1-weighted images and hyperintensity (white) in T2-weighted images

ACA: anterior cerebral artery; AICA: anterior inferior cerebellar artery; CT: computed tomography; GI: gastrointestinal; MCA: middle cerebral artery; MRI: magnetic resonance imaging; PCA: posterior cerebral artery; PICA: posterior inferior cerebellar artery; SCA: superior cerebellar artery; TIA: transient ischemic attack.

Predisposing Factors and Associated Disorders of Cerebral Veins and Sinuses Thrombosis

Primary idiopathic thrombosis

Secondary thrombosis

- Pregnancy
 - Postpartum
 - Head injury
 - Tumors
 - Meningioma
 - Metastatic neoplasia
 - Malnutrition and dehydration (marasmus in infancy)
 - Infection involving sinuses, mastoids, and leptomeninges
 - Hypercoagulable states and coagulopathies
 - Polycythemia
 - Sickle-cell anemia
 - Leukemia
 - Disseminated intravascular coagulation
 - Oral contraceptives
 - Inflammatory bowel disease
 - Nephrotic syndrome
 - Protein S and protein C deficiencies
 - Antithrombin III deficiency
 - Paraneoplastic syndromes
 - Cerebellar degeneration
 - Encephalomyelitis
 - Subacute necrotizing myelopathy
 - Peripheral polyneuropathy
 - Cerebrovascular disease
 - Neuromuscular junction
 - Chemotherapeutic agents (L-asparaginase)
 - Cyanotic congenital heart disease
-

Venous Thrombosis

Vessel involved	Structures involved	Clinical findings
Superior sagittal sinus	<ul style="list-style-type: none"> • Venous drainage from the hemispheres and medial cerebral cortex 	<ul style="list-style-type: none"> • New-onset headaches (simple or severe headaches that can be positionally aggravated) • Increased intracranial pressure <i>Extension of clot into the larger cerebral veins (as is common in septic thrombosis and in a high percentage in the nonseptic type) may cause the following:</i> <ul style="list-style-type: none"> • Convulsive seizures • Hemiplegia • Aphasia • Hemianopia • Lethargy or coma
Lateral sinus	<ul style="list-style-type: none"> • Venous drainage from the posterior fossa • Drainage from the confluence of sinuses (secondary to otitis media and mastoiditis) 	<ul style="list-style-type: none"> • Pain, especially behind the ear (coinciding with acute or chronic otitis or mastoiditis) • Increased intracranial pressure <i>Extension of infection into the veins draining the lateral surface of the hemisphere may cause the following:</i> <ul style="list-style-type: none"> • Jacksonian seizures • Hemiplegia • Gradenigo's syndrome • CNs IX, X, XI (jugular foramen distension) • Drowsiness and coma
<i>Differential diagnosis:</i> cerebral abscess		
Cavernous sinus	<ul style="list-style-type: none"> • CNs IV, V, and/or VI • Internal carotid artery, possibly ophthalmic artery (originates in suppurative processes of the orbit, nasal sinuses, upper half of face) 	<ul style="list-style-type: none"> • Retro-orbital pain • Proptosis • Orbital congestion with edema and chemosis of the conjunctivae and eyelids • Ptosis • Facial sensory loss • Signs of carotid artery occlusion • Visual loss • Disks are swollen, with small hemorrhages

Differential diagnosis: a) orbital tumors in the region of the sphenoid; b) malignant exophthalmos; c) arteriovenous aneurysms

CN: cranial nerve.

Spontaneous Intracerebral Hemorrhage

Spontaneous intracerebral hemorrhage (ICH) accounts for approximately 10% of cases of stroke. Arterial hypertension is by far the most common cause of ICH; other causes are the intracranial aneurysms, vascular malformation, bleeding diathesis, cerebral amyloidosis, brain tumors, vasculitis, or drug abuse.

The clinical features of ICH depend on the location, size, direction of spread, and rate of development of the hematoma. The clinical presentation of lobar hemorrhages is often misinterpreted as a thromboembolic cerebral infarction. Posterior fossa spontaneous hemorrhages occur in 10% of patients with spontaneous hemorrhage, and may affect either the cerebellum or the pons. Differentiation of cerebellar or pontine hemorrhages often is not possible on clinical grounds, since they share the sudden presenting symptoms and often signs. An accurate diagnosis is achieved quickly by computed tomography and magnetic resonance imaging.

Structure involved	Clinical manifestations
Lobar hemorrhage	
Frontal lobe	<ul style="list-style-type: none"> - Abulia - Contralateral hemiparesis - Bifrontal headache (maximum ipsilateral) - Occasionally, mild gaze preference away from the hemiparesis
Parietal lobe	<ul style="list-style-type: none"> - Contralateral hemisensory loss - Neglect of the contralateral visual field - Headache (usually anterior temporal location) - Mild hemiparesis - Occasionally, hemianopia or anosognosia
Temporal lobe	<ul style="list-style-type: none"> - Wernicke's aphasia (dominant temporal lobe) - Conduction or global aphasia (dominant temporal-parietal lobe) - Variable degrees of visual field deficit - Headache around or anterior to ipsilateral ear - Occasionally, agitated delirium
Occipital lobe	<ul style="list-style-type: none"> - Ipsilateral orbital pain - Contralateral homonymous hemianopia

Structure involved	Clinical manifestations
Putaminal hemorrhage	<p>The putamen is the most common site of hypertensive ICH</p> <ul style="list-style-type: none"> – Hemiparesis or hemiplegia and, to a lesser degree, hemisensory deficit – Transient global aphasia with dominant hemispheric lesions – Agnosia or unilateral neglect with nondominant hemispheric lesions – Homonymous hemianopia – Contralateral gaze palsy: the patient looks toward the hematoma and away from the hemiplegia – Alloesthesia: a noxious stimulus on the side of the hemisensory disturbance is perceived at the corresponding area of the other (normal) side
Thalamic hemorrhage	
Findings	<ul style="list-style-type: none"> – Hemisensory deficit and, to a lesser degree, hemiparesis – Anomic aphasia with impaired comprehension, with lesions of the dominant thalamus – Convergence – retraction nystagmoid movements, impairment of vertical gaze, and pupillary near-light dissociation – Downward – inward deviation of the eyes – Unilateral or bilateral pseudo-sixth nerve paresis – Skew deviation – Conjugate gaze palsy to the side of the lesion (wrong side) or conjugate horizontal gaze deviation
Cerebellar hemorrhage	
Symptoms	<p>Most common in the area of the dentate nucleus</p> <ul style="list-style-type: none"> – Sudden occipital headache – Nausea and repeated vomiting – Dizziness, vertigo – Inability to stand
Findings	<ul style="list-style-type: none"> – Variable degrees of alertness – Small reactive pupils – Skew deviation – Ipsilateral gaze palsy – Ocular bobbing and nystagmus toward the gaze; paresis – Ipsilateral peripheral facial weakness – Ipsilateral absence or decrease of corneal reflex – Slurred speech – Gait or truncal ataxia – Bilateral hyperreflexia and Babinski signs

Structure involved	Clinical manifestations
Pontine hemorrhage	
Symptoms	<ul style="list-style-type: none">- Headache, vomiting, vertigo, dysarthria- Sudden loss of consciousness, often progressing into deep coma
Findings	<ul style="list-style-type: none">- Sudden-onset coma- Quadriparesis, quadriplegia- Respiratory abnormalities- Hyperthermia- Pinpoint reactive pupils- Eyes fixed in a central position- Loss of brain stem reflexes, including the oculocephalic (doll's head) and the oculo-vestibular reflexes- Ocular bobbing

ICH: intracerebral hemorrhage.

Spinal Disorders

Failed Back Syndrome

The syndrome involves recurrent or residual low back pain after lumbar disk surgery; the incidence ranges from 5% to 40%.

Incorrect original diagnosis

Permanent nerve root injury from the original disk herniation Deafferentation pain, which is usually constant and burning

Residual or recurrent disk

Postoperative complications

– Immediate

- Permanent injury to the nerve roots from surgery (deafferentation pain, which is usually constant and burning, and is responsible for 6–16% of persistent symptoms in postoperative patients)

- Epidural hematoma

- Infection

- Postoperative swelling

– Late

- Pseudomeningocele, from a dural tear at the time of surgery. *Differential diagnosis* includes: a) postoperative serous fluid collections, b) infected collections

- Epidural fibrosis (scar or granulation tissue formation, causing compression and mechanical distortion of the nerve root)

- Arachnoiditis. Once very common after contrast myelography, particularly with the combination of hemorrhage from myelography/surgery and retained contrast material. *Differential diagnosis* includes: a) Intradural mass, b) CSF tumor spread, and c) spinal stenosis)

- Diskitis. Incidence after lumbar discectomy 0.2%; intractable back pain 1–4 weeks postoperatively after a period of symptomatic relief. *Differential diagnosis* includes: a) neoplasm, b) degenerative disease, and c) osteomyelitis

Insufficient root decompression by residual soft tissue or bone	Stenosis of exit foramen, residual soft tissue such as a synovial cyst
Surgery at the wrong level	
Disk herniation at another level	
Mechanical segmental instability	
Cauda equina tumor	
Lumbar spinal stenosis	Recurrence at the level of the previous operation many years later, secondary stenosis after surgery at the adjacent level or at the level fused in the midline
Causes of back pain unrelated to the original condition	Myofascial syndrome, paraspinal muscle spasm
Psychological factors	Secondary gains, drug addiction, poor motivation, psychological problems

CSF: cerebrospinal fluid.

Diffuse Thickening of the Nerve Root

Carcinomatous meningitis
 Lymphoma
 Leukemia
 Arachnoiditis
 Neurofibroma
 Toxic neuropathy
 Sarcoidosis
 Histiocytosis
 Vascular anomalies (i. e. spinal arteriovenous malformation)

Scar Versus Residual Disk

Magnetic resonance imaging (MRI) without intravenous contrast is at least as good as contrast computed tomography (CT) in distinguishing scar tissue from disk material, yielding an accuracy of 83%. The addition

of gadolinium diethylene-triamine-penta-acetic acid (Gd-DTPA) enhancement further increases the diagnostic accuracy from 89% to 96%. Overall sagittal and axial T1-weighted pre-Gd-DTPA and post-Gd-DTPA MRI remains the single most effective method of evaluating the post-operative lumbar spine patient.

The criteria of importance in evaluating scar tissue versus disk material in the postoperative patient, based on Gd-DTPA-enhanced MRI, can be summarized as follows.

- Scar tissue enhances immediately after injection, irrespective of the time since surgery (some scars continue to enhance for over 20 years)
- Disk material does not enhance immediately after injection
- A smoothly marginated, polypoid anterior epidural mass showing continuity with the parent disk space (except for free fragments) is disk material
- Scar tissue can have a mass effect and may be contiguous with the disk space
- Retraction of the thecal sac toward aberrant epidural soft tissue can be a helpful sign of scar tissue if it is present

N.b. The presence or absence of a mass effect should be a secondary consideration in comparison with the presence or absence of enhancement

Multiple Lumbar Spine Surgery (Failed Back Syndromes)

A history of failed lumbar spine surgery represents a diagnostic and therapeutic challenge for the physician. The first step is to distinguish between patients whose back or leg pain originates from a systemic cause (e.g., pancreatitis, diabetes, abdominal aneurysm) and those with a mechanical problem; a thorough medical evaluation should therefore be undertaken in this group at the same time as the neurosurgical evaluation is carried out.

Patients with profound emotional disturbances and instability (e.g., alcoholism, drug abuse, depression) and those involved with compensation and litigation should undergo a thorough psychiatric evaluation. Even if they are found to have a genuine neurosurgical problem, the psychosocial problem should be dealt with first, as additional low back surgery would otherwise fail again. After exclusion of the psychosocial group of patients, a smaller group of patients with back and/or leg pain due to mechanical instability or scar tissue remains; only those patients with mechanical instability will benefit from additional surgery.

Causes of Failed Back Syndromes

These affect 10–40% of patients after low back surgery. Recurrent or residual back or leg pain, or both, after lumbar disk surgery constitutes the “failed back syndrome” (excluding secondary gain, and other nonmedical causes).

Residual or recurrent disk
Epidural fibrosis, arachnoiditis
Spinal stenosis
Mechanical instability
Surgery at the wrong level
Thoracic, high lumbar disk herniation
Conus tumor
Postoperative complications (e.g. nerve root trauma, hematoma, infection)

Differential Diagnosis

Herniated intervertebral disk

Clinical assessment

- Original disk not removed This may occur if a disk fragment is left in the intervertebral disk space, or if the wrong disk level was removed. Patients will continue to have the preoperative leg pain, due to continued mechanical compression and inflammation of the same nerve root. Patients will wake up from surgery complaining of the same preoperative pain, and will continue without ever being pain free. Patients will benefit from repeat surgery
- Recurrent disk at the same level Patients will develop a sudden onset of leg pain identical to the preoperative pain, after a pain-free period of several months. An additional operation is indicated. In the case of recurrent disk at different level, patients will have a pain-free interval of more than six months, and suffer a sudden onset of leg and/or back pain. The neurological symptoms and the radiological findings, however, will be at a different level from the preoperative condition. Repeat surgery yields very good results

CT scan

- Without enhancement Recurrent disk material causes a nonspecific mass effect, has a density of more than 90 HU, may show a gas or calcium collection and nodularity, does not conform to the margins of the thecal sac, and tends to have sharp margins. The majority of the disk material is centered at the intervertebral disk space

- With intravenous contrast
Herniated disk material does not enhance early on after contrast administration. The disk material, however, enhances on the delayed CT scan images (e.g., 40 minutes after injection of the contrast material). Disks are typically seen as areas of decreased attenuation with a peripheral rim of enhancement, whereas epidural scar enhances homogeneously

MRI

Within six weeks of surgery, the site of the operation shows a large amount of tissue disruption and edema (producing a mass effect on the anterior thecal wall) that is heterogeneously isointense to muscle on T1-weighted images and increased on T2-weighted images. These disruptions heal within two to six months postoperatively. MRI may be used in the immediate postoperative period for a larger-scale view of the thecal SCA and epidural space, to exclude significant hemorrhage, pseudomeningocele, or disk space infection. Even using CT myelography, it is extremely difficult to distinguish between these entities on MRI, as they all appear as nonspecific extradural mass effects. Herniated disks show contiguity with the parent disk space (except for free fragments) and mass effect. Small protruding disks are low in signal intensity on T2-weighted images, whereas larger protruding, extruded, and free fragments can show a central high signal intensity on T2-weighted images. Recurrent herniations display a smooth polypoid configuration, with a hypointense rim outlining the high signal-intensity herniations, and this helps to distinguish the herniated material from the adjacent CSF on T2-weighted images

Fibrosis (scar tissue)

Six weeks to six months after lumbar spinal surgery, there is a gradual replacement of the immediate postoperative changes by posterior scar tissue. Fibrosis can be extradural (the most common type) and intradural (arachnoiditis). Patients with arachnoiditis have a history of multiple lumbar spine operations, with pain-free intervals ranging between one and six months. They usually complain of both back and leg pain in varying degrees, and the neurological evaluation is inconclusive.

The diagnosis of scar tissue versus disk is extremely important. Surgery is not indicated for scar (epidural fibrosis), but may be beneficial if the disk can be diagnosed as a cause of the radiculopathy

- Arachnoiditis
- Myelography The definitive studies for diagnosing arachnoiditis are: The myelographic findings of *mild* arachnoiditis are blunting of the caudal nerve root sleeves, segmental nerve root fusion, and small irregularities of the thecal sac margin. Multisegmental nerve root fusion, with root sleeve obliteration, intradural scarring, and loculation, is seen with *moderate* arachnoiditis. *Severe* adhesive arachnoiditis may cause a myelographic block
 - Postmyelography CT CT scanning reveals nodular or cord-like intradural masses with moderate disease. Sometimes the nerve roots are annealed against the dura, and the thecal SCA appears empty or featureless
 - MRI The MRI findings in arachnoiditis include intradural fibrosis, nerve root clumping, loculation and sacculation, root retraction, and adhesions
- Epidural scar tissue
- CT The best means of trying to identify epidural scar tissue are:
CT scan with and without enhancement (CT without contrast has been found correct 43% of the time, while CT with contrast was correct 74% of the time in differentiating between scar tissue and disk material)
 - Scar tissue causes retraction of the thecal sac to the surgical site, conforming to the thecal sac margin
 - Linear strand-like densities occur within scar tissue
 - The majority of the scar tissue is seen above or below the particular disk level
 - Scar tissue shows attenuation of 75 HU or less, and shows contrast enhancement
 - MRI with enhancement Precontrast and postcontrast MRI has a 96% accuracy in differentiating between scar tissue and disk material
 - Scar tissue enhances consistently immediately after injection on T1-weighted images. This enhancement occurs regardless of the time since surgery, even when surgery was over 20 years previously
 - Scar tissue may occasionally show a mass effect, and should not be used as a major discriminator between epidural fibrosis and disk material

Lumbar spinal stenosis Cauda equina compression from central spinal stenosis results in neurogenic claudication, with bilateral leg pain that begins after walking a short distance. The pain is not well localized, and often is more of a dysesthesia than true pain

Plain radiography	The interpediculate distance increases from T12 to L5. Interpediculate measurements of less than 16 mm at L4–5, or less than 20 mm at L5–1, and canal cross-sectional areas of less than 1.45 cm ² are considered abnormal
CT	CT scanning shows bony encroachment onto the neural elements, and is especially useful in evaluating the lateral recesses and foramina. A cross-sectional area of less than 100 mm ² is abnormal
MRI	Because soft tissue, such as the intervertebral disk and ligamentum flavum, contributes significantly to most cases of stenosis, MRI is useful. Sclerotic bone will have a low signal intensity on T1-weighted images and T2-weighted images, and is recognized by encroachment onto the epidural and foraminal fat. Osteophytes containing fatty marrow are recognized by their high signal intensity on T1-weighted images. Sagittal images are most useful in defining bony foraminal stenosis, or more generalized stenosis secondary to disk degeneration, with lost disk space height and rostrocaudal subluxation of the facets

Lumbar instability Instability of the lumbar spine causes pain on a mechanical basis in the multiple spine surgery patient. A coexisting spondylolisthesis, pseudoarthrosis, or an excessively wide bilateral laminectomy can cause spinal instability. These patients complain of back pain associated with activity (mechanical), and their physical examination may be negative. The diagnosis of lumbar spinal instability is based on plain radiographic features

Radiological elements	Point value
Destruction or loss of function of the anterior elements	2
Destruction or loss of function of the posterior elements	2
Radiographic criteria	4
Flexion–extension radiographs	
– Sagittal plane translation > 4.5 mm or 15%	2
– Sagittal plane rotation > 15° at L1–2, L2–3, and L3–4, > 20% at L4–5, > 25% at L5–S1	2
Cauda equina damage	3
Dangerous loading anticipated	1
<i>Instability is represented by a total score of 5 or more</i>	

CSF: cerebrospinal fluid; CT: computed tomography; HU: Hounsfield unit; MRI: magnetic resonance imaging; SCA: superior cerebellar artery.

Low Back Pain

In the vast majority of patients (over 80%), no specific pathoanatomical diagnosis can be made. Low back pain is the second most common reason for people to seek medical help; its prevalence ranges from 60–90%, and its incidence is approximately 5%. Only 1% develop nerve root symptoms, and only 1–3% of patients have lumbar disk herniation. Low back pain is only a symptom; it can result from several conditions, and the term should therefore not be equated with herniated lumbar disk.

Acute and Subacute Low Back Pain

Acute low back pain is self-limiting, and in the majority of patients, the condition improves within six weeks. Approximately 10% of patients will have persistent symptoms lasting more than six weeks, entering a subacute phase.

Trauma

Musculoligamentous sprain, lumbosacral strain

Myofascial syndrome

A localized pain complaint associated with a tense muscle containing a very tender spot, or trigger point, identifiable by palpation, which may be distant from the source of pain

Spondylolysis, spondylolisthesis

Overuse injuries secondary to repetitive, unrepaired microtrauma are frequent, particularly in athletes engaged in high-impact sports

Posttraumatic disk herniation

Postoperative

Infections

Immunocompromised and debilitated patients, drug abusers, diabetics, and alcoholics are at increased risk. Local spinal tenderness to percussion has an 80% sensitivity as a test for bacterial pyogenic infections, but a low specificity

Spondylitis and diskitis

– Pyogenic spondylitis

Staphylococcus aureus is the most common organism, accounting for 60% of infections. *Enterobacter* accounts for 30%; other organisms are *Escherichia coli*, *Salmonella*, *Pseudomonas aeruginosa*, and *Klebsiella pneumoniae*

– Granulomatous and miscellaneous forms of spondylitis	Granulomatous spondylitis: <i>Mycobacterium tuberculosis</i> most commonly involved; <i>Brucella melitensis</i>
– Fungal spondylitis	Blastomycosis, aspergillosis, actinomycosis, cryptococcosis, and coccidioidomycosis.
– Parasitic spondylitis	<i>Echinococcus</i>
Epidural and subdural abscesses	<i>Staphylococcus aureus</i> is by far the most common organism
Meningitis	Spinal meningitis can be caused by bacterial, fungal, parasitic, or viral organisms, often as a manifestation of cerebral meningitis
Myelitis	Viral infections such as herpesvirus, coxsackievirus, and poliovirus are the most common organisms, and HIV-related myelitis has recently been increasing
Spinal tumors	Patients aged over 50 with unexplained weight loss and relentless pain lasting over four or five months (ranging from three days to over three years) who do not respond to bed rest or other conservative treatment
Extradural spinal cord tumors (55%)	
– Metastatic (> 70%)	<ul style="list-style-type: none"> • Lung (most common in men) • Breast (most common in women) • Lymphoma • Prostate
– Primary spinal cord tumors (30%)	<ul style="list-style-type: none"> • Multiple myeloma (the most common bone tumor; 10–15%) • Osteogenic sarcoma (the second most common primary bone tumor in childhood and adolescence) • Chordoma • Chondrosarcoma • Ewing sarcoma • Giant-cell tumor • Benign bone tumors (osteoid osteoma, osteoblastoma)
Intradural spinal cord tumors (40%)	<ul style="list-style-type: none"> • Meningioma • Nerve sheath tumors • Vascular malformations and tumors • Epidermoid and dermoid cysts and teratomas • Lipoma
Intramedullary spinal cord tumors (5%)	<ul style="list-style-type: none"> • Ependymoma • Astrocytoma • Metastases (carcinoma of the lung or breast, lymphoma, colorectal cancer) • Hemangioblastomas • Lipomas • Schwannomas

Inflammatory

Sacroiliitis

An acute inflammatory disorder that may be seen early in ankylosing spondylitis. It causes morning back stiffness, hip pain and swelling, failure to obtain relief at rest, and improvement with exercise

Referred pain of visceral origin

Patients writhing in pain should be evaluated for an intra-abdominal or vascular pathology; e.g., in aortic dissection, the pain is described as a “tearing” pain, whereas patients with neurogenic low back pain tend to remain still, and only move at intervals to change position

Abdominal aortic aneurysm eroding the vertebrae

Occlusive vascular disease causing radicular or plexus ischemia

Direct involvement of lumbosacral plexus or sciatic nerve

E.g. trauma, tumors, injections into or close to the sciatic nerve

Pathological fracture

Patients at risk for osteoporosis or with known cancer

Lumbar compression fractures

Sacral insufficiency fractures

E.g., patients with rheumatoid arthritis receiving chronic steroid treatment

Chronic Low Back Pain

Of all patients with acute low back pain, 5% continue to have persistent symptoms, the condition becomes chronic after three months. These patients account for 85% of the costs associated with lost working days and sick pay.

All causes of acute and subacute low back pain, as listed above**Degenerative diseases**

Spondylosis, spondylolysis, and spondylolisthesis

“*Spondylosis*” refers to osteoarthritis involving the articular surfaces (joints and disks) of the spine, often with osteophyte formation and cord or root compression

“*Spondylolysis*” refers to a separation at the pars intervertebralis, which allows the vertebrae to slip
 “*Spondylolisthesis*” is defined as the anterior subluxation of the suprajacent vertebra, often producing central stenosis; it is a slipping of one vertebra forward on the one below

- Lumbar spinal stenosis Multiple nerve roots are involved, and the pain in the spine is significantly greater than that in the limb. Symptoms develop when standing or walking. Impairment in the bowel, bladder, or sexual function may occur
- Lateral recess syndrome Single or multiple nerve roots on one or both sides become compressed. Pain in the limb is usually equal to or greater than that in the spine. Symptoms are brought on by either walking or standing, and are relieved with sitting. Testing by straight leg raising may be negative
- Facet arthrosis and synovial cysts
- Lumbar disk disease (bulge herniation) Clinical features include positive straight leg raising and radicular pain in the limb disproportionate to that in the spine. Loss of strength, reflex, and sensation occurs in the territory of the affected root

Inflammatory disorders

- Vertebrae
 - Ankylosing spondylitis
 - Rheumatoid arthritis

- Meninges
 - Arachnoiditis

Metabolic

- Osteoporosis Particularly in postmenopausal women
- Paget’s disease Osteitis deformans
- Hyperparathyroidism
- Diabetic neuropathy
- Gout

Nonorganic causes

- Psychiatric causes
- Malingering or secondary gain E.g., financial, emotional
- Substance abuse

Thoracic Pain

Neurogenic

Thoracic disk herniation

Thoracic spinal tumor

– Extradural

- Metastatic neoplasms (66%)

Metastatic tumors are more common (66%) than primary spinal tumors (30%); the remaining 4% are prevertebral tumors invading the spinal canal. The frequency of skeletal metastases is much higher for some tumors: 84% for prostatic cancer and 74% of breast cancer

- Primary spinal tumors (30%)

- Multiple myeloma
- Osteogenic sarcoma
- Chordoma
- Chondrosarcoma
- Ewing's sarcoma
- Benign tumors and tumor-like conditions (e.g., exostosis, osteoid osteoma, fibrous dysplasia, aneurysmal bone cyst, hemangioma, etc.)

- Intradural, extramedullary

- Meningioma

Represent approximately 25% of primary spinal tumors; 90% of spinal meningiomas are purely intradural, and the remaining 7 – 10% may be extradural. Among the spinal meningiomas, 17% are in the cervical spine, 75 – 81% in the thoracic spine and 2 – 7% in the lumbar region

- Nerve sheath tumors

E.g., schwannoma, neurofibroma, neurinoma, neurilemoma, perineurofibroblastoma

- Spinal vascular malformations

E.g., dural or intradural arteriovenous malformations, cavernous angioma, capillary telangiectasia, venous malformation

- Spinal vascular tumors

E.g., hemangioblastomas

- Epidermoid and dermoid cysts and teratomas

- Spinal lipoma

- Leptomeningeal metastases

– Intramedullary spinal cord tumors

- Ependymoma

- Astrocytoma

- Intramedullary metastasis

Intramedullary lesions
(excluding spinal cord
tumors)

- Multiple sclerosis
- Amyotrophic lateral sclerosis
- Transverse myelitis
- Subacute combined degeneration
- Radiation myelopathy
- Syringomyelia
- Remote effects of cancer
- Paraneoplastic necrotizing myelopathy

Intercostal neuralgia

Herpes zoster

Postthoracotomy syndrome

Musculoskeletal

Muscular

- Strain
- Myofascial pain syndrome
- Polymyalgia rheumatica

Degenerative

- Spondylosis
- Spinal stenosis
- Herniated intervertebral disk
- Facet syndrome

Traumatic

- Vertebral fracture
- Postoperative

Infectious

- Diskitis
- Osteomyelitis
- Paraspinal and spinal abscess
- Meningitis

Neoplastic

Metabolic

- Osteoporosis with vertebral collapse
- Osteomalacia
- Paget's disease

Inflammatory

- Ankylosing spondylitis
- Rheumatoid arthritis
- Arachnoiditis

Deformity

- Scoliosis
- Kyphosis

Visceral referred pain

Heart	T1 – 5 roots; pain referred to chest and arm
Stomach	T5 – 9 roots; pain referred to manubrial xiphoid
Duodenum	T6 – 10 roots; pain referred to xiphoid to umbilicus
Pancreas	T7 – 9 roots; pain referred to upper abdomen or back
Gallbladder	T6 – 10 roots; pain referred to right upper abdomen
Appendix	T11 – L2 roots; pain referred to right lower quadrant
Kidney, glans penis	T9 – L2 roots; pain referred to costovertebral angle
Dissecting aortic aneurysm	T8 – L2; pain referred to costovertebral angle

Nonorganic causes

Psychiatric causes

Malingering

Substance abuse

Radiculopathy of the Lower Extremities

Congenital

- Meningeal or perineural cyst
- Conjoint nerve root

Acquired

- Lumbar spinal stenosis
- Spondylosis, spondylolysis, and spondylolisthesis
- Facet arthrosis and synovial cysts
- Lateral recess syndrome
- Hip joint disease and pelvic abnormalities

Infectious

- Diskitis
- Osteomyelitis
- Paraspinal and spinal abscess
- Herpes zoster
- Meningitis
- Lyme disease

Primary or metastatic tumors

E.g., intra-abdominal or pelvic

Vascular

Especially with iliofemoral occlusive vascular disease (related to exertion, and may be mimicked by intermittent claudication). N.b.: lumbar stenosis often produces numbness and weakness; vascular disease does not

Referred pain

- Visceral
- Retroperitoneal lesions

E.g., neoplastic and inflammatory, and vascular lesions in the chest, abdomen, and pelvis

Piriform syndrome

Since a portion of the sciatic nerve passes through or close to the piriform muscle, the nerve may become compressed and irritated when the muscle is in spasm

Peripheral neuropathies

Spinal mononeuropathies that can be confused with radiculopathies (e.g., diabetic neuropathy, sarcoid spinal mononeuropathy, paraneoplastic sensory neuropathy, combined system disease – vitamin B₁₂ deficiency, pharmaceutical and industrial toxin neuropathy, ischemic neuropathy)

Spinal Cord Lesions

Complete Transection (Fig. 16 m)

Most commonly, the spinal cord section is incomplete and irregular, and the neurological findings reflect the extent of the damage.

Causes include:

Traumatic spinal injuries

Tumor Metastatic carcinoma, lymphoma

Multiple sclerosis

Vascular disorders

Spinal epidural hematoma Secondary to anticoagulation therapy

Spinal abscess

Intervertebral disk herniation

Parainfectious or post-vaccinal syndromes

Neurological manifestations

Sensory disturbances

- Loss of all sensory modalities below the level of the lesion, e.g. pain, temperature, light touch, position sense, and vibration.
- Localized vertebral pain accentuated by vertebral palpation or percussion may occur with destructive lesions (e.g. infections and tumors), and may have some value for locating the lesion. Pain that is worse when recumbent and better when sitting or standing is common with spinal malignancies

Motor disturbances

- Paraplegia or tetraplegia Initially flaccid and areflexic, due to spinal shock; three to four weeks later, becomes hypertonic and hyperreflexic. Complete and lower spinal cord lesions result in flexion at the hip and the knee, whereas incomplete and high spinal cord lesions result in extension at the hip and knee

- Absent superficial abdominal and cremasteric reflexes

- Lower motor neuron signs at the level of lesion Paresis, atrophy, fasciculations, and areflexia

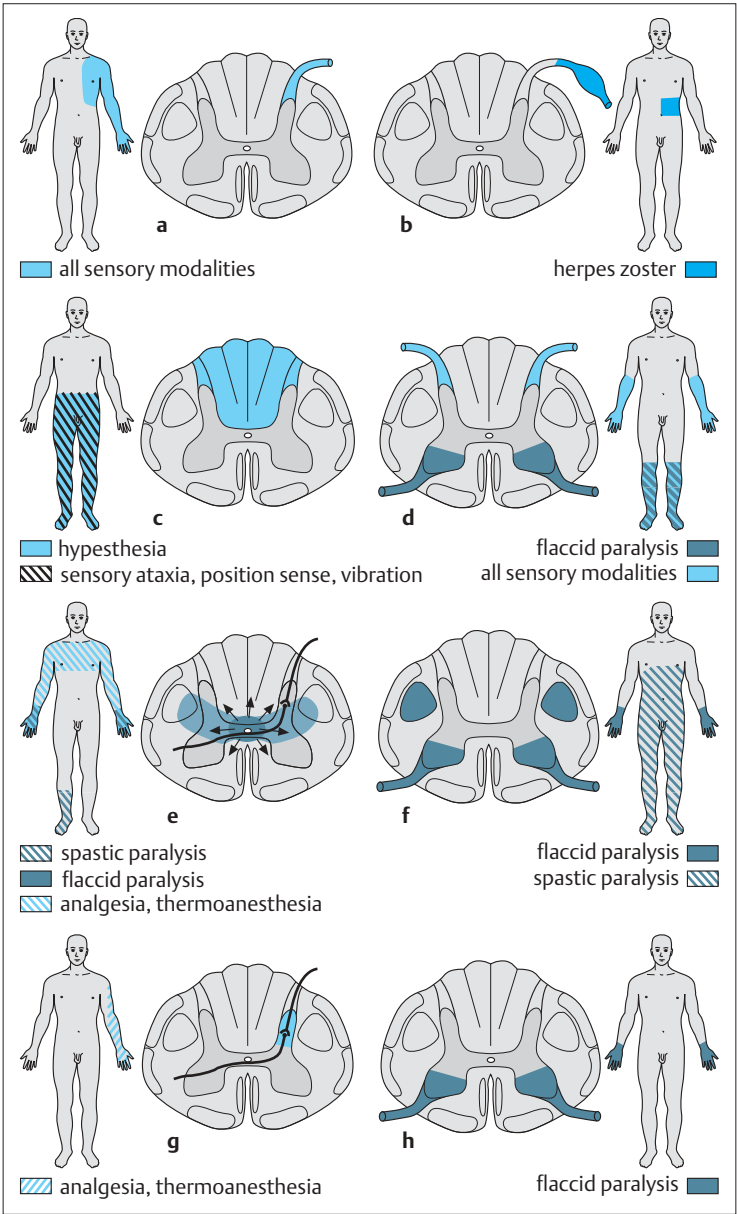


Fig. 16a–h
 Tsémetzis, Differential Diagnosis in Neurology and Neurosurgery © 2000 Thieme
 All rights reserved. Usage subject to terms and conditions of license.

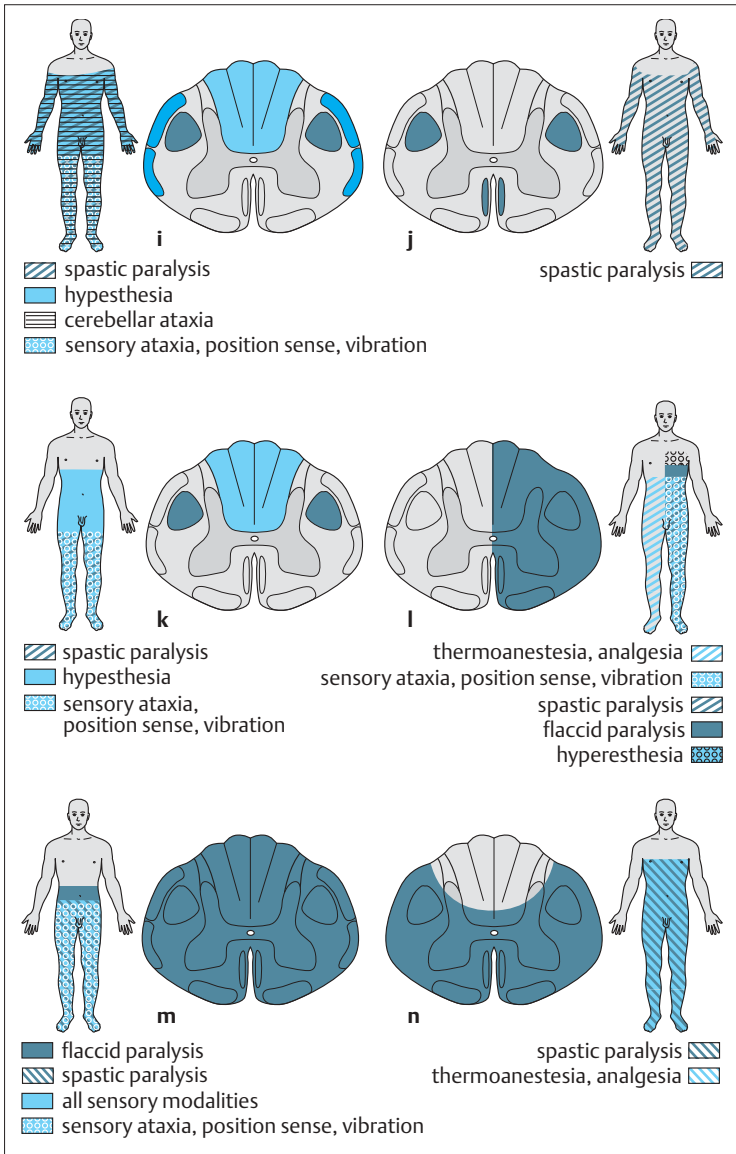


Fig. 16i–n

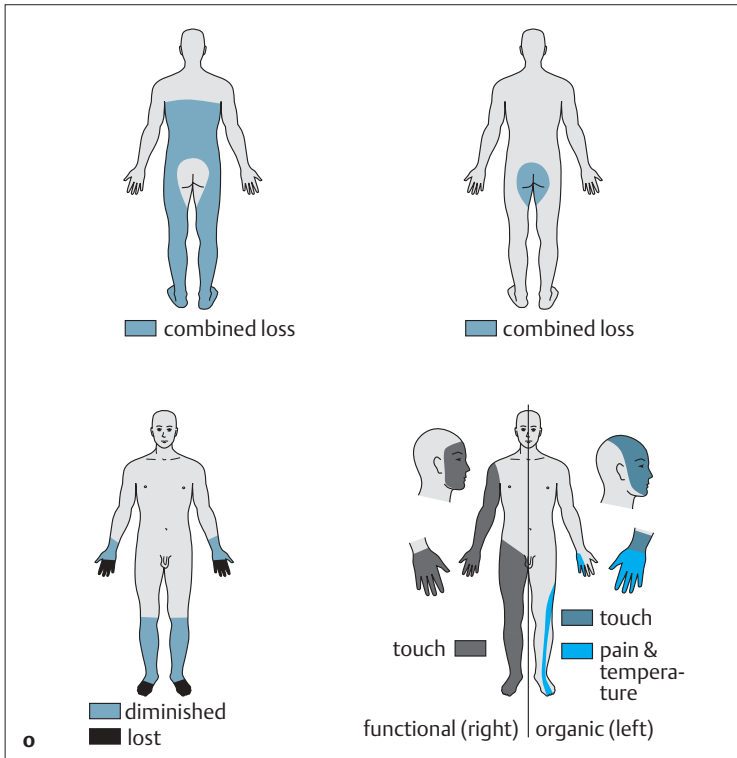


Fig. 16o

Fig. 16 Syndromes of spinal cord and peripheral nerves lesions:

a Syndrome of posterior roots (C4 – T6) lesion causes lancinating pain and abolition of all sensory modalities in the corresponding dermatomes. Interruption of the peripheral reflex arc leads additionally to hypotonia and hypo- or areflexia.

b Syndrome of the spinal ganglion (T6) following viral infections (Herpes zoster) is causing lancinating and annoying pain and paresthesias of the involved dermatomes.

c Syndrome of the posterior columns (T8) selectively damaged by tabes dorsalis (neurosyphilis) results in impaired vibration and position sense and decreased tactile localization. Also tactile and postural hallucinations (as if walking on cotton wool), temporal and spatial disturbance of the extremities sensory gait ataxia (worse in darkness or with eyes closed), and a Roberg’s sign. Patients often develop lancinating pains in the legs, urinary incontinence, and areflexia of the patellar and ankle stretch reflexes.

d Syndrome of the anterior and posterior roots and peripheral nerves (neuronal muscular dystrophy) causes abolition of all sensory modalities, and flaccid paraly-

sis in the corresponding dermatomes and myotomes. There is also areflexia, paresthesias, and occasionally pain. The peripheral nerves appear thickened and sensitive to touch.

e Syndrome of the central spinal cord (C4–T4), as in syringomyelia, hydromyelia, and intramedullary cord tumors, where the central cord damage spreads centrifugally to involve the surrounding spinal cord structures. Characteristically this results in bilateral “vest-like” thermoanesthesia and analgesia with preservation of soft touch sensation and proprioception (i. e., dissociation of sensory loss). Anterior extension with involvement of the anterior horns results in segmental neurogenic atrophy, paresis, and areflexia. Dorsal extension involves the dorsal columns causing ipsilateral position sense and vibration loss. Lateral extension causes ipsilateral Horner’s syndrome (C8–T2 lesions), kyphoscoliosis, and spastic paralysis below the level of damage. Ventrolateral extension affects the spinothalamic tract resulting in thermoanesthesia and analgesia below the spinal cord lesion with sacral sparing due to its lamination (cervical sensation medial, and sacral lateral).

f Syndrome of combined lesions in anterior horns and lateral pyramidal tract (amyotrophic lateral sclerosis or motor neuron disease) syndrome causes lower motor neuron signs (muscular atrophy, flaccid paresis, and fasciculation) superimposed on the symptoms and signs of upper motor neuron disease (spastic paresis and extensor plantar responses). If the nuclei of the medullary cranial nerves are involved, there will be explosive dysarthria dysphagia (bulbar or pseudobulbar paralysis).

g Syndrome of the posterior horns (C5–C8) causes ipsilateral segmental sensory loss, essentially of pain and temperature, but due to absence of damage to the spinothalamic tracts there is preservation of pain and temperature sensation below the level of damage. Spontaneous attacks of pain may develop in the analgesic area.

h Syndrome of the anterior horns (C7–C8) where the anterior horns are selectively involved in acute poliomyelitis and in progressive spinal muscular atrophies resulting in diffuse weakness, atrophy, and fasciculations in muscles of the extremities and the trunk, reduction of muscle tone and hypo- or areflexia of muscle stretch reflexes.

i Syndrome of combined lesions in posterior tracts, spinocerebellar tracts and eventually the pyramidal tracts (Friedreich’s ataxia). The disease commences with loss of position sense, discrimination, and stereognosis, leading to ataxia and Romberg’s sign. Pain and temperature sensations are involved to a lesser extent. Later, spastic paresis appears indicating degeneration of the pyramidal tracts.

j Syndrome of the corticospinal tracts (progressive spastic spinal paralysis) presents initially with heaviness of the legs, progressing to spastic paresis, spastic gait, and hyperreflexia. Spastic paresis of the arms develops later in the course of the disease.

k Syndrome of posterolateral column (T6) (subacute combined degeneration) due to selective damage from vitamin B 12 deficiency or vacuolar myelopathy of AIDS or extrinsic cord compression, resulting in paresthesias of the feet, loss of proprioception and vibration sense and sensory ataxia. Bilateral spasticity, hyperreflexia, and bilateral extensor toe signs. Hypo- or areflexia due to peripheral neuropathy.

l Syndrome of hemisection of the spinal cord (Brown-Séquard syndrome) is characteristically produced by extramedullary lesions and contralateral to the hemisection, ipsilateral loss of proprioception below the level of the lesion, ipsilateral spastic weakness and segmental lower motor neuron and sensory signs at the level of the lesion due to damage of the roots and anterior horn cells at this level.

m Syndrome of complete spinal cord transection (transverse myelitis) causes impairment of all sensory modalities (light touch, position sense, vibration, temperature, and pain) below the level of the lesion. Paraplegia or tetraplegia below the level of the lesion, initially flaccid and areflexic due to spinal shock but progressively hypertonic and hyperreflexic. Segmental lower motor neuron signs (paresis, atrophy, fasciculations, and areflexia). Urinary and anal sphincter dysfunction, sexual dysfunction, anhidrosis, skin changes, and vasomotor instability.

n The anterior spinal artery syndrome presents with an abrupt radicular girdle pain, loss of motor function (flaccid paraplegia), bilateral thermoanesthesia and analgesia, bladder and bowel dysfunction. Position sense, vibration, and light touch are intact.

o Characteristic sensory deficits found in various spinal cord lesions in comparison to peripheral neuropathy: (1) Advanced intraaxial lesion of thoracic cord at T3–T6 (sacral sparing). (2) Cauda equina lesion. (3) Stocking-glove pattern of sensory loss of an advanced stage of peripheral neuropathy. (4) Organic sensory loss follows an anatomic distribution on the left side of the face, upper and lower extremities. Functional facial anesthesia includes the angle of the mandible and may stop at the hair line; functional loss of upper extremity sensation usually cuts off transversely at the wrist, elbow, or shoulder; functional loss of lower extremity sensation cuts off at the inguinal line ventrally, or at a joint or the gluteal fold dorsally, or it may cut off transversely at any lower level.

Autonomic disturbances
below the level of the lesion

- Urinary and rectal sphincter dysfunction
 - Anhidrosis
 - Trophic skin changes
 - Temperature control impairment
 - Vasomotor instability
 - Sexual dysfunction
-

Hemisection (Brown-Séquard Syndrome) (Fig. 161)

The Brown-Séquard syndrome is characteristically produced by extramedullary lesions (e.g., metastases, meningioma, neurofibroma, spinal vascular malformation and vascular tumors, epidermoid and dermoid cysts).

Neurological manifestations

- Sensory disturbances
 - Loss of pain and temperature sensation contralateral to the lesion, usually one or two segments below the level of the lesion
 - Ipsilateral loss of proprioception, especially vibratory and position sense, whereas tactile sensation may be normal or minimally decreased
- Motor disturbances
 - Ipsilateral spastic weakness
 - Segmental lower motor neuron and sensory signs

Central Cord Syndrome (Fig. 16 e)**Caused by:**

Syringomyelia, hydro-myelia

Intramedullary cord lesions E.g. tumors, hematoma

Severe hyperextension neck injuries

Neurological manifestations

Dissociation of sensory loss Thermoanesthesia and analgesia in a “vest-like” bilateral distribution, with preservation of sacral sensation due to lamination of the spinothalamic tract (sacral sparing), light touch sensation, and proprioception

Segmental neurogenic atrophy, paresis, and areflexia

Ipsilateral Horner’s syndrome With C8 –T2 lesions

Spastic paralysis, kyphoscoliosis

Ipsilateral position sense and vibratory loss

Posterolateral Column Disease (Fig. 16k)

Caused by:

Subacute combined degeneration of the spinal cord	Due to vitamin B ₁₂ deficiency
Vacuolar myelopathy	Associated with AIDS
Extrinsic cord compression	E.g., cervical spondylosis

Neurological manifestations

Paresthesias of the feet

Dorsal column dysfunction

- Loss of proprioception and vibration sense

- Sensory ataxia

- Bilateral spasticity, hyperreflexia, and extensor toe signs
- In a case of superimposed neuropathy there may be hyporeflexia or areflexia

AIDS: acquired immune deficiency syndrome.

Posterior Column Disease (Fig. 16c)

The posterior columns are selectively damaged by tabes dorsalis neurosyphilis.

Neurological manifestations

Impaired vibration and position sense

Reduced tactile localization

Tactile and postural hallucinations

Temporal and spatial disturbances

Sensory ataxia (ataxic gait or “double tapping” is characteristic)

Lhermitte’s sign (when the lesion is at the level of the cervical cord)

Anterior Horn Cell Syndromes (Fig. 16h)

Examples of these are the spinal muscular atrophies (progressive spinal muscular atrophy in motor neuron disease, Werdnig–Hoffmann infantile spinal muscular atrophy), in which there is selective damage to the anterior horn cells of the spinal cord.

Neurological manifestations

Diffuse weakness, atrophy, and fasciculations in muscles of the trunk and extremities

Muscle tone is usually reduced

Absent or reduced muscle stretch reflexes

Combined Anterior Horn Cell and Pyramidal Tract Disease

(Fig. 16f)

An example of this is the syndrome of amyotrophic lateral sclerosis (motor neuron disease), in which there are selective degenerative changes in the anterior horn cells of the spinal cord and the brain stem motor nuclei, and in the corticospinal tracts.

Neurological manifestations

Mixed motor disturbances

- | | |
|--|--|
| <ul style="list-style-type: none"> - Diffuse lower motor neuron disease - Upper motor neuron dysfunction - Muscle stretch reflexes - Bulbar or pseudobulbar impairment | <p>All striated muscles may be affected, except the pelvic floor sphincter and external ocular muscles</p> <p>Progressive paresis, muscular atrophy, and fasciculations</p> <p>Paresis, spasticity, and extensor toe signs</p> <p>May be depressed, but are more often exaggerated</p> <p>Dysarthria, dysphagia, tongue spasticity, atrophy, or weakness</p> |
|--|--|

Sensory changes are absent

Vascular Syndromes (Fig. 16n)**Anterior spinal artery syndrome**

The artery supplies the anterior funiculi, anterior horns, base of the dorsal horns, periependymal area, and anteromedial aspects of the lateral funiculi. Spinal cord infarction often occurs in boundary zones or "watersheds," especially at the T1 – T4 segments and the L1 segment

Caused by:

- Aortic dissection
- Atherosclerosis of the aorta and its branches
- After surgery of the abdominal aorta
- Syphilitic arteritis
- After fracture dislocation of the spine

	<ul style="list-style-type: none"> - Vasculitis - Unknown (in a substantial number of patients)
Neurological manifestations	<ul style="list-style-type: none"> - Sudden radicular or “girdle” pain - Thermoanesthesia and analgesia bilaterally - Loss of motor function below the level of ischemia within minutes or hours (e.g., flaccid paraplegia) - Impaired bladder and bowel control
Posterior spinal artery syndrome	The artery supplies the dorsal columns. Infarction in this area of supply is uncommon
Neurological manifestations	<ul style="list-style-type: none"> - Loss of proprioception and vibration sense below the level of lesion - Loss of segmental reflexes

Cauda Equina Mass Lesions

Compression of the lumbar and sacral roots below the L3 vertebral level causes the cauda equina syndrome.

Characteristics of the cauda equina syndrome

- Early bilateral and asymmetrical radicular pain in the distribution of the lumbosacral roots, increased by the Valsalva maneuver
- Absence of the Achilles reflexes (S1 – 2 roots); the patellar reflexes (L2 – 4 roots) have a variable response
- Flaccid, hypotonic, areflexic paralysis affecting the gluteal muscles, posterior thigh muscles, and the anterolateral muscles of the leg and foot (true peripheral-type paraplegia)
- Late asymmetrical sensory loss in the saddle region, involving the anal, perineal, and genital regions and extending to the dorsal aspect of the thigh, the anterolateral area of the leg, and the outer aspect of the foot
- Late sphincter dysfunction; autonomous neurogenic bladder, constipation, impaired erection and ejaculation

Central disk herniation

A small central disk herniation can produce tension and deform the richly innervated posterior longitudinal ligament, with its pain fibers, causing marked low back pain. A larger central disk herniation results in neurological compression of the cauda equina

Tumors of the cauda equina

Ependymoma

Smooth or nodular rings of ependymal cells, surrounding and incorporating the nerves of the cauda equina

Epidermoid and dermoid tumors	Discrete tumor masses, which tend to occur along the cauda equina and may be bound to the surrounding nerve roots
Neurofibromas	Well-circumscribed lesions, initially involving a single nerve root until late in their courses
Meningioma	Very rarely occurs in the lumbar canal
Lipoma	
Metastatic disease of the bones	
Meningeal infiltration by various tumors	

Clinical Differentiation of Cauda Equina and Conus Medullaris Syndromes

Clinical symptom	Conus medullaris	Cauda equina
Spontaneous pain	<ul style="list-style-type: none"> • Uncommon • Relatively mild • Bilateral, symmetrical • Perineum and thighs 	<ul style="list-style-type: none"> • Prominent, early severe • Asymmetrical, radicular
Sensory findings	<ul style="list-style-type: none"> • Saddle distribution • Bilateral, symmetrical • Sensory dissociation (present) presents early 	<ul style="list-style-type: none"> • Saddle distribution • Asymmetrical • Sensory dissociation (absent) presents relatively late
Motor findings	<ul style="list-style-type: none"> • Symmetrical, mild, asymmetrical • Atrophy absent 	<ul style="list-style-type: none"> • Moderate to severe • Atrophy more prominent
Reflex changes	<ul style="list-style-type: none"> • Achilles reflex absent • Patellar reflex normal 	<ul style="list-style-type: none"> • Reflexes variably involved
Sphincter dysfunction	<ul style="list-style-type: none"> • Early, severe • Absent anal and bulbocavernosus reflex 	<ul style="list-style-type: none"> • Late, less severe • Reflex abnormalities less common
Sexual dysfunction	<ul style="list-style-type: none"> • Erection and ejaculation 	<ul style="list-style-type: none"> • Impaired less often

Adapted from: DeJong RN. The neurologic examination: incorporating the fundamentals of neuroanatomy and neurophysiology, 4th ed. Hagerstown, MD: Harper and Row, 1979.

Differential Diagnosis of Extramedullary and Intramedullary Spinal Cord Tumors

Symptom	Extramedullary tumors	Intramedullary tumors
Spontaneous pain	<ul style="list-style-type: none"> • Radicular or regional in type and distribution; an early and important symptom 	<ul style="list-style-type: none"> • Funicular; burning in type, poorly localized
Sensory changes	<ul style="list-style-type: none"> • Contralateral loss of pain and temperature; ipsilateral loss of proprioception (Brown-Sequard type) 	<ul style="list-style-type: none"> • Dissociation of sensation; spotty changes
Changes in pain and temperature sensations in the saddle area	<ul style="list-style-type: none"> • More marked than at level of lesion; sensory level may be located below site of lesion 	<ul style="list-style-type: none"> • Less marked than at level • Sensory loss can be suspended
Lower motor neuron involvement	<ul style="list-style-type: none"> • Segmental 	<ul style="list-style-type: none"> • Can be marked and widespread, with atrophy and fasciculations
Upper motor neuron	<ul style="list-style-type: none"> • Prominent paresis and hyperreflexia 	<ul style="list-style-type: none"> • Can be late and less prominent
Trophic changes	<ul style="list-style-type: none"> • Usually not marked 	<ul style="list-style-type: none"> • Can be marked
Spinal subarachnoid block and changes in spinal fluid	<ul style="list-style-type: none"> • Early and marked 	<ul style="list-style-type: none"> • Late and less marked

Adapted from: DeJong RN. The neurologic examination: incorporating the fundamentals of neuroanatomy and neurophysiology, 4th ed. Hagerstown, MD: Harper and Row, 1979.

Cervical Spondylotic Myelopathy

In its complete form, this condition is characterized by neck pain and brachialgia, with radicular motor sensory reflex signs in the upper extremities, in association with myelopathy. Similar clinical findings can be produced by other causes of spinal cord compression, such as those listed below.

Extradural spinal neoplasms Associated with a more rapid temporal clinical evolution than spondylosis. There is often a history of prior malignancy, and the radiological studies show findings of neoplasia

Metastatic neoplasms

- Lung 53% in men, 12% in women
- Breast 59% in women
- Lymphoma 20% in men, 9% in women
- Prostate 8% in men
- Kidney 12% in men, 6% in women
- Miscellaneous

Primary spinal tumors

- Multiple myeloma 10–15% of cases
- Osteogenic sarcoma
- Chordoma
- Chondrosarcoma
- Benign tumors and tumor-like conditions
 - Vertebral hemangiomas
 - Osteochondroma or exostosis
 - Giant-cell tumors
 - Aneurysmal bone cysts
 - Fibrous dysplasia
- Lipoma

Intradural and extramedullary tumors

Meningioma 25%

Nerve sheath tumors 29%

Vascular malformations and tumors

Epidermoid and dermoid cysts and teratomas 1–2%

Lipoma 0.5%

Intramedullary tumors

Ependymoma 13%, including those found in the filum terminale

Astrocytoma 10%. The most common among tumors arising within the spinal cord per se

Metastases

Chronic progressive radiation myelopathy

Syringomyelia	Most frequently occurs in younger age groups than is typical for cervical spondylosis
Noncompressive forms of myelopathy	
Multiple sclerosis	There is often a history, or findings on examination, of disease above the foramen magnum, such as optic neuritis, nystagmus, or internuclear ophthalmoplegia
Motor neuron disease, or amyotrophic lateral sclerosis	Produces motor disturbances without sensory findings, and eventually signs of lower motor neuron disease are seen in muscles above the foramen magnum. The CSF and spinal imaging studies are not revealing in amyotrophic lateral sclerosis
Subacute combined degeneration due to vitamin B ₁₂ deficiency	In contrast to spondylosis, signs of peripheral neuropathy are often present, and the loss of position sense in the lower extremities is more marked in this type of combined disease. Laboratory findings of vitamin B ₁₂ deficiency are usually diagnostic

CSF: cerebrospinal fluid.

Spinal Hematoma

Patients have local and/or radicular pain, neurological symptoms and signs of spinal cord or cauda equina dysfunction, and rapidly developing paraparesis or tetraparesis.

Herniated disk
 Neoplasm
 – Extradural
 – Intradural and extramedullary
 – Intramedullary
 Abscess
 Sequelae of trauma
 Intramedullary diseases
 – Acute and subacute transverse myelitis
 – Demyelinating disease
 Spinal cord infarction

Spinal Cord Compression

Nonneoplastic causes

Spondylosis

Intervertebral disk herniation

Spinal stenosis and neurogenic claudication

Paget's disease (osteitis deformans)

Osteoporosis

Syringomyelia

Arachnoid cysts

Pyogenic infections

Other infectious and inflammatory diseases

- Tuberculosis
- Fungal infections
- Parasitic disease
- Sarcoidosis
- Rheumatoid arthritis
- Ankylosing spondylitis

Spinal hemorrhage

Intramedullary, subarachnoid, subdural, and epidural

Neoplastic causes

Epidural tumors

- Metastatic

- Lung
- Breast
- Prostate
- Kidney
- Myeloma
- Lymphoma
- Gastrointestinal
- Miscellaneous
- Multiple myeloma
- Osteogenic sarcoma
- Chordoma
- Chondrosarcoma
- Ewing's sarcoma
- Fibrous histiocytoma
- Giant-cell tumor
- Benign tumors

- Primary spinal neoplasms

Intradural and extra-medullary tumors

- Meningioma
- Nerve sheath tumors
 - Schwannomas
 - Neurofibromas
- Vascular malformations and tumors
- Epidural and dermoid cysts and teratomas
- Lipoma

Intramedullary tumors

- Ependymoma
- Astrocytoma
- Intramedullary metastases

Leptomeningeal metastases

Noncompressive myelopathies simulating spinal cord compression

Transverse and ascending myelitis

- Postinfectious and postvaccination myelitis
- Multiple sclerosis
- Devic's disease (optic neuromyelitis)
- Acute necrotizing myelitis

Viral myelitis

- Acute anterior poliomyelitis
- Postpoliomyelitis syndrome
- Herpes zoster
- AIDS-related myelopathies

Spirochetal disease of the spinal cord

- Syphilis
- Lyme disease (*Borrelia burgdorferi*)

Toxic and deficiency myelopathies

- Myelopathy after aortography
- Myelopathy due to intrathecal agents
 - Penicillin, methylene blue, spinal anesthetics, intrathecal chemotherapy with methotrexate, cytosine, arabinoside, and thiotepa

- Spinal arachnoiditis
- Radiation myelopathy
- Electrical injuries

Metabolic and nutritional myelopathy

- Subacute combined degeneration of the cord Multiple nutritional deficiencies
- Nutritional myelopathy Nicotinic acid and several other vitamin deficiencies, as well as caloric malnutrition
- Myelopathy associated with liver disease

Spinal cord infarction

- Arterial infarction
- Venous infarction

Autoimmune diseases

- Sjögren's syndrome
- Systemic lupus erythematosus

Paraneoplastic myelopathy

Neuronal degeneration

- Spinocerebellar ataxia (Friedreich's ataxia)
- Hereditary motor neuron disease
- Charcot-Marie-Tooth disease
- Werdnig-Hoffmann disease

AIDS: acquired immune deficiency syndrome.

Epidural Spinal Cord Compression

Magnetic resonance imaging (MRI) and myelography may identify most spinal epidural illnesses causing myelopathy from spinal cord compression, such as intramedullary tumors, leptomeningeal metastases, radiation myelopathy, arteriovenous malformations, and epidural lipomatosis. Some epidural diseases, however, can be confused both clinically and radiologically with epidural spinal cord compression from systemic tumor, e.g. epidural hematoma, epidural abscess, herniated disk, and, rarely, extradural hematopoiesis.

Intradural and Extramedullary Tumors

Meningioma	25% of primary spinal tumors
Nerve sheath tumors	Among the most common primary spinal tumors, constituting 29% of all cases
Vascular malformations and tumors	
Epidermoid and dermoid tumors	
Teratomas	
Lipoma and epidural lipomatosis	
Drop metastasis from primary brain tumor	E.g. medulloblastoma

Intramedullary Tumors

Ependymoma	13% of primary spinal tumors
Astrocytoma	7% of primary spinal tumors
Intramedullary metastasis	

Leptomeningeal Metastases

The clinical findings consist of early multifocal cranial or spinal nerve dysfunction, symptoms or signs of meningeal irritation, and even changes in the cerebrospinal fluid (CSF), such as mild pleocytosis and high protein. Differentiating between leptomeningeal metastases and other parenchymal or epidural metastases requires the following.

- MRI with gadolinium enhancement of the brain and spine to reveal or exclude any mass lesions
- CSF cytology for malignant cells. The presence of malignant cells confirms the existence of a leptomeningeal tumor, despite any other findings the patient may have

CSF: cerebrospinal fluid; MRI: magnetic resonance imaging.

Radiation Myelopathy

Late or delayed radiation myelopathy takes three forms: progressive myelopathy, lower motor neuron syndrome, and spinal cord hemorrhage.

Progressive myelopathy

- 12–50 months after radiotherapy. Ascending paresthesias and weakness in one leg and a decrease in temperature and pain sensation in the other (Brown–Sequard syndrome) is the first clinical symptom in most patients. Some patients exhibit a transverse myelopathy, with both legs equally affected by weakness and sensory loss that rise to the level of the radiation portal
- CSF analysis is usually normal, but may show an increased protein level
- MRI. During the acute stage, MRI reveals spinal cord swelling, which may lead to a complete spinal block, and contrast enhancement of the area of damage. During the late stages, the spinal cord appears to be atrophic
- Motor conduction velocity in the spinal cord pathways is reduced

Lower motor neuron syndrome (after pelvic radiotherapy for testicular tumors)

- Subacute onset of a flaccid weakness of the legs affecting both proximal and distal muscles with atrophy, fasciculations, and areflexia. Sensory changes are absent, and sphincter function remains normal
- CSF analysis may show increased protein content
- The myelogram is normal
- The electromyogram reveals varying degrees of denervation
- Central conduction velocities are normal

Spinal cord hemorrhage (8–30 years after radiotherapy, and only in a few patients)

- Sudden back pain and leg weakness during a period of a few hours to a few days, in a patient without previous neurological symptoms. The pathogenesis is considered to be hemorrhage from telangiectasia caused by radiotherapy
- MRI reveals acute or subacute hemorrhage in the spinal cord, which may be atrophic, but no other lesions are found

CSF: cerebrospinal fluid; MRI: magnetic resonance imaging.

Transverse and Ascending Myelopathy

Postinfectious or parainfectious myelopathy, postvaccination myelopathy, multiple sclerosis, and acute and subacute necrotizing myelopathy are the most common causes of acute transverse and ascending myelopathy. Patients commonly present with sensory cord symptoms,

primarily from posterior column involvement, such as painful electric shock – like sensations, elicited by neck flexion or extension (Lhermitte’s sign), which involve the body below the neck. The pathogenesis of Lhermitte’s sign is thought to be reversible damage to myelin in the ascending sensory tracts of the spinal cord, causing axons to become abnormally sensitive to mechanical deformation.

The differential diagnosis of Lhermitte’s signs includes:

Spinal metastasis
Cervical spondylosis
Cervical disk herniation
Multiple sclerosis
Posttraumatic syndrome
Subacute combined degeneration
Cisplatin chemotherapy
Cervical radiation

Patients may also present with progressive weakness, sometimes with lower motor neuron signs including fasciculations, in association with sensory loss and autonomic dysfunction such as incontinence and postural hypotension.

-
- CSF analysis typically shows inflammatory changes
 - MRI usually shows a normal spinal cord on T1-weighted images, but hyperintensity can occasionally be identified on T2-weighted images; contrast enhancement may be observed
-

CSF: cerebrospinal fluid; MRI: magnetic resonance imaging.

Epidural Hematoma

Epidural spinal hematomas in cancer patients usually occur spontaneously, because of concurrent severe thrombocytopenia, and less often in systemic vasculitis, as in polyarteritis nodosa.

-
- Rapidly evolving symptoms and signs Acute back pain progressing to sensory and motor loss, within minutes to hours rather than days or weeks
 - CT and MRI
 - No evidence of vertebral involvement by tumor
 - The epidural block usually covers several segments, rather than the one or two segments characteristic of epidural spinal cord compression from other causes
 - The density characteristics of hemorrhage on MRI are different from those of epidural tumor (except for a hemorrhagic tumor)
-

CT: computed tomography; MRI: magnetic resonance imaging.

At times the diagnosis cannot be made without a biopsy. Thrombocytopenia is a contraindication to any surgical removal of the hematoma, which would confirm the diagnosis and provide a treatment for the illness.

Epidural Abscess

Differentiating between leptomeningeal metastases and central nervous system (CNS) infection, particularly in immunosuppressed patients and those with lymphomas, who are susceptible to both illnesses, can be very difficult and confusing. Patients with leptomeningeal metastases develop *early* signs of cranial and spinal nerve abnormalities, whereas patients with CNS infections tend to develop these signs *late*, if at all. The following guidelines can therefore be given.

-
- Signs of meningeal irritation associated with fever and abnormal CSF without neurological abnormalities suggest CNS infection
 - The characteristic appearance on plain radiographs of the spine, demonstrating two vertebral bodies across a disk space, is absent. This is a hallmark of infection, because it is rare for metastatic tumor to cross the disk space and involve two contiguous vertebral bodies
 - Cranial and spinal nerve dysfunction, without meningeal signs and with modest CSF changes, suggests tumor
 - To complicate the diagnosis further (although this is rare), epidural abscess can form at the site of a metastatic epidural tumor
 - Needle biopsy of the involved vertebra is necessary to confirm the diagnosis. Often, needle aspiration and drainage of the spinal abscess is used therapeutically
-

CNS: central nervous system; CSF: cerebrospinal fluid.

Herniated Disk

Cervical or lumbar disk herniation, and rarely thoracic disk herniation, produces local and radicular pain, occasionally associated with dermatomal sensory and motor loss.

Characteristically, the pain of a herniated disk is worse when the patient is sitting or walking, but relief is usually obtained when the patient lies down. Conversely, spinal cord epidural tumor is usually worse in the recumbent position than when sitting or standing. Magnetic resonance imaging with enhancement should establish the diagnosis of disk herniation, as well as identifying cases in which the disk herniation is caused by a vertebral body tumor.

Pediatric Intraspinal Cysts

Spinal Intradural Cysts

Neurenteric cysts

Intraspinal neurenteric cysts form a spectrum that merges with intraspinal teratomas and intraspinal dermoids and epidermoids. More than 60% of the cases are diagnosed in the first 20 years of life; 44% are located totally or partially in the cervical spinal canal, 37% are located in the thoracic spinal canal, and 19% in the lumbosacral spinal canal. The neurological signs and symptoms of a slowly progressing mass are associated by congenital anomalies, such as thickened or pigmented skin, a cutaneous dimple or dermal sinus, or a tuft of hair may occur in the midline of the back

Epidermoid and dermoid cysts

These account for 0.2–2% of primary spinal tumors in adults; in children, however, these cysts represent 3–13% of such spinal tumors, and within the first year of life the incidence is even higher, at 17%. At least 62% of dermoid cysts and 63% of epidermoid cysts occur at or below the thoracolumbar junction. Among intraspinal dermoids, 30% are wholly or partially intramedullary in location, and 28% of intraspinal epidermoids are wholly or partially intramedullary. With regard to associated defects, 25% of cases have posterior spina bifida, and 34% of dermoid cysts and 20% of epidermoid cysts occur in patients with a posterior dermal sinus tract. Eleven of 12 sinus tracts in

	the thoracic region terminated in intradural congenital tumor. Scoliosis may develop as the cyst enlarges in a child. CT and MRI have proved useful in the diagnostic work-up; there is a high signal on T1-weighted and T2-weighted images
Arachnoid cysts	These cysts consist of arachnoid, and are filled with CSF. The cysts are not associated with spinal dysraphism or any other congenital anomalies. They typically occur in the thoracic area, posterior to the spinal cord. They are initially asymptomatic, but when they enlarge in size they can cause back pain, usually relieved when the patient lies down, radicular pain, and paraparesis. Occasionally, kyphoscoliosis will develop as the cyst grows. On MRI, a focal impression of the cord can be seen, with an intensity similar to that of CSF without enhancement
– Developmental	
– Inflammatory	
– Posttraumatic	
Ependymal (neuro-epithelial) cysts	A thin wall consisting of connective tissue lined by a single layer of cells that resemble ependymal cells, similar to a neurenteric cyst. In contrast to the latter, however, the epithelium of the ependymal cells does not have a basement membrane or contain mucin. These cysts are located between C2 and L5, but nearly 45% are at the thoracolumbar junction, and most have intramedullary extensions
Other intramedullary cysts of the conus medullaris	A few intramedullary cysts occur within the conus, and have a thin, transparent wall cyst consisting of narrow bands of glial tissue lined by a layer of ependymal cells
Spinal cysticercosis	The average incidence of intraspinal forms is about 5–6%. The parasites grow in the subarachnoid spinal space, forming multiple cysts, rather than within the spinal cord, where the cysts are usually solitary. Myelography, CT, and MRI are the key diagnostic modalities. The specific diagnosis can be suspected if there is known disease elsewhere, or if there is either eosinophilia in the CSF or a positive complement fixation test for cysticercosis
Chronic spinal subdural hematomas	

CSF: cerebrospinal fluid; CT: computed tomography; MRI: magnetic resonance imaging.

Spinal Extradural Cysts

Congenital extradural spinal cysts	These cysts arise as an evagination or herniation of the arachnoid that gradually enlarges. Its neck eventually closes, creating a cyst that no longer communicates with the CSF space. The cysts are located exclusively or primarily in the thoracic spine in 86% of cases, and less frequently in the cervical region (2.5%) and lumbosacral region (11.5%). Nearly 40% of patients with congenital extradural spinal cysts have Scheuermann's disease (kyphosis dorsalis juvenilis) or preoperative dorsal kyphosis without definite vertebral epiphysitis
Spontaneous spinal nerve root diverticula and cysts (Tarlov cysts)	These cysts are extensions of the subarachnoid space along spinal nerve roots primarily located on the posterior spinal nerve roots and spinal ganglia, containing fluid that is either clear and colorless or faintly yellow. Occasionally, a perineural cyst can become large enough to cause a sciatic or cauda equina syndrome
Occult intrasacral meningoceles	These result from a defect in the embryological development of the spinal meninges in the sacral area, and become symptomatic in adult life, causing pain and urinary dysfunction—suggesting that it enlarges with time, probably due to the hydrostatic effect of the CSF
Posttraumatic or postoperative meningeal diverticula	After spinal fracture dislocation or nerve root avulsion, or after operative laminectomy, the CSF collects and stimulates the formation of a pseudomeningocele
Spinal ganglion cysts and spinal synovial cysts	Cysts arising from the periarticular tissue are distinguished from synovial cysts if they have a synovial lining, and from ganglion cysts if they have no specific lining. Most often, they occur in the posterolateral epidural space, attached to or adjacent to the facet joint at the L4–5 vertebral level, and they are primarily unilateral
Extradural spinal hydatidosis	In about 1–2.5% of patients with hydatid disease there are osseous lesions, and half of these involve the spine. They are located in the cervical spine (10%), thoracic spine (50%), lumbar spine (20%), and sacral spine (20%). Epidural involvement may grow sufficiently to cause neural compression. CT is good at demonstrating the initial involvement of spongy bone, and MRI appears to provide greater detail concerning neural involvement than CT

Spinal cysts associated with ankylosing spondylitis	Rarely, ankylosing spondylitis may be associated with multiple meningeal diverticula, extending into the posterior bony arches of the lumbar spinal canal
Ependymal cysts, neurenteric cysts, epidermoid and dermoid cysts	These are similar but less frequent than their intradural counterparts
Aneurysmal bone cyst	This benign pediatric vascular tumor occurs as a solitary lesion in a long bone or vertebra, especially in the lumbar area. The interior of the cyst is composed of blood-filled cavernous spaces with fibrous walls that contain osteoid and giant cells, and are covered by a thin bony shell. Pain involving the back or neck is an early symptom, and as the tumor enlarges into the spinal canal, symptoms of cord compression or radiculopathy may develop
Other spinal extradural cysts	A large midline mesothelial cyst extending from L5 to S3 with a translucent wall and filled with xanthochromic fluid, and also an intradiscal cyst postoperatively filled with straw-colored fluid, have been reported

CSF: cerebrospinal fluid; CT: computed tomography.

Myelopathy in Cancer Patients

Metastatic cancer

- Epidural
- Leptomeningeal
- Intramedullary

Toxicity from therapy

- Radiation myelopathy
- Myelopathy due to chemotherapy
- Infectious disease
- Vascular disease
- Paraneoplastic syndromes

Lumbar Disk Protrusion

Spinal stenosis	
– Congenital, developmental	Hypertrophic osteoarthritis
– acquired	
– Central lumbar canal stenosis	
– Lateral recess syndrome	
– “Claudication” syndrome of cauda equina	
Spondylolisthesis	Defects in the pars interarticularis and forward slipping of the vertebral body in relation to the vertebra below
Tumor	Primary or metastatic in bone
Infection	
– Acute	E.g., <i>Staphylococcus aureus</i>
– Chronic	E.g., tuberculosis
Paget’s disease	Osteitis deformans
Ankylosing spondylitis	
Pelvic lesions	<ul style="list-style-type: none"> – Lumbosacral plexus involved by abdominal or pelvic mass – Tumor invading the pelvis or sacrum – Hip joint osteoarthritis
Leg lesion	
– Vascular insufficiency	Intermittent claudication
– Peripheral nerve lesion	Tumor, neuropathy
– Local leg lesion	

Disorders of the Spinal Nerve Roots

Radicular pain in nerve root distribution E.g., brachialgia, “girdle” pain, sciatica. Pain is aggravated by: cough (increased intraspinal pressure); movement of that part of the spine; and stretching (e.g., straight leg raising L4, L5, S1; femoral stretch test L2, L3, L4)

Impaired conduction

- Motor Lower motor neuron type (e.g., weakness, tendon reflexes decreased or absent, flaccidity, fasciculations, and atrophy if existing for long enough)
- Sensory E.g., all modalities decreased or absent in dermatome; dermatomes often overlap, so that sensory loss may be subtle. The disorders may affect the spinal roots in the spinal canal or intervertebral foramen

Intrinsic lesions

- Herpes zoster
- Tabes dorsalis
- Inflammatory “radiculitis”

Compressive lesions

- Intervertebral disk protrusion
- Bony lesions
 - Spinal stenosis
 - Osteophytes
 - Metastatic carcinoma
 - Trauma
 - Rare (e.g., Paget’s disease)
- Tumors
 - Schwannoma, neurofibroma
 - Meningioma
 - Other
- Infections E.g., tuberculosis

Foot Drop

When there is paralysis of the dorsal extensor muscles of the foot and the toes (tibialis anterior, extensor digitorum longus, and extensor hallucis longus), which are innervated by the deep peroneal nerve, foot drop occurs. Because the tibialis anterior muscle is innervated from the L4 to S1 roots (especially L5 and to a lesser extent L4), through the sciatic and ultimately the deep peroneal nerves, a lesion in any of these can cause foot drop. The toe extensors are primarily innervated from L5, with some contribution from S1. The causes of foot drop are listed below.

Tsmentzis, Differential Diagnosis in Neurology and Neurosurgery © 2000 Thieme

All rights reserved. Usage subject to terms and conditions of license.

Peripheral causes

(more common)

Peroneal nerve injury

- Superficial peroneal nerve This supplies the peroneus longus and brevis muscles (L5, S1), weakness in which causes loss of foot eversion and plantar flexion, but *not* foot drop. The sensory changes are less helpful, since there is an overlap between the dermatomes; however, there is often sensory loss in the lateral aspect of the lower half of the leg and foot
- Deep peroneal nerve This supplies the tibialis anterior, extensor digitorum longus, extensor hallucis longus, peroneus tertius, extensor digitorum brevis, and the first dorsal interosseous muscles, weakness in which causes isolated foot drop. The sensory loss is minimal, affecting the great toe web space
- Common peroneal nerve This supplies all of the above muscles, except for the tibialis posterior (foot inversion). Damage to the common peroneal nerve causes foot drop, because it supplies all of the foot and toe extensors. The patient cannot dorsiflex the foot, and the toes will drag when the patient walks. There is a sensory loss in the lateral aspect of the lower half of the leg and foot. (The superficial position of the nerve accounts for a common cause of foot drop, the so-called “crossed knee palsy.” Painless foot drop is more likely to be due to peroneal neuropathy than to radiculopathy.)

L5 radiculopathy

Or less commonly, L4. This is most often caused by a herniated lumbar disk (L4–L5 disk space)

- Weakness affecting the peroneus, toe extensors, possibly anterior tibialis. The patient has trouble supporting weight on the heel, or there may be foot drop, with the patient describing the toes becoming caught on the carpet
- Pain and sensory loss over the anterolateral aspect of the affected leg below the knee and extending to the dorsum of the foot and toes, including the big toe
- Diminished or absent internal hamstring tendon reflex

Lumbosacral plexus neuropathy

- Idiopathic plexitis
- Diabetic plexus neuropathy Possibly secondary to vascular injury to nerves
- Vasculitis
- Trauma
- After radiation treatment

Peripheral neuropathy The most common inherited disorder is Charcot–Marie–Tooth syndrome, or peroneal muscular atrophy. Diabetes, alcohol, and Guillain–Barré syndrome account for 90% of cases

Central causes

Cortical lesion in the paracentral lobe of the motor strip Parasagittal meningioma, metastasis. Sensation may be spared

Spinal cord injury

Lumbar Root Syndrome Versus Hip Pain

	Lumbar root syndrome	Hip pain
History	<ul style="list-style-type: none"> • Sudden onset • Pain when sitting • Improvement with standing and walking 	<ul style="list-style-type: none"> • Gradual-onset pain when walking and/or standing • Improvement with sitting
Physical findings	<ul style="list-style-type: none"> • Free hip movements • Sciatic nerve test positive • Lumbar traction test positive 	<ul style="list-style-type: none"> • Restricted hip movement • Sciatic nerve test negative • Lumbar traction test negative
Diagnosis aided by	<ul style="list-style-type: none"> • CT scan • MRI • Myelography (obsolete) 	<ul style="list-style-type: none"> • Plain radiography • Intra-articular injection with a local anesthetic

CT: computed tomography; MRI: magnetic resonance imaging.

Sciatica

Vertebral causes

Intervertebral disk disease In most cases, sciatica is disk related and is caused by degenerative changes of the two lower lumbar motion segments

Spinal stenosis In many cases, caused indirectly by a disorder of the intervertebral disk

Spondylolisthesis	Is usually bilateral, and is little influenced by position changes and/or traction
Spondylitis	Nerve root irritation is bilateral, and not influenced by motion or traction. Night pain is characteristic
Vertebral tumors	Usually metastatic, and less often primary tumors. They cause severe sciatic symptoms, with a bilateral Lasègue's sign and severe intractable pain with segmental radiation
Paget's disease	Rare cause, producing spinal stenosis due to the new bone formation

Extravertebral causes

Hip disease	Severe degenerative or inflammatory joint disease is often mistaken for a lumbar root syndrome, since the two conditions occur frequently and pain radiation into hip and thigh often affects the same areas. Neurological deficits are often discrete or missing; Lasègue's sign and reverse Lasègue's sign are negative; a traction test with traction brace is negative in hip pathology, whereas disk-related pain diminishes with traction, and the patient is better able to bend forward. The diagnosis is confirmed by intra-articular injection of local anesthetic and by radiography
Sacroiliac disease	Inflammatory or degenerative diseases of the sacroiliac joints can cause symptoms similar to the proximal pain area of sciatica
Extravertebral retroperitoneal tumors	Originating from the rectum, uterus or prostate, may produce symptoms of displacement of the lumbosacral nerve plexus when they become large
Aneurysm of the common iliac artery	
Peripheral vascular disease	Patients usually complain of leg pain increased by walking
Sciatic neuropathic disease	
– Diabetic neuropathy	
– Alcoholic neuritis	
– Herpes zoster neuritis	
– Periarthritis nodosa	
– Neuritis caused by leprosy	
Sciatic nerve damage due to injection	There is a local circumscribed tender area at the site of injection, and applying pressure to it elicits projected pain. It also involves symptoms of autonomic nerve involvement, in contrast to lumbar nerve root syndromes

Juvenile Idiopathic Scoliosis

Juvenile idiopathic scoliosis is essentially a diagnosis of exclusion, so that a detailed medical history and physical examination, and a careful review of the radiographs will help yield the correct diagnosis.

Neurofibromatosis

Benign bone tumors E.g., osteoid osteoma

Malignant or benign
intraspinous tumors

Spinal infection

Connective-tissue disease E.g., Marfan's syndrome, Ehlers–Danlos syndrome

Chromosomal abnormalities E.g. Down's syndrome

Congenital scoliosis

Syringomyelia

Tethered cord syndrome

Metabolic bone disease E.g., rickets

Degenerative neurological conditions E.g., Friedreich's ataxia, primary muscle disease

Pediatric disk pathology

Cervicocephalic Syndrome Versus Migraine Versus Ménière's Disease

	Cervicocephalic syndrome	Migraine	Ménière's disease
Headaches	<ul style="list-style-type: none"> • Triggered by certain head positions • Affected by changes in head position • Short duration (position-dependent) 	<ul style="list-style-type: none"> • Spontaneous • Not affected by changes in head position • Pain persists for hours 	<ul style="list-style-type: none"> • Spontaneous • Not affected by changes in head position • Pain persists for hours
Nausea, vomiting	<ul style="list-style-type: none"> • None 	<ul style="list-style-type: none"> • Nausea and vomiting 	<ul style="list-style-type: none"> • Vomiting
Spinal movements	<ul style="list-style-type: none"> • Limitation of cervical spine motion • Cervical muscle spasm 	<ul style="list-style-type: none"> • Free motion 	<ul style="list-style-type: none"> • Not limited
Treatment	<ul style="list-style-type: none"> • Improvement with cervical traction, cervical collar 	<ul style="list-style-type: none"> • Improvement with ergotamine alkaloids 	<ul style="list-style-type: none"> • Improvement with 20% glucose infusion and dehydration with loop diuretics (Lasix)

Differentiation between Spasticity and Rigidity

Spasticity is a component of the pyramidal syndromes; rigidity is a component of the extrapyramidal syndromes. Brain lesions can affect both the pyramidal and extrapyramidal neural pathways, causing mixtures of spasticity and rigidity, as in cerebral palsy.

Spasticity

Rigidity

Clinical findings

Hypertonicity characteristics:

Clasp-knife phenomenon (a catch and yield sensation, elicited by quick jerking of the resting extremity)

Lead-pipe phenomenon (lead-pipe resistance, elicited by a slow movement of the patient's resting extremity)

Clonus

No clonus

Muscle stretch reflexes hyperactive

Muscle stretch reflexes not necessarily altered

Extensor toe sign

Normal plantar reflexes

Hypertonicity distribution:

Monoplegic, hemiplegic, paraplegic, tetraplegic

Usually in all four extremities, but may have a "hemi" distribution

Predominates in one set of muscles, such as flexors of the upper extremity, extensors of the knee, and plantar flexors of the ankle

Affects antagonistic pairs of muscles about equally

Associated neurological signs:

No specific signs

Cogwheeling and tremor at rest

Electrophysiological findings (EMG)

No muscle activity at complete rest

Electrical activity with the muscle as relaxed as the patient can make it

EMG: electromyography.

Peripheral Nerve Disorders

Carpal Tunnel Syndrome

The carpal tunnel syndrome should be considered when there is any unexplained pain or sensory disturbance (e.g., intermittent numbness and acroparesthesia of the hand that is worse at night) and weakness of the abductor pollicis brevis, the lateral two lumbricals, the opponens pollicis, and the flexor pollicis brevis muscles. Carpal tunnel syndrome occurs as a result of compression of the median nerve beneath the carpal tunnel ligament, and affects 1% of the population.

The following physical tests can be helpful in the diagnosis of carpal tunnel syndrome.

- *Median nerve percussion test.* The test is positive when tapping the area over the median nerve at the wrist produces paresthesia in the median nerve distribution. Sensitivity 44%, specificity 94%
- *Carpal tunnel compression test.* The test is considered positive when the patient's sensory symptoms are duplicated after pressure is applied over the carpal tunnel for 30 seconds. Sensitivity 87%, specificity 90%
- *Phalen wrist flexion test.* This test is positive when full flexion of the wrist for 60 seconds produces the patient's symptoms. Sensitivity 71%, specificity 80%
- *Electrodiagnostic tests.* *Sensory conduction studies* are the most sensitive physiological technique for diagnosing carpal tunnel syndrome. Abnormal sensory testing can be found in 80% of patients with minimal symptoms and in over 80% of severe cases, in which "no recordable sensory potentials" are observed. Normal nerve conduction studies are found in 15–25% of cases of carpal tunnel syndrome

Electromyography is normal in up to 31% of patients with carpal tunnel syndrome. Abnormal electromyography with increased polyphasic quality, positive waves, fibrillation potentials, and decreased motor unit numbers of maximal thenar muscle contraction, is regarded as severe and as an indication for surgery

Contributing factors

Ligamentous or synovial thickening

Trauma

Obesity
Diabetes
Scleroderma
Thyroid disease
Lupus
Amyloidosis
Gout
Acromegaly
Paget's disease
Mucopolysaccharidoses

Differential diagnosis

Cervical radiculopathy (C6, C7)

Sensory symptoms	Numbness and paresthesia. May involve the thumb and index and middle fingers, as in carpal tunnel syndrome, but they may often radiate along the lateral forearm and occasionally the radial dorsum of the hand
Pain	In contrast to carpal tunnel syndrome, pain in cervical radiculopathy frequently involves the neck, and may be precipitated by neck movements. Nocturnal exacerbation of pain is more prominent in carpal tunnel syndrome. Patients with radicular pain tend to keep their arm and neck still, whereas in carpal tunnel syndrome they shake their arms and rub their hands to relieve the pain
Weakness and atrophy	This involves muscles innervated by C6 and C7, not the muscles innervated by C8. Brachioradialis and triceps tendon reflexes may be decreased or absent in radiculopathy
Provocation tests	In carpal tunnel syndrome, the symptoms can be reproduced by provocative tests <ul style="list-style-type: none">– By tapping over the carpal tunnel (Tinel's sign)– By flexion of the wrist (Phalen's sign)– When a blood pressure cuff is applied to the arm and compression above systolic pressure is used, median paresthesias and pain can be aggravated (the Gilliat and Wilson cuff compression test)

Electrodiagnostic studies	These are usually diagnostic, although both C6–C7 root compression and distal median nerve entrapment may coexist (double crush injury). Somatosensory evoked response (SSER), electromyography (EMG), orthodromic/antidromic tests, etc.
Brachial plexopathy	This is usually incomplete, and characterized by the involvement of more than one spinal or peripheral nerve, producing clinical deficits such as muscle paresis and atrophy, loss of muscle stretch reflexes, patchy sensory changes, and often shoulder and arm pain, which is usually accentuated by arm movement
– Upper plexus paralysis	<p>Erb–Duchenne type</p> <ul style="list-style-type: none"> • The muscles supplied by the C5 and C6 roots are paretic and atrophic (i.e., the deltoid, biceps, brachioradialis, radialis, and occasionally the supraspinatus, infraspinatus and subscapularis muscles), producing a characteristic limb position known as the “porter’s tip” position (i.e., internal rotation and adduction of the arm, extension and pronation of the forearm, and with the palm facing out and backward) • The biceps and brachioradialis reflexes are depressed or absent • There may be some sensory loss over the deltoid muscle area
– Lower plexus paralysis	<p>Dejerine–Klumpke type</p> <ul style="list-style-type: none"> • The muscles supplied by the C8 and T1 roots are paretic and possibly atrophic (i.e., weakness of wrist and finger flexion and weakness of the small hand muscles), producing a “claw-hand” deformity • The finger flexor reflex is depressed or absent • Sensation may be intact or lost over the medial arm, forearm, and ulnar aspect of the hand • There is an ipsilateral Horner’s syndrome with injury of the T1 root
– Neuralgic amyotrophy	Parsonage–Turner syndrome. This is characterized by acute, severe pain in the shoulder, radiating into the arm, neck, and back. The pain is followed within several hours or days by paresis of the shoulder and proximal musculature. The pain usually disappears within several days. The condition is idiopathic, but is thought to be a plexitis, and may follow viral illness or immunization

- Thoracic outlet syndrome
Also known as cervicobrachial neurovascular compression syndrome. The thoracic outlet syndrome may be purely vascular, purely neuropathic, or rarely, mixed. The true neurogenic thoracic outlet syndrome is rare, occurring more frequently in young women, and affecting the lower trunk of the brachial plexus. Intermittent pain is the most common symptom, referred to the medial arm and forearm and the ulnar border of the hand. Paresthesias and sensory losses involve the same distribution. The motor and reflex findings are essentially those of a lower brachial plexus palsy, with particular involvement of the C8 root causing weakness and wasting of the thenar muscles, similar to carpal tunnel syndrome. However, in contrast to the latter, in the thoracic outlet syndrome wasting and paresis also tend to involve the hypothenar muscles, which derive their innervation from the C8 and T1 roots, and the sensory symptoms involve the medial arm and forearm, whereas the arm discomfort is made worse with movement. Electrodiagnostic studies show evidence of lower trunk brachial plexus dysfunction

Proximal medial nerve neuropathy

Pronator teres syndrome

This results from compression of the median nerve as it passes between the two heads of the pronator teres. *It is characterized by:*

- Diffuse aching of the forearm
- Paresthesias in the median nerve distribution over the hand
- Weakness of the thenar and forearm musculature (ranging from mild involvement to none)
- Pain in the proximal forearm on forced wrist supination and wrist extension

Lacertus fibrosus syndrome

Pain in the proximal forearm is caused on resisting forced forearm pronation of the fully supinated and flexed forearm

Flexor superficialis arch syndrome

Pain in the proximal forearm is caused on forced flexion of the proximal interphalangeal joint of the middle finger

Anterior interosseous syndrome

- Weakness of the flexor pollicis longus, pronator quadratus, and the median-innervated profundus muscles. Impaired flexion of the terminal phalanx of the thumb and the index finger is characteristic
- There is no associated sensory loss

- Entrapment at the elbow (ligament of Struthers)
- Weakness of median-innervated muscles, including the pronator teres
 - Associated loss of the radial pulse when the arm is extended
- Electrodiagnosis
- Nerve conduction studies in proximal median nerve compression syndromes are frequently normal
 - Needle EMG will consistently show neurogenic changes in median-innervated forearm and hand median muscles

EMG: electromyography; SSER: somatosensory evoked response.

Ulnar Neuropathy

Ulnar Entrapment at the Elbow (Cubital Tunnel)

This results from entrapment of the ulnar nerve as it enters the forearm through the narrow opening (the cubital tunnel) formed by the medial humeral epicondyle, the medial collateral ligament of the joint, and the firm aponeurotic band, to which the flexor carpi ulnaris is attached. Elbow flexion reduces the size of the opening under the aponeurotic band, while extension widens it. "Tardy ulnar palsy" results from narrowing of the cubital tunnel secondary to an elbow fracture or in osteoarthritis, ganglion cysts, lipomas or neuropathic (Charcot) joints.

Symptoms include paraesthesia, numbness, or pain in the fourth and fifth fingers, occasionally provoked by prolonged elbow flexion, associated with decreased vibratory perception and abnormal two-point discrimination. Weakness affects the first dorsal interosseous muscle first and most severely. Weakness and wasting of the hypothenar and intrinsic hand muscles result in the loss of power grip and impaired precision movements. The sensory symptoms usually precede weakness. Tinel's sign may be present, and finger crossing is usually abnormal.

- Cervical radiculopathy (C8–T1)
- May cause sensory symptoms in the fourth and fifth fingers, and also along the medial forearm. Although the elbow is a common C8 referral site, pain is more proximal, centering in the shoulder and neck
- Electrodiagnosis
- Ulnar sensory potentials in C8 are intact in radiculopathies, and there are no focal conduction abnormalities across the elbow segment
 - Needle EMG demonstrates denervation in C8–T1 median-innervated thenar muscles, as well as in ulnar-innervated muscles

- | | |
|---|--|
| Thoracic outlet syndrome, lower brachial plexopathy | <ul style="list-style-type: none"> - Sensory symptoms involve not only the fourth and fifth fingers, but also the medial forearm - Weakness involves both the hypothenar and (more severely) the thenar muscles - Electrodiagnostic studies show normal conduction and a lesion in the lower trunk of the brachial plexus |
| Syringomyelia | <ul style="list-style-type: none"> - Dissociated sensory loss is characteristic, with sparing of large-fiber sensation - Median-innervated C8 motor function is impaired as well as ulnar motor function. There are often associated long track findings in the legs - Electrodiagnosis shows normal ulnar sensory potentials, due to the preganglionic nature of the lesion - MRI is diagnostic |
| Motor neuron disease | <ul style="list-style-type: none"> - Sensory disturbances are not found - There is weakness and wasting of intrinsic hand muscles. Thenar muscles as well as the hypothenar muscles are often affected. Fasciculations may be present, indicating the widespread nature of the disease |
| Ulnar nerve entrapment at the wrist or hand (Guyon's canal) | <ul style="list-style-type: none"> - Sensory loss in the medial fourth and fifth fingers. The palmar and dorsal surfaces of the hand are spared due to sensory nerve branching proximal to the wrist level - Weakness predominantly affecting ulnar-innervated thenar muscle relative to the hypothenar muscles |
| - Electrodiagnosis | <ul style="list-style-type: none"> • The most specific study is a prolonged distal motor latency to the first dorsal interosseus compared to the abductor digiti minimi • Needle EMG may demonstrate active or chronic denervation in either thenar or hypothenar muscles, with sparing of ulnar-innervated forearm muscles |

EMG: electromyography; MRI: magnetic resonance imaging.

Radial Nerve Palsy

The radial nerve is a continuation of the posterior cord of the brachial plexus, and consists of fibers from spinal levels C5 to C8. It descends beyond the posterior wall of the axilla, entering into the triangular space. It then continues distally in the spiral groove of the humerus on bare bone.

Within the proximal forearm, it gives off the posterior interosseous branch, which as it continues in the dorsal forearm gives off branches to the remaining extensor muscles of the wrist and fingers.

Compression in the Axilla

This can occur with incorrect use of crutches, improper arm positioning during inebriated sleep, or with a pacemaker catheter. High axillary lesions can produce the following conditions.

-
- Weakness of the triceps and more distal muscles innervated by the radial nerve
 - Abnormal appearance of the hand (wrist drop)
 - Hyporeflexia or areflexia of the triceps (C6–C8) and radial (C5–C6) reflexes
 - Sensory loss in the extensor area of the arm and forearm, and back of the hand and dorsum of the first four fingers
-

Compression within the Spiral Groove of the Humerus

Lesions of the radial nerve occur most commonly in this region. The lesions are usually due to displaced fractures of the humeral shaft after inebriated sleep, during which the arm is allowed to hang off the bed or bench (“Saturday night palsy”), during general anesthesia, or from callus formation due to an old humeral fracture. There may be a familial history, or underlying diseases such as alcoholism, lead and arsenic poisoning, diabetes mellitus, polyarteritis nodosa, serum sickness, or advanced Parkinsonism.

The clinical findings are usually similar to those of an axillary lesion, except that: a) the triceps muscle and the triceps reflex are normal; b) sensibility on the extensor aspect of the arm is normal, whereas that of the forearm may or may not be spared, depending on the site of origin of this nerve from the radial nerve proper.

Lesions distal to the spiral groove and above the elbow—just prior to the bifurcation of the radial nerve and distal to the origin of the brachioradialis and extensor carpi radialis longus—produce symptoms similar to those seen with a spiral groove lesion, with the following exceptions: a) the triceps reflex is normal; b) the brachioradialis and extensor carpi radialis longus muscles are spared.

Compression at the Elbow

Just above the elbow and before it enters the anterior compartment of the arm, the radial nerve gives off branches to the brachialis, coracobrachialis, and extensor carpi radialis longus before dividing into the posterior interosseous nerve and the superficial radial nerve. The posterior interosseous nerve is the deep motor branch of the radial nerve, passing through a fibrous band (the arcade of Frohse) of the supinator muscle in the upper forearm.

Entrapment is thought to be due to the following conditions:

- A fibrotendinous arch where the nerve enters the supinator muscle (arcade of Frohse)
- Within the substance of the supinator muscle (supinator tunnel syndrome)
- The sharp edge of the extensor carpi radialis brevis
- A constricting band at the radiohumeral joint capsule

There are two recognizable clinical syndromes in this disorder—the radial tunnel syndrome and posterior interosseous neuropathy.

Radial tunnel syndrome. The radial tunnel contains the radial nerve and its two main branches, the posterior interosseous and superficial radial nerves. Forced repeated pronation or supination, or inflammation of supinator muscle attachments (as in tennis elbow) may traumatize the nerve, sometimes due to the sharp tendinous margins of the extensor carpi radialis brevis muscle.

The diagnosis is mainly clinical. The condition is characterized by a lateral dull ache deep in the extensor muscle mass of the upper forearm. There is tenderness over the extensor radialis longus muscle, just where the posterior interosseous nerve enters the supinator muscle mass. Pain increases with forced supination, or with resisted extension of the middle finger (the middle finger test) while the patient's elbow and wrist are extended. Although the site of entrapment is similar to that in posterior interosseous neuropathy, in contrast to that condition there is usually no muscle weakness. Surgical decompression relieves the symptoms in most patients.

Posterior interosseous neuropathy (PIN). Structural pathology, such as lipomas, ganglia, rheumatoid synovial overgrowths, fibromas, and dislocations of the elbow, may all account for compression of the radial and posterior interosseous nerves at this site, resulting in PIN.

The condition can also be caused by entrapment, which is thought to have the following causes.

- A fibrotendinous arch where the nerve enters the supinator muscle (arcade of Frohse)
 - Within the substance of the supinator muscle (supinator tunnel syndrome)
 - The sharp edge of the extensor carpi radialis brevis
 - A constricting band at the radiohumeral joint capsule
-

Clinically, there is marked extensor weakness in the thumb and fingers (finger drop). The condition is distinguished from radial nerve palsy by the fact that there is less wrist extensor weakness (no wrist drop), due to sparing of the extensor carpi radialis longus and brevis, and if the extensor carpi ulnaris is paretic, the wrist will deviate radially. The brachioradialis and supinator muscles are also spared. Sensory loss is not present. Pain may be present at the onset, but is usually not a prominent feature of the syndrome.

Electrodiagnostic studies may demonstrate slowing of motor conduction across the elbow segment in severe cases, or slightly reduced distal motor potential amplitudes. Needle electromyography may demonstrate neurogenic change. Surgical release of the posterior interosseous nerve and lysis of any constrictions, including the arcade of Frohse, should be carried out in cases that do not respond to four to eight weeks of expectant management.

Radial Nerve Injury at the Wrist

Wrist injuries frequently involve the superficial radial sensory branch, as a consequence of its exposed position (crossing the extensor pollicis longus tendon; it can often be palpated at this point with the thumb in extension). Tight casts, watch bands, athletic bands, and handcuffs can cause transient compression of the superficial radial sensory branch, resulting in anesthesia, hypesthesia, or hyperesthesia over the dorsum of the radial side of the hand. It is often not the loss of sensation that is troublesome, but the development of painful paresthesias or dysesthesias, which are a much more difficult problem and may be resistant to all forms of treatment.

Nonsurgical therapy involves the removal of precipitating or exacerbating causes, and this is often sufficient to achieve spontaneous recovery of radial nerve function within weeks. Neither steroid injections nor releasing the nerve from adherent scar tissue is usually indicated.

Differential Diagnosis of Radial Palsies

Cerebral lesion	<ul style="list-style-type: none">– Dorsal extension is possible during firm grasping of an object, as an involuntary synesthesia mechanism– Hyperreflexia, pathological reflexes (triceps reflex, finger flexion reflex or Trommer's test, Hoffmann's test)
Radiculopathy of C7 root	<ul style="list-style-type: none">– There is extensor as well as flexor muscle weakness– Neck pain– Sensory disturbances– Sometimes associated with weakness of the thenar muscles
Spinal muscular atrophy	
Myotonic dystrophy of Steinert (Distal atrophy of the forearm)	
Rupture of the long extensor tendons	
Ischemic muscle necrosis at the forearm	

Meralgia Paresthetica (Bernhardt–Roth syndrome)

The lateral cutaneous nerve is a purely sensory branch arising from the lumbar plexus (L2–L3). It passes obliquely across the iliac muscle, and enters the thigh under the lateral part of the inguinal ligament. It supplies the skin over the anterolateral aspect of the thigh. Meralgia paresthetica is a condition caused by entrapment of this nerve as it passes through the opening between the inguinal ligament and its attachment 1–2 cm medial to the anterior superior iliac spine. Numbness is the earliest and most common symptom. Patients also complain of pain, paresthesias (tingling and burning) and often touch–pain–temperature hypesthesia over the anterolateral aspect of the thigh. The condition occurs particularly in obese individuals who wear constricting garments (e.g., belts, tight jeans, corsets and camping gear). Intra-abdominal or intrapelvic processes may directly impinge on the nerve during its long course; the condition can also be due to abdominal distension (as a result of ascites, pregnancy, tumor, or systemic sclerosis), and may follow

an intertrochanteric osteotomy or removal of an iliac crest bone graft if it is taken too close (2 cm) to the anterior superior iliac spine.

The differential diagnosis includes the following conditions:

Femoral neuropathy	Sensory changes tend to be more anteromedial than in meralgia paresthetica, sometimes extending to the medial malleolus and the big toe
L2 and L3 radiculopathy	There is usually an associated weakness of knee extension due to quadriceps paresis, and also impairment of hip flexion due to iliopsoas weakness
Nerve compression by an abdominal or pelvic tumor	There are concomitant gastrointestinal or genitourinary symptoms

Femoral Neuropathy

The femoral nerve arises in the lumbar plexus from branches of the posterior division of the L2–4 roots. The nerve passes between and innervates the iliac and psoas muscles. It then descends beneath the inguinal ligament, just lateral to the femoral artery, to enter the femoral triangle in the thigh, where it divides into the anterior and posterior divisions. The nerve may be damaged by penetrating lacerations or missile wounds, complications of femoral angiography, retroperitoneal tumors or abscesses, irradiation, fractures of the pelvis or femur, surgical table malpositioning, hip arthroplasty, and renal transplantation.

Femoral nerve injury produces weakness of knee extension due to quadriceps paresis. Proximal lesions can also impair hip flexion, due to iliopsoas weakness.

Sensory loss over the anterior and medial aspect of the thigh extends at times to the medial malleolus and the great toe. Electromyography demonstrates neurogenic changes, and electrophysiological studies show reduced motor potential amplitude. The differential diagnosis includes the following.

High lumbar herniated disk	<ul style="list-style-type: none"> – In purely femoral nerve palsy, the function of the adductors and their reflexes remains intact, whereas in an L2–3 root lesion, the adductors are weak – In an L4 root lesion, the tibialis anterior is also involved. – The distribution of sensory loss is characteristic of each type of lesion
----------------------------	--

Lumbar plexus palsies
Muscular dystrophy of
the quadriceps
Lipodystrophy after insulin
injection in diabetics
Arthritic muscle atrophy
Sarcoma of the proximal
femur
Ischemic infarction of
the knee extensors

Peroneal Neuropathy

See the section on foot drop, p. 227.

Tarsal Tunnel Syndrome

Anterior Tarsal Tunnel Syndrome

This involves compression of the deep peroneal nerve as it passes under the extensor retinaculum on the dorsum of the ankle. It is usually related to edema, fractures, ankle sprains, or external pressure from tight boots. This compression results in paresis and atrophy of the extensor digitorum brevis muscle. The terminal sensory branch to the first dorsal web space may be affected, occasionally with Tinel's sign at the ankle.

Posterior Tarsal Tunnel Syndrome

This involves compression of the tibial nerve at the ankle behind the medial malleolus, where it is covered by the lacinate ligament connecting the distal tibia to the calcaneus. It is usually related to local fractures, tumors, and vascular abnormalities. The entrapment results in hypesthesia in the distribution of the medial and lateral plantar nerves, a positive Tinel's sign with percussion, or pressure over the flexor retinaculum below the medial malleolus. Electromyography and nerve conduction velocities are helpful in the diagnosis.

Surgical release of the entrapment is not rewarding as often as in the carpal tunnel syndrome. Conservative measures are used, such as external ankle support (e.g., shoe orthoses) to improve foot mechanics.

Plantar Digital Nerve Entrapment (Morton's Metatarsalgia)

A plantar digital nerve may be compressed where it courses distally between the heads of the adjacent metatarsal bones. It is believed that the syndrome arises because of chronic entrapment and trauma to the digital nerve between the metatarsal heads. The syndrome mainly affects women, who describe pain in the forefoot, particularly in the fourth and third toes, which becomes worse when walking.

Shoe modification and interdigital injection of local anesthetic and steroids may provide significant and long-lasting relief of pain. Surgical treatment can provide benefit in most cases.

The differential diagnosis includes the following.

- Valgus deformity
- Flat foot
- Splay foot
- Calcaneal spur
- Heel pain in Bekhterev's disease
- Sinus tarsi syndrome
- Local osteolysis

Movement Disorders

Chorea

Genetic disorders

- Ataxia telangiectasia
- Abetalipoproteinemia
- Benign familial chorea
- Fahr disease E.g., encephalopathy and basal ganglia calcification
- Hallervorden-Spatz disease E.g., choreoathetosis, rigidity, dystonia, retinitis pigmentosa, and mental deterioration

Drug-induced

- Anticonvulsants As a toxic or an idiosyncratic reaction
- E.g., phenytoin, ethosuximide
- Antiemetics and psychotropic E.g., phenothiazines, haloperidol
- Stimulants E.g., dextroamphetamine, methylphenidate

Systemic disorders

- Hyperthyroidism
- Lupus erythematosus
- Pregnancy
- Sydenham's chorea Cardinal manifestation of rheumatic disease

Dystonia

Focal dystonias

- Blepharospasm
- Drug-induced dystonia
- Torticollis
- Occupational cramp E.g., writer's cramp

Generalized dystonias

- Genetic disorders
 - Cytochrome *b* deficiency
 - Dopa-responsive dystonia
 - Glutaric acidemia
 - Wilson's disease (hepatolenticular degeneration)
 - Idiopathic torsion dystonia

- Systemic dystonias
 - Tumor
 - Active encephalopathy (e.g., hypoxic, infectious, or metabolic)
 - Posttraumatic encephalopathy
 - Postischemic encephalopathy

Blepharospasm

Essential blepharospasm is the most common cause affecting middle-aged or older women, and it never begins in childhood. Blepharospasm in children is almost always drug-induced.

Drug-induced

- L-dopa
- Antihistamines
- Sympathomimetics
- Psychotropic

Wilson's disease

Hepatolenticular degeneration

Huntington's disease

Functional

Hysteria

Encephalitis

Seizures

Absence status, partial complex

Schwartz-Jampel syndrome

Osteochondromuscular dystrophy. Infants have a characteristic triad: blepharophimosis, pursing of the mouth, and puckering of the chin

Myotonia

Tetany

Torticollis (Head Tilt)

Benign paroxysmal torticollis

Occurs in infants and toddlers with a family history of migraine, and goes into remittance spontaneously

Familial paroxysmal choreoathetosis and dystonia

Do not begin in early infancy

Sandifer's syndrome

Intermittent torticollis associated with hiatal hernia

Cervical spine disease

- Syringomyelia/syringobulbia
- Cervical cord tumors
 - Astrocytomas
 - Ependymomas
 - Neuroblastomas
 - Sarcomas
 - Other (neurofibroma, teratoma, dermoid, chondroma)
- Cervicomedullary malformations
 - Chiari malformation
 - Cerebellar malformations (hemisphere hypoplasia, vermal aplasia)
 - Atlantoaxial dislocation
 - Basilar impression

Posterior fossa tumors

- Cerebellar astrocytoma
- Cerebellar hemangioblastoma Von Hippel–Lindau disease
- Ependymoma
- Medulloblastoma

Juvenile rheumatoid arthritis

Eye muscle imbalance

Sternocleidomastoid injuries

- Tic and Tourette's syndrome E.g., motor tics, attention deficits, and obsessive compulsive behavior

Parkinsonian Syndromes (Hypokinetic Movement Disorders)

Classification of Parkinsonism

- | | |
|--|--|
| Primary (idiopathic) parkinsonism | <ul style="list-style-type: none"> - Parkinson's disease - Juvenile parkinsonism |
| Secondary (acquired, symptomatic) parkinsonism | <ul style="list-style-type: none"> - Vascular (multi-infarct) - Infectious (e.g., postencephalitic, slow virus) - Drugs (e.g., antipsychotic, reserpine, α-methyl-dopa, lithium) - Toxins (e.g., carbon dioxide poisoning, methanol, ethanol, mercury) |

- Trauma
- Miscellaneous (e.g. brain tumor, normotensive hydrocephalus, syringobulbia, hypothyroidism, parathyroidism)

Multiple system degenerations

Progressive supranuclear palsy

“Parkinsonism-plus” syndromes

Steele–Richardson–Olszewski syndrome

Multiple system atrophy

- Shy–Drager syndrome
- Striatonigral degeneration
- Olivopontocerebellar atrophy

Cortical–basal ganglionic degeneration

Autosomal dominant Lewy body disease

Heredodegenerative parkinsonism

Huntington’s disease

Wilson’s disease

Hallervorden–Spatz disease

Familial basal ganglia calcification

Familial parkinsonism with peripheral neuropathy

Neuroacanthocytosis

Dementia syndromes

Parkinsonism – dementia – amyotrophic lateral sclerosis complex of Guam

Alzheimer’s disease

Creutzfeldt–Jakob disease

Normal pressure hydrocephalus

Differential Diagnosis of Parkinsonism

Parkinson’s disease is a progressive neurological disease with the following clinical characteristics.

Manifestations (+)	Possible other features (\pm)
Bradykinesia	Dystonia
Rigidity	Dysautonomia
Gait disturbance	Dementia
Tremor	Dysarthria/dysphagia
Asymmetric findings	Myoclonus
Levodopa response/dyskinesia	Sleep impairment
Lewy bodies	Family history

The clinical heterogeneity of Parkinson's disease makes it difficult to differentiate it from other parkinsonian disorders based on the clinical criteria alone. The pathological examination may prove the diagnosis of Parkinson's disease wrong in 10 – 15% of patients. Pathologically, Lewy bodies are present in pigmented neurons of the substantia nigra and other central nervous system areas. There is a therapeutic response to levodopa, which tends to support the diagnosis of Parkinson's disease (in over 77% of patients the response is “good” or “excellent”), but the drug cannot be used to differentiate reliably between Parkinson's disease from other parkinsonian disorders.

Progressive Supranuclear Palsy

The diagnosis of progressive supranuclear palsy (PSP) should be considered in any patient with progressive parkinsonism and a disturbance of ocular motility.

The earliest and most disabling clinical symptom relates to gait and balance impairment. Supranuclear downward gaze palsy is the most important distinguishing feature of PSP, but it may also occur in diffuse Lewy body disease, cortical–basal ganglionic degeneration, and other atypical parkinsonian disorders.

Manifestations (+)	Possible other features (\pm)
Bradykinesia	Dystonia
Rigidity	Dysautonomia
Gait disturbance	Sleep impairment
Dementia	Levodopa response
Dysarthria/dysphagia	Putaminal T2 hypointensity
Eyelid apraxia	
Supranuclear downward gaze palsy	

The pathological findings reflect neuronal degeneration in the basal nucleus of Meynert and in the globus pallidum, subthalamic nucleus, superior colliculi, mesencephalic tegmentum, substantia nigra, locus ceruleus, red nucleus, reticular formation, vestibular nuclei, cerebellum, and spinal cord.

Neurodiagnostic studies are not helpful in confirming the diagnosis of PSP.

Neurochemically, the most striking abnormality is a marked depletion of striatal dopamine, reduction in dopamine receptor density, choline acetyltransferase activity, and loss of nicotine (but not muscarinic) cholinergic receptors in the basal forebrain.

Multiple System Atrophy

Multiple system atrophy (MSA) is characterized clinically by a combination of parkinsonian, pyramidal, cerebellar, and autonomic symptoms. In contrast to Parkinson's disease, rest tremor is usually absent, and the findings are relatively symmetric. The autonomic symptoms are disabling and help differentiate MSA from other parkinsonian disorders.

The pathological features include cell loss and gliosis in the striatum, substantia nigra, locus ceruleus, inferior olives, pontine nuclei, dorsal vagal nuclei, Purkinje cells of the cerebellum, and Onuf's nucleus of the caudal spinal cord.

Neurochemically, low levels of dopamine in the substantia nigra and striatum have been shown in postmortem studies.

Neuroimaging using magnetic resonance imaging (MRI) often reveals areas of bilateral decrease in signal density in the posterolateral putamen on T2-weighted images. Positron-emission tomography (PET) studies showed reduced striatal and frontal lobe metabolism.

Shy-Drager syndrome. Dysautonomia is the most characteristic clinical feature of Shy-Drager syndrome (SDS). Patients show reduced ^{18}F 6-fluorodopa uptake, indicating nigrostriatal dysfunction.

Manifestations (+)

Bradykinesia
Rigidity
Gait disturbance
Dysautonomia
Sleep impairment
Putaminal T2 hypointensity
Levodopa response
Lewy bodies

Possible other features (\pm)

Ataxia
Dementia
Dysarthria/dysphagia
Motor neuron disease
Neuropathy
Oculomotor deficit

Striatonigral degeneration. Respiratory dysregulation with laryngeal stridor and sleep apnea are often prominent clinical features in striatonigral degeneration (SND). Decreased D2-receptor density has been found in patients with SND. Vasomotor impairment in SND has been attributed to a selective loss of tyrosine hydroxylase-immunoreactive neurons in the A1 and A2 regions of the medulla oblongata.

Manifestations (+)	Possible other features (\pm)
Bradykinesia	Dysautonomia
Rigidity	Dystonia
Gait disturbance	Eyelid apraxia
Dysarthria/dysphagia	Motor neuron disease
Putaminal T2 hypointensity	Sleep impairment
Levodopa dyskinesia	
Lewy bodies	

Olivopontocerebellar atrophy. Cerebellar ataxia is the most frequent presenting symptom in patients with olivopontocerebellar atrophy (OPCA). MRI on T2-weighted images shows pancerebellar and brain stem atrophy, enlarged fourth ventricle and cerebellopontine angle cisterns, and demyelination of transverse pontine fibers.

A reduction in dopamine has been found in 53% of cases in the putamen, 35% in the caudate, and 31% in the nucleus accumbens. Mitochondrial deoxyribonucleic acid abnormalities may be important in the pathogenesis of OPCA.

Manifestations (+)	Possible other features (\pm)
Rigidity	Bradykinesia
Gait disturbance	Tremor
Ataxia	Dysautonomia
Dysarthria/dysphagia	Neuropathy
Oculomotor deficit	Sleep impairment
Putaminal T2 hypointensity	Lewy bodies

Corticobasal Ganglionic Degeneration

The most striking features of corticobasal ganglionic degeneration (CBGD) include marked asymmetry of involvement, movement disorders, cortical sensory loss, apraxias and the “alien limb” phenomenon. Dementia is a late feature.

Manifestations (+)	Possible other features (±)
Bradykinesia	Tremor
Rigidity	Dementia
Gait disturbance	Eyelid apraxia
Dysarthria/dysphagia	Lewy bodies
Dystonia	
Limp apraxia	
Myoclonus	
Oculomotor deficit	
Asymmetric findings	

Neuroimaging with computed tomography (CT) shows asymmetrical parietal lobe atrophy, corresponding to the most affected side in 54% of patients and to bilateral parietal atrophy in 40%. Positron-emission tomography (PET) scanning reveals reduced fluorodopa uptake in the caudate and putamen, and markedly asymmetrical cortical hypometabolism, particularly in the superior temporal and inferior parietal lobe.

Pathological features of CBGD include neuronal degeneration in the precentral and postcentral cortical areas, the basal ganglia, and the presence of achromatic neural inclusions in the cortex, thalamus, subthalamic nucleus, red nucleus and substantia nigra. There is a clinical and pathological overlap with “parietal Pick’s disease.”

The dopamine concentration in the striatum and substantia nigra in patients has been found to be reduced in comparison with the concentration in age-matched control individuals.

Diffuse Lewy Body Disease

Diffuse Lewy body disease (DLBD) is considered to be a variant or overlapping condition lying between Alzheimer’s disease and Parkinson’s disease. Clinical differentiation may therefore be difficult. In most patients with DLBD, however, psychosis and dementia are often found to precede parkinsonism (gait disturbance, rigidity, and resting tremor). The differentiation between DLBD and other parkinsonian syndromes, especially progressive supranuclear palsy, is particularly difficult when a patient with parkinsonism and dementia is also found to have oculomotor deficit.

Manifestations (+)	Possible other features (\pm)
Dementia	Bradykinesia
Lewy bodies	Rigidity
Gait disturbance	
Dysautonomia	
Dysarthria/dysphagia	
Limb apraxia	
Myoclonus	
Oculomotor deficit	
Sleep impairment	

Neuroimaging studies, including magnetic resonance imaging (MRI) and positron-emission tomography (PET) scanning, cannot reliably differentiate between Parkinson's disease, Alzheimer's disease, and DLBD.

Immunocytochemical staining techniques using antibodies against ubiquitin have improved the identification of Lewy bodies. More than 30% of patients with Alzheimer's disease have Lewy bodies in the cortex and substantia nigra, whereas all Parkinson's patients have cortical Lewy bodies. In addition to the diffuse distribution of Lewy bodies throughout the basal forebrain, brain stem, and hypothalamus, the lack of neurofibrillary tangles in DLBD helps differentiate it from Alzheimer's disease.

Parkinsonism–Dementia–Amyotrophic Lateral Sclerosis Complex of Guam

Dementia and motor neuron disease are the most frequent presenting features in addition to the parkinsonian findings.

Manifestations (+)	Possible other features (\pm)
Bradykinesia	Ataxia
Rigidity	Dysautonomia
Gait disturbance	Oculomotor deficit
Tremor	
Dementia	
Dysarthria/dysphagia	
Motor neuron disease	

Cervical Dystonia

This is the most common type of dystonia, and it affects the neck muscles, producing repetitive, patterned, clonic (spasmodic) head movements or tonic (sustained) abnormal postures of the head. It is commonly called *spasmodic torticollis*, but since it is not always spasmodic and does not always consist of torticollis (neck turning), the term *cervical dystonia* is preferred.

Idiopathic dystonia

Dystonia secondary to structural causes

Skeletal

- Atlantoaxial dislocation
- Cervical fracture
- Degenerative disk
- Osteomyelitis
- Klippel-Feil syndrome

Fibromuscular

- Fibrosis from local trauma or hemorrhage
 - Postradiation fibrosis
 - Acute stiff neck
 - Congenital torticollis
- Associated with absence or fibrosis of cervical muscles

Infectious

- Pharyngitis
- Local painful lymphadenopathy

Neurological

- Vestibulo-ocular dysfunction
 - Posterior fossa tumor
 - Chiari syndrome
 - Bobble-head doll syndrome
 - Nystagmus
 - Spinal cord tumor/syrinx
 - Hemianopia
 - Extraocular muscle palsies, strabismus
 - Focal seizures
- Fourth cranial nerve paresis, or labyrinthine disease
- Third ventricular cyst

Myoclonus

Posthypoxic

Posttraumatic

Heat stroke

Myoclonic dementias

- Alzheimer's disease
- Creutzfeldt–Jacob disease

Basal ganglia diseases

- Corticobasal ganglionic degeneration
- Parkinson's disease
- Juvenile Huntington's disease
- Adult-onset Huntington's disease
- Olivopontocerebellar atrophy
- Hallervorden–Spatz disease
- Wilson's disease

Medication-induced myoclonus

Toxic myoclonus

Metabolic disorders

- Uremia
- Chronic hemodialysis
- Hepatic failure
- Hypercarbia
- Hypoglycemia
- Hyponatremia
- Nonketotic hyperglycemia

Viral infections

Other disorders

- Multiple sclerosis
 - Electric shock
 - Tumor
 - Decompression illness
 - After thalamotomy
 - After stroke
-

Adapted from: Pappert EJ, Goetz CG. Treatment of myoclonus. In: Kurlan R, ed. Treatment of movement disorders. Philadelphia: Lippincott, 1995: 247–336.

Chorea

Hereditary choreas

- Huntington's disease
- Benign familial chorea
- Chorea – acanthocytosis
- Wilson's disease
- Spinocerebellar degenerations
- Hallervorden–Spatz disease
- Inborn error of metabolism
- Porphyria
- Tuberos sclerosis
- Ataxia – telangiectasia
- Paroxysmal kinetogenic choreoathetosis
- Paroxysmal dystonic choreoathetosis

Metabolic choreas

- Hyponatremia
- Hyponatremia
- Hypocalcemia
- Hyperglycemia
- Hypoglycemia
- Hypomagnesemia
- Hepatic encephalopathy
- Renal encephalopathy
- Hyperthyroidism
- Hypoparathyroidism

Infectious/immunological choreas

- Sydenham's chorea
- Viral encephalitis
- Abscess
- Tuberculous meningitis
- Multiple sclerosis
- Systemic lupus erythematosus
- Behçet's syndrome
- Sarcoidosis

Cerebrovascular choreas

- Basal ganglia infarction, hemorrhage
- Arteriovenous malformation
- Venous angioma
- Polycythemia

Structural choreas

- Posttraumatic
- Subdural/epidural hematoma
- Tumor (primary CNS or metastatic)

Adapted from: Shoulson I. On chorea. Clin Neuropharmacol 1986; 9: 585. CNS: central nervous system.

Tic Disorders

Primary tic disorders

- Tourette's syndrome
- Chronic multiple motor tic disorder
- Chronic multiple vocal tic disorder
- Chronic single motor tic disorder
- Chronic single vocal tic disorder
- Transient tic disorder

Secondary tic disorders

- Inherited
 - Huntington's disease
 - Neuroanthocytosis
 - Torsion dystonia
 - Chromosomal abnormalities
 - Other
- Acquired
 - Drugs
 - Neuroleptics (tardive tics)
 - Stimulants
 - Anticonvulsants
 - Levodopa
 - Trauma
 - Infectious
 - Encephalitis
 - Creutzfeldt–Jakob disease
 - Sydenham's chorea
 - Developmental
 - Static encephalopathy
 - Mental retardation
 - Autism
 - Pervasive developmental disorder
 - Stroke
 - Degenerative
 - Parkinson's disease
 - Progressive supranuclear palsy
 - Shy–Drager syndrome
 - Corticobasal ganglionic degeneration
 - Olivopontocerebellar atrophy
 - Diffuse Lewy body disease
 - Parkinsonism – dementia–ALS complex

ALS: amyotrophic lateral sclerosis.

Tremor

Disorder	Diagnosis
Physiological tremor	Rhythmic oscillations of 8–12 Hz with posture and movement, but without neurological findings; enhanced by: <ul style="list-style-type: none"> – Stress (anxiety, fatigue, emotion, exercise) – Endocrine (adrenocorticosteroids, hypoglycemia, thyrotoxicosis, pheochromocytoma) – Toxins (As, Bi, Br, Hg, ethanol withdrawal) – Drugs (beta-agonists, cycloserine, dopaminergic drugs, methylxanthines, valproic acid; psychiatric drugs: lithium, tricyclics, neuroleptics; stimulants: amphetamines, cocaine)
Essential tremor	Rhythmic oscillations of 4–10 Hz, most noticeable in the extremities, which maintain an antigravity posture (postural tremor). No associated neurological findings. Ethanol suppresses the tremor. The tremor is most prominent in the hands, although the cranial musculature is frequently affected (titubation), and voice tremor may occur
Parkinsonian tremor	A pill-rolling type of tremor of 3–6 Hz, most prominent in the rest and postural positions. The parkinsonian resting tremor is characteristically inhibited by voluntary movements, i. e. there is no kinetic tremor. The tremor affects the hands, chin, lips, legs, and trunk; a head tremor is unusual. Associated with other signs of parkinsonism, including bradykinesia, rigidity, positive glabellar reflexes, and impaired postural reflexes
Cerebellar tremor	Postural tremor of 3–8 Hz, mainly in a horizontal plane and most prominent with fine repetitive action of the extremities (intention tremor). Tremors of the head (titubation) and trunk usually involve midline cerebellar structures. Associated with other signs of cerebellar ataxia
Rubral (midbrain) tremor	A combination of resting, postural, and severe kinetic tremor of 2–5 Hz. This tremor is uncommon but highly distinctive, and is resistant to symptomatic pharmacotherapy
Posttraumatic tremor	Tremor of 2–8 Hz that can occur days to months after a head injury, long after consciousness has been regained
Psychogenic tremor	Tremors are very common in hysteria. The tremors are complex and unclassifiable, have changing characteristics, are clinically inconsistent. The tremor increases with attention and lessens with distractibility. The tremor is unresponsive to antitremor drugs and responsive to placebo. Remission of the tremor occurs with psychotherapy

Disorders Associated with Blepharospasm

Blepharospasm is an involuntary, spasmodic closure of the eyelids that is preceded by increasing frequency and force of blinking. It is a form of focal dystonia, and in most cases, no cause can be found (essential blepharospasm). Combined with oromandibular dystonia, this is sometimes known as Meige's syndrome.

-
- Tardive dyskinesia and dystonia
 - Parkinson's disease
 - Wilson's disease
 - Progressive supranuclear palsy
 - Schwartz–Jampel syndrome
 - Myotonia
 - Tetanus
 - Tetany
 - Ocular disorders (anterior chamber disease)
 - Midbrain disease (infarction or demyelination)
 - Encephalitis
 - Reflex blepharospasm
 - Functional (hysterical)
 - Hemifacial spasm
 - Habit spasms
 - Ticks (e.g., Tourette's syndrome)
 - Autoimmune disorders
 - Sjögren's syndrome
 - Systemic lupus erythematosus
 - Myasthenia gravis
 - Drugs
 - L-Dopa
 - Antihistamines
 - Sympathomimetics
 - Antipsychotics
-

Gait Disorders

Neurological

Central

- Stroke
- Parkinsonism
- Dementia
- Fear of falling

Peripheral neuropathy

- Diabetes mellitus
- Alcoholism
- Vitamin B₁₂ deficiency

Eye and ear

- Presbyopia
- Cataracts
- Benign positional vertigo
- Ménière's disease
- Multiple sensory deficit syndrome

Unknown etiology

- Idiopathic gait disorder

Cardiovascular

Heart

- Atherosclerotic heart disease, class II or greater

Arterial

- Intermittent claudication
- Orthostatic hypotension
- Vertebrobasilar insufficiency

Venous

- Chronic leg edema

Arthritic, musculoskeletal

Joints

- Degenerative joint disease
- Disk disease
- Rheumatic arthritis
- Gout
- Cervical spondylosis
- Congenital or acquired deformity

Bone

- Osteoporosis
- Paget's disease

Muscle

- Thyroid disease
- Immobility

Polymyalgia

From: Hough JC, McHenry MP, Kammer LM. Gait disorders in the elderly. *Am Fam Physician* 1987; 35: 191–6.

Neurological Disorders of Stance and Gait

Supratentorial lesions

White matter disease

- White matter disease in the elderly
Normal histology, but vascular or ischemic disease has been present in cases with pronounced changes on MRI or CT
- Leukoencephalopathies
Familial disorder of white matter disease may manifest itself as impaired gait; e.g., MS, progressive multifocal encephalopathy, AIDS encephalopathy, radiation leukoencephalopathy

Acute vascular disease

- Thalamic astasia
Thalamic infarction and hemorrhage cause inability to stand or walk despite minimal weakness. Patients usually fall backward or toward the site contralateral to the lesion. The lesions are clustered in the superior portion of the ventrolateral nucleus of the thalamus and the supratthalamic white matter
- Capsular and basal ganglia lesions
Small capsular lesions involving the most lateral portion of the ventrolateral nucleus of the thalamus, and multiple bilateral lacunae in the basal ganglia, can be attended by gait impairment

Normotensive hydrocephalus

Significant dilatation of the lateral, third, and fourth ventricles and blunting of the callosocaudal angle causing spastic gait ataxia and urinary disturbances. Fibers destined for the leg region course in the posterior limb of the internal capsule and then ascend in the more medial portion of the corona radiata, near the wall of the lateral ventricle

Bilateral subdural hematomas

Unilateral chronic subdural hematomas cause a mild hemiparesis, speech and language disorders, and apraxia. Bilateral lesions present with gait failure, particularly in elderly individuals

Infratentorial lesions

Pontomesencephalic gait failure

The pedunculopontine region plays an important role in motor behavior. Loss of neurons in the area causes an acute onset of inability to walk, without hemiparesis or sensory loss and lack of cadence or gait rhythmicity. The gait deficit resembles the gait failure experienced by many elderly individuals without a clear anatomical correlate

Vestibular lesions	Unilateral lesions of the vestibular area, e.g., Wallenberg syndrome, MS, and cerebellopontine angle neoplasms, make patients to fall to the side of the lesion; bilateral findings are present in Wernicke's encephalopathy of vitamin B ₁ deficiency
Cerebellar lesions	Acute or progressive balance impairment occurs in cerebellar lesions affecting the flocculonodular lobe, or vestibulocerebellum. Most often, patients with cerebellar lesions tend to fall to the side of the lesion
Myelopathy	The initial manifestation of a myelopathy is often gait or balance impairment
Cervical spondylosis	Advanced disease may lead to tetraparesis with a spastic – ataxic gait, and may be associated with radicular findings, such as pain and reflex changes
Multiple sclerosis	Gait or balance impairment and sensory changes may be the only manifestations of MS involving the spinal cord or, rarely, some of the higher levels of neuraxis

AIDS: acquired immune deficiency syndrome; CT: computed tomography; MRI: magnetic resonance imaging; MS: multiple sclerosis.

Types of Stance and Gait

Watching the patient stand and walk is the single most important part of the entire neurological assessment and examination.

Developmental gaits

Neonatal automatic or reflex stepping	When the infant is held upright and its feet touch the bed surface, it reflexly lifts its legs alternately and steps
Infantile cruising	The infant makes steps when steadied by a parent, or when holding on to a chair
Toddler's gait	Broad-based, short, jerky, irregular steps, a semiflexed posture of the arms, and frequent falls
Child's mature gait	Narrow-based, heel – toe stride, reciprocal swinging of the arms

Neuromuscular gaits

Clubfoot gait	The gait depends on which of a variety of valgus – varus deformities exists
In-toed or pigeon-toed gait	When there is tibial torsion

Lordotic waddling gait	In muscular dystrophy and polymyositis, these patients find it difficult to get up onto, or down from, the examining table, or difficult to stand up from a sitting or reclining position
Toe-drop or foot-drop gait	Because of paralysis of foot dorsiflexion, patients are unable to clear the floor, and consequently jerk the knee high, flipping the foot up into dorsiflexion, and characteristically slapping the foot down again
– Unilateral foot drop	This suggests a mechanical or compressive neuropathy of the common peroneal nerve or L5 root
– Bilateral foot drop, or steppage gait	Due to a symmetrical distal neuropathy of the toxic, metabolic, or familial type, as in alcoholic neuropathy or Charcot–Marie–Tooth progressive peroneal atrophy
Heel-drop gait	Due to paralysis of the tibial nerve, patients are unable to plantarflex the foot, although dorsiflexion is possible
Flail-foot gait	Due to complete sciatic palsy, patients are unable to either dorsiflex or plantarflex the foot
Toe-walking gait	Because of tight heel cords, the child has a limited dorsiflexion of the foot to about 90° and consequently stands on the balls of the feet without a definite heel strike. This type of gait is seen in Duchenne’s muscular dystrophy, in spastic diplegia, and in autistic or other retarded children

Sensory gaits

Painful sole or hyperesthetic gait	When patients set the foot down, they put as little weight on it as possible and raise it as soon as possible, hunching the shoulders
– Unilateral	In Morton’s metatarsalgia, a painful neuroma of an interdigital nerve, or gout
– Bilateral	In painful distal neuropathies of toxic, metabolic or alcoholic in origin
Radicular pain gait or antalgic gait	Compression of the L5 root from a herniated disk causing extreme pain radiating into the big toe, aggravated by coughing, sneezing, or straight leg raising. The back is lordotic, and when patients walk they do not put any weight on the painful leg and take stiff, slow, short strides, with no heel strike. The trunk tilts slightly to the side opposite the pain

Nocturnal flipping-hand gait	In patients with carpal tunnel syndrome, there is an excruciating nocturnal pain in the hand, often waking them and causing them to pace the room flipping or shaking the hand in an effort to obtain pain relief. A pathognomonic gait seen often in autistic and other retarded children, who develop repetitive, self-stimulating mannerisms resembling a variety of flipping-hand gaits
Tabetic or dorsal column or sensory ataxic gait	Resembles a double foot drop. Seen in patients with tabes dorsalis, in whom a syphilitic infection causes degeneration of the dorsal columns of the spinal cords. Patients lift the knees high and slap the feet down, placing them irregularly due to sensory ataxia. When standing, they need to use visual cues to avoid swaying and falling over
Blind person's gait	The slow, deliberate, and searching steps of a blind person are characteristic, and should not confuse an experienced examiner

Cerebellar gaits

Unilateral cerebellar gait	A unilateral cerebellar lesion, most likely caused by neoplasm, infarct, or demyelinating disease, causes ipsilateral cerebellar signs, with the patient presenting dystaxia of volitional movements (veering or falling in one direction) and of volitionally maintained postures, producing a reeling gait
Bilateral cerebellar gait	Bilateral cerebellar signs imply a toxic, metabolic or familiar disorder. Dystaxia of the legs and gait, with little or no dystaxia of the arms, and no dysarthria or nystagmus, suggests a rostral vermis syndrome, most commonly secondary to alcoholism. Truncal ataxia alone implies a flocculonodular lobe or caudal vermian lesion, often a fourth ventricular tumor

Spastic gaits

Hemiplegic gait	Patients circumduct the affected leg, dragging the toe and placing the ball down without a heel strike, with the ipsilateral arm held in partial flexion or, less often, flaccidly at the side
Spastic gaits	Patients walk with stiff legs, not clearing the floor with either foot, giving the appearance of wading through water because they have to work against the spastic opposition of their own muscles, as if walking in thick, sticky mud; the knees tend to rub together in a scissoring action
Pure spastic or paraplegic gait	A pure spastic paraplegic gait without sensory deficits, developing after birth, implies a corticospinal tract disorder, as in familial spastic paraplegia

Spastic diplegic gait	Patients affected by diplegic cerebral palsy have small and short legs in contrast to normally developed chest, shoulders, and arms. In spastic diplegia, there is severe spasticity in the legs, minimal spasticity in the arms, and little or no deficit in speaking or swallowing; whereas in double hemiplegia, there is pseudobulbar palsy and more arm weakness than leg weakness
Spastic – ataxic gait	If, in addition to spasticity, the disease impairs the dorsal columns or cerebellum, as in spinocerebellar degeneration or multiple sclerosis, patients have a wider-based, unsteady gait and take irregular steps
Basal ganglia gaits	
Marche à petits pas (gait with little steps)	Elderly patients with small vessel disease due to arteriosclerosis, appearing as multiple lacunar infarcts in the basal ganglia, develop a characteristic gait with shuffling, short steps, and are unable to lift the feet from the ground. Progress in walking ceases if the patient tries to speak (they are unable to walk and talk or chew gum at the same time)
Parkinsonian gait	Patients with degeneration of the substantia nigra or neuroleptic medication toxicity rise and walk slowly with short steps, lack any arm swing, turn en bloc like a statue rotating on a pedestal, and have a tremor when at rest, which disappears during intentional movement
Festinating gait	When patients are pushed after prior warning, they move forward or backward with tiny steps of increasing speed and decreasing length, as if chasing the center of gravity, and they may fall over
Choreiform gait	When patients with Huntington's or Sydenham's chorea walk, the play of finger and arm movements increases, or may even appear clearly for the first time. Random missteps mar the evenness of the strides, as the choreiform twitches supervene
Spastic – athetoid gait	A combination of athetosis and moderate spastic diplegia or double hemiplegia secondary to perinatal hypoxic damage of the basal ganglia and thalamus has the characteristics of spastic gait, associated with slow, writhing movements of fingers and arms, which tend to increase during walking
Equinovarus dystonic gait	Dystonia may initially manifest in a child as an intermittent inturning of the foot that impedes walking, while in later stages dystonic truncal contortions and tortipelvis may cause the trunk to incline strongly forward

Dromedary gait	Patients with dystonia musculorum deformans may take giant, uneven strides, exhibiting flexions or rising and falling of the trunk, like the ungainly gait of a dromedary camel
Cerebral gaits	Elderly patients with severe bilateral cerebral disease secondary to Alzheimer's disease, multi-infarct dementia, or senility have difficulty in initiating the sequence of movements for rising, standing, and walking. When starting to walk, patients makes several efforts to move the feet, appearing somewhat puzzled—as if searching for lost motor engrams, or the right buttons to press in order to set off
Dancing bear gait	The effort to progress may only result in stepping on the spot, as if trying to free the feet from thick, sticky mud
Apraxic gait	When patients do manage to make progress, the feet cling to the floor as if magnetized
Psychiatric gaits	
Astasia – abasia	The patient tilts, gyrates, and undulates all over the place, proving unwittingly—by not falling during this marvelous demonstration of agility—that strength, balance, coordination, and sensation must still be intact
Sexual behavior and biological orientation gaits	The gait is characteristic of and diagnostic of the biological and behavioral state of a person's brain
Heterosexual male – female gait	

Neurotrauma

Glasgow Coma Scale*

	Response	Score
Eye opening	Spontaneous	4
	To command	3
	To pain	2
	No response	1
Best motor response	Obeys	6
	Localizes	5
	Withdrawal	4
	Flexor	3
	Extensor	2
	No response	1
Best verbal response	Oriented and conversed	5
	Confused conversation	4
	Inappropriate words	3
	Incomprehensible sounds	2
	No response	1

*Teasdale G, Jennett B: Assessment of coma and impaired consciousness. A practice scale. *Lancet* 2: 81–84, 1974

Pediatric Coma Scale

	Response	Score
Eye opening	Spontaneous	4
	To voice	3
	To pain	2
	No response	1
Best motor response	Flexes / extends	4
	Withdraws	3
	Hypertonic	2
	Flaccid	1
Best verbal response	Cries	3
	Spontaneous respiration	2
	Apneic	1

The Unconscious Patient

Intracranial lesions

Cerebrovascular disease

- Hemorrhage
 - Intracerebral
 - Subarachnoid
 - Epidural hematoma
 - Subdural hematoma
- Infarction
 - Arterial occlusion
 - Venous occlusion
- Trauma (closed head injury)
- Epilepsy and postictal states
- Neoplasm
 - Primary
 - Metastatic
- Brain edema
- Infection
 - Meningitis
 - Encephalitis
 - Abscess
- Primary neuronal or glial disorders
 - Progressive multifocal leukoencephalopathy (PML)
 - Creutzfeldt-Jakob disease
 - Adrenoleukodystrophy
 - Gliomatosis cerebri

Toxic and metabolic encephalopathy

Exogenous

- Sedatives or psychotropic drugs
 - Ethanol
 - Barbiturates
 - Opiates
 - Tricyclic antidepressants and anticholinergic drugs
 - Phenothiazines
 - Heroin
 - Amphetamines
- Acid poisons
 - LSD, mescaline
 - Methyl alcohol
 - Paraldehyde
- Other
 - Organic phosphates
 - Cyanide
 - Heavy metals
 - Cardiac glycosides
 - Steroids (insulin)

Endogenous

- Hyperglycemia
 - Ketotic coma
 - Nonketotic coma
- Hypoglycemia
 - Endogenous insulin, liver disease, etc.

- Uremic coma Kidney failure
- Hepatic coma Liver failure
- CO₂ narcosis Pulmonary failure
- Electrolyte disturbance
 - Dehydration
 - Drug-induced
 - Heat stroke
 - Fever
- Endocrine
 - Pituitary apoplexy and necrosis
 - Adrenal (Addison's disease, Cushing's disease, pheochromocytoma)
 - Thyroid (myxedema, thyrotoxicosis)
 - Pancreas (diabetes, hypoglycemia)
- Systemic illness
 - Cancer
 - Sepsis
 - Porphyria

Anoxia

Hypoxic

Decreased blood PO_2 and O_2 content

- Pulmonary disease
- Decreased atmospheric oxygen

Anemic

Decreased blood O_2 content, PO_2 normal

- CO poisoning
- Anemia
- Methemoglobinemia

Ischemia

Decreased cardiac output

Congestive heart failure

- Cardiac arrest
- Severe cardiac arrhythmias
- Aortic stenosis

Decreased systemic peripheral resistance

- Blood loss and hypovolemic shock
- Syncopal attack
- Anaphylactic shock

Intracranial vessel disease

- Increased vascular resistance
 - Subarachnoid hemorrhage
 - Bacterial meningitis
 - Hyperviscosity (polycythemia, sickle-cell anemia)
- Widespread small-vessel occlusions
 - Subacute bacterial endocarditis
 - Disseminated intravascular coagulation (DIC)
 - CNS arteritis (systemic lupus erythematosus)
 - Fat embolism

Mental illness

Conversion hysteria

Catatonic stupor Often a manifestation of schizophrenia

Dissociative or “fugue”
state

Severe psychotic de-
pression

Malingering

CNS: central nervous system; DIC: disseminated intravascular coagulation; LSD: lysergic acid diethylamide; PML: progressive multifocal leukoencephalopathy.

Metabolic and Psychogenic Coma

In unresponsive patients, metabolic disease can be distinguished from psychiatric disease on the basis of differences between the mental state, the motor signs, the breathing pattern, the electroencephalogram (EEG), and the oculovestibular or caloric reflexes.

Comatose patients with metabolic disease

- Confusion, stupor and coma precede motor signs
- The motor signs are usually symmetrical
- The EEG is generally very slow
- Caloric stimulation elicits either tonic deviation of the eyes or, if the patient is deeply comatose, no response
- Seizures are common

Psychologically unresponsive patients

- The EEG is normal
 - Caloric stimulation: there is a normal response to caloric irrigation, with nystagmus having a quick phase away from the side of ice-water irrigation; there is little or no tonic deviation of the eyes. Nystagmus is present
 - Lids close actively
 - No pathological reflexes are present
 - Pupils are reactive or dilated (cycloplegics)
 - Muscle tone is normal or inconsistent
-

EEG: electroencephalogram.

Metabolic and Structural Coma

Metabolic and structural diseases are distinguished from each other by combinations of motor signs and their evolution, and electroencephalogram (EEG) changes.

Comatose Patients with Metabolic Disease

Patients are usually suffering from partial dysfunction affecting many levels of the neuraxis simultaneously, while at the same time the integrity of other functions originating at the same level is retained. In general, a suspicion of metabolic disease should be raised if the following findings are present.

Cognitive and behavioral changes (If these represent the earliest or the only signs)

Cognition

- Poor memory
- Disorientation
- Language impairment
- Inattention
- Dyscalculia

Behavior

- Agitation
- Delusions and/or hallucinations

Diffusely abnormal motor signs (Bilateral and symmetrical)

Tremor

Myoclonus

Bilateral asterixis

EEG Diffusely, but not focally, slow

Acid–base abnormalities Frequent, with hyperventilation and hypoventilation

Pupillary reactions Usually preserved even if the patient is comatose

EEG: electroencephalogram.

Comatose Patients with Gross Structural Disease

Patients generally have a rostrocaudal deterioration that is characteristic of supratentorial mass lesions, which does not occur in metabolic brain disease, and the anatomical defect is not regionally restricted as it is with subtentorial damage. The clinical signs are certainly helpful, but there is too much overlap to allow the diagnosis to be established by the clinical findings alone. It is not uncommon, for example, for patients with hepatic encephalopathy or hypoglycemia to develop focal motor signs such as hemiparesis or visual field defects, which are characteristic of a structural lesion, whereas patients with multiple brain metastases may develop nothing other than a global alteration of cognitive function.

The laboratory screening listed below are therefore essential for excluding structural disease.

CT/MRI with enhancement	E.g., metastases, infection
Lumbar puncture	E.g., infection, meningeal carcinomatosis
EEG	
Hematological work-up	
– Blood cultures	E.g., sepsis, septic emboli
– Full blood count	
– Coagulation tests	E.g., PT, PTT, FDP
– Blood gases	
Biochemical work-up	
– Electrolytes	E.g., Na, K, Ca, Mg, PO ₄
– BUN, creatinine, glucose, lactate	
– Endocrine tests	E.g., FSH, T ₃ , T ₄ , cortisol
– Thiamine, folic acid, vitamin B ₁₂	
Drug levels	E.g., digoxin, anticonvulsants, theophylline, etc.

BUN: blood urea nitrogen; CT: computed tomography; EEG: electroencephalogram; FDP: fibrin degradation product; FSH: follicle-stimulating hormone; MRI: magnetic resonance imaging; PT: prothrombin time; PTT: partial thromboplastin time; T₃: triiodothyronine; T₄: thyroxine;

The patient should be suspected of suffering from structural brain disease, either alone or in combination with metabolic brain disease, if the following findings are present.

Coma-Like States

The basic brain structure that is responsible for arousal is the ascending reticular activating system (ARAS). This system originates in the brain stem reticular formation, and extends to the cortex via the diffuse or nonspecific thalamofrontal projection system. Reticular activation by means of an external stimulus alerts widespread areas of the cortex and subcortex, enabling the patient to be alert and to think clearly, learn effectively, and relate meaningfully to the environment.

If there is damage to the extension of the brain stem reticular system in the thalamus or hypothalamus, the full picture of coma will not occur. Since the brain stem portion of the ARAS is intact, reticular activity innervates the nuclei of the extraocular nerves, and patients can open their eyes and look about. The cortex, however, is not sufficiently stimulated to produce voluntary movement or speech. These patients are in a coma-like state. The characteristics of the coma-like states are presented in the following tables:

Characteristics of coma-like states

Diagnosis	Level of consciousness	Voluntary movements	Eye responses	Speech	Muscle tone	Reflexes	Clinical and pathological studies	EEG findings
Akinetic mutism (deafferentation)	Patient seemingly awake, but silent and motionless	Lack of movement; more often, patients move one side or one arm in a stereotyped fashion in response to noxious stimuli	Eyes dart in the direction of moving objects	Vocalizing little or not at all. With stimulation, can produce normal, short phrases	Usually normal; sometimes slight increase in legs	“Frontal release signs” such as grasping or sucking may be present. Often display signs of corticospinal tract involvement, such as hyperreflexia, and a Babinski sign	Lesions affect: 1) bilaterally the frontal region (anterior cingulate gyri); 2) the diencephalomesencephalic reticular formation and globus pallidus; 3) the hypothalamus; or 4) the septal area. The most common cause is occlusion of the small vessels entering the brain stem from the tip of the basilar artery. Less commonly due to severe acute hydrocephalus, and direct compression by tumors	EEG shows slow wave abnormalities

Characteristics of coma-like states

Diagnosis	Level of consciousness	Voluntary movements	Eye responses	Speech	Muscle tone	Reflexes	Clinical and pathological studies	EEG findings
Persistent vegetative state	Wakefulness accompanied by an apparent total lack of cognitive function.	Usually few or none, depending on the areas of damaged brain.	Eyes open spontaneously in response to verbal stimuli	None, or occasional grunts or groans. Some patients produce a few words	Variable, often increased. Extremities often in flexion	Variable, usually increased with pathological reflexes	Damage to forebrain structures causing severe mental loss but preservation of patient's autonomic or vegetative functions	EEG in several instances essentially isoelectric, but in other cases regained various patterns of rhythm and amplitude; not consistent from one case to the next
Apallic state	Awake; no meaningful interaction with environment	Little or no purposeful movement; mostly reflex or mass movements	Open, searching, but no real eye contact	None, or occasional grunting	Increased in all limbs. Extremities often in bilateral decortication and double hemiplegia	Increased in all extremities, with primitive reflexes. Brain stem reflexes intact	Diffuse bilateral degeneration of the cerebral cortex and absent neocortical function, but relatively intact brain stem function. Sometimes follows anoxia, hypoglycemia, circulatory or metabolic embarrassment, or encephalities	EEG shows severe diffuse slowing. With no response to auditory or noxious stimuli

Cont. ▶

Characteristics of coma-like states

Diagnosis	Level of consciousness	Voluntary movements	Eye responses	Speech	Muscle tone	Reflexes	Clinical and pathological studies	EEG findings
Locked-in syndrome (deafferentation)	Awake, alert, aware of self, and capable of perceiving sensory stimuli	None; motionless	Open, with normal following and good eye contact. Vertical eye or eyelid movements (blinking) are retained. In some cases, lateral gaze is also paralyzed	Aphonia, due to interruption of corticobulbar fibers to the lower cranial nerves	Acute spastic tetraplegia	Increased in all extremities	Damage to the descending motor pathways bilaterally in the upper pontine tegmentum, interrupting all corticospinal and corticobulbar fibers at the level of the abducens and facial nuclei, but sparing the more dorsal reticular formation. Usually due to basilar artery thrombosis with ventral pontine infarction, pontine hemorrhage or tumor, or central pontine myelinolysis. Rarely, tentorial herniation, severe polyneuropathies, or myasthenia gravis may also cause this syndrome	EEG reflects the patient's state of wakefulness

EEG: electroencephalogram.

- Abnormal focal motor signs (including focal seizures) occur, which progress rostrally to caudally, and are asymmetrical
- Neurological signs point to one anatomical area (mesencephalon, pons, medulla)
- Specific cognitive function disorders, such as aphasia, acalculia, or agnosia, appear out of proportion to a general overall decrease in mental state
- The EEG may be slow, but in addition there is a focal abnormality
- The patient is at particular risk of developing one of the complications of cancer that may mimic metabolic brain disease, particularly DIC or meningitis

EEG: electroencephalogram.

Trauma Score

The trauma score is a numerical grading system for estimating the severity of injury. The score consists of the Glasgow Coma Scale (reduced to approximately one-third of its total value) and measurements of cardiopulmonary function. Each parameter is given a number (high for normal and low for impaired function). The severity of the injury is estimated by adding up the numbers; the lowest score is 1, and the highest score is 16.

Parameter	Range	Score
Respiratory rate	10 – 24/min	4
	25 – 35/min	3
	36/min or greater	2
	1 – 9 min	1
	None	0
Respiratory expansion	Normal	1
	Retractive/none	0
Systolic blood pressure	90 mmHg or greater	4
	70 – 80 mmHg	3
	50 – 69 mmHg	2
	0 – 49 mmHg	1
	No pulse	0
Capillary refill	Normal	2
	Delayed	1
	None	0

The following table shows the projected estimate of survival for each value in the trauma score, based on results from 1509 patients with blunt or penetrating injury.

Trauma score	Survival (%)
16	99
15	98
14	96
13	93
12	87
11	76
10	60
9	42
8	26
7	15

Trauma score	Survival (%)
6	8
5	4
4	2
3	1
2	0
1	0

From: Champion HR, Copes WS, Sacco WJ, et al. The Major Trauma Outcome Study: establishing national norms for trauma care. *J Trauma* 1990; 30: 1356–65.

Respiratory Patterns in Comatose Patients

Anatomical level of pathological lesion	Respiratory patterns
Forebrain damage	
Bilateral widespread cortical lesions	
Bilateral thalamic dysfunction	Eupneic, with sighs or yawns
Lesions in the descending pathways anywhere from the cerebral hemispheres to the level of the upper pons	Cheyne–Stokes
Hypothalamic-midbrain damage	
Patients with dysfunction involving the rostral brain stem tegmentum. Lesions have been found between the low midbrain and the middle third of the pons, destroying the paramedian reticular formation just ventral to the aqueduct and fourth ventricle	Sustained regular hyperventilation (despite the prolonged and rapid hyperpnea, patients are hypocapnic and relatively hypoxic, and have pulmonary congestion, leading rapidly to pulmonary edema. This type of breathing can therefore not be termed “primary hyperventilation”)
Lower pontine damage	
Patients have lesions or dysfunction of the lateral tegmentum of the lower half of the pons adjacent to the trigeminal motor nucleus. More prolonged apneusis has developed when the lesions extend caudally to involve the dorsolateral pontine nuclei	Apneustic breathing
Pontomedullary junction damage	
Patients have lesions at the lower pontine or high medullary level	Cluster breathing
Medullary damage or dysfunction	
Follows lesions of the respiratory centers located in the reticular formation of the dorsomedial part of the medulla and extending down to or just below the obex	Ataxic breathing (Biot) or “atrial fibrillation of respiration” (inspiratory gaps of diverse amplitude and length intermingle with periods of apnea)

Pupillary Changes in Comatose Patients

Brain stem areas controlling consciousness are anatomically adjacent to those controlling the pupils. Pupillary changes, therefore, are a valuable guide to the presence and location of brain stem diseases producing coma. Pupillary shape, size, symmetry, and response to light reflect patency or nonpatency of the brain stem and third nerve function. The pupillary light reflex is very sensitive to mechanical distortion, but very resistant to metabolic dysfunction. Abnormalities of this reflex, particularly when unilateral, are the single most important physical sign potentially distinguishing between structural and metabolic coma.

Location of the coma producing structural lesions	Pupils
Sleep or diencephalic dysfunction (metabolic coma)	Small, reacting well to light ("diencephalic pupils")
Unilateral hypothalamic damage or dysfunction	Miosis and anhidrosis (ipsilateral to the lesion)
Midbrain tectal or pretectal damage	Medium-sized (5–6 mm) or slightly large, "fixed" hippus (spontaneous oscillations in size), becoming larger when the neck is pinched (ciliospinal reflex)
Midbrain tegmental damage (third cranial nerve nucleus involvement)	Medium-sized (4–5 mm), often unequal, usually slightly irregular (irregular constriction of the sphincter of the iris results in a pear-shaped pupil), midbrain corectopia (displacement of the pupil to one side), fixed to light and lack of ciliospinal response
Pontine tegmental damage	Pinpoint, constricting to light (due to a combination of sympathetic damage and parasympathetic irritation)
Pontine lateral, lateral medullary, and ventrolateral cervical cord damage or dysfunction	Ipsilateral Horner's syndrome
Peripheral lesions	The light reflex is sluggish or absent, and the pupil becomes widely dilated (7–8 mm) due to sparing of the sympathetic pathways (Hutchinson's pupil). Oval-shaped pupils due to nonuniform paresis of the pupil sphincter, causing an eccentric antagonistic effect of pupil dilators

Spontaneous Eye Movements in Comatose Patients

Location of the coma-producing structural damage	Spontaneous eye movements
Bilateral cerebral damage (bilateral cerebral ischemia), with intact brain stem. Rarely seen in posterior fossa hemorrhage	Periodic alternating gaze (ping-pong gaze). Roving of the eyes over the full swing of the horizontal plane in oscillating cycles of 2–5 seconds
Mid- or lower pontine damage	Nystagmoid jerking of a single eye, in a horizontal, vertical or rotatory fashion and occasionally bilateral disconjugate vertical and rotatory eye movements (one eye may rise and intort as the other falls and extorts)
Intrinsic pontine lesions (hemorrhage, tumor, infarction etc.), extra-axial posterior fossa masses (hemorrhage or infarction), diffuse encephalitis, and toxic metabolic encephalopathies	Ocular bobbing (intermittent, often conjugate, brisk, bilateral downward movement of the eyes, with slow return to the mid-position). When associated with preservation of horizontal eye movements, this becomes a specific finding, but is not pathognomonic of acute pontine injury
Diffuse brain dysfunction and encephalopathy (anoxic coma, or after prolonged status epilepticus). No definite brain stem lesion	Ocular dipping (slow downward eye movement, with fast return to mid-position). Brain stem horizontal gaze reflexes are usually intact
Pontine hemorrhage, viral encephalitis, and metabolic encephalopathy	Reverse ocular bobbing (fast-upward eye movement with a slow return to mid-position)
Pretectal area (acute hydrocephalus)	Pretectal pseudobobbing (arrhythmic, repetitive downward and inward, “V-pattern”, eye movements at a rate ranging from one per three seconds to two per second, with an amplitude of one-fifth to half of the full voluntary range). Often associated with abnormal pupillary light reactions, intact horizontal eye movements, open and often retracted eyelids, a blink frequently preceding each eye movement, and a mute or stuporous patient. This situation requires immediate surgical decompression of hydrocephalus

Severe pontine damage (locked-in patients)	Vertical ocular myoclonus (pendular, vertical isolated movements of the eyes, with a frequency of 2 Hz, and other rhythmic body movements after a six-week to nine-month delay)
--	---

Abnormal Motor Responses in Comatose Patients

Location of the coma producing the structural lesion	Abnormal motor responses
Cerebral hemispheres, diencephalon, precollicular level of the midbrain	Decorticate rigidity (adduction of the shoulder and arm, flexion at the elbow, and pronation and flexion at the wrist; the leg remains extended at the hip and knee)
Intercollicular level of the midbrain, down to the middle of the pontine tegmentum	Decerebrate rigidity (extension and pronation of the upper extremities and forcible plantar flexion of the foot. Produced by noxious stimuli; opisthotonos develops periodically, with hyperextension of the trunk, hyperpronation of the arms, and clenched teeth)
Pontine tegmentum	Abnormal extension of the arms, with weak flexion of the legs
Below the junction between the lower and middle third of the pons, medulla	Flaccid or absent motor response (skeletal muscle flaccidity marks the initial motor phase of acute functional spinal cord transection—"spinal shock")

Infections of the Central Nervous System

Bacterial Infections

Streptococcus pneumoniae
Haemophilus influenzae
Neisseria meningitidis
Staphylococcus aureus
Staphylococcus epidermidis
Streptococcus, group A
Streptococcus, group B
Listeria monocytogenes
Escherichia coli
Proteus mirabilis
Pseudomonas aeruginosa
Mycobacterium tuberculosis
Acinetobacter species

The incidence of bacterial meningitis in the USA is 4–10 cases per 100 000 persons per year. The causative agents vary with the age of the patients. The mortality rates for all types of meningitis are approximately 20%, except in the case of *Haemophilus influenzae* meningitis, in which the mortality is less than 3%.

The classic symptoms in adults are headaches, fever, stiff neck, and further changes in the level of consciousness, photophobia, seizures, vomiting, profuse sweats, myalgia, and generalized malaise. The classic signs of Kerning and Brudzinski are present in about 50% of adults. Cranial nerve palsies (nerves III, IV, VI, and VII) occur in 10–20% of patients. Focal neurological deficits (e.g., dysphasia, hemiparesis) due to ischemia and infarction adjacent to the subarachnoid space are less frequent. Seizures occur in up to 40% of cases. A petechial rash is common with meningococemia (up to 50% of cases) and less frequently with *Staphylococcus aureus*, *Acinetobacter* species, and *Rickettsia* species. Patients may develop signs of raised intracranial pressure, with papilledema, temporal lobe herniation, and coma.

In very young infants and in the elderly, fever and vomiting may be more prominent than headaches, and the signs of meningitis may be minimal.

Viral Infections

RNA Viruses

Enteroviruses	Polioviruses, coxsackievirus A, B, echovirus, and enterovirus. The CNS is the most commonly involved organ system during the spread of human enteroviruses from the alimentary tract. A number of neurological syndromes are recognized, and each can be caused by a number of different types of enteroviruses: e.g., aseptic meningitis, encephalitis, lower motor neuron paralysis, acute cerebellar ataxia, cranial nerve palsies, chronic persistent infections
Arboviruses	Of the 450 RNA viruses transmitted by arthropods, the two most common families causing encephalitis are: a) the Togaviridae (e.g., western equine encephalitis, eastern equine encephalitis, St. Louis encephalitis) and b) the Bunyaviridae (California encephalitis viruses). Encephalitis caused by arthropod-borne viruses accounts for about 10% of all reported cases annually. Arboviruses can produce fulminating encephalitis or aseptic meningitis. Neither the clinical picture nor the laboratory abnormalities distinguish one arbovirus infection from another. In fact, arboviral encephalitis cannot be differentiated from any of the other causes of encephalitis clinically. Similarly, the pathological findings in the brain are also non-specific for arboviral infection. The diagnosis of arboviral infections is made serologically (hemagglutination inhibition, neutralizing antibodies, and complement fixation late in the disease)
Measles	Encephalitis occurs in about 0.5–1.0 of every 1000 measles cases. The clinical picture is characterized by a recurrence of fever and development of headache, lethargy, irritability, confusion, and seizures in up to 56%. The great majority of patients return to normal within 48–72 hours, but about 30% progress to persistent coma. Approximately 15% of patients with measles encephalitis die, and a further 25% develop severe brain damage and neurological deficits, such as mental retardation, seizures, deafness, hemiplegia, and severe behavioral disorders
Mumps	CNS involvement as a complication of mumps occurs in approximately 15% of patients. Meningitis is far more common than encephalitis. The neurological features are the same as in other types of encephalitis, and gradually resolve within one or two weeks. Death occurs in less than 2% of reported cases

Rabies	The symptoms of the neurological phase present in two different types, the “furious” and the “paralytic” presentation. The furious type is characterized by agitation, hyperactivity, bizarre behavior, aggressiveness with attempts to bite other persons, disorientation, and hydrophobia, fever, hypersalivation and seizures, which may cause death in one-quarter of the patients. The paralytic type affects approximately 10–15% of patients, and presents with a progressive, ascending flaccid, symmetrical paralysis or as an asymmetrical paralysis involving the exposed extremity. Death can occur during the acute stage due to cardiac and respiratory abnormalities. The diagnosis can be made by histopathology, virus cultivation, serology, or detection of viral antigen
---------------	--

CNS: central nervous system.

DNA Viruses

Herpesviruses

Herpes simplex virus type 1 (HSV-1)

The reactivation and replication of HSV leads to inflammation and extensive necrosis and edema of the medial temporal lobe and orbital surface of the frontal lobe of immunocompetent patients, producing the characteristic clinical picture. Patients develop fever, headache, irritability, lethargy, confusion and focal neurological signs, such as aphasia, motor and sensory deficits, and seizures (major motor, complex partial, focal, and absence attacks). CSF examination, electroencephalography (widespread, periodic, stereotyped complexes of sharp and slow waves at regular intervals of 2–3 seconds), brain imaging, and biopsy make HSV encephalitis easy to distinguish diagnostically from all other forms of viral encephalitis

Herpes simplex virus type 2 (HSV-2)

Usually, two types of neurological condition may develop:

- Aseptic meningitis; about 5% of cases of aseptic meningitis in the USA are caused by genital HSV-2. The typical clinical picture of headache, fever, stiff neck, and marked CSF lymphocytic pleocytosis is often preceded by pain in the genital or pelvic region
- Encephalitis, identical to that caused by HSV-1, occurring most often in the newborn and rarely in the immunocompromised adult

Varicella zoster virus (VZV) Two neurological conditions usually develop:

- The virus causes chickenpox (varicella) in childhood, becomes latent in the dorsal root ganglia, and reactivates decades later to produce shingles (zoster) in adults. Subacute encephalitis develops against a background of cancer, immunosuppression, and AIDS, and death is common
- Granulomatous arteritis may develop, characterized by an acute focal deficit with TIA or stroke and mental symptoms. The mortality rate is 25%

Cytomegalovirus (CMV) Most congenital CMV infections are asymptomatic, although many carriers develop sensorineural hearing loss and intellectual handicaps, and less often seizures, hypotonia, and spasticity. In severe meningoencephalitis, lethargy and coma occur

Acquired CMV infections in immunocompromised adults, particularly AIDS patients, are very common. CMV is an important cause of encephalitis (progressive dementia, headache, focal or diffuse weakness, and seizures, attributed to CMV vasculitis or foci of demyelination), myelitis, and polyradiculitis (beginning insidiously as a cauda equina syndrome with distal weakness, paresthesias, incontinence, and sacral sensory loss)

Epstein–Barr virus (EBV) EBV causes infectious mononucleosis, and is associated with nasopharyngeal carcinoma and Burkitt's lymphoma. EBV meningoencephalitis affects both immunocompetent and immunocompromised individuals, causing acute cerebellar ataxia, athetosis and chorea, chiasmal neuritis, or in more serious cases, meningoencephalopathy, stupor and coma. DNA of Epstein–Barr virus has been detected in CNS lymphoma tissue

Adenovirus

AIDS: acquired immune deficiency syndrome; CMV: cytomegalovirus; CNS: central nervous system; CSF: cerebrospinal fluid; EBV: Epstein–Barr virus; HSV: herpes simplex virus; TIA: transient ischemic attack; VZV: varicella zoster virus.

Slow Viruses

Subacute sclerosing panencephalitis (SSPE)	SSPE is a chronic measles infection in children between 5 and 15 years and in young adults. The brain shows diffuse and widespread inflammation and necrosis in both the gray and white matter. The disease leads to severe neurological dysfunction (stage 1, decline in school performance and behavioral changes; stage 2, myoclonic jerks; stage 3, decerebrate rigidity and coma; stage 4, loss of cortical functions), and on average, patients survive for about three years
Progressive multifocal leukoencephalopathy (PML)	PML is a subacute demyelinating disease caused by the JC polyomavirus, and usually affects immunocompromised individuals. Patients develop progressive multifocal neurological symptoms and signs (mental deficits 36.1%, visual deficits 34.7%, motor weakness 33.3%, speech deficits 17.3%, loss of coordination 13%, tone alterations 2.7%, miscellaneous 17.3%) that typically result in death within 6–12 months, although they occasionally survive up to 3–5 years
Spongiform encephalopathies or prion diseases	Of the four human diseases (Creutzfeldt–Jakob disease (CJD), Gerstmann–Sträussler–Scheinker syndrome (GSS), kuru, and fatal familial insomnia, CJD is by far the most common, although kuru was the first to be described. Patients with CJD have behavioral disturbances that progress to frank dementia, characterized by memory loss, sleep disorders, intellectual decline, myoclonic spasms, seizures, visual disturbances, cerebellar signs, and lower motor neuron disturbances. Most patients live 6–12 months, and a few up to five years

Human Immunodeficiency Virus (HIV)

Among acquired immune deficiency syndrome (AIDS) patients, 40–60% develop significant neurological symptoms or signs, and approximately 10–20% present with symptoms of neurological illness.

Two forms of meningitis have been described with HIV-1 infection. At the time of seroconversion to HIV-1, most patients develop cerebrospinal fluid (CSF) abnormalities, and a few develop symptoms of headache, meningitis, encephalitis, myelopathy, and plexitis. This acute meningitis is clinically indistinguishable from other forms of aseptic meningitis.

Chronic recurring meningitis can also occur, characterized by headaches and CSF abnormalities without signs of meningeal irritation. Late in the course of the HIV-1 infection, particularly when there is marked immunosuppression, patients may develop HIV-1–associated encephalopathy (AIDS dementia complex), HIV-1–associated myelopathy (spinal vacuolar myelopathy), and neurological problems secondary to opportunistic processes.

Fungal Infections

Cryptococcus neoformans

The point of entry for *Cryptococcus* is the lungs. Pulmonary infection is not evident in healthy individuals, but becomes invasive in immunocompromised patients. Cryptococcal meningitis is the most common CNS infection (50%) in chronically immunosuppressed non-AIDS patients. Cryptococcal meningitis presents as a chronic febrile syndrome with headache. The ensuing meningoencephalitis reflects cognitive changes or dementia, irritability, personality changes, mass lesions with focal neurological deficits, and ocular abnormalities (papilledema, with or without loss of visual acuity, and cranial nerve palsies) in 40% of patients

Zygomycetes (especially *Mucor*, *Rhizopus*)

Rhinocerebral disease typically occurs in patients with diabetic ketoacidosis or leukemia. The infection often begins as ulceration in the paranasal sinuses or in the palate, and may spread along perivascular and perineural channels through the cribriform plate into the frontal lobe, or through the orbital apex into the cavernous sinus. The Mucorales characteristically invade blood vessels, causing thrombosis and hemorrhagic infarctions as well as cerebritis

Aspergillus fumigatus

Aspergillosis involving the CNS has findings similar to those of mucormycosis. CNS aspergillosis may result either from direct extension of nasal cavity and paranasal sinus infection, or more commonly from hematogenous dissemination. By direct extension, *Aspergillus* invades the cavernous sinus and circle of Willis, resulting in angitis, thrombosis, and infarction. In hematogenous spread, septic infarction occurs, with associated cerebritis and abscess formation

Nocardia asteroides

CNS infection occurs in 0.3% of immunocompromised patients, as in AIDS, resulting in fever, headache, focal neurological deficits, and multiple brain abscesses

<i>Candida albicans</i>	Candida CNS infection is a manifestation of disseminated disease, and is associated with intravenous drug use, indwelling venous catheters, abdominal surgery, and corticosteroid therapy. CNS infection with <i>Candida</i> species often results in scattered intraparenchymal granulomatous microabscesses secondary to arteriolar occlusion. Meningitis is a common feature of CNS candidiasis, resulting from invasion of meningeal microvasculature by small groups of yeast cells
<i>Coccidioides immitis</i>	Hematogenous spread of the endospores into the intracranial space results in meningeal inflammation, with infectious purulent and caseous granulomas, particularly at the base of the brain. Multiple coccidioidal microabscesses can be found in the cerebellum and periventricular area, causing secondary hydrocephalus
<i>Blastomyces dermatitidis</i>	Hematogenous dissemination results in blastomycotic meningitis, with an acute or fulminant onset of headache, stiff neck, and focal signs

AIDS: acquired immune deficiency syndrome; CNS: central nervous system.

Parasitic and Rickettsial Infections

Protozoa

Toxoplasma gondii

- Congenital infection
 - Acute *Toxoplasma* infection occurs in pregnant women in 30–45% of, or the entire, gestation period, with the rate of transmission being highest during the third trimester. The CNS involvement consists of hydrocephalus or microcephaly, chorioretinitis, or cerebral calcifications. The *differential diagnosis* includes other congenital (intrauterine) infections, grouped as the TORCH syndrome:
 - Toxoplasmosis
 - Other (syphilis)
 - Rubella
 - Cytomegalovirus
 - Herpes simplex virus
- Acquired infection
 - Children and adults who are at risk for serious toxoplasmosis include those with malignancies, individuals undergoing immunosuppressive therapy for organ transplantation or connective tissue disorders, and most recently, those with AIDS. CNS toxoplasmosis begins with headache, lethargy, seizures, focal neurological abnormalities, and signs of increased intracranial pressure

Amebae

- *Entamoeba histolytica* CNS amebiasis is still an extremely rare complication. CNS amebic cerebritis or abscess usually affects patients who have also had liver abscesses, and results from hematogenous dissemination of amebae. Signs indicating CNS involvement include headache, altered sensorium, fever, convulsions, and focal neurological deficits
- *Naegleria* and *Acanthamoeba* *Naegleria* species produce primary amebic meningoencephalitis in young individuals during the summer months and with a history of aquatic activities. The course of the disease is fulminating, progressing from signs of meningismus to coma in virtually all cases. *Acanthamoeba* species produce a subacute CNS disorder consisting of altered mental status, convulsions, fever, and focal neurological deficits. Affects patients with underlying medical conditions and predisposing factors such as broad-spectrum antibiotics or immunosuppressive therapy, radiation therapy, alcoholism, or pregnancy
- Malaria Cerebral malaria, the most common complication of malaria due to *Plasmodium falciparum*, usually begins abruptly with generalized convulsions and altered sensorium, abnormal posturing, or cranial nerve palsies. Most neurological manifestations persist for 24–72 hours, and then proceed either to death or complete recovery
The *differential diagnosis* of cerebral malaria includes:
 - Metabolic encephalopathy secondary to uremia
 - Drugs or toxins
 - Meningitis (bacterial or viral)
 - Encephalitis (bacterial or viral)
 - Traumatic encephalopathy
 - Brain tumor
- Trypanosomiasis Neurological complications can occur directly from meningoencephalitis, consisting of
 - African: insomnia, headache, loss of concentration, personality changes, hallucinations, and altered sensation
 - American: convulsions or altered level of consciousness. Rarely, CNS granulomas can develop and induce focal neurological deficits

AIDS: acquired immune deficiency syndrome; CNS: central nervous system.

Cestodes

Cysticercosis	The features of CNS cysticercosis depend on the number, location, and size of the cysts and the intensity of the evoked inflammatory response. Cysts can invade cerebral parenchyma and induce seizures (50% of patients), obstruct the CSF flow and produce hydrocephalus (30% of cases), involve the meninges and produce meningitis, occlude vascular structures and cause stroke, or less frequently, involve the spinal cord and cause paraparesis
<i>Echinococcus granulosus</i>	The CNS is involved in only 1–2% of <i>Echinococcus granulosus</i> infections. The larvae usually produce single mass lesions within the brain parenchyma that cause headache, convulsions, personality changes, memory loss, or focal neurological deficits
<i>Taenia multiceps</i>	This can also involve the posterior fossa, leading to signs of increased intracranial pressure or obstructive hydrocephalus
<i>Diphyllobothrium</i> <i>Spirometra</i> species	

CNS: central nervous system; CSF: cerebrospinal fluid.

Nematodes

Visceral larva migrans	
– <i>Toxocara canis</i>	Rare but serious neurological complications occur, including headache, convulsions, or behavioral changes and hemiplegia
– <i>Toxocara cati</i>	
– <i>Baylisascaris procyonis</i>	Raccoon ascaris
Eosinophilic meningitis	
– <i>Angiostrongylus cantonensis</i>	The lung worm of rats. Direct invasion of the CNS produces headache, vomiting, neck stiffness, fever, paresthesias, convulsions and cranial nerve palsies (sixth or seventh nerve) The <i>differential diagnosis</i> of CSF eosinophilia includes: <ul style="list-style-type: none"> • Foreign body • CNS malignancy • <i>Coccidioides immitis</i> meningitis • Cysticercosis • Other parasitic infections (<i>Paragonimus westermani</i>, <i>Gnathostoma spinigerum</i>, or <i>Schistosoma</i> species)

<p>Trichinosis</p> <ul style="list-style-type: none"> – <i>Trichinella spiralis</i> – <i>Trichinella nelsoni</i> – <i>Trichinella nativa</i> <p><i>Strongyloides stercoralis</i></p>	<p>Approximately 10% of patients with symptomatic trichinosis develop neurological complications due to direct larval invasion of the brain (encephalitis) or CSF spaces (meningitis), producing personality changes, headache, meningismus, or lethargy. Later, focal signs such as motor or cranial nerve palsy predominate, and correlate with larval encystment. Additionally, signs of cerebellar dysfunction, convulsions, or peripheral neuropathies may occur, indicating the broad spectrum of neurological complications of symptomatic trichinosis</p> <p>Temperate climates Africa Arctic</p> <p>This nematode is endemic in tropical and subtropical regions, and is excreted in the stools of 0.4–4% of infected humans. The <i>Strongyloides stercoralis</i> larvae penetrate the skin and migrate to the intestines, lungs, and rarely the CNS; in the latter, they producing meningitis, infarction, or brain abscess</p>
---	--

CNS: central nervous system; CSF: cerebrospinal fluid.

Trematodes (Flukes)

<p>Schistosomiasis</p> <ul style="list-style-type: none"> – <i>Schistosoma mansoni</i> – <i>Schistosoma japonicum</i> – <i>Schistosoma haematobium</i> <p>Paragonimiasis</p> <ul style="list-style-type: none"> – <i>Paragonimus westermani</i> 	<p><i>Schistosoma</i> species inhabit the human vascular system in the mesenteric veins (<i>S. mansoni</i> and <i>S. japonicum</i>) or vesical plexus (<i>S. haematobium</i>). Neurological complications are more frequent with <i>S. japonicum</i>, up to 3.5% of infections, including abrupt altered sensorium, extremity weakness, visual disturbances, incontinence, sensory disturbances, altered speech, ataxia, vertigo, neck stiffness, and seizures</p> <p>Immature or mature <i>Paragonimus</i> worms enter the cranium along perivascular tissues, and reside in the cerebral parenchyma, causing focal or generalized convulsions or focal neurological deficits</p>
---	--

Rocky Mountain Spotted Fever

Rickettsia rickettsii

This is transmitted via contact with the wood tick, the dog tick, or the Lone Star tick, with an overall incidence of 0.2–0.5 cases per 100 000 population. The usual neurological features consist of headache, neck stiffness, altered sensorium, and convulsions. Other neurological abnormalities include ataxia, aphasia, neural hearing loss, and papilledema. The neuropathological findings consist of cerebral edema, perivascular and meningeal lymphocytic infiltration, and extensive necrotizing vasculitis

Cat-Scratch Disease

Afipia felis

Rochalimaea henselae

Small Gram-negative bacterium

Neurological complications occur in 2–3% of immunocompetent patients, and the features consist of headache, convulsions, altered level of consciousness, status epilepticus, spinal cord involvement with paraparesis or tetraparesis, and Brown–Sequard syndrome

Central Nervous System Infections in AIDS

Encephalitis	Most common, approximately in 60% of HIV patients
Toxoplasmosis	Most common opportunistic infection, in 20–40% of AIDS sufferers
Cryptococcosis	In 5% of cases
Progressive multifocal leukoencephalopathy (PML)	In 1–4% of cases
Miscellaneous CNS tuberculosis	Incidence ranges from 2% to 18% in AIDS patients
– Neurosyphilis	Present in 1–3% of HIV-infected patients
– Cytomegalovirus infection	
– Herpes simplex	Both HSV-1 and HSV-2
– Varicella zoster	In less than 1% of immunocompromised patients

Acute Bacterial Meningitis

Most Frequent Pathogens by Age Group

Age group	Pathogenic organism
Birth to 6 weeks	<i>Escherichia coli</i> , other Gram-negative organisms Group B <i>Streptococcus</i> <i>Klebsiella</i> <i>Listeria monocytogenes</i> <i>Salmonella</i> <i>Pseudomonas aeruginosa</i> <i>Staphylococcus aureus</i> <i>Haemophilus influenzae</i> <i>Citrobacter</i>
6 weeks to 3 months	<i>Escherichia coli</i> Group B <i>Streptococcus</i> <i>Listeria monocytogenes</i> <i>Streptococcus pneumoniae</i> <i>Salmonella</i> species <i>Haemophilus influenzae</i> , type b
3 months to 6 years	<i>Haemophilus influenzae</i> , type b <i>Streptococcus pneumoniae</i> <i>Neisseria meningitidis</i> <i>Staphylococcus aureus</i>
Adults and children (over 6)	<i>Streptococcus pneumoniae</i> <i>Neisseria meningitidis</i> <i>Listeria monocytogenes</i> <i>Escherichia coli</i> , other Gram-negative organisms
Elderly adults	<i>Streptococcus pneumoniae</i> <i>Haemophilus influenzae</i> , type b <i>Listeria monocytogenes</i>

Most Frequent Pathogens by Predisposing Conditions

Predisposing condition	Pathogenic organism
Intraventricular shunt infections	<ul style="list-style-type: none"> - Coagulase-negative staphylococci (most commonly <i>Staphylococcus epidermidis</i>, accounting for more than 50% of CSF shunt infections) - <i>Staphylococcus aureus</i> (the second most common pathogen involved, in up to 25% of CSF shunt infections)

Predisposing condition	Pathogenic organism
Posttraumatic meningitis* Closed head injury	<ul style="list-style-type: none"> - Gram-negative organisms (isolated in 5–20% of shunt infections, particularly in infants) - Other pathogens: <i>Pseudomonas</i> spp., <i>Streptococcus</i> spp., <i>Propionibacterium acnes</i>, <i>Corynebacterium diphtheriae</i>, <i>Candida</i>
With CSF leak	<ul style="list-style-type: none"> - <i>Streptococcus pneumoniae</i> (65%). <i>Pneumococcus</i> is the predominant organism, presumably due to its common presence in the upper airway - Other streptococci (10%) - <i>Haemophilus influenzae</i> (9%) - <i>Neisseria meningitidis</i> (5%) - <i>Staphylococcus aureus</i> (5%) - Enteric Gram-negative bacilli (4%) - <i>Staphylococcus epidermidis</i> (2%) - <i>Listeria monocytogenes</i>
Postoperative meningitis (transphenoidal hypophysectomy)	<ul style="list-style-type: none"> - <i>Streptococcus pneumoniae</i> (56%) - Aerobic Gram-negative bacilli (26%): <i>Enterobacter aerogenes</i>, <i>Serratia marcescens</i>, <i>Escherichia coli</i>, <i>Pseudomonas aeruginosa</i>, <i>Proteus mirabilis</i>, <i>Klebsiella</i> species - <i>Haemophilus influenzae</i> (8%) - <i>Streptococcus</i> species (6%) - <i>Neisseria meningitidis</i> (2%) - <i>Staphylococcus aureus</i> (2%) <ul style="list-style-type: none"> - Aerobic Gram-negative bacilli (46%): <i>Escherichia coli</i>, <i>Proteus mirabilis</i>, <i>Proteus vulgaris</i>, <i>Pseudomonas aeruginosa</i> - Anaerobes (13%): Gram-positive (peptostreptococci, <i>Clostridia</i>, etc.); <i>Bacteroides fragilis</i>; Gram-negative, other than <i>B. fragilis</i> - <i>Streptococcus</i> species (13%) - <i>Staphylococcus epidermidis</i> (7%) - <i>Staphylococcus aureus</i> (7%) - <i>Haemophilus parainfluenzae</i> (7%) - Diphtheroids (5%)
Immunodeficiency states AIDS: opportunistic infections	<ul style="list-style-type: none"> - <i>Toxoplasma gondii</i>. This is among the most common of the neurological complications in patients with HIV infection. Cerebral toxoplasmosis is seen in 28–40% of AIDS patients

* Hirschmann JV. Bacterial meningitis following closed head injury. In: Sande MA, Smith AL, Root RT, editors. Bacterial meningitis. New York: Churchill Livingstone, 1985. AIDS: acquired immune deficiency syndrome; CNS: central nervous system; CSF: cerebrospinal fluid.
Tsementzis, Differential Diagnosis in Neurology and Neurosurgery © 2000 Thieme
All rights reserved. Usage subject to terms and conditions of license.

Predisposing condition	Pathogenic organism
	<ul style="list-style-type: none"> - <i>Cryptococcus neoformans</i>. Cryptococcal meningitis is commonly associated with AIDS, with an estimated incidence of 2–11% - <i>Coccidioides immitis</i> - <i>Candida albicans</i>. Although 40–60% of AIDS patients develop oropharyngeal or esophageal candidiasis, it rarely affects the brain in patients with AIDS - <i>Listeria monocytogenes</i>. A surprisingly low incidence of cerebral infection is seen, compared to the very high frequency of the organism in patients with other causes of cell-mediated immune deficiency - <i>Mycobacterium tuberculosis</i> and <i>Mycobacterium avium-intracellulare</i>. Involvement of the CNS is not as common as might be expected from the frequency of mycobacterial infection - <i>Treponema pallidum</i>. Syphilis takes a more aggressive course in HIV-seropositive persons, and neurosyphilis is seen with increased frequency in the HIV-positive population - <i>Histoplasma capsulatum</i> - <i>Nocardia asteroides</i> - <i>Streptococcus pneumoniae</i> - Gram-negative bacilli
<p>AIDS: type of cell deficiency</p> <ul style="list-style-type: none"> - T-cell deficiency - B-cell deficiency - Neutropenia 	<ul style="list-style-type: none"> • <i>Salmonella</i> • <i>Listeria monocytogenes</i> • <i>Cryptococcus neoformans</i> • <i>Histoplasma capsulatum</i> • <i>Streptococcus pneumoniae</i> • <i>Haemophilus influenzae</i> • <i>Pseudomonas aeruginosa</i> • <i>Staphylococcus epidermidis</i> • <i>Streptococcus fecalis</i>
<p>Other causes of cell-mediated immune deficiency</p> <ul style="list-style-type: none"> - Bacteria 	<ul style="list-style-type: none"> • <i>Listeria monocytogenes</i>. This is the most common cause of bacterial meningitis in patients with cell-mediated deficiency, despite its rarity in AIDS patients. In renal transplant patients, meningitis appears in 75% of infected cases • <i>Nocardia asteroides</i>. The CNS is involved in approximately one-third of nocardial infections, which are more common in immunocompromised patients

Predisposing condition	Pathogenic organism
– Fungi	<ul style="list-style-type: none"> • <i>Mycobacterium tuberculosis</i> • <i>Cryptococcus neoformans</i>
– Parasites	<ul style="list-style-type: none"> • <i>Coccidioides immitis</i> • <i>Histoplasma capsulatum</i> • <i>Toxoplasma gondii</i>. One of the most common CNS complications occurring in patients with immunodeficiency • <i>Strongyloides stercoralis</i>. CNS complications (meningitis, cerebritis, abscess, diffuse microinfarcts) are rare
Defects of humoral immunity	Immunoglobulin deficiency or splenectomy <ul style="list-style-type: none"> • <i>Streptococcus pneumoniae</i> • <i>Haemophilus influenzae</i> • <i>Neisseria meningitidis</i>
Defects in neutrophils	Neutropenia or abnormalities in neutrophil function
– Bacteria	<ul style="list-style-type: none"> • <i>Pseudomonas aeruginosa</i> • Other Gram-negative bacilli
– Fungi	<ul style="list-style-type: none"> • <i>Staphylococcus aureus</i> • <i>Candida albicans</i> • <i>Aspergillus fumigatus</i> • Mucorales
Medical conditions	
– Diabetes mellitus	<ul style="list-style-type: none"> • <i>Streptococcus pneumoniae</i> • Gram-negative bacilli • Staphylococci • <i>Cryptococcus neoformans</i> • Mucorales
– Alcoholism	<ul style="list-style-type: none"> • <i>Streptococcus pneumoniae</i> • <i>Listeria monocytogenes</i>
– Pneumonia or upper respiratory tract infection	<ul style="list-style-type: none"> • <i>Streptococcus pneumoniae</i> • <i>Neisseria meningitidis</i> • <i>Haemophilus influenzae</i> • Viruses
– Leukemia	<ul style="list-style-type: none"> • Gram-negative bacilli • <i>Staphylococcus aureus</i>
– Lymphoma	<ul style="list-style-type: none"> • <i>Listeria monocytogenes</i>

Chronic Meningitis

Chronic meningitis is defined as persistent signs and symptoms of meningitis that are generally present for four weeks and occasionally associated with encephalitis, and abnormal cerebrospinal fluid (the cerebrospinal fluid shows lymphocytic pleocytosis with elevations of protein and, particularly in fungal meningitis, reduced glucose). The differential diagnosis of chronic meningitis is listed below.

Specific infectious causes

- | | |
|----------------------|---|
| Bacterial meningitis | <ul style="list-style-type: none"> – <i>Mycobacterium tuberculosis</i> – <i>Treponema pallidum</i> (neurosyphilis) – <i>Borrelia burgdorferi</i> (Lyme disease) – <i>Brucella melitensis</i> – <i>Listeria monocytogenes</i> – <i>Nocardia asteroides</i> |
| Fungal meningitis | <ul style="list-style-type: none"> – <i>Cryptococcus neoformans</i> – <i>Coccidioides immitis</i> – <i>Histoplasma capsulatum</i> – <i>Blastomyces dermatitidis</i> – <i>Candida</i> species – <i>Sporothrix schenckii</i> |
| Parasitic meningitis | <ul style="list-style-type: none"> – <i>Cysticercus cellulosae</i>, <i>C. racemosus</i> – <i>Toxoplasma gondii</i> – <i>Angiostrongylus cantonensis</i>, <i>A. costaricensis</i> – Schistosomiasis |
| Viral meningitis | <ul style="list-style-type: none"> – HIV – Echovirus |

Noninfectious causes

- | | |
|---|--|
| Sarcoidosis | |
| Rheumatological and vasculitic diseases | <ul style="list-style-type: none"> – Granulomatous angiitis of the CNS – Vasculitis associated with herpes zoster ophthalmicus – Cogan's syndrome |
| Systemic vasculitides affecting the CNS | <ul style="list-style-type: none"> – Polyarteritis nodosa – Systemic lupus erythematosus – Sjögren's syndrome – Behçet's syndrome – Vogt–Koyanagi–Harada syndrome – Wegener's granulomatosis |

- Chronic meningitis associated with malignancies
- Primary brain tumors (astrocytoma, glioblastoma, ependymoma, PNET tumors)
 - Metastatic tumors (breast, lung, thyroid, renal, melanoma)
 - Meningeal carcinomatosis
 - Chronic benign lymphocytic meningitis
- Chemical meningitis
- Due to intrathecal injection of:
- Contrast agents for radiological studies
 - Chemotherapeutic agents
 - Antibiotics (penicillin, trimethoprim, isoniazid, ibuprofen)
 - Local anesthetics

Immunocompromised patients

- AIDS (HIV infection)
- The main infectious complications that present as chronic meningitis are:
- Toxoplasmosis
 - Cryptococcosis
 - Syphilis
 - Aspergillosis
 - Non-Hodgkin's systemic lymphoma

Hypogammaglobulinemia

AIDS: acquired immune deficiency syndrome; CNS: central nervous system; HIV: human immunodeficiency virus; PNET: primitive neuroectodermal tumor.

Recurrent Meningitis

Recurrent meningitis is defined as repetitive episodes of meningitis associated with an abnormal cerebrospinal fluid followed by symptom-free periods during which the cerebrospinal fluid is normal. The differential diagnosis of recurrent meningitis is given below.

Specific infectious causes

Common bacterial meningitis

- Organisms
 - *Streptococcus pneumoniae*
 - *Haemophilus influenzae*
 - *Neisseria meningitidis*
- Pathophysiological mechanisms
 - Anatomical defects
 - Traumatic: basal skull fractures involving the paranasal sinuses, cribriform plate, petrous bone; postoperative

- Parameningeal infection
 - Congenital: myelomeningocele; dermoid sinus with midline cranial or spinal dermal sinus; petrous fistula; neurenteric cysts
 - Paranasal sinusitis
 - Pyogenic otitis media with chronic mastoid osteomyelitis
 - Cranial or spinal epidural abscess
- Idiopathic recurrent bacterial meningitis
- Defective immune mechanisms
 - Hypoimmunoglobulinemia
 - Postsplenectomy susceptibility in children

Special bacterial meningitis

- Organisms
 - *Mycobacterium tuberculosis*
 - *Borrelia burgdorferi*
 - *Brucella melitensis*
 - *Leptospira* species

Fungal meningitis

- *Cryptococcus neoformans*
- *Coccidioides immitis*
- *Histoplasma capsulatum*
- *Blastomyces dermatitides*
- *Candida* species
- *Sporothrix schenckii*

Parasitic meningitis

- *Cysticercus cellulosae*, *C. racemosus*
- *Toxoplasma gondii*
- *Angiostrongylus cantonensis*, *A. costaricensis*
- Schistosomiasis

Viral meningitis

- HIV
- Echovirus

Noninfectious causes

Sarcoidosis

Rheumatological diseases and vasculitis affecting the CNS

- Systemic lupus erythematosus
- Polyarteritis nodosa
- Behçet's syndrome
- Sjögren's syndrome
- Vogt-Koyanagi-Harada syndrome
- Mollaret's meningitis

Intracranial and intraspinal neoplasms

- Craniopharyngioma
- Ependymoma
- Cerebral hemangioma

CNS: central nervous system; HIV: human immunodeficiency virus.

Conditions Predisposing to Recurrent Bacterial Meningitis

- Anatomical communication with the nasopharynx, middle ear, paranasal sinuses, skin (e.g., congenital dermal sinus tracts), or prostheses (e.g., ventriculoperitoneal or lumboperitoneal shunts)
- Parameningeal inflammatory foci, which can drain to the meninges or cause repeated inflammatory meningeal reactions, leading to clinical meningitis
- Immunodepression (e.g., hypogammaglobulinemia, splenectomy, leukemia, lymphoma, hemoglobinopathies such as sickle-cell anemia, or complement deficiencies)

Conditions Predisposing to Polymicrobial Meningitis

- Fistulous communications
- Tumors neighboring the central nervous system
- Infections at contiguous foci
- Disseminated strongyloidiasis

Spinal Epidural Bacterial Abscess

Organism	Frequency (%)
<i>Staphylococcus aureus</i>	62
Gram-negative rods (aerobic)	18
- (<i>Escherichia coli</i> , <i>Klebsiella</i> , <i>Enterobacter</i> , <i>Serratia</i> , <i>Proteus</i> , <i>Providencia</i> , <i>Arizona</i> , etc.)	
Aerobic streptococci	8
<i>Staphylococcus epidermidis</i>	2
Anaerobes	2
- Gram-positive (e.g., peptococci, peptostreptococci, <i>Clostridia</i>), <i>Bacteroides fragilis</i>	
- Gram-negative, other than <i>B. fragilis</i>	
Other organisms	2
Unknown	6

Neurological Complications of Meningitis

Acute Complications

These occur within the first one or two days of admission, and result from the intense disruption of normal brain function. This is most likely to be produced by synergistic effects between the infecting organism or bacterial products, the host inflammatory response, and alterations of normal brain physiology that result in brain injury. The pathophysiological changes that accompany acute meningitis are: a) brain edema, b) intracranial hypertension, and c) abnormalities of cerebral blood flow, loss of cerebrovascular autoregulation and decreased cerebral perfusion pressure.

Type of complication	Associated organisms	Associated conditions
Seizures – Occur in 15–25% of patients. May be generalized (due to increased ICP or irritative effects of infection), or focal due to increased ICP or venous or arterial infarcts	<ul style="list-style-type: none"> • <i>Streptococcus pneumoniae</i> • <i>Haemophilus influenzae</i> • Group B streptococci • Herpes simplex virus 	<ul style="list-style-type: none"> • Sarcoidosis • Mass lesions • Cortical vein thrombosis
Syndrome of inappropriate release of antidiuretic hormone (SIADH) – Occurs in 30% of children with purulent meningitis within the first 24 h of admission to hospital	<ul style="list-style-type: none"> • <i>Neisseria meningitidis</i> • <i>S. pneumoniae</i> 	
Ventriculitis – Occurs in about 30% of patients and up to 50% of neonates with Gram-negative enteric organism infection		

ICP: intracranial pressure.

Intermediate Complications

These complications become manifest during hospitalization, and may persist after discharge. In some cases, the problems are present earlier in the course of the meningitis but are not recognized until the patient has been in the hospital for a few days, or they do not develop until the disease process has gone on for several days.

Type of complication	Associated organisms
Hydrocephalus – Two types: a) obstructive, due to obstruction of CSF resorption from postinflammatory adhesions of arachnoid granulations; and b) ex vacuo, due to diffuse brain injury and loss and resultant brain atrophy	<i>Haemophilus influenzae</i> <i>Mycobacterium tuberculosis</i> Group B streptococci
Subdural effusions – Common in children; up 25%. Almost all sterile effusions resolve spontaneously, except for a small minority, which may cause pressure phenomena, requiring serial subdural taps	<i>H. influenzae</i> <i>Streptococcus pneumoniae</i>
Fever – In cases of purulent meningitis, fever resolves within 3–4 days of drug therapy. About 10% of children with <i>H. influenzae</i> meningitis have a delayed defervescence over 7–8 days. After a week of therapy, drug fever may occur, although this is most typical after 10–14 days	
Brain abscess – Unusual complication of common bacterial meningitis, except with disease attributable to <i>Citrobacter</i> species, where abscesses develop in approx. 50% of cases, and, rarely, <i>Listeria</i>	<i>Citrobacter</i> species <i>Listeria monocytogenes</i>

CSF: cerebrospinal fluid.

Long-Term Complications

Type of complication	Associated organisms	Associated conditions
Cranial nerve abnormalities	<ul style="list-style-type: none"> • <i>Neisseria meningitidis</i> (nerves VI, VII, VIII) • <i>Mycobacterium tuberculosis</i> (nerve VI) • <i>Borrelia burgdorferi</i> (Lyme disease, nerve VII) 	<ul style="list-style-type: none"> • Sarcoidosis (nerve VII; also VIII, IX, X) • Meningeal carcinomatosis (variable)
<p>Motor handicaps</p> <ul style="list-style-type: none"> – Range from isolated paresis to global injury, leading to tetraplegia. Only 20% of motor handicaps present at discharge persist at one-year follow-up 	<ul style="list-style-type: none"> • <i>Streptococcus pneumoniae</i> 	
<p>Deafness, hearing loss</p> <ul style="list-style-type: none"> – The most common long-term injury in meningitis, with 5–25% of survivors suffering some form of hearing impairment. It is age-specific and pathogen-specific, with neonates and children with <i>S. pneumoniae</i> meningitis having the highest incidence 	<ul style="list-style-type: none"> • <i>Haemophilus influenzae</i> • <i>N. meningitidis</i> • <i>M. tuberculosis</i> • Mumps • <i>S. pneumoniae</i> 	
<p>Impairment of cognitive function</p> <ul style="list-style-type: none"> – May range from milder forms of “learning disability” in approx. 25% to more serious forms of injury, in approx. 2% of children with meningitis 		

Pain

Myofascial Pain Syndrome

Myofascial pain syndrome is a regional musculoskeletal pain disorder which stems from the lack of obvious organic findings and characterized by tender trigger points in taut bands of muscle that produce pain in a characteristic reference zone.

Diagnostic Clinical Criteria

Major criteria

- Regional pain complaint
- Pain complaint or altered sensation in the expected distribution of referred pain from a myofascial trigger point
- Taut band palpable in an accessible muscle
- Exquisite spot tenderness at one point along the length of the taut band
- Some degree of restricted range of motion, when measurable

Minor criteria

- Reproduction of clinical pain complaint, or altered sensation, when pressure is applied at the tender spot
 - Elicitation of a local twitch response by transverse snapping
 - Palpation at the tender spot or by needle insertion into the tender spot in the taut band
 - Pain alleviated by stretching the muscle or by injecting the tender spot
-

From: Simons DG. Muscle pain syndromes. J Man Med 1991; 6: 3–23.

Associated Neurological Disorders

Neuropathies

- Radiculopathy
- Entrapment neuropathies
- Peripheral neuropathy
- Plexopathy

Multiple sclerosis

Rheumatological disorders

- Osteoarthritis
- Rheumatoid arthritis
- Systemic lupus erythematosus

Psychosocial factors

- Psychosomatic or somatoform disorders
- Secondary gain issues
- Adjustment disorders with depression and anxiety

Differential Diagnosis

Mixed tension – vascular headaches	Associated with trigger points in the sternomastoid, suboccipital, temporalis, posterior cervical, and scalene muscles
Thoracic outlet syndrome	Associated with trigger points in the scalene and pectoralis minor muscles
Temporomandibular joint (TMJ) dysfunction	TMJ conditions are often primarily myofascial in origin, with particular trigger point involvement of the temporalis, masseter, and pterygoid muscles
Piriformis muscle syndrome	Pseudosciatica, with entrapment of the sciatic nerve by the involvement of the piriformis muscle and the trigger points identified in this muscle

Postherpetic Neuralgia

This is a common and severe form of neuropathic pain in the elderly, caused by reactivation of the varicella zoster virus, usually a childhood infection. The incidence of postherpetic neuralgia (PHN) after herpes zoster varies between 9% and 15%, with 35–55% of patients continuing to have pain three months later, and 30% having intractable pain for one year. The dermatomal distribution and frequencies of PHN are as follows.

Thoracic dermatome	55%
Trigeminal distribution	20%
Cervical dermatomes	10%
Lumbar dermatomes	10%
Sacral dermatomes	5%

Atypical Facial Pain

The pain usually starts in the upper jaw. Early spread is to the other side, and back to below and behind the ear. Finally, spread onto the neck and the entire half head can occur.

Postherpetic neuralgia	This occurs mainly with first-division herpes; although the whole zone hurts, pain in the eyebrow and around the eye is especially severe. Pain is continual and burning, with severe pain added by touching the eyebrow or brushing the hair. The condition shows a tendency to spontaneous remission
Temporal arteritis	Swelling, redness and tenderness of the temporal artery and a headache in the distribution of the artery are the classic hallmarks of the disease. Diffuse headache can occur
Cluster headache	Migrainous neuralgia. Nocturnal attacks of pain in and around the eye, which may become bloodshot with the nose “stuffed up,” with lacrimation and nasal watering. Bouts last 6–12 weeks and may recur at the same time each year
Temporomandibular joint (TMJ) dysfunction, or Costen’s syndrome	Pain is mainly in the TMJ, spreading forward onto the face and up into the temporalis muscle. The joint is tender to the touch, and pain is provoked by chewing or just opening the mouth. The pain ceases almost entirely if the mouth is held shut and still
Odontalgia	A dull, aching, throbbing, or burning pain that is more or less continuous and is triggered by mechanical stimulation of one of the teeth. It is relieved by sympathetic blockade
Myofascial pain syndrome	Aching pain lasting from days to months, elicited by palpation of trigger points in the affected muscle
Atypical facial neuralgia	Chronic aching pain involving the whole side of the face, or even the head beyond the distribution of the trigeminal nerve. This condition is much more common in women than in men, and is often associated with significant depression

Cephalic Pain

Migraine headache	
– Classical migraine (hemicrania)	A pulsatile headache that starts in the temple on one side and spreads to involve the whole side of the head. Usually self-limiting, lasting from 30 minutes to several hours
– Cluster headache (migrainous neuralgia)	Nocturnal attacks of pain in and around the eye, which may become bloodshot and with the nose “stuffed up,” with lacrimation and nasal watering. Bouts last 6–12 weeks and may recur at the same time each year
– Chronic paroxysmal hemicrania	Unilateral, shooting, drilling headache, associated with lacrimation, facial flushing and lid swelling and lasting 5–30 minutes day or night, without remissions
Temporomandibular joint (TMJ) dysfunction, or Costen’s syndrome	Pain is mainly in the TMJ, spreading forward onto the face and up into the temporalis muscle. The joint is tender to the touch, and pain is provoked by chewing or just opening the mouth. The pain ceases almost entirely if the mouth is held shut and still
Odontalgia	A dull, aching, throbbing, or burning pain that is more or less continuous and is triggered by mechanical stimulation of one of the teeth. It is relieved by sympathetic blockade
Tension headache	Pain is believed to be due to spasm in the scalp and suboccipital muscles, which are tender and knotted. Descriptions such as experiencing tightness like a “band” or the scalp being “too tight” are a frequent clue
Temporal arteritis	Swelling, redness, and tenderness of the temporal artery and a headache in the distribution of the artery are the classic hallmarks of the disease. Diffuse headache can occur
Psychotic headaches	A specific spot on the head is isolated, and bizarre complaints such as “bone going bad,” “worms crawling under the skin,” quickly followed by an invitation to feel the increasingly large lump. Usually nothing other than a normal bulge in the skull is palpable. This condition should always be suspected if the patient offers to locate the headache with one finger. A relentless sense of pressure over the vertex is typical of simple depression headache
Pressure headache	Occurs on waking, is aggravated by bending or coughing, produces a “bursting” sensation in the head, and does not respond well to analgesics

Posttraumatic headaches	Pain occurs as a persistent and occasionally progressive and localized symptom following head trauma, with an onset often many months after the accident. It may relate to an entrapped cutaneous nerve neuroma, extensive base of skull fractures associated with injuries to the middle third of the face, or stripping of the dura from the floor of the middle fossa, after diastatic linear fractures, etc.
Occipital neuralgia	This is commonly a secondary manifestation of a benign process affecting the second cervical dorsal roots of the occipital nerves
Carcinoma of the head and neck	Often a deep, drilling, heavy ache, debilitating in its progressive persistence, regional or diffuse, and induced by carcinoma of the face, sinuses, nasopharynx, cervical lymph nodes, scalp, or cranium
Headaches related to brain tumors or mass lesions	A “cough” or “exertional” headache may be the sole sign of an intracranial mass lesion. Patients often wake up early in the morning with the headaches, which may be more frequent daily, in contrast to the episodic occurrence in migraine. Neural examination may reveal focal abnormalities, as well as papilledema on funduscopic examination
Headaches related to ruptured aneurysms and arteriovenous anomalies	The pain is usually sudden in onset, severe or disabling in intensity, and with a bioccipital, frontal and orbito-frontal location
Carotid artery dissection	May present as an acute unilateral headache associated with face or neck pain, Horner’s syndrome, bruit, pulsatile tinnitus, and focal fluctuation neurological deficits due to transient ischemic attacks. Dissections occur in trauma, migraine, cystic medial necrosis, Marfan’s syndrome, fibromuscular dysplasia, arteritis, atherosclerosis, or congenital anomalies of the arterial wall
Spinal tap headaches	These occur in approximately 20–25% of patients who undergo lumbar puncture, irrespective of whether or not there was a traumatic tap and regardless of the amount of CSF removed. Characteristically, the headache is much worse when the patient is upright, it is often associated with disabling nausea and vomiting, and it improves dramatically when the patient lies flat in bed

Postcoital headaches	<p>Headaches that occur before and after orgasm. The pain is usually sudden in onset, pulsatile, fairly intense, and involves the whole head. The International Headache Society (IHS) classification defines three types:</p> <ul style="list-style-type: none"> – Dull type: thought to be due to muscle contraction, by far the most common type occurring prior to orgasm, and located in the posterior cervical and occipital regions – Explosive type: the pain is excruciating and throbbing, and is thought to be of vascular origin, occurring at the occipital region at or just after orgasm. There is a family history of migraine in 25% of cases – Positional type: secondary to low CSF pressure, presumably due to dural tearing and CSF leakage, becoming worst in the upright position
Exertional headaches	<p>These headaches tend to be throbbing, and are often unilateral and of brief duration (one or two hours). Generally benign in nature and thought to be due to migraine, secondary to increased intracranial venous pressure, to muscle spasm, to sudden release of vasoactive substances, or very rarely due to structural intracranial abnormalities such as Chiari abnormalities, tumors or aneurysms</p>
Headache related to analgesics and other drugs	<ul style="list-style-type: none"> – Analgesics, nonsteroidal anti-inflammatory drugs – Ergot derivatives – Calcium antagonists – Nitrates – Hormones <ul style="list-style-type: none"> • Progesterone • Estrogens • Thyroid preparations • Corticosteroids

CSF: cerebrospinal fluid; TMJ: temporomandibular junction.

Face and Head Neuralgias

Trigeminal neuralgia	<p>The second and third divisions are most commonly involved, and the attacks have trigger points. The symptom may be due to tumors, inflammation, vascular anomalies or aberrations, and multiple sclerosis. Trigeminal neuralgia is the most frequent of all forms of neuralgia</p>
----------------------	---

Glossopharyngeal neuralgia	Attacks, lasting for seconds or minutes, of paroxysmal pains, which are burning or stabbing in nature, and are localized in the region of the tonsils, posterior pharynx, back of the tongue, and middle ear. May be idiopathic, or caused by vascular anatomical aberrations in the posterior fossa or regional tumors
Occipital neuralgia	Attacks of paroxysmal pain along the distribution of the greater or lesser occipital nerve, of unknown etiology
Nasociliary neuralgia	Paroxysmal attacks of orbital pain, caused or exacerbated by touching the medial canthus and associated with edema and rhinorrhea. It is of unknown etiology
Neuralgia of the sphenopalatine ganglion (Sluder's neuralgia)	Short-lived attacks of pain in the orbit, base of nose, and maxilla, associated with lacrimation, rhinorrhea and facial flushing. It affects elderly women, and the cause is idiopathic
Geniculate ganglion neuralgia	Paroxysmal attacks of pain are localized in the ear, caused by regional tumors or vascular malformations
Greater superficial petrosal nerve neuralgia (vidian neuralgia)	Attacks of pain in the medial canthus, associated with tenderness and pain in the base of nose and maxilla, brought out or triggered by sneezing. The cause is idiopathic or inflammatory
Neuralgia of intermedius nerve	Paroxysmal deep ear pain with a trigger point in the ear; of unknown etiology. It may be related to varicella zoster virus infection
Anesthesia dolorosa	Continuous trigeminal pain in the hypalgesic or analgesic territory of the nerve. It occurs after percutaneous radiofrequency lesions or ophthalmic herpes zoster
Tolosa–Hunt syndrome	Episodes of retro-orbital pain lasting for weeks or months, associated with paralysis of cranial nerves III, IV, the first division of nerve V, VI, and rarely VII. There is intact pupillary function. It is caused by a granulomatous inflammation in the vicinity of the cavernous sinus
Raeder's syndrome	Symptomatic neuralgia of the first division of cranial nerve V, associated with Horner's syndrome, and possibly ophthalmoplegia from middle cranial fossa pathology
Gradenigo's syndrome	Continuous pain in the first and second divisions of cranial nerve V, with associated sensory loss, deafness, and sixth cranial nerve palsy. It particularly affects patients with inflammatory lesions in the region of the petrous apex after otitis media

Headache: World Health Organization Classification

1 Migraine

Migraine without aura

Migraine with aura

- Migraine with typical aura
- Migraine with prolonged aura
- Familial hemiplegic migraine
- Basilar migraine
- Migraine aura without headache
- Migraine with acute onset aura

Ophthalmoplegic migraine

Retinal migraine

Childhood periodic syndrome

- May be precursor to or associated with migraine
- Benign paroxysmal vertigo of childhood
 - Alternating hemiplegia of childhood
 - Status migrainosus
 - Migrainous infarction

Complications of migraine

Migrainous disorder not fulfilling the above criteria

2 Tension-type headaches

Episodic tension-type headache

- Episodic tension-type headache associated with disorder of pericranial muscles
- Episodic tension-type headache not associated with disorder of pericranial muscles

Chronic tension-type headache

- Chronic tension-type headache associated with disorder of pericranial muscles
- Chronic tension-type headache not associated with disorder of pericranial muscles

Headache of the tension type not fulfilling the above criteria

3 Cluster headache and chronic paroxysmal hemicrania

Cluster headache

- Cluster headache, periodicity undetermined
- Episodic cluster headache
- Chronic cluster headache

Chronic paroxysmal hemicrania

Cluster headache-like disorder not fulfilling the above criteria

4 Miscellaneous headaches not associated with structural lesions

Idiopathic stabbing headache

External compression headache

Cold stimulus headache

- External application of a cold stimulus
- Ingestion of a cold stimulus (e.g., ice cream)

Benign cough headache

Benign exertional headache

Headache associated with sexual activity

- Dull type
- Explosive type
- Postural type

5 Headache associated with head trauma

Acute post traumatic headache

- With significant head trauma and/or confirmatory signs
- With minor head trauma and no confirmatory signs

Chronic posttraumatic headache

- With significant head trauma and/or confirmatory signs
- With minor head trauma and no confirmatory signs

6 Headache associated with vascular disorders

Acute ischemic cerebrovascular disease

- Transient ischemic attack (TIA)
- Thromboembolic stroke

Intracranial hematoma

- Intracerebral hematoma
- Subdural hematoma
- Extradural hematoma

Subarachnoid hemorrhage

Unruptured vascular malformation

- Arteriovenous malformation
- Saccular aneurysm

Arteritis

- Giant-cell arteritis
- Other systemic arteritides
- Primary intracranial arteritis

Carotid or vertebral artery pain

- Carotid or vertebral dissection
- Carotidynia (idiopathic)
- Postendarterectomy headache

Venous thrombosis

Arterial hypertension

- Acute pressor response to exogenous agent
- Pheochromocytoma
- Malignant (accelerated) hypertension
- Preeclampsia and eclampsia

7 Headache associated with nonvascular intracranial disorder

- | | |
|-----------------------------------|--|
| High cerebrospinal fluid pressure | – Benign intracranial hypertension |
| | – High-pressure hydrocephalus |
| Low cerebrospinal fluid pressure | – Postlumbar puncture headache |
| | – Cerebrospinal fluid fistula headache |

Intracranial infection

Intracranial sarcoidosis, and other noninfectious inflammatory diseases

- | | |
|--|------------------------------|
| Headache related to intrathecal injections | – Direct effect |
| | – Due to chemical meningitis |

Intracranial neoplasm

Headache associated with other intracranial disorder

8 Headache associated with substances or their withdrawal

- | | |
|--|--|
| Headache induced by acute substance use or exposure | – Nitrate/nitrite-induced headache |
| | – Monosodium glutamate-induced headache |
| | – Carbon monoxide-induced headache |
| | – Alcohol-induced headache |
| | – Other substances |
| Headache induced by chronic substance use or exposure | – Ergotamine-induced headache |
| | – Analgesic abuse headache |
| | – Other substances |
| Headache due to substance withdrawal (acute use) | – Alcohol withdrawal headache (hangover) |
| | – Other substances |
| Headache due to substance withdrawal (chronic use) | – Ergotamine withdrawal headache |
| | – Caffeine withdrawal headache |
| | – Narcotic abstinence headache |
| | – Other substances |
| Headache associated with substances but with uncertain mechanism | – Birth control pills or estrogens |
| | – Other substances |

9 Headache associated with noncephalic infection

- | | |
|--------------------------------------|-------------------------|
| Viral infection | – Focal noncephalic |
| | – Systemic |
| Bacterial infection | – Focal noncephalic |
| | – Systemic (septicemia) |
| Headache related to other infections | |

10 Headache associated with metabolic disorder

Hypoxia

- High-altitude headache
- Hypoxic headache
- Sleep apnea headache

Hypercapnia

Mixed hypoxia and hypercapnia

Hypoglycemia

Dialysis

Headache related to other metabolic abnormalities

11 Headache or facial pain associated with disorders of the cranium, neck, eyes, nose, sinuses, teeth, mouth, or other facial or cranial structures

Cranial bone

Neck

- Cervical spine
- Retropharyngeal tendinitis

Eyes

- Acute glaucoma
- Refractive errors
- Heterophoria or heterotropia

Ears

Nose and sinuses

- Acute sinus headache
- Other diseases of nose or sinuses

Teeth, jaws, and related structures

Temporomandibular joint disease

12 Cranial neuralgia, nerve trunk pain, and deafferentation pain

Persistent (contact or tic-like) pain of cranial nerve origin

- Compression or distortion of cranial nerves and second or third cervical roots
- Demyelination of cranial nerves; optic neuritis (retrobulbar neuritis)
- Infarction of cranial nerves; diabetic neuritis
- Inflammation of cranial nerves; herpes zoster, chronic postherpetic neuralgia
- Tolosa-Hunt syndrome
- Neck-tongue syndrome
- Other causes of persistent pain of cranial nerve origin

Trigeminal neuralgia

- Idiopathic trigeminal neuralgia
- Symptomatic trigeminal neuralgia; compression of trigeminal root or ganglion; central lesions

Glossopharyngeal neuralgia – Idiopathic glossopharyngeal neuralgia
 – Symptomatic glossopharyngeal neuralgia

Nervus intermedius neuralgia

Superior laryngeal neuralgia

Occipital neuralgia

Central causes of head and facial pain other than tic douloureux – Anesthesia dolorosa
 – Thalamic pain

Facial pain not fulfilling the criteria in groups 11 or 12

13 Unclassifiable headaches

From: International Headache Classification Committee. ICD-10 guide for headaches. Cephalalgia 1997; 17 (Suppl 19): 1–82.

Pseudospine Pain

Pseudospine pain refers to pain in the back or leg, or both, as the presenting symptom of an underlying systemic (metabolic or rheumatological), visceral, vascular, or neurological disease.

Disease	Clinical features
Vascular disorders	
Abdominal aortic aneurysm	<ul style="list-style-type: none"> – Men over 50 years of age (1–4%) – Abdominal and back pain (12%) – Pulsatile abdominal mass (50% sensitive; better in thin patients)
Visceral disorders	
<i>Gynecological conditions</i>	
Endometriosis	<ul style="list-style-type: none"> – Women of reproductive age (10%) – Cyclic pelvic pain (25–67%) – Back pain (25–31%)
Pelvic inflammatory disease	<ul style="list-style-type: none"> – Young, sexually active women – Ascending infection: endocervix to upper urogenital tract and symptoms of fever and chills, and leukocytosis – Lower abdominal, back and/or pelvic pain – Vaginal discharge, leukorrhea – Dysuria, urgency, frequency

Disease	Clinical features
Ectopic pregnancy	<ul style="list-style-type: none"> – Signs and symptoms of pregnancy: missed period (68%); breast tenderness; morning sickness – Abdominal pain (99.2%), unilateral in 33% (may mimic upper lumbar radiculopathy with radiation to thighs) – Adnexal tenderness (98%), unilateral adnexal mass (54%) – Positive pregnancy test (83%)
<i>Genitourinary conditions</i>	
Prostatitis	<ul style="list-style-type: none"> – Men over 30 years of age; lifetime prevalence 50% – Acute febrile illness and leukocytosis – Dysuria – Lower back and/or perineal pain
Nephrolithiasis	<ul style="list-style-type: none"> – Flank pain with radiation to groin – Fever, chills, ileus, nausea, vomiting – Microscopic hematuria
<i>Gastrointestinal conditions</i>	
Pancreatitis	<ul style="list-style-type: none"> – Men aged 35–45 years, alcohol abuse – Midepigastric abdominal pain, radiating through the back (90%) – Systemic signs (fever, nausea, vomiting) – Elevated serum amylase
Penetrating or perforated duodenal ulcer	<ul style="list-style-type: none"> – Abdominal pain radiating to the back – Free air in abdominal radiography
Rheumatological disorders	
Fibromyalgia	<ul style="list-style-type: none"> – Women (70–90%) aged 34–55 years – Diffuse musculoskeletal pain, typically including posterior neck, upper and lower back – Disturbed sleep, fatigue – Multiple (11–18) tender point sites on digital palpation (important to demonstrate “negative” control points, i.e., mid-forehead or anterior thigh) – Normal radiographs and laboratory values <p><i>Differential diagnosis:</i> Polymyalgia rheumatica, hypothyroidism, Parkinson’s disease, osteomalacia, chronic fatigue, and immunodeficiency syndrome</p>

Disease	Clinical features
Polymyalgia rheumatica	<ul style="list-style-type: none"> - Women aged 50–60 - Abrupt onset of shoulder, neck and upper back, hip, lower back, buttock, and thigh pain and morning stiffness - Elevated ESR (> 40 mmHg) - Dramatic response to low-dose prednisone
Seronegative spondyloarthropathies (ankylosing spondylitis; reactive arthritis; Reiter's syndrome; psoriatic spondyloarthropathy; enteropathic arthropathy)	<ul style="list-style-type: none"> - Male under 40 - Dull, deep, aching back pain in the gluteal or parasacral area - Morning stiffness (gelling) in the back, improved with physical activity - Radiographic sacroiliitis
Diffuse idiopathic skeletal hyperostosis, or Forrester's disease (exuberant ossification of spinal ligaments)	<ul style="list-style-type: none"> - Age over 50–60 - Back stiffness (80%) more often than back pain (50–60%), pain is typically thoracolumbar - Flowing anterior calcification along four contiguous vertebrae, preservation of disk height, no sacroiliac involvement - Normal ESR or C-reactive protein
Piriformis syndrome	<ul style="list-style-type: none"> - Pseudosciatica—buttock and leg pain - Low back pain (50%) - Pain on resisted external rotation and abduction of hip - Piriformis muscle tenderness (transgluteal and transrectal)
Trochanteric bursitis, gluteal fasciitis	<ul style="list-style-type: none"> - Female predominance (75%) - Gluteal and leg pain (64%) - Pain lying on affected side, or with crossed legs (50%) - Pain or tenderness over greater trochanter
Scheuermann's disease (increased fixed thoracic kyphosis with anterior wedging of vertebrae and irregularity of vertebral end-plates)	<ul style="list-style-type: none"> - Females (2:1), aged 12–15 years - Thoracic or thoracolumbar pain in 20–50%; relieved by rest, increased with activity - Increasing fixed thoracic kyphosis - Anterior wedging of three or more contiguous thoracic vertebrae; irregular vertebral end plates

Disease	Clinical features
Adult scoliosis	<ul style="list-style-type: none"> – Back pain, typically at apex of curve – Pseudoclaudication: spinal stenosis – Thoracic curve: uneven shoulders, scapular prominence, paravertebral hump with forward flexion – Lumbar curve: paravertebral muscle prominence
Metabolic disorders	
Osteoporosis	<ul style="list-style-type: none"> – Women over 60 years – Vertebral compression fractures; progressive loss of height and increasing thoracic kyphosis – Pelvic stress fracture: weight-bearing parasacral or groin pain – Chronic mechanical spine pain: increased with prolonged standing, relieved rapidly in supine position
Osteomalacia	<ul style="list-style-type: none"> – Diffuse skeletal pain: back pain (90%), ribs, long bones of the legs – Skeletal tenderness to palpation – Antalgic, waddling gait (47%) – Elevated alkaline phosphatase (94%)
Paget's disease	<ul style="list-style-type: none"> – Bone pain: deep, aching, constant; back pain (10–40%) – Joint pain: accelerated degenerative disease – Nerve root entrapment: hearing loss, spinal stenosis – Deformities: enlarged skull, bowing of long bones, exaggerated spinal lordosis, kyphosis – Increased alkaline phosphatase – Characteristic radiographic appearance
Diabetic polyradiculopathy	<ul style="list-style-type: none"> – Older patients, over 50 years of age – Unilateral or bilateral leg pain, though diffuse, may resemble sciatica; typically worse at night – Proximal muscle weakness and muscle wasting
Malignancy	<ul style="list-style-type: none"> – Patients over 50 years old (75%) – Previous history of malignancy – Constant back pain, unrelieved by positional changes – Night pain – Weight loss: 4.5 kg in three months – Elevated ESR (in 80% of patients), serum calcium, alkaline phosphatase (in 50% of patients)

ESR: erythrocyte sedimentation rate.

Back Pain in Children and Adolescents

Younger children (under the age of 10) develop back pain caused by medical problems (e.g., infections, tumors), whereas older children and adolescents tend to have a greater proportion of traumatic and mechanical disorders.

Developmental disorders

Spondylolysis, spondylolisthesis

Scoliosis

Juvenile kyphosis

Scheuermann's disease

Inflammatory disorders

Diskitis

Vertebral osteomyelitis

Sacroiliac joint infection

Rheumatological disorders

- Juvenile rheumatoid arthritis
- Reiter's syndrome
- Psoriatic arthritis
- Enteropathic arthritis

Reactive arthritis

Tumors

Intramedullary tumors

- Astrocytomas
- Ependymomas
- Drop metastases
- Congenital tumors
- Hemangioblastomas

31% of pediatric spinal column tumors

60% of spinal cord tumors

30% of spinal cord tumors

Extramedullary tumors

- Eosinophilic granuloma
- Osteoblastomas
- Aneurysmal bone cysts
- Hemangiomas
- Ewing's sarcoma
- Chordoma
- Neuroblastoma
- Ganglioneuroma
- Osteogenic sarcoma

Intradural extramedullary tumors

- Nerve sheath tumors
- Meningiomas
- Mesenchymal chondrosarcomas

Congenital tumors

- Teratomas
- Dermoid and epidermoid cysts
- Lipomas

Traumatic and mechanical disorders

Soft-tissue injury

Vertebral compression or end plate fracture

Facet fracture and/or dislocation

Transverse process or spinous process fractures

Chronic degenerative mechanical disorders

- Facet joint or pars interarticularis syndrome
- Disk protrusion or herniation
- Postural imbalances, asymmetries, and/or overload on functional spinal elements
- Overuse syndrome

Nonspinal disorders

Iliac fracture, apophyseal avulsion

Renal disorder

Pelvic/gynecological disorder

Retroperitoneal disorder

Conversion reaction

Low Back Pain during Pregnancy

Herniated lumbar disk (HLD)	The incidence of HDL is one in 10 000. The back pain may be worse when the patient is sitting and standing, and may be relieved when she lies down
Symphysiolysis pubis	Pain in the groin, symphysis pubis and thigh, which may be increased while rising from sitting to standing, and during walking
Transient osteoporosis of the hip	Pain in the hip and groin areas, increasing when carrying weight, and with a Trendelenburg gait—lateral limp at each step
Osteonecrosis of the femoral head	Groin or hip pain radiating to back, thigh, knee and aggravated by weight-bearing or passive hip rotation. May be related to excessive cortisol production in the late stages of pregnancy
Sacroiliac joint dysfunction, pelvic insufficiency, posterior pelvic pain	This is the most common reason for low back pain and discomfort during pregnancy, and may be related to excessive mobility of pelvic joints and altered stress distribution through the pelvic ring

Back Pain in Elderly Patients

Degenerative disorders of the spine	The most common cause of back pain in the elderly is degenerative spondylosis of the spine
Disk herniations	
Spinal stenosis	
Degenerative spondylolisthesis	
Degenerative adult scoliosis	
Neoplastic disorders of the spine	
Primary tumors	
– Benign tumors	<ul style="list-style-type: none"> • Hemangioma • Osteochondroma • Osteoblastoma • Giant-cell tumor • Aneurysmal bone cyst

-
- Malignant tumors
 - Multiple myeloma
 - Solitary plasmacytoma
 - Chordoma
 - Osteosarcoma
 - Chondrosarcoma
 - Ewing's sarcoma

 - Metastatic tumors
 - Lung
 - Colon/rectum
 - Breast
 - Prostate
 - Urinary tract

Metabolic disorders of the spine

Osteomalacia

Differential diagnosis: vitamin D deficiency, gastrointestinal malabsorption, liver disease, anticonvulsant drugs, renal osteodystrophy

Paget's disease

Osteoporosis

Neurorehabilitation

Measures (Scales) of Disability

Glasgow Outcome Scale*

The Glasgow outcome scale has provided a high degree of interobserver reliability, and has proved its usefulness in multicenter clinical studies of head injury.

Score	Outcome
1	Death
2	Vegetative state: unresponsive and speechless
3	Severe disability: depends on others for all or part of care or supervision, due to mental or physical disability
4	Moderate disability: disabled, but independent in activities of daily living (ADLs) and in the community
5	Good recovery: resumes normal life; may have minor neurological or psychological deficits

* Bond, M. R. (1983). Standardized methods of assessing and predicting outcome. In Rosenthal, M. Griffith, Bond MR, Miller JR, (Eds). Rehabilitation of the Head Injured Adult. Philadelphia: F. A. Davis.

Rankin Disability Scale

The Rankin disability scale has a special place in the clinical trials of stroke. Its assessment of both disability and impairment, however, makes it rather insensitive, and it is therefore best used for large population studies that require a simple form of assessment.

Score	Outcome
1	No disability
2	Slight disability: unable to carry out some previous activities, but looks after own affairs without assistance
3	Moderate disability: requires some help, but walks without assistance
4	Moderately severe disability: unable to walk and carry out bodily care without help
5	Severe disability: bed-ridden, incontinent, needs constant nursing care

Barthel Index*

The Barthel index is a weighted scale of 10 activities, with maximum independence equal to a score of 100. Patients who score 100 on the Barthel index can survive without attendant care. Scores below 61 on hospital discharge after a stroke predict a level of dependence that makes discharge to home less likely. The Barthel index is a well-known scale for the assessment and outcome of disability. It has been used in epidemiological studies of stroke, such as the Framingham study, in which patients were evaluated over time after stroke, and to complement impairment measures in multicenter trials of acute interventions for stroke, traumatic brain injury, and spinal cord trauma.

The Barthel index has certain limitations: it has no measure for language or cognition, and, as is the case with most functional assessments, a change by a given number of points does not mean an equivalent change in disability across different activities. However, this index is the best known scale, against which any newer measures have to be compared.

Activities	Help	Independent
Feeding (food needing to be cut up = help)	5	10
Moving from wheelchair to bed and return (including sitting up in bed)	5–10	15
Performing personal toilet (washing face, combing hair, shaving, cleaning teeth)	0	5
Transferring on and off toilet (handling clothes, wiping, flushing)	5	10
Bathing self	0	5
Walking on level surface (or, if unable to walk, propelling wheelchair)	10	15
* Score only when unable to walk	0*	5*
Ascending and descending stairs	5	10
Dressing	5	10
Controlling bowel	5	10
Controlling bladder	5	10

* Mahoney F., Barthel D. Functional evaluation: The Barthel index. *Maryland State Med. J.* 1965; 14: 61–65

Mini-Mental State Examination

The mini-mental examination is the most frequently used cognitive screening test, but it has limited sensitivity in detecting language dysfunction and in determining the cognitive basis for disability in the neurorehabilitation population. Scoring must be considered within educational and age-adjusted norms.

Maximum score	Patient's score	
		Orientation
5	()	What is the (year) (season) (date) (day) (month)?
5	()	Where are we: (state) (country) (town) (hospital) (floor)?
		Registration
3	()	Name three objects, allowing one second to say each, then ask the patient to repeat all three after you said them. Give one point for each correct answer. Continue repeating all three objects until the patient learns all three. Count trials and record
		Attention and calculation
5	()	Serial 7's. One point for each correct response. Stop after five answers. Alternatively, spell word backward
		Recall
3	()	Ask for the three objects named under Registration above. Give one point for each correct answer
		Language
2	()	Name a pencil and watch
1	()	Repeat the following: "No ifs, ands, or buts"
3	()	Follow a three-stage command: "Take a piece of paper in your right hand, fold it in half, and put it on the floor"
1	()	Read and obey the following: "Close your eyes"
1	()	Write a sentence
1	()	Copy a design
–	–	
30	()	

Assess the level of consciousness along a continuum:
Alert — Drowsy — Stupor — Coma

From: Folstein MF, Folstein SE, McHugh PR. Mini-mental state: a practical method for grading the cognitive state of patients for the clinician. *J Psychiatr Res* 1975; 12: 189–98.

Tsmentzis, *Differential Diagnosis in Neurology and Neurosurgery* © 2000 Thieme
All rights reserved. Usage subject to terms and conditions of license.

Neuropsychological Evaluation and Differential Diagnosis of Mental Status Disturbances

Cognitive function	Amnesia (1)	Dementia (2)	Confusion (3)	Aphasia (4)	Aprosexia (5)
Attention	Normal	Normal	Impaired	Normal	Impaired
Memory	Impaired	Impaired	Impaired	Impaired verbal, normal, non-verbal	Variably impaired
Intelligence	Normal	Impaired	Normal	Normal	Normal
Language	Normal	Normal early, impaired later	Normal	Impaired	Impaired
Visuospatial	Normal	Impaired	Impaired	Normal	Normal
“Executive”	Normal	Impaired	Impaired	Normal	Normal

Attention: Tests of attention capacity, such as digit span or mental arithmetic, use subtests of the Wechsler Adult Intelligence Scale—Revised.

Memory: Short-term memory is regarded as “working memory,” in which conscious mental processes are performed, and it is analogous to immediate or primary memory. “Memory tests” include verbal memory tasks, such as learning word lists (Selective Reminding Test), digit supraspan (Serial Digit Learning), paragraph retention (Wechsler Memory Scale), paired associate learning (Wechsler Memory Scale), and tests of nonverbal, visuospatial new learning, such as complex figure recall (Rey–Osterrieth Complex Figure), or learning simple geometric designs (Wechsler Memory Scale).

Intelligence: Usually tested and measured using the Wechsler Adult Intelligence Scale—Revised.

Language: Core linguistic functions are measured by tests of visual naming, aural comprehension, sentence repetition, and verbal fluency from any common aphasia test battery.

Visuospatial: Visual perception, visuospatial reasoning or judgment.

“Executive”: Functions such as abstraction, complex problem solving, reasoning, concept formation, and the use of feedback to guide outgoing behavior (representing frontal lobe functions).

Differential diagnosis:

Amnesia	Dementia, acute confusional state, psychiatric disorders, psychogenic amnesia		
Dementia	Mental retardation, acute confusional states, psychiatric disorders (depression)		
Confusion	Dementia		
Aphasia—major aphasia syndromes:			
<i>Aphasia subtype</i>	<i>Fluency</i>	<i>Comprehension</i>	<i>Repetition</i>
Nominal	Normal	Normal	Normal
Conduction	Normal	Normal	Impaired
Broca's	Impaired	Normal	Impaired
Transcortical motor	Impaired	Normal	Normal
Wernicke's	Normal	Impaired	Impaired
Transcortical sensory	Normal	Impaired	Normal
Global	Impaired	Impaired	Impaired
Mixed transcortical	Impaired	Impaired	Normal
Aprosexia	Amnesia and dementia in early stages, neuro-behavioral disorders (attention disability, insomnia, energy loss, and irritability)		

Karnofsky Scale

The Karnofsky scale grades for disability in neoplastic disease.

Functional status	Score (%)
Normal; no complaints and no evidence of disease	100
Able to carry on normal activity with only minor symptoms	90
Normal activity with effort; some moderate symptoms of disease	80
Cares for self, but unable to carry on normal activities	70
Cares for most needs, but requires occasional assistance	60
Requires considerable assistance to carry on activities of daily living; frequent medical care	50
Disabled; requires special assistance and care	40
Severely disabled; hospitalized, but death not imminent	30
Very sick; requires active supportive treatment	20
Moribund; death threatened or imminent	10

Karnofsky DA, Abelmann WH, Craver LF, et al. The use of the nitrogen mustards in the palliative treatment of carcinoma: with particular reference to bronchogenic carcinoma. *Cancer* 1948; 1: 634–56.

Index

A

abducens nerve palsy 75–6
 Acanthamoeba 291
 accessory nerve neuropathy 78–80
 acquired immune deficiency syndrome (AIDS) 288, 289
 CNS infections 294
 meningitis 296–7, 300
 adenovirus 287
 akinetic mutism 275
 amebal infection 291
 amyotrophic lateral sclerosis 202, 205, 209
 parkinsonism – dementia-ALS complex of Guam 255
 anesthesia dolorosa 312
 ankle, tarsal tunnel syndrome 245
 anosmia 69–70
 anoxia 271
 anterior horn cell and pyramidal tract combined disease 202, 205, 209
 anterior horn cell syndromes 202, 205, 208–9
 antidiuretic hormone (ADH) 167, 168
 aortic aneurysm, abdominal 317
 apallic state 276
 arboviruses 285
 Argyll Robertson pupil 86–7
 arrhythmia, cerebral infarction 159
 arterial hypertension, spontaneous intracerebral hemorrhage 183
 arthrogyrosis 59
Aspergillus fumigatus 289
 ataxia, pediatric 63–5
 atlantoaxial instability 20
 atlas malformations 19
 auditory meatus erosion 117, 118
 autonomic disturbance, pediatric 63
 axilla compression 240
 axis malformations 19

B

back pain
 children 321–3
 developmental disorders 321
 elderly patients 323–4
 inflammatory disorders 321
 traumatic 322
 tumors 321–2
 see also low back pain
 bacterial infection 264, 295–8, 300–1, 302
 Barthel Index 326
 basal ganglia
 calcifications 37–8
 gait 267
 Benedikt's syndrome 170, 171
 Bernhard–Roth syndrome 243–4
Blastomyces dermatitidis 290
 blepharospasm 248, 261
 blindness
 cortical 100–2
 embolic 103, 104–5
 haemodynamic 103, 105
 neurological 104, 106
 ocular 103–4, 105–6
 psychogenic 101
 transient monocular 103–4
 transient visual 104–6
 bone fracture, pathological 195
 Botterell scale 165
 brachial plexopathy 236–7
 brain
 abscess 47, 48, 49, 304
 haematoma 49
 infections 139
 metastases 137–40
 biopsy 137
 differential diagnosis 138–40
 multiple sclerosis lesions 140
 postoperative scar 41
 radiation necrosis 139
 vascular disorders 138
 brain atrophy 44–5, 143–50
 cerebellar 147

 cerebral 147–8
 dementia 148–50
 olivopontocerebellar 253
 brain stem
 multiple cranial nerve palsies 82
 trochlear nerve palsy 72
 vascular syndromes 170–8
 brain tumors
 hemorrhage 136–7
 incidence 3
 postoperative residual 41
 primary 138
 Brown–Séquard syndrome 203, 206–7

C

cancer, myelopathy 225
Candida albicans 290
 cardiac disorders and cerebral infarction 159–60
 cardiac valve defects 159–60
 carotid artery
 dissection 310
 occlusion 168
 trauma 101
 carotid space, hypoglossal neuropathy 81
 carpal tunnel syndrome 234–8
 brachial plexopathy 236–7
 cervical radiculopathy 235–6
 contributing factors 235
 proximal medial nerve neuropathy 237–8
 tests 234
 cat-scratch disease 294
 cauda equina mass lesions and tumors 210–11
 cauda equina syndrome 210–11
 cavernous sinus
 abducens nerve palsy 76
 lesions 128, 129–30
 multiple cranial nerve palsies 82–3
 oculomotor nerve palsy 70–1
 Tolosa–Hunt syndrome 132

- trigeminal neuropathy 74
trochlear nerve palsy 72
venous thrombosis 182
- central cord syndrome 202, 205, 207
- central pathway disorders 93
- cerebral atrophy 147–8
- cerebellar atrophy 147
- cerebellar gait 266
- cerebellar hypoplasia 134
- cerebellopontine angle
anatomy 120
facial nerve palsy 77
trigeminal neuropathy 73
tumors 116–18
- cerebral arteries, occlusion 168, 169
- cerebral arteritis 162–3
- cerebral embolism 159
- cerebral gait 267–8
- cerebral haemorrhage, stages 42–4
- cerebral hemispheres, intracranial tumors 111
- cerebral hypotonia, pediatric 56–7
- cerebral infarction
cardiac disorders 159–60
cardiac valve defects 159–60
myocardial wall abnormalities 160
- cerebral ischemia
arterial thrombosis 180
embolism 179
syndromes 168–9
systemic hypoperfusion 179
vascular lesions 179–80
- cerebral salt-losing syndrome 166–7
- cerebral vein disorders 181
- cerebrovascular disease
arteriopathy 152
atherosclerosis 151
cerebellar hemorrhage 184
cerebral arteritis 162–3
cerebral infarction in young adults 151–4
cervical bruit 162
coagulopathy 152–3
dementia 149
embolism 151
hematological disease 152–3
lobar hemorrhage 183–4
pontine hemorrhage 185
putaminal hemorrhage 184
stroke 163–5
- risk factors 155–8
- thalamic hemorrhage 184
- transient ischaemic attack 161, 163
- vasospasm 152
- cervical bruit 162
- cervical dystonia 256
- cervical radiculopathy 235–6
- cervical spine, disk herniation 222
- cervical spondylotic myelopathy 212–14
non-compressive 214
- cervicocephalic syndrome 232
- cervicomedullary mass, intra-axial 119
- cestodes 292
- chorea 247, 258
- choroid plexus disease 130–1
- choroidal artery occlusion 169
- Claude's syndrome 170, 171
- clivus 127–9
- Coccidioides immitis* 290
- cognitive disability 327, 328
- cognitive function impairment 305
- coma
abnormal motor responses 283
eyes 281, 282–3
metabolic 272–3, 275–8
paediatric 55
psychogenic 272
pupillary patterns 281
respiratory patterns 280
structural 273–8
see also unconscious patient
- coma-like states 278
- confusion 54
- conus medullaris syndromes 211
- Cooperative Aneurysm Study scale 166
- corpus callosum
agenesis 67
lesions 46–7
- corticobasal ganglionic degeneration 253–4
- Costen's syndrome 308, 309
- cranial enlargement, pediatric 68
- cranial nerve disorders 69–84
abducens nerve palsy 75–6
- accessory nerve 78–80
- anosmia 69–70
- facial nerve palsy 77–8
- glossopharyngeal nerve 78–80
- hypoglossal neuropathy 80–1
- meningitis long-term neurological complications 305
- oculomotor nerve palsy 70–1
- trigeminal neuropathy 73–4
- trochlear nerve palsy 72–3
- vagus nerve 78–80
- cranial nerve palsy, multiple 82–4
- craniofacial syndromes 21–2
- craniosynostosis 21–2
- craniovertebral junction abnormalities 18–26
acquired 19–20
associated congenital syndromes 22
associated disorders 23
congenital 18–19
craniofacial syndromes 21–2
craniosynostosis 21–2
developmental 19–20
macrocephaly 23–4
macrocrania 23–4
microcephaly 24–5
microcrania 24–5
pituitary fossa enlarged 26
small 25–6
pneumocephalus 25
- cryptococcosis 289, 294
- cubital tunnel 238–9
- cysticercosis 292
- cytomegalovirus 287

D

- Dandy-Walker complex 133, 134
- Dandy-Walker cyst 133, 135
- deafness 305
- degenerative disease, low back pain 196
- Dejerine syndrome *see* medial medullary syndrome
- dementia 148–50
cerebrovascular disease 149
degenerative disorders 149

head injury 149
 hypoxia 149
 intracranial tumors 150
 metabolic disorders 150
 parkinsonism – dementia
 – amyotrophic lateral
 sclerosis complex of
 Guam 255
 syndromes 250
 demyelinating disease 143–
 50
 cerebellar atrophy 147
 cerebral atrophy 147–8
 dementia 148–50
 multifocal white matter le-
 sions 143–4
 multiple sclerosis-like le-
 sions 144–6
 developmental gait 264
 diabetes insipidus, SIADH
 167–8
 diffuse Lewy body disease
 254–5
Diphyllobothrium 292
 diplopia
 binocular 92–4
 monocular 92
 disability scales 325–6
 disk
 residual material 187–8
see also lumbar disk
 disk herniation 189–90
 cauda equina syndrome
 210
 cervical 222
 lumbar 222, 228
 DNA viruses 286–7
 duodenal ulcer 318
 dystonia 247–8
 focal 261

E

Echinococcus granulosus 292
 elbow, radial nerve compres-
 sion 241–2
 encephalitis 294
 endometriosis 317
Entamoeba histolytica 291
 enteroviruses 285
 epidural abscess 221
 epidural hematoma 220–1
 Epstein–Barr virus 287
 extradural mass 122
 extraocular muscle disorders
 92–3
 eyelids, blepharospasm 261
 eyes
 comatose patients 281,
 282–3

spontaneous movements
 282
see also pupillary syn-
 dromes

F

facial nerve palsy 77–8
 failed back syndromes 186–
 7, 188–92
 causes 189
 differential diagnosis 189–
 92
 psychosocial problems 188
 femoral nerve injury 244
 femoral neuropathy 244–5
 fever 304
 fibrosis, lumbar spine
 surgery 190–1
 flukes 293
 foot drop 227–9
 foramen magnum
 abnormalities 20
 intracranial tumors 119–
 22
 fourth ventricle tumors 113
 Foville syndrome 173, 174,
 177
 fungal infection 289–90,
 298, 299, 301

G

gait
 basal ganglia 267
 cerebellar 266
 cerebral 267–8
 developmental 264
 neuromuscular 264–5
 sensory 265–6
 sexual behavior 268
 spastic 266
 types 264–8
 gait disorders 262–8
 arthritic 262
 cardiovascular 262
 musculoskeletal 262
 myelopathy 264
 neurological 262, 263–4
 gaze palsy, vertical 99
 Glasgow Coma Scale 269,
 278
 Glasgow Outcome Scale 325
 glioma, malignant recur-
 rence 132–3
 gliomatosis cerebri 131
 globus pallidus, basal ganglia
 calcifications 37
 glossopharyngeal nerve neu-
 ropathy 78–80

Gradenigo's syndrome 312
 gyrfiform enhancement 46

H

head injury
 dementia 149
 Glasgow Outcome Scale
 325
 head tilt 248–9
 headache 307, 308, 309, 310–
 11
 WHO classification 313–
 17
 hemiplegia
 acute 65
 progressive 66
 herpes simplex virus 286
 herpes zoster 202, 204
 herpesvirus 286–7
 hip pain 229
 hippus 89
 Holmes–Adie pupil 88
 Horner's syndrome 87–8
 causes 85–6
 neurons 85–6, 88
 human immunodeficiency
 virus (HIV) 288–9
 meningitis 300
 humerus, spiral groove com-
 pression 240
 Hunt–Hess scale 165
 hydrocephalus 304
 normal pressure 44–5
 hyperprolactinemia 142
 hypoglossal neuropathy
 80–1
 hypotonic infant 56–8
 hypoxia, dementia 149

I

infection
 amebal 291
 bacterial 264, 295–8, 300–
 1, 302
 CNS in AIDS 294
 fungal 289–90, 298, 299,
 301
 headache 315
 intraventricular shunt
 295–6
 low back pain 193–4
 parasitic 290–4, 298, 299,
 301
 pediatric disease 62
 rickettsial 294
 viral 285–9, 299, 301
 inflammation, low back pain
 195, 196

- injury, trauma score 278
 internal auditory canal erosive diseases 15–16
 internal auditory meatus tumors 119
 intervertebral disk *see* disk; lumbar disk
 intracerebral hemorrhage cerebellar 184
 lobar 183–4
 pontine 185
 putaminal 184
 spontaneous 183–5
 thalamic 184
 intracranial calcifications 35–8
 congenital 35
 familial 35
 inflammatory 36
 metabolic 35
 neoplasms 36–7
 physiological 35
 vascular 36
 intracranial lesions 270
 intracranial tumors cerebellar hypoplasia 134
 cerebellopontine angle 116–18, 120
 cerebral hemispheres 111
 choroid plexus 130–1
 dementia 150
 enhancing lesions in children/young adults 136
 foramen magnum 119–22
 gliomatosis cerebri 131
 hyperprolactinemia 142
 internal auditory meatus 119
 intraventricular 112–13
 malignant glioma recurrence 132–3
 pineal 114–15
 posterior fossa cysts/anomalies 133–5
 skull base 123–30
 subarachnoid space metastases 140–1
 Tolosa–Hunt syndrome 132, 312
 tumoral hemorrhage 136–7
 intradural mass, extramedullary 122
 intraspinal cysts, pediatric 222–5
 intraventricular shunt infection 295–6
 intraventricular tumors 112–13
- iridoplegia 89
 ischemia 271
- J**
- jugular foramen neuropathies 79
- K**
- Karnofsky scale 329
- L**
- language dysfunction 327, 328
 larva migrans, visceral 292
 lateral medullary syndrome 174, 175, 178
 lateral sinus, venous thrombosis 182
 lateral ventricle tumors 112
 leptomeningeal metastases 217, 218
 leukoencephalopathy, progressive multifocal 288, 294
 Lewy body disease, diffuse 254–5
 Lhermitte's sign 220
 locked-in syndrome 173, 174, 176, 277
 low back pain 186, 193–7
 acute 193–5
 chronic 195–7
 degenerative disease 196
 infection 193–4
 inflammation 195, 196
 metabolic disease 196
 pathological fracture 195
 pregnancy 323
 referred pain of visceral origin 195
 spinal tumors 194
 subacute 193–5
 trauma 193
 lower extremities, radiculopathy 200
 lumbar disk herniation 222, 228
 protrusion 226
 surgery and failed back syndrome 186
 lumbar root syndrome 229
 lumbar spine instability 192
 tenosis 191–2
 lumbar spine surgery fibrosis 190–1
 multiple 188–92
- M**
- macrocephaly 23–4
 macrocrania 23–4
 malaria 291
 Marcus Gunn pupil 88–9
 Marie–Foix syndrome 172, 173, 177
 mastoid destructive diseases 14
 erosive diseases 16–17
 measles 285
 medial longitudinal fasciculus lesion 98
 medial medullary syndrome 175, 178
 medial nerve neuropathy 237–8
 medulla accessory nerve neuropathy 78–9
 glossopharyngeal nerve neuropathy 78–9
 hypoglossal neuropathy 80
 vagus nerve neuropathy 78–9
 vascular syndromes 174–5, 178
 megelencephaly, pediatric 67–8
 Meige's syndrome 261
 Ménière's disease 232
 meningeal enhancement 45–6
 meningitis 284
 bacterial 299, 300–1, 302
 ute 295–8
 chronic 299–300
 eosinophilic 292
 fungal 298, 299, 301
 immunodeficiency states 296–8
 neurological complications 303–5
 acute 303
 intermediate 304
 long-term 305
 parasitic 298, 299, 301
 polymicrobial 302
 postoperative 296
 posttraumatic 296
 recurrent 300–1
 bacterial 302
 viral 299, 301
 mental illness 272
 mental status disturbances differential diagnosis 329
 neuropsychological evaluation 328
 meralgia paresthetica 243–4

- metabolic disorders
 comatose patients 272–3,
 275–8
 dementia 150
 intracranial calcifications
 35
 low back pain 196
 pain 320
 spine 324
 metabolic encephalopathy
 270–1
 methotrexate leukoen-
 cephalopathy 139
 microcephaly 24–5
 microcrania 24–5
 midbrain
 oculomotor nerve palsy 70
 vascular syndromes 170–1
 middle ear
 destructive diseases 14
 erosive diseases 16–17
 midpontine base syndrome
 173–4
 migraine 232, 309, 316
 Millard–Gubler syndrome
 173, 174, 176
 mini-mental state examina-
 tion 326
 miosis 91
 mononeuropathies, pediatric
 66
 monoplegia, acute 66
 Morton’s metatarsalgia 246
 motor handicap 305
 motor neuron disease 202,
 205, 208–9
 pediatric 61
 motor neuron syndrome,
 lower 219
 motor response in comatose
 patients 283
 motor unit disorders, pedi-
 atric 57–8
 movement disorders 247–68
 blepharospasm 248, 261
 cervical dystonia 256
 chorea 247, 258
 dystonia 247–8
 gait 262–8
 hypokinetic 249–55
 myoclonus 257
 parkinsonism 249–55
 tic disorders 259
 torticollis 248–9
 tremor 259–60
 multiple sclerosis, brain le-
 sions 140
 multiple sclerosis-like le-
 sions 144–6
 multiple system atrophy
 252–3
 mumps 285
 muscular dystrophy, neu-
 ronal 202, 204–5
 myasthenic syndromes, pe-
 diatric 60
 mydriasis 89–91
 posttraumatic 89
 myelopathy
 ascending 219–20
 cancer patients 225
 gait disorders 264
 HIV-associated 289
 non-compressive 214, 216–
 17
 progressive 219
 transverse 219
see also cervical spondy-
 lotic myelopathy;
 radiation myelopathy
 myocardial wall abnormali-
 ties, cerebral infarc-
 tion 160
 myoclonus 257
 myopathy
 pediatric 59–60, 61
 ptosis 95
- N**
- Naegleria* 291
 nasopharynx, hypoglossal
 neuropathy 81
 nematodes 292–3
 nephrolithiasis 318
 nerve root diffuse thickening
 187
 neuralgia
 cranial 316–17
 facial 308, 311–12
 head 308, 311–12
 occipital 310
see also postherpetic
 neuralgia
 neurological disease
 incidence 2
 prevalence 1
 neuromuscular blockade 62
 neuromuscular gait 264–5
 neuropathy, pediatric 61
 neurorehabilitation 325–9
 neurotrauma scales 269
Nocardia asteroides 289
- O**
- occipital bone malforma-
 tions 18–19
 occipital neuralgia 310
 ocular motility disturbance
 251
 oculomotor nerve
 binocular diplopia 93
 palsy 70–1
 olivopontocerebellar atrophy
 253
 ophthalmoplegia
 acute 96–7
 internuclear 98
 optic disk, swollen 107–8
 optic nerve
 enlargement 108–10
 idiopathic inflammatory
 pseudotumor 109
 tumors 108–9
 optic neuritis 109
 optic neuropathy 101
 optical system disorders,
 binocular diplopia
 93–4
 orbit
 oculomotor nerve palsy 71
 ptosis 95–6
 orbital fissure
 abducens nerve palsy 76
 oculomotor nerve palsy
 70–1
 trigeminal neuropathy 74
 trochlear nerve palsy 72
 orbital process, multiple
 cranial nerve palsies
 82–3
- P**
- pain
 atypical facial 308
 cephalic 309–11
 metabolic disorders 320
 myofascial 306–7, 308
 postherpetic neuralgia
 307, 308
 pseudospine 317–20
 referred of visceral origin
 195, 199
 rheumatological disorders
 318–20
see also headache
 pancreatitis 318
 papilledema 56, 107–8
 paragonimiasis 293
 paralysis
 flaccid 202, 203, 204, 205
 periodic 62
 spastic 202, 203, 204, 205
 parasellar lesions 27–35,
 128, 129–30
 calcification 38
 inflammatory 34–5

- neoplastic 27, 29–32
 nonneoplastic 32, 34–5
 vascular 34
- parasitic infection 290–4,
 298, 299, 301
- Parinaud's syndrome 170,
 171–2
- parkinsonism 249–55
 classification 249–50
 corticobasal ganglionic
 degeneration 253–4
 differential diagnosis 250–
 1
 diffuse Lewy body disease
 254–5
 heterodegenerative 250
 multiple system atrophy
 252–3
 multiple system degenera-
 tion 250
 progressive supranuclear
 palsy 251–2
- parkinsonism – dementia –
 amyotrophic lateral
 sclerosis complex of
 Guam 255
- Pediatric Coma Scale 269
- pediatric disorders
 acute generalized weak-
 ness 62
 agenesis of corpus callo-
 sum 67
 arthrogyposis 59
 ataxia 63–5
 autonomic disturbance 63
 coma 55
 confusion 54
 cranial enlargement 68
 hemiplegia
 acute 65
 progressive 66
 hypotonic infant 56–8
 infection 62
 megalencephaly 67–8
 monoplegia 66
 motor unit 57–8
 neonatal seizures 50–2
 nonfebrile tonic – clonic
 seizures 53
 papilledema 56
 precocious puberty 59
 progressive distal weak-
 ness 61–2
 progressive proximal
 weakness 59–60
 restlessness 54
 seizures 50–2, 53
 sensory disturbance 63
 solitary radiolucent skull
 lesions without
 sclerotic margins 8–9
- spinal cord 57, 60, 61–2
- pelvic inflammatory disease
 317
- peroneal nerve 227–8
 compression 245
 persistent vegetative state
 276
- pineal gland
 aneurysm 114, 115
 tumors 114–15
- piriformis muscle syndrome
 307, 319
- pituitary
 apoplexy 101
 tumors 26, 27–9
- pituitary fossa
 enlarged 26
 small 25–6
- plantar digital nerve entrap-
 ment 246
- plexopathies, pediatric 66
- pneumocephalus 25
- pons
 abducens nerve palsy 75
 trigeminal neuropathy 73
 vascular syndromes 172–
 3, 176–7
- posterior column disease
 202, 204, 208
- posterior fossa
 congenital cysts/anomalies
 133–4
 cysts 134–5
 tumors 39–40
- posterior interosseous neu-
 ropathy 241–2
- posterolateral column dis-
 ease 203, 205, 208
- postherpetic neuralgia 307,
 308
- precocious puberty 59
- pregnancy
 ectopic 318
 low back pain 323
- progressive multifocal
 leukoencephalopathy
 288, 294
- progressive supranuclear
 palsy 251–2
- prolactin, normal levels 142
- prostatitis 318
- pseudopapilledema 107
- pseudoptosis 96
- psychogenic coma 272
- ptosis 95–6
- pupillary syndromes 86–92
 afferent pupillary defect
 88–9
 Argyll Robertson pupil
 86–7
- bilateral constriction 91–2
 bilateral dilatation 90–1
 diplopia 92–4
 hippus 89
 Holmes–Adie pupil 88
 Horner's syndrome 85–6,
 87–8
 miosis 91–2
 mydriasis 89–91
 posttraumatic mydriasis
 89
 unilateral constriction 91
 unilateral dilatation
 89–90
- pupillary unrest 89
- pupils
 afferent defect 88–9
 comatose patients 281

R

- rabies 285
- radial nerve
 entrapment 241–2
 injury at wrist 242
- radial nerve compression
 at elbow 241–2
 within spiral groove of
 humerus 240
- radial nerve palsy 239–43
 differential diagnosis 243
- radial tunnel syndrome 241
- radiation myelopathy 219
 chronic progressive 213
- radiation necrosis, brain 139
- radiculopathy, lower ex-
 tremities 200
- Raeder's syndrome 312
- Rankin Disability Scale 325
- Raymon–Cestan syndrome
 172–3, 177
- respiratory patterns, coma
 280
- restlessness 54
- retinal disease 101
- retinal vein occlusion 109
- retrobulbar neuritis, acute
 100
- rheumatological disorders
 318–20
- Rickettsia 294
- rigidity 233
- ring enhancing lesions 47–9
- RNA virus infections 285–6
- Rocky Mountain spotted
 fever 294

S

- sagittal sinus, superior 182
- scar tissue in spinal disorders 187–8
- schistosomiasis 293
- sciatica 229–30
 - extravertebral 230
 - vertebral 229–30
- scoliosis 320
 - juvenile idiopathic 231
- seizures
 - disorders 2–3
 - incidence 2–3
 - meningitis neurological complications 303
 - neonatal 50–2
 - movements resembling 50
 - time of onset 51–2
 - nonfebrile tonic–clonic after two years of age 53
- sensory disturbance, pediatric 63
- sensory gait 265–6
- Shy–Drage syndrome 252
- skull base
 - anterior 123, 125
 - central 125–7
 - intracranial tumors 123–30
 - posterior 127–9
- skull lesion
 - multiple radiolucent 10–11
 - solitary radiolucent with sclerotic margins 9 without sclerotic margins 7, 8–9
- skull vault, hyperostosis 11–12
- slow viruses 288
- spastic gait 266
- spasticity 233
- spinal artery syndrome
 - anterior 203, 206, 209–10
 - posterior 203, 210
- spinal cord
 - hemorrhage 219
 - pediatric disorders 57, 60, 61–2
- spinal cord compression 215–17
 - epidural 217–22
 - epidural abscess 221
 - epidural hematoma 220–1
 - leptomeningeal
 - metastases 217, 218
 - neoplastic 215–16
 - nonneoplastic 215
 - radiation myelopathy 219
- spinal cord injury
 - age at 5
 - associated injuries 6
 - ethnic groups 5
 - etiology 6
 - incidence 4
 - neurological level at discharge 6
 - prevalence 5
- spinal cord lesions 201–10
 - anterior horn cell and pyramidal tract combined disease 202, 205, 209
 - syndromes 202, 205, 208–9
 - anterior spinal artery syndrome 203, 206, 209–10
 - causes 201
 - central cord syndrome 202, 205, 207
 - complete transection 201–6
 - hemisection 203, 206–7
 - neurological manifestations 201
 - posterior column disease 202, 204, 208
 - posterolateral column disease 203, 205, 208
 - syndromes 202–6
 - vascular syndromes 203, 206, 209–10
- spinal cord tumors
 - differential diagnosis of intra- and extramedullary 212
 - extradural 213
 - extramedullary 213, 218
 - intradural 213, 218
 - intramedullary 213, 218
- spinal cysts
 - extradural 224–5
 - intradural 222–3
- spinal disorders
 - failed back syndrome 186–7
 - nerve root diffuse thickening 187
 - residual disk material 187–8
 - scar tissue 187–8
- spinal epidural bacterial abscess 302
- spinal hematoma 214
- spinal muscular atrophy 202, 205, 208–9
 - juvenile 60
- spinal nerve root disorders 227
- spinal tumors, low back pain 194
- spine
 - degenerative disorders 323
 - metabolic disorders 324
 - tumors 323–4
- spongiform encephalopathies 288
- stance
 - neurological disorders 263–4
 - types 264–8
- striatonigral degeneration 253
- stroke 163–5
 - cerebral arteritis 162–3
 - Rankin Disability Scale 325
 - risk factors 155–8
 - spontaneous intracerebral hemorrhage 183
- Strongyloides stercoralis* 293
- structural coma 273–8
- structural disease, comatose patients 274–8
- subacute sclerosing panencephalitis 288
- subarachnoid hemorrhage
 - cerebral salt-losing syndrome 167
 - clinical grading scales 165–6
 - SIADH 166–7
- subarachnoid space
 - abducens nerve palsy 75–6
 - hypoglossal neuropathy 80–1
 - metastases 140–1
 - oculomotor nerve palsy 70
 - trochlear nerve palsy 72
- subdural effusion 304
- supranuclear palsy, progressive 251–2
- suprasellar lesions 27–35, 128, 129–30
 - inflammatory 34–5
 - neoplastic 27–32
 - nonneoplastic 32–5
 - vascular 34
- syndrome of inappropriate secretion of antidiuretic hormone (SIADH) 166–8, 303
- syphilis, meningovascular 87
- syringomyelia 214

T

tabes dorsalis 204, 208
Taenia multiceps 292
 tarsal tunnel syndrome 245–6
 temporal arteritis 308, 309
 temporal bone
 destructive diseases 12–14
 diseases affecting 12–17
 erosive diseases 14–17
 temporomandibular joint
 dysfunction 307, 308, 309
 third ventricle tumors 112–13
 thoracic outlet syndrome 307
 thoracic pain 197–9
 musculoskeletal 198–9
 neurogenic 197–8
 visceral referred pain 199
 thrombosis
 primary idiopathic 181
 secondary 181
 venous 182
 tibial nerve 245
 tic disorders 259
 Tolosa–Hunt syndrome 132, 312
 tonic pupil 88
 torticollis 248–9

spasmodic 256
 toxic encephalopathy 270–1
Toxoplasma gondii 290
 toxoplasmosis 294
 transient ischaemic attack 161–2, 163
 transverse myelitis 203, 206
 trauma
 low back pain 193
 score 278–9
 trematodes 293
 tremor 259–60
 trichinosis 293
 trigeminal neuropathy 73–4
 trochlear nerve palsy 72–3
 trypanosomiasis 291

U

ulnar entrapment 238–9
 ulnar neuropathy 238–9
 unconscious patient 270–2
 unilateral pupillary dilatation 90
 see also coma

V

vagus nerve, neuropathy 78–80
 varicella zoster virus 287, 307

ventriculitis 303
 vertebral artery trauma 101
 viral infection 285–9, 299, 301
 visual loss
 bilateral sudden 100–1
 slowly progressing 102
 unilateral sudden 99–100

W

Wallenberg's syndrome *see* lateral medullary syndrome
 weakness
 acute generalized 62
 progressive distal 61–2
 progressive proximal 59–60
 Weber's syndrome 170, 171
 white matter, multifocal lesions 143–4
 World Federation of Neurological Surgeons (WNS) scale 166
 World Health Organization (WHO), headache classification 313–17
 wrist, radial nerve injury 242

Z

zygomycetes 289