


# Laboratory Atlas *of* Anatomy and Physiology

SIXTH EDITION



Douglas J. Eder

Shari Lewis Kaminsky

John W. Bertram

# **Biology**

---

**Laboratory Atlas of Anatomy and  
Physiology  
6th Edition**

**Eder-Kaminsky-Bertram**

*McGraw-Hill*

*A Division of The McGraw-Hill Companies*



**McGraw-Hill Primis**

ISBN-10: 0-39-043548-1

ISBN-13: 978-0-39-043548-4

Text:

Laboratory Atlas of Anatomy and  
Physiology, Sixth Edition

**Eder-Kaminsky-Bertram**



This book was printed on recycled paper.

**Biology**

**<http://www.primisonline.com>**

Copyright ©2008 by The McGraw-Hill Companies, Inc. All rights reserved. Printed in the United States of America. Except as permitted under the United States Copyright Act of 1976, no part of this publication may be reproduced or distributed in any form or by any means, or stored in a database or retrieval system, without prior written permission of the publisher.

This McGraw-Hill Primis text may include materials submitted to McGraw-Hill for publication by the instructor of this course. The instructor is solely responsible for the editorial content of such materials.

# Biology

## Contents

Eder–Kaminsky–Bertram • *Laboratory Atlas of Anatomy and Physiology, Sixth Edition*

<b>Front Matter</b>	<b>1</b>
Credits	1
<b>1. Histology</b>	<b>3</b>
Text	3
<b>2. Human Skeletal Anatomy</b>	<b>47</b>
Text	47
<b>3. Human Muscular Anatomy</b>	<b>71</b>
Text	71
<b>4. Dissection</b>	<b>97</b>
Text	97
<b>5. Specialized Organs</b>	<b>141</b>
Text	141
<b>6. Reference Tables</b>	<b>153</b>
Text	153
<b>Back Matter</b>	<b>180</b>
Index	180



*This page intentionally left blank*

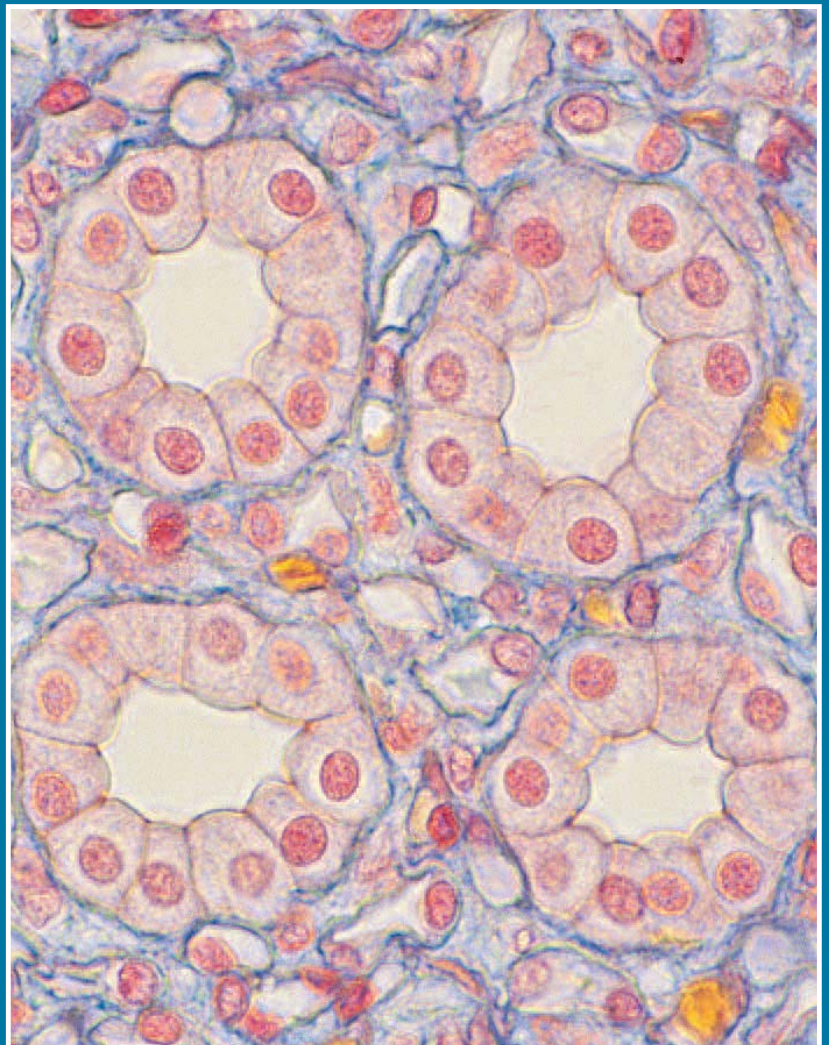
## C R E D I T S

**Chapter 1** Chapter Opener: © Ed Reschke; 1.1, 1.2, 1.3, 1.4, 1.5, 1.6, 1.7, 1.8, 1.9, 1.10, 1.11, 1.12, 1.13, 1.14, 1.15, 1.16, 1.17, 1.18, 1.19, 1.20, 1.21, 1.22, 1.23, 1.24, 1.25, 1.26, 1.27, 1.28, 1.29, 1.30, 1.31, 1.32, 1.33, 1.34, 1.35, 1.36, 1.37, 1.38, 1.39, 1.40, 1.41, 1.42, 1.43, 1.44, 1.45, 1.46, 1.47, 1.48, 1.49, 1.50, 1.51, 1.52: © Ed Reschke; 1.53: Courtesy Bruce Wingard; 1.54, 1.55, 1.56, 1.57A, 1.57B, 1.58, 1.59, 1.60, 1.61, 1.62, 1.63, 1.64, 1.65, 1.66, 1.67, 1.68A : © Ed Reschke; 1.68B: © Camera M.D. Studios; 1.69, 1.70, 1.71, 1.72, 1.73A, 1.73B, 1.74, 1.75, 1.76, 1.77, 1.78, 1.79, 1.80A, © Ed Reschke; 1.80B: © Visuals Unlimited, Inc.; 1.81, 1.82, 1.83, 1.84A, 1.84B, 1.84C, 1.85, 1.86, 1.87, 1.88, 1.93, 1.94, 1.95, 1.96, 1.97, 1.98, 1.99, 1.100, 1.101, 1.102, 1.103, 1.104, 1.105, 1.106: © Ed Reschke **Chapter 2** Chapter Opener: © SPL/Photo Researchers, Inc.; 2.1, 2.2, 2.3, 2.4, 2.5, 2.6, 2.7, 2.8, 2.9, 2.10, 2.11, 2.12, 2.13, 2.14, 2.15A-B, 2.16A, 2.17, 2.18, 2.19A-B, 2.21, 2.22, 2.23, 2.24, 2.25, 2.26, 2.27: Courtesy Douglas Eder, Shari Kaminsky, John Bertram; 2.28: © Dennis Strete; 2.29, 2.30: Courtesy Douglas Eder, Shari Kaminsky, John Bertram; 2.31: © Dennis Strete; 2.32, 2.33, 2.34, 2.35, 2.36, 2.37, 2.38: Courtesy Douglas Eder, Shari Kaminsky, John Bertram **Chapter 3** Chapter Opener: © SPL/Photo Researchers, Inc. **Chapter 4** Chapter Opener: © SPL/Photo Researchers, Inc.; 4.1, 4.2, 4.3, 4.4, 4.5, 4.6, 4.7, 4.8, 4.9, 4.10, 4.11, 4.12, 4.13, 4.14, 4.15, 4.16A-B, 4.17, 4.18, 4.19, 4.20, 4.21, 4.22, 4.23, 4.24A-B, 4.25A-B, 4.26, 4.27A-B, 4.28, 4.29A-B, 4.30, 4.31, 4.32, 4.33, 4.34, 4.35, 4.36A-B, 4.37, 4.38, 4.39, 4.40, 4.41, 4.42, 4.43, 4.44, 4.45: Courtesy Douglas Eder, Shari Kaminsky, John Bertram **Chapter 5** Chapter Opener: © SPL/Photo Researchers, Inc.; 5.1, 5.2, 5.3, 5.4, 5.5, 5.6, 5.7, 5.8, 5.9, 5.10, 5.11: Courtesy Douglas Eder, Shari Kaminsky, John Bertram **Chapter 6** Chapter Opener: © Prof. P. Motta/Univ. “La Sapienza”/Photo Researchers, Inc.

*This page intentionally left blank*

C H A P T E R 1

# Histology

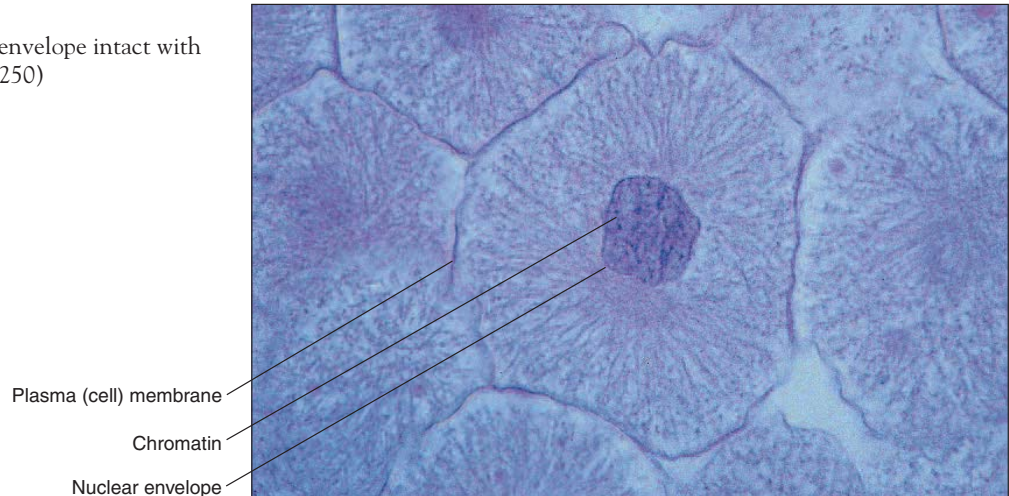


Simple Cuboidal Epithelium

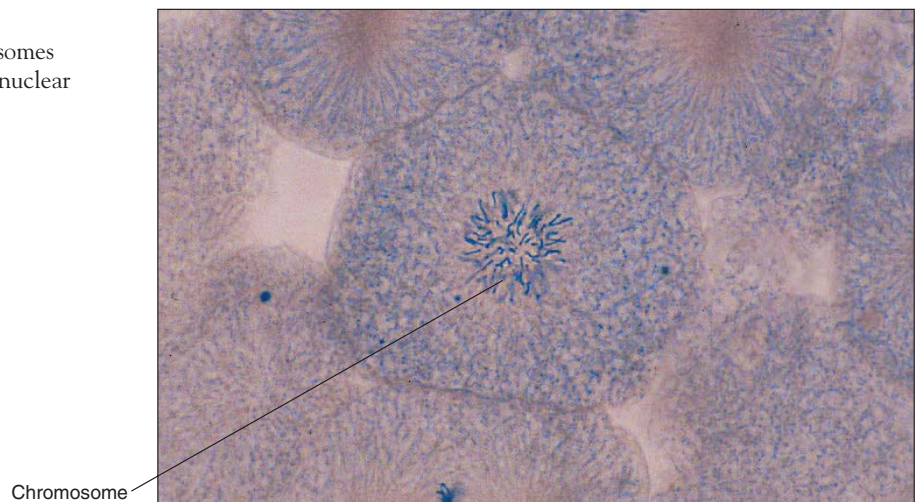
## 2 CHAPTER 1

**Figure 1-1**

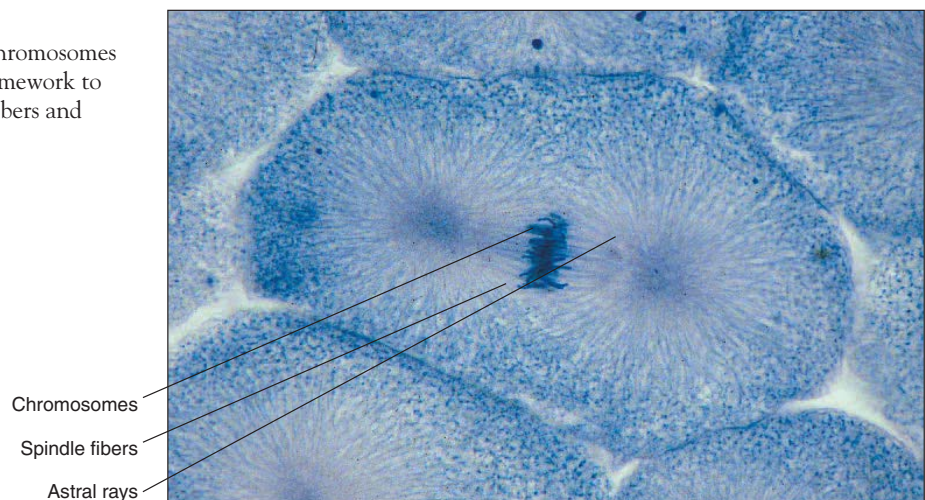
**Interphase** Nuclear envelope intact with chromatin visible. ( $\times 250$ )

**Figure 1-2**

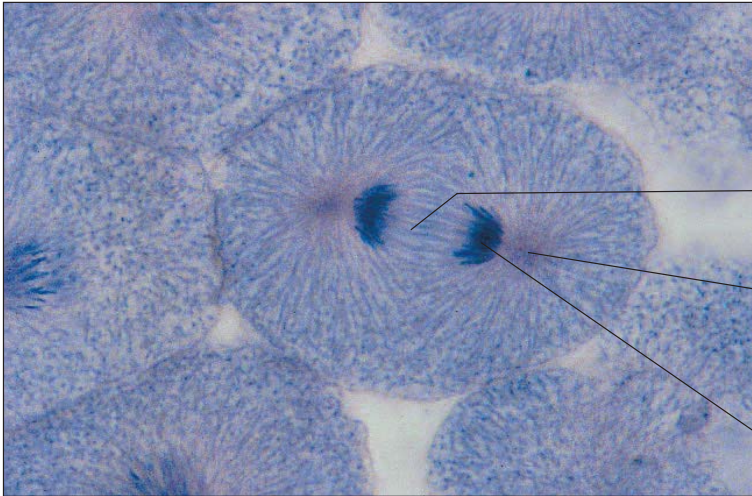
**Prophase** Duplicated chromosomes condensed into visible strands; nuclear envelope absent. ( $\times 250$ )

**Figure 1-3**

**Metaphase** Darkly stained chromosomes positioned by microtubular framework to align at cell equator. Spindle fibers and astral rays visible. ( $\times 250$ )







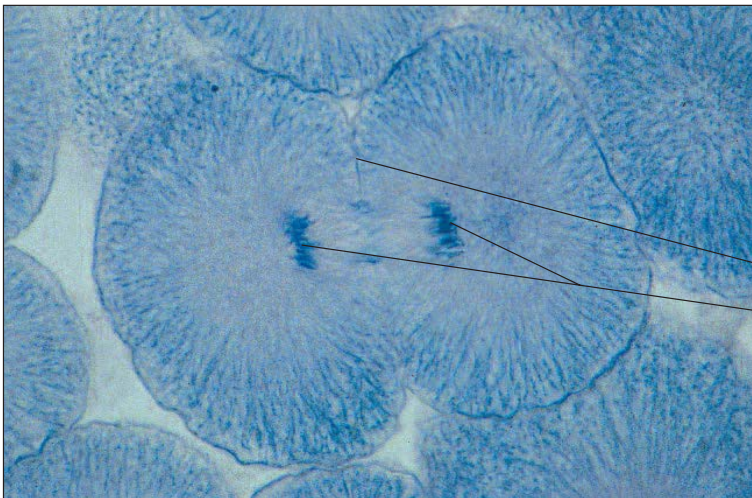
**Figure 1-4**

**Anaphase** Darkly stained chromosomes move to opposite poles under microtubular influence. Spindle fibers and astral rays visible. ( $\times 250$ )

Spindle fibers

Astral rays

Chromosomes



**Figure 1-5**

**Telophase** Separated chromosomes lose microtubular attachments. Belt of actinomyosin forms at equator, assists in formation of new cell membranes and cytokinesis. Cleavage furrow forms two daughter cells. ( $\times 250$ )

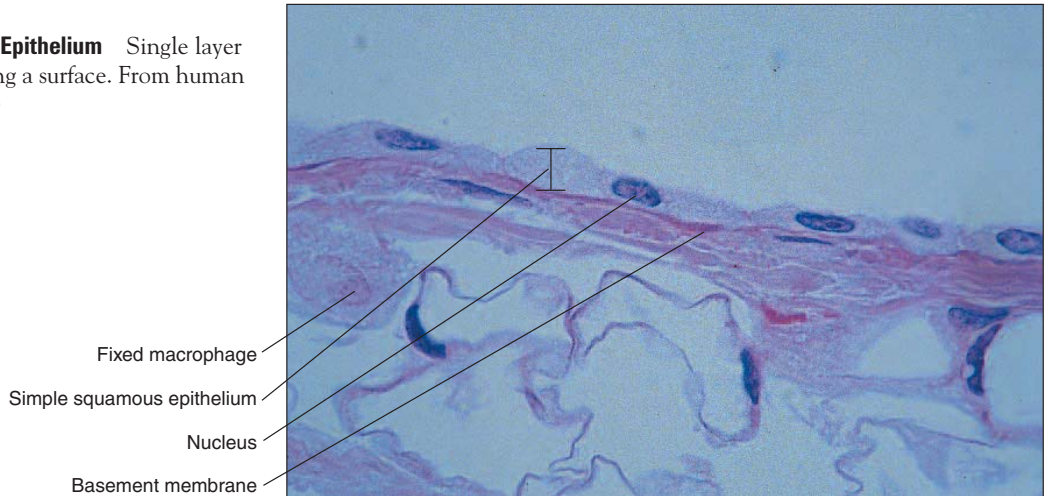
Cleavage furrow at equator

Chromosomes

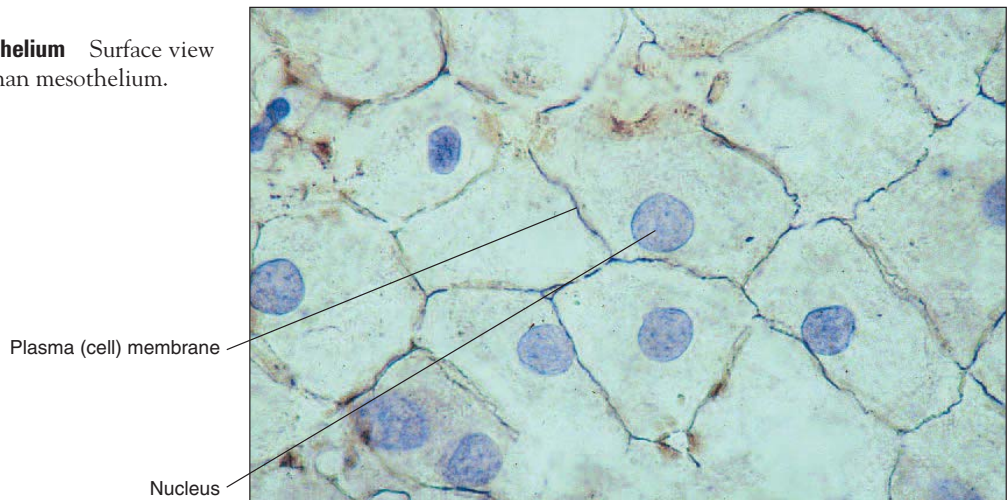
## 4 CHAPTER 1

**Figure 1-6**

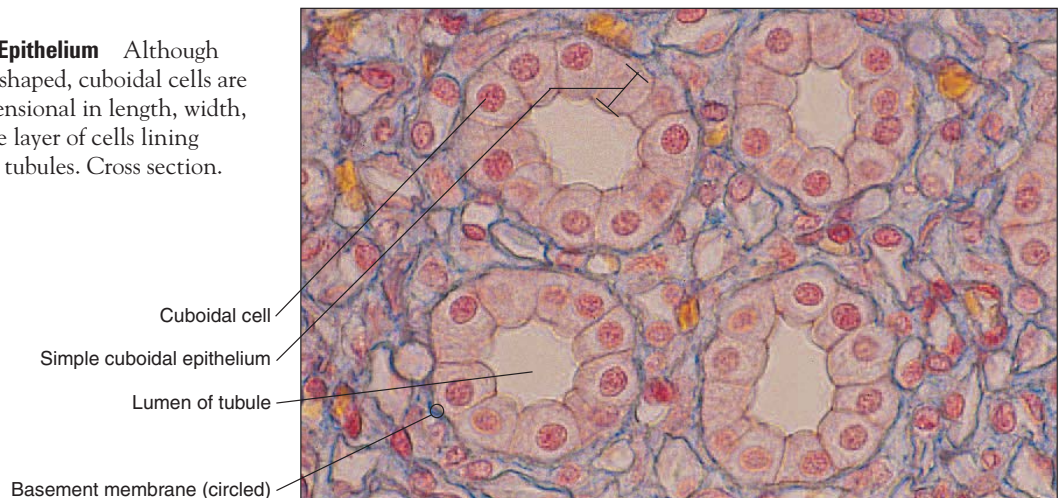
**Simple Squamous Epithelium** Single layer of flat cells covering a surface. From human omentum. ( $\times 250$ )

**Figure 1-7**

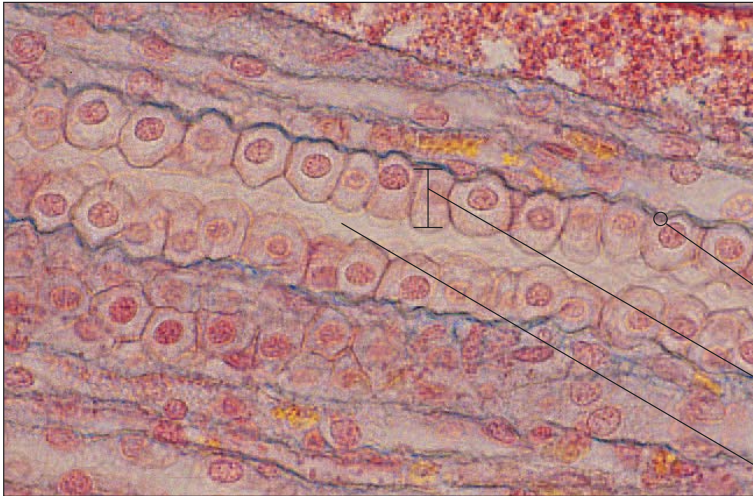
**Simple Squamous Epithelium** Surface view of flattened cells. Human mesothelium. ( $\times 250$ )

**Figure 1-8**

**Simple Cuboidal Epithelium** Although not strictly cube shaped, cuboidal cells are roughly equidimensional in length, width, and depth. Single layer of cells lining surface of kidney tubules. Cross section. ( $\times 250$ )

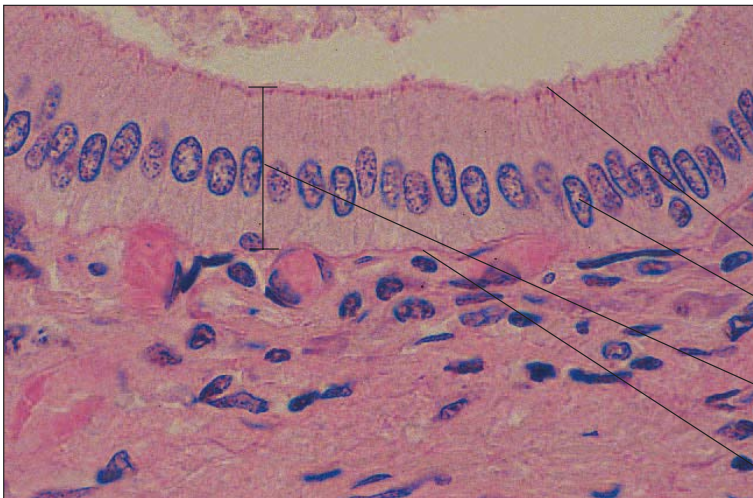






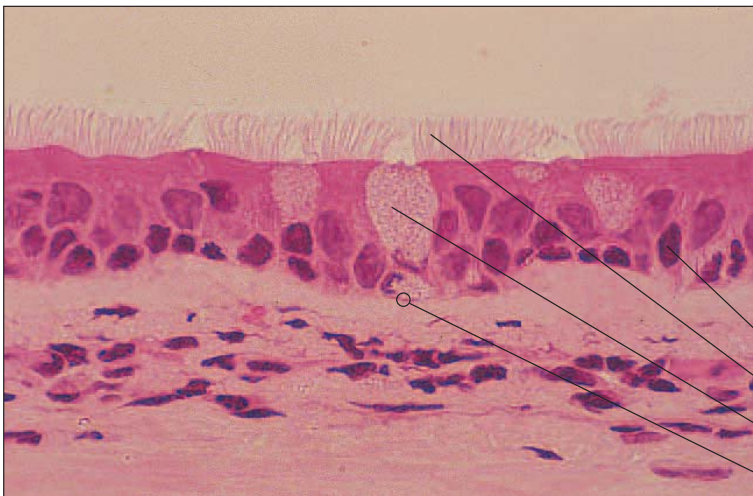
**Figure 1-9**  
**Simple Cuboidal Epithelium** Longitudinal section of kidney tubule. ( $\times 250$ )

Basement membrane  
Simple cuboidal epithelium  
Lumen of tubule



**Figure 1-10**  
**Simple Columnar Epithelium** Cellular height is much greater than width or length. Nuclei generally appear in a row. From pancreatic duct. ( $\times 250$ )

Microvilli  
Nucleus  
Simple columnar epithelium  
Basement membrane



**Figure 1-11**  
**Pseudostratified Ciliated Columnar Epithelium** Nuclei appear to lie in two rows, but in fact all cells in single layer are in contact with basement membrane. Section shows well-defined cilia, three goblet cells, basement membrane, underlying connective tissue. From monkey trachea. ( $\times 100$ )

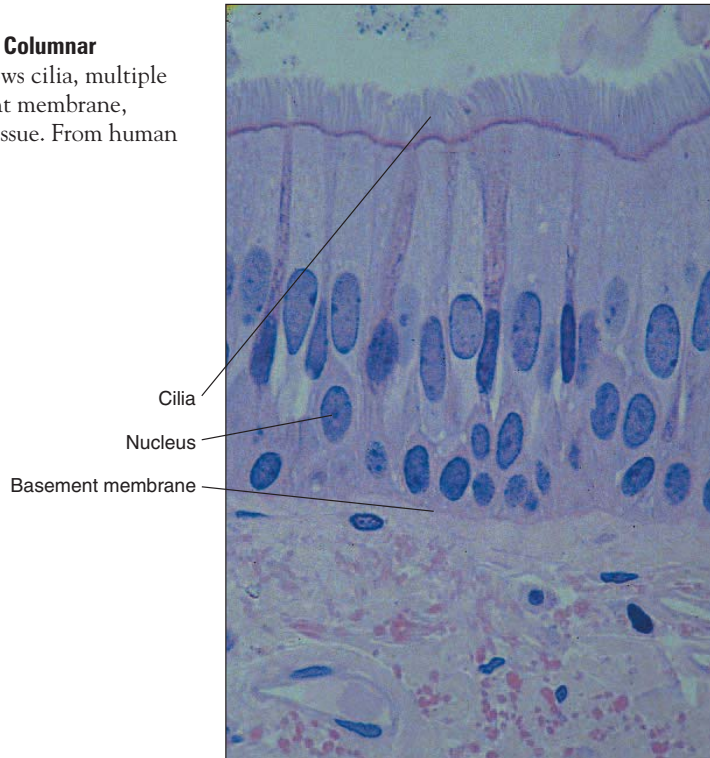
Nucleus  
Cilia  
Goblet cell  
Basement membrane



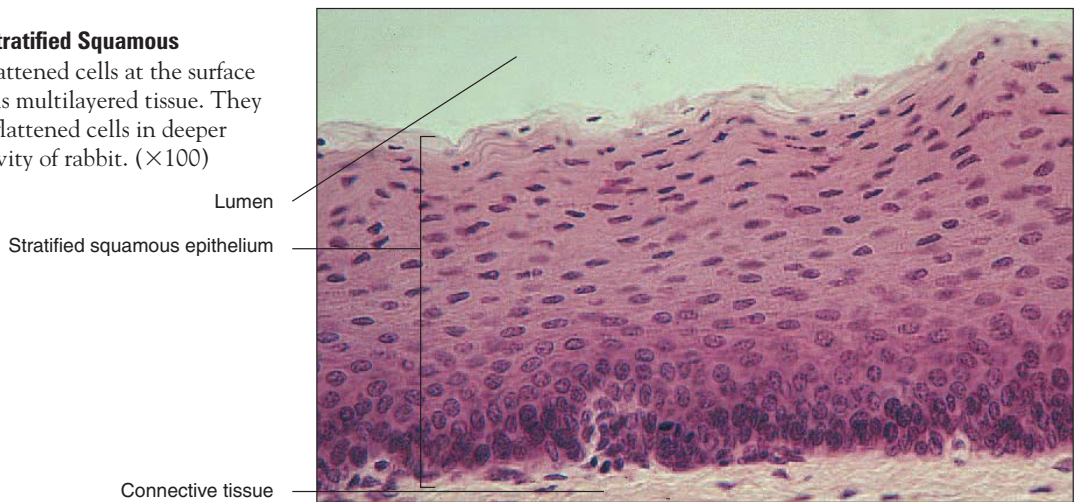
## 6 CHAPTER 1

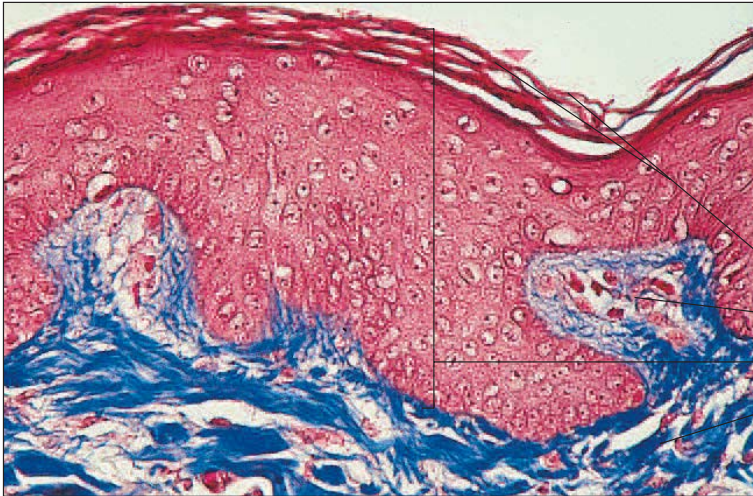
**Figure 1-12**

**Pseudostratified Ciliated Columnar Epithelium** Section shows cilia, multiple layers of nuclei, basement membrane, underlying connective tissue. From human trachea. ( $\times 250$ )

**Figure 1-13**

**Noncornified Stratified Squamous Epithelium** Flattened cells at the surface characterize this multilayered tissue. They arise from less-flattened cells in deeper layers. Oral cavity of rabbit. ( $\times 100$ )

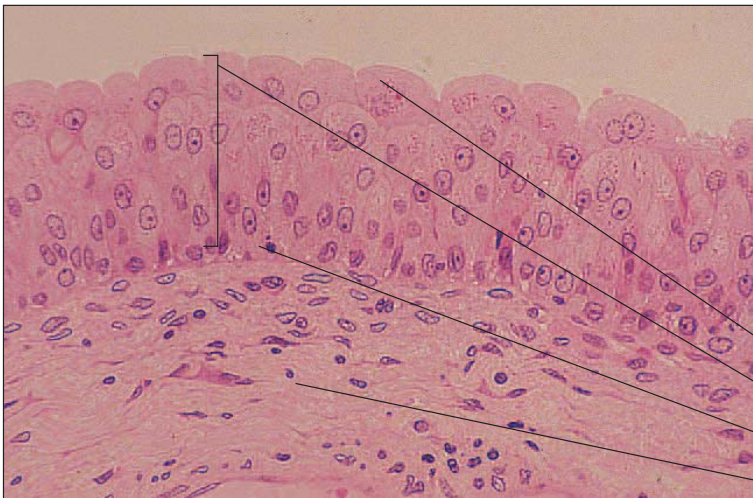



**Figure 1-14**

**Stratified Squamous Epithelium** Flattened, keratinized cells at surface show variations in form in deeper layers. From human skin. ( $\times 100$ )

- Keratinized cells
- Papilla
- Stratified squamous epithelium
- Connective tissue



**Figure 1-15**

**Transitional Epithelium from Urinary Bladder** Umbrella cells stretch and flatten as bladder fills. Basement membrane separates epithelium from underlying connective tissue containing blood vessels. ( $\times 250$ )


- Umbrella cell
- Transitional epithelium
- Basement membrane
- Connective tissue



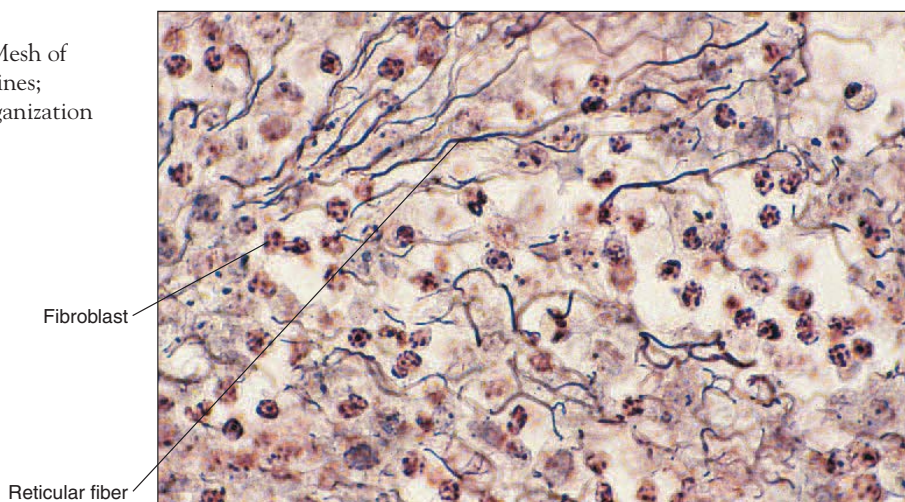
## 8 CHAPTER 1

**Figure 1-16**

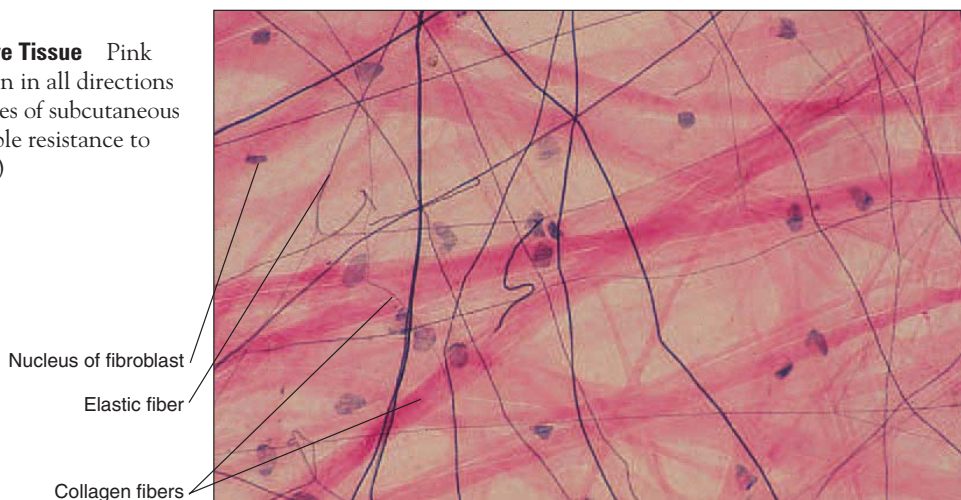
**Elastic Connective Tissue** Extracellular elastic fibers extend parallel in the plane of section. Structure permits tissue elasticity and recoil. From aorta. ( $\times 100$ )

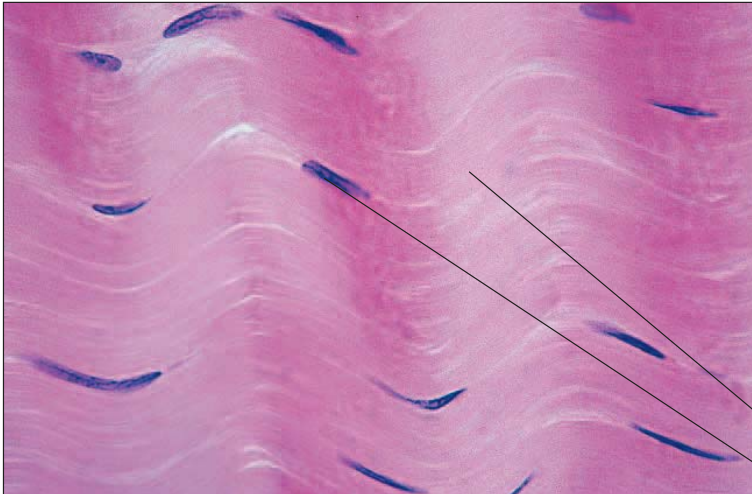
**Figure 1-17**

**Reticular Connective Tissue** Mesh of reticular fibers appears as dark lines; provides scaffold for cellular organization of this lymph node. ( $\times 250$ )

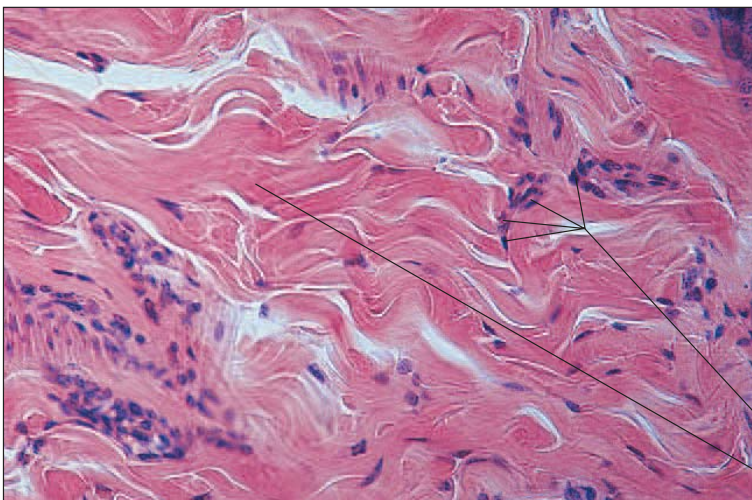
**Figure 1-18**

**Loose (Areolar) Connective Tissue** Pink bands of collagen fibers run in all directions through intercellular spaces of subcutaneous tissue, which permit flexible resistance to mechanical stress. ( $\times 100$ )

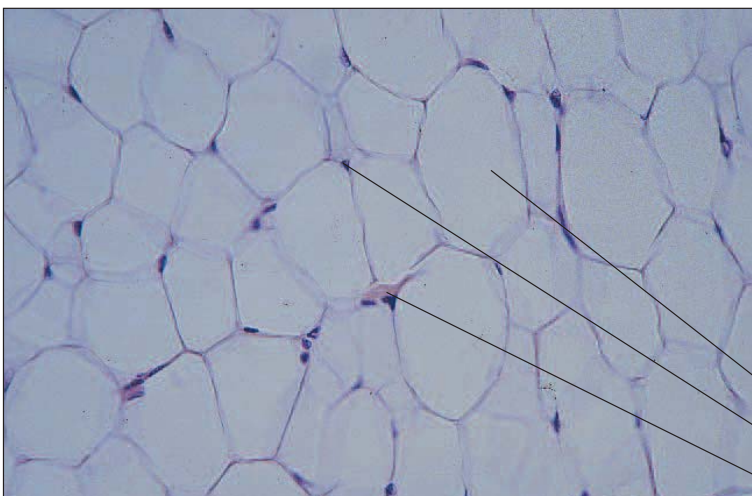




**Figure 1-19**  
**Dense Regular Connective Tissue** Bands of collagen fibers extending in regular, parallel rows resist mechanical stress mainly along course of fibers. Monkey tendon. ( $\times 250$ )



**Figure 1-20**  
**Dense Irregular Connective Tissue** Bands of collagen running in irregular rows give multidirectional tensile strength. Collagen-secreting fibroblasts appear throughout. ( $\times 100$ )



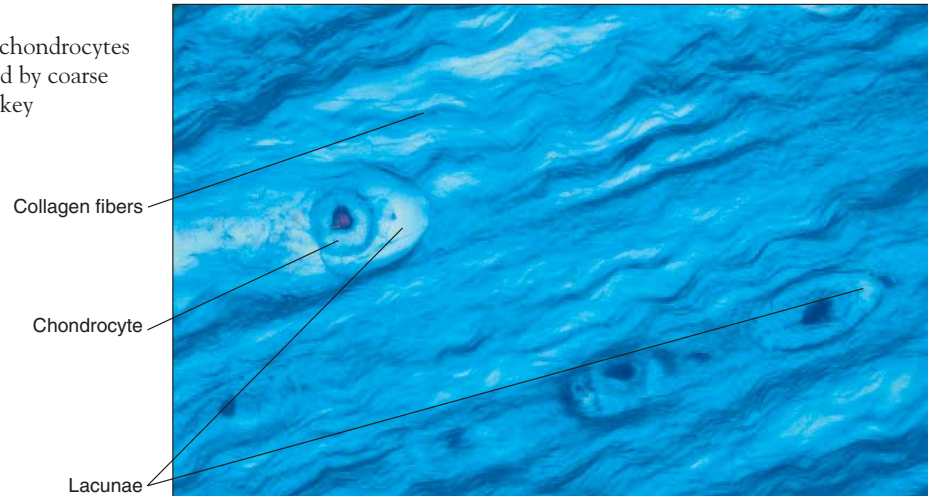**Figure 1-21**  
**Adipose Tissue** Large, clear, polyhedral vacuoles dominate small, eccentrically located cell nuclei of adipocytes. The vacuoles are filled with lipid (fat) molecules. Fine capillaries run through tissue. ( $\times 100$ )



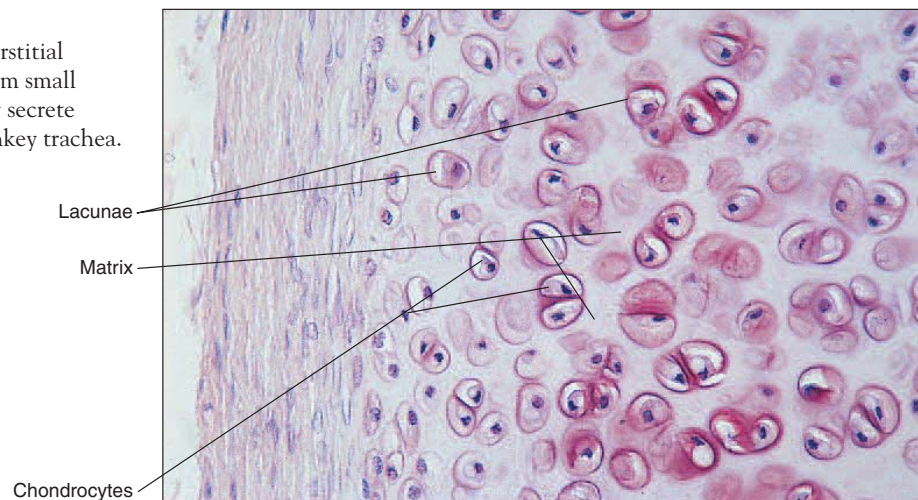
## 10 CHAPTER 1

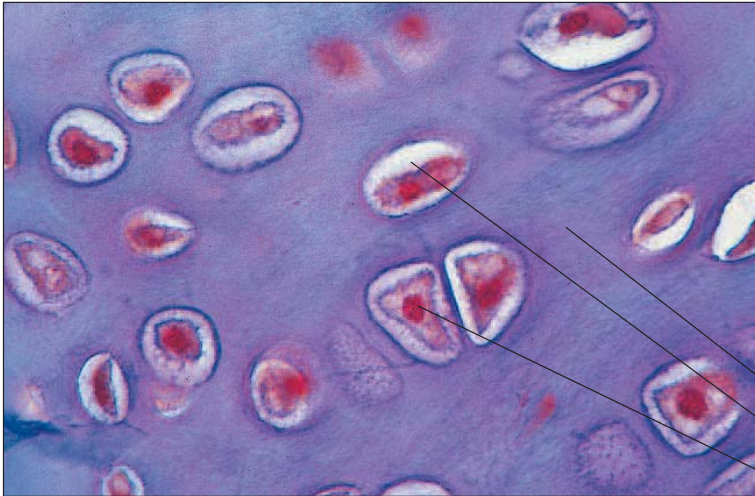
**Figure 1-22**

**Fibrocartilage** Cell nests of chondrocytes in territorial matrix surrounded by coarse extracellular fibers. From monkey intervertebral disc. ( $\times 250$ )

**Figure 1-23**

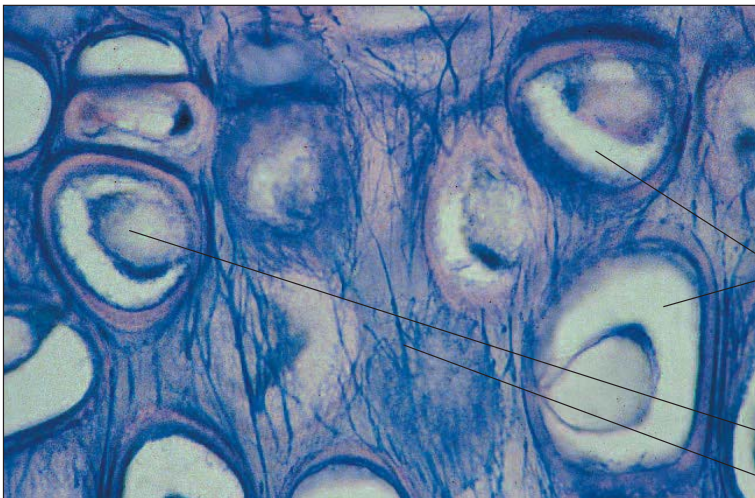
**Hyaline Cartilage** During interstitial growth, cartilage cells often form small clusters and move apart as they secrete extracellular matrix. From monkey trachea. ( $\times 100$ )





**Figure 1-24**  
**Hyaline Cartilage** Artifacts of vacuolation  
forms characteristic lacunae around  
chondrocyte cell bodies. From monkey  
trachea. ( $\times 250$ )

Matrix  
Lacuna  
Chondrocyte



**Figure 1-25**  
**Elastic Cartilage** Extracellular matrix  
contains elastic fibers that confer elastic  
recoil to this tissue. From monkey ear.  
( $\times 250$ )

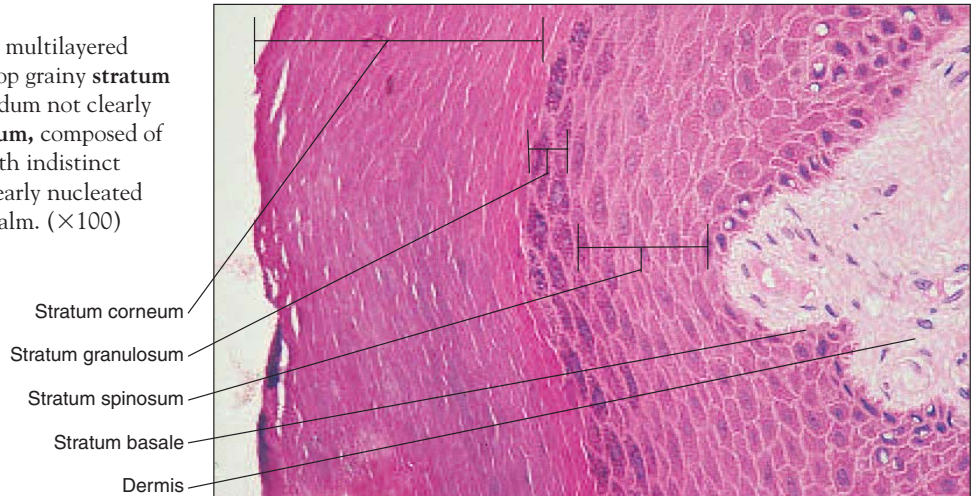
Lacunae  
Chondrocyte  
Elastic fiber



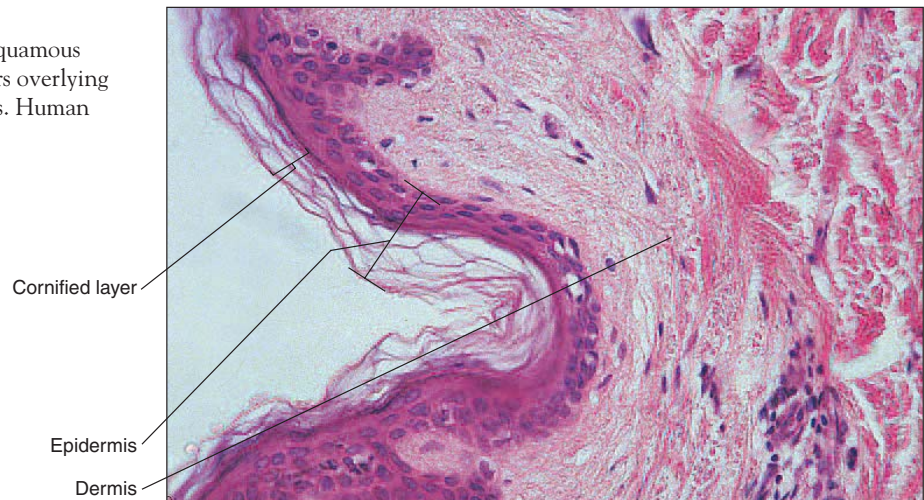
## 12 CHAPTER 1

**Figure 1-26**

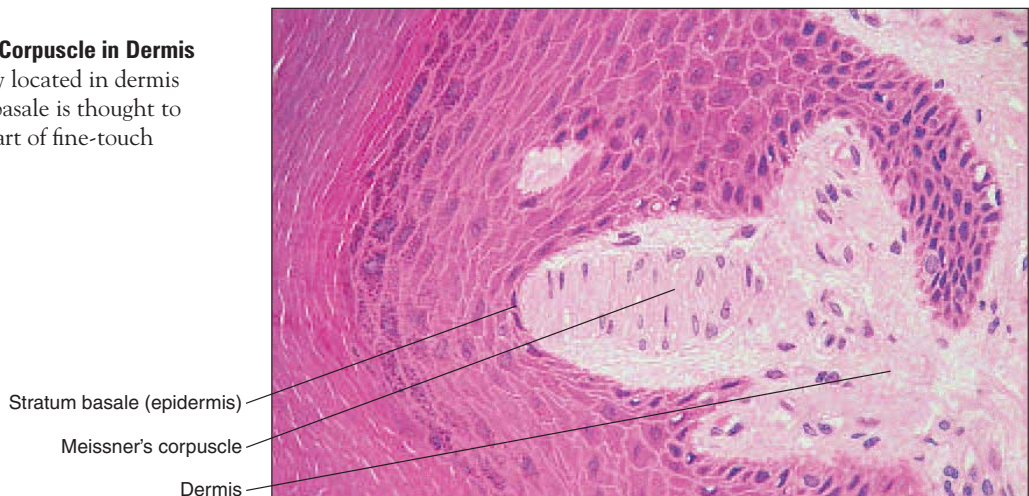
**Skin** Thick, keratinized, multilayered **stratum corneum** rests atop grainy **stratum granulosum** (stratum lucidum not clearly evident). **Stratum spinosum**, composed of irregularly shaped cells with indistinct nuclei, lies atop single, clearly nucleated **stratum basale**. Human palm. ( $\times 100$ )

**Figure 1-27**

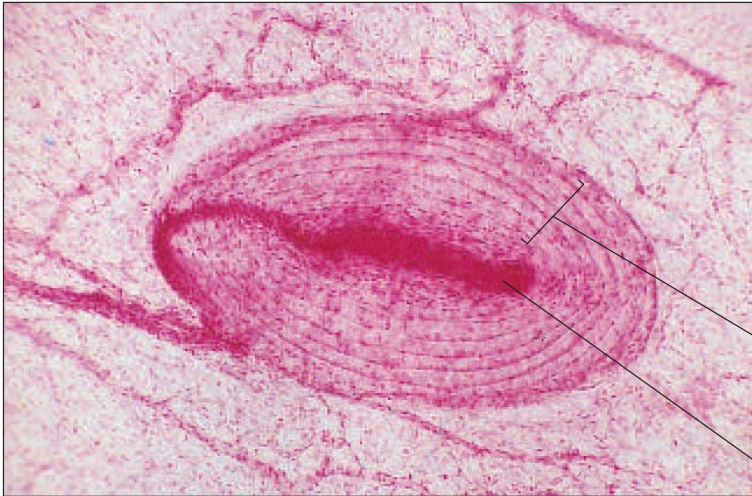**Skin** Epidermis of stratified squamous epithelium with cornified layers overlying connective tissue of the dermis. Human scalp. ( $\times 100$ )

**Figure 1-28****Meissner's (Touch) Corpuscle in Dermis**

Elongated oval body located in dermis just below stratum basale is thought to be responsible for part of fine-touch reception. ( $\times 100$ )







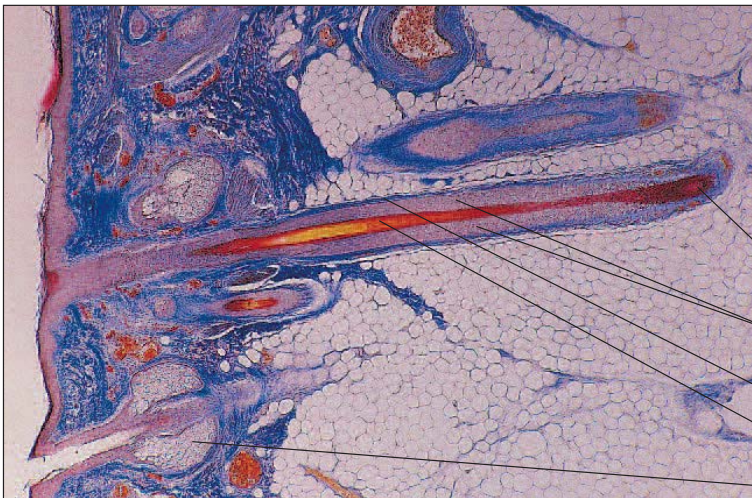
**Figure 1-29**

**Pacinian (Lamellated) Corpuscle**

Encapsulated nerve ending found deep in dermis and throughout interior of body detects pressure. (×25)

Capsule

Free nerve ending



**Figure 1-30**

**Human Scalp with Hair Follicle**

Follicle root, with sheath embedded in pale adipose tissue, has sebaceous glands surrounding it near surface. (×10)

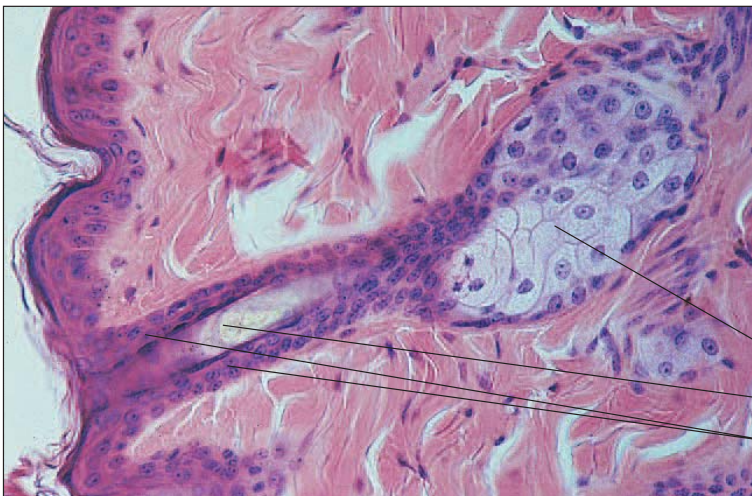
Hair papilla

Hair follicle

Root sheath

Hair root

Sebaceous gland



**Figure 1-31**

**Detail of Sebaceous Gland**

Nucleated germinative cells at base of gland mature and accumulate lipid. At duct, they degenerate and lyse to release their oily product, sebum. (×100)

Sebaceous gland

Hair root

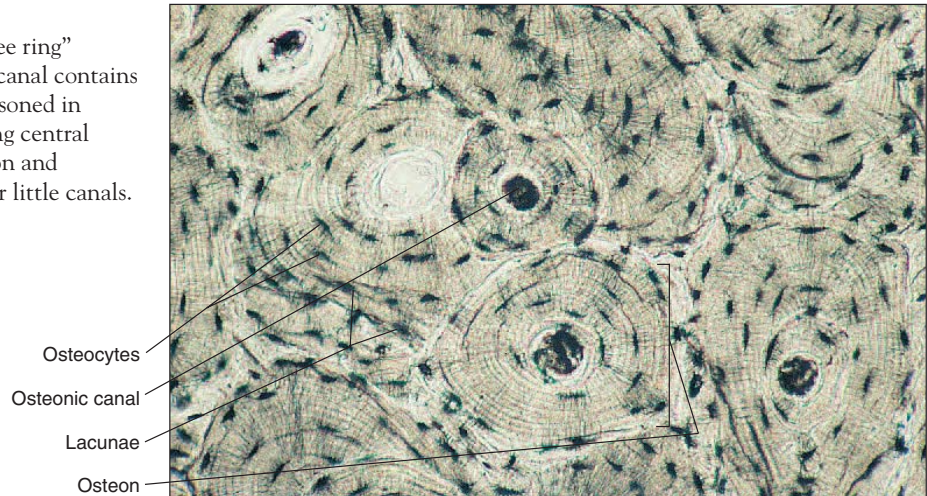
Hair follicle



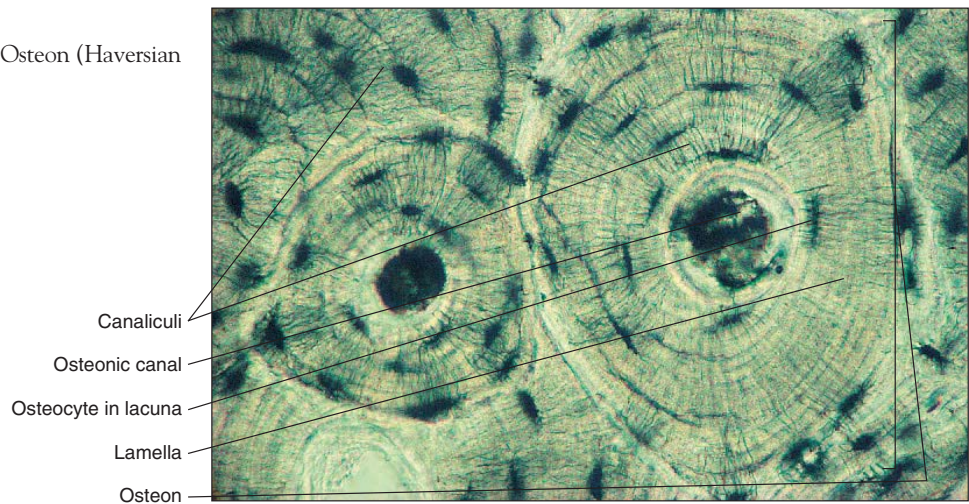
## 14 CHAPTER 1

**Figure 1-32**

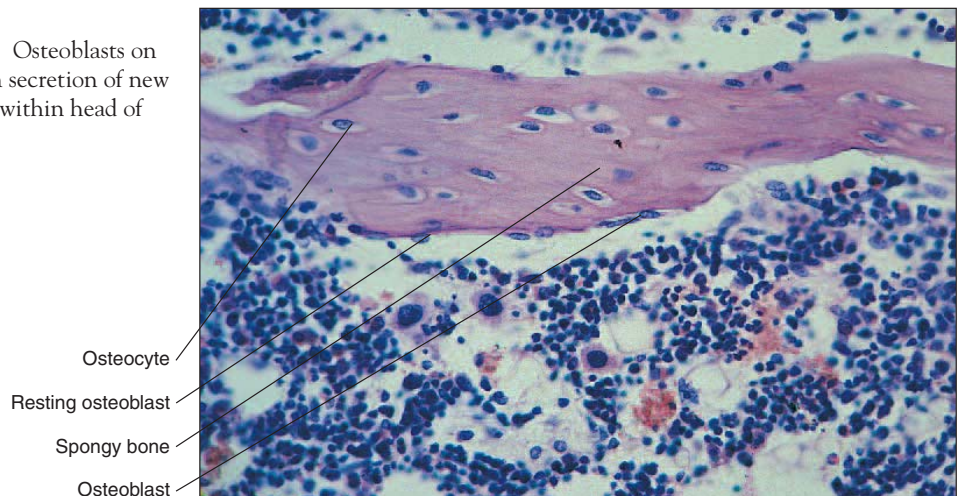
**Compact Bone** Center of “tree ring” structure, osteonic Haversian canal contains blood vessel. Osteocytes imprisoned in small, dark lacunae surrounding central osteonic canal receive nutrition and communicate via canaliculi, or little canals. Human. ( $\times 50$ )

**Figure 1-33**

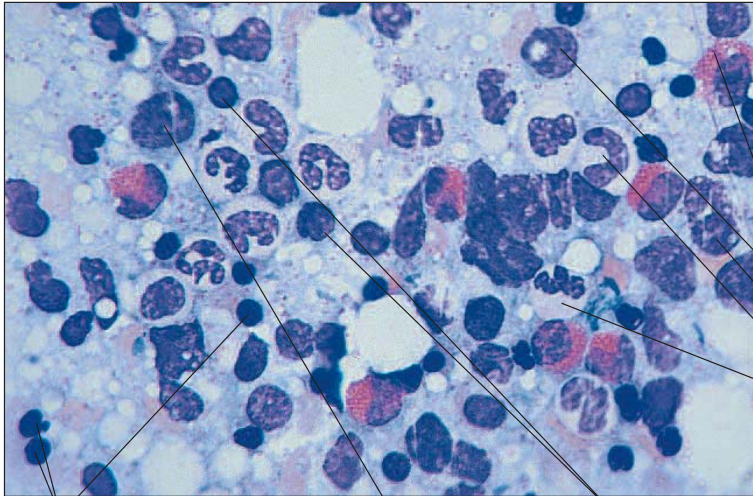
**Detail of Compact Bone** Osteon (Haversian system) evident. ( $\times 100$ )

**Figure 1-34**

**Cancellous (Spongy) Bone** Osteoblasts on spongy bone are engaged in secretion of new bony matrix. Human bone within head of femur. ( $\times 100$ )





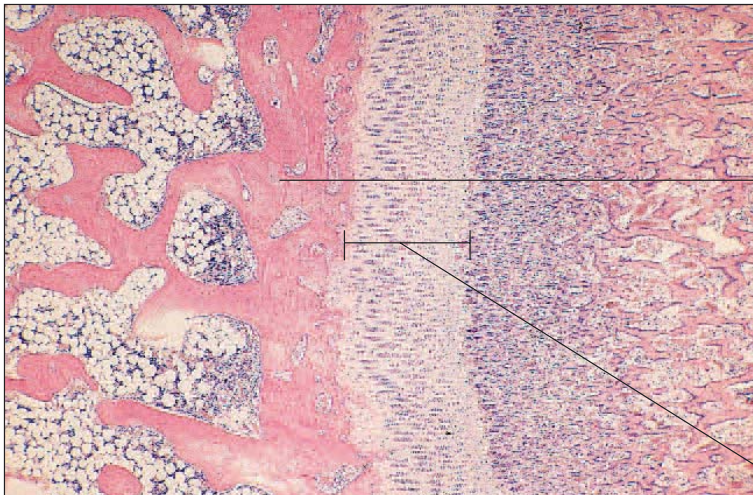


**Figure 1-35**

**Red Bone Marrow** Medullary cavity in the head of long bones of the adult contains stem cells, precursors to red blood cells, and white blood cells and platelets. Human. ( $\times 250$ )

- White blood cell precursors
- Eosinophilic myelocyte
- Myeloblast
- Basophilic myelocyte
- Neutrophilic stab cell
- Neutrophil

- Erythroblasts
- Proerythroblast  
Red blood cell precursors
- Erythroblasts



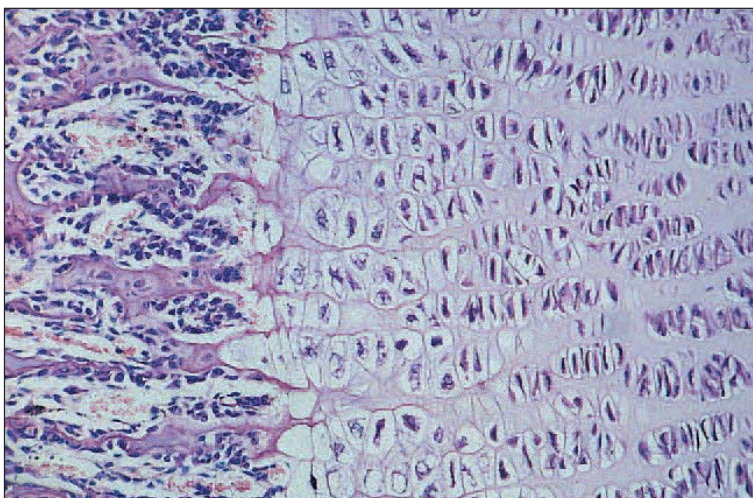
**Figure 1-36**

**Developing Bone at Epiphyseal Plate**

Middle belt of cartilage undergoing primary calcification is replaced by new bone.

- New spongy bone

- Cartilage of epiphyseal plate



**Figure 1-37**

**Detail of Epiphyseal Plate**

Epiphyseal plate cartilage at right transforms into zones of proliferating chondrocytes with primary ossification occurring on their calcified remnants. Newly formed bone appears at left. ( $\times 50$ )

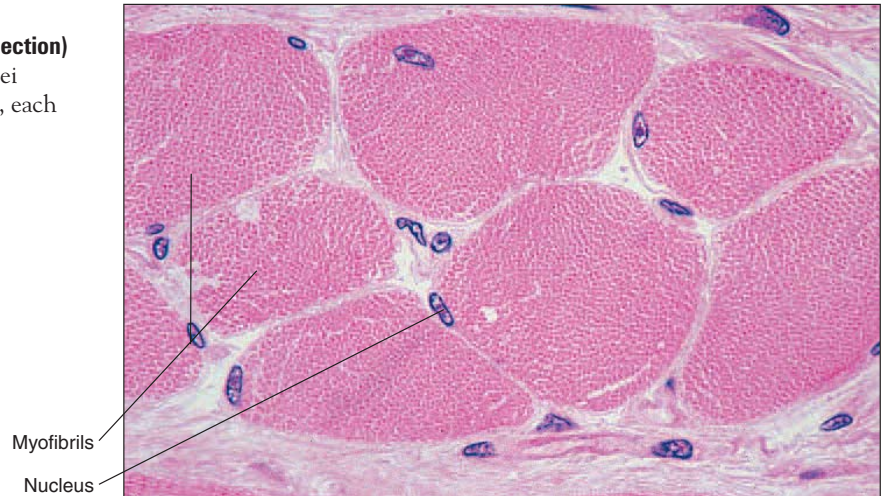
- Ossification
- Cells die
- Older cells enlarge
- Proliferating chondrocytes



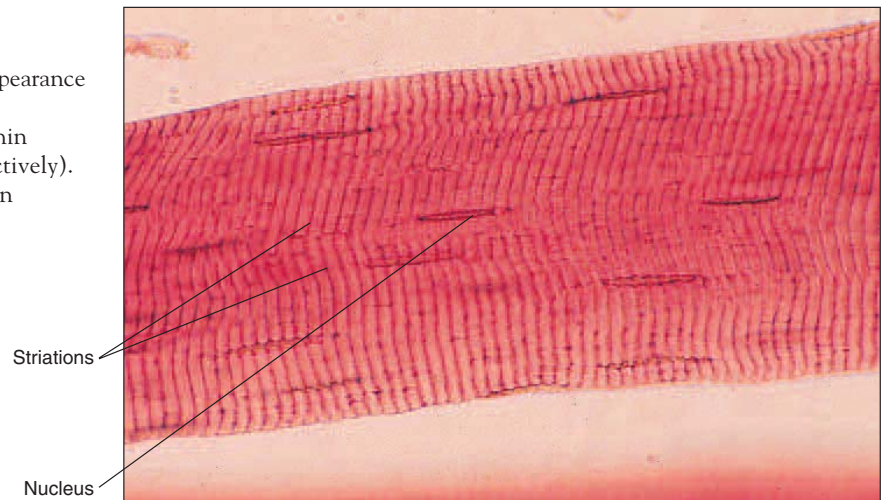
## 16 CHAPTER 1

**Figure 1-38****Striated (Skeletal) Muscle (Cross Section)**

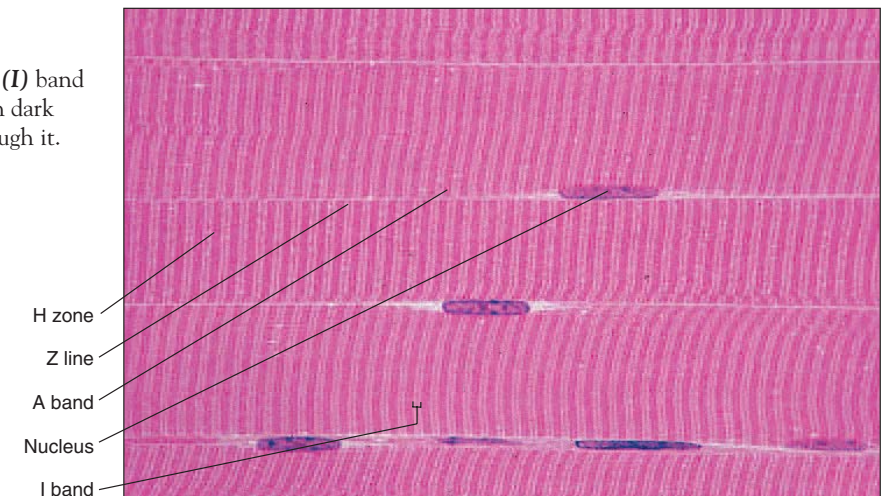
Eccentrically located multiple nuclei accompany individual cells (fibers), each of which contains many myofibrils. Human tongue. ( $\times 250$ )

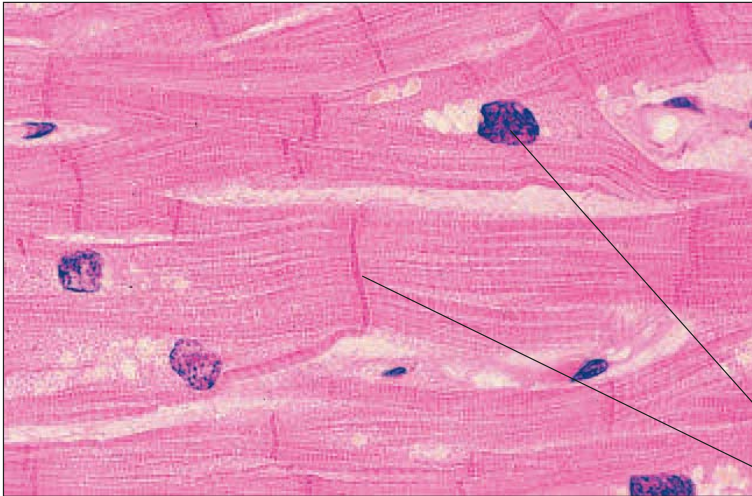**Figure 1-39****Striated (Skeletal) Muscle Fiber**

**(Longitudinal Section)** Banded appearance arises from regular arrangement of overlapping bundles of thick and thin filaments (myosin and actin, respectively). Eccentrically located nuclei are thin and elongated. ( $\times 250$ )

**Figure 1-40****Striated (Skeletal) Muscle Fibers**

**(Longitudinal Section)** Each light (*I*) band has a dark (*Z*) line through it. Each dark (*A*) band has a light (*H*) zone through it. ( $\times 250$ )





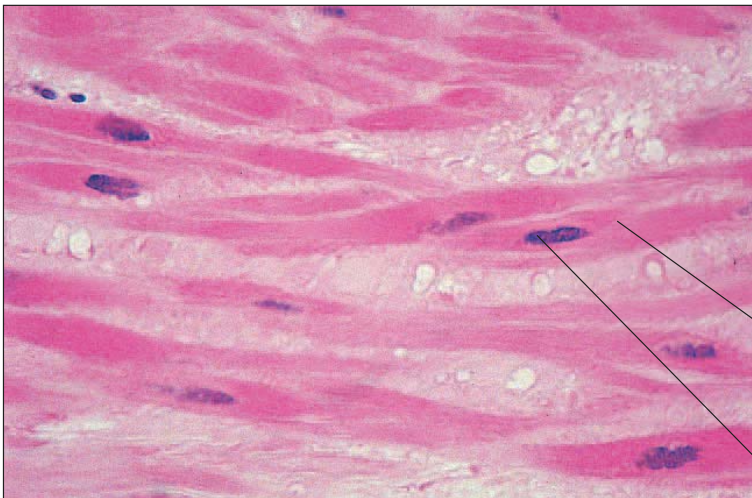
**Figure 1-41**

**Cardiac Muscle (Longitudinal Section)**

Striated muscle fibers branch and anastomose at junctions marked by dark intercalated disks. ( $\times 250$ )

Nucleus

Intercalated disk



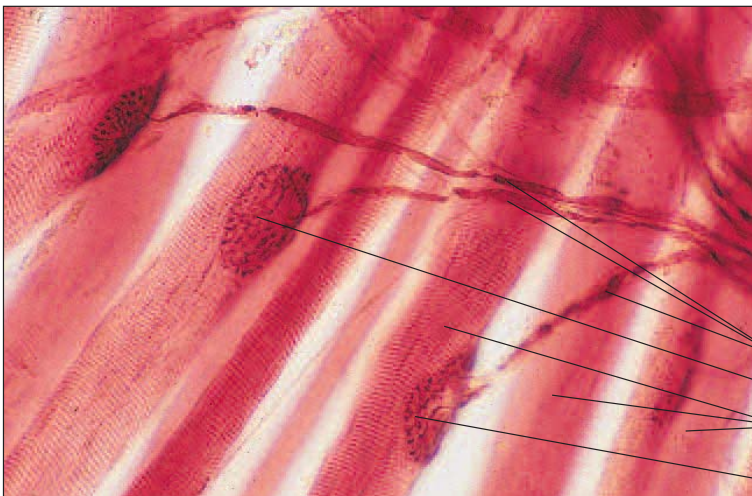
**Figure 1-42**

**Smooth Muscle (Longitudinal Section)**

Canoe- or spindle-shaped muscle cells lack striations, and each has a single, elongated nucleus. ( $\times 250$ )

Smooth muscle cell

Nucleus



**Figure 1-43**

**Innervation of Skeletal Muscle: Motor Endplate**

Branching nerve bundle terminates to form the **myoneural junctions**. Nerve terminals release small quantities of chemical neurotransmitter to stimulate muscle contraction.

Terminal branches of motor neuron

Synaptic bulb

Skeletal muscle fibers

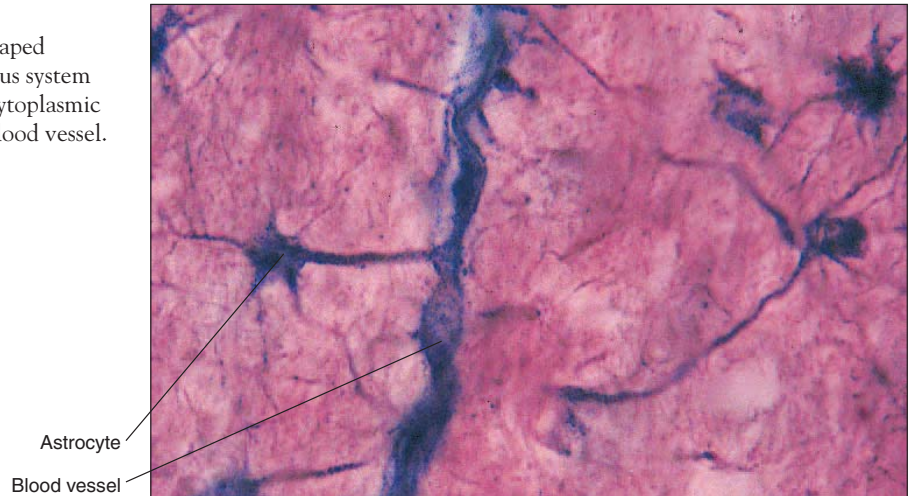
Myoneural junction



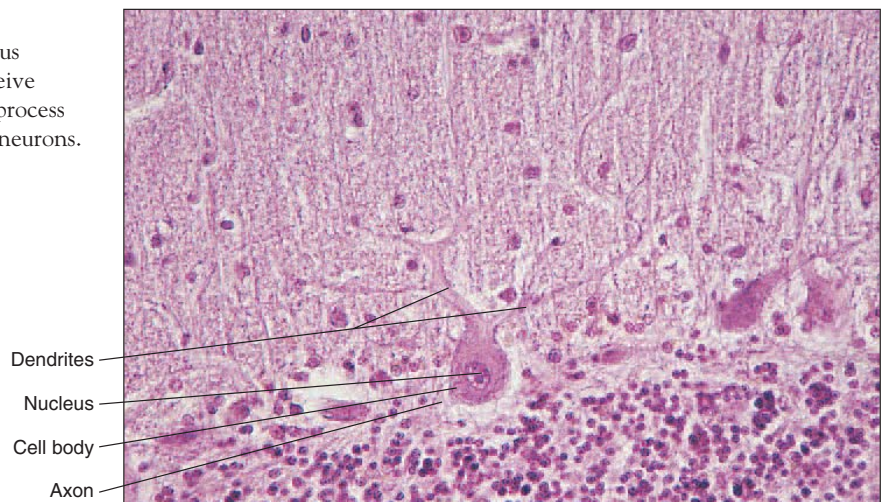
## 18 CHAPTER 1

**Figure 1-44**

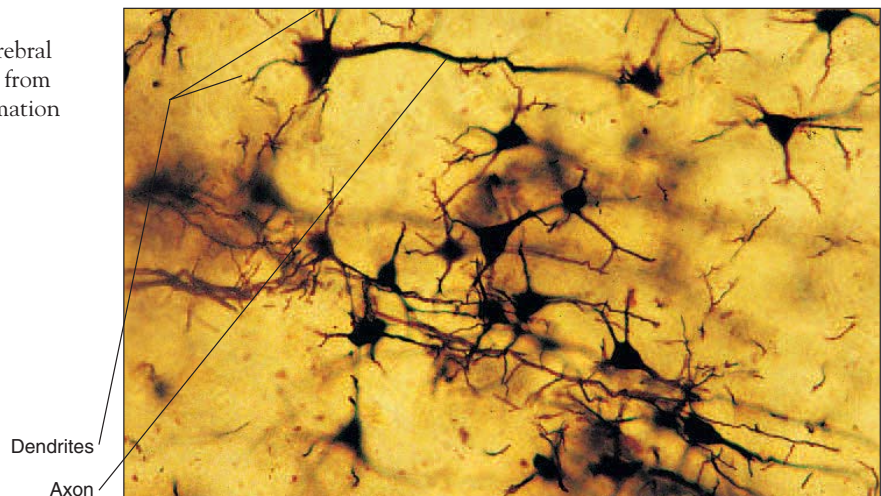
**Astrocytes (Neuroglia)** Star-shaped supporting cells of central nervous system modulate ionic environment. Cytoplasmic extensions make contact with blood vessel. Cat. (Silver stain;  $\times 280$ )

**Figure 1-45**

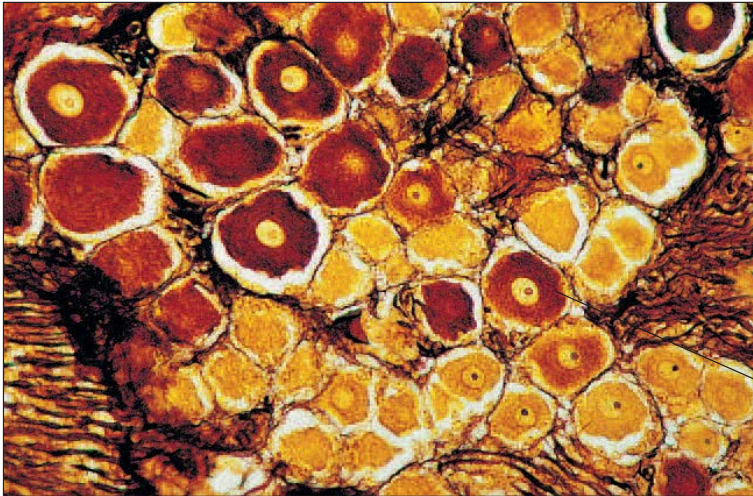**Purkinje Cells (Neurons)** Numerous branched processes (dendrites) receive information for processing. Single process (axon) sends information to other neurons. Human cerebellum. ( $\times 100$ )

**Figure 1-46**

**Pyramidal Cells** Neurons from cerebral cortex directly receive information from hundreds of other cells; send information on to hundreds of others. (Fox-Golgi stain;  $\times 100$ )



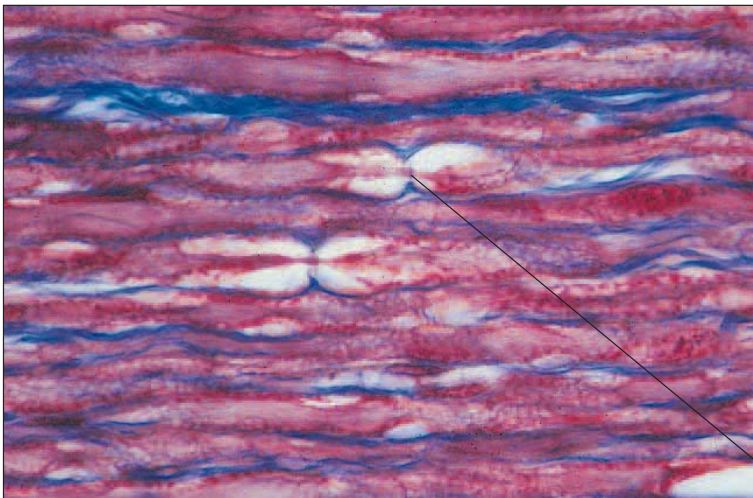




**Figure 1-47**

**Dorsal Root Ganglion** Sensory signals representing pain, temperature, pressure, muscle tension, joint position, and others depend on these cells. Their dendrites collect sensory information throughout the body and axons route it into the spinal cord. ( $\times 100$ )

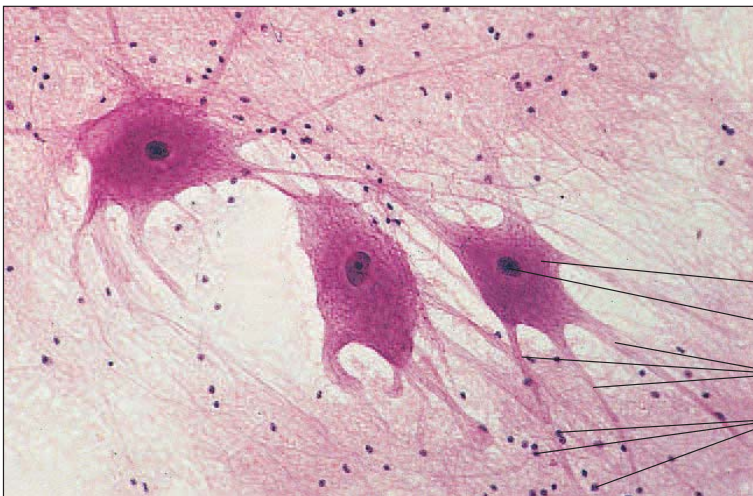
Cell body of neuron



**Figure 1-48**

**Myelinated Nerve Fibers (Longitudinal Section)** Clear areas show dimpling characteristic of nodes of Ranvier. ( $\times 250$ )

Node of Ranvier



**Figure 1-49**

**Motor Neurons of the Spinal Cord** Integrated command information from the brain and sensory signals enter these cells, whose efferent activity controls muscular contraction. Numerous synapses occur on dendrites and cell body (soma). ( $\times 50$ )

Cell body of neuron

Nucleus

Neuronal processes

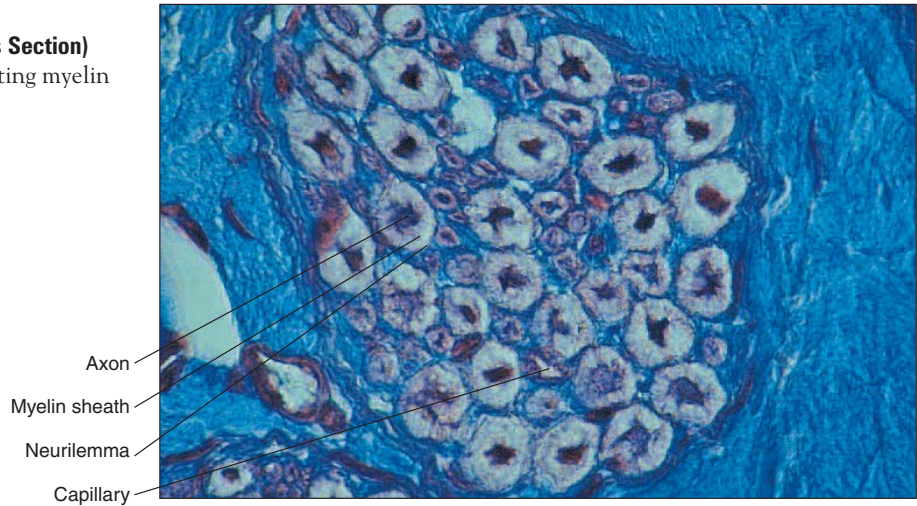
Neuroglia



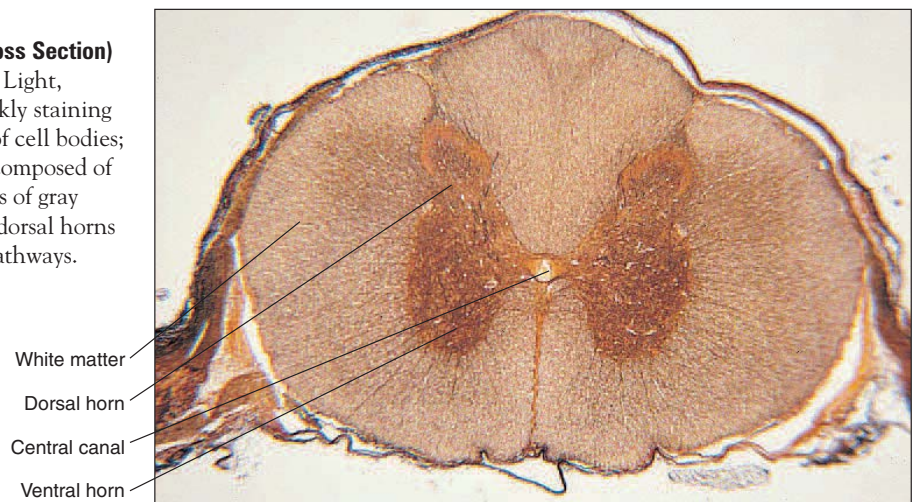
## 20 CHAPTER 1

**Figure 1-50****Myelinated Nerve Fibers (Cross Section)**

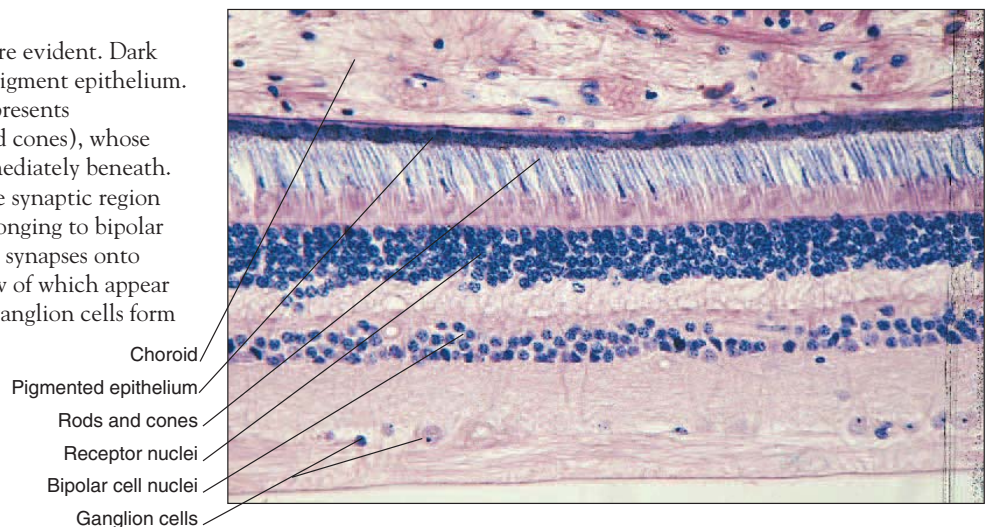
Central core stains dark; insulating myelin appears white. ( $\times 250$ )

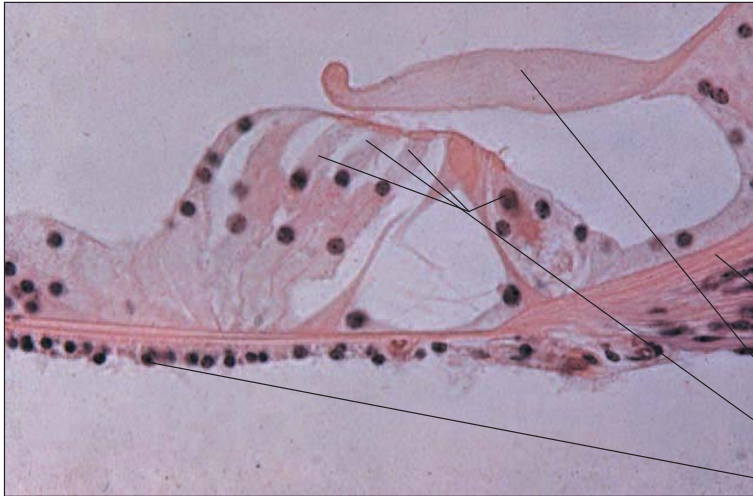
**Figure 1-51****Spinal Cord, Lumbar Region (Cross Section)**

Top is dorsal, bottom is ventral. Light, central dot is central canal. Darkly staining H-shaped region is gray matter of cell bodies; surrounding lighter material is composed of myelinated axons. Ventral horns of gray matter contain motor neurons; dorsal horns contain cell bodies of sensory pathways. ( $\times 4$ )

**Figure 1-52****Retina**

Layered structure evident. Dark line of cells near top is pigment epithelium. Broad, striped region represents photoreceptors (rods and cones), whose nuclei stain heavily immediately beneath. Below receptor nuclei lie synaptic region and a layer of nuclei belonging to bipolar cells. Bipolar cell output synapses onto ganglion cells, only a few of which appear near bottom. Axons of ganglion cells form optic nerve. ( $\times 100$ )

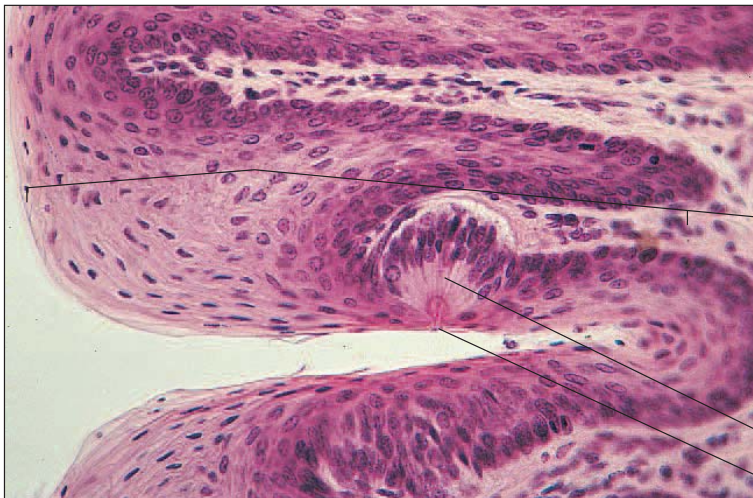




**Figure 1-53**

**The Organ of Corti** Thick finger of tectorial membrane extends from right to stimulate complex of four hair cells (three on left, one on right) of central structure that rests on basilar membrane. Nerve fibers from hair cells exit right to spiral ganglion for processing and transmission of messages to brain. ( $\times 500$ )

Nerve fibers  
Tectorial membrane  
Hair cells of Organ of Corti  
Basilar membrane



**Figure 1-54**

**Taste Bud** Dissolved chemicals enter fungiform papilla through small pore to directly stimulate sensory cells and initiate taste perception. ( $\times 100$ )

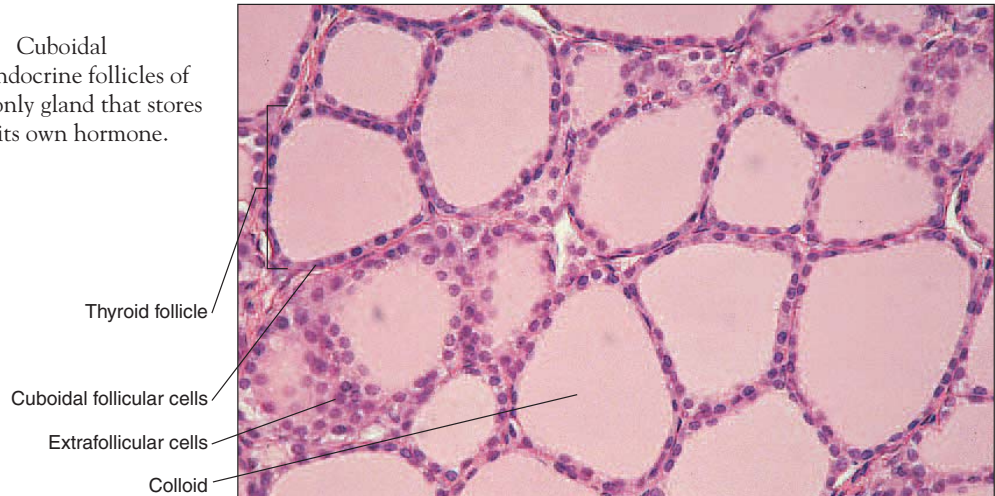
Fungiform papillus  
Taste bud  
Taste pore



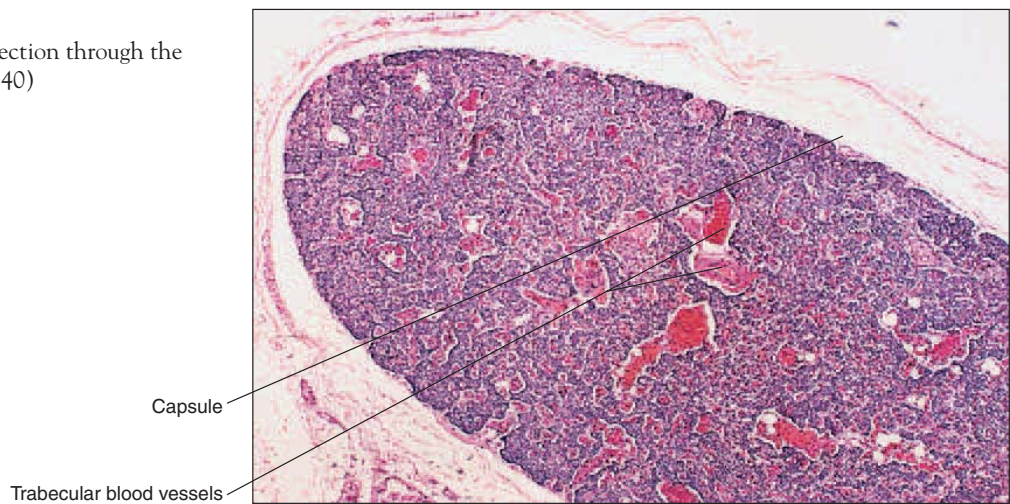## 22 CHAPTER 1

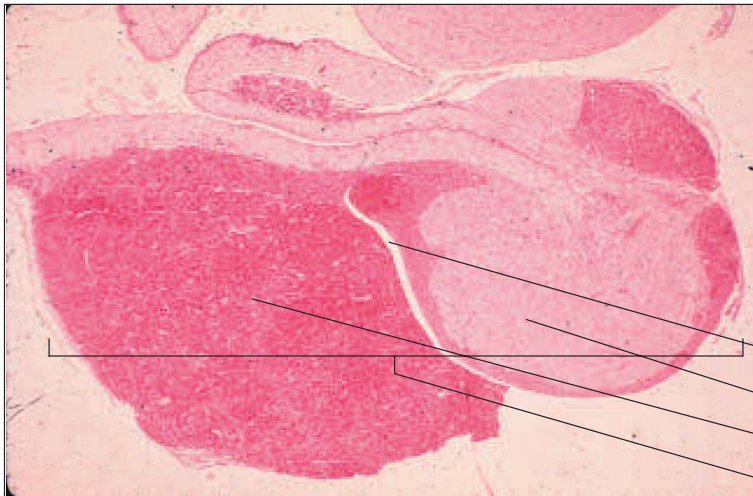
**Figure 1-55**

**Thyroid Gland Follicles** Cuboidal epithelium surrounds endocrine follicles of the thyroid gland, the only gland that stores substantial amounts of its own hormone. ( $\times 100$ )

**Figure 1-56**

**Parathyroid Gland** Section through the parathyroid gland. ( $\times 40$ )

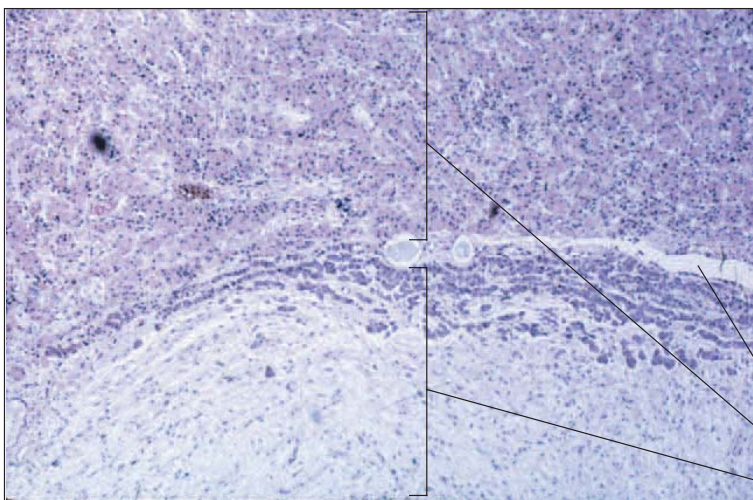




**Figure 1-57a**

**Pituitary Gland** The pituitary gland consists of two components: the posterior component, or neurohypophysis (light stain), consists of mainly nervous tissue, whereas the anterior component, or adenohypophysis (dark stain), consists of a glandular epithelium. ( $\times 10$ )

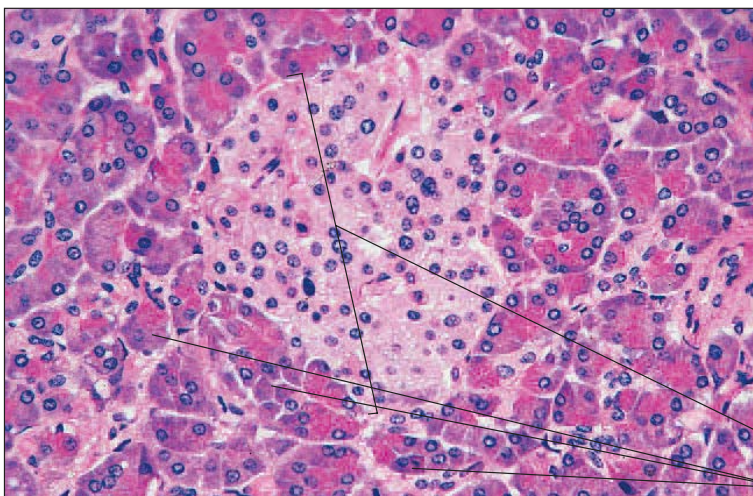
Cleft  
Neurohypophysis  
Adenohypophysis  
Pituitary gland



**Figure 1-57b**

**Pituitary Gland** The cleft between the neurohypophysis and adenohypophysis is visible in this view of the pituitary gland. ( $\times 100$ )

Cleft  
Adenohypophysis  
Neurohypophysis



**Figure 1-58**

**Pancreas** The pancreatic islet of Langerhans cells forms the endocrine portion of the pancreas. Alpha cells secrete glucagon, beta cells secrete insulin, and delta cells secrete somatostatin. The exocrine portion of the pancreas secretes digestive enzymes through a series of ducts.

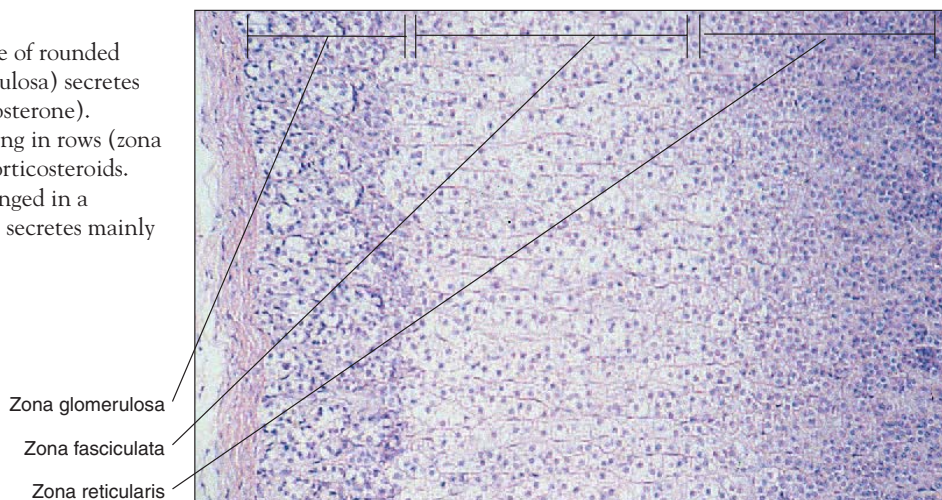
Islet of Langerhans  
Exocrine cells of pancreas



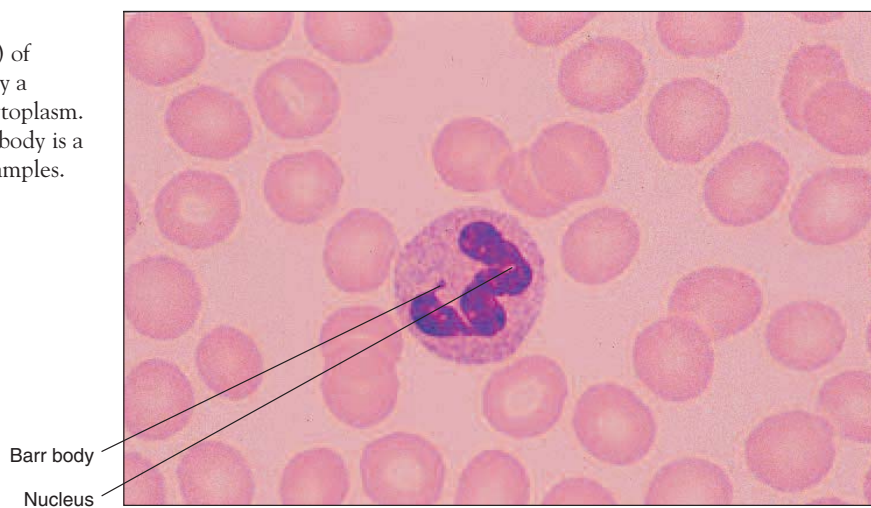
## 24 CHAPTER 1

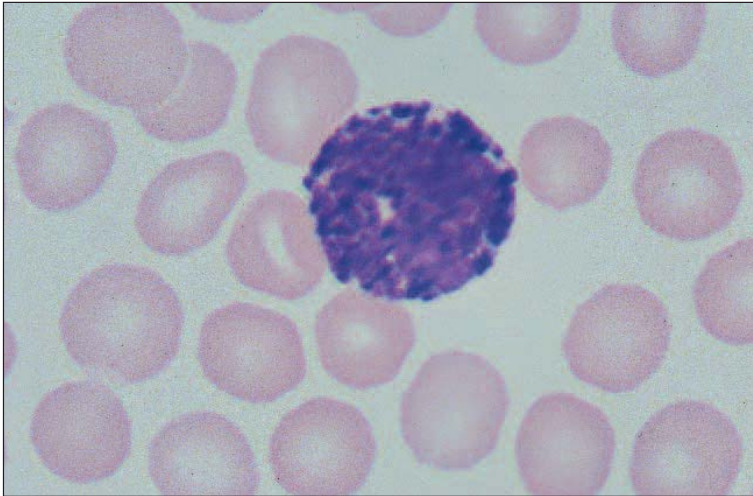**Figure 1-59**

**Adrenal Cortex** Outer zone of rounded groups of cells (zona glomerulosa) secretes mineralcorticosteroids (aldosterone). Middle zone of cells appearing in rows (zona fasciculata) secretes glucocorticosteroids. Innermost zone of cells arranged in a meshwork (zona reticularis) secretes mainly androgens. ( $\times 50$ )

**Figure 1-60**

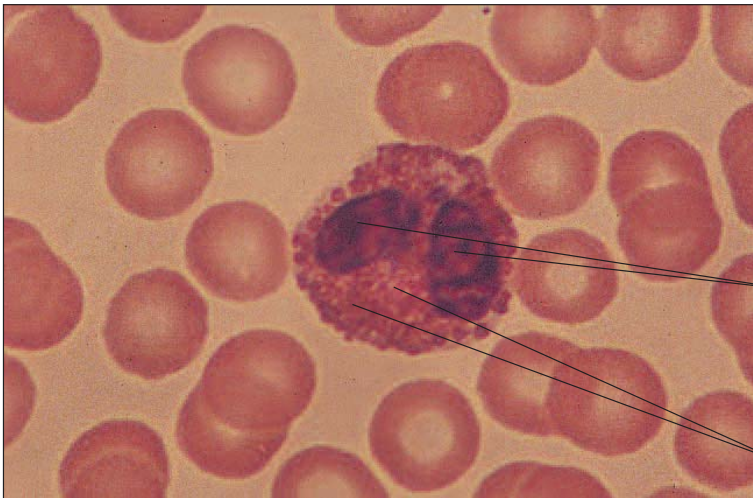
**Neutrophil** Most numerous (65%) of the leukocytes, it is characterized by a multilobed nucleus and granular cytoplasm. Engages in phagocytosis. The Barr body is a feature found only in male blood samples. (Neutral dyes stain;  $\times 640$ )





**Figure 1-61**

**Basophil** Normally the rarest (1%) of the leukocytes, its kidney-shaped nucleus may be almost obscured by cytoplasmic granules. These cells contain numerous chemicals involved in inflammation. (Basic dyes stain;  $\times 640$ )



**Figure 1-62**

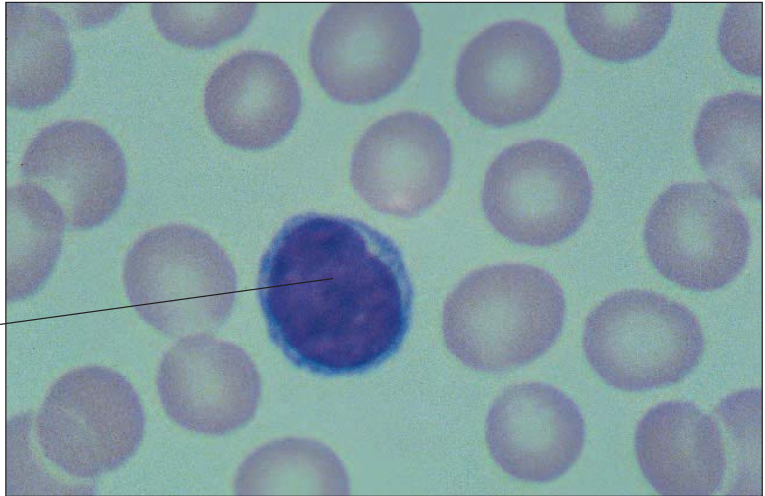**Eosinophil** Relatively rare (6%) leukocyte. Usually identifiable because of red-to-orange-staining cytoplasmic granules. Active during allergic reactions and parasitic infections. (Selective eosin stain;  $\times 640$ )

## 26 CHAPTER 1

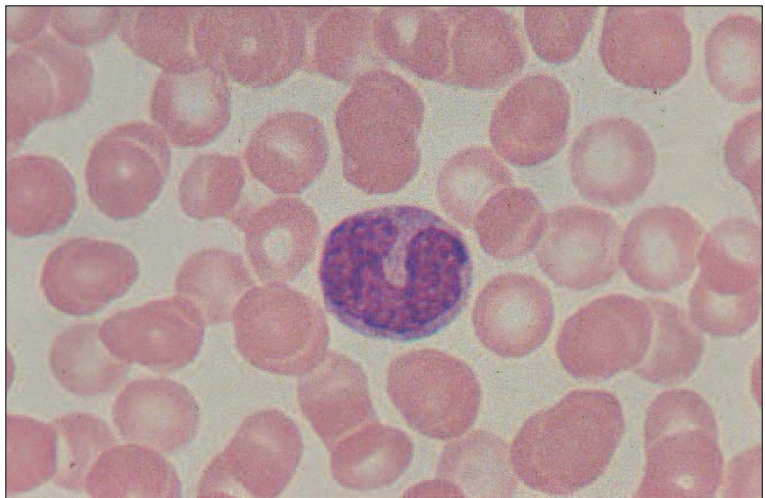
**Figure 1-63**

**Lymphocyte** Common (25%). Characterized by single-lobed, “dented” nucleus surrounded by clear cytoplasm. May be large or small. Heavily involved in the immune response including synthesis of antibodies. ( $\times 500$ )

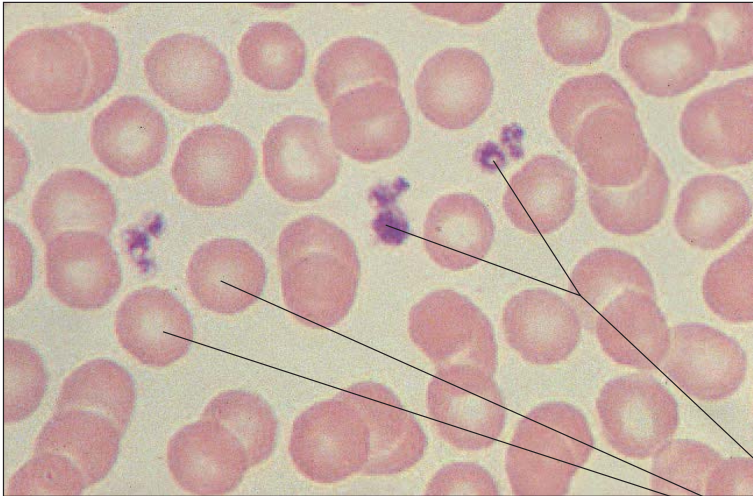
Nucleus

**Figure 1-64**

**Monocyte** Relatively rare (3%). Lobed, often kidney-shaped nucleus is surrounded by clear cytoplasm. Largest of the leukocytes, this cell is a precursor to a macrophage, which engages in phagocytosis. ( $\times 640$ )







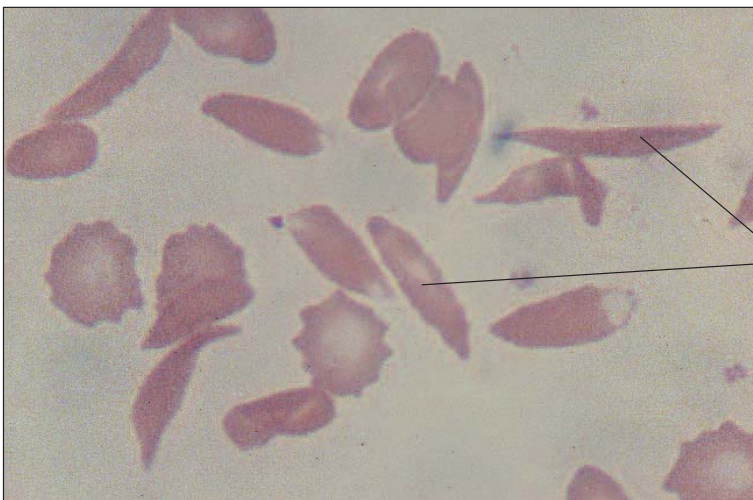
**Figure 1-65**

**Erythrocytes (Red Blood Cells) and Platelets**

Circulating erythrocytes are far more common than any of the leukocytes. Normally they have no nucleus but contain the red pigment hemoglobin, which permits them to transport oxygen and carbon dioxide throughout the body. Typically they assume the shape of a biconcave disk. Their diameter of about 7 microns is useful for comparing sizes of other histological structures. Platelets are cellular remnants of a much larger precursor. These remnants contain numerous chemicals, including those important for clotting and inflammation. Platelets initiate blood clotting by forming a plug at wound sites. ( $\times 500$ )

Platelets

Erythrocytes

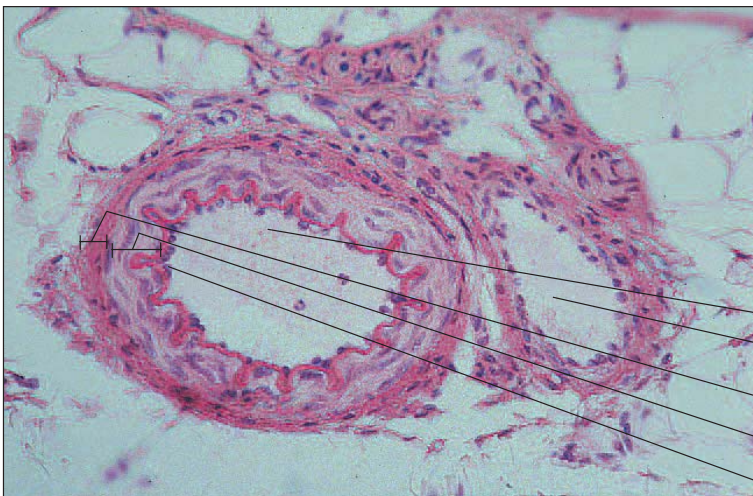


**Figure 1-66**

**Sickle Cell Anemia**

Genetic alteration of hemoglobin results in altered membrane structure and abnormal wavy or elongated, curved shape that often resembles a sickle. Oxygen-carrying capacity is much reduced. ( $\times 500$ )

Sickled red blood cells



**Figure 1-67**

**Artery (A) and Vein (V)**

Blood vessels possess a **tunica intima** that lines the lumen, outside of which is a muscular **tunica media**, and a connective tissue covering, the **tunica adventitia**. The tunica media of arteries is typically much thicker than that of veins. ( $\times 100$ )

A

V

Tunica adventitia

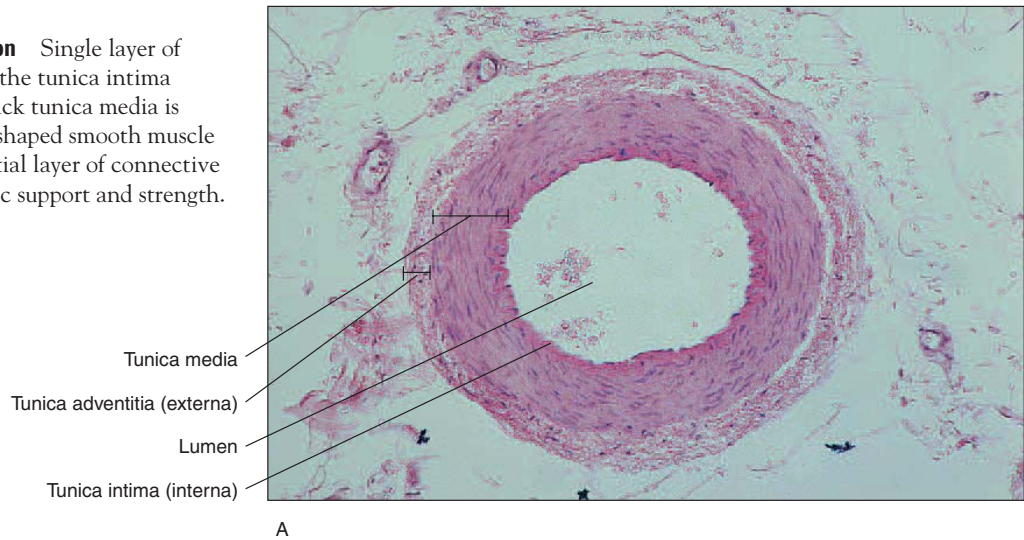
Tunica media

Tunica intima

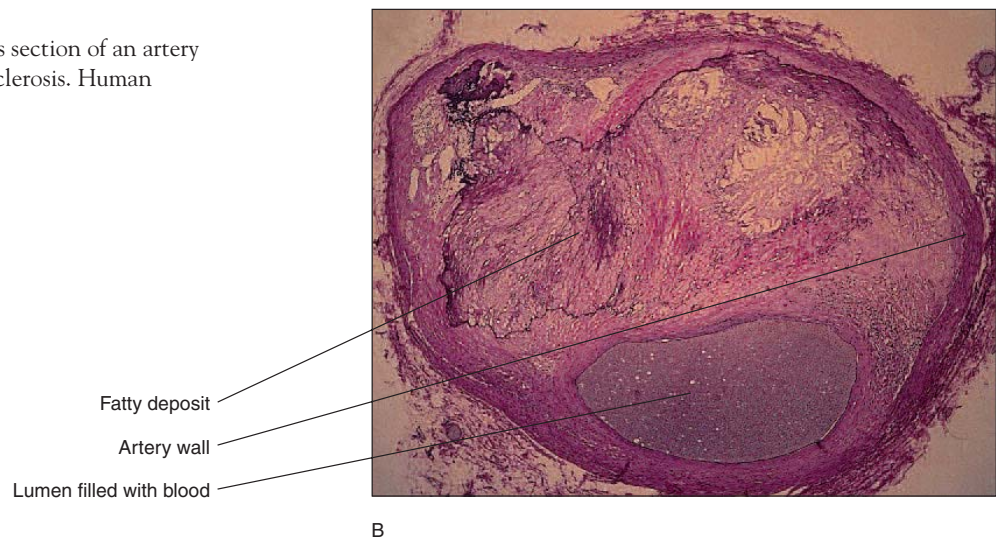
## 28 CHAPTER 1

**Figure 1-68a**

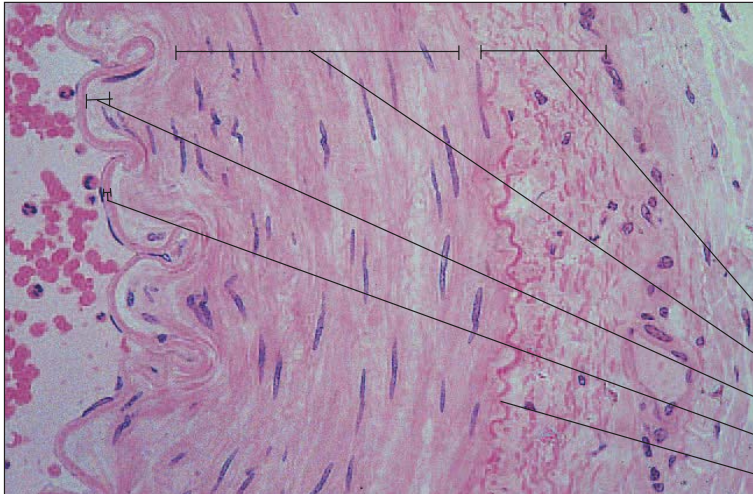
**Arterial Cross Section** Single layer of darkly stained cells, the tunica intima lines the lumen. Thick tunica media is composed of canoe-shaped smooth muscle cells. Outer adventitial layer of connective tissue provides elastic support and strength. ( $\times 50$ )

**Figure 1-68b**

**Atherosclerosis** Cross section of an artery with advanced atherosclerosis. Human coronary artery. ( $\times 40$ )



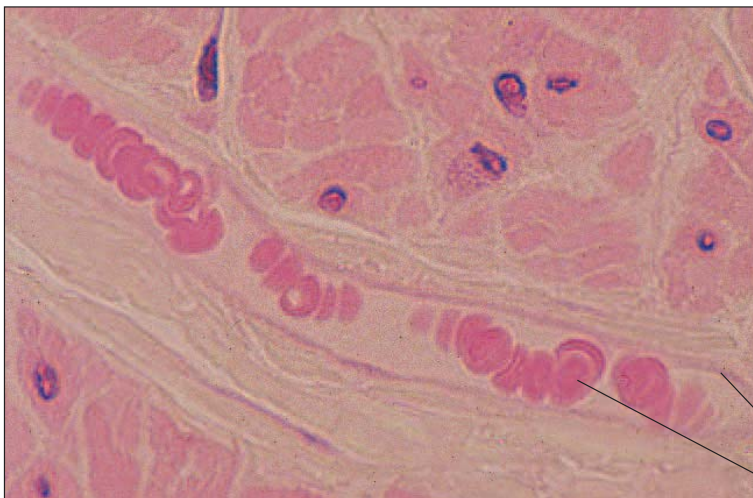




**Figure 1-69**

**Detail of Arterial Wall** Inner endothelial cells of tunica intima (*left*) lie on a basement membrane. A thin layer of smooth muscle cells and elastic tissue (lamina propria) throws this tunic into folds. The tunica media contains multiple layers of smooth muscle cells regularly arranged. A wavy external elastic membrane separates the tunica media from the adventitia. ( $\times 250$ )

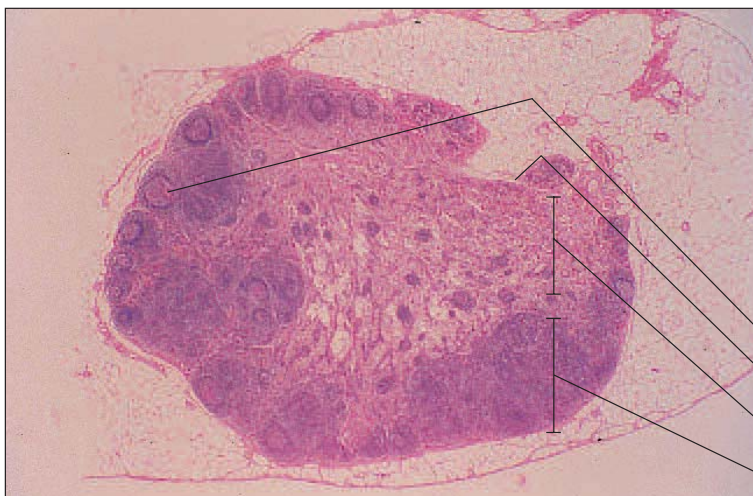
- Tunica adventitia
- Tunica media
- Lamina propria
- Tunica intima
- External elastic membrane



**Figure 1-70**

**Capillary with Red Blood Cells in Single File** Capillary wall is made of flattened endothelial cells without complex tunics, a simple structure that facilitates the exchange of gases, nutrients, wastes, and hormones. ( $\times 400$ )

- Endothelium
- Red blood cell



**Figure 1-71**

**Lymph Node** Outer cortex containing several follicles surrounds medulla, with its narrow, dark medullary cords. Notch is the hilum, through which blood and lymphatic vessels pass. ( $\times 5$ )

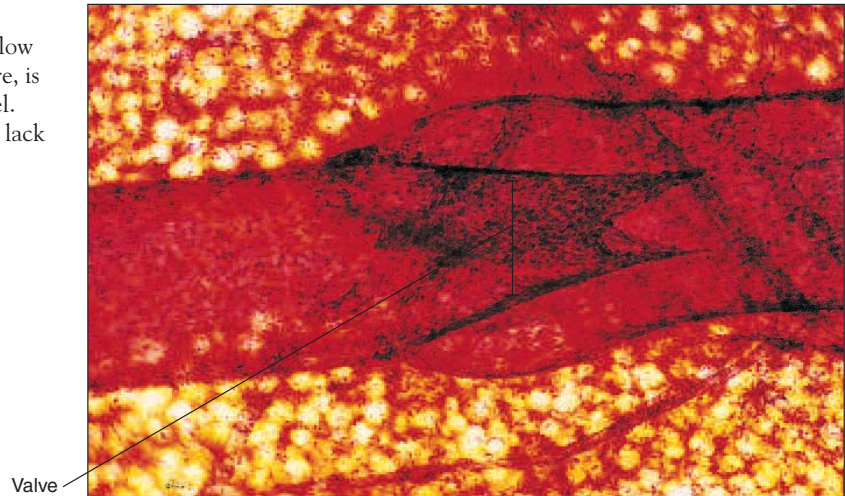
- Follicle (germinal center)
- Hilum
- Medulla
- Cortex



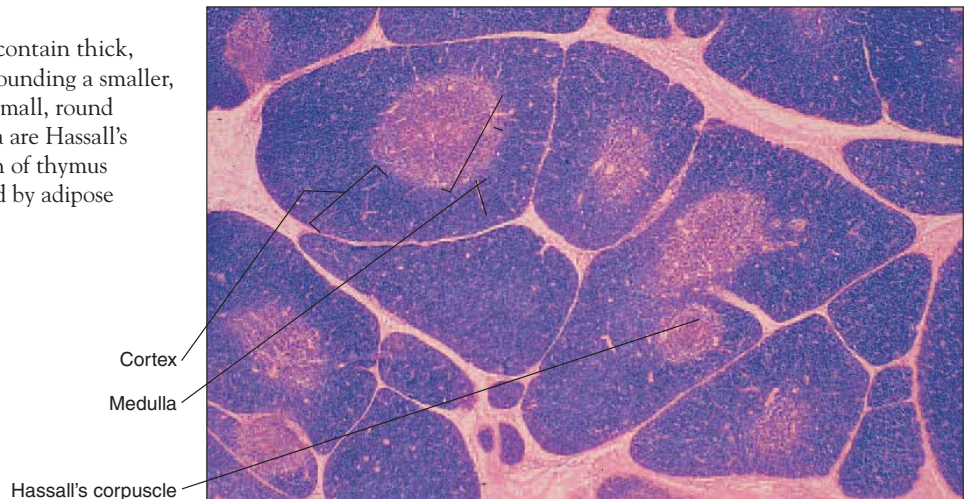
## 30 CHAPTER 1

**Figure 1-72**

**Valve of Lymphatic Vessel** One-way flow of lymph, from left to right in this figure, is ensured by valve action in lymph vessel. Vessels themselves are thin walled and lack musculature; pumping action occurs through compression by neighboring muscles. ( $\times 25$ )

**Figure 1-73a**

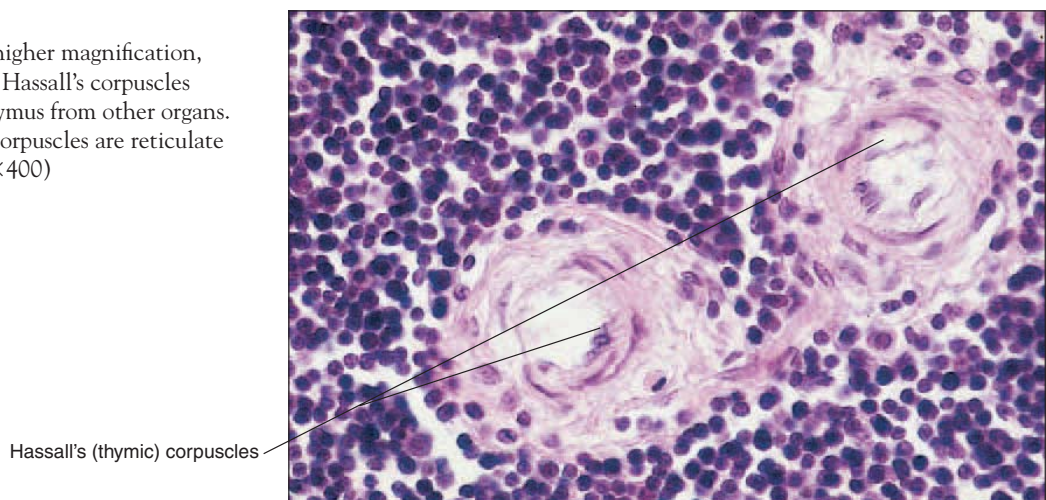
**Thymus** Various lobules contain thick, darkly staining cortex surrounding a smaller, lighter-staining medulla. Small, round cellular patches in medulla are Hassall's corpuscles. In adults, much of thymus degenerates and is replaced by adipose tissue. ( $\times 10$ )



A

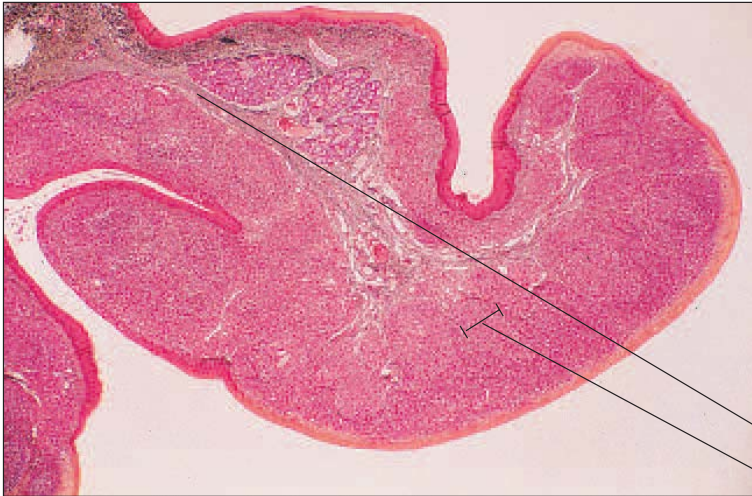
**Figure 1-73b**

**Thymus** Under higher magnification, the appearance of Hassall's corpuscles distinguish the thymus from other organs. Surrounding the corpuscles are reticulate epithelial cells. ( $\times 400$ )



B

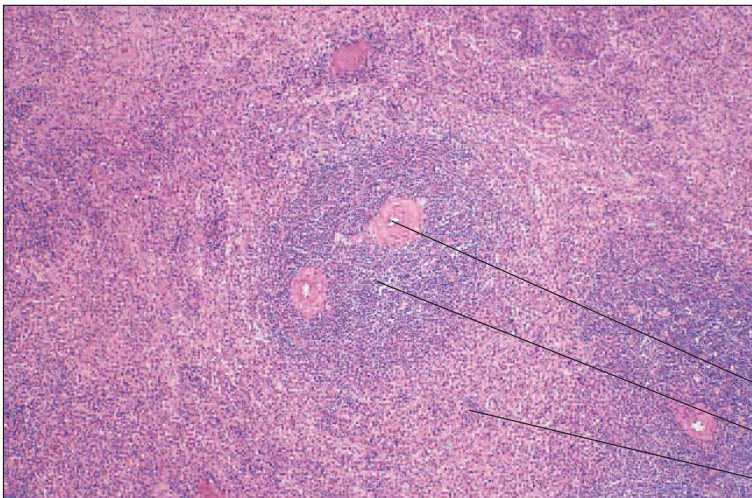




**Figure 1-74**

**Palatine Tonsil** Outer capsule surrounds subcapsular sinus, under which are several large, rounded germinal centers surrounding trabecular arteries and veins. Efferent lymph vessel leads out to upper left. ( $\times 5$ )

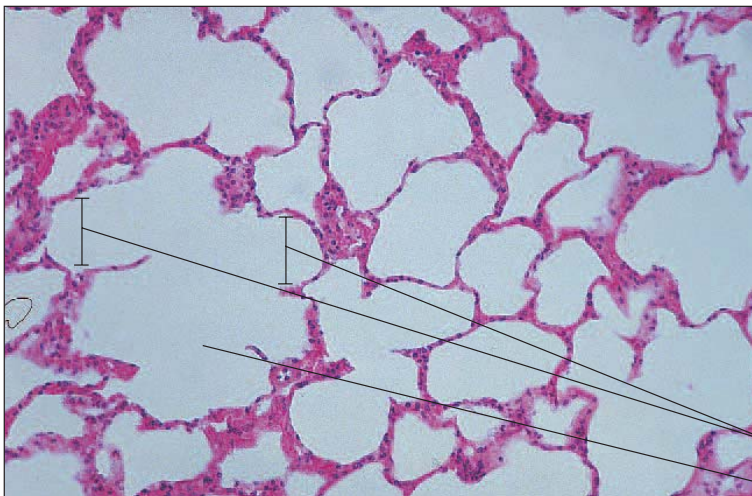
Lymph vessel  
Germinal center



**Figure 1-75**

**Spleen** Central blood vessels are surrounded by area of densely staining white pulp composed of lymphoid cells. Less densely staining red pulp, with fewer cell nuclei, surrounds white pulp. ( $\times 25$ )

Blood vessel  
White pulp  
Red pulp



**Figure 1-76**

**Alveoli of Lung** Thin-walled respiratory exchange surfaces aid in rapid diffusion of gases. Bronchiole terminates at atrium, which acts as entryway into several individual alveoli, greatly multiplying surface area. ( $\times 50$ )

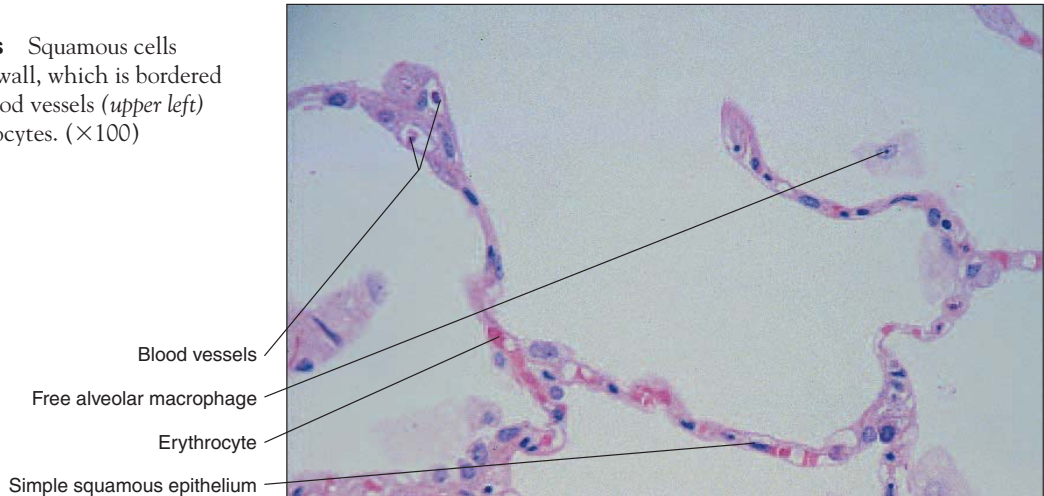
Alveoli  
Atrium



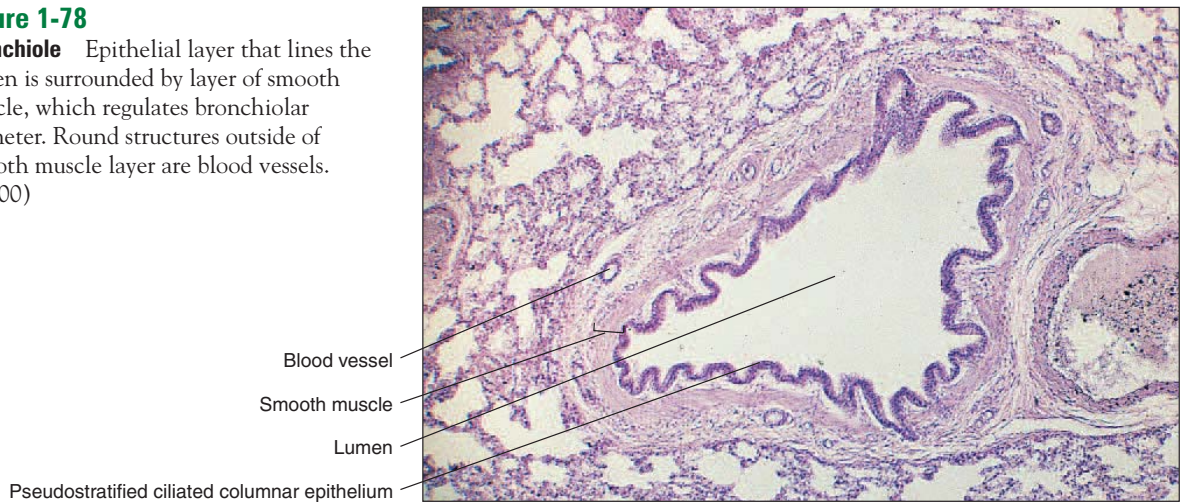
## 32 CHAPTER 1

**Figure 1-77**

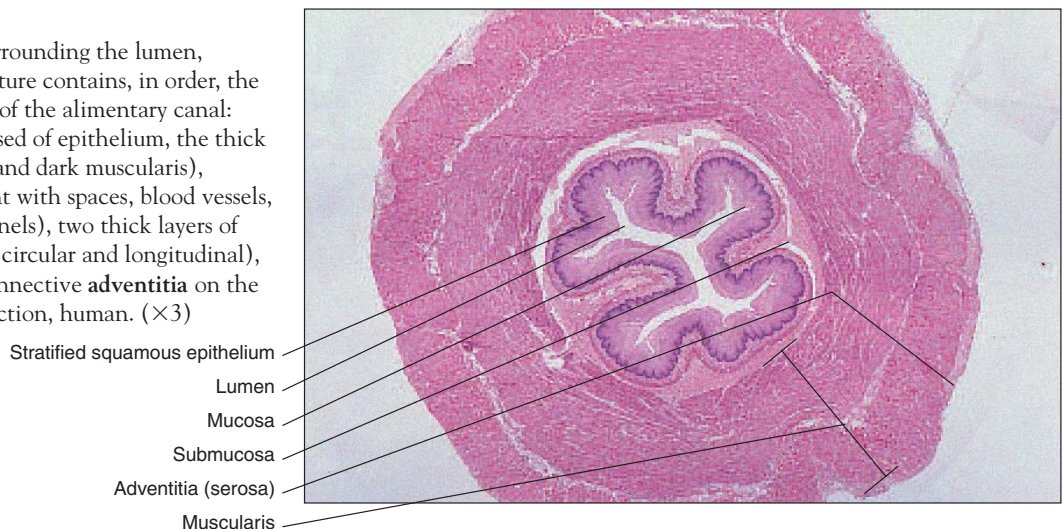
**Details of Alveolus** Squamous cells compose alveolar wall, which is bordered by thin-walled blood vessels (*upper left*) containing erythrocytes. ( $\times 100$ )

**Figure 1-78**

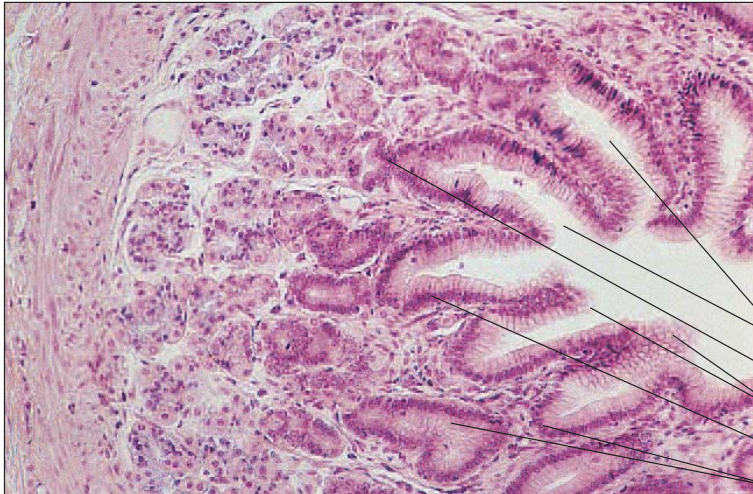
**Bronchiole** Epithelial layer that lines the lumen is surrounded by layer of smooth muscle, which regulates bronchiolar diameter. Round structures outside of smooth muscle layer are blood vessels. ( $\times 100$ )

**Figure 1-79**

**Esophagus** Surrounding the lumen, esophageal structure contains, in order, the four basic layers of the alimentary canal: **mucosa** (composed of epithelium, the thick lamina propria, and dark muscularis), **submucosa** (light with spaces, blood vessels, and lymph channels), two thick layers of the **muscularis** (circular and longitudinal), and the thin, connective **adventitia** on the surface. Cross section, human. ( $\times 3$ )





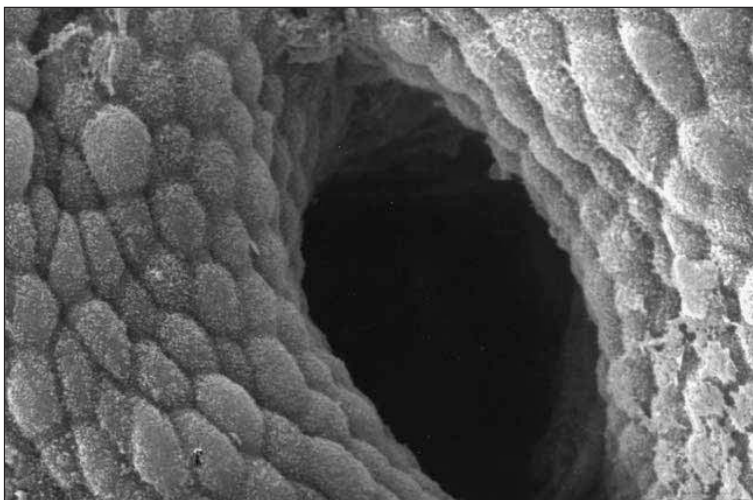


**Figure 1-80a**

**Stomach Mucosa** Visible at entrances to gastric pits are mucus-secreting goblet cells of columnar epithelium. Deeper in pits are acid-secreting parietal cells and enzyme-secreting chief cells. Endocrine-secreting cells near tip of pits are noncolumnar and smaller, with dark, round nuclei. Gastric pits penetrate deep into submucosal layer. Edge of muscularis layer is visible. ( $\times 50$ )

- Gastric pits
- Endocrine cells
- Goblet cells
- Parietal cells
- Chief cells

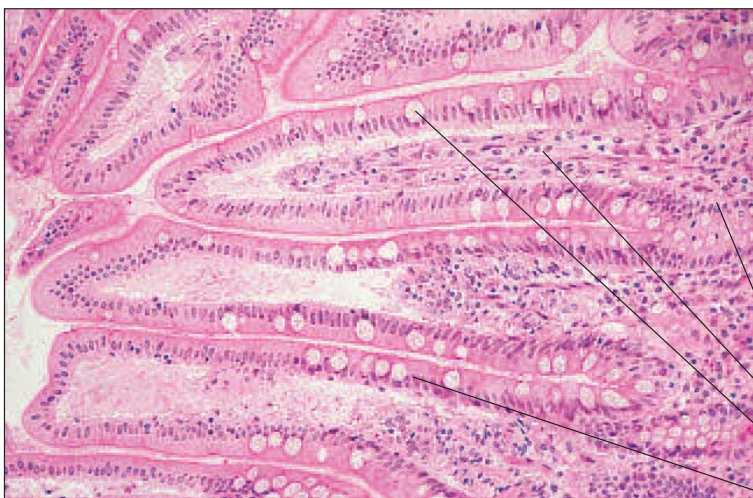
A



**Figure 1-80b**

**Gastric Pit** The opening of a gastric pit into the stomach, surrounded by the rounded apical surfaces of the columnar epithelial cells of the mucosa. Scanning electron micrograph. ( $\times 50$ )

B



**Figure 1-81**

**Small Intestine, Villi of Ileum (Longitudinal Section)** Numerous pale goblet cells punctuate columnar epithelium that covers each villus. Core of villus contains small blood vessels and blind lymph channel (lacteal). Deep in crypts are endocrine cells, identifiable as dark, round nuclei in a noncolumnar cytoplasm. Human. ( $\times 50$ )

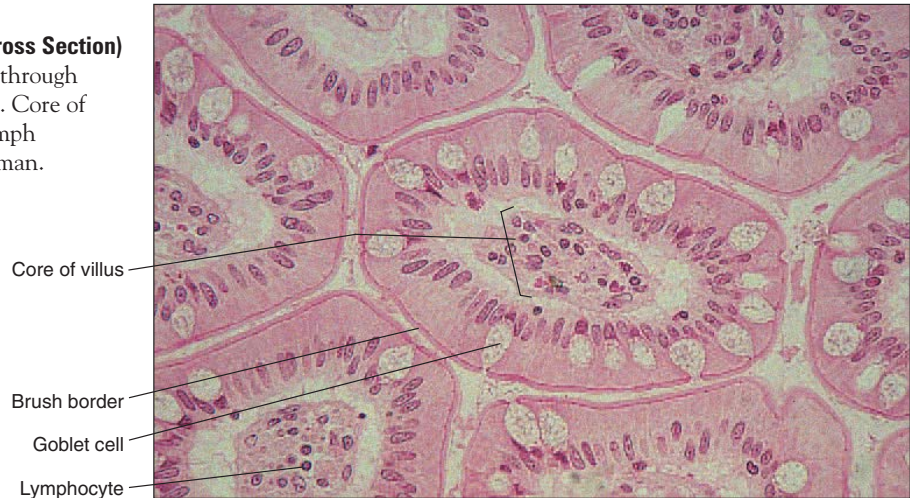- Endocrine cells
- Blood vessel and lacteal
- Goblet cell
- Simple columnar epithelium



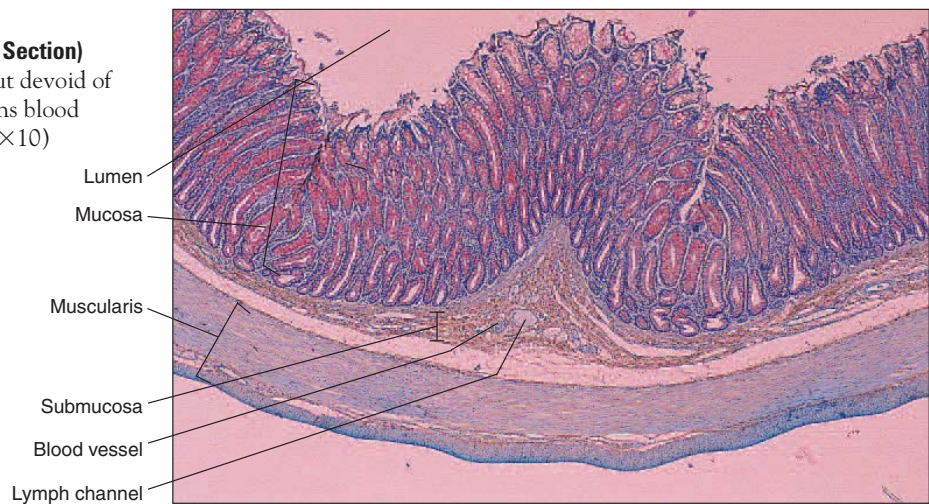
## 34 CHAPTER 1

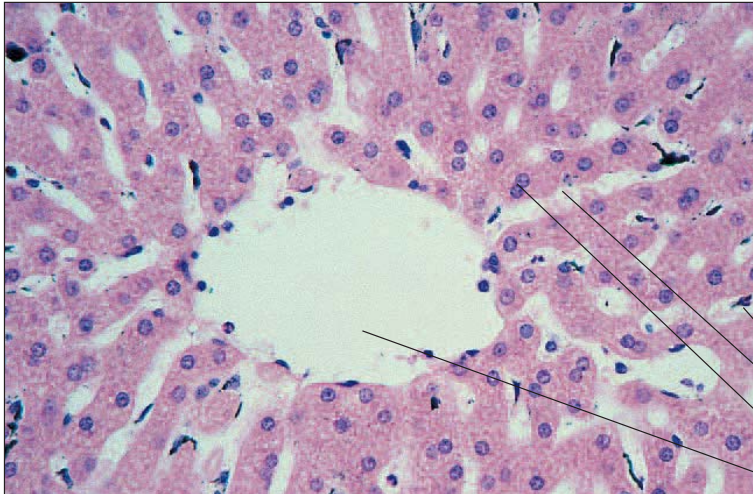
**Figure 1-82****Small Intestine, Villi of Ileum (Cross Section)**

Goblet cells emptying contents through brush border surface are evident. Core of villus contains blood vessels, lymph channels, and lymphocytes. Human. ( $\times 100$ )

**Figure 1-83****Large Intestine (Colon) (Cross Section)**

Surface is thrown into folds but devoid of villi. Thick submucosa contains blood vessels and lymph channels. ( $\times 10$ )





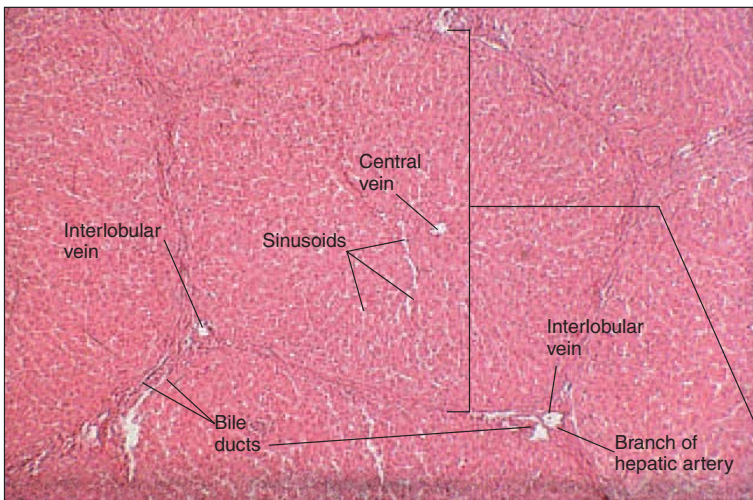
**Figure 1-84a**

**Liver with Central Vein and Sinusoids**

Parenchymal hepatocytes lie in radial arrangement around central vein that is lined with single endothelial layer. Cords of hepatocytes are separated by spaces (sinusoids). Sinusoidal surface is covered by microvilli. ( $\times 100$ )

Kupffer cell  
Sinusoid  
Hepatocyte  
Central vein

A

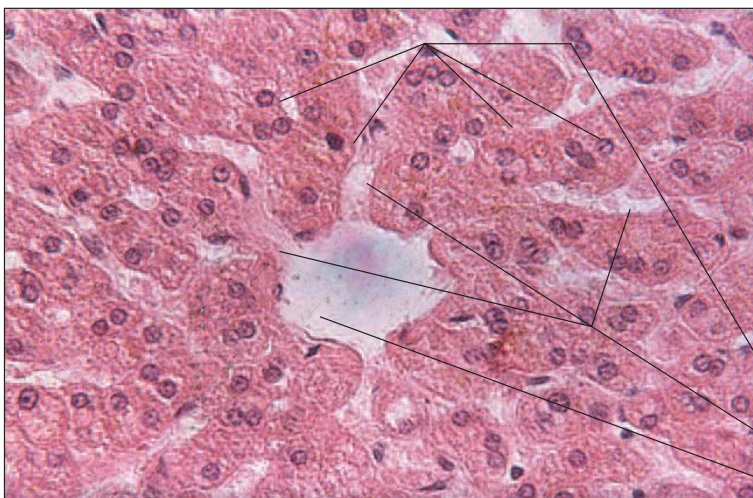


**Figure 1-84b**

**Liver** The liver consists of numerous lobules. A single lobule is in the center of view. At the junction of three adjacent lobes is a bile duct, a branch of the hepatic artery, and a branch of the hepatic portal vein. These three tubes are called a triad. ( $\times 40$ )

Lobule

B



**Figure 1-84c**

**Liver** A single liver lobule consists of a central vein (shown in the center), which collects blood as it flows through narrow endothelial-lined channels, or sinusoids. The cells bordering the sinusoids are called hepatocytes. ( $\times 400$ )

Hepatocytes  
Sinusoids  
Central vein

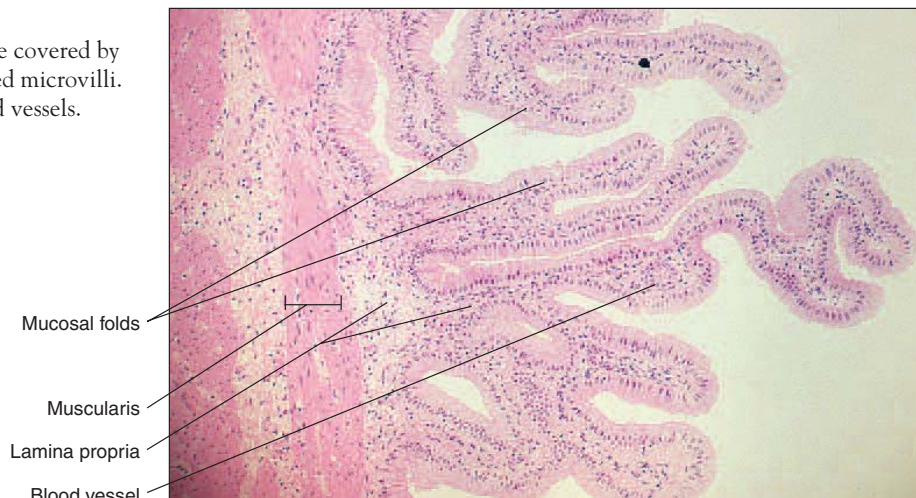
C



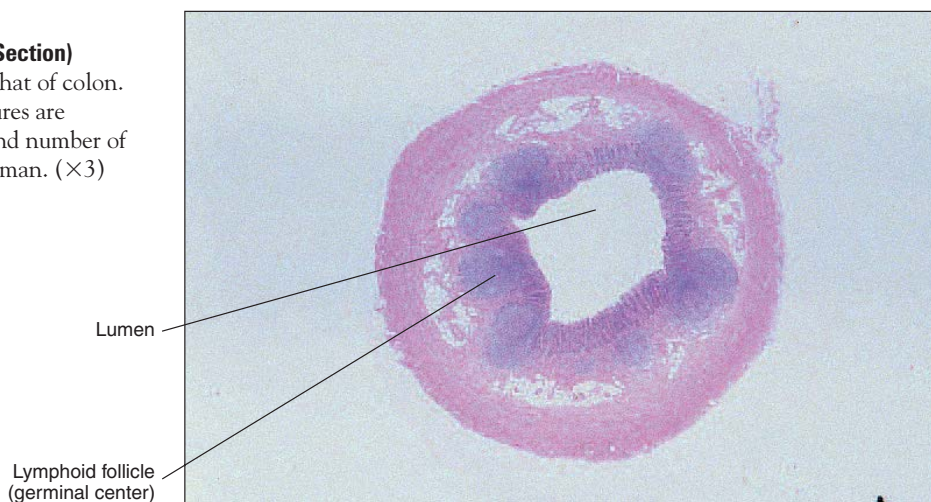## 36 CHAPTER 1

**Figure 1-85**

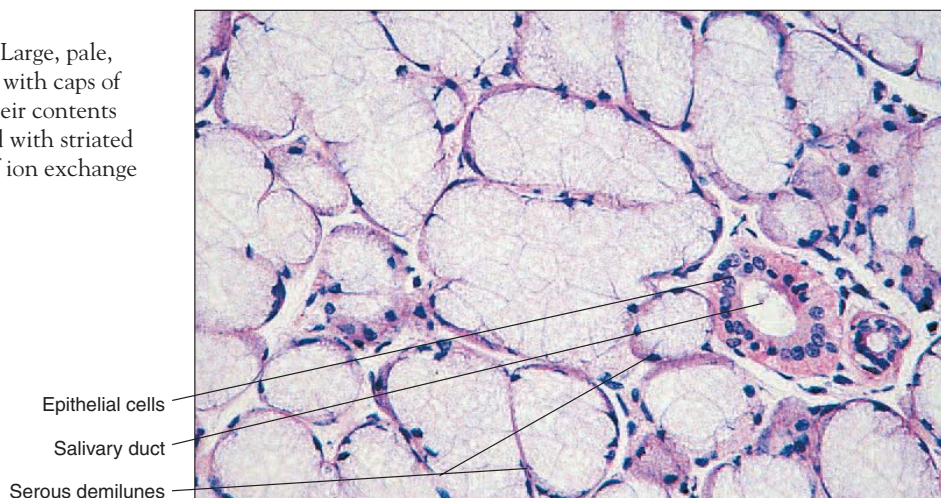
**Gallbladder** Mucosal folds are covered by epithelium with well-developed microvilli. Lamina propria contains blood vessels. ( $\times 25$ )

**Figure 1-86****Vermiform Appendix (Cross Section)**

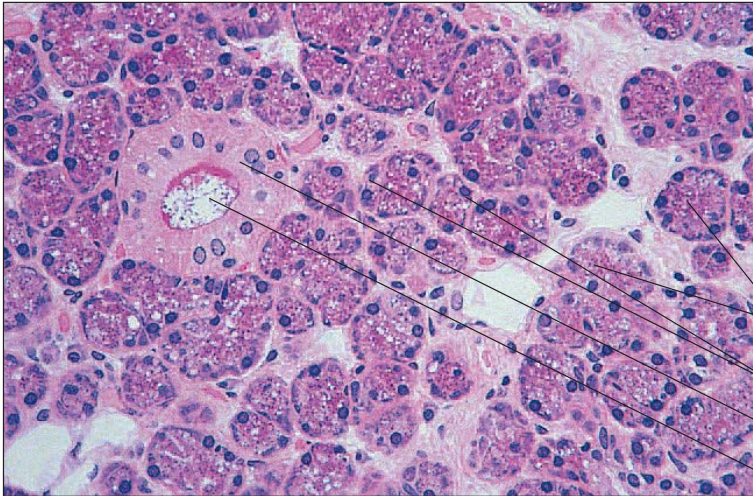
Overall structure resembles that of colon. Large, darkly staining structures are lymphoid follicles, the size and number of which decrease with age. Human. ( $\times 3$ )

**Figure 1-87****Sublingual Salivary Gland**

Large, pale, mucus-secreting cells, some with caps of serous demilunes, secrete their contents into ducts that may be lined with striated epithelial cells indicative of ion exchange activity. ( $\times 100$ )



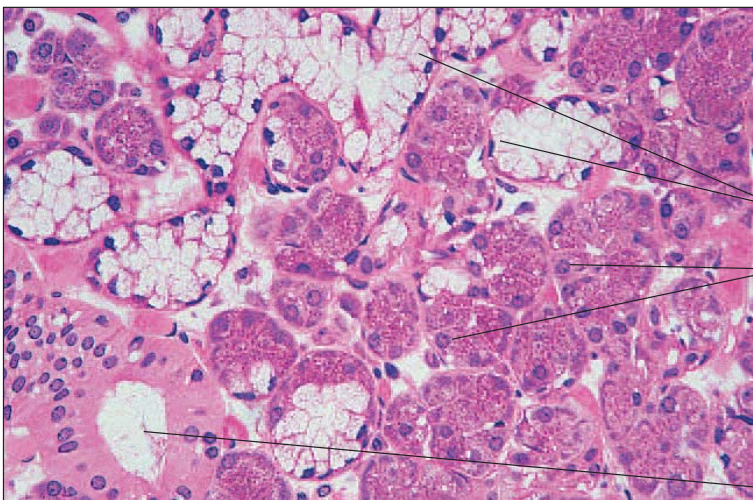




**Figure 1-88**

**Parotid Salivary Gland** Granular serous cells with numerous, large, zymogen granules surround duct. Several tiny ducts run between clusters within the plane of section. Human. ( $\times 100$ )

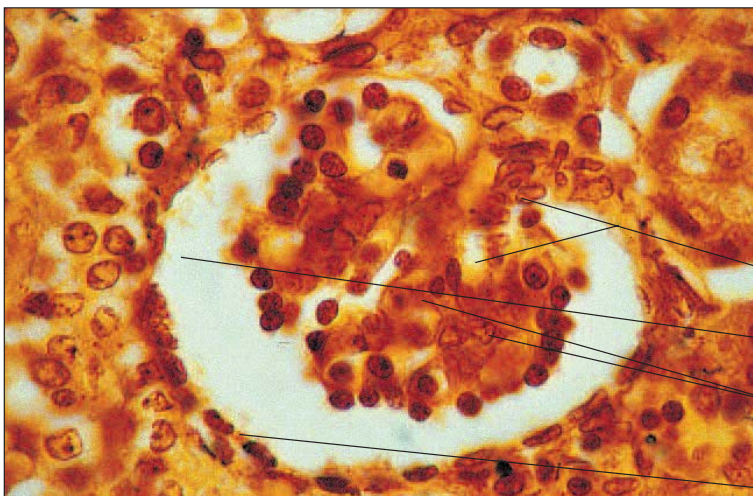
- Zymogen granules
- Serous cells
- Epithelial cells of salivary duct
- Lumen of salivary duct



**Figure 1-89**

**Submandibular Salivary Gland with Mucous (Light Staining) and Serous (Dark Staining) Components** Striated duct is visible at lower left. ( $\times 100$ )

- Mucous cells
- Serous cells
- Lumen of salivary duct



**Figure 1-90**

**Glomerular (Bowman's) Capsule and Glomerulus (Renal Corpuscle)** Tuft of capillaries, surrounded by podocytes, protrudes into space of glomerular capsule. Parietal surface is lined with single layer of simple squamous cells. ( $\times 100$ )

- Glomerulus
- Space in glomerular capsule
- Podocytes
- Squamous cell

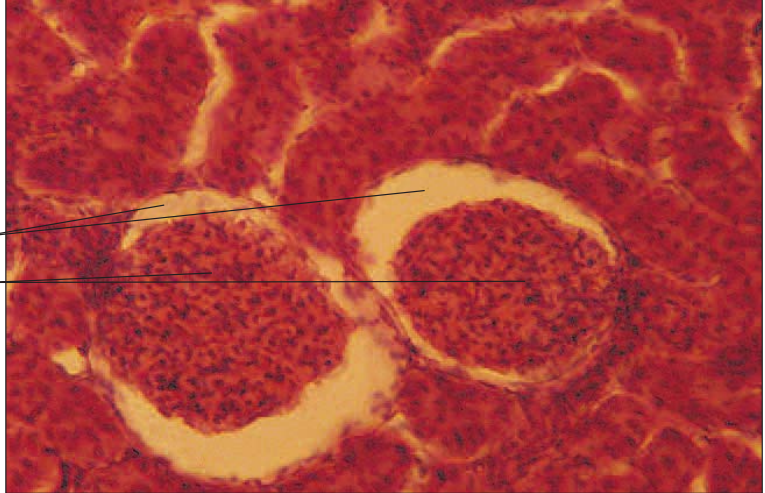


## 38 CHAPTER 1

**Figure 1-91****Two Glomeruli and Glomerular Capsules**

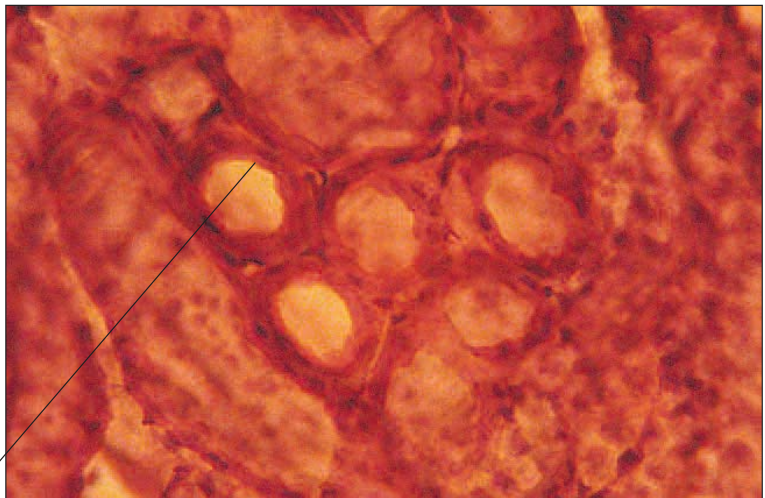
“Lacy” edges of glomerulus on left shows characteristics of pregnancy-induced hypertension (PIH), here induced experimentally in a pregnant rat. ( $\times 50$ )

Space in glomerular capsules  
Glomeruli

**Figure 1-92****Distal Convoluted Tubules Lined with Cuboidal Epithelium**

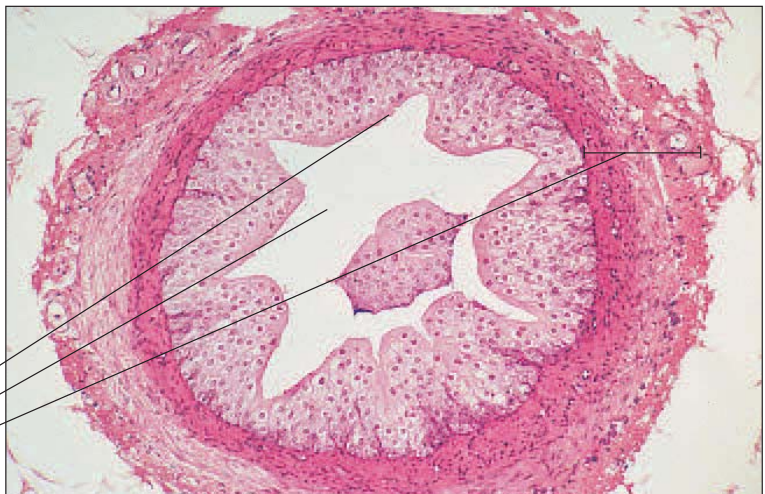Cross section from rat. ( $\times 400$ )

Cuboidal cell

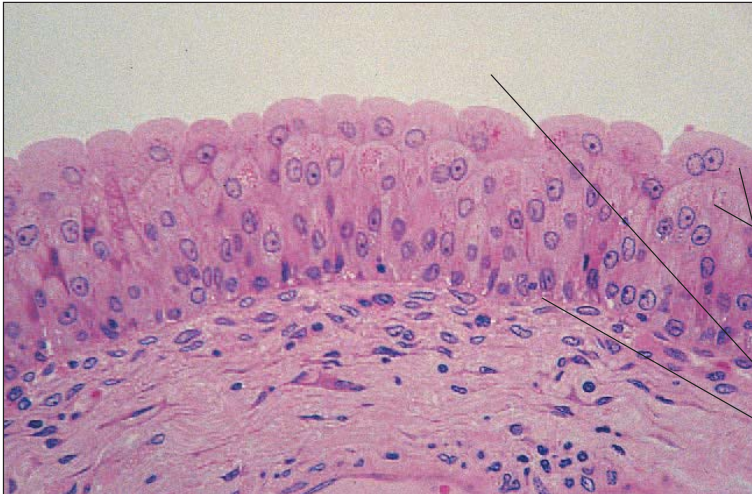
**Figure 1-93**

**Ureter** Star-shaped lumen is lined with transitional epithelium that varies in thickness to change shape as lumen stretches. Delicate lamina propria separates epithelium from alternating layers of circular and longitudinal smooth muscle. ( $\times 25$ )

Transitional epithelium  
Lumen  
Smooth muscle and adventitial  
connective tissue



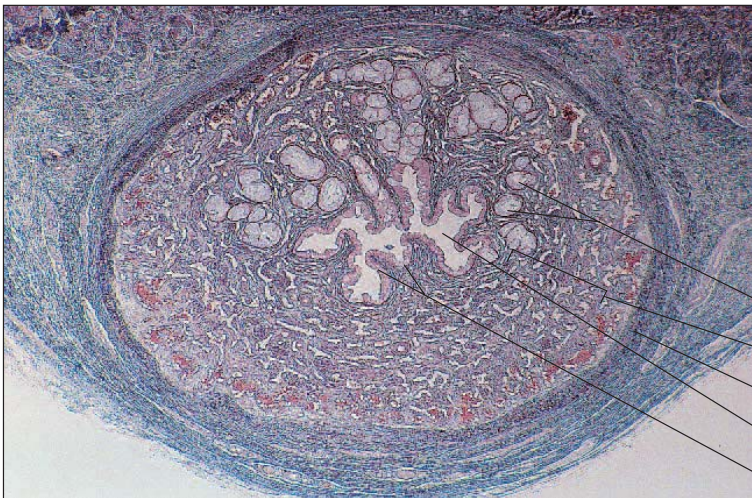




**Figure 1-94**

**Urinary Bladder** Umbrella cells of transitional epithelium stretch and flatten as bladder fills. Basement membrane separates epithelium from underlying connective tissue containing blood vessels. Monkey. ( $\times 100$ )

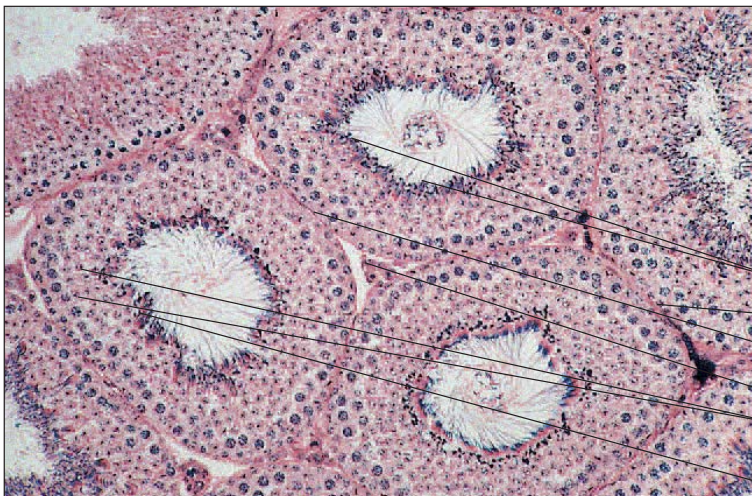Umbrella cells  
Lumen of bladder  
Basement membrane



**Figure 1-95**

**Urethra (within Penis)** Lumen is lined with transitional epithelium and is embedded in corpus spongiosum of the penis. Paraurethral glands located above the lumen in the figure secrete mucus into the urethra. A smooth muscle layer (tunica muscularis) surrounds the urethral structures. ( $\times 10$ )

Paraurethral glands  
Corpus spongiosum  
Tunica muscularis  
Lumen  
Transitional epithelium



**Figure 1-96**

**Seminiferous Tubules of Testis Lined with Sertoli Cells and Germinalivum in Various Stages of Development** Tunica propria surrounds each tubule. Interstitial spaces contain blood vessels and clumps of interstitial (Leydig) cells that secrete testosterone. ( $\times 50$ )

Spermatozoa  
Tunica propria  
Basement membrane  
Interstitial cells  
Spermatocytes  
Sertoli cells

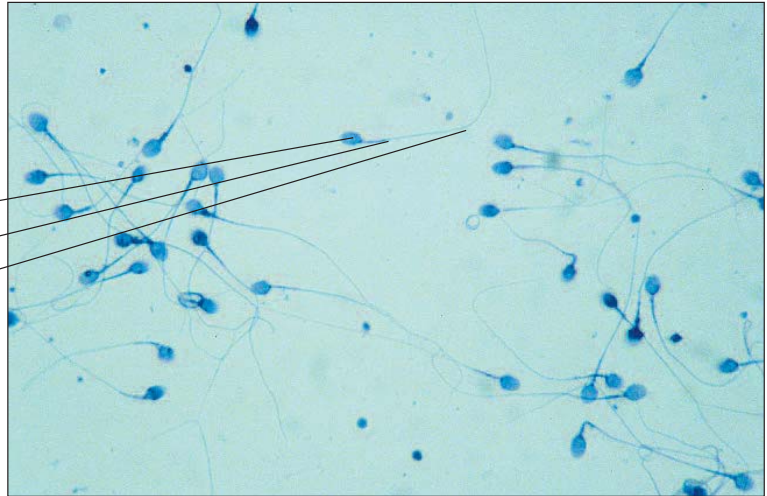


## 40 CHAPTER 1

**Figure 1-97**

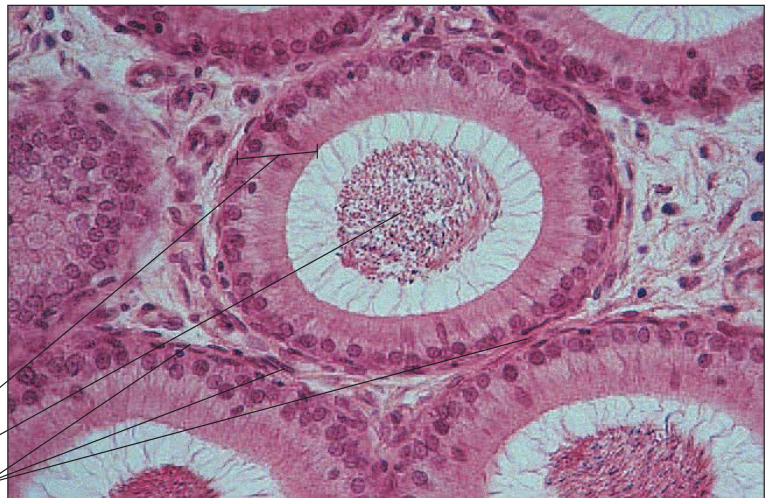
**Spermatozoa** Head contains numerous enzymes and nucleus with DNA. Thick midpiece just behind head is packed with mitochondria. ( $\times 250$ )

Head of sperm  
Midpiece  
Tail

**Figure 1-98**

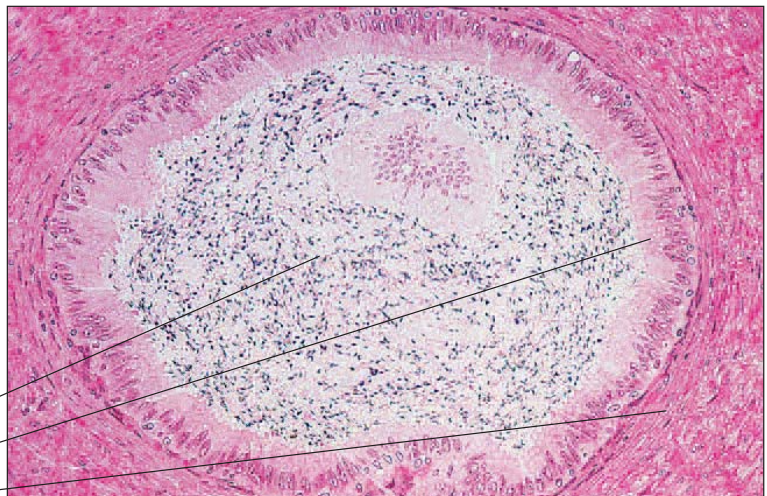
**Epididymis** Tall, pseudostratified columnar epithelium with microvilli surrounds a lumen packed with clumps of spermatozoa. Narrow band of smooth muscle cells encircles each tubule.

Pseudostratified columnar epithelium  
Spermatozoa in lumen  
Smooth muscle

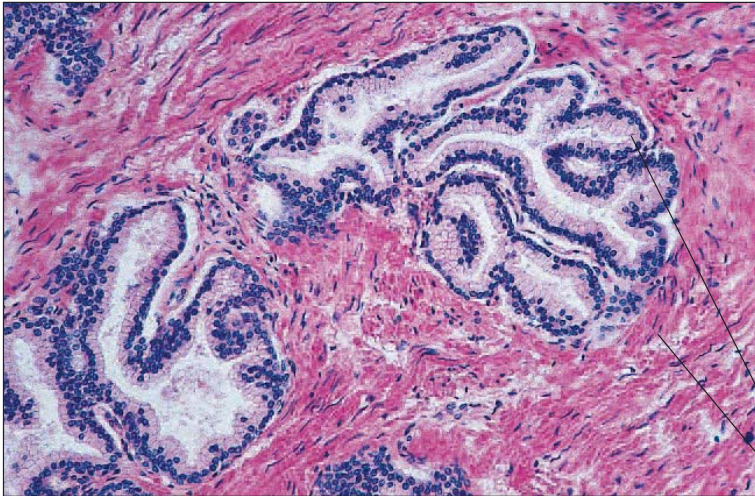
**Figure 1-99**

**Ductus Deferens** Ciliated columnar epithelial cells line a spermatozoa-filled lumen. Three layers of smooth muscle cells surround mucosa, a circular layer between two longitudinal ones. ( $\times 50$ )

Spermatozoa in lumen  
Columnar epithelium of mucosa  
Smooth muscle





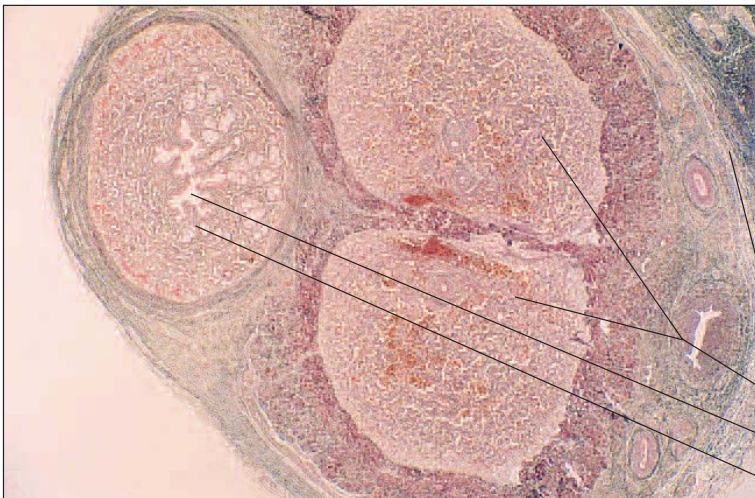


**Figure 1-100**

**Prostate Gland** Mucosal surfaces, lined with tall columnar cells and darkly stained basal nuclei, are arranged in numerous deep folds. Lumina open directly into prostatic urethra. Smooth muscle and fibrocollagenous stroma surround luminal structures. Human. ( $\times 50$ )

Columnar epithelium

Smooth muscle and fibrocollagenous bundles



**Figure 1-101**

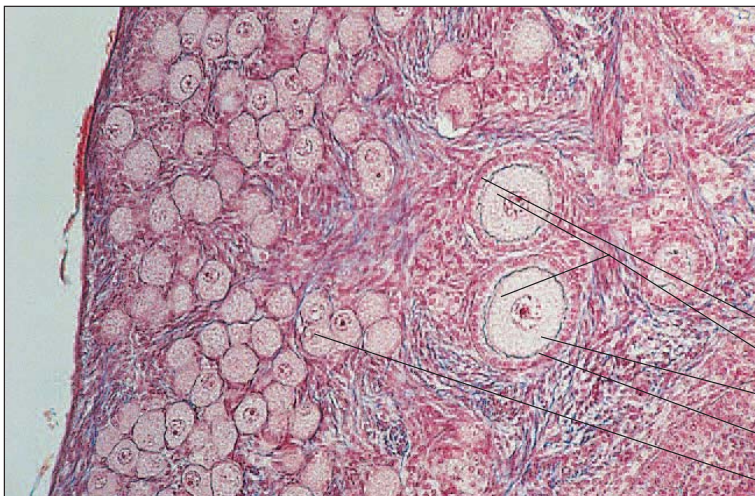
**Penis** Two corpora cavernosa lie superior to single corpus spongiosum containing penile urethra. Septum between corpora cavernosa is incomplete. Dense fibrous connective tissue, tunica albuginea, surrounds the three vascular cavernosa. The inferior aspect appears on the left, the superior aspect on the right. ( $\times 5$ )

Tunica albuginea

Corpora cavernosa

Urethra

Corpus spongiosum



**Figure 1-102**

**Ovary with Numerous Primordial Follicles and Two Primary Follicles** Primordial follicles contain oocytes that are not stimulated to complete the first meiotic division. Two primary follicles each contain an ovum with nucleus and clear surrounding cytoplasm. Thin, clear **zona pellucida** is surrounded by a ring of even cuboidal cells, the **corona radiata**. ( $\times 25$ )

Corona radiata

Primary follicles

Cytoplasm

Membrane of ovum

Primordial follicle

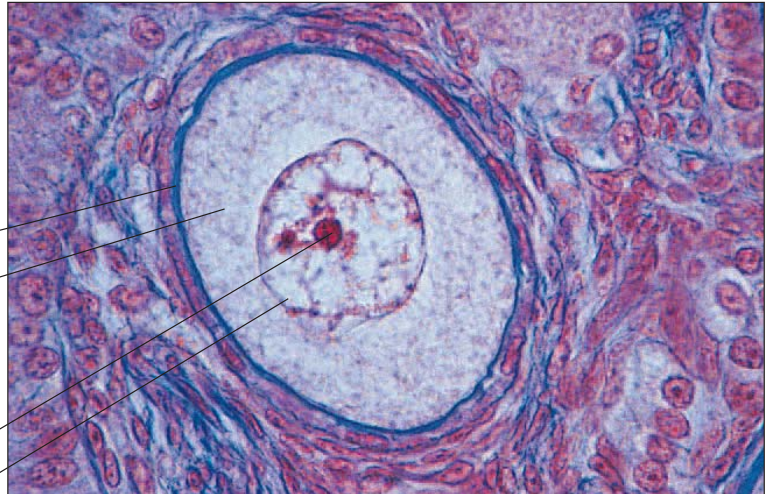


## 42 CHAPTER 1

**Figure 1-103****Detail of Oocyte in Primordial Follicle**

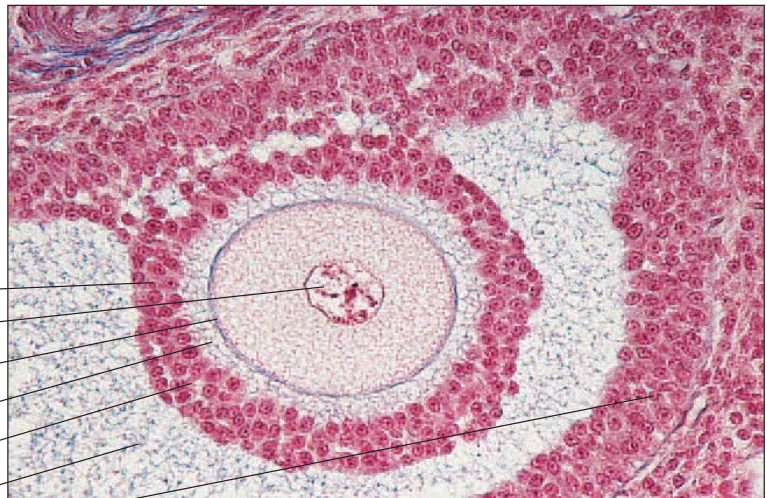Clear nucleus contains well-defined nucleolus. Neither zona pellucida nor corona radiata is evident. ( $\times 250$ )

Plasma membrane of ovum  
Cytoplasm of ovum  
Nucleolus  
Nucleus

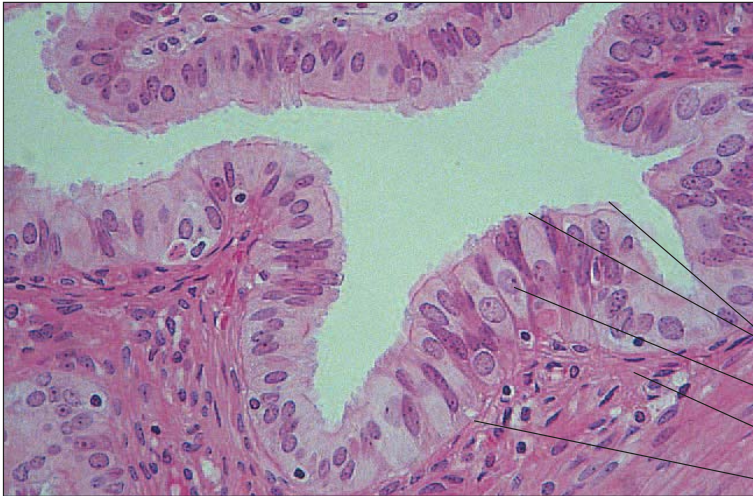
**Figure 1-104****Secondary Ovarian Follicle with Ovum**

Bright zona pellucida surrounds outer membrane of ovum and in turn is surrounded by dark, cellular corona radiata. A large **antrum** has formed where the egg is not anchored to the follicular wall of **granulosa cells**. ( $\times 100$ )

Stratified cuboidal epithelium  
Nucleus  
Membrane of ovum  
Zona pellucida  
Corona radiata  
Antrum  
Granulosa cells of follicular wall



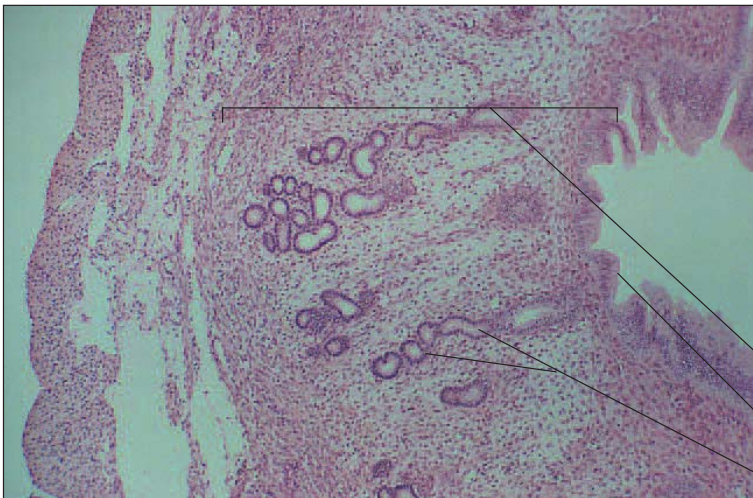




**Figure 1-105**

**Fallopian (Uterine) Tube** Extensive folding of mucosa, lined with ciliated columnar epithelium, is common. Epithelium rests on thin basement membrane and flat connective tissue layer. Rhythmic beating of cilia helps transport ovum toward uterus; cell structure also suggests secretory function. Human. ( $\times 100$ )

- Cilia
- Columnar epithelium
- Connective tissue
- Basement membrane



**Figure 1-106**

**Uterus** Endometrial lining (*right*) during proliferative phase of uterine cycle shows thickening of epithelial surfaces and numerous coiled glandular ducts. ( $\times 25$ )

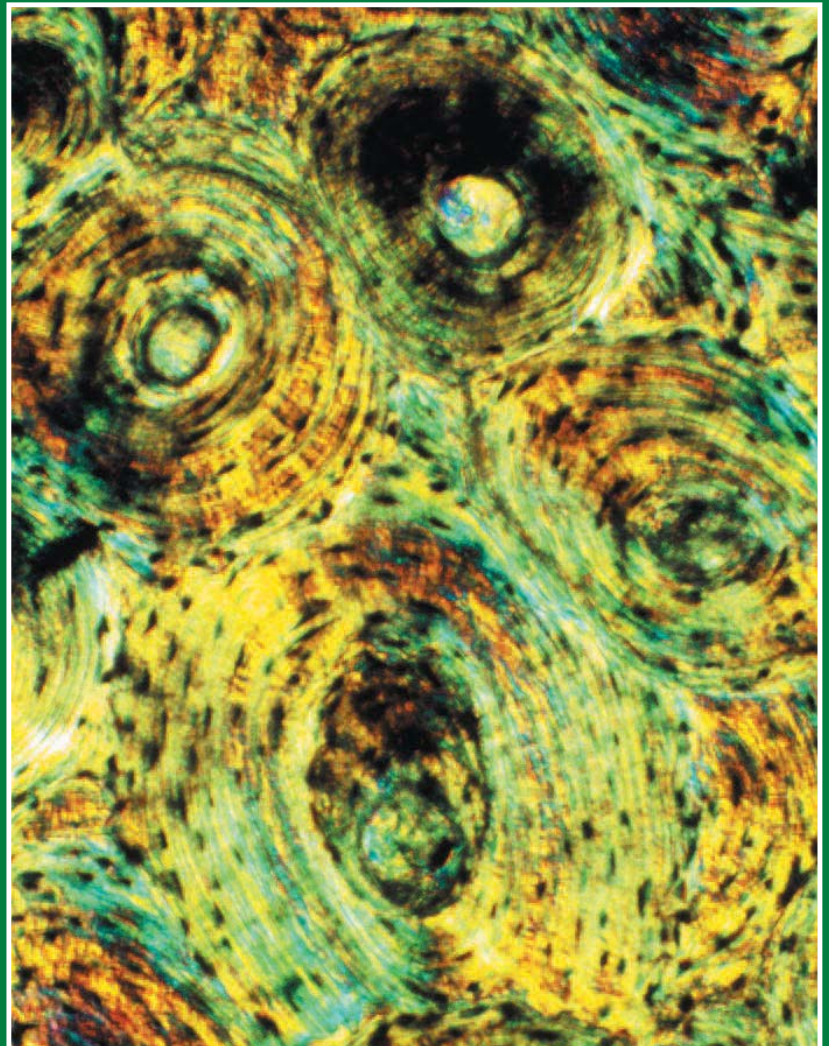
- Endometrium
- Endothelial lining
- Glandular ducts

*This page intentionally left blank*



C H A P T E R 2

# Human Skeletal Anatomy



Compact Bone.  
Light micrograph, magnification:  $\times 265$

46 CHAPTER 2

**Figure 2-1**  
**Skull: Face**

BONES

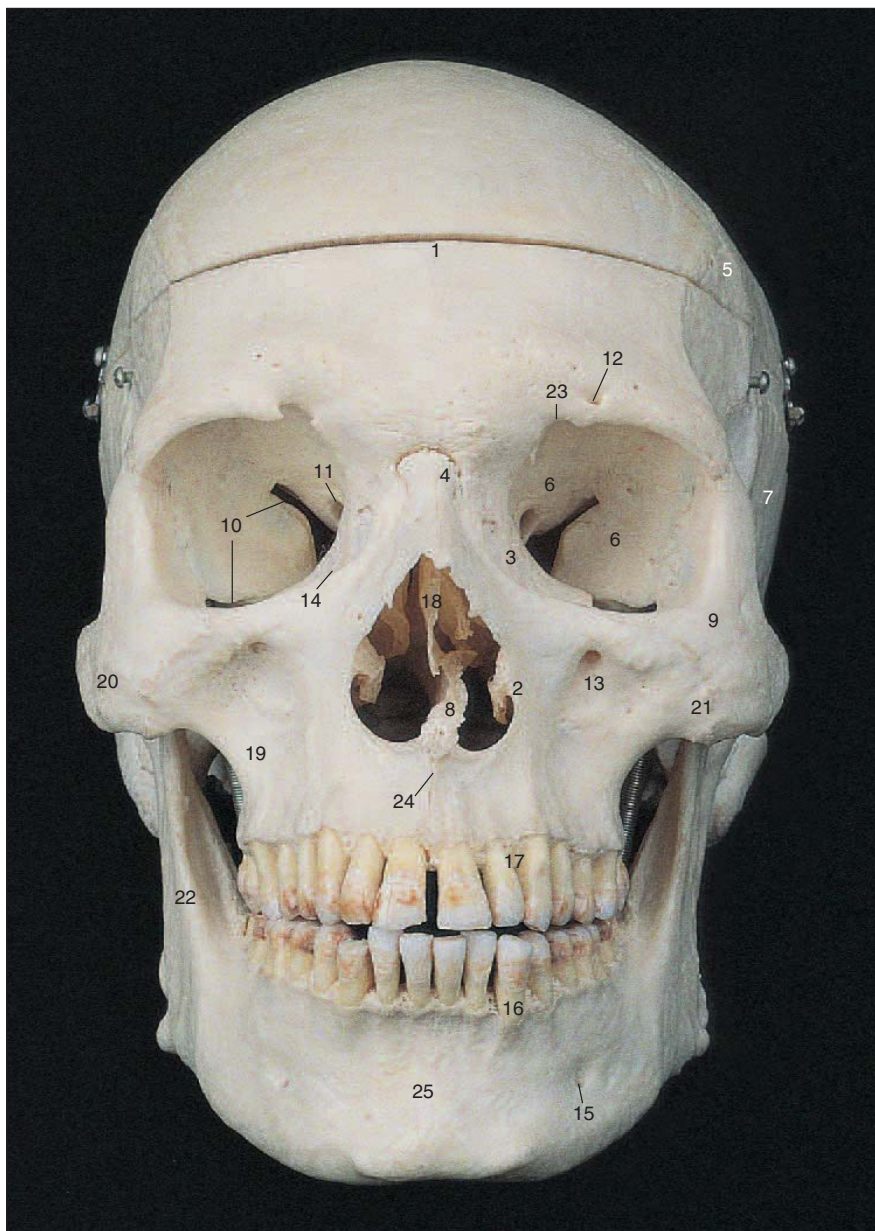
1. Frontal
2. Inferior nasal concha
3. Lacrimal
4. Nasal
5. Parietal
6. Sphenoid
7. Temporal
8. Vomer
9. Zygomatic (malar)
19. Maxilla
25. Mandible

FORAMINA

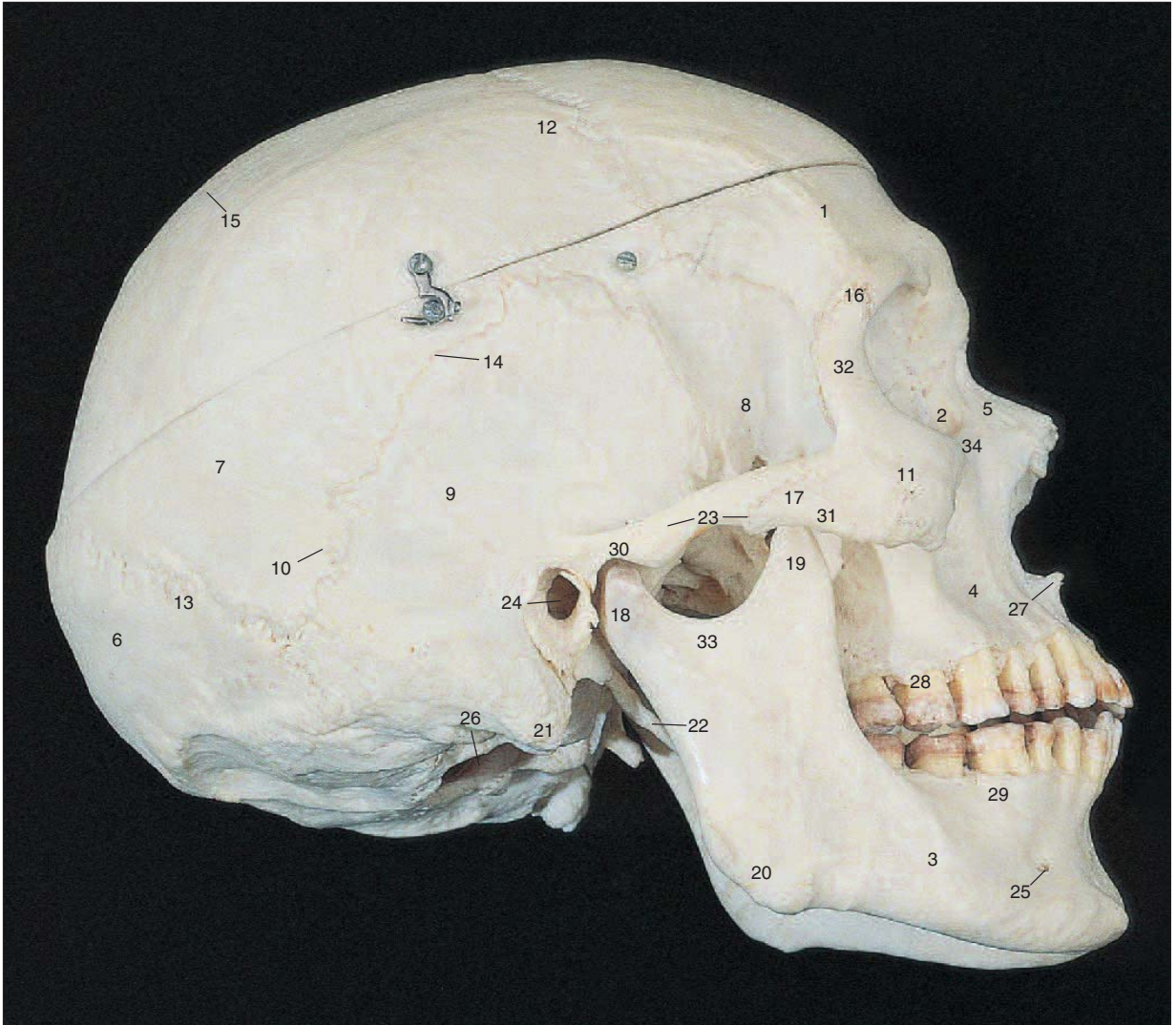
10. Orbital fissure
11. Optic
12. Supraorbital
13. Infraorbital
14. Lacrimal canal
15. Mental

PROCESSES

16. Mandibular alveolus
17. Maxillary alveolus
18. Perpendicular plate of ethmoid
20. Temporal process of malar
21. Zygomatic process of maxilla
22. Mandibular ramus
23. Superior orbital
24. Anterior nasal spine







**Figure 2-2**  
**Skull: View from Right Side**

**BONES**

1. Frontal
2. Lacrimal
3. Mandible
4. Maxilla
5. Nasal
6. Occipital
7. Parietal
8. Sphenoid (greater wing)
9. Temporal
10. Wormian
11. Zygomatic (malar)

**SUTURES**

12. Coronal
13. Lambdoidal
14. Squamosal
15. Sagittal
16. Frontozygomatic
17. Temporozygomatic

**FORAMINA & PROCESSES**

18. Mandibular condyloid process
19. Mandibular coronoid process
21. Mastoid process
22. Styloid process
23. Zygomatic arch

24. External auditory meatus
25. Mental foramen
2. Lacrimal foramen
20. Mandibular angle
26. Foramen magnum
27. Anterior nasal spine
28. Maxillary alveolus
29. Mandibular alveolus
30. Zygomatic process of temporal bone
31. Temporal process of malar
32. Frontal process of malar
33. Mandibular notch
34. Lacrimal canal

48 CHAPTER 2

**Figure 2-3**

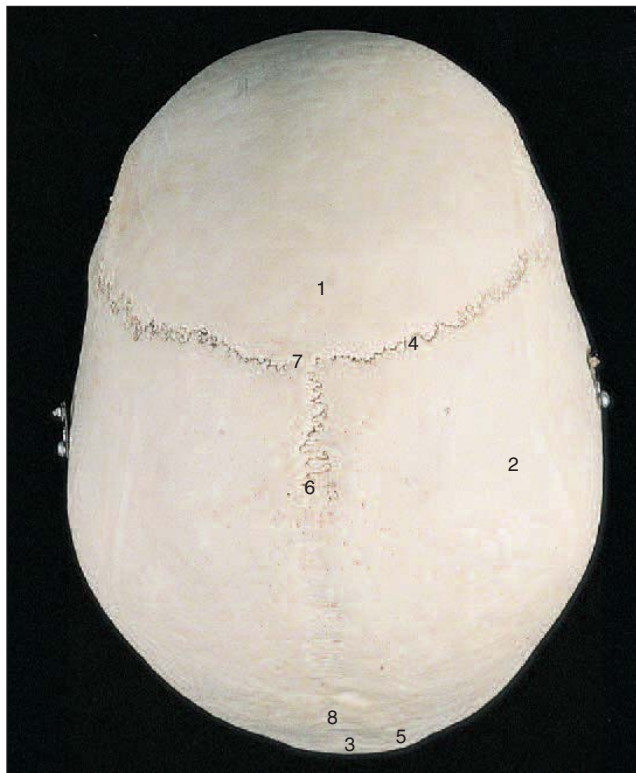
**Skull: Calvarium, Superior Aspect**

BONES

1. Frontal
2. Parietal
3. Occipital

SUTURES

4. Coronal
5. Occipital
6. Sagittal
7. Bregma
8. Lambda



**Figure 2-4**

**Skull: Floor of Cranium, Internal View**

BONES

1. Frontal
2. Occipital
3. Parietal
4. Temporal
5. Ethmoid
6. Sphenoid
- Incus } *not shown*
- Malleus } *not shown*
- Stapes } *not shown*

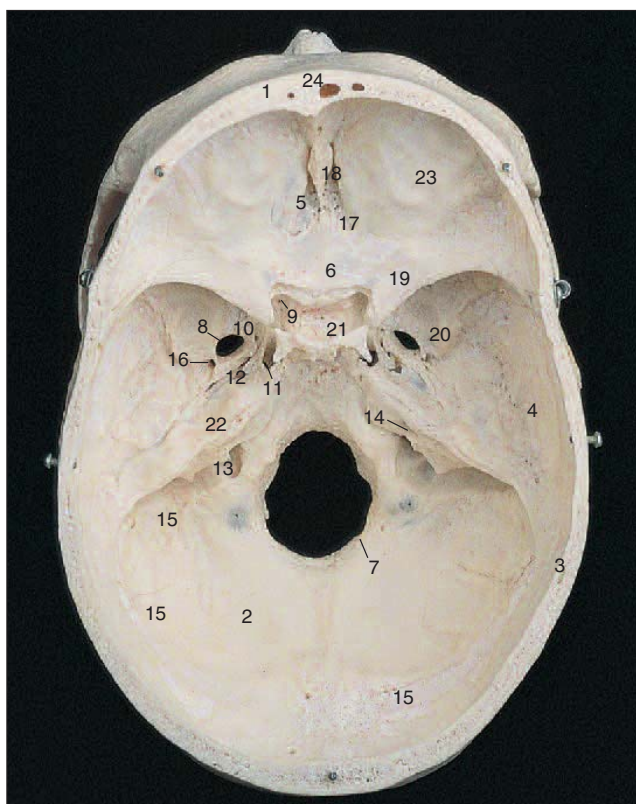
FORAMINA

7. Foramen magnum
8. Foramen ovale
9. Optic foramen
10. Foramen rotundum (not visible-located just anterior to numeral)
11. Foramen lacerum
12. Carotid canal
13. Jugular fossa and foramen

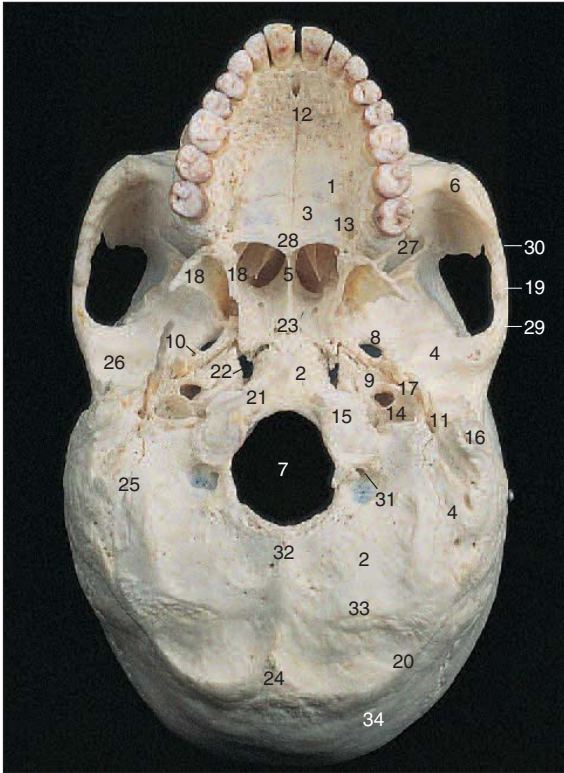
14. Internal auditory meatus
15. Grooves for transverse and sigmoid sinuses
16. Foramen spinosum

PROCESSES

17. Cribriform plate of ethmoid
18. Crista galli
19. Lesser wing of sphenoid
20. Greater wing of sphenoid
21. Sella turcica
22. Petrous portion of temporal bone
23. Orbital plate of frontal bone
24. Frontal sinus







**Figure 2-5**  
**Skull: Base, Viewed from Below**

**BONES**

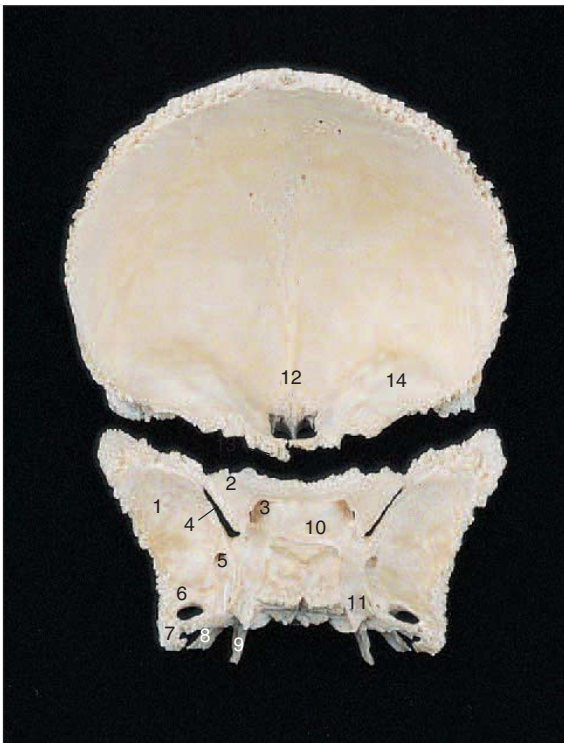
1. Maxilla (palatine process)
2. Occipital
3. Palatine
4. Temporal
5. Vomer
6. Zygomatic (malar)

**FORAMINA**

7. Foramen magnum
8. Foramen ovale
9. Carotid canal
10. Foramen spinosum
11. Stylomastoid
12. Incisive
13. Palatine
14. Jugular
21. Hypoglossal canal
22. Foramen lacerum
27. Inferior orbital fissure
29. Zygomatic process of temporal bone
30. Temporal process of malar
31. Condylar fossa and canal

**PROCESSES, DEPRESSIONS,  
 AND SUTURES**

15. Occipital condyle
16. Mastoid
17. Styloid
18. Medial and lateral pterygoid processes
19. Zygomatic arch
20. Superior nuchal line
23. Occipitospheoid suture
24. External occipital protuberance
25. Occipitotemporal suture
26. Mandibular fossa
28. Posteriornasal spine
32. External occipital crest
33. Inferior nuchal line
34. Highest nuchal line



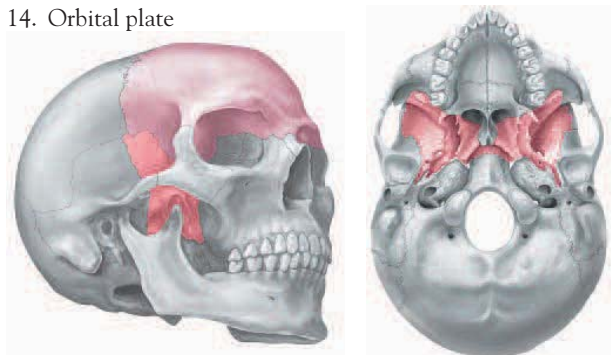
**Figure 2-6**  
**Frontal and Sphenoid Bones: Internal Aspect, Frontosphenooidal Suture Separated**

**PROCESSES AND  
 DEPRESSIONS**

1. Greater wing
2. Lesser wing
8. Lateral pterygoid
9. Medial pterygoid
10. Sella turcica
11. Carotid groove
12. Frontal crest
14. Orbital plate

**FORAMINA**

3. Optic foramen
4. Superior orbital fissure
5. Foramen rotundum
6. Foramen ovale
7. Foramen spinosum
13. Ethmoidal notch  
 (not located in picture)



50 CHAPTER 2

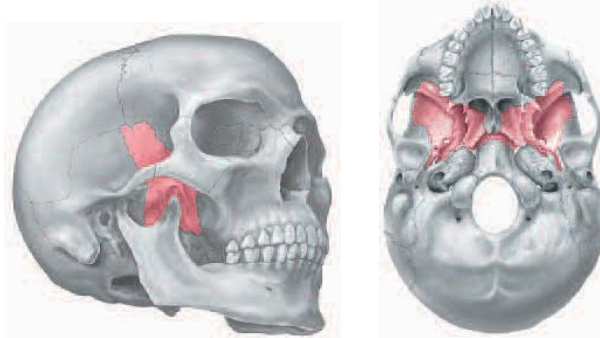
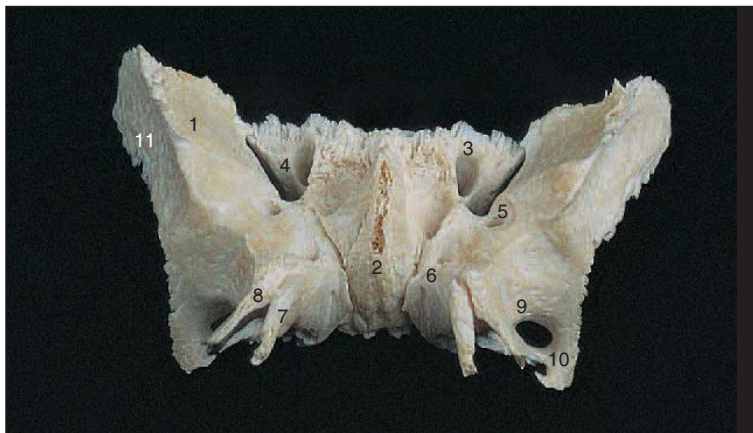
**Figure 2-7**  
**Sphenoid: From the Front**

PROCESSES

1. Orbital surface
2. Rostrum
7. Medial pterygoid
8. Lateral pterygoid
11. Temporal surface

FORAMINA

3. Optic
4. Superior orbital fissure
5. Foramen rotundum
6. Pterygoid canal
9. Foramen ovale
10. Foramen spinosum



**Figure 2-8**  
**Frontal and Zygomatic Bones:**  
**From the Front**

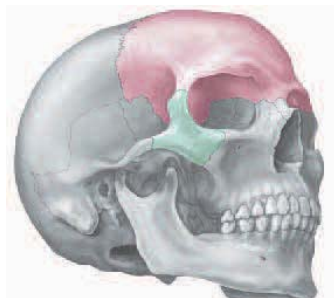
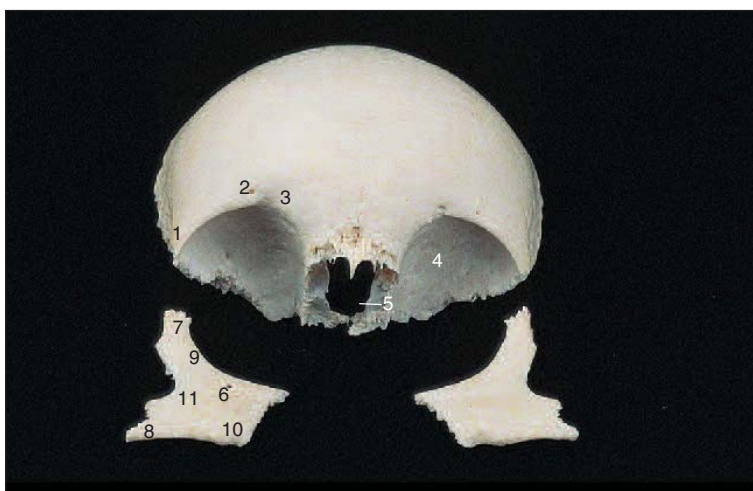
PROCESSES

1. Zygomatic process
4. Orbit
7. Frontal process
8. Temporal process
9. Orbital border
10. Maxillary border
11. Temporal border

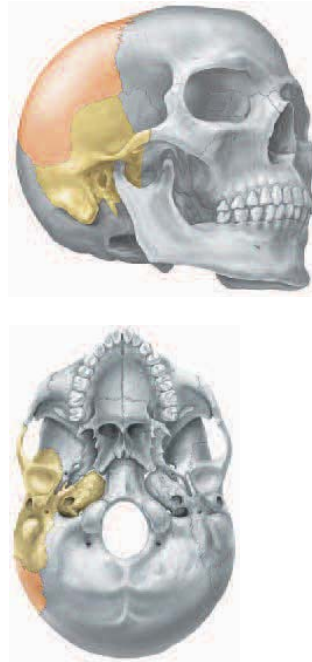
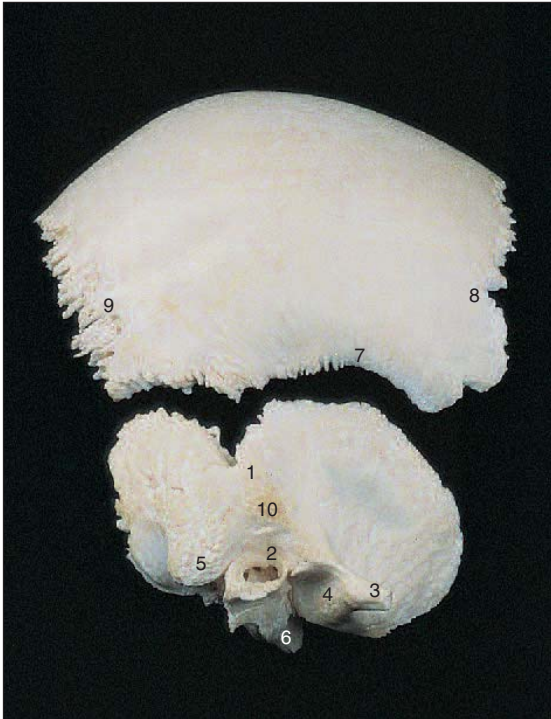NOTE: Supraorbital foramen and notch on right side are separate; on left they are superimposed.

FORAMINA

2. Supraorbital foramen
3. Supraorbital notch
5. Ethmoidal notch
6. Infraorbital foramen



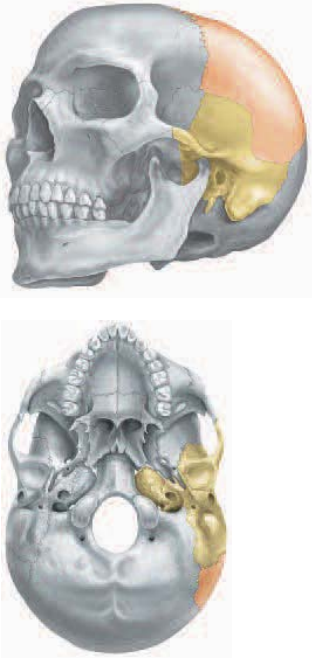
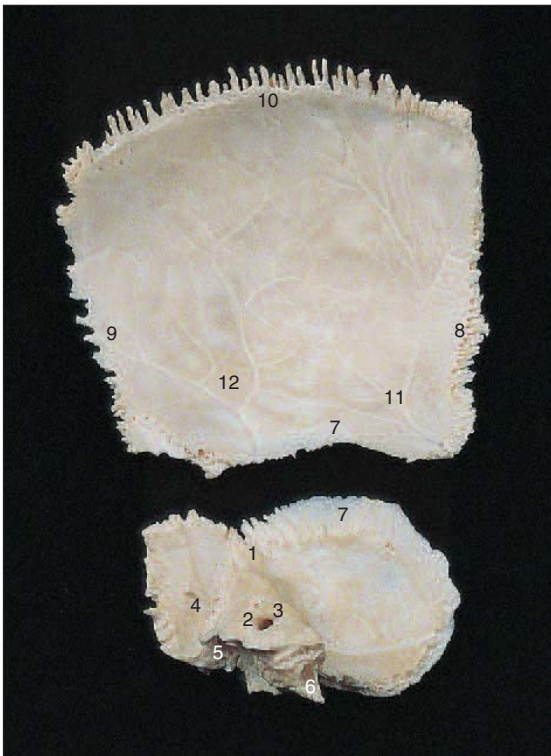




**Figure 2-9**  
**Right Temporal and Parietal**  
**Bones: Exterior Aspect,**  
**Squamosal Suture Separated**

STRUCTURES

1. Parietal notch
2. External auditory meatus
3. Zygomatic process
4. Mandibular fossa
5. Mastoid process
6. Styloid process
7. Squamosal border
8. Frontal border
9. Occipital border
10. Suprameatal triangle



**Figure 2-10**  
**Left Temporal and Parietal**  
**Bones: Interior Aspect,**  
**Squamosal Suture Separated**

STRUCTURES

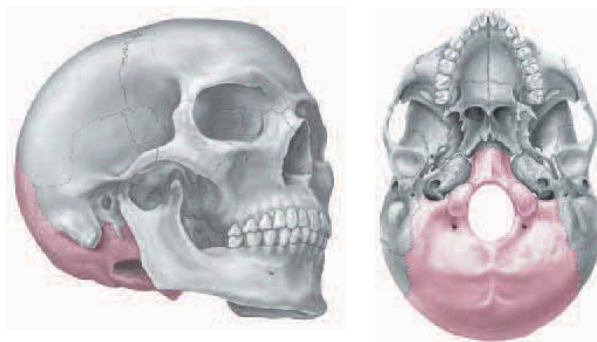
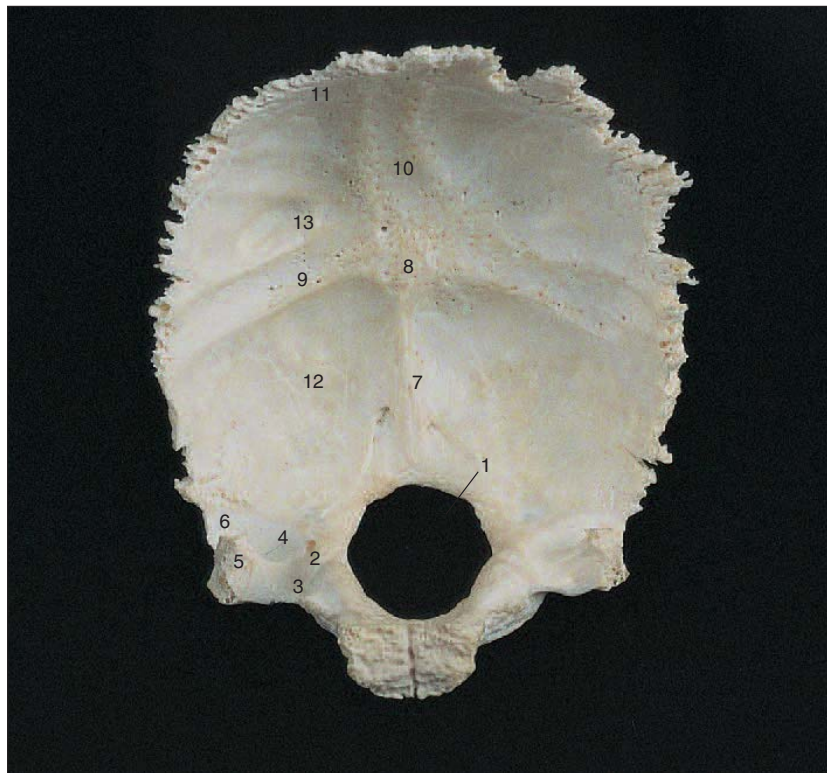1. Parietal notch
2. Internal auditory meatus
3. Petrous portion
4. Groove for sigmoid sinus
5. Mastoid process
6. Styloid process
7. Squamosal border
8. Frontal border
9. Occipital border
10. Sagittal border
11. Furrows for frontal branch of middle meningeal vessels
12. Furrows for parietal branch of middle meningeal vessels

52 CHAPTER 2

**Figure 2-11**  
**Occipital Bone: Interior Aspect**

STRUCTURES

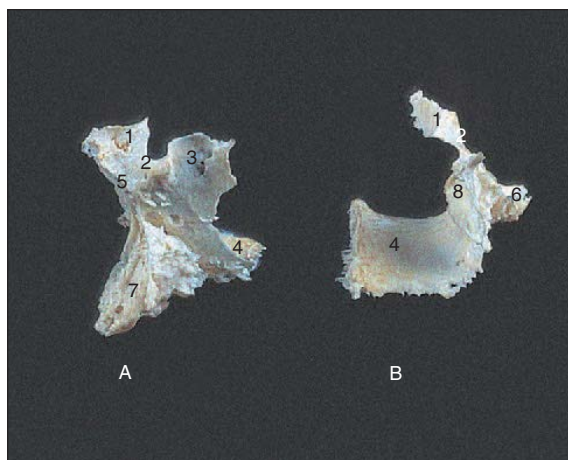
1. Foramen magnum
2. Condylar fossa and canal
3. Jugular notch
4. Groove for sigmoid sinus
5. Jugular tubercle
6. Mastoid margin
7. Internal occipital crest
8. Internal occipital protuberance
9. Groove for transverse sinus
10. Groove for superior sagittal sinus
11. Lambdoidal margin
12. Cerebellar fossa
13. Cerebral fossa



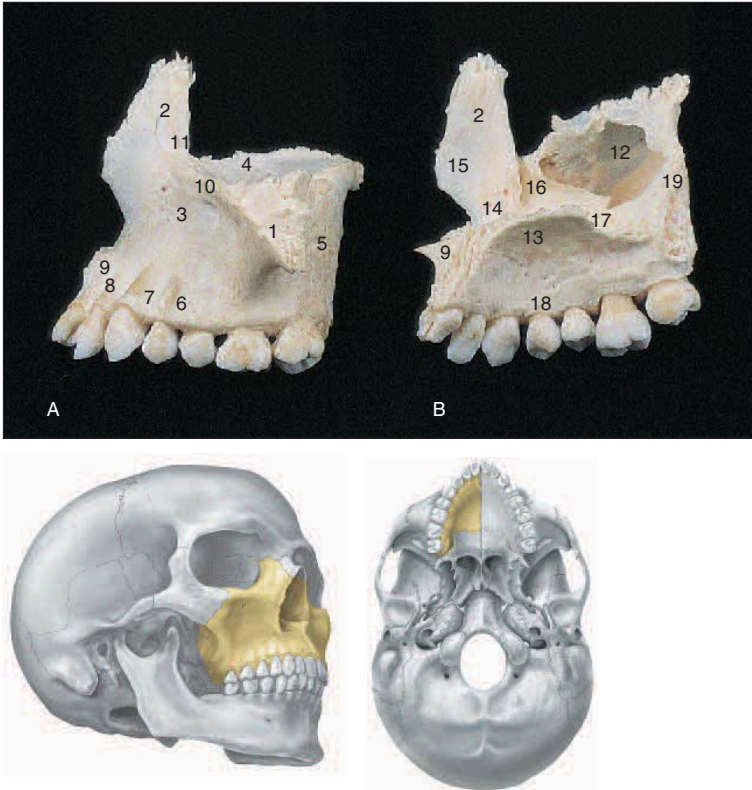
**Figure 2-12**  
**Palatine Bones: (A) Right from Anteromedial View, (B) Left from Anteriosuperior View**

BONES AND PROCESSES

- A. Right palatine bone
- B. Left palatine bone
1. Orbital process
2. Sphenopalatine notch
3. Sphenoidal process
4. Horizontal plate
5. Ethmoidal crest
6. Pyramidal process
7. Maxillary process
8. Vertical plate



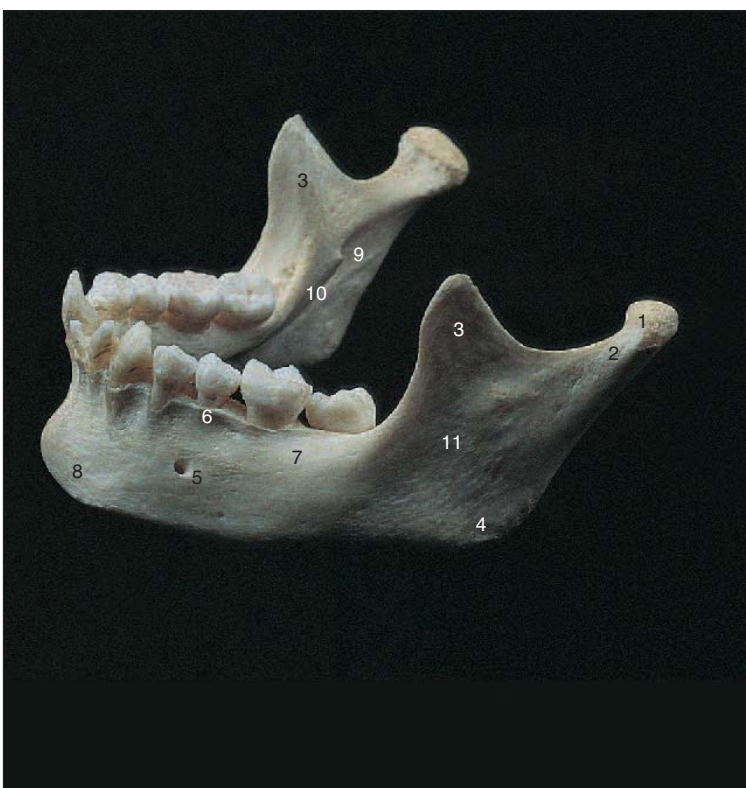



**Figure 2-13**  
**Maxillae: (A) Left from Lateral Aspect,**  
**(B) Right from Medial Aspect**

STRUCTURES

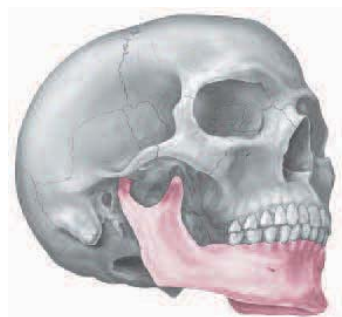
- A. Left maxilla
- B. Right maxilla
  - 1. Zygomatic process
  - 2. Ethmoidal crest
  - 3. Infraorbital foramen
  - 4. Orbital surface
  - 5. Infratemporal surface
  - 6. Canine fossa
  - 7. Canine eminence
  - 8. Incisive fossa
  - 9. Anterior nasal spine
  - 10. Anterior lacrimal crest
  - 11. Nasolacrimal groove
  - 12. Maxillary hiatus and sinus
  - 13. Palatine process
  - 14. Nasal crest
  - 15. Frontal process
  - 16. Middle meatus
  - 17. Inferior meatus
  - 18. Alveolar process
  - 19. Greater palatine canal



**Figure 2-14**  
**Mandible: Left Lateral View**

STRUCTURES

- 1. Mandibular condyle
- 2. Condylod process
- 3. Coronoid process
- 4. Angle
- 5. Mental foramen
- 6. Alveolar process
- 7. Body of mandible
- 8. Mental protuberance
- 9. Mandibular foramen
- 10. Lingula
- 11. Ramus

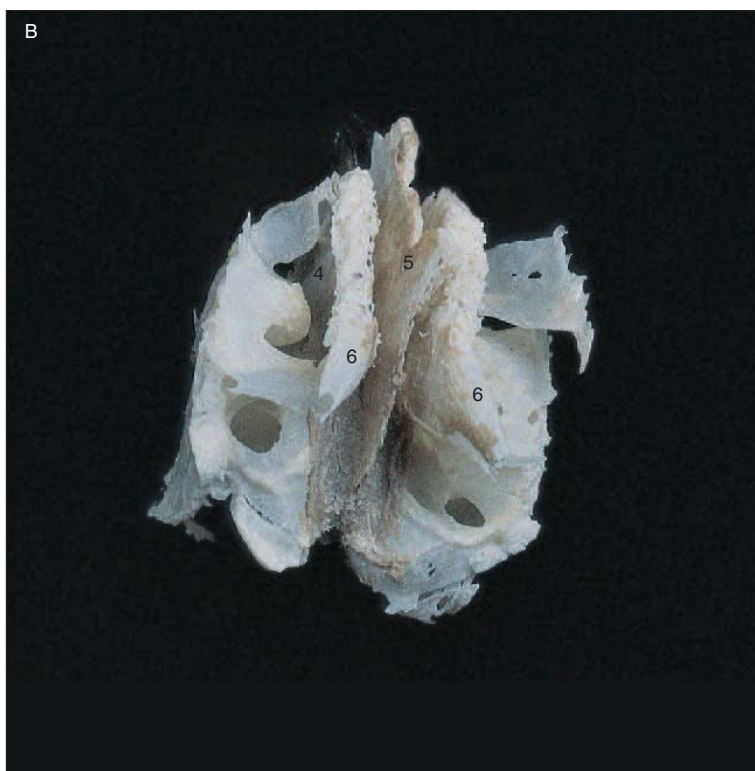
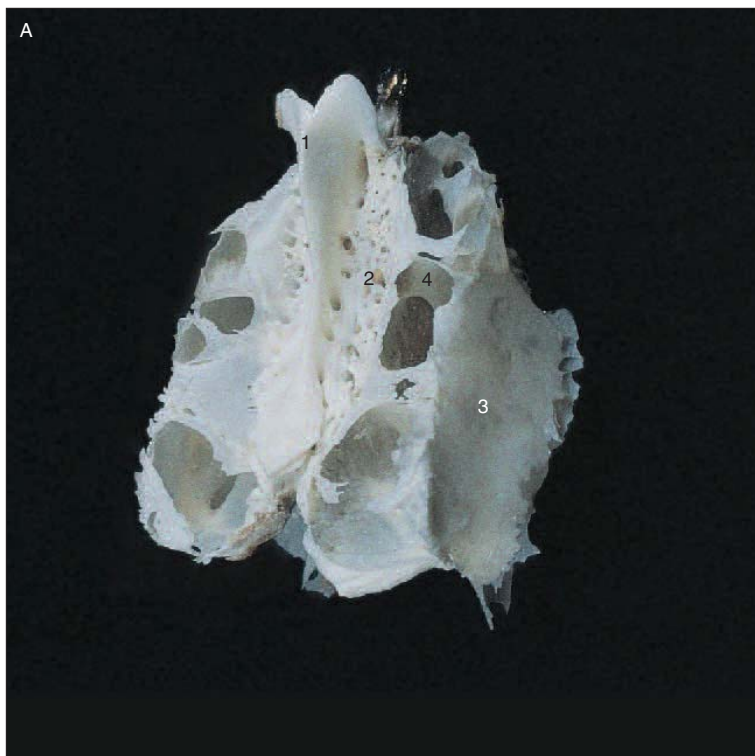
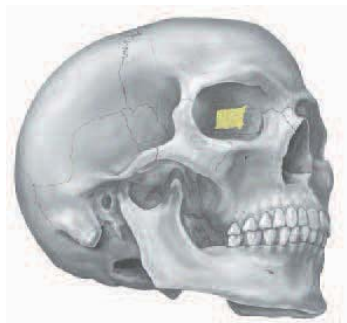

## 54 CHAPTER 2

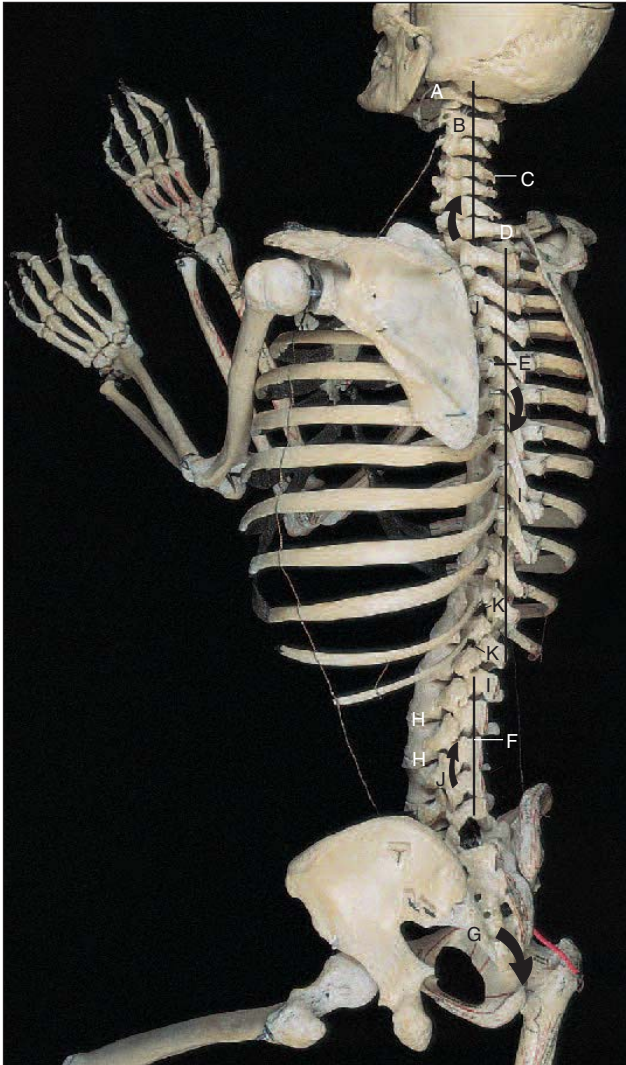**Figure 2-15****Ethmoid Bone:****(A) from Above, Right, and Behind**  
**(B) from Below, Right, and Behind**

## STRUCTURES

1. Crista galli
2. Cribriform plate
3. Orbital plate
4. Ethmoidal labyrinth (with air cells)
5. Perpendicular plate
6. Middle nasal concha



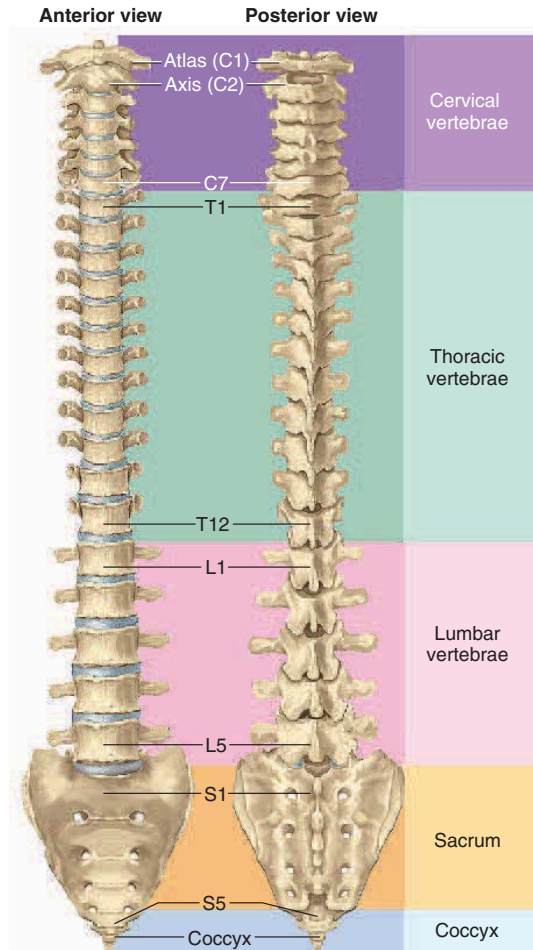




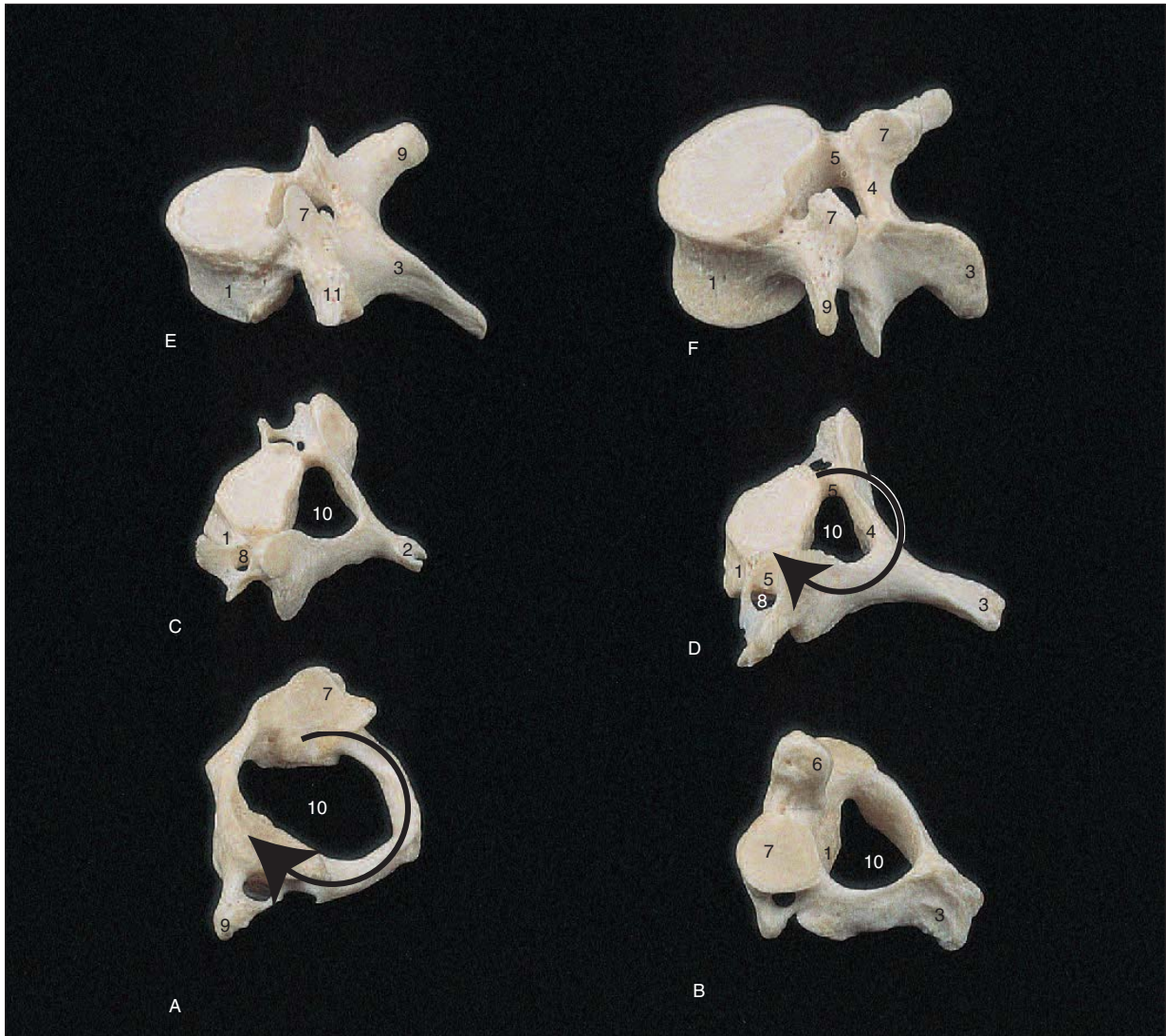
**Figure 2-16a**  
**Vertebral Column: View from**  
**Left and Behind**

**BONES AND STRUCTURES**

- A. Atlas
- B. Axis
- C. 7 Cervical vertebrae (Arrow near C—Cervical curvature)
- D. Mentum nuchae (Spinous process of 7th cervical vertebra)
- E. 12 Thoracic vertebrae (Arrow near E—Thoracic curvature)
- F. 5 Lumbar vertebrae (Arrow near F—Lumbar curvature)
- G. 5 Fused sacral vertebrae (Arrow near G—Sacral curvature)  
 (Not shown 4–5 coccyx)
- H. Intervertebral disk
- I. Spinous processes
- J. Transverse processes
- K. Intervertebral foramen



**Figure 2-16b**  
**The Vertebral Column, Anterior and Posterior Views**



**Figure 2-17**  
**Vertebrae**

**BONES AND STRUCTURES**

A. Atlas

B. Axis

C. Cervical vertebra

D. 7th cervical vertebra

E. Thoracic vertebra

F. Lumbar vertebra

1. Body

(Heavy arrows—Vertebral arches—comprised of lamina and pedicle)

2. Bifid spinous process

3. Monofid spinous process

4. Lamina

5. Pedicle

6. Odontoid process (dens)

7. Superior articular process and facet

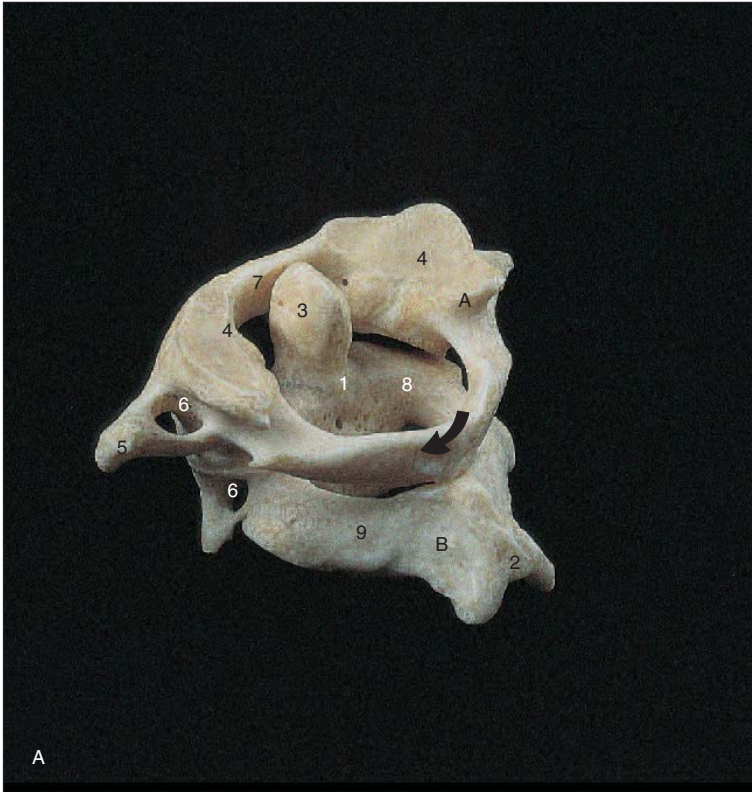8. Transverse foramen

9. Transverse process

10. Vertebral foramen

11. Costal facet

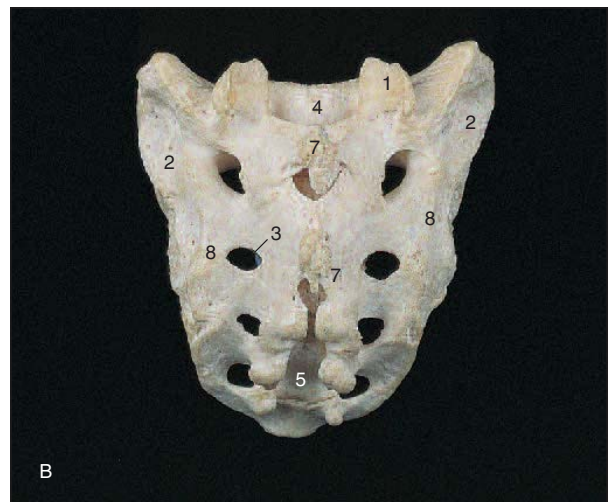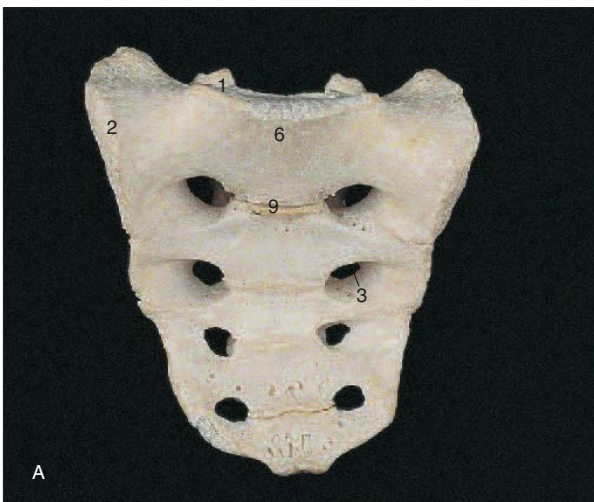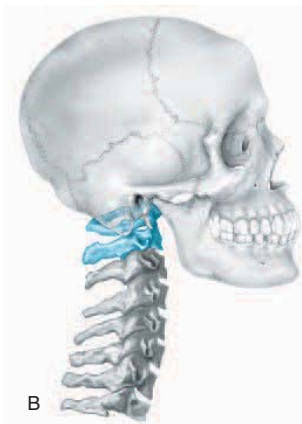




**Figure 2-18**  
**(A) Atlas and (B) Axis Articulated**

STRUCTURES

1. Body of axis
2. Bifid spinous process
3. Odontoid process (dens)
4. Superior articular facet
5. Transverse process
6. Transverse foramen
7. Anterior arch of atlas  
 (Heavy arrow—Posterior arch of atlas)
8. Pedicle of axis
9. Lamina of axis

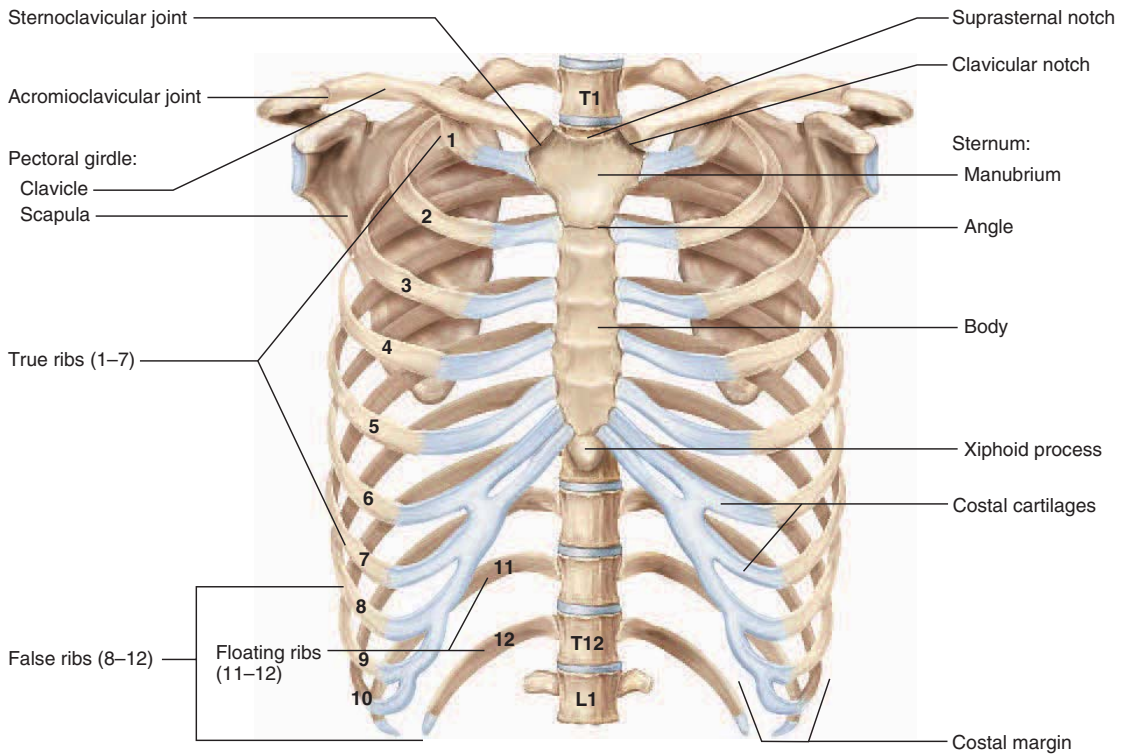


**Figure 2-19**  
**Sacrum (A) Anterior aspect; (B) Posterior aspect.**

STRUCTURES

- |   |  |  |
|---|--|--|
| <ol style="list-style-type: none"> <li>1. Superior articular process and facet</li> <li>2. Auricular surface</li> </ol> | <ol style="list-style-type: none"> <li>3. Sacral foramen</li> <li>4. Sacral canal</li> <li>5. Sacral hiatus</li> <li>6. Sacral promontory</li> </ol> | <ol style="list-style-type: none"> <li>7. Median crest</li> <li>8. Lateral crest</li> <li>9. Site of fusion of 1st and 2nd sacral vertebrae</li> </ol> |
|---|--|--|

58 CHAPTER 2



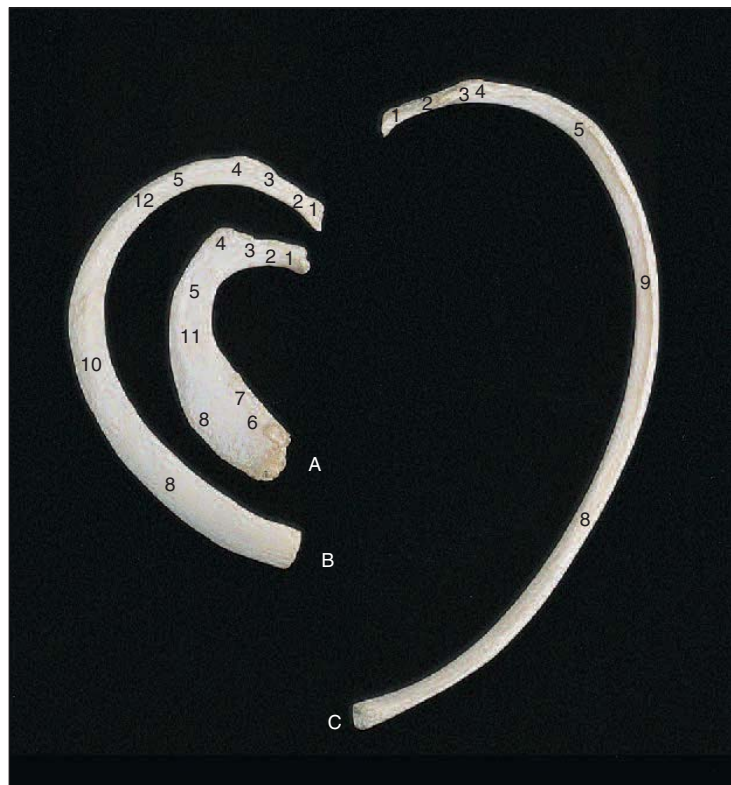
**Figure 2-20** Sternum and Ribs

**Figure 2-21**

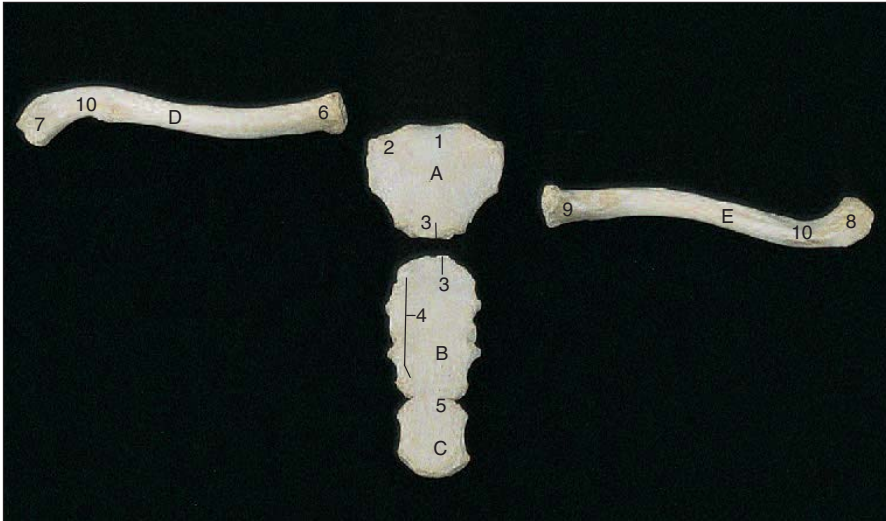
Ribs (A) 1st, (B) 2nd, right side, superior view; (C) 7th, right side, inferior view.

STRUCTURES

1. Head
2. Neck
3. Articular facet
4. Tubercle
5. Angle
6. Subclavian groove
7. Scalene tubercle
8. Body
9. Costal groove
10. Serratus anterior tuberosity
11. Site for attachment of scalenus medius
12. Site for attachment of levator costa



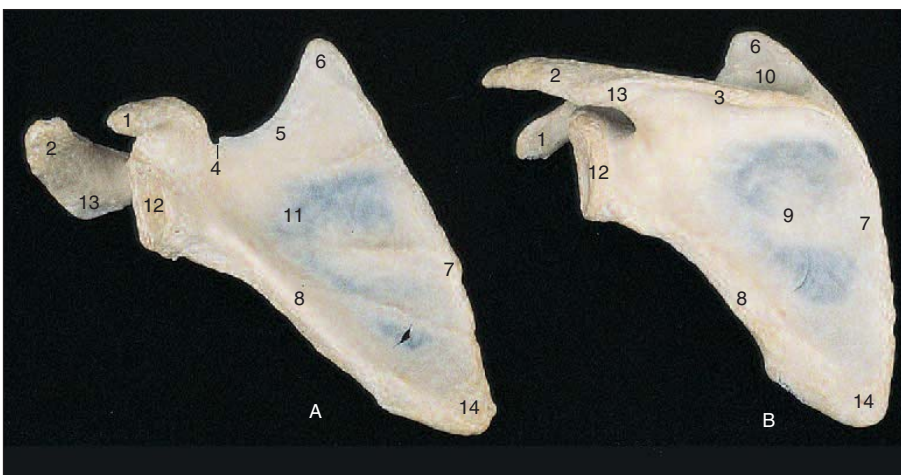




**Figure 2-22**  
**Sternum and Clavicles**  
**Sternum from the front;**  
**(D) Right clavicle from above;**  
**(E) Left clavicle from below.**

BONES AND STRUCTURES

- A. Manubrium
- B. Gladiolus (body)
- C. Xiphoid process
  - 1. Jugular notch
  - 2. Clavicular notch
  - 3. Sternal angle and manubriosternal joint
  - 4. Notches for costal cartilages (2–7)
  - 5. Xiphisternal joint
- D. Right clavicle
- E. Left clavicle
  - 6. Sternal end
  - 7. Acromial end
  - 8. Conoid tubercle
  - 9. Site for costoclavicular ligament
  - 10. Site for deltoid



**Figure 2-23**  
**Scapulae (A) Right scapula,**  
**anterior view; (B) Left**  
**scapula, posterior view.**

BONES AND STRUCTURES

- A. Right scapula
- B. Left scapula
  - 1. Coracoid process
  - 2. Acromion
  - 3. Spine
  - 4. Suprascapular notch
  - 5. Superior border
  - 6. Superior angle
  - 7. Medial (vertebral) border
  - 8. Lateral (axillary) border
  - 9. Infraspinous fossa
  - 10. Supraspinous fossa
  - 11. Subscapular fossa
  - 12. Glenoid fossa
  - 13. Acromial angle
  - 14. Inferior angle

60 CHAPTER 2

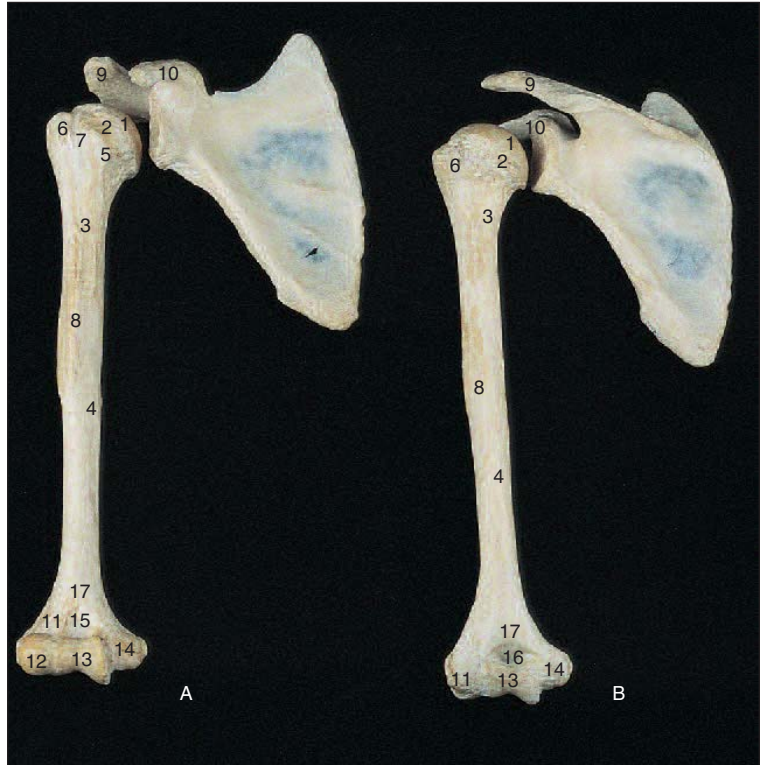**Figure 2-24**

**Humerus with Scapulae**

**(A) Right humerus, anterior view;**  
**(B) Left humerus, posterior view.**

BONES AND STRUCTURES

- A. Right humerus and scapula  
 B. Left humerus and scapula
1. Proximal head (epiphysis)
  2. Anatomical neck
  3. Surgical neck
  4. Shaft (diaphysis)
  5. Lesser tubercle
  6. Greater tubercle
  7. Intertubercular groove
  8. Deltoid tuberosity
  9. Acromion
  10. Coracoid process
  11. Lateral epicondyle
  12. Capitulum
  13. Trochlea
  14. Medial epicondyle
  15. Coronoid fossa
  16. Olecranon fossa
  17. Distal head and surgical neck

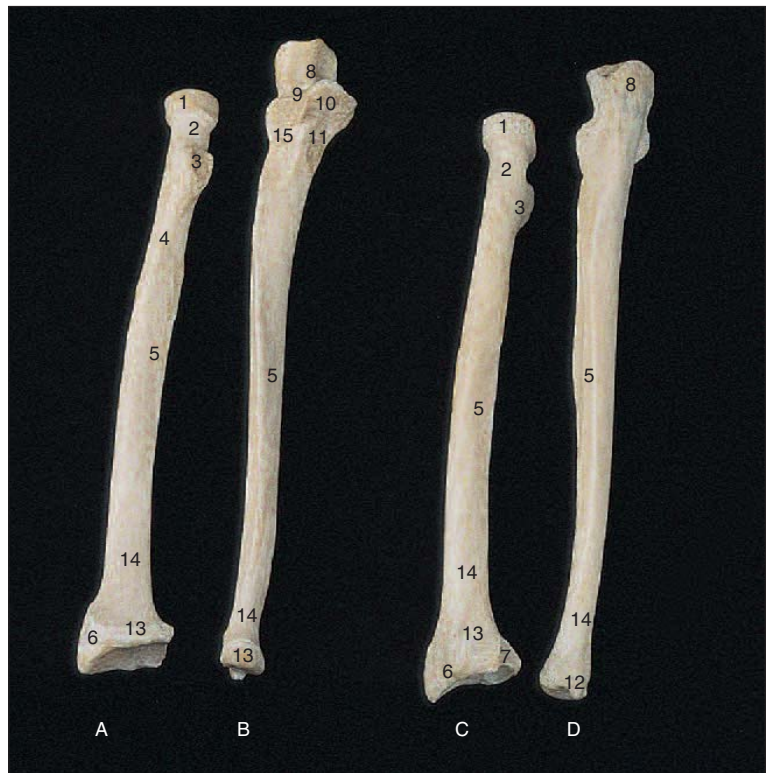

**Figure 2-25**

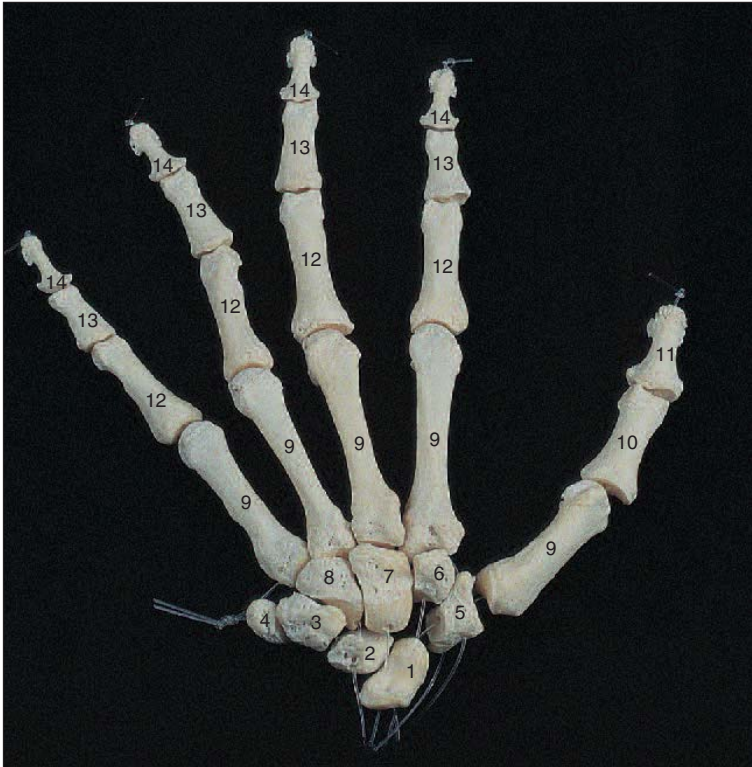**Ulna and Radius Right, anterior view;**  
**Left, posterior view.**

BONES AND STRUCTURES

- A. Right radius  
 B. Right ulna  
 C. Left radius  
 D. Left ulna
1. Proximal head
  2. Neck
  3. Radial tuberosity
  4. Anterior oblique line
  5. Interosseous border
  6. Styloid process of radius
  7. Ulnar notch
  8. Olecranon process
  9. Trochlear notch
  10. Coronoid process
  11. Ulnar tuberosity
  12. Styloid process of ulna
  13. Distal head
  14. Distal neck
  15. Radial notch







**Figure 2-26**  
**Left Hand, Dorsal View**

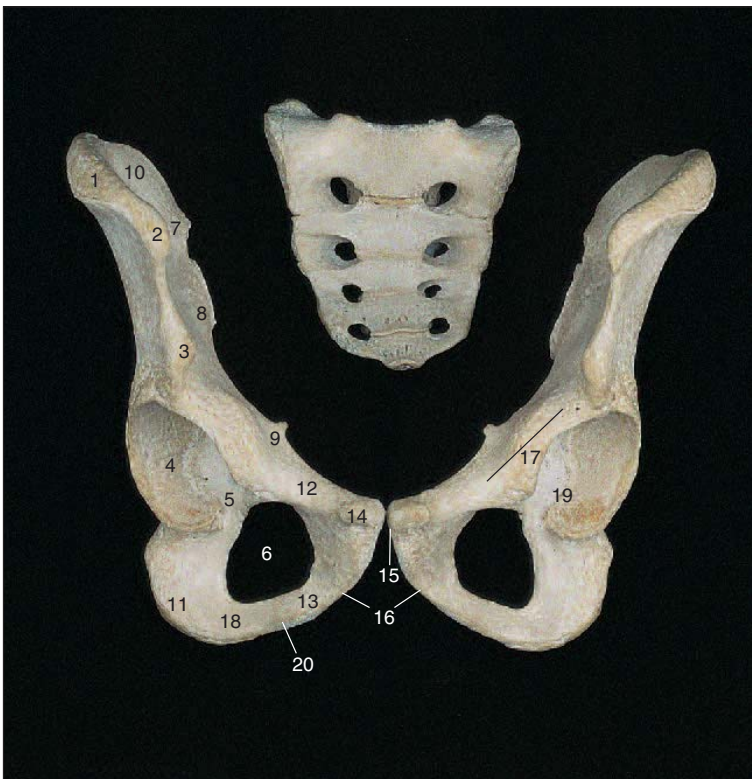
BONES AND STRUCTURES

CARPALS

1. Navicular (scaphoid)
2. Lunate
3. Triangular (triquetrum)
4. Pisiform
5. Greater multangular (trapezium)
6. Lesser multangular (trapezoid)
7. Capitate
8. Hamate
9. METACARPALS 1–5

PHALANGES

10. Proximal phalanx of thumb
11. Distal phalanx of thumb
12. Proximal phalanx of digits 2–5
13. Middle phalanx of digits 2–5
14. Distal phalanx of digits 2–5



**Figure 2-27**  
**Pelvic Bones with Sacrum, Anterior View**

STRUCTURES

1. Iliac crest
2. Anterior superior iliac spine
3. Anterior inferior iliac spine
4. Acetabulum
5. Acetabular notch
6. Obturator foramen
7. Posterior superior iliac spine
8. Posterior inferior iliac spine
9. Ischial spine
10. Iliac fossa
11. Ischial tuberosity
12. Superior pubic ramus
13. Inferior pubic ramus
14. Pubic tubercle
15. Symphysis pubis
16. Pubic arch
17. Iliopectineal line
18. Ischial ramus
19. Iliopectineal eminence
20. Fusion of ischium and pubis

62 CHAPTER 2

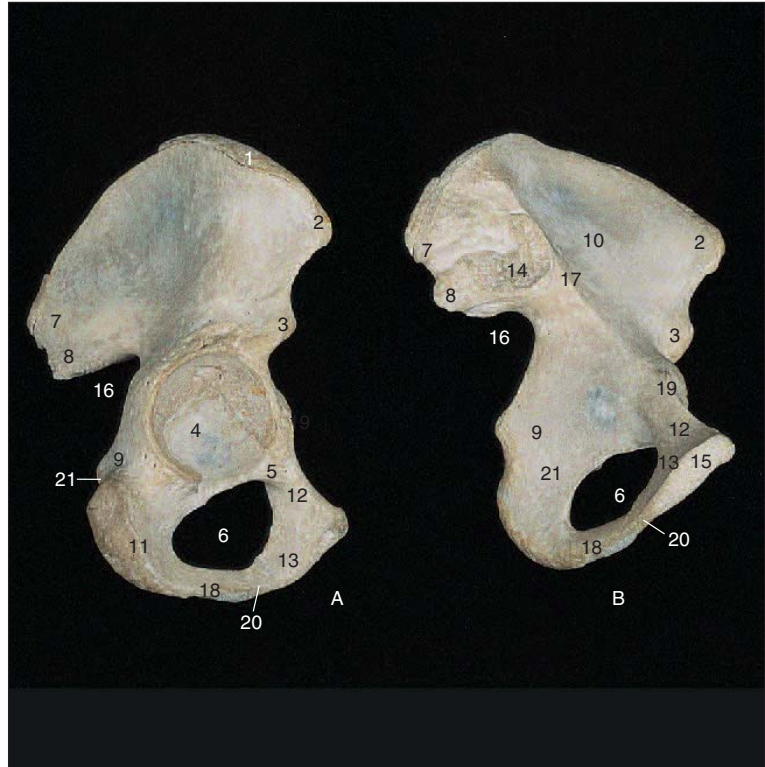
**Figure 2-28**

**Pelvic Bones**

**(A) Right innominate, lateral view;**  
**(B) Left innominate, medial view.**

STRUCTURES

1. Iliac crest
2. Anterior superior iliac spine
3. Anterior inferior iliac spine
4. Acetabulum
5. Acetabular notch
6. Obturator foramen
7. Posterior superior iliac spine
8. Posterior inferior iliac spine
9. Ischial spine
10. Iliac fossa
11. Ischial tuberosity
12. Superior pubic ramus
13. Inferior pubic ramus
14. Auricular surface (for sacroiliac joint)
15. Symphysis pubis (cartilage)
16. Greater sciatic notch
17. Iliopectineal line
18. Ischial ramus
19. Iliopubic eminence
20. Fusion of ischium and pubis
21. Lesser sciatic notch

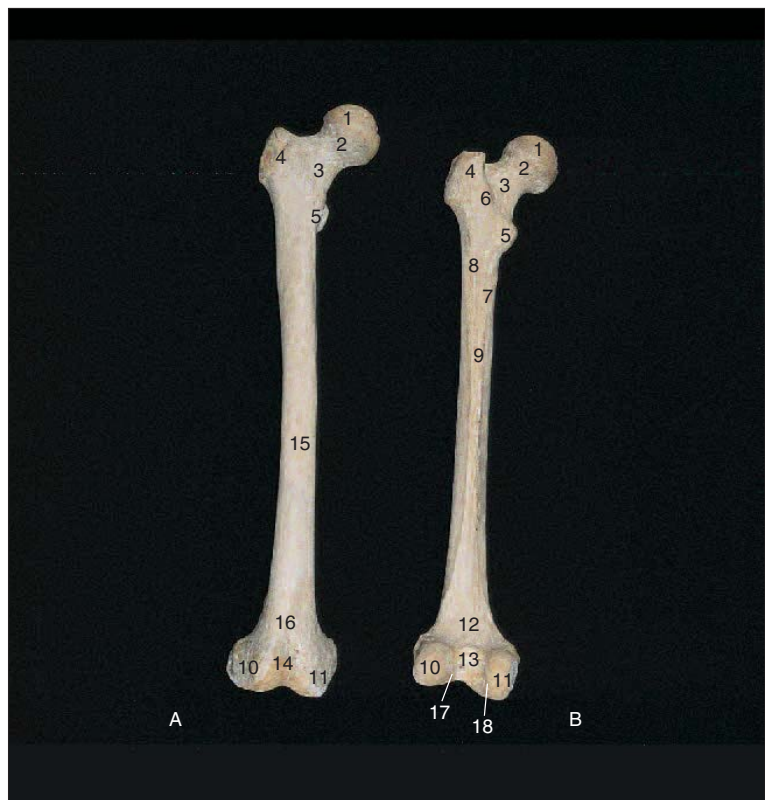


**Figure 2-29**

**Femur (A) Right femur, anterior view;**  
**(B) Left femur, posterior view.**

BONES AND PROCESSES

- A. Right femur
- B. Left femur
1. Proximal head (epiphysis)
2. Anatomical neck
3. Surgical neck
4. Greater trochanter
5. Lesser trochanter
6. Intertrochanteric crest
7. Spiral line
8. Gluteal tuberosity
9. Linea aspera
10. Lateral condyle
11. Medial condyle
12. Popliteal surface
13. Intercondylar fossa
14. Patellar surface
15. Shaft (diaphysis)
16. Distal head and neck
17. Site for attachment of anterior cruciate ligament
18. Site for attachment of posterior cruciate ligament





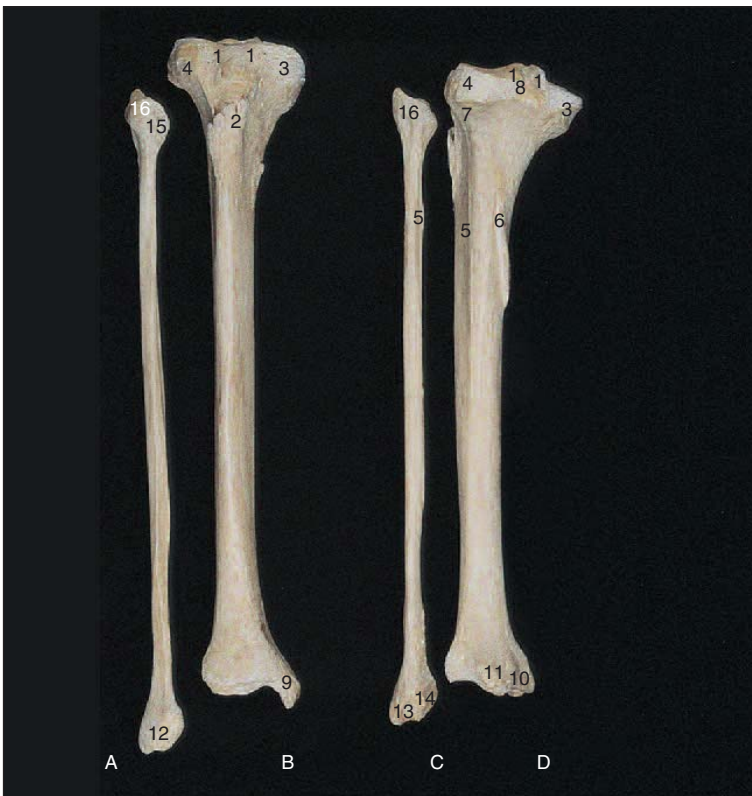

**Figure 2-30**

**Patellae (A) Right patella, anterior surface; (B) Left patella, posterior (articular) surface.**

BONES AND PROCESSES

- A. Right patella
- B. Left patella
  - 1. Base
  - 2. Apex (site for attachment of patellar ligament)
  - 3. Facet for lateral condyle of femur
  - 4. Vertical ridge
  - 5. Facet for medial condyle of femur



**Figure 2-31**

**Tibia and Fibula (A, B) Right tibia and fibula, anterior view; (C, D) Left tibia and fibula, posterior view.**

BONES AND STRUCTURES

- A. Right fibula
- B. Right tibia
- C. Left fibula
- D. Left tibia
  - 1. Tubercles of intercondylar eminence
  - 2. Tibial tuberosity
  - 3. Medial condyle
  - 4. Lateral condyle
  - 5. Interosseous border
  - 6. Soleal line
  - 7. Articular facet for fibula
  - 8. Site for posterior cruciate ligament
  - 9. Medial malleolus
  - 10. Groove for tibialis posterior
  - 11. Groove for flexor hallucis longus
  - 12. Lateral malleolus
  - 13. Groove for peroneus brevis
  - 14. Malleolar fossa
  - 15. Articular facet for tibia
  - 16. Apex (styloid process)

64 CHAPTER 2

**Figure 2-32**  
**Right Foot: Dorsal (Superior) View**

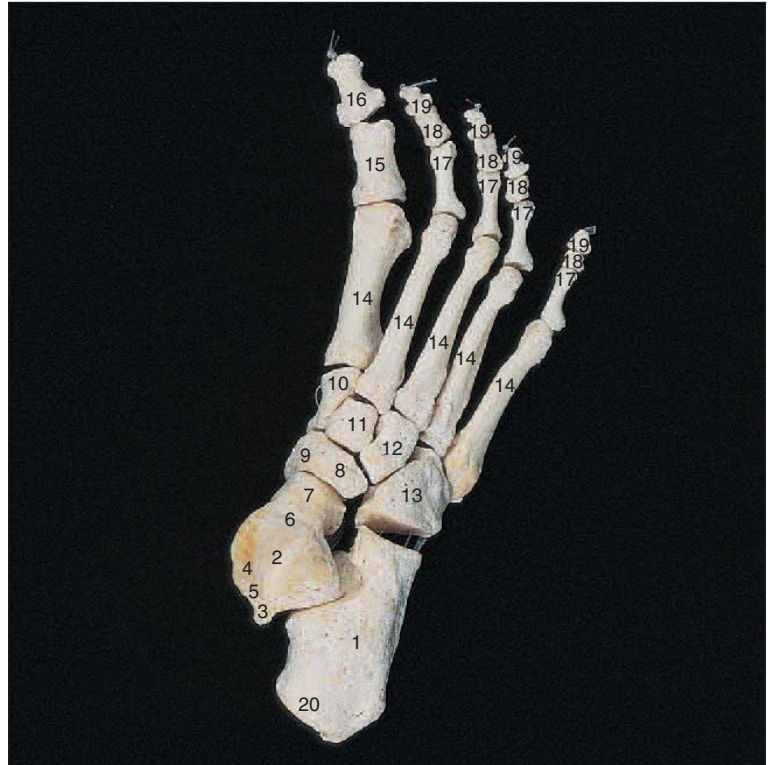BONES AND PROCESSES

TARSALS

1. Calcaneus
2. Trochlear (articular) surface of talus
3. Lateral tubercle of talus
4. Medial tubercle of talus
5. Groove for flexor hallucis longus
6. Neck of talus
7. Head of talus
8. Navicular
9. Navicular tuberosity
10. Medial cuneiform
11. Intermediate cuneiform
12. Lateral cuneiform
13. Cuboid
14. Metatarsals 1–5

PHALANGES

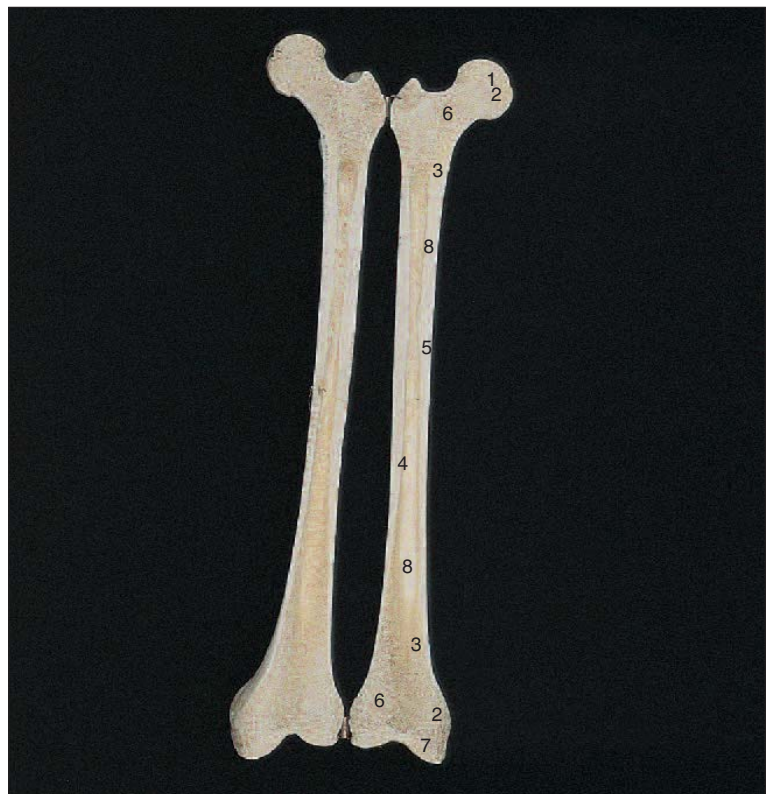15. Proximal phalanx of great toe
16. Distal phalanx of great toe
17. Proximal phalanx of digits 2–5
18. Middle phalanx of digits 2–5
19. Distal phalanx of digits 2–5
20. Site for attachment of Achilles tendon



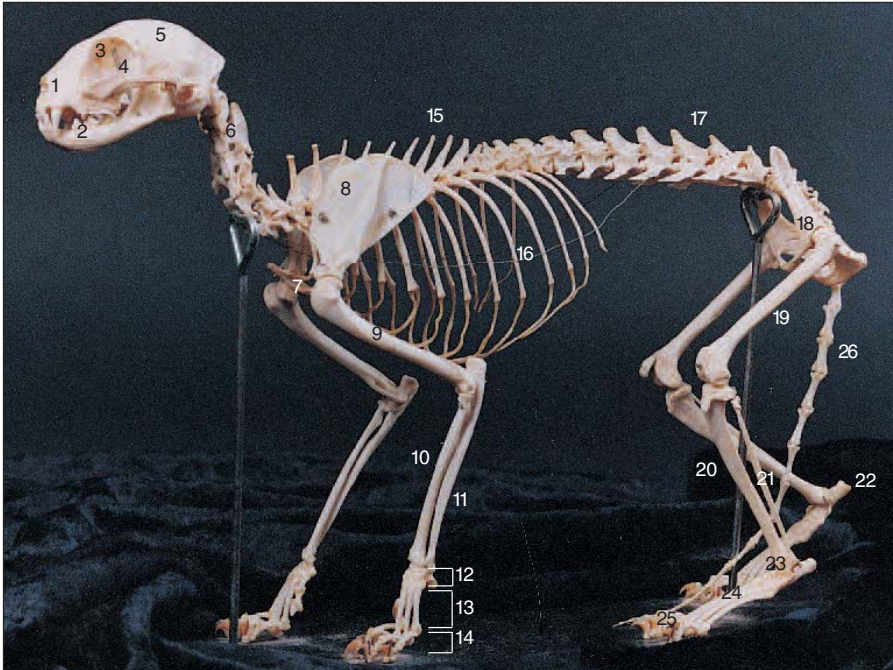
**Figure 2-33**  
**Typical Long Bone Structure**

PROCESSES

1. Proximal head (epiphysis)
2. Anatomical neck (growth plate, metaphysis, epiphyseal plate)
3. Surgical neck
4. Shaft (diaphysis)
5. Compact bone
6. Cancellous (spongy) bone
7. Distal head
8. Medullary (marrow) cavity



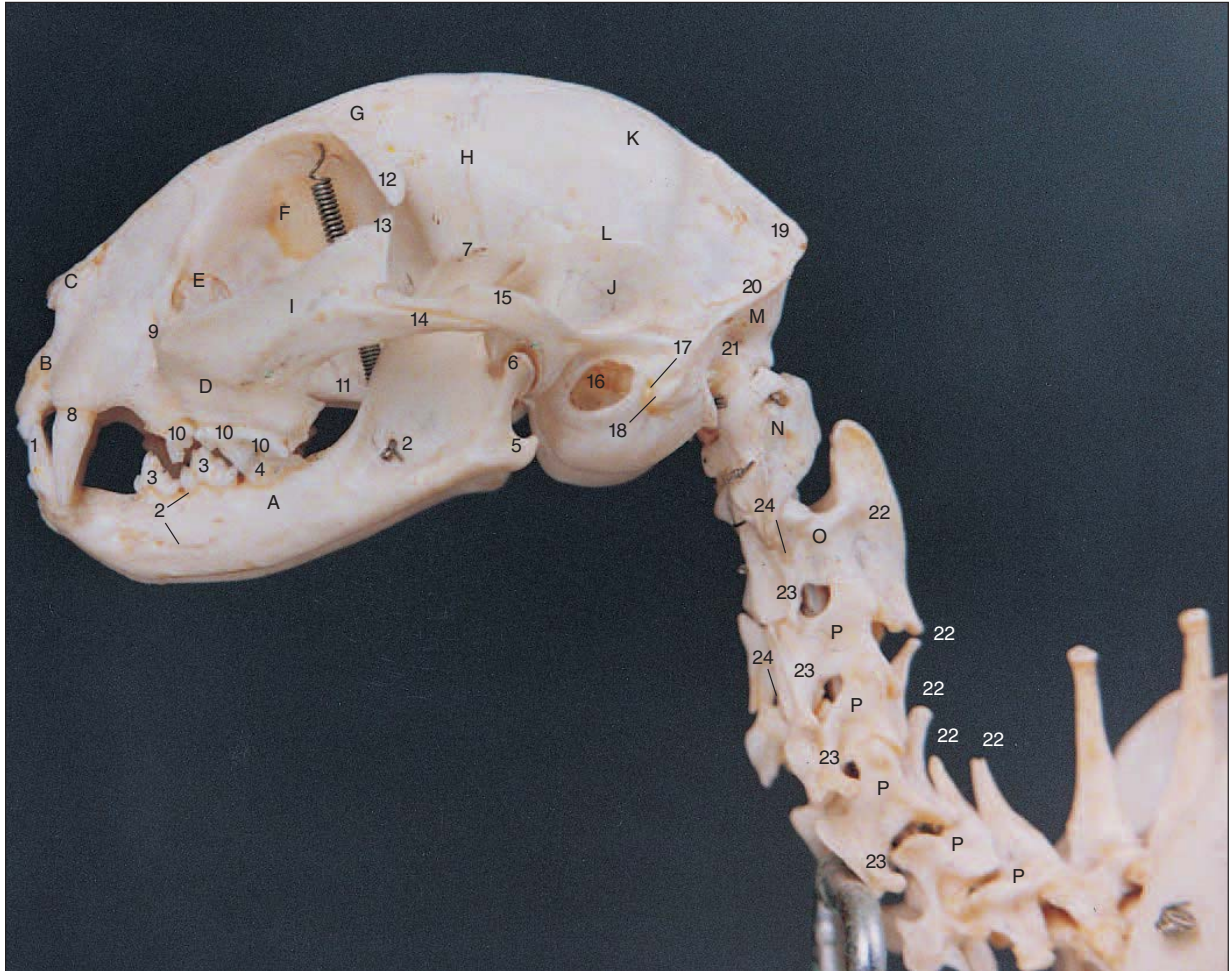




**Figure 2-34**  
**The Cat Skeleton**

1. Maxilla
2. Mandible
3. Orbit
4. Zygomatic arch
5. Cranium
6. Cervical vertebrae (7)
7. Sternum
8. Scapula
9. Humerus
10. Radius
11. Ulna
12. Carpal bones
13. Metacarpal bones
14. Phalanges
15. Thoracic vertebrae (13)
16. Ribs
17. Lumbar vertebrae (7)
18. Pelvis
19. Femur
20. Tibia
21. Fibula
22. Calcaneus
23. Tarsal bones
24. Metatarsal bones
25. Phalanges
26. Caudal vertebrae (21–25)

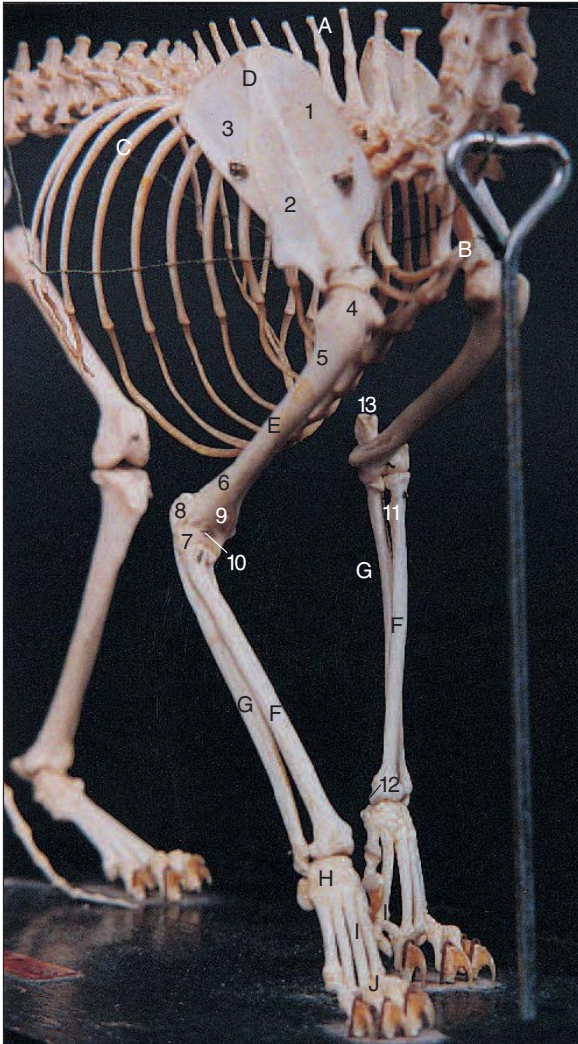
66 CHAPTER 2



**Figure 2-35**  
**Cat Skull, Left Lateral View**

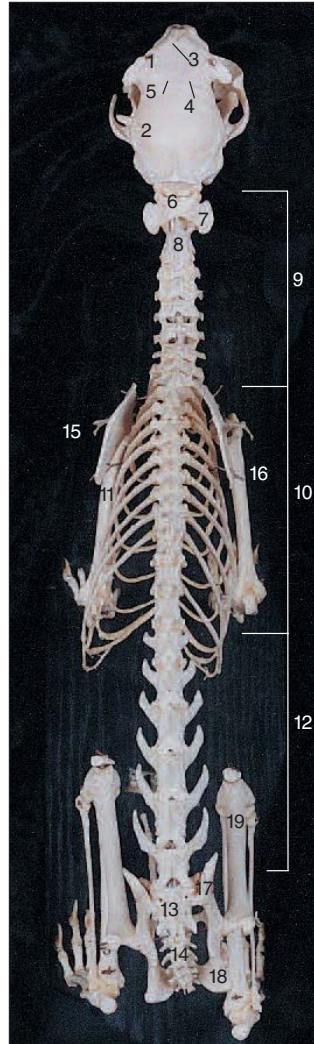
- |  |  |  |
|--|--|--|
| <p>A. Mandible</p> <ol style="list-style-type: none"> <li>1. Lower canine tooth</li> <li>2. Mental foramina</li> <li>3. Lower premolar teeth</li> <li>4. Lower molar teeth</li> <li>5. Angular process</li> <li>6. Condylar process</li> <li>7. Coronoid process</li> </ol> <p>B. Incisive bone</p> <p>C. Nasal bone</p> <p>D. Maxilla</p> <ol style="list-style-type: none"> <li>8. Upper canine tooth</li> <li>9. Infraorbital foramen</li> <li>10. Upper premolar tooth</li> <li>11. Upper molar tooth</li> </ol> | <p>E. Lacrimal bone and fossa</p> <p>F. Orbit</p> <p>G. Frontal bone</p> <ol style="list-style-type: none"> <li>12. Zygomatic process of frontal bone</li> </ol> <p>H. Coronal suture</p> <p>I. Zygomatic bone</p> <ol style="list-style-type: none"> <li>13. Frontal process of zygomatic bone</li> <li>14. Temporal process of zygomatic bone</li> </ol> <p>J. Temporal bone</p> <ol style="list-style-type: none"> <li>15. Zygomatic process of temporal bone</li> <li>16. External auditory meatus</li> <li>17. Stylomastoid foramen</li> <li>18. Mastoid process</li> </ol> | <p>K. Parietal bone</p> <p>L. Squamosal suture</p> <p>M. Occipital bone</p> <ol style="list-style-type: none"> <li>19. External occipital protuberance</li> <li>20. Nuchal crest</li> <li>21. Occipital condyle</li> </ol> <p>N. Atlas</p> <p>O. Axis</p> <p>P. Cervical vertebrae (3–7)</p> <ol style="list-style-type: none"> <li>22. Spinous process</li> <li>23. Transverse process</li> <li>24. Transverse foramen</li> </ol> |
|--|--|--|





**Figure 2-36**  
**Cat Skeleton, Front Right Lateral Aspect**

- |                              |                       |
|------------------------------|-----------------------|
| A. Vertebral spinous process | 8. Lateral epicondyle |
| B. Sternum                   | 9. Medial epicondyle  |
| C. Ribs                      | 10. Radial fossa      |
| D. Scapula                   | F. Radius             |
| 1. Supraspinous fossa        | 11. Radial tuberosity |
| 2. Acromial spine            | 12. Styloid process   |
| 3. Infraspinous fossa        | G. Ulna               |
| E. Humerus                   | 13. Olecranon process |
| 4. Proximal head             | H. Carpal bones       |
| 5. Deltoid tuberosity        | I. Metacarpal bones   |
| 6. Distal head               | J. Phalanges          |
| 7. Trochlea                  |                       |



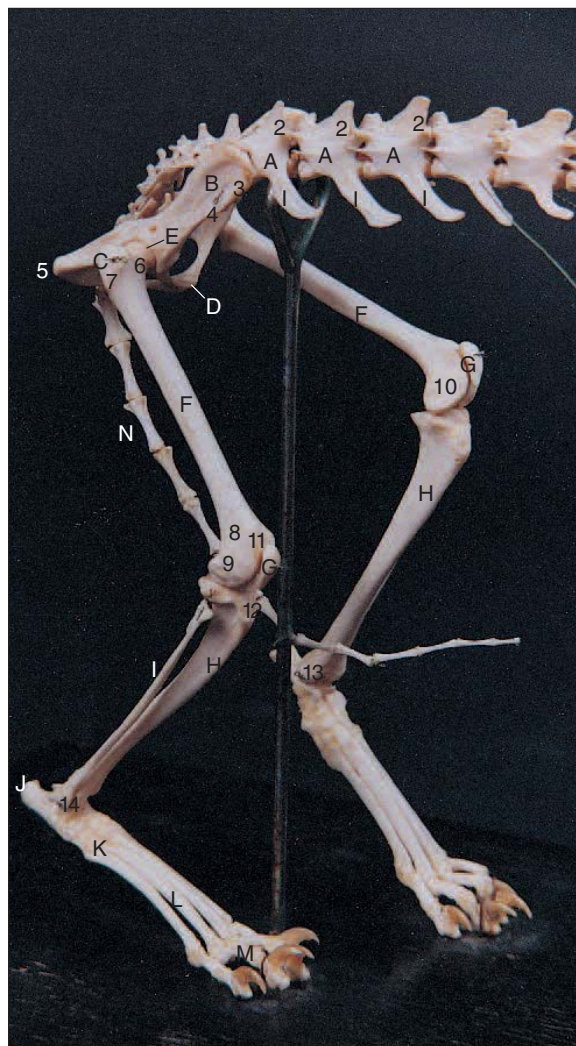
**Figure 2-37**  
**Axial Skeleton of Cat,  
 Dorsal View**

1. Frontal bone
2. Parietal bone
3. Sagittal suture
4. Coronal suture
5. Bregma
6. Atlas
7. Transverse process (wing) of atlas
8. Axis
9. Cervical vertebrae (7)
10. Thoracic vertebrae (13)
11. Ribs
12. Lumbar vertebrae (7)
13. Sacral vertebrae (3)
14. Caudal vertebrae (21–25)
15. Scapula
16. Humerus
17. Ilium
18. Ischium
19. Femur

68 CHAPTER 2

**Figure 2-38**  
**Cat Skeleton, Right Lateral Aspect**

- A. Lumbar vertebrae
  - 1. Transverse processes
  - 2. Spinous processes
- B. Ilium
  - 3. Cranial ventral iliac spine
  - 4. Caudal ventral iliac spine
- C. Ischium
  - 5. Ischial tuberosity
- D. Pubis
- E. Acetabulum
- F. Femur
  - 6. Proximal head
  - 7. Greater trochanter
  - 8. Distal head
  - 9. Lateral condyle
  - 10. Medial condyle
  - 11. Trochlea
- G. Patella
- H. Tibia
  - 12. Tibial tuberosity
  - 13. Medial malleolus
- I. Fibula
  - 14. Lateral malleolus
- J. Calcaneus
- K. Tarsal bones
- L. Metatarsal bones
- M. Phalanges
- N. Caudal vertebrae

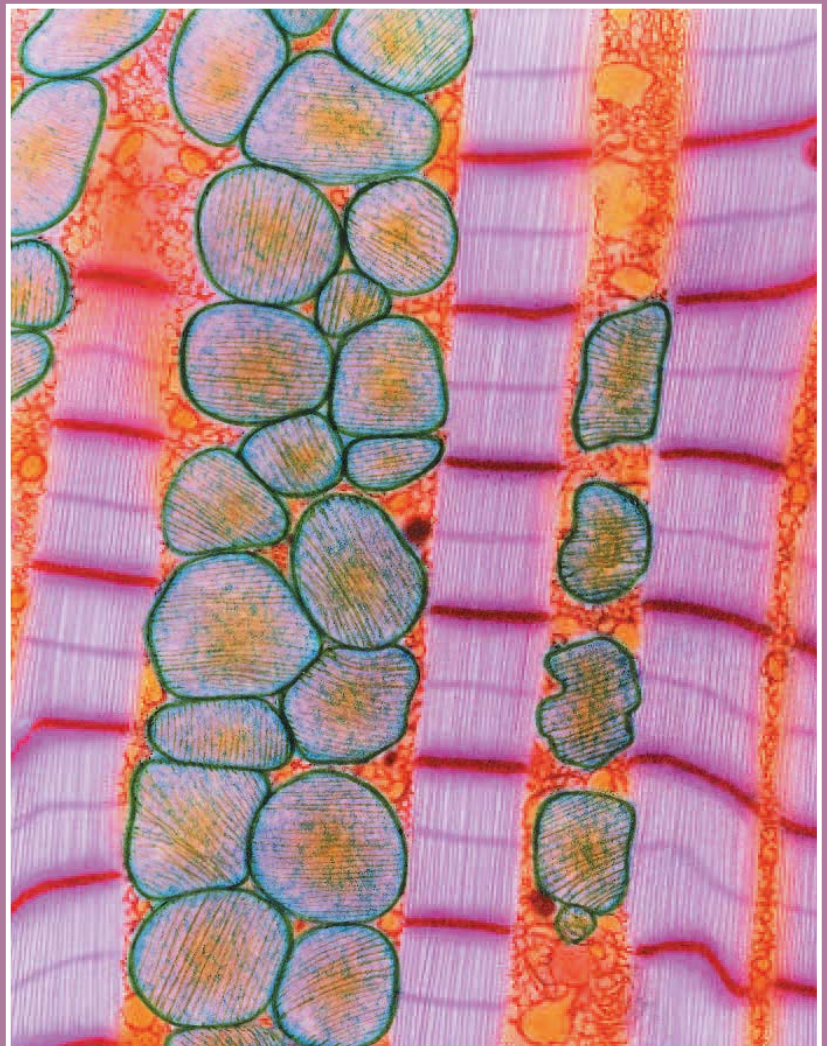




# C H A P T E R

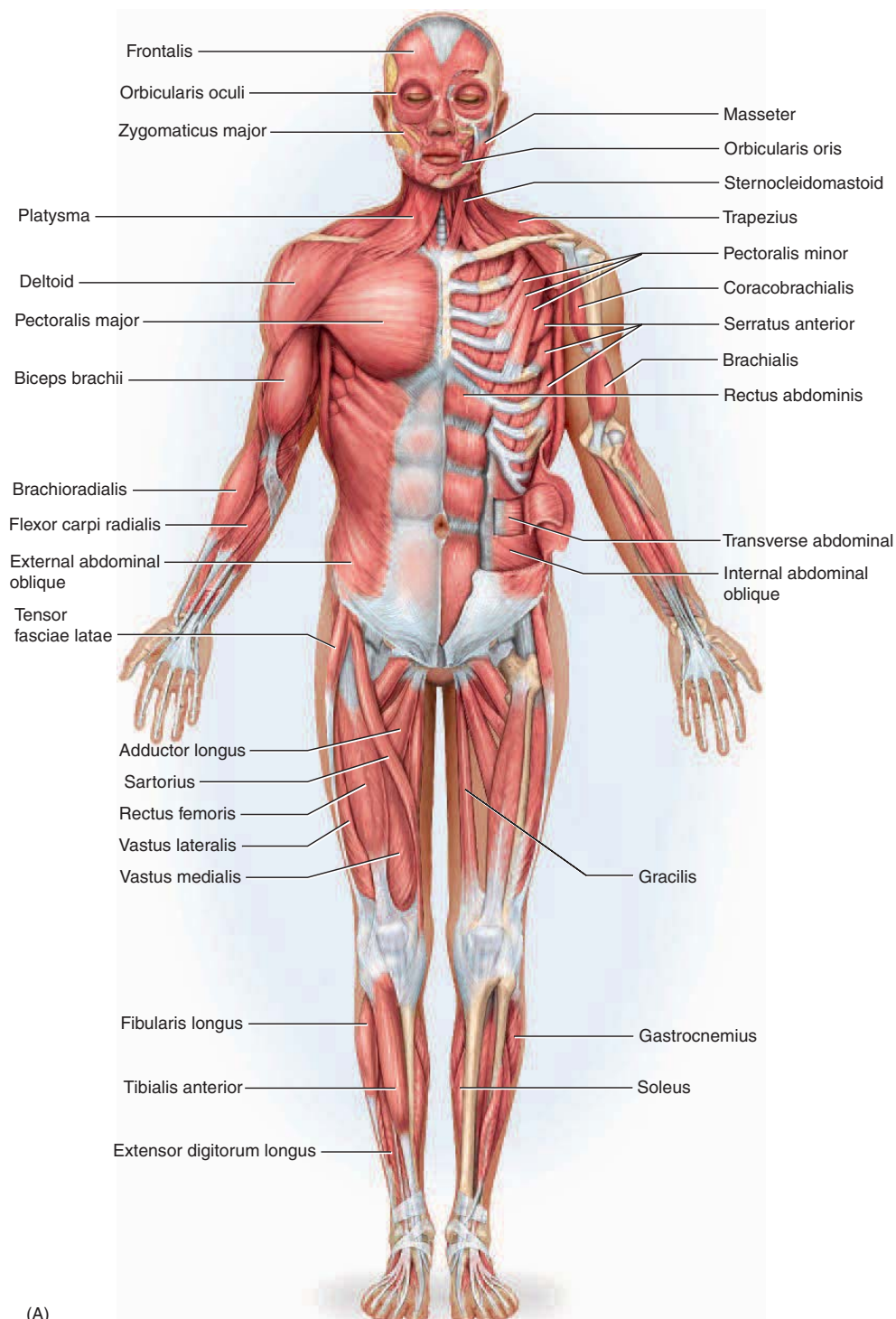
# 3

## Human Muscular Anatomy



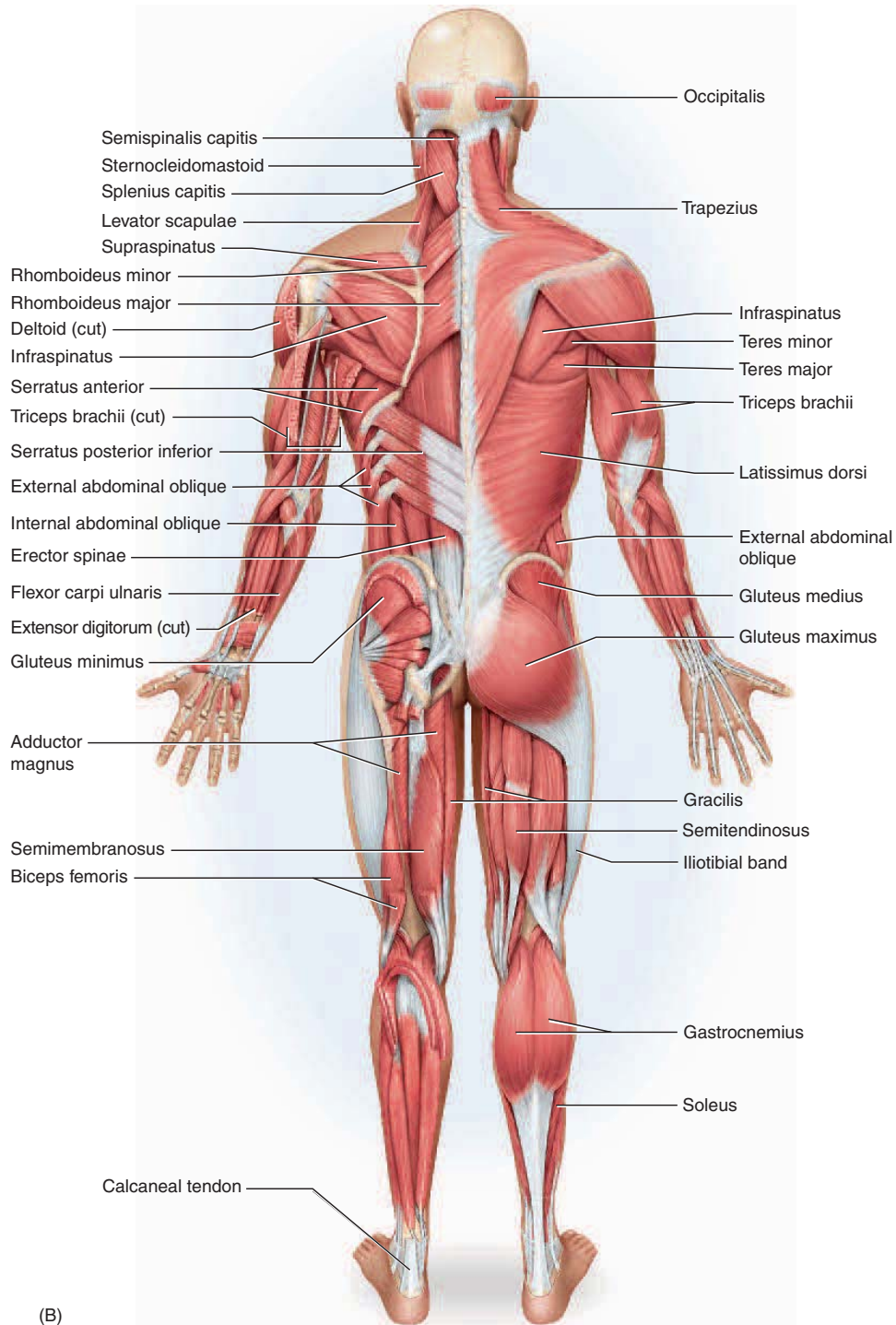
Heart Muscle.  
Colored transmission electron micrograph

## 70 CHAPTER 3



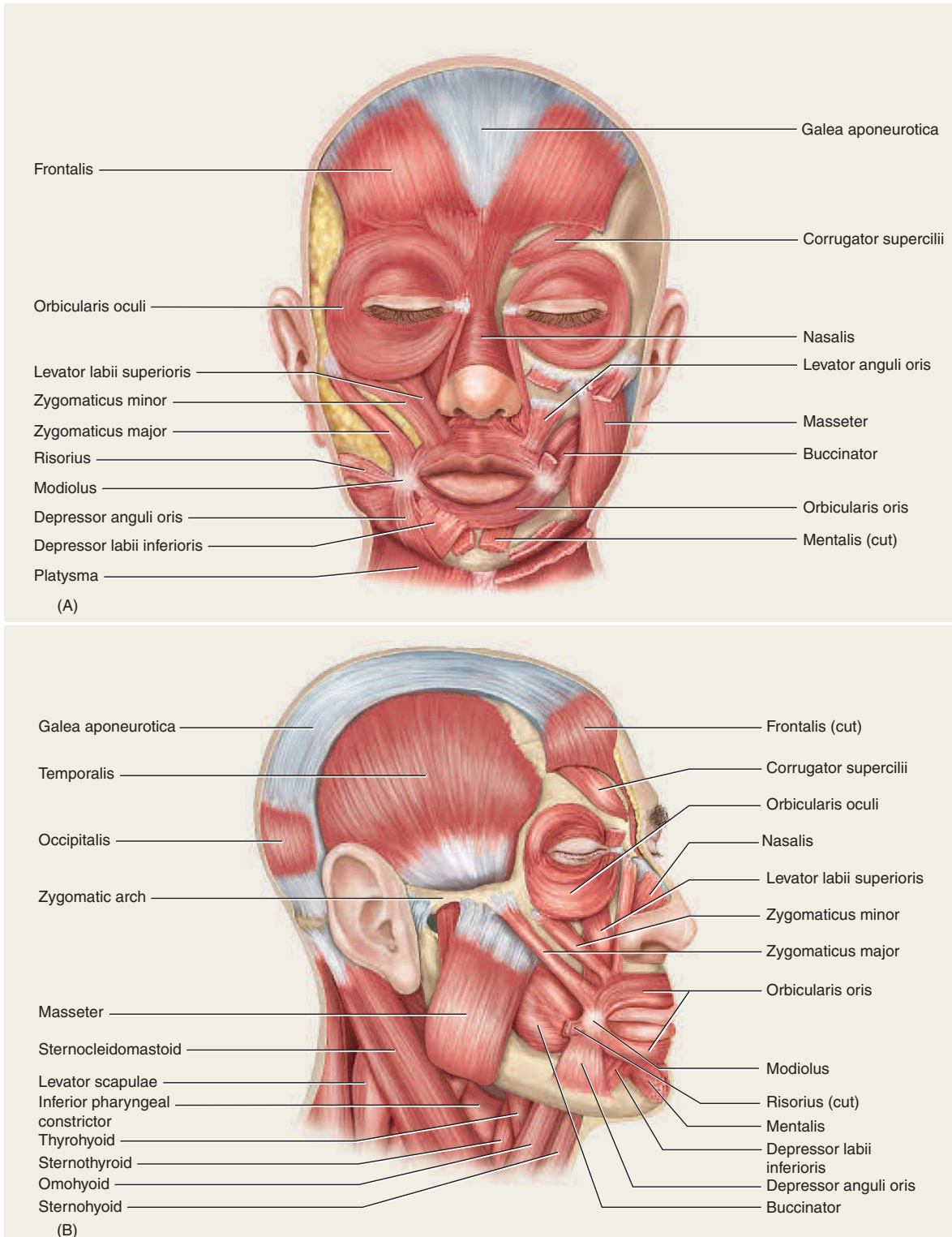
**Figure 3-1**  
Superficial Skeletal Muscles; (A) Anterior view





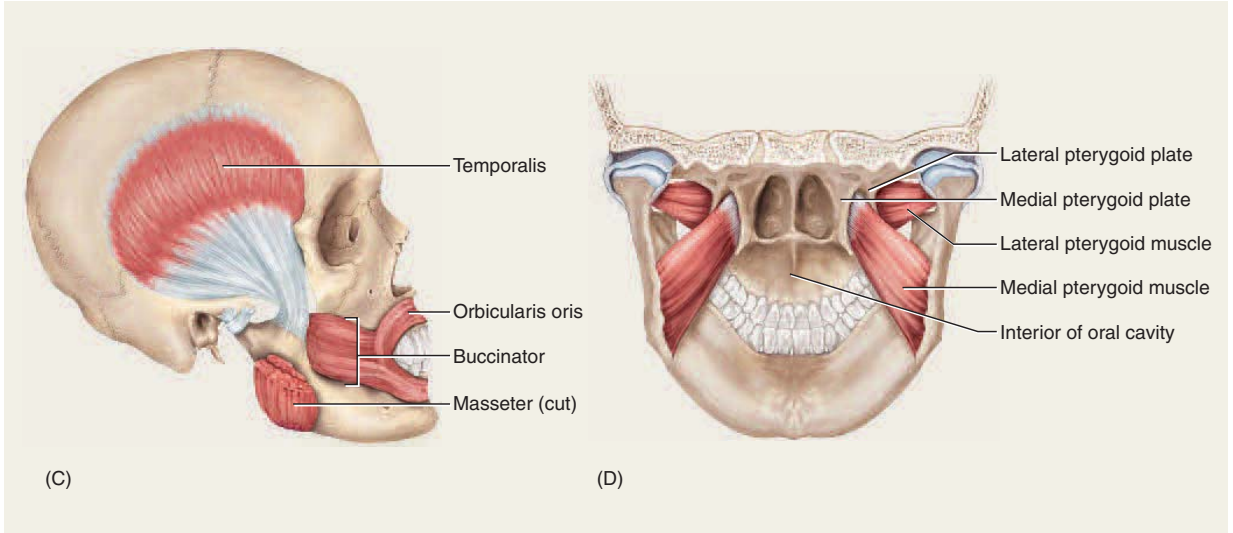
**Figure 3-1—cont'd.**  
**(B) Posterior view.**

## 72 CHAPTER 3

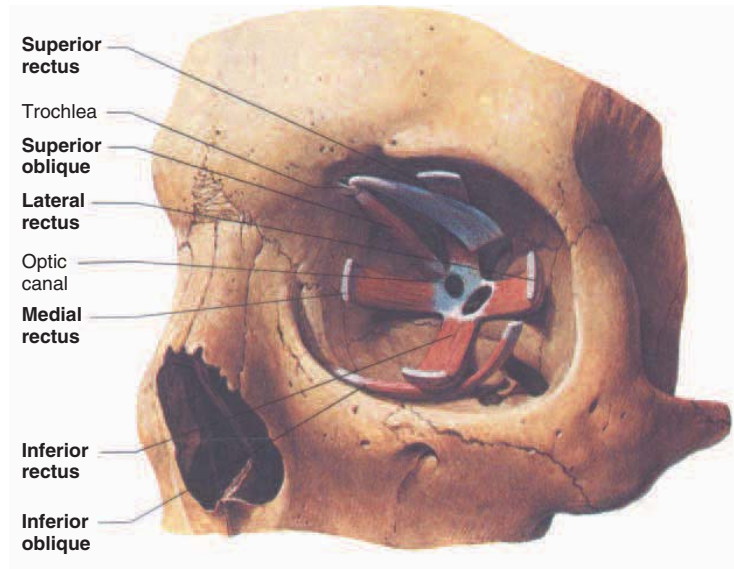


**Figure 3-2**  
(A) Muscles of the head, anterior view; (B) Muscles of the head, lateral view.



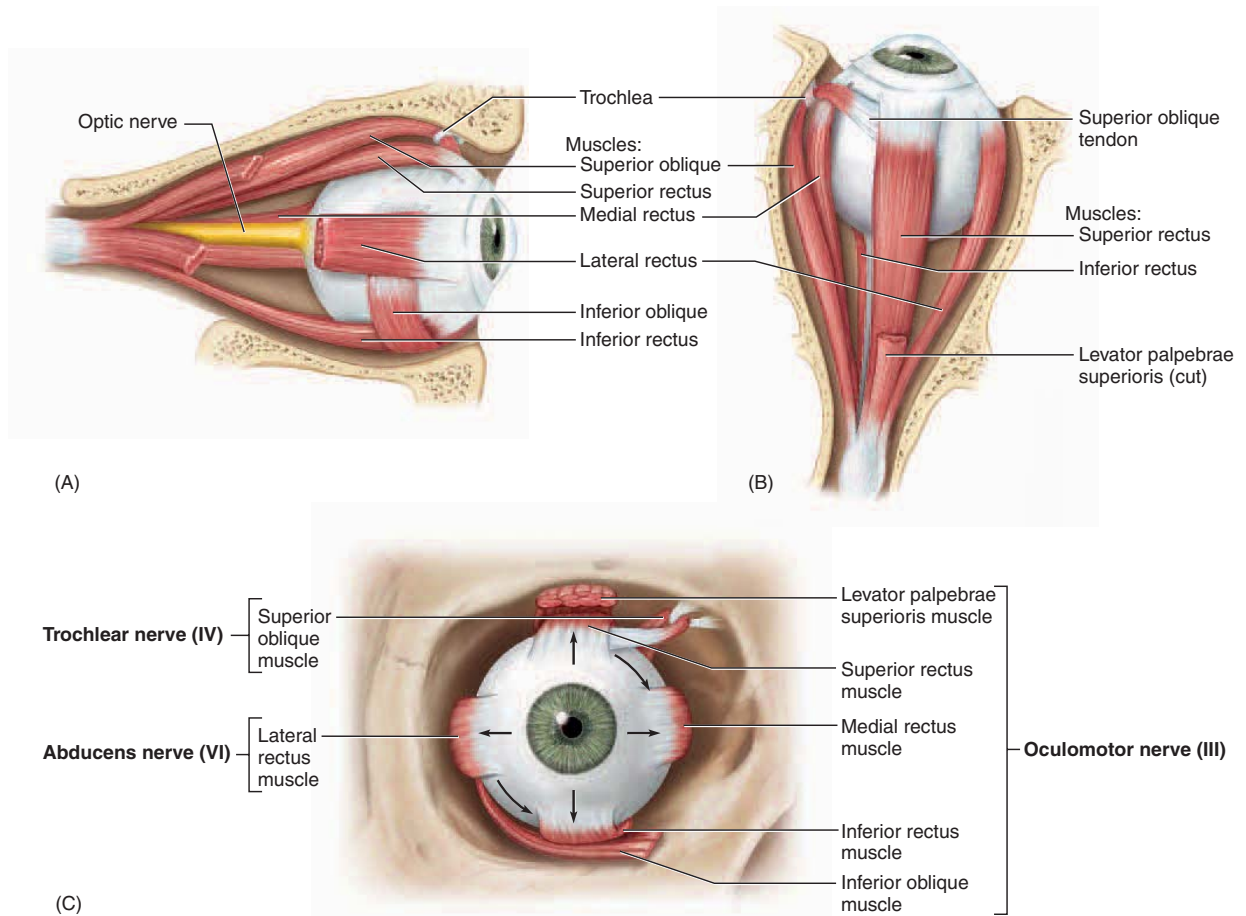


**Figure 3-2—cont'd.**  
(C) Muscles of mastication; (D) The lateral and medial pterygoid muscles.



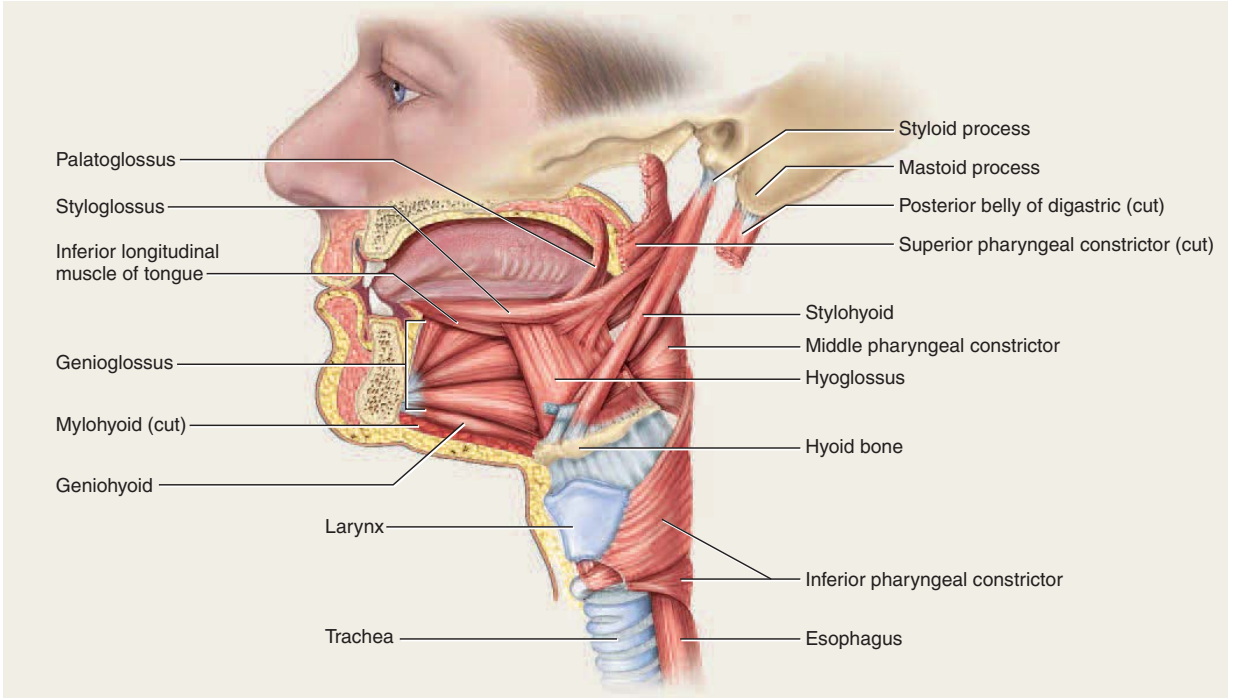
**Figure 3-3**  
Extrinsic Muscles of the Left Eye, Anterior View

## 74 CHAPTER 3

**Figure 3-4**

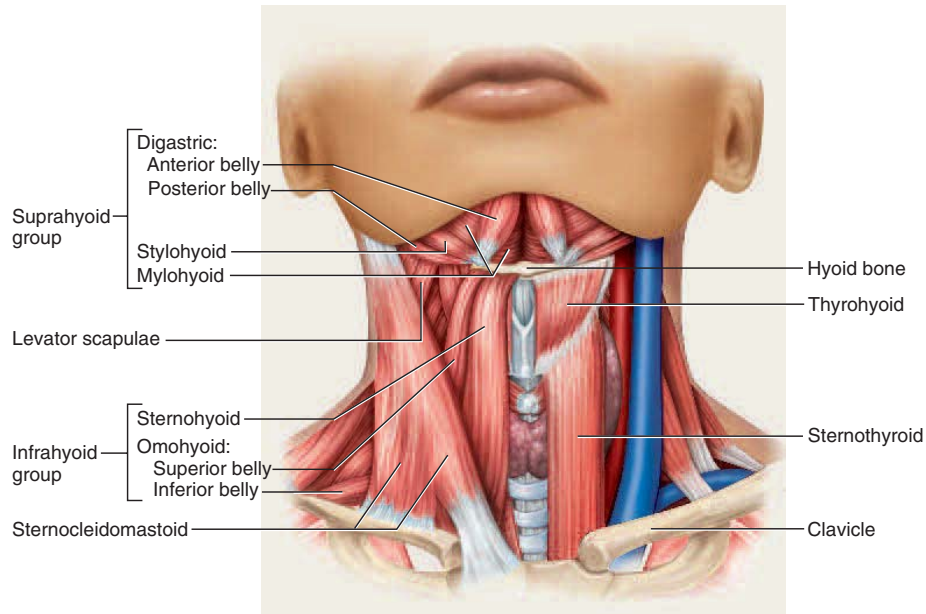
**Extrinsic Muscles of the Eye** (A) Lateral view of the right eye. The lateral rectus muscle is cut to show a portion of the optic nerve; (B) Superior view of the right eye; (C) Innervation of the extrinsic muscles; arrows indicate the eye movement produced by each muscle.



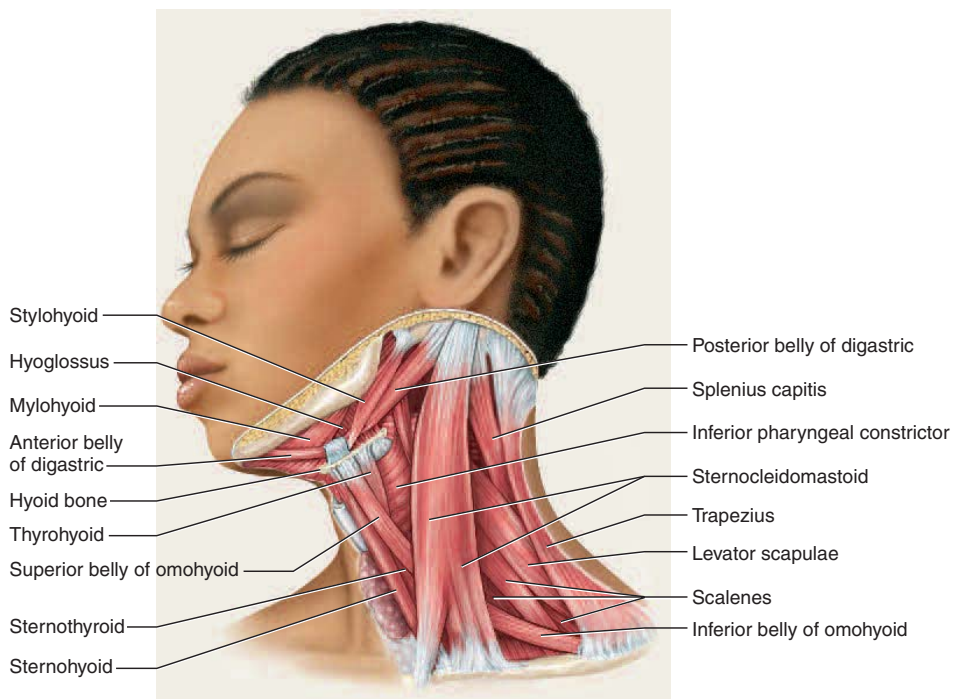


**Figure 3-5**  
Muscles of the Hypoglossal Region and Pharynx

76 CHAPTER 3

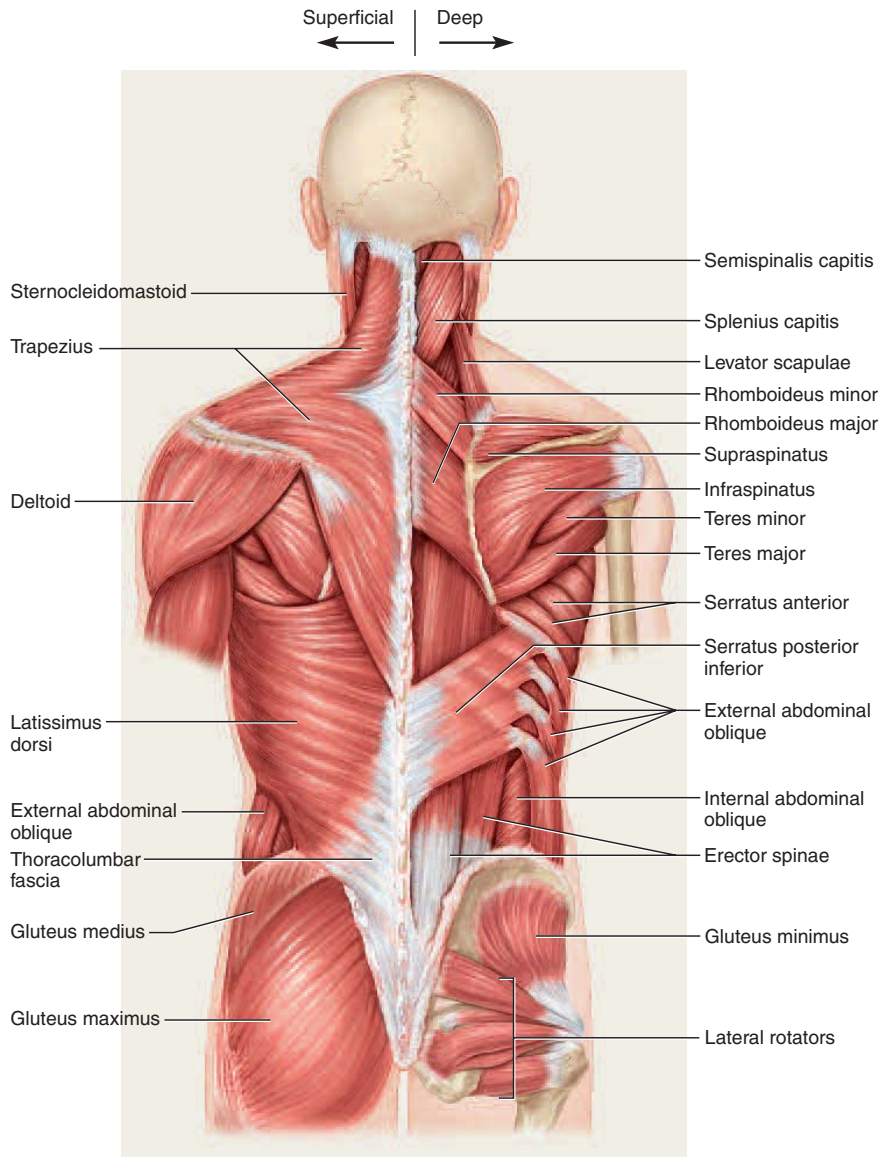


**Figure 3-6**  
Muscles of the Neck, Anterior View



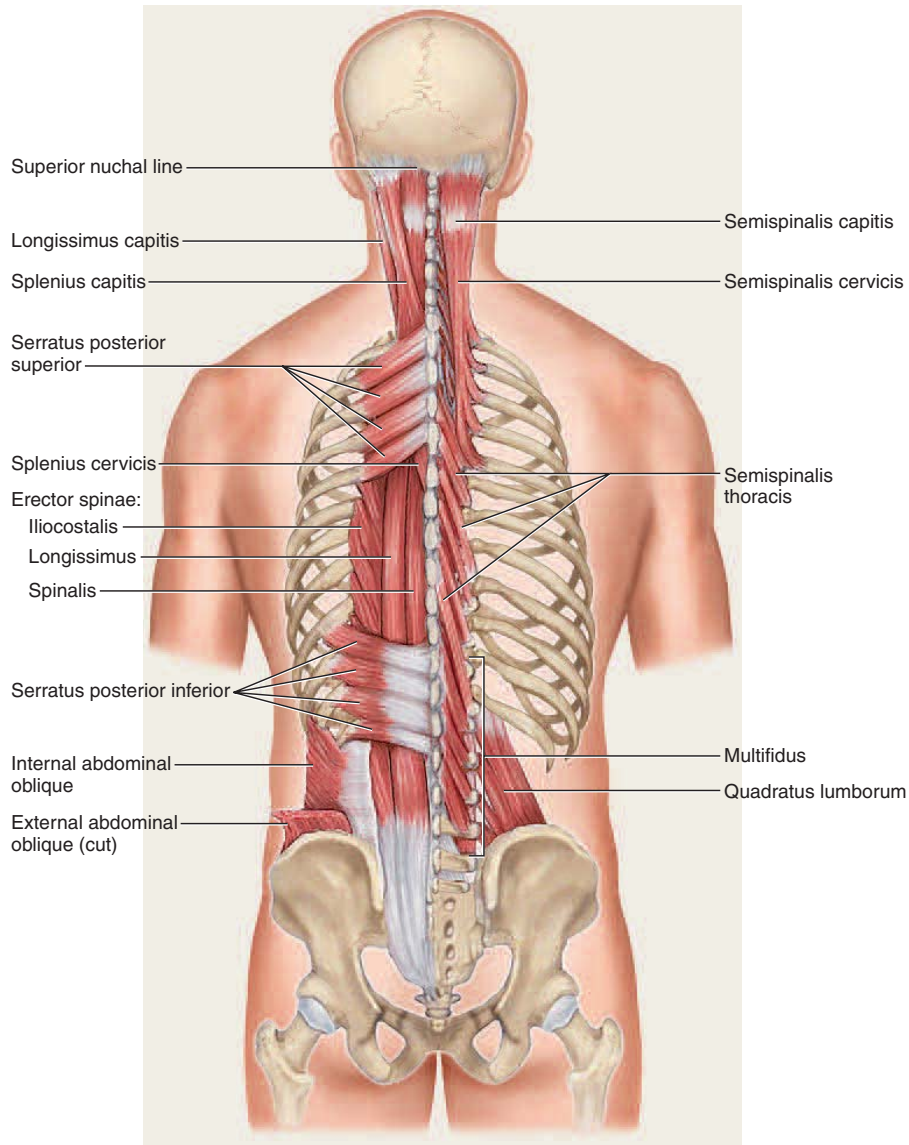
**Figure 3-7**  
Muscles of the Neck, Left Lateral View





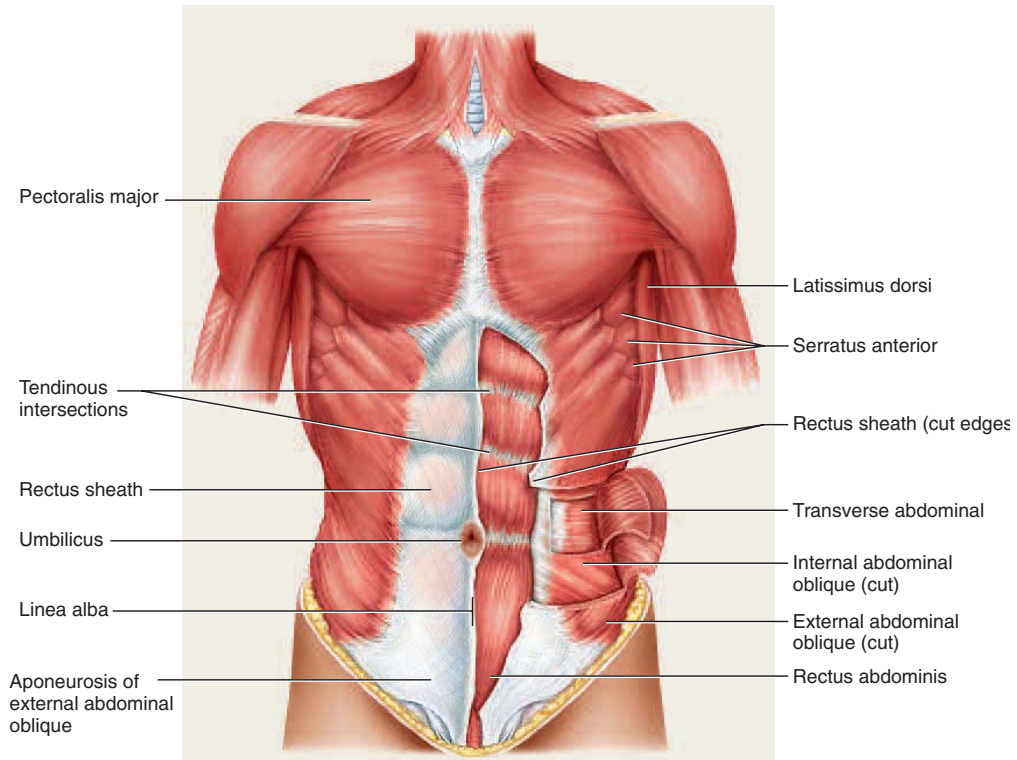
**Figure 3-8**  
**Neck, Back, and Gluteal Muscles** The most superficial muscles are shown on the left, and the next deeper layer on the right.

## 78 CHAPTER 3

**Figure 3-9****Muscles of the Back and Neck**

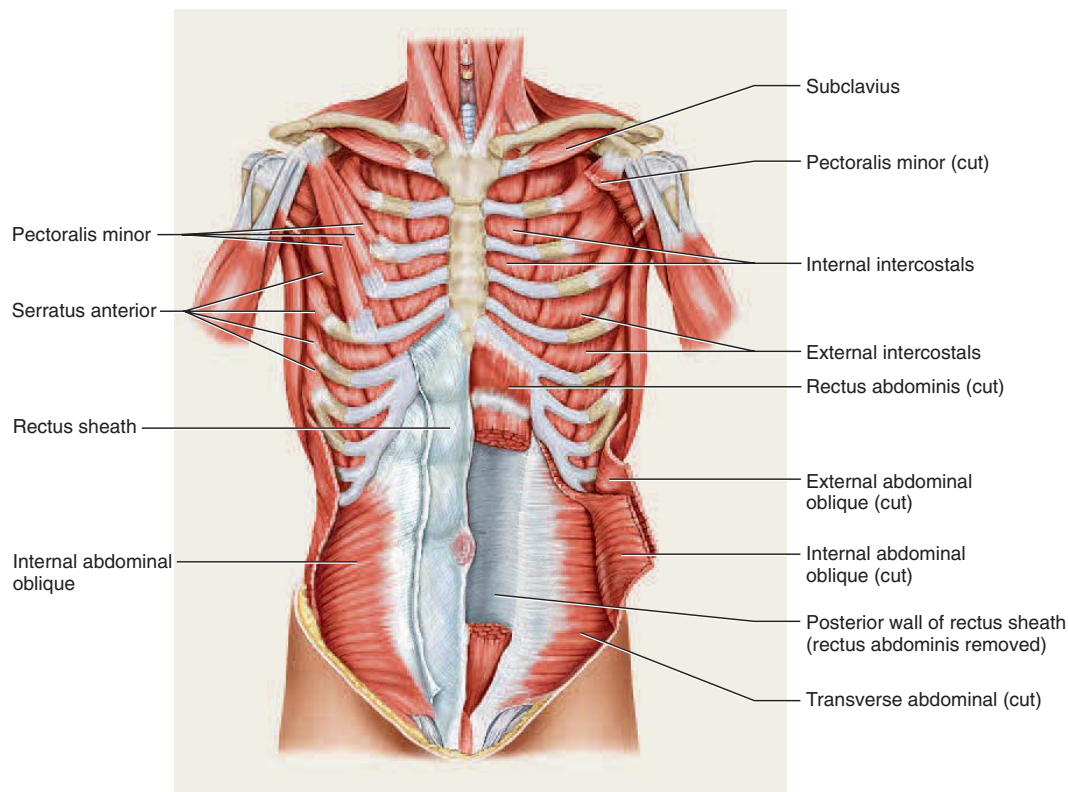
Deep muscles of the back and the neck help move the head and hold the torso erect. The splenius capitis and semispinalis capitis are removed on the left to show underlying muscles. The iliocostalis, longissimus, and spinalis muscles compose the erector spinae muscle.





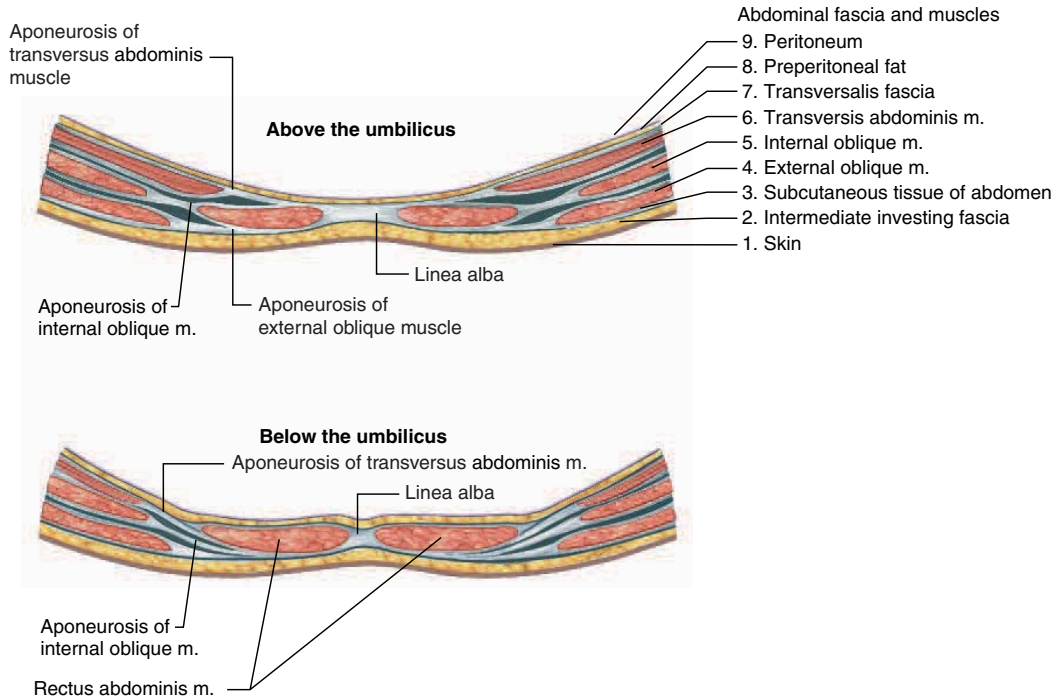
**Figure 3-10**  
**Thoracic and Abdominal Muscles** Superficial muscles. The left rectus sheath is cut away to expose the rectus abdominis muscle.

## 80 CHAPTER 3

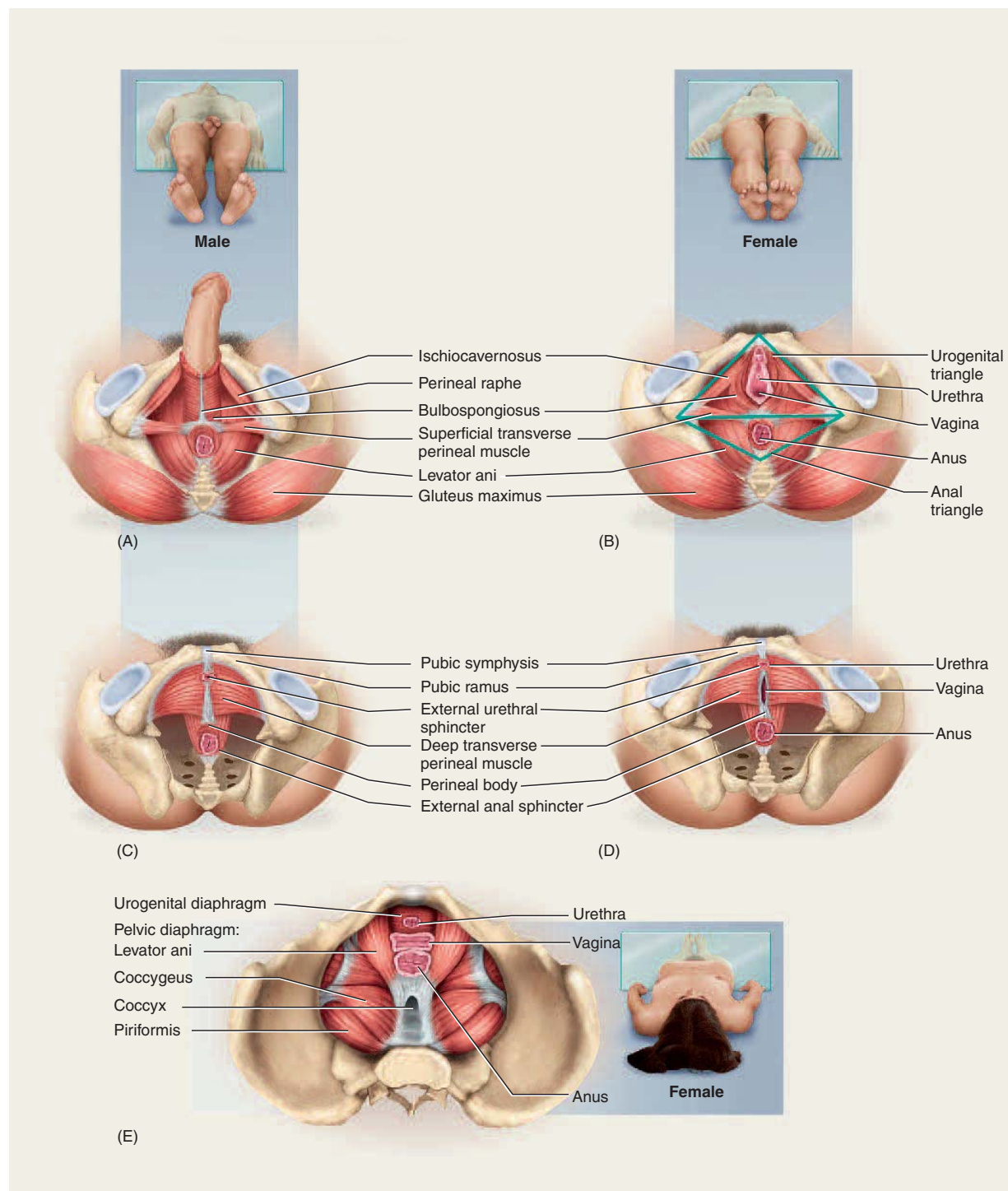
**Figure 3-11**

**Thoracic and Abdominal Muscles** Deep muscles. On the anatomical right, the external abdominal oblique has been removed to expose the internal abdominal oblique and the pectoralis major has been removed to expose the pectoralis minor. On the anatomical left, the internal abdominal oblique has been cut to expose the transversus abdominis, and the rectus abdominis has been cut to expose the posterior rectus sheath.



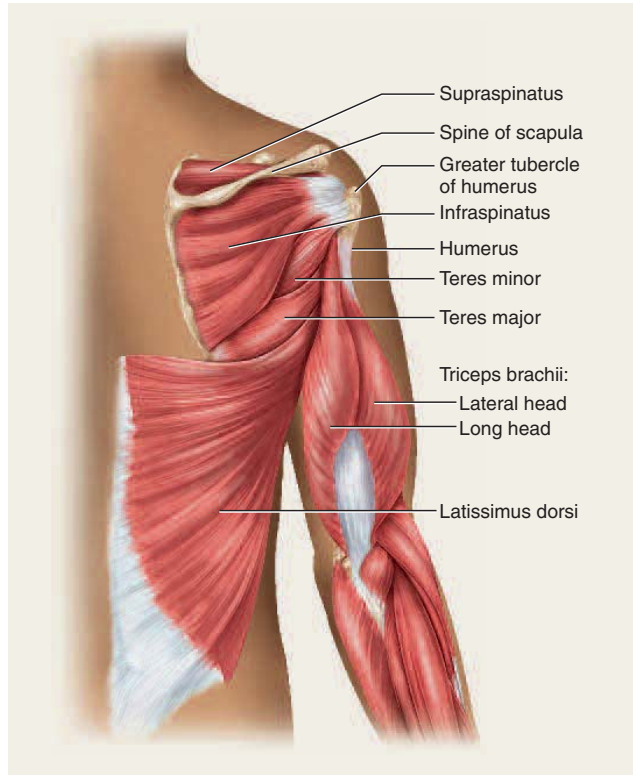


**Figure 3-12**  
**Muscles of the Anterior Abdominal Wall** Cross-sectional  
views of ventral abdominal wall.

**Figure 3-13****Muscles of the Pelvic Floor**

(A, B) The superficial perineal space, inferior view. Triangles of the perineum are marked in B. (C, D) The urogenital diaphragm, inferior view; this is the next deeper layer after the muscles in A and B. (E) The pelvic diaphragm, the deepest layer, superior view (seen from within the pelvic cavity).

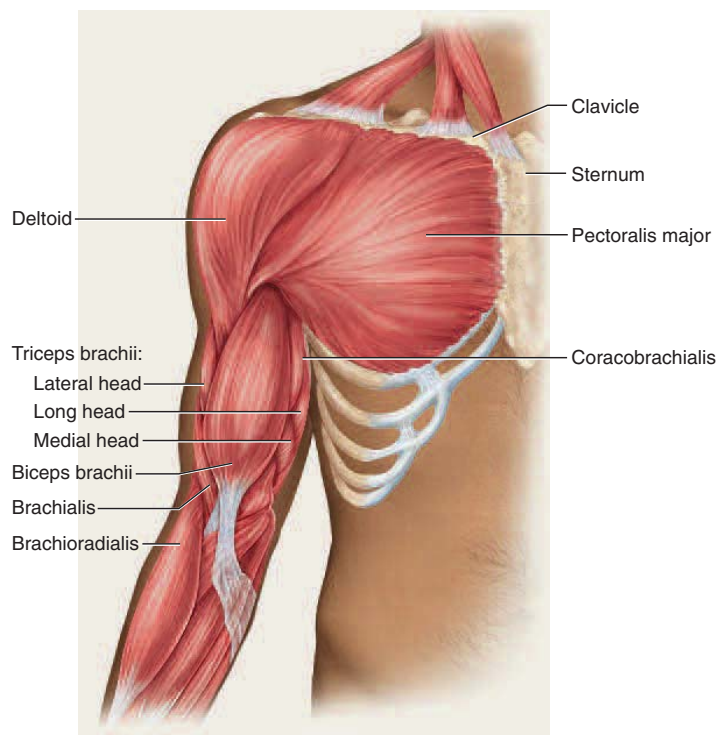




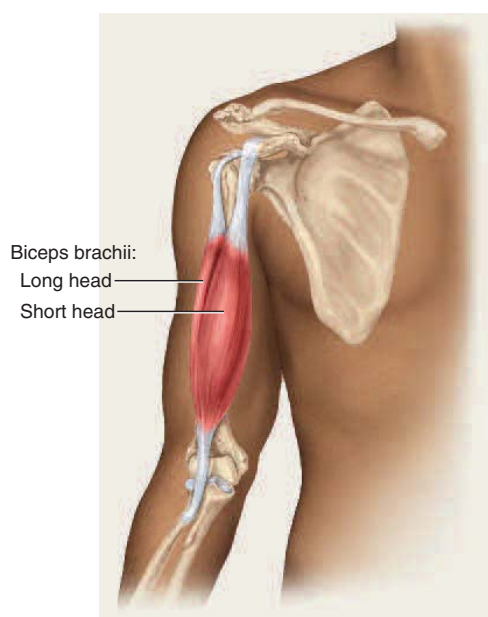
**Figure 3-14**

Muscles of the posterior surface of the scapula and the arm.

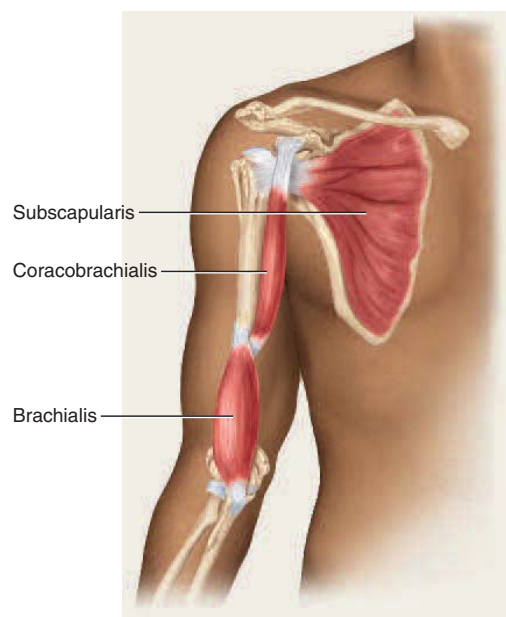
## 84 CHAPTER 3



(A)



(B)

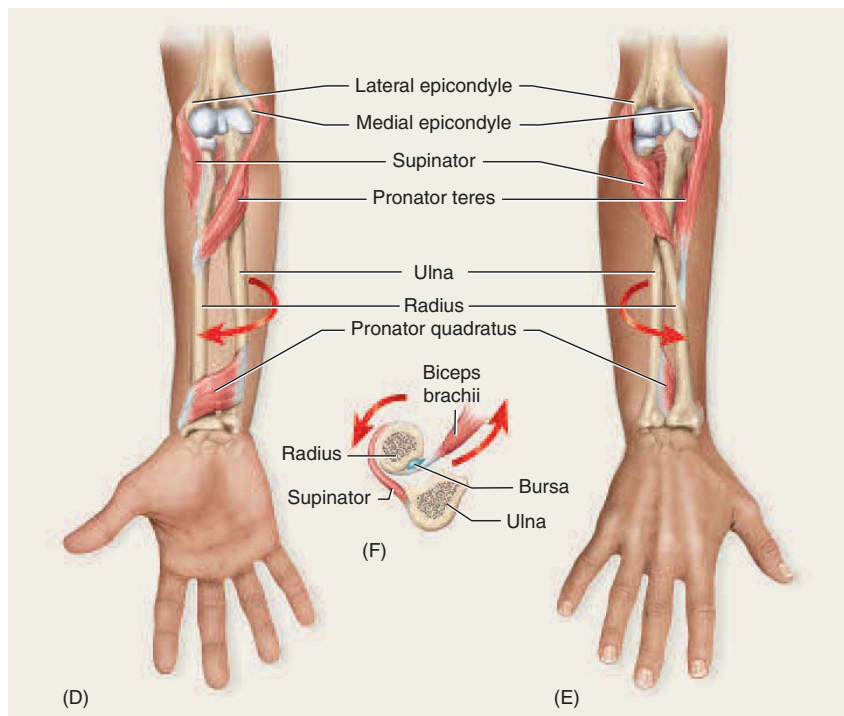
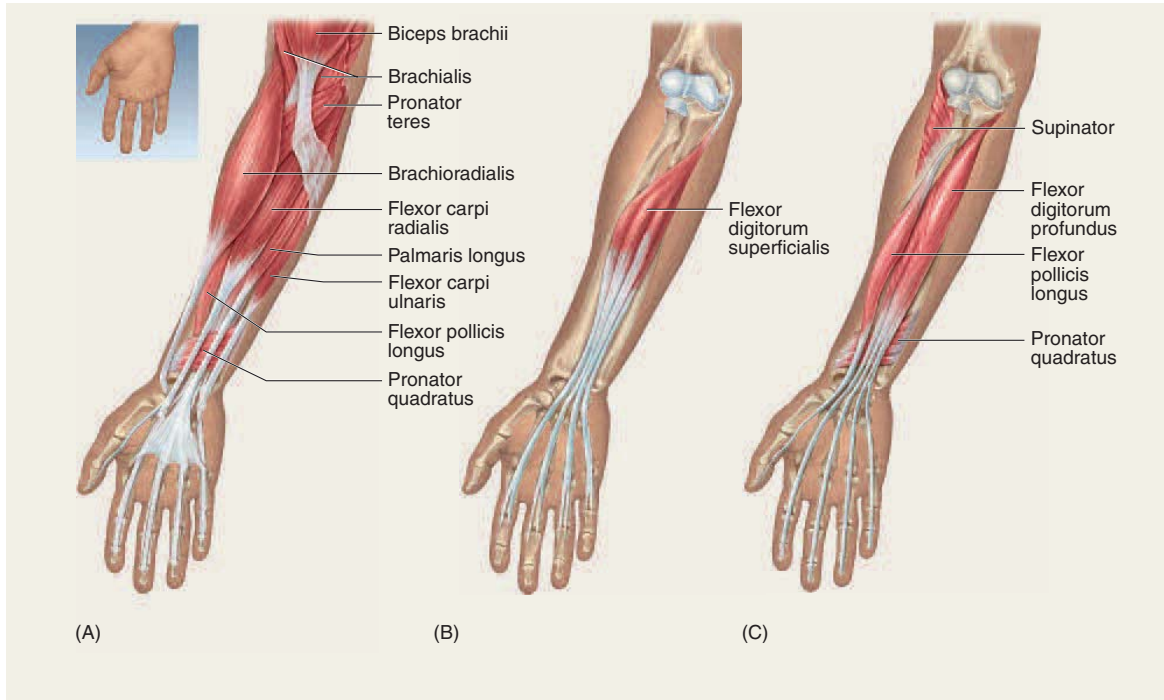


(C)

**Figure 3-15**

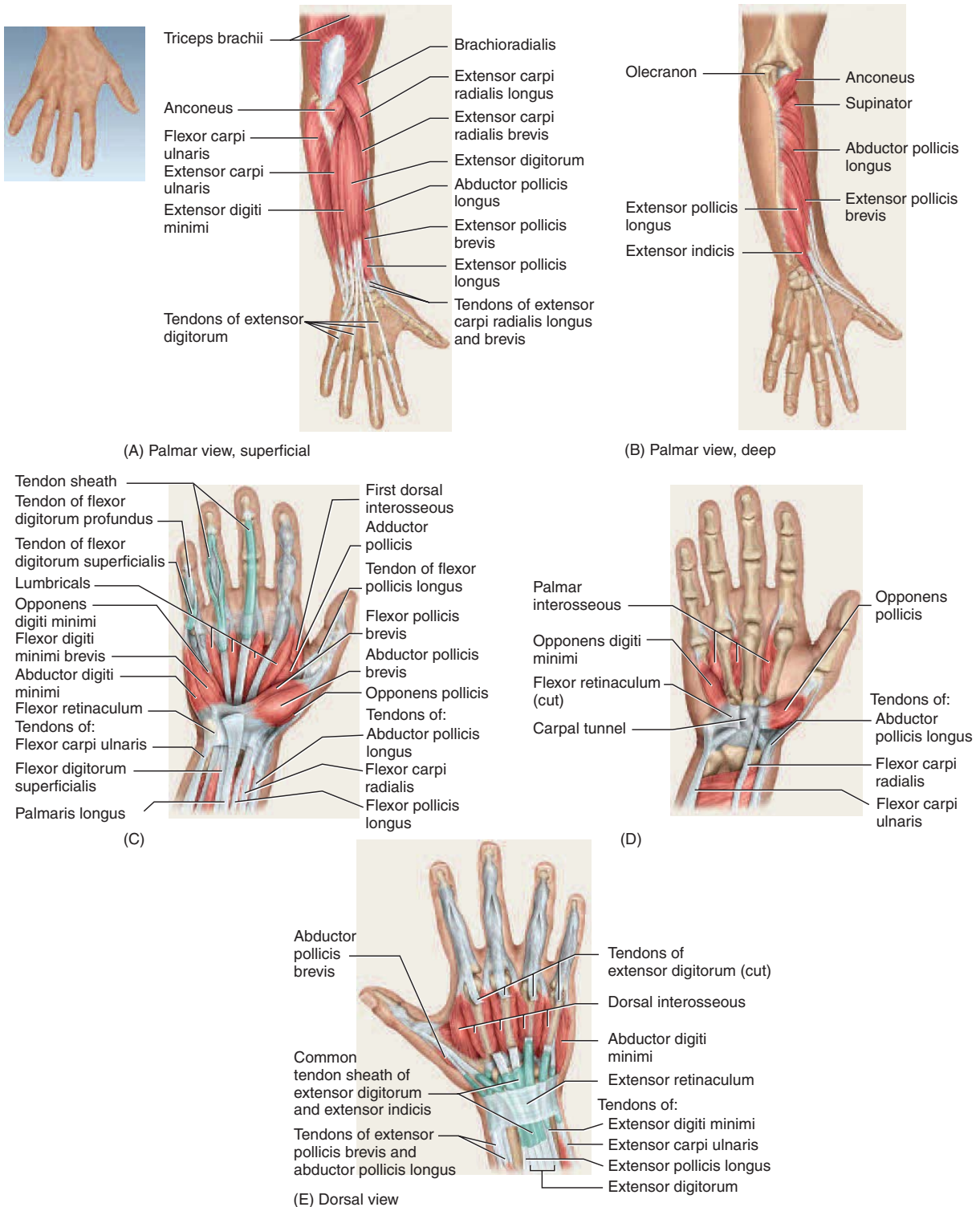
(A) Muscles of the anterior shoulder and the arm, with the rib cage removed;  
(B and C) Isolated views of muscles associated with the arm.





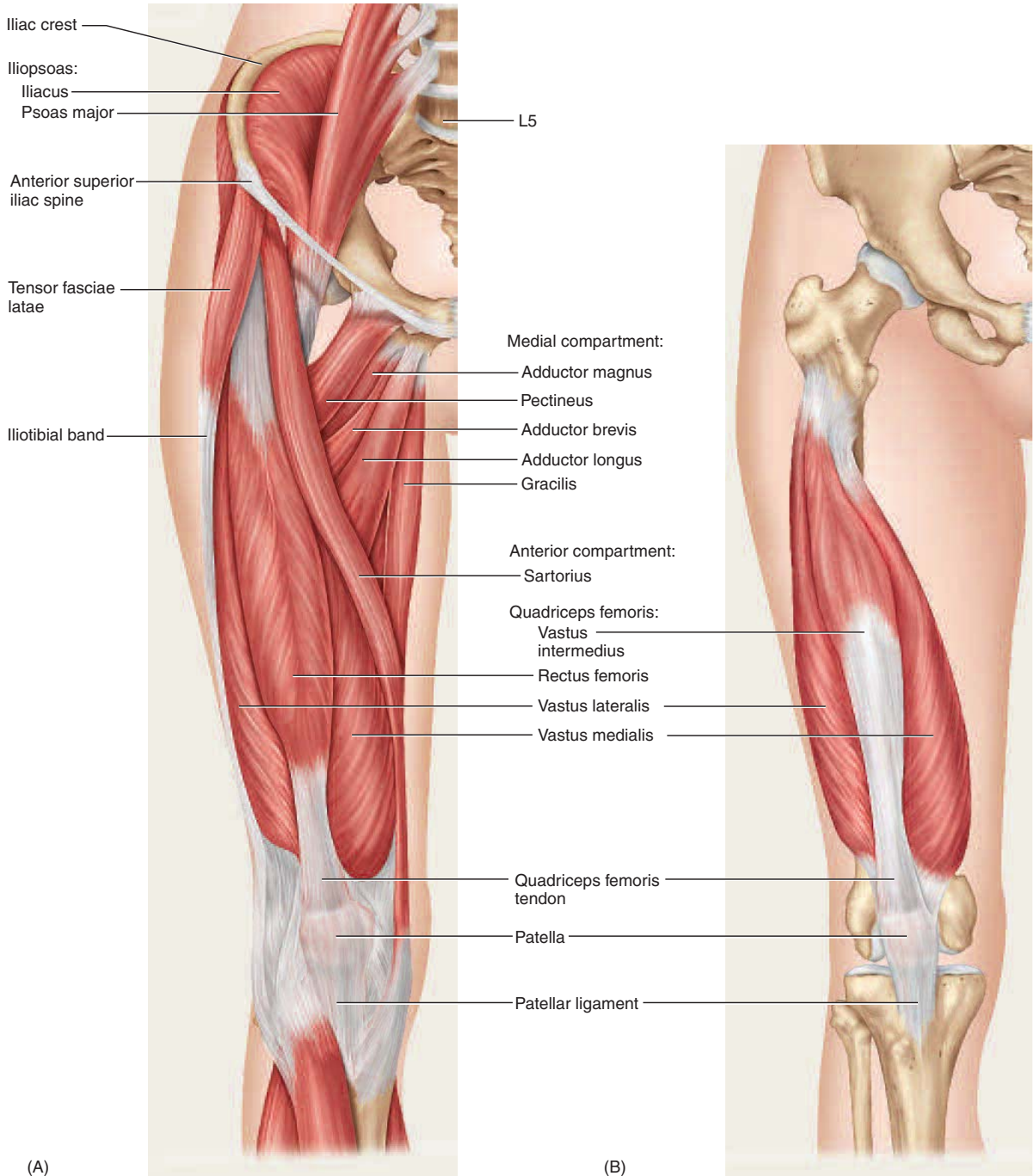
**Figure 3-16**  
**Muscles of the Forearm, Anterior View** (A) Superficial flexors; (B) the flexor digitorum superficialis, deep to the muscles in (A) but also classified as a superficial flexor; (C) deep flexors; (D) supinator, pronator teres, and pronator quadratus during supination; (E) during pronation; (F) during supination.

## 86 CHAPTER 3

**Figure 3-17**

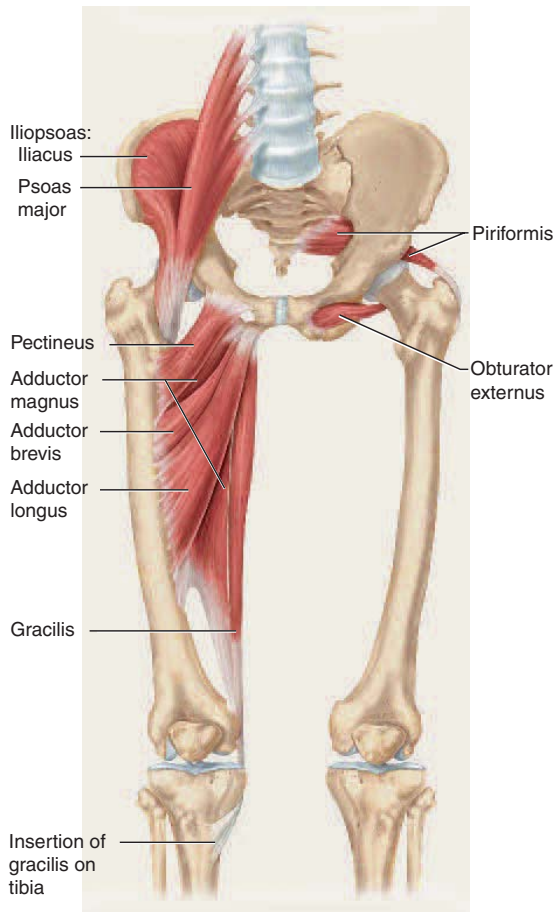
**Muscles of the Forearm, Posterior View, and Muscles of the Hand** (A) Forearm superficial extensors; (B) Forearm deep extensors; (C) Superficial muscles and tendons of the hand, ventral view; (D) Deep muscles and tendons of the hand, ventral view; (E) Major extensor muscles and tendons of the hand, dorsal view.



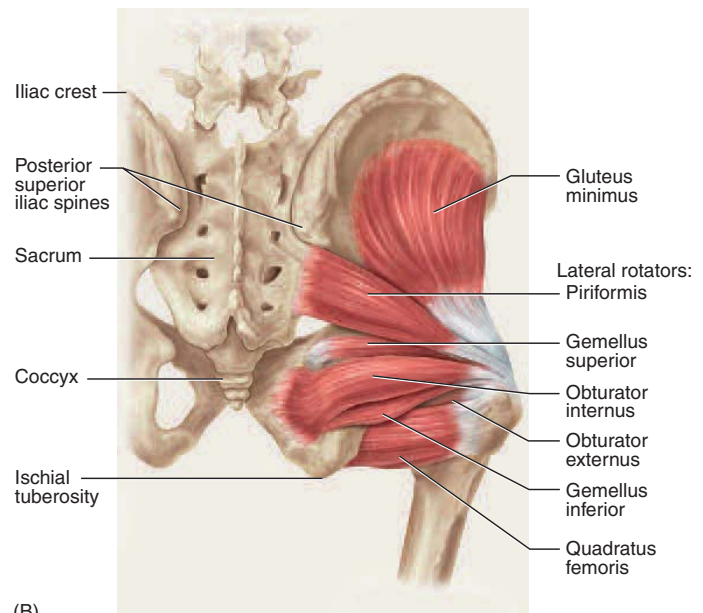


**Figure 3-18**  
**Muscles of the Thigh, Anterior View** (A) Superficial muscles; (B) Rectus femoris and other muscles removed to expose the other three heads of the quadriceps femoris.

## 88 CHAPTER 3



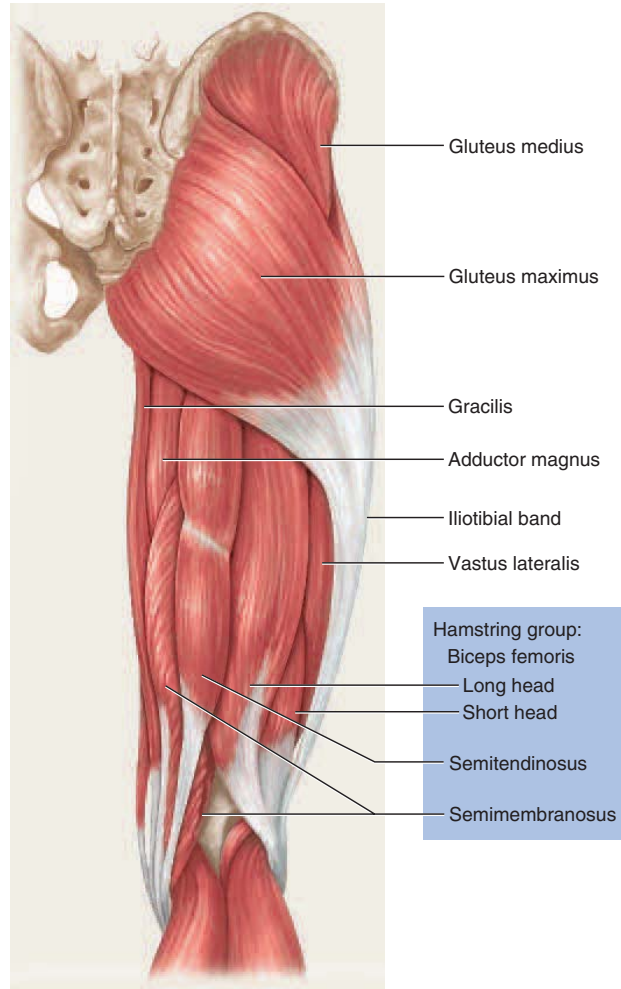
(A)



(B)

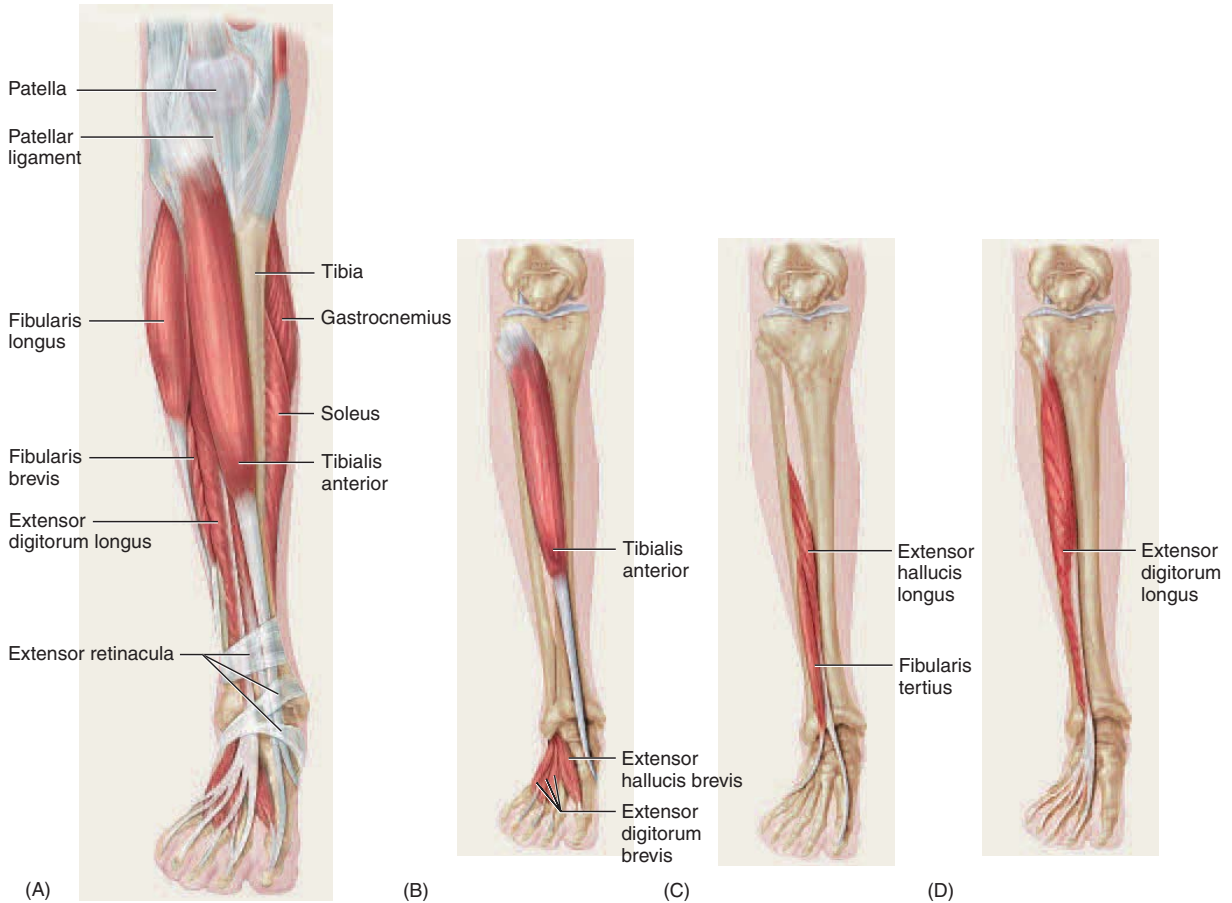
**Figure 3-19****(A) Major adductors of the thigh, ventral view; (B) Deeper muscles of the hip, dorsal view**





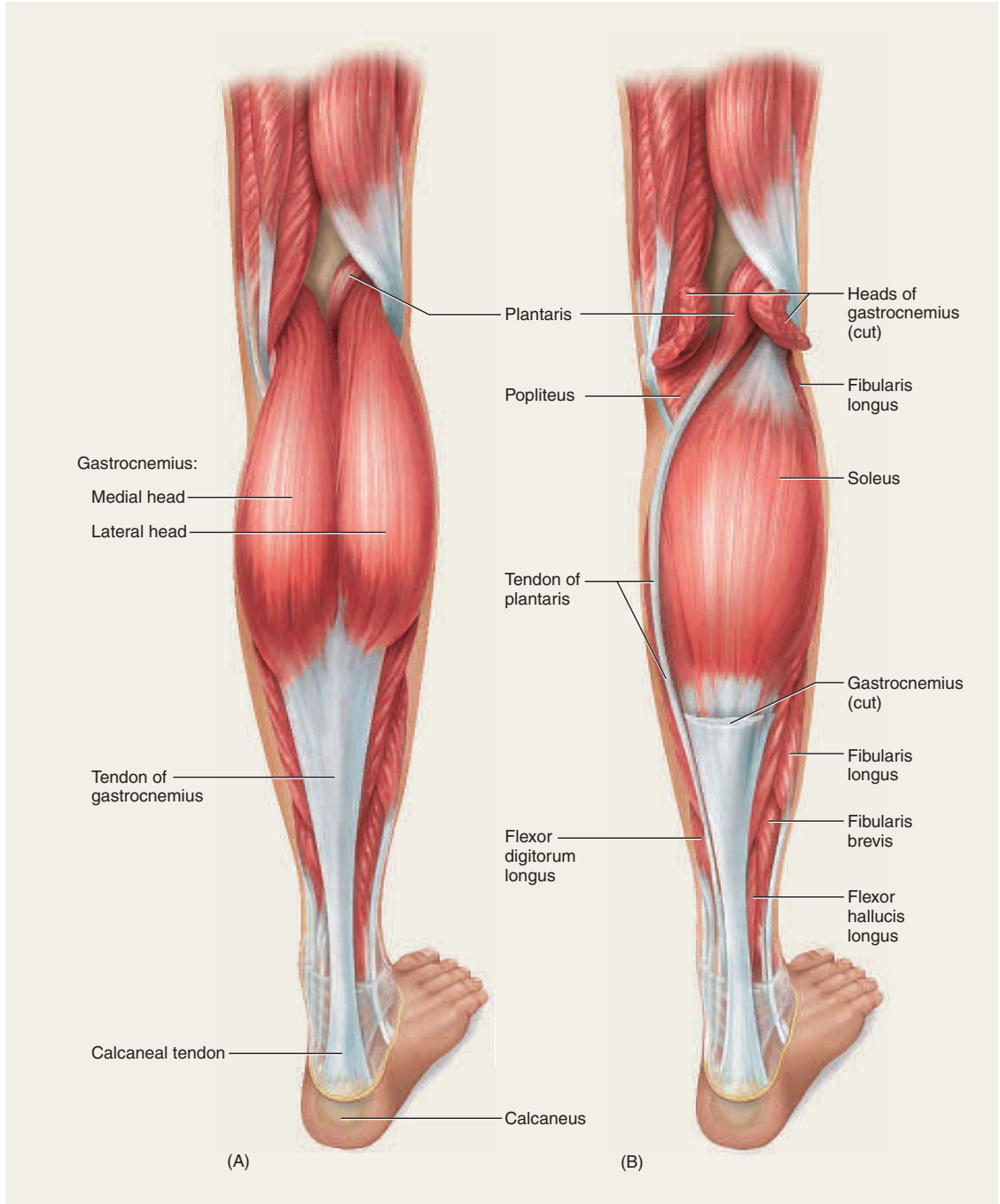
**Figure 3-20**  
Gluteal and Thigh Muscles, Posterior View

## 90 CHAPTER 3

**Figure 3-21**

(A) Muscles of the anterior right leg; (B–D) Isolated views of muscles associated with the anterior leg.

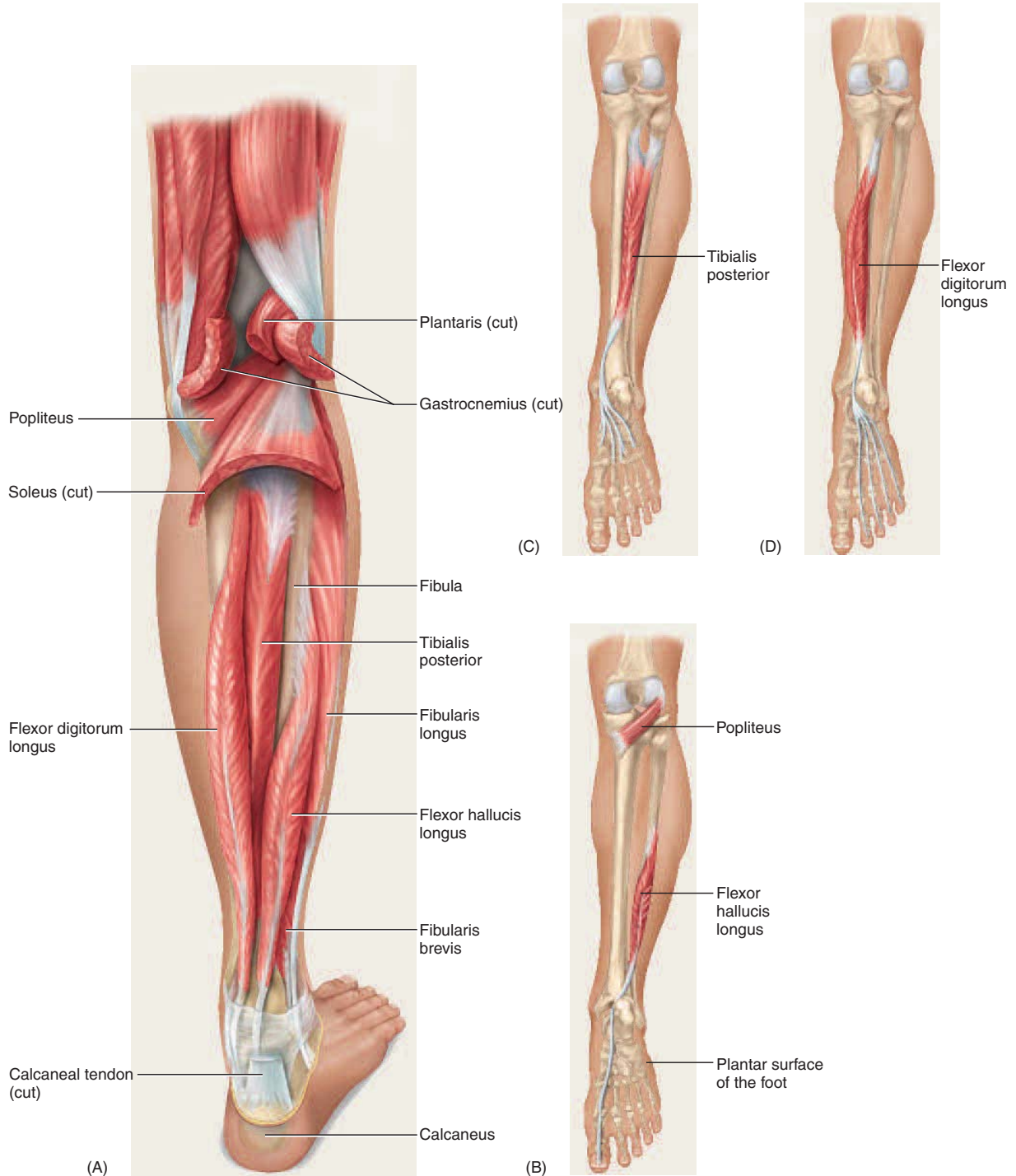




**Figure 3-22**

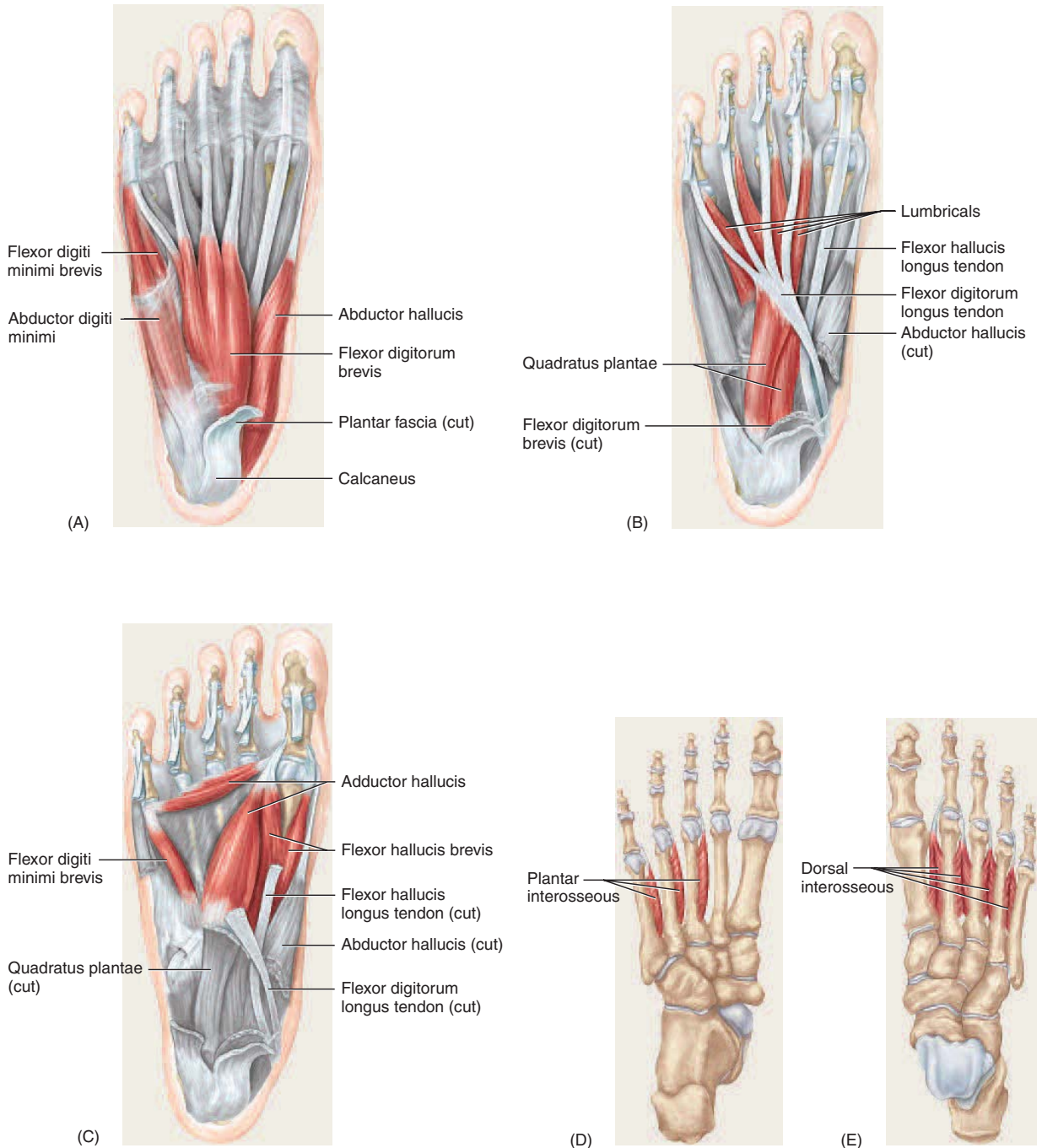
(A) Superficial muscles of the lower right leg; (B) Deeper muscles of the lower right leg.

## 92 CHAPTER 3

**Figure 3-23**

(A) Muscles of the posterior right leg; (B–D) Isolated views of muscles associated with the posterior right leg.





**Figure 3-24**

**Intrinsic Muscles of the Foot**

(A–D) First through fourth layers, respectively, in ventral (plantar) views; (E) Fourth layer, dorsal view.

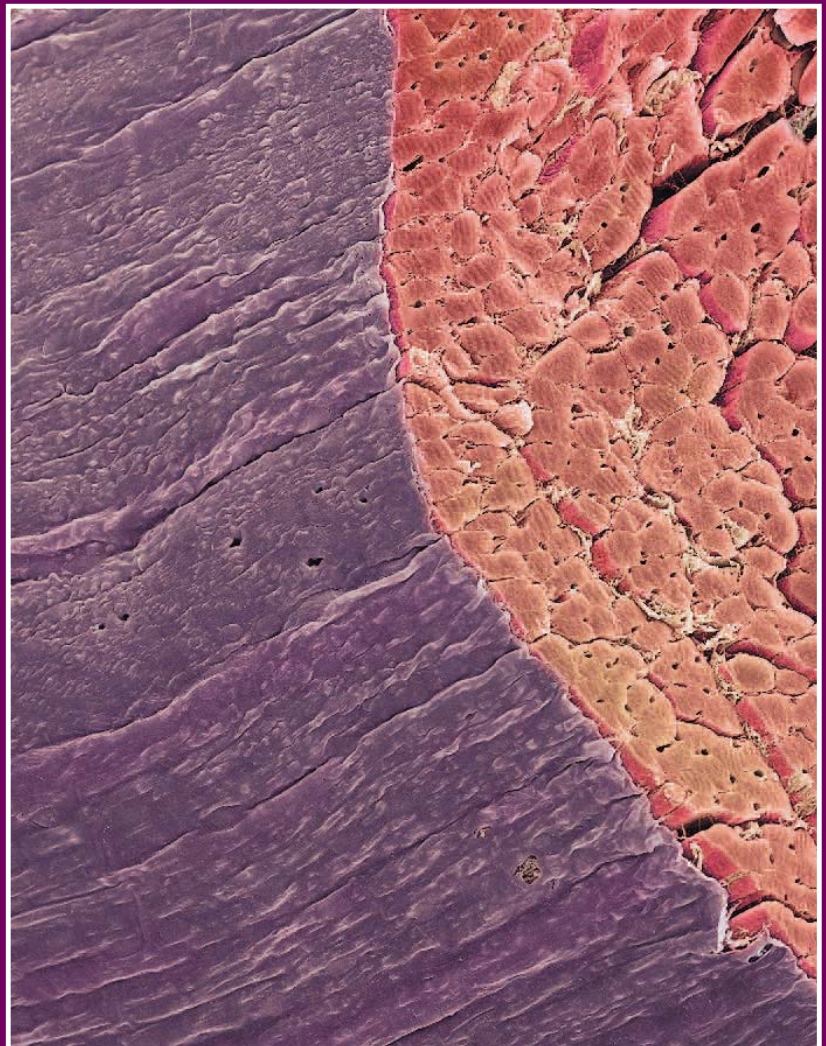
*This page intentionally left blank*



C H A P T E R

4

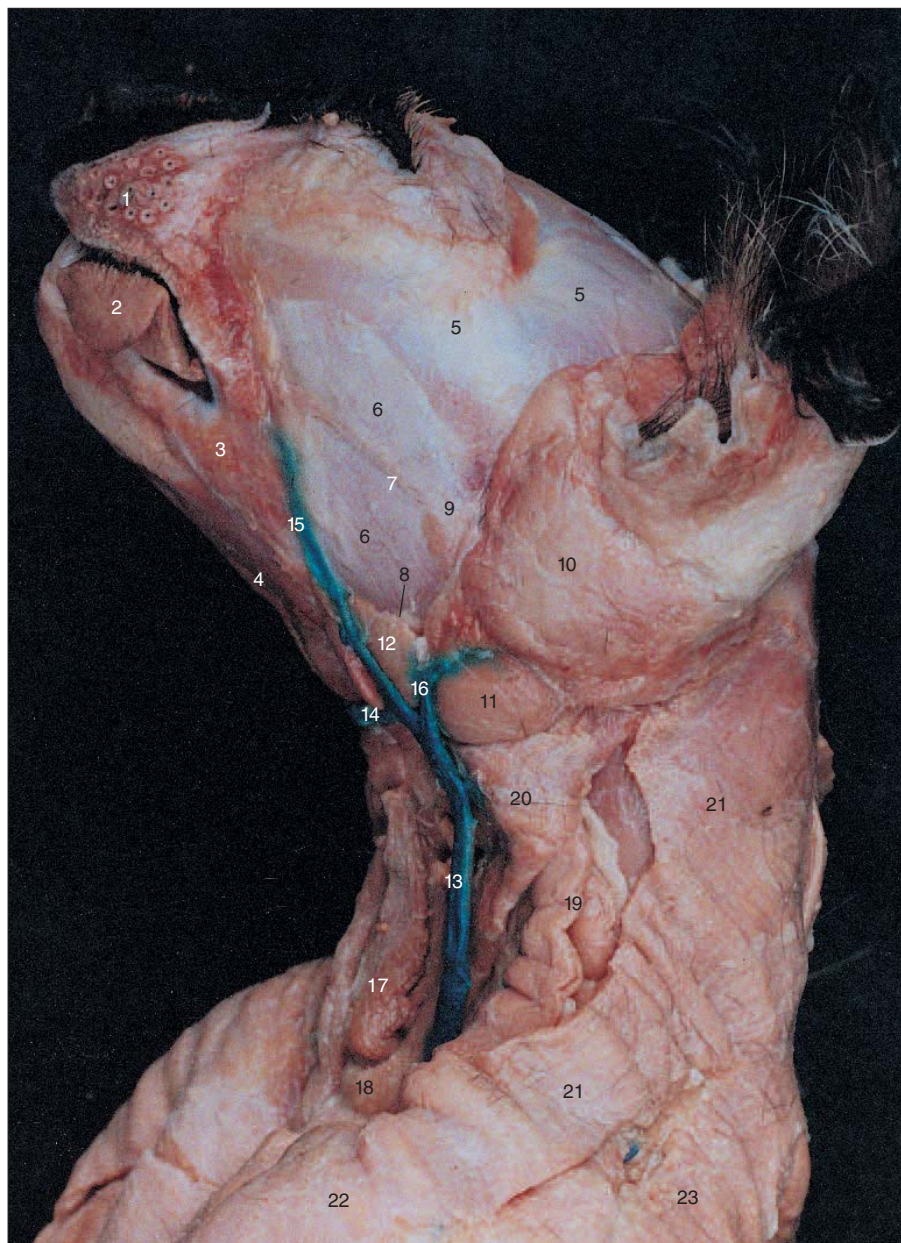
# Dissections



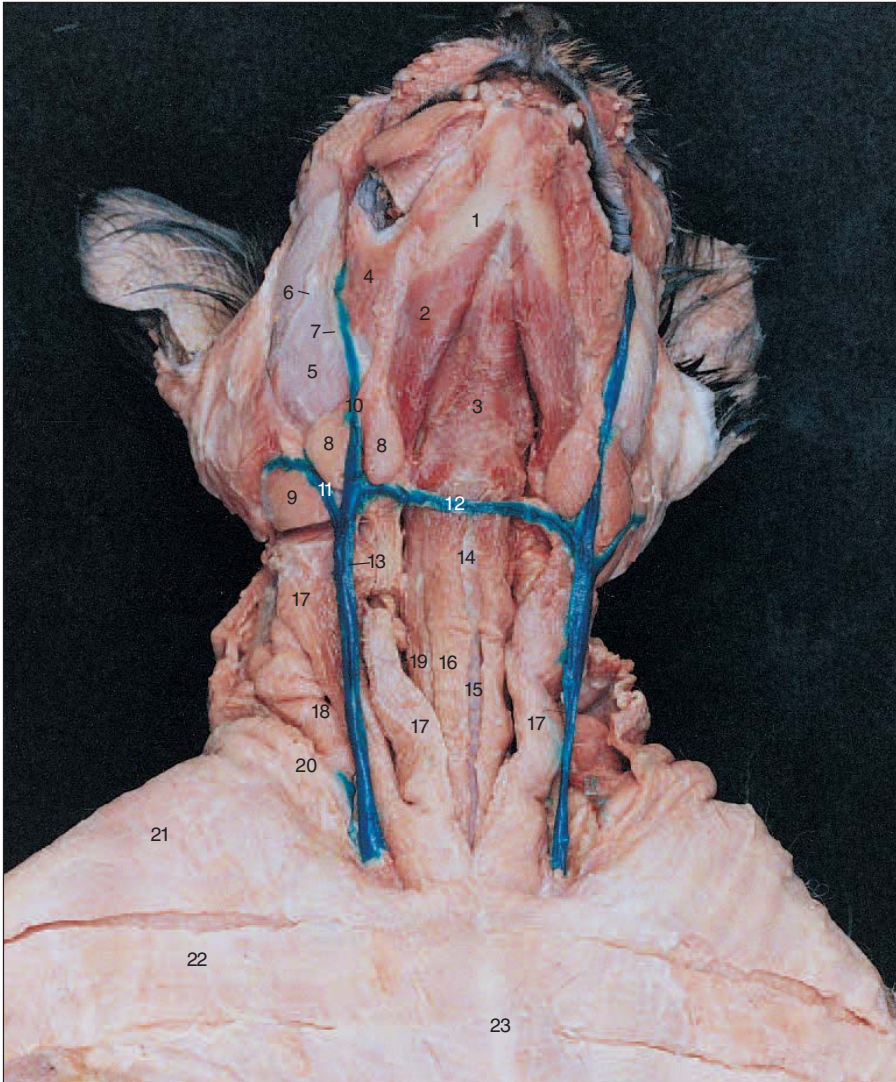
Scanning Electron Micrograph (SEM) of a Transverse Section through Skeletal Muscle

**Figure 4-1**  
**Superficial Anatomy of**  
**Cat Head and Neck,**  
**Left Lateral View**

1. Vibrissal barrels for sensory hairs (whiskers)
2. Tongue
3. Buccinator muscle
4. Digastric muscle
5. Temporalis muscle
6. Masseter muscle
7. Dorsal buccal branch of facial (VII) nerve
8. Ventral buccal branch of facial (VII) nerve
9. Parotid duct
10. Parotid gland
11. Submandibular gland
12. Lymph node
13. External jugular vein
14. Transverse jugular vein
15. Anterior facial vein
16. Posterior facial vein
17. Sternohyoid muscle
18. Sternothyroid muscle
19. Cleidomastoid muscle
20. Sternomastoid muscle
21. Clavotrapezius muscle
22. Clavobrachialis muscle
23. Acromiotrapezius muscle







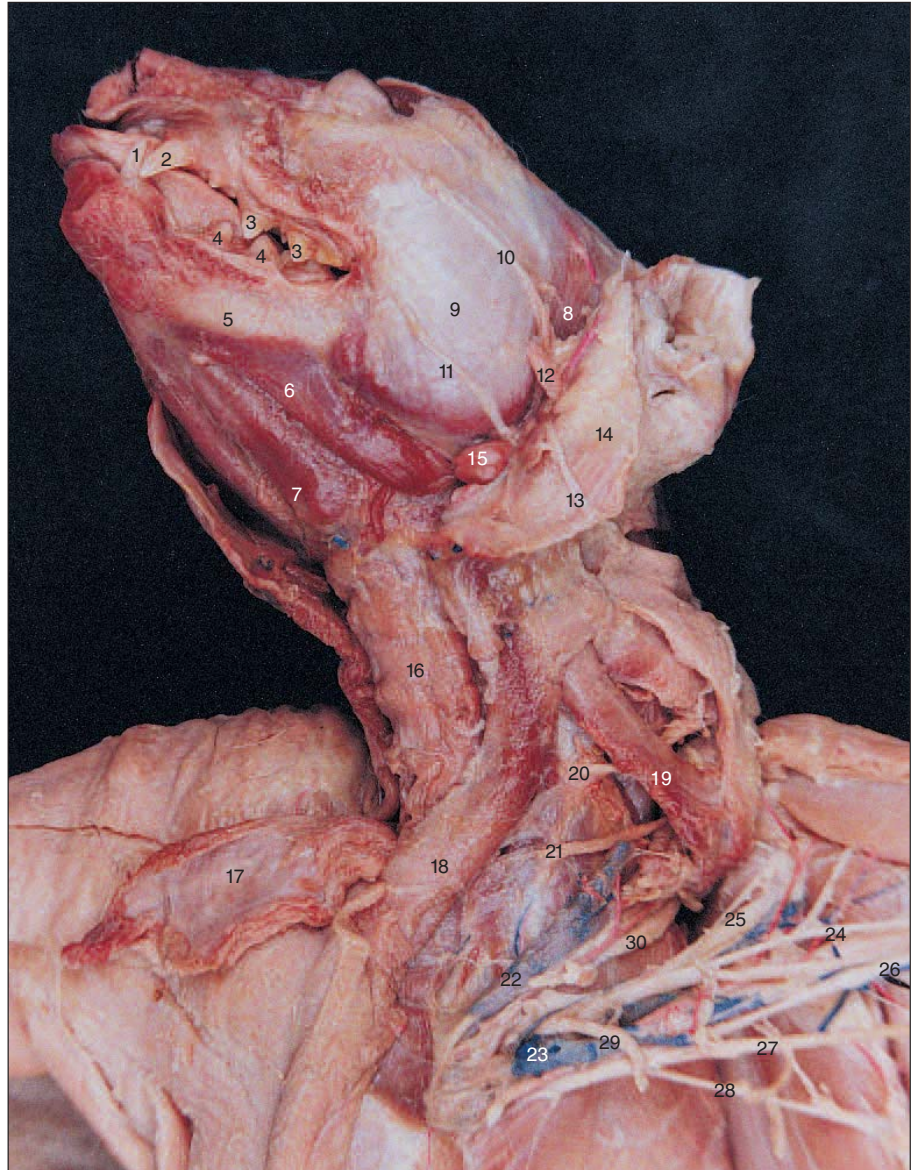
**Figure 4-2**  
**Superficial Anatomy of**  
**Cat Head and Neck,**  
**Ventral View**

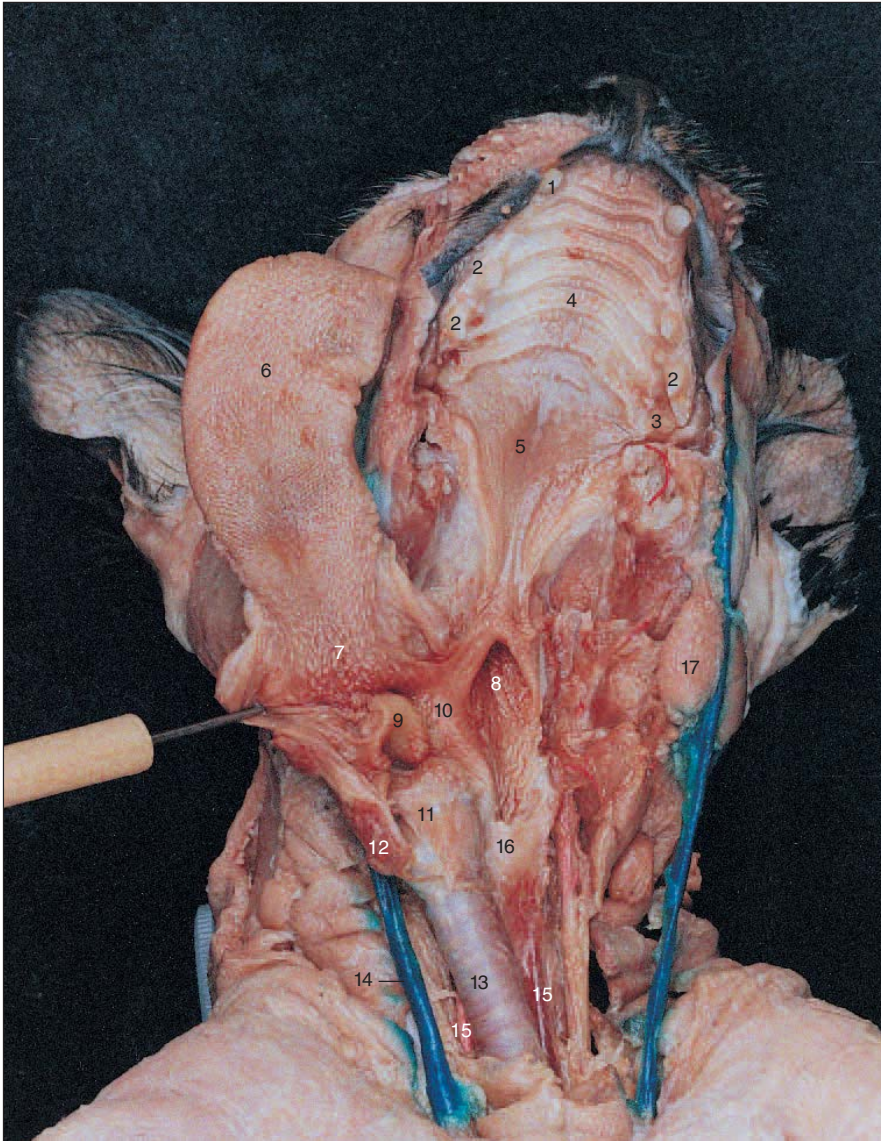
1. Body of mandible
2. Digastric muscle
3. Mylohyoid muscle
4. Buccinator muscle
5. Masseter muscle
6. Dorsal branch of facial (VII) nerve
7. Ventral branch of facial (VII) nerve
8. Lymph node
9. Submandibular gland
10. Anterior facial vein
11. Posterior facial vein
12. Transverse jugular vein
13. External jugular vein
14. Larynx
15. Trachea
16. Sternohyoid muscle
17. Sternomastoid muscle (unavoidably damaged on animal's right side during vascular perfusion)
18. Cleidomastoid muscle
19. Sternothyroid muscle
20. Clavotrapezius muscle
21. Clavobrachialis muscle
22. Pectoantibrachialis muscle
23. Sternum



**Figure 4-3**  
**Deep Anatomy of Cat**  
**Head and Neck, Left**  
**Ventrolateral View**

1. Lower canine tooth
2. Upper canine tooth
3. Upper premolar tooth
4. Lower premolar tooth
5. Body of mandible
6. Digastric muscle
7. Mylohyoid muscle
8. Temporalis muscle
9. Masseter muscle
10. Dorsal branch of facial (VII) nerve
11. Ventral branch of facial (VII) nerve
12. Parotid duct
13. Cutaneous branch of facial (VII) nerve
14. Platysma muscle (reflected)
15. Lymph node
16. Sternohyoid muscle
17. Sternomastoid muscle (reflected)
18. Cleidomastoid muscle
19. Omohyoid muscle
20. 4th cervical nerve
21. 5th cervical nerve
22. Jugular vein
23. Subclavian vein
24. Musculocutaneous nerve
25. Radial nerve
26. Median nerve
27. Ulnar nerve
28. Thoracic nerve
29. Ventral thoracic nerve (cut)
30. Axillary nerve





**Figure 4-4**  
**Deep Anatomy of Cat Head and Neck, Oral Cavity with Mandible Removed**

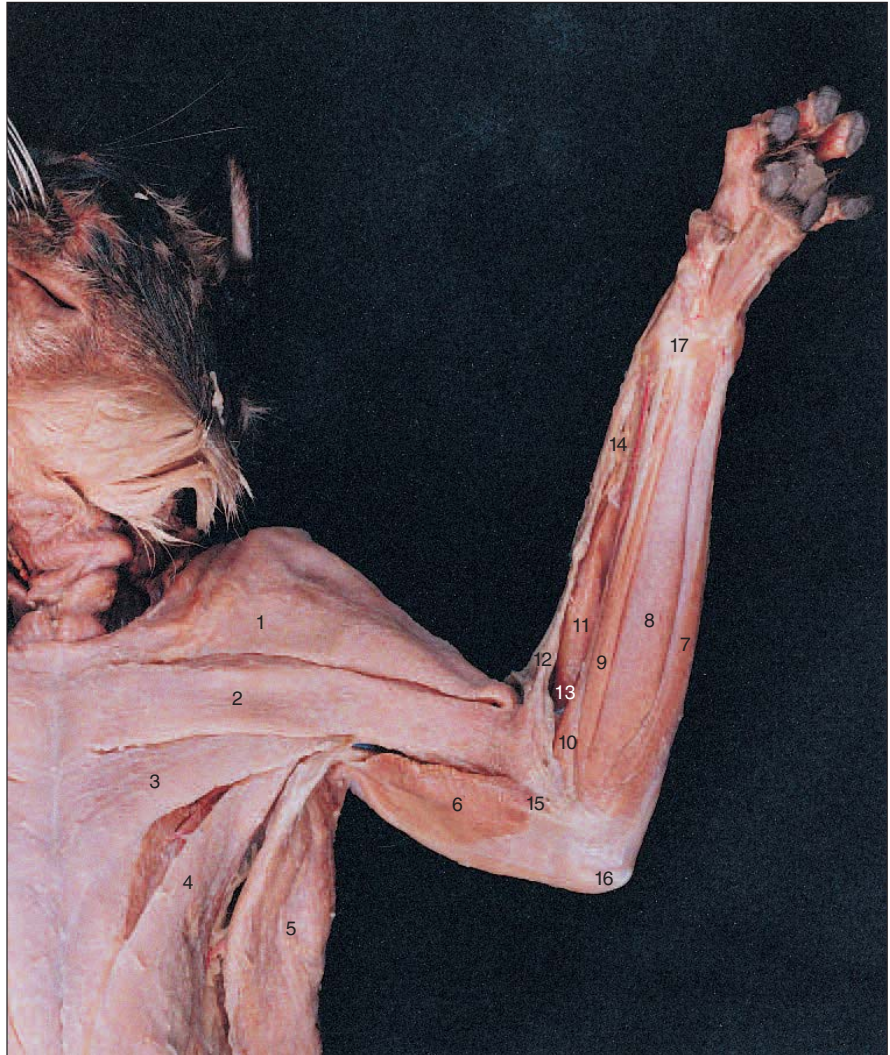
1. Upper canine tooth
2. Upper premolar tooth
3. Upper molar tooth
4. Hard palate with palatine rugae
5. Soft palate
6. Tongue
7. Lingual tonsils
8. Isthmus of fauces
9. Epiglottis
10. Palatine tonsil
11. Larynx
12. Thyroid gland (reflected)
13. Trachea
14. External jugular vein
15. Common carotid artery
16. Esophagus
17. Lymph node

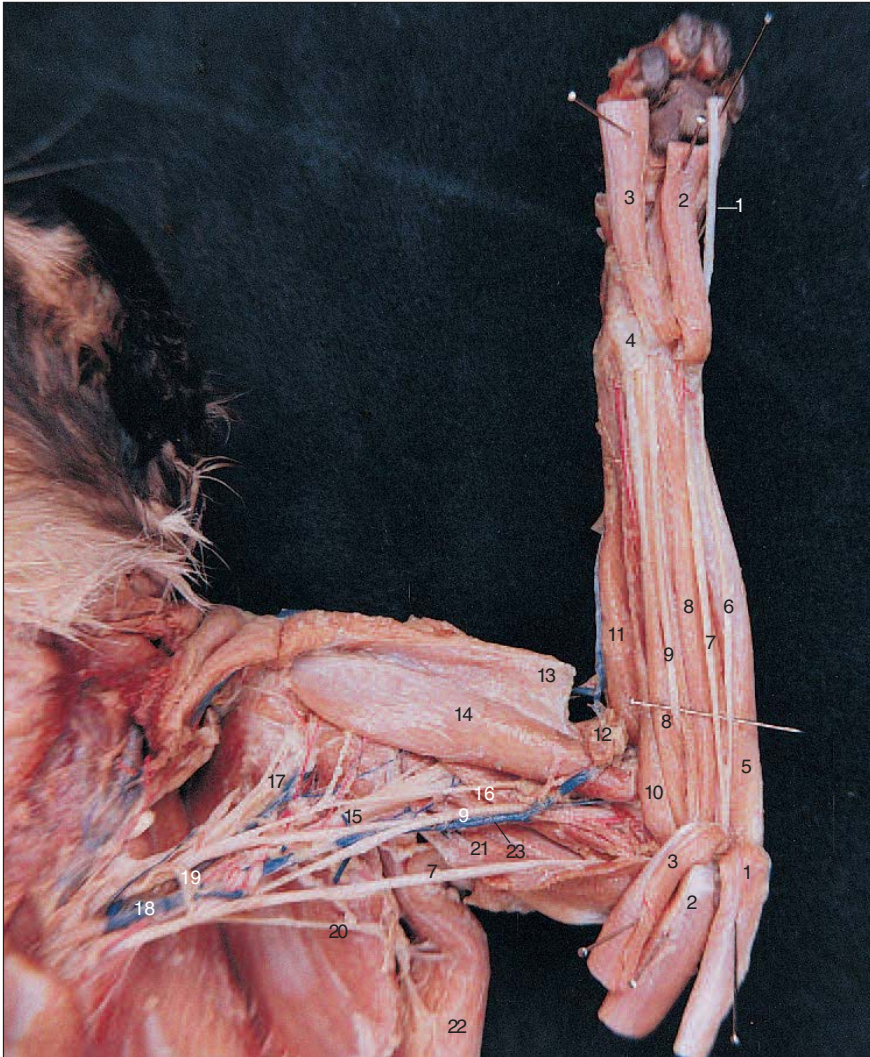


100 CHAPTER 4

**Figure 4-5**  
**Superficial Muscles of the Cat**  
**Thoracic Limb, Ventral Aspect**

1. Clavobrachialis muscle
2. Pectoantibrachialis muscle
3. Pectoralis major muscle
4. Pectoralis minor muscle
5. Latissimus dorsi muscle
6. Epitrochlearis muscle
7. Flexor carpi ulnaris muscle
8. Palmaris longus muscle
9. Flexor carpi radialis muscle
10. Pronator teres muscle
11. Extensor carpi radialis muscle
12. Brachioradialis muscle (cut)
13. Cephalic vein
14. Antebrachial fascia
15. Ulnar nerve
16. Olecranon process of ulna
17. Flexor retinaculum (transverse carpal ligament)



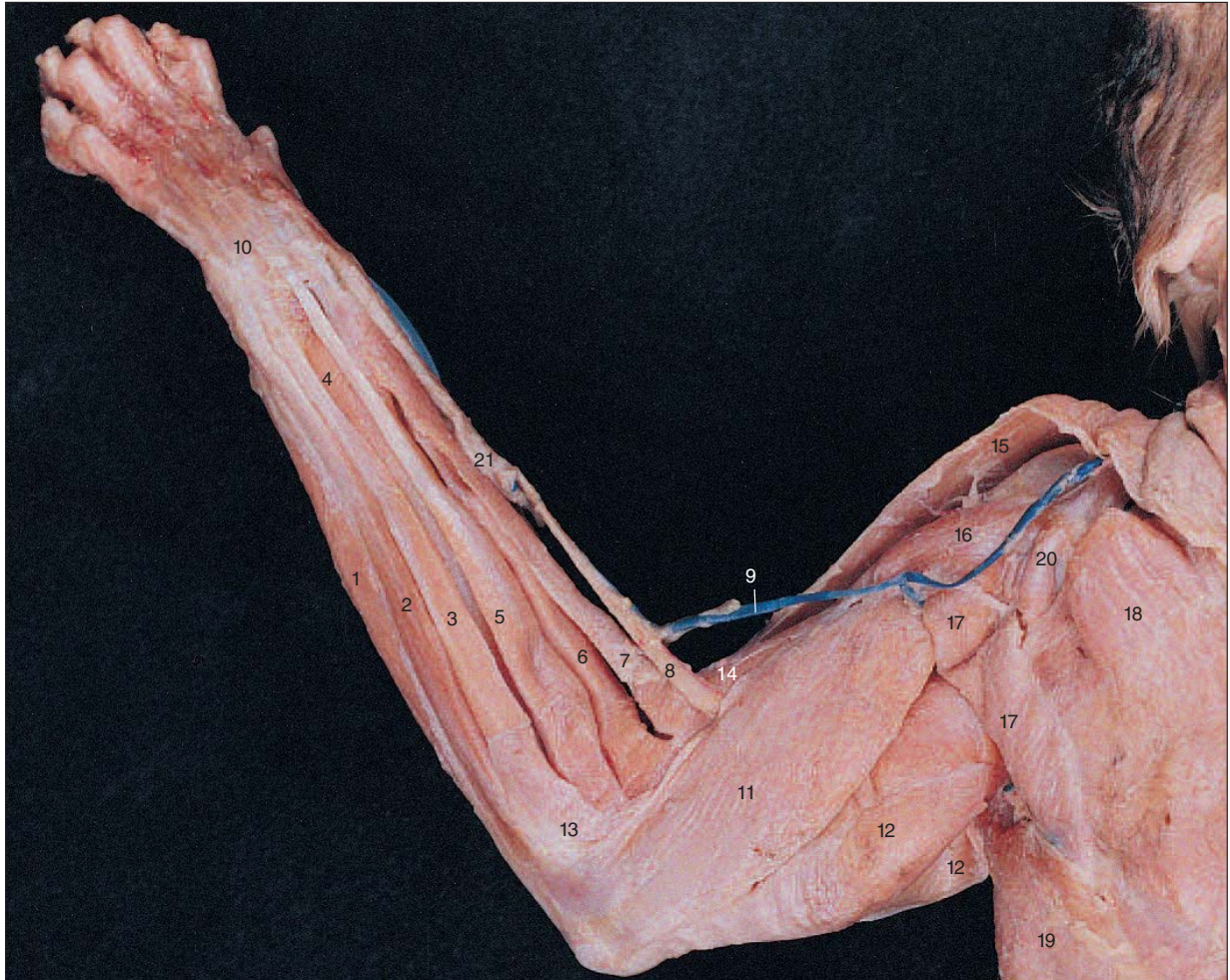


**Figure 4-6**  
**Deep Muscles of the Cat**  
**Left Thoracic Limb,**  
**Ventral View**

1. Flexor carpi ulnaris muscle (cut and reflected)
2. Palmaris longus muscle (cut and reflected)
3. Flexor carpi radialis muscle (cut and reflected)
4. Flexor retinaculum
5. Extensor carpi ulnaris
6. Cutaneous branch of ulnar nerve
7. Ulnar nerve
8. Flexor digitorum profundus
9. Median nerve
10. Pronator teres muscle
11. Extensor carpi radialis muscle
12. Brachioradialis muscle (cut)
13. Clavobrachialis muscle (cut and reflected)
14. Biceps brachii muscle
15. Radial nerve
16. Musculocutaneous nerve
17. Axillary nerve
18. Subclavian vein
19. Ventral thoracic nerve (cut)
20. Thoracic nerve
21. Triceps brachii muscle
22. Latissimus dorsi muscle
23. Brachial vein

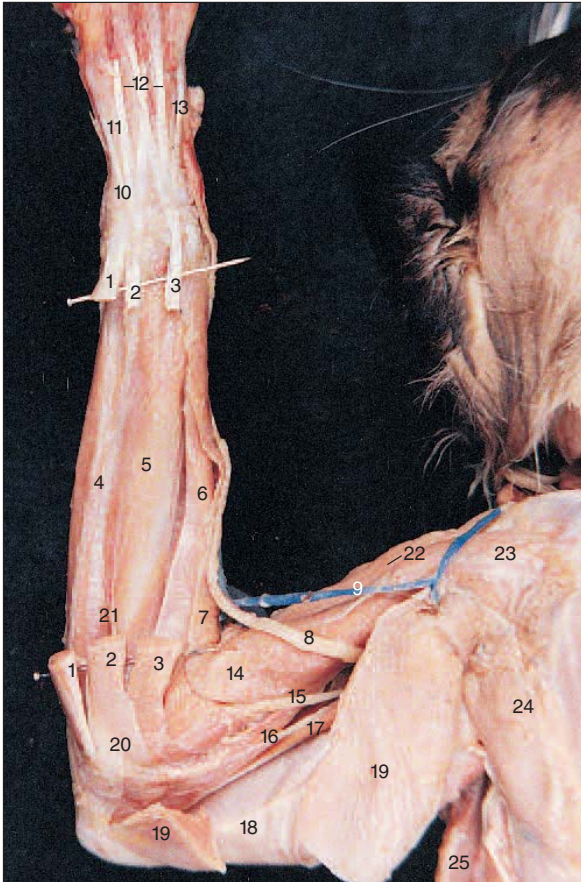


## 102 CHAPTER 4



**Figure 4-7**  
**Superficial Muscles of the Cat Left Thoracic Limb, Dorsal View**

- |  |   |                                |
|--|---|--------------------------------|
| 1. Flexor carpi ulnaris muscle           | 8. Brachioradialis muscle                         | 16. Acromiodeltoid muscle      |
| 2. Extensor carpi ulnaris muscle         | 9. Cephalic vein                                  | 17. Spinodeltoid muscle        |
| 3. Extensor digitorum lateralis muscle   | 10. Extensor retinaculum (dorsal carpal ligament) | 18. Acromiotrapezius muscle    |
| 4. Extensor pollicis brevis muscle       | 11. Triceps brachii muscle (lateral head)         | 19. Latissimus dorsi muscle    |
| 5. Extensor digitorum communis muscle    | 12. Triceps brachii muscle (long head)            | 20. Levator scapulae ventralis |
| 6. Extensor carpi radialis brevis muscle | 13. Anconeus muscle                               | 21. Antebrachial fascia        |
| 7. Extensor carpi radialis longus muscle | 14. Brachialis muscle                             |                                |
|  | 15. Clavobrachialis muscle                        |                                |



**Figure 4-8**

**Deep Muscles of the Cat Left Thoracic Limb, Dorsal View**

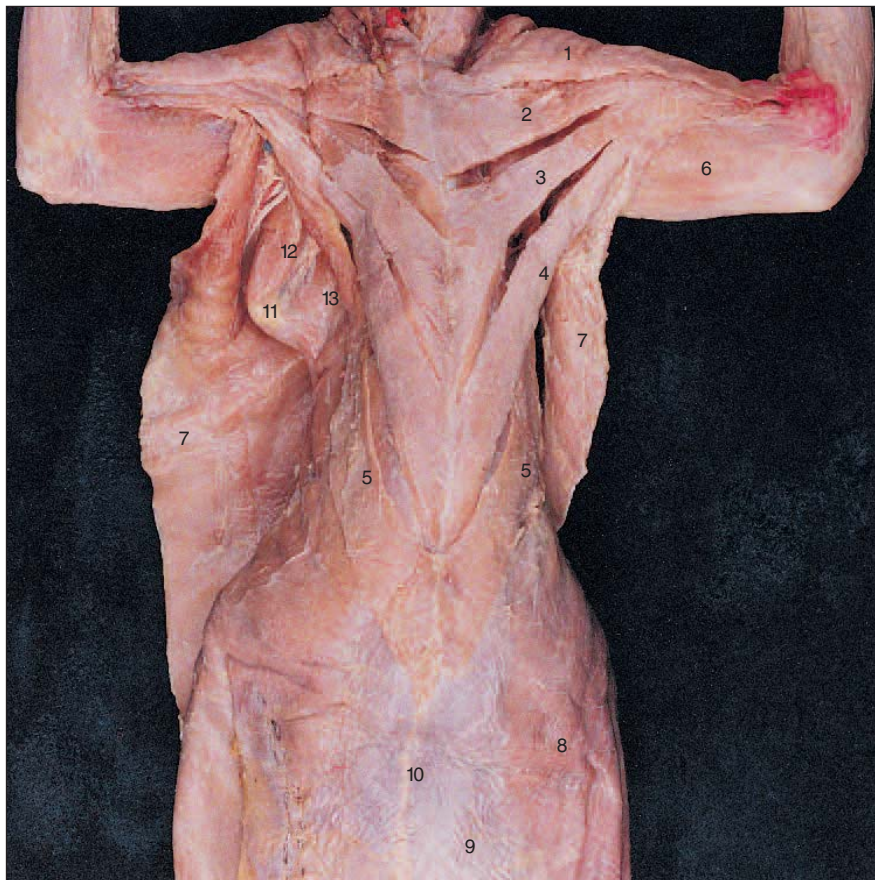
1. Extensor carpi ulnaris muscle (cut)
2. Extensor digitorum lateralis muscle (cut)
3. Extensor digitorum communis muscle (cut)
4. Extensor indicis proprius muscle
5. Extensor pollicis brevis muscle
6. Extensor carpi radialis muscle
7. Brachioradialis muscle
8. Radial nerve
9. Cephalic vein
10. Extensor retinaculum (dorsal carpal ligament)
11. Extensor digiti minimi tendon
12. Extensor digitorum tendons
13. Extensor indicis tendon
14. Brachialis muscle
15. Median nerve
16. Ulnar nerve
17. Triceps brachii muscle (medial head)
18. Triceps brachii muscle (long head)
19. Triceps brachii muscle (lateral head, cut)
20. Anconeus muscle
21. Posterior interosseous nerve
22. Clavobrachialis muscle
23. Acromiodeltoid muscle
24. Spinodeltoid muscle
25. Latissimus dorsi muscle

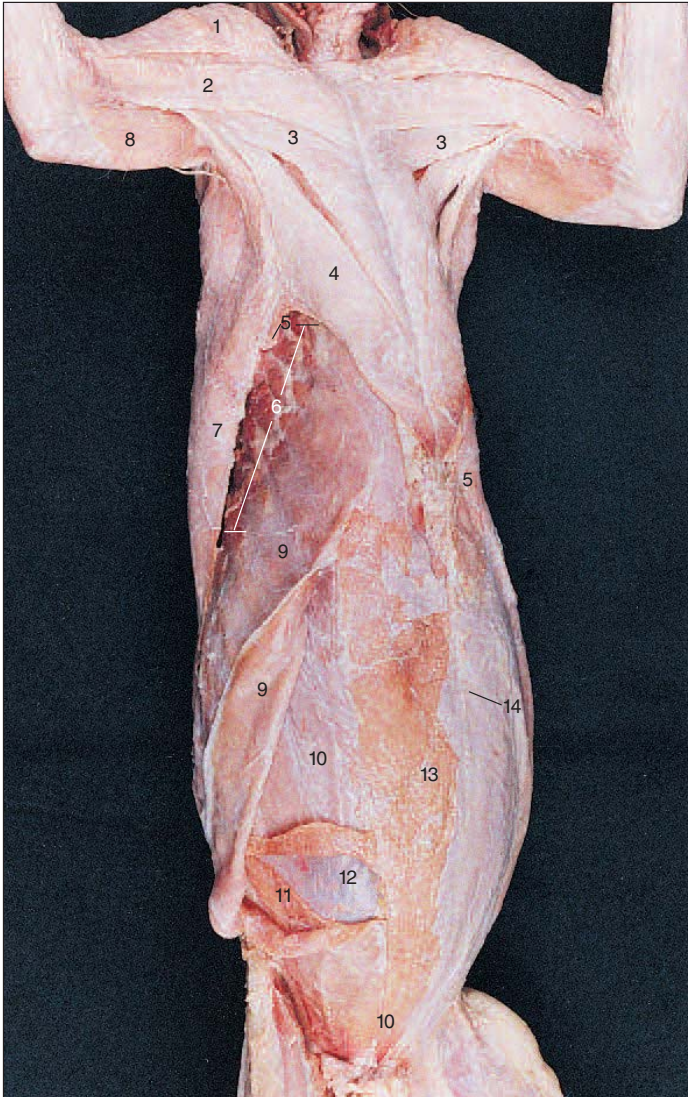

## 104 CHAPTER 4

**Figure 4-9**  
**Superficial Muscles of the**  
**Cat Thorax, Ventral View**

1. Clavobrachialis muscle
2. Pectoantebrachialis muscle
3. Pectoralis major muscle
4. Pectoralis minor muscle
5. Xiphohumeralis muscle
6. Epitrochlearis muscle
7. Latissimus dorsi muscle
8. External oblique muscle
9. Rectus abdominis muscle (deep to aponeurosis)
10. Linea alba
11. Inferior angle of scapula
12. Teres major muscle
13. Subscapularis muscle





**Figure 4-10**  
**Superficial Muscles of the Cat,**  
**Abdomen and Thorax**

1. Clavobrachialis muscle
2. Pectoantebrachialis muscle
3. Pectoralis major muscle
4. Pectoralis minor muscle
5. Xiphohumeralis muscle (removed on right)
6. Serratus anterior muscle
7. Latissimus dorsi muscle (cut to reveal underlying muscles)
8. Epitrochlearis muscle
9. External oblique muscle (partially reflected)
10. Internal oblique muscle (partially reflected)
11. Transversalis abdominis muscle
12. Peritoneum
13. Rectus abdominis muscle
14. Linea alba



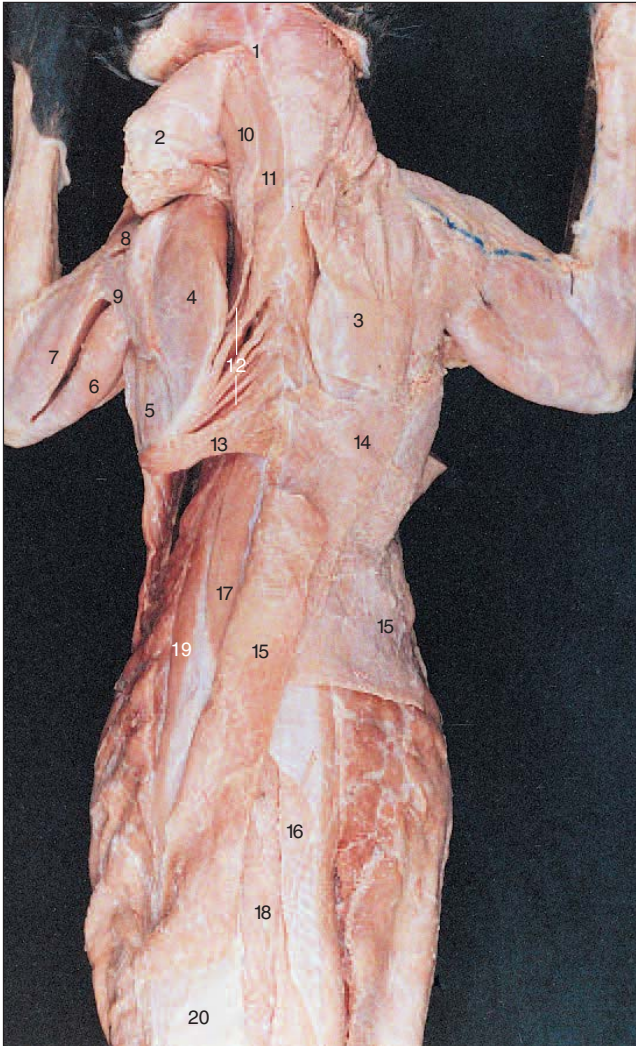106 CHAPTER 4

**Figure 4-11**

**Superficial Muscles of the Cat Neck and Back**

1. Nuchal ligament
2. Clavotrapezius muscle
3. Clavobrachialis muscle
4. Acromiortrapezius muscle (cut and reflected on right)
5. Supraspinatus muscle
6. Acromiodeltoid muscle
7. Spinodeltoid muscle
8. Triceps brachii muscle (long head)
9. Cephalic vein
10. Rhomboideus minor muscle
11. Rhomboideus capitis muscle (occipitoscapularis muscle)
12. Splenius capitis muscle
13. Spinotrapezius muscle
14. Latissimus dorsi muscle
15. Lumbodorsal fascia





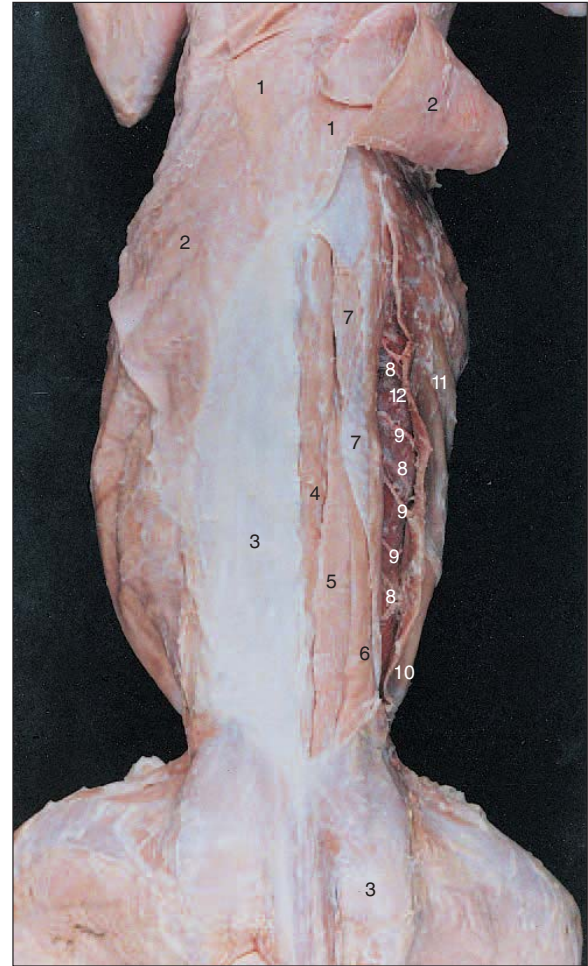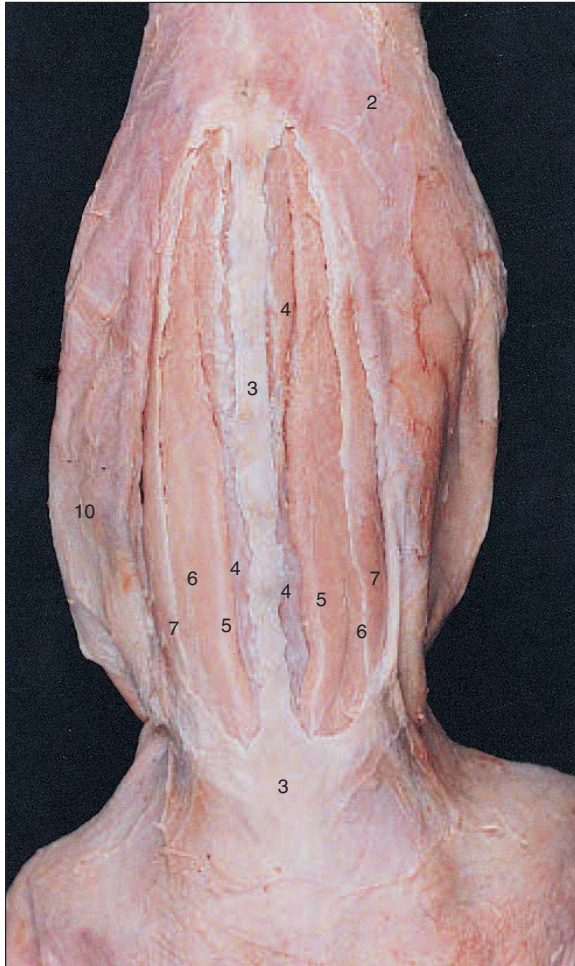
**Figure 4-12**

**Deep Muscles of the Cat Neck and Back**

1. Nuchal ligament
2. Clavotrapezius muscle (reflected on left)
3. Acromiotrapezius muscle (cut, removed altogether on left)
4. Supraspinatus muscle
5. Infraspinatus muscle
6. Triceps brachii muscle (long head)
7. Triceps brachii muscle (lateral head)
8. Acromiodeltoid muscle
9. Spinodeltoid muscle
10. Rhomboideus capitis muscle
11. Splenius capitis muscle
12. Rhomboideus minor muscle
13. Rhomboideus major muscle
14. Spinotrapezius muscle
15. Latissimus dorsi muscle (reflected on left, partially removed on right)
16. Multifidus muscle
17. Longissimus muscle
18. Spinalis muscle
19. Iliocostalis muscle
20. Lumbodorsal fascia (largely removed)



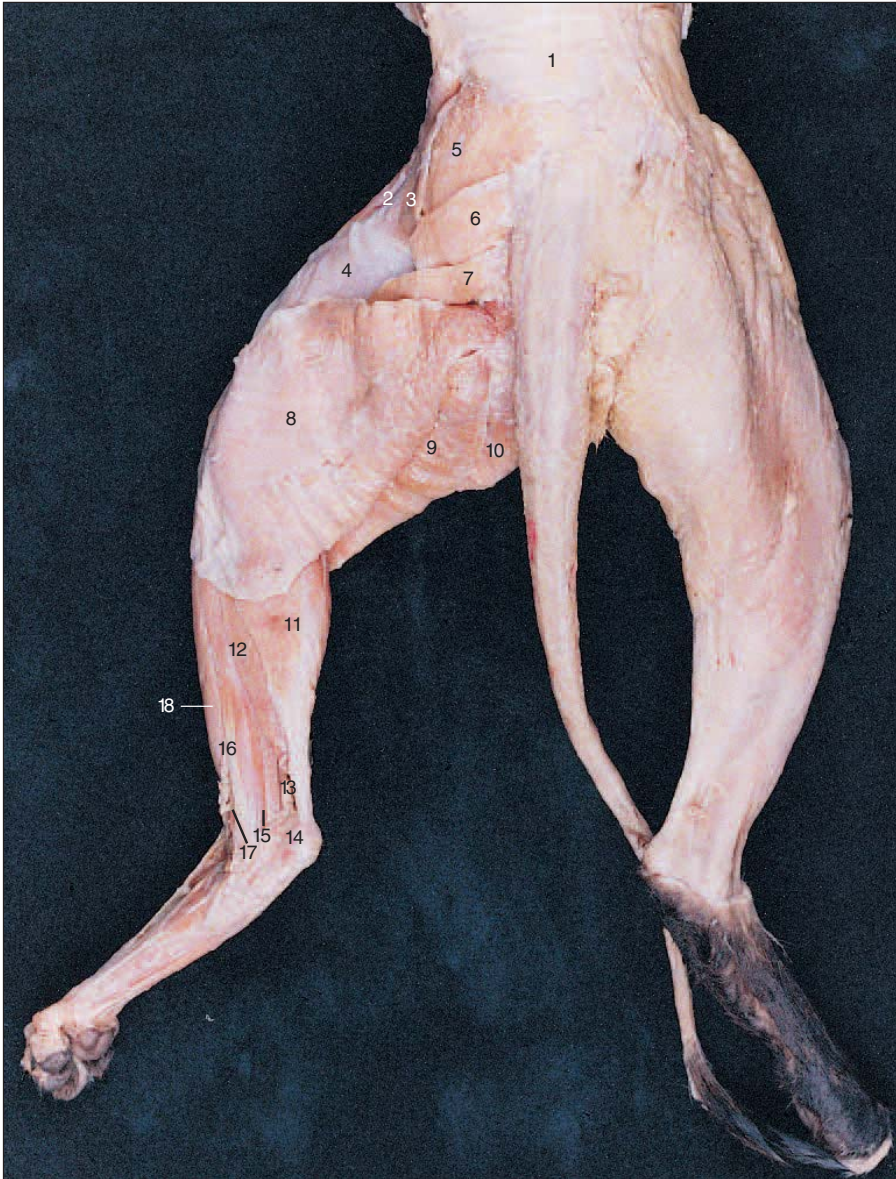
## 108 CHAPTER 4



**Figure 4-13**

**Deep Muscles of the Back of the Cat**

- |  |                                 |                                 |
|--|---------------------------------|---------------------------------|
| 1. Spinotrapezius muscle                             | 5. Spinalis muscle              | 10. External oblique muscle     |
| 2. Latissimus dorsi muscle (cut and rolled on right) | 6. Longissimus muscle           | 11. External intercostal muscle |
| 3. Lumbodorsal fascia                                | 7. Iliocostalis muscle          | 12. Internal intercostal muscle |
| 4. Multifidus muscle                                 | 8. Rib                          |                                 |
|  | 9. Dorsal ramus of spinal nerve |                                 |



**Figure 4-14**  
**Superficial Muscles of**  
**the Cat Left Hind Limb,**  
**Dorsal View**

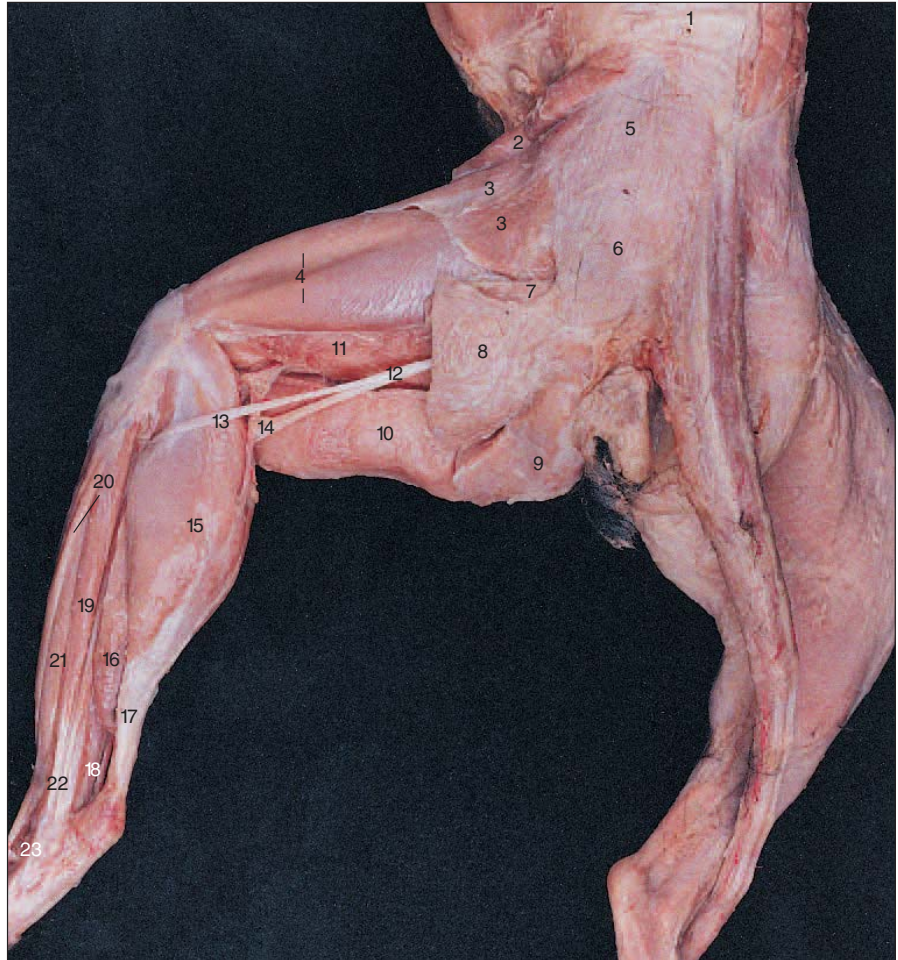
1. Lumbodorsal fascia
2. Sartorius muscle
3. Tensor fascia latae muscle
4. Iliotibial tract
5. Gluteus medius muscle
6. Gluteus maximus muscle
7. Caudofemoralis muscle
8. Biceps femoris muscle
9. Semitendinosus muscle
10. Semimembranosus muscle
11. Gastrocnemius muscle
12. Soleus muscle
13. Achilles tendon
14. Calcaneal tuberosity
15. Flexor hallucis longus muscle
16. Peroneus brevis muscle
17. Peroneus longus muscle and tendon
18. Tibialis anterior muscle

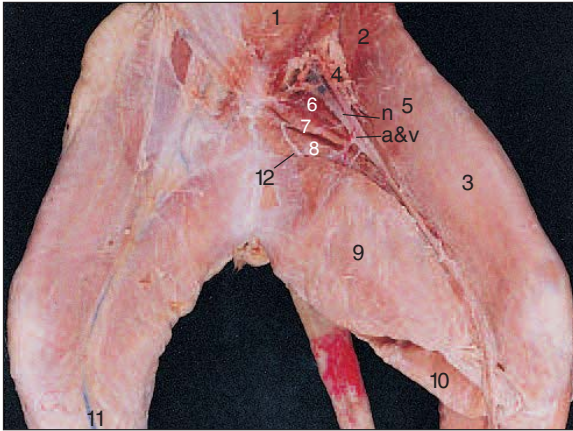


## 110 CHAPTER 4

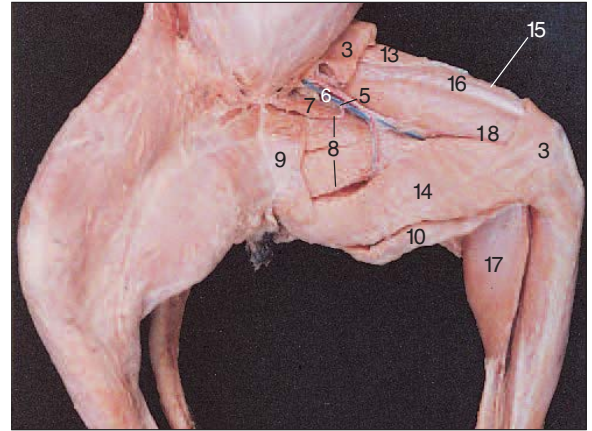
**Figure 4-15**  
**Deep Muscles of the Cat Left**  
**Hind Limb, Dorsal View**

1. Lumbodorsal fascia
2. Sartorius muscle
3. Tensor fascia latae muscle
4. Vastus lateralis muscle
5. Gluteus medius muscle (under fascia)
6. Gluteus maximus muscle (under fascia)
7. Caudofemoralis muscle
8. Biceps femoris muscle (cut)
9. Semitendinosus muscle (cut)
10. Semimembranosus muscle
11. Adductor femoris muscle
12. Sciatic nerve
13. Common peroneal division of sciatic nerve
14. Tibial division of sciatic nerve
15. Gastrocnemius muscle
16. Soleus muscle
17. Achilles tendon
18. Flexor hallucis longus muscle
19. Peroneus longus muscle
20. Tibialis anterior muscle
21. Extensor digitorum longus muscle
22. Proximal extensor retinaculum
23. Distal extensor retinaculum





(A)



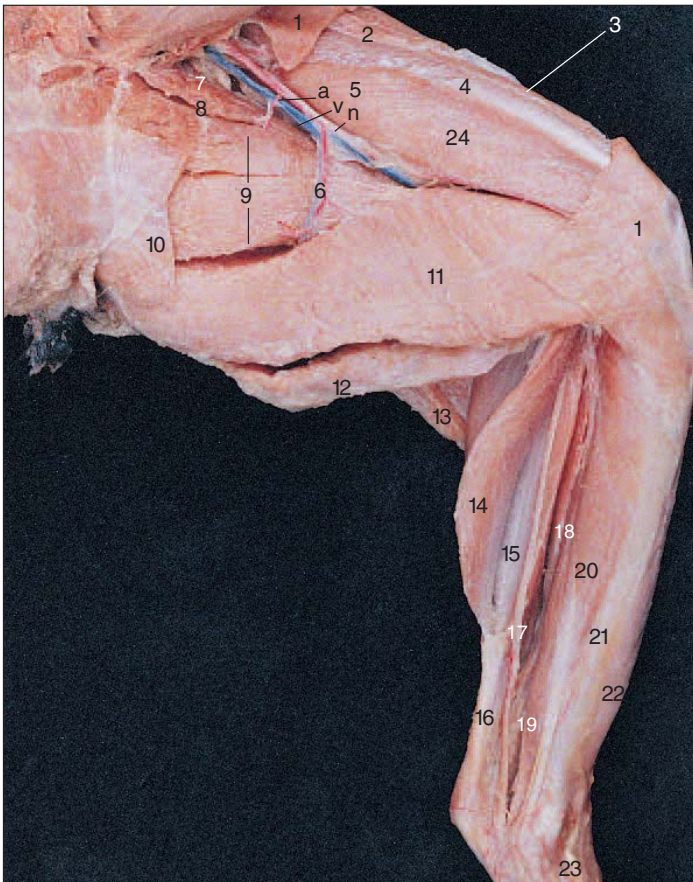
(B)

**Figure 4-16**

**Superficial Muscles of the Cat Left Hind Limb, Medial Aspect**

(A) All superficial muscles intact; (B) Sartorius cut and gracilis removed.

- |  |   |                                |
|--|---|--------------------------------|
| 1. Rectus abdominis muscle                     | 6. Pectineus muscle (deep to blood vessels) | 12. Branch of obturator nerve  |
| 2. External oblique muscle                     | 7. Adductor longus muscle                   | 13. Tensor fascia latae muscle |
| 3. Sartorius muscle (cut in B)                 | 8. Adductor femoris muscle                  | 14. Semimembranosus muscle     |
| 4. Iliopsoas muscle (deep to blood vessels)    | 9. Gracilis muscle                          | 15. Vastus lateralis muscle    |
| 5. Femoral artery (a), vein (v), and nerve (n) | 10. Semitendinosus muscle                   | 16. Rectus femoris muscle      |
|  | 11. Greater saphenous vein                  | 17. Gastrocnemius muscle       |
|  |   | 18. Vastus medialis muscle     |



**Figure 4-17**

**Deep Muscles of the Cat Left Hind Limb, Medial Aspect**

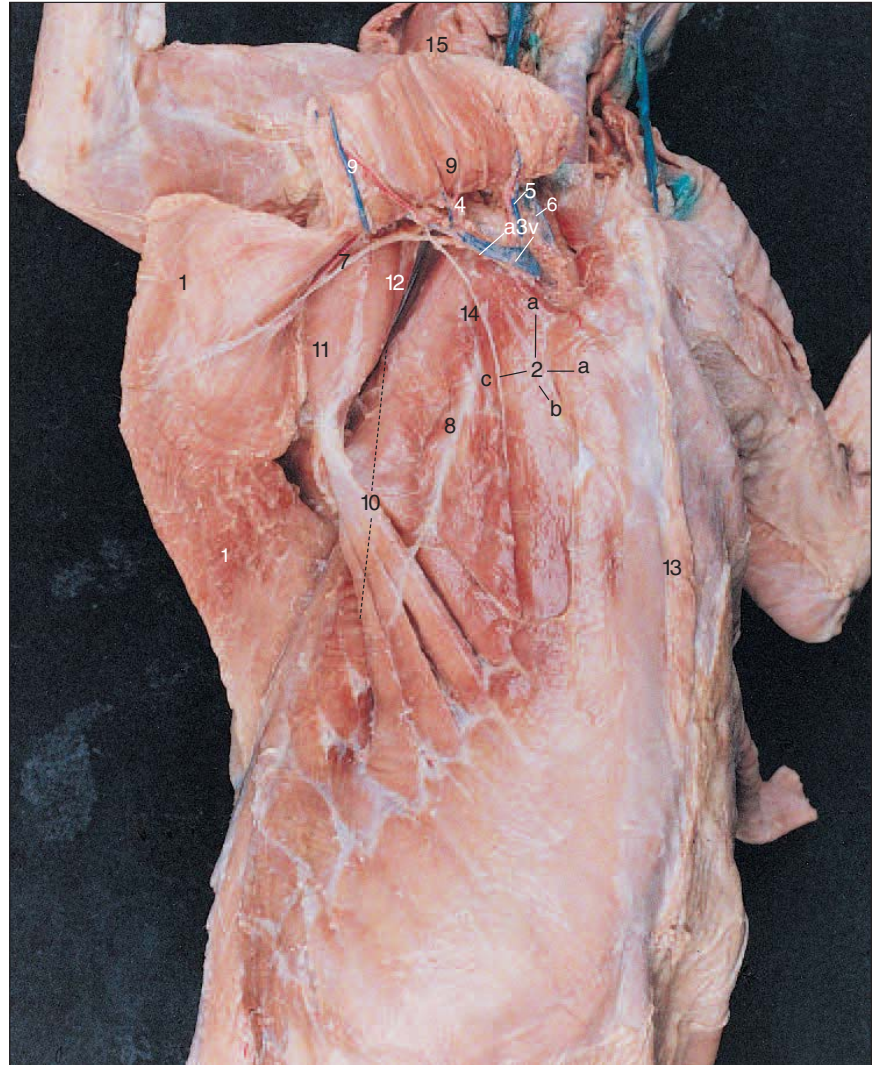
1. Sartorius muscle (cut)
2. Tensor fascia latae muscle
3. Vastus lateralis muscle
4. Rectus femoris muscle
5. Femoral artery (a), vein (v), and nerve (n)
6. Middle caudal femoral artery and vein
7. Pectineus muscle
8. Adductor longus muscle
9. Adductor femoris muscle
10. Gracilis muscle (cut)
11. Semimembranosus muscle
12. Semitendinosus muscle
13. Biceps femoris muscle
14. Gastrocnemius muscle (reflected)
15. Soleus muscle
16. Achilles tendon
17. Posterior tibial nerve
18. Flexor hallucis longus muscle
19. Flexor digitorum longus muscle
20. Tibialis posterior muscle
21. Tibia
22. Tibialis anterior muscle
23. Proximal extensor retinaculum
24. Vastus medialis muscle

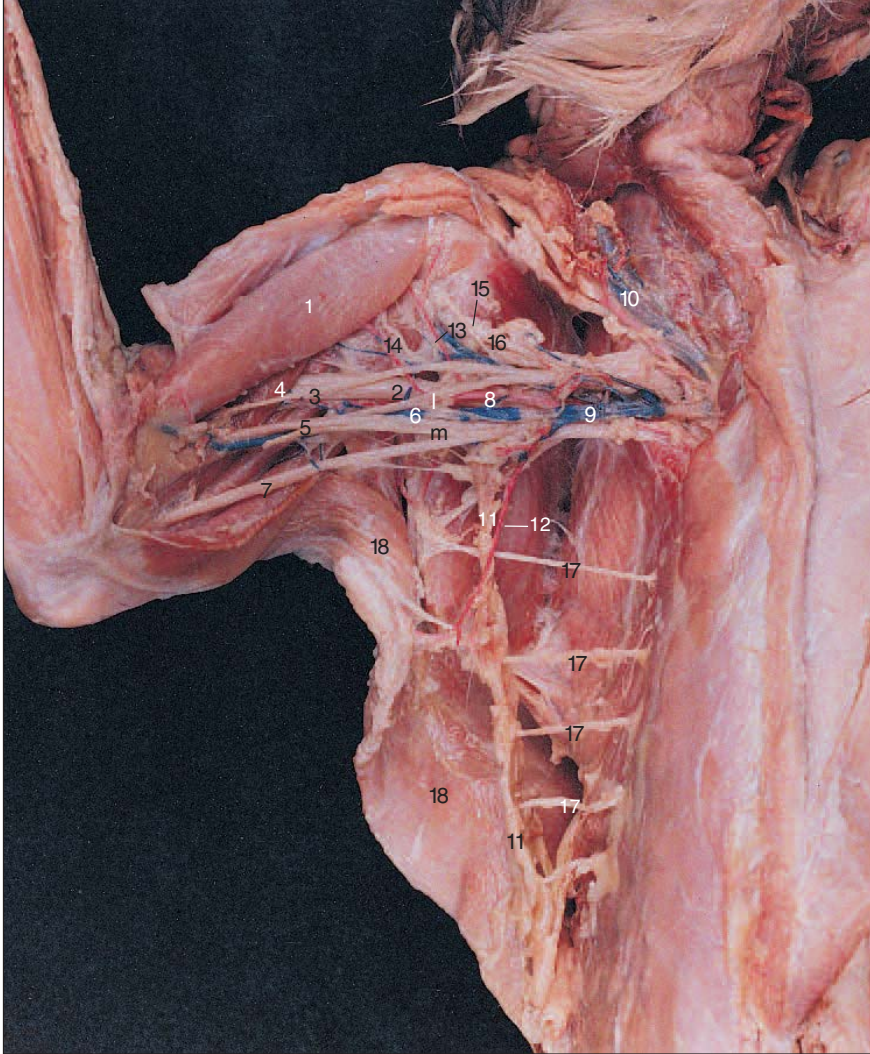


## 112 CHAPTER 4

**Figure 4-18**  
**Deep Muscles of the Cat**  
**Shoulder and Thorax,**  
**Right Ventral View**

1. Latissimus dorsi muscle (reflected)
2. Scalenus muscles
  - a. Anterior (continuous with transversus costarum)
  - b. Medius
  - c. Posterior
3. Axillary artery (a) and vein (v)
4. Radial nerve
5. External jugular vein
6. Internal jugular vein
7. Thoracodorsal nerve
8. Long thoracic nerve
9. Thoracoacromial blood vessels
10. Serratus ventralis muscle
11. Teres major muscle
12. Subscapularis muscle
13. Sternum
14. Ventral thoracic nerve
15. Pectoralis muscles (reflected)





**Figure 4-19**  
**Brachial Plexus of the Cat,**  
**Right Ventral Aspect**

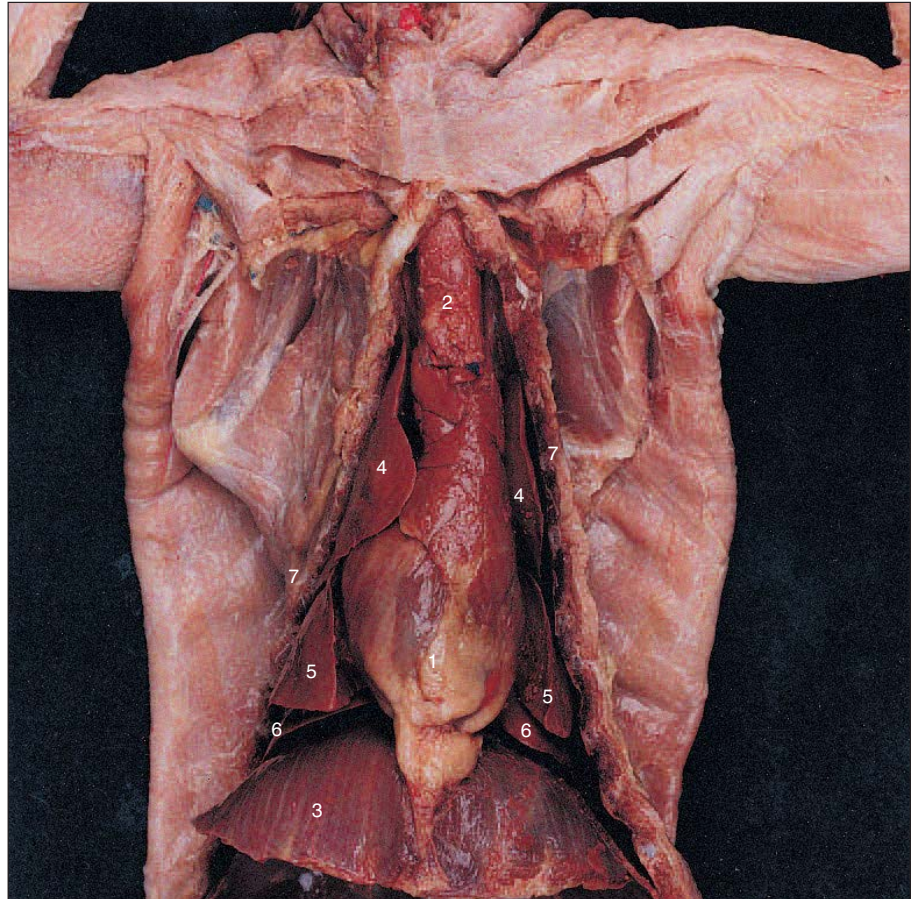
1. Biceps brachii muscle
2. Radial nerve
3. Musculocutaneous nerve
4. Coracobrachialis muscle
5. Median nerve
6. Lateral (l) and median (m) roots of the median nerve
7. Ulnar nerve
8. Axillary artery
9. Axillary vein
10. External jugular vein
11. Thoracodorsal nerve
12. Thoracodorsal artery
13. Thoracoacromial artery
14. Anterior circumflex humeral artery and axillary nerve
15. Caudal subscapular nerve
16. Proximal subscapular nerve
17. Dorsal rami of thoracic nerves
18. Latissimus dorsi muscle (reflected)

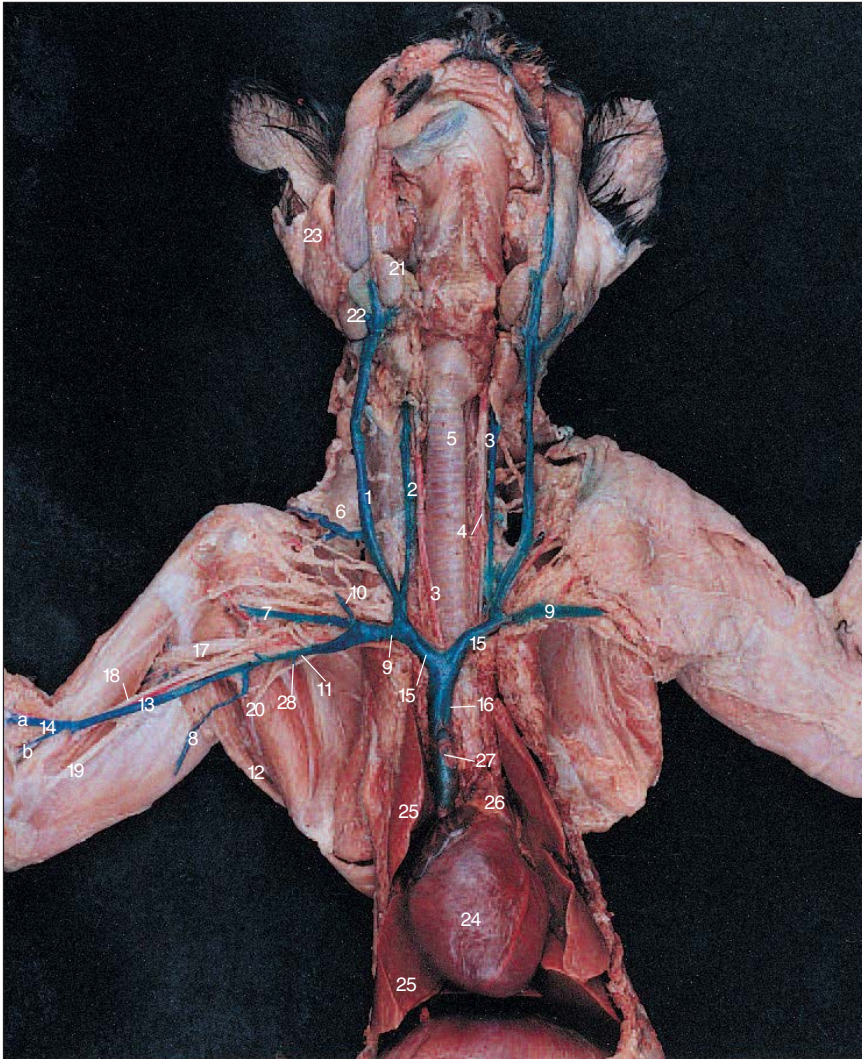


## 114 CHAPTER 4

**Figure 4-20****Thoracic Cavity of the Cat**

1. Heart within pericardium
2. Thymus gland
3. Diaphragm
4. Lung, anterior lobe
5. Lung, middle lobe
6. Lung, posterior lobe
7. Ribs (cut)





**Figure 4-21**  
**Major Veins of the Cat,**  
**Neck and Thorax**

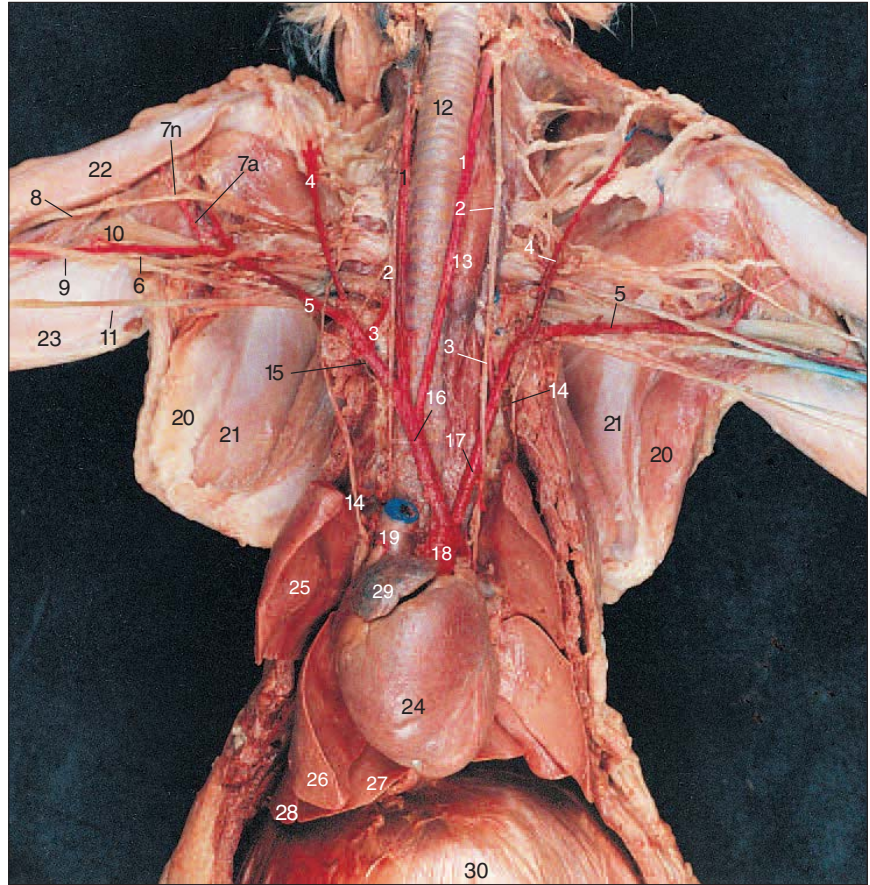
1. External jugular vein
2. Internal jugular vein
3. Common carotid artery (both right and left)
4. Vagus nerve (left)
5. Trachea
6. Transverse scapular vein
7. Subscapular vein
8. Thoracodorsal vein
9. Subclavian vein
10. Ventral thoracic (cut)
11. Axillary vein
12. Latissimus dorsi muscle
13. Brachial vein
14. Median cubital vein with branches
  - a. Radial vein
  - b. Ulnar vein
15. Brachiocephalic (innominate) vein
16. Superior vena cava
17. Radial nerve
18. Median nerve
19. Ulnar nerve
20. Thoracodorsal nerve
21. Lymph node
22. Submandibular gland
23. Parotid gland
24. Heart
25. Lung
26. Thymus gland
27. Anterior thoracic vein (cut) (internal mammary vein)
28. Long thoracic vein (cut)

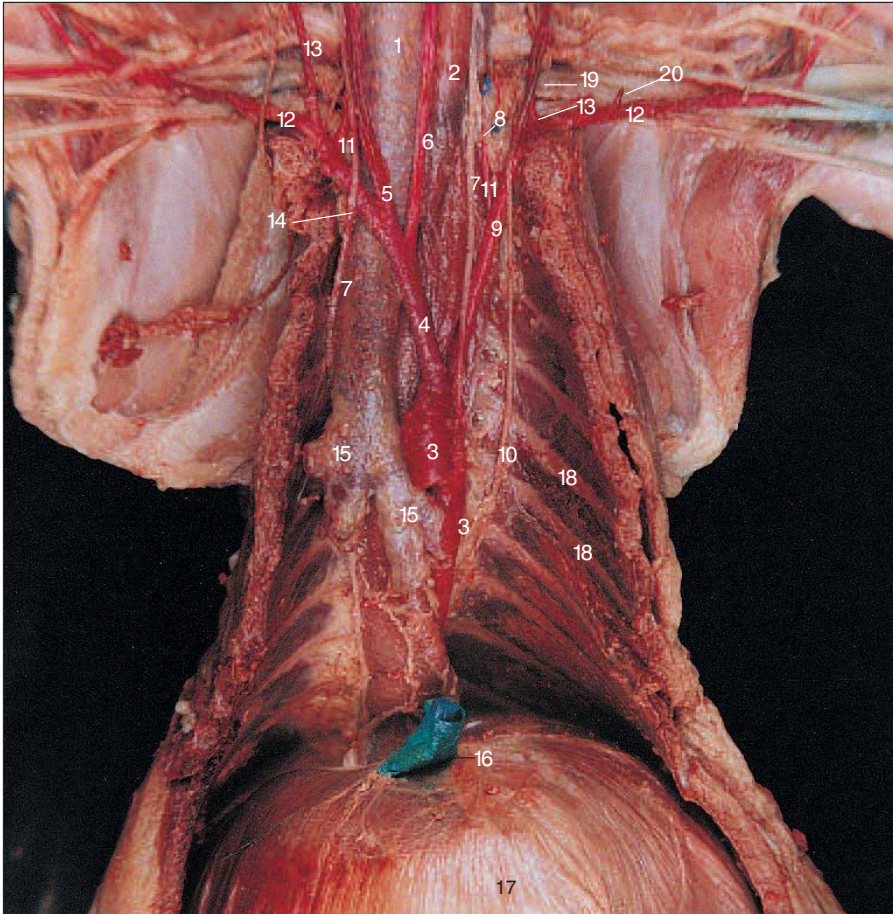


## 116 CHAPTER 4

**Figure 4-22**  
**Major Arteries of the Cat,**  
**Neck and Thorax**

1. Common carotid artery
2. Vagus nerve
3. Vertebral artery
4. Transverse scapular artery
5. Axillary artery
6. Brachial artery
7. Thoraco-acromial artery (a) and nerve (n)
8. Musculocutaneous nerve
9. Median nerve
10. Radial nerve
11. Ulnar nerve
12. Trachea
13. Esophagus (displaced to animal's left from normal position posterior to trachea)
14. Phrenic nerve
15. Right subclavian artery
16. Innominate (brachiocephalic) artery
17. Left subclavian artery
18. Aortic arch
19. Anterior vena cava (cut)
20. Teres major muscle
21. Subscapularis muscle
22. Biceps brachii muscle
23. Triceps brachii muscle (long head)
24. Heart
25. Lung, anterior lobe
26. Lung, middle lobe
27. Lung, mediastinal lobe
28. Lung, posterior lobe
29. Right auricle
30. Diaphragm



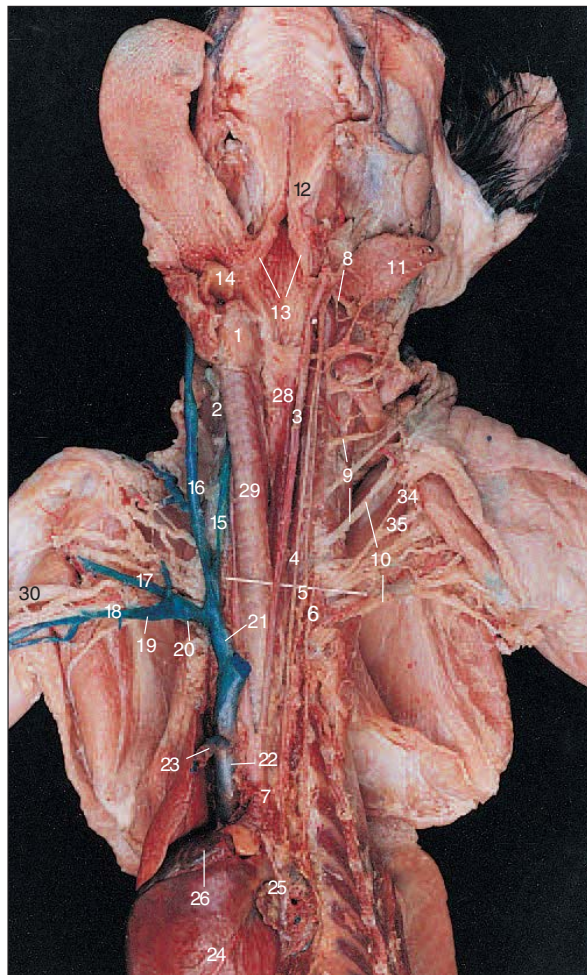


**Figure 4-23**  
Thorax of the Cat, Heart  
and Lungs Removed

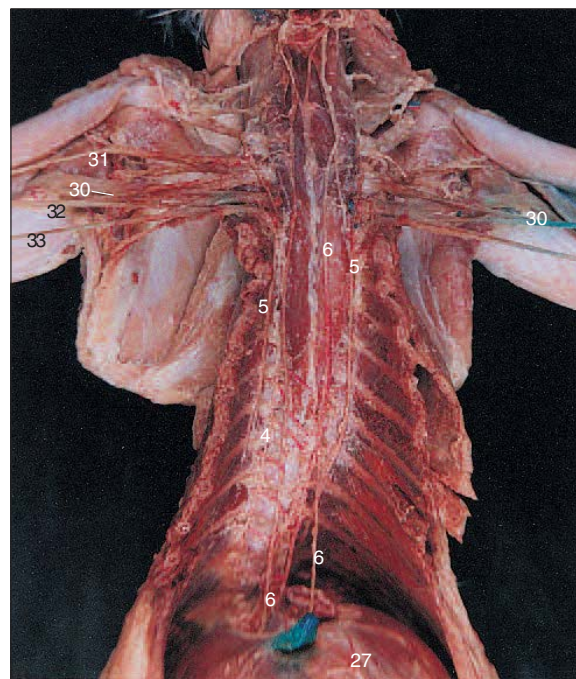
1. Trachea
2. Esophagus
3. Aortic arch
4. Brachiocephalic artery
5. Right common carotid artery
6. Left common carotid artery
7. Vagus nerve
8. Sympathetic trunk
9. Left subclavian artery
10. Phrenic nerve
11. Vertebral artery
12. Subclavian artery
13. Thyrocervical artery
14. Internal mammary artery
15. Right and left primary bronchi
16. Inferior vena cava
17. Diaphragm
18. Rib
19. Transverse scapular artery
20. Subscapular artery (cut)



## 118 CHAPTER 4



A

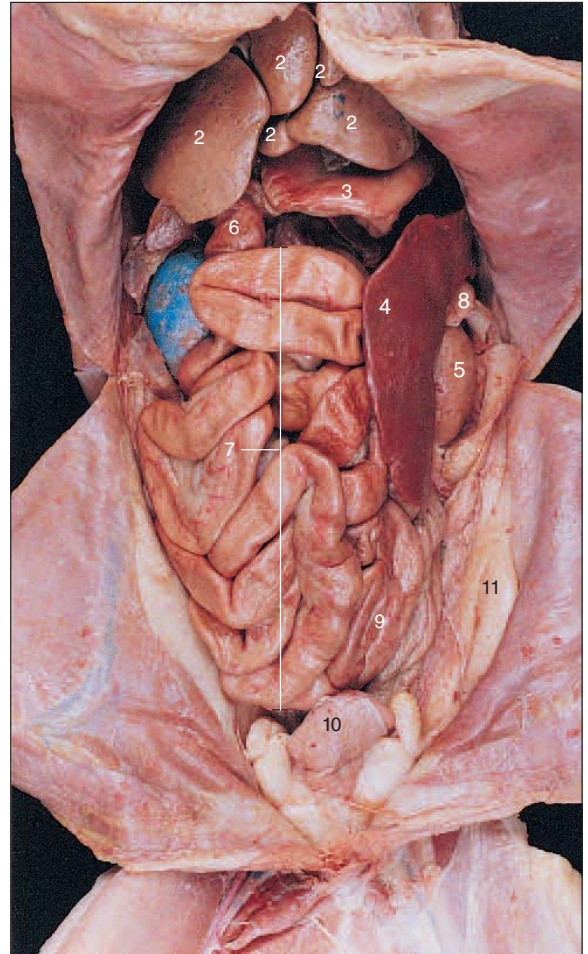
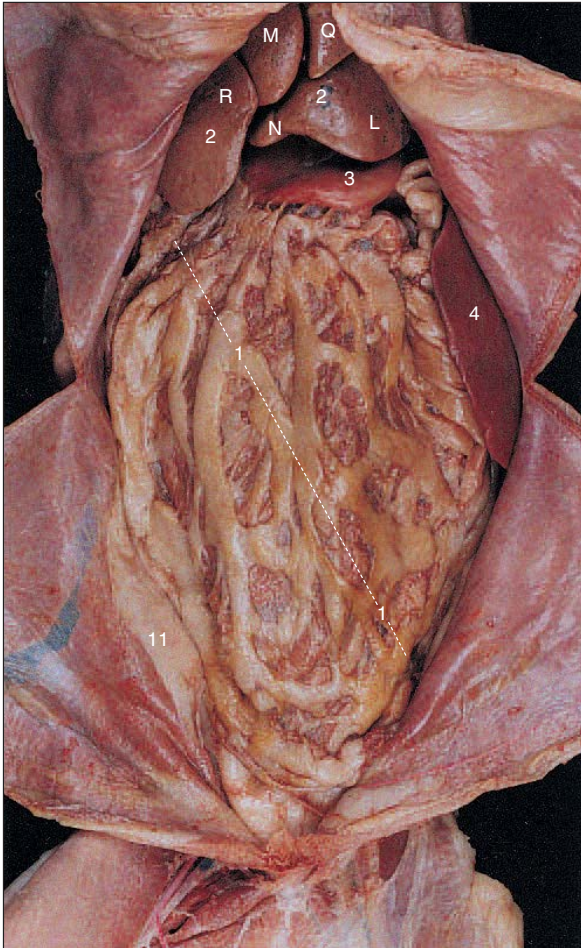

B

**Figure 4-24****Veins, Arteries, and Nerves of the Cat Neck and Thorax**

(A) Veins removed on cat's left side, heart reflected to right;  
(B) Arteries, veins, and thoracic viscera removed.

- |  |  |                                       |
|--|--|---------------------------------------|
| 1. Larynx  | 8. Spinal accessory nerve (XI)                                       | 21. Brachiocephalic (innominate) vein |
| 2. Thyroid gland (reflected)   | 9. Spinal nerves IV, V, and VI                                       | 22. Superior vena cava                |
| 3. Common carotid artery   | 10. Brachial plexus  | 23. Azygous vein (cut)                |
| 4. Vagus nerve   | 11. Lymph node (reflected and pinned)                                | 24. Heart (reflected to cat's right)  |
| 5. Sympathetic trunk (In A, two pins have been placed along sympathetic trunk. Upper pin head is just caudal to swelling of sympathetic trunk, the superior cervical ganglion. Lower transverse pin is just proximal to similar swelling, the middle cervical ganglion.) | 12. Soft palate (cut)  | 25. Right auricle                     |
| 6. Phrenic nerve   | 13. Eustachian tubes (hidden behind reflected tissue of soft palate) | 26. Left auricle                      |
| 7. Aorta   | 14. Epiglottis   | 27. Diaphragm                         |
|  | 15. Internal jugular vein  | 28. Esophagus                         |
|  | 16. External jugular vein  | 29. Trachea                           |
|  | 17. Subscapular vein   | 30. Radial nerve                      |
|  | 18. Brachial vein  | 31. Musculocutaneous nerve            |
|  | 19. Axillary vein  | 32. Median nerve                      |
|  | 20. Subclavian vein  | 33. Ulnar nerve                       |
|  |  | 34. Caudal subscapular nerve          |
|  |  | 35. Axillary nerve                    |



A

B

**Figure 4-25**

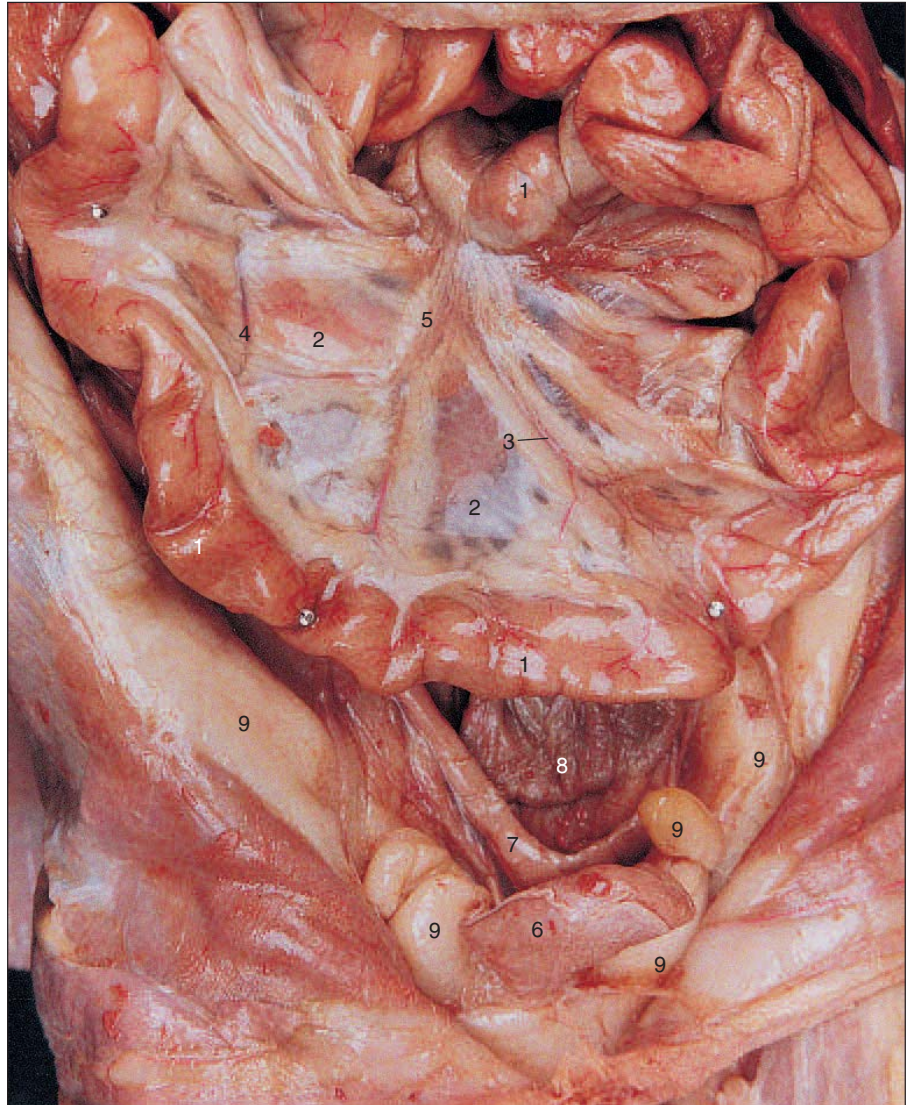
**Abdominal Viscera of Cat** (A) Greater omentum intact; (B) Greater omentum removed.

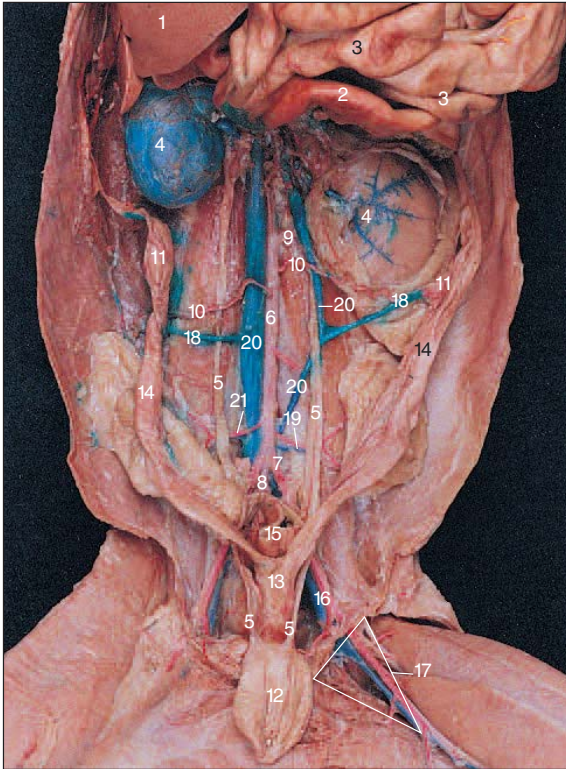
- |                       |  |                                       |
|-----------------------|--|---------------------------------------|
| 1. Greater omentum    | 3. Stomach (greater curvature)         | 9. Large intestine (descending colon) |
| 2. Lobes of the liver | 4. Spleen                              | 10. Urinary bladder                   |
| R. Right lateral lobe | 5. Kidney                              | 11. Abdominal fat                     |
| M. Right medial lobe  | 6. Small intestine (duodenum)          |                                       |
| Q. Quadrate lobe      | 7. Small intestine (jejunum and ileum) |                                       |
| N. Left medial lobe   | 8. Pancreas                            |                                       |
| L. Left lateral lobe  |  |                                       |



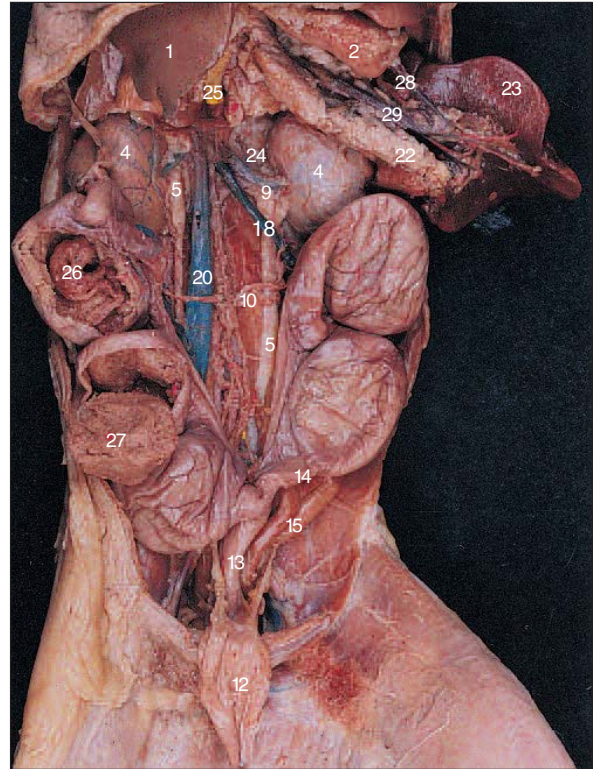
**Figure 4-26**  
**Abdominal Viscera of**  
**the Cat, Mesentery**

1. Small intestine
2. Mesentery
3. Mesenteric artery
4. Mesenteric vein
5. Lymph vessel
6. Urinary bladder
7. Uterus
8. Rectum
9. Abdominal fat





A



B

**Figure 4-27**

**Urogenital System of the Female Cat (A) Nonpregnant; (B) Pregnant.**

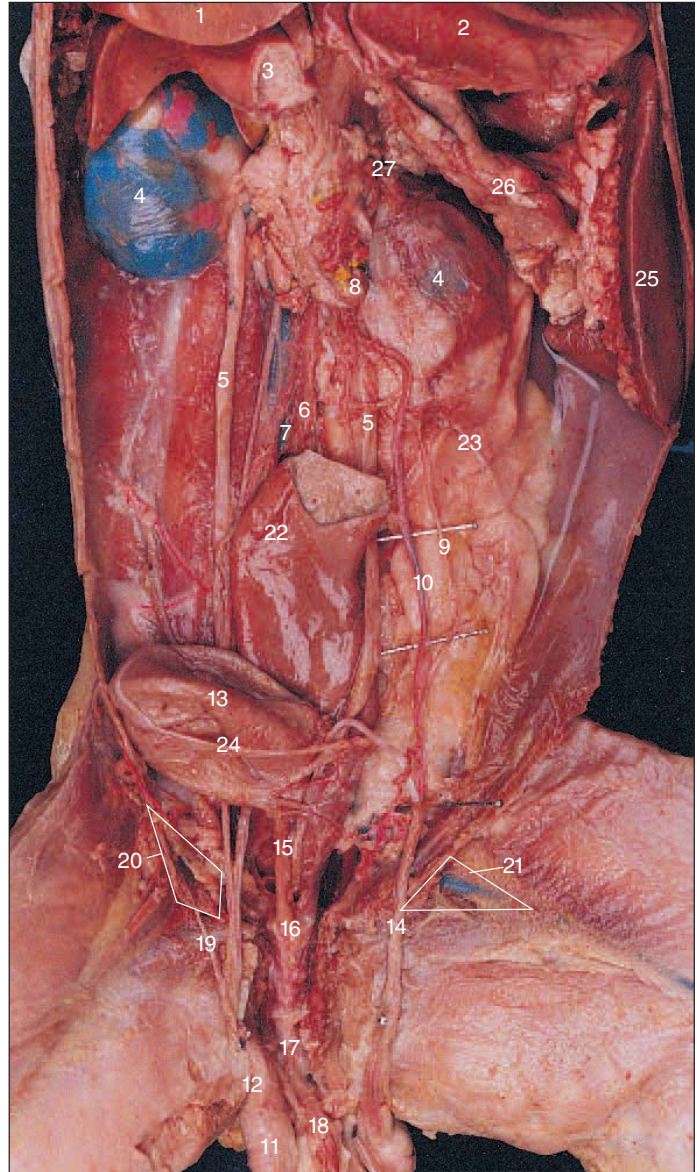
- |                                  |  |  |
|----------------------------------|--|--|
| 1. Liver                         | 12. Urinary bladder (reflected and pinned)   | 20. Abdominal vena cava (split into two parallel vessels in A) |
| 2. Stomach (pylorus)             | 13. Uterus   | 21. Iliolumbar artery  |
| 3. Small intestine               | 14. Uterine horn (in B, left horn contains two fetuses; right horn, three fetuses) | 22. Pancreas   |
| 4. Kidney                        | 15. Rectum (cut in A)  | 23. Spleen   |
| 5. Ureter                        | 16. External iliac artery and vein   | 24. Adrenal gland  |
| 6. Abdominal aorta               | 17. Femoral triangle (containing femoral nerve, artery, and vein)                  | 25. Hepatic portal vein (cut)                                  |
| 7. External iliac artery         | 18. Ovarian vein   | 26. Fetus  |
| 8. Caudal (median sacral artery) | 19. Iliolumbar artery and vein   | 27. Placenta   |
| 9. Renal artery                  |  | 28. Left gastroepiploic vein                                   |
| 10. Ovarian artery               |  | 29. Right gastroepiploic vein                                  |
| 11. Ovary                        |  |  |

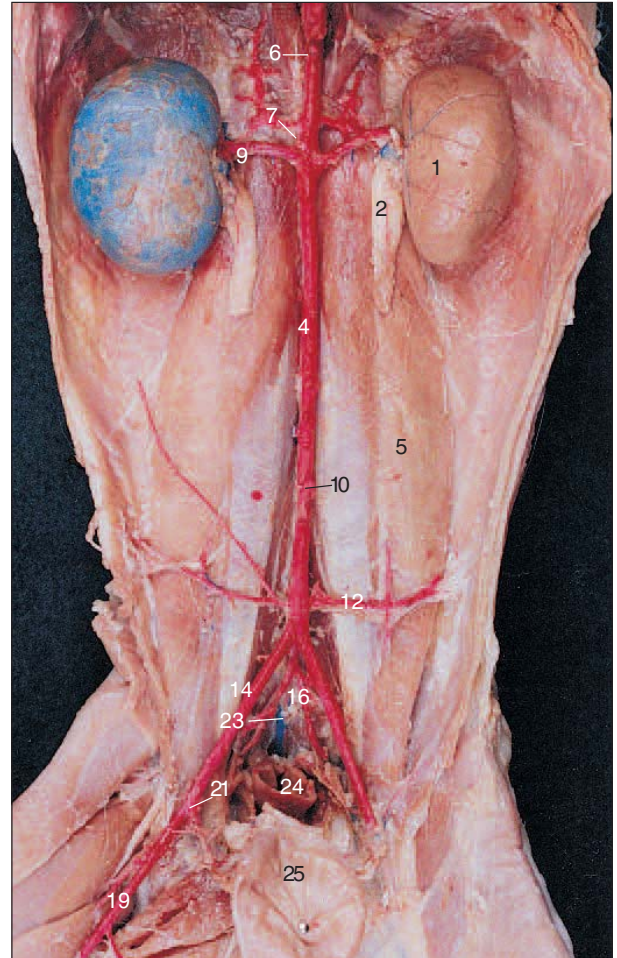
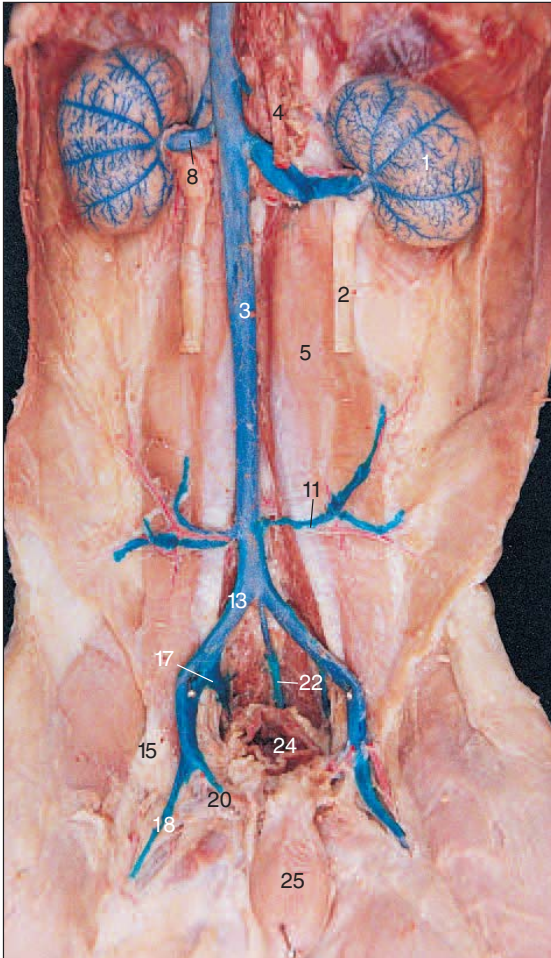


## 122 CHAPTER 4

**Figure 4-28****Urogenital System of the Male Cat**

1. Liver
2. Stomach
3. Small intestine (duodenum, cut)
4. Kidney
5. Ureter
6. Abdominal aorta
7. Abdominal vena cava
8. Renal artery
9. Internal spermatic artery
10. Spermatic vein
11. Testis
12. Epididymis
13. Urinary bladder (reflected)
14. Vas deferens in spermatic cord
15. Urethra
16. Prostate gland
17. Bulbourethral (Cowper's) gland
18. Penis
19. Ligament of cremaster muscle
20. External inguinal ring
21. Femoral triangle
22. Rectum (cut)
23. Lumbar nerve (medial branch)
24. Umbilical (allantoic) artery
25. Spleen
26. Pancreas
27. Adrenal gland





A

B

### Figure 4-29

#### Major (A) Veins and (B) Arteries of the Cat Abdominopelvic Wall

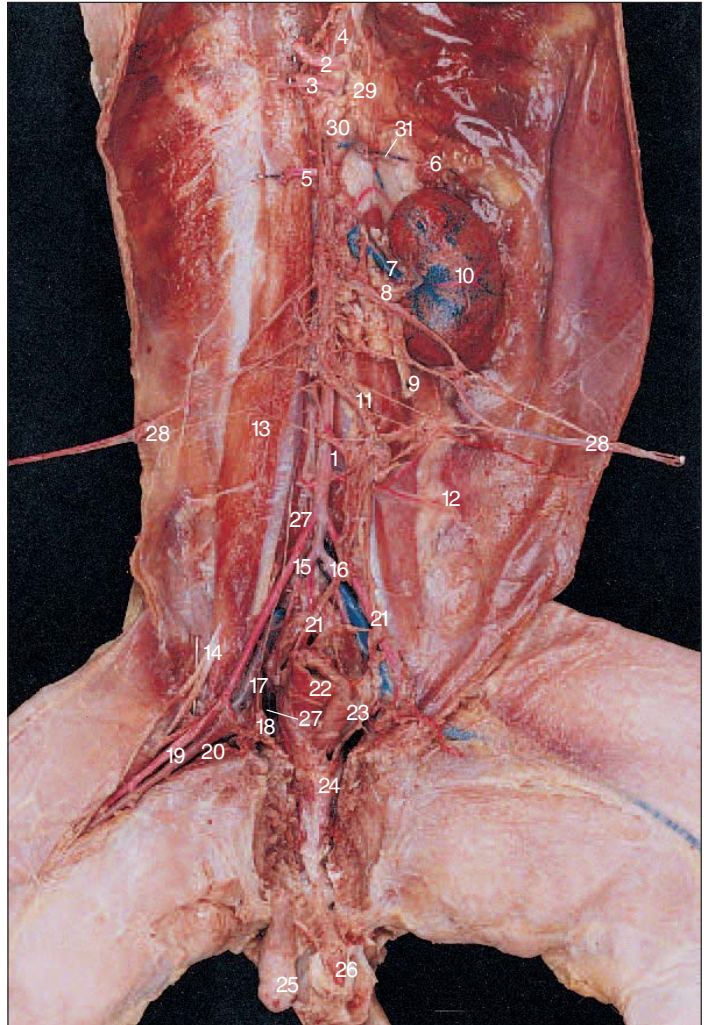
- |   |  |  |
|---|--|--|
| 1. Kidney                                       | 9. Renal artery  | 18. Femoral vein                           |
| 2. Ureter (cut and largely removed)             | 10. Inferior mesenteric artery (cut and removed)           | 19. Femoral artery                         |
| 3. Abdominal vena cava (removed in B)           | 11. Iliolumbar vein  | 20. Deep femoral vein                      |
| 4. Abdominal aorta (cut and removed in A)       | 12. Iliolumbar artery                                      | 21. Deep femoral artery                    |
| 5. Psoas muscle                                 | 13. Common iliac vein                                      | 22. Caudal vein                            |
| 6. Celiac artery (cut and removed)              | 14. External iliac artery (no common iliac artery in cats) | 23. Median sacral (caudal) artery          |
| 7. Superior mesenteric artery (cut and removed) | 15. External iliac vein                                    | 24. Rectum (cut)                           |
| 8. Renal vein                                   | 16. Internal iliac (hypogastric) artery                    | 25. Urinary bladder (reflected and pinned) |
|   | 17. Internal iliac (hypogastric) vein                      |  |

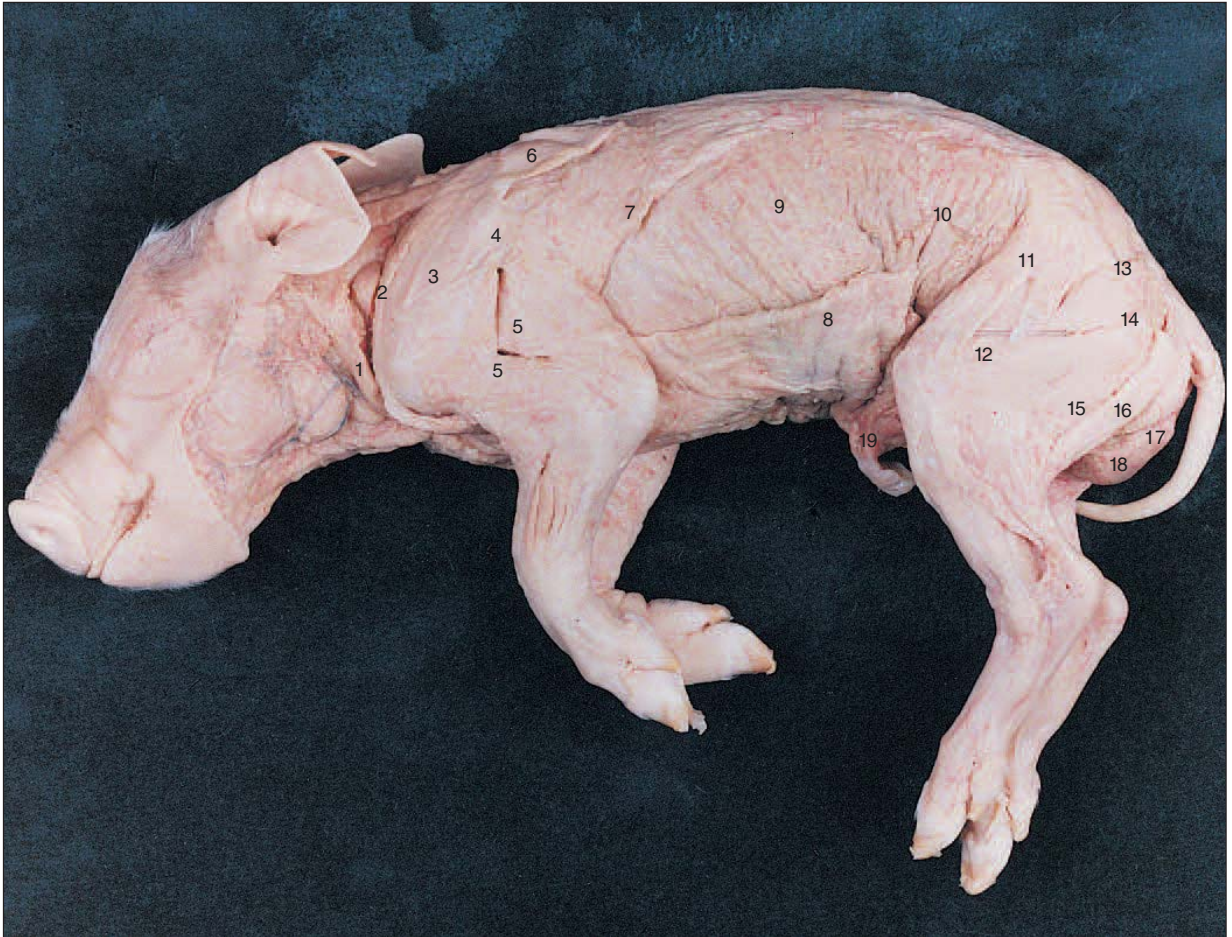


## 124 CHAPTER 4

**Figure 4-30**  
**Nerves and Vessels of the Posterior**  
**Abdominopelvic Wall of the Cat**

1. Abdominal aorta
2. Celiac artery (pinned)
3. Superior mesenteric artery (pinned)
4. Crus of diaphragm
5. Right adrenolumbar (phrenicoabdominal) artery (cut)
6. Adrenal gland
7. Renal vein
8. Renal artery
9. Ureter (cut)
10. Kidney
11. Inferior mesenteric artery
12. Iliolumbar artery
13. Psoas muscle
14. Femoral nerve
15. External iliac artery
16. Internal iliac artery
17. External iliac vein
18. Deep femoral artery and vein
19. Femoral artery
20. Femoral vein
21. Spermatic artery
22. Rectum (cut)
23. Urethra (cut and urinary bladder removed)
24. Prostate gland
25. Testis
26. Penis
27. Genitofemoral nerve
28. Distribution of sympathetic trunk (pinned out bilaterally)
29. Celiac ganglion
30. Superior mesenteric ganglion
31. Left adrenolumbar artery and vein





**Figure 4-31**  
**Superficial Muscles of the Fetal Pig, Left Lateral View**

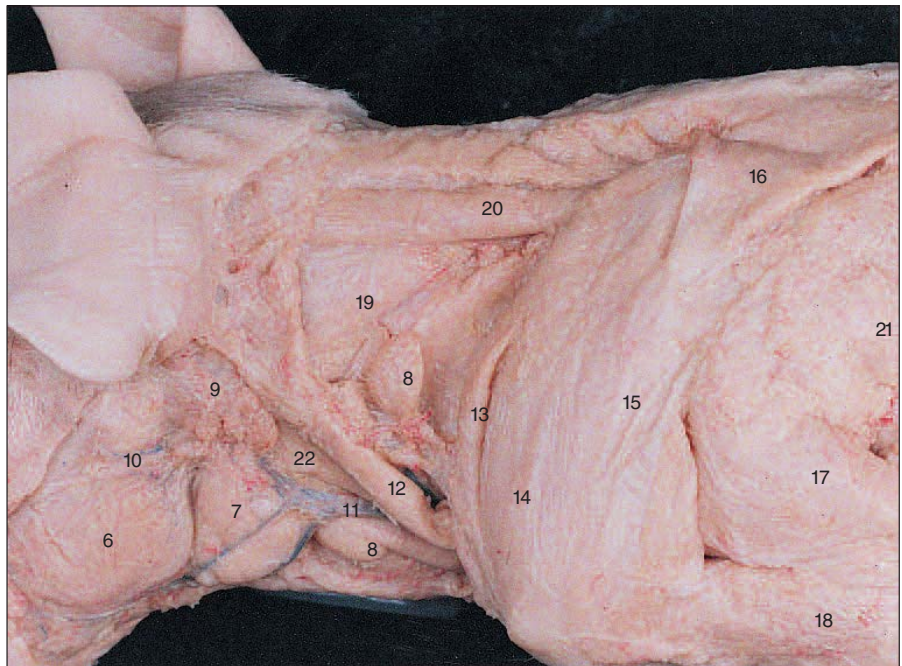
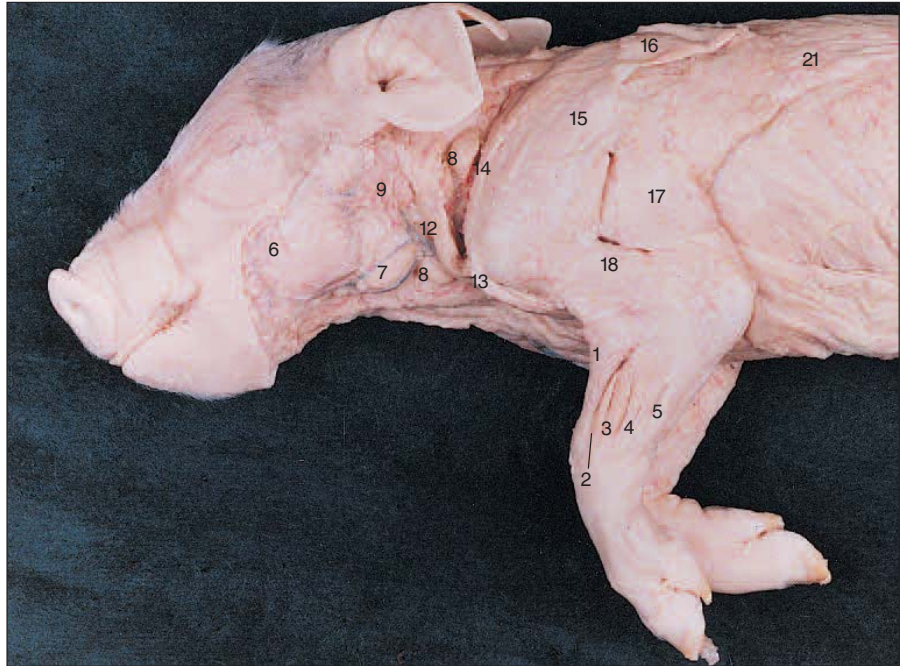
- |                                |  |                            |
|--------------------------------|--|----------------------------|
| 1. Clavotrapezius muscle       | 8. External oblique muscle (cut)       | 15. Biceps femoris muscle  |
| 2. Clavobrachialis muscle      | 9. Serratus anterior muscle            | 16. Semitendinosus muscle  |
| 3. Acromiodeltoid muscle       | 10. Internal oblique muscle            | 17. Semimembranosus muscle |
| 4. Spinodeltoid muscle         | 11. Tensor fascia latae muscle (split) | 18. Testis                 |
| 5. Triceps brachii muscle      | 12. Vastus lateral muscle (under pin)  | 19. Umbilical cord         |
| 6. Spinotrapezius muscle (cut) | 13. Gluteus medius muscle              |                            |
| 7. Latissimus dorsi muscle     | 14. Gluteus maximus muscle             |                            |

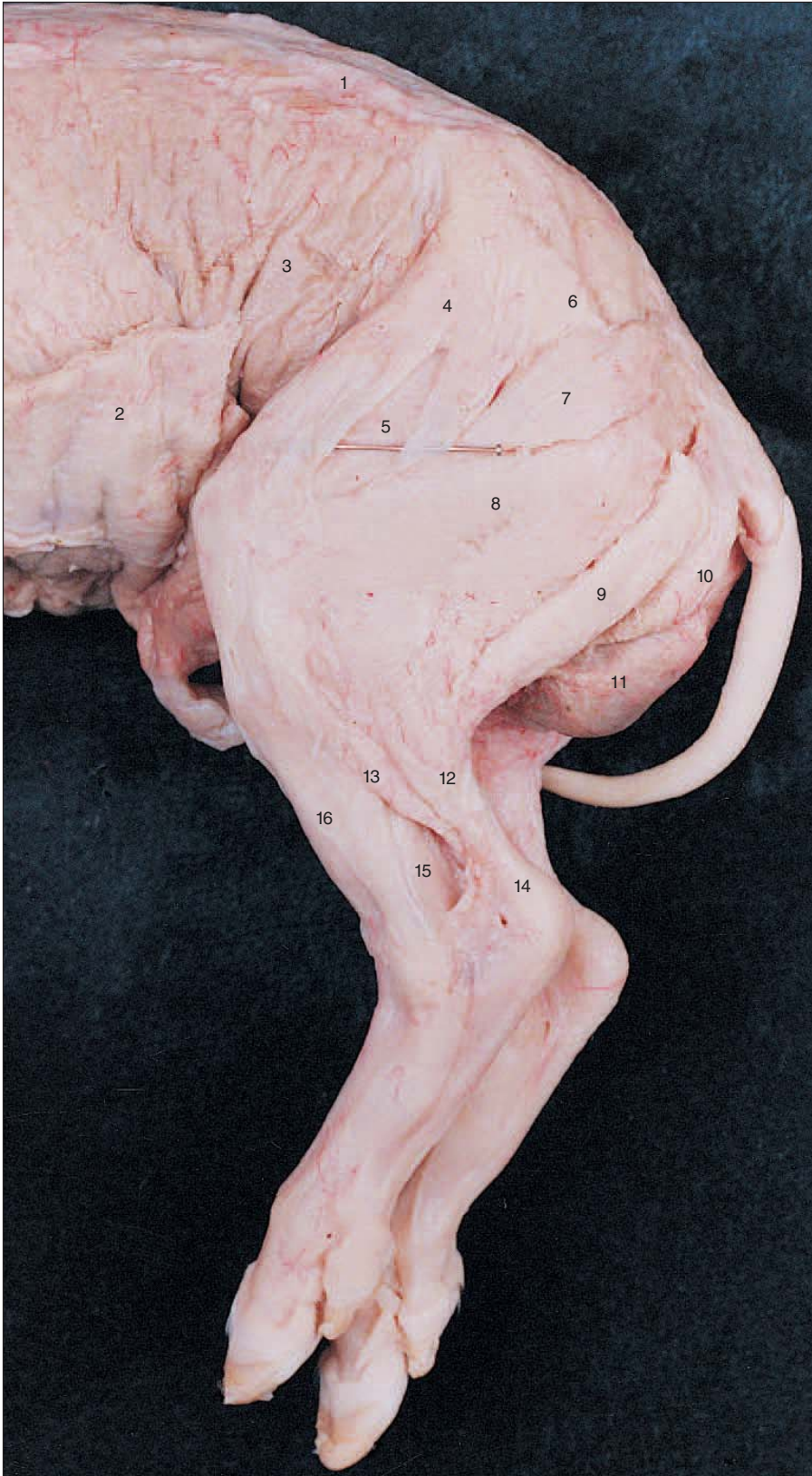

## 126 CHAPTER 4

**Figure 4-32**  
**Superficial Structures of the Neck, Shoulder, and Thoracic Limb of the Fetal Pig, Left Lateral View**

1. Brachioradialis muscle
2. Extensor carpi radialis muscle
3. Extensor digitorum communis muscle
4. Extensor digitorum lateralis muscle
5. Extensor carpi ulnaris muscle
6. Masseter muscle
7. Submandibular gland
8. Lymph node
9. Parotid gland
10. Salivary duct
11. External jugular vein
12. Clavotrapezius muscle
13. Clavobrachialis muscle
14. Acromiodeltoid muscle
15. Spinodeltoid muscle
16. Spinotrapezius muscle (cut)
17. Triceps brachii muscle (long head)
18. Triceps brachii muscle (lateral head)
19. Splenius capitis muscle
20. Rhomboideus capitis muscle
21. Latissimus dorsi muscle
22. Sternomastoid muscle





**Figure 4-33**  
**Superficial Muscles of the**  
**Hind Limb of the Fetal Pig,**  
**Left Lateral View**

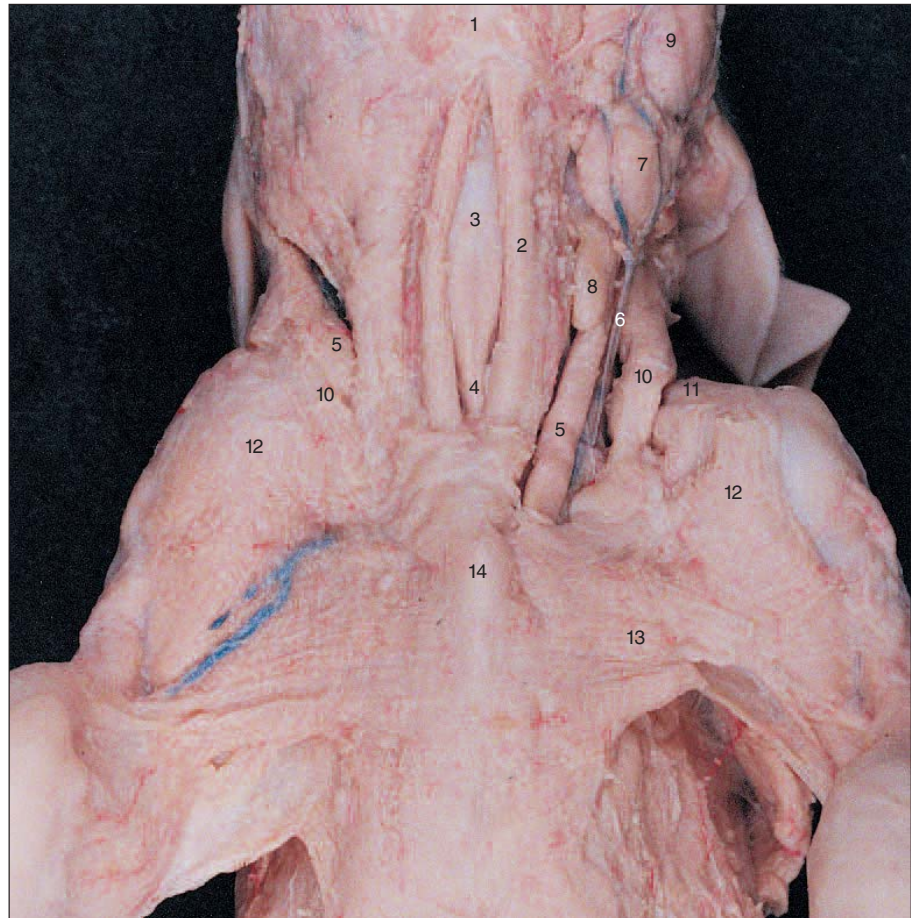1. Lumbodorsal fascia
2. External oblique muscle (reflected)
3. Internal oblique muscle
4. Tensor fascia latae muscle (split)
5. Vastus lateralis muscle (under pin)
6. Gluteus medius muscle
7. Gluteus maximus muscle
8. Biceps femoris muscle
9. Semitendinosus muscle
10. Semimembranosus muscle
11. Testis
12. Gastrocnemius muscle
13. Soleus muscle
14. Achilles tendon
15. Flexor hallucis longus muscle
16. Tibialis anterior muscle

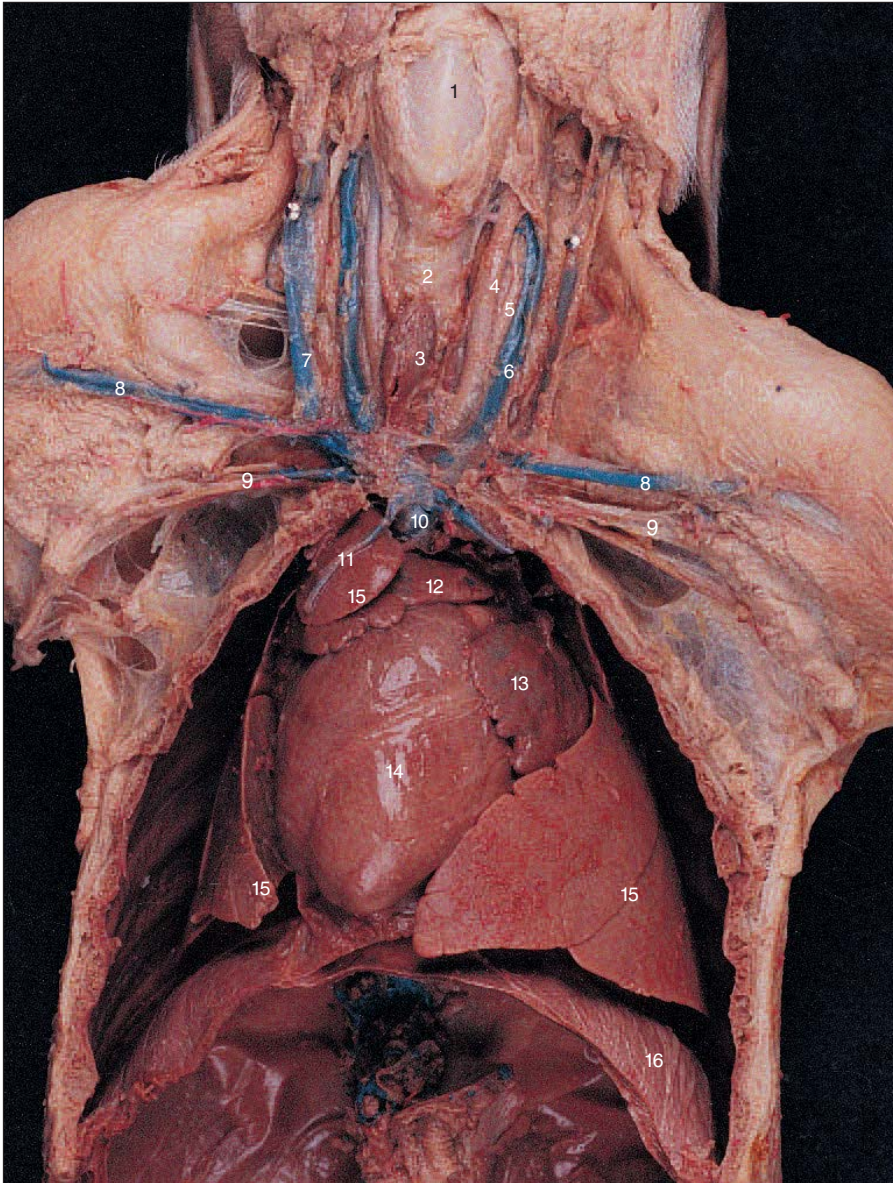


## 128 CHAPTER 4

**Figure 4-34**  
**Superficial Anatomy of the**  
**Fetal Pig Neck and**  
**Shoulders, Ventral View**

1. Mylohyoid muscle
2. Sternohyoid muscle
3. Larynx
4. Trachea
5. Sternomastoid muscle
6. External jugular vein
7. Submandibular gland
8. Lymph node
9. Masseter muscle
10. Clavotrapezius muscle
11. Acromiodeltoid muscle
12. Clavobrachialis muscle
13. Pectoralis major muscle
14. Sternum



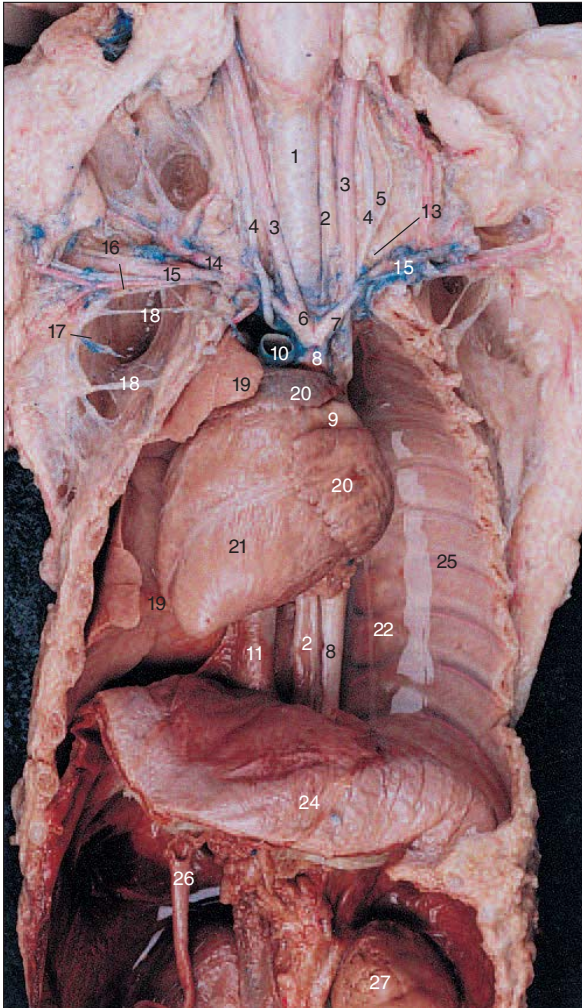


**Figure 4-35**  
**Deep Anatomy of the Fetal**  
**Pig, Neck and Thorax**

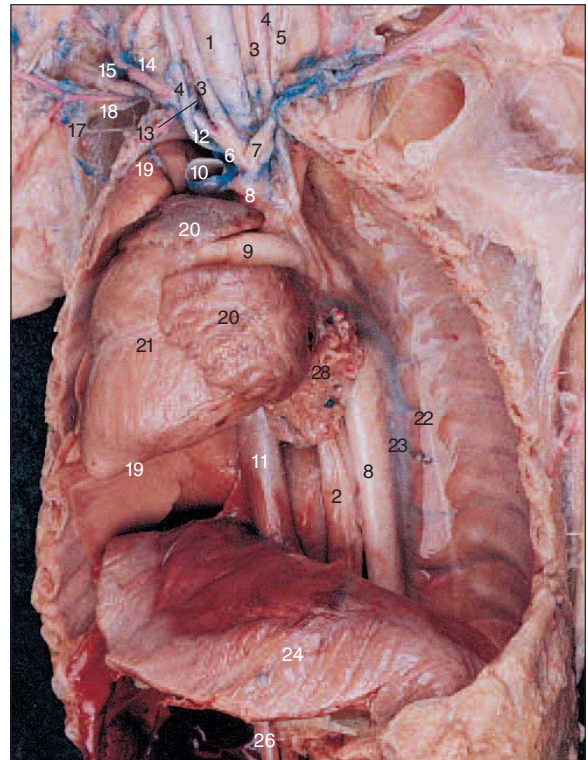
1. Larynx
2. Trachea
3. Thyroid gland
4. Common carotid artery
5. Vagus nerve
6. Internal jugular vein
7. External jugular vein  
(pinned bilaterally)
8. Cephalic vein
9. Subclavian vein
10. Superior vena cava
11. Internal mammary vein  
(cut, laid on lung tissue)
12. Right auricle
13. Left auricle
14. Heart
15. Lung
16. Diaphragm



## 130 CHAPTER 4



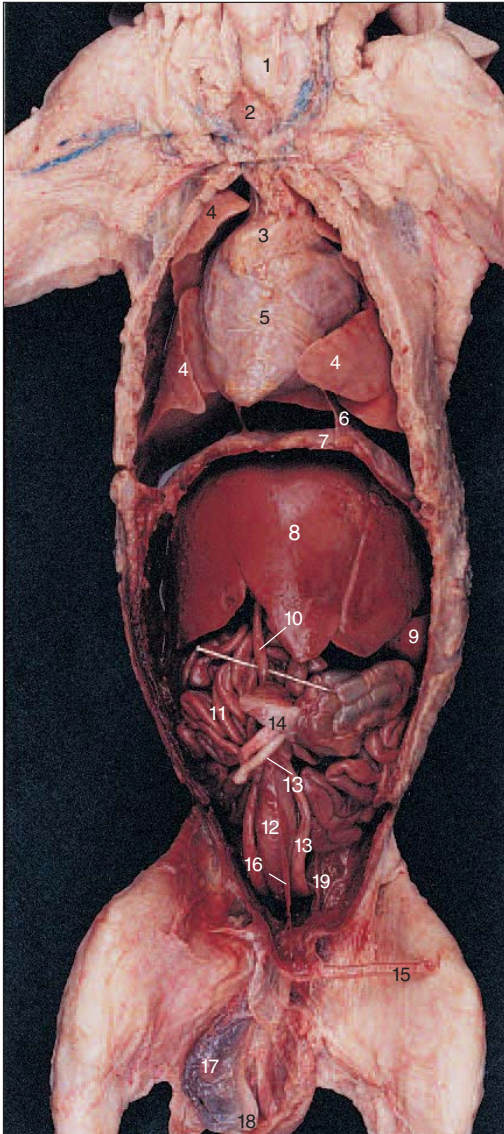
A



B

**Figure 4-36****Arteries of the Neck and Thorax of the Fetal Pig, Left Lung Removed****(A) Heart in normal position; (B) Heart reflected to right.**

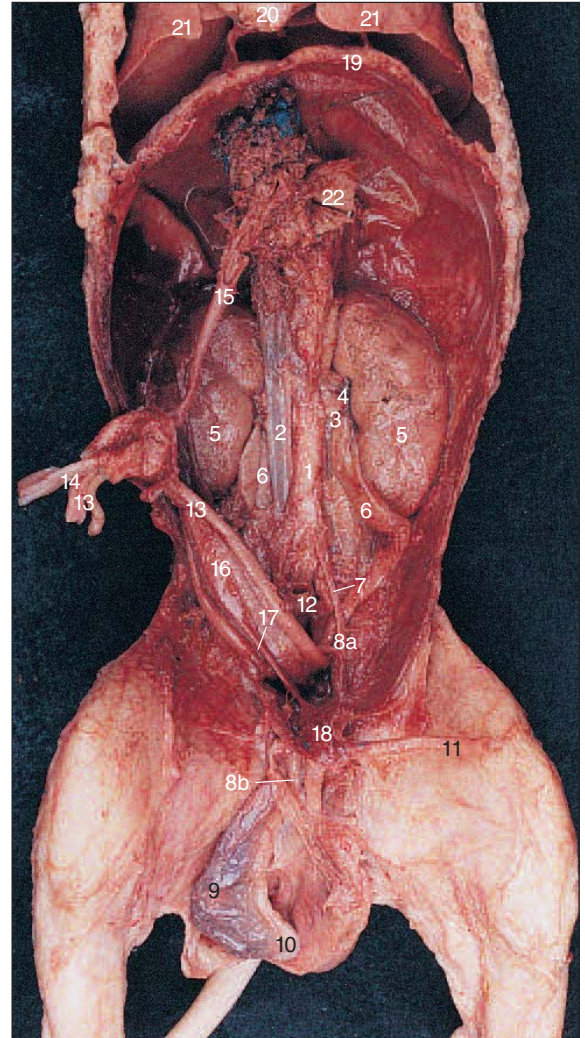
- |  |                                    |   |
|--|------------------------------------|---|
| 1. Trachea                                   | 10. Superior vena cava (cut)       | 21. Heart   |
| 2. Esophagus                                 | 11. Inferior vena cava             | 22. Continuation of sympathetic trunk                       |
| 3. Common carotid artery                     | 12. Subclavian artery              | 23. Azygos vein   |
| 4. Vagus nerve                               | 13. Vertebral artery               | 24. Diaphragm   |
| 5. Sympathetic trunk                         | 14. Transverse scapular artery     | 25. Rib with costal artery and vein                         |
| 6. Right innominate (brachiocephalic) artery | 15. Axillary artery                | 26. Ductus venosus  |
| 7. Left innominate (brachiocephalic) artery  | 16. Radial nerve                   | 27. Kidney  |
| 8. Aorta                                     | 17. Thoracodorsal nerve            | 28. Hilum of left lung (with bronchi and blood vessels cut) |
| 9. Ductus arteriosus                         | 18. Dorsal rami of thoracic nerves |   |
|  | 19. Lung                           |   |
|  | 20. Right and left auricles        |   |



**Figure 4-37**

**Thoracic and Abdominal Viscera of the Fetal Pig, Male**

- |                             |   |
|-----------------------------|---|
| 1. Trachea                  | 12. Urinary bladder   |
| 2. Thyroid gland            | 13. Umbilical arteries  |
| 3. Thymus                   | 14. Skin of umbilicus   |
| 4. Lung                     | 15. Penis   |
| 5. Heart in pericardium     | 16. Urethra   |
| 6. Mediastinal membrane     | 17. Testis  |
| 7. Diaphragm                | 18. Epididymis  |
| 8. Liver                    | 19. Spermatic cord  |
| 9. Spleen                   | (contains spermatic artery and vas deferens, which curves to pass behind base of urinary bladder) |
| 10. Umbilical vein (on pin) |   |
| 11. Small intestine         |   |



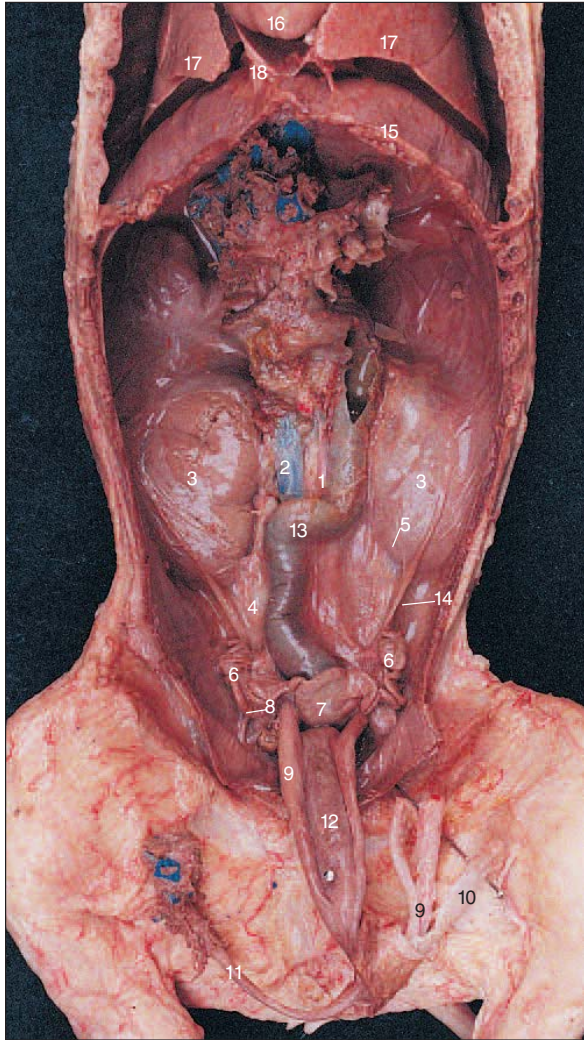
**Figure 4-38**

**Abdominopelvic Cavity of the Fetal Pig, Male, Digestive Viscera Removed**

- |                                     |  |
|-------------------------------------|--|
| 1. Abdominal aorta                  | 14. Umbilical vein                                 |
| 2. Abdominal vena cava              | 15. Ductus venosus (only remnants of liver remain) |
| 3. Renal artery                     | 16. Urinary bladder                                |
| 4. Renal vein                       | 17. Urethra  |
| 5. Kidney                           | 18. Prostate gland                                 |
| 6. Ureter                           | 19. Diaphragm                                      |
| 7. Spermatic artery                 | 20. Heart  |
| 8. a. Vas deferens                  | 21. Lung   |
| b. Vas deferens (in spermatic cord) | 22. Pylorus of stomach (pin in antrum)             |
| 9. Testis                           |  |
| 10. Epididymis                      |  |
| 11. Penis                           |  |
| 12. Rectum (cut)                    |  |
| 13. Umbilical arteries              |  |

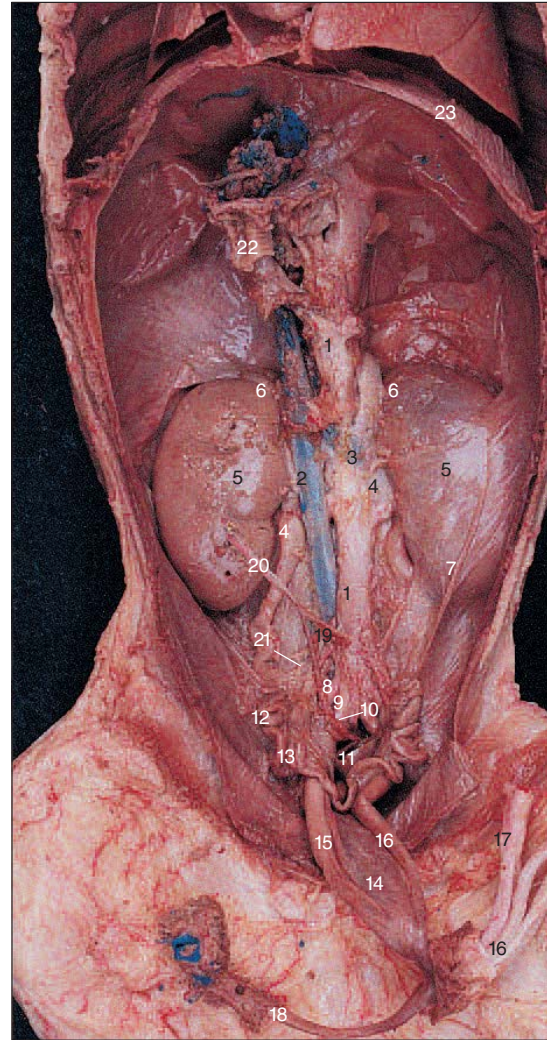


## 132 CHAPTER 4



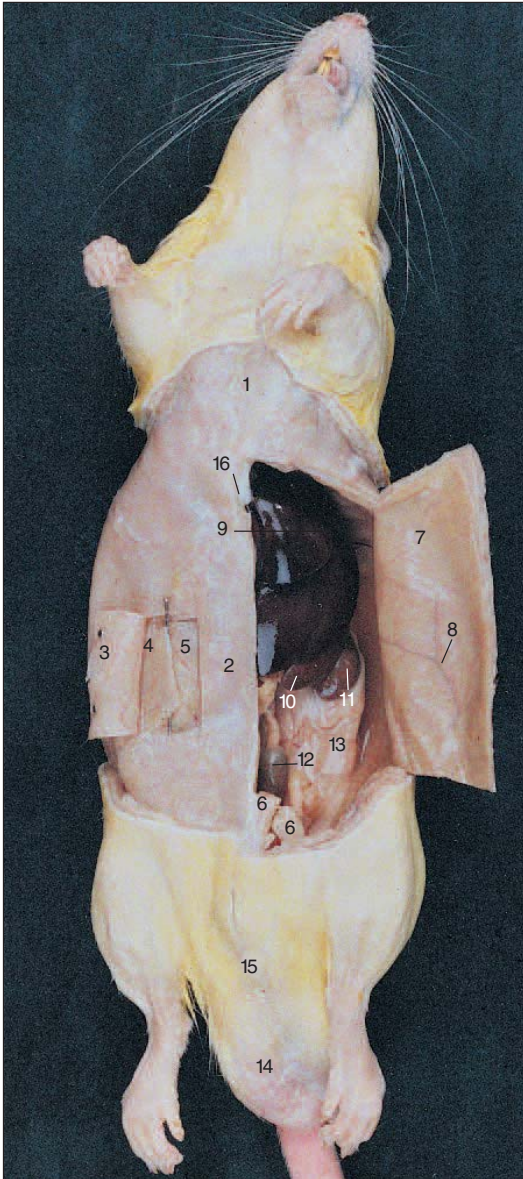
**Figure 4-39**  
Abdominopelvic Cavity of the Fetal Pig, Female, Digestive  
Viscera Removed

- |                              |                            |
|------------------------------|----------------------------|
| 1. Abdominal aorta           | 12. Urinary bladder        |
| 2. Abdominal vena cava       | (reflected and pinned)     |
| 3. Kidney (behind intact     | 13. Sigmoid colon          |
| peritoneum)                  | 14. Suspensory ligament of |
| 4. Ureter (behind intact     | ovary                      |
| peritoneum)                  | 15. Diaphragm              |
| 5. Ovarian artery            | 16. Heart                  |
| 6. Ovary                     | 17. Lung                   |
| 7. Uterus                    | 18. Mediastinal membrane   |
| 8. Uterine horn              |                            |
| 9. Umbilical arteries        |                            |
| 10. Umbilical vein (lying on |                            |
| pin)                         |                            |
| 11. Ductus venosus           |                            |



**Figure 4-40**  
Deep Anatomy of the Abdominopelvic Cavity of the Fetal  
Pig, Abdominal Viscera Removed, Female

- |                            |                             |
|----------------------------|-----------------------------|
| 1. Abdominal aorta         | 14. Urinary bladder         |
| 2. Abdominal vena cava     | (reflected)                 |
| 3. Renal vein              | 15. Urethra                 |
| 4. Ureter                  | 16. Umbilical arteries      |
| 5. Kidney (left kidney     | 17. Umbilical vein          |
| behind peritoneum)         | 18. Ductus venosus          |
| 6. Adrenal gland           | 19. Posterior (inferior)    |
| 7. Suspensory ligament of  | mesenteric artery           |
| ovary                      | 20. Colic artery (pinned to |
| 8. External iliac artery   | kidney for clarity due to   |
| 9. Internal iliac artery   | missing colon)              |
| 10. Median sacral (caudal) | 21. Superior hemorrhoidal   |
| artery                     | artery                      |
| 11. Rectum (cut)           | 22. Remnant of small        |
| 12. Ovary                  | intestine (duodenum)        |
| 13. Uterine horn           | 23. Diaphragm               |



**Figure 4-41**

**General Anatomy of the Male Rat,  
Abdominal Cavity Exposed, Ventral View**

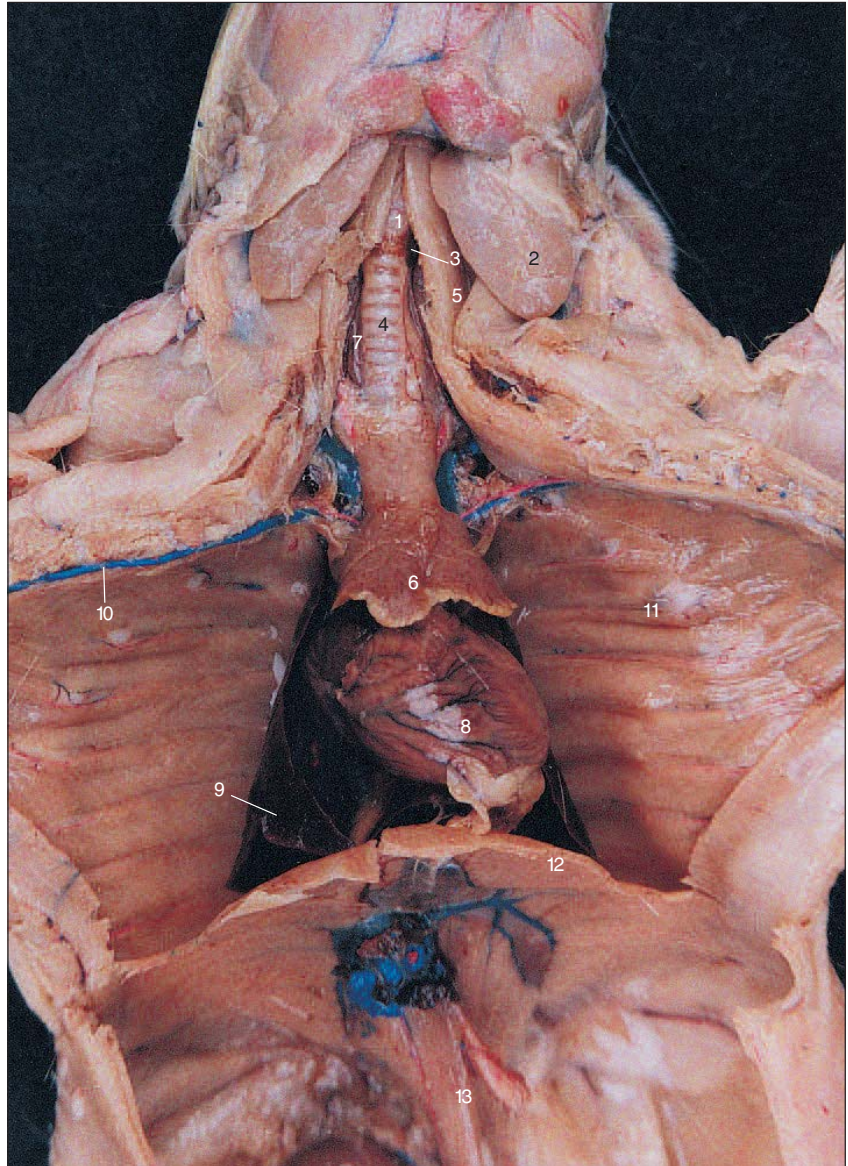
1. Thorax
2. Abdomen
3. External oblique muscle (reflected and pinned)
4. Internal oblique muscle (lying on pin)
5. Transversus abdominis
6. Rectus abdominis
7. Peritoneum
8. Inferior epigastric artery
9. Liver
10. Spleen
11. Kidney
12. Rectum
13. Abdominal fat (small intestine not visible in this photograph)
14. Testis (within scrotum)
15. Penis
16. Sternum (xiphoid process)

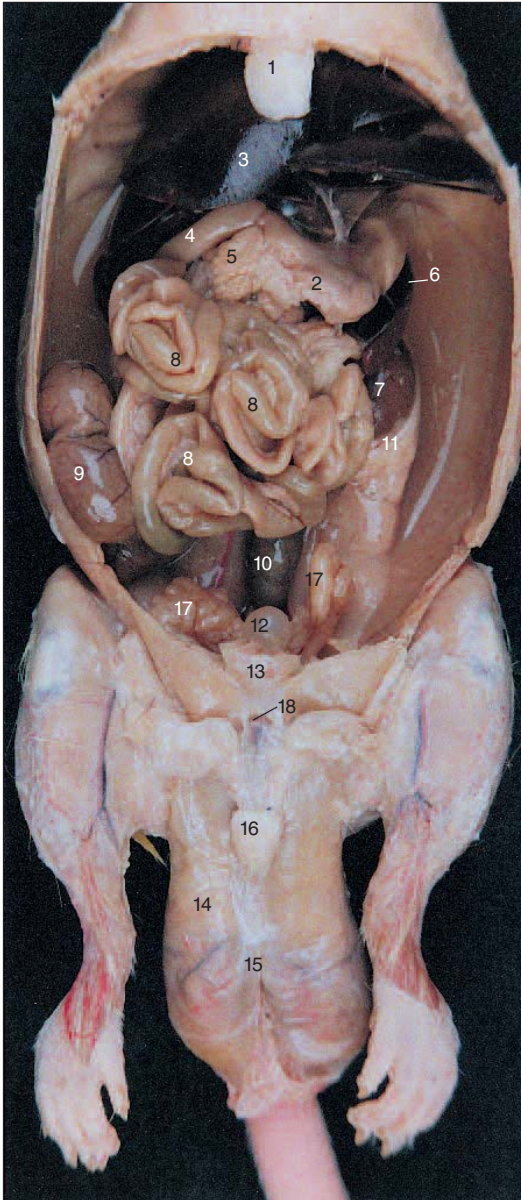


## 134 CHAPTER 4

**Figure 4-42**  
**Deep Anatomy of the Rat,**  
**Neck and Thorax**

1. Larynx
2. Salivary gland
3. Thyroid gland
4. Trachea
5. Sternohyoid muscle  
(unavoidably damaged on  
animal's right side during  
vascular perfusion)
6. Thymus
7. Common carotid artery
8. Heart
9. Lung
10. Internal mammary vein
11. Rib and intercostal artery and  
vein
12. Diaphragm
13. Crus of diaphragm





**Figure 4-43**

**Abdominopelvic Cavity of the Male Rat**

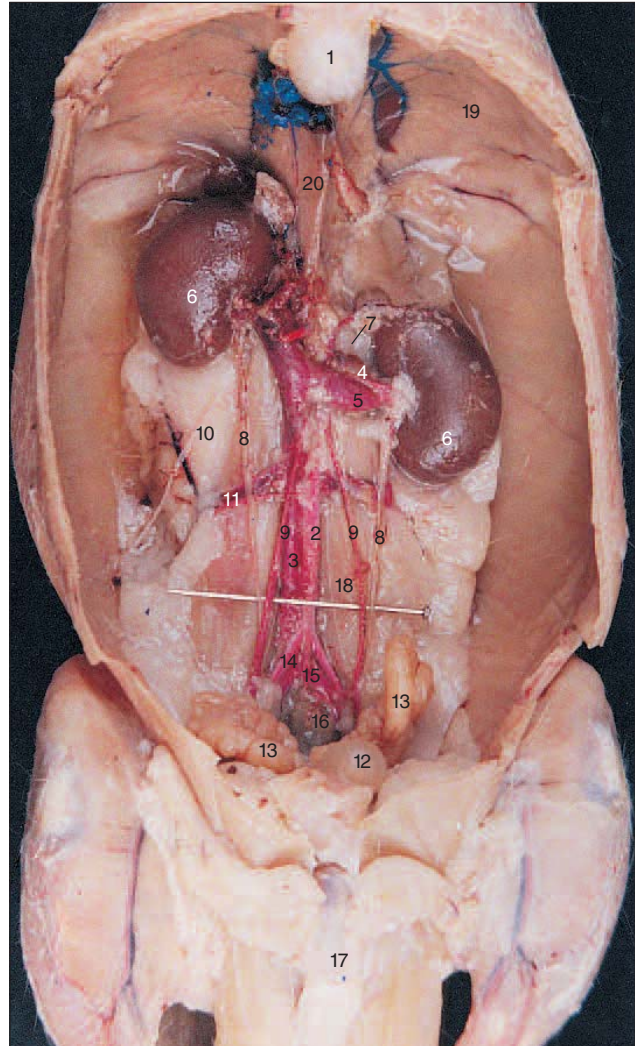
1. Sternum (xiphoid process)
2. Stomach
3. Liver
4. Small intestine (duodenum)
5. Pancreas
6. Spleen
7. Kidney
8. Small intestine (jejunum and ileum)
9. Large intestine (cecum)
10. Rectum
11. Abdominal fat
12. Urinary bladder
13. Rectus abdominis muscle (cut)
14. Testis in scrotum
15. Epididymis
16. Penis
17. Seminal vesicle
18. Cremasteric fascia

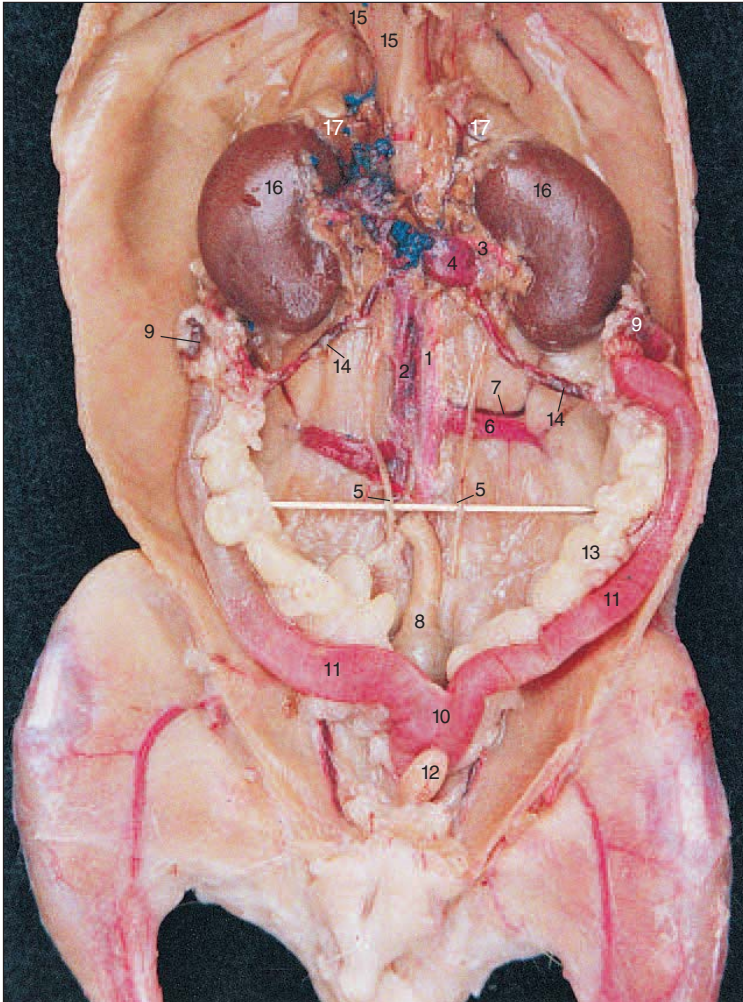


136 CHAPTER 4

**Figure 4-44**  
**Abdominopelvic Cavity of the Rat, Male,**  
**Digestive Viscera Removed**

1. Sternum (xiphoid process)
2. Abdominal aorta
3. Abdominal vena cava
4. Renal artery
5. Renal vein
6. Kidney
7. Adrenal gland
8. Ureter (lying on pin)
9. Spermatic artery (lying on pin)
10. Lumbar nerve (medial branch, extended for clarity)
11. Iliolumbar artery and vein
12. Urinary bladder
13. Seminal vesicle
14. Common iliac artery
15. Median sacral (caudal) artery
16. Rectum (cut)
17. Penis
18. Psoas muscle
19. Diaphragm
20. Crus of diaphragm





**Figure 4-45**

**Abdominopelvic Cavity of the Rat, Female,  
Digestive Viscera Removed**


1. Abdominal aorta
2. Abdominal vena cava
3. Renal artery
4. Renal vein
5. Ureter (lying on pin)
6. Iliolumbar artery
7. Iliolumbar vein
8. Rectum (cut)
9. Ovary
10. Uterus
11. Uterine horn
12. Urinary bladder
13. Abdominal fat
14. Ovarian artery and vein
15. Crus of diaphragm
16. Kidney
17. Adrenal gland



*This page intentionally left blank*

# C H A P T E R 5

## Specialized Organs



Nerve-Muscle Connection  
Light micrograph of neuromuscular synapses

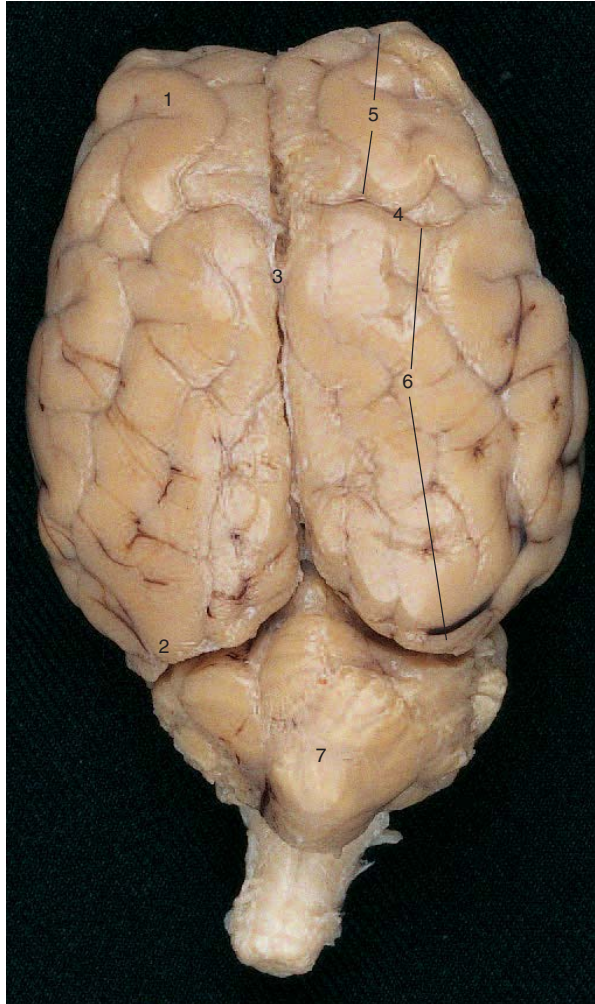


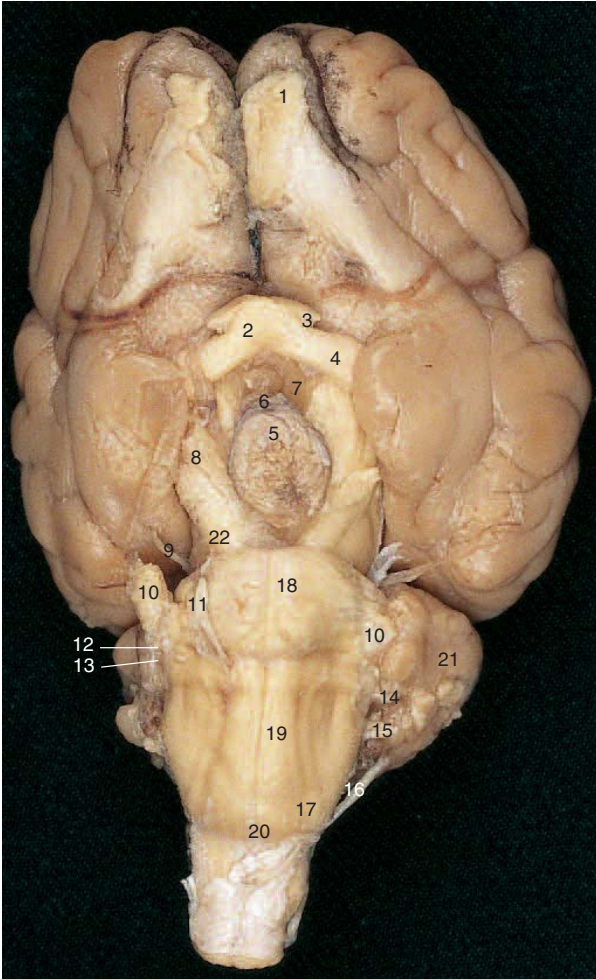
140 CHAPTER 5

**Figure 5-1**

**Sheep Brain, Superior Aspect**

1. Frontal pole
2. Occipital pole
3. Longitudinal fissure
4. Central sulcus (fissure of Rolando)
5. Right frontal lobe of cerebrum
6. Right parietal lobe of cerebrum
7. Cerebellum

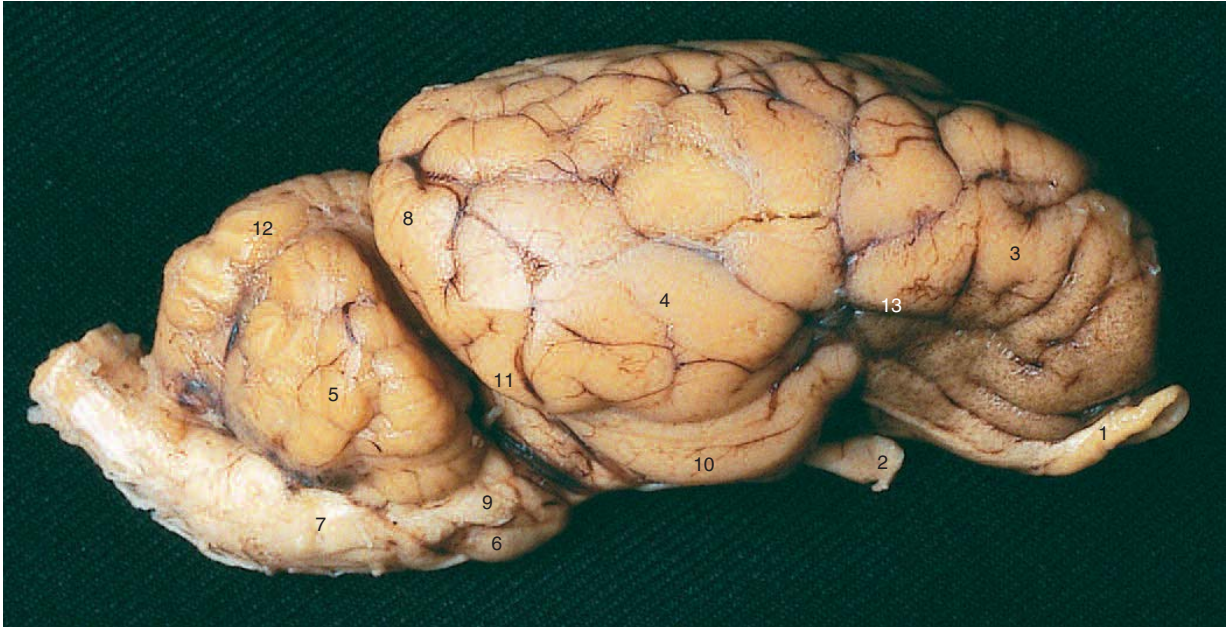




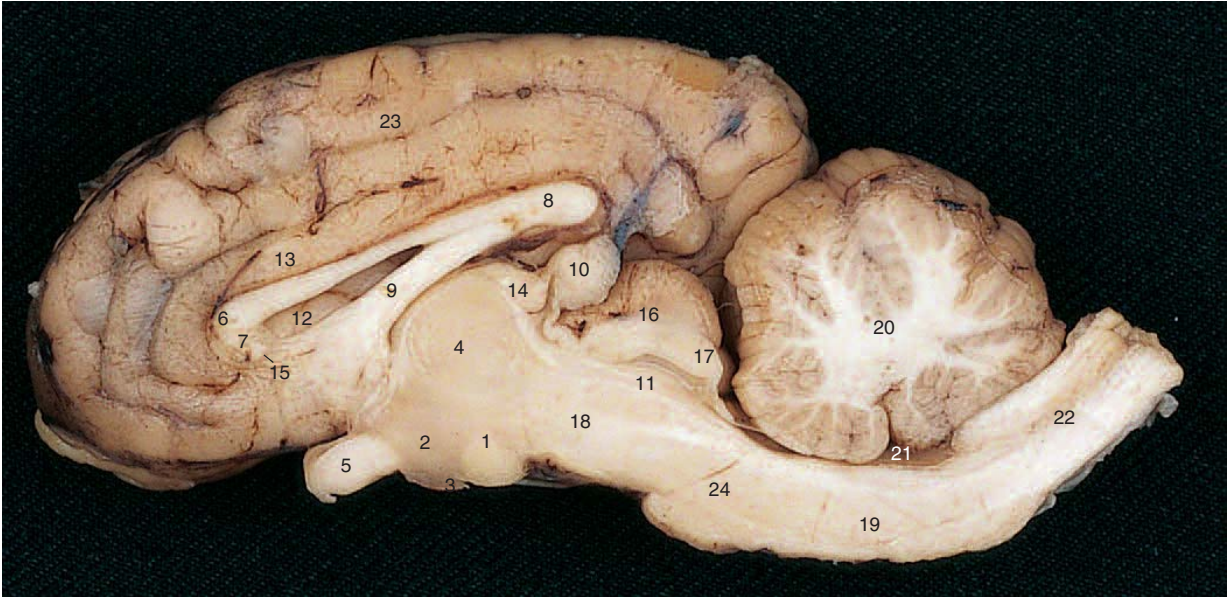
**Figure 5-2**  
**Sheep Brain, Inferior Aspect**

1. Olfactory bulb (cranial nerve I)
2. Optic chiasma
3. Optic nerve (cut) (cranial nerve II)
4. Optic tract
5. Bony remains of sella turcica with pituitary gland
6. Infundibulum (pituitary stalk)
7. Mamillary body
8. Oculomotor nerve (cranial nerve III)
9. Trochlear nerve (cranial nerve IV)
10. Trigeminal nerve (cranial nerve V—cut very short on this brain's left side)
11. Abducens nerve (cranial nerve VI)
12. Facial nerve (cranial nerve VII)
13. Auditory (vestibuloacoustic) nerve (cranial nerve VIII)
14. Glossopharyngeal nerve (cranial nerve IX)
15. Vagus nerve (cranial nerve X)
16. Spinal accessory nerve (cranial nerve XI)
17. Hypoglossal nerve (cranial nerve XII)
18. Pons varolii
19. Medulla oblongata (numeral is on the left pyramid)
20. Pyramidal decussation
21. Cerebellum
22. Cerebral peduncle



**Figure 5-3****Sheep Brain, Right Lateral Aspect**

1. Olfactory bulb (cranial nerve I)
2. Optic nerve (cranial nerve II)
3. Frontal lobe of cerebrum
4. Parietal lobe of cerebrum
5. Cerebellum
6. Pons varolii
7. Medulla oblongata
8. Occipital lobe of cerebrum
9. Midbrain
10. Piriform lobe
11. Trochlear nerve (cranial nerve IV)
12. Vermis of cerebellum
13. Rhinal sulcus



**Figure 5-4**

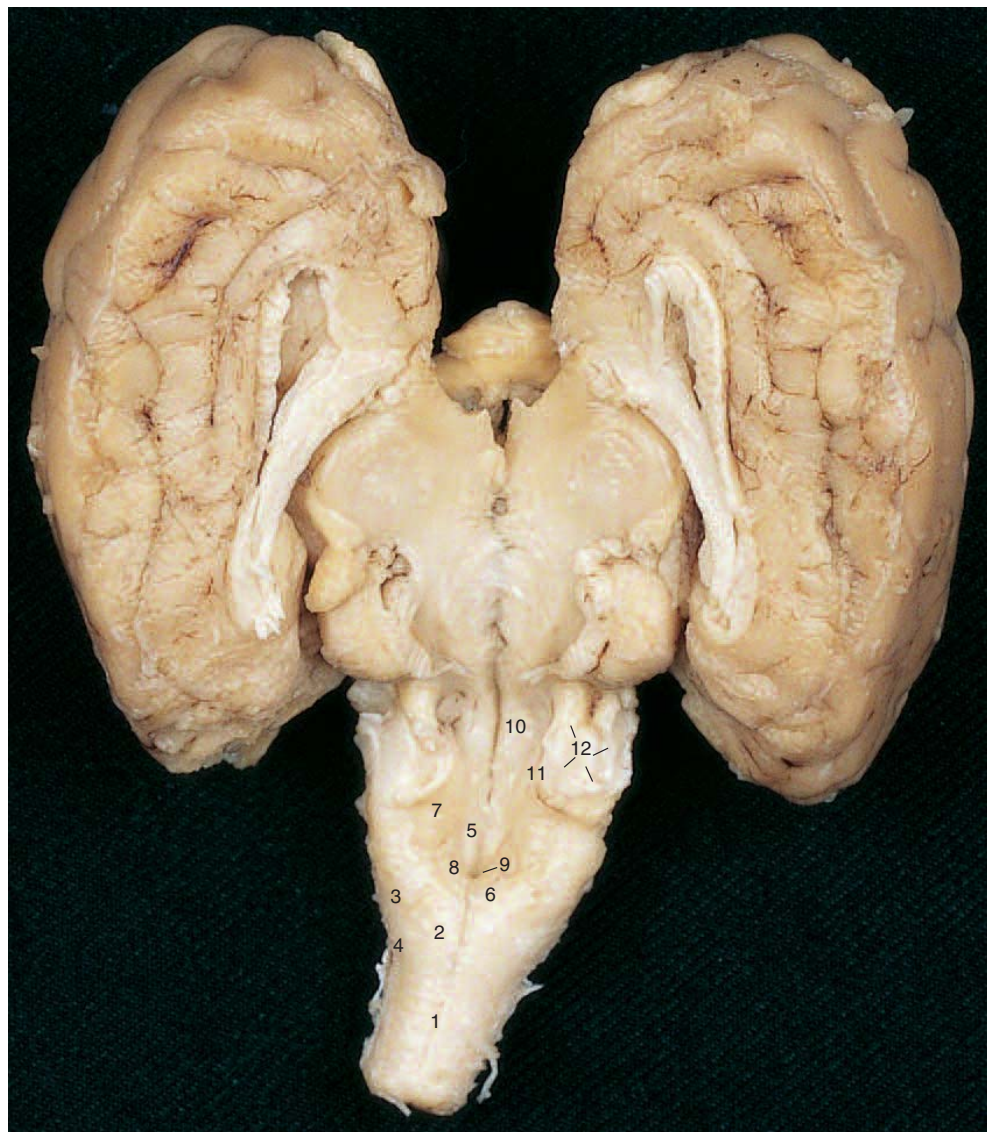
**Sheep Brain, Right Hemisphere, Midsagittal Aspect**

The left and right superior and inferior colliculi together make up four bodies that are collectively called the corpora quadrigemina.

- |   |   |
|---|---|
| 1. Hypothalamus   | 13. Cingulate gyrus                                   |
| 2. Third ventricle  | 14. Habenular commissure                              |
| 3. Infundibulum (pituitary stalk—pituitary gland removed) | 15. Anterior commissure                               |
| 4. Massa intermedia                                       | 16. Superior colliculus                               |
| 5. Optic chiasma  | 17. Inferior colliculus                               |
| 6. Corpus callosum (numeral on the genu)                  | 18. Midbrain  |
| 7. Rostrum of the corpus callosum                         | 19. Medulla oblongata                                 |
| 8. Splenium of the corpus callosum                        | 20. Cerebellum showing the arbor vitae (tree of life) |
| 9. Fornix   | 21. Fourth ventricle                                  |
| 10. Pineal gland  | 22. Central canal of the spinal cord                  |
| 11. Aqueduct of Sylvius (cerebral aqueduct)               | 23. Cerebrum  |
| 12. Lateral ventricle (septum pellucidum removed)         | 24. Pons varolii                                      |

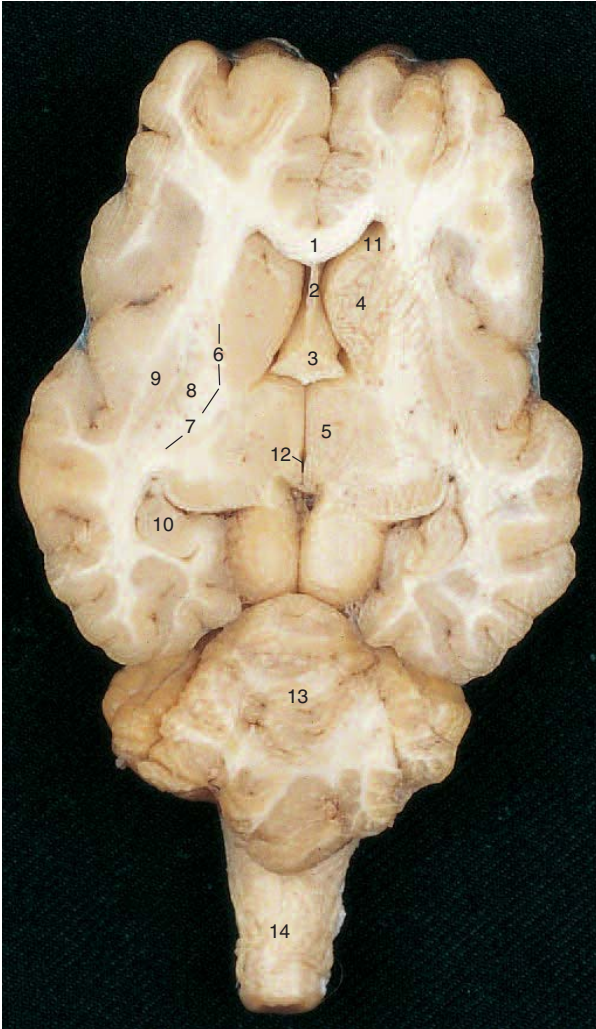


## 144 CHAPTER 5

**Figure 5-5****Additional Structures of the Sheep Brain, Dorsal View of the Floor of the Fourth Ventricle**

Cerebral hemispheres split and cerebellum removed. The obex is visible as a triangular area of grey matter located immediately posterior to the entrance to the central canal. It is bounded on each side by nerves ascending obliquely to the gracile tubercle.

- |                        |   |
|------------------------|---|
| 1. Dorsomedian sulcus  | 7. Statoacoustic area                       |
| 2. Gracile tubercle    | 8. Vagal trigone                            |
| 3. Cuneate tubercle    | 9. Entrance to central canal of spinal cord |
| 4. Trigeminal tubercle | 10. Facial colliculus                       |
| 5. Hypoglossal trigone | 11. Sulcus limitans                         |
| 6. Area postrema       | 12. Cerebellar peduncles (cut)              |

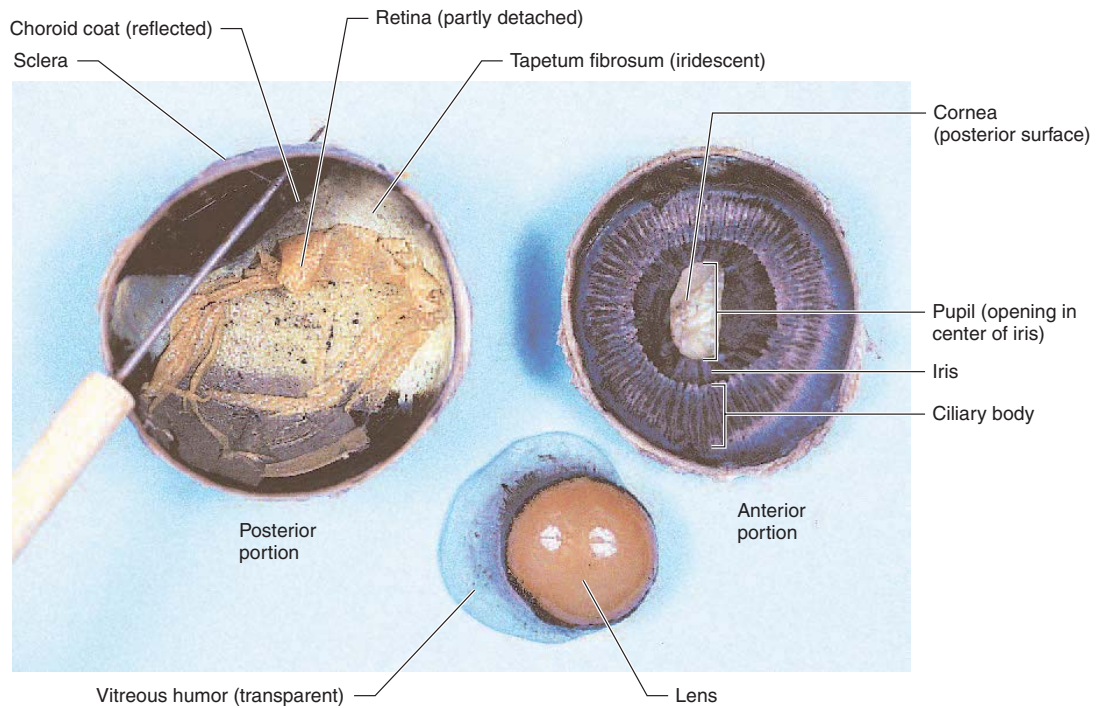


**Figure 5-6**  
**Horizontal Section through Sheep Brain at the Level**  
**of the Internal Capsule**

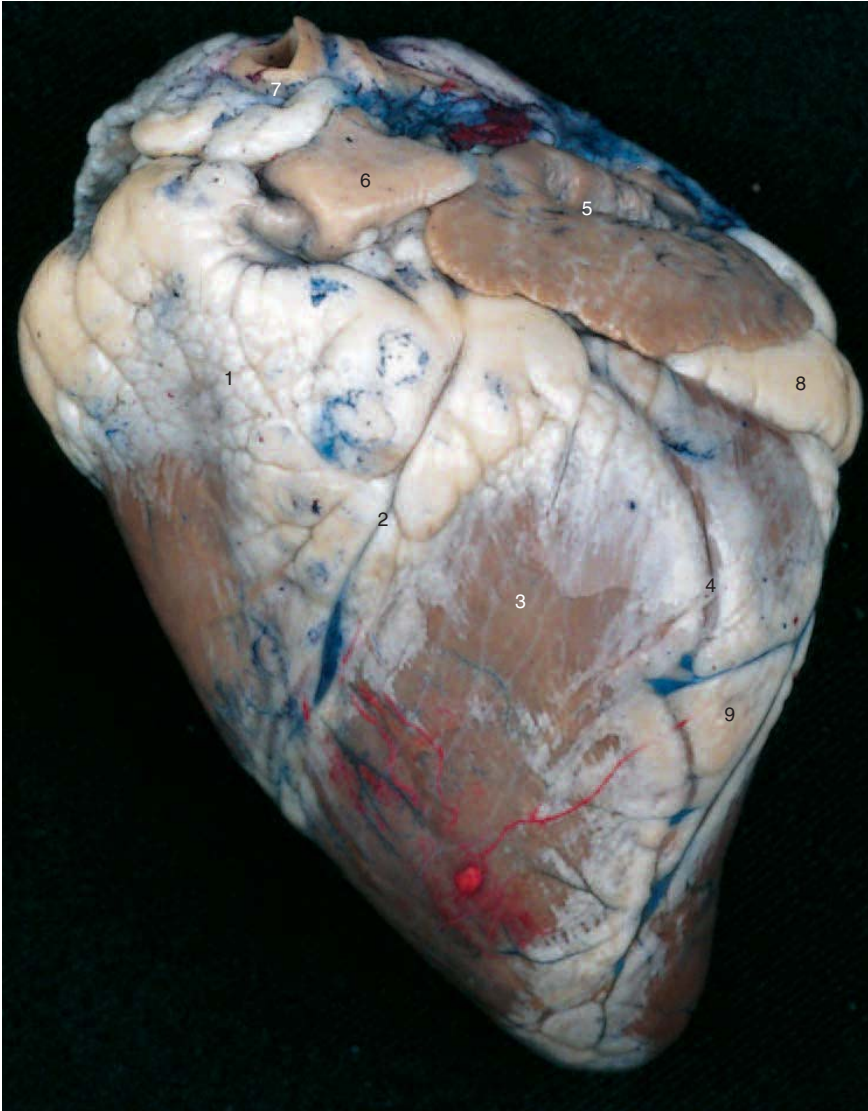
1. Genu of corpus callosum
2. Fornix
3. Stria terminalis
4. Head of caudate nucleus
5. Thalamus
6. Internal capsule, anterior limb
7. Internal capsule, posterior limb
8. Globus pallidus
9. Putamen
10. Hippocampus
11. Lateral ventricle
12. Third ventricle
13. Cerebellum
14. Medulla oblongata



## 146 CHAPTER 5



**Figure 5-7**  
Internal structures of the beef eye dissection.

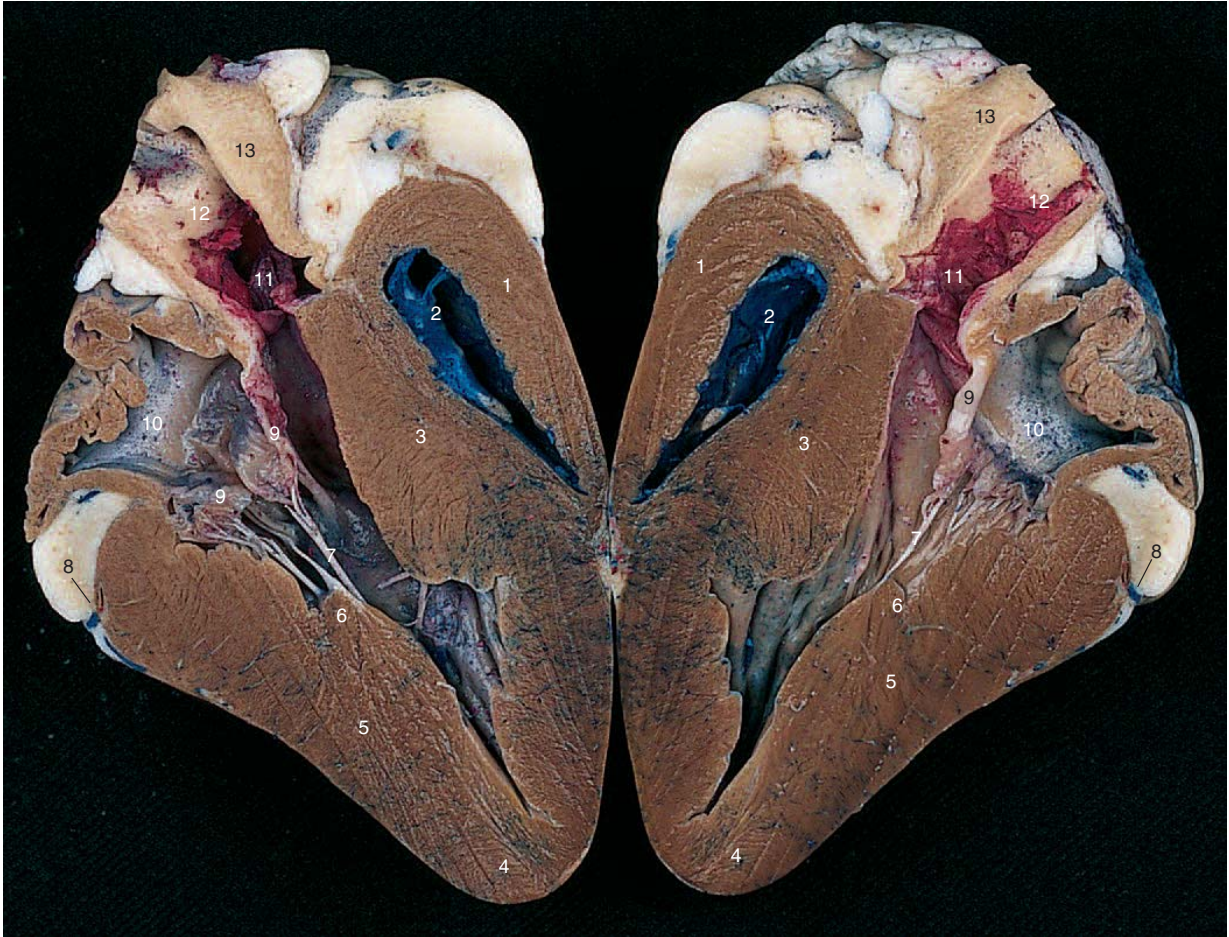

**Figure 5-8**

**Sheep Heart, Anterior Aspect**

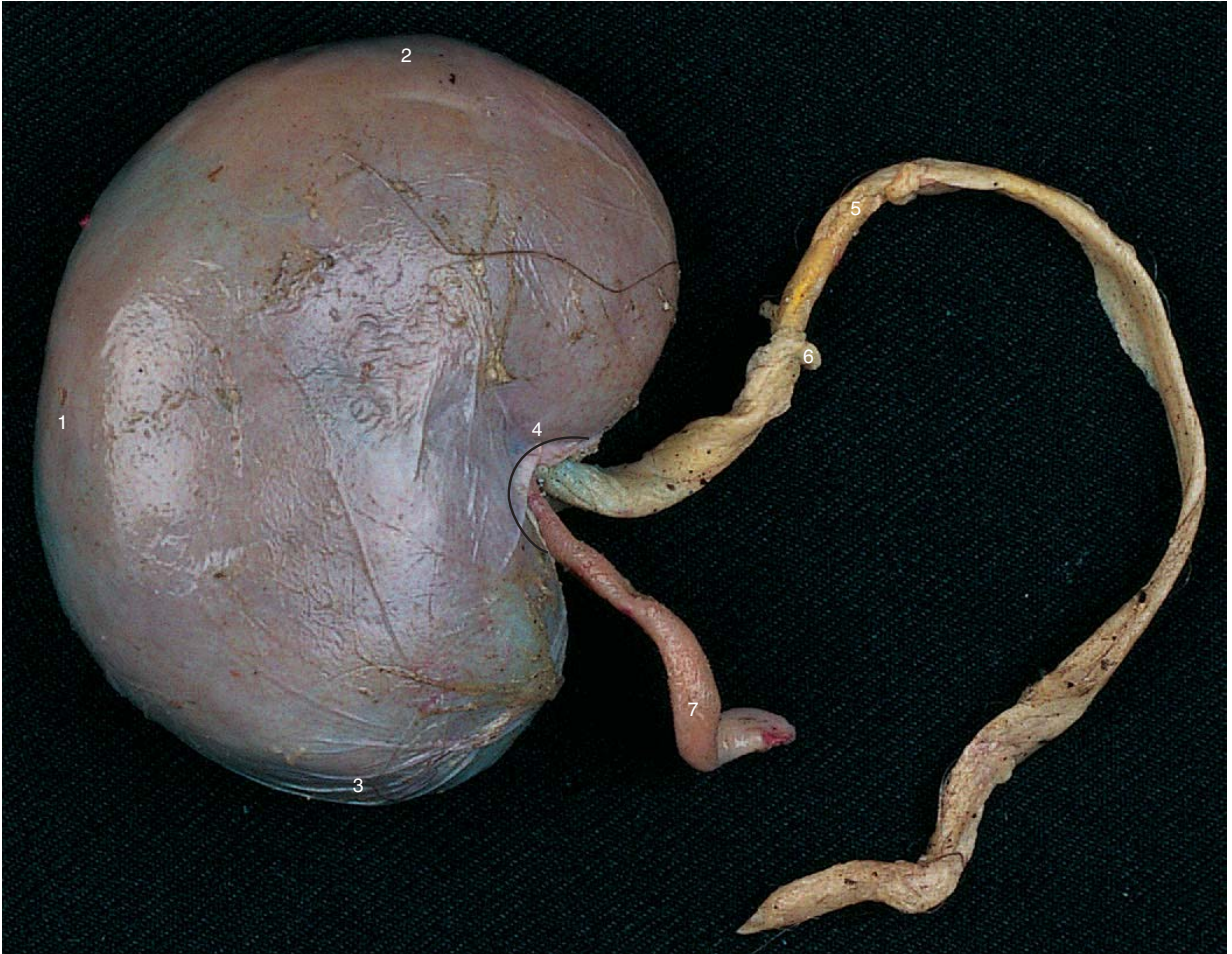1. Right atrium
2. Right coronary artery and anterior cardiac veins
3. Right ventricle
4. Left coronary artery and great cardiac vein
5. Left auricle
6. Pulmonary trunk
7. Aorta
8. Adipose tissue associated with left auricle
9. Left ventricle





**Figure 5-9**  
**Sheep Heart, Sectioned, Anterior Section on Left, Posterior on Right**

1. Free wall of right ventricle
2. Lumen of right ventricle
3. Interventricular septum
4. Apex
5. Free wall of left ventricle
6. Papillary muscle
7. Chordae tendineae
8. Coronary blood vessels
9. Mitral (bicuspid) valve
10. Left atrium
11. Aortic semilunar valve
12. Aorta
13. Pulmonary trunk



**Figure 5-10**  
**Right Sheep Kidney, Anterior Aspect**

1. Convex lateral border
2. Cranial pole
3. Caudal pole
4. Hilum
5. Renal artery
6. Renal vein
7. Ureter

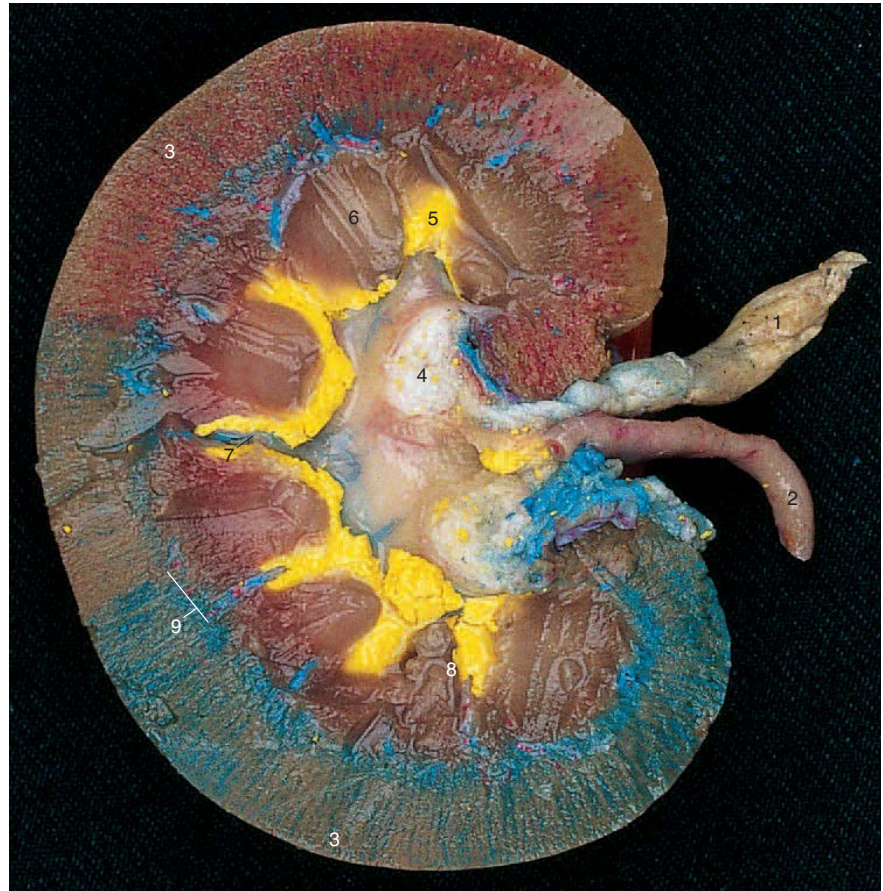


## 150 CHAPTER 5

**Figure 5-11**  
**Sheep Right Kidney,**  
**Sectioned, Ventral View**

Renal columns are extensions of renal cortical tissue into the renal medulla, which is comprised of major and minor calyces and renal pyramids. The renal pelvis is a continuation of the ureter into the kidney. It divides into 2–3 major calyces, each of which may have several minor calyces (shown in this figure in yellow).

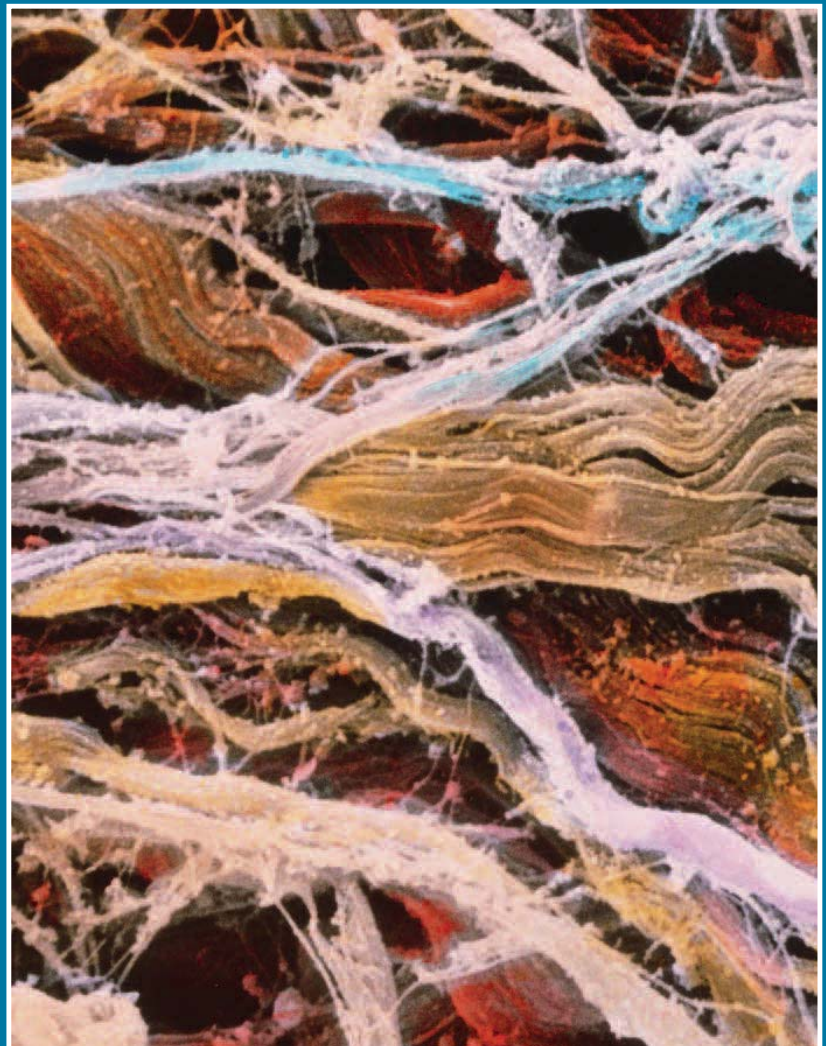
1. Renal artery and vein
2. Ureter
3. Renal cortex
4. Major calyx
5. Minor calyx
6. Renal column
7. Renal pyramid
8. Interlobar artery
9. Area of arcuate arteries and veins



# C H A P T E R

# 6

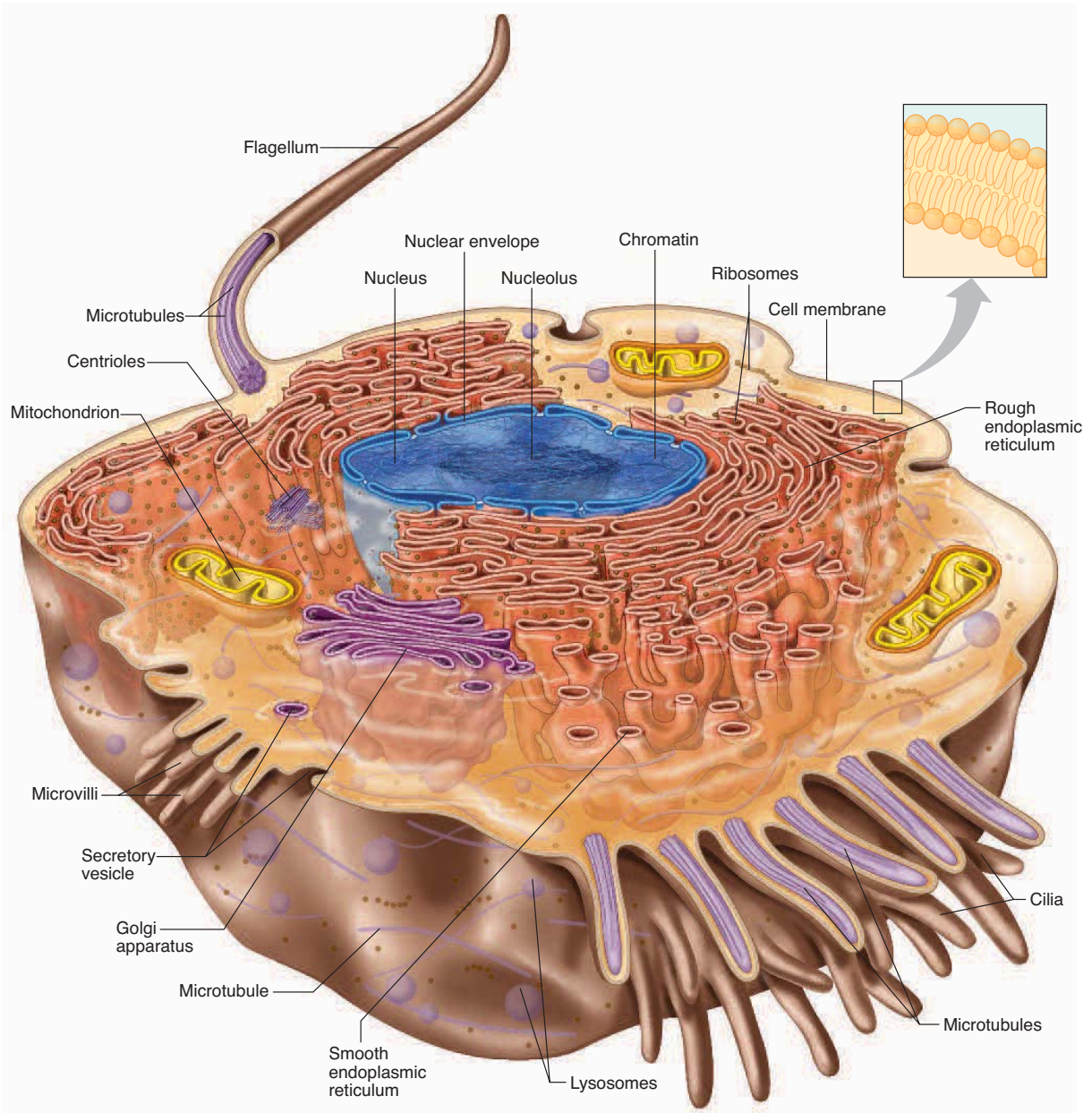
## Reference Tables



Nerve-muscle connection. Light micrograph of neuromuscular synapses.



## 152 CHAPTER 6



**Figure 6-1**  
Generalized Illustration of a Cell

**TABLE 6.1** Structure and function of some cellular components

STRUCTURE	DESCRIPTION AND FUNCTION
<b>MEMBRANOUS</b>	
<b>Plasma membrane</b>	Composed mainly of phospholipid bilayer with globular proteins floating dynamically on, in, and through it. Separates living cell contents from nonliving environment. Maintains cellular integrity. Embedded molecules serve as identifying cell markers (antigens), receptor molecules for hormones and related substances, signal transducers, selective ion channels, and transporter mechanisms.
<b>Endoplasmic reticulum</b>	Complex of membranous canals, sacs, and vesicles. Transports material within the cell; provides attachment for ribosomes; contributes to synthesis of lipids, steroids, and some carbohydrates used to form glycoproteins.
<b>Golgi apparatus</b>	Flattened membranous sacs. Synthesizes and packages carbohydrates and glycoproteins.
<b>Lysosomes</b>	Small membranous sacs. Contain enzymes used in intracellular digestion.
<b>Peroxisomes</b>	Small membranous vesicles. Contain peroxidase enzymes used in breakdown of complex toxins and other organic molecules.
<b>Mitochondria</b>	Small membranous sacs with complex internal structure and separate DNA. Contain enzymes of Krebs cycle; central to carbohydrate metabolism and synthesis of ATP.
<b>Nucleus</b>	Nuclear contents, notably DNA, separated from cytoplasm by porous nuclear envelope.
<b>NONMEMBRANOUS</b>	
<b>Ribosomes</b>	Small structures composed of two parts containing protein and RNA molecules. Often associated with endoplasmic reticulum. Synthesize proteins under instructions of messenger RNA triplet code.
<b>Centrosome</b>	Double structure composed of two, short, rod-like centrioles. Important in distribution of chromosomes during cell division and in formation of cilia.
<b>Microfilaments and microtubules</b>	Composed of protein complexes. Act as cytoskeletal framework. Function in whole-cell and local membrane movements, cellular elasticity, and formation of cellular extensions (e.g., microvilli).
<b>Cilia and flagella</b>	Movable membranous extensions. Important in movement of fluid environment over stationary cell surface (cilia) and cell itself (flagellum of sperm cell).
<b>Nucleolus</b>	Dense object composed of protein and RNA molecules. Essential in ribosome formation.

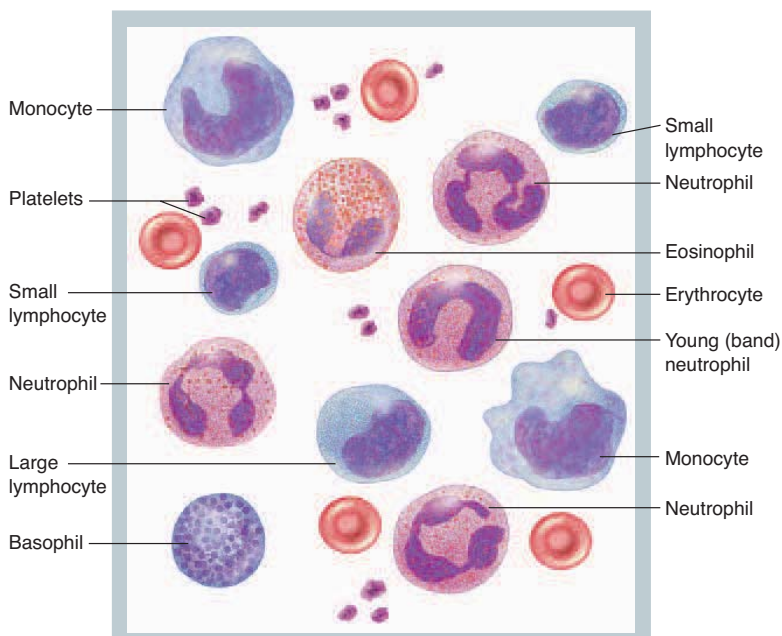


**TABLE 6.2** Some membrane transport processes

PROCESS	DESCRIPTION
<b>PHYSICAL PROCESSES: DO NOT REQUIRE LOCAL EXPENDITURE OF METABOLIC ENERGY</b>	
<b>Bulk flow</b>	Movement of substances from higher pressures toward lower pressures. Examples: movement of gases in and out of ventilatory tree during breathing, movement of blood through arteries and veins due to pumping action of heart.
<b>Diffusion</b>	Movement of ions or molecules from higher concentrations toward lower concentrations due to random molecular collisions. Examples: movement of sodium and potassium ions and glucose molecules in extracellular fluid.
<b>Filtration</b>	Bulk flow through a semipermeable membrane. Example: movement of fluid and small molecules through kidney capillary walls due to hydrostatic pressure.
<b>Dialysis</b>	Diffusion of solute molecules through a semipermeable membrane. Example: passage of lipid-soluble substances, such as steroid molecules, through cell membrane.
<b>Osmosis</b>	Diffusion of water down its concentration gradient through a semipermeable membrane. Osmosis generally operates <i>against</i> concentration gradient of solute(s) to which the membrane is <i>impermeable</i> . Example: net movement of extracellular fluid into the venous ends of capillaries under influence of <i>impermeant</i> plasma proteins.
<b>Facilitated diffusion</b>	Diffusion through an otherwise impermeable membrane by means of carrier molecules. Example: movement of glucose through muscle cell membranes (requires insulin to enhance action of facilitating carriers).
<b>PHYSIOLOGICAL PROCESSES: REQUIRE LOCAL EXPENDITURE OF METABOLIC ENERGY</b>	
<b>Active transport</b>	Carrier-mediated transport of ions or molecules through a living membrane via energy-requiring shape change of carrier molecule. Energy expenditure permits transport from lower to higher concentration. Examples: movement of sodium from inside to outside of resting nerve cells; transport of potassium and calcium from outside to inside cells, thereby causing high internal concentrations of these ions.
<b>Phagocytosis and pinocytosis</b>	Transport of large particles or fluid into a cell via engulfing action of membrane followed by pinching off to form an intracellular vesicle. Both are processes of endocytosis. Example: trapping of bacteria by white blood cells.
<b>Exocytosis</b>	Transport of substances out of a cell by fusion of internal vesicle with cell membrane and release of contents to the exterior. Examples: secretion of hormones and neurotransmitters, such as prolactin and acetylcholine.

**TABLE 6.3** Formed elements of blood

CELL TYPE	DESCRIPTION (WRIGHT'S STAIN)	NORMAL NUMBER (CELLS/ $\mu$ L OF BLOOD)	FUNCTION
<b>Erythrocytes</b> (Red blood cells, RBC)	7.5 $\mu$ diameter, biconcave disk, no nucleus	4–6 million	Transport of respiratory gases (O <sub>2</sub> and CO <sub>2</sub> )
<b>Leukocytes</b> (White blood cells, WBC)		5,000 to 10,000/mm <sup>3</sup>	Aid in defense against infections by microorganisms
<b>Granulocytes</b>			
<b>Neutrophil</b>	12–15 $\mu$ diameter, multilobed nucleus, small pink-purple granules	3,000–7,000 (65% of total leukocytes)	Phagocytosis; elevated in number during acute infections
<b>Eosinophil</b>	10–14 $\mu$ diameter, bilobed nucleus, large orange granules	100–400 (3% of total leukocytes)	Destroys antigen-antibody complexes, phagocytosizes parasites, involved in allergic response
<b>Basophil</b>	8–12 $\mu$ diameter, bilobed, large purple granules that may obscure nucleus	20–50 (1% of total leukocytes)	Contains biogenic amines; releases heparin, histamine, other chemicals during inflammatory response
<b>Agranulocytes</b>			
<b>Lymphocyte</b>	5–16 $\mu$ diameter, round or nucleus, indented, single-lobed nucleus, variable amount of cytoplasm	1,500–3,000 (25% of total leukocytes)	Immune response by direct cellular contact or via antibody production; elevated in infectious mononucleosis; suppressed by steroid therapy
<b>Monocyte</b>	12–20 $\mu$ diameter, horseshoe-shaped nucleus	100–700 (6% of total leukocytes)	Macrophages; phagocytosis
<b>Platelets</b>	2–4 $\mu$ , appear as cytoplasmic fragments	25,000 to 500,000	Coagulation



**Figure 6-2**

**The Formed Elements of Blood**

The structure of red blood cells, white blood cells, and platelets.



**TABLE 6.4** Terms for bone structure

TERM	DEFINITION
<b>Epiphysis</b>	Either rounded end of head of a long bone
<b>Diaphysis</b>	The shaft of a long bone
<b>Anatomic neck</b>	The epiphyseal growth plate
<b>Surgical neck</b>	The narrow part of a long bone, just past the head, where fracture is most likely
<b>Ramus</b>	A branch
<b>Cornu</b>	A horn
<b>Hamulus</b>	A hook
<b>Lingula</b>	A tongue
<b>Foramen (pl. foramina)</b>	A hole; an opening into or through a bone to permit passage of blood vessels, nerves, or ligaments
<b>Fossa</b>	A valley; a relatively deep pit or depression
<b>Fovea</b>	A relatively small pit or depression
<b>Sulcus</b>	A narrow valley
<b>Meatus</b>	A tunnel
<b>Trochanter</b>	A large, blunt, rounded process that serves as a site for muscle attachment
<b>Tubercle</b>	A small, blunt, rounded process that serves as a site for muscle attachment
<b>Tuberosity</b>	A large, rounded, often rough eminence or surface that serves as a site for muscle attachment
<b>Condyle</b>	A large, rounded process at the end of a bone, usually contributing to a joint
<b>Epicondyle</b>	A smaller, rounded process at the end of a bone, on top of a condyle, usually contributing to a joint
<b>Trochlea</b>	A pulley; a smooth, notched surface often found at a joint
<b>Facet</b>	A face; a smooth, nearly flat surface at a joint
<b>Fissure</b>	A crack or cleft
<b>Crest or crista</b>	A narrow ridge
<b>Spine</b>	A pointed ridge
<b>Fontanel</b>	Specifically, six spaces between the cranial bones of the fetal and infant skull prior to closure of the sutures
<b>Second and fifth intercostal spaces</b>	Specifically refers to a place between the 2nd and 3rd rib and a place between the 5th and 6th ribs where the second and first heart sounds, respectively, can be heard especially well

**TABLE 6.5** Bones of the human skeleton

PART OF THE BODY	NAMES OF BONES
<b>AXIAL SKELETON (80 BONES TOTAL)</b>	
<b>Skull (28 bones)</b>	
<b>Cranium (8 bones)*</b>	Frontal (1) Parietal (1 pair) Temporal (1 pair) Occipital (1) Sphenoid (1) Ethmoid (1)
<b>Face (14 bones)</b>	Lacrimal (1 pair) Nasal (1 pair) Palatine (1 pair) Inferior nasal conchae (turbinates) (1 pair) Vomer (1) Maxillae (1 pair) Zygomatic (malar) (1 pair) Mandible (1)
<b>Middle ear (6 bones)</b>	Malleus (1 pair) Incus (1 pair) Stapes (1 pair)
<b>Hyoid bone (1)</b>	
<b>Spinal column (26 bones total)</b>	Cervical vertebrae (7) Thoracic vertebrae (12) Lumbar vertebrae (5) Sacrum (4–5 fused into 1) Coccyx (4–5 fused into 1)
<b>Sternum and ribs (25 bones total)</b>	Sternum (1) True ribs (7 pairs) False ribs (5 pairs)
<b>APPENDICULAR SKELETON (126 BONES TOTAL)</b>	
<b>Shoulder girdle and arm (64 bones total)</b>	Clavicle (1 pair) Scapula (1 pair) Humerus (1 pair) Ulna (1 pair) Radius (1 pair) Carpals (8 pairs; navicular (scaphoid), lunate, triangular (triquetrum), pisiform, greater multangular (trapezium), lesser multangular (trapezoid), capitate, hamate) Metacarpals (5 pairs) Phalanges (14 pairs)
<b>Pelvic girdle and leg (62 bones total)</b>	Os coxae (1 pair: 2 innominate bones each formed by fusion of ilium, ischium, and pubis) Femur (1 pair) Patella* (1 pair) Tibia (1 pair) Fibula (1 pair) Tarsals (7 pairs: talus, calcaneus, navicular, medial cuneiform, intermediate cuneiform, lateral cuneiform, cuboid) Metatarsals (5 pairs) Phalanges (14 pairs)

\*A variable number of rounded bones known as **sesamoid bones** (because of their supposed resemblance to sesame seeds) may appear in various tendons, especially those in the wrist, knee, ankle, and foot. Only two of them, the patellae, are commonly found. **Wormian bones** are found in variable numbers within the suture lines of the skull. While most are commonly smaller than the size of fingernails, some can be surprisingly large.



**TABLE 6.6** Comparison of female and male skeletons

Differences between male and female skeletons are graded, not discrete. Female skeletons can have many masculine features, and vice versa. Nevertheless, there are trends, including those listed below. A typically masculine pelvis is called *android*; a typically feminine pelvis is called *gynecoid*. Many intermediate types exist.

PORTION OF SKELETON	FEMALE	MALE
<b>GENERAL FORM</b>	Bones lighter and thinner Muscle attachment sites smaller and smoother Joint surfaces relatively small	Bones heavier and thicker Muscle attachment sites larger and rougher Joint surfaces relatively large
<b>PELVIS</b>		
<b>Pelvic cavity</b>	Wider in all dimensions Shorter and roomier Pelvic outlet relatively large	Smaller in all dimensions Deeper Pelvic outlet usually obstructed
<b>Sacrum</b>	Short, wide, flat concavity more pronounced in a posterior direction; sacral promontory less pronounced	Long, narrow, with smooth concavity of sacral curvature; sacral promontory more pronounced
<b>Coccyx</b>	More movable and follows posterior direction of sacral curvature	Less movable
<b>Pubic arch</b>	Greater than a 90° angle	Less than a 90° angle
<b>Ischial spine, ischial tuberosity, and anterior superior iliac spine</b>	Oriented outward and farther apart	Oriented inward
<b>Greater sciatic notch</b>	Narrow	Wide

**TABLE 6.7** Extrinsic muscles of the eye

NAME	ORIGIN	INSERTION	ACTION	INNERVATION
<b>Rectus superior</b>	Tendinous ring of tissue that surrounds optic foramen at back of orbit	Top of eyeball	Rolls eye upward	Oculomotor
<b>Rectus inferior</b>		Bottom of eyeball	Rolls eye downward	Oculomotor
<b>Rectus lateralis</b>		Lateral side of eyeball	Rolls eye laterally	Abducens
<b>Rectus medialis</b>		Medial side of eyeball	Rolls eye medially	Oculomotor
<b>Obliquus superior</b>		Top of eyeball under rectus superior, through trochlea	Prevents rotation of eyeball on axis; directs gaze down and laterally	Trochlear
<b>Obliquus inferior</b>	Maxilla at front of orbit	Lateral side of eyeball under rectus lateralis	Prevents rotation of eye on axis; directs gaze up and laterally	Oculomotor

**TABLE 6.8** Facial muscles

NAME	ORIGIN	INSERTION	ACTION	INNERVATION
<b>Buccinator</b>	Maxillary and mandibular alveolar processes	Into orbicularis oris at sides of mouth	Compresses cheek, retracts corner of mouth as in playing a brass musical instrument	Facial
<b>Orbicularis oris</b>	Maxillae, mandible, nasal septum	Fibers encircle mouth, insert on fascia	Puckering, shaping of mouth in speech	Facial
<b>Orbicularis oculi</b>	Maxillae, frontal bone	Fibers encircle orbit	Closes eye, assists in squinting	Facial
<b>Epicranius (occipitofrontalis)</b>	Occipital bone	Skin around eyebrows and above nose	Moves scalp, elevates eyebrows	Facial
<b>Zygomaticus major</b>	Zygomatic bone	Into orbicularis oris at corners of mouth	Retracts and elevates corners of mouth as in smiling	Facial
<b>Zygomaticus minor</b>	Zygomatic bone	Into orbicularis oris of upper lip	Elevates upper lip, assists in smiling	Facial
<b>Levator palpebrae superioris</b>	Lesser wing of sphenoid	Skin of upper eyelid	Elevates upper eyelid	Oculomotor
<b>Corrugator supercilii</b>	Bridge of nose, orbicularis oculi	Skin of eyebrows	Depresses and adducts eyebrows; furrows forehead as in frowning	Facial

**TABLE 6.9** Chewing muscles

NAME	ORIGIN	INSERTION	ACTION	INNERVATION
<b>Masseter</b>	Zygomatic arch and maxilla	Lateral surface of mandible	Closes jaw	Trigeminal
<b>Temporalis</b>	Temporal bone	Coronoid process of mandible	Closes jaw	Trigeminal
<b>Pterygoid (medial and lateral)</b>	Pterygoid processes of sphenoid bone	Medial surface of mandible	Moves jaw from side to side; grates teeth for chewing	Trigeminal



**TABLE 6.10** Muscles of the throat

NAME	ORIGIN	INSERTION	ACTION	INNERVATION
<b>Digastric</b>	Mastoid process of temporal bone	Mandible	Elevates hyoid bone; depresses and retracts mandible	Posterior portion: Facial Anterior portion: Mandibular branch of trigeminal
<b>Mylohyoid</b>	Mandible	Hyoid	Elevates floor of mouth when mandible is fixed; depresses mandible when hyoid is fixed	Mandibular division of trigeminal
<b>Omoxyoid</b>	Superior border of scapula and tendon from clavicle	Hyoid	Depresses hyoid; stabilizes hyoid when opening mouth	C1–C3 via ansa hypoglossi
<b>Sternohyoid</b>	Manubrium of sternum; costal cartilage 1	Hyoid	Depresses hyoid; stabilizes hyoid when opening mouth	C1–C3 via ansa hypoglossi
<b>Sternothyroid</b>	Manubrium of sternum; costal cartilages 1 and 2	Thyroid cartilage	Depresses larynx; stabilizes larynx when opening mouth	Upper cervical nerves via ansa cervicalis and ansa hypoglossi

**TABLE 6.11** Muscles of the tongue

NAME	ORIGIN	INSERTION	ACTION	INNERVATION
<b>Intrinsic muscles: Longitudinal, vertical, and transverse</b>	Within tongue	Within tongue	Change shape of tongue in speaking, chewing, licking	Hypoglossal
<b>Genioglossus</b>	Genu of mandible	Tongue	Depresses and protrudes tongue	Hypoglossal
<b>Hyoglossus</b>	Hyoid	Side of tongue	Depresses and retracts tongue	Hypoglossal
<b>Styloglossus</b>	Styloid process of temporal bone	Inferior and lateral aspect of tongue	Retracts tongue	Hypoglossal

**NOTE:** The three above-named muscles are **extrinsic muscles of the tongue**, so identified because their origins lie outside the muscular tongue itself.

**TABLE 6.12** Muscles of the pharynx and palate

NAME	ORIGIN	INSERTION	ACTION	INNERVATION
<b>Constrictor pharyngis inferior</b>	Cricoid and thyroid cartilages	Median raphe of pharynx	Constricts lower pharynx during swallowing	Glossopharyngeal and vagus
<b>Constrictor pharyngis medius</b>	Greater and lesser cornu of hyoid	Median raphe of pharynx	Constricts middle pharynx during swallowing	Glossopharyngeal and vagus
<b>Constrictor pharyngis superior</b>	Middle pterygoid plate, mandible, floor of mouth	Median raphe of pharynx	Constricts upper pharynx during swallowing	Glossopharyngeal and vagus
<b>Stylopharyngeus</b>	Styloid process of temporal bone	Sides of pharynx; thyroid cartilage	Elevates and dilates pharynx	Glossopharyngeal
<b>Palatopharyngeus</b>	Soft palate	Pharynx	Narrows fauces; depresses palate; elevates pharynx	Glossopharyngeal and vagus
<b>Palatoglossus</b>	Soft palate	Tongue	Narrows fauces; elevates back of tongue	Pharyngeal plexus
<b>Levator veli palatini</b>	Temporal bone and cartilage of Eustachian tube	Soft palate	Elevates soft palate	Glossopharyngeal and vagus
<b>Tensor veli palatini</b>	Sphenoid bone and cartilage of Eustachian tube	Soft palate	Increases tension of soft palate; opens Eustachian tube as in yawning	Mandibular division of trigeminal

**NOTE:** The palatopharyngeus muscle and its mucous membrane covering form the clearly seen arch of the soft palate, from which hangs the uvula. Just anterior to this arch on each side is the palatoglossus muscle, which, with its mucous membrane covering, forms the more lateral and less clearly seen glossopalatine arch. Between these two arches on each side is a fossa that houses the lymph node known as the palatine tonsil.

**TABLE 6.13** Muscles that move the head

NAME	ORIGIN	INSERTION	ACTION	INNERVATION
<b>Sternocleidomastoid</b>	Sternum and clavicle	Mastoid process of temporal bone	Bows head, rotates head	Spinal accessory, C2–C3
<b>Trapezius</b>	Acromial process of clavicle and spine of scapula	Occipital bone, ligamentum nuchae, spines of seventh cervical and all thoracic vertebrae	Extends head, rotates head	Spinal accessory, C3–C4
<b>Obliquus capitis inferior</b>	Spinous process of axis	Transverse process of atlas	Rotates head	Branch of suboccipital
<b>Splenius capitis</b>	Ligamentum nuchae, spines of seventh cervical and top four thoracic vertebrae	Occipital bone and mastoid process of temporal bone	Extends head, rotates head	Middle and lower cervical spinal nerves
<b>Semispinalis capitis</b>	See MUSCLES OF THE VERTEBRAL COLUMN. The capitis division of this muscle inserts on the occipital bone. When the vertebrae serve as the origin and the occipital bone as the insertion, this muscle (bilaterally) extends the head or (unilaterally) draws the head toward the contracting side.			
<b>Longissimus capitis</b>	See MUSCLES OF THE VERTEBRAL COLUMN. The capitis division of this muscle inserts on the mastoid process of the temporal bone. When the vertebrae serve as the origin and the occipital bone as the insertion, this muscle (bilaterally) extends the head or (unilaterally) draws and rotates the head toward the contracting side.			



**TABLE 6.14** Muscles that move the shoulder

NAME	ORIGIN	INSERTION	ACTION	INNERVATION
<b>Trapezius</b>	See MUSCLES THAT MOVE THE HEAD. If origin and insertion are reversed, this muscle causes elevation of shoulders, as in shrugging, by elevating clavicle and scapula.			
<b>Pectoralis minor</b>	Outer surface of third, fourth, and fifth ribs	Coracoid process of scapula	Depresses shoulder, rotates scapula forward and down; can assist in elevating ribs	Long thoracic
<b>Serratus anterior</b>	Outer surface of upper eight or nine ribs	Ventral surface of vertebral border of scapula	Rotates scapula forward and toward thoracic wall; can assist in elevating ribs	Spinal accessory, C3–C4
<b>Rhomboides major</b>	Spines of second to fifth thoracic vertebrae	Vertebral border of scapula	Adducts scapula, rotates slightly upward	Dorsal scapular
<b>Rhomboides minor</b>	Spines of seventh cervical and first thoracic vertebrae	Vertebral border of scapula	Adducts scapula	Dorsal scapular

**NOTE:** The triangle of auscultation is formed at the caudal medial border of the scapula by the edges of the latissimus dorsi, trapezius, and rhomboides muscles.

**TABLE 6.15** Muscles that move the upper arm

NAME	ORIGIN	INSERTION	ACTION	INNERVATION
<b>Pectoralis major</b>	Clavicle, sternum, cartilages of second to sixth ribs	Crest and greater tubercle of humerus	Flexes and adducts arm	Anterior thoracic
<b>Latissimus dorsi</b>	Spinous processes of lower six thoracic and all lumbar vertebrae, sacral spine, iliac crest and lower four ribs	Intertubercular groove of humerus	Extends, adducts, rotates arm medially, draws shoulder down and back	Thoracodorsal
<b>Deltoides</b>	Clavicle and acromion and spine of scapula	Deltoid tuberosity of humerus	Abducts arm	Axillary
<b>Coracobrachialis</b>	Coracoid process of scapula	Medial surface of humerus	Adducts arm; assists in flexion and medial rotation	Musculocutaneous
<b>Teres major</b>	Medial border of scapula	Just distal to lesser tubercle of humerus	Adducts, extends, rotates arm medially	Lower subscapular
<b>Teres minor</b>	Medial border of scapula	Greater tubercle of humerus	Rotates arm laterally	Axillary
<b>Subscapularis</b>	Subscapular fossa of scapula	Lesser tubercle of humerus	Extends and medially rotates arm	Subscapular C5, C6
<b>Supraspinatus</b>	Supraspinous fossa of scapula	Greater tubercle of humerus	Initiates abduction of arm	Suprascapular C5, C6
<b>Infraspinatus</b>	Infraspinous fossa of scapula	Greater tubercle of humerus	Extends and laterally rotates arm	Suprascapular C5, C6

**NOTE:** The rotator cuff is formed from the tendons of the last four muscles named above because together they form a cuff that binds the humerus into the shallow glenoid fossa. A rotator cuff injury involves damage to one or more of these muscles or their tendons.

**NOTE:** Alone, the deltoid cannot initiate the first 15° of abduction, which is a duty of the supraspinatus muscle and its innervation and which is separate from that of the deltoid. Differential assessment of peripheral nerve injury is possible by asking a patient to abduct the arm from anatomical position.

**TABLE 6.16** Muscles that move the lower arm

NAME	ORIGIN	INSERTION	ACTION	INNERVATION
<b>Biceps brachii</b>	Long head: Tuberosity above glenoid cavity of scapula Short head: Coracoid process of scapula	Radial tuberosity	Flexes and supinates arm and forearm	Musculocutaneous
<b>Brachialis</b>	Anterior surface of distal humerus	Tuberosity and coronoid process of ulna	Flexes forearm	Musculocutaneous, radial, and median
<b>Brachioradialis</b>	Supracondyloid ridge of humerus	Proximal to styloid process of radius	Flexes forearm	Radial
<b>Triceps brachii</b>	Long head: Infraglenoid tuberosity of scapula Lateral head: Posterior surface of humerus above radial groove Medial head: Posterior surface of humerus below radial groove	Olecranon process of ulna	Extends forearm	Radial
<b>Anconeus</b>	Lateral epicondyle of humerus	Olecranon process and proximal one-fourth of ulna	Extends forearm	Radial
<b>Pronator teres</b>	Medial epicondyle of humerus, coronoid process of ulna	Middle third of lateral surface of radius	Pronates and flexes forearm	Median
<b>Pronator quadratus</b>	Distal shaft of ulna	Distal shaft of radius	Pronates forearm	Median
<b>Supinator</b>	Lateral epicondyle of humerus, proximal end of ulna	Proximal third of radius	Supinates forearm	Median



**TABLE 6.17** Muscles that move the wrist and hand

NAME	ORIGIN	INSERTION	ACTION	INNERVATION
<b>FLEXORS</b>				
<b>Flexor carpi ulnaris</b>	Ulna; medial epicondyle of humerus	Fifth metacarpal; pisiform and hamate	Flexes and adducts wrist; flexes forearm	Ulnar
<b>Palmaris longus</b>	Medial epicondyle of humerus	Palmar fascia	Tenses palmar fascia; flexes wrist	Median
<b>Flexor carpi radialis</b>	Medial epicondyle of humerus	First and second metacarpals	Flexes and abducts wrist	Median
<b>Flexor digitorum profundus</b>	Ulna	Distal phalanges 2–5	Flexes fingers and wrist	Median and ulnar
<b>Flexor digitorum superficialis</b>	Medial epicondyle of radius	Middle phalanges 2–5	Flexes fingers and wrist	Median
<b>Flexor pollicis longus</b>	Radius	Distal phalanx of thumb	Flexes thumb and wrist	Median
<b>EXTENSORS</b>				
<b>Extensor carpi ulnaris</b>	Ulna; lateral epicondyle of humerus	Metacarpal 5	Extends hand; adducts little finger	Radial
<b>Extensor digitorum</b>	Lateral epicondyle of humerus	Phalanges 2–5	Extends fingers and wrist	Radial
<b>Extensor carpi radialis brevis</b>	Lateral epicondyle of humerus	Metacarpal 3	Extends and abducts wrist	Radial
<b>Extensor carpi radialis longus</b>	Lateral supracondylar ridge of humerus	Metacarpal 2	Extends and abducts wrist	Radial
<b>Extensor indicis</b>	Ulna	Phalanx 2	Extends forefinger and wrist	Radial
<b>Abductor pollicis longus</b>	Posterior ulna and radius; interosseous membrane	Metacarpal 1	Abducts and extends thumb and wrist	Radial
<b>Extensor pollicis longus</b>	Dorsal surface of ulna	Base of thumb, second phalanx	Extends end of thumb	Radial
<b>Extensor pollicis brevis</b>	Dorsal surface of radius	Dorsal surface of thumb, first phalanx	Extends and abducts thumb; abducts wrist	Posterior interosseous

**NOTE:** These last two muscles cross the lateral surface of the wrist to form the **anatomical snuff box**. Extend the thumb laterally to see this structure. The radial artery passes through the snuff box; the pulse can be felt there.

**TABLE 6.18** Muscles that move the chest wall: Breathing

NAME	ORIGIN	INSERTION	ACTION	INNERVATION
<b>NOTE:</b> These muscles are overlaid by the latissimus dorsi, trapezius, and the pectoralis, which are functionally part of the appendicular muscle division.				
<b>External intercostals</b>	Inferior border of rib	Superior border of rib	Draws adjacent ribs together	Intercostal
<b>Internal intercostals</b>	Inferior border of rib	Superior border of rib	Draws adjacent ribs together	Intercostal
<b>Transversus thoracis</b>	Lower one-third of sternum	Costal cartilage of true ribs (except first rib)	Depresses ribs in exhalation	Intercostal
<b>Diaphragm</b>	Xiphoid process, costal cartilages of lowest six ribs, lumbar vertebrae	Central tendon	Depresses floor of thoracic cavity in inhalation	Phrenic
<b>Sternocleidomastoid</b>	See MUSCLES THAT MOVE THE HEAD. If head acts as origin, then this muscle acts to elevate sternum and rib cage.			
<b>Scalenes</b>	Transverse processes of second to seventh cervical vertebrae	First two ribs	Elevates ribs in inhalation	C5–C8
<b>Levatores costarum</b>	Transverse processes of seventh cervical and first eleven thoracic vertebrae	Angle of rib immediately below origin	Elevates ribs in inhalation	Intercostal

**TABLE 6.19** Muscles that move the abdominal wall

NAME	ORIGIN	INSERTION	ACTION	INNERVATION
<b>External oblique</b>	Lower eight ribs	Iliac crest, linea alba	Compresses abdominal contents	Intercostals 8–12, iliohypogastric, ilioinguinal
<b>Internal oblique</b>	Iliac crest, inguinal ligament, lumbodorsal fascia	Costal cartilages of last three or four ribs	Compresses abdominal contents	Same as external oblique
<b>Transversus abdominis</b>	Iliac crest, inguinal ligament, lumbar fascia, costal cartilages of last six ribs	Xiphoid process, linea alba, pubis	Compresses abdominal contents	Intercostals 7–12, iliohypogastric, ilioinguinal
<b>Rectus abdominis</b>	Pubic crest, symphysis pubis	Xiphoid process, costal cartilages of fifth, sixth, and seventh ribs	Flexes trunk, compresses abdominal contents	Intercostals 7–12

**TABLE 6.20** Muscles of the pelvic floor: The pelvic diaphragm

NAME	ORIGIN	INSERTION	ACTION	INNERVATION
<b>Levator ani</b>	Posterior surface of pubis, ischial spine	Coccyx	Support pelvic organs. Supports pregnant uterus, participates in childbirth	Pudendal
<b>Coccygeus</b> (posterior continuation of levator ani)	Ischial spine	Coccyx, sacrum	Same as levator ani	Pudendal
<b>Sphincter ani externus</b>	Coccyx	Central tendon of perineum	Closes anal canal	Pudendal and S4
<b>Sphincter urethrae</b>	Pubic ramus	Central tendon of perineum	Constricts urethra	Pudendal
<b>Ischiocavernosus</b>	Ischial ramus	Corpus cavernosum	Compresses base of penis or clitoris	Pudendal
<b>Transverse perinei</b>	Ischial ramus	Central tendon of perineum	Supports pelvic floor	Pudendal
<b>Bulbospongiosus (male)</b>	Perineum and bulb of penis	Central tendon of perineum	Constricts urethra and erects penis	Pudendal
<b>Bulbospongiosus (female)</b>	Central tendon of perineum	Base of clitoris	Erects clitoris	Pudendal



**TABLE 6.21** Muscles of the vertebral column: Muscles of erect posture

NAME	ORIGIN	INSERTION	ACTION	INNERVATION
<b>NOTE:</b> Muscles of the abdominal wall function as postural muscles.				
<b>Iliopsoas</b>	Postural muscle when femur acts as origin	See MUSCLES LOCATED IN THE ANTERIOR HIP		
<b>ERECTOR SPINAE GROUP</b>				
Composed of three muscle groups, each of which has subgroups. The three major groups are the laterally placed <b>iliocostalis</b> , the intermediately placed <b>longissimus</b> , and the medially placed <b>spinalis</b> .				
<b>Iliocostalis</b> <b>Lumborum</b> <b>Thoracis</b> <b>Cervicis</b>	Iliac crest and all ribs	Ribs or transverse processes roughly six vertebrae above origin	Extends trunk and neck, maintains erect posture, rotates trunk and neck	Dorsal rami of lumbar, thoracic, and cervical spinal nerves
<b>Longissimus</b> <b>Thoracis</b> <b>Cervicis</b> <b>Capitis</b>	Transverse processes of thoracic and lumbar vertebrae	Transverse processes roughly twelve vertebrae above origin, some ribs, and mastoid process of temporal bone	Extends trunk and neck, maintains erect posture, rotates trunk and head	Dorsal rami of lumbar, thoracic, and cervical spinal nerves
<b>Spinalis</b> <b>Thoracis</b> <b>Cervicis</b> <b>Capitis</b>	Spinous processes of upper lumbar and lower thoracic vertebrae	Spinous processes of upper thoracic vertebrae, cervical vertebrae and occipital bone	Extends trunk	Dorsal rami of lumbar and thoracic spinal nerves
<b>Semispinalis</b>	Transverse processes of seventh cervical and thoracic vertebrae	Spinous processes roughly six vertebrae above origin, occipital bone	Extends and rotates vertebral column and head	Dorsal rami of spinal nerves
<b>Multifidus</b>	Pelvic girdle, lumbar vertebrae, transverse processes of thoracic and lower cervical vertebrae	Spinous processes three vertebrae above origin	Extends and rotates trunk	Dorsal rami of lumbar, thoracic, and cervical spinal nerves
<b>Quadratus lumborum</b>	Posterior iliac crest and lower three lumbar vertebrae	Twelfth rib and transverse processes of top four lumbar vertebrae	Lateral flexion of trunk, pelvic extension	T12, L1

**TABLE 6.22** Muscles located in the lateral hip

NAME	ORIGIN	INSERTION	ACTION	INNERVATION
<b>Tensor fasciae latae</b>	Anterior iliac crest	Through iliotibial band to lateral tibia	Tenses and abducts thigh	Superior gluteal

**TABLE 6.23** Muscles located in the anterior hip

NAME	ORIGIN	INSERTION	ACTION	INNERVATION
<b>Iliopsoas</b> Two components: <b>Iliacus and psoas major</b>	Transverse processes of lumbar vertebrae, iliac fossa	Lesser trochanter of femur and iliopubic junction	Flexes and laterally rotates thigh, also flexes trunk	L1–L3
<b>Rectus femoris</b>	See MUSCLES LOCATED IN ANTERIOR THIGH			

**TABLE 6.24** Muscles located in the posterior hip

NAME	ORIGIN	INSERTION	ACTION	INNERVATION
<b>Gluteus maximus</b>	Posterior iliac crest, sacrum, coccyx	Iliotibial tract and gluteal tuberosity of femur	Extends and rotates thigh laterally	Inferior gluteal
<b>Gluteus medius</b>	Lateral surface of ilium	Greater trochanter of femur	Abducts and rotates thigh medially	Superior gluteal
<b>Gluteus minimus</b>	Lateral surface of ilium	Greater trochanter of femur	Abducts and rotates thigh medially	Superior gluteal
<b>Piriformis</b>	Sacrum	Greater trochanter of femur	Abducts and rotates thigh laterally	S1–S2

**TABLE 6.25** Muscles located in the anterior thigh

NAME	ORIGIN	INSERTION	ACTION	INNERVATION
<b>QUADRICEPS FEMORIS GROUP</b>				
<b>Rectus femoris</b>	Anterior inferior iliac spine	Tibial tuberosity via patellar tendon	Flexes thigh and extends leg	Femoral
<b>Vastus lateralis</b>	Greater trochanter and linea aspera	Same as rectus femoris	Extends leg	Femoral
<b>Vastus medialis</b>	Linea aspera of femur	Same as rectus femoris	Extends leg	Femoral
<b>Vastus intermedius</b> (located immediately posterior to rectus femoris)	Anterior surface of femur	Same as rectus femoris	Extends leg	Femoral

**TABLE 6.26** Muscles located in the medial thigh

NAME	ORIGIN	INSERTION	ACTION	INNERVATION
<b>ADDUCTOR GROUP</b>				
<b>Adductor brevis</b>	Inferior pubic ramus	Linea aspera of femur	Adducts, rotates, and flexes thigh	Obturator
<b>Adductor longus</b>	Pubic crest and symphysis pubis	Linea aspera of femur	Adducts, rotates, and flexes thigh	Obturator
<b>Adductor magnus</b>	Ischial tuberosity, ischiopubic ramus	Linea aspera of femur	Adducts, rotates, and flexes thigh	Obturator
<b>Gracilis</b>	Symphysis pubis and pubic arch	Medial surface of tibia	Flexes leg and adducts thigh	Obturator
<b>Pectineus</b>	Pubic spine and iliopubic junction	Pectineal line of femur (distal to lesser trochanter)	Flexes and adducts thigh, rotates thigh laterally	Femoral

**TABLE 6.27** Muscles located in the posterior thigh

NAME	ORIGIN	INSERTION	ACTION	INNERVATION
<b>HAMSTRING GROUP</b>				
<b>Biceps femoris</b>	Long head: Ischial tuberosity Short head: Linea aspera of femur	Lateral portion of head of fibula, lateral tibial condyle	Flexes leg and extends thigh	Tibial and peroneal
<b>Semitendinosus</b>	Ischial tuberosity	Proximal medial tibia	Flexes leg and extends thigh	Tibial
<b>Semimembranosus</b>	Ischial tuberosity	Medial condyle of tibia	Flexes leg and extends thigh	Tibial



**TABLE 6.28** Muscles located in the lower leg

NAME	ORIGIN	INSERTION	ACTION	INNERVATION
<b>Gastrocnemius</b>	Lateral and medial tibial condyles, knee capsule	Calcaneus via Achilles tendon	Plantar flexes foot, flexes leg	Tibial
<b>Soleus</b>	Head of fibula, medial surface of tibia	Calcaneus via Achilles tendon	Plantar flexes foot	Tibial
<b>Plantaris</b>	Linea aspera of femur	Calcaneus via Achilles tendon	Plantar flexes foot, flexes leg	Tibial
<b>Popliteus</b>	Lateral condyle of femur	Posterior tibia	Flexes and medially rotates leg	Tibial
<b>Peroneus brevis</b>	Fibula	Metatarsal 5	Plantar flexes foot	Peroneal
<b>Peroneus longus</b>	Fibula and lateral condyle of tibia	Cuneiform 1; metatarsal 1	Plantar flexes foot	Peroneal
<b>Flexor hallucis longus</b>	Shaft of fibula	Distal phalanx of great toe	Flexes great toe, plantar flexes foot	Tibial
<b>Flexor digitorum longus</b>	Posterior surface of tibia	Distal phalanges of four lateral toes	Flexes toes, plantar flexes foot	Tibial
<b>Tibialis posterior</b>	Interosseous membrane of tibia and fibula	Several tarsals and metatarsals	Plantar flexes foot	Tibial
<b>NOTE:</b> The tendons of the three preceding flexor muscles pass through the ankle just posterior and inferior to the medial malleolus. From posterior to anterior, the order of these tendons is <i>T.</i> posterior, <i>F.</i> digitorum longus, and <i>F.</i> hallucis longus, which has led to their being casually referred to as <i>Tom</i> , <i>Dick</i> , and <i>Harry</i> .				
<b>Extensor hallucis longus</b>	Shaft of fibula, interosseous membrane	Distal phalanx of great toe	Extends great toe, dorsiflexes foot	Deep peroneal
<b>Extensor digitorum longus</b>	Lateral tibial condyle, anterior fibular surface	Middle and distal phalanges of four lateral toes	Extends toes, dorsiflexes foot	Deep peroneal
<b>Tibialis anterior</b>	Lateral condyle and body of tibia	First metatarsal and first cuneiform	Dorsiflexes foot	Deep peroneal
<b>Peroneus tertius</b>	Fibula and interosseous membrane	Metatarsal 5	Dorsiflexes and everts foot	Deep peroneal

**TABLE 6.29** The cranial nerves

NUMBER AND NAME	EXIT FROM SKULL	FUNCTION
<b>I. Olfactory</b>	Cribriform plate of ethmoid	Sensory: Olfaction. Rhythmic sensitivity follows hormonal cycles in females
<b>II. Optic</b>	Optic foramen	Sensory: Vision. Probable efferents may regulate retinal metabolism and structural renewal
<b>III. Oculomotor</b>	Orbital fissure	Motor: Rectus superior, rectus inferior, rectus medius, and obliquus inferior muscles. Sensory: Proprioception Autonomic (parasympathetic): Muscles of iris, ciliary muscle to control lens
<b>IV. Trochlear</b>	Orbital fissure	Motor: Obliquus superior muscle Sensory: Proprioception
<b>V. Trigeminal</b>		
<b>Ophthalmic branch</b>	Orbital fissure	Sensory: Cornea, upper eyelid, scalp, skin of upper face
<b>Maxillary branch</b>	Foramen rotundum	Sensory: Palate and upper jaw, teeth and gums, nasopharynx, skin of cheek, lower eyelid, upper lip
<b>Mandibular branch</b>	Foramen ovale	Sensory: Lower jaw, teeth and gums, anterior two-thirds of tongue, mucous membrane of cheek, skin of lower lip, chin, and ear Motor: Muscles of chewing, throat, middle ear
<b>VI. Abducens</b>	Orbital fissure	Motor: Rectus lateralis muscle Sensory: Proprioception
<b>VII. Facial</b>	Stylomastoid foramen and internal auditory meatus	Motor: Muscles of facial expression, throat middle ear Sensory: Proprioception, taste (anterior two-thirds of tongue), palate Autonomic (parasympathetic): Tear glands, salivary glands, and secretory glands in pharynx
<b>VIII. Vestibulocochlear</b>	Internal auditory meatus	Sensory: Hearing (cochlear branch), balance (vestibular branch)
<b>IX. Glossopharyngeal</b>	Jugular foramen	Sensory: Posterior one-third of tongue, posterior pharynx, taste (posterior one-third of tongue), proprioception Motor: Pharyngeal muscle Autonomic (parasympathetic): Salivary glands, carotid sinus
<b>X. Vagus</b>	Jugular foramen	Sensory: Inferior pharynx, larynx, internal organs Motor: Posterior pharynx, larynx, tongue Autonomic (parasympathetic): Thoracic and abdominal viscera
<b>XI. Accessory</b>	Jugular foramen	Motor: Posterior pharynx, sternocleidomastoid, trapezius muscles Sensory: Proprioception
<b>XII. Hypoglossal</b>	Hypoglossal canal	Motor: Tongue and throat Sensory: Proprioception
<b>XIII. Vomeronasal</b>	Internal to skull	Parts of nasopharynx. May allow desert mammals to sense humidity. Function in humans unknown; may respond to pheromones

Several mnemonic devices exist to aid remembering the names of the 12 standard cranial nerves in order. The most common (and least bawdy) of these is: "On Old Olympus' Towering Tops, A Finn and German Viewed Some Hops." The recently discovered unpaired thirteenth cranial nerve is not contained in this rhyming couplet.

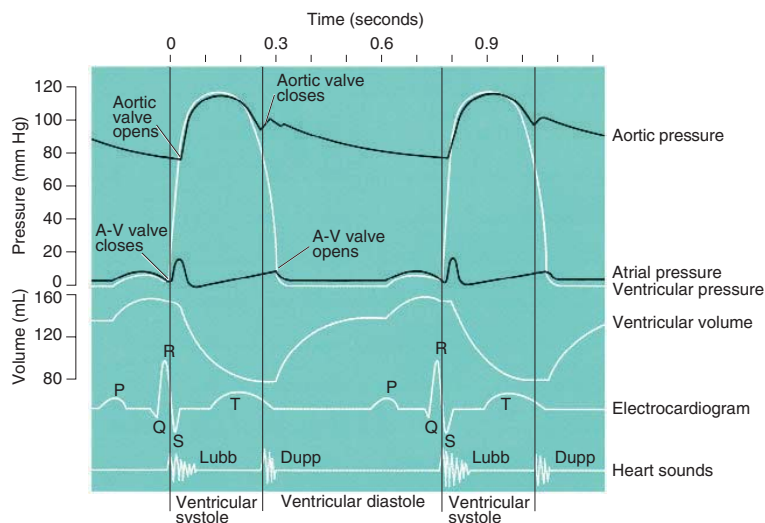
**TABLE 6.30** Spinal nerves and their branches

NERVE	SPINAL COMPONENT	INNERVATION	
<b>CERVICAL PLEXUS: C1, C2, C3, C4</b>			
<b>Superficial cutaneous branches</b>			
Lesser occipital	C2, C3	Skin of scalp above and behind ear	
Greater auricular	C2, C3	Skin in front of, above, and below ear	
Transverse cervical	C2, C3	Skin of anterior aspect of neck	
Supraclavicular	C3, C4	Skin of upper portion of chest and shoulder	
<b>Deep motor branches</b>			
Ansa cervicalis			
Anterior root	C1, C2	Geniohyoid, thyrohyoid, and infrahyoid muscles of neck	
Posterior root	C3, C4	Omohyoid, sternohyoid, and sternothyroid muscles of neck	
Phrenic	C3–C5	Diaphragm	
Segmental branches	C1–C5	Deep muscles of neck (levator scapulae ventralis, trapezius, scalenus, and sternocleidomastoid)	
<b>BRACHIAL PLEXUS: C5, C6, C7, C8, T1</b>			
Axillary	Posterior cord (C5–C6)	Skin of shoulder; shoulder joint, deltoid and teres minor muscles	
Radial	Posterior cord (C5–C8, T1)	Skin of posterior lateral surface of arm, forearm, and hand; posterior muscles of brachium and antebrachium (triceps brachii, supinator, anconeus, brachioradialis, extensor carpi radialis brevis, extensor carpi radialis longus, extensor carpi ulnaris)	
Musculocutaneous	Lateral cord (C5–C7)	Skin of lateral surface of forearm; anterior muscles of brachium (coracobrachialis, biceps brachii, brachialis)	
Ulnar	Medial cord (C8, T1)	Skin of medial third of hand; flexor muscles of anterior forearm (flexor carpi ulnaris, flexor digitorum), medial palm and intrinsic flexor muscles of hand (profundus, third and fourth lumbricales)	
<b>T2, T3, T4, T5, T6, T7, T8, T9, T10, T11, T12:</b>			
No plexus in these segments; branches run directly to intercostal muscles and skin of thorax.			
<b>LUMBOSACRAL PLEXUS: L1, L2, L3, L4, L5, S1, S2, S3, S4, S5</b>			
<b>Lumbar</b>	Iliohypogastric	T12–L1	Skin of lower abdomen and buttock; muscles of anterolateral abdominal wall (external abdominal oblique, internal abdominal oblique, transversus abdominis)
	Ilioinguinal	L1	Skin of upper median thigh, scrotum and root of penis in male and labia majora in female; muscles of anterolateral abdominal wall with iliohypogastric nerve
	Genitofemoral	L1, L2	Skin of middle anterior surface of thigh, scrotum in male and labia majora in female; cremaster muscle in male
	Lateral femoral cutaneous	L2, L3	Skin of anterior, lateral, and posterior aspects of thigh
	Femoral	L2–L4	Skin of anterior and medial aspect of thigh and medial aspect of lower extremity and foot; anterior muscles of thigh (iliacus, psoas major, pectineus, rectus femoris, sartorius) and extensor muscles of leg (rectus femoris, vastus lateralis, vastus medialis, vastus intermedius)
	Obturator	L2–L4	Skin of medial aspect of thigh; adductor muscles of lower extremity (external obturator, pectineus, adductor longus, adductor brevis, adductor magnus, gracilis)
	Saphenous	L2–L4	Skin of medial aspect of lower extremity
	Superior gluteal	L4, L5, S1	Abductor muscles of thigh (gluteus maximus, gluteus medius, tensor fasciae latae)
	Inferior gluteal	L5–S2	Extensor muscle of hip joint (gluteus maximus)
	Nerve to piriformis	S1, S2	Abductor and rotator of thigh (piriformis)
<b>Sacral</b>	Nerve to quadratus femoris	L4, L5, S1	Rotators of thigh (gemellus inferior, quadratus femoris)
	Nerve to obturator internus	L5–S2	Rotators of thigh (gemellus superior, internal obturator)
	Perforating cutaneous	S2, S3	Skin over lower medial surface of buttock
	Posterior femoral cutaneous	S1–S3	Skin over lower lateral surface of buttock, anal region, upper posterior surface of thigh, upper aspect of calf, scrotum in male and labia majora in female
	Sciatic	L4–S3	Composed of two nerves (tibial and common fibular); splits into two portions at popliteal fossa; branches from sciatic in thigh region to “hamstring muscles” (biceps femoris, semitendinosus, semimembranosus) and adductor magnus muscle
	Tibial (sural, medial, and lateral plantar)	L4–S3	Skin of posterior surface of leg and sole of foot; muscle innervation includes gastrocnemius, soleus, flexor digitorum longus, flexor hallucis longus, tibialis posterior, popliteus, and intrinsic muscles of the foot
	Common fibular (superficial and deep fibular)	L4–S2	Skin of anterior surface of the leg and dorsum of foot; muscle innervation includes peroneus tertius, peroneus brevis, peroneus longus, tibialis anterior, extensor hallucis longus, extensor digitorum longus, extensor digitorum brevis
	Pudendal	S2–S4	Skin of penis and scrotum in male and skin of clitoris, labia majora, labia minora, and lower vagina in female; muscles of perineum



**TABLE 6.31** Events of the cardiac cycle

PHASE	ELECTRICAL EVENTS	MECHANICAL EVENTS	HEART SOUND
Late diastole		AV valves open; semilunar valves closed. Blood enters all chambers by passive filling from venae cavae and pulmonary veins.	
Atrial systole	P wave: SA node depolarizes, wave spreads throughout atria. P-R interval: Wave of depolarization reaches SA node. Typical P-R interval (beginning of P-wave to onset of next deviation from baseline) is <0.2 seconds.	Atria contracted in response to depolarizing signal. Blood engorges ventricles, adding to stretch of ventricular walls.	
Isometric ventricular contraction	QRS complex: Depolarization of SA node. Bundle of His, and Purkinje fibers spread depolarization through valve ring into ventricular muscle.	Ventricles contract in response to depolarizing signal. Papillary muscles relax, allowing AV valves to close. Typically, mitral closure slightly precedes tricuspid closure. Reverberation of blood against valve cusps produces low-pitched "lub" of first heart sound. With all valves closed, ventricular pressure rises.	First heart sound (may be split with mitral component preceding tricuspid component)
Ventricular ejection	S-T segment: Entire ventricle is uniformly depolarized.	Ejection begins when ventricular pressures exceed back pressures in aorta and pulmonary trunk. Semilunar valves open, blood from this cycle enters aorta and pulmonary trunk. Maintained depolarization during S-T segment permits efficient, coordinated ventricular emptying.	
Isometric ventricular relaxation	T-wave	Repolarization wave spreads through ventricles, permitting relaxation. As ventricular pressures drop below those of aorta and pulmonary trunk, semilunar valves close. Typically, aortic semilunar closes slightly before pulmonary semilunar. Reverberation of blood against closed valve cusps creates higher-pitched "dub" of second heart sound. Lowered intraventricular pressures permit papillary muscles to pull AV valves open. Ventricular filling begins.	Second heart sound (typically split with pulmonary component slightly following aortic component, especially during inhalation)



**Figure 6-3**  
A Graph of Changes that Occur in Left Ventricle during a Cardiac Cycle

**TABLE 6.32** Major blood vessels and their branches

MAJOR ARTERY	MAIN BRANCHES
Ascending aorta	Coronary arteries (right and left)
Aortic arch	Innominate (brachiocephalic) Left subclavian Left common carotid
Innominate	Right subclavian Right common carotid
Common carotid (right and left)	Internal carotid External carotid
Subclavian (right and left)	Vertebral (right and left) Axillary (continuation of subclavian)
Axillary	Brachial (continuation of axillary)
Brachial	Radial Ulnar
Radial and ulnar	Palmar arches (superficial and deep)
Circle of Willis	Vertebrals join in cranium to form basilar artery, which then divides to form left and right posterior cerebral arteries. Internal carotids, upon entering cranium, become left and right anterior cerebral arteries. A pair of posterior communicating arteries and an anterior communicating artery join the cerebrals to form an arterial anastomosis, the circle of Willis.
Descending aorta	Intercostal arteries and spinal branches Celiac trunk (branches to hepatic, splenic, and right and left gastric arteries) Mesenteric (superior and inferior) Renal (right and left) Gonadal (spermatic or ovarian; right and left) Parietal branches to diaphragm, dorsal skin and skeletal muscles, and spinal cord Common iliac (right and left)
Common iliac	Internal iliac (or hypogastric; right and left) External iliac (right and left)
External iliac	Femoral (right and left)
Femoral	Popliteal (right and left)
Popliteal	Tibial (anterior and posterior; right and left)
Tibial	Plantar arches
MAJOR VEIN	COMMENT
UPPER EXTREMITY (RIGHT AND LEFT)	
Palmar arch (superficial and deep)	
Medial cubital	Connects cephalic and basilic
Median antebrachial	Median antebrachial and median cubital flow into basilic
Radial and ulnar	Radial and ulnar flow into brachial
Basilic and brachial	Basilic and brachial flow into axillary
Cephalic	Cephalic and axillary flow into subclavian
Axillary (continuation of brachial)	Cephalic and axillary flow into subclavian
Subclavian (continuation of axillary)	Flows into innominate (brachiocephalic)

**TABLE 6.32** Major blood vessels and their branches (continued)

MAJOR VEIN	COMMENT
<b>LOWER EXTREMITY (RIGHT AND LEFT)</b>	
Plantar arch	
Dorsal venous arch	
Anterior tibial	Anterior and posterior tibials unite to form popliteal
Posterior tibial	Anterior and posterior tibials unite to form popliteal
Small saphenous	Flows into popliteal
Popliteal	Popliteal and peroneal unite to form femoral
Peroneal	Popliteal and peroneal unite to form femoral
Femoral	Femoral and great saphenous unite to form external iliac
Great saphenous	Femoral and great saphenous unite to form external iliac
External iliac	External and internal iliacs unite to form common iliac
Internal iliac	External and internal iliacs unite to form common iliac
Common iliac	Flows into inferior vena cava
<b>ABDOMEN</b>	
Lumbar (several pairs)	Flows into inferior vena cava and azygous system
Gonadal (spermatic or ovarian; right and left)	Flows directly into inferior vena cava
Renal (right and left)	Flows directly into inferior vena cava
Suprarenal (right and left)	Flows directly into inferior vena cava
Hepatic	Flows directly into inferior vena cava
Mesenteric (superior and inferior)	Flows into hepatic portal system
Splenic	Flows into hepatic portal system
Gastroepiploic (right and left)	Flows into hepatic portal system
Hepatic portal	Conveys blood to liver; hepatic vein flows from liver
<b>THORAX</b>	
Left intercostal	Flows into hemiazygos
Hemiazygos	Flows into azygos
Accessory hemiazygos	Flows into azygos
Right intercostal	Flows into azygos
Azygos	Flows into inferior vena cava
Coronary (right and left)	Flows into right atrium of heart
<b>HEAD AND NECK</b>	
Superior sagittal sinus	
Inferior sagittal sinus	Flows into straight sinus
Straight sinus	Flows into transverse sinus
Cavernous	Flows into petrosal sinus



**TABLE 6.32** Major blood vessels and their branches (continued)

MAJOR VEIN	COMMENT
<b>Petrosal sinus (right and left)</b>	Flows into transverse sinuses
<b>Transverse sinuses (right and left)</b>	Flows into sigmoid sinuses
<b>Sigmoid sinuses (right and left)</b>	Flows into internal jugular vein
<b>Internal jugular</b>	
<b>External jugular</b>	
<b>Vertebral (right and left)</b>	
<b>Brachiocephalic innominate (right and left)</b>	Flows into superior vena cava
<b>Superior vena cava</b>	Flows into right atrium of heart
<b>FETAL SYSTEM</b>	
Placenta → Umbilical vein → Ductus venosus (bypasses liver) → Inferior vena cava → Right atrium of fetus → Mostly through foramen ovale → Left atrium → Left ventricle → Mostly to fetal head → Return to right atrium → Mostly to right ventricle → Pulmonary trunk → Mostly through ductus arteriosus → Descending aorta → Common iliac arteries → Internal iliac arteries → Umbilical arteries → Placenta	

**TABLE 6.33** Major hormones of the pituitary gland

HORMONE	CHEMICAL STRUCTURE	TARGET	REGULATION	MAJOR ACTION
<b>ANTERIOR PITUITARY (ADENOHYPHYSIS)</b>				
<b>Growth Hormone (GH, Somatotropin)</b>	Protein	General	GH Releasing Hormone from hypothalamus	Enhances protein anabolism, fat catabolism; enhances growth, wound healing, positive nitrogen balance
<b>Prolactin (Prl)</b>	Protein	Breast tissue	Inhibited by dopamine (a prolactin-inhibiting hormone) from hypothalamus	In female, mimics many actions of GH during pregnancy; enhances breast tissue anabolism for lactation
<b>Adrenocorticotrophic hormone (ACTH)</b>	Polypeptide	Adrenal cortex	Corticotrophin releasing hormone from hypothalamus	Promotes secretion of glucocorticosteroids by adrenal cortex
<b>Endorphins (several)</b>	Peptide	Central nervous system neurons	Neural activity in hypothalamus in response to stress and probably suckling	Inhibits transmission of pain impulses; enhances feeling of well-being
<b>Thyroid stimulating hormone (TSH)</b>	Glycoprotein	Thyroid gland	Thyroid releasing hormone (TRH) from hypothalamus	Stimulates release of thyroid hormones
<b>Follicle stimulating hormone (FSH)</b>	Glycoprotein	Gonads	Gonadotropin releasing hormone (GnRH) from hypothalamus	Female: Maturation of ovarian follicle; estrogen secretion Male: Sperm production
<b>Luteinizing hormone (LH)</b>	Glycoprotein	Gonads	Gonadotropin releasing hormone (GnRH) from hypothalamus	Female: Rupture of follicle; ovulation Male: Testosterone secretion
<b>POSTERIOR PITUITARY (NEUROHYPHYSIS)</b>				
<b>Antidiuretic hormone (ADH, Vasopressin)</b>	Peptide	Kidney tubules	Neural activity in hypothalamus in response to brain osmoreceptors; stress	Increase water retention; elevation of blood pressure
<b>Oxytocin</b>	Peptide	Breast tissue, uterus	Neural activity in hypothalamus in response to suckling, uterine stimulation	Let down of milk in lactating breast; uterine smooth muscle contractions

**NOTE:** The above-named list of hormones is not an exhaustive list of substances now known to be secreted by the pituitary gland. In addition, the listed hormones are known to have several actions, many of which are also not included.



# INDEX

- A band, 16
- Abdomen  
cat, 119–124  
fetal pig, 131–132  
major veins of human, 175  
muscles of human, 79–81, 165  
rat, 133, 135–137
- Abdominal aorta  
cat, 121, 122, 123, 124  
fetal pig, 131, 132  
rat, 136, 137
- Abdominal fascia, 81
- Abdominal fat  
cat, 119, 120  
rat, 133, 135, 137
- Abdominal muscles  
cat, 105  
human, 79–81, 165
- Abdominal oblique. *See* External abdominal oblique; Internal abdominal oblique
- Abdominal vena cava  
cat, 121, 122, 123  
fetal pig, 131, 132  
rat, 136, 137
- Abdominal viscera  
cat, 119–120  
fetal pig, 131
- Abdominopelvic cavity  
fetal pig, 131, 132  
rat, 133, 135
- Abdominopelvic wall  
muscles of human, 165  
nerves of cat, 124  
venation of cat, 123, 124
- Abducens nerve (VI), 74, 141, 171
- Abductor digiti minimi, 86, 93
- Abductor hallucis, 93
- Abductor pollicis brevis, 86
- Abductor pollicis longus, 86, 164
- Accessory hemizygous vein, 175
- Accessory nerve (XI), 171
- Acetabular notch, 61, 62
- Acetabulum  
cat, 67  
human, 61, 62
- Achilles tendon  
cat, 109, 110, 111  
fetal pig, 127
- Acromial spine, 67
- Acromiodeltoid  
cat, 102, 106, 107  
fetal pig, 125, 126, 128
- Acromion, 59, 60, 84
- Acromiotrapezius, 96, 102, 106, 107
- ACTH (adrenocorticotropic hormone), 177
- Active transport, 154
- Adductor brevis, 87, 88, 169
- Adductor femoris, 110, 111
- Adductor hallucis, 93
- Adductor longus  
cat, 111  
human, 70, 87, 88, 169
- Adductor magnus, 71, 87, 88, 89, 169
- Adductor pollicis, 86
- Adenohypophysis, 23, 177
- Adipocytes, 9
- Adipose tissue, 9
- Adrenal cortex, 24
- Adrenal gland  
cat, 121, 122, 124
- fetal pig, 132  
rat, 136, 137
- Adrenocorticotropic hormone (ACTH), 177
- Adrenolumbar artery, 124
- Adrenolumbar vein, 124
- Adventitia  
alimentary canal, 32  
tunica, 27, 28, 29
- Agranulocyte, 155
- Aldosterone, 24
- Alimentary canal, layers of, 32
- Allantoic artery, 122
- Alpha cells, 23
- Alveolar process of mandible, 53
- Alveolar process of maxilla, 53
- Alveoli, 31, 32
- Anal sphincter, external, 82
- Anal triangle, 82
- Anaphase cell, 3
- Anatomic neck, 156
- Anatomical snuff box, 164
- Anconeus  
cat, 102  
human, 86, 163
- Android skeleton, vs. gynecoid, 158
- Angular process, 66
- Animal dissections  
cat, 96–124  
fetal pig, 125–132  
rat, 133–137  
sheep, 140–150
- Ansa cervicalis, 172
- Antebrachial fascia, 100, 102
- Anterior cardiac veins, 147
- Anterior circumflex humeral artery, 113
- Anterior circumflex humeral nerve, 113
- Anterior commissure, 143
- Anterior facial vein, 96, 97
- Anterior inferior iliac spine, 61, 62
- Anterior lacrimal crest, 53
- Anterior nasal spine of maxilla, 46, 47, 53
- Anterior pituitary (adenohypophysis), 23, 177
- Anterior superior iliac spine, 61, 62, 158
- Anterior thoracic vein, 115
- Anterior tibial vein, 175
- Anterior vena cava, 116
- Antidiuretic hormone (ADH), 177
- Antrum, 42
- Anus, 82
- Aorta  
ascending, 174  
cat, 118  
descending, 174, 176  
fetal pig, 130  
sheep, 147, 148
- Aortic arch  
cat, 116, 117  
human, 174
- Aortic semilunar valve, 148
- Apex, sheep heart, 148
- Aponeurosis  
of external oblique, 81  
of internal oblique, 81  
of transversus abdominis, 81
- Appendicular skeleton, 157
- Appendix, 36
- Aqueduct of Sylvius, 143
- Area postrema, 144
- Areolar connective tissue, 8
- Arm  
bones of human, 60, 157  
major veins of, 174  
musculature of, 83–86, 162, 163
- Arterial wall, 29
- Arteries. *See also specific arteries*  
atherosclerotic, 28  
of cat abdomen/pelvic wall, 123–124  
of cat neck and thorax, 116, 117, 118  
cross section of, 27, 28  
detail of wall of, 29  
of fetal pig neck and thorax, 130  
major human, 174  
wall of, detail, 29
- Ascending aorta, 174
- Astral rays, 2, 3
- Astrocyte, 18
- Atherosclerosis, 28
- Atlas  
cat, 66, 67  
human, 55, 56, 57
- Atrial systole, 173
- Auditory nerve, 141
- Auricular surface, 57, 62
- Auscultation, triangle, 162
- Axial skeleton  
bones of human, 157  
cat, 67
- Axillary artery  
cat, 112, 113, 116  
fetal pig, 130  
human, 174
- Axillary nerve, 98, 101, 118, 172
- Axillary vein, 112, 113, 115, 118, 174
- Axis  
cat, 66  
human, 55, 56, 57
- Axon, 18, 20
- Azygous vein  
cat, 118  
fetal pig, 130  
human, 175
- Back musculature  
cat, 106–108  
human, 77–78
- Barr body, 24
- Basement membrane, 4, 5, 6, 7, 39
- Basilar membrane, 21
- Basilic vein, 174
- Basophil, 25, 155
- Basophilic myelocyte, 15
- Beta cells, 23
- Biceps brachii  
cat, 101, 113, 116  
human, 70, 84, 163
- Biceps femoris  
cat, 109, 110, 111  
fetal pig, 125, 127  
human, 71, 89, 169
- Bicuspid valve, 148
- Bifid spinous process, 56, 57
- Bile duct, 35
- Bipolar cell nuclei, 20
- Bladder. *See* Urinary bladder
- Blood, components of, 24–27, 155. *See also specific components*
- Blood vessels, 27. *See also* Arteries; Capillary; Veins  
alveolar, 32



- artery, 28, 29  
atherosclerotic, 28  
bronchiole, 32  
capillary, 29  
fetal circulatory system, 176  
gallbladder, 36  
large intestine, 34  
major, table of, 174–176  
spleen, 31
- Bone. *See also specific bones*  
cancellous (spongy), 14  
compact, 14  
descriptive terms for, 156  
developing, 15  
structure of long, 64
- Bone marrow, 15
- Bowman's capsule, 37, 38
- Brachial artery, 116, 174
- Brachial plexus, 113, 118, 172
- Brachial vein, 101, 115, 118, 174
- Brachialis, 84, 102, 163
- Brachiocephalic artery, 116, 117, 130
- Brachiocephalic innominate vein, 176
- Brachiocephalic vein, 115, 118
- Brachioradialis  
cat, 100, 101, 102  
fetal pig, 126  
human, 70, 84, 86, 163
- Brain, dissection of sheep, 140–145
- Breathing, muscles involved in, 165
- Bregma suture, 48
- Bronchiole, 32
- Brush border, 34
- Buccinator  
cat, 96, 97  
human, 72, 73, 159
- Bulbospongiosus, 82, 166
- Bulbourethral (Cowper's) gland, 122
- Bulk flow, 154
- Bursa, 85
- Calcaneal tendon, 71, 91, 92
- Calcaneal tuberosity, 109
- Calcaneus  
cat, 65, 67  
human, 64, 91, 92, 93, 157
- Calvarium, 48
- Canaliculi, 14
- Cancellous (spongy) bone, 14, 64
- Canine eminence of maxilla, 53
- Canine fossa, 53
- Canines, cat, 66, 98
- Capillary, 29
- Capitate carpal, 61, 157
- Capitulum, 60
- Cardiac cycle, events of, 173
- Cardiac muscle, 17, 69
- Carotid canal, 48, 49
- Carotid groove, 49
- Carpal tunnel, 86
- Carpals  
cat, 65, 67  
human, 61, 157
- Cartilage  
costal, 58  
elastic, 11  
epiphyseal plate, 15  
fibrocartilage, 10  
hyaline, 10, 11
- Cat  
abdominal musculature, 105  
abdominal viscera, 119–120  
abdominopelvic wall innervation, 124
- abdominopelvic wall venation, 123, 124
- back and neck musculature, 106–108
- brachial plexus, 113
- head and neck anatomy, 96–99
- hind limb musculature, 109–111
- neck and thorax innervation, 118
- neck and thorax venation, 115, 116, 117, 118
- pregnant, urogenital system of, 121
- shoulder musculature, 112
- skeleton of, 65–68
- thoracic cavity, 114
- thoracic limb musculature, 100–103
- thorax musculature, 104–105, 112
- urogenital system of, 121–122
- Caudal artery  
cat, 121, 123  
fetal pig, 132  
rat, 136
- Caudal pole, sheep kidney, 149
- Caudal subscapular nerve, 113, 118
- Caudal vein, 123
- Caudal ventral iliac spine, 67
- Caudal vertebrae (cat), 65, 67
- Caudate nucleus, 145
- Caudofemoralis, 109, 110
- Cavernous vein, 175
- Cecum, 135
- Celiac artery, 123, 124
- Celiac ganglion, 124
- Cell  
alpha, 23  
anaphase, 3  
basophil, 25, 155  
beta, 23  
chief, 33  
delta, 23  
endocrine, 33  
eosinophil, 25, 155  
epithelial, 36  
erythrocyte, 27, 155  
exocrine, 23  
extrafollicular, 22  
ganglion, 20  
goblet, 5, 33, 34  
granulosa, 42  
hepatocyte, 35  
illustration of, 152  
interphase, 2  
interstitial, 39  
lymphocyte, 26, 155  
metaphase, 2  
mitotic, 2–3  
monocyte, 26, 155  
neutrophil, 15, 24, 155  
parietal, 33  
prophase, 2  
Purkinje, 18  
pyramidal, 18  
serous, 37  
Sertoli, 39  
structure and function of components, 153  
telophase, 3  
transport processes, 154  
umbrella, 7
- Cell body (neuron), 18, 19
- Cell membrane, 2, 152, 153
- Cell membrane transport processes, 154
- Central canal, spinal cord, 20
- Central sulcus, 140
- Central tendon, 82
- Central vein, 35
- Centriole, 152
- Centrosome, 153
- Cephalic vein  
cat, 100, 102, 106  
fetal pig, 129  
human, 174
- Cerebellar fossa, 52
- Cerebellar peduncles, 144
- Cerebellum, 140, 141, 142, 143, 145
- Cerebral fossa, 52
- Cerebral peduncle, 141
- Cerebrum, 140, 142, 143
- Cervical nerves, 98, 172
- Cervical plexus, 172
- Cervical vertebrae  
cat, 65, 66  
human, 55, 56, 157
- Chest wall, muscles of, 79–80, 165
- Chewing muscles, 73, 159
- Chief cells, 33
- Chondrocyte, 10, 11
- Chordae tendineae, 148
- Choroid, 20
- Chromatin, 2, 152
- Chromosome, 2, 3
- Cilia, 5, 6, 152, 153
- Ciliated columnar epithelium, 5, 6
- Cingulate gyrus, 143
- Circle of Willis, 174
- Clavicle, 59, 76, 84, 157
- Clavicular notch, 58, 59
- Clavobrachialis  
cat, 96, 97, 100, 101, 102, 104, 105, 106  
fetal pig, 125, 126, 128
- Clavotrapezius  
cat, 96, 97, 106, 107  
fetal pig, 125, 126, 128
- Cleavage furrow, telophase cell, 3
- Cleft, pituitary gland, 23
- Cleidomastoid, 96, 97, 98
- Coccygeus, 82, 166
- Coccyx, 55, 82, 88, 157, 158
- Colic artery, 132
- Collagen fibers, 8, 9, 10
- Colloid, 22
- Colon, 34, 119
- Columnar epithelium, 5, 6, 40, 41, 43
- Common carotid artery  
cat, 98, 115, 116, 117, 118  
fetal pig, 129, 130  
human, 174  
rat, 134
- Common fibular nerve, 172
- Common iliac artery, 136, 174, 176
- Common iliac vein, 123, 175
- Common peroneal division of sciatic nerve, 110
- Compact bone, 14, 45, 64
- Condylar canal, 49, 52
- Condylar fossa, 49, 52
- Condylar process, 66
- Condyle, defined, 156
- Condylloid process of mandible, 53
- Cones, 20
- Connective tissue, 8–9. *See also Cartilage*  
dense irregular, 9  
dense regular, 9  
elastic, 8  
loose (areolar), 8  
reticular, 8
- Conoid tubercle, 59
- Constrictor pharyngis inferior, 161
- Constrictor pharyngis medius, 161
- Constrictor pharyngis superior, 161
- Convex lateral border, sheep kidney, 149

## 180 INDEX

- Convoluted tubules, 38  
 Coracobrachialis, 84, 113, 162  
 Coracoid process, 59, 60, 84  
 Core of villus, 34  
 Cornified layer, skin, 12  
 Cornu, 156  
 Corona radiata, 41, 42  
 Coronal suture  
   cat, 66, 67  
   human, 47, 48  
 Coronary arteries, 148, 174  
 Coronary veins, 148, 175  
 Corpora cavernosa, 41  
 Corpus collosum, 143, 145  
 Corpus spongiosum, 39, 41  
 Corpuscle  
   Hassall's, 30  
   Meissner's, 12  
   Pacinian, 13  
 Corrugator supercilii, 72, 159  
 Cortex  
   lymph node, 29  
   thymus, 30  
 Corti, Organ of, 21  
 Costal cartilage, 58  
 Costal facet, 56  
 Costal groove, 58  
 Cowper's gland. *See* Bulbourethral (Cowper's) gland  
 Cranial nerves, 74, 141, 142, 171  
 Cranial pole, sheep kidney, 149  
 Cranial ventral iliac spine, 67  
 Cranium, 48, 65, 157. *See also* Head; Skull  
 Cremaster muscle ligament, 122  
 Cremasteric fascia, 135  
 Crest, 156  
 Cribriform plate of ethmoid bone, 48, 54  
 Crista, 156  
 Crista galli of ethmoid bone, 48, 54  
 Crus of diaphragm  
   cat, 124  
   rat, 134, 136, 137  
 Cuboid tarsal, 64, 157  
 Cuboidal cell, 4  
 Cuboidal epithelium, 1, 4, 5, 38, 42  
 Cuboidal follicular cells, 22  
 Cuneate tubercle, 144  
 Cutaneous branch of facial nerve, 98  
 Cutaneous branch of ulnar nerve, 101  
 Cytokinesis, 3
- Deep femoral artery, 123, 124  
 Deep femoral vein, 123, 124  
 Deep palmar arch, 174  
 Deep transverse perineus, 82  
 Delta cell, 23  
 Deltoid, 70, 71, 77, 84  
 Deltoid tuberosity, 60, 67  
 Deltoideus, 162  
 Dendrite, 18  
 Dense irregular connective tissue, 9  
 Dense regular connective tissue, 9  
 Depressions, human skull, 49  
 Depressor anguli oris, 72  
 Depressor labii inferioris, 72  
 Dermis, 12  
 Descending aorta, 174, 176  
 Descending colon, 34, 119  
 Dialysis, 154  
 Diaphragm  
   cat, 114, 116, 117, 118  
   fetal pig, 129, 130, 131, 132  
   human, 165  
   rat, 134, 136
- Diaphysis, 62, 156  
 Diffusion, 154  
 Digastric  
   cat, 96, 97, 98  
   human, 75, 76, 160  
 Dissections  
   cat, 96–124  
   rat, 133–137  
   sheep, 140–150  
 Distal convoluted tubules, 38  
 Distal extensor retinaculum, 110  
 Dorsal branch of facial (VII) nerve, 97, 98  
 Dorsal buccal branch of facial (VII) nerve, 96  
 Dorsal horn, spinal cord, 20  
 Dorsal interosseous, 86, 93  
 Dorsal rami of thoracic nerves, 113, 130  
 Dorsal ramus of spinal nerve, 108  
 Dorsal root ganglion, 19  
 Dorsal venous arch, 175  
 Dorsomedian sulcus, 144  
 Ductus arteriosus, 130, 176  
 Ductus deferens, 40  
 Ductus venosus, 130, 131, 132, 176  
 Duodenum, 119, 132, 135
- Ear, bones of middle, 157  
 Elastic cartilage, 11  
 Elastic connective tissue, 8  
 Elastic fiber, 8, 11  
 Endocrine cell, 33  
 Endometrium, 42  
 Endoplasmic reticulum, 152, 153  
 Endorphin, 177  
 Endothelium, 29  
 Eosinophil, 25, 155  
 Eosinophilic myelocyte, 15  
 Epicondyle, defined, 156  
 Epicranium (occipitofrontalis), 159  
 Epidermis, 12  
 Epididymis  
   cat, 122  
   cross section, 40  
   fetal pig, 131  
   rat, 135  
 Epiglottis, 98, 118  
 Epiphyseal plate, 15  
 Epiphysis, 60, 156  
 Epithelium  
   ciliated columnar, 5, 6  
   noncornified stratified squamous, 6  
   pseudostratified ciliated columnar, 5, 6  
   simple columnar, 5  
   simple cuboidal, 1, 4, 5  
   simple squamous, 4  
   stratified squamous, 7  
   transitional, 7, 38  
 Epitrochlearis, 100, 104, 105  
 Erector spinae, 71, 77, 78, 167  
 Erythrocyte, 27, 155  
 Esophagus  
   cat, 116, 117, 118  
   fetal pig, 130  
   human, 75  
   structure of, 32  
 Ethmoid bone, 48, 54, 157  
 Ethmoidal crest of maxilla, 53  
 Ethmoidal crest of palatine bone, 52  
 Ethmoidal labyrinth, 54  
 Ethmoidal notch of frontal bone, 49, 50  
 Eustachian tubes, 118  
 Exocrine cells, pancreatic, 23  
 Exocytosis, 154  
 Extensor carpi digitorum lateralis, 102  
 Extensor carpi radialis, 101, 102, 126
- Extensor carpi radialis brevis, 86, 102, 164  
 Extensor carpi radialis longus, 86, 102, 164  
 Extensor carpi ulnaris  
   cat, 101, 102  
   fetal pig, 126  
   human, 86, 164  
 Extensor digiti minimi, 86  
 Extensor digiti minimi tendon, 102  
 Extensor digitorum, 71, 86, 164  
 Extensor digitorum brevis, 90  
 Extensor digitorum communis, 102, 126  
 Extensor digitorum lateralis, 102, 126  
 Extensor digitorum longus, 70, 90, 110, 170  
 Extensor hallucis brevis, 90  
 Extensor hallucis longus, 90, 170  
 Extensor indicis, 86, 164  
 Extensor indicis proprius, 102  
 Extensor pollicis brevis, 86, 102, 164  
 Extensor pollicis longus, 86, 164  
 Extensor retinaculum, 90, 102  
 External abdominal oblique. *See* External oblique  
 External anal sphincter, 82  
 External auditory meatus, 47, 51, 66  
 External iliac artery  
   cat, 121, 123, 124  
   fetal pig, 132  
   human, 174  
 External iliac vein, 121, 123, 124, 175  
 External inguinal ring, 122  
 External intercostals, 80, 108, 165  
 External jugular vein  
   cat, 96, 97, 98, 112, 113, 115, 118  
   fetal pig, 126, 128, 129  
   human, 176  
 External oblique, 104  
   cat, 105, 108, 111  
   fetal pig, 125, 127  
   human, 70, 71, 77, 78, 79, 80, 81, 165  
   rat, 133  
 External obturator, 88  
 External occipital crest, 49  
 External occipital protuberance, 49, 66  
 External urethral sphincter, 82  
 Extrafollicular cells, 22  
 Extrinsic muscles of the tongue, 160  
 Eye  
   muscles of, 73, 74, 158  
   nerves of, 74  
   retina, 20
- Face  
   bones of, 46–47, 157  
   muscles of, 72, 159  
 Facet, defined, 156  
 Facial colliculus, 144  
 Facial nerve (cranial nerve VII), 96, 97, 98, 141, 171  
 Facial vein, 96, 97  
 Facilitated diffusion, 154  
 Fallopian tube, 42  
 False ribs, 58, 157  
 Fauces, Isthmus of, 98  
 Female cat, urogenital system, 121  
 Female fetal pig, abdominal cavity, 132  
 Female, human  
   fallopian tube, 42  
   male vs. female skeleton, 158  
   oocytes in primordial follicle, 42  
   ovary with follicles, 41  
   pelvic floor musculature, 82  
   secondary ovarian follicle with ovum, 42  
   uterus, 43  
 Female rat, abdominopelvic cavity, 137

- Femoral artery, 111, 121, 123, 124, 174  
Femoral nerve, 111, 121, 124, 172  
Femoral triangle, 121, 122  
Femoral vein, 111, 121, 123, 124, 175  
Femur  
  cat, 65, 67  
  human, 62, 157  
Fetal circulatory system, 176  
Fetal pig, 125–127  
  abdominopelvic cavity, 131, 132  
  hind limb musculature, 127  
  neck and shoulder musculature, 127, 128  
  neck and thorax deep anatomy, 129  
  superficial muscles, 125  
  thoracic and abdominal cavity, 131  
  thoracic limb musculature, 127  
  venation of neck and thorax, 130  
Fetus, cat, 121  
Fibers  
  collagen, 8, 10  
  elastic, 8, 11  
  reticulate, 8  
Fibroblast, 8  
Fibrocartilage, 10  
Fibroc collagenous bundle, 41  
Fibula  
  cat, 65, 67  
  human, 63, 92, 157  
Fifth intercostal space, 156  
Filtration, 154  
First dorsal interosseous, 86  
Fissure, 156  
Flagellum, 152, 153  
Flexor carpi radialis  
  cat, 100, 101  
  human, 70, 84, 86, 164  
Flexor carpi ulnaris  
  cat, 100, 101, 102  
  human, 71, 84, 86, 164  
Flexor digiti minimi brevis, 86, 93  
Flexor digitorum brevis, 93, 111  
Flexor digitorum longus, 91, 92, 170  
Flexor digitorum longus tendon, 93  
Flexor digitorum profundus, 84, 101, 164  
Flexor digitorum superficialis, 84, 164  
Flexor hallucis brevis, 93  
Flexor hallucis longus  
  cat, 109, 110, 111  
  fetal pig, 127  
  human, 91, 92, 170  
Flexor hallucis longus tendon, 93  
Flexor pollicis brevis, 86  
Flexor pollicis longus, 84, 164  
Flexor retinaculum, 86, 100, 101  
Floating ribs, 58  
Follicle  
  hair, 13  
  lymph node, 29  
  primary ovarian, 41  
  primordial ovarian, 41  
  secondary ovarian, 42  
Follicle stimulating hormone (FSH), 177  
Fontanel, 156  
Foot  
  bones of, 64, 157  
  muscles of, 93, 170  
Foramen (foramina), 156  
Foramen lacerum, 48, 49  
Foramen magnum of occipital bone, 47, 48, 49, 52  
Foramen ovale of sphenoid, 48, 49, 50  
Foramen rotundum of sphenoid, 48, 49, 50  
Foramen spinosum of sphenoid, 48, 49, 50  
Foramina. *See also specific foramina*  
Foramina, skull, 46, 47, 48, 49  
Forearm  
  bones of, 60  
  muscles of, 84, 85, 86, 163, 164  
Fornix, 143, 145  
Fossa, defined, 156. *See also specific fossa*, 156  
Fourth cervical nerve, 98  
Fourth ventricle, 143  
Fovea, 156  
Frontal bone  
  cat, 66  
  human, 46, 47, 48, 49, 50, 157  
Frontal border of parietal bone, 51  
Frontal crest of frontal bone, 49  
Frontal lobe of cerebrum, 140, 142  
Frontal pole, sheep brain, 140  
Frontal process of malar, 47  
Frontal process of maxilla, 53  
Frontal process of zygomatic bone, 66  
Frontal sinus, 48  
Frontalis, 70, 72  
Frontozygomatic suture, 47  
Fungiform papillus, 21  
Galea aponeurotica, 72  
Gallbladder, 36  
Ganglion cell, 20  
Gastric pit, 33  
Gastrocnemius  
  cat, 109, 110, 111  
  fetal pig, 127  
  human, 70, 71, 91, 170  
Gastroepiploic vein, 121, 175  
Gemellus inferior, 88  
Gemellus superior, 88  
Genioglossus, 75, 160  
Geniohyoid, 75  
Genitofemoral nerve, 124, 172  
Germinativum, 39  
GH (Growth Hormone, Somatotropin), 177  
Gladiolus, 59  
Glands  
  parathyroid, 22  
  paraurethral, 39  
  parotid, 96, 115, 126  
  pituitary, 23, 177  
  salivary. *See Salivary gland*  
  thyroid, 22. *See Thyroid gland*  
Glenoid fossa, 59  
Globus pallidus, 145  
Glomerular capsule, 37, 38  
Glomeruli, 37, 38  
Glossopharyngeal nerve (cranial nerve IX), 141, 159  
Glucagon, 23  
Glucocorticosteroids, 24  
Gluteal tuberosity, 62  
Gluteus maximus  
  cat, 109, 110  
  fetal pig, 125, 127  
  human, 71, 77, 82, 89, 168  
Gluteus medius  
  cat, 109, 110  
  fetal pig, 125, 127  
  human, 71, 77, 88, 89, 168  
Gluteus minimus, 90, 170  
Goblet cell, 5, 33, 34  
Golgi apparatus, 152, 153  
Gonadal vein, 175  
Gracile tubercle, 144  
Gracilis  
  cat, 111  
  human, 70, 71, 87, 88, 89, 169  
Granulocytes, 155  
Granulosa cell, 42  
Great cardiac vein, 147  
Great saphenous vein, 175  
Greater auricular nerve, 172  
Greater multangular carpal, 61, 157  
Greater omentum, 119  
Greater palatine canal of maxilla, 53  
Greater saphenous vein, 111  
Greater sciatic notch, 62, 158  
Greater trochanter, 62, 67  
Greater tubercle, 60, 83  
Growth Hormone (GH, Somatotropin), 177  
Gynecoid skeleton, vs. android, 158  
H zone, 16  
Habenular commissure, 143  
Hair follicle, 13  
Hair papilla, 13  
Hair root, 13  
Hamate carpal, 61, 157  
Hamstring group, 89, 169  
Hamulus, defined, 156  
Hand  
  musculature of, 86, 164  
  skeletal anatomy, 61  
Hard palate, 98  
Hassall's corpuscle, 30  
Haversian system, 14  
Head. *See also Face*; Skull  
  bones of cat, 66  
  bones of human, 46–54  
  major veins of, 175–176  
  muscles and structures of cat, 96–99  
  muscles of human, 72, 73, 161  
Heart  
  cardiac cycle events, 173  
  cardiac muscle, 17, 69  
  cat, 114, 115, 116, 118  
  fetal pig, 129, 130, 131, 132  
  rat, 134  
  sheep, 147–148  
Hemiazygous vein, 175  
Hemoglobin, 27  
Hemorrhoidal artery, 132  
Hepatic artery, 35  
Hepatic portal vein, 121, 175  
Hepatic vein, 175  
Hepatocyte, 35  
Highest nuchal line of occipital bone, 49  
Hilus  
  left lung of fetal pig, 130  
  lymph node, 29  
Hilus, sheep kidney, 149  
Hind limb  
  bones of cat, 68  
  muscles of cat, 109–111  
  muscles of fetal pig, 127  
Hip musculature, 167, 168  
Hippocampus, 145  
Histology  
  adipose tissue, 9  
  adrenal cortex, 24  
  alveolus, 31, 32  
  anaphase cell, 3  
  artery, 27, 28, 29  
  astrocyte, 18  
  atherosclerosis, 28  
  basophil, 25  
  bronchiole, 32  
  cancellous bone, 14  
  capillary, 29  
  cardiac muscle, 17  
  compact bone, 14  
  dense irregular connective tissue, 9



## 182 INDEX

## Histology—Cont.

- dense regular connective tissue, 9  
 developing bone, 15  
 distal convoluted tubules, 38  
 dorsal root ganglion, 19  
 ductus deferens, 40  
 elastic cartilage, 11  
 elastic connective tissue, 8  
 eosinophil, 25  
 epididymis, 40  
 epiphyseal plate, 15  
 erythrocyte, 27  
 esophagus, 32  
 fallopian tube, 43  
 fibrocartilage, 10  
 gallbladder, 36  
 gastric pit, 33  
 glomerular capsule and glomerulus, 37, 38  
 hair follicle, 13  
 hyaline cartilage, 10, 11  
 interphase cell, 2  
 large intestine, 34  
 liver, 35  
 loose (areolar) connective tissue, 8  
 lymph node, 29  
 lymphocyte, 26  
 Meissner's corpuscle, 12  
 metaphase cell, 2  
 monocyte, 26  
 motor end plate, 17  
 motor neurons of spinal cord, 19  
 myelinated nerve fibers, 19, 20  
 neutrophil, 24  
 noncornified stratified squamous epithelium, 6  
 oocytes in primordial follicle, 42  
 Organ of Corti, 21  
 ovary with follicles, 41  
 Pacinian corpuscle, 13  
 palatine tonsil, 31  
 pancreas, 23  
 parathyroid gland, 22  
 parotid salivary gland, 37  
 penis, 41  
 pituitary gland, 23  
 prophase cell, 2  
 prostate gland, 41  
 pseudostratified ciliated columnar epithelium, 5, 6  
 Purkinje cells (neurons), 18  
 pyramidal cells, 18  
 red bone marrow, 15  
 reticular connective tissue, 8  
 retina, 20  
 sebaceous gland, 13  
 secondary ovarian follicle with ovum, 42  
 seminiferous tubules, 39  
 sickle cell, 27  
 simple columnar epithelium, 5  
 simple cuboidal epithelium, 1, 4, 5  
 simple squamous epithelium, 4  
 skin, 12–13  
 small intestine, 33, 34  
 smooth muscle, 17  
 spermatozoa, 40  
 spinal cord, 20  
 spleen, 31  
 stomach mucosa, 33  
 stratified squamous epithelium, 7  
 striated skeletal muscle, 16  
 sublingual salivary gland, 36  
 submandibular salivary gland, 37  
 taste bud, 21  
 telophase cell, 3  
 thymus, 30  
 thyroid gland follicles, 22  
 transitional epithelium, 7  
 ureter, 38  
 urethra, 39  
 urinary bladder, 39  
 uterus, 43  
 valve of lymphatic vessel, 30  
 vein, 27  
 vermiform appendix, 36  
 Horizontal plate, 52  
 Hormones  
   from anterior pituitary, 177  
   major pituitary, 177  
   from posterior pituitary, 177  
 Humerus  
   cat, 65, 67  
   human, 60, 83, 84, 157  
 Hyaline cartilage, 10, 11  
 Hyoid bone, 75, 76, 157  
 Hypogastric artery, 123  
 Hypogastric vein, 123  
 Hypoglossal canal, 49  
 Hypoglossal nerve (cranial nerve XII), 141, 171  
 Hypoglossal trigone, 144  
 Hypoglossus, 75, 76, 160  
 Hypothalamus, 143  
 I band, 16  
 Ileum, 34, 35, 119, 135  
 Iliac artery. *See* Common iliac artery  
 Iliac crest, 61, 62, 87, 88  
 Iliac fossa, 61, 62  
 Iliac spine, 61, 62  
 Iliacus, 87  
 Iliocostalis  
   cat, 107, 108  
   human, 78, 167  
 Iliocostalis cervicis, 167  
 Iliocostalis lumborum, 167  
 Iliocostalis thoracis, 167  
 Iliohypogastric nerve, 172  
 Ilioinguinal nerve, 172  
 Iliolumbar artery  
   cat, 121, 123, 124  
   rat, 136, 137  
 Iliolumbar vein  
   cat, 121, 123  
   rat, 136, 137  
 Iliopectineal line, 61, 62  
 Iliopsoas, 87, 88, 111, 167, 168  
 Iliopubic eminence, 61, 62  
 Iliotibial band, 71, 87, 89  
 Iliotibial tract, 109  
 Ilium, 67, 68  
 Incisive bone, 66  
 Incisive foramina, 49  
 Incisive fossa of maxilla, 53  
 Incus, 48, 157  
 Inferior angle of scapula, 104  
 Inferior belly of omohyoid, 76  
 Inferior colliculus, 143  
 Inferior epigastric artery, 133  
 Inferior gluteal nerve, 172  
 Inferior longitudinal muscle of tongue, 75  
 Inferior meatus, 53  
 Inferior mesenteric artery, 123, 124  
 Inferior nasal concha, 46, 157  
 Inferior nuchal line of occipital bone, 49  
 Inferior oblique, 73, 74  
 Inferior orbital fissure, 49  
 Inferior pharyngeal constrictor, 72, 75, 76  
 Inferior pubic ramus, 61, 62  
 Inferior rectus, 73, 74  
 Inferior sagittal sinus vein, 175  
 Inferior vena cava, 176  
   cat, 117  
   fetal pig, 130  
 Infraorbital foramen of maxilla, 46, 50, 53, 66  
 Infraspinal, 162  
   cat, 107  
   human, 71, 77, 83, 84  
 Infraspinal fossa, 59, 67  
 Infratemporal surface, 53  
 Infundibulum, 141, 143  
 Innominate artery, 116, 130, 174  
 Innominate vein, 115, 118  
 Insulin, 23  
 Intercaled disk, 17  
 Intercondylar fossa, 62  
 Intercostal. *See* External intercostals; Internal intercostals  
 Intercostal artery, 134  
 Intercostal vein, 134  
 Interlobar artery, 150  
 Interlobular vein, 35  
 Intermediate cuneiform tarsal, 64, 157  
 Internal abdominal oblique. *See* Internal oblique  
 Internal auditory meatus, 48, 51  
 Internal capsule, 145  
 Internal iliac artery, 123, 124, 132  
 Internal iliac vein, 123, 175  
 Internal intercostals, 80, 108, 165  
 Internal jugular vein, 176  
   cat, 112, 115, 118  
   fetal pig, 129  
 Internal mammary artery, 115, 117  
 Internal mammary vein, 129, 134  
 Internal oblique, 165  
   cat, 105  
   fetal pig, 125, 127  
   human, 70, 71, 77, 78, 79, 80, 81  
   rat, 133  
 Internal occipital crest, 52  
 Internal occipital protuberance, 52  
 Internal spermatic artery, 122  
 Interosseous border, 60, 63  
 Interphase cell, 2  
 Interstitial cell, 39  
 Intertrochateric crest, 62  
 Intertubercular groove, 60  
 Intervertebral disk, 55  
 Intervertebral foramen, 55  
 Intestine. *See* Large intestine; Small intestine  
 Intraventricular septum, 148  
 Intrinsic muscles, tongue, 160  
 Ischial ramus, 61, 62  
 Ischial spine, 61, 62, 158  
 Ischial tuberosity  
   cat, 67  
   female vs. male, 158  
   human, 61, 62, 88  
 Ischioavernosus, 82, 166  
 Ischium, 62, 67, 157  
 Islet of Langerhans, 23  
 Isometric ventricular contraction, 173  
 Isometric ventricular relaxation, 173  
 Isthmus of Fauces, 98  
 Jaw  
   bones of, 46, 53  
   muscles of, 75, 159  
 Jejunum, 119, 135  
 Jugular foramen of temporal bone, 48, 49  
 Jugular fossa of temporal bone, 48  
 Jugular notch, 52, 58  
 Jugular tubercle, 52

- Jugular vein, 98. *See also* External jugular vein;  
Internal jugular vein; Transverse jugular  
vein
- Keratinized cell, 7
- Kidney  
cat, 119, 121, 122, 123, 124  
fetal pig, 130, 131, 132  
rat, 133, 135, 136, 137  
sheep, 149, 150
- Kupffer cell, 35
- Lacrimal bone, 46, 47, 66, 157
- Lacrimal canal, 46, 47
- Lacrimal foramen, 47
- Lacrimal fossa, 66
- Lacteal, 33
- Lacunae, 10, 11, 14
- Lambda suture, 48
- Lambdoidal margin, 52
- Lambdoidal suture, 47
- Lamella, 14
- Lamina of axis, 57
- Lamina propria, 29, 36, 38
- Lamina, vertebral, 56
- Large intestine  
cat, 119  
cross section, 34  
rat, 135
- Larynx  
cat, 97, 98, 118  
fetal pig, 128, 129  
human, 75  
rat, 134
- Late diastole, 173
- Lateral condyle, 62, 63, 67
- Lateral cuneiform tarsal, 64, 157
- Lateral epicondyle, 60, 67, 84
- Lateral femoral cutaneous nerve, 172
- Lateral hip muscles, 167
- Lateral malleolus, 67
- Lateral pterygoid muscle, 73
- Lateral pterygoid plate, 73
- Lateral pterygoid process, 49, 50
- Lateral rectus, 73, 74
- Lateral sacral crest, 57
- Lateral tubercle of talus, 64
- Lateral ventricle, sheep brain, 143, 145
- Latissimus dorsi, 162  
cat, 100, 101, 102, 104, 105, 106, 107,  
108, 112, 113, 115  
fetal pig, 125, 126  
human, 71, 77, 79, 83
- Left atrium, sheep heart, 148
- Left auricle  
cat, 118  
fetal pig, 129, 130  
sheep, 147
- Left common carotid artery, 117
- Left coronary artery, 147
- Left intercostal vein, 175
- Left subclavian artery, 116, 117
- Left ventricle, sheep heart, 147, 148
- Leg  
bones of human, 62–64, 157  
major veins of, 175  
musculature of, 87–92, 170
- Lesser multangular carpal, 61, 157
- Lesser occipital nerve, 172
- Lesser sciatic notch, 62
- Lesser trochanter, 62
- Lesser tubercle, 60
- Lesser wing of sphenoid bone, 48
- Leukocytes, 15, 24–26, 155
- Levator angulii oris, 72
- Levator ani, 82, 166
- Levator labii superioris, 72
- Levator palpebrae superioris, 74, 159
- Levator scapulae, 71, 72, 76, 77
- Levator scapulae ventralis, 102
- Levator veli palatini, 161
- Levatores costarum, 165
- Ligament  
nuchal, 106, 107  
patellar, 87, 90
- Linea alba  
cat, 104, 105  
human, 79, 81
- Linea aspera, 62
- Lingual tonsils, 98
- Lingula, defined, 156
- Lingula of mandible, 53
- Liver  
cat, 119, 121, 122  
cross section, 35  
fetal pig, 131  
lobes of, 119  
rat, 133, 135
- Lobules, liver, 35
- Long bone structure, 64
- Long thoracic vein, 115
- Longissimus, 78, 107, 108, 167
- Longissimus capitis, 78, 162
- Longissimus cervicis, 167
- Longissimus thoracis, 167
- Longitudinal fissure, 140
- Loose connective tissue, 8
- Lower canine tooth, 66
- Lower extremities  
major veins of, 175  
muscles of, 87–92, 168–170  
skeletal anatomy, 62–64, 157
- Lumbar nerve, 122, 136, 172
- Lumbar vein, 175
- Lumbar vertebrae, 157  
cat, 65, 67  
human, 55, 56
- Lumbodorsal fascia  
cat, 106, 107, 108, 109, 110  
fetal pig, 127
- Lumbosacral plexus, 172
- Lumbricals, 86, 93
- Lumen of right ventricle, sheep heart, 148
- Lunate carpal, 61, 157
- Lung  
cat, 114, 115, 116  
fetal pig, 129, 130, 131, 132  
rat, 134
- Luteinizing hormone (LH), 177
- Lymph node  
cat, 96, 97, 98, 115, 118  
fetal pig, 126, 128  
histology, 29
- Lymphatic vessel, 30, 120
- Lymphocyte, 26, 155
- Lymphoid follicle, 36
- Lysosome, 152, 153
- Macrophage, 4, 32
- Major calyx, sheep kidney, 150
- Malar bone. *See* Zygomatic bone
- Male cat, urogenital system, 121
- Male fetal pig, abdominopelvic cavity of, 131
- Male, human  
ductus deferens, 40  
epididymis, 40  
female vs. male skeleton, 158  
pelvic floor musculature, 82
- penis, 41
- prostate gland, 41
- seminiferous tubules, 39
- spermatozoa, 39, 40
- urethra, 39
- Male rat, abdominopelvic cavity of, 136
- Malleolar fossa, 63
- Malleus, 48, 157
- Mamillary body, sheep brain, 141
- Mammary artery, 117
- Mammary vein, 129
- Mandible  
cat, 65, 66, 97, 98  
human, 46, 47, 53, 157
- Mandibular alveolus, 46
- Mandibular angle, 47
- Mandibular condyle, 53
- Mandibular condyloid process, 47
- Mandibular coronoid process, 47
- Mandibular foramen, 53
- Mandibular fossa, 49, 51
- Mandibular notch, 47
- Mandibular ramus, 46
- Manubriosternal joint, 59
- Manubrium, 58, 59
- Massa intermedia, 143
- Masseter  
cat, 96, 97, 98  
fetal pig, 126, 128  
human, 70, 72, 73, 159
- Mastication, muscles of, 73, 159
- Mastoid margin, 52
- Mastoid process, 47, 49, 51, 66, 75
- Maxilla  
cat, 65, 66  
human, 46, 47, 49, 53, 157
- Maxillary alveolus, 46, 47
- Maxillary hiatus, 53
- Maxillary process, 52
- Maxillary sinus, 53
- Meatus, 156
- Medial condyle, 62, 63, 67
- Medial cubital vein, 174
- Medial cuneiform tarsal, 64, 157
- Medial epicondyle, 60, 67, 84
- Medial malleolus, 63, 67
- Medial pterygoid muscle, 73
- Medial pterygoid plate, 73
- Medial pterygoid process, 49, 50
- Medial rectus, 73, 74
- Medial thigh muscles, 170
- Medial tubercle of talus, 64
- Median antebrachial vein, 174
- Median crest, 57
- Median cubital vein, 115
- Median nerve, 98, 101, 102, 113, 115, 116, 118
- Median sacral artery  
cat, 121, 123  
fetal pig, 132  
rat, 136
- Median sacral crest, 57
- Mediastinal membrane, 131, 132
- Medulla  
lymph node, 29  
thymus, 30
- Medulla oblongata, 141, 142, 143, 145
- Medullary cavity, 64
- Meissner's corpuscle, 12
- Membrane transport processes, 142
- Meningeal vessels, furrow for, 51
- Mental foramen of mandible, 46, 47, 53, 66
- Mental protuberance of mandible, 53
- Mentalis, 72
- Mentum nuchae, 55

## 184 INDEX

- Mesenteric artery, 120  
 Mesenteric vein, 120, 175  
 Mesentery, 120  
 Metacarpals, 61, 65, 67, 157  
 Metaphase cell, 2  
 Metatarsals, 64, 65, 67, 157  
 Microfilament, 153  
 Microtubule, 152, 153  
 Microvilli, 5, 152  
 Midbrain, 142, 143  
 Middle caudal femoral artery, 111  
 Middle caudal femoral vein, 111  
 Middle ear, bones of, 157  
 Middle meatus, 53  
 Middle nasal concha, 54  
 Middle pharyngeal constrictor, 75  
 Minor calyx, sheep kidney, 150  
 Mitochondrion, 152, 153  
 Mitosis, stages of, 2–3  
 Mitral valve, 148  
 Molars, 66, 98  
 Monocyte, 26, 155  
 Monofil spinous process, 56  
 Motor endplate, 17  
 Motor neurons, spinal cord, 17, 19  
 Mucosa  
   alimentary canal, 32, 34  
   stomach, 33  
 Mucosal folds, gallbladder, 36  
 Multifidus, 78, 107, 108, 167  
 Muscle. *See also* Musculature, dissection specimen; Musculature, human  
   cardiac, 17  
   innervation of, 17, 151  
   smooth, 17  
   striated, 16  
 Muscle fibers, 16–17  
 Muscularis  
   esophagus, 32  
   gallbladder, 36  
   large intestine, 34  
 Musculature, dissection specimen  
   cat, 96–112  
   fetal pig, 125–128  
 Musculature, human, 70–93, 158–170  
   abdominal wall, 81, 165  
   back, 77, 78, 167  
   chest and abdomen, 79–81, 165  
   eye, 73, 74, 158  
   face, 72, 159  
   head and neck, 72–76, 77, 78, 161  
   hip, 87, 88, 167–168  
   lower extremities, 90–93, 167–168  
   mastication, 73, 159  
   pelvis, 82, 166  
   shoulder, 83, 84, 162  
   superficial skeletal muscles, anterior view, 70  
   superficial skeletal muscles, posterior view, 71  
   thigh, 87, 88, 89, 168–169  
   thoracic and abdominal, 79, 80, 165  
   throat, 76, 160  
   tongue, 75, 160  
   upper extremities, 83, 84, 86, 162–164  
   vertebral column, 78, 167  
 Musculocutaneous nerve, 98, 101, 113, 116, 118, 172  
 Myelin sheath, 20  
 Myelinated nerve fibers, 19, 20  
 Myeloblast, 15  
 Mylohyoid, 160  
   cat, 97, 98  
   fetal pig, 128  
   human, 75, 76  
 Myofibril, 16  
 Myoneural junction, 17  
 Nasal bone  
   cat, 66  
   human, 46, 47, 157  
 Nasal concha, 54  
 Nasal crest, 53  
 Nasalis, 72  
 Nasolacrimal groove, 53  
 Navicular carpal, 61, 157  
 Navicular tarsal, 64, 157  
 Navicular tuberosity, 64  
 Neck  
   deep anatomy of rat, 134  
   musculature of cat, 96–99, 106–107  
   musculature of fetal pig, 126, 128  
   musculature of human, 76–78, 160, 161–162  
   venation of cat, 115–116  
   venation of fetal pig, 129, 130  
   venation of human, 175–176  
 Nerve fiber, 19, 20  
 Nerves. *See also specific nerves*  
   of cat abdominopelvic wall, 124  
   of cat neck and thorax, 118  
   cranial, 74, 141, 142, 159  
   eye, 74  
   innervation of skeletal muscle, 17, 151  
   spinal, 172  
 Neurilemma, 20  
 Neuroglia, 18, 19  
 Neurohypophysis, 23  
 Neuron  
   dorsal root ganglion, 19  
   motor neurons of spinal cord, 19  
   Purkinje cells (neurons), 18  
   pyramidal cells, 18  
 Neuronal processes, 19  
 Neutrophil, 15, 24, 155  
 Neutrophilic stab cell, 15  
 Node of Ranvier, 19  
 Noncornified stratified squamous epithelium, 6  
 Nuchal crest, 66  
 Nuchal ligament, 106, 107  
 Nuclear envelope, 2, 152  
 Nucleolus, 152, 153  
 Nucleolus, oocyte, 42  
 Nucleus, 4, 5, 152, 153  
 Oblique. *See* External oblique; Internal oblique  
 Obliquus capitis inferior, 158, 162  
 Obliquus capitis superior, 158  
 Obturator externus, 88  
 Obturator foramen, 61, 62  
 Obturator internus, 88  
 Obturator nerve, 172  
 Occipital bone  
   cat, 66  
   human, 47, 48, 49, 52, 157  
 Occipital border or parietal bone, 51  
 Occipital condyle, 49, 66  
 Occipital lobe of cerebrum, 142  
 Occipital pole, sheep brain, 140  
 Occipital suture, 48  
 Occipitalis, 71, 72  
 Occipitofrontalis, 159  
 Occipitoscapularis. *See* Rhomboideus capitis  
 Occipitosphenooid suture, 49  
 Oculomotor nerve (III), 74, 141, 171  
 Odontoid process, 56, 57  
 Olecranon, 86  
 Olecranon fossa, 60  
 Olecranon process, 60, 67, 100  
 Olfactory bulb, 141, 142  
 Olfactory nerve (I), 141  
 Omohyoid  
   cat, 98  
   human, 72, 76, 160  
 Oocyte, 41, 42  
 Opponens digiti minimi, 86  
 Opponens pollicis, 86  
 Optic canal, 73  
 Optic chiasma, 141, 143  
 Optic foramen, 46, 48, 49, 50  
 Optic nerve (II), 74, 141, 142, 171  
 Optic tract, 141  
 Orbicularis oculi, 70, 72, 159  
 Orbicularis oris, 70, 72, 73, 159  
 Orbit, 50, 65, 66  
 Orbital border of zygomatic bone, 50  
 Orbital fissure, 46  
 Orbital plate of frontal bone, 48  
 Orbital process of palatine bone, 52  
 Orbital surface of maxilla, 53  
 Orbital surface of sphenoid, 50  
 Organ of Corti, 21  
 Organelles, 152, 153  
 Os coxae, 157  
 Osmosis, 154  
 Ossification, 15  
 Osteoblast, 14  
 Osteocyte, 14  
 Osteon, 14  
 Osteonic canal, 14  
 Ovarian artery  
   cat, 121  
   fetal pig, 132  
   rat, 137  
 Ovarian follicle, 41, 42  
 Ovarian vein, 121, 137  
 Ovary  
   cat, 121  
   cross section, 41  
   fetal pig, 132  
   rat, 137  
 Ovum, 41, 42  
 Oxytocin, 177  
 Pacinian corpuscle, 13  
 Palate  
   cat, 99, 118  
   muscles of human, 161  
 Palatine bone, 49, 52, 157  
 Palatine foramen, 49  
 Palatine process, 53  
 Palatine tonsil, 31, 98  
 Palatoglossus, 75, 161  
 Palatopharyngeus, 161  
 Palmar arch, 174  
 Palmar interosseous, 86  
 Palmaris longus  
   cat, 100, 101  
   human, 84, 164  
 Pancreas  
   cat, 119, 121, 122  
   cross section, 23  
   rat, 135  
 Papillary muscle, 148  
 Parathyroid gland, 22  
 Paraurethral gland, 39  
 Parietal bone  
   cat, 66, 67  
   human, 46, 47, 48, 51, 157  
 Parietal cell, 33  
 Parietal lobe of cerebrum, 140, 142  
 Parietal notch, 51  
 Parotid duct, 96, 98  
 Parotid gland  
   cat, 96, 115



- cross section, 37  
fetal pig, 126
- Patellae  
cat, 67  
human, 63, 87, 90, 157
- Patellar ligament, 87, 90
- Patellar surface, 62
- Pectineus  
cat, 111  
human, 87, 88, 169
- Pectoantebrachialis, 97, 100, 104, 105
- Pectoralis major  
cat, 100, 104, 105  
fetal pig, 128  
human, 70, 79, 84, 162
- Pectoralis minor  
cat, 100, 104, 105  
human, 70, 80, 162
- Pedicle, 56, 57
- Pelvic diaphragm, 82
- Pelvis  
bones of cat, 65  
bones of human, 57, 61, 62, 157  
female vs. male, 158  
muscles of human, 82, 166
- Penis  
cat, 122, 124  
cross section, 41  
fetal pig, 131  
rat, 133, 135, 136
- Perforating cutaneous nerve, 172
- Perineal space, 82
- Perineum, 82
- Peritoneum  
cat, 105  
human, 81  
rat, 133
- Peroneal vein, 175
- Peroneus brevis  
cat, 109  
human, 90, 92, 170
- Peroneus longus  
cat, 109, 110  
human, 70, 71, 90, 91, 92, 170
- Peroneus tertius, 90, 170
- Peroxisome, 153
- Perpendicular plate of ethmoid, 46, 54
- Petrosal sinus vein, 176
- Phagocytosis, 154
- Phalanges, 157  
cat, 65, 67  
human, 61, 64, 157
- Pharyngeal constrictor, 72, 75, 76
- Pharynx, 75, 161
- Photoreceptors, 20
- Phrenic nerve, 116, 117, 118, 172
- Physical membrane transport processes, 154
- Pig. See Fetal pig
- Pigmented epithelium, 20
- Pineal gland, 143
- Pinocytosis, 154
- Piriform lobe, sheep brain, 142
- Piriformis, 82, 88, 168
- Pisiform carpal, 61, 159
- PIT. See Pregnancy-induced hypertension (PIT)
- Pituitary gland, 23, 177
- Placenta, 121, 176
- Plantar arch, 175
- Plantar fascia, 93
- Plantar interosseous, 93
- Plantaris, 91, 92, 170
- Plasma membrane, 4, 152  
structure of, 153  
transport processes, 154
- Platelets, 27, 155
- Platysma, 70, 72, 98
- Podocyte, 37
- Pons varolii, 141, 142, 143
- Popliteal artery, 174
- Popliteal surface, 62
- Popliteal vein, 175
- Popliteus, 91, 92, 170
- Posterior belly of digastric, 75, 76
- Posterior facial vein, 96, 97
- Posterior femoral cutaneous nerve, 172
- Posterior hip muscles, 168
- Posterior inferior iliac spine, 61, 62
- Posterior interosseous nerve, 102
- Posterior mesenteric artery, 132
- Posterior pituitary, 177
- Posterior rectus sheath, 80
- Posterior superior iliac spine, 61, 62, 88
- Posterior tibial nerve, 111
- Posterior tibial vein, 175
- Posteriornasal spine, 49
- Pregnancy-induced hypertension (PIT), 38
- Pregnant cat, urogenital system of, 121
- Premolars, 66, 98
- Preperitoneal fat, 81
- Primary bronchii, 117
- Primary ovarian follicles, 41
- Primordial ovarian follicles, 41, 42
- Procerus, 72
- Processes. See *specific processes*
- Prolactin (Prl), 177
- Proliferating chondrocytes, 15
- Pronator quadratus, 84, 163
- Pronator teres, 84, 101, 163
- Prophase cell, 2
- Prostate gland  
cat, 122, 124  
cross section, 41  
fetal pig, 131
- Proximal extensor retinaculum, 110, 111
- Proximal subscapular nerve, 113
- Pseudostratified ciliated columnar epithelium, 5, 6
- Psoas, 123, 124, 136
- Psoas major, 87, 88
- Pterygoid canal, 50
- Pterygoid muscles, 73, 159
- Pubic arch, 61, 158
- Pubic ramus, 82
- Pubic symphysis, 82
- Pubic tubercle, 61
- Pubis, 67, 157
- Pudendal nerve, 172
- Pulmonary trunk, 147, 148
- Purkinje cell (neuron), 18
- Putamen, 145
- Pylorus, 131
- Pyramidal cell, 18
- Pyramidal decussation, 141
- Pyramidal process, 52
- Quadratus femoris, 88
- Quadratus lumborum, 78, 167
- Quadratus plantae, 93
- Quadriceps femoris, 87
- Quadriceps femoris tendon, 87
- Radial artery, 174
- Radial fossa, 67
- Radial nerve, 172  
cat, 98, 101, 102, 112, 113, 115, 116, 118  
fetal pig, 130
- Radial tuberosity, 60, 67
- Radial vein, 115, 174
- Radius  
cat, 65, 67  
human, 60, 84, 157
- Ramus, defined, 156
- Ramus of mandible, 53
- Ranvier, Node of, 19
- Raphe, 82
- Rat, 133–137  
abdominopelvic cavity, 135–137  
deep anatomy of neck and thorax, 134  
general anatomy, 133
- Receptor nuclei, retinal, 20
- Rectum  
cat, 120, 121, 122, 123, 124  
fetal pig, 131, 132  
rat, 133, 135, 136, 137
- Rectus abdominis  
cat, 104, 105, 111  
human, 70, 79, 80, 165  
rat, 133, 135
- Rectus femoris  
cat, 111  
human, 70, 87, 168
- Rectus inferior, 158
- Rectus lateralis, 158
- Rectus medialis, 158
- Rectus sheath, 79, 80
- Rectus superior, 158
- Red blood cell (RBC), 27, 155
- Red bone marrow, 15
- Red pulp, spleen, 31
- Renal artery  
cat, 121, 122, 123, 124  
fetal pig, 131  
rat, 136, 137  
sheep, 149
- Renal column, 150
- Renal corpuscle, 37
- Renal cortex, 150
- Renal pyramid, 150
- Renal vein  
cat, 123, 124  
fetal pig, 131, 132  
human, 175  
rat, 136, 137  
sheep, 149, 150
- Reticular connective tissue, 8
- Reticular fiber, 8
- Retina, 20
- Rhinal sulcus, 142
- Rhomboideus capitis, 106, 107, 126
- Rhomboideus major, 71, 77, 107, 162
- Rhomboideus minor  
cat, 106, 107  
human, 71, 77, 162
- Ribosomes, 152, 153
- Ribs  
cat, 65, 67, 108, 114, 117  
fetal pig, 130  
human, 58, 157  
rat, 134
- Right atrium, 147
- Right auricle, 116, 118, 129, 130
- Right common carotid artery, 117
- Right coronary artery, 147
- Right intercostal vein, 175
- Right subclavian artery, 116
- Right ventricle, 147, 148
- Risorius, 72
- Rods, 20
- Root, hair, 13
- Rostrum of corpus callosum, 143
- Rostrum of sphenoid, 50
- Rotator cuff, 162
- Rough endoplasmic reticulum, 152

## 186 INDEX

- Sacral artery, 123, 132, 136  
 Sacral canal, 57  
 Sacral foramen, 57  
 Sacral hiatus, 57  
 Sacral nerve, 172  
 Sacral promontory, 57  
 Sacral vertebrae, 55, 57, 67  
 Sacrum, 57, 61, 88, 157, 158  
 Sagittal border, 51  
 Sagittal suture, 47, 48  
 Salivary duct  
   cross section, 36, 37  
   fetal pig, 126  
 Salivary gland  
   cat, 96, 97, 115  
   cross section, 37  
   fetal pig, 126, 128  
   parotid, 37  
   rat, 134  
   sublingual, 36  
   submandibular, 37, 96, 97, 115, 126, 128  
 Saphenous nerve, 172  
 Saphenous vein, 175  
 Sartorius  
   cat, 109, 110, 111  
   human, 70, 87  
 Scalenes, 76, 112, 165  
 Scalp, human, 13  
 Scaphoid carpal, 61  
 Scapulae  
   cat, 65, 67  
   human, 59, 60, 83, 157  
 Sciatic nerve, 110, 172  
 Scrotum, 135  
 Sebaceous gland, 13  
 Second intercostal space, 156  
 Secondary ovarian follicle with ovum, 42  
 Secretory vesicle, 152  
 Sella turcica, 48, 49  
 Semimembranosus  
   cat, 109, 110, 111  
   fetal pig, 125, 127  
   human, 71, 89, 169  
 Seminal vesicle, 135, 136  
 Seminiferous tubules, 39  
 Semispinalis, 167  
 Semispinalis capitus, 71, 77, 78, 162  
 Semispinalis cervicis, 78  
 Semispinalis thoracis, 78  
 Semitendinosus  
   cat, 109, 110, 111  
   fetal pig, 125, 127  
   human, 71, 89, 169  
 Serous cell, 37  
 Serous demilune, 36  
 Serratus anterior  
   cat, 105  
   fetal pig, 125  
   human, 70, 71, 77, 79, 80, 162  
 Serratus posterior inferior, 71, 77, 78  
 Serratus posterior superior, 78  
 Serratus ventralis, 112  
 Sertoli cell, 39  
 Sesamoid bones, 157  
 Sheep dissections  
   brain, 140–145  
   heart, 146–148  
   kidney, 149–150  
 Shoulder  
   bones of, 59, 60, 157  
   muscles of, 83–84, 112, 126, 162  
 Sickle cell anemia, 27  
 Sigmoid colon, 132  
 Sigmoid sinuses vein, 176  
 Simple columnar epithelium, 5  
 Simple cuboidal epithelium, 1, 4, 5  
 Simple squamous epithelium, 4  
 Sinusoid, liver, 35  
 Skeleton  
   cat, 65–68  
   human. *see* Skeleton, human  
   terms describing bones of, 156  
 Skeleton, human, 46–64  
   bones of appendicular, 157  
   bones of axial, 157  
   clavicles, 59  
   female vs. male, 158  
   long bone structure, 64  
   lower extremities, 62–64  
   pelvic bones, 61, 62  
   scapulae, 59, 60  
   skull bones, 46–54  
   sternum, 58, 59  
   upper extremities, 60–61  
   vertebral column, 55–57  
 Skin, 12  
 Skull  
   bones of cat, 66  
   bones of human, 46–54, 157  
   muscles of, 72–73  
 Small intestine  
   cat, 119, 120, 121, 122  
   cross section, 33, 34  
   fetal pig, 131, 132  
   rat, 135  
 Small saphenous vein, 175  
 Smooth endoplasmic reticulum, 152  
 Smooth muscle, 17  
 Soft palate, 98, 118  
 Soleal line, 63  
 Soleus  
   cat, 109, 110, 111  
   fetal pig, 127  
   human, 70, 71, 91, 170  
 Somatostatin, 23  
 Somatotropin, 177  
 Sperm, 40  
 Spermatic artery, 124, 131, 136  
 Spermatic cord, 131  
 Spermatic vein, 122  
 Spermatozoa, 39, 40  
 Sphenoid bone, 46, 47, 48, 49, 50, 157  
 Sphenoidal process, 52  
 Sphenopalatine notch, 52  
 Sphincter ani externus, 166  
 Sphincter urethrae, 166  
 Spinal accessory nerve (XI), 118, 141  
 Spinal column. *See* Vertebral column  
 Spinal cord  
   central canal, 143  
   cross section, 20  
 Spinal nerves, 19, 118, 172  
 Spinalis, 78, 107, 108, 167  
 Spindle fibers, 2, 3  
 Spine, defined, 156  
 Spine of scapula, 83  
 Spinodeltoid  
   cat, 102, 106, 107  
   fetal pig, 125, 126  
 Spinotrapezius  
   cat, 106, 107, 108  
   fetal pig, 125, 126  
 Spinous processes, 55, 67  
 Spiral line, 62  
 Spleen  
   cat, 119, 121, 122  
   cross section, 31  
   fetal pig, 131  
   rat, 133, 135  
 Splenic vein, 163  
 Splenium of corpus callosum, 175  
 Splenius capitis  
   cat, 106, 107  
   fetal pig, 126  
   human, 71, 76, 77, 78, 162  
 Splenius cervicis, 78  
 Spongy (cancellous) bone, 14, 15  
 Squamosal border, 51  
 Squamosal suture, 47, 51, 66  
 Stapes, 48, 157  
 Stenoacoustic area, 144  
 Sternocleidomastoid, 70, 71, 72, 76, 77, 161, 165  
 Sternohyoid  
   cat, 96, 97, 98  
   fetal pig, 128  
   human, 72, 76, 160  
   rat, 134  
 Sternomastoid  
   cat, 96, 97, 98  
   fetal pig, 126, 128  
 Sternothyroid  
   cat, 96, 97  
   human, 72, 76, 160  
 Sternum  
   cat, 65, 67, 97, 112  
   fetal pig, 128  
   human, 58, 59, 157  
   rat, 133, 135, 136  
 Stomach  
   cat, 119, 121, 122  
   fetal pig, 131  
   rat, 135  
 Stomach mucosa, 33  
 Straight sinus vein, 175  
 Stratified squamous epithelium, 7  
 Stratum basale, 12  
 Stratum corneum, 12  
 Stratum granulosum, 12  
 Stratum spinosum, 12  
 Stria terminalis, 145  
 Striated (skeletal) muscle, 16, 17  
 Striations, muscle, 16  
 Styloglossus, 75, 160  
 Stylohyoid, 75, 76  
 Styloid process of radius, 60  
 Styloid process of temporal bone, 47, 49, 51, 63, 67, 75  
 Styloid process of ulna, 60  
 Stylomastoid foramen, 49, 66  
 Stylopharyngeus, 161  
 Subclavian artery, 117, 130, 174  
 Subclavian vein  
   cat, 98, 101, 115, 118  
   fetal pig, 129  
   human, 174  
 Subclavius, 80  
 Sublingual salivary gland, 36  
 Submandibular gland  
   cat, 96, 97, 115  
   cross section, 37  
   fetal pig, 126, 128  
 Submucosa, 32  
 Subscapular artery, 117  
 Subscapular fossa, 59  
 Subscapular vein, 115, 118  
 Subscapularis  
   cat, 104, 112, 116  
   human, 84, 162  
 Sulcus, 156  
 Sulcus limitans, 144

- Superficial extensors, 85  
 Superficial flexors, 84  
 Superficial palmar arch, 174  
 Superficial transverse perineus, 82  
 Superior articular facet, 56, 57  
 Superior articular process, 56, 57  
 Superior colliculus, 143  
 Superior gluteal nerve, 172  
 Superior hemorrhoidal artery, 132  
 Superior mesenteric artery, 123, 124  
 Superior mesenteric ganglion, 124  
 Superior nuchal line, 49, 78  
 Superior oblique, 73, 74  
 Superior oblique tendon, 74  
 Superior orbital fissure, 49, 50  
 Superior orbital process, 46  
 Superior pharyngeal constrictor, 75  
 Superior pubic ramus, 61, 62  
 Superior rectus, 73, 74  
 Superior sagittal sinus vein, 175  
 Superior vena cava  
   cat, 115, 118  
   fetal pig, 129, 130  
   human, 176  
 Supinator, 84, 86, 163  
 Supraclavicular nerve, 172  
 Suprameatal triangle, 51  
 Supraorbital foramen, 46, 50  
 Supraorbital notch, 50  
 Suprarenal vein, 175  
 Suprascapular notch, 59  
 Supraspinatus  
   cat, 106, 107  
   human, 71, 77, 83, 84, 162  
 Supraspinous fossa, 67  
 Surgical neck, 156  
 Suspensory ligament of ovary, 132  
 Sutures, skull, 47, 48, 49  
 Sympathetic trunk, 117, 124, 130  
 Symphysis pubis, 61, 62  
 Synaptic bulb, 17  
 Systole, 173
- Talus, 64, 157  
 Tarsals  
   cat, 65, 67  
   human, 64, 157  
 Taste bud, 21  
 Taste pore, 21  
 Tectorial membrane, 21  
 Telophase cell, 3  
 Temporal bone  
   cat, 66  
   human, 46, 47, 48, 49, 51, 157  
 Temporal process of malar, 46, 47, 49  
 Temporalis  
   cat, 96, 98  
   human, 72, 73, 159  
 Temporozygomatic suture, 47  
 Tendinosus intersections, 79  
 Tendon of gastrocnemius, 91  
 Tendon of plantaris, 91  
 Tensor fascia latae  
   cat, 109, 110, 111  
   fetal pig, 125, 127  
   human, 70, 87, 167  
 Tensor veli palatini, 161  
 Teres major  
   cat, 104, 112, 116  
   human, 71, 77, 83, 84, 162  
 Teres minor, 71, 77, 83, 84, 162  
 Testis  
   cat, 122, 124  
   fetal pig, 125, 127, 131  
   rat, 133, 135  
   seminiferous tubules of, 39  
 Thalamus, 145  
 Thigh musculature, 87, 88, 89, 168–169  
 Third ventricle, sheep brain, 143, 145  
 Thoracic nerve, 98, 101  
 Thoracic vertebrae  
   cat, 65, 67  
   human, 55, 56, 58, 157  
 Thoracoacromial artery, 113, 116  
 Thoracoacromial blood vessels, 112  
 Thoracodorsal artery, 113  
 Thoracodorsal nerve, 113, 115, 130  
 Thoracodorsal vein, 115  
 Thoracolumbar fascia, 77  
 Thorax  
   deep anatomy of fetal pig, 129  
   major veins of human, 175  
   muscles of cat, 104–105  
   muscles of human, 79, 80  
   nerves of cat, 118  
   rat, 133, 134  
   venation of cat, 115–116  
 Throat muscles  
   cat, 97  
   fetal pig, 128  
   human, 76, 159  
 Thymus  
   cat, 114, 115  
   cross section, 30  
   fetal pig, 131  
   rat, 134  
 Thyrocervical artery, 117  
 Thyrohyoid, 72, 76  
 Thyroid follicles, 22  
 Thyroid gland  
   cat, 98, 118  
   fetal pig, 129, 131  
   follicles of, 22  
   rat, 134  
 Thyroid stimulating hormone (TSH), 177  
 Tibia  
   cat, 65, 67, 111  
   human, 63, 90, 157  
 Tibial artery, 174  
 Tibial division of sciatic nerve, 110  
 Tibial nerve, 172  
 Tibial tuberosity, 63, 67  
 Tibialis anterior  
   cat, 109, 110, 111  
   fetal pig, 127  
   human, 70, 90, 170  
 Tibialis posterior, 92, 111, 170  
 Tongue, 96, 98  
 Tongue muscles, 160  
 Trachea  
   cat, 97, 98, 115, 116, 117, 118  
   fetal pig, 128, 129, 130, 131  
   human, 75  
   rat, 134  
 Transitional epithelium, 7, 38, 39  
 Transport processes, cell, 154  
 Transversalis abdominis, 105  
 Transversalis fascia, 81  
 Transverse cervical nerve, 172  
 Transverse foramen, 56, 57  
 Transverse jugular vein, 96, 97  
 Transverse perinei, 166  
 Transverse processes, 55, 56, 57, 67  
 Transverse scapular artery, 116, 117, 130  
 Transverse scapular vein, 115  
 Transverse sinuses vein, 176  
 Transversus abdominis  
   human, 70, 79, 80, 81, 165  
   rat, 133  
 Transversus thoracis, 165  
 Trapezium, 61, 157  
 Trapezius, 70, 71, 76, 77, 162  
 Trapezoid carpal, 61  
 Travecular blood vessels, 22  
 Triangle of auscultation, 162  
 Triangular carpal, 157  
 Triceps brachii  
   cat, 101, 102, 106, 107, 116  
   fetal pig, 125, 126  
   human, 71, 83, 84, 86, 163  
 Trigeminal nerve (cranial nerve V), 141, 171  
 Trigeminal tubercle, 144  
 Triquetrum carpal, 61, 157  
 Trochanter, 156  
 Trochlea, 60, 67, 73, 156  
 Trochlear nerve (cranial nerve IV), 74, 141, 142, 171  
 Trochlear notch, 60  
 Trochlear surface of talus, 64  
 True ribs, 58, 157  
 TSH (Thyroid stimulating hormone), 177  
 Tubercle, 156  
 Tubercles of intercondylar eminence, 63  
 Tuberosity, 156  
 Tunica adventitia, 27, 28, 29  
 Tunica albuginea, 41  
 Tunica intima, 27, 28, 29  
 Tunica media, 27, 28, 29  
 Tunica muscularis, 39  
 Tunica propria, 39
- Ulna  
   cat, 65, 67  
   human, 60, 84, 157  
 Ulnar artery, 174  
 Ulnar nerve  
   cat, 98, 100, 101, 102, 113, 115, 116, 118  
   human, 172  
 Ulnar notch, 60  
 Ulnar tuberosity, 60  
 Ulnar vein, 115, 174  
 Umbilical artery, 122, 131, 132, 176  
 Umbilical cord, 125  
 Umbilical vein, 131, 132, 176  
 Umbilicus, 79, 131  
 Umbrella cell, 7, 39  
 Upper extremities  
   bones of, 60, 157  
   major veins of, 174  
   muscles of, 83–86, 162  
 Ureter  
   cat, 121, 122, 123, 124  
   cross section, 38  
   fetal pig, 131, 132  
   rat, 136, 137  
   sheep, 149  
 Urethra  
   cat, 122, 124  
   cross section, 39, 41  
   fetal pig, 131, 132  
   human, 82  
 Urinary bladder, 39  
   cat, 119, 120, 121, 122, 123  
   fetal pig, 131, 132  
   rat, 135, 136, 137  
 Urogenital diaphragm, 82  
 Urogenital system  
   cat, 121–122  
   fetal pig, 131–132  
   rat, 136–137



## 188 INDEX

- Urogenital triangle, 82
- Uterine horn  
cat, 121  
fetal pig, 132  
rat, 137
- Uterine tube, 42
- Uterus  
cat, 120, 121  
fetal pig, 132  
histology, 42  
rat, 137
- Vagina, 82
- Vagus nerve (X), 171  
cat, 115, 116, 117, 118  
fetal pig, 129, 130  
sheep brain, 141
- Valve, lymphatic vessel, 30
- Vas deferens, 122, 131
- Vasopressin, 177
- Vastus intermedius, 87, 168
- Vastus lateralis, 177  
cat, 110, 111  
fetal pig, 125, 127  
human, 70, 87, 89
- Vastus medialis, 70, 87, 111, 168
- Veins. *See also specific veins*  
of cat abdominopelvic wall, 123, 124  
of cat neck and thorax, 115, 118  
histology, 27  
major human, 174–176
- Vena cava, sheep heart, 147. *See also* Abdominal  
vena cava; Anterior vena cava; Inferior  
vena cava; Superior vena cava
- Ventral branch of facial (VII) nerve, 97, 98
- Ventral buccal branch of facial (VII) nerve, 96
- Ventral horn, spinal cord, 20
- Ventral spinous process, 67
- Ventral thoracic nerve, 98, 101, 112
- Ventricular diastole, 173
- Ventricular ejection, 173
- Ventricular systole, 173
- Vermiform appendix, 36
- Vermis of cerebellum, 142
- Vertebrae  
cat, 65, 66, 67  
human, 55–57, 157
- Vertebral artery  
cat, 116, 117  
fetal pig, 130
- Vertebral column  
bones of, 55, 56, 157  
muscles of, 167
- Vertebral foramen, 56
- Vertebral ribs, 58
- Vertebral vein, 176
- Vertebrochondral ribs, 58
- Vertebrosteral ribs, 58
- Vertical plate, 52
- Vestibuloacoustic nerve (VIII), 141, 171
- Vgal trigone, 144
- Vibrissal barrels (cat), 96
- Villi of Ileum, 33, 34
- Vomer, 46, 49, 157
- Vomeronasal nerve (cranial nerve XIII), 171
- White blood cells (WBC), 24–26, 155
- White matter, spinal cord, 20
- White pulp, spleen, 31
- Wormian bones, 47, 157
- Wrist musculature, 164
- Xiphohumeralis, 104, 105
- Xiphisternal joint, 59
- Xiphoid process. *See also* Sternum  
human, 58, 59  
rat, 133
- Z line, 16
- Zona fasciculata, 24
- Zona glomerulosa, 24
- Zona pellucida, 41, 42
- Zona reticularis, 24
- Zygomatic arch  
cat, 65  
human, 47, 49, 72
- Zygomatic bone  
cat, 66  
human, 46, 47, 49, 50, 157
- Zygomatic process of frontal bone, 66
- Zygomatic process of maxilla, 46
- Zygomatic process of temporal bone, 47, 49, 51
- Zygomaticus major, 70, 72, 159
- Zygomaticus minor, 72, 159
- Zymogen granules, 37