

Cathy C. Cartwright  
Donna C. Wallace *Editors*

# Nursing Care of the Pediatric Neurosurgery Patient

Second Edition

 Springer

---

# Nursing Care of the Pediatric Neurosurgery Patient



---

Cathy C. Cartwright • Donna C. Wallace  
Editors

# Nursing Care of the Pediatric Neurosurgery Patient

Second Edition

 Springer

*Editors*

Cathy C. Cartwright  
Department of Neurosurgery  
Children's Mercy Hospital  
Kansas City  
Missouri  
USA

Donna C. Wallace  
Department of Neurosurgery  
Children's Mercy Hospital  
Kansas City  
Missouri  
USA

ISBN 978-3-642-32553-3      ISBN 978-3-642-32554-0 (eBook)  
DOI 10.1007/978-3-642-32554-0  
Springer Heidelberg New York Dordrecht London

Library of Congress Control Number: 2013931753

© Springer-Verlag Berlin Heidelberg 2013

This work is subject to copyright. All rights are reserved by the Publisher, whether the whole or part of the material is concerned, specifically the rights of translation, reprinting, reuse of illustrations, recitation, broadcasting, reproduction on microfilms or in any other physical way, and transmission or information storage and retrieval, electronic adaptation, computer software, or by similar or dissimilar methodology now known or hereafter developed. Exempted from this legal reservation are brief excerpts in connection with reviews or scholarly analysis or material supplied specifically for the purpose of being entered and executed on a computer system, for exclusive use by the purchaser of the work. Duplication of this publication or parts thereof is permitted only under the provisions of the Copyright Law of the Publisher's location, in its current version, and permission for use must always be obtained from Springer. Permissions for use may be obtained through RightsLink at the Copyright Clearance Center. Violations are liable to prosecution under the respective Copyright Law.

The use of general descriptive names, registered names, trademarks, service marks, etc. in this publication does not imply, even in the absence of a specific statement, that such names are exempt from the relevant protective laws and regulations and therefore free for general use.

While the advice and information in this book are believed to be true and accurate at the date of publication, neither the authors nor the editors nor the publisher can accept any legal responsibility for any errors or omissions that may be made. The publisher makes no warranty, express or implied, with respect to the material contained herein.

Printed on acid-free paper

Springer is part of Springer Science+Business Media ([www.springer.com](http://www.springer.com))

---

## Foreword

The Institute of Medicine (IOM) report (2011) *The Future of Nursing: Leading Change, Advancing Health* is the first report from the prestigious IOM to focus solely on the profession of nursing. It challenges nurses to practice to the full extent of their knowledge and experience and to be full partners with physicians and other health professionals to transform health care to provide higher quality, safer, more affordable, and more accessible care. Evidence-based practice and patient-centered care, which includes family, are the expected standard of care. The report speaks to the profession of nursing and all nurses to lead change. Such a responsibility and accountability at the professional and individual level require well-educated nurses in health care delivery and patient care.

The unprecedented knowledge explosion reflected in the development of nursing science is framed against a background of national patient safety and quality outcomes imperatives. The convergence of science and fundamental changes in the health care delivery system are driving the science-based care and practice in nursing and the rapid development in subspecialty professional practice. Nowhere is the phenomenal growth in specialty nursing practice more evident than in neuroscience nursing. New knowledge gained from research and quality improvement is being translated into practice to support evidence-based practice and care. In addition, recognition of the special health problems and needs of neuroscience patients across the age continuum from birth through aging is evident. Age-specific neurological assessment along with comprehensive information of major neurological conditions, treatment, and nursing care is needed as resources for nurses to provide high-quality, safe care and achieve optimal patient outcomes. One area, pediatric neuroscience care, has had a void until recently. Cathy C. Cartwright and Donna Wallace, two expert pediatric neuroscience clinicians, have led the way in addressing the need for a current and reliable resource with the *Nursing Care of the Pediatric Neurosurgery Patient*, now in its second edition. Through a comprehensive approach to the common neurosurgical problems, these two experts share a wealth of knowledge in their text to guide nurses engaged in the care of the pediatric neurosurgical patient. The neurological assessment addressed includes assessment from infants to older children, which sets the foundation for understanding the milestones of human development. A discussion of the common neurological problems and adaptation of care is provided along with detailed perioperative surgical management and care. A particularly important chapter is transition care to adulthood. With improved

treatment options, children with many neurological conditions are surviving to be adults with chronic neurological conditions. The *Nursing Care of the Pediatric Neurosurgery Patient*, 2nd edition, is an excellent resource for all nurses engaged in pediatric neurological patient care.

Joanne V. Hickey, Ph.D., RN,  
ACNP-BC, FAAN, FCCM

---

## Preface

Our humble but ambitious idea to write a book that would serve as a reference for nurses caring for children with neurosurgical conditions came to fruition with the publication of the first edition in 2007. As the first book of its kind, we wondered how it would be received by our colleagues. Would it be a valuable resource, something that both bedside nurses and advance practice nurses would find helpful? We were gratified to find that not only was it well received by nursing but that other health care disciplines also found it to be a valuable resource. Child life specialists, medical students, resident physicians, and even patients and families have used it as a reference.

Although novices in our first edition, we soon realized that we could improve on the second edition. Our colleagues offered enthusiastic suggestions and ideas which have been incorporated in this edition. Authors for each chapter have done a tremendous job updating evidence-based practice, including case studies, parent stories, and numerous illustrations to help explain the pathophysiology, treatment, outcomes, and impact of neurosurgical disorders on patients and families. The authors have again shared their experiences and contributed their expertise to the chapters, and this book would not be possible without them. This edition includes two additional chapters, perioperative care and transition care into adulthood. No neurosurgery book would be complete without discussion of the nurse's role preparing the patient and family for surgery, caring for the patient in the operating room and in the post-anesthesia care unit. Because of the many advances in health care, children with neurosurgical conditions are living into adulthood, and nurses need the tools to help these children and their parents transition smoothly.

The editors would also like to thank Children's Mercy Hospital for providing the atmosphere of learning and support that allows us to care for our patients and families and share what we have learned from them.

Most of all, we are so grateful for the opportunity to be a part of the lives of these children and their families. We learn so much from you. Not only do you let us in when you are most vulnerable but you are willing to share your journey with other families so they might be less anxious as they embark on theirs. Thank you for sharing a part of your lives with us and helping us to understand what it is like to live with a neurosurgical condition. May those that read this book learn from the wisdom you impart.

Kansas City, MO 2012

Cathy C. Cartwright  
Donna C. Wallace





---

## Acknowledgements

I wish to acknowledge Dr. Usiakimi Igbaseimokumo for his support and encouragement and always reminding me to ask “why?” And to Zach, editor extraordinaire and the real reason I am what I am.

C.C.

I wish to thank Dr. Harold Rekate and Dr. Usiakimi Igbaseimokumo for their support and mentoring, in learning about caring for the pediatric neuro-surgical patient.

Of course I must acknowledge my family and friends, who were always so understanding when I needed to work on this book.

Like Cathy, I wish to point out that Zach was an ever-present force who provided any kind of editorial help, whenever it was needed.

D.W.



---

# Contents

<b>1</b>	<b>Neurological Assessment of the Neonate, Infant, Child, and Adolescent</b> .....	1
	Jennifer A. Disabato and Dee A. Daniels	
<b>2</b>	<b>Hydrocephalus</b> .....	37
	Nadine Nielsen and Amanda Breedt	
<b>3</b>	<b>Craniosynostosis and Plagiocephaly</b> .....	85
	Cathy C. Cartwright and Patricia D. Chibbaro	
<b>4</b>	<b>Neural Tube Defects</b> .....	119
	Shona Swenson Lenss	
<b>5</b>	<b>Chiari Malformation and Syringomyelia</b> .....	141
	Susan McGee and Diane Baudendistel	
<b>6</b>	<b>Tumors of the Central Nervous System</b> .....	157
	Tania Shiminski-Maher	
<b>7</b>	<b>Traumatic Brain Injury</b> .....	193
	Angela Hoersting and Jodi E. Mullen	
<b>8</b>	<b>Spine</b> .....	249
	Valorie Thomas and Anne Stuedemann	
<b>9</b>	<b>Neurovascular Disease</b> .....	283
	Theresa M. Gabay and Davonna Ledet	
<b>10</b>	<b>Surgical Management of Epilepsy</b> .....	333
	Patti L. Batchelder	
<b>11</b>	<b>Surgical Management of Spasticity</b> .....	361
	Herta Yu	
<b>12</b>	<b>Infections of the Central Nervous System</b> .....	375
	Gina Weddle	

---

<b>13 Perioperative Care</b> .....	389
Sarah M. Burr and Gail C. Dustman	
<b>14 Transition from Pediatric to Adult Care</b> .....	413
Theresa M. Gabay, Jennifer A. Disabato, and Teresa Schultz	
<b>Index</b> .....	431

---

# Neurological Assessment of the Neonate, Infant, Child, and Adolescent

1

Jennifer A. Disabato and Dee A. Daniels

---

## 1.1 Introduction

### 1.1.1 Importance of Neurological Assessment

Serial, consistent, and well-documented neurological assessments are the most important aspect of nursing care for the pediatric neurosurgical patient. A bedside nurse is often the first to note a subtle change in a child's level of responsiveness, pattern of movement, or signs and symptoms of decline in neurological function. Both keen observation skills and knowledge of the patient's baseline neurological function are essential tools for the pediatric neurosurgical nurse. Rapid response and escalation of care in response to changes in assessment are necessary to prevent secondary complications that can further impede recovery

from a neurological disease or traumatic injury. Potential complications include the inability to protect the airway leading to aspiration, immobility leading to venous stasis and thrombosis, endocrine disorders related to central hormonal regulation, impaired communication, and behavioral issues, among others (Hickey 2009).

It is understood that children are not always under the care and custody of their parents. As used in this book, however, the term "parent(s)" is intended to include family members who have custody of a child, foster parents, guardians, and other primary caregivers.

### 1.1.2 Nursing Approach to Neurological Assessment

Neurological assessment should be an integral part of the entire physical assessment, and aspects can be integrated into the general exam of patients in both inpatient and outpatient settings. The approach to neurological assessment should be systematic and include pertinent health history; e.g., coexisting conditions, developmental status of the child, the nature and extent of the injury or surgery performed, and potential complications (Amidei et al. 2010). Sources of this information are broad and include: the verbal report provided in care transitions, the medical record, the parent caregiver, and nursing and medical colleagues,

---

J.A. Disabato, DNP, CPNP-PC, AC (✉)  
Perioperative Services, Children's Hospital Colorado,  
Aurora, CO, USA

University of Colorado College of Nursing,  
Women, Children and Family Health,  
13120 E. 19th Avenue, C288-11, Aurora,  
CO 80045, USA  
e-mail: jennifer.disabato@ucdenver.edu

D.A. Daniels, MS, RN, CPNP  
Sie Center for Down Syndrome,  
Department of Pediatrics, Children's Hospital Colorado,  
University of Colorado School of Medicine,  
13123 East 16th Ave, B-745, Aurora,  
CO 80045, USA  
e-mail: dee.daniels@childrenscolorado.org

---

Karen W. Burkett was an author on the first edition but did not contribute to the revision of this chapter

including the neurosurgeon, neurologist, and other health-care providers.

Knowledge of physical and developmental disorders not directly associated with the neurological condition, such as renal, cardiac, or pulmonary status is important to a comprehensive approach and enhancing the patient's outcome. Care planning should be a team approach that involves the parents and the multidisciplinary team to assure optimal communication of key information, and avoid unnecessary repetition of tests, or oversight of important clinical findings.

Factors that impact the nurses assessment of the child will be the age and developmental stage of the child, the nature of the child's diagnosis (chronic, acute, static, progressive), the setting in which the assessment takes place (critical care unit, general care are, outpatient clinic, school nurse office), and the information available at the time of the assessment from other members of the multidisciplinary team. Family dynamics and social circumstances can also impact the nurses' approach to the assessment.

### 1.1.3 Diagnostic Imaging and Testing in Neurological Assessment

Diagnostic imaging and other laboratory and electrical testing of the nervous system play an important role in understanding the nature of neurological disorders. The brain, spinal cord, and peripheral neurological system are organs of both intricate structure and complex metabolic, vascular, and cellular function. Diagnostic tools are generally focused on one aspect of the structure or function, but several tests incorporated with a neurological assessment of the child are often the key to an accurate diagnosis and appropriate treatment. Ongoing advances in medicine, technology, and pharmacology have contributed to safer outcomes for children who may need sedation for diagnostic imaging, and the speed of imaging has decreased substantially in recent years.

Advancements in imaging techniques make it easier to consider repeat studies as treatment or recovery progresses, so that changes can be monitored through comparisons to the baseline imag-

ing. However, the use of diagnostic testing in an era of health-care reform calls for all involved to consider the costs associated with a test and query whether the results will truly change the plan or outcome for the patient.

In general, radiographic or digital imaging (such as MRI) are tools to evaluate the structure of the brain and spinal cord, while other diagnostic tests like EEG, SPECT scanning, nuclear medicine scans, and Wada test (intracarotid sodium amobarbital procedure to lateralize language and memory) are evaluating specific functions of the brain. PET scans look at metabolic function and utilization of glucose by the brain. Some tests serve both diagnostic and therapeutic outcomes (Hedlund 2002). Magnetoencephalography (MEG) or magnetic source imaging (MSI) and functional MRIs (fMRI) are methods of localizing areas of abnormality associated with ictal (seizure) onset (Knowlton 2008). Newer technologies allow for evaluation of cerebral blood flow and brain perfusion. Three methods currently in use for monitoring cerebral ischemia include Doppler ultrasound, near-infrared spectroscopy (NIRS) and amplitude-integrated electroencephalogram (aEEG) (Greisen 2006; Iaia and Barker 2008). Table 1.1 is a listing of the most common neurological diagnostic tests and imaging modalities used in pediatrics.

---

## 1.2 Developmental Assessment: Growth and Developmental Tasks by Age

Knowledge of human growth parameters and normal developmental landmarks is critical to the assessment of each age group. The Individuals with Disabilities Education Act (IDEA) Amendments of 1997 (U.S. Department of Education Special Education and Rehabilitative Services 2005) mandate the "early identification of, and intervention for developmental disabilities through the development of community-based systems". This law requires physicians to refer children with suspect developmental delays to appropriate intervention services in a timely manner. Early identification and intervention can

**Table 1.1** Neurological diagnostic and imaging modalities

Diagnostic or imaging modality	Technology utilized	Nursing and patient considerations
X-rays of the skull and vertebral column	X-rays to look at boney structures of the skull and spine, fractures, integrity of the spinal column, presence of calcium intracranially.	Patient should be immobilized in a collar for transport if there is a question of spinal fracture.
Cranial ultrasound	Doppler sound waves to image through soft tissue. In infants can only be used if fontanel is open.	No sedation or intravenous access needed. Used to follow ventricle size/bleeding in neonates/infants.
Computerized tomography with/without contrast	Differentiates tissues by density relative to water with computer averaging and mathematical reconstruction of absorption coefficient measurements.	Non-invasive unless contrast is used or sedation needed. Complications include reaction to contrast material or extravasation at injection site.
Computerized tomography – bone windows and/or three-dimensional reconstruction	Same as above with software capabilities to subtract intracranial contents to look specifically at bone and reconstruct the skull or vertebral column in a three-dimensional model.	No changes in study for patient. Used for complex skull and vertebral anomalies to guide surgical decision-making.
Cerebral angiography	Intra-arterial injection of contrast medium to visualize blood vessels; transfemoral approach most common; occasionally brachial or direct carotid is used.	Done under deep sedation or anesthesia; local reaction or hematoma may occur; systemic reactions to contrast or dysrhythmias; transient ischemia or vasospasm; patient needs to lie flat after and CMS checks of extremity where injection was done are required.
MRI with or without contrast (gadolinium)	Differentiates tissues by their response to radio frequency pulses in a magnetic field; used to visualize structures near bone, infarction, demyelination, and cortical dysplasias.	No radiation exposure; screened prior to study for indwelling metal, pacemakers, braces, electronic implants; sedation required for young children because of sounds and claustrophobia; contrast risks include allergic reaction and injection site extravasation.
MRA MRV	Same technology as above used to study flow in vessels; radiofrequency signals emitted by moving protons can be manipulated to create the image of vascular contrast.	In some cases can replace the need for cerebral angiography; new technologies are making this less invasive study more useful in children with vascular abnormalities.
Functional MRI	Technique for imaging activity of the brain using rapid scanning to detect changes in oxygen consumption of the brain; changes can reflect increased activity in certain cells.	Used in patients who are potential candidates for epilepsy surgery to determine areas of cortical abnormality and their relationship to important cortex responsible for motor and speech functions.
<i>Physiologic imaging techniques – nuclear medicine imaging</i>		
SPECT	Nuclear medicine study utilizing injection of isotopes and imaging of brain to determine if there is increased activity in an area of abnormality; three-dimensional measurements of regional blood flow.	Often used in epilepsy patients to diagnose areas of cerebral uptake during a seizure (ictal SPECT) or between seizures (intraictal SPECT).
SISCOM	Utilizing the technology of SPECT with MRI to look at areas of increased uptake in conjunction with MRI images of the cortex and cortical surface.	No significant difference for patient; software as well as expertise of radiologist is used to evaluate study.
PET	Nuclear medicine study that assesses perfusion and level of metabolic activity of both glucose and oxygen in the brain; radiopharmaceuticals are injected for the study.	Patient should avoid chemicals that depress or stimulate the CNS and alter glucose metabolism (e.g., caffeine); patient may be asked to perform certain tasks during study.

(continued)



**Table 1.1** (continued)

Diagnostic or imaging modality	Technology utilized	Nursing and patient considerations
<i>Electrical studies</i>		
EEG	Records gross electrical activity across surface of brain; ambulatory EEG used may be used for 24–48 h with data downloaded after study; video combines EEG recording with simultaneous videotaping.	Success of study dependent on placement and stability of electrodes and ability to keep them on in children; routine studies often miss actual seizures but background activity can be useful information.
Routine		
Ambulatory		
Video		
Evoked responses	Measure electrical activity in specific sensory pathways in response to external stimuli; signal average produces waveforms that have anatomic correlates according to the latency of wave peaks.	Results can vary depending on body size, age, and characteristics of stimuli; sensation for each test will be different for patient – auditory clicks (BAER), strobe light (VER) or electrical current on skin – somatosensory (SSER).
SSER		
VER		
BAER		
MEG (magneto-encephalography) mapping	Non-invasive functional brain imaging that uses electrodes on the scalp to measure tiny changes in magnetic fields between groups of neurons and projects them onto MRI brain imaging for correlation. Used to assist in localization of seizure foci in evaluation of patients for epilepsy surgery, and to determine the language dominant hemisphere.	Patients will need to remove all metal prior to entry into room. Pacemakers or vagus nerve stimulators (VNS) will cause artifact. VNS should be turned off prior to the study and any magnetic field can affect the function of the VNS.
MSI (magnetic source imaging)	Using a weak magnetic field, images normal and abnormal electrical activity and produces clear images. Messages are sent to the brain via small stimulators on lips and fingers of the patient, and measured and recorded as electrical activity.	
aEEG (amplitude integrated EEG)	Filtered and compressed EEG data used to evaluate long-term trends in background patterns.	Used primarily in neonates to predict neurological outcome following perinatal asphyxia.
<i>Cerebral perfusion studies</i>		
Near infrared spectroscopy (NIRS)	Using light, monitors changes in cerebral tissue oxygenation through functional measurements of differential absorption of hemoglobin at multiple wave lengths.	
Transcranial Doppler (TCD) ultrasound	A non-invasive method of monitoring cerebral circulation (flow velocity) over the middle, anterior and posterior cerebral, ophthalmic, and carotid arteries.	Results indicating low flow velocities after head injury are consistent with low cerebral blood flow, high ICP levels, and a poor prognosis.

Adapted from Disabato and Wulf (1994), and expanded using Iaia and Barker (2008)

*MRI* magnetic resonance imaging, *MRA* magnetic resonance angiography, *MRV* magnetic resonance venography, *SPECT* single photon emission computerized tomography, *SISCOM* subtracted ictal spectroscopy coregistered with MRI, *PET* positron emission tomography, *EEG* electroencephalogram, *SSER* somatosensory evoked potentials, *VEP* visual evoked potentials, *BAER* brainstem auditory evoked potentials, *CNS* central nervous system

have significant impact on later developmental outcomes (Hamilton 2006).

Development is the essential distinguishing feature of pediatric nursing. Normal development is a function of the integrity and maturation of the nervous system. Only with a working knowledge of age-related developmental standards can the examiner be sensitive to the deviations that indi-

cate slight or early impairment of development and an abnormal neurological assessment. An abnormality in development from birth suggests an intrauterine or perinatal cause. Slowing of the rate of acquisition of skills later in infancy or childhood may imply an acquired abnormality of the nervous system or metabolic disease. A loss of skills (regression) over time strongly suggests

an underlying degenerative disease of the central nervous system (Volpe 2009).

Serial measurements can indicate the normal or abnormal dynamics of the child's growth. One key growth measurement important to the neurological assessment of the child is the head circumference. The measurement is taken around the most prominent frontal and occipital bones, that which offers the maximal circumference. How rapidly the head circumference accelerates or decelerates away from the percentile curve can determine if the underlying cause of the growth change is more benign or serious. An example of a benign finding is the presence of extra-axial fluid collections of infancy, which often present with an accelerating head circumference. Generally, the infant with this finding is observed over time, but no intervention is warranted. On the other hand, an accelerating head circumference can also be a sign of increasing intracranial pressure in uncompensated hydrocephalus, which would require immediate evaluation and treatment. A child with a large head in the setting of normal development and normal neurologic exam could be explained by measuring the parents' head circumference, as large heads can be familial.

Voluntary motor skills generally develop in a cephalocaudal and proximodistal progression, as it parallels the process of myelination. Myelin is a phospholipid layer that surrounds the axons of many neurons, which regulate the speed of transmission. First the head, then the trunk, arms, hands, pelvis, legs, bowel, and bladder are brought under voluntary control. Early in life motor activity is largely reflexive, and generalized movements predominate. Patterns emerge from the general to the specific; for example, a newborn's total-body response to a stimulus is contrasted with the older child, who responds through simply a smile or words. So as the neuromuscular system matures, movement gradually becomes more purposeful and coordinated (Schultz and Hockenberry 2011). The sequence of development is the same for all children, but the rate of development varies from child to child.

Finally, as important to a complete neurological exam is an assessment of the child's cognitive and emotional development. These abilities impact directly on expectations of the child's

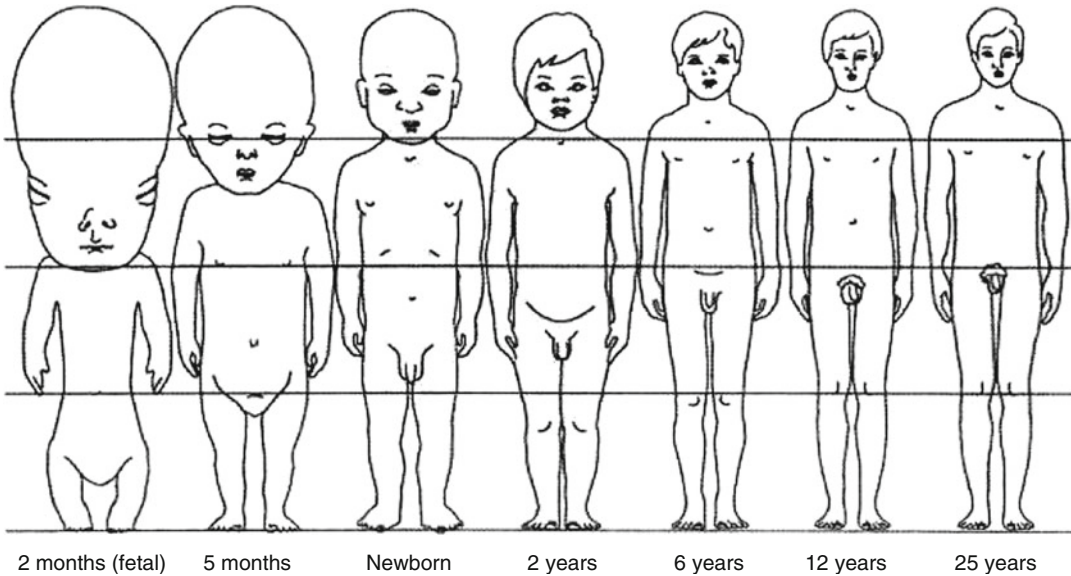
behavioral, social, and functional capabilities. The younger the child, the more developmental history is needed from the parents. Accurate identification of the child's mastery of cognitive and emotional developmental milestones, as it relates to chronological age, is necessary for a comprehensive neurological assessment. It is imperative to note if the child is making steady developmental progress or has experienced regression. If regression is noted, then it is important to note the onset of regression. Documenting examples of regression and the temporal relationship to current symptoms gives further context that may influence the evaluation, diagnosis, and subsequent treatment plan. If the child had significant regression in speech at 18 months of age followed by seizure onset at 3 years of age, this knowledge may lead to further consideration of autism spectrum disorder rather than simply a seizure disorder. This history is imperative in planning a comprehensive evaluation and future treatment plan that would span many health-care disciplines.

## 1.2.1 Neonate

Aside from head shape and size and assessment of fontanelles, there are other aspects unique to the neurological exam of the neonate and/or infant. These are important to understanding the integrity of the nervous system early in life and are detailed in this section. The proportional changes in head and body growth from fetal life to adulthood are depicted in Fig. 1.1 (Santrock JW 1998).

### 1.2.1.1 Maternal and Pregnancy/Labor and Delivery History

An interview with the biological mother, or another familiar with the pregnancy, should include questions about any maternal illness, nutrition status, drug and/or alcohol use, chronic diseases, and any medications taken routinely, including prescription, over-the-counter, and herbal supplements. Important factors to know about the delivery include the administration of anesthesia or drugs and difficulties with the delivery like the need for forceps or vacuum devices.



**Fig. 1.1** Changes in Proportions of the Human Body During Growth (Santrock JW 1998)

Note the infant's Apgar scores. A need for supplemental oxygen, intubation/ventilation, glucose, and abnormalities of bilirubin levels is also important. A history of post-birth infections, a need for medication/oxygen, feeding difficulties, and/or seizures may also indicate underlying problems.

### 1.2.1.2 Physical Appearance

The neonatal period is defined as the first 4 weeks of life. The neonate may be term or premature, and the physical characteristics of neonates vary with their gestational age. Inspection of the shape, symmetry, and mobility of the head of the neonate is critical for evaluating cranial abnormalities or soft tissue injuries. Head circumference at term will range from 34 to 36 cm within the 25–75 % ranges. Neonates outside this range should be accurately plotted on the appropriate growth chart and serially measured (Nellhaus 1968). Further examination of the neonate's head for a patent fontanel, tautness, and approximation of cranial sutures is vital. Fontanels are best palpated when the neonate is in the upright position and not crying. The cranial sutures should be well approximated, especially the coronal, squamosal, and lambdoidal sutures, and should not admit a fingertip. The sagittal suture may be wider in nor-

mal newborns, especially if the baby is premature. A soft, flat, or sunken anterior and posterior fontanel should be palpated. The posterior fontanel may be palpated up to 4 weeks of age. More detailed information and illustrations regarding cranial sutures and related abnormalities can be found in Chap. 3.

Spine assessments include evaluation for abnormal midline lumps, dimples, tufts of hair on the spine, and palpation for vertebral anomalies. Skin markings such as petechiae, hemangiomas, and hypopigmented or hyperpigmented lesions may be present at birth and indicative of neurological congenital conditions. It is important to note the size, location, and number of hypo- or hyperpigmented lesions. In addition, congenital anomalies of the heart, lungs, and gastrointestinal tract may suggest abnormalities of brain development. However, optic or facial dysmorphisms more accurately predict a brain anomaly (American Academy of Pediatrics 1996). Some facial dysmorphisms to note include hyper- or hypotelorism, flat philtrum, thin upper lip, epicanthal folds, unequal size of eyes, nystagmus, microphthalmia, hypoplastic face or facial droop, micrognathia, abnormal shape/size of nose, asymmetry of smile, high-arched palate, congenital cataracts, small or

simple ears, preauricular skin tag/dimple, and cleft lip/palate.

### 1.2.1.3 Functional Capabilities

Neonatal function is primarily reflex activity and necessitates the assessment of infantile automatisms, i.e., those specific reflex movements which appear in normal newborns and disappear at specific periods of time in infancy. Table 1.2 outlines the primitive reflexes in more detail (Slota 1983a). Functional examination may begin by observation of the neonate in supine and prone positions, noting spontaneous activity in each position and presence of primitive reflexes. The posture of the neonate is one of partial flexion with diminishing flexion of the legs as the neonate ages. Observe for hypotonia, which could indicate neurologic deficit or a genetic/metabolic disorder. Look for random movements of the extremities and attempt to distinguish single myoclonic twitches, which are normal, from repetitive movement seen with seizures. Observe for symmetry of movements. Care should be taken to observe for infantile spasms characterized by atonic head drops accompanied by arms rising upward. Some neonates have an excessive response to arousal with “jitteriness” or tremulousness. This is a low-amplitude, rapid shaking of the limbs and jaw. It may appear spontaneously and look like a seizure. However, unlike seizures, jitteriness usually follows some stimulus, can be stopped by holding the limb or jaw, and does not have associated eye movements or respiratory change. When prominent, slow, and coarse, it may be related to central nervous system stress or metabolic abnormalities, but otherwise it is often a normal finding (Kramer et al. 1994; Shuper et al. 1991). Strength is assessed by observing the newborn’s spontaneous and evoked movements and by eliciting specific newborn reflexes. Neonates with neuromuscular conditions may manifest with abnormally low muscle tone (hypotonia), paradoxical breathing, hip dislocation, or contractures. The neonate is capable of reacting to moving persons or objects within sight or grasp, both for large and small objects. Neonates can visually fixate on a face or light in their line of vision (American Academy of

Pediatrics 1996). The quality of the cry can suggest neurological involvement. A term newborn’s cry is usually loud and vigorous. A weak or sedated neonate will cry only briefly and softly, or may just whimper. A high-pitched cry is often associated with a neurological abnormality or increased intracranial pressure (Freedman et al. 2009). Functional capabilities of the preterm infant will vary by gestational age. Premature infants demonstrate less strength and decreased muscle tone compared to a term infant. Table 1.3 provides some of the key changes and the approximate time when selected milestones appear in most premature infants (Yang 2004).

### 1.2.1.4 Vulnerabilities

The most critical need of both the term and premature neonate is for the establishment of adequate respiratory activity with appropriate oxygenation. Respiratory immaturity added to the neurological insults from seizures, congenital conditions, such as spina bifida and genetically linked syndromes as well as intraventricular hemorrhage, and hydrocephalus all have the capability to severely limit the neonates’ ability to buffer these conditions. Infections, an immature immune system, and gastrointestinal deficiencies also can severely compromise the neonate’s ability to dampen the physiological effects of neurological conditions. For the preterm neonate with a neurological disorder, dampening the effects becomes even more crucial and makes the preterm infant vulnerable to multisystem failures. Developmental care teams can be mobilized to augment the neonate’s capacity for optimal growth and interaction with their environment.

### 1.2.1.5 Tips in Approach to Child/Family

Observation of the neonate at rest is the first step in a comprehensive approach to neurological assessment of the neonate. Usually, the head can be inspected and palpated before awakening the neonate and measuring the head circumference. Most neonates arouse as they are unwrapped, and responses to stimulus are best assessed when the neonate is quietly awake. As the neonate arouses further, the strength of his spontaneous and active

**Table 1.2** Interpreting the neurological examination in the young child

Reflexes	Methods of testing	Responses/comments
Palmar grasp P – birth D – 3–4 months	Press index finger against palmar surface; compare grasp of both hands.	Infant will grasp finger firmly. Sucking facilitates grasp. Meaningful grasp occurs after 3 months.
Plantar grasp P – birth D – 8–10 months	Press index finger to sole of foot.	Toes will flex in an attempt to grasp finger.
Acoustic – cochleopalpebral	Create loud noise.	Both eyes blink. This reflex may be difficult to elicit in first few days of life.
Rooting P – birth D – 3–4 months when awake D – 3–8 months when asleep	Stroke perioral skin or cheek.	Mouth will open and infant will turn to stimulated side.
Sucking P – birth D – 10–12 months	Touch lips of infant.	Infant will suck with lips and tongue.
Trunk incurvation (Galants) P – birth D – 2 months	Hold infant prone in one hand and stimulate one side of back about 3 cm from midline.	Trunk will curve to stimulated side.
Vertical suspension positioning P – birth D – 4 months	Support baby upright with hands under axillae.	Legs flex at hips and knees. Legs extend after 4 months. Scissoring of legs indicates spastic paraplegia.
Placing response P – few days after birth D – 10–12 months	Hold baby upright with hands under axillae and allow dorsal surface of foot to touch undersurface of table without plantar-flexing foot.	Infant will flex hip and knee and place foot on table with stepping movement.
Stepping response P – birth D – 3 months	Hold infant upright with hands under axillae and feet flat on table.	Infant will pace forward alternating feet.
Tonic neck reflex P – birth to 6 weeks D – 4–6 months	Turn head to one side.	Arm and leg on same side extend and others flex.
Traction response	Pull infant from supine position to sitting with his hands.	Shoulder muscle movement will be noted.
Perez reflex P – birth D – 3 months	Hold in prone position with one hand and move thumb from sacrum to head.	Infant will extend head and spine, flex knees on chest, cry, and urinate.
Moro reflex P – birth D – 4–6 months	Create loud noise or sudden movement such as extension of the infant's neck.	Infant stiffens, extremities extend, index finger and thumb form C shape, and fingers and toes fan.

Obtained from McGee and Burkett (2000)

*P* present, *D* disappears

**Table 1.3** Age appropriate neuroassessment table (Wallace and Disabato)

Age	Gross motor	Fine motor	Personal/social	Echoes two or more words
Newborn	Head down with ventral suspension Flexion posture Knees under abdomen – pelvis high Head lag complete Head to one side prone	Hands closed  Cortical thumbing (CT)	With sounds, quiets if crying; cries if quiet; startles; blinks	Crying only monotone
4 weeks	Lifts chin briefly (prone) Rounded back sitting head up momentarily  Almost complete head lag	Hands closed (CT)	Indefinite stare at surroundings Briefly regards toy only if brought in front of eyes and follows only to midline Bell sound decreases activity	Small, throaty noises
6 weeks	In ventral suspension head up momentarily in same plane as body Prone: pelvis high but knees no longer under abdomen	Hands open 25 % of time	Smiles	Social smile (1st cortical input)
2 months	Ventral suspension; head in same plane as body Lifts head 45° (prone) on flexed forearms Sitting, back less rounded, head bobs forward Energetic arm movements	Hands open most of the time (75 %) Active grasp of toy	Alert expression Smiles back Vocalizes when talked to  Follows dangled toy beyond midline Follows moving person	Cooing  Single vowel sounds (ah, eh, uh)
3 months	Ventral suspension; head in same plane as body Lifts head 45° (prone) on flexed forearms  Sitting, back less rounded, head bobs forward Energetic arm movements	Hands open most of the time (75 %) Active grasp of toy	Smiles spontaneously  Hand regard  Follows dangled toy 180°  Promptly looks at object in midline Glances at toy put in hand	Chuckles  “Talks back” if examiner nods head and talks Vocalizes with two different syllables (a-a, oo-oo)
4 months	Head to 90° on extended forearms Only slightly head lag at beginning of movement Bears weight some of time on extended legs if held standing Rolls prone to supine Downward parachute	Active play with rattles Crude extended reach and grasp Hands together  Plays with fingers Toys to mouth when supine	Body activity increased at sight of toy Recognizes bottle and opens mouth for nipple (anticipates feeding with excitement)	Laughs out loud increasing inflection No tongue thrust
6 months	Bears full weight on legs if held standing Sits alone with minimal support Pivots in prone Rolls easily both ways Anterior proppers	Reaches for toy  Palmar grasp of cube  Lifts cup by handle Plays with toes	Displeasure at removal of toy  Puts toy in mouth if sitting	Shy with strangers  Imitates cough and protrusion of tongue Smiles at mirror image

(continued)

**Table 1.3** (continued)

Age	Gross motor	Fine motor	Personal/social	Echoes two or more words
7 months	Bears weight on one hand prone Held standing, bounces  Sit on hard surface leaning on hands		Stretches arms to be taken  Keeps mouth closed if offered more food than wants Smiles and pats at mirror	Murmurs “mom” especially if crying Babbles easily (M’s, D’s, B’s, L’s) Lateralizes sound
9 months	Sits steadily for 15 min on hard surface Reciprocally crawls Forward parachute	Picks up small objects with index finger and thumb (Pincer grasp)	Feeds cracker neatly  Drinks from cup with help	Listens to conversation Shouts for attention Reacts to “strangers”
10 months	Pulls to stand  Sits erect and steadily (indefinitely) Sitting to prone Standing: collapses and creeps on hands and knees easily Prone to sitting easily Cruises – laterally Squats and stoops – does not recover to standing position	Pokes with index finger, prefers small to large objects	Nursery games (i.e., pat-a-cake), picks up dropped bottle, waves bye-bye	Will play peek-a-boo and pat-a-cake to verbal command Says Mama, Dada appropriately, finds the hidden toy (onset of visual memory)
12 months	Sitting; pivots to pick up object Walks, hands at shoulder height Bears weight alone easily momentarily	Easy pinch grasp with arm off table Independent release (ex: cube into cup) Shows preference for one hand	Finds hidden toy under cup  Cooperates with dressing  Drinks from cup with two hands Marks with crayon on paper Insists on feeding self	One other word (noun) besides Mama, Dada (e.g., hi, bye, cookie)
13 months	Walks with one hand	Mouthing very little  Explores objects with fingers Unwraps small cube Imitates pellet bottle	Helps with dressing  Offers toy to mirror image  Gives toy to examiner Holds cup to drink, tilting head Affectionate Points with index finger Plays with washcloth, bathing Finger-feeds well, but throws dishes on floor Appetite decreases	Three words besides Mama, Dada Larger receptive language than expressive
14 months	Few steps without support	Deliberately picks up two small blocks in one hand Peg out and in Opens small square box	Should be off bottle  Puts toy in container if asked Throws and plays ball	Three to four words expressively minimum

**Table 1.3** (continued)

Age	Gross motor	Fine motor	Personal/social	Echoes two or more words
15 months	<p>Creeps up stairs</p> <p>Kneels without support</p> <p>Gets to standing without support</p> <p>Stoop and recover</p> <p>Cannot stop on round corners suddenly</p> <p>Collapses and catches self</p>	<p>Tower of two cubes</p> <p>“Helps” turn pages of book</p> <p>Scribbles in imitation</p> <p>Completes round peg board with urging</p>	<p>Feeds self fully leaving dishes on tray</p> <p>Uses spoon turning upside down, spills much</p> <p>Tilts cup to drink, spilling some</p> <p>Helps pull clothes off</p> <p>Pats at picture in book</p>	<p>Four to six words</p> <p>Jargoning</p> <p>Points consistently to indicate wants</p>
18 months	<p>Runs stiffly</p> <p>Rarely falls when walking</p> <p>Walks upstairs (one hand held-one step at a time)</p> <p>Climbs easily</p> <p>Walks, pulling toy or carrying doll</p> <p>Throws ball without falling</p> <p>Knee flexion seen in gait</p>	<p>Tower of three to four cubes</p> <p>Turns pages two to three at a time</p> <p>Scribbles spontaneously</p> <p>Completes round peg board easily</p>	<p>Uses spoon without rotation but still spills</p> <p>May indicate wet pants</p> <p>Mugs doll</p> <p>Likes to take off shoes and socks</p> <p>Knows one body part</p> <p>Very negative oppositions</p>	<p>One-step commands, 10–15 words</p> <p>Knows “hello” and “thank you”</p> <p>More complex “jargon” rag</p> <p>Attention span 1 min</p> <p>Points to one picture</p>
21 months	<p>Runs well, falling some times</p> <p>Walks downstairs with one hand held, one step at a time</p> <p>Kicks large ball with demonstration</p> <p>Squats in play</p> <p>Walks upstairs alternating feet with rail held</p>	<p>Tower of five to six cubes</p> <p>Opens and closes small square box</p> <p>Completes square peg board</p>	<p>May briefly resist bathing</p> <p>Pulls person to show something</p> <p>Handles cup well</p> <p>Removes some clothing purposefully</p> <p>Asks for food and drink</p> <p>Communicates toilet needs</p> <p>Helps with simple household tasks</p> <p>Knows three body parts</p>	<p>Knows 15–20 words and combines 2–3 words</p> <p>Echoes two or more</p> <p>Knows own name</p> <p>Follows associate commands</p>
24 months	<p>Rarely falls when running</p> <p>Walks up and down stairs alone one step at a time</p> <p>Kicks large ball without demonstration</p> <p>Claps hands</p> <p>Overthrow hand</p>	<p>Tower of six to seven cubes</p> <p>Turns book pages singly</p> <p>Turns door knob</p> <p>Unscrews lid</p> <p>Replaces all cubes in small box</p> <p>Holds glass securely with one hand</p>	<p>Uses spoon, spilling little</p> <p>Dry at night</p> <p>Puts on simple garment</p> <p>Parallel play</p> <p>Assists bathing</p> <p>Likes to wash and dry hands</p> <p>Plays with food+ body parts</p> <p>Tower of 8</p> <p>Helps put things away</p>	<p>Attention span 2 min</p> <p>Jargon discarded</p> <p>Sentences of two to three words</p> <p>Knows 50 words</p> <p>Can follow two-step commands</p> <p>Refers to self by name</p> <p>Understands and asks for “more”</p> <p>Asks for food by name</p> <p>Inappropriately uses personal pronouns (e.g., me want)</p> <p>Identifies three pictures</p>

(continued)



**Table 1.3** (continued)

Age	Gross motor	Fine motor	Personal/social	Echoes two or more words
3–5 years	Pedals tricycle Walks up stairs alternating feet Tip toe Jump with both feet	Copies circles Uses overhand throw	Group play Can take turns	Uses three-word sentences
5–12 years	Activities of daily living	Printing and cursive writing	Group sports	Reads and understands content Spells words

(Wallace, D. & Disabato, J. Adapted from Children’s Rehabilitative Services, 2007)

movement can be observed and cranial nerves assessed. Stimulation of selected reflexes, like the Moro reflex, and eye exam are reserved for last, since they usually elicit vigorous crying. The typical cry of an infant is usually loud and angry. Abnormal cries can be weak, shrill, high-pitched, or cat-like. Crying usually peaks at 6 weeks of age, when healthy infants cry up to 3 h/day, and then decreases to 1 h or less by 3 months (Freedman et al. 2009). The ability to console, including the sucking response, can be evaluated whenever the neonate is agitated. The sequence of the examination can always be altered in accordance with the newborn’s state or situation. Excessive stimulation or cooling may cause apnea or bradycardia in the preterm neonate, and components of the exam may need to be postponed until the neonate is stabilized.

## 1.2.2 Infant

### 1.2.2.1 Physical Appearance

Infancy is defined as 30 days to 12 months of age. An infant’s head grows at an average rate of 1 cm per month over the first year. Palpation of the head should reveal soft and sunken fontanels when quiet and in the upright position. A bulging fontanel in a quiet infant can be a reliable indicator of increased intracranial pressure. However, vigorous crying of an infant can cause transient bulging of the fontanel. The posterior fontanels will close by 1–2 months of age with wider variability in the anterior fontanel, often closing between 6 and 18 months of age. If the sutures

close prematurely, and skull shape becomes abnormal, evaluate for craniosynostosis. Delayed closure of the sutures may indicate increased intracranial pressure or hydrocephalus, warranting further evaluation. Inspection of the scalp should include observation of the venous pattern, because increased ICP and thrombosis of the superior sagittal sinus can produce marked venous distention (Dlamini et al. 2010).

Observation of the spine should include an examination for lumps, bumps, dimples, midline hemangiomas, and tufts of hair. Examination of rectal tone for an anal wink should be performed, especially when suspicion is present for a spinal dysraphism. Absence of an anal wink is noted when the anal sphincter does not contract when stimulated or there is a lack of contraction of the anal sphincter during the rectal examination. Identification of a sensory level of function in an infant with a spinal abnormality can be very difficult. If decreased movement of extremities is noted, observe the lower extremities for differences in color, temperature, or perspiration, with the area below the level of spinal abnormality usually noted to be cooler to touch and without perspiration (McGee and Burkett 2000).

### 1.2.2.2 Functional Capabilities

Assessment of the infant’s function requires knowledge of normal developmental landmarks.

### 1.2.2.3 Vulnerabilities

When typical ages for maturation of selected milestones are not reached and/or primitive reflexes persist beyond their expected disappear-

ance, neurological problems may be implicated. Most primitive reflexes such as the Moro reflex have disappeared by the age of 4–6 months, with reflexes of sucking, rooting during sleep, and placing responses lingering until later in infancy. Specifically if there is persistent rigid extension or flexion of the extremities, opisthotonos positioning (hyperextension of the neck with stiffness and extended arms and legs), scissoring of the legs, persistent low tone of all or selected extremities, asymmetry of movement or reflexes, and asymmetrical head rotation to one side, these behaviors alone can suggest central nervous system disease or insult during this rapid period of growth and development (Hobdell 2001).

#### **1.2.2.4 Tips in Approach to Child/Family**

A comprehensive review of the infant's developmental milestones, activity level, and personality is critical when obtaining a history from the parent. Pictures of the infant at birth, home videos, and baby book recordings may trigger additional input to supplement the history. Approach to the physical exam in early infancy (before infant sits alone) at 4–6 months differs from the older infant. During early infancy, they can be placed on the examining table assessing for positioning abilities in prone and supine. Reflexes can be elicited as extremities are examined. The onset of stranger anxiety at 6–8 months of age presents new challenges and can result in clinging and crying behaviors for the infant. Reducing separations from the parent by completing most of the exam on the parent's lap can diminish these responses. This is a time to gain cooperation with distraction, bright objects, smiling faces, and soft voices (Schultz and Hockenberry 2011). Use of picture books between infant and parent can provide an environment to demonstrate language abilities. The assessment should proceed from the least to the most painful or intrusive to maximize the infant's cooperation and is often performed in a toe to head fashion. Evaluation of muscle strength, tone, and cerebellar function should precede the cranial nerve examination with palpation, auscultation, and measurement of the head reserved for last.

### **1.2.3 Toddler**

#### **1.2.3.1 Physical Appearance**

During the toddler years of ages 1–3, brain growth continues at a more gradual rate. Head growth measurements for boys average 2.5 cm and girls slightly less with a 2-cm increase. From age 24 to 36 months, boys and girls both slow to only 1 centimeter per year. The toddler's head size is only one-quarter the total body length. The toddler walks with a wide-based gait at first, knees bent as feet strike the floor flat. After several months of practice, the center of gravity shifts back and trunk stability increases, while knees extend and arms swing at the sides for balance. Improvements in balance and agility emerge with mastery of skills such as running and stair climbing. Inspection of the toddler head and spine are aimed at recognition of subtle neurological abnormalities like new onset torticollis, abnormal gait patterns, and loss of previously achieved milestones.

#### **1.2.3.2 Functional Capabilities**

Cortical development is 75 % complete by the age of 2 years; therefore, the neurological response of the child over 2 years old is similar to that of the adult. Most toddlers are walking by the first year, though some do not walk until 15 months. Assessment of language close to the age of 3 is the first true opportunity for a cognitive assessment.

#### **1.2.3.3 Vulnerabilities**

Greater mobility of the toddler gives them access to more and more objects, and, as exploration increases, this makes them more at risk for injury. Physical limits on their explorations become less effective; words become increasingly important for behavior control as well as cognition. Delayed language acquisition can be identified at this age and may represent developmental issues previously unrecognized. If language delay is suspected, then a referral to speech therapy for a formal evaluation should be initiated by 9–15 months of age.

### 1.2.3.4 Tips in Approach to Child/Family

The neurological exam is approached systematically beginning with an assessment of mental/emotional status and following with evaluation of cranial nerves, motor and sensory responses and reflexes. Much of the neurologic examination can be completed by careful observation before ever laying hands on the child. Watch as the child plays and interacts with his environment. Interactive games such as peek-a-boo and reaching for toys and turning to the sound of the bell can make the examination fun and less traumatic. The toddler may interact better on the parent's lap or floor of the exam room. Initially, minimal physical contact is urged. Later inspection of the body areas through play with "counting toes" and "tickling fingers" can enhance the outcomes of the exam. Exam equipment should be introduced slowly and inspection of equipment permitted. Auscultate and palpate the head when quiet. Traumatic procedures such as head measurements should be performed last. Critical portions of the exam may require patient cooperation, and consideration should be given to completing those components first (e.g., walking and stooping abilities).

## 1.2.4 Preschooler

### 1.2.4.1 Physical Appearance

This period is defined as ages 3–5 years. Visual acuity reaches 20/30 by age 3 and 20/20 by age 4. Handedness is usually established after age 3. If handedness is noted much earlier, spasticity or hemiparesis should be suspected. Note if the child is left-handed and if there is familial history of left-handedness. Bowel and bladder control emerge during this period. Daytime bladder control typically precedes bowel control and girls precede boys. Bed-wetting is normal up to age 4 years in girls and 5 years in boys (American Academy of Pediatrics 2011).

### 1.2.4.2 Functional Capabilities

Although the brain reaches 75 % of its adult size by the age of 2 years, cortical development is not complete until the age of 4 years. Refer to.

### 1.2.4.3 Vulnerabilities

Highly active children face increased risks of injury. Helmet and bike safety programs are essential ingredients to reducing such risks. Given the escalating language abilities of the preschooler, speech and language delays can be detected with a greater assurance than in the toddler period. Persistent bowel or bladder incontinence may indicate a neurogenic bladder that can be a sign of spine anomalies such as a tethered cord.

Preschoolers can control very little of their environment. When they lose their internal controls, tantrums result. Tantrums normally peak in prevalence between 2 and 4 years of age. Tantrums that last more than 15 min, or if they are regularly occurring more than three times a day, may reflect underlying medical, emotional, or social problems as well as expressive language delay.

### 1.2.4.4 Tips in Approach to Child/Family

To maximize the preschooler's cooperation during the neurological assessment, many approaches can be offered. The presence of a reassuring parent can be more comforting to a preschooler than words. The older preschooler may be willing to stand or sit on the exam table, while the younger preschooler may be content to remain in the parent's lap. If the preschooler is cooperative, the exam can proceed from head to toe; if uncooperative, the approach should be as for the toddler exam. Equipment can be offered for inspection and a brief demonstration of its use. Fabricating a story about components of the assessment, such as "I'm checking the color of your eyes" can maximize the child's cooperation or making games out of selected portions. Using positive statements that expect cooperation can also be helpful (e.g., "I know you can open your mouth" or "Show me your pretty teeth").

## 1.2.5 School-Age Child

### 1.2.5.1 Physical Appearance

This is the phase of the middle childhood years aged 5–12. The head grows only 2–3 cm throughout the entire phase. This is a reflection of slower brain growth with myelination complete by 7 years of age (Amidei et al. 2010). Muscular

strength, coordination, and endurance progressively increase throughout this growth period. School children's skills at performing physical challenges like dribbling soccer balls and playing a musical instrument become more refined with age and practice.

### 1.2.5.2 Functional Capabilities

School-aged children are able to take care of their own immediate needs and are generally proficient in the activities of daily living. Motor skills are continuing to be refined. Children at this age participate in extracurricular and competitive activities outside of school in arenas such as academic clubs, sports, art, and music, and a history of socialization should be obtained. Their world is expanding, and accomplishments progress at an individual pace.

School makes increasing cognitive demands. Mastery of the elementary curriculum requires that a large number of perceptual, cognitive, and language processes work efficiently. By 3rd grade, children need to be able to sustain attention through a 45-min period. The goal of reading becomes not only sounding out the words but also understanding the content, and the goal of writing is no longer spelling but composition. By the 3rd or 4th grade, the curriculum requires that children use these fundamentals to learn increasingly complex materials. If this critical leap in educational capabilities is not made, then what appear as subtle deficits in academic performance in 3rd or 4th grade can translate into insurmountable academic challenges in 5th and 6th grade. Recognition and early intervention can minimize deficits and increase self-esteem.

### 1.2.5.3 Vulnerabilities

The most significant vulnerabilities of children this age are injury. They are now mobile, in neighborhoods, playing without constant supervision. Children with physical disabilities may face special stresses because of their visible differences. However, children with silent handicaps (e.g., traumatic brain injury, seizure disorders, hearing deficit) may experience acute and daily stressors, leading to difficulties in peer relationships and school performance.

### 1.2.5.4 Tips in Approach to Child/Family

For the neurological exam of school-age children, they usually prefer sitting and are cooperative in most positions. Most children this age still prefer a parent's presence. The assessment usually can proceed in a head to toe direction. Explaining the purpose of the equipment and significance of the procedure, such as the fundoscopic exam, can further reduce anxiety and maximize consistent findings. The use of stories to prepare them for parts of the exam or a procedure increases their awareness of what to expect and is also helpful in decreasing anxiety.

## 1.2.6 Adolescent

### 1.2.6.1 Physical Appearance

Adolescence is generally considered the time when children undergo rapid changes in body size, shape, physiology, and psychological and social functioning. For both sexes, acceleration in stature begins in early adolescence, but peak growth velocities are not reached until middle adolescence. Boys typically peak 2–3 years later than girls and continue their growth in height for 2 or 3 years after girls have stopped. The development of secondary sex characteristics is usually classified by Tanner's stages of sexual maturity (or sexual maturity ratings) that defines sequential changes in pubic hair, breast changes, and testicular and penile growth (National Institute of Child Health and Human Development 2012).

### 1.2.6.2 Functional Capabilities

Motor skills are refined into an adult pattern. Functional development of this age group is marked by pubertal changes that can affect self-esteem. They are able to construct a reasonable evaluation of consequences for risk-taking behaviors.

### 1.2.6.3 Vulnerabilities

Adolescents are vulnerable to traumatic brain and spinal cord injuries due to frequent engagement in risk-taking behaviors. Injury prevention programs are geared to reduce teens'

participation in risk-taking behaviors like drinking and driving, but knowledge does not consistently control behavior. As an age group, adolescents sustain the highest number of traumatic brain injuries from motor vehicle collisions due to factors including inexperience, distractions from cell phones and texting, peer pressure, unbelted passengers and failure to wear seatbelts. The growth of competitive sports has also contributed to increasing injuries. Teenagers are also vulnerable to the onset of a seizure disorder in the presence of a previously known or unknown low seizure threshold compounded by major hormonal changes that occur during this developmental phase. Adolescents who suffer from chronic neurological disorders face the additional challenge of transitioning from pediatric to adult care settings and providers, which is the topic of a later chapter in this text.

#### 1.2.6.4 Tips in Approach to Child/Family

The assessment of an adolescent can proceed in the same position and sequence as for a school-aged child. Offering the option of a parent's presence is important when developmentally appropriate. If the parent is interviewed alone, it should be done first before the interview with the child to avoid undermining the adolescent's trust. This is also the time to introduce the adolescent to taking ownership for their health care by encouraging them to start making their own appointments, learning how to refill their own prescriptions, and writing down their health questions. For many neurosurgical conditions, the teenager may be anxious about the outcome of the assessment and will want the parent(s) present. It remains important to continue to respect the need for privacy during the spine assessment, along with ongoing explanations of the findings.

### 1.2.7 Developmental Assessment Tools

With the diagnosis of a neurosurgical condition, comes the awareness of potential or realized developmental delays. A comprehensive approach to assessment with a family history, developmen-

tal observations, comprehensive neurological assessment, and developmental screening is indicated. Selected screening tools can aid in identification of developmental disorders defined by prevalence.

In their recommendations for selecting tools, Drotar and colleagues include a useful table that outlines the purpose, population, type of screening instrument, and whether the tool is administered by the practitioner or reported by the parent for each of the following tools: Parents Evaluation of Developmental Status (PEDS), Ages and Stages Questionnaire (ASQ), Bayley Infant Neurodevelopmental Screens (BINS), Cognitive Adaptive Test 1 Clinical Linguistic Auditory Milestone Scale and Expressive Language Scale (CAT, CLAMS, Capute Scales), Language Development Survey (LDS), and the Modified Checklist for Autism in Toddlers (M-CHAT) (Drotar et al. 2008, p. 55). This table is a useful reference for identifying the most appropriate screening tool for identifying a developmental delay in a young child, so that referral can be made for further evaluation by a specialist, and early intervention can occur.

The goal of a comprehensive developmental approach in the hospital or outpatient setting is to determine the most appropriate developmentally based neurosurgical care for the patient. Treatment for identified needs can be better directed toward the developmental age of the child that if different from the chronological age, will impact the assessment and patient care of the child. This developmental information can guide the nurse in planning for the child's home care, including targeted resources such as early intervention services, adapted educational plans, and rehabilitation and therapy services.

## 1.3 Hands-on Neurological Assessment

The importance of a well-documented neurological assessment on a child with a neurological diagnosis cannot be understated. Repeated observations over time can give the nurse information regarding a child's level of neurological irritabil-

ity, motor function, and changes in intracranial pressure. A systematic approach is essential. Repeating the assessment in the same order each time avoids the pitfall of missed information. Bedside assessment should be done when changing caregivers to give the nurse a framework on which to base her description of changes in the assessment (Haymore 2004). The order of the pediatric neurological assessment is generally:

- Appearance and observation
- Level of consciousness
- Cranial nerve assessment (appropriate to the setting)
- Vital signs
- Motor sensory function
- Assessment of reflexes
- Gait and balance
- Assessment of external monitoring apparatus

### 1.3.1 Appearance and Observation

#### 1.3.1.1 Head Size, Shape, and Fontanel

Accurate measurement of occipital-frontal circumference (OFC) reported in centimeters is vital. If the child is unconscious, careful placement of the tape while the patient is supine is important. In children under the age of two with a normally shaped skull, this measurement is taken just above the eyes and over the occipital ridge. Growth charts with OFC norms for age and some genetic syndromes (e.g., trisomy 21) should be used in less acute settings. The widespread use of the electronic medical record (EMR) has made viewing measurements over time significantly easier, regardless of the setting.

Palpation of the scalp is done to look for any alteration in skin integrity and abnormal ridging or splitting of the sutures. In the injured child, care should be taken to both visually examine and palpate the entire scalp for the presence of skin lacerations and/or subgaleal blood or fluid collections that contribute to skin breakdown. In children with thick hair, adequate light and assistance with alignment while moving the child is important. Pressure sores can develop in the posterior scalp over the occipital protuberance, from swelling and prolonged dependent position of the scalp.

Microcephaly is the term used to describe infants whose head does not grow secondary to lack of brain growth. Causes include acquired factors occurring during pregnancy (intrauterine infection, radiation exposure, alcohol, or drug teratogenic effects) and familial syndromes such as familial microcephaly, which is an autosomal recessive disorder. The definition is a head circumference that falls more than 2 standard deviations below the mean for age and sex, when compared with other growth parameters (Nellhaus 1968). The head appears disproportionately small and many of these children have significant neurological disabilities including mental retardation and seizures among others.

Megalencephaly or macrocephaly refers to an unusually large head and skull with a circumference that is greater than 2 standard deviations above the mean for age and sex. There are many causes for this including hydrocephalus, expanding cysts or tumors, endocrine disorders, congenital syndromes, or chromosomal abnormalities. Asymptomatic familial megalencephaly is when the head is large but follows the shape of the growth curve, appears to be genetically determined, and does not result in increased intracranial pressure or other neurological or developmental problems (Purugganan 2006).

### 1.3.2 Level of Consciousness: Level of Arousal and Content of Response

The assessment of level of consciousness is the most important task that the nurse will perform as part of the overall patient assessment. Level of consciousness (LOC) is described in terms specific to both level of arousal and content of response. The primary goal is to identify changes that may indicate deterioration, so that early intervention can prevent further complications that diminish the patient's recovery of function. Most institutions use a standardized tool for serial assessments of level of consciousness. Although adapted from adult versions of tools, early versions were initially used to assess and prognosticate for children who had sustained a traumatic

**Table 1.4** Modified Glasgow Coma Scale for infants and children

Activity	Score	Infant/non-verbal child (<2 years)	Verbal child/adult (>2 years)	
Eye opening	4	Spontaneous	Spontaneous	
	3	To speech	To verbal stimuli	
	2	To pain only	To pain only	
	1	No response	No response	
Motor response	6	Normal/spontaneous movement	Obeys commands	
	5	Withdraws to touch	Localizes pain	
	4	Withdraws to pain	Flexion withdrawal	
	3	Abnormal flexion (decorticate)	Abnormal flexion	
	2	Extension (decerebrate)	Extension (decerebrate)	
	1	No response	No response	
			2–5 years	>5 years
Verbal response	5	Cries appropriately, coos	Appropriate words	Oriented
	4	Irritable crying	Inappropriate words	Confused
	3	Inappropriate screaming/crying	Screams	Inappropriate
	2	Grunts	Grunts	Incomprehensible
	1	No response	No response	No response

Obtained from Marcoux (2005)

Coma scoring system appropriate for pediatric patients

brain injury. However, the use of a standardized tool quickly gained acceptance, and began to be used to assess LOC for all hospitalized children with a neurological alteration, and is commonly referred to as a “neuro check.” The frequency of neuro checks will depend on the neurological problem, patient acuity, and potential for deterioration and is ordered by the managing physician or other provider team member.

In pediatrics, the most commonly used tool is the Modified Glasgow Coma Scale for Infants and Children. See Table 1.4 for this commonly used scale (Marcoux 2005). There are many variants of this scale in use around the country, and newer scales are available as alternatives. These include the Glasgow-Pittsburgh Coma Scale (GCS-P), which has been shown to have similar prognostic accuracy rates when compared to the modified GCS in very small samples (He et al. 2008). Another scale gaining use is the **FOUR – Full Outline of Unresponsiveness** score created and published by Wijdicks and colleagues at the Mayo clinic (Wijdicks et al. 2005). This scoring system was validated in pediatrics with interrater reliability slightly greater than that of the GCS, in the prediction of poor outcomes and morbidity (Cohen 2009) (Fig. 1.2).

Neuroanatomic correlates of consciousness specific to arousal are located in the reticular activating system of the brainstem, just above the midbrain. The assessment of consciousness is closely tied to the assessment of eye findings because of the anatomic proximity of the mid-brain to the nuclei of cranial nerves III, IV, and VI – which together control pupillary responses and extraocular eye movements (EOM). Anatomic correlates of the content of the response (once the child has been aroused) are located in the cerebral cortex. If a patient has an altered level of consciousness, the first step will be to assess arousal (Haymore 2004). The nurse should first attempt to arouse the child from sleep using the least amount of stimulation necessary to evoke a response from the child. Often, the first stimulus is the turning on of a light over the child, followed by auditory stimuli like saying the child’s name, and finally tactile, by touching the child. Each of these should be applied in increasing levels of intensity with a dim light, soft voice, and gentle touch first, followed by a brighter light, louder voice, and firmer tactile stimulation. In cases where this level of stimulus does not cause arousal, noxious stimuli, which

**Fig. 1.2** The FOUR score instructional card (Full Outline of Unresponsiveness) coma scale (Wijdicks et al. 2005)

Eye response (E)
E4 Eyelids open or opened, tracking, or blinking to command
E3 Eyelids open but not tracking
E2 Eyelids closed, open to loud voice, not tracking
E1 Eyelids closed, open to pain, not tracking
E0 Eyelids remain closed with pain
Motor response (M)
M4 Thumbs up, fist, or peace sign to command
M3 Localizing to pain
M2 Flexion response to pain
M1 Exterior posturing
M0 No response to pain or generalized myoclonus status epilepticus
Brain stem reflexes (B)
B4 Pupil and corneal reflexes present
B3 One pupil wide and fixed
B2 Pupil <i>or</i> corneal reflexes absent
B1 Pupil <i>and</i> corneal reflexes absent
B0 Absent pupil, corneal, and cough reflex
Respiration (R)
R4 Not intubated, regular breathing pattern
R3 Not intubated, Cheyne-Stokes breathing pattern
R2 Not intubated, irregular breathing pattern
R1 Breathes above ventilator rate
R0 Breathes at ventilator rate or apnea

would be considered painful to a child who is fully aware, are used.

Noxious stimuli should be forceful, yet not injure the child. Central stimulus should be

applied before peripheral stimulus. Three commonly used central stimuli are the trapezius squeeze, mandibular pressure, and sternal rub. The sternal rub is the most common central



stimulus used in pediatrics. A single-fisted hand is used with the knuckles lightly applied to the child's sternum. Pressure should be for a minimum of 15 s or until a response is obtained, and no longer than 30 s. A response to central stimulus indicates that the movement is a result of a cortical response rather than a spinal or reflex response. If there is no response to central stimulus or the response indicates asymmetry of motor movements, peripheral stimulus to the affected limbs should be applied; for example, place a pencil between two fingers and squeeze the fingers together (Cook and Woodward 2011).

With any stimulus in the less than fully conscious patient, observation of how the child responds is thought of in terms of either a generalized or localized response. A generalized response is one where the child shows general agitation or has increased overall body movement to the stimulus. A localized response is one where the child shows clear evidence of an awareness of where the stimulus is coming from (localizes it). This is evident because the child either reaches to the limb where the stimulus is applied or tries to pull the limb away from the examiner.

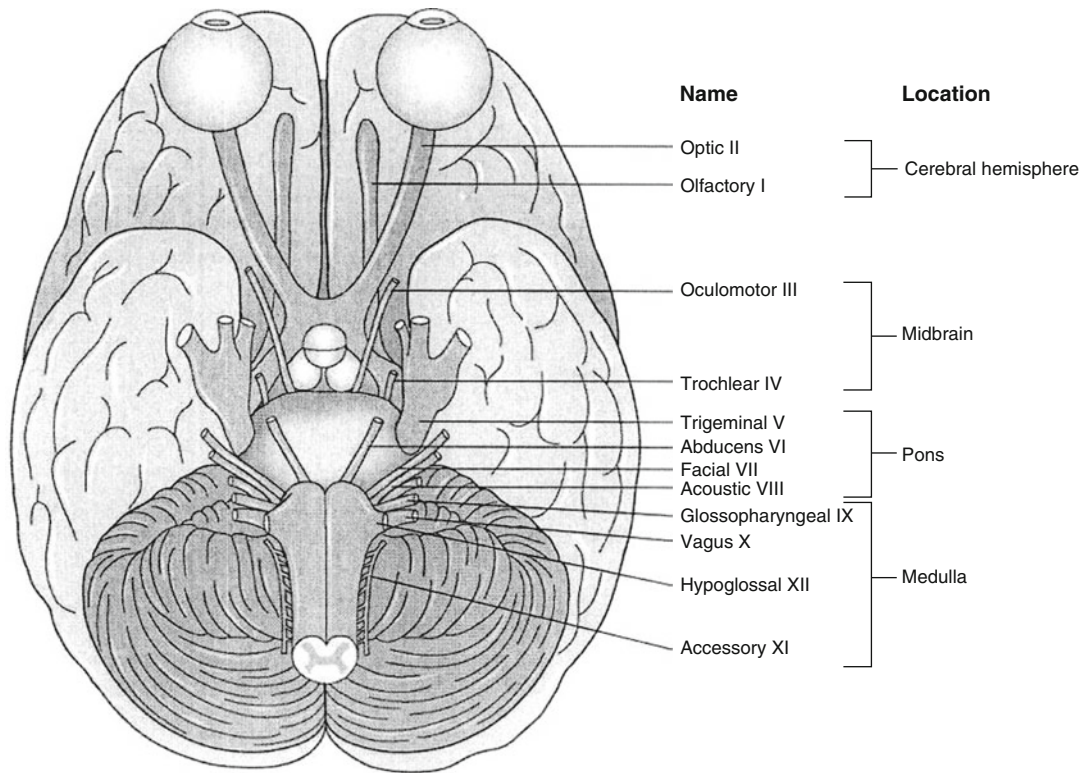
Once it has been determined that the child is arousable, the level or degree of response (content) to the stimulus is assessed. Determining whether a child is oriented to person, place, and time is more challenging because of developmental influences. The pediatric nurse is more likely to report that the child is oriented to the presence of known caregivers, favorite objects (toys or stuffed animals), and other developmentally appropriate stimuli. The ability to follow commands may rely more on the examiner's knowledge of what commands a certain age child would be likely to follow. This assessment distinguishes between simple and more complex commands. Examples of simple commands are "stick out your tongue" and "squeeze my hand." More complex commands involve 2 or 3 steps and require a higher level of processing. An example would be, "can you kiss your bear and give it to your mommy." Parents and others who know the child well are often helpful in assessing subtle changes in awareness.

With a fully awake child, in either the hospital or clinic setting, awareness is assessed by asking the child questions related to place and time, assessing memory by giving them 3 simple words to remember, and asking them to repeat them several minutes later. Children are more likely to be engaged if the examiner is utilizing current events, holidays or school routines, questions about pets, or other topics that are familiar to the child (Amidei et al. 2010).

### 1.3.3 Cranial Nerve Assessment: Brainstem Function

Cranial nerve assessment is an assessment of brainstem function, because nuclei of 10 of the 12 cranial nerves arise in the brainstem. The proximity of these nuclei to the reticular activating system (arousal center) located in the midbrain is the anatomic rationale for assessing cranial nerves in conjunction with level of consciousness. Important neurological functions and protective reflexes are mediated by the cranial nerves and many functions are dependent on more than one nerve. Some of the cranial nerves have both motor and sensory functions. See Fig. 1.3 for a diagram of the base of the brain illustrating the location of the 12 cranial nerves, and Table 1.5 for an overview of all 12 cranial nerves and their functions (Hadley 1994).

The two cranial nerves that do not arise in the brainstem are the olfactory nerve (CN I) and the optic nerve (CN II). The olfactory nerve is located in the medial frontal lobe and is responsible for the sense of smell. This can be difficult to assess in the younger child, so is often omitted unless there is specific concern that there has been damage by swelling or traumatic injury in that area. Taste may also be affected with injuries to CN I. The optic nerve (CN II) is assessed through testing of visual acuity. This may be done more formally with visual screening or more generally by noting if the child's can see objects placed in front of them. The approach to assessing visual acuity depends on



**Fig. 1.3** Diagram of base of the brain showing entrance and exits of the cranial nerves (Hickey 2009)

the setting where the person doing the examination is seeing the patient (American Academy of Pediatrics 1996).

The optic (CN II) and oculomotor (CN III) nerves and the sympathetic nervous system mediate pupillary size and constriction to direct light. Many factors can affect the pupillary response, including damage to the eye or cranial nerves, pressure on the upper brain stem, local and systemic effects of certain drugs, anoxia, and seizures. Pupil size varies with age and is determined by the amount of sympathetic input, which dilates the pupil and is balanced by the parasympathetic input to the oculomotor nerve, which constricts the pupil. Pupillary response in the eye that is being checked with direct light as well as the other pupil (consensual response) are significant in that they can point to where damage to nerves exists. This is an objective clinical sign that can be followed over time (Hickey 2009).

### 1.3.3.1 Visual Field Testing and Fundoscopic Examination

Visual field testing and examination of the optic nerve using an ophthalmoscope (fundoscopic exam) are not performed by the bedside or clinic nurse, but may be done at the bedside by physicians, or advanced practice nurses. In the outpatient setting, if the child is awake and able to cooperate, the examiner will position themselves about 2–3 ft in front of the patient and ask the child to fix their gaze directly in front (usually at the examiner's nose) while bringing a brightly colored object from the periphery (right, left, upper, and lower) into the central visual area. The child is asked to indicate verbally when they see the object entering into view, and this is compared with the timing of the examiner's visualization of the object to determine if there is a gross defect in the visual field. In the non-acute setting, formal visual field testing is done by a pediatric

**Table 1.5** Assessment of cranial nerves in the child

Cranial	Test for function
<i>I Olfactory (S)</i>	
Olfactory nerve, mucous membrane of nasal passages and turbinates	With eyes closed child is asked to identify familiar odors such as peanut butter, orange, and peppermint. Test each nostril separately
<i>II Optic (S)</i>	
Optic nerve, retinal rods, and cones	Check visual acuity, peripheral vision, color vision, perception of light in infants; fundoscopic examination for normal optic disk
<i>III Oculomotor (M)</i>	
Muscles of the eyes (superior rectus, inferior rectus, medial rectus, inferior oblique)	Have child follow an object or light with the eyes (EOM) while head remains stationary. Check symmetry of corneal light reflex. Check for nystagmus (direction elicited, vertical, horizontal, rotary). Check cover-uncover test.
Muscles of iris and ciliary body	Reaction of pupils so light, both direct and consensual, accommodation
Levator palpebral muscle	Check for symmetric movement of upper eyelids. Note ptosis
<i>IV Trochlear (M)</i>	
Muscles of eye (superior oblique)	Check the range of motion of the eyes downward (EOM). Check for nystagmus
<i>V Trigeminal (M, S)</i>	
Muscles of mastication (M)	Palpate the child's jaws, jaw muscles, and temporal muscles for strength and symmetry. Ask child to move lower jaw from side to side against resistance of the examiner's hand
Sensory innervation of face (S)	Test child for sensation using a wisp of cotton, warm and cold water in test tubes, and a sharp object on the forehead, cheeks, and jaw. Check corneal reflex by touching a wisp of cotton to each cornea. The normal response is blink
<i>VI Abducens (M)</i>	
Muscles of eye (lateral rectus)	Have child look to each side (EOM)
<i>VII Facial (M, S)</i>	
Muscles for facial expression	Have child make faces: look at the ceiling, frown, wrinkle forehead, blow out cheeks, smile. Check for strength, asymmetry, paralysis
Sense of taste on anterior two-thirds of tongue. Sensation of external ear canal, lachrymal, submaxillary, and sublingual glands	Have a child identify salt, sugar, bitter (flavoring extract), and sour substances by placing substance on anterior sides of tongue. Keep tongue out until substance is identified. Rinse mouth between substances
<i>VIII Acoustic (S)</i>	
Equilibrium (vestibular nerve)	Note equilibrium or presence of vertigo (Romberg sign)
Auditory acuity (cochlear nerve)	Test hearing. Use a tuning fork for the Weber and Rinne tests. Test by whispering and use of a watch
<i>IX Glossopharyngeal (M, S)</i>	
Pharynx, tongue (M)	Check elevation of palate with "ah" or crying. Check for movement and symmetry. Stimulate posterior pharynx for gag reflex
Sense of taste on posterior third of the tongue	Test sense of taste on posterior portion of tongue
<i>X Vagus (M, S)</i>	
Mucous membrane of pharynx, larynx, bronchi, lungs, heart, esophagus, stomach, and kidneys	
Posterior surface of external ear and external auditory meatus	Note same as for glossopharyngeal. Note any hoarseness or stridor. Check uvula for midline position and movement with phonation. Stimulate uvula on each side with tongue depressor – should rise and deviate to stimulated side. Check gag reflex. Observe ability to swallow

**Table 1.5** (continued)

Cranial	Test for function
<i>XI Accessory (M)</i>	
Sternocleidomastoid and upper trapezius muscles	Have child shrug shoulders against mild resistance. Have child turn head to one side against resistance of examiner's hand. Repeat on the other side. Inspect and palpate muscle strength, symmetry for both maneuvers
<i>XII Hypoglossal (M)</i>	
Muscle of tongue	Have child move the tongue in all directions, then stick out tongue as far as possible: check for tremors or deviations. Test strength by having child push tongue against inside cheek against resistance on outer cheek. Note strength, movement, symmetry

Obtained from Hadley (1994)

*S* Sensory, *M* motor, *EOM* extraocular movement

ophthalmologist and generates a computerized report showing whether the visual field is full or has areas where vision is absent. This baseline determination is required in patients undergoing surgical resection of a lesion, and in particular epilepsy surgery, where cortical resection in the area of the temporal lobe often is proximate to, or overlaps with, the optic nerves as they project from the retina in a posterior fashion to the occipital lobe (Asato et al. 2011). It is also done prior to other surgeries around the optic pathway, so that a baseline assessment can be compared to repeat exams done after surgical intervention.

Fundoscopic examination in the acute setting is utilized to look for evidence of papilledema and/or retinal hemorrhages. The former is a sign of increased intracranial pressure (IICP), generally of a gradual and long-standing nature. The latter is a sign of traumatic injury to the retina as a result of infant shaking in cases of non-accidental trauma or child abuse (Togioka et al. 2009).

Extraocular eye movements (EOMs) are mediated by three cranial nerves (III, IV, and VI) as well as the medial longitudinal fasciculus tract of the midbrain and pons and the vestibular system. Eye movements are observed by using either a light, object (toy works well for younger children), or by having the child follow the examiner's finger. The primary descriptors used to describe EOM's are "intact" or "conjugate" if they are normal, indicating that the eyes move together, and "dysconjugate" when they do not move together. Fixed eye movements, a gaze preference (eyes seeming to fix on either a right or left gaze even if briefly tracking), or roving eye movements indicate damage to nerves and other

brain structures. Nystagmus is defined as involuntary back and forth or cyclical movements of the eyes. The movements may be rotatory, horizontal/lateral, or vertical and often most noticeable when the child gazes at objects in the periphery or that are moving by rapidly. Two to three "beats" of nystagmus in far lateral gaze is considered normal if it is an isolated finding. The presence of persistent nystagmus indicates structural lesions or changes in the brainstem, cerebellum, or vestibular system but can also be present as a result of drug intoxications, notably phenytoin (Schultz and Hockenberry 2011).

The motor component of the trigeminal nerve (CN V) innervates the chewing muscles. The sensory component of this nerve has three branches, each supplying sensation to the eye, face, and jaw. Trigeminal nerve function is evaluated in comatose patients when corneal sensation is tested with a wisp of cotton (referred to as the corneal reflex). A lack of response indicates pressure on or damage to CN V.

The facial nerve (CN VII) innervates the muscles of the face, as well as supplying the anterior two-thirds of the tongue with sensory input allowing for taste of sweet, sour, and salty foods. Looking for symmetry while asking the child to smile, frown, and make a face or "blow-up" their cheeks is the best way to test this nerve. Formal testing of taste is usually deferred in the acute care setting.

The acoustic nerve (CN VIII) is comprised of two divisions. The cochlear division innervates the inner ear and auditory function (hearing). The vestibular division is responsible for balance. A quick, albeit gross, method of testing hearing is

to hold a ticking watch or rubbing strands of hair together near the child's ear and ask if they can hear the sound and describe what it is they are hearing.

Three of the lower cranial nerves IX, X, and XII, glossopharyngeal, vagus, and hypoglossal, respectively, contribute to the function of swallowing and the ability to gag and cough which safeguards the integrity of the airway. Clinicians often refer to these nerves collectively in discussions of "lower cranial nerve dysfunction" as a whole rather than individually. These cranial nerves are especially important in pediatrics because the airway structures are less developed, and more at risk for dysfunction and slow recovery if damaged. Damage to these nerves results in impaired swallowing, a decrease in tongue mobility, and speech articulation problems. These problems lead to excessive drooling, frequent aspiration, and nutritional deficits related to poor oral intake. The usual method of assessing these three nerves is to observe for excessive drooling (indicating inability to swallow secretions), cough and gag with suctioning, and/or use a tongue blade to illicit the gag reflex.

The spinal accessory nerve (CN XI) innervates the sternocleidomastoid and trapezius muscles. It can only be tested in the child who is conscious. Having the child shrug their shoulders and push their head against the examiners hand in both directions is the easiest way to assess CN VI. To test a child in the supine position, have them raise their head off the bed and flex forward against the force of the examiners hand (Hadley 1994).

### 1.3.4 Assessment of Motor Function

Motor function is assessed in all children with neurosurgical diagnoses. Those with a depressed level of consciousness will be observed for the type and quality of movement that occurs to noxious stimuli. The nursing assessment of motor function over time will be integral to the determination of long-term outcome for the child. Motor movements that indicate more significant damage to the neurological system are called abnormal motor reflex posturing or pathological posturing

and are covered in greater detail in the chapter on Traumatic Brain Injury (Chap. 7) of this text.

In the child *without* a depressed level of consciousness, assessment of motor function involves observation of the patients' spontaneous movements, as well as responses to direct commands and tactile stimuli. Key things to observe are the presence of any asymmetries of movement or unusual postures of either the upper or lower extremities. Overall bulk of the muscles and tone is important, especially if there is any question of limb atrophy. In infants, testing of primitive reflexes like the Babinski, Moro, and grasp reflexes assist in the identification of any asymmetries.

Toddlers and preschool-age children respond to the examiner engaging them in play activities. Assessment of spontaneous motor function is done by observation after the child is given objects, toys, or other items to manipulate. Strategies include asking them to give a "high five" with both hands and having them push their feet against your hands. School-age children will enjoy games of strength and are easily encouraged to cooperate. In the ambulatory, clinic or school setting, having the child run after a tennis ball, climb onto an exam table, draw a picture or write their name, heel-and-toe walk, hop, skip, gallop, and/or walk a few stairs while observing is the best way to get an accurate functional motor assessment. Asking the child to hold both hands upright in front of their body for several seconds with their eyes closed will give the examiner the opportunity to look for a drifting down ("drift") of one extremity, which can indicate subtle weakness on one side that may not be noted when testing hand grasp strength (Lucille Packard Children's Hospital 2012).

### 1.3.5 Assessment of Sensory Function

Sensory function is usually assessed in conjunction with motor function. Certain populations of children with neurological abnormalities are more likely to undergo routine assessment of sensory function. These populations include those with spina bifida, spinal cord lesions or injuries as well as those with indwelling epidural analgesia for postoperative pain management.

The response to superficial tactile stimulation is the most common technique used to assess sensation. More complex testing involves using objects that are both sharp and/or dull to determine if the child can discriminate between them. Assessment of the child's ability to feel a vibration can be done with a tuning fork. Proprioception (awareness of the body in space) is tested by having the child identify flexion or extension of their toe while blocking their visualization of the motion ("Is your toe going up or down?").

Like motor function, any asymmetries of sensory function should be noted. In cases of brain or spinal cord injury or after spinal cord surgery, sensation may be asymmetric and should be documented as such. A baseline exam should be documented so accurate comparisons can be made. The accepted tool for documentation of the spinal level where sensation is felt is the dermatome chart, shown in Fig. 1.4 (Conn 1995). A nurse should identify the spinal level at which sensation is present by utilizing either a sharp object or crushed ice in a glove. The examiner first confirms the sensation of the chosen stimulus on a part of the body with normal sensation, then uses the stimulus on the affected area and asks the child to compare with what they have confirmed is "normal." Both anterior and posterior levels are pictured on the chart, which should be readily accessible to nurses who care for these patients. Dermatome levels are also routinely assessed and documented on children with epidural catheters in place to deliver regional analgesia for pain relief in the postoperative period (Pasero et al. 2008).

### 1.3.6 Assessment of Motor Reflexes

Both superficial and deep tendon reflexes (DTR) will be assessed as part of a comprehensive neurological exam. The bedside nurse may not be directly testing the reflexes but is often present during the exam. Superficial reflexes include the abdominal, cremasteric, and gluteal (anal wink) reflex. Deep tendon reflexes include tapping a reflex hammer on the respective tendons in the bicep, tricep, brachioradialis, patella, and Achilles. Deep tendon reflexes are usually the

following scoring system: 0=absent; +1=sluggish; +2=active; +3=hyperactive; +4=transient clonus; and +5=permanent clonus.

The Babinski reflex is a neurological sign elicited by stimulating the lateral aspect of the sole of the foot with a blunt point or fingernail. A positive response is when the toes fan and the great toe dorsiflexes (goes up). Usually the child can dorsiflex the foot and flex the knee and hip. A positive Babinski is normal in an infant and child up to about 18 months of age; around the time a child begins ambulating. After then, the response is considered abnormal and should be documented, and any asymmetry noted (Slota 1983b).

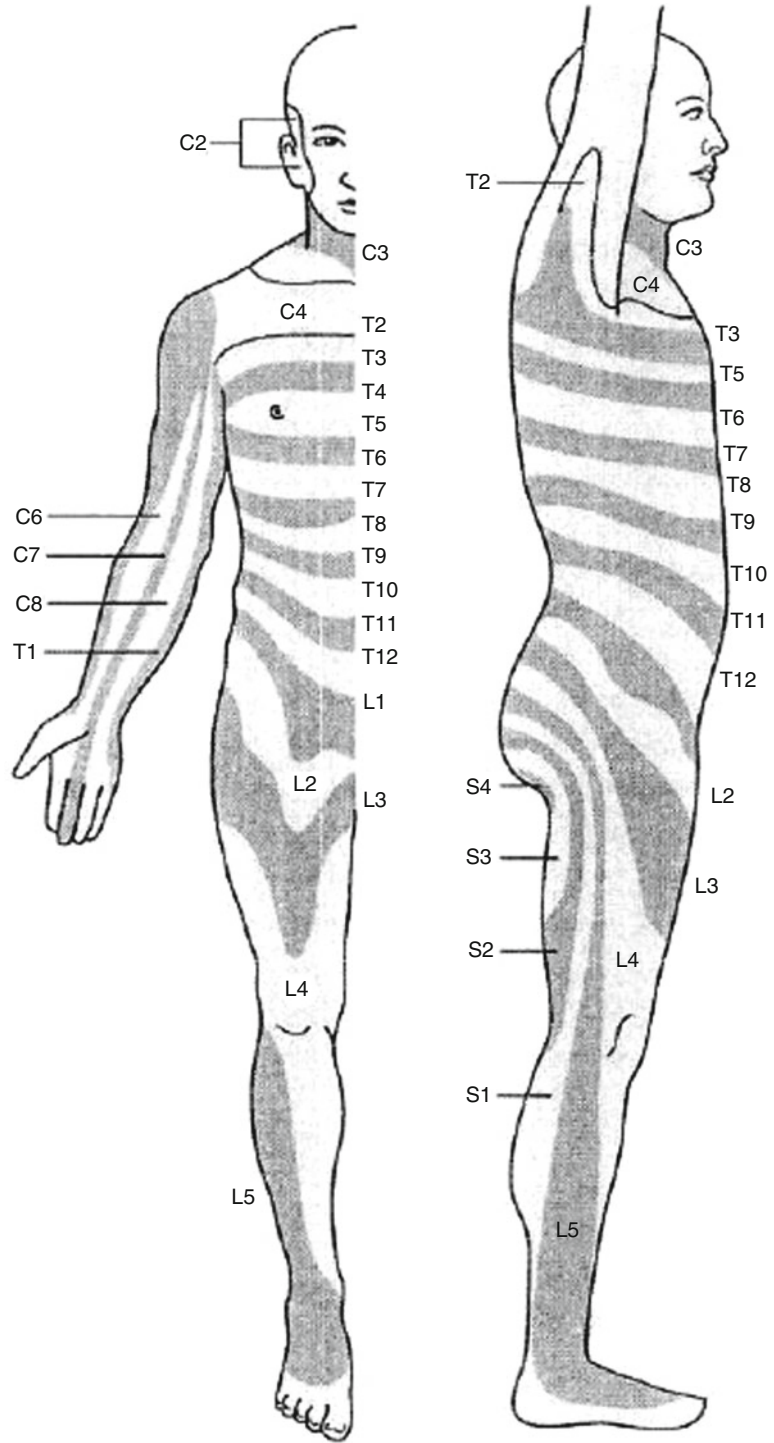
### 1.3.7 Assessment of Gait and Balance

Gait and balance are controlled in part by the cerebellum. Assessment of cerebellar function includes the ability to move limbs smoothly in space and the steadiness of the gait. The extent of the assessment of a child's gait and balance will depend on the ability of the child to cooperate with the assessment. Children who are seen in the acute care setting may be too critically ill or sedated to fully assess, although as the child awakes some simple tests can be done at the bedside for the child who will cooperate.

Ataxia is the term to describe a lack of muscular coordination and can be termed truncal, appendicular (relating to an appendage), or gait ataxia. It often occurs when voluntary muscle movements are attempted. Cerebellar lesions and drug intoxications can be etiologies of ataxia. Children may exhibit ataxia after a seizure in the postictal phase. Some children will exhibit ataxia as a result of a high serum level of an anticonvulsant (Caplin et al. 2009).

Asking the child to walk in their usual casual gait, both forward and backward, is an easy method to test for ataxia. Follow this with a request for the child to walk heel-to-toe on a straight line. A normal heel-toe walk requires the child to hold their arms out from their body to maintain balance. Standing balanced on one foot and then the other is also a way to challenge the child's balance. Children generally respond best

**Fig. 1.4** Dermatome chart used to localize level of spinal nerve function through assessment of cutaneous sensation (Conn 1995)



when these requests are made into a game, using counting techniques and encouragement, or doing the tests with the child.

Testing for appendicular ataxia can be done while seated by having the child touch their finger to your finger held about 12–18 in. in front of them and then touch their nose and go back and forth. This is often more appealing to the child when a stuffed animal is used as a prop. Ask the child to touch the nose several times while moving the animal. It is normal for the child to be slightly less coordinated in their nondominant hand, but movements should be smooth. A coarse tremor while doing this finger to nose testing is called *dysmetria*, which refers to the inability to control the range of a movement. Often the tremor will worsen when the child is near the target, which is referred to as an *intentional* tremor.

Ataxia may be more noticeable when a child is fatigued or late in the day, especially if the child is recovering from a neurological trauma. The same individual should conduct and document the assessment at the same time of the day, so as to not confound the exam findings and to more accurately assess progress in recovery.

### 1.3.8 Assessment of Vital Signs

Concepts related to IICP, including vital sign and fluid balance alterations are covered in greater detail in Chap. 7 of this text. A brief more general overview is contained here.

Neurological alterations can and often do affect vital signs, particularly in the acute care setting. Vital sign assessment is usually done in conjunction with neurological assessment so that the child is disturbed once and the information obtained can be evaluated as a whole to determine if changes in vital signs indicate pending deterioration. Fluid balance, intake, and output are also assessed at this time. Awareness of the relationships between neurological assessment findings, fluid balance, and vital signs in the post-operative neurosurgery patient is essential to avoiding an ominous slide from an alteration in level of consciousness to brainstem herniation and death (Marcoux 2005).

Changes in vital signs are a late sign of increased intracranial pressure (IICP) and require immediate response from the bedside nurse and medical team. Cushing's triad is a descriptor for a pattern of vital signs changes that includes a widening pulse pressure, bradycardia, and altered respiratory patterns including central hyperventilation. These three vital sign changes are seen in close proximity, or simultaneously, before the more ominous signs of pressure affecting the lower medulla, which manifest as a very deep coma evidenced by flaccid muscles, absent reflexes, and fixed and dilated pupils. At this point, vital signs display a low blood pressure, a low pulse, and spontaneous respirations cease. This is termed brainstem herniation and leads to brain death (Hickey 2009).

Temperature dysregulation in the form of hyperthermia occurs because of damage to or pressure around the hypothalamus where the regulation of body temperature occurs. Fever without accompanying signs of infection is often referred to as "central" fever, meaning that it has a neurological origin rather than an infectious cause. In the acutely ill child, it is important that all diagnostic testing (labs, imaging, and cultures including CSF) to rule out infectious causes of elevated temperature have been completed and results are known prior to assuming a fever in a neurosurgical patient is central in origin.

Fluid balance, in particular the signs and symptoms of the syndrome of inappropriate antidiuretic hormone (SIADH) and diabetes insipidus (DI), should be assessed and carefully documented in the acutely ill child with a neurological disorder. Frequent measurements of urine output via an indwelling catheter and labs including serum sodium and osmolality are essential to a determination of whether SIADH or DI is present. Factors such as the administration of diuretics, fluid restrictions imposed to decrease the risk of IICP, and trending of serum electrolyte and osmolality values should be considered when reviewing making a determination of the presence of one of these syndromes. Pressure on or damage to the anterior pituitary gland can lead to SIADH or DI and may have a significant impact on recovery and outcomes. Diabetes insipidus in particular can persist after recovery from acute illness and requires



lifelong treatment with synthetic vasopressin (Schultz and Hockenberry 2011).

### 1.3.9 Assessment of Brainstem Function in the Acute Care Setting: External Monitoring Apparatus, Herniation Syndromes, and Brainstem Reflexes

More detailed information on aspects of neurological assessment that are common in pediatric or neonatal critical care settings is included in chapter 7 on Traumatic Brain Injury. The information here is provided as a brief overview. Progression of brain insult without appropriate identification and treatment will continue to manifest down the brainstem affecting the cranial nerves in succession. As noted above, vital sign changes usually occur late in the cascade of acute progressive neurological deterioration. Assessment of brainstem function in the acute or critical care setting is accomplished with repeated systematic neurological examination and incorporates the use of equipment and technology including intracranial pressure (ICP) monitors, external ventricular drains (EVD), and cerebral perfusion monitors. Careful interpretation of data obtained from these devices is essential. Children with brain injuries, traumatic or otherwise, are at risk for brain herniation from the primary or secondary effects of their injury. In situations where herniation is suspected, clinical tests to determine brainstem function through the assessment of what are referred to as brainstem reflexes are useful for clinical decision making in regard to prognosis for survival.

#### 1.3.9.1 Assessment of External Monitoring Apparatus

The bedside nurse should assess equipment used for neurological monitoring at regular intervals. This is usually done in the same time interval as scheduled for vital signs and neurological assessments. Any concern regarding malfunction of or leakage around a monitoring device should be reported immediately, follow-

ing the specific institutional protocol so that patient safety is assured and risk for infection is minimized. Biomedical technicians should be available for routine equipment evaluation so that equipment is ready and in working order.

An important rule in dealing with equipment or any other technology is to always *look at the patient first*, rather than the machine, as the definitive answer in the interpretation of the findings and their meaning in regard to the patients' status. This is an important lesson as machines can malfunction. If something does not "make sense," the nurse should seek opinions from others and not always assume that the equipment is correct.

#### 1.3.9.2 Herniation

Displacement of brain structures resulting from increased intracranial pressure and compromised cerebral blood flow leads to herniation of brain tissue and an ominous sequence of neurological signs and symptoms. Herniation syndromes are categorized by supratentorial and infratentorial locations. Supratentorial herniation includes cingulate herniation, central herniation, and uncal herniation. These types of herniation syndromes result from expanding lesions in one hemisphere of the brain causing pressure medially, downward, or by displacement against the skull. Infratentorial herniation is from displacement of the cerebellar tonsils below the foramen magnum or in rare cases upward herniation of brain across the tentorium from an expanding lesion in the posterior fossa. Herniation can be reversed with early identification and treatment of the signs and symptoms of IICP but ends in brain death if the rapid progression of events is not halted.

#### 1.3.9.3 Brain Stem Reflexes

One commonly used test for determination of brainstem function in the unconscious child in a comatose state is the assessment of the oculocephalic reflex, which is also referred to as "doll's eyes." This maneuver can only be done if a patient is unconscious and is performed by holding the patient's eyelids open and briskly rotating the head laterally in one direction, then the other.

A normal response is conjugate eye deviation to the opposite side of the head position with return to midline. This is usually documented as “doll eye’s present.” An abnormal response is the eyes moving in the same direction as the head and/or dysconjugate movements and is documented as “doll eyes absent.” The latter indicates damage to the brainstem (Hickey 2009; Schultz and Hockenberry 2011).

Another commonly used test for brainstem function in the comatose child is the assessment of the oculovestibular reflex, referred to as iced-water calorics. This test assesses the function of the vestibular branch of cranial nerve X, the vagus nerve. The test involves irrigating each ear canal with iced water. The child’s head is elevated to about 30° and kept midline. Approximately 5 ml of ice water is drawn into a syringe and attached to a butterfly catheter with the needle cutoff. Another individual holds the child’s eyes open during the rapid injection of the water into the ear canal. A normal response is nystagmus to the opposite side of the ear being irrigated and then a return of the eyes to midline. There is no response in the patient who is brain-dead (Schultz and Hockenberry 2011).

Other brainstem reflexes include the corneal reflex which tests the sensory branch of the trigeminal nerve (CNV) through sensory stimulation of the cornea and the gag reflex which tests the sensory branch of the vagus nerve (CN X) using stimulation of the posterior palate and pharynx. Chapter 7 on Traumatic Brain Injury includes a table with greater detail about these brainstem reflexes.

### 1.3.10 Criteria for Determination of Brain Death in Infants and Children

Testing of brainstem reflexes as described above is one aspect of the clinical exam required for the determination of brain death in pediatrics. The manner and timing of the clinical exam and the examiners performing it are outlined in the recently revised criteria published by the Society of Critical Care Medicine (SCCM) and the

American Academy of Pediatrics (AAP) in 2011. These guidelines were initially established by consensus of a multi-society task force, published in 1987, and considered the standard of practice throughout the country for over two decades. In the last several years, the Society of Critical Care Medicine and the American Academy of Pediatrics convened a multidisciplinary committee that included nurses, to update the guidelines using current evidence, with a goal of addressing gaps and weaknesses of the original recommendations.

The 2011 recommendations for the diagnosis of brain death in neonates, infants, and children include six areas where evidence was gathered, scored, and summarized. These areas are (1) the determination of brain death, (2) prerequisites for initiating a brain death evaluation, (3) number of examinations, examiners, and observation periods, (4) apnea testing, (5) ancillary studies, and (6) declaration of death. The determination is a, “...clinical diagnosis based on the absence of neurologic function with a known irreversible cause of coma. Coma and apnea must coexist to diagnose brain death” (Nakagawa et al. 2011) (p.7 22).

The brain death examination calls for 24 h to pass following cardiopulmonary resuscitation or severe acute brain injury if the neurological exam is not clear or clinical judgment dictates. Two separate exams by two different attending physicians with 24 h required between exams for neonates (37 weeks gestation to 30 days postnatal life), and 12 h for infants 31 days to 18 years. If the EEG or cerebral blood flow testing is consistent with brain death, the interval between exams can be decreased. Two apnea tests are required (Nakagawa et al. 2011).

The guidelines for determination of brain death aim to assure that the clinical exam is consistent with other electrical and radiographic findings to guide health-care providers in their discussions with families about removing a child from life sustaining technology and declaring death. The possibility of organ harvest and donation should be discussed with the family prior to this, according to institutional guidelines, and can proceed if it is deemed appropriate by the organ and tissue donor organization interfacing with the facility, and consent has been given by

**Table 1.6** Comparison of 1987 Pediatric Brain Death Guidelines and the Updated Guidelines for Determination of Brain Death in Infants and Children

Guideline element	1987	2011
Number of exams	Two 2nd exam not required for patients 2–12 months of age if first exam, EEG, and CBF tests indicated brain death	Two, regardless of other studies completed
Length of time to wait prior to first exam	Not specified	24 h following CPR or severe acute injury suggested if clinical judgment dictates or if there are concerns about the exam
Number of examiners	Not specified	Two different attending MDs for first and second exam
Core body temperature	Not specified	>35 °C (95 °F)
Apnea testing	Required, number of tests unclear	Two tests required unless clinically contraindicated; PaCO <sub>2</sub> parameters are specified
Ancillary study recommended	7 days to 2 months: 2 EEGs 48 h apart  2 months to 1 year: 2 EEGs 24 h apart; CBF can replace 2nd EEG  >1 year: no testing	Not required unless clinical exam and apnea test cannot be completed NB to 30 days: EEG or CBF less sensitive, CBF may be preferred
Time of death	Not specified	Time of the second exam and apnea test/ ancillary study

Adapted from Nakagawa et al. (2011)

EEG Electroencephalogram, CBF cerebral blood flow

the child's family or legal guardians. See Table 1.6 comparing the 1987 and 2011 updated guidelines for further clarification and details regarding the criteria for determination of brain death in infants and children.

#### 1.4 Pain Assessment in the Child with a Neurological Diagnosis

Children with neurological abnormalities may suffer pain from either their primary diagnosis, in the postoperative period after neurological surgery, or during procedures that must be performed in the course of medical care (lumbar punctures, IV starts, shunt taps, dressing changes). Some children will unfortunately suffer chronic pain related to peripheral nerve injury or a defect in the ability of the central nervous system to “turn off” the pain impulses and alter the function of the normal negative feedback loop. The last two decades have seen a significant growth in the understanding of pain and how it is manifested, physiologically understood, and treated in the

pediatric population. These advances have led to the availability of comprehensive pain management programs available at most pediatric tertiary care centers in the United States and abroad (Brislin and Rose 2005). Yet, the management of pain in the pediatric neurosurgery patient remains a challenging and complex task.

Neurologically impaired children present a challenging dilemma to health-care providers who are entrusted to assess and manage their pain. One obvious challenge is the difficulty of assessing pain in a developmentally delayed child and the desire to not “over-sedate” so that an accurate neurological assessment can occur. Confounding this issue is the relationship of anxiety to pain, and how to determine which is having more of an impact on the child's overall level of comfort. Another important factor in the neurologically impaired child is the input of the parents and other primary care providers who may have specific experiences and insights that may enhance or diminish their ability to “speak” for the child. Pain in this population of children is very likely under-treated.

**Table 1.7** FLACC (face, legs, activity, cry, and consolability) pain assessment tool

Categories	0	1	2
Face	No particular expression or smile	Occasional grimace or frown, withdrawn, disinterested	Frequent-to-constant quivering chin, clenched jaw
Legs	Normal position or relaxed	Uneasy, restless, tense	Kicking or legs drawn up
Activity	Lying quietly, normal position, moves easily	Squirming, shifting back and forth, tense	Arched, rigid, or jerking
Cry	No cry (awake or asleep)	Moans or whimpers, occasional complaint	Crying steadily, screams or sobs, frequent complaints
Consolability	Content, relaxed	Reassured by occasional touching, hugging, or being talked to, distracted	Difficult to console or comfort
Total score:			

From Merkel et al. (1997)

The FLACC is a behavioral observational tool for acute pain that can be used for infants, toddlers, and preschool children. It may also be useful for cognitively impaired children and adolescents. The patient is observed and the score noted for each category (i.e., face, legs, activity, cry, and consolability). The sum of all categories will give score out of maximum 10

A child's perception of pain is related to both anatomic and physiologic factors, as well as cognitive and behavioral factors. Many involved in pain research agree that a child's response to pain is in part a learned response. Infants and young children may have more atypical responses, whereas older children's pain behaviors are more likely to produce actions from others that lead to pain relief (Stapelkamp et al. 2011). Despite the fact that many children suffer pain needlessly, there are still many barriers that exist to providing adequate pain relief to children. These barriers include personal family beliefs, institutional cultures, and individual nurse, physician, and other health-care provider beliefs.

Pain assessment should be done using validated, age-appropriate scales when the child is able to participate. For those who cannot, because of age and or injury, report their pain, physiologic parameters, observation and response to ordered pain relief measures should be carefully documented and communicated to promote optimal pain relief. Parent report may also be a reliable indicator when the child is unable to participate or is uncooperative.

Although there are many tools now available for assessment of pain in infants and children, because of space constraints, only a few will be highlighted in this text as examples. Institutional approaches should utilize published evidence and

input from specialists from multiple disciplines (nurses, physicians, child-life specialists, psychologists, etc.) to determine the best tools for each setting. Many institutions use the Faces Pain Scale (FPS) – Revised for young children. For children over the age of 10 years, the most common approach to pain assessment is the use of the numerical rating scale. A score of one being no pain and ten being the most pain you could ever experience. One recent study validated the use of the NRS for pediatric patients in comparison to the Faces Pain Scale – Revised and found an acceptable level of validity in two different samples (Miró et al. 2009).

Educating nurses and medical staff regarding use of pain tools is an ongoing endeavor. The use of a validated pain tool does not necessarily correlate with improved outcomes for children in pain. The use of these tools must be tied to protocols for pain management so evaluation of pain relief measures, both pharmacological and non-pharmacological, can occur (Greco and Berde 2005). As complementary and alternative approaches to pain management become more widely accepted, many centers have access to therapists skilled in hypnosis, biofeedback, guided imagery, relaxation techniques, acupuncture, and music and art therapy, among others. Tables 1.7, the FLACC Pain Scale, and Table 1.8, the Premature Infant Pain Profile,

**Table 1.8** Premature infant pain profile (PIPP) assessment tool

Procedure	Indicator	0	1	2	3	Score
	Gestational age	>36 weeks	32–36 weeks	28–32 weeks	<28 weeks	
Observe infant or 15 s for baseline, heart rate, and O <sub>2</sub> sat	Behavioral state	Active awake (eyes open, facial movements)	Quiet awake (eyes open, no facial movements)	Active sleep (eyes closed, facial movements)	Quiet sleep (eyes closed, no facial movements)	
Observe infant for 30 s	Heart rate	0–4 bpm increase	5–14 bpm increase	15–24 bpm increase	>25 bpm increase	
	O <sub>2</sub> sat.	0–2.4 % decrease	2.5–4.9 % decrease	5.0–7.4 % decrease	>7.5 % decrease	
	Brow bulge	None (0–9 % of the time)	Min (10–39 % of the time)	Mod (40–69 % of the time)	Max (>70 % of the time)	
	Eye squeeze	None (0–9 % of the time)	Min (10–39 % of the time)	Mod (40–69 % of the time)	Max (>70 % of the time)	
	Nasolabial furrow	None (0–9 % of the time)	Min (10–39 % of the time)	Mod (40–69 % of the time)	Max (>70 % of the time)	
					Total	

From Stevens et al. (2010)

The PIPP is a bibehavioral observational tool for acute and procedural pain. It can be used to assess full- and preterm neonates. The infant is observed as indicated and their score noted. The sum of all categories will give a score out of a maximum of 21

O<sub>2</sub> sat oxygen saturation, *Min* minimal, *Mod* moderate, *Max* maximal

illustrate the scoring used for these tools used for different age groups (Merkel et al. 1997; Stevens et al. 2010).

Pharmacologic management of pain in children undergoing neurosurgical procedures includes the use of nonsteroidal anti-inflammatory drugs (NSAIDs), opioids, local anesthetics, anti-spasmodics, and other drugs that are continually being developed and trialed in the clinical arena (Teo et al. 2011). In the past several years, novel medications have become available, as a way to target more than one cellular mechanism for pain, although many are not approved for children less than 12 years of age. In the setting of a comprehensive pain management team approach, there may be a role for these agents in certain cases (Randive and Mehta 2012). For children with chronic or neuropathic pain, tricyclic antidepressants like amitriptyline and GABA agonists like gabapentin and pregabalin may be used. Administration of medications can be oral, intravenous via intermittent dosing or patient controlled analgesia (PCA), regional via epidural catheters, transcutaneous (dermal patches), transmucosal (oralettes), and rectal (Rosen and Dower 2011).

Whatever pain medications are chosen, the nurse plays the most important role of any caregiver in assessing, evaluating, documenting, preventing, and educating about pain in the ill child. No medication can ever replace a caring, comforting, confident, reassuring, and truly present nurse to both the child and family in improving the overall comfort and recovery of the hospitalized child experiencing pain for any reason. Close follow-up after hospitalization is needed so that pain continues to abate, and medication use is carefully and consistently coordinated by health-care professionals in the transition between hospital care and primary care (Ali et al. 2010). The nurse in the neurosurgery clinic or the hospital case manager doing telephone follow-up after surgery and discharge from the acute care setting should work closely with home and primary care providers in more complex cases, to assure that pain management is sustained in the transition home.

### Conclusion

The last quarter of the twentieth century witnessed rapid advancements in technology and successful treatments in the field of pediatric

neurosurgery. These advances coincided with the evolution of expanded roles and responsibilities of nurses and an increasing number of advanced practice nurses. As members of health-care teams, nurses have the most direct contact with patients and the opportunity to note signs of neurological abnormalities or subtle clinical changes in a child's condition. Thorough, accurate, and consistently documented neurological assessments can make the difference between recovery and complication, and even life and death. Nurses who have accepted the responsibility of caring for children should strive to develop and consistently apply their neurological assessment skills.

#### **Pediatric Practice Pearls: Pediatric Neuro Assessment Tools # 1**

One useful and inexpensive tool for neurological assessment of both infants and young children is a *small retracting tape measure with a brightly colored push button* for tape retrieval. This simple tool can be used for the following:

- Assessment of OFC (occipital frontal circumference).
- Gross assessment of hearing by watching the response of the child when you pull the tape out close to their ears prior to the OFC measurement.
- Assessment of extraocular eye movements (EOMs) by moving the retracted tape in all visual fields while holding the child's head steady.
- Assessment of cerebellar function by looking for tremor or dysmetria when asking the child to take their "pointer finger" and touch the button and then touch their nose. You can test both hands individually. Children do not usually notice if you put your free hand gently on the hand you do not want them to use.
- Assessment of dexterity when you ask them to pull the tape out and then push

the button to let it go back in – see if you can get them to do it with both hands.

- Assessment of cognitive skills by asking them to put it back into your bag or pocket – hint: toddlers and preschool-aged children may resist giving a toy or object back to the examiner but often will put an item back into something. "Emptying and filling" is part of many of their routine play activities.

#### **Pediatric Practice Pearls: Pediatric Neuro Assessment Tools # 2**

One often useful and inexpensive tool for both neurological assessment of infants and younger children are *small wood blocks with colors, letters, and numbers* on them. These blocks can be disinfected between patients and used for the following:

- The ability to grasp the block(s), bring them to the mouth, transfer them from hand to hand, and clap them together (infants, toddlers)
- The ability to stack or clap two blocks together (manual dexterity), count, name colors, letters, and numbers (cognitive skills)
- The ability to throw the block to the examiner or into the exam bag (coordination, following directions)

#### **Pediatric Practice Pearls: Pediatric Neuro Assessment Tools # 3**

One useful and practical tool for neurological assessment of the toddler or school-age child is the *exam room table using the disposable paper cover*. This simple tool can be used for the following:

- Assessing cerebellar function by checking dexterity, handedness, and also dysmetria or tremor. Tell the child you are going to draw a racetrack on the paper, and the crayon that you provide them is

the car. Ask the child to drive his car carefully through the track. Check for accuracy and ability to complete this task.

- Have the school-age child write a letter or their name. Are the lines smooth or are they jagged due to tremor? Is the child able to grasp and hold a writing object appropriately?
- Draw a clock face and ask the older school-age child to add the numbers to the clock face. If the child only puts numbers consistently on one side of the clock, then this is concerning for a visual field cut and need for further evaluation.
- Have the young child draw a circle, a square, or a stick figure. By 3–6 years of age, a child should be able to draw a circle and square or a stick figure with two to three features.

## References

- Ali S, Drendel AL, Kircher J, Beno S (2010) Pain management of musculoskeletal injuries in children: current state and future directions. *Pediatr Emerg Care* 26(7):518–524. doi: [00006565-201007000-00014](https://doi.org/10.1007/0000-00014) [pii]; quiz 525–518
- American Academy of Pediatrics (1996) Eye examination and vision screening in infants, children, and young adults. *Pediatrics* 98(1):153–157
- American Academy of Pediatrics (2011) Health issues: bedwetting (enuresis). Healthy Children Website. <http://www.healthychildren.org/English/health-issues/conditions/emotional-problems/Pages/Bed-Wetting-Enuresis.aspx>. Accessed March 21, 2012
- Amidei C, Blissett P, Brooks L (2010) Assessment. In: Amidei C (ed) *AANN core curriculum for neuroscience nursing*, 5th edn. American Association of Neuroscience Nurses, Glenview, pp 107–157
- Asato MR, Nawarawong N, Hermann B, Crumrine P, Luna B (2011) Deficits in oculomotor performance in pediatric epilepsy. *Epilepsia* 52(2):377–385
- Brislin RP, Rose JB (2005) Pediatric acute pain management. *Anesthesiol Clin North America* 23(4):789–814, x
- Caplin DA, Austin JK, Dunn D (2009) Epilepsy. In: O'Donohue WT, Tolle LW (eds) *Behavioral approaches to chronic disease in adolescence: a guide to integrative care*. Springer, New York, pp 143–152
- Cohen J (2009) Interrater reliability and predictive validity of the FOUR score coma scale in a pediatric population. *J Neurosci Nurs* 41(5):261–267; quiz 268–269
- Conn PM (1995) *Neuroscience in medicine*. J.B. Lippincott, Philadelphia
- Cook N, Woodward S (2011) Assessment, interpretation and management of altered consciousness. In: Woodward S, Mestecky A-M (eds) *Neuroscience nursing: evidence based practice*. Blackwell Publishing Ltd., West Sussex
- Disabato J, Wulf J (1994) Altered neurologic function. In: Betz C, Hunsberger M, Wright S (eds) *Family centered nursing care of children*, 2nd edn. Saunders, Philadelphia, pp 1717–1840
- Dlamini N, Billingham L, Kirkham FJ (2010) Cerebral venous sinus (sinovenous) thrombosis in children. *Neurosurg Clin N Am* 21(3):511–527
- Drotar D, Stancin T, Dworkin PH, Sices L, Wood S (2008) Selecting developmental surveillance and screening tools. *Pediatr Rev* 29(10):e52–e58
- Freedman SB, Al-Harthy N, Thull-Freedman J (2009) The crying infant: diagnostic testing and frequency of serious underlying disease. *Pediatrics* 123(3):841–848
- Greco C, Berde C (2005) Pain management for the hospitalized pediatric patient. *Pediatr Clin North Am* 52(4):995–1027, vii–viii
- Greisen G (2006) Brain monitoring in the neonate – the Rationale. *Clin Perinatol* 33:613–618, v–vi
- Hadley J (1994) Assessing child health. In: Betz C, Hunsberger M, Wright S (eds) *Family centered nursing care of children*, 2nd edn. Saunders, Philadelphia, pp 458–512
- Hamilton S (2006) Screening for developmental delay: reliable, easy-to-use tools. *J Fam Pract* 55(5):415–422. doi: [jfp\\_0506\\_5505c](https://doi.org/10.1097/000065505c)[pii]
- Haymore J (2004) A neuron in a haystack: advanced neurologic assessment. *AACN Clin Issues* 15(4):568–581. doi: [00044067-200410000-00008](https://doi.org/10.10044067-200410000-00008)[pii]
- He YZ, Wang ZP, Wang J (2008) Value of Glasgow-Pittsburgh Coma Scale scoring in childhood coma. *Zhongguo Dang Dai Er Ke Za Zhi* 10(5):614–616. doi: [1008-8830\(2008\)05-0614-03](https://doi.org/10.1008-8830(2008)05-0614-03)[pii]
- Hedlund GL (2002) Neuroradiology of the central nervous system in childhood. *Neurol Clin* 20(4):965–981, vi
- Hickey J (2009) Neurological assessment. In: Hickey J (ed) *The clinical practice of neurological and neurosurgical nursing*, 6th edn. Wolters Kluwer/Lippincott Williams & Wilkins, Philadelphia, pp 154–180
- Hobdell E (2001) Infant neurologic assessment. *J Neurosci Nurs* 33(4):190–193
- Jaia A, Barker E (2008) Neurodiagnostic studies. In: Barker E (ed) *Neuroscience nursing a spectrum of care*, 3rd edn. Mosby/Elsevier, St. Louis, pp 99–130
- Knowlton RC (2008) Can magnetoencephalography aid epilepsy surgery? *Epilepsy Curr* 8(1):1–5. doi: [10.1111/j.1535-7511.2007.00215.x](https://doi.org/10.1111/j.1535-7511.2007.00215.x)
- Kramer U, Nevo Y, Harel S (1994) Jittery babies: a short-term follow-up. *Brain Dev* 16(2):112–114. doi: [0387-7604\(94\)90045-0](https://doi.org/10.1016/0304-7604(94)90045-0)[pii]
- Lucille Packard Children's Hospital (2012) Neurological Examination. Retrieved from <http://www.lpch.org/DiseaseHealthInfo/HealthLibrary/neuro/neurexam.html>. Accessed 20 Mar 2012

- Marcoux KK (2005) Management of increased intracranial pressure in the critically ill child with an acute neurological injury. *AACN Clin Issues* 16: 212–231
- McGee S, Burkett KW (2000) Identifying common pediatric neurosurgical conditions in the primary care setting. *Nurs Clin North Am* 35(1):61–85
- Merkel SI, Voepel-Lewis T, Shayevitz JR, Malviya S (1997) The FLACC: a behavioral scale for scoring postoperative pain in young children. *Pediatr Nurs* 23(3):293–297
- Miró J, Castarlenas E, Huguet A (2009) Evidence for the use of a numerical rating scale to assess the intensity of pediatric pain. *Eur J Pain* 13(10):1089–1095. doi: [S1090-3801\(09\)00151-7](https://doi.org/10.1016/j.ejpain.2009.07.002)[pii]10.1016/j.ejpain.2009.07.002
- Nakagawa, TA, Ashwal, S, Mathur, M, & Mysore, MR. (2011) Guidelines for the determination of brain death in infants and children: an update of the 1987 task force recommendations. Society of Critical Care Medicine, Section on Critical Care and Section on Neurology of the American Academy of Pediatrics, Child Neurology Society, Critical Care Medicine, 39(9):2139–2155. doi: [00003246-201109000-00016](https://doi.org/10.1097/CCM.0b013e31821f0d4f) [pii]10.1097/CCM.0b013e31821f0d4f
- National Institute of Child Health and Human Development (2012) Pediatric Endocrinology Training Program, Tanner Staging for Females and Males. Retrieved from <https://science.nichd.nih.gov/confluence/display/pe/Clinical+Resources>. Accessed on March 21, 2012
- Nellhaus G (1968) Head circumference from birth to eighteen years. Practical composite international and interracial graphs. *Pediatrics* 41(1):106–114
- Pasero C, Eksterowicz N, Primeau M, Cowley C (2008) The registered nurse's role in the management of analgesia by catheter techniques. *J Perianesth Nurs* 23(1): 53–56
- Purugganan OH (2006) Abnormalities in head size. *Pediatr Rev* 27(12):473–476. doi: [27/12/473](https://doi.org/10.1177/271247306289111)[pii]
- Randive S, Mehta V (2012) Breakthrough pain—novel analgesics. *Curr Clin Pharmacol*. doi: [CCP-EPUP-20120320-003](https://doi.org/10.2165/000020320-0033pii)[pii]
- Rosen DA, Dower J (2011) Pediatric pain management. *Pediatr Ann* 40(5):243–252. doi: [10.3928/00904481-20110412-05](https://doi.org/10.3928/00904481-20110412-05)
- Santrock, JW (1998) Physical growth and development in infancy, in *Physical and Cognitive Development in Infancy*, JW Santrock, ed. Chapter 3. Retrieved from [highered.mcgraw-hill.com/sites/dl/free/0073405515/519572/Santrock\\_ch3.pdf](http://highered.mcgraw-hill.com/sites/dl/free/0073405515/519572/Santrock_ch3.pdf). Accessed on Oct. 27, 2012
- Schultz R, Hockenberry M (2011) The child with cerebral dysfunction. In: Hockenberry MJ, Wilson D (eds) *Wong's Nursing care of infants and children*, 9th edn. St. Louis, Elsevier/Mosby, pp 1507–1566
- Shuper A, Zalzburg J, Weitz R, Mimouni M (1991) Jitteriness beyond the neonatal period: a benign pattern of movement in infancy. *J Child Neurol* 6(3): 243–245
- Slota MC (1983a) Neurological assessment of the infant and toddler. *Crit Care Nurse* 3(5):87–92
- Slota MC (1983b) Pediatric neurological assessment. *Crit Care Nurse* 3(6):106–112
- Stapelkamp C, Carter B, Gordon J, Watts C (2011) Assessment of acute pain in children: development of evidence-based guidelines. *Int J Evid Based Healthc* 9(1):39–50. doi: [10.1111/j.1744-1609.2010.00199.x](https://doi.org/10.1111/j.1744-1609.2010.00199.x)
- Stevens B, Johnston C, Taddio A, Gibbins S, Yamada J (2010) The premature infant pain profile: evaluation 13 years after development. *Clin J Pain* 26(9):813–830. doi: [10.1097/AJP.0b013e3181ed1070](https://doi.org/10.1097/AJP.0b013e3181ed1070)
- Teo JH, Palmer GM, Davidson AJ (2011) Post-craniotomy pain in a paediatric population. *Anaesth Intensive Care* 39(1):89–94
- Togioka BM, Arnold MA, Bathurst MA, Ziegfeld SM, Nabaweesi R, Colombani PM, Abdullah F (2009) Retinal hemorrhages and shaken baby syndrome: an evidence-based review. *J Emerg Med* 37(1): 98–106. doi: [S0736-4679\(08\)00617-3](https://doi.org/10.1016/j.jemermed.2008.06.022)[pii]10.1016/j.jemermed.2008.06.022
- U.S. Department of Education Special Education and Rehabilitative Services (2005) Individuals with Disabilities Education Act. U.S. Department of Education, Washington, D.C., Retrieved from [www.ed.gov/about/offices/list/osep](http://www.ed.gov/about/offices/list/osep)
- Volpe JJ (2009) The encephalopathy of prematurity – brain injury and impaired brain development inextricably intertwined. *Semin Pediatr Neurol* 16(4): 167–178. doi: [S1071-9091\(09\)00063-1](https://doi.org/10.1016/j.spn.2009.09.005)[pii]10.1016/j.spn.2009.09.005
- Wallace, D & Disabato, J (2007) Age appropriate assessment table. Adapted from Children's Rehabilitative Services, St. Joseph's Hospital, Phoenix, AZ
- Wijdicks EF, Bamlet WR, Maramattom BV, Manno EM, McClelland RL (2005) Validation of a new coma scale: the FOUR score. *Ann Neurol* 58(4):585–593. doi: [10.1002/ana.20611](https://doi.org/10.1002/ana.20611)
- Yang M (2004) Newborn neurologic examination. *Neurology* 62(7):E15–E17



Nadine Nielsen and Amanda Breedt

---

## 2.1 Hydrocephalus

Hydrocephalus is a condition resulting from an imbalance between the production and absorption of cerebral spinal fluid (CSF). This imbalance results in an increased volume of spinal fluid, dilation of the ventricular system, and often increased intracranial pressure. Hydrocephalus onset can be acute and occur over hours or days. It may also be chronic and occur over months or years. Hydrocephalus can occur as an isolated condition or one associated with numerous other neurological conditions and diseases.

---

## 2.2 History of Hydrocephalus

The term hydrocephalus is derived from the Greek words “hydro” meaning water and “cephalus” meaning head. The description and treatment of hydrocephalus dates back to the eras of Hippocrates and Galen. Galen (130–200 AD) identified the ventricles. He believed that the soul was purified through the pituitary gland. Waste was discharged via the nose as “pituita.” During the renaissance, Vesalius (1514–1564) described the ventricular system in his original text on human anatomy. A

century later, Franciscus Sylvius (1614–1672) described the cerebral aqueduct. Morgagni (1682–1771) described the pathology of hydrocephalus, and Monro (1733–1817) named the intraventricular foramen. In 1768, Whytt distinguished internal and external hydrocephalus.

Early treatment included bleeding, purging, surgical release of the fluid, puncturing the ventricles to drain the fluid, injection of iodine or potassium hydriodate into the ventricles, binding of the head, application of a plaster of herbs to the head, application of cold wraps to the head, lumbar puncture, and diuretics. Confusion about hydrocephalus persisted into the 1800s. It was thought to be caused by fevers, rheumatism, pulmonary consumption, and worms; however, treatment did not change.

The earliest attempts at surgery occurred during the late 1800s. The first shunts diverted spinal fluid from the ventricles to the subcutaneous or subdural spaces. During the early 1900s, other surgical procedures were attempted to treat the condition. These procedures included surgical removal of the choroid plexus, diversion of spinal fluid through a third ventriculostomy, and continued attempts at shunting, including attempts to shunt into the vascular space. Most of these patients did poorly, and either suffered the consequences of prolonged increased intracranial pressure or died. Many institutions cared for and housed these disabled

---

N. Nielsen, MN, ARNP (✉) • A. Breedt, MN, ARNP  
Department of Neurosurgery,  
Children’s Hospital and Regional Medical Center,  
4800 Sand Point Way N.E., P.O. Box 5371/6E-1,  
Seattle, WA 98105, USA  
e-mail: nadine.nielsen@seattlechildrens.org;  
mandy.breedt@seattlechildrens.org

---

Katherine Pearce, Elisabeth Limbacher, and Donna C. Wallace were authors on the first edition but did not contribute to the revision of this chapter

children with very large heads, small bodies, and severe mental retardation.

Modern shunting procedures began in the 1950s with the introduction of the antireflux valve. The first valves, developed by Nulson and Spitz in 1952, used a spring and steel ball valve. Holter then developed the first slit valve. He was particularly interested in shunt development, as he had a son with a myelomeningocele and hydrocephalus. These first modernized shunts diverted CSF from the ventricles to the right atrium of the heart. The ventricular to peritoneal shunt became the preferred shunt in the 1970s because it allowed for the child to grow and not outgrow the length of the shunt tubing. This has remained the preferred shunt procedure among modern neurosurgeons. Neurosurgeons have also placed shunts leading from the ventricle to the pleural space, gall bladder, ureter, or fallopian tube if the abdominal cavity is not a suitable place to terminate the shunt. Numerous improvements of shunt hardware have occurred in the last four decades.

A genetic understanding of hydrocephalus and diseases associated with hydrocephalus has occurred in the last decade. Such knowledge of genetics has allowed for improved prenatal diagnosis and genetic counseling.

---

### 2.3 Incidence of Hydrocephalus

Hydrocephalus is the most common neurosurgical problem encountered by pediatric neurosurgeons. The overall incidence is difficult to determine, as hydrocephalus can occur as an isolated condition or in conjunction with many other neurological diseases and conditions. The overall incidence of hydrocephalus at birth is 0.5–4 per 1,000 live births. As an isolated congenital disorder, the incidence of hydrocephalus is 0.5–1.5 per 1,000 live births. Hydrocephalus occurs in about 80–85 % of infants born with a myelomeningocele. Because hydrocephalus is associated with so many other diseases and conditions, it is impossible to know how many such children actually exist in the general population. A recent study revealed that pediatric hydrocephalus results in 38,200–39,900 annual hospital admissions, with

total hospital charges of \$1.4–2.0 billion dollars. Hydrocephalus accounts for 3.1 % of all pediatric hospital charges (Simon et al. 2008). Surgeries to place and revise shunts comprise approximately half of a pediatric neurosurgeon's annual operative cases (McLone 2001).

---

### 2.4 Prognosis

The prognosis for children with hydrocephalus has markedly improved with modern shunting. The natural history of unshunted hydrocephalus was studied, and it revealed a 46 % survival rate for 10 years (Laurance and Coates 1962). Of the surviving population, 62 % suffered from intellectual impairment (Laurance and Coates 1962). Children who are adequately treated for hydrocephalus have a considerably better outcome. Their survival rate after 10 years is 95 %, and only 30 % have impaired intellectual function (Shurtleff et al. 1973).

The prognosis of an infant or child with hydrocephalus is mostly dependent on the underlying cause of the hydrocephalus. Prognosis may also be related to the complications that occur, such as shunt malfunctions and infections. The best predictors of a good outcome are the prompt treatment of the hydrocephalus and the ability of the brain to grow normally in the newborn once a functioning shunt is placed. Shunt dependency is associated with a 1 % mortality rate per year (Ditmyer 2004).

---

### 2.5 Classifications of Types of Hydrocephalus

Hydrocephalus is subdivided into several different categories. Communicating and noncommunicating are the most common categories. These terms were previously used interchangeably with obstructive and nonobstructive. The latter terms have fallen from use, as it is believed that in almost all cases of hydrocephalus, there is some obstruction of CSF reabsorption; the exception is the rare state of overproduction of CSF. Hydrocephalus is also subdivided into

**Table 2.1** Classifications of hydrocephalus

<i>Communicating</i>
Congenital
Achondroplasia
Associated with craniofacial syndromes
Acquired
Posthemorrhagic: intraventricular or subarachnoid
Choroid plexus papilloma or choroid plexus carcinoma
Venous obstruction as in superior vena cava syndrome
Postinfectious
<i>Noncommunicating</i>
Congenital
Aqueductal stenosis
Congenital lesions (vein of Galen malformation, congenital tumors)
Arachnoid cyst
Chiari malformations either with or without myelomeningocele
X-linked hydrocephalus
Dandy-Walker malformation
Acquired
Aqueductal gliosis (posthemorrhagic or postinfectious)
Space-occupying lesions such as tumors or cysts
Head injuries

congenital versus acquired and internal versus external (Table 2.1). Other categories include normal pressure hydrocephalus and ex vacuo hydrocephalus.

### 2.5.1 Communicating Hydrocephalus

Communicating hydrocephalus is a condition that results when the arachnoid villi are unable to adequately reabsorb cerebral spinal fluid. Intraventricular or subarachnoid hemorrhage may cause the arachnoid villi to become unable to function adequately, either temporarily or permanently. This is a consequence of the effect of the end products of red blood cell breakdown on the arachnoid villi. Infectious processes such as meningitis may also render the arachnoid villi to be nonfunctional (due to, e.g., toxins or scarring). Communicating hydrocephalus may also be due to the overproduction of CSF. This is rare and is

usually associated with a choroid plexus papilloma or a choroid plexus carcinoma.

### 2.5.2 Noncommunicating Hydrocephalus

Noncommunicating hydrocephalus is a condition that results when the ventricular system does not communicate with the arachnoid villi due to some obstruction in the normal pathways of CSF flow. Consequently, CSF is produced in the ventricular system but cannot flow to the arachnoid villa to be reabsorbed. Such obstruction can occur when pathways are blocked by a tumor, congenital abnormalities of the brain, cysts, inflammation from infection, or any other condition that interferes with the patency of these pathways. Some consider the failure of the arachnoid villi to reabsorb CSF to be an obstruction at the level of the arachnoid villi.

### 2.5.3 Congenital Hydrocephalus

Congenital hydrocephalus is caused by any condition that existed before birth. The hydrocephalus may or may not be present at birth. Examples include aqueductal stenosis, Dandy-Walker malformation, and X-linked hydrocephalus. Congenital hydrocephalus is also associated with myelomeningocele, Chiari malformations, encephalocele, and with prenatal infections such as cytomegalo inclusion virus (CMV) or rubella.

### 2.5.4 Acquired Hydrocephalus

Acquired hydrocephalus is hydrocephalus resulting from a condition that did not previously exist in the patient. The condition either obstructs normal spinal fluid flow, causes overproduction of CSF, or prevents reabsorption of CSF. Examples include tumors that obstruct CSF flow and other space-occupying lesions that were not congenital. Infection in the brain may also occlude small passageways. Overproduction of spinal fluid may be caused by a choroid plexus tumor. Acquired

conditions that interfere with reabsorption of CSF include intraventricular hemorrhage (IVH) and subarachnoid hemorrhage.

### 2.5.5 Internal Hydrocephalus

Internal hydrocephalus refers to ventricular dilation and the associated pathophysiology. The term hydrocephalus is used most commonly to refer to internal hydrocephalus.

### 2.5.6 External Hydrocephalus

External hydrocephalus refers to the accumulation of spinal fluid in either the subarachnoid or subdural spaces. CSF collection in the subarachnoid space may be a benign condition in infancy, which is called benign subdural hygromas of infancy or idiopathic external hydrocephalus of infancy. The neuroimaging characteristics of this condition typically show enlarged frontal subarachnoid spaces and moderately enlarged ventricles. Infants present with rapidly increasing head circumference and sometimes developmental delays. Some children may show temporary or permanent psychomotor delays (Zahl et al. 2011). This is usually a self-limiting condition. The child is usually treated conservatively, although some may require a shunt.

CSF mixed with blood in the subdural space may not be benign and usually requires further investigation and treatment, as it may be related to trauma (possibly nonaccidental trauma). If these fluid collections exert pressure on the brain and cause symptoms or cause very accelerated head growth, surgical treatment may be necessary.

### 2.5.7 Ex Vacuo Hydrocephalus

Ex vacuo hydrocephalus refers to a condition of brain volume loss. The condition may be present at birth. It may be the result of failure of the fetal development of the brain as in schizencephaly (abnormal development of the brain, leading to

the characteristic appearance of abnormal clefts in either one or both cerebral hemispheres) or hydranencephaly (abnormal development of the brain, leading to absence of the cerebral hemispheres of the brain). The brain may also undergo destruction or atrophy from infections, very poor nutrition, or unknown causes. The ventricles become large to “fill the space” where there is an absence of brain tissue and may or may not be under increased pressure. There is technically not an imbalance of CSF production and absorption but rather the actual loss of brain matter.

### 2.5.8 Idiopathic Normal Pressure Hydrocephalus

Idiopathic normal pressure hydrocephalus is primarily a condition of the elderly. It is a condition that occurs with normal intracranial pressure and ventricular dilation. These patients develop symptoms slowly over time. The classic symptoms include dementia, gait difficulties, and urinary incontinence. A shunt may be helpful if the symptoms improve after a lumbar puncture or lumbar drain.

---

## 2.6 Pathophysiology of Hydrocephalus

### 2.6.1 Overview of CSF Production and Flow Dynamics

Most of the CSF (approximately 60 %) is produced in the choroid plexus; the rest is produced in the ependymal of the cerebral ventricles, the aqueduct of Sylvius, and the subarachnoid space. Studies by Milhorat looking at CSF production after choroid plectomy demonstrated that the total amount of produced CSF was reduced by only one-third, thus suggesting that other sites can produce larger amount of CSF (Milhorat 1982). He proposed that CSF is also produced as the result of cellular metabolism of periventricular cortical gray matter. These other areas account for 20–50 % of CSF production. CSF production requires the expenditure of energy (Albright et al. 2007).

### 2.6.2 CSF Pathways

CSF flows from the ventricles, passes through a series of channels, and exits the ventricular system via the fourth ventricle. There are two lateral foraminae on the lateral aspect of the fourth ventricle, named the foramen of Luschka, and medially located opening called the foramen of Magendie. After exiting the fourth ventricle, the CSF flows into the subarachnoid space and up over the convexities of the brain, to be absorbed into the large intracranial sinuses (Albright et al. 2007). Alternative pathways for CSF have been scientifically supported and include lymphatic drainage into the cervical lymphatic chain and paranasal sinuses. After being absorbed, the CSF is returned to the right atrium via the superior vena cava (Albright et al. 2007).

### 2.6.3 Intracranial Pressure

A study of rabbits by Dr. McComb found that CSF flows passively, and absorption of CSF does not require the expenditure of energy (Albright et al. 2007). For each drop of CSF that is produced, the same amount should be absorbed. Several factors affect the flow of CSF, including resistance, which may result from an obstruction or restriction of a pathway. Other considerations include the plasticity of the brain itself, as well as the flexibility of the intracranial venous structures.

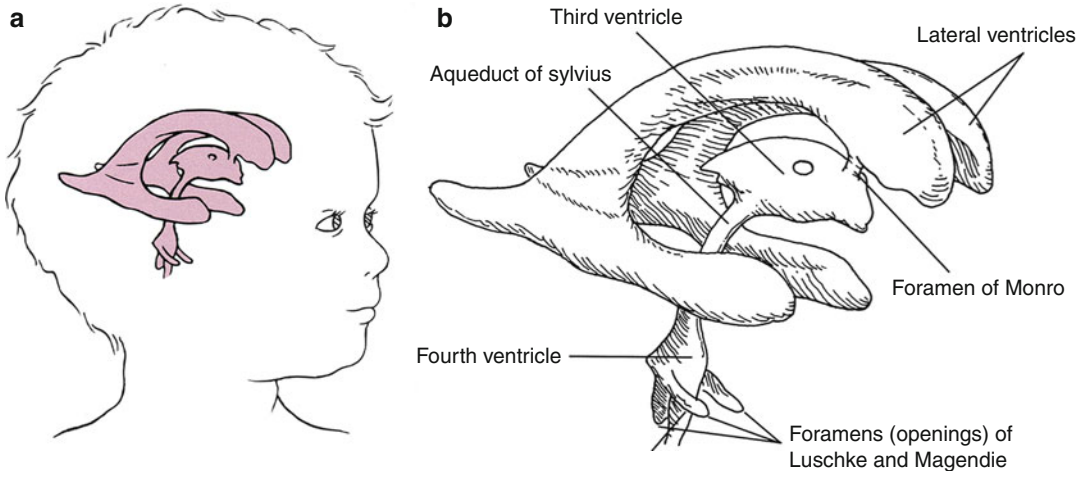
Plasticity refers to the brain inability to change shape. For example, an increase in the intraventricular volume will enlarge the ventricles, causing distortion of the cerebral cortex. As we age, our brain may become stiffer. Neonatal brains are very elastic. Anoxic injury can change the brain's ability to maintain its normal stiffness and can also be hydroplastic. The intracranial venous system includes the dural sinuses which are more rigid than the cortical veins. Cortical veins join the dural sinuses at such an angle that a valvular mechanism is created and a pressure gradient is maintained. The jugular veins, returning the blood to the heart, have no valves. When we stand, negative pressure produced in the jugular

veins causes them to collapse and assist humans in maintaining normal intracranial pressure. Shunting systems are used when the CSF pathways are somehow obstructed. The valves that are used to regulate the flow attempt to mimic normal flow.

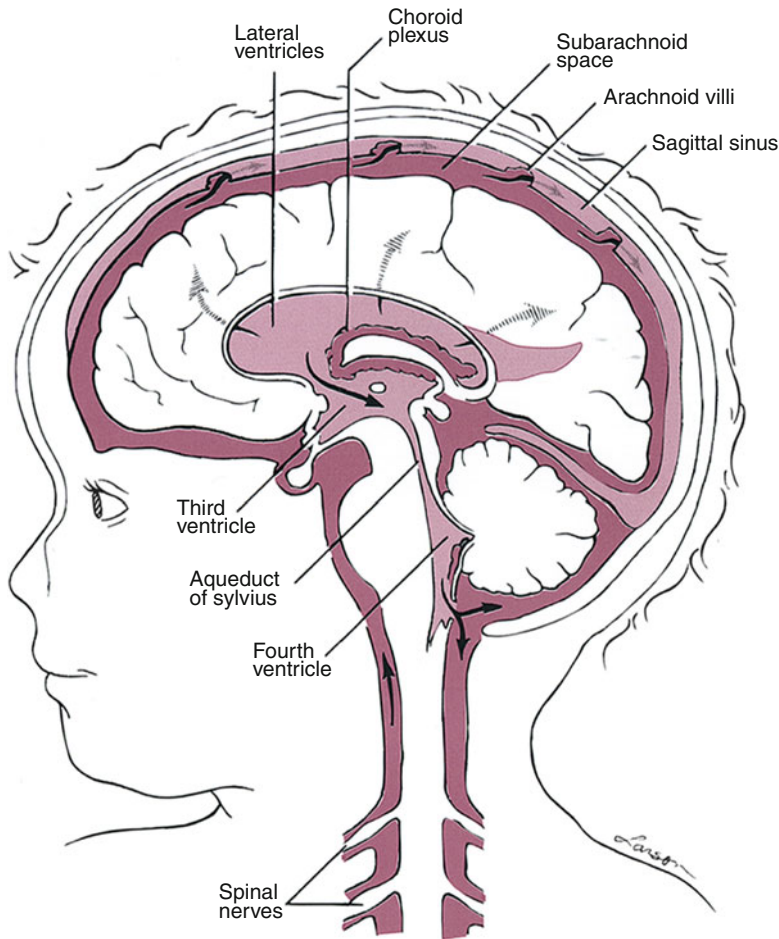
The normal rate of CSF production in infants and children is about 0.33 ml/kg/h. Normal newborns have about 5 ml total volume of CSF. Adults have about 125 ml of total CSF, with about 20 ml located within the ventricles. CSF is produced continually by the choroid plexus, which is located within the ventricles. It is continually reabsorbed by the arachnoid villi (Figs. 2.1 and 2.2).

The pathophysiology of hydrocephalus is much more complex than the radiographic picture. The computed tomography (CT) or magnetic resonance imaging (MRI) scan may reveal many structural changes including enlarged ventricles, thinning of the cortical mantle, distortion of structures, and possible transependymal flow of CSF. These visible changes may also affect the biochemistry, metabolism, and maturation of the brain. Adequate treatment and resolution of the dilated ventricles does not always reverse the other injuries that have occurred to the brain.

Three factors are critical in determining the severity of injury caused by hydrocephalus: age at onset, underlying cause (etiology), and duration of the hydrocephalus. Age is a salient factor because hydrocephalus may affect the normal maturation processes of the brain in addition to the other expected effects of increased intracranial pressure. Furthermore, the underlying disease process responsible for the hydrocephalus may have its own destructive effects on maturation and brain function. Examples of such diseases are encephalitis, meningitis, tuberous sclerosis, and tumors. Treatment of these diseases may also have destructive effects on the brain and brain maturation. For example, radiation treatment of brain tumors in very young children can interrupt normal maturation permanently and development does not always proceed normally, even after the resolution of the hydrocephalus. The duration of the hydrocephalus has a critical



**Fig. 2.1** Illustration of position and configuration of intracranial ventricles



**Fig. 2.2** Illustration of cross section of brain and ventricles shows pathways of CSF flow

role in determining the long-term recovery. Long-standing ventricular dilation and increased intracranial pressure tend to lead to poor recovery of function, even after ventricular size normalizes.

### 2.6.4 Structural Changes

Ventricular dilation seen on the CT or MRI is the hallmark of hydrocephalus. The temporal and frontal horns of the lateral ventricles usually dilate first and are sometimes asymmetrical. This is due to the accumulation of spinal fluid and leads to distortion of the adjacent structures, compression of the nearby white matter, reduction of cerebral cortex, and thinning of the cortical mantle. The ependymal cells lining the ventricles may become damaged and allow transependymal flow of CSF. The septum pellucidum may become damaged, leading to its disappearance and the formation of one large ventricular cavity. In some situations, ventricular size may not change even though pressure is elevated and symptoms are present.

### 2.6.5 Vascular Changes

The distortion of the brain tissue that occurs with hydrocephalus also affects the arteries, veins, and capillaries. Deep vessels are affected the most as they may be directly compressed from the increased ventricular size. Peripheral vessels are also affected as they try to supply the brain tissue that is suffering from the insult of increased intracranial pressure. Blood flow has been shown to be globally decreased to the brain in acute hydrocephalus (Da Silva et al. 1995). Blood flow is primarily decreased to the periventricular white matter in chronic hydrocephalus (Da Silva et al. 1995). Hypoperfusion may cause damage to neurons and glia and interfere with normal maturation of all brain structures.

### 2.6.6 Metabolic Changes

The brain of a child consumes about 50 % of total body oxygen, and an infant's brain consumes

more than 50 %. The adult brain consumes only about 20 % (Sokoloff 1989). The brain uses glucose as its primary source of energy with few exceptions. Therefore, any decrease in cerebral blood flow that decreases the amount of oxygen and glucose available can markedly alter metabolism. This impairment of metabolism may lead to damage to the brain. Furthermore, during infancy and childhood, a significant portion of the energy used by the brain is used for maturational activities such as myelination, neuronal maturation, and protein production. Normal maturation may be disturbed and possibly permanently altered, due to these metabolic alterations.

### 2.6.7 Cerebral Spinal Fluid Changes

Abnormal amounts of spinal fluid in the brain may lead to changes in the CSF itself. Metabolites may accumulate in the CSF during hydrocephalus. Protein levels in the CSF may be altered by the underlying cause of the hydrocephalus. For example, after an IVH, protein levels may be very elevated. If the hydrocephalus damages the ependymal cells lining the ventricles, the CSF may flow out of the ventricles into the periventricular white matter. CSF production may or may not decrease as intracranial pressure increases. As intracranial pressure increases, reabsorption of CSF may increase assuming that the arachnoid villi are functional.

### 2.6.8 Brain Tissue Changes

The white matter surrounding the enlarged ventricles is called the periventricular white matter. As the ventricles dilate, the white matter may become compressed, saturated with CSF, and possibly damaged. Periventricular leukomalacia may result from ischemia to affected white matter. The corpus callosum may also become thinned.

The myelination process may also be delayed in children with hydrocephalus. Myelination occurs in a stepwise fashion during development. If one step is interrupted, it cannot occur at a later

time, and this prevents subsequent steps in the overall process.

The cerebral cortex is also markedly affected by hydrocephalus. The cortex is thinned as it is pushed out by the ventricles and restricted by the skull. Histological changes within the cortex are usually subtle, but damage to cells occurs and results in a change in function.

The goal of treatment of hydrocephalus is to prevent further damage and to restore function. Treatment usually reverses symptoms of acute hydrocephalus. However, timing is critical and treatment should occur before vascular, metabolic, and other changes described interfere with normal maturation and brain function. Without prompt treatment, acute hydrocephalus and increased intracranial pressure can lead to brainstem herniation and death.

## 2.7 Etiologies of Hydrocephalus

Hydrocephalus is primarily a condition of obstructed CSF circulation or absorption. In infants and children, it may be congenital or associated with other congenital abnormalities. It may also be associated with central nervous system (CNS) infection, hemorrhage, tumors, or cysts.

### 2.7.1 Aqueductal Stenosis

In 1900, Bourneville and Noir noted an association between hydrocephalus and stenosis of the aqueduct of Sylvius (Cinalli et al. 2004). The aqueduct of Sylvius is a narrow passageway connecting the third and fourth ventricles. The most common cause of hydrocephalus in children is aqueductal stenosis, and it accounts for 70 % of cases (Greenberg 2010). Hydrocephalus due to aqueductal stenosis is characterized by enlargement of the lateral and third ventricles with a normal fourth ventricle. This constriction of the aqueduct of Sylvius is best seen on MRI scan (sagittal view).

Stenosis of this passageway may be congenital or acquired, although in 50–75 % of cases, the cause may be unknown. It may be associated with

Chiari I malformation, vein of Galen malformation, or Dandy-Walker malformation. Aqueductal stenosis may also be due to an X-linked recessive gene, LICAM mutation, (Langingham et al. 2009) occurring only in males. This is rare and is associated with characteristic adducted thumbs, spastic paraparesis, and mental retardation. Acquired cases of aqueductal stenosis may be the result of hemorrhage, inflammation from infection, or obstruction from a nearby tumor or cyst.

### 2.7.2 Myelomeningocele and Chiari II Malformation

Myelomeningocele is a neural tube defect that occurs during embryonic development resulting in failure of the neural tube to close. This malformation involves the entire CNS. At the level of the spinal defect, there is a midline lesion containing meninges, spinal cord, nerves, and CSF. The bony structures of the spine may be abnormal or absent. Associated abnormalities in the brain include Chiari II malformation, hydrocephalus, and possibly other structural abnormalities.

Chiari II malformation occurs in almost all infants born with myelomeningocele.

It is a malformation of the hindbrain, fourth ventricle, and brainstem and includes herniation of these structures into the cervical spinal canal. Herniation of the brain stem and fourth ventricle may result in obstruction of CSF flow. The development of the hydrocephalus is related to the Chiari II malformation, aqueductal stenosis, venous hypertension in the posterior fossa, and closure of the myelomeningocele (Sgouros 2004a, b).

Hydrocephalus develops in about 85 % of children with myelomeningocele. Approximately 50 % have significant hydrocephalus at birth (Wang and Avellino 2005). About 80–90 % will eventually require a CSF shunt (Dias 2005) or an endoscopic third ventriculostomy. Before modern shunting of these infants in the 1960s, only about 20 % of non-shunted children lived into adulthood. Today, the hydrocephalus can usually be adequately treated. Infants and children who die from this complex condition usually die from the Chiari II malformation and brainstem dysfunction. New



research shows that patients who have undergone prenatal closure of the myelomeningocele have lower rates of hydrocephalus, and in some patients, there was no formation of a Chiari II malformation (Adzick et al. 2011).

Myelomeningocele is discussed in detail in Chap. 4.

### 2.7.3 Chiari I Malformation

Chiari I malformation is one of the four types of Chiari malformations. In Chiari I, the cerebellar tonsils are elongated and herniated into the cervical spinal canal. Chiari I is not associated with myelomeningocele and may be acquired from increased intracranial pressure or occur as an isolated condition.

Hydrocephalus occurs in 10 % of children with Chiari I malformation, most likely due to blockage of CSF flow at the craniovertebral junction. A small posterior fossa may also alter CSF flow. Treatment for patients with symptomatic Chiari I malformation is often a posterior fossa decompression. A small percentage of children develop hydrocephalus after the decompression.

Chiari malformations are discussed in detail in Chap. 5.

### 2.7.4 Dandy-Walker Malformation

Dandy-Walker malformation is a continuum of posterior fossa abnormalities including Dandy-Walker malformation and Dandy-Walker variants. The abnormalities associated with these conditions include cystic dilation of the fourth ventricle, partial or complete absence of the cerebellar vermis, upward displacement of the tentorium, and usually hydrocephalus. Dandy-Walker may be differentiated from a posterior fossa cyst by the atrophy or agenesis of the vermis seen on MRI scan. Dandy-Walker malformation/variant may also be associated with other intracranial abnormalities in 70 % of patients. These abnormalities include agenesis of the corpus callosum, aqueductal stenosis, schizencephaly, holoprosencephaly (failure of the prosencephalon, the embryonic

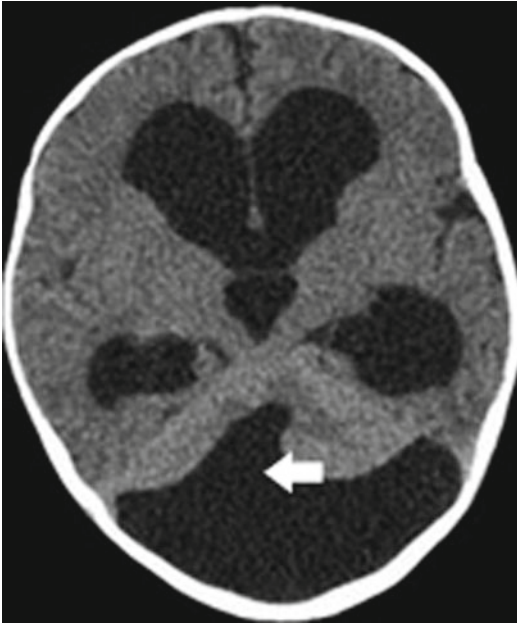forebrain, to sufficiently divide into the double lobes of the cerebral hemispheres, resulting in a single-lobed brain and severe craniofacial defects), neural tube defect, and occipital encephalocele. Dandy-Walker is found in 2–4 % of all children with hydrocephalus (Greenberg 2010). Other abnormalities associated with Dandy-Walker malformation/variant include congenital heart defects, renal malformations, polydactyly/syndactyly, cleft palate, perineal malformations, Klippel-Feil malformation, and facial hemangiomas.

Hydrocephalus occurs in 90 % of children with Dandy-Walker malformation/variant (Greenberg 2010). Initially, it was believed that the hydrocephalus was caused by obstruction of the foramina of Luschka and Magendie. Dandy and Blackfan (1914) believed that the foramina failed to develop or were obstructed due to a prenatal inflammatory process. However, in some cases, the foramina are found to be patent. Also, about 80 % of infants with Dandy-Walker malformation do not have hydrocephalus at birth (Cinalli et al. 2004). The pathophysiology of the hydrocephalus is now felt to be multifactorial. Contributing factors include aqueductal stenosis, basal arachnoiditis from an inflammatory process, abnormally developed subarachnoid space, and venous hypertension from direct pressure from the posterior fossa cyst (Cinalli et al. 2004) (Fig. 2.3).

### 2.7.5 Vein of Galen Malformation

A vein of Galen malformation is a rare vascular malformation. It is a venous aneurysm of the vein of Galen fed by numerous aberrant branches of the carotid or vertebrobasilar vessels. In addition, arteriovenous malformations may occur within the feeding vessels.

Infants with a vein of Galen malformation often present at birth with congestive heart failure and hydrocephalus. They may also develop hydrocephalus later. Hydrocephalus may be caused by the venous malformation causing obstruction of the cerebral aqueduct. Elevated intracranial venous pressure may also decrease CSF reabsorption and cause hydrocephalus (Fig. 2.4a–b).

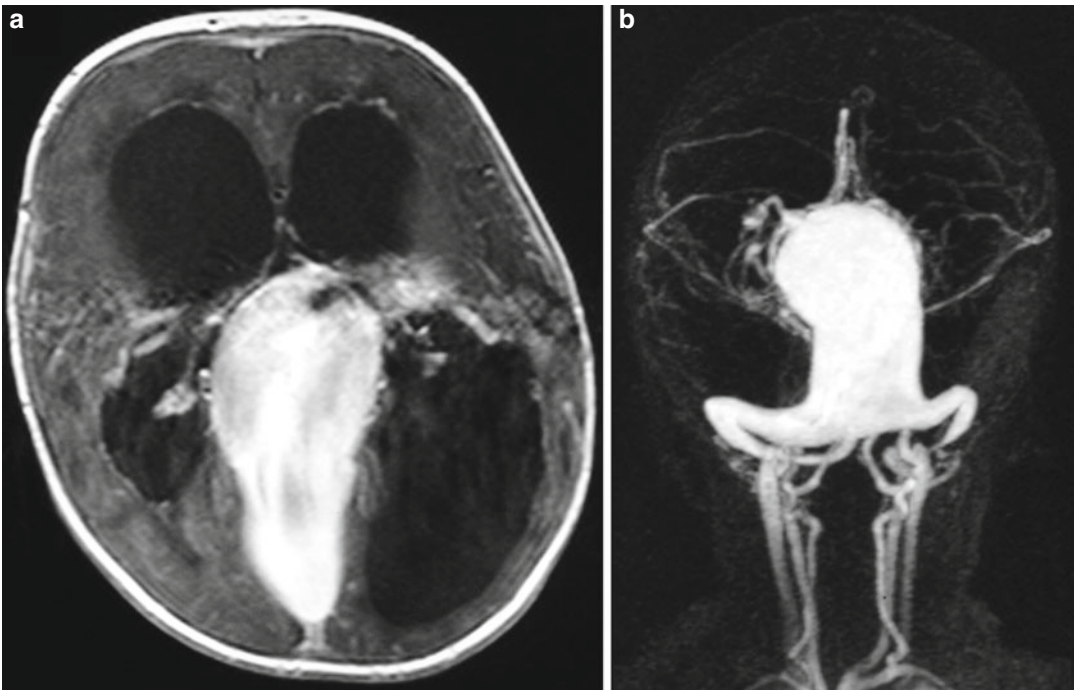


**Fig. 2.3** A 2-month-old female with Dandy-Walker malformation. MRI shows a posterior fossa cyst of the fourth ventricle and subsequent development of severe hydrocephalus

Cerebrovascular diseases are discussed in detail in Chap. 9.

### 2.7.6 Arachnoid Cysts

An arachnoid cyst is a benign congenital cyst occurring within the brain. The cyst forms during fetal development with the splitting of the arachnoid membrane (Raffel and McComb 1994), creating an intra-arachnoid space and the resultant cyst. Most of these cysts do not change or cause any other problems. Such cysts are often found incidentally when a child has a scan for some other reason (i.e., head injury). If the cyst enlarges, it may compress the surrounding structures and cause symptoms from mass effect. Depending on the location, as the cyst expands, it may compress nearby CSF pathways and cause hydrocephalus. A suprasellar cyst may expand upward pressing on the floor of the third ventricle and obstruct the foramen of Monro or aqueduct of Sylvius. A cyst in the quadrigeminal cistern or supracollicular



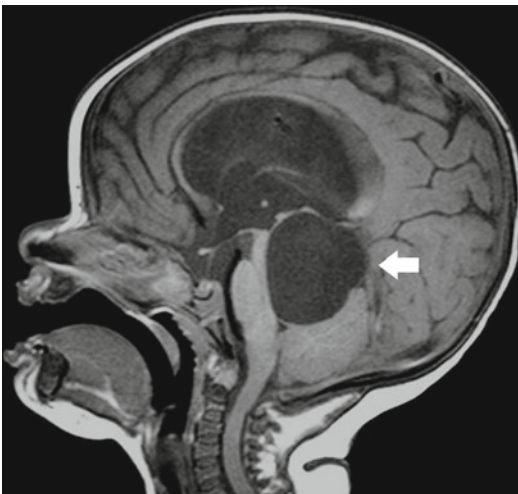**Fig. 2.4** A 4-month-old male with vein of Galen malformation: (a) MRI shows the dilated vein of Galen; (b) cerebral angiogram shows the dilated vein of Galen and the surrounding vasculature

region may cause obstruction of the aqueduct of Sylvius. A posterior fossa arachnoid cyst can cause obstruction at the level of the fourth ventricle. A posterior fossa cyst can be differentiated from a Dandy-Walker malformation by the presence of the cerebellar vermis and a normal appearing fourth ventricle on an MRI. The etiology of expansion of the cyst is unknown.

Surgical intervention is required if hydrocephalus occurs or there are symptoms of mass effect from the cyst. What appears to be an arachnoid cyst may also be associated with a brain tumor. Therefore patients with a newly found cyst require a full MRI of the brain, possibly with contrast, to rule out a tumor. An arachnoid cyst identified before the age of two typically presents with macrocephaly. These cysts are thought to be affected by CSF dynamics, requiring a greater rate of treatment. In Zada's (2007) study, after fenestration, 57 % of patients still required shunt placement (Zada et al. 2007) (Fig. 2.5).

### 2.7.7 Posthemorrhagic Hydrocephalus of Prematurity

The most common cause of hydrocephalus in the premature infant is a germinal matrix hemorrhage. The germinal matrix is a very vascular



**Fig. 2.5** MRI shows a large posterior fossa cyst which effaces the aqueduct of Sylvius and fourth ventricle causing severe hydrocephalus

area in the fetal brain, in the subependymal region located at the level of the foramen of Monro. It is from the very thin-walled germinal matrix vessels that the bleeding is thought to occur in preterm infants. Bleeding can spread, most often to the adjacent ventricles and into the surrounding parenchyma. The germinal matrix gradually involutes after 34 weeks' gestation and nearly disappears by 40 weeks. A grading system has been devised to describe the severity of the bleeding—grades I–IV (Wang and Avellino 2005) (Table 2.2).

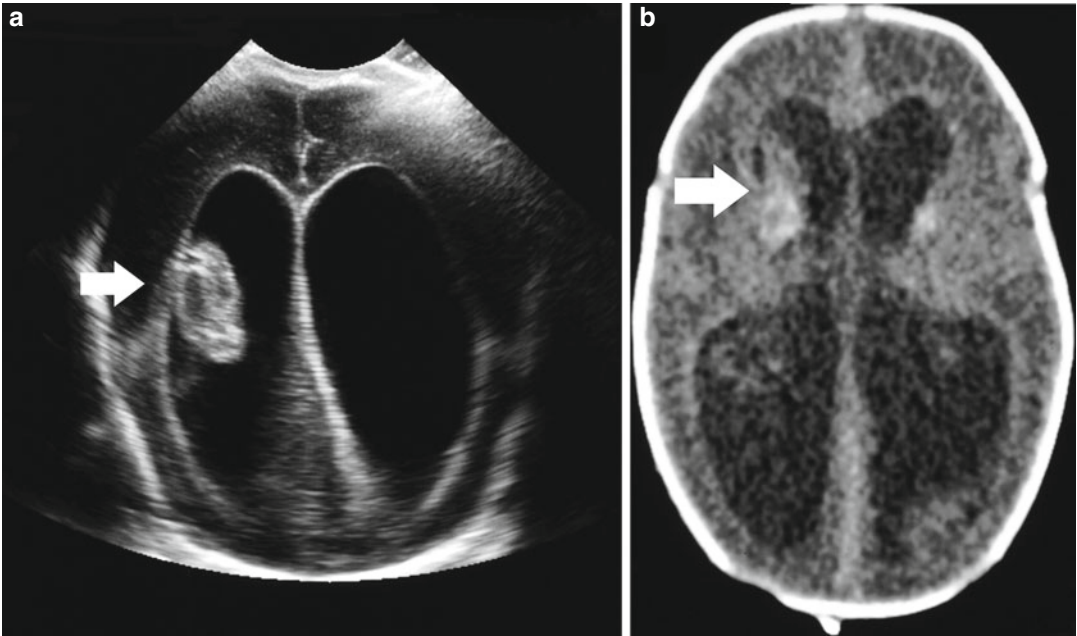
Premature infants less than 34 weeks' gestation with very low birth weight (<1,500 g) are at greatest risk for developing intraventricular hemorrhage (IVH). With current management, 20 % of these preterm infants will develop an IVH. The risk of developing posthemorrhagic hydrocephalus (PHH) is directly related to the extent of the hemorrhage. Hydrocephalus develops in 20–74 % of infants with IVH (Boop 2004). Infants with a Grade I or II bleed do not have hydrocephalus by definition; 55 % of infants with a Grade III hemorrhage and 80 % of those with a Grade IV bleed develop hydrocephalus (Boop 2004). PHH may develop as a result of the accumulation of blood and hemorrhagic debris within the ventricles and subarachnoid spaces (Fig. 2.6). Obstruction of the aqueduct of Sylvius or foramen of Monro may occur. The breakdown of blood may also render the arachnoid villi unable to reabsorb the CSF. Multiloculated hydrocephalus may occur after IVH due to ventriculitis. Ventricular septations may develop causing isolated compartments of fluid within the ventricles.

Many premature infants require surgical intervention to treat the hydrocephalus until it is resolved. About 20–30 % will require permanent

**Table 2.2** Grading of intraventricular hemorrhage

Grade	Extent of hemorrhage (IVH)
I	Subependymal germinal matrix hemorrhage
II	IVH without ventriculomegaly
III	IVH with ventriculomegaly
IV	IVH with parenchymal hemorrhage

Wang and Avellino (2005)



**Fig. 2.6** A 25-week premature male with an intraventricular hemorrhage and subsequent development of hydrocephalus: (a) CUS shows the right-sided intraventricular hemorrhage; (b) CT also shows parenchymal hemorrhage

shunting (Boop 2004). Figure 2.6 illustrates IVH and PHH of prematurity.

### 2.7.8 Postinfectious Hydrocephalus

Intracranial infection at any age may cause hydrocephalus. Hydrocephalus may follow bacterial, fungal, viral, and parasitic infections of the CNS. *In utero*, CNS infections may cause intracranial injury leading to obstruction of CSF flow. Toxoplasmosis may cause inflammation and blockage of the CSF pathways and blockage within the subarachnoid spaces (Ciurea et al. 2004). During the neonatal period, gram-negative bacteria are the leading cause of bacterial meningitis (Ciurea et al. 2004). Gram-negative bacteria may also cause ventriculitis (Ciurea et al. 2004) leading to hydrocephalus.

After the neonatal period, gram-positive bacteria are the leading cause of meningitis. Meningitis and ventriculitis may lead to multiloculated hydrocephalus, a condition where noncommunicating pockets of CSF occur within the ventricles. Viral infections, including CMV, parainfluenza, and

influenza A, can affect ependymal cells leading to acquired aqueductal stenosis and hydrocephalus (Ciurea et al. 2004). Tuberculosis meningitis may cause obstructive hydrocephalus from mass effect of a tuberculoma or cause a communicating type of hydrocephalus by affecting the basal cisterns. Hydrocephalus may develop in conjunction with the intracranial infection or much later after recovery.

Cysticercosis occurs throughout the world. It is rare in the United States but is found throughout Latin America. Humans can acquire the pork tapeworm, *Taenia solium*, by eating undercooked pork or by consuming the tapeworm eggs from food contaminated with human feces. The tapeworm larva enters the body and form cysticerci. Neurocysticercosis results when the cysts enter the brain. The cysts can implant in the parenchyma, ventricles, subarachnoid space, or cisterns. Hydrocephalus can occur when cysts are in the ventricles, subarachnoid space, cisterns, or cause arachnoiditis. In areas such as southern California, Arizona, and New Mexico, neurocysticercosis must be considered as an etiology of hydrocephalus.

### 2.7.9 CNS Tumors

Hydrocephalus is a complicating factor of pediatric brain tumors. Hydrocephalus can be present at the time of diagnosis of the tumor, may occur during or after tumor treatment, or may develop if the tumor reoccurs. Most of the time, hydrocephalus associated with tumors is due to the obstruction of CSF pathways.

About 60 % of brain tumors in children are located infratentorially or in the posterior fossa, occurring in the cerebellum, fourth ventricle, or brainstem. The most common tumors of this region include medulloblastoma, astrocytoma, and ependymoma. Hydrocephalus is common with tumors in this area. It results from obstruction of CSF flow, particularly if the tumor is in the fourth ventricle or exerting pressure on the fourth ventricle. A tectal plate tumor is an indolent tumor of the midbrain and results in hydrocephalus. In all of these tumors, hydrocephalus is often a major contributor to symptoms at the time of diagnosis. If the hydrocephalus is severe, urgent treatment is needed to relieve increased intracranial pressure. Hydrocephalus may also occur from blood and debris in the CSF after tumor resection. Approximately 25–50 % of children will require placement of a permanent shunt (Wang and Avellino 2005) or endoscopic third ventriculostomy after the tumor resection. Certain factors are associated with the need for permanent CSF diversion including age less than 10 years, midline tumors, incomplete tumor resection, CSF infection, and persistent pseudomeningocele (Sainte 2004).

About 40 % of pediatric brain tumors occur in the supratentorial area. The most common site is the suprasellar region, followed by the cerebral hemispheres, thalamus and basal ganglia, pineal region, intraventricular spaces, and meninges. Hydrocephalus is associated with some of these tumors and is usually due to obstruction of CSF flow at the aqueduct of Sylvius. Tumors in the suprasellar region most commonly associated with hydrocephalus are craniopharyngioma and optic pathway glioma. Craniopharyngiomas can also form cysts that exert mass effect that causes symptoms and/or hydrocephalus. Pineal region

tumors are commonly associated with hydrocephalus. Tumors that grow within the ventricles may cause hydrocephalus as a result of overproduction of CSF. There are two types of choroid plexus tumors: choroid plexus papilloma and choroid plexus carcinoma. They arise from the choroid plexus, located within the lateral, third, and fourth ventricles. Occasionally, germ cell tumors and pituitary adenomas may cause hydrocephalus. Hydrocephalus may also occur in patients with neurofibromatosis or tuberous sclerosis secondary to obstruction of CSF flow.

Spinal cord tumors are rare in children. They may be associated with hydrocephalus due to arachnoiditis and elevated protein in the CSF (Fig. 2.7).

Brain and spinal cord tumors are discussed in detail in Chap. 6.

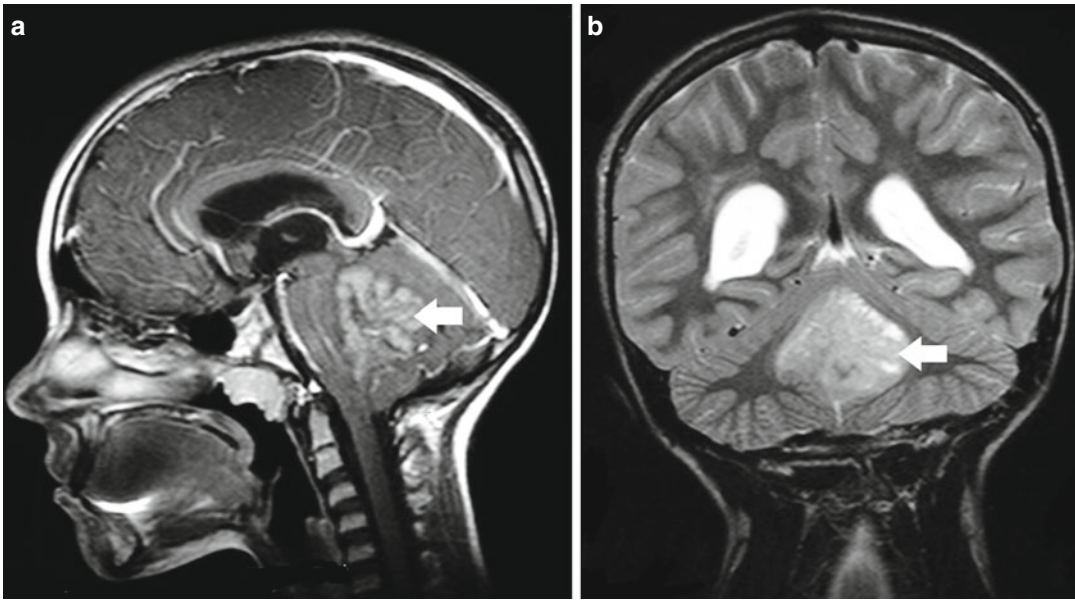
### 2.7.10 Head Trauma

Hydrocephalus may occur after head injury if there is intracranial blood. This is particularly true if there is subarachnoid hemorrhage or IVH. The breakdown of blood may alter the ability of the arachnoid villi to absorb CSF. Debris and blood may also obstruct normal CSF pathways and cause obstructive hydrocephalus.

---

## 2.8 Signs and Symptoms of Hydrocephalus

The signs and symptoms of hydrocephalus in infants and children vary depending on their age, the degree of hydrocephalus at presentation, the primary etiology, and the time over which the hydrocephalus develops. Because of the plasticity of the infant brain and the ability of the cranium to expand, ventriculomegaly can progress without obvious signs of increased intracranial pressure. In premature infants, in which hydrocephalus is caused predominately by IVH, there is a general correlation between the severity of hemorrhage and the degree of hydrocephalus (Table 2.3). Infants with PHH may have minimal symptoms or may exhibit



**Fig. 2.7** (a–b) A 8-year-old female with a posterior fossa brain tumor and hydrocephalus

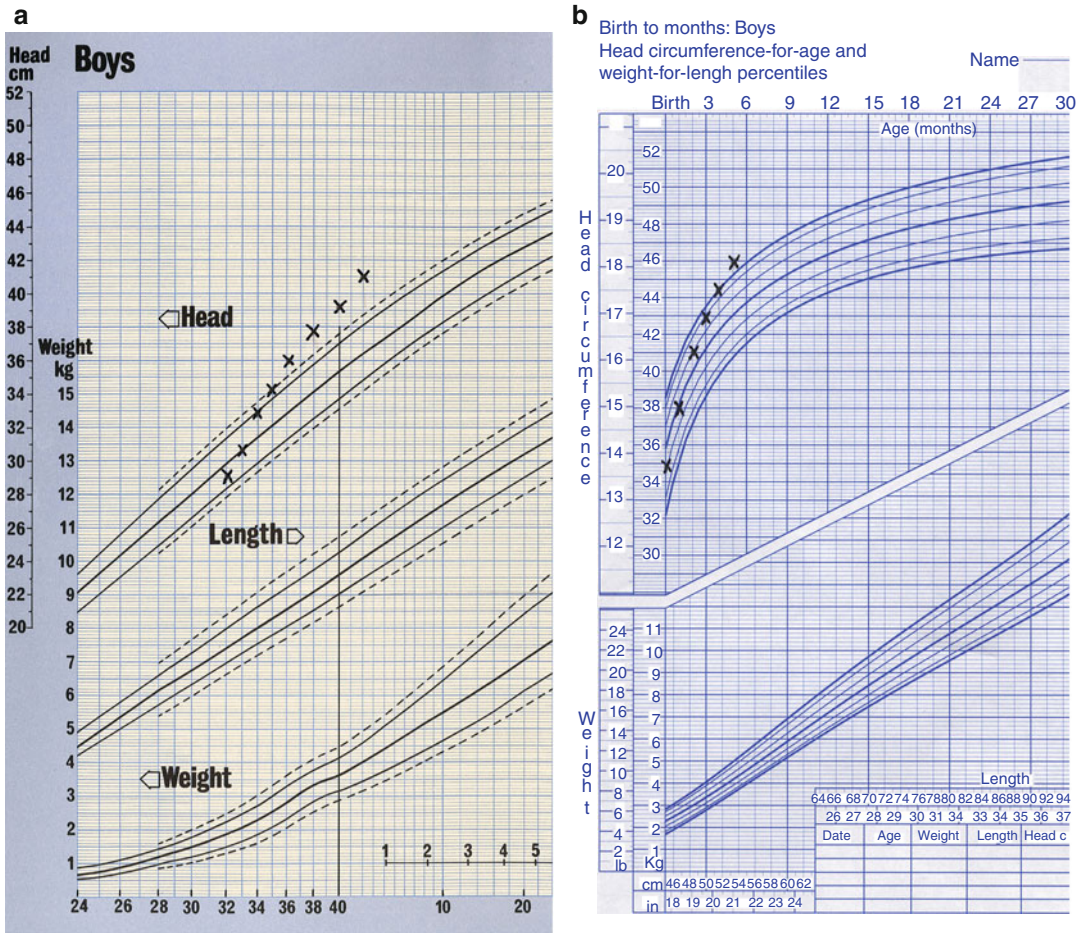
**Table 2.3** Signs and symptoms of hydrocephalus in children

Premature infants	Full-term infants	Toddlers and older
Apnea	Macrocephaly	Headache
Bradycardia	Rapid head growth	Nausea
Hypotonia	Decreased feeding	Vomiting
Acidosis	Increased drowsiness	Irritability
Seizures	Tense fontanelle	Lethargy
Rapid head growth	Vomiting	Delayed development
Tense fontanelle	Distended scalp veins	Decreased school performance
Splayed cranial sutures	Splayed cranial sutures	Behavioral disturbance
Vomiting	Poor head control	Papilledema
Sunsetting eyes	Parinaud's sign	Parinaud's sign
	Sunsetting eyes	Sunsetting eyes
	Frontal bossing	Bradycardia
		Hypertension
		Irregular breathing patterns

increasing spells of apnea and bradycardia. They may also have hypotonia, sunseting eyes, ophthalmoplegia, and seizures. As the ventriculomegaly progresses, the fontanel will bulge, become tense and nonpulsatile, and the cranial sutures become splayed. In a healthy premature infant, the head circumference generally increases about 1 cm a week. In premature infants with progressive ventriculomegaly, the head circumference may increase more rapidly

than normal (when charted on the head growth chart) but may not accurately reflect the rate of increase in ventricular size.

In full-term infants, signs often include macrocephaly and progressively increasing occipital frontal head circumference, crossing percentile curves. Normal head circumference for a full-term infant is 33–36 cm at birth. A normal head circumference increases by approximately 2 cm/month during the first 3 months, by 1.5 cm/month



**Fig. 2.8** Growth charts show the head circumference rapidly crossing percentile curves: (a) premature male infant growth chart; (b) full-term male growth chart

during the fourth and fifth months, and by about 0.5 cm/month from months 6–12 (Fig. 2.8).

Other common signs in full-term infants include a bulging, tense anterior fontanel; splayed cranial sutures; irritability; poor feeding; episodes of spitting up or vomiting; increased sleeping; distended scalp veins; and if the head is large relative to size, poor head control. Visual changes may also be noted and include paralysis of upward gaze (Parinaud’s sign) and sunseting eyes.

Children older than 2 or 3 years may have a more acute presentation of symptoms since the cranial fontanels and sutures are closed, and the skull is no longer able to compensate for the increasing ventricular size. The predominant

symptom is usually a persistent headache that typically occurs upon wakening and is often associated with nausea, vomiting, and lethargy. The child is often irritable. A child who has a gradual onset of hydrocephalus may have more subtle signs, such as delayed development in both motor and cognitive function. Older children often present with decreased school performance and behavioral disturbance. Other less common signs may include papilledema and visual complaints. If hydrocephalus is severe, Cushing’s triad of bradycardia, systemic hypertension, and irregular breathing patterns may occur. This triad denotes a severe case of increased intracranial pressure and requires emergent treatment.

## 2.9 Diagnosis of Hydrocephalus by Imaging Studies

The three major techniques used for diagnosis and evaluation of hydrocephalus are ultrasonography (US), CT, and MRI.

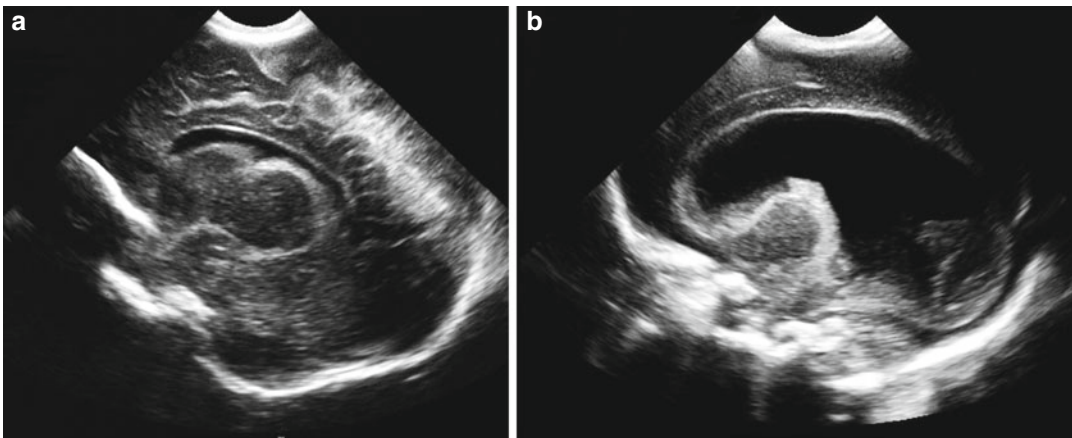
### 2.9.1 Ultrasonography

Prenatal US can be highly reliable and accurate in diagnosing hydrocephalus. Hydrocephalus can be detected in a fetus as early as the later part of the first trimester of pregnancy, although abnormal dilation of the fetus's ventricles are more clearly detectable after 20–24 weeks' gestation (University of California, San Francisco 2000). Although prenatal US can detect an abnormal CSF collection, it may not show the precise site or cause of obstruction. Amniocentesis can often detect the presence of open neural tube defects, such as myelomeningocele, chromosome abnormalities, and *in utero* infections, and may also help indicate the overall health of the fetus. In general, the first trimester development of significant hydrocephalus can be a poor prognostic sign for infant mortality and developmental progress. In some cases, mild ventricular dilation identified by US will resolve by the third trimester (University of California, San Francisco 2000).

Cranial US (CUS) is useful in infants and young children while the anterior fontanel is still open, usually under the age of 18 months (Fig. 2.9). Through the open fontanel, CUS can demonstrate lateral ventricular morphology and intraventricular clots. It is less accurate in its ability to look at the third and fourth ventricles and subarachnoid spaces. For this reason, the precise diagnosis and cause of hydrocephalus is rarely made by CUS alone. It is particularly useful, however, for follow-up screening of infants with untreated and treated hydrocephalus. The equipment is portable, involves no radiation, does not require sedation, and is considerably less expensive than CT/MRI.

### 2.9.2 Computed Tomography (CT)

Since the advent of CT scanning in 1976, it is a common radiologic technique for the diagnosis and follow-up of hydrocephalus. CT images can accurately demonstrate the ventricular size and shape, the presence of blood and calcifications, cysts and shunt hardware. With hydrocephalus, an enlarged ventricular system is usually seen and is typically first seen in the lateral ventricles (Fig. 2.10). CT images can also accurately reflect signs of increased intracranial pressure, such as compressed cerebral sulci, absent subarachnoid spaces over the convexity, and transependymal



**Fig. 2.9** (a) Normal CUS in a 1-month-old female; (b) hydrocephalus in a 3-week-old male

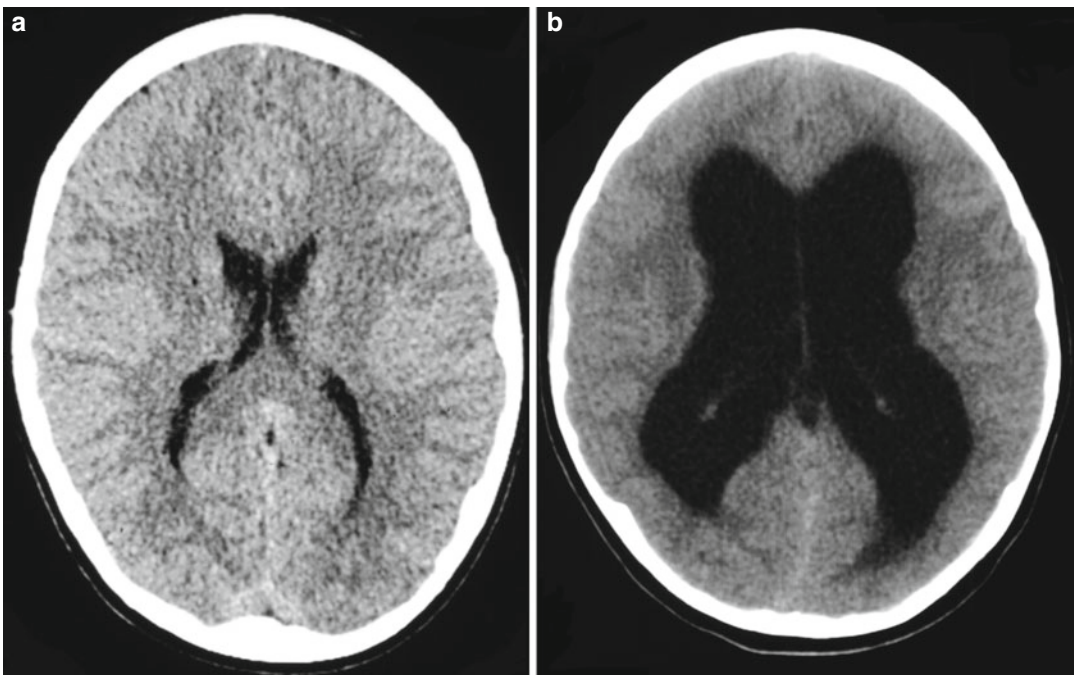


reabsorption of CSF into the white matter. When contrast enhancement is used, tumors, abscesses, and some vascular malformations can be visualized. It is a diagnostic screening tool, taking only a few minutes, and few children need to be sedated for the procedure. CT does expose the patient to radiation, and little is known about the long-term effects of multiple scans. Many providers have concern about the effects of repeated CT scan on the growing brain. Alternatives include low-dose CT or HASTE (limited T2) MR scans. These are acceptable methods for following ventricular size. The Alliance for Radiation Safety has created the “Image Gently” campaign ([www.imagegently.com](http://www.imagegently.com)) to assist providers in obtaining the images they need while decreasing the radiation exposure to the patient.

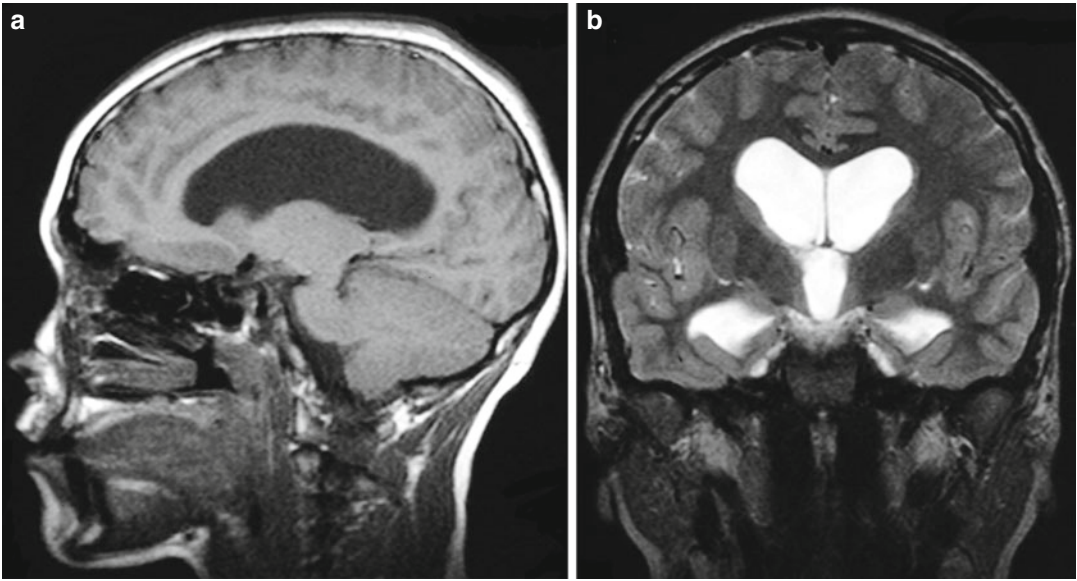
### 2.9.3 Magnetic Resonance Imaging (MRI)

Commercially available MRI was introduced in 1986 and is the examination of choice for revealing the underlying cause of hydrocephalus. It

allows anatomical visualization in the axial, coronal, and sagittal planes, providing detailed information regarding the anatomy and the position and extent of lesions. Subtle findings, such as white matter pathology, dysmorphic anatomy, and characteristics of lesions, can be readily demonstrated. In addition, the aqueduct of Sylvius can be visualized, as well as membranes and loculated ventricular systems. With the addition of gadolinium (an intravenous contrast medium), some neoplasms, infectious and vascular lesions, can be better visualized. CSF flow dynamics can be visualized through the use of phase-contrast cine MRI. This sequence takes only a few extra seconds and allows for real-time flow measurements that are demonstrated on the sagittal plane of the MRI. Furthermore, constructive interference in the steady state (CISS) sequence MRI may be used. This sequence provides great detail of the ventricular system and basal cisterns and may show membranes not otherwise seen on conventional MRI. Both phase-contrast cine MRI and CISS sequence MRI can be very helpful in determining the underlying cause of hydrocephalus. They can also provide valuable preoperative



**Fig. 2.10** (a) Normal CT in a 9-year-old male; (b) hydrocephalus in a 2-week-old male



**Fig. 2.11** A 13-year-old male with aqueductal stenosis and hydrocephalus: (a) Sagittal T1 MRI shows enlarged lateral ventricles (CSF appears *black*); (b) coronal T2 MRI shows enlarged lateral and third ventricles (CSF appears *white*)

information related to the potential success of endoscopic third ventriculostomy, as well as postoperative information by being able to visualize the CSF flow pattern. MRI takes approximately 45 min or longer, and, therefore, young children need to be sedated for the exam. Typically developing children over the age of 5 or 6 can often do the exam without sedation.

The half-Fourier single-shot turbo spin-echo (HASTE) MRI is a limited T2 image that shows ventricular size. It is an alternative to CT, does not expose the child to radiation, and requires no sedation as it is a short study (Penzkofer et al. 2002).

Aqueductal stenosis and hydrocephalus are shown in Figs. 2.11, 2.12, and 2.13, along with cine and CISS MRI scans.

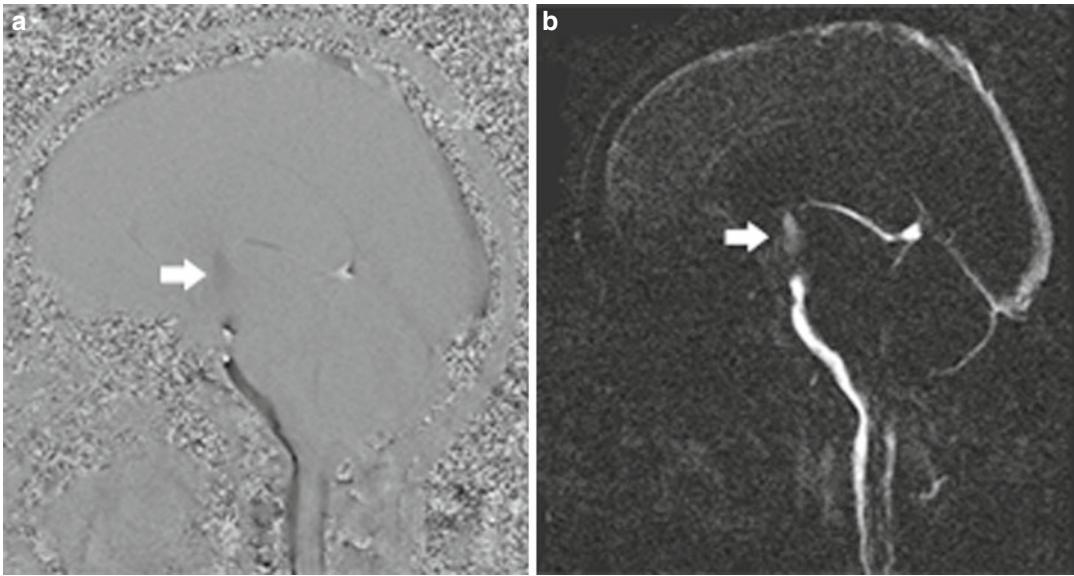
## 2.10 Treatment of Hydrocephalus

### 2.10.1 Medical Therapy

There is currently no medical therapy that definitively treats hydrocephalus effectively. Occasionally, in borderline cases of progressive hydrocephalus and in PHH, diuretics may be

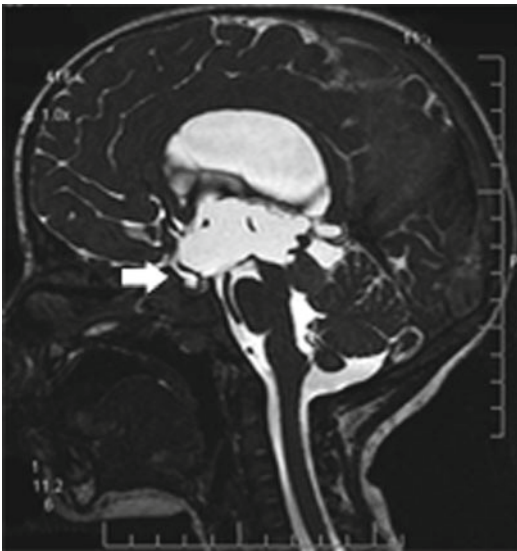
useful as a temporizing measure to try to avoid the need for a permanent shunt. Acetazolamide, a carbonic anhydrase inhibitor, has been shown to decrease CSF production. The dose may be as high as 100 mg/kg/day, and in order for it to be effective, more than 99 % of carbonic anhydrase must be blocked before CSF production decreases significantly. Furosemide, 1 mg/kg/day, has also been used. The mechanism of action is unknown, but it is thought to decrease brain extracellular fluid. Although these have been used historically as temporizing measures, comprehensive analysis of data from clinical trials on diuretic therapy for PHH by the Cochrane Collaboration concluded that acetazolamide and furosemide were neither effective nor safe for the treatment of PHH (Whitelaw et al. 2001).

Serial lumbar or ventricular punctures to evacuate CSF are also used as a temporizing measure. The efficacy of these punctures is controversial, but some centers routinely use them in infants until they are stable enough to tolerate a surgical intervention. The goals are to decrease the ICP and help clear the CSF of toxic chemicals produced by the breakdown of blood. If the infant continues to have inadequate CSF reabsorption, a more permanent shunt may be implanted.



**Fig. 2.12** A 13-year-old male with hydrocephalus secondary to aqueductal stenosis, status post endoscopic third ventriculostomy (ETV). CSF cine flow study demonstrates

CSF flow across the fenestration in the anterior third ventricle: (a) phase-contrast magnitude cine MRI; (b) phase-contrast directional cine MRI



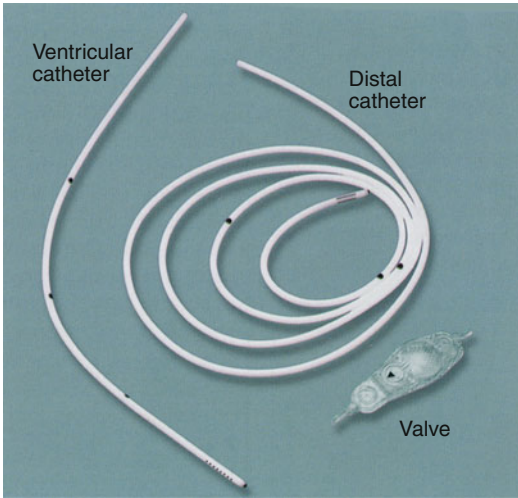
**Fig. 2.13** A 13-year-old male with hydrocephalus secondary to aqueductal stenosis. Preoperative CISS (constructive interference in the steady state) MRI demonstrates the floor of the third ventricle and the position of the basilar artery

## 2.10.2 Surgical Intervention

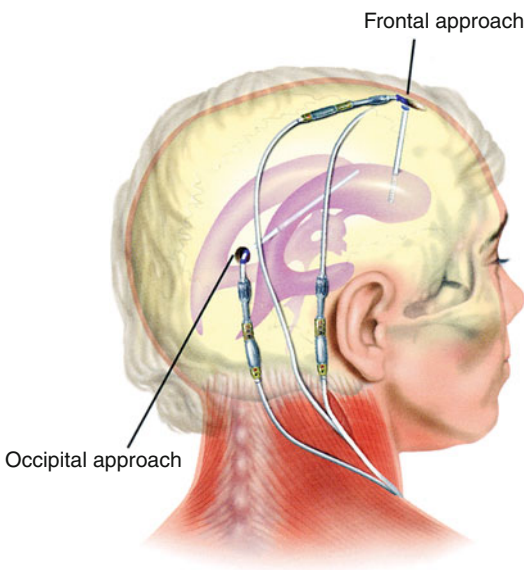
### 2.10.2.1 Shunts

CSF shunting is the most common standard treatment in the long-term management of hydrocephalus. It involves the placement of a ventricular catheter to divert CSF to another body cavity, where it can be absorbed. There are many different shunting devices with different components, all having similar features. The three main components of a shunt are a proximal (ventricular) catheter, a valve, and a distal catheter (Fig. 2.14). The ventricular catheter is a silastic tube that is placed either through a frontal or parieto-occipital approach, usually in the right nondominant cerebral hemisphere, as shown in Fig. 2.15. A burr hole is made in the skull, and the catheter tip is generally placed in the frontal horn of the lateral ventricle. This placement is advantageous because there is less choroid plexus in this area and, therefore, less chance for the holes in the catheter to become occluded.

There are many different valves made by many different manufacturers. They all regulate the flow of CSF by means of a one-way valve. The valves most commonly used in the pediatric setting today



**Fig. 2.14** Shunt components (Courtesy of Medtronic Neurologic Technologies)



**Fig. 2.15** Illustration demonstrates that proximal catheter placement is generally through a frontal or occipital approach

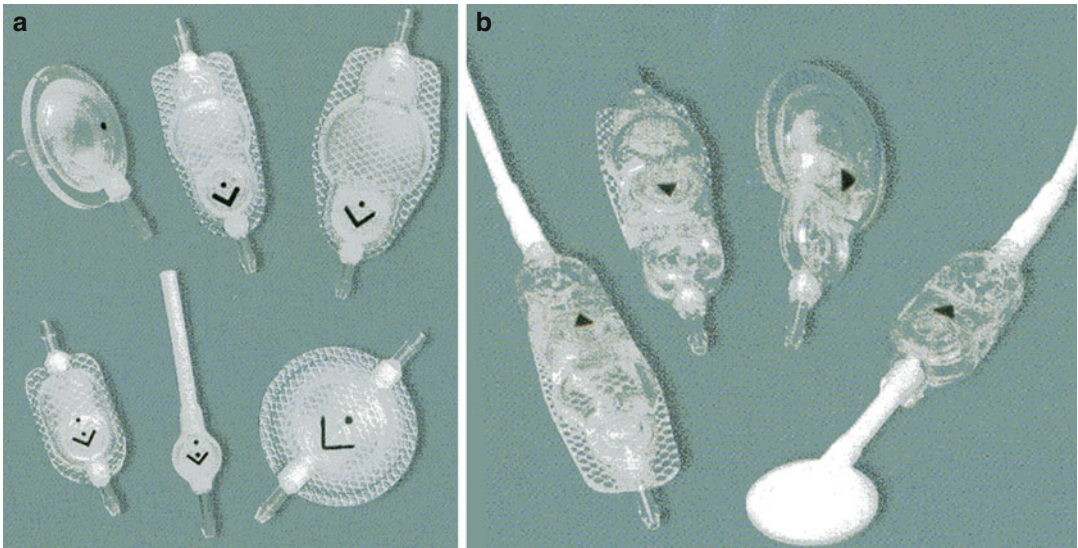
are differential pressure valves, flow-regulating valves, and siphon-resisting valves. The pressure at which the valves open is termed the opening pressure. Typically there are low, medium, and high-pressure valves in each category, referring to opening pressures of approximately 5, 10, and

15 cm H<sub>2</sub>O, respectively. Most valves are differential pressure valves and are designed to open and allow drainage of CSF as the intraventricular pressure rises above the valve's opening pressure. Once the pressure falls below the closing pressure, the valve closes and the flow of CSF ceases. Flow-regulating valves attempt to keep the CSF flow constant despite changing pressure differentials and patient position. Siphon-resisting valves are used to avoid siphoning of CSF and the complication of over-drainage. Siphoning is a phenomenon that occurs in some patients in whom there is gravity-enhanced flow of CSF when the patient is in an upright position. The choice of which valve to use is based on the personal preference of the neurosurgeon and is usually based on training and personal experience. No data exists to support a recommendation of one particular shunt design or valve over another. Fixed pressure valves are shown in Fig. 2.16.

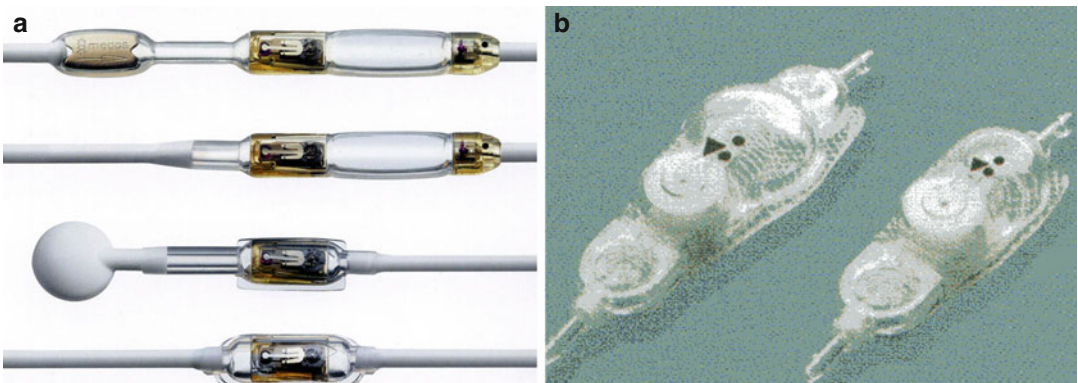
A recent advance in shunt valve technology has been the introduction of programmable valves (Figs. 2.17, 2.18, 2.19, and 2.20).

Programmable valves allow the opening pressure of the valve to be adjusted externally with the use of a special magnetic device. This avoids the need for an operative procedure should the patient need a valve with a different pressure. This type of valve tends to be well suited for the management of difficult cases of over-drainage or under-drainage or in children whose pressure needs are expected to change over time. It is not clear that the benefits outweigh the increased cost in all patients. Since the programmable valve contains a magnet, most valves need to be reprogrammed immediately after all MRIs. Several programmable valves that are not altered by a magnetic field are also available. In these valves, the setting is locked and can only be changed with the manufacturer's specific magnetic programmer. Common everyday household equipment like mobile telephones and computers are not strong enough to affect programmable valves, although special precautions should be taken when the patients are around other strong magnetic sources.

Distal catheters are also made of silastic material. The peritoneal cavity is the preferred and



**Fig. 2.16** (a) Fixed pressure valves; (b) delta valves with siphon control (Courtesy of Medtronic Neurologic Technologies)

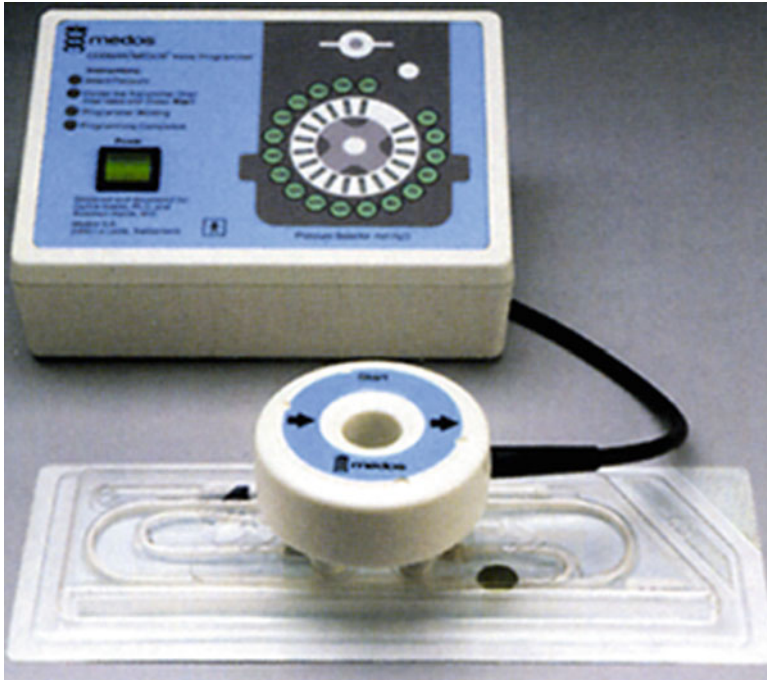


**Fig. 2.17** (a) Codman Hakim programmable valves; (b) strata programmable valves (Courtesy of Medtronic Neurologic Technologies)

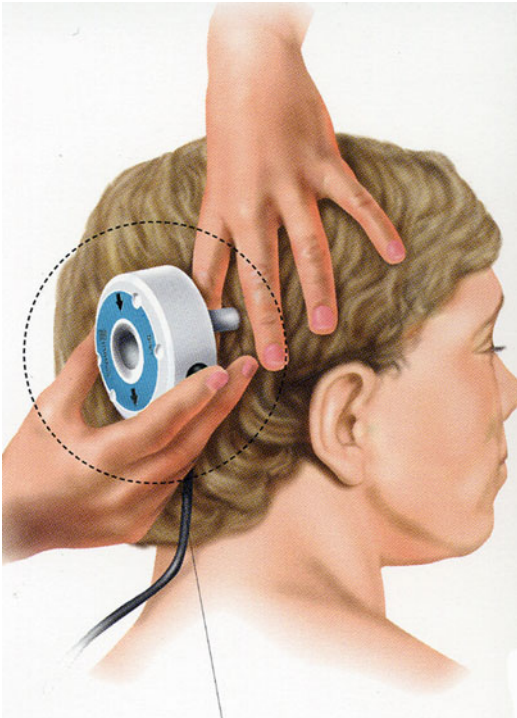
most commonly utilized location for the shunt to terminate. There are two main advantages to placing the distal tubing in the peritoneum. First, if an infection develops, it usually stays localized rather than disseminating, as can happen with shunts placed in the heart. Second, a large amount of tubing can be placed in the peritoneal cavity to allow for growth of the child and minimize the need for revisions during expected childhood growth. In addition, the peritoneal cavity is an extremely efficient site of absorption and is also easily accessible to the surgeons. If the peritoneal cavity is not appropriate for placement of the

distal tubing, either due to an abdominal malformation, post surgical adhesions, infection, or inadequate reabsorption, the second and third choices for the distal catheter placement are the right atrium of the heart or the pleural cavity.

Ventriculoatrial shunts are placed through the neck, into the jugular vein to the superior vena cava and into the right atrium. The shunt tip should lie just above the tricuspid valve, and on plain chest radiograph should be at the superior vena cava/right atrial interface. The tip of the catheter can also be evaluated by looking for it at the level of the sixth/seventh thoracic vertebrae.



**Fig. 2.18** Codman Hakim valve programmer

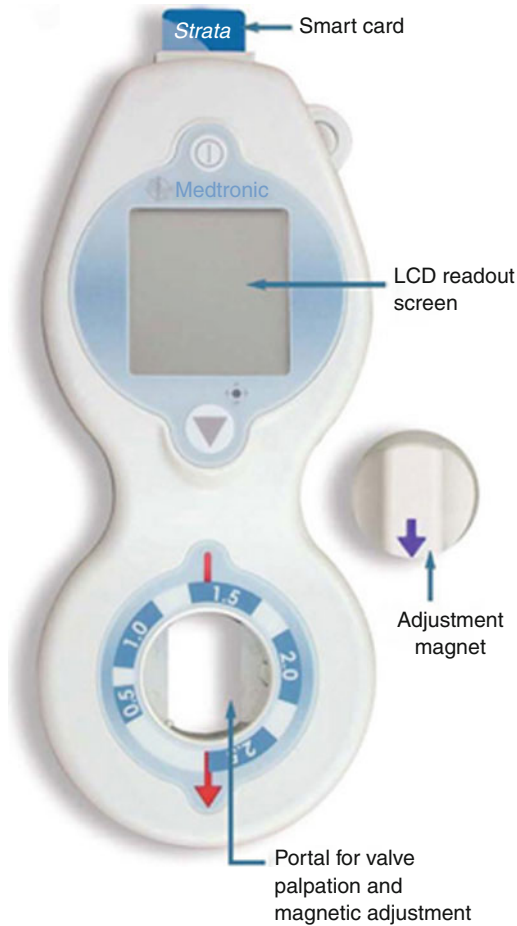


**Fig. 2.19** Illustration demonstrates programming a Codman Hakim programmable valve

If it is above this level, a shunt-lengthening procedure may be indicated. Infants should have a chest x-ray every 6 months and older children every year to make sure the distal placement is adequate.

Ventriculopleural shunts are guided subcutaneously to an area just below the nipple, where an incision is made, and the tube is inserted into the pleural space. There is concern that pleural shunting may be poorly tolerated in the young child due to lack of adequate absorptive pleural surface. In addition, the length of time the pleural cavity retains its absorptive capacity varies from individual to individual. Complications may include respiratory compromise secondary to hydrothorax. Other less common distal placements include the gallbladder and ureter.

Less frequently used in the pediatric population, lumboperitoneal shunts are sometimes used in patients with communicating hydrocephalus, slit ventricle syndrome, or benign intracranial hypertension (pseudotumor cerebri). Although classically performed using a limited laminectomy, percutaneous placement using a Tuohy



**Fig. 2.20** Strata valve programmer (Courtesy of Medtronic Neurologic Technologies)

needle in children over the age of 2 years is now the preferred method of insertion of the catheter into the intradural space (Greenberg 2010) (Figs. 2.21 and 2.22).

### 2.10.2.2 Surgical Endoscopy

A significant development in pediatric neurosurgery has been the evolution of neuroendoscopy and its application in the management of hydrocephalus. It has been used for endoscopic third ventriculostomy, cyst fenestration and septostomy, and shunt placement and retrieval. The pioneering stage of neuroendoscopy began in the early 1900s but quickly fell out of favor due to poor equipment and a high rate of associated morbidity and mortality. In the 1970s, there was

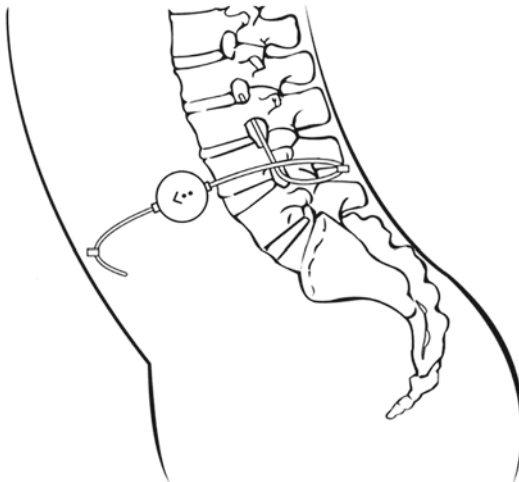
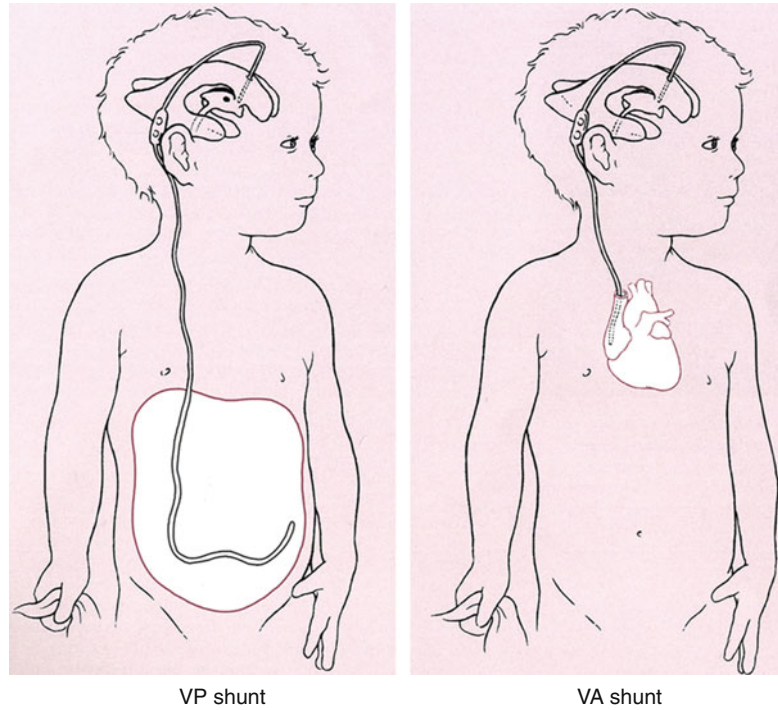
renewed enthusiasm for its use because of improvement in endoscopes, light sources, camera equipment, and instrumentation. In the past decade, there has been a marked increase in the use of endoscopy.

### 2.10.2.3 Endoscopic Third Ventriculostomy

Endoscopic third ventriculostomy (ETV) is used as an alternative to shunting in selected patients with noncommunicating hydrocephalus. The success of the procedure depends largely on proper patient selection. The patients most likely to benefit from the procedure are those with significant obstruction of CSF flow between the ventricles and the subarachnoid space and those with normal CSF absorption between the subarachnoid space and the venous system. An MRI should be done as part of the work-up to confirm that the basilar artery does not lie below the floor of the third ventricle. Such placement of the artery is usually a contraindication for a third ventriculostomy due to the added risk of hemorrhage at the time of surgery. In the past, third ventriculostomy has been controversial, and patients under the age of 6 months have not had uniformly good results (Cinalli et al. 1999). Correct patient selection for an ETV has been shown in multiple studies to be vital in the success of the ETV. Many neurosurgeons now consider the factors identified in the ETV Success Score to identify patients based on the criteria of age, etiology, and previous exposure to shunt hardware (Kulkarni et al. 2009; Oertel et al. 2009). Based on these factors, a score is easily calculated and estimates the percentage probability of a successful ETV. Patients with aqueductal stenosis are, in general, excellent candidates for the procedure. It has also been used successfully in patients with posterior fossa tumors.

The goal of ETV is to bypass the obstruction of CSF by diverting it through the floor of the third ventricle and returning it to the normal subarachnoid space. An endoscope is introduced into the lateral ventricle via a coronal burr hole and advanced through the foramen of Monro and into the third ventricle. Once the thin translucent floor of the third ventricle is visualized, a rigid probe is

**Fig. 2.21** Illustration shows placement of ventriculoperitoneal (VP) and ventriculoatrial (VA) shunts



**Fig. 2.22** Illustration shows lumboperitoneal shunt (LPS) placement

used to puncture the membrane, and the fenestration is enlarged by balloon catheter dilatation. A laser may also be used to fenestrate the floor of the third ventricle. An external ventricular drain with an intracranial pressure monitor may be placed after the procedure and is usually kept clamped (to drainage). This allows monitoring of

the ICP and possible diversion of CSF should the ETV be unsuccessful.

Patency of the third ventriculostomy can be confirmed noninvasively using phase-contrast cine MRI, or CISS sequence MRI, to identify the CSF flow through the fenestration. However, the finding of a patent fenestration does not guarantee that the procedure has been successful. If there is an obstruction to the circulation of CSF further downstream or inadequate absorption within the subarachnoid space, it is possible for the procedure to fail, even in the setting of a patent fenestration. Ventricular size often does not change after an ETV, even though the pressure is normalized in the ventricles.

ETV has an overall success rate of approximately 75 % after 3 years (Teo and Mobbs 2005). With improved selection, this success rate may be as high as 83 % at 5 years (Kulkarni 2009). Failure of ETV can occur early or late. Early failure may be the result of factors including bleeding around the fenestration site, unnoticed additional arachnoid membranes occluding the flow of CSF, or an inadequate size of the fenestration. Late failure can be caused by subsequent



closure of the fenestration by gliotic tissue or arachnoid membrane. Tumor progression and inadequate CSF absorption at the level of the arachnoid villi may result in either early or late failure.

Patients with an ETV require ongoing neurosurgical follow-up as they can exhibit deterioration after months or years of successful ETV. The problem can be potentially serious because failure can develop over a short period of time and may be unpredictable. The patient develops signs and symptoms of increased intracranial pressure and requires further intervention, either another ETV or a shunt.

Choroid plexus cauterization (CPC) may be coupled with ETV. CPC is a process by which the choroid plexus is cauterized bilaterally within the lateral ventricles through an endoscope. This helps to reduce the rate of CSF production. It has been found that combining the CPC with ETV was more successful than ETV alone for treating hydrocephalus in infants less than 1 year of age (Warf and Campbell 2008).

### 2.10.3 Treatment of Hydrocephalus in Specific Malformations/Diseases

#### 2.10.3.1 Posthemorrhagic Hydrocephalus

Infants who develop increasing PHH or become symptomatic need temporizing treatment initially. Some centers will treat these small infants with serial lumbar or ventricular punctures; however, infection is a risk. Repeated ventricular taps may lead to porencephaly (cyst or cavity in the cerebral hemisphere).

In infants who have PHH and are able to tolerate a surgical intervention, a ventricular access device (VAD) can be implanted. This is a catheter that is surgically placed into the ventricle with an attached subcutaneous reservoir. The reservoir can be tapped as often as needed through the skin using a 23-gauge butterfly needle. Most infants with a VAD require a tap every 2–3 days, but some may require taps as often as twice daily.

Another procedure that may be used is the placement of a subgaleal shunt. This is similar to a VAD, but the distal limb of the catheter is left to

drain into a subgaleal pocket, which is created at the time of the placement of the device. The CSF under pressure drains through the catheter and distends the scalp, which allows absorption of the CSF by the galea. In some cases, CSF production may exceed the absorptive capability of the subgaleal space, and intermittent taps of the pocket may be required. When repeated taps are needed through either the VAD or the subgaleal shunt, there is a risk of infection. Alternatively, some providers use a temporary external ventricular drainage device in the management of PHH. This has the advantage of maintaining a constant intraventricular pressure, whereas with the other aforementioned treatments, intraventricular pressure can alternate between being very high and very low. The disadvantage of all of these devices is that the catheters can become clogged from the blood or its by-products or, as previously mentioned, infected.

Eventually, over time, it will become clear whether the PHH is resolving or if the infant will need a permanent shunt placed. It has been demonstrated by studies on temporary measures to treat PHH that lumbar punctures and ventricular taps showed no reduction in ongoing need for VP shunt placement. Despite temporizing measures, only 10–35 % of infants will show resolution of their hydrocephalus (Boop 2004). About 20–30 % will require a permanent shunt. In the majority of these infants, the shunt dependency is usually lifelong. There is currently some debate as to the most appropriate timing for a permanent shunt placement. A shunt should be considered when the CSF is cleared of posthemorrhagic debris and blood and the CSF protein is <500 mg/dl (Rekate 1999). The infant should weigh >1.5 kg (variable), have progressive hydrocephalus (Wang and Avellino 2005), and be otherwise stable (Box 2.1).

#### 2.10.3.2 Myelomeningocele

About 80–90 % of children with myelomeningocele will eventually require surgical CSF diversion (Dias 2005). The treatment of hydrocephalus in the infant with a myelomeningocele usually involves placement of a ventriculoperitoneal shunt. The timing of the shunt placement depends

### Box 2.1. Case Study: A 27-Week Premie with IVH

Baby P was born at 27 weeks gestation. The patient was born via an emergency C-section due to maternal hypertension and preeclampsia. The patient required CPR at birth and was intubated. An initial cranial ultrasound (CUS) revealed bilateral IVH, grade III on the right and grade IV on the left.

Baby P was initially watched closely by the NICU team with daily OFC and twice weekly CUS. The patient was extubated and started on high-flow nasal cannula. The patient was noted to have a gradual increase in head size. The patient was also noted to have an increase in bradycardic and apneic events. CUS revealed slight increase in ventricles.

On day 24 of life, the patient weighed 1.1 kg. Baby P was taken back to the operating room for a placement of a left frontal subgaleal shunt with a Rickham reservoir, which entailed creation of a subgaleal pocket. The patient initially had a stable subgaleal pocket that was fluid filled and soft. The OFC and US remained stable.

However, over the next several weeks, the subgaleal pocket lessened. By 6–7 weeks of life, Baby P was noted to have a rising OFC and fuller fontanel, with splayed sutures. A CUS, done on week 8 of life, revealed the ventricles to be larger. The patient also demonstrated episodic desaturations. The subgaleal reservoir was tapped using sterile technique. 10 cc/kg of CSF was withdrawn per this hospital's policy. The patient tolerated procedure well and his/her clinical status improved.

Baby P's weight was now 2.2 kg. Therefore, the decision was made to take the patient back to the operating room. The patient underwent placement of a ventricular-peritoneal shunt with a programmable valve. The patient tolerated the procedure well and continued to be followed while inpatient with daily OFCs and weekly CUSs. The patient's shunt valve resistance was increased (resulting in decreased flow of CSF) once due to sunken fontanel and overriding sutures. Baby P did well and was discharged home at 3 months of age.

on the severity of the hydrocephalus but historically has been deferred until after the myelomeningocele repair. Waiting until the hydrocephalus clearly progresses allows for the proper selection of infants who need permanent shunting. Placing a shunt at the time of the back closure may also be more difficult, since the infant should not be positioned on the newly closed myelomeningocele repair site. The advantages to doing it simultaneously with the myelomeningocele repair include a decreased risk of a CSF leak from the repair site and a decreased risk of CSF infection. Some neurosurgeons perform an endoscopic third ventriculostomy instead of a shunt, although performing an ETV in infants is debated.

Placement of an external ventricular drain (EVD) at the time of closure is another option; this allows for the decision of a permanent shunt to be deferred and minimizes the risk of leaking from the back closure.

The *in utero* surgical repair of myelomeningocele was studied in a multicenter study funded by the National Institutes of Health. The purpose of the study was to determine efficacy, safety, and benefit of *in utero* closure of the back (Sutton 2005). Prenatal surgery for the myelomeningocele repair performed before 26 weeks' gestation was found to be associated with decreased risk of death, decreased need for a shunt by 12 months of age, improved scores on mental and motor function, and decreased degree of hindbrain herniation associated with Chiari II malformation (Adzick et al. 2011).

### 2.10.3.3 Vein of Galen Malformation

Initial treatment for the neonate is supportive and may include immediate resuscitative efforts with ventilatory support. The goal is stabilization until a transvenous and/or transarterial endovascular approach for embolization can reduce blood flow

through the malformation and feeding vessels. The infant often presents with, or develops, hydrocephalus. However, the placement of a cerebrospinal shunt in an infant or child with a vein of Galen malformation has a very high risk of associated intracranial hemorrhage (Schneider et al. 1992). Many neurosurgeons will try to avoid placing a shunt by initially treating the malformation with embolization. If the malformation can be successfully embolized, it may shrink and the hydrocephalus may resolve. Although treatment has greatly improved outcome, mortality and morbidity of these malformations remains high. These patients can have a wide range of cardiac symptoms related to the increase in venous return to the right atrium and chronically increased preload. Patient's cardiac symptoms can range from mild volume overload to congestive heart failure or cardiogenic shock (Hoang et al. 2009).

#### 2.10.3.4 Intracranial Cysts

Many types of intracranial cysts may occur including arachnoid cysts, choroid plexus cysts, neoplastic cysts, and multiloculated cysts associated with infection, tumors, hemorrhage, or trauma. Arachnoid cysts are often diagnosed as an incidental finding when a CT is done for another reason. At the time of the initial diagnosis of an arachnoid cyst, an MRI is often done to rule out a tumor. An intracranial cyst may cause no mass effect or symptoms. Conservative treatment of such a cyst, including follow-up scans to verify that there is no change, may be adequate. The cyst can cause mass effect with symptoms and noncommunicating hydrocephalus from obstruction of normal CSF pathways. In these cases, surgical intervention is required. Rarely, patients present with hemorrhage into the cyst that may also require surgical intervention.

Neuroendoscopic fenestration of the cyst wall may eliminate the need for a shunt. The surgeon breaks the cyst wall with an endoscope, and the fluid in the cyst is allowed to drain into normal CSF passageways. The goal is to reduce the cyst size and avoid placement of a shunt or, if a shunt is necessary, to avoid placing multiple shunts into noncommunicating spaces. Some surgeons may decide to shunt the cyst first because of the high

rate of cyst reoccurrence after fenestration (Abtin and Walker 1999). If a ventricular shunt is needed, a shunt catheter can be placed into the cyst(s) and another into the ventricle. These catheters can be "y'ed" together into a distal catheter terminating in the peritoneal cavity. The failure rate of multiple shunt catheters is high, and it is difficult to determine which catheters are functional and which are not at the time of malfunction. If the lateral ventricles are loculated (isolated) by membranes or cysts, the surgeon may fenestrate the septum pellucidum (septostomy) to eliminate the need for more than one shunt catheter.

#### 2.10.3.5 Brain Tumors

Approximately two-thirds of children who present with a posterior fossa tumor will have hydrocephalus. A smaller number of children with supratentorial tumors will have associated hydrocephalus at the time of diagnosis. If the hydrocephalus is severe and the child is very symptomatic, an emergent external ventricular drain or shunt may need to be placed. When the surgeon anticipates a resection of the tumor, an external ventricular drain is usually the most appropriate choice because of the risk of shunt failure after tumor surgery due to blood and debris in the CSF from the surgery. If hydrocephalus is present, most neurosurgeons will place an external ventricular drain immediately before a posterior fossa tumor resection. The CSF is allowed to drain for 48–96 h postoperatively, and then the child is gradually weaned from the drainage device over several days. Approximately 25–50 % of these children will be unable to tolerate weaning or removal of the external ventricular drain and will need a permanent shunt (Wang and Avellino 2005) or endoscopic third ventriculostomy (Box 2.2).

---

## 2.11 Complications of Shunts and Treatment

Complications of cerebrospinal fluid (CSF) shunts include mechanical failure of the shunt, infection, and over-shunting. Depending on the location of the distal catheter of the CSF shunt, risks of other complications are possible.

### Box 2.2. Case Study: An 8-Year-Old Boy with Fourth Ventricular Mass

J is an 8-year-old boy who presented with headaches and nausea/vomiting for 1 month. The patient had CT scan that revealed a fourth ventricular mass, measuring  $3 \times 3 \times 2.5$  cm with significant ventriculomegaly and transependymal flow. J was immediately flown to a pediatric neurosurgery center. An MRI of the brain and spine was subsequently done on arrival which showed a homogenous and uniformly enhancing fourth ventricular mass with restricted diffusion and severe hydrocephalus. Spine MRI was normal.

On arrival at this center, J was emergently taken to the operating room for placement of a right frontal external ventricular drain (EVD). J tolerated the procedure well and his symptoms improved. The EVD was drained at a level of 15 cm H<sub>2</sub>O cm above the external auditory meatus. The patient was started on intravenous antibiotics for prophylactic coverage of the drain and high-dose steroids (dexamethasone).

The following day, J was taken back to the operating room for a suboccipital craniotomy and resection of a posterior fossa tumor. Postoperatively, the EVD was set at a level of 10 cm H<sub>2</sub>O. The CSF output initially was bloody and pinkish in color. He had daily sodiums checked which remained stable.

Over the next 3 days, the patient's EVD continued to be monitored. The CSF had less blood products and became straw colored. The patient continued to recover and did remarkably well. Therefore, on day 4 postoperatively, his EVD was raised to 15 cm H<sub>2</sub>O. The patient continued to have no headaches or other symptoms, and the following day the drain was raised to 20 cm H<sub>2</sub>O. While at 20 cm H<sub>2</sub>O, he started to develop headaches and became sleepy. A pseudomeningocele developed at the site of his incision. A limited MRI (HASTE MRI) revealed enlarged ventricles. The patient's EVD was lowered to 15 cm H<sub>2</sub>O since he had failed the attempted wean.

The patient was taken to the operating room the following morning for a placement of a right ventricular-peritoneal shunt which he tolerated well. He was able to be discharged home 4 days later after receiving further therapies.

Pathology revealed the tumor was an ependymoma, grade 2. The patient was enrolled in a study involving treatment with chemotherapy and radiation; he continued to be followed by the neurosurgery team.

### 2.11.1 Shunt Malfunction

Mechanical failure of the shunt can be due to improper placement, obstruction, disconnection, fracture, and migration of the hardware. Malfunctions may occur in the operating room, soon after surgery or years later. However, the most common time for a malfunction is within the first 6 months after placement or revision (McLone 2001).

Obstruction of the shunt hardware comprises 50 % of all CSF complications (Choux et al. 1999). Most often, the obstruction occurs in the proximal portion of the shunt. Total proximal obstruction of the shunt is frequently associated

with rapidly increasing intracranial pressure and requires emergent intervention. The proximal catheter may become obstructed in the operating room or shortly thereafter with blood or air. Proximal occlusion may also be the result of the choroid plexus growing around the proximal portion of the catheter or from blood or other proteinaceous material within the catheter or valve. Occlusion may also be from the catheter being improperly placed during surgery or slipping out of the ventricle later.

If the proximal catheter is obstructed or partially occluded, there may be swelling along the shunt tract over the skull and neck, with minimal signs of shunt failure. Such swelling may also

occur with a functional or partially occluded shunt if there is a large hole in the dura around the shunt catheter, resulting in a CSF leak around the shunt. Obstruction of the distal catheter may be the result of distal infection, scarring, adhesions, or fat occluding the shunt. As the child grows, the distal end of the catheter may slip out of the abdominal cavity. A tract may form allowing CSF to flow beyond the shunt tip, usually failing slowly over time.

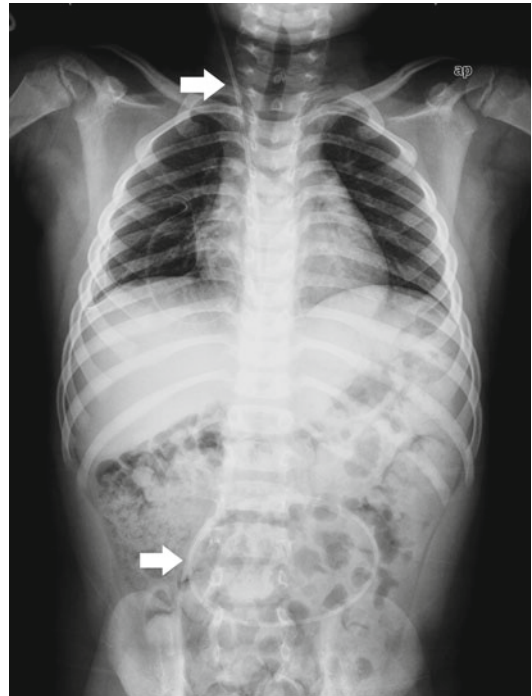
Disconnections happen most often at connection sites between components of the shunt. A disconnection may occur between the proximal catheter and valve or between the valve and distal catheter. Tubing that has been in place for a long time may become fixed by the development of scar tissue around the catheter. Over time, calcification may also develop around the catheter and the catheter itself may degrade. Both the fixation and calcification may lead to catheter breakage with growth, particularly in the neck where there is constant motion (Fig. 2.23). The patient may also develop pain along an old calcified shunt tract.

Migration of the distal catheter may occur to a number of sites, including the scrotum, umbilicus, stomach, mouth, intestine, chest, anus, uterus, internal jugular vein, and coronary sinus. When migration occurs, malfunction of shunt often results from blockage of CSF flow and/or lack of reabsorption of CSF (Greenberg 2010). Infection may also occur in conjunction with migration to another site. Other complications may occur depending on where the distal shunt is located.

### 2.11.1.1 Evaluation and Treatment of Shunt Malfunctions

The initial work-up of the patient with a suspected shunt malfunction includes a thorough history and physical exam. The radiological exam includes shunt series x-rays of the shunt hardware and a CT (without contrast) of the head or limited T2 (HASTE) MRI.

Shunt series x-rays include anterior/posterior and lateral films of the skull, neck, abdomen, and pelvis. These are done to evaluate the continuity of the shunt hardware, location of the hardware,



**Fig. 2.23** Radiograph shows a broken ventriculoperitoneal shunt catheter near the clavicle. The most distal portion of the catheter can be seen in the *bottom* of the peritoneal cavity

valve type, and any other abnormalities. There may be areas of the shunt system that seem translucent on plain films, particularly over the valve and connectors. Comparing the films to previous postoperative films may provide further information about how the shunt hardware appears at baseline. Comparing the films to x-rays of the most common shunt valves and connectors may also be helpful.

The head CT, MRI, or US can also be compared with previous scans. If the patient is symptomatic and the ventricles have increased in size, a shunt failure is usually confirmed. The scan may also reveal other intracranial complications such as improper placement of the proximal catheter or extra-axial fluid or blood.

Ventriculomegaly does not always occur with shunt malfunctions. In some patients, the ventricles remain small due to decreased ventricular compliance. The child who does not demonstrate increased ventricle size with shunt failure needs further testing to evaluate shunt

function. Additional information about shunt function may be obtained by tapping the shunt and measuring the intracranial pressure. This can be done by accessing the shunt via the reservoir or valve with a 23-gauge butterfly needle connected to a manometer. When the shunt is working, there is usually spontaneous flow of CSF through the catheter into the manometer with good respiratory variation; sometimes pulsation will be seen. The lack of CSF flow from the shunt in the presence of normal or dilated ventricles suggests proximal obstruction. If the ventricles are slit-like, no flow may be normal.

Intracranial pressure is measured manually with the manometer. The pressure is measured with the “0” on the manometer at the level of the external auditory meatus (see Sect. 2.13.5 “External Ventricular Drains”). Pressure will vary depending on age and activity of the child (Box 2.1). To obtain a true pressure, the child must be calm. Intracranial pressure measured with a manometer is measured in cm of water (cmH<sub>2</sub>O) (Table 2.4).

A nuclear medicine study (shuntogram) is another test that may be useful in the evaluation of shunt function. A 23-gauge butterfly needle is inserted into the shunt reservoir or valve and the opening pressure is measured. A radioisotope is then injected into the shunt, and gamma camera images are taken of the head, neck, and abdomen to evaluate movement of the tracer. Normal findings of a shuntogram include an opening pressure between 0 and 20 cm of H<sub>2</sub>O (dependent on the age and activity of the child), and radioisotope flows out of the needle hub, clears out of the reservoir and shunt, and disperses freely into the peritoneal cavity (the half-time should be less than 5 min). Both a shunt tap and a nuclear medicine study can sometimes provide confusing results.

If a shunt malfunction is confirmed, the child is taken to the operating room for a shunt revision. Sometimes, a very symptomatic patient without clear diagnostic findings during the work-up may be taken to the operating room to explore the shunt. During a shunt revision, all parts of the shunt are evaluated. Shunt hardware parts that are malfunctioning are replaced (Box 2.3).

**Table 2.4** Normal intracranial pressure for infants and children

Age	Pressure-cm of H <sub>2</sub> O	Pressure-mm of Hg
Neonate	<3	<2
Newborn	2–8	1.5–6
Young child	4–9 1.36 cm of H <sub>2</sub> O = 1 mm of Hg	3–7

Adapted from Wang and Avellino (2005)

### 2.11.2 Shunt Infection

Infection is the second most common complication of cerebrospinal fluid shunts. The incidence is greatest in the first year after placement, with 80 % appearing in the first 6 months. Rates of infection range from 4.1 to 20.5 % per patient and 2.5 to 12.3 % per procedure (Simon et al. 2009a). Patient characteristics can influence risk. Infants and younger children, those with concurrent infection, those who have had a recent shunt revision, those with previous shunt infection, and those with postoperative disruption of the incision exposing the shunt hardware, have a higher risk of shunt infection.

The most common infecting organism is Staphylococci. *Staphylococcus epidermis* (coagulase-negative staphylococcus) is seen in 50–75 % of all shunt infections (Haines 1999). *Staphylococcus aureus* (coagulase-positive staphylococcus), gram-negative organisms (usually *Escherichia coli*, Klebsiella, Proteus, and Pseudomonas), streptococcal species, Neisseria, *Haemophilus influenzae*, and fungi make up the remainder of most infections. Infections with gram-positive organisms correlate with a better outcome than those with gram-negative organisms. The infection usually occurs in one of three ways: (1) via intraoperative contamination, (2) via the bloodstream, or (3) via retrograde travel from a contaminated distal catheter.

#### 2.11.2.1 Evaluation and Treatment of a Cerebrospinal Shunt Infection

If the child has had a recent shunt procedure or a history of shunt infections and presents with symptoms of infection, one should have a high index of suspicion of a shunt infection. If the child

**Box 2.3. Case Study: A 6-Year-Old with Shunt Mal Function**

CS is a 6-year-old male who has a shunt in place due to a history of congenital hydrocephalus caused by aqueductal stenosis. He was shunted at birth. He underwent an endoscopic third ventriculostomy after shunt failure at the age of 3. He did well and then developed symptoms of hydrocephalus again at the age of 5. An MRI was done and revealed that the ETV had closed. He then underwent another shunt placement.

CS presented to the ED with an 18-h history of headache, vomiting, and 6 h of increasing lethargy. He was seen in the ED by the neurosurgical nurse practitioner. Upon exam, he was arousable but sleepy. He was not sure where he was but was asking for his mother. The mother stated that he is a typically developing child and in the first grade. He was complaining of headache and vomited in the ED. His heart rate was in the 60s, and his other VS were normal for age. He could follow some directions such as moving an extremity, but he was not consistently following directions and at times just cried or whimpered. An urgent low-dose CT was done that showed enlarged ventricular size. A shunt series showed that the shunt system was intact, and his Strata valve was set at 1.0, as it had been previously. When he returned from CT, he seemed slightly more somnolent to the mother. His heart rate was occasionally dipping into the 50s. A shunt tap was done, and there was no flow from the shunt. The pressure was measured and found to be  $-10$  cm of water.

Due to the enlarged ventricles, no flow from the shunt tap and negative pressure in the shunt system, a proximal shunt malfunction was presumed. He was taken urgently to the operating room for a shunt revision. He was found to have occlusion of the proximal catheter, and the intracranial pressure was found to be 30 cm of water. A new catheter was placed and attached to the existing valve and distal catheter. Postoperatively, CS was awake and alert. He denied headache and had complaints of being hungry later in the evening. He also denied any memory of the events in the ED. He stayed in the hospital overnight and was discharged the following morning in good condition.

is stable and has not had a shunt procedure in the last several months, the most common diseases of childhood should be ruled out. A thorough physical exam and laboratory work (including complete blood count, C-reactive protein, erythrocyte sedimentation rate, blood cultures, urinalysis, and chest films) may help locate the source of the infection. Most neurosurgeons are reluctant to tap a shunt unless there is clearly no other source of infection, due to the risk of infecting the shunt with the tap.

The child presenting with a shunt infection may range from minimally to gravely ill. The child may have one or more signs and symptoms of infection: fever, irritability, redness and/or swelling over the shunt tract, or redness and/or drainage from shunt incisions. The infected shunt may or may not fail. Therefore, the child may or may not have signs and symptoms of a

shunt malfunction, including headaches, nausea, vomiting, and lethargy. If the distal portion of the shunt is infected, the child may have abdominal symptoms, including pain, tenderness to palpation, and distension. An abdominal CT or US may reveal an intra-abdominal loculated CSF collection.

Diagnosis of a shunt infection is confirmed by a positive CSF culture from the shunt (or a positive culture from explanted hardware). The shunt reservoir is aspirated via a shunt tap for CSF and sent to the lab for glucose, protein, cell count, Gram stain, and culture. The CSF with infection usually shows mild to marked elevation of WBCs. The Gram stain may show the presence of polymorphonuclear leukocytes and bacteria. The glucose may be decreased, and the protein elevated. Infection in the tissues surrounding the reservoir is usually a contraindication to tapping the shunt.

Even presumed sterile aspiration of the shunt in this setting could lead to contamination and subsequent infection of the shunt.

The treatment of a shunt infection varies, but in general principles of treatment of infection in the setting of a foreign body are followed. Cultures are obtained, and intravenous broad-spectrum antibiotics are started to cover the most likely organisms. The shunt hardware is either externalized or totally removed and replaced with an external ventricular drain. Some neurosurgeons may not remove the shunt if it is functional and treat the patient only with intravenous antibiotics. However, this is somewhat controversial.

Once the infecting organism's sensitivities are known, the antibiotics may be altered. The child is treated with intravenous antibiotics until the CSF has been sterile for several days. There is no consistent agreement about the number of days that the CSF should be sterile before the shunt hardware can be reimplanted. Many neurosurgeons also prefer for the CSF to have less than  $50/\text{mm}^3$  white blood cells and the protein to be less than 500 mg/dl before replacing the shunt. Most commonly, the child will receive 5–10 days of treatment before the shunt is replaced. There is also no consistent agreement as to the length of antibiotic treatment after the shunt has been replaced. Factors such as the specific organism, the severity of the infection, and previous history of infections may all affect the length of antibiotic treatment.

Preventing infection is the best way to improve outcome. At present, adherence to meticulous intraoperative aseptic technique and perioperative prophylactic systemic antibiotics are accepted procedures. There is no proven drug of choice or length of treatment after a shunt revision. Most neurosurgeons use intravenous cefazolin, nafcillin, vancomycin, ceftriaxone, or methicillin. Length of treatment varies from one dose to multiple doses (up to 72 h). Antibiotic-impregnated shunt material has been shown to decrease infection rates (Kestle et al. 2011). These catheters may be impregnated with vancomycin, rifampin, clindamycin, or iodine. More studies are currently being done on standardizing protocols to reduce CSF infections. These studies standardize

how the room is set up, number of personnel in the room, double gloving, preparation of skin, antibiotics (Vancomycin and Gentamicin) injected into the shunt intraoperatively, and post-operative care. These protocols have been proven to decrease overall infection rates (Kestle et al. 2011) (Box 2.4).

### 2.11.3 Complications Related to Distal Catheter Location: Ventriculoperitoneal Shunts

The abdominal cavity is the preferred area to place the distal end of a cerebral spinal fluid shunt in most cases. However, the abdomen may be the site of other surgical procedures or diseases. This is particularly an issue in young children with chronic medical conditions. These children may need frequent urological procedures, gastrostomy tube placement and revisions, or other bowel surgeries. Intra-abdominal adhesions, scarring from old procedures, or previous shunt infections may decrease the absorptive capability of the peritoneum. Pseudocysts may develop around the tip of the catheter, with or without infection. The presence of an intra-abdominal infection, such as appendicitis, may or may not infect the shunt and make the abdominal cavity unsuitable for another shunt. The distal catheter may erode into the bowel leading to shunt infection and peritonitis. Other complications that may occur from intra-abdominal shunts include a 17 % risk of inguinal hernia development (if the shunt is placed in young infants whose process vaginalis is still patent) or the development of a hydrocele.

#### 2.11.3.1 Ventriculoatrial Shunts

If the abdomen is not an appropriate site for the distal shunt catheter, it may be placed in the right atrium of the heart. Ventriculoatrial catheters potentially have more serious complications than ventriculoperitoneal catheters. Complications include migration of the shunt into the superior vena cava (usually with failure of the shunt), pneumothorax, endocarditis, shunt nephritis, pulmonary embolism, septicemia, septic emboli, cardiac arrhythmias, cardiac tamponade, detachment



**Box 2.4. Case Study: A 4-Year-Old Child with Shunt Infection**

AB is a 4-year-old female who was born with congenital hydrocephalus. A shunt was placed shortly after birth and revised once in the first year of life and again 5 weeks ago at 4 years of age. She did well after the most recent revision and was discharged on the first postoperative day. She returned for a wound check 2 weeks later. The wound appeared to be healing. She had vague complaints of abdominal pain. Her mother also reported some issues with constipation. The neurosurgery nurse practitioner counseled the mother on constipation management.

She returned 1 week later, still complaining of abdominal pain. On exam, the incisions were healing normally. Palpation of her abdomen revealed that it was soft, slightly distended, and mildly tender. She was afebrile. Labs were ordered, and her WBC was normal; CRP was elevated at 5.4. A low-dose head CT and shunt series were done that showed resolution of her increased ventricle size. An abdominal CT was done showing a loculated fluid collection around the tip of the catheter. A shunt tap was done: glucose 28, protein 140, RBC 2 and WBC 190. Gram stain: moderate polymorphonuclear leukocytes and gram-positive cocci. A diagnosis of a shunt infection was made. She was taken to the operating room where all the shunt hardware was removed and an external ventricular drain was placed. She was started on vancomycin and ceftriaxone. The original culture eventually grew out staph epidermis, and sensitivities showed it was sensitive to nafcillin. The antibiotics were changed to nafcillin. CSF cultures were drawn daily and were negative after the shunt was removed. She received a total of 8 days of IV vancomycin/nafcillin. She was then taken back to the OR for placement of a new ventricular to peritoneal shunt. She received the standard postop dose of antibiotics. She was discharged home the following day.

of the catheter with migration into the coronary sinus, and obstruction of the vena cava system. Shunt nephritis is an unusual complication that can cause proteinuria, hematuria, and decreased kidney function and is often caused by a low-grade infection of the shunt. If shunt infection is suspected, blood cultures and 24-h urine for protein are obtained in addition to the other labs to rule out shunt nephritis. If the patient with a ventriculoatrial shunt presents with fever, blood cultures are always performed to rule out systemic bacteremia.

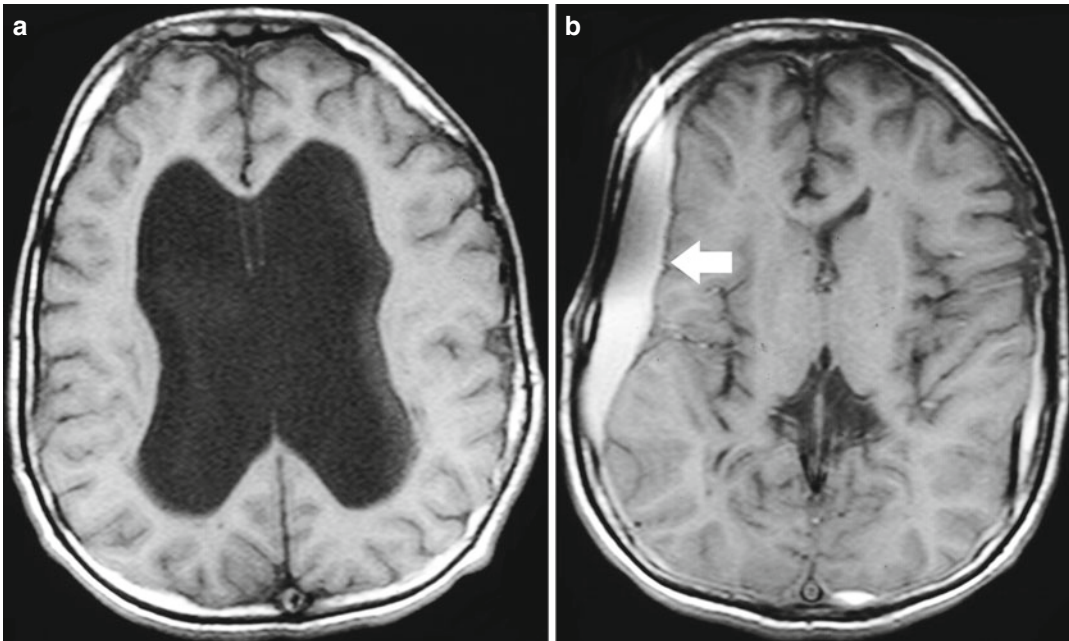
Another problem with ventriculoatrial shunts is that extra tubing cannot be placed into the right atrium to allow for growth. Therefore, infants and young children may outgrow these shunts in months resulting in shunt failure. A ventriculoatrial shunt may require frequent revisions to allow for growth. By examining the chest x-ray, one can diagnose the distal catheter being dislodged from the right atrium. The catheter tip should be visible on plain x-ray at the level of the sixth/seventh thoracic vertebrae.

When examined at autopsy, multiple complications may have occurred around a

ventriculoatrial catheter: fibrinous material may surround the catheter, vegetation may be seen within the wall of the right atrium, and there may be evidence of pulmonary emboli (Marlin and Gaskill 1994).

#### 2.11.4 Lumboperitoneal Catheter Complications

Historically, a number of complications have been associated with lumboperitoneal shunts, including frequent shunt failure, scoliosis, arachnoiditis, back stiffness, back pain, sciatica, neurological changes in the lower limbs, and hindbrain herniation (Olson 2004). These complications have been reduced with changes in shunt hardware and careful preoperative screening. First, with the introduction of percutaneously implanted shunts and improved shunt catheters, the need to perform a laminectomy for shunt placement is now rare. This has reduced the rate of scoliosis and arachnoiditis. Second, preoperative evaluation of patients for hindbrain



**Fig. 2.24** A 15-year-old male with achondroplasia and chronic hydrocephalus: (a) preoperative MRI shows enlarged ventricles; (b) postoperative MRI shows collapsed

ventricles with subsequent development of bilateral (*right* greater than *left*) subdural hematomas

herniation, including a CSF flow study, can help determine when posterior fossa decompression prior to placement of the LP shunt is appropriate. Thorough preoperative evaluation and the use of a higher-pressure valve may decrease the risk and incidence of hindbrain herniation and decrease lumboperitoneal shunt complications (Rekate and Wallace 2003).

### 2.11.5 Over-Drainage Causing Extra-axial Fluid Collection

After a CSF shunt is placed, if the ventricles decompress excessively or too rapidly, extra-axial fluid collections and/or a subdural hematoma may occur. Fragile bridging veins on the brain's surface may tear as the brain falls away from the dura and bleeding can occur creating a subdural hematoma (Fig. 2.24). This is a risk when shunts are placed for the first time in older children. Treatment depends on severity, symptoms, and the type of valve used. If the valve is programmable, the pressure may be temporarily

increased. If not, the valve may need to be replaced with a higher-pressure valve. By allowing the ventricles to remain more dilated, the brain will resume its normal position against the dura and skull. If a subdural hematoma is present, it may need to be drained.

### 2.11.6 Special Diagnostic and Treatment Challenge: Slit Ventricle Syndrome

Approximately 75 % of patients with slit ventricles on scan have no symptoms. Slit ventricle syndrome usually occurs after the shunt has been in place for many years, making it more common in the older child and adolescent; however, younger children and infants may also be affected. Slit ventricle syndrome has been used in the literature to describe a number of different situations that include symptomatic small ventricles. This has led to confusion in choosing the most effective treatment option and evaluating the outcome.

In a review of the literature, Olson (2004) found at least 5 different clinical scenarios in which children have radiologically slit ventricles and headaches. Patterns include an on-off (intermittent) symptom complex, over-drainage and siphoning with negative intracranial pressure (particularly when the patient is upright), recurring proximal ventricular catheter dysfunction/obstruction, chronic subdural collections due to shunt over-drainage, and headaches unrelated to shunt function. Most authors applied the syndrome to an on-off (intermittent) symptom complex. This has further been defined as “severe intermittent headaches lasting 10–90 min associated with smaller than normal ventricles on imaging studies, and a slow refill on valve pumping devices” (Rekate 1999). The pathophysiology supporting these symptoms is that with slit ventricles, the catheter becomes intermittently obstructed with surrounding tissue, the pressure rises, and when it is high enough, the ventricles minimally dilate, allowing the catheter to function again. To avoid confusion, using the term noncompliant ventricle syndrome instead of slit ventricle syndrome has been recommended. Of children with radiologically slit ventricles and headaches, 6–22 % have noncompliant ventricle syndrome (Olson 2004).

The exact mechanism underlying the syndrome is not known and may be a combination of proposed theories. First, because there is a relationship between ventricular pressure and intracranial pressure, when CSF pressure drops, there is an increase in venous congestion and brain elasticity. Second, an increased pressure with subependymal flow can cause subependymal gliosis and periventricular gliosis with increased ventricular wall stiffness. Consequently, a higher than normal intracranial pressure is needed to dilate the ventricles. Third, in newborns, over-shunting leads to radiologically slit ventricles, as well as the development of microcephaly and suture synostosis. Because of the small ventricles, catheters become easily plugged. With a small cranial compartment, ventricular dilatation is restricted and can lead to increased intracranial pressure.

Symptoms are those associated with shunt malfunction (intermittent headaches, nausea,

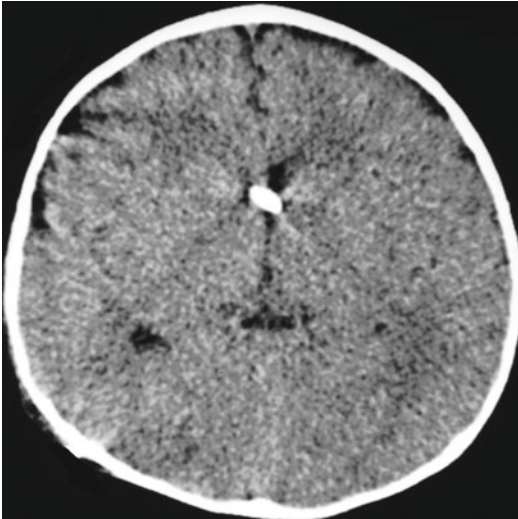
vomiting, and other signs of increased intracranial pressure). Headaches are the most common complaint. In some patients, being upright worsens the symptoms, and lying down improves them.

Evaluation initially involves the typical work-up for shunt malfunction. When the CT is normal, but significant symptoms persist, further studies are warranted. A shuntogram may confirm CSF patency and flow but can be misleading due to the intermittent nature of the problem. Continuous invasive intracranial pressure monitoring may correlate symptoms with pressure. This may be done via a fiberoptic intracranial monitoring device or via an external ventricular drainage catheter attached to an intracranial monitoring device.

Some patients may benefit from antimigraine therapy using propranolol, dihydroergotamine, or amitriptyline. The mechanism by which these drugs work is probably by reducing venous congestion. Propranolol, a beta blocker, cannot be used in children with asthma, as it will render asthma medications (beta-adrenergic agonist bronchodilators such as albuterol) ineffective.

A revision of the shunt is the most common treatment for noncompliant ventricle syndrome. If headaches occur with low pressure, an anti-siphon device may be added, and the valve may be changed to a higher-pressure or programmable valve. These shunt changes may decrease over-drainage and promote slightly larger ventricles, allowing for more consistent shunt function. Multiple changes in ventricular valve pressure are often needed during the evaluation and treatment of noncompliant syndrome. Programmable valves have made this possible without repeated surgical procedures. Before any such changes in an infant, it is important to rule out craniosynostosis, as increasing the valve pressure in this situation could cause a pathological increase in intracranial pressure. Shunt replacement in the setting of small ventricles can be difficult and may require the use of endoscopy.

Success has recently been reported with the placement of a lumboperitoneal shunt in addition



**Fig. 2.25** A 11-month-old male with a ventriculoperitoneal shunt and slit ventricle syndrome. He had many months of irritability and trouble feeding and had several shunt revisions, including the placement of programmable valves and the placement of a lumboperitoneal shunt. He eventually underwent a cranial expansion procedure, and his symptoms improved

to a ventriculoperitoneal shunt (Olson 2004). This may occur due to an added increase in CSF drainage when an increase in intracranial pressure occurs. A potential risk factor with a lumbar shunt in addition to a VP shunt is that if the ventricular catheter fails, hindbrain herniation may occur (acquired Chiari I).

Other surgical procedures have been utilized, including subtemporal decompression, calvarial expansion, and third ventriculostomy. Subtemporal decompression reduces intracranial pressure by removing a portion of the skull. The procedure can be accomplished with low risks, and some recommend this as a first-line treatment for noncompliant ventricle syndrome in patients with synostosis and small calvarium. Calvarial expansion is a much more extensive procedure, and bleeding is a significant risk (Fig. 2.25).

## 2.12 Pseudotumor Cerebri in the Pediatric Population

Another type of CSF absorption problem is a condition known as pseudotumor cerebri (PTC).

It is described as elevated intracranial pressure without hydrocephalus, mass lesion, infection, or hypertensive encephalopathy (Cinalli et al. 1999). PTC is the result of CSF malabsorption or obstruction in the intracranial venous system. Sometimes an exact cause can be found, such as thrombosis, which may be the source of the obstruction. Many times, however, a cause is not found. Thus, PTC is usually a diagnosis of exclusion (Brack et al. 1994).

In the general population, PTC is found in 0.9 per 100,000, but the incidence increases to 90 per 100,000 in obese adult females. There is a female to male predominance of 8:1–2 in adults, but there is no gender predominance in children. Obesity is less frequently a cause of PTC in children. There is a peak incidence in the third decade (range 1–55 years). About 37 % of PTC cases are in children. Ninety percent of children are diagnosed between 5 and 15 years of age, and PTC is rarely seen in infants (Boop 2004).

There are three types or classifications of PTC: primary, secondary, and atypical pseudotumor. The most common form, primary PTC, is idiopathic, and thus the cause is unknown. Secondary PTC presents as the results of another illness or cause. Secondary PTC may be associated with a known neurological disease, the result of a systemic illness (i.e., clotting disorder), or caused by the ingestion or withdrawal of exogenous agents (i.e., vitaminosis A, antibiotics, and others). Finally, atypical PTC presents without papilledema or may be seen in infants. The most common causes of PTC in children include venous thrombosis, steroid withdrawal, malnutrition, or exogenous substances. Obesity, as in the general population, is beginning to be seen more frequently as a cause of PTC in children.

### 2.12.1 Pathophysiology

CSF is absorbed into the venous system after traveling passively through the arachnoid villi. A failure of CSF absorption may be caused by a blockage somewhere in these veins, such as by a thrombus. Right heart failure in infants sometimes leads to PTC by causing a retrograde

elevated intracranial pressure, and thus a CSF absorption problem.

Several exogenous agents have been known to cause PTC. These include vitamin A, chemotherapy agents like vincristine, and some antibiotics. Although there are theories as to how these agents cause changes in CSF absorption pathways at the cellular level, the exact cause of PTC from the ingestion of vitamin A or other medicines remains unclear (Abtin and Walker 1999; Cinalli et al. 1999, 2004).

### 2.12.1.1 Clinical Evaluation

The examiner should obtain a thorough history and perform a complete physical examination, including an age-appropriate neurological examination (please refer to Chap. 1 regarding neurological examination). CT and plain MRI will not aid in diagnosis but are performed to exclude other causes of increased intracranial pressure such as mass lesions (Said and Rosman 2004). Magnetic resonance venograms may show an obstruction or occlusion. A lumbar puncture can demonstrate an elevated opening pressure and is performed with the patient lying in the lateral position. It is important to position patient on their side, as patients placed on their abdomens may have an artificially elevated opening pressure. Retrograde venography is the measurement of the intracranial venous systems via a catheter threaded upward from the femoral vein. Abnormal readings, including elevation of right-sided heart measurements, demonstrate the exact location of an obstruction. This is known as a “gradient.” Ophthalmologic examinations are performed to note any changes in visual fields, papilledema, and other tests of visual acuity. Intracranial pressure monitoring may be done with an intraparenchymal transducer, or similar device. This is helpful to note changes in pressure throughout the day while awake and asleep. Changes in position may also cause elevations in pressures, such as turning the head from side to side, because of venous obstruction on one side. Psychological evaluations may be performed, as there can be complicated comorbid involvement in some patients who receive secondary gain from having headaches that cannot always be diagnosed.

### 2.12.1.2 Treatment

Sometimes PTC may resolve spontaneously. Serial lumbar punctures to remove CSF have been shown to be beneficial in the resolution of PTC. More permanent CSF diversion may be necessary. This includes the implantation of a lumbar shunt with the valve system being the choice of the neurosurgeon. The lumbar shunt communicates with the CSF outside the ventricular system at the level of the subarachnoid space (28). The implantation of a ventricular access device such as a Rickham Reservoir (Codman, Raynham, MA, USA) allows for rapid and accurate measurement of intracranial pressure manometrically with little discomfort to the child. Because the ventricles are small in this condition, the placement of the reservoir is best performed using stereotactic guidance. Shunts from the ventricles to the peritoneum are difficult to maintain because of the small size of the ventricle, and thus the ventricular shunt cannot provide adequate drainage of CSF from the subarachnoid spaces.

Optic nerve sheath fenestrations are performed to reduce pressure on the optic nerve, as well as drain CSF, because the CSF may communicate with the subarachnoid space.

Medication may be helpful by reducing the production of CSF (e.g., acetazolamide, furosemide). This is usually a temporary measure until either a more permanent solution is found or the PTC resolves. Medications are used with caution, as there are side effects that include electrolyte abnormalities.

Obese patients with PTC and stable visual symptoms are best treated with weight loss to avoid shunt placement or optic nerve sheath fenestration (24). Even a small amount of weight loss can reduce intracranial pressure. Bariatric surgery may be considered for a morbidly obese patient who is in their late teens.

### 2.12.1.3 Nursing Care

Sometimes, children are placed in the pediatric intensive care unit for several days, while their intracranial pressure is monitored via an intraparenchymal wire. It is usually inserted in the operating room, under anesthesia, to maintain

strict asepsis and to reduce anxiety. The nurse plays an important role in monitoring elevations in pressure, and assisting the family to keep a “headache diary” during their stay. Monitoring of visual changes is also very important.

Patient and family education is needed so that lifestyle changes can be made to prevent loss of vision and the adaptation to the possible shunt systems. There are several Web sites that provide education to families and allow patients to communicate with one another. Patient and family support are provided by nursing, social service, and psychological intervention as needed.

Finally, there is ongoing research for future cures and diagnosis of PTC, including new ways to measure intravenous pressure. The placement of intracranial stenting devices that bypass a venous obstruction has been done in a small number of adults with some success.

---

## **2.13 Nursing Care of the Hydrocephalus Patient After Surgery**

The most common operations that children with hydrocephalus undergo are shunt placement, shunt revision, and endoscopic third ventriculotomy. Because these children frequently have other diseases related to the hydrocephalus, they often undergo other surgeries to treat a multitude of other problems.

### **2.13.1 Neurological Assessment**

Neurological assessment of the child after surgery to treat the hydrocephalus needs to be done frequently to detect any changes. The surgeon will usually specify the frequency, but assessment should occur every 1–4 h, depending on the condition of the child. An exam that is changing subtly over time may be an indication of failure of the surgical treatment or postoperative complication. The first signs of increasing intracranial pressure are usually subtle and related to mildly increasing somnolence, lack of interest in activities (feeding) or play, and subtle behavioral

changes. Level of consciousness is the most important single indicator of neurological status. Altered level of consciousness may progress to confusion, disorientation, somnolence, lethargy, obtundation, stupor, and coma.

Parents and families are an excellent resource to provide information about their particular child’s developmental level. The signs and symptoms of increasing intracranial pressure may initially be very subtle. Hence, the child’s caretaker is a valuable resource in such assessment and may notice subtle changes before nursing and medical staff.

A thorough neurological assessment starts with watching the child play and interact with those around him. Assessment also includes asking the child if he has a headache. Nonverbal infants and children may exhibit behavioral signs of headache. The child should be examined for his ability to answer questions appropriately and follow directions. Asking a child to move his arms and legs will also allow the examiner to assess muscle strength, tone, and movement. Vital signs should also be assessed. Bradycardia is a sign of increased intracranial pressure and should be closely monitored in the presence of other symptoms. Increased blood pressure is usually not a common finding in children until late in the process of increasing intracranial pressure.

It is important to carefully examine the eyes; checking pupils without further exam is never an adequate exam. The pupils are checked for equality, roundness, and reactivity to light. Dilated and nonreactive pupils are a very late sign of increased intracranial pressure. A “sunseting” appearance to the eyes or the loss of the upward gaze is an abnormal finding and indicative of increased intracranial pressure. The extraocular movements should be intact.

The infant’s head should be examined. The occipital frontal circumference should be measured and documented on a daily basis to determine appropriate head growth. The fontanelles should be palpated with the child upright and calm. The anterior fontanelle should feel soft and pulsatile. A tense or bulging fontanel is suspicious for increased intracranial pressure. The suture lines of the skull should also be examined.

Normal suture lines are palpable and apposed. If they are overriding, the infant may have over-drainage of the shunt. If the sutures are splayed, there is likely increased intracranial pressure.

### 2.13.2 Wound and Dressing Care

The child will usually come from the operating room with a dressing over the incision. The dressing is normally removed or changed during the first few postoperative days. If a dressing is soiled or saturated with blood, most surgeons agree that it should be replaced. If the child is likely to pick at the incision, a dressing may be kept over the incision to prevent infection. Before a child goes home, most surgeons agree the dressing should be changed and the wound inspected for any erythema, drainage, swelling, or infection.

### 2.13.3 Medications

The majority of neurosurgeons will order intravenous postoperative antibiotics to prevent shunt infection. Cefazolin and nafcillin are the most commonly used antibiotics, as gram-positive organisms demonstrate sensitivity to them. Vancomycin may also be used. Length of treatment is variable.

Pain management starts with good pain assessment. Age-appropriate pain assessment scales such as the CRIES (crying, requires increased oxygen administration, increased vital signs, expression, sleeplessness), Objective Pain Scale, and Oucher scale may be used. There is a wide variety of pain experienced by children after surgery for hydrocephalus. Pain may be related to the cranial incision(s), the abdominal incision, the amount of intra-abdominal manipulation, and the tunneling of the distal catheter through the subcutaneous tissue. Other factors influencing pain may include the age of the child, the child and/or family's experience with pain, and the child and family's anxiety. Pain is usually managed with medications although other techniques may be helpful. The first drug of choice is usually acetaminophen. It should be adequately dosed at

10–15 mg/kg/dose, maximum dose of 75 mg/kg/day not to exceed 4,000 mg/day, and can be given orally or rectally. Nonsteroidal anti-inflammatory drugs (NSAIDs) may be used, but they can inhibit platelet aggregation and prolong bleeding time. For this reason, some neurosurgeons do not use NSAIDs during the immediate postoperative period.

If the child needs additional medication for pain, the surgeon's beliefs about pain control in neurosurgical patients may be a factor. Some neurosurgeons will order opiates such as morphine sulfate, oxycodone, or codeine, while others do not want to alter the patient's neurological exam with these drugs. The nurse should not administer these drugs if she is concerned that the pain is due to increasing intracranial pressure or the neurological exam is changing. Other modalities to relieve pain may include age-appropriate relaxation techniques, play therapy, music therapy, massage, distraction, and acupuncture or acupressure.

Some children will experience nausea and vomiting from anesthesia that may be worsened by extensive intra-abdominal manipulation during the surgery. Medications to treat this include metoclopramide and ondansetron. The nurse should not administer these drugs repeatedly if there is a possibility that the nausea and vomiting are due to increasing intracranial pressure. Treating the symptoms and ignoring the underlying cause may result in further increased pressure and delay of needed treatment.

Children who are on antiseizure medications preoperatively should have these resumed as soon as possible. Often, because of vomiting before or after the surgery, doses are missed, so it is helpful to check blood levels of the drugs to ensure they are therapeutic. If the levels are subtherapeutic, extra doses may be ordered. Children with low levels of their antiseizure medications are at increased risk for seizures.

Infants and children require some intravenous fluids after surgery until they can take adequate fluids orally. Fluid loss from vomiting should be replaced. Electrolytes should also be monitored during periods of vomiting. The nurse should assess the child for symptoms of adequate

hydration. Usually the child will receive maintenance fluids postoperatively for at least 12 h. The child with a shunt in place should never have an intravenous line placed into the scalp because of the risk of introducing bacteria to the area around the shunt hardware.

#### 2.13.4 Other Nursing Care

The surgeon will usually specify the position that the child should assume. Elevating the head of the bed 30–45° will enhance shunt function by gravity aiding the flow of the CSF through the shunt. The surgeon may specify that the infant or child be placed flat if he is concerned about over-drainage of the ventricles. If the ventricles are allowed to drain too quickly, the outside of cerebral cortex may pull away from the dura. This may cause tearing of the fragile bridging veins and result in a subdural hematoma. Infants with overriding sutures are usually placed flat to minimize over-drainage. If overriding sutures are allowed to occur for a long period of time, the sutures may fuse prematurely. The nurse should also position the infant or child off of the incision and shunt hardware. Young infants who are allowed to lie on the hardware may experience skin breakdown and shunt infection within hours. X-rays of the shunt system are also done during the postoperative period to assure correct placement of the shunt, that the system is intact, and for any other potential complications (i.e., pneumothorax associated with a ventriculoatrial shunt).

These children have all the other usual postoperative needs of pediatric surgery patients. Nurses should be concerned with adequate diet, good pulmonary care, mobilization issues, skin care, adequate rest, and emotional care.

#### 2.13.5 Extraventricular Drainage

CSF can be temporally diverted outside the body using an extraventricular drain (ventriculostomy or EVD) and may be used with or without intracranial pressure monitoring. It is commonly used

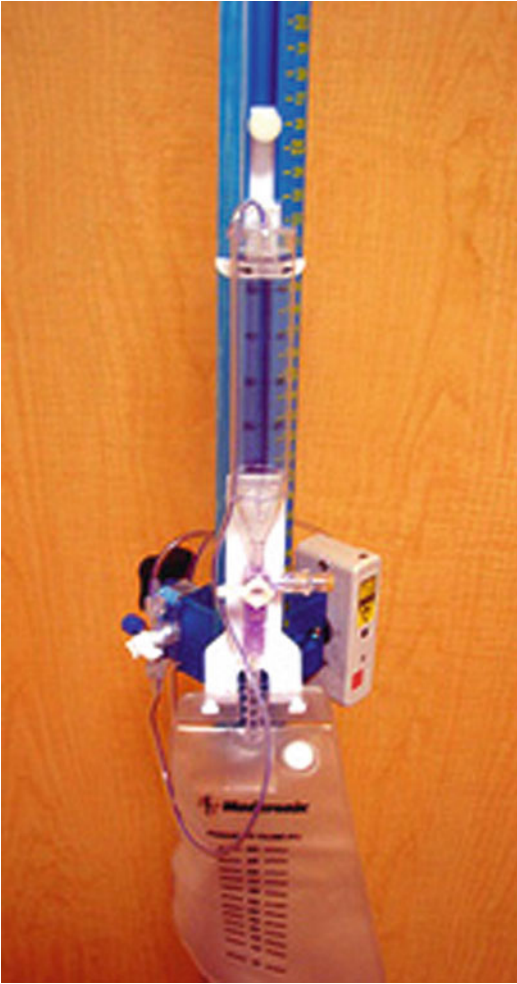in the treatment of shunt infections, in which the colonized shunt tubing, as well as the infected CSF, needs to be removed in order to completely eradicate the infection. Usually the entire shunt system is removed, although occasionally just the distal portion of the shunt is externalized. An EVD is also commonly used after posterior fossa tumor resections, to help drain blood and surgical debris out of the ventricular system. Other uses may include the administration of intrathecal antibiotics, emergent diversion of CSF in acute hydrocephalus, and intracranial pressure monitoring after endoscopic third ventriculostomy and in association with head injury.

Several different drainage systems are available for an EVD, but all have similar features (Fig. 2.26). The ventricular catheter is usually placed in the operating room, which allows for maximal aseptic technique at placement and tunneling of the catheter under the skin before it exits the skin. These two factors may decrease the infection rate with external drains. The ventricular catheter is generally inserted into the frontal horn of the lateral ventricle (on the non-dominant side of the brain) and is connected to the CSF collection chamber via a closed sterile setup.

The surgeon should specify the level that the chamber needs to be placed, as well as the level of the head of bed, in the postoperative orders. The chamber is generally placed in reference to the external auditory meatus, which is at the level of the foramen of Monro. Careful attention needs to be made to assure that the system is set up and measured properly, and that the catheter does not become kinked, dislodged, or disconnected. In addition, it is important to clamp the system before the patient changes position (Fig. 2.26).

The details of CSF drainage need to be monitored regularly and the amount, color, and presence of blood or sediment must be recorded on a frequent basis. The normal amount of CSF that is produced daily is approximately 350–700 ml in adults (Brack et al. 1994). Infants and children produce less, about 0.33 ml/kg/h. Excessive or insufficient CSF drainage is a common complication that may occur. Excessive drainage results when the pressure at which the drainage occurs is





**Fig. 2.26** External ventricular drain (EVD) (Courtesy of Medtronic Neurologic Technologies)

too low. This may be caused by the movement of the child above the predetermined ordered level or increased intracranial pressure secondary to coughing, crying, sneezing, or the Valsalva maneuver. Excessive draining may cause the ventricles to rapidly collapse, leading to a subdural or subarachnoid hemorrhage.

Insufficient CSF drainage may cause increased intracranial pressure, with associated symptoms. Inadequate drainage may be caused by the child moving to a position that is lower than the ordered level, by kinks in the catheter, or by occlusion of the catheter from blood or cellular debris. Occlusion should be suspected if there is no fluctuation of CSF in the catheter with respirations

or with lowering of the chamber. If there is no drainage or fluctuation within the tubing, the neurosurgery team should be notified immediately. If the occlusion in the catheter cannot be dislodged by flushing it, the patient may need to return to the operating room and have a new drain placed. If the system is accidentally pulled apart or broken, the proximal catheter should be clamped immediately, the open tip placed in a sterile covering, and the neurosurgery team notified.

CSF is generally clear and has the same consistency as water. In the presence of infection, it may become cloudy, darker in color, and more viscous. CSF samples are often drawn on a regular basis to monitor the treatment of infection or to rule out infection. The studies completed normally consist of a cell count, levels of glucose and protein, Gram stain, and culture. In the presence of infection, protein and white blood cells are usually elevated, and glucose is usually decreased. Blood is often present after posterior fossa tumor resections. The amount of blood present should be noted as well as any new bleeding.

CSF contains approximately 120 mEq/l of sodium. Therefore, the child's electrolytes should be monitored closely. Some surgeons may want to replace CSF with intravenous normal saline, particularly in younger children.

Other nursing considerations include keeping the head dressing clean, dry, and intact, as well as pain control. Distraction techniques or restraining the child may be necessary to keep the patient from moving or dislodging the catheter.

In patients with posterior fossa tumor resections, there is a chance that the ventricular drain may be weaned and removed completely. This is often done once the cellular debris and blood have cleared. The chamber is raised slowly over 24–96 h and may eventually be clamped. If the patient does not develop signs and symptoms of increased intracranial pressure, and a CT or HASTE MRI does not show enlargement of the ventricular system, the drain may be removed. If there are signs and symptoms of increased pressure and enlargement of the ventricles, the patient will most likely need a permanent shunt or may be a candidate for endoscopic third ventriculostomy.

### 2.13.6 Discharge

Most infants and children can be discharged 24–48 h after a shunt placement or revision. The child undergoing a third ventriculostomy may be in the hospital longer while evaluation of the efficacy of the procedure is carried out. In preparation for discharge, the nurse should discuss with the parents, or other caregiver, wound care, pain management, signs and symptoms of shunt failure and infection, and other issues that may be relevant. The caregiver should be instructed on how to take care of the dressing and/or wound. The surgeon will usually specify recommendations regarding dressings, bathing, and suture removal. The nurse should know what those specifications are and relay them to the family verbally and in writing. Often, families need to go home with dressing supplies if a dressing is to be kept in place.

Most children can be discharged with acetaminophen or ibuprofen for pain. The nurse should give the care provider the appropriate dose for the child. Some surgeons will prescribe a stronger pain medication such as oxycodone or codeine if it is necessary. Parents should be instructed to use any medication cautiously. If the child's pain is increasing over time, the child may be experiencing another shunt failure or infection. Pain is usually expected to be incisional or related to distal catheter implantation by the time of discharge.

The family needs to be instructed on the signs and symptoms of shunt failure and infection. The signs and symptoms may be subtle and confusing in a child already recovering from surgery. The caregivers should be told that an infected shunt may or may not function. Parents should also be advised that any fever during the first month after shunt placement could be related to a shunt infection. The patient's family also needs instruction on what to do if they suspect shunt failure, infection, or have other concerns. If the shunt fails at night or on the weekend, the child still needs immediate evaluation. Each surgeon handles this somewhat differently, and the nurse should know the expectations of the particular

surgeon. Follow-up appointments should also be scheduled.

### 2.13.7 Family Support

The family of a child with hydrocephalus is often quite anxious because the child may need to undergo repeated surgeries, and there are often other major illnesses or conditions associated with hydrocephalus. They may also be concerned about the lifelong implications of hydrocephalus, whether the infant or young child will be normal, have delays, cerebral palsy, or other conditions related to the hydrocephalus (or its etiology). The nurse or physician may not be able to adequately answer such questions and that only further increases parental anxiety.

Families need anticipatory guidance and teaching about hydrocephalus, including what the signs and symptoms are, why they occur, and what needs to be done. They need to understand what tests are done to diagnose hydrocephalus and shunt failure. Sometimes these tests are confusing or inconclusive for the provider. This further confuses families and causes more anxiety. Families also need to know the importance of prompt treatment of suspected shunt failure and have a plan as to how that will occur.

A child with a shunt should be encouraged to live as normal of a life as is possible. If the child does not have other associated conditions or delays, there will usually be no restrictions. If the child is delayed, in a wheelchair, blind, or otherwise disabled, many restrictions will be needed because of the underlying issues. Parents should still be encouraged to treat the child as normally as possible. Some surgeons do not want children with shunts to play rough contact sports such as football or wrestling because of the possibility of damaging the shunt hardware. There is no contraindication to flying in commercial pressurized aircraft.

Children with shunts need good primary care. The primary care provider as well as the parent can follow head growth in infants. A primary provider or nurse may help the family with all

the standard issues that parents face including discipline, toileting, sleep issues, child care, and schooling. These children need all the regular immunizations. The diphtheria-tetanus-pertussis vaccine should be administered to an infant or child with stable neurological conditions, including controlled seizures (Committee on Infectious Diseases 2000). They need good dental care to avoid the possibility of dental carries seeding a shunt infection during a shunt revision. Current American Dental Association guidelines do not recommend any prophylactic antibiotics for any patients containing neurosurgical hardware (including ventriculoatrial shunts) (Lockhart et al. 2007). Some surgeons may still recommend antibiotics before dental work in children who have had repeated shunt infections. Children also need routine vision screening because of the associated visual abnormalities.

Families who have children with hydrocephalus may benefit from a support group. Families may also benefit from information from national organizations such as the following:

### 2.13.7.1 Organizations and Web sites

Hydrocephalus Association  
870 Market Street, Suite 705  
San Francisco, CA 94102  
415-732-7040; 888-598-3789  
[www.hydroassoc.org](http://www.hydroassoc.org)

Hydrocephalus Foundation  
910 Rear Broadway, Rt. 1  
Saugus, MA 01906  
781-942-1161  
[www.hydrocephalus.org](http://www.hydrocephalus.org)

National Hydrocephalus Foundation  
12413 Centralia Road  
Lakewood, CA 90715  
562-402-3532; 888-857-3434  
[www.nhfonline.org](http://www.nhfonline.org)

National Information Center for Children  
and Youth with Disabilities  
PO Box 1492  
Washington, DC 20013  
[www.nichcy.org](http://www.nichcy.org)

Spina Bifida Association of America  
4590 MacArthur Blvd. NW, Suite 250  
Washington, DC 20007-4226  
202-944-3285; 800-621-3141  
[www.sbaa.org](http://www.sbaa.org)

United Cerebral Palsy Association, Inc.  
1660L Street, Suite 700  
Washington, DC 20036  
[www.ucpa.org](http://www.ucpa.org)

## 2.14 Living with Hydrocephalus

Hydrocephalus is a chronic, lifelong condition. Untreated hydrocephalus has a mortality rate of 50–60 %. Surgically treated hydrocephalus in children with minimal or no evidence of irreversible brain damage is associated with a mortality rate of 10 % (Milhorat 1982). Some infants have a shunt placed at birth, require few revisions, and grow to be cognitively and physically normal. Others have a shunt placed and require many revisions, experience complications, and are mildly or markedly developmentally delayed. These ongoing issues with the shunt are not usually the only cause of the developmental abnormalities, but they may contribute to them. Some children with hydrocephalus have other chronic diseases that are associated with or are the cause of the hydrocephalus. Such illnesses include brain tumors, neurofibromatosis, myelomeningocele, craniofacial abnormalities, cerebral palsy, and various brain malformations. The treatment of hydrocephalus is just one aspect of the complicated care that these children require. Many factors affect the outcome of children with hydrocephalus, such as the age at onset, the underlying cause, the timing of the surgical intervention, complications such as repeated shunt failures and infections, and the associated comorbidities of other diseases.

All children with hydrocephalus are at risk for certain associated problems, including cognitive delays, learning disabilities, motor delays, behavioral abnormalities, visual abnormalities, seizures, precocious puberty, and diabetes insipidus. A French study (Hoppe-Hirsch et al. 1998)

evaluated 129 children with shunts. These children were shunted before age 2 years and followed for 10 years. The study found that 60 % had motor disabilities, 25 % had visual or auditory abnormalities, and 30 % had seizures. Sixty percent were in school, some with special services, and their IQs were highly variable. Thirty percent had IQs that were in the normal range above 90, 30–60 % had mild to moderate mental retardation, and 7–20 % had severe mental retardation (16). Many were 1–2 years behind their peers. Behavioral disorders were common.

### 2.14.1 Cognitive Abnormalities

Intellectual function is difficult to predict in the infant and young child. Abnormalities of, and insults to, the CNS may both contribute greatly to impaired function. The younger the child at the age of the onset of hydrocephalus, the greater the risk for intellectual abnormalities. Cognitive difficulties can also be caused by the underlying condition and associated treatment. Shunt infections, especially with gram-negative organisms, can further impair cognitive function. Some infants have extreme hydrocephalus at birth, but once shunted, the brain may grow into the existing space. Some of these children can develop normally. A cortical mantle of less than 5 mm in thickness seems to be predictive of a poor outcome. Cognitive function is also impossible to predict from radiographic studies. Some children are remarkably functional despite markedly abnormal appearing brains on CT and/or MRI scans. Other children have severe intellectual impairment with relatively normal appearing scans.

Sgouros et al. (1995) followed 70 patients with shunts for 16 years. He found that children with IVH and meningitis as the underlying cause of their hydrocephalus did the worst cognitively. Thirty to forty percent of these children had cognitive delays. He also found that two-thirds of these patients were socially independent but living with their parents.

Among children with myelomeningocele and hydrocephalus, cognitive abnormalities are more

pronounced in those with a higher-level defect, as compared to those with a sacral defect. Those that require a shunt (80–85 %) have overall lower IQ scores than those who do not require shunting (Mapstone et al. 1984).

Children with hydrocephalus also have a higher risk of learning disabilities. These children have difficulty with encoding and retrieval in both verbal and nonverbal tasks (Scott 1998). In addition, such children may have difficulty with reading comprehension (Yamada 2002). They also have difficulties with concentration, nonverbal learning, processing complex language, short-term memory, and poor spatial relations. These children are at a higher risk of attention deficit hyperactivity disorder than the general population. Dysmorphology of the cerebellum may be associated with oral and motor speech deficits (Huber-Okraïnc et al. 2002).

Neuropsychological testing of the child will help to better define where the deficits exist. With such knowledge, learning and activities of daily living can be modified to fit the needs of the individual child. Special therapy, such as speech or occupational therapy, may help the child to become more functional.

The importance of social factors must also be considered when evaluating the intellectual function of these children. Those who have access to the most state-of-the-art medical care, therapy services, and educational services may do better functionally than those who do not. Some of these children also need complex care from their families on a daily basis. While some families are well equipped to deal with these demands, other families seem to be in a continual state of crisis, have several children with special needs, have one or both parents absent, or many other problems that make it difficult to care for these children.

### 2.14.2 Motor Disabilities

Sixty percent of children with hydrocephalus have varying degrees of motor abnormalities. The motor deficits are often related to the underlying etiology of the hydrocephalus. Children

with hydrocephalus may have global motor delays and achieve milestones, such as sitting and walking late, or not at all. Hydrocephalus may also affect fine motor control. Such fine motor difficulty may be exacerbated by visual impairments. These children may have trouble learning to write, so keyboards and communication boards may be useful. Premature infants with IVH may develop hydrocephalus and cerebral palsy. The cerebral palsy may be mild and affect only the lower extremities (spastic diplegia), or it may be severe and affect the entire body (spastic quadriplegia).

### 2.14.3 Ocular Abnormalities

Optic atrophy from chronic papilledema was the leading cause of blindness from congenital malformations, before the successful treatment of hydrocephalus. Increased intracranial pressure from hydrocephalus causes pressure on the cranial nerves. The cranial nerves that are involved in eye function are II (Optic), III (Oculomotor), IV (Trochlear), and VI (Abducens). As intracranial pressure increases, signs and symptoms become evident as these nerves are affected. Common findings include limited upward gaze, extraocular paresis, decreased vision, and diplopia (Table 2.5).

Papilledema is a less common finding and is difficult to diagnose in young children. The child is often referred to an ophthalmologist for a complete eye exam, including dilation of the pupil, to correctly diagnose papilledema. Papilledema is not a common finding in children with increased intracranial pressure unless it is chronic.

Ocular abnormalities are a common finding in infants and children with untreated hydrocephalus and during periods of shunt malfunction. If treatment is not prompt, visual damage is a risk, including blindness. Visual deficits are common in children with hydrocephalus. Refractive and accommodative errors are found in 25–33 % of these children. Gaze and movement disorders, such as nystagmus, astigmatism, strabismus, and amblyopia, are found in 25–33 % (Rosen 1998). Abnormalities in vision may be associated with

**Table 2.5** Cranial nerves and eye symptoms

<i>II-Optic nerve</i>
Responsible for transmitting visual images from the eye to the brain
Test: check for light perception, visual acuity, peripheral vision, and normal appearance of the optic disc
<i>III-Oculomotor nerve</i>
Responsible for controlling four of the six muscle groups that move the eye
Medial rectus: moves eye inward
Superior rectus: moves eye upward and in
Inferior rectus: moves eye downward and in
Inferior oblique: moves eye upward and out
Responsible for constriction and accommodation of the pupil and closing of eyelid
Test: have child follow object in six cardinal positions of gaze, check for pupil reaction to light, check for closing of eyelid
<i>IV-Trochlear nerve</i>
Responsible for controlling superior oblique muscle that moves eye inward and down
Test: have child look down and in
<i>VI-Abducens nerve</i>
Responsible for lateral rectus muscle that moves eye temporally
Test: have child look temporally

lower IQ scores. Correctable vision issues should be identified and treated as early as possible so that they do not add to developmental and learning difficulties.

### 2.14.4 Seizures

Hydrocephalus alone is not commonly recognized as a cause of seizures. However, seizures are associated in children with hydrocephalus who have shunts implanted. The incidence of epilepsy in the general population is 1 % in children. The incidence of seizures in children with shunted hydrocephalus is 20–50 % (Sato et al. 2001). Since modern shunting became the standard treatment for hydrocephalus, controversy has existed about shunt procedures and complications of shunts leading to seizures. Children with hydrocephalus have numerous risk factors that increase the risk of seizures. These include age at the original shunt placement, the location of the shunt catheter in the

brain, the actual placement of the shunt catheter, repeated revisions of the proximal catheter, the presence of the hardware itself in the brain, the location of the burr hole, shunt infections, intracranial hemorrhage at the time of shunt placement or revision, repeated episodes of increased intracranial pressure, the presence of tumors or cysts, the underlying etiology of the hydrocephalus, and any associated developmental delay. When a child has seizures, a work-up is indicated including an electroencephalogram. Seizures are not usually a symptom of shunt malfunction although a very small percentage of patients will present with seizures as the main symptom of shunt malfunction.

### 2.14.5 Precocious Puberty

Precocious puberty is defined as the onset of puberty 1–2 years before the expected age. Normal onset of puberty may occur as young as eight in girls and nine in boys. Precocious puberty is fairly common in children with hydrocephalus, myelomeningocele, cerebral palsy, and microcephaly. It can start as early as 5 years of age.

Precocious puberty is presumed to be caused by chronic or intermittent increased intracranial pressure that affects the hypothalamus and pituitary gland. These two areas deep in the brain are responsible for timing the release of gonadotropins and sex hormones. Children who have had many shunt revisions when they are very young are at greater risk for precocious puberty.

Precocious puberty causes the growth plates to close early in the long bones leading to short stature. Additionally, precocious puberty is associated with risk of pregnancy in young children with associated cognitive and behavioral difficulties.

### 2.14.6 Transition to Adulthood

Hydrocephalus is a chronic disorder that will follow children into adulthood. Specifically in a shunted patient, it is a condition that requires regular follow-up and established care in case of a medical emergency, such as a shunt malfunction. A study by Simon et al. (2009a, b) showed that the number of young adults aged 18–35 with hydro-

cephalus that need treatment in the United States is predicted to exceed 40,000 annually within the next two decades. These young adults need access to both expert surgical and medical providers. As pediatric providers, it is vital to prepare patients for transition to adulthood. Studies show that one-half to two-thirds of patients failed to maintain adequate shunt follow-up after transitioning to adult care (Simon 2009). It is recommended to start discussions with families as young as 16 years of age, to establish who their adult provider will be and how transition of care will happen. The hope is to have the young adult establish care while in a healthy state if possible and not have first contact with their new provider in an emergency. It is also important to discuss with families the issue of private insurance versus qualifying for a government-funded program, to ensure adequate accessibility to the healthcare system.

#### Conclusion

The Nurse's Dictionary of Medical Terms and Nursing Treatment (Morton, circa 1898) stated the following about hydrocephalus: "water on the brain, a disease most common in children, and causing the head to swell to an enormous size. The victim is always idiotic. Nourishing diet – cod liver oil; as little fluid as possible." As this chapter has shown, nurses today need to know far more about the condition and its treatment. Most importantly, they need to know that many children with hydrocephalus can lead normal lives because of available surgical treatment. Despite advances in technology and surgical technique, nurses have and will continue to play major roles in achieving the best possible outcomes for these patients.

#### Pediatric Practice Pearls

- If the mother thinks that the child is acting abnormally or that the shunt is not working, there is a high probability that she is right.
- Small ventricles do not assure adequate shunt function.
- Altered mental status is the first and most salient symptom of increased

intracranial pressure, thus the child needs to be awakened for assessment.

- Mental status should be assessed over time for changes. Never give patients with altered mental status, or an unstable exam, medications that could mask the exam and symptoms.

## References

- Abtin K, Walker ML (1999) Congenital arachnoid cysts and the Dandy-Walker complex. In: Albright AL, Pollack IF, Adelson PD (eds) *Principles and practice of pediatric neurosurgery*. Thieme, New York, pp 125–139
- Adzick NS, Thom EA, Spong CY, Brock JW et al (2011) A randomized trial of prenatal versus postnatal repair of myelomeningocele. *N Engl J Med* 364(11):993–999
- Albright A, Pollak I, Adelson P (eds) (2007) *Principals and practice of pediatric neurosurgery*. Thieme, New York
- Boop F (2004) Posthemorrhagic hydrocephalus of prematurity. In: Cinalli G, Maixner WJ, Sainte-Rose C (eds) *Pediatric hydrocephalus*. Springer, Milano, pp 121–131
- Brack M, Taylor AG, Walker ML (1994) Hydrocephalus: etiology, pathologic effects, diagnosis and natural history. In: Cheek WE, Marlin AE, McLone DG, Reigel DH, Walker ML (eds) *Pediatric neurosurgery. Surgery of the developing nervous system*. WB Saunders, Philadelphia, pp 185–199
- Choux M, Dirocco C, Hockley AD, Walker ML (1999) *Pediatric neurosurgery*. Churchill Livingstone, London
- Cinalli G, Saint-Rose C, Chumas P, Zerah M, Brunelle G, Lot G, Pierre-Kahn A, Renier D (1999) Failure of third ventriculostomy in the treatment of aqueductal stenosis in children. *J Neurosurg* 90:448–453
- Cinalli G, Spennato P, Del Basso De Caro ML, Buonocore MC (2004) Hydrocephalus and the Dandy-Walker malformation. In: Cinalli G, Maixner WJ, Sainte-Rose G (eds) *Pediatric hydrocephalus*. Springer, Milano, pp 259–277
- Ciurea AV, Coman TC, Mircea D (2004) Postinfectious hydrocephalus in children. In: Cinalli G, Maixner WJ, Sainte-Rose G (eds) *Pediatric hydrocephalus*. Springer, Milano, pp 201–218
- Committee on Infectious Diseases (2000) Report of the committee of infectious diseases, 25th edn. The American Academy of Pediatrics, Elk Grove Village
- Da Silva MD, Michowicz S, Drake JM et al (1995) Reduced local cerebral blood flow in periventricular white matter in experimental neonatal hydrocephalus restoration with CSF shunt. *J Cereb Blood Flow Metab* 15:1057–1065
- Dandy WE, Blackfan KD (1914) Internal hydrocephalus. An experimental, clinical and pathological study. *Am J Dis Child* 8:406–482
- Dias MS (2005) Neurosurgical management of myelomeningocele spina bifida. *Pediatr Rev* 26:50–58
- Ditmyer S (2004) Hydrocephalus. In: Jackson PL, Vessey JA (eds) *Primary care of the child with a chronic condition*. Mosby, St. Louis, pp 543–559
- Greenberg MS (2010) *Handbook of neurosurgery*. Thieme, New York
- Haines SJ (1999) Shunt infections. In: Albright AL, Pollack IF, Adelson PD (eds) *Principles and practice of pediatric neurosurgery*. Thieme, New York, pp 1177–1185
- Hoang S, Chowdhri O, Edwards M, Guzman R (2009) Vein of Galen malformation. *Neurosurg Focus* 27(5):E8
- Hoppe-Hirsch E, Laroussinie F, Burnett L, Sainte-Rose C, Reiner D, Cinalli G et al (1998) Late outcome of the surgical treatment of hydrocephalus. *Childs Nerv Syst* 14:97–99
- Huber-Okrainec J, Dennis M, Brettschneider J, Spiegler BJ (2002) Neuromotor speech deficits in children and adults with spina bifida and hydrocephalus. *Brain Lang* 80:592–602
- Kestle JR, Riva-Cambrian J, Wellons JC, Kulkarni A, Whitehead WE et al (2011) A standardized protocol to reduce cerebrospinal fluid shunt infection: the hydrocephalus clinical research network quality improvement initiative. *J Neurosurg Pediatr* 8:22–29
- Kulkarni AV, Drake JM, Mallucci CL, Sgouros S, Roth J, Constantini S (2009) Endoscopic third ventriculostomy in the treatment of childhood hydrocephalus. *J Pediatr* 155(2):254–259
- Langingham MV, Nguyen TV, Robert A, Parent AD, Zhang J (2009) Risk factors of congenital hydrocephalus: a 10 year retrospective study. *J Neurol Neurosurg Psychiatry* 80:213–217
- Laurance LM, Coates S (1962) The natural history of hydrocephalus. Detailed analysis of 182 unoperated cases. *Arch Dis Child* 37:345–361
- Lockhart PB, Loven B, Brennan MT, Fox PC (2007) The evidence base for the efficacy of antibiotic prophylaxis in dental practice. *J Am Dent Assoc* 138:458–465
- Mapstone TB, ReKate HL, Nulson FE (1984) Relationship of CSF shunting and IQ in children with myelomeningocele: a retrospective analysis. *Childs Brain* 11:112–118
- Marlin AE, Gaskill ST (1994) Cerebrospinal fluid shunts: complications and results. In: Cheek WR, Marlin AE, McLone DG, Reigel DH, Walker ML (eds) *Pediatric neurosurgery. Surgery of the developing nervous system*. W. B. Saunders Company, Philadelphia, pp 221–231
- McLone DG (2001) *Pediatric neurosurgery. Surgery of the developing nervous system*, 4th edn. W. B. Saunders Company, Philadelphia
- Milhorat TH (1982) Hydrocephalus historical notes, etiology, and clinical diagnosis. In: Section of Pediatric Neurosurgery of the American Association of Neurological Surgeons (ed) *Pediatric neurosurgery. Surgery of the developing nervous system*. Grune & Stratton, New York, pp 192–210
- Oertel JM, Mondork J, Baldauf J, Schroeder HW, Gaab MR (2009) Endoscopic third ventriculostomy for

- obstructive hydrocephalus due to intracranial hemorrhage with intraventricular extension. *J Neurosurg* 111:1119–1126
- Olson S (2004) The problematic slit ventricle syndrome. *Pediatr Neurosurg* 40:264–289
- Penzkofer AK, Pfluger T, Pochmann Y, Meissner O, Leinsinger G (2002) MR imaging of the brain in pediatric patients: diagnostic value of HASTE sequences. *AJR Am J Roentgenol* 179:509–514
- Raffel C, McComb G (1994) Arachnoid cysts. In: Cheek WR, Marlin AE, Reigel DG, Walker ML (eds) *Pediatric neurosurgery. Surgery of the developing nervous system*. W. B. Saunders Company, Philadelphia, pp 104–110
- Rekate HL (1999) Treatment of hydrocephalus. In: Albright A, Pollack I, Adelson D (eds) *Principals and practice of pediatric neurosurgery*. Thieme Medical Publishers, Inc., New York, pp 47–73
- Rekate HL, Wallace D (2003) Lumboperitoneal shunts in children. *Pediatr Neurosurg* 38:41–46
- Rosen S (1998) Educating students who have visual impairments with neurological disabilities. In: Sacks SZ, Silberman RK (eds) *Educating students who have visual impairments with other disabilities*. Paul H. Brooks, Baltimore
- Said RR, Rosman NP (2004) A negative cranial computed tomographic scan is not adequate to support a diagnosis of pseudotumor cerebri. *J Child Neurol* 19:609–613
- Sainte R (2004) Hydrocephalus in pediatric patients with posterior fossa tumours. In: Cinalli G, Maixner WJ, Sainte-Rose G (eds) *Pediatric hydrocephalus*. Springer, Milano, pp 155–162
- Sato O, Yamaguchi T, Ketaaka M, Toyoma (2001) Hydrocephalus and epilepsy. *Childs Nerv Syst* 17:76–86
- Schneider SJ, Wiscoff JS, Epstein FJ (1992) Complications of ventriculoperitoneal shunt procedures or hydrocephalus associated with vein of Galen malformations in childhood. *Neurosurgery* 30:906–908
- Scott MA (1998) Memory functions in children with early hydrocephalus. *Neuropsychology* 12:578–589
- Sgouros S (2004a) Management of spina bifida, hydrocephalus and shunts. *E-Medicine*. Retrieved 9 Sept 2005, from <http://www.emedicine.com/ped/topic2976.htm>
- Sgouros S (2004b) Hydrocephalus with myelomeningocele. In: Cinalli G, Maixner WJ, Sainte-Rose G (eds) *Pediatric hydrocephalus*. Springer, Milano, pp 133–144
- Sgouros S, Malluci C, Walsh AR, Hockley AD (1995) Long term complications of hydrocephalus. *Pediatr Neurosurg* 23:127–132
- Shurtleff DB, Foltz EL, Loeser JD (1973) Hydrocephalus, a definition of its progression and relationship to intellectual function, diagnosis and complications. *Am J Dis Child* 125:688–693
- Simon TD, Riva-Cambrin J, Srivastava R, Bratton SL, Dean JM, Kestle JR (2008) Hospital care for children with hydrocephalus in the United States: utilization, charges, comorbidities, and death. *J Neurosurg Pediatr* 1:131–137
- Simon TD, Hall M, Riva-Cambrin J, Albert E, Jeffries HE, LaFleur B, Dean M, Kestle J (2009a) Infection rates following initial cerebrospinal fluid shunt placement across pediatric hospitals in the United States. *J Neurosurg Pediatr* 4(2):156–165
- Simon TD, Lamb S, Murphy NA, Hom B, Walker ML, Clark EB (2009b) Who will care for me next? Transitioning to adulthood with hydrocephalus. *Pediatrics* 125:1431–1438
- Sokoloff L (1989) Circulation and energy metabolism of the brain. In: Siegel GJ, Agranoff BW, Albers RW (eds) *Basic neurochemistry. Molecular, cellular and medical aspects*. Ravens Press, New York, pp 565–590
- Sutton LN (2005) Spinal dysraphism. In: Rengachary SS, Ellenbogen RG (eds) *Principles of neurosurgery*. Elsevier Mosby, New York, pp 99–115
- Teo C, Mobbs R (2005) Neuroendoscopy. In: Rengachary SS, Ellenbogen RG (eds) *Principles of neurosurgery*. Elsevier Mosby, New York, pp 145–156
- University of California, San Francisco (2000) *About hydrocephalus – a book for families*. (Brochure). Editor, Fudge
- Wang PP, Avellino AM (2005) Hydrocephalus in children. In: Rengachary SS, Ellenbogen RG (eds) *Principles of neurosurgery*. Elsevier Mosby, New York, pp 117–136
- Warf B, Campbell JW (2008) Combined endoscopic third ventriculostomy and choroid plexus cauterization as primary treatment of hydrocephalus for infants with myelomeningocele: long-term results of a prospective intent-to-treat study in 115 East African infants. *J Neurosurg Pediatr* 2:310–316
- Whitelaw A, Kennedy CR, Brion LP (2001) Diuretic therapy for newborn infants with posthemorrhagic ventricular dilation. *Cochrane Database Syst Rev* (2): CD002270
- Yamada J (2002) Neurological origins of poor reading comprehension despite fast word decoding. *Brain Lang* 80:253–259
- Zada G, Krieger MD, McNatt SA, Bowen I, McComb JG (2007) Pathogenesis and treatment of intracranial arachnoid cysts in pediatric patients younger than 2 years of age. *Neurosurg Focus* 22(2):1–5
- Zahl S, Egge A, Helseth E, Wester K (2011) Benign external hydrocephalus: a review, with emphasis on management. *Neurosurg Focus* 34:417–432



Cathy C. Cartwright and Patricia D. Chibbaro

---

## 3.1 Craniosynostosis

Craniosynostosis is the premature closure of one or more of the cranial sutures. Sometimes the entire suture is fused, but even a partial fusion can cause a deformity as the skull growth is restricted. Although the clinical condition of craniosynostosis was described by Hippocrates 400 years BC, effective treatments have only been developed in the last century (Cohen 1986). In 1800, Sömmering described the anatomic structures of calvarial sutures and the results of premature closure (Sömmering 1800). However, it was the German pathologist Rudolf Virchow who first used the term craniostenosis and proposed that “outward growth of the skull is restricted in a direction perpendicular to the prematurely fused suture and compensatory growth occurs in the patent sutures” (Virchow 1851). This restriction of growth in one direction and compensatory growth in others accounts for the classic skull deformities seen in craniosynostosis.

The most common type of craniosynostosis is nonsyndromic craniosynostosis, which is a congenital disorder. Craniosynostosis also occurs in over 90 syndromes, but these usually involve more than one cranial suture and occur far less frequently than nonsyndromic craniosynostosis (Cohen 1993). Cohen listed the known causes of craniosynostosis as genetic conditions (e.g., mutations in fibroblast growth factor receptors); metabolic disorders, such as hyperthyroidism, mucopolysaccharidoses,  $\beta$ -glucuronidase deficiency, and mucopolidoses; hematological disorders; teratogens; and malformations, including microcephaly and encephalocele (Cohen 1986). Secondary craniosynostosis can result from overshunting hydrocephalus; however, true bony fusion of the suture does not occur in shunt-related craniosynostosis (Sun and Persing 1999).

Craniosynostosis is usually recognizable at birth, and the parents may suspect that their baby’s head “just doesn’t look right.” Although molding of the skull can occur during the birth process, this usually normalizes by 3 months of age, whereas the deformities from craniosynostosis continue to worsen as the child’s brain continues to grow. Infants with craniosynostosis have unique characteristics that are not to be confused with birth trauma. Recognizing craniosynostosis early, before 3 months of age, is important so that minimally invasive surgery can be considered instead of the more extensive calvarial vault remodeling required for the older child.

---

C.C. Cartwright, RN, MSN, PCNS (✉)  
Department of Neurosurgery, Children’s Mercy Hospital,  
2401 Gillham Road, Kansas City, MO 64108, USA  
e-mail: c2cartwright@gmail.com

P.D. Chibbaro, RN, MS, CPNP  
Department of Craniofacial Surgery,  
Institute of Reconstructive Plastic Surgery,  
NYU Langone Medical Center,  
307 East 33rd Street, New York, NY 10016, USA  
e-mail: patricia.chibbaro@nyumc.org

**Table 3.1** Classifications of craniosynostosis

Type of craniosynostosis	Suture involved	Incidence (%)	Characteristics
Scaphocephaly (dolichocephaly)	Sagittal	40–60	Bitemporal narrowing Frontal bossing Occipital cupping Palpable sagittal ridge
Anterior plagiocephaly	Coronal	20–30	Vertical dystopia Nasional deviation Flattening of frontal bone on affected side
Trigonocephaly	Metopic	10	Triangular shape Bitemporal narrowing Parietal bossing Hypotelorism Metopic ridge
Posterior plagiocephaly	Lambdoid	1–2	Trapezoid shape Tilted skull base Occipitomastoid bulge

### 3.2 Nonsyndromic Craniosynostosis

Nonsyndromic craniosynostosis, the predominant type of suture fusion, occurs in 1 out of 2,100 children (Lajeunie et al. 1995). The sagittal suture is involved in 40–60 % of these fusions, the coronal suture in 20–30 %, and the metopic suture in 10 % (Hunter and Rudd 1984; Lajeunie et al. 1995; Shillito and Matson 1968). Lambdoid synostosis, while often mistaken for positional plagiocephaly, is rare, occurring in 1–2 % of all craniosynostosis (Vander Kolk and Carson 1994). Multiple suture synostoses involving two or more cranial sutures occur in 4–8 % of nonsyndromic craniosynostosis (Chumas et al. 1997; Hoffman and Raffel 1989) (Table 3.1).

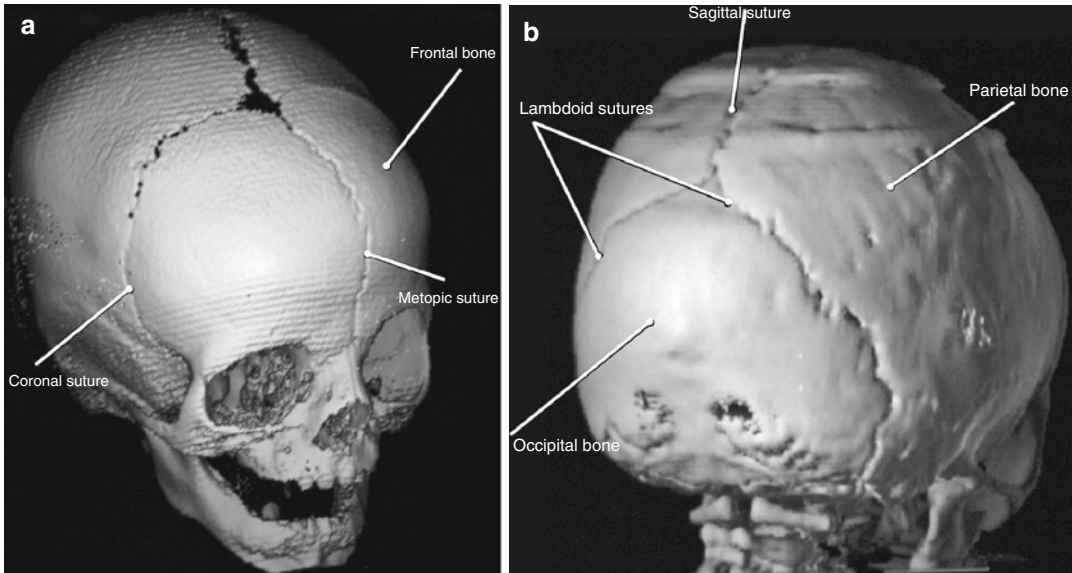
The specific cause of simple nonsyndromic craniosynostosis has not yet been identified. Simple craniosynostosis is usually random in occurrence, but 2–6 % of isolated sagittal synostosis and 8–14 % of coronal synostosis were found to be familial (Cohen 1986; Lajeunie et al. 1996). In utero head restraint has also been named as a cause of craniosynostosis, although it is more commonly seen as positional plagiocephaly (Graham et al. 1979, 1980; Higgenbottom et al. 1980).

The diagnosis is made by physical examination and can be confirmed with radiographs if there is any question about the diagnosis.

Plain skull films allow a look at the patency of the suture in question, but a CT of the head is preferable as the suture can be identified more easily. A CT scan with three-dimensional reconstruction (3D recon) provides further clarity of the skull shape, skull base, and suture patency. Radiodiagnostic testing should be used judiciously, however, because radiation can have deleterious effects on the growing brain (Frush et al. 2003; Didier et al. 2010; Paterson and Frush 2007). There are several campaigns (e.g., Image Gently, Image Wisely) as well as a major focus in the medical and lay press on the importance of increasing efforts to reduce exposure, especially in infants and children (McCarthy et al. 2012). For example, use of the ALARA guidelines (“as low as reasonably achievable”) is recommended in order to achieve the correct dose of radiation (The Joint Commission 2011).

#### 3.2.1 Pathophysiology

The brain is contained in the neurocranium, which comprises the skull base and cranial vault. Each of these two components of the neurocranium develops in different ways. The calvarial vault develops via intramembranous ossification as fibrous membrane (ectomeninx) over the brain, while the skull



**Fig. 3.1** (a, b) Skull bones and sutures most commonly involved in craniosynostosis

base develops through endochondral ossification. After the second month of gestation, ossification centers in the ectomeninx differentiate into an outer periosteum and inner dura. These ossification centers eventually expand or fuse to form the frontal, parietal, and occipital bones (Lemire 1986; Pritchard et al. 1956) (Fig. 3.1). The edges of these sutures contain special cells called the osteogenic front (Decker and Hall 1985). At 16 weeks gestation, sutures form as these osteogenic fronts approach each other (Vermeij-Keers 1990).

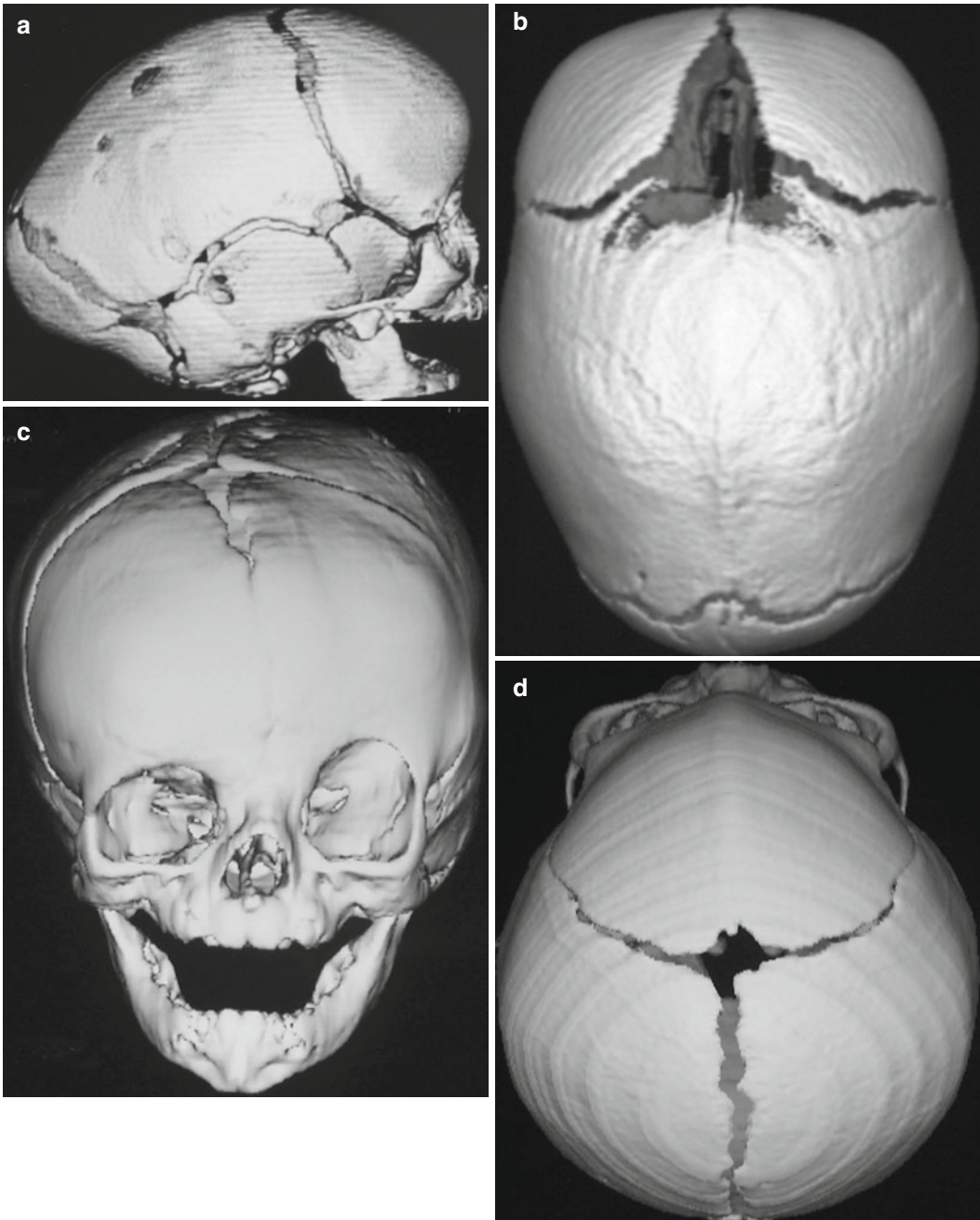
Sutures allow the infant's head to reshape during the birth process and accommodate the expanding brain during rapid growth. Open sutures may also absorb stresses from trauma (Cohen and MacLean 2000). The dura (membrane covering the brain) is essential for suture and calvarial bone growth. The site of suture formation is related to the location of major dural reflections. Dural reflections are bands of dural attachment to the skull base that conform to the early recesses of the brain (Sun and Persing 1999). In infants with brain malformations, these early recesses may be absent and the suture will not form.

Removing the skull in a neonate with intact dura results in the dura regenerating the skull with sutures placed as dictated by the dura (Drake

et al. 1993; Mabutt and Kokick 1979). In other words, neonates and young infants can have portions of or their entire skull removed, and an intact dura will regrow the skull bone with appropriate suture locations. This ability to reossify the skull diminishes as the infant ages.

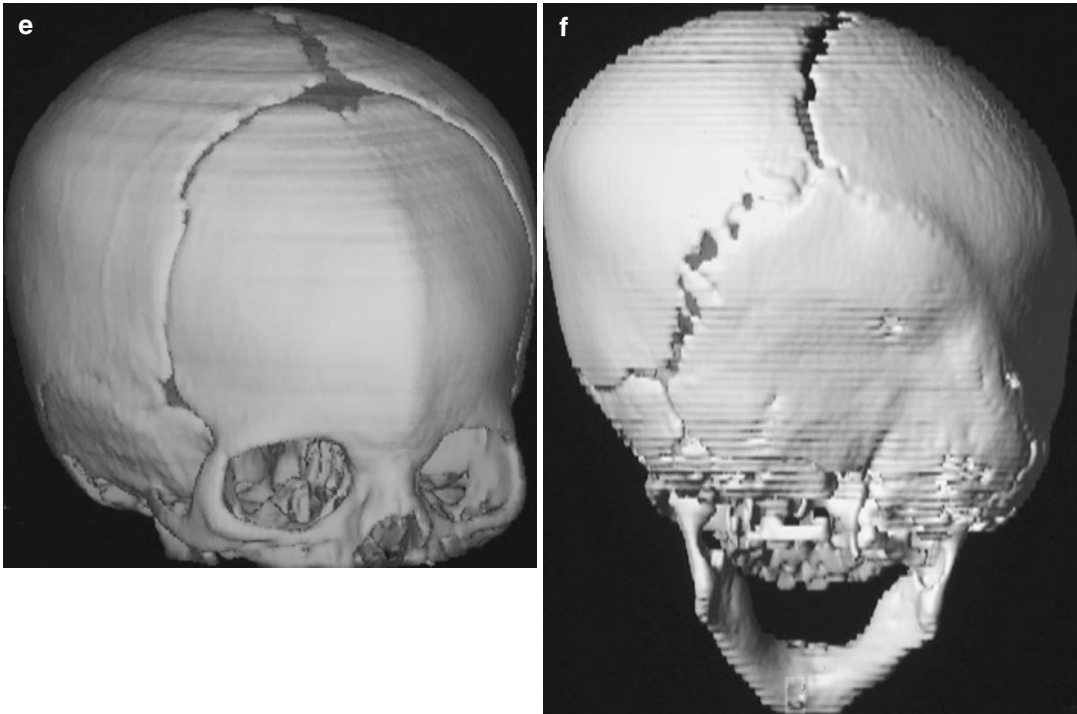
As the brain grows, overall calvarial bone growth occurs from the expanding brain. New bone is deposited at the osteogenic fronts of the open sutures, and this bone deposition at the suture margins is driven by the expanding brain (Sun and Persing 1999). The skull is 35 % of adult size at birth and 90 % by 7 years of age (Ohman and Richtsmeier 1994). The metopic suture closes at approximately 2 years of age, but the other sutures remain open to accommodate brain growth into adulthood. A layer of capsular fibrous tissue surrounding the osteogenic fronts normally keeps the other sutures from fusing (Sun and Persing 1999). Even partial closure of one or more sutures during the period of rapid cranial growth can cause significant skull deformities (Fig. 3.2).

The following characteristics of each of the four most common suture closures can occur singly or in combination, especially if multiple sutures are involved.



**Fig. 3.2** 3D CT reconstructions clearly show the stenosed sutures and skull shapes. **(a)** In sagittal synostosis, the open sutures compensate for brain growth. **(b)** Top of skull shows sagittal synostosis with a closed sagittal suture, open anterior fontanel, and open coronal and lambdoid sutures.

**(c)** Left coronal synostosis showing closed left coronal suture, nasal deviation, and elongation of the left superior orbital rim. **(d)** Metopic synostosis with trigonocephalic shape to the skull. **(e)** Closed metopic suture causes a vertical ridge or keel. **(f)** Right lambdoid synostosis



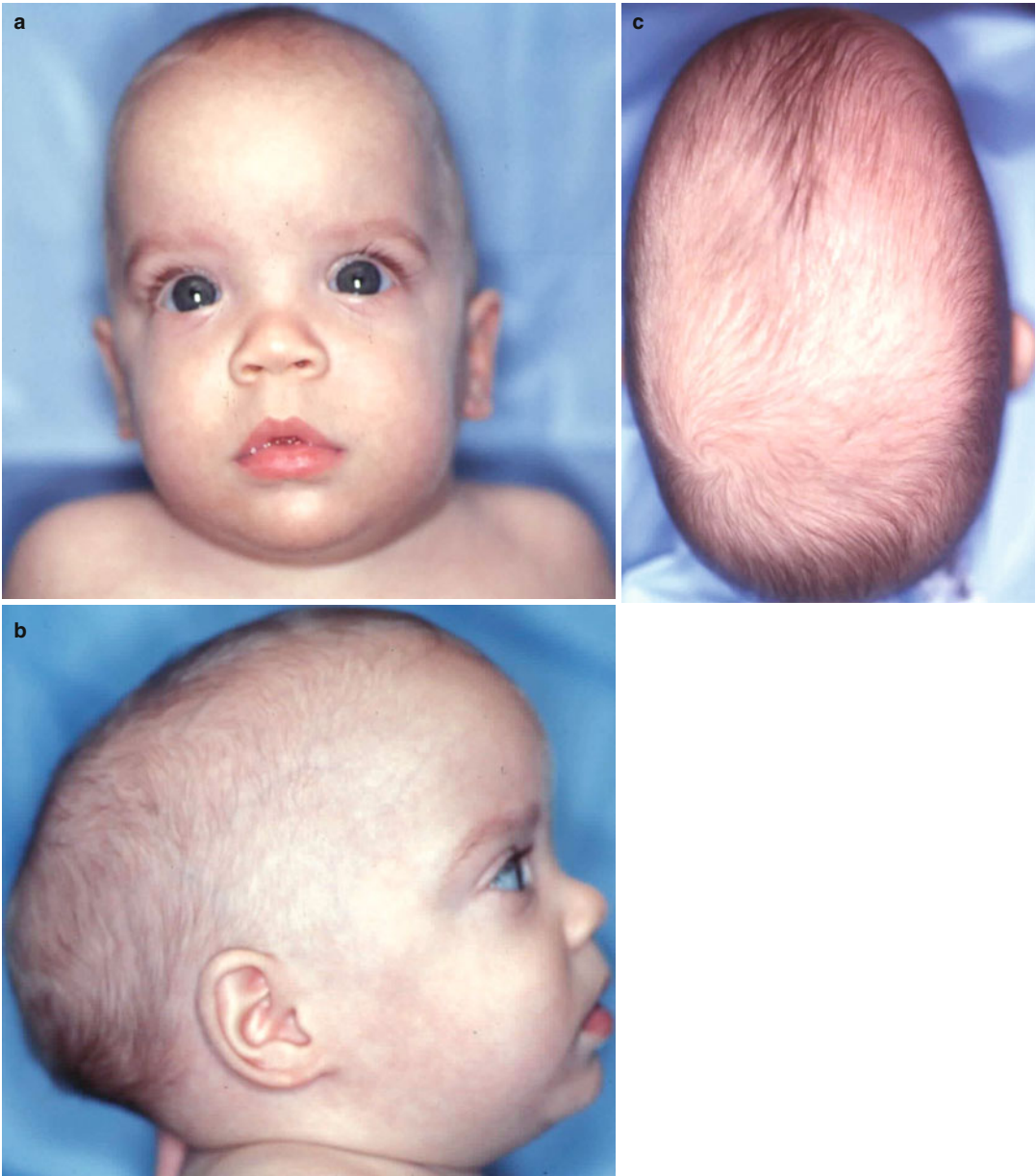**Fig. 3.2** (continued)

### 3.2.2 Sagittal Synostosis

The most common type of craniosynostosis is sagittal, characterized by a scaphocephalic or “boatlike” shape to the skull, various degrees of bitemporal narrowing, frontal bossing, occipital cupping, and a palpable sagittal ridge (Fig. 3.3). Sometimes, the scaphocephalic shape, and especially the occipital cupping, is so prominent that when the infant is lying supine with the back of the head on the mattress, the head is flexed in a way that causes the airway to be compromised. The degree of scaphocephaly is determined by measuring cranial index. Using spreading cranial calipers (GPM Instruments, Switzerland), the distance is measured from euryon to euryon, divided by glabella to opisthocranium and multiplied by 100 (Fig. 3.4). A cephalic index of 83 would be average, with higher numbers indicating a rounder head and lower numbers indicating a more scaphocephalic shape. A special laser scanner can also be used to get measurements and a 3D picture of the skull.

### 3.2.3 Coronal Synostosis

Coronal synostosis, or anterior plagiocephaly, is characterized by vertical dystopia, nasional deviation to the ipsilateral (affected or same) side, flattening of the frontal bone on the ipsilateral side, and bulging of the frontal bone on the contralateral (opposite) side (Fig. 3.5). Strabismus from ipsilateral superior oblique paresis and compensatory contralateral head tilt is present in 50–65 % of unilateral coronal synostosis (Gosain et al. 1996; O’Daniel et al. 1993). It is recommended that the patient see an ophthalmologist familiar with craniofacial disorders for preoperative evaluation. Strabismus surgery is usually needed, as it rarely improves after craniofacial reconstruction (Sun and Persing 1999). However, strabismus surgery corrects or improves the head tilt (Gosain et al. 1996). An anteroposterior (AP) skull film shows a harlequin appearance to the ipsilateral orbit as the superior orbital rim is elongated (Fig. 3.6).

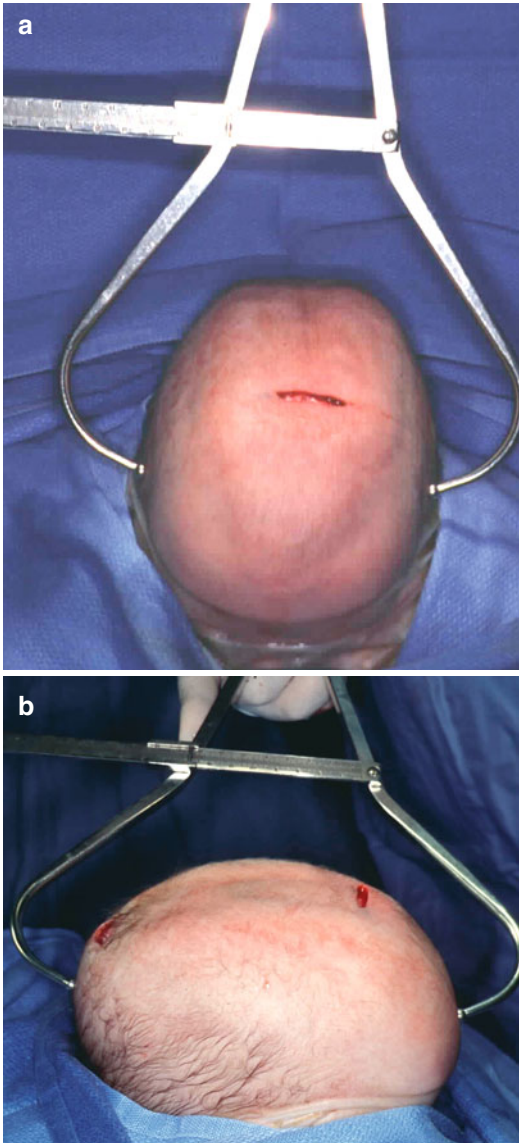


**Fig. 3.3** (a–c) Sagittal synostosis. Note the long, narrow shape to the skull, bitemporal narrowing, occipital cupping, and frontal bossing

### 3.2.4 Metopic Synostosis

Metopic synostosis is characterized by a trigonocephalic or triangular shape to the head when viewed from above. There are various degrees of bitemporal narrowing, parietal bossing, hypotelorism (close-set eyes), and ridging of the

metopic suture that can resemble a keel (Fig. 3.7). A common variation is characterized by a normal shape to the skull, absence of hypotelorism, and just a slight ridging of the metopic suture. Although surgery is not considered in this instance unless the baby exhibits signs of increased intracranial pressure

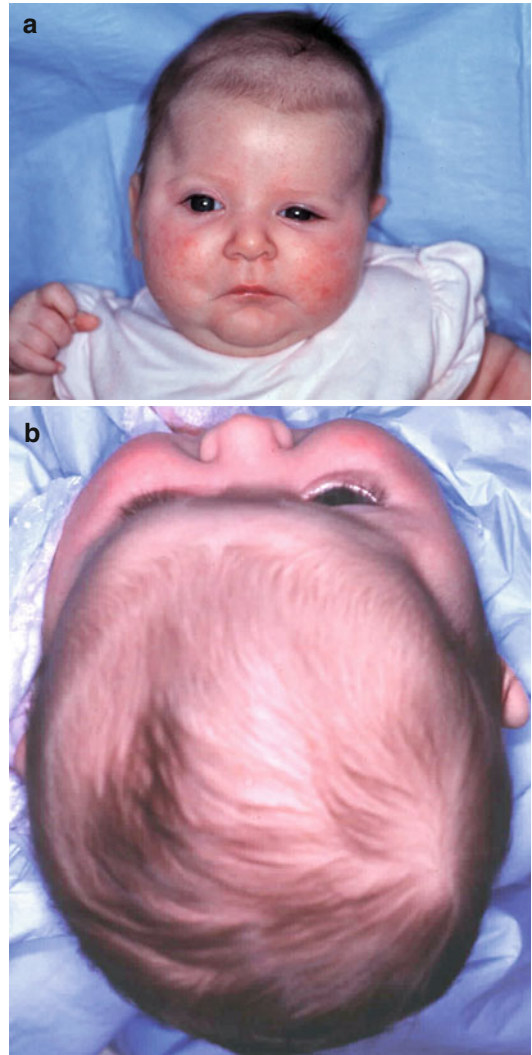


**Fig. 3.4** Cranial calipers are used to measure the cephalic index. (a) Euryon to euryon. (b) Glabella to opisthocranium

(vomiting, lethargy, extreme fussiness, papilledema), the ridge can be “burred down” at a later date if it is still prominent.

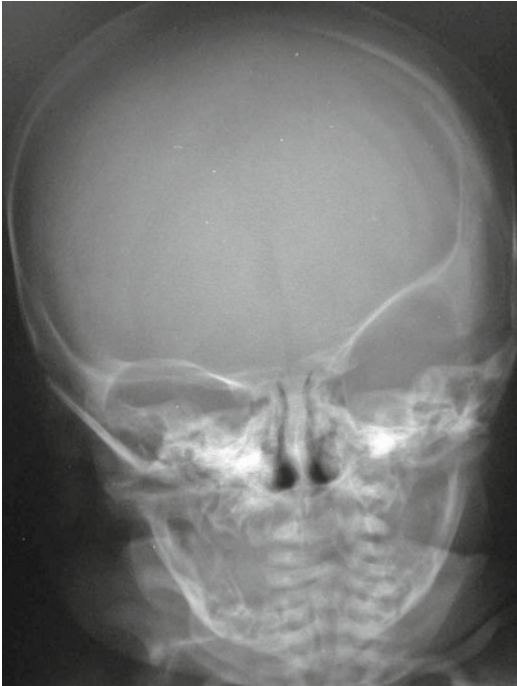### 3.2.5 Lambdoid Synostosis

Lambdoid synostosis or occipital plagiocephaly is characterized by a trapezoid shape to the



**Fig. 3.5** (a, b) Right Coronal synostosis. Note the nasional deviation, flattening of the frontal bone on the ipsilateral side, and vertical dystopia

head when viewed from above, tilted skull base (ipsilateral side displaced inferiorly) and ipsilateral ear displaced inferiorly and posteriorly. The fused lambdoid suture has a palpable ridge, and there is an ipsilateral occipitomastoid bulge. When viewed from behind, the skull base appears tilted (Fig. 3.8). Care must be taken not to confuse true lambdoid synostosis with positional plagiocephaly (Table 3.2). Radiographically, a Towne’s view skull film or CT scan will show a closed lambdoid suture.

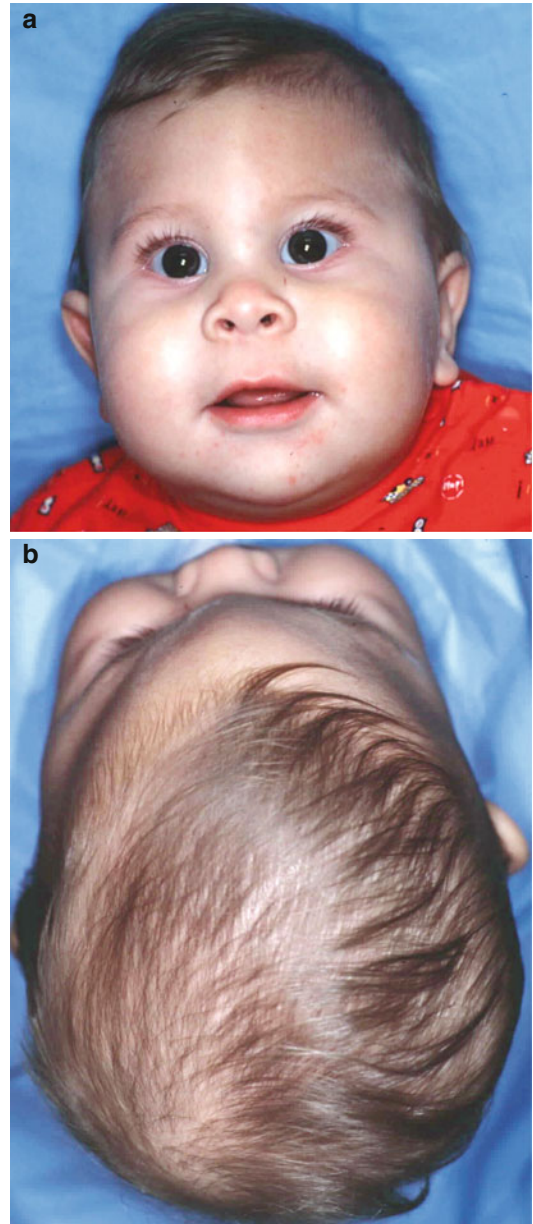


**Fig. 3.6** Skull film shows “harlequin sign” as the superior orbital rim of the affected eye is elongated

### 3.2.5.1 Positional Plagiocephaly

Deformational forces, such as the prenatal head on the mother’s pelvic bone or the birth process itself, can shape the skull. The infant brain grows rapidly during the first several months after birth, and it is this growth that expands the skull into its normocephalic shape. Infant head circumference increases 9 centimeters (cm) during the first 6 months and grows approximately 12 cm during the first year. In comparison, the head circumference increases by only  $2\frac{1}{4}$  cm during the second year after birth and just  $\frac{3}{4}$  cm between the second and third years. Therefore, deformational forces encountered when an infant head lies on a mattress; against a car seat, swing, or stroller; or on any firm surface for prolonged periods of time can have a significant influence during the period of rapid skull growth.

Most babies are born with normocephaly, but their skulls may become progressively more misshapen during the first several weeks after birth because of deformities from unrelieved pressure on the occipital bone. By 2 months of age, a baby

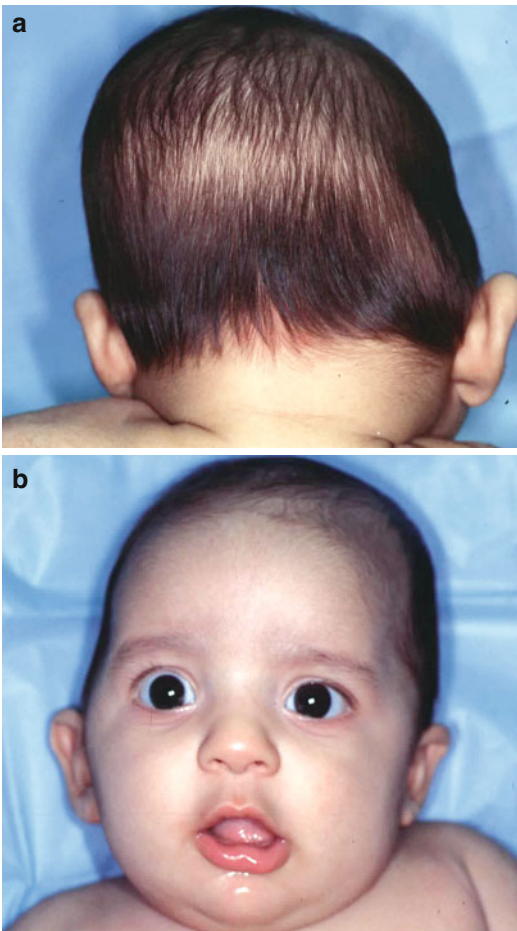


**Fig. 3.7** (a, b) Metopic synostosis. Note the trigonocephalic shape of the skull, bitemporal narrowing, hypotelorism, and ridging of the metopic suture

may have spent approximately 700 h sleeping. If the baby lies supine with the head turned to one side, either from preference or the head has not been rotated to redistribute the deformational forces of gravity, positional plagiocephaly (PP) can result. This condition can be further aggravated



by torticollis, which is a tightening of the sternocleidomastoid or cervical muscles that prevent the infant from turning the head 180° (Rekate 1997).



**Fig. 3.8** (a, b) Lambdoid synostosis. Note the tilted skull base

There has been a significant increase in “deformational” or “positional” plagiocephaly since 1992, when the American Academy of Pediatrics initiated the “Back to Sleep” (BTS) campaign and recommended that infants sleep on their backs or sides to decrease the incidence of sudden infant death syndrome (SIDS) (Kane et al. 1996; Majnemer and Barr 2006; Moon et al. 2011). One referral center reported a ten-fold increase in referrals for occipital plagiocephaly compared with 1991 (Carson et al. 1997). Positional plagiocephaly occurs in 18–19.7 % of healthy infants, depending on age. Thirteen percent of newborns present with PP, and the incidence increases to 16 and 19 % at 6 weeks and 4 months of age, respectively (Hutchinson et al. 2004; Peitsch et al. 2002). There is much controversy in the literature regarding the association between positional plagiocephaly and developmental delays (Collett et al. 2005; Majnemer and Barr 2006).

It is important to differentiate positional plagiocephaly from craniosynostosis, as the treatment for craniosynostosis is surgery and the treatment for plagiocephaly is, with rare exception, nonsurgical. A thorough history and physical examination will help differentiate between the two. Parents of infants with plagiocephaly frequently report that the head shape was normal at birth and that the occipital flattening was noticed later, often by the pediatrician at the 2-month well-baby exam. They also recall their baby preferred to sleep in one position with the head turned to one side. Some babies may prefer to sleep with

**Table 3.2** Comparison of lambdoid synostosis and positional (deformational) plagiocephaly

Lambdoid synostosis	Positional plagiocephaly
Usually present at birth	Usually not present at birth
Trapezoid shape when viewed from above	Parallelogram shape when viewed from above
Ipsilateral ear displaced posteriorly and inferiorly	Ipsilateral ear displaced anteriorly
Bony ridge palpable over closed lambdoid suture	No bony ridge over lambdoid suture
Unilateral occipitoparietal flattening posteriorly	Usually unilateral occipitoparietal flattening but can be bilateral
When viewed posteriorly, there is an ipsilateral occipitomastoid bulge, and the skull base appears tilted	When viewed posteriorly, the skull base is horizontal and no occipitomastoid bulge
Contralateral frontal bossing	Ipsilateral frontal bossing
Radiographic evidence of closed suture (Towne’s view, CT with bone windows, CT with 3D recon)	Radiographic evidence of open sutures
	May have torticollis

the back of the head on the mattress, not turning it to either side. These infants can have flattening of the entire occipital bone, which causes the face to appear very round when viewed from the front.

With positional plagiocephaly, there is no bony ridge palpated along the lambdoid suture, and the base of the skull will be horizontal when viewed from behind. When viewed from above, there is occipitoparietal flattening on the affected side with anterior displacement of the ear, forehead, and malar eminence on the ipsilateral side. This appears to resemble the shape of a parallelogram as one side of the skull is shifted forward (Fig. 3.9). A Towne's view x-ray or CT of the brain with bone windows will clarify the diagnosis by showing open lambdoid sutures. However, if a thorough history and physical examination clearly supports the diagnosis of positional plagiocephaly, imaging is often not necessary. The severity of cranial vault asymmetry can be evaluated by obtaining transcranial anthropometric measurements with a sliding caliper. Two oblique transverse cranial diameters are measured – from the midpoint of the supraorbital rim to the midpoint of the contralateral parieto-occipital scalp. The larger the difference between these two points, the greater the asymmetry (Mulliken et al. 1999; Farkas 1996; Dec and Warren 2011).

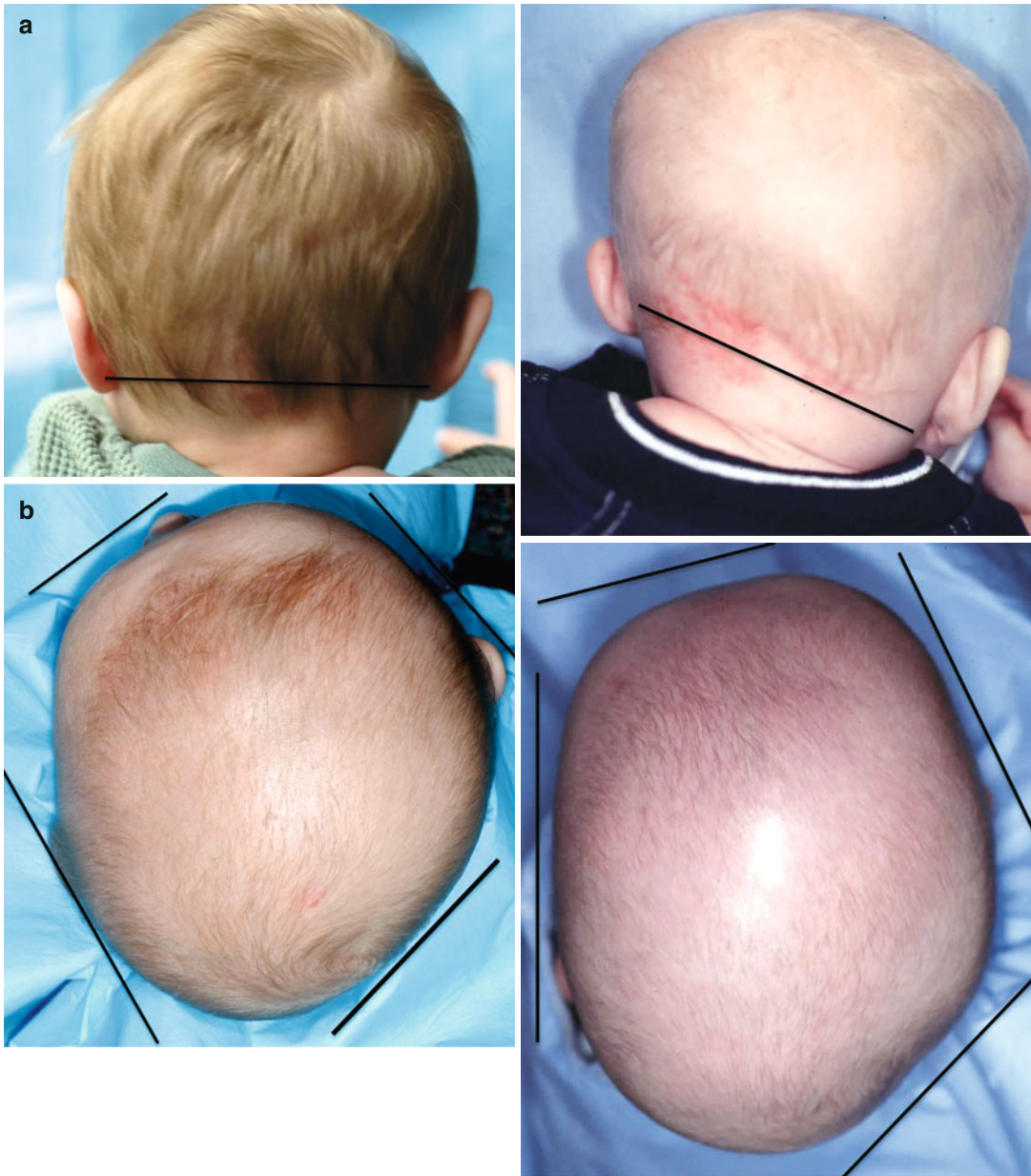### 3.2.5.2 Prevention and Treatment for Positional Plagiocephaly

The prevention of positional plagiocephaly should begin at birth, with education provided by the postpartum nursing staff and continuing at each pediatric well-child care visit by the pediatrician or pediatric nurse practitioner (Table 3.3). Before leaving the hospital, parents should be instructed in principles of “back to sleep/tummy to play.” Although babies should be supine for sleep or naps, it is important to provide “tummy time” to allow strengthening of neck muscles and promote optimal development (Table 3.4). Parents should be taught to reposition their infant's head when lying supine, starting from birth. Mild cases of flatness will resolve over weeks to months if the infant's head is repositioned on a flat surface. Toys or objects of interest can be placed on the

nonpreferential side to encourage the infant to turn his head in the nonpreferential direction. Alternating arms to hold the baby when feeding will also encourage head turning to both sides. “Tummy time,” or placing the baby prone while awake and observed, will decrease gravitational forces on the skull (Koren et al. 2010).

A cranial orthotic device, such as a band or molding helmet, may be used to correct moderate to severe cases of positional molding but only after the parents have attempted all other repositioning strategies without significant improvement in the head shape (Fig. 3.10). Molding therapy is most effective between 4 and 12 months of age, during the time of rapid brain growth. The helmet helps to reshape the skull by restricting the growth in one direction, thus allowing it to expand in the other direction. It is critical to refer these patients to an orthotist experienced in cranial orthotic devices for positional plagiocephaly. Infants typically show significant improvement in head shape over the first several weeks, and significant correction is usually achieved by 3 months (Robinson and Proctor 2009). However, the helmet must be worn at least 23 h each day to get best results. In extremely rare cases of severe deformity, despite repositioning, correction of torticollis, and use of a cranial molding device, surgery may be considered.

Torticollis, or unilateral shortening and fibrosis of the sternocleidomastoid, can prevent an infant from turning his head to the nonpreferential side and cause further deformity to the face. Congenital muscular torticollis is associated with PP in up to 90 % of infants (Rogers 2011). Static stretching exercises can be done to gently stretch the affected sternocleidomastoid muscle. Confirm that there is no cervical spine defect before doing these exercises. A pediatric physiotherapist should be consulted, though parents can be taught to do these exercises at home 5–6 times a day. With the infant lying supine on a flat surface and the head in midline position, the parent can slowly turn the head 90° toward the nonpreferential side, holding the stretched position for 10 s, and then slowly turn the head back to midline. A second person may need to hold the shoulders so they don't turn with the head. If a head tilt is present, the parent



**Fig. 3.9** These pictures illustrate the differences between positional plagiocephaly (*left*) and lambdoid synostosis (*right*). (a) When the skull is viewed from behind, the skull base is horizontal with positional plagiocephaly and

tilted with lambdoid synostosis. (b) When viewed from above, the skull with positional plagiocephaly (*left*) takes the shape of a parallelogram, while the skull with lambdoid synostosis (*right*) takes the shape of a trapezoid

should slowly tilt the head to the contralateral side and hold that position for 10 s (Fig. 3.11). Parents should be informed that these exercises should be done slowly to prevent trauma to the muscle, and that the baby will cry the first few times. However,

within a few days, the muscle will relax and it will be easier to turn the head. The torticollis should resolve within a couple of weeks.

In sternocleidomastoid tumor of infancy, a tumor is palpable in the muscle and can restrict

**Table 3.3** Recommendations for safe sleeping environment/principles of “back to sleep”

Place infant supine for all naps and at bedtime – “back to sleep for every sleep”
Vary the head position by alternating the infant’s head from side to side but do not position on the side
Use a firm sleep surface covered by a tight-fitted sheet
No wedges, crib bumpers, blankets, pillows, loose bedding, or stuffed animals in the crib
Do not use devices that are marketed to decrease the risk of SIDS – e.g., special wedges, positioners, and sleep surfaces
If infant falls asleep in a seat/swing, move to a crib/other flat surface as soon as practical
Room sharing without bed sharing (avoid the risk of entrapment/suffocation) is recommended
Offer a pacifier at bedtime/nap time
Avoid overheating
Avoid smoke exposure and alcohol/illicit drug use during pregnancy and after birth
Breastfeeding is recommended
Do not use home cardiorespiratory monitors as a SIDS-reduction strategy
Infants should be immunized in accordance with the AAP and CDC recommendations
Healthcare professionals in all settings and childcare providers should endorse the SIDS risk-reduction recommendations from birth

Task Force on Sudden Infant Death Syndrome (2011); Koren et al. (2010)

the infant’s ability to turn the head. Stretching exercises may improve this condition, but surgery is usually necessary to remove the mass and lyse the muscle (Kane et al. 1996; ReKate 1997).

Although preventing positional plagiocephaly is ideal, treatment should be instituted as soon as the diagnosis is made. Early intervention during the period of rapid skull growth (first few months of age) will have the best results.

### 3.3 Syndromic Craniosynostosis

Infants with craniosynostosis “syndromes” or “conditions” present with a characteristic group of clinical findings. They have multiple cranial suture synostoses, including the sutures of the cranial base, which result in complex skull and forehead deformities (Bartlett and Mackay 1997). The cranial base

abnormalities are manifested by hypoplasia of the midface and maxilla. These children often have hypertelorism, exorbitism, syndactyly, cleft palate, cardiac anomalies, and eye muscle abnormalities (e.g., strabismus). Depending on the degree of severity, there are frequently associated medical problems, including hydrocephalus, papilledema, respiratory distress, and failure to thrive.

The most common of these conditions are Crouzon, Apert, and Pfeiffer syndromes. Although their etiology is not totally clear and the majority of the reported cases are sporadic, it is known that they have an autosomal dominant mode of inheritance. An affected individual always has a 50 % chance of parenting a child who will be born with the same condition. Mutations in specific fibroblast growth factor receptor (FGFR) gene types for these syndromes have been identified (Ridgeway and Weiner 2004; Rossi et al. 2003).

#### 3.3.1 Crouzon Syndrome

First described by a French neurologist in 1912, this autosomal dominant condition has an approximate incidence of 1 in 25,000 births. It is caused by multiple mutations in the fibroblast growth factor receptor 2 (FGFR2). Common clinical findings in infants with Crouzon syndrome may include bicoronal craniosynostosis, with a resulting short cranium, a broad/flat forehead, sometimes in combination with sagittal and/or lambdoid synostosis (often very severe, as in a child with a cloverleaf deformity), and varying degrees of exorbitism, hypertelorism (wide-set eyes), and maxillary/midface hypoplasia – resulting in a “froglike” face (Fig. 3.12). They are at very high risk for serious ocular abnormalities, including papilledema, optic atrophy, corneal exposure, and proptosis. In severe cases, the globe can actually herniate through the eyelids, often requiring emergency reduction or tarsorrhaphy (partial or complete suturing of the eyelids). They may also have a conductive hearing loss. In general, these children do not have anomalies of the hands or feet (Bartlett and Mackay 1997).

Depending on the severity of the midface hypoplasia (and whether there is choanal atresia), the

**Table 3.4** Strategies to prevent/manage positional plagiocephaly

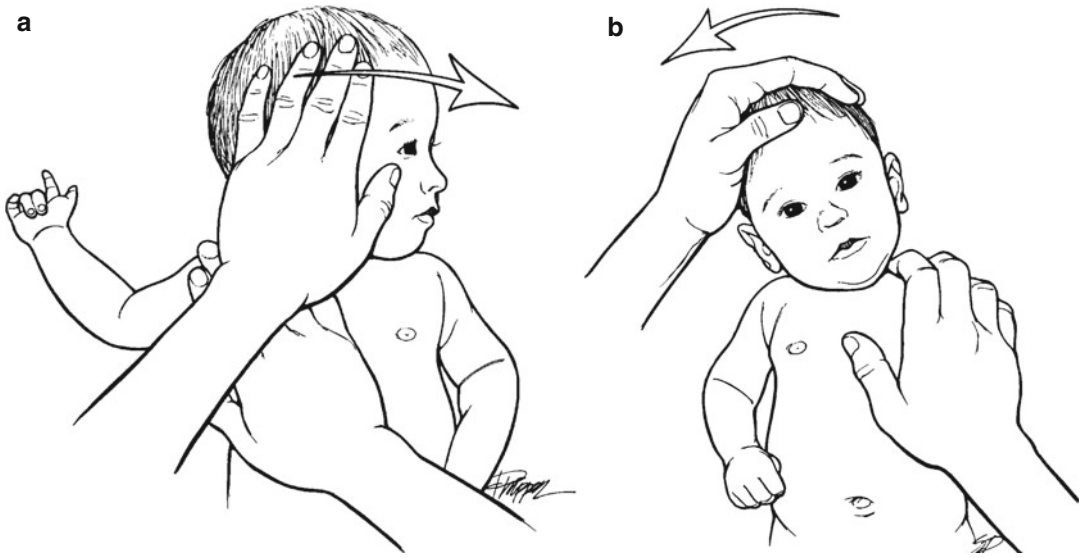
<i>Tummy time</i>
Tummy time activities with the infant in the prone (on the stomach) position should begin at birth
These activities must always occur with the infant awake and supervised
Start with a few minutes per day, 2–3 times per day, and increase the time/frequency as the infant grows
A rolled blanket may be placed under the chest and upper arms for added support
Examples of tummy time/prone to play activities include:
Burping/soothing your infant face down on your lap
Getting down to her level to encourage eye contact
Lying on your back with her, face to face on your chest or tummy
Sliding your hand under tummy/between her legs and carrying her tummy down
Placing her on her tummy for 1–2 min after each diaper change
Lying her on her tummy with a blanket rolled under her and dangling a toy in her face (Pathwaysawareness.org/ EssentialTummyTimeMoves11/05/2011)
<i>Additional strategies to prevent/manage positional plagiocephaly</i>
Carry infant in front/back carriers or infant slings – ensure that the head is up and above fabric, the face is visible, and the nose/mouth are clear of obstructions
Limit time spent in:
Infant seats
Car seats
Bouncy seats
Swings
Strollers
Place toys or objects of interest on infant’s nonpreferential side
Hold/carry infant on nonpreferential side
Alternate arms when bottle feeding to encourage head turning to both sides

**Fig. 3.10** Cranial orthotic device to correct positional plagiocephaly

child may have serious airway compromise and challenges with oral feeding, often requiring management by supplemental oxygen therapy, CPAP (continuous positive airway pressure), tracheostomy, and/or gastrostomy placement. They are also at risk for development of hydrocephalus and/or a symptomatic Chiari malformation, possibly requiring early neurosurgical intervention (Ridgeway and Weiner 2004).

### 3.3.2 Apert Syndrome

Acrocephalosyndactyly type 1, more commonly known as Apert syndrome (after the French neurologist who described the syndrome in 1906), is the most complex of the craniosynostosis syndromes (McCarthy et al. 1990a). The incidence of this autosomal dominant condition is reported as 1/50,000–1/160,000 (Gosain et al. 1996; Bartlett and Mackay 1997). As with Crouzon



**Fig. 3.11** Static stretching exercises (Used with permission Littlefield et al. (2001)). (a) Slowly turn the head to the nonpreferential side, holding the stretch position for 10 s and then returning it to the midline. (b) Slowly tilt the

head to the contralateral side and hold that position for 10 s. (Used with permission from Barrow Neurological Institute. © Barrow Neurological Institute 2001. All Rights Reserved)

syndrome, this condition results from a mutation of the *FGFR2* gene. Infants with Apert syndrome also characteristically have multiple suture craniosynostosis. Their skulls are often very tall and turricephalic (tower-like). They usually present with an extremely flat and elongated forehead, bitemporal widening, and bilateral flattening of the occiput. The nose has a “beaked” appearance (Fig. 3.13). Hydrocephalus and agenesis of the corpus callosum are not uncommon in these children. They also have varying degrees of exorbitism, proptosis, midface/maxillary hypoplasia, and hypertelorism.

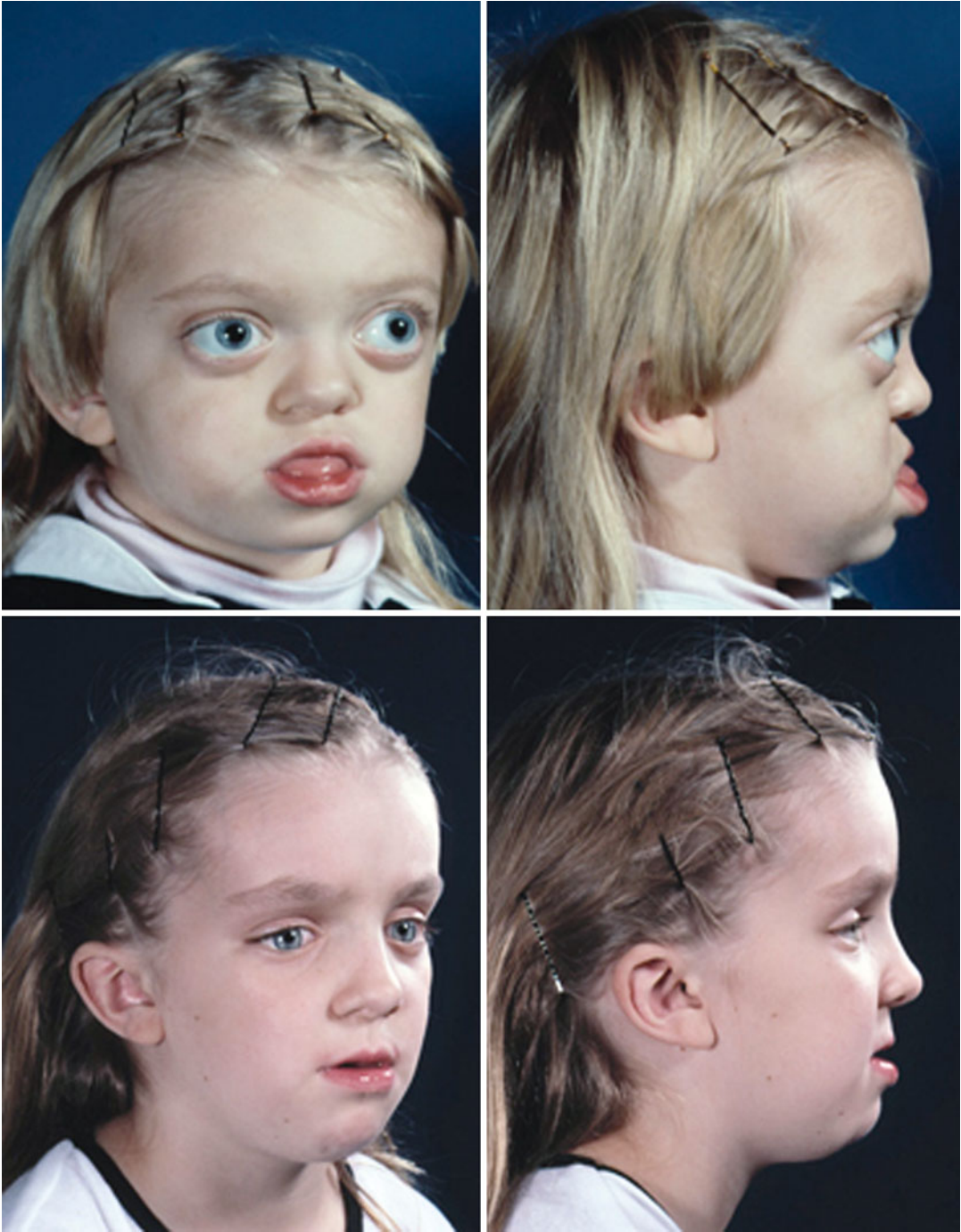
The classic distinguishing finding in infants with Apert syndrome is soft tissue and bony syndactyly (fusion) of the digits of the hands and feet. Many of these infants also have shortening of the upper extremities, dental abnormalities (e.g., anterior open bite), clefts of the secondary palate (they almost always have a very high arched palate), conductive hearing loss, cardiac anomalies, and chronic acne (first noted in infancy). Mental retardation and learning disabilities are higher in this group than in children with Crouzon syndrome, although many of these children develop normal intelligence (Bartlett and Mackay 1997).

### 3.3.3 Pfeiffer Syndrome

This syndrome, also autosomal dominant, has an incidence of approximately 1 in 200,000. It is caused by mutations in *FGFR1* or *FGFR2* (Mooney and Siegel 2002) and, like Apert syndrome, is characterized by multiple suture craniosynostosis, varying degrees of mental retardation, midface hypoplasia, and upper airway anomalies (Ridgeway and Weiner 2004) (Fig. 3.14). These children commonly have very broad thumbs and great toes and sometimes have syndactyly. They can be mistaken for a child with Apert syndrome and require careful assessment and diagnosis by an experienced craniofacial team.

### 3.3.4 Other Syndromes

There are several less commonly occurring craniosynostosis syndromes, including Carpenter, Antley-Bixler, Saethre-Chotzen, and Jackson-Weiss syndromes and craniofrontonasal dysplasia (Fig. 3.15). They are also characterized by craniosynostosis and midface deformities, and the affected infants can have associated neurosurgical, airway, and ophthalmologic problems, requiring assessment and management by a craniofacial



**Fig. 3.12** Patient with Crouzon syndrome. Preoperative (*top*) – note the exorbitism and midface hypoplasia. Postoperative (*below*) – following cranial vault remodeling and midface advancement surgeries

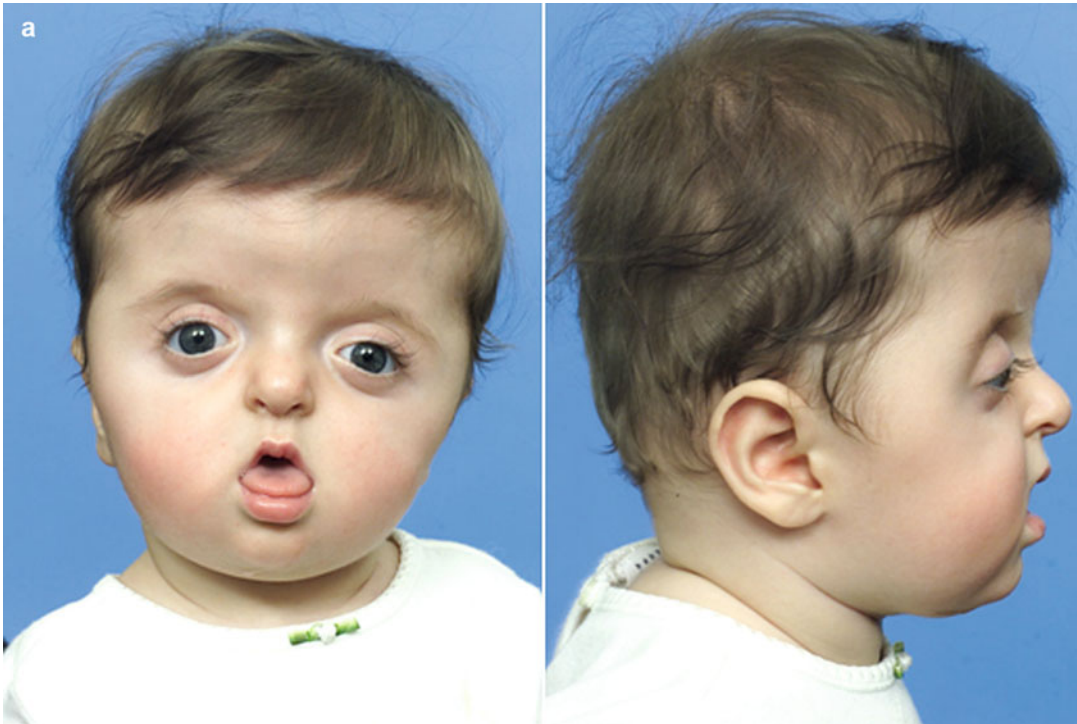team. Additionally, there are almost 100 other “noncraniosynostosis” syndromes in which craniosynostosis may be a finding. Two common examples are Treacher Collins syndrome and craniofacial microsomia.

### 3.3.5 Comprehensive Diagnosis/ Assessment of the Infant with Syndromic Craniosynostosis

In order to comprehensively manage the syndromic child, there must be a team approach to diagnosis and assessment (Table 3.5). When a new patient is referred to a craniofacial center, the team assembles and obtains a full patient history, including the prenatal and birth course, and all medical/surgical information. A detailed feeding history is also obtained. The team psychologist and social worker interview the family in private and complete a psychosocial profile. A complete physical examination

is done, including measurement of head circumference and intraoral evaluation. Any medical records brought to the consult by the family are reviewed, as well as skull films, CT or MRI scans. All members of the team are given the opportunity to question the family and to examine the child.

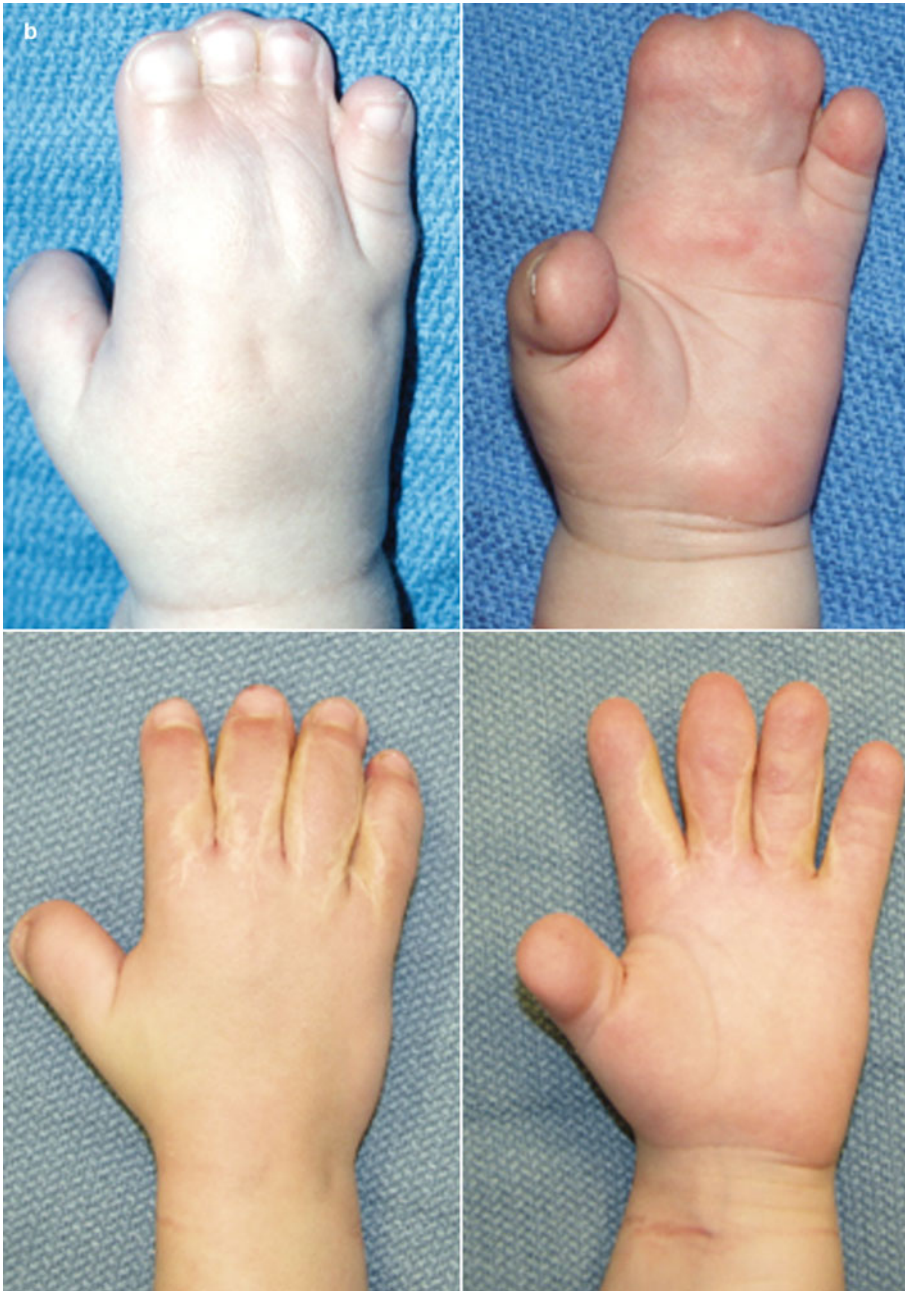The family is encouraged to express their concerns and to ask questions. The team then discusses the child and rereviews all records without the family in the room, in order to allow for an open discussion and exchange of opinions. Treatment options will be prioritized, based on the patient’s individual clinical findings. The team director meets with the family and presents a treatment plan. This may involve further medical workup, especially if there is a concern about airway, eye, or neurosurgical problems (e.g., if there is a suspicion of increased intracranial pressure, hydrocephalus, or a Chiari malformation). Initial surgical intervention will depend on the age of the child at presentation to the team as well as the presence of any medical problems. Often, prior to



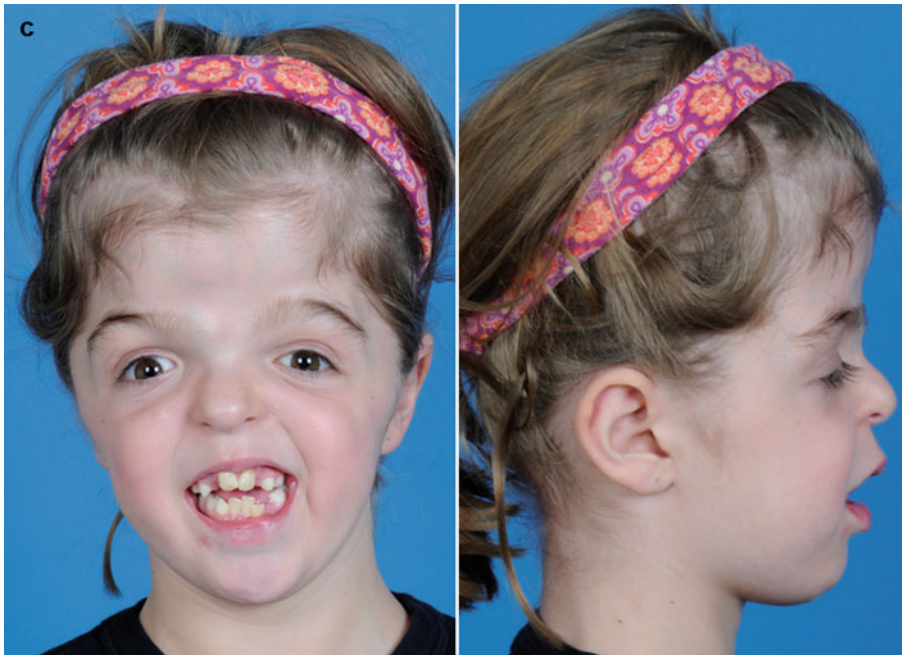**Fig. 3.13** (a) Preoperative patient with Apert syndrome. Note the turribrachycephaly and exorbitism. (b) Same patient (bilateral syndactyly) pre- and postoperative views

(Photos courtesy of Dr. Joseph Upton). (c) Same patient after cranial vault remodeling and midface advancement





**Fig. 3.13** (continued)



**Fig. 3.13** (continued)

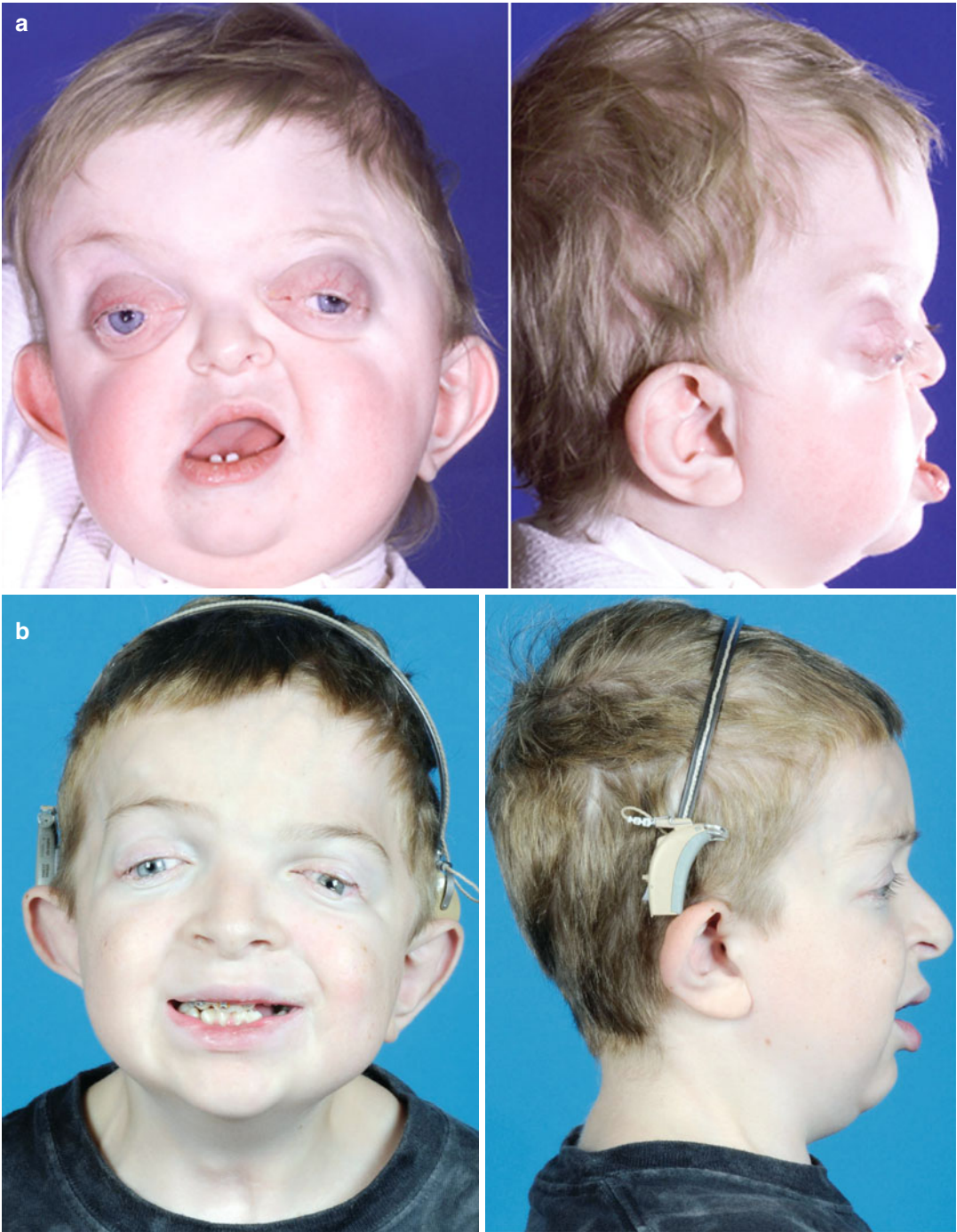
the initial cranial reconstruction, an infant might require placement of a tracheostomy, gastrostomy, ventriculoperitoneal shunt, or could need to undergo a posterior fossa decompression.

### 3.4 Treatment for Craniosynostosis

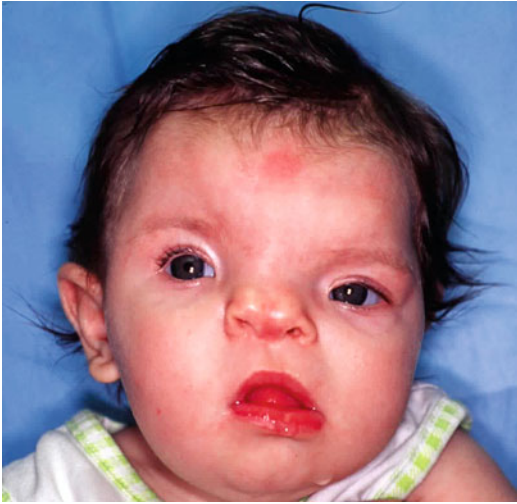The treatment for craniosynostosis is surgical. Unfortunately, some mistakenly believe that surgery is not necessary because the deformity is cosmetic or that the surgery is cosmetic. The American Medical Association defines cosmetic surgery as “surgery performed to reshape normal structures of the body in order to improve the patient’s appearance and self-esteem. Reconstructive surgery is performed on abnormal structures of the body, caused by congenital defects, developmental abnormalities, trauma, infection, tumors or disease. It is generally performed to improve function, but may also be done to approximate a normal appearance” (American Medical Association Policy of House of Delegates 1989). Craniosynostosis is a congenital defect, and surgery to correct it is reconstructive. This may be

an issue of importance for insurance companies or others with authority to approve treatment.

Although surgery for craniosynostosis is reconstructive, it is also done for the cosmetic and psychological benefits, as well as to prevent neurological injury. Children with untreated craniosynostosis look “different” than their peers and are often teased and ostracized. Hats and protective helmets for sports such as biking, football, and baseball don’t fit a misshapen head. Visual disturbances have been reported, especially the characteristic vertical dystopia seen in patients with coronal synostosis. Some children with craniosynostosis can have elevated intracranial pressure which impairs mental development and can lower IQ (Renier 1989; Renier et al. 1982, 1987). Research on the incidence and extent of increased intracranial pressure is limited, due to the ethical considerations of placing intracranial monitors in healthy infants for research purposes. However, Cartwright and Jimenez studied 89 infants with untreated craniosynostosis and found a significant decrease in fussiness and irritability after suture release by endoscopic



**Fig. 3.14** (a) Patient with Pfeiffer syndrome. Bilateral tarsorrhaphies were performed to prevent herniation of the globes. (b) Same patient after cranial vault reconstruction and midface advancement



**Fig. 3.15** Infant with frontonasal dysplasia and right coronal synostosis. Note the hypertelorism and bifid nose

**Table 3.5** Craniofacial team

Craniofacial surgeon	Advance Practice Nurse
Neurosurgeon	Pediatrician
Orthodontist	Psychologist
Geneticist	Otolaryngologist
Speech pathologist	Ophthalmologist
Social worker	Prosthodontist
Audiologist	Pediatric dentist
Oral-Maxillofacial surgeon	Team coordinator

strip craniectomy as compared to preoperatively (Cartwright and Jimenez 2002).

### 3.4.1 Surgical Intervention

In 1888, L.C. Lane performed the first craniectomy to remove a stenosed suture on a 9-month-old infant with microcephaly (Lane 1892). Lannelongue, a French surgeon, performed bilateral strip craniectomies to treat sagittal synostosis in 1890 (Lannelongue 1890). In 1894, Jacobi reported treatment of 33 microcephalic patients with poor results and high mortality rates (Jacobi 1894). This ended surgery for craniosynostosis for the next 30 years. Faber and Town proposed reviving the surgery in 1927 to prevent blindness and other complications (Faber and Towne 1927). In 1943, Faber and Town recommended operat-

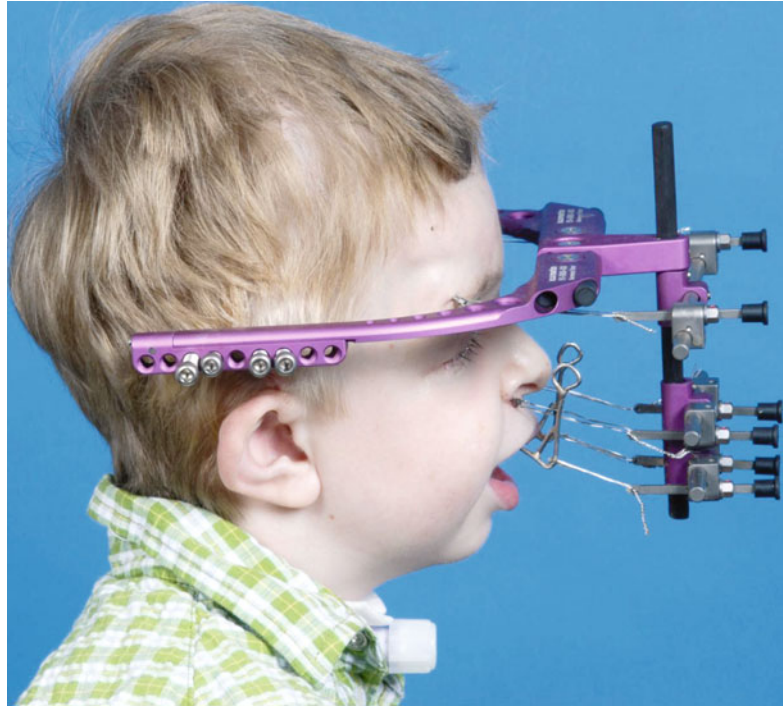
ing at 1–3 months of age for optimal results, and this became generally accepted (Faber and Town 1943).

Currently, most craniofacial centers do not intervene surgically prior to age 3 months (except in the case of an infant with increased intracranial pressure which requires urgent decompression). The typical age range to operate is between 3 and 12 months, depending on the protocol of the center (Bartlett and Mackay 1997; Kabbani and Raghuvver 2004; Panchal and Uttchin 2004). The types of techniques include strip craniectomy (endoscopic or non-endoscopic approaches), fronto-orbital advancement with calvarial vault remodeling (for correction of metopic, unicoronal, bicoronal, and syndromic craniosynostoses), and the pi (extended strip craniectomy) and hung span procedures (specifically for correction of severe sagittal craniosynostosis) (McCarthy et al. 1995, 2002). In syndromic infants with multiple suture synostoses, staged circumferential procedures may be required (Bartlett and Mackay 1997).

Infants with isolated craniosynostosis may be candidates for minimally invasive endoscopic craniectomy, or a more simple strip craniectomy in the case of sagittal synostosis, if diagnosed early – at least before the age of 4 months. Infants older than 4–6 months, as well as most with syndromic craniosynostosis, will require an intracranial fronto-orbital advancement with cranial vault remodeling. However, some infants with multiple suture nonsyndromic synostosis have undergone endoscopic strip craniectomy with good results (Jimenez and Barone 2010). If the child is over age 18 months, bone grafting may be needed at the same time (rib or split cranium), as they are less likely to generate new bone to adequately cover the cranial defects which result from the fronto-orbital advancement. Children with Apert syndrome often require secondary cranial vault remodeling because of the severity of their abnormality (specifically the turricephaly of the skull).

In addition to cranial surgeries, syndromic children may require any one or more of the following: shunt placement, correction of Chiari malformation, eye muscle surgery, choanal atresia repair, syndactyly reconstruction (several stages of surgery to separate the soft tissue and/or

**Fig. 3.16** Boy with Crouzon syndrome with rigid external distraction (*RED*) for midface advancement



bony fusion of the hands), midface advancement, and definitive nasal reconstruction. They also will need many years of specialized orthodontic treatment (Richards 1994).

Between ages 4 and 6 (as early as age 3 in tracheostomy-dependent children), the syndromic patient will often need to undergo correction of their midface hypoplasia, known as a midface advancement. This surgery accomplishes many things, including better eye coverage, improvement in breathing, correction of dental occlusion, and a more “acceptable” facial appearance. If the forehead requires further advancement, it can be addressed at the same time. The surgery can be performed by a “traditional” approach, using rib grafts to stabilize the advanced midface segments (McCarthy et al. 1990), or by a more gradual process, distraction osteogenesis, using either a rigid external halo-type fixation device or an internal device (Cohen and Holmes 2001) (Fig. 3.16). Once the patient reaches skeletal maturity (age 16–21), definitive midface or maxillary advancement (as well as nasal reconstruction) may be indicated.

### 3.4.2 Preoperative Preparation for Intracranial Surgery

Prior to intracranial surgery, all patients have a very specific and detailed preoperative workup, with some of the requirements being specific to the syndromic patient (Table 3.6). An MRI scan (brain and cervical spine) will document whether there is hydrocephalus or a Chiari malformation. If either is detected, the cranial reconstruction may need to be postponed until after a neurosurgical intervention (shunt placement or posterior fossa decompression). A CT scan can also detect hydrocephalus but is most important in confirming the extent of the sutural synostosis, and the 3D reconstructions will assist in surgical planning. A complete eye evaluation, including a dilated fundoscopic examination, is essential to identify the presence of papilledema. This finding will often result in performing an emergency strip craniectomy or in doing a cranial vault reconstruction prior to age 6 months. Other eye abnormalities, such as strabismus (a very common finding in patients with both syndromic and nonsyndromic craniosynostosis), should be

**Table 3.6** Preoperative workup for intracranial surgery

MR scan (brain and cervical spine) <sup>a</sup>
CT scan with 3D reconstruction
Fundoscopic eye evaluation
Pediatric ENT evaluation <sup>a</sup>
Anesthesia consult <sup>a</sup>
Genetics evaluation <sup>a</sup>
Medical photographs
Blood donation
Presurgical testing
Psychosocial consult
Preoperative nursing consult
Family networking

<sup>a</sup>Mandatory for syndromic patients

identified preoperatively, as over 60 % of children will require eye muscle repair after recovering from their cranial surgery (Gosain et al. 1996).

A child with a tracheostomy or any breathing problems must have a thorough evaluation by a pediatric otolaryngologist as well as a presurgical consult with a pediatric anesthesiologist. Preoperative medical photographs (all views) are essential for medical documentation. A complete genetics evaluation should be done prior to surgery, as the child's clinical examination will obviously be affected by the surgery. Presurgical screening (pediatric medical clearance, blood work, history/physical examination, obtaining surgical consent) and appointments with the craniofacial surgeon and the neurosurgeon are scheduled within 3–4 weeks of the procedure. The family is encouraged to donate blood for the patient.

The entire family (including siblings and grandparents) are offered the opportunity to meet with the team psychologist and social worker in order to discuss any concerns and to receive support in dealing with the surgical experience, which has an impact on everyone. Finally, the craniofacial advanced practice registered nurse (APRN) meets with the parents for an extensive preoperative teaching session (Table 3.7). This includes written and verbal information/explanations about the hospitalization, the surgical procedure, postoperative course, and at-home management (Chibbaro 1994). Pre- and postoperative photos

**Table 3.7** Preoperative nursing consult

Review of pre-/postoperative photographs	
Networking to families and support groups/craniofacial websites	
Hospital information	Location of OR, waiting/recovery room, ICU, pediatric unit, visiting policies, rooming-in for parents
Procedure/post-op	Length, description, possible complications, postoperative appearance (drains, IVs, dressings, swelling of eyes, overcorrection of forehead, Foley catheter), length of stay (ICU, hospital)
Home issues	Discharge instructions, signs/symptoms of infection/dehydration, prevention of swelling, activity, diet, postoperative appointments, return to childcare, parents return to work

**Table 3.8** Craniofacial resources/support groups

About Face
<a href="http://www.aboutfaceinternational.org/800-665-FACE">www.aboutfaceinternational.org/800-665-FACE</a>
American Academy of Pediatrics
<a href="http://www.aap.org">www.aap.org</a>
<a href="http://www.healthychildren.org">www.healthychildren.org</a>
American Cleft Palate–Craniofacial Association
Cleft Palate Foundation
<a href="http://www.acpa-cpf.org/800-24-CLEFT">www.acpa-cpf.org/800-24-CLEFT</a>
AmeriFace
<a href="http://www.ameriface.org">www.ameriface.org</a>
CAPPS: Craniosynostosis and Positional Plagiocephaly Support
<a href="http://www.cappskids.org">www.cappskids.org</a>
Children's Craniofacial Association
<a href="http://www.ccakids.com/800-535-3643">www.ccakids.com/800-535-3643</a>
CranioChat
<a href="http://www.craniochat.org">www.craniochat.org</a>
Cranio Kids
<a href="http://www.craniokids.org">www.craniokids.org</a>
Craniosupport
<a href="http://www.craniosupport.info">www.craniosupport.info</a>
FACES: The National Craniofacial Association
<a href="http://www.faces-cranio.org/800-332-2373">www.faces-cranio.org/800-332-2373</a>
Foundation for Faces of Children
<a href="http://www.facesofchildren.org/617-355-8299">www.facesofchildren.org/617-355-8299</a>
Genetic Alliance
<a href="http://www.geneticalliance.org/800-336-GENE">www.geneticalliance.org/800-336-GENE</a>
The Jorge Posada Foundation
<a href="http://www.jorgeposadafoundation.org">www.jorgeposadafoundation.org</a>
National Foundation for Facial Reconstruction
<a href="http://www.nffr.org/212-263-6656">www.nffr.org/212-263-6656</a>
National Organization for Rare Disorders
<a href="http://www.rarediseases.org/800-999-6673">www.rarediseases.org/800-999-6673</a>

Pathways Awareness

[www.pathwaysawareness.org](http://www.pathwaysawareness.org)

Torticollis Kids

[www.torticolliskids.org](http://www.torticolliskids.org)

WCF: World Craniofacial Foundation

[www.worldcf.org](http://www.worldcf.org)

of children who underwent the same procedure are shown, and networking to other families by phone or email is offered, as well as a tour of the pre-op waiting area and the pediatric units. The family is referred to craniofacial support groups and websites (Table 3.8).

### 3.4.3 Surgical Experience

Whenever possible, any type of intracranial procedure should be scheduled as a first case, in order to minimize the physiologic and psychological stress of waiting on the patient and family (Chibbaro 1994). Many centers allow a parent to carry the infant into the operating room, in order to decrease separation anxiety. Once anesthesia is induced by mask, the parent is safely escorted back to the waiting area by the circulating nurse.

After the child is induced with inhaled anesthetic and the parent leaves the room, he or she undergoes a “prep” period, which involves intubation, placement of cardiac and respiratory monitors, multiple intravenous lines (peripheral, central, arterial), a Foley catheter, and corneal protectors. The hair is parted but generally not shaved.

In order to minimize bleeding, the anesthesiologist will maintain the child in a hypotensive state, but one or two units of packed cells are often transfused during the procedure. Once the surgery is completed, one or two Jackson-Pratt drains may be placed, and the incision is closed with absorbable sutures. A gauze head dressing is applied, the corneal protectors are removed, the child is usually extubated and, once stable, is transferred either to the recovery room or the pediatric intensive care unit for initial observation. The total length of the procedure, including

patient preparation, surgical intervention, extubation, and transfer to the postoperative unit, is approximately 4–6 h. This will obviously differ by the specific type of procedure as well as by the surgeon – the most important factor is that the family is prepared for what to expect (Box 3.1).

#### 3.4.3.1 Technique: Fronto-orbital Advancement/Calvarial Vault Remodeling

The primary goal of this procedure is to expand the cranial vault (which increases the intracranial volume) by releasing the prematurely fused suture(s), thus maximizing brain growth and minimizing the possibility of increased intracranial pressure, hydrocephalus, and optic nerve damage. A second goal, which is especially important for the syndromic child, is to advance the retruded supraorbital bar, in order for the globe to receive more adequate coverage and protection. A third, very critical goal (sometimes the primary motivation to intervene surgically in the nonsyndromic infant) is to perform the above procedure in an attempt to normalize the appearance of the child (Bartlett and Mackay 1997; Ridgeway and Weiner 2004).

Once the above prep is completed, a coronal incision (across the top of the head, from ear to ear, often in a “zigzag” pattern to facilitate closure and help with scar camouflage) is made, and the flap is “turned down” over the lower face (Richards 1994). The surgery is done as a “team,” by a pediatric neurosurgeon and a craniofacial surgeon. The neurosurgeon performs the frontal craniotomy. The frontal bone is removed and placed in sterile, saline-soaked gauze. The craniofacial surgeon creates a fronto-orbital bony segment (the “bandeau” or supraorbital bar). The brain is retracted, and the bandeau and cranial bone plates (which are often split in two) are reshaped and advanced into an overcorrected position to allow for increased cranial vault growth (Bartlett and Mackay 1997). The segments are then secured with sutures, wires, and/or absorbable miniplates/screws (Fig. 3.17). The child with a significant turricephaly will require a circumferential reshaping, involving advancement/remodeling of the

### Box 3.1. A Mother's Journey with a Child Who Has Crouzon Syndrome

The day Olivia was born, we were so carefree we missed our exit to the hospital and had to do a complete loop to get back. My water had broken after a long walk on a beautiful day and the delivery had gone fairly well. We heard her cry, that moment of joy all parents hold their breaths for, and then saw the looks and knew something was wrong. What everyone immediately saw was this new baby's prominent eyes. They were quick to call it birth trauma because she was born face up, but something unspoken was wrong. The nurse we developed a relationship with became distant. Our OB disappeared. Everyone around us deflected, except our pediatrician. He took our concerns seriously; he listened with compassion and care, and at our follow-up appointment, he got out a book and pointed to a picture of a person with Crouzon syndrome. "Does this look like Olivia?" Yes. Olivia's features were a match. A geneticist confirmed as much through genetic testing, but he amiably told us Olivia was so mild this would be "our little secret." It felt good to hear at the time, but it was tremendously disappointing later. This time, not unspoken, but a whispered truth: Olivia had a facial difference.

We began to Google everything we could about Crouzon and joined a Yahoo! support group. We learned Olivia needed to see a craniofacial team – a group of doctors, nurses, psychologists, sociologists, etc., with unique expertise treating the physical and emotional needs of people with craniofacial conditions. When we left our first meeting at the hospital, we knew Olivia would need her first surgery at 11 months, as her brain would eventually be strangled by her tightening skull. Olivia is now 3 years old and just completed her fifth operation, this time to remove the halo that has brought the bones of her midface forward to a normal position. Her normal looks now match her vibrant, lovely self, and she can breathe at night without constant apneas. Even with her Crouzon face, Olivia was beautiful. It was easy to discover if you were looking for the right thing. We have always treated Olivia like a normal kid (because she is aside from small bones), but taking a lesson from those who ignored and covered up at first, we are honest with her and those around us, and all of us are better for it. We educate when we can, and protect when we can't.

The group of doctors, nurses, and other care providers on Olivia's craniofacial team give us a great sense of security. Many of the nurses and several doctors have become like family to us. They are quick to give their email address and then happy to keep in touch when a question or concern arises. It's the compassion and understanding these folks provide that you can't necessarily teach. It's the same thing we felt from Olivia's pediatrician when everyone else was more content to retreat. They understand the human element of the care they provide, and they support us in teaching Olivia that her facial difference doesn't have to be a handicap to a healthy, happy life.

frontal bone and supraorbital rim, as well as reduction of the vertical height of the skull. In the more mildly affected patient, only the frontal bone and supraorbital bar are remodeled and advanced into an overcorrected position.

#### 3.4.3.2 Techniques for Sagittal Synostosis

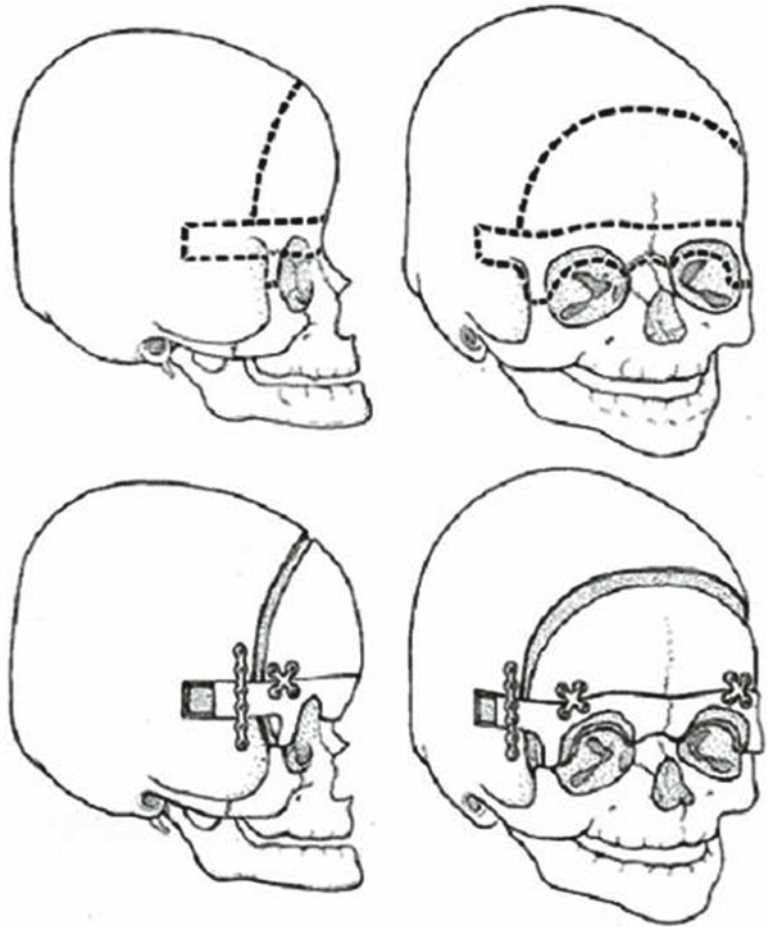
The hung span procedure is frequently performed on children who require a secondary surgery for sagittal synostosis due to increased intracranial pressure. In

some centers, it is the primary surgical intervention in very severely affected infants (McCarthy et al. 2002). The extent of the cranial remodeling depends on the severity of the deformity.

The pi procedure is another type of cranial vault reconstruction to correct sagittal synostosis. It is so named because the craniectomy is made in the shape of the Greek letter  $\pi$ . Barrel-stave osteotomies are made across the parietal bones, and the skull is foreshortened to correct the sca-phocephalic shape (Fig. 3.18).



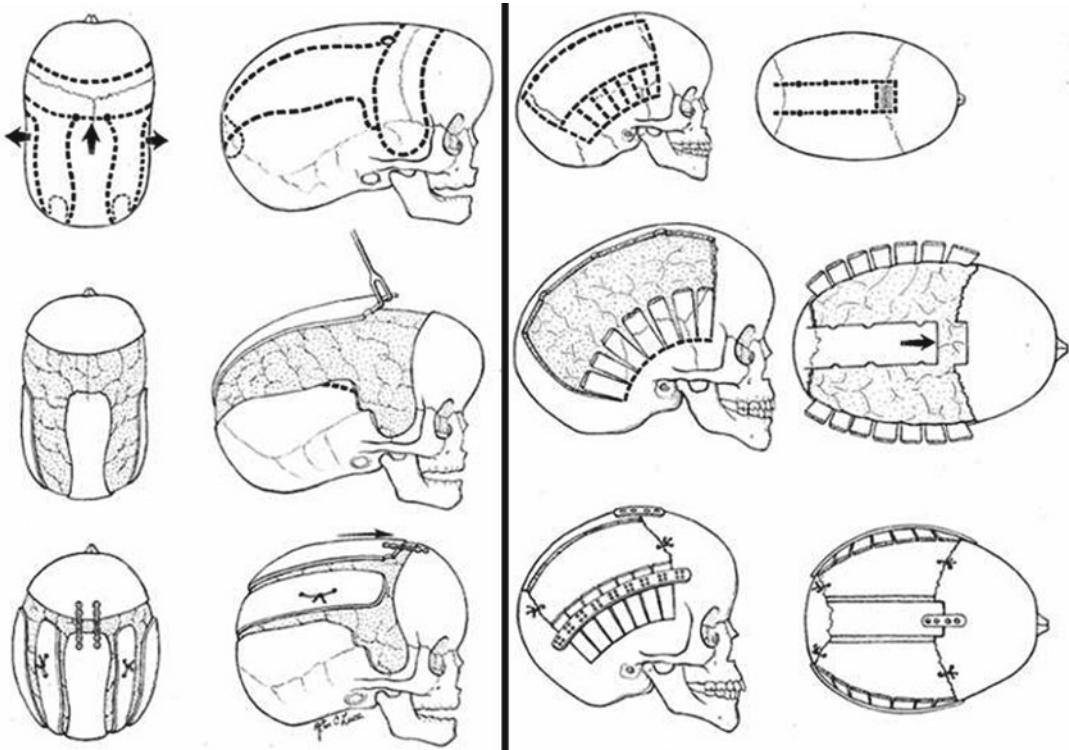
**Fig. 3.17** Line drawing of intracranial fronto-orbital advancement/calvarial vault remodeling surgery



### 3.4.3.3 Postoperative Nursing Management

Following an intracranial procedure, initial nursing care should focus on assessment of neurologic status, postoperative hemostasis, fluid and electrolyte balance, pain management, and presence of infection. Frequent neurologic checks are needed to monitor the child's level of consciousness and to observe for any signs of seizure activity and for a possible CSF leak (keeping in mind that the craniotomy performed carries the potential risk of a dural tear). The drains and suture line need very close monitoring as well as assessment of anemia (frequent hematocrit checks, evidence of hematuria, tachycardia, arrhythmia, pale skin color). An additional blood transfusion may be needed on the operative day or on the first postoperative day. Intravenous antibiotics will continue until discharge; the child will remain on oral antibiotics for approximately 1 week.

The child is usually transferred to the general pediatric unit on the first or second postoperative day. In almost all children, severe swelling of the forehead and eyelids will occur (the eyes will swell shut). Elevating the head of the bed may help make the child feel more comfortable; they often reject iced compresses and should not be forced to use them, as they will not prevent the edema. Parents are prepared for this preoperatively but are often very anxious about it and need reassurance that the swelling will peak on the second postoperative day and will then resolve over a period of 1–2 weeks. The goal is to remove the Foley and most of the intravenous lines on post-op day one and all remaining IVs and the drains/head dressing by the second postoperative day, with hospital discharge by day three or four, depending on the child's ability to tolerate oral fluids (Chibbaro 1994, 1996).



**Fig. 3.18** Pi (*left*) and hung span (*right*) procedures for correction of sagittal craniosynostosis

Throughout the hospitalization, the APRN is in contact with the family and serves as a resource to the nursing staff.

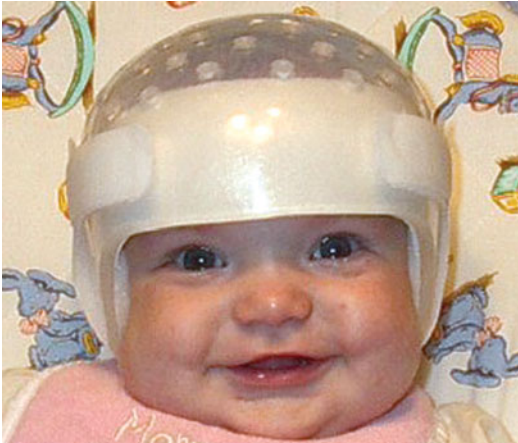#### 3.4.3.4 Postdischarge Management

Prior to discharge, the APRN will meet with the family and review with them the signs and symptoms of postoperative infection and dehydration. Suture line care is reviewed (this is also center dependent, although most centers advocate showering upon discharge, with gentle shampooing to avoid formation of a hematoma). It is advised that the child should avoid contact with playmates or family members who may be ill for the first 2 weeks after surgery. They are reminded that the forehead and eye swelling will resolve and that elevation of the head is helpful. Reassurance is given to parents that injury to the operative site is very unlikely (the bones are very well secured!), and that the child should be allowed to resume ambulation with their supervision. Parents are often very anxious about returning to work and bringing the child back to a caregiver or to a day

care setting, and this will often require additional support and counseling. Postoperative visits are scheduled at 1–2 weeks and then as per the protocol of the craniofacial team.

#### 3.4.3.5 Strip Craniectomy

Although the extensive cranial vault remodeling for correction of craniosynostosis has shown good results, the lengthy operating times and blood transfusions to correct estimated blood loss from 25 to 500 % have led surgeons to use less invasive techniques (Jimenez et al. 2004). The strip craniectomy, traditionally only done for sagittal synostosis, involves removing the stenosed sagittal suture. Blood loss is minimal and the hospital stay is 2–3 days. This is done in the young infant, before 6 months of age, to take advantage of the rapid brain growth during that time as well as the dura's ability to regrow bone. A custom-made molding helmet, worn postoperatively, helps to reshape the head during this period of rapid brain growth, as it overcomes the dural forces that caused the original deformity (Fig. 3.19).



**Fig. 3.19** Custom molding helmet is worn for approximately 1 year to overcome dural forces and reshape the skull

The endoscopic strip craniectomy (endoscopy-assisted wide-vertex craniectomy) is a minimally invasive technique that uses endoscopes to visualize the intracranial area, while a strip of bone containing the stenosed suture is removed (Jimenez and Barone 1998; Ridgeway et al. 2011; Shah et al. 2011). This has been done successfully on the sagittal, coronal, metopic, and lambdoid sutures (and combinations thereof) with blood losses averaging less than 43 cc and usually just an overnight stay in the hospital (Cartwright et al. 2003; Jimenez et al. 2002, 2004; Jimenez and Barone 2010; Rivero-Garvia et al. 2011). These strip craniectomies should be performed on infants less than 6 months of age, and a custom-made molding helmet worn for approximately 1 year postoperatively for best outcomes. The cost of this procedure is substantially less than that of the traditional calvarial vault remodeling (Cartwright et al. 2003).

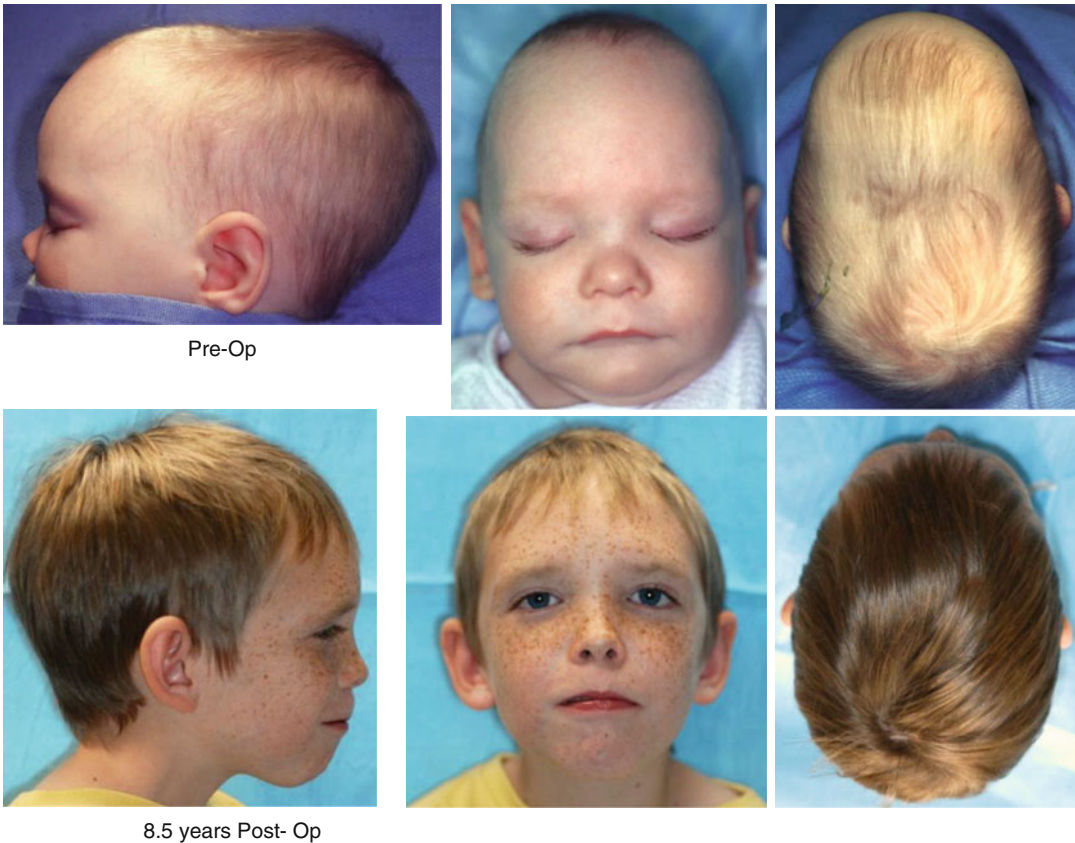As previously discussed, strip craniectomies were first performed over 100 years ago. These earlier surgeons obviously did not have the benefits of today's imaging and less invasive surgical techniques. Moreover, they did not utilize the other key component of a successful procedure – the cranial molding helmet. Strip procedures take advantage of the rapid brain growth in infants. Once the stenosed suture is removed, brain growth forces the head to conform to the shape of the helmet. Since the most rapid brain growth occurs before the age 6 months, strip craniectomies are per-

formed prior to that age. But the helmet must be worn by the infant and replaced at appropriate times. When the helmet has been used properly, the technique has demonstrated excellent results, both short and long term (Figs. 3.20, 3.21 and 3.22) (Boxes 3.2 and 3.3).

#### 3.4.3.6 Nursing Care

Although strip craniectomies are generally less of a surgical risk than cranial vault remodeling, they are not without risk. Preoperative preparation is similar to what is described for cranial vault remodeling, as these patients are also evaluated by members of the craniofacial team. Parents that prefer their infant not receive a blood transfusion for personal or religious reasons may choose the endoscopic strip craniectomy because of the minimal blood loss. Preoperative administration of erythropoietin may be considered to increase the baby's hematocrit. Preoperative photos and anthropometric measurements are taken.

Postoperatively, these infants also need frequent vital signs with neurological assessment to detect any early signs of blood loss, electrolyte imbalance, or neurologic deterioration. Any bleeding from the incision site should be immediately reported to the neurosurgeon. Although some swelling of the head is expected, it usually peaks on postoperative day 2 or 3 and has subsided by 1 week. Rarely do the eyes swell shut. A subgaleal drain may be placed intraoperatively to decrease postoperative swelling and removed the next day. Preoperative diet and activity are usually resumed on the first postoperative day. Pain can be controlled with acetaminophen and oxycodone, with nalbuphine for breakthrough pain. Care should be taken to prevent oversedation whereby the baby is too sleepy to eat. Frequently, these babies are hungry and want to be held and fed, so comfort measures should be used before narcotics. Discharge criteria include a stable hematocrit and vital signs, adequate oral intake, and pain controlled by oral medication. Parents should be instructed to call for increased fussiness not relieved by oral pain medication, decreased level of consciousness or lethargy, vomiting, or drainage from the incision site.

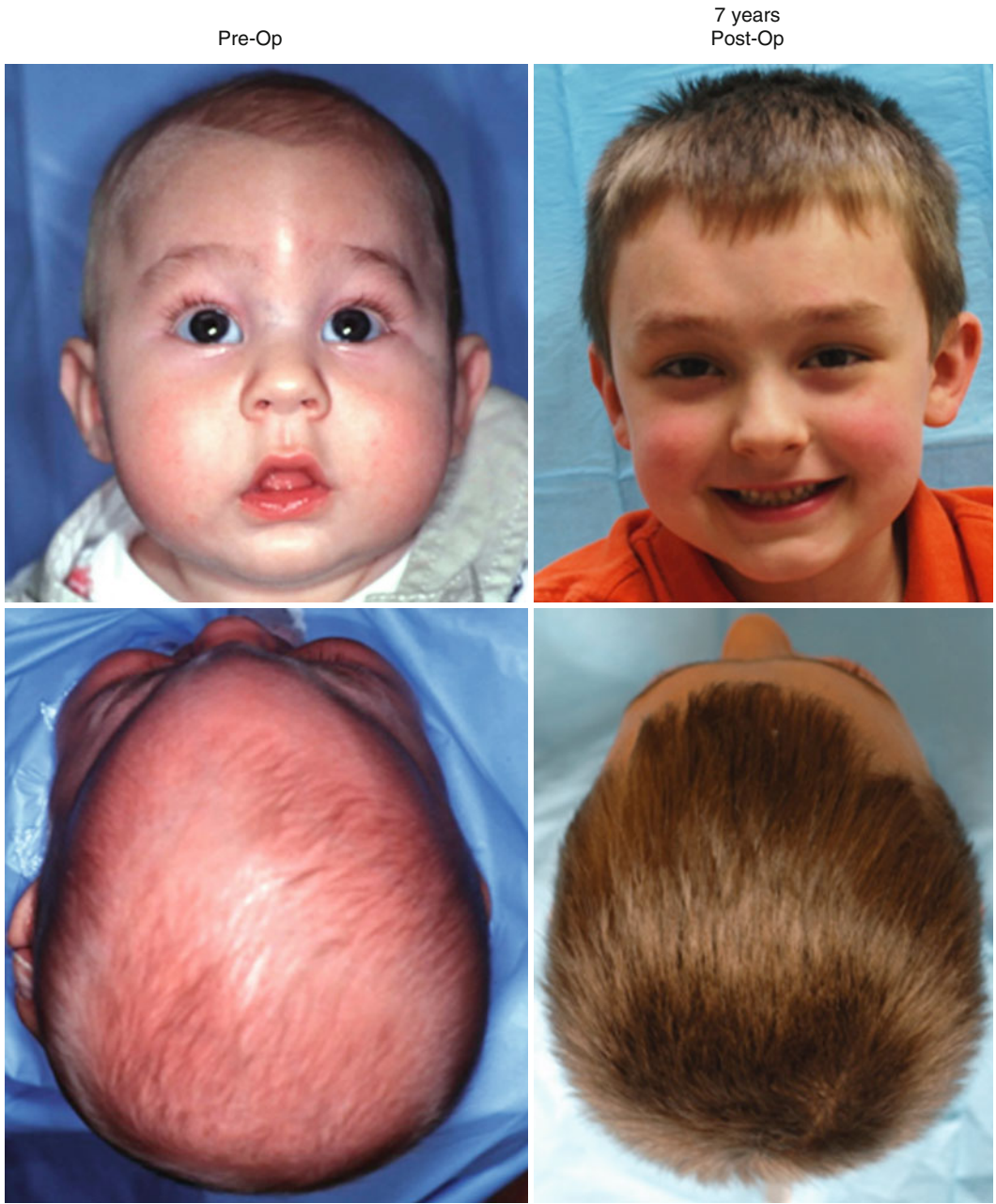

**Fig. 3.20** Boy with sagittal synostosis preoperatively and 8.5 years after endoscopy-assisted wide-vertex craniectomy

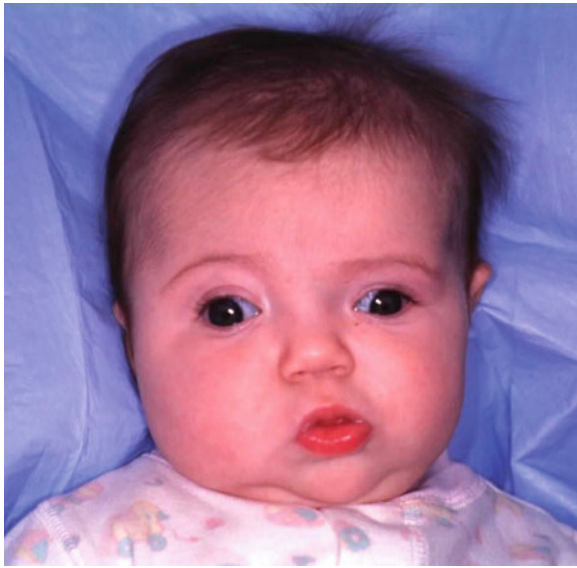The infants are measured for and receive a custom-made molding helmet within 1 week after surgery. Because a strip of bone is missing, many parents become alarmed that their baby's brain may become injured during the time before they receive the helmet. Assure them that no extra precautions need to be taken, other than what they would usually do to protect a baby's head, as the dura, or covering to the brain, is very tough (dura mater means "tough mother").

The molding helmet is worn 23 h a day for about 1 year, with new helmets made as the head

grows and changes shape. Usually, three helmets are required over that year. Visits to craniofacial clinic will be scheduled to check the head shape and fit of the helmet over the course of the year. Anthropometric measurements and pictures will be taken at each visit and compared to those preoperatively. Patients whose parents are not compliant with helmet use, or discontinue it too soon, will have less than optimum results. Parents should be reminded of the importance that the helmet be worn as directed to overcome the dural forces that continue to dictate skull growth and could recreate the deformity.



**Fig. 3.21** Boy with metopic synostosis preoperatively and 7 years after endoscopic strip craniectomy



Pre-Op



6 years Post-Op

**Fig. 3.22** Girl with *right* coronal synostosis preoperatively and 6 years after endoscopic strip craniectomy

### Box 3.2. A Mother's Story: Endoscopic Strip Craniectomy

My husband and I knew exactly what sagittal craniosynostosis was because he had surgery for it when he was only 6 weeks old. So, when our son Dexter was diagnosed with it at 3 weeks, we had an idea of what we were in for.

We set his surgery for the 6-week mark, and my mother-in-law tried to prepare us on what to expect after his surgery. From her description of how my husband looked afterward, we were expecting a swollen gray-colored head and face that would be unrecognizable to us. Well, all I can say is that we were pleasantly surprised to see how far this surgery has come over the last 30 years! Dexter looked amazing! We immediately saw a dramatic improvement in the shape of his head, and with very minimal swelling. His skin color was beautiful, and his temperament changed from fussy to easy going. We are so thankful for this new procedure and would gladly have him

wear a helmet for a year, as opposed to the more invasive option from 30 years ago! The doctors and nurses were wonderful. We are so blessed to have had such skilled and caring professionals taking care of our precious baby boy!

### Box 3.3. A Mother's Story: Endoscopic Strip Craniectomy for Metopic Synostosis

When Cameron was born, we could tell immediately that something was wrong with his skull. As a parent, it was one of the hardest things I have ever been faced with. There is always a fear for the unknown, and I was definitely afraid. I was blessed to have my options placed before me when he was just days old. When we went for his first checkup a few days after being born, I discussed with his pediatrician my fears and she agreed things did not look right. Immediately, we scheduled an appointment with the pediatric neurosurgeon and his

pediatric clinical nurse specialist. As soon as I walked through the door of their office, I was told Cameron had metopic synostosis.

Not quite sure what to do, they explained everything so I could understand it and gave me my options. I had the option of having a more invasive surgery to reconstruct his skull, which would involve more blood transfusions and scarring than I was prepared for. The second option I had was an endoscopic strip craniectomy. This involved making a very small incision with very little blood loss and very little scarring. With the second option, he would have to wear a helmet for about a year if all went well. The helmet would put the necessary pressure where it was needed in order to protect his skull and help it grow and form properly. I chose the second option, believing it would be in Cameron's best interest in the years to come. He went in for surgery, when he was just 21 days old, and did amazing. I was so scared when I first saw him after his surgery but knew that I had made the right choice. Cameron only had to spend about 24 h in the hospital to be sure there were no complications, and a week later, he had his first helmet. He handled everything so well, probably even better than I did. I was very lucky to have an amazing doctor and nurse that were willing to answer all of my questions, day or night, and help me make what I now know was the right decision for my son.

Cameron is now 4 years old and will be starting prekindergarten in the fall. He's very smart and is doing everything his older brother and sister did when they were his age if not more since he is always there doing everything they do. He catches on quickly and is very active; he loves to play outside and get dirty like most kids do. The only time you see his scar is when you are looking for it. I am very happy with the decision I made, and I would do it again if I had to. By looking at him now, you would

never know that there was ever anything wrong with him when he was born.

### Conclusion

The diagnosis of craniosynostosis can be a frightening one for the parents of a child with a skull deformity. It is essential that craniosynostosis is differentiated from positional plagiocephaly early on, so the appropriate treatment can be instituted.

The patient with craniosynostosis requires comprehensive management by an experienced craniofacial team, with surgical intervention being the core component of their treatment. The nursing roles of provider of direct care, patient/family educator, and liaison between the patient, their family, and the rest of the team are key to a successful outcome.

### Pediatric Practice Pearls

- Positional plagiocephaly can be prevented or minimized by following the back to sleep and tummy time strategies recommended by the AAP.
- Early recognition and treatment of craniosynostosis vs. positional plagiocephaly lead to improved outcomes.
- Children with craniosynostosis should receive comprehensive care provided by a craniofacial team.

### References

- American Medical Association Policy of House of Delegates (1989) Definitions of "cosmetic" and "reconstructive" surgery, H-435.992. Council of medical services annual meeting, Chicago, Illinois, p A-89
- Bartlett SP, Mackay GJ (1997) Craniosynostosis syndromes. In: Aston SJ, Beasley RW, Thorne CH (eds) Grabb and Smith's plastic surgery, 5th edn. Lippincott-Raven, Philadelphia, pp 295–304
- Carson BS, James CS, VanderKolk CA, Guarnieri M (1997) Lambdoid synostosis and occipital plagiocephaly: clinical decision rules for surgical intervention. *Neurosurg Focus* 2:e10
- Cartwright CC, Jimenez DF (2002). Fussiness and irritability in patients with craniosynostosis. Paper presented at the AANS/CNS section on pediatric neurological surgery annual meeting, Phoenix, Dec 2002

- Cartwright CC, Jimenez DF, Barone CM, Baker L (2003) Endoscopic strip craniectomy: a minimally invasive treatment for early correction of craniosynostosis. *J Neurosci Nurs* 35(3):130–138
- Chibbaro P (1994) Understanding and managing stressors facing the pediatric craniofacial patient and family. *Plast Surg Nurs* 14(2):86–91
- Chibbaro P (1996) Nursing care of patients with craniofacial anomalies. In: Goodman T (ed) *Core curriculum for plastic and reconstructive surgical nursing*. Anthony J. Jannetti, Inc, Pitman
- Chumas PD, Cinalli G, Arnaud E (1997) Classification of previously unclassified cases of craniosynostosis. *J Neurosurg* 86:177–181
- Cohen MM (1986) Perspectives on craniosynostosis. In: Cohen MM (ed) *Craniosynostosis. Diagnosis, evaluation and management*. Raven, New York, pp 21–56
- Cohen MM Jr. (1993) Sutural biology and the correlates of craniosynostosis. *Am J Med Genet* 47(5):581–616
- Cohen SR, Holmes RE (2001) Internal Lefort III distraction with biodegradable devices. *J Craniofac Surg* 12(3):264–272
- Cohen MM, MacLean RE (2000) *Craniosynostosis: diagnosis, evaluation and management*, 2nd edn. New York: Oxford University Press
- Collett B, Breiger D, King D, Cunningham M, Speltz M (2005) Neurodevelopmental implications of “deformational” plagiocephaly. *J Dev Behav Pediatr* 26:379–389
- Dec W, Warren S (2011) Current concepts in deformational plagiocephaly. *J Craniofac Surg* 22(1):6–8
- Decker JD, Hall SH (1985) Light and electron microscopy of the new born sagittal suture. *Anat Rec* 212:81–89
- Didier RA, Kuang AA, Schwartz DL, Selden NR, Stevens DM, Bardo DME (2010) Decreasing the effective radiation dose in pediatric craniofacial CT by changing head position. *Pediatr Radiol* 40(12):1910–1917
- Drake DB, Pershing JA, Berman DE, Ogle RC (1993) Calvarial deformity regeneration following subtotal calvariectomy for craniosynostosis: a case report and theoretical implications. *J Craniofac Surg* 4:85–89
- Faber HK, Town EB (1943) Early operation in premature cranial synostosis for the prevention of blindness and other sequelae. Five case reports with follow up. *J Pediatr* 22:286
- Faber HK, Towne EB (1927) Early craniectomy as a preventive measure in oxycephaly and allied conditions. With special reference to the prevention of blindness. *Am J Med Sci* 173:701
- Farkas LG (1996) Accuracy of anthropometric measurements: past, present and future. *Cleft Palate Craniofac J* 33:10–18; discussion 19–22
- Frush DP, Donnelly LF, Rosen NS (2003) Computed tomography and radiation risks: what pediatric health care providers should know. *Pediatrics* 112(4):951–957
- Gosain AK, Steele MA, McCarthy JF, Thorne CH (1996) A prospective study of the relationship between strabismus and head posture in patients with frontal plagiocephaly. *Plast Reconstr Surg* 97:881–891
- Graham JM, deSaxe M, Smith DW (1979) Sagittal synostosis: fetal head restraint as one possible cause. *J Pediatr* 95:747–750
- Graham JM, Bardura RJ, Smith DW (1980) Coronal synostosis: fetal head restraint as one possible cause. *Pediatrics* 65:995–999
- Higgenbottom MC, Jones KL, James HE (1980) Intrauterine constraint and craniosynostosis. *Neurosurgery* 6:39–49
- Hoffman H, Raffel C (1989) Craniofacial surgery. In: McLaurin R, Venes JL, Schut L et al (eds) *Pediatric neurosurgery: surgery of the developing nervous system*. WB Saunders, Philadelphia
- Hunter AG, Rudd NL (1984) Craniosynostosis I. Sagittal synostosis: its genetics and associated clinical findings in 214 patients who lacked involvement of the coronal suture. *Teratology* 14:185–194
- Hutchinson BL, Hutchinson LA, Thompson JM, Mitchell EA (2004) Plagiocephaly and brachycephaly in the first two years of life: a prospective cohort study. *Pediatrics* 114:970–980
- Jacobi A (1894) Non nocere. *Med Rec* 45:609
- Jimenez DF, Barone CM (1998) Endoscopic craniectomy for early surgical correction of sagittal craniosynostosis. *J Neurosurg* 88:77–81
- Jimenez DF, Barone CM (2010) Multiple-suture nonsyndromic craniosynostosis: early and effective management using endoscopic techniques. *J Neurosurg Pediatr* 5:223–231
- Jimenez DF, Barone DM, Cartwright CC, Baker L (2002) Early management of craniosynostosis using endoscopic assisted strip craniectomies and cranial orthotic molding therapy. *Pediatrics* 110:97–104
- Jimenez DF, Barone CM, McGee ME, Cartwright CC, Baker L (2004) Endoscopic-assisted wide-vertex craniectomy, barrel stave osteotomies, and postoperative helmet molding therapy in management of sagittal suture craniosynostosis. *J Neurosurg* 100:407–417
- Kabbani MD, Raghuvver TS (2004) Craniosynostosis. *Am Fam Physician* 69(12):2863–2870
- Kane AA, Mitchell LE, Craven KP, Marsh JL (1996) Observations on a recent increase in plagiocephaly without synostosis. *Pediatrics* 97:877–885
- Koren A, Reece SM, Kahn-D’angelo L, Medeiros D (2010) Parental information and behaviors and provider practices related to tummy time and back to sleep. *J Pediatr Health Care* 24:222–230
- Lajeunie E, Le Merrer M, Bonaiti-Pellie C, Marchac D, Renier D (1995) Genetic study of nonsyndromic coronal craniosynostosis. *Am J Med Genet* 55:500–504
- Lajeunie E, Le Merrer M, Bonaiti-Pellie C, Marchac D, Renier D (1996) Genetic study of scaphocephaly. *Am J Med Genet* 62:282–285
- Lane LC (1892) Pioneer craniectomy for relief of mental imbecility due to premature sutural closure and microcephalus. *J Am Med Assoc* 18:49–50



- Lannelongue M (1890) De la craniectomie dans la microcephalie. *CR Acad Sci* 110:1382–1385
- Lemire LJ (1986) Embryology of the skull. In: Cohen MM (ed) *Craniosynostosis. Diagnosis, evaluation and management*. Raven, New York, pp 105–130
- Littlefield TR, Reiff JL, Rekate HL (2001) Diagnosis and management of deformational plagiocephaly. *BNI Q* 17(4):18–25
- Mabutt LW, Kokick VG (1979) Calvarial and suture development following craniectomy in neonatal rabbit. *Anatomy* 129:413–422
- Majnemer A, Barr RG (2006) Association between sleep position and early motor development. *J Pediatr* 149: 623–629
- McCarthy JG, Epstein FJ, Woodsmith D (1990a) Craniosynostosis. In: McCarthy JG (ed) *Plastic surgery*. Saunders, Philadelphia, pp 3013–3053
- McCarthy JG, LaTrenta GS, Breitbart AS (1990b) The le fort III advancement osteotomy in the child under 7 years of age. *Plast Reconstr Surg* 86:633
- McCarthy JG, Glasberg SB, Cutting CB, Epstein FJ, Grayson BH, Ruff G, Thorne CH, Wisoff Z, Zide BM (1995) Twenty year experience with early surgery for craniosynostosis. I. Isolated craniofacial synostosis – results and unsolved problems. *Plast Reconstr Surg* 96:272–284
- McCarthy JG, Bradley JP, Stelnicki EJ, Stokes T, Weiner HL (2002) Hung span method of scaphocephaly reconstruction in patients with elevated intracranial pressure. *Plast Reconstr Surg* 109(6):2009–2018
- McCarthy JG, Warren SM, Bernstein J, Burnett W, Cunningham ML, Edmond JC, Figueroa AA, Kapp-Simon KA, Labow BI, Peterson-Falzone SJ, Proctor MR, Rubin MS, Sze RW, Yemen TA (2012) Parameters of care for craniosynostosis. *Cleft Palate Craniofac J* 49(1 Supplement):1S–24S
- Moon RY, Darnall RA, Goodstein MH, Hauck FR, American Academy of Pediatrics, Task Force on Sudden Infant Death Syndrome (2011) Technical Report – SIDS and other sleep-related infant deaths: expansion of recommendations for a safe infant sleeping environment. *Pediatrics* 128(5):1030–1039. doi:10.1542/peds.2011-2284
- Mooney MP, Siegel MI (2002) *Understanding craniofacial anomalies*. Wiley-Liss, New York
- Mulliken JB, Vanderwoude SL, Hanson M (1999) Analysis of posterior deformational plagiocephaly: deformational vs. synostotic. *Plast Reconstr Surg* 103:371–380
- O’Daniel TC, Milder BO, Marsh JL (1993) Ophthalmologic screening of infants with craniosynostosis. Scientific program of the American Cleft Palate-Craniofacial Association, 50th anniversary meeting, Pittsburgh, 1993
- Ohman JC, Richtsmeier JT (1994) Perspectives on craniosynostosis facial growth. *Clin Plast Surg* 21: 489–499
- Panchal J, Uttchin V (2004) Management of craniosynostosis. *Plast Reconstr Surg* 111:2032–2048
- Paterson A, Frush DP (2007) Dose reduction in paediatric MDCT: general principles. *Clin Radiol* 62(6):507–517
- Peitsch WK, Keefer CH, LaBrie RA, Mulliken JB (2002) Incidence of cranial asymmetry in healthy newborns. *Pediatrics* 110:e72
- Pritchard JJ, Scott JH, Girgis FG (1956) The structure and development of cranial and facial sutures. *J Anat* 90:73–86
- Rekate H (1997) Occipital plagiocephaly: a critical review of the literature. *J Neurosurg* 2:1–14
- Renier D (1989). Intracranial pressure in craniosynostosis: Pre- and postoperative recordings-correlation with functional results. In: Persing JA, Edgerton MT, Jane JA (eds) *Scientific foundations and surgical treatment of craniosynostosis*. Baltimore: Williams and Wilkins, p 263. <http://pathways.org/awareness/parents/tummy-time/tummy-time-help/> accessed October 20, 2012.
- Renier D, Sainte-Rose C, Marchac D, Hirsch JF (1982) Intracranial pressure in craniostenosis. *J Neurosurg* 57:370
- Renier D, Brunet L, Marchac D (1987) IQ and craniostenosis: evolution in treated and untreated cases. In: Marchac D (ed) *Craniofacial surgery*. Springer, Berlin, p 114
- Richards M (1994) Common pediatric craniofacial reconstructions. In: McKenna CJ, Black JM (eds) *The nursing clinics of North America*. W.B. Saunders Co, Philadelphia, pp 791–799
- Ridgeway EB, Weiner HL (2004) Skull deformities. In: Piatt JH (ed) *Pediatric Clin North Am* 51(2): 359–387
- Ridgeway EB, Berry-Candelario J, Grondin RT, Rogers GF, Proctor MR (2011) The management of sagittal synostosis using endoscopic suturectomy and postoperative helmet therapy. *J Neurosurg Pediatr* 7:620–626
- Rivero-Garvia M, Marquez-Rivas J, Rueda-Torres AB, Ollero-Ortiz A (2011) Early endoscopy-assisted treatment of multiple-suture craniosynostosis. *Childs Nerv Syst* 28(3):427–431
- Robinson S, Proctor M (2009) Diagnosis and management of deformational plagiocephaly. *J Neurosurg Pediatr* 3:284–295
- Rogers GF (2011) Deformational plagiocephaly, brachycephaly, and scaphocephaly. Part I: terminology, diagnosis, and etiopathogenesis. *J Craniofac Surg* 22:9–16
- Rossi M, Jones RL, Norbury G, Bloch-Zupan A, Winter RM (2003) The appearance of the feet in Pfeiffer syndrome caused by FGFR1 P252R mutation. *Clin Dysmorphol* 12(4):269–274
- Shah MN, Kane AA, Petersen JD, Woo AS, Nadoo SD, Smyth MD (2011) Endoscopically assisted versus open repair of sagittal craniosynostosis: the St. Louis Children’s Hospital experience. *J Neurosurg Pediatr* 8:165–170
- Shillito J, Matson DD (1968) Craniosynostosis: a review of 519 surgical patients. *Pediatrics* 41:829
- Sömmering ST (1800) *Vom Baue des Menschlichen Körpers*, 1st edn. Voss, Leipzig
- Sun PP, Persing JA (1999) Craniosynostosis. In: Albright L, Pollack I, Adelson D (eds) *Principles and practice of pediatric neurosurgery*. Thieme, New York, pp 219–242

- Task Force on Sudden Infant Death Syndrome (2011) SIDS and other sleep-related infant deaths: expansion of recommendations for a safe infant sleeping environment. *Pediatrics* 128(5):1030–1039. doi:[10.1542/peds.2011-2284](https://doi.org/10.1542/peds.2011-2284)
- The Joint Commission (2011) Sentinel event alert: radiation risks of diagnostic imaging. [www.jointcommission.org/sea\\_issue\\_47/](http://www.jointcommission.org/sea_issue_47/) Accessed 20 oct 2012, Accessed 4 Aug 2011
- Vander Kolk C, Carson B (1994) Lambdoid synostosis. In: Vander Kolk C (ed) *Clinics in plastic surgery*, 21st edn. WB Saunders, Philadelphia, p 575
- Vermeij-Keers C (1990) Craniofacial embryology and morphogenesis: normal and abnormal. In: Strickler M, van der Meulen J, Rapheal B et al (eds) *Craniofacial malformations*. Churchill Livingstone, New York, pp 56–57
- Virchow R (1851) *Über den cretinismus, namentlich in franken und-ber pathologische schadelformen*. *Verh Phys Med Ges Wurzburg* 2:230–244

Shona Swenson Lens

Neural tube defects persist as a common and devastating birth defect affecting the central nervous system, with an incidence rate in the United States of 1 in 1,000 live births (AAP Policy Statement Committee on Genetics 1999; Detrait et al. 2005; Gaskill 2004; Sebold et al. 2005). This spectrum of congenital anomalies is caused by the failure of the neural tube to close during the early weeks of intrauterine development. The outcomes or clinical impacts of neural tube defects are multifaceted: dependent on the anatomic level of the defect, associated brain malformations, severity of hydrocephalus, and whether it is an open or closed defect. A neural tube defect impacts motor and cognitive skills and can range from a mild to severe disability, paralysis, and possibly death. The defect may occur anywhere in the spine to from the neck to buttocks and is defined by the degree of involvement of spinal cord, nerves and vertebral bodies as an open (visible) or closed (hidden) defect and many terms are applied to each (Table 4.1).

environmental factors. The genetic role may involve mutations in genes that contribute to an abnormal or lack of closure of the neural tube between the third and fourth week of uterine development. Clinical studies have shown that families with a known history of a neural tube defect are at a 2–5 % higher risk for a recurrence, which is a 25–50 times higher prevalence than in that of the general population (Detrait et al. 2005; Elwood et al. 1992). Neural tube defects can be linked to various genetic syndromes, including Meckel syndrome; trisomies 13, 18, and 21; and other chromosomal abnormalities or deletion (Detrait et al. 2005).

The environmental risk factors associated with neural tube defects are the maternal health concerns of hyperthermia, malnutrition, maternal obesity or diabetes (Detrait et al. 2005), or medication use, specifically valproic acid. Additionally but rare is the exposure to other teratogens, including thalidomide and Agent Orange (Detrait et al. 2005).

Folic acid, a B vitamin, has shown the strongest link in the reduction of neural tube defects.

## 4.1 Etiology

Despite extensive studies, the precise etiology of neural tube defects is not completely understood, but thought to be from both genetic and

**Table 4.1** Terminology

Open defect	Closed defect
Myelomeningocele	Occult spinal dysraphism
Spina bifida	Spina bifida occulta
Spina bifida aperta	Tethered cord syndrome
Spina bifida cystica	Spinal dysraphism
Spinal dysraphism	

S.S. Lens, MS, CFNP,  
Radiology Associates of Appleton,  
Appleton Medical Center,  
Appleton, WI 54911, USA  
e-mail: shonalenss@yahoo.com

**Table 4.2** Folic acid for prevention of neural tube defects*0.4 mg daily*

All women capable of becoming pregnant should take 0.4 mg (400 mcg) of folic acid daily

*4.0 mg daily*

All women who have a family history of neural tube defect ~ or ~ have had a previous pregnancy affected by a neural tube defect should take 4.0 mg (4,000 mcg) of folic acid daily<sup>a</sup>

From Centers for Disease Control and Prevention (2004)

<sup>a</sup>This is ten times the usual dose and must be prescribed by a qualified practitioner

Research has shown that prenatal folic acid use can decrease the prevalence of open neural tube defects by 50–70 % (AAP Policy Statement Committee on Genetics 1999; Centers for Disease Control and Prevention 2004; Detrait et al. 2005). Folate is the natural form of folic acid and is found in leafy green vegetables (spinach), beans, liver, and citrus fruits. It is not absorbed at a 100 % ratio of the food that is ingested; thus, vitamin supplementation is recommended. Folic acid is a water-soluble synthetic compound used in vitamin supplements and fortified foods. The Centers for Disease Control and Prevention (CDC) and the US Public Health Service (USPHS) recommend that all women of childbearing age who are capable of becoming pregnant should take 400 mcg of folic acid daily, whether or not they are planning a pregnancy, and that women who have had a previous pregnancy or a family history of a neural tube defect take 4,000 mcg of folic acid daily (Table 4.2) (AAP Policy Statement Committee on Genetics 1999; Centers for Disease Control and Prevention 2004). These recommendations are extremely important because the neural tube develops by gestational day 28, often before a woman discovers that she is pregnant. Further, approximately 50 % of pregnancies are unplanned (AAP Policy Statement Committee on Genetics 1999; Henshaw 1998; Park 1999). In 1998, the US Food and Drug Administration mandated food manufacturers to fortify certain grain products with folic acid (AAP Policy Statement Committee on Genetics 1999; Honein et al. 2001). Foods enriched with folic acid may include breads, breakfast cereals, flours, rice,

and pasta. Although the use of folic acid greatly reduces the risk of a neural tube defect, it does not eliminate the risk altogether. Nurses working with women who are capable of pregnancy can be highly effective in educating them about the importance of folic acid supplementation.

---

## 4.2 Epidemiology

Collectively, birth defects are the leading cause of death in infants under 1 year of age (Detrait et al. 2005) and account for up to 21 % of all infant deaths in the United States (National Center for Health Statistics 1993). Neural tube defects are the second leading birth defect that can result in devastating outcomes in infants and children. In the United States, females are affected at a 2:1 higher ratio than males, Caucasians are diagnosed more often than other races, and there is a higher incidence in the eastern states than in the western states (Yen et al. 1992). Fortunately, the overall incidence of neural tube defects in the United States has steadily declined during the past few decades. This may be subsequent to an increased awareness of folic acid supplementation and prenatal diagnosis with elective termination of pregnancy. Prior to 1980, the incidence of neural tube defects in the United States was 1–2 per 1,000 live births (Lary and Edmonds 1996) and decreased further to 0.6 per 1,000 live births in 1989 (Yen et al. 1992). Many ongoing studies reporting incidence are specific to geographic location and cite ratios lower than 1 per 1,000 (Jorde et al. 1984; Roberts et al. 1995; Yen et al. 1992), although most studies seem to cite the average ratio of 1 per 1,000 live births.

---

## 4.3 Pathophysiology

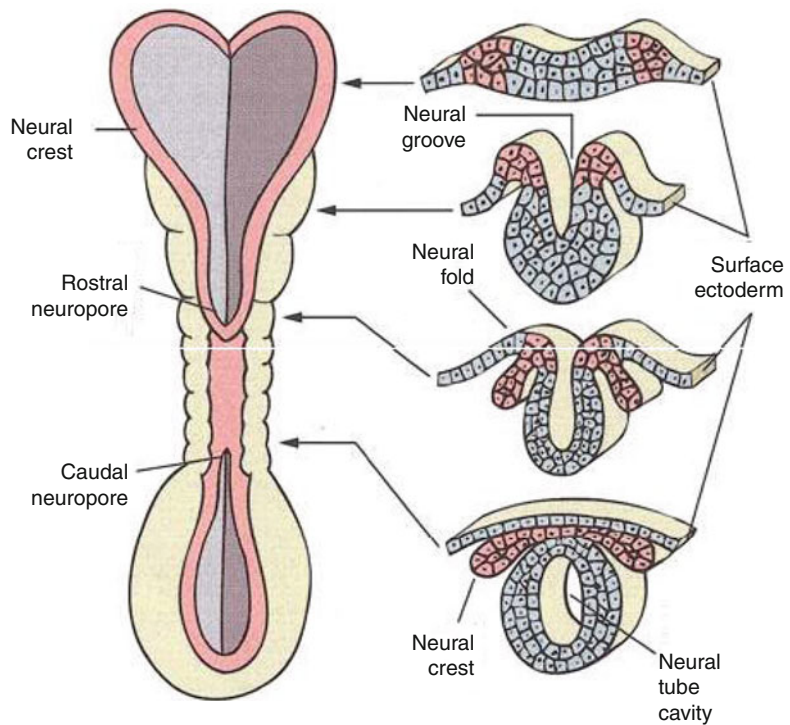
Neurulation is the embryologic formation of the neural plate, neural folds, and neural tube (Table 4.3). The neural tube is the cellular structure that later differentiates into the brain and spinal cord (Fig. 4.1). This process of human embryonic development occurs in 23 stages, each stage lasting 2–3 days. The development of the

neural tube is complete by 28 days of gestation. The neural tube is formed by two different processes called primary and secondary neurulation. Primary neurulation begins immediately after fertilization, or day one of gestation, and consists of the formation of the neural tube from the

rostral (head) to the caudal (bottom) neuropore, which forms into the brain and most of the spinal cord (Park 1999). Secondary neurulation is the process by which the caudal end of the neural tube develops into the lower sacral and coccygeal segments (part of the conus medullaris or end of the spinal cord) (Park 1999). The development of the neural tube begins around 17–19 days of gestation with dorsal thickening of the ectoderm, forming into the neural plate. During days 19–21, the neural plate unfolds and forms a neural groove, and neural folds begin to develop laterally. During days 21–23, the neural folds continue to grow to midline which allows closure of the tube. The neural folds develop into a rostral neuropore and a caudal neuropore. Finally, the closure of the neural tube takes place over 4–6 days. Traditionally, researchers have thought the neural tube closed in the midline cervical area and then closure extended up and down. More recently, evidence seems to indicate that the neural tube closes at several points simultaneously and then extends to the rostral and caudal ends to complete the closure.

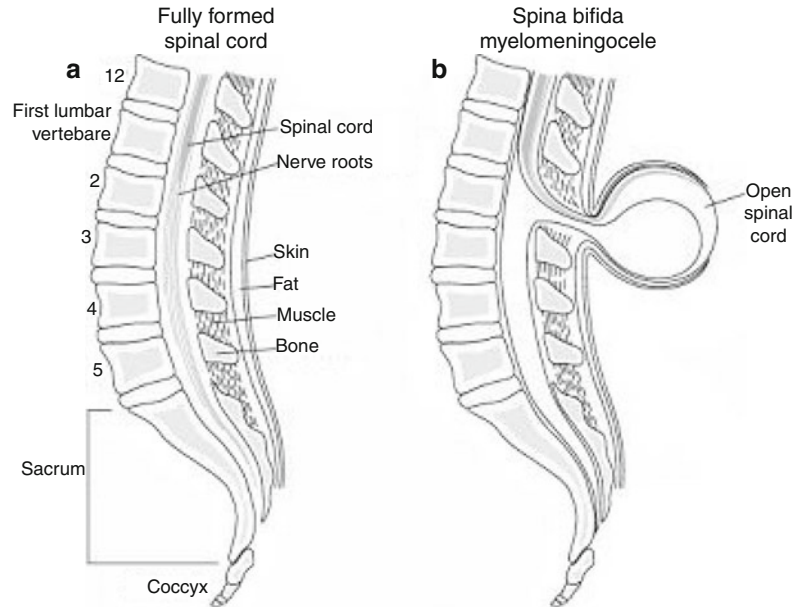
**Table 4.3** Terminology

<i>Ectoderm</i> – the outer layer of cells in the developing embryo
<i>Neural crest</i> – a band of cells in the ectoderm at the margins of the neural tube that form into the cranial and spinal ganglia
<i>Neural fold</i> – one or two longitudinal elevations of the neural plate of an embryo that unite to form the neural tube
<i>Neural groove</i> – a narrow midline groove in the neural tube
<i>Neuropore</i> – an opening of the neural tube
<i>Neural plate</i> – a dorsal thickening of ectoderm in the developing embryo that develops into the nervous system
<i>Neural tube defect</i> – a defect in the embryologic development of the anterior or posterior neuropore during neural tube formation



**Fig. 4.1** Neural tube at the end of the third week. Neural folds have begun to fuse at the cervical level of the future spinal cord. *Right*, cross sections of the neural tube at four different levels. Total length of the neural tube at this time is about 2.5 mm (Printed with permission from McCance and Huether (2002))

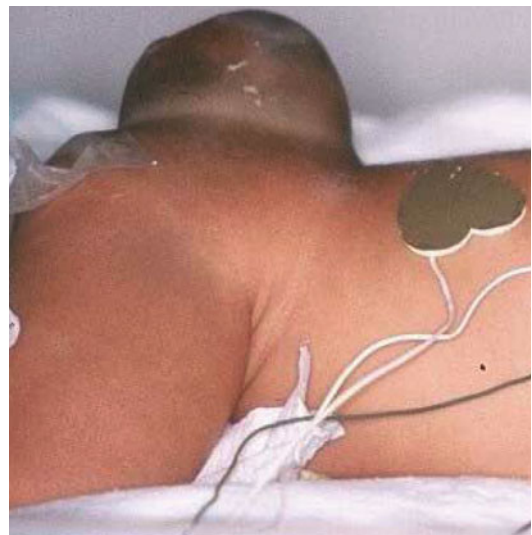
**Fig. 4.2** Normal spinal cord and myelomeningocele. (a) Anatomic diagram showing normal anatomy of spine and spinal cord. (b) A myelomeningocele defect (Printed with permission from University of Wisconsin Hospitals & Clinics Authority, Madison, WI)



#### 4.4 Myelomeningocele (Open Defect)

An open neural tube defect is a complex neurological defect of the central nervous system that results in permanent and potentially severe disabilities. This defect is the result of a deficiency in primary neurulation. The spinal column does not fuse together, allowing outward growth of the spinal contents, including cerebral spinal fluid (CSF), spinal cord, nerves lined with meninges, and sometimes skin (Fig. 4.2). An open defect in the spine is called a myelomeningocele (Fig. 4.3), and the disease process is spina bifida. The defect can occur anywhere in the spinal axis, with 85 % in the lumbosacral spine, 10 % in the thoracic spine, and 5 % in the cervical spine (Cohen and Robinson 2001). Anencephaly is the most serious neural tube defect where part or both cerebral hemispheres of the brain are absent and are not covered by skull. The infant can have an intact brainstem which may allow vital function to continue for a short period, although these infants are often stillborn or die within days after birth.

The prognosis of a myelomeningocele is highly dependent on the size and location of the spinal defect and on the severity of its comorbidities, which include hydrocephalus and Chiari II



**Fig. 4.3** Myelomeningocele (Courtesy of Bermans Iskandar, M.D., Director of Pediatric Neurosurgery, University of Wisconsin, Madison, WI)

malformation. The most common clinical complications are paralysis, hydrocephalus, and bowel and bladder incontinence. The survival rate of spina bifida has increased with advanced and more aggressive surgical intervention. Historically, dating back to the 1960s, infants born with spina bifida were managed conservatively

without surgery. Many infants died from perinatal problems, hydrocephalus, or infection. A study by Laurence in South Wales evaluated children born between 1956 and 1962 that were not surgically treated and found that only 11 % of the children survived to 10–16 years of age (Laurence 1974). Although this is a high rate of mortality demonstrating the natural progression of untreated myelomeningocele, the percentage of survival gave thought to more aggressive treatment. Throughout the 1960s, continued research showed a substantially higher rate of survival for infants who had immediate surgical repair of the myelomeningocele and surgical treatment of hydrocephalus (Park 1999). Ames and Shut (1972) evaluated 171 patients with myelomeningocele that were treated surgically between 1963 and 1968. They found the survival rate continued to improve, climbing to 50–80 % for children 3–8 years old (Ames and Shut 1972).

Later, in the 1970s and 1980s, the trend for aggressive and immediate surgical intervention continued and became the current standard of care. Throughout the 1990s, researchers learned more about the untoward effects of hindbrain herniation and hydrocephalus to the fetus and the overall impact on lifetime livelihood. The medical community questioned if early fetal surgery would be a greater benefit than risk, which launched a landmark 7-year National Institutes of Health-funded trial, called the Management of Myelomeningocele Study (MOMS) from February 2003 through December 2010. The outcome of this study continues to mold and shape the care of these patients.

Today, we understand that although many of these infants are born with significant neurological deficits, many have normal intelligence and the capability to enjoy a productive and fulfilling life. Major factors that affect long-term clinical outcomes are intelligence quotient (IQ), ambulatory function, degree of bowel and bladder function, the presence of hydrocephalus, or symptomatic Chiari II malformation, and upward to 20 % may have seizures in childhood (Liptak 1997). Intellectual ability is strongly influenced by the presence and severity of hydrocephalus, the level of the defect and associated handicap,

and a history of having central nervous system infection (e.g., meningitis). Individuals with myelomeningocele may have below-average cognitive abilities or mild intellectual disability. It is understood that a lower level lesion may correlate with less motor deficit (handicap) and higher intellectual capability. The ability to ambulate is directly correlated to the anatomic level of the spinal defect and subsequent neurological deficit. Children with a lower spinal defect have a greater chance of ambulating. Approximately 95 % of children with lower lumbar or sacral level defects can achieve walking, with or without assistive devices (Sakakibara et al. 2003). The ability to ambulate ranges from independent walking, or requiring assistive mobility devices (orthotic braces, crutches, or walker), to complete dependence on a wheelchair (Fig. 4.4). Bowel and bladder dysfunction is a notable determinant of social acceptance. Some patients may be incontinent of bowel and bladder, while others can achieve “social continence.”

#### 4.4.1 Comorbidities of Myelomeningocele

##### 4.4.1.1 Hydrocephalus

Hydrocephalus is commonly known as “water on the brain” and is the accumulation of cerebral spinal fluid (CSF) inside the ventricles of the brain, causing increased intracranial pressure (ICP). Hydrocephalus can be diagnosed prenatally with an ultrasound or fetal magnetic resonance image (MRI) to determine the presence and severity measured by the size of the ventricles in the fetus. Coniglio et al. (1997) have hypothesized that moderate to severe ventriculomegaly determined by a prenatal high-resolution ultrasound shows a correlation to an overall lower cognitive development quotient (Coniglio et al. 1997). Largely, literature alludes to the fact that progressive hydrocephalus may impinge on brain development. Clinically, it is noted that a higher incidence of hydrocephalus occurs with a high-level myelomeningocele lesion, such as those in the thoracic spine, as opposed to those in the sacral spine.



**Fig. 4.4** Mobility devices. (a) Solid ankle foot orthosis (AFO). (b) Lofstrand crutches. (c) Posterior walker. (d) Fixed frame light weight manual wheelchair (Photos

courtesy of Jim Miedaner, MS, PT, University of Wisconsin Hospital & Clinics, Rehabilitation Clinics, Madison, WI)

Approximately 90 % of infants with spina bifida will require surgical treatment for hydrocephalus, and the majority of infants are shunted within days of birth (McLone 1998). Around 25 %

of infants with a myelomeningocele have obvious signs of hydrocephalus at birth, but the most common time of presentation is at 2–3 weeks after birth (Rekate 1999). In the cases with obvious



signs of hydrocephalus at birth, the surgeon may place a shunt at the same time of surgical repair of the myelomeningocele, or within 24–48 h to reduce the risk of a cerebrospinal fluid leak or wound breakdown after surgery (McLone 1998). In infants who are not shunted, many become symptomatic for hydrocephalus after a myelomeningocele repair due to a buildup CSF.

More recent research by Warf (2005) has shown encouraging findings that support the treatment of hydrocephalus from a myelomeningocele with an endoscopic third ventriculostomy (ETV) and choroid plexus cauterization (CPC) (Warf 2005). An ETV is a procedure to create an opening in the floor of the third ventricle to create free-flowing communication between the ventricle system and basal subarachnoid spaces (Petronio and Walker 2001). A CPC is a procedure that destroys the choroid plexus, where CSF is made within the ventricles. The treatment of hydrocephalus from certain pathology with an ETV is not a new concept in neurosurgery, and researchers are continuing studies to determine the long-term outcome of it used alone and in combination with CPC for treatment of infants with hydrocephalus related to a myelomeningocele.

#### 4.4.1.2 Chiari II Malformation

A Chiari II malformation is a downward herniation of the posterior fossa structures (medulla and cerebellum) into the spinal canal and is present in nearly all infants with myelomeningoceles. This may be the most serious comorbidity as it increases the mortality risk significantly due to potential apnea, stridor, vocal cord paralysis, and difficulty with feeding. It can also cause nystagmus and a lower cranial nerve palsy. Up to 30 % of infants have mild symptoms from compression on the brainstem, feeding difficulties, or gastroesophageal reflux, and less have severe symptoms of weak or absent cry, stridor, apnea or color change, drooling, increased tone in the arms and legs, or arching of the neck (Rekate 1999; Sandler 2010). If untreated, Chiari II can lead to death. Surgical decompression of a Chiari malformation can resolve these symptoms, except when they present immediately after birth, which may indicate irreversible problems from brainstem compromise.

The surgery involves removal of part of the upper cervical vertebrae and expansion of the dura overlying the malformation in order to decompress, or make room for the herniating brain. Another complication that can occur with the presence of a Chiari malformation is syringomyelia, which is a fluid filled cyst (syrinx) that expands within the spinal cord causing neurological symptoms.

#### 4.4.1.3 Bowel and Bladder Dysfunction

The majority of patients with a myelomeningocele have some degree of neurogenic bladder and bowel dysfunction (Anderson and Travers 1993; Cohen and Robinson 2001). The level of the defect is not always predictive of the degree of dysfunction. A urologist is vital to the multidisciplinary team and will evaluate the kidneys and the bladder integrity (elasticity and filling capacity) and initiate a bowel and bladder maintenance program. Common urological tests to evaluate these concerns are a renal ultrasound, voiding cystourethrogram (VCUG), and urodynamics, known as video urodynamic studies. Often, early management of the bowel and bladder dysfunction begins with baseline diagnostic testing, and concurrent testing throughout the lifetime to prevent deterioration of the urinary tract, preserve current level of function, and to ultimately decrease the risk of renal complications. A major goal of neurogenic bladder is to provide socially acceptable continence or “social continence” in the future (Box 4.1). Clean intermittent catheterization several times a day has improved regulation of bladder function and resulted in greater social continence.

#### 4.4.2 Prenatal Screening for Myelomeningocele

Prenatal screening is helpful in the detection of an open neural tube defect and is extremely important in planning a timely and safe delivery. Screening and a consequent diagnosis can be determined with a maternal serum alpha-fetoprotein (MSAFP), ultrasound, or amniocentesis (Coniglio et al. 1997). The MSAFP is done between 14 and 21 weeks and is optimal between 16 and 18 weeks of gestation. If this number is

#### **Box 4.1. A Parent's Perspective: Bowel and Bladder Continence**

Our son was born with a sacral level myelomeningocele. When others see him, they don't see a child with a disability because he does not have any outward signs of spina bifida. He walks normally and has a shunt, but his biggest struggle is with bowel and bladder continence.

We have tried many things over the past 7 years to achieve bowel and bladder continence. We started catheterizing our son when he was 3½ years old. We were taught how to catheterize him during a clinic visit and were sent home with supplies and our memory of what we had learned. After a few difficult weeks, we were on our way to a lifelong routine of cathing every 3–4 h. The bowel issues have been extremely difficult. We have tried several types of bowel programs: enemas and drinks that made him gag from the taste or texture. We were diligent and patient as we could be with each program, but our emotions went up and down as each new promising method failed. After repeated failure to gain control of the bowel continence, we were told about a surgical procedure called the Malone antegrade continence enema (MACE) to help in bowel flushing.

He had the surgery when he was 8 years old. After surgery, things had improved, but he still has daily struggles. Every day after our son comes home from school, he has just enough time to do his homework and to eat supper before we begin our daily bowel program. We go to the “cinematography room” (what we call our bathroom) equipped with a TV/DVD player that is kept in the bathtub behind the shower curtain. He spends the next hour or more on the toilet while we do the “cleanout” procedure.

Our life revolves around the “cleanouts.” He has little time to spend with friends or extracurricular activities, and overnights are almost impossible. We have to plan everything in advance. The stress of his situation is shared by the entire family. It has changed our family routine; mom quit her job to stay home and tend to medical needs, dad is the sole financial provider for the family, and his little sister feels left out at times.

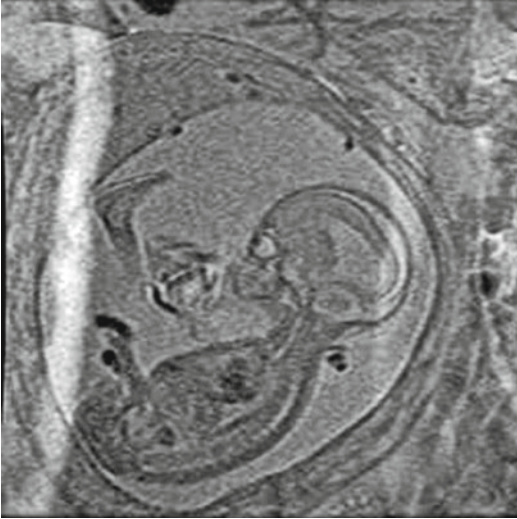
We hope this helps medical professionals understand what goes on behind the scenes of a family dealing with ongoing medical needs. When doctors tell us, it's time to try something new, we brace ourselves for the implications this will have on our family life for the weeks to come.

higher than the normal value range, it may be an indicator of a possible neural tube defect. This is a screening test, and a normal AFP does not completely exclude the possibility of a myelomeningocele. An ultrasound is done between 15 weeks and up to the end of pregnancy for the assessment of the fetal age and general anatomy of the brain and spine (d'Ercole et al. 2003). If a neural tube defect is found, the patient is referred to a perinatologist for a high-resolution ultrasound and possible amniocentesis. Some medical facilities have the capability to do a prenatal ultrafast MRI of the mother's abdomen for structural assessment of the fetus and the severity of hydrocephalus (Fig. 4.5). Fetal blood sampling and chorionic villi sampling are not useful in the determination of an open neural tube defect.

### **4.4.3 Management**

#### **4.4.3.1 Medical Management**

In many cases, an infant with a myelomeningocele is delivered by a planned cesarean section to minimize trauma to the defect during delivery. The infant is immediately assessed by neonatologists, neurosurgeons, and nurses. Initial evaluation of hydrocephalus is done by palpating the fontanel, measuring a baseline head circumference, and obtaining pertinent imaging. A cranial ultrasound can be helpful to determine a baseline assessment of ventricle size, although a CT or MRI will offer a more detailed assessment of the severity of hydrocephalus. A thorough neurological exam is done, the defect is carefully examined, and the spine is assessed for



**Fig. 4.5** MRI of the fetus showing ventriculomegaly (hydrocephalus) (Courtesy of Bermans Iskandar, M.D., Director of Pediatric Neurosurgery, University of Wisconsin Madison, WI)

abnormal curvature. The myelomeningocele may appear as an obvious bubble that sits mid-line somewhere on the spine, filled with CSF, spinal cord, and nerves, with a membranous covering. It can also appear with a ruptured membrane or as an open defect with no membrane covering. Motor function is assessed by observing upper and lower extremities for spontaneous active movements, symmetry, muscle bulk, and tone. The sensory level is evaluated in the trunk and lower extremities. Assess anal wink (gluteal reflex) as a predictor of bowel control. A thorough preoperative examination and appropriate diagnostic testing of medical abnormalities are important to ensure the best possible circumstance prior to surgery.

#### 4.4.3.2 Surgical Management

Dating back to the 1930s, infants born with a myelomeningocele underwent postnatal surgery to close the spinal defect. Over the years, it became understood that closure of the defect and simultaneous shunting of hydrocephalus is optimally done within hours after birth. Delay in surgical treatment can increase both morbidity and mortality because of the increased risk of meningitis. The major goals of surgery are to anatomi-

cally restore the already damaged spinal cord, surrounding nerves and tissues, to manage subsequent hydrocephalus by shunting, and to ultimately preserve the current neurologic function of the neonate.

For a surgical repair of a myelomeningocele, the infant is placed in a prone position. The neurosurgeon will open the sac, close the neural structures, and then close the dura, the fascia, the subcutaneous tissues, and finally the skin. Some defects are so large or complex that a plastic surgeon is consulted to assist in the closure.

Starting in the 1970s, early sonogram screening allowed the opportunity for serial monitoring of the fetal movement as pregnancy progressed. Physicians began to recognize decreased fetal movement in the legs and feet throughout pregnancy, leading to the idea of progressive damage to the open portion of the exposed spinal cord causing increased neurologic damage. Additionally, it was theorized that the hindbrain herniation may result from leakage of cerebrospinal fluid through the open neural tube during a critical time of posterior fossa formation (Manning et al. 2000).

In 1994, physicians conceptualized early closure of the defect to minimize further neurological damage and began intrauterine repair (Box 4.2). Fetal surgery was improved and performed by talented neurosurgeons in the United States, but the potential morbidity and mortality to both fetus and mother raised the question of whether the overall benefit outweighed the overall risk factors. This question launched a major clinical trial designed to compare the outcome of surgical prenatal repair to that of postnatal repair. The Management of Myelomeningocele Study (MOMS) was a randomized controlled trial funded by the National Institute of Child Health and Human Development (a part of the National Institutes of Health) conducted between February 2003 and December 2010 at three designated maternal-fetal surgical centers: the University of California in San Francisco, The Children's Hospital of Philadelphia in Pennsylvania, and Vanderbilt University Medical Center in Nashville, Tennessee (Adzick et al. 2011). No other hospitals throughout the United

#### **Box 4.2. A Parent's Perspective: An Unexpected Journey**

After settling my three small boys for the night, I was beyond my typical nervous laughter when I told my husband that we were expecting our fourth child. I was definitely surprised and cautiously guarded as I wondered how I was going to manage four children under the age of 5. Nothing seemed out of the ordinary, until the day of my scheduled ultrasound. We learned that our baby had spina bifida. We were told of our options: to continue or terminate the pregnancy. After sharing our strong desire to continue the pregnancy, we were told about maternal-fetal surgery. Initially, we were not interested because of the risks involved, but after learning more about some of the promising medical outcomes and the reduced need for a shunt to treat hydrocephalus, we decided to learn more about how the risks outweighed the benefits. We traveled over 1,000 miles away to a center where it was done.

After an agonizing 3-day consultation and medical tests, we decided to undergo the surgery, at 24 weeks' gestation. We hoped that we made a good decision to improve the quality of life for our unborn child. Four days after the surgery as I was flying back home, my thoughts turned to my other children as I looked down at the terbutaline pump-flowing medicine into my body and keeping me from going into premature labor. Our commitment to surgery required many volunteers, friends, and family to keep things going at home. It seemed to be going alright, but what came later tested my strength and endurance.

My unborn son was doing fairly well until around the 28th week of gestation when I started losing amniotic fluid internally from a tear in my uterus at the surgical site. I was hospitalized until my son's delivery at 34 weeks' gestation. When he was born, his lungs were underdeveloped and he was immediately placed on a ventilator. He was hospitalized for 3 weeks and sent home on oxygen and oral tube feedings. Ironically, I had met another family during my pregnancy, and they too were expecting a son with spina bifida. He was born a day later than my son, by a planned C-section with surgery immediately after birth. It was hard *not* to compare our babies. I thought about fetal surgery impacted our situation. While their baby had the typical closure at birth and was discharged from the hospital a few days later, my son was still in the neonatal ICU on a ventilator and very sick from prematurity.

Both my son and I had multiple complications as a result of the fetal surgery, and it was one of the most challenging experiences I have gone through. I am glad we had the option of surgery, but my husband and I still wonder if this was the best decision, especially since he ended up requiring a shunt for hydrocephalus. It was difficult to come to terms with having a child with spina bifida. And it was more difficult with the added stressors of having gone through a prenatal surgery, complicated recovery, premature delivery, and our son's ongoing medical issues.

Our son is 4 years old now, and he is doing great and making progress by leaps and bounds. When I look at him, it is hard to believe that he had so many challenges early on in his life.

States performed prenatal surgery while the trial was ongoing.

The researchers recruited 183 of a planned 200 pregnant women, and the results were based on 158 women. All women enrolled were to deliver at the designated MOMS center by cesarean section around the 37th week of pregnancy and surgery was done by a study-approved surgeon. Women were randomly assigned to a pre-

natal group; one group would undergo fetal repair of myelomeningocele at a MOMS center and were required to stay near the site for the duration of their pregnancy and the comparison group went home for prenatal care until their return to the MOMS center around the 37th week to undergo conventional surgical repair after birth. Inclusion criteria were that of a singleton pregnancy, a defect from T1 and S1, evi-

dence of hindbrain herniation, and maternal age of at least 18 years (Adzick et al. 2011; Danzer and Flank 2008). Exclusion criteria were a fetal anomaly other than myelomeningocele, severe kyphosis, risk of preterm labor, placental abruption, a body mass index of 35 or more, and contraindication to surgery (Adzick et al. 2011; Danzer and Flank 2008).

The results were based on 158 children that were evaluated at 12 and 30 months of age on the basis of physical, neurologic, and developmental testing at the center in which they had either the prenatal or postnatal repair. These children underwent thorough physical examinations, MRI of the head and spine, renal ultrasound and urodynamics, spinal x-ray, and neurodevelopment testing with regard to social, fine, and gross motor skills. One primary outcome at 12 months was a composite of fetal or neonatal death, or the need for cerebrospinal shunting, which occurred in 68 % of the infants in the prenatal surgery group and in 98 % of those in the postnatal surgery group. A second primary outcome at 30 months was a composite score of the mental development and the child's motor function, which also resulted in improvement in the scores collectively. Although the score was based on motor function, there was no significant improvement in mental development alone (Adzick et al. 2011; Danzer and Flank 2008). Overall, reported results compared the prenatal to postnatal group in the rates of shunt placement, no hindbrain herniation, moderate to severe hindbrain herniation, and ability to ambulate independently (Table 4.4). The study was powerful in demonstrating decreased incidence of shunt placement, less severe Chiari II, and increased abilities to ambulate in the prenatal group, but yet, there were some infants that did not benefit and had poor neuromotor outcome.

Prenatal surgery was associated with increased risk of preterm delivery and uterine dehiscence at delivery. Specifically, the prenatal surgery group had higher rates of complications compared to the postnatal group in both the mother and fetus, such as spontaneous membrane rupture, oligohydramnios, and complications associated with prematurity. More than a third of mothers showed

**Table 4.4** Results of prenatal repair as compared to postnatal repair of children with spina bifida at 12 months of age (Adzick et al. 2011)

Prenatal and postnatal myelomeningocele repair		
	Prenatal (%)	Postnatal
Rates of shunt placement at 12 months	40	82
No hindbrain herniation at 12 months	36	4
Moderate to severe hindbrain herniation	25	67
Walk independently	42	21

dehiscence or a thin uterine wall at the hysterectomy site, which increased risk of subsequent pregnancy (Adzick et al. 2011; Simpson and Greene 2011).

The overall results of this study cannot be generalized to all patients with myelomeningocele. It is also recognized that an experienced surgical team is vital for positive outcome of prenatal surgery and that not all geographic locations can provide this level of expertise. These factors, combined with the significance of fetal and maternal risk, support the belief that this option of treatment is a step in the right direction, but may not be considered the gold standard of care in all cases of infants with myelomeningocele.

#### 4.4.3.3 Nursing Considerations

Prenatal diagnosis of a chronic and debilitating disease is a time of shock, anxiety, and despair for families. Nurses can play an instrumental role, offering supportive care to prospective parents and families affected with a congenital malformation. This support can be derived by models of care focusing on emotional, spiritual, and social needs that match the affected family needs (Munson and Leuthner 2007). Nurses have a dual responsibility in caring for a patient with special medical needs: the first is to provide quality nursing care to the patient, and the second is to care for the emotional needs of the family (Box 4.3). It is important to assess the family's ability to cope with their stress

#### Box 4.3. A Parent's Perspective: A Myelo – What?

My second pregnancy seemed to be going along without complications. The triple screen was negative, and I had 3 ultrasounds, ordered by my physician: the first to confirm a due date, second for routine screening at 20 weeks' gestation, and a third late in pregnancy to evaluate amniotic fluid; they were all "normal"! However, the day my daughter was born was the day we learned that she had spina bifida.

After a short, but difficult delivery, the medical staff whisked away a somewhat "purple" looking newborn to the next room with my husband following behind. After several moments of silent panic, I sighed in relief as I heard her cry for the first time. "Thank You, God." I remember mumbling as the doctor worked to repair the trauma my body had endured. Several more minutes passed before a very calm and reassuring female neonatologist approached my bedside to inform me that my daughter had a lesion on her backed called a myelomeningocele. A myelo-what, I thought to myself? She explained that my daughter would need surgery to repair the lesion as soon as possible. They gave me a quick peek at my daughter, and then they took her to neonatal intensive care to prepare her for surgery.

My husband and I sat together in a quiet hospital room. He tried to explain what the surgeon had told him about the surgery and complications of hydrocephalus and the possibility of needing a shunt. The staff gave us a book and some other literature to read as we waited for her to get out of surgery. I hadn't even held my daughter, and here I was, looking at lifeless diagrams and words that would affect the rest of our lives. Although we knew this was important information, nobody wants their child defined by a book or pamphlet. We didn't need to know that this happens one in every 1,000 births. When it comes to any newborn, it is more important for medical professionals to remember that the "human connection" needs to come first. What we needed, right then, was to know that our daughter was going to be ok. We didn't need a book to tell us who our daughter was. We knew that she would show us who she is, and that each detail would emerge in its own order, not like a book divided neatly into chapters.

From our experience, we believe that medical professionals should pass on information with great compassion. Preface the information with the fact that all cases are based on the individual and the unique characteristics of the type of myelomeningocele they have. Shortly after birth, we told our pediatrician that "She is going to write her *own* book, the story of *her* life, and Spina Bifida will only be part of it." Now 5 years old, each day we learn that our daughter has defied many of the "statistics" that we first read about.

and emotions; naturally they may feel overwhelmed or in a state of shock. Nurses can greatly impact the commencement of this life changing event as they offer support and reassurance throughout the process of educating the family.

#### 4.4.3.4 Preoperative Care

As nurses care for families who have a newborn with a myelomeningocele, it is important to assess the parents' current level of understanding of the disease and their ability or willingness to learn. Although the majority of parents have had time to prepare for the birth if the diagnosis was made through prenatal testing, others may have learned

about the diagnosis for the first time after delivery. Obviously, in both instances this is a stressful and overwhelming time for the family. It is important to educate the family about what to expect during the first hours of their baby's life. The newborn infant will be examined by many professionals to determine the presence of other associated abnormalities such as genetic disorders, cardiac, urologic, or orthopedic problems. Preoperative care of the infant with myelomeningocele may vary at each medical center, but there are many basic similarities: (1) cover the myelomeningocele defect with a sterile saline-soaked dressing and avoid drying of the dressing by keeping it moist or cre-

**Table 4.5** Latex products

Patient care items and mechanical equipment	Home and community items	Anesthesia equipment
Adhesive tape	Baby bottle nipples	Ambu bags
Bandages	Elastic on diapers and clothes	Airway mask
Blood pressure cuffs, tubing, and bladders	Pacifiers	Nasal airway
Catheters (gastric, urinary)	Many toys and balloons	Anesthesia bags and tubing
Catheter leg bag straps	Avoid bananas, avocados, kiwi, raw potatoes, tomatoes, and chestnuts (latex-sensitive individuals can have a cross sensitivity to foods that contain polypeptides found in latex)	
Dental equipment (dental dams, bite blocks)	Condoms	
Electrocardiogram pads		
Medication vial ports, intravenous injection ports, and syringe plunger tips		
Stethoscopes		
Rubber gloves		

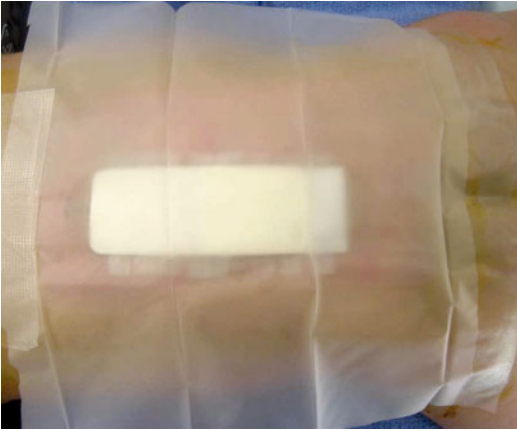
ating a continuous sterile saline drip over the area; (2) place the infant in a prone or lateral recumbent position until surgery; (3) withhold oral feedings to maintain an “aseptic bowel,” thereby decreasing risk of infection to the open defect; (4) administer intravenous antibiotics if ordered by the surgeon; and (5) administer intravenous fluids in lieu of no oral intake until after surgery. Nurses can help a new mother to understand that impending surgery should not be a deterrent to breast-feeding. If the mother is interested in breast-feeding, nurses or a lactation consultant can help to initiate pumping and storing of milk until the baby can be put to breast. Last, educate parents about the surgery, anesthesia care, and what to expect for the immediate recovery.

Patients with spina bifida are at high risk for developing a latex sensitivity or allergy. The natural history of a latex allergy is not well understood. It is believed that an allergy or sensitivity to latex develops from repeated exposure in the hospital environment and from multiple surgeries, particularly when latex comes in contact with mucous membranes (i.e., urinary catheter). Latex is a form of rubber derived from a plant source, the *Hevea brasiliensis* tree, and is found in many medical and home supplies (Table 4.5). Latex reactions vary from mild contact dermatitis to anaphylactic shock or death (Mazagri and Ventureyra 1999). Children

with a known sensitivity can be treated preoperatively with antihistamines and epinephrine.

#### 4.4.3.5 Postoperative Care

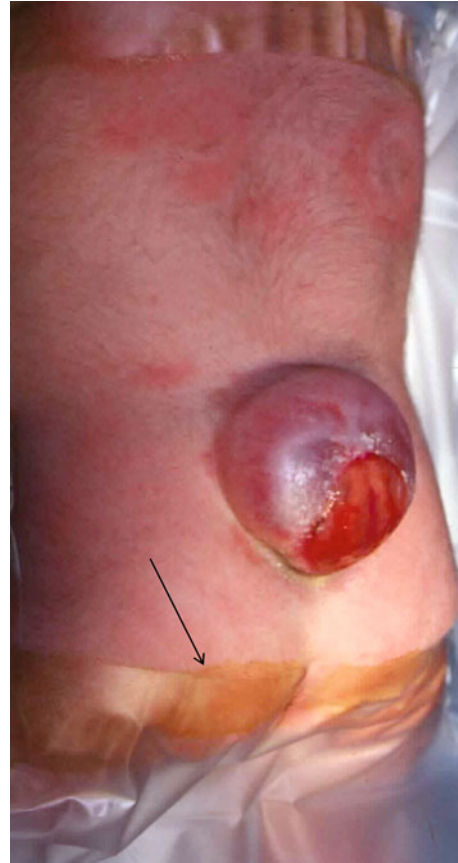It is important to have a well-organized discharge plan in mind as you care for the infant and family for the remainder of the hospitalization. Nursing education is best achieved by the use of a variety of teaching modalities: written materials and verbal instruction and demonstration as you are prepare a family for discharge. Routine postoperative care of the infant after surgery to close the myelomeningocele may include the following: (1) place the infant in a prone or side lying position for up to 3 days (or per surgeon’s preference) to minimize the risk of CSF leaking or wound compromise, (2) cover the incision with a dressing to protect the wound from soiling of urine and feces (Fig. 4.6), (3) administer intravenous antibiotics (per surgeon preference) to minimize risk of infection, and (4) administer intravenous fluids for the first 24 h or until the infant is breast-feeding or taking oral feedings well. Lying flat or horizontal keeps CSF distributed somewhat evenly along the spinal cord and decreases pressure on the myelomeningocele closure, allowing it to heal. Breast-feeding can still be accomplished if the baby is positioned horizontally on a pillow on the mother’s lap. A “mud flap” placed between



**Fig. 4.6** Example of occlusive dressing and drape. The incision is covered by a 4×4 gauze and occlusive dressing. A plastic drape is secured to the top of the buttocks and draped over the back and torso to avoid soiling from the diaper (Courtesy of Bermans Iskandar, M.D., Director of Pediatric Neurosurgery, University of Wisconsin, Madison, WI)

the myelomeningocele and the rectum can keep stool out of the incision (Fig. 4.7). If the infant must be placed supine for any reason, a foam “donut” can be placed around the closed myelomeningocele to prevent pressure on the incision.

Beyond the initial postoperative period, it is important to educate the family about care of the infant at home so they feel more confident transitioning out of the hospital. The family is instructed to monitor the infant for signs and symptoms of infection including fever or redness, swelling or drainage from the incisions and for progressive hydrocephalus. Signs or symptoms of hydrocephalus include fullness of the fontanel, irritability, decreased interest in feedings, lethargy, or projectile vomiting. Daily measurement of head circumference is useful to detect rapid head growth. It is equally important to observe the infant for symptoms indicative of a problem from the Chiari malformation including abnormal breathing, such as stridor, apnea, choking, or gagging. Prospectively, scarring from spinal surgery can result in retethering of the spinal cord that is evidenced by back pain or a change from baseline in bowel and bladder control or degree of mobility. It is important that families understand when to seek immediate medical attention with concerns of progressive hydrocephalus or breathing difficulties.



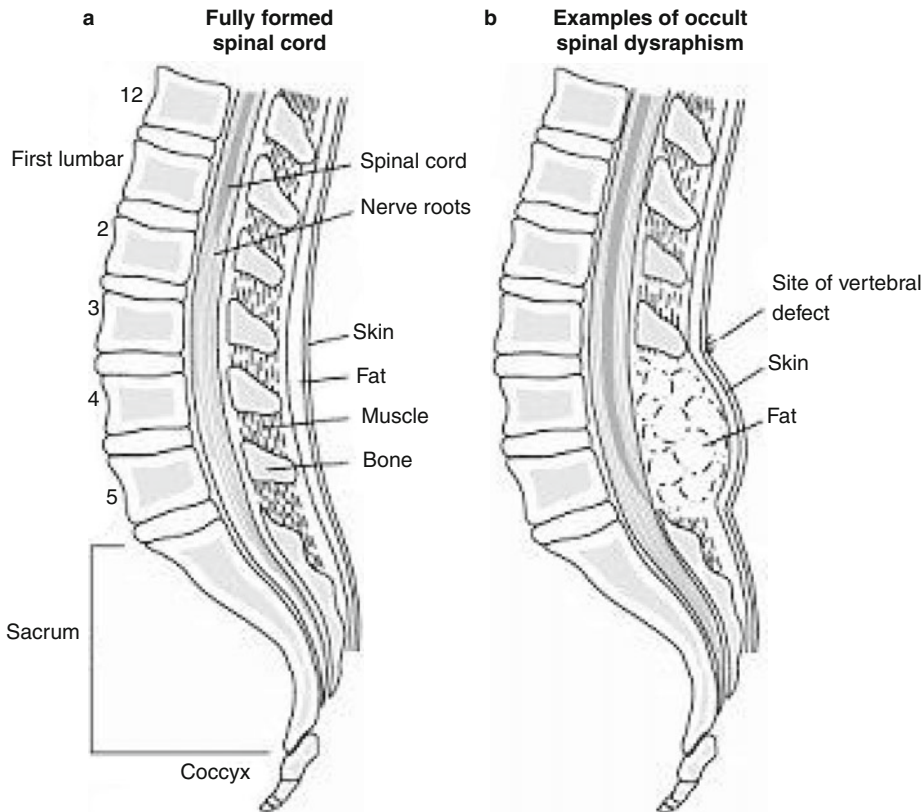
**Fig. 4.7** Plastic “Mudflap” adhered to skin over buttocks to prevent stool and urine from soiling the myelomeningocele

Finally, a multidisciplinary care approach is vital for long-term management of the complex medical needs of a child with spina bifida. The medical team often consists of a neurosurgeon, orthopedic surgeon, rehabilitation specialist, urologist, nurses or nurse practitioners, physical/occupational therapist, and a psychologist. Sometimes, collaborative care with neurology and endocrine specialists is required. This approach to healthcare is essential to offer each child the greatest potential to lead a healthy and productive life.

#### **4.5 Spina Bifida Occulta (Closed Defect)**

A closed neural tube defect is a less devastating neurological defect of the central nervous system, but can result in progressive and possibly





**Fig. 4.8** Normal spinal cord and occult spinal dysraphism. (a) Anatomic diagram showing normal anatomy of spine and spinal cord. (b) Spinal cord with closed neural

tube defect (Printed with permission from University of Wisconsin Hospitals & Clinics Authority, Madison, WI)

permanent neurological deficits. This defect is the result of a deficiency in primary and secondary neurulation. It occurs later in embryologic development, causing abnormal formation of the spine from failure of the vertebral lamina to fuse together properly. The abnormal development of the neural tube and abnormal fusion of the bony vertebrae allows ingrowth of tissues, such as fat or skin, that creates abnormal attachment or tethering of the spinal cord (Fig. 4.8). The closed defect is called spina bifida occulta or occult spinal dysraphism (OSD), which predominantly occurs in the lumbosacral spine (Yamada et al. 2004). There are a spectrum of clinical abnormalities of OSD and each have a different clinical presentation.

These abnormalities include a lipoma or lipomyelomeningocele, dermal sinus tract, split cord malformation (diastematomyelia or diplomyelia), dermoid cysts and tumors, meningocele manqué, or tight filum terminale. All forms of OSD result

in a tethered spinal cord. A tethered spinal cord is characterized by a spinal cord that is positioned abnormally low in the spinal canal because it is “attached” or “anchored” to the surrounding structures. The prognosis of a tethered cord is good when it is diagnosed and surgically treated before neurological deficits occur.

#### 4.5.1 Clinical Presentation

Unlike the open defect, the clinical presentation of OSD is variable. In the majority of patients, signs are obvious on examination, but in some cases there are no signs until symptoms occur. Normally, the end of the spinal cord (conus medullaris) floats freely in the spinal column. At birth, the conus is located at vertebral level L3 and ascends to its normal position of vertebral level L1 by 3 months of age. In a child with OSD, the spinal cord is tethered

**Table 4.6** Cutaneous stigmata of spina bifida occulta

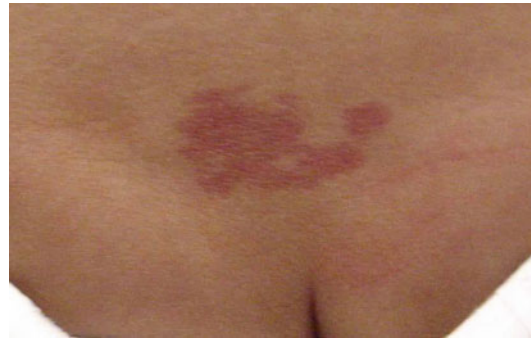Hemangioma
Hypertrichosis (tuft of hair)
Atretic meningocele (cigarette burn)
Dermal sinus tract
Lipoma
Caudal appendage

caudally, and natural linear growth causes progressive tension and stretching of the spinal cord. This causes decreased local blood flow, or ischemia to the nerve cells, thereby causing overt symptoms. The common presentation of signs and symptoms are a skin lesion, pain or weakness of the legs, back pain, change in bowel or bladder control, or orthopedic problems such as scoliosis. The majority of patients diagnosed with a tethered cord will present with one or more of the six characteristic skin lesions of OSD (Table 4.6). These are a hemangioma, hypertrichosis, atretic meningocele, dermal sinus opening, subcutaneous lipoma, or a caudal appendage. Other medical problems that have an association with tethered spinal cord are imperforate anus, cloacal exstrophy, and history of previous spinal surgery. Previous spinal surgery, such as myelomeningocele repair, causes scar tissue and subsequent risk of retethering of the spinal cord. The incidence for a patient with a myelomeningocele to retether at some point in their lifetime is 15–20 % (Gaskill 2004).

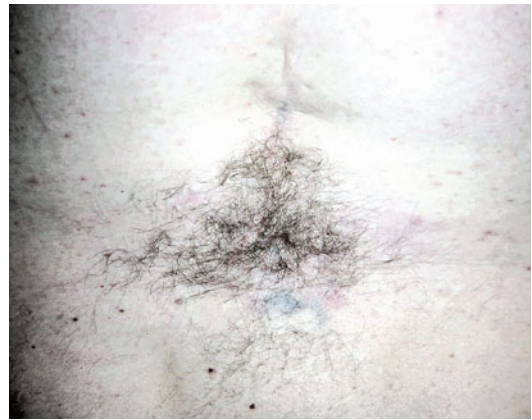#### 4.5.1.1 Cutaneous Anomalies of OSD

One or more of the six characteristic cutaneous lesions occur in up to 70 % of patients diagnosed with a tethered spinal cord (James and Lassman 1981). All midline lesions on the spine are clinically significant for a possible tethered cord, making it important to distinguish between abnormal and benign skin markings. All the skin lesions described in the section to follow are clinically significant for OSD when observed on the back and located in the midline lumbosacral spine.

A *hemangioma* is a flat or raised, pink or red skin lesion that consists of capillary vessels (Fig. 4.9). The examiner needs to distinguish differences between common skin finding and a true hemangioma. For example, infants commonly have a nevus at the base of the skull called a



**Fig. 4.9** Lumbar hemangioma (Courtesy of Bermans Iskandar, M.D., Director of Pediatric Neurosurgery, University of Wisconsin, Madison, WI)

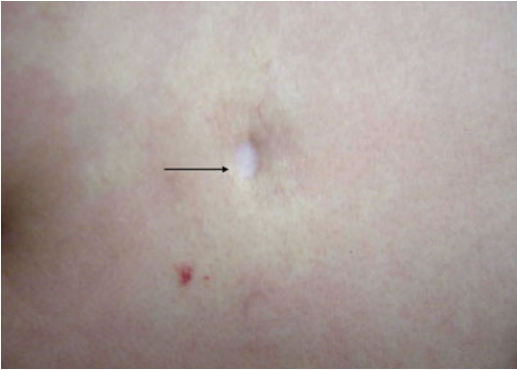


**Fig. 4.10** Hypertrichosis (Courtesy of Bermans Iskandar, M.D., Director of Pediatric Neurosurgery, University of Wisconsin, Madison, WI)

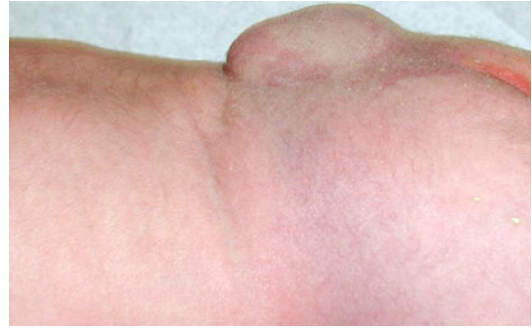
“stork bite,” which is benign. A Mongolian spot (a pigmented black or blue spot) or a nevus (pigmented circumscribed area on skin) may be found in the lumbosacral region and has no clinical significance for OSD.

*Hypertrichosis* is a localized patch or tuft of hair (Fig. 4.10). Hair that is localized and sometimes diffuse is “baby” hair that dissipates over the first months of life and is not indicative of OSD. Hypertrichosis is highly correlated to the malformation called diastematomyelia, which is a split or double spinal cord (James and Lassman 1981).

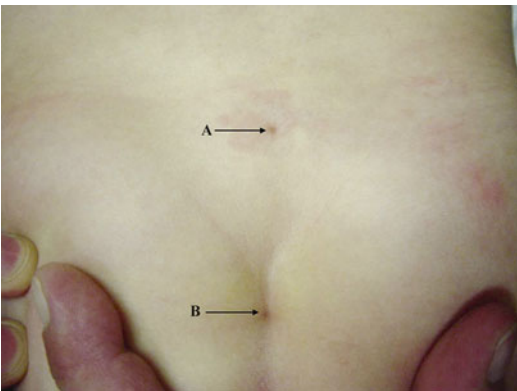
An *atretic meningocele* (*meningocele manque*) is a skin lesion that looks like a scar and is sometimes called a “cigarette burn” (Fig. 4.11). The skin over this lesion may be sensitive to touch. An atretic meningocele presumably indicates that



**Fig. 4.11** Atretic meningocele (Courtesy of Bermans Iskandar, M.D., Director of Pediatric Neurosurgery, University of Wisconsin, Madison, WI)



**Fig. 4.13** Lipomyelomeningocele (Courtesy of Bermans Iskandar, M.D., Director of Pediatric Neurosurgery, University of Wisconsin, Madison, WI)



**Fig. 4.12** Dermal sinus and sacral dimple. (A) Dermal sinus with flat hemangioma. (B) Sacroccocygeal dimple (Courtesy of Bermans Iskandar, M.D., Director of Pediatric Neurosurgery, University of Wisconsin, Madison, WI)

a meningocele (malformation of the meninges) was once present during fetal life and had partially repaired itself. The lesion can be connected to the spinal cord by a tract of fixed fibrous band that extends from the skin to the spinal cord.

A *dermal sinus* is a small hole or opening in the skin that appears as a dimple in the skin (Fig. 4.12). It is often connected to underlying structures by a subcutaneous tract lined with epithelium, bone, dura, or the spinal cord. A dimple found at the level of the coccyx is not suspicious, however, and is termed a benign sacroccocygeal dimple (Fig. 4.12).

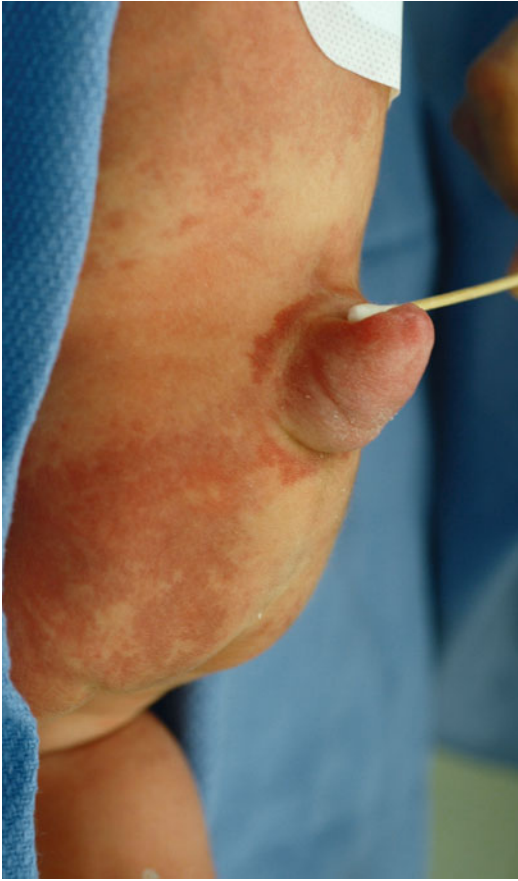A *lipoma* or *lipomyelomeningocele* is a soft tissue mass that is completely covered with skin

(Fig. 4.13). It can grow larger over time as fat grows in proportion to the patient's body weight. A lipoma or lipomyelomeningocele may be an extension of an intramedullary mass within the spinal cord.

A *caudal appendage* appears as a tail or "pseudotail" which presents as a skin-covered round structure that is attached to the skin of the back (Fig. 4.14). It can be discolored or covered with hair, and sometimes it contains cartilage, fat, or other organ-specific tissues. In contrast, a "true" human tail is the remains of an embryonic structure that may contain vertebrae, spinal cord, notochord, sacral artery and vein, muscle, fat, or connective tissue.

#### 4.5.1.2 Orthopedic Findings of OSD

The orthopedic signs of OSD may vary and are not always identified at birth. In fact, clinical signs or symptoms may not be evident until a child has a growth spurt or is walking. Scoliosis or kyphosis, asymmetry of the legs and feet, or deformities of the feet are signs of OSD. For example, one calf may be thinner and the foot on the same side may be smaller or have a higher arch or hammering of the toes. Another orthopedic finding is asymmetry of the buttocks, identified by lateral curve of the upper part of the gluteal crease. On examination, evaluate the spine for abnormal curve, and assess soles of the feet for asymmetry, difference in size or arch, unilateral or bilateral club feet, or for the presence of valgus or varus positioning. If the child is walking, evaluate for inversion or forefoot adduction. It is important to identify the underlying cause of orthopedic anomalies and refer to a



**Fig. 4.14** Pseudotail

specialist for further evaluation if appropriate. Last, vertebral deformities are commonly present with OSD and include anomalies of the laminae, vertebral bodies, disc space, pedicles, or sacrum (sacral agenesis/dysgenesis).

#### 4.5.1.3 Urologic Dysfunction of OSD

Urinary dysfunction may be the first sign of OSD if it has not already been diagnosed from other presenting signs and symptoms. Bladder dysfunction occurs from neurologic injury or defective development of the spinal cord. The overall incidence of urinary problems associated with OSD is not clear. Urinary symptoms may not be evident until a child learns to toilet-train. In the presence of OSD, bladder dysfunction can present at anytime throughout life as urgency, urinary retention, or enuresis (Sakakibara et al. 2003).

Another presenting sign of OSD can be recurrent urinary tract infections.

## 4.5.2 Management

### 4.5.2.1 Surgical Management

Surgery is the treatment of choice for OSD to prevent future neurological deterioration or complications from a tethered spinal cord. There is little data in the literature that compares the natural progression of OSD to cases that are treated surgically, due to ethical considerations of conducting such studies. It is known, however, that management without surgery can be associated with neurological deterioration, and that surgical intervention can halt this progression and sometimes improve function. Early surgical treatment is important to prevent permanent neurological deficits, and surgery can be done anytime after birth. The surgical procedure is called a “tethered cord release,” and it releases the spinal cord so that it can hang freely in the spinal column. Often, intraoperative monitoring; somatosensory evoked potentials (SSEPs), electromyography (EMG), and bladder cystometry is done to monitor the bladder, anal sphincter, and nerve conduction to the lower extremities. Overall, the outcome of surgery is positive. There are many research studies that demonstrate low risk of developing neurological deterioration from the surgery (Anderson 1975; James and Lassman 1981; Keating et al. 1988).

### 4.5.2.2 Medical Management

After surgery, the patient is followed by a neurosurgeon and urologist. The urologist monitors bowel and bladder function through the use of diagnostic testing if necessary. Urodynamic testing is the most sensitive indicator for tethered cord. The neurosurgeon monitors neurological status through examination and surveillance with imaging of the lumbar sacral spine postoperatively. Future radiographic imaging is done if there is a return of symptoms suggestive of retethering of the spinal cord. Last, although rare, if there are chronic problems with lower extremity weakness or difficulties with ambulation, a rehabilitation physician or physiatrist will provide continued medical care.

**Table 4.7** Postoperative care guidelines tethered cord release

Observe for adverse effects from anesthesia (irritability, nausea, vomiting)
Assess pain and medicate as needed
Obtain frequent vital signs and neurologic checks
Keep the head of bed flat for up to 5 days to minimize risk of CSF leak
Log roll every 2 h
Apply protective barrier to incision to avoid exposure to stool or urine
Observe dressing frequently for discharge; if present observe amount, color and notify surgeon
Administer IV hydration until taking PO fluids well
Foley catheter care if needed
Latex precautions (if applicable)

### 4.5.3 Nursing Considerations

The diagnosis of a medical condition is stressful for the patient and family. Nurses can guide families through this process while promoting a positive experience. It is important to provide age-appropriate education to the patient and family about the tethered cord, diagnostic testing, and about referrals, if any, to other specialists. Many parents are concerned about the surgery and the possibility of a permanent bowel and bladder deficit or weakness in the lower extremities.

The preoperative nursing care of a patient with OSD is limited. After the diagnosis is made, appropriate referrals and outpatient diagnostic studies are done. A tethered cord is not an emergency, and the patient will stay home until surgery is scheduled. Prior to surgery, the patient should avoid repetitive flexion and extension of the spine or sudden forceful movements of the body. Back or leg pain is managed with oral medications. Many surgeons will withhold NSAIDs for up to 1 week prior to surgery to minimize intraoperative bleeding.

The postoperative care of a patient with a tethered cord is similar to that of a patient with a myelomeningocele (Table 4.7). As with any hospitalized patient, it is important to have a discharge plan in mind as you prepare the patient and family for transition to home. The family is instructed to monitor their child for signs and

symptoms of infection including fever or wound changes of drainage, swelling, or redness and to notify medical staff immediately with concerns. After a surgery for tethered cord release, when applicable, the child is to avoid all contact sports for a minimum of 4–6 weeks.

## 4.6 Diagnostic Studies for Neural Tube Defects

An ultrasound is low cost and often readily available. It can be used for screening of OSD in newborns before 5–6 months of age, before the posterior elements of the spine are ossified, which obstructs visualization of the spinal cord (Hughes et al. 2003; Korsvik and Keller 1992). An ultrasound, however, does not show the detail for complex anatomy of the spine and possibly the complicated spinal cord abnormalities associated with tethered cord. Postnatal ultrasound is not a common diagnostic test for a myelomeningocele.

### 4.6.1 Radiographic Imaging

Evaluation with plain radiograph anteroposterior (AP) and lateral views of the affected part of the spine can be helpful in determining vertebral anomalies. This is beneficial as an initial screening for OSD but is not diagnostic in either the open or closed defect.

An MRI is a noninvasive and radiation-free test that is commonly used for screening of spinal anomalies. It shows complete and clear anatomical detail of the spine, spinal cord, filum terminale, fat, tumors, or dermoids. A disadvantage to traditional MRI is that it takes a long time and may require sedation of the infant.

A CT scan is an excellent screening tool for detail of bony anatomy. It is commonly used for the diagnosis of hydrocephalus in a patient with a myelomeningocele. A CT scan is quick and does not require sedation; however, there is a small risk of exposure to radiation with each scan.

## Conclusion

Neural tube defects affect thousands of children in the United States each year. Over the past five decades, there have been progressive changes in medical practices, and we have observed greater longevity and overall improved quality in the life in these patients. A major breakthrough in research proved that prenatal folic acid use can prevent the incidence of neural tube defects in up to 70 % of children. Recent studies on prenatal surgery demonstrated improvement of the severity of comorbidities of myelomeningocele, and although there are untoward risks to both the fetus and mother, this study demonstrates advancement in care for these patients. Continued advances in our knowledge of timely treatment and appropriate diagnostic tests for occult spina bifida can decrease the occurrence of long-term neurological deficits. In conclusion, spina bifida and spina bifida occulta can be devastating to the lives of many children. Through the continued research and implementation of evidence-based practice, we can continue to make great strides in the treatment of this potentially devastating neurological disorder.

## Pediatric Practice Pearls

1. Become familiar with the multidisciplinary care needs of a patient with spina bifida to better address their educational and emotional needs while providing holistic nursing care.
2. Cover the surgical incision with an occlusive dressing and rectangular drape secured to the buttocks under the top of the diaper and drape upward over the back to avoid soiling from feces and urine.
3. Provide timely nursing education through a variety of teaching modes at a time that is “right” for the family. An overwhelmed parent has less readiness to learn. Observe nonverbal cues in order to pace your “teachable moments.”

## References

- AAP Policy Statement Committee on Genetics (1999) American Academy of Pediatrics: folic acid for the prevention of neural tube defects. *Pediatrics* 104(2):325–327
- Adzick NS, Thom EA, Spong CY, Brock JW III, Burrows PK, Johnson MP, Howell LJ, Farrell JA, Dabrowiak ME, Sutton LN, Gupta N, Tulipan NB, D’Alton ME, Farmer DL (2011) A randomized trial of prenatal versus postnatal repair of myelomeningocele. *N Engl J Med* 364(11):993–1004
- Ames MD, Shut L (1972) Results of treatment of 171 consecutive myelomeningoceles, 1963 to 1968. *Pediatrics* 50:466–470
- Anderson FM (1975) Occult spinal dysraphism. A series of 73 cases. *Pediatrics* 55:826–835
- Anderson PA, Travers AH (1993) Development of hydro-nephrosis in spina bifida patients: predictive factors and management. *Br J Urol* 72:958–961
- Centers for Disease Control and Prevention (2004) Spina bifida and anencephaly before and after folic acid mandate – United States, 1995–1996 and 1999–2000. *MMWR Morb Mortal Wkly Rep* 53(17):362–365
- Cohen AR, Robinson S (2001) Early management of myelomeningocele. In: McLone DG (ed) *Pediatric neurosurgery; surgery of the developing nervous system*. W.B. Saunders Company, Philadelphia, pp 241–259
- Coniglio SJ, Anderson SM, Ferguson JE (1997) Developmental outcomes of children with myelomeningocele: prenatal predictors. *Am J Obstet Gynecol* 177(2):319–324
- d’Ercole C, Shojai R, Desbriere R, Chau C, Bretelle F, Piechon L (2003) Prenatal screening: invasive diagnostic approaches. *Childs Nerv Syst* 19:444–447
- Danzer E, Flank AW (2008) In utero repair of myelomeningocele: rationale, initial clinical experience and a randomized controlled prospective clinical trial. *Neuroembryology Aging* 4:165–174
- Detrait ER, George TM, Etchevers HC, Gilbert JR, Vekemans M, Speer MC (2005) Human neural tube defects: developmental biology, epidemiology, and genetics. *Neurotoxicol Teratol* 27:515–524
- Elwood JM, Little J, Elwood JH (1992) *Epidemiology and control of neural tube defects*. Oxford University Press, Oxford
- Gaskill SJ (2004) Primary closure of open myelomeningocele. *Neurosurg Focus* 16(2):1–4
- Henshaw SK (1998) Unintended pregnancy in the United States. *Fam Plann Perspect* 30(24–29):46
- Honein MA, Paulozzi LJ, Mathews TJ, Erickson JD, Wong LY (2001) Impact of folic acid fortification of the us food supply on the occurrence of neural tube defects. *J Am Med Assoc* 285(23):2981–2986
- Hughes JA, De Bruyn R, Patel K, Thompson D (2003) Evaluation of spinal ultrasound in spinal dysraphism. *Clin Radiol* 58:227–233

- James CCM, Lassman LP (1981) Spina bifida occulta: orthopaedic, radiological and neurosurgical aspects. Academic Press: Grune & Stratton, London/New York
- Jorde LB, Fineman RM, Martin RA (1984) Epidemiology of neural tube defects in Utah, 1940–1979. *Am J Epidemiol* 119:487–495
- Keating MA, Rink RC, Bauer SB (1988) Neurourological implications of the changing approach in management of occult spinal lesions. *J Urol* 140:1299–1301
- Korsvik HE, Keller MS (1992) Sonography of occult dysraphism in neonates and infants with MR imaging correlation. *Radiographics* 12:297–306
- Lary JM, Edmonds LD (1996) Prevalence of spina bifida at birth – United States, 1983–1990: a comparison of two surveillance systems. *Morb Mortal Wkly Rep Surveill Summ* 45:15–26
- Laurence KM (1974) Effect for early surgery for spina bifida cystica on survival and quality of life. *Lancet* 1:301–304
- Liptak GS (1997) Neural tube defects. In: Batshaw ML (ed) *Children with disabilities*, 4th edn. Paul H Brookes, Baltimore, pp 529–552
- Manning SM, Jennings R, Madsen JR (2000) Pathophysiology, prevention, and potential treatment of neural tube defects. *Ment Retard Dev Disabil Res Rev* 6:6–14
- Mazagri R, Ventureyra EC (1999) Latex allergy in neurosurgical practice. *Childs Nerv Syst* 15:404–407
- McCance KM, Huether SE (2002) Pathophysiology the biologic basis for disease in adults & children, 4th edn. Mosby, St. Louis
- McLone DG (1998) Care of the neonate with a myelomeningocele. In: *Neurosurgery of the neonate*. *Neurosurg Clin North Am* 9(1):111–120. Saunders, Philadelphia
- Munson D, Leuthner SR (2007) Palliative care for the family carrying a fetus with a life-limiting diagnosis. *Pediatr Clin North Am* 54:787–798
- National Center for Health Statistics (1993) Annual summary of births, marriages, divorces, and deaths: United States, 1992. *Mon Vital Stat Rep* 41:1–36
- Park TS (1999) Myelomeningocele. In: Albright AL, Pollack IF, Adelson PD (eds) *Principles and practice of pediatric neurosurgery*. Thieme, New York, pp 125–139
- Petronio J, Walker ML (2001) Ventriculoscopy. In: McLone DG (ed) *Pediatric neurosurgery; surgery of the developing nervous system*. W.B. Saunders Company, Philadelphia, pp 559–562
- Rekate HL (1999) Treatment of hydrocephalus. In: Albright AL, Pollack IF, Adelson PD (eds) *Principles and practice of pediatric neurosurgery*. Thieme, New York, pp 125–139
- Roberts HE, Moore CA, Cragan JD, Fernhoff PM, Khoury MJ (1995) Impact of prenatal diagnosis on the birth prevalence of neural tube defects, Atlanta, 1990–1991. *Pediatrics* 96(5):880–883
- Sakakibara R, Hattori T, Uchiyama T, Kamura K, Yamanishi T (2003) Uro-neurological assessment of spina bifida cystica and occulta. *NeuroUrol Urodyn* 22:328–334
- Sandler AD (2010) Children with spina bifida: key clinical issues. *Pediatr Clin North Am* 57:879–892
- Sebold CD, Melvin EC, Siegel D, Mehlretter L, Enterline DS, Nye JS et al (2005) Recurrence risks for neural tube defects in siblings of patients with lipomyelomeningocele. *Genet Med* 7(1):64–67
- Simpson JL, Greene MF (2011) Fetal surgery for myelomeningocele? Editorial. *N Engl J Med* 364(11):1076–1077
- Warf BC (2005) Comparison of endoscopic third ventriculostomy alone and combined with choroid plexus cauterization in infants younger than 1 year of age: a prospective study in 550 African children. *J Neurosurg Pediatr* 103:475–481
- Yamada S, Won DJ, Yamada SM (2004) Pathophysiology of tethered cord syndrome: correlation with symptomatology. *Neurosurg Focus* 16(2):1–5
- Yen IH, Khoury MJ, Erickson JD, James LM, Waters GD, Berry RJ (1992) The changing epidemiology of neural tube defects: United States, 1968–1989. *Am J Dis Child* 146:857–861

Susan McGee and Diane Baudendistel

## 5.1 Introduction

Chiari malformations are a group of abnormalities of the hindbrain which were originally described by John Cleland in 1883 and then classified in 1891 by Hans Chiari, a German professor. His work, based on autopsy results, created the classic definitions of hindbrain herniation now described as Chiari I (CIM), Chiari II (CIIM), and Chiari III (CIIIM). Although named similarly to the other Chiari malformations, Chiari IV malformation (CIVM) is now recognized as cerebellar hypoplasia and unrelated to the others (Greenberg 2010; Khoury 2011; Oakes et al. 2011; Weprin and Oakes 2001). Syringomyelia refers to the development of a cyst or cavity filled with cerebrospinal fluid (CSF) in the spinal cord. The cyst is known as a syrinx. Despite advances in neuroimaging and embryological work, the natural history of Chiari malformation and syringomyelia remains incompletely understood.

CIM consists of displacement of the cerebellar tonsils below the foramen magnum and is often associated with syringomyelia. CIIM, also known as the Arnold-Chiari malformation, is

associated with myelomeningocele (MM) and includes caudal displacement of the inferior cerebellar vermis, the fourth ventricle, and the medulla into the cervical canal. CIIIM, a rare and severe form, includes a low occipital or high cervical encephalocele in combination with downward displacement of most of the cerebellum, the fourth ventricle, and possibly portions of the brainstem. The Chiari IV represents cerebellar hypoplasia—lack of development of the cerebellum—that is now considered unrelated to the other Chiari malformations (Greenberg 2010; Khoury 2011; Oakes et al. 2011; Weprin and Oakes 2001). The posterior fossa is usually normal in size with an absence of hindbrain herniation (Oakes et al. 2011).

Two other subtypes have been described. The Chiari 0 malformation exhibits normally located cerebellar tonsils in the presence of syringomyelia, abnormal posterior fossa anatomy, and altered CSF dynamics, analogous to Chiari I malformation. The Chiari 1.5 malformation represents a malformation that mimics the Chiari II in the absence of spina bifida (Khoury 2011).

### 5.1.1 Chiari I Malformation

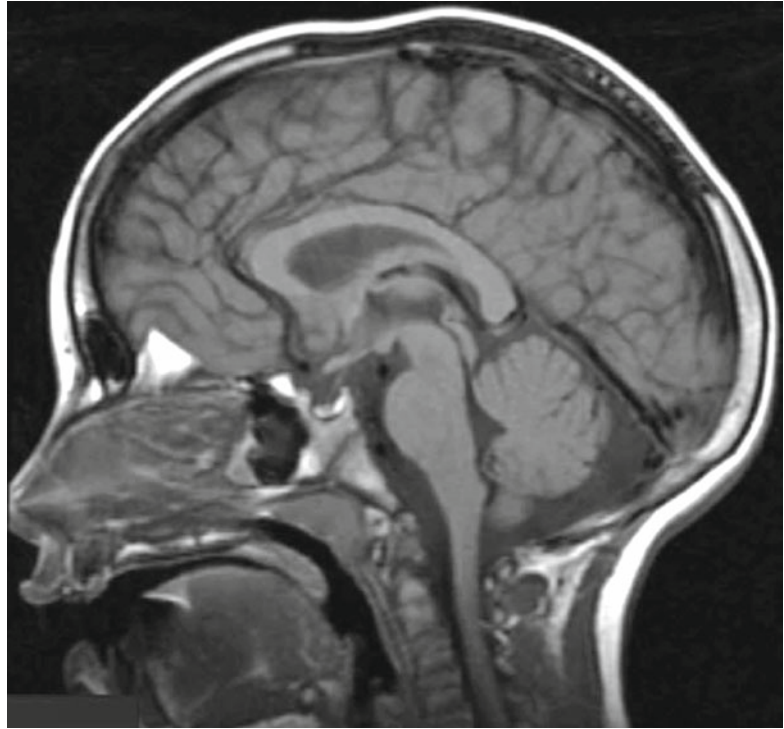
Historically, Chiari malformations were described as developmental anomalies. However, currently, there is evidence to indicate that some CIMs are acquired (Oakes et al. 2011). In addition, debate exists about whether the term malformation, implying faulty formation and supporting the

---

S. McGee, MSN, CNP, RN (✉) • D. Baudendistel, MS, CNP, RN  
Developmental and Behavioral Pediatrics, Pediatric Neurosurgery,  
6769 Mt Pleasant Rd, Ewing, 41039 KY, USA  
e-mail: smcgee@altiusbb.com;  
diane.baudendistel@cchmc.org



**Fig. 5.1** Normal T1 sagittal MRI of a 5-year-old



etiology as a developmental process, accurately describes the range of the Chiari phenomena (Novegno et al. 2008; ReKate 2008). Although the true incidence of CIM is unknown, studies have reported approximately 0.1–0.05 % since the availability of magnetic resonance imaging for diagnosis.

CIM has historically been considered to occur sporadically. However, familial clustering suggests inheritable genetic factors may be present in a small number of cases. Other genetic syndromes have been associated with CIM, such as achondroplasia and Williams syndrome. To identify potential inheritable cases, it is important to obtain a thorough family history.

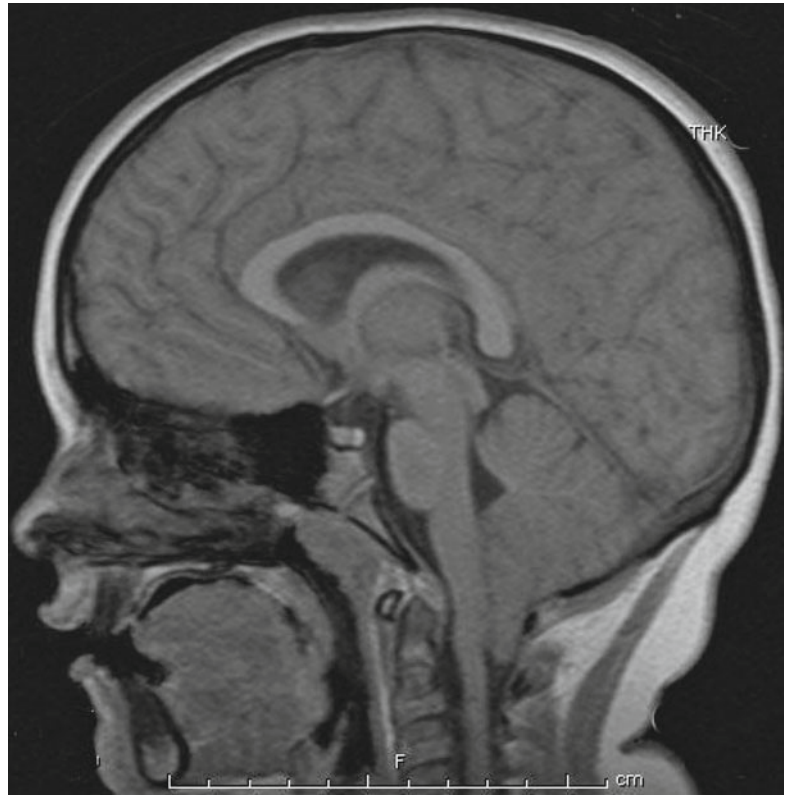
#### 5.1.1.1 Developmental Anomaly

CIM is anatomically the simplest of the Chiari malformations. Magnetic resonance imaging demonstrates descent of the cerebellar tonsils 5 mm or more below the foramen magnum (FM) and occasionally found below the second cervical (C2) level (Figs. 5.1 and 5.2). Cerebellar tonsils that enter the cervical canal but descend less than 5 mm are considered cerebellar ectopia, not meeting the

criteria for the diagnosis of Chiari malformation. Hydrocephalus is uncommon in patients with CIM. Fibrous adhesions or scarring may develop between the dura, the arachnoid, and the cerebellar tonsils. This in turn may cause obstruction of the flow of CSF from the fourth ventricle. Skull-based deformities, such as a small posterior fossa and steep incline of the tentorium, may be present. Basilar impression or invagination, concavity of the clivus, and atlantoaxial assimilation have been associated with CIM (Weprin and Oakes 2001). Although this historically was considered a condition of adulthood, CIMs have been identified in all age groups, including the neonatal population (Lazareff et al. 2002; Menezes 1995; Nohria and Oakes 1991; Yundt et al. 1996).

#### 5.1.1.2 Acquired Anomaly

Chiari I malformations may develop in patients treated for hydrocephalus or pseudotumor with a lumboperitoneal shunt or ventriculoperitoneal shunt (Payner et al. 1994; Weprin and Oakes 2001). Chronic shunting of CSF from the lumbar subarachnoid space to the peritoneal cavity may cause the cerebellar tonsils to move caudally

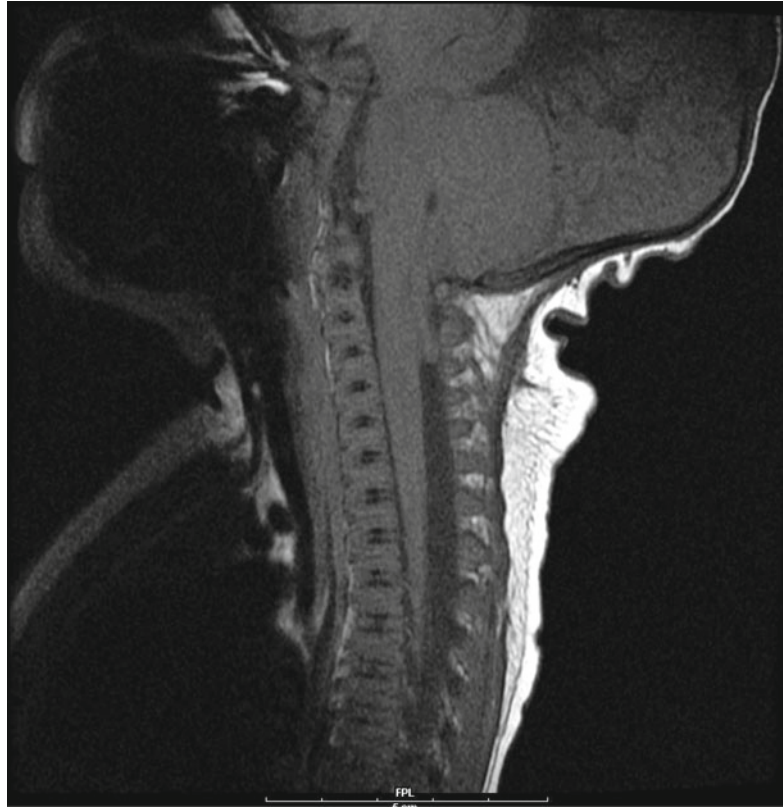
**Fig. 5.2** Chiari I

below the foramen magnum. This descent of the cerebellar tonsils may be reversed by removal of the shunt. In patients with ventriculoperitoneal shunts, it has been reported that the overdrainage of the ventricles caused increased CSF in the subarachnoid space, theoretically changing the pressure gradient and contributing to the downward movement of the cerebellar tonsils. Other authors report that with specific patients and techniques to prevent overshunting, this phenomenon can be avoided (Rekate and Wallace 2003).

### 5.1.2 Chiari II Malformation

The Chiari II malformation is present in nearly all children with myelomeningocele (MM) (Dias 1999). CIIM is probably a primary dysgenesis of the brainstem associated with the neural tube defect and multiple other developmental anomalies present in these MM patients (Greenberg 2010). However, there is evidence that patients undergoing intrauterine repair of myelomeningocele

may not have the typical low-lying tonsils of the CIIM (Adzick et al. 2011; Sutton et al. 1999; Tulipan et al. 1998, 1999), placing into question the theory that this is a primary dysgenesis, and giving support to the hydrodynamic theories of Chiari malformations. Indeed, the Management of Myelomeningocele Study (MOMS) (Adzick et al. 2011) demonstrated that 36 % of the prenatal surgery group had no evidence of hindbrain herniation at the age of 12 months compared to 4 % of the postnatal surgery group. Up to 90 % of MM patients also develop symptomatic hydrocephalus, with 50 % of infants showing evidence of hydrocephalus at birth (Detwiler et al. 1999). In the MOMS study, fewer CSF shunts were placed in infants in the prenatal surgery group by 12 months (40 %) compared to the postnatal group (82 %) ( $p < 0.001$ ) (Adzick et al. 2011). For these patients, the Chiari malformation is more than hindbrain herniation but includes anatomic changes in the supratentorial structures and the skull as well. The posterior fossa abnormalities include caudal descent of the pons, medulla, cerebellar vermis

**Fig. 5.3** Chiari II

and fourth ventricle, “kinking” of the brainstem, “beaking” of the tectum, and aqueductal stenosis (Fig. 5.3). Some associated anomalies of the cerebral hemispheres include polymicrogyria, cortical heterotopias, dysgenesis of the corpus callosum, and a large massa intermedia. Skull deformities include “luckenschadel” or craniolacunia shortening of bony clivus, and enlargement of the foramen magnum (Greenberg 2010). Hindbrain and lower cranial nerve dysfunction is the leading cause of death in children with myelodysplasia (Oakes et al. 2011).

### 5.1.3 Chiari III Malformation

The Chiari III malformation involves descent of most of the cerebellum and brainstem below the foramen magnum and may be associated with a cervical or occipital encephalocele. The encephalocele may contain cerebellum, occipital lobes, and brainstem. Herniation of the fourth and lateral

ventricles may occur. Hydrocephalus is often present (Oakes et al. 2011; Weprin and Oakes 2001).

#### 5.1.3.1 Etiology

Despite being identified in the 1,800 s, a debate still continues about the spectrum of Chiari malformations. Although these malformations have abnormalities of the cerebellum and the cranio-cervical junction in common, they are thought to be distinct conditions with differing etiologic factors (Greenberg 2010; Strayer 2001). Many theories about the etiology have been proposed. Ongoing research brings hope for information that will help in determining best treatment options for this challenging spectrum of disorders (Table 5.1).

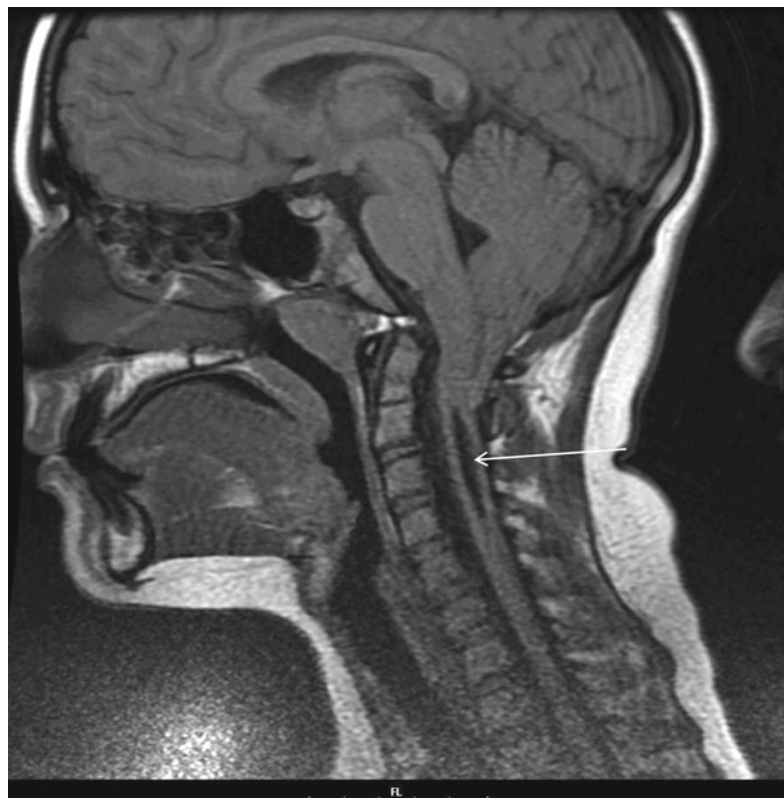
### 5.1.4 Syringomyelia

Syringomyelia (or syrinx) refers to a cavitation or cyst within the substance of the spinal cord

**Table 5.1** Etiology of Chiari malformations

Theory	Mechanism
Hydrodynamic	Hydrocephalus the primary cause
Mechanical	(a) Spinal cord tethering causing abnormal development (b) Abnormal bony structures not providing enough space in the posterior fossa (cephalocranial disproportion)
Variation in pressure gradient	Pressure gradient between the intracranial and spinal compartments forcing the cerebellar tonsils to migrate caudally (craniospinal pressure gradient)
Traumatic birth	Birth trauma causing tonsillar edema and arachnoid scarring

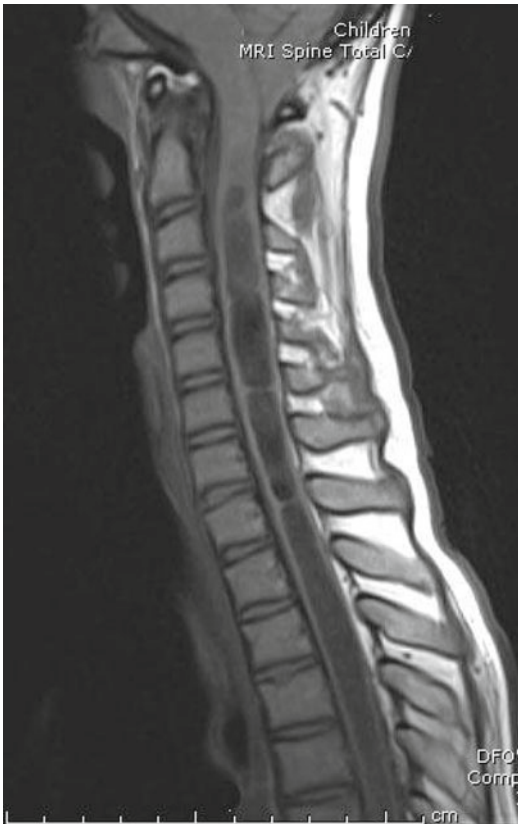Nohria and Oakes (1991); Oakes et al. (2011)

**Fig. 5.4** T1 sagittal MRI showing (arrow) cervical syrinx

extending over many spinal levels (Figs. 5.4 and 5.5). Hydromyelia is a term that describes a distended central canal and is therefore lined by ependymal tissue. The technical difference between these two terms has little clinical significance because the hydrodynamics of both types of cavitations are identical as evaluated by magnetic resonance imaging (MRI). Therefore, medical literature currently uses the term syringomyelia to describe all intramedul-

lary cysts with cerebrospinal fluidlike content (Oakes et al. 2011). Although syringomyelia most often occurs in association with posterior fossa abnormality, a syrinx can also be associated with tumors, injury, and inflammatory processes or may be idiopathic.

Syringomyelia is often associated with Chiari I and II malformations. Syringomyelia is present in 30–85 % of patients with Chiari I malformation (Schijman 2004). The medical literature has



**Fig. 5.5** T1 sagittal MRI showing cervical and thoracic syrinx

posed a variety of mechanisms for the development of the syrinx in patients with Chiari malformations. In general, there is agreement that the abnormal CSF dynamic associated with Chiari malformations produces a net bulk flow of CSF into the central canal (rather than a balanced bidirectional flow through the parenchyma) that can create the syrinx. The presence of syringomyelia will have an impact on symptom presentation, treatment options, and long-term outcomes (Dias 1999; Oakes et al. 2011; Weprin and Oakes 2001). Also, it is important to realize that a new syrinx in patients with CIM with a ventriculoperitoneal shunt may represent a shunt malfunction causing altered spinal cord CSF dynamics.

Presyrinx, first described in 1999, is a reversible state of spinal cord edema caused by alterations in CSF flow, typically in the cervical region. Ongoing clinical examination and serial MRI

imaging are used to monitor progression. The presyrinx may advance to a syrinx if untreated (Goh et al. 2008; Khoury 2011).

## 5.2 Presentation

### 5.2.1 Chiari I Malformation

Before the use of MRI, Chiari I malformations were thought to be a condition that presented in late childhood or adolescence. Occipital and upper cervical headache is the most common presenting symptom in this age group, occurring in 63–69 % of patients (Dias 1999; Hida et al. 1995). The headache may be triggered or exacerbated by Valsalva maneuver, extreme neck movement, or during exertional activity such as sports. Headaches may progress over time and, primarily in younger children, may cause nighttime awakening. Weakness or numbness of one or both arms may be present. Some patients report gait unsteadiness, sensory changes, and dysphagia.

On physical exam, nystagmus, facial hyperesthesia, dysarthria, palatal weakness, or tongue atrophy may be present. Vocal cord paralysis may be present in rare cases. Other possible findings include hyperactive upper extremity reflexes, positive Babinski, weakness of upper and lower extremities, scoliosis, spasticity, and ataxia (Oakes et al. 2011; Weprin and Oakes 2001). The literature indicates, however, that 10 % of all patients with CIM present with headache only and have a normal neurological examination. This percentage may be higher in the pediatric population. A recent study reported findings about 130 children with CIM; 21 % of patients presented with headache only and a normal neurological examination (Yeh et al. 2006). Diagnoses of CIM in children and adolescents are often based on history, symptoms, and radiographic studies, in the absence of focal neurological findings.

The availability of the MRI assisted in the identification of Chiari malformations in the younger child. Infants and the nonverbal child may present with persistent crying and irritability as well as arching of the neck. Respiratory irregularities and recurrent aspirations may, in

**Table 5.2** Categories of patients with Chiari I malformation based on predominant clinical symptoms

General	Spinal	Brainstem	Cerebellar	Combination
Pain: occipital or posterior cervical	Extremity paresthesias	Apnea	Ataxia	Multiple symptoms from different categories
Nausea/vomiting	Weakness	Bradycardia	Clumsiness	
Irritability	Hyperreflexia + Babinski	Dysphagia	Nystagmus	
		Hypotonia		
		Spasticity		
		Facial numbness		
		Dysarthria		
		Aspiration		
		Tongue atrophy		
		Palatal weakness		

Hankinson et al. (2007); Weprin and Oakes (2001)

addition to the brainstem signs noted above, mark the presentation of the youngest patients (Benglis et al. 2011; Oakes et al. 2011). One recent study identified significant differences in the presentation of children 2 years and younger compared to those 3–5 years of age. The younger age group was more likely to present with oropharyngeal symptoms (77.8–38.1 %,  $p=0.01$ ), while the 3–5-year-old subjects were more likely to present with scoliosis (38.1–16.7 %,  $p=0.03$ ) or with syrinx (85.7–27.8 %,  $p=0.002$ ). Although more of their older subjects (3–5-year-olds) presented with headache, this difference was not statistically significant (Albert et al. 2010) (Table 5.2).

### 5.2.2 Chiari II Malformation

Chiari II malformations are present at birth in patients with an open neural tube defect. The literature reports that 18–33 % of these patients will demonstrate Chiari II symptoms (Dias 1999; Weprin and Oakes 2001). The MOMS study provides evidence that prenatal repair of open neural tube defects may lessen the incidence of CIIMs (Adzick et al. 2011). Infants with a symptomatic CIIM have a more rapid and severe onset of symptoms than those who present later in childhood. Symptom presentation early in life is related to higher morbidity and mortality.

Most patients are asymptomatic at birth, but a small group of neonates have respiratory distress.

These patients demonstrate a poor respiratory drive, probably related to brainstem dysfunction. In infancy, respiratory distress including cyanotic spells, central or obstructive apnea, inspiratory stridor, and hoarse or high-pitched cries are the most common presenting signs. New or worsening stridor, accompanied by oxygen desaturation, in an infant with CIIM is considered a medical emergency.

Swallowing dysfunction is the second most common sign of a symptomatic CIIM (Dias 1999). Infants demonstrate poor suck and swallow coordination, nasal regurgitation, projectile emesis, choking, drooling, or pooling of food in the posterior pharynx. As a result, these children may suffer from failure to thrive, repeated episodes of aspiration pneumonia, and chronic gastroesophageal reflux. Nystagmus and vocal cord paralysis may also be present. This combination of symptoms reflects brainstem and lower cranial nerve dysfunction (Dias 1999; Weprin and Oakes 2001). Decreased upper extremity tone is another common sign in young children with a CIIM.

The clinical presentation of symptomatic CIIM in the older child is usually more gradual, with milder symptoms that are often responsive to surgical intervention. Symptoms in this age group include upper extremity weakness, spasticity, decreased function of the lower extremities, headache, neck pain, nystagmus, ataxia, and scoliosis. This group of symptoms is related to dysfunction of the cerebellum and spinal cord. Because these symptoms may progress very

**Table 5.3** Comparison of Chiari I and II malformations

	Chiari I malformation	Chiari II malformation
Brain	Caudal descent of cerebellar tonsils > than 5–7 mm below foramen magnum Peg like or pointed Often asymmetric	Caudal descent of cerebellar vermis, brainstem, and fourth ventricle below the foramen magnum
<i>Common associated radiological findings</i>		
Skull	Underdeveloped occiput	Craniolacunia luckenschadel
	Small posterior fossa	Lemon sign on fetal ultrasound
	+/- Enlarged foramen magnum	Small posterior fossa
	Basilar impression	Enlarged foramen magnum +/- Basilar impression
Spine	Assimilation of the atlas	+/- Assimilation of the atlas
	Progressive scoliosis (10 % in those who also have syringomyelia)	Enlarged cervical canal
	Klippel-Feil deformity	Klippel-Feil deformity Scoliosis
Ventricles and cisterns	Hydrocephalus (3–10 %)	Hydrocephalus (90 %)
		Intrinsic malformation of ventricles including asymmetry, pointed frontal horns, and colpocephaly (enlarged occipital horns)
Spinal cord	Syrinx (40–75 %)	Syrinx (20–95 %)

Khoury (2011); Menezes (1999); Nohria and Oakes (1991)

slowly, a complete history to identify subtle and gradual changes is vital. Presentation in adulthood is rare but would mimic the progression of symptoms of the older child (Table 5.3).

### 5.2.3 Chiari III Malformation

Chiari III malformations are present at birth and are identified by the occipital or high cervical encephalocele. Multiple anomalies of the cerebellum and brainstem accompany the encephalocele, which contains varying amounts of brain tissue. This anomaly is associated with poor prognosis due to the severity of the cranial nerve deficits and developmental and neurological impact. Even with supportive treatment, patients have a short life expectancy (Oakes et al. 2011; Weprin and Oakes 2001).

### 5.2.4 Syringomyelia

The neurological examination should include a thorough sensory evaluation and testing of the

reflexes, in addition to strength testing. Syringomyelia should be suspected in patients that present with scoliosis, leg or foot asymmetries, or abnormal sensory examination. Dysesthetic pain of the trunk or extremities may be present. New or progressive spasticity is another symptom of concern for syrinx. Clumsiness, weakness, and atrophy of the upper extremities also may occur. In myelomeningocele patients, a worsening of urodynamics or changes in baseline motor function should be noted. In patients with Chiari I malformation, urinary incontinence may be a late sign of syringomyelia (Nohria and Oakes 1991; Oakes et al. 2011; Weprin and Oakes 2001).

## 5.3 Diagnostic Tests

Magnetic resonance imaging (MRI) of the brain, craniocervical junction, and spine is the best tool to diagnose Chiari malformations and syringomyelia, as well as to rule out tethered cord. MRI provided a breakthrough in the diagnosis of Chiari malformations, which often present with

vague and nonspecific signs and symptoms. Identifying the compression of the hindbrain and cervical spine as the possible cause of discomfort in these patients aided clinicians in providing useful treatment options. Recognition of Chiari I malformation in the very young child provided them with an opportunity to benefit from advances made in the surgical approach to this condition. Cine MRI may be used to assess CSF flow around the cerebellar tonsils. The location and extent of syringomyelia is best defined by spinal MRI (Sherman et al. 1999).

CT is of limited value in diagnosing Chiari malformations but provides information about the presence of hydrocephalus. In addition, cerebellar tonsillar ectopia may be noted as an incidental finding on CT scan obtained for new symptoms such as headache or head injury. Sleep and swallow studies may be indicated prior to surgery to further evaluate the signs of brainstem or cranial nerve compression. Vocal cord motility may be evaluated if indicated.

Cervical radiographs can identify potential bony instability of the neck. Ultrasonography may provide identification of Chiari malformations and syringomyelia in the neonate and infant, but decisions about surgical intervention are based on MRI findings. Intraoperative ultrasound is used to identify whether bony decompression establishes adequate CSF flow. If CSF flow remains impaired with bony decompression, the surgery may proceed to include duraplasty and fourth ventricular stent (Sherman et al. 1999).

---

## 5.4 Treatment Options for Chiari I Malformation

### 5.4.1 Medical

A child diagnosed with CIM presents a variety of challenges related to developmental considerations and the nonspecific symptoms often associated with this condition. Because the CIM may present with only headache, care must be taken to confirm that the malformation itself is causing the headaches. Children, as well as adults, are subject to a variety of types of headaches. Taking

a thorough history of the type, pattern, and location of the headache and evaluating the effect of conservative treatment are key components of the medical management of these patients. If the headaches can be managed medically, the child may avoid a major surgical procedure. One recent review concluded that children with Chiari I malformation who are not clearly symptomatic and do not have scoliosis or syrinx can be followed conservatively. The development of symptoms and new neurological deficits were extremely uncommon in a group of 124 children followed retrospectively for 1.0–8.6 years (mean 2.83 years) without surgery (Benglis et al. 2011).

Children with known CIM should be followed annually for evaluation of symptom development or progression. MRI imaging with cine of the craniocervical junction to assess CSF flow may be indicated. The parents and child should be advised that the child should avoid contact sports and lumbar punctures.

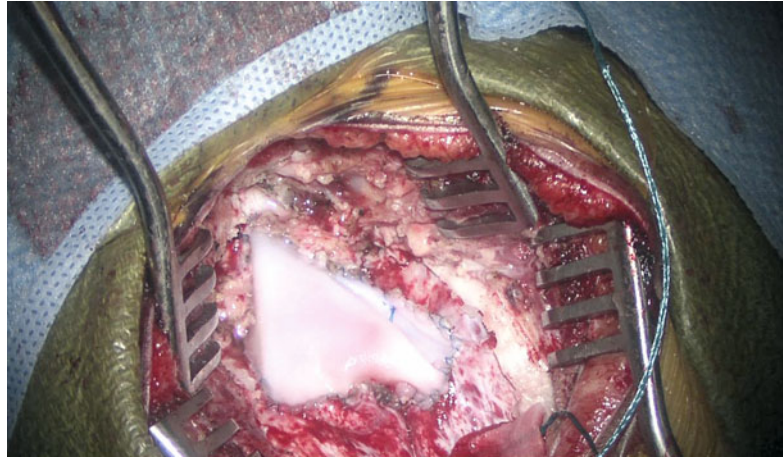
### 5.4.2 Surgical

Early surgery is recommended for symptomatic patients (Hida et al. 1995). Patients who have CIM identified on MRI, and have occipital headaches unrelieved by medical management and/or other signs/symptoms associated with Chiari I malformation, are candidates for surgery. MRI evidence of a syrinx is an additional reason for surgical intervention. Common goals are improvement of presenting symptoms, radiographic reduction of syringomyelia, and arrest or remission of associated scoliosis (Greenberg 2010). If the patient also has hydrocephalus, treatment with a CSF diversionary shunt should precede surgery to treat the CIM.

The surgical procedure is planned to decompress the posterior fossa sufficiently to allow room for CSF to circulate around the cerebellum and the cervical spinal cord (Boxes 5.1 and 5.2). Electrophysiologic neuromonitoring is generally employed. A vertical occipital incision is made to allow for bony decompression of the foramen magnum. Initial suboccipital craniectomy may



**Fig. 5.6** Dural patch graft  
(Courtesy of Dr. Usiakimi  
Igbaseimokumo)



be followed by cervical laminectomy (Greenberg 2010). If the removal of bone allows for adequate CSF flow, as determined by intraoperative ultrasound, the procedure may be completed at this stage (Sherman et al. 1999). If there is continued evidence of impingement on the brainstem and cerebellum, the surgeon may perform a variety of procedures to further decompress the space (Fig. 5.6). This may include intradural exploration, partial dural removal or scoring, duraplasty with graft material or pericranium, plugging of the obex, shunting of the fourth ventricle, and coagulation of the cerebellar tonsils (Dias 1999; Narvaro et al. 2004; Sherman et al. 1999).

### 5.4.3 Nursing Care

The main concerns for nurses taking care of these patients postoperatively are pain management and respiratory compromise, which may be aggravated by narcotic pain medications. In addition, if the dura was opened, the patient is at risk for CSF leak and infection. Surgical treatment without disrupting the dura is limited to the pediatric population and has decreased the incidence of postoperative complications (Sherman et al. 1999). The patient is monitored in the intensive care unit (ICU) for prevention and early detection of potential complications and initiation of pain management.

Pain and stiffness of the neck are due to the incision through the semispinalis capitis and sple-

nius capitis muscles, as well as from opening the dura. Pain management in the early postoperative period includes use of narcotics, preferably by patient (or parent)-controlled analgesia (PCA). When the patient is able to tolerate oral medications, adding nonsteroidal anti-inflammatory medication scheduled around the clock can improve pain scores and decrease the need for narcotics for breakthrough pain. Antispasmodics for neck spasm may also be indicated. Keeping the patient's head maintained in midline position may help minimize spasms.

When surgery includes duraplasty and a fourth ventricular stent, intraoperative stimulation of the area postrema located near the fourth ventricle often causes nausea and vomiting. Antiemetic medications given around the clock are indicated.

Monitoring patients for respiratory compromise is vital. The combination of potential irritation to the brainstem and the need for narcotics can make these patients susceptible to decreased respiratory drive. ICU monitoring until most of anesthesia effects are eliminated limits this complication.

Pseudomeningocele is the most common surgical complication when the dura has been disrupted (Fig. 5.7). This occurs when CSF leaks into the subcutaneous space, causing a fullness of the surgical site (Sherman et al. 1999). To minimize the risk of CSF leak in patients with dural compromise, the operative site should be closely monitored. A short course

**Box 5.1. Chiari I Malformation: Case Study**

DS is a 3-year-old girl who had a 1 month history of headache, clumsiness, difficulty eating, snoring, and nighttime awakening with crying. She was evaluated by her pediatrician for complaints of polydipsia in addition to the above symptoms. An MRI was ordered that showed low, pointed cerebellar tonsils projecting 7 mm below the foramen magnum. Cine images demonstrated restricted CSF flow posterior to the tonsils and anterior to the spinal cord. No syrinx was seen in the cervical region. She also had mild enlargement of the ventricles; her head circumference was at the 25th percentile for her age. Further laboratory studies did not confirm a cause for the polydipsia

Surgery was performed that included removal of the sub occipital bone and ring of C1. Intraoperative ultrasound showed improved decompression with no pistoning of the cerebellar tonsils. The dura was then thinned, and repeat ultrasound showed marked improvement in the appearance of the craniocervical junction (CCJ). Spinal monitoring was done during the entire procedure

DS was monitored in the pediatric intensive care unit over night. Continuous patient/parent-controlled analgesia (PCA) was initiated and managed by the hospital pain team. When she was taking adequate oral fluids, DS was transitioned to oral pain medications such as nonsteroidal anti-inflammatory agents and narcotics for severe pain. In addition, oral muscle relaxants and stool softeners were started. The surgical dressing was removed on postoperative day #2, and incision care consisting of daily washing with soap and water was initiated. DS was discharged to home when the intravenous line was discontinued, and she was taking oral pain medication and getting out of bed with minimal assistance

At her first postoperative appointment (2 weeks after surgery), her parents reported improved sleep, balance, and behavior. DS was sleeping through the night without snoring. Her surgical site was healing well. The absorbable sutures were beginning to fall out spontaneously.

Four months after surgery, a follow-up MRI revealed “marked improvement in the appearance of the CCJ with cerebellar tonsils no longer low lying and adequate CSF at the CCJ”. DS will follow up again with the neurosurgeon in 18 months.

of dexamethasone may minimize symptoms from postoperative edema. Another possible complication is chemical meningitis (or aseptic meningitis). The symptoms include nuchal rigidity, low-grade fever, and headache. If bacterial meningitis has been ruled out, a short course of dexamethasone is the treatment of choice. Chemical meningitis after surgery for Chiari I malformation may be related to the use of dural graft material and/or tissue sealants (Parker et al. 2011).

The usual hospital length of stay is 3–5 days. Discharge criteria include normothermia, adequate oral fluid intake, and pain controlled with oral medications. In addition, it is particularly important for patients who have undergone duraplasty to have a bowel regime that keeps their

movements soft and regular to prevent disruption of the surgical site by straining.

Resolution of symptoms such as headache may be immediate, but other symptoms may take up to 3 months to begin to resolve. Symptoms resulting from long-standing brainstem compression do not always completely resolve (Oakes et al. 2011).

---

## 5.5 Treatment Options for Chiari II Malformation

### 5.5.1 Medical

Imaging for the Chiari II malformation is indicated only when new symptoms occur or when

**Box 5.2. One Family's Chiari Malformation Story**

It was October 31, 2001, when we first got the diagnosis of Chiari malformation for our 1-year-old son. When I heard the words "brain surgery," I felt like the air was sucked right out of my lungs. I can honestly say I remember nothing else that was told to us that day at the doctor's office. Looking back though I guess I knew all along something was wrong but was not sure what to do because at that time Jacob was our only child and I had never been a mother before. As a baby, Jacob never really slept well and there would be periods of crying with his eyes closed or banging his head on things that would last for hours over night. After numerous visits to our pediatrician and being told that our son was just a bad sleeper, I began to assume I was maybe not the best mother.

One afternoon after a morning of crying, I decided to put Jacob down for nap. I went downstairs and heard a very loud noise. Upon entering his room, I realized Jacob had fallen out of his bed and knocked himself unconscious. In the emergency room, we were told that his CT scan looked fine from the fall but that there was a malformation at the base of his brain. Further testing was necessary, and we were told to follow up with our pediatrician to get those things scheduled. As a parent, you believe that you can protect your child from anything, but in this circumstance, that is not true. I found myself totally helpless and lost. I would be holding my son as he was put to sleep for an MRI and having no knowledge as to what they were looking at. All I needed was someone to show me a little compassion and knowledge about what was coming next, to take the time to answer my questions and put some of my fears to rest.

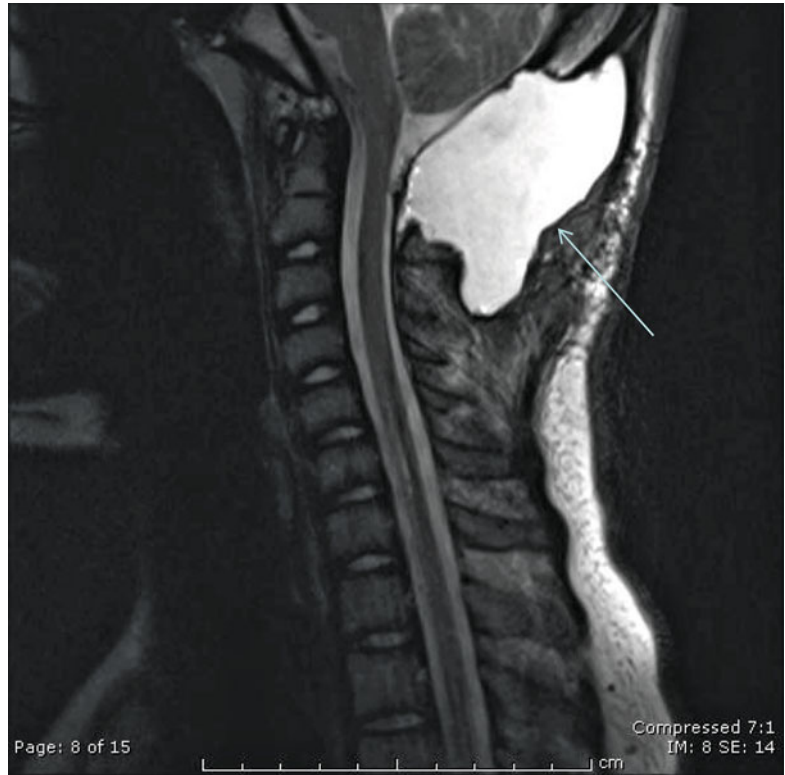Surgery was scheduled, and I was introduced to an angel that will always be a part of my life. A nurse at the neurosurgeon's office who was our surgeon's right hand lady began to take the time and explain in so much detail about the steps we were beginning to take. She spent hours (it felt like) listening and answering questions. Whenever we called scared, nervous, or lost, she made us feel like no one was more important at that moment than our family. If we had not been prepared for surgery and the days after, I do not honestly think we could have survived it.

For Jacob, it took two surgeries to create excellent CSF flow, and today he is just like any other 11-year-old boy. Both surgeries were different though; in the second one, we had an idea of what to expect but still spent every night watching the monitors on Jacob to make sure that he was breathing. The fear after the second surgery was not about hoping we got him home. It was about wondering if we were going to have to do this again in the future.

Two and a half years after Jacob had his last surgery, our second son, Dylan, was beginning his Chiari journey. Dylan's symptoms were totally different than Jacob's, but this time I knew in my gut without a doubt what was going on. Dylan never really spoke or made sounds as an infant, had extreme difficulty drinking his bottles, and, when began moving, always dragged his left leg. As soon as I saw the leg dragging, I called this nurse who I trusted as much as our neurosurgeon. Instead of telling me I was just seeing things or that I was jumping to a conclusion too quickly, she listened to me and offered me resources to find out what was going on. Once we had an MRI showing his Chiari, we scheduled surgery. Dylan's case has always been much worse than Jacob's. To date, he has had four decompressions, and it looks like things have finally resolved. Every night though in the hospital, I would sit by his bed and cry because I felt so guilty that I could not make things better with a kiss (like moms are supposed to) and the following day that same nurse would check in and remind me that things will get better.

Chiari malformation is a frightening diagnosis to any parent and is not an easy recovery the first couple of days after surgery. At that moment in a family's life, the only thing they focus on is their child and getting him or her healed. Compassion, knowledge, and recognition are things that can assist every family during their journey.

**Fig. 5.7** T2 sagittal MRI of (arrow) pseudomeningocele



baseline status deteriorates. Symptoms of concern may include swallowing difficulties, weakness or increased weakness of the upper extremities, new spasticity, or occipital headaches. If the child has shunted hydrocephalus, the shunt should be evaluated first and revised if it is malfunctioning. In the presence of a functioning CSF shunt, evaluation of the CIIM by an MRI of the brain and craniocervical junction is the next step. If the symptoms persist and the MRI shows brainstem compression or obstruction of CSF flow, surgical treatment is indicated. In CIIM, early surgical intervention in the child with symptoms may prevent significant morbidity and mortality (Oakes et al. 2011).

### 5.5.2 Surgical

The surgical intervention for the CIIM parallels that for the Chiari I malformation. Based on the

need for extensive dissection of the brainstem and cranial nerve structures, electrophysiologic neuromonitoring is generally employed. A suboccipital incision is made to allow for removal of the posterior arch of C1 and excision of any extradural constrictive band. Laminectomy is performed to the level of descent of the cerebellar tonsils which may require a 1-, 2-, or 3-level laminectomy. Myelomeningocele patients, unlike the Chiari I malformation patients, have an elongated foramen magnum and, thus, do not require further expansion. The dura should be opened to create CSF flow around the CIIM. Commonly, extremely dense arachnoidal adhesions require lysis. The herniated tonsils may require fulguration (cauterization). A stent spanning the obex, lying within the fourth ventricle proximally and the cervical subarachnoid space distally, is frequently placed. Finally, a dural augmentation graft (allograft or autograft pericranium) is typically sutured into the opened dural margins.

### 5.5.3 Nursing Care

As with the CIM, these patients are monitored after surgery in the ICU or the neonatal intensive care unit. Extensive microsurgical manipulation, involving multiple lower cranial nerves and brainstem structures, places the patient at risk for postoperative neurological deterioration, especially regarding swallowing and ventilation. These patients must be monitored for late extubation, apnea, swallowing dysfunction, and feeding problems after surgery. The risk for CSF leak and infection exists when the dura has been opened. Neck movement limitation and steroids may be indicated to minimize symptoms related to dural opening and postoperative edema. Neck pain and stiffness occur in these patients and must be managed carefully in light of the presence of respiratory compromise preoperatively, especially in the very young patients.

Like CIM patients, discharge criteria include normothermia, adequate oral fluid intake, and pain controlled with oral medications. A bowel regime is needed to keep stool soft and regular to prevent disruption of the surgical site by straining.

---

## 5.6 Treatment Options for Syringomyelia

Left untreated, a syrinx can enlarge or elongate over time causing damage to the spinal cord. When syringomyelia is associated with a Chiari malformation, treatment by posterior fossa decompression of the hindbrain malformation may result in resolution of the syrinx. Primarily in CIIM, symptomatic syringomyelia may persist despite decompressive surgery. In the absence of Chiari malformation, asymptomatic syringomyelia may be observed clinically with yearly clinical examinations and intermittent MRI.

Direct shunting of the syrinx may improve symptoms in those patients who have persistent symptoms after successful posterior fossa decompression or in those patients who have a symptomatic syrinx without a Chiari malformation. Options include syringoperitoneal, syringopleural, and syringosubarachnoid shunts. The shunt

acts to decompress the fluid buildup within the spinal cord, diverting the fluid to another space for reabsorption (Menezes 1999). Similarly, stenting across the obstructed fourth ventricular obex can prevent “water hammering” of CSF into the proximal cervical central canal.

### 5.6.1 Nursing Care

Postoperative care includes incision care, pain management, and evaluation of shunt function. With syringoperitoneal shunting, there will be an incision over the spine at the level of the syrinx and an incision over the abdomen for insertion of the distal catheter. Abdominal pain and bowel function are key areas for nursing assessment.

The syringopleural shunt will have a similar back incision with the distal catheter incision in the lateral chest. Observation of respiratory status is important with this treatment option. Decreased breath sounds and oxygen desaturation may indicate a symptomatic pleural effusion. Indeed, small pleural effusions are typical and generally well tolerated. The patient may have mild tachypnea and low oxygen saturations and may require nasal cannula oxygen supplementation for up to 1 week. If tachypnea or desaturations worsen, the patient may need more intervention including thoracentesis or removal of shunt from the pleural space. Serial chest radiographs may be used to evaluate the patient’s ability to accommodate the pleural fluid being diverted by the shunt.

The syringosubarachnoid shunt requires only one incision to accommodate both the proximal and distal catheters and may be effective in symptom relief.

The use of a shunt to treat syringomyelia requires ongoing follow-up to observe for signs of shunt failure.

---

## 5.7 Patient and Family Education

1. Informed consent: major risks of surgery include bleeding, CSF leak, infection, persistence of symptoms, neurological deficit, and anesthesia complications.

2. Preoperative history and physical examination.
3. Preoperative diagnostic tests that may include swallow evaluation, sleep study, MRI, and developmental assessment.
4. Educational handouts about Chiari malformations and website information recommendations.
5. Incision care after dressing removed.
6. Sutures either dissolvable or removed in about 2 weeks.
7. Activity restrictions: no driving while on narcotics or while neck is stiff; return to school or work in 4–6 weeks.
8. Follow-up imaging: MRI in 4–6 weeks then annually for 5 years (more frequently if syrinx present).
9. Signs and symptoms of shunt failure, for patients requiring shunting of the syrinx.
10. Discharge instructions: incision care with observation for infection or pseudomeningocele; call surgeon's office for headache not responsive to medication and fever greater than 101°F.

### 5.7.1 Outcomes: Short and Long Term

CIM: Successful decompression can provide relief of headache. Symptoms due to cranial nerve or brainstem dysfunction can show improvement over several weeks to months. Follow-up swallow studies are useful to evaluate the effects of treatment when done six or more weeks postoperatively. Ataxia or weakness may also gradually improve. Patients with symptoms other than isolated headaches on presentation benefit from appropriate therapies postoperatively, such as occupational, physical, and/or speech therapy.

MRI imaging should demonstrate improvement in CSF flow around the craniocervical junction by approximately 6 weeks after surgery. A syrinx should radiographically resolve or decrease in size within 3–6 months of posterior fossa decompression. Symptoms may persist in spite of the radiographic improvement (Dias 1999).

CIIM: Better outcomes occur with older children who present with cerebellar dysfunction, spasticity, and weakness. Results in the neonatal

and infant population have been varied, but in general, their outcomes are poorer. CIIM may cause death by respiratory failure (Dias 1999). The rapidity of neurological decline and immediate preoperative neurological status are the most important factors affecting prognosis.

The spectrum of Chiari malformations and syringomyelia present a continuum of challenges to the pediatric patient. The range of effect on quality of life varies from mild, with effective treatments available, to very severe, with minimal or no benefit from medical intervention. Advances in radiographic imaging and surgical techniques have provided opportunities to improve the health status of many of these patients. Advances in nursing research provide the opportunity for nurses and the allied health professionals to further enhance functional level and optimal development of children with this varied spectrum of disorders. Incorporating best practice for the pediatric neurosurgical patient in the areas of wound healing, pain management, prevention of postoperative complications, and effects of hospitalization on development and psychosocial wellness will further enhance the quality of life of this young population.

#### Pediatric Practice Pearls

1. For pain management after posterior fossa decompression, use patient/parent-controlled analgesia; start nonsteroidal anti-inflammatory medications 24 h after surgery and when the patient is taking fluids orally. May require oral narcotics, antispasmodics, and nonsteroidal anti-inflammatory medication.
2. Straining with constipation can disrupt the surgical site and is particularly a risk when the dura has been disrupted. Start a bowel regime when the patient is taking fluids orally to avoid constipation.
3. Relaxation techniques and gentle massage can be helpful during recovery from posterior fossa decompression. Muscle spasms often complicate the pain cycle.

## References

- Adzick NS, Thom EA, Spong CY, Brock JW 3rd, Burrows PK, Johnson MP (2011) A randomized trial of prenatal versus postnatal repair of myelomeningocele. *N Engl J Med* 364(11):993–1004
- Albert GW, Menezes AH, Hansen DR, Greenlee JD, Weinstein SL (2010) Chiari malformation type I in children younger than age 6 years: presentation and surgical outcome. *J Neurosurg Pediatr* 5(6):554–561
- Benglis D, Covington D, Bhatia R, Bhatia S, Elhammady MS, Ragheb J et al (2011) Outcomes in pediatric patients with chiari malformation type I followed up without surgery. *J Neurosurg Pediatr* 7(4):375–379
- Detwiler PW, Porter RW, Reke HL (1999) Hydrocephalus-clinical features and management. In: Choux M, DiRocco C, Hockley AD, Walker ML (eds) *Pediatric neurosurgery*. Churchill Livingstone, London, pp 253–271
- Dias MS (1999) Myelomeningocele. In: Choux M, DiRocco C, Hockley AD, Walker ML (eds) *Pediatric neurosurgery*. Churchill Livingstone, London, pp 33–59
- Goh S, Bottrell CL, Aiken AH, Dillon WP, Wu YW (2008) Presyrinx in children with chiari malformations. *Neurology* 71(5):351–356
- Greenberg MS (2010) *Handbook of neurosurgery*, 7th edn. Thieme Medical Publishers, New York
- Hankinson TC, Klimo P Jr, Feldstein NA, Anderson RC, Brockmeyer D (2007) Chiari malformations, syringohydromyelia and scoliosis. *Neurosurg Clin N Am* 18(3):549–568
- Hida K, Iwasaki Y, Koyanagi I, Sawamura Y, Abe H (1995) Surgical indication & results of foremen magnum decompression versus syringosubarachnoid shunting for syringomyelia associated with Chiari I malformation. *Neurosurgery* 37(4):637–639
- Khoury C (2011) Chiari malformation. In: Patterson MC (ed) *UpToDate*. Wolters Kluwer Health, Philadelphia
- Lazareff JA, Galarza M, Gravori T, Spinks TJ (2002) Tonsillectomy without craniectomy for the management of infantile Chiari I malformation. *J Neurosurg* 97:1018–1022
- Menezes AH (1995) Primary craniovertebral anomalies and the hindbrain syndrome (Chiari I): data base analysis. *Pediatr Neurosurg* 23:260–269
- Menezes AH (1999) Craniovertebral anomalies and syringomyelia. In: Choux M, DiRocco C, Hockley AD, Walker ML (eds) *Pediatric neurosurgery*. Churchill Livingstone, London, pp 151–184
- Narvaro R, Olavarria G, Seshadri R, Gonzales-Portillo G, McLone DG, Tomita T (2004) Surgical results of posterior fossa decompression for patients with Chiari I malformation. *Childs Nerv Syst* 20:349–356
- Nohria V, Oakes WJ (1991) Chiari I malformation: a review of 43 patients. *Pediatr Neurosurg* 16:222–227
- Novegno F, Caldarelli M, Massa A, Chieffo D, Massimi L, Pettorini B et al (2008) The natural history of the chiari type I anomaly. *J Neurosurg Pediatr* 2(3):179–187
- Oakes WJ, Pugh JA, Tubbe RS (2011) Chiari malformations. In: Winn HR (ed) *Youmans neurological surgery*, 6th edn. Saunders, Philadelphia, pp 1918–1927
- Parker SR, Harris P, Cummings TJ, George T, Fuchs H, Grand G (2011) Complications following decompression of Chiari malformation Type I in children: dural graft or sealant? *J Neurosurg Pediatr* 8:177–183
- Payner TD, Prenger E, Berger TB, Crone KR (1994) Acquired Chiari malformations: incidence, diagnosis, and management. *Neurosurgery* 34(3):429–434
- Rekate HL (2008) Natural history of the chiari type I anomaly. *J Neurosurg Pediatr* 2(3):177–178
- Rekate HL, Wallace D (2003) Lumboperitoneal shunts in children. *Pediatr Neurosurg* 38:41–46
- Schijman E (2004) History, anatomic forms, pathogenesis of Chiari I malformation. *Childs Nerv Syst* 20:323–328
- Sherman J, Larson JJ, Crone KR (1999) Posterior fossa decompression without dural opening for the treatment of Chiari I malformation. In: Rensachary SS, Wilkins RH (eds) *Neurosurgical operative atlas*, vol.8 edn. American Association of Neurological Surgeons, Park Ridge, pp 179–183
- Strayer A (2001) Chiari I malformation: clinical presentation & management. *J Neurosci Nurs* 33(2):90–104
- Sutton LN, Adzick NS, Bilaniuk LT, Johnson MP, Crombleholme TM, Flake AW (1999) Improvement in hindbrain herniation demonstrated by serial fetal magnetic resonance imaging following fetal surgery for myelomeningocele. *JAMA* 282(19):1826–1831
- Tulipan N, Hernanz-Schulman M, Bruner JP (1998) Reduced hindbrain herniation after intrauterine myelomeningocele repair: a report of four cases. *Pediatr Neurosurg* 29(5):274–278
- Tulipan N, Hernanz-Schulman M, Lowe LH, Bruner JP (1999) Intrauterine myelomeningocele repair reverses preexisting hindbrain herniation. *Pediatr Neurosurg* 31(3):137–142
- Weprin BE, Oakes WJ (2001) The Chiari malformations and associated syringohydromyelia. In: McClone DG (ed) *Pediatric neurosurgery*. WB Saunders Co, Philadelphia, pp 214–235
- Yeh DD, Koch B, Crone KR (2006) Intraoperative ultrasonography used to determine the extent of surgery necessary during posterior fossa decompression in children with chiari malformation Type I. *J Neurosurgery ( 1 Suppl Pediatrics)* 105:26–32
- Yundt KD, Park TS, Tantuwaya VS, Kaufman BA (1996) Posterior fossa decompression without duraplasty in infants and young children for treatment of Chiari malformation and achondroplasia. *Pediatr Neurosurg* 25:221–226

Tania Shiminski-Maher

---

## 6.1 Introduction

Central nervous system (CNS) tumors are the most common solid tumors in childhood. For example, there are approximately 2,000 brain tumors diagnosed in children each year in the United States. The incidence of CNS tumors is higher in males than females and higher among white children than any other group. While the incidence of reported pediatric brain tumors has been increasing over the past few decades, this is probably because of improvements in diagnostic capabilities and reporting. Recent advances in diagnostic capabilities, aggressive surgical techniques, and multimodal therapy, including radiation and/or chemotherapy, have led to longer survival and even cure of some classifications of pediatric brain tumors (Lieberman and Berger 2001).

Because there are many different kinds of brain tumors, the number of children diagnosed with each particular type is small. Advances in successfully treating each subset of tumor have been a direct result of children being enrolled in clinical trials. The majority of those trials are part of the Children's Oncology Group (COG). Such trials accurately evaluate treatments and recom-

mend standard best treatments for each tumor type. In addition to clinical treatments, COG also conducts biological research focused on identifying possible causes of CNS tumors (Khatua and Jalali 2005). Neurosurgical and technological advances in diagnostic capabilities, radiation techniques, and the use of chemotherapy have radically improved the prognosis for children with CNS tumors over the past few decades. Many CNS tumors carry with the diagnosis a greater than 75 % chance of long-term survival. Unfortunately, for those malignant tumors that have been refractory to treatment, there still has been minimal progress in identifying effective therapies (Albright et al. 2007).

---

## 6.2 Etiology

Despite the research to date, the cause of pediatric central nervous system tumors remains unknown, though both hereditary and environmental factors may be involved. Some CNS tumors have been associated with phakomatoses or hereditary syndromes in children. Examples of tumors with hereditary causes include tuberous sclerosis, which may have tubers within their ventricular system or astrocytomas called subependymal giant cell astrocytomas (SEGAs). Hemangioblastomas are common in children who have von Hippel-Lindau syndrome. Nevoid basal cell syndrome, Turcot syndrome, and Li-Fraumeni syndrome, while very rare, can each be associated with CNS tumors.

---

T. Shiminski-Maher, MS, CPNP  
Department of Pediatric Neurosurgery,  
The Children's Hospital at Montefiore,  
111 East 210th Street, Bronx, NY 10467, USA  
e-mail: tsmaher@montefiore.org



Radiation exposure has been linked to children with pediatric brain tumors. Children who received cranial irradiation in either low or moderate doses have had a higher incidence of brain tumors (Shiminski-Maher and Shields 1995). While there has also been discussion regarding the use of cellular phones and high-power electrical wires being associated with CNS tumors, to date there has been no scientific research to confirm this (Cardis et al. 2010).

Recent advances in molecular biology and cytogenetics have begun to identify possible sites of oncogenesis. Alterations in chromosome 17 have been associated with medulloblastoma and astrocytoma, and loss of chromosome 10 has been associated with glioblastoma. There have been reports of correlation of breast cancer in mothers of children who have medulloblastoma (Shiminski-Maher and Shields 1995). Clinical research in pediatric CNS tumors on the cooperative group level is focusing on biology, not only to identify causes, but also as a step to develop new treatment strategies (Biagi et al. 2003).

---

### 6.3 Nervous System Anatomy

It is essential to have an understanding of normal anatomy to understand the diagnosis and treatment of CNS tumors. The brain sits inside a solid calvarium, the bony structure that is a fixed volume once the sutures are fused. The spinal cord sits inside the hollow vertebrae of the spine. It is the brain and spinal cord that make up the central nervous system. The brain and spinal cord communicate with the arms, legs, and other organs through the peripheral nervous system (PNS). Control of blood pressure, breathing, and hormonal function is carried out primarily in the brainstem by the autonomic nervous system (ANS) (Hickey 2009).

The largest region in the brain is called the cerebrum (also called the supratentorial region). It is made up of two cerebral hemispheres (left and right). The two hemispheres are separated by a large groove, called the cerebral fissure. Deep within the cerebral fissure are a bundle of nerve fibers called the corpus callosum, which transmits information between the two sides. The

cerebrum interprets sensory input from all parts of the body and also controls body movements. It is the part of the brain responsible for thinking, emotions, memory, reasoning, learning, and movement. Symptoms of CNS tumors in this area can be generalized (from changes in intracranial pressure regulation) or focal (from tissue destruction or compressions from the tumor). Focal symptoms include seizures, memory difficulties, headaches, weakness or paralysis of arms and legs, speech abnormalities, personality changes, and visual loss or changes. Generalized symptoms include irritability, lethargy, early morning vomiting, headache, loss of appetite, and behavioral changes (Shiminski-Maher et al. 2002).

The cerebrum is divided into four areas (called lobes) on each side of the brain: the frontal, temporal, parietal, and occipital lobes. The corpus callosum connects the two parts of each lobe. In general, motor function for one side of the body is controlled by the opposite cerebral hemisphere. For example, movement of the arms and legs on the right side of the body is controlled by the left cerebral hemisphere. By early school age, around 5 years, a hand preference is usually identified. A person's speech center is located in the hemisphere opposite hand dominance. This is important when planning treatment for a tumor which is within or adjacent to the speech or motor cortex. In this situation, special preoperative testing may be needed, along with intraoperative monitoring to minimize damage to that area. Younger children have the ability to switch dominance after an injury to the dominant side has occurred or have mixed dominance in terms of speech or motor functioning (Shiminski-Maher et al. 2002).

The frontal lobes process and store information that helps you think ahead, use strategy, and respond to events based on past experiences and other knowledge. A small part of the frontal lobe is involved in articulating speech. Typically, the speech center is found on the side that controls the patient's dominant hand. Another small strip of the frontal lobe helps control movement. Malfunctions in the frontal lobe may lead to poor planning, impulsiveness, and certain types of speech problems. Symptoms are most pronounced if the tumor crosses the corpus callosum

and affects both frontal lobes. Symptoms of tumors of the frontal lobe include seizures, changes in ability to concentrate, poor school performance, or changes in social behaviors and personality. The posterior section of the frontal lobe is the motor area that controls movement of the head and body parts on the opposite side of the body (Shiminski-Maher et al. 2002).

The temporal lobes, located at the sides of the brain, are responsible for speech, language, hearing, and memory. They are also believed to be the center where information taken in from the various senses is integrated, permitting complex thoughts, movements, and sensations to be formulated and acted upon. Within the temporal lobe is the amygdala, which controls social behavior, aggression, and excitement. The hippocampus is involved in storing memory of recent events. Depth perception and sense of time are also controlled by the temporal lobes (Hickey 2009).

Tumors in the temporal lobes can cause atypical seizures, such as staring spells, and memory problems associated with poor school performance. When a tumor grows in the temporal lobes, the brain has a hard time filtering out extra information. Sensory information and memories may start to blend together in unfamiliar ways, resulting in feelings of *déjà vu* in some cases (Shiminski-Maher et al. 2002).

Directly behind the frontal lobes and above the temporal lobes are the parietal lobes. The parietal lobes process sensory information coming in from the body, including data about temperature, pain, and taste. The parietal lobes also control language and the ability to do arithmetic. When the parietal lobes are not functioning properly, sensory information is not processed correctly, and an individual may have a hard time making sense of the environment. The posterior aspect of the parietal lobe, next to the temporal lobe, is important in processing auditory and visual information needed for language (Shiminski-Maher et al. 2002). Abnormal movements or weakness in the arms and legs, memory problems, and seizures are associated with tumors in the parietal areas. During a seizure affecting the parietal lobe, strange physical sensations may

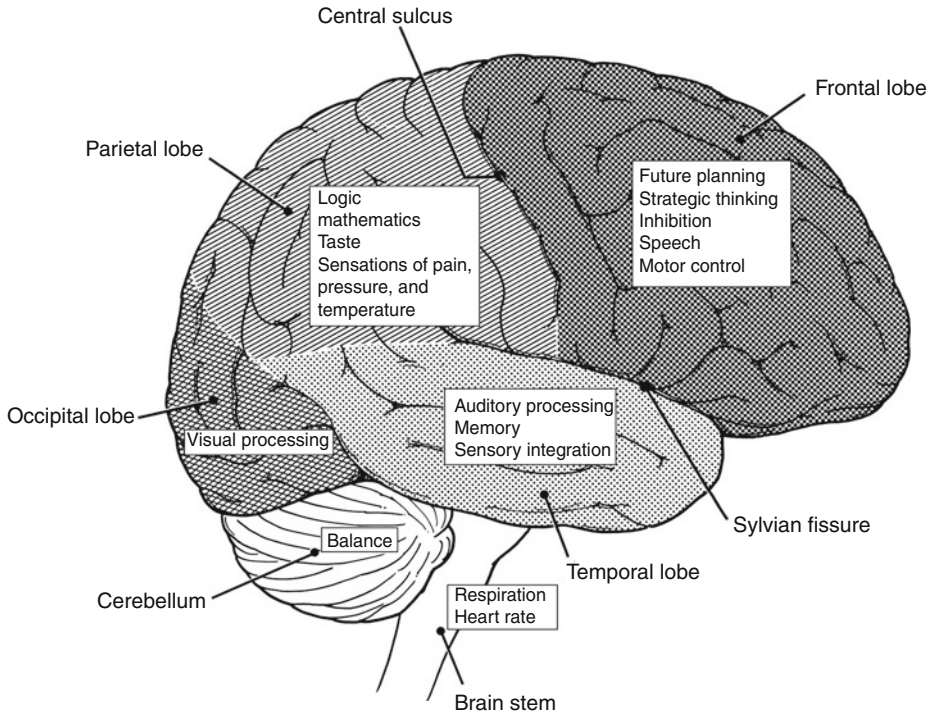
be felt, such as a crushing pressure or a tingle in part of the body (Shiminski-Maher et al. 2002).

The occipital lobes serve as the visual centers of the brain. They are responsible for making sense of the information that comes to the brain from the eyes through the optic nerves. The left occipital lobe deals with input from the right eye and the right lobe deals with input from the left eye. Tumors in the occipital lobe are associated with visual field cut (loss of peripheral vision) on one side or the other (Shiminski-Maher et al. 2002).

The posterior fossa or infratentorium contains the cerebellum, the brainstem, and the fourth ventricle. The cerebellum controls balance, coordination, and the ability to judge distances. It also coordinates cadence and rhythm of speech. The brainstem, which contains the cranial nerves, is the relay center for transmitting and coordinating messages between the brain and other parts of the body. It consists of the midbrain including the thalamus, pons, and medulla. The midbrain contains cranial nerve nuclei that processes vision and hearing, and it also coordinates the sleep and wake cycles. Eye and facial movements are controlled by cranial nerve nuclei located in the pons, which also serves as a link between the cerebellum and cerebrum. The medulla contains the cranial nerves that control breathing, swallowing, heart rate, and blood pressure. The fourth ventricle is a fluid space that connects the upper fluid chambers to the spinal cord and subarachnoid space surrounding the brain (Shiminski-Maher et al. 2002).

Sixty percent of all childhood brain tumors originate in the posterior fossa. Symptoms of tumors in this area of the brain include signs of increased intracranial pressure, weakness of cranial nerve(s), and ataxia. If the tumor grows toward or puts pressure on the fourth ventricle, normal flow of cerebrospinal fluid (CSF) is blocked, causing hydrocephalus. The buildup of fluid in the fourth ventricle causes pressure on vomiting centers that are located here (Shiminski-Maher and Wisoff 1995). Refer to the hydrocephalus chapter for a more in-depth (an) overview of this physiology.

The spinal cord contains the 31 pairs of spinal nerves that exit at various levels in the cervical,



**Fig. 6.1** Normal brain anatomy. (Used with permission from Barrow Neurological Institute. © Barrow Neurological Institute 2000. All Rights Reserved)

thoracic, lumbar, and sacral regions. The spinal cord sits inside the vertebral column, a series of bones that sit upon one another. Nerve impulses travel from the brain down the spinal cord and exit at various levels. They provide sensory and motor stimulation, which result in contraction of muscles in organs in the body, as well as movement of the extremities (Hickey 2009).

Figure 6.1 illustrates normal brain anatomy

## 6.4 Diagnosis: Presenting Symptoms

The diagnosis of a CNS tumor in a child is often difficult to establish. The presenting symptoms of a CNS tumor may be vague or similar to the symptoms of many common childhood illnesses. As there are only approximately 2,000 children diagnosed with CNS tumors annually in the United States, the likelihood of a pediatrician seeing a CNS tumor in the practice in his/her career is remote. It is not unusual to get a history from the family of many trips to a health-care

provider before the actual diagnosis is made. In addition, at diagnosis many parents express a sense of frustration that they have known that something is wrong with their child and they feel that something was “missed” (Meta et al. 2002).

Signs and symptoms vary depending upon the rate of growth and location of the tumor. Table 6.1 summarizes symptoms based upon tumor location and tissue type. Tumors with a short history (less than a month) and/or an acute onset of symptoms tend to be more rapid growing and may be described as aggressive, high grade, or histologically malignant. Those with a long history of vague symptoms or those picked up incidentally tend to be slower growing, low grade, or histologically benign (Shiminski-Maher and Shields 1995).

On physical examination, the child with a CNS tumor may have specific neurological deficits, which correlate with the tumor location. It is possible for a child to have a normal examination, for example, in a situation where the tumor is diagnosed incidentally because of a

**Table 6.1** Brain tumors: diagnosis based on location and symptoms

Part of the CNS	Symptoms of tumors	Types of tumors
Frontal lobes (cerebral hemispheres)	Problems with learning and concentration, changes in behavior, personality changes, seizures, weakness of an arm or leg on opposite side of tumor	Astrocytoma Glioma Rarely PNET or ependymoma
Parietal lobes (cerebral hemispheres)	Seizures, difficulty processing information, language difficulties	Astrocytoma Glioma DNET
Temporal lobes (cerebral hemispheres)	Atypical/partial complex seizures, behavior problems (aggressiveness, impulsiveness)	Astrocytoma Glioma DNET
Occipital lobes (cerebral hemispheres)	Loss of peripheral vision	Astrocytoma Glioma
Cerebellum (posterior fossa) including the fourth ventricle	Problems with balance, uncoordinated gait, increased intracranial pressure, nausea and vomiting	Astrocytoma Glioma Medulloblastoma Ependymoma
Brainstem (posterior fossa) including the fourth ventricle	Increased intracranial pressure, headache, nausea and vomiting, cranial nerve problems including eye movement disruption, decreased hearing, facial asymmetry, breathing or swallowing difficulties, and problems with balance and strength	Astrocytoma Glioma Ependymoma Medulloblastoma (rare)
Midbrain/thalamus	Altered level of consciousness, memory problems, weakness of arms or legs	Astrocytoma Glioma
Diencephalon (hypothalamus, sella, pituitary)	Hormonal secretion disruption (decreased growth, diabetes insipidus, thyroid deficiency, puberty problems), memory and academic problems	Astrocytoma Gliomas Craniopharyngioma Germ cell
Optic pathway	Visual changes: acuity or field cut	
Ventricular system	Increased intracranial pressure, hydrocephalus, memory or academic problems, hormonal changes	Ependymoma Choroid plexus Astrocytoma Glioma Medulloblastoma
Spinal cord	Back pain, scoliosis, weakness in arms or legs, bowel and bladder problems	Astrocytoma Ependymoma

Source: Adapted from Shiminski-Maher et al. (2002)

diagnostic test being performed for another reason (Shiminski-Maher et al. 2002).

## 6.5 Tumors of the Posterior Fossa

Posterior fossa tumor symptoms are most commonly associated with increased intracranial pressure. Symptoms of increased intracranial pressure include double vision, papilledema,

headache, nausea, vomiting, ataxia, and lethargy. This may be due to the pressure exerted by the mass itself or by obstruction of the normal flow of CSF by the tumor. Signs of increased intracranial pressure will be discussed in detail in the next section. Other signs associated with posterior fossa tumors include ataxia, nystagmus, and cranial nerve problems. Cranial nerve deficits are indicative of brainstem involvement (Shiminski-Maher and Wisoff 1995).

### 6.5.1 Presenting Symptoms

Symptoms of supratentorial tumors include hemiparesis, hemisensory loss, seizures, visual field changes, and intellectual problems. Midline tumors, such as those in the hypothalamic or pituitary region, are associated with increased intracranial pressure, visual changes, and/or endocrine issues such as diabetes insipidus or precocious puberty (Shiminski-Maher 1990).

Spinal cord tumors usually present with scoliosis, back or leg pain (which often awakes the child from sleep), weakness or sensory changes in the arms or the legs, and/or bowel and bladder dysfunction. Occasionally, a brain tumor will metastasize to the spinal cord and produce similar symptoms to above (Shiminski-Maher et al. 2002).

### 6.5.2 Diagnosis: Increased Intracranial Pressure and Hydrocephalus

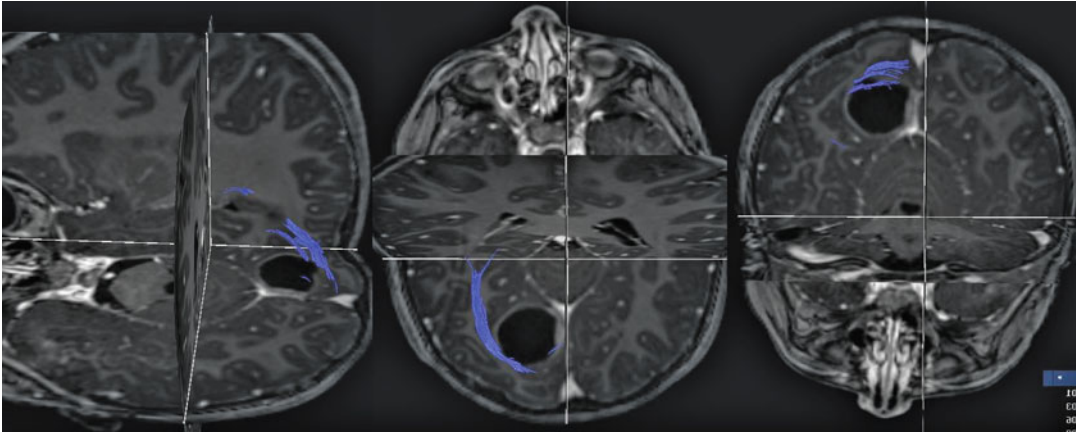
Increased intracranial pressure occurs from the mass of the tumor occupying space within the brain. It can also occur when the tumor causes an obstruction in the flow of CSF, resulting in hydrocephalus (Ryan and Shiminski-Maher 1995). Symptoms of increased intracranial pressure include headache (that awakens from sleep), nausea, vomiting (which often temporarily relieves the nausea and headache), lethargy, double vision or other visual changes, gait instability, memory problems, and decline in academic functioning. Nausea is especially problematic, as the nausea centers are located near the medulla that may be compressed or infiltrated by a tumor. Infants whose sutures are open can increase their head circumference to compensate for the pressure. Infants and children have the ability to compensate for increased intracranial pressure, especially if the tumor is slower growing and pressure increases are subtle. In addition, these symptoms are typical of many childhood illnesses and, therefore, may go unnoticed. Late signs of increased pressure are papilledema, vital sign changes, and severe altered level of consciousness (Lieberman and Berger 2001).

### 6.5.3 Diagnosis: Diagnostic Tests

The diagnosis of a CNS tumor is confirmed with a radiographic study, which is usually ordered by the primary care provider in a child with symptoms suggestive of intracranial or intraspinal pathology. Several other diagnostic tests may also be performed prior to treatment. Obviously, the extent of testing will depend upon the clinical condition of the patient. In general, the more information available to the treating team, the more thorough the plan for maximal surgical removal of the tumor, followed by appropriate adjunctive therapy (Black and Wen 1995).

Until the late 1980s, the computed tomography (CT) scan was the most frequently ordered imaging test. This has been essentially replaced by the magnetic resonance imaging (MRI) scan. Nurses are generally familiar with this diagnostic test, but not necessarily with how it works. A patient having an MRI scan is placed in a machine that contains a strong magnetic field. This magnetic field causes protons in the water molecules in the body to align parallel or antiparallel within the field, and this generates a picture of the neuroaxis (Black and Wen 1995).

MRI is a much more sensitive diagnostic test than the previously utilized computed tomography (CT) scans. Its sensitivity allows for detection of smaller tumors that may be missed with a CT scan. In addition, an MRI provides greater anatomic detail in multiple planes. The administration of a contrast agent (gadolinium diethylenetriaminepentaacetic acid: Gd-DTPA) allows for better visualization of some tumors. Moreover, newer imaging sequences are continually being developed to assist in determining whether a tumor's pathology is malignant or benign or to differentiate between recurrent tumor and treatment changes. In addition, specific sequences may allow the radiologist to predict specific tumor diagnosis. For example, diffusion tractography, a variant of diffusion-weighted MRI, allows tracing of functional tracts in the cerebral white matter, and the optic radiations can be traced through the occipital lobes. This allows planning a surgical route that avoids the optic radiations, limiting the risk for postoperative



**Fig. 6.2** Diffusion tractography of the right optic radiation in a 3-year-old girl with right occipital endependymoma. The right optic radiation (shown in *blue*) abuts the ring-enhancing endependymoma

visual deficit. Figure 6.2 shows this technique (Sundgren 2010).

MR angiography utilizes the magnetic field to display blood vessels within the brain. It is helpful in visualizing the blood supply to a tumor or in identifying vessels that may be compromised because of the tumor. It is a noninvasive way of looking at the blood supply within the CNS and has replaced the conventional angiography in many situations. Angiography is used in a small group of CNS lesions whose differential diagnosis includes tumor versus aneurysm/cavernoma or who have tumors where hemorrhage into the tumor cavity is suspected (Sundgren 2010).

Because the quality of the MRI images is dependent upon the patient lying motionless throughout the study, younger children, and some older ones, will require conscious sedation or anesthesia to perform the test. Sedation protocols vary with the institution, and larger pediatric centers may have blocks of time set aside with anesthesiologists present to efficiently utilize scanner time. If the child shows clinical signs of increased ICP or has hydrocephalus, it may be the physician's preference to insert a drain prior to the MRI scan, especially if the child is intubated (Avellino and Berger 1997).

A CT scan may be the first diagnostic test performed. Some tumors, especially small ones, may not be seen on a CT scan, and most tumors will not be visualized on a CT scan unless contrast is

given. CT scans are most often used during the treatment processes as a screening tool for children who have experienced a change in their neurological status. It can be performed in less than 5 min and is not as sensitive to the child moving as an MRI. The CT scan does expose the child to radiation during the test, and there is a growing awareness of the potential harmfulness of cumulative radiation after many CT scans during the course of the illness (Benz and Benz 2004). For this reason, clinicians will consider alternative testing, such as a fast MRI scan, when ordering a CT scan to avoid the risk of unnecessary radiation exposure (National Cancer Institute 2008).

Other radiodiagnostic tests include positive emission tomography (PET) and single-photon emission computed tomography (SPECT). Both of these tests have been evolving over the past decade, but still remain uncommon because of high cost and limited availability of equipment. Larger academic centers have the ability to perform these tests, which focus on a tumor's metabolism thereby helping clinicians determine the rate of cell growth and to differentiate between active tumor cells and treatment effects. These tests are usually utilized after a specific treatment to evaluate effectiveness (Benz and Benz 2004).

An electroencephalogram (EEG) measures the electrical activity within the brain and may be performed on a patient whose clinical presentation includes a seizure. Patients with tumors that

are associated with difficult to control or generalized seizures undergo continuous EEG monitoring with videotaping in a special epilepsy-monitoring unit. Subdural grids are inserted in some cases to localize speech or motor centers prior to surgical removal of the tumor. A Wada test (intracarotid sodium amobarbital test) may be performed to determine which side of the brain is responsible for speech and memory. This test is slowly being replaced with the functional MRI scan, which attempts to obtain the same information in a noninvasive manner (Cataltepe et al. 2005).

Visual acuity and visual field studies performed by an ophthalmologist are utilized if a patient presents with visual abnormalities. Laboratory tests, including blood and CSF necessary to look for tumor markers or endocrine abnormalities, may also be part of the initial work-up. Serum electrolytes, thyroid levels, and growth hormone levels are necessary for hypothalamic/pituitary tumors. Serum and CSF tumor markers of human chorionic gonadotropin (HCG) or alpha-fetoprotein (AFP) are needed for suprasellar tumors which may be germ cell tumors (Shiminski-Maher et al. 2002).

## 6.5.4 Treatment

Technical advances in medicine and surgery have dramatically changed the management of pediatric CNS tumors over the past two and a half decades. Imaging allows for early diagnosis and treatment of tumors, in addition to monitoring the effects of those treatments. Evolution in the surgical equipment, radiation therapy equipment, and use of chemotherapy for CNS tumors has improved long-term survival and the quality of that survival. Treatment consists of any combination of surgery, radiation therapy, chemotherapy, and observation. Treatment depends upon the location and type of CNS tumor. The tumor location determines the surgical approach. Tumors near eloquent areas may require special planning. The type of tumor refers to its cellular makeup and rate of growth (Shiminski-Maher et al. 2002).

### 6.5.4.1 Surgery

Surgery is the primary and front line treatment for virtually all CNS tumors. On radiology confirmation of a tumor, the child is seen by a neurosurgeon and evaluated for surgery. The goals of surgery are for maximal safe surgical removal and also to provide a tissue diagnosis. It is optimal for a child diagnosed with a CNS tumor to be operated on by a pediatric neurosurgeon whose practice is at least 50 % children. This is because pediatric neurosurgeons are more likely to extensively remove pediatric tumors than general neurosurgeons, and the extent of surgical resection is a significant prognostic indicator (Finlay and Wisoff 1999).

Ideally, surgery should be carried out as efficiently as possible under elective, controlled conditions. This is possible for the child who has minimal clinical symptoms or for whom medical management can temporize symptoms. Placing a child with subtle symptoms of increased intracranial pressure (ICP) on steroids may temporarily relieve the symptoms as they decrease edema around the tumor. Diuretics such as acetazolamide or mannitol may also be utilized to decrease ICP. The child should be monitored carefully for any change in status. In severe situations of increased ICP, intubation with mechanical ventilation is necessary to assure adequate oxygenation to the brain. Any child with significant symptoms or who is unstable should be operated upon immediately. If the child has hydrocephalus, the surgeon may place a ventricular drain to relieve the symptoms prior to the craniotomy for tumor removal. Simply removing the tumor, however, may open blocked CSF pathways and thus relieve the hydrocephalus (Albright et al. 2007).

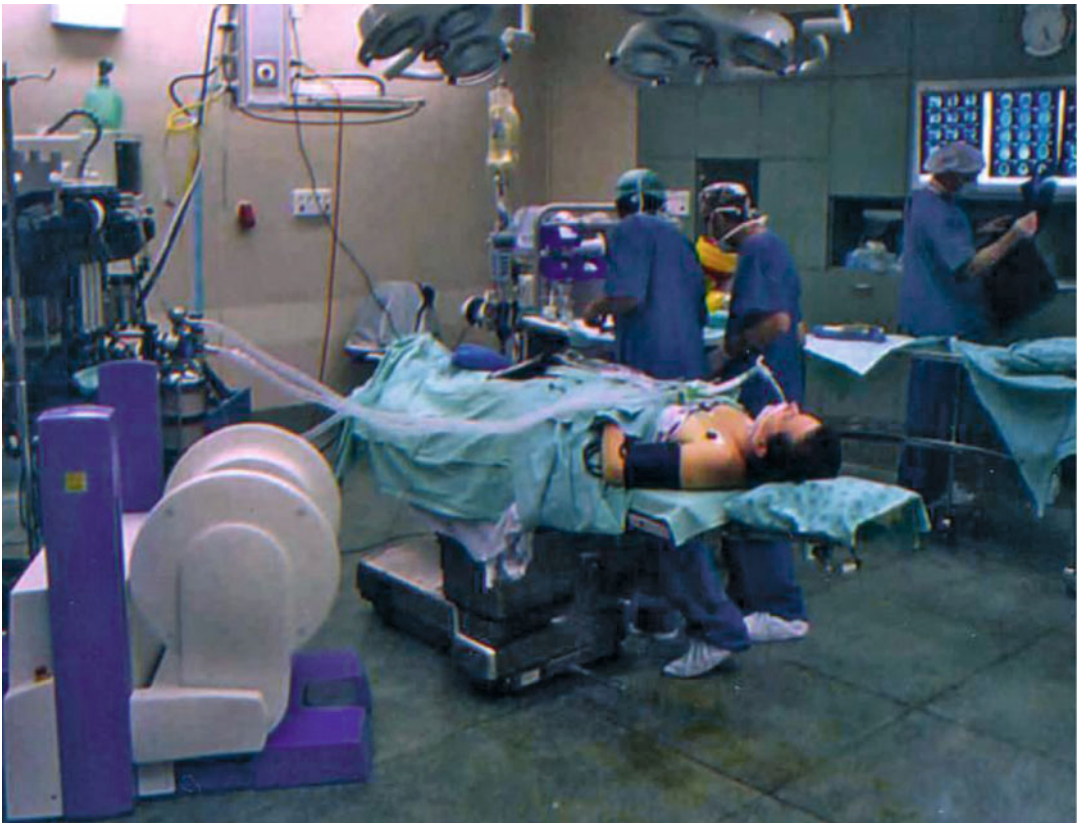Tumors of the hemispheres and posterior fossa are often readily accessible, allowing for gross total surgical resections. Surgical debulking of tumors in the areas of the third ventricle, hypothalamus, optic nerve, and pituitary regions has also become possible. Surgery is not indicated in children with diffuse intrinsic brainstem tumors (most of which are malignant in histology) in which the surgical risks outweigh the benefits of a radical surgical procedure, because the overall

prognosis is not changed with surgery. The exception is the focal tumor that is isolated to one area within the brainstem (either only in the medulla or only in the pons or those at the cervico-medullary junction). These tumors are benign in histology and are possible to remove surgically, thus delaying or avoiding adjunctive treatments (Abbott et al. 1996).

Staged surgical procedures and second-look operations have become a frequently used modality to increase extent of tumor resection and to decrease morbidity. Deep tumors can be approach from two different trajectories to maximize the resection. A surgeon will choose to perform a second operation when the postoperative imaging study shows residual tumor and the pathology is low grade. Second-look operations after a specific treatment modality has been given allow for evaluation of tumor response to the treatment,

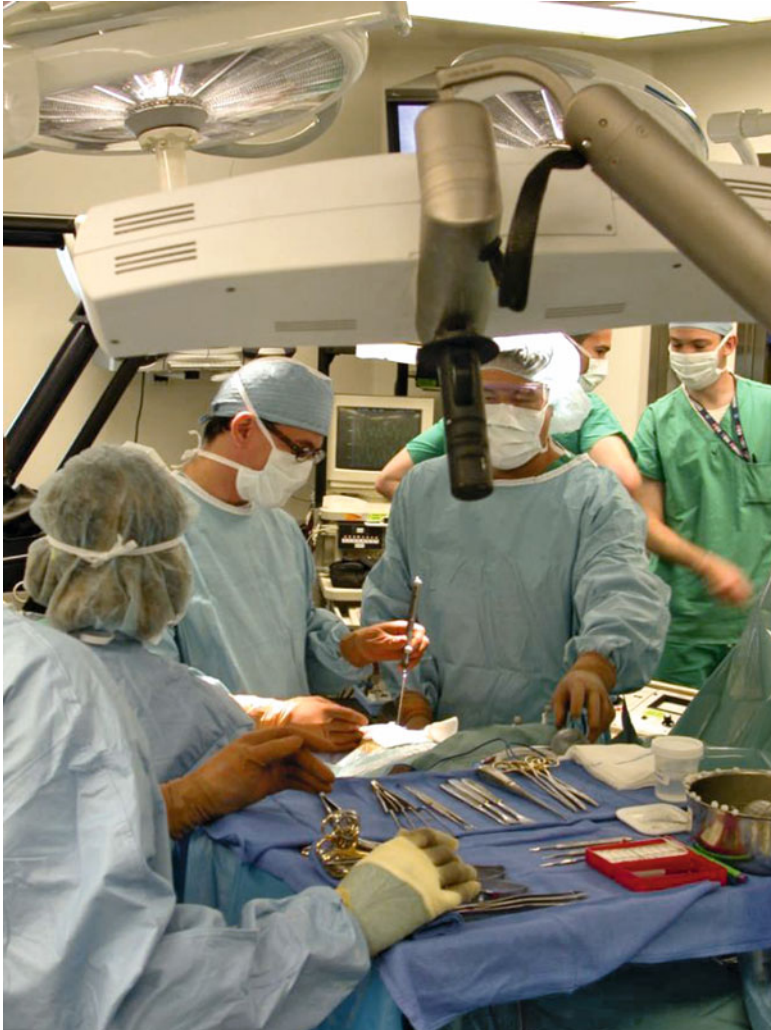as well as the potential for rendering the patient free of disease (Shiminski-Maher and Wisoff 1995).

Standard neurosurgical tools utilized by the surgeon in the operating room include the operating microscope, ultrasonic surgical aspirator, carbon dioxide laser, ultrasound, endoscopy and intraoperative monitoring, such as electrocorticography, and sensory- and motor-evoked potentials (Fig. 6.3). An MRI scan obtained prior to surgery can provide preoperative and intraoperative localization using a frameless navigational system, as shown in Fig. 6.4. In some situations, this allows the surgeon to use a smaller craniotomy to maximally remove the tumor. An ultrasound is used to localize the tumor, and it is usually removed with the ultrasonic surgical aspirator. An endoscope may be used to remove or biopsy a tumor within the ventricular system. The laser is



**Fig. 6.3** Operating room setup





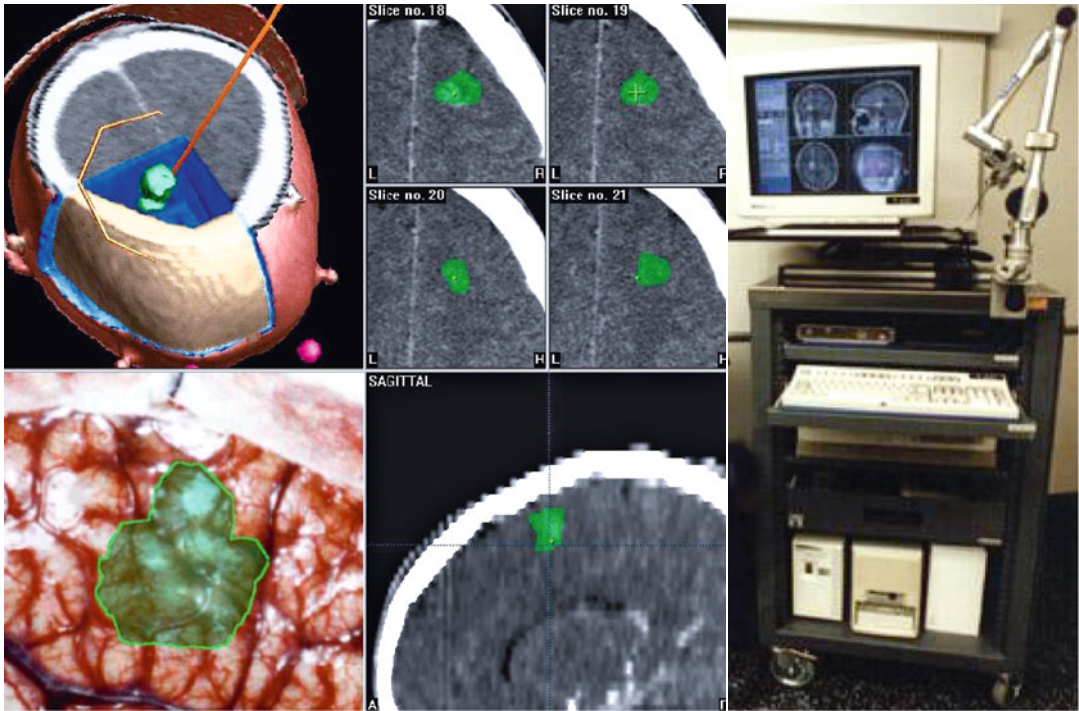
**Fig. 6.3** (continued)

commonly used to remove spinal cord tumors. The endoscope can also be used to perform an anterior third ventriculostomy to treat obstructive hydrocephalus, thus avoiding insertion of a ventriculoperitoneal shunt (Maher and Raffel 2002).

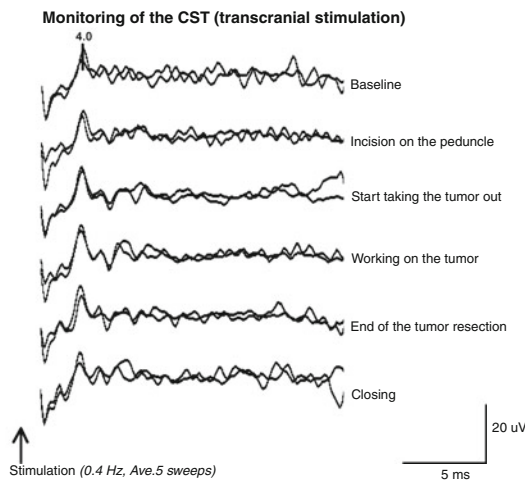
Intraoperative monitoring (called evoked potentials) involves watching the nerve impulses travel from the brain to important functional areas, such as arms, legs, face, eyes, and bowels and bladder (Fig. 6.5). By using this technology during the operation, the surgeon can determine the location of the tumor in relation to important body function, thus maximizing resection while attempting to minimize injury.

Electrocorticography, as shown in Fig. 6.6, allows the surgeon to place electrodes or grids into the cavity after a tumor resection to ensure that any abnormal tissue that can generate a seizure is also removed (Albright et al. 2007).

Localization of the tumor using intraoperative guidance systems has become common in the last decade. An MRI scan is obtained preoperatively with surface markers placed on the scalp. The computerized scan is then sent to the navigational system in the operating room. In the operating room, the surgeon can touch the surface markers upon the scalp, and the computer then generates a picture of the lesion in relation to that specific



**Fig. 6.4** Intraoperative guidance systems



**Fig. 6.5** Use of evoked potentials during tumor resection to monitor motor function

marker. This allows for surgical removal of a tumor through a much smaller craniotomy, reducing recovery time and length of hospitalization. It is extremely efficient in localizing small lesions within the brain. Specific MRI scans can be

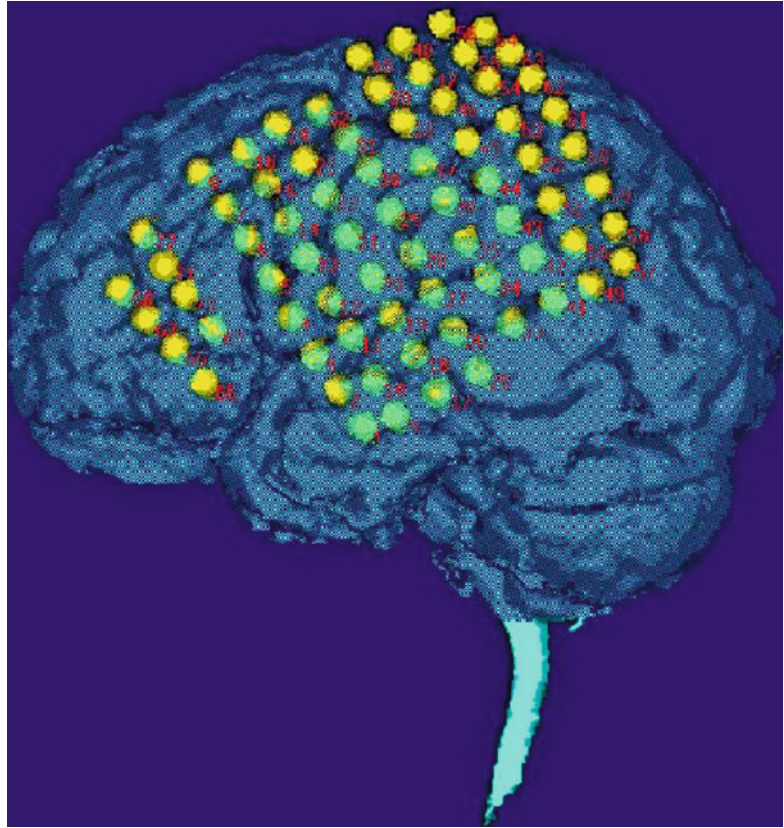
obtained preoperatively to localize the tumor in relation to eloquent areas, such as visual or motor pathways. These systems continue to be modified and improved upon with each generation of equipment (Sundgren 2010).

Hydrocephalus that does not resolve with the removal of tumor, and for which an endoscopic third ventriculostomy is not possible, is treated with insertion of a ventriculoperitoneal shunt. The clinicians must also monitor for the development of hydrocephalus in the weeks or months following surgery secondary to scarring of the CSF pathways from surgery or adjunctive treatments (Ryan and Shiminski-Maher 1995). See the chapter on hydrocephalus for detailed information about the treatment of hydrocephalus.

#### 6.5.4.2 Observation

A postoperative MRI is performed, usually within the first few days after surgery. The purpose of the scan is to evaluate the amount of tumor removed. This scan, combined with the histology of the tumor, will determine the next treatment

**Fig. 6.6** Grid placement for evaluation of seizure focus outside tumor cavity



step. For tumors that are very slow growing, and for which a significant surgical removal has been possible, observation with frequent MRIs may be the only recommendation. The ability to detect subtle changes in tumor growth with the MRI has made clinicians more comfortable in observing these tumors. By such observation, it has been found that many lesions lay dormant or even regress over time. It has also been noted that growth may not be at a steady rate but in “pulses” at certain intervals. Observation may delay the use of more surgery or other treatments (Shiminski-Maher et al. 2002).

Observation may be the treatment of choice at the original diagnosis if the tumor is very small and/or was diagnosed incidentally. MRI is again utilized to monitor the lesion for any change in size over time. Observation is also required following any adjunctive treatment that may be used following surgery. Once a child or adolescent has completed additional treatments for their tumor,

MRI scans and other pertinent diagnostic tests are performed on an interval basis (Shiminski-Maher et al. 2002).

#### 6.5.4.3 Radiation

Many CNS tumors are very sensitive to radiation treatments, also called radiotherapy. Prior to the technical advances in surgery, radiation was the primary treatment for CNS tumors in children. It became clear as children began to survive their CNS tumors, however, that radiation treatments also carried acute and long-term side effects that dramatically impacted the individual’s ability to function. These side effects included cognitive, growth, hormonal, and hearing issues. The intensity of the side effects were directly related to the age of the child at the time radiation was given. In general, younger children were much more vulnerable to significant toxicity than were older children. Radiation treatments can only be administered once and, therefore, should be

employed at the time of minimal disease based upon tumor type and age of the patient. Beginning in the late 1980s, clinicians chose to treat younger children requiring adjunctive treatment with chemotherapy first in an attempt to withhold radiation for as long as possible. This past quarter century has brought about technological advances, which allow for MRI and CT computerized planning of radiation treatments. This allows for focused treatments to the tumor while sparing as much normal brain tissue as possible. Currently, radiation treatments (especially more targeted treatment plans) are being considered for younger children if the tumor is not responsive to chemotherapy (Halpern et al. 2010).

Radiotherapy directs high-energy x-rays called photons at targeted areas within the CNS to destroy tumor cells. Radiation can be given internally or externally, with the majority of pediatric CNS tumors treated with external radiation. A large machine called a linear accelerator delivers external radiation via x-rays (photons) to the precise portion of the CNS where the tumor is located. These photons enter the patient at a high dose and deposit that radiation to the tumor target and beyond. Treatment doses for the majority of CNS tumors are between 45 and 60 cGy. If the tumor has the potential of spreading, or already has spread beyond the primary site, the entire CNS will receive external radiation dosing between 18 and 24 cGy. Radiation treatments are normally given once a day at around the same time. Twice a day treatments (called hyper-fractionation) are another way of delivering radiation treatments. The daily dose is split into two fractions and delivered approximately 12 h apart with the intent on hitting the tumor cells at different times of their cycles and increasing cell death (Halpern et al. 2010).

Conformal radiation therapy is a technique used to target radiation doses to the tumor while limiting the dose to normal tissues. Conformal radiation therapy requires brain imaging with MRI and CT so that the tumor target and critical normal structures can be accurately defined. It is now the accepted standard for radiation treatments for pediatric CNS tumors. There are several specific types of conformal radiation therapy that

utilize photons. 3D conformal radiation therapy uses radiation fields from several directions that overlap at the tumor. In this manner, the tumor receives the high-dose radiation while the normal tissue surrounding it receives a smaller dose. Intensity-modulated radiation therapy (IMRT) is a sophisticated type of 3D conformal therapy that modifies the radiation beam based on the shape of the target to be treated. Another type of sophisticated 3D technique is stereotactic radiosurgery/radiotherapy, which delivers radiation to a small, precisely defined target. Stereotactic radiosurgery is delivered as one single treatment, while stereotactic radiotherapy is multiple fractionated treatments (Kirsch and Tarbell 2004).

Proton beam radiation is another type of conformal treatment. Unlike the other therapies that utilize photons, this uses protons. Protons, unlike photons, enter the patient with a relatively low dose and deposit their energy within the tumor with no exit dose of radiation to the normal tissues beyond the tumor. At this time, however, there are only a handful of centers with a proton machine. Long-term studies documenting the effectiveness of protons on tumor control and toxicity are needed to justify construction of more proton facilities (Yock and Tarbell 2002).

Internal radiation, or brachytherapy, implant therapy, or interstitial therapy, is used much less than external radiation to treat childhood CNS tumors. Brachytherapy uses radioactive seeds or implants which are surgically placed into the tumor cavity. Brachytherapy may be useful in treating CNS tumors because it delivers high-dose radiation directly to the tumor site while sparing surrounding healthy tissue. Unlike external radiation, it provides a continuous low dose of radiation to the tumor rather than intermittent bursts once or twice a day (Halpern et al. 2010).

Children should receive radiation therapy at major medical centers with experience in treating children with CNS tumors. This will ensure that treatments conform to the standards set up by COG. Immobilization devices are necessary to ensure that the radiation beam is directed with precision. Sedation or anesthesia may be required on a daily basis for those who cannot tolerate the immobilization process (Shiminski-Maher et al. 2002).

#### 6.5.4.4 Chemotherapy

Until the 1980s, chemotherapy was not used to treat pediatric CNS tumors. It was felt that the blood–brain barrier would prevent the penetration of chemotherapy into a tumor within the CNS. Chemotherapy, either alone or as part of a multi-modality treatment, is used to treat all malignant CNS tumors and has also been shown to be effective in the treatment of some benign tumors. Cooperative group studies within COG have allowed for testing of specific chemotherapeutic protocols and have been responsible for increasing the progression-free survival in children with CNS tumors. In the past decade, higher doses of chemotherapy followed by stem cell rescue have been used in treating tumors in infants (while delaying radiation treatments) or resistant tumors (Watrall 2009). In addition, researchers have begun to look at the genetic components of specific resistant tumors and tailoring treatments based upon this research (Biagi et al. 2003).

The goal of chemotherapy includes destruction or interruption in growth of tumor cells. The destruction occurs when the chemotherapeutic agent enters the cell and disrupts its proliferative process. In addition to destroying the abnormally growing tumor cells, the chemotherapy also affects normal growing cells such as hair, skin, and blood cells, with common adverse effects that include immunosuppression, hair loss, and nausea and vomiting. For more information, see Table 6.3 (Shiminski-Maher 1990a).

Chemotherapy is given either as a single agent alone or in combination with other drugs. Most treatment plans have a schedule or road map that outlines the drugs given over the treatment plan. Chemotherapy is sometimes given simultaneously with radiation therapy in an attempt to increase radiation's effectiveness. In this case, the chemotherapy is referred to as a radiosensitizer. When these drugs are given in high doses or at frequent intervals over a long period of time, bone marrow suppression can be a major side effect. Autologous stem cell reinfusion can regenerate the bone marrow, thus allowing for dose intensive treatments (Watrall 2009).

#### 6.5.4.5 Rehabilitation

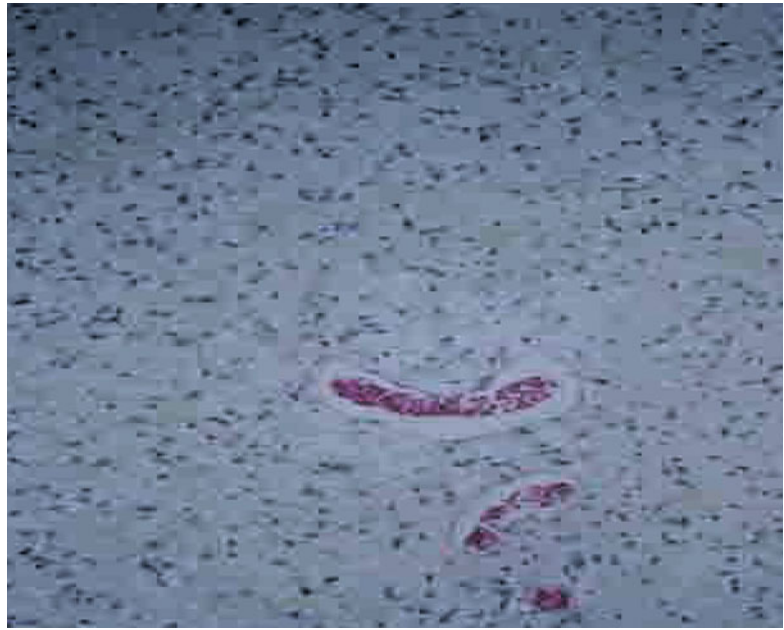Rehabilitation services are a necessary treatment for the majority of children with CNS tumors. The tumor itself or effects of treatments may impair the use of or coordination in an extremity. Problems with speech, language, memory, and processing may also occur. Physical, occupational, and speech therapy as indicated should be initiated immediately and often will continue for months or years depending upon individual needs. Therapies are incorporated into school educational plans with exercise supplements built into daily activities (Shiminski-Maher et al. 2002).

#### 6.5.4.6 Types of Tumors: Malignant Versus Benign

Tumors of the CNS are classified based on the cell from which they originate and by their rate of growth. CNS tumors develop from astrocytes or neuroglial cells. Other tumors develop from neuronal or premature cell lines. After a sample of the tumor is obtained during surgery, a neuropathologist looks at the tumor under a microscope. He determines the type of tumor, depending upon the cell from which it develops and the rate of cell growth. Unfortunately, there is no uniform classification of brain tumors. Different pathologists may look at the same tumor and give it a different name. This can be very frustrating and confusing for families. Names for different types of CNS tumors include astrocytomas, gliomas, glioblastoma multiforme, ependymomas, oligodendrogliomas, gangliocytoma, ganglioglioma, medulloblastoma, PNET, pineal cell tumors, choroid plexus tumors, germ cell tumors, craniopharyngiomas, hemangioblastomas, and dermoid and epidermoid tumors (Petriccione 1993).

The terms malignant and benign are confusing when applied to many CNS tumors. In order to identify if a tumor is malignant or benign, it must be looked at in terms of rate of growth and location. Unlike adult brain tumors, which are primarily histologically malignant or fast growing, childhood brain tumors have a greater likelihood of being histologically benign or slow growing.

**Fig. 6.7** Histology of slow-growing tumor



Slow-growing tumors are technically classified as benign. These tumors, if they are totally removed with surgery, rarely regrow. Many slow-growing tumors, however, are found deep within the brain or brainstem, where aggressive surgery is not possible because of significant risk of damaging adjacent structures. In these cases, other treatments (chemotherapy and/or radiation) are used in an attempt to shrink or halt further tumor growth. Thus, even if a tumor deep in the brain is slow growing, it may require the same treatments as malignant brain tumors—and these treatments can cause the same long-term side effects. Some health-care providers call this “malignant by location.” Figure 6.7 shows the microscopic histology of a slow-growing tumor (Shiminski-Maher et al. 2002).

All fast-growing tumors are considered malignant and cancerous. Figure 6.8 shows the microscopic histology of a malignant CNS tumor. Even if totally removed with surgery, these tumors will usually grow back without further treatment (radiation and/or chemotherapy). Malignant CNS tumors rarely spread to other parts of the body like breast or liver cancer, but most health-care professionals still consider them to be a type of cancer (Shiminski-Maher and Wisoff 1995).

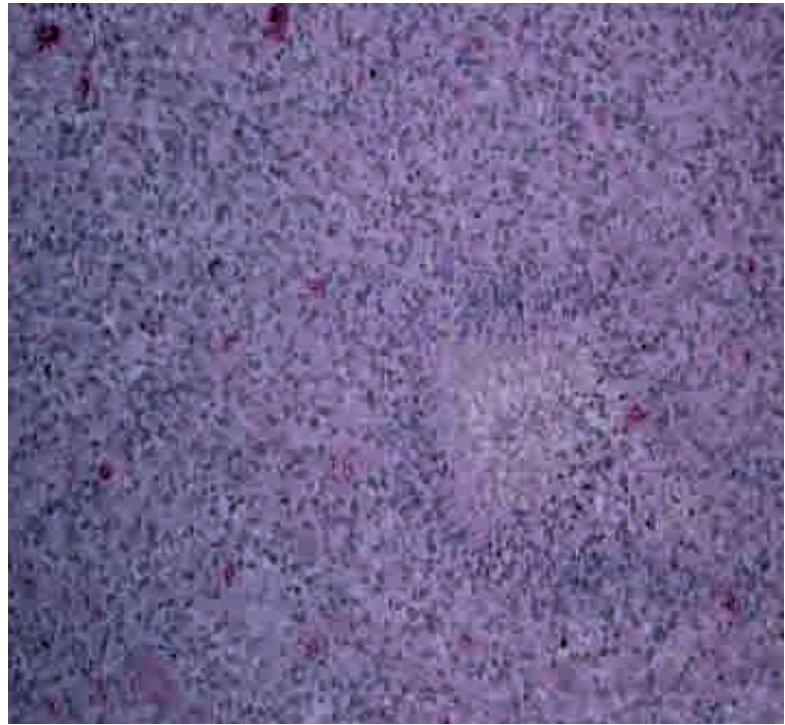
#### **6.5.4.7 Based upon Histology**

Once the tissue diagnosis has been made with a surgical procedure, the next step is to formulate a treatment plan. Postoperative imaging is obtained to determine the extent of tumor removal that has been obtained. This information, along with any other preoperative testing, is summarized, and the next step of care is recommended. Many large centers utilize a tumor board to make treatment decisions. This is a multidisciplinary group including surgeons, oncologists, neuro-oncologists, radiation therapy physicians, radiologists, and other appropriate specialists. A case may be presented to the Tumor Board at various times during the course of the illness when treatment decisions need to be made. A summary of treatments based upon tumor histology is found in Table 6.2. A discussion of treatment plans based on specific pathologic diagnosis follows (Shiminski-Maher et al. 2002).

##### **6.5.4.7.1 Low-Grade Astrocytomas**

Astrocytomas (also called gliomas) make up about one-third of, and are the most common type of, CNS tumor in children. They may be slow growing or very fast growing and can

**Fig. 6.8** Histology of fast-growing tumor



**Table 6.2** Brain tumors: treatment based upon type and location of tumor

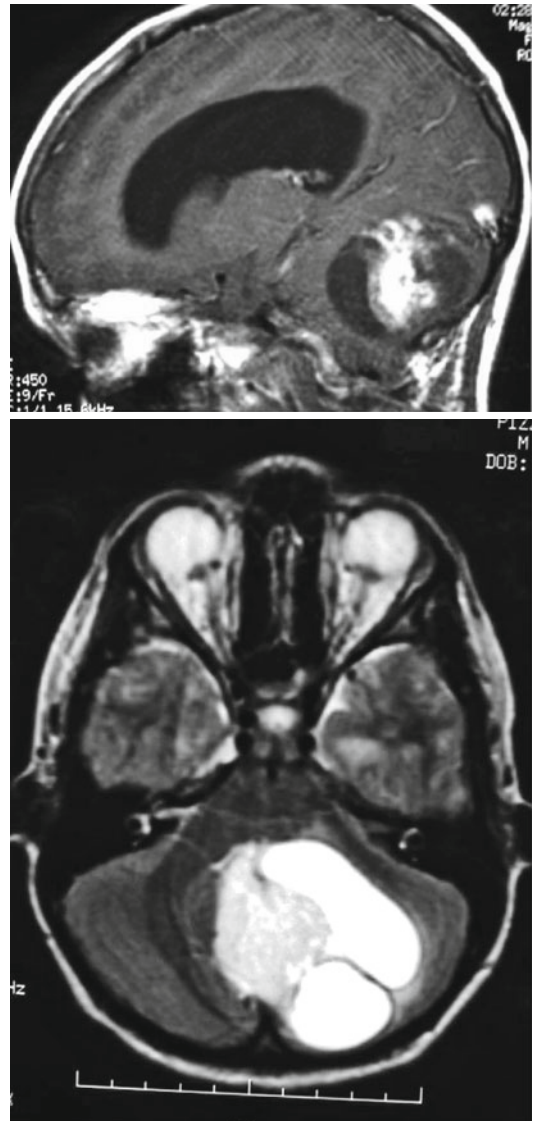
Part of the CNS	Type of tumor	Treatment
Frontal lobes	Astrocytoma	Maximal surgical removal using intraoperative guidance, monitoring, electrocorticography, and MRI; observation between surgical treatments for tumors that are slow growing; chemotherapy and/or radiation may be considered for disease progression in low-grade lesion or for adjunctive treatment for high-grade astrocytomas or gliomas, PNET or ependymoma
Parietal lobes	Glioma	
Temporal lobes	DNET	
Occipital lobes	Rarely PNET or ependymoma	
Cerebellum	Astrocytoma	Maximal surgical removal; observation following surgery for slow-growing tumors with reoperation at progression; chemotherapy and/or radiation for medulloblastoma and ependymoma
	Glioma	
	Medulloblastoma	
	Ependymoma	
Brainstem/fourth ventricle	Astrocytoma	Radiation $\pm$ chemotherapy is standard treatment for diffuse brainstem tumors. Surgery is possible for focal lesions followed by observation, chemotherapy, or radiation
	Glioma	
	Ependymoma	
	Medulloblastoma	
Midbrain/thalamus	Astrocytoma	Conservative surgery or observation for low-grade tumors; observation $\pm$ chemo for low grade; chemotherapy and radiation for germ cell or other high-grade tumors
Diencephalon	Glioma	
Optic pathway	Craniopharyngioma	
Ventricular system	Germ Cell	
	Choroid plexus	
Spinal cord	Astrocytoma	Maximal surgery then observation; radiation for high-grade tumors or tumor progression
	Ependymoma	

Source: Adapted from Shiminski-Maher et al. (2002)

arise anywhere in the brain and spinal cord. About 80 % of astrocytomas are slow-growing in the pediatric population. This includes juvenile pilocytic astrocytoma, low-grade astrocytoma, and optic pathway or hypothalamic gliomas. Slow-growing astrocytomas in the brain arise in the cerebral hemispheres, the cerebellum, or the spinal cord. Surgery is the primary treatment for slow-growing astrocytomas. This is possible in many areas of the cerebrum and always possible in the cerebellum. The most potentially curable form is the cerebellar pilocytic astrocytoma (Fig. 6.9). If there is question of residual tumor after surgery, the surgeon can either reoperate or follow closely with frequent MRI scans and reserve surgery if there is an increase in tumor size. Cerebellar or hemispheric low-grade astrocytomas rarely spread throughout the neuroaxis; thus, spine imaging is not necessary (Maher and Raffel 2004).

Slow-growing astrocytomas account for 75 % of all spinal cord tumors in children (Fig. 6.10). Surgery is the primary treatment, and multiple surgical procedures are usually needed to maintain tumor control. The use of intraoperative monitoring has dramatically improved the safety of radical tumor removal. Radiation therapy is used for tumors that grow despite multiple surgical procedures. Chemotherapy historically has not been given to children with low-grade spinal cord tumors, so its effectiveness is unknown (Jallo et al. 2004).

Low-grade astrocytomas also occur in the diencephalon, specifically in the hypothalamus and optic chiasm (Fig. 6.11). They can be sporadic or associated with neurofibromatosis syndromes. In children, the histological diagnosis is made with the presence of Rosenthal fibers, and they are generally very low in cellularity. The clinical course varies with many lesions remaining dormant for extended periods of time. Treatment is indicated if there is either worsening clinical symptoms or radiographic evidence of tumor growth. Observation with careful clinical examination and serial MRI scans are the treatments of choice. Surgery is indicated only for

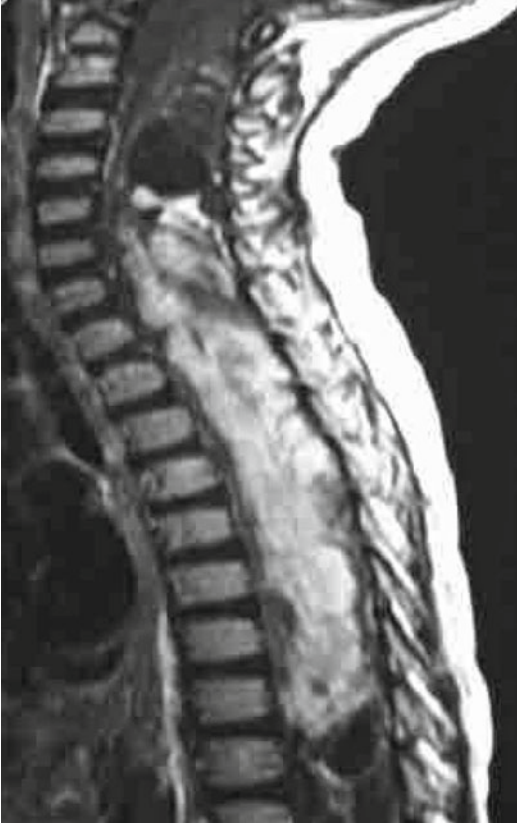

**Fig. 6.9** Cerebellar astrocytoma: sagittal view showing obstructive hydrocephalus. Axial view showing mural nodule

tissue diagnosis or for partial reduction in the size of the tumor. Surgical management of hydrocephalus may be required if the tumor is obstructing normal CSF pathways (Black and Wen 1995).

Additional treatment is given if the MRI shows tumor growth or if the child develops symptoms (usually visual or hormonal). The type of treatment depends upon the age of the child and the growth pattern of the tumor. Treatment





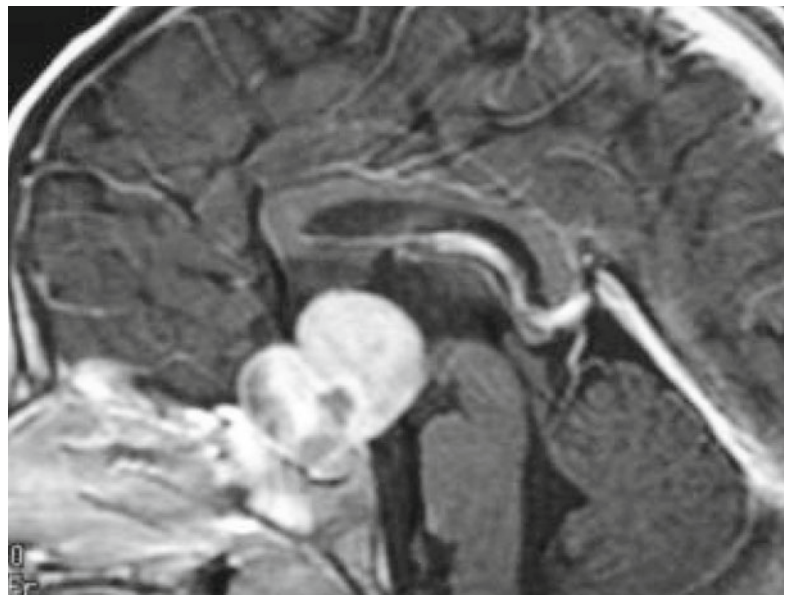
**Fig. 6.10** Spinal cord astrocytoma: sagittal view of solid-enhancing tumor with cyst above and below

may include surgery, but usually is chemotherapy (especially in children less than 10 years old). Radiation therapy is the third treatment option, recommended for the patient with progressive tumor who has failed initial chemotherapy or for the child or adult over age 10. Most neuro-oncologists try to delay radiation therapy for these tumors for as long as possible because of the increased risk of damage to the developing nervous system (Halpern et al. 2010).

#### 6.5.4.7.2 Malignant Astrocytomas

A small number of astrocytoma tumors in the pediatric population grow rapidly, and they are known as malignant astrocytomas. They usually grow in the cerebrum or brainstem and are rarely found in the spinal cord. Types of rapid-growing astrocytomas include high-grade anaplastic astrocytoma, glioblastoma multiforme, and gliomatosis cerebri (Shiminski-Maher et al. 2002).

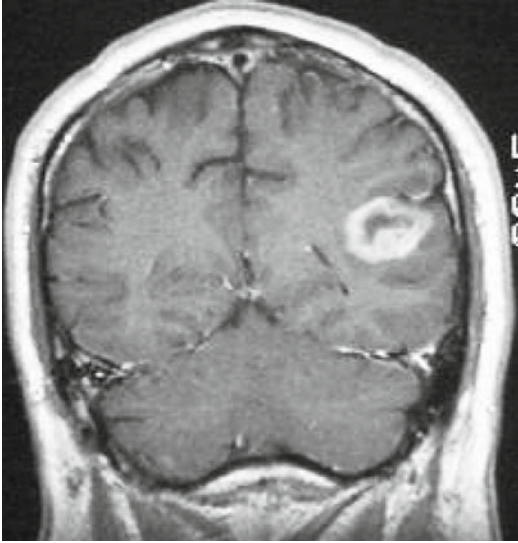
High-grade astrocytomas are difficult to cure even with the most aggressive treatments (Fig. 6.12). Maximal surgical resection appears to be the only significant variable in extending time to progression for this resistant tumor Albright et al. (2000). Radiation therapy remains the standard adjunctive treatment for children



**Fig. 6.11** Optic pathway low-grade astrocytoma

with malignant astrocytomas and, when given after aggressive surgery and with chemotherapy, will prolong time to progression. Chemotherapy windows have included single and multiple agents along with high-dose chemotherapy with

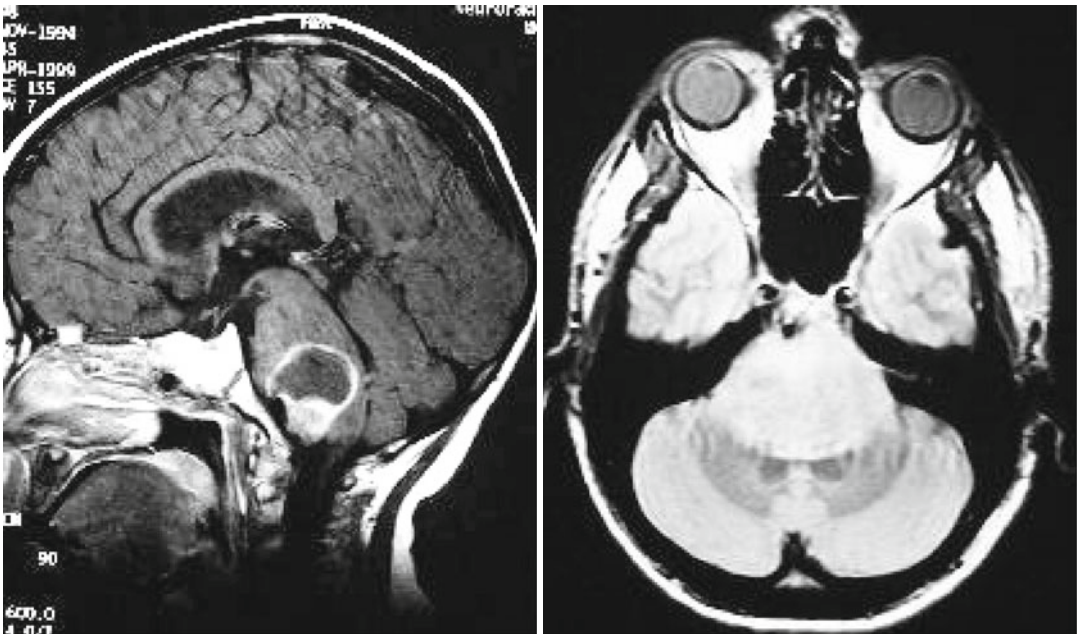
autologous marrow or stem cell rescue. To date, despite multiple cooperative group clinical trials where chemotherapy was given before, during, and following radiation therapy, there has been no significant improvement in event-free survival (Shiminski-Maher et al. 2002).



**Fig. 6.12** Anaplastic astrocytoma: enhancing tumor adjacent to motor strip

### 6.5.5 Brainstem Gliomas

Astrocytomas that grow in the brainstem are called brainstem gliomas. They make up 10–15 % of all pediatric brain tumors. Brainstem tumors can be either low-grade or high-grade astrocytomas. Ninety percent of these tumors are fast growing and cause rapidly developing symptoms. They involve multiple levels of the brainstem and have a diffuse appearance on the MRI scan (Fig. 6.13). Surgery is not an option because aggressive surgery in the brainstem would result in severe neurological impairment. The majority of children diagnosed with a brainstem glioma do not survive more than 2 years beyond diagnosis (Abbott et al. 1996).



**Fig. 6.13** Brainstem glioma: sagittal view of ring-enhancing tumor with axial image of diffuse appearance on T2 image

Radiation therapy is the primary treatment and usually results in an initial decrease in tumor size and improvement in clinical symptoms. Chemotherapy has been added to radiation with no improvement in survival. Unfortunately, usually within a year, the tumor begins to grow again, and adjunctive treatments may provide palliation but are ineffective in curing the tumor (Shiminski-Maher et al. 2002).

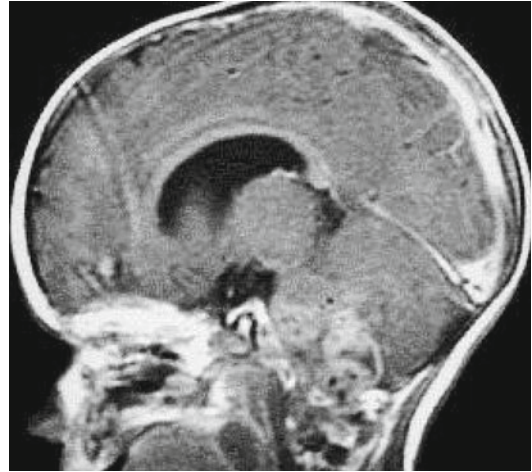
About 10 % of brainstem tumors are slow-growing brainstem gliomas. They are usually focal tumors located in the medulla, pons, or midbrain, and symptoms develop over a long period of time. Unlike the diffuse high-grade lesions, these tumors usually remain confined to one component of the brainstem. Surgical debulking may render the tumor dormant for an extended period of time. Adjunctive treatment alternatives include observation, radiation, and/or chemotherapy (Abbott et al. 1996).

#### 6.5.5.1 Spinal Cord Malignant Astrocytomas

Anaplastic astrocytomas or glioblastoma multiforme is a rare entity in children, but a handful are diagnosed each year. Like the high-grade astrocytomas of the brain, extent of surgical resection may impact time to progression, and radiation treatments may temporarily reduce the size of the tumor. Tumor progression usually occurs within the first year to 18 months, with event-free survival at 5 years rare (Muszynski et al. 2001).

#### 6.5.5.2 Subependymal Giant Cell Astrocytomas (SGCA)

Subependymal giant cell astrocytomas are tumors that are always associated with tuberous sclerosis, which is an autosomal dominant inherited phakomatosis. Clinical symptoms include adenoma sebaceum, seizures, and mental retardation. The tumors only occur in 6–15 % of children with tuberous sclerosis. Most SGCA arise in the lateral ventricle near the foramen of Monro and cause obstructive hydrocephalus. Because death can occur from undiagnosed tumor and hydrocephalus, all children with tuberous sclerosis should be screened radiographically every 2 years for the presence of a lesion. A gross total removal of the tumor is usually



**Fig. 6.14** Ependymoma: sagittal image of enhancing tumor filling the fourth ventricle causing obstructive hydrocephalus

possible, with surgery being the only known effective treatment (Albright et al. 2007).

#### 6.5.5.3 Oligodendrogliomas/ Gangliogliomas/Gangliocytomas

This group of slow-growing glial tumors is rare in children and as a total may comprise less than 5 % of all pediatric CNS tumors. They are so slow growing that a diagnosis is obtained because of headache complaints or a seizure, which results in radiological imaging. They can also be diagnosed incidentally. If surgically accessible, a gross total removal is curative. Observation, with further surgery or radiation therapy if the tumor begins to grow, is recommended (Albright et al. 2007).

#### 6.5.5.4 Ependymoma

Ependymomas make up 8–10 % of childhood brain tumors. They arise from the cells that line the ventricular system. About 70 % of ependymomas occur in the posterior fossa, usually in the fourth ventricle (Fig. 6.14). Ependymomas also occasionally grow in the cerebral hemispheres and in the spinal cord. Because of the risk of spread of tumor to other areas of the neuroaxis, preoperative imaging of the entire CNS is recommended (Albright et al. 2007).

Surgery is the first treatment for ependymomas. Surgical management of hydrocephalus is

also required because of the tumor obstructing flow through the fourth ventricle. It is difficult, however, to totally remove an ependymoma in the fourth ventricle because it is close to the brainstem. As with other tumor types, extent of surgical removal correlates with increased progression-free survival, thus children with fourth ventricular ependymomas tend to have a worse prognosis. Treatment of ependymomas after surgery is controversial. Radiation has been shown to be beneficial in a small group of patients. Chemotherapy has shown some efficacy and continues to be considered along with radiation for tumors that cannot be surgically removed. Although various subtypes of histology have been identified, there appears no significant difference in the length of time to either survival or recurrence. Ependymomas tend to recur locally, and most recurrences occur within 5 years of diagnosis (Maher and Raffel 2004).

#### 6.5.5.5 Medulloblastoma

Medulloblastomas are the most common malignant tumor and account for about 20 % of all CNS tumors in children. These are, by definition, posterior fossa lesions originating in the cerebellum with potential extension into the fourth ventricle and/or brainstem. Because these lesions can interfere with the normal flow of cerebrospinal fluid, hydrocephalus is often present at diagnosis. Medulloblastoma can also grow in the cerebral hemispheres (Fig. 6.15). Unlike most other CNS tumors, medulloblastoma cells can spread throughout the brain and the spinal cord. Twenty-five to forty percent of medulloblastoma tumors spread far from the primary tumor. For this reason, children should have an MRI scan of the entire brain and spine at diagnosis to determine if the tumor has spread. An analysis of CSF (for presence of tumor cells) by lumbar puncture is also done. Rarely, bone metastases occur, usually in less than 5 % of children (Shiminski-Maher et al. 2002).

Treatment plans vary depending upon the child's age at diagnosis, amount of tumor removed, and extent of tumor spread. Surgery (in one or several operations) is the first treatment for medulloblastoma. Total removal is the goal. This is sometimes difficult if the tumor has spread to

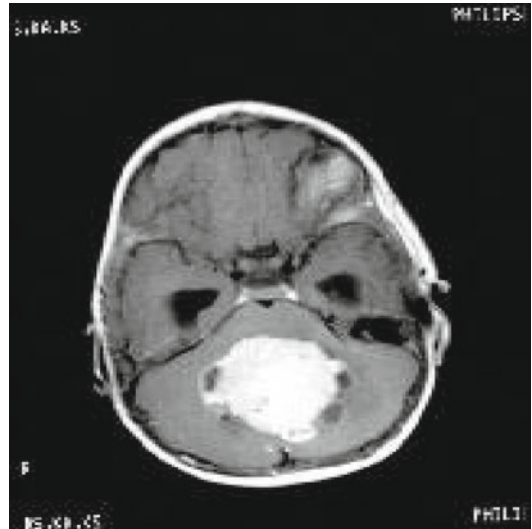
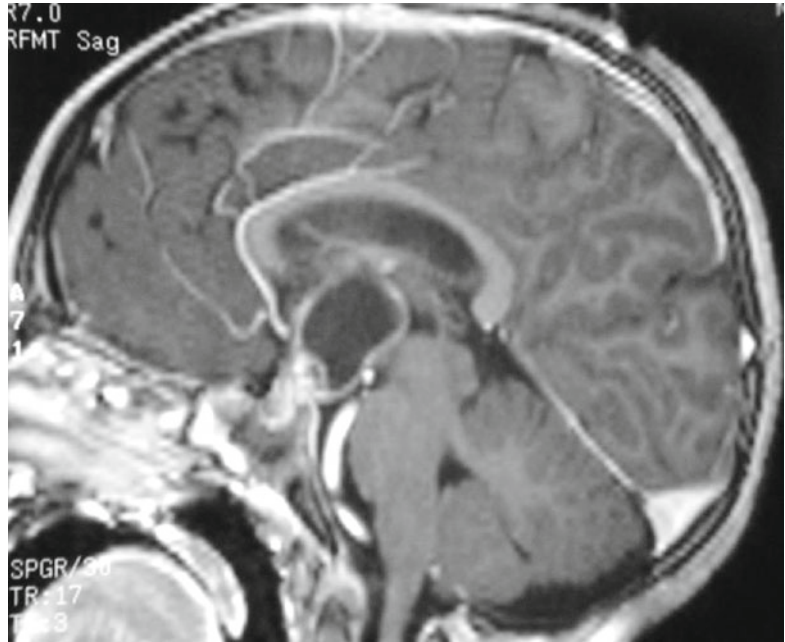


Fig. 6.15 Medulloblastoma

the brainstem or the floor of the fourth ventricle. About 30–50 % of all children will require treatment for hydrocephalus with either a shunt or an endoscopic third ventriculostomy. If not done preoperatively, a neuroaxis MRI scan for drop metastases and a spinal tap for cytology to determine CSF spread must be done immediately postoperatively. Medulloblastoma is very responsive to radiation therapy and to many chemotherapy drugs (Shiminski-Maher et al. 2002).

Medulloblastoma tumors are grouped into two broad categories: standard risk and high risk. A tumor that has been completely removed by surgery and has not spread to other areas of the CNS is called standard risk. Children with standard-risk medulloblastoma receive cranio-spinal radiation and chemotherapy during induction, with a chemotherapy backbone for maintenance. Progression-free survival for this group of children is approximately 75–90 % at 5 years. Those children who are younger than age 3 at diagnosis, who have spread of their disease within the neuroaxis, or who have greater than 5 cm<sup>3</sup> of tumor after surgery are considered high risk. Treatment for these children varies with age. For those younger than age 3, intensive chemotherapy with a tandem stem cell rescue is indicated to achieve a remission, until the child is older than 3 years of age when radiotherapy

**Fig. 6.16** Craniopharyngioma

can be used. Older children receive radiation with or without a radiosensitizing chemotherapy, followed by intensive chemotherapy with autologous stem cell rescue, if necessary (Shiminski-Maher et al. 2002).

#### 6.5.5.6 Primitive Neuroectodermal Tumors (PNET)/Pineoblastoma

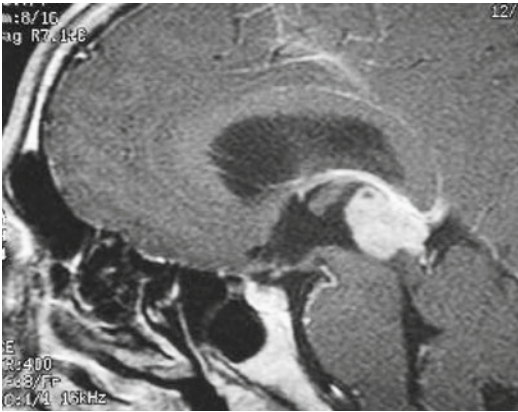
PNET and medulloblastoma were once considered the same type of tumor that arose in different locations in the brain. For many years, the two names were used interchangeably regardless of where the tumor grew. Historically, medulloblastoma was the name given to this tumor when it grew in the posterior fossa and PNET when it grew outside of the posterior fossa in the cerebral hemispheres. A PNET of the pineal gland is referred to as a pineoblastoma. Even though a gross total surgical removal is possible for PNETs depending upon location, their prognosis is generally worse than for children with posterior fossa medulloblastoma. However, they are usually treated with the treatment protocols for high-risk medulloblastoma (Shiminski-Maher et al. 2002).

#### 6.5.5.7 Dysembryoplastic Neuroepithelial Tumors (DNETs)

DNETs are very rare low-grade neuroepithelial tumors that are most common in the first two decades of life. They arise in the supratentorial cerebral cortex, often in the temporal lobes. Clinical presentation is almost always partial complex seizures. Surgery is the primary treatment and employed not only to remove the tumor but to treat the seizure disorder as well. If the entire tumor is not removed, the patient is observed with serial scans (Albright et al. 2007).

#### 6.5.5.8 Craniopharyngiomas

Craniopharyngiomas are the most common suprasellar brain tumor in children accounting for 6–8 % of all CNS tumors (Fig. 6.16). They occur most frequently in children and are rarely seen in the adult population. Despite clinically benign features, their location in the sella is in close proximity the hypothalamus, pituitary, and optic chiasm, resulting in significant morbidity and mortality. They precipitate multisystem abnormalities, including endocrinopathies, visual, cognitive, and social problems either at the time of



**Fig. 6.17** Germ cell tumor

tumor presentation or in conjunction with treatment. Treatment is controversial because aggressive surgery often cures the child but can cause lifelong memory, visual, behavioral, and hormonal problems. Taking out part of the tumor, followed by radiation therapy is a treatment option that can lessen the long-term side effects. Treatment depends upon the location and the size of the tumor and may include surgery from an intracranial or transsphenoidal approach, observation, or focused radiation therapy (Shiminski-Maher and Rosenberg 1990).

### 6.5.5.9 Germ Cell Tumors

Germ cell tumors typically grow in the pineal or suprasellar regions (Fig. 6.17). There are two types of germ cell tumors: pure germinomas and non-germinoma germ cell tumors. Non-germinoma germ cell tumors secrete substances called tumor markers. Doctors can diagnose these tumors by checking the blood or CSF for two markers, called alpha fetal protein (AFP) and beta human chorionic growth factor (bHCG). Therefore, diagnosis of a non-germinoma tumor does not require surgery. If the tumor is very large, however, part of it is removed (debulked) if the neurosurgeon feels it can be done with few to no side effects. Treatment for non-germinoma germ cell tumors includes chemotherapy followed by radiation (Shiminski-Maher et al. 2002).

Pure germinomas are diagnosed by a surgical biopsy. These tumors dramatically respond to radiation and chemotherapy. Radiation therapy is the standard of care for treatment. Recently, physicians have given chemotherapy following surgery, with a reduction in the dose of radiation for those tumors that completely disappear with the chemotherapy. This is an attempt to reduce the dose of radiation needed, possibly reducing long-term side effects. If the tumor disappeared after chemotherapy, the radiation dose is usually reduced (Shiminski-Maher et al. 2002).

### 6.5.5.10 Choroid Plexus Tumors

Choroid plexus papillomas (slow-growing) or choroid plexus carcinomas (fast-growing) arise from the choroid plexus located in the ventricles. The choroid plexus is the part of the brain that produces cerebrospinal fluid. These tumors account for 1–3 % of all childhood brain tumors, and most often occur in infants. The tumor is usually diagnosed simultaneously with hydrocephalus. Surgery followed by observation is the treatment for choroid plexus papillomas. Surgery followed by chemotherapy and radiation is the treatment for choroid plexus carcinomas (Shiminski-Maher et al. 2002).

### 6.5.5.11 Dermoids, Epidermoids, Eosinophilic Granulomas, and Histiocytosis X

Dermoid and epidermoid cysts/tumors arise from dermal and epidermal tissues. They are benign tumors that can be found anywhere in the CNS. Scalp dermoid and epidermoid tumors can be surgically removed and rarely regrow. Intracranial and intraspinal dermoid or epidermoid tumors are rare and are treated with maximal surgical removal (Maher and Raffel 2004).

Eosinophilic granulomas and histiocytosis are tumors which primarily affect the skull or spine. They present as painful lesions, and treatment involves surgical removal with margins whenever possible. Bone grafting may be necessary if there is a large bone defect after the lesion is removed. *Langerhans cell histiocytosis (LCH)*

can be unifocal or multifocal. Unifocal disease is referred to as eosinophilic granuloma and is treated primarily with a surgical removal, and with bone grafting as needed. Multifocal lesions also can occur, and in greater than 50 % of the cases, the lesions involve the pituitary stalk with diabetes insipidus occurring. In the case of multifocal disease, systemic chemotherapy is required (Albright et al. 2007).

---

## 6.6 Infant Tumors

Children diagnosed with a CNS tumor in infancy should be discussed separately. These tumors are more difficult to treat because they are often aggressive histologically and any treatment will have an effect on the rapidly developing brain. The most common types of tumors associated with infancy are astrocytomas, PNETs, ependymomas, and choroid plexus tumors. Surgery is the primary treatment for all infant CNS tumors. If adjunctive treatment is necessary, most clinicians advocate utilizing chemotherapy in an attempt to delay radiation therapy. Radiation is recommended for children less than 3 years of age only as a last resort (Lieberman and Berger 2001).

---

## 6.7 Posterior Fossa Syndrome

Posterior fossa syndrome (also called cerebellar mutism) is a complication of posterior fossa (cerebellum or brainstem) surgery. The most common tumors in this area are medulloblastomas, astrocytomas, and ependymomas. Most children wake up from the surgery moving their arms and legs and responding to questions. In some cases, 24 or more hours later, the child stops talking, may develop weakness of arms and legs, and cranial nerve deficits appear. Emotionally, the children seem disconnected from their environment and may respond by simply crying. These symptoms improve over a period of days in the minimally affected child, but improvement may take months in the

severely affected child. Physical, occupational, and speech therapy should be started immediately. Children who have severe posterior fossa syndrome require transfer to an inpatient rehabilitation center (Kirk et al. 1995).

---

## 6.8 Nursing Care

### 6.8.1 Overview

Nursing management for the child with a CNS tumor is dependent upon many variables, including age at diagnosis, specific type of tumor, neurological deficits, treatments required, and the individual family dynamics present to deal with the illness. All patients and families have a need for education and emotional support throughout all facets of the illness. The management of children with CNS tumors involves a large multidisciplinary team, including nurses, pediatricians, pediatric neurosurgeons, neurologists, oncologists, endocrinologists, radiologists, social work, child life, and radiation oncologists to name a few. Nurses and nurse practitioners are the health-care providers who have the majority of contact with the patient and families both in the hospital and as coordinators of outpatient care. Thus, nurses serve as patient advocates, case managers, and educators in a liaison role between patient/family and various members of the medical team throughout the course of the illness. They are also responsible for coordination of reentry to school and normal life once the acute treatment phase is completed. Nursing intervention is indeed critical at diagnosis and throughout the treatment of pediatric CNS tumors (Shiminski-Maher 1993).

### 6.8.2 Developmental Considerations

It is uniformly accepted that children need to be told of their diagnosis and plan of treatment as soon as possible. Delay in providing information only will escalate the child's fears. Parents may delude themselves into thinking that the diagnosis is a secret, but children are very perceptive.

Nurses can assist parents in providing developmentally appropriate information to their children. Nurses can also ensure that age-appropriate explanations are provided to patients prior to any procedure or treatment given. Educational materials should be provided for the families whether written, video, or access to the Internet. The children and families should be encouraged to ask questions and keep a notebook with information regarding the diagnosis and treatment, as well as tests that have been performed and results (Shiminski-Maher et al. 2002).

### 6.8.3 Diagnosis

The nurse's main responsibility during the diagnostic period is to provide the child and family with information about why various tests are being performed and how to prepare their child or each test. Nursing management of the patient undergoing diagnostic studies includes a large amount of patient/family education and coordination of diagnostic activities. Most young children (and older children whose level of consciousness is altered) receive conscious sedation or anesthesia for their MRI scans. The nurse must monitor the child closely for signs and symptoms of increased intracranial pressure and seizures. If the child is not hospitalized during the diagnostic testing phase, instructions should be given to the family regarding the signs and symptoms of increased intracranial pressure and seizure precautions as indicated. Patient/family education should reinforce information given to the parents, including information on how to contact the medical team with any questions or concerns (Shiminski-Maher 1990).

Obviously, the acuity of the situation will determine the extent of preparation the nurse can provide for the child and family. A neurologically unstable child may go from the emergency room, to the scanner, and then to the operating room. In other situations, the surgery is planned as an elective procedure with the child at home prior to the surgery. Whenever possible, nurses should be present when the physician presents the information about diagnosis and treatment to the child

and family. The nurse will be able to reinforce and clarify information communicated as well as answer some of the many questions that will arise later. The nurse can provide preoperative education, including location of incision, bandages, presence of a drain or shunt postop, and other tubes that may be needed. Diagrams, booklets, and other audio-video tools assist in this preparation. Nurses can also refer the child and family to social work and child-life teams to reinforce this information (Shiminski-Maher 1993).

### 6.8.4 Surgery

Nursing care of the postoperative pediatric CNS tumor patient depends upon the location of the tumor, extent of surgical removal, and clinical condition of the patient. Intraoperative guidance systems have dramatically reduced the size of many craniotomies and thus impacted positively on the recovery period for these children. Where children with CNS tumors would spend 2–5 postoperative days in an intensive care setting 10 years ago, today they spend on average 1–4 days. Intensive care monitoring is based upon level of consciousness. Most children are able to maintain their own airway and are extubated at the end of the surgery. For those children, it is a matter of careful hourly assessment for changes in level of consciousness or increased intracranial pressure for the first 24 h postoperatively. Hourly neurological checks and vital signs will allow nurses to alert the physicians of change in neurological status. Intracranial pressure monitoring is utilized for operations where the child is neurologically impaired preoperatively, if there is a sudden bleed or change in intracranial dynamics during the operation, or if intraoperative monitoring shows a change in the integrity of the nervous system in a specific region. Intracranial pressure can be monitored from a transducer through an externalized drain or, if no hydrocephalus is present, through an external ICP monitor, called an intraparenchymal wire, inserted between the bone and the brain tissue (Hickey 2009).

Surgically removing some or all the tumor is the first step in treating increased intracranial



pressure. The presence of an external drain to remove CSF allows for further controlling the intracranial pressure. Intravenous steroids, most commonly dexamethasone, are used to combat swelling. Further medical management includes the addition of osmotic diuretics such as mannitol and the utilization of intubation and hyperventilation. The prognosis is poorer if the child requires the latter. As in most positive outcomes with medical management, the least amount of medical intervention required usually results in the best outcome in terms of long-term survival and ultimate cure (Shiminski-Maher et al. 2002).

Children are released from the intensive care unit when they are neurologically stable, usually within 24–48 h postoperatively. A steroid taper is begun with the attempt to stop steroids as soon as possible. The long-term side effects of steroids have to be weighed with the side effects of long-term steroid use. These side effects of steroids include increased appetite and weight gain, irritability, difficulty sleeping, and muscle weakness. In addition, long-term steroids can adversely weaken the immune system. It is understood that the use of postoperative steroids makes the exam of a child “better than reality.” Steroids are only increased if there is a severe loss of function in a short period of time in a particular patient (Shiminski-Maher et al. 2002).

The use of postoperative anticonvulsants is necessary for children who presented with seizures preoperatively or for those who have tumors in areas of the brain where seizures can occur because of location. Intra- or postoperative seizures can occur in an area of the brain prone to epileptical activity that is associated with the removal of the tumor or associated interference with normal electrical activity in adjacent areas. Pre- and postoperative 24-h electrocorticography may be necessary for tumors where removal of the tumor and removal of an adjacent seizure focus is necessary. The recent advances in monitoring activity have resulted in long-term remission from the tumor, as well as eventual cure of a seizure problem, with removal of all anticonvulsants, in a tumor associated with seizures (Cataltepe et al. 2005).

Patients who have hypothalamic and pituitary tumors are at risk for the development of diabetes

insipidus (DI), or syndrome of inappropriate secretion of antidiuretic hormone (SIADH), as a result of the tumor or the surgeon injuring the pituitary stalk. In the normal individual, water balance is controlled by the release of vasopressin from the posterior pituitary gland. The hypothalamus produces and releases the hormone, which travels via the pituitary stalk to the posterior pituitary gland where it is stored. Vasopressin is circulated to the kidney where it controls the amount of water retained or excreted. Vasopressin’s hormonal influence controls the salt and water balance within the body. Imbalance in this system secondary to increased or decreased amounts of circulating vasopressin is commonly associated with DI or SIADH. Children with suprasellar, hypothalamic, or pituitary tumors are at risk for primary DI, while SIADH can occur as a result of overtreatment of DI or because of confusion with salt-wasting issues which occur in injury to the posterior fossa and brainstem. Careful monitoring of fluid intake and output, as well as serum and urine sodium levels, is necessary for regulation of water and sodium balance in the body. DI may be permanent or transient depending on the extent of injury to the pituitary stalk. If resolution of this problem is to occur, it usually will do so in the first 2 weeks after surgery (Shiminski-Maher 2000b). For nursing management of sodium problems, refer to brain injury chapter.

The majority of the suprasellar tumors are approached from an intracranial approach. Some tumors, however, may be approached from a transsphenoidal approach or in a two-step transsphenoidal and intracranial procedure. This approach is utilized in older children whose sphenoid sinuses are large enough to accommodate the approach. Postoperatively these children must be monitored carefully for leakage of CSF. Often, their noses are packed for a few days, and they are prohibited from nose blowing or sneezing (Maher and Raffel 2004).

For those children without significant intracranial pressure, seizure, or hormonal problems, careful monitoring is necessary for 24–48 h. Postoperative imaging is necessary within the first 2 days to determine the extent of tumor resection. For those children requiring sedation or anesthesia, nursing coordination is essential.

Physical and occupational therapy is ordered in the immediate postoperative period to begin working with any physical weaknesses that may be evident (Shiminski-Maher et al. 2002).

Pain management is different depending upon location in the CNS. Brain tumor surgery is generally less painful than spinal cord tumor surgery. Postoperative analgesics for intracranial surgery include a short period of opiates such as morphine, with a rapid switch to codeine or oxycodone, with or without acetaminophen. Nonsteroidal anti-inflammatory drugs such as ketorolac or ibuprofen are often used to potentiate the narcotic effects. Spinal cord operations usually require a longer course of opiates, usually with a patient-controlled analgesia (PCA). By the second postoperative day, the patient becomes increasingly mobile, with a decrease in intravenous narcotics and an increase in oral drugs. Switching from opioids to nonsteroidal anti-inflammatory medications while the dexamethasone (steroid) is decreased further aids in mobility (Albright et al. 2007).

Children with severe alteration in intracranial pressure or altered level of consciousness preoperatively, or those who are unstable during surgery, will require longer-term intensive care management postoperatively. Placement in an intensive care unit setting with intensive nursing monitoring is required. Airway, breathing, and circulation are the priorities. These are linked closely with intracranial pressure, which must be monitored constantly. Intake and output, management of fluid and electrolytes, especially sodium, and fluid balance is a key nursing function. Continued interface with the family members by the nurses to keep them up to date on the current clinical situation, as well as providing ongoing education about the illness, is also important. As an individual's clinical condition improves, the patient transitions into a less intensive level of care that focuses on maximal recovery (Albright et al. 2007).

The goal with all postoperative patients is to minimize the time spent in the intensive care unit and initiate rehabilitative treatments while decreasing steroids and any other pain medications as soon as possible. This goal will allow for maximization of physical function with the least

amount of medical support as the next step of the treatment process is identified. Nurses must assist patients and families in participating in physical therapy while minimizing medical support. They must also provide education as to the diagnosis of the tumor and the plan for further treatment (Shiminski-Maher et al. 2002).

### 6.8.5 Observation

For many children with CNS tumors, surgery is the only initial treatment. The next phase of treatment is simply clinical and radiographic observation. Other children get to the observation phase after having any combination of surgery, radiation, and chemotherapy. Whatever the course, families of children with CNS tumors who reach a period of observation do so with a certain amount of fear and anxiety about not having an "active treatment" plan. This period may include treatments which focus on residual clinical issues caused by the tumor and its treatment, such as physical, occupational and speech therapies, seizure medications, or hormonal replacements. MRI scans are needed at specific intervals based upon previous scans (Shiminski-Maher et al. 2002).

Nurses play a key role in the coordination of care in the observation phase. At this time, families often rely on the nurses for emotional support and to answer questions that may arise. They coordinate the scheduling of diagnostic tests and appointments with various medical teams. Nurses educate the parents or caregivers so that they can effectively advocate for their children within the medical and community systems. Education should emphasize return to school and other normal activities as soon as possible. To facilitate this, nurses can provide information and education to the school community regarding the illness and treatment and the importance of the child returning to school with as few limitations as possible (Shiminski-Maher 1993).

### 6.8.6 Radiation Therapy

Nursing intervention throughout radiation treatment involves coordination of the treatment

along with providing education to the child and family regarding the radiation and its potential adverse effects. Coordination of treatment is more complex for younger children who will require daily anesthesia. Ideally, these children should be scheduled in the morning to minimize the time of NPO status. Coordination also includes gaining the cooperation of the children to participate in the radiation treatments. Nurses collaborate with child life and social work in using play therapy to gain cooperation. Children who require positioning in a mold may be allowed to take it home in the evening to practice with it, thus increasing the child's comfort level. Allowing the child to visit the facility several times before the beginning of treatments will also decrease anxiety and increase cooperation (Halpern et al. 2010).

School-age and adolescent patients need support in coping with body issues of hair loss or other physical changes that may occur. While these children may not require sedation or anesthesia for daily treatments, they may need medication to help with the simulation of radiation, a lengthy session, which is the technical planning and measuring session. At this session, the child is marked so that he can be aligned in the same position for each treatment. Radiation markings are small ink marks that should not be scrubbed off in the bath. They do fade over time, and the technologist will mark over them as needed during the treatment (Halpern et al. 2010).

Nursing intervention throughout radiation treatment involves monitoring the patient for any side effects of radiation, as well as educating patients and families. Patients need to be instructed to watch for signs and symptoms of brain swelling as the treatments begin to take effect. This may include a reappearance of the tumor's presenting symptoms which, when not adequately prepared for, causes much anxiety. If the symptoms are dramatically interfering with the child's activities of daily living, a short course of steroids, or boosting of existing steroid dose with a subsequent taper, may improve things. As with surgical patients, steroids are important to treat acute problems but should be tapered as quickly as possible to prevent side effects (Shiminski-Maher et al. 2002).

Nutritional support of these children during radiation is important. Nurses should be monitoring for any decreased appetite or weight loss. Some children may experience nausea and vomiting after the treatment. The parents administering antiemetics prior to the treatment each day can prevent this. Children who lose an excessive amount of weight may require enteral feedings. In this situation, nurses must educate the family on how to provide the feedings (Petriccione 1993).

Toward the end of treatment and for a few weeks after treatment, it is not unusual for the patient to feel fatigue and increased sleepiness. This is usually short-lived, and, as with acute symptoms, severe cases can be treated with a short pulse of steroids. Lastly, children who are receiving craniospinal irradiation must have their complete blood count (CBC) monitored because bone marrow suppression is possible during the spine component of the treatment. Weekly CBCs and other appropriate blood tests are performed on children who are receiving chemotherapy at the same time as the radiation (Halpern et al. 2010).

### 6.8.7 Chemotherapy

The majority of children who receive chemotherapy will follow some type of treatment protocol. This includes very specific road maps or recipes for timing of drug administration and monitoring for side effects. Nursing care of the child receiving chemotherapy includes the actual administration of the drugs in most cases but also, as with radiation therapy, involves coordination of care and patient/family education and support. Monitoring for side effects of chemotherapy is another key nursing function. Common chemotherapy drugs and their side effects are listed in Table 6.3 (Shiminski-Maher et al. 2002).

Nausea and vomiting may occur with some of the chemotherapies. Nursing care includes administration of antiemetics and monitoring for adequate nutrition and hydration. Small, frequent meals may ensure adequate nutrition rather than traditional meal times. Fluid and electrolyte imbalances can occur during administration of chemotherapy and can be intensified in the child

**Table 6.3** Common chemotherapy drugs and side effects

Chemotherapy group	Specific drugs in group	Side effects of group
<i>Alkylating agents</i> : poison cancer cells by interacting with DNA to prevent cell reproduction	Busulfan	Common side effects:
	Carmustine (BCNU)	Myelosuppression
	Carboplatin	Nausea and vomiting
	Cisplatin	Anorexia and weight loss
	Cyclophosphamide (Cytosan)	Stomatitis
	Dacarbazine (DTIC)	Alopecia
	Ifosfamide	Less common but potential side effects:
	Lomustine (CCNU)	Hearing loss (cisplatin, carboplatin)
	Procarbazine	Kidney damage (cisplatin, carboplatin)
Temozolomide (Temodar)	Thiotepa	Hemorrhagic cystitis (cytosan, ifosfamide)
<i>Antimetabolites</i> : starve cancer cells by replacing essential cell nutrients necessary during synthesis phase of the cell cycle	Hydroxyurea	Myelosuppression
	Methotrexate	Skin rashes Photosensitivity Mouth sores
<i>Antibiotics</i> : prevent cell growth by blocking reproduction, weakening the membrane of the cell, or interfering with certain cell enzymes	Bleomycin	Alopecia
		Mouth sores
		Nausea and vomiting
		Anorexia and weight loss
		Lung toxicity
<i>Alkaloids</i> : derived from plant, interrupt cell division by interfering with DNA synthesis, specific enzyme activities, cell division, or disrupting the membrane of the cell to cause cell damage or death	Irinotecan (CPT-11)	Anorexia
	Topotecan	Myelosuppression
	Vinblastine	Nausea and vomiting
	Vincristine	Alopecia
		Peripheral neuropathy Constipation
<i>Hormones/steroids</i> : create a hostile environment that slows cell growth	Dexamethasone	Increased appetite
	Methylprednisolone	Mood changes
	Prednisone	Weight gain Sleep loss
<i>Antiangiogenesis</i> : disrupt the blood supply to a tumor, depriving it of nutrients necessary to grow	Thalidomide	Peripheral neuropathy
		Drowsiness
		Constipation
		Myelosuppression

Source: Adapted from Shiminski-Maher et al. (2002)

with endocrine issues such as diabetes insipidus (Shiminski-Maher 1990).

Immunosuppression is one of the common side effects of chemotherapy; therefore, blood counts are monitored on a frequent basis as per the individual protocol. When blood counts are low, packed red blood cells may be given to treat anemia and platelets given to treat very low platelet levels. Children with decreased white blood cell counts must be isolated from sick people and

must be hospitalized if they have fever or any sign of infection. Some treatment protocols that induce severe immunosuppression advocate the use of marrow stimulants such as neupogen or erythropoietin to increase production of these cells. Immunosuppression is even more pronounced in the patient who has received or is receiving craniospinal irradiation. This radiation can affect the bone marrow's ability to recover following chemotherapy (Shiminski-Maher et al. 2002).

Several of the commonly used chemotherapies for the treatment of pediatric brain tumors also adversely affect hearing and kidney function. Children are routinely monitored with audiograms to assess for any change in hearing. Changes, if they occur, will do so in the high-frequency sounds first. Kidney function is monitored with blood and urine tests. Dose modifications of the chemotherapy are outlined in the protocols if adverse toxicity occurs. Nurses are responsible for checking these results prior to administration of chemotherapy and administering reduced doses as necessary. Peripheral nerve toxicity resulting in pain in the extremities and difficulty walking can also occur with some of the chemotherapies. This is exaggerated in children with CNS tumors who may have weakness from steroids and/or surgery. Nurses must ensure that these children are receiving physical and occupational therapy and, if toxicity is severely impairing activities of daily living, a dose modification as per the individual protocol may be required (Shiminski-Maher et al. 2002).

Nursing care for the child receiving high-dose chemotherapy with peripheral stem cell reinfusion involves all of the above interventions, with toxicities being expected. Such children have a greater chance at fever and neutropenia admissions, increased transfusion requirements, nutritional issues, and neurological complications. These children also spend more time in the hospital and thus are removed from school and other normal activities (Khatua and Jalali 2005).

### 6.8.8 The Multidisciplinary Team

Care of children with CNS tumors requires a multidisciplinary approach. These patients are cared for by neurosurgeons, neurologists, pediatricians, nurses/advance practice nurses, radiologists, endocrinologists, dieticians, neuro-ophthalmologists, neuropsychologists, social workers, child-life specialists, and psychologists to name a few. Primary responsibility for treatment and coordination of care may shift from one subspecialty to another depending upon whether the child is on active or inactive (observation) treatment. It is essential that the patient and

family know which health-care team(s) is coordinating care at any given time. Communication must exist within and between members of each team. This coordination most often falls to the patient, parents, or caregivers. Nurses and nurse practitioners are instrumental in providing parents the information and education that they need to advocate for their children. In situations where patients and/or caregivers are unable to coordinate or advocate, the nurse/practitioner can assume that role. Patients and families look to nurses for coordination of diagnostic testing, explanation and reinforcement of all procedures and surgery, and integration of information given to them regarding the treatment plan and side effects. The nurse can coordinate physician-patient-family conferences as necessary to clarify the current plan of care. In addition, the nurse can identify communication inconsistencies between members of consulting teams (Shiminski-Maher 1993) (Box 6.1).

#### Box 6.1. A Mother's Perspective

I was looking forward to having breakfast on Mother's Day with my two children, Kyle age 5 and Mia age 2. As a single mother, this day holds special meaning. My children are healthy, intelligent, and of course the best looking kids on the planet! I am feeling very blessed and look forward to planning the details of this wonderful day that we will be spending with other family members.

Mia stumbled into the kitchen and she looked awful. She fell to the floor moaning and crying. I knew in my heart that something was terribly wrong. I think I was stunned, because we had been to the family physician as well as various specialists to look into vague complaints such as neck pain and dizziness for the past several months. We could find nothing wrong, and I look back on that time wondering if we could have done things differently. Clearly was I not thinking that there was something very serious going on! Now, my "mother's intuition" kicked in, and I knew that I

needed to take action—now. I decided to take her to my local hospital that my family had known and been a part for many years, and our lives were to be forever changed. We were admitted to the hospital for the first of many tests, including an MRI which was performed the next day. I still was not convinced that there was something seriously wrong. That day was really a blur of tests, tests, and more tests. There was wonderful staff along the way, such as the child-life specialists who made everything so much easier for my child. One of the hospital physicians sat by Mia's bed and told me the news that the MRI showed a large brain tumor. He did not leave my side and offered to stay as long I needed him. He told me how wonderful the neurosurgeon was that we would be meeting the next day. Though I was assured of his skills, he was still a stranger to me. And, I am the kind of person who gathers lots of information before making a decision. This was all happening so fast!

She went to surgery the very next day, and the tumor was totally resected. I was relieved and thought we could now be going home. This was actually the beginning of a very long hospital stay that included chemotherapy, radiation, and a bone marrow transplant. Like many other families, I lived at that hospital. My family helped with the day to day dealings of every life and helped to care for Kyle. I came to know and count on everyone at the hospital, and they too felt like a part of my extended family. I could not have gotten through those terrible months without them!

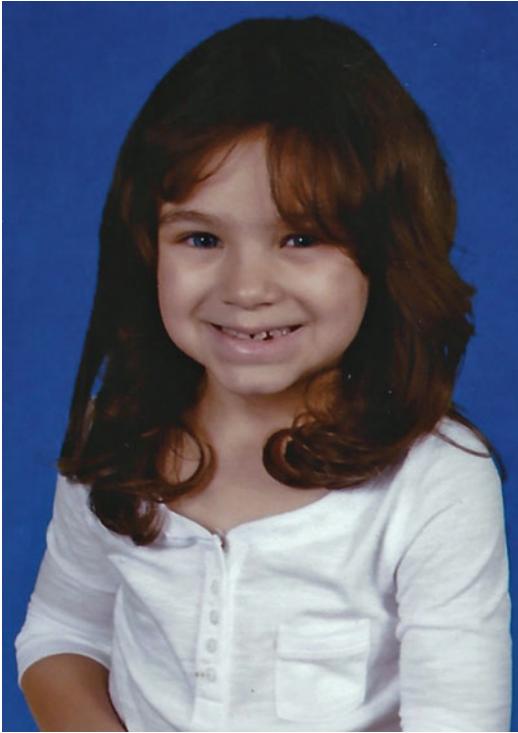Mia slowly turned the corner, and my spirits were lifted when I saw that she was looking forward to doing things for herself again and looked forward to going home. Once again, the staff came through for us, showing their compassion as they prepared us to leave the hospital and reenter our lives on the “outside.” I was scared to go to the

hospital in the beginning, but now, I was really scared to leave this place that took care of us for so long.

I think back on those days, and it seems like such a blur. Mia is doing well, and we have spent one full year of holidays away from the hospital. We will have scary times ahead with each follow-up test and MRI, but for now, we are doing well. I remain so grateful to the staff, especially our nurse practitioner and the entire neurosurgery team. They treated my daughter with such kindness and compassion, as if she was their family member. I am thankful every day for having them and the other staff that takes such good care of her and my family (Figs. 6.18 and 6.19).



**Fig. 6.18** Mia is feeling great!



**Fig. 6.19** Mia goes to the Neurosurgery Clinic and gets good news!

## 6.9 Late Effects of CNS Tumors and Treatment

It is a rare child that manages to complete treatment for a CNS tumor and walk away without some type of late effect. Each child and family will end a treatment phase and need to carve out a new “normal” life pattern. For some, physical changes or handicaps are a constant reminder of the diagnosis and treatment. This new life often includes physical, occupational, and/or speech therapy and coping with learning issues. Others require hormonal replacement or medications for seizure disorders. All survivors of CNS tumors are seen periodically for imaging studies and follow-up with their individual physicians or in a multidisciplinary follow-up clinic (Robinson 2005).

## 6.10 School Reentry: Physical and Neurocognitive Sequelae

Children with CNS tumors often experience disruptions in their education due to repeated

hospitalizations, cycles of treatment and therapy, physical weakness and fatigue, and the cumulative effects of medications, surgery, chemotherapy, and radiation. In addition, many children also have neurological changes, including seizures, behavior disorders, memory problems, or visual deficits. For many children, school is a refuge from the life of a CNS tumor with hospitalizations and procedures. Other children, especially teenagers or those with visible impairments, may dread returning to school. Lastly, subtle learning issues, when not handled in a sensitive manner, can affect a child’s confidence and self-esteem. All of these issues can be managed with good planning and communication via the parents, educators, and health-care providers. Nurses can provide information, guidance, or be an advocate for the parents and/or child. They can also provide the school professionals with information regarding CNS tumors in general and specific issues related to a given child’s plan of care (Shiminski-Maher et al. 2002).

It is helpful for children with CNS tumors to maintain some connection to the school throughout the diagnosis and treatment. Being able to attend school during windows of no active treatment or even during treatment on “off days” is helpful in maintaining relationships. Home schooling or tutoring is often necessary even if the child can attend school some of the time. The majority of children with CNS tumors will ultimately have some type of physical or cognitive impairment, and this requires assessment for an individual education plan (IEP). The extent of the needs will depend upon the location of the tumor and treatments utilized. Those children who have received radiation therapy will have more intensive cognitive issues, specifically with visual spatial skills, memory, attention, speed of information processing, and verbal fluency (Moore 1995).

The IEP mechanism evaluates all aspects of the individual’s learning styles and physical needs, and then a plan is developed as collaboration between parents and professional educators to determine the curriculum and how it will be taught. It may be focused on preparation for college, vocational training, or simply independent living skills with education (spe-

cial or mainstream), speech therapy, physical and occupational therapy, and counseling. Nurses, as part of the health-care team, can interface with the family and school and advocate for an IEP to happen (Shiminski-Maher et al. 2002).

### 6.10.1 Ototoxicity Late Effects

Children who have received cranial radiation or ototoxic chemotherapy have a significant risk of hearing problems that can interfere with their learning potential. High-frequency sounds is the first to be affected and interferes with children's ability to sort out background noise. In a classroom situation, this prevents children from hearing the teacher above peripheral noise. Amplification systems for the child in the classroom may help the child with this problem. More severe ototoxicity can result in substantial hearing loss requiring hearing aids (Moore 1995).

### 6.10.2 Neuroendocrine Late Effects

The most common neuroendocrine effects of CNS tumors and their treatment are hormone deficiencies. This can happen in children who have midline tumors but can also happen after treatment with chemotherapy alone and almost always occurs in the child who has received radiation treatments. Endocrine problems include growth, thyroid, and secondary sex hormonal deficiencies. An endocrinologist who will monitor growth rate and pubertal status, as well as obtain blood tests to check for thyroid and growth hormone deficiency, must follow all children and adolescents with CNS tumors. Films to determine bone age are obtained, prior growth curves evaluated, and linear growth closely monitored. Hormonal replacement is necessary for many of these children, with thyroid replacement taken by mouth and growth and secondary sex hormones given by injection. Nurses can coordinate follow-up appointments and also can teach the child and family about the administration of hormonal replacement (Lerner et al. 2005).

### 6.10.3 Psychological/Social Late Effects

The diagnosis and treatment of CNS tumors can bring with them significant psychological and social sequelae. Body image changes that are visible such as a hemiparesis, facial weakness, or hair loss can adversely affect the development of a positive self-esteem. If the child has missed a lot of school or is having educational difficulties, then completing the educational process is difficult. Nurses can play an integral role in mainstreaming children as early as possible and in connecting these patients with educational specialists and rehabilitation early on to foster as normal a life as possible. As the number of long-term survivors of CNS tumors increases, as has happened with other childhood cancers, there will be a greater need for such specialized clinics and programs of which nursing can have an integral role (Shiminski-Maher et al. 2002).

### 6.10.4 Secondary Cancers: Late Effects

As the long-term survival for all childhood cancers has increased with improvements in treatment, so has the incidence of second primary cancers as a side effect of chemotherapy and more commonly radiation therapy. There are reports of secondary meningiomas or cavernomas after whole-brain irradiation. While the overall number of secondary cancers for all childhood cancers is less than 2 %, there is not enough data in survivors of pediatric CNS tumors to quantify the risk. This will be followed closely in long-term follow-up clinics and as part of future cooperative group studies (Robinson 2005).

### 6.10.5 Recurrence, Death and Dying, and Hospice

Recurrence or progression can happen at any time during treatment or after therapy is completed. When this occurs, the patient's history, clinical information, pathology, and sequential radiology studies are presented at the tumor board and a new treatment plan designed. This may include surgery, radiation (if it has not already



been given), or chemotherapy. Experimental drugs including new chemotherapeutic drugs may be tried in patients who have undergone multiple previous standard treatment modalities. As with all aspects of care, nurses can provide education and emotional support to families in this situation (Shiminski-Maher et al. 2002).

For some children with CNS tumors, there comes a time where treatments have stopped working and the tumor continues to grow. Some families want to try every available treatment and exhaust all possible medical remedies. For those who choose to discontinue active treatment, the focus shifts to end-of-life care, either in the hospital setting, at home on hospice, or a combination of both. Hospice programs not only assist the child in comfort but also allow the family to receive support and counseling as their family member dies (Shiminski-Maher et al. 2002).

### Conclusion

The diagnosis of a CNS tumor in the pediatric population does not always carry the poor prognosis that it did several decades ago. Technology is now available to successfully diagnose, treat, and cure many children with CNS tumors. The MRI helps surgeons plan delicate surgeries and radiation treatments that allow newer machines to deliver more focused doses of radiation and hopefully minimizing side effects. Chemotherapy has been shown to penetrate the blood-brain barrier, and many drugs have been found effective in destroying CNS tumor cells. The enrollment and participation in national clinical trials has significantly impacted our understanding of various subsets of CNS tumors and customizing treatment protocols (Shiminski-Maher et al. 2002).

We know that each tumor is different and that tumors within the same disease groups may behave differently. Children with tumors that are maximally removed with surgery have a much better prognosis and longer period to progression of disease than do tumors that cannot be removed. Slow-growing tumors may remain dormant for months or years without treatment, and some slow-growing tumors will shrink in size with chemotherapy treatments. The greatest success in the treatment of

malignant CNS tumors comes in the areas of medulloblastoma, PNET, and germ cell tumors. Radiation treatments are withheld in younger children whenever possible and also delayed in children with slower growing tumors in an attempt to spare intellectual development. Rehabilitation advances and the existence of special education programs have fostered independent living for long-term survivors of CNS tumors who have neurological impairment. As technology continues to explode, there is good reason to believe that our results in the next generation will continue to improve (Shiminski-Maher et al. 2002).

The complex issues associated with pediatric CNS tumors demand a multidisciplinary health-care team to ensure optimal patient/family care. Nurses and advanced practice nurses are the consistent members of the team (along with the parents or primary caregivers), from diagnosis, through various treatment or observation periods through long-term follow-up. Parents or an identified advocate needs to be in charge to ensure checks and balances in the system so that optimal care is delivered. Patients and families look to nurses for coordination of diagnostic testing, explanation and reinforcement of all procedures and surgery, integration of information given to them by members of the medical team, education regarding the treatment plan and side effects, discharge teaching and planning, and, most important, caring and support throughout the course of the illness and follow-up. As with most things in life, those with the strongest, consistent and most cohesive team will win the championship (Shiminski-Maher 1993).

### Pediatric Practice Pearls

- The extent of tumor resection is the most significant factor in predicting long-term outcome.
- New advances in radiology and treatments have changed and will continue to positively impact the prognosis for children with central nervous system tumors.

- Care of children with CNS tumors requires a multidisciplinary team with nurses serving in the role of educator, coordinator, and advocate.

## References

- Abbott R, Epstein F, Shiminski-Maher T (1996) Tumors of the medulla: predicting outcome after surgery. *Pediatr Neurosurg* 25:41–44
- Albright AL, Sposto R, Holmes E, Zeltzer PM, Finlay JL, Wisoff JH et al (2000) Correlation of neurosurgical subspecialization with outcomes in children with malignant brain tumors. *Neurosurgery* 4:879–885
- Albright L, Pollack I, Adelson P (2007) *Principals and practice of pediatric neurosurgery*. Thieme, New York, pp 477–790
- Avellino A, Berger M (1997) Intensive care management of children with brain tumors. In: Andrews B, Hammer G (eds) *Pediatric neurosurgical intensive care*. The American Association of Neurological Surgeons, Park Ridge, pp 235–256
- Benz M, Benz M (2004) Reduction of cancer risk associated with pediatric computed tomography by the development of new technologies. *Pediatrics* 114:205–209
- Biagi E, Bollard C, Rousseau R, Brennan M (2003) Gene therapy for pediatric cancer: state of the art and perspectives. *J Biomed Biotechnol* 1:13–24
- Black P, Wen P (1995) Clinical imaging and laboratory diagnosis of brain tumors. In: Kaye A, Laws E Jr (eds) *Brain tumors*. Churchill Livingstone, Edinburgh, pp 191–214
- Cardis E et al (2010) Brain tumour risk in relation to mobile telephone use: results of the INTERPHONE international case-control study. *Int J Epidemiol*, 10:1–20
- Cataltepe O, Turnanli G, Yalnizoglu D, Topcu M, Akalan N (2005) Surgical management of temporal lobe-related epilepsy in children. *J Neurosurg* 102(3 suppl):280–287
- Finlay JL, Wisoff JH (1999) The impact of extent of resection in the management of malignant gliomas of childhood. *Childs Nerv Syst* 15:786–788
- Halpern E, Constine L, Tarbell N, Kun L (2010) *Pediatric radiation oncology*. Lippincott Williams & Wilkins, Philadelphia
- Hickey J (2009) *The clinical practice of neurological and neurosurgical nursing*, 6th edn. Lippincott Williams & Wilkins, Philadelphia
- Jallo G, Freed D, Epstein F (2004) Spinal cord gangliogliomas: a review of 56 patients. *J Neurooncol* 68:71–77
- Khatua S, Jalali R (2005) Recent advances in the treatment of childhood brain tumors. *Pediatr Hematol Oncol* 5:361–371
- Kirk E, Howard V, Scott C (1995) Description of posterior fossa syndrome in children after posterior fossa brain tumor surgery. *J Pediatr Oncol Nurs* 12:181–187
- Kirsch D, Tarbell N (2004) New technologies in radiation therapy for pediatric brain tumors: the rationale for proton radiation therapy. *Pediatr Blood Cancer* 42:461–464
- Lerner SE, Huang GJ, McMahon D, Sklar CA, Oberfield SE (2005) Growth hormone therapy in children after cranial/craniospinal radiation therapy: sexually dimorphic outcomes. *J Clin Endocrinol Metab* 12:6100–6104
- Lieberman D, Berger M (2001) Brain tumors during the first two years of life. In: Albright AL, Pollack I, Adelson PD (eds) *Operative techniques in pediatric neurosurgery*. Thieme, New York, pp 125–129
- Maher C, Raffel C (2004) Neurosurgical treatment of brain tumors in children. *Pediatr Clin North Am* 51:327–357
- Mehta V, Chapman A, McNeely PD (2002) Latency between symptom onset and diagnosis of pediatric brain tumors: an Eastern Canadian geographic study. *Neurosurgery* 51:365–373
- Moore IM (1995) Central nervous system toxicity of cancer therapy in children. *J Pediatr Oncol Nurs* 12:203–210
- Muszynski C, Constantini S, Epstein F (2001) Intraspinal intramedullary neoplasms. In: Albright AL, Pollack I, Adelson PD (eds) *Operative techniques in pediatric neurosurgery*. Thieme, New York, pp 193–200
- National Cancer Institute (2008) Radiation risks and pediatric computed tomography (CT): a guide for health care providers. Retrieved from <http://www.cancer.gov/cancertopics/causes/radiation-risks-pediatric-ct>. Accessed 12 Dec 2011.
- Petriccione MM (1993) Central nervous system tumors. In: Foley G, Fochtman D, Mooney KH (eds) *Nursing care of the child with cancer*. W.B. Saunders, Philadelphia, pp 239–253
- Robinson LL (2005) The Childhood Cancer Survivor Study: a resource for research of long-term outcomes among adult survivors of childhood cancer. *Minn Med* 4:45–49
- Ryan J, Shiminski-Maher T (1995) Hydrocephalus and shunts in children with central nervous system tumors. *J Pediatr Oncol Nurs* 12:223–229
- Shiminski-Maher T (1990a) Brain tumors in childhood: implications for nursing practice. *J Pediatr Health Care* 4:122–130
- Shiminski-Maher T (1990b) Diabetes insipidus and syndrome of inappropriate secretion of antidiuretic hormone in children with midline suprasellar brain tumors. *J Neurosci Nurs* 22:220–226
- Shiminski-Maher T (1993) Physician-patient-parent communication complications. *Pediatr Neurosurg* 19:104–108
- Shiminski-Maher T, Rosenberg M (1990) Late effects associated with treatment of craniopharyngiomas in children. *J Neurosci Nurs* 22:220–226
- Shiminski-Maher T, Shields M (1995) Pediatric brain tumors: diagnosis and management. *J Pediatr Oncol Nurs* 12:188–198
- Shiminski-Maher T, Wisoff J (1995) Pediatric brain tumors. *Crit Care Clin North Am* 7:159–169
- Shiminski-Maher T, Cullen P, Sansalone M (2002) *Childhood brain and spinal cord tumors: a guide for families, friends and caregivers*. O'Reilly Associates, Sepastopol

- Sundgren P (2010) Advanced imaging techniques in brain tumors: an issue of neuroimaging. *Neuroimaging Clin N Am*, 4:657–658
- Watral M (2009) Central nervous system tumors. In: Kline N (ed) *Essentials of pediatric hematology/oncology-nursing*. Association of Pediatric Hematology/Oncology Nurses. pp 28–32
- Yock T, Tarbell N (2002) Technology insight: proton beam radiotherapy for treatment in pediatric brain tumors. *Nat Clin Pract Oncol* 1:97–103

Angela Hoersting and Jodi E. Mullen

---

## 7.1 Introduction

### 7.1.1 Epidemiology

Despite prevention efforts, pediatric head trauma remains the most common cause of serious injury and death in children. Seventy-five percent of children who are hospitalized secondary to trauma sustain a traumatic brain injury (TBI). Most pediatric TBI is mild in severity, although central nervous system (CNS) injury is the most common cause of pediatric traumatic death (Greenberg 2010). While the statistics will vary in other countries, those in the United States are illustrative. In the year 2007, there were a total of 5,500 pediatric TBI-related deaths in the United States. The Centers for Disease Control (CDC) data from 1997 to 2007 shows that the rate of TBI-related deaths has decreased in all pediatric age groups. The rate decreased by 8.2 % from 1997 to 2007 and by 11.4 % in the earlier period from 1989 to 1998. The leading causes of TBI-related deaths in young children (birth to 1½ years) are falls, motor vehicle accidents (MVAs), and abuse, whereas the causes in adolescents

shift to MVAs and assaults (Doppenberg and Ward 2008). TBI-related deaths from MVAs are higher in adolescents (12 per 100,000 in 15–24-year-olds) than for any other age group throughout the lifespan (Coronado et al. 2011).

Pediatric TBI is also a substantial contributor to the health-related financial burden in the United States. According to Schneier et al. (2006), 50,658 pediatric (0–17 years) TBI hospitalizations in the year 2000 resulted in over \$1 billion dollars in inpatient expenses. In addition, many childhood survivors of severe TBI are left with varying degrees of permanent disability and require ongoing rehabilitative care.

Pediatric TBI-related injuries are often preventable. Prevention efforts have been directed toward car seat, seat belt, and helmet safety laws, as well as injury prevention education programs (Coronado et al. 2011; Ragheh 2008). The reduction in pediatric deaths in the United States referenced above can be attributed in part to such efforts.

---

## 7.2 Pediatric Anatomy and Physiology in Head Trauma

The adage “children are not just small adults” holds true when discussing pediatric head trauma. The pediatric craniocerebral anatomy increases the child’s vulnerability to head trauma, but also protects against worsened

---

Carol Green and Sherry Kahn were authors on the first edition but did not contribute to the revision of this chapter

---

A. Hoersting, MS, RN, CPNP-AC (✉)  
The Children’s Medical Center of Dayton,  
One Children’s Plaza, Dayton, OH 45404, USA  
e-mail: hoerstinga@childrensdayton.org

J.E. Mullen, MS, RN-BC, CCRN, CCNS  
Pediatric Intensive Care Unit,  
Shands Hospital for Children, University of Florida,  
Gainesville, FL 32610, USA  
e-mail: jodimullen7@gmail.com

severity and outcome. In general, children under the age of 2 years or who are nonverbal require a higher level of suspicion for injury. They lack the ability to communicate what has happened to them and what they are feeling. The exam is often less revealing based on the child's developmental age.

### 7.2.1 Skull

The physically larger and proportionately heavier pediatric cranium, together with the greater laxity of the cervical spine, creates a fulcrum and predisposes children to traumatic injury of the head and cervical spine. An infant's skull consists of a single layer, with open sutures between eight cranial bones. Open cranial sutures are protective against gradual increases in intracranial pressure, such as from tumors or hydrocephalus. Rapidly expanding mass lesions, however, are not tolerated and result in increased intracranial pressure (ICP). The head circumference of infants should be measured and recorded on admission and daily, as a rapidly increasing head circumference is indicative of increased ICP. Presence of bulging or firm fontanelles, with the infant calm and in an upright posture, can also be an indicator of increased ICP. The skull becomes a closed system by 4 years of age (Doppenberg and Ward 2008).

The infant's skull is thinner, softer, and more deformable when fractured, but heals quickly after fracture due to accelerated bone growth. The temporal and parietal regions are the thinnest cranial bones and the most common sites of accidental fracture. The thickest cranial bones are the frontal and occipital. Occipital fractures are related to more serious brain injuries due to the increased force necessary to generate a fracture in the thickest bone of the skull (Greenberg 2010). The pediatric skull can absorb a significant impact with little external evidence of significant intracranial injury. When evaluating the head-injured child, the nurse must consider all external indications, such as bruising, swelling, and lacerations, as well as the mechanism of injury and the degree of neurologic deficit.

### 7.2.2 Brain

The pediatric brain is softer due to higher water content and less white matter myelination. The subarachnoid space is wider. The thin pediatric skull, soft brain, and large subarachnoid space allow increased movement of the brain within the skull, which makes the child more susceptible to brain injury, including extraparenchymal hemorrhage, shearing or tearing of neuronal processes, and diffuse axonal injury (Barkovich 2005; Dias 2004; Doppenberg and Ward 2008). Young children are more susceptible to shear-type injury and less susceptible to mass lesions, with the incidence of mass lesions increasing to that of an adult as the child ages (Doppenberg and Ward 2008). The thin cranium, pliable brain, and open sutures allow infants and toddlers to tolerate mass hemorrhage better than older children. The pressure-volume curve is shifted to the left, meaning that children tolerate acute increases in intracranial volume poorly. Children have a smaller intracranial space, in which smaller increases in volume produce exponentially larger increases in ICP.

---

## 7.3 Initial Evaluation and Resuscitation

Following traumatic injury involving the head or neck, the child should arrive in an emergency department secured on a backboard and wearing a well-fitted cervical collar. A comprehensive multidisciplinary trauma evaluation should be performed to assess for multiple injuries. Immediate baseline neurologic examination should occur simultaneously with evaluation and resuscitation of airway, breathing, and circulation. Neurologic examination should be performed consistently and be clearly documented on arrival and at frequent intervals. Critical evaluation of trends in the neurologic exam, vital signs, and ICP measurements is the most sensitive method of detecting early neurologic deterioration (Andrews and Hammer 1997).

**Table 7.1** Initial history and physical in TBI

<i>Subjective:</i> Witness to mechanism of event (i.e., police, EMT, parent report, photographs), loss of consciousness (LOC), anterograde or retrograde amnesia, witnessed traumatic seizure, abnormal behavior or vomiting, cardiorespiratory compromise/resuscitation, immobilization of cervical spine, improved or worsened exam after initial resuscitation
<i>Objective:</i> General survey for multiple traumatic injuries, including spine. Survey for cranial injury: scalp hematoma; laceration, contusion, or abrasion; open or penetrating intracranial injury. Evidence of basal skull fracture includes: Battle's sign, raccoon eyes, otorrhea, rhinorrhea, and hemotympanum. Facial fractures (LeFort – facial instability or step-off) may indicate serious neurologic injury
<i>Physical examination:</i> General assessment provides suspicion of location and severity of injury
Vital signs, LOC/mental status, GCS, orientation
Cranial nerve exam:
Olfactory nerve (CN I)
Optic nerve (CN II) – assess vision (Snellen card, finger counting, hand motion, light perception). Note: may have temporary cortical blindness 1–2 days after blow to back of head
Oculomotor nerve (CN III) – pupillary size and reaction to light, ptosis, abducted gaze
Oculomotor (CN III), trigeminal (CN IV), and abducens (CN VI) nerves – extraocular eye movements
Trochlear nerve (CN V) – facial sensation, sensory portion of corneal reflex
Facial nerve (VII) – facial movement, motor portion of corneal reflex
Acoustic nerve (CN VIII) – hearing
Glossopharyngeal (CN IX) and vagus (CN X) – intact gag and cough
Motor exam: cooperative – assess strength x4 extremities, uncooperative – movement to noxious stimuli (caution: differentiate seizure from posturing, and avoid mistaking spinal cord reflexive movement as indication of cerebral function)
Sensory exam: cooperative – differentiate tickle and pinch in all extremities, if uncooperative – assess for grimace and vocalization to central painful stimuli
Reflexes: DTRs, Babinski reflex, clonus
<i>History:</i> Any previous head injury – timing, frequency, severity, other PMH such as bleeding dyscrasias, seizures, medications and allergies, NPO status, alcohol or drug use, metabolic abnormality (i.e., IDDM)
Previous developmental or cognitive impairments (Greenberg 2010)

Infants and young children are not able to communicate the circumstances of their injuries. Therefore, the caregiver must rely on the report of parents or other historians regarding previous medical history, baseline neurologic/cognitive/developmental deficits, and vital information to determine the circumstances of the child's injury. Circumstances of the accident or trauma are vital to determine the mechanism of injury and the potential severity of the child's injuries. First responders provide vital information such as a photograph, description of the scene, or a police report. Witnessed loss of consciousness, amnesia before (retrograde) or after (anterograde) the event, posttraumatic seizures, initial clinical evaluation (GCS), cardiorespiratory collapse or hypotension, interventions provided, and patient's response (worsened or improved) should be

included in the paramedic's report to the trauma team (Andrews and Hammer 1997; Dias 2004). Table 7.1 includes elements of the traumatic brain injury history and physical examination.

### 7.3.1 Primary Versus Secondary Mechanism of Injury

Primary injury includes that which is present at impact, to include cortical contusions, lacerations, diffuse axonal injury (DAI), and brainstem injury. Secondary injury is that which develops subsequent to the impact. This includes injury from hemorrhage, edema, hypoxemia, ischemia (increased ICP or shock), and vasospasm. All patient management decisions and interventions are directed at preventing secondary injury (Greenberg 2010).

## 7.4 Neurologic Assessment and Deterioration in Pediatric Head Trauma

### 7.4.1 General Assessment

Inspection for external trauma, such as scalp or facial swelling, abrasions, laceration, or ecchymosis, can indicate traumatic brain injury. Palpable step-off or depression indicates skull fracture, which may be associated with contusion of brain, laceration of dura or brain, and CSF leak. Significant scalp swelling in the infant may be indicative of hemorrhage, which can cause anemia with pallor and tachycardia. A basilar skull fracture in the base of the anterior fossa causes “raccoon eyes” or periorbital ecchymoses and can be associated with rhinorrhea (CSF leak from the nares). Fracture in the base of the middle fossa causes “Battle’s sign,” or postauricular ecchymoses, and can be associated with otorrhea (leak of CSF from the ear). Hemotympanum can indicate temporal or basilar skull fracture. Otorrhea indicates disruption of the tympanic membrane (TM) related to temporal skull fracture. The cervical spine must be immobilized and protected from spinal cord injury until radiographic clearance is accomplished (Dias 2004; Greenberg 2010). The entire spine is immobilized, inspected, and palpated for deformity, swelling, tenderness, and crepitation. Refer to the spine chapter.

### 7.4.2 Vital Functions

Every patient assessment must begin with evaluation of adequate airway, breathing, and circulation, which are vital to sustain life. A decreased level of consciousness after TBI can interfere with protection of the pediatric airway and adequate ventilation. Inadequate ventilation results in hypercarbia and hypoxia, which cause vasodilation and secondary ischemic brain injury. Vasodilation and resultant ischemia contribute to further increases in ICP. Vital control centers located within the brainstem regulate respiratory and cardiac functions. Brainstem pathophysiology can be identified by changes in the vital

signs. The following abnormal respiratory rate and patterns indicate neurologic dysfunction secondary to progressive brainstem compression in increasing ICP (Dias 2004; Greenberg 2010; Hickey 2009):

- Cheyne-Stokes: rhythmic cycles of breaths, which gradually increase in amplitude and then trail off, followed by an expiratory pause; indicates diencephalic injury or bilateral hemispheric dysfunction
- Central neurogenic hyperventilation (rare): increased rate and depth of respirations, indicates pons dysfunction
- Apneustic (rare): a pause at full or prolonged (slow and deep) inspiration, indicates injury to the pons
- Ataxic: no pattern in rate or depth, indicates medulla or lower brainstem dysfunction with impending herniation, indicates injury to the respiratory centers in the medulla (also known as agonal respirations)
- Apnea: respirations cease with herniation

Following loss of autoregulation (the ability of the brain to maintain perfusion despite changes in systemic perfusion), the cerebral blood flow is dependent on the systemic blood pressure. Adequate systemic perfusion is critical following pediatric TBI because hypotension causes secondary injury and is associated with poor outcome (Zebrack et al. 2009; Pigula et al. 1993). Prevention and immediate correction of hypoxia and hypotension are imperative. A study by Zebrack et al. (2009) found that the odds of death and long-term disability were both more than three times higher for children who did not have their hypotension addressed in the field. In children, hypotension is a late sign, which indicates compromised systemic and likely cerebral perfusion. Other earlier indications of poor systemic perfusion include tachycardia, decreased LOC, signs of inadequate skin perfusion (capillary refill > 2 s), and decreased urine output (less than 1 cm<sup>3</sup>/kg/h). Hypertension occurs as a compensatory mechanism to maintain cerebral perfusion in the face of increased ICP. The mechanism, known as Cushing’s response, is activated by decreased cerebral blood perfusion and includes increased systolic blood pressure, widened pulse pressure, and bradycardia

(Hickey 2009). Cushing's triad is a classic presentation of vital signs, including hypertension, bradycardia, and increasingly abnormal respiratory pattern, which is a late and ominous sign of severe increased ICP and impending herniation (Dias 2004; Greenberg 2010; Hickey 2009).

### 7.4.3 Level of Consciousness

The child's level of consciousness (LOC) and whether it is worsening or improving are the most important indicators of neurologic status (Dias 2004; Curley and Moloney-Harmon 2001). The neurologically intact child is awake, alert, and responsive to his/her surroundings. Level of responsiveness varies with the developmental age of the child. Infants should respond to feeding and measures to console them (Curley and Moloney-Harmon 2001). Toddlers and older children should recognize and respond to their parents. Older children and adolescents should be able to follow commands. Children of all ages should respond to and withdraw from painful stimulus. After neurologic injury, pediatric head-injured victims may have degradation in LOC as follows: subtle restlessness, disorientation, and agitation; somnolence (arouses to full consciousness and resumes sleep if not stimulated); lethargy (requires vigorous stimulation to arouse to full consciousness); stupor (nearly unconscious, may moan or withdraw from pain); and finally coma (unresponsive) (Hickey 2009; Greenberg 2010). A worsening LOC suggests neurologic deterioration. Caution should be exercised not to mistake neurologic deterioration for pain or anxiety, as treatment of the same with narcotics or antianxiety agents will further blunt the neurologic exam and delay treatment. Any subtle change from documented baseline, including parental concern that child is "not acting right," must be taken seriously and reported to the physician.

### 7.4.4 Glasgow Coma Scale

The Glasgow Coma Scale (GCS) and the modified pediatric GCS measure the child's level of

consciousness (Table 7.2). As pediatric responses are different from those of adults, the GCS was modified to allow for consistent, objective, serial measurements of the child's level of neurologic responsiveness following TBI. The scale considers the child's best response, following adequate central stimulation to eye opening, motor, and verbal responses, with each assigned a score and the three scores totaled (Hickey 2009; Greenberg 2010). The scores range from 3 (lowest score indicating no response) to 15 (highest score indicating intact neurologic status). A worsening GCS and decreased level of responsiveness indicate a rise in ICP (Dias 2004). A change of two or more points on the GCS score is very significant and should be reported to the physician immediately.

It is important, when assessing responsiveness, for the nurse to use an adequately painful, central stimulus to elicit the child's best response. Application of firm pressure to the mandible, sternum, supraorbital area, or sternocleidomastoid muscle provides an adequate central painful stimulation (Marcoux 2005). Peripheral painful stimulation should be avoided, as it can elicit a spinal reflex. The spinal reflex arc is a response to peripheral sensory stimulation in which the sensory afferent fibers carry stimulation to the dorsal root and spinal cord. The signal synapses in the cord with the motor neuron in the anterior horn. Motor efferent fiber signals travel back to the neuromuscular junction, which elicits a muscle contraction (Hickey 2009; Young et al. 2008). The spinal reflex should not be confused as a demonstration of cerebral function.

The immediate post-resuscitation modified Glasgow Coma Scale (GCS) for Infants and Children score is used to rate the severity of pediatric head trauma, as well as to predict outcome. The severity of head trauma is determined by the following:

- GCS 14–15 = mild head trauma
- GCS 9–13 = moderate head trauma
- GCS < or equal to 8 = severe head trauma (Greenberg 2010)

Coma is defined as the inability to arouse or interact with the environment. A GCS of 8 or less is an operational definition of coma (Greenberg 2010).



**Table 7.2** Modified Glasgow Coma Scale for Infants and Children (Hickey 2009)

Response	Child	Infant	Score
Eye opening	Spontaneous	Spontaneous	4
	Verbal stimuli	Verbal stimuli	3
	Pain only	Pain only	2
	No response	No response	1
Verbal response	Oriented, appropriate	Coos and babbles	5
	Confused	Irritable cry	4
	Inappropriate words	Cries to pain	3
	Incomprehensible words or sounds	Moans to pain	2
	No response	No response	1
Motor response	Obeys commands	Moves spontaneously and purposeful	6
	Localizes painful stimulus	Withdraws to touch	5
	Withdraws to pain	Withdraws to pain	4
	Flexion to pain	Decorticate posture (abnormal flexion) to pain	3
	Extension to pain	Decerebrate posture (abnormal extension) to pain	2
	No response	No response	1

## 7.5 Cranial Nerve (CN) Evaluation

The cranial nerves originate in the brainstem, with CN I through IV from the midbrain, CN V through VIII from the pons, and CN IX through XII from the medulla. Evaluation of cranial nerve and brainstem function is valuable to locate neurologic injury. Rostral (head)-caudal (tail) deterioration with worsening increased ICP manifests as an anatomic “picking off” (dysfunction) of the cranial nerves in chronologic order as the pressure progresses downward through the brainstem. It is critical for the nurse to recognize this subtle deterioration early so that there is potential to reverse the process before herniation and death occur.

### 7.5.1 Visual Acuity

Following TBI, it is essential to assess for presence of bilateral vision, which indicates innervation by the optic nerve (CN II). Presence of a squint to light in an infant indicates intact vision. Vision in older children can be assessed on a continuum progressing from abnormal to normal, including blindness, light perception, hand motion, finger counting, to full baseline vision (Wilson-Pauwels et al. 2010). Presence of papilledema on a fundoscopic exam indicates presence

of increased ICP. This finding presents 12–24 h after injury, however, and its absence should not delay treatment when other findings are consistent with severe brain injury (Dias 2004). The presence of retinal hemorrhages with subdural hematomas is a classic finding in abusive head trauma (AHT) (Vinchon et al. 2005), but can also be seen with high-impact accidental injuries.

### 7.5.2 Pupillary Response

Pupillary response represents a balance between sympathetic and parasympathetic systems, wherein dysfunction in one system results in unopposed action of the other (Dias 2004). Pupillary response is innervated by the third cranial nerve. The pupils are normally equal in size, round, and reactive to light and accommodation, thus the acronym PERRLA. When assessing pupillary response, darken the room. Bring the light in from the periphery, and note direct (same side) and consensual (opposite side) response to light; repeat with the other eye. Accommodation, assessed by directing gaze at a distant object, causes the pupils to dilate. Then gaze is directed to a near object (finger), which causes the pupils to constrict and converge on the near object (Young et al. 2008; Hickey 2009).

Abnormal mydriasis (pupillary dilation) is caused by unopposed sympathetic input, whereas miosis (pupillary constriction) is due to unopposed parasympathetic input (Greenberg 2010). Bilateral dilated (mydriatic) and nonreactive pupils, caused by unopposed sympathetic input, indicate an injury to the oculomotor (CN III) nucleus in the midbrain, or CN III injury due to trauma or increased intracranial pressure (Dias 2004). Unilateral mydriasis in TBI suggests either direct orbital trauma, transtentorial (uncal) herniation, or expanding mass hemorrhage on the same (ipsilateral) side as the dilated pupil. A new finding of pupillary inequality, even by only 1 mm, must be taken seriously and reported to the physician. Bilateral mydriasis can also occur following seizure or medications such as atropine that mimic the sympathetic response. A pharmacologically dilated pupil is very large (7–8 mm), whereas mydriasis due to CN III compression is typically 5–6 mm (Greenberg 2010). The nurse should be aware of what medications are given and notify other caregivers of iatrogenic pupillary dilatation. Miosis occurs with injury to the pons or carotid artery and with administration of narcotics or other miotic drugs.

Hippus is a spasmodic, rhythmic pupillary response to light manifested as alternating dilation and constriction (Greenberg 2010). Hippus can be a normal variant or indicate increasing pressure on CN III, with impending transtentorial herniation (Hickey 2009). Anisocoria (inequality of the pupil size) is a variant of normal in approximately 20 % of the population (Greenberg 2010; Hickey 2009). Physiologic anisocoria is a pupillary difference of <1 mm, whereas pathologic anisocoria due to increased ICP will manifest as a pupillary difference of >1 mm. Common causes of pathologic anisocoria include CN III palsy or compression caused by transtentorial herniation, Parinaud's syndrome, and Horner's syndrome. Parinaud's syndrome, caused by a lesion (tumor) or pressure (increased ICP or hydrocephalus) exerted on the tectum of the midbrain, results in impaired upgaze ("sunsetting"), impaired convergence, dilated and fixed pupils, and lid retraction. Horner's syndrome occurs with interruption of sympathetic input to the eye and face, resulting

in a unilateral reactive miotic pupil, ptosis, and lack of perspiration on the same side of the face.

### 7.5.3 Extraocular Eye Movements

Eye position and movement are controlled by cranial nerves III (oculomotor), IV (trochlear), and VI (abducens), as well as the cerebral hemispheres and the brainstem. Extraocular eye movements (EOM) are assessed by having the conscious child follow the examiner's finger in the pattern of an "H" (cardinal fields of gaze). Cranial nerve injury following TBI is manifested as extraocular eye muscle weakness, resulting in abnormal eye position in the conscious or unconscious child. The third CN innervates four of the six ocular muscles, which control all directions of gaze except downward and inward (CN IV) and lateral (CN VI). When control of eye movement in one direction is lost, there is overcompensation of positioning of the eye in the opposite direction. The following (Table 7.3) is a limited review of abnormal eye position and related etiology (localization of injury) (Young et al. 2008; Dias 2004). Saccadic eye movements (rapid, voluntary movements to search a field) are controlled by the frontal gaze centers, where injury causes deviation toward the lesion. Pursuit movements (slow, involuntary movements keeping the eyes fixated on a moving target) are controlled by the occipital gaze centers.

### 7.5.4 Brainstem Reflex Exam

The trigeminal (CN V) nerve innervates the sensory portion of the corneal reflex, where stimulation of blowing into the child's eye elicits eye closure. The motor response of blinking is innervated by CN VII. A unilateral facial (CN VII) weakness or hearing loss (CN VIII) can occur with a basilar skull fracture. Integrity of the vestibular function (CN VIII) is assessed by performing oculovestibular and oculocephalic testing, which indicates the presence or absence of brainstem function in the comatose patient (Table 7.4) (Greenberg 2010; Wilson-Pauwels et al. 2010). Intact gag and cough reflexes assess

**Table 7.3** Etiology of abnormal eye position in pediatric head trauma

Location of lesion	Eye deviation	Hemiparesis	Other
Frontal lobe injury	Toward lesion	Opposite	
Expanding mass hemorrhage	Toward lesion	Opposite	
Occipital injury	Toward lesion		Hemianopsia (contralateral loss of vision)
Seizure	Away from lesion	Same side	
CN III (oculomotor)	Down and out (exotropia). Also causes: ptosis, dilated pupil, unable to accommodate	Uncal herniation: contralateral hemiparesis or motor posturing	Uncal herniation: unilateral fixed, dilated pupil (↑ICP causes pressure on CN III nucleus)
CN IV (trochlear)	Elevates (inability to look down/in); diplopia		CN IV injury (rare)
CN VI (abducens)	Loss of lateral gaze; inability to abduct. Causes double vision with lateral gaze to affected side; squint and head tilt		↑ICP secondary to trauma, skull (clivus) fracture. Originates in pons; longest intracranial course increases risk of injury
Parinaud’s syndrome	Convergence and accommodation lost; upward gaze palsy (sunsetting sign); pupils fixed, dilated. Infants unable to fix/follow		Elevated ICP, hydrocephalus; mechanism is pressure on the tectum of brainstem

**Table 7.4** Brainstem reflexes assess BS function between the pons and the oculomotor (CN III) nuclei in the midbrain

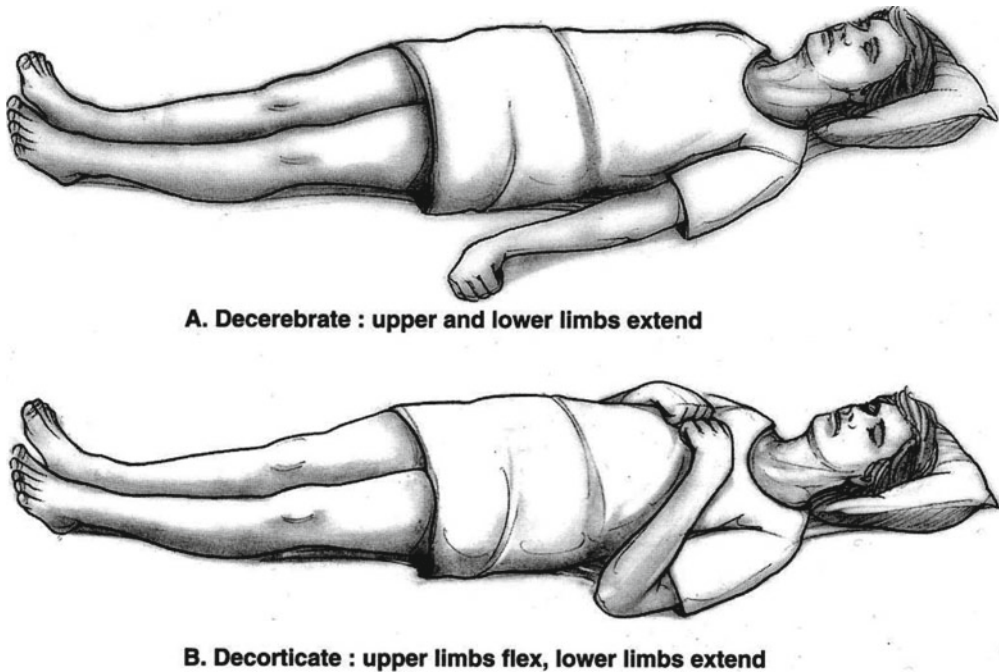
Brainstem reflex	Awake	Comatose	Brain death
Oculovestibular (cold calorics). <i>Caution: must have intact TM. Elevate HOB, 60–100 ml ice water instilled into ear</i>	<i>Awake or obtunded with intact brainstem</i> – slow ipsilateral gaze; then rapid contralateral nystagmus “COWS” (Cold Opposite, Warm, Same). Refers to direction of nystagmus	<i>Comatose</i> – conjugate, tonic eye deviation toward stimulus; no nystagmus	<i>Brain death</i> – no eye movement
Oculocephalic (doll’s eyes). <i>Caution: Do not perform unless C-spine clearance obtained</i>	<i>Awake</i> – eyes move with or away from (contraversive to) lateral head rotation	<i>Comatose with intact BS</i> – contraversive conjugate eye movement (positive doll’s eyes)	<i>Brain death</i> – no eye movement

continuity of the glossopharyngeal (CN IX) and vagus (CN X) nerves.

**7.5.5 Motor Exam**

The infant should have dominant flexor tone, but relax to easily perform full range of motion. The child’s ability to follow command is assessed by asking them to perform a purposeful and reproducible task, such as holding up two fingers. Note whether the child initiates movement spontaneously or what

stimulus is required to elicit movement. Note the symmetry and quality of strength using the following scale: 0 – no muscle contraction; 1 – palpation of trace contraction; 2 – movement without gravity; 3 – movement against gravity, but not resistance; 4 – movement against some resistance; and 5 – movement against full resistance (Hickey 2009). Weakness on the side opposite the lesion with hypertonicity and hyperreflexia indicates cerebral or upper motor neuron injury. Whereas a lower motor neuron injury presents with weakness or paralysis, on the same side as the lesion or bilaterally,



**Fig. 7.1** (a) Abnormal posturing indicates brainstem compression in the comatose patient. Decerebrate posturing with abnormal upper extremity (UE) and lower

extremity (LE) extension (late). (b) Decorticate posturing with abnormal UE flexion and LE extension (early) (Reprinted with permission from Young et al. (2008))

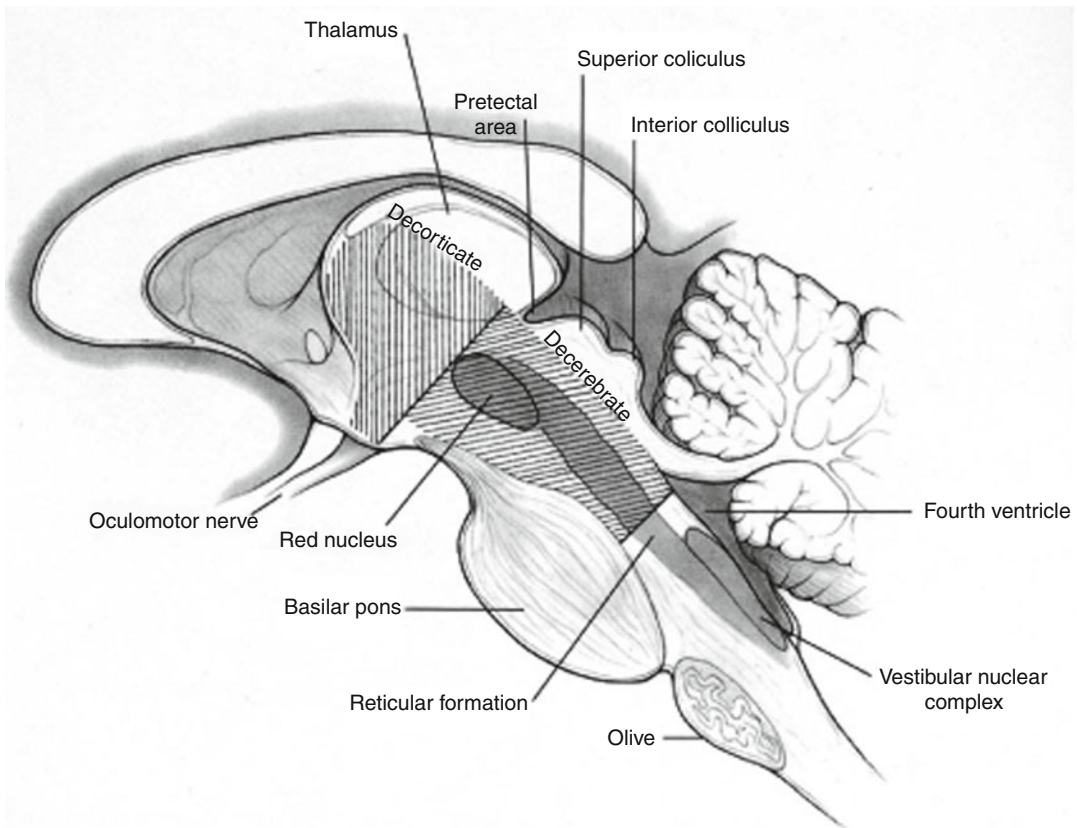
hypotonia, and areflexia. Cerebellar injury results in hyporeflexia, ataxia, and dysarthria (Young et al. 2008).

Abnormal flexion or extension posturing indicates severe traumatic brain injury. Posturing indicates neurologic activity (or inactivity) secondary to brainstem compression and impending herniation in comatose patients (Young et al. 2010). Deterioration of neurologic status occurs in a rostral (head) to caudal (tail) progression. This is true of cranial nerve and brainstem dysfunction with impending herniation. Decorticate posturing implies a more rostral lesion and a better prognosis (Greenberg 2010). Decorticate posture is abnormal flexion of the upper extremities with extension of the lower extremities and is indicative of disinhibition of the corticospinal pathways above the midbrain. Decerebrate posturing implies further deterioration and impending herniation, as it indicates disinhibition of the pons and medulla. Decerebrate posturing includes abnormal extension of the upper and lower extremities (Fig. 7.1). Posturing may be reversible

or may represent impending brain death. Progression from decorticate to decerebrate indicates worsening brainstem function, whereas progression from decerebrate to decorticate indicates improvement. Figure 7.2 illustrates the brainstem centers that are compressed by downward herniation, progressing from decorticate to decerebrate posturing, and finally herniation (brain death) (Young et al. 2008). Posturing may be reversible, but is associated with a more ominous outcome.

### 7.5.6 Reflexes

A reflex is an autonomic nervous system motor response to stimulation (O'Toole 1992). The stimulus (striking tendon) travels via sensory (afferent) fibers to the dorsal ganglion and anterior horn of the spinal cord. The ventral horn relays the motor (efferent) signal back to the muscle, causing a reflexive contraction. This chain of events is referred to as the reflex arc. Deep tendon reflexes (DTR) or muscle stretch reflexes are



**Fig. 7.2** Brainstem compression occurs in a rostral (head) to caudal (toe) progression. Median view of brainstem showing levels of impairment associated with abnormal posturing: Decorticate indicates a more rostral lesion

(above red nucleus); decerebrate indicates a more caudal lesion (midbrain or pons) (Reprinted with permission from Young et al. (2008))

assessed to determine the presence and location of nervous system dysfunction in both conscious and unconscious children. Injury can occur to the central nervous system – brain and spinal cord (upper motor neurons) or the peripheral nervous system (lower motor neurons).

With upper motor neuron (UMN) injury, signals (both excitatory and inhibitory) from the cortex are diminished or cut off, causing the spinal cord to become hyperreflexic. Hyperreflexia indicates injury to the CNS corticospinal tract with resultant irritability in the spinal cord. UMN injury is associated with increased tone, spasticity, clonus (muscle spasm with forceful dorsal flexion of the ankle), and a present Babinski. Unilateral hyperreflexia indicates a CNS injury, such as an expanding mass hemorrhage on the opposite side of the brainstem or cerebral cortex, resulting in increased ICP. Injury to the periph-

eral nervous system (PNS), or lower motor neurons (LMN), is associated with hyporeflexia or areflexia (loss of efferent motor fibers), as well as muscle weakness, flaccidity, and atrophy (Greenberg 2010; Hickey 2009; Young et al. 2008). Hypotonia and atrophy occur due to the loss of LMNs, which innervate muscles and maintain normal tone (Young et al. 2008). Preserved reflexes in a flaccid limb indicate CNS (UMN) injury, not a PNS (LMN) injury.

Babinski sign is present when stroking the plantar surface of the foot, resulting in dorsiflexion of the great toe and fanning of the other toes. This is a primitive reflex seen normally in infants and usually disappears by 10 months of age (range 6–12 months) (Greenberg 2010). Presence of a Babinski sign after age 6 months in TBI is pathologic and indicates injury to the corticospinal tract at any level (Hickey 2009).

### 7.5.7 Supratentorial Versus Infratentorial Injury

The tentorium cerebelli is a fold of the dura mater, separating the cerebral hemispheres from the cerebellum and brainstem. The “tent” is an important landmark, as assessment for deterioration of neurologic status differs based on whether the injury is above the tentorium (supratentorial) or below the tentorium (infratentorial). The tentorium also contains the tentorial notch through which uncal or brainstem herniation occurs with increased ICP. Impending herniation must be recognized early to prevent brain death. Unilateral supratentorial mass lesions cause uncal herniation, evidenced initially by ipsilateral sluggish pupillary response, progressing to ipsilateral pupillary dilation, contralateral hemiparesis, trochlear and abducens cranial nerve paralysis, and a decreased level of responsiveness with eventual rostral-caudal deterioration. The mass effect causes lateral displacement of the midbrain, forcing the opposite cerebral peduncle against the tentorium, producing Kernohan’s notch. This is important to remember when attempting to identify the location of a lesion, as it results in hemiparesis ipsilateral to the expanding mass lesion (Hickey 2009). Bilateral supratentorial lesions, which cause mass effect and increased ICP, progress in a rostral (head) to caudal (tail) progression with impending herniation of the brainstem through the tentorial notch (see Sects. 7.5, 7.5.4, and 7.9.4).

An expanding mass lesion in the posterior fossa (rare in children) results in direct compression on the brainstem and cerebellum, upward herniation, or downward herniation. A primary infratentorial injury affects the reticular activating system (consciousness) directly. Downward compression on the vital cardiac and respiratory centers in the medulla oblongata results in pathologic alteration in vital signs, with respiratory and cardiac arrest (Hickey 2009). More often, posterior fossa lesions in children show progressive deterioration, with or without development of obstructive hydrocephalus, and present with rostral-caudal deterioration or lower cranial nerve deficits. Ataxia (decreased muscle coordination) and dysarthria (discoordinated speech) also occur with cerebellar injury (see Chap. 1).

## 7.6 Radiographic Imaging in Pediatric Head Trauma

For the purpose of this chapter, traumatic intracranial injuries are discussed individually, but in reality any combination of lesions can and does occur. The non-contrast head computerized tomography (CT) is the initial study of choice in pediatric head trauma. Obtaining CT imaging is fast and allows for ease of monitoring of the unstable child with moderate to severe TBI. CT scan is sensitive to hemorrhage, mass effect, and skull fractures. Magnetic resonance imaging (MRI) is more useful in the subacute or chronic stage of injury and should also be considered if CT scan findings do not fully explain the extent of neurologic deficit. Be aware that CT scans do expose the child to radiation, and order them wisely. See Table 7.5 for a comparison of modalities for neuroimaging. Skull radiographs are minimally useful. When obtained in the presence of scalp swelling or other injury, x-rays can reveal skull fractures or intracranial air, which may indicate more serious intracranial injuries. Ultrasound can be useful in neonates and infants with open fontanelles as a screening tool for hemorrhage, although it is limited to allow imaging of the full periphery of the brain. Cerebral ultrasound is useful in identifying the presence of intracerebral hemorrhage (ICH) and intraventricular hemorrhage (IVH), as well as assessment of ventricular size with hydrocephalus. The neuroimaging modality of choice will be discussed in greater detail with each classification of traumatic intracranial injury (Barkovich 2005).

---

## 7.7 Types of Traumatic Brain Injury

### 7.7.1 Birth-Related Traumatic Brain Injury

Traumatic injury to the brain may occur during the birth process. Infants with greater risk for birth-related injuries include those above the 90th percentile for weight. The rate of birth injury is higher in infants weighing more than 3,500 g (Blackburn and Ditzenberger 2007). Birth injuries may also be related to the infant’s

**Table 7.5** Comparison of neuroimaging modalities in pediatric traumatic brain injury

	X-ray	Ultrasound	CT scan	MRI
Timing	Early, especially if scalp swelling, trauma is present	Useful with open fontanel; portable	Fast, immediate posttrauma imaging	Subacute or chronic imaging
Type of injury identified	Skull fracture	Hemorrhage	Scalp swelling	Nonhemorrhagic contusion
	Pneumocephalus	Ventricular size: (hydrocephalus or small, obliterated ventricles with IICP)	Skull fracture	
	Foreign body	Cranial Doppler for vasospasm secondary to SAH	Pneumocephalus	Diffuse axonal injury
	Split cranial sutures with increased ICP		Extraparenchymal hemorrhage: (EDH, SDH, SAH, IVH) Intraparenchymal hemorrhage: (ICH, hemorrhagic contusion) Mass effect: (obliteration of ventricles and cisterns, poor gray-white differentiation, splitting cranial sutures) Hydrocephalus	Early ischemic injury (cerebral infarct) CT scan does not explain neurologic deficit Injury dating in child abuse  MRA (posttraumatic aneurysm)

position during labor and delivery (e.g., breech presentation), as well as cephalopelvic disproportion, where the mother’s pelvis size or shape is not adequate for vaginal birth; difficult labor or delivery; prolonged labor; fetal anomalies; and very low birth weight or extremely premature infants. Some of the more common birth injuries to the neonatal head and brain include extracranial hemorrhage (caput succedaneum, subgaleal hemorrhage, or cephalohematoma), skull fracture, and intracranial hemorrhage (epidural, subarachnoid, subdural, or intracerebellar hemorrhage).

Caput succedaneum, a common finding in the newborn, involves soft tissue swelling of the presenting part of the head in a vertex (head first) delivery. The scalp edema consists of serum or blood or both and may have ecchymosis (bruising), petechiae, or purpura. Caput succedaneum may occur after spontaneous delivery due to pressure of the fetal head against the uter-

ine wall, the cervix, or the vaginal wall, or after use of a vacuum extractor. The scalp edema may cross over suture lines and does not continue to increase in size after delivery. It heals in hours to days and rarely has complications. Nursing care involves parent education about the cause of the tissue swelling and/or discoloration (Hernandez and Glass 2005; Sansoucie and Cavaliere 2003).

Cephalohematoma is a subperiosteal collection of blood secondary to the rupture of blood vessels between the skull and the periosteum. It is typically over the parietal bone, and is usually unilateral, but can occur bilaterally. Cephalohematoma is seen most often in male infants after a prolonged, difficult, or forceps-assisted delivery. The characteristic finding is a firm, tense mass that does not cross the suture lines. It may enlarge slightly by 2–3 days of age and takes weeks to months to resolve, occasionally with residual calcification. The calcified

“lump” gradually subsides as bones grow and reshape. Approximately 10–25 % of cephalohematomas have an underlying linear skull fracture (Volpe 2008). Rarely the cephalohematoma may contain enough blood to affect hematocrit and bilirubin levels. Nursing care involves monitoring and parent teaching about hyperbilirubinemia. Anemic infants should also be evaluated for symptoms of intracranial hemorrhage. Generally, there are no long-term sequelae from a cephalohematoma.

Subgaleal hemorrhage is the most serious extracranial hemorrhage in newborns, though it occurs much less frequently than caput succedaneum and cephalohematoma. Blood collects below the epicranial aponeurosis (connective tissue over the brain) and may spread beneath the entire scalp and down the subcutaneous tissue in the neck. There is a strong association between vacuum extraction and subgaleal hemorrhage. The hemorrhage may be from suture diastasis (separation), linear skull fracture, or fragmentation of the superior margin of the parietal bone. Subgaleal hemorrhage presents as a firm fluctuant mass, crosses suture lines, and may increase in size after birth. Blood loss can be significant, up to 260 ml, exceeding the total blood volume of a full-term infant (Reid 2007). This volume loss into the large potential space between the galea aponeurotica and the periosteum of the skull can necessitate urgent blood transfusion and may contribute to hyperbilirubinemia (Blackburn and Ditzenberger 2007; Volpe 2008). Early detection of this clinical emergency is vital. Nursing interventions include serial measurements of head circumference, inspection of the back of the head and neck for increasing edema, and observation of the ears being pushed forward and lateral. The nurse should also monitor for changes in LOC and decrease in hematocrit along with signs of hypovolemic shock (Barkovich 2005; Schierholz and Walker 2010). Parent teaching includes preparing them for the swelling and discoloration of the face, head, and neck. Lesser lesions resolve in 2–3 weeks (Volpe 2008). Moderate to severe lesions may require intensive care, and up to 25 % of these babies may die (Reid 2007).

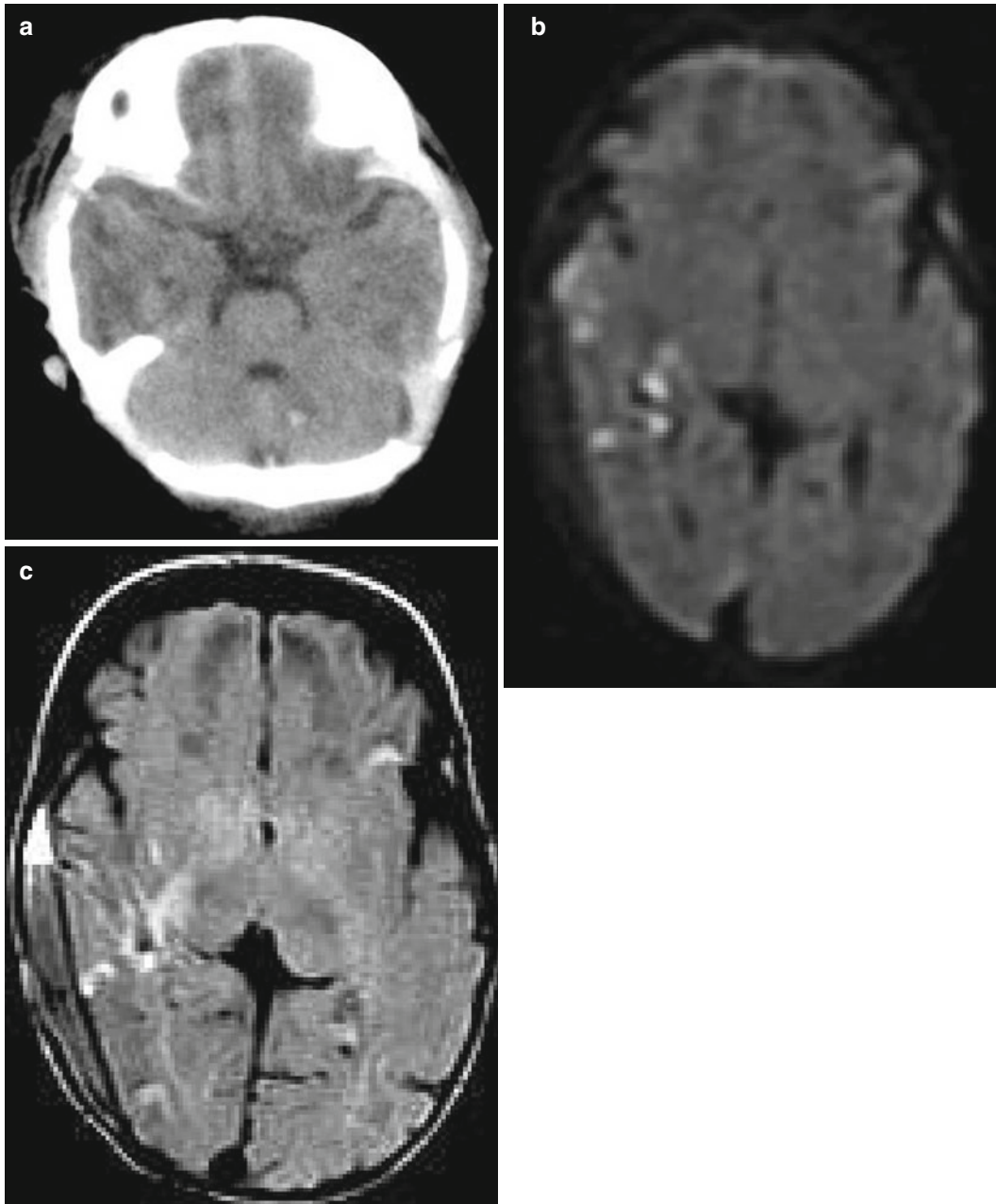
## 7.7.2 Neonatal Skull Fracture

Skull fractures, both depressed and linear, are occasionally seen in the newborn. The fetal skull is flexible, malleable, and poorly ossified, when compared to the adult skull, and thus is often able to tolerate mechanical stressors relatively well. Skull fractures can occur in utero, during labor, with forceps delivery (Fig. 7.3), or during a prolonged or difficult labor. The fetal skull can be compressed against the maternal ischial spines, sacral promontory, or symphysis pubis. Cerebral injury should be suspected when neurologic signs are apparent and there is a history of a difficult delivery. Skull x-ray or CT scan is used to confirm the fracture and identify cerebral contusion or hemorrhage. CT is preferred as it identifies space-occupying hematomas and injury to the underlying brain (Fig. 7.3).

Depressed skull fractures (which are not really fractures, but an indentation of bone) are usually seen after forceps delivery, but occasionally are seen after a spontaneous vaginal or cesarean delivery (Parker 2005). A depressed skull fracture is a visible and palpable dent in the skull, usually over the right parietal bone, and does not cross suture lines. There may be no other symptoms unless there is an underlying cerebral contusion or hemorrhage. A depressed skull fracture may be referred to as a “ping-pong” lesion, as it resembles a dent in a ping-pong ball. The uncomplicated depressed fracture can be manually elevated if it does not occur spontaneously in the first few days (Verklan and Lopez 2011). Manual elevation becomes more difficult later on. Methods to elevate the fracture include gentle pressure, use of a breast pump, or use of a vacuum extractor. Surgical intervention is necessary when the depressed fracture cannot be elevated manually, when bone fragments are in the cerebrum, if neurologic deficits exist, or if intracranial pressure is increased. If there is CSF leakage, antibiotics may be prescribed for prophylaxis. Some infants will require treatment for shock and hemorrhage.

Linear skull fractures are usually seen in the frontal and parietal bones and are often associated with extracranial hemorrhage, such as





**Fig. 7.3** (a–c) Neonate with significant birth trauma after vaginal delivery with forceps. (a) Infant sustained a right parietal depressed skull fracture, scalp swelling (caput succedaneum), bilateral extra-axial hematomas (SDH subdural hemorrhage), right temporal and left cerebellar hemorrhage as seen on computed tomography (CT) images. Subarachnoid hemorrhage was also seen on the tentorium and at the vertex (not shown). (b) Diffusion-weighted magnetic resonance imaging on DOL 7 shows

brain contusion with injury in the right temporal lobe and corpus callosum (not shown). (c) Fast fluid-attenuated inversion-recovery (FLAIR) MRI reveals right temporoparietal SDH and scattered white matter hemorrhage bilaterally (right temporal, bilateral occipital, and left frontal). The infant was treated with observation only; the lesions resolved, and the child did well, without development of hydrocephalus

cephalohematoma. These fractures are diagnosed with skull x-rays and are usually asymptomatic. The exact incidence is unknown as routine x-rays in otherwise healthy newborns are uncommon. Linear fractures are rarely complicated by intracranial hemorrhage (Blackburn 2003). Linear skull fractures in infants may heal in 6 months (Barkovich 2005). They heal spontaneously with no sequelae, unless a dural tear allows the leptomeninges to protrude into the fracture site (i.e., growing fracture of childhood). A cyst may form and grow, causing the fracture to enlarge. Leptomeningeal cyst is rare, occurring in less than 1 % of linear fractures in children under age 3 years (Greenberg 2010). Depressed fractures that are small or treated early have a good prognosis. Larger fractures have a greater risk of sequelae, especially if treatment is delayed. Sequelae are related to the cerebral injury, from either dural hemorrhage or hypoxic event, or both, not from the fracture itself (Blackburn 2003).

Nursing assessment involves supportive care and monitoring of the infant for signs of neurologic dysfunction (increased ICP from hemorrhage, seizures, apnea, and meningitis). Parents may be concerned about brain damage and their infant's appearance if there is a depressed fracture. Parents should be educated to observe their infant for and report signs of increased ICP (irritability, poor feeding, vomiting, hypersomnolence) and growing fracture (growing bulge at fracture site) to the practitioner. They should be instructed to have the fracture site examined at each newborn visit.

### 7.7.3 Intracranial Hemorrhage

Intracranial hemorrhage may occur in the neonate secondary to trauma or hypoxia in the perinatal period (epidural hemorrhage – EDH, primary subarachnoid hemorrhage – SAH, subdural hemorrhage – SDH, intracerebellar hemorrhage) or due to immature structures and hemodynamics in the premature infant (periventricular/intraventricular hemorrhage – P/IVH), especially those under 32-week gestational age at

birth. The pathophysiology of P/IVH involves disruption to the autoregulation of CBF, which is affected by hypoxia and acidosis, leaving the germinal matrix area vulnerable to systemic blood pressure changes. Systemic blood pressure changes may be caused by handling, suctioning, positive-pressure ventilation, hypercapnia, and rapid volume expansion (Blackburn 2003).

### 7.7.4 Epidural Hemorrhage

EDH is a rare occurrence and may be associated with cephalohematoma. It refers to blood collection above the dura mater and below the periosteum (inner surface of the skull). Most cases are associated with a linear skull fracture. Nearly all affected infants have a history of difficult delivery. Signs of increased ICP, including a bulging fontanel, may be apparent in the first hours of life. An emergent CT scan should be performed. Surgical evacuation may be required. Aspiration of the accompanying cephalohematoma has been reported as a means of reducing the epidural lesion (Smets and Vanhauwaert 2010). Untreated lesions may result in death within 48 h.

Nursing care involves prompt recognition and reporting, timely preparation and transport for CT scan, transfer to the appropriate facility, and preparation for surgery. Postoperative nursing care includes supportive care for oxygenation, ventilation, thermoregulation, fluids and nutrition, pain management, and monitoring of neurologic signs. Parents will need support and teaching to understand their infant's condition and participate in the treatment plan. Complications range from none to permanent neurologic deficits and/or seizures.

### 7.7.5 Subarachnoid Hemorrhage

Primary SAH is the most common intracranial hemorrhage in the neonate. SAH occurs in full- and preterm infants, but is more common in the premature infant. Primary SAH consists of venous bleeding into the subarachnoid space (arterial bleeding is usually the cause of SAH in

older children and adults.) The usual site in the neonate is over the cerebral convexities, especially in the posterior fossa (Volpe 2008).

Trauma causing increased intravascular pressure and capillary rupture is associated with SAH in the full-term infant. Asphyxia may cause SAH in the premature infant. Risk factors for SAH include birth trauma, prolonged labor, difficult delivery, fetal distress, and perinatal asphyxia.

The most common presentation of SAH is the asymptomatic premature infant with a minor SAH. The SAH is discovered accidentally with a bloody lumbar puncture during a sepsis work-up or cerebral ultrasound to rule out intraventricular hemorrhage. Another presentation of SAH occurs in a full-term or preterm infant who presents with seizures or apnea at 2–3 days of age. Between seizures, the infant appears healthy. Infants with a massive SAH (quite rare) associated with birth trauma and severe asphyxia have a rapid and fatal course (Blackburn 2003; Volpe 2008).

Ultrasonography or CT is useful to confirm the diagnosis of SAH. If the infant has seizures, other causes of seizures must be eliminated. Blood in the CSF on lumbar puncture may be from SAH or from a bloody tap. Rarely a severe, acute SAH may require a craniotomy. Infants with minor or asymptomatic SAH survive and generally have good developmental outcomes. Up to half of infants with symptomatic SAH, with sustained traumatic and hypoxic injury, have neurologic sequelae. Occasionally, SAH results in hydrocephalus due to CSF obstruction at the level of the arachnoid villi. Periodic cerebral ultrasound evaluation for ventricular size may be indicated. Nursing care involves assessment for seizures and other neurologic signs. Parents will need support and teaching about SAH, so they can understand the needs of their infant.

### 7.7.6 Subdural Hemorrhage

SDH is not unusual after vaginal delivery. Small posterior fossa subdural hematomas are common after uncomplicated vaginal deliveries (Barkovich 2005). The most likely site for hemorrhage is over the cerebral hemispheres. Significant bleeding

over the posterior fossa causes compression of the brainstem, as do dural tears near the great vein of Galen. SDH affects full-term infants more often than preterm infants, usually as a result of precipitous, prolonged, or difficult delivery; use of forceps; cephalopelvic disproportion; breech delivery; or large infant (Reichard 2008; Volpe 2008).

Excessive head molding results in stretching of the falx (folds of dura mater that separate the two cerebral hemispheres and the two cerebellar hemispheres) and tentorium (dura mater between the cerebrum and cerebellum), and venous sinuses, with tearing of the vein of Galen or cerebral or cerebellar veins (Lynam and Verklan 2010). As with SAH, SDH diagnosis depends upon the history and presentation of the infant. If seizures are present, other causes must be excluded. SDH can occur along with SAH; cephalohematoma; subgaleal, subconjunctival, and retinal hemorrhages; skull fractures; and brachial plexus and facial palsies. An MRI or CT will help to confirm the diagnosis. Ultrasound is less reliable. Clinical signs are related to the site and severity of the bleeding. There are three patterns of presentation in infants with bleeding over the cerebral hemispheres (Vinchon et al. 2005). The most common presentation is seen in infants with a minor hemorrhage. They are asymptomatic or have minor signs such as irritability and hyperalertness. The second presentation pattern involves seizures in the first 2–3 days of life. The seizures are usually focal, and other neurologic signs may or may not be present, such as hemiparesis, unequal or sluggish pupils, full or tense fontanel, bradycardia, and irregular respirations. The third pattern of presentation is seen in infants who had no or nonspecific signs in the neonatal period, but then present at 4 weeks to 6 months of age with increasing head size as a result of continued hematoma formation, poor feeding, failure to thrive, altered LOC, and, occasionally, with seizures due to chronic subdural effusion (Volpe 2008).

If the posterior fossa SDH is small, there may be no signs for 3–4 days. As the subdural clot enlarges, signs of increased ICP appear and the infant's condition deteriorates. Infants with significant posterior fossa SDH have abnormal neurologic signs from birth, including stupor or

coma, eye deviation, asymmetric pupil size, altered pupillary reaction to light, tachypnea, bradycardia, and opisthotonos (prolonged, sustained posture with leg extension, trunk arching, and variable arm posture, often extended). As the clot enlarges, there is rapid deterioration with signs of shock in minutes to hours. The infant becomes comatose, with fixed, dilated pupils, altered respirations and heart rate, and finally respiratory arrest.

Care is primarily supportive, including oxygenation and perfusion, thermal management, and fluids and nutrition. Surgical evacuation of bleeding over the temporal convexity with increased ICP may be necessary for infants unable to be stabilized neurologically. Massive posterior fossa hemorrhage requires neurosurgical intervention. Infants at risk for SDH should be monitored for 4–6 months for head size, growth, feeding, activity, LOC, and seizure activity. Aside from supportive nursing care, nurses provide parents education about the cause and prognosis for their infant. Referral to early intervention services is recommended at discharge.

Prognosis varies with the size and severity of the hemorrhage. Infants with SDH, who are asymptomatic or have transient seizures in the neonatal period, do well if there is no associated cerebral injury. Minor posterior fossa hemorrhages rarely have clinical significance (Barkovich 2005). Early diagnosis of large posterior fossa hemorrhage with MRI and CT has improved the outcome for those infants. Most infants with massive bleeding over the tentorium or falx cerebri (near the great vein of Galen) die. Those who survive usually have hydrocephalus and neurologic sequelae.

### 7.7.7 Intracerebellar Hemorrhage

Intracerebellar hemorrhage is more common in preterm than full-term infants. Although rare, it is generally associated with hypoxia in the preterm infant and associated with trauma in the full-term infant.

Intracerebellar hemorrhage may be caused by intravascular factors (vitamin K deficiency, thrombocytopenia), vascular factors (damage due to hypoxia, followed by hypertensive spikes, e.g.,

from too rapid intravenous colloid infusion), and extravascular factors (mechanical deformation of the occiput during forceps or breech delivery in the full-term infant, compression of the compliant skull during caregiving, or the use of constrictive bands around the head, especially in the preterm infant) (Lynam and Verklan 2010; Volpe 2008). Intracerebellar hemorrhage may be a primary bleed or extension of a hemorrhage into the cerebellum.

Infants with intracerebellar hemorrhage either present critically ill from birth, with apnea, a declining hematocrit, and death within 24–36 h, or present less ill with symptoms developing at up to 2–3 weeks of age. Clinical signs include apnea, bradycardia, hoarse or high-pitched cry, eye deviations, facial paralysis, opisthotonos or intermittent tonic extension of the limbs, seizures, vomiting, hypotonia, diminished or absent Moro reflex, and hydrocephalus (Blackburn 2003; Volpe 2008).

Cranial ultrasound and/or CT scan is used for diagnosis. Lack of echogenicity of the cerebellum may be an important finding (Lynam and Verklan 2010). Intracerebellar hemorrhage is frequently diagnosed at autopsy. Treatment is primarily supportive. Surgery may be indicated, including hematoma evacuation or ventriculoperitoneal shunt for hydrocephalus. Nursing care involves supportive care for the infant and care and comfort for the parents/family, including referral for early intervention services after discharge. Prognosis is poor in preterm infant survivors. Full-term infants have more favorable outcomes, but generally with subsequent neurologic deficits, especially motor and variable involvement of intellect. About half of the infants have hydrocephalus (Volpe 2008).

## 7.7.8 Pediatric Traumatic Brain Injury

### 7.7.8.1 Concussion

Historically, concussion was defined as loss of consciousness or amnesia following a blow to the head.

Concussion, as newly defined by the Zurich Consensus Statement on Concussion in Sport, is a complex pathophysiologic process (biochemically

mediated neuronal dysfunction), induced by a direct or indirect traumatic force to the head. Other common features that aid in defining concussion include rapid onset of impaired neurologic function with spontaneous recovery; neuropathologic changes with symptoms reflecting functional rather than structural injury; graded set of symptoms, with or without loss of consciousness; normal neuroimaging; and a sequential course of recovery, with a small number having prolonged post-concussive symptoms (McCrory et al. 2009). Concussion is also frequently referred to as mild traumatic brain injury (MTBI).

The force of a blow to the head is dissipated over the skull and dura mater and then centrifugally to the brain. The brain is a fluid medium with limited compliance, making it deformable and susceptible to neuronal injury. Mechanical forces induce depolarization of an action potential and synchronous cortical neurotransmitter release. On a cellular level, potassium gates open, allowing potassium to move out of the cells. The Na-K-ATPase pump attempts to restore potassium into the cells, but with insufficient energy. Anaerobic metabolism ensues with hyperglycolysis and accumulation of lactate. Calcium flows in to the mitochondria, the power house of the cell, leading to further dysfunction. Enzymes are activated causing cellular dysfunction and apoptosis (microtubules in the axon break down leading to axonal swelling and axotomy). Excitatory neurotransmitters (glutamate, NAA, inflammatory cytokines, free radicals, lactic acid, electrolytes) result in disrupted ion transport, leaky cell membranes, and a hypermetabolic state in the brain. The physiologic result of this complex biochemical cascade is global cerebral depression secondary to energy exhaustion, edema, alteration of the blood-brain barrier, mitochondrial dysfunction, neuropraxia (appears structurally normal on imaging, but with obvious functional abnormality), potential cell alteration, and potential cell death.

Concussion produces brief, non-focal clinical findings such as headache, vomiting, and altered memory or level of consciousness. Early and late concussion symptoms are listed in Table 7.6. The majority (80–90 %) of concussions resolve within a short period of time (7–10 days) (McCrory

**Table 7.6** Signs and symptoms of concussion

Symptoms of concussion (early)	Symptoms of concussion (late)
Headache	<i>Somatic:</i> Headache, dizziness, blurred vision, balance disturbance
Nausea or vomiting	<i>Cognitive:</i> Poor concentration, dementia (cognitive decline, memory dysfunction), impaired judgment
Confusion Amnesia LOC (not a requirement) Vacant stare or expression Delayed verbal or motor response Unable to focus or perform Altered speech Dizziness or vertigo Incoordination	<i>Psychosocial:</i> Emotional lability, depression, personality or behavioral change, easily fatigued, insomnia

et al. 2009). Generally, 50 % remain symptomatic after 1 week, 25 % after 1 month, and 5–10 % after 3–6 months. Children and adolescents may remain symptomatic for a longer period of time (McCrory et al. 2009). Children are often admitted for symptomatic treatment, especially with associated vomiting which is more common in children after minor TBI and concussion (Ragheh 2008). Treatment is focused on management of symptoms (headache, vomiting) with analgesics, antiemetics, and parenteral fluid administration, as well as monitoring for neurologic deterioration.

Concussion is generally associated with normal neuroimaging (Ragheh 2008; Greenberg 2010). Opinion differs on absolute indications to obtain a head CT for MTBI. Indications for imaging suggested in the literature include prolonged loss of consciousness (>1 min), depressed mental status, post-concussive seizures, focal neurologic deficit, persistent or worsening symptoms (headache and vomiting), physical evidence of skull fracture, and high-risk mechanism of injury (McCrory et al. 2009; Greenberg 2010; Kamerling et al. 2003; Simon et al. 2001). Holmes et al. (2011), in a multicenter prospective observational

**Table 7.7** Graduated Return to Play Protocol: applied to children 10 years of age and older; 24 h per step, recurrence of symptoms at any stage requires return to previous step after additional 24-h rest period (McCrory et al. 2009)

Rehabilitation stage	Functional exercise at each stage of rehabilitation	Objective
No activity	Complete physical and cognitive rest	Recovery
Light aerobic exercise	Walking, swimming, or stationary cycling (<70 % maximal predicted heart rate (MPHR))	Increase heart rate
Sport-specific exercise	Skating drills in ice hockey, running drills in football (soccer)	Add movement
Noncontact training drills	Progression to more complex training drills with resistance	Exercise, coordination, cognitive
Full-contact practice	After medical clearance, participate in normal training activities	Restore confidence, assess skills
Return to play	Normal game play	

cohort study ( $N=13,500$ ), found that children with blunt head trauma, initial ED GCS of 14 or 15, and normal head CT scan are at very low risk for subsequent positive findings on neuroimaging and extremely low risk of needing neurosurgical intervention. They concluded therefore that hospitalization for children with mild TBI and normal CT scan is generally unnecessary.

The cornerstone of treatment for MTBI or concussion is complete (physical and cognitive) rest until asymptomatic. Complete physical rest means no training, playing, exercise, or exertion with normal daily activities. Cognitive rest means limited scholastic work, television, extensive reading, video games, or text messaging. Most have gradual resolution of symptoms within 7–10 days, although we know that children can remain symptomatic for a longer period. There is debate regarding the length of the required rest period, with suggestions including a 1-week period after completely symptom-free or requirement of a symptom-free period that is the same length as the symptomatic period.

There is no consensus on grading the severity of concussion or guidelines for when an athlete should return to sports participation following concussion. Concussion-grading scales such as the Cantu, Colorado, and American Academy of Neurology (AAN) Guidelines assign severity of concussion based on loss of consciousness. It is now understood that concussion can occur with and without loss of consciousness. Anterograde amnesia may be a more sensitive indicator of severity. Regarding return to play, the most current

recommendation is that no child be allowed to return to play on the same day in which the concussion occurs (McCrory et al. 2009). In addition, there is agreement that the child and adolescent athlete be symptom-free with exertion, and without medication, prior to returning to the game (Greenberg 2010; Kelly and Rosenberg 1997; Vagnozzi et al. 2005). A gradual return to play protocol offers a structure in which the athlete advances from no activity through graded levels of activity and then returns to full play (Table 7.7). The stepwise rehabilitation takes place over a 1-week period with advancement to the next step every 24 h. If the athlete becomes symptomatic, then they must return to the previous step and try to progress again after a 24-h rest period (McCrory et al. 2009). This author postulates that similar objectives could also be applied to a stepwise return to normal activity and scholastic activities in the nonathlete and children younger than 10 years of age with concussion. Absolute contraindications to play include symptomatic and permanent CNS sequelae such as developmental delay, visual impairment, and posttraumatic hydrocephalus (Greenberg 2010).

Guidelines for return to play are crucial to prevent more severe injury or sudden death caused by second impact syndrome (SIS). Second impact syndrome is a rare condition that occurs when the individual sustains a second TBI while still in recovery phase from an earlier one. Classically, the athlete walks off the field, collapses into coma, and deteriorates rapidly. Cerebral dysautoregulation occurs with vascular

engorgement, cerebral swelling, and malignant cerebral edema, most often resulting in death (50–100 % mortality) (Greenberg 2010). Adolescents and children are far more susceptible to SIS than adults. It has only been seen in athletes less than 20 years of age. Vagnozzi et al. (2005) utilized a rat model where ATP (adenosine triphosphate) and NAA (N-acetylaspartate) levels were measured following repetitive MTBI at varying intervals. Two consecutive mild TBIs occurring within 3 days produced the same biochemical damage as a severe TBI. After 5 days, however, the two mild TBIs acted as two independent events. The conclusion was that the interval of time between injuries is important because the brain is metabolically vulnerable to repeat injury. Multiple concussions within the same season or similar time period deserve special consideration. Medical evaluation and clearance, with imaging, are recommended after the second and third consecutive concussions in one season. It is also recommended that athletes with three concussions in one season, or abnormality on cerebral imaging, terminate participation for the remainder of the season.

Although most have resolution of symptoms within days to weeks following injury, some have persistent cognitive impairment, behavioral issues, or emotional lability, whether the original symptoms have cleared or not (Table 7.6). This phenomenon is known as post-concussive syndrome. Children who remain symptomatic greater than 3 months benefit from formal neuropsychological testing and often require individualized education plans (IEP), either on a temporary or permanent basis to assist them with school performance. Brain MRI is recommended for symptoms persisting greater than 3 months or if symptoms worsen. EEG should be considered if there is suspicion of seizures. Long-term mental health conditions (such as depression) have been reported following MTBI and concussion. Children and particularly adolescents should be evaluated for depression and referred or treated appropriately. Preexisting conditions (mental health disorder, depression, chronic headaches, ADHD, learning, or sleep disorders) must be considered in management of concussion and in some cases may predict

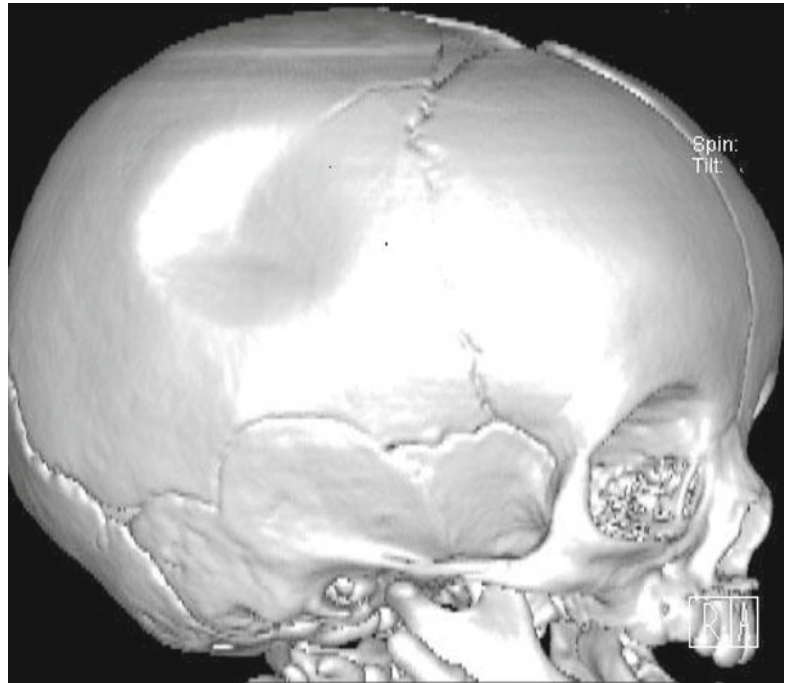
the potential for prolonged or persistent symptoms (McCroory et al. 2009). The psychosocial impact and loss to the child and family can be significant. Education, reassurance, counseling, and a follow-up plan are important to assist families through the recovery period.

Chronic traumatic encephalopathy (CTE) is a neurodegenerative process believed to result from multiple head injuries. It was initially discovered in boxers and more recently has gained recognition with other causes of repeated head trauma (organized sports and repeated abusive head trauma). The pathologic changes include cerebral atrophy, tau-positive inclusion bodies, and neurofibrillary tangles. Disordered memory and executive functioning, as well as behavioral and personality disorders, have been reported. Levels of depression in retired professional athletes, aged 30–39 years, are 19 times higher than the rate of depression in age-controlled counterparts. Multiple suicides in high-profile athletes with diagnosed CTE have brought this condition to the forefront, and additional research is needed to identify measures for prevention, diagnosis, and treatment of CTE (Gavett et al. 2011; Chin et al. 2011).

#### **7.7.8.2 Skull Fractures (Pediatric)**

The pediatric skull provides a protective box, which houses the brain. Forces exerted on the skull are absorbed initially in a centrifugal configuration and then directed inward toward the brain. Fractures occur when the skull cannot withstand the force of impact. As mentioned previously, the pediatric skull is thinner and more flexible when compared to the adult skull, which predisposes the child to significant traumatic brain injury with or without the presence of a skull fracture. A higher degree of suspicion should be maintained in deciding whether to obtain radiographic imaging based on the reported mechanism of injury (Simon et al. 2001). Twenty percent of children presenting with head trauma will have skull fracture. Of these, most do not require surgical intervention. Initial focus in management of skull fractures is identification of any serious underlying acute hemorrhage or brain injury. While skull fractures are readily visible on skull radiographs as thin, dark lines, CT is preferred

**Fig. 7.4** Ping-pong skull fractures occur in newborns and young infants due to the thin, pliable skull and consist of a greenstick fracture and skull depression which resembles a depression in a ping-pong ball



due to the relationship between skull fractures and underlying brain injury in children. Skull fractures are classified by their location (calvarial or basilar), type (linear, closed, open, or depressed), and associated complications (Greenberg 2010; Ragheh 2008).

Linear nondepressed skull fractures comprise 90 % of pediatric skull fractures, occur most frequently in the calvaria (upper portion of the frontal, parietal, and occipital bones), and heal rapidly without intervention (Ragheh 2008). The most common site for linear skull fractures is the parietal bone, which is thinnest of the cranial bones and is most frequently the site of impact in pediatric falls. The frontal and occipital, which are the thickest, require a more severe impact to cause fracture and, therefore, are associated with a higher degree of brain injury. Diastatic fractures occur along a cranial suture line. They are more common in infants and typically result in a widening of the suture.

Young children with a skull fracture and underlying dural laceration may develop a leptomeningeal cyst or growing fracture of childhood. This occurs less than 1 % of the time in children less than 3 years of age. The opening in the dura allows CSF and brain to pulse outwardly

into the area of the fracture, preventing healing and causing outward eversion or growth of the fracture margins. A new soft, pulsatile swelling on the scalp is suspicious for a growing skull fracture, requires imaging with a head CT, and may require surgical repair of the dura and cranioplasty (Ragheh 2008).

Most closed (simple), depressed skull fractures, without underlying brain injury, do not require surgery. Nonsurgical management in this case is not associated with increased risk for seizures or neurologic impairment (Ragheh 2008). Due to rapid brain growth, these fractures tend to remodel to a cosmetically pleasing appearance in young children. Closed and open (compound) depressed skull fractures with evidence of dural tear, parenchymal injury, CSF leak, brain extruding through laceration, and focal neurologic deficit require surgical elevation, debridement of pulped brain, evacuation of hemorrhage, and dural repair. Ping-pong skull fractures occur in newborns and young infants due to the thin, pliable skull and consist of a greenstick fracture and skull depression which resembles a depression in a ping-pong ball (Fig. 7.4). Due to rapid skull growth, most ping-pong fractures heal well



without surgery and mold to become cosmetically acceptable. Elevation is required for underlying brain injury, parenchymal bone fragments, and neurologic deficit. Underlying brain contusion secondary to skull fracture can cause post-traumatic seizures.

Basilar skull fractures occur in the anterior, middle, or posterior fossa at the base of the skull. Structures at the skull base are susceptible to injury and include the carotid artery, venous sinus, cranial nerves, and the middle ear (Ragheh 2008). Basilar skull fractures may be difficult to see on CT, but findings of pneumocephalus and opacification of the mastoid air cells are suggestive. Plain films and clinical findings (CSF otorrhea or rhinorrhea, hemotympanum, Battle's sign, raccoon eyes, cranial nerve injuries) are more sensitive (Greenberg 2010). Temporal bone fractures are classified as transverse (extending across the petrous portion) or longitudinal (extending lateral to medial). Complications associated with transverse temporal bone fracture include sensorineural hearing loss (CN VIII) and facial nerve dysfunction (CN VII), whereas longitudinal temporal fracture can cause hemotympanum, torn tympanic membrane, CSF leak, and conductive hearing loss secondary to bony disruption. In most cases, the hearing loss resolves, but it can be permanent. The middle meningeal artery is housed in a groove of the temporal bone. Laceration by the sharp bony edge of the fracture causes serious life-threatening epidural hematoma formation and need for emergent surgical intervention following temporal bone fracture (Greenberg 2010).

The nursing assessment should include inspection and gentle palpation of the scalp to check for findings consistent with a skull fracture. External evidence of skull fracture includes swelling, hematoma, depression of the scalp, laceration with or without fluid leak, or extruding brain. Basilar skull fractures are identified by external clinical findings. Basilar fracture of the temporal bone results in "Battle's sign," which is postauricular ecchymoses and can be associated with CSF leak from the ear (otorrhea). A frontal basilar fracture results in "raccoon eyes," which is periorbital ecchymoses. CSF leak from the nares

(rhinorrhea) can result secondary to frontal basilar fracture. The majority of cerebrospinal fluid leaks resolve within 7 days without surgical intervention. Nursing care of the patient with CSF leak includes elevation of the head of the bed, restriction of nose blowing, and reporting of fever or other signs of meningitis. The neurosurgeon may need to place a lumbar drain, so the leak can seal. Check with the neurosurgeon before placement of a nasogastric tube, as a frontal fracture through the cribriform plate can allow placement of the catheter into the brain.

### 7.7.8.3 Extraparenchymal Hemorrhage

Extraparenchymal or extra-axial hemorrhages are those occurring outside the brain itself and are defined by the location in which they occur in relationship to the meninges. They include epidural, subdural, and subarachnoid hemorrhages. The presentation and acuity level varies based on the child's age, as well as location and size of the hemorrhage. Small hemorrhages with minimal or no clinical deterioration may be observed with close monitoring and radiographic follow-up, whereas hemorrhages with significant mass effect and a deteriorating or comatose patient require emergent craniotomy and surgical decompression (Doppenberg and Ward 2008). There is a lower incidence of mass hemorrhage in infants and children than in adults. The anatomy of the pediatric brain and skull dissipates the impact of traumatic injury in this population. The protective features include the thin deformable skull, wider CSF spaces, and softer brain. These features not only protect children from mass hemorrhage but also enable children to tolerate hematomas better up to 4 years of age, at which time the child's skull is a closed, rigid box likened to that of an adult. Interestingly, the anatomical differences that are protective against mass hemorrhage also predispose the pediatric patient to shearing injuries and subarachnoid hemorrhage.

### 7.7.8.4 Epidural Hemorrhage

Epidural hematomas (EDH) are less common in infancy and steadily increase in incidence with age. Outcome following EDH is improved in

**Table 7.8** Surgical or nonsurgical management of epidural hematomas (Doppenberg and Ward 2008)

Surgical indications	Nonsurgical management of EDH
Focal neurologic exam, third nerve palsy, increasing drowsiness	Neurologically intact, with only headache, nausea, vomiting, and irritability (sixth nerve palsy without posterior fossa clot may be excepted)
Focal, significant cortical compression, seen with clots >15 mm diameter	Clot in frontal, parietal, or occipital region
Brainstem herniation	Small posterior fossa clot without compression of cortex, fourth ventricle, or brainstem
Epidural clot volume >30 cc	
Midline shift or uncal herniation, with temporal lobe clot	
Concomitant intraparenchymal or subdural hematoma with mass effect	
Associated fracture transversing major dural vessel with neurologic impairment	

children when compared to adults. Epidural hematomas can be either venous or arterial in origin. The frontal, temporal, and parietal regions are typical locations for EDH. In neonates and infants, EDH is usually venous, secondary to tearing of the dural veins (see Sect. 7.7.1). More commonly, especially in older children, EDH results from a tear of the middle meningeal artery, which is housed within a groove of the temporal and parietal bones. This artery is lacerated by the sharp bone edge when the skull fracture is sustained. Infratentorial (or posterior fossa) epidural hemorrhages occur, but are less common in older children (Doppenberg and Ward 2008). The posterior fossa is a common location for an EDH due to the presence of the dural venous sinuses, and EDH is usually associated with fracture. Epidural hematoma in the posterior fossa is more dangerous due to the smaller anatomic space and potential for direct mass effect on the brainstem, and surgery is recommended (Greenberg 2010).

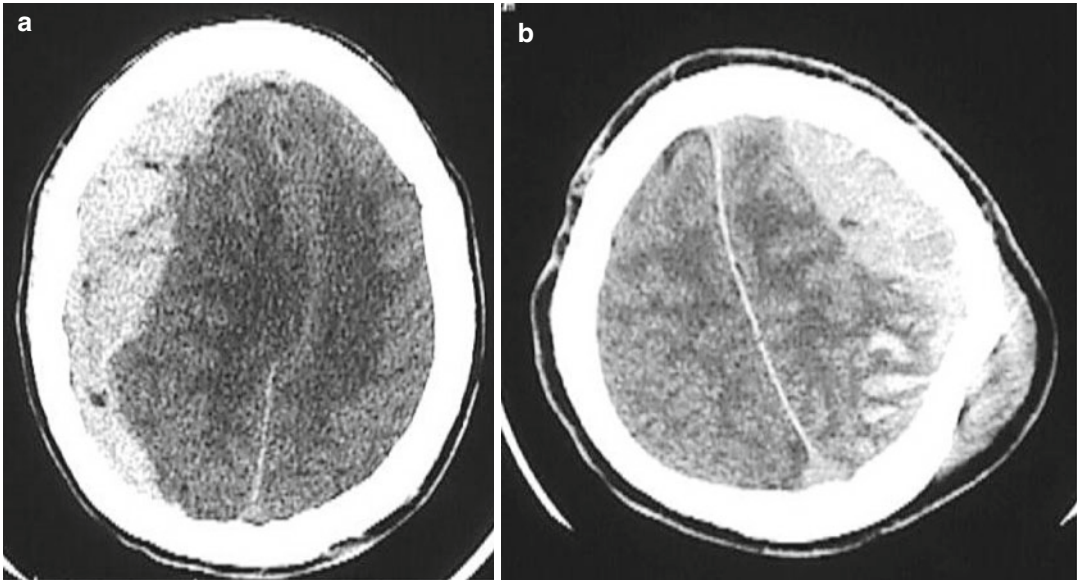
Regardless of the origin, the bleeding creates a space between the dura mater and the periosteum (or inside) of the skull. Clinical presentation of EDH in pediatrics can be delayed due to the plasticity of the child's skull. The hallmark "lucid interval" following EDH may differ in that the child only appears stunned, while the older child or adult will have loss of consciousness. The volume of a rapidly expanding mass lesion (or hemorrhage), however, is not well tolerated even in the more plastic pediatric cranium. The increased intracranial volume results in general increased intracranial pressure. Nursing care and assess-

ment are dependent on the location of the hemorrhage, being either supratentorial or infratentorial, (above or below the tentorium cerebelli), as the clinical presentation and indications of neurologic deterioration with expanding mass lesions vary based on this important landmark (see Sect. 7.5.7). Indications for surgical versus nonsurgical management of EDH are presented in Table 7.8.

Radiographic evaluation of EDH is best accomplished with a CT scan, which reveals a lentiform, hyperdense (bright white), extraparenchymal fluid collection that is contained within the cranial suture lines (Fig. 7.5). The blood is contained within the sutures because of the attachment of the dura to the periosteum. Epidural hematomas are often also associated with CT scan findings of scalp swelling and the presence of a skull fracture in the frontal, temporal, or parietal regions (Barkovich 2005). Common practice is to repeat the radiographic imaging within 6 h for small, nonsurgical EDH.

#### 7.7.8.5 Subdural Hemorrhage

The incidence of subdural hematomas (SDH) is opposite that of EDH in that they are more common in infants and less common in older children. There is more often underlying brain injury associated with SDH than with EDH. Common etiologies for SDH in children include birth trauma, accidental falls, and child abuse. This type of hemorrhage is due to stretching and tearing of the bridging veins in the subdural space or hemorrhage around severe primary



**Fig. 7.5** (a, b) Extraparenchymal hemorrhage. (a) Subdural hematoma shown on CT scan as an acute, crescent-shaped blood collection that crosses suture lines. (b) Epidural hematoma seen on CT scan as a hyperdense, lentiform collection, contained within the suture lines. Also note significant scalp swelling

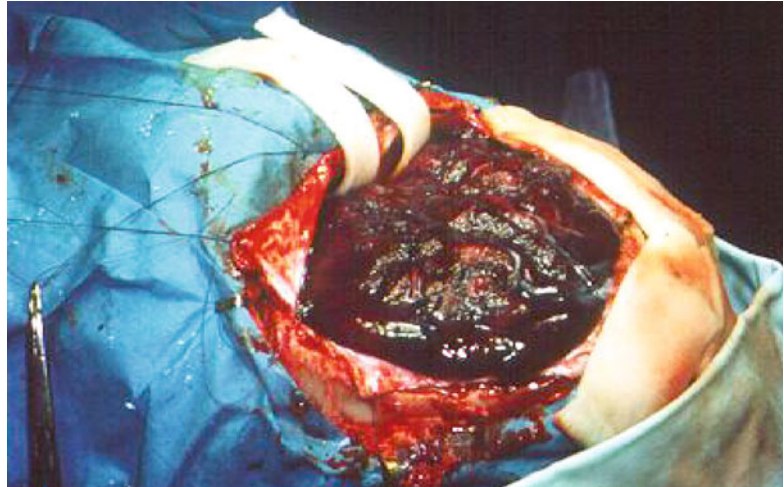
brain injury with laceration (Greenberg 2010). The subdural space is located below the dura mater and above the arachnoid membrane. Hemorrhage in this space is not limited to the suture lines and, therefore, can result in large, bilateral blood collections over the entire convexity (Fig. 7.5). Most occur over the convexities but may also be interhemispheric, along the tentorium, or in the posterior fossa (Greenberg 2010; Ragheh 2008).

Large expanding mass lesions of subdural origin significantly increase intracranial volume and thereby intracranial pressure. Infants with SDH present with seizures, irritability, lethargy, vomiting, and increased head circumference. Older children have decreased level of consciousness, pupil asymmetry, and hemiparesis. Severe increased intracranial pressure results in an irregular respiratory pattern, hypertension, and bradycardia, also known as “Cushing’s triad.” (See Sect. 7.10 Presenting symptoms may be due to the mass effect exerted by the subdural hemorrhage or by the underlying brain injury and possibly cerebral edema. Expansile subdural collections require emergent

craniotomy and evacuation to prevent herniation and death. Needle aspirations can be performed in infants with an open fontanel to temporarily relieve pressure. In contrast, a small SDH in a child with minimal neurologic deficits can be observed closely with follow-up imaging within 8–12 h.

Presence of blood in the subdural space is well visualized on CT scan. Subdural hematomas appear as an acute, crescent-shaped, extraparenchymal blood collection, which crosses the suture lines (Fig. 7.6). Severity of a SDH is based on the size, location, and presence of mass effect. Mass effect with any intracranial lesion is manifested as a right or left shift of the cerebral hemispheres (away from the lesion), effacement (compression) of the ventricles, displacement of the brainstem, and obliteration of the sulcal pattern and is indicative of increased ICP. There may also be underlying brain injury, which is less visible until the clot is surgically decompressed. MRI can be useful to determine the timing (acute versus chronic) of subdural hemorrhages, which can be helpful in an investigation for child abuse (see Sect. 7.7.11) (Barkovich 2005).

**Fig. 7.6** Intraoperative photograph demonstrating a large open craniotomy after severe head trauma. Note the large SDH clot on the surface of the brain



### 7.7.8.6 Subarachnoid Hemorrhage

Subarachnoid hemorrhage (SAH) is common in children with significant head trauma due to the large, vascular subarachnoid space and the soft calvarium (Doppenberg and Ward 2008). Intraparenchymal injury is often associated with the presence of hemorrhage in the subarachnoid space (Barkovich 2005). The subarachnoid space is located between the arachnoid and the pia mater, which is a thin membrane that is adhered to the brain's surface. Cerebrospinal fluid (CSF) is made primarily in the ventricles and then circulates around the brain within the subarachnoid space. Circulation of CSF allows delivery of metabolic substrates, cushions the brain from trauma, and removes waste products. On CT scan images, subarachnoid hemorrhage (SAH) appears bright white and is seen within the gyral and sulcal pattern on the brain's surface, in the interhemispheric fissure, along the tentorium, and within the cisterns. Clearance of subarachnoid blood is fairly rapid as the blood is "washed out" with the circulation of CSF. MRI is not useful to identify SAH, but should be considered in a child with SAH and severe neurologic deficits. MRI can be useful to identify nonhemorrhagic intraparenchymal lesions, which are often associated with SAH.

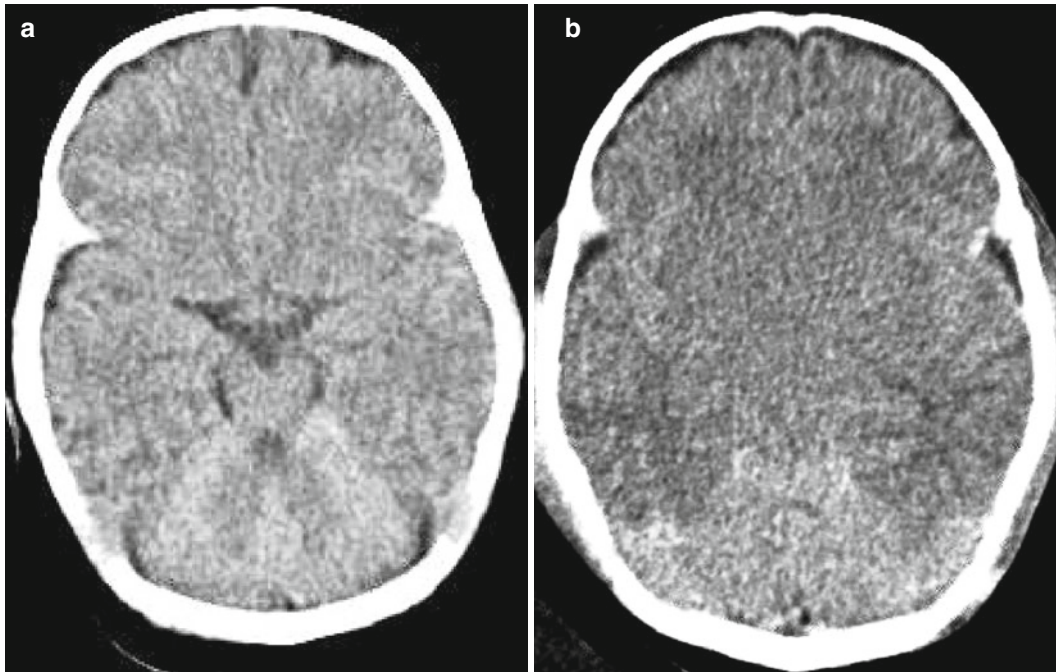
The child with SAH should be observed for irritability, headache, stiff neck, and other signs of irritation to the meninges, similar to the presentation of meningitis. Children can develop

posttraumatic hydrocephalus, especially when SAH or intraventricular hemorrhage (IVH) is present. The presentation of hydrocephalus is identical to that of increased intracranial pressure. Development of hydrocephalus can be seen on CT scan and, when present, requires CSF diversion to prevent increased ICP and possible herniation. Temporary CSF diversion techniques include drainage via a ventriculostomy, and transfontanel tap in an infant with an open fontanel. Permanent CSF diversion requires placement of a shunt, consisting of a ventricular catheter, a one-way pressure-regulated valve, and a distal catheter to divert CSF to the peritoneum, pleural space, or right atrium.

### 7.7.8.7 Parenchymal Injury

Following severe head trauma, children have generalized brain swelling. This is thought to occur due to edema and a process of dysautoregulation, whereby the cerebrovascular resistance decreases, resulting in vasodilation and increased cerebral blood volume. Neuroimaging with CT scan completed 12 h after the injury often appears normal, whereas repeat imaging at 24 h post injury reveals poor gray-white matter differentiation with compressed or absent ventricles, cisterns, and sulcal pattern (Barkovich 2005) (Fig. 7.7).

Mass effect following parenchymal injury can be compartmentalized or global. Mass effect from hemorrhage and surrounding cerebral edema,



**Fig. 7.7** (a) Severe traumatic brain injury (TBI). Early CT scan without evidence of injury, cisterns, and normal extra-axial fluid is maintained. (b) Follow-up CT scan on day 2 showing what is referred to as a “tight” brain, with

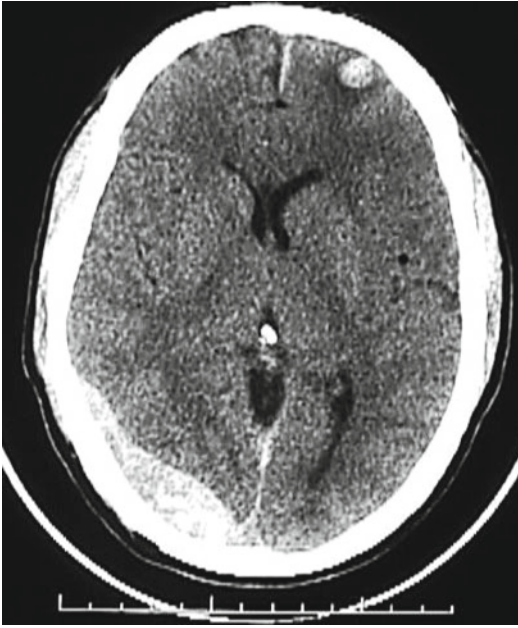generalized edema, poor gray-white matter differentiation, and obliteration of the ventricles, cisterns, and sulcal pattern

when confined to the temporal (middle) cranial fossa, is concerning and can lead to transtentorial (or uncus) herniation. Surgical intervention becomes necessary to prevent impending uncus herniation or other neurologic deterioration. The child with an expanding contusion or mass lesion on the right side and pending uncus herniation will present with a right unilateral dilated pupil and contralateral motor weakness, hyperreflexia, present Babinski, clonus, or posturing. The goal of neurosurgical intervention is to remove the hemorrhage, as well as the injured portion of the brain, to decompress the compartment and reduce related volume and, therefore, pressure (Greenberg 2010). It is paramount for the nurse to carry out interventions to prevent secondary injury (fluid overload, hyponatremia, hypercapnia, hypotension) and prevent life-threatening edema or herniation. Any deterioration in the child’s level of consciousness indicates increasing ICP and should be reported to the physician immediately and documented (see ICP Management section).

#### 7.7.8.8 Contusion

A contusion is a focal bruise (nonhemorrhagic or hemorrhagic) to the surface of the brain, which, based on size and location, can cause neurologic deficits, seizures, local mass effect, and increased intracranial pressure resulting in herniation. Contusion occurs when the skull impacts a stationary object with sudden deceleration, causing the brain to collide with the bony prominences of the frontal, temporal, or occipital skull. The point of initial impact of the brain on the internal skull is referred to as the “coup” injury. The brain, being suspended in fluid, then strikes the opposite side of the skull, which can cause a “contrecoup” injury. The French meaning of the word contrecoup is “counter blow” (Greenberg 2010). Contrecoup injuries are less common in young children, occurring with a frequency of less than 10 % in ages 0–3 years, and 25 % in ages 3–4 years.

Nonhemorrhagic contusions appear as an area of low attenuation on head CT representing



**Fig. 7.8** CT scan demonstrating a typical surface contusion in the left frontal lobe, which was likely a contrecoup injury. Note right posterior SDH. The ventricles are asymmetric secondary to the mass effect of the SDH

associated edema, whereas hemorrhagic contusions appear as areas of high attenuation (Fig. 7.8) (Greenberg 2010). The CT may also reveal an accompanying extra-axial hemorrhage or intracranial air, also known as pneumocephalus. MRI is more sensitive to identify nonhemorrhagic contusions (Barkovich 2005). It is the hallmark for contusions to enlarge subacutely and, therefore, require repeat CT imaging within 12–24 h of the injury (Dias 2004; Greenberg 2010). Close observation in an intensive care unit and repeat imaging is required, but contusions typically coalesce and resolve without surgical intervention. Surgical removal is required for neurologic deterioration. (See Sect. 7.10.) Following resolution of a contusion, encephalomalacia (or “dropout”) of the brain can occur, with the space then being filled with cerebrospinal fluid (Barkovich 2005).

The child with a focal contusion in an eloquent area of brain, such as speech or motor centers, will likely have worsening of their neurologic function specific to the area of injury as the contusion enlarges. Nurses should be aware of the

location of injury and anticipate what deficits may develop. Any change in neurologic function should be reported to the physician immediately. The family should also be warned that the deterioration may occur.

*Posttraumatic seizures (PTS)* are much more common in young children than in adults (Kochanek et al. 2012; Dias 2004; Carney et al. 2003; Holmes et al. 2004) and occur in approximately 10 % of children following head trauma. The majority of PTS are considered early, occurring within 1 week. Fifty percent occur in the first 24 h post injury (Doppenberg and Ward 2008; Ragheh 2008) and are referred to as *impact seizures*. Studies have indicated that children who experienced PTS after blunt head trauma, with a non-focal neurologic exam and a negative CT scan, can safely be discharged to home. Holmes et al. (2004) prospectively observed a cohort study of 63 children under 18 years with blunt head trauma. Head CT was obtained on all of the children. Ten children had findings on CT scan and were admitted to the hospital, three underwent craniotomy, and two had further seizures. The remaining 52 with negative CT imaging were either observed in the hospital or discharged to home. Follow-up revealed that none of the 52 patients with normal CT scan results had further seizures or required neurosurgical intervention.

Seizures result in increased cerebral metabolism and increased ICP and can cause secondary brain injury. The Guidelines from the Society of Pediatric Critical Care Medicine (Kochanek et al. 2012) recommend prophylactic anticonvulsant therapy with phenytoin as a consideration to reduce the incidence of early posttraumatic seizures in pediatric patients with severe TBI. No data has shown that use of anticonvulsants for early PTS in severe TBI reduces the long-term risk of PTS or improves long-term neurologic outcome. Risk factors associated with the occurrence of PTS include location of the lesion, cerebral contusions, retained bone and metal fragments, depressed skull fracture, focal neurologic deficits, loss of consciousness, Glasgow Coma Scale (GCS) score <10, severity of injury, length of posttraumatic amnesia, subdural or epidural hematoma, penetrating injury, chronic alcoholism, and

age. Prolonged anticonvulsant therapy for 6–12 months may be required (Greenberg 2010; Doppenberg and Ward 2008; Dias 2004).

### 7.7.9 Diffuse Axonal Injury

Decreased level of consciousness and generalized increased ICP are more likely with diffuse axonal injury (DAI). DAI occurs when the pediatric skull is subjected to rotational forces during high-velocity acceleration or deceleration injuries. The mechanisms of DAI in children vary by age, with older children and adolescents involved in motor vehicle accidents (MVA) and bicycles versus MVA. Younger children are often pedestrians versus MVA. DAI is rare in infants. The softer, more plastic pediatric brain moves within the skull. This movement is further facilitated by the wider subarachnoid space found in children. Neuronal injury occurs in the softer, unmyelinated pediatric brain, when the axons are stretched until there is sufficient strain to cause the axons to fracture (Barkovich 2005). This tearing may be associated with tearing of blood vessels and tiny petechial hemorrhages (Hickey 2009).

DAI typically occurs at the junctions of gray and white matter, the corpus callosum, the internal capsule, the basal ganglia, and the brainstem. The hallmark presentation for DAI is immediate loss of consciousness (LOC) that often lasts greater than 6 h. Abnormal flexion (decorticate) posturing or extension (decerebrate) posturing can accompany LOC, as well as a variation in the GCS score on serial assessments. Children may also have pupillary and other cranial nerve dysfunction and brainstem abnormalities, which will be reflected in assessment findings. The typical triad of pediatric DAI is hypertension, hyperhidrosis (perspiration), and brainstem abnormalities.

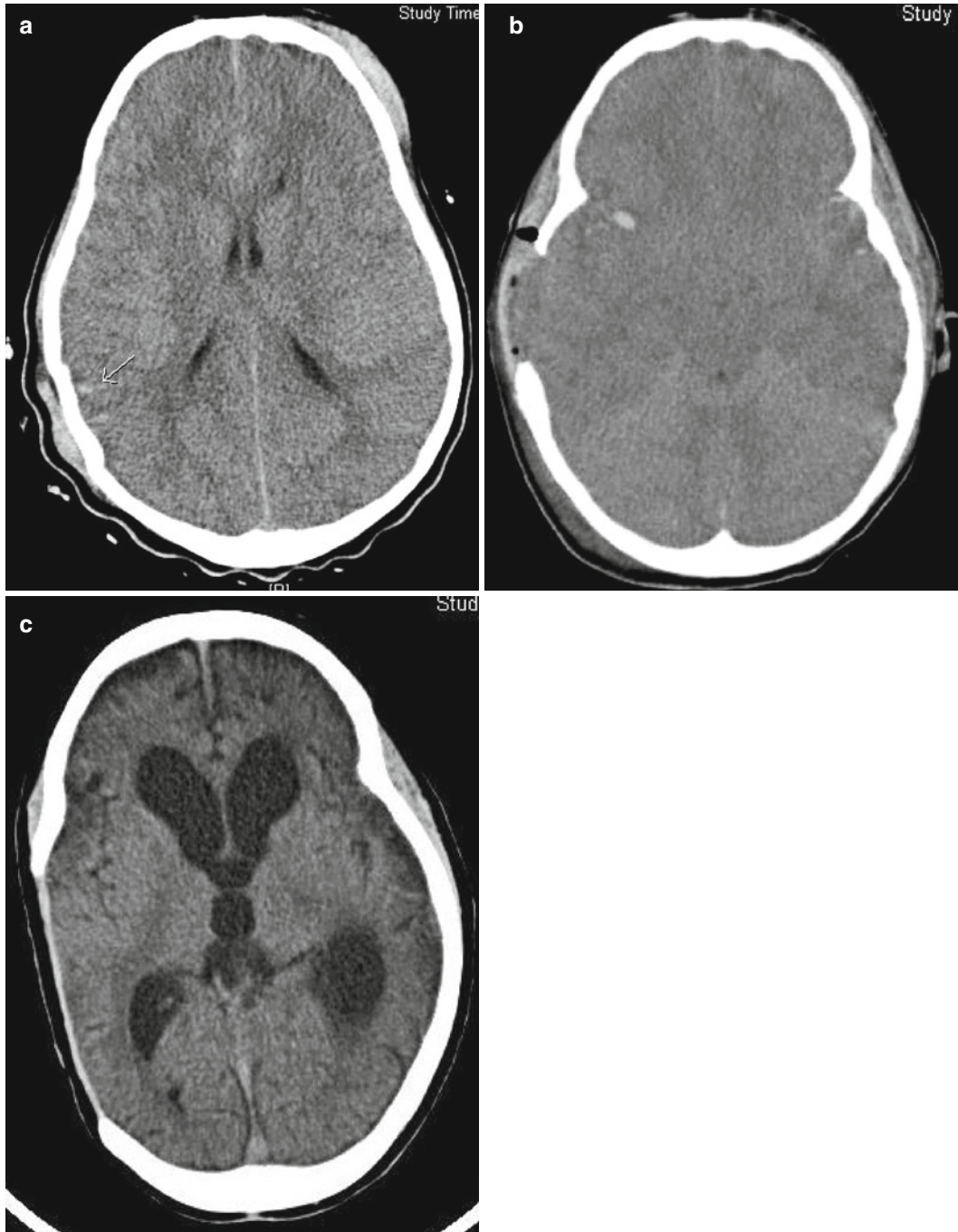
Computerized tomography (CT) is not sensitive enough to diagnose DAI. Magnetic resonance imaging (MRI) is most sensitive to shearing injury and should be considered if the CT scan does not reveal injury sufficient to explain the degree of neurologic deficit (Fig. 7.9). T2 and

gradient echo-weighted MRI sequences are very sensitive to DAI.

There is no definitive treatment for DAI other than supportive care. Children with severe TBI (GCS 3–8) should be monitored and treated for increased intracranial pressure. The presentation and management of increased ICP are discussed elsewhere in this chapter. Pure DAI is associated with mild increased ICP (Ragheh 2008). Greatly increased ICP in children with DAI requires repeat imaging with CT scan for suspected expanding mass lesion (Barkovich 2005). Recovery from DAI is a slow, gradual, and often incomplete process and can continue for weeks or months following DAI (Ragheh 2008). Outcomes depending on the severity of DAI can vary from cognitive and neurologic deficits to severe disability and death (Hickey 2009).

### 7.7.10 Penetrating Craniocerebral Injury

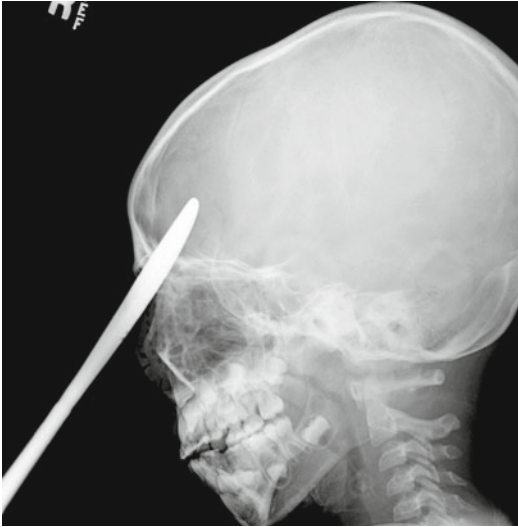
Penetrating craniocerebral injuries (PCI) are less common but more often fatal in children. Poor prognostic factors associated with PCI include presentation in coma and the penetrating object crossing midline through the center of the brain or through the ventricles (Greenberg 2010). Concomitant anoxia results in a grave prognosis. Child survivors of PCI often have compromised quality of life. Causes of PCI include accidental impalement with a random sharp object or firearm injury, suicide, and homicide (Krieger et al. 2008). According to Krieger et al. (2008), two key factors with impalements are penetration through the thin calvarium with high risk for vascular and cranial nerve injuries and infection risk with the foreign body (Fig. 7.10). Gunshot wounds are classified by the caliber or velocity at which the missile (bullet) enters the brain. Low-velocity injuries occur with most handguns and cause tissue injury along a path slightly wider than the bullet. High-velocity PCI occurs with military weapons and hunting rifles and causes additional damage due to a shock wave which pushes the brain tissue away from the bullet. Secondary brain injury occurs with cerebral edema,



**Fig. 7.9 (a–c)** Diffuse axonal injury (DAI). This 5-year-old was struck by a van, sustaining severe closed head injury. **(a)** CT scan on the day of the injury shows a depressed right parietal skull fracture, with overlying soft tissue swelling. The child also sustained right temporal and orbital fractures. Multiple punctate hemorrhages consistent with DAI are seen adjacent to the fracture (*arrow*). **(b)** An intracranial pressure (ICP) monitor was placed. Due to uncontrollable elevated ICP, an emergent decompressive craniectomy was performed (see absent bone flap). Multiple small parenchymal hemorrhages

(DAI) at the gray-white matter junction can be seen on the CT scan. Also note that the brain is “tight” with poor gray-white matter differentiation and complete effacement of the ventricles and sulci. **(c)** Cerebral atrophy and ventriculomegaly are seen on the CT scan performed 6 months after injury. The child survived his injury but is functionally wheelchair bound with severe morbidity. Films compare the CT scan, where the DAI is not apparent, and MRI performed due to neurologic impairment, which was not explained on the CT scan





**Fig. 7.10** Skull x-ray reveals a penetrating cerebral injury, after a 3-year-old fell and was impaled onto a butter knife

low cardiac output, DIC, and intracranial hemorrhage (Greenberg 2010).

Early aggressive hemodynamic stabilization and ICP management are vital. (See Sect. 7.10) Head CT will reveal the gamut of intracranial injuries as well as help distinguish the entry (small, in-driven fragments and beveled edges) and exit wounds (larger and irregular). Skull films may be helpful to identify foreign objects, fractures, and skull or bullet fragments. In impalement, the protruding object must be secured and left in place by the nurse until evaluation and surgical removal by the neurosurgeon. Surgical intervention is recommended for patients who are considered salvageable. Patients with post-resuscitative GCS 3–5 and fixed pupils have mortality rates greater than 80 % and very poor outcomes. Goals of surgery include:

- Removal of foreign object (prevent infection, seizures, aneurysm)
- Removal of necrotic brain (prevent hemorrhage, edema, scar)
- Elimination of mass effect
- Evacuation of hematomas
- Repair of vascular injury
- Closure of dura and scalp
- Placement of ICP monitor (Krieger et al. 2008)

Complications of PCI include disseminated intravascular coagulation (DIC), infection (with or without abscess), and seizures (Krieger et al. 2008). Disseminated intravascular coagulation is an abnormal coagulation/thrombolytic cascade secondary to thrombin release from injured brain and leads to uncontrolled cerebral hemorrhage. Treatment includes replacement of clotting factors such as fresh frozen plasma, cryoprecipitate, and platelets. Infection is common after PCI, especially in low-velocity GSW and impalement, where the rate of infection approaches 43 %. Prophylactic antibiotics are most often used. Repeat cerebral imaging is important to assess for abscess, in the face of fever, new focal neurologic deficits, and change in mental status. Incidence of posttraumatic seizures following PCI has been found to be as high as 50 % (Greenberg 2010); therefore, treatment with antiseizure medications is recommended (see Sect. 7.7.8.8). MRI is contraindicated if none or a portion of the foreign body can be removed (i.e., bullet fragment).

## 7.7.11 Abusive Head Trauma

### 7.7.11.1 Introduction

In 2009, child maltreatment (including abuse and neglect) resulted in 1,770 deaths or 2.34/100,000 children in the United States. Abusive head trauma (AHT) is the leading cause of death from child abuse and the most common cause of severe TBI in infants (Barlow et al. 2001; Keenan et al. 2003; Duhaime 2008). Data from the Kids' Inpatient Database, including coding in hospital discharge databases, was examined to estimate the rate of AHT in the United States at 32.2 cases per 100,000 infants per year (Ellingson et al. 2008). Risk factors for inflicted injury include young parents, low socioeconomic status, single parents, prematurity, and substance abuse (Duhaime 2008). Perpetrators include fathers (37 %), boyfriends (20.5 %), female babysitters (17.3 %), and mothers (12.6 %) (Starling et al. 1995). Retrospective studies have shown that children with AHT are frequently misdiagnosed, resulting in reinjury and deaths (Jenny et al. 1999).

AHT is also known as non-accidental trauma. Common clinical findings include scalp or skull injury, subdural hematoma (SDH), retinal hemorrhage (RH), and other fractures or injuries. The acute and long-term clinical outcome of AHT ranges from mild to severe, with a varied spectrum from full recovery to death or permanent disability. The neuroscience nurse must be knowledgeable of, and suspicious for, indicators of AHT. As healthcare professionals, nurses are mandated to report any suspicion of child maltreatment. A multidisciplinary plan for treatment and investigation is paramount in treating the child with AHT.

### 7.7.11.2 Pathophysiology

Pathophysiology of AHT is complex and may involve more than one occurrence or more than one mechanism of injury (direct trauma, shaking with or without impact, strangulation). The mechanism of the shaken shaken-impact syndrome is well described, including violent shaking, which is often associated with an impact causing sudden deceleration of the head and brain. Shaking an infant is believed to cause an angular deceleration of the child's head sufficient to cause tearing of subdural veins and hemorrhage (Caffey 1974). Injury severity and outcomes worsen when the shaking injury is further compounded by an acute life-threatening event, seizure, or unresponsive presentation, with apnea or hypoxia (Duhaime 2008). Other common injuries associated with AHT include retinal hemorrhages, acute or healing skeletal trauma, external signs of trauma, and signs of physical neglect.

Acute subdural hemorrhage is the most common head injury seen with AHT and typically is extensive collection over the convexities as well as in the posterior hemispheric fissure (Duhaime 2008; Vinchon et al. 2005). Vinchon et al. (2005) found that SDH was present in 81 % of child abuse cases, with AHT accounting for 64 % of all traumatic SDH in infants. Subdurals with mixed density on CT imaging are more frequent in cases of AHT, whereas homogeneous hyperdense subdural is more frequent with accidental head trauma (Tung et al. 2006). Hemorrhages of different density (age) indicate repetitive AHT. MRI

is a more sensitive tool to estimate the age of the hemorrhages and to assess for presence of membranes, indicative of chronic subdurals (Barkovich 2005). Axonal injuries are now believed to be due to diffuse hypoxia and edema (Barkovich 2005). Treatment of subdurals and other types of traumatic brain injuries is the same as for accidental mechanisms and was discussed earlier in this chapter.

Retinal hemorrhage (RH) occurs in both accidental and AHT. Vinchon et al. (2005) found that severe RH (grade 2 or 3) was 100 % specific for the diagnosis of child abuse. It is requisite that grading of RH be determined by a trained ophthalmologist to assure a correct diagnosis and prevent misdiagnosis. Skeletal survey is necessary to assess for skeletal fractures. Skull fractures, spiral fractures of the long bones, metaphyseal fractures, and posterior rib fractures are common fractures associated with child abuse.

### 7.7.11.3 Clinical Presentation

Most infants present with nonspecific clinical findings and without external signs of trauma. Vague presenting symptoms include poor feeding, vomiting, irritability, lethargy, seizure, apnea and unresponsiveness, external ecchymosis, or other marks indicating trauma. Pallor, tachycardia, or poor perfusion may indicate anemia secondary to intracranial hemorrhage. Children may present with minimal or no external signs of AHT, despite significant neurologic sequelae.

The true history of the injury is withheld (Duhaime 2008), leaving the medical team to piece important history and a constellation of clinical findings together to make a diagnosis of AHT. Little or no history of trauma may be given. Or the reported trauma may not match the severity of the child's injury. It is essential to obtain a detailed history of the child's condition from the parent or guardian. The family should be made aware of the need to find out what happened to the child for the purpose of managing the injuries and anticipating complications. The interviewer needs to document a specific account of exactly what happened and the time that it occurred. Determine who was responsible for the child's

care at or around those times. Inquire specifically about any history of trauma, which may have caused the injuries, and if there were witnesses. Inconsistencies in the history between caregivers, or from the same caregiver on separate occasions, are concerning for AHT (Hettler and Greenes 2003). Multidisciplinary team members (i.e., child abuse physician, social worker, children's service board, and law enforcement) will interview the family as part of a detailed investigation for AHT. Input from other physicians, the neurosurgeon, the ophthalmologist, the radiologist, and the nurse is critical to the investigation.

#### 7.7.11.4 Management

Medical care begins with the EMT/paramedics arrival at the scene or upon the child's arrival to the ED. It is important to stabilize the patient's cardiorespiratory status rapidly to prevent further injury. Once the ED physician has suspicion of AHT, the remainder of the multidisciplinary team should be involved. The neurosurgeon must evaluate the child to determine if urgent surgical intervention is warranted.

#### 7.7.11.5 Case Study

A 5-month-old female was brought to ED by EMS for decreased responsiveness. The mother stated the child fell from a changing table onto a hardwood floor a week ago, cried, and vomited. The mother allegedly called 911 for advice. The baby was not brought in for evaluation. She had continued vomiting, fever, and diarrhea and was seen and diagnosed by the PCP with "stomach flu." The infant is now brought to ED by squad for parental concern of decreased responsiveness. The mother denies trauma, other than the fall the week before, but did state that the sibling (age 4) was "rough" with the child. The child is otherwise healthy; there is no family history of abnormal bleeding. The mother is the primary caregiver, and the father works.

#### 7.7.11.6 Exam Findings

*General:* Irritable cry, pale, bulging fontanel

*HEENT:* Pupils sluggish reaction, right gaze preference

*Lungs:* RR 28–32

*CV:* HR 135, ST, blocked PACs, cap refill <2 s

*Abdomen:* Soft, non-tender, no organomegaly, or palpable masses

*Extremities:* Limbs normal, painless to palpation; symmetric, full ROM

*Neurologic:* Child has frequent thrusting movements of the tongue, stiff neck, and global hypotonia; no tonic-clonic movements

*Skin:* Faint blue bruise to left inferior periorbital area; mucus membranes moist

#### 7.7.11.7 Diagnostic Findings

*MRI:* Bilateral frontal extra-axial fluid collections (chronic SDH) and an acute interhemispheric bleed. Figure 7.11 shows bilateral subdural hematomas with formed membranes secondary to AHT.

*Skeletal survey:* Split sutures, no fractures.

*Ophthalmology:* Bilateral RH.

*Lumbar puncture* was "bloody"; RBC = 1,580.

#### 7.7.11.8 Discussion

A multidisciplinary team investigated for possible AHT. She was admitted to the PICU for observation. Bilateral subdural drains were placed with resolution of SDHs. The infant was discharged to a foster home. Investigation failed to prove AHT, and custody was returned to the biological mother. She presented 1 year later with inflicted trauma (2 months after placement with biological parents). Injuries in this admission included:

Left distal radius fracture

Left proximal tibial fracture

Right distal radius fracture

Left distal ulnar fracture

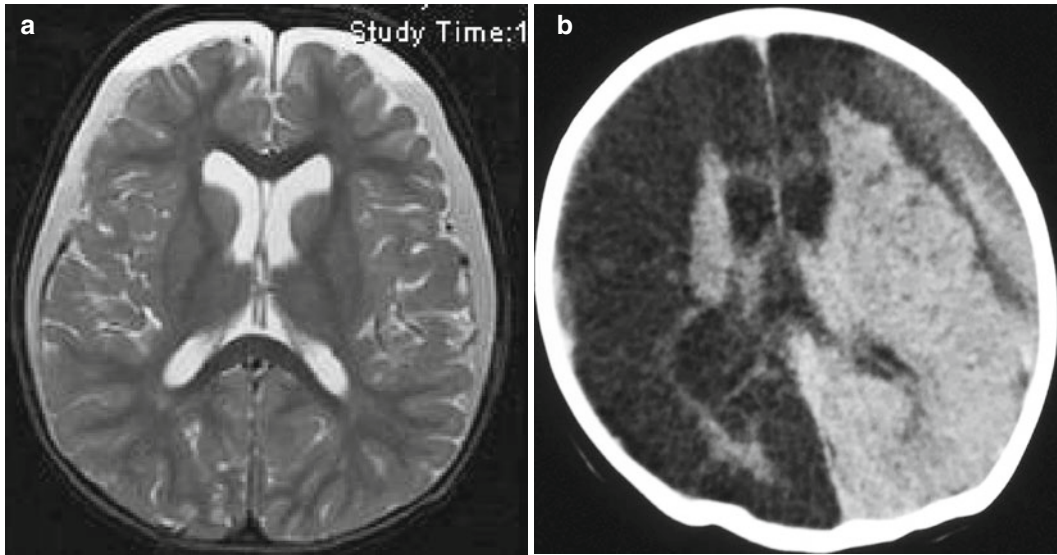
Bilateral optic edema, with retinal hemorrhages

Increased subdural hemorrhages, with mass effect

Multiple ecchymosis throughout the body, bite marks throughout integument

Increased radionuclide bone scan activity, ribs (10 and 11), and left scapula, indicative of fracture

The child is currently doing well after adoption by a caring foster family. She has mild



**Fig. 7.11** (a, b) Abusive head trauma. (a) Bilateral SDH seen on MRI, which reveals two different densities, implying acute and chronic injury. Subdural membranes are present. (b) Severe cerebral atrophy 3 months after infant was shaken

developmental delay and behavioral issues, requiring developmental intervention and rehabilitation therapies.

#### 7.7.11.9 Outcomes

In the acute stage of AHT, the full extent of brain injury on the child's development may not be visible. Imaging 1 year post injury may show extensive atrophy to the brain tissue despite improvement in the patient's neurologic deficits due to the ability of the brain to reassign functions to healthy brain tissue (Barkovich 2005). Research shows that chronic changes, such as cerebral atrophy and ex-vacuo (brain dropout), are present in 40–45 % of AHT (Fig. 7.11) (Cobbs-Ewing et al. 1998).

Information is limited regarding long-term outcome of AHT. Barlow et al. (2001) studied survivors for 59 months, proving that 68 % of the sample had developmental delays at the initial follow-up visit (16 % with mild delays, 16 % with moderate delays, 36 % with severe delays). Study results indicated 60 % had motor deficits, 48 % visual deficits, 20 % seizures, 64 % speech and language deficits, and 52 % behavioral difficulties. Outcomes of AHT, in addition to developmental or cognitive delays, may include

seizure disorder, blindness, cerebral palsy, hydrocephalus, and emotional or behavioral problems. Forty percent have deficits severe enough to impair their life-long ability to live independently (Barlow et al. 2001).

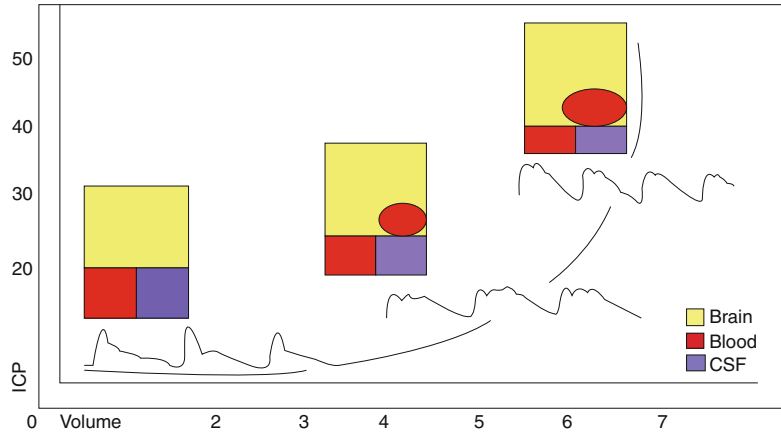
## 7.8 Concepts of Cerebral Physiology

### 7.8.1 Intracranial Dynamics

The skull forms a protective vault, which houses the brain and other cerebral structures. The protection offered by the cranial vault is not infinite. Severe TBI results in cerebral edema, increased intracranial volume, and eventual increased ICP, leading to decreased perfusion, decreased oxygen delivery, and cell death.

The Monroe-Kellie Doctrine recognizes that the skull is a rigid structure and that the sum of the intracranial volumes is constant. Intracranial components consist of brain (80 %), cerebrospinal fluid (CSF) (10 %), and blood within the cerebral vasculature (10 %). The intracranial pressure is determined by the total intracranial volume and intracranial compliance (the change in pressure

**Fig. 7.12** Pressure-volume curve. The Monroe-Kellie Doctrine demonstrates the intracranial contents (brain = yellow, CSF = blue, blood = red). With expanding mass lesion (hemorrhage) in TBI, intracranial volume rises. Pressure rises once compensatory mechanisms fail (pressure-volume curve). Corresponding ICP waveforms are also pictured



which results from a change in volume). When any of the components increase in volume, there must be a compensatory decrease in the others to maintain equilibrium and to prevent an increase in intracranial pressure.

### 7.8.2 Compensatory Mechanisms

The brain is incapable of a decrease in volume. The CSF and the blood compartments can compensate to a point to maintain equilibrium. This is accomplished by forcing intracranial contents out through the foramen magnum (FM) along the craniospinal axis. Given absence of obstructive hydrocephalus, the CSF is most easily displaced from the ventricles and cerebral subarachnoid space into the thecal or spinal subarachnoid space. The intracranial CSF volume can be therapeutically decreased via an external ventricular drain, or, if the ventricles are compressed and the basilar cisterns are patent, a lumbar drain can be utilized to drain CSF (Levy et al. 1995). With severe increased ICP, the CSF ventricles and cisterns are easily compressed and are absent on neuroimaging. Intravenous blood can be displaced through the FM via the internal jugular veins. As pressure continues to increase, arterial blood is displaced, causing decreased cerebral perfusion pressure (CPP) and diffuse cerebral ischemia. Blood flow ceases when the ICP equals the mean arterial blood pressure. The result is massive infarction. Severe cerebral edema or expanding mass lesion

can force the brain downward through the FM, causing cerebral herniation (Greenberg 2010).

### 7.8.3 Intracranial Compliance

Cerebral compliance is defined as the change in ICP, which results from a change in intracranial volume (Hickey 2009). Compliance is a measure of the brain's tolerance of increases in the ICP. Compliance is limited in that ICP will rise once the compensatory mechanisms are exhausted. The pressure-volume curve (Fig. 7.12) demonstrates that initial increases in intracranial volume are tolerated with little increase in pressure, indicating that intracranial compliance is high. Further increases in volume, especially after compensatory mechanisms are exhausted, result in low compliance, and ICP rises quickly. After compliance is lost, progressively smaller increases in intracranial volume are associated with significant increases in ICP. The normal ICP waveform depicts P1 (percussion wave) as the initial sharp peak, which indicates cardiac ejection. The tidal wave, or P2, is the second lower and more rounded peak, which reflects intracranial compliance. With rising ICP and poor compliance, there is a progressive rise in P2, while P1 and P3 rise much less, giving a rounded appearance to the overall pulse wave (Hickey 2009). The bedside nurse should monitor the ICP waveform for worsening intracranial compliance and as an indication of patient intolerance of nursing interventions.

### 7.8.4 Cerebral Blood Flow

Maintenance of cerebral blood flow (CBF) and oxygen delivery is critical to maintain normal cerebral metabolism and to prevent neuronal injury and ischemic cell death. In children, the brain receives 25 % of the total cardiac output and consumes 20 % of the total oxygen content. The brain rapidly becomes ischemic if CBF is decreased or compromised (Hickey 2009). Cerebral autoregulation is a protective mechanism, which balances vasoconstriction and vasodilation, to maintain homeostasis (constant cerebral blood flow) despite changes in systemic circulation. In other words, cerebral autoregulation is a protective process where large changes in systemic circulation result only in small changes in the cerebral circulation (Greenberg 2010). Failure of autoregulation after TBI renders the cerebral circulation completely dependent on the mean arterial blood pressure (MAP) and the cerebral perfusion pressure (CPP). Vasomotor dysfunction occurs and the resultant ischemia causes secondary cerebral injury (Kennedy and Moffatt 2004). Adelson et al. (1997) demonstrated that hypoperfusion was common in the first 24 h after pediatric TBI, when cerebral metabolic demand is highest, and is associated with poor outcomes. Hypotension must be treated aggressively to prevent secondary ischemic injury.

Hyperperfusion, also known as hyperemia, is defined as CBF in excess of metabolic demand (Bayir et al. 2003). Hyperemia following pediatric TBI increases the risk of intracerebral hemorrhage and further increases intracranial pressure, causing secondary ischemic injury. A prospective cohort study by Vavilala et al. (2004) measured cerebral autoregulation with transcranial Doppler ultrasonography in 36 children and found that impaired cerebral autoregulation was greater after moderate to severe TBI in children and was associated with poor outcome. Hyperemia was associated with impaired cerebral autoregulation and poor outcome.

Cerebral blood flow is also affected by changes in partial pressure of carbon dioxide ( $\text{PaCO}_2$ ),  $\text{PaO}_2$ , chemical changes in electrolytes and pH balance, and by increased metabolism due to

seizure activity and fever. The physiologic mechanism for this is a change in the tone or resistance of cerebral arteries due to local tissue biochemical responses. Hypercarbia is the most potent vasodilator, followed by hypoxia, when  $\text{PaO}_2$  falls below 50 %. A low body pH, or acidosis, also causes vasodilation. Presence of fever and seizure activity increases cerebral metabolism and produces vasodilation to meet the increased metabolic demand. Vasodilation increases intracranial blood volume and, after compliance is lost, increases intracranial pressure (Hickey 2009).

Cerebral blood flow is also affected by decreased venous return. Venous return decreases due to increased ICP, as pressure is transmitted to the low-pressure venous system. Decreased cerebral venous return increases cerebral blood volume and further increases ICP. Improper positioning of the child's neck in a rotated position causes compression of the internal jugular vein (IJV) and impedes venous return. The child's head should be positioned midline with the head of the bed elevated to 30° to optimize venous return via the IJV. Increased intrathoracic pressures secondary to high positive end-expiratory pressure (PEEP) with mechanical ventilation can also impede cerebral venous return.

### 7.8.5 Cerebral Metabolism

The brain is dependent on constant delivery of glucose and oxygen for energy production. The neural cells lack the ability to store these critical substrates. Neurons utilize glucose to produce energy, in the form of adenosine triphosphate (ATP), to meet metabolic demand and maintain aerobic metabolism. Oxygen is required to activate the Krebs cycle. Glucose is required to energize the Krebs cycle. Without oxygen and glucose, the Krebs cycle does not function properly, leading to anaerobic metabolism. Anaerobic metabolism produces excess lactate and pyruvate, which contributes to tissue acidosis, decreased ATP, decreased energy, and cell death. Lack of ATP causes failure of the sodium-potassium pump and its protection of the cellular membrane (Hickey 2009). A hypermetabolic state exists after TBI

(Bayir et al. 2003). Seizure control, sedation, analgesia, fever prevention, and barbiturate administration are examples of therapies which aim to decrease the cerebral metabolic demand.

## 7.9 Pathophysiology of Intracranial Hypertension

Primary traumatic brain injury is caused by an impact that directly disrupts brain tissue. Secondary injury is caused by late effects of the primary injury or new injury due to processes which compromise cerebral blood flow and tissue oxygenation. The pathophysiology of secondary injury is complex with many interrelated processes that interfere with cerebral function. These secondary processes include failure of compensatory mechanisms, altered cerebral blood flow (dysautoregulation and resultant hypoperfusion or hyperemia), anaerobic metabolism, excitotoxicity (excitatory amino acids such as glutamate), inflammation (increased permeability of the blood–brain barrier and resultant swelling), cerebral edema, oxidative stress (excess free radicals), and ischemic cascade resulting ultimately in cerebral infarction (Kennedy and Moffatt 2004; Hickey 2009). The final fatal pathway is malignant intracranial hypertension. The majority of our knowledge about increased ICP and the treatments employed are directed at therapies, which attenuate cerebral inflammation, prevent or reduce intracranial hypertension, control cerebral hemodynamics, and facilitate substrate delivery (Krieger et al. 2008).

### 7.9.1 Cerebral Edema

Cerebral swelling is defined as an increase in cerebral blood flow from regional or generalized hyperemia or cerebral blood flow in excess of metabolic demand. Peak swelling usually occurs 2–4 days after the initial injury. Cerebral edema is an increase in brain tissue volume, either local or generalized, due to increased intracellular and extracellular water content (Hickey 2009). There are three types of cerebral edema:

- Vasogenic – extracellular edema of the white matter. Diffuse injury produces an alteration in the permeability of the capillaries of the blood–brain barrier, which is more vulnerable to disruption in the pediatric brain. Plasma and protein leak into the extracellular space locally around brain tumors, infarction, and abscess. Vasogenic edema can also be generalized following TBI (Hickey 2009).
- Cytotoxic – increased intracellular swelling as a result of the ATP-dependent sodium-potassium pump failure, allowing fluid and sodium to accumulate in the cells. Cytotoxic edema results in diffuse brain swelling in both the gray and white matter. Cytotoxicity occurs after hypoxic-ischemic injury and in conditions of hypo-osmolality, such as hyponatremia and SIADH. Edema secondary to hypoxic-ischemic injury peaks at 48–72 h or longer after injury. Vasogenic and cytotoxic injuries occur within hours of injury (Greenberg 2010) and often coexist after TBI (Hickey 2009). Use of osmotic diuretics (mannitol) is useful in acute treatment of vasogenic and cytotoxic edema.
- Interstitial – occurs in severe hydrocephalus where CSF (under pressure) crosses the ependymal tissue, out of the ventricle and into the periventricular white matter.

### 7.9.2 Intracranial Hypertension

Intracranial pressure is the pressure exerted on the intracranial contents. Normal fluctuations of the ICP occur with any mechanism that increases cerebral venous pressure, such as coughing, crying, and the Valsalva maneuver. The normal value for ICP varies with age in children:

- Infants = 1.5–6 mmHg
- Children = 3–7 mmHg
- Adolescents = less than 10–15 mmHg (Greenberg 2010)

Prevention or treatment of intracranial hypertension in severe TBI is critical to maximize a child's outcome and potentially ensure survival. The threshold for treatment of intracranial hypertension is any sustained ICP of 20 mmHg or

higher. No data exists to support treating children at lower thresholds (Carney et al. 2003; Krieger et al. 2008). It is theorized, however, that the optimal ICP treatment threshold may be age dependent, given that normal blood pressures and ICP values are age dependent. Further investigation is needed (Kochanek et al. 2012).

### 7.9.3 Cerebral Perfusion Pressure

Cerebral perfusion pressure (CPP) is an estimated measure of the adequacy of cerebral perfusion. CPP is the difference between the mean arterial blood pressure (MAP) to perfuse the brain and the opposing intracranial pressure (ICP) [thus,  $CPP = MAP - ICP$ ]. The optimal CPP threshold and therapeutic approach to achieve it both remain to be defined. A minimum CPP of 40 mmHg may be considered in children with TBI. Age-specific thresholds in the range of 40–50 mmHg may be considered, with infants at the lower end and adolescents at the upper end of this range (Kochanek et al. 2012). CPP should be determined in a standard fashion with ICP zeroed at the tragus (foramen of Monro or midventricular level) and MAP zeroed to the right atrium with the head of the bed elevated 30°. Cerebral perfusion pressure can be improved through measures that lower the ICP and by measures that raise the MAP (volume or vasopressor administration).

### 7.9.4 Cerebral Herniation Syndromes

The brain is not acutely compressible, but it will shift within the cranium. Excessive pressure gradients between compartments lead to herniation, where part of the brain is herniated into an adjacent compartment (i.e., supratentorial, infratentorial) or into the spinal column. It is important to consider the anatomic landmarks, which separate the intracranial compartments (Hickey 2009). The tentorium cerebelli is a tent-like partition between the cerebrum and the cerebellum. The space above the tentorium is referred to as the supratentorial space, while the space below the

tentorium is referred to as the infratentorial space. The falx cerebri divides the left and right cerebral hemispheres within the longitudinal fissure. The falx cerebelli separates the cerebellum into a left and right side. The foramen magnum (FM) is the opening at the base of the skull through which the brainstem and spinal cord are connected. Three cerebral herniation syndromes, described by Plum and Posner, are demonstrated in Figure 7.13. The cerebral herniation syndromes include cingulate herniation (cingulate gyrus under the falx), uncal herniation (the medial, inferior portion of the temporal lobe, uncus, herniates down through the incisura or tentorial notch into the infratentorial compartment), and central herniation of the cerebellar tonsils and brainstem down through the foramen magnum into the spinal column. Cingulate herniation usually is not clinically significant. Uncal herniation, evidenced initially by ipsilateral sluggish pupillary response, progresses to ipsilateral pupillary dilation, contralateral hemiparesis, trochlear and abducens cranial nerve paralysis, and a decreased level of responsiveness with eventual rostral-caudal deterioration. The mass effect causes lateral displacement of the midbrain, forcing the opposite cerebral peduncle against the tentorium, producing Kernohan's notch (resulting in hemiparesis ipsilateral to the expanding mass lesion) (Hickey 2009). Central herniation causes deterioration in a rostral-caudal pattern, eventually causing cessation of cerebral blood flow and brain death (see Sect. 7.4).

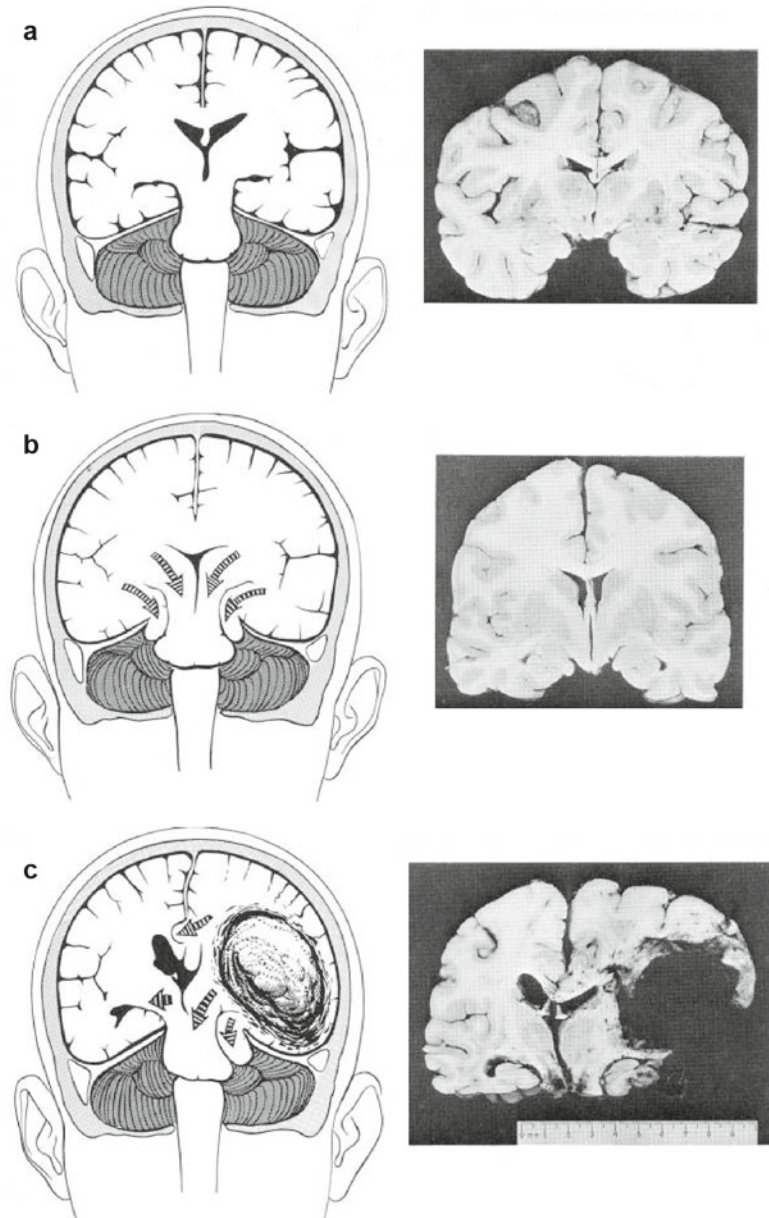
---

### 7.10 Collaborative Management of Intracranial Hypertension

Treatment of the child with a TBI focuses on preventing secondary insults and optimizing functional outcomes. Maintaining CBF and optimizing oxygen and substrate delivery and utilization, while preventing or effectively managing intracranial hypertension, accomplish these goals. Additionally, the child needs to have adequate airway support, effective oxygenation and ventilation, and good perfusion. When these fundamental needs are addressed, the child's chances



**Fig. 7.13** (a–c) Cerebral herniation syndromes. (a) Coronal view: normal relationship of the supratentorial and infratentorial compartments. (b) Central herniation occurs when excessive increased ICP in the supratentorial space causes herniation of the cerebellar tonsils and brainstem through the foramen magnum into the spinal column, causing cessation of cerebral blood flow and brain death. (c) Uncal herniation occurs when the uncus or medial, inferior portion of the temporal lobe herniates downward through the incisura of the tentorium (Reprinted with permission from Plum and Posner (1982))



of meaningful recovery and effective brain injury management are improved.

The main focus of management is to prevent or minimize secondary injuries, such as cerebral ischemia, cerebral edema, and neurochemical alterations. Since hypoxia and hypotension are known to worsen secondary injury by causing cerebral vasodilatation, care must be taken to quickly recognize and treat these mitigating factors (Huh and Raghupathi 2009). In general, the

goal of treatment is to maintain an ICP  $< 20$  mmHg, along with age-appropriate CPP. ICP management interventions include therapies to decrease cerebral volume, control CSF volume, control cerebral blood volume, and decrease cerebral metabolic rate. Because there exists a lack of data from well-designed and controlled pediatric studies to direct the treatment of children with brain trauma, recent guidelines have been released that assimilate the research results that are available and provide

expert consensus on therapies (Carney et al. 2003; Kochanek et al. 2012). There is some evidence in adult studies to suggest that adherence to evidence-based treatment guidelines in severe TBI can lead to improved outcomes (Arabi et al. 2010; Fakhry et al. 2004; Palmer et al. 2001). Figure 7.14 shows an example of a severe TBI treatment guideline utilized in a pediatric intensive care unit. The guideline is based on a tiered gradation system, where tier I is the initial intervention, and then intervention progresses to tier II and tier III as the maximum level of intervention for each category. The level of intervention is advanced to the next tier if set ICP and CPP parameters are not met. In addition, children with severe TBI are more likely to survive when they are transported to a pediatric trauma center if one is available or an adult trauma center with added capabilities to treat children (Potoka et al. 2000; Badjatia et al. 2007).

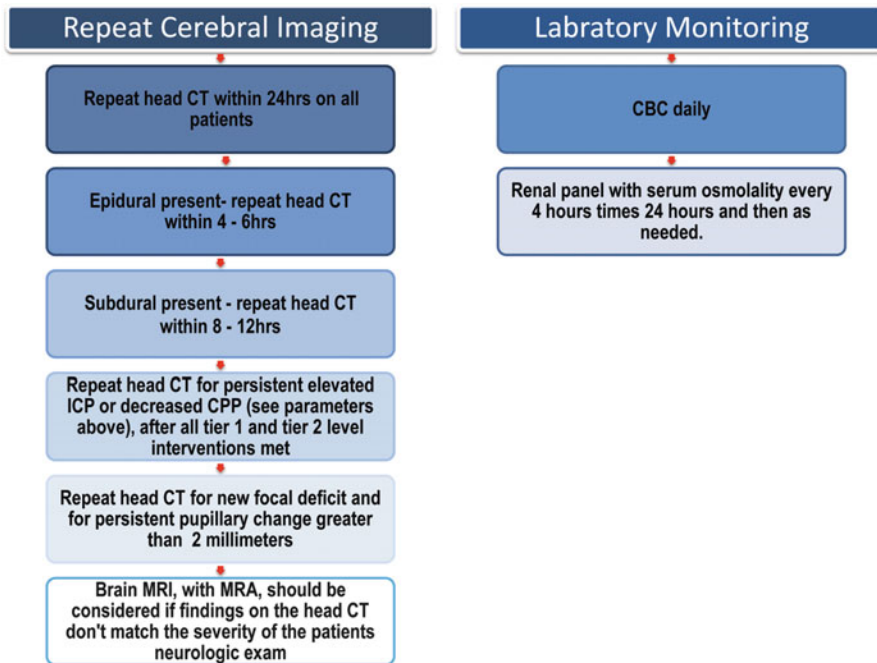
### 7.10.1 Initial Resuscitation

Pre-hospital care of the child with TBI begins at the scene with rapid assessment and support of airway, breathing, and circulation. Supplemental oxygen should be administered and hypoxia (oxygen saturation < 90 % or  $P_aO_2$  < 60 mmHg) avoided. In general, if the GCS is  $\leq 8$ , endotracheal intubation should be considered, although there is no research evidence that supports endotracheal tube intubation over bag-valve-mask ventilation for pre-hospital management (Carney et al. 2003). Upon arrival at a medical center, rapid-sequence intubation should be performed if the CT scan demonstrates diffuse cerebral edema, there is risk of neurologic decompensation, respiratory instability, or loss of protective airway reflexes (Carney et al. 2003). The intubation procedure should include medications to facilitate the process, which do not further increase ICP, such as thiopental, etomidate, lidocaine, and a short-acting, non-depolarizing neuromuscular blocking agent (American Heart Association 2006). Normoventilation ( $P_aCO_2$  35–40 mmHg) should be ensured during initial resuscitation (Carney et al. 2003; Badjatia et al. 2007).

Hypotension has been shown to increase the morbidity and mortality of traumatically brain-injured children (Stocchetti et al. 2010; Badjatia et al. 2007). Because hypotension is a serious and potentially preventable secondary insult, signs of inadequate perfusion should be recognized and treated aggressively. Cerebral perfusion is partially dependent on an adequate MAP; therefore, age-appropriate blood pressure must be maintained to ensure adequate end-organ perfusion and CPP and to prevent ischemia and resultant infarction. The following formula is used to determine median blood pressure (50th percentile) for children greater than 1 year of age:  $90 + (2 \times \text{age in years})$  (American Heart Association 2006). Table 7.9 shows ranges for median to 90th percentile age-related blood pressures in children. Because of the risk of poor outcome for children with systolic blood pressure below the 75th percentile for age, a higher blood pressure should be targeted initially (Badjatia et al. 2007). Children can be severely hypovolemic without demonstrating decreased blood pressure, and so rapid fluid volume resuscitation should occur both at the scene and upon arrival at the hospital. If appropriate amounts of fluid volume resuscitation do not improve signs of inadequate perfusion, vasopressor support should be initiated (Marcoux 2005).

### 7.10.2 Intensive Care Management

The child with TBI should be initially evaluated in the emergency department and then taken to the medical imaging department for further evaluation. Radiographic testing may include cervical spine evaluation, CT scan, and possible MRI. From there, the child may proceed to the operating room for removal of expanding lesions, control of hemorrhage, evacuation of significant hematomas, insertion of an ICP catheter or catheter for extraventricular drainage, or decompressive craniectomy (Figaji et al. 2008; Jagannathan et al. 2007). Although randomized controlled trials of the safety and efficacy of decompressive craniectomy in pediatric patients with severe brain injury have not been undertaken, there are instances when this procedure may lower



Formulated: 11/2011

## General Guidelines

- Central venous access is obtained with central venous pressure (CVP) monitoring. Arterial line placement is performed.
- Maintain order to elevate head of bed 30 degrees, unless instructed otherwise by neurosurgeon.
- Basal metabolic expenditures are now believed to be normal with severe Traumatic Brain Injury. Adequate and early nutrition is vital to recovery. The goal is to begin trophic feeds within 24hrs. In the absence of a basilar skull fracture, a nasoduodenal tube should be placed and trophic feeds started within 72 hours of the injury. If basilar fracture is present, an orogastric tube is preferred. Consider hyperalimentation if aggressive sedation and /or barbiturates are in use.
- Zantac 1mg/kg IV every 8 hours is provided to avoid gastric stress ulcer.
- Prophylactic antibiotic coverage of the ICP monitor: A dose of Zinacef (50mg/kg or max. 1 gram) should be given 0 – 60 minutes prior to placement; and then three doses spaced every 8 hours following placement; then discontinued.
- Lidocaine 1 mg/kg (maximum 50mg/dose and 300mg/day) will be ordered to administer via the ETT prior to endotracheal suctioning to blunt the cough response and associated ICP spikes.
- Avoid glucose containing fluids in the first 48 hours following injury as hyperglycemia has been associated with poor outcome in severe TBI. Treat persistent hyperglycemia aggressively with insulin infusion. Monitor for hypoglycemia, particularly in neonates and infants < 6 months of age.
- Consider pneumatic stockings for patients weighing greater than 50 kilograms, or greater than 14 years of age.

## Nursing Guidelines

- Implement nursing interventions to attain goals for MAP, ICP & CPP:
- Maintain patient in quiet environment with minimal noxious stimuli. Encourage family presence and quiet interaction with patient.
- Avoid prolonged periods of elevated ICP or plateaus in the ICP waveform with interventions, as this is indicative of decreased cerebral perfusion. Provide general skin care, mouth care, and repositioning as tolerated.
- Maintain head midline and HOB elevated as ordered.
- Monitor for and maintain adequate sedation/analgesia/paralysis.
- Titrate sedative and inotropic infusions to maintain patient parameters within ordered goal.
- Ensure integrity of ICP monitor and change dressing routinely per protocol.
- Assess EVD and troubleshoot if ordered to be open to drain, but no drainage.
- Avoid hyperthermia: Monitor temperature and maintain adequate patient temperature by administering antipyretics as ordered . External cooling blanket as ordered to maintain rectal temp 36.5 – 37.5 C. Avoid patient shivering as this can increase heat generation.
- Avoid seizure activity: administer antiepileptics and report seizure activity immediately to MD/NP.
- Liquid tears as ordered.
- Pneumatic stockings as ordered to prevent DVT.
- Do not suction ETT routinely, but rather on as needed basis, and with use of endotracheal or intravenous lidocaine as ordered to blunt cough response and associated ICP spikes.

Formulated:11/2011

**Fig. 7.14** Evidence-based treatment guideline for severe pediatric TBI with Glasgow Coma Scale (GCS) score <.8. The guideline is based on a tiered gradation system, where tier I is the initial intervention; and then intervention progresses to tier II and tier III as the maximum level of inter-

vention for each category. The level of intervention is advanced to the next tier if set ICP and CPP parameters are not met. Used with permission from The Children's Medical Center of Dayton

**Table 7.9** Normal blood pressure in children (50–90th percentile)

Age	Systolic pressure <sup>a</sup> (mmHg)	Diastolic pressure <sup>a</sup> (mmHg)
Birth (3 kg)	50–70	25–45
Neonate (96 h)	60–90	20–60
Infant (6 months)	87–105	53–66
Toddler (2 years)	88–102	42–59
School age (7 years)	97–111	57–72
Adolescent (15 years)	103–127	61–79

National High Blood Pressure Education Program Working Group on High Blood Pressure in Children and Adolescents (2004)

<sup>a</sup>For 50th percentile of height

ICP and improve outcomes. Table 7.10 lists criteria to guide the practitioner in determining if the child is a candidate for decompressive craniectomy. After determining if any surgical intervention is necessary, further head injury management then generally takes place in the intensive care unit.

### 7.10.3 Intracranial Pressure Monitoring

The ability to identify rapidly increasing pressure is crucial in the treatment of severe TBI and in the prevention of cerebral ischemia and infarction. ICP monitoring is recommended for the child with a traumatic brain injury that has a GCS  $\leq 8$  (Carney et al. 2003; Kochanek et al. 2012). It should be noted that the presence of an open fontanel does not negate the utility of ICP monitoring or preclude the development of intracranial hypertension. In addition, a monitor may be placed in the child that has clinical signs of increasing ICP, after major neurosurgical procedures, or when serial neurologic assessments may be masked by sedation, neuromuscular blockade, or anesthesia.

Either a fiberoptic-tipped wire, a microchip sensor, or a fluid-filled catheter system can be placed in the intracranium, which allows for the continuous measurement of ICP. While fiberoptic-tipped devices can be placed in the intraventricular, parenchymal, and less often in the epidural, subdural, and subarachnoid spaces, fluid-filled ICP catheters are generally placed in the intraventricular space, particularly if CSF drainage is desired. Table 7.11 lists potential complications associated with the use of intracranial catheters.

**Table 7.10** Criteria for decompressive craniectomy

1. Severe traumatic brain injury
2. Refractory intracranial hypertension
3. Diffuse cerebral edema on CT imaging within 48 h of injury
4. No episodes of sustained ICP $>40$ mmHg prior to surgery
5. GCS $\leq 4$ at any point prior to surgery
6. Secondary clinical deterioration
7. Evolving cerebral herniation syndrome

<sup>a</sup>Some or all may be present (Carney et al. 2003)

**Table 7.11** Potential complications associated with ICP monitoring catheters

Hemorrhage
Infection
Over-drainage of cerebral spinal fluid
Catheter misplacement
Catheter migration
Catheter obstruction

The fiberoptic-tipped catheter and microchip sensor are zeroed before insertion and require a monitoring unit supplied by the manufacturer for ICP readings. Alternatively, a fluid-filled ventriculostomy catheter system can be set up to allow for the continuous drainage of CSF. This system contains an external strain-gauge transducer that is coupled to the patient's intracranial space through a fluid-filled line. The transducer must be secured at a fixed reference point, usually the foramen of Monroe or midventricular level, which can be approximated by positioning the transducer level with the tragus or external auditory meatus. The system must be

**Table 7.12** Nursing priorities for the child undergoing ICP monitoring

1. Keep the ICP monitoring system operational and intact, ensuring that all connections are secure
2. Prevent strain on the tubing and cables, particularly during patient repositioning and transport
3. Zero and level the system according to manufacturer's recommendations
4. Ensure the transducer of a fluid-filled system is leveled at the appropriate anatomical location, especially after patient repositioning and transport
5. If draining CSF, maintain the drainage chamber at the level ordered
6. Empty the drainage chamber regularly, recording the amount of CSF output
7. Do not allow the air filter of the drainage chamber to get wet
8. Document ICP and CPP readings
9. Note child's ICP response to interventions and ICP trends over time
10. Maintain a dry sterile dressing around the insertion site per hospital policy
11. Monitor for and notify the neurosurgeon of CSF leakage around the insertion site, other drainage, and signs of infection

zeroed to atmospheric pressure and leveled to ensure accuracy of the ICP data. Nursing care of the patient with an ICP monitor is outlined in Table 7.12.

Intracranial hypertension is defined as an ICP  $\geq$  20 mmHg, and treatment designed to reduce ICP and improve cerebral perfusion should be initiated at this point (Brain Trauma Foundation 2007). Prolonged periods of increased ICP and dramatic elevations in ICP are associated with poor outcomes in the pediatric patient (Carney et al. 2003). Depending on the child's age, a CPP threshold of 40–50 mmHg should be maintained at all times during head injury management (Kochanek et al. 2012). In addition to ICP data, evidence of intracranial hypertension should be corroborated by frequent patient assessment, other physiologic parameters, and cranial imaging studies.

#### 7.10.4 Jugular Venous Oxygenation Saturation Monitoring

Continuous measurement of venous saturation can be obtained using a fiberoptic catheter placed retrograde into the jugular vein. This monitoring technique can provide information on cerebral oxygen delivery and consumption and the effectiveness of therapies. Because most of the cerebral circulation drains into one jugular vein, oxygen saturation is measured after cerebral perfusion has occurred. Normal jugular venous oxygen saturation ( $S_{jv}O_2$ ) values are 55–70 %. Values below 55 % indicate inadequate oxygen delivery or utilization within the

injured brain, and treatment interventions should be initiated when the jugular venous saturation is  $<50\%$  (Brain Trauma Foundation 2007). Conditions that decrease  $S_{jv}O_2$  are hypoxia, hypotension, increased ICP, and hypocarbia.  $S_{jv}O_2$  monitoring provides a global picture of CBF and metabolic need, but does not provide any information about oxygen consumption at the site of injury.

#### 7.10.5 Monitoring Partial Pressure of Oxygen

$P_{bt}O_2$  is a measure of cerebral (brain tissue) oxygenation. A microprobe is inserted into uninjured parenchymal brain tissue or the area of primary injury (penumbra) of an intracerebral lesion. While placing the microprobe into uninjured brain tissue will more closely assess global cerebral oxygenation, placement in an intracerebral lesion will provide data regarding cerebral oxygenation in an area most at risk (Haitsma and Mass 2002; Maloney-Wilensky et al. 2009). Either method should give an indication of cerebral oxygenation and ischemia (Maloney-Wilensky et al. 2009). Normal values for non-injured brain tissue range from 20 to 35 mmHg. Instances that can decrease  $P_{bt}O_2$  are hypocarbia, hypoxemia, hyperthermia, decreased CBF and ischemia, decreased CPP, and elevated ICP (Littlejohns et al. 2003). Treatment interventions to improve cerebral oxygenation should begin when  $P_{bt}O_2$  values are  $<15$  mmHg (Brain

Trauma Foundation 2007; Lang et al. 2007; Littlejohns et al. 2003). Values below this have been associated with poor outcomes and death.

### 7.10.6 CSF Drainage

External ventricular drainage of CSF is a common management therapy that is often used in conjunction with ICP monitoring. The CSF is drained to reduce intracranial fluid volume and thus decrease ICP. Drainage can be continuous or intermittent, depending on the child's situation and the neurosurgeon's preference. For instance, drainage may be ordered any time the ICP is above a preselected value for a specified time. Moving the CSF collection device up or down in relation to the reference level point will control the amount of drainage. The higher the drain is above the reference level, the higher the ICP must be for CSF to flow into the collection device. Conversely, lowering the drain will cause CSF to flow at a lower ICP. Care must be taken when draining CSF to treat elevated ICP, as excessive drainage of CSF may cause the lateral ventricles to collapse. In addition, excessive CSF output may lead to hyponatremia, which is corrected with intravenous fluid administration designed to replace the CSF fluid volume.

The use of lumbar CSF drainage has occasionally been reported in pediatric patients with ICP refractory to other management therapies (Carney et al. 2003; Levy et al. 1995; Murad 2008; Kochanek et al. 2012). The lumbar drain is used simultaneously with a functioning ventricular catheter when the basilar cisterns are open. Patients for whom lumbar drainage is contraindicated include those with intracranial masses or shifts because transtentorial herniation could result (Kochanek et al. 2012).

### 7.10.7 Analgesia, Sedation, and Neuromuscular Blockade

Analgesia and sedation are important adjuncts to other treatments for the brain-injured child. Because pain and anxiety contribute to increased

ICP and the cerebral metabolic rate, it is imperative to provide relief from pain, anxiety, and agitation. Additionally, the use of these agents can also facilitate the child's tolerance of other therapies, such as mechanical ventilation and suctioning, intradepartmental transport, and monitoring devices. The nurse is in a vital position to assess, advocate for, and effectively manage the child's level of sedation and analgesia. Depending on practitioner preference, common agents used are opiates, benzodiazepines, and barbiturates. Although routinely used in the adult with traumatic brain injury, the use of continuous infusions of propofol is not recommended for sedation of patients in the pediatric intensive care unit because it has been associated with fatal metabolic acidosis, rhabdomyolysis, and hypoxia.

While the use of short-acting neuromuscular blockade agents may facilitate intubation and the tolerance of therapies, the patient's neurologic exam is blunted. Therefore, these agents are generally used only when the child's agitation and increased ICP persist despite adequate doses of sedation and analgesia. The paralytic agent is generally allowed to wear off at intervals to allow for a complete neurologic examination. Neuromuscular blocking agents should never be used without the concomitant administration of a sedative or analgesia.

### 7.10.8 Hyperosmolar Therapy

Osmotic diuresis for the treatment of the head-injured child is accomplished through the use of mannitol and/or hypertonic saline (HS). While mannitol has been the mainstay of therapy for many years, there is increasing evidence that using HS in children with intractable intracranial hypertension results in a decrease in ICP and subsequent increase in CPP (Khanna et al. 2000; Peterson et al. 2000; Upadhyay et al. 2010; Yildizdas et al. 2006). The nurse should keep in mind that the overall goal is euvolemia (fluid balance); therefore, hyperosmolar therapy may be contraindicated in the presence of hypotension (Brain Trauma Foundation 2007).

After mannitol administration, an osmotic gradient between plasma and parenchymal tissue

develops, drawing fluid from brain tissue into the vascular space. Osmotic diuresis then occurs, which results in a net reduction of brain water content. Further, because of fluid movement, mannitol reduces hematocrit and blood viscosity, improving CBF and reducing blood vessel diameter. ICP and cerebral blood volume decrease almost immediately. Therefore, because of its rapid onset of action, a 20 % mannitol solution is usually administered as a bolus dose of 0.25–1 g/kg body weight (Brain Trauma Foundation 2007; Carney et al. 2003). The nurse should be aware that mannitol may crystallize, so an in-line filter should be used to prevent the administration of any crystals. Serum osmolarity must be monitored when using hyperosmolar therapies. The maximum recommended serum osmolarity when using mannitol is 320 mOsm/l. Because mannitol is excreted unchanged in the urine, renal failure can result with higher serum osmolarity. With chronic administration, mannitol may cause rebound cerebral edema because it is believed to disrupt the blood–brain barrier and accumulate in the interstitial space of the brain parenchyma, causing a reverse osmosis (Carney et al. 2003). Additional side effects of mannitol therapy are dehydration with resultant hypotension following overly effective osmotic diuresis and electrolyte imbalance.

Hypertonic saline works by increasing serum sodium and serum osmolarity, creating an osmotic gradient to pull water from the intracellular and interstitial compartments of the brain, reducing cerebral edema and ICP. Sodium chloride creates a driving force to bring water from the brain into the intravascular compartment in regions with intact blood–brain barrier, thus reducing water content, mass effect, and ICP. In addition, intravascular volume expansion occurs after administration of HS solutions. While there is no change in systemic vascular resistance, MAP increases because of increases in cardiac output and intravascular volume. This increase in MAP can further improve CPP. For acute management of intracranial hypertension, the recommended dose of 3 % HS is 6.5–10 ml/kg (Kochanek et al. 2012). Subsequently, 3 % saline can be administered via continuous infusion at a dose of 0.1–1 ml/kg/h as needed to maintain ICP < 20 mmHg (Carney et al. 2003;

Peterson et al. 2000; Kochanek et al. 2012). An osmolarity up to 360 mOsm/l has been well tolerated in children receiving HS (Carney et al. 2003; Kochanek et al. 2012). Although there are no reports in pediatric studies of HS, a potential side effect in patients with preexisting chronic hyponatremia is osmotic demyelination syndrome (ODS), which involves demyelination, primarily of the pons, that can be noted clinically by the onset of lethargy and quadriparesis. Other possible side effects of the use of HS include coagulopathy, rebound rises in intracranial hypertension, electrolyte imbalance, hyperchloremic acidosis, and the risk of phlebitis if the solution is administered via a peripheral vein.

### 7.10.9 Hyperventilation

During hyperventilation,  $P_a\text{CO}_2$  decreases, resulting in cerebral vasoconstriction and a reduction in cerebral blood volume. Although ICP rapidly decreases in this situation, cerebral perfusion is compromised and ischemia can result (Skippen et al. 1997; Stiefel et al. 2006). Because of these concerns, prophylactic hyperventilation and hypocarbia should be avoided. Mild hyperventilation ( $P_a\text{CO}_2$  30–35 mmHg) may be instituted when other therapies such as adequate sedation and analgesia, neuromuscular blockade, hyperosmolar therapy, and CSF drainage have not been effective in correcting intracranial hypertension (Carney et al. 2003). Depending on practitioner preference, aggressive hyperventilation may be used in the event of acute brain herniation or significant ICP elevation. However, prophylactic severe hyperventilation ( $P_a\text{CO}_2 < 30$  mmHg) should be avoided for 48 h after injury (Kochanek et al. 2012). In this instance,  $P_{bt}\text{O}_2$  and/or  $S_{jv}\text{O}_2$  may be monitored to allow for immediate detection of cerebral ischemia (Stiefel et al. 2006).

### 7.10.10 Temperature Regulation

Hyperthermia is known to increase cerebral metabolic rate and ICP and should be avoided in the traumatically brain-injured child. Core body

temperature may be measured via the bladder or rectal route or through a pulmonary artery catheter. Brain temperature can also be assessed during both  $P_{bt}O_2$  and  $S_{jv}O_2$  monitoring. Because core body temperature measurement may be lower than actual brain temperature (Mcilvoy 2007; Soukup et al. 2002), the nurse may need to institute treatment for fever at a rectal temperature of 37.5 °C, instead of the usual 38.5 °C. Fever can be treated with antipyretics and external cooling devices, although shivering must be avoided because it will further increase cerebral metabolic rate and ICP. Furthermore, it is important to identify and treat the cause of the elevated temperature. Some common causes of fever after a TBI include atelectasis, infection, cerebral irritation from hemorrhage, and injury to the hypothalamus.

Mild to moderate hypothermia (32–34 °C) as a treatment for intracranial hypertension has been considered in both adults and children, although the results do not yet provide clear direction for treatment (Adelson 2009; Adelson et al. 2005; Bourdages et al. 2010; Clifton et al. 2009; Hutchison et al. 2008, 2010; Li et al. 2009; Shafi and Mariscalco 2006; Sydenham et al. 2009). The goal of hypothermia therapy is to slow the body's metabolic processes. In addition, induced hypothermia may improve ICP, increase oxygen supply to areas of ischemic brain, and help prevent seizures (Bernard and Buist 2003). The sequelae of induced hypothermia include increased risk of acquired infection, lactic acidosis, sludging blood flow, cardiac arrhythmias, and seizures. Because controlled hypothermia has not yet shown an improvement in outcome, it is not currently recommended for the treatment of severe TBI in children outside of clinical trials (Adelson 2009; Sydenham et al. 2009). Should hypothermia therapy be initiated, care should be taken to avoid short periods of cooling (<24 h), and the patient rewarmed at a rate of <0.5 °C/h (Kochanek et al. 2012).

### 7.10.11 Barbiturate Therapy

Barbiturates (e.g., pentobarbital) have been used for many years as a therapy for intracranial hypertension that is not responsive to other treat-

ments. Despite this history of use, limited clinical trials have been performed in children, and other studies in adults have not consistently demonstrated improved outcomes (Brain Trauma Foundation 2007). However, in the pediatric patient with a potentially recoverable brain injury that has elevated ICP which is not responsive to other management strategies, barbiturate coma therapy may be used (Carney et al. 2003).

Barbiturates decrease cerebral blood flow and the cerebral metabolic requirements of the brain with a resultant decrease in ICP. As a side effect, barbiturate therapy causes myocardial depression and vasodilation, which results in hypotension. The child who is receiving barbiturate therapy should have cardiovascular parameters, including blood pressure and central venous pressure monitored continuously. The nurse should be prepared to administer fluids and inotropic agents as needed during barbiturate therapy. Continuous electroencephalogram (EEG) monitoring is needed to evaluate burst suppression. The barbiturate is administered via continuous intravenous infusion following a loading dose. The infusion is titrated based on the patient's ICP response and EEG tracing. Since rebound intracranial hypertension can occur after discontinuation of barbiturate therapy, the medication should be weaned slowly over a few days (Brain Trauma Foundation 2007).

### 7.10.12 Hydration and Nutrition

During the first 48–72 h, the child with a TBI should receive intravenous fluid therapy to maintain a euvolemic state. Fluid boluses, including blood products as indicated, may be administered to maintain adequate perfusion, age-appropriate blood pressure, central venous pressure, and urine output. A bladder catheter is essential for monitoring accurate urinary output. The intravenous fluid of choice is usually normal saline, lactated Ringer's, or hypertonic saline. Hypotonic fluids should be avoided and hyponatremia prevented, since both contribute to cerebral edema.

Research results are beginning to suggest a relationship between hyperglycemia and poor outcome from pediatric TBI (Cochran et al. 2003;



Sharma et al. 2009; Smith et al. 2012). In adult studies, the harmful effects of hyperglycemia on the traumatically brain-injured patient have been repeatedly verified (Jeremitsky et al. 2005; Laird et al. 2004; Salim et al. 2009). Because of this, glucose-containing parenteral fluids are normally not used during the first 48 h after injury. Serum glucose must be monitored and appropriate glucose correction therapy initiated prior to the patient becoming hypoglycemic (serum glucose < 75 mg/dl) since this may also result in harm (Faust et al. 2011). The current recommended blood glucose target for most critically ill patients is 140–180 mg/dl (Moghissi, et al. 2009).

Meeting nutritional requirements is of utmost importance. The patient with a TBI requires approximately 130–160% of their expected metabolic expenditures (Bratton et al. 2007). Enteral feedings should begin by 72 h after injury (Vizzini and Aranda-Michel 2011), with full caloric feeds established within 7 days (Bratton et al. 2007). Nutritional formula appropriate for age and caloric requirements is administered via a gastric or transpyloric tube, which can be inserted by the nurse at the bedside (Mehta 2009). In cases where enteral feeding cannot be initiated, total parenteral nutrition should be started. In addition, because the patient is likely to be immobile and receiving opiates, a bowel regimen should be established early and should include a stool softener.

### 7.10.13 Additional Nursing Care

The nurse at the bedside caring for the traumatically brain-injured child has an important role in preventing secondary injury and optimizing outcomes. The nurse must also balance the care needs of the patient with the requirement not to further increase ICP. Vigilance to proper patient positioning is necessary. The head of the bed should be elevated 30°. Moreover, the patient's head should be maintained in a midline position to prevent obstruction of venous outflow, which can further worsen intracranial hypertension. The nurse should check that the cervical collar or tracheostomy ties are not so tight that they

constrict venous outflow. Complications from immobility should be assessed and prevented. The child will need to be repositioned as tolerated, keeping the head in midline with the body. The risk of skin breakdown should be assessed, skin integrity routinely monitored, and prevention measures started for at-risk patients (Curley et al. 2003; Noonan et al. 2006; Schindler et al. 2011). Preventive measure for deep vein thrombus, such as passive range of motion or sequential compression devices, should be initiated as indicated based on the child's age and body size.

Depending on the child's response to stimuli, the environment should be quiet and free from extraneous noise. The nurse will need to determine if the child will tolerate the clustering of care activities or if care needs must be met in increments with rest periods between activities. The child's response, vital signs, ICP, and CPP parameters should be monitored during care activities. For instance, if the ICP rises significantly during care, the nurse may need to cease care and allow the ICP to return to baseline for a period of time before meeting further care needs (Tume et al. 2011). Also, the nurse should assess the child's need for additional analgesia or sedation during care activities that must take place.

Because this child is likely to be intubated and ventilated, the nurse should institute measures to prevent ventilator-associated pneumonia, such as oral care and head of bed elevation. Endotracheal tube suctioning should be initiated based on the child's clinical assessment and should not be performed on a scheduled basis if the patient does not demonstrate the need for suctioning. Coughing during suctioning can increase ICP. Endotracheal lidocaine may need to be administered before endotracheal tube suctioning to blunt the gag and cough response. Preoxygenation is necessary during the suctioning procedure so that hypoxia can be avoided.

During this time of intensive care, the child's family will need much support and education. They are likely to experience uncertainty and fear about their child's recovery and future. The nurse will need to describe the equipment

surrounding the child and should provide the family with anticipatory guidance on what to expect during the child's initial care and recovery. The family may need to be given direction on the role they can assume in the intensive care unit. A family-centered intensive care unit environment that establishes a partnership between the family and the healthcare team is vital. The family may be encouraged to interact with their child and touch the child as appropriate. The nurse should observe the patient's response to this interaction, including ICP response. The presence of family has not been shown to be detrimental to patient outcomes and should be evaluated on a case-by-case basis.

## 7.11 Endocrine Complications

### 7.11.1 Diabetes Insipidus

Diabetes Insipidus (DI) can occur after a traumatic head injury or intracranial surgery because of damage to the cells in the hypothalamus that produce antidiuretic hormone (ADH). DI can also occur after injury to the posterior pituitary gland, whereby the injured gland does not release ADH. When there is not enough ADH present, the collecting ducts and the distal tubules of the kidneys do not reabsorb free water, which results in intravascular volume depletion. Signs and symptoms of DI include large amounts of very dilute urine, severe dehydration, thirst, hypernatremia, and elevated serum osmolality. Excessive thirst in an alert child may also be indicative of DI and often is an effective mechanism to prevent severe dehydration. Table 7.13 lists laboratory values associated with DI.

The treatment for DI includes frequent assessment of laboratory values, as well as accurate calculation of fluid administration and urine output. Fluid resuscitation with isotonic solutions may be needed initially to treat severe volume depletion. After stabilization, fluid volume deficits and ongoing urine volume losses are replaced hourly. An intravenous infusion of vasopressin may become necessary if fluid replacement therapy alone is unsuccessful. For chronic management

**Table 7.13** Selected laboratory values associated with DIa, SIADHb, and CSWc

	DI	SIADH	CSW
<i>Urine</i>			
Specific gravity	<1.005	>1.020	>1.010
Osmolality	<250	>500	>300
Urine output (ml/kg/h)	>3	<1	≥1
Sodium (mEq/l)	<40	>60	>120
<i>Serum</i>			
Osmolality	>305	<275	<275
Sodium	>150	<130	<130

<sup>a</sup>Diabetes insipidus

<sup>b</sup>Syndrome of inappropriate secretion of antidiuretic hormone

<sup>c</sup>Cerebral salt wasting

of DI, desmopressin is administered via the nasal or oral route.

### 7.11.2 Syndrome of Inappropriate Secretion of Antidiuretic Hormone

SIADH involves overproduction or release of ADH from the pituitary. This excess ADH increases the permeability of the collecting ducts and the distal tubules of the kidneys, causing water to be retained. The child can become fluid overloaded and fluid can further shift from the intravascular to interstitial spaces, worsening cerebral edema. Clinically, the child will demonstrate decreased urine output, nausea and vomiting, dilutional hyponatremia with the risk of seizures, and mental status changes. Table 7.13 lists laboratory values associated with SIADH.

The treatment for SIADH, like that for DI, also includes frequent assessment of laboratory values and accurate calculation of fluid administration and urine output. Fluid restriction therapy is usually initiated. The child is also monitored frequently for changes in mental status and seizures. Severe hyponatremia, especially when associated with seizures, is treated with 3 % hypertonic saline via the intravenous route (Clark et al. 2008). Rapid correction of sodium levels should be avoided because this can cause CNS osmotic demyelination syndrome.

### 7.11.3 Cerebral Salt Wasting

Cerebral salt wasting (CSW) is a condition characterized by true loss of body sodium through natriuresis. Though the exact mechanism by which CSW occurs is unclear, it is theoretically caused by natriuretic peptides (Clark et al. 2008). This sodium loss results in decreased plasma volume, increased concentration of nitrogen (in the form of urea) in the blood, and a negative salt balance. Treatment of this condition involves first distinguishing it from SIADH. Fluid and sodium replacement therapies are then initiated, along with ongoing monitoring of serum sodium levels. Table 7.13 lists laboratory values associated with CSW.

---

## 7.12 Postoperative Nursing Care and Complications

Surgical interventions for pediatric head trauma were discussed throughout this chapter and include placement of an ICP monitor with external ventricular drain (EVD) or lumbar drain; craniotomy for elevation of depressed skull fractures; evacuation of hematomas, bony fragments, and pulped brain; and decompressive craniectomy. Postoperative nursing care following neurosurgery includes observation of the vital signs, baseline as well as frequent ongoing neurologic assessments, management of neuro-monitoring devices, monitoring for postoperative complications, and good general postoperative care to include pain management, prevention of infection, nutritional status, and psychosocial support of the child and family (Hickey 2009).

### 7.12.1 Preoperative Baseline

The preoperative and immediate postoperative assessment provides a baseline for comparison when assessing for postoperative deterioration or complications. For consistency, it is ideal for the same nurse to care for the child before and after neurosurgery. When this is not possible, the

nurse assuming care should seek knowledge of the preoperative assessment from the previous caregiver, surgeon, anesthesiologist, post-anesthesia care unit nurse, the medical record, and the parents in order to recognize and anticipate changes in the child's postoperative neurologic assessment.

The conscious child should be prepared for the operative experience in a developmentally appropriate manner. Reassure the child that they will remain asleep and unable to feel pain during surgery and awaken afterward to see their parents. Educate them that pain is expected and that medications will be available to alleviate their pain. Advise them to anticipate a large number of people and equipment to help take the best care of them when they awaken. Parents need to be prepared for the appearance of the child postoperatively with a head turban dressing, ICP/EVD monitor, multiple intravenous lines, monitors, and possible endotracheal tube and ventilator.

### 7.12.2 Assuming Postoperative Nursing Care

Hand-off report following surgery should include type of neurosurgical procedure and region of brain affected, intraoperative complications, anesthetic and analgesic agents used, preexisting medical problems and neurologic deficits, presence of new neurologic deficits since surgery, surgeon's insight on what new deficits may develop, fluid/electrolyte status, lab values, and the postoperative physician's orders (Hickey 2009). Appropriate monitoring equipment should be attached and may include any or all of the following: cardiorespiratory monitor, mechanical ventilation, pulse oximetry, end tidal CO<sub>2</sub>, arterial line, central venous line, ICP monitor, EVD, S<sub>jv</sub>O<sub>2</sub>, and P<sub>bt</sub>O<sub>2</sub> monitoring. Ideally, the reporting nurse and the oncoming nurse should assess the patient together to facilitate a clear understanding of the patient's baseline exam, to decrease the chance of miscommunication, and to prevent missed signs of subtle deterioration (Hickey 2009).

### 7.12.3 Vital Functions

Protection of the pediatric airway following neurosurgery is paramount, whether the child is extubated immediately following neurosurgery or remains intubated and on mechanical ventilation. The nurse should monitor for signs of respiratory distress and assist with bag-valve-mask breathing and reintubation if required. Possible causes of airway or ventilatory deterioration include tube displacement, tube obstruction, pneumothorax, and equipment failure (American Heart Association 2006). Inadequate ventilation results in hypoxia and hypercarbia, which cause increased CBF, ischemia, and increased ICP.

Vital signs should be recorded frequently, according to your institution's policy. Normothermia should be maintained as infants can become cold-stressed very quickly. Fever should be avoided as it increases cerebral metabolic demand. Postoperative tachycardia is expected secondary to the stress response, but it can also indicate anemia, hypovolemia, cardiorespiratory distress, fever, or pain. Bradycardia is very concerning in the child and may indicate increased ICP or hypoxemia, which requires immediate evaluation and treatment. The nurse should maintain euvoolemia by calculating the intake and output totals from surgery and alerting the physician of indications of hypovolemia. Hypovolemia occurs in the neurosurgery postoperative period due to fluid loss and use of osmotic diuretics. Indicators of hypovolemia include low CVP and signs of low cardiac output, including tachycardia; rapid respirations; cool, pale, or mottled skin; low urine output; decreased mental status; and finally hypotension (Hickey 2009). Administration of fluid boluses and vasopressors may be necessary to prevent and treat hypotension, which is a known cause of secondary brain injury and ischemia resulting in further increased ICP and poor outcome (Zebrack et al. 2009). Cushing's response is a late ominous sign of impending cerebral herniation and includes hypertension, bradycardia, and an irregular respiratory pattern (Greenberg 2010; Dias 2004; Hickey 2009). When appropriate, monitor ICP values, evaluate the ICP waveform, and calculate the CPP at frequent intervals (Vernon-Levett 2006).

### 7.12.4 Neurologic Function

A full discussion of neurologic assessment and management of increased ICP precedes this section 7.10. The general neurologic assessment includes assessment of level of consciousness and responsiveness (GCS), pupillary and CN assessment, and motor exam. Serial neurologic assessments are completed as ordered and as the child's condition warrants. A general guideline is to assess every 15 min if the child's condition is deteriorating and then every hour and beyond once the child's condition stabilizes (Vernon-Levett 2006).

### 7.12.5 General Postoperative Nursing Care

Good general postoperative care includes pain management, prevention of infection, nutritional status, and psychosocial support of the child and family. Multiple scales exist for assessment of pediatric pain (see Chap. 1). One such scale should be used consistently to assess pain in the postoperative neurosurgery patient. Pain physiologically increases ICP and should be adequately controlled with administration of analgesics in the post-op period. It is important to note that administration of narcotics and anxiolytics will decrease the patients LOC and responsiveness, blunting the neurologic assessment.

The surgical site should be evaluated for presence of bleeding, dehiscence, wound infection, and CSF leak, all of which should be reported to the neurosurgeon. Bandages should be changed according to institution policy. Enteral nutrition should be started as early as possible to promote wound healing.

### 7.12.6 Postoperative Complications

Postoperative deterioration, including worsening neurologic status compared to preoperative assessment, requires emergency evaluation and treatment as indicated (Greenberg 2010). Worsening neurologic assessment in the postoperative period

warrants repeat imaging with CT scan to rule out hematoma formation, worsening cerebral edema, and acute hydrocephalus.

#### **7.12.6.1 Intracranial Hypertension**

Increased ICP can develop or become worse during neurosurgery or in the postoperative period. Intracranial pressure, ICP waveforms, and calculated CPP values must be monitored and recorded, with deterioration reported to the physician immediately. Cerebrospinal fluid (CSF) can be drained via an EVD, either intermittently or continuously, to therapeutically lower ICP. See previous section 7.10 for full discussion of the pathophysiology, assessment, and management of increased ICP.

#### **7.12.6.2 Seizure**

The incidence of seizures following TBI in children is 10 % and can occur during or following neurosurgery. Seizure activity increases cerebral metabolic demand and, therefore, must be prevented or treated immediately. Prophylactic administration of antiepileptic medications is controversial (see Sect. 7.7.8.8). Management of postoperative seizures includes administration of intravenous antiepileptic medications and insertion of an artificial airway and ventilation if the child is unable to protect the airway. A stat CT scan should be performed to rule out postoperative development of a hematoma (Greenberg 2010). Seizure should be considered as a potential cause of increasing or refractory ICP.

#### **7.12.6.3 Complications After Supratentorial Craniotomy**

Complications related to supratentorial neurosurgery include hemorrhage, cerebral edema, and cerebral ischemia secondary to increased ICP. Swelling is an expected finding after neurosurgery and peaks within 72 h (Hickey 2009). Postoperative hemorrhage should be considered when there is a rapid increase in ICP and bloody output from an EVD or drain. An unexpected decrease in hemoglobin can indicate intracranial hemorrhage. Presence of coagulopathies in the postoperative period should also be considered

as a cause for hemorrhage and managed rapidly. Clinical manifestations of supratentorial complications include symptoms of increased ICP (headache, emesis, decreasing LOC), signs of rostral-caudal deterioration, cranial nerve dysfunction (II – visual deficit; III – ptosis; III, IV, and VI – EOM deficit), focal motor deficits, and seizures. Stat repeat imaging with CT scan is performed. Neurologic deterioration due to an expanding mass lesion requires rapid intubation and control of ventilation, administration of an osmotic diuretic (mannitol), and emergent surgical intervention.

#### **7.12.6.4 Complications After Posterior Fossa Craniotomy**

Postoperative complications after posterior fossa (PF), or infratentorial, craniotomy deserve further discussion. Complications include acute bleeding or clot formation, cerebral edema or swelling, and CSF fistula. Often the first indication of posterior fossa complications is respiratory arrest, prompting many neurosurgeons to delay extubation in the postoperative period for 24–48 h (Greenberg 2010). Hypertension after PF craniotomy can cause hemorrhage from tenuous vessels and precipitates postoperative use of antihypertensives. The child's blood pressure should be monitored closely, with any sudden increases reported to the neurosurgeon immediately.

The PF is a physically small compartment, which contains important structures such as the cerebellum and the brainstem. Cerebral swelling or postoperative hematoma with mass effect on the brainstem can be rapidly fatal. Increased pressure in the PF can cause obstruction of the outlet of the fourth ventricle, resulting in acute hydrocephalus (see Chap. 2). Increased pressure in the PF is associated with rapid change in respiratory pattern and hypertension. Headache, lower cranial nerve dysfunction (III to X), and cerebellar findings, such as ataxia, fine motor, or coordination deficits, are common (Greenberg 2010; Hickey 2009). Pupillary reflexes, level of consciousness, and ICP are not affected until late. An immediate reoperation is indicated to prevent cerebral herniation and is often not

delayed to obtain neuroimaging or transport the patient to the operating room (Greenberg 2010).

CSF fistula occurs in 5–17 % of posterior fossa craniotomies and is evidenced by a persistent leak of clear fluid from the wound. CSF can also accumulate beneath the surgical skin flap (pseudomeningocele) without external leak or fistula. Pseudomeningocele can be observed and may resolve spontaneously. CSF fistula or active leak of CSF requires surgical wound revision. Lumbar drainage or placement of a ventricular shunt may be required if the leak is persistent or to promote healing of the surgical wound (Greenberg 2010). CSF leak is a potential source for infection or meningitis, and prophylactic antibiotics are administered.

---

### 7.13 Outcomes

Outcomes for children with traumatic brain injury can be difficult to predict. Children tend to have better outcomes, especially as compared to adults. Children with more severe injuries have higher mortality rates (Farrell et al. 2004; Jagannathan et al. 2008). Other factors associated with increased mortality include arriving at the hospital comatose, with a CPP < 40 mmHg, and remaining in that state for at least 6 h (Catala-Temprano et al. 2007; White et al. 2001). It is also known that the presence of hypotension and the number of hypotensive episodes have an effect on outcome (Chiaretti et al. 2002; Coates et al. 2005; Hutchison et al. 2010; Schreiber et al. 2002). Additionally, in one study, the inability to maintain CPP  $\geq$  50 mmHg during the first 24 h after injury and the presence of bradycardia in the emergency department were factors associated with mortality (Hackbarth et al. 2002). Finally, the child who experiences brain ischemia and hypoperfusion is more likely to have a poor outcome (Kochanek et al. 2000).

Children with TBI tend to have more impairment than those with other injuries (Johnson et al. 2009; Winthrop 2010). Because of this, rehabilitation must begin early in the recovery period, ideally in the intensive care unit. An interdisciplinary team that includes the child's family is necessary to coordinate treatment. Physical, occupational, and speech

therapists should participate in the child's care as soon as possible. Families will need anticipatory guidance about potential impairments and disabilities their child may experience, as well as about behaviors the child may display. They will also need to develop strategies to advocate for their child's maximal recovery and ongoing needs (Aitken et al. 2009). Because the child's brain is still developing, it is difficult to predict final functional outcome. Children may experience neurocognitive delays or may never reach milestones related to visual-motor abilities, language, cognition, intelligence and school achievement, and behavior (Keenan and Bratton 2006; Keenan et al. 2007). A structured rehabilitation program will provide the child with the best opportunity to meet his or her potential following a TBI.

---

### 7.14 Prevention Efforts

Major prevention efforts have included reduced speed limits, seat belt laws to include a lap and shoulder harness, proper use of child safety seats, and use of safety helmets for bicycling and other activities on wheels. Many local communities and states have passed mandatory bike helmet laws. The difficulty for law enforcement officials becomes how to enforce the law and what, if any, penalty or reward should be placed on the minors and their parents. Nurses should take an active interest in lobbying legislators to continue head trauma prevention efforts and encourage parents to use seat belts and other safety devices. Further, nurses should be advocates for child abuse prevention programs, such as the Period of PURPLE Crying ([www.purplecrying.info](http://www.purplecrying.info) or [www.dontshake.org](http://www.dontshake.org)).

#### Pearls

1. Due to their developmental age, young children are more difficult to assess than older children and adults. Young children may have significant intracranial injury with little external evidence, secondary to the more flexible pediatric skull.

2. Accidental head injury is uncommon under the age of 2 years. In the face of inadequate mechanism of injury, or a change in the explanation of injury, assess for inflicted injury.
3. Establish baseline neurologic assessment and communicate clearly and objectively at change of shift. It is critical for the nurse to recognize early signs of neurologic (rostral (head)-caudal (tail)) deterioration, such as worsening LOC, cranial nerve dysfunction, and posturing, so that there is potential to reverse the process before herniation and death occur. Report any and all changes/deteriorations to the physician immediately.
4. Minimal stimulation must not prevent a good assessment and intervention when necessary; base interventions on patient's response, ICP value, and waveform.
5. When evaluating child for causes of increased ICP, assure that the head of bed is elevated 30° with head midline, that adequate sedation and analgesia are provided as ordered, and that the ventilator and EVD/ICP monitor are functioning appropriately, prior to calling physician.
6. A worsening LOC suggests neurologic deterioration. Caution should be exercised not to mistake neurologic deterioration for pain or anxiety, as treatment of the same with narcotics or anti-anxiety agents will further blunt the neurologic exam and delay treatment. By the same token, abnormal motor posturing should not be mistaken as seizure activity.
7. The classic presentation of an expanding mass lesion is decreased LOC, ipsilateral pupillary dilation, and contralateral hemiparesis.

## References

- Adelson PD (2009) Hypothermia following pediatric traumatic brain injury. *J Neurotrauma* 26:429–436
- Adelson PD, Clyde B, Kochanek PM et al (1997) Cerebrovascular response in infants and young children following severe traumatic brain injury: a preliminary report. *Pediatr Neurosurg* 26:200–207
- Adelson PD, Ragheb J, Muizelaar JP et al (2005) Phase II clinical trial of moderate hypothermia following severe traumatic brain injury. *Neurosurgery* 56: 740–754
- Aitken ME, McCarthy ML, Slomine BS et al (2009) Family burden after traumatic brain injury in children. *Pediatrics* 123:199–206
- American Heart Association (2006) Pediatric advanced life support. American Heart Association, Dallas
- Andrews BT, Hammer GB (1997) The neurological examination and neurological monitoring in pediatric intensive care. In: Andrews BT, Hammer GB (eds) *Pediatric neurosurgical intensive care*. The American Association of Neurological Surgeons, Park Ridge
- Arabi YM, Haddad S, Tamim HM et al (2010) Mortality reduction after implementing a clinical practice guidelines-based management protocol for severe traumatic brain injury. *J Crit Care* 25:190–195
- Badjatia N, Carney N, Crocco TJ et al (2007) Guidelines for prehospital management of traumatic brain injury, 2nd edn. Brain Trauma Foundation, New York
- Barkovich AJ (2005) *Pediatric neuroimaging*, 4th edn. Lippincott, Philadelphia
- Barlow KM, Thomson E, Johnson D et al (2001) Late neurologic and cognitive sequelae of inflicted traumatic brain injury in infancy. *Pediatrics* 116: 174–185
- Bayir H, Kochanek PM, Clar RSB (2003) Traumatic brain injury in infants and children: mechanisms of secondary damage and treatment in the intensive care. *Crit Care Clin* 19:529–549
- Bernard SA, Buist M (2003) Induced hypothermia in critical care medicine: a review. *Crit Care Med* 31:2041–2051
- Blackburn ST (2003) Assessment and management of the neurologic system. In: Kenner C, Lott JW (eds) *Comprehensive neonatal nursing: a physiologic perspective*, 3rd edn. Saunders, Philadelphia
- Blackburn ST, Ditzenberger GR (2007) Neurologic system. In: Kenner C, Lott JW (eds) *Comprehensive neonatal care*, 4th edn. Saunders/Elsevier, St. Louis
- Bourdages M, Bigras JL, Farrell CA et al (2010) Cardiac arrhythmias associated with severe traumatic brain injury and hypothermia therapy. *Pediatr Crit Care Med* 11:408–414
- Brain Trauma Foundation (2007) Guidelines for the management of severe traumatic brain injury, 3rd edn. *J Neurotrauma* 24:S1–S106
- Bratton SL, Chestnut RM, Ghajar J et al (2007) Nutrition. *J Neurotrauma* 24:S77–S82

- Caffey J (1974) The whiplash shaken infant syndrome: manual shaking by the extremities with whiplash-induced intracranial and intraocular bleedings, linked with residual permanent brain damage and mental retardation. *Pediatrics* 54:396–403
- Carney NA, Chesnut R, Kochanek PM et al (2003) Guidelines for the acute medical management of severe traumatic brain injury in infants, children, and adolescents. *Pediatr Crit Care Med* 4:S1–S75
- Catala-Temprano A, Claret Teruel G, Gamba Lasasa FJ et al (2007) Intracranial pressure and cerebral perfusion pressure as risk factors in children with traumatic brain injuries. *J Neurosurg* 106:463–466
- Chiaretti A, Piastra M, Pulitano S et al (2002) Prognostic factors and outcome of children with severe head injury: an 8-year experience. *Childs Nerv Syst* 18:129–136
- Chin LS, Jayarao M, Cantu RC (2011) Inside sports-related head injury: tau inclusion bodies and proteins in a tangle. *AANS Neurosurg* 20:4–7
- Clark L, Preissig C, Rigby MR et al (2008) Endocrine issues in the pediatric intensive care unit. *Pediatr Clin North Am* 55:805–833
- Clifton GL, Drever P, Valadka A et al (2009) Multicenter trial of early hypothermia in severe brain injury. *J Neurotrauma* 26:393–397
- Coates BM, Vavilala MS, Mack CD et al (2005) Influence of definition and location of hypotension on outcome following severe pediatric traumatic brain injury. *Crit Care Med* 33:2645–2650
- Cobbs-Ewing L, Kramer L, Prasad M (1998) Neuroimaging, physical and developmental findings after inflicted and noninflicted traumatic brain injury in young children. *Pediatrics* 102:300–307
- Cochran A, Scaife E, Hansen KW et al (2003) Hyperglycemia and outcome from pediatric traumatic brain injury. *J Trauma* 55:1035–1038
- Coronado VG, Xu L, Basavaraju SV et al (2011) Surveillance for traumatic brain injury-related deaths – United States, 1997–2007. *MMWR Surveill Summ* 60:1–32
- Curley MAQ, Moloney-Harmon PA (2001) *Critical care nursing of infants and children*, 2nd edn. Saunders, Philadelphia
- Curley MAQ, Quigley SM, Lin M (2003) Pressure ulcers in pediatric intensive care: incidence and associated factors. *Pediatr Crit Care Med* 4:284–290
- Dias MS (2004) Traumatic brain and spinal cord injury. *Pediatr Clin North Am* 51:271–303
- Doppenberg WMR, Ward JD (2008) Hematomas. In: Albright AL, Pollack IF, Adelson PD (eds) *Principles and practice of pediatric neurosurgery*, 2nd edn. Thieme, New York
- Duhaime AC (2008) Nonaccidental head injuries. In: Albright AL, Pollack IF, Adelson PD (eds) *Principles and practice of pediatric neurosurgery*, 2nd edn. Thieme, New York
- Ellingson KD, Leventhal JM, Weiss HB (2008) Using hospital discharge data to track inflicted traumatic brain injury. *Am J Prev Med* 34:157–162
- Fakhry SM, Trask AL, Waller MA et al (2004) Management of brain-injured patients by an evidenced-based medicine protocol improves outcomes and decreases hospital charges. *J Trauma* 56:492–499
- Farrell LS, Hannan EL, Cooper A (2004) Severity of injury and mortality associated with pediatric blunt injuries: hospitals with pediatric intensive care units versus other hospitals. *Pediatr Crit Care Med* 5:5–9
- Faust AC, Attridge RL, Ryan L (2011) How low should you go? The limbo of glycemic control in intensive care units. *Crit Care Nurse* 31:e9–e18
- Figaji AA, Fieggan AG, Argent AC et al (2008) Intracranial pressure and cerebral oxygenation changes after decompressive craniectomy in children with severe traumatic brain injury. *Acta Neurochir Suppl* 102:77–80
- Gavett BE, Stern RA, McKee AC (2011) Chronic traumatic encephalopathy: a potential late effect of sport-related concussive and subconcussive head trauma. *Clin Sports Med* 30:179–188
- Greenberg MS (2010) *Handbook of neurosurgery*, 7th edn. Thieme, New York
- Hackbarth RM, Rzeszutko KM, Sturm G et al (2002) Survival and functional outcome in pediatric traumatic brain injury: a retrospective review and analysis of predictive factors. *Crit Care Med* 30:1630–1635
- Haitsma IS, Mass AIR (2002) Advanced monitoring in the intensive care unit: brain tissue oxygen tension. *Curr Opin Crit Care* 8:115–120
- Hernandez JA, Glass SM (2005) Physical assessment of the newborn. In: Thureen PJ, Deacon J, Hernandez JA et al (eds) *Assessment and care of the well newborn*, 2nd edn. Elsevier/Saunders, St. Louis
- Hettler J, Greenes DS (2003) Can the initial history predict whether a child with a head injury has been abused? *Pediatrics* 111:602–607
- Hickey JV (2009) *The clinical practice of neurological and neurosurgical nursing*, 6th edn. Lippincott, Philadelphia
- Holmes JF, Palchak MJ, Conklin MJ et al (2004) Do children require hospitalization after immediate posttraumatic seizures? *Ann Emerg Med* 43:786–790
- Holmes JF, Borgianni DA, Nadel FM et al (2011) Do children with blunt head trauma and normal cranial computed tomography scan results require hospitalization for neurologic observation? *Ann Emerg Med* 58:315–322
- Huh JW, Raghupathi R (2009) New concepts in treatment of pediatric traumatic brain injury. *Anesthesiol Clin* 27:213–240
- Hutchison JS, Ward RE, Lacroix J et al (2008) Hypothermia therapy after traumatic brain injury in children. *N Engl J Med* 358:2447–2456
- Hutchison JS, Frndova H, Lo TY et al (2010) Impact of hypotension and low cerebral perfusion pressure on outcomes in children treated with hypothermia therapy following severe traumatic brain injury: a post hoc analysis of the Hypothermia Pediatric Head Injury Trial. *Dev Neurosci* 32:406–412



- Jagannathan J, Okonkwo DO, Dumont AS et al (2007) Outcome following decompressive craniectomy in children with severe traumatic brain injury: a 10-year single-center experience with long-term follow up. *J Neurosurg* 106:268–275
- Jagannathan J, Okonkwo DO, Yeoh HK et al (2008) Long-term outcomes and prognostic factors in pediatric patients with severe traumatic brain injury and elevated intracranial pressure. *J Neurosurg Pediatr* 2:240–249
- Jenny C, Hymel KP, Ritzen A et al (1999) Analysis of missed cases of abusive head trauma. *JAMA* 281:621–626
- Jeremitsky E, Omert LA, Dunham CM et al (2005) The impact of hyperglycemia on patients with severe brain injury. *J Trauma* 58:47–50
- Johnson AR, DeMatt E, Salorio DF (2009) Predictors of outcome following acquired brain injury in children. *Dev Disabil Res Rev* 15:124–132
- Kamerling SN, Lutz N, Posner J et al (2003) Mild traumatic brain injury in children: practice guidelines for emergency department and hospitalized patients. *Pediatr Emerg Care* 19:431–440
- Keenan H, Bratton S (2006) Epidemiology and outcomes of pediatric traumatic brain injury. *Dev Neurosci* 28:256–263
- Keenan HT, Runyan DK, Marshall SW et al (2003) A population-based study of inflicted traumatic brain injury in young children. *JAMA* 290:621–626
- Keenan HT, Hooper SR, Wetherington CE (2007) Neurodevelopmental consequences of early traumatic brain injury in 3-year-old children. *Pediatrics* 119:e616–e623
- Kelly JP, Rosenberg JH (1997) The diagnosis and management of concussion in sports. *American Academy of Neurology practice parameter*. *Neurology* 48:575–585
- Kennedy CS, Moffatt M (2004) Acute traumatic brain injury in children: exploring the cutting edge in understanding, therapy, and research. *Clin Pediatr Emerg Med* 5:224–238
- Khanna S, Davis D, Peterson B et al (2000) Use of hypertonic saline in the treatment of severe refractory post traumatic intracranial hypertension in pediatric traumatic brain injury. *Crit Care Med* 28:1144–1150
- Kochanek PM, Clark RS, Ruppel RA et al (2000) Biochemical, cellular, and molecular mechanisms in the evolution of secondary damage after severe TBI in infants and children: lessons learned from the bedside. *Pediatr Crit Care Med* 1:4–19
- Kochanek PM, Carney N, Adelson P et al (2012) Guidelines for the acute medical management of severe traumatic brain injury in infants, children, and adolescents, 2nd edn. *Pediatr Crit Care Med* 13:S1–S82
- Krieger MD, Bowen IE, McComb JG (2008) Penetrating craniocerebral injuries. In: Albright AL, Pollack IF, Adelson PD (eds) *Principles and practice of pediatric neurosurgery*, 2nd edn. Thieme, New York
- Laird AM, Miller PR, Kolgo PD et al (2004) Relationship of early hyperglycemia to mortality in trauma patients. *J Trauma* 56:1058–1062
- Lang EW, Mulvey JM, Mudaliar Y et al (2007) Direct cerebral oxygenation monitoring—a systematic review of recent publications. *Neurosurg Rev* 30:99–107
- Levy DI, ReKate HL, Cherny WB et al (1995) Controlled lumbar drainage in pediatric head injury. *J Neurosurg* 83:453–460
- Li H, Lu G, Shi W (2009) Protective effect of moderate hypothermia on severe traumatic brain injury in children. *J Neurotrauma* 26:1905–1909
- Littlejohns LR, Bader MK, March K (2003) Brain tissue oxygen monitoring in severe brain injury: research and usefulness in critical care. *Crit Care Nurse* 23:17–25
- Lynam L, Verklan MT (2010) Neurological disorders. In: Verklan MT, Walden M (eds) *Core curriculum for neonatal intensive care nursing*, 4th edn. Saunders, Philadelphia
- Maloney-Wilensky E, Gracias V, Itkin A et al (2009) Brain tissue oxygen and outcome after severe traumatic brain injury: a systematic review. *Crit Care Med* 37:2057–2063
- Marcoux KK (2005) Management of increased intracranial pressure in the critically ill child with an acute neurological injury. *AACN Clin Issues* 16:212–231
- McCrory P, Meeuwisse W, Johnston K et al (2009) Consensus statement on concussion in sport – the third international conference on concussion in sport held in Zurich, November 2008. *Phys Sportsmed* 37:141–159
- McIlvoy L (2007) The impact of brain temperature and core temperature on intracranial pressure and cerebral perfusion pressure. *J Neurosci Nurs* 39:324–331
- Mehta NM (2009) Approach to enteral feeding in the PICU. *Nutr Clin Pract* 24:377–387
- Moghissi ES, Korytkowski MT, DiNardo M et al (2009) American Association of Clinical Endocrinologists and American Diabetes Association consensus statement on inpatient glycemic control. *Endocr Pract* 15:353–369
- Murad A (2008) Controlled lumbar drainage in medically refractory increased intracranial pressure. A safe and effective treatment. *Acta Neurochir Suppl* 102:89–91
- National High Blood Pressure Education Program Working Group on High Blood Pressure in Children and Adolescents (2004) The fourth report on the diagnosis, evaluation, and treatment of high blood pressure in children and adolescents. *Pediatrics* 114:555–576
- Noonan C, Quigley SM, Curley MAQ (2006) Skin integrity in hospitalized infants and children: a prevalence survey. *J Pediatr Nurs* 21:445–453
- O'Toole MO (1992) *Miller-Keane encyclopedia and dictionary of medicine, nursing, and allied health*, 5th edn. Saunders, London
- Palmer S, Bader MK, Qureshi A et al (2001) The impact on outcomes in a community hospital setting of using the AANS traumatic brain injury guidelines. *J Trauma* 50:657–664
- Parker LA (2005) Part 1: early recognition and treatment of birth trauma: injuries to the head and face. *Adv Neonatal Care* 5:288–297

- Peterson B, Khanna S, Fisher B et al (2000) Prolonged hypernatremia controls elevated ICP in head-injured pediatric patients. *Crit Care Med* 28:1136–1143
- Pigula FA, Wald SL, Shackford SR et al (1993) The effect of hypotension and hypoxia on children with severe head injuries. *J Pediatr Surg* 28:310–316
- Plum F, Posner JB (1982) The diagnosis of stupor and coma, 3rd edn. Oxford University Press, New York
- Potoka DA, Schall LC, Gardner MJ et al (2000) Impact of pediatric trauma centers on mortality in a statewide system. *J Trauma* 49:237–245
- Ragheh J (2008) Accidental head injuries. In: Albright AL, Pollack IF, Adelson PD (eds) *Principles and practice of pediatric neurosurgery*, 2nd edn. Thieme, New York
- Reichard R (2008) Birth injury of the cranium and central nervous system. *Brain Pathol* 18:565–570
- Reid J (2007) Neonatal subgaleal hemorrhage. *Neonatal Netw* 26:219–227
- Salim A, Hadjizacharia P, Dubose J et al (2009) Persistent hyperglycemia in severe traumatic brain injury: an independent predictor of outcome. *Am Surg* 75: 25–29
- Sansoucie DA, Cavaliere TA (2003) Newborn and infant assessment. In: Kenner C, Lott JW (eds) *Comprehensive neonatal nursing: a physiologic perspective*, 3rd edn. Saunders, Philadelphia
- Schierholz E, Walker SR (2010) Responding to traumatic birth: subgaleal hemorrhage, assessment, and management during transport. *Adv Neonatal Care* 10: 311–315
- Schindler CA, Mikhailov TA, Kuhn EM et al (2011) Protecting fragile skin: nursing interventions to decrease development of pressure ulcers in pediatric intensive care. *Am J Crit Care* 20:26–35
- Schneider AJ, Shields BJ, Hostetler SG et al (2006) Incidence of pediatric brain injury and associated hospital resource utilization in the United States. *Pediatrics* 118:483–492
- Schreiber MA, Aoki N, Scott BG et al (2002) Determinants of mortality in patients with severe blunt head injury. *Arch Surg* 137:285–290
- Shafi NI, Mariscalco MM (2006) Considering the use of induced hypothermia in a pediatric patient with traumatic brain injury: a critical appraisal of two meta-analyses. *Pediatr Crit Care Med* 7:468–472
- Sharma D, Jelacic J, Chennury R et al (2009) Incidence and risk factors for perioperative hyperglycemia in children with traumatic brain injury. *Anesth Analg* 108: 81–89
- Simon B, Letourneau P, Vitorino E et al (2001) Pediatric minor head trauma: indications for computed tomographic scanning revisited. *J Trauma* 51:231–237
- Skippen P, Seear M, Poskitt K et al (1997) Effect of hyperventilation on regional cerebral blood flow in head-injured children. *Crit Care Med* 25: 1275–1278
- Smets KJ, Vanhauwaert D (2010) Treatment of cranial epidural hematoma in a neonate by needle aspiration of a communicating cephalohematoma. *Eur J Pediatr* 169:617–619
- Smith RL, Lin JC, Adelson PD et al (2012) Relationship between hyperglycemia and outcome in children with severe traumatic brain injury. *Pediatr Crit Care Med* 13:85–91
- Soukup J, Zauner A, Dopperberg WEM et al (2002) The importance of brain temperature in patients after severe head injury: relationship to intracranial pressure, cerebral perfusion pressure, cerebral blood flow, and outcome. *J Neurotrauma* 19:559–571
- Starling SP, Holden JR, Jenny C (1995) Abusive head trauma: the relationship of perpetrators to their victims. *Pediatrics* 95:259–262
- Stiefel MF, Udoetuk JD, Storm PB et al (2006) Brain tissue oxygen monitoring in pediatric patients with severe traumatic brain injury. *J Neurosurg* 105:281–286
- Stocchetti N, Conte V, Ghisoni L et al (2010) Traumatic brain injury in pediatric patients. *Minerva Anestesiol* 76:1052–1059
- Sydenham E, Roberts I, Alderson P (2009) Hypothermia for traumatic head injury. *Cochrane Database Syst Rev* (1):CD001048
- Tume LN, Baines PB, Lisboa PJG (2011) The effect of nursing interventions on the intracranial pressure in paediatric traumatic brain injury. *Nurs Crit Care* 16:77–84
- Tung GA, Kumar M, Richardson RC et al (2006) Comparison of accidental and nonaccidental traumatic head injury in children on noncontrast computed tomography. *Pediatrics* 118:626–633
- Upadhyay P, Tripathi VN, Singh RP et al (2010) Role of hypertonic saline and mannitol in the management of raised intracranial pressure in children: a randomized comparative study. *J Pediatr Neurosci* 5:18–21
- Vagnozzi R, Signoretti S, Tavazzi B et al (2005) Hypothesis of the postconcussive vulnerable brain: experimental evidence of its metabolic occurrence. *Neurosurgery* 57:164–171
- Vavilala MS, Lee LA, Boddu K et al (2004) Cerebral autoregulation in pediatric traumatic brain injury. *Pediatr Crit Care Med* 5:257–263
- Verklan MT, Lopez SM (2011) Neurologic disorders. In: Gardner SL, Carter BS, Enzman-Hines M et al (eds) *Merenstein and Gardner's handbook of neonatal intensive care*, 7th edn. Mosby Elsevier, St. Louis
- Vernon-Levett P (2006) Neurologic system. In: Slota MC (ed) *Core curriculum for pediatric critical care nursing*, 2nd edn. Saunders/Elsevier, St. Louis
- Vinchon M, Defoort-Dhellemmes S, Desurmont M et al (2005) Accidental and nonaccidental head injuries in infants: a prospective study. *J Neurosurg Pediatr* 102:380–384
- Vizzini A, Aranda-Michel J (2011) Nutritional support in head injury. *Nutrition* 27:129–132
- Volpe JJ (2008) *Neurology of the newborn*, 5th edn. Saunders, Philadelphia
- White JR, Farukhi Z, Bull C et al (2001) Predictors of outcome in severely head-injured children. *Crit Care Med* 29:534–540
- Wilson-Pauwels L, Akesson EJ, Stewart PA et al (2010) *Cranial nerves in health and disease*, 3rd edn. BC Decker, Hamilton

- Winthrop AL (2010) Health-related quality of life after pediatric trauma. *Curr Opin Pediatr* 22:346–351
- Yildizdas D, Altunbasak S, Celik U et al (2006) Hypertonic saline treatment in children with cerebral edema. *Indian Pediatr* 43:771–779
- Young PA, Young PH, Tolbert DL (2008) *Basic clinical neuroscience*, 2nd edn. Lippincott, Baltimore
- Zebrack M, Dandoy C, Hansen K et al (2009) Early resuscitation of children with moderate-to-severe traumatic brain injury. *Pediatrics* 124:56–64

---

## 8.1 Pediatric Spinal Deformity

Pediatric patients may suffer from congenital spinal anomalies and spinal injuries from trauma. Other abnormalities such as infections, tumors, and vascular lesions are discussed in other chapters. These spinal problems are often difficult to diagnose due to the differences in the development of the pediatric spine compared to the adult spine. Congenital spinal anomalies may not be diagnosed until the child is older, often resulting in irreversible neurological damage. Spinal cord injuries are often severe. Because of these concomitant injuries, treatment does not stop when the patient leaves the hospital or the rehabilitation facility; it requires a life-long commitment from the family and patient.

---

## 8.2 Congenital Spine Deformity and Spinal Cord Disorders

In the pediatric age group, spinal deformity may result from various conditions, such as congenital anomalies, neuromuscular conditions, connective tissue disorders, neurofibromatosis, and skeletal

dysplasia including dwarfism (Wiggins et al. 2003). Congenital spine deformity is caused by anomalous vertebral development in the embryo. The actual spinal deformity may not be obvious at birth but progresses in proportion to spinal growth resulting in unbalanced growth of the spine. The rate of curve progression depends on the age of the patient, type and location of the anomaly, and location of the curve (Hedequist and Emans 2007). Minor deformities may seldom be apparent and may be noted for the first time during periods of rapid growth (first 5 years of life and again at adolescence), later in life as they progress, or on a routine radiograph for work up of an unrelated problem. More severe congenital malformations that may result in progressive deformity and multisystem problems, including neurologic complications, have a high incidence of other associated conditions which will be discussed in more detail throughout this section (Dewald et al. 2003).

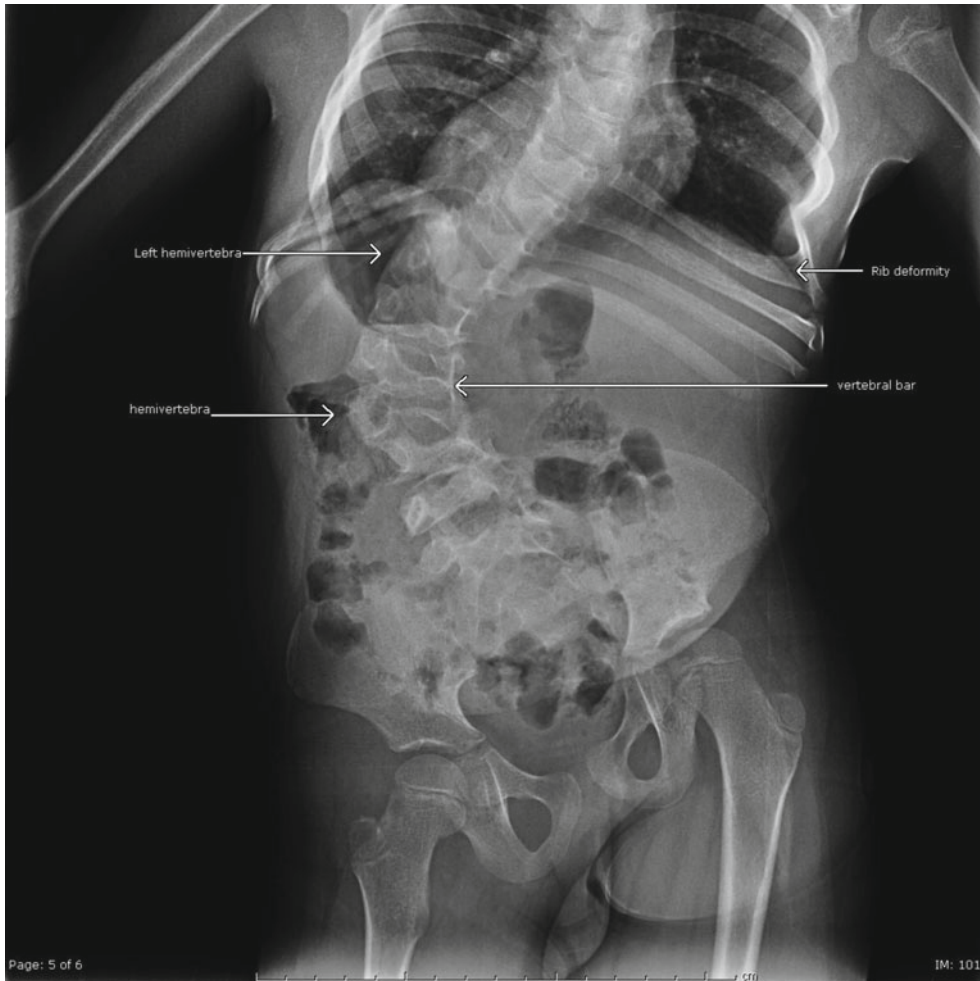
Predominant congenital deformities typically exist as scoliosis, kyphosis, or lordosis. Most are multiplane deformities. A description of a congenital deformity should include the involved area of the spine, the type of vertebral anomaly, and the configuration of the deformity, as these factors will have a direct effect on further evaluation and treatment. Congenital scoliosis or kyphosis is classified as failure of formation, failure of segmentation, or mixed anomalies (Wiggins et al. 2003) (Fig. 8.1).

---

V. Thomas, PNP-BC (✉)  
A. Stuedemann, MSN, RN, CPNP  
Division of Orthopaedic Surgery,  
Children's Mercy Hospitals and Clinics,  
2401 Gillham Road, Kansas City, MO 64108, USA  
e-mail: vthomas@cmh.edu; astuedemann@cmh.edu

---

Laurie Baker, Suzan R. Miller-Hoover, Donna C. Wallace,  
and Sherry Kahn were authors on the first edition but did  
not contribute to the revision of this chapter



**Fig. 8.1** Defects of segmentation (Permission pending)

Approximately 60 % of people with vertebral malformations have associated anomalies either within or outside the spine. The importance of thoroughly searching for associated anomalies cannot be emphasized enough, as a vertebral anomaly that appears relatively benign may be associated with a much more severe and possibly life-threatening condition (Devlin 2012). There is also an increased incidence of spinal cord disorders related to the congenital defect that are more common to some specific syndromes. A few of the more common conditions that are seen in the neurosurgery and orthopedic patients are achondroplasia, Klippel-Feil syndrome, and mucopolysaccharide disorders

(MPS). These will be discussed in more detail later in this section.

### 8.2.1 Etiology

Development of the vertebrae begins at 4–6 weeks of gestation. This is when the mesenchymal mold is formed which is the model for the framework for the secondary cartilaginous and osseous development of the vertebrae (Dewald et al. 2003). Subsequent chondrification and ossification follow this mold. The neural axis is developing at the same time, which explains that many of the children with vertebral anomalies will have neural anomalies as

well. The embryologic insult resulting in the vertebral anomaly is unknown, and there has been no clear-cut genetic etiology of congenital scoliosis to date. In animal models, it has been demonstrated that deformities have been linked with maternal hypoxia at the critical time of gestation (Devlin 2012). There have also been associations with maternal diabetes, ingestion of antiepileptic drugs during pregnancy, and maternal exposure to toxins (Hedequist and Emans 2007).

Congenital vertebral anomalies are rare. The prevalence rate of congenital scoliosis is approximately 1 in 1,000 live births (Hedequist and Emans 2007). Isolated anomalies (hemivertebra) are sporadic with no familial or genetic tendencies. However, there is a 5–10 % risk of similar lesions in siblings or subsequent generations, as well as an increased risk of neural tube defects when there are complex anomalies in multiple locations (Dewald et al. 2003).

## 8.2.2 Related Conditions

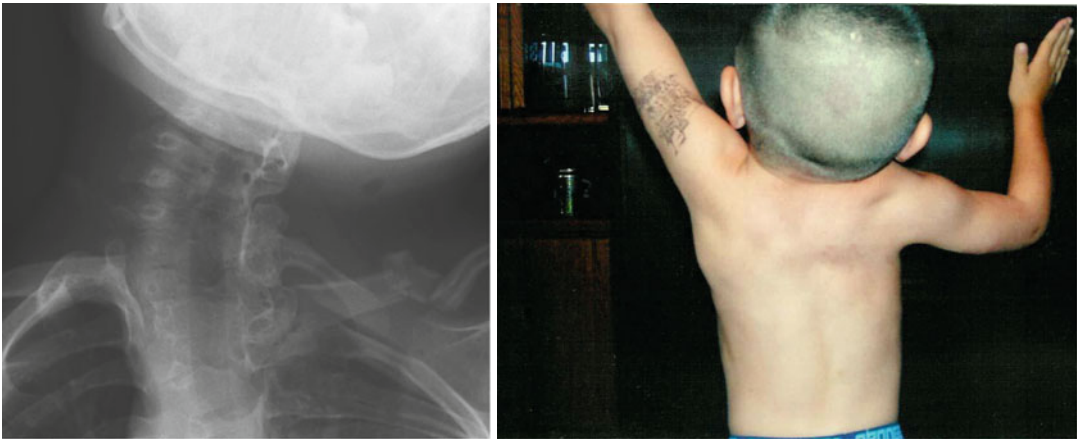
The organ systems that are developing during the same gestational period as the spine may also develop malformations. There are some common malformations that are associated with congenital spinal anomalies, including intraspinal abnormalities. Neural axis abnormalities, such as tethered cord, spinal stenosis, diastematomyelia (split cord), diplomyelia (complete or incomplete doubling of the spinal cord), and syringomyelia (fluid-filled space within the spinal cord), are present in up to 38 % of people with congenital vertebral anomalies. Clinical findings of posterior midline skin lesions like hairy patches or dimples, foot deformity (especially unilateral), muscle weakness, or spasticity may be a red flag as to an underlying intraspinal anomaly. Other anomalies associated with vertebral abnormalities are vertebral anomalies at another level, urinary tract structural abnormalities, cranial nerve palsy, upper extremity hypoplasia, clubfoot, dislocated hip, and congenital cardiac disease. Specifically, the vertebral malformation most often associated with an abnormality of the neural axis is a unilateral unsegmented bar and a same-level contralateral hemivertebra. It has been

estimated that approximately 50 % of this population have an associated neural axis abnormality (Devlin 2012). These may often be occult anomalies such as a tethered cord, intradural lipoma, syringomyelia, or diastematomyelia, which is the most common (Dewald et al. 2003). The clinical signs and radiographic findings of these spinal cord anomalies are discussed in the physical assessment and imaging sections of this chapter. For more information, see Chap. 4.

## 8.2.3 Evaluation of the Child with a Congenital Spine Deformity

As high as 50 % of children with a congenital spine deformity may also have a congenital anomaly of the neural axis or a spinal dysraphism. Some of the forms of spinal dysraphism include spina bifida (spina bifida occulta, meningocele, and myelomeningocele), diastematomyelia, and tethered cord. The symptoms of spinal dysraphisms are difficult to generalize as they are quite varied depending on the type and severity of the malformation. A thorough past medical history with focus on the physical exam should be obtained, keeping in mind the correlation of congenital spine deformity and other congenital anomalies. Detailed questions should be directed as to the child's neurologic status. Age-appropriate questions related to development history, toilet training, bed wettings, changes in bowel or bladder habits, complaints of lower extremity pain, numbness, or weakness are all of great importance in the evaluation of the child's neurologic status. A complete evaluation of the patient should include a comprehensive look at the patient as well as a close evaluation of the spine itself and a neurologic exam.

General patient evaluation should occur throughout the encounter with the child. A full exam should include sitting and standing heights or supine measurements for infants, head circumference, alterations in the shape of the head, and shape, size, and symmetry of the ears and eyes. Assessment of the neck and cervical spine should be noted for range of motion. There are some syndromes, such as Klippel-Feil syndrome (congenital cervical fusions), that commonly have congenital spine deformities that



**Fig. 8.2** A 4-year-old boy with Sprengel's deformity associated with Klippel-Feil syndrome

would limit cervical range of motion. The spine exam itself should focus on trunk and pelvic balance, including the coronal and sagittal planes (Hedequist and Emans 2007). The finding of abnormal kyphosis on physical exam may be postural or congenital and thus should be thoroughly evaluated. Complaints of back pain, muscle fatigue, and stiffness are common in kyphosis. In severe cases, there can be compression of the spinal cord with neurologic symptoms that include weakness, altered sensation, and loss of bowel and bladder control. The chest should be examined for symmetry and deformity. Observation of inspiration, expiration, and the abdominal wall for movement, masses, and hernias may be an indication of a fixed chest deformity (Dewald et al. 2003). Lastly, secondary sexual development should be noted with examination of the genitalia and Tanner staging.

#### 8.2.4 Neurologic Evaluation

Neurologic evaluation can quickly and easily be performed throughout the physical exam. Extremity development, length, and symmetry should be noted, as well as anomalies of the feet like extra or absent toes, cavus, or flat feet (remember that flat feet alone can be a common finding in young children). These can be red flags as to underlying neurologic conditions. Congenital deformities of the upper body and extremities such as Sprengel's deformity (undescended scapula) and syndactyly should also be noted (Fig. 8.2). Further neurologic exam can be performed simply

by observing the child walk, run, and move, noting overall general motor function. Testing of reflexes should be carefully performed. Abdominal reflexes should be symmetric. Asymmetric or depressed reflexes can be symptomatic of a spinal dysraphism. Hyperactive reflexes can be indicative of spinal cord compression (Dewald et al. 2003).

#### 8.2.5 Associated Anomalies

Children with congenital scoliosis are also at risk for abnormalities of the cardiac and genitourinary systems. Congenital heart disease may be found in up to 25 % of children with congenital scoliosis and genitourinary anomalies in as many as 20 % of these patients (Hedequist and Emans 2007). The abnormalities may be benign, asymptomatic and detected during a routine screening or preoperative appointment. They may, however, be quite serious, already diagnosed and have possibly already required treatment. If it is determined through the medical history that these patients have not previously been evaluated for possible cardiac and urologic anomalies, they should be referred to a cardiologist or urologist for further screening and workup.

#### 8.2.6 Diagnostic Studies

When anomalies of the spine are suspected, radiologic study is essential, especially for anomalies of the cervical spine. Early identification

may significantly reduce potential major complications (Albright et al. 1999). Plain x-rays are always a recommended and reliable starting point for radiographic evaluation; however, they may give limited information depending on the age of the patient and the type of anomaly present.

Ultrasound, a simple and very useful type of study, can be a good screening tool in neonates and infants when physical findings suggest an underlying dysraphic lesion. Prenatal findings, family history, and other anomalies may also be an indication for an ultrasound (Albright et al. 1999). Normal vertebral growth and ossification can demonstrate many patterns, as well as be difficult to read on plain films due to the many overlying structures. CT scans are often needed to assess congenital anomalies. This is true especially in the cervical spine. Both CT and MR are especially useful in studying the entire spinal cord and the cervical spine. If any anomaly or malformation is suspected, it is important to image the entire spine as multiple spinal anomalies can commonly present in an individual (Albright et al. 1999).

The incidence of intraspinal abnormalities associated with congenital spine anomalies as detected by MRI has become better defined. In a study by Suh, Sarwark, Vora, and Huang in 2001, there was an incidence of intraspinal anomalies in 31 % in children with congenital spine anomalies. A screening MRI is indicated in patients with a spinal deformity that is known to be associated with neural axis abnormalities because of its capacity to detect clinically unsuspected dysraphia in asymptomatic patients. Other indications would include patients with a progressive deformity, abnormal reflexes, neurological deficits, or major extremity anomalies (Hedequist and Emans 2007). Angiography may be required if vertebral circulation problems are a concern. Some of the intraspinal pathologic conditions that may be found in patients with such conditions include congenital spinal stenosis, tethered cord, syrinx, Chiari malformation, diastematomyelia, and spinal cord tumor (Devlin 2012). Again, as clinical manifestations may not be detectable initially, MR imaging of the entire spinal cord and vertebral column from the foramen magnum to the distal sacrum is essential for complete evaluation. The advantage of MR imaging is that it is a technique that avoids invasive procedures and high radiation exposure.

All systems should be thoroughly reviewed and examined. Frequently, a renal and cardiac consultation is a part of an expanded evaluation.

Computed tomography (CT) is not typically used for serial monitoring and observation of scoliosis; however, it is routinely used in preoperative assessment and planning. CT scans are extremely useful in clearly defining the anatomy and identification of previously unrecognized malformations (Hedequist and Emans 2007). There are concerns regarding high radiation exposure during a CT scan. Today, most institutions typically have written protocols for various scans in order to minimize the amount of radiation that children are exposed to during their scans.

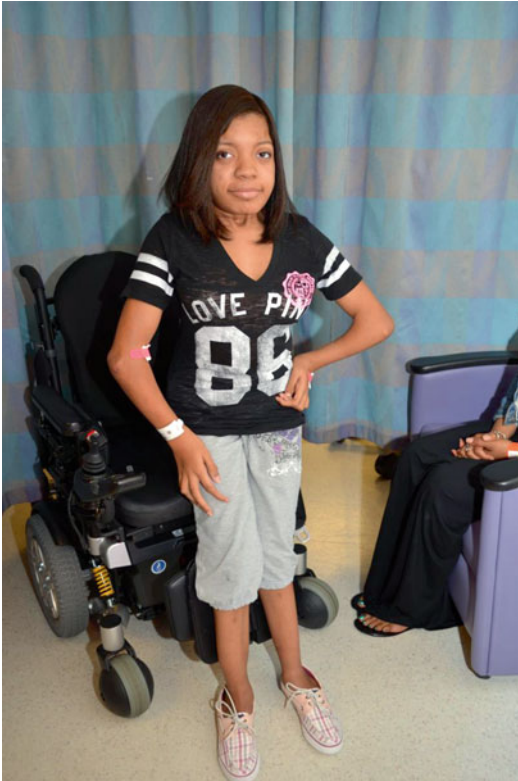Treatment of congenital scoliosis focuses on early recognition, diagnosis, and treatment. Surgical treatment includes early arthrodesis and the routine use of spinal instrumentation for progressive curves. Younger children with congenital deformities may be treated with fusionless surgery by using a growing rod technique. Further discussion of various surgical corrections, fusion, and instrumentation is beyond the scope of the chapter.

### 8.2.7 Skeletal Dysplasias

All conditions of skeletal dysplasia share a common theme of some systemic defect in skeletal development. The categories of spine-related problems common to many of the skeletal dysplasias are instability, stenosis, and deformity, although they may occur concurrently at different levels of the spine and in different planes. Any type of dysplasia may manifest one or more of these problems with some exceptions. The phenotypic variability seen in genetic diseases makes it difficult to predict specific patterns of problems within the skeletal dysplasia groups (Dewald et al. 2003).

The first issue of instability may be a bony or ligamentous issue and usually occurs at the C1–C2 level. Instability is most common in the mucopolysaccharidoses, spondyloepiphyseal dysplasia, and metatropic dysplasia (Dewald et al. 2003). Baseline flexion and extension films of the cervical spine are always indicated. Also, a clinical exam evaluating spasticity, strength, and coordination should be included. An MRI in neutral, flexion, and extension would be indicated if it is





**Fig. 8.3** A young lady with Larsen Syndrome, a connective tissue/skeletal dysplasia disorder associated with congenital spinal instability and spinal cord injury

not clear whether cord compression is developing. Stenosis may occur at any level of the spine. It is most commonly found in achondroplasia (80–90 %) (Dewald et al. 2003). Treatment, typically decompression of the affected region, is determined by the extent and location of the neurologic deficit (Fig. 8.3 and Box 8.1).

#### **Box 8.1. Our Angel**

This story begins the same as many, following the joyous birth of an expected-to-be-healthy child. The delivery was a bit challenging, but it was well worth knowing we had a beautiful baby girl! Immediately, grandmother noticed that the baby had unusually long fingers and hands, but we were not concerned at first. We also noticed that she was not meeting developmental

milestones, even the simple ones like being able to hold her head up. This was the beginning of our journey, meeting with many specialists and undergoing multiple examinations. Finally, a geneticist identified her problem, and it was called Larsen syndrome or Larsen’s syndrome.

We learned that this is a very rare diagnosis that is one of a group of conditions known as “skeletal dysplasias.” It is an inherited condition characterized by congenital interruption of multiple body joints and connective tissue. The children have a characteristic appearance of the face, hands, and multiple skeletal problems. They may have learning disabilities as well.

Identifying the diagnosis was just the beginning. We had to find out who could provide the very best care for her. We began by going online and reaching out to other parents. We found specialists in orthopedics who could stabilize her spine that was compressed by almost 97%! She underwent a fusion and was placed in halo traction for the first 4 years of her life.

We have never lost faith that our little girl would grow up – she is now a freshman in high school! You can see by her beautiful picture that she cares about all the things that most teens do. She chose the picture because she wanted to look her best.

We do have a wonderful support system in place that includes our family, our church, and our many friends. We also have sought out what we feel is the best care possible with the help of other parents from around the country. We have also counted on the surgical specialists, the orthopedic and neuroscience nurses, the many therapists, and her schools to guide and support us.

Most important of all throughout her 14 years of life, the resilience of our daughter and granddaughter has endured. No challenge is too great, no obstacle too much for us to overcome. We have come together and endured it all for our “little angel” because she is worth it all.

## 8.2.8 Spinal Manifestations of Achondroplasia

Achondroplasia is an autosomal dominant genetic disorder affecting endochondral bone formation. It is the most common form of short-limbed dwarfism. The prevalence rate is approximately 1 in 26,000 live births (Wright et al. 2000). Achondroplasia occurs as a result of a mutation of the fibroblast growth factor receptor 3 (FGFR3) gene which is involved in the growth and development of bone (Alman 2002; Shiang et al. 1994). Mutation of this gene results in abnormal chondrocyte maturation causing stunting of bone formation at the epiphyseal plates. The bones in the face, skull base, spine, hands, feet, and proximal long bones, such as the humerus and femur, are especially affected resulting in characteristic features involving these structures (Alman 2002; Poseti 1988). Hydrocephalus, upper cervical spinal cord compression, and spinal stenosis are three neurological problems seen in achondroplasts (Park et al. 2003). The spinal manifestations of achondroplasia will be the primary focus of this section.

Abnormal development of the bones of the skull base results in abnormalities of the foramen magnum, posterior fossa, and brain stem. These abnormalities contribute to compression at the cervicomedullary junction. The diameter of the foramen magnum is significantly decreased in achondroplasia leading to compression of the upper cervical spinal cord and distal medulla (Schnuerer et al. 2001). The foramen magnum is also displaced anteriorly resulting in a shallow posterior fossa. As a result, the brainstem is displaced upward and posteriorly, simulating hyperextension of the neck. The compression on the upper cervical spinal cord is exacerbated further because it is often stretched over the edge of the occipital bone (Kokoska et al. 2001; Kopits 1988).

### 8.2.8.1 Cervicomedullary Compression

Cervicomedullary compression resulting from foramen magnum insufficiency is usually identified in young achondroplastic patients and is a common cause of early morbidity and mortality

in this patient population. It is also thought to be a contributing factor in the hypotonicity and motor developmental delay common in achondroplastic infants. The manifestations of this chronic neurological compression can be wide ranging. Patients may be asymptomatic initially but may develop signs and symptoms of upper spinal cord compression, including paresthesias and paresis, which can be progressive, even leading to quadriplegia. Signs of myelopathy including hyperreflexia and clonus may be evident even in the patient who is apparently asymptomatic. Symptoms such as spastic quadriparesis may not manifest until adulthood in patients with mild, chronic compression. Respiratory manifestations such as hypoventilation and apnea may also occur because of medullary compression. Simple extension of the neck can cause acute compression of the spinal cord at the cervicomedullary junction which could lead to sudden death of the achondroplastic infant (Hunter et al. 1998; Hurko et al. 1988; Morgan and Young 1980; Reid et al. 1988). The foramen magnum eventually increases in size as the child grows, easing the compression at the cervicomedullary junction (Rimoin 1988).

Radiographic evaluation should be undertaken if there is any question of cervicomedullary compromise. Computed tomography (CT) can provide detailed imaging of the bony architecture of the skull base, foramen magnum, and upper cervical spinal column. Measurements of the foramen magnum can be taken from these scans to determine the degree of stenosis. The diameter of the foramen magnum in achondroplastic infants often measures at least 7–9 standard deviations below the mean diameter for non-achondroplastic infants (Hurko et al. 1988). Magnetic resonance imaging (MRI) provides information on the soft tissue structures including the brain stem and upper cervical spinal cord. Compression of these structures is evident with this study and changes within the upper cervical spinal cord can be identified, including atrophy and abnormal signal within the spinal cord itself (Hurko et al. 1988). Any patient who exhibits respiratory abnormalities should undergo thorough evaluation to determine if there is a neurologic component to their respiratory dysfunction. Additional

studies which may be helpful in evaluation of these patients include somatosensory evoked potentials to evaluate brain stem and spinal cord dysfunction and sleep apnea studies to rule out central versus obstructive apnea (Hurko et al. 1988; Reid et al. 1988).

Caution should be exercised in positioning the achondroplastic infant until better control of the head and neck muscles develops. Any position or activity that results in hyperextension of the neck could cause additional impingement of the spinal cord and distal medulla at the craniocervical juncture. Sitting or standing postures without adequate support of the neck and head should be avoided, as well as the use of bouncing type seats (Hurko et al. 1988). Surgical intervention may eventually be required, especially if the child develops progressive neurological decline including respiratory compromise, progressive paresis, or evidence of myelopathy. Surgical intervention would involve decompression of the craniocervical juncture, with partial craniotomy and laminectomy of the upper cervical spine (Hunter et al. 1998; Hurko et al. 1988; Morgan and Young 1980).

### 8.2.8.2 Thoracolumbar Kyphosis and Lumbosacral Hyperlordosis

Abnormal alignment of the spine, including kyphosis in the thoracolumbar junction and hyperlordosis at the lumbosacral junction, is also frequently seen in this patient population and contributes to the congenital spinal stenosis common in achondroplasia. Kyphosis is very common in the achondroplastic child, with more than 90 % of achondroplastic infants under 1 year of age exhibiting a kyphotic deformity (Pauli et al. 1997). Truncal hypotonicity, ligamentous laxity, the large size of the infant's head, flat chest, and protuberant abdomen are thought to be contributing factors to the development of this deformity. Abnormalities of the vertebral body, such as wedging at the apex of the kyphotic deformity, may be evident in some, but not all, of these patients (Ain et al. 2004). Many children will have spontaneous improvement in this deformity

once they begin to sit upright and walk; however, up to one-third of these patients will develop a progressive kyphosis into adulthood (Ain et al. 2002; Lonstein 1988; Pauli et al. 1997).

Hyperlordosis of the lumbosacral juncture, present in children with achondroplasia, becomes evident as the achondroplastic child begins to walk. The incidence of this deformity increases as these children reach adulthood. This deformity is not thought to be a primary disorder of the spine but rather occurs as a result of abnormal forward flexion of the pelvis and a horizontally oriented sacrum (Giglio et al. 1988; Kopits 1988).

Patients with thoracolumbar kyphosis and hyperlordosis of the lumbosacral spine have a very distinct posture. The kyphotic deformity is most notable while patients are in the seated position. The spine assumes a C shape and the patient appears to sit with a slumped posture (Reid et al. 1988). In the standing position, the kyphotic deformity becomes much less noticeable, but exaggeration of the lordotic curve becomes evident. Plain, lateral view x-rays illustrate these abnormalities well. Plain, lateral view x-rays will also demonstrate the presence of remodeling or wedging of the anterior aspect of the vertebral bodies at the apex of the kyphosis. Lateral upright and supine views are helpful in determining the flexibility of these spinal deformities. The presence of anterior vertebral body wedging and immobility of the spinal curvatures increase the possibility that the deformity will progressively worsen over time (Kopits 1988; Pauli 1997).

Parents of achondroplastic children should be instructed to avoid having the child sit in an unsupported position until truncal hypotonia improves. The back should be supported utilizing counter pressure with the hand when the child is held, and only hard-backed seating devices should be used. Periodic radiographic follow-up is important during this time to assess for continued progression of the kyphosis. If the kyphosis is determined to progress or if vertebral body wedging is evident, then bracing utilizing a firm brace such as a thoracolumbosacral orthosis

(TLSO) can be instituted (Kopits 1988; Pauli 1997). In many patients, improvement in the kyphotic deformity will improve with these measures; however, approximately 11 % of these patients will develop persistent and progressive kyphosis (Ain et al. 2004; Kopits 1988). In these cases, surgical intervention involving stabilization with fusion and instrumentation is often necessary. Surgery of this nature in the achondroplastic patient carries a significant risk of neurologic injury (Ain et al. 2004a, b).

### 8.2.8.3 Spinal Stenosis

The overall diameter of the spinal canal in achondroplastic patients is diminished as a result of abnormalities in the development of the bone of the spinal column. Achondroplastic spines have shortened pedicles which cause narrowing of the anterior-posterior diameter of the canal. Additional narrowing of the canal also occurs because the distance between the pedicles is decreased in the achondroplastic spine. Normally, this distance between the pedicles increases as the spine progresses caudally; however, in achondroplasia, this distance progressively narrows in the lower spinal segments. The result is a progressively stenotic canal in the distal spine (Ain et al. 2000; Park et al. 2003). Because achondroplastic patients already have a narrowed spinal canal, they are more susceptible to the stenotic effect due to changes that occur from the aging process such as ligamentous hypertrophy, disc degeneration, and osteoarthritic changes. Thoracolumbar kyphosis and lumbosacral hyperlordosis can also cause additional narrowing of the canal placing added stress on the dura and nerve roots exacerbating the stenosis (Alman 2002; Hunter et al. 1998; Hurko et al. 1988).

Symptoms related to spinal stenosis below the cervicomedullary juncture usually do not become problematic until the late teens. In most cases, symptomatic spinal stenosis does not occur until later in adulthood with the average age of symptom onset occurring late in the third decade of life (Ain et al. 2000; Hunter et al. 1998; Hurko et al. 1988). Low back pain is a very common

complaint in patients with achondroplasia. Neurogenic claudicatory type symptoms are typical in patients with symptomatic spinal stenosis. These symptoms include pain, paresthesias, and weakness involving the lower extremities with walking. The symptoms are often relieved by rest, bending forward, or squatting. A typical scenario is the patient who must lean on a shopping cart in order to complete the task of grocery shopping. The symptoms usually affect both lower extremities and can progress to the point where they are present even at rest. If the stenosis is severe and ongoing, neurologic changes including weakness, abnormal reflexes, spasticity, alterations in sensation and proprioception below the level of the stenosis, and bladder dysfunction may be present (Hurko et al. 1988).

Radiographic evaluation is warranted in any patient experiencing symptoms of spinal stenosis. Plain x-rays are often the first line of evaluation. These x-rays can determine if abnormalities of spinal alignment, degenerative changes such as the presence of osteophytes, degenerative disc disease, and abnormalities of the shape and configuration of the vertebral body complex are present. CT will provide a detailed evaluation of the bony structure of the spine. Myelogram is very useful in evaluating the spinal canal; however, performing the lumbar puncture necessary for the myelogram may prove difficult because of the anatomical changes of the spine in achondroplasia. Magnetic resonance imaging (MRI) provides very detailed information about the soft tissue structures including the spinal cord, ligaments, and intervertebral discs (Morgan and Young 1980).

Treatment of spinal stenosis in achondroplasia is dependent on the severity of the stenosis. Mild symptoms can be managed initially with medications and steroid injections. If the stenosis is severe, symptoms are progressive and limiting. If neurological symptoms, including bowel and bladder dysfunction, are present, surgical intervention would be necessary. Surgery involves decompression of the involved neural structures. Surgery of this nature in this patient population carries a high risk for complication including

neurologic injury. Special care must be taken during the operative procedure due to the limited spinal canal space. Patients are also at a higher risk for the development of spinal instability and stenosis requiring additional surgery (Ain et al. 2003; Nelson 1988; Uematsu et al. 1988).

#### 8.2.8.4 Conclusion

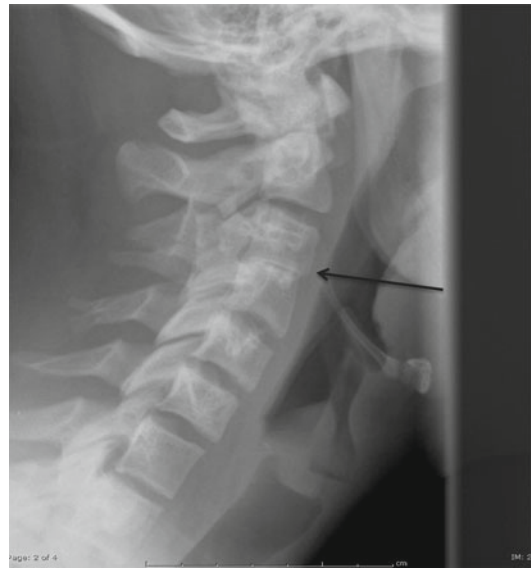Achondroplasia is a complex genetic disorder involving bone and cartilage formation. The manifestations of this disorder result in abnormalities of the craniocervical juncture and the spine. These abnormalities can become problematic at any time throughout the achondroplasts' lifespan; however, cervicomedullary insufficiency and abnormalities of spinal alignment, including thoracolumbar kyphosis and lumbosacral hyperlordosis, are most common in early childhood. Stenosis below the cervicomedullary juncture often does not become symptomatic until later into adulthood but can begin to manifest in the teen years. Early recognition and treatment of these disorders is important to promote normal growth and development of the achondroplastic child.

#### 8.2.9 Klippel-Feil Syndrome

Klippel-Feil syndrome (KFS) was first described in 1912 by Maurice Klippel and Andre Feil (Sullivan and O'Donoghue 2005). This syndrome is a rare, congenital disorder that affects the spine as well as many other body systems. This disorder is characterized by "the congenital fusion of any two of the seven cervical vertebrae" (Sullivan and O'Donoghue 2005). The resulting fusion is caused by a failure of the normal division of the cervical somites vertebrae during early fetal development. Patients with Klippel-Feil syndrome present with a triad of symptoms: short neck, low hairline at the back of the head, and restricted mobility of the upper spine.

##### 8.2.9.1 Diagnosis

Diagnosis is based on clinical presentation and radiographic exam. The clinical presentation var-



**Fig. 8.4** Fused segment of Klippel-Feil syndrome (arrow)

ies because of the number of associated syndromes and anomalies that can occur. Associated abnormalities may include scoliosis, spina bifida, anomalies of the kidneys and the ribs, cleft palate, respiratory problems, and heart malformations. The disorder also may be associated with abnormalities of the head and face, skeleton, sex organs, muscles, brain and spinal cord, arms, legs, and fingers (Curcione and Mackenzie 1995). Careful evaluation is essential as some associated anomalies may be fatal if not recognized and treated.

##### 8.2.9.2 Radiographic Evaluation

Anteroposterior (AP) and lateral views of the cervical spine are done to determine the presence of anomalies. Flexion-extension radiographs should be done if instability or anomalies are suspected or if two fused segments are separated by an open segment (Fig. 8.4). AP and lateral chest radiographs may be done to rule out rib fusions and cardiac involvement. CT scans of the entire spine are useful to determine associated abnormalities. MRI scans are indicated in patients with neurological deficits. These scans may reveal cord

compression, spinal stenosis, and central nervous system anomalies such as syringomyelia. Renal ultrasounds are used to determine renal involvement, and an intravenous pyelography is done to delineate any abnormality found on ultrasound.

### 8.2.9.3 Classification

KFS patients may be placed in three categories when they are determined to be high-risk patients.

- Group 1: C2–C3 fusion with occipitalization of the atlas. Flexion and extension occurs at C1–C2, thereby becoming unstable.
- Group 2: Long fusion below C2 with an abnormal occipital-cervical junction.
- Group 3: Single open space between two fused segments (Curcione and Mackenzie 1995).

### 8.2.9.4 Treatment

Treatment for KFS is focused on relieving associated symptoms. Medical treatment may involve a wide variety of specialists depending on which anomalies are present. A patient with KFS may be seen by a cardiologist, audiologist, and urologist among others. Physical therapy may be useful. Because the spinal anomalies are often progressive in nature, surgical intervention is often necessary to relieve cervical or craniocervical instability and constriction of the spinal cord and to correct scoliosis. Depending on the type of surgery needed, neurosurgery, orthopedic surgery, or both may be necessary to correct the anomalies.

### 8.2.9.5 Outcomes

Careful diagnosis, consistent follow-up, and multidisciplinary care are essential to positive outcomes. Minimally complex patients may lead normal lives with few restrictions. The more associated anomalies the poorer the outcome and the more restrictions on activities of daily living.

### 8.2.9.6 Patient and Parental Education

KFS may be found at any stage of life. This syndrome may be progressive and involve other spe-

cialties. Parents should be informed of the possible related anomalies and the symptoms associated with those anomalies.

### 8.2.9.7 Summary

KFS is a rare congenital anomaly with no known etiology. It is diagnosed based on clinical findings with radiographic confirmation. There may be any number of associated anomalies and syndromes occurring with KFS. Treatment should be initiated soon after diagnosis, especially with those patients who are considered high risk or who have progressive disease processes. Patient outcomes vary and are dependent on the extent and number of associated syndromes and anomalies. Careful evaluation, consistent follow-up, and coordination of providers are essential to positive patient outcomes.

## 8.2.10 Mucopolysaccharide Disorders

Mucopolysaccharide disorders (MPS) were first identified in 1917 (website MPS Society). These inherited disorders are errors of metabolism that are progressive in nature and may not become apparent until later in childhood. The disorder may also be referred to as lysosomal storage disorder (LSD). The lysosomal enzyme normally found in each cell is needed to degrade and recycle glycosaminoglycans. If these enzymes are not degraded and recycled, they accumulate within the cells causing the disease process with progressive damage to the body (Vogel et al. 2004). People affected with these disorders either do not produce enough of any one of the 12 identified enzymes that normally degrade and recycle the sugar chains into proteins, or the enzymes do not work correctly to produce the enzyme necessary for degradation.

### 8.2.10.1 Inheritance

The nature of the disease has an autosomal recessive inheritance and an abnormal gene is inherited from each parent. The odds of receiving the disorder if both parents are affected are 1 out of

**Table 8.1** Syndromes associated with MPS

Type/syndrome	Disease name	Deficiency
MPS I	Hurler/Hurler-Scheie syndrome	$\alpha$ -L-Iduronidase
MPS II	Hunter syndrome	Iduronate sulfatase
MPS III A	Sanfilippo syndrome	Heparan- <i>N</i> -sulfatase
MPS III B	Sanfilippo syndrome	$\alpha$ - <i>N</i> -Acetylglucosaminidase
MPS III C	Sanfilippo syndrome	Acetyl CoA: $\alpha$ -glycosaminide
MPS III D	Sanfilippo syndrome	<i>N</i> -Acetylglucosamine-6-sulfatase
MPS IV A	Morquio syndrome	Glactose-6-sulfatase
MPS IV B	Morquio syndrome	Galactosidase
MPS VI	Maroteaux-Lamy syndrome	<i>N</i> -Acetylgalactosamine-4-sulfatase
MPS VII	Sly syndrome	Glucuronidase
MPS IX		Hyaluronidase
ML II	I-Cell	<i>N</i> -acetylglucosamine-1-phosphotransferase
ML III	Pseudo-Hurler polydystrophy	<i>N</i> -acetylglucosamine-1-phosphotransferase

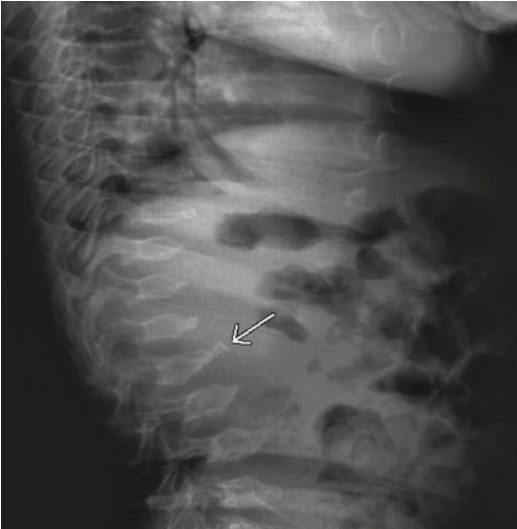
every 4 pregnancies. The unaffected child of parents with the gene has a 2 in 3 risk of being a carrier and a 1 in 3 chance of being a noncarrier of the disorder. The sole exception is MPS type II (Hunter syndrome) as this is X-linked and recessive inheritance. The Hunter gene is carried by a normal female and there is a 50/50 chance of transmission to each of the male offspring. Estimates have the occurrence in population at 1 birth in 31,000 (NCBI website, MPS Society website) (Table 8.1).

### 8.2.10.2 Characteristics

The children with MPS may appear normal at birth and develop normally for the first few years of life. The slow progression of this disorder is related to the gradual buildup of metabolites. Usually, the symptoms that prompt further clinical investigation are the repeated upper respiratory infections, colds, runny noses, and ear infections (MPS Society website). Clinical features may produce neurological complications through impaired signals as damage occurs to neurons affecting motor function and pain receptors. Children with MPS often have mental retardation, hyperactivity, depression, pain, and their growth and development may be stunted. All children with MPS have coarse facial features and skeletal involvement, such as skeletal dysplasia (Cleary and Wraith 1995; Menezes et al.

2001; Neufeld and Muenzer 2001; Scheie et al. 1962). Some may have an absence of the odontoid process or odontoideum. They may have a thoracic gibbus deformity, a form of structural kyphosis. The curvature is not smooth, as the posterior curve is angled sharply, and results in a humpback that is more prominent on forward bend.

Morquio's syndrome, MPS type IV, is another disorder that involves skeletal and spinal problems. Death commonly occurs by age 7 years from hypoxia secondary to a cervical myelopathy and subsequent effects upon the respiratory system (Cleary and Wraith 1995; Menezes 1999). Atlanto-axial instability, scoliosis, and kyphosis of the thoracolumbar spine are problems. There is also a characteristic flattening of the vertebrae with a flame-shaped pattern of ossification (Fig. 8.5). Other characteristics of MPS may include general ligamentous laxity, thought to contribute to atlanto-axial subluxation (Menezes et al. 2001); corneal clouding; speech or hearing impairment; chronic runny nose; hernias; heart disease; development of hydrocephalus; stiff joints; splenomegaly; liver enlargement; diarrhea; and shortened life expectancy. Symptoms appear as the storage of the enzymes increases. The projected life expectancy of children with MPS is 10–20 years (Cleary and Wraith 1995; Neufeld and Muenzer 2001; Scheie et al. 1962; MPS Society website).



**Fig. 8.5** Flame-shaped vertebrae (*arrow*) characteristic of MPS in Morquio syndrome patient

### 8.2.10.3 Diagnosis

The diagnosis of MPS may be made through clinical examination, urine, and tissue testing. Genetic counseling and reviewing family history for at least three generations may assist couples determine if they are carrying the mutated gene responsible for the development of the disorders (Clarke 2005). Prenatal diagnosis utilizing amniocentesis and chorionic villus sampling at 14–17 weeks gestation should be done to determine if the fetus has the defective gene or is affected by the disorder. Clinical signs and symptoms such as chronic otitis media, chronic rhinitis, macrocephaly, chronic respiratory infections, developmental delay, coarse facial features, inguinal or umbilical hernias, or corneal clouding alone do not demonstrate a diagnosis. Further definitive testing such as enzyme specific assays for alpha-L-iduronidase, peripheral blood leukocytes, and plasma or cultured fibroblasts should be ordered (Hall et al. 1978; Neufeld and Muenzer 1995; Neufeld and Muenzer 2001). For an infant suspected of having an inborn error of metabolism, laboratory studies should include complete blood counts, urinalysis, capillary blood gases, electrolytes, glucose, ammonia, urine-reducing substances, urine ketones, plasma and urine

amino acids (quantitative), urine organic acids, and plasma lactate (Burton 1998).

### 8.2.10.4 Treatment

Currently there is not a cure for MPS; therefore, treatment is focused on relieving and treating symptoms as they arise. The FDA approved several medications for use in MPS. Some of the enzyme replacement therapies are specific for a particular disease (Aldurazyme (Iaronidase) in 2003 and Naglazyme in 2005). These enzyme replacement therapies for MPS types I and IV are proving to be useful in the reduction of pain and non-neurological symptoms of MPS. They replace the deficient enzymes and are given IV once a week for life. Bone marrow transplant, to replace lost enzymes, has been utilized; however, some of the children have heart disease due to the disease process and cannot withstand the chemotherapy required for the transplantation of bone marrow. Bone marrow transplantation, along with umbilical cord blood transplants, is showing limited success with improved survival.

## 8.3 Traumatic Spinal Cord





### 8.3.1 Pathophysiology

#### 8.3.1.1 The Pediatric Spinal Column

The immature pediatric spinal column has unique features that increase the spinal cord's susceptibility to injury without obvious evidence of abnormality in alignment or bony integrity. Among those are a higher fulcrum of cervical movement, a larger head to body ratio, wedge-shaped vertebral bodies, underdeveloped uncinate processes, increased elastic interspinous ligaments, and underdeveloped neck and paraspinous muscles. Those anatomic features increase the mobility of the pediatric spinal column, causing it to be hypermobile and more susceptible to flexion and extension type injuries.

Pediatric spinal trauma patients can be divided into two unique groups. The first group is from birth to 8 years of age. The spinal anatomy of



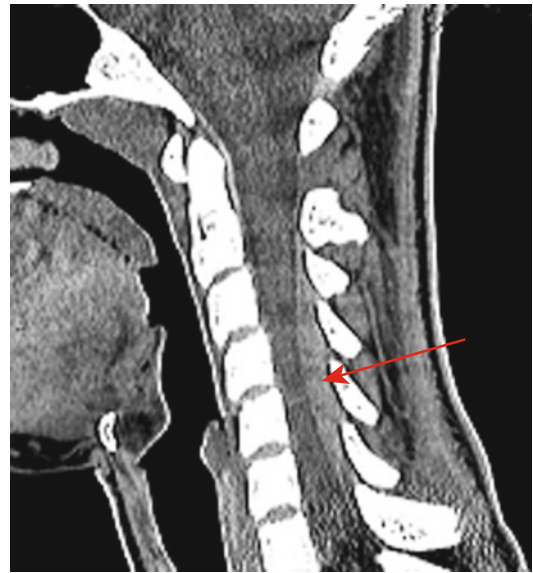
Type I Immature, oval	
Type II Rounded upper corner	
Type III Anterior wedging	
Type IV Mature, rectangular	

**Fig. 8.6** Vertebral shapes (Eubanks et al. 2006)

children becomes more similar to adults by age 8 but may not reach full maturity until age 16–18 years (Bosch et al. 2002; Ergun and Oder 2003). As mentioned, there are specific anatomic differences in the younger age group. First, the fulcrum of cervical movement is higher (C2–C3), as opposed to the adult level (C5–C6) (Grabb 2008). Accordingly, there is a high percentage of cervical spine injuries between occiput and C3 in children under 8 years of age. In a study of 227 children with spinal cord injury (SCI), 87 % of those less than 8 years old had an injury C3 or higher (Khanna and El-Khoury 2006).

The disproportionate size of the head also contributes to the risk of spinal cord injury in children under age 9 (Grabb 2008). The development of head to body ratio is illustrated in Fig. 1.1 in the Assessment chapter. Additionally, the large head is not well supported because the neck muscles are underdeveloped in the younger child. Those factors put the young child at greater risk for flexion-extension injuries to the C-spine.

The spine is also hypermobile related to both the laxity of the intraspinal ligaments and the underdevelopment of the paraspinal musculature



**Fig. 8.7** MRI showing cord compression with epidural bleeding

(Carreon et al. 2004; Lang and Bernardo 1993; Pang et al. 1982). In comparison, the spinal cord is much less elastic. This accounts for higher incidence of subluxation without fractures and spinal cord injury without radiographic abnormality (SCIWORA) in children.

Other anatomic features that increase the mobility of the pediatric spine involve the shape of certain parts of the spinal column. The vertebral bodies are wedge-shaped in children, allowing for slippage anteriorly during flexion. With age, the vertebral bodies mature. They evolve through four basic types: type I – oval immature, type II – rounded upper corner, type III – anterior wedging, and type IV – rectangular, more mature (Eubanks et al. 2006) (Fig. 8.6). Also, the facet joints are much more horizontally oriented in the pediatric spine in comparison to the adult spine. This again allows for translation of the vertebral bodies as the spine is flexed forward or extended back. Further, the uncinat processes, which serve to limit spinal mobility at C3–C7 and T1, particularly as to rotational and lateral movement, are underdeveloped in children under age 10 (Brockmeyer 2006). By contrast, in the adult

spine they are hooklike, projecting upward and articulating with the vertebral level above.

### 8.3.2 Traumatic Spinal Cord Injuries

#### 8.3.2.1 Etiology

Pediatric spine trauma is not common but can be catastrophic if misdiagnosed. Therefore, in the case of high-energy or polytrauma, a child should be assumed to have a spine injury until proven otherwise (Skaggs and Flynn 2006). Trauma from birth accounts for a high prevalence of spinal cord injury in children less than 2 years of age. For children who are 3 up to 8 years of age, common mechanisms include motor vehicle collisions, fall from heights, and abuse or non-accidental trauma. For the age group of 8 and older, additional mechanisms include sports-related injuries, diving, and violence, such as gunshot wounds (Cramer and Scherl 2004).

Traumatic injury to the spinal cord can result in contusion (bruising) or transection or hemisection (complete/partial cutting or tearing) of the cord. Epidural bleeding from trauma can result in cord compression (Fig. 8.7). Any injury to the cord can have a temporary or permanent effect on the functions of the body below the level of the injury. The cord is less elastic than the pediatric spine. Studies of autopsies have shown that the infantile spinal column could be stretched up to 2 in. without disruption, yet the cord can sustain damage or even rupture at a quarter of an inch (Bosch et al. 2002; Dickman et al. 1991). This elasticity of the spinal column compared to the cord helps explain the higher frequency of cord injury in the absence of bony injury (Khanna and El-Khoury 2006).

Injuries to the spinal column include vertebral fractures and/or dislocations, with or without related cord damage. Similar to other bony injuries in children, cervical fractures tend to be avulsions or growth plate separations. The epiphyses (growth plates) tend to be the weak links in the cervical spine (Khanna and El-Khoury 2008). The soft tissues of the spinal column, such as the blood vessels, intraspinal ligaments,

and intervertebral discs, can also sustain traumatic injury.

#### 8.3.2.2 Epidemiology

Less than 5 % of all spinal injuries involve the pediatric patient (Cramer and Scherl 2004). Since the patient may be treated by neurosurgeons and/or orthopedic surgeons, the statistics vary on the number and types of injuries. The neurosurgeon often focuses on the neurologic components of the spinal cord, while the orthopedic surgeon focuses more on the bony injury. Although it is important that spinal cord injury (SCI) statistics be reviewed, the caregiver must be cognizant of these differences and what they may mean to the patient population being studied. Neurosurgery literature reports that 61 % of pediatric spinal injuries are in the cervical region, 11 % are in the thoracic region (T1–11), 14 % are in the thoracolumbar region (T12–L1), and 14 % occur in the lumbar region (L2–S1) (Grabbe 2008). Research reports that approximately 30 % of traumatic SCI in pediatrics present as a trauma to the cord with no bony injury, also known as a SCIWORA (spinal cord injury without radiographic abnormality) (Cramer and Scherl 2004).

Traumatic SCIs are the fourth leading cause of death in the United States in all age groups (Vogel et al. 2004). These injuries are predominantly found in males in their late teens and early 20s. In children under the age of 5, the incidence of females equals males. Before puberty, the unique physical and developmental characteristics of children predispose them to SCI from lap-belt injuries, injuries related to birth, child abuse, delayed onset of neurologic deficits, and high cervical injuries (Vogel et al. 2004). There is a high mortality associated with SCI, and a significant percentage of individuals with SCI will expire prior to reaching the hospital. The mortality rate for pediatric SCI is estimated to be 2.5 times greater than that for adults (Alden and Ellenbogen 2008). Survival is based on the severity and level of the neurologic injury. Quality of life and ability to function in society may be severely affected, especially in those patients who suffer a neurologic and/or motor deficit post SCI.

**Table 8.2** Age-related injuries and symptoms

Age	Level of injury	Symptoms
All-age children	Occiput-C2	Respiratory arrest, quadriplegia
Infants and Toddlers	C1–C2 or C2–C3	Respiratory arrest, quadriplegia
Children 3–8 years	C3–C5	Respiratory arrest, quadriplegia
Children 9–15 years	C4–C7	High injuries: respiratory arrest, quadriplegia
		Low injuries: some spontaneous respirations and some upper extremity movement may persist

Adapted from Dziurzynski (2005)

### 8.3.3 Injury Classifications

#### 8.3.3.1 Spinal Cord Injury Without Radiographic Abnormality

##### Symptomology

Spinal cord injury without radiographic abnormality (SCIWORA) is a syndrome of traumatic SCI without evidence of bony injury like fracture or dislocation on plain radiographs, computed tomography (CT), or myelogram (Dickman 1991). This phenomenon was first described before the advent of magnetic resonance imaging (MRI). Now, MRI is finding abnormalities in some SCIWORA patients, such as ligamentous edema, central disc herniation, epidural hemorrhage, or injuries to the spinal cord itself. But there remain a significant number of patients with normal MRIs. Up to two-thirds of patients diagnosed with SCIWORA are under age 8 (Alden and Ellenbogen 2008). It is rare to see SCI without bony abnormality in patients older than 16 years because of the anatomic and biomechanical differences of the spinal column (Pang 1982).

SCIWORA is most commonly seen in the cervical spine region, but it has also been documented in other areas of the spine (Cirak et al. 2004). Traumatic events such as the application of traction to the neonatal spinal column during delivery, child abuse, falls, sports injuries, or motor vehicle accidents may result in this SCI (Brown et al. 2001; Pang 1982). This injury may occur when the spinal column deforms elastically, stretching it beyond its limits. The spinal column then returns to its normal anatomic alignment without bony injury but with evidence of SCI. As previously discussed, the elasticity of the ligaments of the pediatric spine contributes to

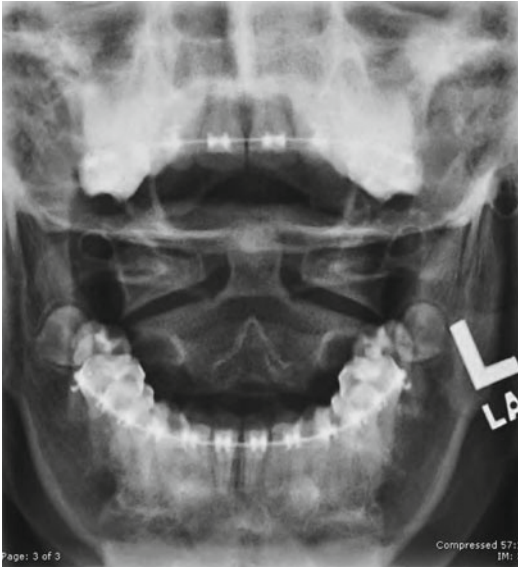this laxity of the spinal column. Another injury that may occur without bony injury due to the elasticity of the spinal column is a concussive injury resulting from a transmission of kinetic energy or concussive force applied to the spine (Bosch 2002; Dickman 1991).

##### Prognosis

The prognosis for recovery following a SCIWORA injury is dependent on the severity of injury at the time of presentation. Incomplete injuries have the best prognosis for a good recovery, whereas complete injuries have the worst prognosis (Bosch 2002; Ergun 2003). In one study, external immobilization for 12 weeks resulted in complete recovery for 39 % of the study population (90 % pediatric), but no recovery in 44 % (Alden and Ellenbogen 2008).

#### 8.3.3.2 C-Spine Injuries

In children, C-spine injuries occurring in the upper C-spine account for more than 60 % of all spinal injuries (Greenberg 2001; Van de Pol et al. 2005). C-spine injuries may be caused by motorcycle crashes, pedestrian accidents, sports activities, bicycle accidents, falls, and motor vehicle accidents. It is estimated that 25–50 % of all SCIs have a related severe head injury (Van de Pol et al. 2005). Whenever a head injury is suspected, both prehospital and hospital personnel should have a high diagnostic suspicion for C-spine injury, as the risk of C-spine injuries is 8.5 times greater with a head injury than without (Dibsie 1998; Morris and McCoy 2004). C-spine injuries, which alter or sever the communication between the brain and sympathetic nervous system in the cord, may lead to hypotension, bradycardia,



**Fig. 8.8** Open-mouth view of odontoid

and/or death (Mattera 1998). The most common level of injury will change with the age of the child (Table 8.2). This pattern generally corresponds with the location of the fulcrum of cervical movement at various ages. The most important intervention provided by prehospital and hospital personnel is stabilization of the spine or C-spine precautions. Stabilization of the spine at the scene of the accident has been shown to reduce the extent of complete SCIs by 10 % (Dibsie 1998; Mattera 1998).

### Diagnosis

In the initial evaluation of a pediatric trauma victim, it is important to first assess the ABC's (Airway, Breathing, and Circulation). Then obtain a thorough past medical history, including any history of trauma, and do a thorough physical exam. Eight key risk factors associated with your physical exam include (1) an unconscious patient; (2) complaints of neck pain; (3) focal neck tenderness; (4) abnormal neurologic findings; (5) reports transients neurologic symptoms, such as weakness, paresthesias, or a burning sensation; (6) physical signs of neck trauma, such as bruising, abrasions, deformity, swelling, or tenderness; (7) significant trauma to head or face; and (8) an inconsolable child (Eubanks et al. 2006).

Children with any of these listed risk factors should be considered to have a potential cervical spine injury and be treated with immobilization. A meticulous neurologic exam is important to help determine the possible level of injury and other differential diagnosis (Skaggs and Flynn 2006). In addition, a child who presents with cardiorespiratory instability or arrest may have a high cervical injury and should be evaluated accordingly (Eubanks et al. 2006).

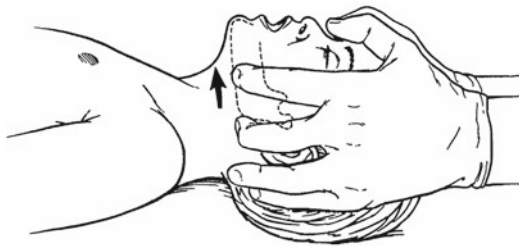
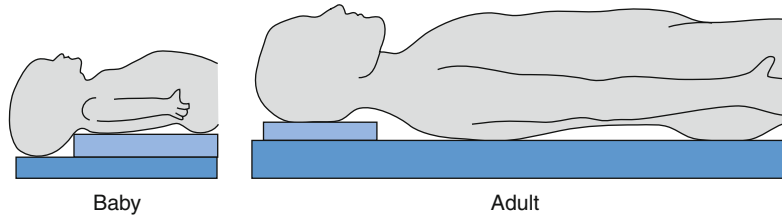
### Radiographic Evaluation

All children with suspected cervical spine injury warrant radiographic evaluation. This always begins with plain radiographs (with the patient in a cervical collar) consisting of the anteroposterior view (AP) and cross table lateral of the cervical spine. This can be combined with an odontoid view (open mouth view) if the child is old enough to cooperate (Fig. 8.8). CAT scan (CT) should be utilized in children who are too young to obtain an odontoid view or in any child who is also having a head CT (Eubanks et al. 2006). If the plain radiographs reveal abnormalities, further investigation utilizing CT and MRI is warranted (Pediatric Orthopaedic Society of North America 2006). As mentioned earlier, plain radiographs may appear normal in young children with a cervical spine injury, i.e., SCIWORA. This is why the physical exam becomes so important in children, as children with a spinal cord injury will have pain on physical exam. Any child with a positive physical exam and normal plain films warrants cervical spine immobilization (Pediatric Orthopaedic Society of North America 2006).

### Cervical Spine Precautions

Cervical spine precautions (stabilization) help prevent further spinal cord and vertebral column damage as well as ensure an adequate airway, ventilation, and perfusion. Immobilization of the spine in the neutral position is the goal of this treatment. To achieve neutral positioning in children, you must take note and accommodate for physical differences due to age and physical maturity. For children under the age of 8 years, one must consider that the head is larger than the torso. It has been shown that the large head and

**Fig. 8.9** Spinal alignment. Reprinted with permission from Hadley (2002)



**Fig. 8.10** Jaw thrust method, airway management (Reprinted with permission from Dziurzynski et al. (2005))

relatively small chest in children force the head and neck into a position of kyphosis. This positioning in flexion may place the immobilized child at risk for further injury. Thus, it is important that backboards with an occipital recess or a double mattress pad under the body be used to raise the torso and assist in lifting the neck out of forward flexion (Eubanks et al. 2006) (*J Bone Joint Surg* 1989;71A:15–22) (Fig. 8.9). Cervical spine immobilization should continue throughout the evaluation process. Correct immobilization includes a combination of a hard cervical collar, appropriate backboard, head and neck blocks, and tape to fix the head (Eubanks et al. 2006).

It is important to maintain a safe airway through the spine immobilization process. The “jaw thrust method” is used to open the airway while maintaining cervical spine stabilization. This technique will place the patient’s head in the recommended position for simultaneous airway opening American Heart Association (2002) (Fig. 8.10). Another consideration is

intubation versus bag-mask ventilation. Although intubation is the preferred method of airway management, not all providers are skilled in this area (American Heart Association 2000). Children can be ventilated easily and for extended periods of time with a bag-mask, especially if a provider skilled in intubation is not readily available (Proctor 2002). A randomized study by Turkstra et al. in 2005 demonstrated, under fluoroscopy, that normal patients who were positioned utilizing cervical spine stabilization demonstrated less cervical spine motion during bag-mask ventilation than during intubation (Turkstra et al. 2005). These findings help support Pediatric Advanced Life Support teaching that only providers experienced in intubation of pediatric trauma victims should perform this procedure in the field (American Heart Association 2000).

Clearing the cervical spine is an important step to avoid missed or delayed diagnosis. First, a physician must rule out any bony or ligamentous injury that may cause instability. Instability that is missed could be disastrous and cause additional cervical cord or nerve root injury. Utilization of a multidisciplinary team can effectively support rapid clearance of the cervical spine. Literature shows on average clearance of a cervical spine takes around 7.5 h in the nonintubated patients and 19.4 h in the intubated child (Eubanks et al. 2006).

There is no national protocol for clearing a pediatric cervical spine. However, there are adult protocols that provide guidelines. It is important with children to focus more closely on clinical assessment than on radiographic clearance, as it is not desirable to expose infants and children to

unnecessary radiation. On the other hand, failure to use imaging can lead to missed diagnoses.

In 2001, a study by Vicellio et al. suggested that cervical spine imaging in children could be reduced by approximately 20 %, if the five low-risk criteria in the National Emergency X-Radiography Utilization Study (NEXUS) decision instrument were utilized to clear the C-spine (Vicellio et al. 2001). While the study urged caution in applying the decision instrument to individual patients, a number of centers adopted it. However, later research found that of 539 children cleared by the NEXUS criteria without radiographs, 90 cervical spine injuries were missed, and 58 of those were in children younger than 8 years of age (American College of Emergency Physicians 2008). That data was compiled in a study that identified eight risk factors associated with C-spine injury: altered mental status, focal neurologic findings, neck pain, torticollis, substantial torso injury, predisposing conditions, diving, and high-risk motor vehicle crash (Leonard et al. 2010). Further research is necessary to refine and validate that 8-variable model. Consequently, it is not recommended that either the NEXUS criteria or the 8-variable model be used to clear the C-spine unless the patient is awake, alert, and able to effectively communicate pain.

Clearing the C-spine in the conscious pediatric patient starts with systematically reviewing any plain radiographs that may have been taken to identify any abnormalities. Again, the child's level of consciousness and developmental age must allow for the appropriate communication of pain. The cervical spine exam is again repeated in the hard collar looking for pain, visible deformity, or notable muscle spasms. If this exam is normal, the physician will remove the collar and repeat the exam. The physician will have the patient perform gentle active range of motion focusing on flexion, extension, and lateral rotation. If this exam is normal, the cervical spine precautions may be cleared and the collar removed. For the child who complains of cervical

tenderness on exam, the hard collar is continued and a repeat exam along with further imaging (MRI) may be used to clear the cervical spine (Eubanks et al. 2006).

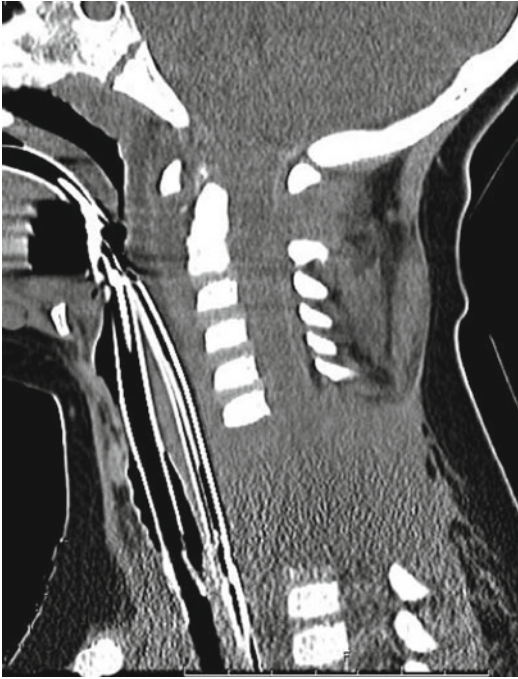### **Common Pediatric Cervical Spine Injuries**

As stated prior less than 5 % of all spine injuries involve children. The most common etiology in all age groups is motor vehicle trauma, while other typical causes in children include falls from heights, sports-related injuries, diving, and non-accidental trauma (Khanna and El-Khoury 2006). The more frequent types of cervical spine injuries in children include atlanto-occipital dislocation (AOD), atlanto-axial (AA) rotatory fixation, atlas fracture, odontoid (dens) injury, and compression fractures. Mortality with cervical spine injury in pediatrics is higher with children than in adults. In a study of 216 children with spinal injuries, a mortality rate of 28 % was reported when compared with a reported 11 % in adults. In contrast, when looking at head injuries, mortality is less in children than with adults (Khanna and El-Khoury 2006).

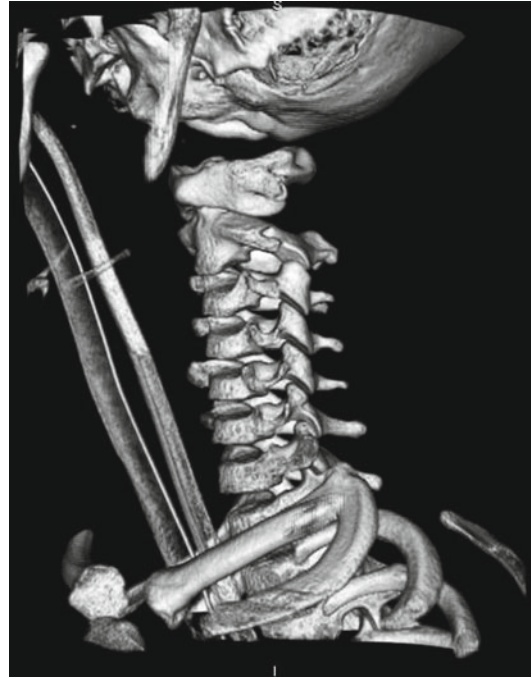#### **8.3.3.3 Atlanto-occipital Dislocation (AOD)**

##### **Pathophysiology**

The axial (load bearing) strength of the cranio-vertebral junction is provided by an intricate system of ligaments at the level of the superior facets of the atlas. This system is compiled of the anterior and posterior atlanto-occipital membranes and two lateral atlanto-occipital ligaments. The atlanto-occipital ligamentous structure supplies the majority of the strength at the craniocervical junction. The atlas ring is seated within a ligamentous complex joining the occiput to the axis. This complex consists of the tectorial membrane, the anterior longitudinal ligament, and the uncial ligament. Stability is also supported by the apical dental ligament and the paired alar ligament (Kenter et al. 2001). These structures are underdeveloped in children thus less resistant to translational forces. In AOD, the forces through the spine cause a disruption through the stabilizing



**Fig. 8.11** Distraction dislocation of C-spine



**Fig. 8.12** 3-D CT scan showing AOD

ligaments and cause the occiput of the skull to dislocate from the atlanto-axial joint of the cervical spine. This injury is commonly seen in high-energy traumas such as motor vehicle accidents or falls (Beaty and Kasser 2010).

This dislocation of the skull from the spine was once thought to be rare and often these children were found dead on arrival. Increased awareness of this injury in pediatric patients along with prompt cervical spine immobilization and rapid transport has increased the survival rate of this injury.

### Classifications

Three types of AOD have been described and account for 85 % of the cases. The remaining 15 % consists of other types of nonclassified, rotational dislocations (Van de Pol et al. 2005).

- Type I: anterior dislocation with the occiput displaced ventrally to the atlas (40 % of cases)
- Type II: longitudinal dislocation (40 % of cases); most unstable (Fig. 8.11)

- Type III: posterior dislocation of the occiput (5 % of cases)

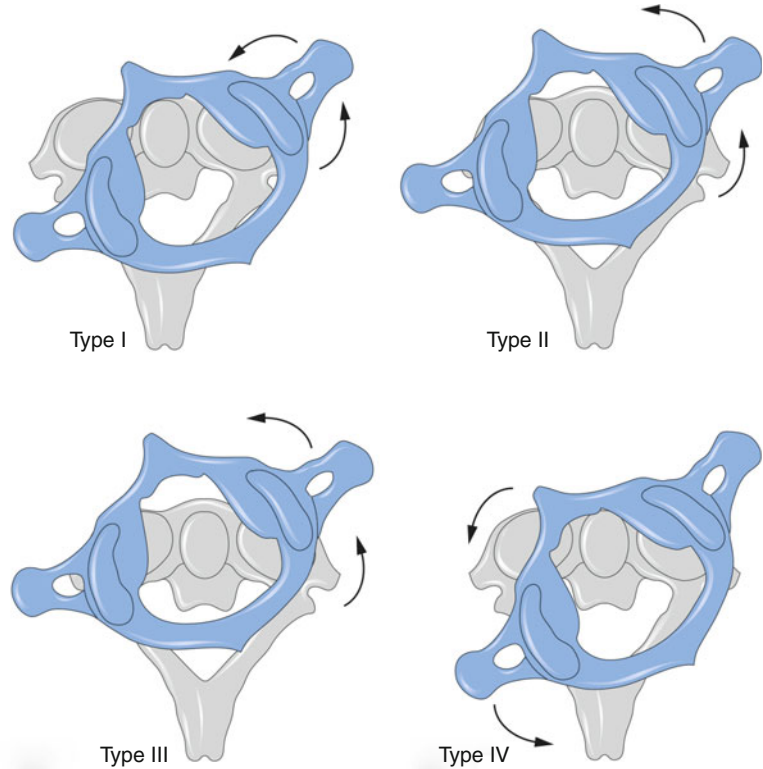
### Diagnosis

Initial symptoms of an AOD may be masked by other distracting injuries. Diagnosis is difficult because this is a ligamentous injury. Common red flags on the physical exam may include the following: cranial nerve dysfunction, vomiting, headache, torticollis, and motor or sensory deficits. Similar to other cervical spine injuries, there is a high association of this injury with head trauma and facial injuries. If the dislocation is severe, the child may have brain stem symptoms such as ataxia and vertigo and have difficulty being ventilated (Beaty and Kasser 2010).

### Radiographic Evaluation

There has been much discussion about which radiographic test and which cervical angle measurement techniques should be used to determine

**Fig. 8.13** Four types of atlanto-axial rotary subluxation. *Type I*: unilateral anterior rotation of the atlas pivoting around the dens with a competent transverse ligament. This is the most common type of fracture. *Type II*: unilateral anterior rotation of the atlas pivoting around the contralateral C1–C2 facet. The atlantodens interval is increased to no more than 5 mm. *Type III*: anterior subluxation of both C1 facets with an incompetent transverse ligament. *Type IV*: posterior displacement of C1 relative to C2 with an absent or hypoplastic odontoid process (Reprinted with permission from Cleary and Wraith (1995))



AOD. In 1999, Berne et al. demonstrated that complete cervical helical CT scans, in addition to the routine radiographs, should be used when a C-spine injury is suspected in a patient with multiple severe injuries (Berne et al. 1999). This study also concluded that complete cervical helical (spiral) CT scans are superior to plain radiographs. In a blinded study done by Dziurzynski et al. in 2005, five methods commonly used to diagnose AOD were compared using plain x-rays and CT scans of the C-spine (Dziurzynski et al. 2005). The objective of the study was to determine the best method to diagnosis AOD. The conclusion of the study was that the sensitivity, specificity, and positive and negative predictive values of all the methods improved, when applied to CT scan, because of better visualization of anatomic landmarks. Thus, CT scans of C-spine may be warranted in all trauma patients thought to have cervical spine injuries.

Lateral cervical spine films can reveal soft tissue swelling and widening of the discs, facet

joints, or posterior elements (Beaty and Kasser 2010). CT scans offer better visualization of the anatomic landmarks thus making identification of AOD easier (Fig. 8.12). MRI is sensitive in detecting ligamentous disruption and instability not readily seen on radiographs (Proctor 2002). A magnetic resonance angiogram (MRA) can also be used to evaluate the vertebral and carotid circulation, as disruption can occur with C-spine injuries (Beaty and Kasser 2010).

### Treatment

Acute treatment should be directed to airway management and support of respiratory and cardiac function. Stabilization of the neck is most often done via surgery with insertion of posterior implants. Acute stabilization of the cervical spine is a top priority (Beaty and Kasser 2010). The child should remain in a rigid collar until seen by a neurosurgeon and an orthopedic surgeon for further treatment recommendations.



### 8.3.3.4 Atlanto-axial Rotary Subluxation (AA Rotary Fixation)

The atlanto-axial joint is the most active joint in the body. It is between C1 (the atlas) and C2 (the axis). Normal range of motion for this joint is about 45° to each side. Trauma to this area is also known as atlanto-axial rotatory dislocation and atlanto-axial rotatory fixation. In most cases of AA rotatory subluxation, the amount of rotation between C1 and C2 is within the normal range, yet the patient is unable to return the head to a neutral (forward facing) position. Thus, the term “fixation” can be used

in place of “subluxation” as the patient’s joint is in a fixed position within the normal range of motion (Khanna and El-Khoury 2006).

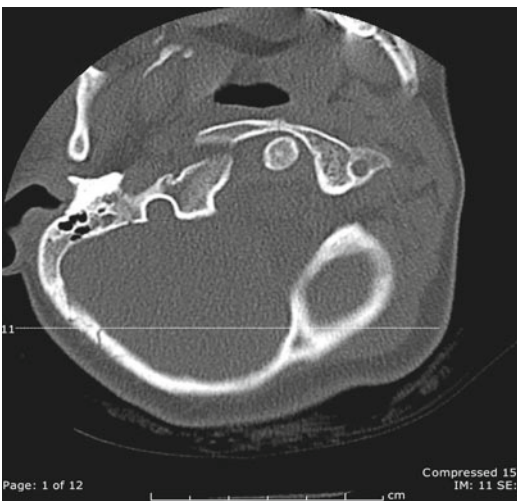
#### Pathophysiology

AA rotatory subluxation is typically caused by inflammation. This can be inflammation from a minor or even unnoticed trauma, infection, or rheumatologic condition. Examples of infectious etiology include an upper respiratory infection or retropharyngeal abscess. The facet joints at C1 and C2 are nearly horizontal to each other. There are two ligaments that stabilize this joint, the transverse ligament and alar ligament. The transverse ligament prevents anterior translation and the alar ligament prevents excessive rotatory motion of the joint. A disruption in either of these ligaments results in AA rotatory subluxation.

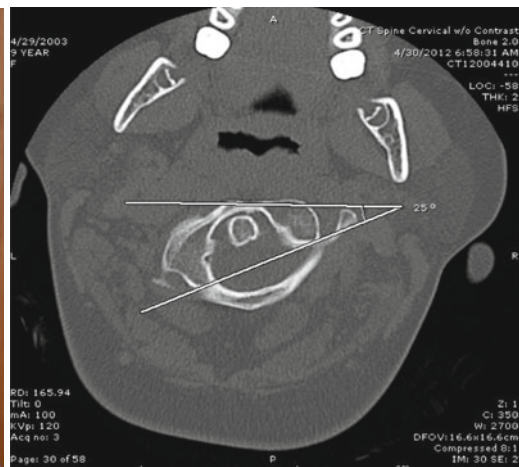

#### Classification

Fielding and Hawkins (1977) identified four types of AA rotatory fixation based on how they appear on radiographs (Fig. 8.13).

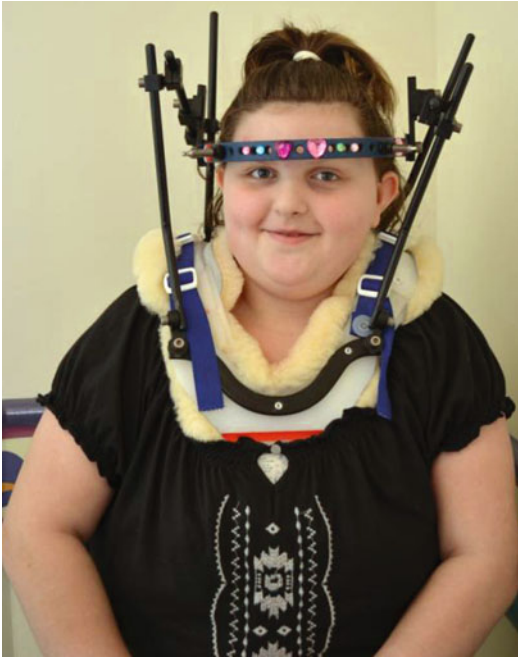- Type I: unilateral anterior rotation of the atlas pivoting around the dens with a competent transverse ligament. This is the most common type of fracture (Fig. 8.14).
- Type II: unilateral anterior rotation of the atlas pivoting around the contralateral C1–C2 facet (Fig. 8.15). The atlanto dens interval is increased to no more than 9 mm.



**Fig. 8.14** Type I: unilateral anterior rotation of the atlas pivoting around the dens with a competent transverse ligament



**Fig. 8.15** A 9-year-old female with C1–C2 rotary fixation after streptococcal infection



**Fig. 8.16** A 9-year-old female in halo vest after inpatient hospitalization and traction as part of treatment for C1–C2 rotary fixation

- Type III: anterior subluxation of both C1 facets with an incompetent transverse ligament.
- Type IV: posterior displacement of C1 relative to C2 with an absent or hypoplastic odontoid process.

### Diagnosis

When examining a child with AA rotary fixation, you will first notice the limited range of motion of the cervical spine. The child will have his/her head rotated to one side in lateral flexion to the other. This is often referred to as the “cocked robin” position. The child will resist any attempt to correct his/her head position (Beaty and Kasser 2010). Often you can see the longer sternocleidomastoid (SCM) muscle spasm from a traumatic torticollis (Khanna and El-Khoury 2006).

### Radiographic Evaluation

Adequate plain radiographs are hard to obtain related to the child’s head being fixed in a flexed position. Physicians will often recommend a CT scan to look for malrotation. A dynamic CT scan

may also be done in place of a regular CT. During a dynamic CT, the patient is actively looking from the right to the left. These images will help diagnose the findings of rotary fixation (Beaty and Kasser 2010).

### Treatment

Treatment depends on the type of AA rotary fixation and the duration of the symptoms. If the patient has been symptomatic for 1 week or less, a soft collar paired with nonsteroidal anti-inflammatory drugs (NSAIDs) and physical therapy should be an adequate treatment plan. When the symptoms have been present for more than 1 week but less than 1 month, the child may be admitted for head halter traction (chin traction) and treated with muscle relaxants and pain medications to help guide C1 back onto C2. If the symptoms have been present for greater than 1 month, more aggressive treatment may be required such as application of halo traction or a pinless halo (Beaty and Kasser 2010) (Fig. 8.16).

### 8.3.3.5 Jefferson or Atlas Fractures

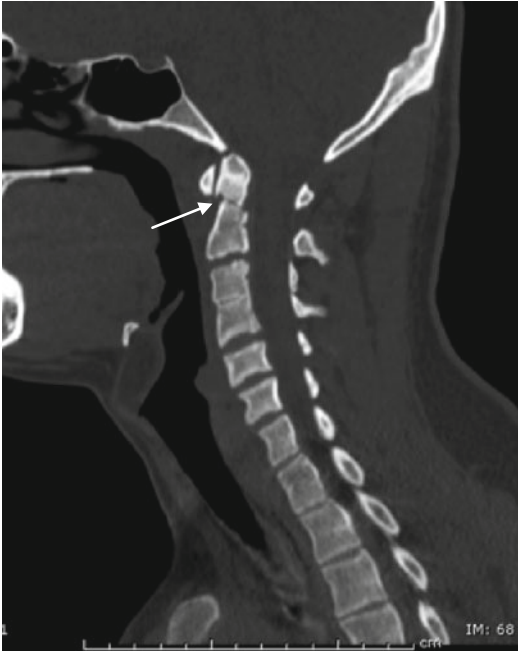The atlas fracture is less common than AA rotary fixation and AOD. It only comprises 5 % of all cervical spine injuries. The C1 burst fracture (Jefferson fracture) is the more common. It is due to an axial load on the spine such as when diving or from hitting the head on the roof of the car in motor vehicle accident (Beaty and Kasser 2010).

### Diagnosis

Presenting symptoms consist of complaints of upper neck pain, although patients are usually neurologically intact. In cases of vertebral artery injury, neurologic injury can occur. This neurologic injury may manifest as Wallenberg’s syndrome with ipsilateral loss of cranial nerves, Horner’s syndrome (meiosis, anhidrosis, and ptosis), ataxia, and loss of contralateral pain and temperature sensation.

### Radiographic Evaluation

An odontoid view shows overlapping of C1 facets on C2 facets. Lateral view shows prevertebral soft tissue widening. Flexion and extension views are usually required to determine transverse



**Fig. 8.17** Odontoid fracture



**Fig. 8.19** A 2½-year-old female in pinless halo after sustaining a type 2 displaced odontoid fracture in a motor vehicle accident



**Fig. 8.18** Pinless halo (OrtoPed 2005)

ligament disruption. A CT scan is often helpful in delineating the exact displacement of fragments and to help diagnose transverse ligament disruption if the odontoid views are not conclusive.

### Treatment

Stable fractures with an intact transverse ligament and nondisplaced or minimally displaced fractures are usually treated in a rigid neck brace for a period of 3 months. Unstable fractures with a ruptured transverse ligament may require placement of a halo. Halo braces may be applied after reduction, but care should be taken to recognize late atlanto-axial instability. Unstable fractures with a greater than 5-mm subluxation of C1 to C2 may require a C1 to C3 fusion (Duke 2005).

### Odontoid (Dens) Fracture

Odontoid fractures (also known as dens fractures) are the most common fracture of the cervical spine in children. The average age of occurrence is usually around 4 years of age. In one study, out of 15 fractures of the cervical spine seen in children 0–7 years of age, 11 of these (73 %) involved the odontoid. There is a positive outcome with no

**Fig. 8.20** A 2½-year-old female with transition from pinless halo hard cervical collar



neurologic or growth disturbances if the fracture is located below the blood supply to the odontoid.

### Pathophysiology

The odontoid fuses with the axis around 6 years of age, but the synchondrosis (growth plate) may be visible on radiographs up to 11 years of age. In young children the fracture tends to run through the weak link of the odontoid which is the synchondrosis. This is below the blood supply and usually given an anterior displacement of the odontoid. In older children the fracture is typically above the synchondrosis and can interrupt the blood supply to the odontoid. This can result in the fracture not healing well causing a nonunion or pseudoarthrosis. This fracture is often from high-velocity injuries such as motor vehicle accidents, head trauma, or fall from heights. During motor vehicle crashes, the sudden deceleration of the body as it is strapped into the car seat while the head continues to move forward causes this fracture (Beaty and Kasser 2010).

### Diagnosis, Radiographic Evaluation, and Treatment

A child with an odontoid fracture will have neck pain, particularly with extension. This fracture can be seen on plain radiographs but may be better visualized with an MRI or CT scan (Fig. 8.17). Treatment depends on the displacement of the fracture. A nondisplaced odontoid fracture requires immobilization using a halo or Minerva orthosis for 6–8 weeks. The surgeon may also choose to use a pinless halo for a nondisplaced odontoid fracture that does not require corrective forces (Figs. 8.18, 8.19, and 8.20). A displaced odontoid fracture may require surgery to reduce the fracture into better alignment (Beaty and Kasser 2010).

### 8.3.3.6 Spinal Cord Injuries Other Than Cervical Spine

#### Thoracic and Lumbar Spine Injuries

Thoracic spinal column injuries are relatively uncommon compared with C-spine injuries in children. They generally fall into one of two types: (1) uncomplicated anterior wedge fractures

or (2) three-column injuries. Lumbar spine injuries in children are frequently associated with lap seat belt use in a motor vehicle accident. This is a flexion-distraction type of injury that too often goes undiagnosed or undertreated (Grabb 2008).

### **Contusions**

Spinal cord contusion is the complete or incomplete transient spinal cord dysfunction which generally resolves in 1–2 days but can also cause permanent damage. A contusion results from the stretching and compression of the spinal cord, which disrupts the gray matter in the spinal cord while preserving the white matter tracks (Adelson and Resnick 1999). Contusions can be associated with edema and/or hemorrhage and can be caused by blunt force, axial loading, flexion-extension, or other mechanism that results in stretching or compression of the cord. Since contusions do not appear on radiographs, they can also be associated with SCIWORA.

### **Brown-Sequard Syndrome**

Brown-Sequard syndrome is an injury to the right or left side of the spinal cord where movements are lost below the level of the injury on the injured side, but pain and temperature sensation are lost on the opposite side of the injury. It is a rare disorder resulting from a lesion on the spinal cord. Prognosis is variable depending upon the cause of the disorder.

### **Anterior Cord Syndrome**

Anterior cord syndrome is an incomplete injury to the motor and sensory pathways in the anterior parts of the spine. Patients are able to feel crude sensation, but movement and detailed sensation are lost in the posterior part of the spinal cord below the level of injury. It is usually caused by compression of the artery that runs along the anterior part of the spinal cord. There is no cure or standard course of treatment, and prognosis is poor for functional recovery.

### **Central Cord Syndrome**

Central cord syndrome is an injury to the center of the cervical spinal cord, producing weakness,

paralysis, and sensory deficits in the arms but not the legs. It is the most common incomplete SCI. It results from damage to large nerve fibers, usually secondary to hyperextension or bony instability in pediatric patients. There is no cure or standard course of treatment (though rest, stabilization, drug therapy, and/or surgery may be part of a program). Most patients recover some neurologic function, according to the fact page of the National Institute for Neurological Disorders and Stroke.

### **Assessment**

A thorough initial neurological assessment is essential to delineate the level of injury and to obtain a baseline for comparison of subsequent assessments to. Continuing assessments will be used to determine improvement or deterioration. Assessments should include basic vital signs, Glasgow Coma Scale, motor function of all muscle groups, sensation levels, and reflexes. It is important to include checking the anal sphincter for contracture, in addition to diaphragmatic function, to delineate respiratory effort and efficacy. The dermatome chart should be used to assess the level of sensation. Any deterioration noted on subsequent examinations should be reported to the care provider and the appropriate treatment should begin to insure that any secondary injury is minimal (Moloney-Harmon and Adams 2001).

### **Treatment**

Treatment begins at the scene of the accident with resuscitation, immobilization, and transport. The main consideration of treatment should be to maintain the patient's airway, breathing, and circulation while decompressing the neural elements and stabilizing the spine to prevent further injury. Basic anatomical and developmental considerations such as future growth, recuperative powers of children, and difficulty in achieving adequate internal or external fixation (halo) in the young child must be a part of the treatment plan.

Halo immobilization has been used successfully in patients <5 years of age and older. The halo ring has more pins (6–8) than the adult version

to distribute the pin pressure around the thinner pediatric skull. The pressure applied by the pins ranges from finger tight to two pounds. Most of the orthosis or vests are custom made using thermoplastic compounds molded to the child and attached with straps. The neurosurgeon, orthotist, or other trained individual will most likely be the ones who tighten pins. Pin site care is done per institutional policy (Carreon et al. 2004).

### **Surgical Treatment**

Injury that requires surgical treatment in the adult patient may only need immobilization in the pediatric patient. Bone and tissue thickness may have a major impact on what orthosis may be applied and what internal constructs may be possible. The vertebrae are partially cartilaginous in the young child, and it may not be possible to apply the same kind of screws or plates that would easily fit a larger patient. Spinal fusion may have a major impact on the developing spine. The spine may not grow normally and scoliosis could result. Therefore, it is important to limit the number of levels fused and to consider the effects of an isolated anterior or posterior fusion on subsequent development of excessive lordosis or kyphosis (Proctor 2002).

### **Role of Steroids**

Several studies are currently looking at the efficacy of high-dose steroids in the initial treatment of spinal cord injury. Despite early enthusiasm, much controversy exists concerning their effectiveness. It should also be noted that there were no pediatric patients included in the National Acute Spinal Cord Injury Study data and that no recommendations were made regarding pediatric patients (Proctor 2002). Each institution will vary in their use of steroids post spinal cord injury. The Congress of Neurologic Surgeons and the American Association of Neurologic Surgeons state that “methylprednisolone for either 24 or 48 h is recommended as an option in the treatment of patients with acute spinal cord injuries that should be undertaken only with the knowledge that the evidence suggesting harmful side effects (vital sign changes, glucose tolerance changes, and possible harm to the developing nervous sys-

tem) is more consistent than any suggestion of clinical benefit” (Proctor 2002).

## **8.3.4 Nursing Care of the Spinal Cord Injury Patient**

### **8.3.4.1 Cervical Collar Care**

Cervical collars support and limit the movement of the neck during the healing process. They may be worn 24 h a day or for comfort depending on the injury. Always refer to your attending physician’s recommendation for collar care and guidelines. Common cervical collar types are as follows: Soft, Philadelphia, Miami J, Aspen, DeRoyal, Cervical-Thoracic Orthotic (CTO) and Cervical-Thoracic-Lumbar Orthotic (CTLSO). Nurses should perform “collar care” at least once per day, if not more often. This includes making sure the collar is fitting well and there are no areas of skin breakdown. Pads are changed when soiled, damp, malodorous, soiled, and otherwise every 24 h. A mild soap and water is all that is needed to clean the pads and collars. Avoid using bleach and other harsh chemicals.

Patients with highly unstable cervical spine injuries should have a provider present at the time of collar care for the first change. Patients with stable cervical spine fractures can have their collar care done by a qualified RN alone. If there is any question about the stability of the cervical fracture, ask the attending physician and document their recommended guidelines for collar care.

Every institution has guidelines for collar care (Louisiana State University Health Sciences Center 2009):

1. Lay patient supine.
2. Unfasten the outside colored Velcro strap on the patient’s left side.
3. Lift open the front portion of the collar to the opposite (right) side.
4. Clean the skin on the anterior portion of the neck.
5. Dry skin and inspect for skin integrity.
6. Reapply the anterior portion of the collar.
7. Roll patient prone.
8. Unfasten the outside colored Velcro closure on patient’s left side.

9. Lift open the opposite (right) side.
10. Clean the posterior portion of the neck as done for the anterior side.
11. After drying and inspecting skin, reapply collar. The patient's chin should be flushed with the end of collar chin piece. The inner trach bar should not be touching the airway. All slack should be removed from collar and back panel should be centered to the front. The back Velcro straps should be symmetrical (Aspen Medical Products 2008).

#### 8.3.4.2 Pin Site Care for Halos

Pin care for halo immobilization is also dependent on an institution's guidelines. Typically, pin care is done daily with either half/half-strength hydrogen peroxide and normal saline or mild soap and water. Pins should be assessed every shift for soreness and increasing erythema or drainage. If these are noted, the provider should be notified to assess the patient and determine the next course of action. If the halo and pins are loose, radiographs may be ordered to assess if the pins are in proper alignment. Redness or drainage at the pin site may indicate infection.

#### 8.3.4.3 Developmental Considerations

Children and adolescents who have sustained spinal cord injuries (SCI) experience unique manifestations and complications related to their injury based on the dramatic developmental changes that occur as they grow (Adelson and Resnick 1999). The pediatric neurosurgery nurse must have a thorough understanding of the child's typical growth and development, complications of SCI, and specific care related to the level and mechanism of injury. This will alleviate unrealistic expectations related to the child's ability to participate in the examination that may cause frustration for the patient, family, and nurse. The pediatric neurosurgery nurse is mindful that small children may not be able to describe their pain or symptoms very well, depending on their age, cognitive function, and injury. A thorough history, when appropriate to obtain, is a vital component to prudent care and will help the nurse understand the child's cognitive level, socioeconomic status, and support system. A

baseline and regular head to toe nursing assessments should be performed, including respiratory and cardiovascular status, skin condition, bowel and bladder management, motor and neurovascular status, nutritional status, and emotional well-being. A multidisciplinary medical team, in conjunction with the patient and family, will provide comprehensive care and management after a spinal cord injury. This management will be individualized to each child and family and include developmentally appropriate education, family-centered care, and anticipatory guidance to address future issues related to growth and development.

Children develop along predictable patterns of physical, intellectual, and emotional growth, thus requiring their care to be dynamic, developmentally sensitive, and appropriate for each age group. SCI patients require long-term care and an essential part of rehabilitation is appropriate patient and family education. The patient needs to be made accountable for his or her own care whenever possible based on age and developmental level. If the child or adolescent is unable to perform their own care, they should be taught to direct their care. Family centered care is also essential and family members should take control of the patient's care when appropriate. Parents also need to be taught to transition control of care to the patient as he or she becomes an adult (see Chap. 13). This education must be individualized to the child's and family's needs. The SCI patient's rehabilitation plan should also include plans to return to school.

#### 8.3.4.4 Secondary Medical Conditions

SCI leads to a variety of changes in the systemic physiology of the child that can cause a number of complications. These complications, or secondary medical conditions, can rival the initial neurologic deficits in their impact on function and quality of life (2?). Secondary medical conditions after SCI are common, severe, and may be as devastating as the underlying injury if not properly cared for. These complications include, but are not limited to, pneumonia, neurogenic bladder and bowel, pressure ulcers, autonomic dysreflexia, spasticity, latex allergy, or deep vein thrombosis.

The nurse needs to be able to care for the patient with the following conditions as well as teach the patient and family how to care for themselves.

#### **8.3.4.5 Neurogenic Bladder**

SCI disrupts both the storage and emptying functions of the bladder, causing a condition referred to as neurogenic bladder. This is the loss of sensation of bladder fullness and the inability to voluntarily initiate urination and to completely empty the bladder, resulting in urinary retention and/or incontinence. The goal of an SCI bladder program is to preserve renal function while eliminating urine at regular and socially acceptable times, avoiding high bladder pressures, retention, incontinence, and infection. Treatment for this is clean intermittent catheterization (CIC). Emptying the bladder is important for protecting the kidneys from refluxing of the urine upward from the full bladder. Patients should be taught how to self-catheterize as soon as they are developmentally ready. They must be able to tell time, recognize the equipment, follow step-by-step instructions, and understand the purpose of equipment. This program can typically be started by the parents at 3 years of age and then taught to the patient around age 5–7, if developmentally appropriate. Managing incontinence is very important to children and adolescents, and they should be motivated to manage this aspect of their own care. Parental or parental designee supervision is necessary for school age children, whereas adolescents may only need assistance with problem solving. Continence is an expectation for school age children and adolescents and must be achieved for the individual to move on to a productive and satisfying adult life, including issues of sexuality and positive self-esteem.

#### **8.3.4.6 Neurogenic Bowel**

Patients with neurogenic bowel syndrome do not feel the urge to have bowel movements and are often unable to control them. To manage a neurogenic bowel, a regular program of bowel care must be instituted. The goal of this program should be to prevent constipation, provide adequate elimination, and preserve bowel function while providing

a convenient, regular, and complete emptying of the bowel. This may be as simple as placing the child on the commode at the same time every day and instructing him or her to bear down, although more detailed programs are often necessary. Stool softeners, laxatives, suppositories, enemas, and digital stimulation may be needed to expedite the process. Privacy, consistency, proper seating, and regularity mixed with patience help ensure success. This program can begin at age 3 years, be supervised during the school age period, and be proficiently performed by adolescents.

#### **8.3.4.7 Pressure Ulcers**

Pressure ulcers commonly occur from unrelieved pressure over bony prominences that results in tissue damage. Because of loss of sensation below the level of the spinal cord lesion, patients often are not aware of skin breakdown. Contributing factors to the development of pressure ulcers include shear, friction, poor nutrition, and changes in the skin physiology below the level of the lesion. Pressure ulcers add tremendous cost to already expensive medical care by causing increased hospital stays, surgical repair, and loss of school or work. If left untreated or undertreated, pressure ulcers may lead to death from sepsis. Good skin care, including prevention of skin breakdown, is essential and begins on day one of hospitalization. Strategies for prevention include daily examination of skin over vulnerable areas; avoidance of immobility and excess moisture in susceptible regions; the use of pressure-relieving wheelchairs, cushions, or other devices; and maintenance of adequate nutritional intake and weight. Children and adolescents should have their positions changed every 2 h while in bed and every hour while sitting in a chair. Their skin needs to remain clean and dry. Treatment for pressure ulcers consists of cleansing, debridement, nutritional support, and management of tissue loads. Parents and patients should be taught the signs of skin breakdown and how to treat them if they should occur.

#### **8.3.4.8 Autonomic Dysreflexia**

Autonomic dysreflexia is a life-threatening complication of SCI that is most often seen in pediatric



patients with T6 or higher injuries. It is a phenomenon manifested by the loss of coordinated autonomic responses to demands on heart rate and vascular tone. An exaggerated response of the sympathetic nervous system to a noxious stimulus below the level of the injury can lead to vasoconstriction and hypertension. A compensatory parasympathetic response produces bradycardia and vasodilation above the level of the lesion. This is due to the lack of supraspinal control of the major splanchnic outflow that leaves the spinal cord at the thoracic vertebrae 6–12 level. Symptoms include elevation of blood pressure by 24–51 mmHg above baseline (depending on the age of the patient), pounding headache, age-defined bradycardia or tachycardia in young children, profuse sweating, piloerection, cardiac arrhythmias, flushing, blurred vision, nasal congestion, or anxiety. Infants and very young children may exhibit sleepiness or irritability.

The most common trigger is bladder distention; however, becoming overheated, kidney stones, urinary tract infections, bowel distention or impaction, pressure ulcers, tight clothing, burns, ingrown toe nails, deep vein thrombosis, menses, pregnancy, labor, fractures, trauma, heterotopic ossification, surgery or invasive procedures, hyperthermia, or any other painful stimulus may also trigger autonomic dysreflexia. Recognition and treatment of symptoms is paramount to preventing this life-threatening process. Assessing and alleviating the triggers is essential. Heart rate and blood pressure measurements should be taken every 2–5 min and antihypertensive medications should be instituted as needed. Caregiver education is essential with children and adolescents prone to this complication. A medical alert bracelet or identification card should be worn or carried at all times.

#### 8.3.4.9 Spasticity

Spasticity is thought to result from the disruption of descending inhibitory modulation of the alpha motor neurons, causing hyperexcitability, which manifests as increased muscle tone and spasms. Fifty percent of all children with SCI are affected by spasticity, and it is usually seen within 1 year after injury, although it tends to lessen in subse-

quent years. Spasticity causes pain, decreased mobility, contractures, and muscle spasms, all of which can interfere with activities of daily living and sleep. The goals of spasticity management include improved function, prevention of complications, and alleviation of discomfort and embarrassment. Some potential benefits of spasticity include decreased muscle atrophy, increased tone to facilitate standing and transfers, promotion of venous return, and decreased risk of deep venous thrombosis and orthostatic hypotension. These positive aspects should be considered when determining the plan of care for the child or adolescent. A comprehensive program of range of motion, stretching, positioning, and use of braces is essential in the management of spasticity to maintain movement and prevent contractures. Relief of triggers is an important part of the management plan and any noxious stimulus may exacerbate spasticity. An example of noxious stimuli which may occur with spasticity and is unique to the pediatric population is hip dislocation.

Baclofen is the drug of choice to manage spasticity that interferes with functioning and is refractory to conservative treatment. Other drugs such as diazepam, clonidine, and tizanidine may be beneficial in spasticity management. A baclofen pump (intrathecal) is an option when other methods of management are not effective.

#### Pediatric Practice Pearls

- Younger children are more prone to cervical spine injuries with flexion-extension forces because of the large size of their heads, increased spine mobility, and ligament laxity.
- Children require appropriate head support and immobilization when on a spine board because of the size and shape of the head that could cause extreme flexion of the cervical spine, further injuring the spine or obstructing the airway.
- Autonomic dysreflexia is an exaggerated and possibly life-threatening auto-

nomnic response to normal innocuous stimuli seen in injuries of the spinal cord at T6 or above. The offending stimulus must be sought and reversed as soon as possible.

- Congenital spine anomalies may be asymptomatic early in life and become apparent with growth or subsequent to injury or inflammation.
- Congenital vertebral anomalies are often associated with renal, cardiac, and spinal cord abnormalities and syndromes, having an insidious onset with slow progression.
- Most motor and sensory signs and symptoms occur below the involved vertebrae.

Please refer to the Chap. 11 on spasticity for a more in-depth discussion.

#### 8.3.4.10 Sexuality and Fertility

One of the most socially important topics to cover with SCI patients is the ability to enjoy sexual intimacy and bear children. Common consequences of SCI related to sexual function include decreased libido, impotence, and infertility. Males may experience difficulties with erections, ejaculation, and fertility. These are important topics for discussion with the patient, covering why problems occur and how they may be treated. Females usually have fewer issues. Sexual response is typically impaired, but ovulation and fertility are generally unaffected. Menstruation, lubrication, pregnancy, labor, and delivery should all be discussed. Personal hygiene surrounding incontinence is an issue for both sexes. This information should also be presented to the parent of a child with SCI as part of the long-term treatment plan. This will help the parents come to terms with the reality of the injury implications and also help them see that there is a future for their child in terms of love, dating, marriage, and children.

### 8.3.5 Summary

Pediatric traumatic spinal cord injuries are often difficult to diagnose due to the differences in the development of the pediatric spine, inconsistent radiographic quality, and because SCIs are relatively rare. Despite the fact that the pediatric spine offers some natural protection from SCI due to its bony and ligamentous structure compliance, SCIs are often severe. These severe injuries are likely due to the high magnitude of force that is necessary to disrupt the tolerance of the pediatric spine. As a result, children often have concomitant neurological injuries that complicate the recovery.

Secondary medical conditions after SCI are both common and severe leading to rehospitalizations and decreased life expectancy. Treatment does not stop when the patient leaves the hospital or the rehabilitation facility; it requires a life-long commitment from the family and patient. The cost to the family and patient is astronomical in terms of support, time, effort, and money. Because these injuries are permanent and devastating, injury prevention is paramount.

Early recognition, diagnosis, referral, and treatment are extremely important for a congenital spinal anomaly. A very thorough history and physical exam is critical in every child who is referred for a congenital vertebral anomaly. This should include screening with MR/CT imaging and possibly ultrasound, urologic exam, genetics, and cardiology referral. Testing early in life is recommended with frequent follow-up.

### References

- Adelson PD, Resnick DK (1999) Spinal cord injury in children. In: Albright AL, Pollack IF, Adelson PD (eds) Principles and practice of pediatric neurosurgery. Thieme, New York, pp 955–972
- Ain MC, Browne JA (2004) Spinal arthrodesis with instrumentation for thoracolumbar kyphosis in pediatric achondroplasia. *Spine* 29:2075–2080
- Ain MC, Elmaci I, Hurko O, Clatterbuck RE, Lee RR, Rigamonti D (2000) Reoperation for spinal stenosis in achondroplasia. *J Spinal Disord* 13:168–173
- Ain C, Shirley E (2004) Spinal fusion for kyphosis in achondroplasia. *J Pediatr Orthop* 24:541–545

- Albright AL, Pollack IF, Adelson PD (1999) Principles and practice of pediatric neurosurgery. Thieme Medical Publishers, Inc., New York, pp 399–411
- Alden TD, Ellenbogen RG (2008) Spinal cord injuries. In: Albright AL, Pollack IF, Adelson PD (eds) Principles and practice of pediatric neurosurgery, 2nd edn. Thieme, New York, pp 925–938
- Alman BA (2002) A classification of genetic disorders of interest to orthopaedists. *Clin Orthop Relat Res* 401:17–26
- American Academy of Orthopaedic Surgeons (2006) Orthopaedic Knowledge Update: Pediatrics (3rd edn.). Rosemount, IL: American Academy of Orthopaedic Surgeons
- American College of Emergency Physicians. ACEP News. June 2008. Studies challenge spine injury criteria for children
- American Heart Association, American Academy of Pediatrics (2002) PALS Provider Manual. American Heart Association
- American Heart Association (2000) Trauma resuscitation and spinal immobilization. In: Hazinski MF, Zaritsky AL, Nadkarni VM, Hickey RW, Schexnayder SM, Berg RA (eds) PALS Provider Manual. American Heart Association, Dallas, pp 253–283
- Aspen Medical Products (2008) Expanded pad care. Retrieved from [http://www.aspencollar.com/products/collar/epc\\_instructions.html](http://www.aspencollar.com/products/collar/epc_instructions.html). Accessed 2 Feb 2010
- Beaty J, Kasser J (eds) (2010) Rockwood and Wilkins' fractures in children, 7th edn. Lippincott Williams & Wilkins, Philadelphia
- Berne JD, Velmahos GC, El-Tawil Q, Demetriades D, Asensio JA, Murray JA et al (1999) Value of complete cervical helical computed tomographic scanning in identifying cervical spine injury in the unevaluable blunt trauma patient with multiple injuries: a prospective study. *J Trauma Injury Infect Crit Care* 47: 896–903
- Bosch PP, Vogt MT, Ward WT (2002) Pediatric spinal cord injury without radiographic abnormality (SCIWORA): the absence of occult instability and lack of indication for bracing. *Spine* 32:2788–2800
- Brockmeyer D (2006) Advanced pediatric craniocervical surgery. Thieme, New York
- Brown RL, Brunn MA, Garcia VF (2001) Cervical spine injuries in children: a review of 103 patients treated consecutively at a level 5 pediatric trauma center. *J Pediatr Surg* 37:1107–1114
- Burton BK (1998) Inborn errors of metabolism in infancy: a guide to diagnosis. *Pediatrics* 102:69–73
- Carreon LY, Glassman SD, Campbell MJ (2004) Pediatric spine fractures: a review of 137 hospital admissions. *J Spinal Disord Tech* 22:477–482
- Cirak B, Ziegfeld S, Knight VM, Chang D, Avellino AM, Paidas CN (2004) Spinal injuries in children. *J Pediatr Surg* 39:607–612
- Clarke JTR (2005) A clinical guide to inherited metabolic diseases, 3rd edn. Cambridge University Press, New York
- Cleary MA, Wraith JE (1995) The presenting features of mucopolysaccharidosis type IH (Hurler syndrome). *Acta Paediatr Int J Paediatr* 84:337–339
- Cramer K, Scherl S (eds) (2004) Orthopaedic surgery essentials: pediatrics. Lippincott Williams & Wilkins, Philadelphia
- Curcione PJ, Mackenzie W (1995) Klipper-Feil a clinical case presentation at The Alfred I. Dupont Institute in Wilmington, Delaware
- Devlin VJ (2012) Spine secrets plus, 2nd edn. Elsevier, Mosby, pp 291–293
- Dewald RL, Arlet V, Carl A, O'Brien M (2003) Spinal deformities, the comprehensive text. Thieme Medical Publishers, Inc, New York
- Dibsie GL (1998) Clearing cervical spine injuries: a discussion of the process and the problems. *Crit Care Nurs Q* 2:26–41
- Dickman CA, Zabramski JM, Hadley MN, Rekatte HL, Sonntag VK (1991) Pediatric spinal cord injury without radiographic abnormalities: report of 26 cases and review of the literature. *J Spinal Disord* 4: 296–305
- Duke Orthopaedics (2005) Atlas fracture/Jefferson fracture. Wheelless' textbook of orthopaedics. Retrieved from <http://www.wheellesonline.com>. Accessed 4 Dec 2005
- Dziurzynski K, Anderson PA, Bean DB, Choi J, Levenson GE, Marin RL et al (2005) A blinded assessment of radiographic criteria for atlanto-occipital dislocation. *Spine* 30:1427–1432
- Ergun A, Oder W (2003) Pediatric care report of spinal cord injury without radiographic abnormality (SCIWORA): case report and literature review. *Spinal Cord* 41:249–253
- Eubanks J, Gilmore A, Bess S, Cooperman D (2006) Clearing the pediatric cervical spine following injury. *J Am Acad Orthop Surg* 14:552–564
- Fielding JW, Hawkins RJ (1977) Atlanto-axial rotary fixation: fixed rotatory subluxation of the atlanto-axial joint. *J Bone Joint Surg Am* 59A:45–55
- Giglio GC, Passariello R, Pagnotta G, Crostelli M, Ascani E (1988) Anatomy of the lumbar spine in achondroplasia. In: Nicoletti B, Kopits SE, Ascani E, Mckusick VA (eds) Human achondroplasia: a multidisciplinary approach. Plenum, New York, pp 227–239
- Grabb PD (2008) Spinal column trauma in children. In: Albright AL, Pollack IF, Adelson PD (eds) Principles and practice of pediatric neurosurgery, 2nd edn. Thieme, New York, pp 908–924
- Greenberg MS (2001) Spine injuries. In: Greenberg MS (ed) Handbook of neurosurgery, 5th edn. Thieme, Stuttgart, pp 686–735
- Hall CW, Liebaers I, Di Natale P, Neufeld EF (1978) Enzymatic diagnosis of the genetic mucopolysaccharide storage disorders. *Methods Enzymol* 50: 439–456
- Hedequist D, Emans J (2007) Congenital scoliosis: a review & update. *J Pediatr Orthop* 27:106–116

- Hadley MN (2002) Management of pediatric cervical spine and spinal cord injuries. *Neurosurgery* 50: S85-S99
- Hunter A, Bankier A, Rogers J, Sillence D, Scott C (1998) Medical complications of achondroplasia: a multi-centre patient review. *J Med Genet* 35:705-712
- Hurko O, Pyeritz R, Uematsu S (1988) Neurological considerations in achondroplasia. In: Nicoletti B, Kopits SE, Ascani E, Mckusick VA (eds) *Human achondroplasia: a multidisciplinary approach*. Plenum, New York, pp 153-162
- Kenter K, Worley G, Griffin T, Fitch RD (2001) Pediatric traumatic atlanto-occipital dislocation: five cases and a review. *J Pediatr Orthop* 21:585-589
- Khanna G, El-Khoury G (2006) Imaging of cervical spine injuries of childhood. *Skeletal Radiol* 36:477-494
- Kokoska ER, Keller MS, Rallo MC, Weber TR (2001) Characteristics of pediatric cervical spine injuries. *J Pediatr Surg* 37:100-105
- Kopits SE (1988) Thoracolumbar kyphosis and lumbosacral hyperlordosis in achondroplastic children. In: Nicoletti B, Kopits SE, Ascani E, Mckusick VA (eds) *Human achondroplasia: a multidisciplinary approach*. Plenum, New York, pp 241-255
- Lang SM, Bernardo LM (1993) SCIWORA syndrome: nursing assessment. *Dimens Crit Care Nurs* 12:247-254
- Leonard JC et al (2010) Fractures associated with cervical spine injury in children after blunt trauma. *Ann Emerg Med* xx(x)
- Louisiana State University Health Sciences Center (2009) Cervical collars: skin care. Retrieved from [http://www.sh.lsuhsu.edu/policies/policy\\_manuals\\_via\\_ms\\_word/Nursing/C-33.pdf](http://www.sh.lsuhsu.edu/policies/policy_manuals_via_ms_word/Nursing/C-33.pdf). Accessed 2 Feb 2010
- Lonstein JE (1988) Anatomy of the lumbar spinal canal. In: Nicoletti B, Kopits SE, Ascani E, Mckusick VA (eds) *Human achondroplasia: a multidisciplinary approach*. Plenum, New York, pp 219-226
- Mattera C (1998) Spinal trauma, new guidelines of assessment management in the out hospital environment. *J Emerg Nurs* 24:523-538
- Menezes AH, Ryken TC, Brockmeyer DL (2001) Abnormalities of the craniocervical junction. In: McLone DG, Marlin AE, Scott RM, Steinbok P, Reigel DH, Walker LM (eds) *Pediatric neurosurgery - surgery of the developing nervous system*, 4th edn. WB Saunders, Philadelphia, pp 400-422
- Menezes AH (1999) Craniovertebral anomalies and syringomyelia. In: Choux M, DiRocco C, Hockley AD, Walker ML (eds) *Pediatric neurosurgery*. Churchill Livingstone, New York, pp 151-183
- Moloney-Harmon PA, Adams P (2001) Trauma. In: Curley MAQ, Moloney-Harmon PA (eds) *Critical care nursing of infants and children*, 2nd edn. Saunders, Philadelphia, pp 947-980
- Morgan DF, Young BF (1980) Spinal neurological complications of achondroplasia: results of surgical treatment. *J Neurosurg* 52:463-472
- Morris CG, McCoy E (2004) Clearing the cervical spine in unconscious polytrauma victims, balancing risks and effective screening. *Anesthesia* 59:464-482
- Nelson MA (1988) Kyphosis and lumbar stenosis in achondroplasia. In: Nicoletti B, Kopits SE, Ascani E, Mckusick VA (eds) *Human achondroplasia: a multidisciplinary approach*. Plenum, New York, pp 305-312
- Neufeld EF, Muenzer J (1995) The mucopolysaccharidoses. In: Scriver CR, Beaudet AL, Sly WS, Valle D (eds) *The metabolic and molecular bases of inherited disease*, 7th edn. McGraw-Hill, New York, pp 2465-2487
- Neufeld EF, Muenzer J (2001) The mucopolysaccharidoses. In: Scriver CR, Beaudet AL, Sly WS, Valle D (eds) *The metabolic and molecular bases of inherited disease*, 7th edn. McGraw-Hill, New York, pp 3421-3465
- OrtoPed. (n.d.). Lerman Noninvasive Pediatric Halo System (Model C-24). Retrieved 2012, from OrtoPed: [http://www.ortoped.ca/pdf/Becker\\_C-24-Lerman-Noninvasive-Pediatric-Halo.pdf](http://www.ortoped.ca/pdf/Becker_C-24-Lerman-Noninvasive-Pediatric-Halo.pdf)
- Park H, Kim H, Hahn S, Yang K, Choi C, Park J, Jung S (2003) Correction of lumbosacral hyperlordosis in achondroplasia. *Clin Orthop Relat Res* 414: 242-249
- Pauli RM, Breed A, Horton VK, Glinski LP, Reiser CA (1997) Prevention of fixed angular kyphosis in achondroplasia. *J Pediatr Orthop* 17:726-733
- Poseti IV (1988) Bone formation in achondroplasia. In: Nicoletti B, Kopits SE, Ascani E, Mckusick VA (eds) *Human achondroplasia: a multidisciplinary approach*. Plenum, New York, pp 109-122
- Proctor MR (2002) Spinal cord injury. *Crit Care Med* 30:S489-S499
- Reid CS, Pyeritz RE, Kopitz SE, Maria BL, Wang H, McPherson RW, Hurko O, Phillips JA (1988) Cervicomedullary cord compression in young children with achondroplasia: value of comprehensive neurologic and respiratory function. In: Nicoletti B, Kopits SE, Ascani E, Mckusick VA (eds) *Human achondroplasia: a multidisciplinary approach*. Plenum, New York, pp 199-206
- Rimoin DL (1988) Clinical variability in achondroplasia. In: Nicoletti B, Kopits SE, Ascani E, Mckusick VA (eds) *Human achondroplasia: a multidisciplinary approach*. Plenum, New York, pp 123-127
- Scheie HG, Hambrick GW, Barness LA (1962) A newly recognized form of Hurler's disease (Gargoylism). *Am J Ophthalmol* 67:753-769
- Schnuerer AP, Gallego J, Manuel C (2001) Basic anatomy and pathology of the spine: core curriculum for basic spinal training. Medtronic Sofamor, Danek, Memphis
- Shiang R, Thompson LM, Zhu Y, Church DM, Fielder TJ, Bocian M, Winokur ST, Wasmuth JJ (1994) Mutations in the transmembrane domain of FGFR3 cause the most common genetic form of dwarfism, achondroplasia. *Cell* 78:335-342
- Skaggs D, Flynn J (2006) *Staying out of trouble in pediatric orthopaedics*. Lippincott Williams & Wilkins, Philadelphia

- Sullivan JA, O'Donoghue DH (2005) Klippel-Feil syndrome. e-medicine. <http://www.emedicine.com/orthoped/topic408.htm>. Accessed 18 May 2006
- Turkstra TP, Craen RA, Pelz DM, Gelb AW (2005) Cervical spine motion: a fluoroscopic comparison during intubation with lighted stylet, GlideScope, and Macintosh laryngoscope. *Anesth Analg* 101: 910–915
- Uematsu S, Wang H, Hurko O, Kopitx SE (1988) The subarachnoid fluid space in achondroplastic spinal stenosis: the surgical intervention. In: Nicoletti B, Kopits SE, Ascani E, Mckusick VA (eds) *Human achondroplasia: a multidisciplinary approach*. Plenum, New York, pp 275–281
- Van de Pol GJ, Hanlo PW, Oner FC, Catelein R (2005) Redislocation in a halo vest of an atlanto-occipital dislocation in a child: recommendations for treatment. *Spine* 30:E424–E428
- Viccellio P et al (2001) A prospective multicenter study of cervical spine injury in children. *Pediatrics* 108(2):e20
- Vogel LC, Hickey KJ, Klass SJ, Anderson CJ (2004) Unique issues in pediatric spinal cord injury. *Orthop Nurs* 23:300–308
- Wiggins GC, Shaffrey C, Abel M, Menezes A (2003) Pediatric spinal deformities. *Neurosurg Focus* 14(1):1–14, Article 3
- Wright MJ, Ain MC, Clough MV, Bellus GA, Hurko O, McIntosh I (2000) Achondroplasia and nail-patella syndrome: the compound phenotype. *J Med Genet* 37(9):E25

Theresa M. Gabay and Davonna Ledet

---

## 9.1 Introduction

Neurovascular malformations are generally congenital lesions that may or may not have a hereditary or familial origin. They can be associated with other pathologies, such as infection or cardiac disorders, or can be a result of trauma or medical treatments (Vananman et al. 2010). Although considered a rare occurrence in the pediatric population, these anomalies have the potential for significant morbidity and mortality, given the life expectancy in this age group (Moore and Agur 1995). The vast majority of pediatric malformations fall into one of the following groups: AVM, cavernous malformation, vein of Galen, aneurysms, venous angiomas, and moyamoya.

---

## 9.2 Vascular Anatomy

Vessels within the vascular blood supply are composed of arteries, veins, and capillaries. Table 9.1 describes the characteristics of these three types of vessels.

---

T.M. Gabay, RN, MSN, APN-BC, CNRN (✉)  
Department of Pediatrics and Neurosurgery,  
The Joseph M. Sanzari Children's Hospital,  
Hackensack UMC, Hackensack, NJ, USA  
e-mail: tgabay@advancedneurosurgeons.com

D. Ledet, RN, MSN, MBA, APN-BC, CNRN  
Department of Neurology,  
St. Jude Children's Research Hospital,  
Memphis, TN, USA  
e-mail: davonna.ledet@stjude.org

## 9.2.1 Cerebral Blood Supply

The cerebral circulation is composed of two very distinct circulatory systems: the arterial and venous systems. The two systems work in unison to maintain appropriate pressure and perfusion within the brain. There are many physiologic and pathologic factors that can affect blood flow in the arteries and veins of the brain, including acid–base balance, oxygen saturation, and systemic blood pressure. Under normal conditions of autonomic regulation, the mean arterial pressure is maintained at 0–10 cm H<sub>2</sub>O (McCance and Huether 2002). This ensures adequate perfusion of the cerebral capillary beds despite changes in systemic blood pressure.

## 9.2.2 Arterial Supply

Arterial blood enters the cranial cavity anteriorly (via the carotid arteries) and posteriorly (via the vertebral arteries). They feed into an anastomotic ring of vessels called the circle of Willis, which gives rise to all the major cerebral arteries (Fig. 9.1). The origin of the brain's anterior arterial system is the right and left common carotids arising from the innominate artery and aortic arch, respectively. Each of these large vessels further branches into the external and internal carotid arteries. The external carotid is responsible for blood supply to the face and scalp. The internal carotid enters the base of the skull via the foramen lacerum. It then twists and divides into several

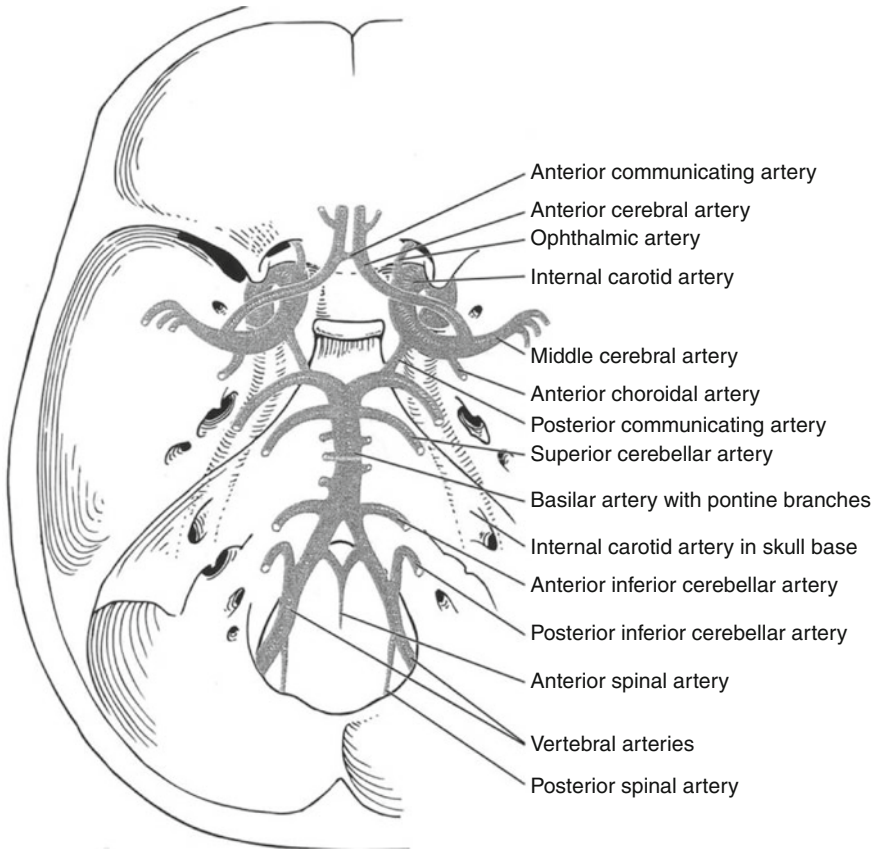
**Table 9.1** Description of arteries, capillaries, and veins

Arteries	Artery walls are composed of three layers: tunica intima, tunica media, and tunica adventitia. There are three types of arteries: elastic arteries, muscular arteries, and arterioles. Thickness of wall layers and differences in makeup of these layers – particularly the tunica media – are elements that further distinguish the different artery types from one another (Moore and Agur 1995)
Elastic arteries	Elastic arteries are the largest type of artery. They expand synchronously with heart contractions and resume their normal shape between contractions (Moore and Agur 1995)
Muscular arteries	These arteries distribute blood to various parts of the body, and for this they are often referred to as <i>distributing arteries</i> . Muscular artery walls consist of circularly disposed smooth muscle fibers. The smooth muscle fibers constrict their lumina upon contraction (Moore and Agur 1995)
Arterioles	Arterioles are the smallest of the arteries. They have a narrow lumina and thick muscular walls. The degree of tonus of the smooth muscle in arteriole walls is primarily responsible for arterial pressure (Moore and Agur 1995)
Capillaries	Capillaries connect arteries to veins. They are made of endothelial tubes and are arranged in a network known as a capillary bed (Moore and Agur 1995). The makeup of a capillary wall consists of a single layer of endothelial cells that are surrounded by a thin basement membrane of the tunica intima. Some capillary walls consist of a single endothelial cell with no tunica media or tunica externa. Other capillaries contain oval windows known as fenestrations within the endothelial cells. A thin diaphragm covers the fenestrations (McCance and Huether 2002)
Veins	Vein walls are thinner than artery walls because of the lower blood pressure in the venous system. They are also fibrous and have a larger diameter. The tunica externa of veins has less elastic tissue than arteries, and as a result, veins do not possess the capacity to recoil as seen in arteries (McCance and Huether 2002). Valves work to permit blood to flow toward the heart and prevent blood from flowing in the opposite direction. There are three types of veins: small, medium, and large. The adventitia of large veins is composed of wide bundles of longitudinal smooth muscle. Venules are the smallest type of vein (Moore and Agur 1995). The smallest venules that are closest to capillaries have an inner lining made up of the endothelium of the tunica intima and surrounded by fibrous tissue. The largest venules that are furthest from the capillaries are made of a thin tunica media that consists of a few smooth muscle fibers (Moore and Agur 1995)

segments (i.e., cervical, petrous) and terminates by dividing into the anterior cerebral artery and middle cerebral artery. Main branches include the ophthalmic artery, the posterior communicating artery, and the anterior choroidal artery (Hinkle et al. 2010). The cortical areas are supplied by the anterior and middle cerebral arteries, as well as the anterior choroidal arteries (Table 9.2).

The two vertebral arteries, which originate from the subclavian arteries, enter the skull through the foramen magnum and then unite at the level of the pons to form the basilar artery. The posterior inferior cerebellar arteries branch off the vertebrals and the anterior inferior cerebellar arteries, superior cerebellar arteries, and posterior cerebral arteries arise from the basilar artery (Fig. 9.1).

The posterior circulation, or the vertebral basilar system, supplies the brainstem, cerebellum, occipital lobe, and parts of the thalamus. The anterior circulation, as described above, supplies the remainder of the forebrain (Hinkle et al. 2010). Occlusion of a specific artery often leads to a characteristic clinical picture (Fig. 9.2). Each major artery supplies a certain territory which is separated from other territories by watershed areas (the border of two vascular territories lying adjacent to each other). The two anterior cerebral arteries are joined together by the anterior communicating artery. This allows for communication of the right and left hemispheres and is important in compensation for blood flow in the event of an occlusion of one of the carotid arteries.



**Fig. 9.1** Circle of Willis. Principal arteries on the floor of the cranial cavity (From Waxman 2003)

**Table 9.2** The cortical areas supplied by the major cerebral arteries

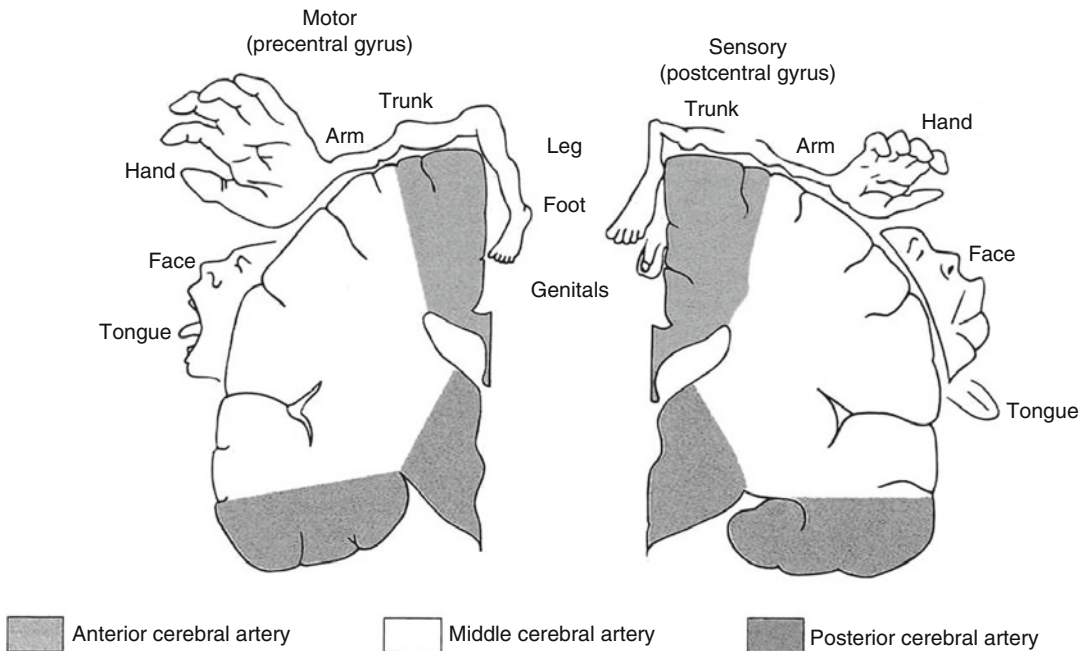
Middle cerebral artery	Supplies many deep lateral aspect of the cerebrum
Anterior cerebral artery	Supplies the anterior frontal lobe and the medial aspects of the hemisphere
Posterior cerebral artery	Supplies the occipital lobe and choroid plexus of the third and lateral ventricles and the lower surface of the temporal lobe
Anterior choroidal artery	Supplies the choroid plexus of the lateral ventricles and the adjacent brain structures supplied by the major cerebral arteries

### 9.2.3 Venous System

The venous system of the brain and coverings is a network of drainage systems that include the veins of brain tissue, dural venous sinuses, dural meningeal veins, and veins between the skull tables (diploic veins). The majority of these veins communicate and, unlike systemic veins, have no valves.

The cerebral veins consist of the superficial cerebral veins and the deep cerebral veins. The superficial cerebral veins, also known as the cortical veins, drain blood from the outer surface of the brain into the large venous channels: the superior and inferior sagittal sinuses, the great cerebral vein of Galen, the straight sinus, and the tentorial veins. Blood from the cerebellar surface is drained by way of the cerebellar veins into the





**Fig. 9.2** Arterial supply and homunculus

superior vermian vein and then into the great cerebral vein, straight sinus, and transverse sinuses. Blood from the inner regions of the brain is drained by the deep cerebral veins (or central veins). The inner regions include the hemispheric white matter, basal ganglia, corpus callosum, and choroid plexus. The deep cerebral veins also drain blood from several cortical areas (Moore and Agur 1995).

Blood supply from the brain drains into the dural venous sinuses and subsequently into the internal jugular veins. The dural venous sinuses are lined with endothelial cells and are found between the endosteal and meningeal layers of the dural mater (Moore and Agur 1995).

### 9.3 Pediatric Stroke

Stroke is the sudden occlusion or rupture of cerebral arteries or veins resulting in focal cerebral damage and clinical neurological deficits. Although it is commonly thought of as an “old person’s disease,” stroke also strikes infants and children and can occur in utero. The risk of

stroke is greatest in the perinatal period, occurring in 1 out of every 4,000 live births (Lloyd-Jones et al. 2009). Symptoms of stroke in children are different than in adults. Seizures are often the first symptom of stroke in a newborn and some present with early handedness (before age 3 years) or developmental delay (Roach et al. 2008). Fifty to eighty percent of children that survive stroke will often have permanent neurological deficits, usually hemiplegia/hemiparesis – the most common form of cerebral palsy in term infants (Kirton and deVeber 2006). Sickle cell disease and congenital or acquired heart disease are the most common risk factors (Roach et al. 2008). Other risk factors include (Roach et al. 2008):

- Head and neck infections
- Inflammatory bowel disease, autoimmune disorders
- Head trauma
- Dehydration
- Maternal history of infertility
- Chorioamnionitis
- Premature rupture of membranes
- Preeclampsia

Boys are at greater risk of stroke than girls, and African American children are at greater risk than Caucasian and Asian children (Lloyd-Jones et al. 2009).

---

## 9.4 Vein of Galen Aneurysmal Malformations

### 9.4.1 Pathophysiology

A vein of Galen aneurysmal malformation (VGAM) is a rare intracranial vascular anomaly typically found in neonates and infants but can also present in older children and adults. It accounts for approximately 1 % of all cerebrovascular lesions overall (Huhn et al. 2006), although it is estimated to account for approximately 30 % of all pediatric vascular malformations (Long et al. 1974). The vein of Galen, or great cerebral vein, lies under the cerebral hemispheres in the subarachnoid space dorsal to the midbrain and drains the anterior and central regions of the brain into the sinuses of the posterior cerebral fossa (Santos et al. 2005). The vein of Galen extends embryologically from the posterior segment of the median prosencephalic vein of Markowski (MProsV) and drains into the vein of Galen (Huhn et al. 2006). MProsV can be identified between the 8th and 11th weeks of gestation, during which time the VGAM is thought to develop. The MProsV is the persistent embryonic channel that forms the aneurysmal or dilated component of the VGAM (Raybaud and Strother 1986). Most of the arterial supply of a VGAM comes from the choroidal arteries or feeders, which include the anterior and posterior choroidal arteries, the pericallosal artery, transmesencephalic branches from the basilar tip, and the proximal posterior cerebral arteries (Gailloud et al. 2005). The VGAM results from multiple fistulous connections or arteriovenous shunts that drain into the MProsV. It is still not known how these arteriovenous shunts actually form. Consequently, the MProsV becomes progressively dilated from the high-pressure flow from the choroidal feeders (Gailloud et al. 2005).

VGAMs can be classified into categories based on their angioarchitecture: choroidal and mural (Lasjaunias 1997). The simplest or choroidal type receives its arterial contribution from the choroidal arteries and a typical interposed network is present before opening into the large venous pouch. This choroidal type has been found mostly in neonates with poor clinical scores (Table 9.3). The second, or mural type, represents direct arteriovenous fistulas within the wall of the MProsV, and it can either be single or multiple. There may also be mixed forms when direct shunts and arterial networks combine (Hoang et al. 2009). Mural VGAMs tend to occur in infants with higher clinical scores. A score between 8 and 12 entails emergency endovascular management (Lasjaunias 1997).

### 9.4.2 Presenting Symptoms

The clinical features of VGAM differ characteristically with the age of presentation (Gold et al. 1964). The larger the arteriovenous shunt, the earlier the anomaly will manifest itself clinically. Symptomatic neonates can present with severe or progressive high-output congestive heart failure with cardiomegaly, as a result of the large volume of blood exerted by a VGAM with high-flow arteriovenous shunts (Gold et al. 1964; Fullerton et al. 2003). Severe pulmonary hypertension can also be a complication. Infants may present with an increasing head circumference secondary to hydrocephalus, seizures, and/or hemorrhage, albeit rare (Gold et al. 1964).

A cerebral “steal” phenomenon, or the siphoning of blood flow away from adjacent brain tissue, can result in cerebral atrophy and periventricular leukomalacia (Pasqualin et al. 1982). The most severe form of the cerebral “steal” phenomenon is often referred to as the melting brain (Alvarez et al. 2007). Mild symptoms in the neonate may include feeding difficulties, tachycardia, and cardiomegaly on chest x-ray (Alvarez et al. 2007). More severe presentations include cardiorespiratory failure, hydrops (large amount of fluid buildup in infant’s tissue) and renal failure (Gailloud et al. 2005).

**Table 9.3** Vein of Galen aneurysmal malformation: neonatal evaluation scoring system

Score	Cardiac function	Cerebral function	Hepatic function	Respiratory function	Renal function
5	Normal	Normal	Normal	Normal	Normal
4	Untreated overload	Subclinical EEG abnormalities	Normal	Tachypnea but finishes bottle feed	Normal
3	Stable treated failure	Intermittent neurological signs	No hepatomegaly, normal function	Tachypnea, does not normally finish bottle feed	
2	Unstable treated failure	Isolated seizure	Hepatomegaly, normal function	Ventilated, normal saturations <25 % added O <sub>2</sub>	Transient anuria
1	Ventilated treated failure	Continuing seizures, neurological signs	Abnormal function	Ventilated, normal	Unstable
0	Resistant to treatment		Coagulopathy, raised enzymes	Ventilated, desaturated	Anuric

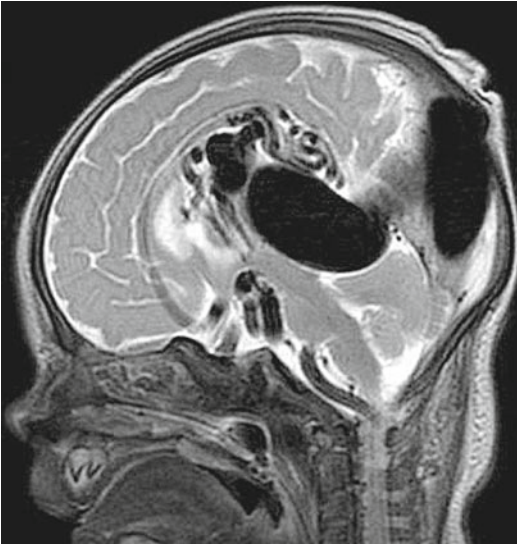Vein of Galen malformation should always be ruled out in neonates born with high-output cardiac failure (Hoang et al. 2009). Cardiac manifestation is typically milder in infants, and they are usually treated symptomatically with diuretics until the embolization procedure can be performed (Alvarez et al. 2007). Milder symptoms in this age group are usually due to a smaller shunt. Other symptoms may include failure to thrive, cranial bruits, dilated scalp veins, proptosis, prominent scalp veins, and epistaxis (Gailloud et al. 2005; Gulati and Kalra 2002; Gupta and Varma 2004).

Noncommunicating hydrocephalus results from aqueductal obstruction or compression of the posterior third ventricle by the VGAM itself, whereas impaired cerebrospinal fluid absorption caused by subarachnoid hemorrhage could contribute to communicating hydrocephalus (Jaegar et al. 1937). Intracranial venous hypertension induced by the VGAM has also been postulated to contribute to the development of hydrocephalus (Zerah et al. 1992). Intracranial bruits caused by the turbulent blood flow, dilated or prominent scalp veins secondary to hydrocephalus, proptosis, and recurrent epistaxis can also present in infants with a VGAM (Gailloud et al. 2005). In older children and adults, headaches tend to be the presenting symptom which may be attributed to a subarachnoid hemorrhage (Gold et al. 1964). Older children may also present with focal seizures and developmental delay.

### 9.4.3 Diagnostic Tests

Transcranial ultrasound will help to localize or identify the lesion, and color Doppler studies can help to delineate the hemodynamics of the lesion (Deeg and Scarf 1990; Rodesch et al. 1994). A typical Doppler finding is that of a large, mid-line cystic structure with arterialized flow and visualization of the feeding arteries (Blaser et al. 2003). Cranial MRI and/or CT scan, with and without contrast administration, will help to establish the venous and arterial vascular anatomy of the lesion, as well as to confirm the diagnosis and define the degree of involvement (Fig. 9.3) (Blaser et al. 2003; Gailloud et al. 2005; Huhn et al. 2006).

Imaging studies in infants will also help determine whether the patient has accompanying hydrocephalus. MR angiography (MRA) will be able to delineate feeding arteries, nidus, and draining veins, as well as distinguish the high-flow feeding vessels from the low-flow venous lesions (Blaser et al. 2003; Santos et al. 2006). In patients being considered for surgery or for endovascular therapy, cerebral angiography may be required to define the extent of aneurysmal dilatation and details for arterial feeders (Huhn et al. 2006). Angiography findings typically show anterior and posterior circulation fistulae supplying a markedly dilated vein of Galen (Blaser et al. 2003). However, cerebral angiography should only be undertaken as a prelude to therapeutic



**Fig. 9.3** Magnetic resonance image (MRI) of a vein of Galen malformation

intervention and is not required purely for diagnosis, as the nature of the condition can be confirmed by MRI (Punt 2004). Cardiac ultrasound may be indicated to assess left ventricular function (Chevret et al. 2002).

## 9.4.4 Treatment Options

### 9.4.4.1 Endovascular Treatment

VGAMs have proven to be very difficult to treat using standard surgical procedures. Fortunately, this condition can now be treated with endovascular embolization. Endovascular embolization involves the injections of embolic agents, such as a synthetic cyanoacrylate glue (*N*-butyl-cyanoacrylate or NBCA) or a variety of coils. Embolic agents encourage blood clotting and closure of the VGAM (Lasjaunias et al. 1991). Onyx (one of the more recently developed liquid embolic substances) has also been used to occlude the arteriovenous fistula on the arterial side (Gailloud et al. 2005; Jankowitz et al. 2008; Lasjaunias et al. 2006). The transarterial approaches are preferred over transvenous endovascular treatments. The literature clearly indicates an improved outcome

and fewer complications associated with the arterial approach, such as potentially impairing normal deep venous pathways (Levrier et al. 2004; TerBrugge 1999, 2006). Using x-ray guidance, this procedure involves the insertion of a micro catheter through the femoral artery that is threaded through the arteries until the tip reaches the site of the arterial feeder. The embolic agent is then injected through the catheter. Sometimes several staged endovascular embolizations are required to help avoid the occurrence of parenchymal bleeds, secondary to “perfusion breakthrough phenomenon” or massive venous thrombosis potentially endangering the normal venous supply (Gailloud et al. 2005). “Perfusion breakthrough” refers to a hemorrhage or swelling developing from abnormal perfusion from the vessels surrounding the recently embolized lesion. Perfusion breakthrough is more prevalent in patients who are hypertensive. Given that most of these hemorrhages occur within the first week after treatment, strict management of the blood pressure in the days post-procedure is imperative.

Non-neurological complications related to embolization are rare (Lasjaunias 1997). Asymptomatic occlusion of the internal iliac artery and the microcatheter getting glued in place have been reported. Repeated punctures of the femoral artery does not seem to cause significant problems.

The timing of endovascular management is usually determined by the severity of the clinical presentation (Gupta and Varma 2004). Emergency embolization in the newborn is considered necessary in cases where congestive heart failure is present and does not respond to medical management (Gupta et al. 2006). Some clinicians feel that the therapeutic window for optimal endovascular management is between 4 and 6 months of age, as long as the infant is hemodynamically stable (Gailloud et al. 2005; TerBrugge 1999). However, excessive delay may lead to intractable hydrocephalus. There are a minority of patients who experience spontaneous thrombosis of the malformation (Cheng et al. 2003; Lasjaunias 1997; Lasjaunias et al. 1991).

#### 9.4.4.2 Surgical Treatment

As a result of advances in endovascular management, surgical obliteration of a VGAM is now only considered in case of failure of, or as an adjunct to, embolization (Gailloud et al. 2005; Huhn et al. 2006). Surgical interventions are indicated for the evacuation of intracranial hematomas and for the management of hydrocephalus. This can be treated either by endoscopic third ventriculostomy or insertion of a ventriculoperitoneal shunt (Gailloud et al. 2005). Shunt placement has been associated with mortality and morbidity such as increased risk of mental retardation (TerBrugge 1999; Zerah et al. 1992). A diversionary procedure should be considered only after the treatment of the VGAM is unsuccessful in reversing or relieving the hydrocephalus.

#### 9.4.5 Nursing Care

One of the primary goals of the nursing care for the neonate with a VGAM is maintaining optimal neurological function. Head circumference measurements should be obtained regularly and monitored carefully to detect hydrocephalus. Patients should be monitored for seizures and managed with antiepileptic medications. Usually, neonates are given phenobarbital and phenytoin. Respiratory interventions should include chest physiotherapy and suctioning to maintain the airway in the ventilated patient. Cardiac management of high-output heart failure is essential. Management includes monitoring of physical activity, oxygen requirements, and adequate caloric intake, and strict input and output records are maintained. Pharmacological management can include inotropic agents (digoxin, dopamine, dobutamine), diuretics (loop diuretics, such as furosemide), and afterload reducing agents (angiotensin converting enzyme inhibitors such as captopril and enalapril). Other important nursing interventions include maintaining skin integrity, infection prevention and early recognition of sepsis, and providing comfort measures of frequent repositioning and pain medications as needed. Additionally, facilitation parent-infant

bonding, normal grieving and coping, and open communication are other means of providing holistic nursing care (TerBrugge 1999).

#### 9.4.6 Family Education

Parents must face the ethically and morally difficult decision of whether or not to treat the child's lesion, particularly for parents of children whose available medical information does not clearly indicate the benefit of one choice over the other (Gailloud et al. 2005). Parents may not fully understand the potentially devastating outcome of a child who is unresponsive to treatment, yet survives, and therefore are ill-prepared to adapt to life with a severely debilitated child. Problems include obtaining medical equipment, financial assistance, and certain support services. It is of utmost importance that therapeutic decision making is a shared process between the clinician and parents. All elements defining the child's best interests must be considered and discussed.

#### 9.4.7 Outcomes

Prior to the advent of endovascular embolization, the prognosis for patients presenting as neonates with congestive heart failure was poor. An earlier review reported mortality rates of 100 % (9/9) for neonates, 68 % (13/19) for infants, and 45 % (5/11) for older children and adults (Gold et al. 1964). Modifications in the application of newer microcatheters, acrylic polymer NBCA, and neonatal care, such as modern imaging and intensive care environment, improved the outlook in a series of 11 patients (Friedman et al. 1993). No mortality had occurred, and 6 out of the 11 patients were functionally normal up to 30 months' follow-up. In a series of 78 neonates, infants, and children that were treated and followed, 7 of these patients died, but 66 % of the 71 patients remaining were neurologically normal, 14 % had transient neurological symptoms, 11.5 % had mild permanent deficits, and 8.5 % had severe permanent deficits (Lasjaunias et al. 1991). In a more

recent series of 27 children undergoing endovascular treatment, 4 of whom died in hospital, 61 % of the 23 surviving patients had no or minor developmental delay, and 64 % had no or mild abnormalities on neurological examination (Fullerton et al. 2003).

Resolution of cardiac failure has also been achieved favorably with embolization. In a series of 5 symptomatic neonates, 1 died of intractable cardiac failure (20 %), whereas control of cardiac failure was achieved by embolization without neurological symptoms in the surviving 4 patients. One of the patients (20 %) demonstrated moderate developmental delay in follow-up (Mitchell et al. 2001). In a larger series of 9 symptomatic neonates who underwent endovascular treatment, 6 patients (66 %) obtained control of cardiac failure and normal neurological functioning, 1 patient died from intractable cardiac failure, and 2 patients (33 %) died later as a result of severe hypoxic-ischemic neurological injury. At 6-month to 4-year follow-up, five infants had no evidence of either neurological or cardiac deficits, and one (11 %) child had mild developmental delay (Frawley et al. 2002).

In another series with 15 patients who underwent embolization, 66 % (10/15) had a complete obliteration of the fistula with an overall mortality rate of 20 % (3/15) secondary to meningitis and intracranial hemorrhage. At a 6-year follow-up, these patients were stable cognitively with overall improvement of their delayed developmental milestones (Gupta et al. 2006).

In a series of 233 patients, endovascular embolization was utilized via the transfemoral approach in patients where angiographic studies demonstrated a 90–100 % occlusion in 55 % of the patients. The neonatal mortality outcome was 52 % (12/23), while the general mortality rate was 10.6 % (23/216). Of note, only three of these deaths were caused by the embolization procedure. In the neonatal population, most of the deaths represented patients whose clinical presentation score was <8 and intervention was not expected to be successful. This study also demonstrated that persistent shunts, if small, can be tolerated and may even resolve spontaneously over time (Lasjaunias et al. 2006).

In a prospective review spanning 21 years, one large center treated 26 patients with VGAMs. At presentation, 12 of the patients presented with congestive heart failure, while 10 presented with hydrocephalus. Five patients did not qualify for surgical interventions because of either mild or severe symptomatology. Of the remaining patients, 12 underwent embolization, and the remaining 9 underwent endovascular surgery. Overall survival rate was 76.9 % (20/26). Of the 21 patients who underwent endovascular treatment, 66/7 % (14/21) went on to experience no delay in development. Those patients who were older at the time of embolization were noted to have more developmental delay as compared to those who were younger at the time of embolization (Li et al. 2010).

In summary, the more current reviews have shown improvement in both morbidity and mortality for the neonatal and pediatric populations. With continued advances in imaging and endovascular therapies, more favorable prognosis for babies and children with VGAM is promising.

---

## 9.5 Cerebral Arteriovenous Malformation in Children

### 9.5.1 Etiology

Cerebral arteriovenous malformation (AVM) are a relatively uncommon vascular lesion. Within the general population, the prevalence is estimated to be between 0.5 and 1 %, which includes asymptomatic patients (Hinkle et al. 2010). Although AVMs are considered to be congenital in origin, few are diagnosed in the first two decades of life. The average age of presentation is 32–40 years old. Approximately 20 % of all AVMs are diagnosed in children (Darsaut et al. 2011; Singhal et al. 2011; Foy et al. 2010). The main difference between adults and children with regard to this lesion is the dramatic presentation of spontaneous hemorrhage as the initial symptom. This is as high as 80–85 % in the pediatric population versus 50–65 % in adults (Niazi et al. 2010).

The majority of cerebral AVMs occur sporadically and have no predilection for race or gender.

Familial cases have been reported but are very rare (Yokoyama et al. 1991). AVMs are known to be associated with a few syndromes, specifically hereditary hemorrhagic telangiectasia (HHT) or Osler-Weber-Rendu disease. About 7.9 % of children with HHT have an AVM. HHT should be considered in children diagnosed with multiple AVM (Griffiths et al. 1998; Horgan et al. 2006; Roach and Riela 1995). Wyburn-Mason syndrome (Bonnet-Dechaume-Blanc) is a rare congenital, nonhereditary disorder characterized by multiple cutaneous nevi, brain and retinal AVM (Roach and Riela 1995).

### 9.5.2 Pathophysiology

AVMs can be very complex neurovascular lesions. They are defined as a tangle of arteries and veins in the brain or on its surface that directly shunts arterial blood to the venous system. There is an absence of normal intervening capillary beds between the two systems. Instead, there is a fairly well-circumscribed center known as the nidus. AVMs have been predominantly described as congenital abnormalities arising from persistent embryonic patterns of blood vessels. It is hypothesized that a defect in the formation of the normal arteriolar capillary network occurs somewhere around the third week of embryogenesis that leads to the malformation (Niazi et al. 2010). Others postulate that AVMs are a consequence of stimulation of vascular growth by blood shunting, genetic errors, and mutations in the genes controlling angiogenesis (Zaidat and Alexander 2006).

AVMs are distinguished from other types of cerebral vascular malformations by their direct anastomosis between arterial and venous channels, without any intervening capillary involvement (Ali et al. 2003; Kondziolka et al. 1999; Roach and Riela 1995). There is no brain parenchyma contained within the nidus. The tangled nidus of the AVM receives direct high-flow arterial blood from multiple feeding arteries. Blood is then shunted straight into the venous drainage system, which is subserved by veins that vary considerably in number, size, and configuration.

The blood vessels become progressively dilated, thereby increasing the risk of rupture and subsequent spontaneous intracranial hemorrhage.

AVMs have a propensity for hemorrhage. The annual incidence of AVM rupture in children is 2–4 % per year (Niazi et al. 2010; Yen et al. 2010; Darsaut et al. 2011). Mortality rate for children is 25 % versus 6–10 % in adults. Often AVMs in children are located in the posterior fossa or are deep-seated in areas such as the basal ganglia or thalamus. Hemorrhages in these regions are generally less tolerated than in the supratentorial areas seen as common AVM sites for adults. It is suspected that AVMs in children may be prone to bleeding due to a more active angiogenesis mediated by vascular endothelial growth factor (VEGF) as opposed to their adult counterparts (Niazi et al. 2010).

Tissues adjacent to the AVM may also be mildly hypoxic as the malformation may be stealing blood from the bordering healthy tissue causing chronic ischemia (Roach and Riela 1995; Smith and Sinson 2006). Such stealing of blood, known as the “steal phenomenon,” results in less devastating neurological symptoms that may herald an impending bleed. This phenomenon is frequently not seen in children.

Secondary pathological changes can include cerebral aneurysms; approximately 7 % of patients with an AVM develop an aneurysm (Smith and Sinson 2006). Most commonly, aneurysms are found on the artery feeding the AVM and are considered pre-nidal. Aneurysms may also occur within the nidus or post-nidal veins. It has been reported that associated aneurysms are higher in adults with AVM than children (41 % vs. 26 % in one series) (Niazi et al. 2010).

### 9.5.3 Presenting Symptoms

As mentioned earlier, the primary symptom of AVM in the pediatric population is intracranial hemorrhage (ICH) (Griffiths et al. 1998; Horgan et al. 2006; Humphreys et al. 1996; Kondziolka et al. 1992, 1999; Muszynski and Berenstein 2001; Punt 2004; Zaidat and Alexander 2006). As the majority of AVMs lie within the cerebral

parenchyma, hemorrhages usually present as a subarachnoid or intraparenchymal bleeds. Clinical symptoms of an intracranial hemorrhage include sudden and severe headache that is often described as the “worst headache ever,” nausea and vomiting, neck stiffness, progressive neurological decline, and rapidly progressing coma (Punt 2004).

Some patients with AVMs may have intermittent or progressive symptoms rather than a single catastrophic event. Occasionally, the evolution may be more gradual and characterized by episodes of moderate headache, followed by focal neurological features over the next several hours. Hemiparesis, hemianopia, and focal seizures are typically seen. This presentation may lead clinicians to believe that the child has sustained a characteristic occlusive episode rather than a hemorrhagic one (Punt 2004). It may, in fact, be periodic small hemorrhages or thrombosis of a portion of the AVM, causing an infarct in the surrounding brain parenchyma that has occurred (Roach and Riela 1995).

Some patients develop progressive neurological deficits over time without evidence of hemorrhage. This presentation may be attributed to the steal phenomenon. In one series, other than ICH (71.6 %), children presented with seizures (15.6 %), headache (5.9 %), and other neurological deficits including cranial nerve palsies (4.3 %). Approximately 2.7 % children were asymptomatic with the AVM found incidentally in this same series (Niazi et al. 2010).

Seizures without features of spontaneous intracranial hemorrhage, or fixed neurological deficit, are seen in 14–20 % of patients (Humphreys et al. 1996; Kondziolka et al. 1999; Punt 2004). The seizures are presumably a result of gliosis of the brain due to chronic ischemia adjacent to the AVM (Kondziolka et al. 1999; Punt 2004). Very large AVMs may produce audible cranial bruits. AVMs with large arteriovenous shunts can also present with heart failure in the infant population (Elixson 1992; Levy et al. 2000; Punt 2004). AVMs in the basal ganglia may produce movement disorders (Punt 2004). Macrocephaly and prominent scalp veins may also be evident.

### 9.5.3.1 Diagnostic Imaging

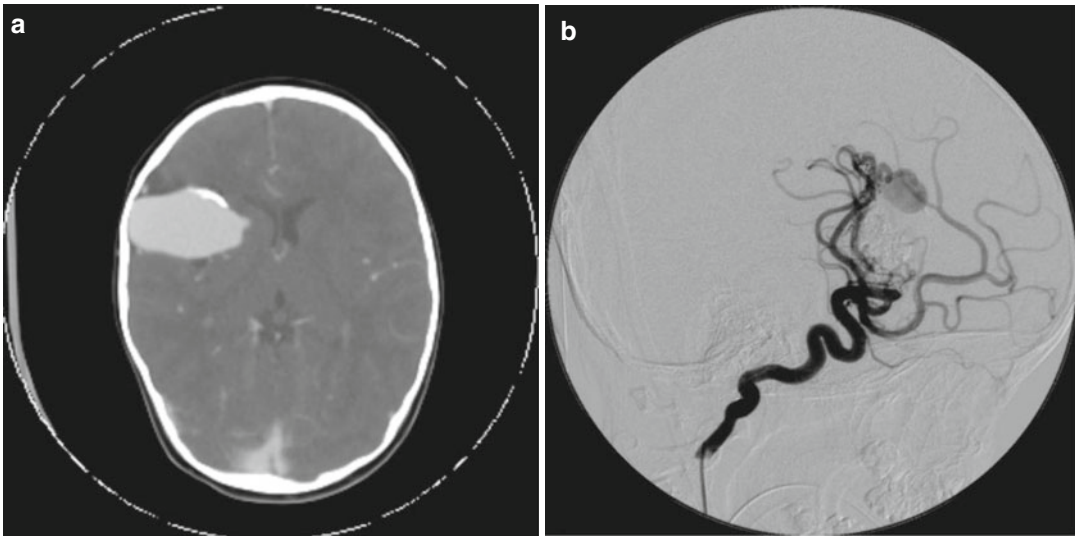
Upon initial presentation of a symptomatic ICH, CT scan should be the first radiological study completed. It is appropriate for identification of hemorrhage and any resulting hydrocephalus or mass effect. A non-contrast CT may also suggest the presence of an AVM if calcifications or dilated vessels are seen. Contrast CT (Horgan et al. 2006; Kondziolka et al. 1999; Meyer et al. 2000), specifically CTA (CT angiogram), will often reveal the vascular nature of the lesion. It will give a rough estimate of the location, size, and drainage of the lesion that is especially useful if other imaging cannot be done due to emergent nature of surgical intervention (Niazi et al. 2010).

MRI and MRA imaging may prove very helpful in diagnosis and planning management strategies. The higher resolution of this technique compared to CT is more specific regarding size and location, as well as helping differentiate from other sources of bleeding such as tumor or cavernoma. MRA may identify anatomy of the vasculature and nidus location/characteristics. Lastly, MRI/MRA technology preoperatively can assist with stereotactic guidance intraoperatively (Niazi et al. 2010).

The gold standard for AVM diagnosis is conventional 4-vessel cerebral angiography (Fig. 9.4). Angiography of an AVM will show abnormally dilated feeding arteries, draining veins, and the location of the tangle nidus (Horgan et al. 2006; Wolfe et al. 2009). Additionally, presence of associated aneurysm or venous anomalies such as ectasia or varices can be identified. Dynamic blood flow through and around the AVM can be evaluated by angiography. The presence of a hematoma may lead to failure to visualize all of the malformation and its feeding vessels. The hematoma may compress and obscure the AVM, so for this reason, it is advisable to perform angiography once the clot retracts/dissolves (Punt 2004; Niazi et al. 2010).

In addition to imaging and clinical assessment, a thorough review of all systems, full coagulation profile, cardiovascular examination, and hematology profile should be completed on every child in order to establish a diagnosis (Ali et al. 2003; Punt 2004).





**Fig. 9.4** (a) Computed tomography scan and (b) angiogram of a saccular aneurysm

### 9.5.4 Treatment

The primary goals of treatment of AVMs in children are to eliminate the risk of future hemorrhage (given annual risk of 2–4 %), control seizures, and relieve symptoms related to vascular steal (Horgan et al. 2006). The success of treatment is dependent on the size of the AVM, its location, and vascular tendencies. The clinical condition of the patient at the time of diagnosis also plays a major role (Niazi et al. 2010). Treatment options of AVMs include microsurgical resection, radiosurgery, endovascular embolization, or a combination of treatment modalities. The option for conservative management of AVM in children has essentially been abandoned, except where high morbidity risk or ineffective treatment is determined (Darsaut et al. 2011; Niazi et al. 2010; Ali et al. 2003; Horgan et al. 2006; Kondziolka et al. 1999; Zaidat and Alexander 2006).

The Spetzler-Martin (SM) grading system (Table 9.4) is a scale developed to predict the results of surgical intervention in adults (Spetzler et al. 2002). It is used in pediatric patients and has also been helpful in predicting outcomes of other interventions as well as surgery (Darsaut et al. 2011). This grading system assigns points to three features of an AVM: the size, area of the

**Table 9.4** Spetzler and Martin grading system

Graded feature	Points assigned
Size of AVM	
Small (<3 cm)	1
Medium (3–6 cm)	2
Large (>6 cm)	3
Eloquence of adjacent brain	
Non-eloquent	0
Eloquent <sup>a</sup>	1
Pattern of venous drainage	
Superficial	0
Deep <sup>b</sup>	1

<sup>a</sup>Eloquent brain: brainstem, cerebellar peduncles, deep cerebellar nuclei, internal capsule, basal ganglia/thalamus, motor strips, speech area, visual cortex

<sup>b</sup>Deep drainage is internal cerebral veins, basal vein of Rosenthal, and precentral cerebellar veins

brain (eloquent and non-eloquent), and the pattern of venous drainage. The sum of the points determines the grading.

Children who present with an acute intracerebral hemorrhage, and associated progressive neurological deficit and/or brainstem compression, require immediate surgery (Horgan et al. 2006; Kondziolka et al. 1992). The main goal of the surgery in acute presentation is to relieve the immediate increased intracranial pressure by evacuation of hematoma and removal of the AVM. Patients often require a cerebral spinal

fluid (CSF) diversionary procedure, specifically insertion of an external ventricular drain.

Ideally, surgical resection of the AVM should be delayed for 2–4 weeks post hemorrhage if a child is clinically stable (Horgan et al. 2006). This allows for resolution of the hematoma and the opportunity for a complete diagnostic workup to be done. Lesions with SM grades I–III tend to have acceptable surgical outcomes: high rate of obliteration (50–90 %), average complication rate of 10 %, and low mortality rate (0–8 %) (Yen et al. 2010). Patients who receive a score of IV and V should only be considered for surgery when significant repetitive hemorrhage occurs, as rates of morbidity and mortality are proportionately higher.

Surgery eliminates the risk of immediate bleeding and improves seizure control (Ali et al. 2003; Hoh et al. 2000; Horgan et al. 2006; Smith and Sinson 2006). Adjuncts to surgery that assist the neurosurgical team with planning and limit surgical complications are stereotactic localization, functional testing, and cortical localization. Monitoring of the patient during the procedure with SSEP (somatosensory evoked potential), MEP (motor evoked potential), EEG (electroencephalogram), and/or BAER (brainstem auditory evoked response) is indicated, especially in higher grade lesions where the potential for significant deficit exists (Darsaut et al. 2011). Intraoperative complications include hemorrhage, parenchymal injury due to sacrificing of vessels or retraction, and incomplete resection. Intraoperative angiography, if available, should always be considered to assess for residual AVM during the procedure.

Immediate complications related to surgical excision of an AVM are hemorrhage, seizures, vasospasm, and retrograde vascular occlusion, with either an arterial or venous thrombosis within the first 12–24 h after surgery (Horgan et al. 2006). These children will require postoperative management in the pediatric intensive care setting. Postoperative hemorrhage may be due to residual malformation or insufficient occlusion of the major arterial inputs and normal perfusion breakthrough phenomenon (Horgan et al. 2006; Smith and Sinson 2006). Normal

perfusion breakthrough can occur after AVM resection, when blood flow that was directed through the AVM is now redistributed. If the perfusion pressure is greater than the autoregulatory capacity of the surrounding brain, swelling or hemorrhage may occur (Horgan et al. 2006).

With advances in stereotactic radiosurgery (SRS) as a treatment modality utilized in children, conventional radiation no longer has a place in the treatment armamentarium. SRS uses high-energy radiation aimed directly on the nidus of the AVM. The radiation induces sclerosis of the blood vessels and ultimately obliterates the AVM by proliferation and thrombosis (Roach and Riela 1995; Niazi et al. 2010; Darsaut et al. 2011).

Whereas microsurgical intervention has the advantage of immediate and definitive treatment in lower SM grade lesions, SRS is recommended for AVMs in deep brain locations and eloquent cortical areas where safe surgical resection is questionable (Niazi et al. 2010; Yen et al. 2010; Darsaut et al. 2011). The main disadvantage of SRS is that obliteration of the malformation occurs over 1–3 years and sometimes up to 5 years. During this period of time, the child continues to be at risk for recurrent hemorrhage (Hoh et al. 2000; Levy et al. 2000; Punt 2004; Smith and Sinson 2006; Smyth et al. 1997). In various modern series, reports of post-radiosurgery hemorrhage rate is between 1.3 and 8.2 %, with the average annual hemorrhage rate equal to an untreated AVM of 2–4 % (Foy et al. 2010).

Stereotactic radiosurgery is a noninvasive procedure that is usually done in the outpatient setting. It is often administered in a single session, but depending on age of the child, location, and size of the lesion, the treatment may be staged to deliver smaller doses at intervals rather than one larger dose. Because of the need to utilize a stereotactic frame, children under 13–16 years of age often do best with sedation or anesthesia initiated prior to frame placement. Stereotactic MRI and/or biplanar stereotactic angiography is then utilized for dose planning. There are several SRS delivery systems, including Gamma Knife (GKS) and linear accelerator (LINAC) (Darsaut et al. 2011; Niazi et al. 2010).

Over the last two decades, there have been several studies that retrospectively examined the clinical outcomes of SRS treatment. Radiosurgery has proven to be most efficacious in smaller lesions (less than 3 cm in size) and in those that receive a mean marginal dose of 20 Gy. Complete obliteration of AVM for these select patients has been reported in the 65–80 % range (Levy et al. 2000). Surveillance of the lesion after treatment varies by center. Typically, angiogram is performed immediately to within the first year of the procedure, followed by annual MRI until the nidus is no longer visualized. At that juncture, or by at least year 5, another angiogram is performed to assess the AVM. Retreatment or alternate treatment should be considered if there is obliteration failure or rebleeding in this time period (Niazi et al. 2010; Foy et al. 2010).

Radiosurgery is seldom performed in children under 2 years of age (Niazi et al. 2010; Levy et al. 2000). Side effects associated with radiation that present around the time of treatment are often transient and due to cerebral edema. AVM size, radiation dose, and AVM location also may influence presence and severity of symptoms (Levy et al. 2000). After radiosurgery has been performed, patients may present with headache, nausea, vomiting, and new onset or increase of seizure activity. Treatment with corticosteroids in the post-procedure phase may help with symptom management, but a small percentage (1–6 %) of these issues may become permanent. Additionally, there have been a few cases of cyst formation and meningioma identification in follow-up (Yen et al. 2010; Darsaut et al. 2011).

The delayed effects of radiation on children can occur weeks to years after treatment. Although there is limited data available given the short history of this treatment modality, complications include hemorrhage, progressive edema, radionecrosis, seizures, and neurological deterioration (Friedlander 2007). So far, the rate of developing neoplasia status posttreatment seems to be less than 1 % (Yen et al. 2010).

Embolization is rarely a solitary treatment option for children with AVMs (Roach and Riela 1995). It is usually an adjunct therapy prior to a surgical resection (Roach and Riela 1995;

TerBrugge 1999), and it is helpful in removing the deep vessels that feed the malformation by inducing partial thrombosis of the malformation. By occluding the flow through the malformation, embolization helps to prevent excessive blood loss during surgery and avoid normal perfusion pressure breakthrough postoperatively (Horgan et al. 2006; Zaidat and Alexander 2006). In large AVMs, complete embolization in one session carries a higher risk of embolization-related hemorrhage so a staged treatment approach is recommended (Roach and Riela 1995; Zaidat and Alexander 2006).

During embolization, a catheter is placed inside the blood vessel and blocks off the abnormal vessels supplying the AVM. Various materials can be used for this procedure, including thrombogenic coils, silk threads, polyvinyl alcohol (PVA) particles, *N*-butyl cyanoacrylate (NBCA) glue, and Onyx-34 liquid embolic. In some institutions, interventionalists use combinations of coils and glue (Lv et al. 2009). The chance of complete obliteration by this method alone is anywhere from 5 to –20 % in recent series, with Onyx showing early promise for higher success rates (Darsaut et al. 2011; Yen et al. 2010; Friedlander 2007). Low obliteration rates result from the inability to embolize all vessels, and over time, AVMs can recanalize, recruit new vasculature, and reestablish AV shunting. Although the patient may have relief of some of the symptoms caused by the AVM after embolization, it is important to keep in mind that the risk of hemorrhage in a partially treated AVM may be reduced but not eliminated (Niazi et al. 2010).

The advantages of embolization over radiosurgery are the elimination of brain edema from radiation, as well as a more immediate effect of lesion reduction prior to surgery. There is, however, a reported complication rate of almost 8 % with embolization, including hemorrhage and other unexpected neurological deficits (Darsaut et al. 2011). AVMs in eloquent areas may have negative outcomes from vessel thrombosis. Some centers perform sodium amytal assessment prior to embolization or opt for radiosurgery instead.

Mentioned earlier, conservative management is used in cases where the AVM is not treatable

due to size or location and is generally associated with poor outcome (Zaidat and Alexander 2006). Patients and families should be counseled to have the child avoid activities that elevate blood pressure excessively, avoid medications or alternative therapies that may have blood thinning properties, and have regular medical monitoring and follow-up. Infants with congestive heart failure from shunting through the low-resistance AVM should be stabilized. Seizures should be treated with anti-convulsant medication. All treatment modalities require angiographic follow-up at appropriate intervals to confirm successful and complete obliteration (Ali et al. 2003; Punt 2004).

### 9.5.5 Outcomes

In the general population, non-treated lesions carry a 10–15 % mortality and 30–50 % morbidity rates (Horgan et al. 2006; TerBrugge 1999). Risk of hemorrhage from an unruptured AVM is 2–4 % per year, which translates into a 30–40 % risk of serious morbidity and a 10–15 % risk of mortality per decade (Horgan et al. 2006; Levy et al. 2000; Maity et al. 2004; Roach and Riela 1995; Smith and Sinson 2006). The greatest risk to a child with an AVM is hemorrhage. Without treatment, the risk for re-hemorrhage is nearly 6 % in the first year after the initial hemorrhage, with a return to 1.5–3 % per year thereafter. Hemorrhage results in damage to normal brain tissue that can lead to loss of normal functional abilities which may be temporary or permanent. The impact of a hemorrhage depends on the location and the extent of associated brain injury. Successful management depends on many factors, including presentation, clinical condition, the age of the child, and neuroanatomical features (size, location, and angioarchitecture) of the lesion (Horgan et al. 2006). Complete surgical excision of the AVM eliminates the risk of bleeding almost immediately. Nearly 50 % of patients with preoperative seizures are eventually seizure-free and off anticonvulsants after resection of the AVM (Horgan et al. 2006).

Excellent or good outcomes can now be achieved in 95 % of children with AVMs who

survive a hemorrhagic event with complete angiographic obliteration achieved in over 90 % (Horgan et al. 2006). A multidisciplinary approach to these malformations, with selection of appropriate treatment modalities done on a case-by-case basis by comprehensive teams, has proved invaluable in these successes. Additionally, children have brain plasticity and the ability to overcome initially poor neurological presentations better than adults (Niazi et al. 2010).

It is imperative that radiological evaluation in the posttreatment period is completed, as there is a risk of incomplete resection or recurrence. Severe complications are reported in approximately 10 % of children, and operative mortality is between 0 and 8 % (Horgan et al. 2006; Roach and Riela 1995). Despite the treatment options and recent advances, limited options for therapy still exist for approximately 10 % of cases. Prognosis for these children continues to be poor (Horgan et al. 2006; Singhal et al. 2011).

---

## 9.6 Cerebral Arteriovenous Fistulas in Children

### 9.6.1 Etiology

Cerebral arteriovenous fistulas (AVFs), excluding the vein of Galen malformation (VGAM), are extremely rare and account for only 1.6–4.7 % of all brain AV malformations in the general public (Lv et al. 2009). Among all intracranial arteriovenous lesions in children, AVFs account for approximately 10 % (Horgan et al. 2006; Zaidat and Alexander 2006). Arteriovenous fistulas can be acquired or congenital in origin (Hoh et al. 2000; Horgan et al. 2006). The exact etiology is unknown, but most AVFs are thought to be multifactorial. Conditions associated with dural AVFs include intracranial venous hypertension, previous sinus thrombosis, thrombophlebitis, tumor, previous neurosurgical intervention, and cranial trauma. Much like arteriovenous malformations, AVFs have a relationship to some childhood syndromes, including HHT—hereditary hemorrhagic telangiectasia (Osler-Weber-Rendu disease), Wyburn-Mason syndrome (Bonnet-Dechaume-Blanc), and

Klippel-Trenaunay-Weber syndrome (Hoh et al. 2000; Horgan et al. 2006).

### 9.6.2 Pathophysiology

Arteriovenous fistulas are abnormal connections between a dural arterial supply and a dural venous channel. There is no intervening capillary channel between the arterial and venous supply which creates conditions for rapid high flow through the vessels (Lv et al. 2009). Unlike the AVM, which has a well-circumscribed discrete nidus, AVFs are composed of a diffuse network of numerous arteriovenous microfistulae (Kondziolka et al. 1992; Zaidat and Alexander 2006). Arteriovenous fistulas are commonly found in the sigmoid-transverse sinus, cavernous sinus, and superior sagittal sinus (Horgan et al. 2006; Kondziolka et al. 1992). Approximately 50 % of all dural AVFs are found in the occipital-suboccipital region (Kondziolka et al. 1992).

In children, AVFs are often solitary entities, but they may also be multiple entities with multiple feeding arteries (Horgan et al. 2006; Kondziolka et al. 1992). Arterial supply and venous drainage patterns vary depending on the location of the fistula (Zaidat and Alexander 2006). Transverse sigmoid dural AVFs are usually supplied by the ipsilateral occipital artery, with additional supply from the anterior and posterior division of middle meningeal arteries, posterior auricular artery, neuromeningeal trunk of the ascending pharyngeal artery, posterior meningeal branches of the ipsilateral vertebral artery, and possibly the meningohypophyseal trunk from the internal carotid artery (Zaidat and Alexander 2006). Venous drainage is variable and can involve the ipsilateral sinus, depending on the degree of sinus obstruction into the contralateral transverse sigmoid sinus or cortical veins (Zaidat and Alexander 2006). Arterial supply from the coronal segments of either or both middle meningeal arteries or superficial temporal artery primarily supplies fistulas that are found in the superior sagittal sinus. Additional supply may be from the anterior falcine artery of the ophthalmic artery and the posterior meningeal branch of the vertebral artery.

Ethmoidal dural AVFs are those along the anterior cranial fossa floor are primarily fed by anterior and posterior ethmoidal branches of the ophthalmic artery and receives a secondary supply from the internal maxillary artery. Venous drainage is usually via a pial vein commonly associated with a venous varix that is directed toward the superior sagittal sinus (Horgan et al. 2006). Cavernous dural AVFs are rarely found in the pediatric population. These fistulas receive arterial supply from dural branches of the cavernous segment of the internal carotid artery and also from distal internal maxillary artery branches, middle/accessory meningeal arteries, and distal branches of the ascending pharyngeal artery. Venous drainage is via superior ophthalmic vein, cavernous sinus, or cortical veins.

AVFs can be associated with other vascular lesions such as AVMs and (Horgan et al. 2006) aneurysms. Neonates and children with dural AVFs develop cerebellar tonsillar prolapse that results from hydrovenous dysfunction of the posterior fossa and is reversible after therapy (Horgan et al. 2006).

### 9.6.3 Presenting Symptoms

Clinical presentation in children with AVFs is variable and specific to age, location, size of the fistula, and the presence of other vascular lesions (Hoh et al. 2000; Horgan et al. 2006; Kondziolka et al. 1992). Location and pattern of drainage are key components of the clinical presentation. Cardiac involvement is absent in the adult population, but in children it is often seen and may be the sole presenting feature (Zaidat and Alexander 2006). Neonates typically present with symptoms of heart failure, cyanosis, and cranial bruits, whereas children outside of the neonate period present with neurological symptoms (Hoh et al. 2000; Horgan et al. 2006; Kondziolka et al. 1992). Children between 1 and 15 months of age are the largest group of patients, typically presenting with hydrocephalus and macrocrania, increased intracranial pressure (ICP), developmental delay, seizures, and subarachnoid hemorrhage (SAH) (Horgan et al. 2006). If a child is 2–15 years of age at time of presentation, their clinical symptoms would often

include headaches, focal neurological deficits, syncope, seizures, and SAH (Horgan et al. 2006).

Hemorrhage from an AVF is relatively uncommon (Hoh et al. 2000; Kondziolka et al. 1992). In one series of 41 patients with 63 AVFs, there was a 17.1 % hemorrhage rate (Weon et al. 2004). Anterior cranial fossa and tentorial dural AVFs almost always drain into a cortical vein and are associated with a high degree of intracranial hemorrhage (Zaidat and Alexander 2006). A dural AVF occurring in the cavernous sinus usually presents with proptosis, cranial bruit, increased intraocular pressure, diplopia, or diminished visual acuity (Kondziolka et al. 1992; Zaidat and Alexander 2006).

AVFs can be classified into three types:

*Type 1* (least risk): Drain via the ipsilateral sinus; these usually present with headaches and bruits but rarely with neurological deficits or hemorrhage

*Type 2* (higher risk): Drain toward the contralateral sinus; these present with more severe symptoms mostly related to increased ICP or papilledema

*Type 3* (highest risk): Drain via cortical veins; these are at greatest risk of ICH or venous infarction

Some dural AVFs can spontaneously progress from type 1 to either type 2 or 3 (Zaidat and Alexander 2006).

### 9.6.4 Diagnostic Imaging

Conventional cerebral angiography remains the preferred diagnostic test for AVFs. A complete evaluation of head and neck vasculature is required (Zaidat and Alexander 2006). Plain chest x-rays are utilized to screen for signs of congestive heart failure: cardiomegaly, pulmonary vascular congestion, and edema.

CT scan features that may suggest AVFs include prominent enlargement of arteries or veins, a large varix, and lack of an obvious nidus (Horgan et al. 2006). CT is valuable for assessing ventricular size or the presence of ischemic infarctions and is also used to rule out parenchymal edema related to venous hypertension, SAH, subdural hematoma, and intraparenchymal hemorrhage (Horgan et al. 2006). Pediatric dural AVFs

can have rather large draining sinuses or veins. Sometimes, the draining sinus may be so massive on imaging that it can be misinterpreted as an extra-axial mass (Zaidat and Alexander 2006).

MRI in combination with ultrasound can expose abnormally enlarged dural arteries, normal pial arteries, thrombosis of the dural sinus, and multiple parenchymal serpentine vessels without a vascular nidus (Zaidat and Alexander 2006). MRI is effective in delineating cerebellar tonsillar prolapse. MRA may demonstrate flow-related enhancement of serpentine vessels, and MRV is used to evaluate for the presence of a thrombosis in the recipient sinus (Zaidat and Alexander 2006).

#### Pearl

- Conventional diagnostic cerebral angiography remains the gold standard for certain vascular malformations including AVF and AVM when complete and thorough evaluation of head and neck vasculature is required.

### 9.6.5 Treatment

Therapy for dural AVFs in the pediatric population must be performed with the understanding that they are potentially life-threatening lesions. The goal of treatment is to interrupt all the feeding arteries as closely as possible to the fistula while leaving the venous drainage intact, thereby obliterating the fistula (Hoh et al. 2000). Medical management with inotropic agents and diuretics is often vital at the onset of cardiac manifestations (Kondziolka et al. 1992).

Treatment options for the AVF include surgical resection, endovascular treatment, or a combination of treatment modalities. Surgery has traditionally been the treatment approach but has been replaced more and more by endovascular embolization. Many brain AVFs are deep and located in eloquent areas that carry high risk for neurological morbidity when addressed surgically. Because there may often be several arterial connections for a single venous channel,

endovascular embolization is often done as a staged transarterial approach (Lv et al. 2009). Use of various agents has been employed, such as balloons, coils, glue, and Onyx-34. The procedure is generally done under general anesthesia via a percutaneous femoral puncture (Weon et al. 2004). Complications that may occur include arterial collateral recruitment from too proximal an occlusion or decreased venous outflow and venous hypertension from an occlusion too distal. Other complications include cerebral edema and hemorrhage. Radiation has been utilized in adults with localized slow flow dural lesions but is not an appropriate treatment in infants or children with extensive dural AVFs (Kondziolka et al. 1992). Depending on the complexity of the fistula, treatment may be either palliative for symptom relief or curative.

#### Pearl

- The goal of surgery is to interrupt all the feeding arteries as close as possible to the fistula while leaving the venous drainage intact.

### 9.6.6 Outcomes

Irreversible brain injury was found in cases where dural AVFs were undiagnosed and in cases where cerebral venous hypertension went unchecked for a long period of time. In cases of early presentation in neonates, no presence of lasting radiological or clinical deficits was seen (Kondziolka et al. 1992).

## 9.7 Intracranial Aneurysms

### 9.7.1 Incidence

The incidence of intracranial aneurysms in children has been estimated at 1 per 1, 000,000 per year. There is a bimodal age pattern, with a peak occurring in the first 2–6 years of life and the second peak occurring in the second decade. Intracranial aneurysms occur predominantly in

males, with a male to female ratio of 1.2–2.8:1 (Punt 2004). A recent review of the literature found that pediatric aneurysms account for 1–5 % of all aneurysms. Cerebral aneurysms are very rare in patients 18 years old or younger but are even rarer in the infant and toddler age group (Huang et al. 2005).

Features of childhood aneurysms which are different than those of adults include (1) a predominant incidence in males versus females; (2) a higher incidence of unusual sites, specifically the posterior circulation, and especially the carotid bifurcation location; (3) a predominance of giant aneurysms that account for 20 % of the aneurysm types seen in children; (4) a lower incidence of multiple aneurysms; (5) a higher incidence of posttraumatic and infectious causes; and (6) a tendency toward a higher frequency of spontaneous thrombotic aneurysms (TerBrugge 1999).

### 9.7.2 Aneurysm Subtypes

There are four different subtypes of aneurysms that are defined by their shape and form: saccular aneurysms (berry aneurysms), fusiform aneurysms (including giant aneurysms), infectious or mycotic aneurysms, and traumatic aneurysms.

#### 9.7.2.1 Saccular Aneurysms (Berry Aneurysms)

Saccular aneurysms are nontraumatic, noninfectious lesions. They are often round with a well-defined neck that connects to a parent artery but also can be broad-based with no stalk or cylindrical. Thought likely to be a result of congenital abnormalities in the media of the arterial wall, saccular aneurysms occur more commonly in the general population, up to 80 % of all aneurysms in some literature (Hinkle et al. 2010). They occur less so in children, but overall have a high incidence of spontaneous rupture or hemorrhage. Statistics of this phenomena range from 35 to 75 % (Jian et al. 2010).

#### 9.7.2.2 Fusiform Aneurysms

Fusiform aneurysms are circumferential dilations involving the arterial wall. They occur in

cerebral arteries, as well as other parts of the body. Although they only account for approximately 5 % of intracranial aneurysms in the general population, fusiform lesions occur more frequently in children. In this age group, they are associated with connective tissue disorders, radiation to the pituitary region, and after resection of craniopharyngiomas (Hetts et al. 2009). Fusiform aneurysms are commonly found in the basilar arteries or terminal portions of the internal carotid arteries and often result from diffuse arteriosclerotic changes.

Often called “dissecting aneurysms,” these lesions have a lower incidence of hemorrhage than saccular aneurysms, but their neurological impact is commonly embolic stroke as acute and subacute dissection events in the vessel wall occur (Hinkle et al. 2010).

“Giant aneurysm” is a term given to lesions that are >25 mm in size. They are rare in adults but were documented in 11–23 % of the cases in the literature (Kakarla et al. 2010; Lasjaunias 2005). Common sites were the basilar artery and the terminal portions of the ICAs. They also tend to produce symptoms typical of space-occupying lesions due to their potential size, and can be mistaken for a tumor on neuroimaging (McCance and Huether 2002; Jian et al. 2010; Hetts et al. 2009).

#### 9.7.2.3 Mycotic or Infectious Aneurysms

Mycotic aneurysms are rare and result from arteritis caused by bacterial emboli (McCance and Huether 2002). These lesions tend to have a lower hemorrhage potential as compared to saccular and fusiform aneurysms. Associated infections include endocarditis and meningoen- cephalitis and immunodeficiencies, both congenital and acquired (Hetts et al. 2009; Lasjaunias et al. 2006). In addition to endovascular and surgical management of these aneurysms, appropriate systemic antibiotic therapy is indicated (Jian et al. 2010; Hetts et al. 2009).

#### 9.7.2.4 Traumatic Aneurysms

Traumatic aneurysms occur as a result of sustained trauma to the arterial wall, causing a fracture that weakens the wall (McCance and

Huether 2002). As would be expected given the mechanism of injury, these aneurysms are commonly seen in vessels near the skull base versus the supratentorium.

### 9.7.3 Etiology

Pediatric aneurysms differ from those of adults in that they are not caused by the classic risk factors associated with adult aneurysms. These potentially modifiable risk factors include hypertension, shear stress, high fat and high cholesterol diets, oral contraceptive use and cocaine, and alcohol and tobacco use (Khoo et al. 1999; Lasjaunias et al. 2006). In addition, typical diseases of the vascular system seen during the fifth, sixth, and seventh decade of life, such as atherosclerosis and degenerative vascular conditions, account for aneurysm peak during these age groups in adults. For this reason, it has been proposed that a vasculopathy (congenital or acquired) predisposes the cerebral vasculature to aneurysm development (Hinkle et al. 2010). Associated conditions of intracranial aneurysms in children include vascular anomalies, cardiac lesions, connective tissue abnormalities, hematological disorders, infections, immunodeficiencies, and phakomatoses. Other miscellaneous causes, such as surgical complications, penetrating head injuries, and radiation therapy, have been reported. As with their adult counterparts, intracerebral aneurysms in children may be due to a combination of genetic and acquired factors (Khoo et al. 1999). Refer to Table 9.5 for a list of causes and pathologies that may be associated with intracranial aneurysms in childhood.

### 9.7.4 Pathophysiology

Numerous theories exist regarding the pathophysiological mechanisms of childhood aneurysm formation. Some state that childhood aneurysms are not congenital in nature but rather are thought to be related to a weakening process of the vessel wall matrix (TerBrugge 1999). Yet other theories propose that aneurysms form because of an



**Table 9.5** Causes and associated pathologies of intracranial aneurysms (Proust et al. 2001; Hettis et al. 2009; Vananman et al. 2010)

<i>Vascular anomalies</i>
Cerebral AVM
Moyamoya
<i>Cardiac lesions</i>
Coarctation of the aorta
Bacterial endocarditis
Atrial myxoma
<i>Connective tissue abnormalities</i>
Marfan's syndrome
Ehlers-Danlos type IV syndrome (rarely in types I and VI)
Fibromuscular dysplasia
Pseudoxanthoma elasticum
<i>Hematological disorders</i>
Sickle cell disease
G-6-PD deficiency
Thalassemia
<i>Infections and immunodeficiencies</i>
HIV/AIDS
Syphilis
Severe combined immunodeficiency
X-linked immunodeficiency
<i>Phakomatoses</i>
NF-1 (especially after radiation therapy)
Tuberous sclerosis
<i>Miscellaneous</i>
Surgery for craniopharyngioma
Radiation therapy
Polycystic kidneys
Penetrating or blunt head injury
Neurocutaneous disorder (PHACE)

internal elastic membrane defect that is attributed to a congenital anomaly, infectious process, and head injury including birth trauma.

The internal carotid artery (ICA) bifurcation is the most common site for pediatric aneurysms and accounts for 29–54 % of all pediatric aneurysms (Maher and Meyer 2006). Some researchers feel that this may be due to the large bifurcation angle. Hemodynamic stress with subsequent impingement of an axial stream of blood causes high shear forces and fenestration of the internal elastic lumina at the apex of the bifurcation. Another theory implicates the augmented blood flow in the vessel wall due to associated vascular anomalies, such as arteriovascular malformations (AVM) or coarctation of the aorta to be causes of

aneurysms in younger age groups (Krishna et al. 2005). The concept of aneurysmal vasculopathies and a redirection of focus to understanding the biology of the type of arterial wall disease that is associated with an aneurysm have been entertained in recent years (Lasjaunias et al. 2006). Aneurysmal subtypes add to the complexity of etiologic theories of aneurysm formation as most case series that examine specific aneurysm subtypes are too small to arrive at a definitive conclusion (Lasjaunias et al. 2006).

### 9.7.5 Presenting Symptoms

It is important to note that most intracranial aneurysms in children are not found incidentally, although with more recent availability of neuroimaging for other neurological issues, some studies report as much as 35 % are incidental findings (Kakarla et al. 2010). The most common presenting symptom in children with an aneurysm is sudden massive intracranial hemorrhage, more specifically subarachnoid hemorrhage (SAH). Like adults, severe and sudden onset of headache, vomiting, meningeal irritation, and increased intracranial pressure occur as a result of the blood from the ruptured aneurysm entering the subarachnoid space. Further symptoms such as focal neurological deficits, deterioration in consciousness, seizures, coma, and retinal hemorrhages occur as a result of progressive bleeding, expansion of the aneurysm, or, in the case of large lesions, mass effect. Retinal hemorrhages are found near blood vessels and may appear flamed shaped, or they may be ovoid and located close to the optic disc. Subhyaloid hemorrhage (blood between the retina and vitreous humor) may occur if the retinal hemorrhages dissect between retinal layers. A sudden increase in intracranial pressure caused by an intracerebral hematoma occurs in approximately one-fourth to one-half of all children (Khoo et al. 1999; Santos et al. 2005).

In cases of giant aneurysms or large fusiform lesions that do not hemorrhage, more subtle signs related to space-occupying lesions may be present, such as intermittent headache, visual changes, and sensory and motor deficits.

### 9.7.6 Diagnostic Tests

In the case of ruptured aneurysms, lumbar puncture and cranial CT are used for initial evaluation (Khoo et al. 1999; Proust et al. 2001). Lumbar puncture (LP) is used to detect blood or xanthochromia in the cerebrospinal fluid (CSF), which is indicative of SAH. Performing an LP is contraindicated if a child has signs and symptoms of increased intracranial pressure (ICP). If either the CT or LP is positive for SAH, contrast-enhanced imaging is indicated. Depending on the child's clinical condition and availability of imaging, this may be MRI/MRA, digital subtraction CT angiography (CTA), or cerebral catheter angiography (Jian et al. 2010).

MRI/MRA is capable of visualizing aneurysms that are greater than 5 mm. MRI is a good tool for demonstrating the aneurysm and for delineation of complications in the case of an aneurismal bleed, such as intraventricular hemorrhage, subdural hemorrhage, intracerebral hematoma, or acute hydrocephalus. Although it is a source of radiation, CTA is faster and is diagnostically more sensitive for aneurysm identification than MRI according to some literature. Still, many institutions proceed directly after CT or LP to the gold standard, catheter angiography, mainly due to the false-negative results that can be seen in the neuroimaging exams (Jian et al. 2010; Santos et al. 2005).

MRI/MRA is used to screen children with non-SAH headaches or seizures and those with strong family history of aneurysms, and significant risk factors or comorbidities (such as Ehlers-Danlos syndrome or polycystic kidney disease). Additionally, this modality is utilized to follow patients with conservative management treatment plans or those that are post treatment.

### 9.7.7 Treatment Options

Over the last 20–30 years, there has been a significant evolution of microneurosurgical techniques and endovascular treatments in pediatric aneurysm management. Moreover, the availability of pediatric neurosurgeons, neuro-radiologists/interventionalists and neurologists

has optimized management for this population (Jian et al. 2010; Hetts et al. 2009).

#### 9.7.7.1 Medical Management

Today, expectant conservative medical management, or “watchful waiting,” is no longer widely used as a definitive therapy (Huang et al. 2005). This may be considered in cases of very complex, eloquent location or multiple/extensive disease but is by far the exception rather than the rule in pediatric patients. Aneurysms in children should be regarded as both an acute and chronic disease. Increased growth of untreated lesions can often be seen in children, as well as recurrence and de novo formation of additional aneurysms, supporting the philosophy of aggressive management and follow-up (Kakarla et al. 2010; Hetts et al. 2009; Jian et al. 2010).

The goal of medical management of children with ruptured and suspected intracranial aneurysms is to provide prompt stabilization in order to prevent secondary complications of hemorrhage. This includes aggressive control of systolic and mean arterial blood pressure in order to prevent continued oozing and rebleeding. Strict fluid control and monitoring is required with the aid of indwelling arterial catheters, central venous lines or Swan-Ganz catheters, and an indwelling urinary catheter. In some children, hydrocephalus and increased ICP may require placement of an EVD (externalized ventricular catheter), and drainage of CSF is carefully titrated (Hinkle et al. 2010). Provision of adequate sedation or analgesia to minimize anxiety and headache must be considered against the need for frequent neurological assessment. Antihypertensive agents, including calcium channel blockers, beta-blockers, and vasodilators, may be required to manage marked hypertension. Anticonvulsant therapy to prevent seizures is often routinely administered.

In the postoperative phase, anticonvulsant therapy is often continued for a period of 6 months, or indefinitely, in situations where extensive cortical destruction has occurred after subarachnoid hemorrhage. High-dose glucocorticoids are given in situations of acute aneurismal subarachnoid hemorrhage. Minimization of fluctuations in intracranial pressure as a result of straining, coughing, and vomiting are controlled

with stool softeners, breathing treatments, and antiemetic medications (Khoo et al. 1999). A fibrinolytic inhibitor is administered to delay lysis of blood clots and minimize the overall risk of rebleeding. Bed rest may be indicated in children who are unable to have immediate surgery.

In cases of SAH, vasospasm is commonly seen in adult counterparts. Although concerning for pediatric patients as well, the literature demonstrates a better tolerance of SAH by children with decreased vasospasm events (Jian et al. 2010; Hetts et al. 2009). It has been proposed that the phenomenon responsible is abundance of leptomeningeal collateral supply to watershed areas in children's brains that prevent ischemia/stroke. Others have postulated that elasticity of the cerebral vasculature and well-preserved autoregulation in this age group are factors (Sharma et al. 2007). This said, the potential for vasospasm is significant and should be monitored for, but more importantly prevented.

Volume expansion and use of cerebroselective calcium channel blockers have been known to help. Close monitoring and prompt identification and treatment are also key in minimizing any deficits. Peak incidence for vasospasm is generally 7–10 days after rupture but can occur between 3 and 14 days post-rupture. Use of transcranial Doppler assessment daily to watch for increasing velocities is recommended during the peak period, often 10–14 days. Any signs of vasospasm, clinically or on imaging, require immediate angiography and possible angioplasty to prevent infarct (Hinkle et al. 2010).

#### 9.7.7.2 Surgical Management

The primary goal in surgical treatment of aneurysms is to remove the abnormality from the circulation while preserving normal vasculature, including the perforating arteries. Up until the last 15–20 years, surgery was the standard of aneurysm management. More recently, endovascular techniques have been used with greater frequency and confidence in pediatrics, either solely or as an adjunct to surgery (Hetts et al. 2009; Jian et al. 2010).

The conventional surgical approach to treating intracranial aneurysms in children is direct

clipping of the aneurysm neck through an open craniotomy. For lesions not amenable to clipping, aneurysm trapping and bypass techniques may be employed (Kakarla et al. 2010). Improvements in neurosurgical equipment (e.g., microsurgical instruments and immobilization devices), as well as pediatric appropriate critical care management, have affected outcomes favorably in children with aneurysms (Kakarla et al. 2010).

Interventional angiography and endovascular occlusion are methods used to treat unusual sites that are commonly seen in children, especially in the posterior circulation and in the treatment of giant aneurysm. In recent years, significant developments have been made in the utilization of selective coiling and balloon occlusion techniques in children by neurointerventionalists. Although these techniques have been used many years in the adult population, history of use in pediatrics has increased in the last two decades (Jian et al. 2010). Early studies report outcomes for initial endovascular treatment to be less favorable than surgical management with regard to obliteration and recurrence rates 82 and 14 %, respectively, for endovascular intervention with 94 and 0 % for surgery (Sanai et al. 2006).

A larger, more recent study (Kakarla et al. 2010) followed patients treated microsurgically for an extended period of time (range 5–120 months), and recurrence rate for this population was 8.6 %. This suggests that over time, no single treatment is curative for a select number of pediatric patients. Many centers now use a combination of modalities to increase obliteration rates and decrease recurrence rates. In a 27-year retrospective medical record review, Hetts et al. (2009) documented crossovers of patients treated initially by coiling to microneurosurgical treatment, as well as incomplete neurosurgical obliterations requiring future endovascular treatment.

As suggested by many pediatric studies, intracranial aneurysms in children have both acute and chronic implications given their potential lifespan. Longitudinal management suggested for these lesions includes angiography at 3–6 months post initial treatment. If no residual aneurysm or recanalization is seen, yearly MRA is proposed, gradually decreasing

to every 5 years (after 3–5 negative annual exams) (Jian et al. 2010). With either evidence of incomplete surgical treatment or new aneurysms/recanalization documented, more frequent evaluation is required.

### 9.7.8 Assessment of Intracranial Aneurysms

Vigilant assessment of children with ruptured intracranial aneurysms is critical in attaining the best possible outcomes as rapidly as possible. The use of grading scales to assess the severity of a ruptured intracranial aneurysm is valuable. Two outcome predication scales commonly used to assess clinical outcomes are the Hunt and Hess Scale and the World Federation of Neurological Surgeons Scale (Cavanagh and Gordon 2002).

#### 9.7.8.1 Hunt and Hess Scale

The Hunt and Hess (HH) Scale is the most commonly used tool to assess subarachnoid hemorrhage. The grades of the scale correspond with the neurological deficits with the level of consciousness and focal deficits (Cavanagh and Gordon 2002). The HH scale is used to predict prognosis and timing of surgical or endovascular intervention Table 9.6 (Drucker 2006).

#### 9.7.8.2 World Federation of Neurological Surgeons Scale

The World Federation of Neurological Surgeons (WFNS) Scale is based on the Glasgow Coma Scale (CGS) with a correction for motor deficits to the CGS (Cavanagh and Gordon 2002) (Table 9.7).

### 9.7.9 Outcomes

A good or excellent outcome can be expected in 70–80 % of all children who have intracerebral aneurysms (Khoo et al. 1999). In recent series, favorable outcomes were seen in up to 95 % of the children followed (Aryan et al. 2006; Sanai et al. 2006). Children tend to have better clinical

outcomes than their adult counterparts. In one large study, mortality reported was 1.3 %, with morbidity as 8 % for infarction and 4 % for new-onset seizures (Hetts et al. 2009).

## 9.8 Venous Angiomas (Developmental Venous Anomaly, Vascular Malformation)

### 9.8.1 Etiology

Venous angiomas (DVA) are considered a subset of developmental venous anomalies that occur because of arrested development. The cause of this arrested development is not known. They are the most common form of vascular malformation and are found at autopsy in approximately 3 % of cases (McCance and Huether 2002). It is generally accepted that they form during intrauterine life (Ruiz et al. 2009). They are viewed by some as anatomical variations resulting from a “hemodynamic need” which causes a subsequent recruitment of “transhemispheric anastomotic pathways” (Lasjaunias et al. 1986). Others consider that these lesions are malformative in nature, formed by an occlusion such as a thrombosis of normal parenchymal veins (Saito and Kobayashi 1981). It is also postulated that these may represent the expression of disturbed fetal angiogenesis and regression (Wilson 1992). DVAs are often seen during MRIs and CT as an incidental finding (Cohen et al. 2010; Ruiz et al. 2009). They are found in both the pediatric and adult populations, with a slightly greater incidence in males (San Millan Ruiz et al. 2007).

### 9.8.2 Pathophysiology

A venous angioma is an extreme variation of veins that drain normal brain tissue within its region of distribution (Khurana 2005). Venous angiomas consist of primitive embryologic veins that form in a radial pattern and feed a central vein or “collector vein” (McCance and Huether 2002). The collector vein is often located on the

**Table 9.6** Hunt and Hess Scale

Grade	Clinical condition
0	Unruptured
I	Asymptomatic or minimal headache, nuchal rigidity
II	Moderate to severe headache, nuchal rigidity, no neurological deficit other than cranial nerve palsy
III	Drowsiness, confusion, mild focal deficit
IV	Stupor, moderate to severe hemiparesis, possible early decerebrate rigidity, and vegetative disturbances
V	Deep coma, decerebrate rigidity, moribund appearance (Cavanagh and Gordon 2002)

**Table 9.7** World Federation of Neurological Surgeons Grading Scale

WFNS grade	Glasgow Coma Score	Motor deficit
I	15	Absent
II	14–13	Absent
III	14–13	Present
IV	12–7	Present or absent
V	6–3	Present or absent

surface of the brain, but it may also be found in the deeper regions (Khurana 2005). The veins of the angioma drain their respective vascular regions (Abe et al. 2003). Normal parenchymal tissue is found between the veins that make up the venous angioma. Venous angiomas are often found near the frontal horns of the ventricles or in the cerebellum (Khurana 2005). While brain parenchyma tissue in between the veins that make up the venous angioma was considered to be normal in the past, histological and radiological studies now indicate that this is not always the rule (Courville 1963; San Millan Ruiz et al. 2007).

The most frequent abnormality noted in a recent series of 84 DVAs was locoregional cerebral atrophy in 29.7 % of the cases, followed by white matter lesions in 28.3 % of the cases and dystrophic calcification in 9.6 % of CT cases (San Millan Ruiz et al. 2007). The most frequent locations of DVAs are at the supratentorial level with a frontal predominance (Lee et al. 1996; San Millan Ruiz et al. 2007). Of significance, DVAs are often associated with other cerebrovascular lesions, the most common and clinically significant being the cavernous malformation (Cohen et al. 2010). Because of this association, when a DVA is diagnosed, other vascular malformations should be considered.

### 9.8.3 Presenting Symptoms

Unless combined with another type of vascular malformation, venous angiomas alone rarely become symptomatic. The most common presenting sign of a venous angioma is seizures without hemorrhage. Hemorrhage is rarely seen with venous angiomas. In the rare case of rupture of a venous angioma, signs and symptoms of a hemorrhage would include sudden onset of headache that may be associated with nausea, vomiting, somnolence, hemiparesis, or other focal neurological deficit. The formation of a thrombus in one or more veins can cause local venous hypertension, resulting in a headache. Venous angiomas may also cause seizures (Khurana 2005). Regional cavernous malformations (CM) are associated with DVAs in 13–40 % of cases (Huber et al. 1996; San Millan Ruiz et al. 2007), and the CMs are considered to be the likely cause of symptoms that were previously attributed to DVAs (McLaughlin et al. 1998; Rigamonti and Spetzler 1988).

### 9.8.4 Diagnostic Tests

Venous angiomas are primarily detected using neuroimaging, as they are usually not problematic. Because most DVAs can be diagnosed with routine CT or MRI, this is the first method utilized. When using MR imaging, the hemodynamic behavior of DVAs is best imaged by digital subtraction angiography (DSA) because of its higher temporal resolution; however, this should only be utilized in cases where hemorrhagic or ischemic infarctions or other associated vascular malformations are suspected (Ruiz et al. 2009; San Millan Ruiz and Gailloud 2010). Cerebral

angiography is the best method to detect a venous angioma. Angiography shows the caput medusae pattern (a cluster of veins that resemble a “head of snakes”) that drains into a collector vein. The caput medusae originate from a main venous trunk (Rodesch et al. 2005). MRI with and without contrast is another good way to image a venous angioma, as it shows the venous angioma along with any other vascular abnormality through multiple imaging sequences. Magnetic resonance venography (MRV) may be able to detect a VA if it is not too small. CT angiography (CTA) may also be used; however, it is not effective in detecting commonly associated vascular malformations, such as a cavernous hemangioma, if it is too small (Khurana 2005).

## 9.8.5 Treatment Options

### 9.8.5.1 Medical Management

Venous angiomas are primarily benign and do not require any form of treatment unless they cause seizures. If seizures are present, neuroimaging can ensure there is no other underlying arteriovenous malformation. If no other arteriovenous malformation is present, anticonvulsant medications are used to treat seizures (Khurana 2005). Although there is a lack of large or controlled studies evaluating conservative management versus management with systemic anticoagulation, medical management of thrombosed DVAs should be guided by experience gained from treating venous sinus thrombosis. This suggests prolonged, systemic anticoagulation could be of benefit in the prevention of clot propagation, improving recanalization, and promoting reversibility of symptoms (Ferro and Canhao 2008; Schaller and Graf 2004).

### 9.8.5.2 Surgical Management

Venous angiomas are frequently associated with cavernous malformations that tend to be problematic and often require surgical intervention. Surgical resection of venous angiomas alone without an associated vascular malformation is only recommended in cases where a patient has suffered a massive or recurrent hemorrhage due

to rupture of the angioma or if the venous malformation is causing debilitating seizures. Resection of venous malformations yields a risk of venous stroke due to venous congestion as venous malformations are thought to drain normal brain tissue (Khurana 2005). The surgical removal of DVAs may result in detrimental ischemic and hemorrhagic complications due to their role in the normal cerebral venous drainage system for the patient (Abe et al. 2003; Senegor et al. 1983).

## 9.8.6 Capillary Angiomas and Telangiectasia

Capillary angiomas and telangiectasias are two distinct entities. They are often mistakenly thought to be interchangeable terms (Santos et al. 2005).

### 9.8.6.1 Capillary Angiomas

In capillary angiomas, the neural tissue is usually gliotic and contains no neurons. The vessels in angiomas tend to be variable in diameter, thin-walled, and they resemble the smaller vessels seen in cavernous angiomas. Capillary angiomas are found in the posterior fossa, primarily in the pons or medulla and occasionally in the cerebellum. They are also found in the subependymal deep cortical region where they are solitary. Capillary angiomas, like telangiectasias, are often discovered as an incidental finding at autopsy. Capillary angiomas may lead to catastrophic hemorrhages because of their location in the brainstem or subependymal region (Santos et al. 2005).

### 9.8.6.2 Telangiectasias

Cerebral telangiectasias are “localized collections of multiple thin-walled vascular channels interspersed within normal brain parenchyma” (Tang et al. 2003). The parenchyma between the vessels in the telangiectasia is normal, and there are normal neurons, a normal concentration of glial cells, and normal fibers with variable ratios, depending on the region of the brain involved. Vessels in telangiectasias tend to be more constant in size

and are morphologically consistent with capillaries found in telangiectasias.

It is difficult to identify these on most imaging modalities, including serial cerebral angiography, CT, conventional MRI, fluid-attenuated inversion-recovery (FLAIR) imaging or diffusion-weighted imaging (Sayama et al. 2009). They are best visualized as small, faintly enhancing lesions on T1-weighted MR imaging with gadolinium enhancement (Sayama et al. 2009).

Telangiectasias are commonly found in the basis pontis. They make up about 4–12 % of vascular formations, but it is rare to encounter symptomatic capillary telangiectasias (Sayama et al. 2009). Usually, they are discovered as an incidental finding at autopsy. However, not all capillary telangiectasias are asymptomatic. A study by Sayama et al. (2009) reviewed a series of 105 cases of capillary telangiectasias. Seven (6.7 %) of the 105 cases demonstrated large capillary telangiectasias. Large telangiectasias were considered to measure over 1 cm. Two of the seven patients were identified as having symptoms likely related to their capillary malformations (Sayama et al. 2009). When symptomatic, the symptoms can include seizures, cranial nerve palsy, confusion, dizziness, visual changes, vertigo, tinnitus, or even progressive spastic paraparesis (Lee et al. 1997; Milandre et al. 1987; Tang et al. 2003). They may often be misdiagnosed as glial tumors or other more serious disease processes (Sayama et al. 2009).

---

## 9.9 Cavernous Malformations

### 9.9.1 Etiology

Cavernous malformations, also known as cavernous angiomas or cavernous hemangiomas, are vascular lesions that can be asymptomatic or present with varying neurological symptoms. Cavernous malformations are found in 0.5 % of the general population and make up 5–10 % of all vascular lesions (Bhardwaj et al. 2009). These lesions are found more frequently with the increased use of imaging studies for surveillance imaging for various disease entities. They are

most commonly seen in the third to fourth decade of life but about 25 % of cavernomas present in childhood (Bigi et al. 2011). Fortuna et al. (1989), in a retrospective review of cavernomas in children, found a bimodal pattern of distribution at 0–2 years of age and 12–14 years of age (Fortuna et al. 1989). There is generally no preference for sex, although some studies show higher female population in very young and spinal cavernomas more prevalent in males than females (Bigi et al. 2011).

The causes of cavernomas are both congenital and de novo. Although the exact cause of cavernomas is unknown, factors associated with de novo formations of cavernous malformations are previous irradiation, genetics, and hormones (Fortuna et al. 1989; Larson et al. 1998; Pozzati et al. 1996). In patients with brain tumors that have received radiotherapy, there is a 3.4 % incidence of these lesions (Bhardwaj et al. 2009). The genetic predisposition for cavernomas is associated with an autosomal pattern of inheritance, with predominance within the Hispanic population. This familial tendency to develop cavernomas has been linked to the CCM 1 locus on the long arm of chromosome 7 in Hispanic families and 7q21–22 in non-Hispanic families (Frim et al. 2001; Yeh and Crone 2006).

### 9.9.2 Pathophysiology

Cavernous malformations are vascular lesions that are composed of cystic vascular spaces lined by a single layer of endothelial cells. There is a distinct absence of smooth muscle elastic fibers which signifies the immaturity of the vessels. The sinusoidal vessels form a compact mass with no intervening neural parenchyma between the vascular structures. The immaturity of the blood vessels, no intervening neural parenchyma, and lack of recognizable arteries and veins differentiate the cavernoma from other vascular lesions. The appearance of a cavernous malformation is that of a discrete, well-circumscribed, reddish mass with distinct lobulations. It is a low-flow lesion which lacks arterial supply and is composed of thin-walled vascular channels in a honeycomb

pattern. It has both cystic and calcified components and is often characteristically referred to as a cluster of mulberries. Cavernomas are separated typically from normal brain tissue by a gliotic plane (Bhardwaj et al. 2009). Several forms have been identified in childhood. They have been classified as solitary, multiple, iatrogenic, and familial lesions. Cavernous malformations most commonly occur in the supratentorial region (DiRocco et al. 1996; Fortuna et al. 1989) and less commonly in the spine and posterior fossa area. In the cerebral hemisphere, cavernomas have been reported in the parietal lobes, periventricular area, temporal lobes, and occipital lobes. They are generally independent lesions but have been found to occur with associated venous malformations, specifically developmental venous anomalies (Kamezawa et al. 2005; Larson et al. 1998). Infratentorial lesion location includes the brainstem with the majority found in the pons versus the medulla or midbrain. In the spine, they are seen more in the cervical and thoracic areas versus lumbar-sacral. Usually, these lesions are identified mid-childhood to adolescence (Bhardwaj et al. 2009.)

Most cavernomas show evidence of recent or remote hemorrhage. They often contain clots and blood products of various stages of evolution within the lesion, as well as calcification and gliosis. These lesions have a propensity to hemorrhage because of the fragility of the sinusoidal channels. Microhemorrhages may not manifest clinically; however, overt hemorrhages result in neurological deterioration. The risk of bleeding of a cavernous malformation is 0.6 % but increases to 4.5 % per year for cavernous malformations with a history of hemorrhage (Frim et al. 2001; Yeh and Crone 2006). There has been some evidence in the literature to suggest that the location of the cavernous hemorrhage influences the rate of hemorrhage, specifically brainstem cavernomas (Larson et al. 1998; Porter et al. 1997, 1999). In the literature, risk of rebleeding of cavernomas in the brainstem has been as high as 34 % (Bhardwaj et al. 2009). However, this may be more related to the eloquence and sensitivity of the surrounding brain to show clinical events, as opposed to other areas of the brain (Larson et al. 1998).

The natural history of cavernomas is that they have a tendency to grow over time. This is one of the characteristics that differentiate them from other vascular lesions (Yeh and Crone 2006). One of the theories regarding the growth of the cavernoma is the hemorrhagic angiogenic proliferation theory. This theory suggests that recurrent microhemorrhages are followed by fibrosis, reorganization, or calcification that leads to growth (Frim et al. 2001; Yeh and Crone 2006). It has also been theorized that cysts occur with clot absorption and re-hemorrhage. The cysts enlarge because of osmotic forces favoring movement of fluid into the cyst cavity. Biological factors, such as estrogen, have also been found to play a role in the growth of cavernous malformations (Fortuna et al. 1989; Frim et al. 2001; Yeh and Crone 2006).

### 9.9.3 Presenting Symptoms

As previously indicated, cavernomas can be asymptomatic. Those that are symptomatic generally present with seizures, hemorrhage, and neurological deficits. Seizures are the most common presenting symptom in children: 45 % of patients with a cavernoma present with seizure, followed by 27 % with hemorrhagic syndrome and 16 % with focal neurological deficits (Fortuna et al. 1989). Children experience headaches and neurological deficits less often than adults. The seizures have been theorized to be related to cortical irritation, the presence of calcification and gliosis around the surrounding parenchyma or the accumulation of iron contained substances produced by silent microhemorrhages (Fortuna et al. 1989; Yeh and Crone 2006). Further symptoms such as headache, nausea and vomiting, deterioration in the level of consciousness, and irritability are related to increased intracranial pressure from hemorrhage. Neurological deficits will be dependent on the location of the cavernoma and can be acute or progressive. The deficit can be a symptom of overt bleeding or gradual enlargement of the lesion causing the brain to become dysfunctional. Although extremely rare in children, patients with spinal cavernomas present with hydrocephalus and myelopathies secondary



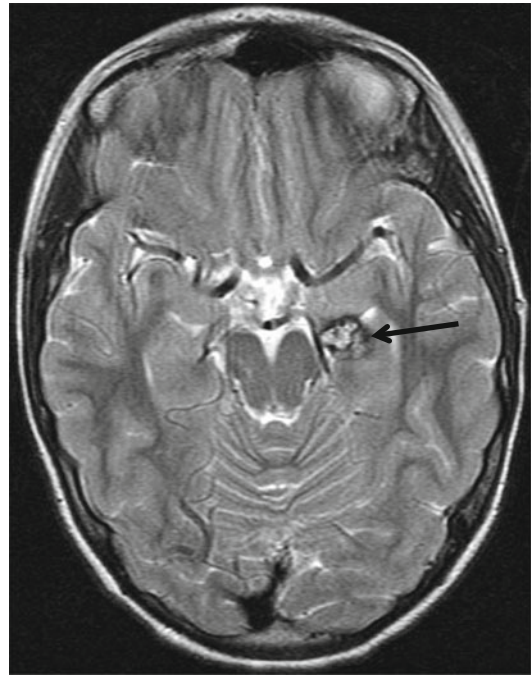
to small hemorrhages and a spinal cord compression. Progressive paraparesis and sensory changes are often usually seen in symptomatic patients with spinal cavernous malformations (Kondziolka et al. 1999).

### 9.9.4 Diagnostic Imaging

Cavernomas are detectable both on CT imaging and on MRI. Non-contrast CTs show cavernous malformations as focal areas of increased density, representing calcium or blood within the brain without mass effect. However, MRI, with its high resolution, is the diagnostic tool of choice for diagnosing cavernous malformations and for their follow-up. On MRI, cavernous malformations are best seen on T2-susceptibility-weighted images, which show high-intensity lobulated lesions (resembling popcorn kernel) surrounded by a low-intensity hemosiderin ring (resembling a bloom). Hemorrhages can produce areas of encephalomalacia, cyst, or calcification. The absence of large flow voids, suggestive of feeding arteries or draining veins, strongly suggests the diagnosis of cavernous malformation (Fig. 9.5). Cavernous malformations can be classified into four types based on their appearance on MR imaging (Table 9.8). There is no role for angiography for these lesions because cavernous malformations do not have the high arterial blood flow. In the face of an acute hemorrhage and concern for AVM, angiography is often done to eliminate that possibility.

### 9.9.5 Treatment

There is no standard treatment for children with cavernous malformations. As each child is individual, each cavernoma needs to be assessed on an individual basis using a risk-benefit approach. It has been generally accepted that cavernomas found incidentally, and that are asymptomatic, do not require treatment. Surveillance for these lesions is recommended with follow-up MRI imaging.



**Fig. 9.5** MRI of cavernous malformation

**Table 9.8** Classification of cavernous malformations based on magnetic resonance imaging

Type I	Subacute bleed hyperintense on T1 weighted sequences
Type II	Popcorn appearance, heterogeneous T1- and T2-weighted sequences
Type III	Isointense/hypointense T1- and T2-weighted images chronic blood products
Type IV	Tiny punctuate foci, hypointense T1- and T2-weighted sequences

Treatment options for a symptomatic cavernoma can be either medical or surgical. Medical management, or conservative therapy, involves the use of antiepileptic drugs for seizures, headache drugs, and physiotherapy. Medical management is considered for lesions with medically controlled seizures, lesions in critical areas without severe symptoms, and cases of multiple cavernous malformations for which the actual symptomatic lesion is unidentified (Fortuna et al. 1989; Yeh and Crone 2006). When considering medical/conservative management, one needs to take into account the cumulative risk of hemorrhage for the child, lifetime costs associated with

antiepileptics, and the long-term effects of being on antiepileptics. This becomes controversial because the curative rate from seizures with a surgical procedure is between 65 and 100 % (Fortuna et al. 1989; Kondziolka et al. 1999). In addition to medical management, patients with multiple lesions should have genetic counseling.

Surgical management is generally considered for symptomatic lesions, lesions showing growth and those with hemorrhage (Fortuna et al. 1989; Yeh and Crone 2006). Location of the lesion near eloquent or superficial areas of the brain needs to be taken into consideration when deciding upon surgical management. The 4–5 % rate for surgical morbidity in non-eloquent areas jumps to 12–25 % in more vital areas. Ideally, any surgical resection of a cavernoma should be delayed for 4–6 weeks after hemorrhagic event to allow for decreased swelling. Use of stereotactic guidance for surgical planning is typical. Optimal resection includes the cavernoma and the hemosiderin ring, which has correlated with better outcomes (Smith and Scott 2010).

The use of stereotactic radiosurgery for the treatment of cavernomas remains controversial. There have been studies pertaining to the adult population using radiation for inaccessible lesions (Tung et al. 1990). But because of the reluctance to expose young children to radiation of the brainstem or cortex, there is limited experience in pediatrics. In this small population, there has been a 3 % mortality rate and a 16 % morbidity seen (Smith and Scott 2010).

For all children with a cavernoma, whether treated or not, initial follow-up MRI is recommended in a 6-week to 6-month time period then annually after that for 2–5 years to look for rebleeding and regrowth of the cavernoma (Smith and Scott 2010).

### 9.9.6 Outcomes

Patients who undergo complete surgical resection of their cavernous malformation are relieved of their symptoms (Kondziolka et al. 1999). The literature regarding seizure resolution indicated that 65–100 % of patients postoperatively show

resolution of their seizures (Fortuna et al. 1989; Kondziolka et al. 1999). In a pediatric series, Fortuna et al. found that 73 % of patients were cured from their seizures, 20 % had improvement, and 3 % experienced worsening symptoms (Fortuna et al. 1989). Location of the cavernoma will also affect the outcome. Deep cavernomas, or those involving the brainstem, are associated with significant morbidity and mortality. In a review of 20 pediatric patients with brainstem cavernomas who underwent surgical excision, 6 had excellent results, 10 had good results with neurological improvement, and 2 had worsening of symptoms (DiRocco et al. 1996).

Recovery of the neurological deficit is dependent of the number of hemorrhagic events. Tung et al. reported that of patients who had experienced a single hemorrhagic event, 80 % of the patients experienced a transient deficit (Tung et al. 1990). Porter, et al. report that one-third of patients experiencing an event will recover fully, one-third will have no significant recovery, and one-third will have partial recovery (Porter et al. 1997).

For patients with spinal cavernomas that present with hydrocephalus, the hydrocephalus resolves post resection (Drucker 2006; Rivera et al. 2003). In regard to functional ability post-resection, the more functional the patient is pre-operatively, the more likely the patient is to do well after the surgical excision of the lesion (Box 9.1).

#### Box 9.1. Matthew's Story

Matthew was a typical high school junior. He was popular, played sports, had a girlfriend, and was looking forward to junior prom and applying to college. So when he had his first seizure, Matthew and his family were unprepared for the battery of tests that yielded his diagnosis of a cavernous angioma (cavernoma) in his left temporal lobe. The neurologist caring for Matthew started him on antiepileptic medication and referred him to a pediatric neurosurgeon.

“We were so blown away by all this,” says his mother. “We never had anyone in the family have something so serious at such a young age. Matthew was afraid that he would have a seizure when he was out with his friends or in front of his girlfriend. He had to stop playing sports. We didn’t know what to do.”

The neurosurgeon evaluated Matthew, his imaging and video EEG results. He recommended surgical resection as his best chance for seizure control with the potential of becoming free of medications in the future. Matthew and his family agreed to the procedure. Since that time, he has been seizure-free and has been weaned from his antiseizure drug.

His dad gets emotional when he talks about the experience: “Matthew is now entering his second year in college. He has his life back and we are forever grateful to our medical team.”

## 9.10 Moyamoya Syndrome

### 9.10.1 Etiology

Moyamoya is a rare vascular disorder that leads to irreversible blockage of the internal carotid arteries. It is a chronic occlusive cerebrovascular disorder of unknown etiology that was initially reported and discovered in Japan (Takeuchi and Shimizu 1957). Moyamoya in Japanese means “puff of smoke” and was named this due to its characteristic appearance of abnormally fine collateral vessels on angiography. The disease is predominantly found in children, has a bimodal presentation at the first and fourth decade of life, and has a female preponderance of 1:1.8 male/female ratio. Although the exact etiology is unknown, the disease has a genetic link carried on chromosomes 1–22 (Ipone et al. 2000). Clinical syndromes and conditions that have been associated with moyamoya include prior radiation therapy to the head or neck, Down syndrome, neurofibromatosis type 1, tuberous sclerosis,

primordial dwarfism, large facial hemangiomas, Fanconi’s anemia, sickle cell disease, and other hemoglobinopathies, autoimmune disorders including Grave’s disease, collagen vascular disorders (including Marfan’s syndrome), congenital cardiac anomalies, renal artery stenosis, infections including tuberculous meningitis and leptospirosis, and fibromuscular dysplasia (Scott and Smith 2009; Smith 2009).

Moyamoya disease refers to the idiopathic form, while moyamoya syndrome refers to those cases where a causative clinical condition has been identified (Ibrahimi et al. 2010). It accounts for approximately 6 % of all causes of pediatric ischemic stroke (Nagaraja et al. 1994; Soriano et al. 1993). Reported incidence of moyamoya in the United States is 0.086 per 100,000, while the incidence in Japan is 0.35 per 100,000 (Uchino et al. 2005; Wakai et al. 1997).

### 9.10.2 Pathophysiology

Moyamoya disease is characterized by progressive intracranial vascular stenosis due to thickening of the intima of the vessel. It is commonly seen in the distal carotid artery, proximal anterior artery, and the middle cerebral arteries (Ohaegbulam et al. 1999). The progressive narrowing leads to a decrease in arterial blood flow resulting in cerebral ischemia. The brain induces the growth of net-like moyamoya vessels in order to establish collateral blood flow to areas distal to the site of vascular stenosis (Hannon 1996). Although it is unclear the exact cause of the thickening of the intima, it has been suggested that it is related to elevated basic fibroblast growth factor, platelet activation, and systemic alterations in cellular function (Ohaegbulam et al. 1999).

### 9.10.3 Presenting Symptoms

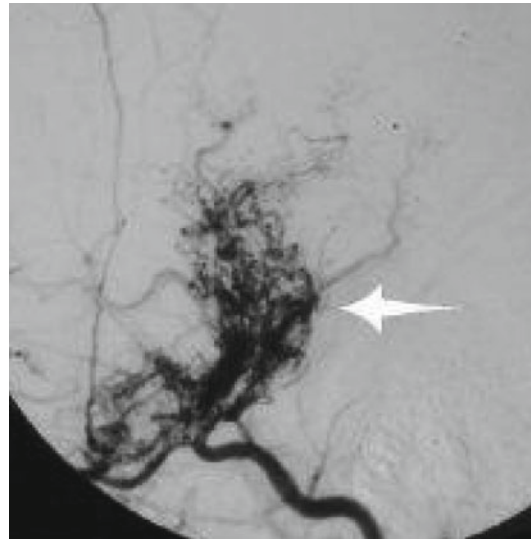
Children with moyamoya present with ischemic symptoms, whereas adult patients tend to present with cerebral hemorrhage (Kitamura et al. 1998). Intracranial hemorrhage associated with

moyamoya is infrequently encountered in the pediatric population (Ibrahimi et al. 2010).

Children present with cerebral ischemia that manifests as monoparesis, hemiparesis, sensory deficits, and dysphasia (Yonekawa and Kahn 2003). Initially, children will develop transient ischemic attacks (TIAs) which can progress to cerebral infarction. TIAs can be precipitated by crying, coughing, hyperventilation, or straining, which ultimately reduces cerebral blood flow. Generally, 40 % of children present with TIAs, 40 % present with stroke, and 80 % present with extremity weakness (Ohaegbulam et al. 1999). Repeated TIAs are manifested predominantly by seizure (20–30 %) and motor hemiparesis (70–80 %), as well as headache and speech difficulties, which are strongly indicative, although not pathognomonic, of moyamoya (Fukui 1997). Choreiform movements have been associated with moyamoya disease, occurring in 3–6 % of patients (Zheng et al. 2006).

#### 9.10.4 Diagnostic Test

Radiologic criteria for moyamoya are (1) stenosis or occlusion at the terminal portion of the internal carotid artery and proximal portion of the anterior cerebral artery and middle cerebral artery, (2) abnormal vascular network near the arterial occlusion, and (3) bilateral involvement (Fukui 1997). The gold standard for both the diagnosis and surgical planning is conventional angiography (Ibrahimi et al. 2010); however, multiple diagnostic techniques can be used to diagnose moyamoya. This disease entity can be characterized radiologically on either angiograms, magnetic resonance imaging (MRI), or magnetic resonance angiography (MRA) (Fig. 9.6). CT findings may demonstrate hypodensities in the watershed areas, suggestive of prior infarctions (Scott and Smith 2009; Smith and Scott 2005; Smith 2009); however, MRI can detect infarcts too small to be seen on CT imaging alone. MRIs show flow voids, and MRAs show stenosis of the cerebral arteries. PET (positron emission tomography) and SPECT (single-photon emission CT) are diagnostic tests used



**Fig. 9.6** Lateral view of a right carotid angiogram showing proliferation of the lenticulostriate arteries forming a moyamoya or “puff-of-smoke” pattern

that give important information regarding the cerebral hemodynamics. The findings are indicative of cerebral perfusion and metabolism which are important factors to take into consideration when planning surgical intervention. EEG is also a helpful diagnostic tool, demonstrating posterior and/or centrottemporal slowing, with a re-buildup phenomenon after the end of hyperventilation (Kodama et al. 1979).

#### 9.10.5 Treatment Options

Currently, there is no curative medical/surgical treatment for moyamoya. Treatment is based on symptom management and begins with medical management transitioning to surgical management, as the etiology of the disease remains unknown. Initially, when the child presents with their first TIA, they may be started on medical therapy. This may include antiplatelets, anticoagulants, NSAIDs, and calcium channel blockers (Ohaegbulam et al. 1999). Treatment transitions to surgical as ischemic episodes progress. The goal of surgical therapy is to increase blood supply to the hypoperfused brain by establishing collateral circulation for the ischemic brain to

prevent cerebral infarct. Multiple types of bypass procedures have been effective for moyamoya and can be classified as direct or indirect bypass. Ultimately, bypass procedures bring blood to the brain and bypass areas of blockage.

Direct bypass, namely, STA-MCA (superficial temporal artery middle cerebral artery anastomosis) is a procedure in which a scalp artery is directly sutured to a brain surface artery and burr holes are placed in the skull to allow for regrowth. This procedure is generally not used in children for they do not have a recipient cerebral artery large enough for anastomosis and are at increased risk for stroke (Ventureya and Vassilyadi 2001).

Indirect bypass involves leptomeningeal anastomosis from the external carotid artery directly on the ischemic brain. Indirect can be either single or multiple depending on the number of vessels used. Single procedures such as EDAS and EMAS (encephaloduroarteriosynangiosis, encephalomyoarteriosynangiosis) are limited in their abilities to form collaterals and hence cover the ischemic area. Failure rate for a single procedure is 20–30 % (Hannon 1996). Hence, multiple indirect bypass procedures have been developed to improve the possibility of revascularization and have a success rate of 94 % (Hannon 1996).

Postoperatively, success is determined by the change in frequency and clinical presentation of the TIAs in the patient. If sufficient collaterals form, TIAs may decrease or disappear within months. However, this is difficult to predict, as patient factors influencing collateral formation are unknown. Postoperative imaging entails angiograms (during the follow-up period), MRA to demonstrate collateral revascularization, and SPEC and PET scans to show improvements in cerebral perfusion.

### 9.10.6 Outcomes

In the 5-year period following diagnosis, approximately 66 % of patients with moyamoya disease experience symptomatic progression, demonstrating a poor long-term outcome in this population (Imaizumi et al. 1998; Scott and Smith 2009). Without surgical intervention, prognosis is poor, with the majority of individuals experiencing

mental decline and multiple strokes because of the progressive narrowing of arteries. The incidence of TIAs may decrease, but the intellectual and motor disturbances tend to increase.

For those patients undergoing surgical revascularization, the neurological status at the time of the surgery appears to be the best prognosticator for favorable long-term outcome (Scott and Smith 2009). Patients who have sustained extensive ischemic morbidity preoperatively do not recover their abilities postoperatively. The risk of stroke in the postoperative period is highest in the first 30 days (Ibrahimi et al. 2010); the risk significantly decreases, with a 96 % chance of being stroke free over the next 5-year period (Smith and Scott 2005).

### 9.10.7 Nursing Care

Close monitoring after surgery is vital in these children. Children postoperatively should be managed in an ICU environment initially. Patient should be sedated and remain normotensive and well hydrated. In the immediate postoperative period, neurological status, arterial blood pressure reading, and fluid status should be carefully monitored to prevent serious ischemic complications. Refer to Section 9.4.5 for Vascular Lesions for further nursing care issues.

### 9.10.8 Patient and Family Education

Family should be educated on signs and symptoms of cerebral ischemia, CVA, and seizures, as well as the importance of follow-up with the neurosurgeon. Follow-up angiography is done during the first year after surgery in order to evaluate the growth of cerebral circulation.

## 9.11 Sinovenous Thrombosis

### 9.11.1 Pathophysiology

Cerebral sinovenous thrombosis (CSVT) is a disease characterized by a blood clot in the sinovenous system. The obstruction can result in

increased ICP and subsequent stroke. The most common sites involved in CSVT are the transverse, superior sagittal, sigmoid, and straight sinuses, and the superficial system is more frequently involved than the deep (Dlamini et al. 2010).

Cerebrovascular venous drainage occurs through both superficial and deep systems through a network of veins and sinuses. Cortical veins that drain into the superior sagittal sinus make up the superficial venous system. The superior sagittal sinus then predominantly drains into the right lateral sinus and the jugular vein in most people. The deep system is comprised of the inferior sagittal sinus and the paired internal cerebral veins, which then join and form the vein of Galen and the straight sinus. This system predominantly drains into the left lateral sinus and jugular venous system (Dlamini et al. 2010; Swaiman and Ashwal 1999).

Because there are no venous valves, cerebral venous drainage is passive, and, consequently, venous flow may potentially reverse and is unresponsive to changes in systemic blood pressure. Cerebrospinal fluid (CSF) is primarily absorbed through the superior sagittal sinus by the arachnoid granulations that protrude into it. When these granulations are not able to absorb CSF, such in the cases of sinus hypertension or venous thrombosis, outflow is obstructed. The consequence of this obstructed outflow includes venous congestion and an increase in capillary hydrostatic pressure, which then drives fluid into the interstitium and produces edema. Ultimately, obstruction of the venous system may present as a mild venous congestion and edema, cortical or subcortical parenchymal ischemia (with or without infarction), and hemorrhage. In some cases, noncommunicating hydrocephalus may be seen (Dlamini et al. 2010; Swaiman and Ashwal 1999).

There are many risk factors for the development of CSVT in the pediatric population, but any time there is local venous stasis, thrombosis can develop. Acute processes include fever, infection (particularly otitis media and mastoiditis), dehydration, anemia, head trauma, or recent intracranial surgery. Chronic processes include congenital heart disease, diabetes, nephrotic syndrome, systemic lupus erythematosus, inflammatory bowel disease, Cushing's syndrome, thyrotoxicosis, and

malignancy (Dlamini et al. 2010). Prothrombic disorders, such as protein C, protein S and anti-thrombin deficiencies, factor V Leiden mutation, and high factor VIII levels, must also be considered as risks.

Sinovenous thrombosis may be under recognized in both neonates and children because of the frequent presentation of nonfocal neurological signs and symptoms. In one series, 2.6 neonatal cases per 100,000 was noted, while between 0.4 and 0.7 per 100,000 childhood cases were noted (Dlamini et al. 2010). Other factors that may contribute to the under-diagnosis of this process include nonspecific imaging techniques, rapid reversal of the thrombosis, and variable anatomy of the cerebral venous system (Dlamini et al. 2010).

Clinical presentation may be nonspecific, nonfocal, or subtle. Seizures, altered levels of consciousness, encephalopathy, and focal neurological deficits including cranial nerve palsies, hemiparesis, hemisensory loss, and diffuse neurological symptoms (including headache, nausea, vomiting) may be present. While seizures are more common in the neonatal population, focal and diffuse neurological signs are more common in infants and older children (Dlamini et al. 2010).

Neurological deficits are present at the time of discharge or at follow-up in 17–79 % of survivors. Even in cases where aggressive treatment with antithrombotic agents, antibiotics, and surgery are used, many children may suffer chronic neurological problems due to increased intracranial pressure (including headache, visual disturbances, and cranial nerve VI palsy), while others are affected by their venous infarction with developmental delays, learning disabilities, hemiparesis, and hemisensory loss. Many of these patients require long-term rehabilitative regimens. Overall, sinovenous mortality is less than 10 % in children, but more than 50 % of neonates have a poor outcome with a high mortality (Dlamini et al. 2010).

### 9.11.2 Diagnostic Imaging

Imaging must be done prior to recanalization. CT without contrast may demonstrate linear

densities in the area of thrombosis, but as the lesion becomes less dense, a contrasted CT may demonstrate the “empty delta” sign, although in 40 % of patients, a CT with contrast may miss the diagnosis of CSVT. MRI with diffusion and perfusion is helpful in detecting venous congestion and in the differentiation of vasogenic and cytotoxic edema, but does not differentiate venous from arterial infarction well. The diagnostic imaging method of choice for CSVT is either CT venography or MRI with venography (MRV), which demonstrates a lack of flow in the cerebral veins (Dlamini et al. 2010). MRI and MRV may demonstrate flow artifacts, and if the diagnosis is in question, high-resolution CT venography or conventional digital subtraction angiography may be required.

### 9.11.3 Medical Treatment

Treatment usually consists of supportive measures and correction of the underlying problem, including correction of dehydration and infectious processes and control of seizures with anticonvulsant medications. There is a lack of controlled trials of anticoagulation in the pediatric population, and case studies in the last 10 years vary on the utilization of antithrombotic agents. While treatment appears to vary by center, overall it appears that older infants and children receive treatment with either parental unfractionated heparin, subcutaneous low-molecular-weight heparin (LMWH), or oral warfarin in the acute care setting for a period of 3–6 months. Hematological parameters should be followed closely during this time, and the risk of further worsening or causing intracranial hemorrhage should be weighed against the risk of supportive treatment only.

### 9.11.4 Surgical Treatment

The use of thrombolysis, thrombectomy, and surgical decompression has been used with success in isolated cases and small series, but no large, controlled, randomized studies have been

performed, either in the adult or the pediatric population (Dlamini et al. 2010).

### 9.11.5 Nursing Care for Ruptured Vascular Brain Lesions

Depending on the lesion, extent of rupture, and location of bleeding, the child may present with a variety of symptoms, from focal neurological deficits to a truly compromised clinical condition. Nursing care focus is on comprehensive assessment and identification of significant neurological changes, as well as prevention of further insults and deterioration of the patient’s clinical status.

### 9.11.6 Monitoring of Neurological Status

Careful monitoring of neurological status and vital signs is critical in assessing the child with a vascular anomaly. Nurses should monitor for signs of increased intracranial pressure (ICP) by observing for signs of changes in the child’s level of consciousness, abnormal cranial nerve findings, pupillary abnormalities, focal motor deficits, and increasing headache. Signs of headache and focal neurological deficits may indicate rebleed or vasospasm. Consistent documentation and communication of the patient’s neurological status must exist among all caregivers assessing the child so that subtle changes in neurological status can be appreciated. Any changes indicative of worsening neurological function need be reported to the neurosurgical team.

### 9.11.7 Cerebral Perfusion: Monitoring and Maintenance

Cerebral perfusion requires careful maintenance and monitoring. Specific neurological signs of decreased cerebral perfusion include complaints of diplopia, headache, and blurred vision. To increase cerebral perfusion, the administration of hypervolemic and/or hypertensive therapy may be

required. In addition to monitoring for signs of decreased cerebral perfusion, children should be monitored for signs and symptoms of vasospasm including the insidious onset of confusion, disorientation, focal neurological deficits corresponding to a specific vascular territory, and decreased level of consciousness. It is also important to maintain the child's blood pressure or BP within the parameters indicated as per institutional protocols. Most often, there is a narrow acceptable window to ensure perfusion, but not hypertension, while a neurovascular lesion is unsecured, or not yet treated, as rebleeding can occur (Hinkle et al. 2010). Administration of hypertensive medications and vasopressors may be required after a hemorrhagic event and post treatment for a vascular malformation, and, if used, their effect must be carefully monitored to keep the BP as close to normal for age as possible. Positioning of the patient in midline position with the head of bed elevated to 30° assists in perfusion and venous drainage (Hinkle et al. 2010).

### 9.11.8 Monitoring for Seizures

Children with vascular lesions have a high propensity for seizure activity in both the preoperative and postoperative phase. Surgical intervention may involve stimulation of the parenchyma that in turn can provoke seizure activity in the postoperative stage, therefore necessitating careful observation of the child for seizure activity. If the child is seizing, anticonvulsants are to be administered, and therapeutic drug monitoring of anticonvulsants is important to ensure adequate dosing. Depending on the type of lesion, location, and treatment, the potential for recurrent seizures must be assessed to determine length of therapy. In many cases, risks for seizure may decrease significantly after definitive treatment for the vascular anomaly is performed, and antiseizure medication may be weaned or stopped. In one series evaluating outcomes of children with various sources of intracranial hemorrhage (ICH), 11 % of the cohort studied went on to develop epilepsy afterward (Beslow et al. 2010). It is important

to educate the family and child regarding seizures and their management.

### 9.11.9 Management of Increased ICP and Hydrocephalus

Some neurovascular lesions, such as aneurysm with significant SAH or AVM with extensive hemorrhage, can result in hydrocephalus and increased intracranial pressure. These patients may require placement of an EVD either prior to securing of the lesion, intraoperatively, or postoperatively. CSF drainage can then be titrated to keep ICP at prescribed parameters. It is important to note that over-drainage of CSF prior to aneurysm clipping or coiling can lead to sudden rebleeding of the aneurysm by alleviating the tamponade effect of normal to slightly elevated ICP. As the child is stabilized post treatment, CSF drainage can be slowly decreased and eventually clamped to determine the need for more permanent shunting. It is not often, but a child may require ventricular-peritoneal shunting for unresolved hydrocephalus (Hinkle et al. 2010).

### 9.11.10 Management of Environmental Stress

To avoid complications related to vascular lesions, precautions should be instituted to decrease the environmental stimulus and minimize stress. Depending on the institution, patients may have an extended stay in the critical care unit during their postoperative period to allow for the child to remain ventilated, sedated, and hemodynamically stable. Further precautions include maintaining the child on bed rest and minimizing stimulus such as bright light, noise, anxiety, and pain. For example, noxious procedures like routine suctioning of endotracheal tubes should be limited. It is also important to limit activities to avoid elevation in blood pressure and ICP. Administration of stool softeners will minimize an increase in ICP from straining. Children who experience extreme agitation may require medication to reduce their level of agitation.



### 9.11.11 Management of Pain and Anxiety

Pain management needs to be addressed along the continuum of care for these patients. Obtaining a child's pain history is critical in helping to gauge their response to pain. Speak with the child and his/her parents to determine how they have responded to pain in the past and what modes of pain management were successful and unsuccessful. This will help in the assessment and treatment of the child's pain. The use of age-appropriate pain scales (e.g., OUCHER scale, Faces scale, numeric rating scale) and observation of physical manifestations such as increased BP, increased respirations, alteration in mood or behavior, and monitoring of vital signs should be completed on an ongoing basis. Particular attention should be given to signs of worsening of headache. Pain management is individualized and can vary from acetaminophen to opioids, depending on institution and surgeon preference. As the field of pediatric pain management expands, use of patient-controlled analgesia (PCA) has been utilized for patients that cannot be managed with bolus doses of analgesics. Identification of intractable pain and appropriate referrals to pain and palliative care teams is important to ensuring comfort for these patients.

Nonsteroidal anti-inflammatory drugs (NSAIDs) can inhibit platelet aggregation and prolong bleeding time. For this reason, it is not generally used in patients with vascular anomalies, particularly if they have had a hemorrhage or are in the immediate postoperative period. The nurse should discuss concerns regarding pain management with the neurosurgical team. In addition to the administration of analgesics, techniques should be employed to provide non-pharmacological modes of pain management through methods such as distraction (e.g., engage in therapeutic play with the child life specialist, experience a visit with a therapy dog, listen to favorite music, and establishment of a quiet, dark environment that is conducive to rest).

Anxiety often accompanies pain and can intensify pain. To reduce anxiety in children, it is important to explain all procedures that will

occur, ensure parental presence when possible for comfort, or provide an anxiolytic if clinical indicated. Risks in muting the symptoms of increased ICP must be weighed against the benefits of providing an anxiolytic. Sedatives such as midazolam, diazepam, and lorazepam may be administered for management of anxiety. As for opioid administration, selection of agent and titration of dosing to ensure acceptable response while preventing oversedation have become a standard of care in the pediatric ICU. However, cardiorespiratory equipment must be available at the bedside to manage respiratory distress or oversedation, with ready access to benzodiazepine antagonists (Humphreys et al. 1996).

The Bromage Sedation Scale (Table 9.9) is a tool often used (in addition to traditional pain scales) to assess the level of sedation in children who receive opioids or sedatives.

### 9.11.12 Management of Nausea and Vomiting

Children often experience nausea and vomiting at presentation of a vascular event and throughout treatment, including postoperatively. Administration of antiemetics such as dimenhydrinate, metoclopramide, and ondansetron may be effective. The nurse should not administer these drugs repeatedly if there is suspicion that the child's nausea and vomiting are due to increased ICP. Intravenous fluids may be required if the child is unable to take adequate fluid orally. For some patients, such as those in the immediate postoperative period, their IV fluids are run above maintenance to allow for adequate cerebral perfusion. With prolonged IV hydration, electrolytes need to be closely monitored.

### 9.11.13 Monitoring for Signs of Infection

Post-neurosurgical or endovascular intervention, the child should be observed of signs of infection. These include fever, discharge from the wound,

**Table 9.9** Bromage sedation scale

0	Awake
1	Occasionally drowsy, easily arousable
2	Frequently drowsy, easily arousable
3	Somnolent, difficult to arouse
S	Normal sleep

From the *HSC Handbook of Pediatrics*, Cheng et al. (2003)

redness or swelling around incision site, stiff neck, vomiting, irritability, and headache. Parents upon discharge need to be educated regarding signs and symptoms of infection, as some infections may be insidious and have latent clinical effects.

#### 9.11.14 General Posttreatment Care

Other needs that require attention include an adequate diet, good pulmonary care, mobilization issues, skin care, adequate rest, and emotional care. Many children who have had an ICH or clinical course of neurological significance will require inpatient rehabilitation once stable. Predictors of poor neurological outcome in this population is age <12 years old, poor functional status prior to treatment, left-sided (supratentorial) and brainstem (infratentorial) location, and high-grade lesion with bleed >2 % of total brain volume (Darsaut et al. 2011; Beslow et al. 2010). Pediatric specific facilities are optimal for these children for the best outcomes. Referral to other professional services, such as social work, occupational therapy, physical therapy, speech and swallowing specialists, neuropsychology/cognitive therapy, and child life services should be initiated if clinically indicated.

#### 9.11.15 Patient and Family Education

Always assess for the level of readiness in a parent of child when providing teaching regarding neurovascular lesions and the treatment. The level of anxiety may prohibit the intake of information and will often require a step-by-step approach to information exchange and teaching. Repeating

and re-explaining of the child's condition and treatment is often required to ensure adequate understanding by parents and children. Teaching aids in the form of handouts, diagrams, web-based teaching tools, or physical models of the brain are excellent tools to use in helping parents and children understand their condition. Allowing parents and child to view their own neuroimaging is often a very effective way to teach about the child's condition.

Parents and children (if age appropriate) should be provided with information on their vascular malformation in both written and verbal forms. In situations where the child is being managed medically by observation, the parents and children (if age appropriate) should be taught to watch for any potential signs and symptoms such as seizure activity or signs of hemorrhage such as severe headache and the emergency action they need to take. Thorough instructions regarding activity restrictions need to be reviewed.

Parents and children should be taught emergency management of seizures – particularly prolonged seizures lasting greater than 5 min. Education regarding a prescribed anticonvulsant medication, side effects, and adverse reactions should be reviewed. Consider prescription of rectal diazepam to be used in case of prolonged seizure in high-risk patients. Daily assessment for the parents' level of understanding of their child's clinical status, treatment plan, and opportunities for teaching needs to be an ongoing process.

At the time of discharge, it is important to again provide written information that indicates the exact name of the child's condition, the type of treatment the child received (including the surgical procedure), the medications required for ongoing management, instructions for dressing and wound care, information on level of activity, follow-up appointments, and contact numbers in case of emergency or questions. In situations where ongoing care will be required in the home, home care arrangements will need to be made. This includes providing the home care agency with accurate and detailed instructions on care and also the name of a contact nurse in whom the

home care agency can contact for further advice if required. If a parent or child is to perform ongoing care in the home, teaching of the procedure and opportunities for return demonstrations must be provided during the child's admission.

When providing web-based information to parents and children, ensure that the information comes from a credible site. Warn parents and children about websites that may provide inaccurate information or are based on mainly anecdotal and personal experiences. While peer support is sometimes appropriate, try to direct families to sites where exchanges are monitored by reliable medical persons or organizations. Many children's hospitals have access to a medical library service within the institution that may provide patients and families with reliable information and resources appropriate to a child's individual condition at no charge or minimal fee. For a list of websites pertaining to neurovascular disease in children, see Appendix 9.1.

#### Pearl

- The Glasgow Coma Scale is the most effective tool that should always be utilized in ongoing monitoring of a child's neurological status whether in the pre-operative or postoperative phase.

## 9.12 Pediatric Spinal Vascular Malformations

Spinal vascular malformations in children are rare. They consist of the same malformations seen in the brain and include cavernous malformations (CM), arteriovenous fistulas (AVF), and arteriovenous malformations (AVM). There have been only a handful of cases of CM of the spinal cord in the literature. The majority of spinal vascular malformations seen in the pediatric population are AVMs (Mawad 1994; Muszynski and Berenstein 2001; Riina et al. 2006; Spetzler et al. 2002) which will be the focus of this section.

### 9.12.1 Etiology

AVMs in the spine are similar in structure to their cerebral counterparts. They are congenital malformations that result from failure of arteriovenous connections to differentiate properly early in embryogenesis. An AVM is a tangle of arteries and veins without the typical intervening capillaries. The result is a so-called high-flow lesion where blood is shunted directly and quickly from the arterial side to the venous (Mawad 1994; Muszynski and Berenstein 2001; Riina et al. 2006; Spetzler et al. 2002; Ventureya and Vassilyadi 2001). AVMs of the spine can have varying numbers of feeding arteries and draining veins. The number and size of vessels involved can vary considerably. As in brain AVMs, the core of these vessels is the nidus where the arterial and venous components meet (Murasko and Oldfield 1990; Spetzler et al. 2002; Ventureya and Vassilyadi 2001). A nidus can be small and compact or large and diffuse. AVMs in children have been shown to increase in size over time secondary to increased flow through poorly differentiated vessels and the ability to recruit collateral vessels or proliferate new ones (Ventureya and Vassilyadi 2001). Poorly differentiated and dilated vessels in an AVM have a propensity for hemorrhage. The overall risk of hemorrhage is 2–4 % per year, and the incidence is cumulative with age. Therefore, children with spinal AVMs have a high lifetime risk of hemorrhage (Ventureya and Vassilyadi 2001). In children, hemorrhage tends to occur bimodally: under the age of 4 years or over the age of 10 years (Kitagawa et al. 2009).

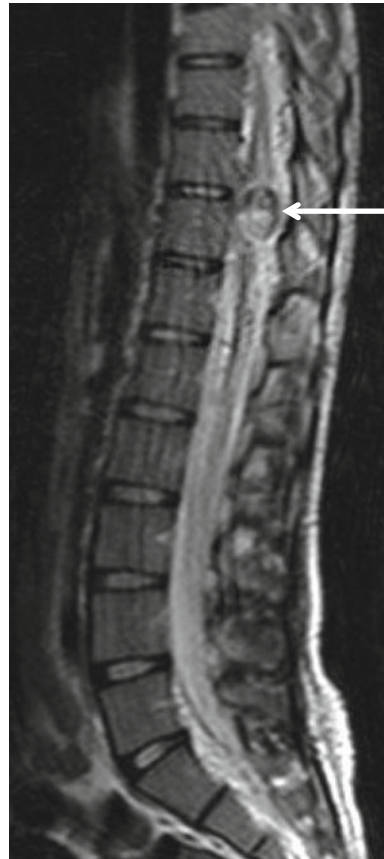AVMs of the spine can exist with a familial tendency. They can also be associated with syndromes including HHT (hereditary hemorrhagic telangiectasia) (Muszynski and Berenstein 2001; Ventureya and Vassilyadi 2001). Most occurrences, however, are often the first within a family. Like their cerebral counterparts, spinal AVMs can have an associated aneurysm; however, such occurrences are rare (Riina et al. 2006; Spetzler et al. 2002; Ventureya and Vassilyadi 2001).

### 9.12.2 Pathophysiology

Spinal AVMs can occur anywhere along the spinal axis, and location of the AVM relative to cord parenchyma can vary. AVMs can arise from vessels on the surface of the cord or within the cord parenchyma itself. AVMs with the nidus involving the cord parenchyma are called intramedullary and are the most frequently occurring in adolescence or young adults (Fig. 9.7) (Riina et al. 2006). They derive their arterial blood supply directly from the spinal cord vasculature, either the anterior or posterior spinal arteries, and often involve very high blood flow and high pressure (Muszynski and Berenstein 2001; Spetzler et al. 2002). Juvenile AVM has an intramedullary nidus, but it is large and compromises the entire spinal cord at that level. Hemorrhage in either type results in acute neurological deterioration, but given the complex nature of the juvenile lesions, they often have a less favorable prognosis (Hinkle et al. 2010).

Extradural-intradural and paraspinal AVMs can involve not only the cord itself but the surrounding tissues including the paravertebral muscles, nerve root foramina, prevertebral area, and the spinal canal (Riina et al. 2006). These AVMs can have an intramedullary component to them but often are on the surface of the cord. Their arterial blood supply typically comes from multiple medullary arteries which, in turn, branch off the spinal arteries (Murasko and Oldfield 1990). They can be large with a large number of arterial feeders and are associated with very high flow. When the AVM involves all tissue types, it is referred to as Cobb's syndrome (Riina et al. 2006; Rodesch et al. 2002; Spetzler et al. 2002). These are very rare but do occur more frequently in the pediatric population than adults.

AVMs affecting the terminal portion of the spinal cord are called conus arteriovenous malformations. They involve the conus medullaris and the cauda equina. The blood supply tends to be from one or more of the spinal arteries, and they are also a high-flow lesion (Riina et al. 2006).



**Fig. 9.7** Picture of intramedullary AVM

Spinal AVMs can produce symptoms secondary to hemorrhage, compression, vascular steal, and venous congestion (Murasko and Oldfield 1990; Spetzler et al. 2002; Riina et al. 2006; Ventureya and Vassilyadi 2001). Hemorrhage can occur in one catastrophic event or in repeated smaller ones. Symptoms produced will vary depending on the location and extent of the hemorrhage. Compression on the cord or nerve roots can result from hemorrhage, the mass of the AVM itself or from largely dilated vessels. Compression can also result from surrounding edema that may be a result of hemorrhage or cord ischemia. Vascular steal is a result of blood being shunted into the malformation and away from arteries supplying the surrounding healthy tissue. Vascular steal leads to ischemia, which can lead to cell

death and cord atrophy. Venous congestion leads to venous hypertension which results in impaired perfusion pressure to the cord and ischemia. Venous congestion can also lead to venous thrombosis causing a spinal cord infarct (Murasko and Oldfield 1990).

### 9.12.3 Presenting Signs and Symptoms

The presenting clinical picture is dependent on the location, size, and the pathophysiology of the AVM. The majority of children will present with an acute hemorrhage. The hemorrhage may be into the subarachnoid space, into the cord parenchyma, or both. Signs and symptoms of an acute hemorrhage include sudden onset of back or neck pain, extremity weakness or loss of function, sensory changes, and bowel and bladder dysfunction. If repeated smaller hemorrhages occur, the pain and neurological deterioration may be nonspecific and subtle in onset. In such cases, the symptoms may go overlooked (Muszynski and Berenstein 2001).

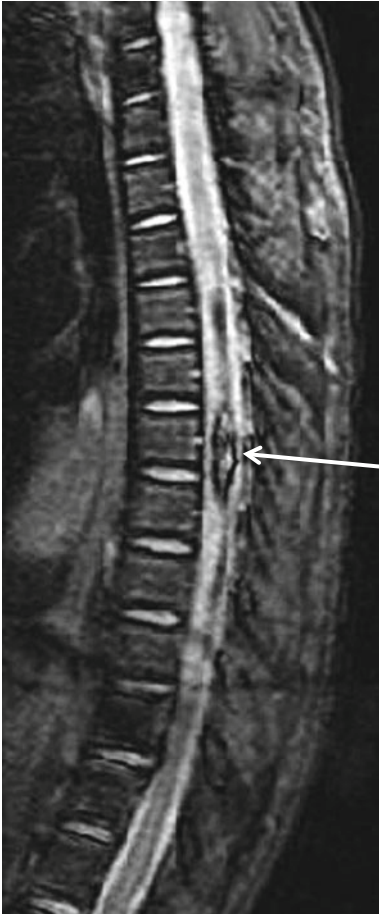Compression and ischemia can also present with pain and loss of motor and sensory function. Pain from compression or ischemia is more likely to be present in affected limbs. The exact location and nature of pain and neurological deficit is dependent on the location of the AVM. For example, an AVM in the cervicothoracic area will cause symptoms in the upper extremities, whereas a conus AVM will cause lower extremity and bowel and bladder dysfunction. Motor dysfunction can range from weakness to paralysis in the affected extremities. Tone may also be affected and can be increased or decreased. Clonus can be a finding in these patients, as well as eventual spasticity requiring intervention if long-standing. Sensory manifestations can result in diminished or heightened perception of stimuli. Diminished sensation can result in a loss of discrimination to touch, temperature, sharpness, and proprioception. Hypersensitivity can result in neuropathic pain with minimal stimulation. Paresthesias such as tingling and numbness may be present. Because of the fragility of the spinal cord, most patients will present with some degree of neurological

dysfunction. The nature and severity of the dysfunction depends on the location of the AVM, presence of hemorrhage, and damage done to the cord.

### 9.13 Cavernous Malformations and Arteriovenous Fistulas of the Spine

Cavernous malformations of the spine are rare in children but do occur. They have been described to occur more frequently in children who have received spinal radiation. They typically present secondary to signs and symptoms following repeated hemorrhages but occasionally are an incidental finding (Riina et al. 2006). Presentation usually occurs in the school-age to adolescent child and most often with an acute paraplegia syndrome (Bigi et al. 2011). The location of spinal CMs is mainly at the cervical or thoracic levels and has a typical appearance on MRI with a focal area of abnormal signal with surrounding hemorrhage of various ages and hemosiderin ring (Fig. 9.8) (Riina et al. 2006). They are angiographically occult. The only treatment option is surgery and is reserved for cases of an easily accessible lesion or significant neurological compromise.

Arteriovenous fistulas of the spine are similar in physiologic structure to their cerebral counterparts. They can occur anywhere on the spine; however, certain types do occur more frequently in the thoracic region (Spetzler et al. 2002). They tend to occur on the surface of the cord versus within the cord parenchyma (Rodesch et al. 2002; Spetzler et al. 2002). There are two types of spinal AV fistulas. Dural AVFs occur in the dural root sleeve and account for the majority of spinal vascular malformations. They more often present in fourth to sixth decade of life rather than in childhood and have slow neurological deterioration in the form of progressive myelopathy from cord compression or vascular steal as they generally do no hemorrhage. The second type, perimedullary AVF, is a congenital lesion for the most part and within the dura. These can hemorrhage acutely. Rapid



**Fig. 9.8** Cavernoma of the spine

neurological deterioration from SAH may be seen. These lesions also have a tendency to present in adulthood rather than in children (Hinkle et al. 2010). Treatment of spinal AV fistulas is most often accomplished with endovascular techniques alone. Surgery is less often required (Rodesch et al. 2005).

### 9.13.1 Diagnostic Tests

All patients with a suspected cord lesion will undergo an MRI of the spine. The MRI will often be performed with and without gadolinium to help differentiate an AVM from other vascular abnormalities or tumor. The presence of blood and its acute or subacute nature, as well as

associated edema, syrinx, or cord atrophy, can be determined on MRI (Mawad 1994; Murasko and Oldfield 1990; Muszynski and Berenstein 2001; Porter et al. 1999).

MR angiography can be performed at the time of the MRI and may be useful in helping to identify the anatomy of the malformation. However, selective angiography remains the gold standard in defining the vascular architecture of the AVM and is absolutely necessary for treatment planning (Mawad 1994; Murasko and Oldfield 1990; Muszynski and Berenstein 2001; Ventureya and Vassilyadi 2001). In the case of an acute hemorrhage, angiography may be postponed until after the clot has resolved, generally in 4–6 weeks, as the presence of the clot can make defining the structure of the AVM difficult.

### 9.13.2 Treatment Options

As with cranial AVMs, the goal of treatment is complete obliteration of the malformation to eliminate the risk of future hemorrhage. However, because of the vulnerability of the spinal cord, this is not always possible. Treatment options include conservative management, surgical excision, and embolization. Often, a combination of these options is used.

Surgery in the acute presentation phase is typically reserved for children who are experiencing continued neurological deterioration, and an emergent need for decompression of the cord exists. This generally is evacuation of the clot. Once decompression is achieved, further workup with angiography and stabilization of neurological function should be done in an attempt to plan for resection of the residual AVM. Sometimes, especially in the case of small AVMs, the AVM may be removed with the clot at the time of the original surgery. AVMs that sit close to or on the cord surface, with a compact nidus, are most amendable to surgery. Some AVMs, given their location and relationship with the cord, are not surgically treatable.

Potential risks of surgery include new hemorrhage and injury to the spinal cord or nerve roots. Both of these would result in worsening

neurological dysfunction. There is also a risk of infection and postoperative CSF leak.

As with cerebral AVMs, endovascular embolization is an important treatment option. Embolization is rarely solely curative with spinal AVMs but may be the only treatment option in lesions that are surgically inaccessible (Riina et al. 2006). Embolization is often used prior to surgery to decrease the number of feeder vessels to the AVM, thus decreasing the risk of hemorrhage. Embolization in the spine involves the same technique and materials used with cerebral lesions. The same risks of post-embolization hemorrhage, venous congestion, and edema exist. All of these could lead to further cord injury and loss of function (Mawad 1994; Muszynski and Berenstein 2001).

When a child presents with acute hemorrhage, a conservative approach is often taken initially if they are neurologically stable. During this phase, symptoms are managed and neurological function is allowed to stabilize. Also during this phase, the clot is allowed to resolve so that a full diagnostic workup can take place. Angiography and treatment planning can proceed most effectively after the hemorrhage has resolved. All treatments pose a risk of causing new deficits or worsening existing ones. Therefore, careful planning and weighing of the risk-benefit ratio will help determine an individual treatment course for each patient.

### 9.13.3 Nursing Care

The most important aspect of nursing care for children with spinal AVMs is serial neurological examinations. The frequency of exams will vary depending on the stage of treatment and should be documented thoroughly. Neurological examination in children is detailed elsewhere in this book. The key point of the neurological exam is to know the child's baseline (or pretreatment) deficits and be able to note changes from that. Following surgery or embolization, it is critical to note changes in existing deficits and whether the changes are for the better or worse. Good and descriptive communication must exist between

all caregivers assessing the child so that subtle changes can be noted. Any sign of worsening neurological function should be reported to the neurosurgical team.

Pain management is important throughout all stages of the patient's care. Pain is most acute following the initial hemorrhage or surgery. In these instances, a combination of narcotics and non-steroidal anti-inflammatory medications is typically used. A muscle relaxant like diazepam may be added if muscle spasms are an issue.

Pain originating from the cord or nerves, called neuropathic or radicular pain, can be particularly difficult to control. Narcotics often are not completely affective in these situations. Certain neuroepileptic drugs, like gabapentin, can be beneficial in helping to control this type of pain. Dosages typically start off once for first day, twice for second day, then three times daily for third day. If a response is not realized in the next 2–3 days, increase each dose to therapeutic response.

Depending on the location of the spinal surgery, the neurosurgeon may request that the patient remain flat for a period of time, typically 24–48 hours. The purpose of this restriction is to help prevent a CSF leak. Generally with this type of resection, the dura is opened and sutured as part of closing the wound, can leak with pressure from sitting and upright positioning. Typically, the patient can lay on their side, prone or supine, as long as they remain flat. Other positioning or activity restrictions may be imposed dependent on the location of the incision and nature of the surgery. These are usually meant to help protect the integrity of the incision and prevent the complication of a CSF leak.

Postoperatively, diligent monitoring of the incision must be part of the nursing assessment, and a CSF leak reported should it occur. Any drainage from the wound that appears watery or leaves a ring sign is concerning for CSF. Additionally, a CSF leak can also present itself as swelling under the incision that continues to grow. Patients with a CSF leak will often experience a severe headache accompanied by nausea. They may also experience dizziness and photophobia. The symptoms are often worse when the

patient is upright and improve when lying down. Managing a CSF leak may include timely resuturing of the incision if there is an external leak to prevent infection, along with strict bed rest. In some cases, a lumbar drain may be placed to drain CSF off and encourage sealing of the leak. On rare occasions, the leak must be surgically repaired.

Positioning and mobility are essential components of nursing care. Care must be taken to ensure frequent turning and range of motion, especially in children who have paralysis or have positioning and activity restrictions. Children who are not immobilized should begin mobilizing as soon as cleared by the neurosurgery team.

Children who have undergone angiography with embolization will have a brief period of immobilization. Typically, the child is required to lie flat for 6 hours following the procedure. This is to prevent bleeding from the arterial puncture site and decrease the risk of thrombus formation. Post-embolization care involves serial neurological checks to monitor for signs of complications as the hemodynamics in the AVM change. It is important to monitor perfusion in the limb where arterial access was gained. Serial checks of pulses and perfusion distal to the puncture site are necessary to monitor for signs of a clot.

Many children who present with spinal AVMs present with neurological deficits. These deficits may improve or possibly resolve with treatment. However, a significant number of these children will have neurological deficits that do not completely resolve and therefore will need initiation of therapies and involvement of the rehabilitation team. Physical and occupational therapy should be consulted and involved from the onset of care. Other disciplines, such as urology and gastroenterology, may be needed dependent on the exact deficits. The sooner a multidisciplinary team is brought together to address each child's specific needs, the sooner discharge planning can become a reality.

Paying attention to the emotional care is an aspect that should not be overlooked. Many of these children will present with new and, likely, life-altering deficits. Coupled with physical pain and the anxiety of the situation, coping may be

difficult. It is important to monitor how the patient and their family are dealing with the situation and offer assistance at an early juncture. Involvement of social work and child life at the onset of diagnosis and treatment is essential. Anger and depression are not uncommon, especially if progress is slow and multifaceted. Providing encouragement to the patient and family is important.

#### 9.13.4 Outcomes

Complete obliteration of the spinal AVM is not always possible. If residual AVM is present, so is a continued risk for hemorrhage. Secondary to the fragility of the cord, presenting deficits are often permanent. However, neurological improvement can continue over several weeks to months.

Family education should focus on not only the disease process and treatments but also on the deficits the child may have and how life adaptations may be possible. The patient and family will rely on the health care team to guide them in addressing such issues as mobility and care at home and at school. There may be a need for adaptive equipment or learning new bowel and bladder management. Good communication between the multidisciplinary team and the family is essential.

#### Conclusions

Neurovascular disease in children is typically the result of a congenital lesion that may be hereditary, inherited, or idiopathic in origin. Although each of these lesions has a low rate of incidence individually, vascular malformations are regularly seen in the pediatric neurosurgery population. Symptoms may be insidious and vague in nature or may present as acute, life-threatening events and can occur at any time. Accurate assessment and diagnosis is essential in ensuring that appropriate treatment is rendered.

It is important for the attending nurse to have an understanding of neurovascular malformations, their treatment and potential outcomes in order to provide these patients with the best possible care. Treatment of neurovascular



disease in pediatrics is improving rapidly. The refinement of neurosurgical instruments and surgical techniques, increased experience in endovascular and radiosurgical treatments, and evolution of medical management philosophies have all contributed to more favorable outcomes in children. Keeping abreast of current “best practice management” by nurses is an important component of comprehensive care for children with neurovascular disease.

### Pearls

- VGAMs typically present in neonates with high-output cardiac failure and during infancy with hydrocephalus, seizures, and rarely hemorrhage. Headaches tend to be the presenting symptom in older children and adults. Older children may also present with focal seizures and developmental delay.
- MRI can be used to diagnose and determine the nature of a VGAM, and cerebral angiography can be used to plan definitive endovascular or surgical intervention.
- Therapeutic decision making regarding management of VGAM should be a shared process between the clinician and the parents.
- AVMs are congenital in origin, relatively uncommon, with no sex predilection.
- Hemorrhage and seizures are the most common presenting features in children presenting with AVMs.
- The greatest risk to a child with an AVM is potential for hemorrhage.
- Children with ruptured aneurysm often have significant headache as a presenting symptom, as well as altered neurological status. Pain management is required; however, the level of sedation must be considered to ensure adequate neurological assessment.
- Support of the patient and family through the process of recovery and rehabilitation is paramount.

## Appendix 9.1: Neurovascular Websites for Parents

[www.aboutkidshealth.ca/EN/ HOWTHEBODYWORKS/Pages/default.asp](http://www.aboutkidshealth.ca/EN/HOWTHEBODYWORKS/Pages/default.asp) (Hospital for Sick Children website – good site for brain anatomy and physiology)

[www.birthmarks.org/info.asp](http://www.birthmarks.org/info.asp) (Arkansas Children’s Hospital site)

[www.childrensmemorial.org/depts/neurocenter/neurosurgery/neurovascular-program.aspx](http://www.childrensmemorial.org/depts/neurocenter/neurosurgery/neurovascular-program.aspx) (Northwestern Children’s Memorial Hospital website)

[www.cincinnatichildrens.org/patients/child/health/](http://www.cincinnatichildrens.org/patients/child/health/) (Cincinnati Children’s Hospital website)

[www.hopkinsmedicine.org/neurology\\_neurosurgery/specialty\\_areas/pediatric\\_neurovascular/conditions/](http://www.hopkinsmedicine.org/neurology_neurosurgery/specialty_areas/pediatric_neurovascular/conditions/) (Johns Hopkins website)

[www.neuroendovascular.northwestern.edu/conditions-we-treat/conditions-treated/pediatric-neurovascular-diseases/](http://www.neuroendovascular.northwestern.edu/conditions-we-treat/conditions-treated/pediatric-neurovascular-diseases/) (Northwestern Radiology website)

<http://neurosurgery.mgh.harvard.edu/neurovascular/> (Massachusetts General Hospital website)

[www.novanews.org](http://www.novanews.org) (National Organization of Vascular Anomalies – NOVA)

## References

- Abe M, Hagihara N, Tabuchi K, Uchino A, Miyasaka Y (2003) Histologically classified venous angiomas of the brain: a controversy. *Neurol Med Chir (Tokyo)* 43:1–11
- Ali MJ, Bendok B, Rosenblatt S et al (2003) Recurrence of pediatric cerebral arteriovenous malformations after angiographically documented resection. *Pediatr Neurosurg* 39:32–38
- Alvarez H, Garcia Monaco R, Rodesch G, Sachet M, Krings T, Lasjaunias P (2007) Vein of galen aneurysmal malformations. *Neuroimaging Clin N Am* 17(2):189–206. doi:10.1016/j.nic.2007.02.005 [Review]
- Aryan HE, Giannotta SL, Fukushima T, Park MS, Ozgur BM, Levy ML (2006) Aneurysms in children: review of 15 years experience. *J Clin Neurosci* 13:188–192
- Beslow LA, Licht DJ, Smith SE, Storm PB, Heuer GG, Zimmerman RA, Feiler AM, Kasner SE, Ichord RN, Jordan LC (2010) Predictors of outcome in childhood intracerebral hemorrhage. *Stroke*. doi:10.1161/STROKEAHA.109.568071
- Bhardwaj RD, Auguste KI, Kulkarni AV, Dirks PB, Drake JM, Rutka JT (2009) Management of pediatric brainstem cavernous malformations: experience over 20 years at the Hospital for Sick Children. *J Neurosurg Pediatr* 4:458–464
- Bigi S, Capone Mori A, Steinlin M, Remonda L, Landolt H, Boltshauser E (2011) Cavernous malformations of the central nervous system in children: presentation, treatment and outcome of 20 cases. *Eur J Paediatr Neurol* 15:109–116

- Blaser SI, Illner A, Castillo M, Hedlund GL, Osborn AG (2003) Pocket radiologist PedsNeuro top 100 diagnoses, 1st edn. WB Saunders, Utah
- Cavanagh SJ, Gordon VL (2002) Grading scales used in the management of aneurysmal subarachnoid hemorrhage: a critical review. *J Neurosci Nurs* 34:288–295
- Cheng A, Williams BA, Sivrahan BV (eds) (2003) The HSC handbook of pediatrics, 10th edn. Elsevier/Saunders, Toronto
- Chevret L, Durand P, Alvarez H, Lambert V, Caeymax L, Rodesch G, Devictor D, Lasjaunias P (2002) Prognosis significance of hemodynamic parameters in neonates presenting with severe heart failure owing to vein of Galen arteriovenous malformations. *Intensive Care Med* 28:1126–1130
- Cohen JE, Boitsova S, Moscovici S, Itshayek E (2010) Concepts and controversies in the management of cerebral developmental venous anomalies. *Isr Med Assoc J* 12(11):703–706
- Courville CB (1963) Morphology of small vascular malformations of the brain. With particular reference to the mechanism of their drainage. *J Neuropathol Exp Neurol* 22:274–284
- Darsaut TE, Guzman R, Marcellus ML, Edwards MS, Tian L, Do HM, Chang SD, Levy RP, Adler JR, Marks MP, Steinberg GK (2011) Management of pediatric intracranial arteriovenous malformations: experience with multimodality therapy. *Neurosurgery*. doi:[101227/NEU.0b013e3182181c00](https://doi.org/10.1227/NEU.0b013e3182181c00)
- Deeg K, Scarf J (1990) Colour Doppler imaging of arteriovenous malformation of the vein of Galen in a newborn. *Neuroradiology* 32:60–63
- DiRocco C, Iannelli A, Tamburrini G (1996) Cavernomas of the central nervous system in children. *Acta Neurochir* 138:1267–1274
- Dlamini N, Billingham L, Kirkham FJ (2010) Cerebral venous sinus (sinovenous) thrombosis in children. *Neurosurg Clin N Am* 21(3):511–527
- Drucker DE (2006) Neurologic disorders. In: Nettina S (ed) Lippincott manual of nursing practice, 8th edn. Lippincott Williams Wilkins, Philadelphia, pp 465–557
- Elixson EM (1992) Intracerebral arteriovenous malformations presenting as neonatal congestive heart failure. *Crit Care Nurs Clin North Am* 4:537–542
- Ferro JM, Canhao P (2008) Acute treatment of cerebral venous and dural sinus thrombosis. *Curr Treat Options Neurol* 10(2):126–137
- Fortuna A, Ferrante L, Acqui L, Mastronardi L, Acqui M, d'Addetta R (1989) Cerebral cavernous angioma in children. *Childs Nerv Syst* 5:201–207
- Foy AB, Wetjen N, Pollock BE (2010) Stereotactic radiosurgery for pediatric arteriovenous malformations. *Neurosurg Clin N Am* 21:457–461
- Frawley GP, Dargaville PA, Mitchell PJ, Tress BM, Loughnan P (2002) Clinical course and medical management of neonates with severe cardiac failure related to vein of Galen malformation. *Arch Dis Child Fetal Neonatal Ed* 87:144–149
- Friedlander RM (2007) Arteriovenous malformations of the brain. *N Engl J Med* 356(26):2704–2712
- Friedman DM, Verma R, Madrid M, Wisoff JH, Berenstein A (1993) Recent improvement in outcome using transcatheter embolization techniques for neonatal aneurysmal malformations of the vein of Galen. *Pediatrics* 91:583–596
- Frim DM, Gupta N, Scott RM (2001) Cavernous malformations. In: McLone DG (ed) Pediatric neurosurgery. Surgery of the developing nervous system. Saunders, Philadelphia, pp 1097–1104
- Fukui M (1997) Current state of study on Moyamoya disease in Japan. *Surg Neurol* 47:138–143
- Fullerton HJ, Aminoff AR, Ferriero DM, Gupta N, Dowd CF (2003) Neurodevelopmental outcome after endovascular treatment of vein of Galen. *Neurology* 61:1386–1390
- Gailloud P, O'Riordan DP, Burger I, Levrier O, Jallo G, Tamargo RJ, Murphy KJ, Lehmann CU (2005) Diagnosis and management of vein of Galen aneurysmal malformations. *J Perinatol* 25:542–551
- Gold AP, Ransohoff J, Carter S (1964) Vein of Galen malformation. *Acta Neurol Scand* 40:1–31
- Griffiths PD, Blaser S, Armstrong D et al (1998) Cerebellar arteriovenous malformations in children. *Neuroradiology* 40:324–331
- Gulati S, Kalra V (2002) An uncommon variety of vein of Galen malformation. *Indian Pediatr* 39(3):307–308 [Case Reports]
- Gupta AK, Varma DR (2004) Vein of Galen malformations: review. *Neurol India* 52(1):43–53 [Review]
- Gupta AK, Rao VR, Varma DR, Kapilamoorthy TR, Kesavadas C, Krishnamoorthy T, Purkayastha S (2006) Evaluation, management, and long-term follow up of vein of Galen malformations. *J Neurosurg* 105(1):26–33. doi:[10.3171/jns.2006.105.1.26](https://doi.org/10.3171/jns.2006.105.1.26) [Case Reports]
- Hannon K (1996) Pial synangiosis for treatment of Moyamoya syndrome in children. *AORN J* 64:540–560
- Hetts SW, Narvid J, Sanai N, Lawton MT, Gupta N, Fullerton HJ, Dowd CF, Higashida RT, Halba VV (2009) Intracranial aneurysms in childhood. *AJNR Am J Neuroradiol*. 33:1315–1324
- Hinkle JL, Guanci MM, Stewart-Amidei C (2010) Cerebrovascular events of the nervous system. In: Bader MK, Littlejohns LR (eds) AANN core curriculum for neuroscience nurses, 5th edn. AANN, St. Louis
- Hoang S, Choudhri O, Edwards M, Guzman R (2009) Vein of Galen malformation. *Neurosurg Focus* 27(5):E8. doi:[10.3171/2009.8.FOCUS09168](https://doi.org/10.3171/2009.8.FOCUS09168) [Comparative Study Review]
- Hoh B, Ogilvy C, Butler W et al (2000) Multimodality treatment of nongalenic arteriovenous malformations in pediatric patients. *Neurosurgery* 47:346–358
- Horgan M, Florma J, Spetzler RF (2006) Surgical treatment of arteriovenous malformations in children. In: Alexander M, Spetzler RF (eds) Pediatric neurovascular disease: surgical, endovascular, and medical management. Thieme, New York, pp 104–115
- Huang J, McGirt MJ, Gailloud P, Tamargo RJ (2005) Intracranial aneurysms in the pediatric population: case series and literature review. *Surg Neurol* 63:424–433
- Huber G, Henkes H, Hermes M, Felber S, Terstegge K, Piepgras U (1996) Regional association of develop-

- mental venous anomalies with angiographically occult vascular malformations. *Eur Radiol* 6(1):30–37
- Huhn SL, Lee JA, Steinberg GK (2006) Surgical treatment of vein of Galen malformations in children. In: Alexander M, Spetzler RF (eds) *Pediatric neurovascular disease*. Thieme, New York, pp 116–128
- Humphreys RP, Hoffman H, Drake J, Rutka J (1996) Choices in the 1990s for the management of pediatric cerebral arteriovenous malformation. *Pediatr Neurosurg* 25:277–285
- Ibrahimi DM, Tamargo RJ, Ahn ES (2010) Moyamoya disease in children. *Childs Nerv Syst* 26(10):1297–1308. doi:10.1007/s00381-010-1209-8 [Review]
- Imaizumi T, Hayashi K, Saito K, Osawa M, Fukuyama Y (1998) Long-term outcomes of pediatric moyamoya disease monitored to adulthood. *Pediatr Neurol* 18(4):321–325 [Comparative Study Research Support, Non-U.S. Gov't]
- Ipone T, Ikezaki K, Susuzaki T (2000) Linkage analysis of Moyamoya disease on chromosome 6. *J Child Neurol* 15:179–182
- Jaegar JR, Forbes RP, Dandy WE (1937) Bilateral congenital cerebral arteriovenous communication aneurysm. *Trans Am Neurol Assoc* 63:173–176
- Jankowitz BT, Vora N, Jovin T, Horowitz M (2008) Treatment of pediatric intracranial vascular malformations using Onyx-18. *J Neurosurg Pediatr* 2(3):171–176
- Jian BJ, Hettis SW, Lawton MT, Gupta N (2010) Pediatric intracranial aneurysms. *Neurosurg Clin N Am* 21:491–501
- Kakarla UK, Beres EJ, Ponce FA, Chang SW, Deshmukh VR, Bambakidis NC, Zabramski JM, Spetzler RF (2010) Microsurgical treatment of pediatric intracranial aneurysms: long-term angiographic and clinical outcomes. *Neurosurgery* 67:237–249
- Kamezawa T, Hamada J, Niirō M, Kai Y, Ishimaru K, Kuratsu J (2005) Clinical implication of associated venous drainage in patients with cavernous malformations. *J Neurosurg* 102:24–28
- Khoo LT, Wallace MJ, McComb JG, Levy ML (1999) Pediatric aneurysmal disease. In: Albright AL, Pollack I, Adelson PD (eds) *Principles and practice of pediatric neurosurgery*. Thieme, New York, pp 1133–1152
- Khurana VG (2005) Venous angiomas: developmental venous anomaly (DVA). Retrieved from <http://www.brainaneurysm.com/dva.html>. Accessed on September 19, 2011.
- Kirton A, deVeber G (2006) Cerebral palsy secondary to perinatal ischemic stroke. *Clin Perinatol* 33:367–386
- Kitagawa RS, Mawad ME, Whitehead WE, Curry DJ, Luerssen TG, Jea A (2009) Parasagittal arteriovenous malformations in children. *J Neurosurg Pediatr* 3:425–428
- Kitamura F, Fuku M, Oka K, Masushima T, Kurokawa T, Hasuo K (1998) Moyamoya disease. *Handb Clin Neurol* 2:293–306
- Kodama N, Aoki Y, Hiraga H, Wada T, Suzuki J (1979) Electroencephalographic findings in children with moyamoya disease. *Arch Neurol* 36(1):16–19
- Kondziolka D, Humphreys RP, Hoffman H et al (1992) Arteriovenous malformations of the brain in children: a forty year experience. *Can J Neurol Sci* 19:40–45
- Kondziolka D, Pollock B, Lunsford LD (1999) Vascular malformations: conservative management, radiosurgery and embolization. In: Albright A, Pollack I, Adelson PD (eds) *Principles and practice of pediatric neurosurgery*. Thieme, New York, pp 1017–1031
- Krishna H, Wani AA, Behari S, Banerji D, Chhabra DK, Jain VK (2005) Intracranial aneurysms in patients 18 years of age or under, are they different from aneurysms in adult population? *Acta Neurochir* 147:469–476
- Larson J, Ball W, Bove K, Crone K, Tew J Jr (1998) Formation of intracerebral cavernous malformations after radiation treatment for central nervous system neoplasia in children. *J Neurosurg* 88:51–56
- Lasjaunias P (1997) Vein of Galen aneurysmal malformation. In: Lasjaunias P (ed) *Vascular diseases in neonates. Infants and children* Berlin. Springer, Germany, pp 67–202
- Lasjaunias P, Burrows P, Planet C (1986) Developmental venous anomalies (DVA): the so-called venous angioma. *Neurosurg Rev* 9(3):233–242 [Review]
- Lasjaunias P, Garcia-Monaco R, Rodesch G, TerBruggeK ZM, Tardieu M, de Victor D (1991) Vein of Galen malformation. Endovascular management of 43 cases. *Childs Nerv Syst* 7:360–367
- Lasjaunias PL, Chng SM, Sachet M, Alvarez H, Rodesch G, Garcia-Monaco R (2006) The management of vein of Galen aneurysmal malformations. *Neurosurgery* 59(5 Suppl 3):S184–S194; discussion S183–S113
- Lee C, Pennington MA, Kenney CM 3rd (1996) MR evaluation of developmental venous anomalies: medullary venous anatomy of venous angiomas. *AJNR Am J Neuroradiol* 17(1):61–70
- Lee RR, Becher MW, Benson ML, Rigamonti D (1997) Brain capillary telangiectasia: MR imaging appearance and clinicohistopathologic findings. *Radiology* 205(3):797–805
- Levrier O, Gailloud P, Souei M, Manera L, Brunel H, Raybaud CA (2004) Normal galenic drainage of the deep cerebral venous system in 2 cases of vein of Galen aneurysmal malformations (VGAM). *Childs Nerv Syst* 20:91–97
- Levy E, Niranjana A, Thompson T et al (2000) Radiosurgery for childhood intracranial arteriovenous malformations. *Neurosurgery* 47:834–842
- Li A-H, Armstrong D, terBrugge KG (2010) Endovascular treatment of vein of Galen aneurysmal malformation: management strategy and 21-year experience in Toronto. *J Neurosurg Pediatr* 7(1):3–10. doi:10.3171/2010.9.peds0956
- Lloyd-Jones D, Adams R et al (2009) Heart disease and stroke statistics 2009 update: a report from the American Heart Association Statistics Committee and Stroke Statistics Subcommittee. *Circulation* 119:e1–e161
- Long DM, Seljeskog EL, Chou SN, French LA (1974) Giant arteriovenous malformations of infancy and

- childhood. *J Neurosurg* 40(3):304–312. doi:10.3171/jns.1974.40.3.0304
- Lv X, Li Y, Jiang C, Wu Z (2009) Endovascular treatment of brain arteriovenous fistulas. *AJNR Am J Neuroradiol* 30:851–856
- Maher CO, Meyer FB (2006) Surgical treatment of cerebral aneurysms in children. In: Alexander MJ, Spetzler RF (eds) *Pediatric neurovascular disease*. Thieme, New York, pp 83–89
- Maity A, Shu H, Tan J et al (2004) Treatment of pediatric intracranial arteriovenous malformations with linear-accelerator-based stereotactic radiosurgery: the University of Pennsylvania experience. *Pediatr Neurosurg* 40:207–214
- Mawad ME (1994) Interventional radiology. In: Cheek WR (ed) *Pediatric neurosurgery: surgery of the developing nervous system*. WB Saunders, Philadelphia, pp 539–544
- McCance KL, Huether SE (2002) *Pathophysiology: the biologic basis for disease in adults children*, 4th edn. Mosby, St. Louis
- McLaughlin MR, Kondziolka D, Flickinger JC, Lunsford S, Lunsford LD (1998) The prospective natural history of cerebral venous malformations. *Neurosurgery* 43(2):195–200; discussion 200–201
- Meyer P, Orliaguet G, Zerah M et al (2000) Emergency management of deeply comatose children with acute rupture of cerebral arteriovenous malformations. *Can J Anaesth* 47:758–766
- Milandre L, Pellissier JF, Boudouresques G, Bonnefoi B, Ali Cherif A, Khalil R (1987) Non-hereditary multiple telangiectasias of the central nervous system. Report of two clinicopathological cases. *J Neurol Sci* 82(1–3): 291–304
- Mitchell PJ, Rosenfeld JV, Dargarville P, Loughnan P, Ditchfield MR, Frawley G, Tress BM (2001) Endovascular management of vein of Galen aneurysmal malformations presenting in the neonatal period. *AJNR Am J Neuroradiol* 22:1403–1409
- Moore KL, Agur AM (1995) *Essential clinical anatomy*. Williams Wilkins, Toronto
- Murasko K, Oldfield E (1990) Vascular malformations of the spinal cord and dura. *Neurosurg Clin N Am* 1:631–652
- Muszynski C, Berenstein A (2001) Interventional radiology. In: McClone D (ed) *Pediatric neurosurgery: surgery of the developing nervous system*. WB Saunders, Philadelphia, pp 1155–1171
- Nagaraja D, Verma A, Taly AB, Kumar MV, Jayakumar PN (1994) Cerebrovascular disease in children. *Acta Neurol Scand* 90(4):251–255
- Niazi TN, Klimo P, Anderson RCE, Raffel C (2010) Diagnosis and management of arteriovenous malformations in children. *Neurosurg Clin N Am* 21: 443–456
- Ohaegbulam C, Magge S, Scott M (1999) Moya Moya disease. In: Albright AL, Pollack I, Adelson PD (eds) *Principles and practice of pediatric neurosurgery*. Thieme, New York, pp 1077–1089
- Pasqualin A, Mazza C, Da Pian R, Dala BB (1982) Midline giant arterio-venous malformations in infants. *Acta Neurochir* 64:259–271
- Porter P, Willinsky R, Harper W, Wallace C (1997) Cerebral cavernous malformations: natural history and prognosis after clinical deterioration with or without hemorrhage. *J Neurosurg* 87:190–197
- Porter R, Detweiler P, Spetzler R, Lawton M, Baskin J, Derksen P, Zabramski J (1999) Cavernous malformations of the brainstem: experience with 100 patients. *J Neurosurg* 90:50–58
- Pozzati E, Acciarri N, Tognetti F, Marliani F, Giangaspero F (1996) Growth, subsequent bleeding and de novo appearance of cerebral angiomas. *Neurosurgery* 38: 662–670
- Proust F, Toussaint P, Garnieri J, Hannequin D, Legars D, Houtieville J, Freger P (2001) Pediatric cerebral aneurysms. *J Neurosurg* 94:733–739
- Punt J (2004) Surgical management of paediatric stroke. *Pediatr Radiol* 34:16–23
- Raybaud CA, Strother CM (1986) Persisting abnormal embryonic vessels in intracranial arteriovenous malformations. *Acta Radiol Suppl* 369:136–138
- Rigamonti D, Spetzler RF (1988) The association of venous and cavernous malformations. Report of four cases and discussion of the pathophysiological, diagnostic, and therapeutic implications. *Acta Neurochir* 92(1–4):100–105
- Riina H, Lemole M, Spetzler R (2006) Surgical treatment of spinal vascular malformations in children. In: Alexander MJ, Spetzler RF (eds) *Pediatric neurovascular disease*. Thieme Medical, New York, pp 129–134
- Rivera P, Willinsky R, Porter P (2003) Intracranial cavernous malformations. *Neuroimag Clin North Am* 13: 27–40
- Roach ES, Riela A (eds) (1995) *Pediatric cerebrovascular disorders*, 2nd edn. Futura, New York
- Roach ES, Golomb MR, Adams R et al (2008) Management of stroke in infants and children: a scientific statement from a Special Writing Group of the American Heart Association Stroke Council and the Council on Cardiovascular Disease in the Young. *Stroke* 39: 2644–2691
- Rodesch G, Hui F, Alvarez H, Tanaka A, Lasjaunias P (1994) Prognosis of antenatally diagnosed vein of Galen aneurysmal malformations. *Childs Nerv Syst* 10:79–83
- Rodesch G, Hurth M, Alvarez H, Tadie M, Lasjaunias P (2002) Classification of spinal cord arteriovenous shunts: proposal for a reappraisal – the bicetre experience with 155 consecutive patients treated between 1981 and 1999. *Neurosurgery* 51:374–380
- Rodesch G, Hurth M, Alvarez H, Tadie M, Lasjaunias P (2005) Spinal cord intradural arteriovenous fistulae: anatomic, clinical, and therapeutic considerations in a series of 32 consecutive patients seen between 1981 and 2000 with emphasis on endovascular therapy. *Neurosurgery* 57:973–981

- Ruiz DS, Yilmaz H, Gailloud P (2009) Cerebral developmental venous anomalies: current concepts. *Ann Neurol* 66(3):271–283. doi:10.1002/ana.21754 [Review]
- Saito Y, Kobayashi N (1981) Cerebral venous angiomas: clinical evaluation and possible etiology. *Radiology* 139(1):87–94
- San Millan Ruiz D, Gailloud P (2010) Cerebral developmental venous anomalies. *Childs Nerv Syst* 26(10):1395–1406
- San Millan Ruiz D, Delavelle J, Yilmaz H, Gailloud P, Piovani E, Bertramello A, Rufenacht DA (2007) Parenchymal abnormalities associated with developmental venous anomalies. *Neuroradiology* 49(12):987–995. doi:10.1007/s00234-007-0279-0
- Sanai N, Quinones-Hinojosa A, Gupta NM et al (2006) Pediatric intracranial aneurysms: durability of treatment following microsurgical and endovascular management. *J Neurosurg* 104:82–89
- Santos CC, Sarnat HB, Roach ES (2005) Cerebrovascular disorders. In: Menkes JM, Sarnat HB, Maria BL (eds) *Child neurology*. Lippincott Williams Wilkins, Philadelphia, pp 1–76
- Santos CC, Sarnat HB, Roach ES (2006) Cerebrovascular disorders. In: Menkes JM, Sarnat HB, Maria BL (eds) *Child neurology*. Lippincott Williams Wilkins, Philadelphia, pp 843–844
- Sayama CM, Osborn AG, Chin SS, Couldwell WT (2009) Capillary telangiectasias: clinical, radiographic, and histopathological features. *J Neurosurg* 113(4):709–714. doi:10.3171/2009.9.jns09282
- Schaller B, Graf R (2004) Cerebral venous infarction: the pathophysiological concept. *Cerebrovasc Dis* 18(3):179–188
- Scott RM, Smith ER (2009) Moyamoya disease and moyamoya syndrome. *N Engl J Med* 360(12):1226–1237. doi:10.1056/NEJMra0804622 [Review]
- Senegor M, Dohrmann GJ, Wollmann RL (1983) Venous angiomas of the posterior fossa should be considered as anomalous venous drainage. *Surg Neurol* 19(1):26–32
- Sharma BS, Sinhas S, Mehta VS, Suri A, Gupta A, Manapatra AK (2007). Pediatric intracranial aneurysms: Clinical characteristics and outcome of surgical treatment. *Child Nerv Syst* 23:327–333
- Singhal A, Adirim T, Cochrane D, Steinbok P (2011) Pediatric patients with poor neurological status and arteriovenous malformation hemorrhage: an outcome analysis. *J Neurosurg Pediatr* 7:462–467
- Smith JL (2009) Understanding and treating moyamoya disease in children. *Neurosurg Focus* 26(4):E4. doi:10.3171/2000.01.FOCUS08306 [Review]
- Smith ER, Scott RM (2005) Surgical management of moyamoya syndrome. *Skull Base* 15(1):15–26
- Smith ER, Scott RM (2010) Cavernous malformations. *Neurosurg Clin N Am* 21:483–490
- Smith M, Sinson G (2006) Intracranial arteriovenous malformations. <http://www.emedicine.com/med/topic3469.htm>. Retrieved 9 Jan 2006.
- Smyth M, Sneed P, Ciricillo S et al (1997) Stereotactic radiosurgery for pediatric intracranial arteriovenous malformations: the University of California at San Francisco experience. *J Neurosurg* 97:48–55
- Soriano SG, Sethna NF, Scott RM (1993) Anesthetic management of children with moyamoya syndrome. *Anesth Analg* 77(5):1066–1070
- Spetzler RF, Detwiler P, Riina H, Porter RW (2002) Modified classification of spinal cord vascular lesions. *J Neurosurg Spine* 96:145–156
- Swaiman KF, Ashwal S (1999) *Pediatric neurology principles & practice*, from <http://books.google.com/books?id=BNpsAAAAMAAJ>. Accessed on September 19, 2011.
- Takeuchi K, Shimizu K (1957) Hypoplasia of bilateral internal carotid arteries. *Brain Nerve* 19:37–43
- Tang S-C, Jeng J-S, Liu H-M, Yip P-K (2003) Diffuse capillary telangiectasia of the brain manifested as a slowly progressive course. *Cerebrovasc Dis* 15(1–2):140–142
- TerBrugge K (1999) Neurointerventional procedures in the pediatric age group. *Childs Nerv Syst* 15:751–754
- TerBrugge K (2006) Endovascular treatment of vein of Galen malformations in children. In: Alexander M, Spetzler RF (eds) *Pediatric neurovascular disease: surgical, endovascular and medical management*. Thieme, New York, pp 176–185
- Tung H, Giannotta SL, Chandarasoma P (1990) Recurrent intraparenchymal hemorrhages from angiographically occult vascular malformations. *J Neurosurg* 73:174–180
- Uchino K, Johnston SC, Becker KJ, Tirschwell DL (2005) Moyamoya disease in Washington State and California. *Neurology* 65(6):956–958. doi:10.1212/01.wnl.0000176066.33797.82 [Research Support, N.I.H., Extramural Research Support, U.S. Gov't, P.H.S.]
- Vanaman MJ, Hervey-Jumper SL, Maher CO (2010) Pediatric and inherited neurovascular diseases. *Neurosurg Clin N Am* 21:427–441
- Ventureya E, Vassilyadi M (2001) Arteriovenous malformations. In: McLone D (ed) *Pediatric Neurosurgery: Surgery of the developing Nervous System*. WB Saunders, Philadelphia, pp 1105–1111
- Wakai K, Tamakoshi A, Ikezaki K, Fukui M, Kawamura T, Aoki R, Ohno Y (1997) Epidemiological features of moyamoya disease in Japan: findings from a nationwide survey. *Clin Neurol Neurosurg* 99 Suppl 2:S1–S5 [Research Support, Non-U.S. Gov't]
- Waxman SG (2003) *Clinical neuroanatomy*, 25th edn. Lange Medical Books/McGraw Hill, New York, p 171
- Weon YC, Yoshida Y, Sachet M, Mahadevan J, Alvarez H, Rodesch G, Lasjuanias P (2004) Supratentorial cerebral arteriovenous fistulas (AVFs) in children: review of 41 cases with 63 non choroidal single-hole AVFs. Springer, Austria, Published online December 13, 2004
- Wilson CB (1992) Cryptic vascular malformations. *Clin Neurosurg* 38:49–84
- Wolfe TJ, Hussain SI, Lynch JR, Fitasimmons B, Zaidat OO (2009) Pediatric cerebral angiography: analysis of utilization and findings. *Pediatr Neurol* 40(2):98–101

- Yeh D, Crone K (2006) Cavernous malformations in children. In: Alexander M, Spetzler RF (eds) Pediatric neurovascular disease: surgical, endovascular, and medical management. Thieme, New York, pp 65–71
- Yen CP, Monteith SJ, Nguyen JH, Rainey J, Schlesinger DJ, Sheehan JP (2010) Gamma knife surgery for arteriovenous malformations in children. *J Neurosurg Pediatr* 6:426–434
- Yokoyama K, Asano Y, Murakawa T et al (1991) Familial occurrence of arteriovenous malformations of the brain. *J Neurosurg* 74:585–589
- Yonekawa Y, Kahn N (2003) Moyamoya disease. *Adv Neurol* 92:113–118
- Zaidat O, Alexander M (2006) Endovascular treatment of cerebral arteriovenous malformations in children. In: Alexander M, Spetzler RF (eds) Pediatric neurovascular disease: surgical, endovascular, and medical management. Thieme, New York, pp 167–175
- Zerah M, Garcia-Monaco R, Rodesch G, TerBrugge K, Tardieu M, de Victor D, Lasjaunias P (1992) Hydrodynamics in vein of Galen malformations. *Childs Nerv Syst* 8:111–117
- Zheng W, Wanibuchi M, Onda T, Liu H, Koyanagi I, Fujimori K, Houkin K (2006) A case of moyamoya disease presenting with chorea. *Childs Nerv Syst* 22(3):274–278. doi:[10.1007/s00381-004-1104-2](https://doi.org/10.1007/s00381-004-1104-2) [Case Reports Research Support, Non-U.S. Gov't]

Patti L. Batchelder

---

## 10.1 Introduction

Epilepsy is the most common neurologic disorder of childhood with 5 % of all children and adolescents experiencing a seizure by the age of 20. Of those individuals, 25 % will go on to develop epilepsy (Lee and Adelson 2004; Snead 2001). Epilepsy is commonly defined as two or more unprovoked seizures separated by at least 24 h (Linehan and Berg 2011). An unprovoked seizure is one that occurs in the absence of an acute event, such as a traumatic brain injury or metabolic disturbance. The majority of individuals with epilepsy will obtain good seizure control with antiepileptic medications. However, up to 30 % will be intractable to medical therapy (Zupanc et al. 2010). Medically intractable epilepsy can have devastating consequences on the developing brain, as can side effects from antiepileptic medications. Certain persons with medically intractable epilepsy, particularly those with identifiable lesions, malformations, or associated syndromes, may be candidates for surgery to help treat or even cure their epilepsy. Undertaken in the right patient, epilepsy surgery can allow for improved neurologic outcomes, independence, and overall better quality of life.

---

P.L. Batchelder, RN, MSN, PNP-BC  
Department of Neurosurgery, Children's Hospital  
Colorado, University of Colorado School of Medicine,  
13123 E. 16th Ave Box 330, Aurora, CO 80045, USA

---

## 10.2 Seizures

Initially, in a child's workup, it is important to distinguish true epileptic seizures from non-epileptic behaviors. Non-epileptic events like breath-holding spells, syncope, and rhythmic self-stimulatory behaviors can be confused with seizures (Lee and Adelson 2004). A complete and detailed history, thorough physical exam, and adjunct testing such as an electroencephalogram (EEG) can help diagnose seizure activity. An EEG records the electrical onset and progression of a seizure.

A seizure is a change in neurological functioning secondary to hypersynchronous discharges in cortical neurons (Linehan and Berg 2011). The specific neurologic changes that are seen during a seizure depend on the areas of brain affected. Seizure semiology is a description of the signs and symptoms displayed by a patient during a seizure. A universal classification system for seizures was first developed in 1964 by the Commission on Classification and Terminology of the International League Against Epilepsy (ILAE). The International Classification of Epileptic Seizures (ICES) was then revised in 1981 and 1989 to include epilepsies and epileptic syndromes. This classification system defines seizures based on EEG findings and clinical manifestations. It provides a common nomenclature for providers across disciplines to describe seizures and the possible underlying pathology (Kellinghaus and Luders 2011;

Loddenkemper 2011). Other classification systems, such as the Semiology Seizure Classification (SSC) by Luders et al. (1998), have been proposed. This system classifies seizures solely on semiology. The ILAE classification is more widely used, but some propose that a combination of the two systems may provide the most accuracy (Kellinghaus and Luders 2011).

### 10.2.1 Seizure Types

Globally, seizures can be classified as partial or generalized with further subdivisions within these classifications. Partial seizures involve an area of cortex that can vary in size but are isolated to one hemisphere. Simple partial seizures tend to involve a small area of cortex and consciousness is not impaired. Complex partial seizures involve a larger area of cortex and consciousness is impaired. Often, there is memory loss around the seizure event. Clinical manifestations in both types of partial seizures can be motor, sensory, somatosensory, autonomic, or psychic in nature depending on the area of cortex involved. Both types of seizures can stay limited to the initial area of onset, or they can spread. Simple partial seizures can progress into complex partial, which in turn can progress into a generalized seizure (Kellinghaus and Luders 2011).

Generalized seizures occur when both hemispheres are affected. Generalized seizures can be idiopathic (with onset in both hemispheres), or they can be the result of secondary spread from one hemisphere to the other (generalization). Generalized seizures are further described as tonic-clonic, tonic, clonic, myoclonic, atonic, and absence. Tonic-clonic seizures are the most common type of generalized seizure and are commonly referred to as grand mal. They are manifested by a loss of consciousness and an abrupt sustained contraction of multiple muscles (tonic phase), including respiratory muscles. The patient may fall and be incontinent and often becomes cyanotic. A clonic phase then follows which involves repetitive convulsive movements throughout the body (Kellinghaus and Luders 2011).

Tonic seizures involve an abrupt contraction of muscles resulting in rigidity of the extremities and neck. Often, there is turning of the head and deviation of eyes to one side. Clonic seizures are typically characterized by repetitive muscle contractions. Myoclonic seizures, often called myoclonic jerks, are sudden, brief, and very strong muscle contractions that last less than 2 seconds. They may be confined to a specific area of the body or they may occur all over. Atonic seizures are a sudden and complete loss of muscle tone. They too can manifest in a specific area of the body or they can affect many muscle groups. When this occurs, they are referred to as drop attacks. Absence seizures are characterized by a sudden arrest in the individual's activity. A blank stare or slight deviation of the eyes is accompanied by a lack of response to any external stimuli. Absence seizures can be accompanied by tonic, clonic, and atonic components (Kellinghaus and Luders 2011; Tatum 2011).

Seizures of all types can last a few seconds to several minutes. Some are self-limiting, with the seizure activity stopping on its own. Others require the administration of antiepileptic drugs to stop them. Status epilepticus is recurring seizure activity without a period of recovery in between. All individuals with epilepsy are at risk for status epilepticus.

Careful identification of the semiology of seizures helps to determine appropriate treatment. Initial treatment of epilepsy begins with placement on an antiepileptic drug (AED). The choice of particular AED is based on the type of seizure, possible seizure etiology, frequency of seizures, and the presence of associated syndromes. A single AED will control seizures for the majority of individuals with epilepsy (Tsur et al. 2011). In a study by Kwan and Brodie (2000), 64% of newly diagnosed patients with epilepsy had their seizures controlled with medication. Of these patients, 47% responded to the first AED tried. Another 13% responded to a second drug when the first failed, but only 1% became seizure free when trying a third. An additional 3% became seizure free with the combination of two AEDs, leaving 36% of their study population with medically intractable seizures (Kwan and Brodie 2000; Holmes 2002).



Medical management of seizures beyond the use of AEDs is fairly limited. The ketogenic diet can be an effective treatment for some individuals but is not without drawbacks and risk (Nordli and De Vivo 2011). High-dose vitamin B supplementation may control seizures for a very small number of patients with a rare form of vitamin B deficiency (Neubauer et al. 2011). However, the number of patients well controlled on either of these therapies is small. The mainstay of medical management is AEDs, and there is a high risk of becoming intractable for those not responding to the first one or two drugs tried.

### 10.3 Intractable Epilepsy

The definition of medically intractable epilepsy varies slightly among providers. One widely accepted definition is debilitating seizures that exist despite maximal medical management (Lee and Adelson 2004; Snead 2001). However, ambiguity exists as to the exact definition of “debilitating,” as it is dependent on seizure type, frequency, and the individual patient. What might be acceptable for one patient may be debilitating for another (Lee and Adelson 2004). A grand mal seizure occurring once or twice a month in an older child trying to attend school has a different impact than the same seizure frequency in an infant. There is also no consensus as to what is considered “maximal medical management,” nor on the number or combination of medications that must be tried, the length of time one must be treated, or the type or number of seizures that must occur before being considered intractable. Despite the lack of consensus, there is considerable agreement that intractable epilepsy exists when there have been two failures to become seizure free on two or more medications (Cross et al. 2006; Holmes 2002; Lee and Adelson 2004; Snead 2001).

It is important to identify individuals with intractable epilepsy as early as possible. The sooner these individuals are identified, the sooner other therapies, such as surgery, can be considered. Certain risk factors have been identified that are associated with the development of intractable

epilepsy. The first is a patient’s initial response to medical management. Kwan and Brodie (2000) found that response to the first AED tried was a strong predictor of intractability. Of the 53 % of patients who did not respond to the first AED tried, only 17 % went on to become seizure free with the use of other medications (Kwan and Brodie 2000). Further, the number of seizures a person experienced before treatment was also found to be a strong predictor. Among patients who had more than 20 seizures prior to initiating treatment, 51 % experienced intractable epilepsy, as compared to only 29 % of patients who had experienced fewer seizures (Kwan and Brodie 2000; Holmes 2002). There are also specific etiologies of epilepsy and epilepsy syndromes that are known to be associated with intractability. These include temporal lobe epilepsy, cortical dysplasia, tuberous sclerosis, Sturge-Weber syndrome, Rasmussen’s syndrome, hemimegalencephaly, and the presence of focal lesions such as tumors (Cross et al. 2006; Holmes 2002; Kwan and Brodie 2000; Snead 2001). Individuals with such etiologies and syndromes, as well as those who have already shown themselves to be intractable, should be referred for consideration of surgery.

Studies have shown that the effect of poorly controlled seizures on the brain, particularly the developing brain, can be devastating and result in significant cognitive decline (Albright et al. 2001; Farwell et al. 1985; Holmes 2002; Jokeit and Ebner 1999). Not only are children with intractable epilepsy more likely to have lower IQs than their healthy counterparts, but their IQs have also been shown to decline progressively over time the longer their seizures are uncontrolled (Farwell et al. 1985). Similarly, antiepileptic medications can adversely affect cognitive and behavioral development. Antiepileptic drugs work by decreasing the excitability of neurons; thus, they can also impair cognition. These effects are heightened when polypharmacy and increased doses are needed (Meador 2011).

Seizures also have a tremendous social and financial impact on affected children and their families. Not only can the actual occurrence of seizures socially isolate a child and his or her

family, but the social stigmata that still exist around epilepsy can be isolating as well. Seizures persisting into adolescence and adulthood can severely limit independence and overall quality of life (Cross et al. 2006; Holmes 2002; Phi et al. 2010). Finally, although rare, sudden unexplained death in epilepsy (SUDEP) affects at least 1 in 1,000 individuals per year (Nashef 1997).

---

## 10.4 Surgical Candidate Selection and Preoperative Workup (Phase I)

There is some debate regarding the appropriate time to refer a patient with epilepsy for surgery. Many argue that only individuals who have shown themselves to be medically intractable should be referred. However, others contend that individuals with identified abnormalities or syndromes should be referred earlier in hopes of avoiding the side effects of ongoing seizures and AEDs altogether. Regardless of when an individual is identified as a potential candidate, the goal of epilepsy surgery is to eliminate or decrease the number of seizures, reduce exposure to AEDs, and limit the long-term effects of both on neurodevelopment (Cross et al. 2006; Holmes 2002; Lee and Adelson 2004; Snead 2001; Vendrame and Loddenkemper 2010).

All patients being considered for epilepsy surgery should be referred to a center with the necessary resources available for appropriate evaluation and workup. Appropriate evaluation requires a multidisciplinary team with specific expertise in pediatric surgical epilepsy. This team includes epileptologists, neurosurgeons, advanced practice nurses, neuropsychologists, therapists, EEG technicians, and psychiatrists. Phase one of the evaluation involves gathering information from a detailed history, physical exam, EEG, and imaging. Information is analyzed to begin to identify where the seizure onset is located. A detailed history can provide information regarding behaviors observed before, during, and after a seizure. It also provides information regarding age at onset, progression of seizures, and seizure semiology. The physical exam can reveal neurologic deficits that may be

associated with affected areas of the brain. A scalp EEG can show areas of epileptiform discharges and can often lateralize onset and show other areas of potential onset. However, the scalp EEG in and of itself is limited, as rapid generalization and distortion by tissue can misrepresent the area of onset.

### 10.4.1 Imaging

Various imaging modalities have become increasingly more sophisticated and sensitive at not only detecting structural abnormalities but also in identifying areas of differing metabolism that are associated with seizure onset. All patients undergo a brain MRI looking for structural abnormalities that may be causing seizures. Examples of structural abnormalities include neoplastic or vascular lesions, cortical anomalies such as cortical dysplasia (abnormally formed cortex) and heterotopias (normal gray matter in an abnormal location), or mesial temporal sclerosis (neuron loss and scarring in the temporal lobe). With the continued advancements in MRI, very subtle abnormalities can be detected. CT may be useful in identifying areas of calcification, which are not well visualized on MRI. Functional MRI (fMRI) looks at changes in blood flow related to neuronal activity. This is an advancing field in epilepsy imaging that can identify potential areas of seizure focus and help to map out neurologic functions, specifically motor activity and language.

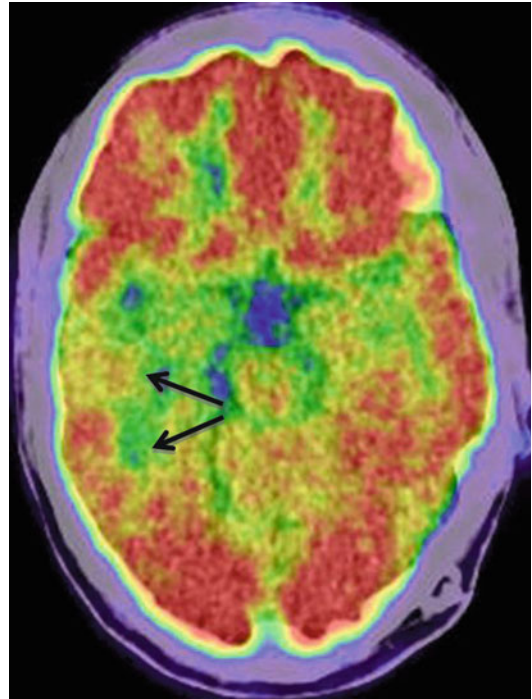
Imaging can also identify abnormalities of metabolism that indicate potential areas of epileptogenesis. Positive-emission-tomography (PET) and single-proton-emission-tomography (SPECT) scan both work on the principle that increased neuronal activity results in increased blood flow and increased metabolic demand. Areas of epileptogenic focus tend to be hypometabolic during times when a seizure is not actively occurring (interictal) and hypermetabolic with increased blood flow during a seizure (ictal). PET scan is generally performed interictally. An agent, typically FDG (fluorodeoxyglucose), is injected intravenously, and the brain is then scanned looking for areas of hypometabolism, as evidenced by

decreased agent uptake. SPECT uses a different agent (HMPAO) which is often injected during the ictal phase. Scans are then obtained looking for areas of increased uptake. A second SPECT scan can be obtained interictally looking for areas of decreased uptake. Often, the two scans are compared, and the subtraction between the two can provide additional information (Lee and Adelson 2004) (Figs. 10.1 and 10.2).

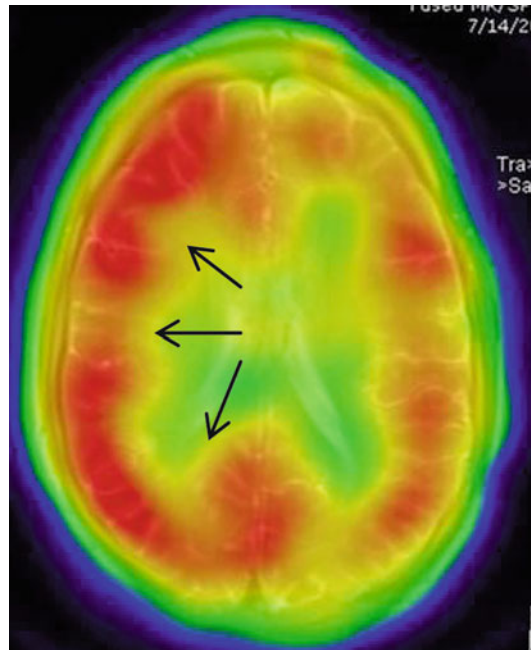
Magnetoencephalography (MEG) is an emerging form of imaging technique being used for localization of epilepsy. MEG measures neuronal activity by measuring the magnetic fields produced by electrical activity. Unlike scalp EEG monitoring, MEG allows for direct measurement of the electrical activity without distortion from surrounding tissues (Lee and Adelson 2004). Potential areas of seizure onset are seen as spikes on MEG and have been shown to correlate with epileptogenic areas identified with subdural electrodes. MEG may be useful in helping to define possible areas of seizure onset in patients with normal MRIs (Hader et al. 2004). Because MEG is not yet widely available, its utility and efficacy are less well established.

#### 10.4.2 vEEG monitoring

Imaging and initial scalp EEG are essential pieces of information to begin localizing seizure onset. However, the gold standard for characterizing seizures is inpatient video-EEG monitoring (vEEG). With vEEG monitoring, a patient is admitted for a minimum of 24 hours to a neuromonitoring unit (NMU). Scalp electrodes are placed and the patient is monitored continuously. An NMU has patient rooms specially equipped to provide continuous EEG and video monitoring. A camera captures the clinical manifestations of seizures, while simultaneous continuous EEG captures the electrical activity of the brain during and between seizures. vEEG is an invaluable source of information, as it records not only the electrical onset and spread of the seizure but also the corresponding physical behaviors. Patients are monitored until they have had enough seizures to provide information regarding localization of



**Fig. 10.1** Interictal PET scan showing decreased uptake in right posterior temporal occipital lobes (note the lack of redness shown by the arrows)



**Fig. 10.2** Ictal SPECT showing increased uptake in right hemisphere (note increased redness in area shown by arrows)

seizure onset, spread, and duration. If need be, medications are withdrawn to help promote seizures. vEEG provides information regarding likely areas of seizure onset. It also allows for the correlation of behaviors seen during ictal and interictal activity. It can also identify seizure-like behaviors that are not based on abnormal brain electrical activity (pseudoseizures).

### 10.4.3 Cognitive Evaluations

Another critical piece to the workup of a potential surgical candidate is neuropsychological testing. This involves various cognitive tests performed by a psychologist experienced in the needs and concerns of the pediatric epilepsy patient. One purpose of this testing is to establish a baseline of preoperative functioning. It also identifies problem areas that may be made worse by surgery. Identifying the presence of premorbid deficits can also help in making the decision whether to proceed with surgery. For example, if certain deficits that would be expected postoperatively already exist, that can be key information in the decision to proceed. Neuropsychological testing can also help to determine cerebral dominance for language and memory. However, if the patient is old enough to cooperate, a much more sensitive test for establishing dominance is the Wada test.

A Wada test, when indicated, can be used to help determine hemispheric dominance of language and memory. Depending on the proposed surgical procedure, this information may be important in determining whether or not surgical resection would impair these functions. The procedure is technically a cerebral angiogram. The internal carotid is accessed with a catheter from the femoral vein, and a barbiturate, typically sodium amobarbital, is then injected. Patients are put through a series of age-appropriate language and memory tasks looking for impairment caused by the medication. If language ceases or memory is impaired while injecting one hemisphere, then dominance is established. If the seizure focus is felt to arise in that hemisphere, then the patient may be at more risk for language and cognitive

deficits postoperatively. One limitation of this study is that patients must be old enough to participate as they must be awake for the actual testing. The arterial accessing can be done under anesthesia with reversal of agents prior to testing. Additional limitations exist in children less than 10 years of age as language lateralization is not always identifiable in this age group (Schevon et al. 2007).

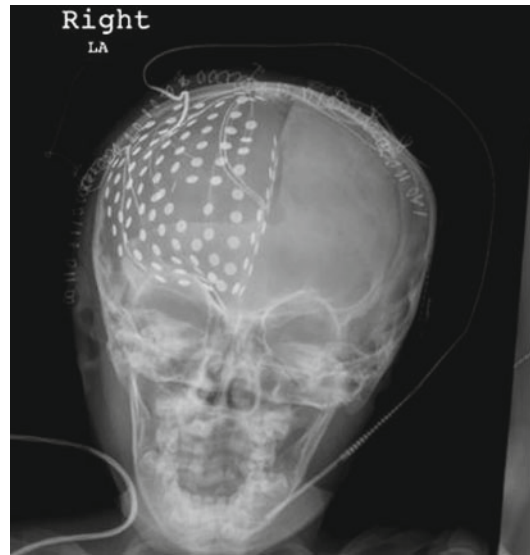
The goal of the preoperative evaluation is to attempt to identify the focus of seizure onset in relation to eloquent cortex for functions such as memory, language, cognition, and sensorimotor (Cross et al. 2006; Harvey et al. 2008; Holmes 2002; Lee and Adelson 2004; Schevon et al. 2007). Data from the various sources is compared and analyzed in an attempt to “map out” eloquent cortex and seizure onset. Factors complicating this in children include incomplete functional maturation, level of patient cooperation, and the abnormal functional organization that can result secondary to malformed cortex and lesions (Schevon et al. 2007). Data gleaned from the various sources is reviewed and compared by the multidisciplinary epilepsy group. At times, the information is concordant with regard to localization of seizure onset, but other times it is not. More often, the information may lateralize to a single hemisphere but have imprecise or discordant data regarding specific localization of onset. For example, imaging may reveal a subtle abnormality in the left temporal lobe, but vEEG may suggest onset in the left frontal or parietal lobes. If all data is concordant and associated with a specific lesion, surgery may proceed without further testing. Conversely, if concordant data shows multifocal or bilateral onset, no further testing is needed as that patient is not a candidate for potentially curative surgery. A patient may, however, be a candidate for palliative procedures such as corpus callosotomy or vagus nerve stimulator. If a patient is a potential candidate for resective surgery and their information requires further clarification, they will need further invasive monitoring (phase II). Also, if the seizure onset lies near eloquent brain, invasive monitoring is indicated so that cortical mapping can occur.

## 10.5 Phase II Monitoring

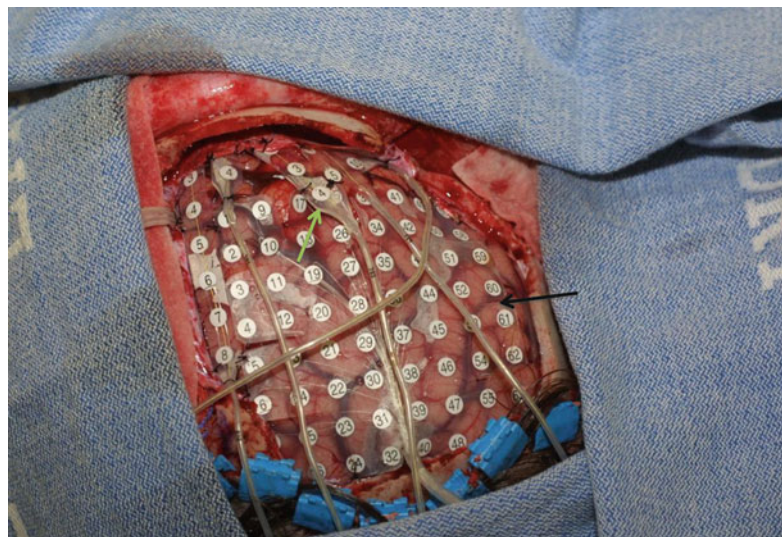
Phase II monitoring involves direct recording from electrodes placed surgically on the brain surface or deep in the brain tissue (depth electrodes). A craniotomy is performed and subdural electrodes are placed over the area of suspected onset and surrounding tissue. Electrodes have been successfully placed in children of all ages, from infant through adolescence. Most often, the implantation of intracranial electrodes is planned with the intent to perform resective surgery, if possible, at the time of electrode removal. Hence, a prolonged hospital stay is planned with the family. A peripherally inserted central catheter (PICC) may be placed during the initial surgery because of the need for prolonged intravenous (IV) access.

Electrodes come in various strip and grid configurations. Different ones are used to provide the best coverage over the desired areas of monitoring (Fig. 10.3). Electrodes are normally placed on the surface of the brain, but depth electrodes can, if needed, be placed deep within the brain parenchyma. The exact configuration and number of electrodes placed depends on what areas of the brain need to be monitored. Typically, electrodes are only placed over one hemisphere, but single-strip electrodes may be placed over the other hemisphere if there is concern for an area of

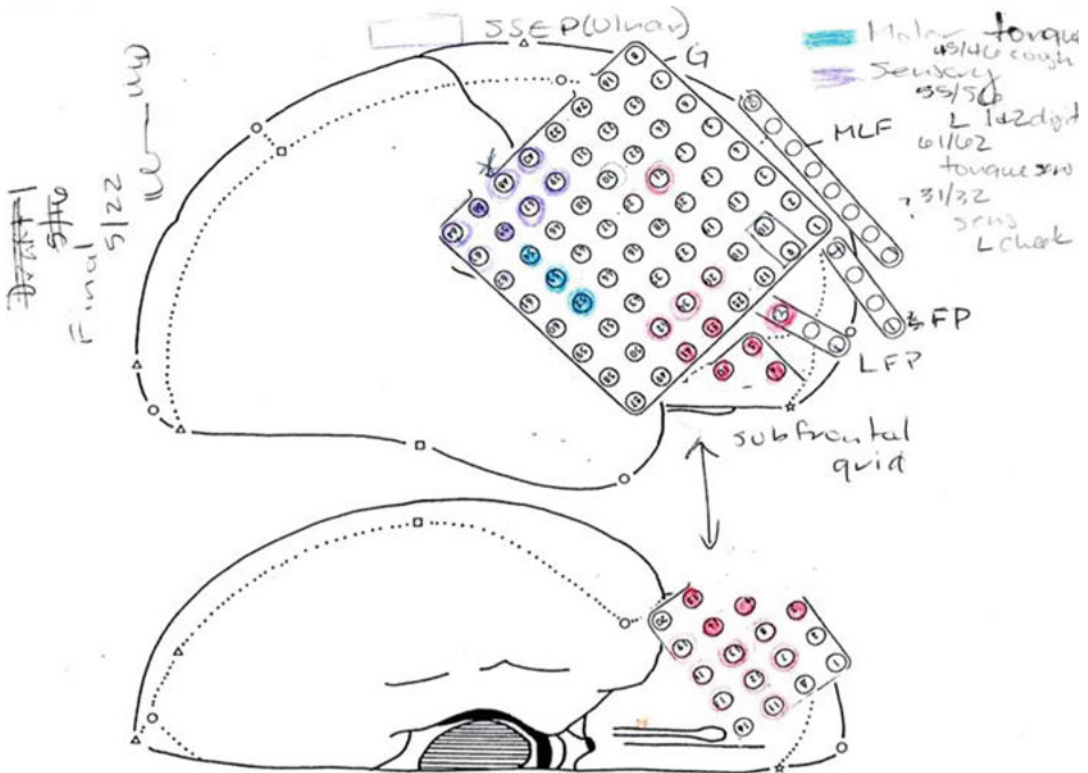
onset in the contralateral hemisphere (Fig. 10.4). Following electrode placement, the bone flap is left out, and the wound is closed with the electrodes in place. The patient then undergoes continuous vEEG monitoring. This provides the most direct EEG monitoring available. Medications can be withdrawn if needed to induce seizures. Electrodes can be left in place for days to weeks in order to capture a sufficient number of seizure



**Fig. 10.4** Skull x-ray showing postoperative subdural electrode placement



**Fig. 10.3** Subdural electrodes in place. *Black arrow* denotes large grid. *Green arrow* denotes a strip electrode



**Fig. 10.5** Brain “map” showing eloquent functions in monitoring area

events. Once enough seizures have been captured to provide information regarding onset, the same electrodes can be used for direct stimulation of the brain and “mapping” of surrounding eloquent cortex. This information is then used in planning the resection (Fig. 10.5).

Depending on the location of onset, this information allows resection to occur safely without deficit or for appropriate planning with the family regarding what deficit to expect. At times, such mapping and monitoring will show that resection is not possible as too significant of a deficit will be inflicted. It is important that the area of seizure onset is established prior to mapping, as mapping can trigger episodes of status epilepticus resulting in the need to administer AEDs.

### 10.5.1 Nursing Care of the Patient Undergoing Phase II Monitoring

Patients typically spend their first postoperative night in the PICU. Ideally, continuous EEG

recordings should take place during this time. Often, patients will not experience seizure activity during this initial postoperative phase, but if they do it should be captured. If stable on postoperative day number one, patients will be transferred to the NMU. The NMU should be staffed by nurses who are not only proficient in caring for neurosurgical patients but also in recognizing and responding to seizure activity. NMU rooms are equipped with monitoring systems that alert nursing staff to seizure activity on the continuous EEG. Family members are also instructed to push an “alert button” when they feel that seizure activity is occurring. These patients are at risk for episodes of status epilepticus, especially as AEDs are weaned or when mapping is occurring. Each patient must have a clearly outlined rescue plan stating which AED is to be used in what order and after what length of time.

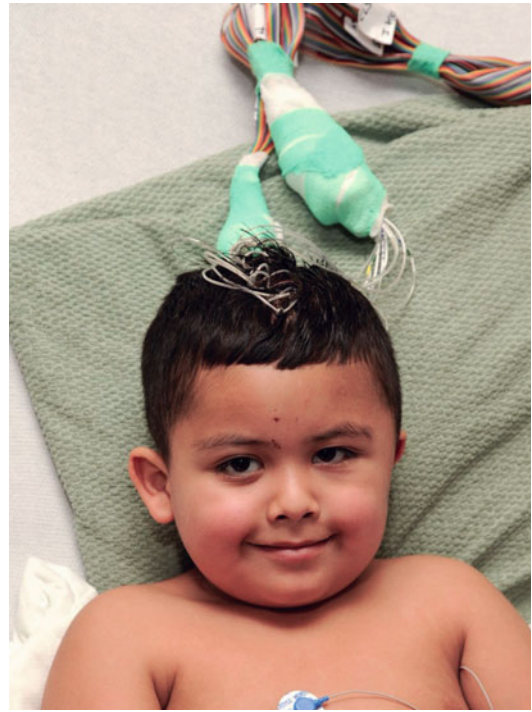Pain management is an important aspect of postoperative care. A combination of narcotic and non-narcotic medications seems to provide the best control, and nurses must be constantly

sensitive to this. Narcotics typically do not significantly deter seizures from occurring and need not be withheld. All patients are different in their tolerance of implanted electrodes. Some patients experience pain that is easily controlled, resume normal diets, and have fairly uneventful postoperative courses. Other patients may have poorly controlled pain, experience protracted nausea and vomiting, or display irritability and some degree of cognitive depression throughout the entire time the electrodes are in place. This could be related to cortical irritation and swelling caused by the electrodes. Often, a short course (24–72 h) of dexamethasone may be used in the initial postoperative period and may need to be extended in some cases.

In some centers, with the electrodes left in place, the bone flap is left off. It is important for all care givers to be alert for this and avoid pressure or trauma to that side of the head. Drainage from the incision while the electrodes are in place is not uncommon and can vary greatly from large to small amounts on a daily basis. The need for prolonged antibiotics with implanted electrodes is a matter of surgeon preference but largely is not done. Most children inherently leave their leads alone, but restraints may be needed if wound and electrode integrity are threatened. EEG monitoring is continuous and should not be disconnected unless an absolute emergency warrants it. As such, the patient is restricted to the bed and immediate surrounding area. This can be challenging for the patient and family, and distractive activities should be employed. Careful attention to developmental and emotional needs is essential. Family members are encouraged to stay with the patient and be an active member of the team. The participation of therapists, child life specialists, school specialist, and other ancillary services is invaluable for the overall success of the monitoring process (Fig. 10.6).

### 10.5.2 Complications of Subdural Electrodes

There are risks with surgically implanted electrodes. The electrodes themselves are thin and



**Fig. 10.6** Patient with implanted subdural electrodes

pliable and are generally well tolerated. However, especially in the immediate postoperative period, there is the risk of acute hematoma formation, cerebral edema, vascular compression, and inflammation (Johnston et al. 2006; Lee and Adelson 2004). Any of these can cause varying degrees of mass effect on the brain, resulting in increased intracranial pressure, and possible need for emergent return to the OR for electrode removal. Complications such as these are uncommon and typically seen only in the first 24–48 h postoperatively. There exist small risks of infection and cerebral spinal fluid leak. There is a risk that grids will be implanted – only to show that resective surgery is not possible due to multiple areas of onset or seizure onset in eloquent cortex. It is possible that despite withdrawal of medication and various activities to induce seizures, seizures may not occur during the monitoring period. Subdural electrodes can be left in place for up to 3–4 weeks, but concerns for infection or intolerance may warrant removal sooner. Status epilepticus may occur as AEDs are withdrawn or during mapping.

## 10.6 Epilepsy Surgery

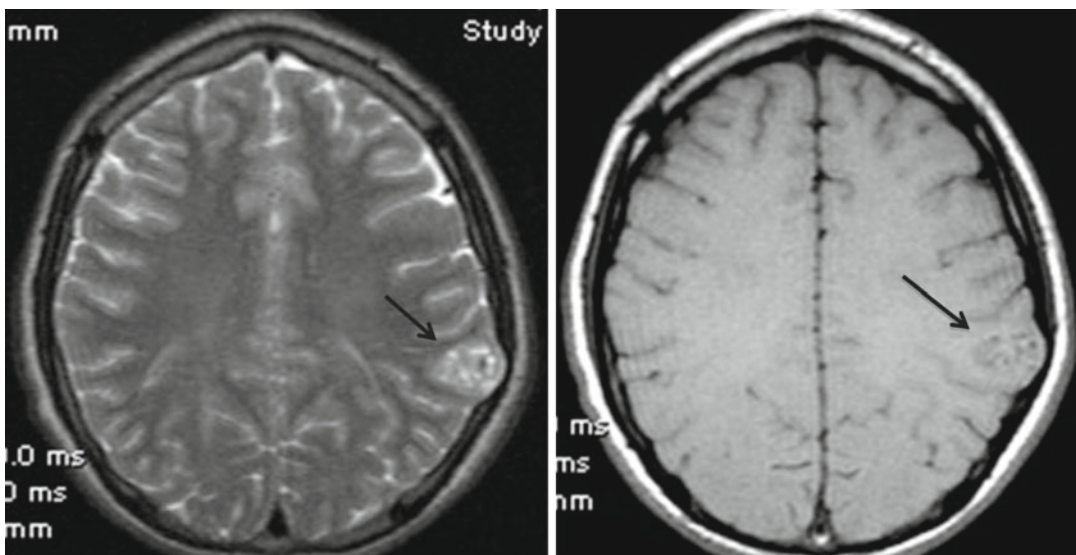
Once the focus of seizure onset has been identified and surrounding brain has been mapped, if necessary, decisions are made regarding the type of surgery that can be offered. Generally, there are two types of epilepsy surgery, potentially curative and palliative. Potentially curative procedures are offered to those with onset within one hemisphere. The exact procedure offered is dependent not only on the area of seizure onset but also on the underlying cause of the epilepsy. Potentially curative procedures include lesionectomy, temporal lobectomy, extratemporal resections, and hemispherectomy. Individuals who have bilateral or multifocal onset are not candidates for potentially curative surgery. However, they may be candidates for palliative procedures, including corpus callosotomy or vagus nerve stimulator.

### 10.6.1 Lesionectomy

Lesionectomies are the removal of a well-defined lesion, such as a tumor, vascular malformation, or hamartoma, that has been shown to be the site of seizure onset. Resection may take place with or without phase II monitoring. Phase II monitoring

may be needed if there is concern for potential seizure onset in the surrounding cortex, if the margins of the lesion are not clearly defined, or if the lesion's location does not fully explain seizure semiology. Phase II monitoring also allows for cortical mapping so that potential postoperative deficits can be fully understood and avoided if possible. The most common tumor types seen in association with intractable epilepsy are DNET, ganglioglioma, and astrocytoma, but any tumor can be epileptogenic. Benign tumors that may not require resection from an oncology perspective may need resection in order to treat intractable epilepsy. If a tumor is present, but seizures are well controlled on easily managed and well-tolerated AEDs, resection may not be necessary. Individuals undergoing epilepsy surgery for a well-defined lesion have the highest likelihood of becoming seizure free (Ogiwara et al. 2010; Tellez-Zenteno et al. 2010; Zupanc et al. 2010) (Fig. 10.7).

Risks specific to a lesionectomy include injury to eloquent brain. The exact deficits seen depend on the area of brain affected. There is also a risk of incomplete resection of the epileptogenic focus resulting in continued seizures. This is more likely if the lesion is not clearly defined, lies close to eloquent cortex, or if it is associated with other unseen abnormalities like mild dysplasia. Results



**Fig. 10.7** T2-(left) and T1-(right) weighted MRI images showing epileptogenic lesion (ganglioglioma) in left posterior parietal lobe as indicated by the arrows



from a lesionectomy may be improved with intraoperative electrocorticography which allows direct recording from the brain to identify areas of abnormal electrical activity near the lesion that may be epileptogenic.

### 10.6.2 Temporal Lobectomy

Temporal lobe epilepsy (TLE) is one of the most common epilepsy syndromes amenable to surgical treatment. With onset often in childhood, it accounts for up to 75 % of adolescents and adults that undergo epilepsy surgery (Velasco and Mather 2011). Because of its commonality, it is one of the most studied forms of epilepsy surgery (Holmes 2002; Lee and Adelson 2004; Tellez-Zenteno et al. 2005; Velasco and Mather 2011). Mesial temporal sclerosis (MTS) is the most frequent pathology found in intractable TLE (Rathmore et al. 2011; Velasco and Mather 2011). Mesial temporal structures include the hippocampus, parahippocampal gyrus, and the amygdala. Sclerosis is scarring and atrophy secondary to neuronal loss that can be caused by such insults as infection, traumatic injury, or hypoxic events. Often, the insult occurs in a neonate or infant, with seizure onset in childhood (Velasco and Mather 2011). Seizures can also arise from the temporal cortex more laterally. Here, pathology leading to seizures tends to be related to lesions (tumors, vascular) or malformations of cortical development. It is not unusual for temporal lobe seizures to result from MTS, along with pathology elsewhere in the temporal lobe. Such “dual pathology” may not always be readily evident during the presurgical evaluation. Seizures arising within the temporal lobe spread quickly to involve all of the temporal lobe, medial structures, adjacent lobes (frontal and parietal), and the contralateral temporal lobe, making the exact identification of ictal onset difficult. Different techniques are used for temporal lobectomy. Resection can involve just the mesial structures (amygdalohippocampectomy) with or without varying degrees of temporal lobe resection, from full to partial (Snead 2001). The extent of resection can also vary depending on whether or not

dominance has been established. The temporal lobe plays a significant role in language, and if the child is old enough for dominance to be established, a more limited resection of the lateral posterior temporal lobe will be done on the dominant side. Outcomes for temporal lobectomy are generally very good with seizure-free rates reported as high as 84 %, higher (>90 %) for specific candidates, and marked improvement in seizure control for greater than 90 % of patients (Foldvary et al. 2000; Holmes 2002; Rathmore et al. 2011; Skirrow et al. 2011; Tellez-Zenteno et al. 2005; Zupanc et al. 2010).

### 10.6.3 Complications of Temporal Lobe Surgery

The temporal lobe is responsible for many memory and language functions. Therefore, potential complications following temporal lobe surgery involve deficits in these areas. The temporal lobe is the location of the primary auditory cortex and plays a role in auditory perception. Postoperatively, patients having undergone a temporal lobectomy are at risk for problems with comprehension of verbal stimuli, naming, and verbal memory impairment. The hippocampus is involved in long-term memory and in making new memories, so impairment can be seen there as well. In the younger child, language is less likely to be affected, or may recover more quickly, as language rarely completely lateralizes before age 10 (Lee and Adelson 2004). In individuals where the anterior temporal lobe has been resected, a partial homonymous superior quadrantanopsia can be expected postoperatively secondary to disruption of the optic radiations (Lee and Adelson 2004). Sometimes referred to as the “pie in the sky” defect, this visual field cut involves the left or right upper quadrant in each eye and affects the side opposite of the resection. For example, a right temporal lobectomy will result in a defect in the left upper quadrant in both eyes. There is also a risk of CN III (oculomotor) injury resulting in impaired eye movements and a ptosis, as medial temporal structures lie immediately adjacent to the third nerve at the tentorial edge (Holmes 2002).

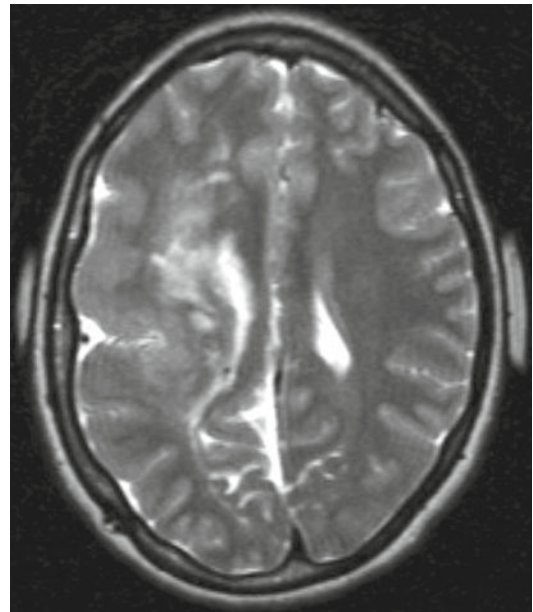
### 10.6.4 Extratemporal Resections

The temporal lobe is the most common site of seizure onset, with the frontal lobe second. Seizures can arise from the parietal and occipital lobes as well, although occipital onset is less common (Burgess 2011). Resection of a seizure focus can involve a full or partial lobectomy as well as portions of multiple lobes, depending on the causative pathology and its location. Seizure onset in extratemporal epilepsy typically occurs early in life, often in infancy, and can be quite severe. Therefore, extratemporal resections account for the largest number of epilepsy operations among younger children (Holmes 2002; Snead 2001; Vendrame and Loddenkemper 2010).

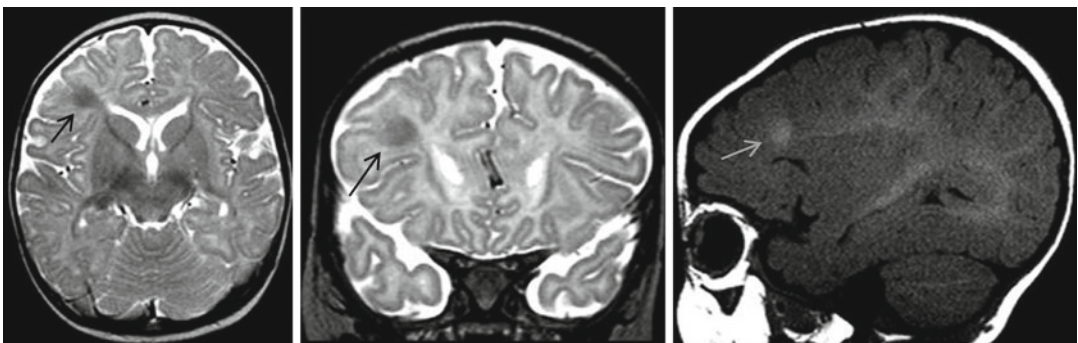
Malformations of cortical development (MCD), in particular cortical dysplasia, are a leading cause of extratemporal epilepsy in children (Cross et al. 2006; Krsek et al. 2009; Phi et al. 2010). Malformations of cortical development are the result of neurons failing to migrate in their proper formation during development, leading to an area of disorganized cortex. The area can vary in size from quite small to involving an entire hemisphere, as in hemimegalencephaly (Di Rocco et al. 2006; Hader et al. 2004; Krsek et al. 2009; Phi et al. 2010) (Figs. 10.8 and 10.9). Polymicrogyria and schizencephaly are also forms of cortical malformation that are often associated with epilepsy. The term cortical dysplasia is used to describe a wide variety of cortical malformations that can involve not only varying amounts of the brain but also a broad

spectrum of histopathology (Di Rocco et al. 2006). A classification system has been developed to better characterize cortical dysplasia (Blumcke et al. 2011). The pathology, location, and association with other epileptic syndromes greatly affect not only the treatment but also the outcomes of resection.

Extratemporal resections are more challenging than temporal. The seizure focus is more difficult to localize, particularly in the frontal lobe, where the large surface area and deep structures make precise EEG localization problematic (Holmes 2002). Areas of malformation can be



**Fig. 10.9** Right hemimegalencephaly. Note the widened gyral pattern and dysmorphic ventricle on the right



**Fig. 10.8** Focal cortical dysplasia of the frontal lobe (indicated by arrow)

difficult to see on MRI, and functional studies do not always correlate to these abnormalities (Holmes 2002; Lee and Adelson 2004; Snead 2001). Furthermore, even when a focal area of cortical abnormality is seen, it is not always clear how much of the surrounding brain is also epileptogenic. When seizures have been ongoing, it is likely that some degree of surrounding neocortex has been irritated or damaged and contributes as a seizure focus. Seizure foci in extratemporal epilepsy are more likely to overlap with eloquent cortex, which is more difficult to map in the parietal and occipital lobes (Lee and Adelson 2004). Because of these challenges, most patients with extratemporal onset will usually require phase II monitoring to help define the full area of seizure onset and its relation to eloquent cortex.

Seizure outcomes for extratemporal resections can vary dramatically, with seizure-freedom rates reported as low as 18 % and as high as 59 %. Numbers improve to 75 % when patients having a significant reduction in seizures are included (Hader et al. 2004; Holmes 2002; Krsek et al. 2009; Phi et al. 2010; Tellez-Zenteno et al. 2005; Zupanc et al. 2010). The main prognostic indicator of seizure freedom postoperatively is the ability to completely resect the epileptogenic zone. This is difficult to do with cortical dysplasia where boundaries are ill defined and lie near or within eloquent brain. Multiple studies have shown that complete resections carry the highest seizure-free percentages (Hader et al. 2004; Holmes 2002; Krsek et al. 2009; Lee and Adelson 2004; Phi et al. 2010; Tellez-Zenteno et al. 2005, 2010; Zupanc et al. 2010). Frontal lobe resections result in higher degrees of seizure freedom than parietal or occipital (Zupanc et al. 2010).

### 10.6.5 Complications of Extratemporal Resections

Injury to eloquent cortex is the main risk of extratemporal resections. Deficits seen can vary greatly depending on the part of the brain involved. Cortical mapping during phase II identifies functions within and surrounding the epileptogenic area. Resections are undertaken

with the attempt to resect all of the seizure focus while sparing function. This can lead to incomplete resection of seizure focus, acquired neurologic deficit, or both. Depending on the deficit and the severity of the seizures, choices are made regarding how much of a deficit is acceptable in an attempt to make the patient seizure free. Clearly, seizure freedom becomes irrelevant if a patient is neurologically devastated postoperatively. Undertaking a major surgery without any improvement in seizure control, even with sparing of neurologic function, is likewise of no benefit. Such decisions require close counsel of epilepsy team members, the family, and patient if possible. Motor sensory deficits recover fairly well following insult, as do language skills, in younger children. In the child less than 8 years, the plasticity of the brain allows for good recovery. Significant visual deficits, however, may be more difficult to overcome. Incomplete resections of seizure focus lead to incomplete seizure control. Studies have shown that long-term seizure control rates (>5 years) are lowest among extratemporal resections (Krsek et al. 2009; Phi et al. 2010; Tellez-Zenteno et al. 2005; Zupanc et al. 2010).

### 10.6.6 Hemispherectomy

Hemispherectomy was first described by Walter Dandy in 1928 to treat malignant brain tumors (Smellie-Decker et al. 2007). The procedure did not achieve tumor control, but the patients had fair neurologic outcomes, and the technique continued to evolve (Hader et al. 2004). Its use in the treatment of intractable epilepsy began in the 1980s (Limbrick et al. 2009). Traditional hemispherectomies involve removal of the entire hemisphere and are now less commonly used. A functional hemispherectomy is more commonly done and involves a complete temporal lobectomy and amygdalohippocampectomy, with disconnection of the frontal, parietal, and occipital lobes. The affected hemisphere is disconnected from the other but structurally still present.

A hemispherectomy should be considered in a child with a congenital or acquired abnormality

that affects one entire hemisphere resulting in severe unilateral seizures. Seizures should clearly lateralize to one hemisphere with poor localization of onset due to multiple sites within the hemisphere. They must have a relatively normal contralateral hemisphere to be a candidate. Often, the seizures are not only intractable but quite debilitating. Patients usually must show baseline motor impairment with a contralateral hemiparesis and limited use in the affected hand. In such children, the affected hemisphere is likely providing little useful function. Many are significantly developmentally delayed from multiple seizures which can number over 100 per day.

In the correct patient, hemispherectomies render a seizure-free outcome ranging from 43 to 90 % (Bien et al. 2005; Harvey et al. 2008; Limbrick et al. 2009; Tellez-Zenteno et al. 2005; Zupanc et al. 2010). Long-term follow-up (>5 years) shows that seizure freedom is maintained, and late seizure reoccurrence rates are much lower than in extratemporal resections (Vendrame and Loddenkemper 2010). In the majority of hemispherectomy patients, even without complete abolishment of seizures, improved cognitive and motor functioning is seen (Limbrick et al. 2009). Widespread cortical dysplasia, hemimegalencephaly (hemispheric cortical dysplasia), encephalomalacia, neonatal or perinatal infarction, Rasmussen's encephalitis, and Sturge-Weber syndrome are all etiology associated with progressive catastrophic epilepsies leading to hemispherectomy (Cross et al. 2006; Harvey et al. 2008; Holmes 2002; Limbrick et al. 2009; Snead 2001).

### 10.6.7 Complications of Hemispherectomy

Complications unique to hemispherectomy include the certainty of a dense hemiparesis and homonymous hemianopsia on the contralateral side. With physical and occupational therapy, it is remarkable how quickly and to what extent motor function recovers. Over the course of weeks to a few months, the majority of hemispherectomy

patients regain motor function that is equal to or better than their preoperative baseline. Particularly in younger patients, the recovery is often nearly complete.

Homonymous hemianopsia is a field cut in one-half of the visual field in both eyes. The field cut exists on the contralateral side from the operation. Though the defect does not fully recover, improvement is seen over time. Functional improvement is clearly seen as the brain compensates for the defect. Postoperatively, patients may be noted to have a "gaze preference" to the same side as the surgery raising concern for cranial nerve dysfunction. However, in hemispherectomy patients, this "gaze preference" is likely related to the field cut.

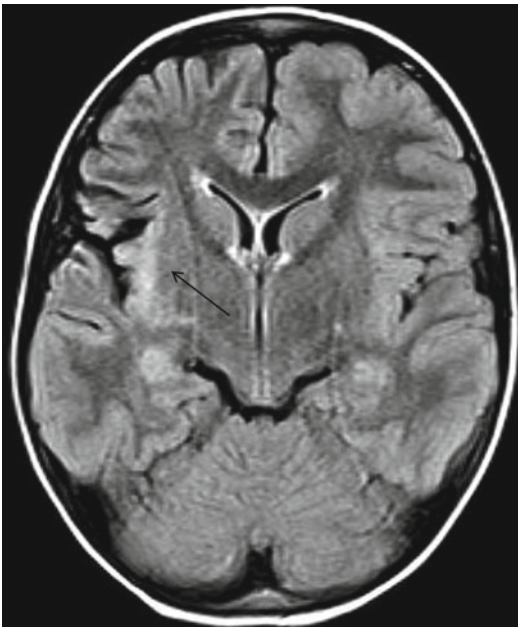
Depending on the degree of function in the resected hemisphere, postoperative patients may display varying degrees of disturbances in language, memory, or cognition. Again, these defects typically recover quite well, especially in the younger child where dominance has not yet been established (Holmes 2002; Lee and Adelson 2004). Good recovery is expected in most patients, if the deficits exist at all, as many of the eloquent functions have likely lateralized to the good hemisphere as a result of their disease. Hydrocephalus is another risk associated with hemispherectomy. Although rates are lower with functional compared to traditional hemispherectomies, the rate is still reported to between 18 and 30 % (Holmes 2002; Lee and Adelson 2004; Limbrick et al. 2009).

## 10.7 Epilepsy Syndromes

### 10.7.1 Rasmussen's Encephalitis

Rasmussen's encephalitis (RE) is a rare, chronic inflammatory disorder of the brain that is characterized by unilateral hemispheric atrophy, progressive decline in neurologic function, and intractable epilepsy. It was first described in 1958 by Theodore Rasmussen and his colleagues. The cause is not known. Both viral and autoimmune etiologies have been researched, but the cause remains unclear. Histopathology of

involved brain tissue does show lymphocyte infiltration. RE typically only involves one hemisphere, although bilateral involvement has been reported (Bien et al. 2005; Dubeau 2011). Onset is predominantly in childhood, with an average age of 6 years, but cases have been reported in adults. Presentation is generally triphasic starting with a “prodromal stage” characterized by onset of low-frequency seizures and mild hemiparesis. An “acute phase” follows which is characterized by frequent seizures, progressive hemiparesis, hemianopsia, and progressive cognitive decline. The first phase can last up to 8 years, with the acute phase typically lasting 4–8 months. The last phase or “residual phase” is characterized by stable neurologic dysfunction and intractable epilepsy, although seizure frequency is typically less. Not all patients are hemiplegic (Bien et al. 2005). Seizures in RE are typically partial motor and are intractable to AEDs. Hemispherectomy is the only treatment for RE that has provided seizure relief and improved neurologic function (Dubeau 2011) (Fig. 10.10).

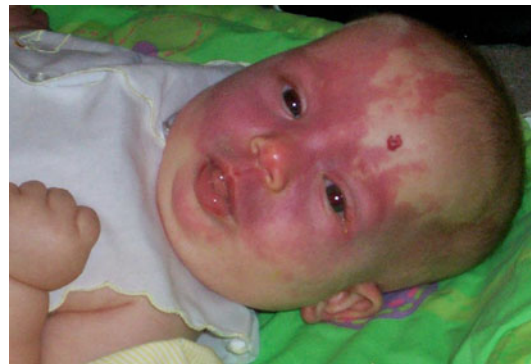

**Fig. 10.10** Rasmussen’s encephalitis. MRI FLAIR image showing right-sided atrophy as evidenced by a widened Sylvian fissure. Also note the increased signal in the area indicating inflammation (indicated by arrow)

### 10.7.2 Sturge-Weber Syndrome

Sturge-Weber syndrome (SWS), also known as encephalotrigeminal angiomas, is a rare neurocutaneous syndrome affecting approximately 1 per 50,000 live births. The cause is not known but is felt to be related to an error early in fetal development. SWS is characterized by unilateral facial nevus, dural and leptomeningeal angiomas, hemangiomas of the choroid, and congenital glaucoma (Di Rocco and Tamburrini 2006). The nevi, which typically have a port-wine appearance, can vary in size and are generally located on one side of the face. Distribution is usually along the region of the trigeminal nerve innervation (Di Rocco and Tamburrini 2006) (Fig. 10.11). The leptomeningeal angiomas is typically present on the same side as the nevus but has been reported bilaterally in as many as 15 % of cases. Angiomas can cause chronic cortical ischemia leading to calcification and laminar cortical necrosis (Gupta 2011) (Figs. 10.12 and 10.13). Epilepsy is a common symptom in SWS, affecting 75–90 % of patients. Seizure onset can occur at any age, including early adulthood, but the median age for onset is 6 months (Di Rocco and Tamburrini 2006; Gupta 2011).

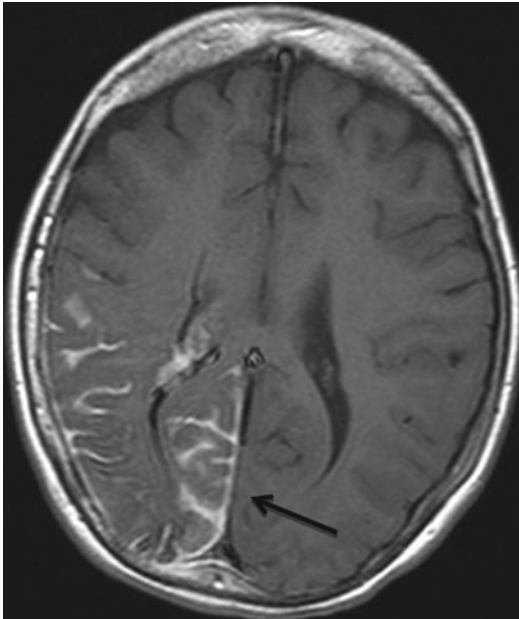
Pharmacological control of seizures has been reported in up to 40 % of patients with SWS, but many will be medically intractable. Seizure onset in the first year of life has been associated with a higher risk of intractability (Di Rocco and Tamburrini 2006). In patients with unilateral



**Fig. 10.11** Patient with Sturge-Weber syndrome. Most nevi are unilateral but can be bilateral

hemispheric involvement and intractable epilepsy, surgical intervention should be considered. The decision should be made as soon as possible, since there is some evidence that the angiomas can be progressive. Early intervention can not only treat the seizures but also stop the progression

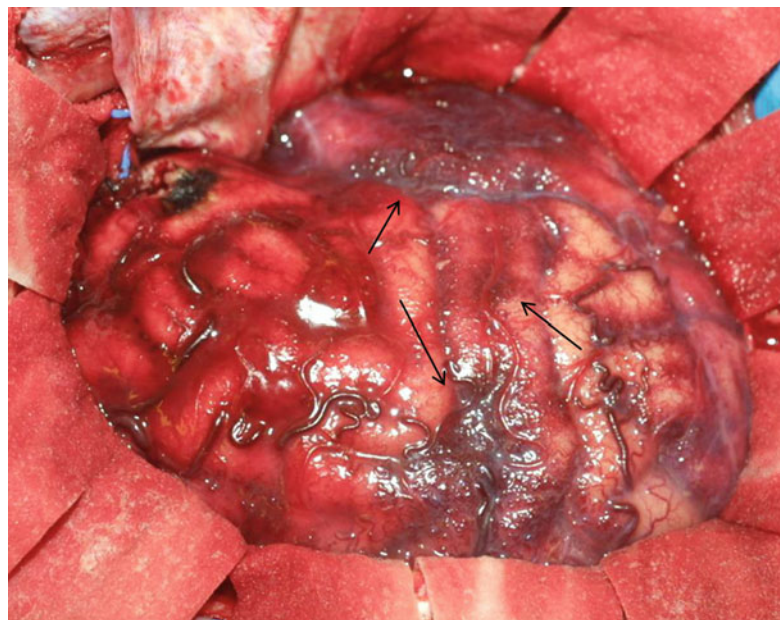
of brain involvement and neurologic decline (Gupta 2011). The extent of involvement, and the information obtained from the preoperative workup, will dictate what surgical procedure is recommended. Procedures include lobectomies, tailored resections, and hemispherectomies. All surgical techniques have shown improvement in seizure outcome, but hemispherectomy patients have the highest seizure-free rate at long-term follow-up (Di Rocco and Tamburrini 2006).



**Fig. 10.12** MRI of SWS patient showing right occipital hypervascularity as indicated by arrow

### 10.7.3 Tuberos Sclerosis

Tuberous sclerosis complex (TSC) is a genetic disorder that affects multiple systems with variable phenotypic expression. TSC results from a mutation in the TSC1 gene on chromosome 9 and occurs in 1 of 10,000 births (Connolly et al. 2006). TSC is characterized by various lesions involving the skin, heart, retina, kidneys, and brain. The most common neurologic manifestation is seizures, affecting 80 % of patients with TSC. Seizures are caused by tubers in the brain which are lesions made up of dysplastic neurons, giant balloon cells, and glial components (Connolly et al. 2006; Gupta 2011). Tubers are epileptogenic in differing degrees. They can



**Fig. 10.13** Intraoperative photo of patient with SWS. Note abnormal blood vessels over the surface of the cortex (indicated by arrows)

occur in multiple locations throughout the brain, so the seizure type and pattern seen can vary. Medical management with AEDs is the initial treatment of seizures for TSC patients, but patients may become intractable and should be considered for surgery (Connolly et al. 2006).

Surgical resection of a single tuber shown to be the focus of onset can result in good seizure control. Unfortunately, many patients with TSC have multiple tubers, and the removal of one may result in another becoming the epileptogenic focus. Therefore, preoperative workup and candidate selection becomes challenging and requires careful identification of the number of tubers present, and whether one or several are the epileptogenic focus. As in all surgical candidates, this information will dictate what surgery, if any, is proposed.

Research has shown high rates of seizure alleviation or significant reduction in TSC patients with epilepsy surgery (Connolly et al. 2006; Gupta 2011). Timing of surgery is important as TSC can be a progressive disease. TSC patients exhibit a higher incidence of mild to moderate mental retardation that is likely associated to the duration and severity of seizures (Connolly et al. 2006). Again, earlier identification of potential candidates is better. Not all TSC patients will be candidates for resective surgery, but even those that are not may be candidates for a palliative surgery, such as corpus callosotomy or vagus nerve stimulator (Fig. 10.14).

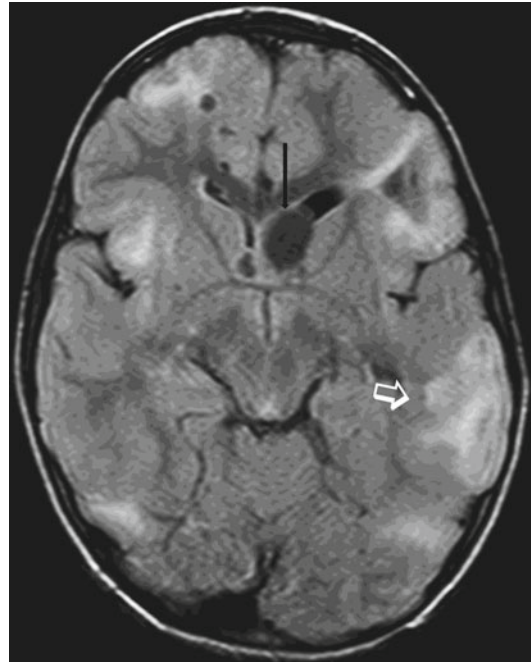
## 10.8 Palliative Surgical Procedures

### 10.8.1 Corpus Callosotomy

In individuals with intractable generalized seizures without an epileptogenic focus, corpus callosotomy may be a surgical option. Corpus callosotomy is a palliative, not curative, procedure involving resection of the corpus callosum. By resecting the corpus callosum, the tracts that allow seizure spread from one hemisphere to the other are removed. The procedure is primarily indicated for patients suffering from intractable drop attacks secondary to generalized tonic or

atonic seizures (Jalilian et al. 2010; Snead 2001). Patients considered for this procedure are cognitively impaired with severe and debilitating epilepsy.

There are two approaches to this procedure, partial and complete resection. If the child possesses any meaningful language, an anterior two-thirds resection is undertaken, thereby preserving the posterior tracts. If a child is severely disabled without any meaningful language, then a complete resection is recommended as it provides the best control (Jalilian et al. 2010). The goal of corpus callosotomy is not to achieve freedom from seizures but to improve quality of life. Therefore, outcome data focuses not on seizure freedom but on significant reduction in drop attacks. When looked at from this perspective, the corpus callosotomy can be quite successful, with reduction rates reported in nearly 100 % of complete resections and 75 % of partial (Jalilian et al. 2010; Lee and Adelson 2004; Snead 2001; Tellez-Zenteno et al. 2005; Zupanc et al. 2010).



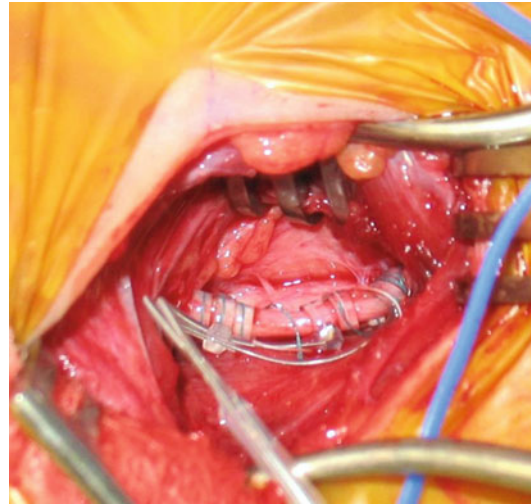
**Fig. 10.14** Diffusion-weighted MRI of tuberous sclerosis patient. *White arrow* shows a large tuber. The other high-signal areas are also tubers. The *black arrow* shows a subependymal giant cell tumor

Complete resection carries the risk of a disconnection syndrome that results from the somatosensory, auditory, and visual disorientation caused by removing the corpus callosum (Jalilian et al. 2010; Smellie-Decker et al. 2007; Snead 2001). Cutting the tracks that prevent seizures from spreading also disconnects the pathway of information sharing from one hemisphere to the other. Thus, many patients undergoing this operation will typically experience a period of being “stunned” where existing cognitive abilities will be diminished. The more functional a patient was prior to surgery, the more severe these deficits may seem. Most deficits will improve significantly over a fairly short period of time (Lee and Adelson 2004).

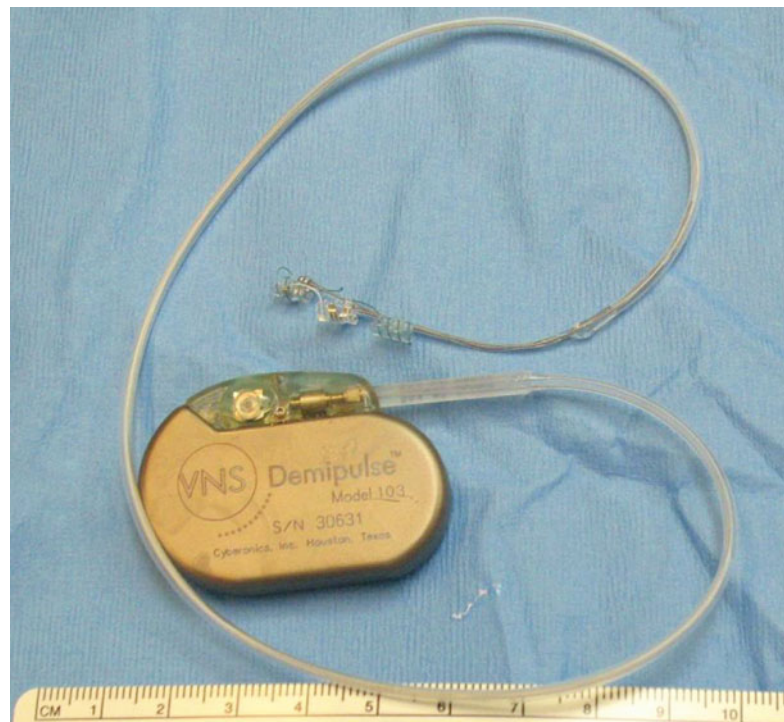### 10.8.2 Vagal Nerve Stimulator

The vagal nerve stimulator (VNS) is another palliative option in children with medically intractable epilepsy who are not surgical candidates. An impulse generator that emits electrical impulses is implanted under the skin in the chest. Attached to the generator are leads that are placed on the vagus

nerve (Figs. 10.15 and 10.16). The generator emits an intermittent current in an on/off pattern. Patients can also place a magnet over the device and trigger an impulse during a seizure. It is not clear why the VNS works, but it is thought that the electrical impulses increase the excitability of neurons, thereby increasing their inhibition and



**Fig. 10.16** VNS leads attached to vagus nerve



**Fig. 10.15** VNS generator



reducing seizures (Kabir et al. 2009). The VNS is both antiepileptic, in that it decreases seizure frequency and helps control seizures, and also an anticonvulsant because it can stop a seizure in progress. The result is fewer and less severe seizures. A reduction of seizures by 50 % or greater is reported in as many as 75 % of patients (Cross et al. 2006; Lee and Adelson 2004; Kabir et al. 2009). Few patients will be rendered seizure free with a VNS, but improved seizure control and improved quality of life scores are reported by the majority of patients and families (Kabir et al. 2009; Snead 2001; Benifla et al. 2006).

Placement of the VNS is a well-tolerated procedure that is normally done as an outpatient. The device is placed on the left side, as stimulation of the left vagus nerve has fewer cardiac affects. The device and leads are typically placed through a single incision above the left clavicle. Once the device is in place, some centers will turn on the device at a low voltage while in the operating room. Others will turn the device on at later date in clinic. In either scenario, every 1–2 week follow-up visits are planned while the device is “ramped up.” Impulse output is increased until desired effects on seizure frequency are seen or side effects prevent further increase.

Side effects from stimulation of the vagus nerve can include bradycardia when stimulation is first initiated. This tends to be brief, immediately upon starting the device and generally does not reoccur. A hoarse voice, hiccupping, coughing, and drooling have been seen in association with vagal nerve stimulation. Side effects tend to be voltage dependent and often remit once the nerve gets used to the current. It is not uncommon to see temporary reappearance of the symptom each time the VNS is turned up. The main risks of VNS implantation include a very small possibility of injury to the vagus nerve. There is a small risk of infection (reported 1–3 %) which results in the need to explant the device (Benifla et al. 2006; Kabir et al. 2009). There is also the risk that the surgery is undertaken to implant the device without any noticeable improvement in seizures. The VNS contains a lithium battery that will eventually wear out, requiring the device to be changed. Average battery life is 6 years but

depends greatly on the particular device and individual generator settings.

---

## 10.9 Complications of Epilepsy Surgery

Complications specific to individual procedures have already been discussed, but there are potential complications that are inherent to all resective epilepsy surgeries. With the exception of VNS, all epilepsy surgeries carry the risk of problems with cerebral spinal fluid (CSF) dynamics. This can range from a CSF leak to hydrocephalus. It is not uncommon for CSF to collect under the skin in what is called the subgaleal space. Typically, a CSF collection here will decrease over time and resolve on its own. If a subgaleal fluid collection fails to resolve over time or is continuing to increase in size, then concerns for hydrocephalus are raised. If CSF leaks through the incision, then there is an increased risk for infection and sutures may need to be applied to stop the leak. As noted previously, hemispherectomy has the highest association of hydrocephalus, but it can develop after any resective seizure surgery.

Infection is a risk inherent to any surgical procedure, and epilepsy surgery carries infection rates that are similar to other neurosurgical procedures. The overall rate of infection is quite low, with studies reporting rates from 2 to 9 %. There is no statistical difference between patients who underwent phase II monitoring and those who did not (Johnston et al. 2006; Zupanc et al. 2010). When infections occur, there is the added concern of involvement of the bone flap in the infection. Therefore, these children are often treated with several weeks of antibiotics.

There are surgical risks involved with every craniotomy. These include the risk of acute hemorrhage causing mass effect, cerebral edema, and vascular compromise that could lead to stroke. The risk of new neurologic deficits is also inherent to any resective surgery, as addressed elsewhere in this chapter. The exact deficits seen depend on the area of the brain that has been injured either by the resection itself or as a result

of secondary events such as stroke or ischemic injury. When undertaking epilepsy surgery, the goal is always to have a significant reduction or elimination of seizures without inflicting significant neurologic injury. Most of the epilepsy surgeries have a significant degree of risk to them. It is essential that families have a full understanding of these potential risks before proceeding with the surgery. They must understand the characteristics of potential complications and what that may mean for them and their child should the complication occur. This information is as critical, if not more so, than understanding the likelihood of seizure freedom.

---

## 10.10 Nursing Care Following Resective Surgeries

Following resective surgeries, patients will be monitored in the PICU until they are stable enough to be cared for in the general pediatric areas. The most important aspect of postoperative nursing care is serial neurologic examinations. A detailed description of a neurological examination in children is described elsewhere in this book (Chap. 1) so will not be detailed here. The frequency of the exam will vary depending on what stage of recovery the patient is in. Obviously, neurological exams should be performed very frequently as the child emerges from anesthesia so that a new postoperative baseline can be established. It is important for the nurses in the immediate postoperative phase to be familiar with the patient's preoperative baseline as comparison. New deficits, as well as any neurologic improvements, should be noted. Once a new baseline is established, it is essential that good and descriptive communication exists between all caregivers assessing the child so that subtle changes can be noted. Any sign of worsening neurologic function should be discussed with the neurosurgical team. Nurses caring for these patients need to be familiar with the various operations and the potential complications inherent to them.

Pain management is important throughout the child's postoperative course. All patients are different in the degree of pain they experience as

well as the length of time they experience it. A combination of narcotics and non-narcotics are used. IV medications are required initially with transition to orals once the patient can tolerate taking medications by mouth. Various pain scales exist, but the same scale should be used for the same patient to allow for consistent assessments between care providers. This also allows for the establishment of a pain medication "routine" that can be followed across shifts for consistent pain control. Nurses should take an active role in anticipating pain needs and use a combination of patient parameters to help make decisions about medications and dosing. Patients with neurologic compromise can have behaviors that appear to be associated with pain but may actually represent agitation, global disorganization, or even seizures. It is essential that nurses caring for these patients be able to discern the difference. The ability to do so makes the nurse an even more valuable part of the team. Having a good understanding of the child's baseline neurologic exam and level of functioning can help in differentiating the source of behaviors. Good communication between individual care providers and the family is also essential.

Postoperative craniotomy patients are at risk for disorders associated with fluid and electrolyte balance, such as DI, SIADH, or cerebral salt wasting. It is important to monitor both fluid intake and output as well as lab values for serum sodium. Hyponatremia can develop quite quickly over the course of a shift and can lead to increased brain swelling, altered mental status, and seizures. Electrolytes are typically monitored closely within the first 24–48 h and, once stability is established, can be followed less closely. Nurses should recognize that most patients will exhibit a transient large increase in their urine output somewhere between 12 and 24 h after surgery. This can be concerning but usually represents the normal diuresis of intraoperative fluids and should not last more than a few hours. The nurse should be aware of urine output parameters that would warrant notification of the neurosurgical team.

The use of postoperative drains, particularly external ventricular drains (EVD), is not uncommon with epilepsy surgery. Jackson-Pratt (JP)

drains and subdural drains may also be used. It is important for the nurse to understand the function of the drain and its collection system as well as what space the drain is draining. This allows for the nurse to know what type of fluid and how much output is expected. The exit site should be carefully monitored for drainage. If drainage does exist, then it is essential to assess whether or not the drainage is CSF. Drainage of CSF through an incision, or around an exiting catheter, can increase the risk of infection. The neurosurgery team should be notified whenever this occurs so that appropriate measures can be taken to stop it.

Fever occurring in the first 72 h postoperatively is expected and is not a concern for infection. Fever in this time frame is often seen as a reaction to general anesthesia, most likely from atelectasis, and should be treated accordingly. Nurses should be aware that fever can significantly impact the neurologic exam of a postoperative neurosurgical patient. It is not uncommon to see a fairly significant decline in the neurologic exam of a febrile patient, and care must be taken to assure that the exam returns to baseline when the fever abates. After the initial 72 h, fevers carry a different significance and should prompt investigation of the source. Postoperative infections typically do not present within the first week of surgery, but postoperative complications like atelectasis or urinary tract infection could be the source.

Specific postoperative incision care will vary greatly by institution and surgeon. In general, the wound and operative area should be monitored for the presence of drainage, swelling, or erythema. Some degree of drainage is often present in the first 24 h following surgery. However, drainage persisting past that time needs to be monitored closely by the surgical team. Characteristics of the drainage should be noted to help determine whether it represents expected serosanguinous drainage or if it is CSF. The nurse should have a good understanding of when the surgical team needs to be notified regarding drainage. Any drainage that occurs after the immediate post-op period, especially if the wound had been dry for a period of time, is concerning

for wound breakdown, infection, or CSF leak. Wound breakdown can result from poor healing or a broken stitch, but it can also be a sign of developing infection or hydrocephalus.

Patients remain at risk for seizures postoperatively. Nurses caring for these patients must be comfortable with recognizing and treating seizures. A rescue medication plan must exist for each patient following surgery. Postoperative seizures are fairly uncommon following epilepsy surgery; however, they do occur. When they do, that does not mean that the operation has failed. There is a risk for seizures associated with any brain surgery, as the operation causes irritation and inflammation in the brain. The nurse can play an important role in the reassurance of parents who are understandably concerned over the presence of a seizure. Postoperative neurosurgical patients can also display behaviors that can look like seizures but are not. Again, nurses experienced in caring for epilepsy patients can help decipher seizures from non-epileptiform behaviors. Continuous EEG may be used postoperatively to determine whether seizures are truly occurring.

Postoperative care of the epilepsy patient involves a large, multidisciplinary team. Many patients will require an extended hospital stay for rehabilitation needs. This can be stressful to the family and child. Paying attention to the emotional aspects of care is important. Nurses are the constant provider among a larger group that will change over time. They are in the perfect position to provide support and education to the family and child. Nurses play an important role as advocates and liaisons for the family. Families are not only dealing with the stress of a prolonged hospital stay but are also coping with understanding the needs of their children postoperatively and what changes (good and bad) are going to occur in their lives. It is important to monitor how the patient and family are coping with the overall situation and offer assistance at an early juncture. Anger, frustration, and depression can occur even when the outcome has been good. The nurse is essential in providing encouragement, support, and resources to the family and child.

### 10.11 Outcomes of Epilepsy Surgery

When discussing outcomes of epilepsy surgery, it is important to consider not only seizure frequency but also quality of life. Classification systems to categorize outcomes are important so that results from different therapies can be compared. The most commonly used classification system for defining seizure outcome is the classification developed by J. Engel in 1993 (Engel et al. 1993) (Table 10.1). This system is widely used and provides a uniform method to analyze outcomes. In this system, seizure outcome is based on the number of seizure events a patient experiences postoperatively. It excludes seizures seen in the first few weeks postoperatively and includes four classes ranging from “free of disabling seizures” to “no worthwhile

improvement” (Jehi et al. 2011). Criticisms of this system include the use of ambiguous terms like “disabling seizures,” “almost seizure-free,” and “worthwhile improvement” (Wieser et al. 2001). These category headings are subject to interpretation and lead to a high variability in reported results. One center may consider any reduction in seizures over 50 % to be worthwhile, whereas another center may require greater than 75 %. Furthermore, the definition of disabling seizures can vary greatly. Another criticism is that centers may not utilize the subcategories that exist for each classification (Wieser et al. 2001). These criticisms lead the International League Against Epilepsy to propose a revised classification system in 2001 (Table 10.2). This system more clearly defines seizure occurrence by distinctly categorizing those who are completely seizure free from those with just auras. It also defines seizures based on seizure days per year rather than events, thus classifying patients who may seize infrequently but do so with clusters. The ILAE system also added a category for patients with worsening seizures which was lacking in Engel’s system (Wieser et al. 2001). Both systems are easy to use and provide a way to systematically classify seizure outcomes. Further, they have both been shown to have excellent inter-rater reliability and have been found to be comparable to each other (Durnford et al. 2011).

In looking at all surgical procedures to treat epilepsy, seizure freedom (or significant reduc-

**Table 10.1** Engel’s classification of postoperative outcome

<i>Class I: Free of disabling seizures<sup>a</sup></i>
A. Completely seizure free since surgery
B. Nondisabling simple partial seizures only since surgery
C. Some disabling seizures after surgery but free of disabling seizures for at least 2 years
D. Generalized convulsions with AED discontinuation only
<i>Class II: Rare disabling seizures (“almost seizure free”)</i>
A. Initially free of disabling seizures but has rate seizures now
B. Rare disabling seizures since surgery
C. More than rare disabling seizures since surgery but rare seizures for the last 2 years
D. Nocturnal seizures only
<i>Class III: Worthwhile improvement<sup>b</sup></i>
A. Worthwhile seizure reduction
B. Prolonged seizure-free intervals amounting to greater than half the follow-up period but not <2 years
<i>Class IV: No worthwhile improvement</i>
A. Significant seizure reduction
B. No appreciable change
C. Seizures worse

Source: Engel et al. (1993)

<sup>a</sup>Excludes early postoperative seizures (first few weeks)

<sup>b</sup>Determination of “worthwhile improvement” will require quantitative analysis of additional data such as percentage seizure reduction, cognitive function, and quality of life

**Table 10.2** ILAE classification of postoperative outcome

Class 1. Completely seizure free; no auras
Class 1a. Completely seizure free since surgery; no auras
Class 2. Only auras; no other seizure
Class 3. 1–3 seizure days/year ± auras
Class 4. 4 seizure days/year to 50 % reduction in baseline number of seizure days/year; ± auras
Class 5. <50 % reduction in baseline seizure days to 100 % increase in baseline seizure days; ± auras
Class 6. >100 % increase in baseline number of seizure days; ± auras

Source: Weiser et al. (2001)

tion in seizures) is highest among patients with temporal lobectomies, followed by hemispherectomies, with resections for cortical dysplasia showing some of the lowest rates for non-palliative procedures (Phi et al. 2010; Tellez-Zenteno et al. 2005, 2010; Zupanc et al. 2010). Patients having a defined, identifiable lesion on MRI are 2.5 times more likely to be seizure free after surgery than those without a defined lesion, and those with a lesion in the temporal lobe do best of all (Tellez-Zenteno et al. 2010). The presence of a well-defined lesion allows for a higher probability of complete resection of the focus. Epileptogenic foci defined by vague imaging findings, metabolic studies, and cortical EEG mapping carry a higher probability of leaving epileptogenic tissue behind. Also, resections near eloquent areas have a higher risk of incomplete resection (Tellez-Zenteno et al. 2005; Zupanc et al. 2010). Cortical dysplasia, for example, carries one of the lowest seizure-free rates. This is due to the fact that the extent of the dysplasia is not always evident on imaging or EEG monitoring allowing for incomplete resection.

Multiple factors certainly play into seizure outcome, particularly the etiology of the epilepsy, age of the child, duration of the seizures, and the presence of dual pathologies or syndromes. Long-term seizure control has been shown to decline at 2 and at 5 years. One explanation for this is recruitment of new epileptogenic foci. The cortex surrounding an identified epileptic focus may not appear to be epileptogenic on initial workup, but it may become so once the main seizure focus is removed. Then, as AEDs are being withdrawn, it becomes active. It is also thought that AED resistance worsens over time, thus allowing for recurrence of seizures (Tellez-Zenteno et al. 2005).

Quality of life (QOL) outcomes are as important as seizure outcomes. QOL outcomes look at cognitive, behavioral, and social functioning. More recent studies are showing that early surgical intervention can result not only in seizure reduction but improvements in quality of life as well (Mikati et al. 2010; Zupanc et al. 2010). No QOL outcome classification system exists, although this has been proposed by the ILAE

(Wieser et al. 2001). There are some surveys available that measure QOL based on parent and patient perception of such things as well-being, cognitive functioning, behavioral functioning, and social activity. They generally include assessments of seizure impact on quality of life (Zupanc et al. 2010). As would be expected, better QOL scores are reported postoperatively by patients with seizure-free or near-seizure-free outcomes. QOL scores are also significantly higher for surgically treated patients than for patients worked up for surgery but not operated on (Mikati et al. 2010). Families of patients operated on at a younger age with good outcomes also report better quality of life (Mikati et al. 2010; Zupanc et al. 2010).

QOL outcomes showed no change or limited change among teenagers and young adults, however, regardless of seizure outcome. Despite good or complete seizure control, this age group still reported low QOL outcomes (Zupanc et al. 2010). This is likely due to the fact that despite improved seizures, many of these individuals experienced social isolation, poor performance in school, high unemployment, and low rates of independence. It is believed that when control of seizures comes in adolescents or adulthood, these individuals have likely had long-standing intractable epilepsy leading to significant effects on cognition, academic performance, self-esteem, and social skills. Corrective surgery may have come at too late of a juncture to have an impact on major life skills (Mikati et al. 2010; Zupanc et al. 2010). Depression and other psychiatric disturbances are common with epilepsy and may not improve even after a successful surgery. Results such as these serve as another argument for considering epilepsy surgery earlier rather than later in children with intractable seizures. Early intervention prevents injury to the developing brain from intractable seizures and medications, allowing the child to develop more normally. As epilepsy surgery continues to be considered earlier in an individual's disease, it will be interesting to see if QOL data improve among adolescents and adults (Box 10.1).

**Box 10.1. Epilepsy Surgery Case Study**

M. A. was born at 29 weeks gestation requiring initial care in the NICU. Neonatal complications included mild respiratory distress, feeding disturbance, and a PDA which was closed with indomethacin. He did well, without lasting effects, and was discharged home at 2 months. Head ultrasounds had been performed as part of his neonatal care and were found to be normal. He experienced no seizures. He was growing well, and developing normally, until 7 months of age. He had no known medical problems, and he had never experienced a febrile seizure. There was no family history of seizures.

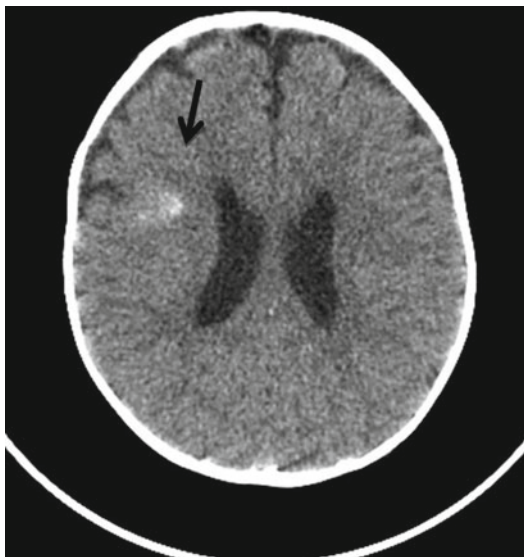At 7 months, he had his first seizure which involved left-sided twitching and gaze deviation to the left. An EEG was scheduled by his PCP, but, before this could be done, he acutely developed an episode of dense left hemiparesis and leftward gaze. His parents brought him to the emergency department where, by that time, he was found to have a normal neurologic exam. A CT scan showed a 3-cm area of abnormality in the inferior frontal region with calcifications and vague abnormal density. An MRI was done showing focal cortical dysplasia in the right frontoparietal region. There was also an area of cortical abnormality in the right inferior occipital lobe. He was started on Tegretol and discharged home.

M. A. continued to experience multiple daily seizures despite the Tegretol, so he was started on Trileptal. He had better seizure control but continued to experience daily seizures. He was admitted to the NMU for vEEG monitoring. His AEDs were withdrawn and he experienced several typical seizures. Video monitoring showed his seizures to consist of a blank stare, eye movements back and forth, twitching in the left side of his face, and snorting noises. The EEG showed ictal onset from the right cerebral hemisphere, particularly the right parietal and temporal regions. Interictal EEG showed normal background EEG for his age. Because of the focal cortical abnormalities on imaging, and EEG onset from the same area, he was felt to be a candidate for resective surgery.

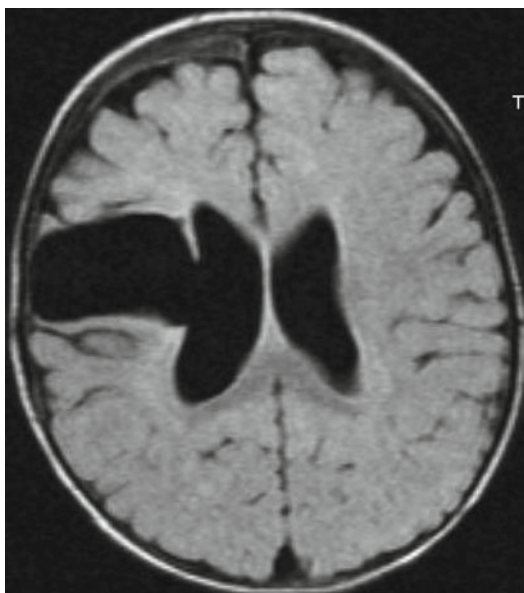
At 9 months of age, he underwent phase II monitoring with a right frontotemporal parietal craniotomy for implantation of subdural electrodes. He was monitored and mapped in the NMU. His seizures were found to be arising from the frontoparietal area of dysplasia. No seizures were noted to arise from the occipital area. Four days later, he was taken back to surgery where the electrodes were removed and the area of seizure focus was resected (Figs. 10.17 and 10.18). He spent his first postoperative night in the PICU and then was transferred to the neurosurgery floor. He had an uneventful postoperative course. He had no seizures following surgery. He was discharged home on postoperative day number 5 on Dilantin and Trileptal.

Prior to surgery, he had a normal neurological and developmental exam for a 9-month-old, corrected 2 months for his prematurity. He was vocal, playful, rolling over, and pushing up on all fours. He had no neurologic deficits. Postoperatively, he had a moderate left-sided weakness, greater in arm than leg, but no other deficits. The weakness improved postoperatively. At his 2-month post-op visit, he was noted to use the left arm purposefully. He would bear weight and try to “cruise” when put into a standing position. He was noted to have mildly increased tone on the left.

M. A. is now 6 years old and has been seizure free since surgery (Engel class Ia). He is off all seizure medications. His Dilantin was stopped 10 days postoperatively, and his Trileptal was stopped 2 years postoperatively. He does have a residual mild left hemiparesis, but he is fully ambulatory and active. He runs, is on a soccer team, and has purposeful use of his left arm and hand. He is in the first grade and is meeting or exceeding expectations comparable to his peers. He has not yet undergone formal neuropsychological testing given his age but will in the future.



**Fig. 10.17** Area of calcification and subtle cortical abnormality suggesting cortical dysplasia



**Fig. 10.18** Postoperative MRI showing resection of seizure focus

### Conclusions

Epilepsy surgery is a safe and effective treatment option for individuals with intractable seizures. New and continually improving imaging, monitoring, and operative techniques make epilepsy surgery an option for patients of all ages. Careful workup and consideration of surgical candidates is leading to a high success rate of

seizure control and improved quality of life outcomes. Once reserved for only the most severe cases, epilepsy surgery is now being considered as a treatment option earlier in a child's disease. With earlier intervention comes an improved cognitive outcome, as the brain is spared detrimental exposure to seizures and AEDs. Though there are risks associated with epilepsy surgery, the overall reported outcomes are still superior to reported outcomes for continued trials of antiepileptic medications. The goal of epilepsy surgery remains curing or significantly decreasing the number of seizures while preserving the child's development, intellect, and quality of life. As advancements in workup and surgical technique continue, this goal will be reached in all surgical patients, not just the majority.

### Pediatric Pearls

1. All patients being monitored in the NMU are at risk for episodes of status. Make sure that a clear plan of action is readily available should status occur. The action plan should include what AEDs to give, in what order, after what length of time, as well as who is to be notified. The plan should also clearly identify which concerns to address with neurosurgery and which to address with neurology.
2. Given that epilepsy surgery patients require a multidisciplinary team, nurses need to play a consistent role as communicator and advocate for the family.
3. Differentiating between seizures and behaviors related to pain or altered mental status can be difficult. It is important to know each child's typical seizure semiology and their baseline neurologic functioning to help with this distinction.
4. Narcotics will not deter seizures during monitoring and should not be withheld for this reason.
5. Surgical epilepsy patients typically require long hospital stays. It is important to involve ancillary services such as child life specialists, play therapists, and school resources.

## References

- Albright AL, Pollack IF, Adelson PD (2001) Operative techniques in pediatric neurosurgery. Thieme, New York
- Benifla M, Rutka JT, Logan W, Donner EJ (2006) Vagal nerve stimulation for refractory epilepsy in children: indications and experience at The Hospital for Sick Children. *Childs Nerv Syst* 22:1018–1026
- Bien CG, Granata T, Antozzi C, Cross JH, Dulac O, Kurthen M, Lassmann H, Mantegazza R, Villemure JG, Spreafico R, Elger CE (2005) Pathogenesis, diagnosis and treatment of Rasmussen encephalitis: a European consensus statement. *Brain* 128:454–471
- Blumcke I, Thom M, Aronica E, Armstrong DD, Vinters HV, Palmini A, Jacques TS, Avanzini G, Barkovich AJ, Battaglia G, Becker A, Cepeda C, Cendes F, Colombo N, Crino P, Cross JH, Delalande O, Dubeau F, Duncan J, Guerrini R, Kahane P, Mathern G, Najm I, Ozkara C, Raybaud C, Represa A, Roper SN, Salamon N, Schulze-Bonhage A, Tassi L, Vessani A, Spreafico R (2011) The clinicopathologic spectrum of focal cortical dysplasias: A consensus classification proposed by an ad hoc Task Force of the ILAE Diagnostic Methods Commission. *Epilepsia* 52:158–174
- Burgess R (2011) Localization and field determination in electroencephalography. In: Wyllie E (ed) *Wyllie's treatment of epilepsy: principles and practice*, 5th edn. Lippincott Williams & Wilkins, Philadelphia
- Connolly MB, Henderson G, Steinbok P (2006) Tuberous sclerosis complex: a review of the management of epilepsy with emphasis on surgical aspects. *Childs Nerv Syst* 22:896–908
- Cross JH, Jayakar P, Nordli D, Delalande O, Duchowny M, Wieser HG, Guerrini R, Mathern G (2006) Proposed criteria for referral and evaluation of children for epilepsy surgery: recommendations of the Subcommittee of Pediatric Epilepsy Surgery. *Epilepsia* 47:952–959
- Di Rocco C, Battaglia D, Pietrini D, Piastra M, Massimi L (2006) Hemimegalencephaly: clinical implications and surgical treatment. *Childs Nerv Syst* 22:852–866
- Di Rocco C, Tamburrini G (2006) Sturge-Weber syndrome. *Childs Nerv Syst* 22:909–921
- Dubeau F (2011) Rasmussen encephalitis (chronic focal encephalitis). In: Wyllie E (ed) *Wyllie's treatment of epilepsy: principles and practice*, 5th edn. Lippincott Williams & Wilkins, Philadelphia
- Durnford AJ, Rodgers W, Kirkham FJ, Mullee MA, Whitney A, Previtt M, Kinton L, Harris M, Gray WP (2011) Very good inter-rater reliability of Engel and ILAE epilepsy surgery outcome classifications in a series of 76 patients. *Seizure*. doi:10.1016/j.seizure.2011.08.004
- Engel JJ, Van Ness PC, Rasmussen TB, Ojemann LM (1993) Outcome with respect to epileptic seizures. In: Engel JJ (ed) *Surgical treatment of the epilepsies*, 2nd edn. Raven Press, New York, pp 609–621
- Farwell JR, Dodrill CB, Batzel LW (1985) Neuropsychological abilities of children with epilepsy. *Epilepsia* 26:395–400
- Foldvary N, Nashold B, Mascha MS, Thompson A, Lee N, McNamara JO, Lewis DV, Luther JS, Friedman AH, Radtke RA (2000) Seizure outcome after temporal lobectomy for temporal lobe epilepsy. *Neurology* 54:630–634
- Gupta A (2011) Epilepsy in the setting of neurocutaneous syndromes. In: Wyllie E (ed) *Wyllie's treatment of epilepsy: principles and practice*, 5th edn. Lippincott Williams & Wilkins, Philadelphia
- Hader WJ, Mackay M, Otsubo H, Chitoku S, Weiss S, Becker L, Snead OC, Rutka JT (2004) Cortical dysplasia lesions in children with intractable epilepsy: role of complete resection. *J Neurosurg* 100(2):110–117
- Harvey S, Cross JH, Shinnar S, Mathern BW, ILAE Pediatric Epilepsy Surgery Survey Taskforce (2008) Defining the spectrum of international practice in pediatric epilepsy surgery patients. *Epilepsia* 49:146–155
- Holmes G (2002) Epilepsy surgery in children: when, why, and how. *Neurology* 58(suppl 7):S13–S20
- Jalilian L, Limbrick DD, Steger-May K, Johnston J, Powers AK, Smyth MD (2010) Complete versus two-thirds corpus callosotomy in children: analysis of outcome. *J Neurosurg Pediatr* 6:257–266
- Jehi L, Martinez-Gonzalez J, Bingaman W (2011) Outcome and complications of epilepsy surgery. In: Wyllie E (ed) *Wyllie's treatment of epilepsy: principles and practice*, 5th edn. Lippincott Williams & Wilkins, Philadelphia
- Johnston JM, Mangano FT, Ojemann JG, Park TS, Trevathan E, Smyth M (2006) Complications of invasive subdural electrode monitoring at St. Louis Children's Hospital 1994–2005. *J Neurosurg* 105(5 Suppl):343–347
- Jokeit H, Ebner A (1999) Long term effects of refractory temporal lobe epilepsy on cognitive abilities: a cross sectional study. *J Neurol Neurosurg Psychiatry* 67:44–50
- Kabir SMR, Rajaraman C, Ritty C, Zaki HS, Kemeny AA, McMullan J (2009) Vagus nerve stimulation in children with intractable epilepsy: indications, complications, and outcome. *Childs Nerv Syst* 25:1097–1100
- Kellinghaus C, Luders HO (2011) Classification of seizures. In: Wyllie E (ed) *Wyllie's treatment of epilepsy: principles and practice*, 5th edn. Lippincott Williams & Wilkins, Philadelphia
- Krsek P, Maton B, Jayakar P, Dean P, Korman B, Rey G, Dunoyer C, Pacheco-Jacome E, Morrison G, Ragheb J, Vinters HV, Resnick T, Duchowny M (2009) Incomplete resection of focal cortical dysplasia is the main predictor of poor postsurgical outcome. *Neurology* 72:217–223
- Kwan P, Brodie M (2000) Early identification of refractory epilepsy. *N Engl J Med* 342:314–319
- Lee J, Adelson P (2004) Neurosurgical management of pediatric epilepsy. *Pediatr Clin North Am* 51:441–456



- Limbrick DD, Narayan P, Powers AK, Ojemann JG, Park TS, Bertrand M, Smyth MD (2011) Hemispherotomy: efficacy and analysis of seizure recurrence. *J Neurosurg Pediatr* 4:323–332
- Linehan C, Berg AT (2011) Epidemiologic aspects of epilepsy. In: Wyllie E (ed) *Wyllie's treatment of epilepsy: principles and practice*, 5th edn. Lippincott Williams & Wilkins, Philadelphia
- Loddenkemper T (2011) Classification of the epilepsies. In: Wyllie E (ed) *Wyllie's treatment of epilepsy: principles and practice*, 5th edn. Lippincott Williams & Wilkins, Philadelphia
- Luders HO, Acharya J, Baumgartner C et al (1998) Semiological seizure classification. *Epilepsia* 39: 1006–1013
- Meador KJ (2011) Cognitive effects of epilepsy and anti-epileptic medications. In: Wyllie E (ed) *Wyllie's treatment of epilepsy: principles and practice*, 5th edn. Lippincott Williams & Wilkins, Philadelphia
- Mikati MA, Ataya N, Ferzli J, Kurdi R, El-Banna D, Rahi A, Shamseddine A, Sinno D, Comair Y (2010) Quality of life after surgery for intractable partial epilepsy in children: a cohort study with controls. *Epilepsy Res* 90:207–213
- Nashef L (1997) Sudden unexpected death in epilepsy: terminology and definitions. *Epilepsia* 38:56–58
- Neubauer BA, Hahn A, Tuxhorn I (2011) Progressive and infantile myoclonic epilepsies. In: Wyllie E (ed) *Wyllie's treatment of epilepsy: principles and practice*, 5th edn. Lippincott Williams & Wilkins, Philadelphia
- Nordli DR, De Vivo DC (2011) The ketogenic diet. In: Wyllie E (ed) *Wyllie's treatment of epilepsy: principles and practice*, 5th edn. Lippincott Williams & Wilkins, Philadelphia
- Ogiwara H, Nordli DR, DiPatri AJ, Alden TD, Bowman RM, Tomita T (2010) Pediatric epileptogenic gangliogliomas: seizure outcome and surgical results. *J Neurosurg Pediatr* 5:271–276
- Phi JH, Cho BK, Wang KC, Lee JY, Hwang YS, Kim KJ, Chae JH, Kim IO, Park SH, Kim SK (2010) Longitudinal analyses of the surgical outcomes of pediatric epilepsy patients with focal cortical dysplasia. *J Neurosurg Pediatr* 6:49–56
- Rathmore C, Panda S, Sarma PS, Radhakrishnan K (2011) How safe is it to withdraw antiepileptic drugs following successful surgery for mesial temporal epilepsy? *Epilepsia* 52:627–635
- Schevon CA, Carlson C, Zaroff C, Weiner HJ, Doyle WK, Miles D, Lajoie J, Kuzniecky R, Pacia S, Vazquez B, Luciano D, Najjar S, Devinsky O (2007) Pediatric language mapping: sensitivity of neurostimulation and WADA testing in epilepsy surgery. *Epilepsia* 48: 539–545
- Skirrow C, Cross JH, Cormack F, Harkness W, Vargha-Khadem F, Baldeweg T (2011) Long-term intellectual outcome for temporal lobe surgery in childhood. *Neurology* 76:1330–1337
- Smellie-Decker M, Berlin J, Leonard T, Salazar C, Strother KW (2007) Surgical management of epilepsy. In: Cartwright C, Wallace D (eds) *Nursing care of the pediatric neurosurgery patient*. Springer, Germany
- Snead OC (2001) Surgical treatment of medically refractory epilepsy in childhood. *Brain Dev* 23:199–207
- Tatum WO (2011) Atypical absence seizures, myoclonic, tonic, and atonic seizures. In: Wyllie E (ed) *Wyllie's treatment of epilepsy: principles and practice*, 5th edn. Lippincott Williams & Wilkins, Philadelphia
- Tellez-Zenteno JF, Dhar R, Wiebe S (2005) Long-term seizure outcomes following epilepsy surgery: a systematic review and meta-analysis. *Brain* 128:1188–1198
- Tellez-Zenteno JF, Ronquillo LH, Moien-Afshari F, Wiebe S (2010) Surgical outcomes in lesional and non-lesional epilepsy: a systematic review and meta-analysis. *Epilepsy Res* 89:310–318
- Tsur VG, O'Dell C, Shinnar S (2011) Initiation and discontinuation of antiepileptic drugs. In: Wyllie E (ed) *Wyllie's treatment of epilepsy: principles and practice*, 5th edn. Lippincott Williams & Wilkins, Philadelphia
- Velasco TR, Mather GW (2011) Surgical treatment of refractory temporal lobe epilepsy. In: Wyllie E (ed) *Wyllie's treatment of epilepsy: principles and practice*, 5th edn. Lippincott Williams & Wilkins, Philadelphia
- Vendrame M, Loddenkemper T (2010) Surgical treatment of refractory status epilepticus in children: candidate selection and outcome. *Semin Pediatr Neurol* 17:182–189
- Weiser HG, Blume WT, Fish D, Goldensohn E, Hufnagel A, King D, Sperling MR, Luders H (2001) ILAE Commission Report: Proposal for a new classification of outcome with respect to epileptic seizures following epilepsy surgery. *Epilepsia* 42:282–286
- Wieser HG, Blume WT, Fish D, Goldensohn E, Hufnagel A, King D, Sperling MR, Luders H (2001) Proposal for a new classification of outcome with respect to epileptic seizures following epilepsy surgery. *Epilepsia* 42:282–286
- Zupanc ML, dos Santos Rubio EJ, Werner RR, Schwabe MJ, Mueller WM, Lew SM, Marcuccilli CJ, O'Connor SE, Chico MS, Eggenger KA, Hecox KE (2010) Epilepsy surgery outcomes: quality of life and seizure control. *Pediatr Neurol* 42:12–20

Herta Yu

---

## 11.1 Spasticity

### 11.1.1 Pathophysiology

Spasticity is a disorder of motor function characterized by an increase in muscle tone and exaggerated deep tendon reflexes. Increased muscle tone can affect the quality of life for a child so that it may be difficult to perform simple everyday tasks. For example, the lower extremities may be so tight that it is nearly impossible to put on trousers, let alone perform good hygiene. It can be painful, interfere with sleep, and impair growth and development. The treatment of spasticity should be as least invasive as possible and should allow the child and caregiver to have the best quality of life.

Research over the past several decades offers various theories to explain the mechanism of spasticity; yet the anatomy and pathophysiology are still not fully understood. Spasticity can occur as the result of any damage or lesion within the central nervous system (CNS) which impairs the mediation of inhibitory impulses down the descending motor pathways, thus impeding or preventing relaxation (Gallichio 2004; Goldstein 2001; Priori et al. 2006; Vanek et al. 2010).

Spasticity is the result of a failure to inhibit a nerve impulse within the reflex arc (Fig. 11.1).

There must be a reflex arc for muscle movement to occur. The reflex arc is the neural pathway that a nerve impulse follows and is thought to be the basic neural circuit that contributes to spasticity. It contains an afferent or sensory neuron, an efferent or motor neuron, and an effector muscle. The afferent (sensory) neurons originate in the muscle spindles of the muscle and are also located in the gray matter of the dorsal (or posterior) horn of the spinal cord. They transmit impulses from the receptors to the CNS. Interneurons also rise from the dorsal horn of the spinal cord and are only found in the CNS, not in the peripheral nervous system. An interneuron transmits impulses between sensory and motor neurons.

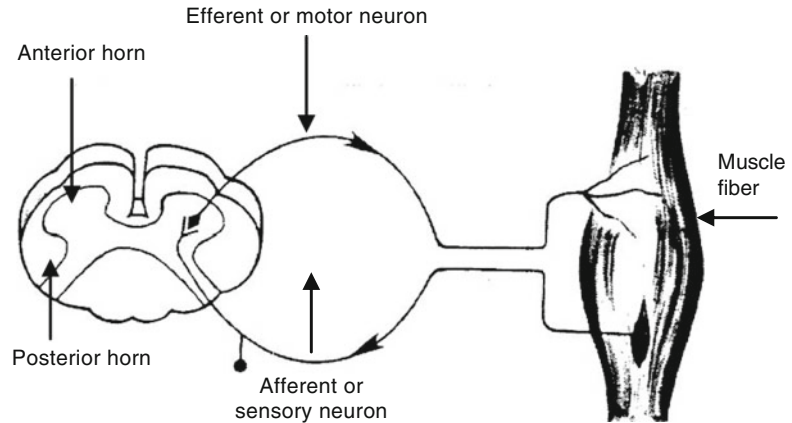
The efferent (motor) neurons have their cell bodies in the ventral (or anterior) horn of the spinal cord and carry impulses from the CNS to the effector muscle. Stimulation of the sensory neuron causes the flow of chemical transmitters across the synaptic space to depolarize the next neuron and continue the flow of the impulse to the muscle cell. The muscle cell sends a signal back to the sensory neuron that the action is completed and inhibition occurs, creating relaxation. Spasticity occurs when there is an increase in activation of the reflex arc and lack of inhibition. This creates a loop which continues to stimulate the muscle fibers and may spread to other muscle groups (Moss and Manwaring 1992; Satkunam 2003).

---

Mary Szatkowski was an author on the first edition but did not contribute to the revision of this chapter

---

H. Yu, RN, MN, CNN©, NP-Paed  
Department of Neurosurgery, Hospital for Sick Children,  
555 University Ave., Toronto, ON M5G 1X8, Canada  
e-mail: herta.yu@sickkids.ca

**Fig. 11.1** Reflex arc

Spasticity presents as an involuntary, velocity-dependent increase in tonic stretch reflexes, meaning that a sudden rapid stretch would elicit greater resistance to movement than a slow steady sustained stretch (Sheean 2002). Spasticity may have a cerebral or spinal origin, with damage located in the cerebral cortex, brainstem, or spinal cord levels. Cerebral causes of spasticity include cerebral palsy, intracranial hemorrhage, hydrocephalus, brain tumor, multiple sclerosis, stroke, or head injury. Spinal causes include spinal injury, inflammatory disease, and nontraumatic conditions resulting in spinal compression (Vanek et al. 2010).

The clinical presentations of spasticity include increased muscle tone, exaggerated reflexes, flexor and extensor spasms, persisted primitive reflexes, clonus, and decreased coordination. In severe cases, the patient may develop contractures and musculoskeletal deformities resulting in physical disabilities and severe pain (Rosigno 2002). In addition, many patients with spasticity experience fatigue, sleep disturbance, anxiety, depression, immobility, infections, and decreased cognitive development. Spasticity has devastating consequences affecting function, comfort, care delivery, and quality of life (Dietz 2000). Table 11.1 shows the clinical presentations of spasticity and the symptomatic and functional problems created.

Management of spasticity requires a multidisciplinary approach involving the patients, their families, and members of the healthcare team, including medical personnel, rehabilitative services, nurses, social workers, and patient care coordinators. The primary goal for treating spasticity is to improve

**Table 11.1** Clinical presentation and complications

Clinical presentation	Complications
Increased muscle tone, stiffness	Symptomatic problems:
Increased deep tendon reflexes	Fatigue, sleep disturbance
Persistent primitive reflexes	Stress
Contractures	Bone deformity
Clonus	Pain
Clasp-knife rigidity	
Decreased coordination, strength, and endurance	Functional problems:
	Daily personal care
	Difficulty with positioning and mobility
	Impaired ambulation
	Depression and anxiety
	Psychosocial deficits

the quality of life for the child, parents, and other family members. Treatment plans will differ according to the underlying condition, the severity of spasticity and its effects, and the needs and requirements of the patient and family. The objectives of treatment may be directed toward any one or more of the following: to increase mobility, prevent adverse effects and complications related to spasticity, promote comfort, or facilitate easier caregiving (Goldstein 2001).

There are various therapeutic treatment modalities for spasticity, but there is no one single treatment that is appropriate for all patients. Some

children may require a progression of various treatments as they age or as their spasticity increases. Selection of the treatment modality or combinations of modalities needs to focus on what is most appropriate for each individual patient. All parties involved need to have a clear uniform understanding of the objectives and expectations of the treatment (Steinbok 2006; Adams and Hicks 2010).

Conservative management with rehabilitative services, such as physiotherapy, or occupational therapy for passive stretch exercise, positioning, and splinting, may be appropriate for mild presentations of spasticity, especially during early stages of cerebral or spinal injury. Rehabilitative services may be effective in preventing the complications related to spasticity. There are a number of oral antispasticity agents that are helpful, especially to help manage generalized spasticity. However, these pharmacological agents cause numerous systemic adverse effects that may impact on the quality of life of the patient. In addition, the responses to oral antispasticity agents are not consistent in children (Thompson et al. 2005; Mullarkey 2009; Satkunam 2003).

---

## 11.2 Botulinum A Toxin

The use of botulinum A toxin (Botox) to treat focal spasticity has been gaining favor over the past 10–15 years. Botox is a mildly invasive, non-neurosurgical, and temporary treatment for moderate spasticity. Studies over the past decade have shown that Botox has evolved into an effective antispasticity agent for both adults and children. Botox is injected directly into the targeted muscle and causes temporary paralysis of the muscle. It acts by inhibiting acetylcholine release at the neuromuscular junction and affects the muscle spindles and afferent nerve fibers (Koman et al. 2003; Ward et al. 2006; Wong 2003; Guettard et al. 2009). The effect of Botox is temporary, lasting 3–6 months depending on individual child, and requires repeated injections. As the severity of spasticity progresses, more invasive, permanent neurosurgical treatments will be

needed, such as continuous intrathecal baclofen therapy or selective dorsal rhizotomy.

---

## 11.3 Baclofen

Baclofen is recognized as a medication that is effective in reducing the tone and symptoms of spasticity. It is structurally similar to gamma-aminobutyric acid (GABA). GABA is a primary inhibitory neurotransmitter in the CNS that promotes relaxation. Spasticity develops when the damage in the CNS impairs the release of GABA from the descending motor neuron that innervates muscle fibers, which would cause them to relax. Baclofen is a GABA agonist and binds to presynaptic GABA receptors to restrict calcium influx at the presynaptic terminal, thereby inhibiting the release of excitatory neurotransmitters across the synaptic junction at the level of the spinal cord to decrease muscle tone (Albright and Ferson 2006).

Baclofen can be administered both orally and intrathecally via an implanted pump. The primary goals for treatment with baclofen are to decrease muscle tone and improve the functional status of the patient.

Major adverse effects of baclofen administered orally or intrathecally include sedation, somnolence, seizure activity, muscle weakness, orthostatic hypotension, dizziness, headaches, and ataxia. Withdrawal of the medication is another major consideration related to baclofen treatment. Baclofen withdrawal may result in rebound severe spasticity, rigidity, tachycardia, hypotension, hyperthermia, and seizures. Some of these symptoms can be life-threatening, thus it is important that the medication be given at the appropriate doses and not withdrawn abruptly. Table 11.2 shows the characteristics of both oral and intrathecal baclofen.

### 11.3.1 Oral Baclofen

Baclofen in the oral preparation was first introduced in the 1920s to treat epilepsy and then used for spasticity in the 1960s to reduce muscle tone

**Table 11.2** Overview of baclofen

Oral baclofen	Intrathecal baclofen
Lipophilic, rapidly absorbed and partially metabolized in liver, and excreted by kidneys	Delivered directly into the spinal subarachnoid, intrathecal space
Does not readily pass the blood-brain barrier, therefore have relatively low concentrations in the spinal cord and CSF	Allows high levels to diffuse along the spinal cord without cerebral side effects
Large dose to achieve effect	Only fractions of oral dose to achieve effect
Withdrawal occurs with symptoms relieved once medication reestablished	Withdrawal symptoms are more severe and may become life-threatening if left untreated for greater than 24–48 h

and spasticity (Dario and Tomei 2004). When baclofen is administered orally, the drug is rapidly absorbed and partially metabolized in the liver and then excreted in the kidneys unchanged. The half-life is about 3.5 h. Oral baclofen does not readily cross the blood–brain barrier and requires large doses to reach therapeutic concentrations in the cerebrospinal fluid (CSF) at the desired spinal levels. Within the CSF, concentration of the drug is equally distributed in the supraspinal and spinal levels, resulting in the unwanted CNS side effects mentioned above (Krach 2001). Large oral doses can produce adverse reactions and, as previously stated, extremely high doses can be life-threatening, leading to coma or even death (Von Koch et al. 2001).

### 11.3.2 Intrathecal Baclofen

Intrathecal baclofen (ITB) was first approved in the United States for use to treat spasticity of spinal origin in 1992 and subsequently to treat spasticity of cerebral origin in 1996 (Albright and Ferson 2006). ITB infuses directly into the CSF at the targeted spinal level. High drug concentrations of ITB are found in the CSF at only fractions of the oral dose required to achieve the same therapeutic effects. Some reports indicate intrathecal doses at only one-hundredth of the oral dose are necessary to reach the same effect (Albright and Ferson 2006; Rizzo et al. 2004). The half-life of ITB is about 5 h (Krach 2001). Clearance of ITB is via caudalcephalic bulk flow similar to the flow of CSF in the spine at about 30 ml/h. The drug concentration in the cerebral or brainstem levels is only about one-quarter

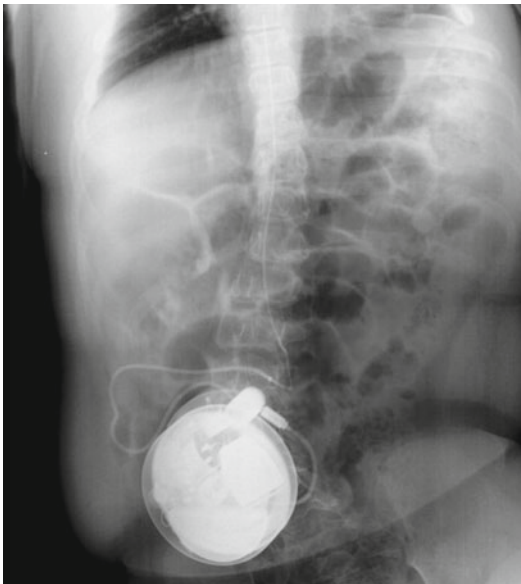
of the concentration found in the lumbar spine region following ITB administration. The risks of dose-related adverse effects and overdose are greatly minimized (Bergenheim et al. 2003; Fitzgerald et al. 2004; Vitztum and Olney 2000). See Table 11.2.

Withdrawal symptoms are more severe and much more problematic with ITB, as compared to oral administration. In addition, abrupt disruption of baclofen administration may result in rhabdomyolysis with elevated plasma creatinine kinase level, renal and hepatic failure, disseminated intravascular coagulation, and sometimes death if therapy is not restarted promptly (Douglas et al. 2005; Mohammed and Hussain 2004). This condition is also known as neuroleptic malignant syndrome and can be life-threatening.

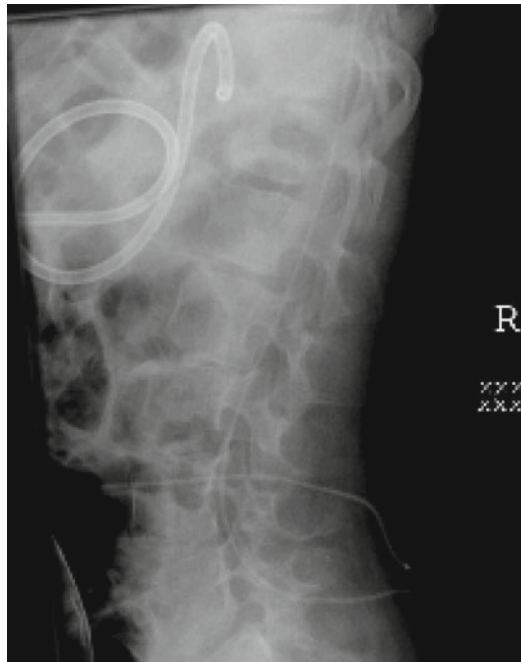The use of ITB for managing spasticity is highly supported in the literature. Recent longitudinal studies support both efficacy and safety in the continuous use of ITB for children with spasticity as well as other movement disorders caused from various underlying conditions, including cerebral palsy, stroke, multiple sclerosis, myelomeningocele, and head or spinal injury (Bergenheim et al. 2003; Krach et al. 2010; Morton et al. 2011; Ramstad et al. 2010; Ward et al. 2009).

### 11.3.3 Intrathecal Baclofen Pump System

ITB therapy is administered via an implantable pump system. The implantable pump is inserted into the subcutaneous tissue of the abdominal wall. A catheter is connected to the exit port, then tunneled around to the back through the



**Fig. 11.2** Pump implanted in the abdomen the pump is implanted into the subcutaneous tissue in the abdomen. The catheter is connected to the exit port and threaded around to the back and inserted in the intrathecal space in the lumbospine (Courtesy of Dr. Drake)



**Fig. 11.3** Catheter threaded into the spine catheter is threaded from the pump to the spine where it enters the intrathecal space at the lumbar levels and then threaded upward to the appropriate predetermined thoracic or cervical levels

subcutaneous tissue, and inserted into the intrathecal space at the level of the lumbar spine. Once the catheter is in the intrathecal space, its tip is threaded up to the appropriate targeted spinal level predetermined by the neurosurgeon, usually within the upper thoracic levels. Figures 11.2 and 11.3 illustrate the location of pump implantation and catheter placement.

The ITB pump is a circular device that contains a reservoir to hold the medications and has an injection port for the medication and a catheter access port (Fig. 11.4). Contrast may be injected through this access port to radiographically assess pump function and catheter integrity when complications are suspected. The pump is powered by a battery that generally lasts about 5–7 years. When the battery runs low, the pump would need to be replaced. An external handheld programmer (Fig. 11.5) that includes a computer, printer, and programming head is used to interrogate the pump or to program the pump to deliver prescribed doses of medication to meet the needs of the patient.

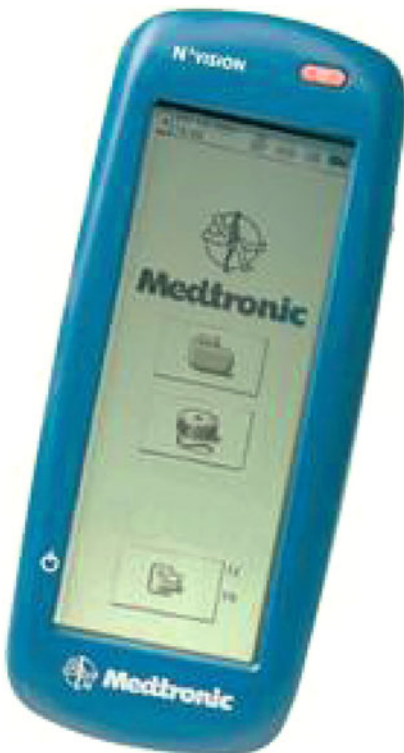
Using the Medtronic SynchroMed II pump as an example, there are two available capacities: 20 and

40 ml. It measures about 3.5 in. in diameter and about 1.5 in. deep for the smaller volume and 2.5 in. for the larger volume. The batteries of these pumps presently last about 7 years.

Refills of ITB into the reservoir are required at regular intervals to ensure continuous supply of medication. It is important to know the maximum capacity of the pump reservoir in order to facilitate appropriate refill schedules. Care and adherence to sterile procedures are highly recommended during pump refill, as there have been reports of pump infections related to repeated refills (Dario and Tomei 2004; Dario et al. 2005; Vender et al. 2005). The pump also has built-in alarms set to warn the child and parents when the reservoir needs to be refilled and when the battery is running low.

The primary practitioner can set the soft but audible reminder alarm that beeps intermittently at 2–3 days prior to the reservoir's predicted refill date. This alarm will alert the patient and caregivers that refilling is needed. A more continuous

**Fig. 11.4** Photograph of Medtronic SynchroMed II pump (Photo courtesy of Medtronic, Inc.)



**Fig. 11.5** Photograph of the Medtronic SynchroMed II handheld programmer (Picture courtesy of Medtronic, Inc.)

emergent alarm is preset to go off a few months prior to the end of the battery life and serves to remind family members and primary practitioners to arrange surgery dates to change the pump.

### 11.3.3.1 Patient Selection

ITB therapy is indicated for those patients with spasticity from conditions of cerebral or spinal origin that has been unresponsive to oral antispasmodics. Patients suffering from unacceptable adverse effects from effective doses of oral antispasmodics may also be considered for ITB (Dario and Tomei 2004). The patient needs to be assessed for function and level of spasticity to establish a baseline by which to compare effectiveness of ITB treatments during a screening trial. The most common scale used to assess spasticity is the Ashworth Scale scores (Awaad et al. 2003; O'Donnell and Armstrong 1997; Vanek et al. 2010). The Ashworth Scale is a subjective 5-level scale, ranging from no increase in tone to rigidity in flexion or extension of affected limbs, as described in Table 11.3. A severity level of three on the spasticity score may be a good indication

**Table 11.3** Spasticity levels

Score	Description of spasticity level
1	No increase in tone
2	Mild increase in tone, giving a catch when affected limb is moved in flexion or extension
3	More marked increase in tone but affected limb can be easily flexed
4	Considerable increase in tone; passive movements difficult with affected limb
5	Affected limbs rigid in flexion or extension

for consideration for ITB therapy. In addition, assessment should include feedback from the parents regarding the child's quality of life.

### 11.3.3.2 Trial Dosing

Selected patients then need to undergo a screening process or test dosing to ensure they will respond positively to ITB prior to surgically implanting the pump. Traditionally, the child will be admitted into hospital for surgical insertion of a temporary lumbar drain and receive three consecutive increasing doses of ITB over 2–3 days. The test doses are usually 50, 75, and 100 mcg.

The effects peak at about 4 h, and the child is assessed for any signs of improved spasticity (Vitztum and Olney 2000). This testing method poses many risks for the child in regard to CSF leakage from the lumbar drain site and respiratory complications related to bed rest during the testing period.

The more recent approach to testing is a same-day admission where the child receives a single ITB dose of 50–100 mcg via lumbar puncture. The child is observed and any response to the dose is recorded, and the child is then discharged home. This is the current desired method for testing, as it minimizes potential risks posed by the traditional method. In addition, the test dose does not determine the eventual dosing, but only that the patient shows a response (Keenan 2010).

### 11.3.3.3 Complications of ITB Therapy

There are many complications associated with intrathecally administered baclofen. Similar to CSF shunts, ITB delivery systems are foreign devices with different parts and few connections. ITB therapy has inherent risks of developing complications that are classified into the following

categories: skin or wound, catheter related, pump apparatus, and infection.

Skin- or wound-related complications are associated with the physical and overall health of the child. Many children with cerebral palsy or other spastic illnesses are malnourished, suffer physical deformities, and are immobilized or bedridden, which compromise skin integrity and predispose them to poor healing and wound complications. Most commonly, development of a seroma (fluid around the pump pocket) occurs in response to inflammatory healing process after surgery. The seroma can become excessive and provoke related problems, such as skin breakdown, dehiscence of the incision, CSF leakage, and superficial wound infection. Adherence to careful wound closure helps to minimize the space of the pocket around the pump and can greatly reduce the development of a seroma. Additionally, application of an elastic abdominal binder or abdominal wrapping can prevent seroma development. Pocket effusions can occur at a later date resulting in some CSF tracking along the catheter and may require tapping of the effusion and application of the binder again (Vender et al. 2005). Skin breakdown or erosion of the skin around the pump can result from stretching and continuous compression of the skin by the implanted pump (Boviatsis et al. 2004; Atiyeh et al. 2006).

Catheter-related complications are by far the most frequent problems. These complications include catheter breakages, microfracture, puncture, kinking, migration from the intentional level, or disconnections, either at the port or at the connection sites (Dawes et al. 2003; Follett et al. 2003; Ridley and Rawlins 2006). These complications cause disruption of ITB flow to the patient. The child usually presents in the emergency room with increased spasticity, decreased level of consciousness, pain, and other symptoms indicative of ITB withdrawal. X-rays can assess the placement of catheter and any disconnections or kinks within the catheter system. If no disconnections or possible kinking is noticed, then the integrity of the catheter should be investigated further by injecting contrast in the catheter access port to identify breakage or fractures.



Pump-related complications are few but may be serious. There are reports of cases where the pump flips over in the abdominal cavity (Gooch et al. 2003). This phenomenon is associated with the development of seromas creating a space for the pump to move from its implanted space. Other pump-related complications are linked to the electronic mechanism of the pump itself, resulting in pump failure and under- or over-delivery of the medication. Any confirmed catheter or pump complications necessitate surgical intervention to repair, reinsert, and reestablish medication infusion.

#### 11.3.3.4 Infection

The most serious complication associated with ITB therapy is infection. Infection can originate from the pump, the catheter, or the wound bed (Fitzgerald et al. 2004). Possible causes of pump infection can be attributed to the surgical procedure, contamination of the pump apparatus at the time of surgery, and poor sterile technique when accessing the port for medication refill. Untreated or poorly treated surgical wound site infections may eventually contaminate the pump and catheter.

Pump infections pose the greatest threat to patients, as they may potentially lead to a series of adverse consequences. Bacteria invading the wound and pump may spread along the catheter and enter the spinal canal causing CSF infection or meningitis. Treatment of pump infections involves a process that needs to be initiated promptly to avoid such consequences. When a pump infection is suspected, oral baclofen should be restarted promptly, the pump and associated hardware removed, and the patient started on an extensive course of antibiotic therapy. When the infection is resolved, the pump is reinserted and therapy reestablished (Boviatsis et al. 2004). This process must be carried out efficiently to avoid inducing withdrawal symptoms and life-threatening sequelae of rhabdomyolysis with acute renal and hepatic failure.

#### 11.3.3.5 Nursing Considerations

Nurses can play an important role in the care of patients with spasticity and selection for pump

insertion and can add to the success of treatment. Nurses are in a unique position to coordinate necessary resources and communicate with members of the multidisciplinary team. During each stage of the ITB therapy process, nurses have distinct and important functions. These stages can be divided into (1) planning and screening stage, (2) preoperative preparation stage, (3) immediate postoperative hospitalization stage, and (4) follow-up and monitoring stage.

#### Trial Screening Stage

During the planning and trial screening stage of ITB therapy, nurses need to provide appropriate education to children and their parents to help them understand test procedures as well as the potential benefits and complications. The family needs to have complete disclosure of all possible issues and barriers involved with ITB treatment. Nurses can help patients and families identify their goals for treatment and decide if ITB is the appropriate therapy. The nurse can coordinate the services of a social worker to help facilitate available resources for financial support to the family for long-term medication costs. If the trial screening test fails, family members require empathetic emotional support and education about other available resources to the patient for spasticity management.

#### Preoperative Preparation Stage

During this stage, nurses can help to prepare the child to become physically and emotionally ready to undergo surgery and pump implantation. A thorough assessment of the patient's physical condition, nutritional status, clinical presentation, and family readiness can help minimize the risk for potential complications.

The child needs to be in optimum physical condition before surgery. Children with spasticity tend to have poor nutritional intake as a result of their underlying disease. Compounding poor intake, these children are frequently in nutritional catabolic states (i.e., burning calories at greater rates than intake) (Stallings et al. 1995). The resulting picture presents undernourished children with low body weights, disturbed immune systems, and poor skin integrity. All these

conditions predispose the children to infection and seroma development.

During this preoperative stage, bringing together a team of dietician/nutritionist, physical therapists, occupational therapists, social worker, and nurses to work with the family will optimize the physical condition of the patients and address any health problems.

### **Postoperative Stage**

The postoperative stage is focused primarily on prevention of both surgical and pump-specific complications. Infection is again the major concern in this stage. The Centers for Disease Control and Prevention (1999) recommends a 24-h course of prophylactic antibiotics postoperatively. Any extended length of antibacterial course would be unwarranted unless actual infection is evident. A firm abdominal binder may prevent seroma development and the associated issues.

The contractures and physical deformity associated with spastic disease predispose patients to develop postoperative complications associated with surgery, such as atelectasis, aspiration pneumonia, ileus, and hemodynamic and electrolyte imbalances. Nursing care should encourage mobility, hygiene, and nutrition to facilitate healing. Meticulous skin care that includes frequent turning and repositioning, along with provision of adequate nutrition, will help prevent the skin-/wound-related problems and postoperative complications.

Pain associated with the surgical incision may exaggerate spasticity in the immediate postoperative period. Adequate pain management is necessary to promote activities and healing. Postoperative analgesics given at regular intervals to maintain appropriate serum levels are highly recommended to promote comfort. In addition, management of postoperative nausea and vomiting is equally important in this patient population.

### **Follow-up and Continuous Monitoring**

A child with a baclofen pump requires dedication and commitment on the part of the patient and parents. It is important that the family keep regularly scheduled follow-up appointments with

the entire healthcare team. Missed or delayed appointments may provoke life-threatening and withdrawal conditions. Long-term studies show that adjustments of doses are required for many years after implantation (Motta et al. 2007; Plassat et al. 2004). In many cases, drug tolerance and drug sensitivity can become problems with therapy. Dose change requirements are exaggerated during altered states of health, including fevers and colds. Family members should report any physical and functional changes, possible technical pump problems, or withdrawal symptoms to their care provider. This stage is a complete partnership between patient, family, and medical team. Review and evaluation of the risks and benefits of the therapy occur constantly.

Unlike other surgeries, insertions of baclofen pumps are similar to insertion of CNS shunts. Once the operative incision is made, an unbreakable bond is established between the family and the healthcare team. Continual support and education from the entire healthcare team help ensure success for ITB therapy and positive outcomes.

Management of spasticity with ITB therapy should follow a systematic approach and a multidisciplinary team perspective. The patient requires continuous care from a primary practitioner to assess, monitor, and titrate the medication dosing according to the patient's changing needs. The neurosurgeon does not only insert the pump but is required to follow up on possible complications and ensure pump function. Of course, the most important partner will be the parents who will assume responsibility to care for and ensure the child continues with follow-up appointments for assessment, monitoring, and refills.

When considering ITB therapy, the family must be aware and understand the time commitment and the persistent financial cost of maintenance of therapy as well as the unexpected emergency costs should complications arise. Though most insurance companies in the United States cover the care surrounding the insertion of the ITB, some countries do not. Therefore, the decision for ITB therapy needs the family's emotional, physical, and financial commitment as

well as considerations of the patient-focused goals of therapy.

Although ITB therapy is efficacious, it may not be the ideal therapy for all patients. The following two cases can illustrate the need for careful decision making.

In case 1, ITB therapy was proposed to an 11-year-old boy who has severe spasticity related to cerebral palsy. He was wheelchair bound, had mild contractures in his lower extremities, and was experiencing extremely painful spasms throughout the day. His parents were unsure about ITB therapy but eventually agreed. Following implantation, the patient experienced multiple complications with catheter breakage and disconnections, CSF pooling at the spinal catheter site, seroma and pocket effusion formation, and an episode of pump infection requiring explantation and reimplantation. In a time span of 2 years, this patient underwent five surgical procedures related to complications. Extensive discussions took place with parents and the healthcare team to reevaluate whether this was the appropriate treatment for him. However, his parents insisted that ITB was the best treatment. During the times when he was free of complications, his parents witnessed his increase in comfort level. They expressed how comfortable he was in his wheelchair and how heartwarming it was to see him smiling and laughing and at times making jokes, which was seldom seen prior to ITB therapy.

In case 2, the patient was another boy at the age of 14 years when the pump was implanted. This patient had severe spasticity related to cerebral palsy. The patient was wheelchair bound but able to stand with a specially made caged walker. The most worrisome concern to his mother was the child's sleep disturbance. His mother expressed the long nights she sat up carrying him or holding him in her lap to rock him to sleep. As he was growing, his mother was finding it extremely taxing on her physically to provide the physical care. The mother had read about ITB therapy and pursued it with his doctors. She advocated for this therapy for about a year and finally had the pump inserted. The financial component was advocated by her social worker

and her child's disability case worker, and provincial funding for the surgery was obtained. Following implantation, this patient demonstrated a great decrease in tone and had better sleep. He did experience one complication with catheter disconnection that required surgical repair. However, his mother expressed that she may have made a mistake advocating for this therapy. She described how the patient now has a flat affect and is much more sedated throughout the day, despite adjustments at lower dosages. She voiced that this patient was not her "boy" as she knew him. She was provided with much nursing support, both physically and emotionally, to realize the positive results of the ITB treatment. However, she continued to express that, given the outcomes, she is not sure if she would make the same decision again.

---

## 11.4 Selective Dorsal Rhizotomy

Selective dorsal rhizotomy (SDR) is a neurosurgical procedure done mainly to relieve spasticity in the lower extremities of children with cerebral palsy. The surgery is targeted at the lower lumbar levels ideally from L2 to S1 (Grunt et al. 2011; Steinbok et al. 2006). SDR incompletely severs the posterior or sensory lumbosacral rootlets and reduces the excitatory impulses to the spinal cord from the lower extremities. At present, rhizotomy is the only treatment that provides permanent reduction in spasticity quickly and effectively (Hesselgard et al. 2005).

The idea of rhizotomy to treat "violent neuralgic pains" was first suggested in 1888 by a New York neurologist named Dr. Charles Dana in a letter to Dr. Robert Abbe. This idea was put into action by Dr. Abbe on a select few patients. He found that, indeed, cutting nerves relieved spasticity and the accompanying pain but also resulted in loss of needed sensation and function (Moss and Manwaring 1992). In 1908, Foerster, a German neurologist, used rhizotomy to treat spasticity in cerebral palsy by sectioning the posterior lumbar nerve roots. However, this procedure resulted in less than favorable outcomes. The procedure was later revised in the late 1970s

by Fasano and his colleagues in Italy to develop a technique that separated the dorsal root into individual nerve fibers called fascicles or rootlets. By using electrical stimulation, he cut selected fascicles, relieving the most severe spastic symptoms without losing the desirable sensory function. This procedure was further modified by Peacock and his colleagues in 1987 to include multilevel laminectomy to provide better visualization of the rootlets (Hesselgard et al. 2005; Ou et al. 2010; Steinbok et al. 2006).

### 11.4.1 Patient Selection

Currently, patients are carefully evaluated and selected for SDR. Ideal candidates are usually children that have walked, have the potential to attain ambulation with rhizotomy, have spasticity that interferes with functions such as sitting, or have hip dislocations caused by spasticity (Abbott 1999). Review of patient records and a physical examination are done by a team consisting of a neurologist, physical and occupational therapists, orthopedist, developmental specialist, and a pediatric neurosurgeon. Patients are screened based on their muscle strength and contractures as well as their ability to cooperate with therapists. Although previous orthopedic procedures may not exclude the child from selection, they will need to have more extensive testing to qualify. Selected candidates for SDR should be motivated to work with their therapist post surgery, as therapy is a major component for success with SDR. Patients who have dystonia in conjunction with spasticity, truncal ataxia, and contracture are contraindicated for SDR (Goldstein 2001).

Patients are usually between the ages of 4 and 9 years, as they have been found to have the best response. Children younger than 4 years generally are not able to cooperate fully with physical therapy, nor do they have the developed muscle strength to get the full benefit of the surgery. MacWilliams et al. (2011) compared functional outcomes in children chosen for surgery that were older than 10 years to younger cohorts and also compared age-matched cohorts who were undergoing orthopedic procedures and nonsurgical

procedures. The results concluded that gait improvements were less than with orthopedic procedures, and that children over 10 years with SDR had a decline in function. Although selection for SDR may include other factors, age and desired outcomes should be carefully considered.

### 11.4.2 Procedure

A rhizotomy is performed to relieve spasticity in the areas where the reflex arcs are the most pathological. The patient is taken to the operating room and given a short-acting muscle relaxant for intubation and to allow the neurosurgeon to access the area. The paralysis is then reversed to permit electric stimulation and recording, which is done to identify the specific root level and differentiate between motor and sensory nerve bundles as they exit the foramen. The patient continues under anesthesia and may also be given a narcotic to relieve the pain of the electric stimulation. The sensory bundles are separated into rootlets. Then the rootlets are gently separated and stimulated to test the effect on various muscles and to find the ones creating the spasticity. The rootlets that stimulate an abnormal reflex arc to the muscles and cause tetany are cut (Cheek 1996).

### 11.4.3 Postoperative Nursing Care

Postoperative pain control is a vital part of nursing considerations. Aside from the incisional pain and soft tissue pain from the laminectomy, there may be dysesthesia of the lower extremities resulting from manipulation of the nerve rootlets (Hesselgard et al. 2005). The patient may feel a burning sensation in the back and legs from the severed nerves. It is exacerbated with movement or any change in sensations, such as hot or cold, or movement of clothing or linens. There are several interventions for managing postoperative pain: continuous intravenous infusion of opioids, epidural fentanyl, and intrathecal opioids. Also, regular oral analgesics can be an adjunct to the aforementioned methods. The goal is to provide steady maximum pain control to achieve comfort

while limiting side effects (Hesselgard et al. 2005). The patient should be monitored for undesirable side effects during pain management, such as respiratory depression, excessive sedative, excessive nausea and vomiting, pruritus, and muscle spasms. Valium may be used in addition to analgesia to control spasms.

Once the burning pain subsides, there may be a change in sensations like a feeling of “pins and needles” or a patchy numbness to the legs and/or feet. This change in sensation may resolve or may be permanent (Abbott 1999; Institute for Neurology and Neurosurgery 2004).

Postoperatively, the patient is positioned on either side or prone for the first 1–2 days. The patient often wants to curl up in a fetal position after surgery. The application of knee splints may be considered to help to hold the legs in a natural extended position. The children usually have an indwelling catheter inserted or are diapered since they are on strict bed rest. Physical therapy is started on the third postoperative day and continues after discharge.

Complications from SDR include general post-surgical risks, such as infection of the incision, CSF leak, and urinary tract infection. Regular bowel movements and perineal hygiene are important. Change in bowel and bladder function may occur, especially a temporary urinary retention, requiring close monitoring. Patients with a history of asthma or recent respiratory infection should be monitored closely for respiratory complications, as the bed rest protocol and positioning may increase the risk of aspiration and pneumonia.

Long-term results from rhizotomy are as varied as the patients themselves. Approximately 80 % of rhizotomy patients have some improvement in spasticity. Some children go on to require further surgeries to correct shortened tendons or hip dislocations. Longitudinal studies identify sustained improvements in spasticity over 5–10 years following SDR; however, it is unclear whether this sustained improvement is purely the result of SDR or is a combination of therapy and other treatments. Outcomes of SDR in regard to the neurologic changes are very specific. The effects are mostly consistent with dysfunction in the spinal reflex arc and not the supraspinal

reflexes. The changes include decreased deep tendon reflexes, clonus, and the velocity-dependent hypertonia, thereby improving gait function and possible ambulation.

All children who undergo SDR need rigorous physiotherapy. Some children will require further surgeries to correct shortened tendons or hip dislocations. Some patients may later also require Botox injections (Tedroff et al. 2011; Grunt et al. 2011). Further work on measuring the effectiveness of SDR targeting the improvements of spasticity and functional outcomes is required.

### Pediatric Practice Pearls

1. Rapid withdrawal of intrathecal baclofen, whether from pump removal, pump malfunction, or incorrect dosing, can result in severe withdrawal symptoms and death. Appropriate doses of oral baclofen should be used in the interim.
2. It is imperative that parents of children that are candidates for ITB understand the long-term commitment they must make for follow-up.
3. Videotaping the patient before rhizotomy and at 6 weeks, 3 months, etc. after surgery will show the parents how much progress has been made.
4. Explain to parents that after undergoing a rhizotomy, some children may lose previously obtained function. It takes a while to regain back some skills, such as walking, as it is necessary to retrain muscle groups to do these functions.

## References

- Abbott R (1999) Selective dorsal rhizotomy. <http://cerebronet.net/firms.com/selective.htm>. Retrieved 16 Aug 2005
- Adams M, Hicks AL (2010) Spasticity; pathophysiology, assessment, and management. In: Lin VW (ed) *Spinal cord medicine: principles and practice*. Demos Medical Publishing, New York
- Albright AL, Ferson SS (2006) Intrathecal baclofen therapy in children. *Neurosurg Focus* 21(2):1–6

- Atiyeh BS, Hayek SN, Skaf GS, Araj AA, Chamoun RB (2006) Baclofen pump pocket infection: a case report of successful salvage with muscle flap. *Int Wound J* 3:23–28
- Awaad Y, Tayem H, Munoz S, Ham S, Michon AM, Awaad R (2003) Functional assessment following intrathecal baclofen therapy in children with spastic cerebral palsy. *J Child Neurol* 18:26–34
- Bergenheim AT, Wendelius M, Shahidi S, Larsson E (2003) Spasticity in a child with myelomeningocele treated with continuous intrathecal Baclofen. *Pediatr Neurosurg* 39:218–221. doi:10.1159/000072476
- Boviatsis EJ, Kouyialis AT, Boutsikakis I, Korfas S, Sakas DE (2004) Infected CNS infusion pumps: is there a chance for treatment without removal? *Acta Neurochir* 146:463–467
- Center for Disease Control and Prevention, (1999) Guideline for prevention of surgical site infection. *Infect Control Hosp Epidemiol* 20(4):250–278
- Cheek WR (1996) Atlas of pediatric neurosurgery. W.B. Saunders Company, Philadelphia
- Dario A, Tomei G (2004) A benefit-risk assessment of baclofen in severe spinal spasticity. *Drug Saf* 27(11):799–818
- Dario A, Scamoni C, Picano M, Fortini G, Cuffari A, Tomei G (2005) The infection risk of intrathecal drug infusion pumps after multiple refill procedures. *Neuromodulation* 8(1):36–39
- Dawes WJ, Drake JM, Fehlings D (2003) Microfracture of a baclofen pump catheter with intermittent under- and overdose. *Pediatr Neurosurg* 39(3):144–148
- Dietz V (2000) Spastic movement disorder. *Spinal Cord* 38:389–393
- Douglas AF, Weiner HL, Schwartz DR (2005) Prolonged intrathecal baclofen withdrawal syndrome. *J Neurosurg* 102:1133–1136
- Fitzgerald JJ, Tsegaye M, Vloeberghs MH (2004) Treatment of childhood spasticity of cerebral origin with intrathecal baclofen: a series of 52 cases. *Br J Neurosurg* 18(3):240–245
- Follett KA, Burchiel K, Deer T, Dupen S, Prager J, Turner MS et al (2003) Prevention of intrathecal drug delivery catheter-related complications. *Neuromodulation* 6(1):32–41
- Gallichio JE (2004) Pharmacologic management of spasticity following stroke. *Phys Ther* 84(10):973–981
- Goldstein EM (2001) Spasticity management: an overview. *J Child Neurol* 16(1):16–23
- Gooch JL, Oberg WA, Grams B, Ward LA, Walker ML (2003) Complications of intrathecal baclofen pumps in children. *Pediatr Neurosurg* 39:1–6
- Grunt S, Becher JG, Vermeulen RJ (2011) Long-term outcome and adverse effects of selective dorsal rhizotomy in children with cerebral palsy: a systematic review. *Dev Med Child Neurol* 53:490–498. doi:10.1111/j.469-8749.2011.03912.x
- Guettard E, Roze E, Abada G, Lemesle C, Vidailhet M, Laurent-Vannier A et al (2009) Management of spasticity and dystonia in children with acquired brain injury with rehabilitation and botulinum toxin A. *Dev Neurorehabil* 12(3):128–138. doi:10.1080/17518420902927994
- Hesselgard K, Reinstrop P, Stromblad LG, Unden J, Romner B (2005) Selective dorsal rhizotomy and post-operative pain management. *Pediatr Neurosurg* 43:107–112. doi:10.1159/000098382
- Institute for Neurology and Neurosurgery (2004) Rhizotomy. <http://nyneurosurgery.org/cp/thizhist.html>. Retrieved 16 Aug 2005
- Keenan E (2010) Spasticity management, part 3: surgery and the use of intrathecal baclofen. *Br J Neurosci Nurs* 6(1):12–18
- Koman LA, Smith B, Balkrishnan R (2003) Spasticity associated with cerebral palsy in children. *Paediatr Drugs* 5(1):11–23
- Krach LE (2001) Pharmacotherapy of spasticity: oral medications and intrathecal baclofen. *J Child Neurol* 16(1):31–36
- Krach LE, Kriel R, Day SM, Strauss DJ (2010) Survival of individual with cerebral palsy receiving continuous intrathecal baclofen treatment: a matched-cohort study. *Dev Med Child Neurol* 52:672–676. doi:10.1111/j.1469-8749.2009.03473.x
- MacWilliam BA, Johnson BA, Shuckra AL, D'Astous JL (2011) Functional decline in children undergoing selective dorsal rhizotomy after age 10. *Dev Med Child Neurol* 53:717–723. doi:10.1111/j.1469-8749.2011.04010.x
- Mohammed I, Hussain A (2004) Intrathecal baclofen withdrawal syndrome – a life-threatening complication of baclofen pump: a case report. *BMC Clin Pharmacol* 4(6):1–5. doi:10.1186/1472-6904-4-6
- Morton RE, Gray N, Vloeberghs M (2011) Controlled study of the effects of continuous intrathecal baclofen infusion in non-ambulant children with cerebral palsy. *Dev Med Child Neurol* 53:736–741. doi:10.1111/j.1469-8749.2011.04009.x
- Moss SD, Manwaring KH (1992) Relief of spasticity for children with cerebral palsy using selective posterior rhizotomy. *Phoenix Child Hosp Pediatr Rev* 4(1):5–11
- Motta F, Buonaguro V, Stignani C (2007) The use of intrathecal baclofen pump implants in children and adolescents: safety and complications in 200 consecutive cases. *J Neurosurg* 107:32–35. doi:10.3171/PED-07/07/032
- Mullarkey T (2009) Considerations in the treatment of spasticity with intrathecal baclofen. *Am J Health Syst Pharm* 66(Suppl 5):s14–s22. doi:10.2146/ajhp0108c
- O'Donnell M, Armstrong R (1997) Pharmacologic interventions for management of spasticity in cerebral palsy. *Ment Retard Dev Disabil Res Rev* 3:204–211
- Ou C, Kent S, Miller S, Steinbok P (2010) Selective dorsal rhizotomy in children: comparison of outcomes after single-level versus multi-level laminectomy technique. *Can J Neurosci Nurs* 32(3):17–24

- Plassat R, Verbe BP, Menei P, Menegalli D, Mathe JF, Richard I (2004) Treatment of spasticity with intrathecal baclofen administration: long-term follow-up, review of 40 patients. *Spinal Cord* 42:686–693
- Priori A, Cogiamanian F, Mrakic-Sposta S (2006) Pathophysiology of spasticity. *Neurol Sci Supp* 4(27):s307–s309. doi:10.1007/s10072-006-0647-2
- Ramstad K, Jahnsen R, Lofterod B, Skjeldal OH (2010) Continuous intrathecal baclofen therapy in children with cerebral palsy – when does improvement emerge? *Acta Paediatr* 99:1661–1665. doi:10.1111/j.1651-2227.2009.01596x
- Ridley B, Rawlins PK (2006) Intrathecal baclofen therapy: ten steps toward best practice. *J Neurosci Nurs* 38(2):72–82
- Rizzo MA, Hadjimichael OC, Preinigherova J, Vollmer TL (2004) Prevalence and treatment of spasticity reported by multiple sclerosis patients. *Mult Scler* 10:589–595
- Roscigno CI (2002) Addressing spasticity-related pain in children with spastic cerebral palsy. *J Neurosci Nurs* 34(3):123–133
- SatkunamLE(2003)Rehabilitationmedicine:3.Management of adult spasticity. *CMAJ* 169(11):1173–1179
- Sheehan G (2002) The pathophysiology of spasticity. *Eur J Neurol* 9(Suppl 1):3–9
- Stallings VA, Cronk CE, Zemel BS, Charney EB (1995) Body composition in children with spastic quadriplegic cerebral palsy. *J Pediatr* 126:833–839
- Steinbok P (2006) Selection of treatment modalities in children with spastic cerebral palsy. *Neurosurg Focus* 21(2):1–8. doi:10.3171/foc.2006.21.2.5
- Thompson AJ, Jarrett L, Lockley L, Marsden J, Stevenson VL (2005) Clinical management of spasticity. *J Neurol Neurosurg Psychiatry* 76:459–463. doi:10.1136/jnnp.2004.035972
- Tedroff K, Lowing K, Jacobson DN, Astrom E (2011) Does loss of spasticity matter? A 10-year follow-up after selective dorsal rhizotomy in cerebral palsy. *Dev Med Child Neurol* 53(8):724–729. doi:10.1111/j.1469-8749.2011.03909x
- Epud 18 May 2011
- Vanek ZF, Menkes JH, Carcione J, Talavera F, Lopate G, Benbadis S, Berman SA (2010) Spasticity. *eMedicine Neurol*. <http://www.emedicine.com/neuro/topic706.htm>. Retrieved 21 Jan 2004
- Vender LR, Hester S, Rekito A, Lee MR (2005) Baclofen intrathecal pump delivery systems, avoidance and management of complications in adult and pediatric patients: part 2. *Contemp Neurosurg* 27(2):1–5
- Vitztum C, Olney B (2000) Intrathecal baclofen therapy and the child with cerebral palsy. *Orthop Nurs* 19(1):43–48
- Von Koch CS, Park TS, Steinbok P, Smyth M, Peacock WJ (2001) Selective posterior rhizotomy and intrathecal baclofen for the treatment of spasticity. *Pediatr Neurosurg* 35:57–65
- Ward AB, Molenaers G, Colosimo C, Berardelli A (2006) Clinical value of botulinum toxin in neurological indications. *Eur J Neurol* 13(Suppl 4):20–26
- Ward A, Hayden S, Dexter M, Scheinberg A (2009) Continuous intrathecal baclofen for children with spasticity and/or dystonia: goal attainment and complications associated with treatment. *J Paediatr Child Health* 45:720–726. doi:10.1111/j.1440-1754.2009.01601.x
- Wong V (2003) Evidence-based approach of the use of botulinum toxin type A (BTX) in cerebral palsy. *Pediatr Rehabil* 6(2):85–96. doi:10.1080/1363849031000139306

Gina Weddle

## 12.1 Brain Abscess, Epidural Abscess, and Subdural Empyema

Intracranial abscess is a complication of common pediatric conditions including meningitis, sinusitis, dental disease, and otitis media (Hicks et al. 2011; Menon et al. 2008). Intracranial abscess affects areas from superficial to deep including the epidural space, subdural space, and parenchyma tissue. Although rare in pediatrics, intracranial abscess poses a serious life-threatening condition for the child. This section will focus on these processes and their relationships to one another.

### 12.1.1 Etiology

The yearly incidence of brain abscess is 4 cases per million (Frazier et al. 2008). One-fourth of brain abscesses occur in children less than 15 years of age with a peak incidence between 4 and 7 years (Leonard et al. 2006). The incidence for both subdural empyema and epidural abscess combined approximates 13–25 % of all intracranial infections, with epidural abscesses being rare (McLone 2001).

The infective process depends on (1) the quantity of microorganisms that are involved, (2) their virulence, (3) the immunological status of the patient, and (4) the timeliness of clinical diagnosis and treatment (McLone 2001). The most common organism seen in intracranial abscesses is *Streptococci*, specifically the viridians *Streptococci* group which is a common nasal/oral colonizer (Long et al. 2008). After *Streptococci*, *Staphylococci* are the second most common organisms, followed by gram-negative organisms, anaerobic organisms, and common pathogens that cause meningitis particularly *Pneumococcus* and group B beta-hemolytic *Streptococci* (Long et al. 2008). In the case of intracranial abscess caused as a complication of sinusitis, polymicrobial infections are not uncommon.

Intracranial abscesses originate from many different sources, which include contiguous site infections (i.e., chronic otitis media, mastoiditis, dental procedures, sinusitis, or ruptured dermoid tumor), distant pathological states (i.e., cyanotic congenital heart disease, chronic lung infections, pulmonary arteriovenous fistulae from Osler-Weber-Rendu syndrome), head trauma (i.e., open depressed skull fractures, gunshot wound), neurosurgical procedures, and cryptogenic sources (Saez-Llorens 2003). The most common etiology for brain abscesses is hematogenous, while contiguous spread is seen more in subdural empyemas and epidural abscesses. Those with congenital heart disease, especially Tetralogy of Fallot, will have an increased risk of abscess with prevalence

---

G. Weddle, DNP, RN, CPNP-AC  
Department of Infectious Diseases,  
The Children's Mercy Hospital, 2401 Gillham Road,  
Kansas City, MO 64108, USA  
e-mail: gweddle@cmh.edu



between 6 and 51 % (Frazier et al. 2008). This is due to the lack of filtering provided by the lungs and hypoxic brain tissue, which is favorable for abscess formation (Greenberg 2006). Brain abscess rarely occurs in children less than 2 years of age, but when it does occur, it is usually secondary to meningitis (Albright et al. 1999; Heilpern and Lorber 1996; Long et al. 2008).

### 12.1.2 Pathophysiology

Contiguous spread of an infection to the brain leads to an area of infection adjacent to the source and is the second most common cause of intracranial abscess (Long et al. 2008). This is evident by the fact that a brain abscess, or subdural empyema, from otitis media will most likely occur in the temporal lobe, while those originating from the frontal or ethmoid sinus will occur in the frontal lobe. This type of spread results from direct extension through the bone, between bony sutures, or via extension through venous structures (Heilpern and Lorber 1996). Epidural abscesses can occur in conjunction with osteomyelitis of the skull. Subdural abscess as a complication of meningitis can occur in conjunction with thrombophlebitis, venous stasis, ischemia, and infarction. Common organisms of contiguous spread include *Streptococcus*, *Staphylococcus*, Enterobacteriaceae, and anaerobic bacteria (Long et al. 2008; McLone 2001).

Hematological spread usually originates from a cardiac or pulmonary source and usually extends through the distribution of the middle cerebral artery. Hematogenous seeding is the most common cause of brain abscess in children (Long et al. 2008). A risk factor for hematogenous seeding is a child with a congenital heart defect, specifically a defect with right to left shunting (i.e. Tetralogy of Fallot or Transposition of the great vessels). Hematogenous seeding can additionally occur as a result of endocarditis or septic thrombophlebitis where septic vegetations are dislodged from the heart valve and seed the brain. This type of spread tends to form at the gray-white matter junction, and abscesses due to this process are usually multiple, which

makes this type unique. Common organisms associated with hematogenous seeding include *Streptococcus*, *Staphylococcus*, and *Haemophilus* species (Tekkok and Erbenig 1992).

Head trauma and neurosurgical procedures produce abscesses and empyemas, which contain organisms native to the skin. The most common organisms include *Staphylococcus*, *Streptococcus*, and gram-negative species. In the setting of penetrating trauma, polymicrobial infections and unusual environmental organisms can be seen. Fungal infective processes are rare in the child and are usually associated with immunodeficiency, immunological suppression after organ transplantation, chemotherapy, or from congenital disease (Osenbach and Loftus 1992). Other factors that place a child at risk for invasive fungal disease include broad-spectrum antibiotics, total parenteral nutrition, and steroid use.

There are four stages of abscess maturation. Days 1–3 consist of early inflammatory changes, with some necrosis and edema. Days 4–9, inflammatory changes increase as fibroblasts, and leukocytes are recruited to the area of central necrosis and edema. Early capsule formation begins on days 10–13, with maturation complete on day 14 (Heilpern and Lorber 1996).

### 12.1.3 Presenting Symptoms

The most common presenting signs and symptoms include headache (92 %), fever (85 %), nausea/vomiting (62 %), and lethargy (23 %) (Hicks et al. 2011). Focal neurological deficit can be seen and usually related to the affected area of the brain. Frontal lobe includes behavioral changes, speech disorder, hemiparesis, and papilledema. Temporal lobe involvement can manifest as third cranial nerve palsy, aphasia, and motor dysfunction of the face or arm. Parietal lobe manifestation includes visual field defects, dyspraxia, and homonymous hemianopia. Neurological deficit, including cranial nerve palsies, hemiparesis, or decreased mental status, can occur in up to 50 % of cases. Most problems seen are due to increased intracranial pressure and can result in vomiting, lethargy, and even seizures.

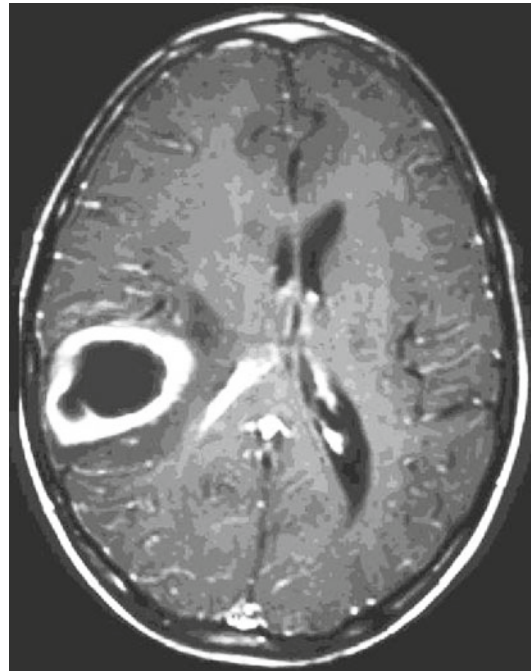
In interviewing the patient or the family, it is important to recognize any recent or chronic infections, especially of the head, ears, nose, or throat. Antibiotic use may play a role in emergence of resistant organisms, and pretreatment with antibiotics may affect culture results. Also inquire about fevers, headache, nasal or ear drainage, and earache.

Nurses should note any recent dental procedures, head trauma, and neurosurgical or otolaryngology procedures. Further, the caregiver needs to inquire about history regarding congenital disease, immune deficiencies, as well as sick contacts.

On exam, note the general appearance of the child and document whether the child is interactive, lethargic, or irritable. Inspect and palpate the skull for tenderness, trauma, or swelling. Check the ears for drainage, and look at the mouth and throat for exudate, erythema, dental caries, or swelling. Be sure to perform a full cranial nerve exam and look for asymmetry or dysfunction. For infants, it should be determined if there are any signs of failure to thrive (i.e., poor growth, lack of appetite, or delay in development). In an infant, inspect for reactivity of pupils, check for conjugate gaze, measure head circumference, and note whether the fontanels are bulging or if the sutures are splayed. Assess motor strength and sensation in all four extremities. If the child has concurrent meningitis, you may notice signs of meningismus including neck stiffness or photophobia. Auscultate the heart for murmurs, clicks, or dysrhythmias. Observe for clues of right to left heart shunting such as cyanosis, clubbing, and tachypnea.

#### 12.1.4 Diagnostic Test

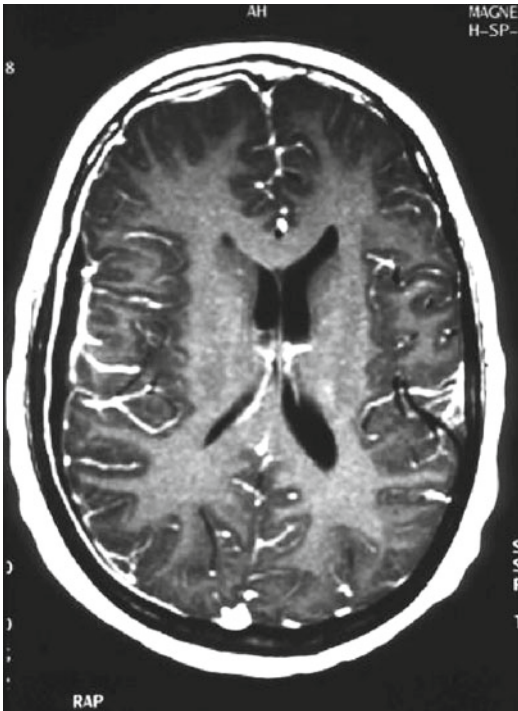
Initial testing will involve obtaining a serum white blood count (WBC), blood cultures, erythrocyte sedimentation rate (ESR), and C-reactive protein (CRP). Unfortunately, the serum WBC may be normal or mildly elevated in 60–70 % of cases, while blood cultures are usually negative. ESR will become elevated but may be normal in some cases, such as congenital cyanotic heart



**Fig. 12.1** T1-weighted MRI with contrast demonstrating a ring-enhancing lesion suspicious for intracranial abscess

disease, whereas polycythemia lowers the ESR. CRP becomes elevated with any type of infection and is more of an acute phase protein than ESR but is nonspecific like ESR (Greenberg 2006). The yield of a lumbar puncture depends on whether the infection is in contact with the intracranial CSF spaces. A lumbar puncture may reveal an elevated WBC, decreased glucose, elevated protein, or isolation of infective organism, all of which provide valuable information indicating an infective process. If a lumbar puncture is to be considered, it must be done with caution due to the concern of herniation, especially in the presence of increased ICP.

Contrasted head computed tomography (CT) or magnetic resonance imaging (MRI) is recommended with MRI being preferable due to superior visualization of brain matter and fluid collections (Figs. 12.1 and 12.2). In infants, cranial ultrasonography may reveal fluid collections with echogenic boundaries. Operative biopsy or drainage of the abscess for all ages will bring forth a diagnosis and in most cases identify the



**Fig. 12.2** T1 weighted MRI with contrast revealing right-sided enhancement along the cortical surface of the brain with a hypointense (dark-appearing) fluid collection representing a subdural empyema

pathogen. Aerobic, anaerobic, fungal, and acid-fast bacilli cultures are recommended to help identify an organism.

### 12.1.5 Treatment Options

For brain abscesses, surgical treatment is determined based on clinical status, mass effect, location of the abscess, failure of lesions to improve with 1–2 weeks of antibiotic therapy, or the need to obtain organism for culture and susceptibilities. Surgical treatment consists of needle aspiration or excision. Medical management may be considered if treatment is begun early in the infection, improvement is seen with initiation of treatment, the lesions are smaller than 3 cm, or the abscess is located in an eloquent brain area.

For subdural empyemas and epidural abscesses, surgical treatment is indicated in most cases. But like brain abscesses, surgical drainage

will depend on the size of the abscess and clinical status of the patient. The surgical therapy can range from simple burr holes to a large craniotomy, with possible conversion to a craniectomy if the bone flap is infected. In infants with subdural empyemas, medical management usually suffices, but in certain cases transfontanel needle aspiration or burr holes are needed.

Antibiotic therapy should be started immediately upon determination of intracranial infection. Initial antibiotics for empiric therapy for all intracranial suppurative processes should include medications that cross the blood–brain barrier. Typically, vancomycin is used for gram-positive organisms, a third generation cephalosporin for gram-negative organisms, and metronidazole for anaerobic coverage (Long et al. 2008). Clindamycin is increasingly being used for *Staphylococcus*, *Streptococcus*, and anaerobic infections. However, clindamycin does not have any gram-negative coverage and does not cross the blood–brain barrier, so it would not be a treatment option with intracranial abscess.

Once the bacteria is cultured and identified, antibiotic therapy is tailored to suit. Caution should be used in narrowing antibiotic coverage too far as some intracranial abscess are polymicrobial in nature and certain organisms can be difficult to grow, particularly anaerobic organisms. Intravenous antibiotic therapy is usually needed for 6–8 weeks. Length of therapy will depend on the clinical course, organisms identified, and whether the patient underwent surgical drainage.

A distinctive form of posttraumatic brain abscess seen in children results from penetrating injuries to the orbital region, as well as other areas of the skull. These injuries are caused by such things as pencil tips, wooden sticks, wooden toys, and lawn darts. Treatment involves prompt surgical debridement. The use of prophylactic antibiotic therapy for penetrating brain injury to prevent meningitis or abscess depends on the degree of contamination and location. A broad-spectrum cephalosporin with good blood–brain barrier penetration with metronidazole would be recommended, or a carbapenem such as meropenem would give gram-positive, gram-negative,

and anaerobic coverage. In general, prophylaxis should consist of a short course of therapy, typically 5–7 days. Prophylaxis will not totally eliminate the risk of infection, and a prolonged course of prophylaxis will only encourage infections with multidrug-resistant organism. With all penetrating trauma, tetanus status should be documented and updated as needed.

### 12.1.6 Nursing Care

Nursing care is focused on observation of the patient, with special attention paid to any change in the neurological exam. Serial exams will allow the nurse to distinguish any signs of deterioration which should be reported immediately. Age-appropriate neurological exam is key to the nursing care of these patients. Mental status, irritability, cranial nerve exam (especially pupil reactivity), motor and sensory testing, reflexes, as well as fever curves will help dictate care. Inspect incisions or wounds for increasing tenderness, erythema, drainage, and dehiscence. Ensure proper and timely delivery of antibiotics. Monitor fluid and electrolyte status closely, since this can change drastically with deleterious effects. Attempt to keep head of bed raised to at least 30° to help protect against elevated ICP, and provide a quiet environment that does not overstimulate the patient. Be sure all caregivers and visitors undergo thorough hand washing before and after visiting.

### 12.1.7 Patient and Family Education

Upon discharge to home, educate the patient and family to monitor for any type of change in neurological status. For infants, family should call the physician if they detect any change in alertness, difficulty in arousing, irritability, decreased feeding, bulging fontanelles, seizures, or intractable vomiting. Also, the family should note fevers, and any temperature greater than 101.5 F warrants a call to the physician. The patients should be kept away from sick contacts during their convalescence. Discharge instructions should cover

wound care, activity, follow-up, and medications. Home health nursing care may be needed for long-term intravenous antibiotic therapy.

### 12.1.8 Outcome

The prognosis for survival and neurological morbidity depends on the patient's level of consciousness at presentation, rapid onset, or rapid progression of disease (Long et al. 2008). Mortality rates range from 5 to 15 % (Long et al. 2008; Menon et al. 2008). Morbidity remains a problem, with patients experiencing seizures (10–30 %), hemiparesis (10–15 %), cranial nerve palsy (5–10 %), hydrocephalus (5–10 %), and behavioral or intellectual problems (Long et al. 2008). The younger population, especially those under 2 years of age, has a high risk of learning disability:

- Treatment consists of antibiotic therapy, as well as surgical intervention when indicated.
- Time is essential because rapid intervention leads to improved outcome.

---

## 12.2 Neurocysticercosis

Neurocysticercosis is a common parasitic infection of the central nervous system that is a leading cause of seizures and epilepsy in developing countries (Leonard et al. 2006). It dates back to the time of ancient Greece, where it was known as the disease of the swine. Since the seventeenth century, it has been recognized as a disease which affects humans, and only since the second half of the nineteenth century has this pathogen been studied and understood. It is one of the few conditions included in a list of potentially eradicable infectious disease of public health concern, but it still remains a problem in our world today (Garcia and Del Brutto 2005).

### 12.2.1 Etiology

Worldwide distribution is higher in areas with poor sanitation. Neurocysticercosis is highly

endemic in Latin America, Mexico, Eastern Europe, Asia, Africa, and Spain. Hispanic race has more prevalence of neurocysticercosis due to countries of origin. The World Health Organization (WHO) estimates that 50,000 people die each year, worldwide, from neurocysticercosis. Because immigration rates have continued to increase in the United States along with increasing international adoption, the incidence of this disease is on the rise in the United States. Neurocysticercosis is currently one of the most common parasitic diseases of the central nervous system in the United States and a leading cause of epilepsy among Hispanic children living in US metropolitan areas along the Mexican border (Gershon et al. 2004).

*Taenia solium* is the parasite responsible for neurocysticercosis. Parasite infections result when the adult pork tapeworm ingestion occurs from eating undercooked pork contaminated with the organism called *Taenia solium* (Leonard et al. 2006). The pig is the intermediate host, where ingested larvae cysts embed themselves in the pig's muscle. Transmission can occur by ingesting eggs of the pork tapeworm or via the fecal-oral route (Wallin and Kurtzke 2004).

Incubation period from time of infection to presenting symptoms can be years. This has implications for the nurse practitioner, as many born in developing countries do not know they are infected and can present with symptoms once settled in the United States (Wallin and Kurtzke 2004). Due to the long incubation period, age does not seem to predispose a person, although it is rare to see a child under the age of 2 years diagnosed with neurocysticercosis.

### 12.2.2 Pathophysiology

Upon reaching the human GI tract, the egg's thin outer membrane will dissolve, releasing the inner oncosphere or larvae. Oncospheres are released into the intestines and then migrate through the blood and lymphatic system before being distributed into tissues where they form cysts (Wallin and Kurtzke 2004). The oncospheres readily cross the intestinal lining but are usually destroyed by the immune system.

They will escape the defenses of the host if they reach immunologically privileged sites, such as the central nervous system or eyes. In the CNS, the larvae tend to lodge in the small arterioles at the gray-white interface of the cerebral hemispheres and at the leptomeninges (Albright et al. 1999; Choux et al. 1999). However, the larvae can invade any part of the central nervous system, and once they invade, they will each mature into a cysticercus with a life span of approximately 18 months. The cysticercus is characterized by a head, body, four suckers, and some 20 pairs of hooks arranged as a crown (Choux et al. 1999).

The immunological response to the cysticercus lays the foundation for what is known as neurocysticercosis and manifests pathological changes like gliosis, necrosis, vasculitis, blockage of CSF drainage, meningitis, intracranial hypertension, and demyelination. Specifically with neurocysticercosis, the cysts form in the central nervous system. The types of infestation can be categorized according to location. These are parenchymal, meningeal, intraventricular, spinal, or mixed. Even once the cysticercus has died, inflammatory reactions can continue to occur for years (Fig. 12.3).

### 12.2.3 Presenting Symptoms

The most common presenting symptoms are seizures, headache, and intracranial hypertension. Parenchymal forms manifest as convulsive disorders, motor or sensory deficit, or deterioration of consciousness. Meningeal involvement presents with photophobia, headache, nausea, vomiting, nuchal rigidity, and cranial nerve palsies (particularly II, V, VI, VII). Intraventricular infestation may manifest as intermittent acute hydrocephalus, which may result in loss of consciousness with position changes as the cyst blocks the flow of spinal fluid. Hydrocephalus with increased intracranial pressure is associated with a higher mortality rate. Spinal involvement has not been documented in children but presents in adults as motor or sensory deficit, with a combination of upper and lower motor neuron pathology.

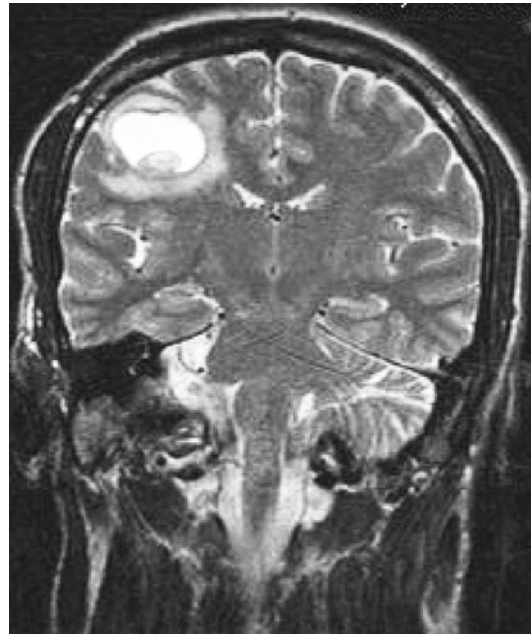
### 12.2.4 Diagnostic Tests

Diagnosing is made with neuroimaging with CT or MRI (Saenz et al. 2006). Imaging can reveal active cysts with or without calcified granulomas that represent nonviable cysts. In active disease, a ring-enhancing cyst is noted on CT or MRI, which may have surrounding edema. On these images, the larvae can sometimes be seen within the walls of the cyst (Fig. 12.3).

Confirmation can be obtained on serum and cerebral spinal fluid (CSF) with the enzyme-linked immunotransfer blot (EITB) assay that is used to detect the antibody to *T. solium* (Mody et al. 2005). This type of testing has a sensitivity of 98 % and specificity of 100 %, but in patients with only a single brain lesion, up to 30 % test negative (Garcia et al. 1991; Richards and Schantz 1991). CSF enzyme-linked immunosorbent assay (ELISA) for detection of antibodies or antigens to *T. solium* is also available and has a sensitivity of 87 % and specificity of 95 % (Rosas et al. 1986).

### 12.2.5 Treatment Options

Treatment is controversial and is based on the number of viable cysts seen on imaging. Treatment can cause an inflammatory host response, and, therefore, if antiparasitic therapy is initiated, it should be done in combination with steroid therapy (Marconi et al. 2006). Antiparasitic agents that are used for treatment include albendazole (15 mg/kg/day) and praziquantel (100 mg/kg/day) and should only be considered when multiple viable cysts are seen (Sotelo 2004). The risks and benefits must be weighed before initiation of therapy. Patients without evidence of active disease, as evident by only calcified granulomas, do not require treatment and should receive supportive care with anticonvulsant therapy. In cases of encephalitis and intracranial hypertension, antiparasitic therapy is contraindicated because treatment may cause exacerbation of cerebral swelling and edema, leading to herniation and death (Gershon et al. 2004). Other medical management focuses on antiepileptic drugs (AEDs), steroids, analgesics, and osmotic agents. As stated, steroids have a significant role with the initiation



**Fig. 12.3** T2 weighted MRI showing a cystic lesion in the right parietal lobe with a nodule on the inferior aspect which represents the larvae of *Taenia solium*

of antiparasitic therapy, since the destruction of the cysticerci may lead to significant and devastating inflammatory responses, resulting in increased intracranial pressure and even death.

Surgical therapy is indicated for the removal of space-occupying lesions causing significant mass effect and for the removal of seizure foci that are refractory to AEDs. Endoscopic removal is an option for ventricular lesions, and CSF diversion is often needed to treat communicating or obstructive hydrocephalus. In the case of obstructive hydrocephalus due to intraventricular neurocysticercosis, an attempt should be made to remove the lesion before shunting.

### 12.2.6 Nursing Care

Nursing care is essential during the administration of antiparasitic agents. Analgesics will play a major role, since many will experience headaches during antiparasitic therapy. One must also be on guard for signs of increased intracranial pressure, such as lethargy, vomiting, increasing headache, and unresponsiveness.

Steroid administration should be initiated prior to antiparasitic therapy. Seizure precautions should be enforced to protect the child from injury.

### 12.2.7 Patient and Family Education

Neurocysticercosis can cause rapid deterioration, which can ultimately result in death. During discharge education, this needs to be emphasized, and the family should be instructed to seek immediate medical attention for any change in neurological status. Education should also focus on medications, since the child may be discharged on an AED, as well as an antiparasitic agent or steroids.

Since a large proportion of pediatric patients inflicted with neurocysticercosis may be of Hispanic descent or from a part of the world other than the United States, an interpreter may be needed to help overcome the communication barrier. In addition, cultural issues may need to be addressed, and special help may be sought from the hospital or community to help bridge any gaps. The family members should be screened for disease, especially if the family comes from an endemic part of the world. Also, the patient and family should be taught how the disease is transmitted. Education should focus on frequent hand washing and sanitary handling of food. If the family and patient plan to travel to endemic areas, or areas with poor sanitation, caution should be undertaken in the consumption of foods from unsanitary restaurants or street vendors.

### 12.2.8 Outcome

Morbidity and mortality are based on whether the disease process is complicated or not. Most cysts are benign and resolve in 2–3 months. Children with a single cyst that can be controlled symptomatically have a favorable prognosis. If neurocysticercosis is treated properly, a cure rate of 90 % can be achieved in children. The real cure will not come from the treatment of the disease but only with the eradication of the parasite.

Complications include increased intracranial pressure and difficulty controlling seizures, resulting in hydrocephalus, papilledema, and headaches; therefore, symptomatic management is crucial. Although complications are on the rare end of the spectrum, prognosis is less favorable when they are present.

With proper treatment, lesions will often disappear, seizures will resolve, and imaging studies will normalize. For these patients, AEDs may be tapered off in 2 years (Gershon et al. 2004). However, in one study, there was a reported rate of 50 % for seizure recurrence following cessation of AEDs after 2 years of treatment, indicating that the effects of neurocysticercosis on epilepsy may be lifelong (Nash et al. 2004). This may be the result of a permanent structural abnormality caused by neurocysticercosis that is responsible for the seizure foci. It is not known for certain the long-term effects on mental and cognitive development, but it is suspected that it plays a negative role.

---

## 12.3 Shunt Infections

Shunts continue to be the mainstay of treatment for hydrocephalus. These devices have reduced the morbidity and mortality of hydrocephalus but can become the target of infection. When this occurs, the child may suffer serious negative consequences, and treatment is needed immediately. The care of patients experiencing a shunt infection is, unfortunately, a common event that nurses will encounter often in a neurosurgical setting.

### 12.3.1 Etiology

The incidence of shunt infections averages between 5 and 15 % (Rehman et al. 2010). Shunt infections most often result from colonization of the device by normally nonpathogenic skin flora. They usually occur soon after placement, with 70 % of shunt infections occurring within 2 months of placement and 80 % within 6 months (Gardner et al. 1985; George et al. 1979; Keutcher and Mealey 1979; Schoenbaum et al. 1975).

Ascending infections can occur, specifically with a ventricular peritoneal shunt in the setting of intra-abdominal infection, a ventricular pleural shunt in the setting of complicated pneumonia, and a ventricular atrial shunt in the setting of bacteremia. The main risk factors for shunt infection that have consistently been reported in the literature are length of procedure, skin condition, presence of open neural tube defect, and younger age. Other implicated risk factors include etiology of hydrocephalus, number of shunt revisions, site of shunt revision, type of shunt, concomitant infection, condition of skin, and number of people in operating room (Choux et al. 1999).

### 12.3.2 Pathophysiology

Shunt infections are unique from other types of CNS infections because they involve a foreign body. Often, the shunt becomes colonized at time of placement. Infection can also occur from wound breakdown, retrograde colonization from the distal end, or hematogenous seeding. The bacteria are able to adhere to the foreign body and secrete glycolipids, which help protect the bacteria from host defenses (Albright et al. 1999). More than two-thirds of shunt infections are caused by *Staphylococcal* species. The most common is coagulase-negative *Staphylococcus*, specifically *Staphylococcus epidermidis*, followed by *Staphylococcus aureus*. Other organisms that cause shunt infections include gram-negative bacilli, such as *Escherichia coli* and *Klebsiella* species. Indolent infections can be seen with *Corynebacterium* and *Propionibacterium* which are typical skin colonizers. In neonates, the common pathogens include gram-negative organism and *Candida* species.

### 12.3.3 Presenting Symptoms

Symptoms at presentation consist of signs of increased intracranial pressure including headache, lethargy, nausea, vomiting, irritability, seizure, and mental status changes. Additionally,

due to the infection, fever and abdominal or pleural pain (depending on the location of the distal end of the shunt) can be seen. In neonates, the presentation may manifest as apneic spells, irritability, lethargy, or a bulging fontanelle. A patient may additionally present with tenderness, erythema, or cellulitis over the shunt tract. Shunt nephritis is unique to a ventriculovascular shunt in which immune complexes are deposited in the renal glomeruli causing proteinuria and hematuria.

### 12.3.4 Diagnostic Tests

Initial evaluation begins with serum white blood cell count (WBC), erythrocyte sedimentation rate (ESR), C-reactive protein (CRP), and blood cultures. In 25 % of shunt infections, the WBC will be normal, while in another 33 %, it will be greater than 20,000 cells/mm (McLone 2001). ESR and CRP are nonspecific but are rarely normal in shunt infections. Blood cultures will be positive in about 33 % of shunt infections, unless the distal end is in a vascular structure, which brings the rate of positive cultures to 90 % (Greenberg 2006). Collection of CSF via a shunt tap is desirable, since the fluid collected is in direct contact with the shunt. The fluid is sent for glucose, protein, cell count with differential, gram stain, and culture. CSF studies suggestive for infection include low glucose, high protein, and elevated WBC (Table 12.1). Head CT is not useful to determine infection but can show worsening hydrocephalus indicating shunt malfunction secondary to possible infection. Ultrasound or CT of the abdomen may be useful to determine the presence of a peritoneal cyst, also known as pseudocyst, which is suggestive of infection. If infection of a VA shunt is suspected, an echocardiogram should be obtained to assess for the presence of vegetations.

### 12.3.5 Treatment Options

Medical management with antibiotics alone has a low success rate and requires weeks to months



**Table 12.1** CSF values according to age (Gardner et al. 1985)

Age group	WBC/mm <sup>3</sup>	Protein (mg/dl)	Glucose (mg/dl)	Glucose ratio (CSF: plasma)
Preemie	10	150	20–65	0.5–1.6
Term infant	7–8	80	30–120	0.4–2.5
Infant 1–12 months	5–6	15–80	40–80	0.5
Infant 1–2 years	2–3	15	40–80	0.5
Young child	2–3	20	40–80	0.5
Child 5–15 years	2–3	25	40–80	0.5
Adolescent and adult	3	30	40–80	0.5

of treatment. Typical treatment requires initiation of antibiotics and removal or externalization of the shunt system. When the shunt is removed, CSF drainage can be provided by means of an external ventricular drain (EVD), intermittent ventricular taps, or lumbar punctures in the case of a communicating hydrocephalus. If the shunt is externalized, it is done distal to the site of ventricular insertion, usually at the level of the clavicle. Initial antibiotic therapy consists of vancomycin and a third-generation cephalosporin. Once identification of an organism is obtained, antibiotic therapy can be tailored to the organism, and the addition of rifampin or an aminoglycoside can be added for synergistic effect. Intraventricular injection of preservative-free antibiotics via an externalized shunt or EVD is utilized in conjunction with systemic IV therapy to further enhance treatment. The patient is reimplanted with a new shunt based on clearance of CSF and preference of the surgeon (Box 12.1).

#### Box 12.1. Case Study

Laura is a 3-year-old girl with a right ventriculoperitoneal (VP) shunt admitted to the hospital for headache and purulent drainage from her scalp incision. She had a VP shunt placed at 1 year of age, and her last revision was 3 weeks prior to admission. The neurosurgeon took her to the operating room for removal of her VP shunt and placement of a ventriculostomy. Her CSF and wound were cultured and grew methicillin-resistant

*Staphylococcus aureus*. CSF glucose = 54, protein = 110, WBC = 150, and RBC = 2,050. The infectious disease service was consulted, and initially she was started on IV vancomycin at 15 mg/kg every 6 h and IV ceftriaxone 50 mg/kg every 12 h. The ceftriaxone was discontinued when the cultures grew MRSA. They recommended drawing CSF from the ventriculostomy every other day, weekly screening labs consisting of liver function tests (LFT), complete blood count with differential (CBC with diff), basic metabolic panel (BMP), and vancomycin trough. They also recommended continuing vancomycin for 2 weeks after her first negative CSF culture although the shunt could be replaced after 5–7 days of negative CSF cultures. A PICC (peripheral intravenous central catheter) was placed to facilitate administration of the vancomycin. On hospital day 3, her CSF cultures were negative and remained so through her treatment.

On hospital day 3, the EVD site began growing staph aureus and rifampin 200 mg po. BID was added. Laura went back to the operating room so the EVD site could be changed. She had her shunt replaced 7 days after the EVD was changed per infectious disease recommendations. She was eventually discharged with home health continuing her course of vancomycin and rifampin for 2 weeks post EVD removal and a return to neurosurgery clinic in 2 weeks.

Subacute bacterial endocarditis (SBE) prophylaxis is not indicated for patients with a shunt (American Academy of Pediatric Dentistry Clinical Affairs Committee 2009). VP shunts are not in the vascular space, and although a ventricular atrial shunt is in the vascular space, the American Heart Association has found no evidence of an increased risk of infection following dental procedures; therefore, SBE prophylaxis is not indicated (American Academy of Pediatric Dentistry Clinical Affairs Committee 2009). Indications for SBE prophylaxis are patients with a prosthetic cardiac valve, prosthetic material used for cardiac valve repair, previous history of endocarditis, unrepaired cyanotic congenital heart disease, completely repaired congenital heart disease with prosthetic material, repaired congenital heart disease with residual defects at the site of a prosthetic patch, and cardiac transplant recipients who develop valvulopathy (American Academy of Pediatric Dentistry Clinical Affairs Committee 2009).

### 12.3.6 Nursing Care

Antibiotic therapy must remain on a tight schedule with no interruptions in treatment. Delay or missed antibiotics could lead to resurgence of the pathogen and delay the time for reimplantation. If the child's shunt is externalized, or an external ventricular drain is placed, care should be taken to keep the exit site clean and dry. It is acceptable to place antibiotic or betadine ointment on the shunt wound initially, but more than 3 days of this treatment may cause the skin to macerate and prevent good healing. It is best to keep it clean and dry and to keep it covered with a sterile occlusive dressing, especially if the child is likely to pick and touch the wound or catheter.

Keeping the child occupied through playtime, schoolwork, or child life activities will

help distract the child during their hospitalization. Pain and irritability are issues with shunt infections, and the child may experience headaches and fevers. Treatment with acetaminophen and ibuprofen helps to alleviate these symptoms in most children, but occasionally you may need to employ stronger agents, such as hydrocodone, morphine, or nalbuphine.

### 12.3.7 Patient and Family Education

It is vital to instruct parents and patients on the warning signs of shunt infections. Fever, headache, lethargy, anorexia, nausea, vomiting, irritability, and redness along the shunt track are all possible signs of oncoming shunt infection. After the shunt is revised, inform the family that infection recurrence is highest during the first 6 months, so constant surveillance is needed during this critical time. If the child is to be discharged on antibiotics, careful instruction needs to be given on proper delivery and schedule. Instructions on wound care and activity, as well as follow-up, will ensure a smooth transition from the hospital to home.

### 12.3.8 Outcome

Most children do well with proper and timely treatment. Mortality and morbidity depend on the virulence of the pathogen and underlying host factors, including immunosuppression (Long et al. 2008). A history of a shunt infection predisposes a child to future shunt infections and malfunctions, as opposed to those without a history (Kanev and Sheehan 2003). Chronic and repeated shunt infections are associated with intellectual, psychological, and neurological deficits with a lower IQ by 20 points, but little evidence supports this outcome for a single infection that is treated promptly and successfully (Albright et al. 1999; Fobe 1999; Kanev and Sheehan 2003). Instruct parents to look for signs of developmental delay, and encourage them to seek assistance quickly if such issues arise.

## 12.4 Postoperative Infections

Postoperative infections are always a concern but can usually be prevented. Nursing plays a big role in this process.

### 12.4.1 Etiology

The etiology for postoperative infections depends on anatomical location of the infection. Keep in the mind the 5 Ws of postoperative fevers: wind, water, wound, walking, and wonder drug. The timing after surgery when a fever occurs dictates which process is the most likely culprit. For wind, this usually refers to lung processes, which occur in the first 48 h postoperative. Atelectasis is the source and, if not properly addressed, will evolve into pneumonia by postoperative days 3–5. Water involves urinary processes from indwelling foley catheters, which become the source of fevers around postoperative days 3–5. Wound processes, such as wound infection and meningitis, can also present by postoperative days 3–5, while abscesses present later in the hospital course, usually starting after postoperative day 10. Walking refers to deep venous thrombosis and thrombophlebitis, which are a common finding in adults during postoperative days 6–10, but less common with the pediatric population. Wonder drug does not refer to an infective process, but simply refers to medications that can cause fever in patients, such as phenytoin, or those which induce an allergic reaction.

### 12.4.2 Pathophysiology

The usual source for infection is bacterial, with viral and fungal being less likely. Pulmonary infections occur most often due to the underinflation of lungs postoperatively but can result from aspiration. The pathogen will vary depending on the mechanism involved. Urinary tract infections occur due to the foley acting as conduit for bacteria to enter or from urinary retention that can result from opioid use. Sepsis can arise from bacterial introduction into the

circulatory system from a central venous catheter but also can arise from a secondary source such as complex UTI. Postoperative wound infections occur from introduction of bacteria into the surgical bed during surgery. Skin flora is usually the culprit, but other pathogens not native to the skin are also implicated.

### 12.4.3 Diagnostic Tests

Initial evaluation involves fever curves and a white blood cell count with differential. Further testing can include blood culture, urinalysis, urine culture, sputum culture, and chest x-ray. If a postoperative CNS infection such as meningitis is suspected, a lumbar puncture can be diagnostic. Other studies for postoperative wound infections may include a wound culture, needle aspiration of fluid, CT with contrast, or MRI with contrast.

### 12.4.4 Treatment Options

The best treatment is prevention. Immediate mobilization after surgery, removal of indwelling catheters, and initiation of functional pulmonary toilet are key maneuvers in this preventive effort. Once infection is diagnosed, antibiotic therapy is indicated and should be tailored to the causative pathogen. If the infection involves the wound, surgical incision, drainage, and debridement may be indicated. In the unfortunate case of an infected prosthesis, such as a shunt or spinal hardware, removal is usually the treatment, as a foreign body can produce a breeding ground for bacteria.

### 12.4.5 Nursing Care

Nursing care has the main responsibility of prevention. This involves ambulating or getting the patient up into a chair in the immediate postoperative period. Some children refuse to use incentive spirometry or are too young to do so. Encouraging the children to blow soap bubbles,

a pinwheel, or party horn also helps to expand the lungs and prevent atelectasis. Removal of indwelling devices, such as foley catheters, arterial blood pressure lines, and central venous catheters, in a timely manner is essential.

Surgical dressing should be left intact until the surgeon does the initial dressing change. If the initial dressing becomes soiled or is saturated, the physician should be notified immediately. In some cases, it suffices to keep the wound open to air after the initial surgical dressing is removed, but in other situations where the incision can become contaminated from bodily fluids, or if the patients continue to touch the incision, a dry dressing may be in order. If vigilance from the nursing staff or parents is not effective in preventing a child from touching his wound, elbow restraints or mitten gloves may be utilized. Avoid frequent use of wound ointments because they can delay healing or cause wound breakdown.

Antibiotics need to be kept on a tight time schedule, and antipyretics such as acetaminophen and ibuprofen are utilized to keep the patient comfortable. Routine use of antipyretics is not recommended because it may mask fevers and blunt the body's attempt to rid itself of infection.

#### 12.4.6 Patient and Family Education

Instructing the family and patient on signs of infection will assist in early detection. Postoperative wound care should be a primary focus on discharge teaching. Problems with wounds that require reporting to the physician include erythema, drainage, increased pain, fever, and dehiscence. If the patient is to be discharged on antibiotics, teaching regarding the administration, timeliness, and duration should be addressed.

#### 12.4.7 Outcome

Postoperative infections resolve with proper and timely treatment. The morbidity and mortality remain low, except in cases where detection and treatment were delayed.

#### Pediatric Practice Pearls

- In the presentation of fever, headache, and focal neurological deficit, nurses must be suspicious for infective intracranial process.
- Neurocysticercosis can occur anywhere in the CNS, and its presentation usually manifests as seizures or symptoms and signs related to increased intracranial pressure.
- *Taenia solium* is the parasite responsible for neurocysticercosis, and its transmission occurs via the fecal-oral route seen in the improper handling of foods.
- The average incidence of shunt infection is 5–15 %.
- In neonates, infection may manifest as apneic spells, irritability, and bulging fontanel.
- Once the infection is cleared, the shunt can be reimplemented, but the child will be at a higher risk for future infections.
- Most postoperative infections are preventable.
- Maintain good pulmonary toilet, encourage incentive spirometry as well as deep breathing and coughing, and mobilize the patient as soon as possible.
- When appropriate, remove all indwelling catheters and tubes promptly.
- Report fevers immediately; avoid routine use of antipyretics because this will mask fevers which cause a delay in detection.

#### References

- Albright AE, Pollack IF, Adelson PD (1999) Principles and principles of pediatric neurosurgery. Thieme, New York
- American Academy of Pediatric Dentistry Clinical Affairs Committee (2009) Guideline on antibiotic prophylaxis for dental patients at risk for infection. *Pediatr Dent* 7(suppl):215–218
- Choux M, Concezio DR, Hockley A, Walker M (1999) Pediatric neurosurgery. Churchill Livingstone, New York
- Fobe JL (1999) IQ in hydrocephalus and myelomeningocele. Implications of surgical treatment. *Arq Neuropsiquiatr* 57:44–50

- Frazier J, Ahn E, Jallo G (2008) Management of brain abscesses in children. *Neurosurg Focus* 24(6):E8
- Garcia HH, Del Brutto OH (2005) Neurocysticercosis: updated concepts about an old disease. *Lancet Neurol* 4:653–661
- Garcia HH, Martinez M, Gilman R et al (1991) Diagnosis of cysticercosis in endemic regions. *Lancet* 338: 549–551
- Gardner P, Leipzig T, Phillips P (1985) Infections of central nervous system shunts. *Med Clin North Am* 69:297–314
- George R, Leibrock L, Epstein M (1979) Long-term analysis of cerebrospinal fluid shunt infections: a 25 year experience. *J Neurosurg* 51:804–811
- Gershon AA, Hotez PJ, Katz SL (2004) Krugman's infectious diseases of children. Mosby, Inc, St Louis
- Greenberg MS (2006) Handbook of neurosurgery. Thieme, New York
- Heilpern KL, Lorber B (1996) Focal intracranial infections. *Infect Dis Clin North Am* 10:879–898
- Hicks C, Weber J, Reid J, Moodley M (2011) Identifying and managing intracranial complications of sinusitis in children. *Pediatr Infect Dis* 30(3):220–226
- Kanev PM, Sheehan JM (2003) Reflections on shunt infection. *Pediatr Neurosurg* 39:285–290
- Keutcher TR, Mealey J (1979) Long term results after ventriculoatrial and ventriculoperitoneal shunting for infantile hydrocephalus. *J Neurosurg* 50:179–186
- Leonard R, Adickes ED, Brumback RA (2006) Neurocysticercosis. *J Child Neurol* 21(7):589–590
- Long SS, Pickering LK, Prober CG (2008) Principles and practice of pediatric infectious diseases, 3rd edn. Churchill Livingstone, New York
- Marconi VC, Garcia HH, Katz JT (2006) Neurocysticercosis. *Curr Infect Dis Rep* 8(4):293–300
- McLone DG (2001) Pediatric neurosurgery: surgery of the developing nervous system. WB Saunders, Philadelphia
- Menon S, Bharadwaj R, Chowdhary A, Kaundinya DV, Palande DA (2008) Current epidemiology of intracranial abscesses: a prospective 5 year study. *J Med Microbiol* 57:1259–1268
- Mody R, Nield L, Stauffer W, Kamat D (2005) Seizures in a 20-month-old native of Minnesota: a case of neurocysticercosis. *Pediatr Emerg Care* 21(12):860–862
- Nash TE, Del Brutto OH, Butman JA (2004) Calcific neurocysticercosis and epileptogenesis. *Neurology* 62: 1934–1938
- Osenbach R, Loftus C (1992) Diagnosis and management of brain abscess. *Neurosurg Clin N Am* 3:403
- Rehman A, Rehman T, Bashir H, Gupta V (2010) A simple method to reduce infection of ventriculoperitoneal shunts. *J Neurosurg Pediatr* 5(6):569–572
- Richards E, Schantz PM (1991) Laboratory diagnosis of cysticercosis. *Clin Lab Med* 11:1011–1028
- Rosas N, Sotelo J, Nieto D (1986) ELISA in the diagnosis of neurocysticercosis. *Arch Neurol* 43:353–356
- Saenz B, Ruiz-Garcia M, Jimenez E, Hernandez-Aguilar J, Suastegui R, Larralde C, Sciutto E, Fleury A (2006) Neurocysticercosis: clinical, radiologic, and inflammatory differences between children and adults. *Pediatr Infect Dis J* 25(9):801–803
- Saez-Llorens X (2003) Brain abscess in children. *Semin Pediatr Infect Dis* 14:108–114
- Schoenbaum SC, Gardner P, Shillito J (1975) Infections of cerebrospinal fluid shunts: epidemiology, clinical manifestations and therapy. *J Infect Dis* 131: 543–552
- Sotelo J (2004) Neurocysticercosis – is the elimination of parasites beneficial? *N Engl J Med* 350(3):280–282
- Tekkok IH, Erbeni A (1992) Management of brain abscess in children: review of 130 cases over a period of 21 years. *Childs Nerv Syst* 8:411–416
- Wallin M, Kurtzke J (2004) Neurocysticercosis in the United States: review of an important emerging infection. *Neurology* 63(9):1559–1564

Sarah M. Burr and Gail C. Dustman

Whether a child is having a minor outpatient surgery, scheduled inpatient surgery, or an emergent lifesaving procedure, it is an extraordinary stressor for the child and family (Wollin et al. 2004). Nurses play an important role in mitigating this stress for the child and family as well as in ensuring the safety of the patient throughout the perioperative process. Perioperative care of the pediatric patient includes providing preoperative information and guidance to the family, the physical assessment and preparation of the patient prior to surgery, the care of the patient in the operating room (OR), and the care of the patient after surgery in the postanesthesia care unit (PACU).

concerned with their child's health than with their own and thus desire detailed information regarding the anesthesia process and surgery itself (Kain et al. 1997). Of particular concern to parents is the induction of anesthesia, emergence from anesthesia, and postoperative pain and nausea (Wisselo et al. 2004). A study by Kain and colleagues (1997) demonstrated that providing parents of children undergoing general anesthesia very detailed information regarding the anesthesia process and potential risks did not increase parental anxiety, and by doing so, parents have the opportunity to make a fully informed choice.

The perioperative nurse and anesthesia provider should ensure that information is given to the parents regarding premedication, induction of anesthesia, side effects of anesthesia, and postoperative pain management. A variety of modalities should be utilized when providing education to parents prior to surgery, such as combinations of written information, audiovisual information, and verbal information. Parents can also be involved in the meeting with a child-life specialist, who provides information regarding the perioperative period to the child through demonstration and role-play.

Ideal timing of parental preparation is 5–7 days prior to surgery (Wisselo et al. 2004). With scheduled neurosurgical procedures, this preparation can occur through mailings of written materials and/or videotape, during a health-screening telephone call made by a nurse, as well as part of a preoperative visit to the hospital to meet with an anesthesiologist and the neurosurgery team. Even prior to emergent procedures, it is important to

---

## 13.1 Preoperative Care

### 13.1.1 Providing Information and Guidance

#### 13.1.1.1 Parental Preparation: Information Giving

An important part of the perioperative process is providing information to the parents of children undergoing surgery. Parents frequently are more

---

S.M. Burr, BSN, RN, CPN, CPAN (✉)  
Post Anesthesia Care Unit, Children's Mercy Hospital,  
2401 Gillham Road, Kansas City, MO 64108, USA  
e-mail: smburr@cmh.edu

G.C. Dustman, RN, BSN, CNOR, RNFA  
Children's Mercy Hospital,  
2401 Gillham Road, Kansas City, MO 64108, USA  
e-mail:gdustman@cmh.edu

provide time for parents to receive adequate information, time to process that information, and an opportunity to have their questions answered. Providing parents with additional preparation and information lessens anxiety and increases overall satisfaction with the perioperative period (Hatava et al. 2000).

### **13.1.1.2 Psychological Preparation of the Child**

It is estimated that as many as 60% of children undergoing anesthesia and surgery in the United States experience significant anxiety preoperatively (Kain et al. 2002). Anxiety and fear prior to surgery can prolong the induction of anesthesia, increase postoperative pain and analgesic requirements, and lengthen the recovery period (Kain et al. 2002). Moreover, this anxiety and fear may also lead to maladaptive postoperative changes in behavior that interfere with the daily functioning of the child. Thus, preparation of the child before surgery is an important part of the perioperative process. Both behavioral interventions (such as preparation programs that utilize education through therapeutic play) and pharmacological interventions (such as premedication with sedatives) are available to treat preoperative anxiety in children.

Behavioral preoperative preparation programs for children are highly recommended in the psychological and medical literature (Leack 2007). Most major pediatric hospitals offer such programs to children and their parents. These preparation programs may provide narrative information; a tour of the preoperative holding area, the operating suite, and recovery room; therapeutic role-play using dolls; child-life preparation or coping skills education; and relaxation skills for children and their parents. Similar to adults, children benefit the most if they participate in the program 5–7 days prior to surgery (Wisselo et al. 2004). It is important to consider each child's age and developmental needs to provide a program that will be effective in reducing preoperative anxiety.

Child-life specialists play an important role in the behavioral preoperative preparation programs as well as preoperatively on the day of

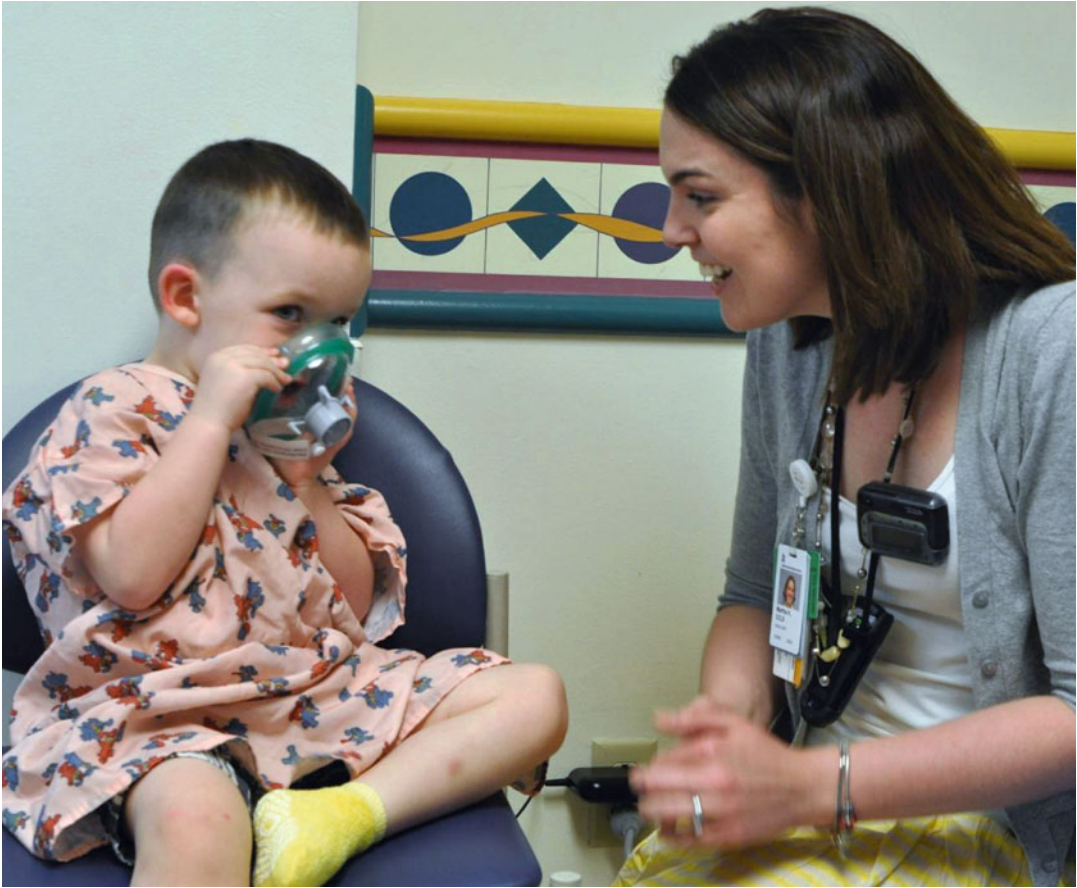surgery. Child-life specialists facilitate coping and the adjustment of children and parents by providing play experiences, presenting information about the events and procedures, and establishing supportive relationships with children and parents (Kain et al. 1998a). To make information accessible to children, child-life specialists incorporate descriptions of the sensations that children will experience, provide opportunities for children to examine and manipulate equipment to be used in their care, and encourage rehearsal with dolls (Kain et al. 1998a). Child-life preparation has been shown to effectively reduce anxiety in the preoperative holding area and upon separation from parents (Kain et al. 1998a) (Fig. 13.1).

### **13.1.2 Preoperative Consultations and Assessment**

#### **13.1.2.1 Surgeon/Anesthesiologist**

The preoperative consultation and evaluation may occur the day of the procedure or at a separate visit up to 1 month before the surgical date. This visit is often referred to as preoperative testing. The preoperative surgical evaluation should focus on identification of potential factors associated with frequently occurring perioperative complications and on those with high potential morbidity or mortality (Burd et al. 2006). In most cases, children at risk can be identified by a detailed history and physical examination performed by a qualified health-care provider, such as the surgeon, advanced practice nurse, or the anesthesiologist. Additional laboratory studies or other investigational studies are typically not necessary (Burd et al. 2006).

However, the pediatric neurosurgery patient may require additional studies. A preoperative visit and testing, therefore, is recommended for the scheduled pediatric neurosurgical patient, particularly for patients that are high-risk with comorbidities. Any laboratory or additional studies will be ordered at this visit and obtained prior to the day of surgery. Even if additional studies are not needed, any surgical patient with a health history and a surgical procedure that



**Fig. 13.1** Child-life specialist helps patient become more familiar with oxygen mask

inherently raises the risk of undergoing anesthesia should have a preoperative visit. The following figure provides an algorithm of indicators for a preadmission testing visit (Table 13.1).

In addition to a detailed history and physical, the surgeon and the anesthesiologist will obtain informed consent from the parent(s) or legal guardian of the child. The surgeon will discuss with the family the underlying condition for which the surgery has been recommended, a detailed description of the procedure, the risks, benefits and alternatives to the procedure, and the possible outcomes that may occur after surgery. Aspects of the anesthetic are similarly presented by the anesthesiologist. Opportunity is provided for questions and clarification prior to the signing of consent. Although much of the informed consent discussion occurs between the surgeon or anesthesiologist and

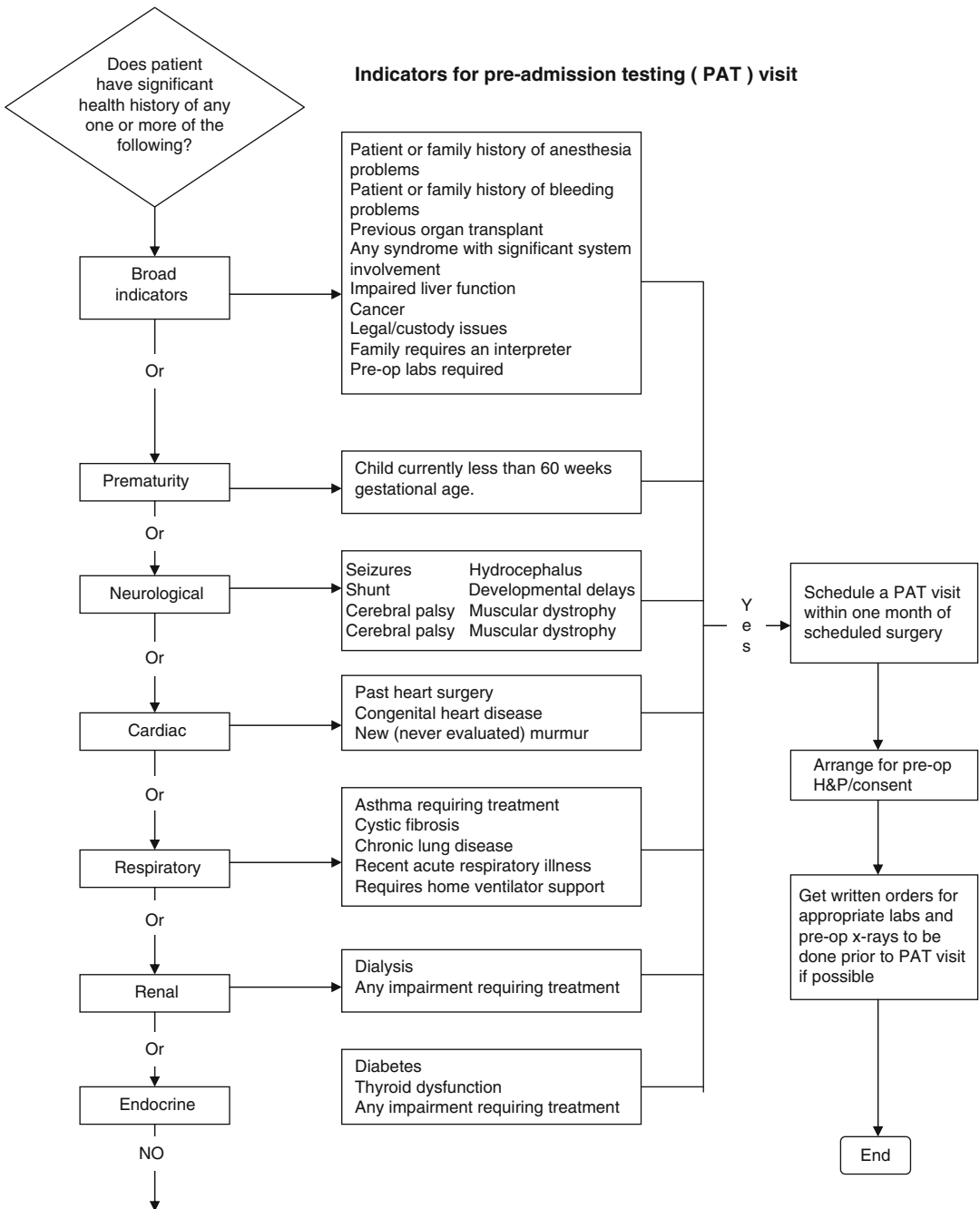
the parent, the input of the patient must also be solicited, as may be developmentally appropriate. The procedure should be explained to the child in a manner that the child understands. For older children, assent (the agreement of someone who is not competent to give legally valid informed consent) should be sought. During the consent process with the anesthesia provider or during the visit with the child-life specialist, the child is also given the opportunity to choose the “flavoring” or scent of anesthesia gas that will be used during induction. Standard options include bubble gum, strawberry, banana, grape, and orange.

### 13.1.2.2 Nursing

If the pediatric neurosurgical patient does not have a preoperative visit, typically a nurse working in the perioperative area will make a telephone call to



**Table 13.1** Indicators for preadmission testing (PAT) (Developed at Children’s Mercy Hospitals and Clinics, Kansas City, MO)



obtain a health screening as well as to provide helpful information about what the parents and child can expect on the day of surgery. Standard questions asked during the health-screening phone call or during the initial nursing health history obtained on the day of surgery include:

- Presence of any allergies or adverse reactions to food, medications, or latex
- Current medications including any over-the-counter medicines, inhalers, ointments, vitamins, or herbal supplements
- Birth history

- Meeting developmental milestones/developmentally appropriate for age
- Review of systems, specifically the presence of heart, lung, liver, or kidney issues
- Diagnosis of a seizure disorder, thyroid disorder, diabetes, or asthma
- Diagnosis of any other health conditions or syndromes
- Use of medical equipment (ventilator, CPAP, oxygen, monitors, etc.)
- Previous surgeries
- History of any problems with anesthetics or bleeding disorders in the patient and/or biological family
- Immunization status
- Recent exposures to contagious illnesses
- Presence of recent or chronic illness, particularly respiratory illnesses
- If an adolescent female, start of menarche and date of last menstrual period

At the preoperative visit, if any, and on the day of surgery, a nurse will perform a physical assessment on the pediatric surgical patient. The nurse's physical assessment includes a brief head-to-toe examination, focusing in detail on the condition of the skin, particularly at the proposed surgical site, neurological status and function, and cardio-respiratory status and function. The nurse will obtain the child's current height and weight, and if under 3 years of age, or if indicated, head circumference. The child's vital signs, including blood pressure, heart rate, respiratory rate, oxygen saturation, and temperature, are also obtained and recorded preoperatively and used as baseline data for the perioperative period.

### 13.1.3 Physical Preparation

#### 13.1.3.1 Labs

Routine laboratory testing of the pediatric surgical patient is no longer recommended. Laboratory testing should be determined by the medical condition of the child and the nature of the surgery to be performed. For the pediatric neurosurgery patient, laboratory tests that may be necessary for surgical management include a complete blood count (CBC) with differential

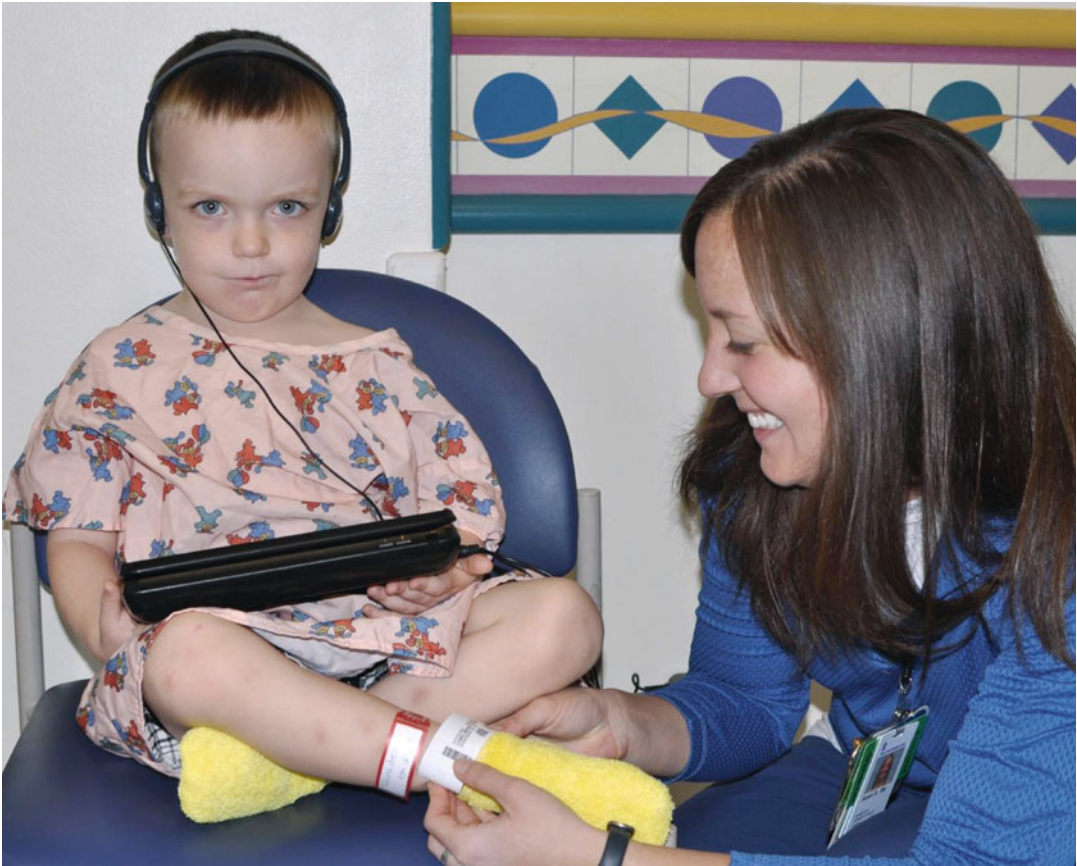(including hemoglobin and hematocrit), a complete or basic metabolic panel (CMP/BMP), and any others specifically indicated for the patient. Depending on the facility, females over the age of 10 years may need to provide a urine sample for a UCG or blood sample for an HCG pregnancy test.

#### 13.1.3.2 Blood

Depending on the type of neurosurgery, it may be necessary for the child to undergo blood typing in case of the need for a blood transfusion during the procedure. For the patient who has little or no need for a blood transfusion, a type and screen should be ordered and completed. In a type and screen, the blood bank will determine the patient's blood type and screen for antibodies, but no units of blood will be crossmatched and set aside in the blood bank for that patient until requested by the advanced practice nurse or physician. If the need for blood is expected or likely, then a type and cross is necessary. With a type and cross, units of blood will be crossmatched and held for the patient in the blood bank. If a child needs a transfusion, packed red blood cells are the preferred product, as it provides the benefits of increasing the oxygen-carrying part of the blood without adding too much extra volume. The patient who undergoes a type and screen or cross will obtain a special blood identification band that should be on the patient at all times. Care must be taken to maintain the integrity of the blood band so that identification information is readable (Fig. 13.2).

#### 13.1.3.3 Images

Imaging tests may be necessary for a pediatric neurosurgery patient before proceeding to surgery. Depending on the nature of the condition, the patient, and the preference of the surgeon, the child may undergo x-rays, a CT or MRI scan with or without contrast, or with an image-guided protocol to help guide the surgeon. It may be necessary for the child to undergo sedation in order to obtain these images. Imaging provides the neurosurgeon with vital information necessary to perform the procedure as well as a baseline in order to monitor changes in the patient's condition over time.



**Fig. 13.2** Nurse checks identification and blood bands on day of surgery

#### **13.1.3.4 Dietary Restrictions**

Prior to surgery, it is necessary for the patient to fast in order to reduce the risk of aspiration while under anesthesia. Children have higher fluid requirements for size than adults, and prolonged preoperative fasting may cause dehydration, hypoglycemia, ketosis, and discomfort from hunger. Therefore, the standard preoperative fasting for pediatric patients as recommended by the American Society of Anesthesiologists is clear liquids up to 2 h before surgery, breast milk up to 4 h before surgery, and infant formula, milk, or regular diet up to 6 h before surgery. It is important that the perioperative nurse clearly communicate and review the preoperative dietary restrictions with the patient and family. Utilizing the teach-back method in which the parent repeats back the eating and drinking instructions can help to ensure that the information has been clearly

communicated and received. A violation of these dietary restrictions could result in a delay or cancellation of surgery or, if not detected, an increased aspiration risk to the patient.

#### **13.1.3.5 Preoperative Medication**

Anxiolytic medications can be used in conjunction with or as an alternative to behavioral programs to reduce preoperative anxiety in the pediatric surgical patient. In addition to decreasing anxiety, preoperative anxiolytics provide amnesia for the separation of the patient from the family, create a quiet environment during the induction of anesthesia, and can also provide analgesia. Midazolam is the most common anxiolytic used preoperatively in children, as it has a rapid onset of action, is highly effective, and has low toxicity. The preferred method of administration of midazolam is orally in the preoperative

holding area. Within 10–20 min of oral administration, patients experience amnesia (typically will not remember separation from parents or induction of anesthesia), decreased anxiety, and light sedation.

Other common preoperative anxiolytics used in pediatrics include clonidine and diazepam. Like midazolam, both can be given orally. Clonidine and diazepam take about 30–45 min to begin to take effect and thus must be given earlier than midazolam in the preoperative intake process. Both clonidine and diazepam have the additional benefit of also acting as analgesics.

Children who receive a preoperative medication for anxiety should be continually monitored in the holding area in order to ensure the child's safety. They should be held by their parents or placed on a cart. Heart rate, respiratory rate, and oxygen saturation should be monitored. It is important to note that in susceptible individuals, anxiolytic medications, particularly midazolam, can cause a paradoxical reaction with increased anxiety, aggressive or violent behavior, uncontrollable crying or verbalization, and similar effects. Thus, it is important for clinicians and parents of the child to determine if utilizing a premedication will be advantageous for the well-being of the child.

### **13.1.3.6 Separation from Parents Versus Parental Presence upon Induction of Anesthesia**

Depending on the facility where a child undergoes surgery, either the child will go back to the operating room accompanied by only the operating room nurses, or a parent will also accompany the child and be present during the induction of anesthesia. At facilities in which parental presence at induction is not the norm, children may receive a premedication anxiolytic to aid in the separation and induction process. The practice of parental presence at induction is a common method used to decrease perioperative anxiety, and this practice has significantly increased in the United States during the past decade (Burd et al. 2006). Early studies of this practice showed that parental presence at induction was less effective at reducing anxiety, when compared to

premedication with oral midazolam (Kain et al. 1998b). But more recent studies have shown that, if selectively applied and proper parental preparation is done, it can be an effective alternative to premedication (Kain et al. 2002).

For parental presence during induction, it is first and foremost important to ensure patient safety. If the anesthesia provider suspects that the child may have airway problems during induction, or the child is too young to warrant parental presence, then no parent will be present. Studies have shown that children who benefit the most from parental presence are those older than 4 years of age who have either a calm baseline personality or a mother who has a calm baseline personality (Kain et al. 1998b). If parental presence is acceptable to the anesthesia provider and family, the parent selected must want to be present and willing to undergo preoperative preparation for the experience (Romino et al. 2005). The parent should be informed about the sequence of events, how the child will look during anesthesia induction, and how the child may react, as well as what the parent's role will be. The parent may sit next to the child or comfort the child in the parent's lap as inhalation anesthesia commences. Parents are encouraged to touch, sign, tell stories, and reassure their child during anesthesia induction. The parent is escorted from the induction area/operating room when the child is no longer aware of his/her surroundings. It is helpful for a nurse to act as a support for the parent during this process and help to guide them as necessary.

The potential benefits of parental presence during induction include avoiding the need for premedication, avoiding the child's resistance to separation from parents, and decreasing perioperative anxiety and postoperative behavioral problems related to perioperative anxiety (Kain et al. 2002). An additional benefit is a more positive perioperative experience for the family. Presence at induction is viewed favorably by parents as most believe that they have contributed to reducing their child's stress and are themselves less anxious and more satisfied (Kain et al. 2000). Patients and parents who will benefit from presence at induction should be considered on a case-by-case basis, and as stated, it is key that proper

parent selection and preparation occur in order to be effective.

### **13.1.4 Advance Preoperative Activities of OR Nurses**

It is incumbent on the perioperative nurse to ensure that everything that could be needed is present on the day of surgery for each scheduled patient. In the days or even weeks before the scheduled surgical procedure, any instruments, implantable devices, and other special equipment requested by the surgeon will be ordered. This could involve customization of an implant for a specific patient, which would require that the nurse send scans, radiographs, and/or measurements to the company manufacturing the implant. It may also be necessary to educate the nursing staff on the specifics of a particular item so that all will be familiar with it on the day of surgery.

---

## **13.2 Intraoperative Care**

### **13.2.1 Introduction**

The intraoperative care of the pediatric neurosurgical patient is a collaborative effort involving the nursing staff, anesthesia providers, surgeons, and other health-care professionals with the goal to achieve the best possible outcome for patients and their families. Nurses in the perioperative setting are multifaceted, and they function in various capacities. They may scrub or circulate. They may be assistants during surgery, or registered nurse first assistants (RNFA), acting in collaboration with and under the direction of the surgeon. They may also be advanced practice nurses, such as pediatric nurse practitioners (PNP) or clinical nurse specialists (CNS). Each role is vital to the team as a whole. These nurses are educators and preceptors, teaching new operating room nurses their respective roles and responsibilities and educating future health-care professionals about the scope of practice of the perioperative nurse. Perioperative nurses provide patient care within the framework of the nursing

process, utilizing skill in patient assessment, care planning, intervention, and assessing patient outcomes (Spry 2005). The perioperative nurse depends on knowledge of surgical anatomy, physiologic alterations, and their consequences for the patient, intraoperative risk factors, potentials for patient injury and the means of preventing them, and psychosocial implications of surgery for the patient and significant others. This knowledge enables the perioperative nurse to anticipate needs of the patient and surgical team and rapidly initiate appropriate nursing interventions. This is part of patient advocacy, of doing for the patient what needs to be done to provide a safe and caring environment (Meeker and Rothrock 1999).

### **13.2.2 Day of Surgery: Preparation of the Operating Room**

On the day of surgery, each member of the surgical team arrives at the operating room suite and dons hospital-approved, facility-laundered surgical attire. All head hair is covered by a surgical hat, and a surgical mask is required once a sterile field is created (Association of PeriOperative Registered Nurses AORN 2010). Each member of the team has an assigned task. There may be a scrub nurse, an RNFA, and one or two circulating nurses, depending on the acuity of the case. All members of the team participate in getting the operating room readied for the procedure. Each flat surface and operating light in the room is wiped with germicidal cloths and allowed to air-dry. All equipment in the operating room is placed in position for the scheduled procedure. The placement differs depending on the procedure. The operating table is prepared for the patient, taking into consideration the patient's size and the procedure being performed. A warming/cooling device is placed on the operating table to assist in the maintenance of normothermia. Perioperative hypothermia is estimated to occur in 50–90 % of all cases. It can lead to increased intraoperative bleeding, postoperative tachycardia, impaired wound healing, and greater postoperative discomfort (Meeker and Rothrock 1999). An impervious

drape and then the bed linens are applied to the table. Positioning of the patient for the procedure is carefully considered, and all needed positioning aids are secured. These may include gel rolls and gel pads, gel head rings, foam head rings, foam padding, bean bags, and arm boards to aid in positioning and prevent skin breakdown during the procedure.

The air-handling system is assessed to ensure that a positive air pressure environment is maintained in the operating room in which the procedure will occur. Appropriate ventilation systems are important in controlling infection by minimizing microbial contamination (Meeker and Rothrock 1999). The ambient air temperature is elevated to assist in the patient's thermoregulation during anesthetic induction. A forced-air machine and appropriate-size blanket are made available for anesthesia's use during each procedure. Each piece of equipment in the operating room is tested to make sure it is in optimal operating condition. These may include the suction apparatus, fluid warming unit, smoke evacuation system, electrocautery unit, microscope, power drill, neuronavigation system, the ultrasonic aspirator, lasers, and the Mayfield or horseshoe headrest apparatus.

The patient's most recent MRI, CT scan, or radiographs are displayed and reviewed by the surgical team, along with the patient's past medical history. The patient's weight and any allergies and sensitivities are noted. If the neuronavigation system is to be utilized, the team ensures that the correct MRI scan is loaded into the system, and that the needed attachments are verified by the unit and are ready for use. Surgeon-specific irrigating solutions and intraoperative medications are retrieved from the pharmacy, paying careful attention to any documented allergies or sensitivities. Anti-embolism stockings or sequential compression devices are brought to the room to be placed on the patient, once anesthetized, for prevention of venous pooling and subsequent formation of deep vein thromboses.

If the patient has been typed and screened for blood products, a call is placed to the blood bank to determine how many units of product are available for the patient. If neurophysiologic monitoring or

corticography has been requested, the technician's availability is ascertained. The same is true for any manufacturer's representative who might accompany a piece of new equipment or an implantable device. If intraoperative radiographs are to be taken, the radiology technician is notified of the projected start time of the surgery.

Each surgical specialty may have surgeon-specific preference cards. It is the responsibility of the scrub nurse to ensure that the appropriate instruments and supplies are gathered for each procedure. The surgical team then prepares the sterile field, using strict sterile technique. Each piece of equipment or item to be placed on the sterile field is examined for any breach in sterility. Every product expiration date is examined. Sterile drapes are utilized to create the sterile field, and each item introduced to the field is done so in a manner that maintains the item's sterility and integrity. Once a sterile field is created, it is constantly guarded and maintained (Association of Perioperative Registered Nurses AORN 2010). This is the responsibility of the entire surgical team, throughout the procedure. Traffic flow is kept to a minimum, with as little movement as possible, to diminish the number of airborne microbial contaminants entering the field.

With the operating room ready, the scrub nurse goes to the scrub sink and performs a surgical hand scrub, using an antimicrobial surgical scrub agent with a sponge/brush and nail cleaner. The scrub should last at least 5 min and includes all surfaces of the nails, fingers, hands, and arms up to 2 in. above the elbow. During this process, the arms are held away from the body, in a flexed position, with the fingertips pointing upward (Spry 2005). In recent years, alcohol-based hand rub products have become available. Prior to use of these products, it is necessary to perform a thorough nail cleaning and hand washing with soap and water. The hands and arms are then rinsed and dried, using a clean towel. The product is then applied and rubbed until dry. The scrub nurse reenters the operating room and dons a sterile gown and sterile gloves and begins to organize the sterile field.

### 13.2.2.1 Readying the Patient for the Operative Procedure

It is the circulating nurse who goes to preoperative holding to retrieve the patient. Usually, this nurse is the last member of the perioperative team to interview the patient and family, and it is *this* nurse who is the patient's advocate throughout the entire intraoperative process. By now, the surgeon has visited the patient and family and has obtained consent for the procedure. If laterality (right or left side) is an issue for the scheduled surgical procedure, the surgeon may have also marked the surgical site with his or her initials. The anesthesia provider has interviewed the family and has determined that the patient is well enough to undergo the scheduled procedure and has met the NPO parameters. The anesthesia provider has also obtained consent for a general anesthetic.

The circulating nurse introduces himself or herself to the patient and family and reviews the patient's chart. Of primary concern to the circulating nurse is the proper identification of the patient. It is best practice that the patient's identity be confirmed by using at least two identifiers (name, date of birth, and medical record or account number) (The Joint Commission 2012). The circulating nurse will verify that the child's wristband is in place and accurate. Some hospitals may also issue wristbands to parents, while others have different policies regarding parental identification. Whatever the institutional policy, the circulating nurse must verify the identity of the parent/legal guardian so that information about the child is obtained from and given to proper, legally authorized persons. If the use of blood products is anticipated, the nurse also checks to see that an identification blood band is present on the patient and this number is documented on the patient's chart.

The preoperative nursing documentation is reviewed, as is the anesthesia assessment and anesthesia consent. A current history and physical should be present and signed by the surgeon. The circulating nurse assesses the developmental level of the child, checks motor function, and checks the condition of the child's skin. All home medications are reviewed. Results of any ordered lab

tests or radiographs are present and reviewed with the anesthesia provider and the surgeon as necessary. Baseline vital signs are reviewed, and any preoperative medication administration is noted.

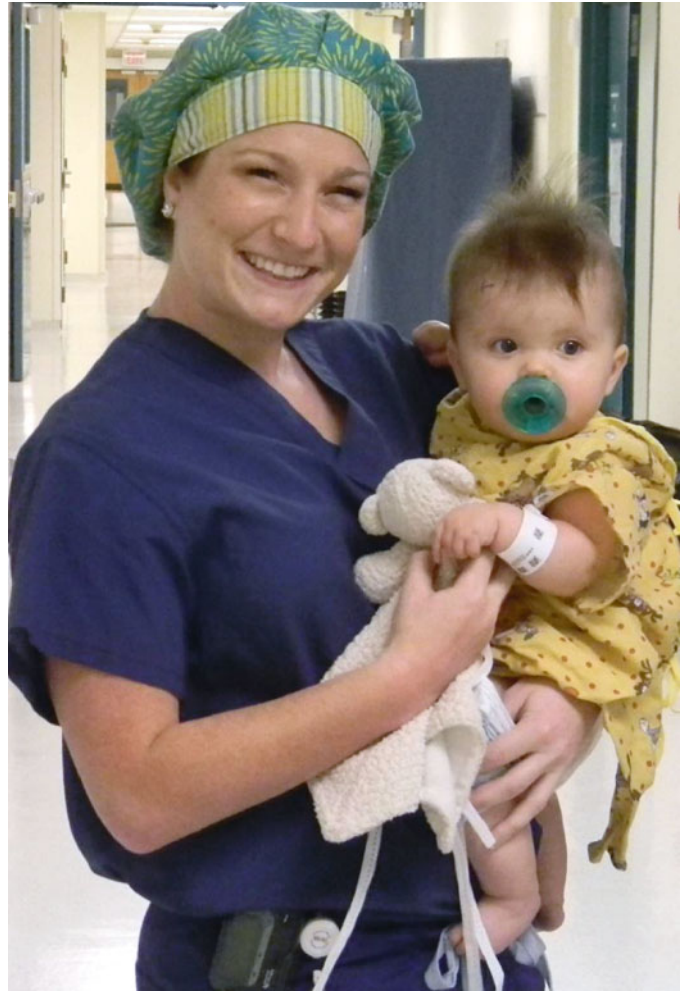A verbal confirmation of the NPO status and any allergies or sensitivities is received from the parent/legal guardian. The parent is asked to describe the procedure that their child will be undergoing, to acknowledge their understanding of the procedure, and their signature is verified on the operative consent. The circulating nurse then explains what will happen to the child from the time the family unit is separated until they are reunited once again. The family is told that they will be notified by phone when the procedure has begun and that they will be given updates as the procedure progresses. The child's and family's anxiety levels are assessed, and every attempt is made to develop a comfortable relationship with this family unit in a very short amount of time. All of the family's questions are answered as honestly as possible.

Allowing the child to bring a toy or blanket with them to the operating room gives the child a familiar item in foreign surroundings and may increase their sense of security (Association of PeriOperative Registered Nurses AORN 2010). The goal is always to minimize the ordeal of separating the child from the family, and, as previously discussed, some facilities even permit a parent to accompany the child into the OR. To allow the child a sense of autonomy, they may walk to the operating room, if able. If unable or premedicated, they may be carried or brought in their hospital bed, radiant warmer, wagon, wheelchair, stroller, or a stretcher, utilizing safety straps to prevent falls during transport (Fig. 13.3).

### 13.2.2.2 Anesthesia

Upon entering the operating room with the patient, the circulating nurse will introduce the patient to the operative team. The patient will have assistance transferring to the operating table, if needed, and noise will be kept to a minimum, providing a quiet and calm environment. The patient's modesty will be protected at all times. Care of the patient at this time is under the direction of the anesthesia provider and his or her

**Fig. 13.3** Carrying the child to the operating room can sometimes be less scary than riding on a cart



team. The circulating nurses and RNFA are present to support their efforts and to protect the patient. Warm blankets are placed over the patient and a seat belt is utilized as a safety measure.

An oxygen saturation probe is attached to the finger, EKG pads and leads are placed, a temperature monitor is placed in the patient's axilla, and a blood pressure cuff is applied. Anesthetic induction may be accomplished with an IV induction or with anesthetic gasses and a mask. Once the patient is asleep, an appropriately sized endotracheal tube or laryngeal mask is placed by the anesthesia provider, with the assistance of the circulating nurse, and it is secured. If a peripheral IV is not present, one is started at this time by the anesthesia team. For craniotomies, it is preferable to have two, large-bore peripheral IVs and an

arterial line placed. A CVP line may be placed, as well. The patient's eyes are lubricated and gently kept closed with tape or a Tegaderm. A urinary catheter, with urimeter, is placed by the circulating nurse and secured. Sequential compression stockings or anti-embolism stockings are then applied, if indicated.

A dispersive electrocautery pad is applied as close to the surgical incision site as possible. The pad is a disposable, adhesive foil pad, covered with foam and impregnated with electrolyte gel. Electrosurgery utilizes electric current to cut and coagulate tissue. The purpose of the dispersive pad is to return current released from the electrosurgery handpiece, thereby diminishing the heat that builds in the surrounding tissues and returning the current to the generator



(Phillips 2007). It acts as a ground pad for the patient, preventing electrical burns.

### 13.2.2.3 Positioning

With the assistance of the surgeon, the patient is positioned on the operating table for the procedure. The team takes into consideration the potential for tissue injury, peripheral nerve injury, musculoskeletal stress and strain, and crush injury from moving table parts. The patient's dignity is maintained as much as possible during the positioning process. Also, of consideration are the surgeon's need for adequate exposure of the surgical site and the anesthesiologist's accessibility to the patient (Phillips 2007). It is the responsibility of the entire surgical team to assure that each patient leaves the operating room with no injury related to intraoperative positioning. This is accomplished under the direction of the anesthesia provider. The patient is positioned safely, maintaining proper body alignment. Care is taken to protect the patient's skin, especially over bony prominences, and to ensure that peripheral nerves are not stretched or depressed, which can cause permanent damage. All extremities are secured to prevent them from falling from the operating table or resting on any hard surfaces (Meeker and Rothrock 1999). Many types of positioning aids are utilized to accomplish this in the safest manner possible for the patient.

For most craniotomies for tumor resection, the Mayfield headrest is utilized (Fig. 13.4). It attaches to the head of the operating table and is a three-point skull fixation apparatus. It is applied by the surgeon as a final step in the positioning process and can be utilized with the patient in the supine, lateral decubitus, or prone position. For Chiari decompression and posterior fossa tumor resection, the patient is in the prone position with the head fixed in the Mayfield headrest (Fig. 13.5). Although care is taken to apply appropriate pin pressure, occasionally a CSF leak or epidural hematoma can result from penetrating the inner table of the skull. For ventriculoperitoneal shunt placement and vagal nerve stimulator placement, the patient is usually in the supine position with the head turned to the left or right (Fig. 13.6). For lumbar shunt placement and baclofen pump

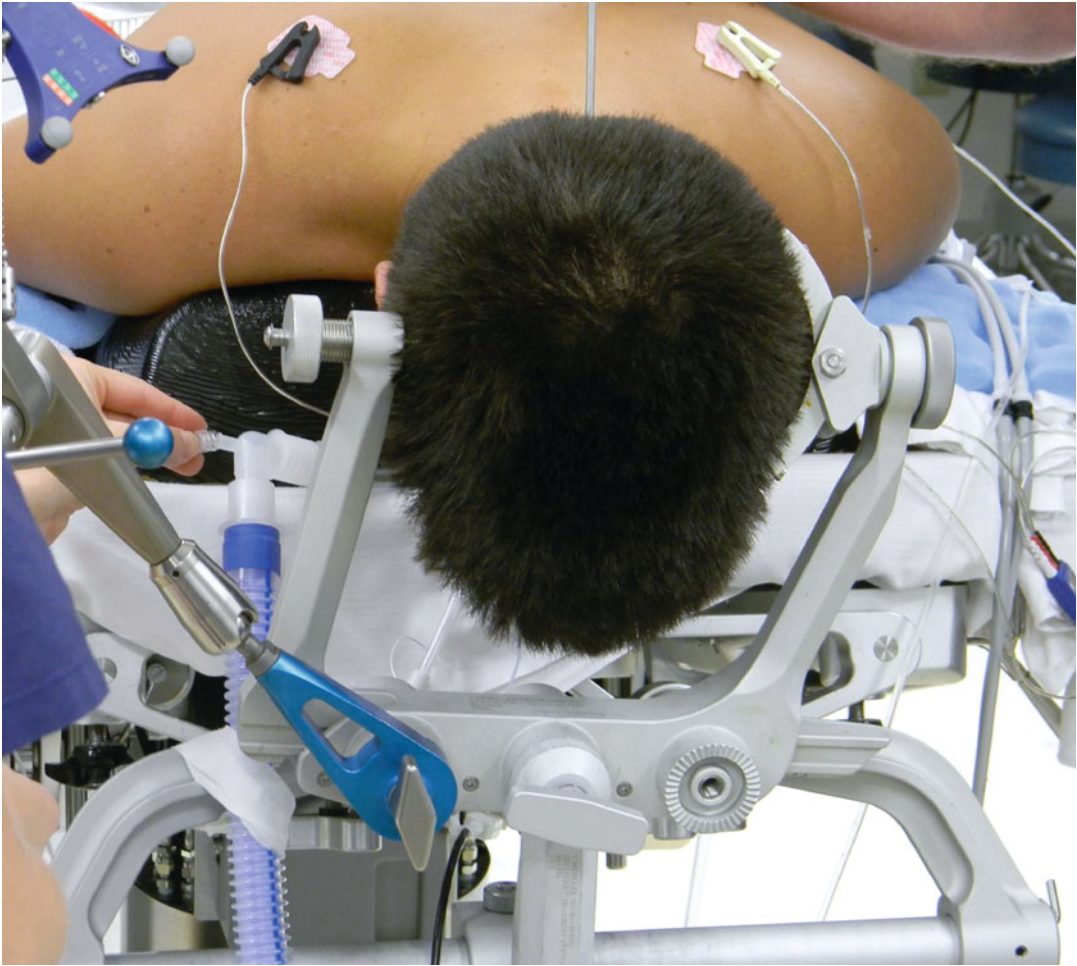
placement, the patient is in the lateral decubitus position (Fig. 13.7).

### 13.2.2.4 Surgical Time-Out

The Joint Commission, which accredits and certifies health-care organizations in the United States, has established a 2012 National Patient Safety Goal as the elimination of wrong site, wrong patient, and wrong procedure surgery (The Joint Commission 2012). Accordingly, it is recommended that, once the patient is positioned and secured, the entire surgical team participates in a surgical time-out. This includes, but is not limited to, review of the patient's name, allergies, procedure, position, whether antibiotics have been given, and the presence of any special instruments, implants, or services. Each member of the team must verbalize their agreement in order for the procedure to go forward.

### 13.2.2.5 Surgical Procedure

The preparation of the patient's skin for surgery is a two-step process. In the first step, the circulating nurse performs a sterile scrub preparation of the skin around the site of the surgical incision. The circulating nurse dons sterile gloves and uses sterile supplies during the scrub prep. The prep site is dried utilizing dry, sterile towels. The purpose of this scrub is to reduce the number of gross contaminants and oils that may block penetration of the antiseptic agent on and near the incision site (Association of PeriOperative Registered Nurses AORN 2010). The choice of scrub agent is determined by the surgeon, taking into account any patient allergies or sensitivities, the condition of the skin, and the type of contaminants. An odorless agent that produces a nice lather effect and is nonirritating to the skin is most typically preferred (Rothrock 2007). The second step is for the scrub nurse or the surgeon to apply an antiseptic or antimicrobial agent. While the patient's skin is being scrubbed by the circulating nurse, the surgeon and the surgical assistant will perform surgical hand scrubs and don sterile gowns and gloves. The surgeon will then apply a topical antiseptic agent to the surgical site (Fig. 13.8). The selected solution should decrease the microbial count of the skin rapidly, be applied quickly,



**Fig. 13.4** The patient's head is secured in a Mayfield headrest, a 3-point fixation device

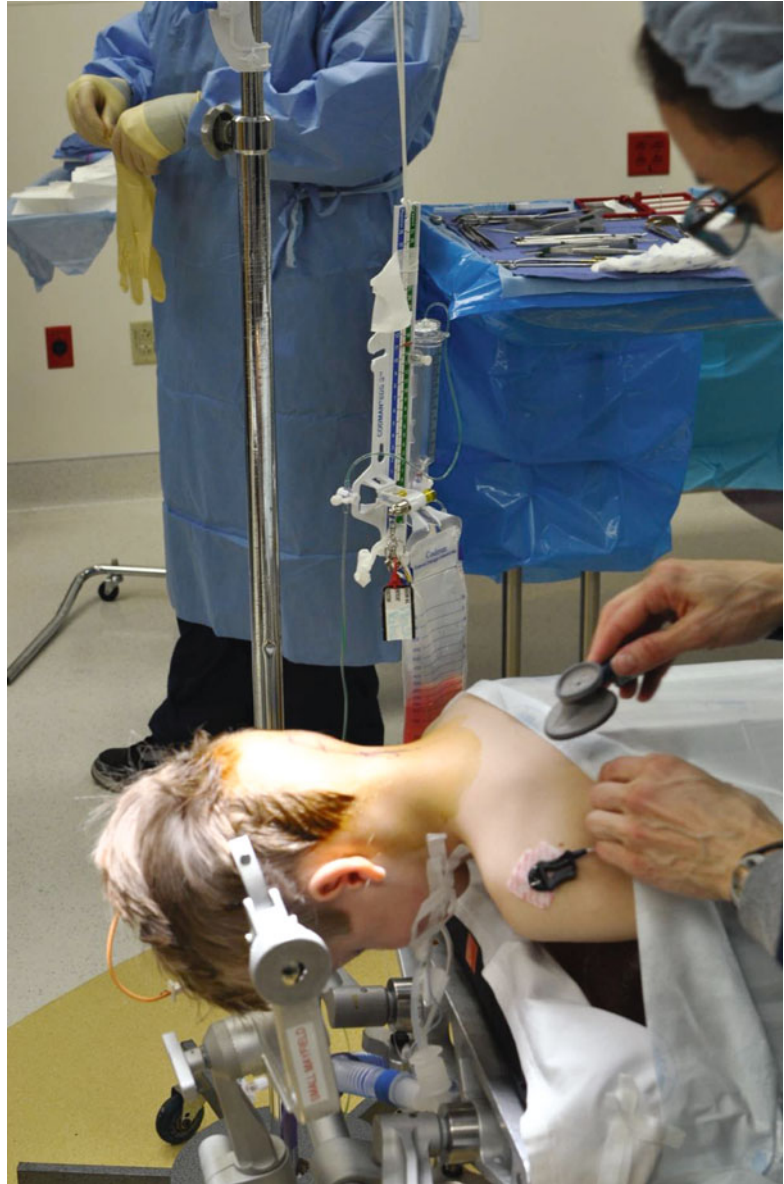
remain effective throughout the procedure, and be nonirritating. Alcohol preparations, tincture of iodine, chlorhexidine preparations, and iodophors meet these criteria (Fox et al. 2000). This antimicrobial agent is allowed to air-dry prior to draping the patient with sterile towels and sheets (Association of PeriOperative Registered Nurses AORN 2010).

Once the patient is prepped and draped, the scrub nurse and the circulating nurse accomplish the initial counts of sharps and sponges. These numbers are documented on a dry-erase board in clear sight of the surgical team and will reflect any changes made to these counts throughout the procedure. Counts will be meticulously performed by the scrub and circulating nurses

throughout the procedure, when there is a change in scrub personnel and at the completion of the procedure. These counts protect the patient from an injury caused by a retained foreign object (Association of PeriOperative Registered Nurses AORN 2010). When the surgical procedure begins, the circulating nurse calls the waiting family and gives them a brief report. The family is updated throughout the procedure by the circulating nurses or the neurosurgical advanced practice nurses.

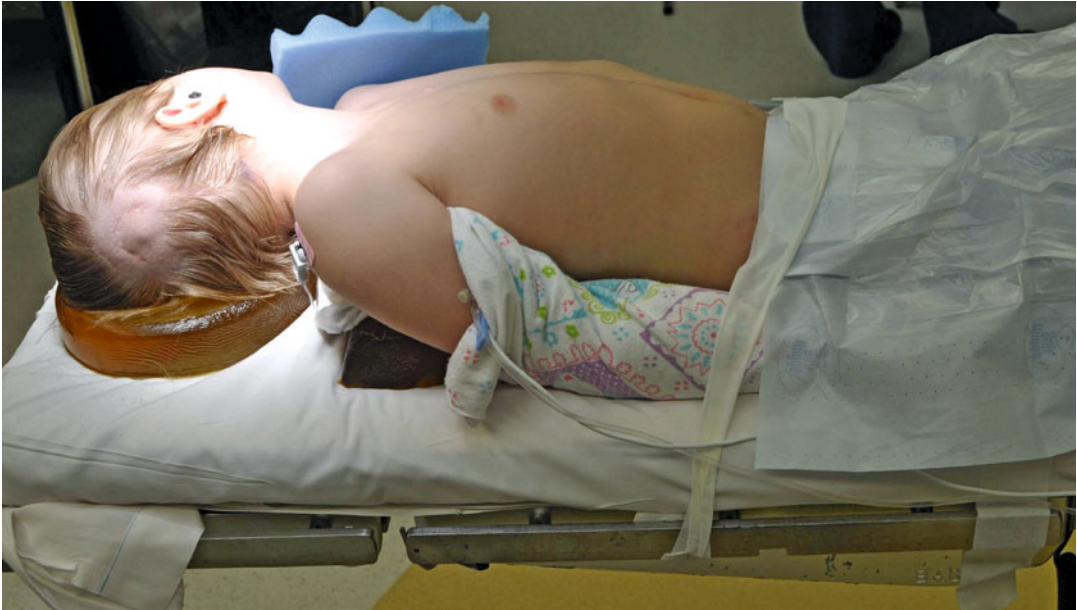The circulating nurse documents what happens to the patient from the moment of entry into the operating room until the moment of departure. The patient assessment and nursing diagnoses are recorded, and each specific nursing intervention in

**Fig. 13.5** Anesthesia provider checks for breath sounds in preparation for posterior fossa tumor resection. Note the ventriculostomy

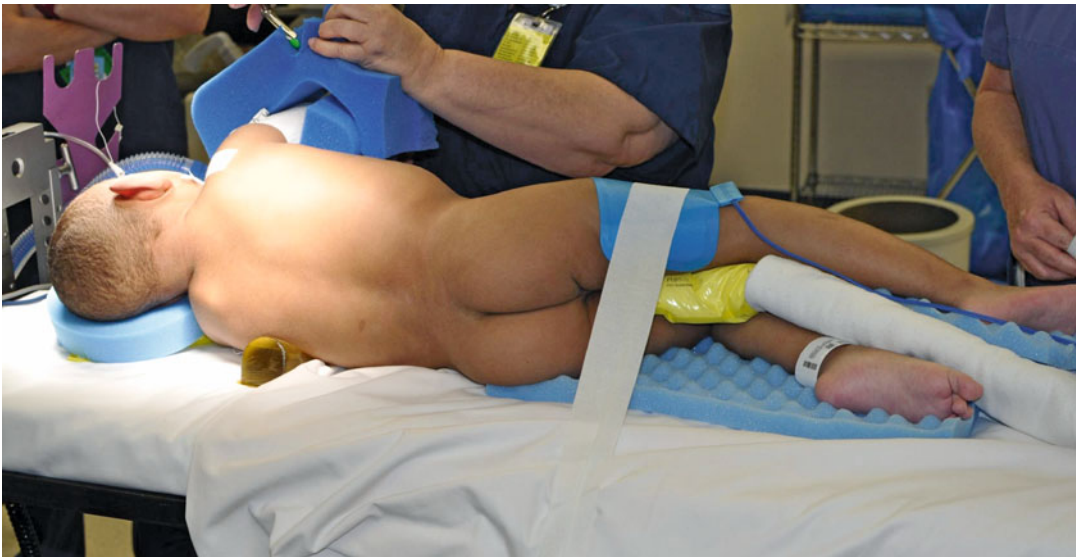

the plan of care has an expected, desired outcome. The patient's responses to these interventions and deviations from the expected outcomes are recorded, as well. For example, an expected outcome would be that the patient is free from signs and symptoms of injury related to positioning. Other information documented includes, but is not limited to, times in and out of the operating room; times of incision and closure; the persons present during the procedure and their roles; patient

positioning and positioning aids utilized; placement of catheters and drains, personnel placing them, and their sizes and lot numbers; placement of the electrocautery dispersive pad and the personnel placing it; electrocautery unit used with the selected settings; warming devices used, type of unit, and their respective temperature settings; location of skin preparation; skin preparation solutions used and the personnel applying them; intraoperative medication administration, including



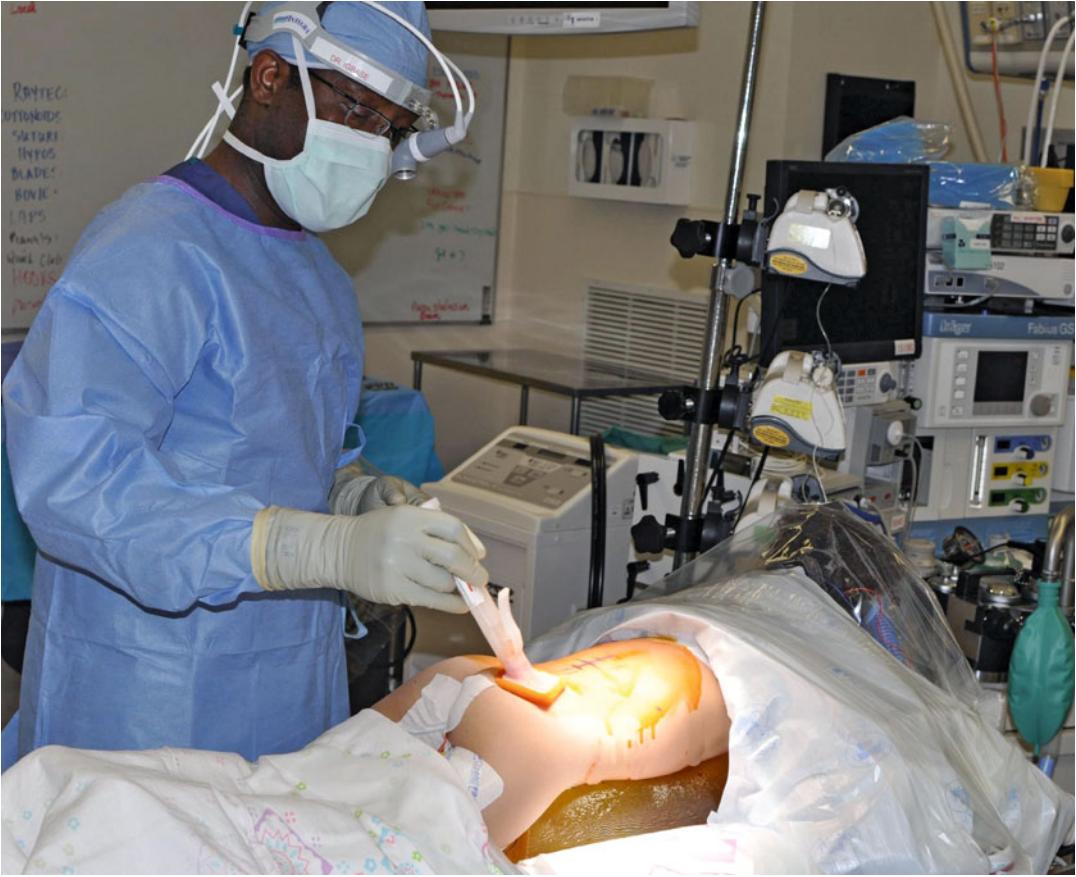**Fig. 13.6** Positioning for revision of right occipital ventriculoperitoneal shunt. A gel ring is used to position the head



**Fig. 13.7** Intraoperative positioning for baclofen pump or lumbar drain. Note the blue electrocautery pad placed on right thigh and foam padding to prevent skin breakdown over bony prominences

dose and mode of application and personnel applying; specimen and culture collection; placement of implanted medical devices and all FDA tracking information; wound classification; instruments, sharps, and sponge counts; and times of communication with waiting family members.

All specimens taken during the procedure are sent immediately to pathology or to the surgeon's lab of choice. All sent specimens include a patient label, a description of the specimen, the time and date the specimen was procured, and the initials of both the scrub nurse and the circulating nurse.



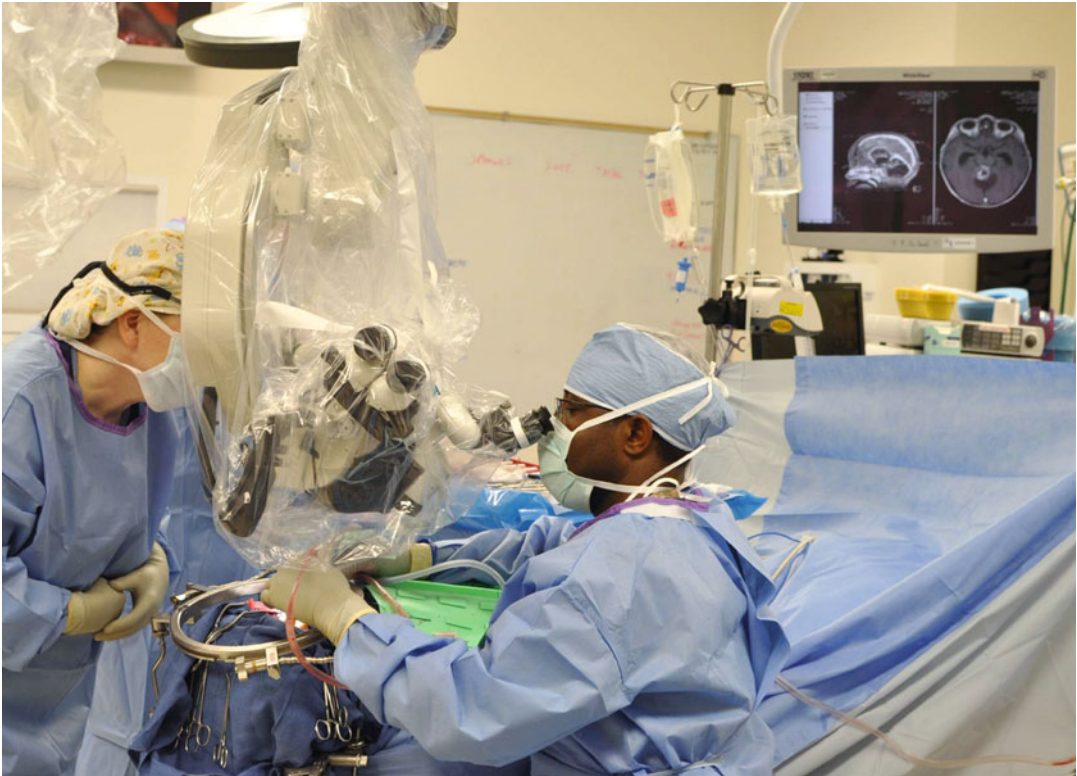**Fig. 13.8** The neurosurgeon applies an antimicrobial agent to the skin in preparation for lumbar laminectomy and tethered cord release

If the surgeon is requesting that a frozen section be taken, the phone number into the operating room is also included so that the pathologist and the surgeon can communicate about the results. A frozen section provides the surgeon with a preliminary tissue identification and can aid in determining the scope of the tumor resection (Fig. 13.9).

The circulating nurse is also attuned to the physiologic changes occurring to the patient while in the operating room. In collaboration with the anesthesia provider, close attention is paid to the patient's temperature, heart rate, blood pressure, oxygen saturation, ventilation, IV fluid administration, intraoperative laboratory results, urine output, and estimated blood loss. Estimated blood loss is documented on the same dry-erase board as the sharp and sponge counts and is meticulously updated by the circulating nurse.

### 13.2.2.6 Hair

Hair should not be removed from the surgical site unless required (Rothrock 2007). The need to remove hair is based upon surgeon preference and the procedure to be performed. If hair is to be removed, it is done with clippers, not a razor, by the surgeon after the child is secured on the operating table. Shaving is not recommended as it has been shown that postoperative wound infection rates are higher for those patients that are shaved preoperatively as compared to those who have no shave prep or a small amount of hair clipped (Rothrock 2007). Hair that is clipped is placed in a bag with a patient label and sent out of the operating room with the patient for the family. Sometimes this is a child's first haircut and may become part of a baby book! Every attempt is made to clip as little hair as possible as we know that this loss of hair affects each patient's body



**Fig. 13.9** The neurosurgeon uses the microscope and image-guided MRI to assist with tumor resection

image. At the close of the procedure, the nurses will perform a hair wash, if needed, to remove blood and proteins that have collected in the hair during the surgery, and a dressing may be applied to the surgical incisions. The first glimpse of their child after a surgical procedure can be very overwhelming and emotional for parents, and loss of hair may be the first thing they see.

#### **13.2.2.7 Transfer of Care**

Prior to leaving the operating room, the circulating nurse will call the pediatric intensive care unit (PICU) and give a verbal report to the nurse who will care for the patient. If the patient is to be recovered in the postanesthesia care unit (PACU), a verbal report will be given upon arrival by the circulating nurse to the nurse recovering the patient. The anesthesia provider will give a verbal report to these nurses as well. Any personal items brought to the operating room by the patient will be labeled with a patient identification and sticker transferred with the patient to these units.

## **13.3 Postoperative Care**

### **13.3.1 Criteria for PACU Recovery**

During the neurosurgical procedure, it is important for the surgeon and anesthesiologist to collaborate together, not only to ensure optimum patient outcomes but also to determine what will be the best immediate recovery course for the patient. The surgeon and anesthesiologist should take into account the complexity of the neurosurgical procedure, intraoperative occurrences, age of the child, preoperative condition of the child, and other comorbidities when deciding where the patient will go after the OR. Options include patient recovery in the postanesthesia care unit (PACU), and then transfer of care to the pediatric intensive care unit (PICU) or to a regular inpatient medical/surgical unit, or the patient may require an immediate transfer of care to the PICU. Reasons pediatric neurosurgical patients may require an immediate transfer to the PICU include

the need for continued mechanical ventilation to manage increased intracranial pressure, substantial blood loss during the procedure, or potential for neurologic deterioration.

Historically, patients who underwent a neurosurgical procedure required at least an overnight stay in the intensive care unit (ICU) to ensure close monitoring and frequent neurological assessments. Many facilities, however, are transitioning from this practice of routine post-neurosurgery ICU stays to a regular surgical unit stay for postoperative patients who meet an established set of criteria. This change in practice arose due to challenges with access to ICU beds and the cancellation of surgeries because of lack of available nurses for the ICU setting (Douglas and Rowed, 2005). Criteria to determine which postoperative neurosurgical patients should go to the ICU or the surgical unit immediately following their anesthetic recovery in the PACU are based on patient diagnosis, preoperative condition, comorbidities, the surgical procedure, intraoperative complications, and postoperative status (Douglas and Rowed). Regardless of whether the patient goes to the PICU or the surgical unit, the standard of care should remain the same. Moreover, as Westcott and Dunn (1998) state, “the demands of neurosurgical nursing require that nurses manage acute situations and pick up subtle changes in a patient’s condition to ensure proper treatment is given promptly. The nature of many neurosurgical conditions is such that small changes in function are often early signs of life-threatening conditions” (p. 421). It is important, therefore, that if the patient is transferred to a surgical unit rather than the PICU in the immediate postoperative period, nurses specifically trained to care for pediatric neurosurgical patients are available to provide care.

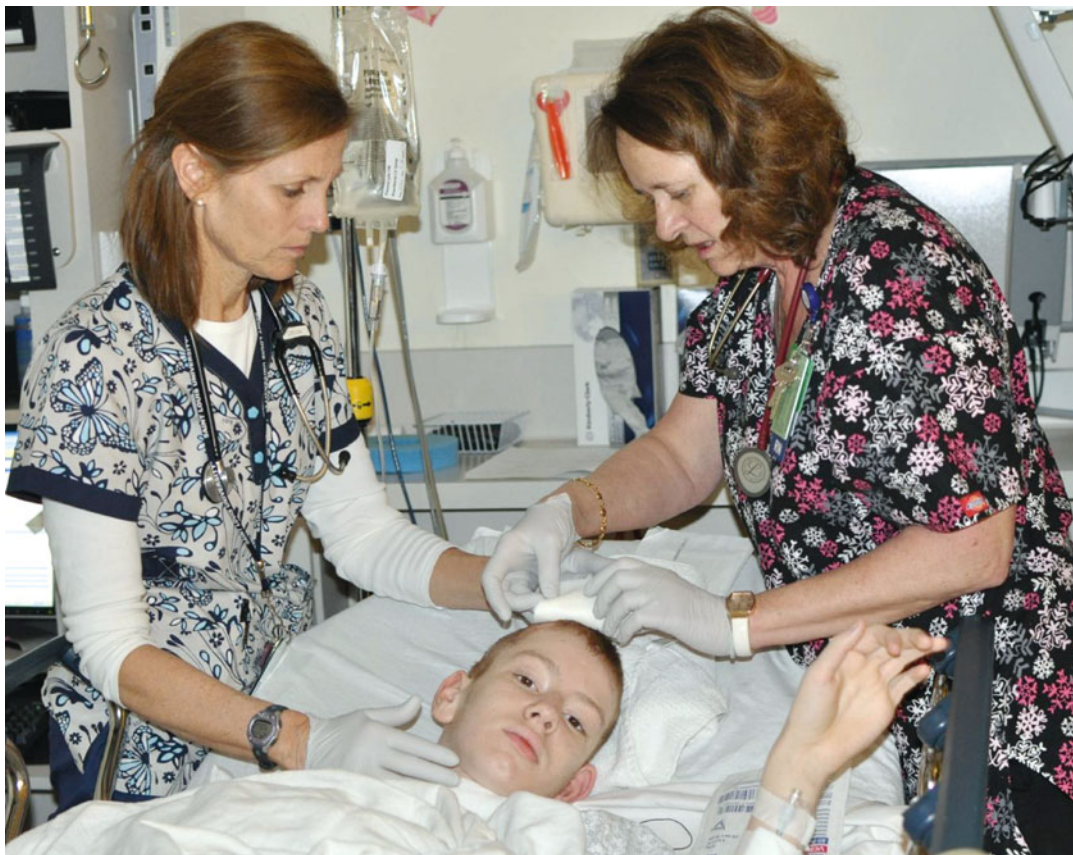### 13.3.2 PACU Recovery

The typical duration of stay in the PACU after a neurosurgical procedure is 1–2 h. Upon arrival to the PACU, a primary nurse and one to two secondary nurses are ready to take over caring for the patient. The circulating OR nurse and anesthesia provider provide a detailed report to

the primary PACU nurse, including surgical procedure, dressing, drains, intraoperative fluids and blood products given, medications administered, urine output, blood loss, and any other important occurrences during the intraoperative period. The PACU nurses apply monitors to the patient, including cardiorespiratory, continuous oxygen saturation, and blood pressure, and obtain a full set of vital signs. Once report has been completed and all questions and concerns have been addressed, the care of the patient now resides in the PACU nursing staff, who report to and consult directly with the anesthesia providers as needed during the patient’s PACU stay (Fig. 13.10).

While the patient recovers in the PACU, the nursing staff is responsible first and foremost in maintaining the patient’s airway. Depending on the facility, patients may arrive to the PACU still intubated with an endotracheal tube or laryngeal mask airway, or they may be extubated and require supplemental oxygen, whether via blowby oxygen or other more aggressive airway interventions. PACU nurses are specially trained to assess and manage airway complications and provide necessary interventions including breathing treatments, chin lifts, jaw thrusts, use of continuous positive airway pressure, oral or nasal airways, and provide manual ventilation via bag and mask as needed. Instances in which the PACU nurse is not able to maintain the airway, the anesthesia providers are immediately available to intervene and provide assistance. Other key aspects of the care provided in the PACU include a focused assessment of the patient, routine checks of vital signs, monitoring for potential complications, and treatment of pain and/or nausea and vomiting.

The primary nurse caring for the patient initially determines when the patient is ready for discharge from the PACU and transfer to the PICU or medical/surgical unit. Once the patient has met certain criteria, such as a maintained airway, is arousable and able to respond appropriately, has stable vital signs, has achieved an adequate level of pain relief, and the surgical site remains secure, the primary nurse initiates a bedside consult with the anesthesia provider to obtain a discharge order. The anesthesia provider in collaboration with the



**Fig. 13.10** Nurses in PACU redress craniotomy incision

neurosurgery team and PACU nurse determines at this final step in the perioperative process that the patient is ready for transfer and that the postoperative level of care required (ICU or medical/surgical unit) remains appropriate for this patient.

### 13.3.3 Parental Presence

Similar to parental presence at induction of anesthesia, the presence of parents in the PACU varies from facility to facility. Regardless of facility policy, parental presence always is dependent on the postoperative condition of the child and the psychological preparation of the parent(s). The ability of the anesthesia provider and perioperative nurses to anticipate which children may develop serious postoperative complications requiring critical intervention, thereby postponing

parental presence in these cases until the child is stabilized, is also key when implementing a program of parental presence upon anesthesia emergence (Hall et al. 1995).

Findings from a study by Burke and colleagues (2009) found that parents felt comfortable in the PACU setting and reported a high degree of helpfulness in comforting their child. While the Burke et al. study found that parental presence did not decrease agitation upon emergence from anesthesia in young children, there was a significant psychosocial benefit to the parents. Nurses in the study rated parent helpfulness as high, and parent upset, anxiety, and fear very low, indicating that parental presence does not hinder patient care (Burke et al. 2009). In the case of children with special health-care needs, the parent can assist the child and enhance the staff's ability to assess the child. The anesthesia provider and perianesthesia



nurses should consider these potential benefits of the presence of parents in the immediate postanesthesia period but must also ensure that patient safety comes first.

### 13.3.4 Parental and Patient Guidance

Whether or not parents will be present in the PACU, it is important that a member of the neurosurgery or perioperative team provide information to the parents and patient (as is developmentally and age appropriate) about what to expect postoperatively. Typically, the neurosurgery patient will have at least one intravenous catheter, if not multiple, and may have an arterial or central line too. The patient will be on a continuous cardiorespiratory monitor and pulse oximetry monitor as well as have blood pressure monitored at intervals. The patient may have an indwelling urine catheter in place to closely monitor output and may have drains coming from the surgical site that drain blood or cerebral spinal fluid. If the patient goes directly to the ICU from the OR, he or she will likely still have an endotracheal tube in place and will be manually ventilated until placed on a mechanical ventilator.

In addition to the medical monitors and devices in place, it is also important to provide parents a general description about what to expect in regards to the child's appearance. The child may appear pale. There may be dressings at the surgical site that have drainage ranging from bloody to serous. The child may also have facial swelling due to prone positioning during the procedure, the particular procedure itself, or an imbalance in fluid status. Parents and the child should be reassured, as needed, concerning postoperative appearance and the presence of monitors or devices in order to alleviate any anxiety or fears.

### 13.3.5 Assessment

After a neurosurgical procedure, close observation with serial neurologic examinations and hemodynamic monitoring is helpful for the prevention and early detection of postoperative complications. In the PACU and the immediate

postoperative period, a full set of vital signs including heart rate, respiratory rate, blood pressure (arterial pressure if invasive monitoring is present), oxygen saturation, temperature, and pain should be obtained and a focused neurologic exam performed every 15 min or more often if needed. Refer to Chap. 1 regarding how to perform a neurologic assessment. In the immediate postoperative period, a full neurologic assessment may not be possible, as the patient will be sedated and/or drowsy. The nurse should at the minimum monitor responsiveness (alert, verbal, tactile, pain, unresponsive), pupil size, symmetry and reaction to light, as well as symmetry and strength of movement of facial muscles and extremities if the patient is able to follow commands.

Postoperatively, the surgeon will place a specific set of orders regarding the care of the child. For the neurosurgery patient, the nurse should pay particular attention to how high to elevate the head of the bed (such as 15° or 30°) or specific positioning and movement of the patient (e.g., supine, prone, or log roll). If the patient has any surgical drains, including an external ventricular drainage (EVD) system, the nurse should note whether the drains should be opened or closed, and what level they should be set at, and monitor the output for amount, color, and clarity. Prior to moving or repositioning the patient, care should be taken that the EVD is closed to the patient to prevent sudden changes in the drainage of cerebral spinal fluid and intracranial pressure. The patient may require postoperative labs. These should be obtained as soon as possible and results provided to the ordering physician, as further interventions may be needed.

### 13.3.6 Monitoring and Treatment of Potential Complications

Key complications that nurses and other health-care providers should monitor for in the immediate postoperative period include respiratory dysfunction, bleeding, diabetes insipidus, cerebral salt-wasting syndrome, nausea and vomiting, and pain. Airway edema may occur from the presence of an endotracheal tube for intubation during the

procedure, particularly with procedures that require prone positioning. Use of intravenous steroids (e.g., dexamethasone), nebulized breathing treatments with racemic epinephrine, or continued endotracheal intubation may be required to treat the airway edema. With surgery to the posterior fossa region of the brain, early postoperative swelling may cause respiratory control to be compromised, leading to postoperative respiratory failure and the need for continued intubation and mechanical ventilation.

Postoperative bleeding may occur after any surgical procedure. To detect postoperative bleeding in the post-neurosurgical patient, close monitoring and frequent assessments for changes in the neurologic exam are important as well as monitoring the output of any surgical drains. A decrease in responsiveness/level of consciousness, presence of posturing, or a change in pupil size, symmetry, and reaction to light are key indicators of a postoperative head bleed. The surgeon should be immediately notified. The patient will likely need to return to the OR as soon as possible in order to obtain the best possible outcome.

Diabetes insipidus is another possible complication after neurosurgery in the region of the hypothalamus and pituitary gland. Nurses should monitor for excessive dilute urine output. This condition can be managed acutely with an intravenous infusion of vasopressin.

Cerebral salt-wasting syndrome and resulting hyponatremia may also occur after a surgical procedure in the brain. In cerebral salt-wasting syndrome, excessive renal sodium is excreted from a centrally mediated process. Hyponatremia results, with primary symptoms being polyuria, or excessive urine output due to inadequate sodium retention in the body, polydipsia (excessive thirst), and dehydration. Severe hyponatremia can be detected by the following symptoms: muscle cramps, dizziness, tachycardia or bradycardia, hypotension, facial flushing, nausea/vomiting, decreased level of consciousness, and seizures. Treatment includes hydration via IV fluids and administration of sodium to correct the deficiency.

Postoperative nausea and vomiting can occur after any surgical procedure but is particularly harmful in the post-neurosurgery patient as it can cause sudden rises in intracranial pressure.

Postoperative nausea and vomiting should be treated with a nonsedating antiemetic. Prophylactic treatment of postoperative nausea and vomiting with a 5-HT<sub>3</sub> serotonin reuptake inhibitor (e.g. ondansetron) is often used as well. Following craniotomies in children, however, the use of ondansetron prophylactically was not effective in decreasing the incidence of vomiting (Furst et al. 1996). Alternative antiemetics may need to be utilized.

### 13.3.7 Assessment and Treatment of Pain

After any surgical procedure, the assessment and treatment of pain is key to a successful recovery. In the past 20 years, many changes in the understanding and treatment of acute pain in infants and children have occurred. It is now understood that infants and children experience a severity of postoperative pain similar to adults and thus should be provided with adequate treatment.

To assess pain in the immediate postoperative period, health-care providers utilize a variety of methods. Vital signs are examined for indication of pain, such as elevated heart rate, respiratory rate, and blood pressure. Behaviors are observed, including facial expression, movement of legs/extremities, activity (posturing/movement), cry, and consolability (FLACC pain scale). If awake and able to comprehend and cooperate, the child may also be able to indicate his or her pain by utilizing a scale, such as FACES or VAS (visual analogue scale) which indicates the intensity of pain on a continuum from no pain to the most pain one could possibly experience (Hockenberry and Wilson 2009).

The World Health Organization provides a clinical ladder for pain treatment depending on the degree of pain from mild to severe. For mild pain, nonsteroidal anti-inflammatory drugs (NSAIDs) or acetaminophen should be given via the oral route. NSAIDs and acetaminophen act through inhibition of the enzyme cyclooxygenase, thereby blocking the synthesis of prostaglandins that stimulate free nerve endings of the peripheral nervous system. These agents have a ceiling effect so that after a certain plasma concentration is achieved, no further analgesia is provided by increasing the dose.

For moderate pain, NSAIDs or acetaminophen with a weak opioid (such as oxycodone, hydrocodone, or codeine) can be given orally. Or IV opioids may be used via patient-controlled analgesia (PCA), which is a continuous infusion of opioid with as needed rescue doses, or fixed-interval dosing of an opioid. In pediatrics, common opioids used include fentanyl, morphine, and hydromorphone. Opioids can cause respiratory depression when administered, and thus care must be taken to closely monitor the patient's respiratory status.

For severe pain, IV opioid by PCA or regional anesthetic techniques (such as nerve blocks or a continuous epidural infusion) should be used along with continued use of an NSAID or acetaminophen. If a patient is unable to tolerate an oral prostaglandin inhibitor, IV ketorolac (NSAID) may be used. Ketorolac is contraindicated in patients who have bleeding disorders or in settings in which acute hemorrhage is a concern; therefore, it may not be indicated for use in the postoperative neurosurgery patient.

When opioids are chosen for postoperative analgesia, three choices must be made: (1) which opioid to use, (2) the mode of administration, and (3) the route of administration. For the immediate postsurgical pediatric patient, fentanyl is usually the first choice of anesthesia providers for treatment of moderate to severe pain, administered via IV on an "as needed" basis in intervals up to every 5 min, at a dose of 0.5 mcg/kg. If fentanyl is contraindicated or ineffective, morphine or hydromorphone is utilized. Most neurosurgical patients will not have a PCA, regional block, or continuous epidural infusion, but rather will be treated with IV narcotics on an "as needed" basis in order to accurately monitor the child's neurological status (Box 13.1).

#### **Box 13.1. Case Study**

A 4-year-old child named Sophia presents at the neurosurgery clinic after a referral from her pediatrician. Over the past month, her mother reports that she has a sudden loss of appetite, vomiting, and headaches. She has taken her child to the pediatrician

three times in the last month with the symptoms being attributed to a virus and then her vision. After an eye exam revealed normal vision, Sophia's mother insisted on referral to a specialist. Normally a bubbly little girl who likes to play with Barbie dolls, she is now quiet and listless.

After a normal neurological exam, the neurosurgeon orders an MRI to try to determine the cause of Sophia's symptoms, particularly the worsening and debilitating headaches. Results of the MRI reveals Sophia has a ping-pong-sized tumor pressing on her brainstem in the posterior fossa region. Posterior fossa tumors are the most common childhood brain tumor.

With a diagnosis of a brain tumor, the neurosurgeon informs Sophia's mother of the need for surgery. A surgery date is selected and preoperative visit planned. At the preoperative visit, Sophia and her parents meet with a perioperative nurse who asks health history questions, performs a head-to-toe assessment, obtains height/weight and vital signs, and provides general information about what to expect on the day of surgery. The anesthesia provider and neurosurgeon provide information regarding their particular roles in the procedure and obtain consent. Preoperative labs are ordered including a complete blood count (CBC), basic metabolic panel (BMP), and a type and cross as posterior fossa tumors pose a high risk for blood loss. Sophia meets with a child-life specialist, who gives her a tour of the preoperative area, the OR, and the PACU and helps Sophia role-play with her favorite Barbie doll on how to obtain vital signs and the induction of anesthesia.

The day before Sophia's surgery, her preoperative labs are completed and a blood band placed on her wrist. Instructions are provided to keep the band clean and dry. Her parents are also informed of when Sophia needs to stop eating and drinking.

On the day of surgery, Sophia and her parents are anxious but prepared. The preoperative nurse obtains a set of vital signs and places the family in the preoperative holding room. The anesthesiologist and neurosurgery team meet with the family to answer any further questions or concerns. At this facility, parental presence is allowed at induction and in the PACU. Sophia's mother is provided with instructions by the preoperative nurse on what to expect and on her role in the process. When it is time for surgery, Sophia and her mother follow the OR nurses back to the OR suite. Sophia lies down OR table, with her mother holding her hand, and the two sing a favorite song together as Sophia goes to sleep with anesthesia gas administered via a mask, just as Sophia did with her doll at her preoperative visit with the child-life specialist. Sophia's mother is then escorted to the OR waiting room where she and her husband will receive hourly updates from the OR nurse.

After completion of the surgery, it is determined by the neurosurgeon and anesthesiologist that Sophia is stable enough to recover in the PACU. She had minimal blood loss, vital signs were stable throughout the procedure, and she was a healthy child prior to her diagnosis with the posterior fossa tumor. Sophia arrives to the PACU still intubated, and the PACU nurse decides to wait until Sophia is extubated and stable before having her parents present. Sophia is extubated without complication and is reunited with her parents in the PACU. She is pale and drowsy with some facial swelling but overall stable. After approximately 1 h in the PACU, she is transferred to the ICU for continued care. Sophia's parents, while they underwent a very stressful day with their child undergoing surgery for a brain tumor, were overall satisfied by the perioperative experience because of the preparation, high level of communication, and incorporation of their presence in the process.

### Pediatric Practice Pearls

- Include the child in preoperative conversations with the family, as chronologic and developmental age allows.
- A preoperative visit is highly encouraged for the neurosurgical pediatric patient who is high-risk with other comorbidities.
- Preparation of the parent and guidance during the process is key if a parent will be present at induction and/or during the initial recovery period. Remember, patient safety always comes first.
- Make the separation of the child from the family as gentle as possible. Make the trip to the operating room a fun one for the child. Blowing some bubbles and a piggyback ride go a long way toward helping make the child feel at ease!
- Always call the family at the start of the procedure and continue to give them updates at regular intervals. Waiting family members feel very helpless as the care of their child is now out of their control. Regular communication with the family does much to allay their fears.
- If the intraoperative plan of care changes from what has been previously discussed with the family, alert them of the change. Let them know if their wait time will be increased.
- Honesty is always the best policy. If you cannot answer a question, find someone who can!
- Have the family write down any questions they may have so that they can discuss them with the surgeon postoperatively.
- The neurosurgical team and anesthesia provider should make a collaborative decision regarding the initial plan of care for the recovery process. Factors that should be considered when deciding where the patient will initially recover after surgery include the complexity of the neurosurgical procedure, intraoperative occurrences, age of the child, preoperative condition of the child, and other comorbidities.

- After a neurosurgical procedure, close observation and frequent vital sign and neurological assessments should be performed by nurses specifically trained to care for pediatric neurosurgical patients.
- Key complications that nurses and other health-care providers should monitor for in the immediate postoperative period include respiratory dysfunction, bleeding, diabetes insipidus, cerebral salt-wasting syndrome, nausea and vomiting, and pain.

## References

- Association of PeriOperative Registered Nurses (AORN) (2010) Perioperative standards and recommended practices. Association for Perioperative Registered Nurses, Denver
- Burd RS, Mellender SJ, Tobias JD (2006) Neonatal and childhood perioperative considerations. *Surg Clin North Am* 86:227–247. doi:10.1016/j.suc.2005.12.010
- Burke CN, Voepel-Lewis T, Hadden S, DeGrandis M, Skotcher S, D'Agostino R, Walton S, Malviya S (2009) Parental presence on emergence: effect on postanesthesia agitation and parent satisfaction. *J Perianesth Nurs* 24:216–221. doi:10.1016/j.jopan.2009.03.014
- Douglas, M. & Rowed, S. (2005). The implementation of a postoperative care process on a neurosurgical unit. *J. Neurosci Nurs.* 37:329–333
- Fox VJ, Rothrock JC, Vaiden RE (2000) Core curriculum for the RN first assistant, 3rd edn. AORN, Denver
- Furst SR, Sullivan LJ, Soriano SG, McDermott JS, Adelson PD, Rockoff MA (1996) Effects of ondansetron on emesis in the first 24 h after craniotomy in children. *Anesth Analg* 83:325–328
- Hall PA, Payne JF, Stack CG, Stokes MA (1995) Parents in the recovery room: survey of parental and staff attitudes. *Br Med J* 310:163–164
- Hatava P, Olsson GL, Lagerkanser M (2000) Preoperative psychological preparation for children undergoing ENT operations: a comparison of two methods. *Paediatr Anaesth* 10:477–486
- Hockenberry MJ, Wilson D (2009) Wong's essentials of pediatric nursing, 8th edn. Mosby, St. Louis
- Kain ZN, Wang SM, Caramico LA, Hofstadter M, Mayes LC (1997) Parental desire for perioperative information and informed consent: a two-phase study. *Anesth Analg* 84:299–306
- Kain ZN, Caramico LA, Mayes LC, Genevro JL, Bornstein MH, Hofstadter MB (1998a) Preoperative preparation programs in children: a comparative examination. *Anesth Analg* 87:1249–1255
- Kain ZN, Mayes LC, Wang SM, Caramico LA, Hofstadter MB (1998b) Parental presence during induction of anesthesia versus sedative premedication: which intervention is more effective? *Anesthesiology* 89:1147–1156
- Kain ZN, Mayes LC, Wang SM, Caramico LA, Krivutza MA, Hofstadter MB (2000) Parental presence and a sedative premedicant for children undergoing surgery: a hierarchical study. *Anesthesiology* 92:939–946
- Kain ZN, Caldwell-Andrews A, Wang SM (2002) Psychological preparation of the parent and pediatric surgical patient. *Anesthesiol Clin North America* 20:29–44
- Leack KM (2007) Perioperative preparation of the child and family. In: Browne NT, McComiskey CA, Flanigan LM, Pieper's P (eds) *Nursing care of the pediatric surgical patient*, 2nd edn. Jones and Bartlett Publishers, Boston, pp 3–16
- Meeker MH, Rothrock JC (1999) Alexander's care of the patient in surgery, 11th edn. Mosby, Inc, St. Louis
- Phillips N (2007) Berry and Kohn's operating room technique, 11th edn. Mosby, Inc., St. Louis
- Romino S, Keatley V, Secrest J, Good K (2005) Parental presence during anesthesia induction in children. *AORN J* 81:780–792
- Rothrock JC (2007) Alexander's care of the patient in surgery, 13th edn. Mosby, Inc., St. Louis
- Spry C (2005) Essentials of perioperative nursing, 3rd edn. Jones and Bartlett Publishers, Sudbury
- The Joint Commission (2012) Hospital National Patient Safety Goals. [http://www.jointcommission.org/standards\\_information/npsg.aspx](http://www.jointcommission.org/standards_information/npsg.aspx). Accessed on 3 May 2012
- Westcott E, Dunn V (1998) An exploration of the value of specialist neurosurgical nurses. *NT Res* 3:421–431
- Wisselo TL, Stuart C, Muris P (2004) Providing parents with information before anaesthesia: what do they really want to know? *Paediatr Anaesth* 14:299–307
- Wollin S, Plummer J, Owen H, Hawkins R, Materazzo F, Morrison V (2004) Anxiety in children having elective surgery. *J Pediatr Nurs* 19:128–132

Theresa M. Gabay, Jennifer A. Disabato,  
and Teresa Schultz

## 14.1 Introduction

Many children are now able to survive into adulthood with conditions that only a few decades ago lead to early demise. Nurses are now seeing these children grow into productive adults. This chapter reviews the current state of transition care in the United States, and recently published evidence about the challenges and proposed models. There are examples of how healthcare providers are handing patients off to the adult care system. Several national experts have contributed to this chapter that provides an overview, current recommendations and identifies the nurses role in this complex issue.

---

T.M. Gabay, RN, MSN, APN-BC, CNRN (✉)  
Department of Pediatrics and Neurosurgery,  
The Joseph M. Sanzari Children's Hospital  
at Hackensack UMC, Hackensack, NJ, USA  
e-mail: tgabay@advancedneurosurgeons.com

J.A. Disabato, DNP, CPNP-PC, AC  
Women, Children and Family Health,  
University of Colorado, Anschutz Medical Campus,  
College of Nursing, Aurora, CO, USA  
e-mail: jennifer.disabato@ucdenver.edu

T. Schultz, RN, MSN, CPNP-PC, AC  
Department of Neurosurgery,  
Gillette Children's Specialty Healthcare,  
St. Paul, MN, USA  
e-mail: tschultz@gillettechildrens.com

### Vignette

Natalie is a 21-year-old female who you have seen in your neurosurgical practice for several years. She will be 22 years old in 2 months, and you, like her parents, are thrilled with her achievements. She recently graduated high school and wants to work in her family business and attend college part-time.

These are significant milestones for someone who was born at 28 weeks gestation, survived an intraventricular hemorrhage as a neonate, and has endured despite her shunted hydrocephalus, cerebral palsy, seizures, and spasticity. Her current health care providers are her pediatrician, pediatric neurologist, pediatric gastroenterologist, and pediatric orthopedist. Her mother confides in you that she has not addressed who will care for Natalie once she reaches her next birthday, stating:

I don't know what we will do if she has a shunt malfunction. I know the neurosurgical team will see us, but we will have to go to the adult ER and can't stay in the PICU like we always do. I really need to find a primary care doctor (PCP) who is here at this hospital, knows how to care for her and help us find the specialists Natalie will need to keep her well.

The transition from adolescence to adulthood is challenging for any youth. The psychological, behavioral, and social growth that occurs during this stage of life allows for gradual assumption of personal responsibility and independence (Mennito and Clark 2010). For the majority of adolescents, the transition is successful when they are productive and meaningfully engaged in society (Park et al. 2011). This is different for each individual but is often measured by financial independence, gainful employment, and the ability to care for oneself. For youth with special needs, transition into adulthood is at best challenging, if not often impossible. Many will continue to live with their families and have significant limitations of cognitive, psychological, and social skills.

What will eventually occur, despite these limitations, is the transition to adult health care providers. It is an expected and desired outcome of pediatric care in the general adolescent population that usually occurs in a smooth fashion. For those who have multiple medical issues, however, transfer of care is more complicated.

With the advances in health care over the last three to four decades, there has been an increase in the survival of children with chronic childhood-onset diseases. It is estimated that each year, 500,000 children with special health care needs (CSHCN) will transition to adult practitioners (Mennito and Clark 2010). Those with neurosurgical and neurological disorders that persist into adulthood are significant in numbers and encounter frequent and multiple barriers to adequate care once they have “aged out” of pediatric services (Vinchon and Dhellemmes 2007; Camfield and Camfield 2011). For the diagnosis of hydrocephalus alone, it is predicted that the number of young adults between the ages of 18 and 35 that will need treatment in the United States will exceed 40,000 annually in the next two decades (Simon et al. 2009).

Young adults with spina bifida, hydrocephalus, and childhood neoplasms of the central nervous system are now commonly seen in neurosurgical practices. In many of these patients, even though the initial disorder is well controlled or stabilized during childhood, problems commonly arise during the aging process. For the spina bifida patient, premature degeneration of the spinal cord can result in

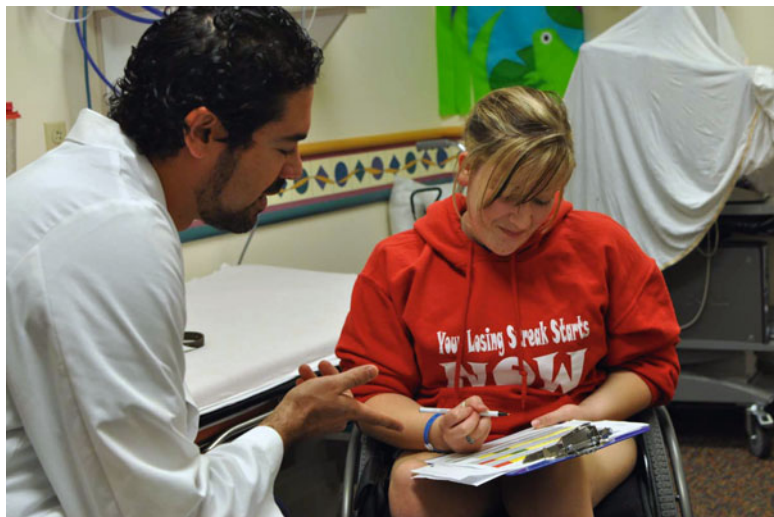loss of function such as walking. In patients with hydrocephalus, endoscopic third ventriculostomy and shunt devices have been known to fail with aging. Lastly, in children with tumors of the brain or spine, delayed sequelae from treatment (new brain lesions or cognitive effects after radiation therapy) can surface or intensify in later years (Vinchon and Dhellemmes 2007).

Chronic neurological disorders starting in childhood can also have progressive symptoms and a greater impact on the individual as they age. Patients with cerebral palsy often have significant deterioration of mobility and increased pain as adults. Epilepsy presents many new challenges in adulthood including social isolation, unemployment, and depression. The developmentally delayed or autistic child can become increasingly difficult to manage over time for aging parents and care providers who have little resources or new therapies to offer (Camfield and Camfield 2011).

As children began to survive diseases that they once previously died from prior to the 1970s and 1980s, it became apparent to the United States and the rest of the world that there were service disparities among adolescents and young adults with special health care needs (Slap 2009). This was attributed to various factors: individual state policies, institutions, insurance coverage, training of care providers, and patient and family issues. In 1984, Surgeon General C. Everett Coop cohosted the first national invitational conference that focused on the needs of older adolescents who had chronic or disabling disorders. This led to a subsequent Surgeon General conference in 1989: “Growing Up and Getting Medical Care: Youth with Special Health Care Needs (YSHCN)” (Blum 1995). It established a national agenda for training, research, and program development with a goal of establishing a health care system allowing for seamless transition of care for YSHCN.

Additionally, both the Individuals with Disabilities Act (IDEA) of 1997 and *Healthy People 2010* (Mennito and Clark 2010) included specific standards for YSHCN. They stipulated that these individuals receive services that will result in successful transition not only in health care but also in all aspects of adult life including education, work, and independent living.

**Fig. 14.1** 16 years old participates in planning her next follow up visit in a spina bifida transition clinic



### 14.1.1 2002 Joint Consensus Statement on Transition

Supported by the Maternal and Child Health Bureau (MCHB) of the US Department of Health and Human Services, a joint consensus statement coauthored by the American Academy of Pediatrics (AAP), the American Academy of Family Physicians (AAFP), and the American College of Physicians (ACP)-American Society of Internal Medicine was published in 2002. The goals of the policy statement were to ensure that by the year 2010, all physicians who provide primary or subspecialty care to YSHCN understand the rationale for transition from child-oriented to adult-oriented health care, have the knowledge and skills to facilitate that process, and know if, how, and when transfer of care is indicated (AAP et al. 2002).

Transition medicine is defined as a coordinated and deliberate process of movement of the patient from pediatric-centered care to adult-oriented care, thereby optimizing his/her ability to assume adult roles and responsibility (Mennito and Clark 2010). The statement has outlined six critical steps to achieving this goal: (1) find a health care professional who assumes responsibility for current and future coordination (medical home); (2) obtain mandatory transition training for primary care physicians; (3) create a medical summary that is current and accessible; (4) write a transition plan by 14 years of age, prepared jointly

by the health care provider, patient, and family; (5) adhere to adolescent preventive care guidelines; and (6) have continuous health insurance that compensates for transition planning and care coordination (AAP et al. 2002). These steps remain the standards that give rise to pilot projects, practice models, and national initiatives to improve the transition of YSHCN.

In 2005, the AAP issued a subsequent policy statement recommending that primary care physicians provide a “medical home” for children with special needs (Slap 2009). Recognizing the uncoordinated care that often precedes transition, the pediatrician is central to this model of delivering primary care that is accessible, comprehensive, coordinated, continuous, family centered, and culturally effective (Labhard 2010).

### 14.1.2 2005/2006 National Survey on Transition

To assess state and national progress toward meeting the core outcomes for transition for YSHCN, the MCHB developed and funded two national surveys. The first was conducted in 2001 and focused on assistance with health care and educational/vocational planning for youth 13 years and older. Performance on meeting the medically related outcome was low, at 15 %, and the bureau felt that the educational and vocational components were not applicable to all CSHCN.



The subsequent survey in 2005/2006 was restructured to specifically evaluate parental discussions with their child's PCP regarding transition. Nationwide, random phone surveys were conducted to identify caregivers who had a CSHCN, and 18,198 respondents with youth 12–17 years of age were identified. In addition, a referent sample of 1,862 children without special health care needs was used for comparison.

There were four components assessed through the survey, and all had to be met for the youth to meet the overall transition core outcome. The first three were based on discussions that parents/caregivers had with the child's PCP regarding (1) shifting care to adult providers, (2) future adult health care needs, and (3) change in health insurance. The last component measure, (4) encouragement by PCP for child to take responsibility for his/her own care, was based on parent perception.

Overall, 41 % of the YSHCN met the transition core outcome, but there was variation in meeting each of the components. Shifting to an adult provider was discussed 42 % of the time. This question was eliminated if the child's PCP was a family care provider versus a pediatrician. Discussions about the youth's adult health care needs occurred per 62 % of respondents. The most consistently met component (78 %) was encouragement by the current provider for the child to take responsibility for their health care. Discussions regarding upcoming changes to health care insurance had the lowest score at 34 % (AAP et al. 2002). It was considered that because the YSHCN in the survey were 17 years old or less and public or private programs usually cover children until 21, this topic was not as urgent as others (Lotstein et al. 2009).

Some factors related to a lower likelihood of meeting outcomes were lower socioeconomic populations, non-Hispanic black or Hispanic race/ethnicity, living in a non-English-speaking home, and male gender. Additionally, the children most impacted by their health issues and who did not have a medical home or were uninsured also fell short of meeting the outcome criteria. The significance of this data is that these are the groups that have had difficulty in navigating complex health care systems in previous research and are most often dependent on consistent access

to medical services. As a result of this survey, addressing these disparities has become a high priority (Lotstein et al. 2009).

Interestingly, the referent sample (children without special health care needs) had similar rates of meeting the transition core outcome. The core components had a slight increase for the referent group in the area of changes to health insurance and encouraging responsibility for health care needs by providers (AAP et al. 2002).

Although there were some limitations to the survey, including lack of parental awareness of discussions the PCP had directly with the child and satisfaction the youth and family had regarding the discussions, this survey identified gaps in the transition process. Efforts by federal government agencies, such as the MCHB and Social Security Administration, and private and public insurers have focused on preparation for transition for all youth, with or without special care needs (Lotstein et al. 2009).

### **14.1.3 2008 AAP Report on the State of Transitions**

Progress on the initiatives set forth by the 2002 consensus statement has been reported by the American Academy of Pediatrics. Included was a current literature review, parallel initiatives, and active programs targeting the transition of care for YSHCN. One of the most important findings that came out of the report was that despite the vested interest of the medical community effecting change on this subject, there was a lack of evidence-based data regarding best practices (Mennito and Clark 2010).

### **14.1.4 Literature Focused Broadly on Care Transition for Children and Youth with Special Health Care Needs (CYSHCN)**

A comprehensive systematic review and analysis of 43 transition studies published from 1982 to 2003 authored by Betz and Redcay (2003) summarized 26 descriptive studies: 12 focused on program outcomes and 4 on tool development.

Eighteen studies reported on transition barriers, including lack of institutional support, limited resources and clinical guidelines, lack of financial reimbursement, and poor communication between providers. Nearly 63 % of the studies recommended transition service strategies for success. Primary among them was the need for a coordinated, organized process and increased community resources. Disease-specific education was noted as an important component of transition planning in 15 studies. Self-management, an indicator of self-sufficiency, was reported in 9 studies, and programs to aid in self-determination were listed as important in 10 studies. This systematic analysis reveals that program development for transition services is in the early stages, and there is little information on actual transition interventions with regard to objectives and frequency, timing, and number of provider encounters. In summarizing the review, Betz suggests that future work be based on substantive conceptual frameworks, exploring the use of reliable and valid instruments, and the evaluation of larger samples (Betz 2004).

---

## 14.2 Barriers to Successful Transition

### 14.2.1 Patient and Family

Transition is a process that takes time, especially when the adolescent has special and complex medical needs. Although the plan should be addressed at 14 years of age (AAP et al. 2002; Sanders et al. 2009), families have difficulty conceptualizing their adolescents as eventual adults. For parents of a child who is significantly disabled, care has been a full-time job (Rekate 2009). Many have long-term, intimate relationships with their pediatric providers and do not want to leave (Woldorf 2007). There is trust, familiarity, and perceived lack of knowledge and experience of adult-oriented health care providers (Mennito and Clark 2010).

Additionally, adult care rarely engages the entire family which is conversely basic to child-centered care. The “adult culture” is disease-focused with the expectation of independence of

patients, whereas the “pediatric culture” is attentive to the needs of the patient within a family system (Mennito and Clark 2010). This may make parents feel that they will be excluded from the decision-making process and lead to further reluctance for transition (Binks et al. 2007).

Caregivers who have a low level of expectation for YSHCN will often have impact on the youth’s self-image, motivation, self-determination, and ability to manage responsibly. If parents have difficulty envisioning successful attainment of generic skills needed to be a responsible adult, they will put off the transition process. Retention in a pediatric-oriented health care system sends the message that adolescents with a disability are incapable of being adults and effects how they are viewed by society (Ried 2010).

Some of the barriers for patients to attain successful transition include the patient’s developmental level, type and complexity of medical and mental health issues, family dynamics, family resources, and reluctance to take responsibility or “grow up” (Woldorf 2007). These barriers can therefore impact the youth’s ability to acquire skills in the areas of self-care, health care decision-making, and self-advocacy that are needed to become responsible and independent (Sawicki et al. 2011).

Sawyer and Aroni provide insight into self-management in adolescents with chronic illness and emphasize that the age group is generally focused on the present, even when made aware of implications of current health decisions on future health status. It is important that the adolescent be the informant of their own health care needs. “The developmental approach to these competing views provides an understanding that young people learn by doing, which at times means learning from their mistakes” (Sawyer and Aroni 2005). Rather than advocating specific rules for success, they suggest that providers should reflect and practice techniques to promote self-management in a developmental framework.

There are many children with neurological diseases that have significant cognitive impairment. They may never have the ability to become responsible for themselves on any level and generally remain under the care of their families. For this group of youth, their clinical condition precludes them from participation in the

transition process. For others, there are various levels of cognitive function and ability as they mature. Having an environment that fosters function and social independence as much as possible despite the challenge of a disability is paramount (Ried 2010).

Adolescents with neurological and neurosurgical issues, not unlike any other YSHCN, often have the same issues as their developing peers. They may have low self-esteem, feelings of inadequacy about their bodies, and experience social isolation (Labhard 2010). These may be magnified, especially in a youth who has spina bifida or spinal cord injury or has frequent seizures. Medical self-care (intermittent bladder catheterizations, taking medications, etc.) is not a priority but a nuisance to the teen and further separates them from their peers (Labhard 2010). In addition to asking the YSHCN to assume responsibility for their care, this is also the time they are asked to eventually leave the medical team that has come to know and accept them. This can add to their feelings of rejection and isolation (Binks et al. 2007).

#### 14.2.2 Primary and Specialty Care Providers

Just like the child's parents, the pediatric health care provider often has difficulty in "letting go." Pediatric providers frequently develop mutually satisfying long-term relationships with their patients characterized by a high level of trust by the patient and parents. This extensive history with the patient and family results in a cultivated professional and social relationship (Woldorf 2007). Additionally, pediatricians have a vested interest in the child with complex medical needs after many years of involvement in various aspects of care. Transition can therefore be emotionally discomforting for the provider as well as the patient/family. Many medical professionals, psychiatrists, for example, receive training in termination of patient-provider relationships. Historically, pediatric-trained providers do not.

Patterns of interaction during pediatric care encounters are established early on and are generally geared toward parental needs (Callahan

et al. 2001). Adaptations to the adolescent patients' growing independence need to be intentional on the part of the provider. This can be difficult to achieve in a busy clinic environment when the patient and parent are comfortable with the current patterns and have not been asked to think about transition until it is imminent.

System challenges in the pediatric setting include both a lack of resources to coordinate and communicate information about care transfer and a clear written procedure or pathway to follow. Each professional may address a specific aspect of transition care, but no one individual is responsible for follow-up and coordination. Health insurance coverage issues, identifying adult providers available to assume care, and completion of legal documents for guardianship of patients who are unable to manage their own affairs are other very important tasks necessary for successful transition (Jurasek et al. 2010).

Often, there is a sense of distrust of the ability of adult care providers to manage patients with childhood diseases by pediatric providers (Binks et al. 2007; Woldorf 2007). In a national survey that evaluated physicians' views on barriers to primary care in YSHCN (Okumura et al. 2010), 62 % of pediatric providers thought that it would be difficult to find an internist that would care for a young adult with a childhood-onset disorder. Additionally, adult care is often fragmented and lacks the multidisciplinary team approach that young adults with disorders like spina bifida or cerebral palsy desperately need (Binks et al. 2007).

On the receiving end, adult care providers often have limited training, knowledge, and experience (and sometimes limited interest) in caring for young adults with childhood disease processes (Binks et al. 2007). In a national survey published by Okumura and associates (2010), 24 % of general internists reported lack of training as a significant barrier to caring for young adults with special health care needs (ASHCN).

A telephone survey of 1,236 US physicians regarding perceptions of their preparation and its impact on the attitudes toward adults with chronic illness found that most physicians reported inadequacy of training in ten chronic illness

competencies. These include chronic pain, developmental milestones, psychosocial issues, patient education, assessment of caregiver needs, and interdisciplinary teamwork. Compared with internists, family practice physicians were more likely to report sufficient training in seven of the ten competencies ( $p < .05$ ). More training had a positive influence on attitudes toward care of the chronically ill. The authors conclude that, given the increasing number of individuals with chronic illness in the United States, modifications in medical residency training are needed to better prepare physicians (Darer et al. 2004).

In a random two-phase mail survey of internists done by the American Board of Medical Specialties, 134 respondents listed concerns that the authors placed into six categories: patient maturity, psychosocial needs, family involvement, provider competency, transition coordination, and health system issues. In the second phase of the survey, 65 providers cited lack of training in congenital childhood-onset disorders, lack of training in adolescent needs, financial pressures limiting time, and families' high expectations as some of the most important issues and barriers (Peter et al. 2009).

Noted by Camfield and Camfield (2011), there are many types of chronic neurological disorders starting in childhood that have anticipatory issues in adulthood. Some disorders are static or manageable in childhood, cerebral palsy and neurofibromatosis, for example, but become progressive with more serious manifestations as a natural course. Brain tumors may have been cured in childhood, but the young adult may have late effects from chemotherapy and radiation treatments, including new malignancies, intractable epilepsy, and cognitive deficits. Children who have significant developmental delays are often more difficult to manage as adults. Consider the child with severe autistic disorder who has limited communication and may have some aggressive behaviors. These examples illustrate just some of the challenges in assuming care of young ASHCN.

In the adult specialty setting, providers may be allotted less time per patient and need to quickly become familiar with a lengthy medical history, as well as copious, potentially incomplete medical

records sent from the pediatric facility. Hence, the initial visit may occur with the provider lacking a full picture of the patient's neurological/neurosurgical disease course, general health status, social situation, and quality of life. They also begin their relationship with a patient who is often unaware of what to expect regarding the new provider-client relationship and the adult care system. There is clearly a need for a period of adjustment and more proactive patient assistance during this time (Callahan et al. 2001; Tuffrey and Pearce 2003).

Some additional factors facing adult providers noted by a work group at Children's Hospitals and Clinics in Minnesota (Berkowitz 2009) were time constraints and lack of resources. Many adult providers' salaries are productivity based. The more time spent with a patient, the less they earn. ASHCN most often require longer than the average 15-min appointment. A busy office practice schedule would need to be adjusted to accommodate these types of patients. In general, internists do not have availability of care coordinators or social workers. These resources would be beneficial to ASHCN who are frequently complex and have many concomitant medical and psychosocial needs. A key to the perception of high-quality chronic illness care was improved office-based support, which allows improved coordination with subspecialists and other resources (Okumura et al. 2008).

### 14.2.3 Environment

During the 2008 American Society for Pediatric Neurosurgeons (ASPN) meeting, members in attendance were polled about views and practices regarding transition of their patients (Rekate 2009). One of the demographics components was practice facility. Of the responders, 78 % practiced in free-standing children's hospitals where they could not continue to care for patients once they reached a certain age of maturity. This was usually at 18 or 21 years old. For the remainder of the respondents, the neurosurgeon practiced in a children's hospital within a larger hospital or in a general facility with

pediatric units. Although 89 % of the hospitals took patients greater than 18 years of age, only 44 % took patients over 21 years of age.

For YSHCN, the majority will receive care in an adult facility once they mature. The patient and family may find themselves suddenly in unfamiliar surroundings. These facilities tend to focus on the patient and treating disease rather than the family and holistic-approached care. Additionally, hospitals that primarily serve adults may not have the equipment or resources to care for a patient that is 26 years old, yet has the developmental ability of a toddler and weighs 20 Kg (Berkowitz 2009).

Goodman and associates (2011) analyzed data on patients hospitalized in 30 academic children's hospitals over a 10-year period. The growth rate of admissions/discharges was examined for three age groups: pediatric (<18 years old), transitional (18–21 years old), and adult (>21 years old). Although individuals above the pediatric age group were a small portion of inpatients within these facilities, this amounted to thousands of "adults" annually. These groups had higher numbers of inpatient days, disproportionately higher charges, and were more frequently readmitted than their pediatric counterparts. Over the course of the study, admissions of patients aged 18–21-years old increased steadily and disproportionately to increases in pediatric populations. This led to the prediction that both transitional and adult groups will continue to increase in numbers in years to come. Another review auditing admissions to the Royal Children's Hospital in Australia over a 10-year period saw annual admissions of young adults >18 years of age more than double (Lam et al. 2005). Contributing factors were thought to be complexity of disease of these patients and the failure of transition planning for adult care.

#### 14.2.4 Insurance

For children with chronic health care needs, health care cost coverage is provided by a spectrum of payment systems. Many have state or

federal coverage with the remainder under private insurance or charity care (Simon et al. 2009). State Title V programs vary from state to state and may limit coverage until 21 years old. Those who have state Medicaid may be terminated at 18 years old. Some adults may qualify for SSI and full Medicaid benefits based on disability and financial criteria (Sanders et al. 2009). Private insurance companies must allow children to stay on their parents' plans up to 26 years of age due to recent legislation changes in the United States.

For adolescents and young adults with medical coverage, transition to an adult provider may be limited to providers that will accept these payment programs (Sanders et al. 2009). Additionally, there is no obligation on the part of private payers to continue covering services at a pediatric facility when they could be rendered at a contracted adult-based hospital (Simon et al. 2009). The same holds true for specialist providers, including neurosurgeons and neurologists. For adolescents and young adults without coverage, care often needs to take place in the area's primary care center or local health department utilizing charity care programs.

#### 14.2.5 Health Information and Records

Children who have long-standing neurosurgical and neurological disorders can have extensive medical records. It is not unusual for them to have various health care providers over the years and in multiple geographic locations. Although the current pediatrician and neurosurgical team has a good handle on the child's medical history and events, adult providers assuming care will have a daunting task of familiarizing themselves with the patient who comes with boxes of records. Furthermore, the Health Insurance Portability and Accountability Act limits the sharing of personal medical information with the parents. In the absence of a durable medical power of attorney or permission by the individual, requests for medical records and information must be made by the patient rather than a parent (Rekate 2009).

### 14.3 Programs, Clinics, and Care Models

#### 14.3.1 Care Model: The Medical Home

The “medical home” is a care model to ensure the delivery of quality, comprehensive, and cost-efficient health care services. First on the list of the six critical steps to transition to adult care, the American Academy of Pediatrics (AAP) supports providers in establishment of this model for their patients through websites, literature, and formal training opportunities (AAP website, [www.medicalhome.org/](http://www.medicalhome.org/)). The highlights of this model include (1) family-centered partnerships: care that recognizes that the family is essential to the child’s care and is a constant in their life; (2) community-based systems: family-centered, coordinated care networks that promote well-being and development for all youth and their families; (3) transitions: continuous health care services across the continuum of pediatric to adult care; and (4) value: appropriate funds that support and sustain the medical home (Duke and Scal 2011).

There are three distinct processes of the medical home that are interrelated but central to this model: preventative care, acute illness management, and chronic condition management. For patients with complex medical needs, there may need to be comanagement of certain aspects of care. The primary care physician, in conjunction with various specialists, will work with the patient and family to ensure complete and continuous care (AAP Clinical Report 2011). It is this unique partnership between the family unit and health care professionals that will be instrumental in developing an individualized transition plan. Furthermore, the process and timing of transition to adult primary care and specialists should follow the algorithm included in the Clinical Report by the AAP on Medical Home Transition, 2011 (Table 14.1).

The above-referenced clinical report and algorithm reflect the latest guidelines and recommendations on transition of all adolescents to adult health care but has an expanded component

addressing those with special and chronic health care needs. This important initiative is led by the AAP Council on Children with Disabilities (COCWD) and funded by the National Center for Medical Home Implementation (a cooperative between the AAP and MCHB) as well as the COCWD. The ultimate goal is to provide assistance for medical home providers and their patients and families to ensure a smooth transition to adult care practitioners through the advancement of practice-based processes, including planning, decision-making, and documentation. Additionally, it provides a structure for training, research, and continuing education so that “best practice” for transition can be established and shared among other providers (AAP Clinical Report 2011).

The pediatric primary care medical home should establish office policy regarding transition for all adolescents as recommended by the AAP guidelines. By doing so, the policy can be addressed at the appropriate ages and a plan for transition established based on the individual’s needs. This is helpful as each provider in the practice can follow and adjust the plan as needed and document steps followed and goals achieved. Assessing readiness of the patient and family to proceed with the tasks of transition is the responsibility of the medical home.

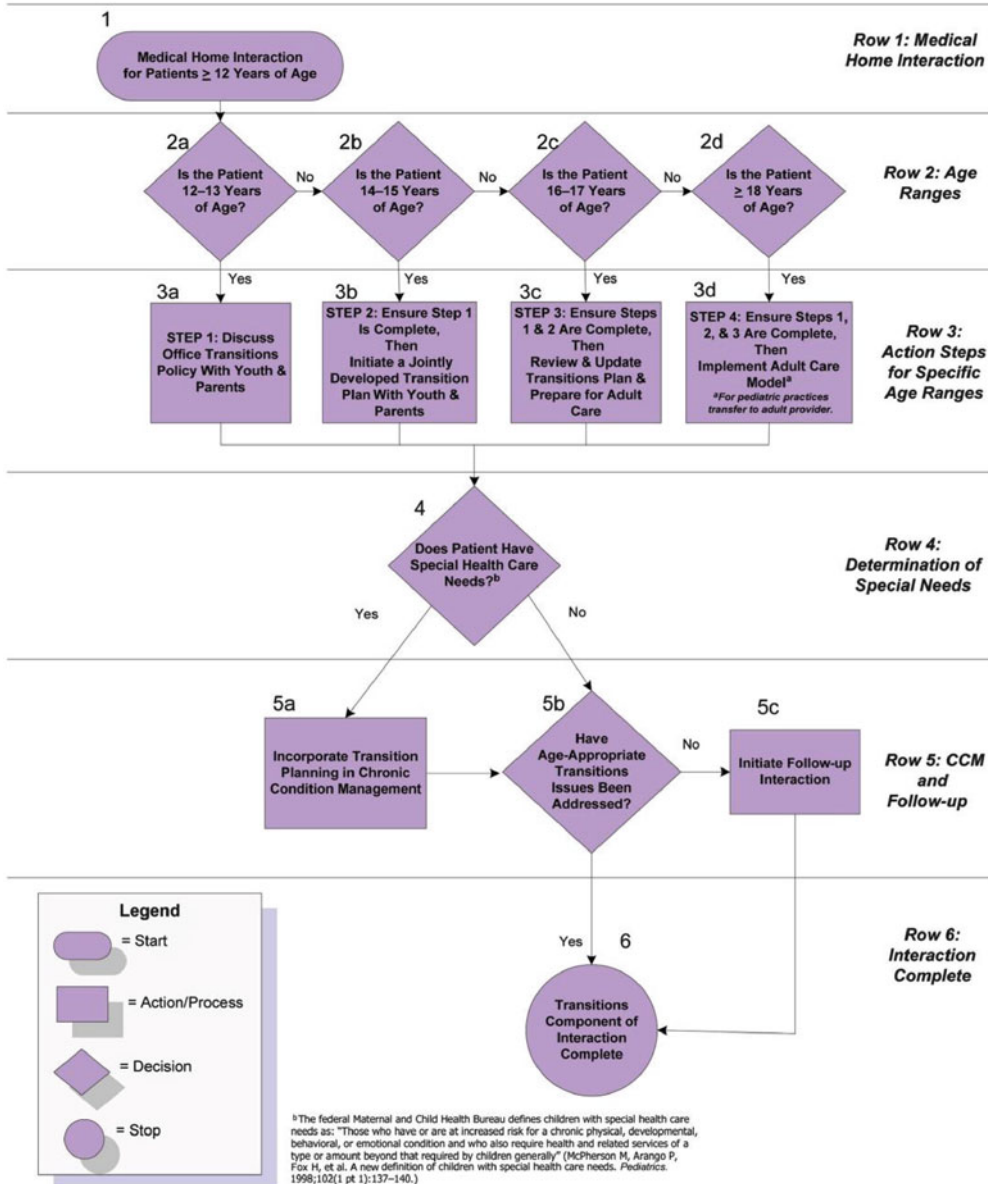
Although the provider, patient, and family are always core members of the “transition team,” the receiving provider and other medical subspecialists (pediatric and adult) will need to be intimately involved in the process for YSHCN. This may result in many clinical challenges for the medical home. Stated previously, adult providers have verbalized their inexperience and lack of education as a barrier to care of ASHCN. In addition, the lack of adult medical subspecialists, financial incentives, and care coordination support has also been cited. Often, even with the best planning and attention to the transition process, ASHCN may end up with “ad hoc” medical care due to system barriers that impact the adult medical home care model.

It is consistently documented in the literature how fragmented care and lack of a designated

**Table 14.1** Health care transition planning algorithm for all young and young adults within a medical home interaction


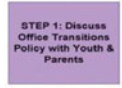
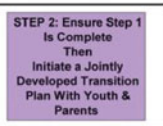

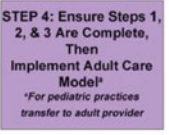





FROM THE AMERICAN ACADEMY OF PEDIATRICS

### Health Care Transition Planning Algorithm for All Youth and Young Adults Within a Medical Home Interaction



APPENDIX 1

Table 14.1 (continued)

		<p>7. Initiate first step in the health care transition planning process at age 12.</p>	
<p>Is the Patient 12-13 Years of Age?</p> <p>Is the Patient 14-15 Years of Age?</p> <p>Is the Patient 16-17 Years of Age?</p> <p>Is the Patient ≥ 18 Years of Age?</p>		<p><b>2a, 2b, 2c, 2d. Age Ranges.</b> By age 12, conduct surveillance to assess any special health care needs. Start actual transition planning by age 14. By ages 16-17, transition planning should be well established. At age 18, initiate an adult model of care for most youth, even if there is no transfer of care. If transition planning does not occur on the schedule described by the algorithm, a concentrated effort is required (eg, special visits) to successfully complete the process.</p>	
<p><b>3a.</b> Every practice should have a written transition policy that is prominently displayed and discussed with youth and families. The policy should explicitly state the practice's expectations and care process for the health care transition of their adolescent patients to an adult model of care.</p>			
	<p><b>3b.</b> The practice should utilize a standard transition plan that can be adapted for each patient's needs. This tool should include components to obtain an accurate assessment of the patient's ability to successfully transition. Providers should interview youth and family members to identify needs and to assess the intentions and motivations for youth independence.</p>		
<p><b>3c.</b> Transitions plans must be reviewed regularly and updated as necessary. The provider must also perform surveillance for changes in the youth's medical status and address youth and family concerns that may warrant changes in transition goals. Failure to achieve transition readiness goals warrants reevaluation of the existing plan, and increased frequency of medical home interventions/visits. A "pretransfer" visit to the adult medical home could be conducted during the year before the transfer.</p>			
 <p><i>*For pediatric practices transfer to adult provider</i></p>	<p><b>3d.</b> Transition to an adult model of care occurs appropriate for youth's developmental level. This is followed as appropriate by transfer to an adult medical home. Complete medical records should be delivered to the adult provider, along with a portable summary, which is also provided to the patient or guardian. For children and youth with special health care needs, direct communication between pediatric and adult providers is essential, as adult medical personnel may be unfamiliar with certain pediatric conditions.</p>		
<p><b>4.</b> Transition planning for children and youth with special health care needs should include specific chronic condition management (CCM) activities such as: use of registries; care plans; care coordination; CCM office visits; and comanagement with medical subspecialists. Transition goals must be individualized to account for variations in the complexity of a youth's condition and in the youth's intellectual ability and guardianship status.</p>			
	<p><b>5a.</b> Youth with special health care needs require an expanded transition planning process. Transition planning in CCM includes addressing the exchange of complex health information; competencies for self-care; transfers of specialty care; and issues related to insurance, entitlements, guardianship, and eligibility for adult services. In a medical home, such youth may have a written care plan as part of the medical record. At age 14, this plan should include a section titled "transition plan," which should be expanded and developed as the youth approaches age 18 and beyond.</p>		
<p><b>5b.</b> Use of transition planning tools and readiness checklists facilitate the provider's ability to ensure that all age-appropriate transition issues have been addressed. Each action step must be completed in order, even if this means the provider has to schedule specific visits to initiate and complete steps missed earlier in the process in order to catch up before the next visit.</p>			
	<p><b>5c.</b> Focused tasks involving little detail or complexity can be addressed by the medical home care coordinator, medical provider, or other appropriate staff through telephone or electronic media. More complex issues may necessitate face-to-face office visits.</p>		
<p><b>6.</b> The provider is finished with the transition tasks for that specific interaction or visit; transition planning is an ongoing activity that occurs at every interaction.</p>			

APPENDIX 1 CONTINUED



**Table 14.2** Examples of tools available to healthcare teams for the transitioning patient

Organization	Key components of tool
Adolescent Health Transition Project (AHTP) Washington State	Notebook “Working Together for Successful Transition” (Washington State Adolescent Health Transition Project 2006) Self-assessment tool: medical needs, independent care, need for assistance Health history summary tool “What’s the plan?” office visit tool
Epilepsy Foundation of Metropolitan New York	Transition planning packet (Epilepsy Foundation of Metropolitan New York 2008) Includes tool “Transition Checklist/Readiness Assessment” Completed by youth and reviewed with primary care provider
Florida Department of Health Children’s Medical Services	Health care transition guide “When You’re 18, You Are in Charge of Your Health” 30-page booklet (Reiss 2009) Utilizes photos, quizzes, and self-assessment tools focus on medical and nonmedical rights/responsibilities of adulthood Definitions, websites, and resources included Tool for talking to health care providers: “Give information, Listen and learn, Ask, Decide, Do (GLADD)”
FloridaHATS: Collaboration of Florida Department of Health Children’s Medical Services, Florida Developmental Disabilities Council, and other partners	Comprehensive website that includes: Web-based training tools that provide continuing education credit to health care providers/teams Directory of available services for youth and their families Extensive resources and web links providing information on various topics

coordinating provider have led to inadequate follow-up (Kaufman et al. 1994; Buxton and Punt 1998). For example, in the United Kingdom where there is universal health care, it is estimated that up to two-thirds of patients with shunts older than 16 years of age go without routine assessment of function (Tomlinson and Sugarman 1995). Multiple anecdotes of patients suffering probable, preventable morbidity and mortality are noted in the literature. In the United States, as mentioned earlier, young adults outgrow state and federal health care support, have significant difficulty in obtaining any public or private reimbursement plans, and also face the same issues in obtaining consistent monitoring of their chronic neurosurgical conditions.

Furthermore, the lack of a family-centered care (FCC) philosophy in the adult world has led to delay or omission of care, unmet health care needs, and unmet needs for family support services (Duke and Scal 2011). Keeping the family in the loop of care for young ASHCN, increased medical reimbursement, and training of

medical-pediatric providers are current and future goals for advancement of the medical home.

### 14.3.2 Established Programs for Transition

The need for effective tools and models to support transition care for youth with special health care needs (YSHCN) has been addressed over the last several years by individual state health departments, specialty organizations, and institutions with varying degrees of detail and available resources. Table 14.2 shows examples of tools that have been developed.

### 14.3.3 Clinic Models

Although uncommon, there are several programs in the United States that provide comprehensive care to youth and young adults with special health care needs (YASHCN). Some focus on the transitional

**Table 14.3** Examples of care models for the transitioning young adult with disabilities

Program	Patient population	Core principles
Gillette Lifetime Specialty Healthcare	Youth into adulthood	Team approach clinic: pediatric and adult primary care and subspecialists involved based on individual need
Gillette Children's, St. Paul, MN	Childhood-onset disabilities Specialties: spina bifida cerebral palsy neuromuscular	Goal: continuum of care through adulthood Provide education on potential health risks, preventative measures, personal care, sexuality Hands-on life skills (cooking, cleaning, etc.) Inpatient component of care: adult unit utilizing Lifetime Specialty providers to manage adult-onset medical issues (hypertension, diabetes, pregnancy)
Primary Children's Medical Center Salt Lake City, UT	Youth into young adulthood Childhood-onset disabilities Specialty: hydrocephalus	Team approach clinic: medicine-pediatric-trained providers in addition to traditional internists and pediatricians Utilizes surgical and medical subspecialists as needed Goal: eventual transition to adult providers without specific age determinant Strong support services component (mid-level practitioners, nursing, social work) and outpatient services (psychiatry, physical therapy, nutrition) Significant focus as educational environment for generalists to gain experience with childhood-onset disease processes
JaxHATS Jacksonville, FL	Ages 16–26 years Chronic medical or developmental disorders Limited to populations in surrounding counties	Determination of individual need through intake information packet Development and implementation of transition plan Goal: ongoing assessment with end result of transition to adult services before age 26

process with an endpoint of complete transition to adult providers. Others will actually provide care throughout childhood into adulthood. Table 14.3 provides highlights of program examples.

#### 14.3.4 Physician Training: WISHES

As mentioned earlier in this chapter, one of the barriers to comprehensive care of ASHCN is the lack of knowledge and training that internal medicine residents receive during their educational years for this population. The 2002 Joint Consensus Statement included the recommendation for primary care provider education on transition processes. To address this mandate, Patel and O'Hare (2010) created the Working Initiative for Special Health Education Services (WISHES) curriculum. The goals of this program are (1) to create and administer a health curriculum

pertinent to YSHCN, (2) to train internal medicine and pediatric residents as care providers for YSHCN and educate health care professionals about the importance of transitions to adult care, and (3) to facilitate the transition of YSHCN from pediatric to adult providers.

These goals are actualized utilizing several strategies. Participation in formal joint conference series with disease-specific transition presentations and core seminars on advocacy are expectations of both residency programs. Additionally, all residents work with patients in inpatient and outpatient settings, focusing on some of the chronic, life long conditions such as spina bifida, cerebral palsy, autism, and epilepsy. There is also a training program for ancillary health care professionals that is linked to this curriculum.

Although this program is in its early stages of implementation, future goals for WISHES are

evaluation of effectiveness of the current training and expansion of existing successful components to a national level.

#### 14.4 Special Considerations for Transition of Pediatric Neurosurgery Patients to Adult Care

Transition to adult care providers is a process that takes several years in the best of circumstances, and stakeholders (patients, families, and providers) still may face significant barriers for success. For YSHCN, specifically those with childhood neurosurgical issues, obstacles that are unique to this population have been identified in current literature (Vinchon and Dhellemmes 2007; ReKate 2009).

First, the spectrum of neurosurgical disease in children is different from their adult counterparts. The clinical significance of certain brain insults, such as arachnoid cysts and subdural hematoma, tends to be more dramatic and requires neurosurgical intervention in pediatric patients (Vinchon and Dhellemmes 2007). There is a high incidence of hydrocephalus and other congenital disorders in this population (spina bifida, tumors, and perinatal trauma of the CNS). These diagnoses collectively have been examined in many series concerning transition (Ried 2010; Simon et al. 2009; Sanders et al. 2009; Camfield and Camfield 2011).

One of the most common lifelong neurosurgical conditions that develop in early childhood is hydrocephalus. Although the exact number of persons currently with this condition is unknown, annually it is the diagnosis for 69,000 patients at discharge in the United States, of which half are children (Patwardhan and Nanda 2005). As a sole diagnosis, hydrocephalus in children accounts for nearly 40,000 admissions, upward of 433,000 inpatient days, and cumulative hospital charges of 2.0 billion US dollars each year (Simon et al. 2008). Based on current treatment patterns and numbers, it is projected that young adults (ages 18–35 years) will exceed 40,000 in the next two decades (Simon et al. 2009).

For the pediatric neurosurgeon, management of hydrocephalus and placement and revision of CSF shunts are significant components of practice

(ReKate 2009). In general neurosurgery, adult-onset hydrocephalus is infrequent by comparison and is often acquired after trauma or brain tumor. With extensive experience, the pediatric neurosurgeon is adept at troubleshooting shunt issues that may have subtle or atypical symptoms commonly be seen in childhood-onset disease.

With the advancement of neurosurgical procedures in the last 30–40 years, including surgical shunting and myelomeningocele (MM) repair/closure, one of the greatest medical challenges today is caring for young adults with spina bifida (ReKate 2009). During childhood, health care for these patients is often coordinated and comprehensive. Many are followed in MM clinics with multiple subspecialists available to the patient and family. Once transferred to adult care, there are limited medical subspecialties available (Slap 2009), and care is reported as fragmented (Binks et al. 2007). Primary care providers are overwhelmed, complications are overlooked, and, as parent advocates age, there is decreased involvement in care (Camfield and Camfield 2011). Furthermore, the child with MM who was functionally and medically stable through childhood and early adolescence can have significant and rapid deterioration of gait and walking, premature aging of bones, and neuro-orthopedic issues in young adulthood. There is increased morbidity and mortality in this population during or shortly after transition from tethered cord, syringomyelia, and shunt failure (Vinchon and Dhellemmes 2007). How much the lack of medical resources plays a part in this is unclear.

For patients who have been “cured” of a pediatric brain tumor or vascular incident, the latent effects of treatment may become apparent years later in adolescence or young adulthood. It is not unusual for these children to have cognitive issues and ADHD later in life from prior radiation and chemotherapy treatments. Additionally, these “survivors” may go on to have intractable epilepsy during adulthood (Camfield and Camfield 2011). The ability for adult practitioners to recognize and appropriately manage these patients becomes challenging with little experience to guide them.

So what to do about transitioning these special children to adult neurosurgical practices? For some patients, they are fortunate in that their

neurosurgeons have “double citizenship” and can take care of them cradle-to-grave. For many others, their pediatric practitioners must hand them off to adult providers due to regulations and resource limitations that restrict their scope of practice (Vinchon and Dhellemmes 2007). Some of the mentioned care models in this chapter have attempted to address this difficult task.

From a professional standpoint, there are several organizations that are heavily involved in examining issues related to childhood-onset neurosurgical disorders. The section on neurological surgery of the AAP has been vocal in advocating for transition planning and defining strategies for this complex patient population. The Joint Section of Pediatric Neurological Surgery of the American Association of Neurological Surgeons (AANS) and Congress of Neurological Surgeons (CNS), which was established as a forum for sharing pediatric neurosurgical experiences and promotes education, research, and patient care standards, also has put the topic of transition high on their list of priorities. The American Society of Pediatric Neurosurgeons (ASPN) has recently updated their vision statement to include the reality of pediatric neurosurgical problems persisting into adulthood. The role these professional societies play in the support of viable care models is an important one. Although there is most likely not one care model that will fit all regions and situations, these organizations can establish guidelines that can be customized to individual neurosurgical practices (Rekate 2009).

---

## 14.5 Issues Specific to Nursing and Scope of Practice

Just like their physician counterparts, nursing professionals will undoubtedly experience increased exposure to the growing number of youth and adults with special health care needs. These complex patients are no longer limited to pediatric or subspecialty practices. Adult primary care, occupational medicine, and other various inpatient and outpatient environments of care will continue to see an influx of this population.

In response to this phenomenon, nursing curricula need to include education and clinical

training that will prepare future providers to meet the needs of adults with childhood-onset disabilities (Binks et al. 2007). Important skills will include the ability to interact with patients who have cognitive and communication deficits, and specific strategies to incorporate patient advocates during the patient encounter. Nurses who traditionally practice the “clinician-patient” model may need to learn how to incorporate an advocate while fostering autonomy and acceptance of the ASHCN. In addition, nurses need to balance caring for multiple complex (and often overwhelming) medical needs with preventative management (Binks et al. 2007).

Experienced pediatric neuroscience nurses have the advantage of practicing under this model of care. Many of the common neurological and neurosurgical conditions start at birth or early childhood and are typically managed in primary care and subspecialty environments. Pediatric neuroscience nurses who care for the transitioning adult have experience in clinical assessment related to the neurosurgical condition, patient and family teaching, and developmental knowledge; all which are an asset to facilitating a plan of care. Referrals to community resources, coordination of care with other providers, and facilitation/implementation of therapies are well within the nurses’ scope of practice. These activities can be time-consuming, and primary care physicians may find it difficult to incorporate them into their practice (Woldorf 2007). The value of nursing support to any program that manages YASHCN cannot be understated.

With regard to advanced practice, nurses have been integral to many transition programs. Betz and Redcay (2003) described an innovative nursing model for a transition clinic led by family nurse practitioners and is based in part on the Creating Healthy Futures model used in the educational system. The clinic was unique in that it provided comprehensive services to adolescents and young adults and involved extensive prescreening, identification of unique needs, and follow-up to assure successful transition (Betz and Redcay 2003). Outlined in a later report, the role of the advanced practice nurse (APN) as a transition services coordinator for the clinic was described, as well as the skills

necessary to provide care and serve as a case manager and community liaison for this underserved population (Betz and Redcay 2005). Most transition clinic models reinforce the unique role of the nurse, clinical nurse specialist, or nurse practitioner as key to the success of the clinic and the confidence of the patient.

Certain limitations of APN scope of practice have become an issue as the pediatric population ages. Pediatric nurse practitioners (PNPs) who have traditionally cared for the child with hydrocephalus and spina bifida may be prohibited from doing so once the patient exceeds age 21 years. Depending on Board of Nursing regulations, which vary from state to state, a PNP may be practicing outside her/his scope of practice by managing a 23-year-old. In another state, it may be within the scope if the patient has a chronic “pediatric onset” problem. It is vital that each APN knows what the practice statement or policy is for the state she/he practices in.

### Conclusion

The pediatric neurosurgical patient often has chronic lifelong conditions such as hydrocephalus and spina bifida that require comprehensive and competent health care through adulthood. As discussed in this chapter, there are often significant barriers to successful transition that need to be addressed universally. Planning for the process of transition and ensuring that health care providers are adequately educated in care of complex patients with childhood-onset diseases are essential. Additionally, the support services of nursing and social work need to be included in these programs. Their roles are vital to ensure coordination of services and specialists as needed by the individual patients. Financial considerations and the environment of care need to also be in line with the aging of these YSHCN as they move into the adult health care arena. Although there are many innovative programs and clinics in existence, lack of “best practice” based on evidence is a major gap in the realization of national standards of care. Much still needs to be done (Box 14.1).

### Box 14.1. The Gillette Children’s Specialty Healthcare Experience

Comprehensive clinics caring for adults with childhood-onset disabilities are rare, but some do exist. Gillette Children’s Specialty Healthcare in St. Paul, Minnesota, has a 100-year history of caring for children with disabilities. In 2001, Gillette Lifetime Specialty Healthcare opened to include adults with developmental and childhood-onset disabilities.

At Gillette, the transition process begins at around the age of 14. As discussed above, this process can – and should – take several years. Collaboration between the patients, the pediatric and adult providers, and the family is important in planning comprehensive care that reflects the preferences, needs, and priorities of the patient and the family. Therefore, Gillette utilizes a team approach. That means that a pediatric subspecialty provider may see an adult patient in the Lifetime clinic as part of their continued care. It is also the case that pediatric subspecialists transition the patient to an adult provider to be seen in the Lifetime clinic. Gillette also employs adult providers at Lifetime to assist in coordinating care for these complex patients, working with their subspecialists and their primary care provider.

As a result of transitioning from the pediatric-focused Gillette Children’s, Gillette Lifetime aims to improve the quality of life of adults with childhood-onset disabilities while educating about potential health risks, preventative measures, and personal care. Patients have access to a therapy kitchen, where daily activities such as cooking and cleaning are explored and practiced. Education regarding sexuality and relationships is made available, and women have access to female exams. Preventative measures, such as examining skin and feet routinely for wounds which, if left un- or undertreated can become life threatening,

are also taught. Gillette Lifetime specializes in treating people who have cerebral palsy, neuromuscular conditions, and spina bifida.

Gillette Children's Specialty Healthcare offers inpatient care for adults with childhood-onset disabilities as a part of continued care. The adult inpatient unit utilizes Gillette Lifetime providers as needed to care for individual patients. Most, but not all, of these patients are seen and followed in the Gillette Lifetime clinic. Adult medical providers are available to assist subspecialists with management of adult-onset medical issues and care, such as hypertension, diabetes, and pregnancy.

- Gillette Children's Transition Clinic. <http://www.gillettechildrens.org>
- Jax Hats. <http://www.jaxhats.ufl.edu>
- National Dissemination Center for Children with Disabilities. <http://nichcy.org/resources>
- Primary Children's Medical Center. <http://www.intermountainhealthcare.org/hospitals/primarychildrens/services/pages/service.aspx?service=Pediatric%20Special%20Care%20Program>
- Washington State Adolescent Health Transition Project. <http://www.dept.washington.edu/healthr/>

### Pediatric Practice Pearls

- Patients are encouraged to actively participate in their health care decision-making process beginning around 14 years of age.
- Pediatric care providers need to be able to transfer medical records to the adult care providers.

### Resources

- American Academy of Pediatrics – National Center for Medical Home. Tools and resources. <http://test.medical-homeinfo.org>
- *Bright Futures*. Age-specific guidelines on best practices. <http://www.brightfutures.org>
- *Envisioning My Future: A Young Person's Guide to Health Care Transition*. [http://media.ichp.ufl.edu/cms/cms\\_booklet.pdf](http://media.ichp.ufl.edu/cms/cms_booklet.pdf)
- Epilepsy Foundation. <http://www.epilepsyfoundation.org>
- FloridaHats: Graduating from Pediatric to Adult Health Care. <http://www.floridahats.org>

### References

- American Academy of Pediatrics American Academy of Family Physicians, & American College of Physicians – American Society of Internal Medicine (2002) A consensus statement on health care transitions for young adults with special health care needs. *Pediatrics* 110(6 pt 2):1304–1306
- American Academy of Pediatrics, American Academy of Family Physicians, & American College of Physicians, Transitions Clinical Report Authoring Group (2011) Supporting the health care transition from adolescence to adulthood in the medical home. *Pediatrics* 128:182–200. doi: [10.1542/peds.2011-0969](https://doi.org/10.1542/peds.2011-0969)
- Berkowitz S (2009) Transitioning adolescents to adult care: putting theory into practice. *Minn Med* 92(3):42–44
- Betz CL (2004) Transition of adolescents with special health care needs: Review and analysis of the literature. *Issues Compr Pediatr Nurs* 27:179–240
- Betz CL, Redcay G (2003) Creating Healthy Futures: an innovative nurse-managed transition clinic for adolescents and young adults with special health care needs. *Pediatr Nurs* 29(1):25–30
- Betz CL, Redcay G (2005) Dimensions of the transition service coordinator role. *J Spec Pediatr Nurs* 10(2):49–59. doi: [JSPN010 \[pii\] 10.1111/j.1744-6155.2005.00010.x](https://doi.org/10.1111/j.1744-6155.2005.00010.x)
- Binks J, Barden W, Burke T, Young N (2007) What do we really know about the transition to adult-centered health care? A focus on cerebral palsy and spina bifida. *Arch Phys Med Rehabil* 88(8):1064–1073. doi: [10.1016/j.apmr.2007.04.018](https://doi.org/10.1016/j.apmr.2007.04.018)
- Blum R (1995) Transition to adult health care: setting the stage. *J Adolesc Health* 17:3–5
- Buxton N, Punt J (1998) Failure to follow patients with hydrocephalus shunts can lead to death. *Br J Neurosurg* 12(5):399–401

- Callahan S, Winitzer R, Keenan P (2001) Transition from pediatric to adult-oriented health care: a challenge for patients with chronic disease. *Curr Opin Pediatr* 31:310–316
- Camfield P, Camfield C (2011) Transition to adult care for children with chronic neurological disorders. *Ann Neurol* 69:437–444. doi: [10.1002/ana.22393](https://doi.org/10.1002/ana.22393)
- Darer J, Hwang W, Pham H, Bass E, Anderson G (2004) More training needed in chronic care: a survey of US physicians. *Acad Med* 79(6):541–548
- Duke N, Scal P (2011) Adult care transitioning for adolescents with special health care needs: a pivotal role for family centered care. *Matern Child Health J* 15:98–105. doi: [10.1007/s10995-0547-1](https://doi.org/10.1007/s10995-0547-1)
- Epilepsy Foundation of Metropolitan New York (2008) Transition Planning, in Care Book, English & Spanish, [http://www.epilepsyfoundation.org/search/index.cfm/NY\\_CareBK\\_EnglishSpanish.pdf](http://www.epilepsyfoundation.org/search/index.cfm/NY_CareBK_EnglishSpanish.pdf). Accessed March 12, 2012
- Goodman D, Hall M, Levin A, Watson R, Williams R, Shah S, Slonim A (2011) Adults with chronic health conditions originating in childhood: inpatient experience in children's hospitals. *Pediatrics* 128:5–13. doi: [10.1542/peds.2010-2037](https://doi.org/10.1542/peds.2010-2037)
- Jurasek L, Ray L, Quigley D (2010) Development and implementation of an adolescent epilepsy transition clinic. *J Neurosci Nurs* 42(4):181–189
- Kaufman B, Terbrock A, Winters N, Ito J, Klosterman A, Park T (1994) Disbanding a multidisciplinary clinic: effects on the health care of myelomeningocele patients. *Pediatr Neurosurg* 21(1):36–44
- Labhard S (2010) Transitioning to adulthood with disabilities: a holistic approach. *Top Spinal Cord Inj Rehabil* 16(1):1–16. doi: [10.1310/sci1601-1](https://doi.org/10.1310/sci1601-1)
- Lam P, Fitzgerald B, Sawyer S (2005) Young adults in children's hospitals: why are they there? *Med J Aust* 182(8):381–384. doi: [lam10648\\_fm](https://doi.org/10.10648_fm) [pii]
- Lotstein D, Ghandour R, Cash A, McGuire E, Strickland B, Newacheck P (2009) Planning for health care transitions: results from the 2005–2006 national survey of children with special health care needs. *Pediatrics* 123:e145–e152. doi: [10.1542/peds.2008-1298](https://doi.org/10.1542/peds.2008-1298)
- Mennito S, Clark J (2010) Transition medicine: a review of current theory and practice. *South Med J* 103(4):339–342
- Okumura M, Heisler M, Davis M, Cabana M, Demonner S, Kerr E (2008) Comfort of general internists and general pediatricians in providing care for young adults with chronic illnesses of childhood. *J Gen Intern Med* 23(10):1621–1627. doi: [10.1007/s11606-008-0716-8](https://doi.org/10.1007/s11606-008-0716-8)
- Okumura M, Kerr E, Cabana M, Davis M, Demonner S, Heisler M (2010) Physician views on barriers to primary care for young adults with childhood-onset chronic disease. *Pediatrics* 125:e748–e754. doi: [10.1542/peds.2008-3451](https://doi.org/10.1542/peds.2008-3451)
- Park M, Adams S, Irwin C (2011) Health care services and the transition to young adulthood: challenges and opportunities. *Acad Pediatr* 11(2):115–122
- Patel M, O'Hare K (2010) Residency training in transition of youth with childhood-onset chronic disease. *Pediatrics* 126:S190–S193. doi: [10.1542/peds.2010-1466P](https://doi.org/10.1542/peds.2010-1466P)
- Patwardhan R, Nanda A (2005) Implanted ventricular shunts in the United States: the billion-dollar-a-year cost of hydrocephalus treatment. *Neurosurgery* 56(1):139–144
- Peter N, Forke C, Ginsburg K, Schwarz D (2009) Transition from pediatric to adult care: internists' perspectives. *Pediatrics* 123(2):417–423. doi: [10.1542/peds.2008-0740](https://doi.org/10.1542/peds.2008-0740) [pii]
- Reiss J (2009) When you're 18 you are in charge of your health: health care transition guide for young adults. Institute for Child Health Policy at the University of Florida, Gainesville
- Rekate H (2009) The pediatric neurosurgical patient: the challenge of growing up. *Semin Pediatr Neurol* 16(1):2–8. doi: [10.1016/j.spen.2009.03.004](https://doi.org/10.1016/j.spen.2009.03.004)
- Ried S (2010) Transition of youth from pediatric to adult care: physician's perspective and recommendations. *Top Spinal Cord Inj Rehabil* 16(1):38–47. doi: [10.1310/sci1601-38](https://doi.org/10.1310/sci1601-38)
- Sanders R, Kuo D, Levey D, Cheng T (2009) Transitioning adolescents to adult care and adulthood: is it time yet? *Contemp Pediatr* 26(12):46–55
- Sawicki G, Lukens-Bull K, Xiaoping Y, Demars N, Huang I, Livingood W, Reiss J, Wood D (2011) Measuring the transition readiness of youth with special health-care needs: validation of the TRAQ – Transition Readiness Assessment Questionnaire. *J Pediatr Psychol* 36(2):160–171. doi: [10.1093/jpepsy/jsp128](https://doi.org/10.1093/jpepsy/jsp128)
- Sawyer S, Aroni R (2005) Self-management in adolescents with chronic illness. What does it mean and how can it be achieved? *Med J Aust* 183(8):405–409. doi: [saw10483\\_fm](https://doi.org/10.10483_fm) [pii]
- Simon T, Riva-Cambrin J, Srivastava R, Bratton S, Dean J, Kestle J (2008) Hospital care for children with hydrocephalus in the United States: utilization, charges, comorbidities, and deaths. *J Neurosurg Pediatr* 1(2):131–137
- Simon T, Lamb S, Murphy N, Hom B, Walker M, Clark E (2009) Who will care for me next? Transitioning to adulthood with hydrocephalus. *Pediatrics* 124(5):1431–1437. doi: [10.1542/peds.2008-3834](https://doi.org/10.1542/peds.2008-3834)
- Slap G (2009) Promoting lifelong health for adolescents and young adults with special health care needs. *Pediatrics* 124:1469–1470. doi: [10.1542/peds.2009-1662](https://doi.org/10.1542/peds.2009-1662)
- Tomlinson P, Sugarman I (1995) Complications with shunts in adults with spina bifida. *BMJ* 311:286–287
- Tuffrey C, Pearce A (2003) Transition from paediatric to adult medical services for young people with chronic neurological problems. *J Neurol Neurosurg Psychiatry* 74(8):1011–1013
- Vinchon M, Dhellemmes P (2007) The transition from child to adult in neurosurgery. *Adv Tech Stand Neurosurg* 32:3–24
- Washington State Adolescent Health Transition Project (2006) Working Together for Successful Transition: Washington State Adolescent Transition Resource Notebook, Publication Number 970–110, Washington State Department of Health, <http://www.dshs.wa.gov/health.shtml>. Accessed March 19, 2012
- Woldorf J (2007) Transition adolescents with special healthcare needs: potential barriers and ethical conflicts. *J Spec Pediatr Nurs* 12(1):53–55

# Index

## A

### Abusive head trauma

- diagnostic findings, 224
- management, 224
- outcomes, 225
- retinal hemorrhages, 223, 224
- shaken impact syndrome, 223
- skeletal fractures, 223
- subdurals, 223–225

### AED. *See* Antiepileptic drug (AED)

### After surgery

- neurological assessment, 32, 74, 136
- organizations and web sites, 79
- wound and dressing care, 75

### ALARA guidelines, 86

### Analgesia, sedation, and neuromuscular

- blockade, 233, 235, 236

### Anencephaly

- complications, 122
- historically, 122
- prognosis, 122
- survival rate, 122

### Anesthesia

- anesthetic induction, 389, 390, 394–397, 399, 407, 410
- dispersive electrocautery pad, 399
- positioning, 184, 400, 402
- sequential compression stockings, 399

### Anesthesia provider

- parental preparation, 389
- preoperative preparation programs, 106, 395
- psychological preparation of the child, 407

### Angiomatosis, 347, 348

### Antiepileptic drug (AED), 251, 310, 334–336, 340–342, 347, 349, 354–357, 381, 382

### Antley-Bixler, 98

### AOD. *See* Atlanto-occipital dislocation (AOD)

### Apert syndrome

- syndactyly, 97, 98, 100
- turriccephalic, 98

### Apnea, 12, 29, 30, 50, 108, 125, 132, 147, 154, 196, 207–209, 223, 255, 256

### Apneustic, 196

### Aqueductal stenosis, 39, 44, 45, 48, 54, 55, 59, 67, 144

### Arachnoid cysts, 39, 46–47, 63, 426

### Arterial fistulas of the spine

- diagnostic tests, MRI/MRA, 323
- nursing, 324–325
  - pain management, 324
- obliteration, 323
- outcomes, 325
- risks, 323–325
- symptoms, 322, 325
  - edema, 324
- treatments, 323–324
- websites, 326

### Assessment, 1–34, 74–75, 83, 98, 100–102, 109, 111, 126, 154, 155, 181, 188, 195–198, 203, 207, 208, 214, 215, 220, 231, 233, 234, 238–242, 244, 251, 253, 262, 266, 274, 276, 293, 296, 303–305, 316, 318, 319, 324–326, 352, 355, 367–369, 389–393, 396, 398, 401, 406, 408–412, 419, 424, 425, 427

### Ataxic, 196

### Atlanto-axial Rotary Subluxation (AA Rotary Fixation)

- atlanto-axial joint, 270
- atlas fracture, 270
- classification, 270–271
- nonsteroidal antiinflammatory drugs (NSAIDs), 271
- pathophysiology, 270
- traction, 271
- treatments, 271

### Atlanto-occipital dislocation (AOD)

- anterior longitudinal ligament, 267
- atlanto axial joint, 268
- axial load, 267
- classification, 268
- diagnosis
  - cranial nerve dysfunction, 268
  - head trauma, 268
  - radiographs, 268–269
  - ventilation, 268
- skull dislocation, 268
- treatment, 269

### Autoregulation, 196, 207, 227, 304



**B**

- Baclofen
  - intrathecal baclofen, 364
  - intrathecal baclofen pump system, 364–370
    - infection, 368
    - nursing care, 368
    - wound complications, 367
  - oral, 363–364, 368, 372
- Barbiturate therapy, 237
- Bed-wetting, 251
  - adolescent, 14
- Birth-related traumatic brain injury
  - caput succedaneum, 204, 205
  - cephalohematoma, 204–205
  - depressed skull fractures, 205, 206
  - intracranial hemorrhage, 204, 205
  - leptomeningeal cyst, 213
  - linear skull fractures, 205, 207
  - ping-pong, 205
  - skull fracture, 204–208, 210, 212–214
  - subgaleal hemorrhage, 204, 205, 208
- Blood-brain barrier, 170, 190, 210, 228, 236, 364, 378
- Botulinum A toxin, 363
- Brain abscess
  - acidfast bacilli cultures, 378
  - aerobic, 378
  - anaerobic, 375, 376, 378, 379
  - B beta-hemolytic *Streptococci*, 375
  - burr holes, 378
  - chronic otitis media, 375, 376
  - computed tomography (CT), 377
  - congenital heart defect, 375, 376
  - craniectomy, 378
  - C-reactive protein (CRP), 377
  - dental procedures, 375, 377
  - diagnostic test, 377–378
  - erythrocyte sedimentation rate (ESR), 377
  - excision, 378
  - fungal, 376, 378
  - Haemophilus*, 376
  - magnetic resonance imaging (MRI), 377, 378
  - mastoiditis, 375
  - needle aspiration, 378
  - Pneumococcus*, 375
  - presenting symptoms, 376–377
  - sinusitis or ruptured dermoid tumor, 375
  - Streptococci*, 375
  - subdural empyemas, 375–379
  - surgical drainage, 378
  - treatment options, 378–379
  - vancomycin, 378
- Brain death, 27–30, 200, 201, 203, 229, 230
  - guidelines, 29, 30
- Brainstem, assessment of function, 20–24, 28–29
- Brainstem herniation
  - infratentorial, 203
  - supratentorial
    - central, 28, 230
    - cingulate, 28, 229
    - uncal, 28, 203, 230

## Brainstem reflex exam

- facial, 199
- oculocephalic, 199, 200
- oculovestibular, 199, 200
- trigeminal, 199
- vestibular, 199, 200

**C**

- Capillary angiomas and telangiectasia
  - brainstem cavernomas, 309, 311
  - cavernous malformations, 308
  - classification, 309
  - cystic vascular spaces, 308
  - diagnostic imaging, 310
  - genetic counseling, 311
  - lifetime costs, 310
  - pathophysiology, 308–309
  - spinal cavernomas, 308, 309
  - stereotactic radiosurgery, 295
  - telangiectasias, 307–308
- Carbapenem, 378
- Carpenter, 98
- Cavernous malformations and arteriovenous
  - fistulas of the spine
    - edema, 323, 324
    - MR angiography, 323
    - MRI, 322, 323
    - nursing care, 324–325
    - outcomes, 325
    - symptoms, 322, 324
    - websites, 326
- CBF. *See* Cerebral blood flow (CBF)
- Central nervous system (CNS) tumors, 49, 157–191
- Central neurogenic hyperventilation, 196
- Cephalic index, 89, 91
- Cephalosporin, 378, 384
- Cerebral arteriovenous fistulas
  - diagnostic imaging
    - CT scan, 299
    - MRA/MRV, 299
    - MRI, 299
  - endovascular treatment, 299
  - etiology, 297–298
  - pathophysiology, 298
  - presenting symptoms, children
    - cardiac, 298
    - cranial bruits, 298, 299
    - cyanosis, 298
    - neonatal symptoms, 298
  - treatments
    - complications, 300
    - outcomes, 300
    - surgical resection, 299
- Cerebral arteriovenous malformation in children
  - corticosteroids, 296
  - effects, 296
  - complications of surgery
    - hemorrhage, 294, 295
    - occlusion, 295

- seizures, 294, 295
- vasospasm, 295
- diagnostic imaging
  - calcification, 293
  - CT angiogram, 293
  - MRI/MRA, 293
  - vessel angiogram, 293, 294
- embolization, 294, 296
- etiology, 291–292
- outcomes, 297
- pathophysiology
  - cerebral aneurysms, 292
  - genetic errors, 292
  - hemorrhage, 292
  - nidus, 292
- presenting symptoms
  - headache, 293
  - macrocephaly, 293
  - seizure, 293
- treatments
  - corticosteroids, 296
  - effects of radiation, 296
  - embolization, 294, 296
  - microsurgical resection, 294
  - radiosurgery, 294–296
  - Spetzler and Martin grading scale, 294
  - timing of treatments, 294–296
  - vasospasm, 295
- Cerebral autoregulation, 227
- Cerebral blood flow (CBF), 2, 4, 28–30, 43, 196, 207, 227–230, 234, 236, 237, 241, 313
- Cerebral edema, 212, 216, 217, 220, 225, 226, 228, 230, 231, 233, 236, 237, 239, 242, 296, 300, 341, 351
- Cerebral herniation syndromes, 229, 230, 233
- Cerebral metabolism, 219, 227–228
- Cerebral perfusion pressure (CPP), 226, 227, 229–232, 234–236, 238, 241–243
- Cerebral spinal fluid (CSF)
  - drainage, 56, 72, 73, 76, 77, 233, 235, 236, 303, 317, 353, 380, 384
  - production and flow dynamics
    - intracranial pressure (ICP), 41–43
    - pathways, 41
  - values according to age, 384
- Cheyne-Stokes, 196
- Chiari 0, 141
- Chiari 1.5, 141
- Chiari decompression, 400
  - surgical time-out, 400
- Chiari I
  - cerebellar tonsils, 45, 142, 148, 149, 151
  - dysphagia, 146, 147
  - encephalocele, 39, 141
  - etiology, 44, 142
  - foramen magnum, 141, 142, 148, 151, 153
  - headache, 146, 147, 149, 151
  - lumboperitoneal shunt, 142
  - malformation, 44, 45, 141–143, 145–151, 153
  - scoliosis, 146–149
  - vocal cord paralysis, 146
- Chiari II
  - amniocentesis, 125
  - bowel and bladder dysfunction, 125
  - brainstem dysgenesis, 143, 144
  - comorbidities, 122, 125
  - endoscopic third ventriculostomy, 44, 125
  - fetal surgery, 129
  - hydrocephalus, 44–45, 62, 122, 123, 143, 148, 153
  - latex products, 131
  - Management of Myelomeningocele Study (MOMS), 143, 147
  - maternal serum alpha-fetoprotein (MSAFP), 125
  - MOMs study, 143, 147
  - multidisciplinary care approach,
    - long-term management of, 132
  - nursing considerations, 154
  - postoperative care, 154
  - prenatal screening, 125–126
  - prenatal ultrafast MRI, 126
  - preoperative care, 154
  - renal ultrasound, 125
  - respiratory distress, 147
  - spina bifida, 122
  - surgical management, 125, 129, 153
  - swallowing dysfunction, 147
  - urodynamics, 125
  - voiding cystourethrogram (VCUG), 125
- Chiari III, 141, 144, 148
  - encephalocele, 144, 148
- Chiari IV, 141
- Chiari malformation
  - antiemetic medications, 150
  - chemical meningitis, 151
  - discharge criteria, 151, 154
  - nursing care, 150–151, 154
  - outcomes, 155
  - pain management, 150, 154, 155
  - patient and family education, 154–155
  - pseudomeningocele, 150, 153, 155
  - surgery
    - duraplasty, 150
    - neuromonitoring, 153
  - treatment options, 144, 146, 149–157
- Child-life specialists
  - dietary restrictions, 394
  - imaging tests, 393
  - laboratory testing, 393
  - preoperative consultation, 390–393
  - preoperative medication, 394–395
  - separation from parents vs. parental presence upon
    - induction of anesthesia, 395–396
- Chronic traumatic encephalopathy (CTE), 212
  - Battle's sign, 214
- Circle of Willis
  - description of arteries, capillaries, and veins, 283, 285
  - venous system, 285
- Circulating nurse, 107, 396, 398–401, 403–405

- Clearing Cervical spine, 266, 267  
 AOD, 267  
 atlanto-axial (AA) rotatory fixation, 267  
 axial (load bearing), 267  
 classifications, 268  
 clinical assessment, 266  
 cranial nerve dysfunction, 268  
 CT scans, 268  
 developmental age, 267  
 diagnosis, 266  
 head trauma, 268  
 imaging, 267  
 mortality, 267  
 muscle spasms, 267  
 NEXUS, 267  
 radiographic evaluation, 268–269  
 treatment, 269  
 type I, 268  
 type II, 268  
 type III, 268  
 ventilated, 266, 268
- Clinical nurse specialists, 115, 396, 428
- Collaborative management of intracranial hypertension  
 evidence-based treatment guideline, 231, 232  
 initial resuscitation, 231  
 intensive care management, 231–233
- Coma, 18, 19, 27, 29, 74, 197–198, 209, 211, 219, 220, 232, 237, 274, 293, 302, 305, 306, 320, 364
- Compensatory mechanisms, 196, 226, 228
- Complications of shunts  
 atrial shunts, 383  
 LP shunts, 70  
 over drainage, 56  
 slit ventricle syndrome, 58  
 treatment  
 shunt infection, 66–68  
 shunt malfunction, 64–66  
 lumboperitoneal catheter complications, 69–70  
 over-drainage, 70  
 slit ventricle syndrome, 70–72
- Concussion  
 return to play protocol, 211  
 signs and symptoms, 210
- Congenital spine deformity and spinal cord disorders  
 achondroplasia, 250, 254–258  
 anomalies, 249–253, 258  
 birth defects, 251, 255  
 congenital anomalies, 249, 251, 253  
 connective tissue disorders, 249  
 evaluation  
 age-appropriate questions, 251  
 back pain, 252  
 bowel and bladder changes, 251  
 development history, 251  
 general patient evaluation, 251  
 loss of bowel and bladder control, 252  
 past medical history, 251  
 physical exam, 251  
 spine measurements, 251
- Klippel-Feil syndrome, 250–252, 258
- kyphosis, 249, 252, 256–258, 260  
 lordosis, 249  
 mucopolysaccharide disorders, 250, 259  
 neurofibromatosis, 249  
 neuromuscular conditions, 249  
 related conditions  
 clinical findings, 251  
 congenital cardiac disease, 251  
 diastematomyelia, 251  
 dimples, 251  
 diplomyelia, 251  
 foot deformity, 251  
 hairy patches, 251  
 muscle weakness, 251  
 spinal stenosis, 251  
 tethered cord, 251  
 urinary tract structural abnormalities, 251
- scoliosis, 249, 251, 252, 253, 258–260  
 skeletal dysplasia, 249, 253–254, 260  
 tissue disorders, 249
- Continuous epidural infusion, 410
- Contusion  
 contrecoup, 218, 219  
 coup, 218
- Coronal synostosis  
 harlequin sign, 89, 92  
 nasional deviation, 89, 91  
 strabismus, 89  
 superior oblique paresis, 89  
 vertical dystopia, 89, 91
- Corpus callosotomy, 338, 342, 349
- Cortical dysplasia, 3, 335, 336, 344–346, 355–357
- Cortical mapping, 338, 342, 345
- CPP. *See* Cerebral perfusion pressure (CPP)
- Cranial calipers, 89, 91
- Cranial nerve (CN) evaluation, 17, 20–24
- Cranial orthotic device  
 band, 94  
 molding helmet, 93
- Craniofacial center  
 calvarial vault remodeling, 104  
 cosmetic surgery, 102  
 craniofacial team, 98, 108, 110, 111, 115  
 distraction osteogenesis, 105  
 endoscopic strip craniectomy, 104, 111, 113–115  
 fronto-orbital advancement, 104, 109  
 hung span procedures, 104, 108  
 pi, 104, 108  
 preoperative preparation for intracranial surgery, 105–107  
 reconstructive surgery, 102  
 strip craniectomy, 104, 105, 110–111, 113–115  
 surgery, 104
- Craniofacial resources/support groups, 106
- Craniofrontonasal dysplasia, 98
- Craniosynostosis, 12, 71, 85–115  
 anterior plagiocephaly, 89  
 coronal suture, 86, 88  
 craniofacial team, 98, 108, 110, 111, 115

lambdoid suture, 88, 91–96, 111  
 metopic suture, 86–88, 90, 92  
 posterior plagiocephaly, 86  
 sagittal suture, 86, 88, 110  
 scaphocephaly, 89  
 surgery  
   calvarial vault remodeling, 85, 104, 109, 111  
   cosmetic surgery, 102  
   distraction osteogenesis, 105  
   endoscopic strip craniectomy, 104, 111, 113–115  
   fronto-orbital advancement, 104, 109  
   hung span procedure, 104, 108  
   molding helmet, 94, 110–112  
   pi procedure, 104, 108  
   post discharge management, 110  
   postoperative nursing management, 109–110  
   preoperative preparation, 105–107  
   reconstructive surgery, 102  
   strip craniectomy, 104, 105, 110–111, 113–115  
   trigonocephaly, 88, 90, 92  
 Crouzon syndrome  
   bicoronal craniosynostosis, 96  
   hypertelorism, 96, 98  
   tarsorrhaphy, 96  
 CTE. *See* Chronic traumatic encephalopathy (CTE)  
 Cushing's response, 96, 241  
 Cyclooxygenase, 409

## D

DAI. *See* Diffuse axonal injury (DAI)  
 Dandy-Walker malformation, 45  
 Decompressive craniectomy, 221, 231, 233, 240  
 Dermatome, 25, 26  
 Developmental assessment  
   adolescent, 15–16  
   infant, 12–13  
   neonatal, 5–12  
   preschooler, 14  
   school age child, 14–15  
   toddler, 13–14  
   tools, 16

## Diagnosis

airway, 258  
 common injuries  
   AA rotatory subluxation, 271  
   AOD, 268, 269  
   mortality, 263, 267  
 C spine precautions  
   age, 265, 267  
   backboard, 266  
   clearing C-spine, 266  
   clinical assessment, 266  
   head size, 265–266  
   imaging, 267  
   immobilization, 265, 266  
   muscle spasms and, 267  
   NEXUS study, 267  
   positioning, 265, 266  
 level of consciousness, 162, 181

presenting symptoms  
   double vision, papilledema, 161  
   increased intracranial pressure and hydrocephalus,  
     161, 162, 298, 309, 380  
   radiographic evaluation, CT, 215, 253, 255, 258, 265,  
     269, 271–273  
   risk factors, 72, 265

## Diagnostic studies

### Diagnostic tests

angiography, 253  
 contrast, 3, 162, 163, 288, 303, 307  
 cranial irradiation, 158  
 CT scan, 3, 137, 149, 162, 163, 253, 288, 299, 303,  
   306, 307, 313, 377, 381, 383, 386  
 EEG, 2, 163–164, 313  
 etiology, 286, 291, 292, 375  
 imaging in neurological assessment  
   Doppler ultrasound, 2, 3  
   EEG, SPECT, 2–4  
   magnetic source imaging (MSI) and functional  
     MRIs (fMRI), 2, 3  
   MEG, 2, 4  
   PET, 2, 3  
 MR angiography, 163, 288, 293, 299, 303, 313, 323  
 MRI scan, 2, 3, 137, 148–149, 155, 162, 163,  
   288–289, 303, 306, 313, 323, 377, 381, 386  
 radiographic tests  
   Doppler, 2, 3, 288  
   fMRI, 2  
   MEG, 2, 4  
   MSI, 2, 4  
   PET, 3, 163, 313  
   SPECT, 2, 3, 163, 313  
 SEGAs, 157  
 ultra sound, 137, 253  
 x-rays, 253  
 Diffuse axonal injury (DAI), 194, 195, 204, 220, 221  
 Dura, 65, 70, 76, 87, 110, 112, 125, 127, 135, 142, 150,  
   151, 153–155, 196, 203, 207, 208, 210, 213,  
   215, 216, 222, 257, 322, 324  
 Dysplasia, 2, 98, 104, 249, 253–254, 260, 302,  
   312, 335, 336, 342, 344–346, 355–357

## E

Ectomeninx, 86, 87  
 EEG. *See* Electroencephalogram (EEG)  
 Electroencephalogram (EEG), 2, 4, 30, 82, 163, 237,  
   295, 333  
 Eloquent cortex, 338, 340–342, 345  
 Endocrine Complications  
   cerebral salt wasting (CSW), 240  
   diabetes insipidus, 239  
   outcomes, 243  
   postoperative complications, 241–243  
   prevention efforts, 243–244  
   syndrome of inappropriate secretion of antidiuretic  
     hormone, 239  
 Endoscopic third ventriculostomy (ETV), 59–61  
   choroid plexus cauterization (CPC), 61

Epidural hemorrhage, 204, 207, 214–215, 264

Epilepsy surgery

complications, 351–352

complications CSF leak, 351

complications infection, 351

complications stroke, 351

extratemporal resections, 344–345

lobectomy, 345

hemispherectomy, 345–346

imaging

CT, 336

fluorodeoxyglucose (FDG), 336

functional MRI, 336

magnetoencephalography (MEG), 337

MRI, 336

positive emission tomography (PET), 336

single-proton-emission-tomography (SPECT), 336

video EEG, 337

lesionectomy, 342–343

electrocorticography, 343

lobectomy, 342

nursing care following resective surgeries

electrolytes, 352

fever, 353

incision care, 353

pain management, 352

postoperative drains, 352

seizures, 352, 353

outcomes

Engel's classification of postoperative

outcome, 354

international league against

epilepsy (IALE) classification

of postoperative outcomes, 354

quality of life (QOL), 355, 357

“pie in the sky” defect, 343

temporal lobectomy

mesial temporal sclerosis (MTS), 343

temporal lobe epilepsy (TLE), 343

Epileptogenic, 336, 337, 342, 343, 345, 348, 349, 355

Etiology

maternal diabetes, 251

maternal diabetes, ingestion of antiepileptic drugs, 251

maternal hypoxia, 251

## F

Faces pain scale (FPS), 31

Fentanyl, 371, 410

Fibroblast growth factor receptors

anterior plagiocephaly, 86

coronal suture, 86

lambdoid, 86

metopic suture, 86

plagiocephaly, 86

posterior, 86

posterior plagiocephaly, 86

sagittal suture, 86

scaphocephaly, 86

suture, 86

trigonocephaly, 86

FLACC, 31, 409

Fluorodeoxyglucose (FDG), 336

Folic acid, 119, 120, 138

FPS. *See* Faces pain scale (FPS)

Functional MRI (fMRI), 336

## G

GCS. *See* Glasgow Coma Scale (GCS)

Generalized seizures

absence, 334

atonic, 334

atonic, and absence, 334

clonic, 334

idiopathic, 334

myoclonic, 334

tonic, 334

tonic-clonic, 334

Glasgow Coma Scale (GCS), 18, 195, 197–198, 211, 219, 220, 222, 231–233, 241, 274, 305, 320

Gram-negative

nursing care, 379

outcome, 379

patient and family education, 379

Gram-positive, 48, 66, 69, 75, 378

## H

Handedness, 14, 33, 286

Head growth, 13, 40, 50, 74, 78, 132

Head trauma, 49, 193–194, 196–198, 200, 203, 211, 212, 217, 219, 222–225, 240, 243, 268, 273, 286, 315, 375–377

Hemimegalencephaly, 335, 344, 346

Hemispherectomy, 342, 345–348, 351, 355

Herniation

cingulated herniation, central herniation, and uncal, 28

infratentorial herniation, 28

supratentorial herniation, 28

Homonymous superior quadrantanopsia, 343

Hydration and nutrition, 184, 237–238

Hydrocephalus

acquired, 39–40

classifications

communicating, 39

non communicating, 39

communicating, 39

congenital, 39

external, 40

ex vacuo, 39, 40

history, 37–38

incidence, 38

internal, 40

noncommunicating, 39

normal pressure hydrocephalus, 40

prognosis, 38

signs and symptoms, 49–51

growth, 50  
 treatment, 54–63, 74, 81, 125, 167  
 medical therapy, 54–55  
 Hydromorphone, 410  
 Hydromyelia, 145  
 Hyperosmolar therapy  
 hypertonic saline, 235  
 mannitol, 235, 236  
 Hyperventilation, 27, 182, 196, 236, 313

## I

Ictal, 2–4, 336–338, 343, 356  
 Image gently, 53, 86  
 Image wisely, 86  
 Imaging studies  
 computed tomography (CT), 41, 52–53, 279  
 magnetic resonance imaging (MRI), 53–54,  
 149, 155, 162  
 rapid sequence or haste MRI, 54  
 (HASTE) MRI, 54  
 ultrasonography, 52, 279  
 Individuals with Disabilities Education Act (IDEA)  
 infant, 12–13  
 neonate, 5–12  
 toddler, 13–14  
 Induction of anesthesia, 389, 390, 394–396, 407, 410  
 Interictal, 336–338, 356  
 International Classification of Epileptic  
 Seizures (ICES), 333  
 Intracerebellar hemorrhage, 204, 207, 209  
 Intracranial abscess, brain abscess  
 beta-hemolytic streptococci, 375  
 chronic otitis media, 375  
 congenital heart defect, 376  
 dental procedures, 375  
 diagnostic tests  
 C-reactive protein (CRP), 377  
 CT, 377  
 cultures (aerobic, anaerobic, fungal, AFB), 378  
 erythrocyte sedimentation rate (ESR), 377  
 MRI, 377, 378  
 haemophilus, 376  
 mastoiditis, 375  
 nursing care, 379  
 outcome, 379  
 patient and family education, 379  
 pneumococcus, 375  
 presenting symptoms, 380  
 ruptured dermoid tumor, 375  
 sinusitis, 375  
 streptococci, 375  
 subdural empyema, 375–379  
 treatment options  
 craniectomy, 378  
 excision, 378  
 needle aspiration, 378  
 surgical drainage, 378  
 vancomycin, 378  
 Intracranial aneurysms  
 diagnostic tests

CT, 303  
 LP, 303  
 microneurosurgical, 303  
 MRI/MRA, 303  
 etiology, 301  
 fusiform aneurysms, 300–301  
 Hunt and Hess (HH) scale, 305  
 medical management  
 EVD, 303  
 stabilization, 303  
 mycotic or infectious aneurysms, 301  
 pathophysiology, 301–302  
 presenting symptoms  
 headache, vomiting, meningeal irritation, 302  
 retinal hemorrhages, 302  
 subhyaloid hemorrhages, 302  
 saccular aneurysms, 300  
 surgical management  
 traumatic aneurysms, 301  
 world federation of neurological surgeons  
 scale, 305  
 Intracranial compliance, 65, 225, 226  
 Intracranial electrodes, 339  
 Intracranial hemorrhage, 63, 82, 204, 205, 207, 222, 223,  
 242, 291–293, 299, 302, 312, 316, 317, 362  
 Intracranial hypertension, 58, 228–229, 233–238, 241,  
 242, 380, 381  
 Intracranial pressure monitoring  
 catheters, 233  
 intracranial hypertension, 233  
 nursing care, 234  
 Intractable epilepsy, 333, 335–336, 342, 345–348, 350,  
 355, 419, 426  
 Intramembranous ossification, 86  
 Intraoperative care  
 air handling system, 397  
 anesthetic induction, 397  
 dispersive electrocautery pad, 399  
 electrocautery unit, 397  
 positioning, 400  
 preparation of operating room, 396–397  
 sequential compression stockings, 397  
 shaving, 404  
 surgical time out, 400  
 ultrasonic aspirator, 397

## J

Jackson-Weiss syndromes, 98  
 Jefferson fracture  
 C1-burst fracture, 271  
 odontoid/ dens fracture, 272–273  
 spondylosis, 273  
 Wallenberg syndrome, 271  
 Jefferson or atlas fractures  
 C1 burst fracture, 271  
 Odontoid (Dens) fracture, 272–273  
 spondylosis, 273  
 Wallenberg's syndrome, 271  
 Joint commission  
 Jugular venous oxygenation saturation monitoring, 234

**K**

- Ketogenic diet, 335
- Ketorolac, 183, 410
- Klippel-Feil syndrome
  - abnormalities, 258
  - classifications, 258
  - congenital cervical fusion, 258
  - diagnosis, patient and parental education, 259
  - radiographs, 258–259
  - surgery, 259
  - treatment, 259

**L**

- Lambdoid synostosis
  - Towne's view, 91
  - trapezoid, 91
- Level of consciousness, 17–20, 24, 27, 74, 109, 111, 161, 162, 181, 183, 196, 197, 210, 216, 218, 220, 241, 242, 267, 305, 309, 316, 317, 367, 379, 409
- Living with hydrocephalus
  - cognitive abnormalities, 80
  - motor disabilities, 80–81
  - ocular abnormalities, 81
  - precocious puberty, 82
  - seizures, 81–82

**M**

- Magnetoencephalography (MEG), 337
- Malformations of cortical development (MCD), 343, 344
- Mapping, 4, 338, 340–342, 345, 355
- Mayfield headrest, 400, 401
- MCD. *See* Malformations of cortical development (MCD)
- Metopic synostosis, 88, 90–92, 113–115
  - hypotelorism, 90
- Metronidazole, 378
- Monitoring partial pressure of oxygen, 234–235
- Monroe-Kellie doctrine, 225, 226
- Motor exam
  - babinski, 202
  - clonus, 202
  - decerebrate posturing, 201
  - decorticate posturing, 201
  - lower motor neuron (LMN), 200
  - upper motor neuron, 200
- Moyamoya syndrome
  - choreiform, 313
  - diagnosis
    - angiography, 313
    - bypass, 314
    - CT, 313
    - indirect bypass, 314
    - MRI, 313
    - PET, 313
    - SPECT, 313
    - superficial temporal artery middle cerebral artery anastomosis (STA-MCA), 314
    - symptomatic, 314
    - treatment, 313–314
  - dysphasia, 312
  - etiology, 312
    - pathophysiology, 308–309
  - hemiparesis, 313
  - ischemic symptoms, 312
  - monoparesis, 313
  - MRAs, 313
  - nursing care, 314
  - pathophysiology, 312
  - presenting symptoms
    - choreiform movements, 313
    - dysphasia, 313
    - hemiparesis, 313
    - ischemia, 313
    - monoplegia, 313
    - seizures, 313
    - transient ischemic attacks (TIA), 313
  - TIAs, 313
- Mucopolysaccharide disorders
  - associated syndromes
    - atlantoaxial instability, 260
    - ligamentous laxity, 260
  - atlanto-axial instability, 260
  - bone marrow transplant, 261
  - inheritance, 259–260
  - lysosomal storage disorder (LSD), 259
  - odontoideum, 260
  - syndromes associated with MPS, 260
  - treatment, 261
    - bone marrow transplant, 261
    - umbilical cord transplant, 261
  - umbilical cord blood transplants, 261
- Myelomeningocele
  - bowel and bladder dysfunction
    - renal ultrasound, 125
    - urodynamics, 125
    - voiding cystourethrogram (VCUG), 125
  - comorbidities, 123
  - complications, 125
  - history, 62
  - hydrocephalus, 123–125
    - endoscopic third ventriculostomy, 125
  - latex, 131
  - multidisciplinary care, 132
  - nursing considerations, 129–130
  - prenatal screening
    - amniocentesis, 125
    - fetal MRI, 126
    - maternal serum alpha-fetoprotein (MSAFP), 125
  - prognosis, 122
  - surgical management, 127–128
    - fetal surgery, 127
    - management of myelomeningocele study (MOMs), 127
    - postoperative care, 131–132
    - preoperative care, 130–131
  - survival rate, 122
- Myelomeningocele and Chiari II malformation, 44–45

## N

- Nerve blocks, 410
- Nervous system anatomy
  - autonomic, 158
  - autonomic nervous system (ANS), 158
  - brainstem
    - hydrocephalus, 159
    - medulla, 159
    - midbrain, 159
    - pons, 159
    - spinal nerves, 159
    - thalamus, 159
  - cerebellum, 159, 160
  - cerebrum, 158, 159
  - corpus callosum, 158
  - focal, 158
  - frontal, temporal, parietal, and occipital lobes, 158
  - lobes
    - frontal, 158, 159
    - occipital, 158, 159
    - parietal, 158, 159
    - temporal, 159
  - posterior fossa, 159
    - cerebellar changes, 159
  - spinal cord, 158, 159
- Neural tube defects
  - myelomeningocele, 122–123
  - occult spinal dysraphism, 133
  - spina bifida aperta, 119
  - spina bifida cystic, 119
  - spina bifida occulta, 132–133
  - spinal dysraphism, 133
  - tethered cord syndrome, 119
- Neurocranium, 86
- Neurocysticercosis
  - diagnostic tests, 381
  - nursing care, 381–382
  - outcome, 382
  - parasite, 382
  - patient and family education, 382
  - pork tapeworm, 380
  - presenting symptoms, 380
  - taenia solium, 3
- Neurological assessment
  - cranial nerves, 20–21
  - FOUR coma scale, 19
  - gait and balance, 25–26
  - glasgow coma scale, 197–198
  - motor exam, 200
  - reflexes, 19
  - sensory exam, 24–25
- Neuromonitoring unit (NMU), 337, 340, 356, 357
- Neuropsychological testing, 80, 212, 338, 356
- Neurovascular
  - anatomy
    - arterial blood supply, 321
    - cerebrovascular blood flow, 283
    - description of arteries, capillaries, and veins, 284
    - homunculus, 286
    - disease, 283–326
    - venous system
      - cerebral veins, 285
      - dural venous sinuses, 285, 286
      - internal jugular, 286
- Neurulation
  - ectoderm, 120
  - neural fold, 121
  - neural groove, 121
- Nonsteroidal anti-inflammatory drugs (NSAIDs), 32, 75, 137, 183, 271, 313, 318, 409
- Normal blood pressure in children, 233
- NSAIDs. *See* Nonsteroidal anti-inflammatory drugs (NSAIDs)
- Nursing Care
  - audiograms, 186
  - autonomic dysreflexia, 277–278
  - cervical collar care, 275–276
  - chemotherapy, 184–187
    - audiogram, 186
    - endocrine dysfunction, 185
    - hospice, 189
    - kidney function, 186
    - neutropenia, 186
    - ototoxicity, 189
    - psychological effects, 189
    - school re-entry, 188
    - secondary cancers, 189
  - common chemotherapy drugs and side effects, 184, 185
  - developmental considerations, 180–181
  - diabetes insipidus (DI), 182
  - intracranial pressure
    - monitoring, 181
  - kidney function, 186
  - neuroendocrine, 189
  - neurogenic bladder and bowel, 277
  - neutropenia, 186
  - ototoxicity, 189
  - pain management, 150, 154, 240, 241
  - pin site care for Halos, 276
  - pneumonia, 238, 372
  - pressure ulcers, 277
  - psychological, 73
  - radiation therapy, 183–184
  - school re-entry, 188
  - secondary cancers, 189
  - sexuality and spinal cord injury, 275, 279
  - spasticity, 278
  - surgery
    - diabetes insipidus (DI), 182
    - increased intracranial pressure, 181
    - pain management, 183
    - sympathetic nervous system, 278
- Nursing care after surgery
  - neuro assessment, 74–75
  - wound care, 75
- Nursing care issues, 314



**O**

Oncogenesis, 158  
 Ossification centers, 87  
 Osteogenic fronts, 87

**P**

PACU. *See* Postanesthesia care unit (PACU)

Pain assessment, 30–32, 75

Parental presence

FACES, 409  
 FLACC pain scale, 31  
 monitoring and treatment of potential complications, 408–409  
 opioid, 410  
 oxycodone, 410  
 pain, 409–410  
 parental and patient guidance, 408

Partial seizures

complex, 334  
 simple, 334

Pathophysiology and hydrocephalus, 40–44

Pathophysiology of intracranial hypertension, 228

Patient controlled analgesia (PCA), 32, 150, 151, 183, 318, 410

PCA. *See* Patient controlled analgesia (PCA)

Pediatric intensive care unit (PICU), 73, 107, 151, 224, 231, 235, 340, 352, 356, 405, 406, 413

Pediatric nurse practitioners (PNP), 94, 396, 428

Pediatric spinal vascular malformations

acute hemorrhage, 212, 324  
 compression, 267  
 etiology, 267, 291–292, 297–298, 301  
 hereditary hemorrhagic telangiectasias (HHT), 291  
 ischemia, 292, 293  
 pathophysiology, secondary symptoms, 292  
 presenting signs and symptoms, 292–293  
 spinal, 293  
 symptoms, 292–293

Pediatric stroke

infants, 286  
 perinatal period, 286  
 risk factors, 286

Penetrating craniocerebral injury, 220–222

Perioperative care, 389–412

Perioperative nurses

air-handling system, 397  
 Association of PeriOperative Registered Nurses (AORN), 397, 398, 400, 401  
 electrocautery unit, 397, 402  
 preparation of operating room, 396–397  
 scrub nurse, 396, 397, 400, 401, 403  
 ultrasonic aspirator, 397

Pfeiffer syndrome, 98, 103

Phakomatoses, 157, 301

Phase II monitoring, 338–341, 345, 351, 356

PICU. *See* Pediatric intensive care unit (PICU)

PNP. *See* Pediatric nurse practitioners (PNP)

Port-wine appearance, 347

Positional plagiocephaly

back to sleep, 93, 94, 96

deformational forces, 92

orthotist

back to sleep (BTS), 94  
 static stretching exercises, 94

sudden infant death syndrome (SIDS), 93, 96

torticollis, 93–95

tummy time, 94, 97

Positive emission tomography (PET), 336, 337

Postanesthesia care unit (PACU), 389, 405–411

Posthemorrhagic hydrocephalus of prematurity

cysticercosis, 48  
 gram-positive bacteria, 48  
 multiloculated hydrocephalus, 48

Postoperative care

criteria for PACU recovery, 405–406  
 FACES, 409  
 FLACC pain scale, 409  
 management and treatment of potential complications, 408–409

pain, 409–410

parental and patient guidance, 408

parental presence in PACU, 407–408

visual analogue scale (VAS), 409

Postoperative infections, 110, 353, 386–387

vs. of fever, 353, 386, 387

Postoperative nursing management

molding helmet, 112  
 postdischarge management, 110

Posttraumatic seizures, 195, 214, 219, 222

Premature infant pain profile, 31, 32

Preoperative care

dietary restrictions, 394  
 imaging tests, 393  
 indicators for PAT, 392  
 laboratory testing, 393  
 parental preparation, 389–390, 395  
 parental presence upon induction of anesthesia, 395–396  
 preoperative consultation, 390–391  
 preoperative medication, 394–395  
 preoperative preparation programs, 390  
 psychological preparation of the child, 390  
 separation from parents, 393–394

Pressure-volume curve, 194, 226

Pseudo seizures, 338

Pseudotumor cerebri in the pediatric population

classification, 72  
 evaluation, 73  
 pathophysiology, 72–73  
 treatment, 73–74

Pupillary response

anisocoria, 199  
 facial, 199  
 hippus, 199  
 Horner's syndrome, 199, 271  
 miosis, 199  
 mydriasis, 199  
 oculocephalic, 28, 199  
 oculovestibular, 29, 199, 200  
 Parinaud's syndrome, 199  
 ptosis, 195, 199

- saccadic eye movements, 199
  - sunsetting, 199, 200
  - sunsetting eyes, 50, 51
  - trigeminal, 199
  - vestibular, 199
- R**
- Rasmussen's encephalitis, 346–347
  - Rasmussen's syndrome, 335
- Reflexes
- Babinski, 24, 25, 194
  - brainstem herniation, 19
  - clonus, 195, 202
  - deep tendon reflexes (DTR), 25, 201, 361, 372
  - Kernohan's notch, 203, 229
  - magnetic resonance imaging (MRI), 203, 204, 206, 208
  - reticular activating system, 203
  - skull radiographs, 203
  - tentorium cerebella, 203, 215
- Registered nurse first assistants (RNFA), 396, 399
- S**
- Saethre-Chotzen, 98
  - Sagittal synostosis, 86, 88–90, 104, 108, 110, 112
  - Scalp electrodes, 337
  - Second impact syndrome, 211
  - Seizure, 2, 5, 109, 123, 158, 195, 286, 333, 361, 386, 392, 418
  - Seizure focus, 168, 182, 336, 338, 344, 345, 355–357
  - Selective dorsal rhizotomy
    - barriers, 371
    - nursing care, 371–372
    - patient selection, 371
    - procedure, 371
  - Semiology, 333, 334, 336, 342, 357
  - Semiology seizure classification (SSC), 334
  - Shaving, 404
  - Shunt infections
    - diagnostic tests, 66–67, 383
    - etiology, 382–383
    - nursing care, 76
    - outcome, 385
    - pathophysiology, 383
    - patient and family education, 78, 385
    - pseudocyst, 68
    - symptoms, 383
    - treatment, 66–68, 383–385
    - VA shunt, 68–69
  - Single-proton-emission-tomography (SPECT), 336, 337
  - Sinovenous thrombosis
    - anemia, 315
    - bromage sedation scale, 318, 319
    - cerebral perfusion, 316–317
    - chronic diseases, 315
    - clotting disorders, 324
    - CT, 315, 316
    - dehydration, 316
    - diagnostic imaging, 315–316
    - fever, 318
    - head trauma, 375
    - increased ICP, 317
    - infection, 318–319
    - management of nausea and vomiting, 318
    - medical treatment, 316
    - MRI, 316
    - nausea, 318
    - neurosupportive therapy, 316
    - nursing care, 316
    - pain management, 318
    - pathophysiology, 314–315
    - risks/causes, 317, 318
    - seizure management, 317
    - surgical treatment, 316
    - thrombectomy, 316
    - trauma, 315
  - Skeletal dysplasias
    - achondroplasia, 255
    - achondroplastic child, 256
    - adulthood, 256–258
    - apnea, 256
    - brain stem, 255, 256
    - cervicomedullary compression, 255–256
    - cervicomedullary junction, 257
    - C shape, 256
    - CV compression symptoms, 255–256
    - decompression, 254, 256
    - fibroblast growth factor receptor, 255
    - foramen magnum, 255
    - hydrocephalus, 255
    - hyperreflexia, 255
    - hypoventilation, 255
    - lumbosacral hyperlordosis, 256–257
      - adult, 256
      - C shaped posture, 256
    - medullary compression, 255–256
    - myelogram, 257
    - neurogenic claudicatory, 257
    - paresis, 255, 256
    - paresthesias, 255, 256
    - posterior fossa, 255
    - sleep apnea, 256
    - spinal stenosis, 255
    - thoracolumbar kyphosis, 256–257
  - Skull
    - basilar skull fracture, 196, 199, 214
    - depressed skull fracture, 205, 206, 213, 219, 240, 375
    - diffuse axonal injury, 194, 195, 220, 221
    - fontanel, 194
    - head circumference, 194
    - initial history and physical, 195
    - leptomeningeal cyst, 207
    - linear skull fracture, 205, 207, 213
    - neonatal skull fracture, 205–207
    - neurologic assessment and deterioration, 196–198
    - occipital fractures, 194
    - ping pong fracture, 213
    - pressure-volume curve, 226

- Spasticity  
 clinical presentation and complications, 362  
 pathophysiology, 361
- Spina bifida occulta  
 atretic meningocele, 134, 135  
 caudal appendage, 134, 135  
 club feet, 135  
 cutaneous stigmata, 134  
 dermal sinus opening, 134  
 dermal sinus tract, 133, 134  
 dermoid cysts and tumors, 133  
 diagnostic studies, 137  
 diastematomyelia, 133, 134  
 diplomyelia, 133  
 electromyography (EMG), 136  
 filum terminale, 133, 137  
 hemangioma, 134, 135  
 hypertrichosis, 134  
 kyphosis, 135  
 lipoma or lipomeningocele, 133–135  
 meningocele manque, 133, 134  
 nursing considerations, 137  
 orthopedic findings, 135–136  
 scoliosis, 134, 135  
 somatosensory evoked potentials (SSEPs), 136  
 split cord malformation, 133  
 subcutaneous, 134, 135  
 surgical management, 136  
 tight filum terminale, 133  
 urologic dysfunction  
 enuresis, 136  
 urinary tract infections, 136
- Spinal cord injury  
 causes  
 contusion, 274  
 dislocation, 264, 267  
 fractures, 273  
 hemisection, 263  
 transection, 263  
 etiology, 263  
 pathophysiology  
 anatomic features of pediatric spine, 261, 263  
 fulcrum, 261, 262
- SCIWORA  
 bradycardia, 264  
 C-spine injury, 264–265  
 head injury, 264  
 hypotension, 264  
 injury level and age, 263, 264  
 ligamentous edema, 264  
 prognosis, 264
- Spine, 3, 44, 94, 119, 148, 158, 194, 249, 309, 364, 414,  
 Sprengel's deformity, 252
- SSC. *See* Semiology seizure classification (SSC)
- Status epilepticus, 334, 340
- Sturge-Weber syndrome, 335, 346–348
- Subacute bacterial endocarditis (SBE) prophylaxis  
 nursing care, 385  
 outcome, 385  
 patient and family education, 385
- Subarachnoid hemorrhage, 39, 49, 77, 206, 207, 214,  
 217, 288, 298, 302, 303, 305
- Subdural hemorrhage, 206–209, 215–216, 223, 224, 303
- Subependymal giant cell tumor, 349
- Sudden unexplained death in epilepsy (SUDEP), 336  
 video-EEG, 337–338
- SUDEP. *See* Sudden unexplained death in epilepsy  
 (SUDEP)
- Surgical  
 complications  
 infection, 65–69, 240  
 obstruction, 64, 65, 69, 71, 72  
 hand scrub, 397, 400  
 shunt intervention  
 fixed pressure, 56, 57  
 flow-regulating, 56  
 placing the distal tubing, 57  
 programmable valves, 56–58  
 siphon-resisting valves, 56  
 tubing placement, 57
- Symptoms  
 posterior fossa  
 diplopia, 299  
 hydrocephalus, 298  
 increased ICP, 299  
 papilledema, 299
- Syringomyelia  
 hydromyelia  
 dysphagia, 146, 147  
 headache, 146  
 neuromonitoring, 149  
 respiratory distress, 147  
 scoliosis, 148  
 surgery, 149  
 swallowing dysfunction, 147  
 vocal cord paralysis, 146
- nursing care  
 antiemetic medications, 150  
 chemical meningitis, 151  
 discharge criteria, 151  
 pseudomeningocele, 150
- outcomes, 155
- patient and family education, 154–155
- syrix, etiology, 145
- treatment options  
 duraplasty, 150  
 neuromonitoring, 149, 153  
 syringoperitoneal shunt, 154  
 syringopleural shunt, 154  
 syringosubarachnoid shunts, 154  
 treatment options, 154
- Syrinx, 125, 141, 144–149, 154, 155, 323  
 etiology, 144
- T**
- TBI. *See* Traumatic brain injury (TBI)
- Temperature regulation, 236–237
- Temporal lobe epilepsy (TLE), 335, 343
- Thoracic and lumbar spine injuries

- anterior cord syndrome, 274
- Brown-Sequard syndrome, 274
- central cord syndrome, 274
- contusions, 274
- distraction, 274
- SCI, 274
- steroids, 275
- TLE. *See* Temporal lobe epilepsy (TLE)
- Transition
  - barriers, 417–418
  - consensus statement, 415
  - health information and medical records, 420
  - insurance, 414–416, 420
  - models, 424–425
  - tools, 421–424
- Traumatic brain injury (TBI)
  - diffuse axonal injury, 195, 204, 220, 221
  - endocrine complications
    - cerebral salt wasting, 240
    - diabetes insipidus, 239
    - syndrome of inappropriate antidiuretic hormone (SIADH), 239
  - epidemiology, 193
  - evidence based treatment guideline, 231, 232
  - initial history and physical, 195
  - initial resuscitation, 231
  - intensive care management, 231–233
  - neurological assessment and deterioration, 196–198
  - nursing care, 240
  - outcomes, 243
  - postoperative complications, 241–242
  - pressure volume curve, 226
  - prevention, 243
- Traumatic spinal cord injury
  - airway, 265, 266
  - anatomic features, 261, 262
  - bradycardia, 264
  - cervical spine precautions, 265–267
  - contusion (bruising), 263
  - C-spine injuries, 265–267
  - diagnosis, 265
  - dislocations, 267–269
  - epidemiology, 263
  - etiology, 263
  - fractures, 263
  - head injury, 264
  - hemisection, 263
  - hypotension, 264
  - immobilization, 264–266
  - ligamentous edema, 264
  - pathophysiology, 267–268
  - positioning, 265, 266
  - prognosis, 264
  - radiographic evaluation, 265
  - risk factors, 265, 267
  - SCIWORA, 264
  - sympathetic nervous system, 21
  - transection, 263
  - unconscious patient, 265
  - vertebral bodies, 262
- Treacher Collins syndrome, 100
- Treatment
  - brachytherapy, 169
  - chemotherapy, 170–180, 184–190, 376, 426
  - COG, 157, 167
  - conformal radiation therapy, 169
  - diuretics, 27, 37, 54, 182, 228, 241, 288, 290, 299
  - electrocorticography, 165, 182, 343
  - intraoperative guidance systems, 166, 181
  - intraoperative monitoring, 136, 158, 165, 166, 173, 181
  - linear accelerator, 169, 295
  - radiation, 158, 164, 168–169, 176, 183–184
  - staged protocol, 253, 317, 393
  - staged surgical procedures, 165
  - stem cell transplant, 170, 175, 178, 186
- Tuberous sclerosis, 41, 49, 157, 176, 302, 312, 335, 348–349
- Tubers, 157, 348, 349
- Tumors
  - etiology, 157–158
  - hemangioblastomas, 170
    - phakomatoses, 157, 302
  - medulloblastoma, 157, 161, 169, 172, 177–178, 180
  - nevoid basal cell, 157
  - oncogenesis, 158
  - radiation, 168–169
  - SEGAS, 157
  - turcot, 157
  - types
    - astrocytomas, 49, 158, 161, 170, 172, 342
    - benign, 170, 179, 342
    - brain stem gliomas, 175–176
    - choroid plexus tumors, 39, 49, 170, 179, 180
    - craniopharyngiomas, 49, 161, 170, 172, 178–179, 301
    - dermoid tumors, 372
    - dysembryoplastic neuroepithelial tumors (DNETs), 161, 172, 178, 342
    - eosinophilic granulomas, 179–180
    - ependymomas, 49, 64, 161, 163, 170, 172, 176–177
    - epidermoid tumors, 170, 179
    - gangliocytomas, 170, 176
    - gangliogliomas, 170, 176, 342
    - germ cell tumors, 49, 170, 179, 190
    - glioblastoma multiforme, 170, 174, 176
    - gliomas, 49, 161, 170, 172–175, 342
    - hemangioblastomas, 157, 170
    - histiocytosis X, 179–180
    - histology, 171
    - infant tumors, 162, 180
    - Langerhans cell histiocytosis (LCH), 179
    - low-grade astrocytomas, 173–174
    - malignant, 177
    - malignant astrocytomas, 174–175
    - malignant versus benign, 170–171
    - medulloblastoma, 49, 158, 161, 170, 172, 177–178, 190
    - oligodendrogliomas, 170, 176

Tumors (*cont.*)

- pineal cell tumors, 170
- posterior fossa syndrome, 180
- primitive neuroectodermal tumors (PNET), 141, 170, 172, 178, 180, 190
- spinal cord malignant astrocytomas, 176
- subependymal giant cell astrocytomas (SGCA), 176
- Von Hippel-Lindau, 157

## V

- Vagal nerve stimulator (VNS), 338, 342, 349
  - complications of epilepsy surgery, 351–352
  - CSF leak, 351, 400
  - electrolytes, 352
  - Engel's classification, 354
  - fever, 353
  - ILAE classification of postoperative outcome, 354
  - incision care, 353
  - infection, 351
  - International League Against Epilepsy, 354
  - nursing care following resective surgeries, 352–353
  - outcomes of epilepsy surgery, 354–357
  - pain management, 352
  - postoperative drains, 352–353
  - postoperative outcome, 354
  - Quality of life (QOL), 355
  - seizures, 351–353
  - stroke, 351, 352
- Vascular anatomy
  - arterial supply, 283–285
  - cerebral blood supply, 283
- Vein of Galen (VOG) aneurysmal malformations
  - choroidal, 287
  - congestive heart failure, 287, 289–291
  - cranial MRI and/or CT scan, 288
  - diagnostic studies
    - color Doppler, 288
    - CT, 288
    - MR angiography, 288
    - MRI, 289
  - dural venous sinuses, 285–286
  - homunculus, 286
  - jugular veins, 286
  - MProSV, 287
  - mural, 287
  - nursing
    - cardiac management, 290
    - head circumference, 290
    - medication, 290
    - outcomes, 290–291
  - pathophysiology
    - median prosencephalic vein of Markowski (MProV) choroidal, 287
    - mural, 287
  - pharmacological management, 290
  - score, 287, 288
  - surgical treatments, 290
  - symptoms

- cardiomegaly, 287–288
- congestive heart failure (CHF), 287
- hydrocephalus, 288–291
- hydrocephalus, 287
- pulmonary hypertension, 287
- steal, 287

## treatments

- embolic agents, 289
- endovascular embolization, 289
- onyx, 289
- perfusion breakthrough, 289

## Venous angiomas, pathophysiology

- CT or MRI, 306
- variation, 305
- veins, 305
- World Federation of Neurological Surgeons Scale, 305

## Venous anomalies

- brainstem cavernous malformations
  - classification, 309
  - diagnostic imaging, 310
  - genetic counseling, 311
  - medications, 307, 312
  - stereotactic radiosurgery, 311
  - symptoms, 309–310
  - treatments, 310–311
- capillary angiomas, 307
- cavernous malformations (cav mal), 308–312
- diagnostic tests, 306–307
- medical management, 307
- pathophysiology, venous variants, 308–309
- spinal cavernous malformations, 310, 311
  - cystic vascular spaces, 308
- surgical management, 307
- telangiectasias, 307–308

## Visual acuity, 14, 20, 22, 73, 81, 164, 198, 299

## Visual analogue scale (VAS), 409

## Vital signs, 17, 27–28, 74, 75, 111, 137, 162, 181, 194–197, 203, 238, 240, 241, 274, 275, 316, 318, 393, 398, 406, 408–412

## brainstem, 27, 28, 196, 203, 410

## von Hippel-Lindau syndrome, 157

## W

## Wada test, 2, 164, 338

## Working Initiative for Special Health Education Services (WISHES), 425–426

## nursing, 427

## Y

## Young adults with special health care needs (YASHCN), 424, 427

## Youth with Special Health Care Needs (YSHCN)

- barriers, 417–420
- consensus statement, 415, 416
- health information and records, 420
- insurance, 420
- models, 421–426