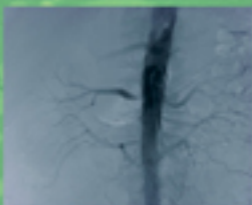

Edited by  
**Richard Hopkins**  
**Carol Peden**  
**Sanjay Gandhi**



# **Radiology for Anaesthesia and Intensive Care**

**Second Edition**

CAMBRIDGE

Medicine

CAMBRIDGE

[www.cambridge.org/9780521735636](http://www.cambridge.org/9780521735636)

This page intentionally left blank

# Radiology for Anaesthesia and Intensive Care

---

Second edition



# **Radiology for Anaesthesia and Intensive Care**

---

Second Edition

**Richard Hopkins,  
Carol Peden and  
Sanjay Gandhi**



**CAMBRIDGE**  
UNIVERSITY PRESS

CAMBRIDGE UNIVERSITY PRESS  
Cambridge, New York, Melbourne, Madrid, Cape Town, Singapore,  
São Paulo, Delhi, Dubai, Tokyo

Cambridge University Press  
The Edinburgh Building, Cambridge CB2 8RU, UK

Published in the United States of America by Cambridge University Press, New York

[www.cambridge.org](http://www.cambridge.org)

Information on this title: [www.cambridge.org/9780521735636](http://www.cambridge.org/9780521735636)

© Cambridge University Press 2010

This publication is in copyright. Subject to statutory exception and to the provision of relevant collective licensing agreements, no reproduction of any part may take place without the written permission of Cambridge University Press.

First published in print format 2009

ISBN-13 978-0-511-64156-5 eBook (NetLibrary)

ISBN-13 978-0-521-73563-6 Paperback

Cambridge University Press has no responsibility for the persistence or accuracy of urls for external or third-party internet websites referred to in this publication, and does not guarantee that any content on such websites is, or will remain, accurate or appropriate.

Every effort has been made in preparing this publication to provide accurate and up-to-date information which is in accord with accepted standards and practice at the time of publication. Although case histories are drawn from actual cases, every effort has been made to disguise the identities of the individuals involved. Nevertheless, the authors, editors and publishers can make no warranties that the information contained herein is totally free from error, not least because clinical standards are constantly changing through research and regulation. The authors, editors and publishers therefore disclaim all liability for direct or consequential damages resulting from the use of material contained in this publication. Readers are strongly advised to pay careful attention to information provided by the manufacturer of any drugs or equipment that they plan to use.

To my parents, loving wife Ila and  
inspirational children Sanchit and Sahaj.  
*Sanjay Gandhi*

To Martin for his continuing support.  
*Carol Peden*

To my loving family – Carol, Rhys and  
Rheanna and my parents.  
*Richard Hopkins*





# Contents

*Contributors* page ix  
*Acknowledgements* xi  
*Introduction* xiii  
*About the FRCA examination* xv  
The Primary examination xv  
The Final examination xv  
Preparation xvi  
Competency-based training and assessment xvi  
*The pre-operative assessment* xix  
Looking at X-ray films as part of the pre-operative assessment xix  
Association of Anaesthetists of Great Britain and Ireland xix  
Royal College of Radiologists xix  
Task Force on Preanaesthetic Evaluation of the American Society of Anaesthesiologists xx

---

- 1. Imaging the chest** 1  
How to read a chest X-ray 2
- 2. Imaging the abdomen** 59  
Plain abdominal X-rays 60  
Case illustrations: plain films and CT 62
- 3. Trauma radiology** 96  
Chest trauma: case illustrations 97  
Blunt abdominal and pelvic trauma: case illustrations 104
- 4. The cervical spine** 129  
Introduction: clearing the cervical spine 130  
Non-traumatic conditions affecting the cervical spine 142  
Trauma of the cervical spine 155
- 5. CT head** 172  
Principles of CT image formation and interpretation 173  
Principles of interpreting CT head 176  
Case illustrations 177
- 6. Anaesthesia in the radiology department. MRI and interventional radiology** 209  
Anaesthesia in the radiology department 210  
MRI: principles of image formation 212  
MRI: anaesthetic monitoring 216  
MRI: case illustrations 223  
Interventional procedures: case illustrations 233
- 7. Ultrasound** 250  
Introduction 251  
Ultrasound imaging: principles of image formation 251  
Applications of ultrasound for patients on intensive care units 255  
Ultrasound guided procedures 259  
Ultrasound guided procedures: *needle visualisation* 259  
Ultrasound imaging: case illustrations 271

## Contents

- Echocardiography for patients  
on intensive care units  
R. Orme and C. McKinstry 279
- Ultrasound guided regional  
anaesthesia  
Julie Lewis and Barry Nicholls 287

---

*Index* 305

# Contributors

---

## **Marcus Bradley**

Consultant Neuroradiologist  
Frenchay Hospital  
Bristol  
UK

## **Lai Peng Chan**

Vancouver General Hospital  
British Columbia  
Canada

## **Chris Cook**

Consultant Radiologist  
Department of Radiology  
Weston General Hospital  
Weston-super-Mare  
UK

## **Danial Fox**

Consultant Radiologist  
Radiology Department  
Musgrove Park Hospital  
Taunton  
UK

## **Sanjay Gandhi**

Consultant Radiologist  
Department of Clinical Radiology  
Frenchay Hospital  
Bristol  
UK

## **Richard Gee**

Vancouver General Hospital  
British Columbia  
Canada

## **Richard Hopkins**

Consultant Radiologist  
Department of Radiology  
Cheltenham General Hospital  
Cheltenham  
UK

## **Lyn Jones**

Consultant Radiologist  
Department of Clinical Radiology  
Frenchay Hospital  
Bristol  
UK

## **Cieran Keogh**

Vancouver General Hospital  
British Columbia  
Canada

## **Julie Lewis**

Specialist Registrar in Anaesthesia  
Plymouth Hospitals NHS Trust  
Derriford Hospital  
Plymouth  
UK

## **Caleb McKinstry**

Consultant Anaesthetist  
Department of Anaesthesia  
Cheltenham General Hospital  
Cheltenham  
UK

## **Peter Munk**

Vancouver General Hospital  
British Columbia  
Canada

## **Barry Nicholls**

Consultant in Anaesthesia and Pain  
Management  
Taunton & Somerset NHS Foundation  
Trust  
Musgrove Park Hospital  
Taunton  
Somerset  
UK

**Savvas Nicolaou**

Vancouver General Hospital  
British Columbia  
Canada

**Robert Orme**

Consultant Anaesthetist  
Department of Anaesthesia  
Cheltenham General Hospital  
Cheltenham  
UK

**Carol Peden**

Consultant in Anaesthesia and Intensive  
Care Medicine  
Royal United Hospital  
Bath  
UK

**James K. Ralph**

Consultant Anaesthetist  
University Department of Anaesthesia  
The Queen Elizabeth Hospital  
Birmingham  
UK

**J. Mark Regi**

Specialist Registrar in Radiology  
Bristol Training Scheme  
Bristol  
UK

**Julie Searle**

Consultant Radiologist  
Department of Radiology  
Cheltenham General Hospital  
Cheltenham  
UK

**Ian Taylor**

Consultant Anaesthetist  
Department of Anaesthesia  
Queen Alexandra Hospital  
Portsmouth  
UK

# Acknowledgements

The authors would like to express their appreciation and thanks to the following contributors for their involvement in the project.

Dr Caleb McKinstry. In addition to Dr McKinstry's ultrasound chapter, he was heavily involved in updating the book and advising about changes to the second edition. He has advised on the planning of several of the chapters and has written sections within the chest, abdominal and c spine chapters. He has written and advised on matters relating to the anaesthetic exam. He proof read and helped edit many of the sections. We are deeply indebted for his contribution and expert advice. The second edition of the book would not have been possible without his energy, enthusiasm and commitment.

Dr Ian Taylor. Advised on content and updates to second edition.

Dr Lyn Jones. Advised and contributed sections of the interventional radiology section. Her advice and input is particularly recognised for the vascular interventional radiology components.

Mr Chris Cassop. His input into the MRI section was integral in updating the second edition.

Dr Mat Shaw. For his contribution to the abdominal section.

Dr Tariq Ahmed. For his contribution to the abdominal section.

Images contributed by Dr L Marchenko, Dr M Gibson, Dr G McGann.

*Richard Hopkins*

*Carol Peden*

*Sanjay Gandhi*

*February 2009*



# Introduction

This book has been written for anaesthetists and intensive care doctors working in hospital practice. The material in the book covers all the common pathologies encountered in hospital anaesthetic practice and intensive care. Included are the core radiological requirements for the FRCA examination, but it is also ideally suited for doctors preparing for the Diploma in Intensive Care Medicine. It is not only intended as an examination revision aid, but also as a general radiological or revision text in anaesthetic radiology. In addition to the more commonly encountered areas such as chest and abdominal imaging, particular attention has been given to the topics of cervical spine imaging and blunt trauma. Sections covering trauma imaging of the chest, abdomen, pelvis, cervical spine and head are included.

An excellent knowledge of anatomy is crucial when interpreting any radiological investigation. Particular attention has been paid to illustrating relevant radiological anatomy. For each body system (chest and cardiovascular, abdomen and pelvis, and head), the radiological anatomy of both conventional radiographs and CT is discussed in some detail. This appears at the beginning of the relevant chapters. For instance, Chapter 1, *Imaging the chest*, includes detailed diagrams of the cardiac silhouette, the mediastinal outline and the anatomy that appears on a conventional chest radiograph. In addition, the anatomy visible on chest CT is explained and illustrated.

Technology in radiology is advancing rapidly, especially in the fields of cross-sectional imaging such as CT and MRI. Clinicians require a basic understanding of how various imaging modalities work in order to be able to interpret the images correctly. The basic principles of image formation in CT, MRI and ultrasound are explained. Special attention is paid to the unique problems encountered in MRI scanners with particular regard to patient monitoring and support systems.

In radiology, a diagnosis is often made by recognizing patterns of disease. Various imaging patterns (air space shadowing, interstitial lung patterns, pulmonary nodules, etc.) often have a broad differential diagnosis. Final diagnosis is dependent upon clinical history, imaging features and further laboratory investigations. The clinical case scenarios in the book have been written to include clinical history, results of investigations and the radiology. For each case, a differential diagnosis is given where appropriate and anaesthetic management is discussed.

## Second edition

Hospital practice has progressed since the first edition of this book was published in 2003. Probably the biggest change over this period has been the widespread introduction of picture archiving and communication systems (PACS). This has revolutionized imaging departments and the way in which hospitals acquire, store and distribute medical diagnostic imaging. Most UK hospitals are now 'filmless' with clinicians viewing scans and X-rays on computer screens. This has improved the availability of medical imaging for the anaesthetist. All imaging modalities (plain X-rays, CT, MRI, ultrasound, etc.) are now accessible to hospital clinicians in locations scattered around the hospital and not just in the radiology department. There are improved learning and teaching opportunities as a result.

CT scanning has continued to develop with technological advances, the widespread use of multi-slice spiral CT and new versatile CT work stations. CT is the workhorse of modern

medical imaging. The second edition has been updated to include sections on multi-slice CT, image manipulation and new scanning techniques such as CT angiography.

Ultrasound is a rapidly expanding imaging modality and is now undertaken by many different hospital specialists including anaesthetists. This is partly due to the improved size, portability and cost of ultrasound systems. The ultrasound chapter has been expanded for the second edition with new sections on ultrasound guided regional anaesthesia, echocardiography in the setting of ITU and further additions to reflect its extensive use in central line placement.

New interventional techniques have been validated in the last few years, for instance, new minimally invasive techniques such as endovascular aneurysm repair (EVAR). New material has been written to revise and update the relevant chapters.

The format of the book remains unchanged, with a general introduction to most chapters followed by a number of clinical cases presented in question and answer format. To derive the maximum benefit from each chapter, it is recommended that the introduction to the main chapters is read prior to attempting the accompanying clinical cases.



# About the FRCA examination

Updated for the current edition by Ian Taylor

James K. Ralph and Carol J. Peden

The examination for Fellow of the Royal College of Anaesthetists is in two parts. These two parts are known as the Primary and Final examinations. Each part comprises both written and Short Oral Examination (SOE), with the Primary also including an 'OSCE' (Objective Structured Clinical Examination).

There are currently ongoing revisions to the Primary and Final FRCA Examinations to be introduced during 2009–11, so it is recommended to visit the RCA website to get up-to-date information relating to eligibility for, and format of, the examinations.

A good knowledge of radiological topics as applied to clinical practice is essential to attain the FRCA.

## The Primary examination

The Primary examination is designed to assess trainees who are on a Postgraduate Medical Examination and Training Board (PMETB) approved training programme in anaesthesia or an acute care common stem (ACCS) trainee with anaesthesia as their chosen specialty. The details of eligibility can be found in the regulations for the Primary and Final FRCA examinations published by the RCA; however, it is recommended that candidates should not sit the Primary FRCA OSCE and SOE until at least half way through their basic level training programme in anaesthesia, i.e. most will have completed 12 months. The Primary examination examines both the relevant basic sciences and clinical practice of anaesthesia undertaken in the Basic Level Training (ST1-2) and consists of three parts: MCQ, OSCE and SOE. Candidates are expected to demonstrate a good understanding of the fundamentals of clinical anaesthesia practice. With particular reference to radiology, this includes the selection and interpretation of relevant pre-operative investigations and the basic principles of ultrasound and the Doppler effect. Radiological images that may be encountered will appear in the OSCE section of the examination. Interpretation will take the form of short questions based on chest radiographs, neck and thoracic inlet films, abdominal fluid levels/air/masses, skull films and other imaging investigations (simple data only). The SOE in the Primary examination does not currently include X-ray interpretation.

## The Final examination

The Final examination is designed to assess trainees who have passed the Primary examination, been awarded the UK Basic Level Training Certificate, the UK SHO Training Certificate or the Irish Certificate of Completion of Basic Specialist Training and are at least one-third of the way through their intermediate level training programme in anaesthesia. Final examination candidates are expected to have a thorough knowledge of medicine and surgery, appropriate to the practice of anaesthesia, intensive care and pain management. This

includes pre-operative assessment and selection and interpretation of appropriate investigations. It also includes knowledge of diagnostic imaging and the appropriate anaesthesia and sedation, pre-anaesthetic preparation and techniques appropriate for adults and children for CT scan, MRI and angiography and post-investigation care. An understanding of the principles of imaging techniques including CT, MRI and ultrasound is also required.

The Final examination is also divided into four parts: MCQ, SAQ and two SOEs. Radiology-related questions may arise in any of these sections.

There are two structured SOEs: SOE 1 (50 minutes) – Clinical Anaesthesia – is where radiological images will occur. This viva consists of a long case and three short cases. During the first 10 minutes, you will have the opportunity to view, on your own, clinical information related to the long case, including radiological images (usually a chest X-ray), followed by 20 minutes of questioning on this material. There are easy marks to be had if you have practised X-ray interpretation. An ordered, sensible approach to the chest X-ray will also give the examiners the impression that you are safe and experienced – practise and impress them! During the final 20 minutes you will be asked questions on three further clinical topics. In this section further images may be used to form the basis for questions, e.g. a CT scan to discuss head injury management.

In SOE 2, where questions are based on basic science topics, subjects could include the physical principles of MRI or ultrasound, and their clinical applications.

## Preparation

Preparation for the examination should start by obtaining and reading the current syllabus for the examinations which form the ‘knowledge’ sections of the relevant Competency Based Training documents and the examination regulations, which can be obtained from the RCA. A period of intensive study is a prerequisite to success but also realistic viva practice from consultant colleagues and recent successful examination candidates. It is important to develop a system for reviewing and presenting X-rays and, again, practice with colleagues, and preferably a radiologist, will refine your technique.

## Competency-based training and assessment

Becoming a safe and competent anaesthetist is not only about passing the appropriate examinations; workplace assessments must be successfully completed by a trainee to achieve the Basic, Intermediate and Higher/Advanced Level Training Certificates in order to receive accreditation. At Basic Level Training the trainee must be able to interpret simple radiological images showing clear abnormalities including chest radiographs, CT and MRI scans of head (showing fracture and haemorrhage), neck and thoracic inlet films, plus films showing abdominal fluid levels/air. At Intermediate Training level and above, the anaesthetist should understand the implications of different radiological procedures in their anaesthetic care of the patient and be able to establish safe anaesthesia or sedation within the confines and limitations of the X-ray department where a wider range of interventional procedures is occurring. Intermediate and Advanced Training in Intensive Care Medicine requires the clinician to be competent in the interpretation of radiological investigations performed on critically ill patients and to understand how radiological investigations can be used to aid management of those patients.

## Recommended reading

*The CCT in Anaesthetics. Manuals for Trainees and Trainers, Parts I–IV.* Royal College of Anaesthetists, 2007–2008.

RCA website: <http://www.rcoa.ac.uk>.

*Guide to the FRCA Examination. The Primary.* Royal College of Anaesthetists, September 2007.

*Guide to the FRCA Examination. The Final.* Royal College of Anaesthetists, June 2008.

*The Clinical Anaesthesia Viva Book.* Mills SJ, Maguire SL, Barker JM (eds) London: Greenwich Medical Media, 2002.



# The pre-operative assessment

James K. Ralph

## Looking at X-ray films as part of the pre-operative assessment

Pre-operative assessment consists of the consideration of information from multiple sources that may include the patient's medical record, interview, physical examination and findings from medical tests and evaluations. Pre-operative tests may be indicated for various purposes including:

- discovery or identification of a disease or disorder that may affect peri-operative anaesthetic care,
- verification or assessment of an already known disease, disorder or therapy,
- formulation of specific plans and alternatives for peri-operative care.

Any test required for a patient should be ordered with the reasonable expectation that it will result in benefit, such as a change in the timing or selection of a technique or appropriate pre-operative optimization, that exceeds any potential adverse effects.

A number of guidelines and publications by various working parties and taskforces exist with advice on which investigations are appropriate, when they are appropriate and in which individuals.

## Association of Anaesthetists of Great Britain and Ireland<sup>1</sup>

Blanket routine pre-operative investigations are inefficient, expensive and unnecessary. Medical and anaesthetic problems are identified more efficiently by the taking of a history and by the physical examination of patients. It should be remembered that pre-operative investigations can themselves be the cause of morbidity.

Departments should have policies on which investigations should be performed. These should reflect the patient's age, co-morbidity and the complexity of surgery. Chest X-rays should be arranged in accordance with the recommendations from the Royal College of Radiologists in conjunction with local hospital policy.

## Royal College of Radiologists<sup>2</sup>

The pre-operative chest X-ray is not routinely indicated. Exceptions are before cardio-pulmonary surgery, likely admission to ITU or suspected malignancy or TB. Anaesthetists may also request chest X-rays for dyspnoeic patients, those with known cardiac disease and the very elderly. Many patients with cardio-respiratory disease have a recent chest X-ray available; a repeat chest X-ray is not then usually required.

## Task Force on Preanesthetic Evaluation of the American Society of Anesthesiologists<sup>3</sup>

The Task Force 'agreed that pre-operative tests including chest X-ray should not be ordered routinely. The Task Force agreed that pre-operative tests might be performed on a selective basis for the purpose of guiding or optimising management ...'

'The Task Force agreed that the clinical characteristics to consider when deciding whether to order a pre-operative chest X-ray include smoking, recent upper respiratory tract infection (URTI), chronic obstructive pulmonary disease (COPD) and cardiac disease. The Task Force agreed chest X-ray abnormalities may be higher in such patients but does not believe that extremes of age, smoking, stable COPD, stable cardiac disease or recent resolved URTI should be considered unequivocal indications for chest X-ray.'

In their review of the literature, they noted that routine chest X-rays were reported as abnormal in 2.5%–60.1% of cases (20 studies) and led to changes in management in 0%–51% of cases found to be abnormal (9 studies). Indicated chest X-rays were reported as abnormal in 7.7%–65.4% of cases (18 studies) and led to a change in management in 0.5%–74% of cases (9 studies). In other words, there is a wide range of reported abnormality in both routine and indicated chest X-ray, many of which do not result in a change in patient management.

In summary, the pre-operative chest X-ray is not routinely indicated. It should be preceded by a thorough history and physical examination and ordered if these elicit an indication consistent with departmental policies in conjunction with recommendations from the Royal College of Radiologists. This should result in requests for chest X-rays that have a higher probability of showing an abnormality, which will then be acted on with a change in patient management whilst minimizing risk to the patient.

## References

1. *Preoperative Assessment. The Role of the Anaesthetist.* Association of Anaesthetists of Great Britain and Ireland, 2001.
2. *Making the Best Use of a Department of Clinical Radiology: Guidelines for Doctors*, 6th edition. Royal College of Radiologists, 1998 (ISBN 1872599370).
3. Practice Advisory for Preanesthetic Evaluation. A Report by the American Society of Anesthesiologists Task Force on Preanesthetic Evaluation, 2001.

Chapter

1

# Imaging the chest

---

How to read a chest X-ray 2

Case histories: plain films  
and CT 9

## How to read a chest X-ray

Reading a chest X-ray requires a methodical approach that can be applied to all films so that abnormalities are not overlooked. Clinicians and radiologists develop an individual approach, but there are certain core areas that should be looked at on all films. These may be inspected in any order – this is largely down to personal preference. Listed below is the outline of a method which can be applied to read chest X-rays.

### Initial quick review of film

To identify any obvious abnormality.

### Systematic analysis

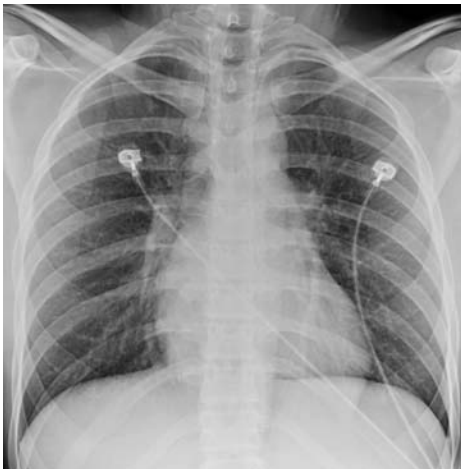#### Label

Verify the patient's identity. In examination situations look at the name, if present, as this can give a clue to sex and ethnic background.

#### Projection and patient position

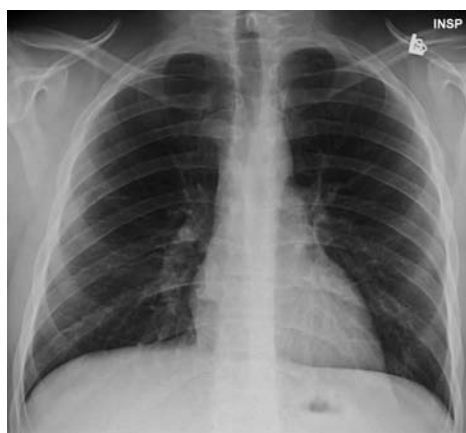Postero-anterior (PA) is the preferred projection as this does not produce as much radiographic magnification of the heart and mediastinum as an antero-posterior (AP) projection. A PA film is taken with the film cassette in front of the patient and the beam delivered from behind with the patient in an upright position. Portable films and those taken on intensive care are all AP projection. Patient position causes important, although sometimes subtle, variations in appearance. The supine position causes distension of the upper lobe blood vessels, which may be confused with elevated left atrial pressure (see Fig. 1.1).

Films taken in the AP projection are usually labelled as such, but to avoid difficulties when describing films in examinations the use of the term 'frontal projection' is often helpful.

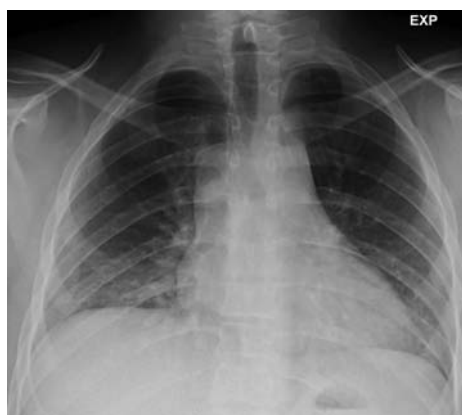

**Figure 1.1.** AP supine chest X-ray. Note the distended upper lobe vessels.





**Figure 1.2.** PA chest X-ray in inspiration.



**Figure 1.3.** PA chest X-ray in expiration. The same patient as in Fig. 1.2. Note the crowding of the vascular markings in the lung bases.

A lateral X-ray is used to localize lesions in the AP dimension, locate lesions behind the left side of the heart or in the posterior recesses of the lungs. A left lateral (with the left side of the chest against the film and the beam projected from the right) is the standard projection. The heart is magnified less with a left lateral as it is closer to the film. To visualize lesions in the left hemithorax, obtain a left lateral film and for right-sided lesions a right lateral.

Expiratory films are used to assess air trapping in bronchial obstruction such as a foreign body. A pneumothorax always appears larger on an expiratory film and occasionally a small pneumothorax may only be visible on expiration. Films may be accidentally taken in expiration, resulting in spurious magnification of the heart and mediastinum.

### Side marker

Dextrocardia is easily missed if the side marker is not identified.

### Quality of film

- *Penetration* – the vertebral bodies should just be visible through the cardiac silhouette.
- *Rotation* – the medial aspect of the clavicles should be symmetrically positioned on either side of the spine.
- *Inspiration* – the diaphragm should lie at the level of the sixth or seventh rib anteriorly. A poorly inspired film results in magnification of the mediastinal structures. Crowding of the pulmonary vasculature may mimic lower lobe pathology (see Figs. 1.2 and 1.3).

### Large airways, lungs and pleura

The 'lung shadows' are composed of the pulmonary arteries and veins. Apart from the pulmonary vessels, the lungs should appear black because they contain air. Examine the lungs for density variation. Compare the rib interspaces on the right with those on the left. Compare the right side with the left just as you would if auscultating the chest. Look all the way out to the periphery of the lungs. Look at the overall lung vascularity and compare one side

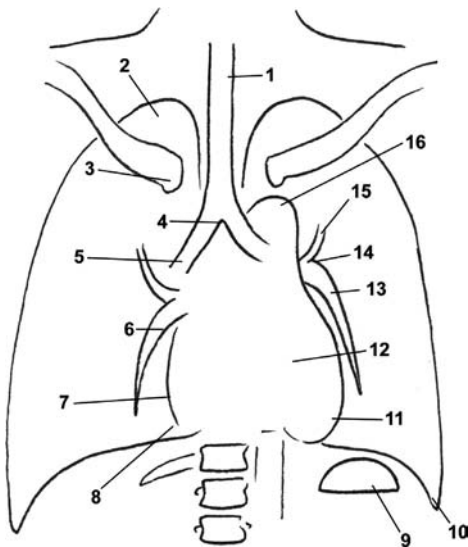
with the other. It is important to look at the main airways – the trachea and the main bronchi. Check the trachea for deviation or narrowing.

Look at the pleural surfaces and the fissures, if visible. Check for masses, calcifications, fluid or pneumothorax.

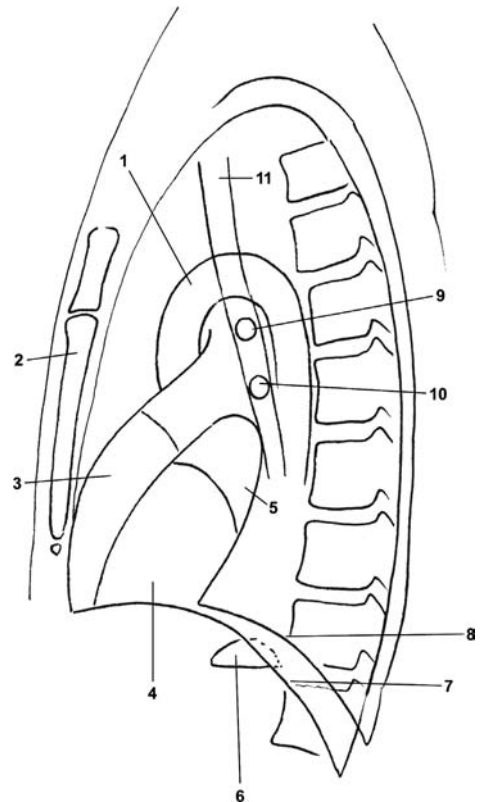
It is helpful to divide the lungs into zones when describing abnormalities. The upper zone extends from the apex to the inferior border of the second rib anteriorly, the mid zone from the inferior border of the second rib to the inferior border of the fourth rib anteriorly, and the lower zone from the fourth anterior rib to the diaphragm.

### Heart and mediastinum

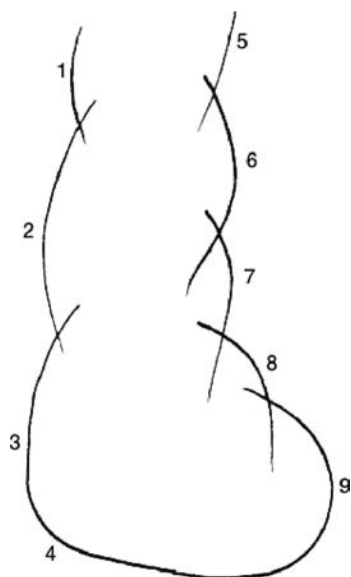
Examine the cardiac outline identifying all the heart borders and the outline of the great vessels (see Figs. 1.4 and 1.5). Check that there are not any abnormal densities projected through the cardiac silhouette. Look at the aortic and pulmonary artery outlines. The heart and mediastinal outline are made up of a series of 'bumps' (see Fig. 1.6). On the right side,



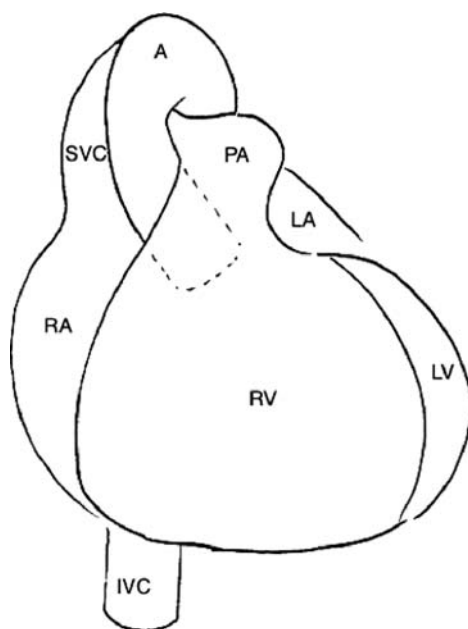
**Figure 1.4.** Diagram of normal frontal chest X-ray: 1. trachea, 2. right lung apex, 3. clavicle, 4. carina, 5. right main bronchus, 6. right lower lobe pulmonary artery, 7. right atrium, 8. right cardiophrenic angle, 9. costophrenic angle, 10. left ventricle, 11. descending thoracic aorta, 12. left lower lobe pulmonary artery, 13. left hilum, 14. left upper lobe pulmonary vein, 15. left upper lobe bronchus, 16. aortic arch.



**Figure 1.5.** Diagram of normal lateral chest X-ray: 1. ascending thoracic aorta, 2. sternum, 3. right ventricle, 4. left ventricle, 5. left atrium, 6. gastric air bubble, 7. right hemidiaphragm, 8. left hemidiaphragm, 9. right upper lobe bronchus, 10. left upper lobe bronchus, 11. trachea.



**Figure 1.6.** The 'bumps' which make up the cardiac silhouette: 1. right brachiocephalic vein, 2. ascending aorta and superimposed SVC, 3. right atrium, 4. inferior vena cava, 5. left brachiocephalic vessels, 6. aortic arch, 7. pulmonary trunk, 8. left atrial appendage, 9. left ventricle.



**Figure 1.7.** Cardiac chambers and great vessels: LA, left atrial appendage; RA, right atrium; LV, left ventricle; RV, right ventricle; IVC, inferior vena cava; SVC, superior vena cava; PA, pulmonary artery; A, ascending aorta.

there are right brachiocephalic vessels, the ascending aorta and superior vena cava, the right atrium and the inferior vena cava. On the left side, there are four 'moguls' in addition to the left brachiocephalic vessels: these are the aortic arch, the pulmonary trunk, the left atrial appendage and the left ventricle. The size and shape of each of these structures need to be looked at for signs of enlargement or reduction in size. The right heart border is created by the right atrium alone (the right ventricle is an anterior structure, therefore does not contribute to any heart borders on a PA film) – this is a question examiners love to ask (see Fig. 1.7).

Heart size can be estimated using the cardiothoracic ratio. The cardiac measurement is taken as the greatest transverse heart diameter and is compared to the greatest internal width of the thorax. A ratio of greater than 0.5 is often used in clinical practice to indicate cardiomegaly on a PA film (0.6 on an AP film).

Look at the position of the hila and their density – compare the left with the right side. Tumours and enlarged lymph nodes can occur here making the hila appear bulky. On a frontal X-ray, increased hilar density may be the only sign of a mass lying in front of, or behind the hilum.

## Diaphragm

Check the shape, position and clarity/sharpness of both hemidiaphragms. Both costophrenic angles should be clear and sharp. The cardiophrenic angles should be fairly clear – cardiophrenic fat pads can cause added density. The right hemidiaphragm is usually slightly higher than the left – up to 1.5 cm. On the lateral film, the right hemidiaphragm is seen in its entirety

but the anterior aspect of the left hemidiaphragm merges with the heart, so is not seen (see Fig. 1.14).

## Bones

This is an area which is frequently overlooked.

- *Ribs*: The ribs are a common site for fracture or metastatic deposits, but the remainder of the skeleton must also be carefully examined. Identify the first rib and carefully trace its contour from the spine to its junction with the manubrium. Each rib must be carefully and individually traced in this manner, initially for one hemithorax and then the contralateral side. A useful trick is to rotate the image on its side; rib fractures may then appear more obvious.
- *Thoracic spine*: Look at the thoracic spine alignment – is it straight or is there a scoliosis? Take particular care to exclude pathology from the thoracic spine in trauma patients when even moderate malalignment can be overlooked when projected through the heart or mediastinal shadows.
- *Clavicles, scapulae and humeri*: Fractures and dislocation of the humerus are often obvious when looked for. Look for fractures, metastatic deposits, abnormal calcifications or evidence of arthritis around the shoulders.

## Soft tissues

A visual examination should be routinely performed on the chest wall, the neck and both the breast shadows. Look for surgical emphysema and abnormal calcification. With reference to the breast shadows, be sure to check whether there are two breast shadows and whether there is symmetry of size, shape and position. The lung field missing a breast will appear a little darker than the other side.

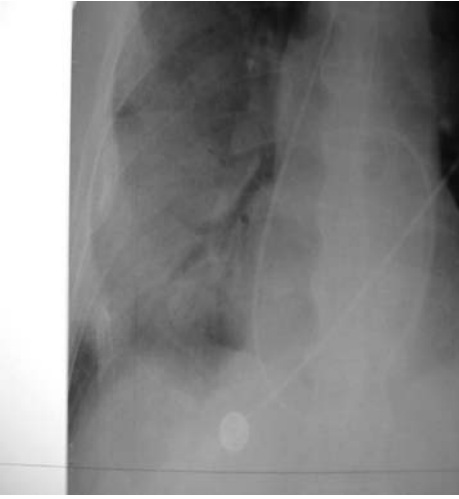## Review areas

These review areas are sites where pathology is commonly missed and warrant a second look before any chest X-ray is reported as normal:

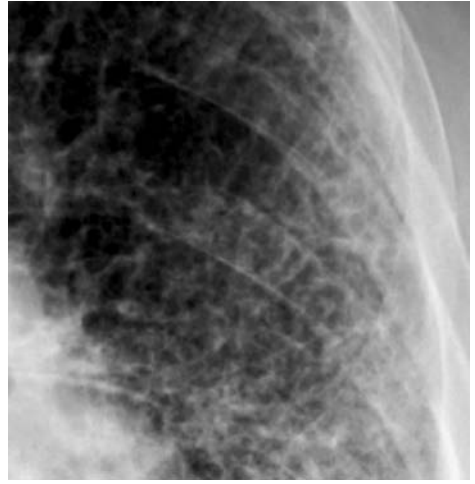- Breasts (symmetry/mastectomy).
- Below the diaphragm (do not forget that the lungs extend below the diaphragm, also look at the upper abdomen for surgical clips/calcification/pneumoperitoneum).
- Behind the heart (hiatus hernia/lung nodules/left lower lobe collapse).
- Thoracic spine and paraspinal lines (trauma).
- Clavicle (nodule behind medial end and eroded lateral end).
- Shoulder (dislocation).
- Apices (pancoast tumour).
- Hila (assess position, size and density).
- Lung parenchyma.
- Bones, especially ribs (look for metastases or fractures).

## Principles of chest X-ray interpretation

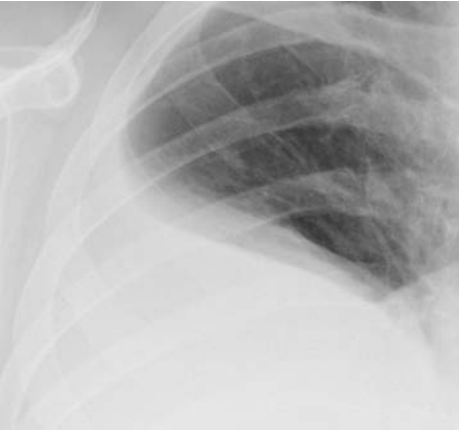Having looked at the chest X-ray, it remains to classify the signs into a radiographic pattern. Particular radiographic patterns have a list of diagnostic possibilities. At its simplest, a chest X-ray abnormality can be classified into increased or decreased density. Patterns



**Figure 1.8.** Air space opacification/consolidation. Note the 'fluffy' or 'cotton wool-like' appearance. Air bronchograms are a sign of consolidation but are often not visible on chest X-ray.



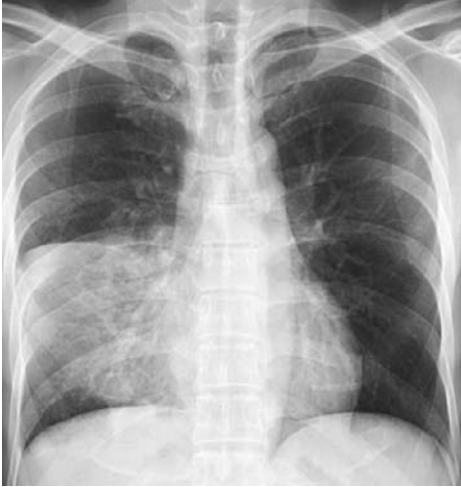**Figure 1.9.** Interstitial opacification. Note the 'mesh-like', reticular pattern. Small nodules and Kerley B lines may also be seen in interstitial disease.



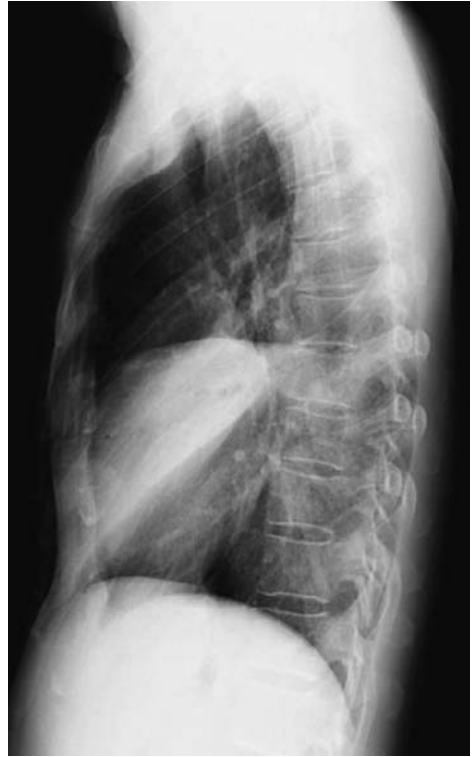**Figure 1.10.** Pleural effusion. Note the meniscus-like arc at the interface between the fluid and the chest wall.

of increased density include nodules and masses, air space opacification or consolidation (see Fig. 1.8),<sup>1</sup> interstitial opacification (see Fig. 1.9) and pleural disease such as pleural effusion (see Fig. 1.10).

An important radiological sign that can help to detect and localize pulmonary abnormalities is the 'silhouette sign'.<sup>1, 2</sup> The mediastinal silhouette is visible on a chest X-ray because it is bordered by aerated lung. When consolidation (which is soft tissue density) abuts a mediastinal border, that border becomes obscured. For example, the right middle lobe is an anterior structure and lies adjacent to the right atrium. The only clue to pathology causing increased density in the right middle lobe (such as collapse or consolidation) may be obscuration of



**Figure 1.11.** Right middle lobe consolidation. Note the silhouette sign with loss of clarity of the right heart border.



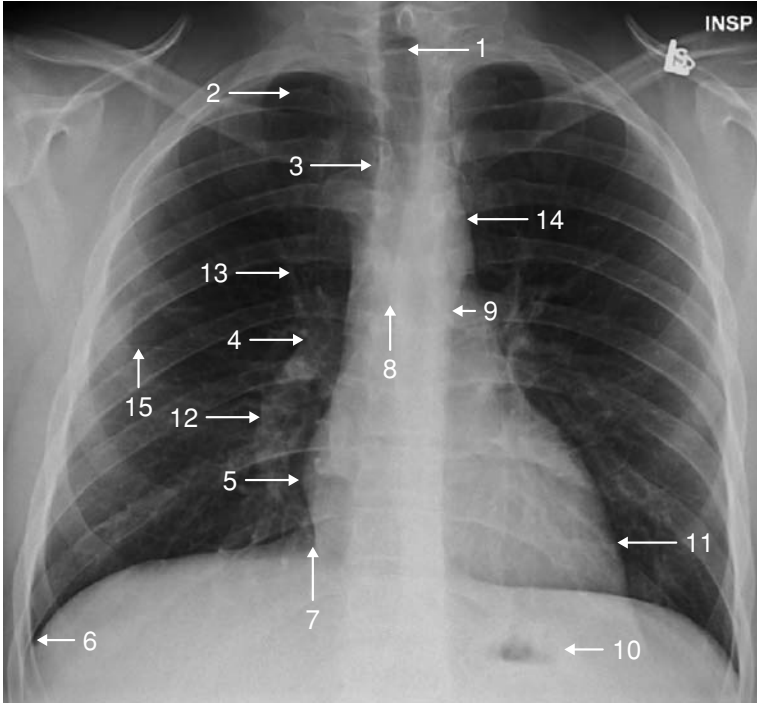
**Figure 1.12.** Lateral chest X-ray showing right middle lobe consolidation. Note the consolidation is bordered by the horizontal fissure superiorly and oblique fissure posteriorly.

the right heart border (see Figs. 1.11 and 1.12). The right middle lobe has little contact with the diaphragm, so right middle lobe opacification does not result in obscuration of the right hemidiaphragm. Similarly, obscuration of the left heart border usually indicates pathology in the lingular segment of the left upper lobe, which lies adjacent to the left ventricle. By contrast, pathologies causing increased density in a lower lobe result in loss of clarity of part or all of the relevant hemidiaphragm.

## Case histories

### Question 1

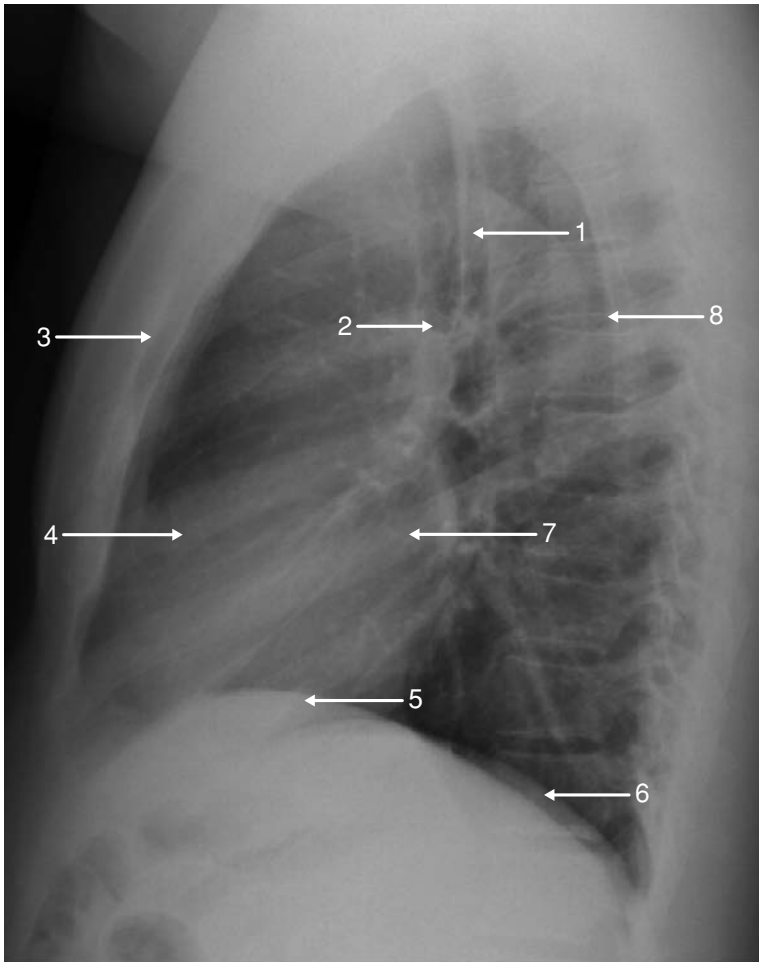
- Name the normal structures on these chest X-rays (Figs. 1.13 and 1.14).



**Figure 1.13.** Quiz case.

### Answer (Fig. 1.13)

1. Trachea
2. Lung apex
3. Right para-tracheal stripe
4. Right hilum
5. Right atrium (not ventricle!)
6. Right costophrenic angle
7. Right cardiophrenic angle
8. Carina
9. Descending thoracic aorta
10. Gastric air bubble
11. Left ventricle
12. Right lower lobe pulmonary artery
13. Right upper lobe pulmonary vein
14. Aortic arch
15. Horizontal fissure



**Figure 1.14.** Quiz case.

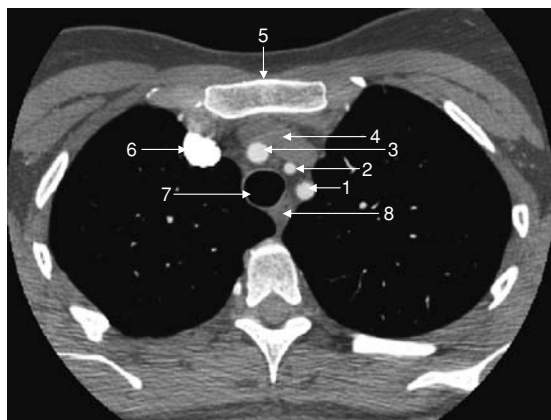
### Answer (Fig. 1.14)

1. Trachea
2. Aortopulmonary window
3. Sternum
4. Right ventricle
5. Right hemidiaphragm
6. Left hemidiaphragm
7. Left atrium
8. Scapula

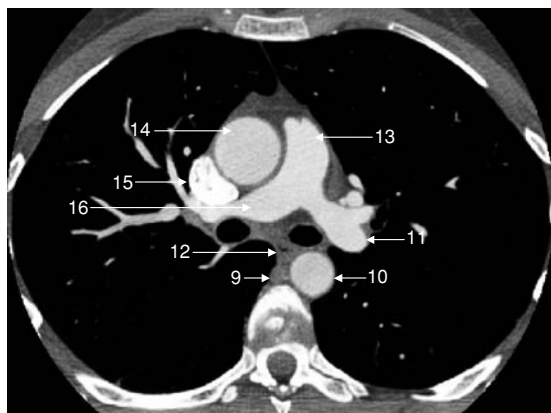

## Question 2

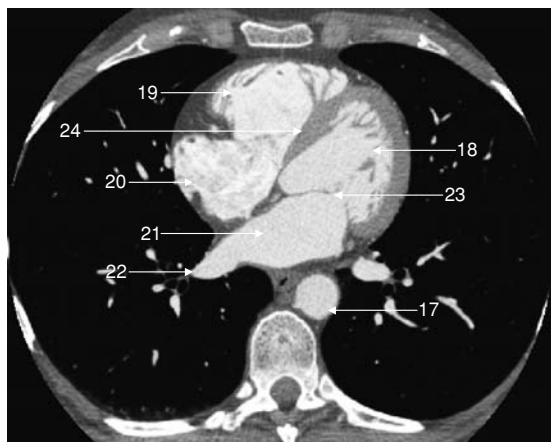- Name the structures on these CT scans (Figs. 1.15–1.19).



**Figure 1.15.** Quiz case.



**Figure 1.16.** Quiz case.



**Figure 1.17.** Quiz case.

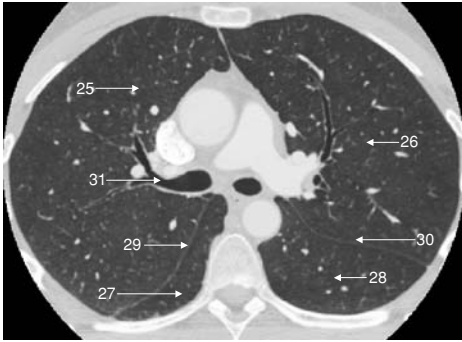


Figure 1.18. Quiz case.

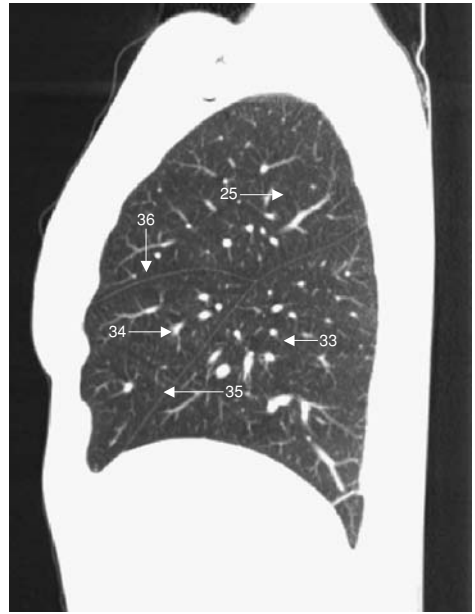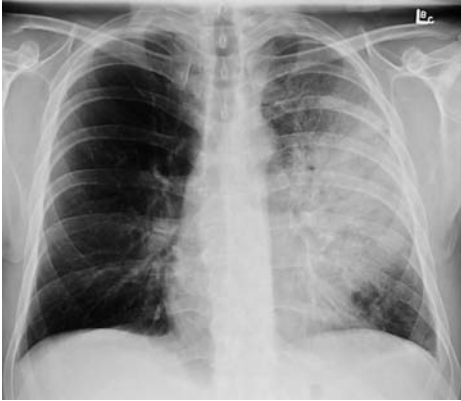


Figure 1.19. Quiz case.

## Answer

1. Left subclavian artery
2. Left common carotid artery
3. Brachiocephalic artery
4. Left brachiocephalic vein
5. Sternum
6. Right brachiocephalic vein
7. Trachea
8. Oesophagus
9. Azygous vein
10. Descending aorta
11. Left lower lobe pulmonary artery
12. Oesophagus
13. Main pulmonary artery
14. Ascending aorta
15. Superior vena cava (SVC)
16. Right pulmonary artery
17. Descending aorta
18. Left ventricle
19. Right ventricle
20. Right atrium
21. Left atrium
22. Right inferior pulmonary vein

23. Mitral valve
24. Interventricular septum
25. Right upper lobe
26. Left upper lobe
27. Right lower lobe
28. Left lower lobe
29. Right oblique fissure
30. Left oblique fissure
31. Right upper lobe bronchus
32. Right upper lobe
33. Right lower lobe
34. Right middle lobe
35. Right oblique fissure
36. Horizontal fissure



**Figure 1.20.** Quiz case.

65-year-old female. Productive cough, pyrexia and dyspnoea.

### Question 3

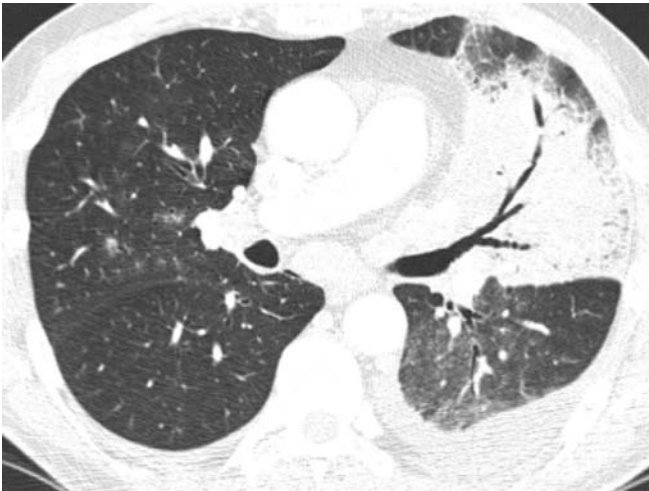- What is the diagnosis (Fig 1.20)?
- What are the complications?

### Answer

#### Left upper lobe pneumonia

There is air space opacification in the left mid and lower zones, obscuring the left heart border (see also Fig. 1.21). There are many causes of air space opacification (see Table 1.1 for an abbreviated list). Identification of the cause often depends on the clinical scenario.

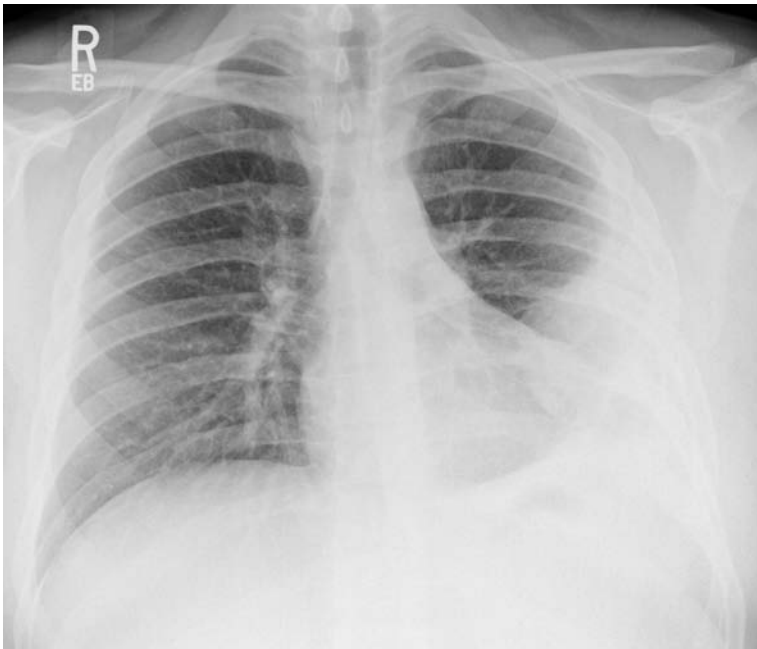
Complications of pneumonia include para-pneumonic effusion which can progress to empyema (see Fig. 1.22), abscess formation (see Fig. 1.23) and Acute Respiratory Distress Syndrome (ARDS). CT is not indicated routinely in the investigation of pneumonia, but is



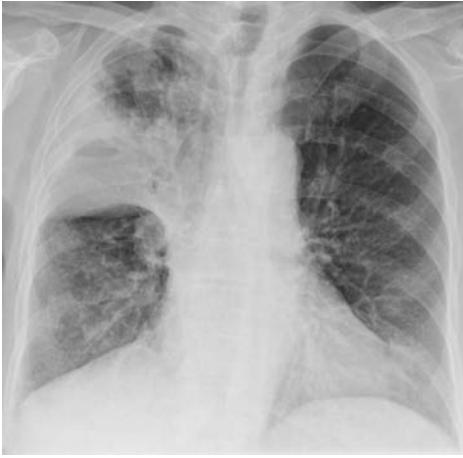**Figure 1.21.** CT (lung windows) demonstrating left upper lobe consolidation. Note the prominent air bronchograms. The consolidation abuts the left heart border which leads to obscuration of the heart border on the chest X-ray (silhouette sign).

**Table 1.1.** Causes of consolidation/air space shadowing

<b>Acute</b>	
■ <b>Pneumonia</b>	
• Bacterial	
• TB	
• Viral	
• Fungal	
■ <b>Pulmonary oedema</b>	
• Cardiogenic	NB: in acute MI the heart size may be normal
• Non-cardiogenic	e.g. renal failure, neurogenic, aspiration, ARDS
■ <b>Haemorrhage</b>	
• Contusion (trauma)	
• Vasculitis	
• Infarction	
<b>Chronic</b>	
■ <b>Pneumonia</b>	
• TB	
• Post-obstructive pneumonia	
■ <b>Malignancy</b>	
• Bronchioloalveolar cell carcinoma	
• Lymphoma	
■ <b>Others</b>	
• Organizing pneumonia	
• Sarcoidosis	
• Eosinophilic pneumonia	



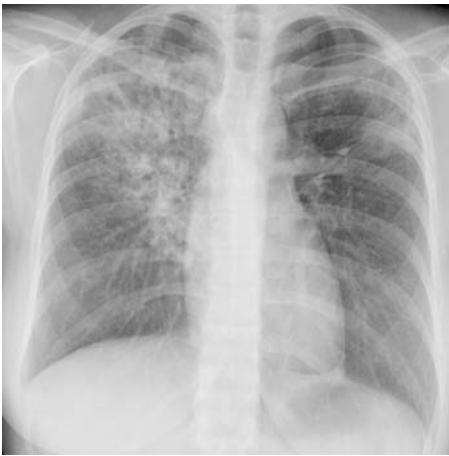**Figure 1.22.** Empyema. There is a left-sided pleural collection which tracks up the chest wall and has a convex medial border.



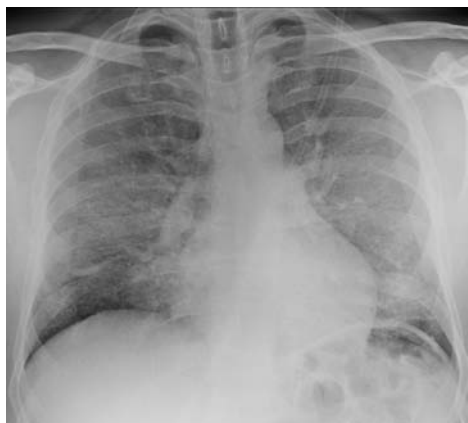**Figure 1.23.** Abscess in the right upper zone. Note the air–fluid level. The inferior border of the abscess is defined by the horizontal fissure, indicating that the pathology is in the upper lobe.

helpful in the assessment of complications or underlying pulmonary or mediastinal pathology (e.g. neoplasia). Ultrasound is helpful in assessing the location and presence of loculated pleural effusions.<sup>3</sup>

Radiological patterns of pneumonia can vary, depending on the organism.<sup>4</sup> For example, tuberculosis classically causes patchy consolidation affecting the upper lobes and apical segments of the lower lobes (see Fig. 1.24) which may progress to cavitation.<sup>5</sup> *Mycoplasma pneumoniae* may give rise to air space and/or an interstitial pattern.



**Figure 1.24.** Tuberculosis. Note the bilateral, patchy, upper lobe consolidation with cavitation in the right upper lobe.



**Figure 1.25.** Quiz case.

55-year-old woman. Dry cough and dyspnoea.  
Undergoing treatment for non-Hodgkin's lymphoma.

## Question 4

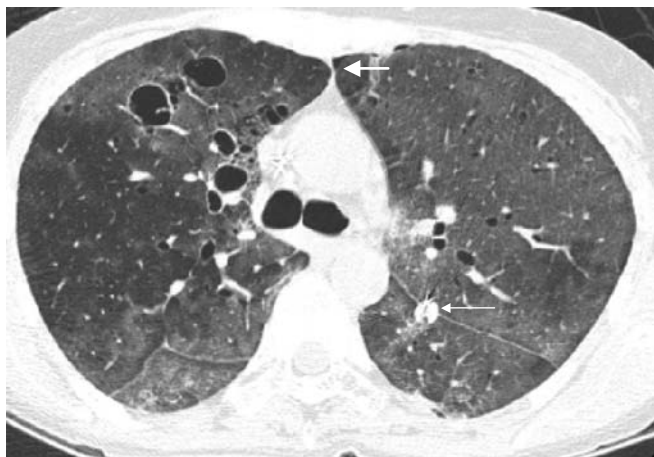
- What is the diagnosis (Fig. 1.25)?

## Answer

### ***Pneumocystis pneumonia***

The chest X-rays show hazy bilateral opacification sparing the lung bases and apices. The CT (see Fig. 1.26) (performed later in the course of the illness) shows ground glass opacification (that is, opacification that does not obscure the pulmonary vessels). Note the presence of characteristic thin-walled cysts in the right upper lobe. These predispose to pneumothorax.

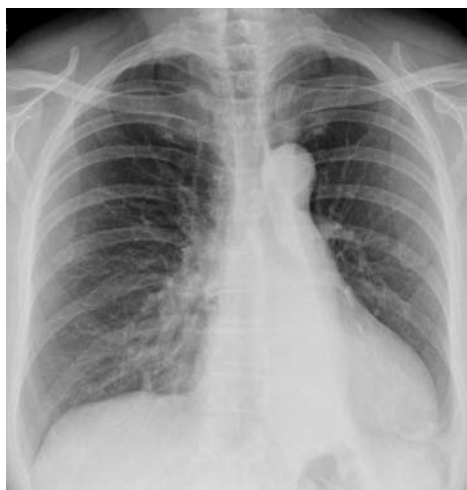*Pneumocystis pneumonia* (the causative fungus has been reclassified as *Pneumocystis jiroveci*) is particularly associated with HIV-infected patients with a CD4<sup>+</sup> count of less than



**Figure 1.26.** CT of *Pneumocystis pneumonia*. There is ground glass opacification bilaterally and thin-walled cysts in the right upper lobe. A chest tube is seen in the left oblique fissure (thin arrow), with a tiny left anterior pneumothorax (thick arrow).

200 cells/mm<sup>3</sup>, although it has become less common in the developed world due to the advent of chemoprophylaxis and anti-retroviral therapy. It can also occur in the setting of immunocompromise secondary to chemotherapy (as in this case) or prolonged steroid use. Viral pneumonias can give rise to a similar radiographic picture. High-resolution CT is much more sensitive and specific than chest X-ray in the diagnosis of opportunistic infections<sup>6</sup> and can help localize abnormalities for targeted bronchoalveolar lavage.





**Figure 1.27.** Quiz case.

72-year-old smoker. Haemoptysis and cough.

## Question 5

- What does the chest X-ray (Fig. 1.27) show?

## Answer

### Left lower lobe collapse

Lobar or segmental collapse occurs in large airway obstruction with subsequent resorption of air from the affected lung. Causes are listed in Table 1.2. Bronchogenic malignancy is one of the commonest causes and the case study illustrates the subtle signs on plain X-ray. Subsequent CT imaging of this patient demonstrated a malignant neoplasm originating in the left lower lobe bronchus (see Fig. 1.28). In left lower lobe collapse, the silhouette of the medial

**Table 1.2.** Causes of lobar collapse

#### ■ Endoluminal mass (common)

- Neoplasm (bronchial carcinoma, carcinoid, endoluminal metastases)
- Mucus plug/inflammatory exudate (e.g. asthmatics)
- Foreign body (commonest cause in children)
- Misplaced endotracheal tube

#### ■ Bronchial wall (rare)

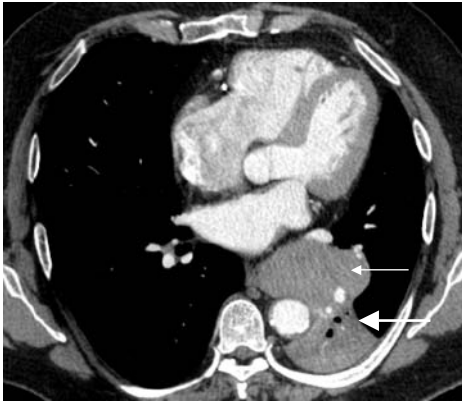
- TB
- Sarcoidosis

#### ■ Extrinsic compression (rare)

- Lymph nodes
- Aneurysm

**Table 1.3.** X-ray signs of lobar collapse

<ul style="list-style-type: none"> <li>■ <b>Wedge-shaped opacity caused by the collapsed lobe</b> (specific pattern for each lobe)</li> </ul>
<ul style="list-style-type: none"> <li>■ <b>Volume loss</b> <ul style="list-style-type: none"> <li>• Movement of fissures</li> <li>• Hilar shift</li> <li>• Mediastinal shift</li> <li>• Elevation of the hemidiaphragm</li> </ul> </li> </ul>
<ul style="list-style-type: none"> <li>■ <b>Compensatory hyperinflation (translucency) of other lobes</b></li> </ul>



**Figure 1.28.** CT (mediastinal windows) of left lower lobe collapse. Note the soft tissue mass (thin arrow) proximal to the collapsed left lower lobe (thick arrow).

aspect of the hemidiaphragm and the descending aorta is lost because it is no longer outlined by adjacent aerated lung. A triangular opacity is seen projected through the cardiac outline. The lung collapses posteriorly and medially.

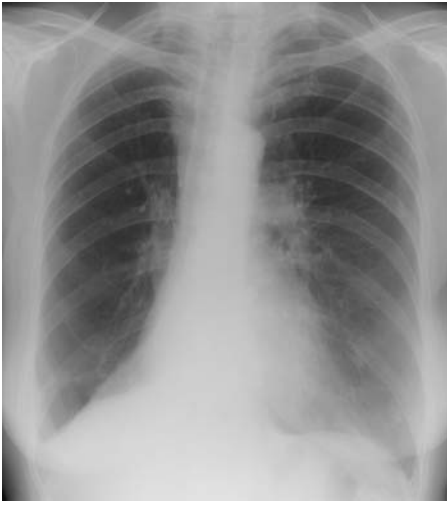The five lobes collapse in different directions to produce different patterns although there are some common features (see Table 1.3).<sup>7</sup> Right lower lobe collapse is similar to left lower lobe collapse (Figs. 1.29 and 1.30).

### Right upper lobe collapse

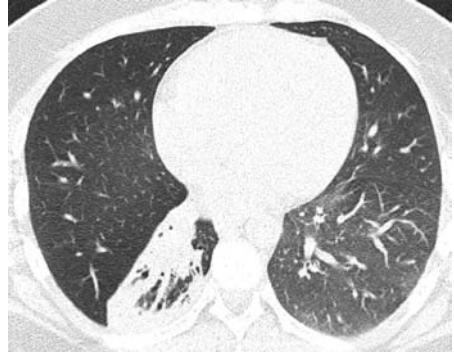The right upper lobe collapses against the mediastinum and thoracic apex creating a triangular opacity with a well-defined inferior margin (caused by the horizontal fissure) radiating from the hilum. If there is an outward bulge at the right hilum, this is good evidence that a hilar mass is responsible for the collapse (see Figs. 1.31 and 1.32).

### Left upper lobe collapse

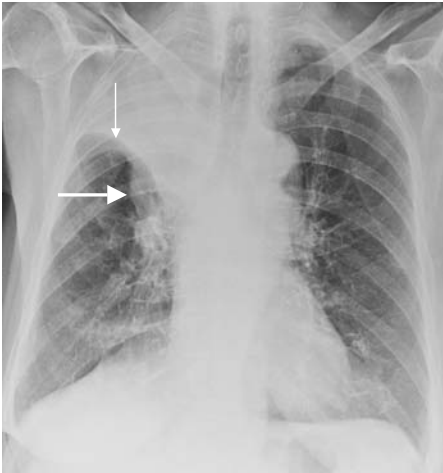This does not mirror right upper lobe collapse due to the absence of a middle lobe. The left upper lobe collapses forward against the anterior chest wall. The lower lobe expands behind it. The chest X-ray appearance is of a hazy density in the mid and upper zones which fades away laterally and inferiorly (see Figs. 1.33 and 1.34). The collapsed lobe is adjacent to the left cardiac and mediastinal border, so this silhouette is completely lost.



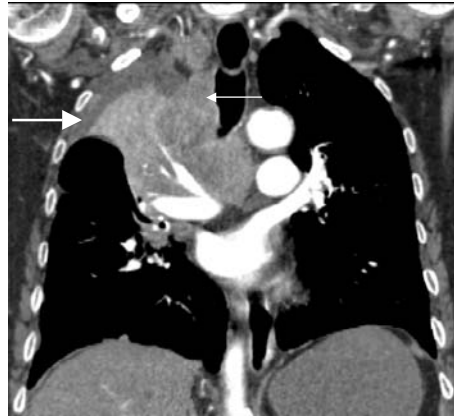**Figure 1.29.** Right lower lobe collapse. There is a triangular opacity adjacent to the right heart border with loss of clarity of the medial aspect of the right hemidiaphragm.



**Figure 1.30.** CT of right lower lobe collapse. Note how the lobe collapses posteriorly and medially.



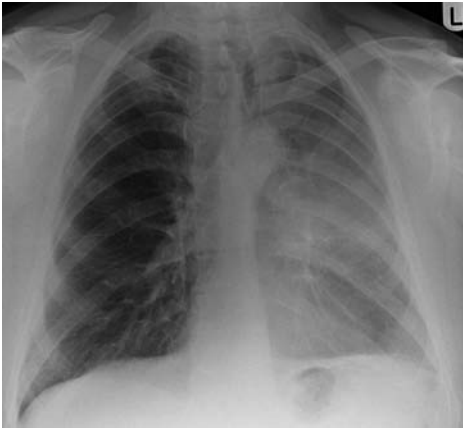
**Figure 1.31.** Right upper lobe collapse. Note the well-defined inferior border caused by the horizontal fissure (thin arrow) and the mass at the right hilum (thick arrow).



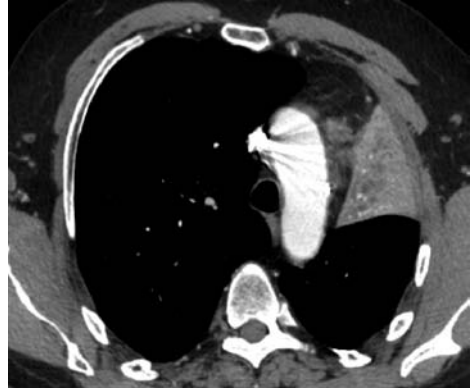**Figure 1.32.** Coronal CT of right upper lobe collapse. Note how the lobe collapses against the mediastinum. In addition to the collapsed lobe there are enlarged mediastinal nodes (thin arrow) and associated pleural fluid (thick arrow).

### Middle lobe collapse

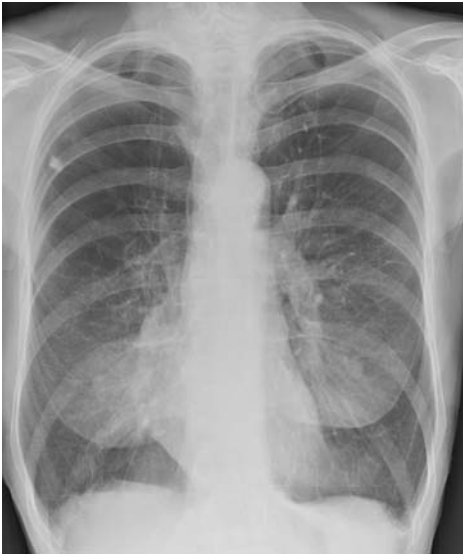This is easily missed on the frontal film and is often more obvious on a lateral projection. On the frontal projection, there is a vague increase in density seen in the right lower zone and the normally sharp right heart border is blurred. On a lateral projection the collapsed middle lobe forms a triangular opacity with its apex at the hilum and base projecting towards the sternum (see Figs. 1.35 and 1.36).



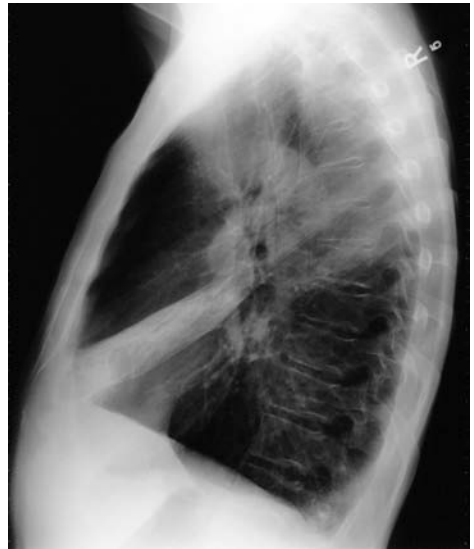**Figure 1.33.** Left upper lobe collapse. There is hazy density in the left mid and lower zones which fades out laterally. There is evidence of volume loss as evidenced by the trachea deviation to the left. There is a silhouette sign with loss of the left heart border as the collapsed lung lies adjacent to the heart.



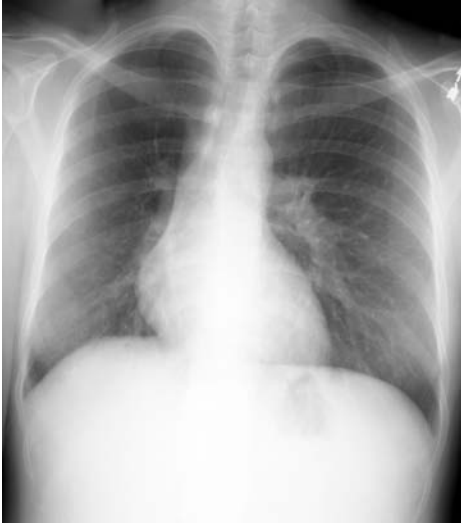**Figure 1.34.** CT of left upper lobe collapse. Note how the lobe collapses anteriorly against the chest wall.



**Figure 1.35.** Right middle lobe collapse. Note the loss of outline of the right heart border.

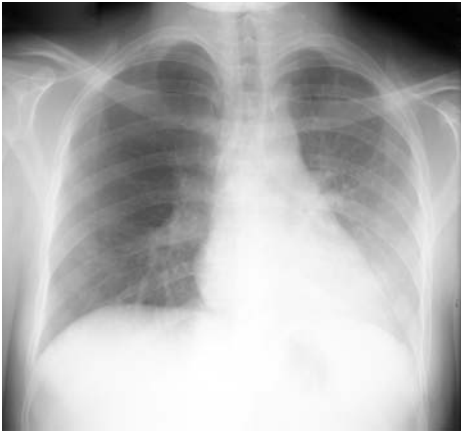

**Figure 1.36.** Lateral chest X-ray of right middle lobe collapse. The triangular opacity is the collapsed middle lobe, bordered by the horizontal fissure superiorly and the oblique fissure posteriorly.



**Figure 1.37.** Quiz case.

24-year-old patient living in home for educational special needs.  
Breathless and distressed.



**Figure 1.38.** Quiz case.

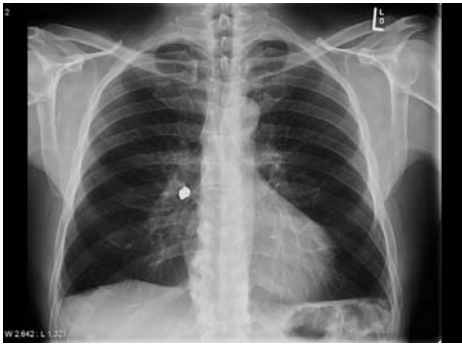
## Question 6

- What do the chest X-rays (Fig. 1.37, inspiration; Fig. 1.38, expiration) show?
- What is the management?

## Answer

### Aspiration of foreign body

The films are taken in inspiration and expiration giving the clue that the suspected diagnosis is an inhaled foreign body. The inspiratory film shows loss of volume of the right hemithorax with shift of the mediastinum to the right. On the expiratory film, there is air trapping on the affected side as the foreign body has prevented complete expiration from the right lung. If the film is examined carefully, there is an opacity in the right main bronchus which is an inhaled foreign body.



**Figure 1.39.** Aspirated dental crown within the right lower lobe bronchus.

Management involves bronchoscopy, either rigid or flexible, and extraction of the foreign body. Forceps, baskets and Fogarty balloons can be used to try and grasp the foreign body.

### Endobronchial foreign body

Aspiration of a foreign body can be a life-threatening event. If the object is large enough to occlude the airway, death can rapidly occur from asphyxia. Foreign bodies may be easily seen on plain film (Fig. 1.39) but most foreign bodies will be radiolucent, so air trapping or atelectasis may be the only sign.<sup>8</sup> Atelectasis may not develop for 24 hours. In the paediatric age group, if the chest X-ray is non-diagnostic, fluoroscopy may be used to observe diaphragmatic and mediastinal shift due to air trapping. In equivocal cases, CT may provide additional information.

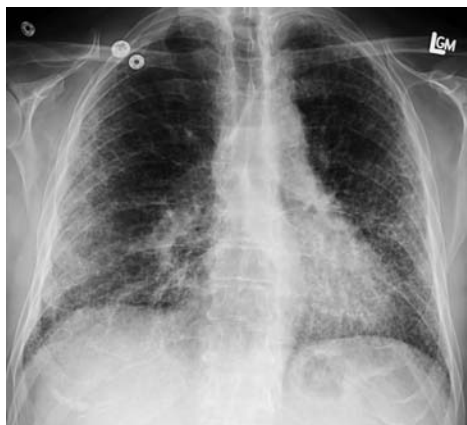The commonest age group is 16 and below, particularly age 1–3. Commonly aspirated objects include nuts, seeds, bone fragments, small toys, food or teeth. Until the age of 15, the angles made by the mainstem bronchi with the trachea are equal, so aspiration is equally likely into either bronchus. With age, the right mainstem bronchus makes a straighter course from the larynx and trachea so, after the age of 15, objects are more often found on the right side.

Symptoms include cough, wheeze, stridor, dyspnoea and cyanosis. Organic foreign bodies can swell or induce an inflammatory response with granulation tissue. Swelling and bleeding can make removal difficult.

Complications include:

- Mediastinitis
- Air trapping/local emphysema
- Atelectasis/lobar collapse
- Post-obstruction pneumonia
- Abscess
- Bronchiectasis
- Stricture formation

Complications are reduced with prompt extraction (less than 24 hours). Anaesthetic management of the small child who has inhaled a foreign body is a common examination question.



**Figure 1.40.** Quiz case.

68-year-old man.  
Admitted with acute on chronic dyspnoea. Inspiratory crackles at lung bases.

## Question 7

- What is the diagnosis (Fig. 1.40)?

## Answer

### Pulmonary fibrosis

There is a fine linear and nodular pattern of increased density in both lungs, predominantly in the lower zones. The heart outline is 'shaggy' – the appearances are of an interstitial lung pattern. The most common cause is idiopathic pulmonary fibrosis (formerly known as cryptogenic fibrosing alveolitis), but an identical picture may be seen in connective tissue diseases and asbestosis. The lung volumes are reduced unless there is co-existing chronic obstructive pulmonary disease. High-resolution CT (HRCT) demonstrates honeycombing (Fig. 1.41) in a peripheral distribution. Ground glass opacification may also be present. This can sometimes correlate with active inflammation and increased likelihood of response to immunosuppressant therapy.

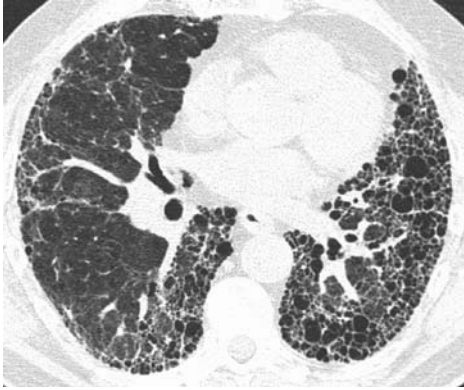Interstitial processes such as sarcoidosis and old TB (Fig. 1.42) tend to affect the upper zones. The common causes of an interstitial pattern on chest X-ray are listed in Table 1.4.

### Interstitial diseases

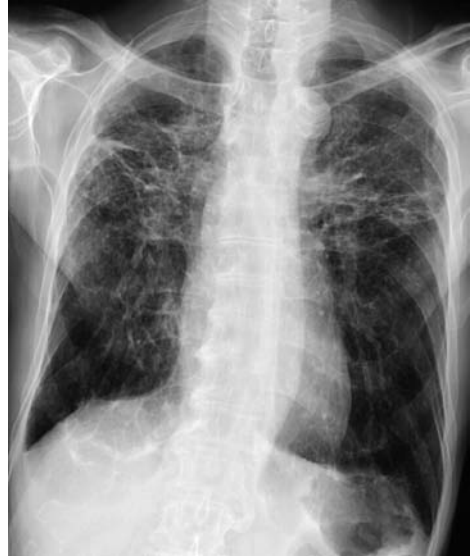Interstitial pattern shadowing is caused by thickening of the tissue surrounding the alveoli and capillaries in the lung.

Various types of interstitial pattern shadowing are described and these can occur in isolation or in combination such as reticulo-nodular:

- Fine netting: reticular,
- Coarse mesh: honeycomb pattern,
- Fine lines: linear,
- Innumerable tiny nodules: nodular.



**Figure 1.41.** HRCT demonstrating honeycombing in the periphery of the lung. No significant ground glass opacification is seen.



**Figure 1.42.** Fibrosis secondary to tuberculosis. There is a linear pattern of increased density in the upper zones bilaterally with associated loss of volume and elevation of the hila.

**Table 1.4.** Causes of interstitial pattern shadowing

■ **Pulmonary fibrosis**

- Idiopathic pulmonary fibrosis
- Asbestosis
- Sarcoidosis
- Connective tissue disease
- Drugs reaction

■ **Interstitial pulmonary oedema**

■ **Lymphangitis carcinomatosa**

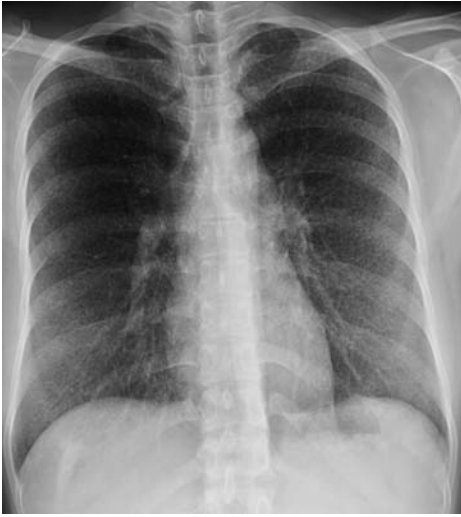■ **Infection**

- *Mycoplasma*
- *Pneumocystis*
- Old TB

■ **Paediatric**

- Cystic fibrosis
- Acute bronchiolitis (also overinflation and small patches of consolidation)
- Oxygen toxicity





**Figure 1.43.** Quiz case.

28-year-old male.  
This patient is breathless, febrile and unwell. He has recently arrived from Africa.

## Question 8

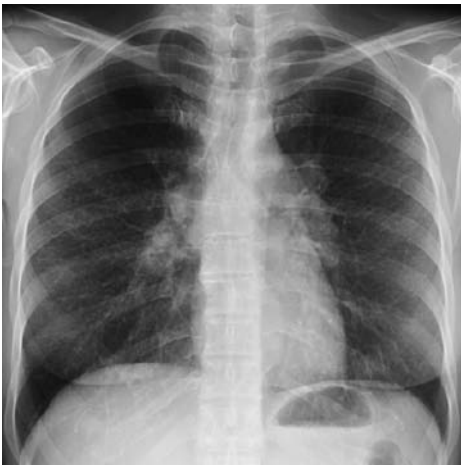- What is the diagnosis (Fig. 1.43)?
- What precautions must you take with this patient?
- If ventilation is required what further measures must be taken?

## Answer

### Miliary nodules

There are multiple tiny (the size of millet seeds) nodules in both lungs. The patient is from Africa and is unwell, making miliary TB the most likely diagnosis. Barrier nursing in isolation should be undertaken.

TB is spread by the respiratory route, so precautions must be taken to sterilize ventilation equipment following use. Disposable equipment should be used where possible and bacterial

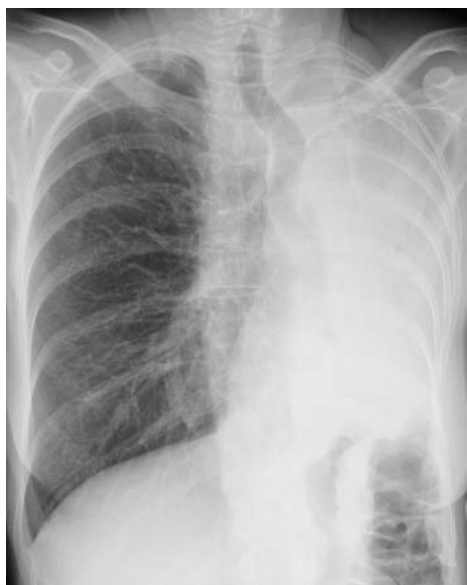

**Figure 1.44.** Sarcoidosis. The hila are bulky with a lobulated contour consistent with lymphadenopathy. There is a subtle nodular pattern limited to the mid zones.

**Table 1.5.** Commoner causes of multiple tiny pulmonary nodules

■ <b>Miliary TB</b>
■ <b>Other infections</b> (e.g. fungal)
■ <b>Sarcoidosis</b>
■ <b>Miliary metastases</b> (e.g. thyroid, melanoma)
■ <b>Healed chicken-pox pneumonia</b> (calcified)
■ <b>Pneumoconiosis</b>

filters should be used to protect the ITU ventilator. Medical and nursing staff are at risk of infection, so full face masks and eye protection should be worn during procedures involving the airway. In a well patient consider sarcoidosis, especially if there is hilar lymphadenopathy (see Fig. 1.44) or pneumoconiosis (old films would help in this latter differential). Any history of primary malignancy is important, as metastases (particularly from thyroid carcinoma) can rarely give rise to a miliary pattern. Haematogenous metastases tend to go to the bases and inhaled dusts to the apices. Table 1.5 lists some of the commoner causes of multiple tiny nodules.



**Figure 1.45.** Quiz case.

76-year-old man.  
Life-long smoker.  
Cough and haemoptysis.

## Question 9

- What is the diagnosis (Fig. 1.45)?

## Answer

### Collapse of the left lung

There is almost total collapse of the left lung, due to an underlying bronchogenic malignancy. Note the volume loss, as evidenced by deviation of the trachea and heart towards the opaque hemithorax.

In evaluating an opaque hemithorax, the key feature to identify is the direction of mediastinal shift (see Table 1.6). For example, a massive pleural effusion will result in shift of the mediastinum away from the opaque hemithorax (see Fig. 1.46).

**Table 1.6.** Causes of an opaque hemithorax

#### ■ Mediastinal shift towards opaque side

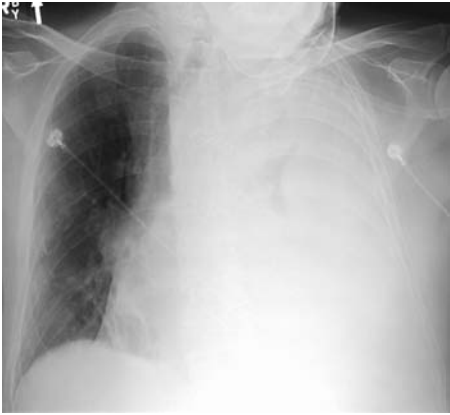- Lung collapse
- Pneumonectomy: look for surgical clips and thoracotomy (rib resection)

#### ■ Mediastinal shift away from opaque side

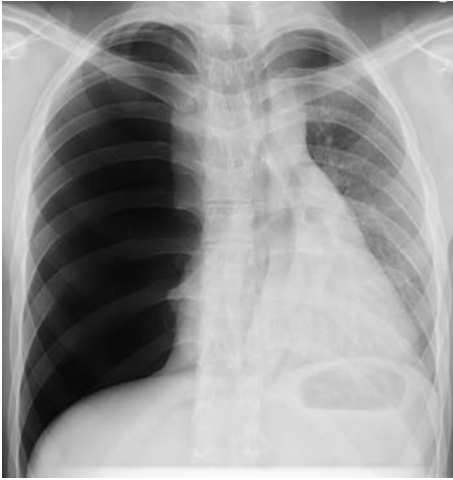- Massive pleural effusion: usually exudative. Metastases/mesothelioma, empyema, haemothorax, chylothorax

#### ■ No mediastinal shift

- Extensive consolidation: pneumonia
- Combination of pleural effusion and collapse



**Figure 1.46.** Massive left pleural effusion. Note the deviation of the trachea and heart away from the opaque hemithorax.



**Figure 1.47.** Quiz case.

34-year-old male.  
Pleuritic chest pain. Short of breath.

## Question 10

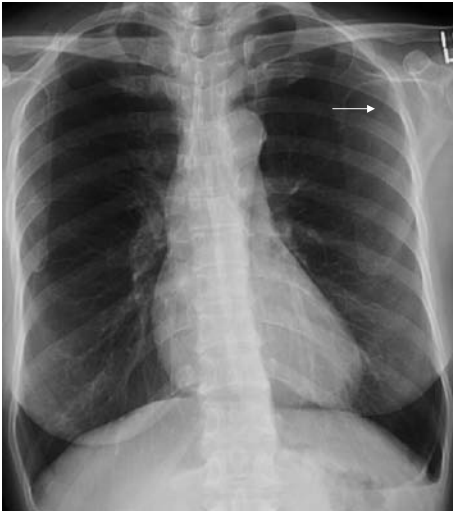- What is the diagnosis (Fig. 1.47)?

## Answer

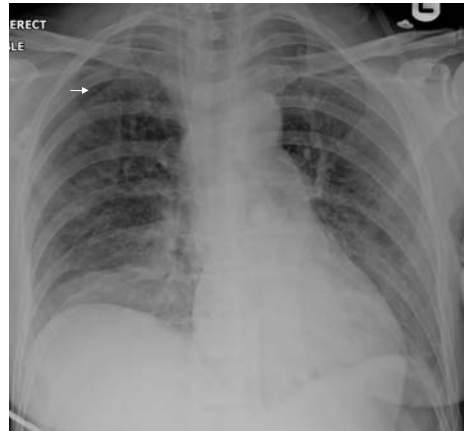### Tension pneumothorax

There is a large right-sided tension pneumothorax with mediastinal shift to the left side and depression of the right hemidiaphragm. A chest drain needs to be inserted urgently.

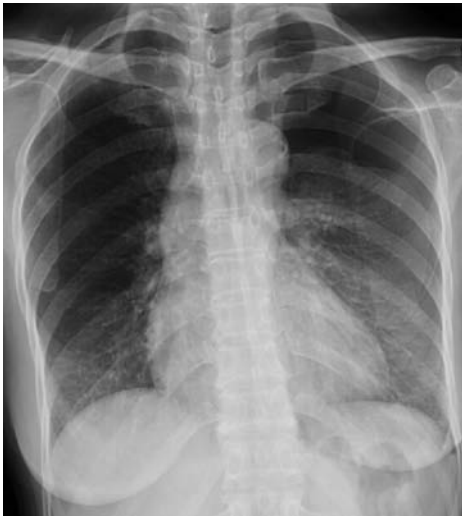A small pneumothorax may be subtle, and may be mimicked by skin folds on AP films – look for the absence of lung markings peripheral to a sharp pleural edge (Figs. 1.48 and 1.49).<sup>9</sup>



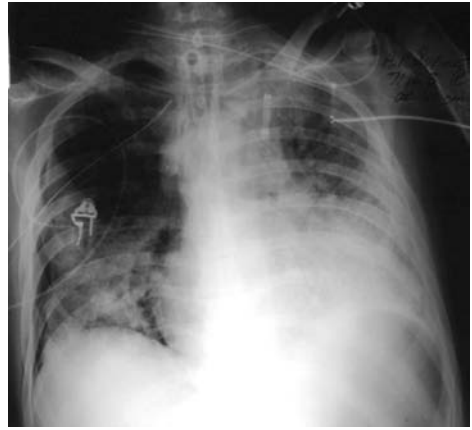
**Figure 1.48.** Inspiratory chest X-ray demonstrating a small left pneumothorax (arrow). Note the lack of lung markings beyond the lung edge.



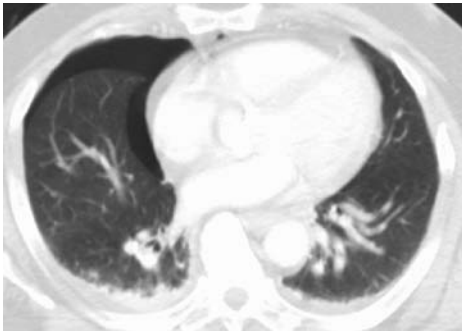**Figure 1.49.** Right skin fold. Note the lung markings extending beyond the 'apparent' lung edge (arrow).



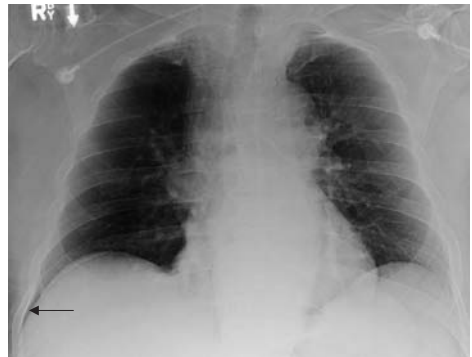**Figure 1.50.** Chest X-ray of the same patient as in Fig. 1.48 but taken in expiration. The lung becomes smaller in expiration. The pneumothorax does not change, so occupies a greater proportion of the hemithorax, increasing in conspicuity.



**Figure 1.51.** Supine pneumothorax. The patient has a tracheostomy and right-sided chest drain in situ. The right heart border is clearly seen because it is outlined by air.



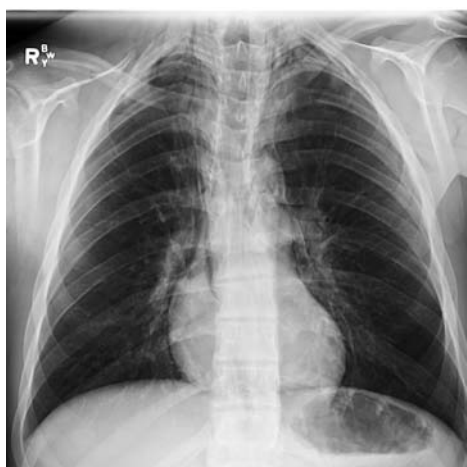**Figure 1.52.** CT of a supine pneumothorax. Note how the air collects anteriorly and adjacent to the heart border.



**Figure 1.53.** Supine pneumothorax. Note the sharply defined right costo-phrenic recess (arrow).

If there is still doubt, expiratory films may be helpful, as pneumothoraces usually appear larger on expiration (see Fig. 1.50).

In a supine patient, air collects anteriorly, often adjacent to the cardiac silhouette causing it to appear sharper than usual (see Figs. 1.51 and 1.52). Another subtle sign of a supine pneumothorax is the deep, sharply defined costo-phrenic recess (Fig. 1.53). In the intensive care setting a tension pneumothorax may occur without complete collapse of the lung, due to stiffness of the lung.



**Figure 1.54.** Quiz case.

17-year-old male asthmatic admitted with sudden onset chest pain.

## Question 11

- What is the diagnosis (Fig. 1.54)?

## Answer

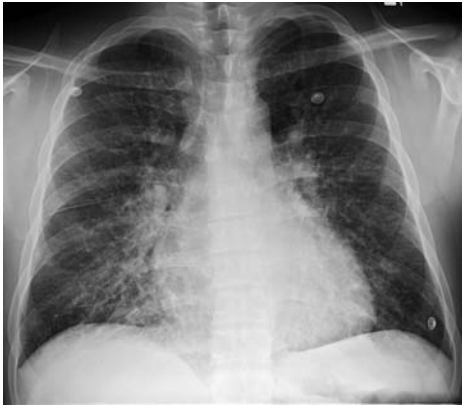### Pneumomediastinum

Streaky gas shadows are seen in the mediastinum, extending into the root of the neck. A linear opacity seen paralleling the left heart border represents the mediastinal pleura displaced by mediastinal air.

The causes of pneumomediastinum are listed in Table 1.7. The most important diagnosis to exclude, if there is a history of vomiting followed by chest pain, is Boerhaave's syndrome.<sup>10</sup> Once the diagnosis has been made, and a serious cause such as perforated viscus or trauma has been excluded, no further treatment is required.

**Table 1.7.** Causes of pneumomediastinum

<ul style="list-style-type: none"> <li> <ul style="list-style-type: none"> <li>■ <b>Perforated hollow viscus</b> (traumatic or iatrogenic)           <ul style="list-style-type: none"> <li>• Oesophagus</li> <li>• Trachea/bronchi</li> <li>• Nasopharynx</li> </ul> </li> <li>■ <b>Facial trauma</b></li> <li>■ <b>Post-surgical</b> <ul style="list-style-type: none"> <li>• Facial</li> <li>• Neck</li> <li>• Mediastinal</li> </ul> </li> <li>■ <b>Alveolar rupture</b> <ul style="list-style-type: none"> <li>• Asthma</li> <li>• Mechanical ventilation</li> <li>• Other causes of elevated intra-thoracic pressure (e.g. valsalva, inhalation drug abuse)</li> </ul> </li> </ul> </li> </ul>
------------------------------------------------------------------------------------------------------------------------------------------------------------------------------------------------------------------------------------------------------------------------------------------------------------------------------------------------------------------------------------------------------------------------------------------------------------------------------------------------------------------------------------------------------------------------------------------------------------------------------------------------------------------------------------------------------



**Figure 1.55.** Quiz case.

56-year-old man admitted with acute chest pain.

## Question 12

- What is the most common cause (Fig. 1.55)?

## Answer

### Interstitial pulmonary oedema from left ventricular failure

The heart is enlarged, septal lines (Kerley B-lines) are present in the periphery of both lower zones, and there is upper lobe blood diversion (increased number and size of upper lobe vessels compared with lower zone vessels the same distance from the hila). Ischaemic heart disease is the commonest cause. The radiographic pattern of cardiogenic pulmonary oedema depends on the left atrial pressure and its rate of increase (see Table 1.8).<sup>11</sup>

Pulmonary oedema is usually bilateral. Causes of unilateral pulmonary oedema include acute mitral regurgitation post-myocardial infarction (Fig. 1.56), patients nursed on one

**Table 1.8.** Signs of increasing pulmonary venous hypertension

#### ■ Vascular redistribution

- Upper lobe vessels (arteries and veins)
- Increased in diameter
- Lower lobe vessels reduced in size

#### ■ Interstitial oedema

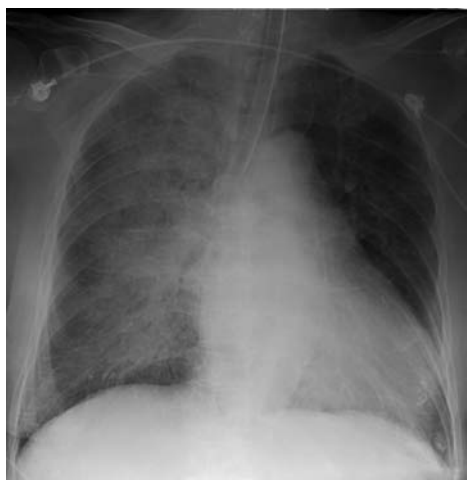- Kerley B-lines
- Fluid in the fissures
- Peribronchial cuffing

#### ■ Pleural effusions

#### ■ Alveolar oedema

- Air space opacification (the classic perihilar 'bat wing' distribution is rare)
- Clears rapidly with diuretics





**Figure 1.56.** Unilateral pulmonary oedema. There is perihilar air space opacification and peripheral septal lines in the lower zone of the right hemithorax. This is caused by acute mitral regurgitation in the setting of papillary muscle rupture. The regurgitant jet is directed toward the right lung.

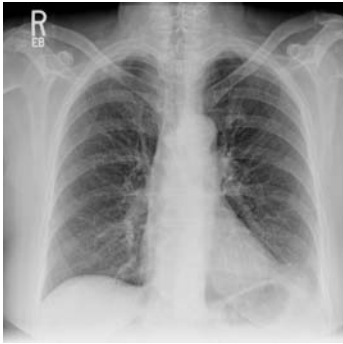side, rapid thoracocentesis and sparing of a severely diseased lung (e.g. asymmetrical emphysema).

### Comment

Although in hospital practice the commonest cause of pulmonary oedema is left ventricular failure, the other causes (see Table 1.9) should also be considered if only to exclude them. Distinction can be difficult on the chest X-ray alone. Heart size, age and symptoms may give an indication of the diagnosis. In cases of elevated pulmonary venous pressure, different X-ray signs develop progressively as it rises. Response to treatment, e.g. diuretics, is helpful if there is doubt about the diagnosis.

**Table 1.9.** Causes of pulmonary oedema

■ <b>Cardiogenic</b>
● Ischaemic
● Cardiomyopathy
● Aortic/mitral valvular disease
■ <b>Non-cardiogenic</b>
● Near drowning
● Aspiration
● ARDS (refer to Fig. 1.75)
● Raised intracranial pressure
● Renal failure/fluid overload



**Figure 1.57.** Quiz case.

34-year-old female. Taking oral contraceptive pill.  
Immobilized for compound tibial fracture.  
Suddenly short of breath.

## Question 13

- What is the diagnosis (Fig. 1.57)?
- What other methods of diagnostic imaging are available?

## Answer

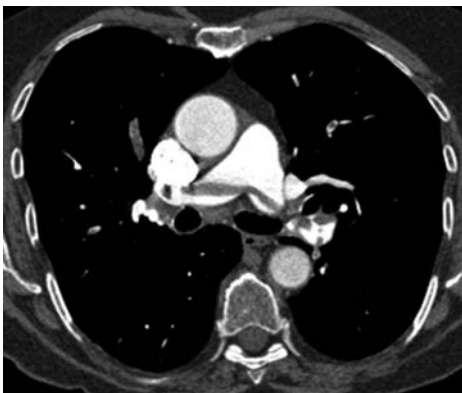
### Pulmonary embolism

There is a focal area of consolidation abutting the left hemidiaphragm. This is known as Hampton's hump. It represents haemorrhage/infarction secondary to pulmonary embolism. It is a relatively specific but rare sign of pulmonary embolism.

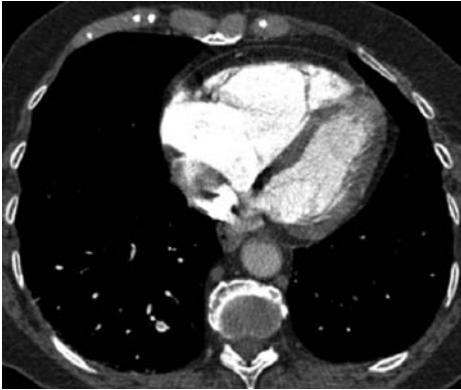The chest X-ray may be normal in pulmonary embolism or may demonstrate non-specific abnormalities such as linear atelectasis, small pleural effusion and elevated hemidiaphragm. A prominent central pulmonary artery, focal oligoemia or Hampton's hump are rare but more specific radiological signs.

The indication for more complex imaging depends on the clinical probability and the D-dimer result (see BTS guidelines<sup>12</sup>).

CT pulmonary angiography is the investigation of choice for most patients with suspected pulmonary embolism, and will reliably identify clot down to subsegmental level with greater than 90% sensitivity and specificity (Fig. 1.58). It may also give an indication of right heart



**Figure 1.58.** CT pulmonary angiogram. Filling defects are seen in the pulmonary trunk extending into both main pulmonary arteries consistent with emboli.

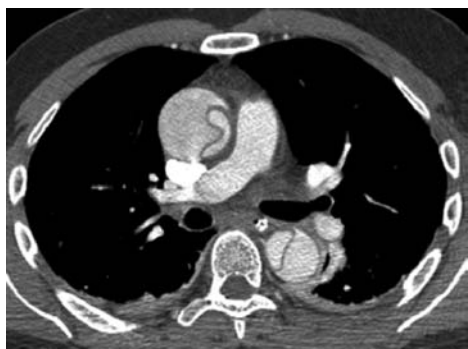


**Figure 1.59.** CT pulmonary angiogram. There is marked dilatation of the right heart with straightening of the interventricular septum (the septum normally bows towards the right ventricle due to higher left ventricular pressures) consistent with right heart strain.

compromise (see Fig. 1.59)<sup>13</sup> and may identify an alternative cause for the patient's symptoms, such as pneumonia or rib fracture.

Radio-isotope ventilation/perfusion (V:Q) scanning gives a lower radiation dose, but is often indeterminate, particularly if there is pre-existing cardiopulmonary disease. Its use is therefore usually limited to younger patients with a normal CXR.

Pulmonary angiography is no longer used in the routine investigation of patients with suspected pulmonary embolism.



**Figure 1.60.** Quiz case.

71-year-old male. Sudden onset of severe, tearing chest pain.

## Question 14

- The chest X-ray was normal. What does the CT show (Fig. 1.60)?

## Answer

### Aortic dissection

The features demonstrated on the CT scan are an aortic intimal flap and a false lumen, involving both the ascending and descending aorta.

The chest X-ray is often unhelpful. Radiological signs of aortic dissection that may be present include widened mediastinum (a non-specific finding, particularly on an AP film) and displacement of intimal calcification.

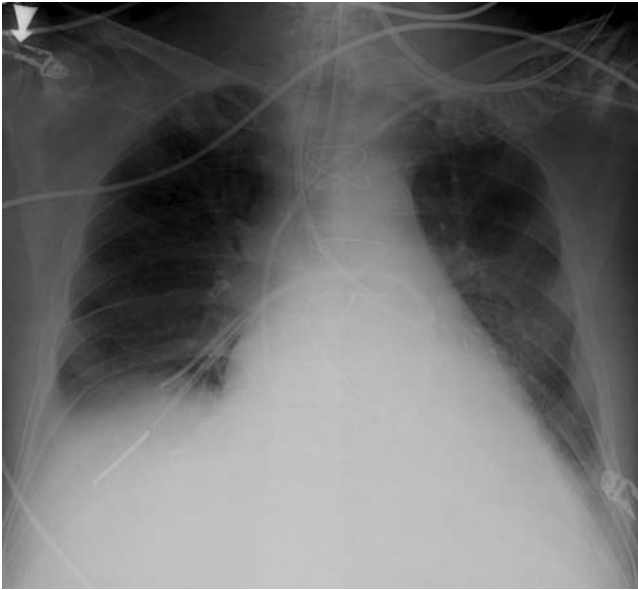Aortic dissection has a peak incidence in the sixth to seventh decade with a male predominance. The associated risk factors are hypertension and medial degeneration. A variety of congenital diseases are associated with dissection and these include Marfan's and Ehlers-Danlos syndrome. Pregnancy and cardiac catheterization are further risk factors.

The aorta is composed of three layers (intima, media and adventitia) and dissection is characterized by haematoma in the media of the aortic wall. The separation of the intima from the adventitia finally creates a false lumen that continues for a variable distance. If the dissection ruptures through the adventitia, haemopericardium or haemothorax can result.

### Stanford classification<sup>14</sup>

- Type A: involving ascending aorta or arch.
- Type B: limited to descending aorta (distal to left subclavian artery).

Patients with Stanford type-B dissection are usually treated medically with management of hypertension. A new treatment option is the percutaneous insertion of a covered aortic stent. Type A dissections may be treated by surgical repair of the aortic root. Contrast-enhanced multislice CT has replaced angiography as the investigation of choice, and can accurately diagnose both the dissection and its complication.<sup>15</sup> Other imaging options are transthoracic and trans-oesophageal echocardiography, and rarely MRI.



**Figure 1.61.** Quiz case.

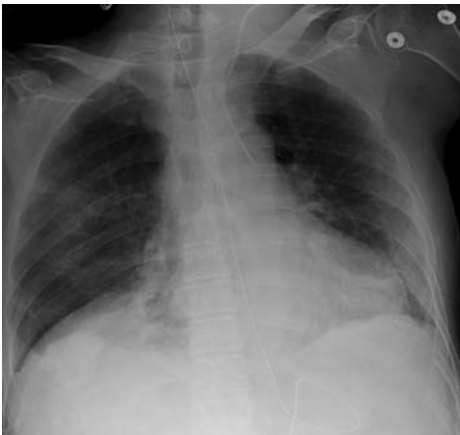46-year-old patient on intensive care unit.

## Question 15

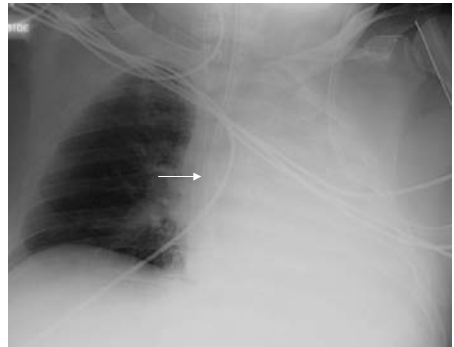- What does the chest X-ray (Fig. 1.61) show?

## Answer

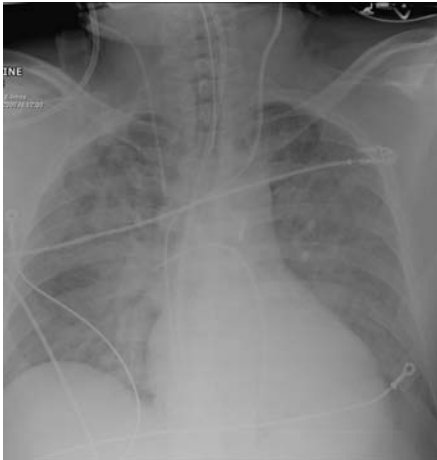The tip of the nasogastric tube is in a right lower lobe bronchus and the more proximal part of the tube is coiled in the left main bronchus. There is also a left subclavian pulmonary artery catheter whose tip is too peripheral in a lower lobe artery, and should be withdrawn into the



**Figure 1.62.** The left internal jugular line tip is within the aorta.



**Figure 1.63.** The endotracheal tube is in the right main bronchus (arrow) and there is complete collapse of the left lung.

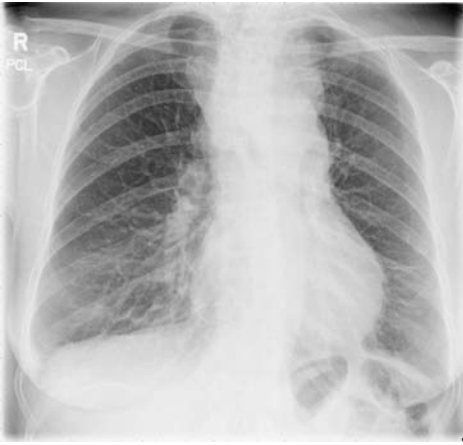

**Figure 1.64.** The intra-aortic balloon tip can be seen in the descending aorta (arrow). There is an endotracheal tube, right internal jugular line and pulmonary catheter in situ which are in satisfactory positions. Extensive airspace opacification is noted bilaterally, which in this case was due to acute pulmonary oedema.

interlobar artery. The endotracheal tube is satisfactorily positioned. There is increased density behind the heart in keeping with left lower lobe atelectasis/consolidation. This is a very common finding after cardiac surgery (note sternotomy wires and left internal mammary artery clips).

Checking the position of all tubes and lines is crucial for films taken on intensive care units. This should be done meticulously for each line or tube by tracing it with the eye throughout its course.<sup>16</sup> Figures 1.62 and 1.63 demonstrate two other examples of commonly misplaced lines or tubes.

Figure 1.64 demonstrates the expected position of an intra-aortic balloon pump (arrow), which should be in the proximal descending aorta just distal to the subclavian artery.



**Figure 1.65.** Quiz case.

Chest X-ray taken prior to lymph node biopsy.

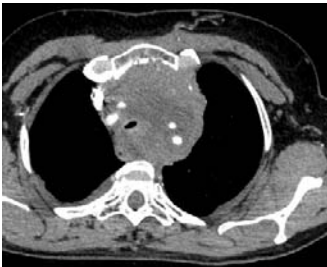## Question 16

- What is the diagnosis (Fig. 1.65)?
- Are there any precautions necessary prior to anaesthesia?

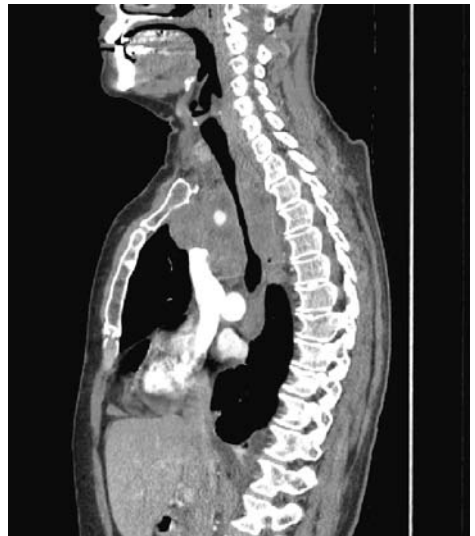## Answer

Anterior mediastinal mass secondary to lymphoma (see Figs. 1.66 and 1.67).

Anterior mediastinal masses pose a significant risk for anaesthesia, particularly in children.<sup>17</sup> Large masses are elevated from the major airways by intercostal muscular tone. Anaesthesia relaxes these muscles, which may then lead to dynamic airway obstruction.



**Figure 1.66.** There is a large mass in the superior mediastinum, which is encasing the great vessels. The trachea is significantly narrowed.



**Figure 1.67.** The sagittal CT in the same patient better demonstrates the extent of the tracheal narrowing.

Inability to ventilate, leading to death, has been described, but is rare. Patients are at high risk of major post-operative respiratory complications. Tracheal compression of 50% or more is a sensitive predictor of intra-operative problems. Local anaesthesia should be used where possible. If general anaesthesia is mandatory, maintenance of spontaneous ventilation is the key.

### Mediastinal masses

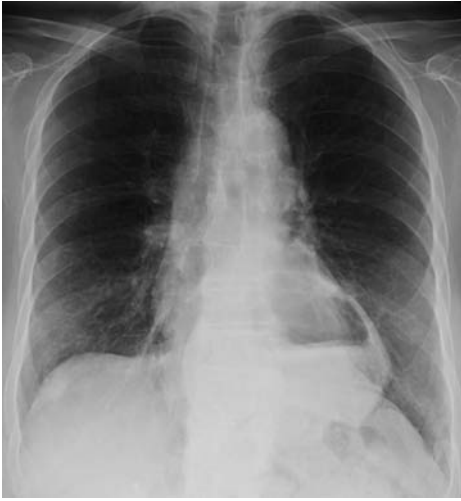Mediastinal masses are traditionally classified according to their location in the mediastinum: anterior, middle and posterior mediastinum.<sup>18</sup> It is possible to localize these with reasonable accuracy on plain films by assessing which silhouette has been lost. If, for example, part of the silhouette of the ascending thoracic aorta or heart border is blurred, then the mass must be anterior. If the lung hilum is seen projected through the mass, and the hilum is of normal appearance, then the abnormality cannot be in the middle mediastinum. Posterior mediastinal masses may be identified by the loss of the thoracic spine contour or the descending thoracic aorta outline. Other clues of a posteriorly sited mass are abnormalities of the adjacent ribs or bony involvement of the spine. Large masses often involve more than one mediastinal compartment.

Lateral chest X-ray will confirm the position in the mediastinum. CT (or less commonly MRI) is routinely used to give further anatomical detail of mediastinal masses (Table 1.10).

**Table 1.10.** Mediastinal masses

<p>■ <b>Anterior mediastinum – anatomical space between sternum and anterior pericardium</b></p> <ul style="list-style-type: none"> <li>● Thyroid</li> <li>● Lymph nodes</li> <li>● Thymic tumour</li> <li>● Teratoma</li> <li>● Ascending aortic aneurysm</li> </ul>
<p>■ <b>Middle mediastinum – anatomical space between anterior pericardium and posterior pericardium/posterior tracheal wall</b></p> <ul style="list-style-type: none"> <li>● Lymph nodes</li> <li>● Aortic arch aneurysm</li> <li>● Bronchogenic cyst</li> </ul>
<p>■ <b>Posterior mediastinum – anatomical space between posterior pericardium/posterior tracheal wall and anterior aspect of thoracic spine</b></p> <ul style="list-style-type: none"> <li>● Hiatus hernia</li> <li>● Lymph nodes</li> <li>● Descending aortic aneurysm</li> <li>● (Neurogenic tumours and other paravertebral masses – anatomically outside mediastinum, although usually considered with posterior mediastinal masses)</li> </ul>





**Figure 1.68.** Quiz case.

64-year-old patient.

## Question 17

- What is the condition (Fig. 1.68)?
- What anaesthetic precautions are necessary?

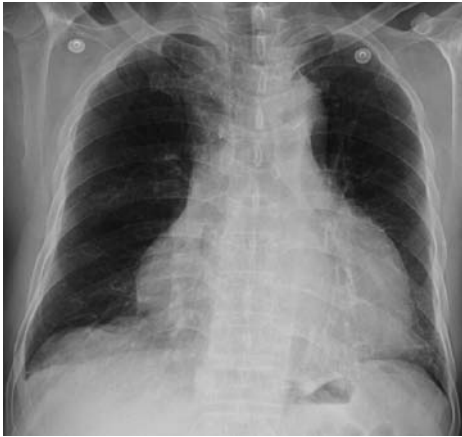## Answer

### Hiatal hernia

A mass with an air–fluid level is seen projected over the heart, crossing the midline. If the findings were more subtle (e.g. without an obvious air–fluid level), a lateral X-ray could be performed.

A hiatal hernia is herniation of the stomach through the oesophageal diaphragmatic hiatus into the thorax. Hiatal hernias are described as incarcerated when they are irreducible. Hiatal hernias are a frequent incidental finding on CT scans.

Other causes of gas-containing mediastinal structures include gastric pull-through post-oesophagectomy. Achalasia can also produce a large mediastinal gas shadow (sometimes with a fluid level). Aspiration is a potential risk of general anaesthesia or sedation. Regional anaesthesia should be considered if appropriate for the surgery. The patient should be given an H<sub>2</sub> antagonist or proton pump inhibitor as pre-medication. If general anaesthesia is undertaken, a rapid sequence induction with cricoid pressure should be performed and the trachea intubated with a cuffed tube.



**Figure 1.69.** Quiz case.

64-year-old female. Recent history of increasing breathlessness.

## Question 18

- What is the diagnosis (Fig. 1.69)?

## Answer

### Pericardial effusion

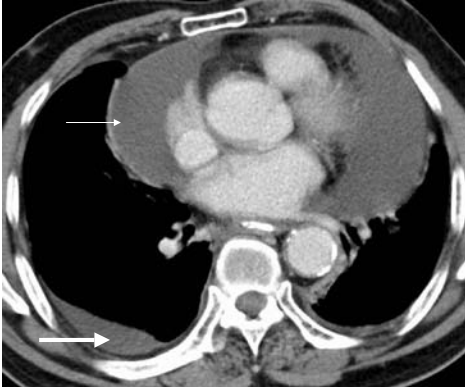
There is marked enlargement of the ‘cardiac’ silhouette, which has a globular configuration. There are no signs of cardiac failure.

There is a differential for enlargement of the cardiac silhouette on chest X-ray (see Table 1.11). It is important to remember that the cardiac silhouette comprises both the heart and pericardium. Clinical signs which may give a clue to the diagnosis include quiet heart sounds, elevated JVP and pulsus paradoxus. Small complexes may be present on ECG. Echocardiography is the investigation of choice; however, CT can elegantly demonstrate unsuspected pericardial effusions (see Fig. 1.70).

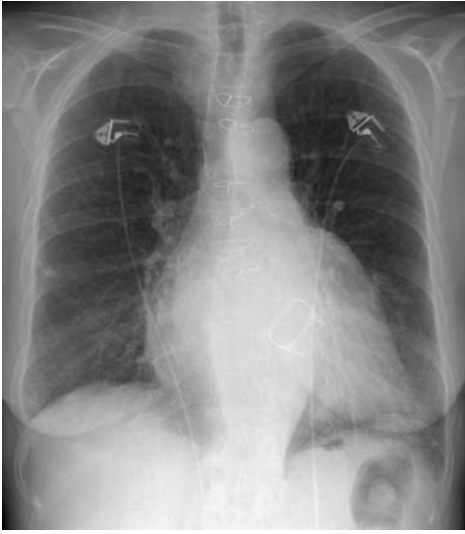**Table 1.11.** Causes of enlarged ‘cardiac’ silhouette

- Ischaemic heart disease
- Valvular heart disease
- Congenital heart disease
- Dilated cardiomyopathy
  - Viral
  - Alcohol (Fig. 1.38)
  - Metabolic
- Pericardial effusions

In left ventricular hypertrophy from hypertension or aortic stenosis, the cardiac silhouette does not dilate until late in the natural history.



**Figure 1.70.** The CT demonstrates a large pericardial effusion (thin arrow). There is also a small right pleural effusion (thick arrow).



**Figure 1.71.** Quiz case.

53-year-old female. Atrial fibrillation.

## Question 19

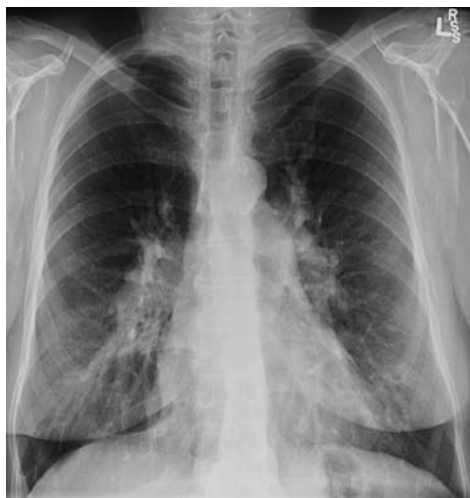- What is the diagnosis (Fig. 1.71)?

## Answer

The heart is enlarged, with a prominent left atrial appendage and 'double' right heart border (also a sign of left atrial enlargement). A prosthetic mitral valve is noted. There is upper lobe blood diversion in keeping with pulmonary venous hypertension.

### Mitral valve disease

Pure mitral stenosis secondary to rheumatic fever is now rare, and results in left atrial enlargement with 'sparing' of a non-dilated left ventricle. Mixed mitral valve disease or pure mitral regurgitation results in both left atrial and ventricular enlargement. Both may result in pulmonary oedema. Other pulmonary manifestations of mitral stenosis (e.g. haemosiderosis and ossification) are very rare.<sup>19</sup>



**Figure 1.72.** Quiz case.

## Question 20

▪ Comment (Fig. 1.72) on:

1. Cardiac size.
2. Pulmonary vascularity.
3. A possible cause.

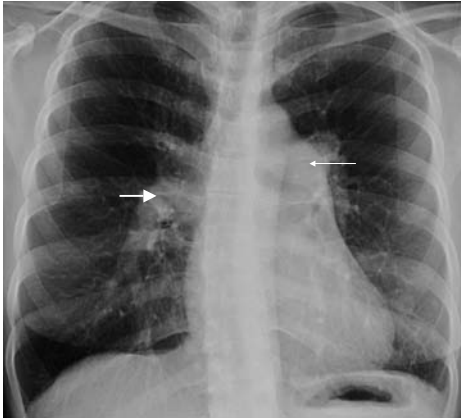
## Answer

The heart is enlarged. The pulmonary trunk and proximal pulmonary arteries are enlarged. There is pulmonary arterial hypertension. The aortic arch is relatively small. Atrial septal defect (ASD) is the cause in this case.

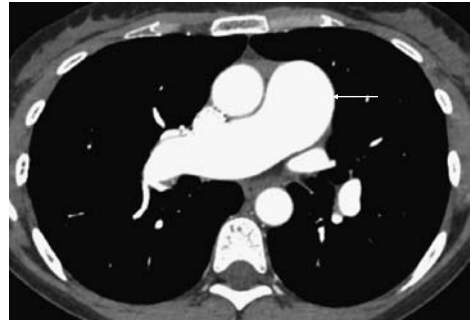
### Atrial septal defect

ASD causes increased pulmonary arterial flow due to blood being shunted from the left to the right atrium and, subsequently, through the pulmonary arteries and veins. This overcirculation causes pulmonary plethora making both the central and more peripheral vessels appear distended. The right atrium, right ventricle and pulmonary artery and veins become enlarged. The vessels appear crisper than pulmonary venous hypertension (due to lack of oedema) and upper lobe distension is absent. After time, persistent over-circulation through the pulmonary arteries results in increased pulmonary resistance and rapid tapering of the pulmonary arteries (pruning). Reversal of the shunt can occur with time – Eisenmenger syndrome.

Left to right shunt is an uncommon cause of pulmonary hypertension. In the absence of a shunt the central pulmonary arteries are typically enlarged with rapid pruning of the peripheral arteries (see Figs. 1.73 and 1.74).



**Figure 1.73.** Primary pulmonary hypertension. Note the enlarged pulmonary trunk (thin arrow) and proximal pulmonary arteries (thick arrow).

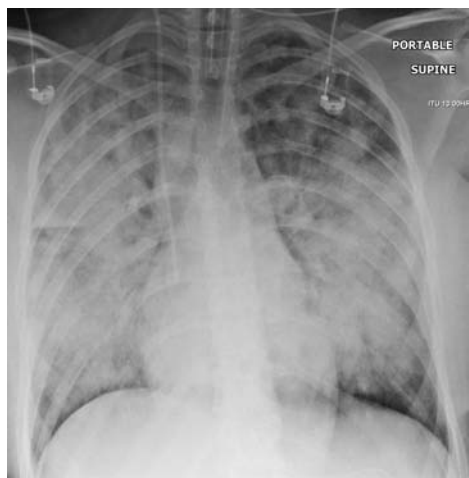


**Figure 1.74.** CT of primary pulmonary hypertension. The pulmonary trunk (arrow) and main pulmonary arteries are significantly enlarged.

Echocardiography confirms the diagnosis and will often detect a shunt. The imaging algorithm may also include CT pulmonary angiography, MRI, ventilation–perfusion scanning and cardiac catheterization.<sup>20</sup> Idiopathic pulmonary hypertension is a diagnosis of exclusion. The common causes of pulmonary hypertension are listed in Table 1.12.

**Table 1.12.** Causes of pulmonary hypertension

- Primary pulmonary arterial hypertension
- Chronic lung disease (cor pulmonale)
- Pulmonary emboli
- Chronic pulmonary venous hypertension, e.g. mitral valve disease
- Congenital heart disease with left to right shunts
  - ASD
  - VSD
  - PDA



**Figure 1.75.** Quiz case.

54-year-old male.  
Vented on the intensive care unit.

## Question 21

- Describe the radiological signs (Fig. 1.75).
- What is the differential diagnosis?
- How can the differential diagnosis be limited?

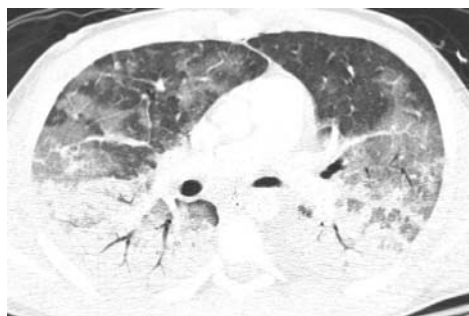
## Answer

The patient is ventilated and has a central venous catheter (CVC) and ECG monitoring. There is widespread bilateral air space shadowing. The cardiac size is normal.

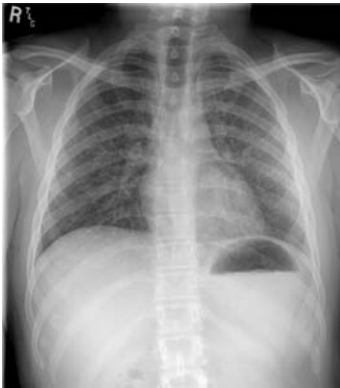The differential diagnosis for such an appearance includes cardiogenic and non-cardiogenic pulmonary oedema (ARDS or acute lung injury), diffuse pulmonary haemorrhage and severe pneumonia. The clinical details and laboratory tests will often give an idea of the underlying aetiology.

The diagnosis in this case was ARDS.

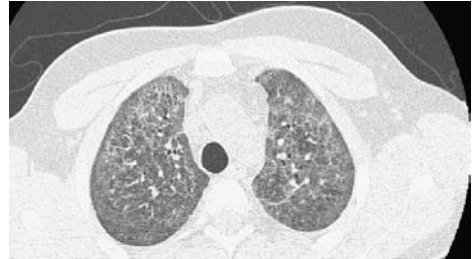CT features of ARDS in the acute exudative phase characteristically show dependent consolidation with more anterior ground glass shadowing (Fig. 1.76).<sup>21</sup> In the sub-acute fibroproliferative phase, the chest X-ray and CT appear more reticular (Figs. 1.77 and 1.78). CT is more sensitive than chest X-ray in the detection of complications, such as pleural



**Figure 1.76.** CT of ARDS. There is bilateral dependent consolidation – note the air bronchograms. Anteriorly there is ground glass opacification (i.e. opacification not obscuring the pulmonary vessels).



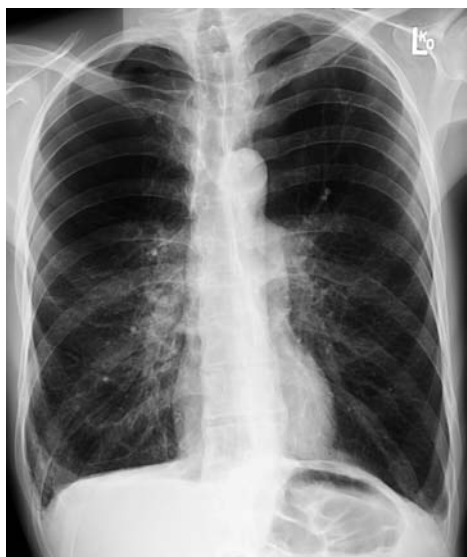**Figure 1.77.** Fibrotic ARDS. Note the increased interstitial markings bilaterally.



**Figure 1.78.** CT of fibrotic ARDS. Patchy ground glass opacification is noted and there are prominent reticular opacities. Note the predominantly anterior distribution of the changes. It is thought that the dependent consolidation seen in the acute phase protects the posterior lung regions from the effects of mechanical ventilation.

effusion and pneumothorax. The chest X-ray and CT may normalize, but patients with prolonged ARDS may be left with established fibrosis and pneumatoceles (thin-walled intra-parenchymal areas of air trapping which occur in the recovery phase of staphylococcal pneumonia, contusion or ARDS).





**Figure 1.79.** Quiz case.

46-year-old smoker.  
On surgical waiting list for hernia surgery.

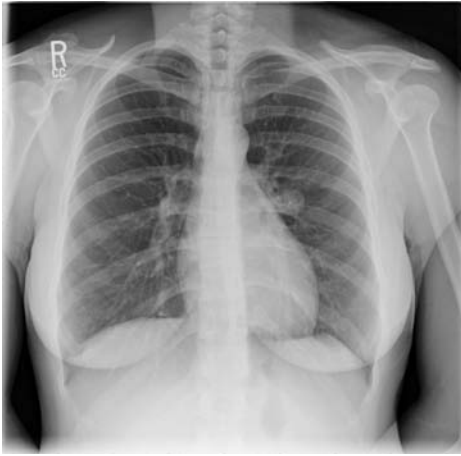
## Question 22

- What is the diagnosis (Fig. 1.79)?

## Answer

### Emphysema

There is hyper-expansion of both lungs with flattening of the diaphragm. At the level of the diaphragm there are eight anterior ribs (normal is fewer than seven). There are decreased lung markings in the upper and mid zones. The heart size is usually normal, unless cor pulmonale has developed or there is co-existing cardiac disease.



**Figure 1.80.** Quiz case.

42-year-old woman. History of recurrent chest infections, awaiting laparoscopy for complex ovarian cyst.

## Question 23

- Describe the abnormality seen on the chest X-ray (Fig. 1.80).
- What are the most likely differential diagnoses?

## Answer

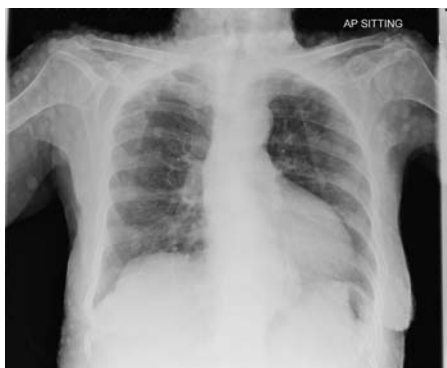### Solitary pulmonary nodule in the left mid zone

In this clinical setting you must consider a solitary metastasis from an ovarian carcinoma, but there is a wide differential diagnosis including primary lung tumour (see Table 1.13). This case was proven to be a carcinoid tumour.

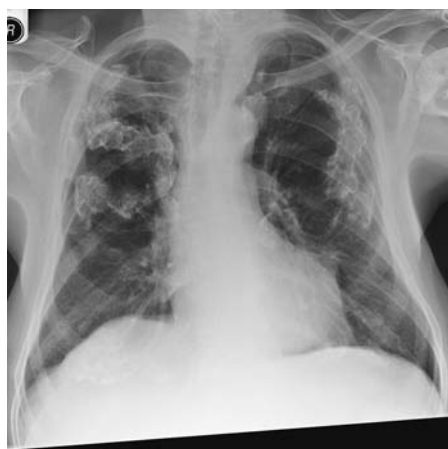A nodule is defined as being less than 3 cm in diameter, with a mass being greater than 3 cm. There are mimics of pulmonary nodules on a chest X-ray including nipple shadows,

**Table 1.13.** Causes of a solitary pulmonary nodule

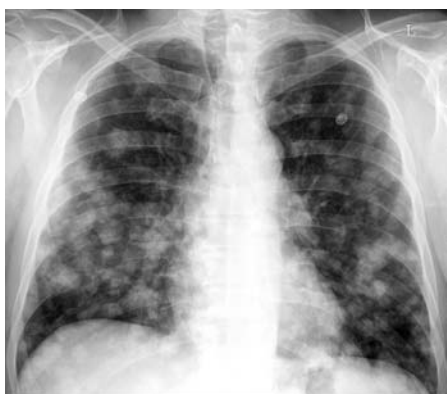■ Tumour
● Primary bronchogenic carcinoma
● Solitary metastasis
● Benign (carcinoid, hamartoma)
■ Infection
● Round pneumonia (usually children)
● Fungal
■ Other
● Infarction
● Granuloma (TB, sarcoidosis, rheumatoid nodule, Wegener's)
● Traumatic (contusion)
● AVM



**Figure 1.81.** Neurofibromatosis. The 'apparent' lung nodules are caused by skin neurofibromata. Note the nodules projected outside the chest wall.



**Figure 1.82.** Characteristic appearance of calcified pleural plaques.



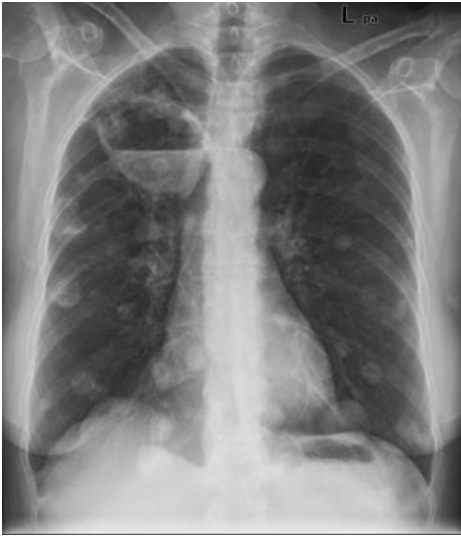**Figure 1.83.** There are multiple pulmonary nodules of varying sizes in both lungs. This case was metastases which is by far the commonest cause of multiple pulmonary nodules.

other skin lesions (see Fig. 1.81), bone and pleural lesions (see Fig. 1.82). A repeat chest X-ray with nipple markers is usually sufficient to clarify nipple shadows. CT is rarely needed.

There is a different differential diagnosis for multiple pulmonary nodules (Fig. 1.83) (see Table 1.14).

**Table 1.14.** Causes of multiple pulmonary nodules

■ Tumour
● Metastases
● Lymphoma
■ Infection
● Abscesses/septic emboli (if central venous line)
● Fungal infection (if neutropaenic)
■ Granuloma
● TB, Wegener's, sarcoidosis, rheumatoid arthritis



**Figure 1.84.** Quiz case.

54-year-old male.  
Recent haemoptysis and weight loss.

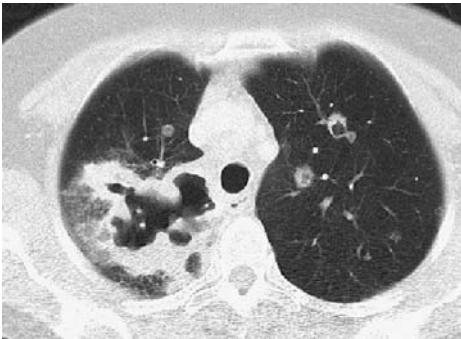## Question 24

- Describe the radiological findings (Fig. 1.84).

## Answer

There is a large cavitating mass with an air–fluid level in the right upper zone, with multiple bilateral pulmonary nodules, many of which are also cavitating (see also Fig. 1.85). The diagnosis in this case was metastatic squamous cell carcinoma of the lung. Causes of lung cavitation are listed in Table 1.15.

Cavitating malignancy can appear similar to infectious cavities. These may be primary bronchogenic malignancy or metastatic disease such as head and neck squamous carcinoma. Cavitating malignancy tends to have more nodular, thicker walls (more than 15 mm) than infection (less than 5 mm).

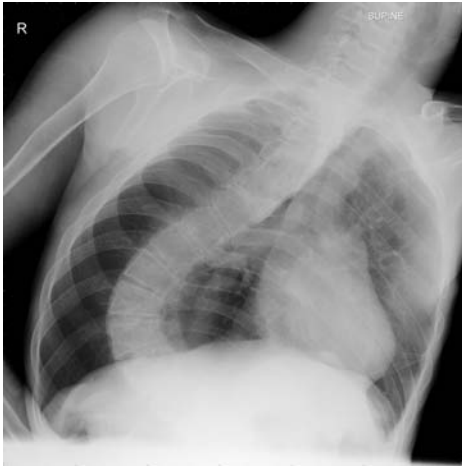


**Figure 1.85.** The CT demonstrates a large thick-walled cavity in the right upper lobe. Several of the smaller nodules are also cavitating.

**Table 1.15.** Causes of lung cavities

■ Infection
● Pyogenic abscess (including septic emboli)
● TB
● Fungal (particularly <i>Aspergillus</i> if immunocompromised)
■ Tumour
● Primary bronchogenic carcinoma
● Metastases (usually squamous cell carcinoma)
■ Other
● Wegener's granulomatosis
● Cavitating infarct (rare)

Mimics of cavitating lesions include pneumatoceles, emphysematous bullae and cystic bronchiectasis.



**Figure 1.86.** Quiz case.

38-year-old patient.  
Chronic musculoskeletal deformity.

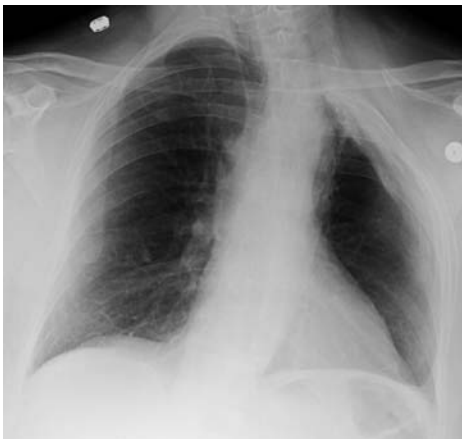## Question 25

- What is this deformity (Fig. 1.86)?
- How is it likely to affect respiratory function?

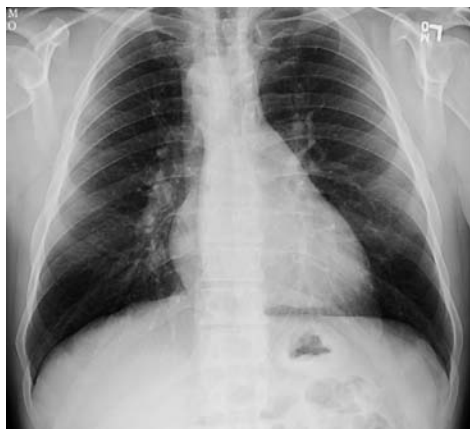## Answer

### Kyphoscoliosis

Respiratory function can be affected by the chest wall deformity, resulting in alveolar hypoventilation.<sup>22</sup> The likelihood of impairment in respiratory function is related to the maximum angle of curvature of the scoliosis (Cobb angle). Type II respiratory failure with subsequent cor pulmonale can occur. Chest wall deformity is also seen in patients who were treated for pulmonary tuberculosis with thoracoplasty prior to widespread availability of antibiotics (see Fig. 1.87). Marked chest wall deformity occurs often with considerable volume loss and sometimes with other stigmata of TB such as pleural calcification.



**Figure 1.87.** Left-sided thoracoplasty.



**Figure 1.88.** Quiz case.

Pre-operative chest X-ray in a 23-year-old female with an infective exacerbation of asthma.

## Question 26

- What is the diagnosis (Fig. 1.88)?

## Answer

### Right-sided aortic arch

The commonest type of right-sided aortic arch (with an aberrant left subclavian artery) is usually an incidental finding on a chest X-ray (as in this case), but does have a low prevalence of congenital heart disease.<sup>23</sup>

Right-sided aortic arch is a subtle abnormality that can result in an apparently 'normal' appearing X-ray. Hopefully this situation (i.e. when you are unable to spot an abnormality on the film) will not arise (in a viva). In a viva-type situation, the examiner has chosen a normal looking film because the findings are subtle and he/she is assessing whether you have a systematic approach. There are certain diagnoses which are easily made if you remember to look. A list of these is given below. It can be worth specifically looking for these, if no abnormality is immediately apparent, as it creates a bad impression if you miss something elementary like a left lower lobe collapse. If the film looks normal, check the review areas again. This not only helps to pass examination vivas, but is also a good clinical practice and will improve your day-to-day assessment of chest X-rays.

In particular, look for:

- dextrocardia,
- mastectomy,
- left lower lobe collapse,
- pneumothorax,
- right middle lobe collapse.

## References

- Hansell DM, Bankier AA, MacMahon H *et al*. Fleischner Society: glossary of terms for thoracic imaging. *Radiology* 2008; **246**: 697–722.
- Marshall GB, Farnquist BA, MacGregor JH *et al*. Signs in thoracic imaging. *J Thorac Imaging* 2006; **21**: 76–90.
- Yang PC, Luh KT, Chang DB *et al*. Value of sonography in determining the nature of pleural effusion: analysis of 320 cases. *Am J Roentgenol* 1992; **159**: 29–33.
- Gharib AM, Stern EJ. Radiology of pneumonia. *Med Clin North Am*. 2001; **85**: 1461–91.
- Leung AN. Pulmonary tuberculosis: the essentials. *Radiology* 1999; **210**: 307–22.
- Gruden JF, Huang L, Turner J *et al*. High-resolution CT in the evaluation of clinically suspected *Pneumocystis carinii* pneumonia in AIDS patients with normal, equivocal, or nonspecific radiographic findings. *Am J Roentgenol* 1997; **169**: 967–75.
- Woodring JH, Reed JC. Radiographic manifestations of lobar atelectasis. *J Thorac Imaging* 1996; **11**: 109–44.
- Mu LC, Sun DQ, He P. Radiological diagnosis of aspirated foreign bodies in children: review of 343 cases. *J Laryngol Otol*. 1990; **104**: 778–82.
- O'Connor AR, Morgan WE. Radiological review of pneumothorax. *Br Med J* 2005; **330**: 1493–7.
- Teh E, Edwards J, Duffy J *et al*. Boerhaave's syndrome: a review of management and outcome. *Interact CardioVasc Thorac Surg* 2007; **6**: 640–3.
- Gluecker T, Carpasso P, Schnyder P *et al*. Clinical and radiological features of pulmonary edema. *Radiographics* 1999; **19**: 1507–31.
- British Thoracic Society Standards of Care Committee Pulmonary Embolism Guideline Development Group. British Thoracic Society guidelines for management of suspected acute pulmonary embolism. *Thorax* 2003; **58**: 470–83.
- Ghaye B, Ghuysen A, Bruyere PJ *et al*. Can CT pulmonary angiography allow assessment of severity and prognosis in patients presenting with pulmonary embolism? What the radiologist needs to know. *Radiographics* 2006; **26**: 23–40.
- Daily PO, Trueblood HW, Stinson EB *et al*. Management of acute aortic dissections. *Ann Thorac Surg* 1970; **10**: 237–47.
- Castaner E, Andreu M, Gallardo X *et al*. CT in nontraumatic acute thoracic aortic disease: typical and atypical features and complications. *Radiographics* 2003; **23**: S93–110.
- Zarshenas Z, Sparschu RA. Catheter placement and misplacement. *Crit Care Clin* 1994; **10**: 417–36.
- Pullerits J, Holzman R. Anaesthesia for patients with mediastinal masses. *Can J Anaesth* 1989; **36**: 681–8.
- Whitten CR, Khan S, Munneke GJ *et al*. A diagnostic approach to mediastinal abnormalities. *Radiographics* 2007; **27**: 657–71.
- Woolley K, Stark P. Pulmonary parenchymal manifestations of mitral valve disease. *Radiographics* 1999; **19**: 965–72.
- Screaton NJ, Gopalan D. Pulmonary arterial hypertension. In: Muller NL, Silva CIS, eds. *Imaging of the Chest*. Saunders, 2008; 936–63.
- Desai SR. Acute respiratory distress syndrome: imaging of the injured lung. *Clin Radiol* 2002; **57**: 8–17.
- Bergofsky EH. Respiratory failure in disorders of the thoracic cage. *Am Rev Respir Dis* 1979; **119**: 643.
- Stewart JR, Kincaid OW, Titus JL. Right aortic arch: plain film diagnosis and significance. *Am J Radiol* 1966; **97**: 377–89.



Chapter

# 2

## Imaging the abdomen

---

Plain abdominal X-rays 60

Case illustrations: plain films  
and CT 62

## Plain abdominal X-rays

A systematic approach to plain abdominal X-rays will help to avoid errors in interpretation. The standard abdominal views are erect and supine AP views. Abdominal X-ray interpretation depends upon the assessment of the bowel gas pattern, solid organ outlines, a search for abnormal calcification and a review of the skeleton. A search should be made for extraluminal gas.

### Bowel gas pattern

Distinguishing large from small bowel may be difficult. The presence of solid faeces, distribution, calibre and mucosal pattern of the bowel helps in deciding whether a particular loop of bowel is stomach, small intestine or colon. The presence of solid faeces indicates large bowel, which may also be recognized by the incomplete haustral band crossing the colonic gas shadow. Haustra are usually present in the ascending and transverse colon but may be absent from the splenic flexure and descending colon. The valvulae conniventes of the small bowel are closer together and cross the width of the bowel. The distal ileum when dilated can appear smooth which makes differentiation more difficult. Small bowel when obstructed is generally centrally positioned with numerous loops of tighter curvature than large bowel. Small bowel calibre is variable but the upper limit of normal is approximately 3.0 cm. Maximum calibre of the colon on plain films is taken to be 5.0 cm in diameter and the maximal caecal diameter 9 cm.<sup>1</sup>

### Solid organs

The liver edge, renal outlines and splenic tip may all be demonstrated. The liver is seen in the right upper quadrant and extends downwards a variable distance. The tip of the right lobe may be seen extending below the right kidney – a normal variant called a Reidl's lobe. The spleen may be visualized (especially in slim individuals) even when of normal size. It enlarges inferiorly and towards the left lower quadrant. It is often possible to identify both kidneys and the psoas shadows within the retro-peritoneum. Soft tissue masses or abscess can sometimes be identified on plain films. An abscess generally has a rather heterogenous density due to the presence of gas and necrotic tissue. Mass lesions are of soft tissue density and will displace bowel gas shadows.

### Calcification

Calcification should be identified and located anatomically. In some locations (such as vascular calcification) it is common and benign. Vascular calcification may be seen within the aorta, splenic artery in the left upper quadrant or in the pelvis. Calcified renal tract stones should be looked for around the renal outlines and along the line of the ureters. Some causes of renal calcification are presented in Table 2.1. More rarely calcified gallstones are seen in the right upper quadrant or a calcified (porcelain) gall bladder. A calcified pancreas is diagnostic of chronic pancreatitis. Other causes of pelvic calcification include phleboliths, calcified fibroids and rarely calcification in ovarian teratoderms. The latter may also contain teeth and hair. See normal abdominal X-ray case (see Fig. 2.1).

**Table 2.1.** Causes of renal calcification

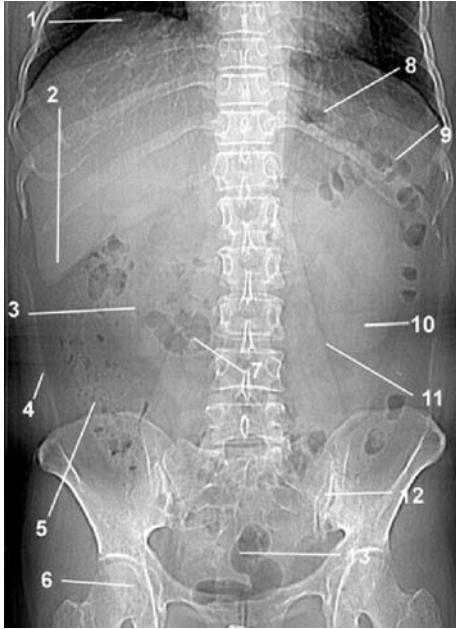
<b>Renal calculi</b>
■ Irregular calcification
• TB
• Carcinoma
• Renal artery calcification
<b>Nephrocalcinosis (renal parenchymal calcification)</b>
■ Medullary
• Medullary sponge kidney
• Renal tubular acidosis
• Hypercalcaemia
■ Cortical
• Transplant failure
• Acute cortical necrosis

A careful methodical examination of all the structures of the plain abdominal film will help to avoid errors in diagnosis. The cases below have been chosen specifically to demonstrate the more commonly encountered pathologies in anaesthetic practice, the FRCA examination, and in those patients admitted to intensive care units.

## Case illustrations: plain films and CT

### Question 1

- Name the normal structures labelled on the abdominal X-ray (Fig. 2.1).



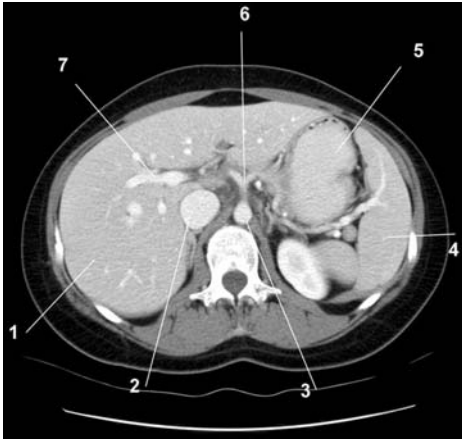
**Figure 2.1.** Quiz case.

### Answer

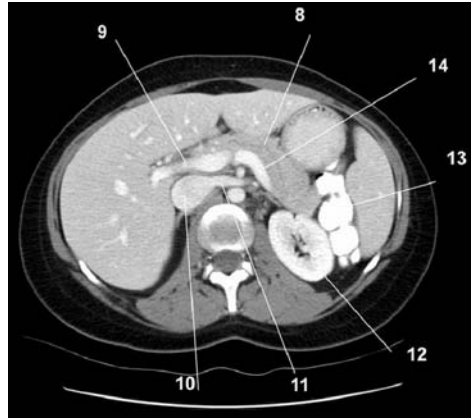1. Right hemidiaphragm
2. Liver outline
3. Right kidney
4. Peritoneal fat line
5. Ascending colon
6. Right hip
7. Small bowel gas shadow
8. Stomach gas bubble
9. Splenic flexure
10. Lower pole of left kidney
11. Left psoas shadow
12. Left sacro-iliac joint
13. Sigmoid colon

## Question 2

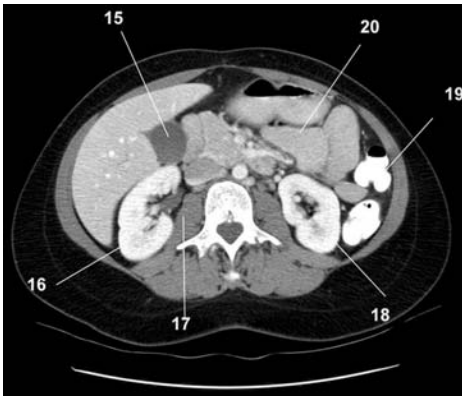- Name the structures on these abdominal CTs (Figs. 2.2–2.5).



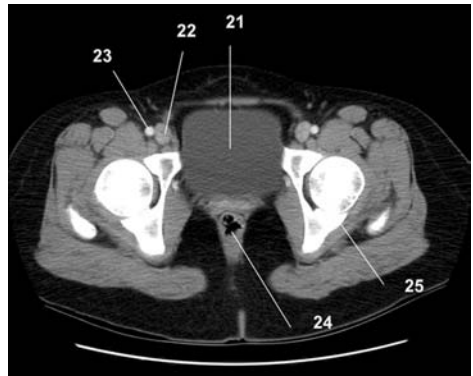**Figure 2.2.** Quiz case.



**Figure 2.3.** Quiz case.



**Figure 2.4.** Quiz case.

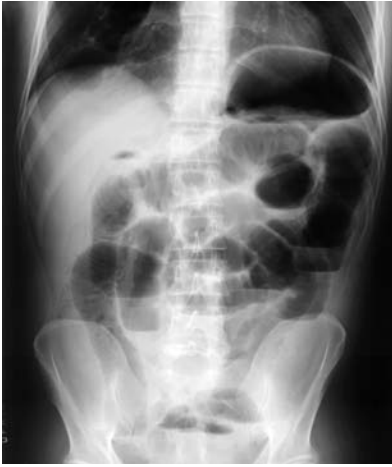

**Figure 2.5.** Quiz case.

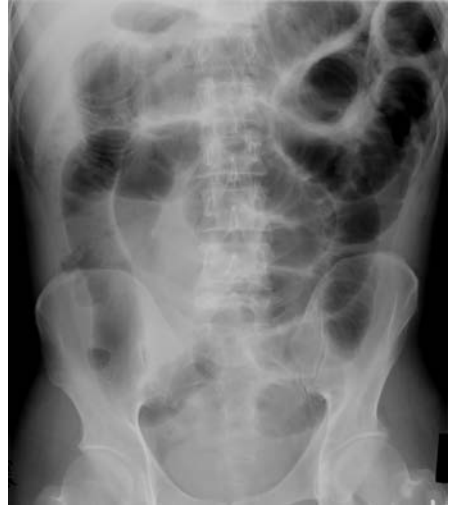## Answer

1. Right lobe of liver
2. IVC
3. Aorta
4. Spleen
5. Stomach
6. Coeliac axis
7. Right portal vein
8. Pancreas
9. Main portal vein
10. IVC

11. Left renal vein
12. Left kidney
13. Colon
14. Splenic vein
15. Gall bladder
16. Right kidney
17. Psoas
18. Left kidney
19. Colon
20. Small bowel
21. Bladder
22. Femoral vein
23. Femoral artery
24. Rectum
25. Left femoral head



**Figure 2.6.** Quiz case.



**Figure 2.7.** Quiz case.

62-year-old patient.  
Colicky abdominal pain.  
Tinkling bowel sounds.

### Question 3

- In what position were the films (Figs. 2.6 and 2.7) taken?
- Describe the abnormality on the abdominal X-ray.
- What is the management?

### Answer

#### Small bowel obstruction

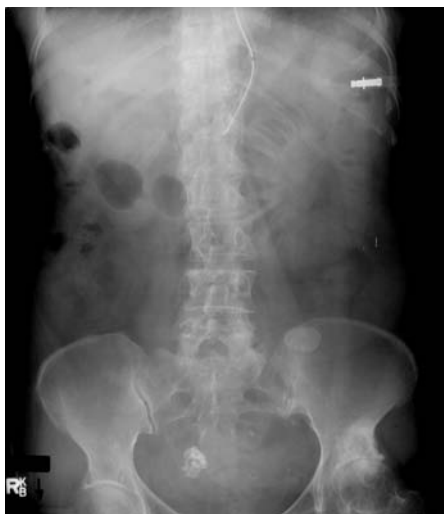The films were taken erect (Fig. 2.6) and supine (Fig. 2.7).

The erect X-ray shows multiple dilated gas-filled loops of bowel with several air–fluid levels. The supine film shows multiple tightly coiled loops of centrally positioned small bowel. Gas bubbles are seen trapped against the anterior mucosal surface. The appearances are of small bowel obstruction. Referral should be made to a surgical firm. Dehydration and electrolyte imbalance should be corrected and a nasogastric tube should be passed.

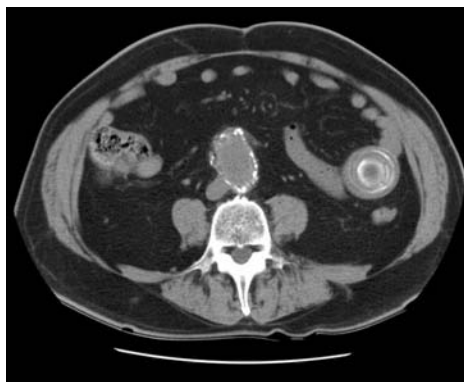#### Comment

Mechanical small bowel obstruction (SBO) characteristically has multiple loops of dilated, centrally positioned bowel. There are frequently numerous loops of tight curvature. These are clearly seen when gas filled, but can be very much more subtle should they be fluid filled. An erect film demonstrates multiple air–fluid levels. If loops are predominantly fluid filled, then only a few scattered gas bubbles may be seen trapped against the mucosal surface. This is known as the ‘string of beads’ sign and is a useful sign in confirming SBO in the otherwise gasless abdominal radiograph. A paucity of large bowel gas can be a helpful sign.

Although SBO often occurs due to post-operative adhesions or inguinal hernia, other aetiologies will give similar appearances and these cannot be easily differentiated on the plain

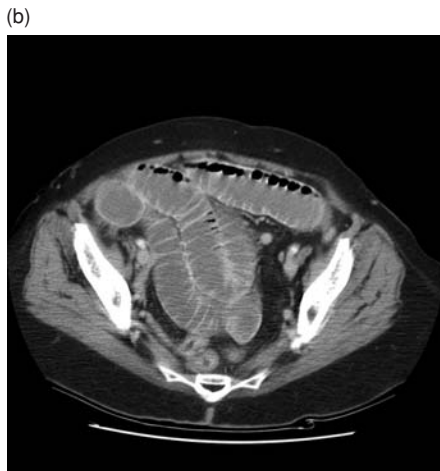
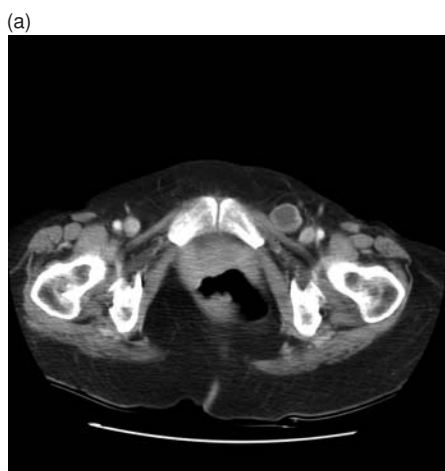
**Figure 2.8.** Plain film gallstone ileus. The impacted gallstone is seen projected over the left sacro-iliac joint. A gas-filled loop of small bowel is present in the left upper quadrant. Faint branching gas shadow in the right upper quadrant. Note also the calcified pelvic fibroid.



**Figure 2.9.** CT gall stone ileus. The impacted gallstone is seen in the lumen of the ileum in the left flank.

AXR. In cases of SBO, the hernial orifices should be scrutinized for incarcerated bowel. Gallstone ileus is a rare cause of SBO, which can give a classical appearance on AXR. This occurs when a large gallstone (over 2.5 cm) passes from the gall bladder into the small bowel. If the stone is calcified, then it may be seen on the abdominal film (see Fig. 2.8). This is usually identified in the right iliac fossa, where it impacts in the terminal ileum commonly 60 cm proximal to the ileo-caecal valve (narrowest part of the small bowel) causing SBO (see Fig. 2.9).

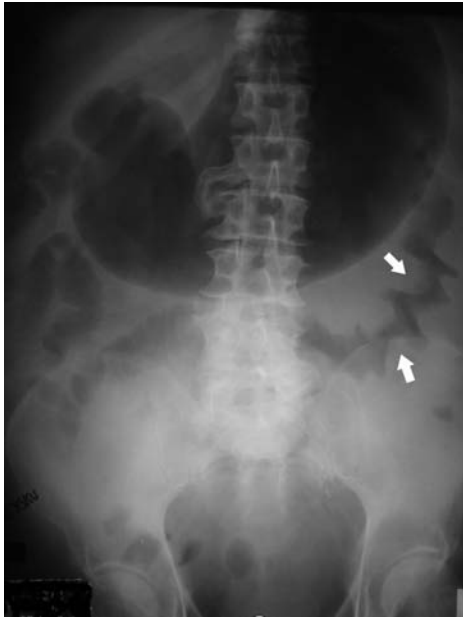

**Figure 2.10.** CT scan showing a left-sided femoral hernia causing small bowel obstruction. A calibre change is present at the site of the hernia. The small bowel loops are dilated proximal to the hernia.



What is the role of CT in the investigation of SBO?

CT is the imaging investigation of choice for patients with suspected SBO. It is accurate in confirming the presence of SBO, determining the level and identifying the cause for SBO.<sup>2</sup> Large bowel and small bowel can easily be distinguished on CT scans and an accurate assessment of small bowel calibre is possible. If there are both dilated and normal small bowel loops, the search for a single transition point will often indicate the site and type of pathology causing SBO. Abdominal wall hernias, internal hernias, mesenteric volvulus, adhesions and tumours are readily diagnosed on CT<sup>3</sup> (see Fig. 2.10). CT can be very helpful in planning surgical management.



**Figure 2.11.** Quiz case.

64-year-old patient.

This patient has a history of diabetes and had reconstructive vascular surgery for peripheral vascular disease 8 days ago. He received intravenous broad spectrum antibiotics for a surgical wound infection and now has bloody diarrhoea.

## Question 4

- What are the radiological signs (Fig. 2.11)?
- What is the diagnosis?

## Answer

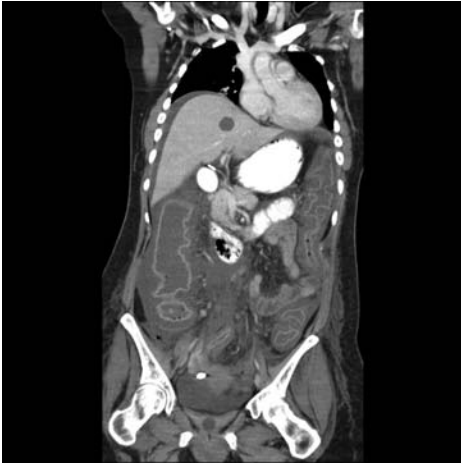This case demonstrates colonic wall thickening, 'thumb printing' (bowel wall oedema) and a distended stomach. The diagnosis is pseudomembranous colitis.

### Pseudomembranous colitis

Plain abdominal X-rays are abnormal in about one-third of patients. The radiological findings include moderate gaseous distension of the small and large bowel, the haustral folds are frequently shaggy and irregular and 'thumbprinting' is often identified particularly in the transverse colon (as in Fig. 2.11).<sup>4</sup> There is overlap with the appearance seen in acute inflammatory bowel disease and other types of infective colitis.

The diagnosis of pseudomembranous colitis can be suggested from the CT findings, which show diffuse colonic thickening, oedema and mucosal enhancement (see Fig. 2.12).

Pseudomembranous colitis is caused by an overgrowth of the commensal anaerobe *Clostridium difficile*. Commonly, it is a complication of antibiotic therapy, particularly ampicillin, amoxicillin, clindamycin and the cephalosporins. Antibiotic disturbance of the normal gut flora appears to allow overgrowth of toxigenic strains of *C. difficile*. The clinical and pathological effects are the result of toxin production. Further predisposing causes include bowel obstruction and co-existent debilitating disease, e.g. leukaemia. The clinical picture is

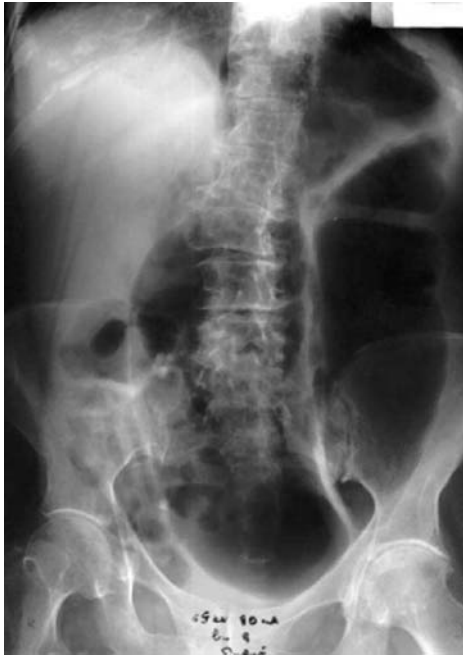

**Figure 2.12.** CT scan showing marked wall thickening, oedema and mucosal enhancement in a patient with pseudomembranous colitis.

of profuse diarrhoea, abdominal cramps and tenderness. A yellow exudative pseudomembrane, haemorrhagic areas and mucosal ulcers are seen on colonoscopy.

Complications include bowel perforation and peritonitis. Barium enema is contraindicated.

Treatment is with oral metronidazole, or oral vancomycin in more severe cases. Colectomy is occasionally necessary.



**Figure 2.13.** Quiz case.

86-year-old female.  
The patient has had several episodes of abdominal pain and distension. She is now vomiting.

## Question 5

- What is the diagnosis (Fig. 2.13)?

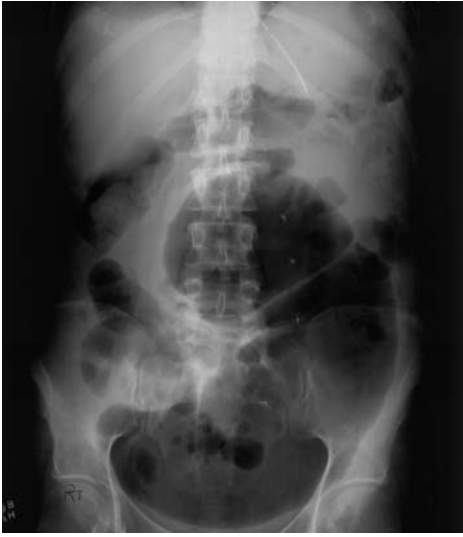## Answer

### Sigmoid volvulus

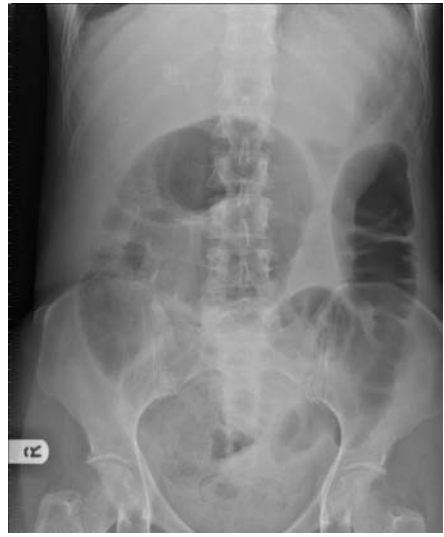This is a rotation of the sigmoid colon about its own mesenteric axis, which produces complete intestinal obstruction. It is most commonly seen in the elderly or in those with psychiatric disorders taking medication. Venous congestion leading to infarction can occur. On the plain abdominal film a hugely dilated loop of bowel is seen extending up out from the pelvis. The inverted 'U' loop is commonly devoid of haustra and is seen to extend as far as the liver in the right upper quadrant, and to the tenth thoracic vertebra superiorly. The inferior convergence of the two limbs of the loop is often left sided. There may be some secondary loops of dilated large bowel associated with these appearances. True sigmoid volvulus can sometimes be difficult to distinguish from gas-filled and distended loops which are not twisted.<sup>5</sup> Sigmoidoscopy can be both diagnostic and therapeutic by releasing flatus. Approximately half of patients have a further episode of volvulus within 2 years.

Caecal volvulus is much less common than sigmoid volvulus. In caecal volvulus, the caecum is seen to revolve around its axis to lie across the midline in the left upper quadrant/central abdomen (Fig. 2.14).

In the Western world large bowel obstruction is most commonly caused by colon cancer followed by diverticulitis. Signs on the abdominal X-ray are of gaseous distension of the large bowel down to the level of obstruction, sometimes with accompanying small bowel



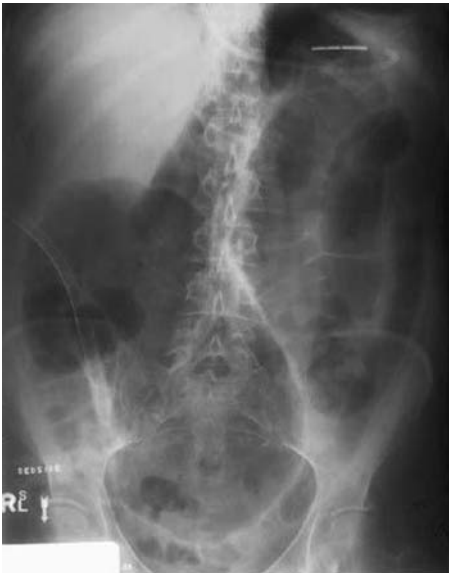**Figure 2.14.** Caecal volvulus.



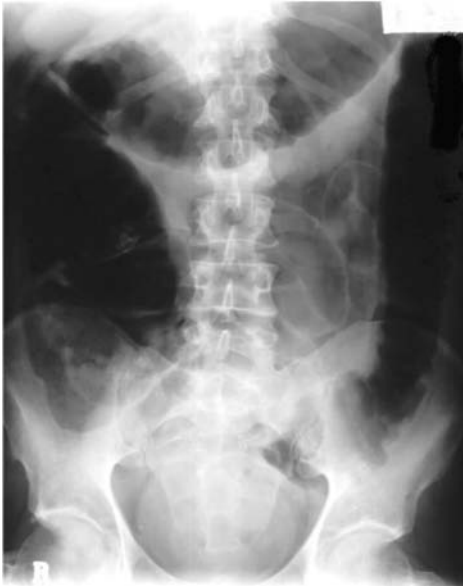**Figure 2.15.** Large bowel obstruction.

dilatation. In a minority of patients with a competent ileocaecal valve no small bowel distension is seen (Fig. 2.15). Other causes include intussusception or extrinsic compression.

When the ileocaecal valve is incompetent, both large and small bowel distension is present and appearances are similar to paralytic ileus. In paralytic ileus both the large and small bowel can become dilated which can extend down into the sigmoid colon and rectum (see Fig. 2.16). Paralytic ileus has many causes including peritonitis, trauma, surgery, drugs and electrolyte disturbance. The absence of peristalsis means that fluid and gas accumulate; differentiation from low large bowel obstruction may be difficult.



**Figure 2.16.** Pseudo-obstruction. This can be difficult to distinguish from distal large bowel obstruction. Large and small bowel distension is usually present with reduced small bowel distension on serial films. If concern persists an instant enema can be performed.



**Figure 2.17.** Quiz case.

51-year-old patient.  
Recurrent rectal bleeding, admitted with acute abdominal pain.

## Question 6

- What is the diagnosis?
- What are the radiological features (Fig. 2.17)?

## Answer

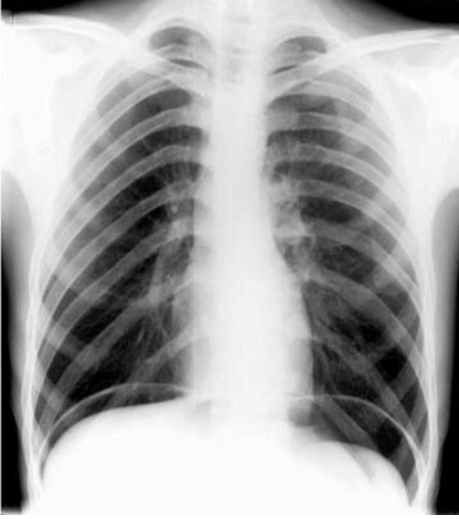### Pan colitis and perforation

The whole of the colon is distended. There is thickening of the mucosa which is oedematous. In the centre of the film there are several dilated loops of small bowel and their inner and outer walls are both visible. This latter feature indicates free gas within the peritoneal cavity.

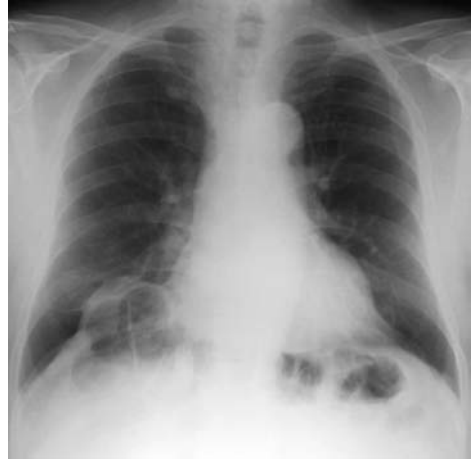The appearances of the bowel are characteristic of a pan colitis (affecting the whole colon) typical of ulcerative colitis. The bowel has clearly perforated. The term megacolon is frequently applied in cases of transmural fulminant colitis when the bowel loses motor tone and dilates to a transverse diameter of greater than 5 cm. The term *toxic* megacolon should be reserved for cases of dilatation with systemic toxicity, abnormal clinical signs (peritonism, fever) and abnormal laboratory indices (raised inflammatory markers, leukocytosis and left shift). The clinical setting is usually accompanied by profuse bloody diarrhoea. Mortality is up to 20%; barium enema is contraindicated. Ulcerative colitis is the commonest cause but others include Crohn's disease, amoebiasis, *Salmonella* and pseudomembranous and ischaemic colitis.

### Extraluminal gas

Normally, bowel gas is only present within the bowel lumen. Signs of extraluminal gas or pneumoperitoneum can be identified at various locations. Free gas is mobile and will move to different positions depending on whether the X-ray has been taken erect or supine. Gas may



**Figure 2.18.** Erect chest X-ray. Pneumoperitoneum – air under the diaphragms.

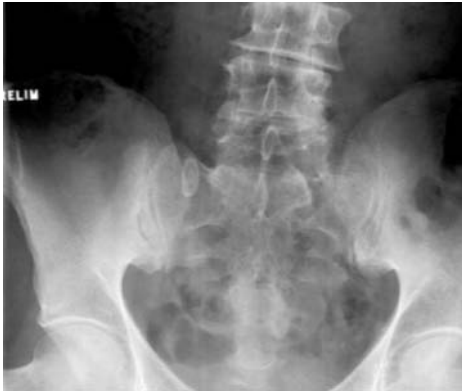

**Figure 2.19.** Colonic interposition simulating pneumoperitoneum.

outline the liver or falciform ligament or lie adjacent to bowel. Normally, only the inner margin of the bowel is visualized on the abdominal X-ray. This is due to the air–mucosa interface, where there are different densities. The outer margin, however, is not seen clearly since the serosal surfaces merge with other adjacent bowel wall loops of similar density. However, free intra-peritoneal gas will also clearly outline the outer serosal margin of the bowel. The bowel wall thus appears as a thin ‘pencilled’ line with gas on both sides. This appearance is known as Rigler’s sign. Gas may be visible under the hemidiaphragms on an erect chest or abdominal film (Fig. 2.18).

Free gas may be seen after bowel perforation or following laparotomy. In adults, post-laparotomy pneumoperitoneum persists for up to 7 days but is absorbed very much more quickly in children, usually by 24 hours.

Interposition of colon between the liver and the diaphragm (chilaiditis syndrome) can simulate pneumoperitoneum (Fig. 2.19). Haustration of the bowel can usually be identified but, if there is doubt, then a left lateral decubitus film should be performed.



**Figure 2.20.** Quiz case.

46-year-old male.

This patient has presented with acute right iliac fossa pain.

You have been asked to assess him prior to exploratory laparotomy.

## Question 7

- What is the X-ray (Fig. 2.20) abnormality?
- What is the likely diagnosis?

## Answer

There is an oval opacity overlying the right sacral ala. The appearances are typical of a faecolith or appendolith. This calcified faecal material can occur in the appendix or a large bowel diverticulum. This sign alone is non-specific and can be seen in normal people, but in conjunction with right iliac fossa pain, appendicitis is the most likely diagnosis. Other X-ray signs seen in appendicitis include a sentinel loop (atonic dilated loop of ileum), right lower quadrant haze due to swelling/oedema and a mass indenting the caecum.<sup>6</sup>

Plain film signs of appendicitis are non-specific and relate to an era of medical imaging prior to the use of ultrasound and CT scanning. Ultrasound has high specificity in diagnosing appendicitis, but it is operator dependent; visualization of the appendix can be obscured by bowel gas and it is technically difficult in obese patients<sup>7</sup> (see Fig. 2.21).

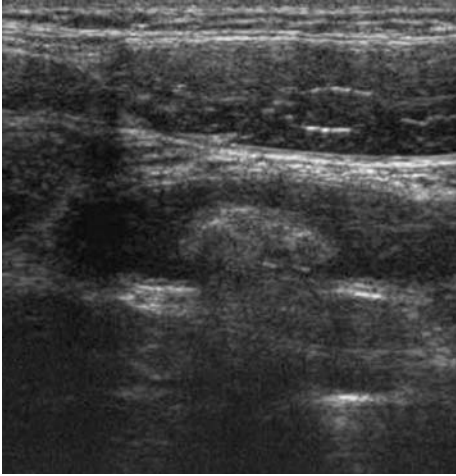
CT is an accurate modality for diagnosing acute appendicitis; it does not have the same problems inherent to ultrasound. CT signs of appendicitis include a dilated appendix, mucosal swelling, stranding and an appendicolith may or may not be present<sup>8</sup> (see Fig. 2.22).

A pragmatic approach to the investigation of patients with suspected acute appendicitis is to use ultrasound in paediatric patients, young adults and pregnant women in order to reduce the radiation dose. CT is suggested for older adults or in cases where there is a mass in the RIF. CT can help distinguish caecal tumour from appendix abscess or an inflammatory mass.

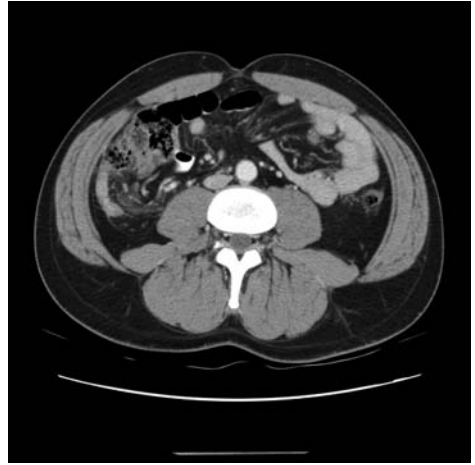Conditions which cause abdominal calcification on the plain film include the following:

- calcified aortic aneurysm,
- calcified gall stones,
- renal/ureteric/bladder stones,
- pancreas: chronic pancreatitis (Fig. 2.41),



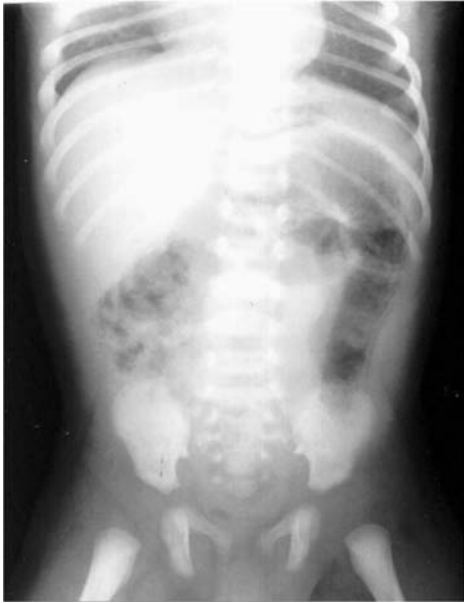

**Figure 2.21.** US appendicitis. The echogenic structure is an appendolith.



**Figure 2.22.** CT scan. Appendicitis. Inflamed appendix with thickening and adjacent stranding.

- appendolith: appendicitis,
- liver calcification: granuloma, old abscess, some metastases,
- uterine fibroids.



**Figure 2.23.** Quiz case.

14-day-old male child.

## Question 8

- What is the diagnosis (Fig. 2.23)?
- What are the common associations?
- What co-existent respiratory problems are frequently encountered?

## Answer

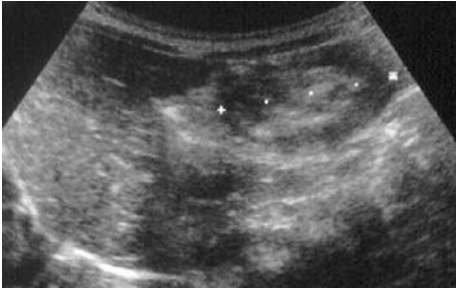### Necrotizing enterocolitis

Gas can be seen in the wall of a distended loop of bowel (probably the transverse and descending colon). It is difficult to differentiate large from small bowel in the neonate based on bowel distribution alone. The abdomen is rather featureless elsewhere.

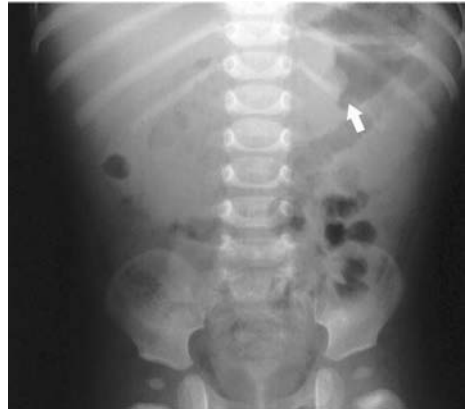Other recognized radiological signs of necrotizing enterocolitis (NEC) include small and large bowel dilatation, a *bubbly* appearance to the bowel, gas in the portal venous system and bowel perforation. NEC most commonly (but not exclusively) affects premature neonates. Barium enema is contraindicated. In adults, gas in the bowel wall often indicates bowel infarction and has a poor prognosis. It should not be confused with pneumatosis cystoides intestinalis.

Associations of NEC:

- prematurity,
- Hirschsprung's disease,
- bowel obstruction (e.g. meconium ileus or atresia)
- it is frequently co-existent with respiratory problems of the ventilated neonate such as hyaline membrane disease.



**Figure 2.24.** Quiz case.



**Figure 2.25.** Quiz case.

Age 2.  
This child presented with abdominal pain, and blood-stained mucus PR.

## Question 9

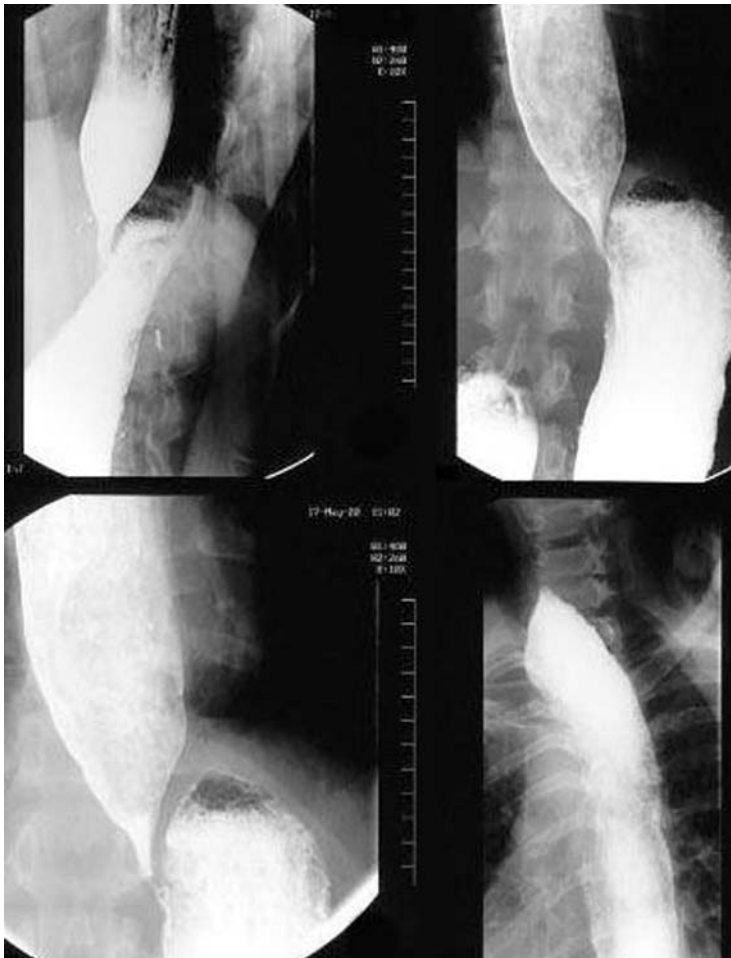- What do the abdominal film and the ultrasound (US) (Figs. 2.24 and 2.25) show?
- What would you request next?
- What precautions are necessary?

## Answer

### Intussusception

The abdominal film demonstrates a soft tissue mass in the left upper quadrant in the region of the transverse colon. This is outlined clearly on one side by gas in the colon distal to it. This is the lead point of an intussusception – the clinical history is extremely suggestive in a child of this age. The ultrasound (US) confirms a mass which is characteristic of an intussusception.

Air enema/pneumatic reduction is the preferred initial method of treatment. This requires fluid resuscitation and IV antibiotics prior to the procedure. This should only be carried out in a centre with paediatric surgical cover. The procedure fails in a proportion of cases and open surgical reduction may be necessary. Pneumoperitoneum, peritonitis and hypovolaemic shock are contraindications to the technique. A large bore Foley catheter is inserted into the rectum and the buttocks are taped together. Air is insufflated using a pump with a pressure gauge that has a valve mechanism to prevent excessive pressures. The lead point of the intussusception can be followed fluoroscopically and usually reduces fairly easily (success rate is up to 90%) but there may be some hold-up at the ileocaecal valve level. When the intussusception reduces, the small bowel can be seen to suddenly fill with a puff of gas. Bowel perforation is a potential complication and this may splint the diaphragm compromising respiration. A large bore needle should be kept to hand and used to decompress a pneumoperitoneum. Incomplete reduction and recurrence in up to 10% are further complications.



**Figure 2.26.** Quiz case.

48-year-old female.  
Dysphagia, chest pains  
and choking episodes.

## Question 10

- What is the diagnosis (Fig. 2.26)?
- What is the importance of this condition in anaesthetic practice?

## Answer

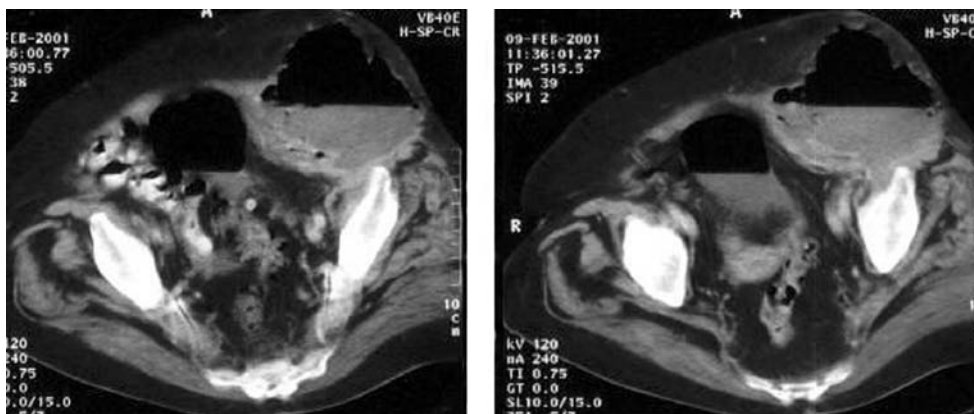
### Achalasia

This is a condition of middle age caused by a reduced number of ganglion cells in the myenteric plexus. There is failure of relaxation of the lower oesophageal sphincter in response to swallowing. There is absence of peristalsis in the mid and lower oesophagus which dilates to produce a megaesophagus. Symptoms include dysphagia, weight loss, regurgitation and chest pain. Sometimes, the chest X-ray is diagnostic and an air–fluid level can be seen in a dilated oesophagus. On barium examination, there is a characteristic bird beak deformity at the gastro-oesophageal junction. Manometry will demonstrate an absent primary peristaltic wave and tertiary contractions.<sup>9</sup>

The differential diagnosis includes infiltrating carcinoma, scleroderma and Chagas' disease.

The aim of treatment is to reduce the pressure of the lower oesophageal sphincter. Medical therapies include long-acting nitrates or calcium channel blockers. Further options include injection with botulinum toxin, balloon dilatation (which may be repeated if necessary) and surgery – oesophagomyotomy, which can be performed laparoscopically.

Complications include coughing, regurgitation, pneumonia and lung abscess. Patients are at high risk of aspiration and appropriate anaesthetic precautions are necessary.



**Figure 2.27.** Quiz case.

86-year-old female patient.  
Unwell, pyrexia. Elevated white blood count.

## Question 11

- What are the therapeutic options for this lesion (Fig. 2.27)?

## Answer

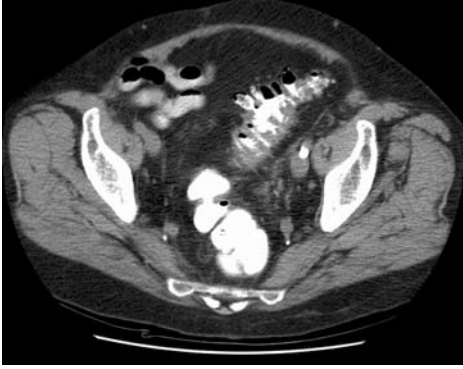### Diverticular abscess

There is a 10–12 cm abscess cavity with an air–fluid level in the left flank. Immediately adjacent to the abscess is a loop of bowel affected by diverticular disease with signs of direct communication.

Therapeutic options are either to insert a drainage tube under CT or ultrasound guidance or to proceed to laparotomy. If there is a large fistulous communication, then the surgical option would be favoured. Although the origin of the abscess is probably diverticular, the differential diagnosis includes a perforating colonic tumour.

**Table 2.2.** Colonic diverticulitis CT features

- Diverticula often visible on CT as round oval focus protruding from bowel wall (may fill with oral contrast)
- Streaky peri-colic fat
- Bowel wall thickening
- Intestinal obstruction
- Fluid or gas in peritoneum
- Fistulation into:
  - Bladder (look for an air–fluid level)
  - Small bowel, vagina, cutaneous
- Abscess or peri-colic collection

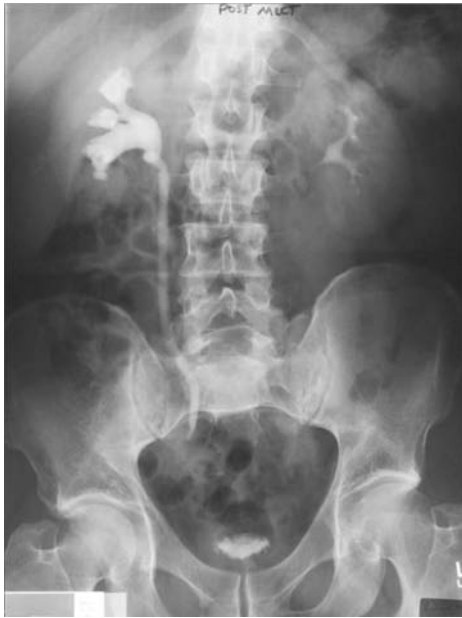

**Figure 2.28.** Diverticular disease CT. The sigmoid colon wall is thickened and there are multiple diverticula. Note oral contrast in sigmoid colon.

Colonic diverticulosis is an acquired herniation of the colonic mucosa and submucosa through the muscle layers. It is a condition more prevalent in developed countries with up to 50% of individuals affected by the seventh decade. The aetiology is linked to a diet lacking in roughage.

Diverticulitis is a complication of diverticulosis caused by faecal impaction in the mouth of a diverticulum leading to obstruction of the diverticulum and inflammation/infection. The sigmoid colon is the site most frequently affected. Presentation is with colicky pain in the left lower quadrant, tenderness and often a palpable mass. CT is very accurate in diagnosis.<sup>10</sup> Some of the CT features are presented in Table 2.2.

Complications include diverticular haemorrhage, abscess formation, perforation, fistula and colonic stricture formation (see Fig. 2.28).



**Figure 2.29.** Quiz case.

41-year-old male patient.  
2-day history of right loin pain.

## Question 12

- What does the film (Fig. 2.29) demonstrate?
- What further film is required to make the diagnosis?

## Answer

### Obstructed right ureter

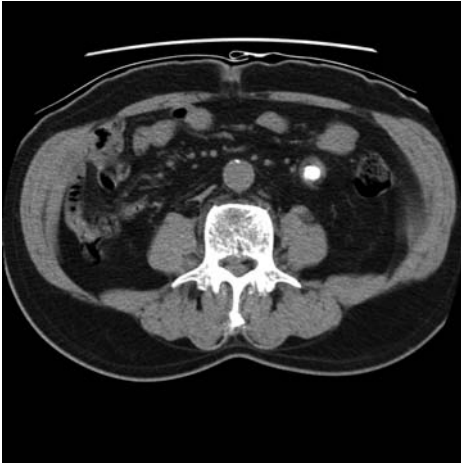This film is the post-micturition film of an IVP series. It shows mild hydronephrosis of the right kidney and a mildly dilated right ureter. Contrast is seen as far as the right sacral region but no further. This indicates the level of obstruction of the ureter. Contrast has drained from the normal left ureter and collecting system. The commonest cause of ureteric obstruction is stone disease or urolithiasis. A preliminary/control film (prior to the administration of contrast) is always taken as part of the IVP series. It is necessary to check for the presence of radio-opaque calculi. The majority of stones are mixed stones containing calcium salts. Symptoms at presentation are dependent on the location of the stone.

- Upper tract: asymptomatic, flank pain, fever
- Ureter: colicky flank pain radiating to the groin
- Lower urinary tract: asymptomatic, pain radiating to perineum, penis, buttocks

The probability that a ureteric stone will pass spontaneously is dependent on its size:

- 80% <4 mm
- 50% 4–6 mm
- 20% >8 mm





**Figure 2.30.** CT KUB. The ureteric stone is causing hydronephrosis, hydroureter and ureteral oedema.

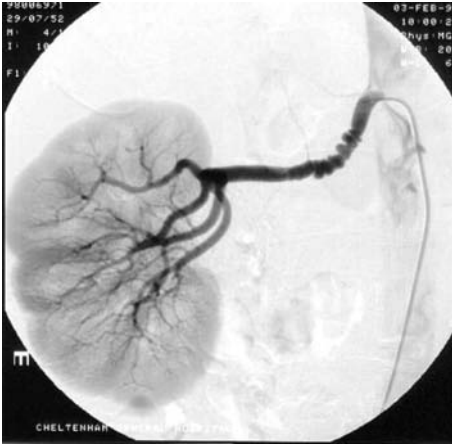
With the increasing availability of CT as an imaging modality, its use in the investigation of urolithiasis has increased. Correlation between plain film radiography and CT has demonstrated that a significant proportion of stones are ‘missed’ on plain film due to their small size, low density and the problems with overlying bowel gas and bones.<sup>11</sup>

The signs on non-contrast enhanced CT scans or ‘CT KUB’ indicating ureteric stones include:

- Ureteral wall oedema (see Fig. 2.30)
- Hydronephrosis
- Hydroureter
- Perinephric or periureteral stranding

#### **Causes of intraluminal ureteric obstruction**

- Opaque calculus (calcium stones),
- Non-opaque calculus (uric acid, xanthine stones),
- Blood clot,
- Papillary necrosis,
- Fungus ball.



**Figure 2.31.** Quiz case.

26-year-old female.  
Poorly controlled hypertension.

### Question 13

- What is the diagnosis (Fig. 2.31)?
- What is the radiological treatment?

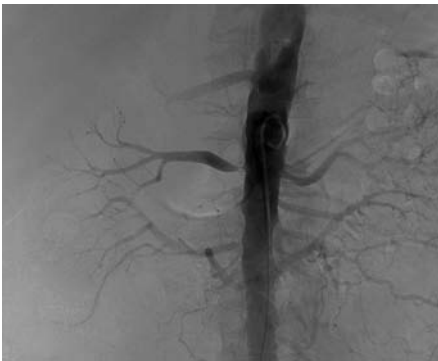### Answer

#### Renal artery stenosis

This selective renal artery arteriogram is characteristic of fibromuscular dysplasia of the renal artery. There are alternating areas of stenosis and aneurysm.

This is the commonest cause of renovascular hypertension in young adults and children. The mid and distal portions of the artery are affected. There is a female predominance. The renal arteries are not the only vessels that can be involved. The carotid artery or other aortic branches can also be affected, but less commonly than the renal arteries.

Atherosclerotic renal artery stenosis is a different disease entity. It affects the middle-aged population, the proximal portion of the artery or the ostium is involved (Fig. 2.32) and it is associated with atherosclerosis of the aorta and its other branches.



**Figure 2.32.** Atherosclerotic right-sided renal artery stenosis. Note the distribution – affecting the proximal portion of the renal artery.

### Pathophysiology of hypertension

Renal artery stenosis causes reduced renal blood flow and a reduced glomerular filtration rate (GFR). The response from the regulatory system in the juxtaglomerular cells of the kidney is to increase renin production. This results in increased levels of angiotensin I, which is then converted to angiotensin II in the lung (by angiotensin converting enzyme, ACE). Angiotensin II is a vasoconstrictor, which leads to renovascular hypertension. It also stimulates aldosterone release from the adrenal glands. A particular feature of renovascular hypertension is the worsening renal function observed in response to ACE inhibitors.<sup>12</sup>

Management options for renal artery stenosis (atherosclerotic and fibromuscular dysplasia) include surgical revascularisation, percutaneous transluminal angioplasty (PTA) and percutaneous transluminal angioplasty with stenting (PTAS). Outcome measures of importance include the technical success of the procedure, restenosis rate, renal function and blood pressure reduction. Balloon angioplasty/PTA for fibromuscular dysplasia has a technical success rate of over 90% and a cure rate of 40%–60%.<sup>13</sup> PTA in patients with atheroma is less successful with a technical success rate of 75% and only 57%<sup>14</sup> in cases of ostial stenosis. The figures for ostial stenosis are improved with the use of stents/PTAS. The primary technical success rate is 88% with a restenosis rate of 14%.<sup>14</sup>

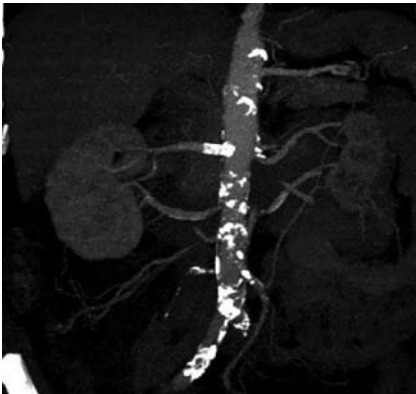
### Cross-sectional imaging

#### CT angiography

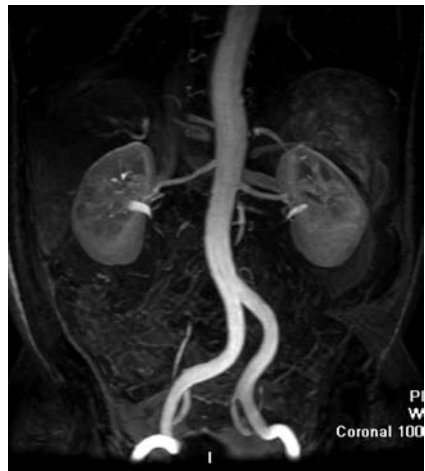Uses a pump injection of iodinated contrast media to produce accurate anatomical images of the renal arteries (see Fig. 2.33). The technique can exacerbate renal impairment in patients with pre-existing renal failure. It has been shown to have good correlation with the findings of conventional angiography.<sup>15</sup>

#### MR angiography

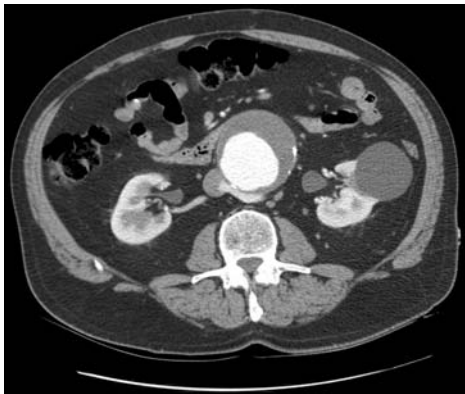This technique uses IV gadolinium contrast instead of iodinated IV contrast. Studies have validated its sensitivity (100%) and specificity (90%) in demonstrating the vascular anatomy of the proximal/main renal artery.<sup>16</sup> Accessory renal arteries and branch arteries are not well shown (Fig. 2.34).



**Figure 2.33.** CT renal arteriogram following stent placement.



**Figure 2.34.** MRI renal arteriogram.



**Figure 2.35.** Quiz case.

72-year-old male.  
Pulsatile mass in abdomen.

## Question 14

- What is the diagnosis (Fig. 2.35)?
- What are the treatment options?

## Answer

### Abdominal aortic aneurysm (AAA)

This is usually regarded as an aorta of greater than 3 cm diameter and is most prevalent in elderly men. Other risk factors include smoking, hypertension and family history. The natural history of the condition is of gradual expansion, which can lead to spontaneous rupture. Larger aneurysms tend to enlarge more rapidly.<sup>17</sup> In cases of aortic aneurysm rupture, pre-hospital mortality is up to two-thirds of patients and the mortality of those reaching emergency surgical repair is around 40%.<sup>18</sup> The risk of rupture increases as the size of the aneurysm expands.

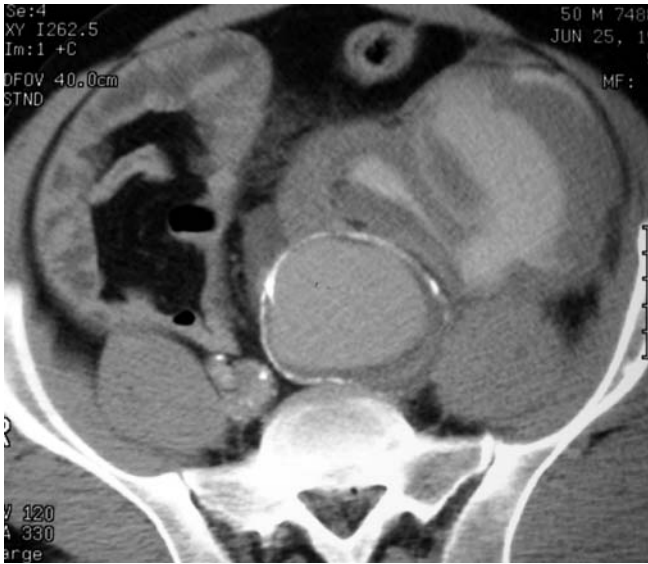
Surgical mortality in small aneurysms (4.0–5.5 cm) is between 5% and 6% if performed electively.<sup>19</sup> In the case of small aneurysms, regular ultrasound surveillance every 6 months is recommended. The UK small aneurysms trial (4.0–5.5 cm aneurysms) showed no benefit in overall mortality for those offered early surgery.<sup>19</sup> Indications for surgery include rupture, symptomatic aneurysms, rapid expansion and asymptomatic aneurysms over 6 cm (although the size is controversial).

### Clinical presentation

This is frequently with an asymptomatic pulsatile abdominal mass.

### Ruptured AAA

Patients with AAA rupture can have a range of symptoms such as vomiting, abdominal pain, back/flank pain, a pulsatile abdominal mass or collapse. Most AAAs rupture into the left retroperitoneum (Fig. 2.36). The retroperitoneum will initially contain the leak but direct rupture into the peritoneum or continued leaking will progress to cardiovascular compromise, cardiac arrest, collapse and, if untreated, death. Ruptured AAA is often misdiagnosed due to the non-specific presentation.<sup>20</sup>



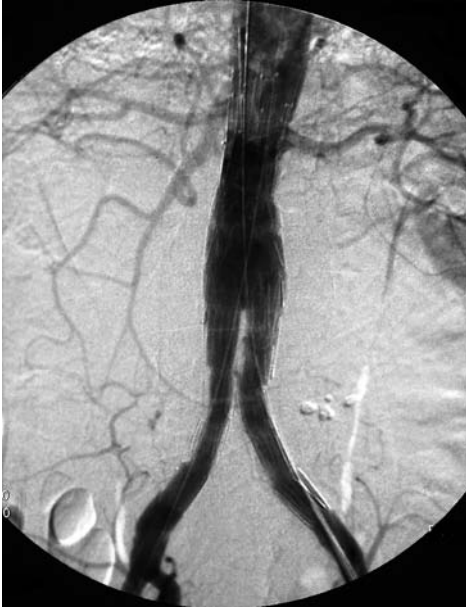**Figure 2.36.** Rupture of AAA.

CT imaging of aneurysms should provide information on:

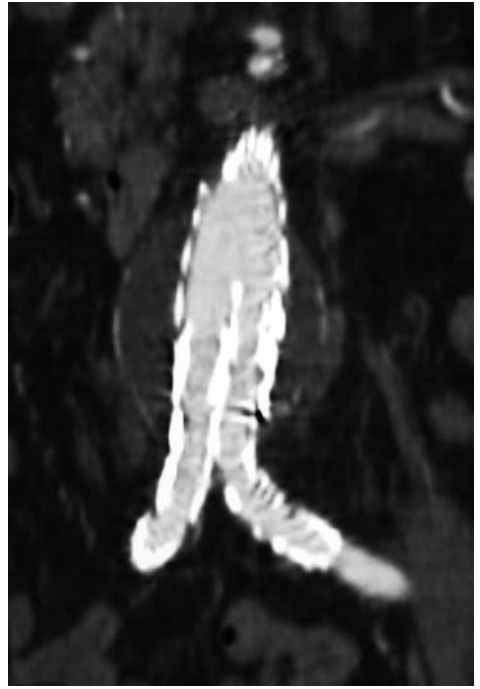- aneurysm size and morphology,
- proximal extent of the aneurysm to determine the site of clamping of the aorta (origin of the renal arteries),
- presence and course of accessory renal arteries,
- the course of the left renal vein (retroaortic) (see Fig. 2.35),
- extension into iliac arteries,
- imaging should include the chest to exclude lung neoplasm or COPD.

#### Endovascular aneurysm repair (EVAR)

This method of aneurysm repair prevents the need for laparotomy and aortic cross-clamping. A prosthetic graft is placed within the aortic lumen via a femoral artery approach. The stent graft is deployed using X-ray guidance. Aorto-aortic, bifurcated aorto-iliac or aorto-uniiliac (with femoro-femoral crossover) prostheses exist. Proximal and distal cuffs anchor the prosthesis in place and a tight seal aims to exclude the aneurysm from the circulation (Figs. 2.37 and 2.38). Additional endovascular or surgical procedures may be needed, such as iliac artery stents, occlusion of selected vessels and femoro-femoral bypass grafts. Patients are often discharged after 1–2 days. If successfully excluded from the circulation, a reduction in aneurysm expansion is achieved. The main complication is endo-leak (most commonly from retrograde collateral flow into the aneurysm sac via aortic branches). Longer-term technical complications include stent migration and stent wire fracture. The National Institute for Health and Clinical Excellence (NICE) has assessed the technique and concluded ‘current evidence on the efficacy and short-term safety of stent-graft placement in abdominal aortic aneurysm appears adequate to support the use of this procedure’.<sup>21</sup> Not all aneurysms have a suitable morphology for this type of repair. Research into the technique is on-going. Local anaesthesia

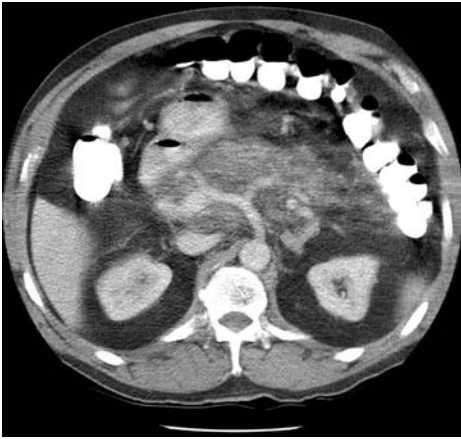

**Figure 2.37.** Image acquired during the process of stent placement with intra-arterial guide wires.



**Figure 2.38.** CT reconstruction showing the dense/metallic stent across the aneurysmal aorta.

with sedation, epidural, combined spinal/epidural anaesthesia and general anaesthesia have all been used with success for this procedure, and local preferences will dictate the technique of choice. Arterial monitoring, wide bore venous access and urinary catheterization are necessary. Ischaemic leg pain can be problematic and may be managed with opiate infusions such as remifentanyl.



**Figure 2.39.** Quiz case.

Male patient aged 53.  
Alcoholic.  
36 hours of severe abdominal pain.  
Admitted to the intensive care unit following presentation to the accident and emergency unit where he had a blood pressure of 90/50, elevated amylase and hypocalcaemia.

## Question 15

- What does the CT scan (Fig. 2.39) show?
- How can the severity of this condition be graded?
- What are the predisposing factors and the complications?

## Answer

### Acute pancreatitis

The pancreas is swollen and oedematous and has failed to enhance following intravenous contrast media. There is streaky increased density in the fat adjacent to the pancreatic tissues; the appearances are of diffuse, acute pancreatitis.

### Imaging

Ultrasound is frequently used to investigate patients with acute abdominal pain, but overlying bowel gas often limits the ability to visualize the entire pancreatic gland. Its main use in the setting of acute pancreatitis is to evaluate the gall bladder and biliary tree to detect gallstones. It is also useful in the evaluation of pseudocyst or fluid collections.

CT has good specificity in diagnosing pancreatitis, although in up to one-third of patients with acute pancreatitis (especially mild pancreatitis) no detectable change in the size or appearance of the pancreas is evident. A range of CT appearances are recognized – normal, gland enlargement, peripancreatic inflammation, single fluid collection and multiple fluid collections. Work has been done to try and predict (on the basis of CT) which patients are at greater risk of fatal pancreatitis. The key criterion is the presence of pancreatic necrosis. Pancreatic necrosis can be diagnosed when segments of the pancreas fail to enhance on contrast-enhanced CT. The site of pancreatic necrosis can further predict disease severity. The presence of peripancreatic fluid collections is also associated with poor prognosis.<sup>22</sup>

### Severity assessment of acute pancreatitis

Early identification of patients with potentially severe acute pancreatitis is important, as patients with delayed transfer to intensive care units have higher mortality.

### Scoring systems

Several clinico-biochemical scoring systems exist for the assessment of the severity of acute pancreatitis, with the Ranson and Imrie criteria being commonly used. These are designed to predict the severity of clinical course in an individual patient. The Ranson criteria comprise 11 criteria requiring up to 48 hours to be collected.<sup>23,24</sup>

#### Ranson criteria<sup>23</sup>

Age greater than 55.

*On admission or at diagnosis:*

- blood glucose above 200 mg/dl,
- WCC greater than 16 000 per mm<sup>3</sup>,
- lactate dehydrogenase above 350 IU/l,
- aspartate transaminase above 250 IU/l.

Within 48 hours:

- HCT decrease by more than 10%,
- serum urea increase by 0.7 mmol/l,
- serum calcium below 2 mmol/l,
- fluid sequestered greater than 6 l,
- PaO<sub>2</sub> below 8 kPa,
- base deficit greater than 4 mmol/l.

One of the problems with the Ranson criteria is that they are valid only after 48 hours of disease onset.

The acute physiology and chronic health evaluation (APACHE) score can be used at any point during the disease, but is quite cumbersome for routine clinical use. Attempts have been made to make this more user-friendly, e.g. APACHE II criteria. UK ICUs commonly use APACHE II; the score is dependent on the acute physiological variables in the first 24 hours after ICU admission.

### Management

Supportive care is necessary with close clinical observation and early identification of complications. Patients with severe acute pancreatitis require early transfer to the intensive care unit and invasive monitoring. Treatment is mainly supportive and includes IV fluid and electrolyte replacement, nutritional support and analgesia, and support of respiratory dysfunction. Antibiotics and drugs aimed at reducing pancreatic secretions are of no proven value. Strategies such as peritoneal lavage, fresh frozen plasma, gabexate and H<sub>2</sub> blockers have been tried and their use is unproven. New treatments focusing on the cytokine cascade are currently under investigation. Indications for intervention include impacted gallstones, complicated pseudocyst, pancreatic abscess and infected necrosis.

### Causes

- Gallstones: 30%–40%,
- Alcohol: 30%–40%,
- Hypercalcaemia: 10%,
- Infections: CMV, mumps,



- Congenital anatomical anomalies: pancreas divisum,
- Trauma/post-ERCP,
- Drugs: contraceptive pill, steroids,
- Idiopathic: 10%,
- Other metabolic causes: hyperlipidaemia type I and V,
- Hereditary pancreatitis (affects children).

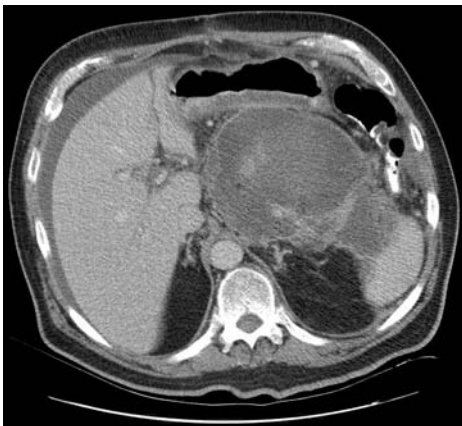
### Systemic complications

- Hypotension,
- Respiratory failure (15%–55%): atelectasis, pneumonia, pleural effusions, ARDS,
- Renal failure,
- Metabolic: hypocalcaemia,
- Coagulopathy: disseminated intravascular coagulation (DIC).

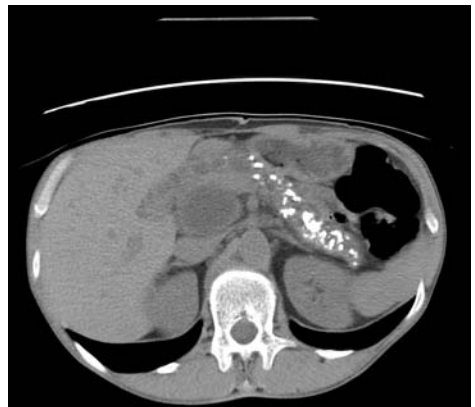### Local complications

- Pseudocyst formation: 10% (Fig. 2.40),
- Abscess: in 10%, 2–4 weeks following severe pancreatitis,
- Fistula formation,
- Biliary obstruction,
- Haemorrhage,
- Splenic artery pseudoaneurysm: in up to 10% of severe pancreatitis,
- Enzymatic erosion of splenic artery: may rupture into pseudocyst,
- Splenic vein thrombosis.

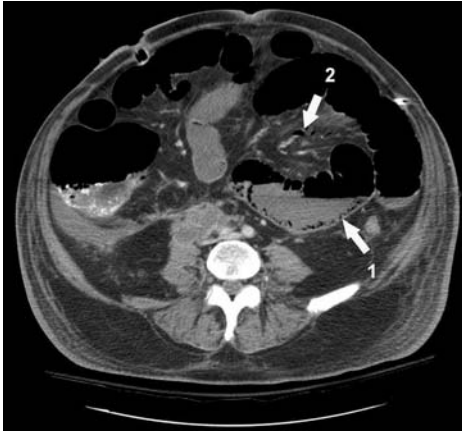
Pseudocyst formation is not limited to acute pancreatitis and may follow chronic pancreatitis (see Fig. 2.41).



**Figure 2.40.** Pseudocyst. Large fluid-filled pseudocyst anterior to pancreas.



**Figure 2.41.** Chronic pancreatitis and pseudocyst. Note the dense amorphous calcification throughout the pancreas.



**Figure 2.42.** Quiz case.

44-year-old male patient.  
Ventilated on intensive care.  
Septic and hypotensive.  
Blood pressure maintained with inotropes including noradrenaline.

## Question 16

- What does the CT scan (Fig. 2.42) show?

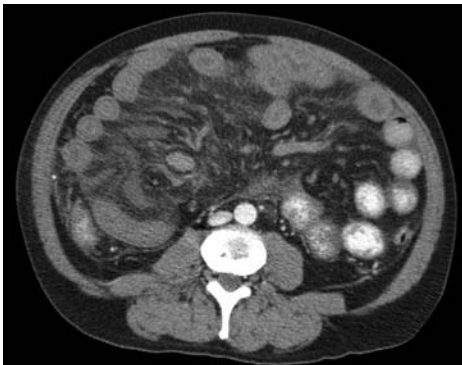## Answer

### Small bowel infarction

There are multiple tiny bubbles of gas in the wall of the small bowel – pneumatosis intestinalis (arrow 1). There is gas in the mesenteric veins (arrow 2) and the bowel is mildly dilated and filled with fluid. Portal vein gas (in the liver) is a further sign seen in up to one-third of patients. This is located peripherally in the liver whereas pneumobilia (gas in the biliary tree) is distributed more centrally.

### Acute mesenteric ischaemia

This is caused by narrowing or occlusion of the superior mesenteric artery (SMA) or vein (SMV). Occlusive emboli can originate from mural thrombus, AF or abnormal heart valves. Drugs such as dopamine, noradrenaline or illegal drugs like cocaine predispose to the condition by redistributing intestinal blood flow. Abdominal sepsis, pro-thrombotic states, malignancy and liver cirrhosis all predispose to thrombosis of the SMV see (Fig. 2.43).



**Figure 2.43.** CT showing small bowel infarct due to superior mesenteric vein (SMV) thrombosis, small bowel oedema and infiltration in the mesentery.

Clinical presentation is typically with the acute onset of vomiting, severe abdominal pain and diarrhoea (often blood stained). Physical examination often reveals a soft abdomen with variable signs of peritonism. Investigations may show metabolic acidosis, increased amylase levels or increased lactate dehydrogenase.<sup>25</sup> Acute mesenteric ischaemia is a medical emergency, which can have a high mortality depending on the promptness of diagnosis and the extent of small bowel infarction. CT imaging has high specificity in making the diagnosis.<sup>26</sup>

### **Imaging findings**

- Luminal thrombus or narrowing of the SMA/SMV,
- Bowel wall thickening,
- Lack of mucosal enhancement,
- Mesenteric fat infiltration especially with venous thrombosis,
- Pneumatosis intestinalis,
- Gas in portal vein/mesenteric veins.

### **Chronic mesenteric ischaemia**

This is caused by atheroma, narrowing or occlusion of the celiac artery, superior mesenteric or inferior mesenteric arteries. Clinical presentation is with post-prandial pain, which classically subsides after 1–2 hours, often associated with weight loss due to 'food fear'.

## References

- Grainger RG, Allison DJ. The abdomen: the plain abdominal radiograph – the acute abdomen. *Diagn Radiol* 1997; **4**: 889.
- Megibow AJ. Bowel obstruction – evaluation with CT. *Radiol Clin North Am* 1994; **32**: 861–70.
- Balthazar EJ, George W. CT of small bowel obstruction. *Am J Radiol* 1994; **162**: 255–61.
- Boland GW, Lee MJ, Cats A, Mueller PR. Pseudomembranous colitis: diagnostic sensitivity of the abdominal plain radiograph. *Clin Radiol* 1994; **49**: 473–5.
- Young WS, Englebrecht HE, Stoker A. Plain film analysis of sigmoid volvulus. *Clin Radiol* 1978; **29**: 553–60.
- Graham DA, Johnson FH. The incidence of radiographic findings in acute appendicitis compared to two hundred normals. *Milit Med* 1969; **131**: 272–6.
- Lee JH. Sonography of acute appendicitis. *Semin Ultrasound CT MR* 2003; **24**(2): 83–90.
- Jacobs JE. CT imaging in acute appendicitis: techniques and controversies. *Semin Ultrasound CT MR* 2003; **24**(2): 96–100.
- Levine MS. Update on oesophageal radiology. *Am J Radiol* 1990; **155**: 933–41.
- Horton KM. CT evaluation of the colon: inflammatory disease. *Radiographics* 2000; **20**(2): 399–418.
- Federle MP, Anne VS, Chen JJ. Urolithiasis III 3 48 *Diagnostic Imaging*. Amirsys, 2004.
- Levenson DJ, Dzau VJ. Effects of angiotensin-converting enzyme inhibition on renal haemodynamics in renal artery stenosis. *Kidney Internat* 1987; **31**(Suppl 20): 173–9.
- Sos TA, Pickering TG, Sinderman K. Percutaneous transluminal renal angioplasty in renovascular hypertension due to atheroma of fibromuscular dysplasia. *N Engl J Med* 1983; **309**: 274–9.
- van de Ven PJ, Kaatee R, Beutler JJ *et al*. Arterial stenting and balloon angioplasty in ostial atherosclerotic renovascular disease: a randomised trial. *Lancet* 1999; **353**(9149): 282–6.
- Olbricht CJ, Paul K, Prokop M *et al*. Minimally invasive diagnosis of renal artery stenosis by spiral computed tomography angiography. *Kidney Int* 1995; **48**(4): 1332–7.
- Loubeyre P, Trolliet P, Cahen R *et al*. MR angiography of renal artery stenosis: value of the combination of three-dimensional time-of-flight and three-dimensional phase-contrast MR angiography sequences. *Am J Radiol* 1996; **167**(2): 489–94.
- Bernstein EF, Chan EL. Abdominal aortic aneurysm in high-risk patients. Outcome of selective management based on size and expansion rate. *Ann Surg* 1984; **200**(3): 255–63.
- www.ncepod.org.uk. Abdominal aortic aneurysm: a service in need of surgery? 2005 Report.
- Mortality results for randomised controlled trial of early elective surgery or ultrasonographic surveillance for small abdominal aortic aneurysms. The UK Small Aneurysm Trial Participants. *Lancet* 1998; **352**(9141): 1649–55.
- Johansson G, Swedenborg J. Ruptured abdominal aortic aneurysms: a study of incidence and mortality. *Br J Surg* 1986; **73**(2): 101–3.
- National Institute for Health and Clinical Excellence, IP Guidance Number: IPG163.
- Balthazar EJ, Ranson JH, Naidich DP, Megibow AJ, Caccavale R, Cooper MM. Acute pancreatitis: prognostic value of CT. *Radiology* 1985; **156**(3): 767–72.
- Ranson JHC, Rifkind KM, Roser DF *et al*. Prognostic signs and the role of operative

- management in acute pancreatitis. *Surgery, Gynecol Obstet* 1974; **139**: 69–81.
24. Ranson JH. Etiological and prognostic factors in human acute pancreatitis: a review. *Am J Gastroenterol* 1982; **77**(9): 633–8.
25. Hansen KJ, Wilson DB, Craven TE *et al.* Mesenteric artery disease in the elderly. *J Vasc Surg* 2004; **40**(1): 45–52.
26. Horton KM. Computed tomography evaluation of intestinal ischemia. *Semin Roentgenol* 2001; **36**(2): 118–25.

Chapter

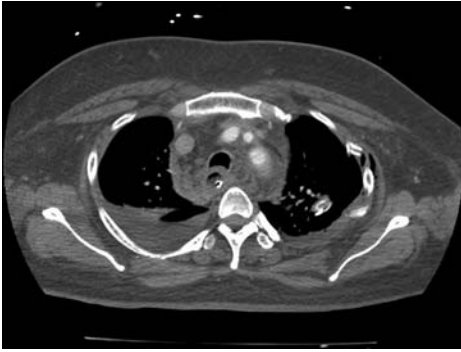# 3

## Trauma radiology

---

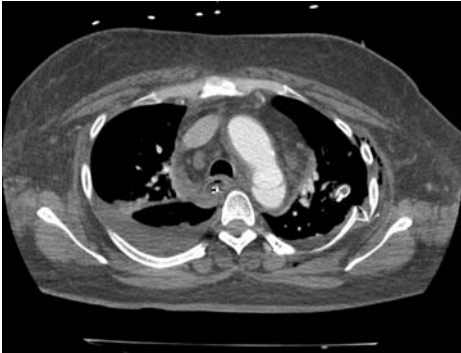
Chest trauma: case  
illustrations 97

Blunt abdominal and pelvic trauma:  
case illustrations 104



**Figure 3.1.** Quiz case.

47-year-old male.  
 High speed road traffic accident.  
 Chest pain, breathless.  
 You are asked to assist in the emergency unit with a view to admission to intensive care. A chest drain has already been placed.  
 Widened mediastinum on the chest X-ray.  
 A CT scan of the chest (Figs. 3.1 and 3.2) was performed.



**Figure 3.2.** Quiz case.

## Chest trauma: case illustrations

### Question 1

- What are the injuries?

### Answer

#### Traumatic aortic injury

Traumatic aortic injury is a major cause of mortality in patients with blunt thoracic trauma. The commonest cause is road traffic accidents, but other causes include falls and blast injuries, the common mechanism of injury being deceleration. Blunt trauma/ decelerating injuries are very different from penetrating injuries. In blunt trauma, anatomical areas of concern include the aorta, great vessels, heart, abdominal organs, spine, airway and digestive tract. The most frequent location of aortic injury is at the aortic isthmus;<sup>1</sup> the injury is caused by shearing stress between the aortic arch and the descending thoracic aorta. Most aortic tears are in a transverse direction and involve the layers of the aorta to varying degrees. Patients with complete tears including the intima, media and adventitia 'bleed out'

and die prior to hospital admission. This accounts for the 80%–90% of patients who sustain aortic injury and die prior to hospital admission.<sup>2</sup> Most patients who reach hospital alive have a tear at the aortic isthmus involving the intima and media, with a pseudoaneurysm maintained by the adventitia.

Rapid assessment, diagnosis and treatment is essential as aortic injury is an unstable condition. Clinical assessment and triage with reference to the spectrum of other potential injuries is required.

### Imaging investigations

Most patients are initially imaged with plain film radiography followed by CT or angiography depending on initial radiographic findings and the spectrum of other injuries.

#### Chest X-ray

Numerous signs on the chest X-ray have been described in association with traumatic aortic injury. These signs are identified secondary to the associated mediastinal haematoma rather than the aortic injury itself. Widening of the mediastinum on chest X-ray is caused by mediastinal blood. This is not usually due to aortic bleeding as this leads to sudden death. Mediastinal blood can come from injury to other vessels, e.g. azygous or paraspinal vessels. Other signs include rightward tracheal shift, rightward deviation of any nasogastric tube, right paratracheal widening and widening of the paraspinal lines, upper rib fractures and a left apical pleural cap. Two of the most valuable signs are loss of contour of the aortic arch and contour abnormalities of the superior mediastinum.<sup>3</sup>

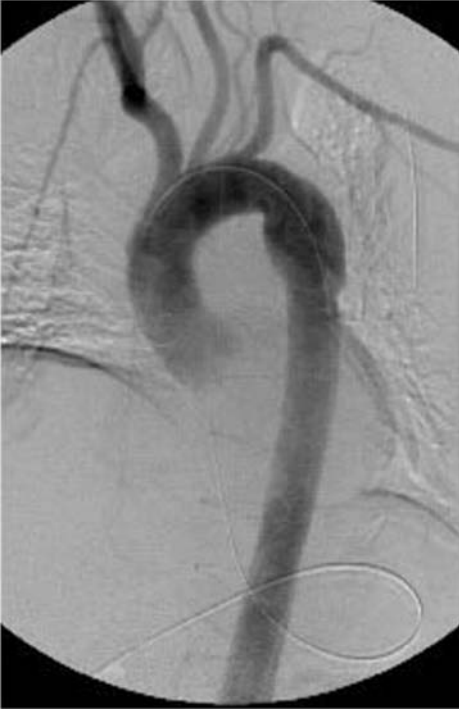#### CT scanning

The recent technological advances of CT scanning with the advent of multislice spiral CT and increased computing power make it the ideal modality with which to assess polytrauma patients. Rapid CT examination can be used to evaluate the brain, spine, aorta, chest, abdominal organs and the bony pelvis. A single IV contrast injection is used to scan the vascular anatomy and also the solid organs in different 'phases' of contrast enhancement. Reconstructed images can help with interpretation. Direct CT signs of aortic injury (intimal flap, contour abnormality) are more specific (99%) than indirect signs (mediastinal or periaortic haematoma) (87%).<sup>4</sup> Potential areas which can be difficult to evaluate include the aortic root (due to cardiac motion) and the anatomical variants of the isthmus, e.g. ductus diverticulum. CT is an excellent way of identifying mediastinal haematoma; it will visualize contour abnormalities of the aorta. The example above (Figs. 3.1 and 3.2) demonstrates acute aortic injury with mediastinal blood and an intimal flap within the lumen of the aorta. In addition, there are rib fractures and pleural effusions.

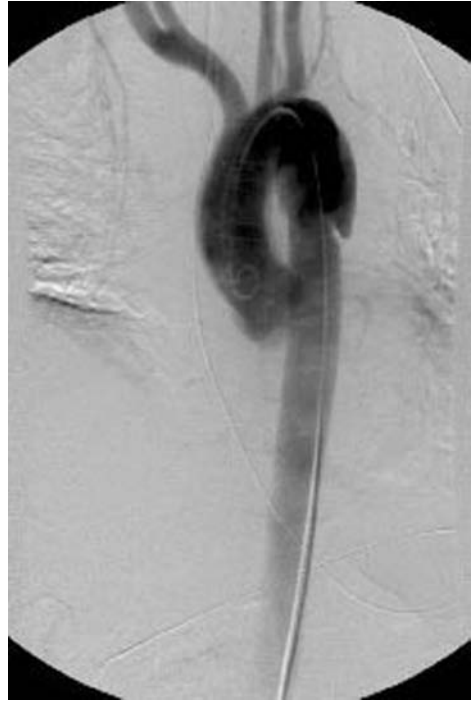#### Angiography

This has traditionally been regarded as the standard reference technique for evaluating patients with traumatic aortic injury. The typical appearance of acute aortic injury is



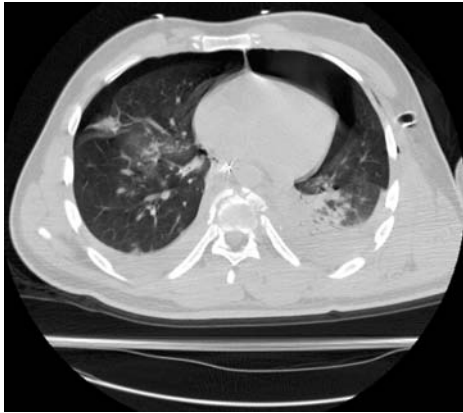


**Figure 3.3.** Angiogram of acute aortic injury. There is a focal bulge immediately distal to left subclavian artery. This is a typical site for acute aortic injury seen in deceleration accidents.



**Figure 3.4.** Angiogram of acute aortic injury. This projection has been chosen to best illustrate the dissection/intimal flap which is seen projecting into the aortic lumen. This corresponds to the intimal flap seen on the contrast enhanced CT (Fig. 3.2).

demonstrated in Figs. 3.3 and 3.4. There is abnormal outpouching of the aorta just distal to the origin of the left subclavian artery. The angiographic appearance is of a contained pseudoaneurysm. In addition, there is a linear component due to an intimal flap seen distal to the pseudoaneurysm. Traditionally, treatment has been with prompt surgical repair but angiography and stent grafting is emerging as an alternative technique.



**Figure 3.5.** Quiz case.

A call has come from a paramedic team that a male aged 38 is shortly arriving in the emergency unit. He has sustained steering wheel injuries to the chest following a high-speed motor vehicle accident.

## Question 2

- How are you going to deal with the initial assessment and management?
- What does the CT scan (Fig. 3.5) show?
- What are the main injuries sustained in blunt chest trauma?

## Answer

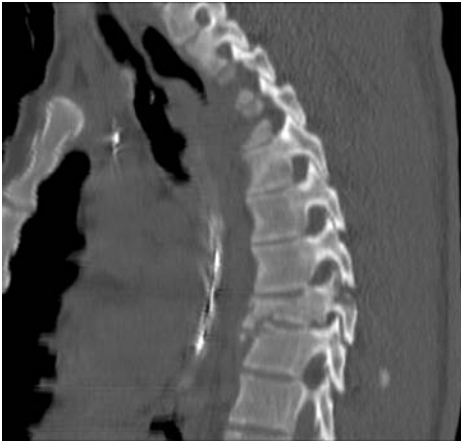
Initial assessment and management should follow Advanced Trauma Life Support (ATLS) guidelines<sup>5</sup> – A, B, C, D, E. A cervical spine injury should be assumed in any patient with multi-system trauma. It is beyond the scope of this text to cover the detail of ATLS management guidelines.

X-rays should be used judiciously and should *not* delay patient resuscitation. The AP chest film and AP pelvis may provide information that can guide resuscitation of the patient with blunt trauma. Chest X-rays may detect potentially life-threatening injuries that require treatment and pelvic films may demonstrate fractures of the pelvis that indicate the need for early blood transfusion. A lateral cervical spine X-ray that demonstrates an injury is an important finding, whereas a negative or inadequate film does not exclude cervical spine injury. These films can be taken in the resuscitation area, usually with a portable X-ray unit, but should not interrupt the resuscitation process.

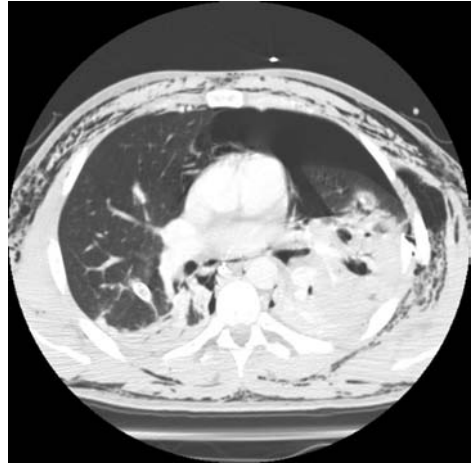
### Blunt chest trauma (see Fig. 3.5)

The example demonstrates bilateral pleural effusions, a left pneumothorax, contusion of the left lung and a left-sided chest tube. There is also a burst fracture of T9 vertebral body. This is seen in sagittal section in Fig. 3.6. Blunt thoracic trauma such as steering wheel injury has a high potential for causing life-threatening thoracic injuries. Approximately 20% of trauma-related deaths are attributable to chest injuries. The mechanisms include rapid deceleration, direct impact and compression. Systematic evaluation of the chest X-ray is an important facet of early management after the primary survey and initial resuscitation.

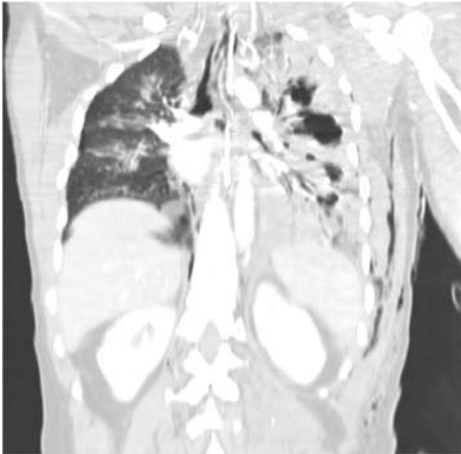
The chest X-ray or CT for blunt trauma can be divided into systems for the purposes of ensuring that all areas are looked at.



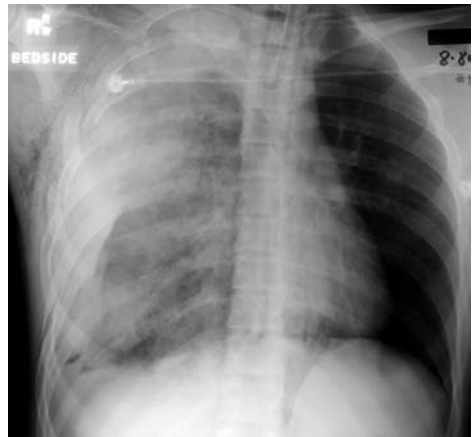**Figure 3.6.** Chest trauma. Thoracic spine reconstruction sagittal plane. This shows a burst fracture also seen on axial images (see Fig. 3.5).



**Figure 3.7.** Chest trauma. There is extensive contusion involving the left lung, a left-sided pneumothorax and extensive subcutaneous emphysema. Several pockets of gas are noted within the left lung contusion at the level of a left-sided rib fracture; these are pulmonary lacerations.



**Figure 3.8.** Chest trauma. CT coronal reformat. Pulmonary contusion and laceration. There is extensive opacification of the left hemithorax with several air-filled pockets indicating the site of pulmonary laceration.



**Figure 3.9.** Flail chest. The diagnosis is made by observing paradoxical chest wall movement in combination with multiple right-sided rib fractures on the chest X-ray. Note the surgical emphysema and lung contusion.

### Potential sites of injury in blunt chest trauma

#### Skeleton

*Rib fractures* – The positive identification of rib fractures means that the underlying lung must be examined for contusions, haemothorax, pneumothorax or laceration (Figs. 3.7 and 3.8). The presence of multiple fractures or the combination of anterior and posterior fractures can cause a flail segment (see Fig. 3.9). The upper ribs (1–3) are protected by the

bony framework of the upper limb. The scapula, humerus and clavicle, along with their muscular attachments, provide a barrier to rib injury. Fractures of the scapula, first or second ribs or the sternum suggest a magnitude of injury that places the head, neck, spinal cord, lungs and great vessels at risk for serious associated injury. Because of the severity of the associated injuries, mortality can be as high as 35%. Pain from rib fractures can precipitate hypoventilation and atelectasis. Adequate analgesia is essential.

*Flail chest (Fig. 3.9)* – In a flail chest injury paradoxical motion of the free-floating segment of chest wall occurs during respiration. This means that, during inspiration, the affected segment moves inwards in the opposite direction to the rest of the thoracic cage. Lateral chest wall injuries are the commonest cause and the injury usually consists of fractures in at least two sites in multiple adjacent ribs. If the pulmonary condition worsens, the paradoxical movement of the chest wall becomes more severe, making respiration more inefficient. In the unconscious patient the chest wall muscles do not splint the area and the flail effect is more pronounced.

The diagnosis is clinical and depends upon recognizing paradoxical chest wall movement in the presence of multiple fractures on the chest X-ray. Work of breathing is increased severalfold and ventilatory insufficiency can develop rapidly. The injuries are also usually very painful. This injury should not be underestimated; assisted ventilation may be necessary. The patient should be monitored and considered for observation in an HDU or ITU. Thoracic epidural analgesia is often used to provide pain relief to facilitate deep breathing and clearing of secretions.

*Thoracic spine* – Make a point of tracing the contour of the thoracic spine on the frontal radiograph. Reconstructions can be performed from spiral CT (see Fig. 3.6). The most common fractures are anterior compression fractures and burst fractures, most of which occur at the thoraco-lumbar junction.

Check for shoulder dislocation, clavicle or scapulae fractures and sternal injuries.

### **Pulmonary contusion**

Pulmonary contusion is defined as focal injury with oedema, alveolar and interstitial haemorrhage. It is the most common potentially lethal chest injury. The respiratory failure may be subtle and develops over time rather than occurring instantaneously. Patients need careful monitoring and re-evaluation for several days after the injury.

The initial presentation is usually with hypoxia and air space shadowing (Fig. 3.9) is present on the X-ray or CT. This is normally non-segmental, often peripheral and adjacent to the area of trauma. Other causes of air space shadowing seen in trauma patients include aspiration, atelectasis and pulmonary oedema (cardiogenic and non-cardiogenic). Management is with oxygen therapy either with a positive pressure mask or mechanical ventilation. Owing to the high force required to cause contusion, there are often other accompanying injuries. In contrast, due to the increased compliance of the chest in children, pulmonary contusion can occur in the absence of rib fractures.

Pulmonary laceration can occur secondary to shear forces in blunt trauma (Figs. 3.7 and 3.8) or in penetrating injury. This is easy to miss if there is surrounding contusion. It is characterized by collections of air within surrounding contusion.

*Pneumothorax* – There must be a high index of suspicion for pneumothorax in blunt chest trauma – it occurs in over one-third of cases. If there are clinical suspicions of tension (tracheal deviation away from the side of the pneumothorax, dilated neck veins, hyper-resonant percussion note over one hemithorax and absent breath sounds, hypoxia and hypotension), then the chest must be decompressed immediately by inserting a large bore needle into the second intercostal space in the mid clavicular line of the affected hemithorax. This must be done before obtaining a chest X-ray. Subsequent chest drain insertion is usually performed in the fourth or fifth interspace in the mid axillary line. Even small pneumothoraces can be clinically relevant in the setting of trauma, as these will potentially enlarge if positive pressure ventilation is required.

*Haemothorax* – Large volumes of blood can accumulate in the pleural space and this can cause hypovolaemia as well as ventilatory problems from the mass effect. Sites of bleeding include intercostal vessels, internal mammary artery, the mediastinal great vessels or abdominal viscera in the presence of diaphragmatic rupture. The diagnosis is made by identifying fluid on the X-ray and sampling the fluid in the pleural space.

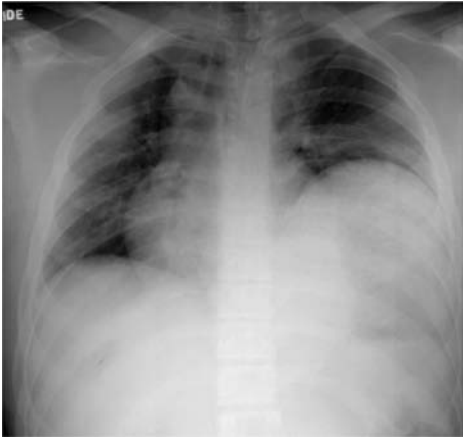Massive haemothorax results from a rapid accumulation of more than 1500 ml of blood in the chest cavity. It is most commonly caused by a penetrating wound that disrupts the systemic or hilar vessels. It may also result from blunt trauma.

### **Cardiac injury**

The most anterior of the heart chambers – the right ventricle and right atrium – are the most frequently injured. A combination of cardiac enzyme elevation, ECG changes (usually significant conduction abnormalities), echocardiography and thallium scintigraphy can be used to assess cardiac contusion.

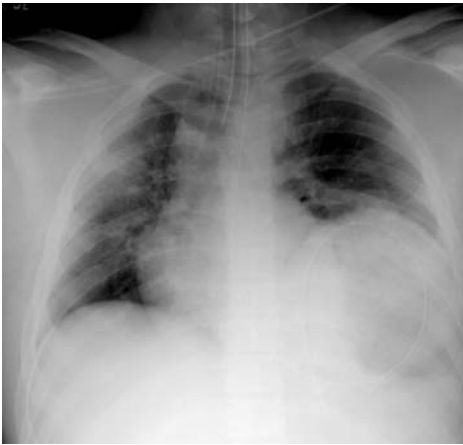### **Pericardial tamponade**

This is seen more often in association with penetrating trauma. Clinical signs are unreliable in the resuscitation setting but can include venous pressure elevation, hypotension and muffled heart sounds. Prompt transthoracic echocardiography may be a valuable way of assessing the pericardium but has a false negative rate of about 5%. Examination of the pericardial sac may form part of a focused abdominal ultrasound examination performed by a trauma team properly trained in its use. If found, pericardial tamponade frequently requires drainage. Underlying causes include cardiac rupture, aortic disruption and cardiac contusion.



**Figure 3.10.** Quiz case.

53-year-old male patient.  
Assessed in the emergency department following motor vehicle accident.  
Splenic laceration diagnosed on ultrasound scan.  
Progressive deterioration in respiratory function.



**Figure 3.11.** Quiz case.

## Blunt abdominal and pelvic trauma: case illustrations

### Question 3

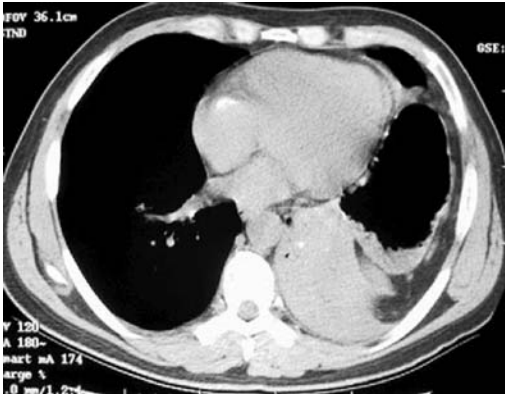
- What do the X-rays (Figs. 3.10 and 3.11) which were taken 8 hours apart demonstrate?

### Answer

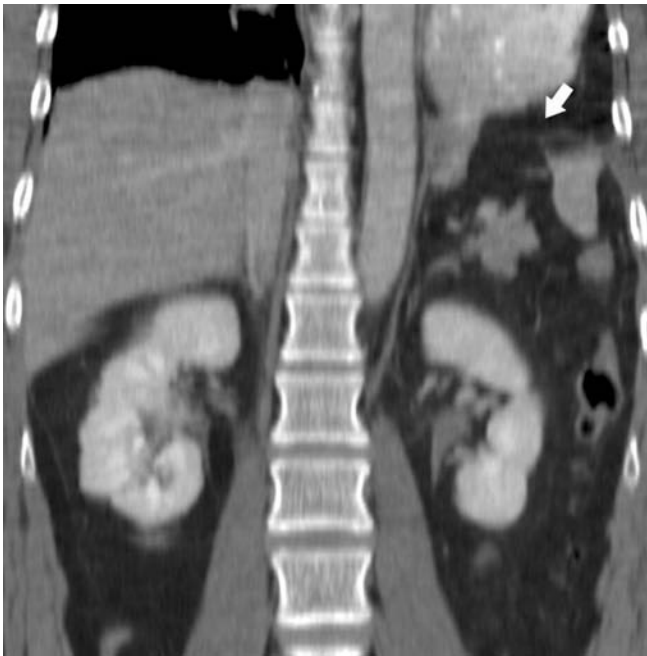#### Diaphragmatic rupture

There is an opacity in the left hemithorax above the left hemidiaphragm on the first film. The second film demonstrates a nasogastric tube above the diaphragm in the stomach (verified after CT (Fig. 3.12)). The stomach has passed into the left hemithorax through a rupture in the left hemidiaphragm.

Diaphragmatic rupture can follow either blunt or penetrating abdominal trauma but patients may be asymptomatic for months or years following trauma. Up to 90% of diaphragmatic ruptures diagnosed are left sided. Injuries frequently associated with diaphragmatic rupture include:



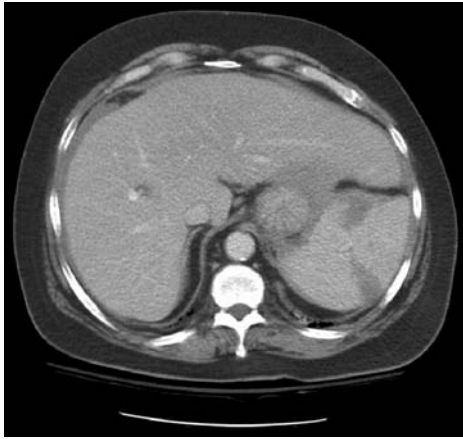
**Figure 3.12.** Diaphragm rupture CT. The stomach and mesenteric fat has herniated into the left hemithorax. Other signs of traumatic diaphragmatic rupture on CT include discontinuity of hemidiaphragm/abnormal contour and herniation of colon, small bowel or abdominal contents into chest.



**Figure 3.13.** Diaphragm rupture. Coronal reformat. The outline of the diaphragm is lost and the stomach is seen herniated into the left hemithorax.

- fracture of lower ribs,
- perforation of hollow viscus,
- rupture of spleen.

Diaphragm rupture can be a difficult diagnosis to make. When gross, chest X-ray changes can include bowel or nasogastric tube displacement into the chest, but signs may only be subtle, such as loss of contour of the diaphragm silhouette. If there is herniation of a hollow viscus into the chest, there may be constriction at the point of herniation – collar sign. The most common finding on CT is abrupt discontinuity of the diaphragm. Sagittal and coronal reformatted images can improve the sensitivity and specificity of CT in making the diagnosis (see Fig. 3.13).



**Figure 3.14.** Quiz case.

36-year-old male.  
Road traffic accident.  
Left upper quadrant pain, free fluid seen on ultrasound.

## Question 4

- What is the management of this condition (Fig. 3.14)?

## Answer

### Splenic laceration

The contrast-enhanced CT scan shows a large splenic laceration with haematoma in the left upper quadrant, which is surrounding the spleen.

### Management of blunt splenic trauma

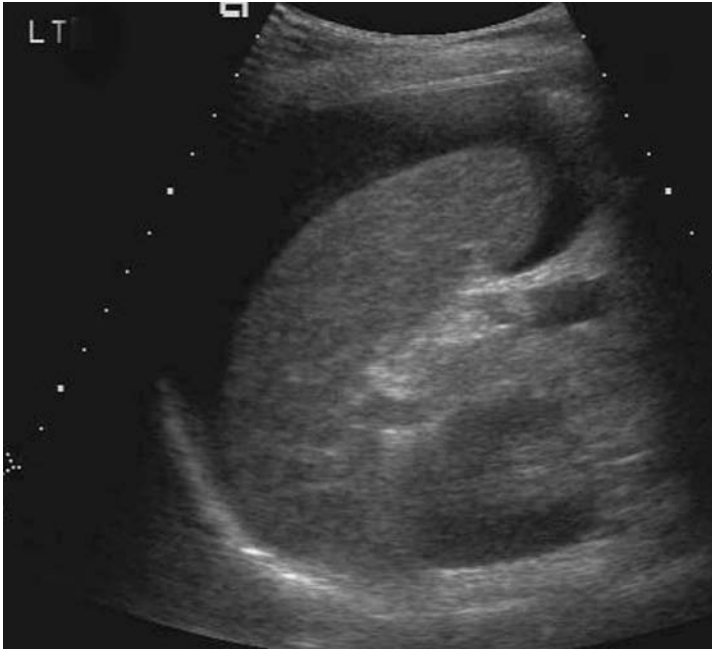The spleen is the most commonly injured organ in the abdomen, either the result of blunt abdominal trauma or penetrating injury.

### Imaging modalities

#### Ultrasound

Focused abdominal sonogram for trauma (FAST) is an established technique which attempts to identify abdominal free fluid and associated abdominal injuries. A number of sites are examined – the hepatorenal and splenorenal spaces, the paracolic gutters, pericardium and Pouch of Douglas in the pelvis. The technique is operator dependent and of limited use in the presence of surgical emphysema or in obese patients. Accuracy is similar to that of diagnostic peritoneal lavage (DPL). Ultrasound can demonstrate splenic laceration, adjacent fluid (Fig. 3.15) or splenic haematoma, but the technique is often limited by pain and patient immobility. FAST can be used as an effective triage tool. In the presence of free fluid/haemoperitoneum, haemodynamically unstable patients generally need laparotomy; however, further evaluation with CT is appropriate for stable patients. Sensitivity and specificity of these studies range from 85%–95%.<sup>6–8</sup>





**Figure 3.15.** Abdominal ultrasound demonstrating free peritoneal fluid. In the setting of blunt abdominal trauma this is usually haemoperitoneum.

## CT

Contrast-enhanced CT gives excellent visualization of the spleen and left upper quadrant and in many hospitals it is now the preferred modality of imaging. It will also demonstrate any associated injuries, e.g. renal injury or rib fractures. Just under a half of patients with splenic injury have left-sided rib fractures. CT signs include subcapsular haematoma, intraparenchymal haematoma, laceration or fragmentation. Splenic injury can be acute or delayed (usually due to rupture of subcapsular haematoma). Delayed rupture is usually in the first 7–10 days following the injury. Injuries may occur inadvertently during abdominal surgery or following trivial trauma, especially if the spleen is abnormal, e.g. malaria or infectious mononucleosis.

Surgical opinion varies regarding the need for splenectomy. Although splenic trauma grading systems exist,<sup>9</sup> e.g. The American Association for the Surgery of Trauma (AAST), see below. The grading system is a poor predictor of which patients will require splenectomy.

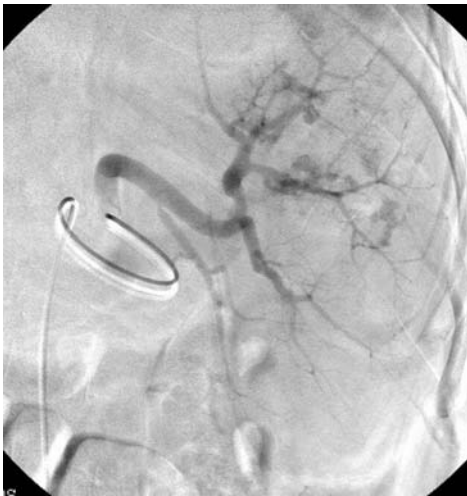Surgical splenectomy is avoided where possible due to the subsequent risk of pneumococcal infection. Patients with cardiovascular instability require resuscitation and early surgery. Surgical options include splenectomy or splenic conservation (splenic conservation needs to preserve more than 20% of tissue).<sup>10</sup>

Approximately one-third of patients fail conservative management. Monitoring should include cardiovascular signs and haematocrit. Children can often be managed conservatively, as they have an increased proportion of low-grade injuries and they have fewer multiple injuries. If conservative management is successful, then patients should have limited physical activity for 6 weeks and avoid contact sports for 6 months.<sup>11</sup>

**Table 3.1.** AAST grading of splenic injury

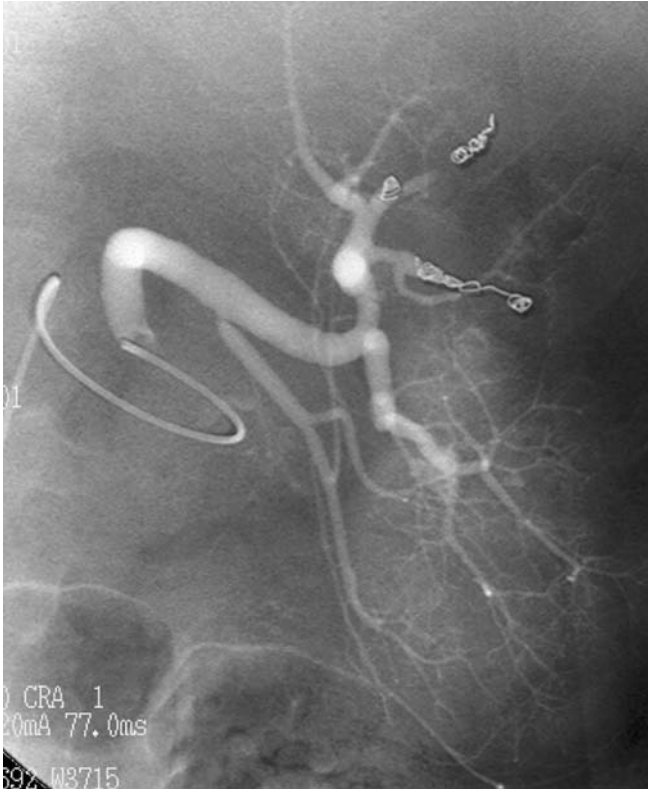Grade I	Subcapsular haematoma of less than 10% of surface area Capsular tear of less than 1 cm in depth
Grade II	Subcapsular haematoma of 10%–50% of surface area Intra-parenchymal haematoma of less than 5 cm in diameter Laceration of 1–3 cm in depth and not involving trabecular vessels
Grade III	Subcapsular haematoma of greater than 50% of surface area or expanding and ruptured Subcapsular or parenchymal haematoma Intra-parenchymal haematoma of greater than 5 cm or expanding Laceration of greater than 3 cm in depth or involving trabecular vessels
Grade IV	Laceration involving segmental or hilar vessels with devascularization of more than 25% of the spleen
Grade V	Shattered spleen or hilar vascular injury

Reproduced with permission from The American Association for the Surgery of Trauma and Lippincott, Williams and Wilkins.



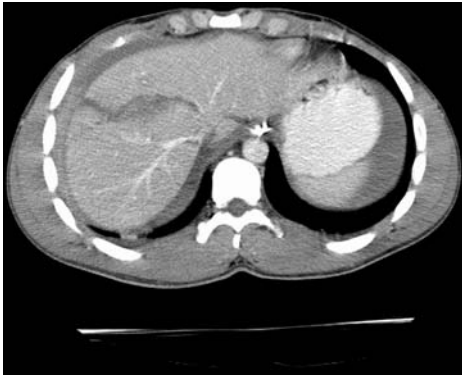**Figure 3.16.** Angiogram: 1 week following blunt splenic trauma. Multiple pseudoaneurysms are demonstrated.

Complications following splenic trauma include recurrent bleeding, delayed rupture and pseudoaneurysm formation (Fig. 3.16). Pseudoaneurysm formation is a predictor for failure of non-operative management and is reported in up to 10% of patients on delayed imaging.<sup>12</sup> This is diagnosed by identifying an intra-parenchymal contrast blush on CT or angiography.



**Figure 3.17.** Angiogram following coil embolization of pseudoaneurysms. The spleen is preserved following blunt splenic trauma whenever possible to reduce the risk of subsequent infection. Aggressive imaging follow-up and coil embolization have helped to reduce the rate of splenectomy for blunt abdominal trauma.

Coil embolization (Fig. 3.17) can be used to treat acute splenic bleeding (at the time of initial injury) and in the management of pseudoaneurysm formation. Splenic artery embolization can be selective or superselective; the main complication is splenic infarction, related to the volume of devascularized tissue.



**Figure 3.18.** Quiz case.

Male patient, age 41. Motor vehicle accident not wearing seat belt.  
Abdominal pain.  
On physical examination, the patient is shocked and there is abdominal guarding.

## Question 5

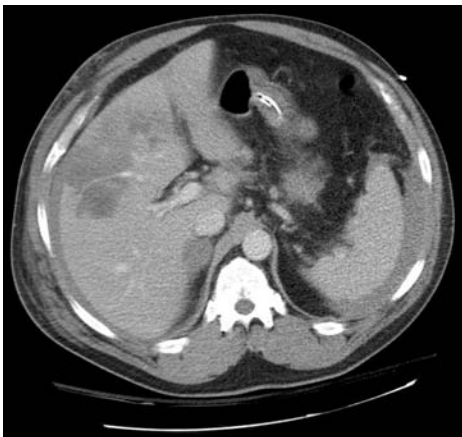- What does the CT (Fig. 3.18) show?

## Answer

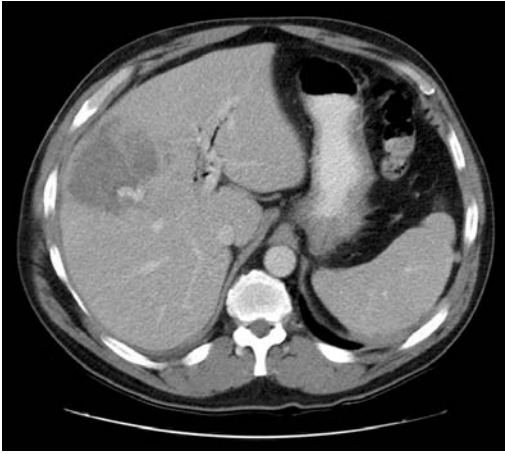
### Liver trauma

The CT demonstrates an extensive liver laceration through the right lobe of the liver. There is widespread free fluid within the peritoneal space seen around the liver and also the spleen.

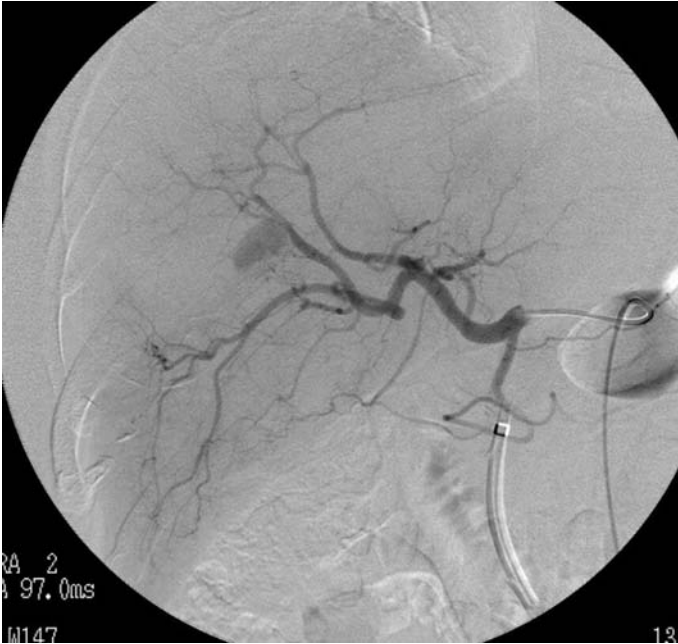
The liver is the second most commonly injured intra-abdominal organ. This is partly related to its large size, fixed position and relative friability. If the liver capsule is torn, intra-peritoneal haemorrhage can be extensive due to the rich dual blood supply of the liver. Delayed rupture is not encountered following liver trauma unlike splenic trauma. The most commonly injured sites are segments 6, 7 and 8. Left lobe injuries are less common but are associated with injuries of other retroperitoneal structures, e.g. duodenum and pancreas. Surgical series have demonstrated that 80% of traumatic liver injuries can be treated conservatively unless there is haemodynamic instability.<sup>13,14</sup> Surgical literature indicates that a high proportion of liver injuries have stopped bleeding at the time of laparotomy.



**Figure 3.19.** Liver trauma. There is a large non-enhancing laceration/haematoma in the right lobe of liver with haemoperitoneum around both the liver and spleen.

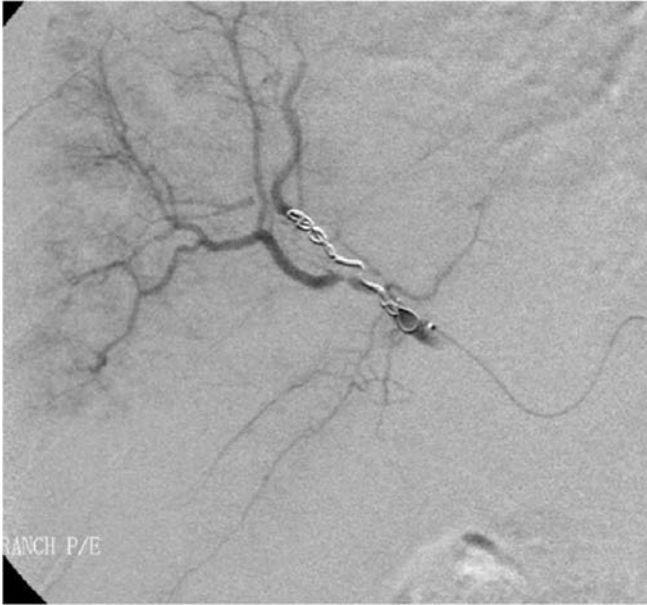

**Figure 3.20.** Liver trauma, pseudoaneurysm. Dense intra-parenchymal contrast blush (in the arterial phase) adjacent to the liver haematoma – 8 days following the initial injury.



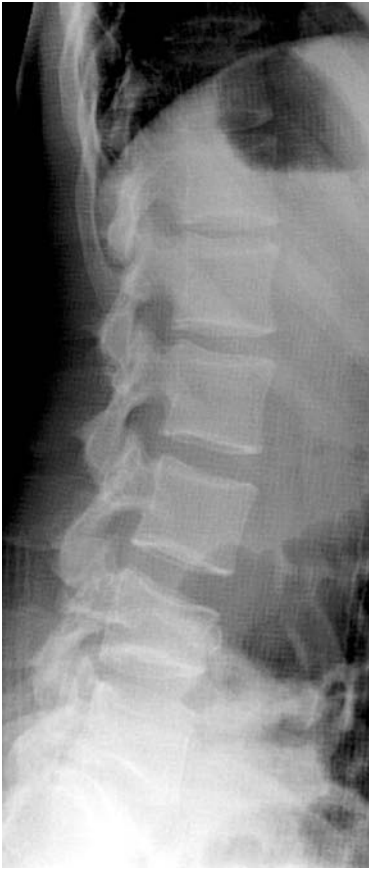**Figure 3.21.** Blunt abdominal trauma, liver trauma. Right hepatic artery angiogram demonstrating pseudoaneurysm.

Contrast-enhanced CT is the investigation of choice in blunt abdominal trauma.<sup>15</sup> On CT, liver lacerations appear as non-enhancing irregular, linear, round or branching regions of low attenuation. Lacerations can extend to the visceral surface sometimes as irregular jagged lines. Intra-parenchymal haematomas appear as mass-like, low density non-enhancing regions (Fig. 3.19). Subcapsular haematomas extend around the capsule in a lenticular pattern compressing the underlying liver. Periportal low density is frequently encountered in the setting of blunt abdominal trauma and has been linked to aggressive fluid resuscitation.



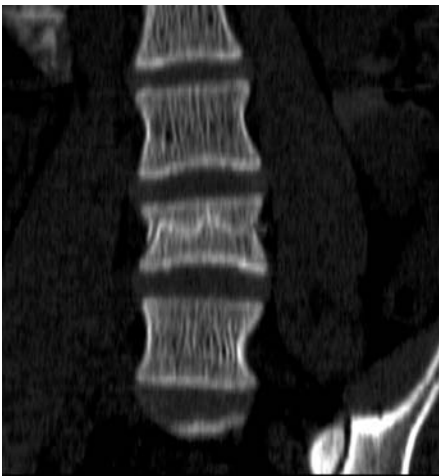**Figure 3.22.** Blunt abdominal trauma, liver trauma. Right hepatic artery angiogram following coil embolization, demonstrating no filling of the previously identified pseudoaneurysm.

CT findings can help predict the type of treatment required, either operative treatment or angiography. Transcatheter embolization can reduce transfusion requirement and facilitate healing without the need for surgery.<sup>16</sup> Complications following liver trauma include recurrent bleeding, pseudoaneurysm formation, bile duct injury, biloma and fistula formation, e.g. arterio-portal fistula. Pseudoaneurysms appear as intense foci of contrast enhancement seen best on arterial phase imaging (see Fig. 3.20). These can be treated with coil embolization (see Figs. 3.21 and 3.22). Early intervention with coil embolization, percutaneous drainage, ERCP and stenting of bile duct injuries has helped reduce the proportion of patients requiring surgery following liver trauma.

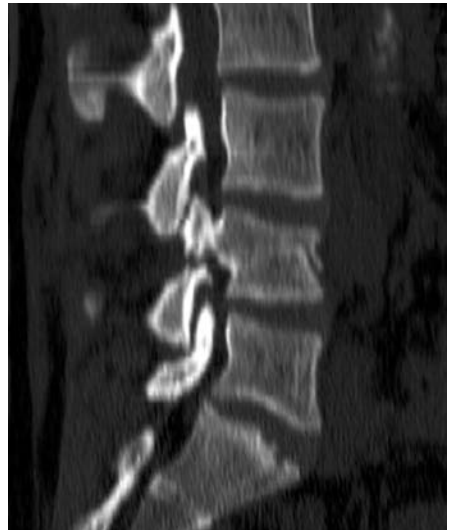

**Figure 3.23.** Quiz case.

28-year-old female patient.  
Involved in high-speed motor vehicle accident restrained by 'lap-type' seat belt.  
On physical examination there is bruising in a lap belt distribution.



**Figure 3.24.** Quiz case.



**Figure 3.25.** Quiz case.

## Question 6

- What does the imaging (Figs. 3.23–3.25) show?
- What other injuries should be considered?

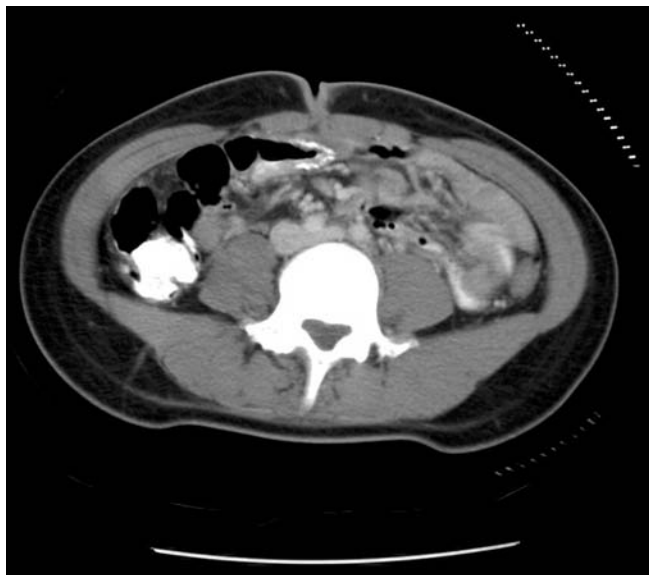## Answer

### Chance fracture of L4

A Chance fracture is commonly associated with use of 'lap-type' seat belts in high-speed motor crashes. A Chance fracture is a horizontal vertebral fracture caused by a flexion injury. The body bends around the fulcrum of the belt and causes an injury in the horizontal plane. The fracture line extends through the neural arch and vertebral body. A lateral X-ray or sagittal reconstruction best demonstrates the injury. Since the fracture runs in the axial plane, a routine axial CT may miss a Chance fracture.

There is a high incidence of intra-abdominal injuries associated with Chance fracture. Both solid organ (pancreas) and bowel injuries (duodenum) are associated with Chance fracture. The abdominal CT scan of the same patient demonstrates jejunal small bowel thickening and extravasation of oral contrast medium in keeping with jejunal injury and perforation (see Fig. 3.26).

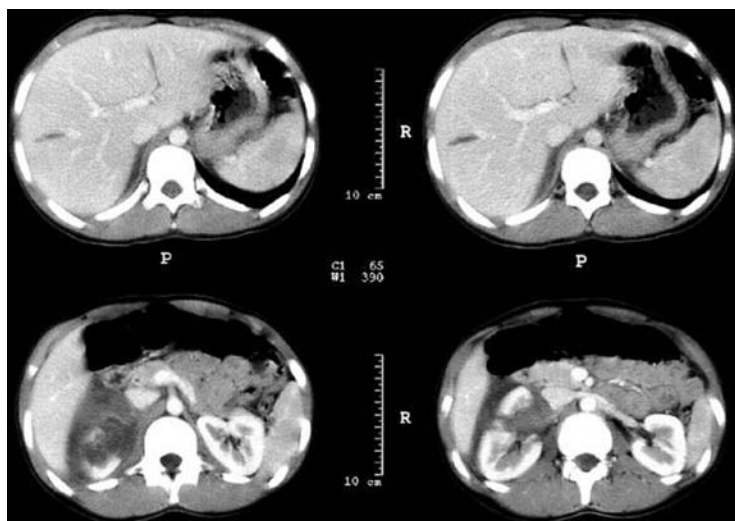
Clinical signs of bowel trauma may be absent, minimal or delayed beyond the first 24 hours. The small bowel contents are of neutral pH and sterile so do not induce rapid peritoneal signs. Morbidity and mortality from bowel injury increases if surgical intervention is delayed – this is especially true of duodenal injury. The CT findings of duodenal injury may be subtle with only tiny extraluminal gas bubbles, or minimal duodenal fold thickening. Small bowel injury usually occurs at points of fixation such as the ligament of Treitz or



**Figure 3.26.** Lap-type seat belt injury: jejunal and mesenteric injury. In the left flank there is free contrast in the peritoneal space surrounding loops of small bowel. Solid organ or bowel injury should be 'expected' in the presence of a Chance fracture.



the ileocaecal valve. Only the most minor small bowel or mesenteric injury can be treated with non-operative management. Signs on CT include wall thickening (due to haematoma), intra-peritoneal air, extravasation of oral contrast and sentinel clot adjacent to bowel. Intra-peritoneal air can be present in the absence of hollow viscus injury due to pneumothorax (via the diaphragm) or subcutaneous dissection from the chest.



**Figure 3.27.** Quiz case.

12-year-old girl.  
Fall from horse. Pain in right upper quadrant.

## Question 7

- What is the diagnosis (Fig. 3.27)?
- How would you manage the case?

## Answer

### Blunt renal trauma

There is a laceration from the cortical surface through the parenchyma of the right kidney communicating with the hilum – renal fracture. There is perinephric haemorrhage and fluid surrounding the kidney. The kidney remains well perfused. In addition, there is a laceration through the right lobe of the liver.

The majority of renal injuries are from blunt trauma. Flank pain, bruising and haematuria can accompany renal trauma but are a poor indicator of the extent of disease. Haematuria may be absent in cases of renal pedicle injury or traumatic renal vein thrombosis. It is necessary to correlate clinical findings with the mechanism and severity of trauma.

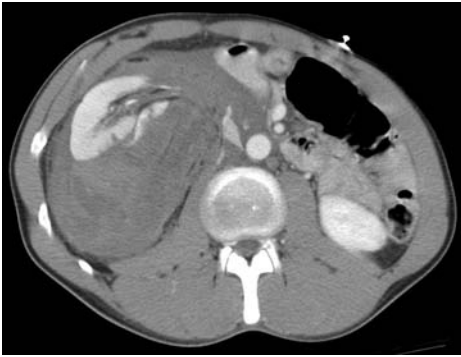The role of imaging is to assess the extent of injury – trauma grading (see Table 3.2) and to determine the function of the contralateral kidney. Contrast-enhanced CT is the gold standard for assessing renal trauma (Fig. 3.28). Delayed CT images are important when imaging for renal trauma to check for urine leak. Renal lacerations are irregular low-density areas in the parenchyma.

Lacerations through the hilum which contact two cortical surfaces are termed fractures. The majority of renal injuries can be managed without the need for surgery even in the presence of major laceration or urine leak. Grades 1 and 2 are managed non-operatively with excellent results; patients have normal functioning kidneys on follow-up imaging. Most patients with grade 3 and 4 injuries are managed non-operatively. Close monitoring of patients with grade 3 and 4 injuries with use of percutaneous drainage and angiographic embolization (Fig. 3.29) has reduced the laparotomy rate in this group.

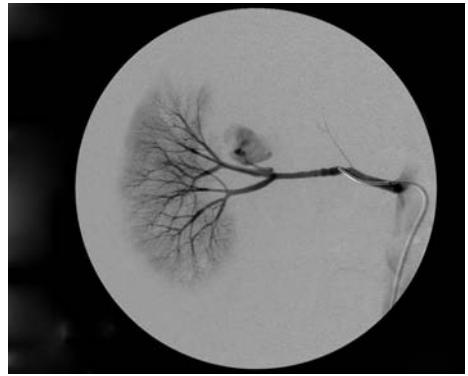**Table 3.2.** Grading of blunt renal trauma (American Association for the Surgery of Trauma)

1.	Renal contusions and subcapsular haematoma
2.	Cortical laceration less than 1 cm in depth and non-expanding perirenal haematomas
3.	Parenchymal lesion extending more than 1 cm into renal substance, extension into the collecting system or evidence of urinary extravasation
4.	Laceration involving the collecting system, traumatic thrombosis of a segmental renal arterial branch and injuries to the main renal artery not associated with renal devascularization
5.	Renal fragmentation or renovascular pedicle injury

Reproduced with permission from The American Association for the Surgery of Trauma and Lippincott, Williams and Wilkins. From Moore *et al.* 1989<sup>17</sup>

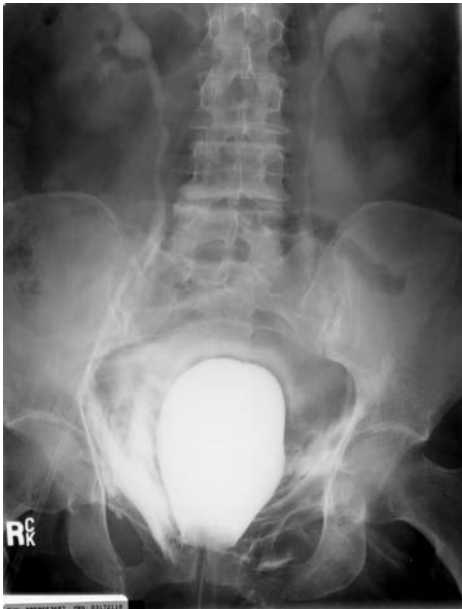

**Figure 3.28.** Renal trauma. There is a large right-sided perinephric haematoma surrounding the right kidney which is displacing it anteriorly.



**Figure 3.29.** Renal angiogram. There is active bleeding/contrast extravasation from a segmental renal artery.

Moderate urine leaks can be managed conservatively with ureteric stenting. Persistent large urine leak, pelvi-ureteric junction avulsion, enlarging central or subcapsular haematoma, extensive avascularized parenchyma and shock in the presence of intra-peritoneal or retro-peritoneal haematoma need surgical intervention. Attempted salvage of a devascularized kidney is controversial, but may not be attempted if the contralateral kidney is normal.



**Figure 3.30.** Quiz case.

Male aged 28.  
Road traffic accident.  
Pelvic fractures on plain radiograph. Frank haematuria.

## Question 8

- What is this study and what does it demonstrate (Fig. 3.30)?

## Answer

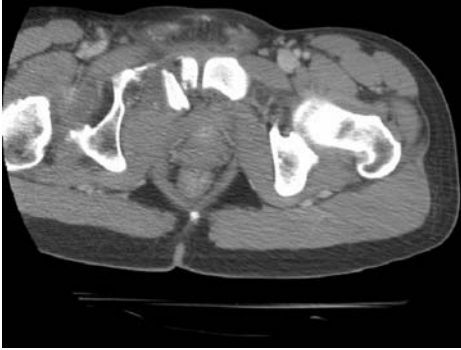
Cystogram with extra-peritoneal bladder rupture. The cystogram demonstrates extravasation of contrast into the extra-peritoneal space around the bladder. Note the multiple pelvic fractures.

### Lower genitourinary trauma

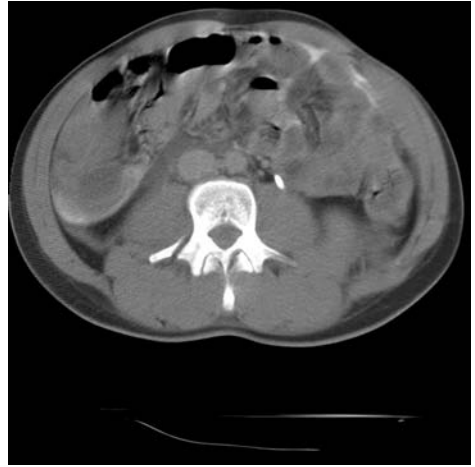Bladder injuries are most common following blunt trauma and 85% are associated with pelvic fractures. Urethral injury (particularly of the proximal segment) is also usually associated with pelvic fracture and is mainly a male problem. Pelvic pain, inability to void, high riding prostate on PR examination and haematuria are all clues to urethral or bladder trauma.

Bladder injuries are best classified as either intra-peritoneal (15%–35%) or extra-peritoneal (65%–85%). Intra-peritoneal rupture is usually caused by a burst injury of the bladder dome in a distended bladder and infrequently by pelvic fractures. Extra-peritoneal injuries are associated with penetration injury from pelvic fractures especially pubic bone fractures (95%).

Imaging investigations should include plain films to diagnose the presence of pelvic fractures and a retrograde urethrogram if urethral injury is suspected. The latter should be performed prior to Foley catheter insertion (if urethral injury is suspected). A retrograde cystogram is a reliable method of assessing the presence of bladder injury. Two hundred and fifty millilitres of water-soluble contrast medium are introduced into the bladder through a Foley



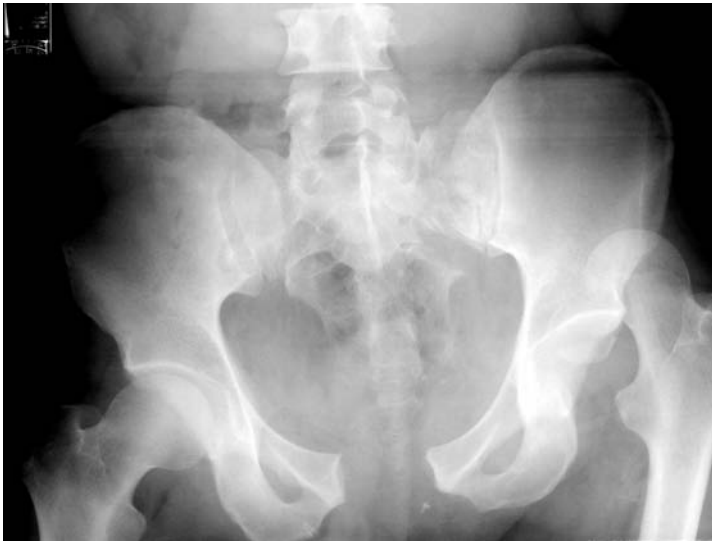**Figure 3.31.** Bladder trauma. Pelvic fractures should raise the suspicion of bladder trauma. Either delayed CT images or a CT cystogram can be performed.



**Figure 3.32.** Intra-peritoneal bladder rupture. Delayed CT imaging demonstrates dense contrast (excreted in the urine) in the peritoneal space. The normal mechanism is a blunt injury to the full bladder which ruptures into the peritoneal space.

catheter. CT cystography is often the most convenient method, as acute trauma patients often have additional indications for CT. Alternatively, fluoroscopy can be used when frontal and lateral views are obtained with images also taken post-void.

Flame-shaped extravasation superior and lateral to the bladder indicate extra-peritoneal rupture (see Fig. 3.30). Intra-peritoneal injury is manifested by contrast throughout the peritoneal cavity, outlining bowel and in the paracolic gutters. Delayed CT imaging may demonstrate bladder rupture and also any associated bony pelvic injuries (see Figs. 3.31 and 3.32). It is less sensitive than cystography. The importance of identifying intra-peritoneal rupture is that surgical repair is required acutely. Extra-peritoneal ruptures are treated conservatively with catheter drainage and antibiotics unless a cystogram at 7–10 days demonstrates persistent leakage.



**Figure 3.33.** Quiz case.

Male aged 29.  
Road traffic accident.

## Question 9

- What type of fracture is demonstrated (Fig. 3.33)?
- What are the main complications from pelvic fractures?

## Answer

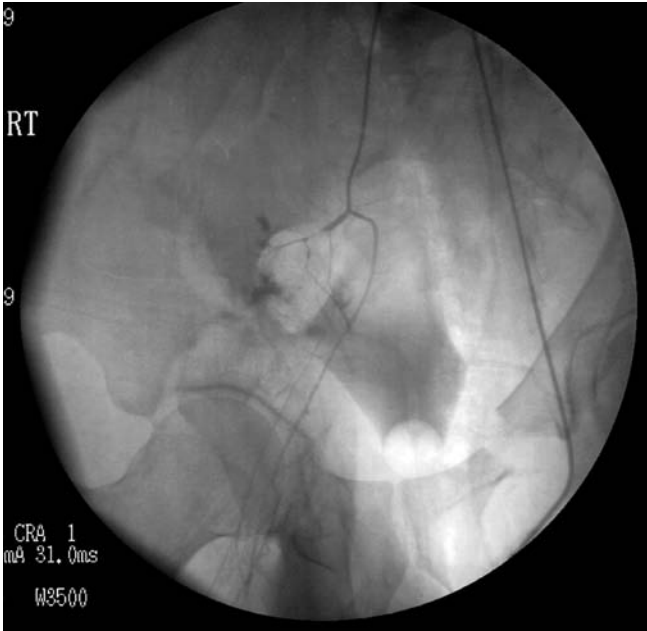
Open book pelvic fracture with diastasis of the symphysis pubis and sacro-iliac joint. Dislocation of the left femur.

Considerable force is required to cause a pelvic fracture and there is a high association with injury to distant organs – brain injury, liver laceration and aortic disruption.

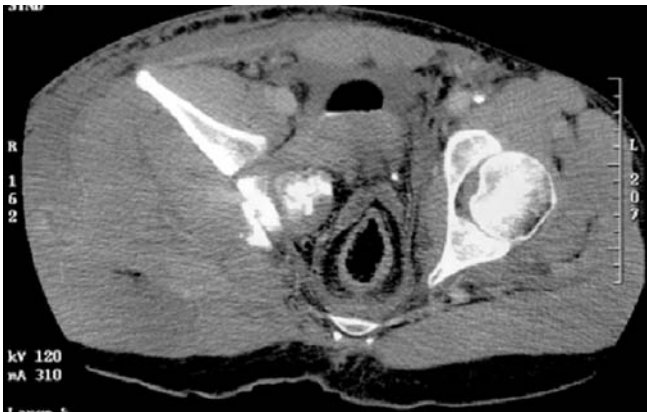### Complications of pelvic fractures

- Haemorrhage: can be life threatening,
- Bladder injury: consider cystogram,
- Urethral injury: consider urethrogram (prior to bladder catheter insertion),
- Prostate injury,
- Vaginal injury,
- Rectal and perineal injury,
- Neurological injury,
- Sepsis from bowel or urinary tract injury

The pelvis is supplied by an extensive venous plexus and several major arteries. Initial management of a major pelvic disruption associated with haemorrhage requires haemorrhage control and rapid fluid resuscitation. Simple techniques such as wrapping the ‘open book’ pelvic injury in a sheet to try to stabilize the pelvic ring can temporarily improve haemostasis but control of haemodynamically unstable patients needs urgent surgery

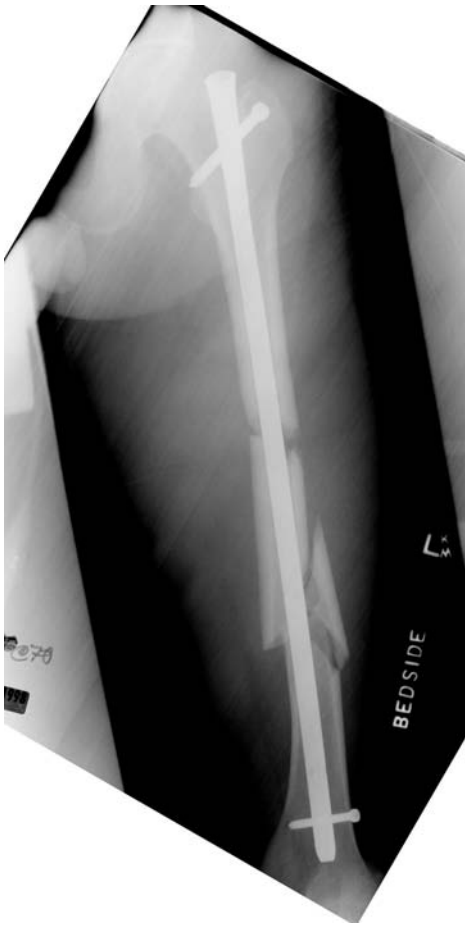

**Figure 3.34.** Angiogram in patient with pelvic fracture demonstrating active bleeding. This was subsequently coiled.



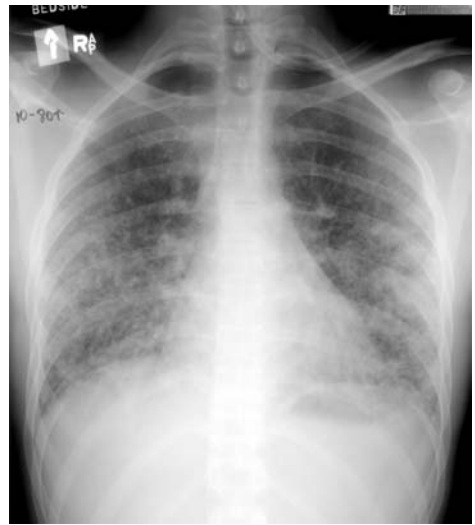
**Figure 3.35.** Contrast enhanced CT scan. Note the right-sided pelvic fractures and the contrast extravasation from active bleeding.

or angiography (Fig. 3.34). Pelvic surgery may decompress tamponaded retro-peritoneal haematoma and for this reason angiography may be preferred. Certain anatomical locations predispose to vessel injury (Fig. 3.35). Injuries of the sciatic notch, crush injuries of the sacrum and vertical shear injuries can all result in arterial tears.



**Figure 3.36.** Quiz case.

24-year-old man.  
Motorcycle accident.



**Figure 3.37.** Quiz case.

## Question 10

- What complication (Figs. 3.36 and 3.37) has occurred?

## Answer

### Femoral diaphysis fracture with fat embolism

As with pelvic fractures, a significant force is required to fracture the femoral diaphysis – it is the strongest bone in the body. The femoral shaft has a rich blood supply



and femoral fractures are often associated with considerable blood loss and haematoma formation.

### **Fat embolism**

Fat embolism is usually associated with long bone or pelvic trauma, but can rarely be associated with parenteral lipid infusion or corticosteroid treatment. The traditional explanation is that fat droplets from the bone marrow escape into the venous system and pass to the lung (and the brain via arteriovenous shunts). A second explanation is that altered internal homeostasis in the severely traumatized patient causes systemic release of fatty acids and chylomicrons which subsequently coalesce to give fat embolization. Fat embolization is a clinical diagnosis. Clinical features include hypoxia, tachycardia and fever. Red/brown petechial spots may appear over the trunk and axillae and, if present, are virtually diagnostic. Retinal, subconjunctival and oral haemorrhages are also sometimes seen.

The chest X-ray shows bilateral diffuse pulmonary infiltrates which appear 24–48 hours following the clinical picture. The CT head appearance may be normal but can show white matter petechial haemorrhages or changes consistent with microvascular injury.

Treatment is supportive.

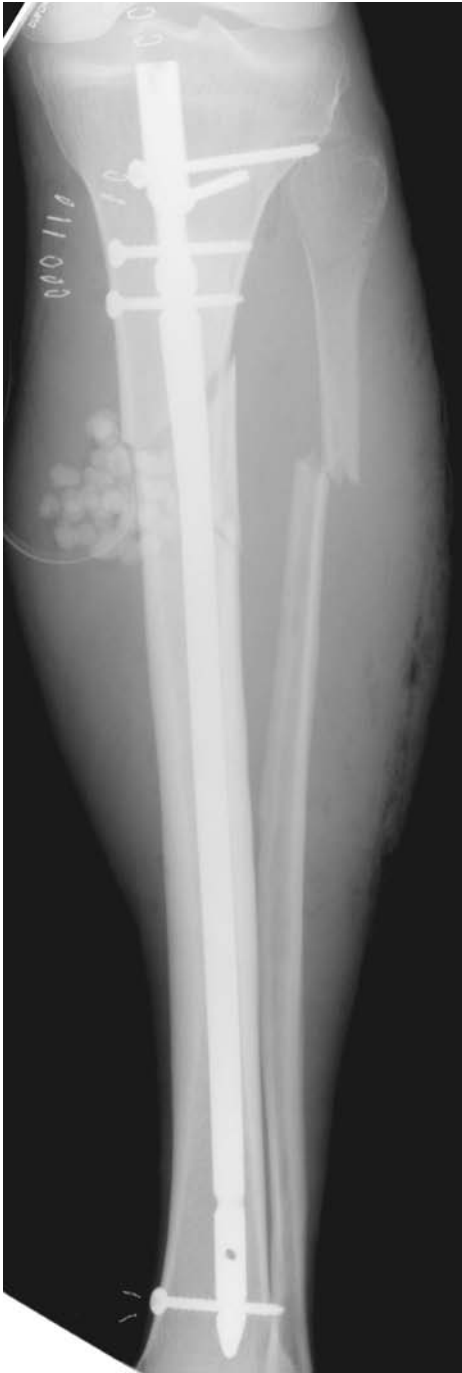### **Complications of femoral fractures**

- Haemorrhagic shock,
- Vascular injury,
- Neurological injury,
- Infection (with open fractures),
- Respiratory complications:
  - Fat embolism (see Fig. 3.37),
  - Adult respiratory distress syndrome,
- DVT and pulmonary embolism,
- Compartment syndrome (Fig. 3.38),
- Complications related to the fracture: shortening, malrotation, non/delayed union.

### **Compartment syndrome**

Compartment syndrome (or Volkmann contracture) occurs when perfusion pressure falls below tissue pressure in a fixed-volume body compartment. The condition is most frequently associated with long bone fracture (Fig. 3.38) particularly of the tibia but has also been described in several other body compartments including femur, upper limb, abdomen and buttock. High energy trauma, long bone fractures, crush or penetrating injury, burns and vascular injury are all predisposing factors. When tissue pressure rises above perfusion pressure, capillary filling is impaired and tissue ischaemia results. Clinical symptoms include severe pain and burning. Sensory loss followed by motor nerve dysfunction may be present on clinical examination.

Measurement of compartment pressure should be undertaken if compartment syndrome is considered. Debate exists regarding the threshold pressure at which to perform fasciotomy but above 30 mmHg is recommended by many. Early fasciotomy (within 6 hours) following the onset of compartment syndrome can be limb saving. If fasciotomy is delayed, permanent nerve damage, loss of limb and death can result. The presence of a pulse is not helpful in



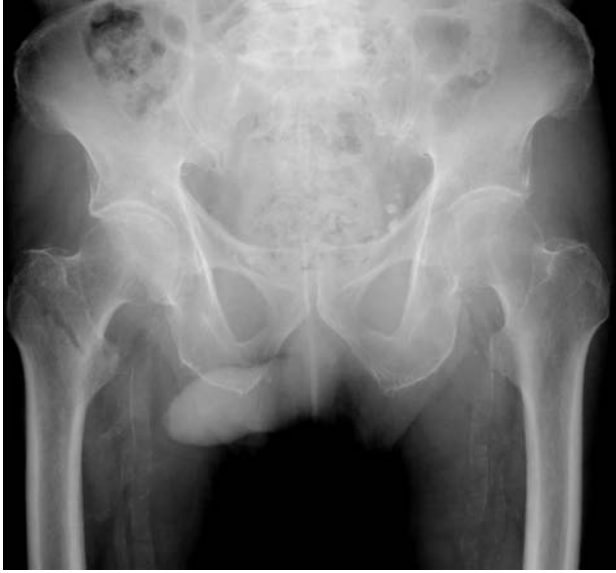**Figure 3.38.** Tibial fracture – compartment syndrome. Note the antibiotic beads and considerable soft tissue swelling. The patient later had a fasciotomy.

excluding compartment syndrome; if fasciotomies are delayed until the pulse is lost, the limb is likely to be unsalvageable.

Epidural analgesia has been associated with failure to recognize compartment syndrome. For this reason its use should be avoided if there is a risk of compartment syndrome. If considered, it should always be discussed in advance of insertion with the surgical team.

## Question 11

- What type of fracture (Fig. 3.39) is this?
- How does the classification of hip fractures relate to healing?
- What are the main causes of morbidity and mortality following hip fracture?



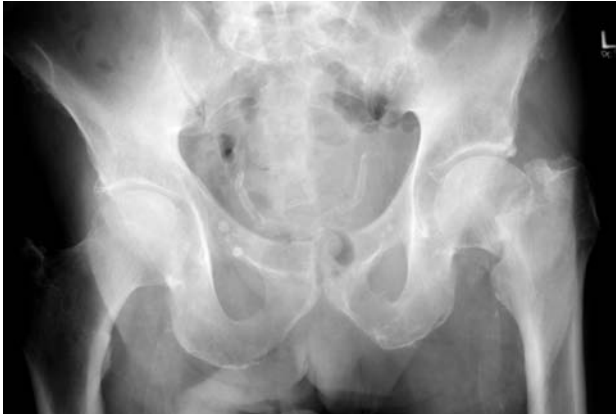**Figure 3.39.** Quiz case.

## Answer

### Intertrochanteric fracture of the hip

#### Hip fracture classification

1. Femoral head fractures,
2. Femoral neck fractures (Fig. 3.40),
3. Intertrochanteric fractures,



**Figure 3.40.** Femoral neck fracture.

4. Trochanteric fractures,
5. Subtrochanteric fractures.

The anatomical site of a fracture has a significant impact on healing. Femoral head and femoral neck fractures are both intra-capsular, whereas intertrochanteric, trochanteric and subtrochanteric fractures are extracapsular. Intra-capsular fractures are more prone to complications of healing such as avascular necrosis.

This is a consequence of the critical blood supply to the region. Blood supply is derived from three main sources which include:

- perforating branches of medial and lateral circumflex artery,
- inferior and superior gluteal arteries,
- obturator artery (posterior branch).

In the majority of people the foveal artery, which runs with the ligamentum teres to reach the femoral head, is insufficient to supply the entire femoral head.

Femoral neck fractures, especially if displaced, frequently lead to avascular necrosis of the femoral head due to disruption of the interosseus and capsular vessels (which run with the periosteum of the femoral neck).

Mortality and morbidity associated with hip fractures is considerable. Mortality is greatest in the elderly, between 7% and 10% at 1 month and increasing for up to 1 year afterwards. The immediate mortality after repair of fractured neck of femur may be less when spinal anaesthesia is used rather than a general anaesthetic, possibly because of a reduction in thromboembolic complication and post-operative confusion. A Cochrane review found there was insufficient evidence comparing regional with general anaesthesia to rule out clinically important differences.<sup>18</sup>

Morbidity due to surgery and anaesthesia:

- Mal/non-union,
- Infection,
- Pneumonia,
- DVT and pulmonary embolism,
- Muscle wasting.

The problems following fractured neck of femur are closely linked to immobilization. In the months following hip fracture reduced ambulation and mobility leads to a loss of independence, reduced quality of life and often depression in the elderly.

## References

1. *Advanced Trauma Life Program for Doctors*, 6th edn. Chicago: American College of Surgeons, 1997.
2. Kadir S. *Diagnostic Angiography*. Philadelphia: W.B. Saunders Co, 1986; 124–71.
3. Parmley LF, Mattingly TW, Manion WC. Nonpenetrating traumatic injury of the aorta. *Circulation* 1958; **17**: 1086–101.
4. Stark P, Cook M, Vincent A, Smith DC. Traumatic rupture of the thoracic aorta. A review of 49 cases. *Radiology* 1987; **27**(9): 402–6.
5. Mirvis SE, Shanmuganathan K, Buell J, Rodriguez A. Use of spiral computed tomography for the assessment of blunt trauma patients with potential aortic injury. *J Trauma* 1998; **45**(5): 922–30.
6. Rhea JT, Garza DH, Novelline RA. Controversies in emergency radiology. CT versus ultrasound in the evaluation of blunt abdominal trauma. *Emerg Radiol* 2004; **10**(6): 289–95.
7. Doody O, Lyburn D, Geoghegan T, Govender P, Monk PM, Torreggiani WC. Blunt trauma to the spleen: ultrasonographic findings. *Clin Radiol* 2005; **60**(9): 968–76.
8. Boulanger BR, McLellan BA, Brennehan FD *et al*. Emergent abdominal sonography as a screening test in a new diagnostic algorithm for blunt trauma. *J Trauma* 1996; **40**(6): 867–74.
9. Traumascore. Trauma.org. Available at <http://www.trauma.org/archive/scores/ois.html>.
10. Longo WE, Baker CC, McMillen MA *et al*. Nonoperative management of adult blunt splenic trauma. Criteria for successful outcome. *Ann Surg* 1989; **210**(5): 626–9.
11. Smith JS Jr, Cooney RN, Mucha P Jr. Nonoperative management of the ruptured spleen: a revalidation of criteria. *Surgery* 1996; **120**(4): 745–50; discussion 750–1.
12. Davis KA, Fabian TC, Croce MA *et al*. Improved success in nonoperative management of blunt splenic injuries: embolization of splenic artery pseudoaneurysms. *J Trauma* 1998; **44**(6): 1008–13; discussion 1013–15.
13. Jennings GR, Poole GV, Yates NL *et al*. Has nonoperative management of solid visceral injuries adversely affected resident operative experience? *Am Surg* 2001; **67**(6): 597–600.
14. Kirby RM, Braithwaite M. Management of liver trauma. *Br J Surg* 2000; **87**(12): 1732.
15. Carrillo EH, Wohltmann C, Richardson JD *et al*. Evolution in the treatment of complex blunt liver injuries. *Curr Probl Surg* 2001; **38**(1): 1–60.
16. Harper HC III, Maull KI. Transcatheter arterial embolization in blunt hepatic trauma. *South Med J* 2000; **93**(7): 663–5.
17. Moore EE, Shackford SR, Pachter HL *et al*. Organ injury scaling – spleen, liver and kidney. *J Trauma* 1989; **29**: 1664.
18. Parker MJ, Handoll HH, Griffiths R. Anaesthesia for hip fracture surgery in adults. *Cochrane Database Syst Rev*. 2004 Oct 18; (4): CD000521.

Chapter

# 4

## The cervical spine

---

Introduction: clearing the  
cervical spine 130

Non-traumatic conditions affecting  
the cervical spine 142  
Trauma of the cervical spine 155

## Introduction: clearing the cervical spine

The cervical spine has been traditionally divided into an upper segment (skull base, C1 and C2) and a lower segment comprising C3–C7. This is not arbitrary and is based on embryological, morphological and physiological differences. The characteristics of these two segments become particularly relevant when considering the effects of trauma. The level most commonly injured is C2 which accounts for 24% of all cervical spine fractures.

The cervical spine attains an importance to the anaesthetist as proper head position is important for successful orotracheal intubation. The oral, pharyngeal and laryngeal axes must be aligned for direct laryngoscopy. The head needs to be elevated at least 10 cm above the shoulders to align the pharyngeal and laryngeal axes. Also, the atlanto-occipital joint needs to be extended to achieve the straightest possible line from the incisors to the glottis.<sup>1</sup> A difficult airway is characterized by a limited range of motion at the cervical spine or temporomandibular joint. It can be encountered in conditions such as diffuse idiopathic skeletal hyperostosis (DISH), ankylosing spondylitis, rheumatoid arthritis, juvenile rheumatoid arthritis, Klippel–Feil syndrome (congenital fusion of upper cervical segment) and in the presence of suspected or unknown spinal injury (fracture) in which orotracheal intubation might be contraindicated.

## The examination

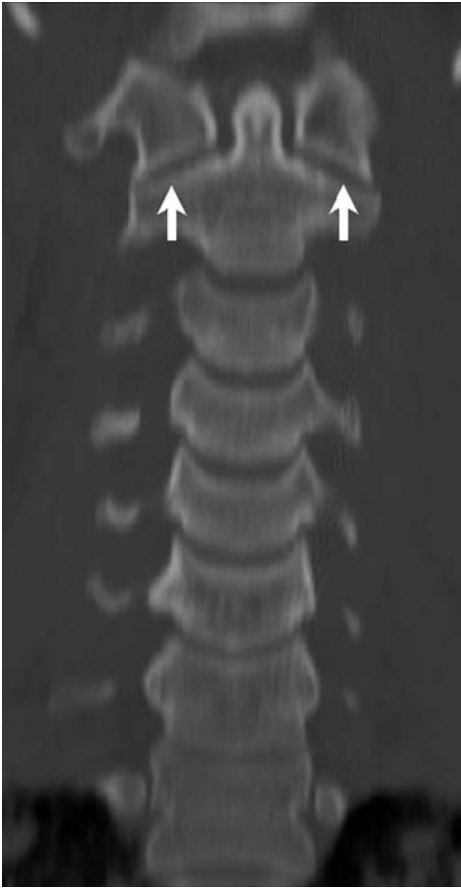There is diversity of opinion regarding the initial imaging of a patient suspected of having a cervical spine injury. It is generally accepted that patients with suspected acute cervical spine injury are initially evaluated using plain film radiography. The minimum should include at least three projections: an anteroposterior (AP) view, a lateral view and an open mouth odontoid view.<sup>2</sup> Depending on the clinical scenario and physical condition of the patient, other useful plain film projections include oblique views which might add visualization of the neuroforamina and facet joints and in a trauma situation they might be extremely helpful in visualizing the postero-lateral aspects of the lower cervical and upper thoracic vertebrae. Secondly, a swimmer's view in a trauma situation might also be helpful. This is usually obtained with one arm extended above the head and one by the side and helps to visualize the C7/T1 junction. Thirdly, flexion–extension views might be helpful where atlanto-axial subluxation is a possibility or ligamentous damage is suspected and are usually done in trauma situations when the patient is in severe pain but the initial radiographs appear normal. This must be done under close medical supervision. The patient must control the movement himself or herself as muscle guarding will help prevent an injury.

In most trauma cases, the cervical spine may be cleared by excellent complete lateral visualization of the cervical spine, open mouth odontoid view and AP views at the risk of missing significant fractures in fewer than 1% of cervical spinal injuries.<sup>3</sup>

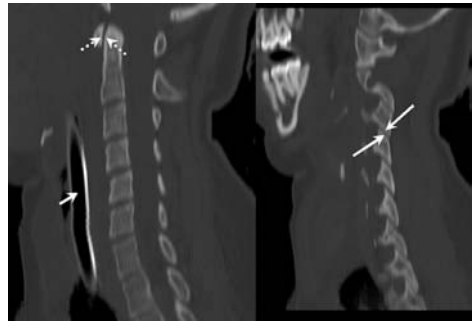
Depending on the clinical scenario, cervical CT (computed tomography) may be used as a screening examination (patients with neurological deficit, severe head injury, high-risk mechanism, unconscious, multi-injured patient) or as a complementary technique to radiography. Usually, magnetic resonance imaging (MRI) is indicated in all patients with partial or progressive neurological deficit after cervical spinal injury and in patients with potential mechanical instability caused by ligamentous injury or associated disc space injury.

In trauma situations, the examination of the cervical spine must cover the area from the base of the skull through the seventh cervical segment. If the cervicothoracic junction is not





**Figure 4.1.** Normal cervical spine. Coronal CT reconstruction. Normal relationship of C1 lateral masses to articular facets of C2 shown with arrows.



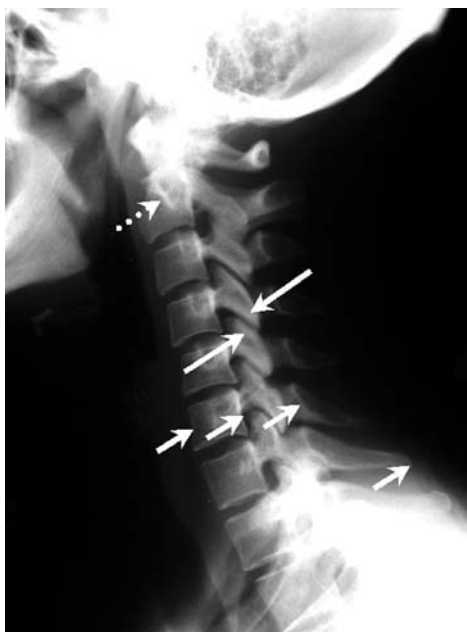**Figure 4.2.** Normal cervical spine. Sagittal CT reformats. Endotracheal tube (short solid white arrow) and normal atlantodens interval (dotted arrows) with normal vertebral body alignment. Normal facets demonstrated (long white solid arrows).

completely visualized by plain film radiograph, then this needs to be cleared by computed tomography (Figs. 4.1 and 4.2).

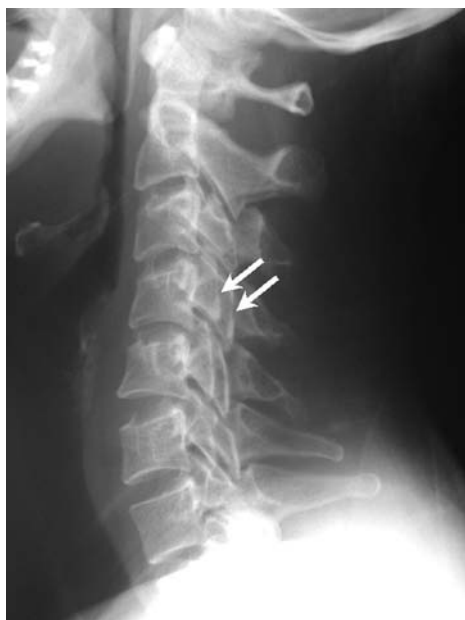The quality of the radiographic examination is extremely important. It must be of optimum technical quality to demonstrate both soft tissue and bony anatomy.

### General statements: plain film radiography

The lateral radiograph (Fig. 4.3) is the single most important component in the radiographic assessment of the acutely injured cervical spine. Proper patient positioning is essential in obtaining a true lateral radiograph. The degree of lateral is assessed usually by the superimposition of the paired articular masses (Fig. 4.4). Usually, the degree of rotation of the head is indicated by:



**Figure 4.3.** Normal lateral radiograph. This demonstrates all seven cervical vertebrae, down to the cervicothoracic junction. There is normal alignment of vertebral bodies, spinolaminar line and interspinous distances. In particular, the prevertebral soft tissue thickness in the retropharyngeal (anterior to C2) and retrotracheal (anterior to C6) regions is normal. Facet joints are demonstrated with long solid white arrows. Solid short arrows point to normal anterior vertebral line, posterior vertebral line, spinolaminar line, and posterior spinous process line to be intact. Projecting over the C2 body is the sclerotic ring known as the Harris ring (dotted arrow), and this is intact. If disrupted, this is suggestive of a type 3 odontoid fracture.

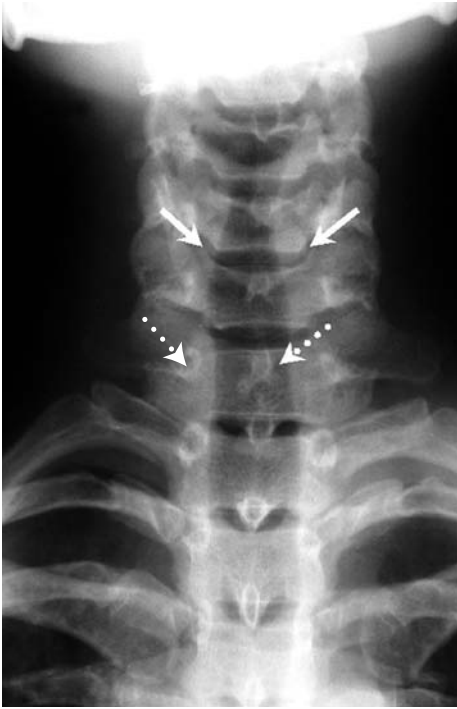

**Figure 4.4.** Rotated lateral radiograph. Lack of superimposition of the articular masses, giving the appearance of double articular facets (arrows).

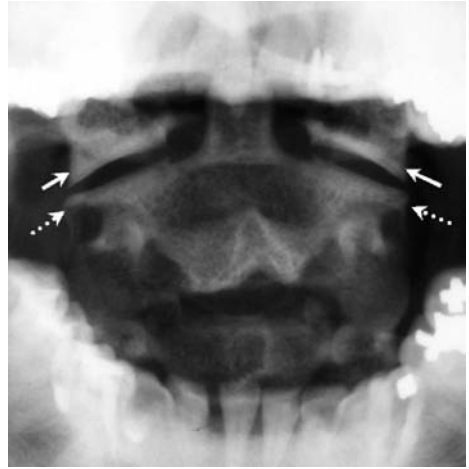
1. lack of superimposition of the angles of the mandible,
2. the articular masses and facet joints becoming superimposed upon the vertebral bodies, and lack of superimposition of the facet joints, resulting in a 'bat-wing' or 'bow-tie' appearance.

If the entire body is rotated, there is usually a uniform distance between the posterior cortical margins of the articular masses at each level. If the head is rotated, there is usually a greater distance between the posterior margins of the articular masses and a concomitant decrease in the lamina space. This can be differentiated from a unilateral facet dislocation in which there is usually a component of both flexion and rotation.<sup>2</sup> Thus, on top of the rotation, there is usually anterior translation of one vertebral segment relative to another by more than 4 mm indicating the flexion component of the injury.

AP radiographs of the cervical spine (Fig. 4.5) usually visualizes the cervical spine from C3 to the upper thoracic segments. They provide valuable evidence of flexion injuries such



**Figure 4.5.** Normal AP radiograph. The AP view usually only demonstrates C3–C7. The uncovertebral joints (solid arrows) and spinous processes (dotted arrows) can be evaluated. Note the equidistance between the spinous processes.



**Figure 4.6.** Normal odontoid process view or 'open mouth' peg view. This view best evaluates the alignment of the lateral masses of C1 (solid arrows) on the articular pillars of C2 (dotted arrows), the space on either side of the dens with respect to the C1 lateral masses (lateral atlantodens interval), and the odontoid process (dens).

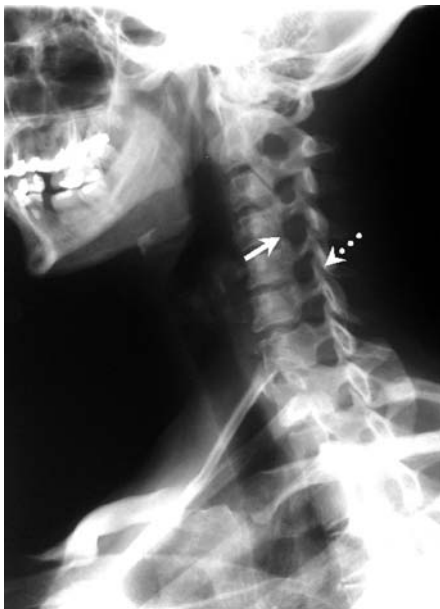as anterolisthesis, facet dislocation, clay shoveler's fracture (see Question 13) and burst fractures of the lower cervical spine. Frontal projection is the only plain film study in which the uncovertebral body process fracture can be identified.<sup>4</sup>

The open mouth projection (Fig. 4.6) is designed to demonstrate the atlanto-axial relationship in the AP projection. It is valuable in recognizing fractures of the lateral mass of C1, a Jefferson burst fracture (see Question 7), high- and low-dens fractures and atlanto-axial rotary subluxation/dislocation.

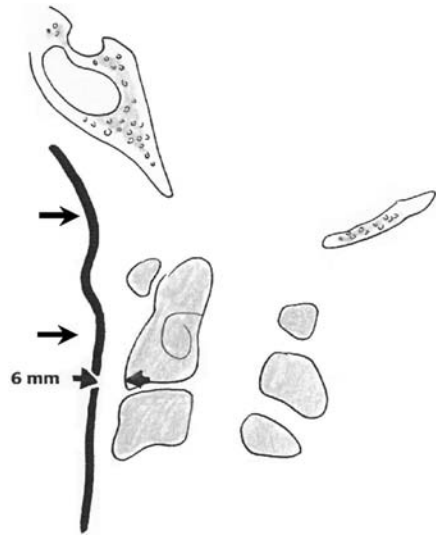
Occasionally, oblique views are helpful in demonstrating not only the intervertebral foramen and facet joint alignment, but also providing additional views of the cervicothoracic junction for alignment<sup>2</sup> (Fig. 4.7).

## Normal cervical spine

After assessing that the lateral radiograph is a true lateral, the following lines should always be checked.



**Figure 4.7.** Oblique view of cervical spine. This is helpful in demonstrating not only the intervertebral foramen (solid arrow) and facet joint alignment (dotted arrow), but also providing additional views of the cervicothoracic junction for alignment.



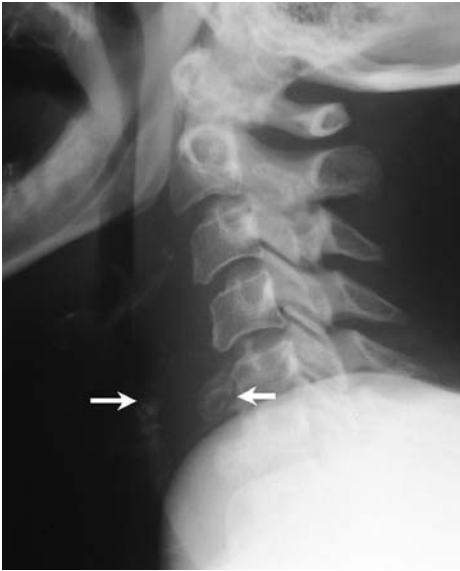**Figure 4.8.** Normal cervical cranial pre-vertebral soft tissue contour. Craniocervical pre-vertebral soft tissue contour (black line between arrow levels) should have a concave, convex (over C1 anterior arch) and concave contour. A measurement of more than 5–7 mm at the C2 level is abnormal, and anterior to vertebra C4–C7 less than 20–22 mm.

### Soft tissue contour

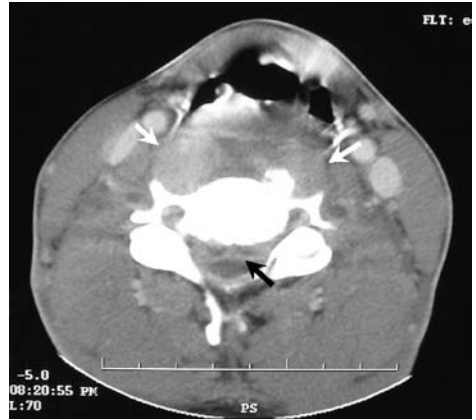
The normal contour of the pre-vertebral soft tissue shadow along both the cervical cranium and cervical thoracic junction is extremely important (Fig. 4.8). The cervical cranial pre-vertebral soft tissue contour should follow the contour of the anterior cortex of the atlas, axis and caudal portion of the clivus. At the cervical thoracic junction, the normal contour of the pre-vertebral soft tissue should also follow the contour of the anterior cortex of the lower cervical vertebral bodies and demonstrate no convexity as it dips and tucks into the thoracic inlet.<sup>2,4</sup> Prominence of the soft tissue contour may indicate haemorrhage, which can be the most prominent radiographic sign of subtle cervical-spine fracture (Figs. 4.9 and 4.10). Various measurements have been described in the literature regarding pre-vertebral soft tissue thickness. However, the most reliable is the cervical soft tissue thickness present anterior to the cortex of the body of C2<sup>2</sup>, while the remainder are usually unreliable and variable. Anterior to vertebra C2, the distance should be less than 6 mm, and anterior to vertebra C4–C7 less than 20–22 mm.

### Clearing the craniocervical junction

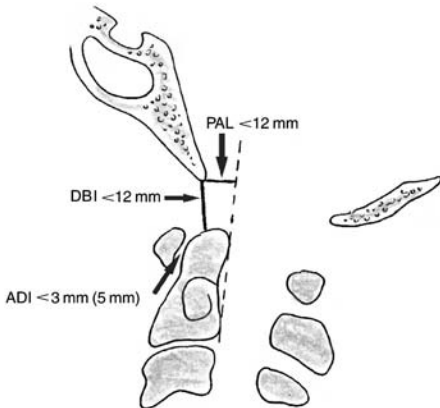
The atlantodental interval (Fig. 4.11) normally is less than 3 mm in adults whether or not the head is flexed or extended. In children under 8 years of age, the distance has been reported to be as much as 4–5 mm (particularly in flexion) secondary to the greater ligamentous laxity.<sup>5</sup>



**Figure 4.9.** Prominence of the soft tissue contour. Cervical spine osteomyelitis, with pre-vertebral abscess. Lateral cervical spine. This lateral cervical-spine radiograph shows marked widening of the lower pre-vertebral soft tissues (arrows) anterior to the C5 level with bony destruction of the C4 vertebral body. This was due to pre-vertebral abscess in association with cervical osteomyelitis. Gas can sometimes migrate into this potential space from aerodigestive tract injuries. Haemorrhage identified here may be the most prominent radiographic sign of a subtle cervical-spine fracture.

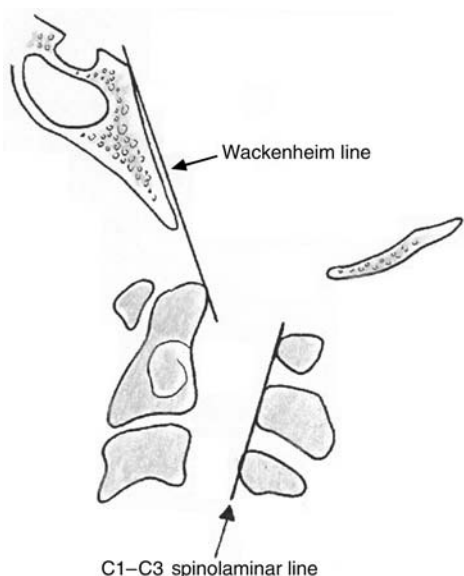


**Figure 4.10.** Transverse CT image with IV contrast. The CT image shows a large pre-vertebral abscess (white arrows) from C5 osteomyelitis. An epidural abscess component is also present encroaching on the thecal sac (black arrow).

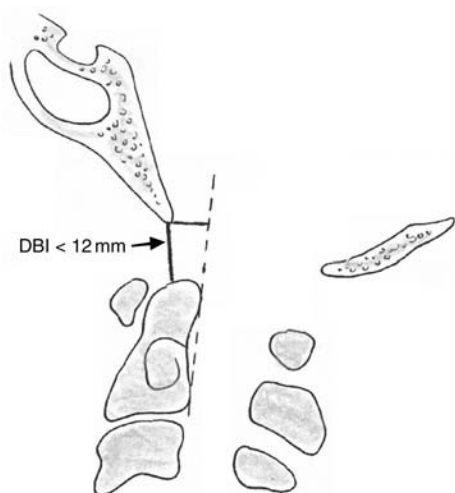


**Figure 4.11.** The atlantodental interval ADI normally is less than 3 mm in adults whether or not the head is flexed or extended. In children under 8 years of age, the distance has been reported to be as much as 4–5 mm. DBI (dens basion interval) <12 mm. PAL (posterior axial line) <12 mm.

Anterior pseudosubluxation (physiological subluxation) of C2 on C3 or C3 on C4 is a normal finding on the lateral cervical spine in children (usually under 8 years of age or young adults) and is due to greater ligamentous laxity. This is caused by the relative laxity of the ligaments combined with the shallow facet joints seen in these young adults. To distinguish it



**Figure 4.12.** Diagram of C1–C3 spinolaminar line, and Wackenheim's line. Spinolaminar line intact. Wackenheim clivus line should intersect the posterior aspect of the odontoid process; however, this is not as reliable as the DBI or PAL line in assessing for occipito-atlantal dissociation, given that this line can vary with the steepness of the clivus, or the angulation of the odontoid process.



**Figure 4.13.** Craniocervical dissociation. The DBI is normal if less than 12 mm. When the interval is greater than 12 mm, this indicates craniocervical dissociation.

from true subluxation, one must draw a line from the spinal lamina of C1 to the spinal lamina of C3 (Fig. 4.12). This is known as the postero-cervical line and it establishes that the apparent subluxation is physiological. Usually, the spinal lamina line of C2 should not be offset by more than 1 mm from the postero-cervical line. The radiographic absence of this postero-spinal lamina line usually at C1 reflects incomplete fusion of the posterior arches, which is relatively common and precludes use of the C1/C3 spinal lamina relationships discussed. In older people, there may be osteophytic extension beyond this line, and this may be ignored.

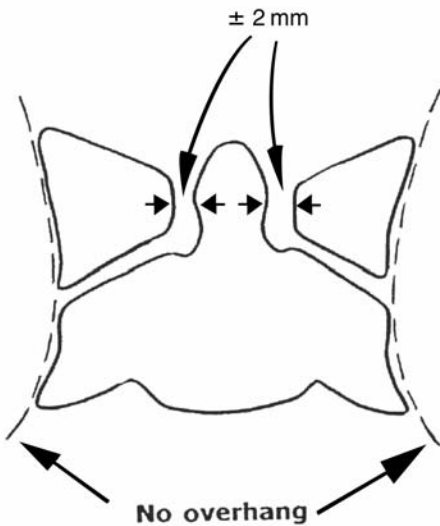
The best means of detecting subtle displacements at the craniocervical junction (dislocation/subluxations) is usually the measurement of the shortest distance between the dens and the basion, and the shortest distance between the posterior axial line (PAL) and the basion, not exceeding 12 mm (Fig. 4.13)<sup>2</sup>.

### Important caveat

Large pre-cervical haematoma is a common finding amongst serious maxillofacial fractures (Le Fort spectrum).<sup>4</sup> This should be considered when abnormal cervical cranium pre-vertebral soft tissue thickening is identified, and precludes using the pre-vertebral soft tissue interface prominence as a means of identifying cervical-spine fractures.

### Open mouth AP radiograph

Usually, on the neutral AP open mouth radiograph, the margin of the atlas and the axis are aligned. The distance between the peg and the lateral masses of C1 should also be equal.



**Figure 4.14.** Diagram of AP peg view. This diagram demonstrates the LDI (lateral dens interval) which should be symmetric. This can be asymmetric, due to rotation. No 'overhang' of the C1 lateral masses should be present.

Lateral translation of C1 on C2 is normally less than 2 mm. Side-to-side difference in the lateral atlantodens interval exceeding 2 mm is considered abnormal<sup>4</sup> (Fig. 4.14).

It is important to remember the sclerotic ring (Harris ring) that is usually seen to project over the C2 vertebral body represents superimposition of the pedicles of C2. When this is disrupted, it signifies a type 3 odontoid fracture (fracture of the body of C2), and can be the only clue in revealing a type 3 fracture. This can be deficient posteriorly and inferiorly due to the superimposition of the foramina transversarium of C2.<sup>2</sup>

Additional lines to be checked on the lateral radiograph (Fig. 4.15) include the anterior and posterior margins of the vertebral bodies known as the anterior and posterior vertebral body lines. These should be gently curved and continuous. Thirdly, the spinal lamina line is drawn along longitudinally through the sclerotic line at the junction of the spinous process with the lamina and should also form a smooth continuous arc. The exception to this rule is that there may be a slight step of less than 2 mm in the spinous process arc, especially in children. A step greater than 2 mm is abnormal and may indicate a fracture or dislocation. Fourthly, a continuous concave line should follow along the tips of the spinous processes. Usually the same disruption of the antero-vertebral line can be seen in anterior subluxations as is normally seen with cervical degenerative joint disease change. Anterior listhesis of 2–3 mm is usually seen in severe degenerative disc disease and, if more than 3 mm, it needs to be further evaluated depending on the clinical scenario with either flexion/extension views or a CT scan.

### AP view

The spinous processes should lie in a straight line (remembering that there are bifid spinous processes within the cervical spine), and must be approximately equidistant from the levels above and below. If the spinous processes do not lie in a straight line, it is suggestive of a facet joint dislocation.

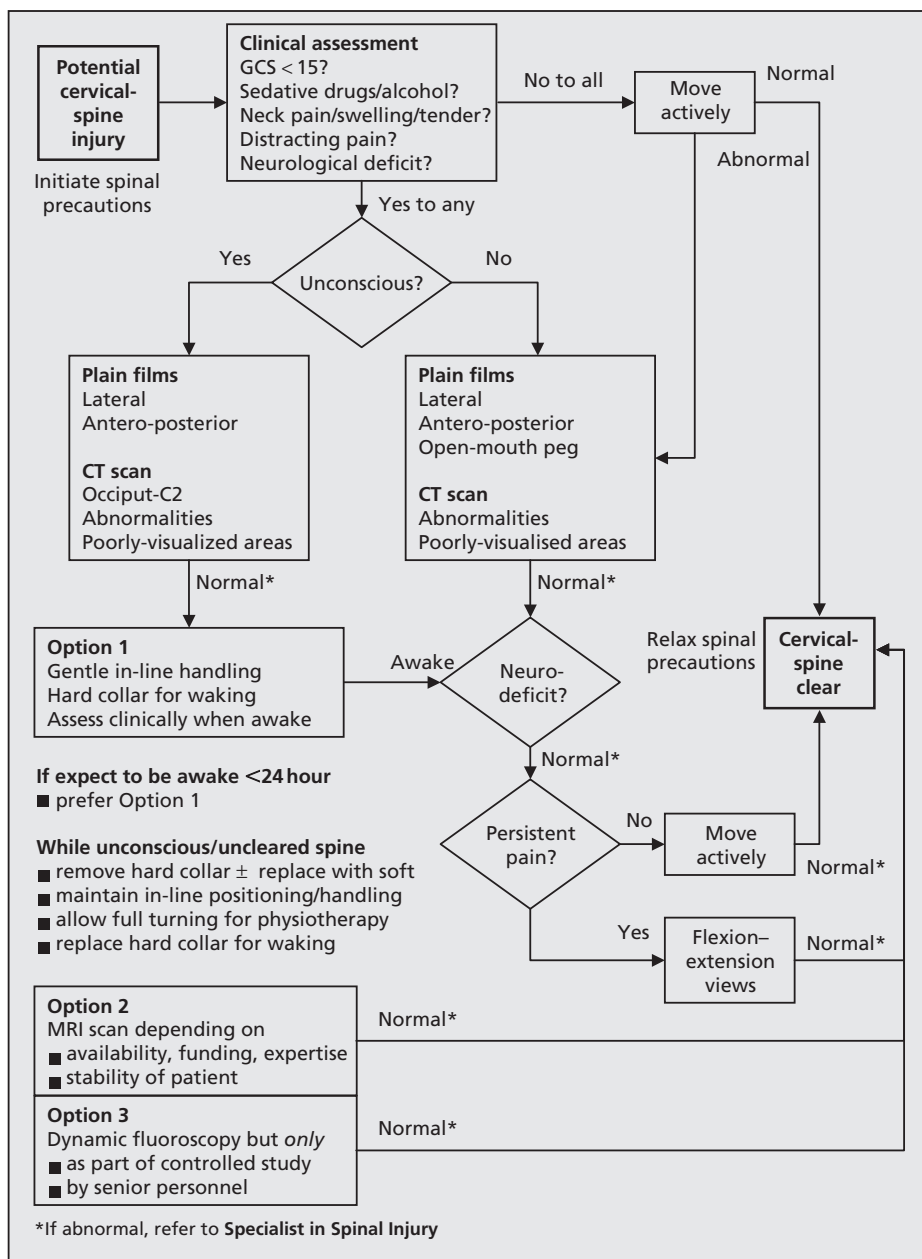
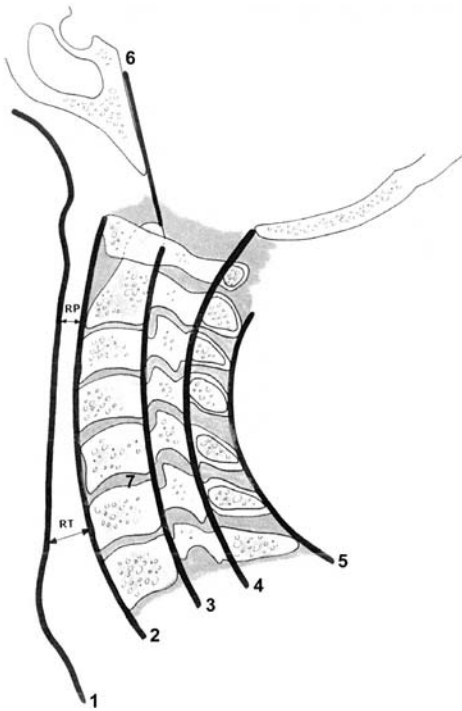


Figure 4.15. Cervical spinal clearance algorithm (British Trauma Society. Courtesy of Dr P. Oakley).

**Special caveats**

The lateral view of the upper cervical spine and lower part of the skull is an important area in evaluating vertical subluxation of the odontoid process into the foramen magnum. There are certain measurements that are helpful in determining atlanto-axial migration/cranial settling





**Figure 4.16.** Normal alignment lines: 1. pre-vertebral soft tissue line, 2. anterior vertebral body line, 3. posterior vertebral body line, 4. spinolaminar line, 5. interspinous process line, 6. clivus to dens line (Wackenheim line), 7. disc space height. The interval between lines 3 and 4 represents the spinal canal. RP retropharyngeal soft tissue thickness (anterior to C2) normally less than 6 mm. RT retrotracheal soft tissue thickness (anterior to C6) less than 21 mm.

or vertical migration of the odontoid process (terms that are often used interchangeably) (Fig. 4.16). This condition can be seen in rheumatoid arthritis, trauma, Paget's disease and congenital conditions such as Down's syndrome.<sup>6</sup>

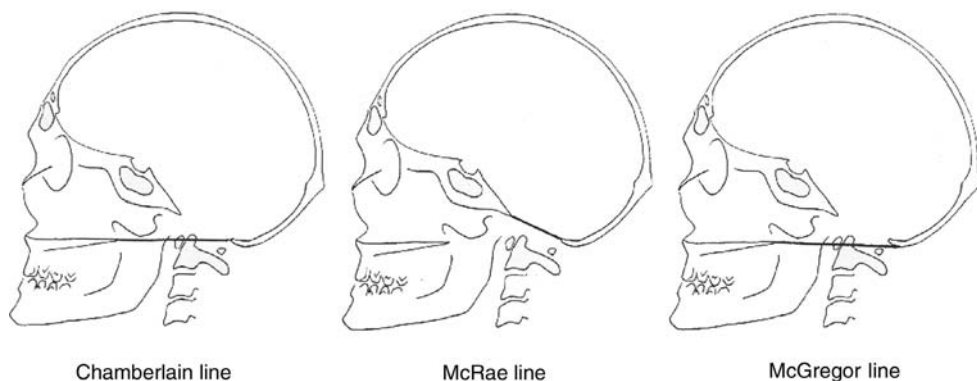
### Second caveat

Stenosis on a lateral radiograph can be inferred if the AP dimension of the canal measures less than 16 mm at C1/C2 or usually less than 13 mm from C3 through to C7 (see Fig. 4.15). However, canal stenosis is most accurately assessed on CT and MRI, and MRI can also display intrinsic cord abnormalities.<sup>6</sup>

## Injury to the cervical spine

One of the most important questions in suspected cervical injury is the question of stability of a fracture or a dislocation. Stability of the vertebral column usually depends on the integrity of the major skeletal components, discs, apophyseal joints and ligamentous structures. Radiographic findings that indicate instability according to Daffner<sup>7</sup> are displacement of vertebrae greater than 4 mm, widening of the interspinous or interlamina spaces, widening of the apophyseal joints, widening and elongation of the vertebral canal, widening of the interpedicular distance in the transverse and vertical planes, and disruption of the posterovertebral body line. Only one of these features needs to be present to make a radiographic assumption of an unstable injury.

The cervical spine can be cleared clinically only in the fully conscious, unintoxicated and cooperative patient in whom there is no neck pain, no bony tenderness, no abnormal neurology, no distracting injuries and pain-free full range of neck movements.



**Figure 4.17.** Atlanto-axial impaction cranial settling. *Chamberlain line*: posterior margin of hard palate to posterior margin of foramen magnum (opisthion). Normally tip of dens up to 3 mm above this line. *McRae line*: anterior margin of foramen magnum (basion) to posterior margin of foramen magnum (opisthion). Normally dens below this line. A perpendicular line from the apex of dens should cross the McRae line in the anterior quarter. *McGregor line*: postero-superior margin of hard palate to most caudal part of occipital curve of skull. Normally dens tip up to 5 mm above this line. In studies, the most reliable and practical line is the McRae line.

Mechanisms of cervical spinal trauma are hyperflexion, hyperextension and compression. Usually, the six cervical spine injuries considered to be unstable are bilateral locked facets, type 2 odontoid fractures, flexion teardrop fracture, hangman's fracture (depending on degree of displacement), Jefferson's fracture, and a burst fracture with involvement of the posterior elements or associated compression fracture of more than 25% of the affected vertebral body.

### Clearing the cervical spine in the unconscious/obtunded patient

There is no clear consensus on the best way to clear the cervical spine in victims of blunt trauma with altered mental status. Plain radiography may not detect injury to ligaments and some of these may be significant, unstable injuries. There are problems associated with maintaining cervical immobilization in the unconscious patient for a prolonged period. The hard collar can cause raised intracranial pressure (greater in patients with a head injury) and skin damage and ulceration. Maintenance of the supine position affects drainage of secretion and the need for log-rolling is nurse intensive.

Recent guidelines from the Intensive Care Society recommend that the cervical spine be cleared within 48 to 72 hours. These guidelines recommend plain films supplemented by helical CT of the entire cervical spine; however, modern CT reconstructions can reproduce the images gained by plain radiography. This will detect over 99% of injuries. If normal, many clinicians will remove the cervical immobilization, and clinically clear the spine when the patient is conscious. Management of the trauma patient on intensive care is made more straightforward if imaging of the cervical spine is undertaken simultaneously with CT scanning of the brain, obviating the requirement for a repeat journey to CT with the inherent risks of transportation.

Options are summarized in Fig. 4.15.

## Summary

*Recall evaluation of the lateral cervical spine film in trauma* (Figs. 4.16, 4.17)

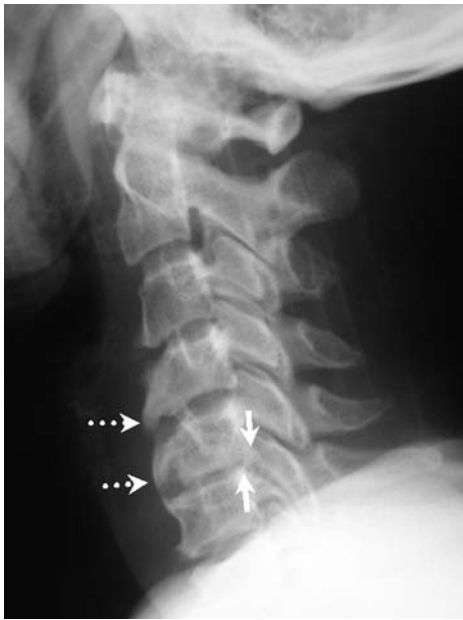Countdown to T1; all seven cervical vertebrae should be seen well. Evaluate the thickness of the retropharyngeal/retrotracheal space. Less than 5–7 mm anterior to the vertebra at C1/C3 and less than 20–22 mm anterior to the vertebra C4–C7.

### **Assess the four parallel lines for incongruity**

The four parallel lines to be assessed for incongruity are: antero-vertebral line – anterior to the vertebral bodies; postero-vertebral line – posterior to the vertebral bodies; spinal lamina line; and posterior spinous line (tips of the spinous processes).

The atlantodental interval should be evaluated; no more than 3 mm in adults and less than 5 mm in children less than 8 years of age. If abnormal, suspicion of disruption of the transverse ligament is raised.

Evaluate the disc spaces for narrowing or widening as a result of an acute flexion or extension injury.



**Figure 4.18.** Quiz case.

74-year-old patient.  
History of non-specific neck stiffness and pain for 3–4 years.

## Non-traumatic conditions affecting the cervical spine

### Question 1

- What is the diagnosis (Fig. 4.18)?
- Are there any implications for anaesthesia or intubation?

### Answer

#### Cervical spondylosis

##### Definitions

- Spondylosis: Non-specific degenerative process of the spine.
- Spondylolisthesis: Anterior subluxation of one vertebral body on another.
- Spondylolysis: Failure of the neural arch manifesting as a defect in the pars interarticularis.<sup>6</sup>

Degenerative changes that affect the spine include subchondral sclerosis, osteophyte formation and joint space narrowing. Changes found in degenerative disc disease include disc space narrowing, discogenic sclerosis, vacuum disc phenomenon and associated anterior and posterior end-plate osteophyte formation. Osteophyte formation may also encroach on the neural foramina (resulting in stenoses) leading to radicular symptoms.

Degenerative changes may also involve the fibrous articulations, tendons or sets of ligaments attached to the bones leading to a condition known as DISH – diffuse idiopathic skeletal hyperostosis.<sup>5</sup>

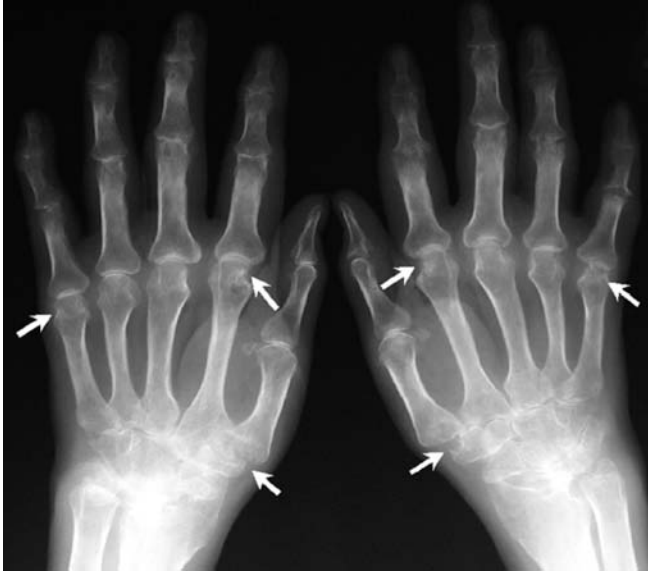The complications of degenerative joint disease to the spine are usually degenerative spondylolisthesis or spinal stenosis.

The clinical significance is that these changes may result in limited mobility making an intubation difficult. They may also result in spinal claudication, cervical myelopathy or radiculopathy. Stenosis of the spine may take the form of central spinal canal stenosis, stenosis of the lateral recess or narrowing of the neural foramina. Spinal stenosis can be assessed using plain film radiography, but is better evaluated using computed tomography or MRI, if indicated clinically.

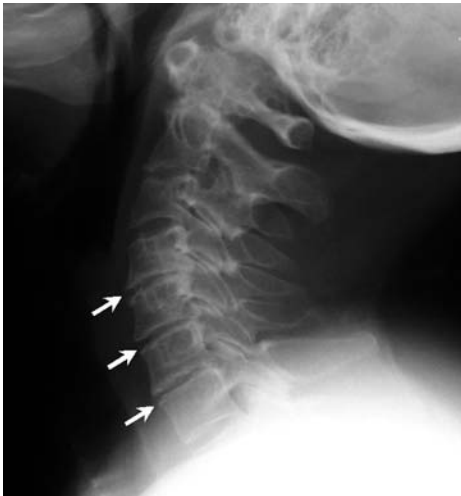The most common level of the cervical spine to be involved by cervical spondylosis is the C5/C6 disc space level, and this is most commonly seen in middle-aged people and beyond.

## Question 2

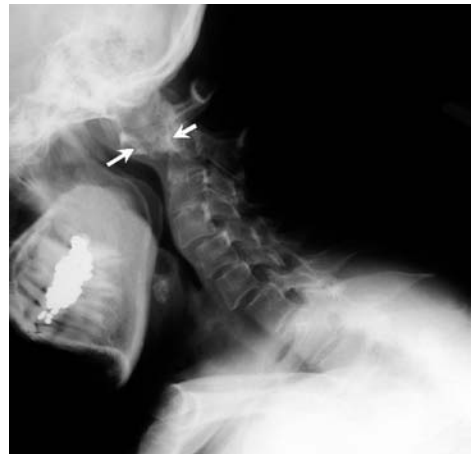- How may this condition (Figs. 4.19–4.21) affect intubation?
- What are the other manifestations of this condition?



**Figure 4.19.** Quiz case.



**Figure 4.20.** Quiz case.



**Figure 4.21.** Quiz case.

## Answer

### Craniocervical junction and cervical spine abnormalities

Certain conditions that affect the craniocervical junction and cervical spine are clinically relevant to anaesthetists. These conditions can result in difficult endotracheal intubation, owing

to limited mobility of the head and neck. Inability to extend the head and flex the neck (sniffing position) can prevent the anaesthetist from achieving the ideal position for direct visualization of the glottic opening which requires alignment of the three axes, i.e. the mouth, pharynx and trachea.

### Rheumatoid arthritis

Rheumatoid arthritis is a progressive chronic systemic inflammatory disorder affecting primarily the synovial joints. Women are three times more commonly affected than men. Characteristically, it is a symmetrical inflammatory arthropathy affecting peripheral small joints, i.e. hands and feet, which may also affect larger joints (hips, knees and elbows). It usually commences with progressive pain, stiffness and joint swelling. Early findings include periarticular soft tissue and tendon sheath swelling. Deformities in the hands include the swan-neck and boutonniere deformities, ulna deviation at the MCP joints and carpal drift in volar and palmar directions.

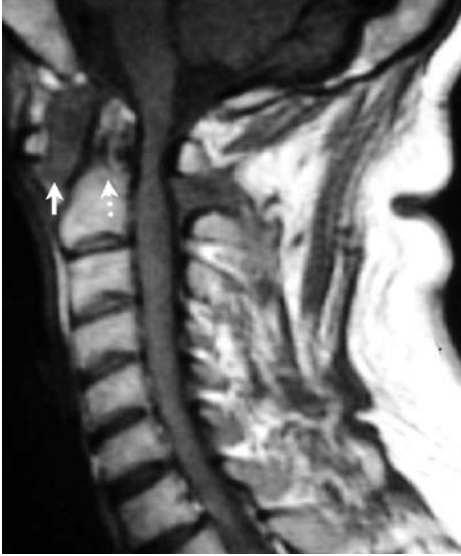Bony changes include symmetric narrowing of the joint space associated with marginal or central erosions and periarticular osteopenia. Subchondral sclerosis is minimal or absent and formation of osteophytes is usually lacking unless end-stage disease is present. Joints commonly affected are the MCP joints, the radial and ulnar styloid processes, the distal radio-ulna joints, and the carpus where ankylosis or bony resorption and erosions may occur.

More than 80% of patients with moderate to severe rheumatoid arthritis have radiographic evidence of cervical-spine involvement (Figs. 4.20 and 4.21). Do not assume the cervical spine is normal. The most characteristic radiographic findings involve the odontoid process, the atlanto-axial joint and the apophyseal joints of the subaxial spine. The erosive changes usually affect the odontoid process resulting in loosening of the insertion of the transverse ligament of the atlas. This leads to instability allowing anterior subluxation of the atlas on the axis. This may result in cervical spinal cord compression. This is frequently accompanied by a vertical translocation of the odontoid process, also known as cranial settling. The laxity of the transverse ligament is usually apparent on the lateral radiograph. The findings are accentuated by flexion when there is a marked increase in the atlantodental interval. It can require surgical intervention with the usual procedure being a posterior fusion.<sup>5,6</sup>

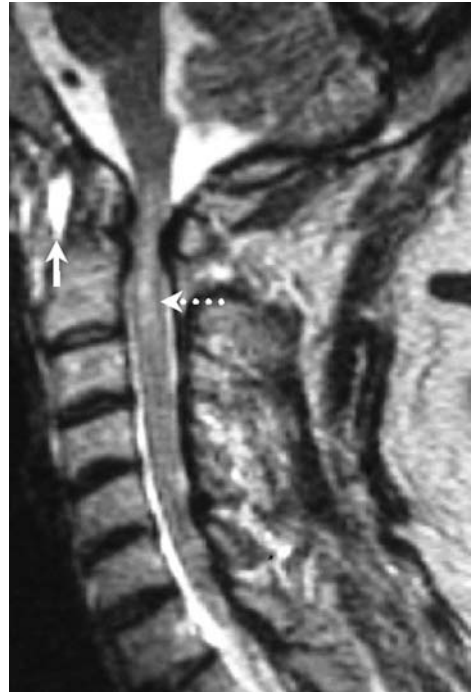Atlanto-axial subluxation in rheumatoid arthritis is usually progressive and the greater the degree of myelopathy, the higher the risk of sudden death. The end result of vertical migration of the odontoid process (cranial settling) leads to compression of the pons and medulla. Rheumatoid granulation (inflammatory pannus) behind the odontoid also contributes to this effect and vertebral artery obstruction may also play a role. The degree of erosion of C1 usually correlates with the extent of superior migration of the odontoid process.<sup>6</sup>

MRI is the best test to evaluate the compression of the upper cord and pons/medulla as this best demonstrates the location of the odontoid process, the extent of inflammatory pannus and associated oedematous changes to the spinal cord<sup>6</sup> (Figs. 4.22 and 4.23). Commonly, rheumatoid arthritis may affect the apophyseal joints or disc spaces in the subaxial cervical spine; further changes include subluxation, bone destruction or even ankylosis. If the discs are involved, there may be erosion or even fusion.

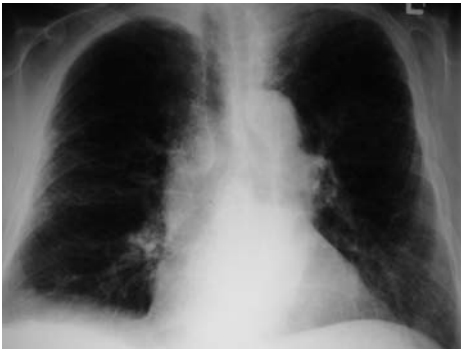Pulmonary manifestations include unilateral pleural effusions, pulmonary fibrosis (Figs. 4.24 and 4.25) affecting the lower lobes and rheumatoid nodules which may be single



**Figure 4.22.** MRI (T1) of cervical spine in rheumatoid arthritis. There is added tissue of intermediate signal (solid arrow) between the dens and anterior arch of C1, with widening of the anterior atlanto-axial interval, with erosion of the dens (dotted arrow) and compression on the spinal cord.

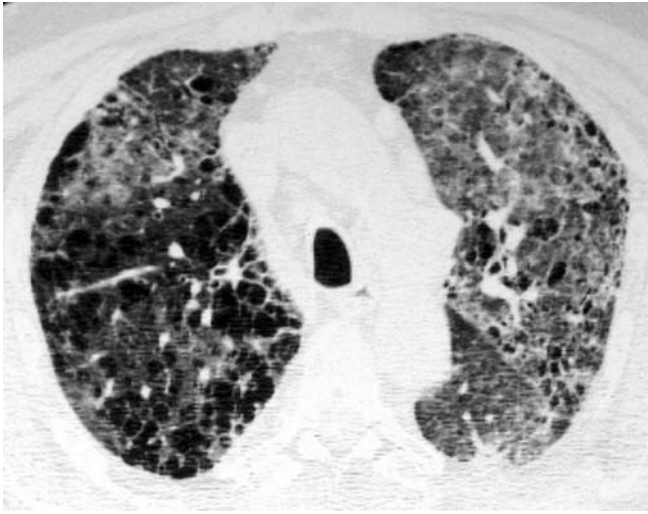


**Figure 4.23.** MRI (T2) of cervical spine in rheumatoid arthritis. Images show high-signal material anterior (solid arrow) to the odontoid process. This indicates an inflammatory pannus. Pannus can also be present around the attachments of the transverse and cruciate ligaments. MRI is also useful for showing degree of compression on the cervical cord, and also demonstrates increased signal within the cord, due to cervical myelopathy (dotted arrow).



**Figure 4.24.** Rheumatoid arthritis. Lung manifestations chest X-ray – basal fibrosis.

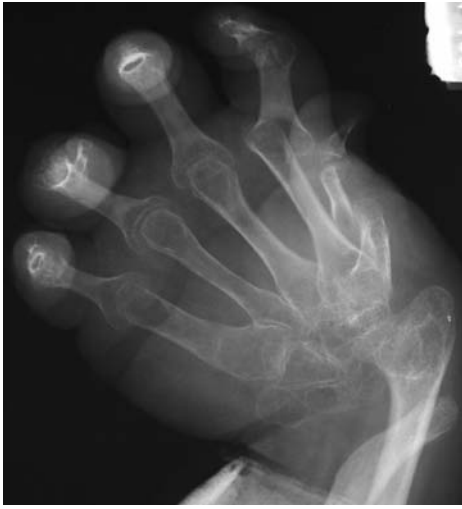



**Figure 4.25.** Rheumatoid arthritis. Lung manifestations. There is extensive end-stage pulmonary fibrosis (honeycombing), with thickened interlobular septae and ground glass density (representing activity of disease) due to rheumatoid lung.

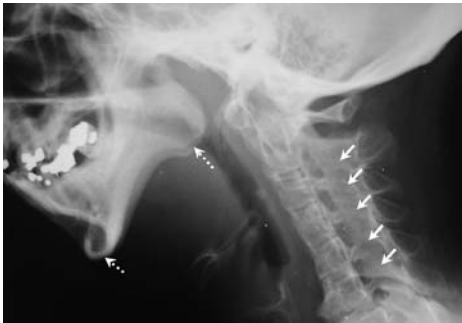or multiple and are commonly subpleural in location. Caplan's syndrome is rheumatoid nodules in the lungs of coal miners with silicosis. The most common early manifestation is bronchiolitis obliterans (respiratory bronchiolar inflammation with air trapping/mosaic perfusion and bronchiectasis).<sup>8</sup> This is usually identified on high-resolution CT scans with expiratory views. Pulmonary complications in rheumatoid arthritis are most commonly seen in men with seropositive disease.

The anaesthetist should always assess neck movement in patients with rheumatoid arthritis. Recent flexion/extension neck views or MRI should be examined for evidence of atlanto-axial subluxation, or subluxation of other cervical vertebrae. If the neck is unstable, the case should be managed by a consultant anaesthetist. If the patient has temporomandibular joint involvement reducing mouth opening, then the airway management becomes even more problematical. Regional techniques should always be considered. If intubation is required, then awake fibre-optic intubation may be used. If the neck is unstable, a hard collar and sandbags should be used while the patient is unconscious to prevent neck movement.

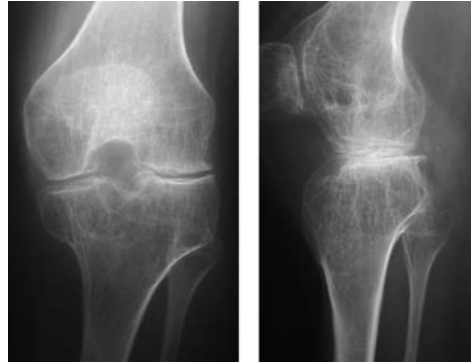


**Figure 4.26.** Quiz case.

23-year-old female patient with a chronic rheumatological condition.



**Figure 4.27.** Quiz case.



**Figure 4.28.** Quiz case.

### Question 3

- What are the features that will affect anaesthetic management (Figs. 4.26–4.28)?
- What is the condition?

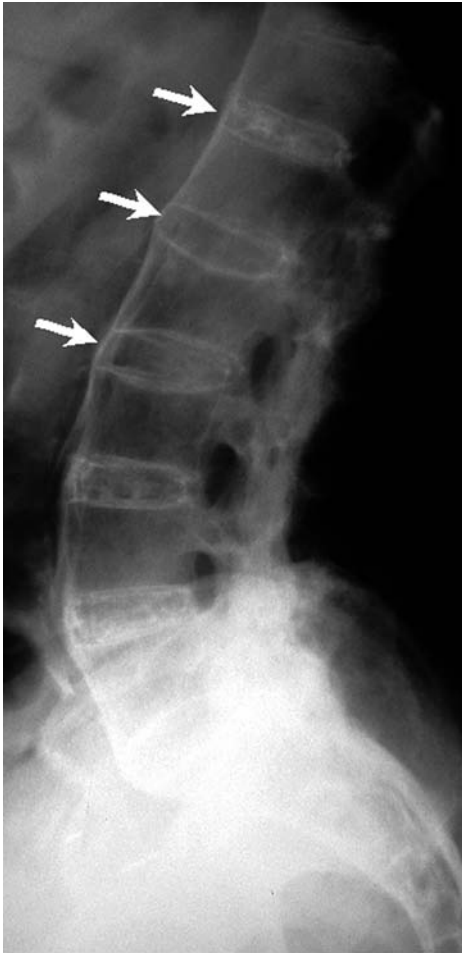
### Answer

#### Juvenile rheumatoid arthritis

Juvenile rheumatoid arthritis (JRA) is a chronic inflammatory synovial disease usually affecting children. Girls are more frequently affected than boys. This disease exhibits many of the features of adult rheumatoid arthritis. There are three additional features that are almost pathognomonic of this condition when present. First is periosteal reaction that is usually seen along the shafts of the proximal phalanges and metacarpals, next is joint ankylosis that may occur not only in the wrist but also in the interphalangeal articulations (Fig. 4.26). Fusion of the apophyseal joints of the cervical spine is a characteristic finding (Fig. 4.27), in addition to fusion of the posterior elements. The last of the pathognomonic features is growth abnormality. Altered bone growth is a common finding because the onset of JRA usually

occurs before the closure of the growth plates. Involvement of the epiphyseal regions often leads to fusion of the growth plates with resultant retardation of bone growth. Paradoxically, this might also precipitate premature acceleration of growth due to stimulation of the growth plate by resultant hyperaemia. The enlargement of the epiphyses of the distal femur usually leads to characteristic overgrowth of the condyles in the knee<sup>5</sup> (Fig. 4.28).

The implication for anaesthesia is that there is limited mobility of the spine due to the bony ankylosis, and there is usually micrognathia due to the growth disturbance. These factors can make intubation extremely difficult.



**Figure 4.29.** Quiz case.

46-year-old male patient.  
Haematemesis requiring central line insertion and resuscitation.

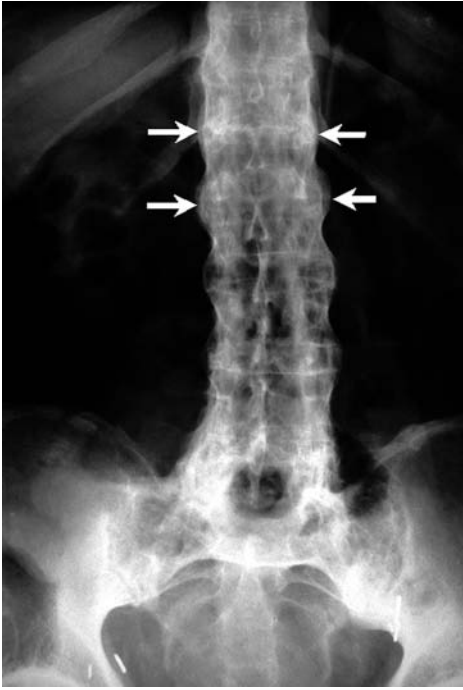## Question 4

- What is the condition (Figs. 4.29–4.32)?
- What are the implications for the anaesthetist?
- What may have precipitated the haematemesis?

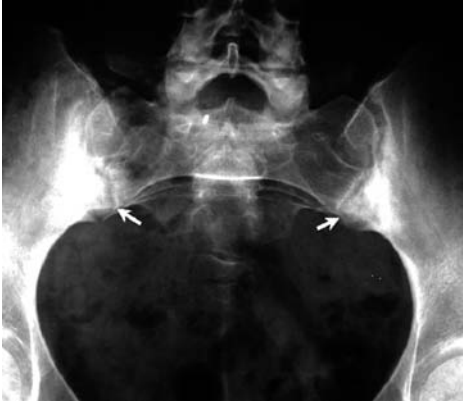## Answer

### Ankylosing spondylitis

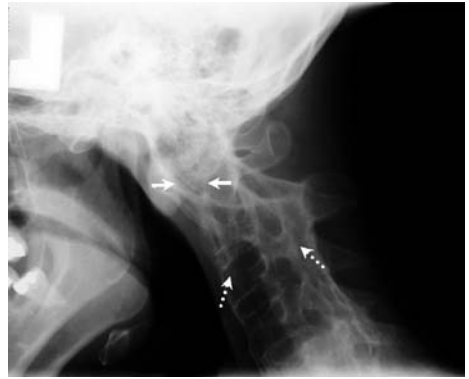Ankylosing spondylitis is a chronic progressive inflammatory arthritis principally affecting the synovial joints of the spine and adjacent soft tissues, as well as the sacro-iliac joints. Peripheral joints such as the hips, shoulders and knees may also be involved. It usually presents in young men and women, being seven times more frequently seen in men with an insidious onset of lower back pain and stiffness. There is an extremely strong link to the antigen HLA-B27, with approximately 97% of patients being positive for this antigen. These



**Figure 4.30.** Quiz case.



**Figure 4.31.** Quiz case.



**Figure 4.32.** Quiz case.

patients do exhibit extra-articular features of the disease including iritis, pulmonary fibrosis, cardiac conduction defects, aortic incompetence, spinal cord compression and amyloidosis.<sup>5</sup>

### Radiographic features

Squaring of the anterior border of the lower thoracic and lumbar vertebrae is one of the earliest radiographic features of ankylosing spondylitis, best demonstrated on the lateral radiograph of the spine (Fig. 4.29). As the condition progresses, delicate desmophytes are formed bridging the vertebral bodies; these have a vertical rather than horizontal orientation, distinguishing them from osteophytes of degenerative disease. Paravertebral ossifications are also

common. Apophyseal joint and vertebral body fusion usually occur later on in the course of the disease. This leads to a pathognomonic radiographic finding known as the 'bamboo spine' (Fig. 4.30). Sacro-iliac joint involvement is usually present with sacro-iliitis being the hallmark of AS. Most patients will have abnormal sacro-iliac joints radiographically on initial presentation. This is usually a bilateral and symmetric process initially affecting the iliac side of the joint, and progressing along the inferior synovial portion of the joint. The initial signs are osteoporosis, loss of cortical definition, superficial erosions and focal sclerosis with eventual obliteration of the sacro-iliac joint space with resultant bony ankylosis<sup>5</sup> (Fig. 4.31).

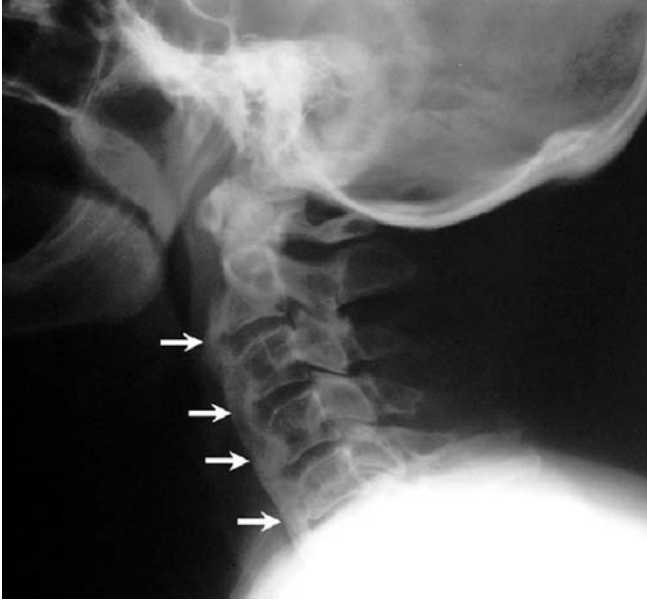Complications of ankylosing spondylitis in the cervical spine include atlanto-axial subluxation (Fig. 4.32), which may become fixed with multilevel spinal fusion. Ankylosing spondylitis patients are more prone to fractures following relatively minor trauma. The fixed spinal segments can result in increased mechanical forces with the formation of a pseudoarthrosis with resultant deformity and bone loss. Ankylosing spondylitis patients are also more predisposed to infection of the spine with tuberculosis.

The implications for anaesthesia include difficulties in endotracheal intubation as well as the problems in ventilation associated with a poorly compliant thoracic cage and possibly pulmonary fibrosis affecting the upper lobes. Given the effects on the spine described, this might also affect the application of an epidural anaesthetic.

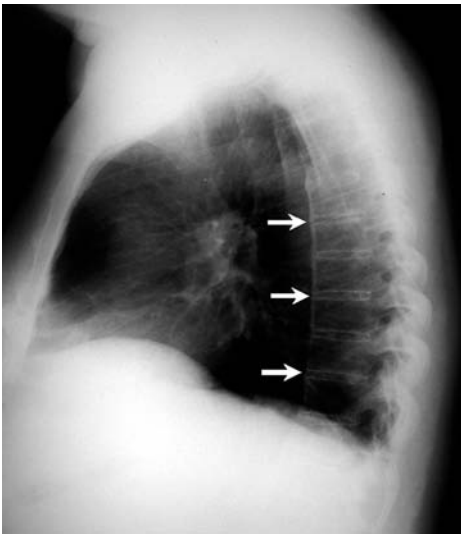
Long-term use of non-steroidal anti-inflammatory drugs may be complicated by upper gastrointestinal bleeding.

## Question 5

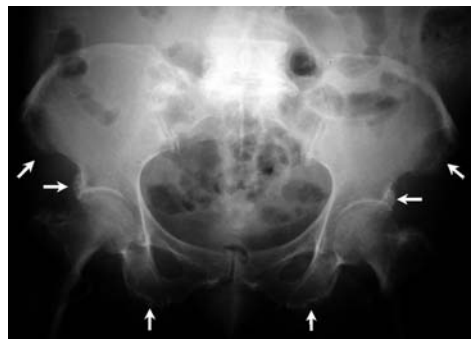- What is the diagnosis (Fig. 4.33)?
- How is it distinguished from ankylosing spondylitis?



**Figure 4.33.** Quiz case.



**Figure 4.34.** Quiz case.



**Figure 4.35.** Quiz case.

## Answer

### **Diffuse idiopathic skeletal hyperostosis (DISH)**

This condition is characterized by flowing ossification along the anterior aspect of the vertebral bodies extending across the disc space. This occurs in the absence of any degenerative, traumatic or post-infectious changes, i.e. the disc space heights are well maintained and there is no disc space loss. It usually affects Caucasians, with a male predominance, and is usually seen in patients in their mid-60s.

Most cases occur in the thoracic and lumbar spine (greater than 90% of cases), with the cervical spine involved in greater than 70% of cases (Fig. 4.33). The sacro-iliac joints are spared which can help to differentiate this condition from ankylosing spondylitis.

Patients may have early morning stiffness and mild limitation of activities. They may also present with dysphagia due to compression of the oesophagus between the prominent flowing osteophytes and the rigid laryngeal structures that commonly calcify as people get older.

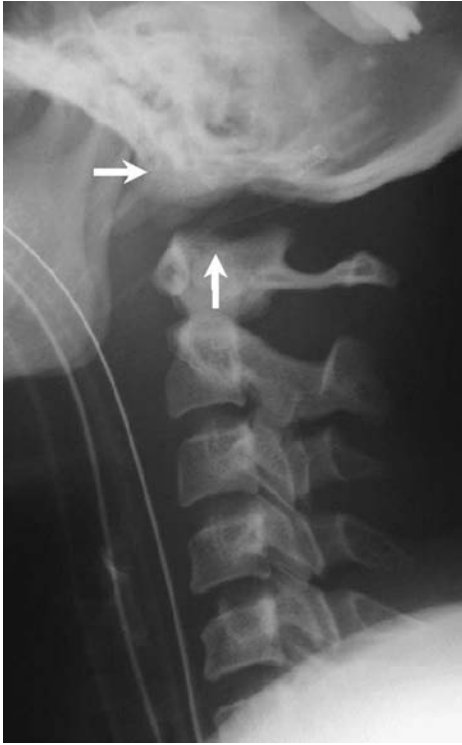This condition is associated with hyperostosis at sites of tendon and ligament attachment to bone, ligamentous ossification and osteophytosis involving the axial and appendicular skeleton.<sup>5</sup> This is best demonstrated on a lateral radiography of the spine (Fig. 4.34). This condition needs to be distinguished from the previously described 'bamboo spine' seen in ankylosing spondylitis. The sacro-iliac joints are usually spared in DISH, and usually no par-vertebral ossification is seen (Fig. 4.35).



## Trauma of the cervical spine

### Airway management in the patient with a suspected cervical spine fracture

Cervical spine injuries occur in 2%–5% of blunt trauma patients and of these 7%–14% are unstable. All trauma patients should be managed as if they have a cervical spine injury (airway management with cervical spine control – ATLS guidelines) until the neck is cleared. As long as manual in-line neck stabilization is applied, rapid sequence induction of anaesthesia followed by direct laryngoscopy and oral intubation appears to be safe. If intubation is not urgent, an awake fibre-optic intubation is another option. If intubation of the patient with a potential cervical spine injury fails, or appropriate experienced personnel are unavailable, the laryngeal mask airway or one of its various modifications are alternatives.



**Figure 4.36.** Quiz case.

28-year-old male patient.  
The patient required cardio-pulmonary resuscitation during ambulance transfer to hospital.

## Question 6

- What is the prognosis (Fig. 4.36)?

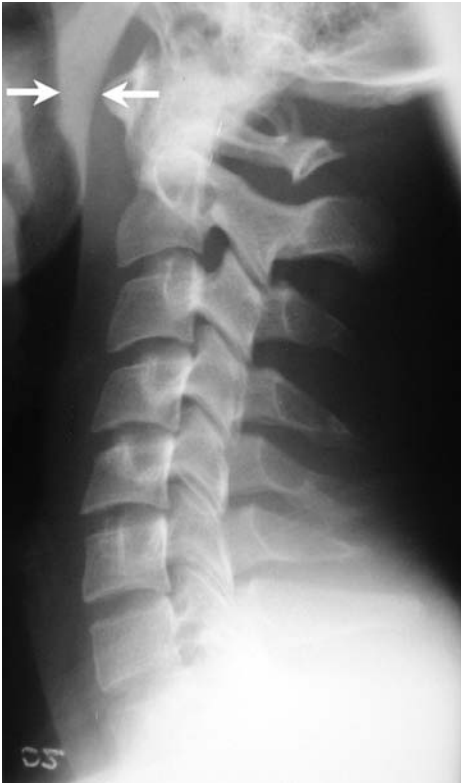## Answer

### Occipito-atlantal dissociation

This is a generic term that refers to disruption of the occipito-atlantal articulation that includes partial (subluxation) or complete (dislocation) disruption.<sup>2</sup>

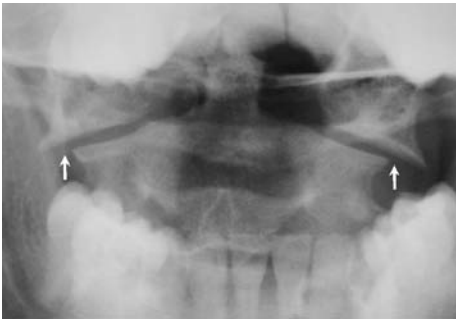
Stability of this joint complex is primarily ligamentous. Frank occipito-atlantal dislocation is usually a fatal injury (Fig. 4.36). However, with occipito-atlantal subluxation patients may be neurologically intact. Other forms of presentation are bulbar-cervical dissociation, lower cranial nerve deficits with or without cervical cord injury, or worsening neurological deficit with application of cervical traction.

The diagnosis is easily made by measuring the dens basion interval (DBI) (Fig. 4.13). The distance does not exceed 12 mm in adults or children.



**Figure 4.37.** Quiz case.

Male patient. Manual labourer. Struck (whilst wearing protective helmet) on top of head. Glasgow Coma Score 15/15. Neurologically intact. Complaining of neck pain.



**Figure 4.38.** Quiz case.

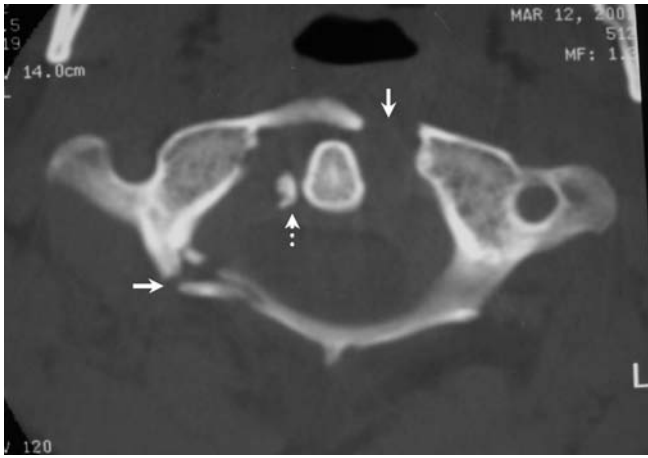
## Question 7

- What is the injury (Figs. 4.37–4.40)?

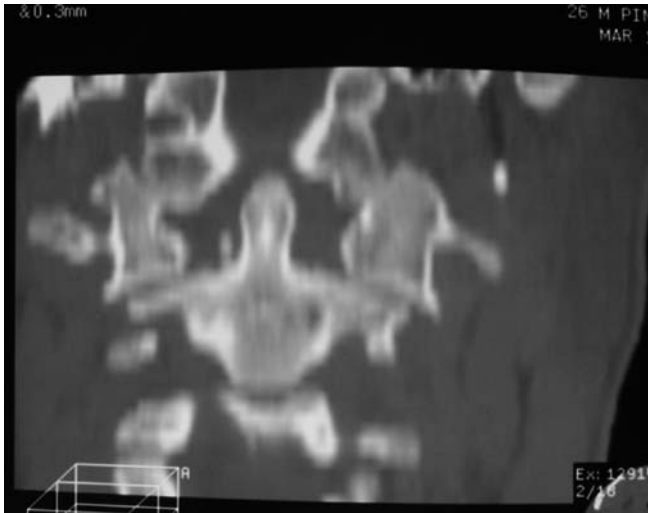## Answer

### Jefferson fracture

This is usually the result of a vertical compression force ('blow out' fracture). The classic Jefferson fracture involves fractures of both the anterior and posterior arches bilaterally. Usual radiographic features are displacement of the lateral masses of C1 beyond the margins of the



**Figure 4.39.** Quiz case.

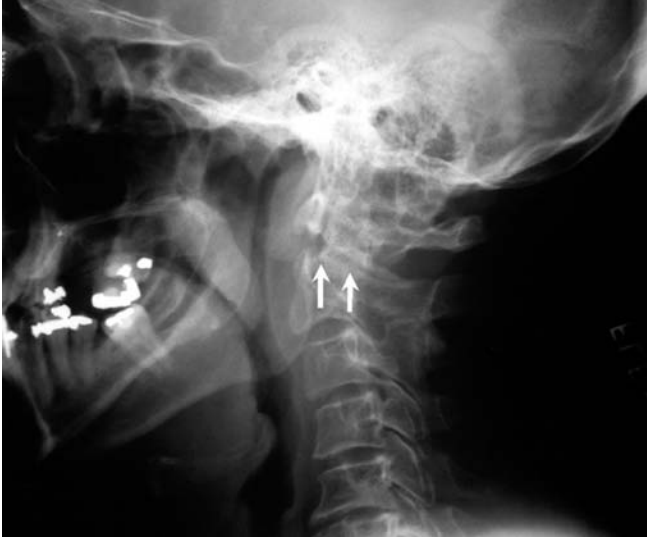

**Figure 4.40.** Quiz case.


body of C2 (Figs. 4.37 and 4.38). There is approximately a 41% chance of an associated C2 fracture, thus CT including C1–C3 is recommended<sup>6</sup> (Figs. 4.39 and 4.40). One important caveat: the lack of fusion of the posterior arch may be seen in adults as a congenital anomaly defined by smooth margins. This fracture is usually unstable. Usually no neurological deficit is isolated, due to fragments being forced outwards.

## Question 8

- Describe the type of fracture (Figs. 4.41 and 4.42).



**Figure 4.41.** Quiz case.



**Figure 4.42.** Quiz case.

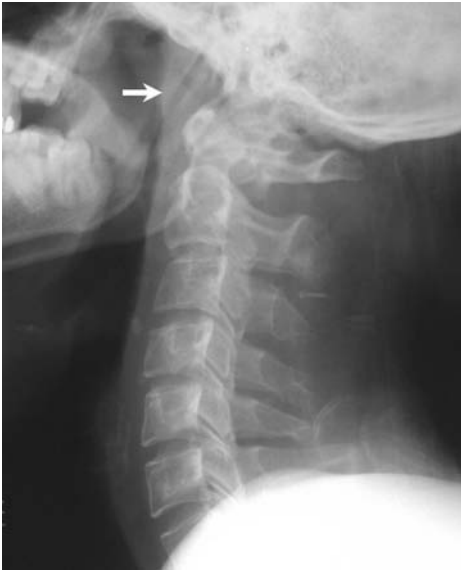## Answer

### Odontoid fracture

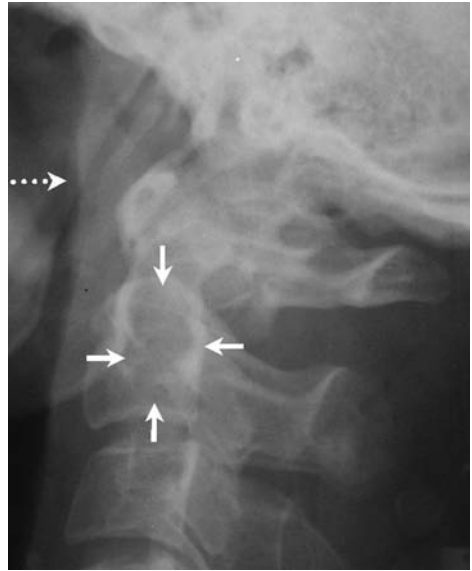
There are three types:

- Type 1 – the tip of the odontoid is involved (rare, usually stable).
- Type 2 – is a fracture of the base of the odontoid (unstable) (Figs 4.41 and 4.42).
- Type 3 – is a fracture through the base of the odontoid that extends through the body of the C2 vertebra.

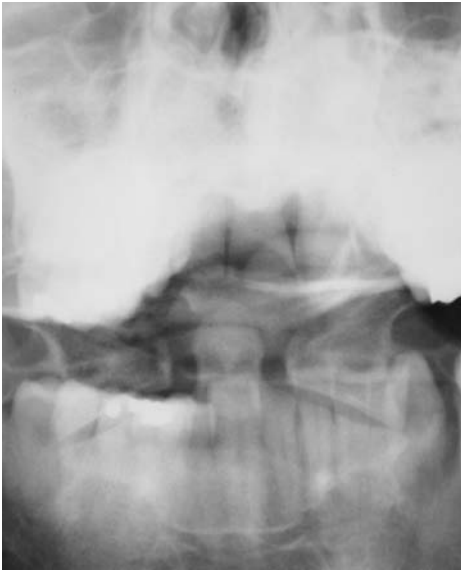This is usually a stable injury with a good prognosis, and is identified on the lateral by disruption of Harris' ring<sup>6</sup> (Figs. 4.43–4.45).



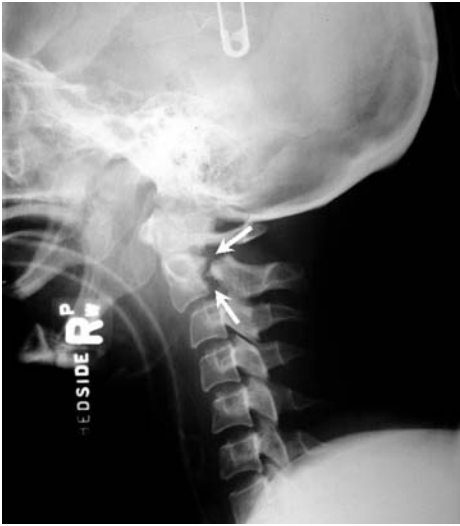**Figure 4.43.** Dens fracture. Lateral cervical spine. A break in the inferior margin of the sclerotic ring found in the body of C2 (Harris' ring), along with pre-vertebral soft tissue swelling (arrow). This indicates a type 3 dens fracture. This can be the only view where this type of fracture is identified – on the AP odontoid view (Fig. 4.44) the fracture is not visible.



**Figure 4.44.** Odontoid fracture (dens fracture). Lateral cervical spine (close up of Fig. 4.42). Disruption of this ring (solid arrows) may be the only sign of a dens fracture. Soft tissue thickening at C1 level is also present (dotted arrow).

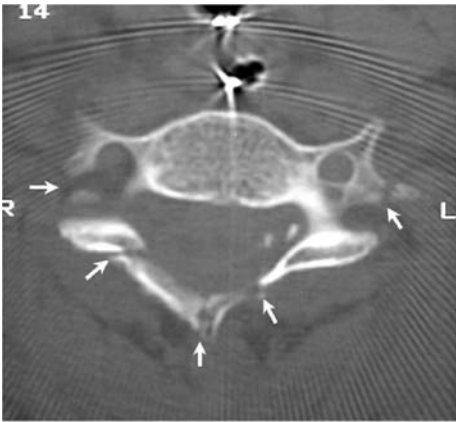

**Figure 4.45.** Odontoid (dens fracture). AP peg view. Same patient as Fig. 4.42. A fracture through the body of C2 is not appreciated on the odontoid peg view.



**Figure 4.46.** Quiz case.

56-year-old female with long history of depression. Attempted hanging.



**Figure 4.47.** Quiz case.

## Question 9

- What is this injury called (Figs. 4.46 and 4.47)?

## Answer

### Hangman's fracture

This is a traumatic spondylolisthesis of the C2 vertebral body resulting from hyperextension and distraction seen with hanging and from hyperextension and axial loading in motor vehicle accidents when the chin strikes the dashboard.

The radiographic features are:

- bilateral pars interarticularis fractures of C2 (Figs. 4.46 and 4.47),
- anterior dislocation of the C2 vertebral body,
- anterior inferior avulsion fracture associated with the rupture of the anterior longitudinal ligament,

- pre-vertebral soft tissue swelling (which can be absent at times).

This type of fracture is associated with a high incidence of head injury. The fracture is usually stable; however, instability can be identified by:

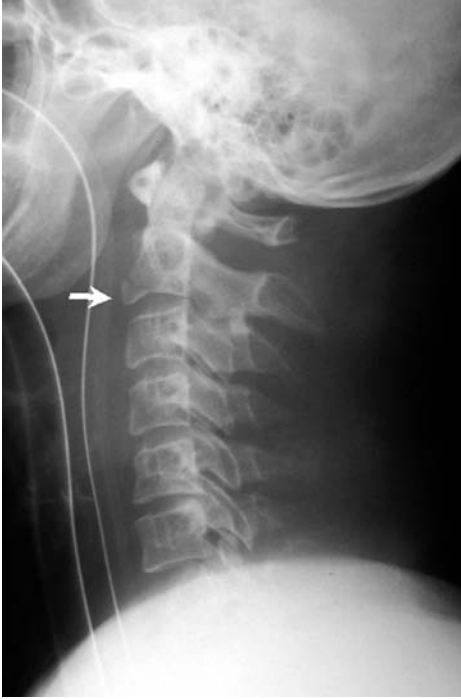- marked anterior displacement of C2 on C3 particularly if the degree of displacement exceeds more than 50% of the AP diameter of the C3 vertebral body,
- marked motion on flexion/extension films,
- excessive angulation greater than 11 degrees.

Neurological deficit is rare, non-union is rare and 90% usually heal with immobilization only.<sup>6</sup>

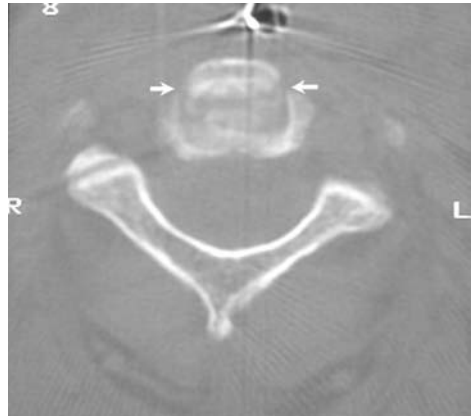


## Question 10

- What is the mechanism of this fracture (Figs. 4.48 and 4.49)?



**Figure 4.48.** Quiz case.



**Figure 4.49.** Quiz case.

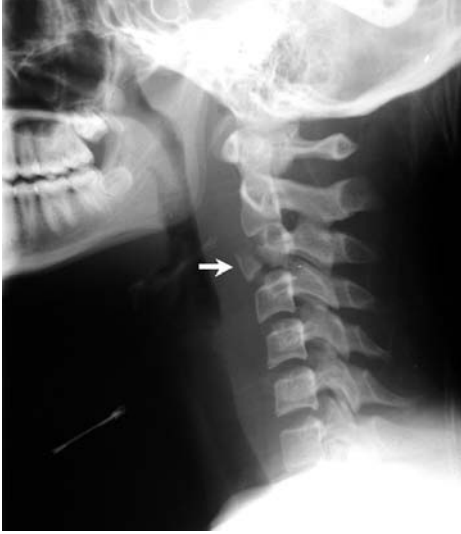## Answer

### Extension teardrop fracture

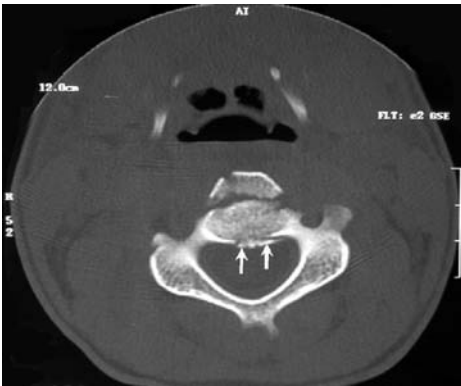This is usually the result of a hyperextension injury, caused by a force delivered to the face or the mandible that drives the head and neck into an abnormal extension. The extension teardrop fracture is a relatively large triangular fragment with its vertical height equal to or greater than its transverse width. The fracture fragment usually arises from the antero-inferior corner of the involved vertebra, most commonly the C2 vertebral body (Figs. 4.48 and 4.49). This is an avulsion fracture at the site of insertion of the intact anterior longitudinal ligament during hyperextension of the head and upper cervical spine. Extension teardrop fractures are more common in older patients with osteoporosis and degenerative disease of the spine. This is usually a stable injury in flexion and unstable in extension.<sup>2,6</sup>

## Question 11

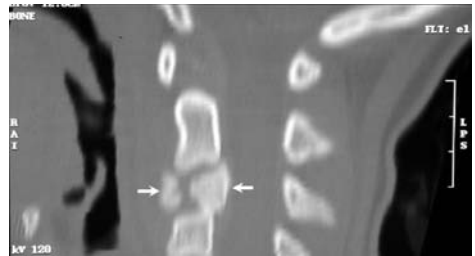
- What is the name of this fracture (Figs 4.50–4.52)?
- What are the radiological features?



**Figure 4.50.** Quiz case.



**Figure 4.51.** Quiz case.



**Figure 4.52.** Quiz case.

## Answer

### Flexion teardrop injury

This usually results from a severe flexion injury, often caused by diving into shallow water, that results in posterior ligament disruption and an anterior compression fracture of the involved vertebral body. The radiographic features include:

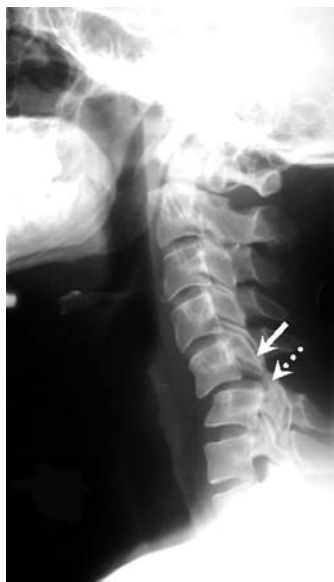- antero-vertebral body avulsion fracture representing the teardrop fragment,
- postero-vertebral body subluxation or displacement with the disruption of the postero-longitudinal ligament and compromise of the spinal canal with resultant anterior compression of the spinal cord.

Other features include fracture of the spinous process and widening of the interspinous distance due to disruption of the interspinous ligaments, and pre-vertebral haematoma associated with anterior ligament disruption.<sup>2,5</sup>

This is an unstable injury due to complete disruption of the disc, anterior and posterior ligaments and the facet joints. MRI may help assess the integrity of the disc and ligaments. Patients are often quadriplegic, although some may be neurologically intact.

## Question 12

- What is this injury (Fig. 4.53)?
- Is this injury associated with spinal cord damage?



**Figure 4.53.** Quiz case.

## Answer

### Locked facet injury

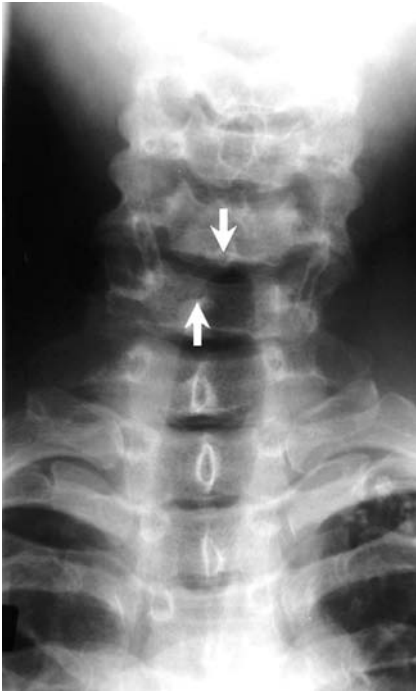This is usually the result of a severe flexion injury, which can result in disrupting the normal relationship between the facets. The inferior facet of the level above is usually posterior to the superior facet of the level below. Facets that are just before the point of locking are known as perched facets.

Flexion and rotational injury will result in a unilateral locked facet while an extreme hyperflexion force will result in a bilateral locked facet. Bilateral locked facets usually present with cervical spinal cord injury and injury to the cervical roots.

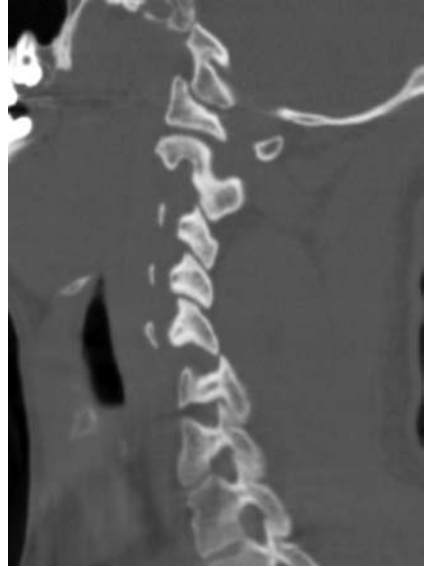Diagnosis is usually made on the lateral cervical spine and AP radiographs. Both unilateral and bilateral locked facets will often produce subluxation. Horizontal subluxation of greater than 3.5 mm of one vertebral body on another or greater than 11 degrees of angulation of one vertebral body relative to the next indicates ligamentous instability.

In unilateral facet dislocation, the AP view of the spinous process above the subluxation rotates to the same side as the locked facet (see Fig. 4.54). On the lateral cervical-spine radiograph, 'bow-tie' or 'bat-wing' appearances of the locked facets are seen referring to visualization of the left and right facets at the level of the injury instead of the normal superimposition of the facet joints.

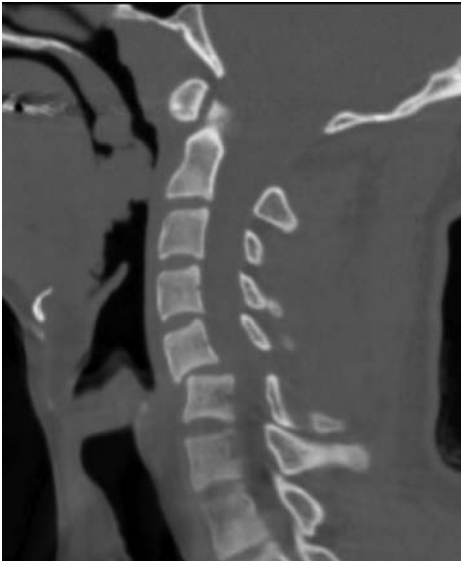Subluxation may be seen in unilateral locked facets. However, it is almost always seen in bilateral locked facets with usually greater than 25% of the vertebral body being subluxed anteriorly relative to the vertebral body below. Disruption of the posterior ligamentous complex may produce widening of the interspinous distance and there may also be a widening



**Figure 4.54.** Locked facets. AP cervical spine. There is malalignment of the spinous processes (arrows) at the C5–C6 level corresponding to the level of locked facets (Fig. 4.53). Incidental nodular densities and smooth pleural thickening at the left lung apex are calcified granulomas and pleural reaction related to previously healed TB.



**Figure 4.55.** CT scan sagittal reformatted image demonstrating perched facet joints.



**Figure 4.56.** CT images can be reconstructed in different planes to best demonstrate the anatomy of interest. This sagittal image is taken in the midline.

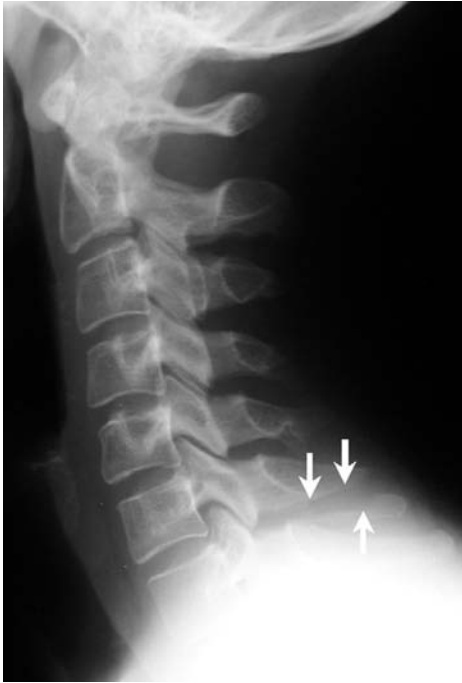of the disc space. Oblique films may help better demonstrate the locked facets which usually will be seen blocking the neural foramina.

CT will clearly demonstrate both unilateral and bilateral locked facets. Sagittal reformat-  
ted images are particularly helpful in the diagnosis of facet dislocation (Figs. 4.55 and 4.56).

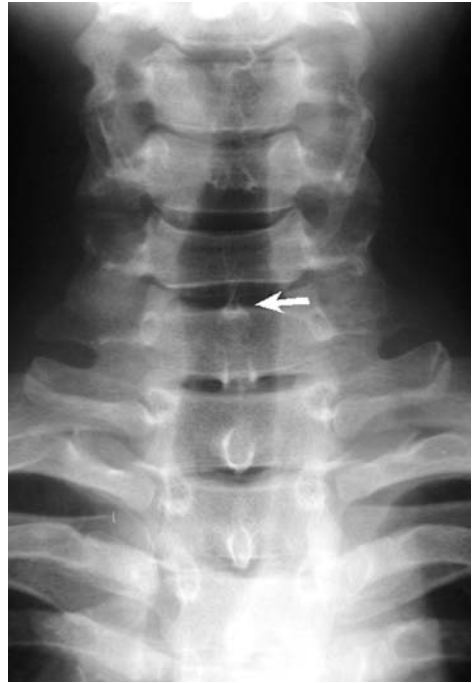MRI may be utilized to assess integrity of the disc space and exclude an extruded disc that  
could be impinging on the spinal cord.<sup>1,2,5,6</sup>

### Question 13

- What is this injury (Figs. 4.57 and 4.58)?
- What is the mechanism?
- Is the fracture stable?



**Figure 4.57.** Quiz case.



**Figure 4.58.** Quiz case.

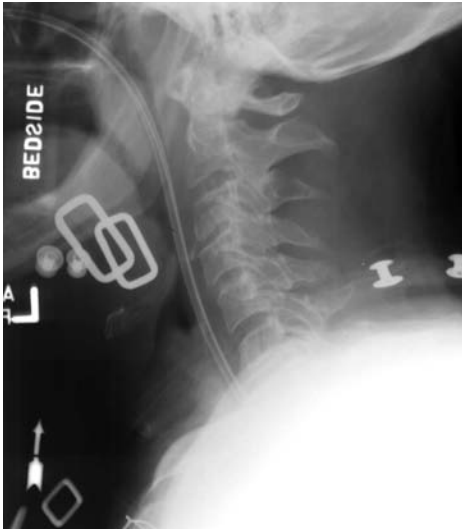### Answer

#### Clay shoveler's fracture

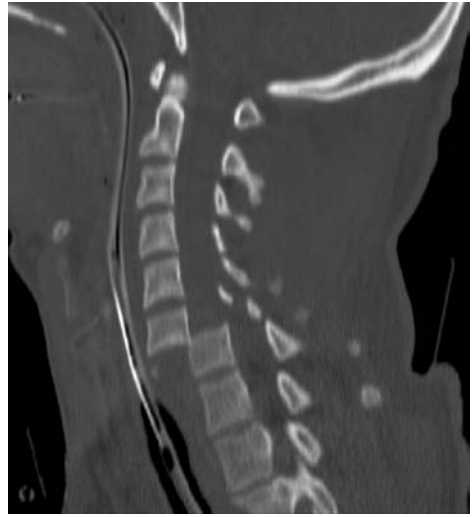This is a fracture of the spinous process seen involving the lower cervical spine, usually C7. Initially described in workers who used to shovel clay – during the throwing phase, the clay may stick to the shovel, jerking the trapezius or other muscles which are attached to the cervical spinous processes resulting in an avulsion fracture. This fracture may also occur with a whiplash injury or injuries that displace the arms upwards, neck hyperflexion, or a direct blow to the spinous process.

The fracture is stable. If the patient is neurologically intact, further imaging with flexion/extension views or CT is recommended – to rule out occult fractures that might have been missed on plain films. A rigid collar may be used as needed for pain.

The lateral plain film shows an avulsion type fracture involving the spinous process and on the AP view a 'ghost sign' is seen referring to a double spinous process of C6 and C7 (Fig. 4.58) resulting from usually caudal displacement of the fractured spinous process.<sup>2,5,6</sup>



**Figure 4.59.** Inadequate cervical spine film showing down to C6.



**Figure 4.60.** CT sagittal reconstruction demonstrating fracture dislocation of the C6–C7.

### Complete radiographic assessment

The need to adequately image the cervical spine from C1 to C7–T1 cannot be overemphasized. The examples above (Figs. 4.59 and 4.60) demonstrate the pitfalls of incomplete examination of the cervical spine. If the complete cervical spine cannot be visualized on plain films, then cross-sectional imaging is mandatory.



## References

1. Lyerly HK, Gaynor JW. *The Handbook of Surgical Intensive Care*, 3rd edition, 1992. St Louis: Mosby Year Book.
2. Harris JH Jr, Mirvis SE. *The Radiology of the Acute Cervical Spine Trauma*, 3rd edition, 1996. Baltimore, MD: Williams & Wilkins.
3. MacDonald RK, Schwartz ML, Mirich D, Sharkey PW, Nelson WR. Diagnosis of cervical spine injury in motor vehicle crash victims: how many X-rays are enough? *J Trauma* 1990; **30**: 392–7.
4. Emergency and Trauma Radiology, 2000. Categorical Course Syllabus, American Roentgen Ray Society Meeting.
5. Greenspan A. *Orthopedic Radiology. A Practical Approach*, 3rd edition, 2000. Philadelphia: Lippincott Williams and Wilkins.
6. Greenberg MS. *Handbook of Neurosurgery*, 5th edition, 2001. Stuttgart, New York: Thième.
7. Daffner RH. Thoracic and lumbar vertebral trauma. *Orthop Clin N Am* 1990; **21**(3): 462–82.
8. Müller NL, Fraser RL, Colman NC. *Radiologic Diagnosis of Disease of the Chest*, 2001. Philadelphia: WB Saunders.

Chapter

# 5

## CT head

---

Principles of CT image formation  
and interpretation 173

Principles of interpreting  
CT head 176  
Case illustrations 177

## Principles of CT image formation and interpretation

### How does CT work?

CT (computed tomography) was developed by Sir Godfrey Hounsfield in 1972 for which he received the 1979 Nobel Prize for Medicine. The first scanners were very slow and only capable of imaging the head; however, advances in gantry engineering and computer technology have made the CT scanner the workhorse of modern medical imaging with a huge range of applications.

All CT scanners use X-rays to produce anatomical images; however, there have been enormous developments over the years in how this is achieved. The information is presented conventionally as sequential slices providing far more information than conventional plain film radiography and significantly increasing diagnostic accuracy; however, as good as CT has become over the years, it cannot completely replace analysis of pathological specimens.

At its most basic, a CT scanner comprises a gantry, a table for the patient and, in an adjacent control room, the operational computer console. Within the gantry is a ring through which the patient is fed during scanning. An X-ray tube shoots a beam of X-rays through the patient to a set of detectors on the opposite side of the ring. The X-ray tube and detectors are separated by a fixed angle from each other and both are rotated around the ring several times per second, shooting and detecting the X-rays from all angles in that particular plane. These data are then analysed and the computer can reconstruct the slice from which they were taken using mathematical algorithms.

The thickness of the slice is determined by the width of the beam perpendicular to the gantry and controlled by beam collimation, i.e. limited by lead plates near to the X-ray source. All anatomical structures contained within the slice at any point will be presented in the final image. The table then moves the patient a distance equal to the thickness of the slice and the whole process begins again. It is repeated several times until the area of interest has been covered.

### What are attenuation, density and Hounsfield units?

Each X-ray beam will pass through the patient and the amount of X-ray detected on the other side is determined by the structures it passes through on the way. Metal and bone weaken, or attenuate, the X-ray beam significantly, whereas air and fat do so to a far lesser degree. The detectors convert the attenuated X-ray beams into electrical signals and then into numbers, which when solved, much like a very large simultaneous equation, can be displayed graphically as a slice. The most important characteristic for beam attenuation is tissue density and each pixel in the slice is given a number based on the calculated density. By convention the densities are expressed in Hounsfield units (HU) ranging from  $-1024$  to  $+3096$ . Some of the more common HU values are (approximately): air  $-1024$ , lung  $-500$ , fat  $-80$  to  $-20$ , water  $0$ , soft tissues  $+40$  to  $+80$ , bone  $+400$  to  $+1500$ , metal  $+2000$  and more.

### What is windowing?

When displaying CT images, a greyscale is used to represent the numbers of density. Higher densities are presented conventionally as whiter than the lower densities. However, the human eye can only distinguish a few levels of intensity at one time (around 20 or 30). This explains why, when looking towards a bright light source, such as when driving at night

towards another car with headlights on full-beam, the detail of other things in our field of view are lost; many of the intensity levels are used up by the bright light source and there are fewer intensity levels available to resolve the things which really need to be resolved, i.e. the road ahead. CT images therefore can be manipulated to display all the structures of interest within the grey area of the greyscale. This is called windowing. The window has a level, WL, signifying the centre of the greyscale, and a width, WW, the full range of numbers contained within the greyscale. All pixels with a density value above an upper limit are shown as pure white and all pixels below a lower limit are shown as pure black. As an example, CT of the head may be displayed with a WL of 40 and WW of 80. All HU from  $-1000$  to  $0$  are black, all HU over  $+80$  are white and the range from  $0$  to  $+80$  are shades of grey. This narrow window width centred on soft tissue allows good contrast for the structures inside the cranium, most of which are similar to water or soft tissue. These windows are useless for showing bony detail, for example, which will appear as a white area with no definition.

## What are spiral CT and multi-slice CT?

The broad principle of CT scanning has remained unchanged over the years, but technological advances have been accompanied by changes in the algorithms used. The first scanners would produce single slices of information, perhaps 10 mm thick, the volume of interest being contained within sequential slices. The basic CT described above would be similar to the earliest scanners and small variations in the angle of the slice could only be achieved by tilting the gantry and rescanning. There have been several stages of development since then, along with some new terminology.

In order to produce sequential slices, the tube and detectors within the gantry would rotate through  $360^\circ$ , and because there are power cables and a data transfer cable attached to the equipment as it rotates, the gantry apparatus would have to be reset, reversing through  $360^\circ$  before the next slice could be scanned. One of the advances in CT technology was the development of the slip-ring, allowing continuous power feed and data transfer as the gantry rotated in one direction only. Spiral CT continuously scans the patient as the table feeds through the gantry. This produces a volume of data for the region scanned and requires modification of the mathematical algorithms for the reconstruction. It is much quicker and allows reconstructions in multiple planes, not only the plane in which it was originally scanned.

With multi-slice CT, a single gantry rotation will capture multiple slices, e.g. with a four-slice CT, each gantry rotation captures four slices of data. The great advantages of multi-slice CT, which is used in conjunction with spiral technique, are its speed and its consequent ability to cover large anatomical areas very quickly in great detail, because there is no associated reduction in image quality. Multi-slice spiral CT allows very detailed multiplanar and three-dimensional reconstructions, which can be tremendously powerful in many situations:

1. Spinal trauma – allowing triplanar reconstructions.
2. Vascular imaging – producing 3D angiographic studies to almost replace conventional catheter angiography.
3. Pulmonary embolus – now the gold standard for diagnosis.
4. Luminal imaging – virtual CT bronchoscopy and virtual CT colonoscopy.
5. Cardiac imaging – the latest 64-slice machines are capable of CT coronary angiography.

Scanners under development will scan hundreds if not thousands of slices at once with even more applications.

## What is intravenous contrast medium?

Intravenous contrast used in CT is an iodine-based substance similar to that used for IVUs (intravenous urograms) and numerous other radiological procedures such as angiography. The iodine in the contrast is particularly good at absorbing those X-rays in the energy range typically used in diagnostic imaging. The effect is an apparent increase in density of any structure in which the contrast is found at the time of scanning, increasing the HU value. Contrast is used to distinguish between different soft tissues with a similar HU value on the unenhanced (pre-contrast) scan, but this will only work if there is a difference in blood flow between the adjacent tissues. A good example is the CT pulmonary angiogram. On the plain scan, the pulmonary arteries, pulmonary veins, flowing blood and clotted blood have very similar HU values and the boundaries between them are indistinguishable. A contrast bolus would be timed to be in the pulmonary arteries at the time of scanning. It is only flowing blood in the pulmonary arteries which will contain contrast, so an embolus will be outlined clearly with contrast making it visible. By using various timings, sometimes scanning the same area several times as the contrast flows through it in the arterial and then venous phases, the desired information can be extracted. Contrast is predominantly excreted rapidly via the kidneys, but also more slowly via the liver through the biliary system. Delayed images will show contrast in the urinary bladder or, if scanned much later, in the gall bladder.

Modern contrast media are far safer than those used in the early days of radiology and are very well tolerated; however, there are potential side effects including vomiting, allergy ranging from pruritis to anaphylaxis, and renal dysfunction (only a significant risk in patients with pre-existing renal impairment or patients with diabetes taking metformin).

## CT protocols

A CT protocol is made up of a number of variable factors, which are decided prior to scanning, in order to give the best chance of producing a diagnostically useful study. In many cases the quality of the images now achievable on modern scanners has made protocols more forgiving; however, an incorrect protocol can still lead to non-diagnostic examinations. Protocols are designed optimally to image a particular organ or body system. Some of the variables included in a protocol include:

- patient positioning; supine conventionally, but prone scans useful for lung bases and for CT colonography,
- scanning mode; sequential slices or spiral,
- slice thickness, e.g. 0.5 mm or 10 mm; thinner slices allow better 3-D reconstructions,
- IV contrast; unenhanced, enhanced or both,
- timing of the IV contrast bolus; 15s pulmonary artery, 25s aorta, 45–60s portal venous,
- oral contrast; either iodinated contrast (most cases), or water contrast (pancreatic studies),
- rectal or bladder contrast; often for staging tumours in these regions,
- intrathecal contrast; for CT myelography, used in patients who cannot have MRI,
- breath holding; when examining the chest, modern scanners rarely require more than a few seconds,
- gantry tilt; obsolete for spiral multi-slice CT scanners, but still used for CT head scans (traditional),
- use of additional drugs, e.g. hyoscine to arrest bowel movement.

These are only a few examples and even these are changing, e.g. the contrast bolus does not have to be timed, but can be watched and the scan initiated once the contrast has reached the desired region (bolus tracking).

Modern CT scanners also have the ability to provide functional data in certain circumstances. Cerebral perfusion imaging has been developed in a research setting over the last few years, but it is now beginning to find a place in clinical practice. CT perfusion (CTP) imaging is performed by repeatedly scanning over a section of the brain while a tight bolus of contrast is injected. HU values of the blood vessels and brain parenchyma change with time and calculations can then be made to extract information about cerebral blood flow, cerebral blood volume and the transit time of blood through the brain. There are many applications of CTP, for example, in the management of acute stroke, but this is beyond the scope of this chapter.

## Principles of interpreting CT head

It is essential that the basics are done to perfection prior to any attempts at analysis of the images. The patient name and the date of the examination should be checked and there may be other important information on the film which may influence interpretation, such as whether the scan was performed pre- or post-intravenous contrast. By convention, and this applies to most radiological imaging, images are shown with the right hand side of the patient on the left hand side of the image – just like a CXR. Imagine a supine patient viewed from their feet.

CT scans of the head are usually presented on brain windows (Figs. 5.1–5.10), but are also frequently presented on bone windows (Figs. 5.11–5.12), particularly in the context of trauma. Typical brain windows are centred at 40 HU with a range of 80 HU (WL 40 and WW 80 respectively). A WL of 40 HU is ideal for the brain, which is predominantly of soft tissue density. A WW of 80 HU is a particularly narrow range, but this will resolve the very small differences in tissue density within the brain, for example, between grey matter and white matter. These values are also optimal for demonstrating many intracranial pathologies. To view the skull, for example, when looking for fractures, both the window level and width are increased.

A hard copy of a CT head scan is usually shown on a sheet of film. It will only show a single window setting and a separate sheet is required for each separate window; however, with the advent of soft copy reporting, windows can be varied by the reviewer on a workstation allowing far more flexibility in windowing, and it also allows more advanced reconstructions of the data and other manipulations in order to best illustrate the anatomy or pathology.

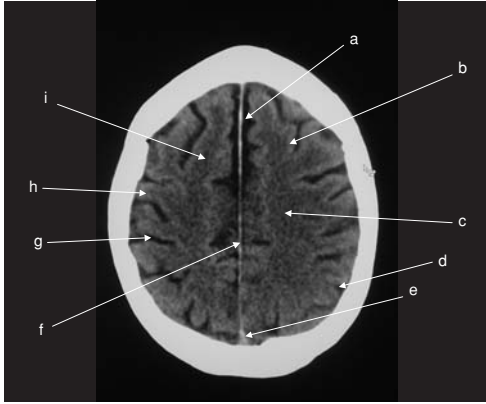
The majority of CT head scans performed in the acute setting whether medical or traumatic are unenhanced – that is without any intravenous contrast. Knowing whether a CT head scan was performed with or without contrast is extremely important because contrast, which is seen in the vessels or at sites where there is a breakdown in the blood–brain barrier such as in inflammatory or neoplastic processes, can easily be confused with acute haemorrhage or calcification.

Most importantly, assessment of head CT depends on a good knowledge of normal brain anatomy.

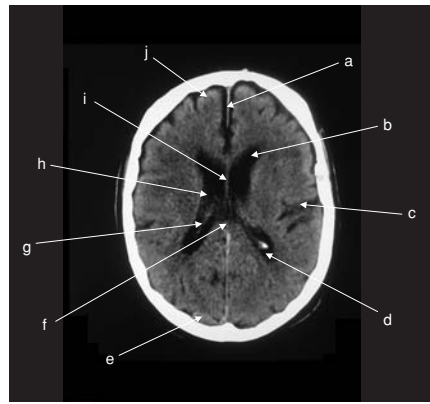
## Case illustrations

### Question 1

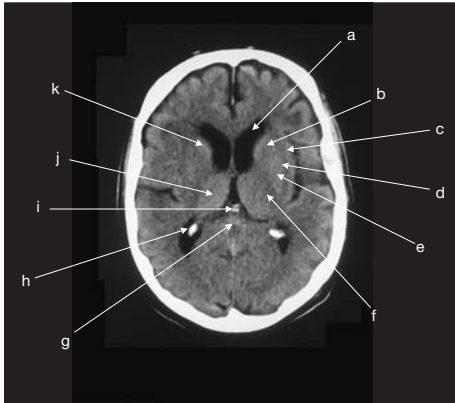
- Can you identify all the labelled structures in Figs. 5.1 to 5.12?



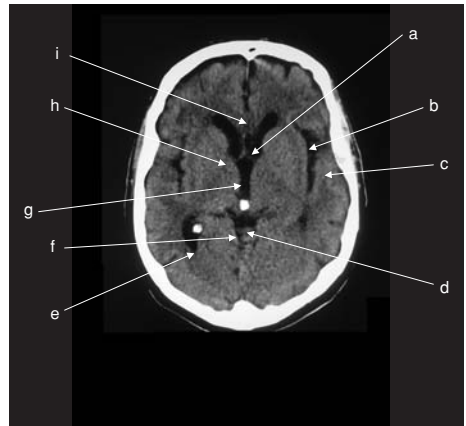
**Figure 5.1.** (a) interhemispheric fissure; (b) grey matter (appears relatively dense); (c) corona radiata (white matter tracts radiating to cortex); (d) left central sulcus (divides frontal from parietal lobe); (e) superior sagittal sinus; (f) falx cerebri (made of double layer of dura mater); (g) sulcus (groove between gyri); (h) gyrus (folding of cerebral cortex increases surface area); (i) white matter (lower density than grey matter).



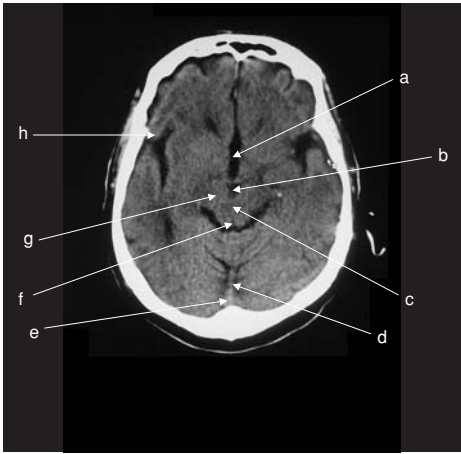**Figure 5.2.** (a) falx cerebri; (b) frontal horn of left lateral ventricle; (c) left Sylvian fissure (divides frontal from temporal lobes); (d) trigone of left lateral ventricle; (e) pole of right occipital lobe; (f) splenium of corpus callosum; (g) choroid plexus (produces CSF); (h) body of right lateral ventricle; (i) septum pellucidum (divides lateral ventricles); (j) pole of right frontal lobe.



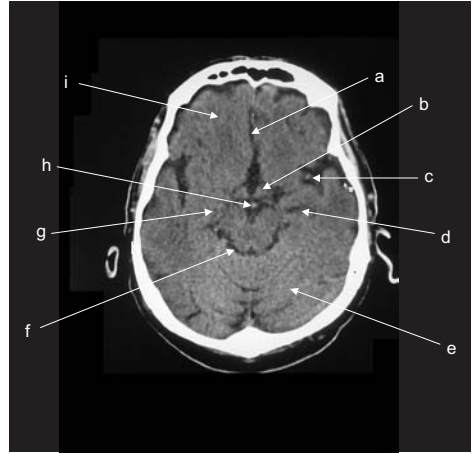
**Figure 5.3.** (a) frontal horn of left lateral ventricle; (b) anterior limb of left internal capsule (white matter tracts); (c) left insula cortex; (d) left external capsule; (e) left lentiform nucleus (made of globus pallidus and putamen); (f) posterior limb of left internal capsule (carries corticospinal tract); (g) vein of Galen (drains deep structures into straight sinus); (h) calcification within right choroid plexus (normal); (i) calcification of pineal gland (normal); (j) right thalamus; (k) head of right caudate nucleus.



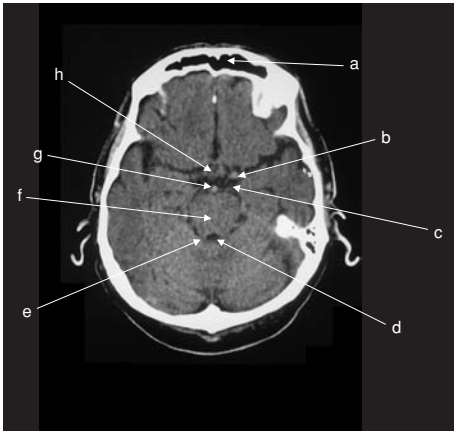**Figure 5.4.** (a) left foramen of Monroe (connects left lateral to third ventricle); (b) left Sylvian fissure; (c) left temporal lobe; (d) vermis of cerebellum; (e) occipital horn of right lateral ventricle; (f) incisura (free edge of tentorium cerebelli); (g) third ventricle; (h) genu of right internal capsule; (i) genu of corpus callosum.



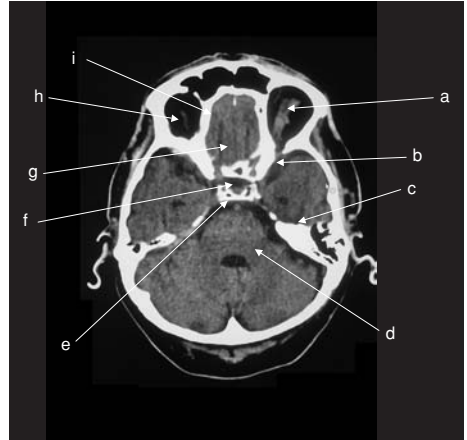**Figure 5.5.** (a) third ventricle; (b) interpeduncular cistern (CSF space between cerebral peduncles); (c) midbrain (upper part of brainstem); (d) falx cerebelli (double layer of dura between cerebellar hemispheres); (e) torcula Herophili (confluence of sagittal and straight sinuses); (f) cerebral aqueduct of Sylvius (connects third and fourth ventricles); (g) right cerebral peduncle (connects brainstem to cerebrum); (h) operculum of right Sylvian fissure (cortex at edge of fissure).



**Figure 5.6.** (a) interhemispheric fissure; (b) hypothalamus; (c) branches of left middle cerebral artery in Sylvian fissure; (d) temporal horn of left lateral ventricle; (e) left cerebellar hemisphere (folds called folia rather than gyri); (f) quadrigeminal cistern (CSF space posterior to midbrain); (g) right uncus (medial part of temporal lobe); (h) termination of basilar artery; (i) right frontal lobe.

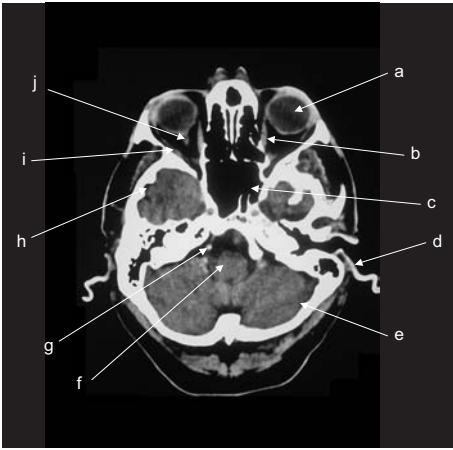


**Figure 5.7.** (a) frontal sinus; (b) termination of left internal carotid artery; (c) suprasellar cistern (CSF space above pituitary fossa); (d) fourth ventricle; (e) right superior cerebellar peduncle; (f) pons (middle part of brainstem); (g) basilar artery; (h) optic chiasm.

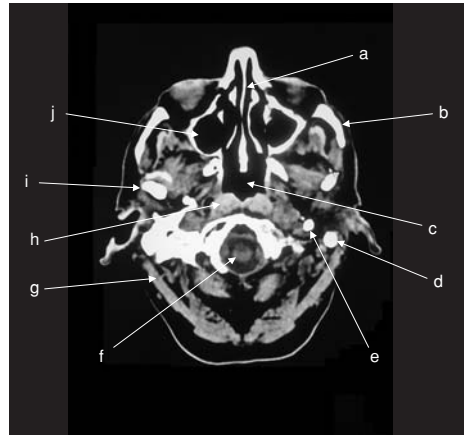


**Figure 5.8.** (a) left superior rectus and levator palpebrae superioris; (b) left sphenoid ridge (separates anterior from middle cranial fossa); (c) left petrous ridge (separates middle from posterior cranial fossa); (d) left middle cerebellar peduncle (connects cerebellum to brainstem); (e) dorsum sellae (posterior part of sella turcica); (f) pituitary fossa (pituitary usually difficult to see); (g) right gyri recti (inferior part of frontal lobe); (h) right superior ophthalmic vein (drains orbit to cavernous sinus); (i) anterior cranial fossa (supports frontal lobes).

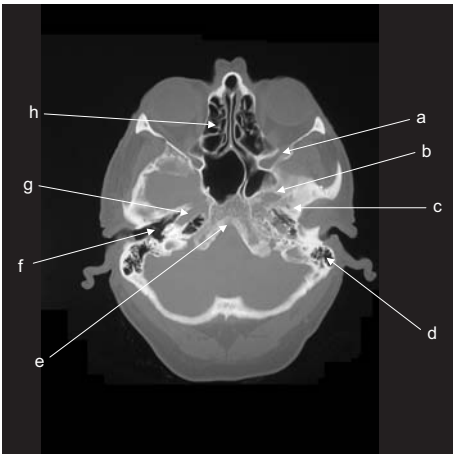




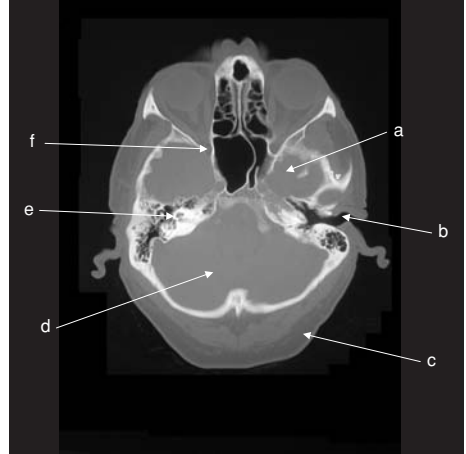
**Figure 5.9.** (a) left globe; (b) left medial rectus; (c) left sphenoid sinus; (d) left pinna; (e) posterior cranial fossa (contains cerebellum); (f) medulla oblongata; (g) right vertebral artery; (h) right middle cranial fossa (supports temporal lobe); (i) right lateral rectus; (j) right optic nerve.



**Figure 5.10.** (a) nasal septum; (b) left zygomatic arch; (c) nasopharynx (posterior to nasal cavity and superior to oropharynx); (d) left mastoid process; (e) left styloid process; (f) spinal cord; (g) right neck extensor muscle; (h) pre-vertebral muscle (right longus capitis); (i) right condylar process of mandible; (j) right maxillary antrum.



**Figure 5.11.** (a) left inferior orbital fissure; (b) left foramen ovale (carries mandibular division of trigeminal nerve); (c) left foramen spinosum (carries middle meningeal artery); (d) left mastoid air cells; (e) clivus; (f) right middle ear; (g) right carotid canal; (h) right ethmoid air cells.

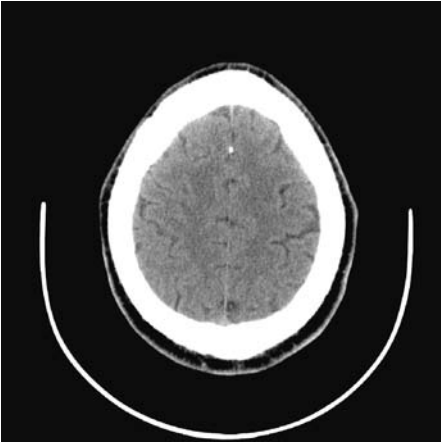


**Figure 5.12.** (a) left middle cranial fossa; (b) left external auditory meatus; (c) subcutaneous fat; (d) posterior cranial fossa; (e) right cochlea (in petrous temporal bone); (f) right superior orbital fissure.

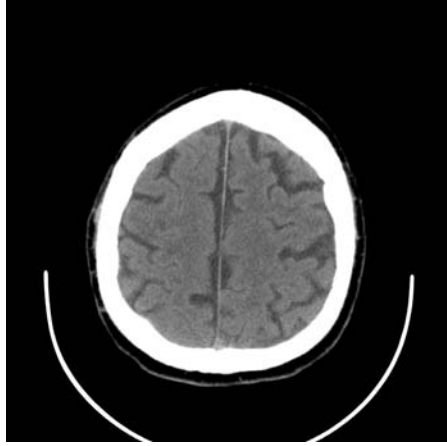
## Answer

These are all normal structures, which can be identified on CT. The images from Figs. 5.1 to 5.10 are presented on brain windows, and Figs. 5.11 and 5.12 on bony windows.

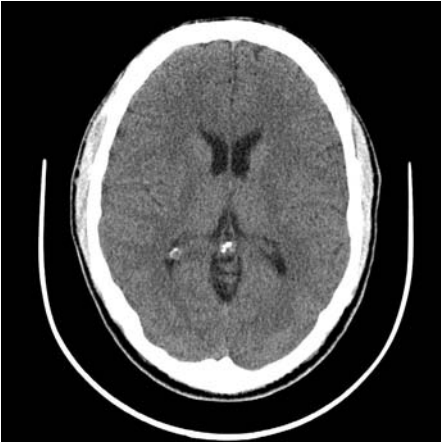(a)



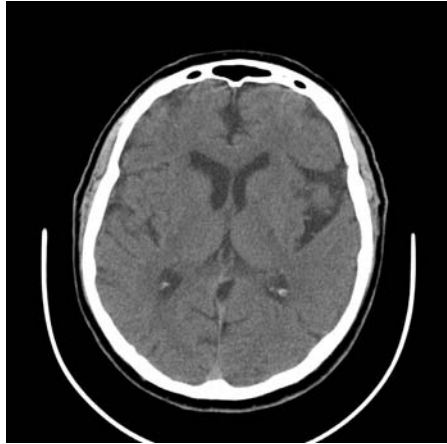
(d)



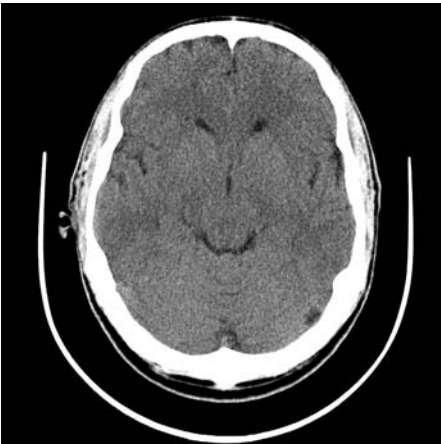(b)



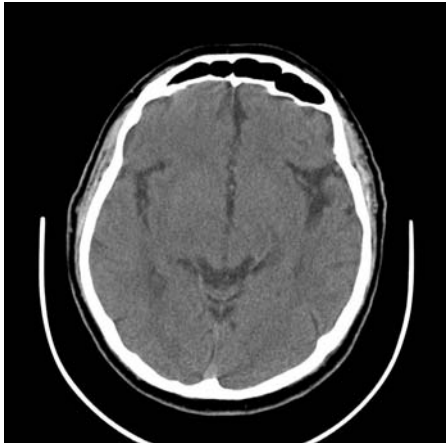
(e)



(c)



(f)

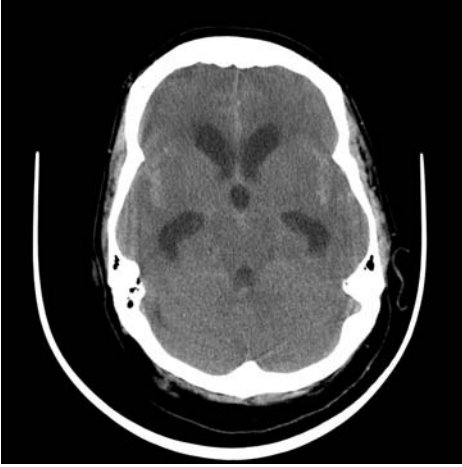

**Figure 5.13.** The left-hand column (a-c) of images is from a patient aged 30, the right-hand column (d-f) patient is aged 70. The overall cerebral volume has decreased in the older patient.

To describe in great detail each of these anatomical structures and their anatomical relations is beyond the scope of this book, but there is more than enough detail in these images for basic interpretation of CT head in most instances.

Look at Fig. 5.13. This demonstrates another element of normality which needs to be taken into account when looking at CT of the brain. The left-hand column is from a patient aged 30, the right-hand column patient is aged 70. Note the overall cerebral volume has decreased causing a relative increase in the size of the CSF spaces. Both the cortical sulci and the volume of the ventricular system have increased in size. The Sylvian fissure also appears more prominent. In teenage children the CSF spaces are sometimes almost completely lost and mistaken for cerebral swelling.

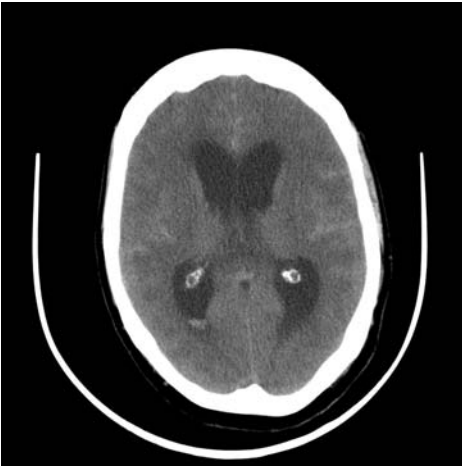
(a)



**Figure 5.14.** Quiz case.

54-year-old female. Sudden onset headache followed by collapse. Admitted with markedly depressed level of consciousness.

(b)



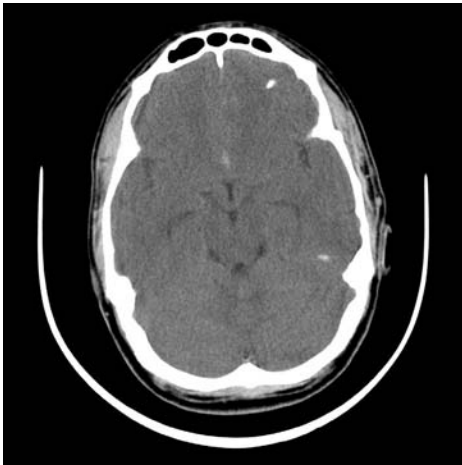## Question 2

- What is the diagnosis on the CT scan (Fig. 5.14)?
- What is the initial anaesthetic management?
- What are the common causes?
- What further investigations are necessary?
- What are the complications?

## Answer

### Subarachnoid haemorrhage

There is extensive blood in the subarachnoid spaces, best seen in the Sylvian fissures bilaterally with intraventricular blood and gross hydrocephalus.



**Figure 5.15.** Another patient with a subarachnoid haemorrhage (the blood is best seen in the interhemispheric fissure).

Acute blood on CT, when viewed on brain windows, is hyperdense to the brain parenchyma. The usually black CSF spaces are now white, in the interpeduncular fossa, the Sylvian fissures and cortical sulci. The increased density of fresh blood compared to CSF also means that it lies in dependent areas such as in the occipital horns of the lateral ventricles. The lateral ventricles and the third ventricle are markedly dilated. The temporal horns of the lateral ventricles often show the earliest signs of hydrocephalus. In this example they are very enlarged, but Fig. 5.15 demonstrates very mild hydrocephalus in another patient with a subarachnoid haemorrhage (the blood is best seen in the interhemispheric fissure). Hydrocephalus in patients with subarachnoid haemorrhage is usually of the communicating type, due to a failure of CSF reabsorption, where the obstruction occurs at the level of the arachnoid granulations in the dural sinuses. Occasionally, it is of the non-communicating type, caused by a haematoma obstructing CSF flow out of the ventricular system at the level of the aqueduct or fourth ventricle.

### Initial anaesthetic management

The initial anaesthetic management depends in part on the patient's consciousness level; however, they should still be assessed using the standard ABC.

- Airway
- Breathing
- Circulation

The patency of the airway should be maintained, high flow oxygen therapy initiated, IV access attained and monitoring attached. Any abnormalities in ABC should be treated immediately before moving on to the next phase of assessment. There are additional issues to consider in a patient with a reduced level of consciousness. The Glasgow Coma Score, a useful method to assess level of consciousness, is made of three components as listed in Table 5.1.

For patients who have a GCS level of 15 (the maximum) or 3 (the minimum), the scoring of each of the constituents is clear; however, for intermediate GCS levels, it is far more informative to give the numbers of each part, e.g. E3 V3 M4 rather than simply GCS 10. Patients

**Table 5.1.** The Glasgow Coma Score

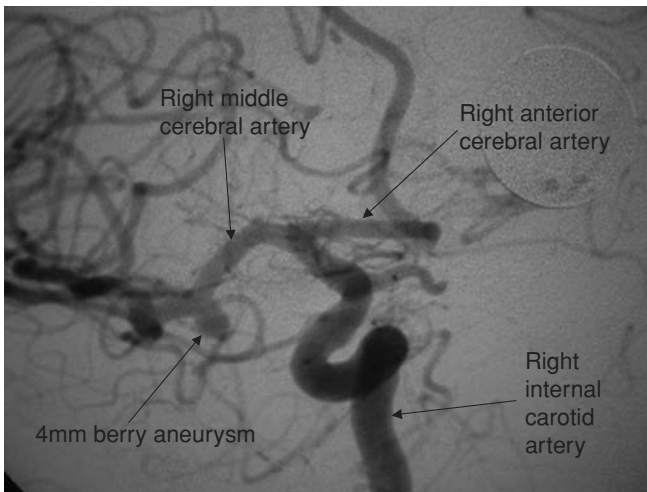
	E – Best EYE response
4	Spontaneous eye opening
3	Eye opening to speech
2	Eye opening to pain
1	No eye opening
	V – Best VERBAL response
5	Orientated (able to give name and age)
4	Confused (answering some questions)
3	Inappropriate word
2	Incomprehensible sounds
1	No verbal response
	M – Best MOTOR response
6	Obeys commands
5	Localizes to pain
4	Withdraws from pain
3	Flexes to pain (decorticate)
2	Extends to pain (decerebrate)
1	No motor response

Reprinted from Teasdale G, Jennett B. Assessment of coma and impaired consciousness. A practical scale. *The Lancet*, 1974; **2**: 81–84. Copyright 1974, with permission from Elsevier.

with an acute intracranial pathology such as subarachnoid haemorrhage are likely to have raised intracranial pressures (ICP) and ICP is one of a number of factors which influence brain oxygenation. Raised ICPs can reduce cerebral blood flow and cerebral perfusion pressure (CPP), but this can also be counteracted by raising the mean arterial pressure (MAP), the maintenance of which is crucial to prevent secondary brain injury.

A rapid sequence induction with cricoid pressure should be used to prevent aspiration. Intravenous anaesthetic agents and short-acting opioids should be used to prevent any further rise in intracranial pressure. Muscle relaxants and additional anaesthetic drugs should be given to prevent coughing on the endotracheal tube and the patient should be ventilated to normocapnoea. In these circumstances the anaesthetist will need to accompany the patient to the CT scanner. A crude definition of coma is a GCS of 8 or less and, at this level, patients should be considered for intubation and ventilation. Patients with a GCS of greater than 8 may also need intubation for CT if they are restless and uncooperative or if their airway is in any way compromised. Sedation should be avoided in patients with neurological injury requiring a CT scan of the brain.

After the CT scan, the patient should be kept intubated and ventilated, and returned to an intensive therapy area while the case is discussed with the local neurosurgeons. The use of



**Figure 5.16.** Cerebral angiogram: essential investigation following spontaneous subarachnoid haemorrhage.

mannitol and frusemide to decrease ICP, oral nimodipine to prevent vasospasm and intravenous normal saline replacement to counteract cerebral salt wasting may also be advised. If the regional neurosurgical unit is at another hospital, the patient should be transferred, intubated and ventilated by an experienced anaesthetist according to current local guidelines.

In practice, many cases of subarachnoid haemorrhage present with a sudden onset headache without depressed levels of consciousness and are therefore unlikely to come into contact with anaesthetists. Patients who have a subarachnoid haemorrhage have a positive CT scan in over 90% of cases; however, as a caveat to this, in some cases, because either the blood load is small or a number of days have passed since the onset of the symptoms, the CT scan will be negative. A negative CT scan does not exclude the diagnosis and if the history is suggestive a lumbar puncture to look for blood breakdown products (xanthochromia or bilirubin) is essential.

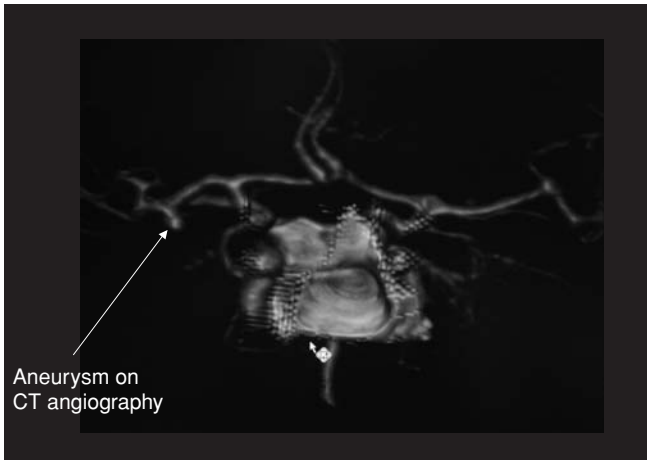
### Common causes

Spontaneous subarachnoid haemorrhage is caused by berry aneurysms in the majority of cases. Aneurysms usually form at the bifurcation of the cerebral vessels; the anterior communicating artery is the single most common site, followed by the posterior communicating artery and then middle cerebral artery.

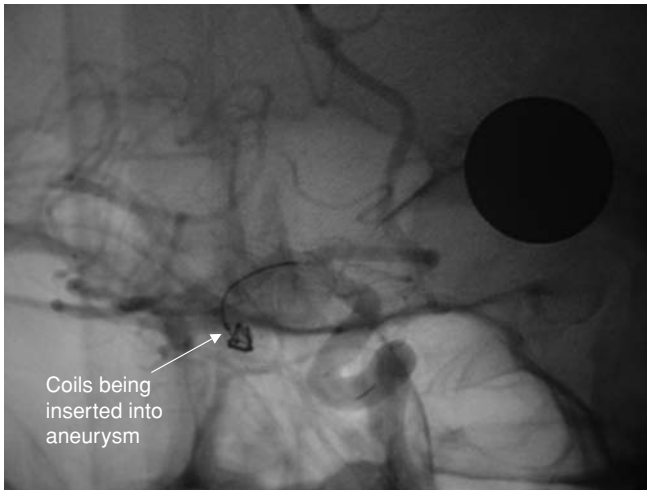Very occasionally the haemorrhage may be due to an arteriovenous malformation, dural arteriovenous fistula or a tumour, but in approximately 15%–20% of cases no specific cause will be found on further investigation. The blood is usually seen localized anterior to the midbrain and the diagnosis is of a perimesencephalic haemorrhage, presumed to be of venous origin and with an excellent prognosis. In the context of trauma, subarachnoid haemorrhage is very common, but not usually seen in isolation.

### Further investigations

For spontaneous subarachnoid haemorrhage, if further treatment is deemed appropriate, then investigation with formal cerebral angiography is essential (Fig. 5.16). CT angiography (Fig. 5.17) and MR angiography are useful adjuncts particularly when planning treatment, but berry aneurysms causing the haemorrhage can be as small as 1–2 mm and



**Figure 5.17.** CT angiography showing a berry aneurysm.



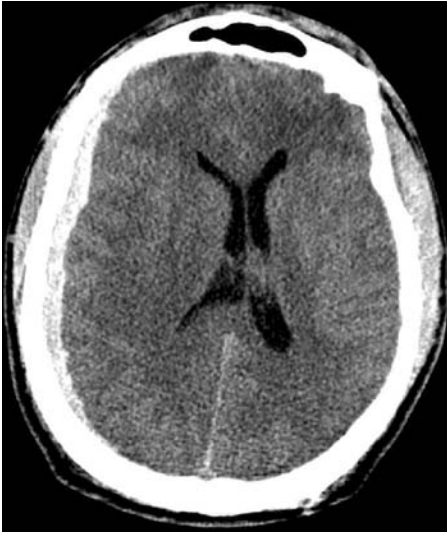**Figure 5.18.** Cerebral angiogram. The aneurysm is packed with platinum coils.

it is currently beyond the capability of cross-sectional imaging reliably to detect the small aneurysms. Treatment is now usually endovascular, the aneurysm being packed with platinum coils (Fig. 5.18).

### Complications

1. Communicating hydrocephalus from failure of absorption of CSF by the arachnoid villi.
2. Non-communicating, obstructive hydrocephalus from haematoma in the aqueduct and fourth ventricle.
3. Vasospasm, often in the second week, producing brain ischaemia or infarction in associated territory.
4. Very high rebleeding rate of up to 15% at 24 hours and 40% at 1 month if left untreated.





**Figure 5.19.** Quiz case.

56-year-old male. Alcoholic patient who has recently fallen.

### Question 3

- How old is the abnormality?
- Report the CT in Fig. 5.19.
- What is the further management?

### Answer

#### Acute subdural haematoma

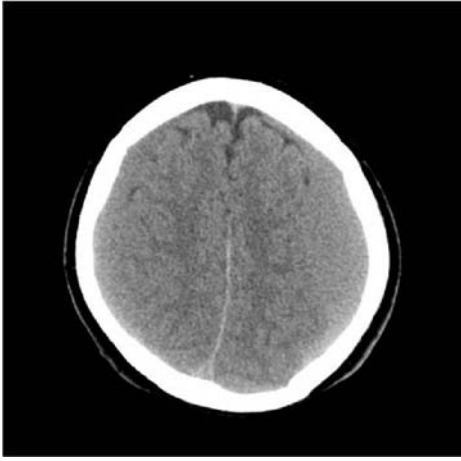
There is a large high-density crescentic extra-axial collection (outside the brain parenchyma) around the right cerebral hemisphere. The appearances are of an acute subdural haematoma (SDH). The crescentic shape, with a concave inner border and a convex outer border, and the extensive spread, crossing the line of skull sutures, tell us that this is in the subdural space and the high density (approximately 70 HU) is typical of acute haemorrhage less than a week or so old. There is also midline shift to the left.

The subdural space lies between the dura mater and the arachnoid mater. Unlike the extradural space, the subdural space is not limited by sutures and it also extends into the inter-hemispheric fissure along the falx cerebri and over the tentorium cerebelli, but not across the midline. So, as a general rule an extra-axial collection which crosses a suture is more likely to be subdural than extradural.

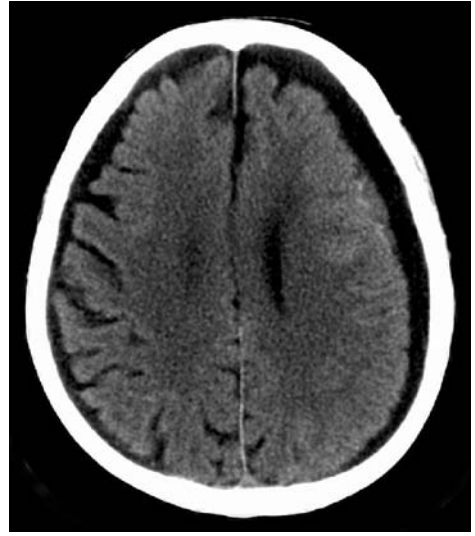
Bleeding into the subdural space occurs when the bridging veins, which connect the cerebral cortex and the dural sinuses, are torn, e.g. trauma or deceleration injury. This happens when there is differential movement between the brain and the skull. People with a degree of cerebral volume loss are at greater risk of an SDH due to the increase in size of the subarachnoid spaces, for example the elderly and alcoholics.

Subdural blood changes density with time allowing estimation of the age of the collection. An acute SDH gradually loses its density over time (see Figs. 5.19–5.21):

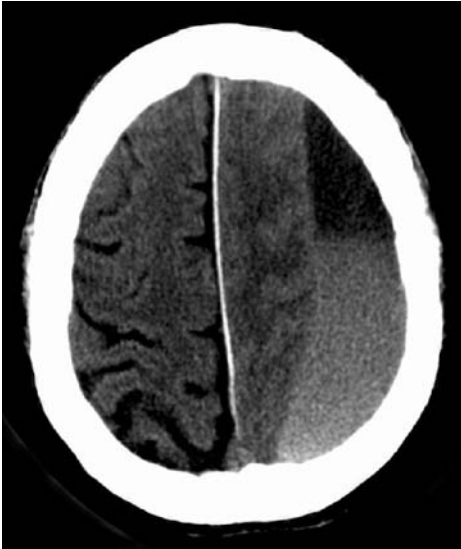- hyperdense to brain: up to 1 week or so (acute SDH),
- isodense to brain: around 1–3 weeks (subacute SDH),
- hypodense: beyond 3–4 weeks (chronic SDH).



**Figure 5.20.** Subacute subdural haemorrhage.



**Figure 5.21.** Bilateral chronic subdural haemorrhages.



**Figure 5.22.** Rebleed into a chronic subdural collection. Acute on chronic subdural haemorrhage.

Sometimes the diagnosis is not clear-cut; an apparent collection is not always caused by blood and it may not even be located in the subdural space. Small collections are easy to miss and can be mistaken for extradural haematomas for example. Large collections can also be misinterpreted, especially when isodense to brain. The differential diagnosis includes effusions, not uncommonly seen as sequelae of meningitis in children, and enlarged subarachnoid spaces due to a loss of cerebral volume. The density can also be misleading in patients with a coagulopathy (such as when taking warfarin) or with a low haemoglobin. In both these examples the density may appear reduced despite being acute. People of any age can

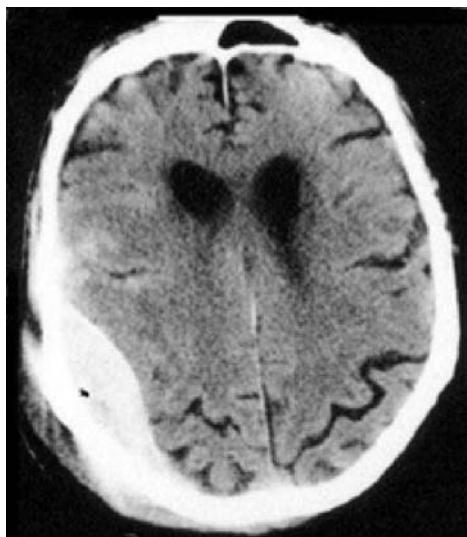have an SDH, but the presentation is variable. The young are more likely to present following significant head trauma, but the elderly may present with dementia or unsteady gait and no history of trauma. When an infant presents with an SDH, but without any reasonable history of trauma or underlying medical condition to explain it, non-accidental injury by a carer should be considered as a possibility. When looking at a CT scan for an SDH, the following checks can be helpful pointers to the diagnosis:

- sulci may not reach the brain surface adjacent to the collection,
- ipsilateral ventricular compression and midline shift may occur,
- broader windows of around 200 HU can make collections more conspicuous.

Finally, there is a propensity for a rebleed to occur into a chronic subdural collection in some patients. In these cases the images have a characteristic mixed acute on chronic picture with the dense acute blood layering in dependent areas (Fig. 5.22).

### **Further management**

A neurosurgical opinion should be sought as to whether they would consider drainage.



**Figure 5.23.** Acute extradural haemorrhage. Note the small pocket of gas.

Anaesthetic support has been requested for this patient who presented with deteriorating GCS level following a blunt head injury sustained in a road traffic accident.

## Question 4

- What are the key points in the anaesthetic management?
- Report the CT (Fig. 5.23).
- What is the pathogenesis?
- What is the management?

## Answer

### Anaesthetic management

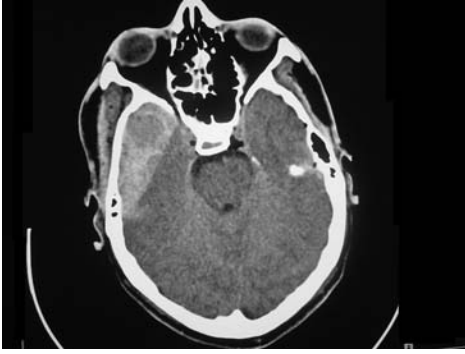
The patient should be managed as described in Question 2; however, in the case of head injury patients often have associated cervical spine injuries and they should be managed as such until proven otherwise. During intubation, inline cervical stabilization must be performed and the hard collar, sandbags and tapes replaced after intubation. It is also important to ensure there are no other life-threatening traumatic injuries to the chest, abdomen and pelvis, in particular, and they are haemodynamically stable before going to the CT scan.

### Extradural haematoma

There is a biconvex, high-density, extra-axial collection in the right parietal region causing local mass effect on the adjacent brain, but no midline shift. There is also a small amount of air within it (the low density focus adjacent to the skull). The appearances are of an acute extradural haematoma (EDH). The air is a tell-tale sign of a skull fracture, often through the paranasal sinuses or mastoid air cells, but this cannot be seen on these window settings.

### Pathogenesis

Dural arteries lie closely bound to the inner table of the skull and, when the bone is fractured in severe head trauma, these arteries are torn causing an EDH. Occasionally, EDHs are due to damage to a venous sinus rather than an artery. The collection lies between the dura mater and the skull, stripping the dura with characteristic radiological appearances. Unlike SDHs,

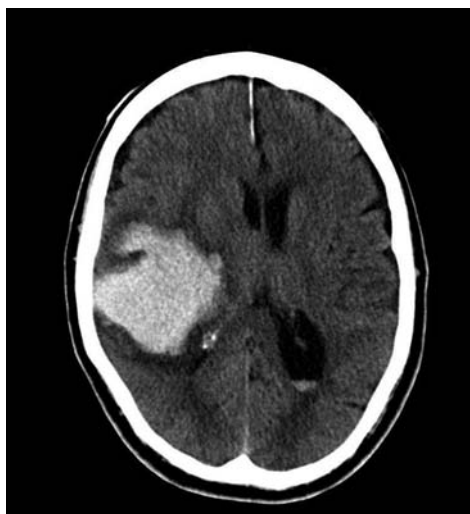

**Figure 5.24.** Bleeding into an EDH can be so brisk that it does not have time to clot which leaves a lower density area in the centre of the collection.

EDHs are usually limited by skull sutures, but not the dural attachments, such as the falx cerebri. The most common site is under the pterion, the thinnest part of the skull in the temporoparietal region, under which point the anterior branch of the middle meningeal artery runs. The bleeding into an EDH can be so brisk that it does not have time to clot which leaves a lower density area in the centre of the collection (Fig. 5.24).

### Specific management

The so-called classic presentation involves a lucid period; the initial trauma causes a brief loss of consciousness with good recovery followed by a further dramatic decrease in GCS as the haematoma enlarges. Many do not present in such a typical manner with somnolence for 24 hours following the initial injury. Whatever the manner of presentation, EDHs are a neurosurgical emergency. Not all EDHs require evacuation, but all patients should be transferred to a neurosurgical ward for observation as clinical deterioration can be rapid and the haematoma can be quickly evacuated as needed.



**Figure 5.25.** Quiz case.

72-year-old female. Past history of poorly controlled hypertension. Collapsed at home.

## Question 5

- What is the diagnosis (Fig. 5.25)?
- What are the common causes?

## Answer

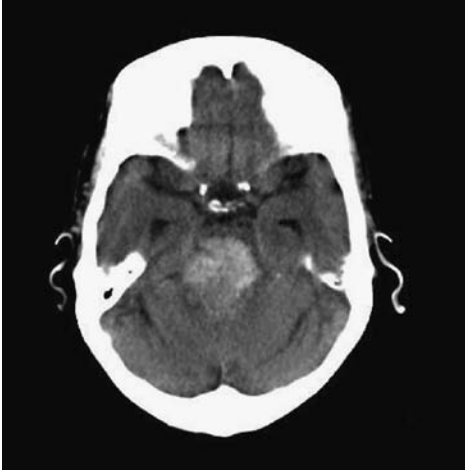### Intracerebral haematoma

There is a large area of high density in the right cerebral hemisphere centred on the posterior limb of the internal capsule. It is causing significant mass effect, effacing the trigone of the right lateral ventricle and midline shift to the left. There is also intraventricular extension, a fluid level present in the occipital horn of the left lateral ventricle. This is most likely to be a spontaneous intracerebral haematoma secondary to hypertension.

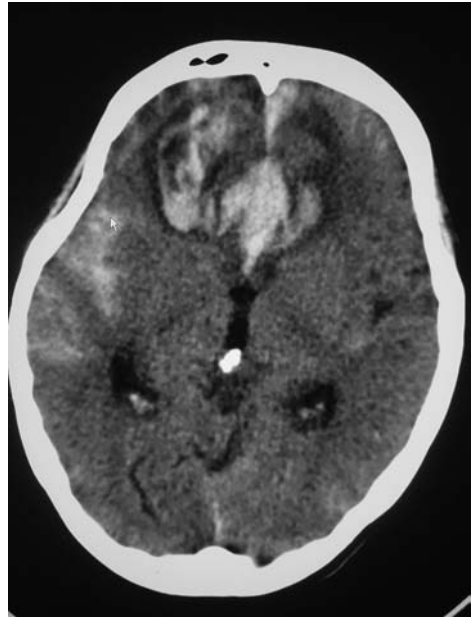
### Common causes

- Hypertension:
  - external capsule basal ganglia
  - pons (Fig. 5.26)
  - thalamus
  - cerebellum
- aneurysm (Fig. 5.27),
- arteriovenous malformation,
- trauma,
- anticoagulation,
- haemorrhagic transformation of an infarction (Fig. 5.28).

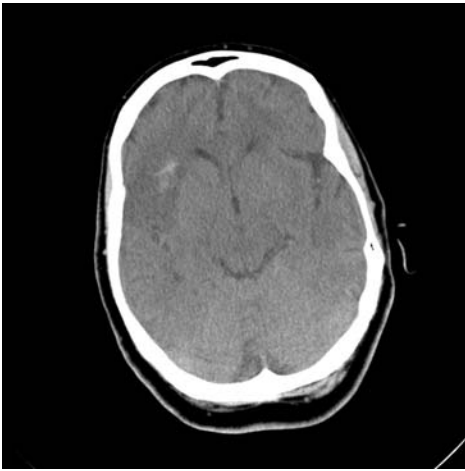Primary intracerebral haemorrhage is less common than infarction, with haemorrhage accounting for around 15% of strokes, but it often has a worse prognosis. The acute haematoma is normally rounded homogeneous and hyperdense with most cases being



**Figure 5.26.** Intracerebral haematoma in the pons.



**Figure 5.27.** Intracerebral haematoma due to aneurysm.



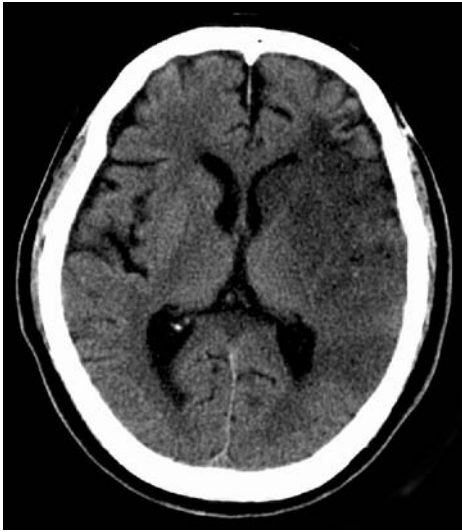**Figure 5.28.** Large infarct with a secondary petechial type haemorrhage.

located in or around the lentiform nucleus. The thalamus and pons are other common sites. Micro-aneurysms on the lenticulostriate arteries may be the underlying cause in many cases where hypertension is present, but in the older patients amyloid angiopathy is a common cause of intracerebral haemorrhage (this can only be confirmed pathologically and the haematoma is often peripheral), and vascular abnormalities should be considered when the patient is younger and not hypertensive. Trauma only rarely causes this type of haemorrhage in isolation. When there has been a large infarct, secondary petechial type haemorrhage occurs in the majority of cases as a matter of course (as in Fig. 5.28), but occasionally a

full haematoma much like the primary bleeds can develop. There will always be a significant clinical deterioration in these cases.

An unenhanced CT scan should always be performed in the first instance when intracerebral haemorrhage is suspected to distinguish acute blood from avid contrast enhancement of a tumour for example. Mass effect is often smaller than a tumour of a similar size, but the haematoma can rupture into the ventricular system and then cause hydrocephalus. As the clot retracts, a surrounding rim of low-density oedema appears. Over a period of 1–2 weeks, the haematoma decreases in density starting in the periphery and working centrally.





**Figure 5.29.** Quiz case.

71-year-old male. Dysphasia and hemiparesis.

## Question 6

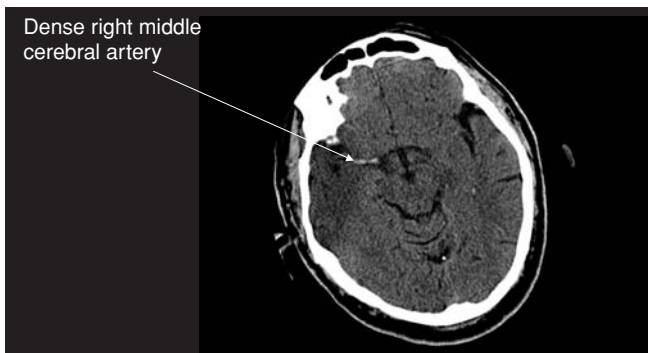- Report the CT (Fig. 5.29).
- What features of the history and physical examination are important?
- What investigations should be performed?

## Answer

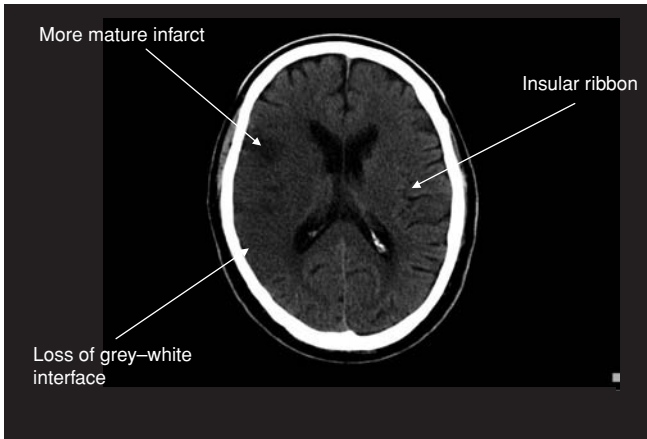
### Infarction of the left middle cerebral artery territory

There is a large area of low density involving both grey and white matter in the left cerebral hemisphere and there is loss of grey–white differentiation. This is a recent infarction of the entire left middle cerebral artery territory.

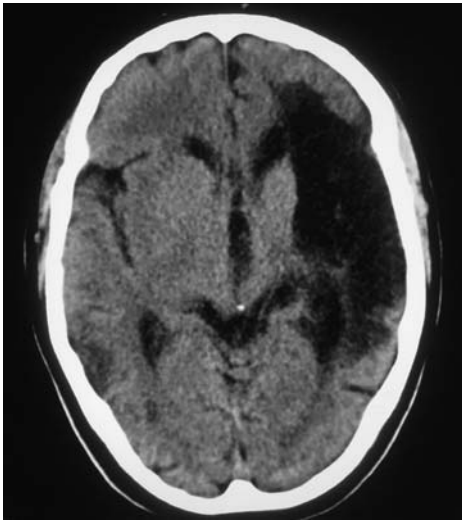
The imaging features of cerebral infarction gradually evolve with time. Very early scans within 3 hours of onset of symptoms will be normal. After that time very subtle changes may be apparent. These include the appearance of the dense middle cerebral artery sign, caused by clot in the lumen of the vessel (Fig. 5.30), and the loss of the grey–white interface, for



**Figure 5.30.** Dense middle cerebral artery sign, caused by clot in the lumen of the vessel.



**Figure 5.31.** Loss of the grey–white interface in the insular ribbon – an early sign of an infarct. This patient has two infarcts of different ages.



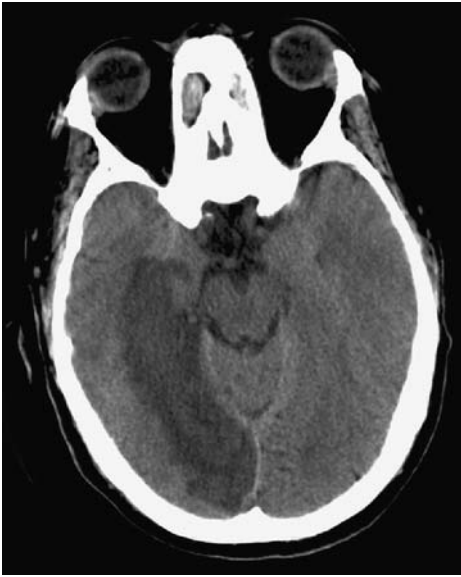**Figure 5.32.** Middle cerebral artery territory infarct. This usually produces hemiparesis, and dysphasia when the dominant hemisphere is affected.

example the insular ribbon (Fig. 5.31). As the infarct matures, it becomes less dense and Fig. 5.31 demonstrates how two infarcts of different ages can sometimes be seen. Over the next week or so the infarct swells causing mass effect with possible consequences including depressed consciousness, uncal herniation (coning) and death. The final stage of an infarct is a cavity with a similar density to CSF (Fig. 5.32).

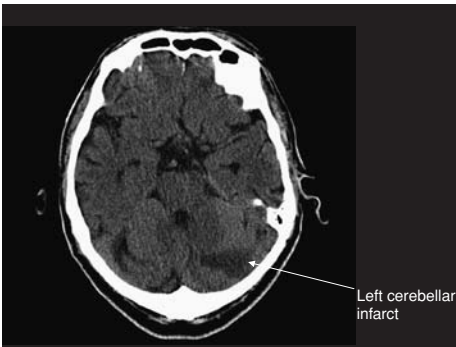
Infarcts can be confidently diagnosed when the low density corresponds to an arterial territory and the clinical history is appropriate. Some patients may have longer histories and other pathologies such as gliomas, which can appear similar, should also be considered in these cases.

### Important clinical considerations

Presentation relates to the part of the brain affected. Infarction of the middle cerebral artery territory usually produces hemiparesis, and dysphasia when the dominant hemisphere is



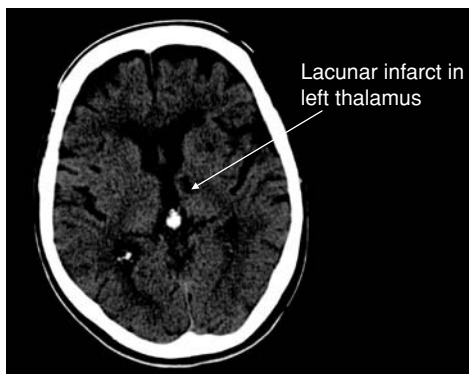
**Figure 5.33.** Posterior cerebral artery infarct. Infarction. Visual loss (homonymous hemianopia) is a dominant symptom.



**Figure 5.34.** Cerebellar infarct. This usually produces ataxia.

affected, usually the left side (Fig. 5.32). Visual loss (homonymous hemianopia) is a dominant symptom when there is a posterior cerebral artery infarct (Fig. 5.33), but is also a feature of middle cerebral artery infarcts due to damage to white matter pathways. When there is a carotid artery occlusion, the anterior cerebral artery territory on that side may be protected by good collateral supply from the anterior communicating artery. Cerebellar infarcts (Fig. 5.34) produce ataxia. Another type of infarct is a lacunar infarct (Fig. 5.35). In these cases there is occlusion of the lenticulostriate end arteries. Despite being very small, these infarcts can often be very debilitating due to their strategic location in the basal ganglia, thalamus and internal capsule.

In the acute phase, the treatment of stroke is often supportive with good nursing care being paramount. This is best provided by dedicated acute stroke units. Maintaining hydration, feeding and when present controlling pyrexia and hyperglycaemia are very important in these early stages. In everyone with suspected stroke, CT scanning should



**Figure 5.35.** Lacunar infarct. Due to occlusion of the lenticulostriate end arteries.

be performed within 24 hours and aspirin therapy instituted immediately if there is no haemorrhage.

In hyperacute stroke where patients present to hospital within a few hours of onset it is possible to intervene with thrombolytic drugs (commonly tPA). The benefits of intravenous thrombolysis are reduced after 3 hours from onset, but intra-arterial thrombolysis may be effective for up to 6 hours from onset. For infarcts of the posterior circulation due to a basilar artery thrombosis intra-arterial treatments may be effective well beyond 6 hours. New devices are constantly being developed for the interventional management of acute stroke, many under active evaluation at the time of writing; however, for these treatments to be an option, patients require a rapid transfer to hospital, assessment, CT scanning and initiation of therapy. Advanced imaging techniques, such as perfusion imaging, CT angiography and MRI, are being used to assist in the management of these patients. At present, very few strokes get to hospital and are appropriately assessed within this time frame, so thrombolysis and interventional treatments are rarely an option, but with a huge culture change towards acute stroke and patients being transferred to specialist centres immediately this is likely to change over the coming years. Detailed information on these changes is beyond the scope of this chapter.

### Investigations

Secondary prevention is very important to prevent further strokes. The main risk factors for stroke are hypertension, smoking, hypercholesterolaemia, obesity, atrial fibrillation and carotid stenosis and investigations should be directed to this end.

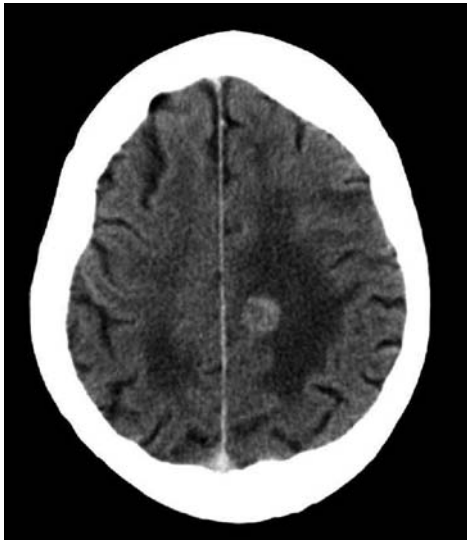#### Physical examination

- Hypertension,
- AF, heart murmurs, carotid bruits,
- Stigmata of raised cholesterol.

#### Further investigations

- ECG,
- Echocardiogram, carotid Doppler or CTA/MRA of the neck vessels,
- Blood lipid profile.

Appropriate treatments for any abnormality should be instituted and all patients should be on antiplatelet therapy unless otherwise contraindicated. Patients in atrial fibrillation should be started on warfarin, hypertensive patients started on antihypertensive therapy and many patients should be treated with a statin.



**Figure 5.36.** Quiz case.

Patient with previous history of breast carcinoma, now with recent onset headaches.

## Question 7

- What is the abnormality in Fig. 5.36?
- What further test is necessary?

## Answer

### Cerebral metastasis

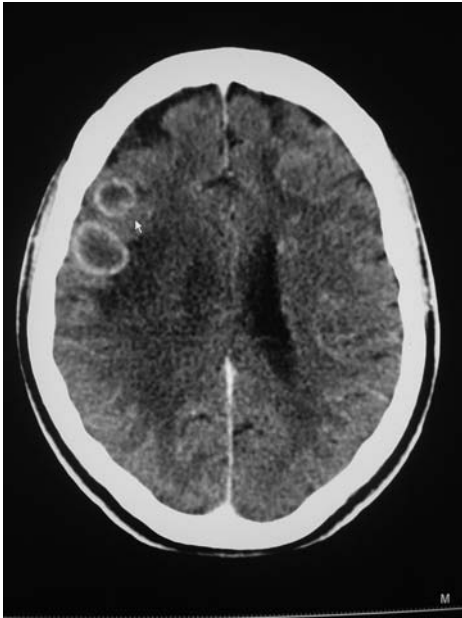
There is an extensive area of low density in the left cerebral hemisphere surrounding a small rounded mass in the posterior left frontal lobe. In conjunction with the history, the appearances are highly suggestive of cerebral metastasis.

The low density is typical of the vasogenic cerebral oedema seen with metastases. Vasogenic oedema is characterized by apparent involvement of the white matter and sparing of the grey matter interdigitating with the cortex. Tumours and abscesses are most likely to produce this type of oedema. The alternative, cytotoxic oedema, appears to involve both grey and white matter and corresponds to areas of cell death as with infarction (see images in Question 6).

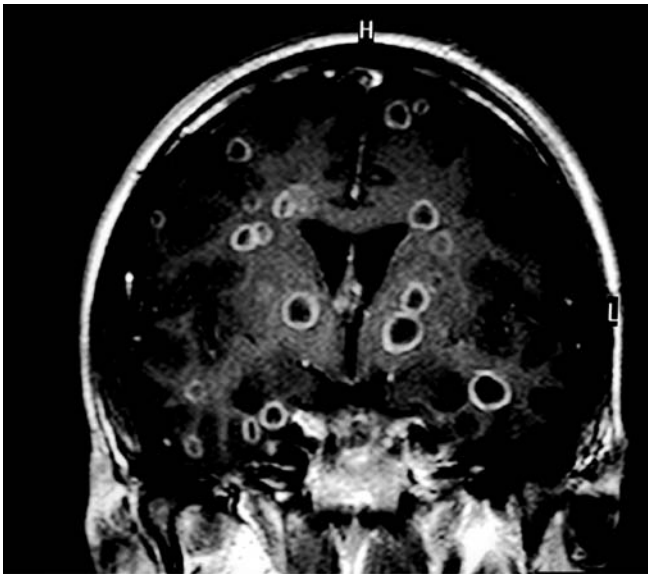
When lesions are multiple, metastatic disease is statistically more likely than when solitary; however, for most intracranial tumours, to be certain of the diagnosis, histological tissue analysis must be performed. The main differential diagnosis of either solitary or multiple lesions are multiple cerebral abscesses. Clinical features such as a short history with a fever, raised white cell count and raised inflammatory markers would support the latter. Figure 5.37 shows multiple ring enhancing lung metastases, and Fig. 5.38 shows a T1-weighted enhanced MRI of multiple abscesses, the appearances of which are very similar.

### Consider repeat examination with contrast

An entirely normal unenhanced CT scan of the brain is not sufficient to completely exclude intracranial metastatic disease. Intravenous contrast can improve the sensitivity of imaging, particularly when looking for multiple lesions within an area of vasogenic oedema, but is

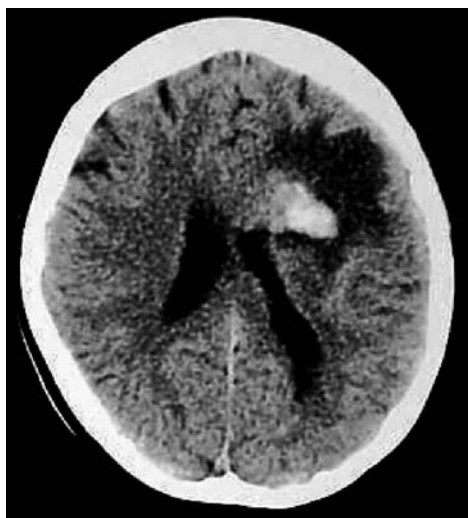

**Figure 5.37.** Multiple ring enhancing lung metastases.

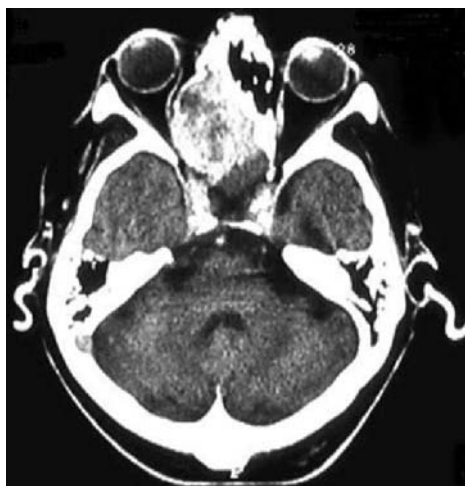


**Figure 5.38.** T1-weighted enhanced MRI of multiple abscesses (a similar appearance to the enhancing metastases).

more likely to be helpful in increasing specificity once an abnormality has been identified. It may help distinguish a vascular lesion from a tumour or a tumour from an abscess, for example. In this case there was only a little extra enhancement making post-contrast images very similar to unenhanced scans and no new lesions were identified. Multiple lesions would be managed differently to a solitary intracranial metastasis as it may be possible to remove one or two lesions or treat them with stereotactic radiosurgery, whereas this is not possible with widespread disease.



**Figure 5.39.** Malignant melanoma dense (white) metastases.



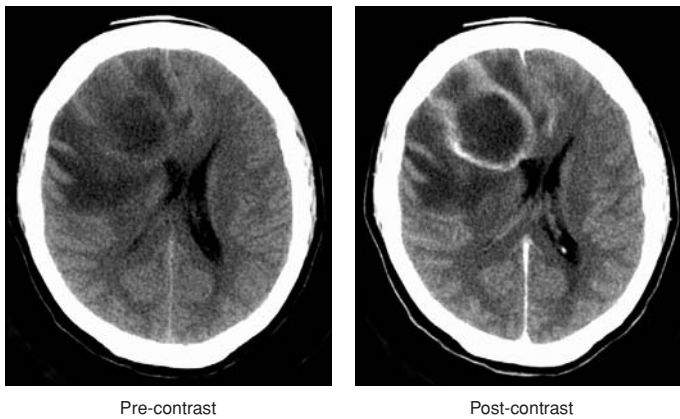
**Figure 5.40.** Metastasis from a renal cell carcinoma in the nasal cavity. This illustrates the need to interrogate the whole image and in particular to look at certain sites where disease is commonly missed.

Of course, if there is no known primary, a search for the primary site may be necessary. As a general rule, the density of cerebral metastases is very variable and the primary site cannot be inferred from the CT appearances; however, malignant melanoma does produce characteristically dense (white) metastases (Fig. 5.39).

Of course, metastases on a CT head do not necessarily have to be located within the brain. Figure 5.40 shows a bony metastasis from a renal cell carcinoma in the nasal cavity. This illustrates an important point with imaging, that is the need to interrogate the whole film and in particular to look at certain sites where disease is commonly missed. These review areas must be checked before the study is reported. Examples of review areas and often missed pathology on a CT head:

- skull base (for malignant disease, such as metastases or chondrosarcoma),
- pituitary fossa (tumours),
- paranasal sinuses (fluid),
- temporal lobes (low density seen in herpes simplex encephalitis),
- sulci (isodense subdural or subarachnoid blood),
- top slice (parafalcine meningioma),
- basal cisterns, especially the interpeduncular fossa (blood, e.g. SAH),
- bone windows (fractures or metastatic disease in the skull vault).





**Figure 5.41.** Quiz case.

49-year-old male with a history of bizarre behaviour for several weeks; more rapid deterioration over past few days.

## Question 8

- Describe the abnormal radiological signs (Fig. 5.41).
- What is the differential diagnosis?
- What urgent management should be considered?

## Answer

### Radiological signs

There is a ring-enhancing lesion in the right frontal lobe, which is surrounded by extensive vasogenic oedema. The abnormality has marked mass effect with deviation of the midline to the left side, effacement of the frontal horn of the right lateral ventricle and basal cisterns.

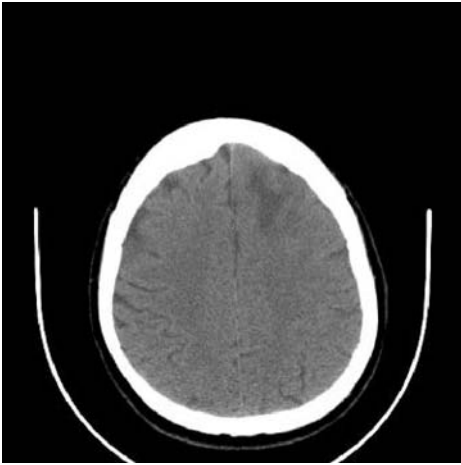
### Malignant brain glioma

The differential diagnosis for intracerebral ring-enhancing lesions includes:

- primary brain tumour (glioblastoma multiforme),
- metastases (Question 7),
- cerebral lymphoma (only when immunocompromised, for example, in AIDS),
- abscess (pyogenic or fungal).

Given the history of gradual deterioration, pyogenic abscess is very unlikely. Corticosteroids to reduce the oedema can improve symptoms in the short term. This lesion was biopsied and was found to be a glioblastoma multiforme.

Glioma is the generic term used to encompass glial cell tumours and it includes astrocytomas, oligodendrogliomas and ependymomas. The commonest is the astrocytoma, but radiologically it is impossible to distinguish the tumours with any degree of certainty. Low-grade astrocytomas (Fig. 5.42) may appear as a small area of low density due to oedema which can be difficult to distinguish from an infarct. Presentation may be with headache, seizures or with a neurological deficit. They usually do not enhance and have an indolent course; however, most eventually turn into higher grade aggressive tumours. This may take 10 years or more in many cases. Oligodendrogliomas are often found in the frontal lobes and frequently calcify. When any of these tumours revert to a high grade, there will be rapid tumour enlargement, central necrosis (a hallmark of high grade tumours) and strong enhancement.

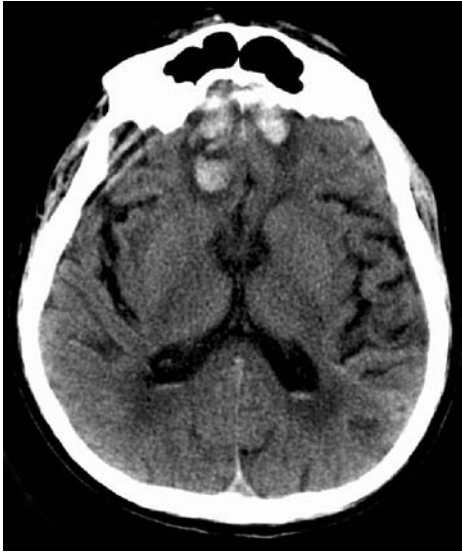

**Figure 5.42.** Low grade astrocytoma. This can be difficult to distinguish from an infarct.

Cell lines are also less differentiated and this is known as a glioblastoma multiforme or GBM. Prognosis of GBM is universally poor.

### **Management**

Neurosurgical assessment and sampling of any ring-enhancing lesion to exclude pyogenic abscess is essential if there are no signs of sepsis or an obvious source of infection, although MRI diffusion-weighted imaging (DWI) can be used to differentiate tumour from abscess pre-operatively. If the clinical picture is that of sepsis, then possible sources would include frontal sinusitis, mastoiditis or blood-borne infection from endocarditis. The latter tends to give rise to multiple abscesses. The possibility of AIDS or altered immunity should be kept in mind as cerebral toxoplasmosis appears very similar to pyogenic abscess.



**Figure 5.43.** Quiz case.

Head injury following high alcohol consumption. Reduced conscious level. You are called to the accident and emergency department to help manage this patient.

## Question 9

- What is secondary brain injury?
- What is the immediate management?
- What is the abnormality on the CT (Fig. 5.43)?

## Answer

### Secondary brain injury

Head injury accounts for approximately a third of all trauma deaths and is the leading cause of death and disability in young adults. A large proportion of head trauma follows road traffic accidents. Primary brain injury is acquired as a direct result of the trauma and is not preventable other than by modifying environmental factors which reduce the risk and severity of injury in the first place. Examples include wearing helmets when cycling, wearing high visibility clothing as a pedestrian, etc. Secondary brain injury occurs after the initial insult and is the result of cerebral hypoxia and ischaemia due to a number of compounding factors. It is secondary brain injury, which can be reduced by appropriate medical care.

### Immediate management

There are a number of specific ways to ensure that risks of secondary brain injury are limited; however, care as always revolves around the ABC of resuscitation.

- Airway (with cervical spine control)
  - Check the airway is clear.
  - If there is airway compromise intubate with a rapid sequence induction, cricoid pressure and in-line cervical spine stabilization.
  - Pass an orogastric tube in the acute phase, never a nasogastric due to the risk of undiagnosed basal skull fracture.

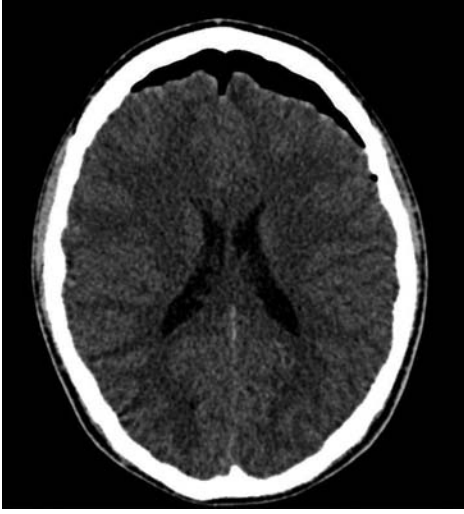- Breathing
  - Aim for SpO<sub>2</sub> of 95%.
  - Ventilate if the patient is intubated for airway protection or for ventilatory failure.
  - Aim for PaCO<sub>2</sub> of 4.0–4.5 kPa avoiding hyper and hypocapnia.
- Circulation
  - Keep systolic BP around 120 mmHg (maintain CPP at 70 mmHg).
  - Two large IV cannulae should be sited.
- Disability
  - Assess neurological state using GCS (Table 5.1).
  - Prevent further neurological injury by treating seizures and hyperglycaemia.
  - Prevent hyperthermia.
  - Maintain ICP 20–25 mmHg (if direct monitoring available).
  - Look for evidence of raised ICP including pupillary dilatation, motor posturing and progressive neurological deficit and consider mannitol (0.25–0.5 g/kg).
  - Ensure adequate sedation.
  - Nurse 30° head up and do not obstruct venous return.
- Exposure
  - Extracranial injuries are common, especially of the cervical spine, and these should be actively sought.

### Cerebral contusions in both frontal lobes

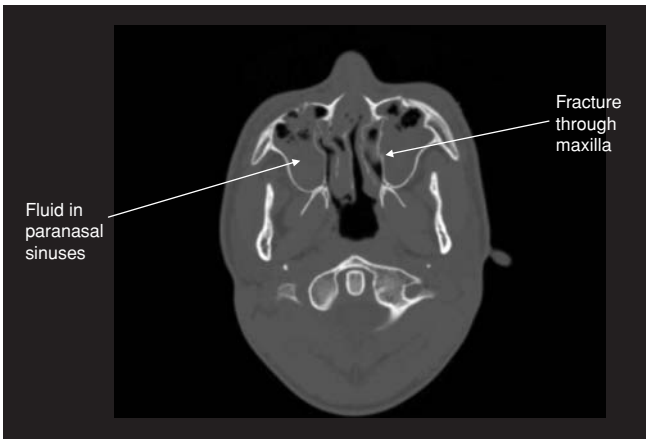
A wide range of appearances are seen on CT head scans performed for severe head injury. Some of these patterns have already been discussed earlier in the chapter and include extradural haematomas, often associated with skull fractures (see Question 4) and subdural haematomas (see Question 3). Subarachnoid blood may also occur, but usually in a distribution that is atypical for aneurysmal bleeds (see Question 2).

Another of the common injuries seen after severe head injury is the cerebral contusion. A contusion is the consequence of the soft brain impacting on the hard skull and it stands to reason that this type of damage is seen in peripheral locations. The usual sites for cerebral contusions are in the inferior frontal lobe (as in the case of Fig. 5.43), frontal and temporal poles and less commonly over the cerebral convexity. Contusions appear in the early stages as very peripheral areas of parenchymal high density due to blood. Contusions in some patients swell rapidly, often referred to as ‘blossoming’, causing a rise in ICP, hence the need for close neurosurgical supervision including ICP monitoring for the first 48 hours. As they mature, they appear as areas of low density due to gliosis. Contusions occur in the brain underlying the point of impact (the ‘coup’ injury) but also in the brain opposite the site of impact (the so-called ‘contre-coup’ injury), although the use of these terms is disputed with some preferring to suggest that contusions occur in stereotypical locations (inferior frontal and temporal poles) whatever the point of impact.

When head trauma is severe, haemorrhage is frequently seen in more than one compartment, and this holds true here where there is also intraventricular blood. Any combination of subdural haematoma, extradural haematoma, contusion, subarachnoid bleeding and even



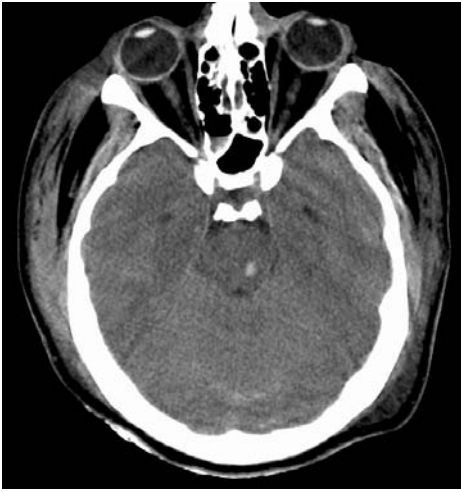**Figure 5.44.** When air is present the source of the air should be sought and bone windows reviewed. This patient had extensive fractures throughout the skull base.



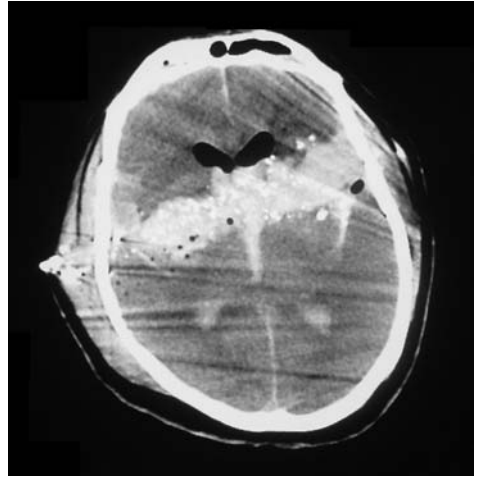
**Figure 5.45.** Bone window showing several facial fractures.

intraparenchymal haematoma may occur. There are, of course, other cranial injuries to consider including facial fractures, calvarial fractures and basal skull fractures. One sign to look for with basal skull fractures is intracranial air (Fig. 5.44). When air is present, the source of the air should be sought and bone windows reviewed (Fig. 5.45). This patient had extensive fractures throughout the skull base. Skull base fractures can cause many complications including meningitis, hearing loss, blindness and caroticoavernous fistulae. Head trauma can also cause dissection of cervical vertebral and carotid arteries, which can often lead to areas of ischaemia and even infarction of the respective territories.

Paradoxically, it is sometimes the patient with the most severe of blunt head injuries with the most normal scans. Diffuse axonal injury is a shearing injury caused by rotational trauma and it produces areas of micro-haemorrhage in locations such as the corpus callosum, grey-white interfaces and dorsolateral midbrain (Fig. 5.46). These areas of haemorrhage are often so small that CT is not able to detect them acutely and MRI is required for full evaluation. Also, if there is global hypoxic-ischaemic injury, due to respiratory arrest related to head trauma



**Figure 5.46.** Diffuse axonal injury. It produces areas of micro-haemorrhage in locations such as the corpus callosum, grey-white interfaces and dorsolateral midbrain.



**Figure 5.47.** Gunshot wound to the brain is rare, but often fatal.

for example, then there may be nothing on the CT other than a subtle loss of definition at the grey-white interface if scanned very early.

Finally, a gunshot wound to the brain is rare, but often fatal (Fig. 5.47) and many will never reach a CT scanner. More commonly, penetrating brain injuries are caused by bone fragments being pushed in from a depressed skull fracture or foreign bodies such as sticks entering the cranium accidentally via the thin bone of the orbital roof.

# Anaesthesia in the radiology department. MRI and interventional radiology

Anaesthesia in the radiology department *C.J. Peden* 210

MRI: principles of image formation *Dr J.M. Regi* 212

MRI: anaesthetic monitoring *Dr J.K. Ralph and Dr C.J. Peden* 216

MRI: case illustrations

*Dr J.M. Regi* 223

Interventional procedures: case illustrations *Dr C. Cook* 233

## Anaesthesia in the radiology department

Anaesthesia in the radiology department produces challenges for the anaesthetist which include:

1. equipment which is not in current use elsewhere in the hospital,
2. inadequate monitoring devices,
3. piped medical gases may not be supplied,
4. radiology personnel may be unaware of anaesthetic problems,
5. bulky equipment may limit space around, and access to the patient,
6. the magnetic field and radiofrequency (RF) currents in magnetic resonance imaging (MRI) require special precautions,
7. lighting may be poor and the environment may be colder than an operating theatre,
8. recovery facilities may not be available.

The most important message from these is 'skilled anaesthetic assistance is essential'. The Association of Anaesthetists of Great Britain and Ireland (AAGBI) has made recommendations for the standards of monitoring during anaesthesia,<sup>1</sup> which is essential reading for all anaesthetists. One section of this document states, 'The AAGBI regards it as essential that certain core standards of monitoring must be used whenever a patient is anaesthetised. These standards should be uniform irrespective of duration or *location* of anaesthesia.'

These recommendations also state, 'When there is a known potential hazard to the anaesthetist, for example, during imaging procedures, facilities for remotely observing and monitoring the patient must be available.'

Guidelines also exist to ensure the safe management of sedated and anaesthetized patients in radiology,<sup>2,3</sup> although unfortunately these are often not adhered to in many departments. The current guidelines (1992) of the Royal College of Anaesthetists and the Royal College of Radiologists<sup>2</sup> suggest that a designated consultant anaesthetist should take responsibility for anaesthetic matters in the radiology department. Their responsibilities should include:

- ensuring adequate provision of resuscitation equipment and drugs,
- advising on the design of rooms where sedation and anaesthesia are to be administered,
- the provision of recovery areas,
- establishing guidelines for sedation in radiology,
- training radiologists in the management of sedated patients.

These guidelines are currently being updated in response to the increasing numbers of complex procedures carried out in radiology, and to the Joint College's document on sedation practices.<sup>3</sup>

## Hazards to anaesthetists

Radiation exposure to the anaesthetist working with investigative radiology procedures is not normally high. The real radiation risks occur during interventional procedures where 'screening' is frequently performed. However, adequate protective precautions should always be taken. The anaesthetist should distance themselves as far as possible from the radiation source during imaging. Pregnant anaesthetists should avoid involvement in radiological procedures.



## Anaesthesia for diagnostic radiology

The anaesthetist is most commonly involved in the management of patients having computerized tomography (CT) or MRI investigations. The patients can be divided into elective and emergency categories.

Elective investigations require sedation or anaesthesia to render the small child, or rarely the uncooperative adult, immobile. Most diagnostic radiological procedures are not painful, but the patient must remain motionless during the examination. The newest CT systems can generate images very rapidly and MRI is getting faster; however, some of the more complex examinations in MRI may still take up to 20 minutes for one scan and up to 1 hour for the whole examination.

Emergency patients require the presence of an anaesthetist for their safe management and *they should not be moved from the resuscitation area until they are stable*. Movement around the hospital of recently admitted trauma or seriously ill medical patients for investigation should be as rigorously planned as inter-hospital transfer. The sections on equipment, preparation for transfer and monitoring of the Intensive Care Society Guidelines<sup>4</sup> for transport of the critically ill adult can equally be applied to the in-hospital transfer of patients from accident and emergency or ICU to radiology. Intubation for all emergency patients should be performed with a rapid sequence induction and cricoid pressure on a tipping trolley. Once the airway has been established, checked and secured the patient can then be transferred onto the X-ray table.

## Anaesthesia or sedation?

There are many articles discussing the relative merits of anaesthesia or sedation for radiological investigations, and many different sedative and anaesthetic techniques have been used. Whichever option is chosen, all patients should be seen, fully assessed, and have had appropriate investigations performed. Patients may attend as day cases and day case management should be applied. When planning anaesthesia or sedation for radiological procedures, the length of procedure, accessibility of the airway, underlying medical condition and the need for rapid recovery must be considered, and the most appropriate agents used.

Not all patients require general anaesthesia or sedation; infants may sleep through relatively long examinations if the study is performed after a feed and they are well wrapped up to keep them warm. Play therapy has been effective in persuading children over the age of 4 years to undergo MRI without anaesthesia or sedation. Adults who suffer from severe anxiety or claustrophobia can be positioned prone in the magnet bore, reassured and, if necessary, counselled before anaesthesia or sedation is attempted.

Although many anaesthetists in the UK choose anaesthesia to render small children immobile for radiological investigation, worldwide sedation is most commonly used. In children's hospitals, multidisciplinary sedation teams have demonstrated excellent success rates and safety records for sedation for radiological procedures. What appears to be important is not the use of a specific sedative or regimen, but the presence of an organized team dedicated exclusively to paediatric sedation, which deals with relatively large numbers of patients. Sedating children, however, particularly in non-specialist centres, can be difficult and unpredictable; the advantages of general anaesthesia are that it has a more rapid and controlled onset and immobility is guaranteed. Sick children may be better managed with general anaesthesia; certainly, if there is any question of raised intracranial pressure, then sedation is inappropriate and potentially dangerous.

If anaesthesia is chosen, short-acting agents should be used. Investigative procedures are usually painless and therefore the use of potent long-acting opioids is inappropriate. Total intravenous anaesthesia may be ideal due to its rapid recovery characteristics and low incidence of induced nausea and vomiting. It is worth remembering when planning anaesthesia (or sedation) for MRI that infusion pumps will malfunction above a certain level of magnetic field strength (30 G). The airway should be secured in whatever way is suitable for that patient and for the procedure. It is generally inappropriate, even if it is possible, to hold the patient's airway during an X-ray procedure as the anaesthetist is then forced to remain close to the radiation source. The laryngeal mask offers the ideal alternative for the patient who does not need endotracheal intubation.

At the end of the procedure, the patient should be transferred to a recovery area and managed by trained recovery personnel. They should not be discharged to the ward until they have met standard post-anaesthetic care unit discharge criteria.

The anaesthetist working in the radiology department must balance the needs of the radiologist, and increasingly of the surgical team, whilst maintaining adequate anaesthesia and patient homeostasis and minimizing risks to the patient, staff and themselves.

## MRI: principles of image formation

Magnetic resonance imaging is a rapidly expanding field within radiology and new applications are constantly being found for this imaging modality. It has the advantage of not using ionizing radiation and is often the best modality for studying soft tissues such as muscle, nerves and brain. Its main uses fall within the fields of neurology, orthopaedics, oncology and paediatrics at present (see Table 6.1).

### How is an MR image produced?

MRI uses a magnetic field rather than X-rays or other forms of ionizing radiation to produce an image. Put simply, the patient is placed in a strong magnet and radiowaves are sent in. The

**Table 6.1.** The main uses of MRI at present

■ Neurology
● Brain
● Spinal cord
● Brachial plexus
■ Orthopaedics
● Lumbar spine
● Knee
● Shoulder
■ Paediatrics
● Brain
● Oncology
■ Oncology
● Staging malignancy

radiowaves are then turned off and the patient emits signals. These signals are received and used to create or construct a picture.

In a little more detail, the body is made up of atoms, which consist of a nucleus surrounded by a shell of electrons. Within the nucleus are found positively charged particles called protons. These can be thought of as small bar magnets, as they possess a charge and their own magnetic field. All protons are spinning around an axis and can be said to possess a spin. When the patient is placed in the very strong magnetic field of the MRI scanner, all the body's protons align themselves – approximately half facing north and the other half facing south. The protons do not sit still in these positions, but precess or spin like a spinning top. The protons will spin faster in stronger magnetic fields.

A radiowave is sent into the magnet; this is called a radiofrequency (RF) pulse. The RF pulse transfers energy to the protons and disturbs their alignment. Energy is only transferred when the RF pulse and the protons have the same frequency; this is called 'resonance'. This is where the resonance in magnetic resonance comes from. This RF pulse causes the protons to line up and spin in phase. The moving magnetic field created by the proton causes an electrical current and this can be picked up by an antenna or an external RF coil. This is the MRI signal.

We can only make an image from these signals if we know the location in the body that the signal came from. A gradient is placed across the magnetic field, which has a different strength at each point of the patient's cross-section. This allows us to trace the exact location of each signal. It is the gradient coil which produces the loud banging during an MRI study.

When the RF pulse is switched off, the whole system relaxes back to its original state. As the protons return to their original state, they release energy or signal. There are two basic types of relaxation – 'T1' and 'T2', which can both be measured and reconstructed. These signals are sampled at different points during proton relaxation and are built up into MR images. It is possible to produce a number of different MR sequences by varying the timing, type and number of RF pulses that the protons are exposed to. Different sequences are also created by choosing different points during the T1 and T2 relaxation to sample the signals.

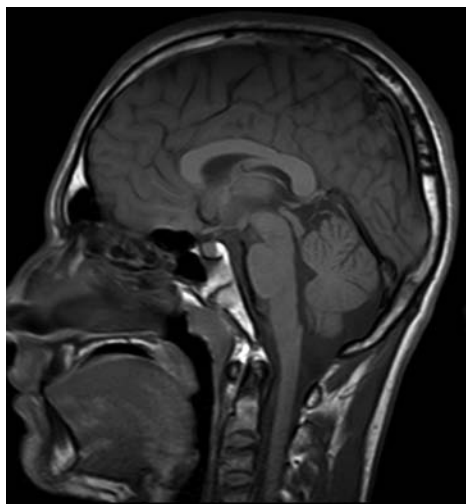
## How is tissue contrast created?

You will notice that radiologists describe tissues in MRI as having either high or low 'signal' in contrast to describing the 'density' of a tissue as you would in a CT image. The protons within different tissues have different relaxation characteristics and this produces the contrast between them. This allows us to see clearly the difference between fluid, muscle and fat. Tissue contrast in MRI is variable between the different sequences and an understanding of the sequence used is required in order to interpret the images.

The body's basic reaction to disease, whether infection, trauma or neoplasia, is inflammation. This leads to an increase in free water molecules. Water is well shown by certain MRI sequences, notably T2 and STIR sequences, and this is the basis for much of MR imaging. While MRI is very sensitive to water and inflammation, unfortunately it is sometimes not very specific.

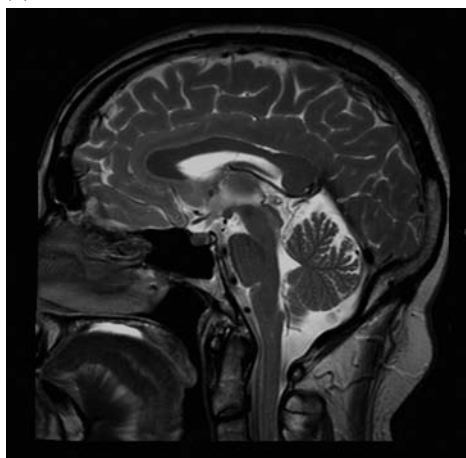
To define a tissue or pathology accurately a radiologist will often compare its appearance on both T1 and T2 sequences. There are a myriad of different MRI sequences that can be

(a)



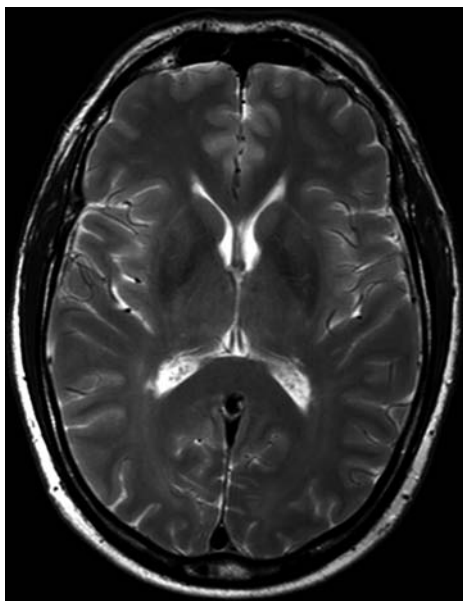
**Figure 6.1a.** T1-weighted sagittal MRI image through the brain. Note the CSF is dark grey, fat is white and brain is mid-grey.

(b)



**Figure 6.1b.** T2-weighted sagittal MRI through the brain. Note the CSF is bright, fat is white and brain is mid-grey.

(c)



**Figure 6.1c.** T2-weighted axial MRI through the brain. MRI sections can be acquired in the axial, sagittal or coronal plane.

produced, but only a few are commonly used for most routine examinations. These are summarized below.

- T1-weighted images (see Fig. 6.1)
  - T1 shows anatomy very well.
  - Most tissues return low signal on T1-weighted images. Water is black on T1.
  - Only a few tissues return high signal on T1, including fat, subacute blood, melanin, proteinaceous fluid and contrast media.

- T2-weighted images
  - T2 shows pathology or inflammation well.
  - Water and inflammation are white on T2, therefore it is a good basic sequence for identifying pathology.
  - Fat is high signal on T2 (as well as T1).
- STIR
  - Heavily T2-weighted sequence.
  - High signal from fat is suppressed, so that high signal pathology and fluid stand out.
  - Commonly used in musculoskeletal imaging.
- FLAIR
  - T2 weighted.
  - High signal from CSF is suppressed – good for detecting subtle brain lesions.
  - Used predominantly in central nervous system imaging.

Some tissues show low signal or no signal (black) on all sequences:

- cortical bone
- calcification
- tendons/ligaments
- metal
- gas.

## MR angiography (MRA)

May be used to study arteries or veins. The signal intensity from flowing blood is variable and depends on several factors including the sequence used and the speed and direction of flow. On T1 and T2 sequences flowing blood has no signal, so produces a signal void.

On the specific MRA sequences, such as ‘time of flight’, flowing blood produces a high signal, whilst all signal from the surrounding, static tissue is suppressed. MRA is non-invasive, does not involve radiation and has an accuracy approaching conventional angiography in some diagnostic situations.

## Contrast agents in MRI

Despite the excellent inherent tissue contrast in MR images, intravenous contrast medium is often given to highlight abnormal tissue. Chelates of the paramagnetic substance gadolinium are used – they shorten the relaxation times of nearby protons, which results in high signal on T1-weighted images. Contrast is only used with T1-weighted images. Gadolinium has similar pharmacokinetics to the iodinated contrast media used in CT – it is distributed throughout the intra- and extravascular spaces, does not cross the intact blood–brain barrier, is hyperosmolar and is excreted renally. The same precautions need to be taken with patients in renal failure. Administration of gadolinium is not recommended in those patients with a creatinine of over 200 mmol/l and use caution in those with a creatinine of 150 mmol/l. The frequency of adverse reactions is around 2%–5%, although most are mild (nausea, urticaria, etc.). Anaphylactoid reactions are rare, but have been reported. It is likely that these are due to additives in the contrast rather than to the gadolinium itself.

## MRI vs. CT

MRI and CT are not generally interchangeable examinations; the choice depends on the likely pathology and the body part in question. CT remains the imaging modality of choice for most chest and abdominal pathology.

### Advantages of MRI

1. No ionizing radiation.
2. Superior soft tissue contrast.
3. Direct multiplanar capabilities; however, the newer multislice CT scanners are able to reconstruct images in any plane from the data that is acquired axially.

### Disadvantages of MRI

1. Longer imaging times, minutes vs. seconds. Some cardiac scans can take up to an hour to complete. This also means that MR is not suitable for the acutely unwell patient or trauma scans that need to be as fast as possible.
2. MR images are very susceptible to artefact. Images may be degraded by metal artefact, patient movement, breathing, bowel peristalsis and cardiac pulsation. The latter is reduced by the use of cardiac gating techniques, whereby data is only acquired during a certain short part of the cardiac cycle.
3. Most MR scanners are not patient friendly – they are very enclosed and noisy such that claustrophobic patients and children may not tolerate a scan. This, together with the relatively long scanning time, means that children are more likely to require sedation or general anaesthetic.
4. All monitoring and resuscitation equipment to be used within the scanner must be MRI compatible.
5. Contraindications to MRI are not uncommon.

## MRI: anaesthetic monitoring

MRI produces additional challenges to the anaesthetist,<sup>5,6</sup> in addition to those described earlier, due to the effects of the magnetic field and RF currents used in MRI.

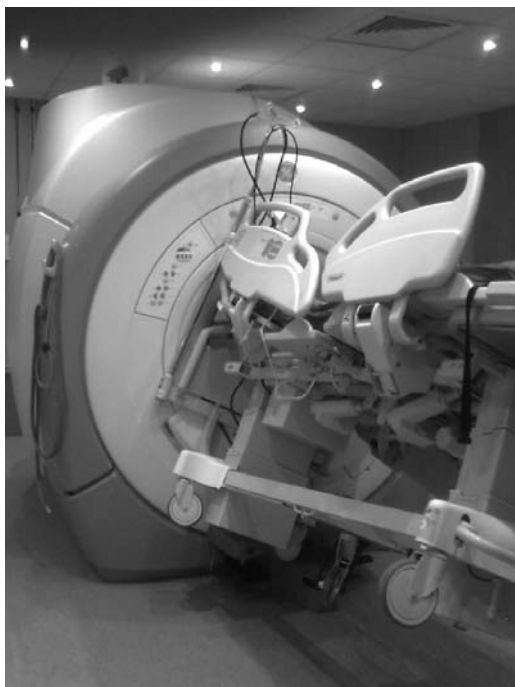The main problems are:

- the high magnetic field with associated risks of ferromagnetic attraction,
- the narrow magnet bore in which the patient is completely enclosed,
- malfunction of monitoring equipment,
- degradation of the MR images by the presence of monitoring equipment.

The advent of low field 'open' MR systems reduces some of the anaesthetist's problems; the patient is visible, access to the patient is easier and the environment is less claustrophobic. However, the 'open' magnet operates at low field strength and is suitable only for certain types of investigation.

## Magnetic field strength and ferromagnetic attraction

Magnetic field strength is measured in tesla (T). One tesla is equal to 10 000 G. The Earth's magnetic field at the surface is in the order of 0.5–2.0 G. Clinical MRI systems in the UK operate between 0.05 and 3.0 T, that is 500–30 000 times the Earth's surface magnetic field.



**Figure 6.2.** The strong magnetic field of MRI can be potentially dangerous for the patient or anaesthetist.

The anaesthetist should know the extent of the magnetic field he or she is working in. A useful measure is the 5 G line; this is the field strength at which pacemakers will dysfunction, electrical equipment may start to malfunction and magnetic tape such as that on credit cards will be erased. Infusion pumps will malfunction at a field strength of 30 G. At a field strength of approximately 50 G, the attractive force on ferromagnetic objects becomes significant, and an object such as a bed or oxygen cylinder can become a dangerous projectile accelerating into the magnet bore, 'the missile effect' (see Fig. 6.2). *The anaesthetist should consider the magnetic field to be permanently on.* It is very expensive to shut down the field and not without risk. Never assume that, in case of emergency, the magnetic field can be turned off.

## Patient and staff hazards

All MRI units operate certain patient and personnel exclusions because of the risks of ferromagnetic attraction. Everybody entering the unit should complete a screening questionnaire. Pacemakers, automatic defibrillators, infusion pumps and neurostimulators may malfunction at very low field strengths and patients with these devices should not be allowed anywhere near the magnetic field. Many implanted prosthetic devices are non-ferromagnetic. Objects of unknown ferrous content can be tested with a hand-held magnet. Some ferromagnetic items pose little threat to the patient, such as joint prostheses, as they are firmly anchored. They will, however, cause artefacts when scanned with MR, which can severely degrade the images. There are some items where any movement would be critical, such as intra-cerebral aneurysm clips or intra-ocular metallic fragments, and patients with these *in situ* must not be placed in the magnetic field unless their non-magnetic content is known unequivocally. The newer types of heart valves are not ferromagnetic and flow changes or

heating do not seem to cause problems. There are extensive and frequently updated reviews of the magnetic susceptibilities of biomedical implants available. Regularly updated, web-based MRI safety manuals are available listing most implantable medical devices and whether or not they are MR compatible. Safety manuals should be available in most MR scanners.

No patient should be taken near an MR system if there is any uncertainty about the safety of any prosthetic device, implant or surgical clip as disasters have occurred. Plain X-rays can be used to search for metal fragments, if there is concern about their presence.

## Contraindications to MRI

### Absolute

- Cardiac pacemakers.
- Implanted cardiac defibrillators.
- Cochlear implants.
- Any other implanted device which is electrically/magnetically operated.
- Metallic ocular foreign bodies (X-ray orbits if any doubt).
- All cerebrovascular aneurysm clips and some other ferromagnetic implants.

### Relative

Whilst most orthopaedic devices are made from titanium and are safe, caution should be taken with any recently inserted prosthesis, i.e. less than 4 weeks.

Pregnancy – there is no evidence as yet that MRI has any harmful effects on the fetus; however, data is limited. There is a theoretical risk of teratogenicity in the first trimester, and MRI should be particularly avoided at this time. However, a clinical decision has to be made as to whether the benefits of the examination outweigh any potential risk. Pregnant staff should be able to opt out of working in the MRI suite, if they wish.

Other devices of note are cardiac stents, most of which are safe in an MRI scanner after 4 weeks. Counter-intuitively endoscopically inserted gastrostomies (PEGs) are safe but radiologically inserted gastrostomies (RIGs) should not be scanned.

## Electromagnetic radiation – potential bioeffects

During MRI the patient is exposed to three different types of electromagnetic radiation which are potentially hazardous to human tissue:

- the static magnetic field,
- the gradient magnetic fields used for image localization,
- the RF electromagnetic fields used to generate images and to manipulate the proton nuclei in different imaging sequences.

If applied at sufficiently high levels, these may cause heating, vertigo, involuntary muscle contraction and even ventricular fibrillation. Exposure limits are set by the National Radiological Protection Board (NRPB). Field strength for clinical use has an upper limit of 2.0 T, gradient-varying magnetic fields must be kept at less than 3 T/s and RF must be limited to 2 W/kg over 1 g of tissue and 0.4 W/kg averaged over the whole body. In current practice these are not exceeded.



## Monitoring patients in an MRI system

The changing gradient magnetic fields used for image localization, and the RF currents used to excite the proton nuclei, can induce currents and heating in monitoring leads. Induced currents cause interference with monitoring devices, and have resulted in serious burns to the patient. Precautions must be taken to minimize the risks to patients; these include:

- Only *MR compatible equipment* in intact condition should be used ('MR compatible' – the device does not harm the patient and has been demonstrated to neither significantly affect the quality of the diagnostic information nor have its operation affected by the MR device).
- All probes and leads not in use should be removed from the patient.
- Cables and sensors should be placed away from the examination area.
- Cables should not form loops within the magnet bore and should be separated from the patient's skin.
- ECG leads should be braided together to minimize loop formation.

Monitoring equipment can also generate RF; for example, liquid crystal display screens may appear to have a continuous display, but may actually be turning on and off at high frequency. The generated RF can be conducted through the patient interface connections (e.g. ECG leads) into the imaging environment and can cause distortion of the MR image. If monitoring equipment is positioned outside of the RF screening around the magnet (now usually in the walls of the magnet room), the monitoring leads can act as aerials picking up RF currents in the general environment and conducting them into the imaging area. Monitoring leads entering the magnet room from outside should pass through low pass filters to exclude signal in the range which interferes with the operating frequency of the MR system. MR 'compatible' commercially available monitoring equipment is contained in a RF screened enclosure. Sensors in this type of equipment may also be shielded, for example, to prevent the LED cycling in the pulse oximeter probe from causing further interference.

Main power supplies can carry interference through the RF screen, and monitoring equipment should use an adequately filtered and isolated power source or be run by batteries. Batteries are strongly ferromagnetic, and battery-powered monitoring equipment must be very firmly secured within the magnetic field.

## Anaesthesia for MRI

Piped medical gases are essential and the installation of an isolated filtered AC power circuit and RF filters will minimize interference from monitoring equipment. Purchase of an MRI-compatible anaesthetic machine and ventilator, and fibre-optic monitoring systems will reduce potential problems. MRI-compatible anaesthetic machines with MRI-compatible ventilators are now made by most of the major manufacturers; these can be sited adjacent to the magnet bore minimizing the length of breathing systems. Space for resuscitation, induction and recovery from anaesthesia will enhance patient safety and increase patient throughput.

In my opinion (C.J. Peden) patients are best anaesthetized outside the magnet room and then transferred into the magnet suite once they are stable and their airway has been secured. The airway of a patient whose head goes first into the magnet is completely inaccessible; in addition, a 'receiver coil' is placed around the area being examined, which in the case of a head scan reduces space for tubes and connections. All connections must be plastic. The laryngeal

mask is widely used for MRI, and a mask with no ferromagnetic components is specifically made for MRI.

Anaesthetists who have not worked in the MRI environment will be surprised by the level of noise generated during an examination. The gradient magnetic fields produce a loud thumping or tapping, which can be very disconcerting for the awake patient, and may necessitate deeper levels of sedation or anaesthesia than might otherwise be required.

Anaesthesia can be maintained with a volatile agent or intravenously. The motor of infusion pumps may start to malfunction at field strengths of 30–50 G, and extended infusion lines are required.

## Intensive care patients

MRI shows much greater detail of the central nervous system than CT. Therefore, imaging requests for adult and neonatal intensive care patients with neurological problems are increasing. It is possible to examine these patients with MRI but it needs planning and plenty of time. The main problems are caused by the number of lines and infusion pumps attached to the patient. These should be disconnected unless absolutely essential. Those infusions that must be continued need extensions of adequate length to keep the pumps outside the 30 G line.

Another potential problem with sick infants is maintenance of body temperature as the MR environment is cold and air conditioned to ensure optimal system function. Infants should be returned immediately, at the end of the examination, to a transport incubator.

## Micro-shock

There is a theoretical risk of micro-shock being induced by the passage of conducting fluid such as 0.9% saline, through central venous or pulmonary artery catheters in contact with heart muscle in critically ill patients, or by the induction of current in intravascular pacing wires. This possibility has been investigated in an animal model and there appears to be little risk to patients with a central venous catheter. Epicardial pacing wires are potentially unsafe and should be removed if MRI is essential. There has been a report of a pulmonary artery catheter with a thermistor wire that melted during MRI! All patients referred for MRI procedures with cardiovascular catheters and accessories that have internally or externally positioned conductive wires or similar components should not undergo MRI, unless the catheter is removed, due mainly to the risk of excessive heating in the wires.

## Conclusion

Anaesthesia and monitoring in the MRI suite need to be maintained to the same standards as expected in the operating theatre. Extra challenges are produced by the environment of the radiology department and additionally by the unique nature of the MRI suite.

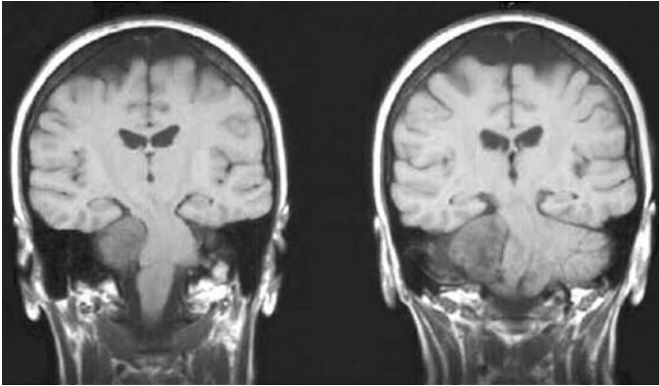
Patient and staff may be endangered by the missile effect of ferromagnetic attraction on everyday objects as well as on equipment and surgical implants. Implanted electronic devices may malfunction at very low magnetic field strength, serious burns may result from currents induced in monitoring leads and micro-shock may be induced in intravascular or epicardial devices.

The magnetic, RF and gradient fields may cause artefact interference with monitoring devices, especially ECG and pulse oximetry.

These challenges are overcome by meticulous attention to detail, the design of RF-screened MRI suites and the use of commercial monitoring systems developed specifically for the MRI environment which are both safe for patients and do not distort or degrade the images produced.

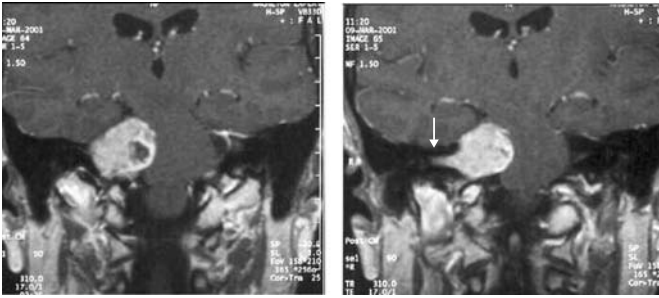
## References

1. *Recommendations for Standards of Monitoring during Anaesthesia and Recovery.* Association of Anaesthetists of Great Britain and Ireland, 2000.
2. *Sedation and Anaesthesia in Radiology.* Report of Joint Working Party of the Royal College of Anaesthetists and the Royal College of Radiologists, 1992.
3. *Implementing and Ensuring Safe Sedation Practice for Healthcare Procedures in Adults.* Academy of Medical Royal Colleges, 2001.
4. *Guidelines for the Transport of the Critically Ill Adult.* Intensive Care Society, 2002.
5. Peden CJ. Monitoring patients during anaesthesia for radiological procedures. *Curr Opin Anaesth* 1999; **12**: 405–10.
6. *Guidelines for the Provision of Anaesthetic Services in Magnetic Resonance Units,* Association of Anaesthetists. 2002.



**Figure 6.3.** Quiz case.

55-year-old female.  
Long history of unilateral tinnitus, deafness, and now ataxia.  
Below is a T1-weighted coronal image of the head before and following IV gadolinium (Figs. 6.3 and 6.4).



**Figure 6.4.** Quiz case.

## MRI: case illustrations

### Question 1

- From where does this lesion arise?
- What is the diagnosis?

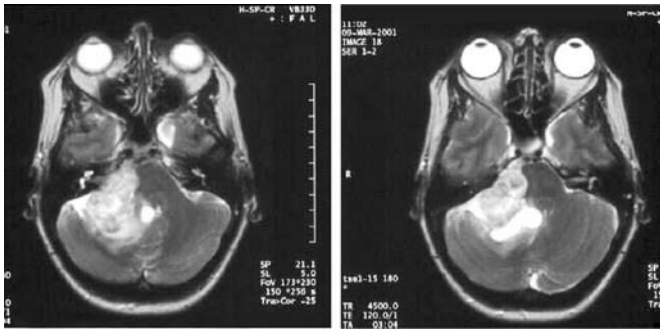
### Answer

#### Acoustic neuroma

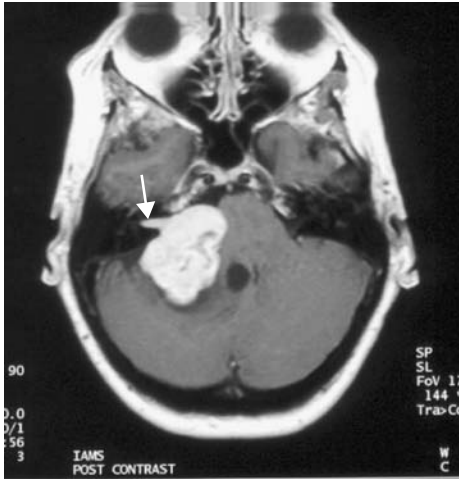This lesion arises within the right internal auditory canal (arrow) and bulges into the cerebellopontine angle. There is compression of the cerebellum and midline shift to the left. The lesion is very well circumscribed, and enhances intensely following IV gadolinium. The appearances are characteristic of an acoustic neuroma or schwannoma, of which this is a very large example.

#### Comment

Acoustic neuromas or schwannomas typically have this ‘ice cream cone’ appearance as they emerge from the internal auditory canal seen well on the axial images (Figs. 6.5 and 6.6). This appearance helps to differentiate them from meningiomas of the cerebellopontine angle.

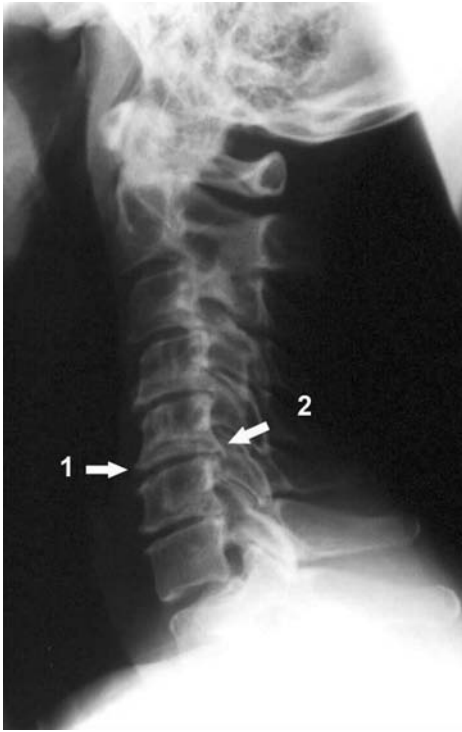

**Figure 6.5.** Acoustic neuroma axial T2-weighted image. The tumour is of high signal. Note the high signal from the CSF identifying it as a T2-weighted image.



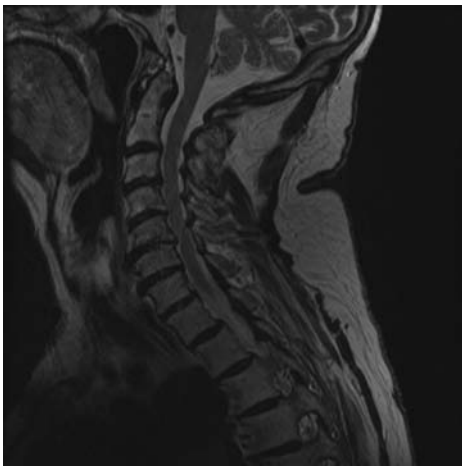**Figure 6.6.** Acoustic neuroma axial post-gadolinium. Note how the tumour grows along the internal auditory meatus – one of the characteristic signs of acoustic neuroma.

Acoustic neuromas (85%) arise from the vestibular portion of the eighth cranial nerve and 15% from the cochlear division. They may be sporadic, typically occurring in middle age, or associated with type 2 neurofibromatosis. They are slow growing but may eventually cause facial sensory loss, weakness, ataxia, long tract signs and hydrocephalus due to compression of the fourth ventricle.



**Figure 6.7.** Quiz case.

68-year-old female.  
During assessment for a general anaesthetic she reports a painful, stiff neck.  
On examination, neck movement is severely restricted and precipitates pain and paraesthesia in the right arm.  
A lateral cervical spine X-ray and MRI scan of the neck were performed.



**Figure 6.8.** Quiz case.

## Question 2

- What are the plain film (Fig. 6.7) findings?
- What additional information does the MR image (Fig. 6.8) provide?

## Answer

### **Degenerative cervical spondylosis with spinal stenosis**

The plain film shows reduced intervertebral disc heights from C4 to C7; there are small anterior osteophytes of the C3 to C7 vertebral bodies (Fig. 6.7) (arrow 1). There are large posterior osteophytes at the C5/C6 level (arrow 2).

The sagittal T2-weighted image (Fig. 6.8) shows narrow dehydrated discs at multiple levels. There are low signal (black) osteophyte-disc bars protruding posteriorly, most markedly at the C5/C6 level. These represent bulging degenerate discs, together with osteophytes from the margins of adjacent vertebral bodies.

There is narrowing of the spinal canal at the C5/C6 level, with obliteration of the subarachnoid space (this normally contains the high signal cerebrospinal fluid) and impingement upon the spinal cord. This should also be confirmed with axial images.

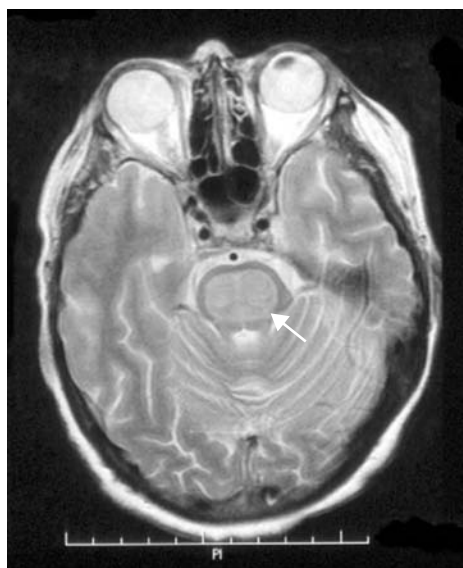
### **Comment**

Degenerative disease of the cervical spine can cause stenosis of the nerve root foramina and, less commonly, the spinal canal (particularly in those people with a congenitally narrow canal) due to a combination of several factors (see below). Degenerative disease of the cervical spine or osteoarthritic changes are referred to as cervical spondylosis. Changes include:

- bulging intervertebral discs,
- vertebral end-plate osteophytes,
- ligamentum flavum 'hypertrophy' (the ligament buckles due to osteoarthritis of the underlying facet joints).

Spinal canal and nerve root foraminal stenosis is well shown on MRI; abnormal high signal may be seen within the spinal cord on T2-weighted images, if there is actual cord compression. Classically, nerve root compression causes pain, paraesthesiae and lower motor neurone signs in the upper limbs. Spinal cord compression causes a myelopathy with additional upper motor neurone signs below the level of impingement, and sometimes urinary symptoms. It should be noted that the patient's symptoms often do not correspond well to the extent of degeneration seen in the cervical spine on MRI.





**Figure 6.9.** Quiz case.

50-year-old male.  
 7-day history of gastroenteritis. He was severely dehydrated and confused.  
 Plasma sodium of 120 mmol/l. Hypertonic saline was given to correct it; 24 hours later, he developed flaccid weakness in all four limbs, and difficulty in swallowing. He has been admitted to ITU and an MRI scan performed. This is a T2-weighted axial image of the brain (Fig. 6.9).

### Question 3

- What is the abnormality?
- What conditions are associated with this diagnosis?
- What is the prognosis?

### Answer

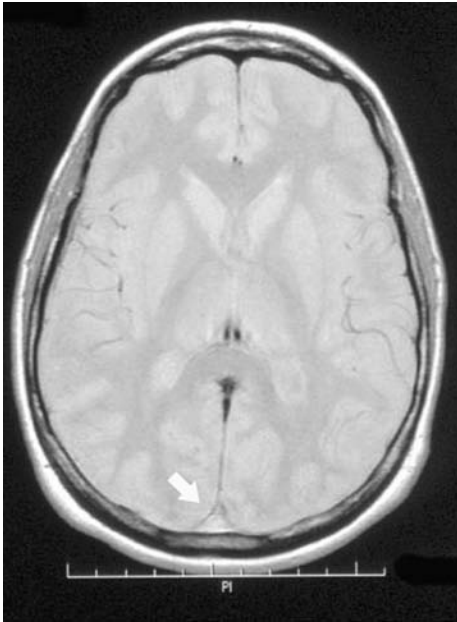
#### Central pontine myelinolysis (CPM)

There is a large oval-shaped area of high signal within the pons (arrow). This represents demyelination. This is central pontine myelinolysis. This is a rare condition in which there is massive demyelination involving the pons and sometimes the basal ganglia, thalami and internal capsule. Signs include cranial nerve palsies (particularly the fourth, fifth and sixth cranial nerve), pyramidal signs in the limbs, bulbar signs and coma.

#### Causes

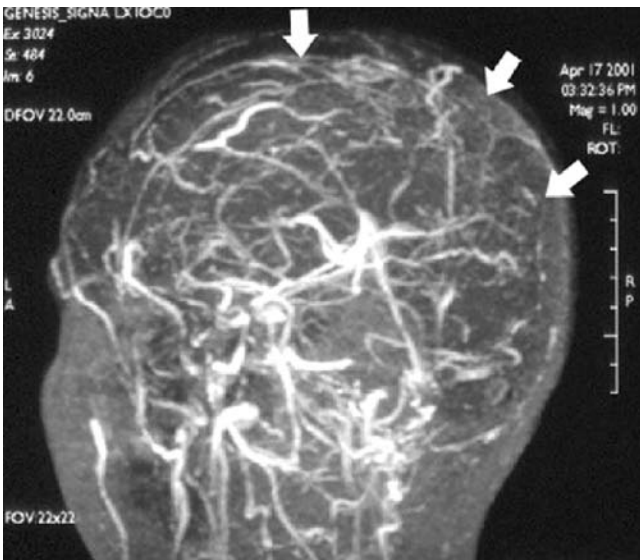
- Hyponatraemia, which is rapidly corrected.
- Chronic alcoholism.
- Chronic liver disease.

The prognosis is poor – the 6-month survival rate is approximately 10% and residual neurological deficits are common. In this case, CPM may have been avoided by giving 0.9% saline as the initial resuscitation fluid, with frequent electrolyte analysis, aiming to correct the hyponatraemia by no more than 10–12 mmol/l in 24 hours.



**Figure 6.10.** Quiz case.

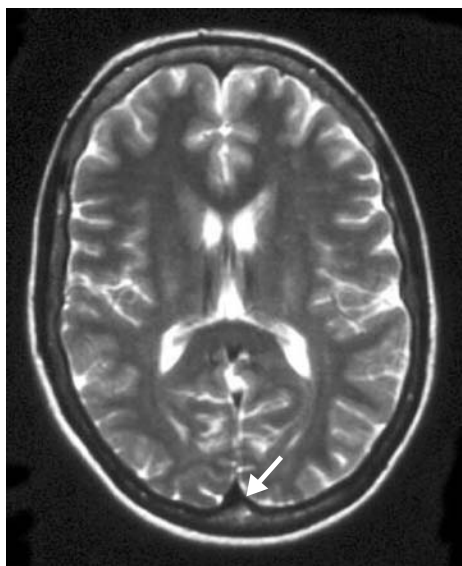
28-year-old pregnant female with hyperemesis gravidarum. Persistent vomiting and dehydration over the past 36 hours. Severe headache and now some left-sided weakness. Shown on the left is a proton-density weighted axial image of the brain (Fig. 6.10), and below is a sagittal MRV image (Fig. 6.11).



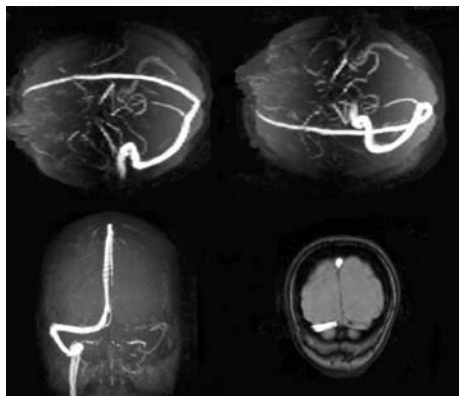
**Figure 6.11.** Quiz case (arrows).

## Question 4

- What is the diagnosis?
- State some predisposing factors.



**Figure 6.12.** Normal – flow-void coming from the sagittal sinus (arrow).



**Figure 6.13.** Transverse sinus thrombosis MRV.

## Answer

### Superior sagittal sinus thrombosis

The axial image shows high signal thrombus within the superior sagittal sinus posteriorly (arrow) (Fig. 6.10), where flowing blood would normally produce a 'flow-void' as in the normal T2-weighted image (Fig. 6.12). The MRV image shows a lack of signal in the expected position of the superior sagittal sinus (arrows) (Fig. 6.11). A further case of sinus thrombosis on MRV (transverse sinus thrombosis) is demonstrated in Fig. 6.13.

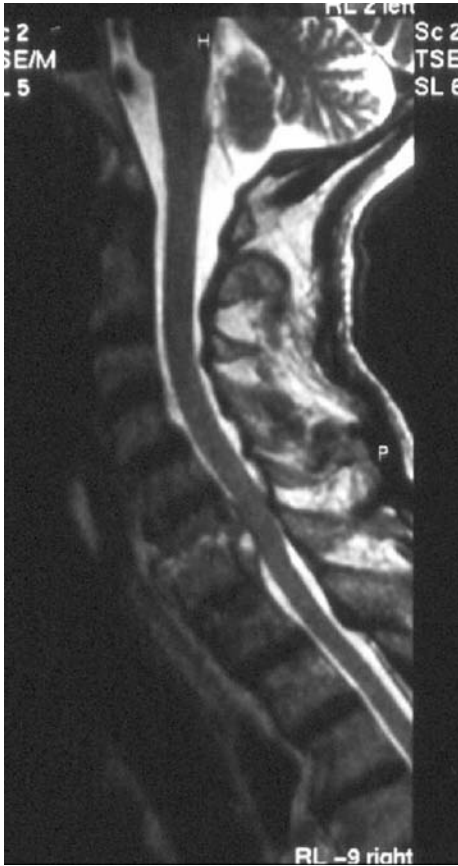
### Predisposing factors

- Pregnancy.
- Oral contraceptive.
- Thrombophilia.
- Dehydration.
- Systemic malignancy, e.g. childhood leukaemia.
- Sinusitis and other local sepsis.
- Intracranial tumours, e.g. meningioma.

### Comment

Intracranial sinus thrombosis may also be diagnosed with contrast enhanced CT or cerebral angiography; however, MRI is the investigation of choice when the diagnosis is suspected. It is sensitive and non-invasive – in contrast to conventional cerebral angiography.

Presenting symptoms include headache, seizures, focal neurological deficits and coma. Sinus thrombosis may lead to venous infarction, haemorrhage and cerebral oedema.



**Figure 6.14.** Quiz case.

36-year-old intravenous drug user.  
Long history of neck pain, malaise and low grade fever.  
This is a T2-weighted sagittal image of the cervical spine (Fig. 6.14).

## Question 5

- What is the cause of this patient's symptoms?
- What other groups are at risk of this condition?

## Answer

### Discitis with epidural abscess

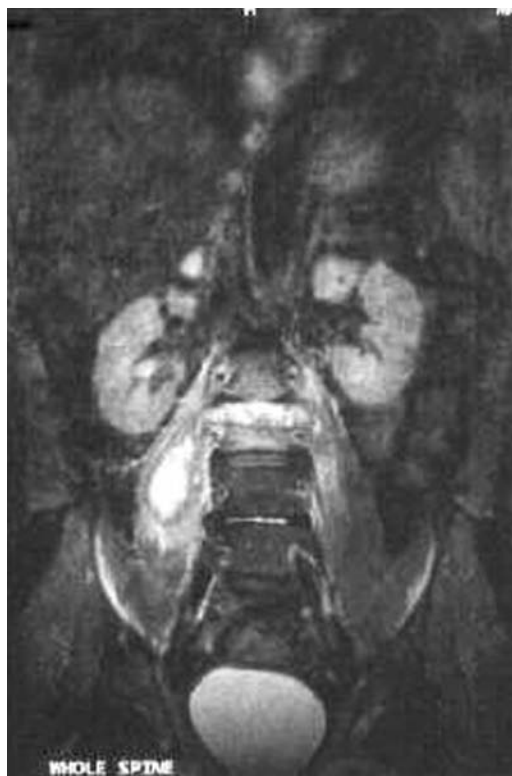An area of high signal (white) is seen within the C6/C7 disc space, representing fluid and inflammatory change. There is destruction of the end plates of the C6 and C7 vertebral bodies, which are reduced in height. Some high signal is seen bulging posteriorly into the anterior epidural space – this is an epidural abscess.

### Groups at risk of spinal infection

Children – haematogenous spread of infection to a vertebral body or a vascularized intervertebral disc; usually in the lumbar spine.

Adults:

- Intravenous drug users.
- Diabetics.



**Figure 6.15.** Lumbar discitis and psoas abscess. Coronal STIR image sequence, this is a fat suppression sequence in which pathology usually appears high signal. In this example, the lumbar intervertebral disc and both adjacent vertebral bodies are of high signal. There is an abscess extending into the right psoas muscle.

- Immunosuppression, e.g. steroids.
- Alcoholics.
- Genito-urinary infections and instrumentation.
- Post-spinal surgery.

Infection starts as a vertebral osteomyelitis which then ‘ruptures’ into the disc space. It may occur at any level, but most commonly in the lumbar spine.

### Comment

Epidural abscess usually occurs as a complication of vertebral osteomyelitis or discitis, as in this case, and may cause nerve root or spinal cord compression. Prior to the era of MRI, diagnosis was by the invasive technique of myelography. Spinal infection may also spread anteriorly, leading to a retropharyngeal abscess in the cervical region, or psoas abscess in the lumbar spine (see Fig. 6.15). The condition is a neurosurgical emergency frequently requiring surgical drainage, decompression and stabilization to prevent spinal cord infarction.

## Interventional radiology

Anaesthetic support is occasionally required for patients undergoing interventional procedures in the radiology department and this input is likely to increase as interventional procedures grow ever more complex, and may indeed partly replace some of the procedures previously undertaken in the operating theatre. The anaesthetist should be aware of a range of procedures, since they may be called upon to provide adequate sedation and analgesia for the case to be performed safely. Furthermore, some knowledge is also necessary of the variety of interventional procedures available and their potential complications, since the patient may be under the care of the anaesthetic team either before or after such a procedure.

Most intervention is performed using fluoroscopy ('screening'), CT or ultrasound image guidance (ultrasound dealt with in Chapter 7). Fluoroscopic guidance may, of course, be performed either in the X-ray department or in theatre using a mobile image intensifier. Since both CT and fluoroscopy involve the use of ionizing radiation, anaesthetists should have a basic knowledge of radiation protection.

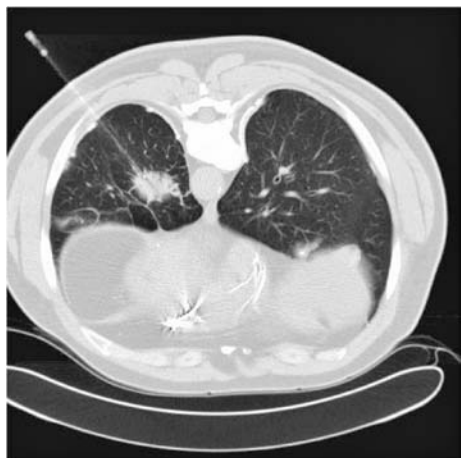MRI intervention is performed in some specialized centres, but it accounts for only a very small proportion of the overall number of cases carried out. MRI intervention usually requires a specialized 'open' MRI scanner (one that allows access for the operator to the patient rather than the patient being enclosed within the scanner) as well as the use of non-ferromagnetic (MR compatible) equipment. The high demand on MRI scanners also limits the use of this modality for time-consuming interventional procedures.

## Interventional procedures: case illustrations

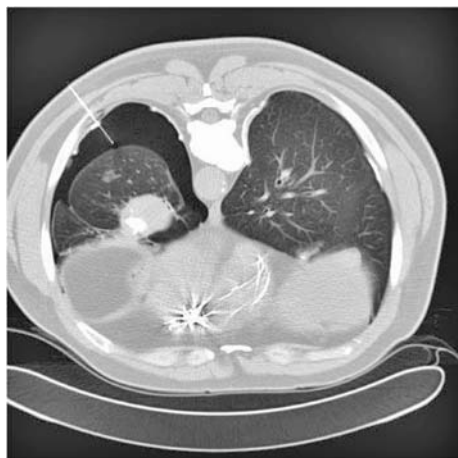The following cases serve to illustrate some of the more common interventional procedures and their potential complications.

### Question 6

- What is this procedure (Figs. 6.16 and 6.17)?
- What complication has occurred?
- What are the contraindications?
- What are the potential complications?



**Figure 6.16.** Quiz case.



**Figure 6.17.** Quiz case.

### Answer

#### CT-guided lung biopsy complicated by pneumothorax

Lung biopsy is usually performed to confirm (histologically) the diagnosis of carcinoma of the lung, and it is performed either under CT guidance, or occasionally by using fluoroscopy or ultrasound. Preliminary tests include pulmonary function, full blood count and clotting studies. The reader is referred to current British Thoracic Society guidelines. It is commonly accepted that the FEV1 should be greater than 1.0, or greater than 35% of the predicted value

**Table 6.2.** Contraindications to lung biopsy

1.	Patient with single lung (unable to tolerate small pneumothorax)
2.	Severe COPD
3.	Mechanical ventilation (increased pneumothorax risk)
4.	Bullae in vicinity of lesion to be biopsied
5.	Vascular lesion – AVM
6.	Pulmonary artery hypertension
7.	Bleeding disorder

for the individual patient. The platelet count should be over 50 000, and the international normalized ratio (INR) be less than 1.3 at the time of the procedure. Antiplatelet drugs should be discontinued for 7 days prior to biopsy. At the time of the procedure, a venous line should be sited and the patient should have their oxygen saturation and pulse monitored. Resuscitation equipment should be available including chest drain or a pleur-evac device.

Patients are positioned supine or prone according to the necessary access for the biopsy needle. The subcutaneous tissues are infiltrated with local anaesthetic (care being taken not to transgress the pleura with the local anaesthetic needle). A fine needle aspiration (FNA) biopsy (20 or 22 gauge) or core biopsy (18–20 G) may be performed according to lesion position and local preference, using either a single needle introduction or as part of a coaxial system. The needle is advanced under imaging guidance until it is confirmed to be within the lesion, and samples are then taken during suspended respiration. Immediate cytopathology within the X-ray department is sometimes available to ensure adequate cellularity of the FNA sample. Some operators suggest that the patient should subsequently lie on the side of the biopsy as this may promote atelectasis and reduce alveolar size and it has been suggested that this may help prevent pneumothorax by tamponading the puncture site.

Diagnostic accuracy of 85%–95% is usually achieved, depending on needle type, number of passes and position of the lesion.

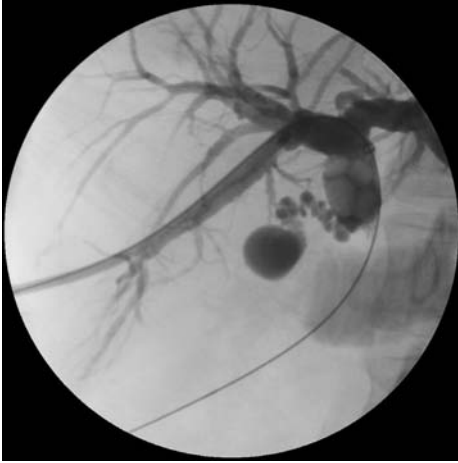For complications of lung biopsy, see below.

### Complications

1. *Pneumothorax* (see Fig. 6.17): The risk of post-lung biopsy pneumothorax is often quoted as between 5% and 15%, but actually the rate depends upon the imaging modality used for its detection and the type of lesion biopsied. Indeed, the pneumothorax rate of small deep lesions when evaluated by CT may be as much as 60%, although the vast majority of these will not be clinically significant. Emphysematous changes, multiple pleural punctures, core biopsies and positive pressure ventilation all increase the risk of pneumothorax.
2. *Haemorrhage*: Haemoptysis may be seen in up to 15% of cases, but is usually self-limiting. Haemothorax due to iatrogenic trauma to an intercostal artery can also occur. The risk is increased when using a posterior approach, where the intercostal artery may not lie within the sub-costal groove. Pulmonary haemorrhage is often seen on post-biopsy CT, but this is not usually clinically significant.
3. Air embolus has been described.

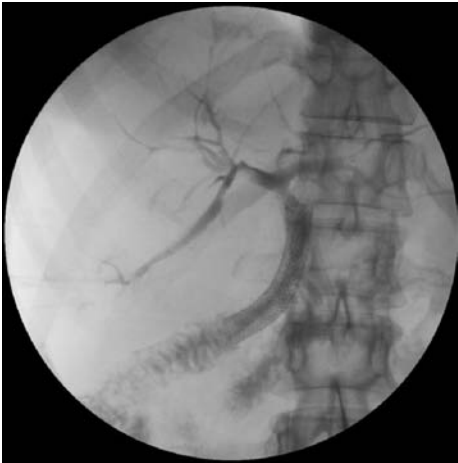Many centres perform a localized CT immediately post-biopsy followed by a CXR at 2 hours post-procedure (according to BTS guidelines) for detection of pneumothorax or other complications. It has been shown that the development of pneumothorax after this time is exceptionally rare. Patients are monitored (pulse, blood pressure, oxygen saturations) for 4 hours prior to discharge home.





**Figure 6.18.** Quiz case.

58-year-old patient with a 3-week history of back pain and jaundice. CT scanning has demonstrated a large mass in the pancreas. The common bile duct and intrahepatic ducts are dilated. ERCP was attempted but it was not possible to access the common bile duct.



**Figure 6.19.** Quiz case.

## Question 7

- What procedure has been performed (Figs. 6.18 and 6.19)?
- How is this device deployed?

## Answer

### Percutaneous transhepatic cholangiogram and biliary stent

A percutaneous transhepatic cholangiogram (PTC) is performed in cases of biliary obstruction when:

- ERCP has failed to cannulate the papilla.
- ERCP is not possible (previous Bilroth II gastrectomy, choledochojejunostomy).

The common causes of biliary obstruction include:

- gallstones,
- pancreatic carcinoma,

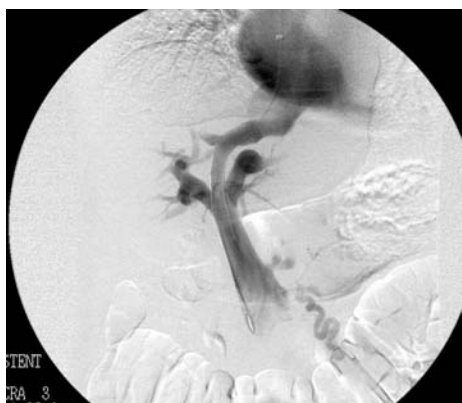
- cholangio carcinoma,
- extrinsic compression from liver metastases,
- benign strictures, e.g. post-biliary surgery.

The majority of PTCs, however, are performed for cases of inoperable pancreatic carcinoma or cholangio carcinoma, which have been demonstrated on imaging, e.g. CT or endoscopic ultrasound (EUS). They are performed in order to palliate the symptoms of obstructive jaundice; usually severe itching causing painful excoriation.

The procedure is performed by passing a fine (22 gauge) needle percutaneously into the biliary tree using a combination of ultrasound and fluoroscopic guidance. Radiographic contrast is then injected to form a cholangiogram and demonstrate the anatomy of the biliary tree. This demonstrates the cause and exact site of the biliary obstruction.

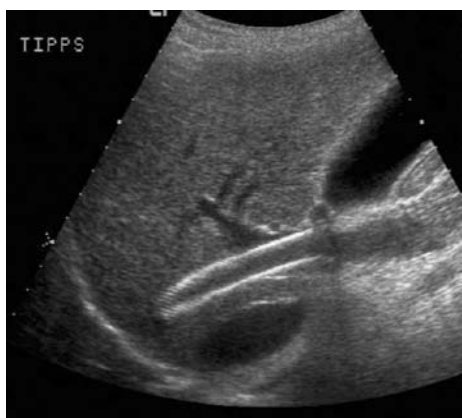When access to the biliary tree has been established, a catheter and wire combination are used to reach the site of obstruction and an attempt is made to traverse the lesion, pass into the distal common bile duct and from there into the duodenum. When a wire has been passed as far as the duodenum, this allows the deployment of a metallic stent (tube prosthesis) to permanently relieve obstruction. Stent patency is usually checked at the time of the procedure (see Fig. 6.19). The percutaneous placement of metallic biliary stents renders biliary resection difficult or impossible, and thus such stents are usually reserved for palliative or inoperable cases.

The procedure can be painful and many centres employ anaesthetic support in the radiology department.

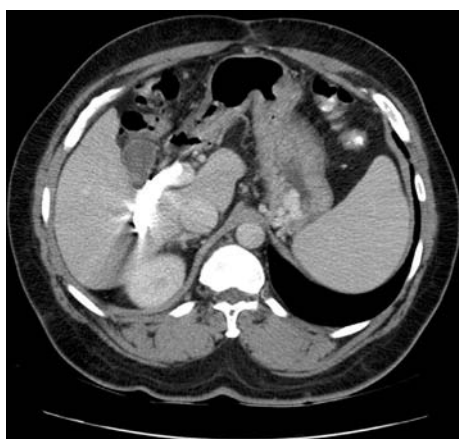

**Figure 6.20.** Quiz case.

53-year-old man.  
Hepatitis C positive for 16 years following a blood transfusion.  
Bleeding oesophageal varices.



**Figure 6.21.** Quiz case.



**Figure 6.22.** Quiz case.

## Question 8

- What is the therapeutic intervention that has been performed (Figs. 6.20–6.22)?
- What are the indications for this procedure?
- What are the complications?

## Answer

### Transjugular intrahepatic porto-systemic shunt

Surgical porto-systemic shunts have been created in the past to treat portal hypertension, e.g. portocaval or splenorenal shunts. A similar result can now be achieved less invasively using transjugular intrahepatic porto-systemic shunt (TIPS). This involves forming an artificial channel between a hepatic vein and an intrahepatic branch of the portal vein (Table 6.3).

### Procedure

Using a cutaneous approach, a communication tract is created between a hepatic vein and the portal vein to decompress portal hypertension.

**Table 6.3.** Indications for TIPS

- Acute variceal haemorrhage
- Recurrent variceal haemorrhage
- Portal hypertensive gastropathy
- Intractable ascites
- Hepatic chylothorax
- Budd–Chiari syndrome

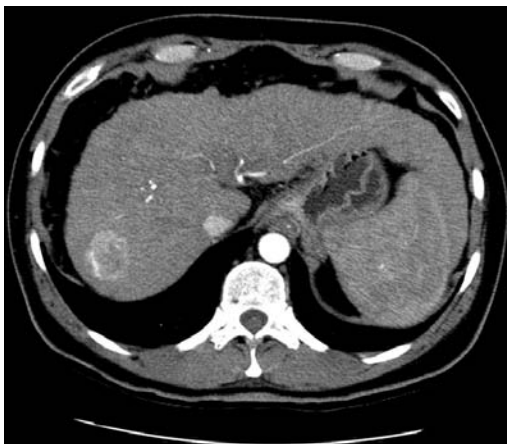The hepatic veins are catheterized using the right internal jugular vein for access (via the SVC and right atrium). A passage is created from the hepatic vein into the portal vein through liver parenchyma. Direct measurement of the systemic and the portal pressures is then made. The tract is then dilated with a balloon. A metallic stent is deployed in order to try and maintain the tract against the recoil of the surrounding liver parenchyma. The resultant reduction in portal venous pressure can then be measured. In general, a gradient of less than 12 mmHg is the target. Serial dilations of the stent can be performed until satisfactory pressure levels have been reached. Varices can be embolized at this stage (if required) using a catheter passing through the stent into the portal veins for access. In patients who may go on to liver transplantation, the stent should occupy less than half of the extrahepatic portal vein.

### Complications of TIPS

- Technical failure or incorrect positioning,
- Shunt failure/obstruction (resulting in rebleeding from varices),
- Encephalopathy,
- Hepatic injury.

### Cirrhosis and portal hypertension

The commonest cause of portal hypertension is cirrhosis secondary to alcoholic liver disease or chronic hepatitis B or C (see Fig. 6.23); further causes are listed in Table 6.4. Imaging



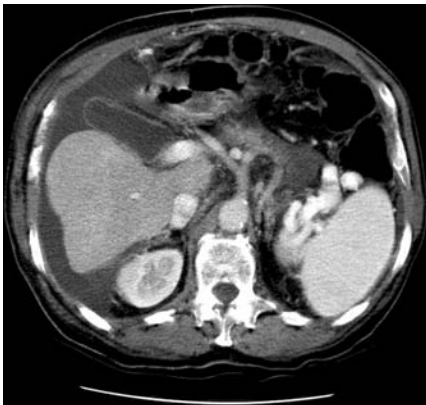**Figure 6.23.** Liver cirrhosis complicated by hepatoma. The liver has an irregular, nodular outline which is typical of cirrhosis. Hepatomas, such as this example, have avid arterial enhancement.

**Table 6.4.** Causes of portal hypertension

■ Pre-hepatic
● Portal vein compression/thrombosis
■ Hepatic
● Cirrhosis (Fig. 6.23)
● Hepatic fibrosis (congenital/acquired)
● Cystic fibrosis
● Chronic malaria
● Schistosomiasis
■ Post-hepatic
● Budd–Chiari syndrome
● Constrictive pericarditis

**Table 6.5.** Sites of porto-systemic collaterals

■ Oesophageal
■ Coronary vein
■ Para-umbilical
■ Abdominal wall
■ Perisplenic (Fig. 6.24)
■ Splenorenal
■ Gastric
■ Mesenteric
■ Haemorrhoidal



**Figure 6.24.** Hepatitis C cirrhosis complicated by portal hypertension. There is a moderate volume of ascites and dramatic varices at the splenic hilum.

features of cirrhosis and portal hypertension include liver nodularity, reversal of portal blood flow (demonstrated on ultrasound), porto-systemic collateral vessels, splenomegaly, ascites and complications such as hepatoma. Porto-systemic collateral vessels occur at many sites (see Table 6.5) as a consequence of portal hypertension (see Fig. 6.24).

## Question 9

- What procedure has been carried out?
- What are the indications and what are the common complications (Fig. 6.25)?

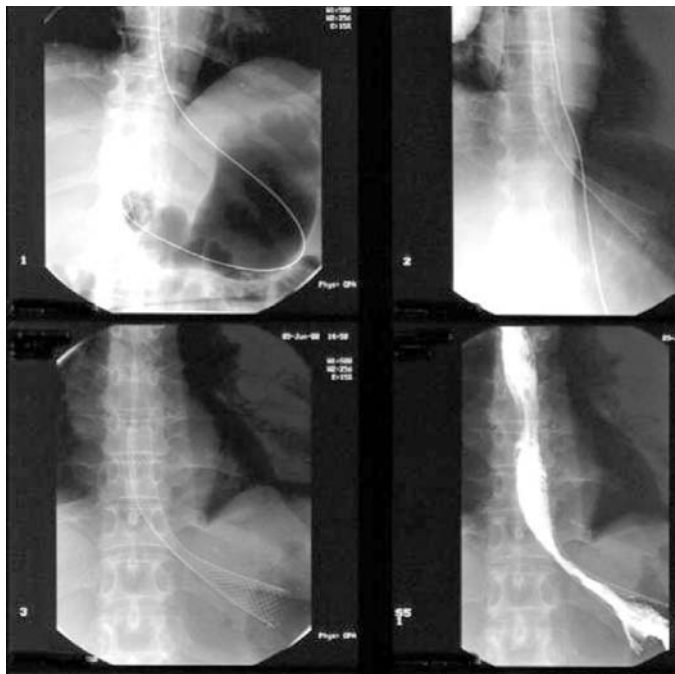

Figure 6.25. Quiz case.

## Answer

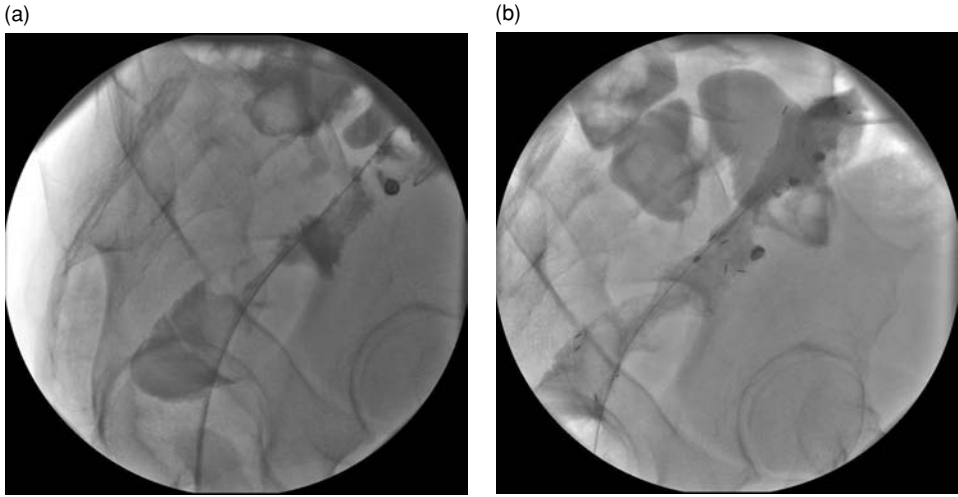
### Oesophageal stent

There is a metallic oesophageal stent, which has been inserted into the lower oesophagus. Oesophageal stents are typically used for cases of oesophageal obstruction; usually for inoperable oesophageal malignancy, but occasionally in cases of extrinsic compression due to mediastinal lymphadenopathy (secondary to carcinoma of the breast or bronchus) and very rarely in the treatment of malignant oesophageal fistulae. Oesophageal stents may be placed either by the interventional radiologist, or the endoscopist. The patient is treated like any other endoscopy with mild sedation, and does not usually require specific anaesthetic assistance.

Oesophageal stents are made from a metal mesh, which is partly covered by a plastic membrane to prevent tumour in-growth. Some stents are available with anti-reflux valves within them to help prevent acid reflux from the stomach. Such stents are often used if the stent is placed across the gastro-oesophageal junction. Many stents contain a cotton purse string at one end. Very rarely, this may be needed by the endoscopist to remove or re-locate the stent.

Complications of stent placement include the following:

*Retrosternal pain* is often seen initially after stent placement and powerful analgesia may be required. Exceptionally, the stent may have to be removed in such cases.



**Figure 6.26.** (a) and (b) Colo-rectal stent. The initial image shows a narrow irregular stricture at the junction of the recto-sigmoid colon. The second image is of the metallic stent once in position.

*Gastro-oesophageal* reflux is also commonly seen and requires anti-reflux or acid suppression therapy (proton pump inhibitors, etc.). It is often helpful to elevate the head of the bed.

*Food bolus obstruction* can occur and expert dietary advice is usually given; fizzy drinks, for example, may be beneficial following meals to help clear any food debris from around the stent.

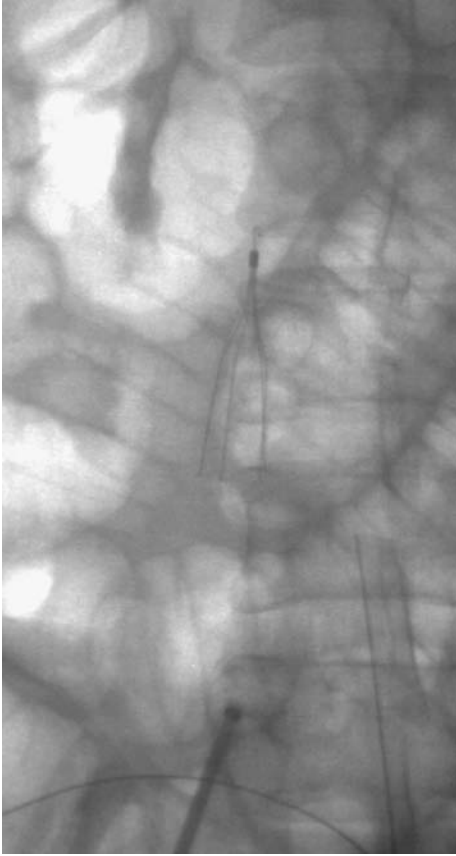*Tumour ingrowth* can lead to re-stenosis and ultimately re-occlusion. The plastic membrane over the meshwork helps prevent this, although a degree of tumour ingrowth may help prevent migration.

Other complications include *oesophageal perforation* and *stent migration*. In the case of the latter, the migrated stent usually comes to rest in the stomach, and no intervention other than stent replacement is necessary.

Colo-rectal stenting can also be performed (see Fig. 6.26). This is used in cases of large bowel obstruction as a definitive palliative procedure or as a temporizing measure prior to colonic surgery. The stent decompresses the large bowel obstruction so that elective surgery is possible after formal bowel preparation and work-up. The stent is then removed at surgery with the diseased bowel.

## Question 10

- What is this device (Fig. 6.27)?



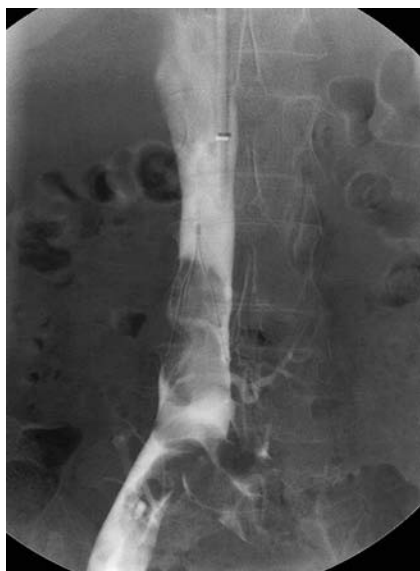**Figure 6.27.** Quiz case.

## Answer

### **Inferior vena cava (IVC) filter**

Pulmonary embolism is a significant cause of morbidity and mortality. Normally, patients with DVT or PE are treated with anti-coagulation therapy. As many as 20% of patients will have recurrent thrombo-embolic events. The purpose of IVC filters is to prevent thrombi generated in the pelvic veins and lower limbs embolizing to the right side of the heart and into the pulmonary circulation (Fig. 6.28). Ideally, highly efficient filtration without impedance to blood flow is required.





**Figure 6.28.** IVC filter, note abundant clot proximal to it.

### Indications

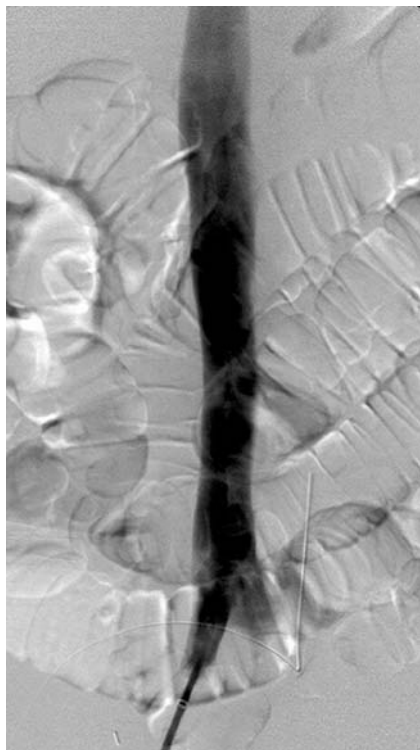
A small proportion of patients suffering from thrombo-embolic disease will have a contraindication to normal anti-coagulation therapy. This may be due to recent intracerebral haemorrhage, gastro-intestinal haemorrhage, or due to the presence of extensive oesophageal varices. Patients with a history of thrombo-embolism may require urgent surgery. In these cases, an IVC filter may be indicated. Occasionally, filters are placed if there is a history of recurrent thrombo-embolic disease despite anti-coagulation. Furthermore, a retrievable filter may be used in patients at high risk of pulmonary emboli, such as those with previous emboli undergoing pelvic surgery or in cases of orthopaedic trauma (Table 6.6).

### Placement

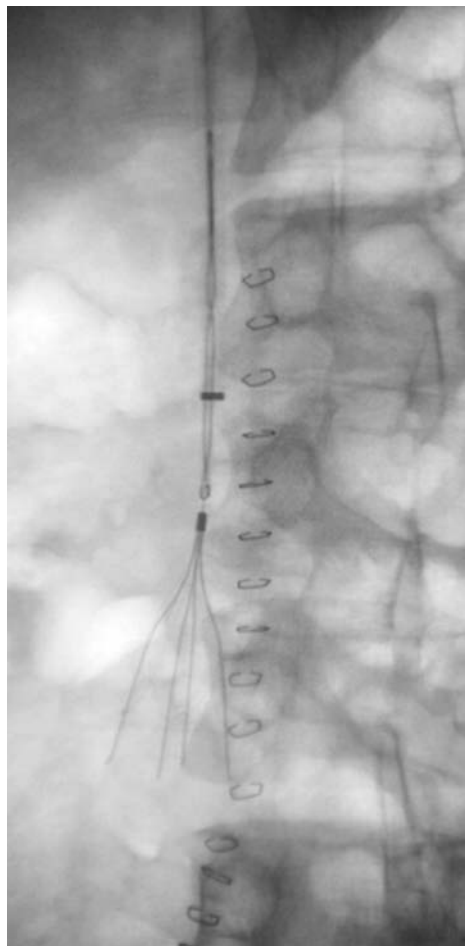
Initially, the jugular vein or common femoral vein is punctured, and a vascular sheath is placed. The right-sided veins are usually chosen as they are more anatomically ‘in line’ with the IVC, and there is usually an operator preference to work on the right side of the patient.

**Table 6.6.** Indications for IVC filters

<b>Accepted indications</b>
1. Contraindication to anti-coagulation
2. Complication of anti-coagulation
3. Failure of anti-coagulation with recurrent pulmonary emboli or an inability to achieve adequate anti-coagulation
4. Massive PE with residual DVT in patient at risk of further PE
<b>Further indications</b>
1. Severe trauma without documented PE or DVT; closed head injury, spinal cord injury, multiple long bone or pelvic fractures
2. High-risk patients, intensive care patients



**Figure 6.29.** Cavagram. This demonstrates normal anatomy and lack of luminal thrombus. The level of the renal veins is an important landmark to guide the site for filter deployment.



**Figure 6.30.** Removable IVC filter.

Vene-puncture is often performed under ultrasound guidance, and this also confirms that the access vein is patent and not thrombosed. A catheter is advanced as far as the lower IVC and a cavagram is performed (Fig. 6.29) to assess the level of the renal veins, and the presence of accessory renal veins or caval thrombi. The diameter of the inferior vena cava is measured, as significant dilatation may predispose to filter migration. The filter is then deployed below the renal veins. This is important to prevent any obstruction to renal vein outflow which might predispose to renal vein thrombosis. Different types of filter exist such as Bird's Nest filter or Greenfield filters.

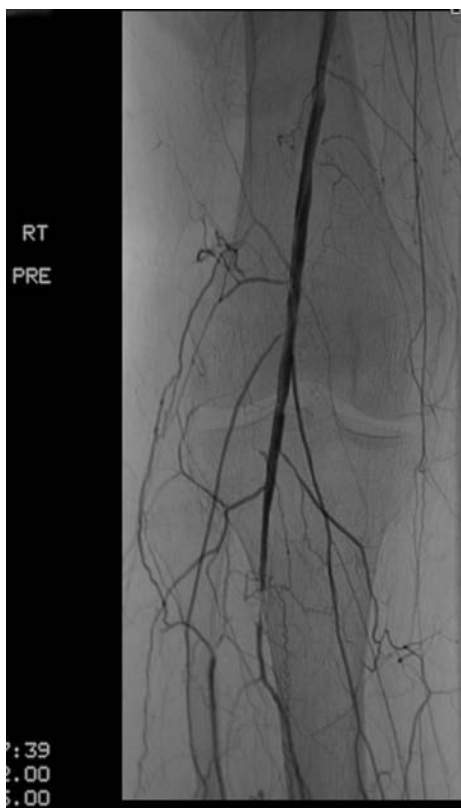Retrievable filters are a relatively recent development (Fig. 6.30), which depending on the type used are ideally removed at between 14 days and 3 months following deployment. These are ideal in the young patient who is only temporarily at risk of thrombo-embolic disease.

**Table 6.7.** Complications of IVC filters

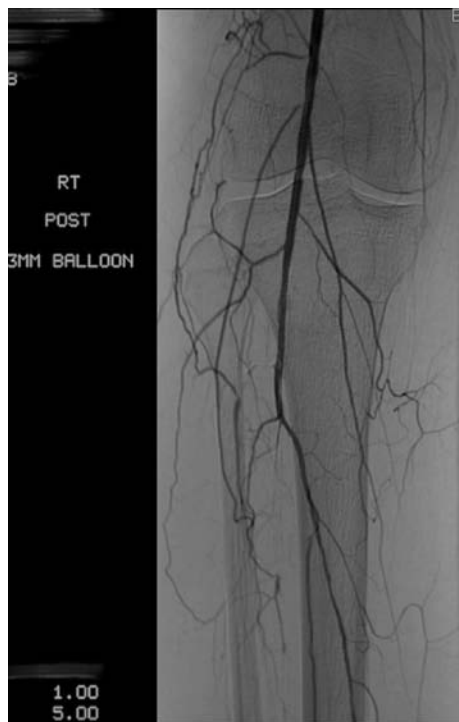- Misplacement of filter
- Migration of filter
- Caval penetration
- Filter embolization
- Caval occlusion

### Complications

There is a low risk of thrombosis either within the IVC or within the access vein. This can cause significant morbidity if it leads to bilateral lower limb swelling and oedema. Erosion of the IVC wall and filter migration are further rare complications (see Table 6.7).



**Figure 6.31.** Quiz case.



**Figure 6.32.** Quiz case.

Elderly patient with a history of severe ischaemic leg pain.

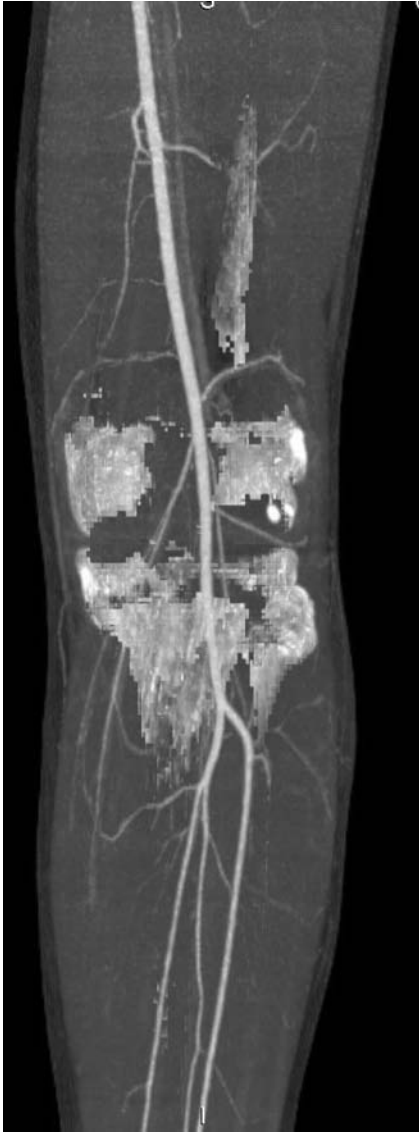## Question 11

- What investigation has been performed?
- What subsequent procedure has been performed?

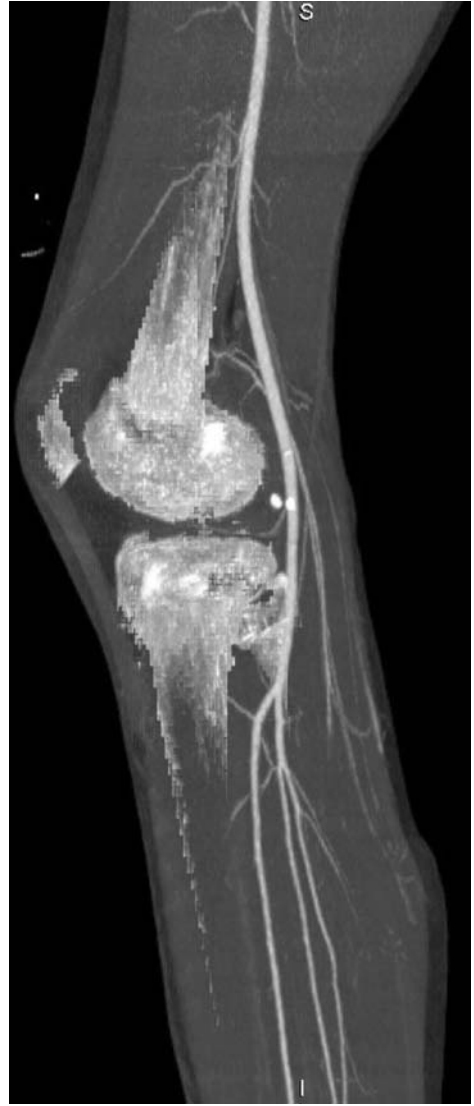## Answer

The examination is an angiogram of the lower limb. The first image shows occlusion of the posterior tibial artery. The second image has been taken following a balloon angioplasty. Patency of the diseased segment has been re-established.

Duplex ultrasound examination is often the initial investigation undertaken for presumed leg ischaemia, although this is highly operator dependent. Duplex ultrasound is a readily available and accurate method of peripheral arterial evaluation, without the need for either ionizing radiation or contrast material.



**Figure 6.33.** CT arteriogram in a 16-year-old following dislocation of the knee. No evidence of vascular injury is shown. CTA does not require the same specialist interventional skills needed for angiography which makes it a useful technique 'out of hours'.



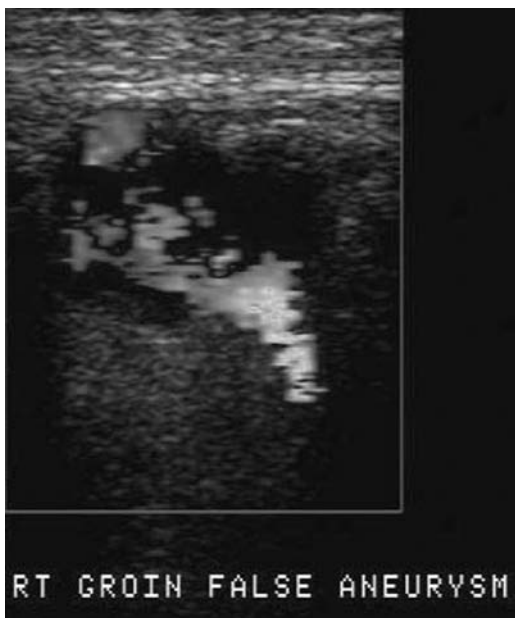
**Figure 6.34.** Sagittal reformatted image from CTA.

In many hospitals, however, further evaluation is also performed. Until recently, this was undertaken using diagnostic angiography. Advances in cross-sectional imaging technology mean that other options for investigation now include CT angiography (CTA), or magnetic resonance angiography (MRA) according to local availability and expertise.

CT angiography (Fig. 6.33 and 6.34) is a technique that requires the injection of iodinated contrast medium followed by rapid scanning using multi-detector spiral CT, from the pelvis

**Table 6.8.** Complications from angiography

■ Systemic
● Contrast reaction
● Deterioration in renal function secondary to contrast load
■ Puncture site
● Bleeding
● Haematoma
● Pseudoaneurysm formation (Fig. 6.35)
● Infection
■ Vessel
● Thrombosis occlusion
● Embolism of clot or plaque; air embolus
● Dissection of vessel wall



**Figure 6.35.** Arterial pseudoaneurysm Doppler image. This is a complication of arterial puncture, usually when a large introducer sheath has been used. It is a non-endothelialized space in communication with the artery which contains pulsating arterial blood. Treatment methods include surgery, ultrasound-guided compression which is painful and time-consuming or ultrasound-guided thrombin injection.

to the ankles. The radiation dose of this technique is high, and interpretation can be difficult and time consuming, particularly discriminating between calcified plaque and IV contrast. It is necessary to view the 'CT data' on a workstation which allows reconstruction of the images. In this way the images can be viewed in a coronal plane. In the emergency setting CTA can be a useful diagnostic technique, particularly 'out of hours' when specialist vascular radiologists may be unavailable. Magnetic resonance angiography is an alternative modality which benefits from its lack of ionizing radiation and the fact that potentially nephrotoxic iodinated contrast agent is not required. Coronal reconstructions can be generated by specialist radiographic staff. It is slightly more time-consuming to perform than CTA, and

as with any MR examination, specialist non-magnetic injectors and support equipment are required.

Clinical cases are usually discussed at a vascular multi-disciplinary meeting before proceeding to vascular intervention. Interventional vascular radiology, like all branches of interventional radiology, requires close collaboration between radiologists and clinicians.

Complications from angiography are rare; bleeding from the puncture site is the most common, occurring in approximately 3% (see Table 6.8).

## Further reading

Baum SA. *Abram's Interventional Radiology*, 2005. Boston, MA: Lippincott Williams and Wilkins.

Cook CKL. *The Radiology Survival Guide: For Students and Junior Doctors*, 2007. London: Quay Books/Mark Allen Publishing.

Kandarpa K, Aruny JE. *Handbook of Interventional Radiologic procedures*, 3rd revised edition, 2001. Boston, MA: Lippincott Williams and Wilkins.

Kessel D, Robertson I. *Interventional Radiology: A Survival Guide*, 2005. Oxford, UK: Churchill Livingstone.

---

Introduction	251	Ultrasound imaging: case illustrations	271
Ultrasound imaging: principles of image formation	251	Echocardiography for patients on intensive care units	279
Applications of ultrasound for patients on intensive care units	255	Ultrasound-guided regional anaesthesia	287
Ultrasound-guided procedures	259		
Ultrasound-guided procedures: needle visualization	259		



## Introduction

The use of ultrasound in anaesthesia and intensive care has expanded rapidly, due to the increased dissemination of ultrasound skills, NICE guidelines recommending the use of ultrasound in line placement, and the advent of high-quality, affordable, portable ultrasound machines. Machines vary in cost and complexity, from basic machines designed purely for line placement, to full systems capable of high resolution imaging for nerve blocks and with full echocardiographic capability. Affordable, complex machines now lie within the grasp of the small district general hospital.

## Ultrasound imaging: principles of image formation

Ultrasound (US) appeared as a medical imaging modality in the 1980s. The origins of US are in sonar, used for purposes of naval navigation; ultrasound is also used in engineering for the detection of flaws in metal pipes. Ultrasound is an imaging modality that relies upon the use of sound waves, which are transmitted into the body and are then reflected back again from the structures being examined. The sound used is of a very high frequency, above the range of normal hearing, 2.5–15 MHz (1 MHz = 1 million cycles/second).

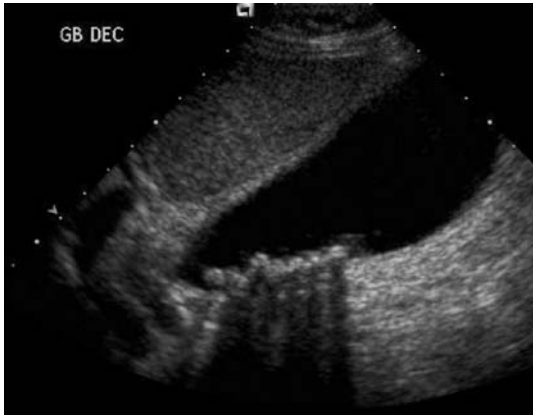The device which both transmits the sound pulses and receives the returning echoes is called a transducer. The transducer is both a transmitter *and* a receiver. It contains a piezoelectric crystal, which is able to convert electrical signal into sound and then convert the returning sound wave back into electrical signals again. Sound is a longitudinal mechanical wave, which follows similar rules to those that govern light waves. It can be reflected, absorbed and refracted by a medium such as the human body.

The ultrasound image is produced by the reflected part of the US beam. Different reflecting surfaces or interfaces within the body reflect sound to different degrees. The proportion of the beam reflected depends on two factors, the tissue's acoustic impedance and the US beam's angle of incidence with the reflecting surface. The reflection depends on the acoustic impedance of the two materials at reflective interfaces. The greater the difference in acoustic impedance between two structures the greater the percentage reflection. Acoustic impedance is a product of a material's density and the velocity of sound in that material. The acoustic impedance of a few structures is listed below; the values themselves are not important but serve to illustrate why for example soft tissue/bone and soft tissue/air interfaces produce almost complete reflection (Fig. 7.1). At a soft tissue/air interface, 99.9% of the beam is reflected. This means virtually none of the beam is transmitted any further into the patient (Table 7.1).

A strongly reflective structure (echogenic structure) appears as a bright white area on the image, whereas an area which does not return any echoes (anechoic structure) appears black on the final image. An ultrasound image is a map of reflectivity of the body part scanned.

**Table 7.1.** Acoustic impedance ( $\text{g}/\text{cm}^2 \text{ s} \times 10^{-5}$ )

Air	0.0004
Fat	1.38
Bone	7.8
Liver	1.65
Kidney	1.62



**Figure 7.1.** Gall bladder containing gallstones. The large difference in acoustic impedance between the calcified gallstone and the surrounding bile means virtually all of the sound is reflected. This causes 'acoustic shadowing' beyond the stones.

Organs containing multiple interfaces will produce multiple echoes and this is characteristic of solid organs like liver, spleen and kidneys. Structures containing no interfaces will appear anechoic/echo-free, such as liquid or urine in the bladder.

Absorption of the ultrasound beam occurs due to frictional forces within a medium. This leads to energy removal from the beam, which is then converted to heat. Absorption and scattering both contribute to the attenuation or propagation loss of the beam. There is a linear relationship between frequency and absorption. Doubling the frequency of the probe roughly doubles the absorption. This is the reason why a high frequency probe does not have such good tissue penetration as a low frequency probe. **High frequency probes are less good at looking at deep anatomical structures.**

Every ultrasound image is composed of a discrete number of lines of echo data placed side by side to appear continuous. Multiple lines of data are built up as the ultrasound beam sweeps through the field of view. In order to build up each of the single lines of data, the time taken for the returning echo is measured. This allows the depth of the reflecting interface to be determined. Each sweep of the ultrasound beam produces one frame of data (composed of multiple lines). Many complete sweeps are performed every second, which produces the frame rate (frames per second). The operation is analogous to the operation of a television camera. At any one moment, the ultrasound beam is scanning along one of the many lines of sight which will ultimately form the image. The image is constantly updated at the prevailing frame rate. This can be frozen and hard copy images produced.

### Probe frequency

Sound travels in air at 330 m/s, and in tissues at an average velocity of 1540 m/s. Frequency and wavelength are related by the formula:

$$\text{Propagation velocity} = \text{frequency} \times \text{wavelength}$$

To achieve a wavelength of 1 mm, the frequency has to be 1 500 000 Hz or 1.5 MHz. Obviously, a much higher resolution than 1 mm is required for nerve imaging, and probes of up to 15 MHz are used for this purpose, allowing for a resolution of less than 0.1 mm to be



**Figure 7.2.** TGC Control. These 'sliders' are used to give a boost to returning echoes from different depths.

achieved. The resolution of the picture produced depends on the wavelength of the sound wave used. ***The resolution of the picture therefore depends on the frequency of the probe.***

There is a trade-off between resolution and penetration. Higher frequency transducers allow better resolution, but as the frequency is increased penetration is reduced. As a general rule, the highest frequency transducer should be used to achieve the penetration required. The other advantage of high frequency probes is the 'divergence' of the beam. The ultrasound beam has a parallel zone close to the probe and a diverging zone more distant from it. The parallel or useful portion of the beam is longer for high frequency transducers.

Several assumptions are inherent in ultrasound imaging, for example, that sound travels at a fixed speed in tissues, that sound is reflected and not refracted, and that sound travels in straight lines. Unfortunately, these assumptions are not always correct, and this can lead to artefacts being generated. Discussion of these artefacts is beyond the scope of this chapter. Recommended further reading can be found at the end of the chapter.

## Ultrasound image display

The image displayed is a reconstruction created from the returning echoes. Greyscale imaging assigns a shade of grey to a returning echo depending on its intensity. This is then displayed on a monitor with highly reflective, 'echogenic' areas shown as white or bright and poorly reflective 'echo-poor' areas seen as dark grey or black.

Various controls are used to regulate the intensity of echoes from various depths so as to optimize the image.

### Time gain compensator (TGC)

This control is designed to give a uniformly 'grey' image to superficial and deep structures, so that there is consistency between the appearance of close and distant structures. The control gives a boost to low intensity echoes returning from deep anatomical areas. The adjustment is usually on the keyboard as a number of sliding controls (see Fig. 7.2).

### Coarse gain

This control increases all the echoes from all depths. This has the effect of increasing the brightness of the whole screen.

### Depth control

This allows the image to be expanded or contracted to give either a 'zoomed in' or 'wide angle' view of the anatomy. (See further comments in needle visualization section.)

### Focus

This should be set at the level of maximum interest.

## Doppler ultrasound

The apparent change in frequency produced by relative movement between a sound emitter and receiver is called the Doppler effect (Christian Doppler, 1805–1853). This principle is used in ultrasound systems to provide information about blood flow. This may simply be in the form of audio information, a spectral display or as colour Doppler displays. Two main ways of obtaining Doppler information can be used:

1. Continuous wave ultrasound beam – information presented as an audio signal and/or a spectral display. Continuous wave Doppler lacks any form of depth localization.
2. Pulsed Doppler sends out repeated pulses at a controlled rate, waiting for the return signal before a new pulse is transmitted. This provides both velocity and positional information from the target, e.g. flowing blood.

## Duplex Doppler

Duplex Doppler is a term used to refer to a combination of greyscale and pulsed Doppler display. It allows the operator accurately to position the site from which the Doppler signal is obtained. The machine produces a greyscale image with a line of sight along which there is a Doppler acquisition marker/gate. The position and size of the gate can be varied within the ultrasound image, so that it lies within the vessel or area of interest. When the machine is switched into Doppler mode, a real-time Doppler spectral display appears on the monitor. This can be used to assess flow direction, resistance, evidence of spectral broadening and peak velocity.

## Colour Doppler and power Doppler

The disadvantage of duplex Doppler is that, at any moment in time, Doppler information is only being acquired from one single location. Colour Doppler and power Doppler allow detection of flow over a large area of the field of view. Colour Doppler imaging involves assessing a nominated area for evidence of Doppler shifts and then colour coding those regions. It allows assessment to be made of the relative velocity and direction of blood flow. Colour images of moving blood and greyscale images both appear in real time. Power Doppler is more sensitive in detecting blood flow but the velocity and direction of flow cannot be assessed.

Clinical applications for the use of Doppler are numerous and include:

- carotid artery assessment (carotid artery stenosis),
- peripheral Doppler venography (deep venous thrombosis),
- echocardiography,
- assessment of flow in any of the intra-abdominal vessels, e.g.

- aorta (aneurysm), inferior vena cava (thrombosis),
- portal veins (direction of flow), hepatic veins (patency), varices,
- renal arteries (stenosis).

Doppler can be used to assess the vascularity of tissues such as tumours or inflammatory lesions.

## Optimizing the image

Viewing conditions can affect the diagnostic quality of the final image. Ambient light needs to be reduced as much as possible. This is particularly important in busy ward or intensive care environments. Closing curtains and turning off overhead lights can make a big difference.

Imaging ‘presets’ are programmed into most mid and high specification machines. These are predetermined factors which optimize the final image; they vary for different anatomical areas. The area to be scanned is selected from a menu of alternatives such as ‘thyroid’, ‘abdomen’, ‘small parts’, ‘gynaecology’, etc. It is important to check the appropriate preset has been chosen.

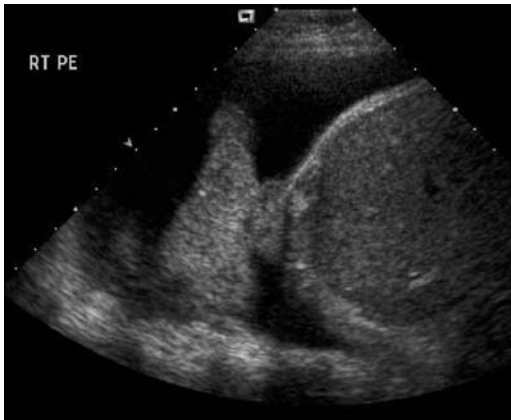## Applications of ultrasound for patients on intensive care units

Ultrasound imaging has a huge variety of applications for patients on intensive care units. These include both diagnostic and therapeutic applications; some of the more common applications are listed below. Ultrasound is readily portable and can often be performed at short notice. The size of machines and the quality and resolution of images has improved over the last decade. It is a versatile imaging modality with many applications on intensive care units.

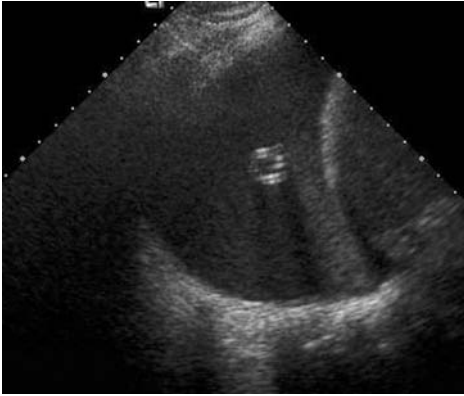
## Thoracic

### Diagnostic applications

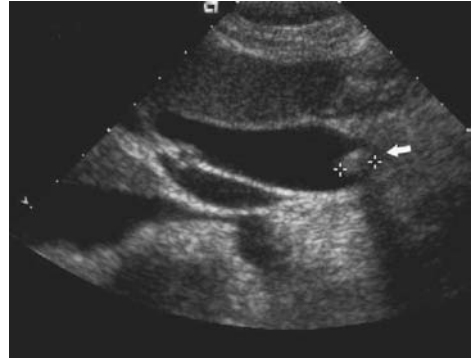
- Echocardiography,
- Pleural effusions (see Fig. 7.3),
- Empyema,
- Pleural biopsy.



**Figure 7.3.** Pleural effusion. The collapsed lung can be seen within the pleural fluid. Fluid is readily identified using ultrasound whether in the pleural space or within the abdomen.



**Figure 7.4.** Pleural effusion drainage – pigtail catheter. The insertion of pigtail and Seldinger type drains is performed most safely using ultrasound guidance.



**Figure 7.5.** Dilated bile duct. The diameter of the duct can be accurately measured with ultrasound and in cases of obstruction, the cause may be identified such as this gallstone. Duct size increases with age or following cholecystectomy.

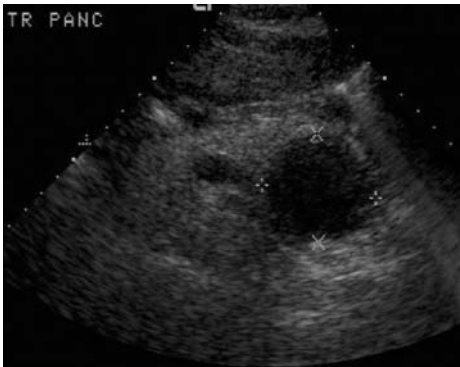
### Therapeutic applications

- Fluid aspiration,
- Chest drain insertion (see Fig. 7.4),
- Percutaneous tracheostomy insertion.

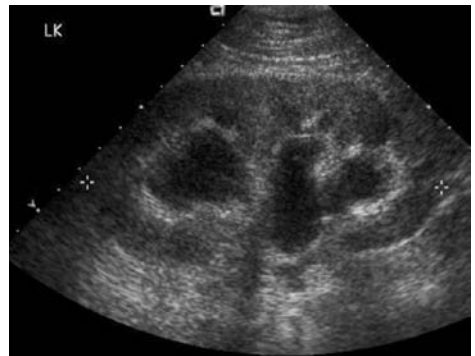## Abdomen

### Diagnostic applications

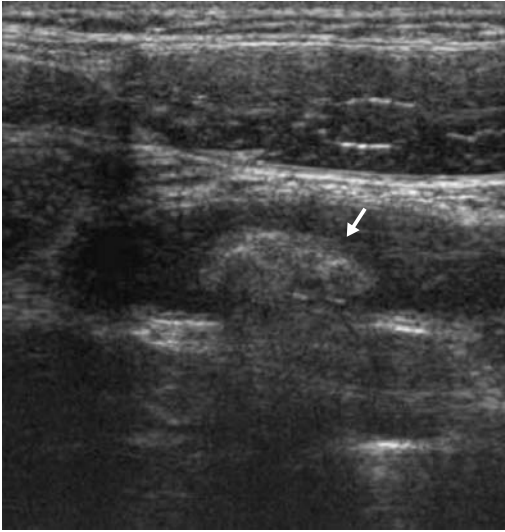- Biliary disease – gallstones (see Fig. 7.1), bile duct obstruction (see Fig. 7.5), cholecystitis,
- Pancreatic disease and its complications, e.g. pancreatitis and pseudocysts (see Fig. 7.6),
- Renal disease – stones, hydronephrosis (see Fig. 7.7), parenchymal thickness, etc.,



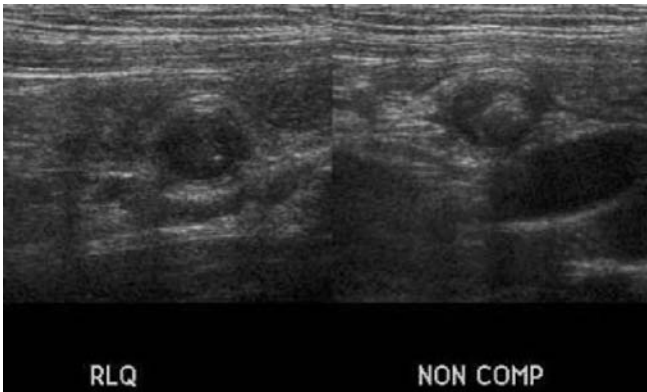
**Figure 7.6.** Pancreatic pseudocyst. This is one of the complications of pancreatitis which is readily diagnosed on ultrasound. If the collections become infected, then ultrasound-guided drainage is appropriate. Sterile collections do not usually require drainage.



**Figure 7.7.** Hydronephrosis. The pelvicalyceal system is dilated. Proximal causes of obstruction such as proximal calculi can be diagnosed on ultrasound; the ureters are, however, poorly seen except the distal few centimetres at the vesicoureteric junction.



**Figure 7.8.** Appendicitis. Ultrasound has poor sensitivity but high specificity in the diagnosis of appendicitis. Features include a 'lith', (arrow) a blind ending, non-compressible loop of bowel 6 mm or greater in diameter and surrounding fluid.



**Figure 7.9.** Appendicitis. Images in transverse section demonstrating failure of compression of the appendix.

- Bowel pathology – appendicitis (see Figs. 7.8 and 7.9),
- Abdominal trauma – solid organ injury with free fluid (Fig. 7.10), ascites.

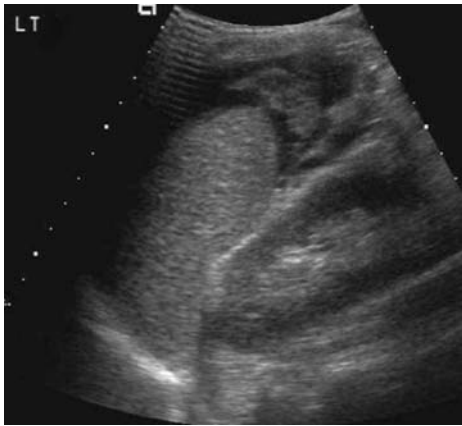### Therapeutic applications

- Gall bladder drainage,
- Pseudocyst/ascitic drainage,
- Abscess drainage (see Figs. 7.11 and 7.12).

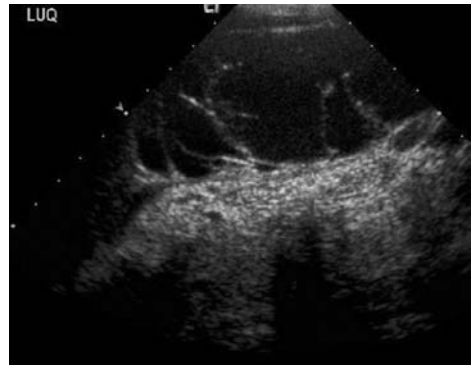
## Vascular: arterial and venous

### Diagnostic applications

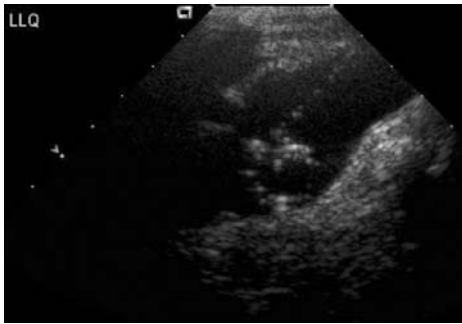
- Ischaemic limbs.
- Deep vein thrombosis (upper and lower limbs) (see Fig. 7.13).



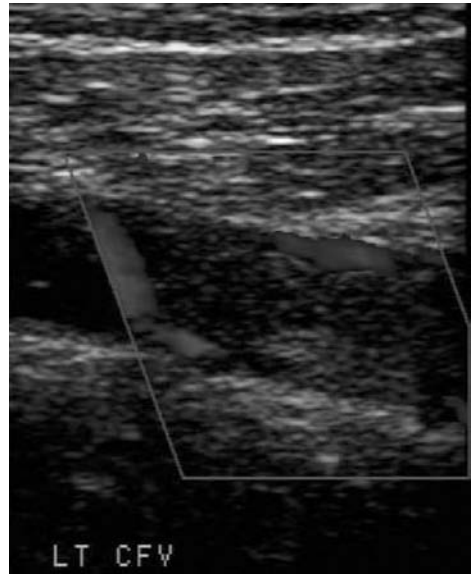
**Figure 7.10.** Free fluid from splenic trauma. Ultrasound is extremely sensitive in the identification of free fluid. In the setting of trauma, the *absence* of free fluid is very useful in excluding intra-peritoneal haemorrhage. It has largely replaced diagnostic peritoneal lavage (DPL).



**Figure 7.11.** Abdominal abscess in a patient with diverticular disease.



**Figure 7.12.** Drainage of abdominal abscess. Ultrasound is the imaging modality of choice for the drainage of suitable abdominal abscesses. Real-time visualisation is possible for the insertion of pigtail drains – which are well seen on ultrasound. This is a portable technique which can be used on intensive care units.



**Figure 7.13.** DVT. A combination of greyscale ultrasound and Doppler ultrasound is used in the diagnosis of deep vein thrombosis. A normal vein can be compressed; it demonstrates phasic flow in time with respiration and squeezing on the limb augments blood flow. Deep vein thrombosis interrupts flow and prevents complete compression of the vein. The clot is frequently directly visualized. The technique is eminently suitable for patients on intensive care units, many of whom are at high risk of DVT.



**Therapeutic applications**

- Guided insertion of central venous lines and arterial lines.

**Musculoskeletal****Diagnostic applications**

- Septic arthropathy.

**Therapeutic applications**

- Joint aspiration.
- Ultrasound-guided regional anaesthesia.

**Ultrasound-guided procedures**

Ultrasound can be used to guide an extremely wide range of procedures including guided central line insertion, pleural aspiration, regional anaesthesia, marking sites for safe insertion of chest drains, solid organ or tumour biopsy and various abdominal work. There are several advantages of ultrasound over other forms of imaging, which make it extremely useful for sick or ventilated patients and especially those with numerous support tubes and patients on intensive care units who cannot be moved.

**Ultrasound-guided procedures: needle visualization**

Image guidance is required to enable an ever-increasing number of procedures, interventions and minimally invasive techniques to be carried out. Most imaging modalities (screening/fluoroscopy, CT, MRI, ultrasound) can be used for image guidance, each with its advantages and inherent problems. Ultrasound image guidance is a versatile technique which can be used for a huge variety of different procedures. Some of the advantages and disadvantages are listed in Table 7.2.

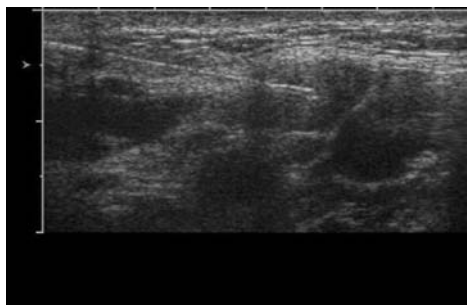
**Table 7.2** Advantages and disadvantages of ultrasound

*Advantages*

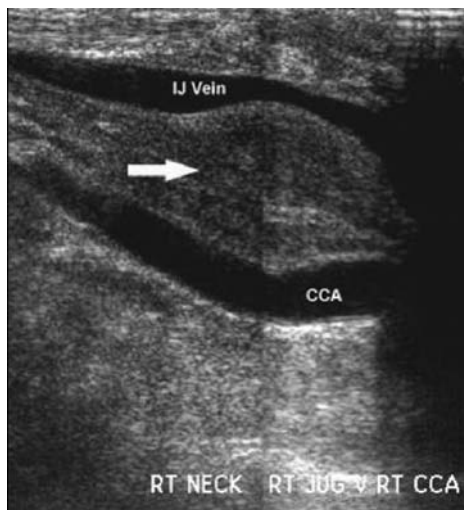1. Portable – patients need not be moved
2. No ionizing radiation
3. Imaging is in real time so allowance can be made for patient movement or breathing during interventional procedures
4. Imaging is not restricted to fixed planes, e.g. sagittal, coronal

*Disadvantages*

1. Small field of view
2. Image quality is restricted in large, obese patients
3. Bowel gas impairs image quality
4. Ultrasound is operator dependent and requires specialist training



**Figure 7.14.** Clear visualization of the biopsy needle, from skin surface to the target organ.



**Figure 7.15.** Large haematoma between the carotid artery and the internal jugular vein. A complication of central line placement.

The main skills necessary are a steady hand, reasonable hand–eye coordination, knowledge of the regional anatomy and a basic understanding of the ultrasound scanning equipment. Once learnt, the skills required can be applied and adapted for use in other ultrasound-guided procedures. For example, the skills learnt for abdominal paracentesis can equally be applied to drainage of pleural effusions.

## Objectives for ultrasound-guided interventional procedures

Irrespective of the type of ultrasound-guided intervention, whether chest drainage, abdominal paracentesis or regional guided anaesthesia, the ‘gold standard’ is to visualize the interventionist’s needle from the skin surface to the target area (Fig. 7.14); if the needle tip can be visualized at all times, this minimizes the risk of inadvertently causing traumatic injury to the adjacent anatomy. For instance, in central line placement, ultrasound visualization can help to avoid complications such as carotid puncture, pneumothorax and haematoma formation (Fig. 7.15), and its use has been recommended by NICE for this purpose.<sup>1</sup>

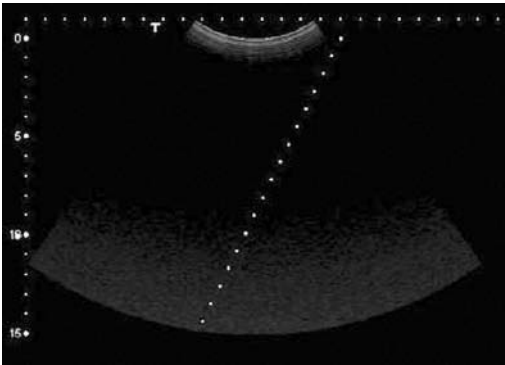
## Needle visualization and scan technique

In the setting of ultrasound-guided biopsy, two basic techniques can be employed; either a ‘freehand’ technique, in which the interventional needle and the ultrasound probe are held separately in different hands, or a needle guide technique.

A needle guide is a device which fixes a biopsy needle to the side of an ultrasound probe (Fig. 7.16). The ultrasound machine displays a trajectory corresponding to the predicted line of passage of the affixed needle (Fig. 7.17). This enables small focal lesions to be targeted, e.g. liver biopsy. It is a safe method for trainees to use when initially learning biopsy procedures, but some operators find the technique limiting and cumbersome, preferring to use a freehand method.



**Figure 7.16.** Probe and needle guide. This device is suitable for procedures such as liver biopsy.



**Figure 7.17.** The display shows the line or trajectory which the affixed needle will take. The probe position and angle is manipulated so that the target structure is along this line. The needle can then be advanced towards the target.

The freehand technique is advised for central line placement, chest drain insertion and abdominal paracentesis, as this technique is more flexible, but still aims to see the needle from skin surface to the target organ in real time.

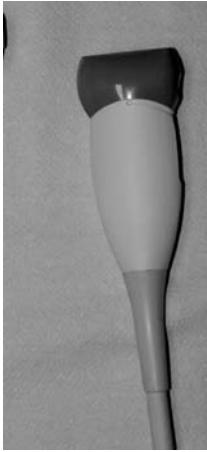A number of components or skills are required in order to undertake ultrasound image guidance as part of a procedure. It is necessary to recognize the anatomy of the area that is being examined. This comes with experience and through having a good knowledge of the dissection anatomy and also of the common ultrasound appearance of the main structures. A degree of hand-eye coordination is required in order to guide the needle in the appropriate direction.

## Application of ultrasound physics to optimize visualization

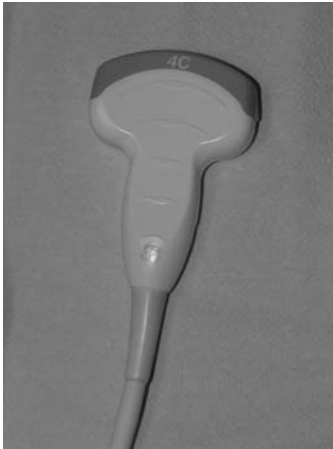All ultrasound-guided procedures require an understanding and application of ultrasound physics to optimize the visualization of a needle.

### Probes

It is important to select the correct probe for any ultrasound-guided procedure. For procedures involving superficial structures, such as central line placement or regional anaesthesia, a linear high-frequency probe (e.g. 12 MHz) is the most appropriate (Fig. 7.18). For procedures involving deeper structures, either in the chest or in the abdomen, a curvilinear probe of lower (often variable) frequency is recommended (e.g. 3.5–5 MHz) (Fig. 7.19).



**Figure 7.18.** High frequency linear probe.



**Figure 7.19.** Curvilinear probe.

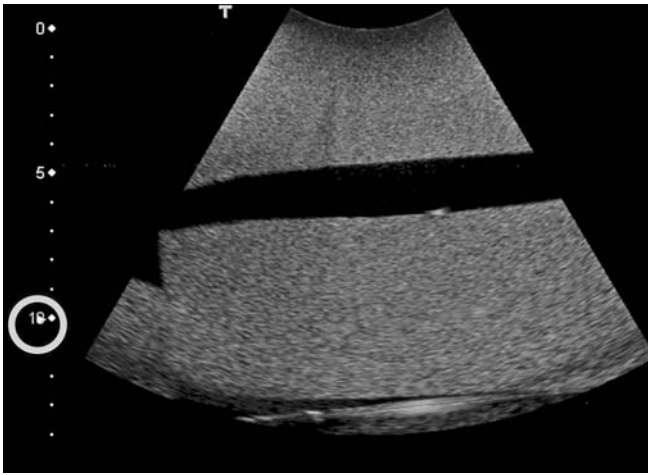
Probe choice relates to the trade off between beam attenuation/penetration and resolution. High frequency probes have excellent resolution but are readily attenuated and only penetrate into the superficial structures. Lower frequency probes have poorer spatial resolution, but their attenuation is less and they penetrate further, into deeper tissues.

## Probe frequency

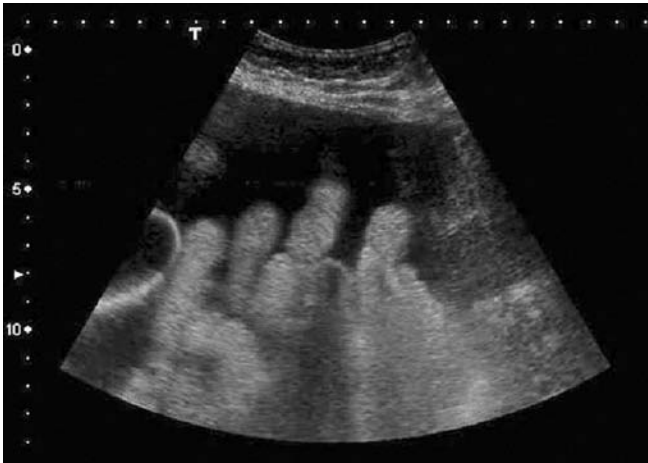For probes of variable frequency, the highest appropriate frequency should be selected, thus maximizing resolution of the area in question.

## Focus

The focal point should be positioned at the area of anatomical interest. Most ultrasound machines have a marker on the side of the display, which indicates the position of the focus (Fig. 7.20). If the focus is set too deep, relative to the target anatomy, then the spatial resolution in the area of interest is reduced.



**Figure 7.20.** The focus should be positioned at or slightly above the target area. This maximizes visualization of the needle during passage from the skin to the target. This image is from a 'biopsy phantom' and the arrow (circled) indicates the position of focus.



**Figure 7.21.** Abdominal ascites. The bowel loops can be clearly seen amongst the free fluid.

## Depth

The depth needs to be adjusted so that the area of interest occupies the majority of the display on the ultrasound screen. There is little point in demonstrating the anatomy deep or peripheral to the target organ.

## Overall gain and TGC

These should be adjusted to produce a satisfactory image before starting the procedure. A uniform display of suitable intensity is required.

## Initial scan

Before any intervention is undertaken, an initial scan should be performed to familiarize the operator with the anatomy of the target area, the adjacent organs and any pathological structures or free fluid (Fig. 7.21). It helps in the planning of the procedure and, in particular,



**Figure 7.22.** A probe cover protects the ultrasound probe and helps maintain sterile conditions.

the angle of approach. Vital anatomy between the skin surface and the target area can be identified. The various settings on the machine (listed above) can be adjusted at this stage to optimize the image.

It can be helpful to place a mark on the skin at this stage either with a marker pen or by making an impression on the skin with the reverse end of a green needle or finger nail. This will help when creating a sterile field and injecting local anaesthetic.

## Probe covers and patient preparation

After this initial scan has been performed, the patient can be draped and a sterile field prepared.

A probe cover is recommended for the majority of interventional procedures (Fig. 7.22). This serves to keep the area as sterile as possible and also protects the probe to some degree. A number of different commercial probe covers are available. These are fairly supple, shaped polythene sleeves, which can be applied around the probe and the transducer cable. Non-sterile gel is applied directly to the transducer before the cover is applied. Sterile gel is required to couple the covered probe to the skin surface. This is applied to the outside of sterile probe cover.

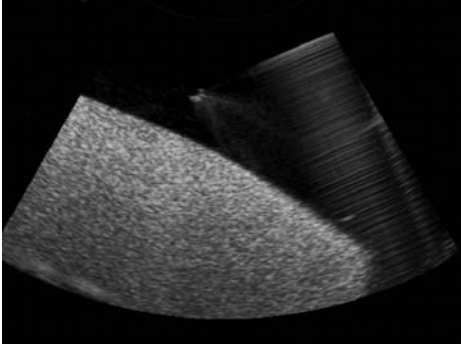
The patient is draped and local anaesthetic is drawn up.

## Hand position

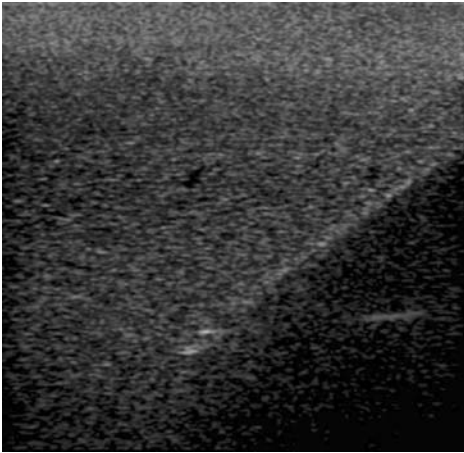
When starting the procedure, the probe needs to be held rock solid without moving it at all. This should give a clear steady image that includes:

- the target organ,
- needle track,
- just below the skin puncture site.

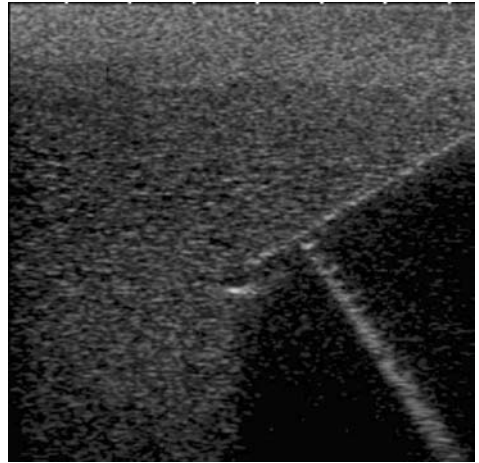
It is often most effective to hold the transducer in the non-dominant hand so that local anaesthetic can be introduced with the dominant hand. Once the optimal image of the target organ is obtained, fixing the scanning hand is necessary. This can be accomplished by resting the little finger and 'ulnar border' of the hand on the patient's skin to give added stability. Local anaesthetic can then be infiltrated down to the target organ. It is most useful to visualize the



**Figure 7.23.** Bright reflection from the needle tip, shaft and reverberation artefact.



**Figure 7.24.** Small needle 22 G.



**Figure 7.25.** Larger needle 16 G producing a more visible reflection.

local anaesthetic needle down to the target organ, so that angles and distances can be assessed before any larger interventional needles are introduced.

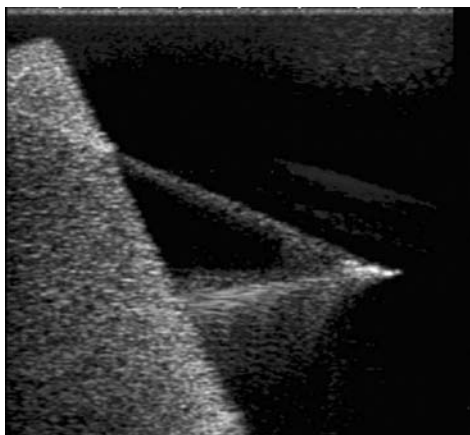
## Why do we see the needle?

There are a number of reflections which enable the interventional needle to be visualized (Fig. 7.23). Reflections can be identified from:

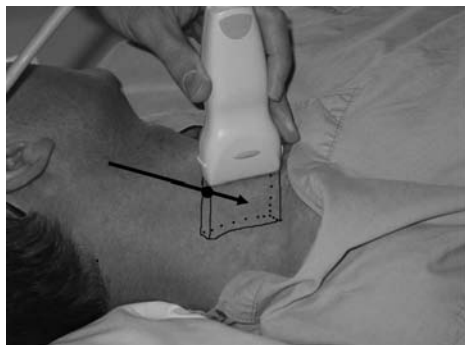- needle tip,
- shaft of the needle,
- reverberation artefact from within the bevel of the needle.

## Needle gauge

Larger bore needles are more easily visualized than small needles,<sup>2</sup> for instance, a 22 gauge needle is less visible than a 16 gauge needle (Figs. 7.24 and 7.25).



**Figure 7.26.** The background has an effect on needle visibility. It is better seen against anechoic fluid.



**Figure 7.27.** The transducer scans a thin volume or slice of tissue. The needle can only be seen whilst within this section.

### Background medium

The background medium through which the interventional needle is passed has an effect on its conspicuity. The needle can be more easily visualized if the background structure is anechoic, e.g. fluid (Fig. 7.26), than when it passes through an echogenic structure such as echogenic fat.

A number of specialized needles have been created by commercial manufacturers. These include specially coated shafts and tips, e.g. the shaft may be roughened. Operators may find these of some benefit, but often they are unnecessary, particularly if a careful scanning technique is used.

### How to improve needle visibility when struggling

Needle movement can help visibility; rotating the needle, making short movements in the long axis of the needle or sometimes passing the stylet through the outer needle can improve visualization. Movement of the stylet in this way introduces a minute amount of air which is echogenic/white, but if too much is introduced visibility is significantly reduced.

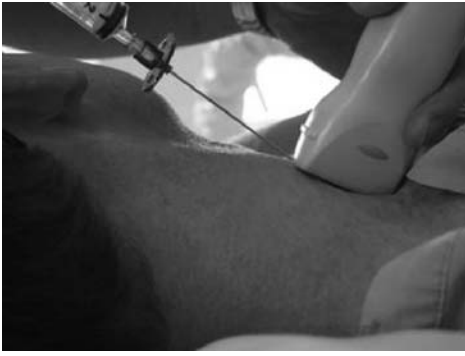### Longitudinal or transverse approach?

It is often helpful to imagine that the ultrasound probe scans a very thin 'volume' of tissue, deep to the transducer (Fig. 7.27). The needle is only visualized whilst it is within this volume. If the needle remains within the scan plane volume along its entire length, then the entire needle length will be completely visualized.

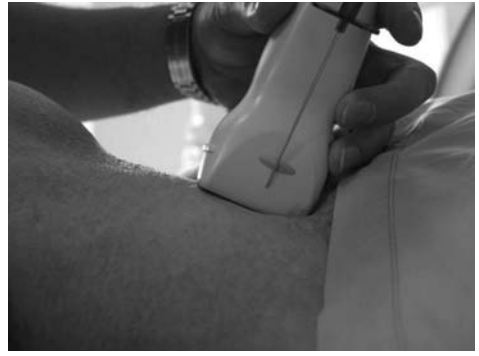The interventional needle can be passed either in a longitudinal direction (Fig. 7.28) relative to the footprint of the probe or transversely to it (Fig. 7.29). If the needle is passed longitudinally, it is possible to see the needle in its entirety, and for this reason (although it is a slightly more difficult technique to learn), this is the recommended method.

The alternative method is to pass the needle transversely, across the scan plane/volume, i.e. transversely relative to the footprint of the probe. This will mean that only the portion of the needle within the scan plane is visualized, but not the needle shaft above or below this thin



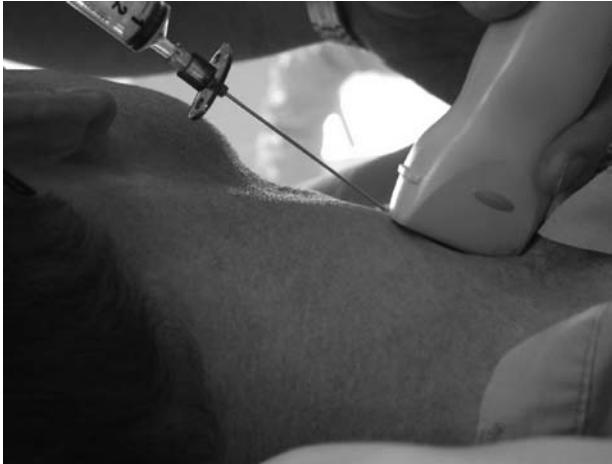

**Figure 7.28.** Needle passed in a longitudinal direction relative to the probe.

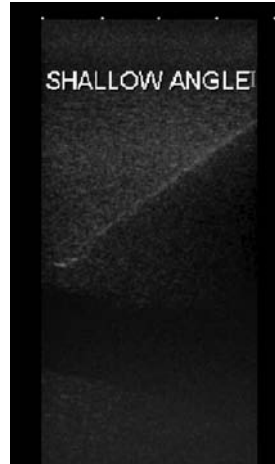


**Figure 7.29.** Needle passed transversely relative to the probe.

(a)



(b)

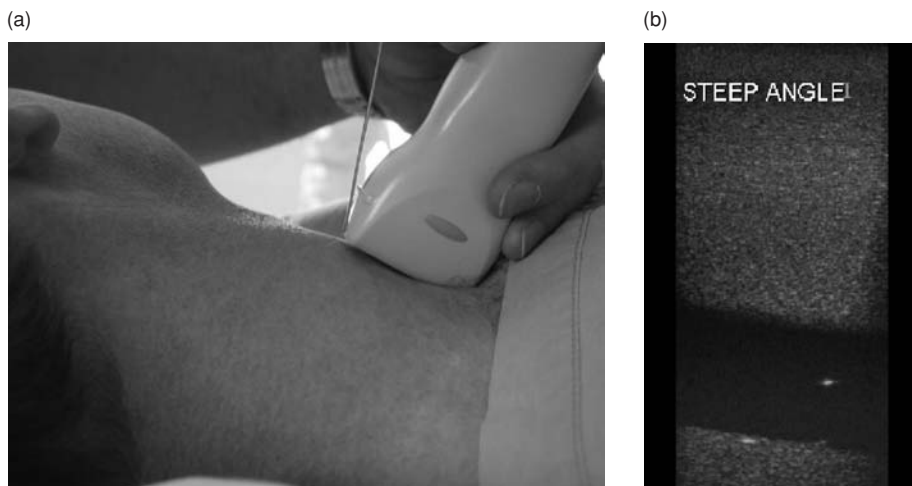


**Figure 7.30(a),(b).** Flat needle angle with good reflection and better needle visibility.

section. It is therefore possible that the tip of the needle is some distance away from the visualized portion. If this method is used, care must be exercised and particular attention directed to following the 'tip' of the needle. If this fundamental point is not understood, in inexperienced hands the transverse method can be falsely reassuring (misinterpreting the needle shaft for the needle tip), and for this reason the 'longitudinal' method is recommended.

## Angles of approach of the needle

The best reflection from the shaft of an interventional needle is obtained when it is perpendicular to the direction of the ultrasound beam. This produces a bright white reflection that is easily identified. Consequently, an angle of approach which is as shallow as possible should be used (Fig. 7.30). A steeper angle means that the reflection from the shaft of the needle will be less good and the needle will be less visible (Fig. 7.31). Owing to the variable anatomy in patients, a compromise often has to be struck between track length and the optimum angle for visualization.



**Figure 7.31(a),(b).** Steep needle angle. The needle visibility is reduced.

## Checks undertaken prior to passing the interventional needle

Once the local anaesthetic has been infiltrated, it is worth undertaking a couple of quick checks prior to passing the interventional needle, whether this is a Kellet needle, biopsy needle, spinal needle or a mounted drainage catheter.

It is suggested that the orientation of the probe is checked prior to passing the interventional needle. This is performed by quickly touching the footprint of the probe whilst watching the ultrasound screen. In this way, when the needle is finally passed, it will appear on the screen in the expected position. Once the ultrasound probe is applied to the skin, confirming the position can be performed by pressing reasonably hard on the patient's skin surface and watching the ultrasound screen to identify the area of tissue movement.

The needle can then be advanced with real-time visualization from the skin surface to the target area.

## Tips when struggling

The main problem usually encountered is a failure to visualize the needle, although it has been passed a short distance into the patient. A few tips are listed below to help with this situation.

**Stop:** In any medical procedure, if difficulties are experienced, often the best initial step is to stop and reappraise the situation. There are few situations when pausing for a short time will have any adverse consequences.

**Look at your hand position:** By doing this, it is often apparent that the needle is some distance from the ultrasound probe. Alternatively, the angle of trajectory of the needle may be incorrect.

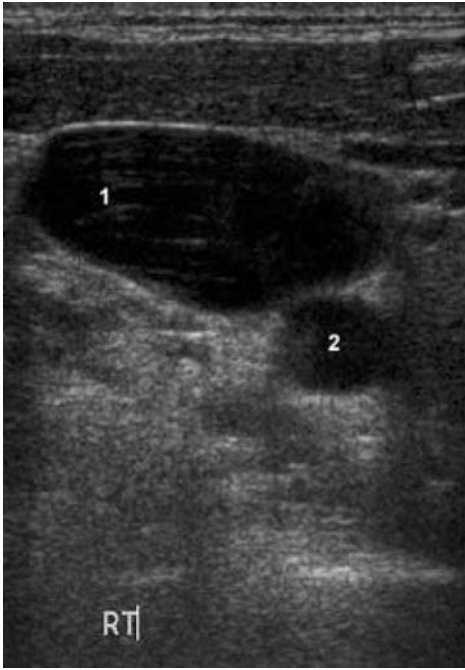
**Only move one hand at a time:** When 'searching' for a poorly visualized needle, there is a temptation both to move the needle and the US transducer at the same time. It can be better to fix the needle or the transducer and have only one moving at any one time.

**Separate the probe movements:** When starting out in US guided techniques it is a useful exercise mentally and physically to separate out the different movements of the transducer. The probe can be rotated about the axis of the cable. It can be rocked along its longitudinal axis using 'heel-to-toe' movements. It can be angled from side to side along its long axis. These rotating movements are in addition to moving or translating the physical position of the probe.

These movements are quite complex when occurring in combination so, when the needle is not well seen, separating out the components of probe movements can be a way of improving needle visibility.

## References

1. NICE *Central venous catheters – ultrasound locating devices: Technology Appraisal Guidance No. 49*.  
[www.nice.org.uk/guidance/TA49](http://www.nice.org.uk/guidance/TA49).
2. Hopkins R, Bradley M. Rough or smooth? In-vitro visualisation of biopsy needles with ultrasound. *Clin Radiol* 2001; **556**(6): 499–502.



**Figure 7.32.** Quiz case.

47-year-old female.  
Requires central line insertion. Neck ultrasound.  
Transverse plane.

## Ultrasound imaging: case illustrations

### Question 1

- Name the structures in the image (Fig. 7.32).
- Briefly outline how ultrasound can be used to guide central line insertion.

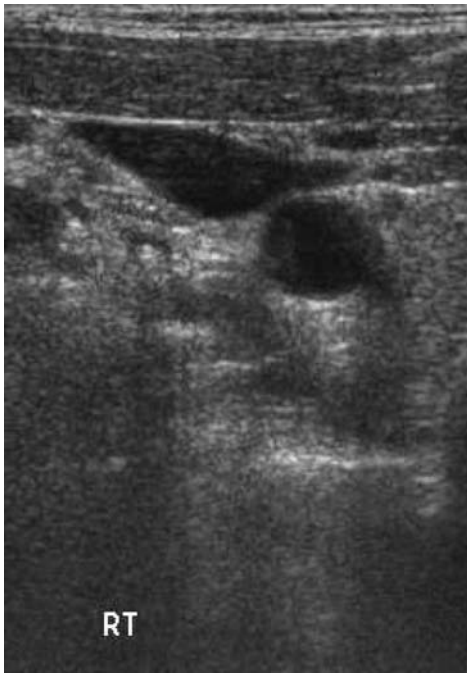
### Answer

#### Ultrasound guidance central line insertion

The internal jugular vein (no. 1) and the common carotid artery (no. 2) are adjacent structures in the neck. US image guidance is invaluable when inserting jugular venous central lines.

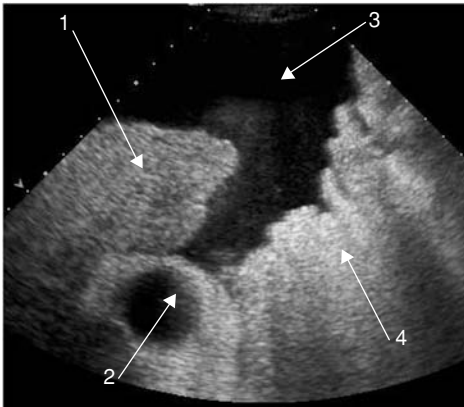
A high frequency probe should be selected. If no previous lines have been inserted, the right side is generally chosen as this is the larger vein with a more direct course to the SVC. Scanning the neck will identify the course of the jugular, confirm patency and the relationship to the carotid and assess whether there are any intervening structures such as lymph nodes. The jugular is thin-walled, its calibre varies with respiration and it can be occluded with mild compression (Fig 7.33). The carotid is smaller, thick-walled, and can be seen pulsating. The carotid cannot be occluded with mild pressure. Once the internal jugular is identified using these criteria, then a puncture site can be chosen and a mark made on the skin superficial to this.

The skin is then cleansed with antiseptic solution and local anaesthetic infiltrated. The patient is positioned with head down tilt. The jugular is then punctured using an introducer needle (18 gauge) and blood is aspirated into a connected syringe to confirm a venous puncture. The puncture is performed under direct US visualization. It should be possible to



**Figure 7.33.** Jugular vein compression.

follow the needle tip from the subcutaneous layers into the vein. A guide wire is inserted through the needle. The introducer needle is then withdrawn, leaving the guide wire. The central line is then inserted over the guide wire. Air embolus is a theoretical complication when the system is open to the atmosphere, e.g. withdrawing the wire. Complications of line insertion include carotid puncture, pneumothorax and haematoma formation in the soft tissues of the neck (see Fig. 7.15). Ultrasound should reduce the incidence of these complications.



**Figure 7.34.** Quiz case.

Male patient aged 67. Alcoholic. The image is a longitudinal image from the right upper quadrant.

## Question 2

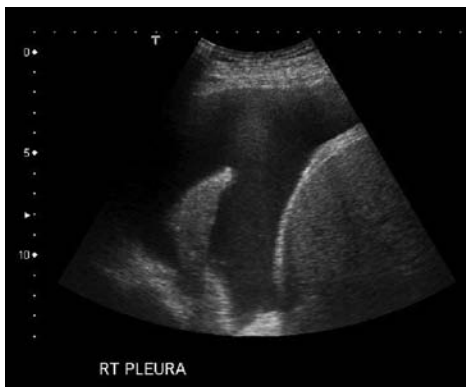- What are the structures labelled 1–4 (Fig. 7.34)?
- Briefly describe how to perform an abdominal paracentesis.

## Answer

The image shows a view of the right upper quadrant – 1 liver, 2 gall bladder, 3 ascitic fluid and 4 bowel loops. The liver has an irregular surface contour compatible with cirrhosis due to alcohol.

### Abdominal paracentesis

A preliminary ultrasound should initially be undertaken to confirm the presence of ascitic fluid and its relationships with the adjacent anatomical structures. The structures of particular interest include the liver, gall bladder and bowel. Whilst performing this initial scan, it is helpful to plan the approach and angle of any subsequent drainage tube. An entry site is chosen, which can be marked. The ultrasound machine should be adjusted at this stage to optimize the image – see section above.

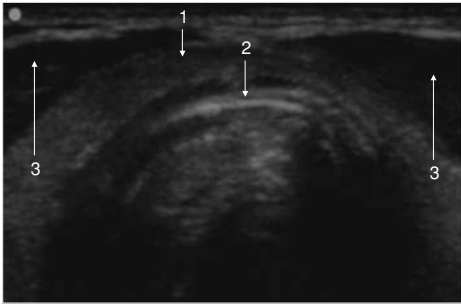


**Figure 7.35.** Large pleural effusion.

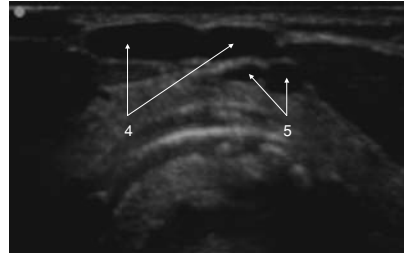
A sterile field is then prepared and the patient draped with sterile green towels. A probe cover should be applied to the ultrasound probe. Local anaesthetic is then infiltrated down to the peritoneal surface. The needle can be followed to the peritoneal surface with ultrasound which serves to anaesthetize the track in its entirety, but also allows the angle of approach to be rehearsed prior to passing the drainage tube. An introducer needle is then passed, followed by a guide wire. The introducer needle is removed and then the track is dilated up to the required size using serial dilatations. For most clinical situations 8 french or 10 french is adequate. The final drainage tube is then passed under direct vision and secured.

A similar method is used during the drainage of pleural effusions (see Fig. 7.35).





**Figure 7.36.** Quiz case.



**Figure 7.37.** Quiz case.

39-year-old man requiring percutaneous tracheostomy.

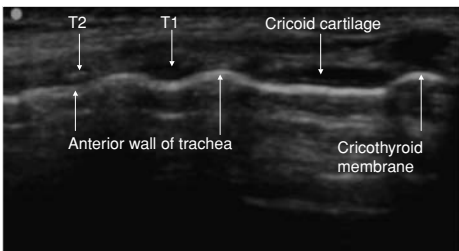
### Question 3

- What are the labelled structures, pre- and post- a valsalva manoeuvre (Figs. 7.36 and 7.37)?
- Briefly describe how ultrasound can be of benefit in guiding percutaneous tracheostomy.

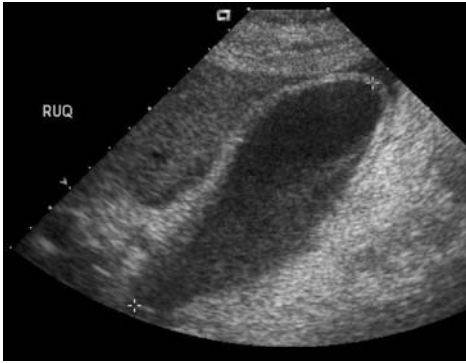### Answer

The trachea (1), pre-tracheal fascia (2) and the sternomastoid muscles (3) can be seen in the pre-valsalva images. Post-valsalva, the anterior jugular veins (4) and smaller accessory veins (5) can be seen.

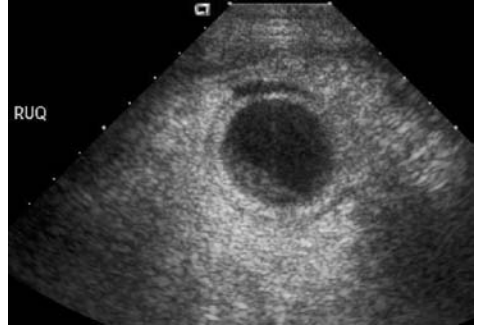
Ultrasound can be used to aid tracheostomy by identifying large veins overlying the puncture site, allowing for them to be either avoided or ligated. Sagittal ultrasound can be used to allow for the tracheostomy to be sited at the correct level, which should ideally be at cricoid/T1 or T1/T2 (Fig. 7.38). Siting percutaneous tracheostomies too high can lead to difficulties in swallowing, siting them too low can lead to major complications resulting from immediate puncture of major vessels, pneumothoraces or delayed erosion into and subsequent rupture of vessels such as the innominate artery or aortic arch. The bright line is caused by reflection at the tissue/air interface at the anterior tracheal wall; the high signals below this interface are artefactual and it is not possible to visualize structures below this interface. The cartilages appear black.



**Figure 7.38.** Sagittal ultrasound of the trachea.



**Figure 7.39.** Quiz case.



**Figure 7.40.** Quiz case.

44-year-old patient with extensive burns complicated by sepsis.  
Ventilated on intensive care unit.  
Fever, leukocytosis, elevated liver enzymes and bilirubin.

## Question 4

- What is the diagnosis (Figs. 7.39 and 7.40)?
- What are the main complications?
- What are the treatment options?

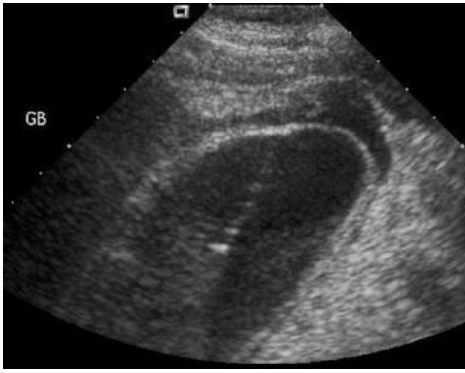## Answer

### Acalculous cholecystitis

Acalculous cholecystitis is gall bladder inflammation in the absence of gall bladder calculi. It is most frequently seen in patients who are hospitalized and are acutely unwell. Risk factors include:

- severe medical illness,
- post-surgical patients,
- burns,
- trauma,
- parenteral nutrition,
- ventilation,
- prolonged fasting.

As can be seen from the list above, the risk factors are often fulfilled by patients on intensive care units. Clinical presentation may be non-specific with fever, pain (either right upper quadrant or generalized abdominal pain), leukocytosis and elevated liver enzymes or bilirubin. A small proportion of patients with acalculous cholecystitis are made up of outpatients and children. Diagnosis is more straightforward in this group. On the intensive care unit, it is a difficult diagnosis to make both clinically and radiologically. Delay in diagnosis and the related/predisposing conditions means that it is associated with a high degree of morbidity and complications. Complications include gall bladder perforation, gangrene and emphysematous cholecystitis.



**Figure 7.41.** Acalculous cholecystitis. Percutaneous cholecystostomy. Using local anaesthesia at the bedside, with ultrasound guidance a drainage catheter can be placed into the gall bladder. A locking pigtail drain can be placed as either a one-step trocar insertion or with serial dilatation over a wire. A transhepatic route may reduce the risk of inadvertent drain movement. Note the echoes from the needle.

Ultrasound features include gall bladder wall thickening, gall bladder wall oedema, pericholecystic fluid, intramural gas, gall bladder distension and an ultrasonographic Murphy's sign. Several of the ultrasound features are non-specific – such as gall bladder wall thickening, which can be seen with other conditions, e.g. hypoalbuminaemic states and heart failure. Early follow-up looking for interval change can be helpful if the diagnosis is in doubt. CT is an alternative imaging modality, but is clearly less portable.

#### Treatment options

- Open cholecystectomy.
- Laparoscopic cholecystectomy.
- Percutaneous cholecystostomy (see Fig. 7.41).
- Percutaneous aspiration.

## Bibliography

1. Aldrich JE. Basic physics of ultrasound imaging. *Crit Care Med* 2007; 35(5 Suppl):S131-7.

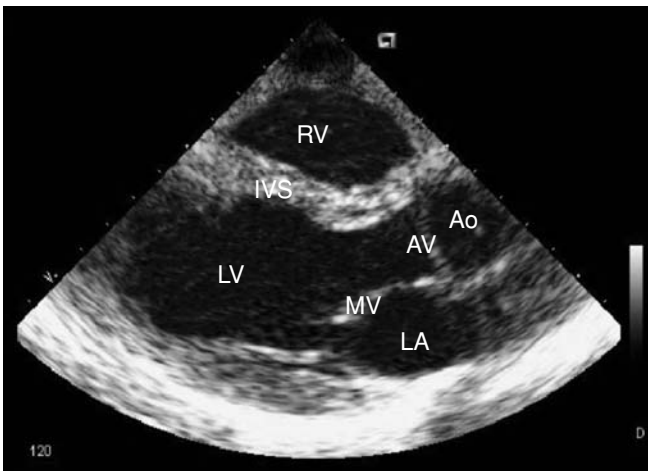
## Echocardiography for patients on intensive care units

Echocardiography is widely used in the diagnosis and management of cardiovascular disease. It permits real-time direct visualization of the heart, thereby demonstrating cardiac anatomy and allowing for measurement of cardiac function and identification of a wide range of pathology. Whilst a comprehensive review of echocardiography is beyond the scope of this section, it is important for the anaesthetist to have a basic working knowledge of echocardiography, its indications and its limitations. In addition, there is growing interest in the application of echocardiography in managing the acutely unstable patient and in the haemodynamic assessment and management of patients on the intensive care unit.

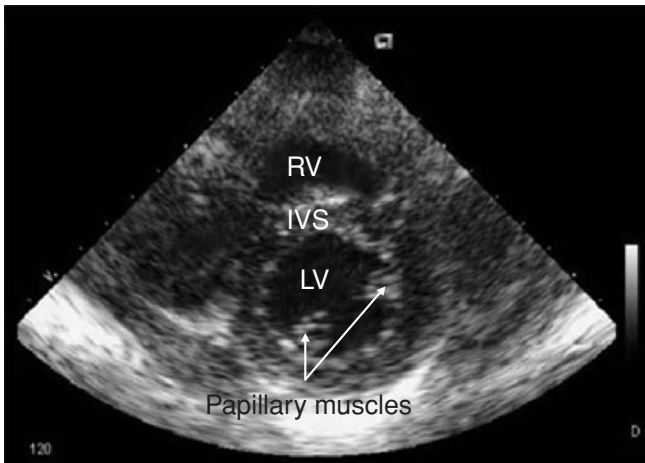
### Transthoracic echocardiography (TTE)

The anatomical location of the heart is in the mediastinum, behind the sternum and ribs and adjacent to the left lung. Despite the acoustic barrier these structures create, a number of 'windows' exist, which permit visualization of the heart, either between the rib spaces or inferiorly via the epigastrium. TTE typically utilizes frequencies in the range of 2 to 4 MHz. The probe has a deliberately small footprint to 'see' between the narrow rib spaces. To optimize views, patients are usually positioned semi-recumbent and tilted to the left. A number of standard views are thus achieved, as shown in Figs. 7.42–7.45.

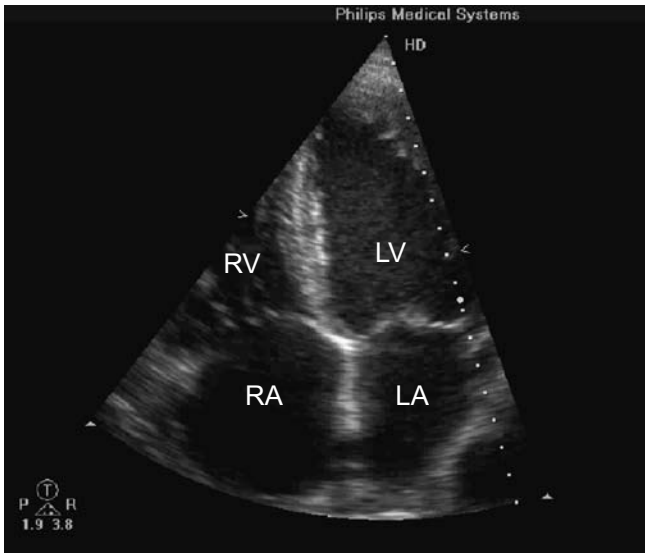
- Parasternal views – these are typically obtained from the second, third or fourth intercostal spaces immediately lateral to the left sternal edge. The long axis view (Fig. 7.42) effectively slices the heart lengthways from its apex (displayed on the left of the screen) to the aortic valve and ascending aorta (displayed on the right of the screen), whilst the short axis view (Fig. 7.43) displays these structures in cross-section.
- Apical views – obtained from the cardiac apex. A four-chamber view is shown (Fig. 7.44).
- Subcostal view (Fig. 7.45) – obtained with the transducer positioned in the epigastrium, pointing towards the tip of the left scapula; this may be more readily achieved with the patient supine.



**Figure 7.42.** Long axis view.



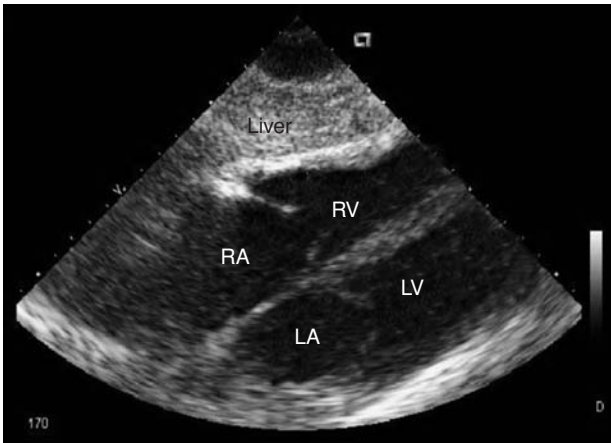
**Figure 7.43.** Short axis view.



**Figure 7.44.** Four-chamber view.

A comprehensive study should be performed whenever possible. Accurate characterization of cardiac structure and function and the quantification of severity of pathology rely on the utilization of the full range of ultrasound modalities that are available:

- Two-dimensional echocardiography:  
Standard 2-D pictures are displayed in B-mode (brightness) where the strength of the reflected ultrasound signal along all scan lines is represented on a greyscale as with standard ultrasound.
- M-mode (motion mode):  
Guided by a 2-D image, a display of brightness along a single scan line against time is produced. M-mode is typically used for accurate measurement of cardiac dimensions and the timing of events in the cardiac cycle.



**Figure 7.45.** Subcostal view.

- **Continuous-wave (CW) and pulsed wave (PW) Doppler:**  
The frequency shift produced by moving red blood cells is used to calculate flow velocities. With CW Doppler, ultrasound is transmitted and received continuously along a single scan line and this allows for measurement of high flow velocities, but it is not possible to determine from which point of the line the high velocity signal arises. With PW Doppler, a small region of the heart is interrogated intermittently by 'packets' of ultrasound, allowing for measurement of flow velocities in specific regions; however, high flow velocities above 1 m/s cannot be measured with PW Doppler because of a phenomenon called aliasing.
- **Colour-flow Doppler:**  
A visual representation of multiple PW Doppler signals from a particular area of interest superimposed on a 2-D image, thereby permitting blood flow to be displayed as colour. By convention, flow away from the transducer is displayed as blue whilst flow towards the transducer is displayed as red (Blue Away Red Towards = BART).

## Left ventricular function

Left ventricular systolic function is normally determined by the measurement of ejection fraction (EF). This is best determined from apical views where measurements of left ventricular volume are made at end systole and end diastole, usually by tracing the endocardial border in at least two different planes, thereby allowing EF to be calculated:

$$EF (\%) = \frac{LV \text{ end diastolic volume} - LV \text{ end systolic volume} \times 100}{LV \text{ end diastolic volume}}$$

There are some pitfalls with this technique, since EF may be overestimated if areas of impaired contractility are not included within the views made to make the measurement. Skilled echocardiographers can produce reliable estimates of EF from visual assessment. Generally, LV function is graded as follows:

- Normal – EF > 50%
- Mild impairment – EF 40% to 50%
- Moderate impairment – EF 30% to 40%
- Severe impairment – EF < 30%

LV diastolic function and RV function assessments are more complex and beyond the scope of this book.

## Indications for pre-operative echocardiography

Echocardiography is a commonly requested pre-operative investigation. The usefulness of echocardiography in this context has significant limitations. It must be understood that a standard echocardiogram is unable to quantify functional reserve as the study is performed at rest. For instance, even in the presence of severe coronary artery disease, left ventricular function is usually normal in patients without a previous myocardial infarction.

In accordance with British Society of Echocardiography guidelines, the following are accepted indications for pre-operative echocardiography:

- documented ischaemic heart disease with reduced functional capacity (<4 METS),
- unexplained shortness of breath in the absence of clinical signs of heart failure in the presence of an abnormal ECG or CXR,
- murmur in the presence of cardiac or respiratory symptoms,
- murmur in an asymptomatic individual in whom clinical features or other investigation suggest severe structural heart disease.

## Stress echocardiography

Stress echocardiography is used increasingly in the evaluation of patients with known or suspected ischaemic heart disease and may also be used in pre-operative cardiac risk stratification prior to major non-cardiac surgery. It is also useful in patients who, for physical reasons, are unsuitable for exercise ECG testing. Echocardiography is performed either during physical exercise or pharmacological stress, typically with an escalating infusion of dobutamine, in order to look at the presence of abnormal cardiac contraction in response to stress when blood flow is insufficient to meet demand. It may also be used to detect areas of hibernation that may improve with revascularization. However, stress echocardiography is time and resource hungry and is not widely available outside tertiary centres.

## Transoesophageal echocardiography (TOE)

TOE utilizes the close anatomical relationship between the lower oesophagus and stomach and the heart, which permits the use of higher frequency ultrasound (usually in the order of 5 to 6 MHz), thereby improving image quality. However, this is a semi-invasive procedure and therefore carries a small amount of risk (mortality of around 1:10 000).

Indications for TOE include:

- suspected endocarditis; TOE has a much greater sensitivity than TTE but TTE should usually be attempted first
- evaluation of prosthetic valve function, particularly if in the mitral position
- investigation for suspected patent foramen ovale
- suspected aortic dissection or traumatic aortic injury
- evaluation of mitral valve disease prior to surgical intervention
- investigation for intracardiac thrombus.



TOE is also widely used peri-operatively in patients undergoing cardiac surgery and there is a growing body of evidence to support this practice. In particular, it is widely used for high risk revascularization, valve replacement or repair and aortic surgery.

## Focused echocardiography

There is growing acceptance that abbreviated 'focused' echocardiography can provide a rapid assessment of the haemodynamically unstable patient. A number of protocols have been developed:

- 'FEER' – Focused Echocardiographic Evaluation in Resuscitation
- 'FATE' – Focused Assessed Transthoracic Echocardiography

Common to both approaches is the use of standard 2-D views only with no use of Doppler modalities with the goal of recognizing a set number of key pathologies:

- acute right ventricular dilatation,
- pericardial effusion/tamponade,
- gross hypovolaemia,
- severe left ventricular failure.

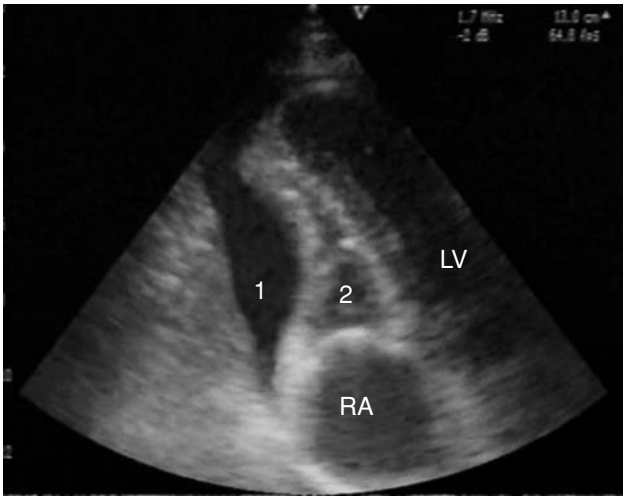
In FEER, echocardiography is also performed during cardiopulmonary resuscitation to rapidly identify potentially reversible causes of cardiac arrest. Published evidence has shown that the basic echocardiographic skills necessary for these diagnoses to be made can be rapidly acquired and maintained.

## Training in echocardiography

At present, achieving formal competency in echocardiography requires comprehensive training. This involves both MCQ exams and the submission of logbooks. In the UK the British Society of Echocardiography runs the accreditation for both TOE and TTE. Currently, this training is involved and lengthy, and more focused training is being considered for use in intensive care and emergency medicine.

## Bibliography

- Leeson P, Mitchell A, Becher H, eds. *Echocardiography*, 1st edn. Oxford, UK: Oxford University Press, 2007.
- Kaddoura, S. *Echo Made Easy*, 2nd edn. Oxford, UK: Churchill Livingstone, 2001.



**Figure 7.46.** Quiz case.

This 61-year-old male presented with hypotension, acute renal failure and a profound metabolic acidosis with a history of blunt chest trauma 2 weeks previously. A focused echocardiogram was performed to identify the cause of shock.

## Question 1

- What does the echocardiogram show (Fig 7.46)?
- How would you treat this patient?

## Answer

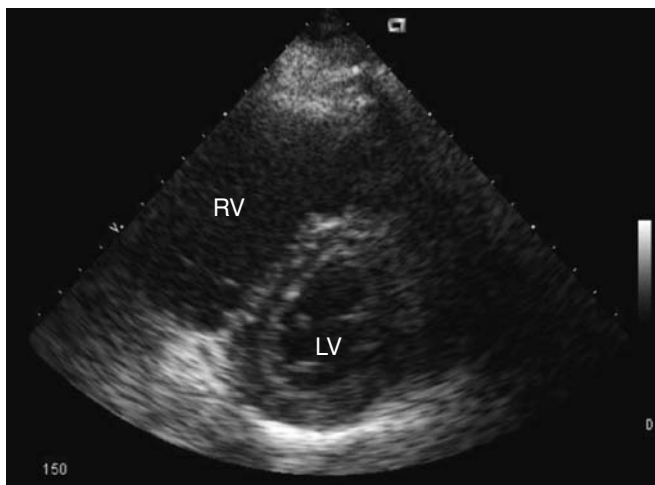
This parasternal long axis view (Fig 7.46) shows a dark, echo-free space (1) surrounding the heart. The right ventricle (2) is collapsed. This is a large pericardial effusion and is perhaps the simplest pathological process to detect with echocardiography.

The development of tamponade physiology is largely dependent upon the speed of accumulation of fluid. A small amount of fluid (100 to 200 ml) may be sufficient to cause tamponade in the acute setting; conversely several litres may accumulate over a period of weeks without any haemodynamic effects. Tamponade results in impairment of venous return to the right and consequently left heart as the pressure rises in the pericardial sac. The diagnosis is notoriously difficult to make clinically and requires a high index of suspicion.

Other echocardiographic features that may be observed include:

- right atrial collapse in systole,
- right ventricular collapse in diastole,
- a 'swinging' heart,
- exaggerations of RV and LV filling (using PW Doppler), which is clinically manifest as a pulsus paradoxus.

Prompt treatment is indicated by means of pericardial drainage. Commercially available Seldinger type pericardiocentesis kits containing appropriate needles and drains are available. Echocardiography allows the ideal drainage point to be determined, gives an indication of insertion depth and may allow needle visualization. The technique is performed under aseptic conditions. The needle is inserted either via the epigastrium, just below the xiphisternum, aiming towards the tip of the left scapula, or from the apex. Constant aspiration is applied until fluid is freely drained. A drain is left in situ. An echocardiogram should be performed after the procedure to confirm successful drainage.



**Figure 7.47.** Quiz case.

59-year-old male with acute respiratory failure, tachycardia and hypotension.

## Question 2

- What does the echocardiogram show (Fig. 7.47)?
- What is the differential diagnosis?
- How would you treat this patient?

## Answer

This is a parasternal short axis view of the heart at the level of the mitral valve. Normally, the right ventricle is seen as a relatively small structure adjacent to the LV but under conditions of either pressure or volume overload the RV rapidly dilates, as is seen here. The interventricular septum appears relatively flat and the LV cavity is starting to take on a D-shape consistent with RV overload.

Acute RV dilatation is strongly suggestive of pulmonary embolus (PE) and is a well-validated echocardiographic sign; however, it can occasionally also be seen in other causes of acute cor pulmonale such as the acute respiratory distress syndrome.

In the subcostal and apical views the width of the RV just below the tricuspid valve should be no greater than 60% of the LV. In this case LV appears relatively small, and at end systole almost complete obliteration of the LV cavity was seen, a sign consistent with under filling of the LV. This sign may also be seen in patients with hypovolaemia.

In the absence of significant lung pathology on CXR, this finding should prompt the consideration of thrombolysis for massive PE. A full history and examination may reveal other features consistent with the diagnosis.

## Ultrasound-guided regional anaesthesia

### Introduction

Successful regional anaesthesia relies on the accurate location of the target nerve and the placement of local anaesthetic around the nerve. Historically, nerve identification has relied on surface anatomical landmarks to locate the injection site and then either pops, clicks or paraesthesia to identify the position of the needle close to the nerve.

For the last 25 years, peripheral nerve stimulation (PNS) has replaced paraesthesia, using a small electric current passed through the needle to stimulate the nerve. The identity of the nerve is confirmed by the muscle twitch seen (contraction of the muscles supplied by the nerve) and the proximity of the needle to the nerve is implied by the current needed to depolarize the nerve. The current needed is inversely proportional to the distance of the needle from the nerve (1 cm from nerve – 5 mA, 2 mm from nerve – 0.5 mA); therefore, the closer the needle is to the nerve, the less current needed.

All these techniques are essentially blind and use an indirect method to locate and identify the nerve, but more importantly to predict success. What blocks the nerve is 'the local anaesthetic', its spread cannot be accurately predicted using these techniques and as such until now, all local anaesthetic techniques carry an inherent failure rate of 5%–20%, depending on the skill of the operator.

Medical ultrasound has been used for more than 40 years, but its use in anaesthesia has only developed recently. Although sporadically used in the 1980s, its expense, portability and availability precluded routine use. Throughout the 1990s a growing body of evidence, mainly from enthusiastic individuals, e.g. Dr Stephan Kapral, Vienna, demonstrated its potential use in regional anaesthesia.

It was not until the development of high resolution portable ultrasound machines that this became a practical reality. Since 2000 and on the back of NICE 49 guidelines, these machines have become commonplace within our hospitals and a growing body of evidence is developing to support the use of ultrasound in regional anaesthesia.

### Benefits of ultrasound-guided regional anaesthesia (USGRA)

1. Target nerves can be visualized.
2. Surrounding structures can be seen (major vessels, pleura, abdominal cavity and contents), and avoided.
3. Needles can be seen throughout their passage and needle–nerve relationship observed (no direct nerve contact).
4. Local anaesthetic spread is observed and directed to surround the target nerve, by altering needle position.
5. Reduced volume of local anaesthetic can be used (approx. 50% reduction on PNS techniques).
6. Improved success rates.
7. Reduced patient discomfort.
8. Reduced complications and side effects.

Ultrasound is a highly operator-dependent imaging modality and a thorough understanding of the physics of ultrasound and the machine's capabilities is necessary. It is important also

to understand how the ultrasound beam interacts with the tissues, developing the picture and common artefacts. Good hand–eye coordination is essential to be able to hold a stable picture whilst introducing a needle close to the nerve.

With ultrasound ‘you only see what you know’ and good anatomical knowledge is the cornerstone of both clinical ultrasound and regional anaesthesia. Before using any technique, a sound understanding of the relevant anatomy, clinical indication and limitation is essential.

## Machines

There are now many machines available which are suitable for USGRA (Sonosite® – M Turbo, GE® – Logic-E, Esaote® – Mylabs 25 & Philips HD11) (see Fig. 7.48), the choice depends upon budget and preference. Certain machine capabilities are desirable, including:

- Portability and ease of use (multiple clinicians of varying expertise).
- Quick start (boot-up time) – for emergency and rapid diagnostics and use.
- Multiple probe facilities – high frequency probe >10 MHz, low frequency 2–5 MHz and increasingly phased array/micro-convex probes for lung/cardiac imaging.
- Doppler – ideally both colour-flow Doppler and power Doppler.
- PACS/Dicom compatibility and easy storage/retrieval of data (video loops/still images).
- Enhanced imaging techniques essential – harmonic frequency.
- Modulation/beam steering/multibeam technology, etc.

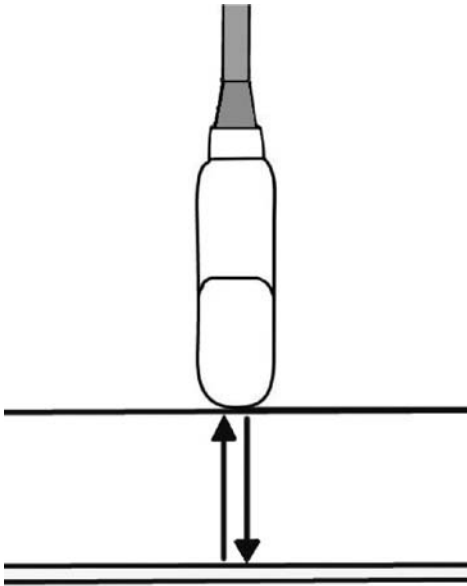
## Physics

Frequency / resolution / depth

- Most nerves are superficial and small (<1 cm diameter) and, as such, high resolution is needed.

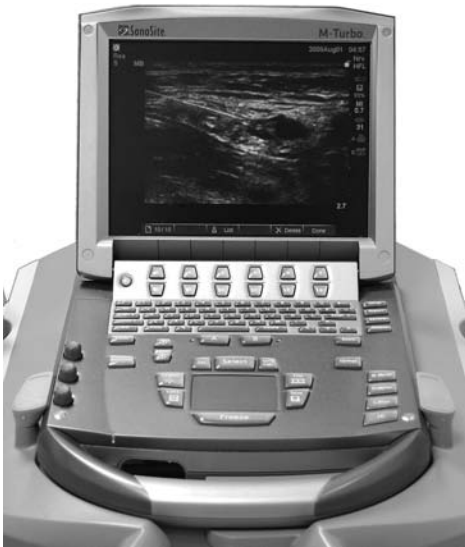

Figure 7.48. Ultrasound machine.



**Figure 7.49.** Anisotropy – Ultrasound probe at 90°.

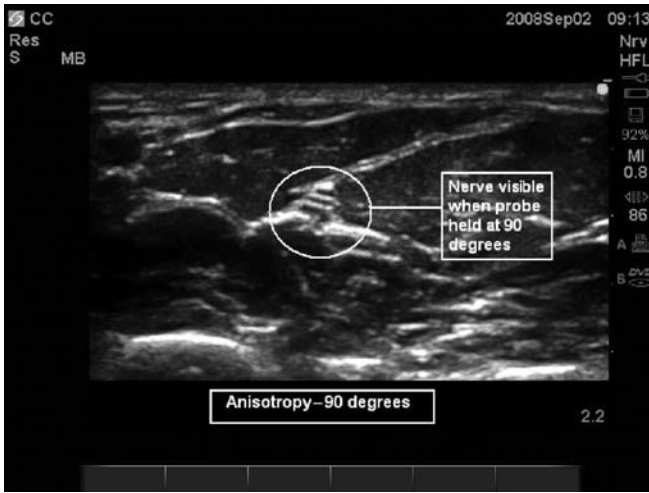
- Resolution is dependent on US frequency; the higher the frequency the better the resolution. For USGRA, frequencies of >10 MHz are ideal for small superficial nerves, e.g. brachial plexus.
- For deeper nerves and larger structures 2–5 MHz may be appropriate, e.g. lumbar plexus, sciatic nerve and obese patients.
- Attenuation of the beam occurs at increasing depth; the higher the frequency the greater the attenuation. High frequency probes are ONLY suitable for superficial structures <5 cm.
- *‘Use the highest frequency probe available for the depth of the structures you wish to image’* (linear 8–18 MHz, curvilinear 2–5 MHz).
- The size of the probe (footprint) may limit access in some cases.

### Anisotropy

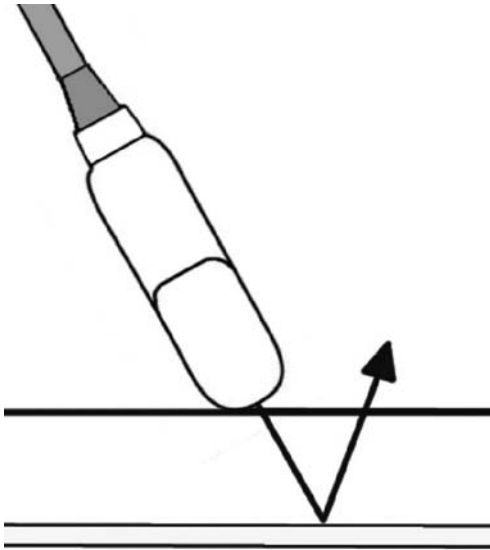
- Using ultrasound, structures will be seen most clearly when they are imaged at 90° to the ultrasound beam (angle of insonation); this is called anisotropy (Figs. 7.49, 7.50, 7.51, 7.52).
- The structure of tissues can also make them more or less anisotropic – tendons are highly anisotropic and nerves moderately so.
- The sciatic nerve is very anisotropic – care must be taken to alter the angle of the probe to optimize the image received.

### Artefacts

- Not all that is seen is real – artefacts are common using US and must be recognized. Common artefacts include:



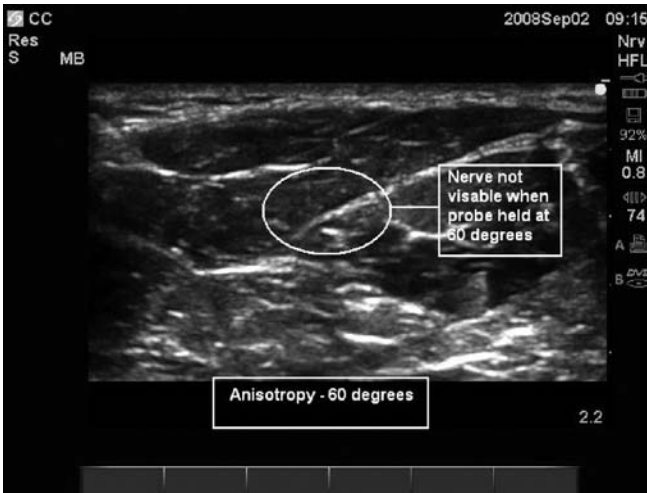
**Figure 7.50.** Anisotropy – US at 90°.



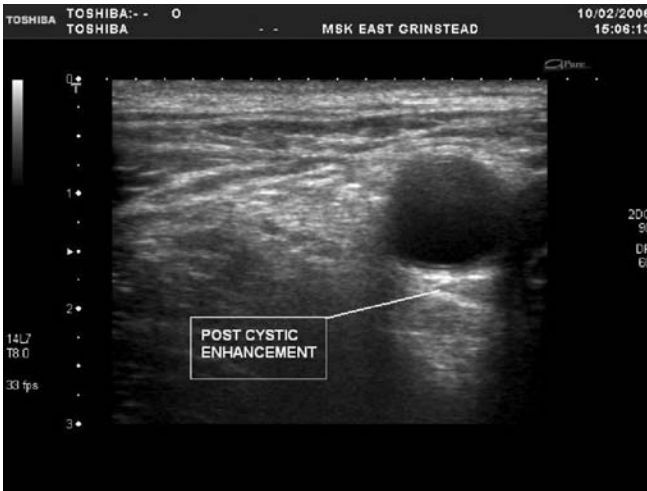
**Figure 7.51.** Anisotropy – probe at 60°.

- Post-cystic enhancement – bright echo behind all fluid field cavities (Fig. 7.53.)
- Drop-out shadow – dark shadow found beneath/behind bone.
- Needle reverberation – multiple echoes at increasing depth due to repeat reflection (Fig. 7.54).
- Air artefact – ultrasound doesn't pass through air, so 'white-out' is seen if air is in the injectate.

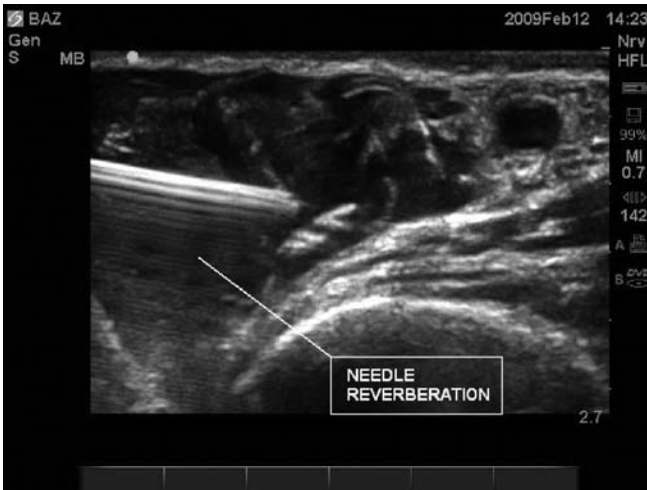




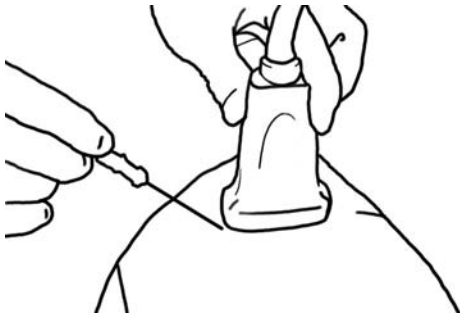
**Figure 7.52.** Anisotropy – ultrasound probe at 60°.



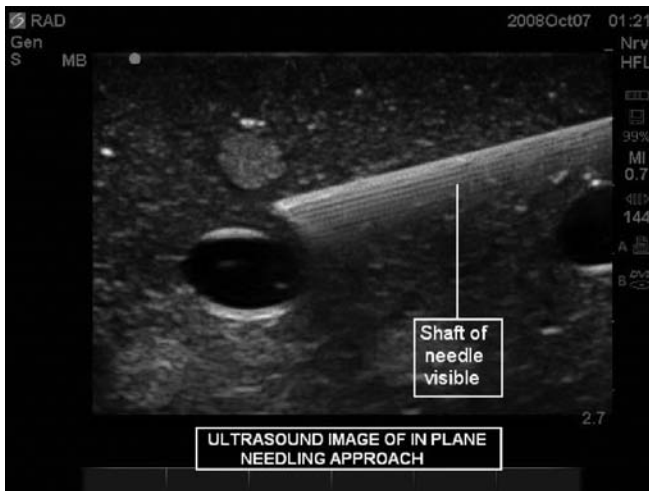
**Figure 7.53.** Post-cystic enhancement.



**Figure 7.54.** Needle reverberation.



**Figure 7.55.** In plane approach.

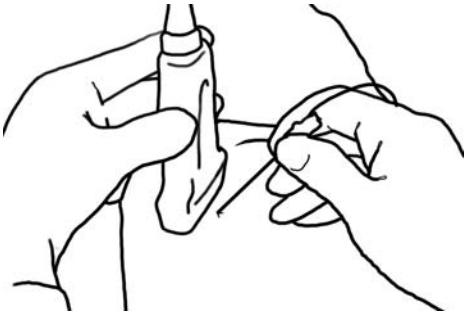


**Figure 7.56.** In plane approach – US scan.

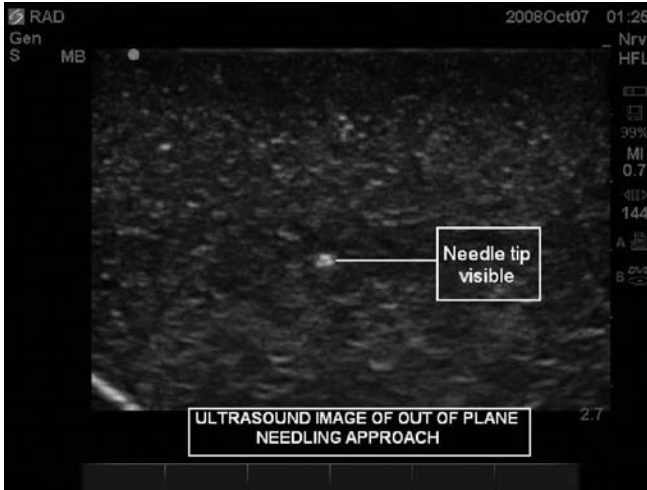## Needles and needling technique

The holy grail in USGRA is to find a needle that can be clearly seen at all angles and at increasing depths. Coating the needle, scoring the shaft and multifaceting the tip are techniques used to increase needle visibility. At present, there is no one needle that is obviously better than another. Factors that affect needle visibility include:

- Gauge – larger needles will be more clearly seen (16 G vs. 22 G).
- Angle and depth – the shallower the trajectory, the better the reflection (parallelism). At increasing depth, it is difficult to see any needle clearly.
- Plane of vision – needles can be inserted either using an in-plane (along the long axis of the probe, parallel to the ultrasound beam) or out-of-plane technique (at right angles to the long axis of the probe, across the ultrasound beam), both of which will affect visibility:
  - In-plane – the US beam is very narrow (1 mm); if the needle is held within this beam it can be seen clearly throughout its entire length (Figs. 7.55 and 7.56).
  - Out of plane – at any one time, ONLY the part of the needle that crosses the beam will be seen (Figs. 7.57 and 7.58).
- Needle manipulation – to improve needle visibility and identification of the tip, the needle can be agitated (small moments), the probe angle changed, the needle rotated (bevel



**Figure 7.57.** Out of plane.



**Figure 7.58.** Out of plane – US scan.

towards the probe – better reflection), or a small volume of local anaesthetic injected (hydrolocation – distension of tissues at needle tip).

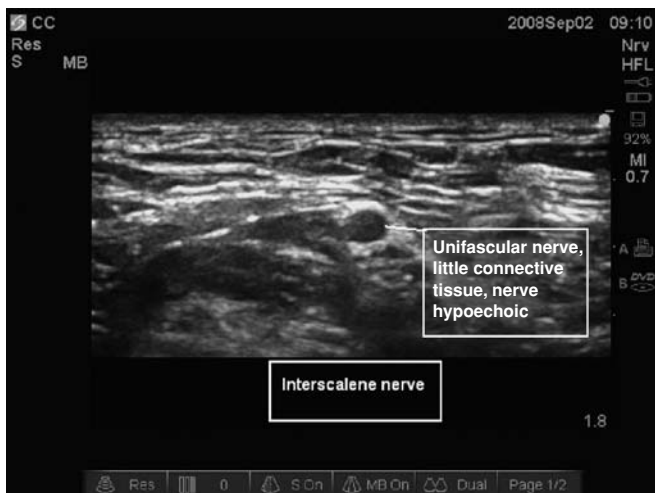
## Patients

As with all regional anaesthetic techniques, choose the technique most appropriate for the patient.

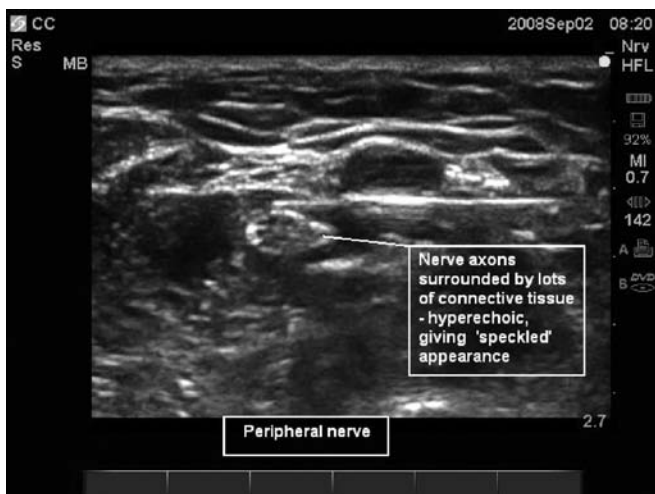
- Anatomical variation; this may be responsible for increased failure in PNS techniques and is extremely common in the brachial plexus.
- Not all patients are good echogenic subjects; this is probably due to water content in tissues and fat. 'Bad fat' is very globular and has a similar effect to bathroom glass, causing multiple refractions and a poor image. This is often independent of size/shape.
- Obesity makes it difficult to visualize deep structures, e.g. infraclavicular, sciatic and lumbar.

## Ultrasound appearance of nerves

Nerves are a collection of axons arranged into fascicles and enclosed in and surrounded by connective tissue (endoneurium, perineurium). The ratio of connective tissue to neuronal



**Figure 7.59.** Nerve cross-section.



**Figure 7.60.** Nerve cross-section.

tissue varies, being low in more proximal nerves and higher in distal nerves. Neuronal tissue is dark (hypoechoic) and connective tissue bright (hyperechoic) (Figs. 7.59 and 7.60).

This gives the typical pattern of a dark black nerve in the interscalene region (little connective tissue – unifascicular nerve) and a speckled bright nerve (lots of connective tissue supporting multiple branches within) in the periphery, e.g. distal median nerve.

The shape of the nerve is determined by its position and compression by other tissues. The sciatic nerve appears flattened as it is compressed between large thigh muscles.

## Application

USGRA can be used in most situations where a nerve block would be performed using nerve stimulation, but has distinct limitations in deep blocks and in obese patients. It does, however, have significant benefits over PNS in certain situations:

- Where a reduction in the dose of local anaesthetic used is required – this may be important in paediatrics, the elderly (often <40 kg), in patients with liver or renal failure or as a rescue technique where local anaesthetic has already been administered.
- Where the use of PNS is difficult or limited:
  - Pain – patient with a fracture or dislocation.
  - Nerve dysfunction or damage – where identification or stimulation is difficult, e.g. diabetics, peripheral vascular disease. In these patients the sciatic nerve may be impossible to stimulate even at current of >5 mA.
  - Failure to locate nerve – in patients displaying anatomical variation, the nerve is more likely to be identified and successfully blocked with direct visualization.
- Where there is difficulty in identifying surface anatomical landmarks, either due to patient's shape and size or following surgical intervention, e.g. excision lateral end of clavicle.

## Techniques

Ultrasound techniques can be learnt and practised initially on models. Although time consuming at first, once proficient, blocks can be performed faster than with nerve stimulation techniques. The choice of an in-plane or out-of-plane approach will depend on operator skill and nerve/plexus to be blocked. An in-plane approach may be easier to learn initially, with the use of a nerve stimulator to confirm correct identification of the structure.

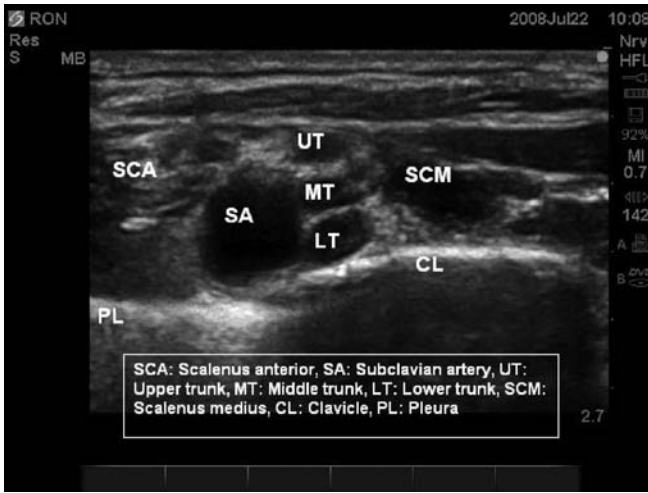
The nerves in the brachial plexus are very superficial and ideal for USGRA; all commonly used approaches (interscalene, axillary) can be performed with ultrasound and certain approaches (supraclavicular, infraclavicular) have found renewed enthusiasm due to the improved safety and success that ultrasound affords. The lumbosacral plexus offers a different challenge to ultrasound. Depth and adjacent bony structures obscure and limit visibility. More commonly used techniques (femoral, distal sciatic and popliteal) can be performed at any level where the nerves are identified.

## Pictures of common areas of interest

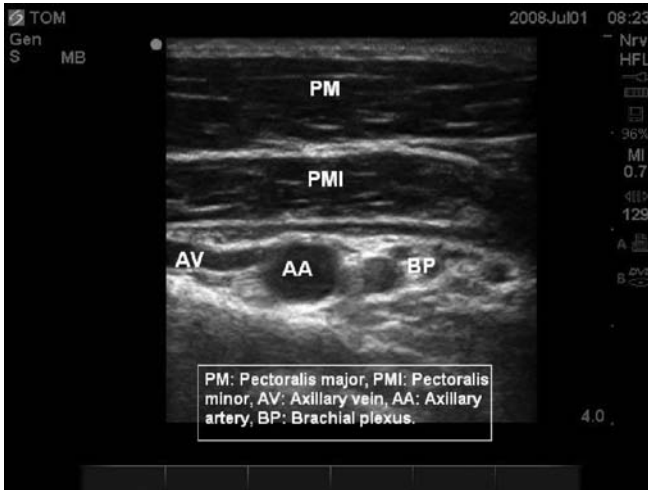
- (Fig. 7.61) Supraclavicular
- (Fig. 7.62) Infraclavicular
- (Fig. 7.63) Axillary
- (Fig. 7.64) Sciatic
- (Fig. 7.65) Popliteal
- (Fig. 7.66) Rectus sheath
- (Fig. 7.67) Ilioinguinal

## Practical application of ultrasound-guided regional anaesthesia – 'a how to guide'

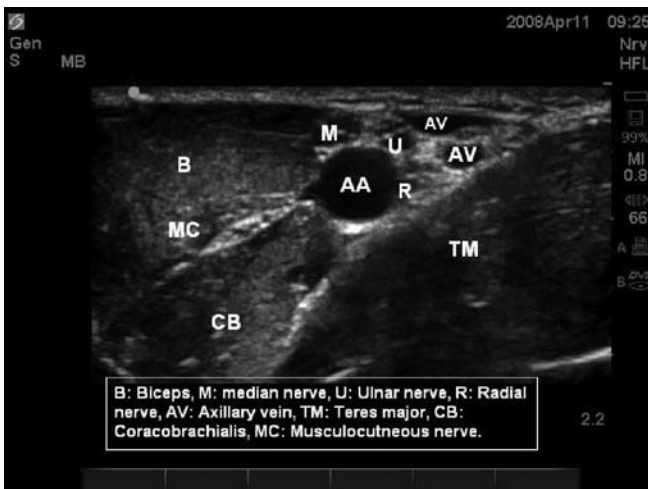
- Position patient and machine – ergonomically.
- Select probe – access required and depth of the proposed technique.
- Optimize machine settings – for preset parameters use nerve, vascular or small parts.
- Place probe on the skin – preliminary scan.



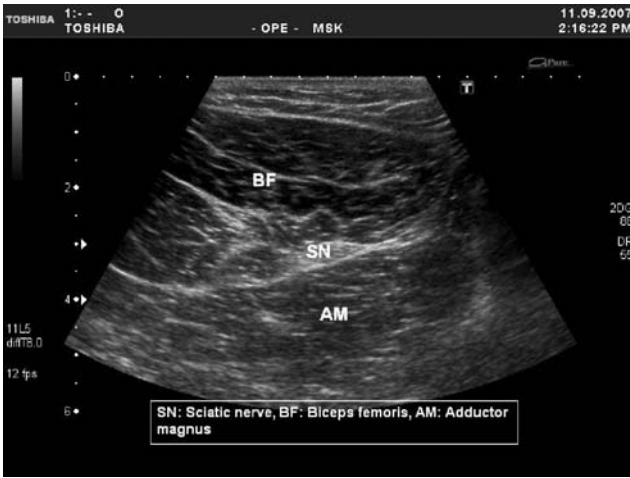
**Figure 7.61.** Supraclavicular anatomy.



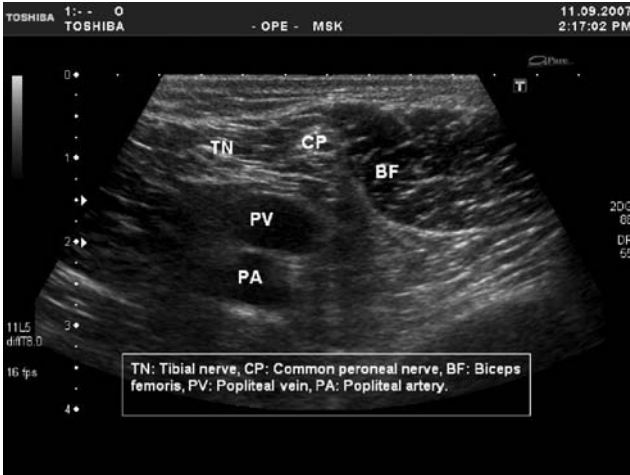
**Figure 7.62.** Infraclavicular anatomy.



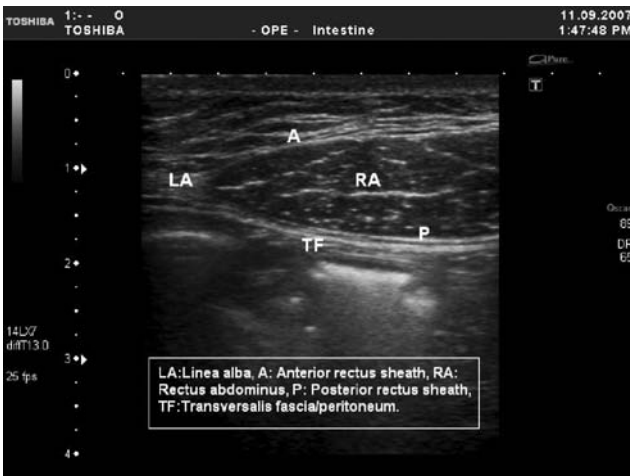**Figure 7.63.** Axillary anatomy.



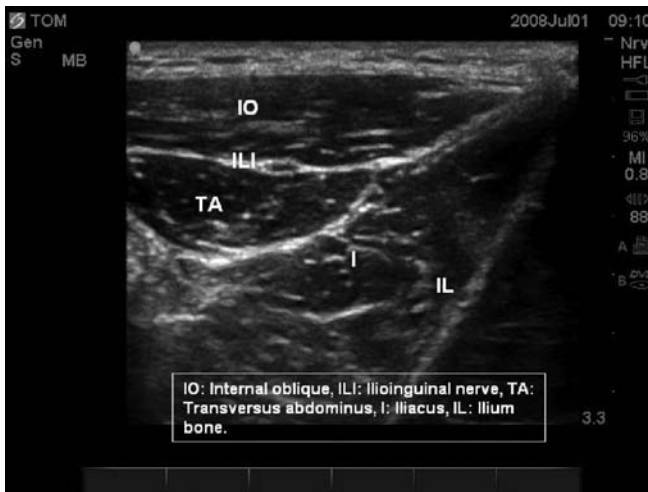**Figure 7.64.** Sciatic mid-thigh anatomy.



**Figure 7.65.** Popliteal anatomy.



**Figure 7.66.** Rectus sheath anatomy.



**Figure 7.67.** Ilioinguinal anatomy.

- Orientate probe to reflect hand movements – mark on the probe/screen.
- Find reference structure – nerve/artery/muscle.
- Adjust depth of field – focus beam where applicable, maintain structure of interest in the middle of the screen.
- Gain control adjustment will alter brightness (grey/white scale).
- Identify nerve/plexus of interest.
- (A.R.T) Align/rotate/tilt the probe to obtain the best picture.
- Doppler or colour pulsed Doppler will distinguish nerves from vessels.
- Determine needle entry point by gently pressing on the skin, watching for tissue movement on the screen, mark.
- Apply protective cover to probe and disinfect skin.
- Place probe on the skin, infiltrate skin and subcutaneous tissues (under direct vision).
- Insert needle through the skin – identify needle tip. (Do not advance unless the needle tip is identified.)
- Direct the needle to lie adjacent to the nerve.
- Identify nerve with peripheral nerve stimulator (where applicable).
- Inject 0.5 ml local anaesthetic – observe spread and then inject volume sufficient to encircle the nerve.

## Golden rules of USGRA

- Never advance the needle unless you can identify the needle tip at ALL times.
- Never deliberately contact the nerve – place the needle next to the nerve.
- Observe injection – if unable to see spread of local anaesthetic, consider intravascular injection/needle tip not in scan plane.
- Injection should be resistance free and painless – if not – STOP – reposition needle.
- If the nerve swells on injection – STOP – consider intraneural injection.



## Case illustrations

### Question 1

Male 38, dislocated shoulder playing rugby, repeated failed attempts at reduction in A&E with sedation. Shoulder has now been dislocated for more than six hours. Patient is in pain with associated nausea and vomiting.

- What type of peripheral nerve block would be appropriate here and why?
- What structures can you identify on ultrasound?
- What are the advantages of using USGRA rather than a PNS technique?

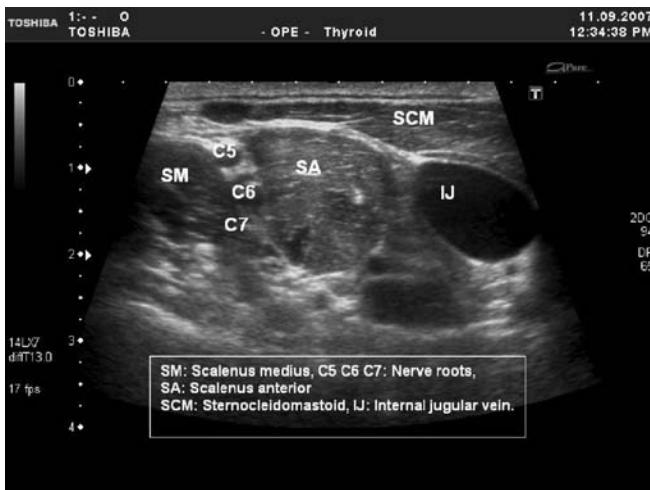
### Answer

The interscalene approach to the brachial plexus routinely blocks the C5, C6 and C7 nerve roots, which supply the shoulder joint and the muscles surrounding it (rotator cuff, deltoid and biceps). All approaches below this level, e.g. infraclavicular and axillary, do not reliably block the suprascapular nerve (branch of the upper trunk), the major sensory nerve to the shoulder joint.

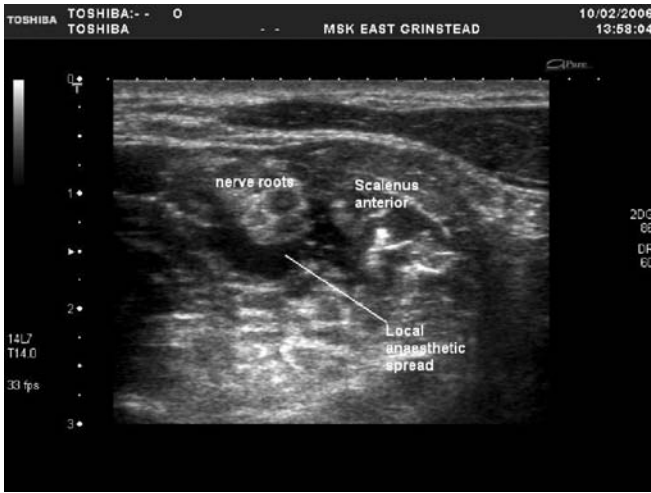
On ultrasound, the internal jugular vein and carotid artery can be identified medially to the anterior and middle scalene muscles. The roots can be easily identified between these two muscles and blocked with local anaesthetic. (Figs. 7.68 and 7.69).

Using ultrasound guidance reduces the volume of local anaesthetic needed, improves patient comfort (no painful muscle contractions) and reduces complications (inadvertent vascular injection, epidural or intrathecal puncture).

After transfer to theatres, an interscalene block is performed under ultrasound guidance using 20 ml lidocaine 1.5% – no stimulator used. Pain free in 5 min – shoulder reduced after 10 minutes with no sedation – patient comfortable and very happy.



**Figure 7.68.** Interscalene anatomy.



**Figure 7.69.** Interscalene block – showing spread of local anaesthetic.

## Question 2

86-year-old female with mild dementia, living in a nursing home, fell sustaining a fractured neck of femur, arriving in A&E in pain.

- How would you provide analgesia while avoiding opiates to prevent worsening her confusion?
- What are the complications of this technique?

## Answer

The femoral nerve supplies the muscle and skin of the anterior thigh and femur; blocking this reduces both the pain from a fractured femur and the associated muscle spasm. The variation in distance (0.5–3.0 cm) of the nerve from the femoral artery and its close association to these vascular structures make this a potentially risky block in inexperienced hands. Originally performed in A&E departments blindly or with PNS, this block has a high incidence of failure and complications (inadvertent intravascular injection). The femoral nerve and these surrounding structures are easily visualized using ultrasound.

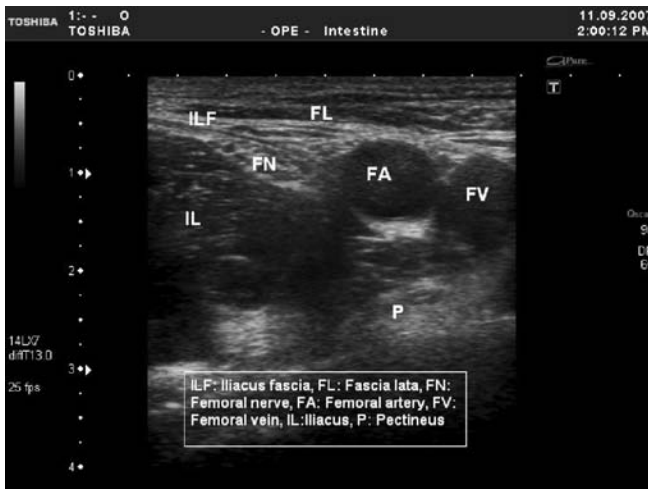
These complications are much reduced by use of USG, provided the technician is appropriately trained. In an A&E setting this is especially important as non-anaesthetists will be performing the block.

## Question

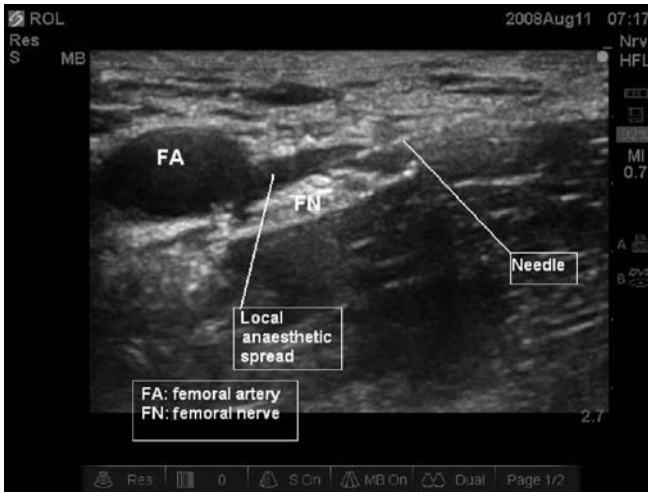
What structures can you identify?

## Answer

Structures seen medially to laterally: femoral vein, artery and nerve, superficial to deep fascia lata and iliacus fascia (Figs. 7.70 and 7.71).



**Figure 7.70.** Femoral nerve anatomy.



**Figure 7.71.** Femoral nerve – the ultrasound image shows the needle and local anaesthetic spread.

Not wishing to give this patient large doses of morphine and worsen her confusion, a femoral nerve block is performed in A&E using ultrasound guidance; 20 ml 0.25% levobupivacaine is injected under direct vision around the femoral nerve (using a nerve stimulator would be too painful). Within 15 minutes the patient is almost pain free, a Thomson's splint is placed on the leg with minimal discomfort and the patient transferred to the orthopaedic ward.

### Question 3

76-year-old male scheduled for an elective right hemicolectomy, previous history of coronary stents and present medication includes aspirin and clopidogrel. The patient has declined an epidural.

- What regional anaesthetic technique could be offered as an alternative to epidural?
- What are the advantages and disadvantages of this technique?

### Answer

The innervation of the anterior abdominal wall is from anterior divisions of spinal nerves that run between the transversus abdominus and internal oblique layers. If local anaesthetic is placed between these fascial planes, it will spread widely, blocking unilaterally T7–T12 spinal nerves. This is called a transversus abdominus plane (TAP) block.

Advantages include:

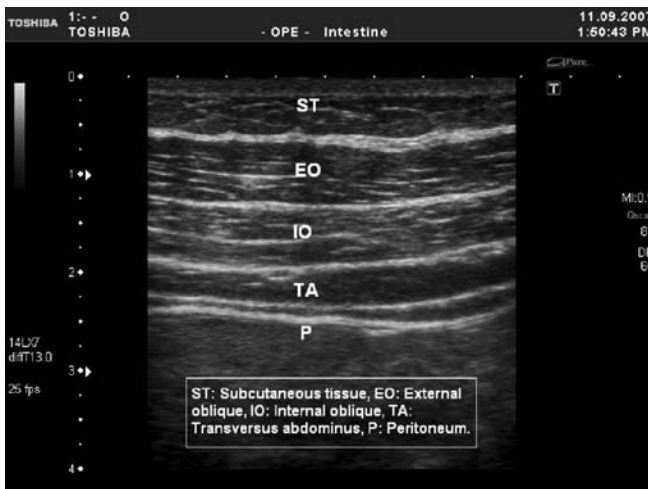- avoidance of complications associated with epidural,
- safe to use in the anti-coagulated patient,
- minimal risk of vessel/peritoneal perforation under ultrasound guidance,
- reduces dose of opiate required for effective pain relief,
- catheter can be placed for continuous infusion to prolong duration of block.

Disadvantages include:

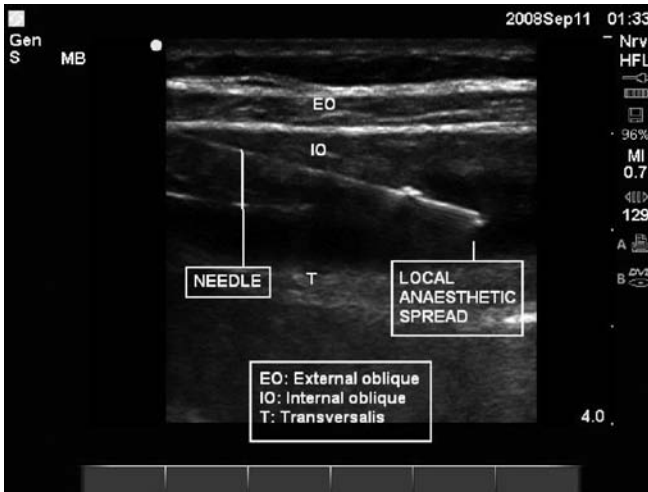
- probably not efficacious enough for use as sole analgesic post-operatively,
- requires additional equipment,
- risk of local anaesthetic toxicity if large doses used,
- does not always give predictable spread of anaesthetic between fascial planes.

### Question

Can you identify the muscles layers of the anterior abdominal wall and in which plane should the local anaesthetic be injected?



**Figure 7.72.** Transversus abdominus block (TAP).



**Figure 7.73.** TAP – showing needle and infiltration of local anaesthetic.

## Answer

Superficial to deep: external oblique, internal oblique and transversus abdominus. The plane is between internal oblique and transversus abdominus (Figs. 7.72 and 7.73).

Bilateral TAP blocks are performed under ultrasound guidance, 20 ml 0.375% levobupivacaine is injected on each side. This in combination with a multi-modal post-operative analgesic regime achieves almost complete pain relief in the post-operative period, with the patient using less than 10 mg of morphine within the first 48 hours.

# Index

---

- abdominal aortic aneurysm, 86–8
- abdominal CTs, 63–4
- abdominal paracentesis, 273–4
- abdominal trauma
  - blunt renal trauma, 117
  - Chance fracture of L4, 114–15
  - diaphragm rupture, 104–5
  - focused abdominal sonogram for trauma (FAST), 106
  - liver trauma, 110–12
  - splenic laceration, 106–9
- abdominal X-rays, 60, 62
  - bowel gas pattern, 48, 60
  - calcification, 61
  - solid organs, 60
- acalculous cholecystitis, 276–7
- achalasia, 43, 78–9
- acoustic neuroma, 223–4
- air space shadowing, 15
- airway management, 155
- anaesthesia
  - challenges, 210
  - diagnostic radiology, 211
  - hazards to anaesthetists, 210
  - monitoring, 210
  - safe management of patients, 210
  - sedation versus anaesthesia, 211–12
- angiography, *see* CT angiography *and* MR angiography
- angiotensin II, 85
- anisotropy, 289
- ankylosing spondylitis, 150–2
- anterior mediastinal masses, 41–2
- aortic aneurysm rupture, 86
- aortic arch, 57
- aortic dissection, 38
- aortic injury, 97–9
- appendicitis, 74
- appendoliths, 74
- ARDS, 49–50
- aspiration of foreign body, 23–4
- atrial enlargement, 46
- atrial septal defect, 47–8
- biliary stent, 235–6
- bladder injuries, 118–19
- blunt abdominal trauma, *see* abdominal trauma
- blunt chest trauma, 100–2
- Boerhaave's syndrome, 33
- bowel gas pattern, 60
  - extraluminal gas, 72–3
  - small bowel infarction, 92
  - small bowel obstruction, 65–7
- bowel trauma, 114–15
- brain glioma, 203–4
- brain injury, 205–8
- caecal volvulus, 70
- calcification, 61, 74
- Caplan's syndrome, 147
- cardiac enlargement, 34–5, 44–8
- cardiac injury, 103
- cavitating malignancy, 55
- central line insertion, 271–2
- central pontine myelinolysis (CPM), 227
- cerebral contusions, 206
- cerebral infarction, 195–9
- cerebral metastasis, 200–2
- cervical spine
  - airway management with fractures, 155
  - ankylosing spondylitis, 150–2
  - clay shoveler's fracture, 169–70
  - craniocervical junction, 144–5
  - diffuse idiopathic skeletal hyperostosis (DISH), 154
  - extension teardrop fracture, 163
  - flexion teardrop injury, 164–5
  - hangman's fracture, 161–2
  - imaging, 130–3
  - importance in intubation, 130
  - injury, 139–41
  - Jefferson fracture, 157–8
  - lateral view, 138–9
  - locked facet injuries, 166–8
  - occipito-atlantal dissociation, 156
  - odontoid fracture, 159
  - open mouth AP radiograph, 136–7
  - pre-cervical haematoma, 136
  - rheumatoid arthritis, 145–9
  - segments, 130
  - soft tissue contour, 134
  - unconscious/obtunded patients, 140
- cervical spondylosis, 143, 225–6
- Chance fracture of L4, 114–15
- chest trauma
  - aortic injury, 97–9
  - blunt chest trauma, 100–2
  - cardiac injury, 103, 285
  - pulmonary contusion, 102–3
  - steering wheel injuries, 100

- chest X-rays  
 air space shadowing, 15  
 bones, 6  
 diaphragm, 5  
 heart and mediastinum, 4–5  
 interpretation, 6–8  
 interstitial pattern  
 shadowing, 26  
 labels, 2  
 large airways, lungs and  
 pleura, 3, 4  
 opacification, 7, 8, 14, 17  
 projection and patient  
 position, 2–3  
 quality of film, 3  
 review areas, 6, 57  
 side marker, 3  
 silhouette sign, 7  
 soft tissues, 6
- children, 211, 220
- cholangiogram, 235–6
- cholecystitis, 276–7
- cirrhosis, 238–9, 273
- claustrophobia, 211
- clay shoveler's fracture, 169–70
- Clostridium difficile*, 68
- colitis  
 necrotizing enterocolitis, 76  
 pan colitis, 72  
 pseudomembranous, 68–9
- collapsed lung, 29
- colonic diverticulitis, 80
- colo-rectal stents, 241
- compartment syndrome, 123–5
- competency-based training  
 and assessment, xvi
- contrast medium, 175, 215
- craniocervical junction, 144–5
- CT angiography, 85, 247–8  
 complications, 245
- CT-guided lung biopsy, 233–4
- CT pulmonary angiography,  
 36–7
- CT scans  
 acute subdural haematoma,  
 187–9  
 analysis, 176, 181  
 attenuation, 173
- brain injury, 205–8
- cerebral infarction, 195–9
- cerebral metastasis, 200–2
- extradural haematoma,  
 190–1
- Hounsfield units, 173
- image formation, 173
- intracerebral haematoma,  
 192–4
- intravenous contrast  
 medium, 175
- malignant brain glioma,  
 203–4
- MRI versus CT, 216
- multi-slice CT, 174
- protocol variables, 175–6
- spiral CT, 174
- subarachnoid haemorrhage,  
 182–3
- tissue density, 173
- windowing, 173–4
- degenerative cervical  
 spondylosis, 225–6
- dens fracture, *see* odontoid  
 fracture
- dextrocardia, 3
- diagnostic radiology, 211
- diaphragm rupture, 104–5
- diffuse idiopathic skeletal  
 hyperostosis (DISH), 154
- discitis, 230–1
- diverticular abscess, 80–1
- Doppler ultrasound, 254
- duplex ultrasound, 246, 254
- echocardiography, 279  
 focused echocardiography,  
 283  
 left ventricular function,  
 281–2  
 pre-operative, 282  
 stress echocardiography, 282  
 training, 283  
 transoesophageal (TOE),  
 282–3  
 transthoracic (TTE), 279–81
- Eisenmenger syndrome, 47
- emergency patients, 211
- endotracheal tubes, 40
- endovascular aneurysm repair  
 (EVAR), 87–8
- epidural abscess, 230–1
- extension teardrop fracture,  
 163
- faecoliths, 74
- fasciotomy, 123
- fat embolism, 123
- femoral fractures, 122–5  
 intertrochanteric fracture of  
 the hip, 126–7
- femoral nerve block, 301–2
- flexion teardrop injury, 164–5
- focused abdominal sonogram  
 for trauma (FAST), 106
- focused echocardiography,  
 283
- FRCA examination, xv–xvi
- gadolinium, 215
- gallstones, 60
- Glasgow Coma Score (GCS),  
 183–4
- glioma, 203–4
- haemothorax, 103
- Hampton's hump, 36
- hangman's fracture, 161–2
- head injuries, 190, 205–7
- hiatal hernia, 43
- hip fractures, 126–7
- Hounsfield units, 173
- HU values, *see* Hounsfield  
 units
- ileocaecal valve, 71
- inferior vena cava (IVC) filters,  
 242–3, 245
- intensive care patients, 220
- intensive care units  
 echocardiography, *see*  
 echocardiography  
 ultrasound, 255



- interstitial pattern shadowing, 26
- intertrochanteric fracture of the hip, 126–7
- interventional radiology, 232
- intracerebral haematoma, 192–4
- intracranial sinus thrombosis, 229
- intravenous contrast medium, 175
- intussusception, 77
- Jefferson fracture, 157–8
- juvenile rheumatoid arthritis, 148–9
- kidneys, 60
- kidney stones, 60, 61
- kidney trauma, 117
- kyphoscoliosis, 56
- lap belt injury, 114
- large bowel obstruction, 70–1
- laryngoscopy, 130
- left ventricular function, 281–2
- leg ischaemia, 246
- liver, 60  
  cirrhosis, 238–9, 273  
  portal hypertension, 238–9
- liver trauma, 110–12
- lobar collapse, 19–21
- locked facet injuries, 166–8
- lung biopsy, 233–4  
  contraindications, 233
- lung cavitation, 54–5
- lung collapse, *see* lobar collapse *and* collapsed lung
- malignant brain glioma, 203–4
- mediastinal masses, 41–2
- micro-shock, 220
- miliary nodules, 27–8
- mitral valve disease, 46
- MR angiography, 85, 215, 246–9  
  complications, 248–9
- MRI  
  anaesthesia, 219–20  
  anaesthetic monitoring, 216  
  bioeffects of electromagnetic radiation, 218  
  contraindications, 218  
  contrast agents, 215  
  CT versus MRI, 216  
  hazards, 218, 221  
  image formation, 212–13  
  intensive care, 220  
  magnetic field strength and ferromagnetic attraction, 216–17  
  main uses, 212  
  micro-shock, 220  
  monitoring patients, 219  
  tissue contrast, 213–15
- multi-slice CT, 174
- nasogastric tubes, 39
- National Radiological Protection Board (NRPB), 218
- necrotizing enterocolitis, 76
- needle gauge, 265
- needle visualization, 259–69  
  problems and tips, 268–9
- needling technique, 292–3
- neuronal tissue, 293–4
- obesity, 293, 294
- occipito-atlantal dissociation, 156
- odontoid fracture, 159
- oesophageal stents, 240–1
- oesophagectomy, 43
- oesophagus, 78
- opaque hemithorax, 28–9
- open book pelvic fractures, 120
- orotracheal intubation, 130
- pan colitis, 72
- pancreatitis, 60, 89–91
- paralytic ileus, 71
- patient archiving and communication systems (PACS), xiii
- pelvic trauma  
  bladder injuries, 118–19  
  Chance fracture of L4, 114–15  
  complications of fractures, 120–1  
  femoral fractures, 122–5  
  intertrochanteric fracture of the hip, 126–7
- percutaneous tracheostomy, 275
- percutaneous transhepatic cholangiogram (PTC), 235–6
- pericardial effusion, 44, 285
- pericardial tamponade, 103, 285
- peripheral nerve stimulation, 287, 293–5
- Pneumocystis pneumonia*, 17–18
- pneumomediastinum, 33
- pneumonia, 14–16
- pneumoperitoneum, 77
- pneumothorax, 3, 31–2, 103  
  lung biopsy, 233–4
- portal hypertension, 238–9
- porto-systemic shunts, 233, 239
- pre-operative assessment, xix–xx
- pre-operative echocardiography, 282
- pseudomembranous colitis, 68–9
- pulmonary contusion, 102–3
- pulmonary embolism, 36–7, 286  
  inferior vena cava (IVC) filters, 242–5
- pulmonary fibrosis, 25

- pulmonary hypertension, 46–8
- pulmonary nodules, 27–8, 52–5
- pulmonary oedema, 33–5
- pulmonary venous hypertension, 34
- radio-isotope  
ventilation/perfusion scanning, 37
- Ranson criteria, 90
- regional anaesthesia, *see* ultrasound-guided regional anaesthesia
- Reid's lobe, 60
- renal artery stenosis, 84–5
- renal tract stones, *see* kidney stones
- renal trauma, 117
- rheumatoid arthritis, 145–9
- ring enhancing lesions, 203–4
- scoliosis, 56
- sedation, 211–12
- sigmoid volvulus, 70
- silhouette sign, 7
- sinus thrombosis, 229
- small bowel infarction, 92–3
- small bowel obstruction, 65–7
- spinal stenosis, 225–6
- spiral CT, 174
- spleen, 60
- splenic laceration, 106–9
- spondylosis, 143, 225
- stress echocardiography, 282
- stroke, *see* cerebral infarction
- subarachnoid haemorrhage, 182–3  
anaesthetic management, 183–5  
common causes, 185  
complications, 186  
further investigations, 185–6
- subdural haematoma, 187–9
- superior sagittal sinus thrombosis, 229
- tamponade, 285
- tension pneumothorax, 31–2
- thrombo-embolic disease  
inferior vena cava (IVC) filters, 242–3, 245
- tracheostomy, 275
- transjugular intrahepatic porto-systemic shunt (TIPS), 237–9
- transoesophageal echocardiography (TOE), 282–3
- transthoracic echocardiography (TTE), 279–81
- transversus abdominus plane (TAP) block, 303–4
- trauma  
abdominal, *see* abdominal trauma  
chest, *see* chest trauma  
pelvic, *see* pelvic trauma
- ultrasound  
abdomen, 256–7  
abdominal paracentesis, 273–4  
acalculous cholecystitis, 276–7  
advantages and disadvantages, 259  
central line insertion, 271–2  
coarse gain, 253  
colour Doppler and power Doppler, 254  
depth control, 254  
Doppler ultrasound, 254–5  
duplex Doppler, 254  
focused abdominal sonogram for trauma (FAST), 106  
image display, 253–4  
image formation, 251–2  
intensive care units, 255  
musculoskeletal, 259  
optimizing the image, 255  
percutaneous tracheostomy, 275  
probe frequency, 253
- thoracic, 255–6  
time gain compensator (TGC), 253  
use in anaesthesia, 251  
vascular, 257–9
- ultrasound-guided procedures, 259–60  
angles of approach of the needle, 267  
background medium, 266  
checks prior to passing the interventional needle, 268  
depth, 263  
focus, 262  
hand position, 264–5  
initial scan, 263–4  
longitudinal or transverse approach, 266–7  
needle gauge, 265  
needle visualization, 265, 266  
objectives, 260  
probe covers and patient preparation, 264  
probe frequency, 262  
probes, 261–2  
problems and tips, 268–9  
time gain compensator (TGC), 263
- ultrasound-guided regional anaesthesia, 287–8  
anatomy, 295  
anisotropy, 289  
appearance of nerves, 293–4  
application, 294–5  
femoral nerve block, 301–2  
frequency, resolution and depth, 288–9  
interscalene approach to the brachial plexus, 299  
machines, 288  
needles and needling technique, 292–3  
patients, 293  
techniques, 295–8  
transversus abdominus plane (TAP) block, 303–4
- unconscious patients, 140
- ureteric obstruction, 82–3
- Valsalva manoeuvre, 275
- Volkman contracture, 123