

# Single Incision Laparoscopic and Transanal Colorectal Surgery

Wai Lun Law  
Conor P. Delaney  
*Editors*

 Springer

---

# Single Incision Laparoscopic and Transanal Colorectal Surgery



---

Wai Lun Law • Conor P. Delaney  
Editors

# Single Incision Laparoscopic and Transanal Colorectal Surgery

 Springer

*Editors*

Wai Lun Law, MBBS, MS,  
FRCS (Edin.)  
The University of Hong Kong  
Queen Mary Hospital  
Hong Kong  
China, People's Republic

Conor P. Delaney, MCh, PhD, FRCSI,  
FACS, FASCRS  
Case Western Reserve University  
University Hospitals Case  
Medical Center  
Cleveland, OH, USA

ISBN 978-1-4614-8901-6 ISBN 978-1-4614-8902-3 (eBook)

DOI 10.1007/978-1-4614-8902-3

Springer New York Heidelberg Dordrecht London

Library of Congress Control Number: 2013953693

© Springer Science+Business Media New York 2014

This work is subject to copyright. All rights are reserved by the Publisher, whether the whole or part of the material is concerned, specifically the rights of translation, reprinting, reuse of illustrations, recitation, broadcasting, reproduction on microfilms or in any other physical way, and transmission or information storage and retrieval, electronic adaptation, computer software, or by similar or dissimilar methodology now known or hereafter developed. Exempted from this legal reservation are brief excerpts in connection with reviews or scholarly analysis or material supplied specifically for the purpose of being entered and executed on a computer system, for exclusive use by the purchaser of the work. Duplication of this publication or parts thereof is permitted only under the provisions of the Copyright Law of the Publisher's location, in its current version, and permission for use must always be obtained from Springer. Permissions for use may be obtained through RightsLink at the Copyright Clearance Center. Violations are liable to prosecution under the respective Copyright Law.

The use of general descriptive names, registered names, trademarks, service marks, etc. in this publication does not imply, even in the absence of a specific statement, that such names are exempt from the relevant protective laws and regulations and therefore free for general use.

While the advice and information in this book are believed to be true and accurate at the date of publication, neither the authors nor the editors nor the publisher can accept any legal responsibility for any errors or omissions that may be made. The publisher makes no warranty, express or implied, with respect to the material contained herein.

Printed on acid-free paper

Springer is part of Springer Science+Business Media ([www.springer.com](http://www.springer.com))

---

## Preface

Over the past 2 decades, we witnessed rapid development in minimally invasive surgery and this has brought about significant improvement in surgical outcome. Reduction of incision-associated complications such as adhesions, surgical site infection, and incisional hernia is considered an important advantage of laparoscopic surgery.

Laparoscopic colorectal surgery started in the early 1990s and currently most colorectal resections can be performed with laparoscopy. In most cases, however, the procedure is laparoscopically assisted one and an incision is usually required to retrieve the specimen and to restore the bowel continuity.

The quest towards a more minimally invasive approach has led to the development of surgical technique to reduce the size and number of incisions. Natural orifice transluminal endoscopic surgery (NOTES) has gained tremendous enthusiasm in the last decade. However, the platform and the instruments are far from mature for general application.

Single incision laparoscopic surgery (SILS), although not a totally new concept, has emerged in recent years as an alternative to NOTES and some regard the umbilicus as a natural orifice. Nowadays, operations of different complexity can be performed using SILS and these include most colorectal procedures. SILS involves manipulation of laparoscopic instruments within a small access device and acquisition of a new set of skills is needed.

TEM was developed in 1983 by Gerhard Buess and the technique enables transanal excision of rectal lesions under direct vision. It represents both a minimally invasive and a natural orifice approach to rectal lesions. Over many years, TEM was confined to local excision of early rectal lesions. Recently with the increased interest in natural orifice surgery, the scope of TEM has been expanded to more complex operations. TEM and SILS are becoming more popular minimally invasive approaches to colorectal diseases. The skills for both techniques are similar in many aspects. Therefore, we decided to produce a book with the objective to help general and colorectal surgeons to acquire these two increasingly applied techniques.

“Single incision laparoscopic and transanal surgery” is written with the objective to introduce SILS for colorectal surgery and TEM to surgeons. It is divided into two sections. The first section concentrates on single incision laparoscopic colorectal surgery. It starts with the introduction of the instruments and skills needed for SILS. This is followed by individual colorectal procedures, from simple right colectomy to restorative proctocolectomy. The outcomes and currently available outcome data are also discussed.

In the second section, the chapters are on TEM. The indications, techniques, and outcomes of the procedures for local excision are described and the following chapters are on the advanced application of TEM.

The contributors are experts in the fields with vast experience in SILS or TEM. In this book, individual procedures are illustrated in detail and the tricks for a successful operation are described. We hope that this book can encourage surgeons with experience in laparoscopic colorectal surgery to acquire the knowledge and skills of SILS and TEM, rendering these techniques as part of their armamentarium. The book also serves as an introduction of SILS and TEM to general surgeons, surgical fellows, and residents who would like to learn these skills for their practice.

Hong Kong, China  
Cleveland, OH, USA

Wai Lun Law  
Conor Delaney

---

# Contents

<b>1 Platforms and Instruments (Principles of Single-Incision Laparoscopic Colorectal Surgery, Available Platforms and Instruments)</b> .....	1
Skandan Shanmugan and Bradley J. Champagne	
<b>2 Single Incision Laparoscopic Right Colectomy</b> .....	11
Deborah Nagle	
<b>3 Single Incision Laparoscopic Left Colectomy</b> .....	19
Dominic C.C. Foo and Wai Lun Law	
<b>4 SILS Total Colectomy and Proctocolectomy with Ileal Pouch-Anal Anastomosis (IPAA)</b> .....	29
Deborah S. Keller and Conor P. Delaney	
<b>5 Low Anterior Resection and Total Mesorectal Excision</b> .....	35
Léon Maggiori and Yves Panis	
<b>6 Tricks and Routes to Success</b> .....	41
Kelly A. Garrett and Sang W. Lee	
<b>7 Robotic Single Port Colorectal Surgery</b> .....	49
Byung Soh Min, Sami Alasari, and Avanish Saklani	
<b>8 Current Evidence for Single-Incision Laparoscopic Colectomy</b> .....	61
Jensen T.C. Poon and Wai Lun Law	
<b>9 Local Excision (LE) for Low Rectal Cancer (RC): From Mucosectomy to Endolumen Loco-Regional Resection (ELRR)—Tips and Tricks</b> .....	67
Giovanni Lezoche and Emanuele Lezoche	
<b>10 Hybrid NOTES Colectomy for Left-Sided Colonic Tumors</b> .....	85
Alex Lik Hang Leung, Hester Yui Shan Cheung, and Michael Ka Wah Li	



**11 Transanal Endoluminal Total Mesorectal Resection (TETMR) by Transanal Endoscopic Microsurgery (TEM)..... 93**  
Emanuele Lezoche, Giancarlo D’Ambrosio, Pietro Ursi,  
and Giovanni Lezoche

**12 Transanal Excision: Development, Technique, and Evidence..... 101**  
Laurel Blair, Dominique McKeever, and John H. Marks

**Index..... 115**

---

## Contributors

**Sami Alasari** Yonsei University College of Medicine, Seoul, South Korea

**Laurel Blair** Division of Colorectal Surgery, Main Line Health Systems, Wynnewood, PA, USA

**Bradley J. Champagne** Department of Surgery-Colorectal, Case Medical Center, Cleveland, OH, USA

**Hester Yui Shan Cheung** Department of Surgery, Pamela Youde Nethersole Eastern Hospital, Hong Kong, China

**Giancarlo D'Ambrosio** Department of Surgery, University La Sapienza, Rome, Italy

**Conor P. Delaney** Division of Colorectal Surgery, Department of Surgery, University Hospitals-Case Medical Center, Case Western Reserve University, Cleveland, OH, USA

**Dominic C.C. Foo** Queen Mary Hospital, The University of Hong Kong, Hong Kong, China

**Kelly A. Garrett** Division of Colon & Rectal Surgery, Weill-Cornell Medical College, NY Presbyterian Hospital, New York, NY, USA

**Deborah S. Keller** Division of Colorectal Surgery, Department of Surgery, University Hospitals-Case Medical Center, Case Western Reserve University, Cleveland, OH, USA

**Wai Lun Law** Department of Surgery, Queen Mary Hospital, The University of Hong Kong, Hong Kong

**Sang W. Lee** Weill Cornell Medical College, New York-Presbyterian Hospital, New York, NY, USA

**Alex Lik Hang Leung** Department of Surgery, Pamela Youde Nethersole Eastern Hospital, Hong Kong, China

**Emanuele Lezoche** Department of General Surgery, Surgical Specialities and Organ Transplantation, 'Paride Stefanini' at University of Rome, Rome, Italy

**Giovanni Lezoche** Department of General Surgery, University 'Politecnica delle Marche', Ancona, Italy

**Michael Ka Wah Li** Department of Surgery, Pamela Youde Nethersole Eastern Hospital, Hong Kong, China

**Léon Maggiori** Department of Colorectal Surgery, Beaujon Hospital, Assistance publique-Hôpitaux de Paris, Clichy, France

**John H. Marks** Division of Colorectal Surgery, Main Line Health Systems, Wynnewood, PA, USA

Department of General Surgery and Digestive Oncology, Fellowship for Minimally Invasive Colorectal Surgery and Rectal Cancer Management, Lankenau Medical Center, Professor, Lankenau Institute of Medical Research, University Nice Sophia-Antipolis, Centre Hospitalier University, Nice, France

**Dominique McKeever** Division of Colorectal Surgery, Main Line Health Systems, Wynnewood, PA, USA

**Byung Soh Min** Yonsei University College of Medicine, Seoul, South Korea

**Deborah Nagle** Section of Colon and Rectal Surgery, Beth Israel Deaconess Medical Center, Harvard Medical School, Boston, MA, USA

**Yves Panis** Pôle des Maladies de l'Appareil Digestif, Service de Chirurgie Colorectale, Hôpital Beaujon, Assistance Publique des Hôpitaux de Paris (APHP), Université Paris VII (Denis Diderot), Clichy, France

**Jensen T.C. Poon** Department of Surgery, Queen Mary Hospital, The University of Hong Kong, Hong Kong

**Avanish Saklani** Yonsei University College of Medicine, Seoul, South Korea

**Skandan Shanmugan** Division of Colon and Rectal Surgery, University of Pennsylvania Health System, Philadelphia, PA, USA

**Pietro Ursi** Department of Surgery, University La Sapienza, Rome, Italy

# Platforms and Instruments (Principles of Single-Incision Laparoscopic Colorectal Surgery, Available Platforms and Instruments)

Skandan Shanmugan and Bradley J. Champagne

## Introduction

In 2013, conventional laparoscopic colorectal surgery has become a safe and effective alternative to open colorectal surgery. Furthermore, laparoscopic surgery has been proven to be associated with better outcomes, reduction in postoperative pain, shorter hospital stay, and earlier return to normal activity [1–3]. These advantages have also been achieved without compromising oncological outcomes [4–7]. In standard laparoscopic surgery, three to five ports are routinely required. Despite the small skin and fascial incisions (5–12 mm), patients do experience pain and discomfort over port sites. There are also inherent risks to visceral and epigastric vessels during port introduction and development of port-site incisional hernias [8]. Furthermore, public perception has recently become swayed as surveys have shown that patients have a negative perception of surgical scars and would prefer “scarless” surgery [9]. The drive to move toward incision-less or scarless surgery without compromising surgical principles and safety has led to the development of single-incision laparoscopic surgery. There are several acronyms for single-incision laparoscopic

surgery given the various competing port devices and platforms developed by industry manufacturers (Table 1.1).

SILCS (single-incision laparoscopic colorectal surgery) represents a potential advance in minimally invasive approaches to colorectal disease. Although widely promoted, data for improved outcomes are virtually absent but preliminary data demonstrate that SILCS can be performed safely in selected patients by experienced surgeons [10]. The actual benefits of single incision compared with multiple-port laparoscopic colectomy are not immediately evident and may be beyond that of simple cosmetics. This will be discussed elsewhere in this textbook.

Despite the growing enthusiasm for SILCS, there are several challenges compared with standard multi-port laparoscopic colectomy. Handling straight instruments in parallel with the laparoscope through a small incision decreases the range of movement for the surgeon and complicates camera use by the assistant. These difficulties become evident during colorectal surgery because, unlike laparoscopic cholecystectomy or appendectomy, SILCS often requires operating in different abdominal quadrants. Furthermore, the learning curve of undetermined length still exists for multi-port laparoscopy and is more exhaustive than for other minimally invasive procedures.

Multi-port laparoscopic colectomy traditionally relies on the principles of triangulation and traction/counter-traction to facilitate the precise dissection of anatomical planes.<sup>11</sup> These essential principles require significant modification to

---

S. Shanmugan, M.D. (✉) • B.J. Champagne, M.D.,  
F.A.C.S., F.A.S.C.R.S.  
Department of Surgery-Colorectal, Case Medical  
Center, 11100 Euclid Avenue, Cleveland, OH 44106,  
USA  
e-mail: brad.champagne@uhhospitals.org

**Table 1.1** Historical acronyms used to describe single-incision laparoscopy

SPA	Single-port access
SILS	Single-incision laparoscopic surgery
OPUS	One-port umbilical surgery
E-NOTES	Embryonic natural orifice transumbilical endoscopic surgery
SIMPLE	Single-incision multi-port laparo-endoscopic surgery
SPS	Single-port surgery
VSUS	Visibly scarless urological surgery
SIL	Single-incision laparoscopy
SPL	Single-port laparoscopy
R-NOTES	Robotic-assisted natural orifice transumbilical endoscopic surgery
U-NOTES	Umbilical natural orifice transluminal endoscopic surgery
LESS	Laparo-endoscopic single-site surgery
SLaPP	Single laparoscopic port procedure
NOTUS	Natural orifice transumbilical surgery
SLiPP	Single laparoscopic incision and port procedure

successfully perform single-port laparoscopic surgery. The cornerstone of SILCS is the utilization of a single port with 2–4 trocar place holders. Limitations of this approach include a confined working space, the crossing or clashing of instruments, off-field vision, and the intermittent loss of pneumoperitoneum. To overcome these barriers, surgeons and industry have worked together to improve the design of both access ports and instruments. These novel platforms and devices are the focus of this chapter. It should be emphasized that despite the technical adjustments required in SILCS, the intra-abdominal procedural steps match the standardized techniques of laparoscopic colectomy as discussed in subsequent chapters.

## Laparoscopes


The choice of a laparoscope for single-incision laparoscopic colorectal surgery should be based on operator preference and clinical application. When deciding upon a camera system for SILCS the following attributes should be considered.

A 5 mm diameter scope takes up less space inside the access port and leaves a 10–12 mm port free for larger instruments such as a reticulating endoscopic stapling device. Secondly, it is advisable to use a laparoscope with a cable connection on the posterior rather than lateral aspect allowing rotation without interfering with instruments. The problem of the lateral light cable of regular telescopes and the bulky camera heads clashing with the instruments can be done away with by the use of a telescope with a coaxial light cable. In addition, using an extra-long or bariatric laparoscope staggered with regular-sized instruments may allow the free movement of the camera head away from the surgeon's hands. Some surgeons prefer the assistant to sit so that the assistant's hands move in a different plane, reducing the external interference. Integrated digital cameras also minimize external bulk and give more space.

Manufacturers have now developed a full range of laparoscopes that include 5 and 10 mm versions with 0°, 30°, or 45° direction of views in standard and high definition (720p). The newest advancements of laparoscopes to facilitate SILCS are the deflecting or articulating scopes, such as the EndoEYE™ by Olympus (Fig. 1.1). These laparoscopes are equipped with an advanced flexible tip design that provides a 100° view in all directions that can be fixed at any angle with a toggle switch. These articulating scopes are ideal for SILCS as they eliminate the need to exchange 0° scopes with angled scopes. They can also eliminate the crossing interference with parallel instruments while still providing a head-on directional view. It must however be noted that use of this instrument has a learning curve. If an internally flexible scope is not available, then an externally flexible scope will at least remove the assistant's hands from the surgeon's field.

## Access Ports

Regardless of which platform is used, most SILCS begin with a vertical midline incision at umbilicus for entry into the peritoneum. The midline linea-alba is void of muscles and vascular structures and therefore minimizes postoperative pain and the



**Fig. 1.1** A rigid laparoscope compared to an internally flexible scope

potential for inadvertent vascular injuries. It is our practice to use a vertical midline incision and sharp dissection to enter the peritoneum under direction vision with the use of S-retractors. Entry is confirmed with a blunt hemostat or finger to minimize the risk of injury to intra-abdominal organs and vessels. Depending on the particular procedure, point of entry anywhere in abdomen may be utilized with this technique. For example, if a protective stoma is planned, one should consider the stoma site for entry and extraction. The size of the particular incision is based on the specific device used. Most ports should utilize at least one 10–12 mm trocar and two to three 5 mm trocars with side ports for CO<sub>2</sub> insufflation and smoke evacuation. There are several single-incision platforms at your disposal (Fig. 1.2) and four of them will be discussed in detail in this chapter. They all have similarities in function with only minor deviations.

When choosing a platform one should consider the following technical considerations:

1. The ability to maintain a consistent seal and pneumoperitoneum
2. Trocar size and instruments that will be utilized
3. The proper spacing that will be required
4. Size of the specimen and extraction site

## Glove-Port Technique

The glove-port technique emerged as a means to perform single-incision laparoscopic surgery in a simple, low-cost, and easily reproducible manner. The access device was made by a standard wound protector (a small size or extra small size wound protector and a size 6, non-latex, sterile glove. The wound protector is introduced through the small umbilical incision. The surgical glove was fixed to the outer ring of the wound protector. Access ports are utilized through the glove's finger tips (Fig. 1.3).

### Advantages

- Simple
- Reproducible
- Cost

### Disadvantages

- Poor seal
- Lack of rigidity

## SILS™: Covidien

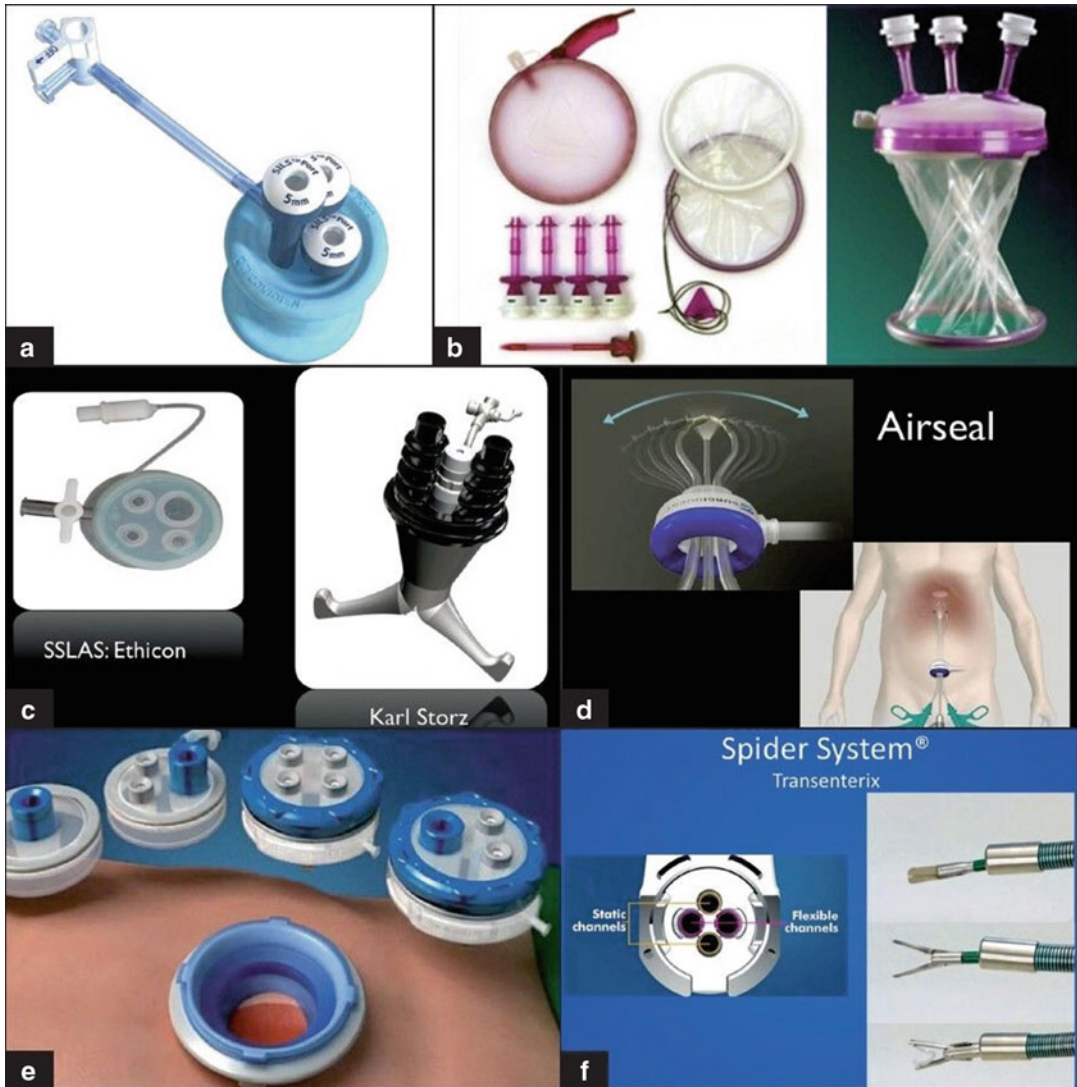
This platform utilizes a 2–4 cm vertical incision at the skin. This is deepened through the fascia to the same length. A Kelly or Hemostat clamp is used to grasp the inner edge of the blue foam port and then guided into the peritoneum. Trocars are inserted prior to insufflation (Fig. 1.4).

### Advantages

- Pliable foam offers enhanced mobility
- Can interchange a 5 mm port with a 12 mm port
- Readily reinserted

### Disadvantages

- Fixed length so not applicable for morbidly obese patients
- Instrument “sword fighting”
- Lack of wound protector for extracorporeal resection or anastomosis



**Fig. 1.2** The available single-incision platforms: (a) SILS™ Port by Covidien; (b) GelPoint® by Applied Medical; (c) SSLAS® by Ethicon; (d) Xcone® by Storz; (e) Airseal® by SurgiQuest; (f) SPIDER® by Spider surgery

### GelPoint®: Applied Medical

This platform utilizes a variable vertical incision length of 2–7 cm. A sleeve, similar to a wound protector, is then inserted into the peritoneum and rolled secure to the abdominal wall. Trocars are introduced into the GelSeal cap extra-peritoneally before the cover is secured to the sleeve and insufflation is established. Trocars (5–12 mm) are inserted at the discretion of the operator but are usually triangulated. The

GelPoint is equipped with a smoke evacuator as a side port (Fig. 1.5).

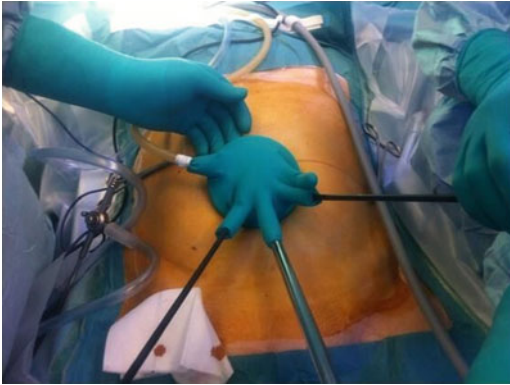#### Advantages

- Low internal profile, wider external profile
- Trocars can be relocated with ease with adequate spacing
- User friendly

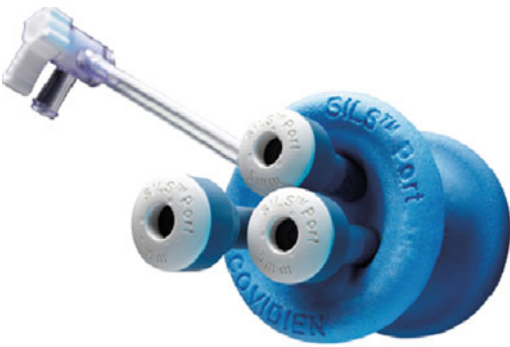#### Disadvantages

- Larger incision
- Trocars may slip out
- Additional guidance required upon entry





**Fig. 1.3** The Glove-port technique



**Fig. 1.4** SILS™ access port

### **TriPort™ and QuadPort™: Advanced Surgical Concepts**

TriPort access ports are the newer generation version of the original R-port systems. This platform uses either a 10–30 mm incision (TriPort) or a 15–50 mm incision (QuadPort). It is recommended that insertion be done using the introducer provided, with blunt dissection into the abdominal cavity with the distal ring of the TriPort attached. The distal ring is subsequently ejected with a thumbswitch, excess sleeve removed, and ring tightened before insufflation (Fig. 1.6).

#### Advantages

- Adjustable to abdominal wall thickness
- Low internal profile
- Removal cap and wound protector

#### Disadvantages

- Gel is susceptible to damage and leaks
- Instrument “sword fighting”

## **Instruments**

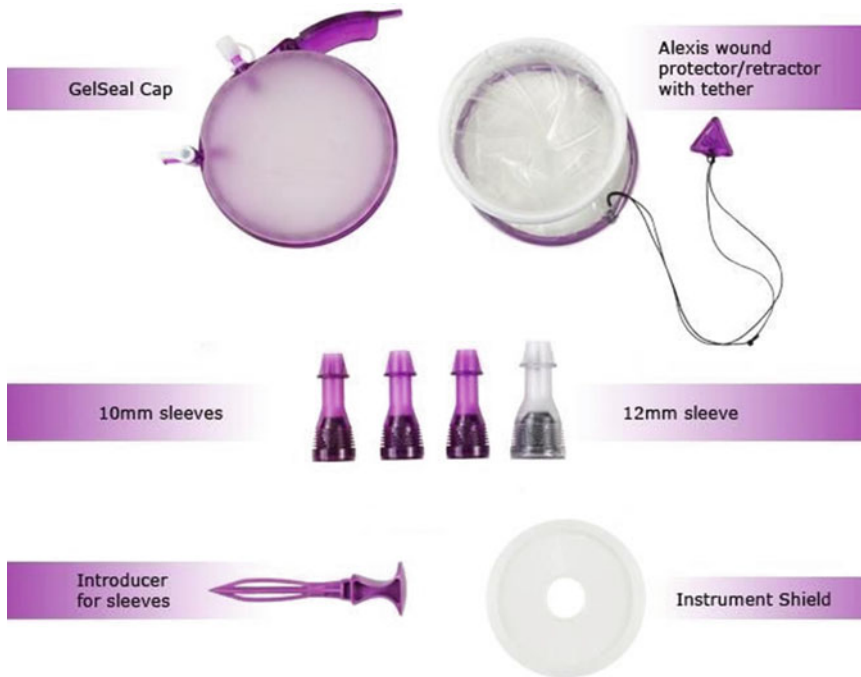
With the exponential growth and popularity of multi-port laparoscopy, numerous manufacturers are now also producing a wide array of instruments that can also be utilized for single-port laparoscopy. Standard laparoscopic instruments can still be used for single-port surgery and often in combination with specialized single-port equipment. Fixed straight instruments do offer the advantage of complete rigidity and therefore transmit applied force, retract consistently, and provide tactile feedback. Instruments specifically for SILCS are ideally 5 mm and available in standard (33–34 cm) and long (44–45 cm) shaft lengths. Long instruments generally allow the assistant to avoid interference with the operating surgeon. For performing SILCS, one must have the following instruments at the operator’s disposal: atraumatic bowel graspers, Maryland dissectors, Metzenbaum scissors, and Allis clamps. Monopolar (hook cautery) and bipolar (LigaSure™, HARMONIC®, scissor cautery) energy devices are utilized in SILCS as they are in multi-port laparoscopic colectomy and to the operator’s discretion and preference. However, the occasional loss of traction and counter-traction unique to SILCS may force the surgeon to use bipolar energy on a more regular basis.

With its growing popularity, newer technologies for SILCS have emerged and their advantages and limitations are discussed below.

## **Straight Instruments**

The advantages of using straight laparoscopic instruments for single-incision laparoscopic colorectal surgery are its familiarity, availability, and cost-effectiveness. The challenge of using straight instruments for SILCS is the loss of triangulation and therefore the necessary traction and counter-traction needed to achieve mesocolic dissection and isolation of significant structures. The confined space and parallel instrumentation lead to “sword-fighting” or “chopsticks” effect among the working instruments and between the laparoscopes. This occurs because the right-handed





**Fig. 1.5** GelPoint® access port



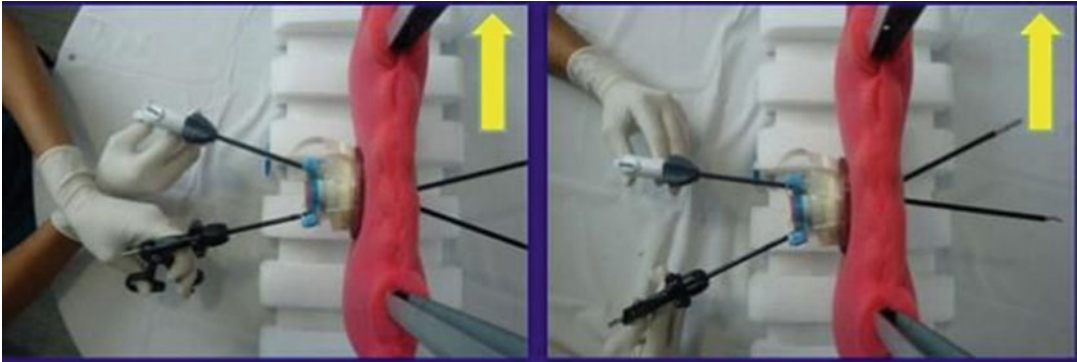
**Fig. 1.6** TriPort™ and QuadPort™

instrument automatically gravitates to the left of the operative field and vice versa. This can be minimized by simply staggering the instruments at the port site and during entry into the abdominal cavity. Trained surgeons can further avoid the clashing effect by “crisscrossing” the straight instruments in the operative field and switching hands (Fig. 1.7). This technique usually requires the surgeon to be facile with his/her non-dominant

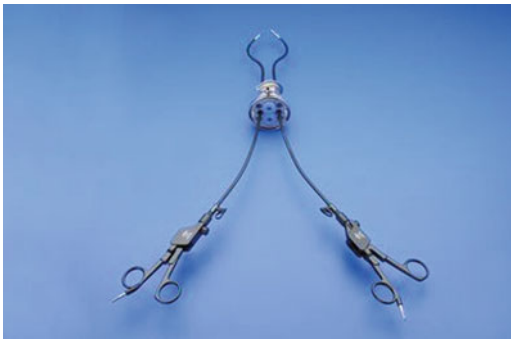hand as the majority of dissection has now shifted to the opposite hand.

### Curved Instruments

New technologies in instrumentation have tried to circumvent the “sword-fighting” effect with the introduction of curved or angled instruments.



**Fig. 1.7** Instruments crossed internally and hands switched externally



**Fig. 1.8** Newer generation curved instruments with increased angulation and external separation (Storz)

Curved instruments cannot be passed through conventional trocars which are straight and rigid. They can, however, be passed through some of the newer generation of access devices which have a very low profile inside and outside the abdominal cavity. Curved instruments avoid internal interference, yet have traded one learning curve for another. As angled instruments are directed toward the target planes the surgeon's hands can collide externally as the instruments move toward one another. This is overcome by the cross-hand technique whereby the operator's left hand operates the instrument on the right, and vice versa. While this technique may overcome, it adds another complex layer to an already steep learning curve. In addition, with the crossing of two instruments internally, they may compete for the same space in a vertical plane, which may limit their motion in the abdomen. Some newer generation curved instruments have been modified with a larger

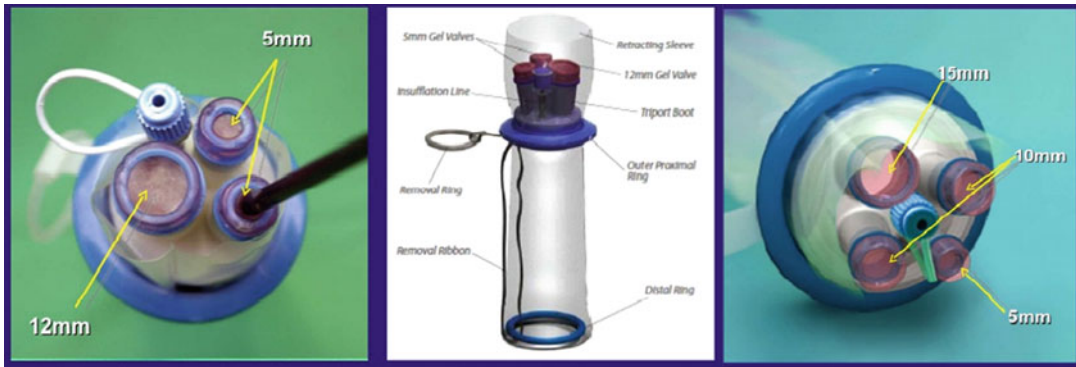
external curvature to accommodate internal triangulation with more external separation (Fig. 1.8). Curved instruments are more cost-effective than the newer flexible instruments and negatively impact tactile feedback.

### Flexible Instruments

Flexible or articulating instruments are advantageous for their increased freedom of movement and facilitating internal triangulation. The angle of the tip of these instruments can usually rotate 360° around its axis (Fig. 1.9). Despite their appeal, flexible instruments are not without their limitations. There is an adjustment period to the external ergonomics of these instruments before one can handle them dexterously. The bulky handle can cause crowding externally which can be compensated with alternating shaft lengths. Furthermore, the flexibility of these instrument sacrifices some rigidity and significantly eliminates tactile feedback. Finally, the cost-effectiveness of these newer technologies must once again be balanced with the clinical indication and user capabilities.

### Technical Tips

There is a significantly longer learning curve with single-incision laparoscopic colorectal surgery beyond standard laparoscopy. The procedural principles and cornerstones for laparoscopic colectomies must be adhered to while navigating the



**Fig. 1.9** SILS™ flexible hand instruments

confined space of a single incision. Therefore, the surgeon must use every weapon in their armamentarium to facilitate a dissection similar to the one experienced during multi-port laparoscopic colectomies. For example, using a bipolar device that safely permits blunt dissector may be advantageous. This facilitates dissection in SILCS by helping identify anatomical planes without the benefit of traction and counter-traction.

Proper instrument planning and unique combinations may also be utilized. Optimal instrument position allows proper tissue retraction, essential for the effective dissection in the normal anatomical tissue planes. Placing several parallel instruments, as required in single-port surgery, makes this considerably more difficult. The use of at least one flexible or curved instrument can adjust the angle enough to allow improved triangulation; however this usually requires the surgeon's instruments to cross, necessitating counterintuitive external movements. This can result in a degree of external crowding of instruments, and clashing of instruments should be expected and allowed for, especially during the training in these procedures. For instance a nuanced surgeon may utilize two straight instruments but a less ambidextrous surgeon may use a left-handed angled instrument and a right-handed straight for dissection. For more robust retraction, a right-handed curved instrument is utilized and straight left instrument. This instrument versatility can help compensate for beginners and trainees.

SILCS is one of many methods to accomplishing the goal of a safe and effective surgical

outcome. Therefore, an accessory 3–5 mm port through a lateral incision can also be utilized for further retraction without significant compromise to cosmetics. If difficulty is encountered, it is easy to convert SILCS to a standard laparoscopic colectomy by adding a few trocars. If need be, SILCS can also be converted to a hand-assisted colectomy by removing the access port in place of GelPort™ or similar device or to an open colectomy with the use of a wound protector. This “single-port rescue” or conversion should not be considered a sign of defeat if it ultimately achieves the aforementioned goals. A nuanced surgeon performing SILCS therefore must obviously be facile with multi-port laparoscopic colectomy and open techniques.

## Conclusion

The principles of SILCS should mirror its predecessors of open and laparoscopic colorectal surgery in that the goal is the safe and appropriate surgical resection. However, the skill-set required for SILCS is different from standard laparoscopic colectomy. In particular, traction and counter-traction achieved by instrument triangulation in standard laparoscopic colectomy (and open surgery) is difficult in SILCS. Newer advancements in laparoscopes, access ports, and instruments combined with technical nuances and skills can be used to compensate for the initial limitations of single-incision laparoscopic colorectal surgery.

---

## References

1. Schwenk W, Haase O, Neudecker J, Muller JM. Short term benefits for laparoscopic colorectal resection. *Cochrane Database Syst Rev.* 2005;3: CD003145.
2. Kuhry E, Schwenk WF, Gaupset R, Romild U, Bonjer HJ. Long-term results of laparoscopic colorectal cancer resection. *Cochrane Database Syst Rev.* 2008; 2:CD003432.
3. Aly EH. Laparoscopic colorectal surgery: summary of the current evidence. *Ann R Coll Surg Engl.* 2009; 91:541–4.
4. Lacy AM, Garcia-Valdecasas JC, Delgado S, et al. Laparoscopy-assisted colectomy versus open colectomy for treatment of non-metastatic colon cancer: a randomised trial. *Lancet.* 2002;359:2224–9.
5. The Clinical Outcomes of Surgical Therapy Study Group. A comparison of laparoscopically assisted and open colectomy for colon cancer. *N Engl J Med.* 2004;350(20):2050–9.
6. Jayne DG, Guillou PJ, Thorpe H, UK MRC CLASICC Trial Group. Randomized trial of laparoscopic-assisted resection of colorectal carcinoma: 3-year results of the UK MRC CLASICC Trial Group. *J Clin Oncol.* 2007;25(21):3061–8.
7. Buunen M, Veldkamp R, Hop WC, Colon Cancer Laparoscopic or Open Resection Study Group et al. Survival after laparoscopic surgery versus open surgery for colon cancer: longterm outcome of a randomised clinical trial. *Lancet Oncol.* 2009;10(1):44–52.
8. Lee SW, Milsom JW, Nash GM. Single-incision versus multiport laparoscopic right and hand-assisted left colectomy: a case-matched comparison. *Dis Colon Rectum.* 2011;54:1355–61.
9. Li W, Xu H, Wang ZK, Fan ZN, Ba SD, Zou DW, et al. Natural orifice transluminal endoscopic surgery (NOTES): patients' perceptions and attitudes. *Dig Dis Sci.* 2011;56:2415–22.
10. Makino T, Milsom JW, Lee SW. Single-incision laparoscopic surgeries for colorectal diseases: early experiences of a novel surgical method. *Minim Invasive Surg.* 2012;2012:783074.

---

# Single Incision Laparoscopic Right Colectomy

# 2

Deborah Nagle

---

## Patient Selection

### Indications

All the benign and malignant indications for colon resection apply to single incision laparoscopic colectomy (SILC) and multiport laparoscopic colectomy (MPLC) as well as open colon and rectal surgery (Table 2.1). As always, ideal patient candidates for initial cases are those healthy patients who are close to their ideal body weight, who have not been previously operated and who have a benign disease process.

### Contraindications

Unstable patients or those with a life-threatening pathology (such as perforation and peritonitis) are not suitable candidates for laparoscopic colectomy.

Several relative contraindications exist for SILC, similar to MPLC. Patient who have had peritonitis or multiple previous surgeries are less likely to be successfully operated by a laparoscopic approach. Patients with complex anatomy due to their disease process, for example Crohn's

disease with fistulae and obstruction, may not be amenable to laparoscopic identification of anatomic landmarks. Patients who have bowel obstruction and significant bowel distension are often best served by an open approach because adequate pneumoperitoneum, and therefore visualization, cannot be secured around the distended bowel. There may be literally no space within which to work. Finally, patients with a large palpable mass or phlegm on after induction of general anesthesia will require a commensurate incision for specimen extraction and may be best served by open laparotomy. Unstable patients or those with a life-threatening pathology (such as perforation and peritonitis) are not suitable candidates for laparoscopic colectomy.

---

## Transitioning from MPLC to SILC

Although SILC is closely related to MPLC, some differences are present between the two techniques and thoughtful planning of training and practice is important. First, because the instruments are placed in parallel through one incision, the instruments must be managed in the same, or collinear, planes. This can lead to "boxing," or instrument clashing, externally instead of "sword-fighting" internally. The level of the ports and the instruments must be staggered to help minimize this problem.

Tissue management can be more challenging in SILC. Triangulation of instruments internally is lost with SILC and the motion of the instruments

---

D. Nagle, M.D. (✉)

Section of Colon and Rectal Surgery, Beth Israel  
Deaconess Medical Center, Harvard Medical School,  
Boston, MA 02215, USA  
e-mail: dnagle@bidmc.harvard.edu

**Table 2.1** Common conditions treated by laparoscopic colectomy

Indication
Polyps and polyp syndromes
Malignancy
Inflammatory bowel disease
Diverticulitis
Ischemic colitis
Rectal prolapse
Volvulus
Constipation
Colostomy and reversals

must often be back and forth, rather than side to side. Therefore, suspension of the tissue, rather than traction, may be most useful. Management of the tissues requires precise visualization and exposure. More specifically in laparoscopic colon and rectal surgery than other laparoscopic surgeries, the tissues that are manipulated are not all resected. It is important to avoid mechanical or thermal injury to surrounding and adjacent structures. Tissue management includes using a traumatic graspers on bowel to help avoid any injury to bowel that will not be resected.

Aside from choosing an alternative access device to MPLC, there is no special equipment needed. Access devices are available from several major device manufacturers. The same surgical instrumentation used for MPLC can be utilized for SILC.

Skills courses, video observation training and proctoring can all be important components of safe skill acquisition prior to, and in addition to, clinical practice.

---

## Techniques

### Operating Room

As with any laparoscopic colectomy, a moveable operating table is essential for positioning the patient for optimal exposure of the target organ. Because Trendelenberg and other steep positions are employed during the case, some surgeons place the patient on a conforming beanbag or use tape across the chest to secure the patient.

The patient's arms are tucked bilaterally to allow for ease of surgeon movement around the table. If the patient is too large to safely tuck both arms the left arm should be tucked to facilitate surgeon movement around the table while the right arm remains extended.

Even for right-sided operations, low lithotomy position is ideal for minimally invasive laparoscopic colorectal surgery because it affords free access to all aspects of the abdominal wall. The surgeon or assistant can stand between the patient's legs for upper or lateral abdominal work. For MPLC in lithotomy position, it is most important that the patient's thighs be at or below the plane of the anterior-superior iliac spine to allow for free movement of the laparoscopic instruments in the field. This is less important in SILC since all instruments are placed through the umbilical incision.

Prior to induction of anesthesia, subcutaneous heparin is given and compression boots are placed and activated. An indwelling urinary catheter may be placed at the surgeon's discretion. An orogastric tube is placed for decompression of the stomach, which is particularly helpful for visualization during mobilization of the hepatic flexure. Appropriate perioperative antibiotics are given within 30 min of incision.

The patient is prepped and draped with the entire abdominal wall exposed in order to always be prepared for the possibility of conversion to a multiport or an open procedure.

The video monitor should be positioned ipsilateral to the target organ, that is, in the right lower quadrant, at a height that allows for neutral positioning of the surgeon's neck. The surgeon stands opposite the target organ, on the left side of the patient. The assistant may stand next to the surgeon in the cephalad position. The operating table height should be lowered so that when the abdomen is insufflated the surgeon can operate with his or her shoulders level. Sometimes standing on a platform will add ergonomic advantage when the patient's abdomen is large or protuberant. A consistent operating room team of nurses and technicians familiar with laparoscopic colectomy will facilitate flow and ease of the operation.



## Access Devices, Optics and Instrumentation

### Access Devices

There is an array of principles for port placement for MPLC, but there is standardized umbilical access device placement for SILC. Most surgeons use a vendor designed platform with openings for trocars. An insufflation port is part of the device. Three, sometimes four, trocars are placed through the device. The level or height of both the ports and the instruments must be staggered at the level of the device to help minimize instrument clashing externally, or boxing.

Most instruments and devices can be used through 5 mm ports. The sole limitation on port size selection currently is that endoscopic staplers must be placed through a 10/12 port. A 5 mm trocar can always be up-sized later in the case if needed. Trocars should be oriented toward the operative target for the surgeon's ergonomic benefit.

### Optics

Optimal visualization is key to a safe and expeditious surgery. Special considerations for SILC optics include the need to stagger the position of the instruments externally at the access port site. A 30° down scope will facilitate visualization. When using a straight scope, a bariatric length is recommended in order to keep the camera apparatus away from the instruments at the umbilicus, again to reduce clashing. Alternatively, flexible tip scopes that can deflect within the field to change the angle of view can be used. Video monitors should be placed at a height to facilitate neutral positioning of the neck and shoulders as the surgeon operates. The monitors must be mobile so that they can be moved to accommodate changing operative fields.

### Energy Devices

In order to perform intra-corporeal soft tissue mobilization and vascular division we utilize instruments such as thermal sealing devices that seal tissue by melting it. All thermal sealing devices have some lateral spread of heat for a few mm that occurs with activation of the instrument. It is important to have the device applied only to

the tissue that is to be sealed or divided. It is also important to be able to visually verify a clear zone around the device. The advantage to use of the thermal sealing device in SILC is that it can also be used as a grasper and a retractor.

There is some evidence that thermal sealing of vessels is associated with fewer mishaps than stapling vascular structures [1]. However, all devices can fail and it is important to have a backup plan for management of bleeding vessels. An endoscopic looped suture can be very useful to stop bleeding from a pedicle that has failed another technique.

Monopolar cautery can be used in association with scissors or other instrumentation. It is crucial to avoid any electrical injury to surrounding tissues from arcing along instrumentation. Any unsheathed portion of an instrument is live with electrical current and can cause injury to surrounding structures. Intuitively, it seems more likely to occur in the setting of collinear instrument management. Because of this particular risk of arcing of current and remote thermal injury to tissues, many surgeons simply do not use monopolar energy in single incision laparoscopic surgeries.

### Staplers and Wound Protection

Division of the colon requires endoscopic staplers, which come in different lengths and may have the ability to articulate. For right colectomy, many surgeons will simply divide the bowel extracorporeally. A wound protection device for the abdominal wall site of extraction is used to minimize bacterial contamination and tumor implantation. If the platform for single incision laparoscopic surgery does not include a sleeve for the abdominal, a separate sleeve can be placed.

---

## Appendectomy, Extended Appendectomy or Partial Cecectomy

The patient is prepared in the manner described above after induction of anesthesia. The umbilicus is everted and a vertical incision is made through the umbilicus for a distance of 2.5–3 cm. The fascia is opened and the selected access

device is placed under direct visualization. Trocars are staggered in height, if appropriate, and arranged as a triangle with the apex pointing away from the right gutter. Therefore two working ports will lead and the camera port will be lateral and behind the instruments. Pneumoperitoneum is established. The camera is placed through the lateral, or left side, trocar. A 10/12 mm trocar will be required for division of the appendix or cecum. It is often easier to work with 5 mm trocars throughout the dissection and then exchange for a 10/12 mm trocar when preparing to staple.

Using the superior trocar, grasp and elevate the appendix. Dissect and isolate the base of the appendix using the inferior trocar. The appendiceal mesentery can be divided with a stapler, or a thermal sealing device. After the appendix is isolated, exchange the inferior trocar for a 10/12 mm trocar. Staple the base of the appendix in the usual manner. The appendix is then placed in an endoscopic retrieval bag through the 10/12 port and removed.

The incision is closed at the fascia and the skin after the access device is removed.

---

## Right Colectomy

The patient is prepared in the same manner described above and the access device is placed. The umbilicus is everted and a vertical incision is made through the umbilicus. For colectomy, the fascial incision may need to be slightly larger to accommodate the extraction of the specimen without trauma to the tissues. The fascia is opened for 3–4 cm and the selected access device is placed under direct visualization.

There are three distinct anatomic approaches to right colectomy: medial, lateral and inferior. The inferior approach is used infrequently and is not particularly suited for single incision approach.

With *medial-to-lateral* approach, the first operative goal is division of the ileocolic vascular pedicle and the associated right colon mesentery. This approach is optimal in many patients undergoing SILC because the lateral attachments of the colon to the side wall are another “retractor”

that facilitates tissue management. The mesentery is grasped at the colonic end of the vascular pedicle and elevated toward the right side wall. Usually the right hand or most superior port is the best point of access for this retraction. Enough traction is created to give the typical “bowstring” appearance to the vessels that is needed for their safe identification. It is crucial that the duodenum be identified and avoided at the base of the vascular pedicle. Using the left hand through the most inferior port, an adequate window is created around the vessels and they are divided by a thermal sealing device. Thus, a window is created in the mesentery inferior to the duodenum. This plane is then used to continue dissection in the retroperitoneal plane out to the right side wall. The right hand provides traction on the mesentery by suspending it as the grasper pushes out to the right side wall. Dissection can continue lateral and superior to the duodenum in this plane, as well, with hand-over-hand exchange of tissue between the instruments. The mesentery is divided up to the middle colic vessels in this fashion.

The mesentery between the ileum and the ileocolic pedicle is then sequentially divided by suspending the pedicle in one hand and walking the thermal sealing device up the plane to the terminal ileum.

The colon is then mobilized out of the right gutter in the manner described below in the lateral-to-medial approach to right SILC.

The *lateral-to-medial approach* replicates the standard open technique of right colectomy. The cecum is grasped and rolled medially using an instrument in the right hand in the superior trocar. The appendix is freed from any attachments. Care is taken to identify the right ureter at the pelvic brim. Dissection should be above and lateral to the ureter. Using a thermal sealing device, the White line of Toldt is incised and the colon is sequentially mobilized up the right gutter to the hepatic flexure. After the peritoneal attachments are incised, a gentle sweeping maneuver moving the colon to the midline will display the attachments for division. A common mistake is to drift dissection too far laterally and dissect out in the abdominal sidewall, including under or lateral to the kidney.



When the hepatic flexure is reached, the patient is placed in reverse Trendelenberg to allow gravity to aid in exposure. The operating instrument is placed in the superior trocar. The gastrocolic omentum is elevated cephalad taken off the transverse colon. Downward traction is applied to the hepatic flexure and the attachments are then taken down through the superior port. The attachments are divided so that the colon is mobilized to the level of the middle colic vessels. Care is taken to work lateral to and below the duodenum as the colon is rolled down toward the pelvis. Adequacy of mobilization can be assessed by bringing the flexure to the pelvic brim and the cecum to the midline with a grasper.

The specimen can then be exteriorized and the resection and anastomosis completed extracorporally. It is important to place a locking grasper on the lead point for exteriorization, i.e., the appendix or cecum, prior to performing extraction to facilitate specimen retrieval.

A wound protecting sleeve is placed through the incision if it is not already part of the access device. The specimen is exteriorized. If the mesentery was not divided intra-corporally it can be divided at this time. The bowel is divided with staplers and a side-to-side functional end-to-end anastomosis is created with standard technique, either stapled or hand-sewn. The anastomosis is then returned to the abdominal cavity and the abdomen is re-insufflated. There is no data to support closure of the mesentery and this is not commonly performed in laparoscopic colectomy. Careful inspection for hemostasis and any abnormality is performed before the access device is withdrawn and the fascia is closed.

Prior to closure of the fascia, it is easy to perform a TAPP (transabdominal pre-peritoneal) block of the abdominal wall with local anesthesia. The fascia may also be infiltrated primarily.

The *Inferior approach* to laparoscopic right colectomy is less commonly used, but can be helpful in the setting of a large mass in the cecum that makes clear identification of the ureter more important or when the medial mesenteric anatomy is not clear. However, these are two situations where the single incision laparoscopic approach may be quite limited. Large masses are difficult

to control with just one functional retractor. The approach begins by reflecting the cecum and terminal ileum mesentery cephalad to expose and incise the junction of the visceral and parietal peritoneum. Retraction is accomplished through the inferior trocar with the grasper pushing the tissue “up and away” from the pelvic brim. The superior trocar is used to incise the peritoneum. A gentle sweeping motion will peel the colon and mesentery off the retroperitoneum without injury to the ureter or vasculature. The duodenum is encountered directly at the cephalad end of this dissection. The duodenum is deflected posteriorly and the operative plane continues on top of the duodenum with judicious use of energy to divide attachments. After successful posterior mobilization, the lateral attachments and mesentery are divided as previously described.

## Postoperative Care

Routine postoperative fast-track or enhanced recovery pathways are employed after SILC. The patient is treated with multimodality pain medications, including the TAPP and/or local block performed at closure. Nonsteroidal anti-inflammatory medications are administered intravenously from the operating room and subsequently for 72 h. Intravenous and oral acetaminophen are given as appropriate and, finally, patient controlled anesthesia with narcotic is offered.

Feeding is offered ad lib on postoperative day one. Early ambulation and incentive spirometry are encouraged. When patients pass flatus and tolerate a regular diet and oral pain medications they may be discharged home.

## Complications

Any operation carries a risk of bleeding and infection. The risks specific to colectomy and laparoscopic surgery apply to single incision laparoscopic right colectomy. Postoperative ileus, obstruction, and anastomotic leak are seen with equal frequency in multiport laparoscopic and single incision laparoscopic right colectomy [2].

## Current Experience with Right SILC

The first case reports of single incision laparoscopic right colectomy appeared in 2008 [3].

In the next several years, several case series were published comparing SILC-Right to MPLC-Right surgeries. There were small numbers of patients in these series. However, safety and feasibility of the SILC approach were shown. Most authors found no significant differences in multiple parameters between the two laparoscopic approaches. These parameters include operative time, nodal harvest, morbidity and length of hospital stay [4–7].

A larger multicenter, case-matched series was published in 2012 with 330 patients, 234 of which were right colectomies. There were no significant differences between SILC and MPLC for conversion rate, complications, reoperation rate or readmission to the hospital. In this review, postoperative day one pain scores were significantly lower using the SILC approach [8]. Another larger case-controlled series of 100 patients undergoing SILC and MPLC-Right found that operative time was significantly shorter in the SILC group [2].

The question of whether oncologic outcomes are equivalent arises with any newer surgical technique. Within the papers referenced in the preceding discussion, a portion of the patients in each group were operated for malignancy. Lymph node harvest as a surrogate marker for adequate oncologic resection was equivalent in all case comparisons. A recent study specifically compared oncologic outcomes for SILC-Right versus MPLC-Right in 159 patients. The colectomy groups were similar in clinical characteristics. There was no difference in complications between the groups. Oncologic resection, as assessed by lymph node harvest and proximal and distal margins, was equivalent. Tumor characteristics were equivalent. At 24 months mean follow up, disease-free survival was not significantly different between the SILC and MPLC groups [9].

Two meta-analyses have recently compared the outcomes between SILC and MPLC. The first review of 15 studies and 1,026 patients found

variable methodology throughout the studies. There was no difference between the groups in conversion to open laparotomy, morbidity or operative time. After analysis, it was concluded that SILC procedures led to a significantly shorter postoperative length of stay as well as shorter skin incision [10]. A second meta-analysis of essentially the same pool of data came to the same conclusions: hospital length of stay and incision length are shorter with SILC [11].

Laparoscopic surgery has been a significant advance in perioperative patient care for many different surgical approaches, including colectomy. SILC is equivalent to MPLC in outcomes. SILC may be of additional marginal benefit to patients for hospital length of stay, postoperative pain and cosmesis as it relates to incision length. Advanced laparoscopic skills are required to perform SILC. For surgeons with an advanced skill set, the practice and performance of SILC-Right is an excellent way to extend their skills.

---

## References

1. Marcello P, Roberts P, Rusin L, Holubkov R, Schoetz D. Vascular pedical ligation techniques during laparoscopic colectomy. *Surg Endosc.* 2006;20(2):263–9.
2. Velthuis S, van den Boezem P, Lips D, Prins H, Cuesta M, Sietses C. Comparison of short-term surgical outcomes after single-incision laparoscopic versus multiport laparoscopic right colectomy: a two-center, prospective case-controlled study of 100 patients. *Dig Surg.* 2012;29(6):477–83.
3. Bucher P, Pugin F, Morel P. Single port access laparoscopic right hemicolectomy. *Int J Colorectal Dis.* 2008;23:1013–6.
4. Waters J, Guzman M, Fajardo A, Selzer D, Wiebke E, Robb B, et al. Single-port laparoscopic right hemicolectomy: a safe alternative to conventional laparoscopy. *Dis Colon Rectum.* 2010;53(11):1467–72.
5. Ramos-Valadez D, Patel C, Ragupathi M, Pickron B, Haas E. Single-incision laparoscopic right hemicolectomy; safety and feasibility in a series of consecutive cases. *Surg Endosc.* 2010;24:2613–6.
6. Adair J, Gromski M, Lim R, Nagle D. Single-incision laparoscopic right colectomy: experience with 17 consecutive cases and comparison with multiport laparoscopic right colectomy. *Dis Colon Rectum.* 2010;53:1549–54.
7. Boone B, Wagner P, Ganchuk E, Evans L, Zeh H, Bartlett D, et al. Single-incision laparoscopic right

- colectomy in an unselected patient population. *Surg Endosc.* 2012;26:1595–601.
8. Champagne B, Papaconstantinou H, Parmar S, Nagle D, Young-Fadok T, Lee E, et al. Single-incision versus standard multiport laparoscopic colectomy. *Ann Surg.* 2012;255(1):66–9.
  9. Yun J, Yun S, Park Y, Cho Y, Kim H, Lee W, et al. Single-incision laparoscopic right colectomy compared with conventional laparoscopy for malignancy: assessment of perioperative and short-term oncologic outcomes. *Surg Endosc.* 2013;27(6):2122–30.
  10. Maggiori L, Gaujoux S, Tribillon E, Bretagnol F, Panis Y. Single-incision laparoscopy for colorectal resection: a systematic review and meta-analysis of more than a thousand procedures. *Colorectal Dis.* 2012;14(10):e643–654.
  11. Fung A, Aly E. Systematic review of single-incision laparoscopic colonic surgery. *Br J Surg.* 2012;99(10):1353–64.

# Single Incision Laparoscopic Left Colectomy

# 3

Dominic C.C. Foo and Wai Lun Law

## Introduction

Since its introduction in the early 1990s, laparoscopic colonic resection has been more widely applied [1, 2] and has become the standard approach for the treatment of different colonic diseases in some centers. Compared to open surgery, laparoscopic resection has been shown to have advantages such as less operative blood loss, reduced postoperative pain, shorter period of postoperative ileus, quicker recovery and a shorter hospital stay. In the treatment of colon cancer, data from randomized trials showed that the oncologic outcome was not compromised [3–10]. As colorectal surgeons become more proficient in conventional laparoscopic colonic surgery, they are aspired to further improving outcome and reducing surgical trauma by reducing the number and the size of incisions. Single incision laparoscopic surgery (SILS) has fast become the new feasible option for colonic resection.

The potential benefits of SILS include better cosmetic results and patient satisfaction. Issues

like reduction in postoperative pain and faster recovery compared to conventional laparoscopic surgery (CLS) remain debatable. A recent randomized control trial comparing SILS and CLS colonic resections demonstrated significantly lower pain score during the early postoperative period as well as a shorter hospital stay [11]. The possibility of less bleeding, incisional hernias and port-site recurrences has been suggested by some studies, although these are yet to be proven by randomized controlled trials [12–15].

Several case series showed that SILS for colonic resections were feasible [13, 16–21]. SILS, however, has not become a widely adopted procedure [22, 23]. The main hurdle is the need for adaptation of surgical techniques to overcome the pitfalls in SILS. Technical difficulties stem from the lack of triangulation, overcrowding and clashing of instruments, lack of counter traction, and coaxial alignment of the camera and operating instruments resulting in poor visualization of operating field. There are also concerns over prolonged operating time and increase in cost. However, currently available data do not substantiate these concerns [24–26]. This chapter aims to focus on the technical aspect of SILS left colectomy, i.e., sigmoidectomy and anterior resection.

## Preoperative Evaluation

The common indications of left colectomy are colonic cancer, diverticular disease, inflammatory

---

D.C.C. Foo, M.B.B.S., F.R.C.S. (Edin.)  
Queen Mary Hospital, The University of Hong Kong,  
Hong Kong, China

W.L. Law, M.S., M.B.B.S., F.R.C.S. (Edin.),  
F.A.C.S. (✉)  
Innovative and Minimally Invasive Surgery, Queen  
Mary Hospital, The University of Hong Kong,  
Pokfulam Road, Hong Kong, China  
e-mail: lawwl@hkucc.hku.hk

bowel disease, sigmoid volvulus and colonic polyp not amenable to endoscopic removal.

Similar to any patient planning for major operations, the coexisting medical comorbidities should be evaluated and optimized. A preoperative anesthetic assessment is mandatory prior to surgery, especially in elderly patients with medical comorbidities.

Colonoscopic confirmation of the diagnosis and localization of the lesion is required. For small lesions, it is advisable to perform endoscopic tattooing of the lesion to facilitate intraoperative identification.

For colonic malignancies, staging with a contrast enhanced computed tomography is required. Distant metastases would preclude curative resection but more importantly, the size and location of tumor, local invasion to surrounding structures, i.e., the abdominal wall, left ureter and bladder, should be ascertained.

## Patient Selection

Patient selection criteria are similar to that of CLS. The prerequisite is ability to tolerate general anesthesia and pneumoperitoneum. There should not be any uncorrected coagulopathy. Unique to SLS is the size of the lesion, which directly determines the length of the wound to retrieve specimen. SLS is not advisable for lesions larger than 4–5 cm as the benefit of a concealed incision of SILS is lost [27]. A high body mass index could increase the difficulty of SILS [11, 23, 28], although studies have shown the feasibility of SLS in patients with BMI up to 40 kg/m<sup>2</sup> [16].

## Patient Preparation

Mechanical bowel preparation is generally not required [29–31], with the exception when intraoperative colonoscopy is anticipated in patients where the exact location is not obvious. Nevertheless, it is advisable to give sodium phosphate enema preoperatively to evacuate the rectum to facilitate the introduction of the circular stapler for intracorporeal anastomosis.

The authors routinely give second-generation cephalosporin and metronidazole as prophylactic antibiotics on induction of general anesthesia. Urethral catheterization is performed to decompress the bladder and for monitoring of urine output throughout the perioperative period.

The patient is put in the modified lithotomy position in which the hips are abducted and slightly extended and the knees flexed. Thromboembolic deterrent stockings and intermittent pneumatic calf compression is used to prevent deep vein thrombosis. The body is secured to the table with head down and left side up during the mobilization of the left colon. The arms should be tucked and patient's sacrum should be at the distal edge of the operating table.

## Equipment

Although SILS can be performed using a single incision with ordinary low profile trocars and with rudimentary devices such as a surgical glove on a wound protector, specialized single port access devices can facilitate the procedures. Examples include the TriPort™ Access System (Olympus, Japan), SILS™Port (Covidien, USA) and OCTO™ Port (Dalim, Korea). They are specialized devices, which provides three to four ports ranging from 5 to 12 mm for laparoscopic instruments. They share a common feature of allowing maneuverability of laparoscopic instruments within the system. Most of them also have a mechanism of retracting the abdominal wall. There are case series reporting the technique of inserting multiple trocars via a single abdominal incision without the use of single port access device. However, there is a concern of air leak and decreased degree of freedom between trocars [15, 32, 33]. The use of several conventional laparoscopic trocars through a Gelport (Applied Medical, USA) has been described as well [34].

Laparoscope with a deflectable tip has the advantage of allowing better field of vision without compromising the range of movement of other laparoscopic instruments and minimizes clashing. Examples include the Deflectable Tip EndoEYE™ Video Laparoscope (Olympus, Japan) and the IdealEye™ (Stryker, USA).

Likewise, articulating laparoscopic instruments, which give extra flexibility, have been used to overcome the loss of triangulation in SILS from their straight counterparts. These bending instruments have either a pre-bent curved shaft, or an articulating section, controllable by a knob at the handle. However, adaptation is needed to use these bended or articulated instruments. In one study, articulating instruments were shown to result in lower performance compared to straight laparoscopic instruments in both expert and novice surgeons [35]. In another study, articulating instruments have not been shown to have better performance nor shorter learning curve in SILS [36].

The authors prefer a long bariatric 10 mm 30° laparoscope (Karl Storz, Germany) with a three-chip high-resolution camera and traditional straight laparoscopic instruments. The use of laparoscope with a deflectable tip requires additional skill and adaptation from the assistant. The long laparoscope can minimize crowding of the instruments. Furthermore, by manipulating the direction of the light cable of a 30° rigid scope, the direction of vision can be adjusted. While straight laparoscopic instruments are tools that most laparoscopic surgeons are already familiar with, their use in SILS provides the surgeon the same tactile and haptic feedback as in CLS and therefore allows a smooth transition from CLS to SILS. The feasibility of using straight laparoscopic instruments in SILS colectomy has been well described in the literature [27, 37–39]. A single port access system, which provides four ports, can add one instrument for retraction although this may result in overcrowding of instruments.

---

## Operative Technique

### Entry to Peritoneal Cavity

The authors utilize a transumbilical cutdown to gain access to the peritoneal cavity. A 2.5 cm longitudinal incision is made at the umbilicus. The subcutaneous fat is dissected with the help of a pair of retractors. The fascial layer is incised until the peritoneum is encountered. The peritoneum is opened and the

peritoneal cavity is entered under direct vision. A laparoscopic exploration of the peritoneal cavity using a traditional camera port is performed to assess the pathology and the feasibility of SILS. The fascia defect is then enlarged to 2–3 cm to house the single port access device. Pneumoperitoneum is created with carbon dioxide insufflation at a pressure of 12 mmHg.

The size of incision ranges from 3 to 4 cm in the literature [22, 27, 40]. However, the final size of incision is usually longer than the incision needed to house the single port access device, and is largely determined by the size of the specimen. Although the fascia could be further undermined under the skin incision, SILS colectomy should usually be considered for lesions smaller than 4–5 cm. A larger lesion will require a bigger incision to retrieve the specimen.

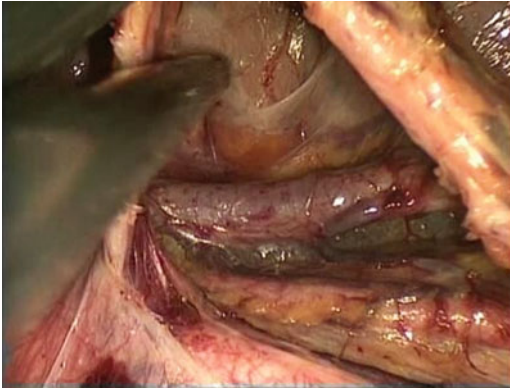
### Mobilization of Left Colon

After laparoscopic exploration and identification of the pathology, the patient is put in a Trendelenburg and left side up position. The small bowel is retracted out of the pelvis towards the right side of the upper abdomen with atraumatic forceps. We prefer to visualize the origin of inferior mesenteric artery and preferably the inferior mesenteric vein beneath the duodenum before dissection. As in CLS, the small bowel is kept out of the operative field mainly by gravity.

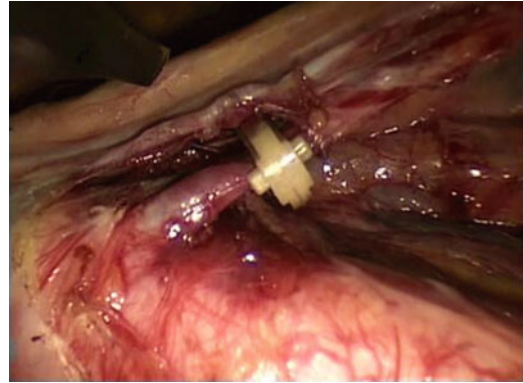
### Medial to Lateral Approach

The authors usually adopt the medial to lateral approach as in CLS. Although some surgeons prefer to keep close to the bowel in benign cases of benign, the authors prefer to dissect at the avascular plane posterior to the inferior mesenteric artery even in cases of benign pathologies. The sigmoid mesentery is lifted upwards to visualize the inferior mesenteric artery under the cover of the peritoneum. The right leaf of the peritoneum lining the sigmoid mesentery is incised at the level of the sacral promontory. Various energy devices like the Sonosurg™ ultrasonic cutting and coagulation system (Olympus, Japan), LigaSure™ vessel



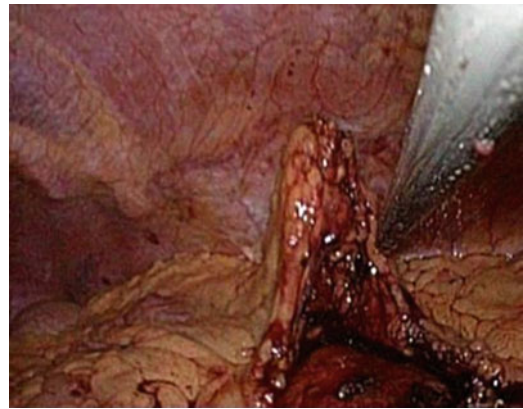


**Fig. 3.1** Sigmoid mesentery being separated from underlying retroperitoneal structures with the left ureter and gonadal vessels in view



**Fig. 3.2** Clipping of the inferior mesenteric artery before dividing

sealing system (Valleylab, USA) and the Harmonic Ace™ (Ethicon, USA) or bipolar scissors can be used. After incising the peritoneum, with the aid of pneumo-dissection and traction of the mesentery towards the upward direction, the plane between the sigmoid mesentery and the retroperitoneum should be readily identified. The plane is further developed by use of both sharp and blunt dissection towards lateral aspect. Along the way, retroperitoneal structures including the left ureter, the gonadal vessels, hypogastric nerves and the left common iliac artery should be identified and preserved (Fig. 3.1).



**Fig. 3.3** Use of transabdominal suture for retraction

### Tips for Retraction in SILS

- In SILS colectomy, one would need to accustom to the lack of retraction from an assistant. It is often useful to use a laparoscopic Debakey forceps with opened jaws to tent up the sigmoid mesentery. The alternative is to use a laparoscopic fan retractor.
- In order to avoid the “chopstick effect,” some of the dissection needs to be performed by the “cross out” (Fig. 3.2).
- Brunner described the technique of transabdominal sutures, using a straight needle, to retract the sigmoid colon in SILS colectomy [33] (Fig. 3.3).
- Leroy utilizes the flexible sigmoidoscopy to aid in the retraction of sigmoid colon, using its tip angulation and endoscope torque. An anvil is

also passed transanally into the colon by a flexible introducer, and with the use of an extracorporeal magnet, the sigmoid colon could be lifted up for medial dissection [41].

### Ligation of IMA and IMV

After dissecting the sigmoid mesentery from the retroperitoneal structures, the inferior mesenteric artery (IMA) is identified as the tubular structure that tense up the mesentery. It is skeletonized, clipped with either 5 mm Hem-o-lok (Teleflex Medical, USA) or 10 mm Lapro-clip (Covidien, USA) and divided close to its origin (Fig. 3.2). One must distinguish it from the left ureter before dividing it. The mesentery is divided towards further

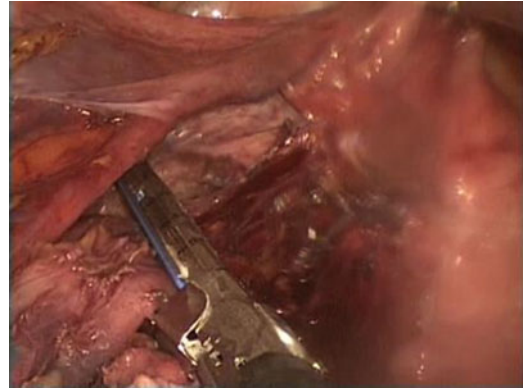
lateral until the inferior mesenteric vein (IMV) is identified. The vein is traced proximally towards the lower border of the pancreas, and clipped and divided. Currently available bipolar devices with the ability to divide vessels up to 7 mm can also be used to control the major vessels. After dividing the inferior mesenteric vessels, the dissection continued further upwards towards the splenic flexure of the colon, separating the mesentery from the pancreas.

### Taking Down Splenic Flexure

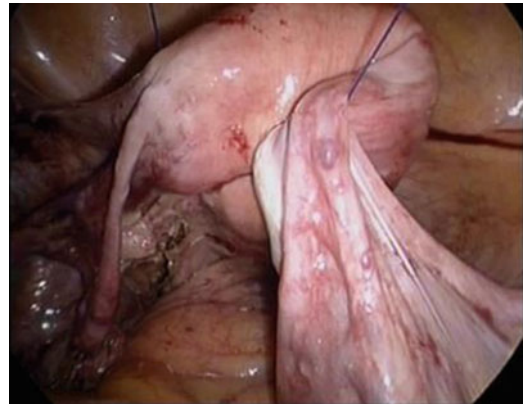The lateral peritoneal attachment of the sigmoid colon is incised along the line of Tolddt. With the medial to lateral approach, the sigmoid mesentery has already been separated from the underlying retroperitoneal structures, thereby leaving only a thin layer of peritoneum to be incised. Sharp dissection of the peritoneum is continued in the cephalic direction. With the descending colon retracted towards the medial side, its mesentery is separated from the retroperitoneum and the pancreas by blunt dissection. Care should be taken not to exert excessive traction, which may result in splenic laceration. To take down the splenic flexure of colon, one would need to grasp the greater omentum towards the cephalic direction and tension will be created to the colomental adhesions by gravity. These adhesions together with the gastrocolic ligament are incised until the lesser sac is entered. The dissection is continued laterally until the line of dissection rendezvous with the one created from lateral dissection. One should remember the dissection is not made between the greater omentum and the spleen. In this way, the chance of splenic laceration is minimized.

### Transection of Colon and Performing Colorectal Anastomoses

Once the splenic flexure of the colon is taken down, the lateral peritoneal attachment of sigmoid colon to the pelvis is also divided and the mobilization of the left colon is complete.



**Fig. 3.4** Applying the laparoscopic linear stapler for distal transection

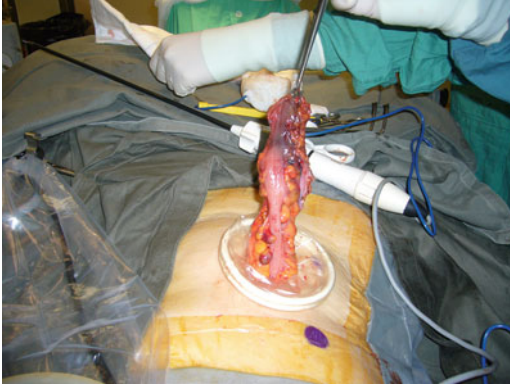

**Fig. 3.5** Using transabdominal sutures to sling the uterus

The double stapling method is used for performing colorectal anastomoses. At the level of distal transection, the mesorectum is divided at the level of transection with cautery or energy devices. The rectum is transected with a laparoscopic linear stapler with an articulating mechanism, e.g., EchelonFlex™ Endopath® 60 mm stapler (Ethicon, USA) and EndoGIA™ with Tri-Staple™ 60 mm stapler (Covidien, USA) (Fig. 3.4). In female patients, the uterus could be slung by transabdominal sutures to facilitate this step (Fig. 3.5).

The application of the transverse stapler across the rectum for transection may be difficult through the umbilical single incision. The authors usually mobilize the rectum adequately so that it can be retract anteriorly towards the

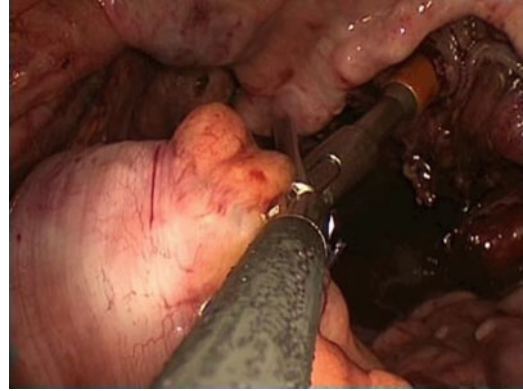




**Fig. 3.6** Retrieval of the specimen through the umbilical incision

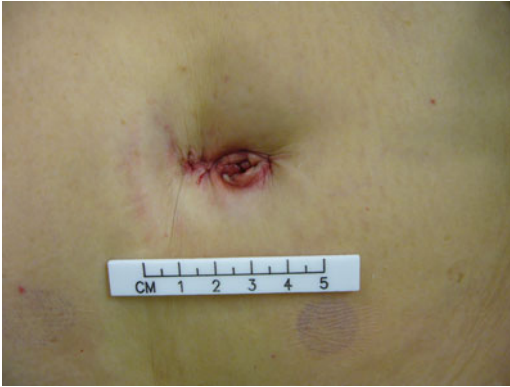abdominal wall. The stapler is placed posterior to the rectum and angulated anteriorly at its tip so that a staple line at right angle to the bowel can be achieved.

The midline wound is used to retrieve the specimen. Many a time, the single port access device is removed and a double-ring wound retractor, e.g., Alexis<sup>®</sup> wound retraction system (Applied Medical, USA), is inserted to facilitate the retrieval of the specimen (Fig. 3.6). The stump of IMA and IMV together with the left colon is delivered through the wound. The level of proximal transection is chosen. The line of dissection of the mesentery starts from the stump of the pedicle towards the intended level of proximal transection. The mesentery is then divided between ligatures. Care must be taken to preserve the marginal artery of Drummond supplying the part of colon later used to anastomose with the rectum. The proximal transection is then performed with diathermy and the specimen is delivered. Adequate blood supply could be confirmed by bleeding from the transection edge. A purse-string suture is applied, either by hand-sewn or a purse-string instrument, and tied after inserting the anvil of a circular stapler. After hemostasis is ensured, the colon with the anvil secured in it is brought back to the peritoneal cavity. After reinserting the single port access device, pneumoperitoneum is reestablished. The assistant would introduce the circular stapler, e.g., DST Series<sup>™</sup>



**Fig. 3.7** Performing intracorporeal anastomosis with the circular stapler

EEA<sup>™</sup> 28 mm (Autosuture, Covidien, USA) or CDH29A (Ethicon, USA) transanally towards the rectal stump. Intracorporeal colorectal anastomosis is performed (Fig. 3.7). Before closing and firing of the circular stapler, one would need to ascertain no twisting of the colon. The mesentery of the left colon should be at the posterior position, aligning with the mesorectum. There should be adequate length of the colon without tension on the anastomoses. The final part of the operation includes performing colonoscopy to check for any bleeding from the anastomosis, the color and thus the viability of colon and lastly, to perform an air leak test. The anastomosis is submerged in the pelvis filled with saline and the bowel is occluded proximally. The rectum is inflated with air endoscopically. Air bubbles persistently emerging from the pelvis would indicate a leak. Both proximal and distal doughnut from the circular stapler should be complete ring. The distal doughnut should be sent for section as the distal resection margin. A final check on the hemostasis is performed, any residual fluid is aspirated and any remaining laparoscopic gauze is removed. Unless otherwise indicated, it is not a routine to place a drain. The wound is closed by opposing the fascia with interrupted sutures. 0.5 % Chirocaine<sup>®</sup> is used to infiltrate the wound for postoperative pain control. The skin is closed with subcuticular absorbable sutures (Fig. 3.8).



**Fig. 3.8** Final incision

### Lateral to Medial Approach

The lateral to medial approach could be used as an alternative when there are difficulties or poor progress in establishing an avascular plane between the sigmoid mesocolon and the retroperitoneum by the medial to lateral approach. This is a laparoscopic version of the open approach used to mobilize the sigmoid colon. With gentle traction of the sigmoid colon towards medial direction, the lateral peritoneal attachment is incised along the white line of Toldt. The avascular plane between mesocolic and retroperitoneal fat is followed and separated by both sharp and blunt dissection. The gonadal vessels and the left ureter, which is more medial, are seen. In thin patients, the left common iliac artery is seen as a pulsating tubular structure. All these structures are to be protected. The dissection is continued further upwards. Splenic flexure is taken down in a similar fashion as the medial to lateral approach. The lateral dissection is then extended down to the pelvis. With the sigmoid colon fully medialized and the important retroperitoneal structures protected, the colon is retracted towards the upward and lateral direction. The peritoneum lining the sigmoid mesocolon is then incised medial to the inferior mesenteric artery. The inferior mesenteric artery and vein are ligated and divided. The transection of colon and intracorporeal anastomosis could then be performed.

### Conversions

SILS colectomy can be converted to hand-assisted laparoscopy, multiport laparoscopy or open laparotomy. Ineffective retraction resulting from redundant colon or bulky tumor can be dealt with conversion to multiport laparoscopy. However, conversion to laparotomy is usually necessary for bowel, ureteric or major vascular injury and tumor invasion into nearby structures, i.e. T4 disease. Presence of significant adhesions would, depending on its severity, mandate conversions either to multiport laparoscopy or laparotomy. In one systematic review of over 1,000 SILS colectomies by Maggiori, which includes right-sided, left-sided, subtotal and total colectomies, the conversion rate to multiport laparoscopy and laparotomy was 7 % and 1 % respectively, [26]. Vestweber reported a conversion to open rate of 4.7 % out of 150 anterior resections, sigmoidectomies and left hemicolectomies, in which the majority of cases were operated for diverticular diseases [42].

### Postoperative Management

The patient would be managed according to a standard enhanced recovery protocol. They would be given fluid as soon as they are fully awake. The blood pressure, pulse and urine output would be monitored. Oral analgesics like paracetamol or celecoxib would be given [11]. Nasogastric tubes are not required for uneventful operations [43]. On the first postoperative day, urinary catheter will be taken off and mobilization starts. Chest physiotherapy commenced with the use of incentive spirometry. Diet would be gradually stepped up. The return of bowel sound is usually unreliable and the absence of it does not preclude oral intake. Patient should be ready to be discharged on the second to third day after an uneventful operation. Any signs of postoperative ileus like abdominal distension warrants a halt to further increase in oral intake and an abdominal X-ray is often helpful. Increasing abdominal pain, fever, leukocytosis, and prolonged ileus mandate further investigations for postoperative complications.

## Complications

Complications from SILS are similar to that of CLS. Early minor complications include wound infection, ileus, urinary retention and respiratory complications. Major complications include anastomotic bleeding, anastomotic leak, intra-abdominal collection, thermal bowel injury, acute coronary events and renal failure. Delayed complications like incisional hernia [17, 44] and anastomotic strictures [44] have been reported. In one systematic review of 38 studies by Fung, with 565 patients undergoing SILS colectomy, the overall complication rate was 10.8 % [45].

## Conclusion

Single incision left colectomy represents a step forward in reducing surgical trauma and aims to further improve outcome in minimally invasive surgery. It is feasible but technically demanding. Specialized equipments are available to facilitate the surgery. Adaptation from CLS to SLS requires surgeons to acquire additional skills and capabilities as well.

## References

- Cooperman AM, Katz V, Zimmon D, Botero G. Laparoscopic colon resection: a case report. *J Laparoendosc Surg.* 1991;1(4):221–4.
- Jacobs M, Verdeja JC, Goldstein HS. Minimally invasive colon resection (laparoscopic colectomy). *Surg Laparosc Endosc.* 1991;1(3):144–50.
- Lacy AM, Delgado S, Castells A, Prins HA, Arroyo V, Ibarzabal A, Pique JM. The long-term results of a randomized clinical trial of laparoscopy-assisted versus open surgery for colon cancer. *Ann Surg.* 2008; 248(1):1–7.
- Law WL, Lee YM, Choi HK, Seto CL, Ho JW. Impact of laparoscopic resection for colorectal cancer on operative outcomes and survival. *Ann Surg.* 2007; 245(1):1–7.
- Laurent C, Leblanc F, Wütrich P, Scheffler M, Rullier E. Laparoscopic versus open surgery for rectal cancer: long-term oncologic results. *Ann Surg.* 2009; 250(1):54–61.
- Clinical Outcomes of Surgical Therapy Study Group. A comparison of laparoscopically assisted and open colectomy for colon cancer. *N Engl J Med.* 2004; 350(20):2050–9.
- Lai JH, Law WL. Laparoscopic surgery for colorectal cancer. *Br Med Bull.* 2012;104:61–89.
- Guillou PJ, Quirke P, Thorpe H, Walker J, Jayne DG, Smith AM, Heath RM, Brown JM, MRC CLASICC trial group. Short-term endpoints of conventional versus laparoscopic-assisted surgery in patients with colorectal cancer (MRC CLASICC trial): multicentre, randomized controlled trial. *Lancet.* 2005;365(9472): 1718–26.
- Veldkamp R, Kuhry E, Hop WC, Jeekel J, Kazemier G, Bonjer HJ, Haglind E, Pahlman L, Cuesta MA, Msika S, Morino M, Lacy AM, Colon cancer Laparoscopic or Open Resection Study Group (COLOR). Laparoscopic surgery versus open surgery for colon cancer: short-term outcomes of a randomised trial. *Lancet Oncol.* 2005;6(7):477–84.
- Hewett PJ, Allardyce RA, Bagshaw PF, Frampton CM, Frizelle FA, Rieger NA, Smith JS, Solomon MJ, Stephens JH, Stevenson AR. Short-term outcomes of the Australasian randomized clinical study comparing laparoscopic and conventional open surgical treatments for colon cancer: the ALCCaS trial. *Ann Surg.* 2008;248(5):728–38.
- Poon JT, Cheung CW, Fan JK, Lo OS, Law WL. Single-incision versus conventional laparoscopic colectomy for colonic neoplasm: a randomized, controlled trial. *Surg Endosc.* 2012;26(10):2729–34.
- Uematsu D, Akiyama G, Magishi A, Nakamura J, Hotta K. Single-access laparoscopic left and right hemicolectomy combined with extracorporeal magnetic retraction. *Dis Colon Rectum.* 2010;53(6): 944–8.
- Katsuno G, Fukunaga M, Nagakari K, Yoshikawa S, Ouchi M, Hirasaki Y. Single-incision laparoscopic colectomy for colon cancer: early experience with 31 cases. *Dis Colon Rectum.* 2011;54(6):705–10.
- Keshava A, Mackenzie S, Al-Kubati W. Single-port laparoscopic right colonic resection. *ANZ J Surg.* 2010;80(1–2):30–2.
- Rieger NA, Lam FF. Single-incision laparoscopically assisted colectomy using standard laparoscopic instrumentation. *Surg Endosc.* 2010;24(4):888–90.
- Ramos-Valadez DI, Patel CB, Ragupathi M, Bokhari MB, Pickron TB, Haas EM. Single-incision laparoscopic colectomy: outcomes of an emerging minimally invasive technique. *Int J Colorectal Dis.* 2011; 26(6):761–7.
- van den Boezem PB, Sietses C. Single-incision laparoscopic colorectal surgery, experience with 50 consecutive cases. *J Gastrointest Surg.* 2011;15(11): 1989–94.
- Geisler D, Garrett T. Single incision laparoscopic colorectal surgery: a single surgeon experience of 102 consecutive cases. *Tech Coloproctol.* 2011;15(4): 397–401.
- Ross H, Steele S, Whiteford M, Lee S, Albert M, Mutch M, Rivadeneira D, Marcello P. Early multi-

- institution experience with single-incision laparoscopic colectomy. *Dis Colon Rectum*. 2011;54(2):187–92.
20. Chew MH, Wong MT, Lim BY, Ng KH, Eu KW. Evaluation of current devices in single-incision laparoscopic colorectal surgery: a preliminary experience in 32 consecutive cases. *World J Surg*. 2011;35(4):873–80.
  21. Keshava A, Young CJ, Mackenzie S. Single-incision laparoscopic right hemicolectomy. *Br J Surg*. 2010;97(12):1881–3.
  22. Law WL, Fan JK, Poon JT. Single-incision laparoscopic colectomy: early experience. *Dis Colon Rectum*. 2010;53(3):284–8.
  23. Gaujoux S, Bretagnol F, Ferron M, Panis Y. Single-incision laparoscopic colonic surgery. *Colorectal Dis*. 2011;13(9):1066–71.
  24. Champagne BJ, Papaconstantinou HT, Parmar SS, Nagle DA, Young-Fadok TM, Lee EC, Delaney CP. Single-incision versus standard multiport laparoscopic colectomy: a multicenter, case-controlled comparison. *Ann Surg*. 2012;255(1):66–9.
  25. Ramos-Valadez DI, Ragupathi M, Nieto J, Patel CB, Miller S, Pickron TB, Haas EM. Single-incision versus conventional laparoscopic sigmoid colectomy: a case-matched series. *Surg Endosc*. 2012;26(1):96–102.
  26. Maggiori L, Gaujoux S, Tribillon E, Bretagnol F, Panis Y. Single-incision laparoscopy for colorectal resection: a systematic review and meta-analysis of more than a thousand procedures. *Colorectal Dis*. 2012;14(10):e643–54.
  27. Leblanc F, Champagne BJ, Augestad KM, Stein SL, Marderstein E, Reynolds HL, Delaney CP. Single incision laparoscopic colectomy: technical aspects, feasibility, and expected benefits. *Diagn Ther Endosc*. 2010;2010:913216.
  28. Ramos-Valadez DI, Patel CB, Ragupathi M, Bartley Pickron T, Haas EM. Single-incision laparoscopic right hemicolectomy: safety and feasibility in a series of consecutive cases. *Surg Endosc*. 2010;24(10):2613–6.
  29. Slim K, Vicaut E, Launay-Savary MV, Contant C, Chipponi J. Updated systematic review and meta-analysis of randomized clinical trials on the role of mechanical bowel preparation before colorectal surgery. *Ann Surg*. 2009;249(2):203–9.
  30. Jung B, Pählman L, Nyström PO, Nilsson E, Mechanical Bowel Preparation Study Group. Multicentre randomized clinical trial of mechanical bowel preparation in elective colonic resection. *Br J Surg*. 2007;94(6):689–95.
  31. Contant CM, Hop WC, van't Sant HP, Oostvogel HJ, Smeets HJ, Stassen LP, Neijenhuis PA, Idenburg FJ, Dijkhuis CM, Heres P, van Tets WF, Gerritsen JJ, Weidema WF. Mechanical bowel preparation for elective colorectal surgery: a multicentre randomised trial. *Lancet*. 2007;370(9605):2112–7. Erratum in *Lancet*. 2008;371(9625):1664.
  32. Bucher P, Pugin F, Morel P. Single-port access laparoscopic radical left colectomy in humans. *Dis Colon Rectum*. 2009;52(10):1797–801.
  33. Brunner W, Schirnhofner J, Waldstein-Wartenberg N, Frass R, Weiss H. Single incision laparoscopic sigmoid colon resections without visible scar: a novel technique. *Colorectal Dis*. 2010;12(1):66–70.
  34. Merchant AM, Lin E. Single-incision laparoscopic right hemicolectomy for a colon mass. *Dis Colon Rectum*. 2009;52(5):1021–4.
  35. Martinec DV, Gatta P, Zheng B, Denk PM, Swanström LL. The trade-off between flexibility and maneuverability: task performance with articulating laparoscopic instruments. *Surg Endosc*. 2009;23(12):2697–701.
  36. Santos BF, Reif TJ, Soper NJ, Hungness ES. Effect of training and instrument type on performance in single-incision laparoscopy: results of a randomized comparison using a surgical simulator. *Surg Endosc*. 2011;25(12):3798–804.
  37. Gaujoux S, Maggiori L, Bretagnol F, Ferron M, Panis Y. Safety, feasibility, and short-term outcomes of single port access colorectal surgery: a single institutional case-matched study. *J Gastrointest Surg*. 2012;16(3):629–34.
  38. Ragupathi M, Nieto J, Haas EM. Pearls and pitfalls in SILS colectomy. *Surg Laparosc Endosc Percutan Tech*. 2012;22(3):183–8.
  39. Velthuis S, van den Boezem PB, Lips DJ, Prins HA, Cuesta MA, Sietses C. Comparison of short-term surgical outcomes after single-incision laparoscopic versus multiport laparoscopic right colectomy: a two-center, prospective case-controlled study of 100 patients. *Dig Surg*. 2012;29(6):477–83.
  40. Yang TX, Chua TC. Single-incision laparoscopic colectomy versus conventional multiport laparoscopic colectomy: a meta-analysis of comparative studies. *Int J Colorectal Dis*. 2013;28(1):89–101.
  41. Leroy J, Cahill RA, Asakuma M, Dallemagne B, Marescaux J. Single-access laparoscopic sigmoidectomy as definitive surgical management of prior diverticulitis in a human patient. *Arch Surg*. 2009;144(2):173–9.
  42. Vestweber B, Galetin T, Lammerting K, Paul C, Giehl J, Straub E, Kaldowski B, Alfes A, Vestweber KH. Single-incision laparoscopic surgery: outcomes from 224 colonic resections performed at a single center using SILS. *Surg Endosc*. 2013;27(2):434–42.
  43. Ramírez JM, Blasco JA, Roig JV, Maeso-Martínez S, Casal JE, Esteban F, Lic DC, Spanish working group on fast track surgery. Enhanced recovery in colorectal surgery: a multicentre study. *BMC Surg*. 2011;11:9.
  44. Vestweber B, Straub E, Kaldowski B, Paul C, Alfes A, Haaf F, Vestweber KH. Single-port colonic surgery: techniques and indications. *Chirurg*. 2011;82(5):411–4.
  45. Fung AK, Aly EH. Systematic review of single-incision laparoscopic colonic surgery. *Br J Surg*. 2012;99(10):1353–64.

---

# SILS Total Colectomy and Proctocolectomy with Ileal Pouch-Anal Anastomosis (IPAA)

# 4

Deborah S. Keller and Conor P. Delaney

---

## Background

While laparoscopic colorectal surgery decreases surgical morbidity, it still requires three to four incisions, with the risks of bleeding, hernia, and incrementally decreases cosmesis at each post site [1]. Single-incision laparoscopic surgery (SILS) was introduced to further the enhanced outcomes of traditional laparoscopy. Studies have proven SILS feasible and safe [2–9]. From early reports, SILS has similar short-term outcomes compared to traditional laparoscopic surgery. In published studies, operative time, conversion to open surgery, estimated blood loss, surgical site infection, and hospital readmissions were all comparable [2, 8, 10, 11] (Table 4.1). For colorectal cancer, SILS procedures have shown comparable oncologic outcomes to traditional laparoscopic surgery, with sufficient surgical margins and number of harvested lymph nodes [6, 7, 12]. Further, SILS has distinct benefits. Among the proposed benefits are better cosmesis, reduced pain, and faster time to flatus and PO intake [4, 7, 8, 13].

The reduction in pain translated to less total narcotic use and lower pain scores in the immediate perioperative period [13].

The cosmetic benefit of a single incision is a major attraction for some patients. The potential advantages of a small skin incision include not only a better cosmetic result but also a lower rate of port-site-related complications [12]. In some studies, SILS has also shown a significantly shorter length of stay (LOS) with a demonstrated LOS more than 1 day shorter compared to multi-port laparoscopy [8, 11].

There are few reports of SILS total colectomy and proctocolectomy, specifically with ileal pouch-anal anastomosis (IPAA). Geisler et al. reported the initial experience for SILS restorative proctocolectomy on a familial adenomatous polyposis patient; the abdomen was accessed through a 2.5 cm incision sited preoperatively for the temporary ileostomy, resulting in a nearly scarless procedure [14]. After the promising initial case, Geisler et al. reported five cases of SILS total proctocolectomy with IPAA [15]. There were no conversions to traditional laparoscopic or open procedures in the case series. The LOS was comparable to laparoscopic (median 4 days, range 3–6 days). Two patients had postoperative small bowel obstructions that resolved with non-operative management. Fichera et al. published results of nine consecutive patients with medically refractory Ulcerative Colitis who underwent a SILS total abdominal colectomy [16]. No intraoperative complications or conversions to multi-port laparoscopy or open surgery occurred.

---

D.S. Keller, M.S., M.D. • C.P. Delaney, M.D., M.Ch.,  
Ph.D., F.R.C.S.I., F.A.C.S., F.A.S.C.R.S. (✉)  
Division of Colorectal Surgery, Department of Surgery,  
University Hospitals-Case Medical Center, Case  
Western Reserve University, 11100 Euclid Avenue,  
7 Lakeside, Cleveland, OH 44106-5047, USA  
e-mail: Deborah.Keller@uhhospitals.org;  
Conor.Delaney@uhhospitals.org



**Table 4.1** Published reports of single-incision laparoscopic colectomy

Author	Year	Patients	BMI	Mean OR time (min)	LOS (d)	Incision length (cm)	R/L
Bucher	2008	1	N/A	158	N/A	3	1/0
Remzi	2008	1	35	115	4	3.5	1/0
Rieger	2009	7	24.3	89	5.4	3.1	6/1
Geisler	2009	1	24	172	4	2	TPC
Merchant	2009	1	N/A	N/A	3	2.5	1/0
Remzi	2009	1	25.8	198	3	3	0/1
Bucher	2009	1	26	213 <sup>a</sup>	N/A	2	0/1
Law	2009	1	N/A	180	3	3	0/1
Chambers	2009	6	N/A	82	1.9	2.5	2/1 <sup>b</sup>
Leroy	2009	1	21	90	4	2	0/1
Champagne	2010	165		135	4.6		
Bucher	2010	1	22	125	2	2	0/1
Adair	2010	17	26.2	139	5	3	17/0
Gandhi	2010	24	28.5	143	2.7	3.8	19/5
Papaconstantinou	2011	29	30	128.8	3.4	4.9	29/0
Chen	2011	18	23.3	175	5	4	18/0
Lee	2011	46	25	135	4.6	5.1	24/22
Fichera	2011	10	21.9	139	5.1	–	TPC
McNally	2011	27	27	114	3	–	14/8 <sup>c</sup>
Wu	2011	27	–	180	7	4.1	8/18 <sup>d</sup>
Ross	2011	39	25.6	120	4.4	4.2	30/9
Ramos-Valadez	2012	20	27.7	159.2	3.2	3.3	0/20
Champagne	2012	29	28	134.4	3.8	3.7	19/10
Walters	2012	100	26	105	4		100/0

*N/A* not available, *TPC* total proctocolectomy, *BMI* body mass index, *R* right sided surgery, *L* left sided surgery, *LOS* length of stay, *min* minutes, *d* days

<sup>a</sup>Concomitant cholecystectomy

<sup>b</sup>In addition: two TPC and one abdominal colectomy with ileorectal anastomosis

<sup>c</sup>In addition, five SILS transverse colectomies

<sup>d</sup>In addition, one TPC

Bowel function returned on mean postoperative day 1.7, and patients tolerated a solid diet on mean postoperative day 3. The mean postoperative LOS was 5.2 days [16]. These initial results suggest that SILS total colectomy and restorative proctocolectomy may lead to improvements in short-term outcomes in selected patients. However, long-term outcome data and randomized prospective trials are needed. Currently, a significant improvement in recovery time, hospital LOS or postoperative complications compared to traditional laparoscopic colorectal surgery would make SILS a cost effective and efficient surgical approach [5].

## Procedures

### SILS Total Proctocolectomy with Ileal Pouch-Anal Anastomosis

The patient is placed supine on the operating table on a bean bag to prevent movement in Trendelenburg position. After induction of general anesthesia, the patient's legs are placed in yellow fin stirrups. An oro-gastric tube and Foley catheter are inserted, and the patient is prepped and draped in routine sterile fashion.

The primary monitor is placed on the left side of the patient at the patient's epigastrium level.

The secondary monitor is placed on the right side of the patient at the same level. The primary operating surgeon stands on the right side of the patient with the assistant standing on the patient's left, and moving to the right side, caudal to the surgeon once ports have been inserted. A 0° camera lens is used.

The insertion of the SILS port (SILS port, Covidien, Norwalk, CT) is performed through a 2.5 cm incision. If a temporary diverting loop ileostomy is planned, the single-port trocar is inserted through a 2.5 cm incision made at the ileostomy site. If no diverting ileostomy is planned, a 2.5 cm incision made through the umbilicus for the single-port device. The peritoneum is entered, and a 2.5 cm fascial incision is made. Then, the SILS port is placed into the peritoneal cavity with the assistance of a curved clamp.

After entry, the abdominal cavity is inspected. The greater omentum is reflected over transverse colon and small bowel moved to the left upper quadrant to create a working space. The ileocolic pedicle is defined and divided with an energy source, and a medial to lateral mobilization of the cecum and ascending colon is performed. The dissection is taken superiorly to the duodenum and pancreas, and laterally to the abdominal sidewall. During mobilization of the right colon, care is taken to protect the ureter and duodenum. The hepatic flexure is mobilized superiorly, joining with the previous dissection plane. The remaining lateral attachments of the right colon are mobilized, and the right colon is reflected to the midline. The small bowel mesentery and superior mesenteric arcade are mobilized up to the third portion of the duodenum. The transverse colon is mobilized, taking the greater omentum and protecting the gastroepiploic arcade, entering the lesser sac.

The splenic flexure is taken down with a medial approach and brought to the midline. The descending colon is mobilized along the lateral sidewall, and brought to the midline. The transverse mesocolon is then displayed. The middle colic vessels are then carefully defined and divided close to the colon, protecting the stomach and the superior mesenteric vessels.

The patient is then placed into Trendelenburg position. The rectosigmoid is mobilized carefully, staying very close to the inferior mesenteric vessels to protect the presacral autonomic nerves and ureters, which are defined and protected. A low ligation of the inferior mesenteric artery is performed with an energy source. The left colic vessels and upper sigmoid branches are taken half way up the mesentery. An energy source is used to develop a plane in the mesorectum close to the rectum. For a SILS approach, an intramesenteric dissection is often easier than a standard total mesorectal dissection—type dissection. The pelvic dissection is performed preserving and protecting the ureters, retroperitoneal planes, and perirectal and pelvic nerves. Hemostasis is assured.

After fully mobilizing the entire intra-abdominal colon, a rectal mobilization is performed down to the anal canal, carefully observing the fascial planes. The extent of mobilization is confirmed by digital palpation. A 5 mm port in the single port is replaced with a 12 mm port, and the rectum is divided with a 45 mm laparoscopic stapler cartridge, usually requiring two firings. The single-port device is replaced with a wound protector, and the rectum and colon are removed. A suitable position with maximal reach into the pelvis without tension is identified on the small bowel. The terminal ileal mesentery is divided with an energy source. The bowel is transected. An 18–20 cm ileal pouch is measured and fashioned with two firings of the GIA-100 stapler. The internal lumen is inspected. Cautery or sutures are used to achieve complete hemostasis. A pursestring is inserted and the anvil of the EEA 28 positioned in the pouch. The TA 30 staple line is oversewn with 3-0 Vicryl, and the crotch buttressed with a 3-0 Vicryl. The pouch is evaluated to assure it is healthy and then returned to the abdomen. The single-port device is reinserted. The small bowel mesentery is mobilized up to the duodeno-jejunal flexure, if this has not been possible prior to specimen removal. If necessary, the peritoneum over the superior mesenteric artery can be opened (“laddered”) with scissors and cautery to improve reach of the ileal pouch

into the pelvis. An ileoanal anastomosis is then fashioned without torsion or tension. The stapler donuts are checked to ensure they are intact, and an air test is performed to assure there is no leak. Complete hemostasis is assured, and the abdomen is irrigated.

If a stoma is being fashioned, the terminal ileum is confirmed to be adequately mobilized and orientation is confirmed. An appropriate portion is brought out through the single-port incision at the ileostomy. The stoma is matured over a rod, with sutures of 3-0 Caprosyn. A single figure of 8 #1 polyglycolic acid suture is placed in the fascia to make a snug ostomy aperture, and an ostomy appliance was applied.

### **SILS Total Abdominal Colectomy**

The patient is placed supine on the operating table on a bean bag to prevent movement in Trendelenburg position. After induction of general anesthesia, the patient's legs are placed in yellow fin stirrups. An oro-gastric tube and Foley catheter are inserted, and the patient is prepped and draped in routine sterile fashion.

The primary monitor is placed on the left side of the patient at the patient's epigastrium level. The secondary monitor is placed on the right side of the patient at the same level. The primary operating surgeon stands on the right side of the patient with the assistant standing on the patient's left, and moving to the right side, caudal to the surgeon once ports have been inserted. A 0° camera lens is used.

The insertion of the SILS port (SILS port, Covidien, Norwalk, CT) is performed through a 2.5 cm incision. If a temporary diverting loop or end ileostomy is planned, the single-port trocar is inserted through a 2.5 cm incision is made at the ileostomy site. If no diverting ileostomy is planned, a 2.5 cm incision is made through the umbilicus for the single-port device. The peritoneum is entered, and a 2.5 cm fascial incision is made. Then, the SILS port is placed into the peritoneal cavity with the assistance of a curved clamp.

After entry, the abdominal cavity is inspected. The greater omentum is reflected over transverse colon and small bowel moved to the left upper quadrant to create a working space. The ileocolic pedicle is defined and divided with an energy source, and a medial to lateral mobilization of the cecum and ascending colon is performed. The dissection is taken superiorly to the duodenum and pancreas, and laterally to the abdominal sidewall. During mobilization of the right colon, care is taken to protect the ureter and duodenum. The hepatic flexure is mobilized superiorly, joining with the previous dissection plane. The remaining lateral attachments of the right colon are mobilized, and the right colon is reflected to the midline. The small bowel mesentery and superior mesenteric arcade are mobilized up to the third portion of the duodenum. The transverse colon is mobilized, taking the greater omentum and protecting the gastroepiploic arcade, entering the lesser sac.

The splenic flexure is taken down with a medial approach and brought to the midline. The descending colon is mobilized along the lateral sidewall, and brought to the midline. The transverse mesocolon is then displayed. The middle colic vessels are then carefully defined and divided close to the colon, protecting the stomach and the superior mesenteric vessels. The sigmoid mesentery is divided too close to the rectosigmoid junction.

The extent of mobilization is confirmed. A point of transection on the rectum above the peritoneal reflection is identified. Hemostasis is assured. A 5 mm port in the single port is replaced with a 12 mm port, and the rectum is divided with a 45 mm laparoscopic stapler cartridge, usually requiring two firings. The single-port device is replaced with a wound protector, and the specimen is removed. The terminal ileum is divided with a GIA stapler. The specimen is removed and wide margins confirmed. The single port is reinserted so that orientation of the small bowel and rectum can be defined. Then, a side-to-side functional end anastomosis is fashioned with a GIA 80 stapler. After assuring there is no internal bleeding, the bowel is closed with a TA 60 stapler. The staple line and crotch of the anastomosis are



oversewn with 3-0 Vicryl, and the bowel is returned to the abdomen. The fascia is closed with looped 1 Maxon, and the skin is closed with 4-0 Vicryl and Steri-Strips.

If a stoma is being fashioned, the terminal ileum is confirmed to be adequately mobilized and orientation is confirmed. An appropriate portion is brought out through the single-port incision at the ileostomy. The stoma is matured over a rod, with sutures of 3-0 Caprosyn. A single figure of 8 #1 polyglycolic acid suture is placed in the fascia to make a snug ostomy aperture, and an ostomy appliance was applied.

## References

1. Nagpal AP, Soni H, Haribhakti S. Hybrid single-incision laparoscopic restorative proctocolectomy with ileal pouch anal anastomosis for ulcerative colitis. *Indian J Surg.* 2010;72(5):400–3.
2. Adair J, Gromski MA, Lim RB, Nagle D. Single-incision laparoscopic right colectomy: experience with 17 consecutive cases and comparison with multiport laparoscopic right colectomy. *Dis Colon Rectum.* 2010;53(11):1549–54.
3. Bucher P, Pugin F, Morel P. Single port access laparoscopic right hemicolectomy. *Int J Colorectal Dis.* 2008;23(10):1013–6.
4. Chambers WM, Bicsak M, Lamparelli M, Dixon AR. Single-incision laparoscopic surgery (SILS) in complex colorectal surgery: a technique offering potential and not just cosmesis. *Colorectal Dis.* 2011;13(4):393–8.
5. Champagne BJ, Lee EC, Leblanc F, Stein SL, Delaney CP. Single-incision vs straight laparoscopic segmental colectomy: a case-controlled study. *Dis Colon Rectum.* 2011;54(2):183–6.
6. Chen WT, Chang SC, Chiang HC, Lo WY, Jeng LB, Wu C, Ke TW. Single-incision laparoscopic versus conventional laparoscopic right hemicolectomy: a comparison of short-term surgical results. *Surg Endosc.* 2011;25(6):1887–92.
7. Kim SJ, Ryu GO, Choi BJ, Kim JG, Lee KJ, Lee SC, Oh ST. The short-term outcomes of conventional and single-port laparoscopic surgery for colorectal cancer. *Ann Surg.* 2011;254(6):933–40.
8. Papaconstantinou HT, Sharp N, Thomas JS. Single-incision laparoscopic right colectomy: a case-matched comparison with standard laparoscopic and hand-assisted laparoscopic techniques. *J Am Coll Surg.* 2011;213(1):72–80. discussion 80–2.
9. Huscher CG, Mingoli A, Sgarzini G, Mereu A, Binda B, Brachini G, Trombetta S. Standard laparoscopic versus single-incision laparoscopic colectomy for cancer: early results of a randomized prospective study. *Am J Surg.* 2012;204(1):115–20.
10. Ramos-Valadez DI, Ragupathi M, Nieto J, Patel CB, Miller S, Pickron TB, Haas EM. Single-incision versus conventional laparoscopic sigmoid colectomy: a case-matched series. *Surg Endosc.* 2012;26(1):96–102.
11. Vasilakis V, Clark CE, Liasis L, Papaconstantinou HT. Noncosmetic benefits of single-incision laparoscopic sigmoid colectomy for diverticular disease: A case-matched comparison with multiport laparoscopic technique. *J Surg Res.* 2013;180(2):201–7.
12. Bulut O, Nielsen CB, Jespersen N. Single-port access laparoscopic surgery for rectal cancer: initial experience with 10 cases. *Dis Colon Rectum.* 2011;54(7):803–9.
13. Champagne BJ, Papaconstantinou HT, Parmar SS, Nagle DA, Young-Fadok TM, Lee EC, Delaney CP. Single-incision versus standard multiport laparoscopic colectomy: a multicenter, case-controlled comparison. *Ann Surg.* 2012;255(1):66–9.
14. Geisler DP, Condon ET, Remzi FH. Single incision laparoscopic total proctocolectomy with ileopouch anal anastomosis. *Colorectal Dis.* 2010;12(9):941–3.
15. Geisler DP, Kirat HT, Remzi FH. Single-port laparoscopic total proctocolectomy with ileal pouch-anal anastomosis: initial operative experience. *Surg Endosc.* 2011;25(7):2175–8.
16. Fichera A, Zoccali M. Single-incision laparoscopic total abdominal colectomy for refractory ulcerative colitis. *Surg Endosc.* 2012;26(3):862–8.

Léon Maggiori and Yves Panis

---

## Introduction

Minimally invasive approach is one of the major technical advances observed in surgery during the past 20 years. It has become the standard approach for many benign and malignant diseases. As such, laparoscopy is now widely used for colorectal surgery. Compared to open surgery it provides various well-known benefits, including faster return of bowel function, less pain, shorter hospital stay, lower morbidity and cosmetic advantage [7, 26]. Moreover, many studies have demonstrated the oncologic safety of laparoscopic colon cancer resection [9, 18, 38], as it is associated with similar results in terms of local control and survival, compared to standard open surgery. Furthermore, we have recently demonstrated, at a national level, that laparoscopy was independently associated with a lower postoperative mortality rate in colorectal cancer surgery [29].

On the other hand, the safety of the laparoscopy for rectal cancer management was initially questioned, mainly because of high rates of conversion and postoperative morbidity in subgroup analyses of the first randomized control

trial (CLASICC trial) comparing open to laparoscopic approaches [18]. More recently, additional randomized control trials, specifically focusing on rectal cancer, demonstrated the safety of this minimally invasive approach, even in this indication [21, 26, 37].

Interest in laparoscopy led to the development of more minimally invasive surgical approaches such as mini-laparoscopy, NOTES (Natural Orifice Transluminal Endoscopic Surgery) and more recently single port laparoscopy. This latter technique is a technical refinement of the laparoscopic approach and consists of using a single multichannel port site, allowing the introduction of a camera and several instruments with only a 25–50 mm skin incision. In addition to the well-known advantages of laparoscopy, the main advantages of single port laparoscopy might be improved postoperative pain, postoperative recovery, and cosmetic results. To date, single port laparoscopy has been reported for various surgical procedures, and published experiences regarding more complex procedures such as colorectal surgery are rapidly growing. Although single port laparoscopy for colorectal resections was initially only performed for benign disease, there is now an increasing experience for regarding colorectal malignancy.

As for laparoscopic approach in rectal cancer management, single port laparoscopy for rectal procedures raises some concern about feasibility and safety of this technically demanding surgery. In this chapter we will review the published literature about single port laparoscopy for low

---

L. Maggiori, M.D. • Y. Panis, M.D., Ph.D. (✉)  
Department of Colorectal Surgery, Pôle des Maladies de l'Appareil Digestif (PMAD), Beaujon Hospital, Assistance publique-Hôpitaux de Paris (AP-HP), University Denis Diderot (Paris VII), 100 boulevard du Général Leclerc, 92110 Clichy, France  
e-mail: yves.panis@bjn.aphp.fr

anterior resection and total mesorectal excision (TME) and we will describe our routine surgical technique for such cases.

---

## Literature Review

### Single Port Total Mesorectal Excision

Hamzaoglu et al., in January 2011, were the first to publish their experience with single port laparoscopic sphincter-saving excision for rectal cancer [19]. They reported a series of four patients. Two of them underwent a partial mesorectal excision with colorectal anastomosis and two underwent a TME. Results were encouraging as no additional laparoscopic port or conversion to laparotomy was required, intraoperative blood loss ranged from 50 to 200 mL, operative time ranged from 240 to 480 min, and no postoperative complication was observed.

Since, several studies were published on the topic. After reporting our two initial cases of TME for cancer by single port approach [13], we reported the results of 25 single port laparoscopic colorectal procedures in a case-matched study, including three cases of single port laparoscopic proctectomy [14]. This study suggested the feasibility of this single port approach, as we did not observe any difference of postoperative mortality and morbidity, as compared to the standard multiport laparoscopic approach. In 2011, Bulut et al., reported ten consecutive cases of rectal cancer treated by single port laparoscopic approach with good postoperative results [3]. On the same way, Kim et al. [22] reported 73 colorectal cancer patients treated by single port surgery, including 32 rectal cancers. In this latter comparative, although not randomized, study, postoperative morbidity was similar as compared to patients operated by multiport laparoscopy, but both return to normal bowel function and postoperative hospital stay were significantly shorter in single port patients. Finally, two other recent papers reported 19 [39] and eight [5] patients, respectively, with rectal cancer treated by single port, also with satisfactory postoperative results.

In 2012, we performed a systematic review and meta-analysis on single port laparoscopic colorectal surgery [27], including all studies published as of December 2011. We identified 20 studies [2–6, 11–17, 19, 23–25, 30, 32, 35, 36], all of retrospective design, which reported a total of 105 rectal procedures, including 55 low anterior resections (52 %), four abdomino-perineal resections (4 %), and 46 total proctocolectomies (with or without ileal-pouch anal anastomosis) (44 %). Of these studies, only three were case-matched studies [5, 14, 25], all of them comparing single port to standard multiport approaches. One of the main conclusions of this meta-analysis was the questioned technical feasibility of single port laparoscopic rectal surgery, as only 67 % were successfully completed through a SIL approach. Indeed, conversion to multiport laparoscopy was needed in 32 cases (30 %) and conversion to laparotomy was needed in three cases (3 %).

On the other hand, this meta-analysis demonstrated that postoperative outcomes of single port laparoscopic rectal surgery were acceptable, as compared to the standard multiport approach. Pooled postoperative 30-day mortality rate was 0.2 % and meta-analysis of the comparative studies showed no difference of postoperative morbidity rates between single port laparoscopy and multiport laparoscopic surgery (Odds-Ratio: 0.84 [0.61; 1.15];  $p=0.27$ ). Furthermore, we suggested that single port approach might be associated with some benefits as compared to the multiport approach as the single port approach was associated with a significantly shorter total skin incision (Weighted mean difference:  $-0.52$  [ $-0.79$ ;  $-0.25$ ];  $p<0.001$ ) and a significantly shorter length of postoperative hospital stay (Weighted mean difference:  $-0.75$  [ $-1.30$ ;  $-0.20$ ];  $p=0.008$ ), as compared to the multiport approach. Finally, this meta-analysis stressed out the point that single port laparoscopic surgery might be acceptable regarding the oncologic results obtained. Indeed, all reported surgical margins were negative (R0) and all studies reported a mean number of harvested lymph nodes of 12 or more. However, to date, long-term follow-up of single port TME for rectal cancer was not reported

in any study and both overall and disease free-survivals remain unknown.

Similarly, two additional literature reviews have recently been published on the same topic [10, 28]. The first one [28] suggested that single port laparoscopic approach was feasible and safe when performed by surgeons highly experienced in laparoscopy. The authors concluded that, despite technical difficulties, single port laparoscopy might be associated with potential benefits (i.e., size of the incision, hospital stay, operative time) as compared to its multiport counterpart, but those remain yet to be proven objectively. The second review, focusing only on colon cancer [10], suggested that single port laparoscopic approach may be associated with a lower postoperative morbidity rate, as compared to the results of large randomized control trials of multiport laparoscopic approach.

More recently, two small-sampled randomized studies have been recently reported on single port laparoscopic colonic surgery [20, 31], although they did not include rectal procedures. The first one, authored by Poon et al., included 50 patients and demonstrated significantly shorter hospital stay and lower postoperative pain in patients operated by single port [31]. The second study in 32 patients demonstrated that operative results were similar in both single port and standard laparoscopy groups [20].

### **Transanal-Transabdominal Total Mesorectal Excision**

Several authors published their experience with transanal-transabdominal TME. Different surgical techniques were reported, mostly because of variations of the percentage of the TME dissection performed through the transanal approach. Indeed this transanal dissection may vary from an isolated intersphincteric dissection, as we previously described [13], to a complete TME [8], associated with a single port transabdominal approach.

The complete transanal TME derives from the NOTES technique, initially described in bovine [1] and human cadaver [40], and firstly described in human using a multiport laparoscopic assistance

by Sylla et al. [33]. In 2011, Tuech et al. reported the first case of complete transanal TME with a single port laparoscopic assistance in a 45-year-old for a low rectal adenocarcinoma [34]. Finally, in September 2012, Dumont et al. reported the first series of four patients with rectal cancer treated with this approach [8]. Results were encouraging, as additional laparoscopic port or conversion to laparotomy was not required, mean intraoperative blood loss was 175 mL, and all surgical margins were classified R0. After a mean follow-up of 3 months, Wexner scores indicated no severe incontinence in any patient. The authors concluded that this technique was feasible despite the limited working space in the pelvis area. Furthermore, they hypothesized that this transanal approach for TME may be superior to the transabdominal TME for large pelvic tumors, minimizing the risk of perforation and presacral bleeding. However, to date, no study compared the results of the transanal TME to those obtained after transabdominal approach. In our Department, we consider that a total transanal TME present two major drawbacks: firstly, the major anal sphincter required might jeopardize the postoperative anal function; secondly, a hand-sewn coloanal anastomosis is the rule after this technique, irrespective of the tumor distance from the anal verge and therefore even in mid rectal cancer where stapled anastomosis is feasible. For these reasons, when a hand-sewn anastomosis is indicated (i.e., low rectal cancer) we always begin the TME dissection from a perineal approach but only up to approximately 5–6 cm from the dentate line. Subsequently, we routinely performed a standard abdominal laparoscopic approach.

In their study, Dumont et al. advocate to reserve this technique to patients requiring an intersphincteric dissection for oncologic reasons, i.e., tumors located at 2 cm or less of the anal verge.

---

### **Surgical Technique**

We routinely perform transabdominal approach with stapled low colorectal anastomosis for single port laparoscopic rectal cancer management,

reserving the transanal-transabdominal with hand-sewn anastomosis for patients requiring either a standard coloanal anastomosis on the dentate line (rectal tumor located at less than 3 or 4 cm from the dentate line, for which stapled anastomosis will be very difficult by abdominal approach) or for intersphincteric dissection for lesions located at less than one cm from the dentate line.

### **Transabdominal Approach and Stapled low Colorectal Anastomosis**

The surgeon and a first assistant are positioned on the right of the patient. A second assistant is placed on the left. As we always perform a diverting lateral ileostomy in rectal cancer cases, the single port device is placed through a 25 mm skin incision in the right lower quadrant, at the precise stoma location. The procedure is performed using a 5 mm laparoscope with a 0° tip, a 5 mm Ultracision Harmonic scalpel (Ethicon Endosurgery, Spreitenbach, Switzerland), a 10 mm endoscopic linear stapler, and conventional straight 5 mm laparoscopic graspers. We routinely use the Octoport for single port (Landanger).

Single port TME is performed using the same technique as for standard laparoscopic TME with a medial-to-lateral approach. It begins by a medial approach (after placing the patient in 30° Trendelenburg with 20° right lateral tilt position, using one assistant grasper and the gravitational force) with vein division, dissection of the pancreas from below, mobilization of the transverse and left mesocolon, and after a clear identification of the left ureter, division of the inferior mesenteric artery. Then, splenic flexure mobilization and left colonic mobilization is finished laterally. During the step of splenic flexure mobilization, and because frequently the single port is too far for the splenic flexure, we add a 5-mm trocar on the left lower quadrant which help for this step, and which will be used for the suction drain left in place in the pelvis at the end of the operation. TME is then performed down to the pelvic floor. The rectum is distally transected using an endoscopic linear stapler using one or two cartridges.

The specimen is extracted through the single port incision in the right lower quadrant. The colon is proximally transected and prepared, allowing the insertion of a circular stapler anvil. The colon is returned in the abdominal cavity, the single port device is reinserted, and the pneumoperitoneum is reestablished. A low side-to-end colorectal anastomosis is then mechanically performed using a transanally inserted circular stapler. A pelvic suction drain is placed and the last ileal loop is exteriorized through the site of insertion of the single port laparoscopic device.

### **Transabdominal—Transanal Approach with Hand-Sewn Coloanal Anastomosis**

For transabdominal—transanal approach, we routinely use a primary transanal approach. With the patient in lithotomy position, a Lone Star Retractor System (Lone Star Medical Products, Inc, Stafford, TX) is introduced for surgical exposure. The anal canal is divided circumferentially according to the level of the tumor (i.e., at least 10 mm distal to the lower edge of the tumor). An intersphincteric dissection is then performed up to 5 cm above the dentate line. During this dissection, the anorectal lumen is closed as soon as possible with a running suture, in order to avoid any subsequent tumor spillage and for traction and exposure during the dissection. The transabdominal approach is then performed using the same technique as depicted above, except that the specimen is extracted through the anal canal and a hand-sewn side-to-end coloanal anastomosis is performed.

---

### **Conclusion**

Published studies regarding single port laparoscopic TME are scarce and no randomized control trial is available to date. However, review of the literature suggests that single port laparoscopic TME is technically demanding but feasible and safe. Furthermore, it may be associated with improved postoperative outcomes



as compared to the standard multiport approach. Long-term results of this procedure and well-designed prospective studies are eagerly waited, as they will allow complete demonstration of the outcomes associated with this novel minimally invasive approach.

## References

- Bhattacharjee HK, Buess GF, Becerra Garcia FC, Storz P, Sharma M, Susanu S, et al. A novel single-port technique for transanal rectosigmoid resection and colorectal anastomosis on an ex vivo experimental model. *Surg Endosc.* 2011;25:1844–57.
- Bulut O, Nielsen CB. Single-incision laparoscopic low anterior resection for rectal cancer. *Int J Colorectal Dis.* 2010;25:1261–3.
- Bulut O, Nielsen CB, Jespersen N. Single-port access laparoscopic surgery for rectal cancer: initial experience with 10 cases. *Dis Colon Rectum.* 2011;54:803–9.
- Chambers WM, Bicsak M, Lamparelli M, Dixon AR. Single-incision laparoscopic surgery (SILS) in complex colorectal surgery: a technique offering potential and not just cosmesis. *Colorectal Dis.* 2011;13:393–8.
- Champagne BJ, Papaconstantinou HT, Parmar SS, Nagle DA, Young-Fadok TM, Lee EC, et al. Single-incision versus standard multiport laparoscopic colectomy: a multicenter, case-controlled comparison. *Ann Surg.* 2012;255:66–9.
- Chew MH, Wong MT, Lim BY, Ng KH, Eu KW. Evaluation of current devices in single-incision laparoscopic colorectal surgery: a preliminary experience in 32 consecutive cases. *World J Surg.* 2011;35:873–80.
- Clinical Outcomes of Surgical Therapy Study Group. A comparison of laparoscopically assisted and open colectomy for colon cancer. *N Engl J Med.* 2004;350:2050–9.
- Dumont F, Goere D, Honore C, Elias D. Transanal endoscopic total mesorectal excision combined with single-port laparoscopy. *Dis Colon Rectum.* 2012;55:996–1001.
- Fleshman J, Sargent DJ, Green E, Anvari M, Stryker SJ, Beart Jr RW, et al. Laparoscopic colectomy for cancer is not inferior to open surgery based on 5-year data from the COST Study Group trial. *Ann Surg.* 2007;246:655–64.
- Fung AK, Aly EH. Systematic review of single-incision laparoscopic colonic surgery. *Br J Surg.* 2012;99:1353–64.
- Gash KJ, Goede AC, Chambers W, Greenslade GL, Dixon AR. Laparoendoscopic single-site surgery is feasible in complex colorectal resections and could enable day case colectomy. *Surg Endosc.* 2011;25:835–40.
- Gash KJ, Goede AC, Kaldowski B, Vestweber B, Dixon AR. Single incision laparoscopic (SILS) restorative proctocolectomy with ileal pouch-anal anastomosis. *Surg Endosc.* 2011;25:3877–80.
- Gaujoux S, Bretagnol F, Au J, Ferron M, Panis Y. Single port access proctectomy with total mesorectal excision and intersphincteric resection with a primary transanal approach. *Colorectal Dis.* 2011;13:e305–7.
- Gaujoux S, Maggiori L, Bretagnol F, Ferron M, Panis Y. Safety, feasibility, and short-term outcomes of single port access colorectal surgery: a single institutional case-matched study. *J Gastrointest Surg.* 2012;16:629–34.
- Geisler D, Garrett T. Single incision laparoscopic colorectal surgery: a single surgeon experience of 102 consecutive cases. *Tech Coloproctol.* 2011;15:397–401.
- Geisler DP, Condon ET, Remzi FH. Single incision laparoscopic total proctocolectomy with ileopouch anal anastomosis. *Colorectal Dis.* 2010;12:941–3.
- Geisler DP, Kirat HT, Remzi FH. Single-port laparoscopic total proctocolectomy with ileal pouch-anal anastomosis: initial operative experience. *Surg Endosc.* 2011;25:2175–8.
- Guillou PJ, Quirke P, Thorpe H, Walker J, Jayne DG, Smith AM, et al. Short-term endpoints of conventional versus laparoscopic-assisted surgery in patients with colorectal cancer (MRC CLASICC trial): multicentre, randomised controlled trial. *Lancet.* 2005;365:1718–26.
- Hamzaoglu I, Karahasanoglu T, Baca B, Karatas A, Aytac E, Kahya AS. Single-port laparoscopic sphincter-saving mesorectal excision for rectal cancer: report of the first 4 human cases. *Arch Surg.* 2011;146:75–81.
- Huscher CG, Mingoli A, Sgarzini G, Mereu A, Binda B, Brachini G, et al. Standard laparoscopic versus single-incision laparoscopic colectomy for cancer: early results of a randomized prospective study. *Am J Surg.* 2012;204:115–20.
- Kang SB, Park JW, Jeong SY, Nam BH, Choi HS, Kim DW, et al. Open versus laparoscopic surgery for mid or low rectal cancer after neoadjuvant chemoradiotherapy (COREAN trial): short-term outcomes of an open-label randomised controlled trial. *Lancet Oncol.* 2010;11:637–45.
- Kim SJ, Ryu GO, Choi BJ, Kim JG, Lee KJ, Lee SC, et al. The short-term outcomes of conventional and single-port laparoscopic surgery for colorectal cancer. *Ann Surg.* 2011;254:933–40.
- Lauritsen ML, Bulut O. Single-port access laparoscopic abdominoperineal resection through the colostomy site: a case report. *Tech Coloproctol.* 2012;16:175–7.
- Leblanc F, Makhija R, Champagne BJ, Delaney CP. Single incision laparoscopic total colectomy and proctocolectomy for benign disease: initial experience. *Colorectal Dis.* 2011;13:1290–3.
- Lee SW, Milsom JW, Nash GM. Single-incision versus multiport laparoscopic right and hand-assisted left

- colectomy: a case-matched comparison. *Dis Colon Rectum*. 2011;54:1355–61.
26. Lujan J, Valero G, Hernandez Q, Sanchez A, Frutos MD, Parrilla P. Randomized clinical trial comparing laparoscopic and open surgery in patients with rectal cancer. *Br J Surg*. 2009;96:982–9.
  27. Maggiori L, Gaujoux S, Tribillon E, Bretagnol F, Panis Y. Single-incision laparoscopy for colorectal resection: a systematic review and meta-analysis of more than a thousand procedures. *Colorectal Dis*. 2012;14:e643–54.
  28. Makino T, Milsom JW, Lee SW. Feasibility and safety of single-incision laparoscopic colectomy: a systematic review. *Ann Surg*. 2012;255:667–76.
  29. Panis Y, Maggiori L, Caranhac G, Bretagnol F, Vicaut E. Mortality after colorectal cancer surgery: a French survey of more than 84,000 patients. *Ann Surg*. 2011;254:738–44.
  30. Podolsky ER, Curcillo 2nd PG. Single port access (SPA) surgery—a 24-month experience. *J Gastrointest Surg*. 2010;14:759–67.
  31. Poon JT, Cheung CW, Fan JK, Lo OS, Law WL. Single-incision versus conventional laparoscopic colectomy for colonic neoplasm: a randomized, controlled trial. *Surg Endosc*. 2012;26:2729–34.
  32. Ross H, Steele S, Whiteford M, Lee S, Albert M, Mutch M, et al. Early multi-institution experience with single-incision laparoscopic colectomy. *Dis Colon Rectum*. 2011;54:187–92.
  33. Sylla P, Rattner DW, Delgado S, Lacy AM. NOTES transanal rectal cancer resection using transanal endoscopic microsurgery and laparoscopic assistance. *Surg Endosc*. 2010;24:1205–10.
  34. Tuech JJ, Bridoux V, Kianifard B, Schwarz L, Tsilivlidis B, Huet E, et al. Natural orifice total mesorectal excision using transanal port and laparoscopic assistance. *Eur J Surg Oncol*. 2011;37:334–5.
  35. Uematsu D, Akiyama G, Narita M, Magishi A. Single-access laparoscopic low anterior resection with vertical suspension of the rectum. *Dis Colon Rectum*. 2011;54:632–7.
  36. van den Boezem PB, Sietses C. Single-incision laparoscopic colorectal surgery, experience with 50 consecutive cases. *J Gastrointest Surg*. 2011;15:1989–94.
  37. van der Pas MH, Haglind E, Cuesta MA, Furst A, Lacy AM, Hop WC, et al. Laparoscopic versus open surgery for rectal cancer (COLOR II): short-term outcomes of a randomised, phase 3 trial. *Lancet Oncol*. 2013;14(3):210–8.
  38. Veldkamp R, Kuhry E, Hop WC, Jeekel J, Kazemier G, Bonjer HJ, et al. Laparoscopic surgery versus open surgery for colon cancer: short-term outcomes of a randomised trial. *Lancet Oncol*. 2005;6:477–84.
  39. Vestweber B, Galetin T, Lammerting K, Paul C, Giehl J, Straub E, et al. Single-incision laparoscopic surgery: outcomes from 224 colonic resections performed at a single center using SILS. *Surg Endosc*. 2013;27:434–42.
  40. Whiteford MH, Denk PM, Swanstrom LL. Feasibility of radical sigmoid colectomy performed as natural orifice transluminal endoscopic surgery (NOTES) using transanal endoscopic microsurgery. *Surg Endosc*. 2007;21:1870–4.



Kelly A. Garrett and Sang W. Lee

---

## Introduction

Enthusiasm for single-incision laparoscopic colectomy (SILC) has increased since its introduction in the 1990s. The rationale for this minimally invasive technique is to decrease the morbidity of multiple laparoscopic ports, including pain and incisional hernia and also to improve cosmesis. However, this concept introduces new challenges and limitations to the field of laparoscopy. In comparison to the first reported procedures such as single-port appendectomy and nephrectomy, single-port colectomy is more complex because it involves a mobile organ that needs to be mobilized and retracted. With respect to this aspect of the procedure, triangulation can be difficult especially with the need to visualize multiple quadrants of the abdomen [1]. In addition, traditional straight laparoscopic instruments and laparoscopes can hinder the progression of the procedure because of “sword fighting” and assistants interfering with the surgeon. Clearly the goal of the single-port procedure is the same as the conventional multiport procedure; however it can be a challenge, especially during the learning curve to overcome such hurdles.

---

K.A. Garrett • S.W. Lee, M.D. (✉)  
New York-Presbyterian Hospital, Weill Cornell  
Medical College, 1315 York Avenue, 2nd Floor,  
New York, NY 10021, USA  
e-mail: sal2013@med.cornell.edu

---

## Patient Selection

Even before the actual procedure is performed there are tricks that will help one succeed with single-port colectomy. As in any type of surgery, there is always an “ideal patient” [2]. It has been suggested that contraindications to the single-incision technique are the same as for the standard laparoscopic colectomy [3]. However, in a procedure that is already technically challenging, it is essential to choose cases that will be straightforward. The aim would be to help the case progress as smoothly as possible, especially in the initial cases that one performs.

In order to avoid a patient with an abundance of intra-abdominal fat that will obscure tissue planes and inhibit good tissue retraction, it would be wise to choose patients with a low body mass index (BMI). In many of the first case reports and case series, subjects typically had BMI under 30. In a recent review of 38 articles, that included 565 patients, median BMI was 25.8 kg/m<sup>2</sup> [1]. Moreover, in a report in 2010, operative times were found to be statistically significantly longer in patients with a BMI > 25 kg/m<sup>2</sup> [4]. In addition, some of the single-port access devices may not be long enough to be secured in a patient with a very thick abdominal wall without becoming dislodged and losing pneumoperitoneum [5].

Past surgical history is another factor that should be included in patient selection criteria. Obviously patients with multiple previous abdominal surgeries can be expected to have

some degree of adhesions and scar tissue. This can negatively impact the initiation and progression of the case. Similarly, the nature of the disease process should also be taken into account. It is prudent to start off with patients that have benign disease such as a benign polyp that cannot be resected colonoscopically as opposed to a patient with diseases that are associated with an inflammatory process such as diverticular disease or inflammatory bowel disease. Sigmoid colectomy for diverticulitis can be one of the most technically challenging procedures to perform laparoscopically. Even in expert hands, the likelihood of converting from multiport laparoscopy to an open approach is high [6]. These inflammatory disease processes tend to obscure tissue planes, ostensibly making the procedure more technically difficult.

---

### Surgeon Experience

As important as it is to select the appropriate or ideal first patients to perform SILC, it is paramount to be the ideal surgeon to perform these cases. In the United States, the percentage of colectomies performed laparoscopically still remains well under 25 % [7]. SILC poses additional skill requirements which can serve as an impediment. In a study which evaluated SILC performed for the first time by surgeons who were highly experienced in multiport laparoscopic colectomies, colectomy was found in majority to be harder ergonomically [8]. The learning curve associated with SILC is unclear. It will certainly depend on the surgeon's baseline laparoscopic skills and experience. The studies that investigated the learning curve associated with multiport laparoscopy found that conversion rates, complications rates, and operative times significantly improved after 40 cases [9]. It is difficult to conclude from this data what the learning curve associated with SILC will be. But, it is intuitive that the learning curve for SILC is almost certainly higher than multiport laparoscopic colectomy, especially for a surgeon who is not experienced in laparoscopic techniques.

SILC should therefore be performed by surgeons who are already skilled in laparoscopic colon surgery [10].

---

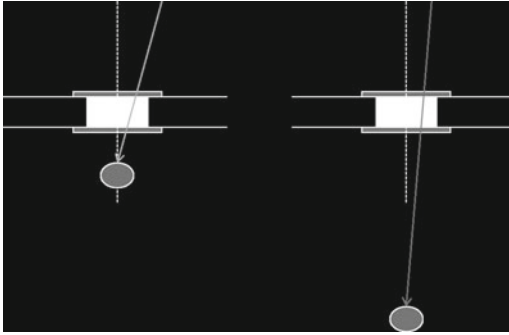
### Selection of Initial Procedure

In a recent systematic review of single-incision laparoscopic colectomies, the most common surgical procedure performed using a single-incision technique was right hemicolectomy ( $n=279$ ), followed by sigmoidectomy ( $n=27$ ) and anterior resections ( $n=8$ ) [11]. The reason for the preponderance of reported single-incision right colectomy cases is likely due to the fact that it is relatively easier to perform than the other procedures. The likelihood of success with single-incision laparoscopic technique is probably greater if right sided rather than left-sided colon pathologies are tackled initially.

---

### Overcoming Technical Challenges

Single-incision laparoscopic surgery poses several technical challenges in comparison to multiport laparoscopic surgery. In single-incision surgery, the camera and the laparoscopic instruments are introduced into the abdomen through a small single incision. Because of close proximity of instruments placed though a confined space, the clashing of instruments is unavoidable and the maintenance of tissue triangulation is tricky. As a result, there is significant decrease in range of motion. The difficulty becomes more pronounced when working in an operative field located farther away from the incision (Fig. 6.1). As the distance between the incision and the operative field increases, the instruments begin to work in parallel to each other and it becomes impossible to maintain tissue triangulation. This in turn, increases the complexity of retraction, exposure and dissection of the colon. In the following section, we highlight some of the steps that can be taken in order to overcome some of these technical difficulties.



**Fig. 6.1** Tissue triangulation gets lost when working away from the incision. As the distance between the incision and the operative field increases, the instruments begin to work parallel to each other and it becomes impossible to maintain tissue triangulation

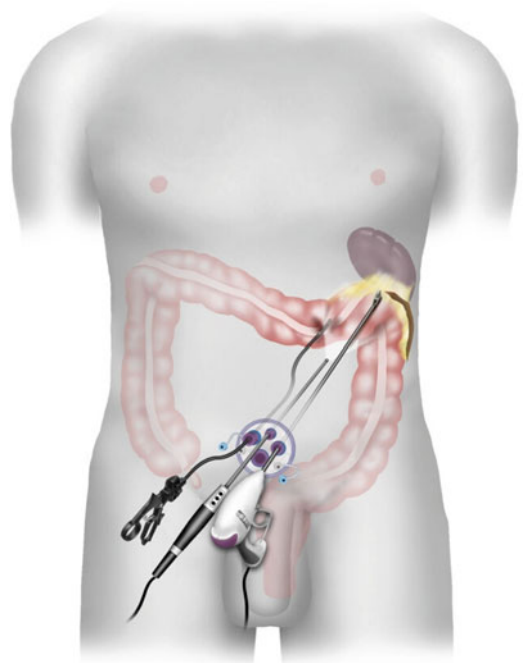
## Positioning and Assistants

Positioning of the patients during these cases is very important. As there is only minimal instrumentation through a single port, tissue retraction is limited. Because of this, gravity and native tissue attachments are frequently used as major tools of retraction. Therefore, it is many times necessary to put the patient in steep Trendelenberg position or airplane the patient to one side. It is beneficial to have an operating room table that can perform these maneuvers. In addition, placing a patient in yellow fin stirrups or in modified lithotomy position is also recommended as it allows the operating surgeon to stand in between the legs when accessing the upper abdomen. Owing to the use of extreme positions that may be necessary, the patient should be secured to the operating table using a bean bag or tape.

As in any abdominal case, good assistance is the key to the success of the procedure. In SILC, it is helpful to have a good assistant that has superior camera skills and is capable of operating a flexible and angled laparoscope if one is being used.

## Access Devices, Ports, and Port Placement

There are many different access devices on the market today for single-incision laparoscopy. Early reports describe using a surgical glove or

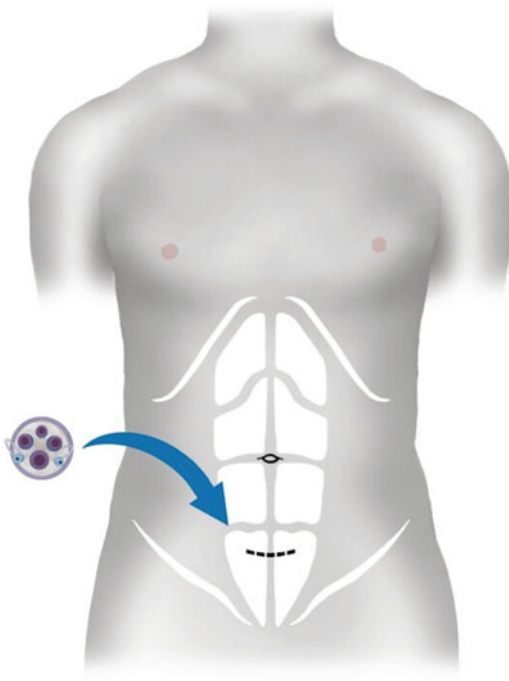


**Fig. 6.2** The use of a single-incision access device increases the freedom of motion by distributing the anchoring points of the instruments over a 2D space

placing multiple traditional ports through the same fascial incision. Although economical, these are not durable and can result in a “swiss cheese” defect of the fascia. One study showed that the use of trocars without a single-incision device can result in loss of pneumoperitoneum and delay during the surgery [12]. It may be advantageous to use single-incision access devices which incorporate an expanding wound retractor that can maximize wound exposure. The use of a single-incision access device also increases the freedom of motion by distributing the anchoring points of the instruments over a two dimensional space (Fig. 6.2).

## Location of Incision

For right colectomies, an incision can be made transumbilically or periumbilically. Both incision sites allow for the best visualization of the pathology and allow for the fascial incision to be extended without significant lengthening of the skin incision [10]. A transumbilical incision is



**Fig. 6.3** For left-sided resections and rectal pathologies, a Pfannenstiel incision can be used

beneficial because it allows for the best cosmesis, as the incision can be almost completely hidden within the umbilicus. For left-sided resections and rectal pathologies, either periumbilical or Pfannenstiel incision can be used (Fig. 6.3). The Pfannenstiel incision is preferred by the authors for left-sided resections because it provides some advantages over the periumbilical approach. The most technically demanding portions of the operation during a SIL left colectomy are splenic flexure take down and the distal rectal dissection and transection. In patients with a favorable body habitus, a Pfannenstiel incision allows distal rectal dissection and transection to be performed directly through the incision in hybrid open fashion. This site allows for good visualization of the region of concern and may decrease operative time.

Once the access device is placed and exploration confirms the region of concern, specific placement of the ports within the access device can make the procedure easier. As with multiport laparoscopy, triangulation is tantamount. Although this can be difficult in single-port surgery, it is possible to recreate triangulation, albeit

in a limited manner. We have found that if the apex of the triangle points toward the pathology, this can make the procedure less complicated.

## Laparoscopes and Instruments

As with access devices and ports, there are no standardized laparoscopes or instruments for SILC. In a paper analyzing nine articles with seven different laparoscopic surgery teams, a variety of laparoscope sizes, tips, and angulations were used. No team used the same laparoscope [13]. The authors have found that a conventional angled (30 or 45°) laparoscope or a flexible tip scope is the best for these procedures. Straight laparoscopes are easy to use and most surgeons are familiar with them from multiport laparoscopic surgery. Flexible tip laparoscopes are more challenging to use and for this reason it is beneficial to have a camera operator who is accustomed to using this equipment. Flexible scopes allow the camera operator to stand away from the surgeon and can help avoid instrument and camera clashing. On the other hand, most flexible tip laparoscopes have a fairly long deflection tip which can make obtaining a wide overview of the operative field difficult. The incorporated end-on light source allows for avoidance of competition for space at the port site [14]. Longer scopes are also available and these can similarly be useful for positioning of surgeon and assistant. In addition, a smaller 5 mm scope can allow placement of a 10 or 12 mm instrument.

Although there are many flexible instruments available on the market, in our experience standard straight laparoscopic instruments are preferred. This has been recommended by other groups as well [5, 15]. Use of flexible instruments can be confusing and make the procedure more complicated because of counter-intuitive movements. Use of straight bariatric length instruments can be useful especially through Pfannenstiel incisions as they can also help to avoid crowding at the port site and have the added length to reach places such as the splenic flexure [15]. In addition, using instruments with

variable lengths can allow manipulation of instruments externally in different planes, making it more likely to avoid collisions [16]. As experience broadens, use of curved and articulating flexible instruments may be incorporated.

## Technique

As mentioned, many of the challenges with SILC are related to limited working space, visualization, and triangulation of instruments. As previously described, one way to avoid clashing of instruments externally is to use instruments of differing lengths. Some surgeons find it useful to use a combination of regular and bariatric length instruments and an extra-length laparoscope with a special adaptor which get the light cords out the way. Fixed curved shaft instruments that are specially designed for single-incision surgeries may also be useful. These instruments are reusable and have handles similar to straight instruments. The purpose of the curved tip is to restore some degree of the loss of triangulation (Fig. 6.4).

In SILC, it is often not practical to place a fourth trocar for retraction purposes. Because of this, it is critical to maintain strong tension on the specimen during dissection and retraction. Another method to avoid problems with dissection is to perform hand maneuvers that are not usually recommended in conventional laparoscopy, specifically, a “cross-over” technique whereby the instruments are crossed internally after insertion through the port [2, 11].

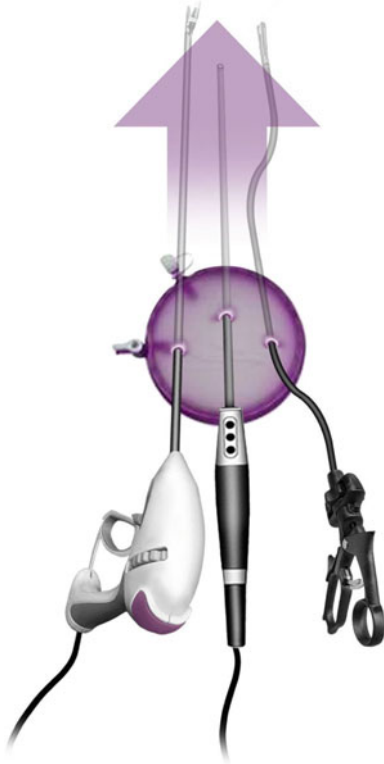Typically laparoscopes and instruments are placed in the triangular configuration with the laparoscope placed the apex of the triangle and the two instruments at the base (Fig. 6.5). As the operation proceeds and the operative field changes, it is critical to turn the face plate of the single-incision access device so that the apex of the “triangle” points toward the operative field. This will allow maximum working space and avoid clashing of instruments. One way to avoid clashing of instruments during repositioning and regrasping is to pull back with the instrument until it clears the stationary instrument and come underneath the other instrument to regrasp.



**Fig. 6.4** Fixed curved instruments may be helpful in preventing clashing of handles and restoring some tissue triangulation

## Right Colectomy

Typically for all SILS procedures, the patient is placed in modified lithotomy position in yellow fin stirrups. For right colectomy, the authors will place a transumbilical or periumbilical single-incision access device. Once the port is placed and pneumoperitoneum is established, either a 5 or a 10 mm, 30°, rigid laparoscope is placed. Dissection is performed medial to lateral similar to the method we would use for a conventional multiport laparoscopic procedure. The ileocolic vessels are identified and isolated. The vessels are divided with a bipolar energy device. The mesentery is then elevated off of the retroperitoneum. The duodenum is identified and protected. The colon is then mobilized from its lateral attachments. At this point, the hepatic flexure is mobilized using angled instruments. Because dissection needs to be performed at a farther distance and the instrument fulcrum is fixed, angled instruments combined with the aforementioned



**Fig. 6.5** It is critical to turn the face plate of the single-incision access device so that the apex of the “triangle” points toward the operative field. This will allow maximum working space and avoid clashing of instruments

crossover technique can offer increased range of motion. Generally the authors do not divide the bowel intracorporally. Once mobilization is complete, the port is removed and wound protector is placed if the port that is being used does not have a protective sleeve. The specimen is exteriorized and transected. Anastomosis is performed and the bowel is placed back within the abdominal cavity. The fascia is then closed with interrupted figure of eight sutures or with a running looped suture followed by skin closure.

### Left Colectomy or Sigmoid Colectomy

As previously discussed, for left and sigmoid colectomies, the authors typically approach this through a Pfannenstiel incision. Dissection is carried out medial to lateral similar to multiport

laparoscopy. The inferior mesenteric vessels are isolated and the left ureter is identified. The vessels are then ligated with a bipolar energy device. The mesentery is then lifted off of the retroperitoneum towards the white line of Toldt. Attention is then turned to the lateral attachments which are taken down toward the splenic flexure. Again, depending on the size of the patient, it may be necessary to switch to angled instruments for splenic flexure takedown because of the distance from the incision. Once the splenic flexure is mobilized, attention is directed back into the pelvis. Dissection of the mesorectum and division of the rectosigmoid can be done laparoscopically through the port or using the open technique through a wound protector. One of the advantages of using a Pfannenstiel incision for this approach is that the anastomosis and rectal dissection can be done through the port incision in an open technique.

### Conclusion

Single-incision laparoscopy is challenging. There are no standard techniques that have been established as of yet since this modality is still early in this stage of infancy. SILC may be considered even more difficult than other single-port procedures because it involves mobilization and dissection of such a mobile organ. As with most new surgical technologies, it is paramount to maximize success with SILC by choosing the ideal patients for initial cases. To ensure progress of the case, it may be necessary to use methods that are generally avoided in multiport laparoscopy such as crossing of the hands or frequent changing of instruments. In addition, this technique should be and large be used by surgeons that are facile in multiport laparoscopy.

### References

1. Fung AK, Aly EH. Systematic review of single-incision laparoscopic colonic surgery. *Br J Surg*. 2012;99(10):1353–64.
2. Adair J, Gromski MA, Lim RB, Nagle D. Single-incision laparoscopic right colectomy: experience with 17 consecutive cases and comparison with multi-



- port laparoscopic right colectomy. *Dis Colon Rectum*. 2010;53(11):1549–54.
3. Boone BA, Wagner P, Ganchuk E, et al. Single-incision laparoscopic right colectomy in an unselected patient population. *Surg Endosc*. 2012;26(6):1595–601.
  4. Ramos-Valadez DI, Patel CB, Ragupathi M, Bartley Pickron T, Haas EM. Single-incision laparoscopic right hemicolectomy: safety and feasibility in a series of consecutive cases. *Surg Endosc*. 2010;24(10):2613–6.
  5. Goel R, Lomanto D. Controversies in single-port laparoscopic surgery. *Surg Laparosc Endosc Percutan Tech*. 2012;22(5):380–2.
  6. Laurent SR, Detroz B, Detry O, Degauque C, Honore P, Meurisse M. Laparoscopic sigmoidectomy for fistulized diverticulitis. *Dis Colon Rectum*. 2005;48(1):148–52.
  7. Weber WP, Guller U, Jain NB, Pietrobon R, Oertli D. Impact of surgeon and hospital caseload on the likelihood of performing laparoscopic vs open sigmoid resection for diverticular disease: a study based on 55,949 patients. *Arch Surg*. 2007;142(3):253–9; discussion 259.
  8. Ross H, Steele S, Whiteford M, et al. Early multi-institution experience with single-incision laparoscopic colectomy. *Dis Colon Rectum*. 2011;54(2):187–92.
  9. Dagash H, Chowdhury M, Pierro A. When can I be proficient in laparoscopic surgery? A systematic review of the evidence. *J Pediatr Surg*. 2003;38(5):720–4.
  10. Wong MT, Ng KH, Ho KS, Eu KW. Single-incision laparoscopic surgery for right hemicolectomy: our initial experience with 10 cases. *Tech Coloproctol*. 2010;14(3):225–8.
  11. Makino T, Milsom JW, Lee SW. Feasibility and safety of single-incision laparoscopic colectomy: a systematic review. *Ann Surg*. 2012;255(4):667–76.
  12. Ostrowitz MB, Eschete D, Zemon H, DeNoto G. Robotic-assisted single-incision right colectomy: early experience. *Int J Med Robot*. 2009;5(4):465–70.
  13. Leblanc F, Champagne BJ, Augestad KM, et al. Single incision laparoscopic colectomy: technical aspects, feasibility, and expected benefits. *Diagn Ther Endosc*. 2010;2010:913216.
  14. Remzi FH, Kirat HT, Kaouk JH, Geisler DP. Single-port laparoscopy in colorectal surgery. *Colorectal Dis*. 2008;10(8):823–6.
  15. Ragupathi M, Nieto J, Haas EM. Pearls and pitfalls in SILS colectomy. *Surg Laparosc Endosc Percutan Tech*. 2012;22(3):183–8.
  16. Romanelli JR, Earle DB. Single-port laparoscopic surgery: an overview. *Surg Endosc*. 2009;23(7):1419–27.



---

# Robotic Single Port Colorectal Surgery

# 7

Byung Soh Min, Sami Alasari, and Avanish Saklani

---

## Introduction and History

Single port surgery is an emerging technique in minimal access surgery and its real benefit in current stage is debatable. This is because, while single port surgery is not ergonomically efficient and requires high level of technical proficiency its benefits seem limited to cosmesis and subjective patient satisfaction. This dilemma becomes more acute when it comes to oncologic surgery, in other words whether surgeons can maintain the same quality of surgery with this new technique or is there trade-off/compromise between access ports and quality of surgery? In this chapter we will seek answers for these questions. We believe that with robotic surgical system for single port surgery will enable more surgeons to perform single port surgery without compromising on quality.

The first published report of single port surgery, although it may be different from modern technique, came in 1971 [1]. The authors reported a successful series of tubal sterilization using a special instrument he specifically made for his single port procedure. Then, in 1992 the laparoscopic single port emerged again by Pelosi et al. from gynecology. He reported a successful single port subtotal hysterectomy [2]. With increasing popularity of laparoscopic technique, more and more surgeons have become interested in minimally invasive surgery (MIS). The increase in uptake of MIS led to explosive increase in novel MIS techniques. Natural orifice transluminal endoscopic surgery (NOTES) was a revolutionary concept and succeeded in getting a lot of hype, however, its clinical application as an alternative to laparoscopic approach, at this moment, seems remote. One of the major obstacles in NOTES is technology; i.e., lack of instruments or system to enable surgeons overcome technical and ergonomic challenges [3]. In contrast, laparoscopic single port approach seems to have some benefits over NOTES; in the sense that surgeons are able to perform this with available technology and conventional (multiport) laparoscopic instruments. A stepwise approach (i.e., from conventional multiport to reduced port and then to single port) seems to have rationale and may help overcome the learning curve with reduced efforts. Moreover, some laparoscopic experts consider single port surgery as a bridge between conventional (multiport) laparoscopic surgery and NOTES [4]. Starting from relatively

---

B.S. Min, M.D., Ph.D. (✉)

Department of Surgery, Yonsei University College of Medicine, 50 Yonsei-ro Seodaemun gu 120-752, Seoul, South Korea

Severance Robot and Minimally Invasive Surgery Center, Yonsei University Health System, Seoul, South Korea  
e-mail: bsmin@yuhs.ac

S. Alasari, M.D. • A. Saklani, M.S., F.R.C.S.  
Department of Surgery, Yonsei University College of Medicine, 50 Yonsei-ro Seodaemun gu 120-752, Seoul, South Korea

simple procedures such as appendectomy and cholecystectomy, the application of single port technique has been expanding to include procedures like hysterectomy, nephrectomy, and more complex general surgical procedures [5, 6]. In late 2008, Bucher et al., was first to publish about the single port laparoscopic right hemicolectomy [7]. Since then the number of articles published about single port laparoscopic colorectal surgery has increased exponentially and each report describes different techniques and tips, which may raise an issue of standardization of the technique.

With the Robotic era, the first single port robotic surgery was reported in 2008 by Kaouk et al. [8]. He succeeded in performing radical prostatectomy, pyeloplasty, and radical nephrectomy using current da Vinci S(tm) surgical robotic system with conventional arms (not da Vinci single site). The first case report of single port robotic right hemicolectomy was published at the end of 2009 by Ostrowitz et al. They also used da Vinci S system with conventional two robotic arms and scope [9]. Since then, multiple robotic single port surgeries published for cholecystectomy, and hernia repair as well as colorectal surgery [10–12] and they use da Vinci S or Si system either with conventional arms or single site platform.

## Definitions and Terminologies

Several terminologies have been used in literature to describe single port surgery. We reviewed the literature and summarized abbreviations that are currently used (Table 7.1).

Although the terminologies may be different, they all indicate a type of MIS that primarily introduces multiple (more than 2) laparoendoscopic (or robotic) instruments through a single access port (usually through trans-umbilicus incision) or skin incision. To avoid possible confusion, in this chapter we will use the terms “single port surgery,” “laparoscopic single port surgery” and “robotic single port surgery,” unless otherwise defined by cited studies.

**Table 7.1** Summary of the terminology definitions

Terminology	Abbreviation
Single-incision surgery	SIS
Single port surgery	SPS
Single access surgery	SAS
Single port laparoscopic surgery	SPLS
Single port robotic surgery	SPRS
Single-incision laparoscopic surgery	SILS <sup>a</sup>
Single-incision robotic surgery	SIRS
Single port access	SPA
One port umbilical surgery	OPUS
Laparoendoscopic single site surgery	LESS
Single site laparoscopy	SSL
Robotic single site surgery	RSS
Natural orifice trans-umbilical surgery	NOTUS

<sup>a</sup>SILS is trademark of Covidien

## Access Ports for Single Port Surgery

Different kinds of access ports are commercially available and include SILS port (Covidien; Mansfield, MA), R-Port (ASC, Wicklow, Ireland), homemade port using a surgical glove and Alexis wound retractor (Applied Medical, Santa Margarita, CA, USA), GelPort or GelPoint (Applied Medical, Santa Margarita, CA, USA), OCTO Port (Dalim, Korea), TriPort and QuadPort (Olympus, Japan), and Da Vinci SS platform (intuitive, USA). Apart from da Vinci Single Site platform which is exclusively for robotic single port surgery and is attached to da Vinci Si system, almost all of the access ports are originally for laparoscopic single port surgery. A few of these access ports have been evaluated in literature. Thus far, among commercially available access ports, only SILS port [9] and GelPort [13] have been used in published literature on robotic single-incision surgery. Based on these reports, the SILS port seems to have limitation in the size of the whole access port. It tends to be too small for robotic instruments which are bulkier than laparoscopic instruments, and space between the instruments is inadequate, which results in frequent arm collision and limitation of range of motion. Another limiting factor is that there is limited room for a third robotic arm or for an assistant. Gelport may be a better alternative

because it allows the surgeon to design individual port configurations within the access port, and may help overcome the limitations in space, crowding of robotic arms, and external clashing.

Our preference is a homemade port using a surgical glove and Alexis wound retractor. The glove port offers multiple advantages over commercially available products. Its construction is simple and additional cost is negligible since the Alexis wound retractor would have been used in standard laparoscopic or multiport robotic colorectal surgery for specimen extraction. Other major benefits of this port include accommodation of variable abdominal wall thickness and the virtual absence of air-leaks which frequently hinder procedures involving standard MIS ports [12].

### Laparoscopic Single Port Colorectal Surgery Overview

Laparoscopic single port surgery has been widely described for appendectomy and cholecystectomy. Although most reports have small numbers related to a single surgeon's experiences, information pooled from these series regarding access port evaluation and technical tips make a firm base for performing more complex and multi-quadrant procedures like colorectal surgery [14].

Another factor that has facilitated single port surgery has been the evolution in surgical tools such as advanced articulating or flexible instruments including even energy devices, staplers and endoscopes.

In a large systematic review, Makino et al. in 2012, examined the safety and feasibility of single port laparoscopic colorectal surgery for both benign and malignant conditions [15]. He reviewed 23 studies including 378 patients. The conversion rate was 1.6 % (6 cases) to open, 1.6 % (6 cases) to hand assisted laparoscopy colectomy (HALC) and 4 % (14 cases) to conventional multiport laparoscopy. Additional laparoscopic ports were required in 12 patients out of 247 (4.9 %). The overall mortality and morbidity rates were 0.5 % (2 cases) and 12.9 % (45 cases) respectively. The causes of death were pulmonary embolism and metastasis for a palliative case. Of the

four case matched studies two studies showed shorter hospital stay for the single-incision laparoscopy than HALC and multiport laparoscopy. One study reported lower postoperative pain in SPLS over multiport and HALC. The readmission rate reported in two studies were 6.3 and 13.8 %, and when compared to multiport surgery found not to be significantly different. The reported complications from laparoscopic single port surgery in literature were ileus, wound infection/hematoma, and anastomotic bleeding/leakage, which are also observed in multiport surgery as well as conventional open. Makino in his review concluded that despite the technical difficulty, in early series of highly selected patients laparoscopic single port colorectal surgery was found to be safe and feasible under highly skilled surgeons. However standardization of the technique, learning curve, and long-term evaluation are still in infancy and need to be evaluated in large randomized controlled trials.

### Why Robotic Single Port Surgery?

Robotic colorectal surgery was reported in 2002 by Weber et al. [16]. Since then this has been adopted by colorectal surgeons in high volume specialized centers. Recently meta-analysis and several large systematic reviews have confirmed the safety and feasibility of robotic colorectal surgery without inferiority in oncological outcome. Furthermore, randomized controlled trials are ongoing to provide a better level of evidence for this procedure. The advantages of the robotic approach articulated in published robotic papers largely focus on better high-definition 3-D vision, filtration of physiologic tremor, human-wrist-like motion of robotic instruments, stable camera control, better ergonomics, and reduction of the fatigue associated with conventional laparoscopy.

These advantages of the robotic interface help overcome many of the limitations of single port surgery such as internal and external collisions, difficulty in achieving traction for triangulation, loss of ergonomics, body fatigue, instability of the camera, poor positioning with the assistant, and lack of stereotactic sense due to a two dimensional view. Although efforts have been

**Table 7.2** Single port colorectal operative outcome

Author	Study type	Patient no./ Procedure	Port type	Incision length (cm) <sup>a</sup>	OR time (min) <sup>a</sup>	EBL (mL) <sup>a</sup>	Con.
Ostrowitz	Case report	3 RHC	3 Ports+SILS	4	152	75	1 to lap due to air leak
Singh	Case report	1 RHC	GelPort	4	179	Minimal	0
Lim	Retrospective	20 AR	Glove+Alexis	4.7	167.5	24.5	0

OR operative time, EBL estimated blood loss, Con. conversion, Lap laparoscopic  
 Note: <sup>a</sup>All results in mean

made to minimize the above limitations with use of articulated instruments and special cameras, the results have been less than perfect with limited adoption by laparoscopic surgeons. This is more so in colorectal surgery where multi-quadrant access is required. By adopting the robotic system to single port approach, theoretically surgeons can have stable and 3D operative view, and human-wrist-like functioning robotic instruments that allow adequate traction and counter-traction. In addition, the surgeon can restore intuitive control of the instruments in the operative field despite the instruments being crossed by reassigning the hands at the console so that the instrument in the operative field corresponds to the appropriate hand on the console.

There are, however, some potential drawbacks of using the robotic system to perform single port surgery. Because the robotic arms are bigger than laparoscopic instruments, a larger size skin incision may be necessary. Additionally, this may also limit the ability to introduce additional laparoscopic instruments through the access port as is commonly done in laparoscopic single port surgery.

## Robotic Single Port Colorectal Surgery Overview

The first robotic single port surgery for radical prostatectomy was published by Kaouk et al. This was followed by pyeloplasty and nephrectomy; since then, several animal as well as human trials have been published for numerous benign and malignant procedures. In the colorectal field, robotic single port surgery is still a novel technique and only a few surgeons have reported their results in literature (Tables 7.2 and 7.3).

**Table 7.3** Short-term outcome

Author	LOS (days) <sup>a</sup>	COMP.	LN <sup>a</sup>	Margins	Mortality
Ostrowitz	3.6	0	22	Negative	0
Singh	4	0	14	Negative	0
Lim	6	0	16.8	Negative	0

LOS length of stay, COMP. complication, LN lymph node  
 Note: <sup>a</sup>All results in mean

Ostrowitz et al. was the first to publish about robotic single port colectomy in 2009 [9]. He reported a three robotic single port right hemicolectomy using Da Vinci S system and three ports including a camera inserted through one incision. The incision was through or around the umbilicus with a 4 cm length incision. There were no reported complications. The average operative time was 152 min. The first case was converted to non-robotic single-incision right hemicolectomy during mobilization of the ascending colon, due to uncontrollable air leakage around the ports. The second and third cases were successfully completed without air loss by purse-stringing sutures around each individual port and the use of the SILS port, respectively.

Singh et al. in 2010 reported the first case of robotic single port right hemicolectomy [13]. He performed the procedure using a Gelport as an access port through a 4 cm abdominal incision. Their operative time was 179 min and estimated blood loss was minimal. There were no reported intra/postoperative complications. In 2012 Lim et al. published a multimedia article about robotic single port anterior resection for sigmoid colon cancer [12]. They reported short-term results of 20 patients who underwent this procedure. The mean estimated blood loss was 24.5 mL (range 5–230). The mean operative time was 167.5 min (range

112–251), and there were no conversions. The median skin incision length was 4.7 cm (range 4.2–8). The mean proximal and distal resection margins were 12.9 (range 7.5–25.1) and 12.3 cm (range 4.5–19.2), respectively. The mean harvested lymph node was 16.8 (range 0–42). The immediate postoperative pain score was 2.8 (range 1–5) and 1.4 [1–3] on the first postoperative day. The mean length of hospital stay was 6 days (range 5–9). Obias et al. reported their comparative study between robotic and laparoscopic single port colectomy [17]. They compared 11 patients having robotic single port colectomy to ten patients receiving laparoscopic single port colectomy. In the robotic group all of the patients had single port right hemicolectomy with three conversions to conventional laparoscopy. There were three cases of postoperative complications (ileus, anastomotic bleeding, and wound infection). The laparoscopic group consisted of hemicolectomies and ileocecectomies. One case was converted to open due to adhesions and one case had postoperative bleeding requiring drainage. There was no statistically significant difference in measured clinical parameters between the two groups.

---

## Technical Consideration

Laparoscopic single port surgery is reported to be limited by the coaxial arrangement of the instruments. Although it may not be as frequent as in laparoscopy, arm collision is still a significant problem in robotic single port surgery. Joseph et al. in 2010 reported a chopstick surgery technique to use the robotic arms through a single incision without collision [18]. He conducted an experimental study using the Da Vinci S robot in a porcine model to perform cholecystectomy and nephrectomy with three laparoscopic ports introduced through a single incision. The chopstick arrangement crosses the instruments at the abdominal wall so that the right instrument is on the left side of the target and the left instrument on the right. This arrangement prevents collision of the external part of robotic arms. To correct for the change in handedness, the robotic console is

instructed to drive the left instrument with the right hand effector and the right instrument with the left. Both procedures were satisfactorily completed with no external collision of the robotic arms in acceptable times and with no technical complications. He concluded that the chopstick surgery significantly enhances the functionality of the surgical robot when working through a small single incision.

In our experience, arm collision seems to be more complex than that can be resolved with a single solution. Theoretically to make an optimal chopstick arrangement, the crossing point should be the remote center of robotic arms and should be located at the level of skin incision. However, in procedures that deal with a wide range of motion in the peritoneal cavity it is often difficult to keep the crossing point fixed at the ideal location. Inadequate location of the crossing point, subsequently, may result in arm collision. Choosing an adequate access port seems to be another key to success. Ostrowitz et al. reported that the very first case of robotic single port surgery had to be converted due to air leak. He associated this with dilatation of the port site caused by external clashing of the large robotic arms when he was trying to use them parallel to each other without crossing [9]. According to the authors, they succeeded in subsequent cases using SILS port (Covidien) without an air leak. Singh et al. reported a successful case of robotic single port right colectomy using Gelport as an access port [13]. They made a 4-cm sized skin incision and put a Gelport into it. Because they didn't need to puncture abdominal fascia to insert individual ports, they could avoid excessive stretch of the wound and therefore could prevent air leak during the surgery and could reduce postoperative wound pain. Lim et al. demonstrated a glove-port technique and suggested similar advantages as Gelport [12]. An additional advantage of their technique is the availability of a third robotic arm and an assistant port through the five fingers of a glove port. The very low comparative cost of a glove is also an obvious advantage of this technique.

## Robotic Single Site Platform

The robotic single port platform developed by Intuitive Surgical incorporates the principle of crossing the instrument arms internally with the ability of reassigning hands at the console (Fig. 7.1).

The set includes a multichannel access port with four cannulas and an insufflation valve. Two curved cannulas are for robotically controlled instruments, and the other two cannulas are straight; one cannula is 8.5 mm and accommodates the robotic endoscope, and the other cannula is a 5-mm bedside-assistant port. The curved cannulas are integral to the system, since their configuration allows the instruments to be positioned to achieve triangulation of the target anatomy. This triangulation is achieved by crossing the curved cannulas through the access port. Same-sided hand-eye control of the instruments is maintained through assignment of software of the Si system that enables the surgeon's right hand to control the screen right instrument even though the instrument is in the left robotic arm and, reciprocally, the left



**Fig. 7.1** Robotic single port platform by Intuitive

hand to control the screen left instrument even though the instrument is in the right robotic arm. The second part of the platform is a set of semirigid, nonwristed instruments with standard da Vinci instrument tips. The potential disadvantages of this set may be that it is limited to two arms while we need three arms in colorectal surgery. They do not have a wrist at the distal end of the instrument and that the traction and grasping power of the instruments are weaker than conventional ones. This platform reported to be helpful in relatively simple procedures like cholecystectomy and some minor urological procedures.

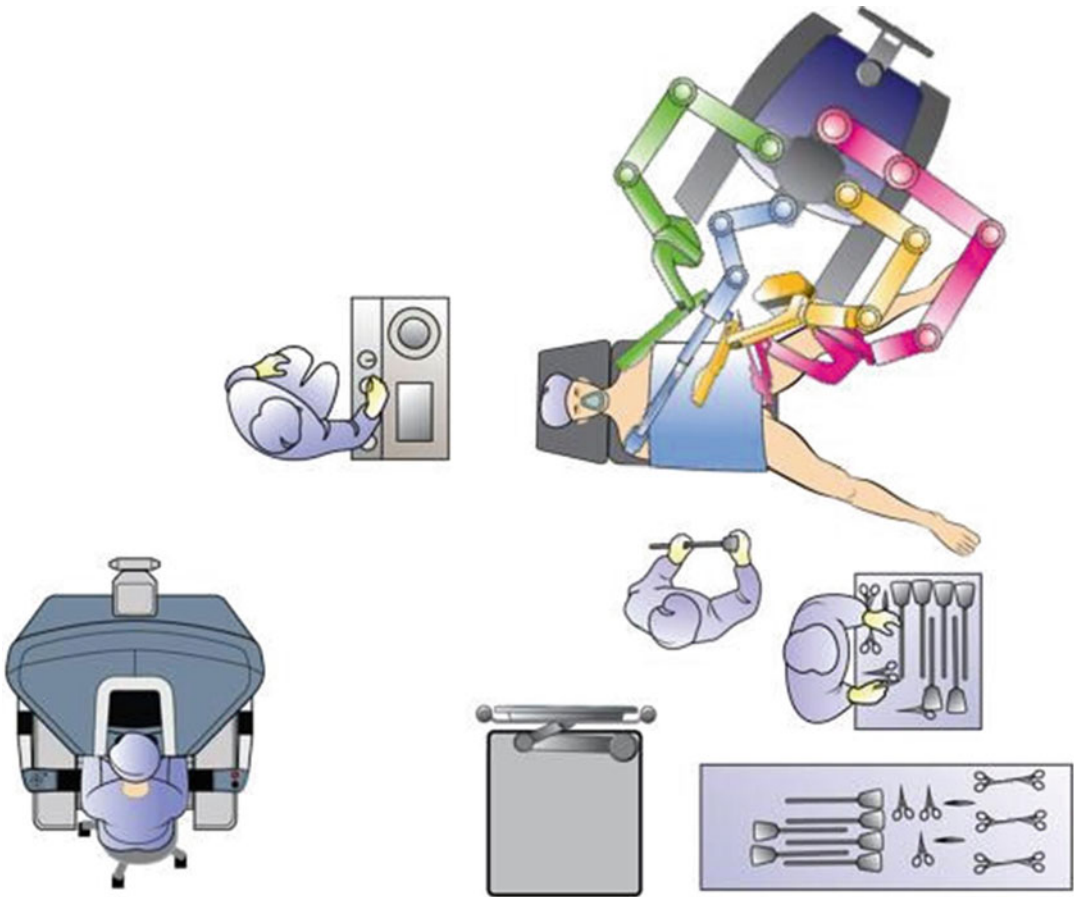
## Surgical Technique

### Patient Selection

Benign diseases including diverticular disease and inflammatory bowel disease-related conditions may be good indications for this technique. At this point, the efficacy of single port surgery for malignant disease is controversial and surgeons should consider its limitations and potential benefits that has been shown by current evidences seriously before they apply this technique to the patients. Early stages of colon cancer that confined to colon wall (T1–3) without lymph node metastasis (N0) may be candidates of this technique when the patients fully understands and when the informed consents are properly signed.

Technical limitation of the technique should be taken into consideration at the time of patient selection. Sigmoid colon diseases seem to be the best fit for the resection. Proximal descending colon may not be adequate because splenic flexure mobilization is sometimes limited especially when the patient is obese or/and tall. Rectum distal to peritoneal reflection may also be inadequate because the limited reach of the instruments. Especially currently available laparoscopic staplers have limited angulation that proper resection of distal rectum can seldom be made. Robotic stapler which is currently not available may make difference in near future.





**Fig. 7.2** Operation room set up

### Patient Position and Operating Theatre Setting

The patient is adequately padded and safely secured to the operating table in the Lloyd-Davis position with 15° Trendelenburg and 30° right side tilt. The patient-side robotic cart is positioned and locked in a 70° angle with the foot of the bed on the patient's left side at the level of the umbilicus and a 15° tilt toward the patient's head (Fig. 7.2).

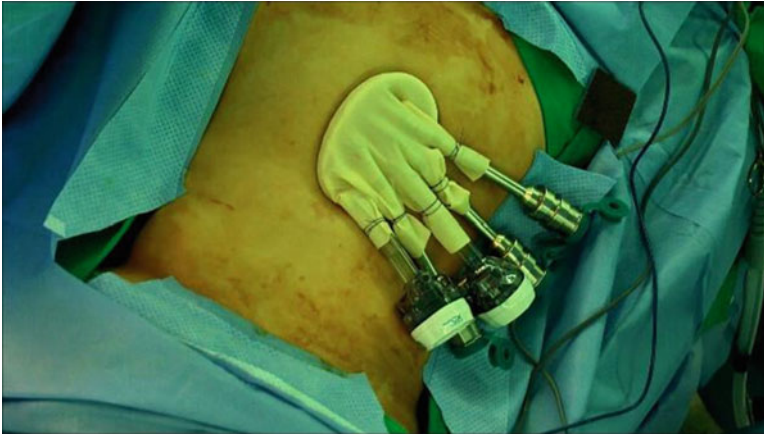
### Surgical Technique

The access device is a port constructed from a small size Alexis wound retractor manufactured

by Applied Medical and a size 7 right-handed surgical glove. Initially, a 3.5 cm vertical trans-umbilical incision is made. Once the Alexis wound retractor is placed into the peritoneal cavity in the standard manner, the surgical glove is affixed to the outer ring and folded onto itself to take up the slack of the plastic sleeve of the Alexis wound retractor. This ensures that the inner and outer rings fit snugly against the abdominal wall preventing an air leak (Fig. 7.3).

Two 12 mm trocars are then inserted into the third and the fifth finger of the glove. Three 8 mm robotic metal trocars are inserted into the remaining three fingers in the configuration depicted in Fig. 7.1. The trocars are secured to the glove with silk ties. The 30° up laparoscope is docked via the third finger 12 mm trocar. The other 12 mm trocar





**Fig. 7.3** Homemade glove port

is for the assistant's use. The assistant stays directly at the patient's right side. The robotic arms are numbered 1–3 and are coupled with the three 8 mm robotic trocars. The monopolar scissors, the bipolar grasper, and the double fenestrated grasper are handled by arms #1–3 respectively. Instruments on arm #1 and arm #2 are controlled by the da Vinci console operating surgeon, using the right and left hand, respectively. The double fenestrated grasper will be anchored to the robotic arm #3, which will be mainly used for static retraction and will be operated by surgeon's right hand when necessary (Fig. 7.4).

After pneumoperitoneum is established through the assistant's 12 mm port, the sigmoid colon mesentery is retracted supero-anteriorly using the double fenestrated grasper on arm #3. Peritoneum of the left mesocolon is incised superiorly from the sacral promontory, identifying the inferior mesenteric artery (IMA) along the way. After skeletonization, the IMA is ligated and divided at the root level with robotic Hem-o-lock clips, preserving the hypogastric nerve plexus. The peritoneal incision is then extended up to the duodenojejunal junction, exposing the inferior mesenteric vein (IMV). The IMV is temporarily spared, so as to utilize its 'tenting effect', which is caused by the traction of the small bowel during the medial-to-lateral mobilization of colonic mesentery. Medial-to-lateral dissection is then performed until the lower border of pancreas superiorly and Toldt's line laterally, identifying

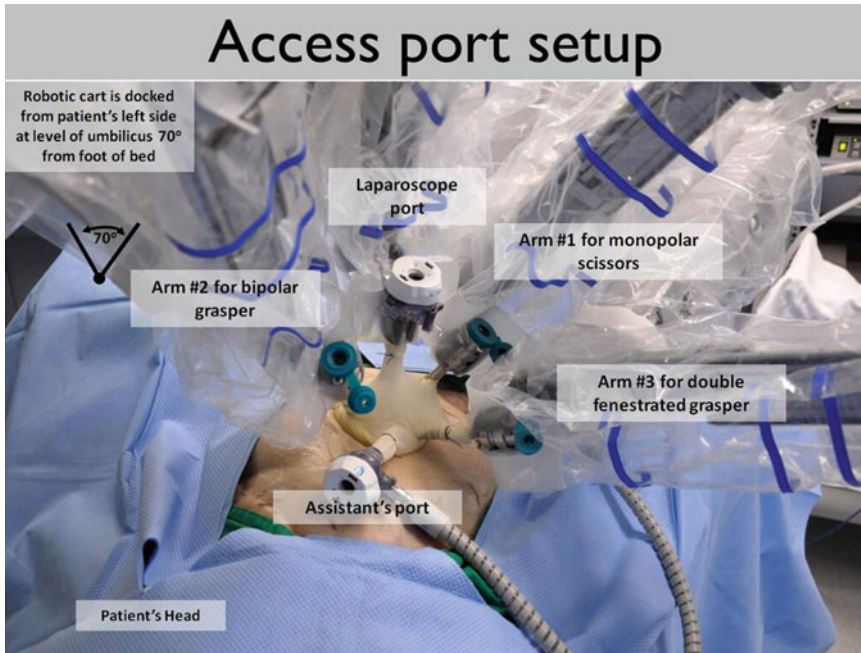
and protecting vital structures such as the left ureter and gonadal vessels. The left colon is then freed laterally up to the splenic flexure. The posterior side of upper rectum is mobilized to facilitate later application of circular stapler for anastomosis.

Following complete mobilization of the left colon, the mesentery and mesorectum are then divided using an energy-based device robotically or if preferred, by the patient-side assistant. The assistant then divides the distal resection margin using an articulating endostapler. One of the robotic instruments is usually disengaged, and the robotic arm uncoupled to make space for comfortable movement by the assistant. The robot is then undocked and the colon is exteriorized through the Alexis wound retractor. The IMV is ligated and the proximal margin is transected between a purse-string clamp and a bowel clamp. The anvil of the circular stapler is inserted into the proximal colonic segment and secured with a purse-string. Finally, the port is reconstructed and the anastomosis is completed laparoscopically using a circular stapler.

---

## Outcomes

Since single port is still in its early stage, there are no long-term results for this procedure published so far. We have been performing robotic single port colectomies since 2009 and have thus



**Fig. 7.4** Port setup after all robotic arms docked

far completed 73 cases. These have include the following procedures: right hemicolectomy (33 cases), anterior resection for sigmoid colon cancer (37 cases), and low anterior resection (2 cases). In our experience, we have been able to complete 96 % using the single port technique. Conversions included one right hemicolectomy, one anterior resection, and one low anterior resection and all these were conversions-to-multiport robotic colectomies. Two conversions of right hemicolectomy and anterior resection were occurred during our initial experience and were due to arms-collision and reach-limitation. The recent conversion of single port low anterior resection was due to not being able to apply endostapler properly from umbilical port and we had completed all the dissection using single port technique except distal rectal division. Because currently available endostaplers have limited flexion angle, we could not divide distal rectum properly from umbilical port and had to make an additional port in suprapubic area from which we were able to apply endostapler. We have found that splenic flexure taking down in tall obese

patients and pelvic dissection (total mesorectal excision) were the most challenging part of our technique and our patient selection for the technique is based on these technical limitations. However we look forward to technological advance in near future including new staplers that allow more flexion angle, which enable us to overcome current limitations (Table 7.4).

### Learning Curve

Because the procedure is not well standardized and relatively, no single study has been published about the learning curve. Currently available reports are all from robotic/laparoscopic experts who already have passes their learning curves in either robotic or laparoscopic multiport surgery. Possible issues regarding the learning curve of robotic single port surgery are: whether training in multiport robotic surgery is mandatory, whether training in single or multiport laparoscopic surgery is mandatory and how we do we shorten the learning curve and so on.

**Table 7.4** Summary of our experience of robotic single port colectomy

Parameter	Value	
Gender	Male	36
	Female	37
Types of surgery	Right hemicolectomy	33
	Anterior resection	37
	Low anterior resection	2
Age (mean, years)		54.3
Body mass index (mean, kg/m <sup>2</sup> )		23.2
AJCC stage	I	34
	II	21
	III	17
Lymph node harvest (mean)		19.8
Resection margin involvement		0
Conversion (to multiport)		3 (4.1 %)
Operation time (mean, min)		167.2
Estimated blood loss (mean, mL)		40.2
Mortality (within postoperative 30 days)		0
Overall morbidity (within postoperative 30 days)		13 (17.8 %)
Length of stay (mean, days)		6.2

## Future Innovation for Single Port Robotic Surgery

The ideal robotic platform for single port surgery should have a low external profile, the possibility of being deployed through a single access site, and the possibility of restoring intra-abdominal triangulation while maintaining the maximum degree of freedom for precise maneuvers and strength for reliable traction.

Several robotic prototypes for single port surgery are being tested.

The Single Port Laparoscopy Bimanual Robot (SPRINT) is part of a major Array of Robots Augmenting the Kinematics of Endoluminal Surgery (ARAKNES) program coordinated by Dario and Cuschieri and funded by the EU Framework 7 program [19]. This robot has a 3-D high-definition television imaging system and is operated through a console in the sterile field so that the surgeon is not remote from the patient. This robot comprises of two arms with six degrees of freedom that can be individually inserted and removed in a 30–35 mm-diameter

umbilical access port. The system is designed to leave a central lumen free during operations, thus allowing the insertion of other laparoscopic tools [20]. Preliminary in vitro testing by Sanchez et al. [21] from Italy suggested that in the near future, the robot could become a reliable system in the field of robotic single port surgery.

The group of Oleynikov from USA is also developing a multi-dexterous miniature in vivo robotic platform that is completely inserted into the peritoneal cavity through a single incision [22]. The platform consists of a multifunctional robot and a remote surgeon interface. The robot has two arms and specialized end effectors that can be interchanged to provide monopolar cautery, tissue manipulation, and intracorporeal suturing capabilities. Its use has been demonstrated in multiple non-survival porcine studies.

Moreover, another new surgical robot is being developed and tested by investigators from Japan [23]. The robot consists of a manipulator for vision control, and dual tool tissue manipulators can be attached at the tip of a sheath manipulator. The group of Simaan described a novel insertable robotic effectors platform with integrated stereovision and surgical intervention tools for SPRS. This design provides can be inserted through a single 15-mm access port. Dexterous surgical intervention and stereovision are achieved by the use of two snakelike continuum robots and two controllable charge-coupled device cameras [24].

## Conclusion

Single port robotic colorectal surgery is still in infancy. While single port Robotic Colorectal surgery is feasible in selected cases, further evolution of technique and technology may be required for complex procedures (Rectal cancer) for universal adoption. Research and development is ongoing to develop appropriate platform for single port robotic surgery.

It is possible that the platforms for robotic single port surgery may evolve to be organ specific i.e. the robotic platform for gall bladder may be different from the one for colorectal surgery.

## References

1. Thompson B, Wheelless RC. Outpatient sterilization by laparoscopy. A report of 666 patients. *Obstet Gynecol.* 1971;38(6):912–5.
2. Pelosi MA, Pelosi 3rd MA. Laparoscopic supracervical hysterectomy using a single-umbilical puncture (mini-laparoscopy). *J Reprod Med.* 1992;37(9):777–84. PubMed PMID: 1453397.
3. Rattner D, Kalloo A, Group ASW. ASGE/SAGES Working Group on Natural Orifice Transluminal Endoscopic Surgery. October 2005. *Surg Endosc.* 2006;20(2):329–33.
4. Abe N, Takeuchi H, Ueki H, Yanagida O, Masaki T, Mori T, et al. Single-port endoscopic cholecystectomy: a bridge between laparoscopic and transluminal endoscopic surgery. *J Hepatobiliary Pancreat Surg.* 2009;16(5):633–8. PubMed PMID: 19373428.
5. Jung YW, Kim YT, Lee DW, Hwang YI, Nam EJ, Kim JH, et al. The feasibility of scarless single-port transumbilical total laparoscopic hysterectomy: initial clinical experience. *Surg Endosc.* 2010;24(7):1686–92. PubMed PMID: 20035346.
6. Ponsky LE, Cherullo EE, Sawyer M, Hartke D. Single access site laparoscopic radical nephrectomy: initial clinical experience. *J Endourol.* 2008;22(4):663–6. PubMed PMID: 18324901.
7. Bucher P, Pugin F, Morel P. Single port access laparoscopic right hemicolectomy. *Int J Colorectal Dis.* 2008;23(10):1013–6. PubMed PMID: 18607608.
8. Kaouk JH, Goel RK, Haber GP, Crouzet S, Desai MM, Gill IS. Single-port laparoscopic radical prostatectomy. *Urology.* 2008;72(6):1190–3. PubMed PMID: 19041022.
9. Ostrowitz MB, Eschete D, Zemon H, DeNoto G. Robotic-assisted single-incision right colectomy: early experience. *Int J Med Robot.* 2009;5(4):465–70. PubMed PMID: 19806602.
10. Kroh M, El-Hayek K, Rosenblatt S, Chand B, Escobar P, Kaouk J, et al. First human surgery with a novel single-port robotic system: cholecystectomy using the da Vinci Single-Site platform. *Surg Endosc.* 2011;25(11):3566–73. PubMed PMID: 21638179.
11. Tran H. Robotic single-port hernia surgery. *JSLs.* 2011;15(3):309–14. PubMed PMID: 21985715; PubMed Central PMCID: 3183567.
12. Lim MS, Melich G, Min BS. Robotic single-incision anterior resection for sigmoid colon cancer: access port creation and operative technique. *Surg Endosc.* 2012;27(3):1021. PubMed PMID: 23052525.
13. Singh J, Podolsky ER, Castellanos AE, Stein DE. Optimizing single port surgery: a case report and review of technique in colon resection. *Int J Med Robot.* 2011;7(2):127–30. PubMed PMID: 21394870.
14. Trastulli S, Cirocchi R, Desiderio J, Guarino S, Santoro A, Parisi A, et al. Systematic review and meta-analysis of randomized clinical trials comparing single-incision versus conventional laparoscopic cholecystectomy. *Br J Surg.* 2013;100(2):191–208. PubMed PMID: 23161281.
15. Makino T, Milsom JW, Lee SW. Feasibility and safety of single-incision laparoscopic colectomy: a systematic review. *Ann Surg.* 2012;255(4):667–76. PubMed PMID: 22258065.
16. Weber PA, Merola S, Wasielewski A, Ballantyne GH. Telerobotic-assisted laparoscopic right and sigmoid colectomies for benign disease. *Dis Colon Rectum.* 2002;45(12):1689–94; discussion 95–6. PubMed PMID: 12473897.
17. V O, editor. Robotic versus laparoscopic single port right hemicolectomy. Chesapeake Colorectal Society meeting Apr 2011.
18. Joseph RA, Salas NA, Johnson C, Goh A, Cuevas SP, Donovan MA, et al. Video. Chopstick surgery: a novel technique enables use of the Da Vinci Robot to perform single-incision laparoscopic surgery. *Surg Endosc.* 2010;24(12):3224.
19. Tang B, Hou S, Cuschieri SA. Ergonomics of and technologies for single-port laparoscopic surgery. *Minim Invasive Ther Allied Technol.* 2012;21(1):46–54. PubMed PMID: 22066862.
20. Piccigallo M, Scarfogliero U, Quaglia C, Petroni G, Valdastris P, Menciasci A, et al. Design of a novel bimanual robotic system for single-port laparoscopy. *IEEE-Asme T Mech.* 2010;15(6):871–8. PubMed PMID: WOS:000285361700006; English.
21. Sanchez LA, Petroni G, Piccigallo M, Scarfogliero U, Niccolini M, Liu C, et al. Real-time control and evaluation of a teleoperated miniature arm for Single Port Laparoscopy. *Conf Proc IEEE Eng Med Biol Soc.* 2011;2011:7049–53. PubMed PMID: 22255962.
22. Dolghi O, Strabala KW, Wortman TD, Goede MR, Farritor SM, Oleynikov D. Miniature in vivo robot for laparoendoscopic single-site surgery. *Surg Endosc.* 2011;25(10):3453–8. PubMed PMID: 21487861.
23. Kobayashi Y, Tomono Y, Sekiguchi Y, Watanabe H, Toyoda K, Konishi K, et al. A surgical robot with vision field control for single port endoscopic surgery. *Int J Med Robot.* 2010;6(4):454–64. PubMed PMID: 20949430.
24. Ding J XK, Goldman R, et al. Design, simulation and evaluation of kinematic alternatives for insertable robotic effectors platforms in single port access surgery. *EEE International Conference on Robotics and Automation; Anchorage, AK, May 3–8, 2010.*

---

# Current Evidence for Single-Incision Laparoscopic Colectomy

8

Jensen T.C. Poon and Wai Lun Law

---

## Introduction

The standard of care for patient in colorectal surgery had undergone rapid and revolutionary change in the last few decades. The successful application of laparoscopic surgery in colorectal resection results in remarkable improvement of short-term postoperative outcomes. After laparoscopic colorectal resection, patients have less wound pain and infection, prompt return of gastrointestinal function and hence, can be discharged early after operation, compared to open colorectal resection [1–3]. In recent years, effort to further minimize the abdominal incision has been a focus in research and development of laparoscopic surgery worldwide. The natural orifice trans-luminal endoscopic surgery (NOTES) is being actively explored and is considered as the ultimate pursuit of endeavor in minimally invasive surgery. The applicability of NOTES is, however, limited because of lack of suitable instruments at present. However, advancement of technology enables laparoscopic surgery to be done through a single incision made on abdominal wall via a special single port device. All laparoscopic instruments can be inserted through different channels in the single port device to perform operation

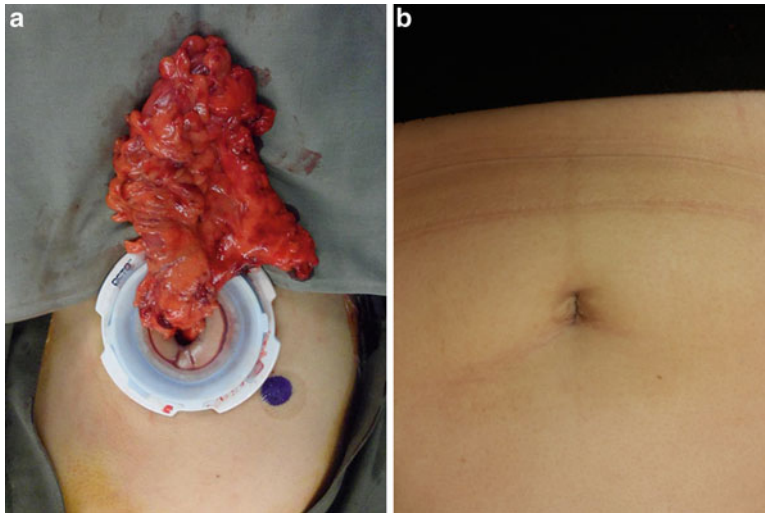
within abdomen or thorax. The desire to perform SILS actually began before conventional laparoscopic surgery was popularized in general surgery. In 1974 and 1991, Junker and Pelosi had reported their successful attempt of doing laparoscopic tubal ligation and hysterectomy with single umbilical puncture respectively [4, 5].

When compared to conventional laparoscopic surgery, the potential benefit of SILS includes mainly better [1] cosmetic outcomes and [2] reduction of abdominal trauma and as results, earlier recovery. By operating through a vertical trans-umbilical incision, SILS can have the wound hidden very well within the umbilicus. The cosmetic result of SILS can be very good and patient can be virtually scarless after operation (Fig. 8.1a, b). The number of abdominal incision is reduced in SILS and it will be logical to expect less operative trauma, post-operation pain and hence, earlier recovery. On the other hand, SILS increases the difficult of laparoscopic operation remarkably. It requires high surgical skills to overcome the problems incurred due to crowding of instruments, coaxial view from the laparoscope and lack of retraction from assistant during SILS. Hence, many surgeons criticize SILS for concern of increase in operating time and cost and complication rate. However, SILS has been applied successfully in many types of surgery including gynecology and pediatric surgery, cholecystectomy, colorectal resection, gastric and hernia surgery. Among them, single-incision laparoscopic colectomy (SILC) is one of the fastest growing SILS in terms of popularity and evidence

---

J.T.C. Poon, M.S., F.R.C.S.Ed (Gen) (✉)  
W.L. Law, M.S., F.R.C.S.Ed  
Department of Surgery, Queen Mary Hospital,  
The University of Hong Kong, 102 Pokfulam Road,  
Hong Kong  
e-mail: jp@hkma.org; lawwl@hku.hk





**Fig. 8.1** (a) Single-incision laparoscopic anterior resection. (b) Wound after single-incision laparoscopic anterior resection

in the literature. In this chapter, we reviewed the current evidence for SILC.

### Case Reports and Series for Feasibility of SILC

In 2008, both the groups of Remzi et al. [6] and Bucher et al. [7] published successful single-incision laparoscopic right hemicolectomy for polyps according to oncologic principles. In 2009 and 2010, Leory et al. [8] and Law et al. [9] reported on their successful experience of sigmoidectomy and left hemicolectomy respectively via SILC approach. The initial success on segmental colorectal resection by SILC approach definitely had provoked a strong enthusiasm among other surgeons to contemplate on this surgery. Complicated laparoscopic colorectal resections including total colectomy or restorative proctocolectomy were also reported [10]. In very short time, there were a lot of case series reporting experiences in SILC. Among them, seven reports [11–17] included more than 20 patients in their series. These seven reports included 265 patients who were highly selected; they were young and non-obese with mean age of 47–69 and mean body mass index (BMI) of 22.5–27. The pathology included both benign and malignant diseases. Most of the patients had segmental colectomy and three case series were solely for right hemicolectomy [11, 12, 15]. The need of con-

version to conventional laparoscopic colectomy (CLC) as defined by need of additional port is reported to be zero in three series and ranged from 3.33 to 18 % in the other four series. Geisler and Garrett [13] reported SILC for 102 consecutive patients including both segmental and total colectomy. This is the largest case series in the literature which included complex colorectal resection (23 total colectomies and 20 restorative proctocolectomies). Because 11 patients who had IPAA required one additional port for deep pelvic retraction and placement pelvic drain, high conversion rate of 18 % was reported by the series of Geisler and Garrett [13]. Overall, the incidence of series adverse event was not high from SILC and altogether, these seven cases series reported three anastomotic bleeding and one mortality because of sudden cardiopulmonary collapse. In light of experience from these reports, SILC appeared to be a feasible and safe approach of colectomy for selected patients in the hands of skilled surgeons.

### SILC Versus Conventional Laparoscopic Colectomy

#### Comparative Studies

New surgical procedure which revolutionizes the previously well accepted practice usually draws



strong skepticism and criticism. Since the difficulty of operation increases remarkably in SILC when compared to CLC, it is reasonable to worry that SILC increase the time, cost, and even complication rate of operation. The potential benefits, e.g., less wound pain, faster recovery that SILC claims to offer are also strongly questioned. For surgeons who find the learning curve of SILC steep, they will consider the effort required to overcome the technical hurdle is not justified by the doubtful benefit. Although preliminary evidence supports the feasibility and safety of SILC, the controversy about SILC can only be resolved by good quality studies which compare SILC to the current standard, which is conventional multiport laparoscopic colectomy (CLC).

Currently, most of the evidence on assessment of SILC against CLC is provided by comparative studies. Outcomes of SILC are compared with patients who have CLC either in the past or in the similar time without randomization. Literature search found more than 20 reports from comparative studies on the two procedures. Most of earlier reports consisted of small number of patient with between 10 and 30 patients in each group, hence, carried little weigh in providing evidence for comparing the two procedures. The results of all these small scale studies were evaluated by a meta-analysis [18] which concluded that the results SILC are comparable to CLC.

Four reports [19–22] which were published during 2011–2013 had more than 50 patients in each group and only one [20] of them was included in the previous meta-analysis. The important results from these four studies were summarized in Table 8.1 and discussed here together. All the four study included mainly young patients with good operative risk. The mean age of patients ranged from 57.7 to 71 and more than 80 % of patients belonged to American Society of Anesthesiologist classification (ASA) 1 and 2. The comparative studied reported by Kim et al. and Champagne et al. had the largest number of patients (total of 179 and 330, respectively) with both colon and rectal resection. On the other hand, Velthuis et al. [21] and Yun et al. [22] reported on right hemicolectomy only. All four studies reported similar age

and BMI, operative risk and complication rate between SILC and CLC. Single-incision laparoscopic colectomy is commonly thought to be a longer procedure because of the expected difficulty. However, only Kim et al. reported a significantly longer operation time by SILC. The two comparative studies on right hemicolectomy by Velthuis et al. [21] and Yun et al. [22] actually found that SILC had shorter operating time than CLC. On the other hand, the other two studies by Kim et al. [20] and Champagne et al. [19] found SILC to have less blood loss, reduced post-operation pain or narcotic usage. While the reduction of wound pain in SILC can be logically associated with the reduction in number of wound, the authors did not discuss about the observation of reduced blood loss or operating time in the SILC group. Kim et al. [20] also reported that SILC had significantly shorter hospital stay than CLC (9.8 vs. 15.5 days;  $p < 0.001$ ). Unfortunately, the hospital stay of SILC and CLC in this report is exceptionally long. Therefore, it is difficult to interpret the meaning of this finding. Bias on case selection between the two groups is the biggest shortcoming of comparative study without randomization of subjects. It is certain that for any benefit observed in SILC procedure to be recognized widely, it have to withstand the test of well conducted randomized controlled trial (RCT).

## Randomized Controlled Trials

At present, there are only two reports from RCT comparing SILC and CLC [23, 24]. They are both published in 2012 and included small sample size. Huscher et al. [23] reported randomization of 16 patients into each arm, however, the primary end point of outcome measurement and method for sample size calculation were not provided. In this RCT, all procedures were for colon cancer and were performed by a single surgeon; division of vessel was done with bipolar energy device. In SILC cases, transabdominal sutures were used to aid retraction, specimen was retrieved transvaginally via posterior colpotomy in some female patients and there was one conversion to CLC. When compared to CLC, SILC

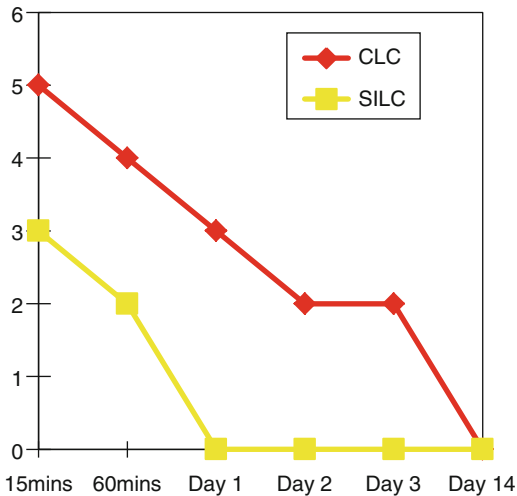
**Table 8.1** Summary of findings from large comparative series on SILC vs. CLC

Authors	Kim et al. (2011)	Champagne et al. (2011)	Velthuis et al. (2012)	Yun et al. (2013)
Study setting	Single surgeon	Multicenter	Two centers Five surgeons	Single center Five surgeons
Patient number (SILC/CLC)	73/106	165/165	50/50	66/93
Body mass index (SILC/CLC)	22.7/25.6 ( $p=0.37$ )	27/27.4	25/25	23.8/24.2 ( $p=0.346$ )
Procedure	Colon and rectal resection	Colon and rectal resection	Right hemicolectomy	Right hemicolectomy
Operating time (minutes) (SILC/CLC)	274/254 ( $p=0.008$ )	119/115 ( $p=0.85$ )	97/112 ( $p<0.001$ )	131/143 ( $p=0.078$ )
Blood loss (ml) (SILC/CLC)	282/418 ( $p=0.008$ )	30/50 ( $p=0.023$ )	Not available	Not available
Conversion from SILC to CLC	Not available	11 %	4 %	Not available
Bowel function (days) (SILC/CLC)	Flatus passage 2/3 ( $p=0.004$ )	Not available	Not available	Bowel motion 3/3
Pain (SILC/CLC)	Frequency of narcotic use 2.2/3.5 ( $p=0.029$ )	Day 1 VAS score 4.9/5.6 ( $p=0.005$ )	Not available	Not available
Overall complication (SILC/CLC)	31.5 %/36.8 % ( $p=0.524$ )	43 %/48 % ( $p=0.622$ )	34 %/34 %	9.1 %/15.1 % ( $p=0.335$ )
Anastomotic leakage (SILC/CLC)	6.8 %/6.6 %	Nil/1.2 % ( $p=0.499$ )	2 %/6 % ( $p=0.617$ )	Not available
Tumor size (cm) (SILC/CLC)	5.5/4.6 ( $p=0.645$ )	Not available	4.8/4.6 ( $p=0.647$ )	4.0/4.1 ( $p=0.805$ )
TMN stage $\geq$ III (SILC/CLC)	50 %/39.8 % ( $p=0.184$ )	Not available	Not available	30.3 %/32.3 %
Lymph node harvested for cancer (SILC/CLC)	29.3/23.2 ( $p=0.488$ )	Not available	14/12.5 ( $p=0.158$ )	24/27 ( $p=0.068$ )

was reported to have no significant difference in operating time (124 min vs. 147 min, respectively), number of lymph node harvested (16 vs. 18, respectively), complication rate (31 % vs. 18 %, respectively), and time to resumption of solid diet (3 days vs. 3 days, respectively). The hospital stay was 7 days vs. 6 days, respectively. The post-operation pain was not presented.

Since the number of abdominal incision is reduced, reduction of wound pain is expected to be the immediate benefit of SILC. However, post-operation pain was only reported by a few studies. The authors of this chapter completed an RCT to compare SILC and CLC with post-operation pain as the primary end point of outcome

measurement and included 25 patients in each arm in order to have an 80 % power of test at the type 1 error of 5 % [24]. All procedures were done by two experienced laparoscopic surgeons. Vascular control was done by clips and specimen was extracted through abdominal incision. All SILC procedures were done by conventional straight laparoscopic instrument with no adjunct used to aid retraction and no conversion to CLC. This RCT included only patient with good operative risk (ASA 1–3), small benign or malignant colonic tumor ( $\leq 4$  cm), and BMI  $<30$ . In this RCT, both patients and research staff who record the pain score after operation were blinded to the type of procedure. All patients received a standard



**Fig. 8.2** Comparison of postoperative pain score between SILC and CLC

anesthetic and pain management protocol during the perioperative period. The two groups of patients had similar demographics, pathology, and type of procedures. Compared to the CLC group, the SILC group had slightly longer operating time (124 min vs. 155 min, respectively), less blood loss (80 mL vs. 50 mL, respectively), less lymph node harvested (20 vs. 16, respectively) and less analgesic use (16 mg vs. 12 mg morphine, respectively) but the difference was all statistically insignificant. However, patients in the SILC group had less wound pain from 15 min to day 3 after operation and the difference was statistically significant during 60 min to day 2 post-operation (Fig. 8.2). Patient with SILC also had shorter median hospital stay (4 days vs. 5 days;  $p < 0.001$ ). The finding of this RCT provided strong evidence that SILC is associated with reduction in postoperative wound pain when compared to CLC and it might contribute to earlier discharge of patient after surgery. However, SILC was found to harvest less lymph node than CLC. Although the difference was statistically insignificant and the median number of lymph node harvested [16] from SILC was still better than acceptable standard of 12. This trend towards less lymph node harvested should alarm the attention of surgeons to adhere with good oncologic principle when performing SILC for cancer patient.

## Learning Curve of SILC

Single-incision laparoscopic colectomy is more difficult than conventional laparoscopic surgery. However, many studies reported similar operating time between SILC and CLC. The reason for faster procedure time in SILC is seldom discussed but it may reflect that the technique SILC is not that difficult in hands of experienced laparoscopic surgeons. Little is known about how many conventional laparoscopic colectomies one has to do before he/she should attempt SILC. The steepness of the learning curve for SILC is another big concern if this procedure will be practiced widely and subsequently by trainees. There is no formal study regarding learning curve of SILC but Kim et al. [20] reported in his single surgeon series that the operating time for SILC reduced significantly after 48 cases and became comparable to that required for CLC. While the experience of SILC is accumulating fast in many centers, formal analysis on learning curve of SILC shall be available in short time.

## Summary

The feasibility and safety for SILC is demonstrated by many case series, comparative studies, and only two randomized trials. Two large series comparative studies [19, 20] and one RCT [24] which measured postoperative pain as primary outcome proved that SILC is associated with less pain and earlier discharge after operation. In contrary to the common belief, most reports showed that the procedure time of SILC is not significantly longer than CLC. Other short-term operative outcomes of the two procedures are similar. However, some important information about SILC is still not available from the literature at present. There is no analysis on cost and learning curve of SILC. The patient satisfaction after SILC has also not been evaluated. If better cosmetic result remains to an important drive for doing SILC, its impact to patient satisfaction should be studied.

It is important to stress that most of SILC in these reports with good results were done by highly skilled laparoscopic surgeon and in good

risk patient with low BMI. Even when SILC is performed safely in the competent hands, its benefit are likely to be modest and will only be widely recognized if they can be reproduced by more prospective randomized trials. Single-incision laparoscopic colectomy may augment the benefit the laparoscopic surgery to selected patients but is definitely not for every surgeon, every patient.

## References

- Clinical Outcomes of Surgical Therapy Study Group. A comparison of laparoscopically assisted and open colectomy for colon cancer. *N Engl J Med*. 2004;350(20):2050–9.
- Lacy AM, Garcia-Valdecasas JC, Delgado S, Castells A, Taura P, Pique JM, et al. Laparoscopy-assisted colectomy versus open colectomy for treatment of non-metastatic colon cancer: a randomised trial. *Lancet*. 2002;359(9325):2224–9.
- Poon JT, Law WL, Wong IW, Ching PT, Wong LM, Fan JK, et al. Impact of laparoscopic colorectal resection on surgical site infection. *Ann Surg*. 2009;249(1):77–81.
- Junker H. [Laparoscopic tubal ligation by the single puncture technique (author's transl)]. *Geburtshilfe Frauenheilkd*. 1974;34(11):952–5.
- Pelosi MA, Pelosi 3rd MA. Laparoscopic hysterectomy with bilateral salpingo-oophorectomy using a single umbilical puncture. *N J Med*. 1991;88(10):721–6.
- Remzi FH, Kirat HT, Kaouk JH, Geisler DP. Single-port laparoscopy in colorectal surgery. *Colorectal Dis*. 2008;10(8):823–6.
- Bucher P, Pugin F, Morel P. Single port access laparoscopic right hemicolectomy. *Int J Colorectal Dis*. 2008;23(10):1013–6.
- Leroy J, Cahill RA, Asakuma M, Dallemagne B, Marescaux J. Single-access laparoscopic sigmoidectomy as definitive surgical management of prior diverticulitis in a human patient. *Arch Surg*. 2009;144(2):173–9; discussion 9.
- Law WL, Fan JK, Poon JT. Single incision laparoscopic left colectomy for carcinoma of distal transverse colon. *Colorectal Dis*. 2010;12(7):698–701.
- Leblanc F, Makhija R, Champagne BJ, Delaney CP. Single incision laparoscopic total colectomy and proctocolectomy for benign disease: initial experience. *Colorectal Dis*. 2011;13(11):1290–3.
- Boni L, Dionigi G, Cassinotti E, Di Giuseppe M, Diurni M, Rauseri S, et al. Single incision laparoscopic right colectomy. *Surg Endosc*. 2010;24(12):3233–6.
- Boone BA, Wagner P, Ganchuk E, Evans L, Zeh HJ, Bartlett DL, et al. Single-incision laparoscopic right colectomy in an unselected patient population. *Surg Endosc*. 2012;26(6):1595–601.
- Geisler D, Garrett T. Single incision laparoscopic colorectal surgery: a single surgeon experience of 102 consecutive cases. *Tech Coloproctol*. 2011;15(4):397–401.
- Katsuno G, Fukunaga M, Nagakari K, Yoshikawa S, Ouchi M, Hirasaki Y. Single-incision laparoscopic colectomy for colon cancer: early experience with 31 cases. *Dis Colon Rectum*. 2011;54(6):705–10.
- Keshava A, Young CJ, Mackenzie S. Single-incision laparoscopic right hemicolectomy. *Br J Surg*. 2010;97(12):1881–3.
- Ramos-Valadez DI, Patel CB, Ragupathi M, Bokhari MB, Pickron TB, Haas EM. Single-incision laparoscopic colectomy: outcomes of an emerging minimally invasive technique. *Int J Colorectal Dis*. 2011;26(6):761–7.
- Ross H, Steele S, Whiteford M, Lee S, Albert M, Mutch M, et al. Early multi-institution experience with single-incision laparoscopic colectomy. *Dis Colon Rectum*. 2011;54(2):187–92.
- Yang TX, Chua TC. Single-incision laparoscopic colectomy versus conventional multiport laparoscopic colectomy: a meta-analysis of comparative studies. *Int J Colorectal Dis*. 2013;28(1):89–101.
- Champagne BJ, Papaconstantinou HT, Parmar SS, Nagle DA, Young-Fadok TM, Lee EC, et al. Single-incision versus standard multiport laparoscopic colectomy: a multicenter, case-controlled comparison. *Ann Surg*. 2012;255(1):66–9.
- Kim SJ, Ryu GO, Choi BJ, Kim JG, Lee KJ, Lee SC, et al. The short-term outcomes of conventional and single-port laparoscopic surgery for colorectal cancer. *Ann Surg*. 2011;254(6):933–40.
- Velthuis S, van den Boezem PB, Lips DJ, Prins HA, Cuesta MA, Sietes C. Comparison of short-term surgical outcomes after single-incision laparoscopic versus multiport laparoscopic right colectomy: a two-center, prospective case-controlled study of 100 patients. *Dig Surg*. 2012;29(6):477–83.
- Yun JA, Yun SH, Park YA, Cho YB, Kim HC, Lee WY, et al. Single-incision laparoscopic right colectomy compared with conventional laparoscopy for malignancy: assessment of perioperative and short-term oncologic outcomes. *Surg Endosc*. 2013;27(6):2122–30.
- Huscher CG, Mingoli A, Sgarzini G, Mereu A, Binda B, Brachini G, et al. Standard laparoscopic versus single-incision laparoscopic colectomy for cancer: early results of a randomized prospective study. *Am J Surg*. 2012;204(1):115–20.
- Poon JT, Cheung CW, Fan JK, Lo OS, Law WL. Single-incision versus conventional laparoscopic colectomy for colonic neoplasm: a randomized, controlled trial. *Surg Endosc*. 2012;26(10):2729–34.

## Local Excision (LE) for Low Rectal Cancer (RC): From Mucosectomy to Endolumen Loco-Regional Resection (ELRR)—Tips and Tricks

Giovanni Lezoche and Emanuele Lezoche

Local treatment of low non-advanced (lna) rectal cancer (RC) is a matter of debate. In the literature, operations with different wideness and depth are included under the term: *local excision* (LE).

This variability in wideness and depth, together with the different ability in the staging of the disease and the non-homogeneous criteria in selection of patients can explain the different percentage of local recurrences (LR) reported in the literature following LE.

Transanal endoscopic microsurgery (TEM) was introduced by Buess in 1983 into the clinical practice for the treatment of large benign polyps of the rectum, and later employed to remove early rectal cancer. Despite the relevant technical advantages related to image magnification, lighting, depth perception, etc., the clinical results of LE by TEM are not encouraging (Table 9.1).

Since 1992 we have introduced this technique in our institution, and more than 950 operations have been performed by TEM for benign and malignant lesions of the rectum. The lesson we learned from this experience is that in order to obtain good clinical results two conditions must be met:

1. A correct patient selection
2. An adequate local exeresis

---

G. Lezoche, M.D., Ph.D.

Department of General Surgery, University 'Politecnica delle Marche', Via Conca 71, 60126 Ancona, Italy

E. Lezoche, M.D., F.A.C.S. (✉)

Department of General Surgery, Surgical Specialities and Organ Transplantation, 'Paride Stefanini' at University of Rome, Rome, Italy  
e-mail: emanuele.lezoche@uniroma1.it

---

### Patient Selection at the Admission

- In case of malignancy, the lesion must be localized in the extraperitoneal portion of the rectum. Usually neoplasia can be easily palpated at *finger exploration* and if the lesion is adherent to the narrow structures or fixed, the patient is not eligible for the LE.
- The diameter must not exceed 4 cm, preferably 3.
- The use of the vital dye technique during *flexible endoscopy* is advisable to define the tumor limits especially in flat neoplastic lesions and in case of multifocal adenomas with degenerated areas. The routinary use in the clinical practice of NBE, and of image analysis systems seems promising in accurately identifying the neoplasia margins.
- According to our protocol, during vital dye endoscopy, 5/6 *biopsies* are performed all around the lesion at a minimum distance of 1 cm from the identified tumor margins on apparently normal mucosa. Each biopsy site is identified with a number and then sent to the morphologist. *Tattooing* is performed at each biopsy site so that during endoluminal surgery the black spots will guide the excision line (Fig. 9.1).
- *Rigid rectoscopy* must be performed in all patients candidates to TEM for two reasons: (1) to define the *circumferential tumor involvement* and consequently the most appropriate patient's position on the operative table (Fig. 9.2); patient must be placed in prone

**Table 9.1** Local recurrence

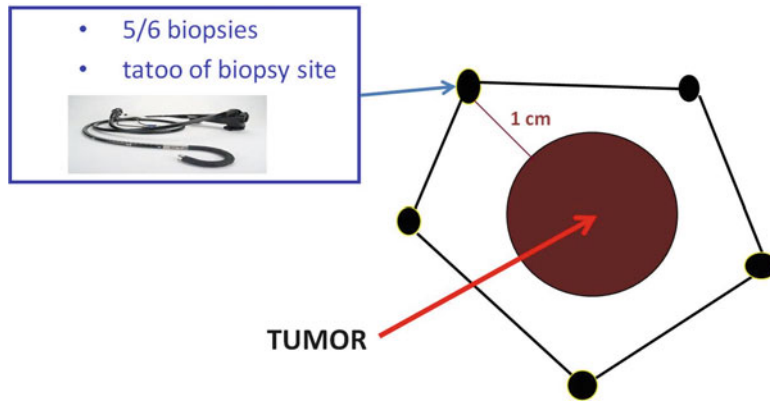
Author and year	Patient with TEM	LR
Winde [7] (1996)	24 T1	4 %
Mentges [8] (1996)	56 T1	7 %
Lee [9] (2003)	52 T1	4 %
Palma [10] (2004)	18 T1	6 %
Duek [11] (2005)	25 T1	0 %
Floyed [12] (2006)	53 T1	7.5 %
Guerrieri [13] (2006)	58 T1	0 %
Lezoche [14] (2012)	50 T2 with nRCT	8 % (distant Rec. 4 %)
Ganai [15] (2006)	21 T1, 1 pt RCT	9.5 %
Stipa [16] (2006)	23 T1, 4 with RT	8.6 %; only TEM 11 %
	21 T2, unknown number with RT	9.5 %
Maslekar [17] (2007)	27 T1 (all R0)	0 %
	22 T2 (19 R1)	18 %
Bretagnol [18] (2007)	28 T1	10.7 %
Whitehouse [19] (2007)	23 T1	26 %
Zacharakis [20] (2007)	14 pts T1	7.1 %
	11 pts T2	42.8 %
Moore [21] (2007)	39 pts T1-2-3 (TEM+RT in some T2-3)	8 % (overall) (2 pts with LR staged preoperative cT3)
Speake [22] (2008)	31 T1	5.7 % (overall)
	4 T2	
	(all R0)	(only distant Rec. 5.7 %)
Serra-Aracil [23] (2008)	16 pts T1	6.2 %
	9 pts T2	22.2 %
Koebrugge [24] (2008)	20 pts T1	4.1 % (overall)
	1 pt T2	
	1 pt T3	
Bach [25] (2009)	230 T1	18.6 %
	107 T2	29.3 %
Jeong [26] (2009)	16 T1	5 % (overall)
	3 T2	T1 0 %
	1 T3	T2 16 %
	(3 pts nRCT+TEM)	T3 0 %
De Graff Ej [27] (2009)	80 pts T1 (all R0)	24 %
Doornebosch [28] (2010)	88 pts T1 (all R0)	20.5 %
Christoforidis [29] (2009)	25 pts T1	12 %
	12 pts T2	25 %
Tsai [30] (2010)	51 pts T1	9.8 %
	17 pts T2: 5 pts TEM+RT	23.5 %
Allaix [31] (2012)	9 pts T2: nRT+TEM	0 %
	32 pts T2: TEM	26 %

LR local recurrence, RT adjuvant radiotherapy, nRT neoadjuvant radiotherapy, RCT adjuvant radiochemotherapy, nRCT neoadjuvant radiochemotherapy, R0 no microscopic residual tumor

position for anterior and supine for posterior lesions. For lateral tumors in lateral position lying on the side that is ipsilateral to the lesion. In other words, if the lesion is on the right side

of the rectum, the patient is placed in 90° right lateral jack-knife position with legs' support (Fig. 9.3). (2) Furthermore, rigid rectoscopy is routinely employed to perform *macrobiopsies*





**Fig. 9.1** Tattooing at each biopsy site so that the black spots will guide the excision line

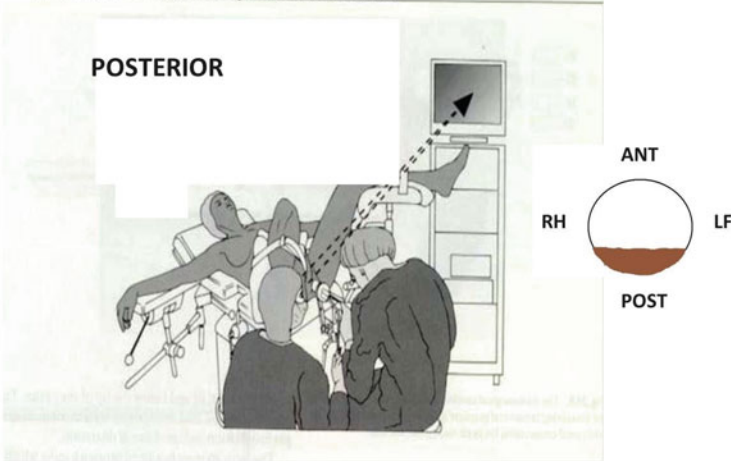
using the old shape forceps (Fig. 9.4) to provide to the morphologist an adequate amount of tissue for grading and histological evaluation.

- *Histology*: Undifferentiated and mucous tumors are not eligible for LE and must be treated with TME; therefore morphologist must work on *macrobiopsies* that involve muscularis propriae in order to give an accurate evaluation of T stage and G grading (lymphatic, neuronal, and vessel infiltration). According to recent observations, after neoadjuvant therapy (NT) tumor grading is not predictive of clinical evolution. In case of T1, it is mandatory that the morphologist check the invasion of tumoral cells into the submucosa (Sm 1–3). In T1 Sm3 the risk of metastasis in loco-regional lymphatic nodes is too high to limit the treatment to an LE (Fig. 9.5). In selected cases with the tumor close to dentate line or in high risk patients, it is reasonable to combine LE with radiotherapy (RT) to avoid more aggressive surgery as TME.
- *Endoscopic mucosectomy*: In the last years mucosectomy by flexible endoscope has been performed more and more frequently. This technique utilizes electrocoagulation to dissect and the high temperature destroys the submucosa layer making; it is impossible for the morphologist to determine the Sm grading. The lack of this crucial parameter makes the full thickness LE unwise. All T1 patients who previously had mucosectomy must undergo

an operation to remove at least the nodes adjacent the tumor such as TME (or ELRR see specific chapter). Consequently before performing a mucosectomy of a potentially malignant lesion the patient should be informed that the technique could cause a loss of an important prognostic parameter. *Therefore the use of flexible endoscopy mucosectomy should be discouraged in low rectal lesions with high risk of malignancy (presence of a diameter >2 cm, ulceration, etc.)*

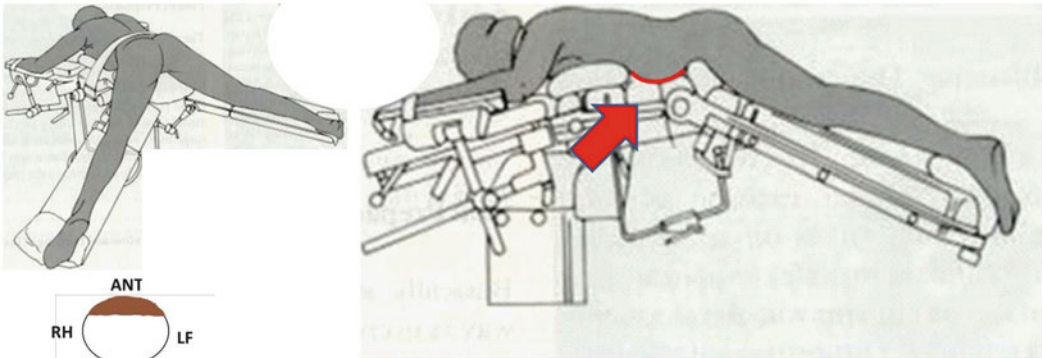
- *Imaging tumor stage (iT)*: Endorectal ultrasound (EUS) is mandatory to differentiate T1 vs. T2 RC; unfortunately as EUS is unable to evaluate the submucosa infiltration despite the technological improvement, macrobiopsies are necessary. It is advisable that before performing any endoluminal operation the surgeon carry out an EUS to give him the spatial location and dimension of the lesion. It follows then that the use of a 3D ultrasound system is recommended. *Pelvic MR* is mandatory in every stage of RC. New MR technology gives a reliable differentiation between T2 and T3 lesions (such as EUS), and it is able to identify adjacent organs infiltration and suspicious nodes (false negative inferior to 10 %). In near future, the introduction in the clinical practice of new MR dyes or new MR techniques such as diffusion-weighted imaging (DWI) will significantly improve the diagnosis of malignant nodes. Low rectal tumors have a significant risk of lung and/or bone metastasis.

- Position on the operative table

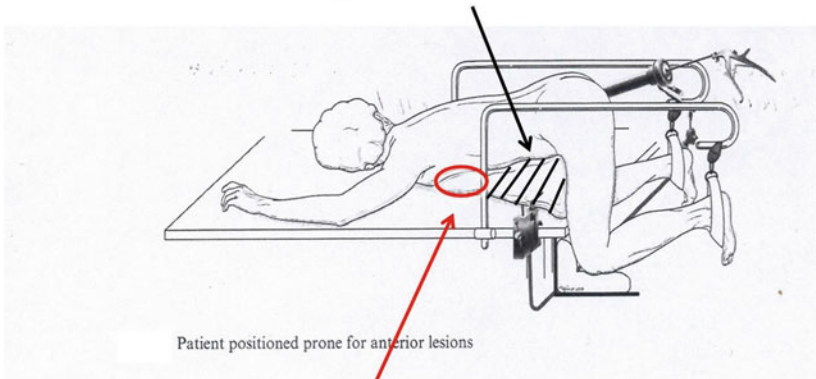


- Position on the operative table

**ANTERIOR**

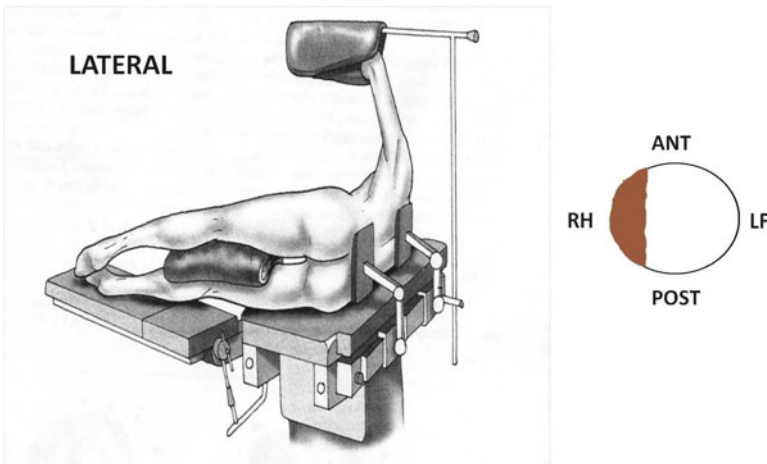


Free space for abdominal distension

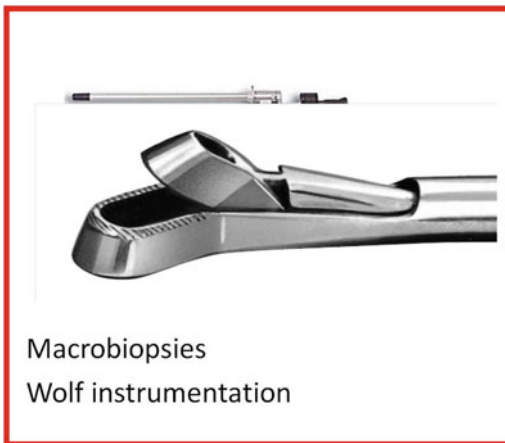

**Fig. 9.2** Position on the operating table

- Position on the operative table



**Fig. 9.3** Lateral position on the operating table



**Fig. 9.4** Macrobiopsy using Wolf instrumentation

Therefore total-body *CT* provides useful information. Although the role of *PET-CT* is still controversial in staging, it seems to be promising for early detection of recurrences. In our protocol, all patients who underwent local treatment perform a *PET* scan at 6 months after surgery.

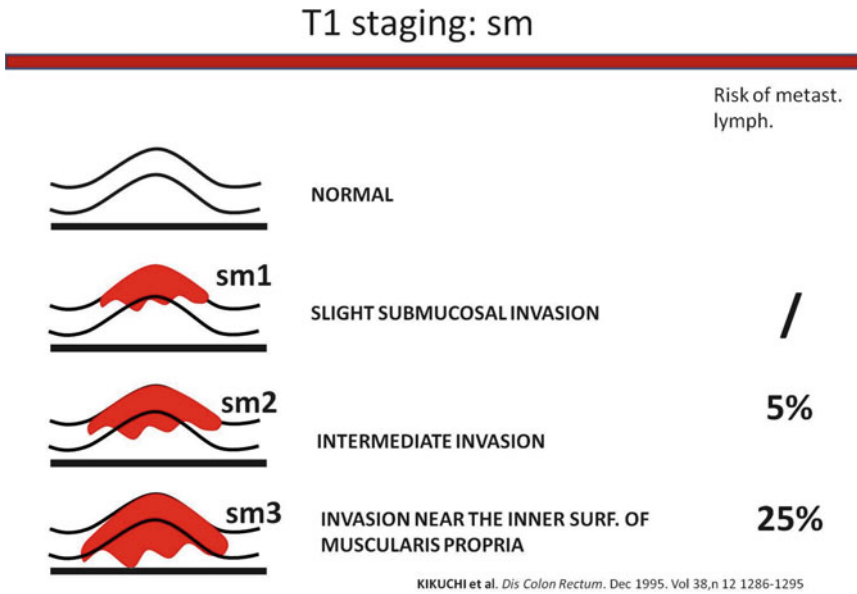
- *Manometry*: Preoperative study of the sphincter function is advisable in patients with low rectal tumors. In all elderly patients it is important to study preoperatively the sphincter to evaluate risk of postoperative incontinence that can onset in the first months after

TEM procedure. Furthermore it is useful for any possible medical-legal implications.

- From 1992 we have employed radiotherapy for local treatment of RC and in absence of literature data regarding the risk of suture dehiscence after TEM we employed the so-called “sandwich” radiotherapy (2.5 G preoperatively and 2.5 G 1 month after TEM procedure). After 1995 NT has been routinely employed in all T2 and more advanced RC. The indications to NT and local treatment for T1 and T2, N0 low rectal cancer are reported in Figs. 9.6 and 9.7 respectively.

## Neoadjuvant Treatment

- From the literature, it is evident that neoadjuvant treatment (NT) reduces the risk of local recurrence and may increase survival. In patients eligible for LT long-course high-dose radiotherapy (lchdRT) is preferable to the short one for several reasons: (a) lchdRT increases down staging and tumor downsizing percentage. In a series of 100 non-advanced RC (iT2-T3 N0) lchdRT determines down staging in over 40 % and in 90 % of patients a tumor downsizing over 30 %. Tumor mass reduction is particularly helpful



**Fig. 9.5** T1 staging: sm

ELRR in early rectal cancer

**INDICATIONS ELRR**

## T1 Sm 1 – 2

T Kikuchi stages:  
sm 1,2. & no histological risk

- US  $\varnothing \leq 3-4$  cm,
- MR & CT **Negative Nodes** ( $\varnothing \leq 5$  mm, isoechogenic, regular shape);
- Located in extra peritoneal rectum
- Non fixed, soft to manual palpation

T1 Sm3 No Responders → TME

**Fig. 9.6** ELRR in early rectal cancer: indications

during endoluminal manipulations required for local excision; (b) lchdRT presumably gives a “sterilization” effect on metastatic deposits of loco-regional lympho nodes. (c) After lchdRT (combined with chemio) at 45 days a complete clinical response is observed in 15 % of cases and these patients can be

recruited for “watch and wait” strategy. The full dose of 50,4 Gy can be administered also in elderly patients. Contraindications are rare; the possible side effects are generally well tolerated and in such cases the length of treatment is prolonged. Ninety-five percent of patients complete the full course.

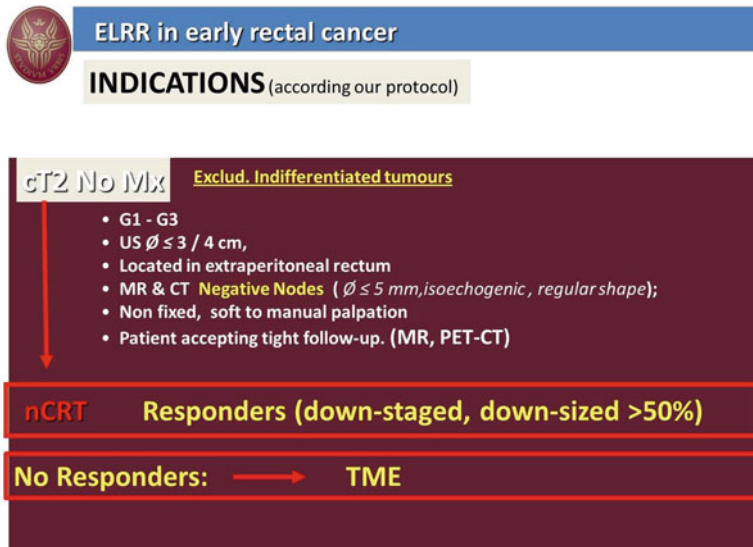


Fig. 9.7 ELRR in early rectal cancer: indications

### Preoperative Staging (After NT Staging)

No data are available in the literature to define when is the best timing to restage the tumor after NT. According to our protocol at the end RT the patient is submitted to a clinical examination to evaluate if the lesion has responded or not to radiotherapy. In case of no significant responses a further image evaluation is performed at 3/4 weeks and then the patient undergoes TME or APR!

In the event of a significant clinical response the staging usually is scheduled at 45 days after the end of NT. In the last years it has been observed that delaying the post-NT staging of further 2/3 weeks the percentage of patients with complete clinical response (CCR) increases.

After radiotherapy the evaluation of tumor response is mainly based on two parameters: tumor downsizing by imaging and Tumor Regression Grading (TRG) by histology.

- *Imaging after NT* is a complex and difficult matter requiring the services of specifically trained radiologist. The actinic-induced edema and scar tissue make the interpretation of

imaging and the correct evaluation of tumor volume difficult. *EUS* and *MR* are routinely employed to evaluate the tumor mass reduction after NT.

- *Tumor response grading*: This score follows the same criteria proposed by Mandard criteria for the esophageal cancer. To have a reliable TRG, the morphologists need of an adequate volume of tissue. Therefore “macro-biopsies” must be performed.
- In our series of patients, recurrences were observed only in patients not responding to NT. Now we consider eligible for local treatment *only responders to NT (downstaged or tumor downsized >50 %)*. Following this criteria, no recurrences were observed at a 3 years follow-up in the last 40 T2 patients treated with endoluminal loco-regional resection (ELRR).
- Several authors suggest to prolong the period of time, between the end of radiotherapy and local resection. Now, in case of significant response to RT, we wait at least 2 months, and this policy seems not to increase the intraoperative difficulties, the risk of suture leaks or other postoperative complications.

---

## Informed Consent

- Written and detailed information regarding *state of the art of local treatment* must be provided to the patient. The informed consent form will include all the therapeutic options (APR, TME, local excision, ELRR, watch and wait in case of complete clinical response), the risk of each approach in terms of intra- and postoperative complications, as well as the oncological long-term results.
- If the patients choose an endoluminal treatment, they must accept to be submitted to a close follow-up.

---

## Adequate Local Excision/Resection by TEM

### Surgeon Skill

TEM is a complex and difficult procedure that requires a specific *skill* that can be achieved only after prolonged training on the simulator. Several different exercises are recommended.

Dissection generally is easily acquired as soon as a good coordination of the instruments is achieved.

To perform a fluent suturing it is necessary to spend at least 2/3 h by day at the simulator during 3 or 4 weeks. Particular attention must be dedicated to another exercise whose aim is to improve the surgeon's ability to reach in a blind fold manner a predetermined point. This exercise is very important! In fact, brisk bleeding may occur from hemorrhoidal arteries during resection of the mesorectum. These vessels have a relevant flux that in a few seconds can fill the operative field and obscure the vision. The amount of blood delivered from the artery can be higher than the volume that the suction cannula can remove. Consequently the surgeon must be able to localize and coagulate the bleeding source under every circumstances. In the meantime, blood can cover the lens thereby completely obscuring the vision. I like to underline that only the TEM optics can be washed under the pedal control.

To develop this ability, its marking with a black spot the operative field of the simulator can be useful; then the operator must touch the spot several times under 3D vision. The exercise is then repeated in blind conditions as to verify the possible errors.

The surgeon who wants to perform TEM should have a simulator and spent several hours practicing on it. Only when he has reached a good skill should he start the clinical activity, and performing only easy and benign cases at the early stage of his learning curve

---

## Anesthesia

Rectal surgery does not necessarily require *general anesthesia* but it must be remembered that the operative time of TEM especially when the surgeon is new at it can be long.

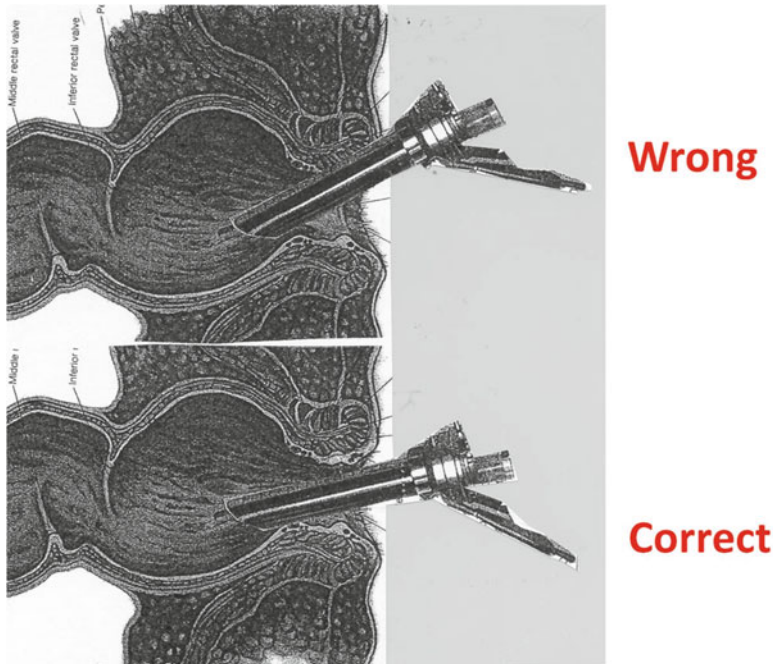
General anesthesia is preferable for both patient and surgeon, but when otherwise indicated, TEM can be performed with spinal anesthesia combined with deep sedation. In this case the surgeon must refrain from using an extreme Trendelenburg position.

---

## Patient Position

- The correct *patient position* on the operative table is crucial to the success of the procedure.
- The *operative field* must be in a position corresponding to the sixth hour of the rectoscope. In case of circumferential lesions, as well as in case of large degenerated villous adenomas, it may be necessary to change the position of the patient during the procedure.
- The *operative table* must be widely mobile on the transversal as well as on the longitudinal plane.
- If the *prone position* is necessary, a crossbar must be placed to raise the pubic bones and so preventing the abdomen from leaning on the operative bed. In this way the abdomen distention by the endoluminal CO<sub>2</sub> insufflation is possible. This trick is very important because during TEM procedure the rectum distention is necessary to obtain an adequate operative field.





**Fig. 9.8** Correct positioning of the rectoscope must to avoid any further sphincter stretch

### Rectoscope Placement

- *Sphincter dilatation* must be performed slowly and gently and to reach a complete anal dilatation requires some minutes. Any improper stretching of the sphincter fibers must be avoided particularly in elderly patients. The *rectoscope introduction* must be gentle.
- During TEM the *position* of the rectoscope must always be placed strictly parallel to the main axis of the anal canal, to avoid any further sphincter stretch (Fig. 9.8).
- Particular attention must be paired in not compressing the sphincter fibers against the adjacent bone structures. This negligence can seriously damage the sphincter functions considering also the prolonged duration of the procedure.

### Instrumentation for Transanal Surgery

- *Instrumentations*: Three different instrumentations are available on the market. The most frequently employed are by Storz and Wolf.
- *Electric scalpel*: Technical characteristics of the cutting/coagulation system is another

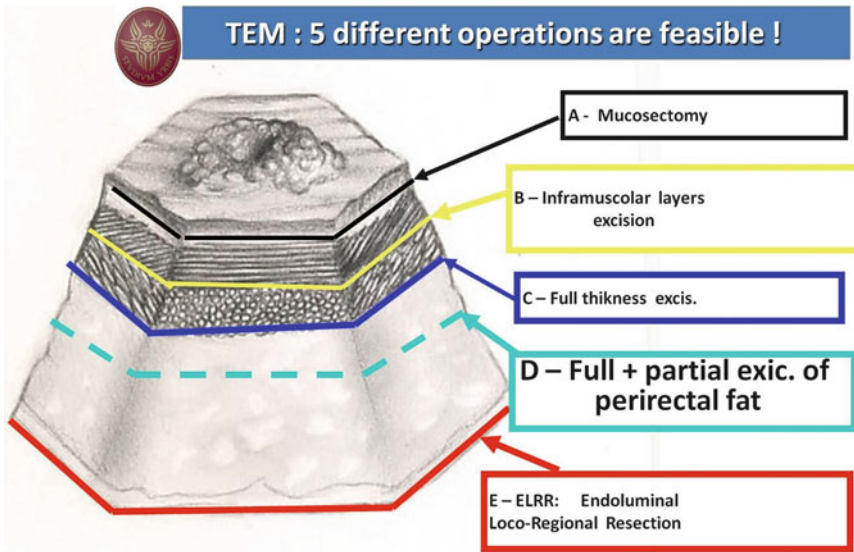
The last one has been developed by Prof. Buess from the early 1980s. It is the only one to give an excellent stereoscopic vision as well as other advantages including a system to wash the optic “in situ”. Wolf Company provides also a specifically developed equipment to automatically regulate the endoluminal CO<sub>2</sub> pressure. This balances the depression induced by the suction of a self-regulating rotative pump maintaining a constant pressure in the rectal lumen and a continuous gas circulation that removes smokes produced by the electrocoagulation. Furthermore, Wolf Company provides a miniaturized system that allows suction and simultaneous electrocoagulation to irrigate the operative field and to cut utilizing a sharp needle that is exteriorized automatically from the instrumentation activating the cutting pedal. It is evident that the Wolf equipment if compared with the Storz system is more advanced but at the same time is more complex and expensive.

important issue to pay attention to. It is useful to remember that the operative field of the TEM procedure is very small and so the presence of few cc of blood can completely cover the operative field. Therefore it is necessary to have an efficient electrocoagulation system that also works underneath liquids or blood. ERBE has developed a series of instrumentations that utilize high-frequency electric power that work under liquid and for these characteristics are generally utilized for urologic procedures. One of these has been developed to control the above described miniaturized system, produced by Wolf, so when the surgeon activates the yellow pedal of the cutting function, the needle is pushed automatically out from the instrumentation tip, which performs very precise and sharp incisions by cutting with the needle. When coagulation is required, the needle is automatically pulled back by pressing on the blue pedal, while the cannula aspirates blood at the same time, making coagulation more efficient.

---

## Surgical Procedures

- *Optics position* in the rectoscope. To obtain the best operative conditions it is necessary that both the oculars show a very small portion of the inferior wall of the rectoscope.
- *Check*: First the surgeon must check that all instrumentations are properly working: electroknife, endoluminal insufflation system, irrigation and suction. The surgeon must then check that the binocular lens provides a complete vision of the neoplasia.
- *Lavage*: Before starting the endoluminal resection or the manipulations of the mucosa it is advisable to wash repeatedly the rectal lumen with diluted betadine and then saline alone, in order to remove residual feces, mucous secretions and neoplastic cells' spelling. The lavage may also play a role in rectal bacteria control.
- *Mucosa incisional line*: The identification of the correct incisional line out of pathological mucosa is an important issue. There are generally two different approaches to solve the problem: (1) Before cutting the mucosa, most surgeons first perform a series of electric coagulations all around the visible margins of the neoplasia. The mucosa is then divided along these spots, taking care to stay 1 cm from neoplasia margin. In our opinion this approach is acceptable only for lesions that did not undergo NT, as in case of benign or T1 lesions. On the contrary it is important to take into account that in case of T2 early cancer the patient must undergo NT radiotherapy. And as above reported and only patients with a tumor mass reduction of at least 50 % after NT are eligible for local resection. Consequently if we follow this rule it is very probable that the incision line will fall on tissue that before NT was neoplastic. The reason why we disagree with the approach described above is that, according to our data [1], nests or clouds of tumor cells are present in the large majority of specimens removed in patients with complete clinical response CCR after NT. At present time, significance of these residual cells is unknown and for this reason we follow a prudential approach (2). In pag. 2 it has been already described the methodology that we routinely employ to identify the correct incisional line. Around the tumor on histologically proved normal mucosa tattoo spots are performed at the distance of 1 cm from the tumor. The mucosa will be cut following a line that joints all the tattoo spots. Only in this way we are sure to obtain clear margins. As already mentioned we consider mandatory to remove all the neoplasia harboring tissue before NT, including also 1 cm of histologically proven normal mucosa. Consequently, the extension of the excision area is much wider compared to that obtained according to the standard described in technique [2].
- *Free margins around tumor*: To save an adequate margin of normal mucosa (at least 1 cm)



**Fig. 9.9** Five different types of excision/resection for TEM

it is important not only for oncological reasons but also for avoiding neoplasia squeezing. The specimen manipulations must be conducted applying the grasper forceps only on the normal mucosa surrounding the lesion.

### Endoluminal Excisions/Resections by TEM

*Surgical dissection:* The technical advantages of TEM instrumentation allows a precise dissection of the different layers of the rectum so that five different types of excision/resection can be performed (Fig. 9.9).

1. *Mucosectomy:* it is an easy procedure. Once the mucosa is open it is possible to make a smooth dissection utilizing the suction and coagulation cannula and only short and soft coagulations are needed.
2. *Inframuscular layers dissection:* it is a difficult dissection that can be performed only by surgeon specifically trained in TEM procedures and is indicated only for the treatment of large benign lesions localized in the intraperitoneal rectum. It has the purpose to obtain a specimen

that allows the morphologist to evaluate the Sm parameter (see pag. 3, Patient Selection at the Admission, *Histology*) in case of degenerated adenomas. Saving the external muscular layer the risk of peritoneal contamination with malignant cells is avoided. The instrument required for this dissection is the electric knife/needle. The surgeon pulls up the internal layer (mucosa around the lesion) with a soft grasper and then dissects the circular rectal muscle layer utilizing the electro-cutting until the longitudinal fibers are clearly identified.

3. *Full thickness excision:* This technique is easily performed in case of lesions localized in the posterior or lateral extraperitoneal rectum. In case of anteriorly localized tumors in females, the dissection between the rectal and the vaginal wall must be performed cautiously avoiding electrocoagulation for the risk of recto-vaginal fistulas. On the contrary, in male patients the dissection of the rectal wall from the prostatic capsula requires frequent coagulations.
4. *Full thickness excision with partial exeresis of the perirectal mesorectum:* The division of the mesorectum, as in case of posterior

lesions, requires an efficient high-frequency electric scalpel to obtain a perfect coagulation of the numerous vessels. The Harmonic Scalpel or the Radiofrequency coagulator (Ligasure) can be employed instead of the electric scalpel.

5. *Endoluminal loco-regional resection (ELRR)*: According to our experience this technique is recommended in all malignant lesions. We employ this approach also in benign polyps larger than 2 cm or more in diameter. In fact, in our series lesions diagnosed as benign at the preoperative staging were classified as malignant in over 10 % of the cases at definitive histology (8 % T1 and 2 % T2), despite careful preoperative screening (by routine EUS, MR, and several macrobiopsies of the lesion). The rationale of this technique is to remove the largest amount of lymphatic tissue to detect the existence of metastatic nodes in order to have a more reliable staging and a consequent treatment (TME).

This approach has the advantage that *in case of posterior or lateral lesions*, the deep plane of dissection of the specimen corresponds to the avascular plane of the mesorectal fascia (the so-called *holy plane* of traditional surgery). Therefore the electrocoagulation of the vessels tributary of the mesorectum occurs mainly at the level of the lateral dissection. During the incision of oral rim due to the tumor-induced neoangiogenesis the vascular net at this level is rich with important vessels that can bleed freely creating trouble to the operator. This can be the most difficult part of the operation so we recommend to perform the dissection using the sucking cannula with electric coagulation.

*In case of anterior tumors*, in *female* the dissection should start as far as possible laterally where the recto-vaginal septum is thicker. Only when the right layer is reached the smooth dissection should move at the level of the posterior part of the vaginal wall, utilizing the cannula as a smooth dissector and avoiding electrocoagulation as much as possible.

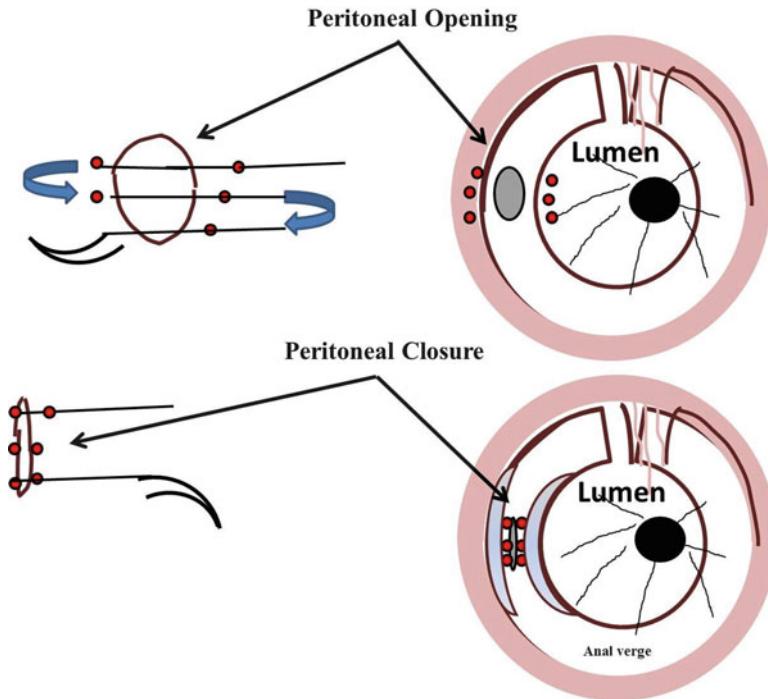
In *man*, it is important to achieve the correct plane of the basal dissection that is obtained following the surface of prostatic capsula.

---

## ELRR: How to Perform

### Posterior and Lateral Lesions

- The incision of the rectal rim should start from hours 8 to 3 following an incision line according to the above described technique. In the majority of cases we treat low rectal lesions so that the incision reveals the fibers of the internal sphincter muscle that can be partially removed if required by the imaging evaluation, taking into account the preoperative manometric values.
- Once the avascular plane is reached, the mesorectum is easily dissected away from the pelvic floor.
- Then lateral dissection of the specimen must be performed. At this level significant branches of the hemorrhoidal arteries must usually be coagulated, therefore radiofrequency or ultrasound energy can be useful to avoid important bleeding.
- Dissection then proceeds, alternatively moving from left to right in order to complete the ring of the incision line.
- Relevant arteries are usually found during dissection of the oral side as above described. This part of the operation is generally the last and the most difficult one because direct vision may be obscured by the presence of the mobilized specimen between the lens of the rectoscope and the working field. The difficulties at this point are related to the volume of the specimen.
- To improve vision and to better control the remaining area to dissect, it is useful to overturn the specimen towards the oral side of the lumen and carefully dissecting the last part of the mesorectum that still gives blood supply to the specimen.



**Fig. 9.10** Opening of the peritoneal cavity

- The changing color to violet in the mucosa is the sign of an adequate devascularization of the specimen.

## Anterior Lesions

### Female

- In this case the mucosal incision starts from hours 3 o'clock to 5. In this way it is possible to identify the vagina wall laterally where some perirectal fat is present. The rationale of this approach is to reduce the risk of direct penetration into the vaginal wall.
- Once the correct plane has been identified, it is easy to perform a smooth dissection of the rectum-vaginal septum. In this phase it is very important to avoid any electric coagulation.
- During this maneuver it is recommendable to introduce a surgeon's finger of the left hand in the vagina for better control of the instrumental pressure applied during smooth dissection with the right hand.

### Male

- The incision of the rectal wall may start from hours 8 to 3, as for posterior lesions, and the prostate white capsula can be easily recognized.
- It is very important to identify the right plane in order to avoid significant bleeding from the prostatic gland.
- Only in this case the dissection will be without bleedings.
- Severe bleeding may occur if the capsula is damaged. In this case, spray electrocoagulation by argon is recommended.
- Even in obese patients the presence of fatty tissue at this level is limited.

## In Case of Opening of the Peritoneal Cavity

During dissection an opening of the peritoneal cavity can occur (in our experience in 6 % of ELRR). We do not observe postoperative complications and hospitalization was not prolonged in all 54 patients in which a peritoneal opening occurred (Fig. 9.10).



- We recommend to close the opening immediately after utilizing the grasper in order to avoid a prolonged CO<sub>2</sub> insufflation of the abdominal cavity that can easily reduce the operative field.
- The best technique to close the opening is to stitch with the needle the mucosa far away from rim crossing all the layers of the rectal wall, then the residual mesorectum and the peritoneal serosa in one side. Then the needle must cross in the reverse way the other side of the opening.
- If the closure is delayed to remove the CO<sub>2</sub> insufflated in the abdominal cavity, it is recommendable to insert a Verres needle at the umbilicum.

graduated cylinder. Of course this evaluation is by default, because the electric coagulation dehydrates the specimen. Nevertheless it does give a reasonable measure of the volume. Then the specimen margins are dyed with methylene blue. Finally the specimen is pinned to cork table and fixed in formalin.

*Mobilization of the rims:* In order to facilitate suture of the rectal walls and to avoid tension on the suture line, it is helpful to perform a wide dissection at the deep level of the oral side rim. This dissection should be performed at the level of the avascular plane (“holy plane”). Since most lesions are located in the lower rectum, it is generally impossible to mobilize the anal rim of the defect.

---

## After the End of Dissection

*Washing the defect:* Once the specimen has been removed, irrigation of the cavity with a solution of betadine and saline (1:2) is strongly recommended by introducing two large Nelaton tubes in the rectal wall defect. It is reasonable to believe that bacteria contamination of the defect can determine postoperative sequelae. After that only saline is employed to remove betadine, the remaining solution can cause fever and chills in the first 36 postoperative hours.

## Intraoperative Histological Evaluation of the Rims

In order to avoid R1 resection, two half rings of the rims are removed performing a full thickness excision of the rectal wall. Both the half rings are marked with blue dye on the side of the defect so that the morphologist can exclude intraoperatively the presence of residual tumor.

*Nucleotide-guided mesorectal excision (NGME)*

As the defect has been washed we perform routinely the research of the sentinel node according to the technique described in following pages.

*Specimen:* First the volume of the specimen is measured by placing it into normal saline in a

---

## Closure of the Defect

*Suture:* Several running sutures are utilized to close the defect of ELRR. A double zero PDS suture with a half ring needle is used; at the end of the suture a silver clip is placed and it is advisable that the length of the suture line should not be less than 4 cm and not exceed 6 cm. A longer line makes suturing motion difficult inside the rectum ampulla. In case of a mucosectomy, the suture can be limited to the mucosa.

- To close the wide defect created after *ELRR* it is necessary that the needle introduced into the mucosa at the distance of 1 cm from the defect then crosses the rectal wall and exits at the bottom of the perirectal fat in one side of the defect. Then the needle must cross in a reverse way the other margin of the defect, and so on a running suture is performed.
- In case of very large resections, first we place a stitch in the middlebrow of the defect to approximate the two rims (oral and caudal) leaving enough space to manipulate the needle (Fig. 9.11).
- Then the right-handed surgeon generally place the first stitch at the level of the right side of the defect as seen by the operator, then proceeding with the suture from right to left. Each one of these suture is pooled and tied by a silver clip (Figs. 9.12 and 9.13).

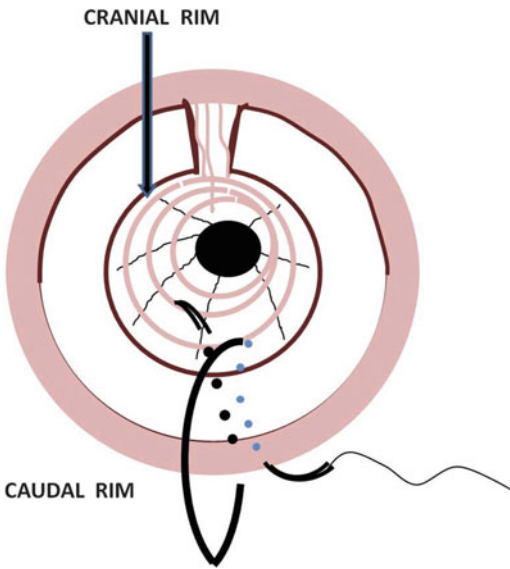


- The suture of the left side especially for wide defects is the most difficult part of the operation because the suture is performed in the upper part of the operative field (at hour 11) where vision and particularly the instrument motion are difficult.

*Filling of the defect with glue:* Before closing the last stitch it is suggested to fill the defect, left behind the suture, with 10 cm<sup>3</sup> of FloSeal (Ethicon J&J). If the defect is not filled with glue, there is a

higher risk of fluid collection and of a septic evolution of the collection, which is probably an important cofactor in determining suture leaks.

*Filling the rectal ampulla with sponges:* At the end of the operation, after removal of the operating rectoscope, the rectal ampulla is filled with two or three iodine sponges. This is aimed at avoiding or reducing the volume of residual cavity left behind the suture and to reduce the bacteria growth. The sponges are removed after 48 h.

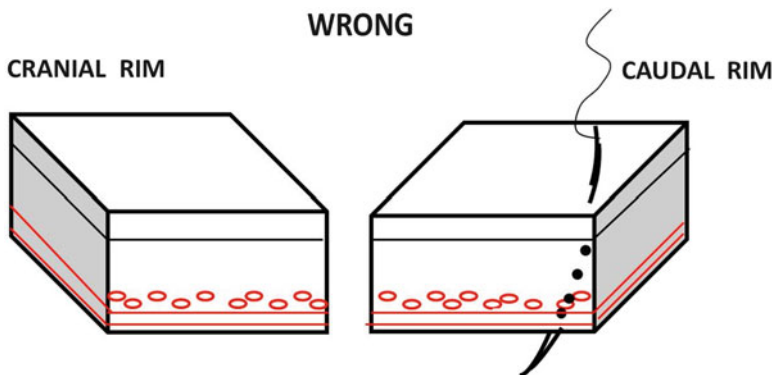


**Fig. 9.11** Stitching of the middle row of the defect to approximate the two rims (oral and caudal), leaving enough space to manipulate the needle

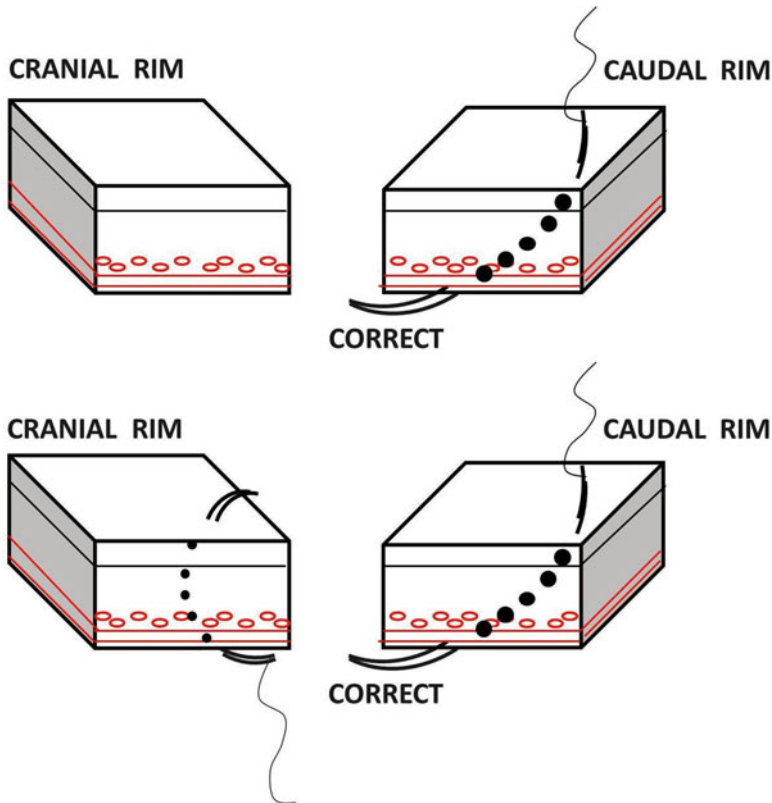
### Nucleotide-Guided Mesorectal Excision

NGME is an original technique developed with the purpose of increasing the number of removed nodes in order to evaluate if a salvage TME is necessary. Despite extensive local resection of ELRR, the correct evaluation of the histopathological N parameter may be a cause of concern due to the limited number of lymph nodes usually removed during the TEM procedure.

*Technique:* After induction of anesthesia, injections of radionuclide are performed around and behind the tumor through a rectoscope or anoscope and by means of a spinal or endoscopic needle. As the ELRR is performed and the specimen removed, the residual defect is washed with a solution of provide one to ten iodine (Iodoten,



**Fig. 9.12** Procedure performed by a right-handed surgeon, who generally places the first stitch at the level of the right side of the defect as seen by the operator, then proceeds with the suture from right to left. Each one of these sutures is pooled and tied by a silver clip



**Fig. 9.13** Procedure performed by a right-handed surgeon, who generally places the first stitch at the level of the right side of the defect as seen by the operator, then proceeds with the suture from right to left. Each one of these sutures is pooled and tied by a silver clip

SANTAS Srl, Tortona) and normal saline. Then the probe of a gamma camera (encased in a sterile package) is inserted through the TEM rectoscope to accurately explore the residual cavity in order to detect any area of residual radioactivity. In case of a signal at least ten times the baseline radioactivity the high activity tissue is marked with metal clips and excised by TEM. All specimens are scanned by the gamma camera in order to detect the areas with high radioactivity that are marked with stitches as an aid for the pathologist to detect the lymph nodes intraoperatively and/or for definitive histology.

*Rational:* The success of local resection, even in the management of early rectal cancer, is strongly related to the risk of metastases in non-removed nodes. According to the literature, accuracy rates in defining lymph node involvement of EUS, CT, PET-CT, and MRI are 65–81 %, 54–70 %, 75 %,

and 40–94 %, respectively. When performing routine EUS, CT, and MRI, the risk of nodal status understating does not exceed 10–5 %.

The rational of NGME technique is based on the progression of tumor cells within the lymphatic system so that histology of sentinel node predicts the status of the remaining nodes. In the literature, in low rectal cancer without unfavorable histologic characteristics no skip metastatic nodes are reported. Therefore NGME technique is useful to guide perirectal fat excision in order to include a larger number of lymph nodes during ELRR by TEM.

## Conclusion

To become a skilled surgeon of TEM techniques, long training is requested. Unfortunately the vision of the operator is different from the vision

reproduced on the screen not only because the screen gives a 2D image, but more than anything else the width of the operative field is significantly smaller than what the other surgeons can see; so the most difficult parts of the operation is visible only to the operator. This limitation makes the learning process more difficult. Different from laparoscopic surgery the working space of TEM is very limited so that the instruments moved by two hands can easily conflict. Microsurgery requires more delicate maneuvers and every risk of bleeding must be minimized. All surgeons are not comfortable with pelvic anatomy viewed from perineal side. Therefore when large endoluminal resection of the rectum is performed the surgeon must be very prudent and must have a perfect control of instruments manipulation, especially in blind conditions related to bleedings.

## References

1. Lezoche E, Guerrieri M, Paganini AM, Baldarelli M, De Sanctis A, Lezoche G. Long-term results in patients with T2-3 N0 distal rectal cancer undergoing radiotherapy before transanal endoscopic microsurgery. *Br J Surg*. 2005;92(12):1546–52.
2. Buess G, Hutterer F, Theiss J, Böbel M, Isselhard W, Pichlmaier H. A system for a transanal endoscopic rectum operation. *Chirurg*. 1984;55(10):677–80.
3. Kikuchi R, Takano M, Takagi K, Fujimoto N, Nozaki R, Fujiyoshi T, Uchida Y. Management of early invasive colorectal cancer. Risk of recurrence and clinical guidelines. *Dis Colon Rectum*. 1995;38(12):1286–95.
4. Carrara A, Mangiola D, Pertile R, Ricci A, Motter M, Ghezzi G, Zappalà O, Ciaghi G, Tirone G. Analysis of risk factors for lymph nodal involvement in early stages of rectal cancer: when can local excision be considered an appropriate treatment? Systematic review and meta-analysis of the literature. *Int J Surg Oncol*. 2012;2012:438450. doi:10.1155/2012/438450. [Epub 2012 Jun 19](#).
5. Dahlberg M, Glimelius B, Pählman L. Improved survival and reduction in local failure rates after preoperative radiotherapy: evidence for the generalizability of the results of Swedish Rectal Cancer Trial. *Ann Surg*. 1999;229(4):493–7.
6. Hospers GA, Punt CJ, Tesselaar ME, Cats A, Havenga K, Leer JW, Marijnen CA, Jansen EP, Van Krieken HH, Wiggers T, Van de Velde CJ, Mulder NH. Preoperative chemoradiotherapy with capecitabine and oxaliplatin in locally advanced rectal cancer. A phase I-II multicenter study of the Dutch Colorectal Cancer Group. *Ann Surg Oncol*. 2007;14(10):2773–9.
7. Winde G, Nottberg H, Keller R, Schmid KW, Bünte H. Surgical cure for early rectal carcinomas (T1). Transanal endoscopic microsurgery vs. anterior resection. *Dis Colon Rectum*. 1996;39(9):969–76.
8. Mentges B, Buess G, Effinger G, Manncke K, Becker HD. Indications and results of local treatment of rectal cancer. *Br J Surg*. 1997;84:348–51.
9. Lee W, Lee D, Choi S, Chun H. Transanal endoscopic microsurgery and radical surgery for T1 and T2 rectal cancer. *Surg Endosc*. 2003;17:1283–7.
10. Palma P, Freudenberg S, Samel S, Post S. Transanal endoscopic microsurgery: indications and results after 100 cases. *Colorectal Dis*. 2004;6:350–5.
11. Duek SD, Krausz MM, Hershko DD. Transanal endoscopic microsurgery for rectal cancer. *Isr Med Assoc J*. 2005;7:435–8.
12. Floyd ND, Saclarides TJ. Transanal endoscopic microsurgical resection of pT1 rectal tumors. *Dis Colon Rectum*. 2006;49:164–8.
13. Guerrieri M, Baldarelli M, Morino M, Trompetto M, Da Rold A, Selmi I. Transanal endoscopic microsurgery in rectal adenomas: experience of six Italian centres. *Dig Liver Dis*. 2006;38:202–7.
14. Lezoche E, Baldarelli M, Lezoche G, Paganini AM, Gesuita R, Guerrieri M. Randomized clinical trial of endoluminal locoregional resection versus laparoscopic total mesorectal excision for T2 rectal cancer after neoadjuvant therapy. *Br J Surg*. 2012;99:1211–8.
15. Ganai S, Kanumuri P, Rao RS, Alexander AI. Local recurrence after transanal endoscopic microsurgery for rectal polyps and early cancers. *Ann Surg Oncol*. 2006;13:547–56.
16. Stipa F, Burza A, Lucandri G, Ferri M, Pigazzi A, Ziparo V. Outcomes for early rectal cancer managed with transanal endoscopic microsurgery: a 5-year follow-up study. *Surg Endosc*. 2006;20:541–5.
17. Maslekar S, Pillingier SH, Monson JR. Transanal endoscopic microsurgery for carcinoma of the rectum. *Surg Endosc*. 2007;21:97–102.
18. Bretagnol F, Merrie A, George B, Warren BF, Mortensen NJ. Local excision of rectal tumours by transanal endoscopic microsurgery. *Br J Surg*. 2007;94:627–33.
19. Whitehouse PA, Armitage JN, Tilney HS, Simson JN. Transanal endoscopic microsurgery: local recurrence rate following resection of rectal cancer. *Colorectal Dis*. 2008;10:187–93.
20. Zacharakis E, Freilich S, Rekhraj S, Athanasiou T, Paraskeva P, Ziprin P, Darzi A. Transanal endoscopic microsurgery for rectal tumors: the St. Mary's experience. *Am J Surg*. 1945;2007:694–8.
21. Moore JS, Cataldo PA, Osler T, Hyman NH, Cristoforidis. Transanal endoscopic microsurgery is more effective than traditional transanal excision for resection of rectal masses. *Dis Colon Rectum*. 2008;51:1026–30.
22. Speake D, Lees N, McMahon RF, Hill J. Who should be followed up after transanal endoscopic resection of rectal tumours? *Colorectal Dis*. 2008;10:330–5.

23. Serra-Aracil X, Vallverdú H, Bombardó-Junca J, Pericay-Pijaume C, Urgellés-Bosch J, Navarro-Soto S. Long-term follow-up of local rectal cancer surgery by transanal endoscopic microsurgery. *World J Surg.* 2008;32:1162–7.
24. Koebrugge B, Bosscha K, Ernst MF. Transanal endoscopic microsurgery for local excision of rectal lesions: is there a learning curve? *Dig Surg.* 2009;26:372–7.
25. Bach SP, Hill J, Monson JR, Simson JN, Lane L, Merrie A, et al. A predictive model for local recurrence after transanal endoscopic microsurgery for rectal cancer. *Br J Surg.* 2009;96:280–90.
26. Jeong WK, Park JW, Choi HS, Chang HJ, Jeong SY. Transanal endoscopic microsurgery for rectal tumors: experience at Korea's National Cancer Center. *Surg Endosc.* 2009;23:2575–9.
27. De Graaf EJ, Doornebosch PG, Tollenaar RA, Meershoek-Klein Kranenbarg E, de Boer AC, Bekkering FC, van de Velde CJ. Transanal endoscopic microsurgery versus total mesorectal excision of T1 rectal adenocarcinomas with curative intention. *Eur J Surg Oncol.* 2009;35:1280–5.
28. Doornebosch PG, Ferenschild FT, de Wilt JH, Dawson I, Tetteroo GW, de Graaf EJ. Treatment of recurrence after transanal endoscopic microsurgery (TEM) for T1 rectal cancer. *Dis Colon Rectum.* 2010;53:1234–9.
29. Christoforidis D, Cho HM, Dixon MR, Mellgren AF, Madoff RD, Finne CO. Transanal endoscopic microsurgery versus conventional transanal excision for patients with early rectal cancer. *Ann Surg.* 2009;249:776–82.
30. Tsai BM, Finne CO, Nordenstam JF, Christoforidis D, Madoff RD, Mellgren A. Transanal endoscopic microsurgery resection of rectal tumors: outcomes and recommendations. *Dis Colon Rectum.* 2010;53(1):16–23.
31. Allaix ME, Arezzo A, Giraudo G, Morino M. Transanal endoscopic microsurgery vs. laparoscopic total mesorectal excision for T2N0 rectal cancer. *J Gastrointest Surg.* 2012;16:2280–7.

---

# Hybrid NOTES Colectomy for Left-Sided Colonic Tumors

# 10

Alex Lik Hang Leung, Hester Yui Shan Cheung, and Michael Ka Wah Li

---

## Introduction

Short-term benefits of laparoscopic colectomy for colonic cancer have been proved in different clinical trials [1–3]; patients will benefit from less post-operative pain, reduced pain-related and wound-related complications, as well as faster return of bowel function. However, abdominal incisions for retrieval of the specimen are associated with increased postoperative pain and sometimes wound-related complications, compromising the benefits of minimally invasive surgery.

Natural Orifice Transluminal Endoscopic Surgery (NOTES) can completely abolish wound pain and wound-related complications [4, 5]; however, it has many technical limitations. To maximize the benefits of minimally invasive surgery, Natural Orifice Specimen Extraction (NOSE) is an alternative for specimen retrieval and is one further step towards “incisionless” surgery. There are a number of reports with promising results on the application of NOSE in laparoscopic colorectal resection [6–17]; both transanal and transvaginal specimen retrieval have been described.

---

A.L.H. Leung, M.B.B.S., F.R.C.S. (✉)  
H.Y.S. Cheung, M.B.Ch.B., F.R.A.C.S.  
M.K.W. Li, M.B.B.S., F.R.C.S.  
Department of Surgery, Pamela Youde Nethersole  
Eastern Hospital, 3 Lok Man Road, Chai Wan,  
Hong Kong, SAR, China  
e-mail: alexlikhang@yahoo.com.hk

Herein, we describe a novel technique of laparoscopic colectomy without mini-laparotomy, known as hybrid NOTES colectomy, for patients suffering from left-sided colonic tumors. In this technique, colonic mobilization, transection, and colorectal anastomosis are performed laparoscopically, but specimen is extracted through an anatomical passage, i.e., the anus, using the Transanal Endoscopic Operation (TEO) device (Karl Storz Endoscopy, Tuttlingen, Germany). Without a mini-laparotomy, wound-related complications can therefore be avoided.

---

## Indications and Contraindications

This technique can be suitably applied to patients with left-sided colonic tumor from splenic flexure to upper rectum when the tumor size is 4 cm or below (as measured in computed tomography). Tumors larger than 4 cm in size are contraindicated; such tumors are too large to be safely extracted transanally via the TEO device, which itself measures 4 cm in diameter. Mid- or low-rectal tumors necessitate total mesorectal excision and division of the rectal tube at the anorectal junction, which precludes placement of the TEO device in the lower rectum. Another contraindication is the presence of anal stricture, which precludes insertion of the TEO device. Finally, patients presenting with acute surgical emergencies and the presence of synchronous tumors are also contraindications of this technique.

## Operating Room Setup and Recommended Instruments

The availability of advanced and user-friendly instruments is the first step of a successful operation.

We perform this “hybrid NOTES” colectomy in our integrated endolaparoscopic suite where the stands of video, optional systems, and energy sources are mounted onto the ceiling for easy maneuvering, and various laparoscopic and endoscopic instruments can be plugged in and used conveniently. The success of operation depends on team work. Cooperation between abdominal surgeon, perineal surgeon as well as camera assistant is essential. Experienced anesthesiologists and scrub nurses are important team members to ensure a smooth and successful operation.

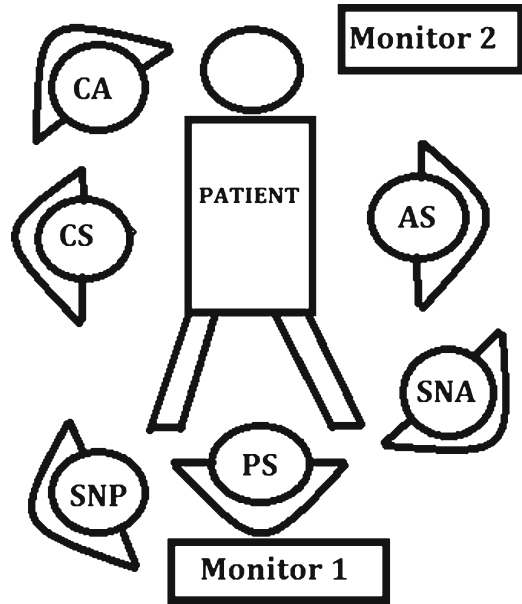
### Recommended Instruments Are as Follows

- 30° laparoscope
- Atraumatic bowel graspers, e.g., debakey grasper
- Energy source, such as ultrasonic dissector or LigaSure (Covidien, Norwalk, Conn)
- Endoscopic clips or endo-staplers for vascular control
- Non-cutting endo-staplers or cotton tapes for proximal and distal exclusion of tumors
- Cutting endo-staplers for bowel transection
- TEO device (Karl Storz Endoscopy, Tuttlingen, Germany)
- Circular staplers for bowel anastomosis

## The Surgical Procedure

### Preparation

Computed tomography should be reviewed to estimate the size of the lesion, as lesion larger than 4 cm precludes the use of the TEO device. Preoperative colonoscopic tattooing is important



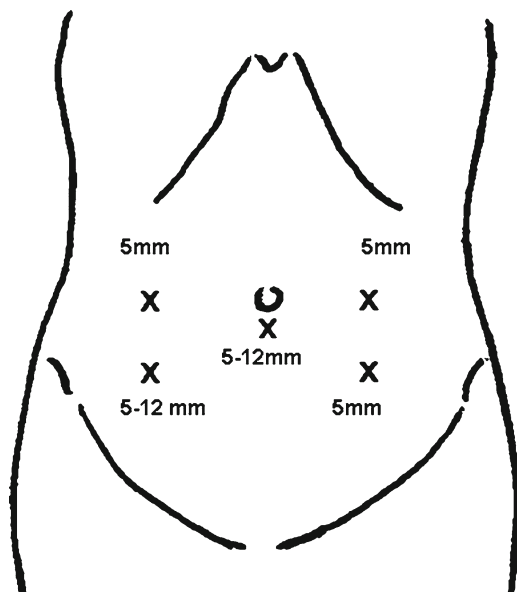
**Fig. 10.1** Positions of surgeons. *CS* chief abdominal surgeon, *AS*: assistant surgeon, *CA* camera surgeon, *PS* perineal surgeon, *SNA* scrub nurse for abdominal part, *SNP* scrub nurse for perineal part

for small lesions; alternatively, lesions can be localized by preoperative colonoscopy in the integrated endolaparoscopic suite. Mechanical bowel preparation was given the day before operation. Prophylactic antibiotic was given on induction.

### Position of the Patient and Trocar Placement

The positions of the surgical team, the equipment, and the port sites are shown in Figs. 10.1 and 10.2, respectively. The patient is put in the Lloyd-Davies position, with both legs abducted and slightly flexed so that the perineal surgeon could insert the TEO device with ease. Sacral support is used to raise the pelvis; the tip of the coccyx should be readily palpable from below. During operation, the patient is put in a 20–30° Trendelenburg position with a right-side-down tilt to get rid of the small bowel from the operative field. The chief surgeon uses a 5 mm port and a 5–12 mm port in the right iliac fossa which



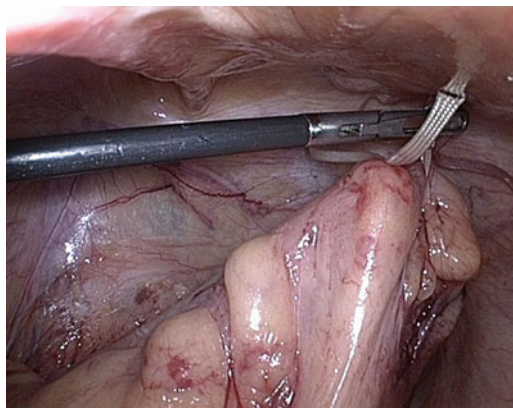


**Fig. 10.2** Port sites for the hybrid NOTES colectomy

allows passage of endo-staplers or endo-clips. The assistant surgeon uses two 5 mm ports in the left iliac fossa.

### The Lateral to Medial Approach

After pneumoperitoneum is established, a thorough diagnostic laparoscopy is first performed to localize the tumor and to look for any peritoneal deposits and ascitic fluid. In female, if the uterus is in the way, the uterus can be slung up by sutures through the abdominal wall to improve exposure. The operation is started with a lateral first approach (our preference) along the white line of Toldt. The left-sided colon is mobilized and the left ureter is identified and protected. The assistant surgeon provides counter-traction of the colon by holding a cotton tape which was passed through the sigmoid mesentery (Fig. 10.3). During medial dissection, the assistant surgeon retracts the sigmoid colon towards the abdominal wall to tent up the mesentery. A mesenteric window is made in the sigmoid mesocolon and dissection is carried out upwards. The inferior mesenteric vessels are then dissected out and divided by vascular staplers or between endo-clips



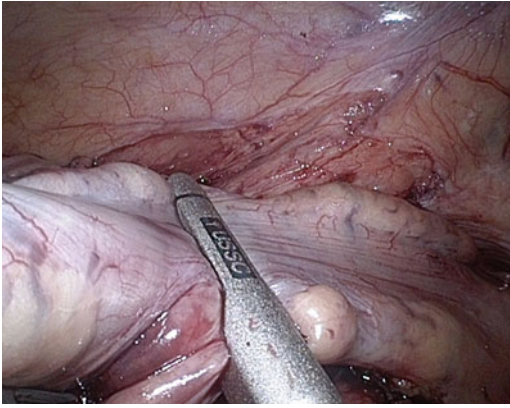
**Fig. 10.3** The assistant surgeon provides counter-traction of the colon by holding a cotton tape

### Mobilization of the Rectum

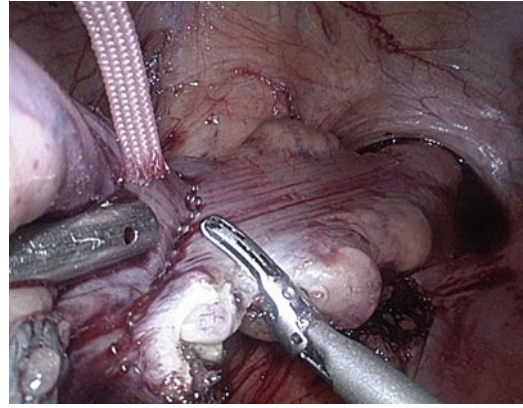
Presacral dissection is carried out distal to the tumor. Attention should be paid to preserve the hypogastric nerves. The distal level of transection should be 5 cm distal to the tumor. The mesentery at the intended level of transection is divided. The abdominal surgeon uses a pair of atraumatic laparoscopic bowel forceps to occlude the bowel just proximal to the “nude” rectal tube; the perineal surgeon then quickly carries out distal cytotoxic rectal lavage with povidone-iodine solution so as to reduce the risk of tumor seeding and peritoneal contamination. Non-cutting endo-staplers are applied at the chosen level distal to the tumors to exclude the tumor distally (Figs. 10.4 and 10.5). An alternate way to exclude the tumor is by tying the colon with a cotton tape.

### Insertion of the TEO Device and the Passage of the Anvil

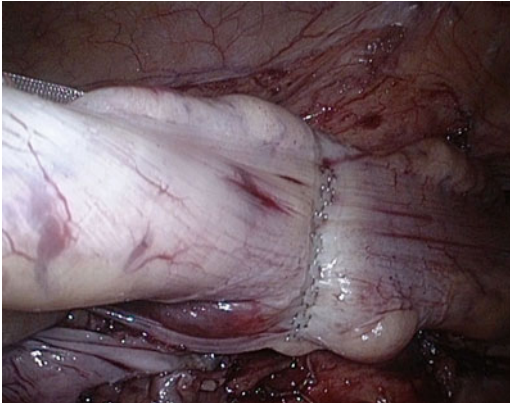
Next the perineal surgeon inserts the TEO device (Fig. 10.6) through the anus and it is fixed externally. The abdominal surgeon then divides the rectum just distal to the staple line or the cotton tape by energy device until the rectal stump is opened (Fig. 10.7). The TEO device helps to maintain pneumoperitoneum by simultaneously insufflating the rectum with carbon dioxide. The rectal stump is kept opened by grasping the edge



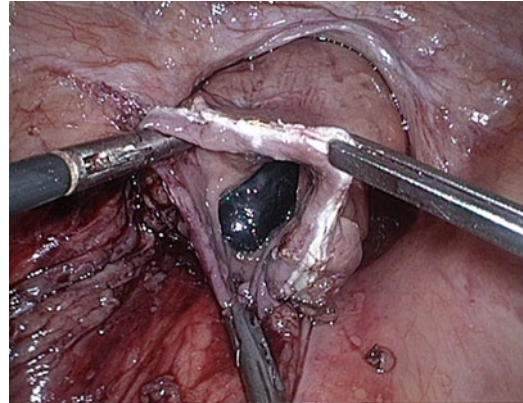
**Fig. 10.4** Non-cutting endo-staplers are applied at the chosen level distal to the tumors to exclude the tumor distally



**Fig. 10.7** The rectum is divided just distal to the staple line



**Fig. 10.5** Non-cutting endo-staplers are applied at the chosen level distal to the tumors to exclude the tumor distally



**Fig. 10.8** The rectum is kept opened by grasping the edge of the rectal stump using atraumatic forceps



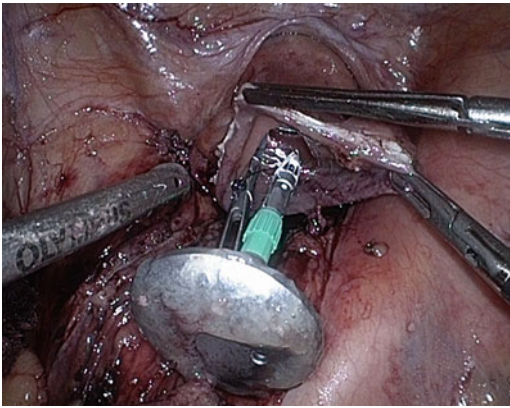
**Fig. 10.6** The TEO device inserted through the anus

of the rectal stump on either side using atraumatic forceps (Fig. 10.8). The detachable anvil (with the spike anchored on it) of a 31-mm circular stapler (DST Series EEA; AutoSuture, Norwalk, CT) is then passed via the TEO device and manipulated into the peritoneal cavity by the perineal surgeon under direct vision (Fig. 10.9).

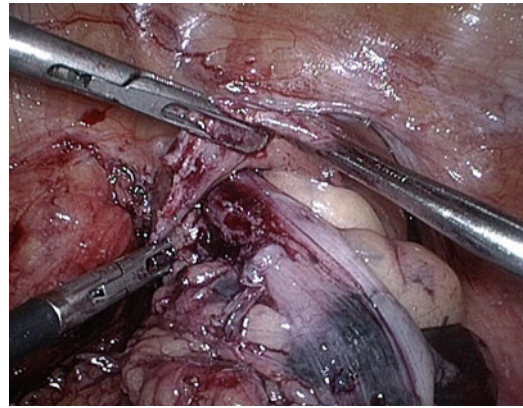
### Proximal Transection and Specimen Retrieval

Next the colonic mesentery at the intended level of proximal bowel division is divided. The

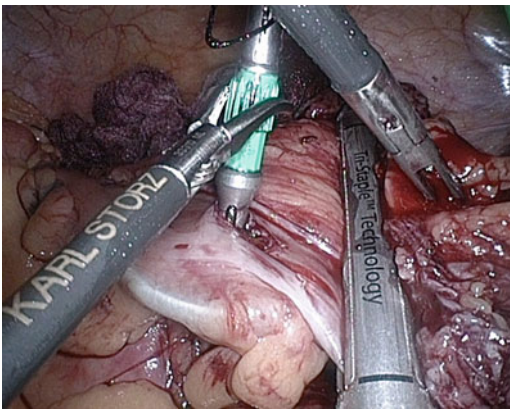




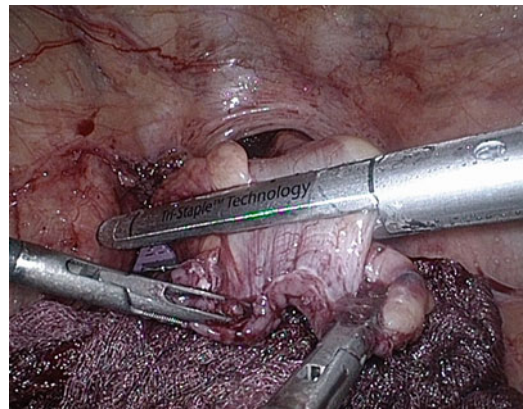
**Fig. 10.9** The anvil is passed through the TEO device into the peritoneal cavity



**Fig. 10.11** The specimen is extracted via the TEO device



**Fig. 10.10** The colon is transected proximal to the colotomy site



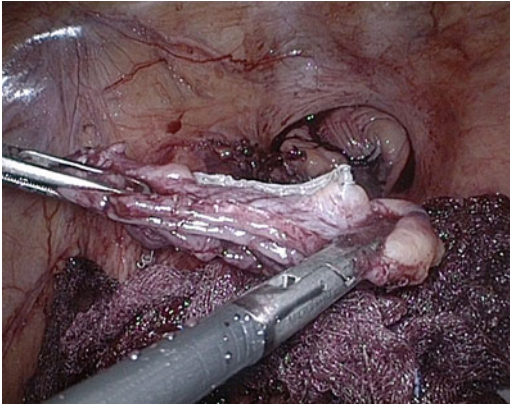
**Fig. 10.12** The rectal stump is closed by firing an endo-stapler

abdominal surgeon fires a non-cutting endo-stapler at a point about 5 cm distal to the intended line of bowel division to exclude the colon from the tumor below. Again, a cotton tape is an alternative of a non-cutting endo-stapler. A colotomy is then made immediately proximal to the proximal staple line or cotton tape, and the anvil is gently inserted through the colotomy into the proximal colon. The abdominal surgeon then carefully manipulates the anvil such that the spike is delivered through the anti-mesenteric side of the colon, proximal to the intended line of division; the spike can then be easily removed via the 5–12 mm port in the right iliac fossa. The colon is finally transected proximal to the colotomy site by a cutting endo-stapler. The specimen

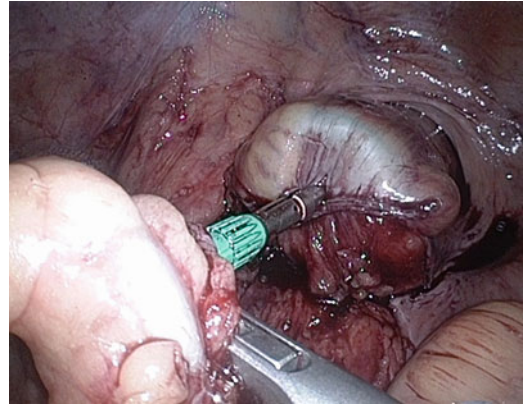
now becomes free (Fig. 10.10). Under laparoscopic and endoscopic guidance, the resected specimen is slowly extracted through the TEO device (Fig. 10.11). The TEO device serves as a stable conduit against tumor seeding and protects the rectum and anus from injury during specimen retrieval. This technique avoids the need to create a mini-laparotomy wound for specimen retrieval.

### Colorectal Anastomosis

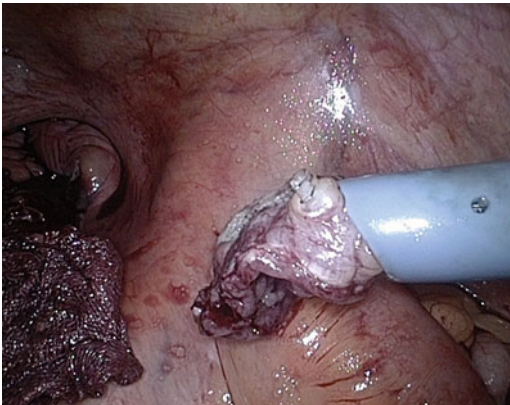
The abdominal surgeon applies traction to the edge of the opened rectal stump and fires another cutting endo-stapler to close the rectal stump (Fig. 10.12.)



**Fig. 10.13** The rectal tissue remnant is removed via the 5–12 mm port



**Fig. 10.15** A circular stapler is used to fashion a side to end colorectal anastomosis



**Fig. 10.14** The rectal tissue remnant is removed via the 5–12 mm port

The tiny rectal tissue remnant is removed via the 5–12 mm port (Figs. 10.13 and 10.14).

During the last operative stage, the TEO device is removed. We use the circular stapler to fashion a tension-free intracorporeal side to end colorectal anastomosis in usual manner (Fig. 10.15). At the end of operation, an on-table colonoscopy is routinely performed to check for any staple line bleeding. At the same time, the gas leak test is performed to ensure an air-tight anastomosis. Finally, the fascial layers of the sub-umbilical port and the 5–12 mm port are closed, and the skin is approximated with steri-strips. No drain is required.

---

## Postoperative Care

Fluid diet is allowed on the first postoperative day; this is stepped up to solid diet as tolerated by the patient. The urinary catheter is usually removed in the first postoperative day too. Mobilization exercise is continued throughout the postoperative period. Majority of patients are discharged on the fourth or fifth postoperative day.

---

## Conclusion

Without specimen-retrieval incision, this hybrid NOTES technique can minimize the postoperative pain and the risk of wound-related complications.

---

## References

1. Clinical Outcomes of Surgical Therapy Study Group. A comparison of laparoscopically assisted and open colectomy for colon cancer. *N Engl J Med.* 2004;350:2050–9.
2. Veldkamp R, Kuhry E, Hop WC. Laparoscopic surgery vs. open surgery for colon cancer: short-term outcomes of a randomised trial. *Lancet Oncol.* 2005;6:477–84.
3. Guillou PJ, Quirke P, Thorpe H, et al. Short-term end-points of conventional vs. laparoscopic assisted surgery in patients with colorectal cancer (MRC CLASSIC trial): multicenter, randomised controlled trial. *Lancet.* 2005;365:1718–26.

4. Willingham FF, Brugge WR. Taking NOTES: transluminal flexible endoscopy and endoscopic surgery. *Curr Opin Gastroenterol.* 2007;23:550–5.
5. Flora ED, Wilson TG, Martin IJ, et al. A review of natural orifice transluminal endoscopic surgery (NOTES) for intra-abdominal surgery experimental models, techniques, and applicability to the clinical setting. *Ann Surg.* 2008;247:583–602.
6. Cheung HYS, Leung ALH, Chung CC, et al. Endo-laparoscopic colectomy without mini-laparotomy for left-sided colonic tumors. *World J Surg.* 2009;33:1287–91.
7. Hara M, Takayama S, Sato M, et al. Laparoscopic anterior resection for colorectal cancer without minilaparotomy using transanal bowel reversing retrieval. *Surg Laparosc Endosc Percutan Tech.* 2011;21:e235–8.
8. Nishimura A, Kawahara M, Suda K, et al. Totally laparoscopic sigmoid colectomy with transanal specimen extraction. *Surg Endosc.* 2011;25:3459–63.
9. Leroy J, Costantino F, Cahill RA, et al. Laparoscopic resection with transanal specimen extraction for sigmoid diverticulitis. *Br J Surg.* 2011;98:1327–34.
10. Knol J, D'Hondt MD, Dozois EJ, et al. Laparoscopic-assisted sigmoidectomy with transanal. Specimen extraction: a bridge to NOTES? *Tech Coloproctol.* 2009;13:65–8.
11. Saad S, Hosogi H. Laparoscopic left colectomy combined with natural orifice access: operative technique and initial results. *Surg Endosc.* 2011;25:2742–7.
12. Diana M, Wall J, Costantino F, et al. Transanal extraction of the specimen during laparoscopic colectomy. *Colorectal Dis.* 2011;13 suppl 7:23–7.
13. Franklin Jr ME, Liang S, Russek K. Natural orifice specimen extraction in laparoscopic colorectal surgery: transanal and transvaginal approaches. *Tech Coloproctol.* 2013;17 suppl 1:63–7. Epub 19 Dec 2012.
14. Leroy J, Diana M, Wall J, et al. Laparo-endoscopic single-site (LESS) with transanal natural orifice specimen extraction (NOSE) sigmoidectomy: a new step before pure colorectal Natural Orifices Transluminal Endoscopic Surgery (NOTES®). *J Gastrointest Surg.* 2011;15:1488–92.
15. Franklin Jr ME, Liang S, Russek K. Integration of transanal specimen extraction into laparoscopic anterior resection with total mesorectal excision for rectal cancer: a consecutive series of 179 patients. *Surg Endosc.* 2013;27:127–32.
16. Makris KI, Rieder E, Kastenmeier AS, et al. Transanal specimen retrieval using the transanal endoscopic microsurgery (TEM) system in minimally invasive colon resection. *Surg Endosc.* 2012; 26:1161–2.
17. Saad S, Hosogi H. Natural orifice specimen extraction for avoiding laparotomy in laparoscopic left colon resections: a new approach using the McCartney tube and the tilt top anvil technique. *J Laparoendosc Adv Surg Tech A.* 2010;20:689–92.



# Transanal Endoluminal Total Mesorectal Resection (TETMR) by Transanal Endoscopic Microsurgery (TEM)

Emanuele Lezoche, Giancarlo D'Ambrosio, Pietro Ursi, and Giovanni Lezoche

## Introduction

Until 1940 all patients with distal rectal cancer (RC) underwent abdominal perineal resection (APR) with permanent colostomy. In 1948 Dixon demonstrated that rectal resection and colorectal reconstruction was a safe and available alternative [1]. The introduction of surgical stapling devices and the development of total mesorectal excision (TME) by Heald in 1982 established anterior resection as the gold standard procedure for most curable rectal cancer [2]. TME technique has facilitated pelvic autonomic nerves preservation and it has emphasized the achievement of negative circumferential resection margins (CRM) and distal resection margins (DRM), thus optimizing both patient's quality of life and oncological outcomes. Although the distal margin at 5 cm has been advocated in the past [3] more data suggest that 2 cm is enough [4, 5]. On the other hand, resection margins of 1 cm can be appropriate for selected patients treated with pre-operative chemoradiation [6]. These progresses have inspired the diffusion of restorative technique for treating middle and low rectal tumors.

E. Lezoche (✉) • G. D'Ambrosio • P. Ursi  
Department "Paride Stefanini", "Sapienza"  
University of Rome, Policlinico Umberto 1,  
Rome, Italy  
e-mail: emanuele.lezoche@uniroma1.it

G. Lezoche  
Clinica Chirurgica, Ospedale "le Torrette",  
Politecnico delle Marche University, Ancona, Italy

The introduction of the double-stapling technique (DST) by Knight and Griffen has been another significant step in carrying out a low colorectal anastomosis [7]. However, DST has still some technical problems in sphincter preservation, including difficulties in performing colo-anal anastomosis in low rectal cancer, anastomotic stenosis, anastomotic leakage, failure of stapler applying, etc.

In 1984 Marks [8] proposed TATA (TransAbdominal TransAnal) technique to treat low rectal cancer. The main advantage of this transanal approach is the preliminary identification of tumor distal margin and the early dissection of the distal part of perineal muscles in order to detect perirectal tumoral invasion and verify the possibility to perform a sphincter saving procedure. On the contrary, in open or laparoscopic TME the dissection starts at the level of the left colonic vessels with the isolation and ligation of pedicles and left colon mobilization. So that the most complex part of the operation, related to the isolation of the distal rectum/mesorectum is performed at the end of the procedure.

Transanal endoscopic microsurgery (TEM), proposed by Buess in 1983 [9] for benign lesions, appeared as a technique to relieve loco-regional rectal surgery, providing full-thickness excision with an excellent view and control of the entire rectum. It has proven to be technically superior to conventional transanal approaches with significant lower recurrence rates [10]. According to several authors [11, 12], it is currently the best local technique to treat early rectal tumors, for its



technical characteristics TEM allows a more accurate assessment of resection margins. Furthermore, from the late 1990s, the authors have developed a wider endoluminal resection for small iT1-2 N0 RC that include all the mesorectum adjacent the neoplasia. This operation has been named Endoluminal Loco-Regional Resection (ELRR). If combined with neoadjuvant therapy ELRR has shown, in a prospective randomized trial in selected patients with low iT2 N0 RC at a follow up of 10 years, the same oncological results obtained by TME [13].

On the basis of the experience achieved with ELRR the authors have developed a technique to perform transanally the TME utilizing modified TEM instrumentations. The dissection starts intraluminally cutting transversally the rectal wall to achieve the same dissection planes utilized in traditional TME. We named this original technique Transanal Endoluminal Total Mesorectal Resection (TETMR).

## Methods

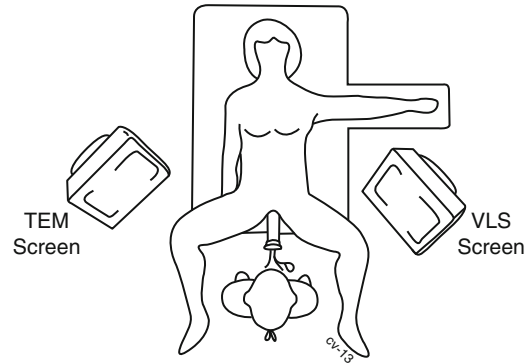
### Patient Preparation

It consists of:

1. Colonic washout with 5 l of PEG (Selg-Esse<sup>®</sup> 1000) the day before surgery.
2. A short-term antibiotic prophylaxis with metronidazolo (Deflamon<sup>®</sup>) and ampicillin+sulbactam (Unasyn<sup>®</sup>) 1 h before operation to prevent sepsis. In patients who underwent several monthly cycles of neomicina for diverticular disease, the antibiotic prophylaxis was administered for 3 days before surgery.
3. A continuous lavage of the rectum with saline containing diluted 1:10 Betadyne<sup>®</sup> 10 % was performed for 5 min before the placement of the TEM instrumentation.

### Instrumentation

A full set for laparoscopic surgery and a set for TEM must be arranged in the operative theatre as shown in Fig. 11.1.




**Fig. 11.1** A full set for laparoscopic surgery and a set for TEM

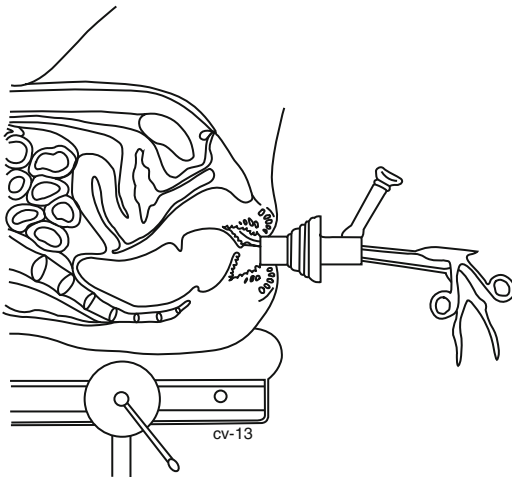
### Modified TEM instrumentation

To perform “TETMR” the 12 cm rectoscope and the working insert of TEM instrumentation has been modified by Richard Wolf (Tuttlingen—Germany) according to the author’s suggestions.

1. The shape of the 12 cm rectoscope has been modified by cutting the clarinet tip so two results have been achieved: a vertical section has been obtained and the rectoscope becomes significantly shorter (Fig. 11.2), therefore allows to work easily in the upper part of the operative field (Fig. 11.3). The modified distal edge of the rectoscope pressing the external anal margin makes possible to widen the canal anal and to perform a circular transversal incision of the mucosal layer between the anal verge and the pectinate line. The deep dissection is carried out in relation to the tumor extension as assessed by imaging (MR and Transanal US) performed before neoadjuvant treatment. The internal sphincter (that is easily identified), can be totally or partially removed if necessary.
2. The “working insert” (also named “operative faceplate”) has been modified so that the new model has a 10 mm hole to introduce a standard laparoscope locking it Fig. 11.4. Standard TEM optics have the advantages of a 3D view and an excellent magnification of the details due also to the perfect lighting; these technical features facilitate identification of the correct dissection plane, but at the same time have the default of a very narrow view of the operative field.



**Fig. 11.2** A modified 12-cm rectoscope



**Fig. 11.3** The upper part of the operative field

replace TEM optics with the 0° laparoscope that allows a wider view.

3. Alternatively a 30°, 5 mm laparoscopy held by the assistant, can be placed in the sealing insert to increase lighting and to obtain a wider field of vision on the laparoscopic screen.

---

### Patient's Position

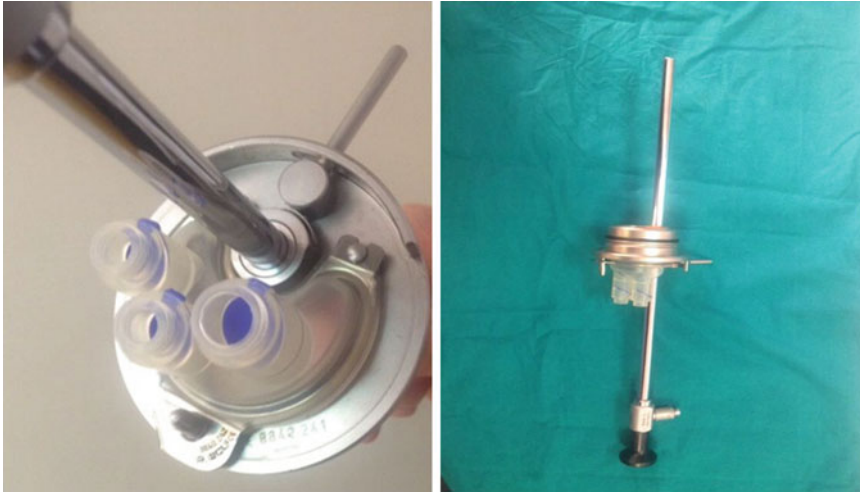
#### Posterolateral Lesions

The patient is placed on the operative table in Trendelenburg lithotomic position with the legs supported in stirrups.

#### Anterior Lesions

Patient is initially placed in prone position, for more detail see the chapter Tips and Tricks... page....

This can cause the loss of the surgeon's bearing. To avoid this situation it can be useful, once a large cavity has been created in the pelvis, to



**Fig. 11.4** The “working insert” (also named “operative faceplate”)

This position is generally employed only in case of anterior lesion in female patients. As matter of fact the dissection of the recto-vaginal septum is the most delicate part of the operation that requires to work in the best conditions. According to the TEM technique, the lesion must always be placed as close as possible to 6 o’clock of the operative field and patient must be rotated on the operating table to obtain the ideal operative placement during the whole surgical procedure. In male patient, the well-trained surgeon in TEM procedures can perform a 360° dissection maintaining the patient on the operative bed in the same position in order to minimize operative time.

## Surgical Technique

### Step 1 (by TEM Instrumentation)

- A. Posterior Lesions

Surgery starts with a mucosal transverse circular incision at 1 cm from the lower margin of the neoplasia (A). The dissection may partially include the internal sphincter or it may follow the intersphincteric plane. A full-thickness incision is performed by electrocautery down to reach the “Holy plane” described by Heald. Then the sur-

geon continues the anterior isolation of the rectum rotating the operative bed both to the left and to the right in order to modify the working area until a 360° dissection has been achieved. The smooth dissection is facilitated by the CO<sub>2</sub> insufflation that cranially pushing back the rectal stump. The excellent TEM view allows to preserve the integrity of mesorectal fascia (B–C) and parasympathetic pelvic plexus (D).

- B. Anterior Lesions

Before starting the transanal access, in female patient it can be useful to stitch the uterus by laparoscopy technique to suspend it to the anterior abdominal wall. At the beginning of our experience the patient was placed in prone position then in the last three cases a supine position was utilized. Only in female patients with large tumors is the prone position is recommendable. The dissection starts by identifying the lower margin of the neoplasia and as for posterior lesions, it can partially enclose the internal sphincter or it may follow the intersphincteric plane. The next dissection is performed moving from the lateral side to the middle line, that allows to identify the recto-vaginal septum or prostatic capsule and seminal vesicles in males so completely removing the Denonvilliers’ fascia. By maintaining the prone position, the surgeon can continue the dissection rotating the patient laterally on both

sides, so the complete mesorectum excision is reached. During the dissection a steel Trendelenburg position and the CO<sub>2</sub> insufflation cranially push down rectal stump, obtaining a wide operative field. As soon as possible, to prevent further CO<sub>2</sub> bowel insufflation, luminal liquid leak and tumor cell's spillage, the distal cut edge of the rectal stump is closed with a purse string suture. Tumoral reimplantation is unlikely after radiotherapy.

### Step 2 (by TEM Instrumentation)

If the patient was previously in a prone position, he must now be placed supine. By changing the working insert of TEM it is possible to work utilizing a 30°, 10 mm laparoscopic optic in order to obtain a wider view of the operative field (E). In this way the surgeon works utilizing the laparoscopic screen until the rectal stump with mesorectum is totally dissected as far as the peritoneal reflection is reached.

### Step 3 (by TEM Instrumentation)

Dissection continues to the peritoneal reflection. This level can be easily identified by transillumination with an accessory laparoscopic optic. Then a washing of the residual cavity in order to sterilize the operative field is performed with Betadine®.

### Step 4 (Laparoscopic Instrumentation)

Three (occasionally four) trocars are usually placed. The inferior mesenteric vein (IMV) is divided then the inferior mesenteric artery (IMA) beyond the origin of the left colic artery. The laparoscopic mobilization of splenic flexure and of the transverse colon is performed as usual.

Then the isolation of the intraperitoneal rectum and the section of the pelvic peritoneum is

performed in order to achieve the complete mobilization of the rectum, the descending and of transverse colon. A Pfannestiel mini-laparotomy is performed to resect the rectum. The specimen is sent to the morphologist to assess intraoperatively free margins. Before the closure of mini-laparotomy the colon is pulled out through the anus to perform colo-anal anastomosis.

Alternatively, the whole rectal stump covered with a plastic drape can be pulled out through the TEM rectoscope, out the anus. So the specimen is resected to perform the colo-anal anastomosis.

When specific and dedicated devices are available, mobilization of left colon, splenic flexure, vascular section and loco-regional lymphadenectomy, will be totally performed by the transanal approach avoiding the abdominal step, to accomplish a NOTES complete procedure.

### Step 5

Finally a trans-sphincteric drainage is placed and the protective ileostomy is carried out.

---

## Clinical Experience

From October 2008 eight patients (5 males and 3 females) with ultralocal rectal cancer (<3 cm from pectinate line) were selected to undergo to TETMR. All patients underwent a long course of neoadjuvant Radiochemotherapy (nRCT) and subscribed an informed consent reporting the possibility of stoma and the new surgical technique. Median age was 66 years (41–77). On the specimen mean tumor diameter was 3 cm (1–5 cm) and the definitive staging was: one pT3N1, one pT3N0, four pT2N0 and two pT0N0. Ileostomy was performed at the end of the procedure in four patients.

Mean operative time was 450 min (360–600). Longer operative time was required at the beginning of the experience, due principally to the need to modify the patient position on the operative bed. No intraoperative complications occurred.

The following postoperative complications were observed: one female developed a pelvic abscess in tenth p.o. day and an ileostomy was performed, 2 months later this patient developed a thin recto-vaginal fistula that was treated by rectal stent. After 3 months the MR and endoscopy assessed the complete healing of the fistula, so the stent was removed and ileostomy closed. Other postoperative complications included: 2 leakages of colo-anal anastomosis and pelvic abscesses, both treated by percutaneous drainage, and one temporary urinary incontinence.

Late complications included two anastomotic stenosis in patients with pelvic abscess. Both were treated by dilatations and stenting. All patients were enrolled in a 3 months program of close follow up with a imaging and clinical check planning. At present only one patient died of cardiac disease, 1 year and half after TETMR. All others (seven) patients are disease free.

---

## Discussion

The previous experience of 450 RC treated by ELRR has provided us with the necessary skill to complete pelvic dissection by TEM following the same planes utilized in open or laparoscopic TME.

Only after we mastered a thorough understanding of the new view of anatomy that moves from the anus to the upper part of the rectum, we decided to perform the “standard” TME utilizing the previous described TEM instrumentation. The TEM vision offers significantly advantages (like 3D vision, lighting and magnification) but at the same time there is the disadvantage of a narrow operative field that can mislead the surgeon. For this reason, we recommend to follow all the procedure also the under the view of a 30°, 5 mm laparoscope introduced through the third middle silicon sealing valve of the TEM working insert.

On the bases of the previous reported advantages in mind, we asked ourselves:

why should we uphold the surgical tradition of performing TME starting from the abdominal cavity and so so far from the tumor?

In our opinion TETMR represents a remarkable innovation in the treatment of low or ultralow rectal cancer that has the same advantages of the Marks procedure but provides a better view together with ideal working conditions.

Other techniques to preserve the sphincter have recently been proposed as an example APPEAR described by Williams [14]. This procedure is however significantly more invasive and doesn't allow to perform low resections if compared TETMR. If the imaging performed before nRCT showed tumor invasion, the latter makes possible to extend, under direct vision, the resection to the adjacent structure to the lower mesorectum.

Other Authors have utilized TEM to perform a NOTES sigmoid or rectal-sigmoid resection [15–18]. As far as we know the first TME performed by TEM belongs to our series and it was conducted in October 2008, and also another author has reported a similar approach [19].

---

## Conclusions

TETMR is a feasible operation for surgeons expert in TEM procedures and it is possible that, for the advantages that it offers, it will become in a few years the most chosen operation to treat low/ultralow RC. In the near future utilizing properly developed instrumentations it will be possible to utilize the rectoscope with the modified working insert as platform to perform all the abdominal steps of TME, so realizing a complete NOTES operation.

---

## References

1. Dixon CF. Anterior resection for malignant lesions of the upper part of the rectum and lower part of the sigmoid. *Ann Surg.* 1948;128(3):425–42.
2. Heald RJ, Husband EM, Ryall RD. The mesorectum in rectal cancer surgery—the clue to pelvic recurrence? *Br J Surg.* 1982;69(10):613–6.
3. Williams NS, Dixon MF, Johnston D. Reappraisal of the 5 centimeter rule of distal excision for carcinoma of the rectum: a study of distal intramural spread and of patients' survival. *Br J Surg.* 1983;70(3):150–4.

4. Andreola S, Leo E, Belli F, Lavarino C, Bufalino R, Tomasic G, Baldini MT, Valvo F, Navarra P, Lombardi F. Distal intramural spread in adenocarcinoma of the lower third of the rectum treated with total rectal resection and coloanal anastomosis. *Dis Colon Rectum*. 1997;40(1):25–9.
5. Wilson SM, Beahrs OH. The curative treatment of carcinoma of the sigmoid, recto sigmoid, and rectum. *Ann Surg*. 1976;183(5):556–65.
6. Guillem JG, Chessin DB, Shia J, Suriawinata A, Riedel E, Moore HG, Minsky BD, Wong WD. A prospective pathologic analysis using whole-mount sections of rectal cancer following preoperative combined modality therapy: implications for sphincter preservation. *Ann Surg*. 2007;245(1):88–93.
7. Griffen FD, Knight Sr CD, Whitaker JM, Knight Jr CD. The double stapling technique for low anterior resection. Results, modifications, and observations. *Ann Surg*. 1990;211(6):745–51.
8. Marks G, Mohiuddin M, Borenstein BD. Preoperative radiation therapy and sphincter preservation by the combined abdominotranssacral technique for selected rectal cancers. *Dis Colon Rectum*. 1985;28(8):565–71.
9. Buess G, Theiss R, Günther M, Hutterer F, Pichlmaier H. Transanal endoscopic microsurgery. *Leber Magen Darm*. 1985;15(6):271–9.
10. Dias AR, Nahas CS, Marques CF, Nahas SC, Ceconello I. Transanal endoscopic microsurgery: indications, results and controversies. *Tech Coloproctol*. 2009;13(2):105–11.
11. Hiroko K. Transanal endoscopic microsurgery for rectal tumors: a review. *Perm J*. 2012;16(2):45–50.
12. Lezoche E, et al. Transanal endoscopic microsurgery for 135 patients with small nonadvanced low rectal cancer (iT1-iT2, iN0): short- and long-term results. *Surg Endosc*. 2011;25(4):1222–9. Epub 7 Oct 2010.
13. Lezoche E, et al. Randomized clinical trial of endoluminal locoregional resection versus laparoscopic total mesorectal excision for T2 rectal cancer after neoadjuvant therapy. *Br J Surg*. 2012;99(9):1211–8.
14. Williams NS, Murphy J, Knowles CH. Anterior perineal PlanE for ultra-low anterior resection of the rectum (the APPEAR technique): a prospective clinical trial of a new procedure. *Ann Surg*. 2008;247(5):750–8.
15. Whiteford MH, Denk PM, Swanström LL. Feasibility of radical sigmoid colectomy performed as natural orifice transluminal endoscopic surgery (NOTES) using transanal endoscopic microsurgery. *Surg Endosc*. 2007;21(10):1870–4. Epub 21 Aug 2007.
16. Sylla P, Rattner DW, Delgado S, Lacy AM. NOTES transanal rectal cancer resection using transanal endoscopic microsurgery and laparoscopic assistance. *Surg Endosc*. 2010;24(5):1205–10.
17. Lacy AM, Adelsdorfer C. Totally transrectal endoscopic total mesorectal excision (TME). *Colorectal Dis*. 2011;13 Suppl 7:43–6.
18. Marks JH. TEM as a Platform for NOTES. *J Gastrointest Surg*. 2011;15(8):1313–5.
19. Rouanet P, Mourregot A, Azar CC, Carrere S, Gutowski M, Quenet F, Saint-Aubert B, Colombo PE. Transanal endoscopic proctectomy: an innovative procedure for difficult resection of rectal tumors in men with narrow pelvis. *Dis Colon Rectum*. 2013; 56(4):408–15.



Laurel Blair, Dominique McKeever,  
and John H. Marks

---

## Defining TEM

### Historical Perspective

Transanal endoscopic microsurgery (TEM) was first clinically applied by Buess et al. in 1983 in response to the increasing need for improved surgical access to resect benign and early stage malignant rectal lesions [1]. Prior to the development of this technology, surgical options for the treatment of endoscopically unresectable rectal polyps were confined to either standard transanal local excision

or radical surgery. TEM is a fundamental minimally invasive technique in the colorectal surgical armamentarium which facilitates clear visualization and access to the entire rectum [2].

### Overview

TEM's appeal is the fact that it provides the surgeon with the ability to transanally excise lesions that were previously inaccessible [3]. It involves an operating rectoscope through which full-thickness or submucosal excision, hemostasis, and subsequent closure of the defect with a running suture are performed [4]. This operation could be classified both as the original Natural Orifice Transluminal Endoscopic Surgery (N.O.T.E.S) and as single-port surgery. It involves the introduction of a "port" (the operating rectoscope) through a natural orifice, the anus, and the use of specially developed curved instruments which allow for access to the majority of the rectum. Currently there are an estimated 430 TEM systems in use around the world with approximately 45 systems available in the United States [5]. This technology has a steep learning curve; however, once employed by an experienced surgeon, it has the propensity to fundamentally alter the surgical treatment of rectal adenomas, low risk carcinomas, and more advanced cancers after neoadjuvant therapy.

---

L. Blair, M.D. • D. McKeever, B.A. (✉)  
Division of Colorectal Surgery, Main Line  
Health Systems, Wynnewood, PA, USA  
e-mail: blairl-02@mlhs.org;  
dmckeever02@comcast.net

J.H. Marks, M.D., F.A.C.S., F.A.S.C.R.S.  
Division of Colorectal Surgery, Main Line Health  
Systems, Wynnewood, PA, USA

Lankenau Medical Center, Wynnewood, PA, USA

Lankenau Institute of Medical Research,  
Wynnewood, PA, USA

Department of General Surgery and Digestive  
Oncology, University Nice Sophia-Antipolis, Centre  
Hospitalier University, Nice, France

Marks Colorectal Surgical Associates,  
100 E. Lancaster Avenue, MOB W, Suite 330,  
Wynnewood, PA 19096, USA  
e-mail: marksj@mlhs.org

## Equipment

### Set up

Presently there are two companies offering TEM equipment, Richard Wolf Medical Instruments Corporation (Vernon Hills, Illinois) and TEO equipment of Storz (Karl Storz GmbH & Co., Tuttlingen, Germany). Regardless of the TEM system being used, it is important to understand the fundamental tenets of equipment use.

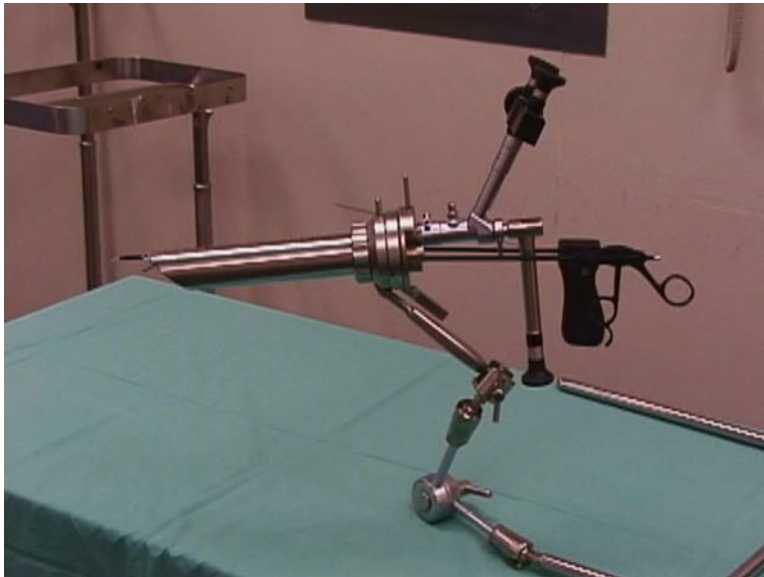The TEM system consists of an operating proctoscope which has a removable faceplate and four ports. The proctoscope is 4 cm in diameter and is held in place by a Martin arm, which has three joints all tightened by one knob, and attaches to the operating table (Fig. 12.1). One of the four ports is used to introduce the optical stereoscope, one for suction, and two for instrument insertion. The optical stereoscope (10 mm instrument) employs two eye pieces which allow for three dimensional vision with a 75° field of view and a 50° downward viewing angle. An added benefit is the ability to utilize a 5 mm 40° accessory teaching scope which allows the procedure to be projected onto standard laparoscopic monitors for

easier viewing. Another option involves utilizing a 30 or 50° scope with a camera attachment and performing the case watching the monitor. This is ergonomically superior, but the stereoscopic vision is lost.

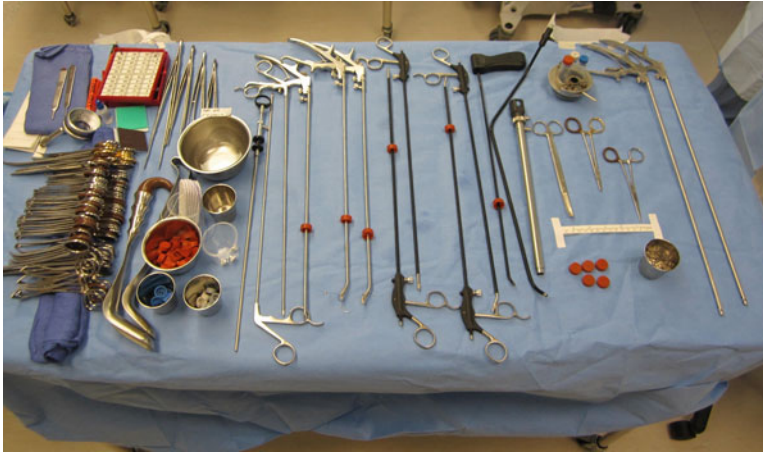
Several authors extol the benefits of the combined multifunctional endosurgical unit which automatically regulates suction, irrigation, and gas insufflation to maintain a constant intrarectal pressure of 12–15 cm H<sub>2</sub>O [6]. Maintaining constant intrarectal pressure is essential, as this facilitates visibility of the operative field. If the rectum does not distend properly, or if the system does not maintain a constant intrarectal pressure, this is a sign that there is an air leak in the system. This is the most frequently encountered problem that the TEM surgeon must learn to troubleshoot as loss of pneumorectum results in complete loss of surgical view [6]. The constant insufflation from the TEM unit avoids the billowing effect seen when distending the rectum with a laparoscopic insufflator.

### Instruments

In order to permit mobility within the 4 cm operating proctoscope, a unique design element has



**Fig. 12.1** Proctoscope held in place by Martin arm



**Fig. 12.2** TEM surgical instrument table

been built in to each of the TEM instruments, notably that they are all angled instruments. A slight bend in the instrument shaft near the working end allows for maximal ergonomic positioning and function within the closed operating field [7]. The need for intracorporeal knot tying is circumvented by the use of a clip applicator which applies a silver clip to each end of the suture material. Several other innovative instruments are available to improve the TEM operating experience, particularly the multifunctional TEM 400 instrument by Erbe (ERBE Elektromedizin GmbH, Tübingen, Germany). Many surgeons use the 5-mm ultrasonic harmonic scalpel which facilitates hemostatic dissection particularly when traversing the mesorectum; however, we favor the angled cautery device [7]. Unfortunately, the multifunctional ERBE instrument which allows for suction, irrigation, and cautery in one instrument is not currently available in the United States (Fig. 12.2).

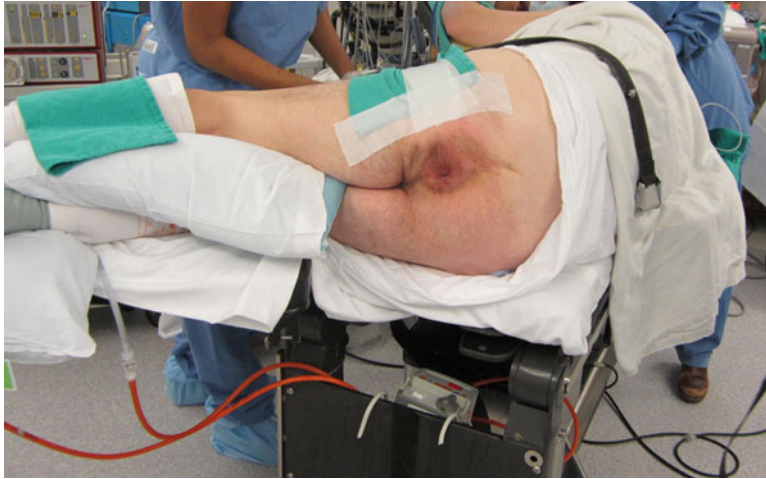### Patient Positioning

In order to facilitate efficient surgical resection, patient positioning is paramount. There are several principles which must be applied to TEM positioning to allow for optimal surgical visibility: the bevel of the scope must face down at the lesion, and the lesion must be maintained at the

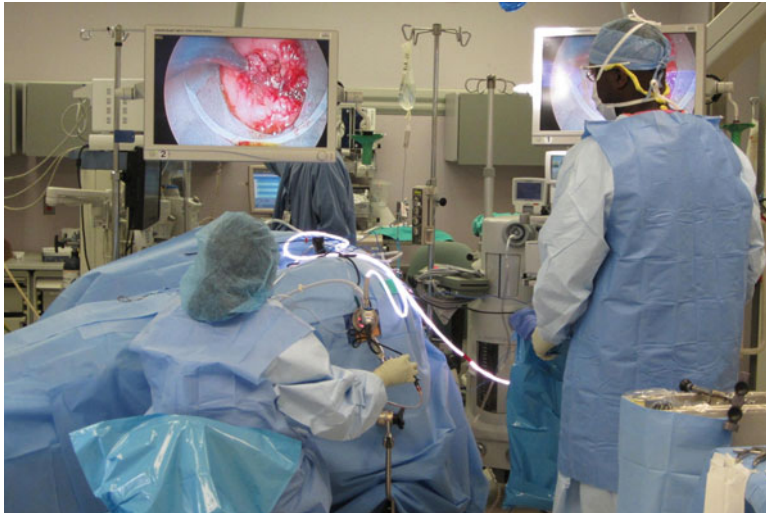center of the operating rectoscope throughout the dissection. Because the operation is performed through a 20 cm long operating rectoscope there is very little movement of the instruments either up/down or left/right. The lens system occupies the upper 180° of the rectoscope, therefore it is imperative that the lesion is in the bottom half of the scope. Scheduling should make mention of patient position so that all team members are aware. Also of note, full-thickness excision is historically felt to be possible extraperitoneally up to the 20 cm level posteriorly, the 12 cm level anteriorly, and the 15 cm level at each respective side wall [7]. Particular attention must be paid to positioning as it has been referred to as the most important aspect of this operation [6]. Higher lesions can be approached by experienced TEM surgeons, but a lesion where entry into the peritoneum is possible should be avoided by surgeons early in their TEM learning curve (Fig. 12.3).

### Personnel Positioning

The surgeon will be seated between the patient's legs, the operating table and surgeon's stool can be adjusted to promote a comfortable operating environment. The accessory scope must be inserted and imaging routed to the external monitor to allow for visualization by residents, medical students, and operating room staff.



**Fig. 12.3** Patient in right lateral position prior to draping



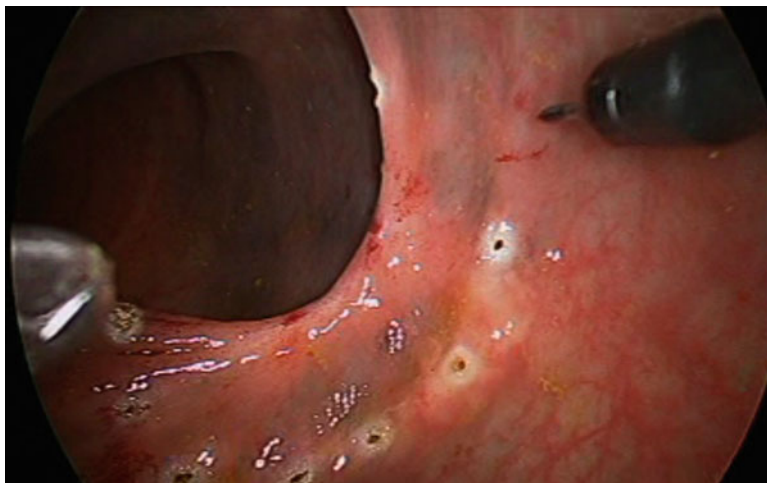
**Fig. 12.4** Personnel positioning during TEM with patient in right lateral position

The multifunctional endosurgical unit will be positioned close to the operating field where the tubing can safely reach the field. The scrub nurse should be positioned opposite the endosurgical unit, and the surgical assistant should be seated next to the surgeon (Fig. 12.4).

### Operative Technique

As previously discussed, positioning is of the utmost importance as the lesion is optimally in

the bottom 180° of the scope to allow adequate reach. Correspondingly, posterior lesions are best managed with modified lithotomy, anterior lesions with prone positioning, left-sided lesions necessitate left side down, and right-sided lesions must be addressed with right side down. After the patient is prepped and draped, the anus is gently dilated, and the 4 cm operating proctoscope inserted. The scope must then be manipulated until an ideal placement of the lesion is identified in the lower half of the operating proctoscope. To do this a glass faceplate is employed and the



**Fig. 12.5** Margin of lesion marked with electrocautery

scope is manipulated similar to a large rigid sigmoidoscope.

Once the desired visual field has been obtained, the operating proctoscope is secured to the table via the Martin arm, and the operating faceplate is closed on the end of the scope. The rubber sleeves and caps are placed onto the working ports, and must be kept lubricated with mineral oil as drying and cracking of the caps are a possible cause of intraoperative air leak with subsequent loss of pneumodistention.

Attention must now be turned to the set up of the multifunctional endosurgical unit. There are four important pieces of tubing associated with this apparatus which provide continuous insufflation, regulation of intrarectal pressure, irrigation, and roller-pump suction. All of the attachments are suited only for the proper tubing connectors which avoids possible connection mistakes.

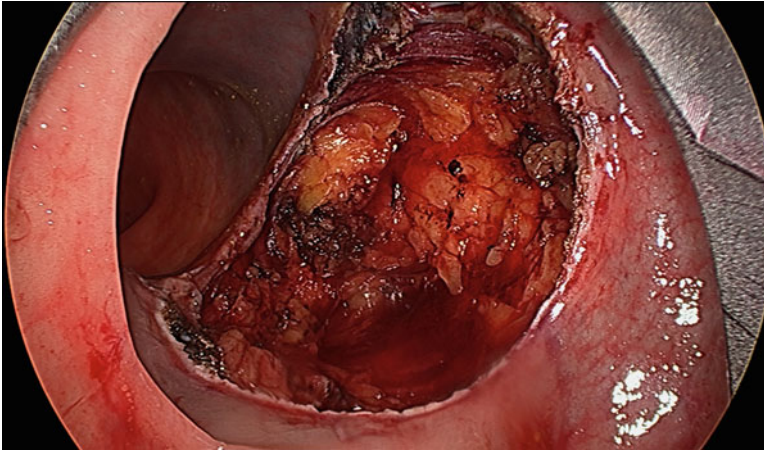
After proper set up of the operative field, the lesion is infiltrated using local anesthetic with epinephrine to aid in hemostasis. At this point in time the margin of the lesion is marked out using electrocautery (Fig. 12.5). A 5 mm margin is ideal for adenomas, and 10 mm for carcinomas which are amenable to TEM resection. It is important to perform this step now as it is often hard to be certain of margins once cautery artifact, blood, and smoke obscure the operative field. Additionally by performing this, the surgeon confirms his/her ability to reach all margins of the lesion.

Full-thickness excision is required for all malignant lesions, while adenomas can be excised in either a full-thickness or submucosal plane (Fig. 12.6). Dissection is carried out using electrocautery. Care must be taken when addressing anterior lesions, as the peritoneal reflection may be present at varying levels. Entry into the peritoneal cavity used to be an absolute contraindication for this approach. It is still advisable to avoid high anterior lesions early in one's TEM experience. As experience has grown we recognize that this can be safely managed transanally. The possibility of the need for an abdominal operation and even proximal diversion must be discussed preoperatively with every patient. This should be an exceedingly rare event. In the event of this rare complication, expectant management is a key tenet as patients can potentially develop intra-abdominal sepsis requiring reoperation. After successful dissection, all wounds should be irrigated and subsequently closed with a running transverse suture (Fig. 12.7).

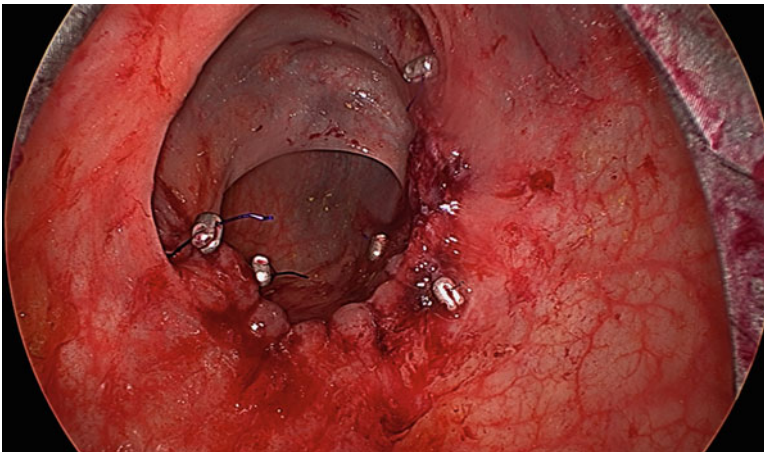
### Technical Pearls

Patient positioning is very important and can be referred to as the most important principle of TEM. Remembering to reposition the operating rectoscope is of the utmost importance. This allows the TEM resection to proceed in the most





**Fig. 12.6** Full-thickness local excision



**Fig. 12.7** TEM running anastomosis

efficient fashion by continuing to keep the lesion in the bottom of the scope. The TEM proctoscope must be entirely encompassed by the anus to allow for adequate pneumorectum, which can be difficult to achieve below the 5 cm level. Lesions which are located in the very distal rectum (below the 5 cm level) may be better addressed with conventional local excision. Many experienced TEM surgeons have become so accustomed to the superior view afforded by this technology that they prefer to use the TEM scope. To facilitate this more complicated dissection, one must change from a bevelled to a flat operating scope. In this situation, the closure is often done in a conventional transanal fashion.

Air leak is by far the most frustrating situation encountered by the TEM surgeon. Air leak leads to loss of pneumorectum and potentially complete collapse of the operative field. When encountered it is important to evaluate an air leak in a systematic fashion. Trouble shooting the dreaded airleak involves checking all equipment tubing and connections, as well as the rubber caps which are present on the faceplate for any cracks or pinholes.

There are several key pieces of information which must be kept in mind when manipulating the TEM instruments. First, the instruments should always remain in parallel, and should not cross over each other. There is very little



movement in the horizontal axis as one is operating through a 20 cm tube. To gain mobility the instruments are moved in and out and rotated slightly, utilizing the angle of the instrument to gain reach and mobility. Instruments should be lubricated with mineral oil to reduce wear and tear on the face plate caps which can lead to loss of operative visibility and to reduce the annoyance of drag on your instrument as you are trying to dissect. The suction catheter should be maintained in the proximal neck of the rectoscope, well out of the operative field of view, and away from the rectal wall. By keeping the suction out of the operating field, the surgeon increases the mobility of the working instruments.

When suturing the defect closed, the surgeon must carefully pass the needle from hand to hand. Dropping the suture needle may necessitate repositioning of the rectoscope, and will subsequently lead to delay in progression of the operation. The suture material must be kept short in length or a significant amount of time will be required to simply pull the suture material through the tissue. Generally we recommend a 10 cm stitch length. If the surgical resection margins necessitate an extensive resection, the large defect which ensues must be closed with multiple sutures. Fortunately even after closure of a large defect, the patency of the rectal lumen is assured as the surgeon has been closely monitoring it through the 4 cm operating proctoscope for the duration of the closure.

---

## Indications

### Benign Disease

The benefit of TEM is obvious when radical surgery can be avoided in the treatment of benign rectal lesions. The technique of TEM was first developed and applied to lesions in the mid and upper rectum which were either difficult to reach, or completely inaccessible via traditional transanal approaches. Several authors postulate that TEM is both more effective and will lead to better long term outcomes when used to treat benign rectal lesions. The reason for this is the clear advantage of superior visibility, particularly

of the proximal margin. Additionally the rate of piecemeal excision is greatly reduced with this approach [8].

Moore et al. reviewed their data regarding 171 patients who underwent TEM versus traditional transanal excision and they report a statistically significant decrease in the rate of local recurrence following TEM in the resection of benign rectal adenomas [8]. The authors attribute this decrease in local recurrence to the removal of nonfragmented TEM specimens, as well as the decreased positive margin rate associated with TEM. This data confirms the fact that TEM affords the surgeon a better view of the operative field, as well as better instrumentation promoting both complete excision and adequate resection margins necessary to prevent recurrence.

Another institutional review of 15 years experience in TEM resection of rectal adenomas by Guerrieri et al. revealed in addition to decreased recurrence rate, TEM is also a low morbidity procedure with no reported mortality. TEM provides for the safe removal of rectal adenomas up to 20 cm from the anal verge. The observed rate of recurrence in this study was 4 % at 84 months follow-up [9].

### Malignancy

The indications for local excision with or without TEM in the treatment of early stage rectal cancer have been debated for years in the literature. A large number of trials have reported high local recurrence rates for rectal cancer treated with local excision. In the 1990s, Bleday and Steele reported on 48 patients treated with full-thickness local excision, resulting in 10 % failure rate for T1 cancers and a 40 % failure rate for T2 cancers [10]. Later that decade, the CALBG group, in a study of 110 patients treated with local excision, reported a similar failure rate for T1 cancers of 6 % and a 14 % failure rate for T2 cancers. Notably, 15 % of resections had positive margins [11]. Rothenberger's group out of the University of Minnesota reported in 2000 that of 108 patients treated with local excision, 18 % of T1 cancers recurred as well as 47 % of T2 cancers [12].

In 2005, the same group further reported on 151 patients treated with local excision with failure rates of 19 % for T1 and 45 % for T2 cancers [13]. Also in 2005, the Cleveland Clinic published a study of 52 local excisions and a failure rate of 29.4 % for T1 lesions [14]. The data from these trials led Rothenberger et al. to conclude that local excision alone is inappropriate treatment for T2 rectal cancer [12].

The Norwegian rectal cancer group published a study in 2005 examining T1 cancers treated with radical resection versus local excision. Of the 256 patients treated with radical surgery, 6 % had local recurrence. Node positivity occurred in 11 % of T1 cancers, and as expected with early cancers, 100 % of the resections were R0. On the other hand, 38 patients were treated with local excision. The failure rate for these patients was 12 % and there was a 17 % R2 resection rate [15]. Interestingly, the local excision failure rate in the experiences cited above is similar to the node positivity rate for T1 cancers treated with radical resection. Based on the high rate of positive margins in this group, it is surprising that the local recurrence rate is not even higher. Lymph node involvement for T1 cancers after radical resection is 6–12 % and failure rate after local excision in these trials is 6–29 % in the reports just mentioned. There are two possible explanations for this: persistence of untreated cancer in lymph nodes not resected during local excision or implantation of tumor cells at the time of surgery due to incomplete resection or handling of the tissue transanally. TEM surgery coupled with neoadjuvant therapy addresses both of these issues.

A pressing question when considering treatment options for rectal cancer remains: is there a role for radiation in stage I rectal cancer? Should preoperative radiation be utilized in early stage cancers of the rectum in conjunction with local excision? The MRC CR07 trial, a multicenter randomized study, compared preoperative radiation therapy to selective use of postoperative radiation therapy in 1,350 rectal cancer patients treated with radical resection. They found improved local recurrence rates, all of which were statistically significant, for cancers treated with radiation preoperatively—T1: 1.9 %, T2:

1.9 %, T3: 7.4 %; for cancers treated selectively with postoperative radiation—T1: 2.8 %, T2: 6.4 %, T3: 15.4 %. The trial concluded that there is a significant improvement in local control for stages I, II, and III rectal cancer after preoperative radiation therapy, and they advocate the use of preoperative treatment for all stages [16, 17].

Our experience represents the first in the world performing local excision in conjunction with preoperative radiation therapy in 1984 at Jefferson University Hospital [18]. We have continued to employ the Marks and Mohiuddin method and in 2004, reported on an experience with 44 patients with T2N0 disease in the distal 7 cm of the rectum, all treated with local excision. Twenty five percent of these patients were treated with TEM; the remainder were treated using transanal approaches. We found an overall local recurrence rate of 6.9 % and a 5-year survival of 91 %. There was a complete response after neoadjuvant therapy in 23 % of patients, none of which had a local recurrence [19]. We further compared our experience with 73 T2 rectal cancers treated neoadjuvantly followed by TEM versus total mesorectal excision (TME). The local recurrence rate in the TEM group was 3.3 % compared to 2.3 % in the TME group. This difference was not statistically significant. Similarly, the difference in 5-year survival did not reach statistical significance: 95 % in the TEM group versus 97 % in the TME group [20]. Lezoche, as mentioned elsewhere, has published comparable results for cancers treated neoadjuvantly followed by full-thickness local excision. His local recurrence rate was 5 % and he saw an 89 % survival rate [21].

### **Patient Preparation and Selection**

It is clear that patient selection is key, as local excision alone does not address any involved lymph node. Additionally, a key consideration is whether the patient can tolerate a radical procedure. Therefore, an evaluation of the patient's fitness, as well as a thorough initial evaluation of the rectal lesion, is critical. As is typical with colorectal cancer patients in general, evaluation begins with obtaining a CT of the chest, abdomen and pelvis and a CEA. A meticulous digital rectal

examination is the single most important component of the preoperative evaluation. From the digital rectal exam, we are able to assess the following about the tumor: clinical stage, position, level, size, ulceration, fixation, adjacent organ involvement, and relationship to the peritoneal reflection. Tumors that are fixed, deeply ulcerated, or involve adjacent organs are not suited for local excision. Tumors greater than 3–4 cm in diameter can be difficult to address with local excision as the defects created are usually greater than 50 % of the circumference and therefore can be challenging to close. We recommend using a flexible and/or rigid sigmoidoscope in conjunction with a digital rectal exam. In fact, it is very helpful to use both in those tumors that are above the reach of the finger. The flexible scope provides a clearer picture of the lesion, while the rigid scope offers a more accurately delineates tumor position. Proper patient positioning at surgery depends largely upon tumor location. Patients are placed in lithotomy if their tumors are positioned posteriorly; patients are placed in the prone jackknife position if their tumors are found to be anterior. Anteriorly based tumors above the middle rectal valve should be approached cautiously as they may lie above the peritoneal reflection which can result in a challenging closure if one enters into the peritoneal cavity. Local excision is an ideal approach for tumors with the following characteristics: small, mobile, in the distal rectum and posteriorly located. Contraindications to local excision without neoadjuvant therapy include poorly differentiated histology or the presence of lymphovascular invasion [22].

Tumors should be evaluated radiographically to better discern the depth of invasion of the tumor preoperatively. Endorectal ultrasound (ERUS) is helpful in delineating the depth of invasion in early stage rectal cancers with approximately 90 % accuracy, and in identifying mesorectal adenopathy with 70 % accuracy. Nodes visualized on ERUS are likely metastatic and should prohibit the use of TEM on otherwise healthy rectal cancer patients without utilizing neoadjuvant therapy. Pelvic MRI is becoming more commonly used for staging. It is used to

assess adjacent organ involvement, but is not ideal in delineating T1 from T2 cancers. This limited resolution, along with the questionable accuracy of MRI in differentiating benign from malignant nodes, decreases its value in determining suitability for local excision. Additionally, prior biopsy or polypectomy can affect the accuracy of both of these radiographic modalities. The thermal injury that results from these energy sources can potentially obscure the differentiation between the layers of the rectal wall. Again, while we advocate using ERUS and/or MRI, the exam with flexible and/or rigid sigmoidoscopy and most importantly, digital rectal examination is of paramount importance.

One must consider what approach will be taken if an invasive component is found in the TEM specimen. If the lesion is felt to be benign, we recommend performing a submucosal TEM excision. If on examination by the pathology department an invasive component is found, more radical surgery will be recommended.

Further pathologic subclassification of T1 tumors can provide information regarding the risk of lymph node metastasis and in turn, local recurrence. The depth of invasion into the submucosa can be designated as SM1, SM2, or SM3. In a study involving 182 patients, Kikuchi et al. reported that no patients with SM1 lesions had lymph node metastasis. However, 10 % of SM2 patients and 25 % of SM3 patients did have metastases to the lymph nodes. They found that SM3 was an independent, statistically significant risk factor for lymph node metastases [23].

Unfortunately, the best predictor for lymph node involvement is still the tumor T stage. Studies of patients undergoing proctectomy show the following mesorectal node positivity: for a T1 cancer, nodal involvement ranges from 5 to 12 %; for T2 cancers in the range of 17–25 %; and in T3 cancers from 40 to 60 % [24–28].

To date, ERUS remains the gold standard for determining node positivity although, more and more interest has been generated by the excellent results of Gina Brown and her group when looking at MRI studies of rectal cancer [29]. However, even noted by such distinguished experts as the late Doug Wong, “fine distinction between deep

tumors of one T stage and early tumors of the next T stage [...] are often difficult to make. Additionally regional lymphatic involvement is often difficult to determine because endorectal ultrasound cannot detect nodes further away in the mesorectum or find micrometastatic disease in a perirectal lymph node” [30].

Local recurrence after local excision can be attributed to four factors, two of which have been previously mentioned:

1. *Untreated involved lymph nodes*: Local persistence of the cancer as the lymph nodes have not been treated either surgically or sterilized with radiation.
2. *Tumor implantation at the time of surgery*: The basic tenets of colon and rectal surgery are to exclude the cancer with a clamp or stapler and then irrigate and have your margin of resection at that point, distal to the clamp. Unfortunately, when operating within the lumen of the rectum with a live cancer in place, this is always a challenge and speaks of the need for irrigation of the operative field with tumoricidal agent once the tumor is removed.
3. *Tubular lymphatic spread or persistence at the time of surgery*: Lymph node resection in an endoluminal fashion can be carried out only for perirectal nodes that may be found immediately deep to the cancer itself. Furthermore, the ability to identify which patients have lymph node metastases impacts markedly the way the patient is addressed.
4. *A positive margin leaving a residual cancer (i.e., an R1 resection)*: Using a transanal approach makes it challenging to achieve adequate margins, especially good cephalad margins, which leads to a higher local recurrence rate with local excision.

Local excision alone is an inadequate treatment for early stage rectal cancer. It is a sufficient approach for the medically compromised patient, cancers arising in a polyp, and early T1 cancers. It is insufficient for more advanced T1 cancers which require a more aggressive approach, such as the use of neoadjuvant therapy. Chemoradiation holds promise to diminish the high failure rate for T1 and T2 cancers. By combining the techniques

of local excision and chemoradiation, the problem of persistent disease from untreated lymphatics is addressed.

## Special Anatomic Considerations

The anatomy of the rectum and its relationship to the peritoneal reflection must be well understood as it is essential to identify any entry into the peritoneal cavity which occurs during TEM dissection. The posterior rectum is invariably extraperitoneal, the lateral rectum is intraperitoneal for its proximal third, and the anterior rectum is largely intraperitoneal with only the distal third below the peritoneal reflection [3]. Lateral lesions involving one third or more of the lumen, commonly extend anteriorly, and the risk of peritoneal entry must be considered.

Anteriorly the distal rectum is adjacent to the vagina in women and the prostate in men. For this reason, as well as a low cul-de-sac, anterior lesions are challenging, with intraperitoneal entry and fistulous formation representing significant postoperative complications [3]. The extraperitoneal rectum will heal by secondary intention, while any entry into the peritoneal cavity must undergo suture repair and close observation for the development of intraperitoneal sepsis [3]. We advocate closure of all wounds, intra- and extraperitoneal.

---

## Results

### Alteration in Continence

TEM employs a 40 mm operating proctoscope which is inserted into the rectum after serial dilation. While we have only seen two patients with transient incontinence after TEM surgery this remains a significant concern in the surgical community. Several authors have investigated the concern that the proctoscope alters postoperative continence more thoroughly. Cataldo et al. examined this potential complication in a prospective assessment of functional outcomes using two patient assessed quality scores and found no decrease in clinical continence following TEM

surgery [3]. Kennedy et al. noted a decreased anal resting pressure on manometry studies, however, as discussed by Cataldo et al. there was no reduction in clinical continence [3]. The major issues patients encounter after TEM surgery are due to the decreased capacitance of the rectal wall after a significant resection. This resultant urgency generally improves gradually over time.

## Postoperative Complications

Complication rates for TEM range from 6.7 to 9.8 % and include bleeding, perforation, and wound dehiscence [31]. Other authors list fever, fistula formation, rectal stenosis, and urinary dysfunction and quote a 10.3 % complication rate as compared to a 17 % complication rate associated with local excision [3].

Marks et al. review TEM for the treatment of rectal cancer and not surprisingly identify an increase in the complication rate following neoadjuvant radiation therapy [31], as one is suturing irradiated to irradiated tissue rather than reapproximating healthy tissue for an anastomosis as is done in an LAR. The major morbidity is that of wound separation. This occurred in 26 % of those who underwent radiation therapy prior to TEM resection, compared to 0 % in the nonirradiated group. As expected the majority of these complications were wound related, with 91 % of these wound complications being successfully treated without additional surgery [31].

## Oncologic Results

TEM has comparable outcomes to local excision for early stage rectal cancer. Buess published a 4 % local recurrence rate following TEM for T1 rectal cancer [3]. Saclarides reviewed recurrence rates following TEM resection for T1 rectal cancer and found a range from 2.2 to 10 % [5].

Resection of T2 rectal cancer by local excision has had reported recurrence rate of 0 to 40 % [5]. However, when T2 rectal cancer was treated with neoadjuvant radiation therapy followed by TEM, local recurrence rates were reduced to the 2.85 % range in a group of 35 patients as reported

by Lezoche et al. [32]. Our group published a matched case control study of T2 rectal cancers treated with chemoradiation in 2011 which demonstrated a 3.3 % local recurrence rate with TEM which was not statistically different from a 2.3 % local recurrence rate after TME in 73 patients [33]. Further investigation is needed to better understand the role of TEM in rectal cancer treatment, but current results are promising.

---

## Challenges

### Expensive Equipment

There are approximately 430 TEM systems in use worldwide, with only 45 systems in the United States [5]. One barrier to the widespread use of TEM technology is equipment cost. In addition, authors postulate that the lack of a specific Centers for Medicare and Medicaid procedure code has led to decreased implementation of the technique due to decreased surgeon reimbursement.

### Difficult Technique

There is a steep learning curve associated with TEM technology. In his review of the technique Saclarides recommends an intense didactic course with hands-on experience prior to applying TEM in practice [5]. As discussed in the section on technique there are several frustrating issues which can routinely be associated with the TEM equipment, the most frequently identified of which is “air leak” [5]. Air leak can occur secondary to a variety of equipment problems and if not corrected will lead to complete loss of visibility if pneumorectum cannot be maintained.

The instruments used in TEM are particular to this technology and must be used in parallel, as crossover of instruments leads to awkward movement and loss of precision [5]. In addition, the rectal defect must be sutured closed at the end of the resection, and the surgeon must take care not to drop the needle as subsequent search for the needle may require repositioning of the entire apparatus leading to an increase in overall procedure



time [5]. While none of these problems represent significant barriers, in aggregate they present an obstacle to adaptation.

### Limited Indications

TEM is currently a wonderful tool for accessing adenomas located almost anywhere in the rectum up to the rectosigmoid junction. Applications include benign polyps, and in the case of rectal cancer, T1 lesions without evidence of lymphovascular invasion, or T2 lesions with neoadjuvant radiation therapy can be safely addressed. Anterior lesions should be approached with care by the TEM novice due to the proximity of the peritoneal reflection. Consequently any evidence of lymphovascular invasion should be addressed with intra-abdominal surgery.

---

## New Techniques

### Transanal SILS

Since the advent of single-port surgery, the surgical community has struggled to define a role for this innovative surgical technique. One form of single-port surgery is known as transanal minimally invasive surgery or TAMIS [34]. This technique involves the use of an Applied Port (Applied Medical, Rancho Santa Margarita, CA) or SILS port (Covidien, Mansfield, MA) for transanal resection. Some authors are employing TAMIS as an alternative to TEM [35]. Other authors are using TAMIS as an extension of laparoscopy to obtain access to the deep pelvis when performing a proctectomy or similar procedure. Regardless of the indication, it is clear that TAMIS is an exciting new technology which is still in its infancy, but has the potential to expand on the endoluminal surgical forefront.

---

### Notes

Another emerging surgical technique is known as Natural Orifice Transluminal Endoscopic Surgery or NOTES. This approach boasts

decreased pain due to the obviation of the need for a skin incision [36]. NOTES is a form of so called incisionless surgery, allowing the surgeon to approach the diseased organ endoluminally. Several methods have been described including transgastric, transvaginal, and transrectal access points to varying disease processes.

TEM has been proposed as a platform for performing NOTES procedures as it is an already established endoluminal method of performing surgery [33]. One group has already successfully performed 12 rectosigmoid resections in the setting of a bovine *ex vivo* experimental model using the TEM platform [37]. As surgery progresses to smaller and smaller incisions it is only natural that incisionless surgical techniques be pursued. Clearly more research into this cutting edge technology is necessary prior to its implementation in the world of surgery; however, initial reports are promising.

---

## References

1. Buess G, Kipfmuller K, Ibald R, Heintz A, Hack D, Braunstein S, Gabbert H, Junginger T. Clinical results of transanal endoscopic microsurgery. *Surg Endosc*. 1988;2:245–50.
2. Cataldo PA, O'Brien S, Osler T. Transanal endoscopic microsurgery: a prospective evaluation of functional results. *Dis Colon Rectum*. 2005;48:1366–71.
3. Cataldo PA. Transanal endoscopic microsurgery. *Surg Clin North Am*. 2006;86:915–25.
4. Buess GF, Misra MC, Bhattacharjee HK, Becerra Garcia FC, Bansal VK, Torres Bermudez JR. Single-port surgery and NOTES: from transanal endoscopic microsurgery and transvaginal laparoscopic cholecystectomy to transanal rectosigmoid resection. *Surg Laparosc Endosc Percutan Tech*. 2011;21(3):e110–9.
5. Saclarides TJ. Transanal endoscopic microsurgery. *Semin Laparosc Surg*. 2004;11(1):45–51.
6. Saclarides TJ. TEM/local excision: indications, techniques, outcomes, and the future. *J Surg Oncol*. 2007;96:644–50.
7. Burghardt J, Buess G. Transanal endoscopic microsurgery (TEM): a new technique and development during a time period of 20 years. *Surg Technol Int*. 2006;14:131–7.
8. Moore JS, Cataldo PA, Osler T, Hyman NH. Transanal endoscopic microsurgery is more effective than traditional transanal excision for resection of rectal masses. *Dis Colon Rectum*. 2008;51:1026–31.
9. Guerrieri M, Baldarelli M, de Sanctis A, Campagnacci R, Rimini M, Lezoche E. Treatment of rectal adenomas



- by transanal endoscopic microsurgery: 15 years' experience. *Surg Endosc*. 2010;24:445–9.
10. Bleday R, Breen E, Jessup JM, Burgess A, Sentovich S, Steele G. Prospective evaluation of local excision for small rectal cancers. *Dis Colon Rectum*. 1997;40:388–92.
  11. Steele GD, Herndon JE, Bleday R, Russell A, Benson A, Hussain M, Burges A, Tepper J, Mayer R. Sphincter-sparing treatment for distal rectal adenocarcinoma. *Ann Surg Oncol*. 1999;6:433–41.
  12. Mellgren A, Sirivongs P, Rothenberger A, Madoff R, Garcia-Aguilar J. Is local excision adequate therapy for early rectal cancer? *Dis Colon Rectum*. 2000;43(8):1064–71.
  13. Mellgren A, Goldberg J, Rothenberger D. Local excision—some reality testing. *Surg Oncol Clin N Am*. 2005;14(2):183–96.
  14. Madbouly K, Remzi F, Erkek B, Senagore A, Baeslach C, Khandwala F, Fazio V, Lavery I. Recurrence after transanal excision of T1 rectal cancer: should we be concerned? *Dis Colon Rectum*. 2005;48(4):711–21.
  15. Endreseth B, Myrvold H, Romundstad P, Hestvik U, Bjerkeset T, Wibe A. Transanal excision vs. major surgery for T1 rectal cancer. *Dis Colon Rectum*. 2005;48(7):1380–8.
  16. Sebag-Montefiore D, Stephens R, Steele R, Monson J, Grieve R, Khanna S, Quirke P, Couture J, de Metz C, Myint A, Bessell E, Griffiths G, Thompson L, Parmar M. Preoperative radiotherapy versus selective postoperative chemoradiotherapy in patients with rectal cancer (MRC CR07 and NCIC-CTG C016): a multicenter, randomised trial. *Lancet*. 2009;373(9666):811–20.
  17. Marks G, Mohiuddin M, Masoni L, Pecchioli L. High-dose preoperative radiation and full-thickness local excision. *Dis Colon Rectum*. 1990;33(9):735–9.
  18. Mohiuddin M, Marks G, Bannon J. High-dose preoperative radiation and full thickness local excision: a new option for selected T3 distal rectal cancers. *Int J Radiat Oncol Biol Phys*. 1994;30(4):845–9.
  19. Annamaneni R, Marks J, Hamdan W, Curran T, Mohiuddin M, Marks G. Full thickness local excision of prospectively staged T2 rectal cancers after neoadjuvant radiation/chemoradiation. Poster presented at: Society of Surgical Oncology Annual Cancer Symposium; 2005.
  20. Mizrahi B, Marks J, Dalane S, Marks G. T2 rectal cancer: a comparison of radical surgery and local excision by transanal endoscopic microsurgery following neoadjuvant therapy. Poster presented at: American Society of Colon & Rectal Surgeons Annual Scientific Meeting; Hollywood, FL; 2009.
  21. Lezoche E, Guerrieri M, Paganini A, Baldarelli M, De Sanctis A, Lezoche G. Long-term results in patients with T2-3 N0 distal rectal cancer undergoing radiotherapy before transanal endoscopic microsurgery. *Br J Surg*. 2005;92(12):1546–52.
  22. Saclarides T. Transanal endoscopic microsurgery: a single surgeon's experience. *Arch Surg*. 1998;133(6):595–9.
  23. Kikuchi R, Takano M, Takagi K, Fujimoto N, Nozaki R, Fujiyoshi T, Uchida Y. Management of early invasive colorectal cancer. *Dis Colon Rectum*. 1995;38(12):1286–95.
  24. Wibe A, Syse A, Andersen E, Tretli S, Myrvold H, Soreide O. Oncological outcomes after total mesorectal excision for cure for cancer of the lower rectum: anterior vs. abdominoperineal resection. *Dis Colon Rectum*. 2004;47(1):48–58.
  25. Sitzler P, Seow-Choen F, Ho Y, Leong A. Lymph node involvement and tumor depth in rectal cancers: an analysis of 805 patients. *Dis Colon Rectum*. 1997;40:1472–6.
  26. Brodsky J, Richard G, Cohen A, Minsky B. Variables correlated with the risk of lymph node metastasis in early rectal cancer. *Cancer*. 1992;69:322–6.
  27. Killingback M. Local excision of carcinoma of the rectum: indications. *World J Surg*. 1992;16:437–46.
  28. Blumberg D, Paty P, Guillem J, Picon A, Minsky B, Wond W, Cohen A. All patients with small intramural rectal cancers are at risk for lymph node metastasis. *Dis Colon Rectum*. 1999;42:881–5.
  29. Brown G, Radcliffe A, Newcombe R, Dallimore N, Bourne M, Williams G. Preoperative assessment of prognostic factors in rectal cancer using high-resolution magnetic resonance imaging. *Br J Surg*. 2003;90:355–64.
  30. Kim H, Wong W. Role of endorectal ultrasound in the conservative management of rectal cancers. *Semin Surg Oncol*. 2000;19:358–66.
  31. Marks JH, Valsdottir EB, DeNittis A, Yarandi SS, Newman DA, Nweze I, Mohiuddin M, Marks G. Transanal endoscopic microsurgery for the treatment of rectal cancer: comparison of wound complication rates with and without neoadjuvant radiation therapy. *Surg Endosc*. 2009;23:1081–7.
  32. Lezoche E, Guerrieri M, Paganini A, Feliciotti F. Long-term results of patients with pT2 rectal cancer treated with radiotherapy and transanal endoscopic microsurgical excision. *World J Surg*. 2002;26:1170–4.
  33. Marks J. TEM as a platform for NOTES. *J Gastrointest Surg*. 2011;15:1313–5.
  34. Albert M, Atallah S, deBeche-Adams T, Izfar S, Larach SW. Transanal minimally invasive surgery (TAMIS) for local excision of benign neoplasms and early-stage rectal cancer: efficacy and outcomes in the first 50 patients. *Dis Colon Rectum*. 2013;56(3):301–7.
  35. Atallah S, Albert M, Larach S. Transanal minimally invasive surgery: a giant leap forward. *Surg Endosc*. 2010;24:2200–5.
  36. Lacy A, Adelsdorfer C. Totally transrectal endoscopic total mesorectal excision. *Colorectal Dis*. 2011;13(7):43–6.
  37. Bhattacharjee HK, Buess GF, Becerra Garcia FC, Storz P, Sharma M, Susanu S, Kirschniak A, Misra M. A novel single-port technique for transanal rectosigmoid resection and colorectal anastomosis on an ex vivo experimental model. *Surg Endosc*. 2011;25:1844–57.

# Index

## A

Appendectomy, 13–14

## C

Chopstick surgery technique, 53

Curved laparoscopic instruments, 6–7

## E

EndoEYE™, 2

Endoluminal loco-regional resection (ELRR)

anterior lesions, 78, 79

malignant lesions, 78

posterior/lateral lesions, 78–79

Extended appendectomy, 13–14

## F

Flexible laparoscopic instruments, 7, 8

Full thickness excision, 77–78

## G

Glove-port technique, 3, 5, 55, 56

## I

Ileal pouch-anal anastomosis, 30–32

Inframuscular layers dissection, 77

## L

Left colectomy

clinical presentation, 19

complications, 26

equipment, 20–21

patient preparation, 20

patient selection, 20

postoperative management, 25

preoperative evaluation, 19–20

technique

colon transection, 23–24

colorectal anastomoses, 24–25

inferior mesenteric artery ligation, 22

inferior mesenteric vessel ligation, 23

lateral to medial approach, 25

left colon mobilization, 21

medial to lateral approach, 21–22

peritoneal cavity incision, 21

retraction, 22

splenic flexure, take down, 23

Left-sided colonic tumor, surgery for. *See* Natural orifice

transluminal endoscopic surgery (NOTES)

colectomy, hybrid

Local excision/resection, rectal cancer

informed consent, 74

local recurrence, 67, 68

neoadjuvant treatment, 71–73

patient selection

endoscopic mucosectomy, 69

histology, 69, 72

imaging tumor stage (iT), 69, 71

manometry, 71

rigid rectoscopy, 67–71

tattooing, 67, 69

vital dye technique, 67

preoperative staging, 73

transanal endoscopic microsurgery

anesthesia, 74

betadine and saline wash, 80

defect closure, 80–82

electric scalpel, 76

endoluminal excisions/resections, 77–78 (*see also*

Endoluminal loco-regional resection (ELRR))

free margins around tumor, 76–77

instrumentation, 75–76

intraoperative histological rims evaluation, 80

lavage, 76

mucosa incisional line, 76

nucleotide-guided mesorectal excision, 81–82

optics position, 76

patient positioning, 74

peritoneal opening, 79–80

rectoscope placement, 75

surgeon skill, 74

## M

Mucosectomy, 69, 77

**N**

- Natural orifice specimen extraction (NOSE), 85
- Natural orifice transluminal endoscopic surgery (NOTES) colectomy, hybrid
  - indications and contraindications, 85
  - operating room setup, 86
  - postoperative care, 90
  - procedure
    - colorectal anastomosis, 89–90
    - lateral to medial approach, 87
    - patient positioning, 86–87
    - preparation, 86
    - proximal transection and specimen retrieval, 88–89
    - rectal mobilization, 87, 88
    - TEO device insertion, 87–88
    - trocar placement, 86–87
  - recommended instruments, 86
- Nucleotide-guided mesorectal excision (NGME), 80–82

**P**

- Partial cecectomy, 13–14
- Proctocolectomy, total. *See* Total proctocolectomy

**R**

- Randomized controlled trials (RCT)
  - post-operation pain, 64–65
  - transabdominal sutures, 63–64
- Right colectomy
  - access devices, 13
  - complications, 15
  - contraindications, 11
  - energy devices, 13
  - incision, 14
  - indications, 11
  - inferior approach, 15
  - lateral-to-medial approach, 14–15
  - medial-to-lateral approach, 14
  - operating room, 12
  - optics, 13
  - outcomes, 16
  - postoperative care, 15
  - SILC vs. MPLC, 11–12
  - staplers and wound protection, 13
  - tissue management, 11–12
- Rigid rectoscopy, 67–71, 75
- Robotic colorectal surgery
  - access port, 50–51
  - advantages, 51–52
  - drawbacks, 52
  - future innovation, 58
  - learning curve, 57
  - literature reviews, 52–53
  - medical history, 49–50
  - outcomes, 56–58
  - robotic single site platform, 54
  - safety and feasibility, 51
  - surgical technique

- anastomosis, 56
- docked robotic arms, 56, 57
- glove port, 55, 56
- inferior mesenteric vessel ligation, 56
- medial-to-lateral dissection, 56
- operating room settings, 55
- patient positioning, 55
- patient selection, 54
- peritoneal incision, 56
- port reconstruction, 56
- trocars insertion, 55–56
- vertical transumbilical incision, 55
- technical consideration, 53
- terminology, 50

**S**

- SILS™, 3, 5
- Single-incision laparoscopic colectomy (SILC)
  - case reports and series, 62
  - vs. conventional laparoscopic colectomy
    - comparative studies, 62–64
    - randomized controlled trials, 63–65
  - learning curve, 65
  - left colectomy (*see* Left colectomy)
  - right colectomy (*see* Right colectomy)
  - short-term postoperative outcomes, 61
  - skills
    - access devices, ports, and port placement, 43
    - assistant, 43
    - conventional angled laparoscope/flexible tip scope, 44
    - fixed curved shaft instruments, 45
    - hand maneuvers, 45
    - incision location, 43–44
    - initial procedure selection, 42
    - left colectomy/sigmoid colectomy, 46
    - patient positioning, 43
    - patient selection, 41–42
    - right colectomy, 45–46
    - straight laparoscopes, 44–45
    - surgeon experience, 42
    - technical challenges, overcoming, 42–43
    - triangular instrument configuration, 45, 46
    - triangulation, 41
- Single-incision laparoscopy
  - access ports
    - GelPoint®, 4, 6
    - glove-port technique, 3, 5
    - SILS™, 3, 5
    - technical considerations, 3
    - TriPort™ and QuadPort™, 5, 6
    - vertical midline incision, 2–3
  - bipolar device, 8
  - challenges, 1
  - conversion, 8
  - instrument planning and unique combinations, 8
  - instruments
    - curved instruments, 6–7
    - flexible instruments, 7, 8

- straight instruments, 5–7
  - laparoscope, 2, 3
  - limitations, 2
  - medical history, 1–2
- Straight laparoscopic instruments, 5–7
  
- T**
- Total abdominal colectomy
  - abdominal cavity access, 32
  - benefits, 29
  - incision, 32
  - outcomes, 30
  - patient positioning, 32
  - 8 #1 polyglycolic acid suture, 33
  - published reports, 29–30
  - rectum transection, 32
  - side-to-side functional end anastomosis, 32–33
  - splenic flexure, 32
- Total mesorectal excision (TME)
  - rectal cancer, 35
  - single port TME
    - postoperative outcomes, 36–37
    - reviews, 37
    - technical feasibility, 36
  - transanal-transabdominal excision
    - with hand-sewn coloanal anastomosis, 38
    - transabdominal with stapled low colorectal anastomosis, 38
    - transanal *vs.* transabdominal approach, 37
- Total proctocolectomy
  - cosmetic benefits, 29
  - outcomes, 30
  - published reports, 29–30
  - technique
    - abdominal cavity access, 31
    - ileal pouch-anal anastomosis, 32
    - incision, 31
    - patient positioning, 30–31
    - 8 #1 polyglycolic acid suture, 32
    - rectal mobilization, 31
    - splenic flexure, 31
- Transanal endoluminal total mesorectal resection (TETMR)
  - complications, 98
  - double-stapling technique, 93
  - instrumentation, 94
  - laparoscopic procedure, 97
  - medical history, 93
  - operative time, 97
  - patient positioning
    - anterior lesions, 95–96
    - posterolateral lesions, 95
  - patient preparation, 94
  - protective ileostomy, 97
  - transanal endoscopic microsurgery
    - anterior lesions, 96–97
    - endoluminal loco-regional rectal surgery, 93–94
    - laparoscopy, 95
    - peritoneal reflection, 97
    - posterior lesions, 96
    - prone positioned patient, 97
    - rectoscope, 94, 95
    - working insert, 94–96
- Transanal endoscopic microsurgery (TEM)
  - anatomic considerations, 110
  - challenges
    - difficult technique, 111–112
    - expensive equipment, 111
    - limited indications, 112
  - contenance, 110–111
  - equipment
    - instruments, 102–103
    - setup, 102
  - historical perspective, 101
  - indications
    - benign disease, 107
    - malignancy, 107–108
  - local excision/resection (*see* Local excision/resection, rectal cancer)
  - NOTES, 112
  - oncologic outcomes, 111
  - operative technique
    - anastomosis, 105, 106
    - anesthesia, 105
    - full-thickness excision, 105, 106
    - margins of lesion, 105
    - multifunctional endosurgical unit set up, 105
    - proctoscope insertion, 104–105
  - overview, 101
  - patient positioning, 103, 104
  - patient preparation and selection, 108–110
  - personnel positioning, 103–104
  - postoperative complications, 111
  - technical pearls
    - air leak, 106
    - instrument placement and lubrication, 106–107
    - operating rectoscope reposition, 105–106
    - patient positioning, 105
    - suture, 107
  - TETMR (*See* Transanal endoluminal total mesorectal resection (TETMR))
  - transanal SILS, 112
- Transanal-transabdominal total mesorectal excision
  - with hand-sewn coloanal anastomosis, 38
  - with stapled low colorectal anastomosis, 38
  - transanal *vs.* transabdominal approach, 37
- Triangulation, 41–45
- TriPort™ and QuadPort™, 5, 6