

*Short Textbook of*

# **SURGERY**

With Focus on Clinical Skills

<http://vip.persianss.ir/>





# *Short Textbook of*

# **SURGERY**

**With Focus on Clinical Skills**

*(A Core Text including Long and Short Cases,  
Operative Surgery and Viva with Orthopedics and Fractures)*

**Himansu Roy** MD MS FAIS  
Assistant Professor  
Department of Surgery  
Medical College  
Kolkata, West Bengal, India

*Foreword*

**M Mukhopadhyay**



**JAYPEE BROTHERS MEDICAL PUBLISHERS (P) LTD**

**New Delhi • Panama City • London**

Published by

**Jaypee Brothers Medical Publishers (P) Ltd**

**Corporate Office**

4838/24 Ansari Road, Daryaganj, **New Delhi** - 110002, India

Phone: +91-11-43574357, Fax: +91-11-43574314

Website: www.jaypeebrothers.com

**Offices in India**

- **Ahmedabad**, e-mail: ahmedabad@jaypeebrothers.com
- **Bengaluru**, e-mail: bangalore@jaypeebrothers.com
- **Chennai**, e-mail: chennai@jaypeebrothers.com
- **Delhi**, e-mail: jaypee@jaypeebrothers.com
- **Hyderabad**, e-mail: hyderabad@jaypeebrothers.com
- **Kochi**, e-mail: kochi@jaypeebrothers.com
- **Kolkata**, e-mail: kolkata@jaypeebrothers.com
- **Lucknow**, e-mail: lucknow@jaypeebrothers.com
- **Mumbai**, e-mail: mumbai@jaypeebrothers.com
- **Nagpur**, e-mail: nagpur@jaypeebrothers.com

**Overseas Offices**

- **Central America Office, Panama City, Panama**, Ph: 001-507-317-0160, e-mail: cservice@jphmedical.com, Website: www.jphmedical.com
- **Europe Office, UK**, Ph: +44 (0) 2031708910, e-mail: info@jpmepub.com

**Short Textbook of Surgery**

© 2011, Jaypee Brothers Medical Publishers

All rights reserved. No part of this publication should be reproduced, stored in a retrieval system, or transmitted in any form or by any means: electronic, mechanical, photocopying, recording, or otherwise, without the prior written permission of the author and the publisher.

This book has been published in good faith that the material provided by author is original. Every effort is made to ensure accuracy of material, but the publisher, printer and author will not be held responsible for any inadvertent error (s). In case of any dispute, all legal matters are to be settled under Delhi jurisdiction only.

*First Edition* : **2011**

ISBN 978-81-8448-983-5

*Typeset at* JPBMP typesetting unit

*Printed at*

**Dedicated to**

*My  
Parents  
Teachers  
and  
Students*

<http://vip.Persianss.ir/>



## Foreword

It is a great pleasure for me to see Dr Himansu Roy as an author of *Short Textbook of Surgery—A Core Text including Long and Short Cases, Operative Surgery and Viva with Orthopedics and Fractures*. He is known to me since his student days and is presently a faculty in the Department of General Surgery, Medical College, Kolkata, West Bengal, India

The book is written in a point-to-point, step-wise pattern which will be very much helpful for the students preparing for the MBBS examination. This is a concise core text with adequate emphasis on clinical and operative surgery and also viva voce.

The book is informative and up-to-date with plenty of color photographs, figures and line diagrams which will be very helpful for easy understanding and assimilation of the subject.

I hope this book will be of great help to both the undergraduate and postgraduate students.

**M Mukhopadhyay** MBBS MS  
Professor and Head  
Department of General Surgery  
Medical College  
Kolkata, West Bengal, India



# Preface

It is really a vexed problem which I have felt since my student days both as an undergraduate and postgraduate trainee, to properly assimilate and reproduce the various topics in surgery during examination, even after consulting the comprehensive textbooks on the subject.

This has haunted me over the years to write a book which may be a tool to overcome this problem. The contents of the book have been divided into three parts. The first part deals with the physiological and basic aspects of surgery, the second with the various topics of surgery and orthopedics in a systematic manner, while the third is concerned with the practical and viva voce examination in surgery. The book also covers the specialties like anesthesia, radiology and oncology related to surgery.

Thus, I have tried to cover the entire field of surgery with particular emphasis on those chapters which are required for examinations by both undergraduate and postgraduate students.

The operative surgery section is intended to provide a step-by-step account of various procedures with reference to relevant surgical anatomy and supported by diagrams, wherever needed.

Viva voce involves facing the examiner across the table and is a nerve-wrecking experience. The art of answering the oral questions is to remain as simple as possible. The contents of the viva section have been presented keeping this fact in mind.

Although intended primarily for the undergraduates and those preparing for the postgraduate entrance tests, the postgraduate trainees will also find this book an enjoyable reading.

I have consulted many books and journals freely during preparation of this book, a list of which has been given at the end as bibliography.

I would feel my endeavor rewarded if the students find the book useful to pass the hurdles of examinations successfully.

Lastly, constructive criticisms and suggestions are always welcome from the readers and lovers of the subject.

**Himansu Roy**





# Acknowledgments

I would first like to express my gratitude to Prof (Dr) SN Banerjee, Director of Medical Education, Prof (Dr) Indrajit Saha, Joint Secretary, Department of Health and Family Welfare, Swastha Bhavan, Salt Lake City, Kolkata, West Bengal, India for giving me necessary permission to publish this book.

I would also like to express my thanks and gratitude to the following persons, for their help and encouragement:

- Dr M Mukherjee, Professor and Head; Dr TK Choudhury, Professor of Surgery; Dr KN Das, Professor of Surgery; Dr MK Das, Dr D Gautam, Associate Professors; Dr DK Das, Dr R Roy, Dr S Chatterjee, Dr K Maity, Assistant Professors and other faculty members of the Department of Surgery, Medical College, Kolkata, West Bengal, India.
- Dr S Mukherjee, Professor, Department of Surgery, RG Kar Medical College, Dr S Saha, Professor; Dr D Roy, Associate Professor, Department of Surgery, NRS Medical College, Kolkata, West Bengal, India.

I would like to thank Dr SK Sinha, Professor and Head and Dr TK Dutta, Associate Professor, Department of Pathology, Medical College, Kolkata, West Bengal, India for allowing me to take the photographs of surgical pathology specimens.

I am grateful to Dr Kamalesh Biswas, Diploma in Orthopedics (PGT), for helping me to write the orthopedics portion of the book.

I would like to express my gratitude and thanks to Librarians Sri Manas Bhattacharya and Smt Arundhati Basak and Assistant Librarian, Sri Satyajit Samanta, Medical College, Kolkata, West Bengal, India for providing me with various reference books and journals.

I am indebted to my wife Smt Maumita Roy and daughter Mouli whose constant inspiration and support acted as a moving force for the completion of this work.

I am grateful to Dr K Sur, Deputy Visiting Pediatrician, Ramkrishna Mission Seva Pratisthan and VIMS for his untiring help in many ways.

My deep appreciation remains for Shri Jitendar P Vij (Chairman and Managing Director), Mr Tarun Duneja (Director-Publishing), Mr Sabyasachi Hazra and Mr Sujay Dey (Kolkata branch) and all the members of M/s Jaypee Brothers Medical Publishers, New Delhi, India, for their help and encouragement in publishing this book.



# Contents

## PART I: GENERAL SURGERY

### Section 1 – Physiological Basis of Surgery

<b>1. Shock</b> .....	<b>3</b>
• Definition 3 • Clinical Features 3 • Classification of Shock 3 • Stages of Shock 3	
• Pathogenesis 3 • Organ Changes in Shock 4 • Investigations and Assessment 4 • Treatment 5	
<b>2. Wound Healing</b> .....	<b>6</b>
• Introduction 6 • Wound Healing 6 • Inflammation 6 • Formation of Granulation Tissue (Organization) 8 • Collagen Synthesis 9 • The Healing Sequence 11 • Regulation of Wound Healing by Growth Factors 11 • Factors Influencing Wound Healing 12 • Disorders of Scarring 13	
• Healing of Specialized Tissues 13 • Classification of Wounds 14 • Types of Wound 14	
<b>3. Hemorrhage and Blood Transfusion</b> .....	<b>16</b>
• Hemorrhage 16 • Estimation of the Amount of Blood Loss 17 • Blood Transfusion 17	
• Massive Transfusion 19 • Plasma and Blood Substitutes 19 • Preservation and Storage of Blood 19	
• Preparation for Blood Transfusion—Blood Grouping, Antibody Screening and Cross Matching 20	
• Hazards or Complications of Blood Transfusion 21 • Autologous Transfusion 22	
<b>4. Hemostasis and Coagulation</b> .....	<b>23</b>
• Phases of Hemostasis 23 • Inhibitors of Coagulation 24 • General Mechanism 25	
• Fibrinolysis 26 • Laboratory Tests for Hemostasis 26 • Acquired Disorders of Coagulation 27	
• Congenital Disorders of Coagulation 29 • Platelet Disorders 29 • Investigation of a Patient with Bleeding Disorders 30 • Hypercoagulable States and Thrombotic Disease or Thrombophilia 30	
<b>5. Fluid and Electrolyte Balance</b> .....	<b>32</b>
• Introduction 32 • Fluid Compartments 32 • Interpretation of Fluid Balance 33 • Which Fluids Go Where? 34 • Normal Water and Electrolyte Balance 35 • Disorders of Fluid and Electrolyte Balance 36 • Fluid Therapy 40 • Fluid Replacement 41 • The Fluid Rule 42	
<b>6. Acid-base Balance</b> .....	<b>43</b>
• Introduction 43 • Body Fluid Buffer Systems 43 • Role of the Lungs 44 • Role of the Kidneys 44	
• Definition of Acid-base Terms 46 • Metabolic Acidosis 46 • Metabolic Alkalosis 47 • Respiratory Acidosis 48 • Respiratory Alkalosis 49	
<b>7. Nutrition in Surgery</b> .....	<b>50</b>
• Introduction 50 • Assessment of Nutritional Status 50 • Indications of Nutritional Support 51	
• Nutritional Requirements 52 • Nutrient Mixing 52 • Routes for Nutritional Support—Enteral or Parenteral Nutritional Support 52 • Enteral Nutrition 52 • Total Parenteral Nutrition 53	
• Complications 54	
<b>8. Endocrine and Metabolic Response to Injury</b> .....	<b>55</b>
• Introduction 55 • Systems Controlling the Response 55 • Metabolism after Injury 57 • Factors Determining the Magnitude of Metabolic Response 59 • Factors Reducing the Metabolic Response and Quick Recovery 59	

**Section 2 – Surgical Infection and Burn**

**9. Surgical Infections ..... 60**  
 • Definition 60 • Determinants of Infection 60 • Source of Infection 61 • Folliculitis, Furuncle, Carbuncle 61 • Hydradenitis Suppurativa 62 • Abscess 62 • Cellulitis 63 • Lymphangitis and Lymphadenitis 63 • Erysipelas 63 • Dog and Cat Bite Wounds 64 • Drug Injection Abscess 64 • Necrotizing Fasciitis 64 • Gas Gangrene 64 • Tetanus 64 • Infections of Hand and Foot 65 • Fibrous Flexor Sheaths 66 • Foot Infections 67 • Fungal Infections 69 • Hospital Acquired (Nosocomial) Infections 69 • Surgical Infections of Abdomen 71 • Surgical Infections of Thorax 72 • Pathogens in Surgical Infection 72 • Antibiotics 72 • Antibiotic Policy 73

**10. Burns ..... 75**  
 • Definition 75 • Classification of Burns 75 • Pathophysiology 76 • Systemic Effects of Burn 76 • Treatment 77 • Other Types of Burn Injury 78 • Complications of Burn Injury 78 • Postburn Contracture 78

**Section 3 – Skin and Cysts**

**11. Keloid and Hypertrophic Scar ..... 80**  
 • Hypertrophic Scar 80 • Keloid 80

**12. Tumors of the Skin ..... 82**  
 • Classification 82 • Papilloma 83 • Basal Cell Carcinoma 83 • Squamous Cell Carcinoma 84 • Melanoma 85 • Marjolin’s Ulcer 87 • Hemangioma 87 • Lipoma 88 • Neurofibroma 89 • von Recklinghausen’s Disease 89 • Plexiform Neurofibromatosis 89 • Cutaneous Neurofibromatosis 90

**13. Skin Grafting ..... 91**  
 • Types of Skin Graft 91 • Procedure of Partial Thickness Graft 91

**14. Cysts ..... 93**  
 • Cyst 93 • Dermoid Cyst 93 • Sebaceous Cyst 94 • Mesenteric Cyst 94

**Section 4 – Specialties Related to Surgery**

**15. Principles of Anesthesia ..... 96**  
 • Preoperative Evaluation and Premedication 96 • Techniques of Anesthesia 99 • General Anesthesia 99 • Monitoring during Anesthesia 105 • Recovery from General Anesthesia 105 • Regional Anesthesia 105 • Local Anesthetic Agents—Pharmacology 106 • Types of Regional Anesthesia 106 • Spinal Anesthesia 107 • Epidural Anesthesia 108 • Extradural Sacral Block or Caudal Block 108 • Some Common Postoperative Complications 108

**16. Clinical Oncology ..... 112**  
 • Neoplasm 112 • Sarcoma 112 • Carcinoma 113 • Disorders of Growth 113 • Etiology of Cancer 113 • Growth and Spread of Malignant Neoplasms 114 • Treatment of Cancer 114

**17. Imaging in Surgery ..... 118**  
 • Plain Radiograph 118 • Mammography 118 • Special Radiological Techniques using Contrast Media 118 • Ultrasonography 119 • CT Scan and Magnetic Resonance Imaging 120 • Radioisotope Scan 120

**PART II: SYSTEMIC SURGERY INCLUDING ORTHOPEDICS**

***Section 5 – Head and Neck Swellings***

**18. Salivary Glands** ..... 123  
 • Surgical Anatomy 123 • Parotid Swellings 124 • Parotid Fistula 126 • Submandibular  
 Calculi 126 • Carcinoma of Submandibular Salivary Gland 127

**19. The Gums and Jaws** ..... 128  
 • Jaw Tumors 128 • Epulis 128 • Odontomes 128 • Dental Cyst 129 • Dentigerous Cyst 129  
 • Adamantinoma 130 • Tumors of the Jaw Bones 130

**20. Cleft Lip and Cleft Palate** ..... 131  
 • Embryology 131 • Cleft Lip 131 • Cleft Palate 132

**21. The Tongue and Lip** ..... 134  
 • Surgical Anatomy 134 • Ulcers of Tongue 135 • Glossitis 136 • Tumors of Tongue 136  
 • Lip 138

**22. Neck Swellings** ..... 139  
 • Surgical Anatomy 139 • Classification 139 • Ranula 139 • Sublingual and Cervical Dermoid 140  
 • Branchial Cyst 142 • Branchial Fistula 142 • Cystic Hygroma 143 • Cold Abscess 143  
 • Cervical Lymphadenopathy 144 • Carotid Body Tumor 145 • Sternomastoid Tumor 145  
 • Pharyngeal Pouch 145

***Section 6 – Endocrine Surgery***

**23. Thyroid Gland** ..... 146  
 • Surgical Anatomy 146 • Physiology 148 • Investigations—Tests of Thyroid Function 149  
 • Congenital Anomalies 150 • Goiter 151 • Non-Toxic Goiter 151 • Toxic Goiter  
 (Thyrotoxicosis) 152 • Solitary Thyroid Nodule 154 • Neoplastic Goiter 156 • Autoimmune  
 Thyroiditis (Hashimoto’s Disease) 158 • Subacute Thyroiditis 158 • Riedel’s Thyroiditis 159

**24. Parathyroids** ..... 160  
 • Anatomy 160 • Physiology 160 • Hyperparathyroidism 160 • Hypoparathyroidism 162

**25. The Adrenal Glands** ..... 163  
 • Development 163 • Anatomy 163 • Histology 163 • Tumors of Adrenal Medulla 163  
 • The Adrenal Cortex 165 • Adrenal Incidentaloma 167 • Adrenal Insufficiency 168

***Section 7 – Vascular Surgery***

**26. Arterial Disorders** ..... 169  
 • Arterial Occlusion 169 • Intermittent Claudication (Ischemic Muscle Pain) 169 • Atherosclerosis 170  
 • Critical Limb Ischemia 170 • Arterial Dilatation Aneurysm 170 • Abdominal Aortic Aneurysm 171  
 • Gangrene 172 • Pressure Sores 174 • Raynaud’s Syndrome 174 • Thoracic Outlet  
 Syndrome 175 • Buerger’s Disease 175

**27. Varicose Vein, Deep Vein Thrombosis, Pulmonary Embolism** ..... 177  
 • Varicose Vein 177 • Deep Vein Thrombosis 180 • Pulmonary Embolism 181

**28. Lymphatics and Lymph Nodes** ..... 182  
 • Diseases of the Lymphatics 182 • Diseases of the Lymph Nodes 183

**Section 8 – Gastrointestinal Surgery**

**29. Esophagus and Diaphragm ..... 187**  
 • Esophagus 187 • Dysphagia 188 • Achalasia of the Cardia (Cardiospasm) 188 • Plummer-Vinson Syndrome (Paterson and Kelly Syndrome) 189 • Tumors of the Esophagus 189  
 • Carcinoma of Esophagus 189 • Diaphragmatic Hernia 190 • Congenital Diaphragmatic Hernia 190 • Eventration of Diaphragm 190 • Acquired Diaphragmatic Hernia 190

**30. Stomach and Duodenum ..... 192**  
 • Anatomy 192 • Congenital Hypertrophic Pyloric Stenosis 193 • Gastritis 193 • Peptic Ulcers 194 • Duodenal Ulcer 195 • Perforated Gastric or Duodenal Ulcer 196 • Peptic Ulcer Hemorrhage 196 • Pyloric Stenosis 197 • Gastric Ulcer 198 • Gastric Carcinoma 199  
 • Zollinger-Ellison Syndrome 200

**31. Small Intestine ..... 201**  
 • Small Intestine 201 • Intestinal Tuberculosis 202 • Ulcerative Tuberculosis 202 • Hyperplastic Ileocecal Tuberculosis 202 • Crohn’s Disease 202 • Diverticular Disorders 203 • Short Bowel Syndrome 204 • Typhoid Enteritis 205 • Neoplasms 205 • Enterocutaneous Fistula 206

**32. Large Intestine ..... 207**  
 • Anatomy 207 • Blood Supply 207 • Lymphatic Drainage 208 • Nerve Supply 208  
 • Hirschsprung’s Disease 208 • Ulcerative Colitis 209

**33. The Appendix ..... 211**  
 • Surgical Anatomy 211 • Anatomical Positions 211 • Blood Supply 211 • Appendicitis 212  
 • Laparoscopic Appendectomy 214 • Neoplasms of the Appendix 214 • Carcinoid Tumor 214 • Adenocarcinoma 214 • Malignant Mucocele 214

**34. Intestinal Obstruction ..... 215**  
 • Intestinal Obstruction 215 • Paralytic Ileus 217 • Neonatal Intestinal Obstruction 217  
 • Intussusception 218 • Volvulus 219

**35. Rectum and Anal Canal ..... 221**  
 • Rectum 221 • Anal Canal 222 • Prolapse of Rectum 223 • Colorectal Carcinoma 224  
 • Anorectal Anomalies 226 • Hemorrhoids (Piles) 227 • Anorectal Abscess 228 • Fistula In Ano 228 • Anal Fissure (Fissure In Ano) 229

**Section 9 – Hepatobiliary, Pancreas and Spleen**

**36. Liver ..... 230**  
 • Surgical Anatomy 230 • Functional Anatomy: Hepatic Segments 230 • Microscopic Anatomy 231  
 • Functions of Liver 232 • Amebic Liver Abscess 232 • Pyogenic Liver Abscess 232 • Hydatid Cyst of Liver 233 • Liver Neoplasms 234 • Portal Hypertension 235 • Budd-Chiari Syndrome 238

**37. Gallbladder ..... 239**  
 • Surgical Anatomy 239 • Congenital Disorders of Gallbladder 240 • Gallstone 240  
 • Cholecystitis 242 • Stones in the Common Bile Duct 243 • White Bile 244 • Courvoisier’s Law 244 • Surgical Jaundice (Obstructive Jaundice) 244 • Carcinoma Gallbladder 245

**38. Pancreas ..... 246**  
 • Surgical Anatomy 246 • Physiology 247 • Pancreatitis 248 • Surgery 251 • Pancreatic Cysts 251  
 • Pseudopancreatic Cyst 251 • Tumors of the Pancreas 252

**39. Spleen ..... 254**  
 • Surgical Anatomy 254 • Blood Supply 254 • Functions 254 • Splenomegaly 255  
 • Splenectomy 255 • Splenic Injury (Rupture Spleen) 255

**Section 10 – Umbilicus, Abdominal Wall, Peritoneum and Herniae**

- 40. Umbilicus and Abdominal Wall** ..... 256  
 • Embryology 256 • Anomalies of Development 256 • Diseases of the Umbilicus 257  
 • Abdominal Wall 258
- 41. The Peritoneum** ..... 260  
 • Surgical Anatomy 260 • Peritoneal Cavity 260 • Peritonitis 260 • Subphrenic Abscess 262  
 • Pelvic Abscess 262 • Special Types of Peritonitis 262
- 42. Hernia** ..... 264  
 • Definition 264 • Inguinal Hernia 264 • Nyhus Classification for Groin Hernia 267 • Differential  
 Diagnosis of Groin Swellings 267 • Special Varieties of Inguinal Hernia 267 • Recurrent Inguinal  
 Hernia 267 • Strangulated Inguinal Hernia 268 • Laparoscopic Inguinal Hernia Repair 268  
 • Femoral Hernia 268 • Femoral Sheath 269 • Epigastric Hernia 270 • Umbilical Hernia 270  
 • Adult Umbilical Hernia 270 • Incisional Hernia 271 • Some Rare External Herniae 273

**Section 11 – Breast Surgery**

- 43. The Breast** ..... 274  
 • Surgical Anatomy of the Breast 274 • Benign Breast Disease 275 • Aberrations of  
 Normal Development and Involution (ANDI) 276 • Infective Disorders 277 • Miscellaneous  
 Conditions 278 • Presentation of Breast Disease 279
- 44. Malignant Disease of the Breast** ..... 280  
 • Carcinoma of the Female Breast 280 • Treatment of Breast Cancer 282

**Section 12 – Urology**

- 45. Symptoms of Urinary Disease** ..... 283  
 • Symptoms 283 • Nonspecific Symptoms 283 • Physical Examination of the Genitourinary  
 System 284 • Investigations of the Urinary Tract 284
- 46. Kidney and Ureter** ..... 286  
 • Embryology 286 • Surgical Anatomy 286 • Relations 287 • Congenital Anomalies of Kidneys  
 and Ureters 287 • Horseshoe Kidney 288 • Polycystic Kidney 288 • Solitary Renal Cyst 289  
 • Hydronephrosis 289 • Renal Stone 290 • Ureteric Stone 292 • Renal Infection 293 • Acute  
 Pyelonephritis 294 • Pyonephrosis 294 • Perinephric Abscess 295 • Renal Carbuncle 295  
 • Chronic Pyelonephritis 295 • Renal Neoplasms 295 • Nephroblastoma (Wilms' Tumor or  
 Embryoma of the Kidney) 295 • Adenocarcinoma (Hypernephroma) 296 • Tumors of Renal Pelvis  
 and Ureter 297 • Squamous Cell Carcinoma of Renal Pelvis 297
- 47. Urinary Bladder** ..... 298  
 • Embryology 298 • Surgical Anatomy 298 • Common Congenital Anomalies of Urinary  
 Bladder 299 • Cystitis 300 • Schistosomiasis of the Bladder 302 • Thimble Bladder 303 • Tumors  
 of the Bladder 303 • Carcinoma of the Bladder 303 • Urinary Incontinence 304 • Retention of  
 Urine 305 • Vesical Fistula 306 • Urinary Diversion 306 • Ileal Loop Conduit 307 • Neurogenic  
 Bladder 307
- 48. Renal Failure and Transplantation** ..... 309  
 • Acute Renal Failure 309 • Chronic Renal Failure 310 • Renal Transplantation 311
- 49. Urethra and Penis** ..... 313  
 • Urethra 313 • Phimosis 315 • Paraphimosis 315 • Carcinoma Penis 316 • Peyronie's Disease 317



<b>50. Prostate</b> .....	<b>318</b>
• Surgical Anatomy 318 • Histology 318 • Relations 319 • Blood Supply 319 • Physiology 319	
• Development 319 • Benign Enlargement of Prostate (Benign Prostatic Hypertrophy) 319	
• Carcinoma Prostate 321	
<b>51. Testis and Scrotum</b> .....	<b>323</b>
• Embryology 323 • Descent of Testis 324 • Testes 324 • Undescended Testis 325 • Testicular Torsion 326 • Testicular Tumor 327 • Hydrocele 328 • Varicocele 329 • Epididymal Cyst 330	
• Spermatocele 330 • Degeneration Cysts 330 • Epididymo-orchitis 330 • Elephantiasis of Scrotum 331 • Idiopathic (Fournier's) Gangrene of Scrotum 332	

### Section 13 - Trauma

<b>52. Evaluation and General Management of Trauma</b> .....	<b>333</b>
• Injury Control 333	
<b>53. Head Injury</b> .....	<b>336</b>
• Classification 336 • Pathology 336 • Management 337 • Intracranial Hemorrhage 338	
• Fracture of Skull Bone 338	
<b>54. Thoracic Trauma</b> .....	<b>339</b>
• Types 339 • Management 339 • Investigations 340 • Specific Injuries 340 • Traumatic Hemothorax 341 • Pulmonary Contusion 341 • Tracheal and Bronchial Injury 341	
• Cardiovascular Injury 341 • Cardiac Contusion and Rupture 341 • Diaphragmatic Injury 342 • Esophageal Injury 342	
<b>55. Abdominal Trauma</b> .....	<b>343</b>
• Classification 343 • Management 343 • Laparotomy 344 • Specific Injuries 344	
• Retroperitoneal Hematoma 346 • Damage Control Surgery in Major Trauma 346	
• Abdominal Compartment Syndrome 347	
<b>56. Genitourinary Tract Trauma</b> .....	<b>348</b>
• Kidney Injury 348 • Ureteric Injury 349 • Bladder Injury 349 • Injuries to the Urethra 350	

### Section 14 - Orthopedics

<b>57. Fractures and Dislocations—General Considerations</b> .....	<b>352</b>
• Definitions 352 • Classification of Fractures 352 • Healing of a Fracture 353 • Treatment of Fracture 354 • Reduction 354 • Complications of Fractures 356	
<b>58. Fractures and Dislocations of the Upper Limb</b> .....	<b>362</b>
• Fracture Clavicle 362 • Dislocation of Shoulder 362 • Fracture Through the Proximal Humerus 364 • Fracture of the Shaft of Humerus 364 • Supracondylar Fracture of Humerus 365	
• Dislocation of the Elbow 366 • Fracture of the Radius and Ulna 366 • Fracture Dislocations of the Forearm 366 • Pulled Elbow 367 • Colle's Fracture 368 • Fracture of Scaphoid 369	
<b>59. Fractures and Dislocations of the Lower Limb</b> .....	<b>370</b>
• Dislocation of the Hip 370 • Fracture of the Neck of the Femur 371 • Fracture Shaft of Femur 373 • Condylar Fractures of Femur 374 • Fracture Patella 374 • Traumatic Dislocation of Patella 375 • Soft Tissue Injuries of the Knee 375 • Meniscal Injury 376 • Fractures of Shafts of Tibia and Fibula 377 • Fractures of Single Leg Bone 378 • Ankle Fractures 378 • Fracture Calcaneum 379 • Ruptured Tendo-Achilles 379	
<b>60. Osteomyelitis</b> .....	<b>380</b>
• Definition 380 • Types 380 • Acute Pyogenic Osteomyelitis 380 • Chronic Osteomyelitis 382	



## Contents

<b>61. Bone Tumors</b> .....	<b>384</b>
• Benign Tumors 384 • Malignant Tumors 385 • Secondary Carcinoma of Bone 389 • Tumor-like Conditions of Bone 389	
<b>62. Tuberculosis of Bones and Joints</b> .....	<b>391</b>
• Tuberculosis of Spine 391 • Tuberculosis of Hip 394 • Tuberculosis of Knee 396	
<b>63. Perthes Disease</b> .....	<b>397</b>
• Perthes Disease 397	
<b>64. Congenital Dislocation of Hip</b> .....	<b>399</b>
• Definition 399 • Etiology 399 • Pathological Anatomy 399 • Clinical Features 399 • Investigations 400 • Treatment 400	
<b>65. Congenital Talipes Equinovarus and Other Deformities of the Foot</b> .....	<b>402</b>
• Deformities of Foot 402 • Talipes Equinovarus 403 • Congenital Talipes Equinovarus 403	
<b>66. Miscellaneous Affections of the Soft Tissues</b> .....	<b>406</b>
• Bursitis 406 • Tenosynovitis 406 • Dupuytren's Contracture 406 • Mallet Finger 407 • Trigger Finger 407 • De-Quervain's Disease 407 • Ganglion 408 • Compound Palmar Ganglion 408 • Carpal Tunnel Syndrome 408 • Tennis Elbow 409 • Golfer's Elbow 409 • Plantar Fasciitis 409 • Marrant Baker's Cyst 409 • Ruptured Biceps Tendon 410 • Frozen Shoulder 410	
<b>67. Amputations</b> .....	<b>411</b>
• Indications 411 • Types 411 • General Principles—Closed Type 412 • Complications of Amputation 412 • Recommended Ideal Length of the Stump 412 • An Ideal Amputation Stump 413	

## PART III: PRACTICALS AND VIVA IN SURGERY

### Section 15A – Clinical Surgery (Long Cases)

<b>68. Writing a Surgical Long Case</b> .....	<b>417</b>
• Introduction 417 • General Plan of Writing a Surgical Long Case 417	
<b>69. Examination of a Swelling or Tumor</b> .....	<b>420</b>
• General Plan of Examination of a Swelling or Tumor 420	
<b>70. Examination of an Ulcer</b> .....	<b>422</b>
• General Plan of Examination of an Ulcer 422	
<b>71. Thyroid Swelling</b> .....	<b>424</b>
• General Plan of Examination of Thyroid Swelling 424 • Primary Thyrotoxicosis 429 • Thyroid Carcinoma 432 • Nontoxic Multinodular Goiter 434 • Hypothyroidism 436 • Retrosternal Goiter 436	
<b>72. Breast Carcinoma</b> .....	<b>437</b>
• General Plan of Examination of a Case of Carcinoma Breast 437 • Early Carcinoma of Breast 440 • Locally Advanced Breast Carcinoma 445 • Breast Carcinoma with Distant Metastasis 445 • Breast Reconstruction 446	
<b>73. Abdomen</b> .....	<b>448</b>
• General Plan of Examination of an Abdominal Case 448 • Gastric Carcinoma 453 • Gastric Outlet Obstruction (Pyloric Stenosis) due to Complication of Chronic Duodenal Ulcer 457 • Chronic Duodenal Ulcer 459 • Chronic Cholecystitis 463 • Mucocele of Gallbladder 465 • Obstructive	

Jaundice due to Periampullary Carcinoma 466 • Obstructive Jaundice due to Stone in CBD 468  
 • Obstructive Jaundice due to Carcinoma of Gallbladder 469 • Obstructive Jaundice due to  
 Postcholecystectomy; Stricture of CBD 470 • Hydatid Cyst of Liver 471 • Pseudocyst of  
 Pancreas 474 • On Examination of Abdomen 474 • Carcinoma of Colon 475

**74. Hernias ..... 479**  
 • General Plan of Writing a Case of Hernia 479 • Reducible Indirect Inguinal Hernia 480  
 • Incisional Hernia 482

**75. Renal Cases ..... 484**  
 • General Plan of Writing a Renal Case 484 • Renal Cell Carcinoma 485 • Hydronephrosis 486

**76. Varicose Vein ..... 489**  
 • General Plan of Writing a Case of Varicose Vein 489 • Varicose Vein 491

**77. Buerger’s Disease ..... 494**  
 • General Plan of Examination of a Case of Peripheral Vascular Disease and Gangrene  
 (Buerger’s Disease) 494 • Buerger’s Disease 496

**78. Orthopedic Long Cases: Hip Joint ..... 499**  
 • General Plan of Examination of Hip Joint 499 • Tuberculosis of Hip 502 • Perthes  
 Disease 506 • Caries Spine 507 • Osteomyelitis 510 • Nonunited Fracture Neck of Femur 512

***Section 15B – Clinical Surgery (Short Cases)***

**79. Skin and Subcutaneous Tissue ..... 514**  
 • Introduction 514 • Sebaceous Cyst 514 • Dermoid Cyst 515 • Hemangioma 515  
 • Lipoma 516 • Neurofibroma 517 • Keloid 518 • Basal Cell Carcinoma 518 • Squamous Cell  
 Carcinoma 519 • Malignant Melanoma 520 • Marjolin’s Ulcer 522

**80. Neck Swellings ..... 524**  
 • Ranula 524 • Cystic Hygroma 524 • Branchial Cyst 525 • Branchial Sinus 525 • Thyroglossal  
 Cyst 525 • Tubercular Cervical Lymphadenopathy 526

**81. Salivary Glands ..... 527**  
 • Parotid Swelling (Mixed Parotid Tumor) 527 • Carcinoma of Parotid Gland 528 • Parotid  
 Fistula 530 • Chronic Submandibular Sialoadenitis due to Submandibular Duct Calculus 530  
 • Carcinoma of Submandibular Salivary Gland 531

**82. Mouth and Oral Cavity ..... 532**  
 • Cleft Lip 532 • Cleft Palate 532 • Carcinoma Tongue 532 • Carcinoma Lip 534

**83. Hernia, Breast and Abdominal Wall ..... 535**  
 • Congenital Hernia 535 • Epigastric Hernia 535 • Umbilical Hernia 536 • Femoral  
 Hernia 536 • Lumbar Hernia 536 • Desmoid Tumor 536 • Raspberry Tumor 537  
 • Vitellointestinal Fistula or Persistent Vitellointestinal Duct 537 • Urachal Fistula 537 • Breast 538

**84. External Genitalia and Urethra ..... 540**  
 • Testicular Tumor 540 • Undescended Testis 541 • Hydrocele 542 • Encysted Hydrocele of  
 the Cord 543 • Varicocele 544 • Filariasis of Scrotum 544 • Phimosis 545 • Hypospadias 546  
 • Carcinoma Penis 546

**85. Orthopedics—Short Cases ..... 549**  
 • Cubitus Valgus 549 • Cubitus Varus 549 • Wrist Drop 550 • Claw Hand 551 • Ganglion 552  
 • Genu Varum 552 • Genu Valgum 553 • Semimembranosus Bursitis 553 • Recurrent Dislocation  
 of Patella 554 • Congenital Talipes Equinovarus 555 • Exostosis 555 • Osteosarcoma 556

***Section 16 – Operative Surgery***

<b>86. The Thyroid</b>	<b>557</b>
• Introduction 557 • Thyroidectomy 557 • Operations of the Thyroid 557 • Steps of Operation of Total Thyroidectomy 558 • Postoperative Complications 559 • Important Preoperative Management 560	
<b>87. The Breast</b>	<b>561</b>
• Simple Mastectomy 561 • Radical Mastectomy 561 • Modified Radical Mastectomy (Patey's Operation) 562 • Drainage of Breast Abscess 562 • Fibroadenoma 564	
<b>88. The Abdomen—General</b>	<b>565</b>
• Abdominal Incisions and Closure 565 • Individual Incisions 565 • Closure of Abdominal Wounds 567 • Exploratory Laparotomy 567 • Colostomy 568 • Loop Ileostomy 569	
<b>89. Stomach and Duodenum</b>	<b>570</b>
• Surgical Anatomy of Vagus Nerves 570 • Types of Vagotomy 570 • Gastrojejunostomy 571 • Operation for Peptic Ulcer Perforation 572 • Gastrectomy 572 • Pyloromyotomy—Ramstedt's Operation 573 • Heller's Esophagocardiomyotomy 574	
<b>90. Hepatobiliary and Pancreas</b>	<b>575</b>
• Cholecystectomy 575 • Laparoscopic Cholecystectomy 576 • Choledocholithotomy 578 • Choledochoduodenostomy 579 • Cystogastrostomy 579	
<b>91. The Spleen: Splenectomy</b>	<b>581</b>
• Indications 581 • Preoperative Care 581 • Steps of Operation 581	
<b>92. The Appendix: Appendicectomy</b>	<b>583</b>
• Surgical Anatomy 583 • Indications 583 • Steps of Operation 583	
<b>93. Small Bowel</b>	<b>585</b>
• Small Bowel Resection and Anastomosis 585 • Meckel's Diverticulectomy 586 • Strictureplasty 587 • Feeding Jejunostomy 587 • The Roux Loop 588	
<b>94. Large Bowel</b>	<b>589</b>
• Right Hemicolectomy 589 • Left Hemicolectomy 590 • Sigmoid Colectomy 591 • Colostomy 591 • Abdominoperineal Resection (APR) of Rectum 591 • Rectal Prolapse Operations 593	
<b>95. Anal and Perianal Operations</b>	<b>594</b>
• Hemorrhoidectomy 594 • Anal Fissures 595 • Anal Stretching 595 • Operation for Fistula In Ano (Fistulectomy) 595	
<b>96. Hernia</b>	<b>596</b>
• Operations for Inguinal Hernia 596 • Inguinal Hernia Repair in Infants and Children—Herniotomy 596 • Inguinal Hernia Repair Operations in Adults (Herniorrhaphy and Hernioplasty) 597 • Strangulated Inguinal Hernia 598 • Laparoscopic Hernia Repair 598 • Femoral Hernia Repair 598 • Operation for Epigastric Hernia 599 • Operation for Infantile Umbilical Hernia 599 • Operation for Adult Umbilical Hernia 599 • Operation for Incisional Hernia 599	
<b>97. Operations on Urology</b>	<b>602</b>
• Nephrectomy 602 • Open Surgery for Renal Calculi 603 • Anderson-Hynes Pyeloplasty 603 • Operation for Ureteric Stones—Ureterolithotomy 604 • Suprapubic Cystostomy 605 • Prostatectomy 605 • Circumcision 606 • Meatotomy and Meatoplasty 607 • Amputation of Penis 607 • Orchidopexy 609 • Orchidectomy 609 • Operation of Hydrocele 610 • Operation of Varicocele 611	

<b>98. Vascular Surgery</b> .....	<b>613</b>
• Lumbar Sympathectomy 613 • Operations for Varicose Vein 614 • Trendelenburg's Operation and Stripping of Long Saphenous Vein 614 • Ligation of Calf Perforators (Cockett and Dodd's Procedure) 615 • Saphenopopliteal Ligation and Stripping 615 • Multiple Phlebectomies 616 • New Alternative Treatments 616	
<b>99. Some Minor Surgical Procedures</b> .....	<b>617</b>
• Establishing an Intravenous Line 617 • Venepuncture 617 • Venesection 617 • Insertion of Nasogastric Tube 618 • Insertion of Intercostal Drain 618 • Lymph Node Biopsy 619 • Excision of Sebaceous Cyst 619 • Excision of Lipoma 620 • Operation for Ingrowing Toenail 620 • Catheterization 620 • Urethral Dilatation 621	
<b>100. Orthopedic Operations</b> .....	<b>622</b>
• Patellectomy 622 • Excision of Medial Semilunar Cartilage 622 • Intramedullary Nailing 623 • Nerve Repair 624 • Tendon Repair 624	

**Section 17 – Viva Voce in Surgery**

<b>101. Surgical Pathology (Specimens)</b> .....	<b>626</b>
• Introduction 626 • Gastrointestinal Specimens 626 • Urology Specimens 633 • Orthopedic Specimens 636	
<b>102. Problems</b> .....	<b>638</b>
• Introduction 638 • Gastrointestinal Surgery 638 • Thyroid 643 • Breast 643 • Trauma 644 • Urology 646 • Preoperative Preparations 647	
<b>103. X-rays</b> .....	<b>649</b>
• Introduction 649 • Plain X-ray Abdomen 649 • Radiopaque Shadows in Plain X-ray 651 • Chest X-ray 653 • Contrast Films 654 • Oral Cholecystography 657 • Endoscopic Retrograde Cholangiopancreatography 658 • T-tube Cholangiography 658 • Intravenous Urogram or Pyelogram 659 • Ultrasonography 660 • CT Scan and MRI 660 • MRI Scan 660 • Orthopedic X-rays 661	
<b>104. Instruments</b> .....	<b>664</b>
• Introduction 664 • Parts of a Typical Surgical Instrument 664 • Instruments for Preparing and Draping 664 • Instruments for Skin Incision 665 • Instruments for Hemostasis 666 • Retractors 667 • Dissecting Forceps 668 • Tissues Holding Forceps 669 • Scissors 670 • Instruments for Tissue Approximation and Wound Closure 670 • Polyglactin Sutures 671 • Gastrointestinal Clamps 673 • Occlusion Clamps 673 • Crushing Clamps 675 • Instruments used in Biliary Tract Surgery 675 • Instrument used in Rectal Surgery 676 • Instruments for Genitourinary Surgery 678 • Ordinary Catheters 678 • Self-retaining Catheters 679 • Bougie or Urethral Dilator 680 • Pyelolithotomy Forceps (Nephrolithotomy Forceps) 680 • Suprapubic Cystolithotomy Forceps 681 • Special Instruments in General Surgery 681 • Orthopedic Instruments 682 • Sterilization 685	

<i>Bibliography</i> .....	<b>687</b>
<i>Index</i> .....	<b>693</b>

# **PART I**

# General Surgery



## Chapter 1

## Shock

- Definition
- Clinical features
- Classification of shock
- Stages of shock
- Pathogenesis
- Organ changes in shock
- Investigation and assessment
- Treatment

**DEFINITION**

Clinically shock is defined as an entity showing signs of collapse following under-perfusion of cells and tissues.

Physiologically it is a state following upset of homeostasis between blood volume and vascular capacity. Disparity between blood volume and vascular capacity can be produced by:

1. Reduction in blood volume
2. Increase in the vascular bed
3. By both the above mechanisms.

**CLINICAL FEATURES**

- Pinched face, shrunken eyes, cold clammy skin
- Deadly pallor
- Rapid thready pulse
- Hypotension
- Sweating
- Shallow sighing respiration
- Oliguria.

**CLASSIFICATION OF SHOCK: (SEE TABLE 1.1)****STAGES OF SHOCK**

- Early compensated shock
- Progressing “decompensated shock”
- Irreversible shock.

**PATHOGENESIS**

Shock, regardless of its cause, initiates a series of pathophysiological changes aimed at protecting the organism and preserving its vital functions as follows.

**Sympathoadrenal Response**

The fall in blood pressure due to inadequate cardiac output is sensed by the stretch receptors located in the aortic arch and carotid sinus with the consequent sympathoadrenal stimulation.

- The Vasomotor Center (VMC) activity is increased resulting in an enhanced peripheral resistance and the blood pressure is maintained. The heart rate increases (H.R. 1/BP Mary’s Law) to restore the cardiac output.
- The reflex increase is sympathetic activity is further augmented by stimulation of peripheral (carotid and aortic bodies) and central (ventral surface of medulla) chemoreceptors. Hypoxia (O<sub>2</sub> Lack) is the main stimulus to peripheral chemoreceptors whereas changes in pH have predominantly central effects.

The increased sympathetic cardiac activity increases the rate and strength of myocardial contraction. The arteriolar constriction is selective. The blood flow to skin, skeletal muscle, salivary glands, intestines, liver, and kidneys is reduced. The skin becomes cold,

salivary secretion stops and mouth becomes dry, intestines manifest impaired digestion and water absorption.

However, blood flow to essential organs like brain, heart, diaphragm and intercostal muscles is maintained.

**Neuroendocrine Response**

In case of true or apparent (e.g. sepsis, anaphylaxis, etc.) hypovolemia, there will be increased secretion of ACTH, growth hormone, glucagon, ADH, catecholamines and cortisol.

ADH helps in the reabsorption of H<sub>2</sub>O from the distal renal tubules. Glucagon stimulates gluconeogenesis and glycogenolysis thereby causing hyperglycemia and increased osmolarity which helps in the fluid shift from the interstitium to the intravascular compartment.

**Activation of the Renin Angiotensin System**

Due to decreased renal blood flow there is secretion of renin from the juxtaglomerular apparatus which leads to the formation of angiotensin, a potent vasoconstrictor which stimulates aldosterone secretion resulting in Na and H<sub>2</sub>O retention and increase of blood volume.

**Microcirculatory Changes**

Due to intense sympathoadrenal and neuroendocrine response following hypovolemia there will be selective diversion of blood flow

**Table 1.1: Etiological classification of shock**

Type of Shock	Cause	Mechanism
I. Hypovolemic shock	Hemorrhage, diarrhea, burn, etc.	There is depletion of circulating blood volume.
II. Cardiogenic shock	<ul style="list-style-type: none"> <li>• Myocardial infarction</li> <li>• Pulmonary embolism</li> <li>• Cardiac tamponade</li> <li>• Constrictive pericarditis</li> </ul>	There is pump failure or obstruction to flow.
III. Distributive shock		
a. Septic shock	Overwhelming bacterial infection	There is increased capacity of vascular bed due to profound decrease in peripheral vascular resistance. Same as above
b. Anaphylactic shock	There is antigen, antibody reaction releasing a number of chemical substances mainly histamine and SRS-A	
c. Neurogenic shock	Also called vasovagal or psychogenic shock	There is sudden decrease in peripheral vascular resistance and pooling of blood mainly in the limb muscles, causing a reduced venous return, cerebral hypoxia and unconsciousness

through meta-arteriolar shunt or thoroughfare channels as the closure of pre- and postcapillary sphincters occur (Fig. 1.1).

In the irreversible phase of shock, there is relaxation of the precapillary sphincters while postcapillary sphincters remain constricted and blood gets sequestered in the microcirculatory unit.

### Cellular Changes

The cellular changes are due to ischemia. Lack of oxygen and accumulation of waste products cause cell membrane dysfunction. Thus in muscle, the resting transmembrane potential can change from -90 to -60 mV.

Na and H<sub>2</sub>O enter the cell and K leaves it, which results in cellular swelling. Mitochondrial dysfunction occurs in prolonged shock, which

will cause diminished ATP production. There is also lysosomal disruption with resultant release of lysosomal enzymes and intracellular autodigestion occurs. Widespread cellular damage may lead to multiorgan dysfunction syndrome (MODS).

Thus, the final pathway of shock is cell death. When large numbers of cells from vital organs have reached this stage shock becomes irreversible and death occurs.

This concept of irreversibility is important because it emphasizes the need to prevent the progression of shock.

### Release of Prostaglandins

Tissue damage in shock stimulates the release of various inflammatory mediators including stimulation of phospholipase A2 and hence Arachidonic acid metabolism, pro-

ducing eicosanoids viz. Prostaglandins and leucotrienes (Fig. 1.2).

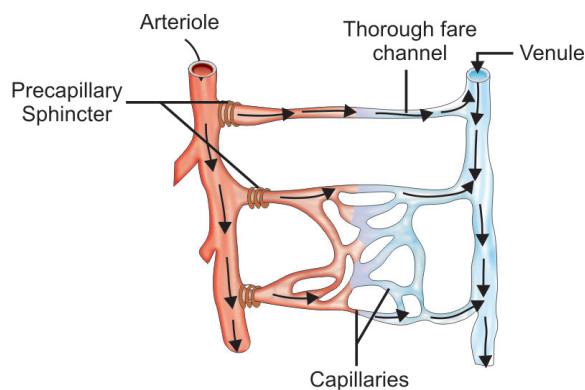
### ORGAN CHANGES IN SHOCK

If shock continues to the irreversible stage, end organ damage and multiorgan dysfunction syndrome occurs as follows.

- i. Lungs—Adult respiratory distress syndrome (ARDS) and shock lung.
- ii. Kidney—Acute renal failure due to acute tubular necrosis.
- iii. Liver—Centrilobular necrosis and fatty change.
- iv. GI Tract—Hemorrhagic gastroenteropathy and ulceration.
- v. Brain—Hypoxic encephalopathy and confusion.
- vi. Heart—Subendocardial hemorrhage, fatty changes.
- vii. Disseminated intravascular coagulation or DIC.

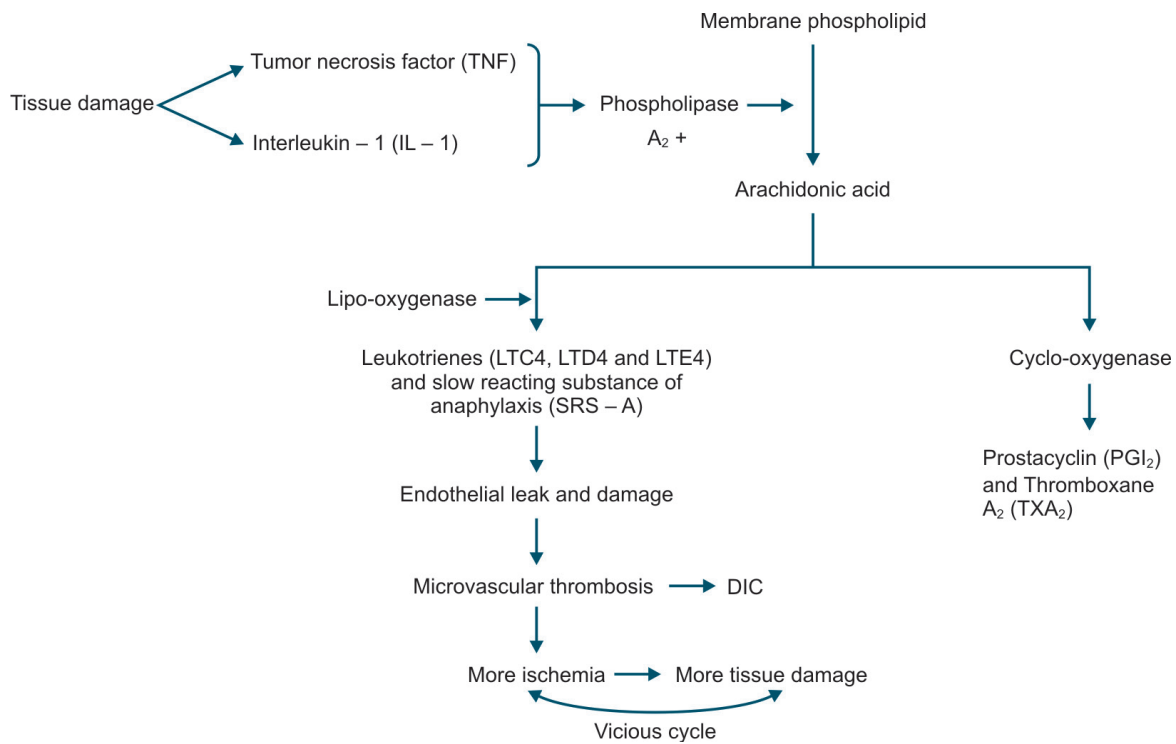
### INVESTIGATIONS AND ASSESSMENT

1. Recording of urine output, pulse, BP, temperature and respiratory rate.
2. Hb%, urea, electrolytes, creatinine and platelet count.
3. Blood grouping and cross matching.
4. Blood culture and estimation of arterial blood gases.
5. ECG and cardiac enzymes.



**Fig. 1.1:** A microcirculatory unit





**Fig. 1.2:** Release of prostaglandins

+ = Stimulation.

## TREATMENT

### Resuscitation

- To ensure clear airway, adequate breathing and circulation.
- Provision of 100 percent oxygen by a face mask.

### Specific Treatment

- Hypovolemic shock**
  - The patient is kept in head down position.
  - Fluid replacement—Crystalloid solution like Ringer lactate is ideal in situations where Na and H<sub>2</sub>O loss is predominant and will also serve as initial treatment in hemorrhagic shock. Blood transfusion is advised in hemorrhagic shock and plasma transfusion in case of burns.
- Septic Shock**
  - Aim of treatment is to control infection and improve the hypovolemic state, caused by endotoxin induced peripheral vasodilatation. Blood culture should be done before antibiotic administration. A combination of 3rd generation cephalosporin, aminoglycoside and metronidazole should be effective against most organisms.
  - inotrope use is indicated in severely ill patients to maintain cardiac output.
- Cardiogenic shock**
  - The patient should have complete bed rest and be monitored in a coronary care unit.
  - Pain relief with Inj. Morphine or Pethidine HCl.
  - Pharmacologic support
    - Inotropes—Like Dopamine and Dobutamine for pump failure.
    - Thrombolytic therapy with Aspirin and Streptokinase in case of myocardial infarction.
    - Diuretics, cardiac glycosides and ACE inhibitors for patients with heart failure.
  - Temporary cardiac pacing will increase cardiac output and heart rate in bradyarrhythmias.
- Anaphylactic shock**
  - Inj. Adrenaline – 0.5 ml 1 in. 10000 s.c.
  - IV steroids and antihistaminic.

# Chapter 2

## Wound Healing

- Introduction – Regeneration and repair
- Wound healing
- The healing sequence
- Regulation of wound healing by growth factors
- Factors influencing wound healing
- Disorders of scarring
- Healing of specialized tissues
- Classification of wounds
- Types of wound

### INTRODUCTION

Healing is the body's replacement of destroyed or lost tissue by viable tissue.

Tissue replacement is achieved in two ways:

- Regeneration:** Is the process whereby lost specialized tissue is replaced by proliferation of surrounding undamaged specialized cells, reestablishing the anatomical and functional integrity.
- Repair:** Is the replacement of lost tissue by granulation tissue which matures to form scar tissue.

The process of wound healing concerns the tissue response to injury. It is therefore, useful to enumerate the causes of tissue loss or destruction.

- Traumatic excision
  - Surgical,
  - Accidental
- Physical, chemical and microbial agents. These all give rise to inflammation and in sufficient dose lead to necrosis.
- Ischemia which leads to necrosis.
- Radiotherapy.

### Regeneration

Different tissues vary in their regenerative capacity. A helpful guide to the expected reaction to damage of any tissue is given by the division of somatic cells into three types. Viz.:

- Labile cells**— Are those which under normal conditions continue to multiply

throughout life replacing cells that are lost, e.g. cells of the epidermis, the lining mucosa of the alimentary, respiratory and urinary tract, the endometrium, the hematopoietic bone marrow and lymphoid cells.

- Stable cells**—Normally cease multiplication when growth ceases but retain mitotic ability during adult life so that some regeneration of damaged tissue may occur. This group includes liver, pancreas, renal tubular epithelium, thyroid and adrenal cortex and many types of mesenchymal cells.

- Permanent cells**—Lose their mitotic ability in infancy, e.g. neurons of the CNS, renal glomeruli, sensory organs, striated muscle and adrenal medulla.

Following injury labile tissues heal by regeneration, with little or no repair. Permanent tissues are incapable of regeneration and heal entirely by repair. Most organs show evidence of both processes.

### WOUND HEALING

The problems of wound healing involve a number of tissues including bone, muscle and tendon but it is the skin which assumes the greatest significance in the clinical setting. Ofcourse, the basic mechanisms appear to be very similar in all tissues that undergo repair.

In considering the healing of a skin wound two types are usually distinguished.

- A clean wound with closely apposed margins*—An incised wound. It heals by first intention (primary intention) and is characterized by the formation of only minimal amount of granulation tissue.
- An open or excised wound*—Here healing occurs by secondary intention as the edges cannot be apposed, e.g. by sutures. Wound infection also prevents healing by first intention.

### The Phases of Wound Healing

It is traditional to divide the events of wound repair into phases, but this is some what artificial as there is marked overlap and interdependence between the phases. Nevertheless it is helpful to discuss the subject under distinct headings viz. (See the healing sequence given later in this chapter).

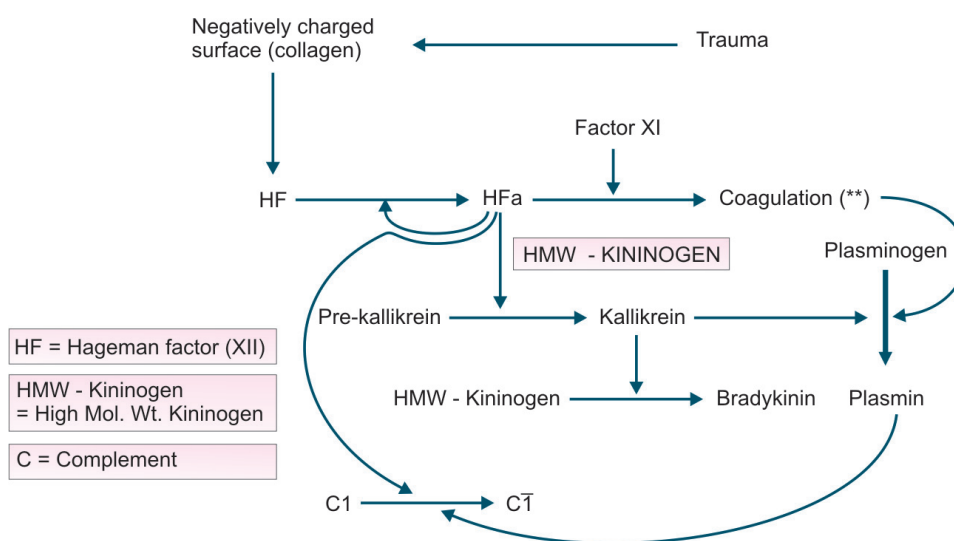
- Inflammation
- Formation of granulation tissue with angiogenesis (organization) and
- Collagen — Matrix formation and remodeling (scar formation).

### INFLAMMATION (2-3 DAYS)

A disturbance of blood vessel integrity due to tissue injury exposing the blood to collagen and subendothelial parenchyma is generally

Platelet organelle		
Types of organelle	Contained Mediator	Function
1. α - Granules	Platelet factor IV Platelet derived growth factor (PDGF) Fibronectin Transforming growth factor (TGF) & αβ	Leukocyte chemotaxis Fibroblast proliferation. Angiogenesis and granulation tissue formation. TGFα – causes endothelial cell proliferation
2. Dense bodies	Serotonin histamine epinephrines	Vasodilatation (histamine) Collagen synthesis (serotonin), Vasoconstriction (serotonin and epinephrine)
3. Lysosomes	Elastase, collagenase antitrypsin, α <sub>2</sub> - macroglobulin	

**Fig. 2.1:** Three types of platelet organelles and their contained mediators involved in hemostasis and initiation of the inflammatory phase



**Fig. 2.2:** The interrelationships of the coagulation – Kinin, fibrinolytic and complement systems and their hypothetical activation by trauma.

\*\*Plasminogen is converted to plasmin by a component of the clotting cascade viz. (i) Thrombin and (ii) Tissue plasminogen activator (tPA) produced by damaged endothelial cells, in presence of fibrin.

considered the initiating factor in wound healing. Even this initial phase is complex. Blood extravasates, contorts tissue surfaces, and initiates an acute inflammatory response, concurrently a hemostatic response is initiated. Hemostasis consists of three components: Vasoconstriction, platelet activation and coagulation.

### Vascular Response

An initial period of intense vasoconstriction follows direct vascular trauma. Vasoconstriction of the arterioles is rapid but transient, seldom lasting more than minutes. The significant mediators are products of platelets activated

by contact with exposed subendothelial collagen.

The earliest circulating cell or cell fragment detected in the injury site is the platelet. Platelets contain three types of organelles involved in hemostasis and initiation of the inflammatory phase (Fig. 2.1).

Vasoconstriction is followed promptly by vasodilatation, which is mediated by histamine. Histamine is packaged in vesicles contained by mast cells, platelets and basophils. The flow of blood through the part is thereby increased. At the same time the endothelium of smaller vessels becomes more permeable, permitting exudation of plasma-like fluid

into the tissue spaces and on to the surface of the wound. This is well seen in the blister fluid of a burn.

Although the chemical mediators are unknown, direct neutrophil – endothelial cell interactions are associated with increased vascular permeability. The increased permeability and consequent edema formation probably represent interplay of multiple systems. (Coagulation – kinin, fibrinolytic and complement systems) (Fig. 2.2). For example, Prostaglandins E<sub>1</sub> and E<sub>2</sub> are poor edema producers themselves but augment the edema induced by histamine and bradykinin.

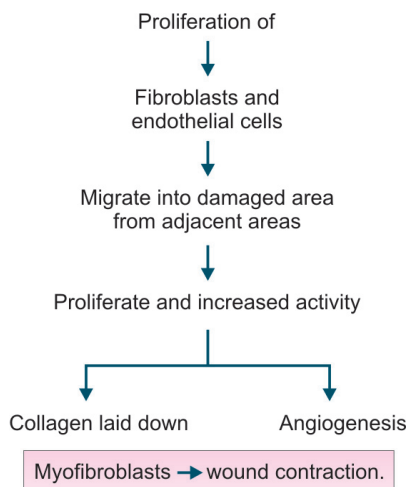
## Cellular Response

Very soon after exudation of plasma, the white cells of the blood – polymorphs and monocytes escape into the tissues by diapedesis and contribute to the defence by scavenging dead cells, necrotic tissue and foreign material at the site of injury.

In the absence of infection or contamination, the inflammatory phase is rapidly succeeded by proliferation of collagen and wound repair, but effective healing cannot take place where inflammation continues. The macrophage appears to be the crucial controller cell at this stage of repair. Growth factors secreted by macrophages viz. Fibroblast growth factor, FGF, Macrophage derived growth factor, (MDGF), etc. stimulate migration of fibroblasts, epithelial cells and endothelial cells to the wound.

## FORMATION OF GRANULATION TISSUE (ORGANIZATION) (DAY 3-14)

This occurs as below:



It is also called the proliferative phase (approx. 2 weeks) because the later phases of inflammation and early phases of fibroplasia are better described in terms of the cellular events namely stages of cell migration and proliferation.

This phase comprises

- Fibroblast migration.
- Capillary ingrowth (i.e. angiogenesis) and
- Matrix formation including
  - Collagen synthesis with rapid gain in tensile strength

- Wound contraction and
- Epithelialization.

## Fibroblast Migration and Proliferation

Simultaneously with the development of new blood vessels, long spindle-shaped fibroblasts stream from the perivascular connective tissue and begin to proliferate and move into the wound.

- The first step is to turn off the inflammatory response, achieved by decreasing the production of inflammatory mediators and inactivation of those already present. Inflammatory factors may be disabled and removed by wound macrophages. The disappearance of tissue neutrophils in the wound appears to be due to their short lifespan, as well as, decreased extravascular migration. The mechanism of extravascular migration is unclear and may be influenced both passively and actively by endothelial cells.
- Fibroblasts produce both type I and type III collagen within 10 hrs after injury. There is evidence of increased wound collagen synthesis. By day 5 to 7 collagen synthesis has peaked and then declines gradually.
- Mediators of fibroblast proliferation and migration include C5A, Fibronectin and growth factors—specifically PDGF, FGF (Fibroblast Growth Factor), and possibly TGF –  $\beta$ . Elaboration of enzymes such as collagenase and plasminogen activators by both the differentiating fibroblast and the macrophage facilitates cellular migration into the wound.

Hyaluronic acid is normally found in the cartilage. The early extracellular matrix is rich in hyaluronate and fibronectin and both facilitate cellular migration. When hyaluronate levels drop, migration ceases.

Fibronectin receptors on the fibroblast are proteins which pass through the entire cell-membrane. It attaches fibroblasts to collagen. The dynamic fibronectin – fibroblast coupling is called the fibronexus. Fibronectin is found whenever cell migration occurs and fibronexus to collagen is followed by enhanced proliferation of fibroblasts. There is simultaneous proliferation and migration of endothelial cells.

Fibronectin is linked to processes of epithelialization, migration, matrix contraction

and angiogenesis and disappears after cellular migration is accomplished by processes that are incompletely understood.

## Angiogenesis

Additional migrating, proliferating cells involved in filling wound matrix are the endothelial cells needed to build vessels to supply nutrients. Angiogenesis refers to the process by which vessels grow into a previously avascular space.

From about the third day, new vessels originate as capillary sprouts in response to local angiogenic factors. The sprouts are often solid at first but they unite with one another or join a capillary already carrying blood and develop a lumen. These newly formed capillaries are very delicate, lacking a basement membrane and behave as if actually inflamed. They leak protein rich fluid with escape of some red cells and polymorphs migrate from them. Within a few days of the establishment of circulation, some of the new vessels differentiate into arterioles and venules by the acquisition of muscle cells either by migration from pre-existing larger blood channels or by differentiation from mesenchymal cells.

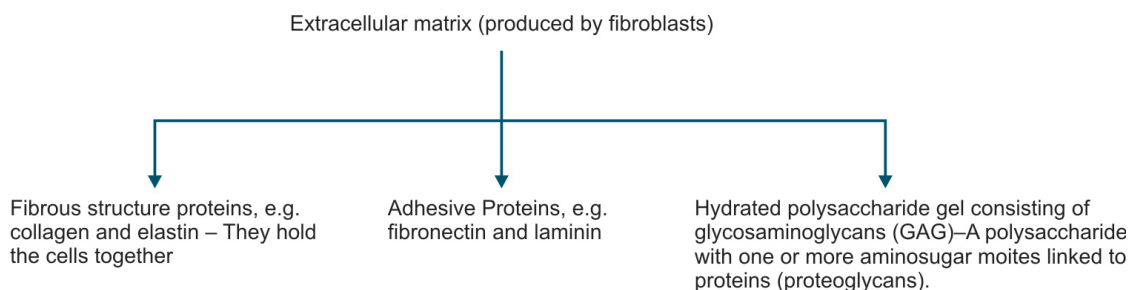
The angiogenic factors have been identified from diverse tissue sources such as kidney salivary glands, corpus luteum, thyroid and lymphoid cells. The latter source is the most pertinent to wound healing. Lymphocytes, Macrophages, Neutrophils and mast cells have demonstrated angiogenic activity.

One factor for new vessel growth is fibroblast growth factor (acidic and basic). Acidic and basic FGF initiate endothelial cell proliferation and cell migration both *in vivo* and *in vitro*.

Transforming growth factors (TGF –  $\alpha$  and TGF –  $\beta$ ) – have *in vivo* angiogenic potential.

- TGF  $\alpha$  directly stimulates endothelial cell proliferation.
- TGF  $\beta$  is released by platelets and activated lymphocytes. TGF  $\beta$  stimulates granulation tissue formation and neovascularization *in vivo* however it inhibits *in vitro* endothelial cell proliferation.

Endothelial cell proliferation is stimulated by a low wound  $PO_2$  in the early stages but growth of vessels is later enhanced by a



high wound PO<sub>2</sub> which is also necessary for the synthesis of collagen responsible for the complete formation of the vessels.

### Matrix Formation

(Matrix = collagen fibers plus the ground substance and the adhesive proteins). See the flow chart of extracellular matrix above.

### Ground Substance, i.e. Hydrated Cell

Four main groups of glycosaminoglycans have been chemically differentiated

1. Hyaluronic acid — nonsulfate type.
  2. Chondroitin and dermatan sulfate
  3. Heparin sulfate
  4. Keratan sulfate.
- } Sulfated type

Hyaluronic acid is not bound to protein and seems to facilitate cellular migration during repair after which it is degraded by hyaluronidase. The role of proteoglycans in wound repair is not clear.

Fibronectin anchors the fibroblast to collagen and laminin is part of the basal lamina

that promotes the attachment of the epithelial cells.

Plasma fibronectin is synthesized by hepatocytes and reaches the wound site by extravascular extravasation. It is closely associated with the fibrin clot. Tissue fibronectin is synthesized by macrophages, endothelial cells and fibroblasts and is the characteristic fibronectin of mature wound matrix.

### COLLAGEN SYNTHESIS

Collagen is the most abundant protein in the body and forms the major structural component of many organs. Production of collagen remains a major process in wound repairs for several weeks after wound closure and the collagen continues to undergo remodeling for 2 yrs. or more until the injured tissue is finally restored.

- Fibroblasts are the major cell type to synthesize collagen.
- The synthesis involves a progression in the combination of amino acids to form chains which associate to form molecules

and then association of molecules to form fibrils, which aggregate into fibers or bundles.

The first stages of synthesis take place intracellularly to produce procollagen molecules which undergo processing to collagen fibrils in the extracellular space.

There are known to be at least 13 different genetically distinct collagen types, six of which occur in human skin.

### Intracellular Synthesis (See fig 2.3)

#### Transcription and Translation

- In the nucleus, the genes are activated and there is transcription from DNA to mRNA for each different procollagen (α) chains.
- Translation on polysomes (polyribosomes) of the RER (Rough Endoplasmic Reticulum), the three polypeptide chains being synthesized simultaneously. Newly synthesized pre-pro (α) chains are intruded into the lumen of the RER.

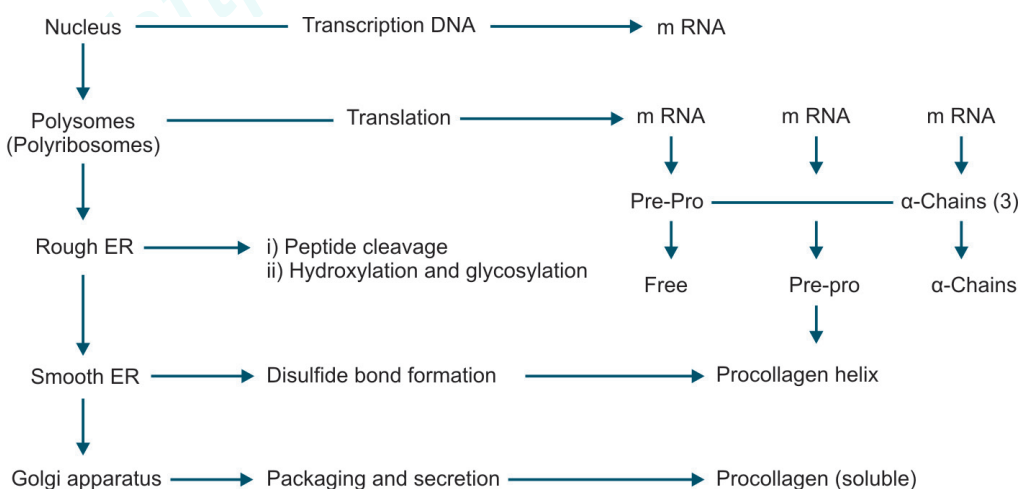


Fig. 2.3: Intracellular synthesis of collagen



### Post-translational Modification

- i. The pre-pro peptide which is thought to act as a signal or leader for intrusion into the RER lumen is removed.
- ii. Hydroxylation of proline and Lysine residues in the Pro  $\alpha$ -chains. The enzymes responsible are prolyl 3-hydroxylase, Prolyl 4-hydroxylase and Lysyl hydroxylase and require the following cofactors viz.  $\text{Fe}^{++}$ ,  $\text{O}_2$ , Ascorbic acid and  $\alpha$ -ketoglutarate. The non-enzymatic glycosylation of some of the hydroxy lysine residues takes place at this stage.
- iii. In the cisternae of the smooth ER, Pro  $\alpha$ -chains are converted to procollagen by the formation of disulfide bonds (SS - Bonds), and they begin to assume a trihelical structure.
- iv. The procollagen molecules are stabilized by hydroxy proline and secreted via the Golgi apparatus into the extracellular space.

### Extracellular Synthesis

- i. The first step is the activation of the procollagen molecule by the cleavage of amino- and carboxy peptide ends (i.e. N and C extension peptides of 15-20 amino acids which prevent intracellular formation of large collagen fibers) by amino and carboxy peptidases. Lack of or defects in one of these enzymes results in defective fibers, e.g. Ehlers-Danlos disease (Type VII).
- ii. Self-assembly of collagen molecules into fibrils.
- iii. Cross-linkage of fibrils to form fibers of high tensile strength.

### Why self-assembly?

The collagen fibrils (macromolecules) are polarized so that they lie end to end with

adjacent molecules overlapping lengthwise by a quarter of their length and bound to their neighbors by cross-linkages.

Finally the fibrils are arranged in the form of a meshwork resembling a knitted fabric, so that while the individual fibrils are non-extensible the tissue as a whole can be stretched and moulded in conformity with the movements of the body.

So, extracellular synthesis in brief

- i. Cleavage of C- and N-terminal peptides  $\rightarrow$  Formation of Insoluble Procollagen
- ii. Self-assembly  $\rightarrow$  Collagen fibrils
- iii. Cross linkages  $\rightarrow$  Collagen fibers

### Types of Collagen

There are at least five different types of collagen derived from different structural genes as described below (Table 2.1).

### Collagen Lysis and Regulation of Collagen Metabolism

Collagenases are formed at the site where they are required, e.g. in healing wounds by macrophages, polymorphs and regenerating epidermal epithelium. The collagenase is secreted directly on to the fiber by a closely apposed cell and this splits the fiber so that fragments may be ingested by macrophages. Splitting is more likely to occur in fibers with few or unstable cross-links.

### Regulation

- The macrophage appears to be the key cell in regulating collagen elaboration by fibroblasts. Experiments show a marked decrease in wound collagen and defective healing in wounds depleted of macrophages. Conversely when macrophages were injected into wounds, increased collagen deposition and better healing occurred. Presumably the macrophage exerts its effect by secreting growth factors

(MDGF or Macrophage derived growth factors).

- The build up of propeptides, released in the transformation of procollagen to collagen inhibits collagen synthesis and thus provides a feedback for switching off the process of synthesis. The failure of the feedback system may be a contributory factor in excessive scarring (Fig. 2.3).

### Wound Contraction

Healing of an open excised wound is aided by contraction of the surface area in sites where the skin is mobile and loosely attached to underlying tissue.

It is a common place observation that the eventual scar is nearly always much smaller than the original wound, even as small as a quarter of the original area.

The shrinkage is greatest where the skin and underlying tissues are mobile, e.g. over the neck or abdomen. It is almost negligible on the chest wall or over the subcutaneous surface of the tibia.

The shrinkage is barely perceptible during the lag phase (syn. Inflammatory phase), but then again it proceeds rapidly for a time and then slows down. The contraction process is due to the pull on the wound margins by some fibroblasts known as myofibroblasts.

This initial shrinkage must be distinguished from contracture or cicatrization which may occur if healing is delayed or if the scar is subject to recurring trauma, e.g. when a wound crosses a joint.

### Epithelialization

Restoration of the epithelial cell layer involves mobilization of cells in the basal layer of epidermis extending from 3-4 mm. around the wound edge. Migration and proliferation of cells continue relentlessly as long as there are denuded areas. Contact inhibition occurs as epithelial cells come into contact

**Table 2.1: Types of collagen with their chain composition and tissue distribution.**

Collagen type	Chain composition	Tissue distribution
I	Two identical chains $\alpha_1$ (I) <sub>2</sub> and one $\alpha_2$ (I)	All connective tissues (Dermis, bones, tendon, dentine, cornea, 90% of collagen in body)
II	Three identical chains $\alpha_1$ (II) <sub>3</sub>	All cartilages, Eye
III	Three identical chains $\alpha_1$ (III) <sub>3</sub>	Early scar tissue, fetal and infant connective tissue
IV	Three identical chains $\alpha_1$ (IV) <sub>3</sub>	Epithelial and endothelial, Basement membranes
V	Two identical chains $\alpha_1$ (V) <sub>2</sub> and one $\alpha_2$ (V)	Intersitial tissue and blood vessels.

with each other. Finally the cells differentiate and assume keratinocyte function and the cell layer gradually increases in thickness, in some cases by as much as 1 mm/day.

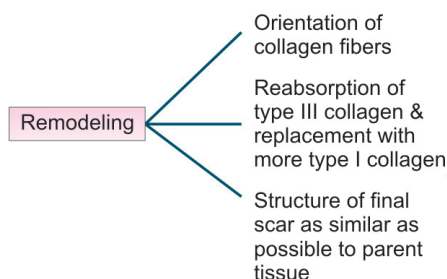
Whereas in a wound closed primarily, epithelialization may be complete by 48 hrs, in wounds healing by secondary intention, migration of cells does not occur until an adequate bed of granulation tissue exists, usually at 4 to 5 days.

Epithelialization is under control of growth factors such as FGF - 7 (known as keratinocyte growth factor) and epidermal growth factor (EGF).

### Remodeling (Scar Formation) - (Day 7 to 1 yr)

Remodeling means collagen reorientation along lines of stress. The process occurs in the context of a fine balance between the synthesis and degradation of collagen.

The scar reaches maturity in a period which varies widely but usually lies between 6-12 months. At this time the collagen is dense and avascular and the scar is pale and flat. Remodeling is aimed to reestablish the connective tissue matrix that was destroyed by the tissue injury.

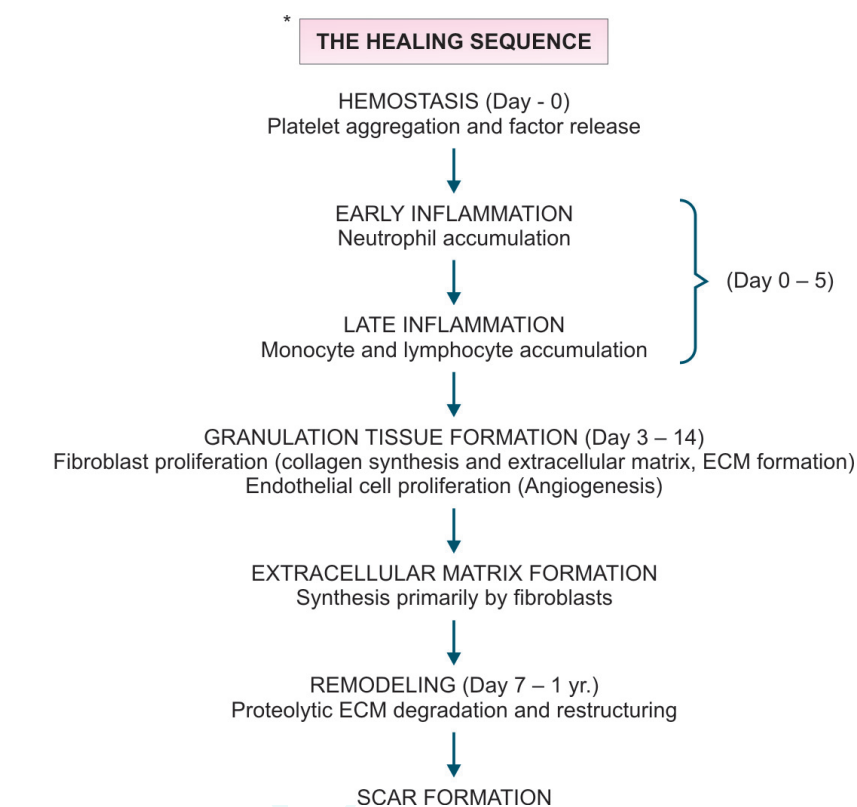


### THE HEALING SEQUENCE

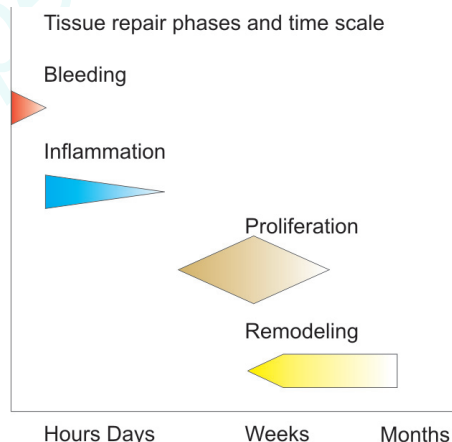
This can be described in brief as follows:  
See figs 2.4A and B

### REGULATION OF WOUND HEALING BY GROWTH FACTORS

It is becoming clear that the control of wound healing on a molecular level is regulated by a group of peptide growth factors, known as cytokines. Cytokines are a group of soluble proteins, produced by a number of cells in the body which act as messengers in cellular communication.



**A**



**B**

**Figs 2.4A and B:** The healing sequence and different tissue repair phases with respect to their duration

Cells producing cytokines include lymphocytes (T and  $\beta$  lymphocytes and natural killer cells => called lymphokines, e.g. Interleukin 1 or IL<sub>1</sub>, IL<sub>2</sub>, etc.)

- Monocytes and macrophages called monokines
- Mast cells
- Keratinocytes
- Epithelial cells and

- Vascular endothelial cells called endothelial cell factors.

### How the Cytokines Act?

They may act in an autocrine fashion on the same cell type which produces them or they may exert a paracrine effect to stimulate cells of other types in the vicinity. At times they spill over into the circulation to function as

hormones in response to hemorrhage, sepsis, inflammation and other types of injury.

### Mechanism of Action

Binding of the cytokine to a cell surface receptor results in a change in conformation of the receptor which signals the intracellular cell machinery to undergo a number of changes that results in increased cellular RNA and protein synthesis, with altered cell behavior, e.g. cell division, etc.

To date, the following growth factors have been shown to play a pivotal role in wound healing.

- i. **TGF –  $\beta$  (vide also Angiogenesis above):** It is present in high concentration in blood platelets and is released instantaneously into the wound at the site of injury. It is also synthesized by macrophage, neutrophils and activated lymphocytes. TGF –  $\beta$  is a potent stimulator of the synthesis of the matrix proteins such as collagen and fibronectin and the proteoglycans. It also stimulates neovascularization due to *in vivo* endothelial cell proliferation as well as fibroblast proliferation.
- ii. **PDGF (Platelet derived growth factor):** It is released from the  $\alpha$ -granules of the platelets inducing fibroblast proliferation, matrix production and maturation of connective tissue. It is also synthesized by macrophages and endothelial cells.
- iii. **Basic FGF (Fibroblast growth factor):** It is responsible for new vessel growth hence, known as angiogenesis peptide. It causes proliferation of vascular smooth muscle cells and endothelial cells. It is present in macrophages.
- iv. **EGF Epidermal growth factor:** EGF and its homolog transforming growth factor, (TGF)  $\alpha$  are important in epithelialization. It is chemotactic and a mitogen for epithelial cells. It is also responsible for fibroblast proliferation, the synthesis of fibronectin and has a role in angiogenesis. These are also released from the  $\alpha$ -granules of platelets.
- v. **IGF or Insulin growth factor,** Tumor necrosis factor or TNF, Interleukin – 1 and numerous other growth factors and cytokines are likely to be present in the wounds. Their roles are still uncertain.

It is easy to imagine the uses of growth factors if they could be employed in the clinical situation. Some of the clinical and

experimental evidence suggests that it might become possible to manipulate the cellular components of healing and eliminate the unfavorable scar by the application of the right combination of growth factors. This could ultimately lead to the elimination of scar formation and production of scarless healing.

Functionwise growth factors can be divided as follows:

1. Monocyte chemotaxis – PDGF, FGF, TGF –  $\beta$ .
2. Fibroblast proliferation and migration - TGF –  $\beta$ , PDGF, basic FGF, EGF, TNF
3. Angiogenesis – basic FGF (bFGF)
4. Collagen synthesis – TGF –  $\beta$ , PDGF
5. Collagenase secretion - TGF –  $\beta$ , PDGF, FGF, EGF.

### FACTORS INFLUENCING WOUND HEALING

A number of factors can alter the rate and efficiency of healing. These factors are local and systemic as follows.

#### Factors Adversely Affecting Wound Healing

##### Local

1. Infection
2. Ischemia, e.g. shock, anemia compartment syndrome, tension.
3. Foreign body
4. Radiation injury
5. Excessive movement.

##### Systemic

1. Poor nutrition, e.g. Deficiency of Vit. C, Vit. A, Vit. B<sub>1</sub>, B<sub>6</sub> and riboflavin, trace element deficiency, protein deficiency.
2. Diabetes mellitus
3. Corticosteroid therapy
4. Uremia
5. Jaundice
6. Malignancy
7. Old age.

##### Infection

This is the most important factor in the failure of wounds to heal. Infection disrupts and delays the healing process. The overall collagen synthesis is reduced and the collagen breakdown is enhanced.

Infection is least common in clean elective surgery (usually 1-2%). In potentially contaminated surgery when respiratory, biliary, urinary, and gastrointestinal tracts are opened the incidence increases to 5-10 percent. In abdominal surgery, when the peritoneal cavity is already soiled or contaminated with bacteria at the time of operation, the infection rate is approx. 20 percent.

Certain drugs like steroids and cytotoxics inhibit resistance to infection as do the effects of prolonged anesthesia and hypotension.

### Blood Supply

An adequate tissue perfusion is essential for providing optimum nutrition and oxygenation to the wound.

Any decrease in O<sub>2</sub> supply to the wound impairs collagen deposition, angiogenesis and epithelialization.

Wounds in richly vascularized skin, e.g. on the face will heal more rapidly than those at sites where dermal blood flow is less, e.g. the pretibial skin.

### Irradiation

This damages DNA and disrupts the intracellular metabolism. It interferes with healing by inhibiting cell proliferation in both epithelial and mesenchymal cells.

### Corticosteroids

Exogenous steroids impair healing especially when started in the first three days after injury. Wounds in steroid treated patients have scanty macrophage infiltrate with a consequent lack of macrophage derived growth factors. Corticosteroids also impair contraction of open wounds.

### Malnutrition

Malnutrition impairs wound healing. Patients after major surgery may not be expected to have a normal oral intake for 7-10 days and IV nutrition becomes necessary. Patients with chronic illness and those who have had multiple operations over a few weeks or months are at risk for wound complications.

Protein calorie malnutrition impairs healing. Vit. C is a cofactor in collagen synthesis so that its deficiency will lead to defective collagen synthesis and rapid degradation.



## Diabetes Mellitus and Uremia

Poor wound healing and infection are serious risk in an uncontrolled diabetic. Uremia patients deposit collagen poorly but mechanism is not well-understood.

## DISORDERS OF SCARRING

### Hypertrophic Scar

It is an exaggeration of the normal process of healing and rarely continues to worsen after 6 months. Glycosaminoglycan contents are abnormal in hypertrophic scars. Studies indicate that the level of hyaluronic acid is less than half that of normal skin while the level of chondroitin sulfate is six times higher. Either the chondroitin sulfate continues to be formed in the hypertrophic scar or it is not removed.

#### Treatment

Spontaneous resolution occurs taking several years but resolution can be hastened by application of elastic pressure garments, steroid injections or application of silastic gel.

### Keloids

They are similar to hypotrophic scar but continue to enlarge after 6 months and invade neighboring uninvolved skin.

Common sites are upper chest, ear lobe, shoulder, neck and 'beard area' keloids are more common in colored races and some people appear to be more prone. Infection in the wound predisposes its development. Infections along natural skin creases (Langer's lines) rarely develop keloids.

Keloid is raised from the surface and show claw-like growing edges into the surrounding normal skin. Itching is an important symptom.

#### Treatment

- Keloids often recur after excision.
- Intralesional injection of Triamcinolone is an effective treatment but may require to be repeated as a course.
- Low dose radiotherapy is sometimes effective.

## HEALING OF SPECIALIZED TISSUES

### Neural Tissue

The response to injury differs between the central and peripheral nervous system.

In the CNS, nerve cells of the brain, spinal cord or ganglia are destroyed; they cannot be replaced by proliferation of other nerve cells. Healing is restricted to a connective tissue response, which involves gliosis.

In contrast, peripheral nerves have considerable regenerative capacity. The rate of regeneration of the axons is 4-5 mm a day (average 1-1.5 mm./day) following approximation of the cut ends with fine sutures.

It cut ends cannot be approximated without tension, the gap can be bridged with a nerve graft, e.g. sural nerve or a substitute such as freeze thawed muscle graft which act as a conduit.

### Intestine

- Gut mucosa** – Damage confined to the gut mucosa is repaired by reepithelialization without scarring.
- Gut wall** – Wounds or ulceration extending through to the submucosa and underlying muscle always leaves a permanent fibrous scar.
- Stomach and small bowel** – Have a plentiful blood supply, contain relatively few pathogenic bacteria so that leakage after anastomosis is uncommon.
- Esophagus and large bowel** – Have weaker walls and poorer blood supply and heal less well after surgery. Disruptions of the intestinal wall are usually recognized clinically by the 4th-6th postoperative day.

The connective tissue of the submucosa is the strongest layer of the gut wall and sutures or staples in this layer maintains apposition until tensile strength is regained.

### Bone (Healing of Fracture)

This occurs through the followings stages:

- Hematoma formation** – Following injury torn vessels form a hematoma between the fracture ends.
- Traumatic inflammation** – An inflammatory response leads to ingress of

fibroblasts, collagen synthesis and granulation tissue formation. Later on macrophages invade the fracture site and phagocytose blood clot and tissue debris.

- Callus formation** – Within a day or two there is a rapid proliferation of osteoblast from the elevated periosteum overlying each fracture end to form the callus (Latin meaning hard). The callus is the hard bone like substance between the fracture ends.
- New bone formation** – This is caused by osteogenic cells spreading from the medullary and periosteal callus. (Bridging phase).
- Remodeling** – At the bridging phase, the anatomical and radiological appearance of the bone is still abnormal over the ensuing years, external (Heaped up outside the outline of the bone) and internal (part inside the medullary cavity) callus are gradually absorbed and the fracture site is remodeled to near normal.

See also healing of a fracture in orthopedic section.

### Muscle

The regeneration capacity depends on the extent of injury of the skeletal muscle. If the endomyseum is intact, complete restoration of structure and function occurs.

If there is damage to the surrounding matrix, there is scar tissue formation and loss of function.

Scarring also occurs during the healing of smooth muscle and cardiac muscles which possess no regenerative capacity.

### Liver

After a single short-lived injury such as drug induced necrosis or acute hepatitis, the liver heals completely by regeneration.

Repeated injury as in alcoholic abuse or chronic hepatitis leads to collapse of the reticulin framework, production of collagen by mesenchymal cells and irregular nodular regeneration resulting in cirrhosis.

### Kidney

Regeneration is virtually confined to the tubular epithelium and is seen for example after acute tubular necrosis. Otherwise injury results in loss of glomeruli and scarring.

## CLASSIFICATION OF WOUNDS

The most useful classification of wounds from a practical point of view is that of Rank and Nakfield, who divide them into tidy and untidy wounds, the features of which are given in table 2.2.

### Wound Excision

The most important step in the management of any untidy wound is wound excision. The process is sometimes called 'wound toilet' or 'debridement'. The former implies washing and the latter implies laying open or fasciotomy. All these processes may be important in wounds management but do not describe the excision of devitalized tissue, which is the most important process. For this reason, 'wound excision' is preferred.

In order to excise a wound, adequate anesthesia (local, regional or general) must be provided. Where possible a bloodless field also aids identification of structures. In the limbs a pneumatic tourniquet is used.

Excision should proceed in a systematic fashion, dealing with each tissue layer in turn, usually starting with the superficial and then moving to deeper structures. Longitudinal structures such as blood vessels, nerves and tendons are identified and exposed but left in continuity. This approach to radial wound excision is sometimes called a 'pseudotumor' approach. As the end of wound excision the wound should resemble an anatomical dissection and normal bleeding should be observed from each layer. In very extensive wounds, serial wound excisions replace this radical approach as the same would threaten the viability or function of the part, e.g. limbs concerned.

Hence, in brief wound excision involves (i) removal of all contaminated and devitalized tissue (ii) the procedure is sometimes called the 'pseudotumor approach' (iii) in very extensive wounds serial wound excisions are made instead of pseudotumor approach.

## TYPES OF WOUND

The followings are the different types of injuries viz.

1. Bruise or contusion and hematoma
2. Abrasions and friction burns

**Table 2.2: The features of tidy and untidy wound.**

<i>Tidy wound</i>	<i>Untidy wound</i>
Are made by sharp cuts	Usually involves crushing and tearing and contain devitalized tissues.
Can be closed primarily	Needs conversion to tidy wound before closure is considered.
Examples are surgical incisions and cuts from glass or knives	These wounds result from crushing, avulsion or burns. Fractures are common and may be multifragmentary.
	<i>Treatment</i> – Once the untidy wound is converted to a tidy one by wound excision, it can be safely closed or allowed to heal by second intention.

3. Puncture wounds and bites
4. Laceration
5. Avulsion injury
6. Crush injury.

### Bruise or Contusion

Means a discoloration of the skin due to an extravasation of blood into the underlying tissues. There is no abrasion of the skin.

### Hematoma

If the amount of bleeding is sufficient to create a localized collection in the tissues it is described as a hematoma. Initially the collection is fluid which clots within minutes or hours and again liquify after a few days.

#### Treatment

- i. Bruises require no specific management. Time required to clear is extremely variable.
- ii. Hematoma — Usually resolves spontaneously, large hematomas are drained by open surgery or aspirated by a large bore needle taking adequate antiseptic precautions.

### Abrasions and Friction Burns (Abrasi - L. Abredere, to Scrape off)

Abrasion is a shearing or superficial injury to skin or mucous membrane from scrapping or rubbing. Most abrasions (except full thickness skin loss) heal by epithelialization.

Friction burns are similar with an element of thermal damage. Treatment – same as burn.

### Puncture Wounds and Bites

A puncture wound is an open injury in which foreign material and organisms are carried deeply into the underlying tissues. A common cause is standing on a nail or other sharp object.

The danger of this type of wound is abscess formation deep within the tissues in 24 to 48 hrs.

**Bites:** Are a particular type of puncture wound associated with high incidence of infection from mouth organisms. There may be a combination of deep laceration and crushing. All bites require careful wound excision to avoid deep infection.

### Laceration

A laceration or cut is the result of contact with a sharp object. It is the surgical equivalent of an incised wound. It is important to take the history properly to know the amount of force that was involved. The clinical examination must therefore assess the integrity of all structures in the area: Arteries, Nerves, Muscles, Tendons and ligaments.

The ideal form of management of an incised wound is surgical inspection, cleaning and closure. The wound must be thoroughly inspected to ensure that there is no damage to deep structures. If any found, it must be repaired.

All patients sustaining open wounds should have prophylaxis against tetanus and a broad spectrum antibiotic when there is any contamination.

### Avulsion Injury

Avulsion injuries are open injuries with a severe degree of tissue damage. Such injuries

occur when hands or limbs are trapped in moving machinery, e.g. roller producing a degloving injury.

Degloving is caused by shearing forces that separate tissue planes, rupturing their vascular interconnections and causing tissue ischemia. This most frequently occurs between the subcutaneous fat and deep fascia. Degloving injuries can be open or closed and localized or circumferential. It can occur in just the subcutaneous plane or in multiple planes. When it is found between muscles and fascia and between muscles and bone, it is an indication that a severe high energy injury has occurred. This has limited potential for primary healing.

Similar injuries occur as a result of run over road traffic accident injuries in which friction from rubber tires will avulse skin and subcutaneous tissue from the underlying deep fascia. The history should raise the suspicion of the examiner. It is often possible to pinch the skin and lift it upwards, revealing

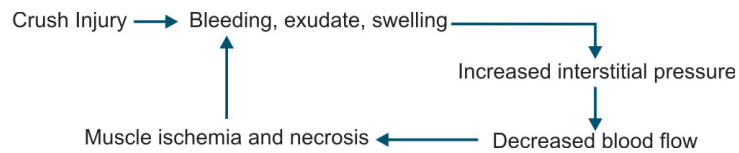
its detachment from the normal deep anchorage. The damage of degloving injury is that skin necrosis will slowly but inevitably appear over the following few days. The treatment of such injuries is to identify the area of devitalized skin and to remove it, de-fat it and then reapply it as a full thickness skin graft.

### Crush Injury

Crush injuries are a further variant of blunt injury and are often accompanied by degloving and compartment syndrome (See flowchart above).

Injury to tissues within a closed facial compartment leads to bleeding, exudate and

Thus, the cycle of events in the developing compartment syndrome can be represented as follows:



swelling of these tissues and increased interstitial pressure. As the interstitial pressure rises above capillary perfusion pressure, the blood supply to the viable tissues is reduced resulting in further ischemic tissue injury and swelling. This vicious cycle causes a worsening compartment syndrome with muscle ischemia and nerve ischemia progressing to muscle necrosis, skin necrosis and limb loss. Muscle necrosis may result in renal failure. (Muscle necrosis  $\Rightarrow$  Myoglobinuria  $\Rightarrow$  Acute tubular necrosis  $\Rightarrow$  Renal failure).

This process can be arrested by early recognition and decompression of the affected compartment(s) by fasciotomy.

# Chapter 3

## Hemorrhage and Blood Transfusion

- Hemorrhage
- Clinical features of hemorrhage
- Estimation of the amount of blood loss
- Blood transfusion
- Massive transfusion
- Plasma and blood substitutes
- Preservation and storage of blood
- Preparation for blood transfusion – blood grouping, antibody screening and cross-matching
- Hazards or complications of blood transfusion
- Autologous transfusion

### HEMORRHAGE

Hemorrhage is usually a serious matter and its control is one of the important duties of a surgeon. He should be able to detect the source of the bleeding and to estimate its amount. Further he should know how to stop the bleeding and restore the blood lost by fluid and blood transfusion.

#### Types of Hemorrhage

Hemorrhage may occur from an artery, from a vein or from capillaries.

#### Arterial Hemorrhage

Arterial blood is bright red and comes in a spurting jet which rises and falls in time with the pulse. If bleeding continues for a long time and especially when electrolyte solutions are given as a replacement of blood loss, the blood can become quite watery in appearance.

#### Venous Hemorrhage

If the blood is coming from a vein, it is dark red and flows steadily without spurts. It is not the fact that bleeding from veins poses a lesser problem than hemorrhage from high pressure arteries. Hemorrhage from large and especially deep seated veins, e.g. the common femoral or jugular, can tax the ingenuity of

the most experienced surgeon and therefore should not be taken lightly.

#### Capillary Hemorrhage

Is bright red and may be quite a rapid ooze. If continuing for many hours, blood loss can become serious, as in hemophilia.

#### Hemorrhage from a Wound

When a wound is sustained, either due to operation or trauma hemorrhage may take place immediately, after a few hours or after a few days. Depending upon the time at which it occurs, it is classified as follows.

1. Primary hemorrhage is that which takes place at the time of the injury or operation.
2. Reactionary hemorrhage usually occurs within 24 hours (average 4-6 hours) and is most commonly due to slipping of a ligature or dislodgement of a clot. Alternatively it may occur due to the fact that the artery went into spasm at the time of the injury but later the spasm passed off, with resulting hemorrhage.
3. Secondary hemorrhage takes place one or two weeks after the injury or operation and is due to infection and sloughing of part of the wall of an artery.

Predisposing factors are pressure of a drainage tube, the presence of a fragment of

bone, a ligature in an infected area and cancer. It is also a complication of arterial surgery and amputations. There may be 'warning' hemorrhages in the form of bright red stains on the dressing followed by a sudden severe hemorrhage. A warning hematemesis may occur in the case of a peptic ulcer and is a danger signal that is not to be ignored. In advanced cancer, the erosion of a main vessel, e.g. carotid or uterine by a locally ulcerating growth may result in quick and merciful termination of the patients life.

Secondary hemorrhage is especially common after anorectal operation. This is due to the presence of a certain degree of infection along with moisture which causes maceration of the tissues. Hemorrhoidectomy wounds are especially prone to this complication because they involve division and ligation of the arteries supplying the piles.

#### External and Internal Hemorrhage

**External hemorrhage:** Is visible, that is, revealed hemorrhage, e.g. when the femoral artery is cut across. The quantity of blood lost is easy to estimate, in such a case.

**Internal hemorrhage:** Is invisible or concealed hemorrhage as in the case of rupture of the spleen, ruptured ectopic gestation

or fracture of the femur. In certain cases, concealed hemorrhage can become revealed as in hematemesis or melena from a peptic ulcer or hematuria following blunt trauma to the kidney.

### Clinical Features of Hemorrhage

The signs and symptoms of blood loss are as follows: there is increasing pallor and a rising pulse rate. The patient is restless and in advanced cases there are deep sighing respirations, a condition, which is called air hunger. The skin is cold and moist, the veins are empty and there is thirst.

Pulse and BP should be recorded every 15 to 30 min. When they stabilize they can be recorded every 2 to 4 hours. The BP is normal at first and falls only after a good deal of blood has been lost. Therefore, even if the blood pressure is normal it is possible that severe hypovolemia may be present. In such a situation the BP is maintained by shutting off large parts of the vascular bed by vasoconstriction in the nonessential organs.

Any further loss of blood volume can lead to sudden collapse and even death.

It is therefore, important to palpate the hands and feet to see if they are warm or cold. If they are warm it means, there is no vasoconstriction and implies that the blood volume is sufficient. On the other hand cold extremities indicate serious hypovolemia with respect to the volume of blood lost.

Hemorrhage can also be classified as follows:

**Class I hemorrhage:** With loss of blood less than 15 percent of total blood volume (TBV). This produces very little effect on pulse or BP.

**Class II hemorrhage:** With loss of 15-30 percent of TBV, produces tachycardia and decreased pulse pressure.

**Class III hemorrhage:** i.e. loss of more than 30 percent of TBV with tachycardia, tachypnea, hypotension, oliguria and impaired mental status.

Replacement: Blood loss of upto 20 percent of TBV should be replaced with crystalloid solutions like Ringer's lactate, 20 to 50 percent loss with crystalloids and red blood cell concentrate and loss greater than 50 per-

cent with crystalloids, red blood cells and albumin or plasma.

### ESTIMATION OF THE AMOUNT OF BLOOD LOSS

Before the blood loss during a hemorrhage is replaced, the clinician should arrive at a rough estimate of the amount of blood lost. It is not always easy to estimate the exact amount of blood lost during trauma or operation. However, the following guidelines may be helpful.

- (i) Blood clot—A blood clot of the size of a closed fist is about 500 ml in volume.
- (ii) Swelling in closed fractures — In fracture of the tibia, if a moderate degree of swelling is present, 500 to 1500 ml of blood may have been extravasated into the muscles. In a fracture of the femur as much as two liters of blood may be lost into the tissues.
- (iii) Swab weighing—Perhaps the best method of estimating blood loss during operations is to weigh the swabs used to mop up the blood and to deduct their preoperative weight. The resulting total obtained (1 gm = 1 ml) is added to the volume of blood collected in the suction or drainage bottles. A delicate weighing scale is required for this purpose. In extensive operations such as radical mastectomy or partial gastrectomy, the swab weighing total should be multiplied by a factor of 1.5 and for even more extensive operations like abdominoperitoneal resections of the rectum by 2. This is because the blood, plasma and water are lost from the vascular system because of evaporation from open wounds into the tissues and through sweating and expired water via the lungs.
- (iv) Measurement of the hemoglobin level, the hematocrit (Hct), central venous pressure (CVP), cardiac output and urine output.

All of the above parameters are reduced in severe hemorrhage. Hence, their measurements will provide an estimate of the amount of blood loss.

### Treatment

Treatment of hemorrhage is divided into two parts viz. the arrest of bleeding and the replacement of the lost blood.

I. Arrest of bleeding or hemostasis: The following are the surgical means of hemostasis.

- (a) Pressure and packing: The first aid treatment of hemorrhage from a wound is application of pressure dressing made from anything soft and clean. The dressing or pack should be bound tightly.

The forefinger and thumb or roller gauge pack is used to control epistaxis.

Double balloon in the esophagus and stomach is used to control the bleeding from the esophageal varices by the pressure of the inflated balloons.

- (b) Position and rest: Elevation of the limbs, e.g. the patient with varicose veins employs gravity to reduce bleeding. Elevation also helps in vasoconstriction.

(c) Operative techniques.

- Artery forceps (Hemostats) and clips are mechanical means of controlling bleeding by pressure. The clamped vessel can be ligated with catgut, cotton, silk etc. or it can be coagulated with diathermy.
- The part or whole of a bleeding viscus may have to be excised for example splenectomy or partial hepatectomy.

A ruptured kidney is treated conservatively if possible.

II. The replacement of the lost blood— This is carried out by blood transfusion or by infusion of plasma substitutes or expanders, e.g. albumin, dextran like dextran 70 or dextran 40 and gelatin, e.g. hema-cel, gelofuschine, etc.

## BLOOD TRANSFUSION

### Introduction

Blood transfusion can be a life-saving procedure. However, it can also be followed by serious reactions due to incompatibility and otherwise. Therefore, blood should be transfused only when really indicated and stringent precautions should be taken before and during the transfusion. This is all the more important because of the rising incidence of AIDS and hepatitis, along with intravenous drug abuse.



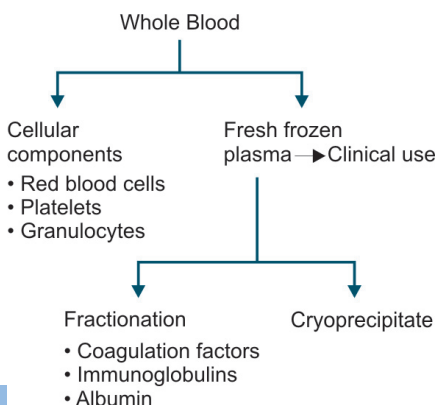
## Indications for Blood Transfusion

- Following hemorrhage which may be due to:
  - Trauma with severe blood loss.
  - Bleeding from pathological lesions, e.g. from the gastrointestinal tract.
  - Major operative procedures in which a fair amount of blood is lost, e.g. radical mastectomy or abdominoperineal resection.
- After extensive burns where a good deal of blood is lost in the burnt skin.
- Postoperatively in a patient who has become severely anemic from infection.
- Preoperatively in a patient who has become severely anemic and surgery is indicated urgently, i.e. when there is inadequate time for effective iron or other replacement therapy or if the anemia is unresponsive to therapy, e.g. aplastic anemia.
- In a patient with bleeding disorder, e.g. Hemophilia or thrombocytopenia either to prevent hemorrhage or to arrest it.

## Blood Components and Products

During the early years of blood banking the whole blood was exclusively used for transfusion. But in recent times, most blood collected from donors is processed into blood components and products. By this the patient gets the maximum benefit at a minimum risk and the components thus saved are conserved for other patients.

The term blood component includes the various parts of blood that are separated by conventional technology like centrifugation, freezing and thawing, etc. or by cell separator machines. When more sophisticated chemical or manufacturing processes are involved, the term plasma derivatives or fractions are used.



## Whole Blood

Whole blood should be reserved for acute blood loss even here packed red cells plus crystalloid or colloid solutions are acceptable alternatives.

## Packed Red Cells

Red blood cell concentrates or packed cells consist of whole blood from which the plasma has been removed volume of one unit is 350 ml. and shelf-life 35 days at 4°C.

Washed RBCs are used in patients who cannot tolerate granulocyte and platelet debris normally present in RBC concentrates.

## Indications

Patients with chronic anemia with Hb < 7 gm per dl.

In elderly patients, small children and patients in whom introduction of large volumes of fluid may cause cardiac failure.

Packed red cells are suitable for most forms of transfusion therapy including major surgery especially in association with clear fluids.

## Platelet Rich Plasma and Platelet Concentrates

These are:

- Platelets suspended in plasma.
- Shelf-life is 5 days at room temperature (22°C).
- They are used to treat patients with severe thrombocytopenia; platelet count should be raised to 100000 to prevent bleeding in the thrombocytopenic patient.
- It is desirable to use platelets that are ABO or Rh compatible. Since the concentrate contains red cells Rh+ve donors should not be used for Rh-ve recipients.
- Platelet transfusion may result in transfusions of the hepatitis virus.
- Platelet transfusion are ineffective in some situations like (i) Multiple transfusion, here the platelets may be destroyed by alloantibodies (ii) When the cause of thrombocytopenia is destruction by autoantibodies (iii) In DIC (iv) In hypersplenism.

## Granulocyte Transfusions

These are useful in patients who are neutropenic to prevent and treat infections. Extraction of large number of leukocytes from donors can be accomplished by continuous flow blood

separators employing differential centrifugation or Nylon fiber filter systems. It has a very short shelf-life of 24 hours at room temperature.

## Albumin 4.5%

Repeated fractionation of plasma by organic liquids followed by heat treatment results in this plasma fraction. It has the advantage of being free from the risk of producing hepatitis. It is a colloid solution, useful in shock due to burns, acute pancreatitis and intestinal obstruction. However, it has limited availability and expensive.

## Fresh Frozen Plasma ⇒ FFP

- It is a good source of all the coagulation factors prepared by centrifugation of donor whole blood within 4 hours of collection and frozen at -30°C.
- Shelf life of 12 months at -30°C.
- A unit is typically 200 – 250 ml.
- Should be used within 1 hour of thawing.
- Indications of FFP transfusion.
  - In patients with multiple coagulation defects resulting from hepatic insufficiency.
  - In DIC (Disseminated intravascular coagulation).
  - Where labile clotting factors (V and VIII) have been depleted by the transfusion of very large volumes of old stored blood.

## Cryoprecipitate ⇒ Cold Coprecipitate

- This is produced by slow thawing of FFP at 40°C. This is rich in factors VIII, XIII, fibrinogen and VWF.
- Shelf-life of 12 months at -30°C
- Indications:
  - In the treatment of patients with hemophilia. The advantage of cryoprecipitate is its simplicity of administering large quantities of factor VIII in relatively small volumes by IV injection.

## Factor VIII Concentrate

It is used for treatment of hemophilia and von Willebrand disease.

## Factor IX Concentrate

Contains factor IX, X and XI. It is used in the treatment of hemophilia β (Christmas disease) and congenital deficiencies of factors X and XI. When combines with factor

VII concentrate it is more effective than FFP in the treatment of severe hemorrhage due to excessive warfarinization and liver disease.

### SAG – Mannitol (SAG – M) Blood

Because of the increasing need for blood products, the use of SAG–mannitol (SAG–M) is becoming more common. Whole blood from which plasma has been removed and replaced by a crystalloid solution of sodium chloride, Adenine, Glucose anhydrous and mannitol is being used. This procedure maintains good cell viability but the product contains practically no protein (albumin). In the case of top up transfusions for anemia, this will not constitute a problem.

In healthy adults, the plasma albumin level will not be compromised by a replacement transfusion of upto four units of SAG – M blood, after which whole blood should be used. If this is not available, more SAG – M blood may be given supplemented by one unit (400ml) of 4.5 percent human albumin solution for every two units of SAG – M blood. After eight units of SAG – M red cells have been transfused, the need for FFP and platelets should be considered, after first checking the coagulation status and platelet count.

### MASSIVE TRANSFUSION

It is defined as transfusion of total blood volume in less than 24 hours.

#### Complications

1. Bleeding—Massive transfusion of stored blood can produce dilutional effect on platelets and clotting factors, especially factors V, VIII, IX. FFP should be given prophylactically and platelet concentrates if level is  $< 50 \times 10^9$ /liter.
2. Metabolic acidosis due to acid load in stored blood.
3. Hyperkalemia—In the absence of renal failure this usually does not pose a problem.
4. Fall in 2-3 PG level—This leads to a less efficient oxygen delivery. With CPD anticoagulant, however this problem is reduced.
5. Hypothermia—Blood warmer to be used.

6. Citrate toxicity—This occurs because of finding of ionized  $Ca^{++}$  and results in cardiac toxicity, tetany, etc.
7. Adult respiratory distress syndrome (acute lung injury).
8. DIC (Disseminated Intravascular Coagulation).

### PLASMA AND BLOOD SUBSTITUTES

#### Plasma Substitutes

Colloids are regarded as plasma substitutes. They do not dissolve into a true solution and can not pass through a semipermeable membrane, contain high Mol. Wt–molecules and remain in the intravascular compartment longer than crystalloids, providing the oncotic pressure.

**Use:** If massive bleeding has occurred or is taking place, the lost blood must be replaced promptly. If blood is not available, immediately, at least the normal blood volume must be reestablished, using one of the following plasma substitutes available.

1. Albumin 4.5 percent  $\Rightarrow$  vide above
2. Dextran — Are glucose polymers of different molecular-weights producing an osmotic pressure similar to that of plasma. They induce rouleaux formation of the red blood cells and therefore, interfere with blood grouping and cross matching. So the blood sample for these tests must be taken before dextran is infused.
  - Dextran 40 (Average Mol. Wt. 40,000), called Low Mol. Wt. Dextran (Lomodix).
  - Dextran 70 (Average Mol. Wt. 70,000), also called High Mol. Wt. Dextran.
  - Half life – 16 hours. Dextran 40 is filtered by the kidney but Dextran 70 is not therefore Dextran 70 stays in circulation longer.
  - Dextran interfere with platelet function and may be associated with abnormal bleeding and the total infusion should not exceed 1000 ml.
3. Gelatins (hemacel/gelofusin)
  - Half life – 8 to 10 hours.
  - There is low incidence of allergic reaction.
  - Mol. Wt. – 30,000.

Hemacel contains  $K^+$  and  $Ca^{++}$  therefore, if mixed with citrated blood in a giving set leads to coagulation.

Advantages of plasma substitutes are that they are relatively nontoxic, inexpensive, can be stored at room temperature, do not require compatibility testing and do not transmit infections.

Adverse effects include anaphylaxis, fever, and rash. Such effects being more frequent with starch based products.

#### Red Cell/Blood Substitutes

Two groups of substances are considered:

##### Hemoglobin Solutions

- Early attempts to prepare hemoglobin solutions consisted of pooling outdated blood, breaking open the RBCs, and extracting the hemoglobin molecules. This solution is termed stroma-free hemoglobin.
- The hemoglobin solutions are polymerized and pyridoxylated because normal Hb outside the red blood corpuscles become dimer from the tetrameric form and excreted by the kidneys and these problems can be overcome by pyridoxylation. The resultant solution has the same oxygen carrying capacity as normal blood.
- Clinical trials are underway to determine the efficacy of the solutions for acute blood loss and perioperative applications.
- Recently hemoglobin based RBC substitutes have been produced from bovine hemoglobin, human hemoglobin and recombinant hemoglobin.

##### Perfluorocarbons (PFCs)

PFCs are good solvent for all gases. About 40ml of  $O_2$  will dissolve in 100 ml of PFC. Several PFCs have been tested in humans with limited success. The long-term effects on liver and immune system are not known.

### PRESERVATION AND STORAGE OF BLOOD

Blood is a fluid which perfuses all organs and tissues in the body. It is a vehicle for nutrients, oxygen and waste products from metabolic activity. It transports hormones, coagulation factors and antibodies.

#### Banked Whole Blood

Deleterious changes occurring during storage:
 

- i. Decreased red cell survival: During storage red cells progressively lose their

capacity to survive in a recipient's circulation, after transfusion. Thus if a 14 day old stored blood is used, 50 percent of red cells will survive 60 days after transfusion, whereas only 25 percent of the RBCs will survive 60 days if a 28 day old stored blood is used.

- ii. There is loss of cellular ATP which is one of the major factors in the decline in cell viability.
- iii. There is decreased concentration of 2 to 3, Diphosphoglycerate (DPG) in RBCs and this is associated with shift of the oxygen dissociation curve to the left so that oxygen is less readily given up to the tissues.
- iv. pH changes from 7.0 to 6.88 due to acid load (Lactic acid increases from 20 to 150 mg/dl in 21 days).

### Anticoagulants in Use

- ACD (Acid-citrate dextrose) — It is a mixture of citric acid, trisodium citrate and dextrose and has been used for many years. But this is now replaced by CPD.
- CPD (Citrate phosphate dextrose) — It is mixture of citric acid, trisodium citrate, sodium dihydrogen phosphate and Dextrose. It is less acid and viability of red cells is better preserved.
- CPDA — It is a citrate – phosphate – dextrose – adenine mixture. The ATP content of stored red cells can be largely restored by incubation with adenine, and the inclusion of adenine in the anticoagulant mixture improves the maintenance of red cell viability. Hence, CPDA is now commonly used.

Temperature at which blood is stored is -4°C. At temperature above 10°C, there is rapid deterioration of red cells.

### Components of a Unit of Blood

- One unit (pint) of blood contains 450 ml of blood and 63 ml of CPDA anticoagulant. The number of red cells is such that transfusion of one unit of blood will raise Hb level by 1 gm/dl.
- Granulocytes are not viable in stored blood.
- Platelets are viable only if the blood is less than 24 hours old.
- Clotting factors II, VII, IX, and XI are stable in stored blood while labile

factors V and VIII rapidly deteriorates at 4°C but are stable in fresh plasma and cryoprecipitate when stored frozen at -30°C.

- Each unit of blood contains 10 gm of Albumin, 2 gm of gammaglobulin and 0.7 gm fibrinogen.

### PREPARATION FOR BLOOD TRANSFUSION – BLOOD GROUPING, ANTIBODY SCREENING AND CROSS-MATCHING

Routinely the entire blood grouping and cross matching procedure takes at least 2 hours even if no difficulties are encountered.

### ABO Grouping

Genes for the antigens of the ABO blood group system (A and B antigens) is located on the long arm of chromosome 9.

ABO blood grouping at room temperature is done routinely. The red cells are centrifuged and plasma is discarded. The cells are washed by repeated suspensions in normal saline followed by centrifugation and discarding the supernatant.

A 2 percent suspension of cells in normal saline is prepared. One drop of cell suspension and one drop of patient's serum on a slide are gently agitated and agglutination observed. Agglutination means antigen - antibody reaction has occurred. Type 'O' red blood cells have no agglutinogens and therefore, do not react with either anti-A or anti-B serum. The table below illustrates the presence (+) or absence (-) of agglutination with each of four different types of blood.

Red blood cell type	Sera	
	Anti A	Anti B
O	-	-
A	+	-
B	-	+
AB	+	+

Type A blood has A agglutinogens (antigen) and therefore agglutinates with anti - A agglutinins (antibody). Similarly type B blood agglutinates with anti B serum. Type AB has both A and B agglutinogens and agglutinates with both types of serum.

### Rh Grouping

In 1940, Landsteiner and Weinmann discovered the Rh blood group system. The gene for the Rhesus antigen (D or Rho) of the Rh blood group is located on chromosome 1.

There are three closely linked gene loci which produce the Rh system—C, D and E and their alleles c, d, and e. These genes give rise to the red cell antigens C, D, E, c, d and e.

Of these the type D antigen is widely prevalent in the population (85 %) and is also considerably more antigenic than the other Rh - antigens. Therefore anyone who has this type of antigen is said to be Rh - positive whereas persons who do not have D - antigen are said to be Rh - negative. In our population about 85 percent is Rh+ve and 15 percent is Rh-ve.

Unlike the ABO blood group system, the Rh antibody is not naturally occurring. This means that an anti Rh antibody will not occur in the plasma of an Rh-ve person unless, he or she is challenged by the Rh antigen, e.g. by transfusion or transplacental passage of Rh+ve red cells.

Anti Rh antibodies are IgG type incomplete antibodies requiring Coombs reagent to produce agglutination (antiglobulin test).

### Other Blood Group Antigens

In addition to the ABO and RhD antigens, hundreds of other RBC blood groups have been discovered and several are well known to the blood bank for their hemolysis causing antibodies. These clinically significant blood groups include the Kell (K), Duffy (fy), Kidd (JK), MNS<sub>s</sub> and other blood group systems. These antigens are much less immunogenic than the RhD antigen but the antibodies are seen frequently enough to be of concern for safe transfusion.

### Antibody Screening

This involves testing of the patient's serum for the presence of any Kell, Duffy, Kidd or other minor blood group antibodies which will cause significant agglutination.

### Cross-Matching of Blood (Compatibility Testing)

Cross matching or compatibility testing consists of excluding *in vitro* antibody activity against donor cells which if given would provoke a transfusion reaction.



Having chosen blood of the same ABO and Rh groups as the recipient the donor's red cells must be tested against the recipient's serum. The donor's serum is much less important because any antibodies it may contain should be so diluted by the recipient's plasma as to become insignificant.

### How It is Done?

This is done by adding serum in 2:1 ratio to 3 percent donor cells suspended in normal saline; the mixture is then incubated at 37°C for 45 min. following which it is examined for agglutination or even hemolysis which indicates incompatibility.

No single procedure detects all clinically important antibodies but as a minimum, the indirect antiglobulin test should always be performed if possible. In this the antiglobulin reagent (of animal or monoclonal origin) is added to cells which have been incubated as above. Any cells coated with patient's antibody will then agglutinate, again indicating incompatibility.

### HAZARDS OR COMPLICATIONS OF BLOOD TRANSFUSION

- Immunological complications.
- Infections complications
- Miscellaneous, e.g. congestive cardiac failure, air embolism, coagulation defects, complications due to massive transfusion (see above).

### Immunological Complications

The immunologically mediated reactions may be directed against red or white blood cells, platelets or plasma antigens (of Donor's blood), e.g. IgA.

### Reactions Due to Red Blood Cells

#### Immediate Hemolytic Transfusion Reactions (HTR)

Most reported deaths from transfusion reactions result from ABO incompatible transfusion. Most have occurred when a person with type O blood received type A RBCs because of a clerical error in identification at the time the blood sample was drawn, during laboratory processing or when the unit was administered.

- 5 to 10 ml of blood is sufficient to cause reaction.
- Mechanism — Anti A or Anti B antibodies (IgG or IgM both of which fix complement) in the recipient will attach to donor red cells, activate complement and cause complement mediated destruction of the RBCs (Type II hypersensitivity).
- Clinical features—The conscious patient may become aware immediately that something is wrong. The patient develops a rigor, fever and pain in the loins. In patients under general anesthesia, there will be excess local oozing at the site of operation and hypotension.
- Preventive measures:
  - i. Accurate grouping and cross matching.
  - ii. Accurate collection and storage under strict aseptic conditions.
  - iii. Blood should not be vigorously shaken or heated.
  - iv. The date of expiry should be duly noted before transfusion. Any evidence of hemolysis should be looked for.
- Treatment
  - i. Immediate stoppage of transfusion and a fresh specimen of venous blood and urine from the patient is sent together with the residue of all the used units of donor blood to the laboratory for checking.
  - ii. Catheterization to record the urine output and a close watch of the patient's pulse and B.P.
  - iii. Furosemide 80 to 120 mg is given to provoke a diuresis and repeated if the urine output falls below 30 ml per hour. Dialysis may be necessary.
  - iv. Antihistamines and hydrocortisone often gives beneficial results.

#### Delayed Hemolytic Transfusion Reactions

Typically occurs 5 to 10 days after transfusion. Cause: Titers of antibodies in the patient may have been below the sensitivity of an antibody screen or major cross match. When the patient is transfused, reexposure of the antigen, to the patient's memory cells causes, renewed synthesis of antibody which may take a few hours to a few weeks to develop. Common antibodies include Kidd and Rh. This reaction is most common in patients

who have become sensitized through transfusion or pregnancy.

It is suspected when jaundice appears some days after transfusion or when the hemoglobin concentration fails to rise by the expected amount or drops unexpectedly.

### Incompatible White Cells

- Simple febrile reactions which occur either during or shortly after a transfusion.
- Most often they are due to the presence of recipient's white cell antibodies complexing with donor leukocytes and causing the release of pyrogens from the monocytes and granulocytes. The white cell antibodies in the recipient are formed as a result of previous transfusions or pregnancies.
- Febrile reactions may be quite severe but usually last only a few hours. If they are troublesome in patients requiring further transfusions, leukocyte depleted blood may be given.
- Most reactions respond, however to slowing the transfusion and giving aspirin or paracetamol.

Transfusion related acute lung injury (TRALI) or transfusion associated ARDS.

It occurs as a result of incompatibility between donor antibodies and recipient granulocytes. Signs and Symptoms occur within 6 hours—fever, dyspnea and non cardiogenic pulmonary edema, PCWP < 18 mm Hg.

Treatment—O<sub>2</sub>, PEEP, furosemide and Dopamine, recovery usually occurs within 24 to 48 hours. (PEEP – Positive end expiratory pressure)

### Incompatible Platelets

Post-transfusion purpura may occur in patients who have been previously sensitized to a foreign platelet antigen. On subsequent exposure they mount a secondary response, which causes destruction of the patient's own platelets.

### Adverse Reactions of Plasma

- a. Urticaria results from the allergic reaction to plasma products in the donor blood. Here the patient's IgE antibody complexes with a protein present in the donor's plasma. It is treated by stopping

the transfusion and giving an antihistaminic drug (Chlorpheniramine 10 mg).

- b. Severe anaphylactic reaction can occur due to anti-IgA formed as a result of previous transfusion in subjects who either lack IgA or who belong to a different IgA subclass.

### Infectious Complications

The following infections can be transmitted by blood transfusion

- a. Viral—Hepatitis B, Hepatitis C and Hepatitis D, HIV, cytomegalovirus (CMV) and Epstein – Barr virus.  
b. Bacterial—Syphilis, brucellosis.  
c. Protozoal—Malaria, Chagas disease.

**Hepatitis B:** All donors are routinely screened for Hbs Ag. All patients requiring multiple transfusions and all health care workers should be vaccinated against hepatitis B.

**Hepatitis C:** Majority of cases are seen as post-transfusion hepatitis. 50 percent of infected patients develop chronic hepatitis and 10 percent of patients, cirrhosis or hepatoma.

**Hepatitis D:** The virus uses HbsAg as its coat and cannot exist without HbsAg. This is fortunate because screening for HbsAg is all that is required to exclude the virus.

**HIV:** Can be transmitted by cellular elements and plasma.

**CMV:** Susceptible groups include immature neonates, immunosuppressed patients and pregnant mothers seronegative for CMV. In these patients, blood must be filtered to remove the leukocytes which transmit the intracellular virus.

**Malaria:** In areas where malaria is endemic, a course of antiprotozoal therapy is usually prescribed along with the transfusion. In non-endemic areas, travelers, who have recently resided in an endemic area, are excluded from donation.

### Miscellaneous Complications

1. *Congestive cardiac failure*—This can occur if blood is transfused too rapidly especially in the elderly or when there is cardiovascular insufficiency. If blood has to be transfused in a case of anemia, it is better to give packed red cells. At the same time, the transfusion should be given slowly over a period of many hours.
2. *Air embolism*— Air may be sucked into an open vein at the end of the transfusion. If a drip chamber is used which contains a plastic float, that plugs the exit when the fluid falls to a low level this complication is prevented. Collapsible bags for blood and IV fluids are also relatively safe, unless they have been punctured by a needle for adding some drug to the infusate.
3. *Coagulation defects*— These may arise as follows:
  - i. Stored blood is low in platelets, factor V and VIII. Therefore, if large volumes of stored blood are used, these factors may get diluted and hemorrhage can occur.
  - ii. Disseminated intravascular coagulation (DIC)—This commonly follows ABO incompatibility, when coagulation takes place in the blood vessels, the various coagulation factors namely fibrinogen, factor II, V, VIII and platelets get used up, so that hemorrhage results. For the treatment of DIC, these factors have to be replaced.

### AUTOLOGOUS TRANSFUSION

This means transfusion of patients own blood. It acts as an alternative to homologous transfusion with the advantages in safety and cost.

It may be given in the following forms:

- a. Preoperative autologous deposit.
- b. Preoperative isovolemic hemodilution and
- c. Peroperative blood salvage.

### Preoperative Autologous Deposit (PAD)

Donation criteria consists of

- Hemoglobin > 10 gm/dl.
- Active infection is a contraindication
- Donation is ill advised in presence of severe cardiorespiratory disease, e.g. recent myocardial infarction, angina, left main coronary artery stenosis, etc.

The minimum accepted Hb level for surgery is 9 gm/dl. A unit is taken each week and 500 ml of saline is infused to maintain the intravascular volume and 200mg of ferrous sulfate per day, started. Two to four units of blood are predeposited in this way, the final donation being made not less than 72 hours prior to surgery. Blood is screened for HIV, Hepatitis and syphilis and grouped, “Cross over” for use on other patients is prohibited.

### Preoperative Isovolemic Hemodilution

For some operations like cardiopulmonary bypass 1 to 2 units of blood may be withdrawn, just before surgery. The amount is replaced with crystalloids or colloids. Blood is infused postoperatively. This procedure not only restores much of the individuals red cells but also provides platelets.

### Peroperative Blood Salvage

Blood is collected from the operation site, filtered to remove the cellular debris, activated clotting factors, etc. by a cell salvage machine and then reinfused to the patient during the operation.

It is contraindicated in presence of sepsis or malignancy.

# Chapter 4

## Hemostasis and Coagulation

- Phases of hemostasis
- Inhibitors of coagulation
- General mechanism of coagulation
- Fibrinolysis
- Laboratory tests for hemostasis
- Acquired disorders of coagulation
- Congenital disorders of coagulation
- Platelet disorders
- Investigation of a patient with bleeding disorders
- Hypercoagulable states and thrombotic disease (thrombophilia)

### PHASES OF HEMOSTASIS

The term hemostasis means arrest of bleeding. It occurs in three phases whenever a vessel is severed or ruptured. Viz.

- Reflex vasoconstriction.
- Platelet aggregation and plug formation, also called *Primary hemostasis*.
- Coagulation (formation of solid fibrin) and clot retraction. (Clot–Fibrin fibers formed due to the coagulation process enmesh platelets, blood cells and plasma to form the clot).

This is also called *secondary hemostasis*.

### Vasoconstriction

Immediately after injury, the first response designed to control hemorrhage is contraction of the blood vessel wall, which reduces the diameter of the vessel and thus the size of the opening. This spasm results from nervous reflexes (sympathetic activity), local myogenic spasm and local humoral factors from the traumatized tissues. This spasm serves to reduce the bleeding while platelets gather in the wound and the coagulation process is initiated.

Vasoconstriction also occurs in response to Thromboxane A<sub>2</sub>, a product of arachidonic acid metabolism in platelet membranes.

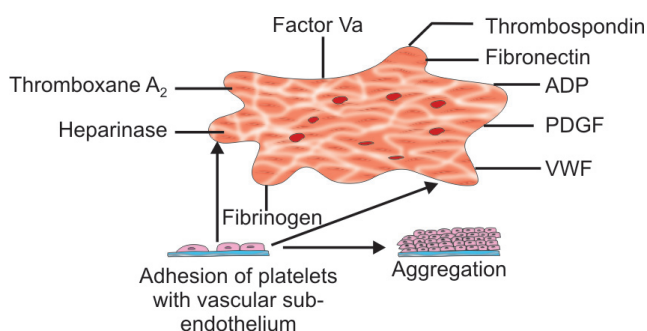
Thromboxane A<sub>2</sub> also activates platelets and aggregates them. The principal mechanism of aspirin's anticoagulant action at low dosage is the inhibition of thromboxane A<sub>2</sub> production.

### Platelet Aggregation and Plug Formation (Fig 4.1)

Platelet plug formation occurs within seconds of injury and is of prime importance in stopping blood loss from capillaries, small arterioles and venules whereas the third phase of hemostasis (formation of solid fibrin) requires several minutes for completion. The fibrin strands which are produced strengthen the primary hemostatic plug. This reaction is particularly important in larger vessels and prevents recurrent bleeding hours or days after the initial injury. Although presented as separate phases, platelet plug formation and coagulation are closely linked, e.g. activated platelets accelerate plasma coagulation (Platelet phospholipids interact with factors Xa, Va and Ca<sup>++</sup> in the production of prothrombinase) and products of the plasma coagulation reaction, such as thrombin, stimulate platelet aggregation.

Effective hemostatic plug formation requires three critical events — Platelet adhesion, granule release and platelet aggregation (Fig 4.1):

- Platelet adhesion**—Endothelial damage exposes blood to collagen and other tissues to which platelets are prone to adhere. (A coat of glycoprotein on the surface of platelets causes it to avoid adherence to normal endothelium and yet to adhere to injured vessel wall). The mechanism of adhesion is complex. Plasma von Willebrand factor (VWF) binds specifically to exposed collagen in the subendothelial tissue. The platelet has a receptor, called glycoprotein 1b on its surface for the bound von Willebrand factor that then serves as the bridge between subendothelial tissue and the platelet. Receptor engagement activates the platelet.
- Granule release or platelet release reaction**—Following activation there is flattening of the adherent platelets on the damaged tissue and degranulation. (Platelet contains α-granules and dense granules in the cytoplasm).
  - Ca<sup>++</sup>, serotonin and adenosine diphosphate (ADP) are released from the dense granules and
  - Several proteins including the von Willebrand factor, fibronectin, thrombospondin and a heparin neutralizing protein (platelet factor 4) are released from the alpha (α) granules.



**Fig. 4.1:** Events in primary hemostasis (i.e. platelet aggregation and plug formation), PDGF = Platelet derived growth factor

c. **Platelet aggregation**—Released ADP modifies the platelet surface so that fibrinogen can attach to a complex formed between membrane glycoproteins IIB and IIIa, thereby linking adjacent platelets into a hemostatic plug. No aggregation of platelets occurs in the absence of fibrinogen. Figure 4.1 shows the platelet plug formation

Whether or not blood clotting occurs depends on a delicate balance between these two groups of substances.

Under normal circumstances, anticoagulants predominate and blood does not clot. However, coagulation of the blood begins within seconds of an injury to the vascular endothelium and a clot does develop.

Fibrin fibers formed due to the coagulation process, enmesh platelets, blood cells and plasma to form the clot.

### Coagulation and Clot Retraction

#### Basic Theory

Within the blood are the circulating procoagulants (substances promoting coagulation) that when activated, promote fibrin formation. Other substances in the blood act as anticoagulants.

#### Procoagulants or Blood Clotting Factors

They are a series of different plasma proteins, especially  $\beta$ -globulins. They are inactive forms of proteolytic enzymes, when converted to active forms, their enzymatic

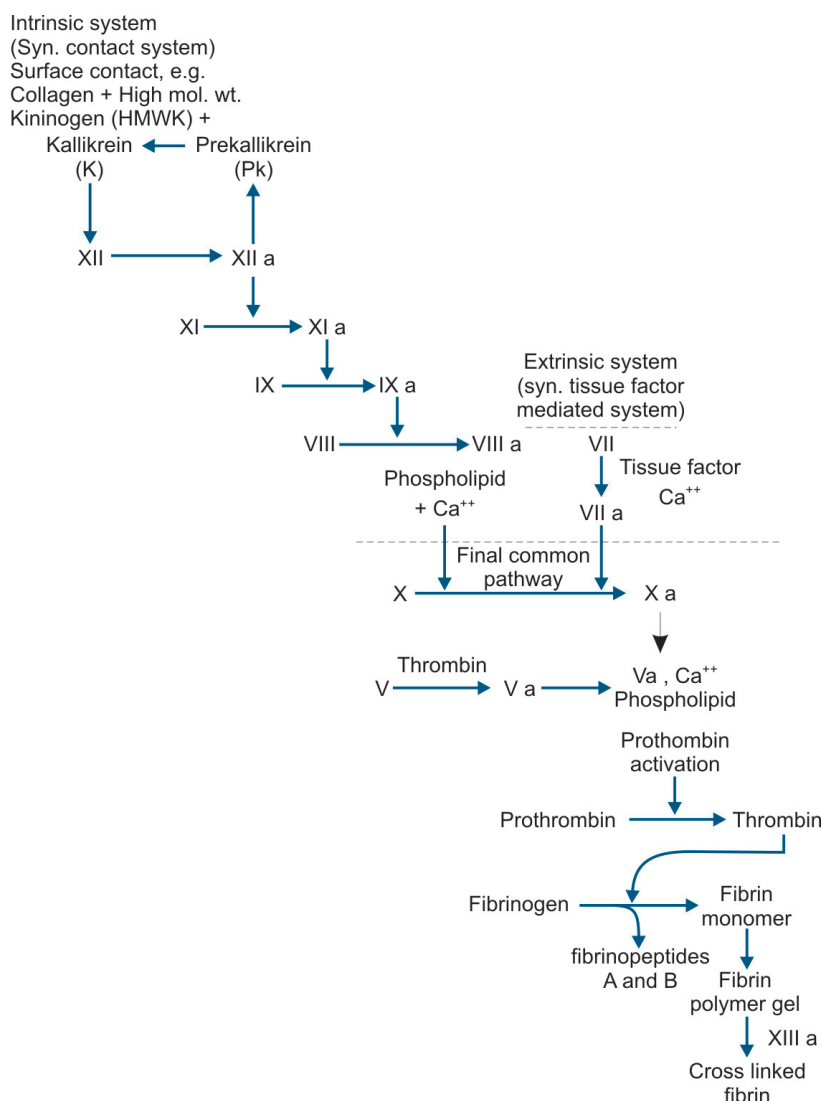
actions cause the successive cascading reactions of the clotting process. The clotting factors are designated by Roman numerals viz.

### INHIBITORS OF COAGULATION

1. **Blood flow**—The rapid flow of blood carries away the thrombin, other procoagulants and products of platelet activation. The diluted circulating procoagulants are then removed within minutes by the reticuloendothelial system.
2. **Endothelial factors**—Intact endothelium is covered with a single layer of negatively charged protein that repels clotting factors and platelets and thus, is thrombus resistant. If neither factor XII nor platelets are activated, coagulation cannot be initiated. Intact endothelium synthesizes prostacyclin ( $PGI_2$ ) which inhibits platelet aggregation.
3. **Circulating anticoagulants** –
  - a. Antithrombin III or AT III, (an alpha globulin + Thrombin) blocks the enzymatic effect of Thrombin on fibrinogen.
  - b. Protein C—Protein C + Thrombin becomes activated protein C (a protease) after it is bound to endothelial cell protein, called Thrombomodulin (TM). Activated protein C then reduces thrombin formation by inactivating activated factor V and VII both of which are

Clotting factor	Synonym
1. Fibrinogen	Factor I
2. Prothrombin	Factor II
3. Tissue thromboplastin	Factor III, Tissue factor
4. Calcium	Factor IV
5. Factor V	Proaccelerin, Labile factor
6. Factor VII	Serum prothrombin conversion accelerator (SPCA), proconvertin, stable factor.
7. Factor VIII	Antihemophilic factor (AHF), Antihemophilic globulin
Factor VIIIc	Coagulant subcomponents of AHF
Factor VIII: VWF	von Willebrand factor required in platelet adhesion. It is synthesized by vascular endothelium and absent in von Willebrand's disease.
8. Factor IX	Christmas factor, plasma thromboplastin component (PTC)
9. Factor X	Stuart factor
10. Factor XI	Plasma thromboplastin antecedent (PTA)
11. Factor XII	Hageman factor
12. Factor XIII	Fibrin stabilizing factor.

Factor XII, XI prekallikrein and High Mol. wt. Kininogen (HMWK) – These four primary proteins comprise the contact activation system which coordinates the three other systems viz. the complement system, the coagulation system and the fibrinolytic system after tissue injury.



**Fig. 4.2:** The extrinsic, intrinsic and the final common pathway of blood coagulation

important in forming the prothrombinase complex (see Fig 4.2).

c. Protein S—Activates plasminogen in the presence of Protein C. The inhibitory function of Protein C is enhanced by Protein S. Reduced levels of ATIII/ Protein C and S will result in a hypercoagulable or pre-thrombotic state.

**4. Fibrinolytic system**

It comprises:

- Tissue plasminogen activator, t PA.

- Streptokinase and Urokinase } Converts plasminogen to plasmin and do not require fibrin.

**GENERAL MECHANISM (FIG 4.2)**

Clotting takes place in three essential steps

1. Formation of prothrombinase or prothrombin activator in response to the blood vessel injury.
2. Prothrombin activator catalyses the conversion of prothrombin into thrombin.

3. Thrombin acts as an enzyme to convert fibrinogen into fibrin threads that enmesh platelets, blood cells and plasma to form the clot itself.

**Formation of Prothrombin Activator (Also Called Prothrombinase)**

Prothrombin activator is generally considered to be formed in two basic ways, although in reality these interact constantly with each other viz.

- (i) The extrinsic or tissue factor mediated pathway.
- (ii) The intrinsic or contact pathway.

*The Extrinsic Pathway*

In the extrinsic pathway, the phospholipids come from traumatized tissues extrinsic to the blood whereas in the intrinsic system, phospholipids come from the traumatized platelets intrinsic to the blood.

In the extrinsic pathway, traumatized tissue releases a complex of several factors, called tissue thromboplastin which includes phospholipids from the membranes of the tissues and a lipoprotein complex containing an important glycoprotein that functions as a proteolytic enzyme.

The lipoprotein complex of tissue thromboplastin forms a complex with blood coagulation factor VII and in the presence of Ca<sup>++</sup> ions, results in activated factor VII, which activates factor X of the final common pathway.

- Factor VIIa also activates factor IX of the intrinsic pathway more directly and provides an important link between the intrinsic and extrinsic coagulation pathways.
- Factor VII and three other coagulation factors viz. II, IX and X are synthesized in the liver and require Ca<sup>++</sup> and Vit K for biologic activity.

*The Intrinsic Pathway*

In the intrinsic pathway, three plasma proteins Hageman factor (Factor XII), High Mol. wt. Kininogen (HMWK) and prekallikrein (PK) are thought to form a complex on vascular subendothelial collagen. After binding of HMWK, factor XII is slowly converted



to an active protease, XIIa which then converts both PK to Kallikrein and factor XI to its active form (XIa). Kallikrein in turn accelerates XII conversion to XIIa while XIa activates factor IX. Activated factor IX acts with factor VIII and phospholipids from the injured platelets to activate factor X and the final common pathway.

N.B.:One should remember two bleeding disorders at this step.

- i. Factor VIII deficiency producing classic hemophilia, so factor VIII is also called antihemophilic factor, AHG.
- ii. Platelet deficiency giving rise to thrombocytopenia.

### Conversion of Prothrombin to Thrombin

Activated factor X is the protease that splits prothrombin to thrombin in the presence of factor V, calcium and phospholipids. Although prothrombin conversion can take place on various natural and artificial phospholipid rich surfaces, it accelerates several thousand folds on the surface of activated platelets.

### Conversion of Fibrinogen to Fibrin

Thrombin formed in the above reaction converts fibrinogen into fibrin. Thrombin has other functions in hemostasis viz. (i) it activates factors V, VIII and XIII and (ii) stimulates platelet aggregation and secretion.

Following the release of fibrinopeptides A and B from the alpha and beta chains of fibrinogen, the modified molecule now called fibrin monomer, polymerizes into an insoluble gel. The fibrin polymer is then stabilized by cross-linking of individual chains by activated factor XIII, a fibrin stabilizing factor (vide the figure above). XIIIa also serves as a stimulant to fibroblast growth.

### FIBRINOLYSIS (FIG. 4.3)

Clot lysis and vessel repair begin immediately after the formation of the definitive hemostatic plug. There are three major activators of the fibrinolytic system. Hageman factor fragments, urokinase (UK) and tissue plasminogen activator (tPA). The principal physiologic activator, tPA diffuses from endothelial cells

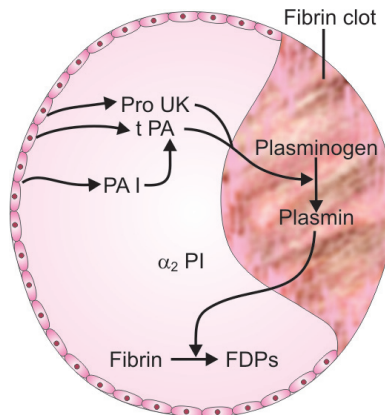


Fig. 4.3: A schematic diagram of fibrinolytic pathway.

and converts plasminogen absorbed to the fibrin clot, into plasmin.

Plasmin then degrades fibrin polymer into small fragments which are cleared by the monocyte – macrophage scavenger system. Although plasmin can also degrade fibrinogen, the reaction remain localized, because (1) tPA activates plasminogen more effectively only when it is adsorbed to fibrin clots and (2) Any plasmin that enters the circulation is rapidly bound and neutralized by the  $\alpha_2$  plasmin inhibitor. In addition, endothelial cells release a plasminogen activator; inhibitor (PAI) which blocks the action of tPA.

In Figure 4.3 tPA, i.e. tissue plasminogen activator released from endothelial cells enters the fibrin clot and activates plasminogen to plasmin. Any free plasmin is complexed with  $\alpha_2$  PI ( $\alpha_2$  – Plasmin inhibitor). Fibrin is degraded to low Mol. wt. fragments, abbreviated as FDPs (Fibrin degradation products).

### Clot Retraction

Within a few minutes after clot is formed, it begins to contract and usually expresses most of the fluid, from the clot within 20 to 60 min. The fluid expressed is called serum as all its fibrinogen and most of the other clotting factors have been removed. Thus, serum cannot clot because of lack of these factors.

Cause of clot retraction → Clot retraction depends on fibrin binding to receptors on activated platelets, the actinomycin microfilaments of which contract.

## LABORATORY TESTS FOR HEMOSTASIS

Coagulation tests are carried out on blood anticoagulated with sodium citrate. Tests must be carried out on fresh samples as coagulation factors are labile and if there is undue delay in sending a specimen to the laboratory there will be spurious prolongation of the clotting times.

### Prothrombin Time

Measurement of the prothrombin time (PT) assesses the functional capacity of the extrinsic system and is sensitive to isolated or combined deficiencies of factors II, V, VII, X and fibrinogen.

Rabbit brain extracts (Rich in Tissue factor) and calcium are added to the test plasma and the time taken for a clot to develop is measured.

### Prothrombin Time Ratio

The results of a prothrombin time are usually expressed as a ratio, comparing the result obtained on the patient's test plasma to that obtained on a normal plasma sample.

Prothrombin Time Ratio = PT (S) of Test sample/PT of normal sample.

The normal Prothrombin Time Ratio should be close to 1.0., The international normalized ratio (INR) is for practical purposes the same as the Prothrombin Time Ratio.

### Kaolin – Cephalin Clotting Time

Kaolin, phospholipid and calcium are added to the test plasma and the time taken for a clot to appear is measured. Kaolin activates factor XII, just like collagen. The Kaolin – Cephalin clotting time (CT) thus, tests function of the intrinsic pathway and is sensitive to isolated or combined deficiencies of factors XII, XI, X, IX, VIII, V, II or fibrinogen.

### Thrombin Time

Thrombin is added to patient plasma and the time taken for a clot to develop is measured. The thrombin time (TT) is prolonged when the fibrinogen level is low or in the presence of inhibitors of thrombin, e.g. Heparin.

### Platelet Count

Normal range is 1.5-4 lacs/cmm (150 – 400 × 10<sup>9</sup>/liter). Significant bleeding may occur when

the count falls below  $80 \times 10^9$ /liter. Abnormal bleeding may occasionally occur if platelet function is abnormal, even when the platelet count is normal or even increased, e.g. Myelodysplasia, Polycythemia, etc.

### Bleeding Time

The bleeding time is a simple test of platelet function. The normal bleeding time is less than 9 min. The bleeding time will be prolonged in association with thrombocytopenia and disorders associated with defective platelet function, e.g. von Willebrand's disease, some cases of myeloproliferative disease. etc.

### ACQUIRED DISORDERS OF COAGULATION

The following six disorders are responsible for most acquired bleeding defects viz.

1. Disseminated intravascular coagulation (DIC)
2. Liver disease
3. Vitamin K deficiency
4. Massive blood transfusion
5. Anticoagulants
6. Acquired coagulation factor inhibitors.

### Disseminated Intravascular Coagulation

#### Etiopathogenesis

Disseminated intravascular coagulation (DIC) is a consequence of explosive activation of the coagulation cascade throughout the vascular tree. Paradoxically this results in a bleeding tendency and symptoms related to vascular occlusion are relatively rare. This is because the initial thrombus formed in response to the triggering of DIC undergoes rapid lysis by plasmin. As the initial trigger persists, further cycles of coagulation and instantaneous lysis rapidly result in the depletion of coagulation factors, including fibrinogen and consumption of platelets.

The principal causes of DIC encountered in clinical practice are as follows:

1. Severe burns, head injury, gunshot wounds producing tissue damage.
2. Severe infections, e.g. Septicemia causing severe endothelial injury.
3. Malignant disease, e.g. metastatic carcinoma, leukemia.

4. ABO incompatible blood transfusion intravascular hemolysis.
5. Obstetric disorders, e.g. abruptio placentae, septic abortion, eclampsia, retained dead fetus.
6. Intravascular hemolysis, e.g. systemic absorption of hypotonic fluids after prostatectomy, infusion of hypotonic saline, etc.

#### Clinical Features

In overt cases, there is widespread bruising with extensive purpura, persistent oozing of blood from surgical wounds and venepuncture sites.

Bleeding from mucosal surfaces, e.g. epistaxis is common.

#### Laboratory Findings

- Both clotting time and prothrombin time are markedly prolonged. The thrombin time is also prolonged reflecting depletion of fibrinogen. The fibrinogen level is usually  $< 1\text{g/liter}$  (Normal 2 to 4 g/liter).
- Platelet count may be as low as  $50 \times 10^9/\text{L}$  in severe cases.
- Examination of blood film reveals fragmented erythrocytes.
- Elevated fibrin degradation products, especially D-dimer level in serum.

#### Treatment

1. *Identification of the cause*—Treatment of the underlying condition removes the stimulus for further consumption of coagulation factors.
2. Fresh Frozen Plasma (FFP) should be infused, as this is a good source of coagulation factors, including fibrinogen.
3. *Cryoprecipitate*—Cryoprecipitate is a very good source of fibrinogen and has the advantage of being more concentrated so that volume overload may be avoided. If available cryoprecipitate should be given as well as fresh frozen plasma.
4. *Platelet concentrates*—Platelet concentrates should also be transfused. Ten to twelve packs should suffice as initial therapy. There is no convincing evidence that administration of antithrombin III concentrates is beneficial.
5. *Whole blood*—It is important not to overlook the fact that patients often need blood in addition to plasma products. Maintenance of circulating blood volume

and an adequate Hb level are important objectives as tissue hypoxia will only exacerbate DIC.

6. Contrary to what might be imagined, administration of inhibitors of fibrinolysis, e.g. Tranexamic acid are of no value in the treatment of DIC. The use of such agents may precipitate overt thrombosis.

It is usually possible to control the situation by judicious use of blood products and treatment of the underlying cause.

### Liver Disease

The liver is the principal site of synthesis of nearly all clotting factors viz. fibrinogen, prothrombin, factors V, VII, IX, X, XI. Both acute and chronic liver diseases are thus frequently associated with hemostatic abnormalities. Thrombocytopenia of moderate severity ( $50 - 100 \times 10^9/\text{L}$ ) is a frequent finding in patients with chronic liver disease.

Also, in chronic liver disease, there is increased fibrinolytic activity associated with a decreased plasma level of naturally occurring  $\alpha_2$  - antiplasmins.

The most frequent hemorrhagic problems are esophageal and GI hemorrhage as well as bleeding from biopsy sites and during and after surgery. Bleeding into soft tissues is only rarely encountered.

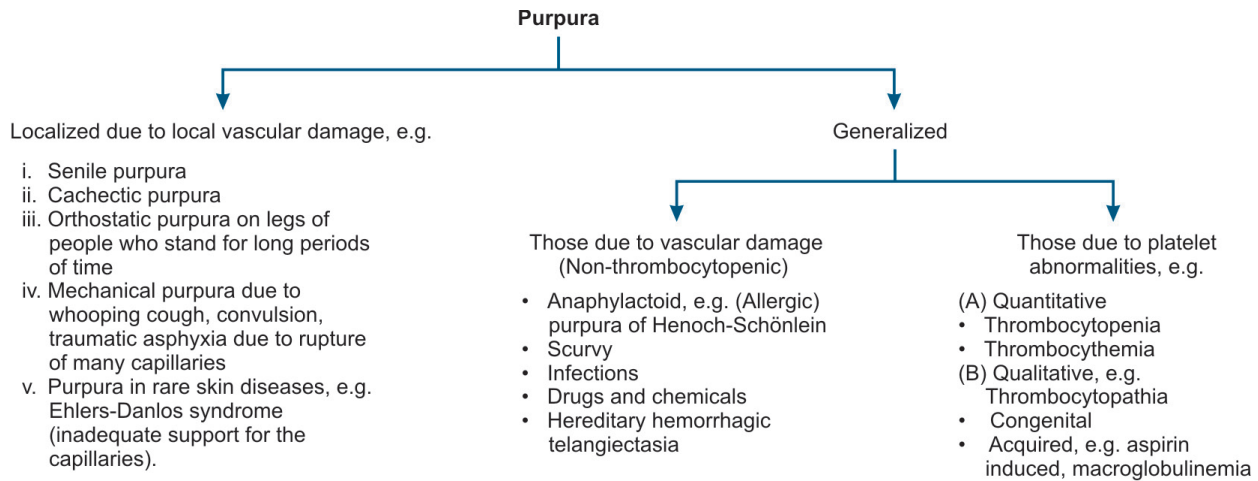
The most common laboratory findings are a marked reduction in the level of all coagulation factors in plasma except factor VIII. Both Prothrombin time and clotting time are prolonged.

#### Treatment

1. Administration of vitamin K when its deficiency is suspected.
2. Fresh frozen plasma contains all the coagulation factors. Usually two to three bags will suffice to correct the hemostatic defect.
3. Inhibitors of fibrinolysis, e.g. tranexamic acid and may be useful in the management of upper GI bleeding.

### Vitamin K Deficiency

Vitamin K is necessary for the synthesis of coagulation factors II (Prothrombin), VII, IX and X. Vitamin K is not soluble and is absorbed effectively only in the presence of



**Flow chart 4.1:** Various types of purpura

bile salts. Some vitamin K is also synthesized by endogenous bacterial flora resident in the small intestine and colon. Although there is theoretically a 30 day store of vitamin K in the normal liver, in certain conditions patients become deficient within 7 to 10 days.

#### Cause of Deficiency

- There are three major causes of vitamin K deficiency viz. inadequate dietary intake, intestinal malabsorption and loss of storage sites due to hepatocellular disease.
- Acute vitamin K deficiency is particularly common in patients recovering from biliary tract surgery who have no dietary intake of vitamin K, have T- tube drainage of bile and are on broad spectrum antibiotics. Vitamin K deficiency is also seen in chronic liver disease, particularly primary biliary cirrhosis and in some malabsorption states, e.g. celiac disease, intestinal fistulae, etc. Deficiency of vitamin K is associated with prolongation of both the prothrombin time and partial thromboplastin time. The platelet count is normal and the thrombin time and plasma fibrinogen concentration are normal. The latter helps in the exclusion of DIC. Typical hemorrhagic manifestations are easy bruising and bleeding from sites of injury or from the gums or GI tract.

#### Treatment

1. Parenteral administration of 10 mg of vitamin K rapidly restores vitamin K levels in

the liver and permits normal production of the coagulation factors dependent on vitamin K.

2. Severe hemorrhage can be treated with fresh frozen plasma which immediately corrects the hemostatic defect.

#### Massive Blood Transfusion

Blood collected in citrate phosphate dextrose with added adenine (CPDA) has a shelf life of 35 days at 4°C. However levels of all the coagulation factors decline during storage. Platelets in stored blood also rapidly lose their viability.

Massive transfusion is defined as the transfusion of stored blood that are greater in volume than a patient's normal blood volume in less than 24 hrs., creates several risks not encountered with a lesser volume or rate of transfusion.

Complications: See the chapter Hemorrhage and Blood Transfusion.

#### Anticoagulants

Consumption of anticoagulants will result in a bleeding tendency, e.g. when urgent surgery is carried out in a patient on anticoagulant therapy like warfarin who is unconscious and full medical details are not available.

Administration of streptokinase as thrombolytic therapy, e.g. for myocardial infarction within 10 days or so after surgery or other invasive procedure such as biopsy may be hazardous as serious bleeding may ensue.

#### Treatment

- a. In case of life-threatening hemorrhage → Inj Vit K 5 mg by slow IV infusion and a concentrate of factors II, IX, X and factor VII concentrate if available.
- b. In less severe hemorrhage—To withhold warfarin for 1 or more days and Vit K – 0.5 to 2 mg IV if necessary.

#### Acquired Coagulation Factor Inhibitors

Heparin is the most common acquired clotting factor inhibitor and should be quickly recognized in the laboratory with the help of a heparin filter. Circulating anticoagulants or inhibitors are usually IgG antibodies which interfere with coagulation reactions.

Antifactor VIII antibodies are seen in postpartum females, in patients on various drugs, as part of the spectrum of autoantibodies in systemic lupus erythematosus patients and in normal elderly individuals.

#### Treatment

- Most of the postpartum inhibitors remit after 12 -18 months after its occurrence, usually several months after a normal pregnancy.
- Hemorrhage in patients with specific inhibitors, e.g. factor VIII, IX or V may require treatment with massive plasma or concentrate infusion, the use of activated prothrombin complex concentrates (Factors II, VII, IX, X, protein C and S) to bypass the antibodies against VIII or IX



and plasmapheresis or exchange transfusion to lower antibody titer.

## CONGENITAL DISORDERS OF COAGULATION

- Hemophilia
- Other inherited factor deficiencies.

### Hemophilia

It is by far the most common among the hereditary clotting disorders and is the classical example of a disease inherited as a sex linked recessive characteristic. The affected males exhibit the disease while the females merely transmit it to the next generation. It can rarely affect a female if she is the offspring of an affected father and mother who carries the trait.

Antihemophilic factor (AHF) is a large (265000 Da), single chain protein which regulates the activation of factor X by proteases generated in the intrinsic coagulation pathway. It is synthesized in the liver parenchymal cells (VIIC, the coagulant subcomponents of AHF) and circulates complexed to Von Willebrand factor (VWF) which is synthesized by the vascular endothelium.

### Clinical Features

The patient may present with spontaneous hemarthroses, hemorrhage or prolonged bleeding after injury or operation.

Patients with more than 5 to 20 percent of normal factor activity rarely experience spontaneous bleeding but may bleed extensively after trauma or during surgery. Patients with 1 to 5 percent more activity have prolonged bleeding with minor injuries but rarely develop spontaneous hemarthroses. In patients with <1 percent activity, frequent hemarthrosis and severe bleeding episodes develop.

The diagnosis is suggested by an elevated PTT, normal PT and bleeding time. Factor activity assays confirm the diagnosis.

### Treatment

- Successful surgery among hemophiliacs is possible with available factor VIII concentrate.
- Fresh frozen plasma is effective in mild cases only as large quantities have to be administered to attain optimal factor

VIII level and these may result in circulatory overload.

- The cryoprecipitate however is preferable as it has a high biological activity and only a small volume infusion would suffice.
- A recent development has been the oral administration of factor VIII loaded liposomes to raise factor VIII level.

### Christmas Disease or Hemophilia B

Christmas disease (Factor IX deficiency) is clinically indistinguishable from factor VIII deficiency and has an X-linked recessive mode of inheritance. It is much less common than hemophilia.

The treatment of choice is replacement by purified factor IX concentrate.

### Other Factor Deficiencies

Very occasionally, patients with isolated congenital deficiencies of other coagulation factors may be encountered. Deficiencies of fibrinogen, factor V, X, VII, XI or XIII may be associated with a serious bleeding tendency.

Specific plasma derived concentrates of most of these coagulation factors are available commercially.

## PLATELET DISORDERS

Some terms:

1. Petechiae — Hemorrhages less than 2 mm in diameter.
2. Ecchymoses—Diffuse flat hemorrhages larger than this, i.e. 2 mm.
3. Hematoma — If there is a definite swelling the lesion is called hematoma.
4. Purpura — Purpura is defined as any condition in which there is bleeding into the skin (Petechiae, ecchymoses, hematoma, etc.).

Purpura is peculiar to states of vascular damage (Vascular purpura or non-thrombocytopenic purpura) and platelet inadequacy. See the flow chart 4.1 above for various types of purpura

### Thrombocytopenia

Platelets are anucleate fragments, derived from bone marrow megakaryocytes that circulate for approximately 10 days after leaving

the bone marrow. Approximately 30 percent of the total platelet mass is sequestered in the spleen in a separate but slowly equilibrating pool. Because only a small fraction of circulating platelets is consumed during hemostatic reactions, most platelets live out their full life span and are removed from the circulation only when they become senescent. Platelet distribution and life span however are dramatically changed in pathologic states. Either accelerated destruction or enhanced pooling of platelets eventually causes thrombocytopenia if platelet loss exceeds the ability of the marrow to compensate by increasing platelet production.

### Definition

A platelet count of less than 1,00,000/cmm generally constitutes thrombocytopenia with platelet counts between 40,000 and 1,00,000/cmm, bleeding may occur after injury or surgery. Spontaneous bleeding may occur with platelet counts between 10,000 and 20,000/cmm. At platelet counts of below 10,000/cmm spontaneous bleeding is frequent and often severe.

### Etiology

Thrombocytopenia may be due to three factors

1. Increased platelet destruction
2. Increased platelet consumption
3. Failure of platelet production.

### Increased Platelet Destruction

- i. Idiopathic Thrombocytopenic Purpura (ITP)—It is an IgG mediated autoimmune disorder against platelets. Spleen sequesters the sensitized platelets and then destroys them. So, splenectomy is of value in this condition.
- ii. SLE
- iii. Drug induced, e.g. Heparin, Gold salts, Quinine, Sulphonamides, Penicillins, etc. (ii) and (iii) both are associated with immunological platelet destruction.

### Increased Platelet Consumption

- i. Disseminated intravascular coagulation (DIC).
- ii. Thrombotic thrombocytopenic purpura (TTP) associated with microangiopathic hemolytic anemia and platelets are used in the formation of thrombus.

It affects many organs, has an acute course and a very high mortality rate. It may be spontaneous or in association with pregnancy, carcinoma, infection or chemotherapy.

Treatment:

- Prednisolone — 1 mg/kg/day orally.
- Aspirin — 325 mg/day orally and daily plasmapheresis using FFP (Fresh Frozen Plasma).

### Failure of Platelet Production

By bone marrow, e.g. aplastic anemia, acute leukemia and conditions of excessive bone marrow replacement, e.g. myelofibrosis, multiple myeloma and secondary carcinoma.

Other causes, e.g. dilutional thrombocytopenia—Following massive blood transfusions as the stored blood contains nonviable platelets.

### Thrombocythemia

Here platelet count is  $> 10$  lacs/cmm. Yet there is a severe bleeding tendency. The platelets vary in size and show evidence of dysfunction, e.g. impaired release reaction and impaired liberation of factor 3. It is found in myeloproliferative disorders such as chronic myelogenous leukemia, myeloid metaplasia and essential thrombocytosis.

Furthermore it may be complicated by venous thrombosis despite the tendency to hemorrhagic manifestations.

### Qualitative Platelet Dysfunction

1. Acquired defects—Usually result from uremia (impaired release reaction), liver disease and from the use of such drugs as Aspirin, NSAIDs and betalactum antibiotics. Treatment is aimed at the underlying cause. For severe bleeding platelet transfusions may be necessary. Aspirin blocks the release of ADP and hence, platelet aggregation (See phases of hemostasis page 23).
2. von Willebrand Disease (VWD)—It is an autosomal disorder characterized by a prolonged bleeding time secondary to a qualitative or quantitative deficiency of VWF (von Willebrand Factor). Treatment is done with transfusion of factor VIII concentrate which contains high concentration of VWF. Cryoprecipitate also corrects the bleeding time in patients

with VWD but carries the risk of viral transmission.

3. Congenital platelet disorders—Platelet membrane defects
  - a. Glanzmann's Thrombasthenia or disease — It is inherited as an autosomal recessive trait. Platelets from patients with this disease are missing or markedly deficient in the glycoprotein IIb – IIIa complex. Their platelets do not bind fibrinogen and cannot form aggregates.
  - b. Bernard Soulier syndrome—Have markedly reduced platelet adhesion and cannot bind VWF to their platelets owing to a deficiency in glycoprotein 16 – complex. It is also inherited as autosomal recessive trait. Both the above conditions are characterized by markedly impaired hemostasis and recurrent episodes of severe mucosal hemorrhage. Treatment — Transfusion with normal platelets.

## INVESTIGATION OF A PATIENT WITH BLEEDING DISORDERS

### History

Patient's history is the cornerstone of hemostatic assessment. The history should be taken with the goal of determining whether the patient may have a defect in primary hemostasis, secondary hemostasis or both.

Failure of the primary phase of hemostasis (Platelet plug formation occurring over minutes) results in immediate bleeding, i.e. bleeding soon after the hemostatic stress, e.g. childbirth, surgical or dental procedures. Patients with a platelet disorder typically have signs of skin or mucosal bleeding such as petechiae, frequent bruising, epistaxis, and menorrhagia and prolonged bleeding after minor injuries.

A defect in the secondary phase of hemostasis (fibrin clot formation) is associated with "Delayed bleeding".

The defect may be due to a disorder of fibrin clot formation or cross – linking, i.e. clotting factor deficiencies, or due to a lack of regulation of the fibrinolytic system, i.e.  $\alpha_2$  antiplasmin or plasminogen activator inhibitor (PAI) deficiency, which results in premature clot lysis or both.

Patients with one or more clotting factors deficiency typically describe delayed development of soft tissue hematoma or hemarthrosis.

### Medication

The medications that affect platelet function and coagulation, e.g. Aspirin, NSAID, Ethanol, contraceptives or anticoagulants should be determined.

### Family History

A family history of bleeding should be elicited.

### Physical Examination

Should include signs of liver or kidney disease, malignancy or malnutrition. One should inspect the patients skin, oral mucosa and joints for evidence of joint bleeding. Spleen is tested for any enlargement.

### Laboratory Testing

It is not necessary to perform tests of hemostasis on all patients scheduled for elective surgery. However, if a history of possible bleeding tendency emerges during outpatient investigation, patients should certainly be referred for investigation prior to surgery.

Basic tests of coagulation include prothrombin time, Kaolin-Cephalin clotting time and the platelet count. When the platelet count is normal or even elevated, a bleeding time should be measured to exclude the possibility of congenital or acquired defects of platelet function.

When bleeding is encountered during surgery and there is no obvious source of hemorrhage, prothrombin time, clotting time and platelet count should be requested in the first instance. The administration of two or three units of fresh frozen plasma is a useful practical measure until the cause is identified. Platelet concentrates should be given if the platelet count is below  $50 \times 10^9$ /liter.

## HYPERCOAGULABLE STATES AND THROMBOTIC DISEASE OR THROMBOPHILIA

### Introduction

The term hypercoagulable state or thrombophilia refers to clinical situations or disor-

ders in which patients manifest an unusual predisposition to thrombosis.

Under normal circumstances, natural anticoagulant mechanisms ensure maintenance of blood fluidity or if there is vascular injury, limit and localize thrombus formation, at the site of such injury. Thrombosis occurs when this process is unregulated and clot formation occurs at an inappropriate place and time.

### Types/Etiology

In clinical practice, patients suspected of having a thrombotic tendency are separated into two pathophysiologic categories viz.

- i. Primary or inherited hypercoagulable states.
- ii. Secondary or acquired hypercoagulable states.

#### Inherited Forms

- i. Antithrombin III deficiency
- ii. Protein C deficiency
- iii. Protein S deficiency
- iv. Dysfibrinogenemia

#### Acquired Disorders

- i. Lupus anticoagulant or anticardiolipin antibody syndrome.
- ii. Occult or overt malignancy.
- iii. Pregnancy or postpartum state.
- iv. Oral contraceptive or estrogen therapy (They lower the ATIII level).
- v. Immobilization.
- vi. Postoperative especially orthopedic and gynecologic surgeries.
- vii. Myeloproliferative disorders, e.g. polycythemia chronic myelogenous leukemia.
- viii. Homocystinuria.

### Clinical Features

Hypercoagulable states manifest in several ways. The most common presentation consists of venous thrombosis of the iliofemoral system with or without pulmonary embolism.

- Another well-characterized disorder is the migratory thrombophlebitis in patients with underlying carcinoma and other conditions.

- Patients who are hypercoagulable may also present with thrombosis at unusual sites, e.g. mesenteric, portal, hepatic (Budd – Chiari syndrome), subclavian or axillary, cerebral, retinal and renal veins. Such thrombotic events may occur either spontaneously as isolated incidents or in association with predisposing risk factors.

There are also disorders in which thrombotic events occur primarily on the arterial side of the circulation, e.g. cerebrovascular events, myocardial infarction, peripheral vascular disease, etc.

### Inherited Forms

Antithrombin III inactivates factors IX, X, XI and thrombin. Protein C and its cofactor protein S are vitamin K dependent proteins which inactivate factors V and VIII. Hence patients with deficiency of ATIII, protein C and S are particularly vulnerable to the development of deep venous thrombosis (DVT) and pulmonary embolism after surgery if adequate precautions are not taken.

### Acquired Disorders

Lupus anticoagulant was first described in patients with SLE but is more commonly found in other conditions and in people who are perfectly well. The lupus anticoagulant is an anticardiolipin antibody (IgG, IgA or IgM immunoglobulin) which prolong coagulation tests by binding to phospholipids. The aPTT is affected more than PT. The former is not corrected by the addition of normal plasma to the patients own plasma. There may be thrombocytopenia. Despite these findings, the patient is paradoxically at risk of thrombosis and there is no undue risk of hemorrhage (even in association with surgery).

### Management of Thrombophilia

#### Anticoagulation Therapy

Anticoagulation is used to prevent thrombosis and thromboembolic events to cover surgery and pregnancy in patients with documented thrombophilia.

### Heparin

Standard low dose Heparin (5000 units 12 hrly SC) is perfectly satisfactory for general surgery. Treatment of venous thrombosis requires a higher daily dose, typically given as 100 – 150 units/kg IV bolus, followed by 1000-2000 units per hour or 18 units/kg/hour continuous IV. aPTT should be measured before initiation of Heparin and 6 hrs after the initial bolus. A therapeutic PTT of 1.5 – 2 times the control (Approx. 50 – 80sec) should be maintained. Once the aPTT is stable, daily monitoring is performed.

### Warfarin

Oral anticoagulation with vitamin K antagonist, warfarin is usually begun after 1 or 2 days of IV heparin therapy. Dose- 10 mg/day for 3 days the subsequent dose is adjusted as per result of prothrombin time testing which should be 1.5 to 2.5 times the control value. For most adults the maintenance dose is 5 mg/day. Once the prothrombin activity is stable, bimonthly checks are sufficient.

### Antiplatelet Therapy

#### Aspirin

Aspirin inhibits platelet synthesis of thromboxane A<sub>2</sub>. It is useful in the prevention of TIA (Transient Ischemic Attacks), stroke, myocardial infarction, etc. Dose 80 to 325 mg/day orally.

#### Fibrinolytic Therapy

Recombinant tissue plasminogen activator (rtPA), e.g. Alteplase, Reteplase, as well as streptokinase are used for lysis of catheter, venous and peripheral arterial thrombi.

- In antithrombin III deficiency, plasma derived concentrates of ATIII are available and may be given in addition to subcutaneous heparin to cover surgical procedures. Concentrates of protein C and S are not yet available.
- Affected women should not take estrogen containing oral contraceptives or hormone replacement therapy after the menopause.

# Chapter 5

## Fluid and Electrolyte Balance

- Introduction
- Fluid compartments
- Interpretation of fluid balance
- Which fluids go where?
- Normal water and electrolyte balance
- Disorders of fluid and electrolyte balance
- Fluid therapy
- Fluid replacement
- The fluid rule

### INTRODUCTION

It has been noted that inadequate rehydration and oliguria prior to surgery carries with it a high mortality, morbidity and greater length of hospital stay. Thus if the cells of the body are to function efficiently, their internal environment, i.e. the composition of extracellular and intracellular fluids, must remain constant. For this, it is necessary that water and different electrolytes used up in the various metabolic processes be replaced in like amounts. In the normal healthy person this takes place by ingestion of appropriate quantities of water and food as dictated by thirst and appetite, both of which are extremely elegant mechanisms of regulation of the internal environment. We are not sufficiently cognizant of their accuracy because we take them for granted.

When oral intake is not possible for one reason or the other, the same must be provided by an alternative route, commonly intravenously. For this purpose, one must know, the normal amounts of fluids and salts ingested and excreted everyday. At the same time in many surgical illnesses as well as after operations, excessive quantities of water and salts are lost. In such situations, we must know how to assess the amounts lost, in order to replace them accurately.

Therefore, fluid and electrolyte management is a very important part of the care of surgical patients.

### FLUID COMPARTMENTS

Water accounts for 60 percent of normal body weight in an average adult male. In an average adult female having more fat, the water content is about 10 percent less while the new-born infants are 75 percent water.

The higher water content in children is mainly because of larger surface area, poorer concentrating power of the kidneys and their increased metabolic activity. It is thus obvious that besides sex total body water content also varies with age, body weight and body fat content.

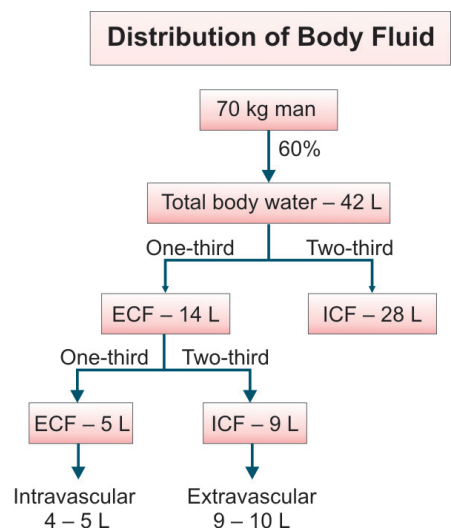
The distribution of body fluid is shown in Figure 5.1. For the traditional 70 kg man, the total body water TBW is 42 liters. This is distributed according to the rule of thirds, with two-thirds of TBW (42 liters) being intracellular (high potassium and low sodium concentrations) while one-third of TBW (14 liters) is extracellular (high sodium and low potassium concentrations).

The extracellular compartment is further divided into thirds by the capillary membrane: Two-thirds extravascular and one-third intravascular.

Thus Fluid Compartments as shown in Figure 5.1 are

Total body water in a 70 kg man is 60 percent = 42 liters.

- Two-thirds is intracellular = 28 liters
- One-third is extracellular = 14 liters
- Two-thirds of the extracellular compartment is extravascular = 9 liters
- One-third of the extracellular compartment is intravascular = 5 liters



**Fig. 5.1:** Distribution of fluid in the adult body, the 'rule of thirds'. ECF - Extracellular fluid, ICF - Intracellular fluid

The extravascular compartment is contributed by the interstitial fluid and lymph, water in dense connective tissue and cartilage, inaccessible bone water and transcellular water. Transcellular water is formed by the secretory activity of cells separated by a layer of epithelium. It includes cerebrospinal fluid, intraocular, pleural, peritoneal and synovial fluid, digestive secretions and gut luminal fluid and volume is relatively small (Approximately 1 to 1.5 liter).

If the transcellular compartment is very large, it may be called the 'third space' because fluid in this compartment is not readily exchangeable with the rest of the extracellular fluid (ECF).

In practice, it is difficult to define the boundary between the extracellular and intracellular water because some of the extracellular water is sequestered in dense connective tissue, cartilage and especially bone and cannot equilibrate rapidly with the other portions of the extracellular fluid viz. plasma, interstitial fluid and lymph. About 15 percent of body's water is present in dense connective tissue and bone and is liable to be included in the intracellular moiety in equilibration measurement.

### The Normal Distribution of Electrolytes in the Body Water

The electrolyte composition of the intracellular and extracellular fluids in quite distinct:

In the intracellular fluid, the principal cations are potassium and magnesium and the principal anions are phosphate and protein.

In the extracellular fluid, the predominant cation is sodium and the principal anions are chloride and bicarbonate.

The approximate distribution of electrolytes in the body fluids is as follows:

Ion	Extra-cellular fluid (mmol/l)	Intra-cellular fluid (mmol/l)
<b>Cations</b>		
i. Na <sup>+</sup>	135–145	4–10
ii. K <sup>+</sup>	3.5–5	150
iii. Ca <sup>++</sup> consied	1.0–1.25	0.001
iv. Ca <sup>++</sup> total	2.12–2.65	–
v. Mg <sup>++</sup>	1.0	40

### Anions

i. Bicarbonate	25	10
ii. Cl <sup>-</sup>	95–105	15
iii. Phosphate	1.1	100
iv. Organic anions	3.0	0
v. Protein	1.1	8

The electrolytes perform two main functions:

1. They are the principal solutes in the body fluids and therefore, account for most of their osmotic pressure.
2. The concentration of individual ions influences the properties and behavior of excitable membranes, e.g. Nerve cells and the performance of many intracellular enzymes.

### INTERPRETATION OF FLUID BALANCE

To understand fluid balance one need to know from which compartment or compartments fluid is being lost in various situations and in which compartments fluids will end up when administered to the patient.

For practical purposes, one should only consider the plasma, the interstitial space, the intracellular space and the barriers between them viz. the capillary membrane and the cell membrane.

### The Capillary Membrane

The barrier between the plasma and interstitium is the capillary endothelium, which allows the free passage of water and electrolytes (small particles) but restricts the passage of larger molecules such as proteins.

The osmotic pressure generated by the presence of colloids (Kolla, GK – glue + eidos – form) on one side of membrane which is impermeable to them is known as the colloid osmotic pressure or COP.

Only a small quantity of albumin (Mol. wt – 69000) crosses the membrane and it is mainly responsible for the difference in COP between the plasma and the interstitium.

The osmotic effect of proteins is about 50 percent greater than would be expected for the proteins alone. The reason for this is that most proteins are negatively charged, attracting positively charged ions such as sodium – the Gibbs-Donnan effect. These positively charged ions are osmotically active and therefore increase the effective osmotic pressure.

The colloidal osmotic pressure is about 25 mm Hg and tends to draw fluid into the

capillary while the hydrostatic pressure difference between capillary and interstitium tends to push fluid out. This balance was first described by physiologist Henry Starling at London in 1896.

### Starling Hypothesis

The distribution of ECF between plasma and interstitial space is regulated at the capillaries and lymphatics. The forces tending to drive fluid out of the blood vessels are:

- i. The hydrostatic pressure in the vessel and
- ii. The colloidal osmotic pressure also called the oncotic pressure of the interstitial fluid while the forces tending to draw fluid into the blood vessels are: 1. The colloid osmotic (oncotic pressure) of the plasma and 2. The tissue hydrostatic pressure.

### Starling's Equation

Movement of fluid = K [(Capillary hydrostatic pressure + Tissue oncotic pressure), Outward pressure – (Capillary oncotic pressure + Tissue hydrostatic pressure), i.e. Inward pressure, K = Filtration constant for the capillary membrane

**Edema**—Excessive extravascular accumulation of fluid results in edema formation.

### Causes:

- Increased capillary hydrostatic pressure, e.g. venous obstruction, fluid overload.
- Decreased capillary oncotic pressure, e.g. causes of hypoproteinemia like nephrotic syndrome, cirrhosis, etc.
- Increased tissue oncotic pressure resulting from increased capillary permeability due to burn or inflammation.
- Decreased tissue hydrostatic pressure.

### The Cell Membrane

The barrier between the extracellular and intracellular space is the cell membrane. This is freely permeable to water but not to sodium ions, which are actively pumped out of cells. Sodium is therefore mainly an extracellular cation as already said, while potassium is the main intracellular cation.

Water moves across the cell membrane in either direction if there is any difference in osmolality between the two sides.

**Osmolality of Plasma:** Osmolality expresses the osmotic pressure across a selectively permeable membrane and depends on the number of particles in the solution, i.e. ions and unionized molecules, not their



size. For dilute solutions, the osmotic activity is very nearly equal to the actual concentration of the particles: A solute concentration of 1 millimole per liter has an osmotic activity of 1 milliosmole per liter. A millimole is one-thousandth of a mole or gm molecular weight. Thus one millimole of  $\text{Cl}^-$  is 35.5 mg. The osmotic activity of electrolytes depends on the number of ions. Thus 58.5 mg of NaCl in 1 liter of water becomes 23 mg of Na and 35.5 mg  $\text{Cl}^-$ , the concentration of each ion is 1 millimole per liter but the osmotic activity of the solution is due to both ions and will be 2 milliosmoles per liter.

The total osmotic activity of plasma (measured by depression of freezing point) is normally 290 – 310 milliosmoles per kg water. Expressing each solute in the same terms (millimoles per liter), Na (140), Cl (100) are clearly the predominant contributors, followed by  $\text{HCO}_3^-$  (27), K, urea and glucose (about 5 each) with much smaller contribution from calcium, magnesium, protein, phosphate, etc. Since the major contributors to plasma osmolality are sodium, urea and glucose, the plasma osmolality can be calculated from the following formula.

$$\text{Osmolality (mmol/kg)} = 2 \times \text{Na (mmol/l)} + \text{urea (mmol/l)} + \text{glucose (mmol/l)}$$

It should be noted that

Osmolality = Solute concentration per kg of solvent (usually water) and

Osmolarity = Solute concentration per liter of solution.

In most biological fluids, the two are very similar, but the procedures used (determinations of freezing point and vapor pressure) measure osmolality (in milliosmoles per kg water) rather than osmolarity.

It is to be noted that the colloids contribute very little to total osmolality as the number of particles is small although, as stated above they play an important role in fluid movement across the capillaries.

## WHICH FLUIDS GO WHERE?

### Movement of Water Between Compartments

#### Intravascular Compartment

This compartment is the 'port of entry' for intravenous fluid administration. Colloid

(blood, albumin or gelatin solution) will remain within this compartment because the capillaries are impermeable to the colloid, water will then be retained by osmosis. If one liter of colloid is administered to a shocked patient with an intravascular volume of say, 3 liters the resultant intravascular volume will be 4 liters, an increase of 33 percent.

#### Extravascular (Interstitial) Compartment

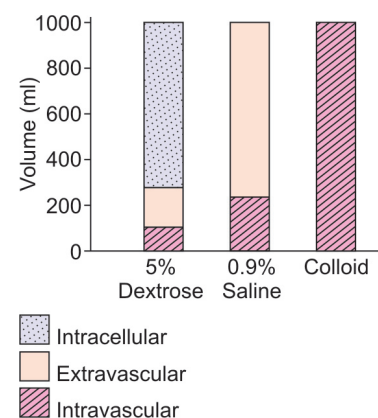
If normal saline (0.9%) containing  $\text{Na}^+$  and  $\text{Cl}^-$  at concentration of 150 mmol/liter is infused into a patient, the sodium will pass freely out of the vascular compartment but remains in the extracellular compartment because the capillary wall is freely permeable to sodium and water, while the cell membrane is freely permeable to water but not to sodium, 0.9 percent saline thus expands only the extracellular compartment.

If 1 liter of 0.9 percent saline is administered to an actually shocked patient with an intravascular fluid volume down from 4 to 3 liters, it will initially expand the intravascular volume dependent on its rate of infusion but soon it gets distributed throughout the extracellular space. Thus from Figure 5.2 addition of 1 liter of normal saline would increase the ECF volume from 13 liters (3 liters intravascular + 10 liters interstitial) to 14 liters, an increase of about 8 percent. The intravascular volume will then only increase from 3 liters to 3.25 liters.

#### Intracellular Compartment

This is the single largest compartment. The cell membrane is freely permeable to water but impermeable to sodium. If a liter of 5 percent dextrose is administered to an actually shocked patient with an intravascular volume of 3 liters, it will first expand. The intravascular volume dependent on its rate of infusion but soon it gets distributed throughout the extracellular space since capillary endothelium is freely permeable to water and dextrose.

In a short period of time, all of the infused dextrose will be metabolized leaving only water. This reduces the osmolality of the ECF. Since osmolality must be the same inside and outside the cells water will move



**Fig. 5.2:** Efficacy of intravenous infusions expanding the body fluid compartments.

from ECF to ICF until the osmolalities are the same.

From Figure 5.2, it can be seen that the TBW will be increased uniformly from 41 to 42 liters, an increase of 2.5 percent. Thus, the intravascular volume will be increased by 2.5 percent from 3 liters to 3.08 liters (Fig. 5.2).

Therefore, while resuscitating an acutely shocked patient in whom perfusion is compromised, it is critical to expand the intravascular compartment. From the above description, it is clear that only colloid or blood produces a sustained and significant expansion of this compartment as shown below.

#### Which fluids go where? (Fig. 5.2)

- Colloid stays in the vascular compartment.
- Saline (0.9%) stays in the extra cellular compartment.
- Dextrose (0.5%) eventually goes to all compartments.

### Relative Fluid Deficit

'Absolute' fluid deficits are the result of actual fluid loss 'Relative' fluid loss occurs when fluid shifts between compartments, creating a deficit in one, even when there is no overall fluid deficit. The most common examples are

- Septic shock that expands the vascular compartment due to vasodilatation producing relative hypovolemia.
- Third space losses – expands the extracellular compartment. This may be

considerable and are often underestimated. If an organ with a large surface area such as bowel, is handled and traumatized, even small degrees of edema can increase the extravascular volume considerably. It causes relative hypovolemia taking water and sodium from the intravascular compartment.

## NORMAL WATER AND ELECTROLYTE BALANCE

### Water Balance

We take in water as food and drink and also make about 350 ml per day as a result of the oxidation of carbohydrates to water and carbon-dioxide, known as the metabolic water.

This has to balance the output. Water is lost through the skin and from the lungs: These insensible losses amount to about 1 liter a day. Urine and feces account for the rest. A typical balance is shown in Table 5.1.

**Table 5.1: Average daily water balance for a sedentary adult in temperate conditions**

Input (ml)	Output (ml)
a. Drink – 1500	a. Urine – 1500
b. Food – 750	b. Feces – 100
c. Metabolic – 350	c. Lungs – 400
	d. Skin – 600
Total – 2600	Total – 2600

**Maintenance fluid:** (Given as per kg body wt.)

The precise water requirements of a particular patient depend on size, age and temperature. Surface area (1.5 liters H<sub>2</sub>O m<sup>-2</sup> daily) is the most accurate guide, but it is more practical to use body weight giving adults 30 to 40 ml/kg fluid daily.

Children require relatively more water than adults. The simplest rule of thumb method to calculate their requirements is the 4, 2, 1 rule.

- For the first 10 kg 4 ml. kg<sup>-1</sup>, hr<sup>-1</sup>
- For the next 10 kg 2 ml. kg<sup>-1</sup>, hr<sup>-1</sup>
- For each additional kilogram, 1 ml. kg<sup>-1</sup>, hr<sup>-1</sup>

**Table 5.2: Composition of cations and anions in plasma.**

Cations (meq/L)	Anions (meq/L)
Na – 142 (Range 137-148)	Cl – 103 (Range 99-108)
K – 5 (Range 4.0-5.5)	HCO <sub>3</sub> – 24 (Range 21-27)
Ca – 3 (Ionized Fraction)	other anions – 8 (include HPO <sub>4</sub> , SO <sub>4</sub> and organic acids eg. ketoacids)
Mg – 1.5	Protein – 16 (Range 15-20)
Total – 150 (approx.)	Total – 150 (approx.)

Thus maintenance fluid requirements for a 25 kg child would be 65 ml.h<sup>-1</sup>

- 4 ml. kg<sup>-1</sup>, hr<sup>-1</sup> for first 10kg = 40 ml.h<sup>-1</sup>
- 2 ml. kg<sup>-1</sup>, hr<sup>-1</sup> for next 10kg = 20 ml.h<sup>-1</sup>
- 1 ml. kg<sup>-1</sup>, hr<sup>-1</sup> for remaining 5 kg – 5 ml.h<sup>-1</sup>
- So total = 65 ml.h<sup>-1</sup>

### Electrolyte Balance

#### Daily Electrolyte Requirement

The average requirements of sodium and potassium are 1mmol. Kg<sup>-1</sup>.day<sup>-1</sup> of each element. Humans are very efficient at conserving sodium and can tolerate much lower sodium intakes but they are less good at conserving potassium. There is an obligatory loss of potassium in urine and feces and patients who are not given potassium become hypokalemic. As potassium is mainly an intracellular cation, there may be a considerable fall in total body potassium before the plasma potassium falls.

#### Electrolyte Balance

When inorganic salts are in solution as in the extracellular or intracellular fluids of the body, they dissociate into ions. Ions are of two kinds!

- Cations which are electropositive and
- Anions which are electronegative.

Collectively these are the electrolytes. The cations include sodium, potassium, calcium and magnesium. The anions include chloride, phosphate, bicarbonate and sulfate. In any solution, the concentrations of cations must be equal to that of anions. This is shown in the Table 5.2 of the composition of plasma.

Recently system international units (SI units) are used in many countries and it is better to express concentration of

electrolytes in millimoles per liter (mmol/liter). It is seen that the figures for sodium, potassium, chloride and bicarbonate remain unchanged in mmol/liter as compared to mEq/liter.

N.B.: In order to convert concentrations of ions in mg/dl to mEq/liter, a simple formula is used viz. mg per 100 ml × 10/Equivalent wt. of element.

To convert concentration of substances including ions from mg/dl to mmol/liter, a similar formula is used except that the molecular wt. of the substance is substituted for the equivalent weight of the element.

Plasma proteins are not measured in mmol/liter but in g/liter.

The distribution of the salts within the fluid compartments of the body controls the passage of water through the cell walls and maintains acid base equilibrium. It is essential to optimize both sodium balance and potassium balance in surgical patients as well as to know the dangers of imbalance of either electrolyte.

### Sodium Balance

Sodium is all important in sustaining the cationic level of the extracellular fluid.

Total body sodium = 5000 mmol (112 gm approx.) of which 50 percent is in the extracellular fluid, 5 percent in the intracellular fluid and 45 percent is in the bone.

#### Regulation

(a) Renal:

- Glomerular filtration rate—If this is reduced, e.g. after a sudden reduction in blood volume following severe hemorrhage, the amount of sodium excreted in the urine is decreased and sodium is retained (as about 80% of the sodium is

normally reabsorbed by the proximal convoluted tubule).

- ii. Aldosterone — Secreted by the zona glomerulosa of adrenal cortex is the most powerful conservator of sodium. It has an important influence on the exchanges on Na, K and hydrogen in the distal tubule. The secretion of Aldosterone is stimulated by decreased ECF volume and decreased renal perfusion pressure. The mechanism involves the renin-angiotensin system and results in increased Na reabsorption by the distal tubule. Expansion of the blood volume has the converse effect.
- (a) ADH mechanism: Retention of sodium leads to retention of water under the influence of antidiuretic hormone (ADH) or vasopressin secreted by supraoptic and paraventricular nuclei of hypothalamus and stored in the posterior pituitary. It conserves water by increasing reabsorption from the distal tubules and collecting ducts. A reduction of blood volume and increased concentration of Na<sup>+</sup> in the plasma stimulates ADH secretion and vice versa.
  - Excretion: Through Kidney (10-100 mmol), sweat (10-60 mmol) and stool (0-20 mmol).
  - Recommended adult intake/day -> oral - 50 - 140 mmol - in food and drinks, IV-1 to 2 mmol/kg.
  - Absorption site - small intestine.

### Potassium Balance

Potassium is almost entirely intracellular (98%), only 2 percent is present in the extracellular fluid.

- Total body potassium—3500 mmol approximately.
- Daily requirement ranges from 50 to 100 mmol/day. Each day a normal adult ingests approximately 1 mmol/kg of potassium in food. Fruit, milk and honey are rich in this cation.
- Excretion—Mainly through urine, a very small quantity through feces and sweat.
- Urinary excretion — 50 to 80 mmol/day.

## DISORDERS OF FLUID AND ELECTROLYTE BALANCE

### Disturbance of Water Balance

#### 'Pure' Water Depletion (i.e. water loss in excess of sodium deficit or dehydration)

##### Causes

1. Diminished intake—This may result from lack of availability or difficulty or inability to swallow because of painful conditions of the mouth and pharynx or obstruction in the esophagus.
2. Increased loss:
  - i. From the lungs after tracheostomy. This loss may be as much as 500 ml in excess of the normal insensible loss (which is about 400 ml from the lungs). After tracheostomy humidification of the inspired air is an important preventive measure.
  - ii. Lack of ADH producing diabetes insipidus.
  - iii. Unresponsiveness of the renal tubules to ADH, e.g.
    - a. Nephrogenic diabetes insipidus.
    - b. Hypokalemia
    - c. Hypercalcemia.

##### Clinical Features

- There is increased osmolality of the ECF producing weakness and intense thirst. The urinary output is diminished and specific gravity increased.
- The increased serum osmolality also causes water to leave the cell producing intracellular dehydration. As the water leaves the cells, it is accompanied by potassium ions. Eventually hypotension and coma occur due to intracellular dehydration of vital organs.
- Fever — This is important in infants.

##### Plasma Changes

Serum Na and total protein though normal initially, rise in concentration in the late stage. Plasma urea rises because of increased urea reabsorption from the tubules and not due to renal failure. Hb, concentration and

PCV are minimally changed because of a loss of water from the red cells.

##### Treatment

This is done by increased water intake orally through a Ryles tube in mild cases and intravenous 5 percent dextrose in water in more severe cases until urine output improves to more than 0.5 ml/Kg/hr.

#### 'Pure' Water Excess

##### Causes

This is called water intoxication or over hydration and is encountered under the following conditions:

- a. Excessive intake:
  - i. The commonest cause in the surgical wards in the large infusions of 5 percent glucose solution to postoperative patients. This cannot be excreted rapidly because of the tendency to salt and water retention after traumatic incidents.
  - ii. Urinary Bladder washout during TURP due to excessive uptake of water (and glycine) from irrigation fluid.
- b. Diminished excretion:
  - i. Poor renal function, e.g. Acute renal failure. The administration of large amounts of water will result in water intoxication.
  - ii. Excessive secretion of ADH, e.g. Syndrome of inappropriate secretion of ADH (SIADH) seen in some cases of oat cell cancer of lung.

##### Clinical Features

There is decreased osmolality of the extracellular fluid producing intracellular edema, as excess water moves freely into the cells. The patient may become drowsy, stuporous or even comatose with convulsions due to cerebral edema. Nausea and vomiting may be present, pulse and BP remains normal.

Laboratory tests show a falling hematocrit, serum Na and other electrolyte concentration.

##### Treatment

- Stoppage of 5 percent glucose infusion if any and preventing excess water drink.
- In patients with altered consciousness with convulsions, diuresis should be



induced with frusemide injections. The hypo-osmolar state is corrected by giving hypertonic (5.85%) saline.

### Disturbances of Sodium Balance

#### Sodium (and Water) Deficiency -> Serum $[Na^+] < 130 \text{ mmol/L}$

A low serum sodium may be the result of either water retention or  $Na^-$  Depletion, separately or in combination.

#### Causes

- Excessive loss:
  - From the gastrointestinal tract—
    - The most frequent cause of sodium depletion seen in surgical practice is obstruction of small intestine with its rapid loss of gastric, biliary, pancreatic and intestinal secretions by antiperistalsis and ejection, by vomiting or aspiration.
    - Pyloric stenosis, intestinal and biliary fistulae have a similar effect.
    - Severe diarrhea due to cholera, acute gastroenteritis, ulcerative colitis, dysentery will cause hyponatremia.
  - Excessive sweating.
  - Renal losses—Salt losing nephritis (There is high level of urinary sodium.) and diuretic therapy.
- Low intake
  - Postoperative hyponatremia due to large infusions of saline free solutions like 5 percent glucose to postoperative patients.
  - Inadequate oral intake, e.g. coma, oropharyngeal disease, esophageal disease.
- Inappropriate antidiuretic hormone secretion (SIADH) — (Excess water retention), e.g. bronchogenic carcinoma, head injury, lobar pneumonia.
- 'Sick cell' syndrome — Loss into cells.  $Na^-$  enters into damaged cells due to defect in  $Na^- K^-$  ATPase pump.

#### Clinical Features

- The clinical features of hyponatremia with salt and water depletion are due to extracellular dehydration. Patient has a sick, haggard anxious appearance with sunken eyes due to reduced tissue turgor and eyeball tension.

- Skin is cold, clammy, hypotension, rapid thready pulse which becomes impalpable in advanced cases of hypovolemia and vasoconstriction.
- Nausea, vomiting and muscle cramps may be present. Urine is scanty, dark in color, of a high specific gravity and except in cases of salt losing nephritis, contains little or no chloride.

#### Plasma Changes

There is a reduced plasma volume evidenced by raised levels of proteins, PCV and hemoglobin. A rising plasma urea indicates renal failure.

#### Treatment

- Na loss: Treatment is with isotonic saline as the sodium loss is invariably accompanied by water loss. Infusion of 0.9 percent saline should be carefully conducted with monitoring of serum electrolytes and the measurement of urinary sodium which will increase with repletion. The amount of sodium required by the sodium depleted patient may be calculated as follows.  

$$\text{Na deficit in mmol} = (140 - \text{plasma } [Na^+]) \times \text{Body wt in kg} \times 0.6.$$
- Hyponatremia due to water intoxication including SIADH: It is dangerous to infuse isotonic saline in this situation as sodium depletion is not of primary importance and ECF is already expanded. The first step is to stop all fluids and to prevent excess water intake as mentioned above.

#### Sodium (and Water) Excess (Syn: Hypernatremia)

Normal Na concentration of plasma is between 135 to 145 mmol/liter. Hypernatremia is said to be present when the plasma serum Na concentration is above 145 mmol/liter.

#### Causes

#### Reduction of Body Water, i.e. Dehydration

- Insufficient intake of water.
- Water loss through kidneys: Osmotic diuresis occurs due to renal failure or Diabetic ketoacidosis in absence of renal failure when large quantities of ketone bodies and glucose are excreted causing polyuria and dehydration.

- Extrarenal water loss, e.g.
  - Sweating
  - Hyperventilation—A bad prognostic sign and gives rise to a pure water loss.

#### Reduction of Body Water Absent or of Low Significance

- Excessive infusion of 0.9 percent saline solution intravenously in the early post-operative period.
- Voluntary overingestion by a mentally deranged patient.

#### Clinical Features

With the retention of sodium, there is an increase in osmolality of the ECF and ADH is secreted from the posterior pituitary and water is retained from the distal renal tubule to increase the volume of ECF.

Puffiness of the face is the only early sign. In infants there is increased tension in the anterior fontanelle. Pitting edema should be sought especially in the sacral region (4.5 liters of fluid must be accumulated in the tissue space to get sacral edema). Body weight increases with fluid retention and pulmonary edema may kill the patient.

#### Treatment

Treatment is directed at managing both the fluid change and the possible underlying cause.

- If the hypernatremia is a reflection of water depletion, then increasing the water intake by infusing 5 percent dextrose solution will suffice since water deficits are drawn from both ICF and ECF.
- With sodium excess, restriction of sodium intake is important together with specific treatment of the underlying cause. Calculation of water requirement is based on total body water as below:  

$$\text{Normal } (Na^+) / \text{Estimated } (Na^+) = \text{Reduced TBW} / \text{Normal TBW}.$$
 So, 
$$\text{Reduced TBW} = \text{Normal plasma } (Na^+) / \text{Estimated Plasma } (Na^+) \times \text{Normal TBW}.$$

$$\text{Water deficit} = \text{Normal TBW} - \text{Reduced TBW}.$$

$$\text{TBW} = \text{Total body water which is } 0.6 \times \text{Body wt. in Kg}.$$
 Hypernatremia should be corrected slowly so that no more than half the water deficit should be replaced in the first 12 to 24 hrs. Rapid correction of hypertonicity may cause central nervous system function to deteriorate.

**Table 5.3: Causes of potassium deficiency****1. Inadequate intake**

- Potassium free intravenous infusion.
- Reduced oral intake, e.g. coma, oropharyngeal disease, esophageal disease.

**2. Excessive loss****A. Gastrointestinal**

- Vomiting or diarrhea.
- Fistula loss, e.g. duodenal fistula.
- Villous adenoma of rectum – the profuse mucus discharge from these tumors is high in potassium.

**B. Renal**

- Osmotic diuretic
- Excessive mineralocorticoid effects, e.g. primary hyperaldosteronism (Conn's syndrome)
  - Glucocorticoid excess, e.g. Cushing's syndrome, exogenous steroids.

following starvation. It is estimated that 100 to 120 mg (2.5 – 3.0 mmol/gm) Potassium are liberated with every gram of nitrogen.

Conversely, the administration of glucose and insulin diverts the extracellular potassium into the cells, where it aids in the deposition of glycogen.

Potassium is actively secreted by the distal tubules of the kidney and this is potentiated by aldosterone and to a lesser extent by cortisol and Deoxycorticosterone. Thus potassium depletion occurs in primary hyperaldosteronism (Conn's syndrome) and in Cushing's syndrome.

The causes of hypokalemia are enumerated in the Table 5.3

**Clinical Features**

- Muscular weakness — Potassium deprivation impairs cellular function. Muscular weakness is a feature of this. This is not confined to the skeletal musculature, but affects the smooth muscle of the gut also and may lead to paralytic ileus and abdominal distension.
- Cardiac arrhythmias, e.g. irregularity of heart rate.
- ECG changes — Flattened T waves with ST segment depression and prominent 'U' waves and prolonged QT interval. It has diagnostic value.
- Renal dysfunction — There is decreased concentrating ability as renal tubular function is impaired. This gives rise to polyuria and polydipsia.

**Diagnosis**

- ECG findings.
- Hypertension—It suggests hyperaldosteronism or glucocorticoid excess.
- Renal K<sup>+</sup> excretion—If this is the cause of K<sup>+</sup> depletion, urinary excretion is more than 20 to 25 mmol/l or per day. If gastrointestinal losses have occurred, urinary excretion is less than 20 to 25 mmol/liters or per day.

**Treatment**

Correction of K-depletion is done either increasing dietary intake, e.g. Milk, fruit juices and honey or supplementation with K salts (KCl is the ideal agent). In hospital practice effervescent tablets of potassium chloride, 2g can be given by mouth 6 hourly.

**Intravenous Potassium**

When IV KCl is given, 20 mmol of K<sup>+</sup> hourly is a safe rate of administration and should not be exceeded except under serious circumstances, e.g. plasma (K<sup>+</sup>) 2 mmol/l or less and even then with careful ECG monitoring by a skilled clinician. The urine output must be adequate and frequent estimations of serum potassium levels are vital to avoid excess infusion. Severe hypokalemia should be treated in an intensive care environment.

**Hyperkalemia (Potassium Excess)**

Hyperkalemia means high serum K<sup>+</sup> levels and not the total body potassium excess that is dangerous to life. A plasma level above 7.5 mmol/l produces clinical symptoms. In most patients with hyperkalemia, total body potassium remains normal or may even be lower than normal.

**Causes**

- Excessive intake:
  - A rapid infusion of K containing IV fluid in conditions of hypokalemia.
  - Massive blood transfusion.
- Inadequate excretion
  - This is mostly seen in patients with acute renal failure and is rare in chronic renal failure.
  - Addison's disease — Due to lack of aldosterone.
  - Diuretics which inhibit K<sup>+</sup> secretion, e.g. spironolactone, triamterene, amiloride, etc.
- Shift of potassium from tissues into the plasma, e.g.
  - Tissue damage, e.g. massive injuries, especially if there is severe muscle damage.
  - Hemolysis.
  - Metabolic acidosis, hypoxia and shock – Na-K-ATPase pump is impaired resulting in a shift of K<sup>+</sup> out of the cells.
  - Insulin deficiency — It limits tissue uptake and causes hyperkalemia.

**Clinical Features**

The clinical features of K<sup>+</sup> retention are somewhat vague. Confusion, apathy and sensory disturbances (Paresthesia) are often present and rather unexpectedly there may

**Disturbance of Potassium Balance****Potassium Depletion (Hypokalemia)**

Potassium deficiency is present if the serum potassium value is less than 3.5 mmol/liter, the normal range being 3.5 to 5.0 mmol/l. It must be remembered that intracellular potassium deficiency may be present even though the plasma concentration is normal and that deficiency is to be expected if oral feeding has been withheld for more than 4 days. Estimation of K<sup>+</sup> in the urine or aspirated gastrointestinal contents serves as a guide to the rate of depletion and the replacement necessary.

Potassium depletion is usually the result of excessive losses from the gastrointestinal or renal tract. When potassium leaves the cells, it is rapidly excreted by the kidneys as the body possesses no means of intensive potassium retention comparable with those of sodium.

An unobtrusive loss of K<sup>+</sup> from the cells into the plasma and then into the urine occurs under the following circumstances.

- Whenever water is mobilized from the cells, e.g. during water deprivation.
- Whenever cell protein is broken down, e.g. as a normal response to trauma or

be severe muscular weakness as in potassium depletion.

### Diagnosis

Whenever the condition is suspected a serum  $[K^+]$  estimation and ECG are diagnostic (Fig. 5.3).

The ECG shows initially peaked 'T' waves and loss of P wave, then the development of abnormal QRS complexes preceding ventricular fibrillation.

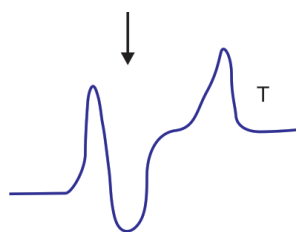


Fig. 5.3: ECG Pattern in hyperkalemia

### Treatment

Recognition and control of hyperkalemia is a medical emergency.

- i. All forms of potassium administration should be stopped immediately.
- ii. A good urine output must be ensured by giving adequate fluids and if required frusemide.
- iii. In severe hyperkalemia,  $[K^+] > 8$  mmol/l. 50 to 100 ml of 50 percent dextrose along with 10 to 20 units of plain insulin should be given IV every 2 hourly until serum  $K^+$  comes down to normal.
- iv. Infusion of  $NaHCO_3$ , 1 to 2 mmol/Kg in a liter of 5 percent glucose is infused to correct acidosis.
- v. Calcium exchange resins, such as Resonium, which exchange sodium for potassium ions in the gastrointestinal tract may be of value. It is given orally or in the form of enema (15 – 20 gm, 6 – 8 hourly).
- vi. In patients with severe hyperkalemia or renal failure, Hemo and peritoneal dialysis will effectively control it.

### Calcium Abnormalities

The total amount of calcium in the body is about 1000 gms, most of which is found in the bones. The normal daily intake is 1 to 3 gm. Most of this is excreted via the GI tract and about 200 mg is excreted in the urine per day. The normal serum calcium level is 8.5 to 10.5 mg/dl (2.2 to 2.6 mmol/liter). About

half of this is nonionized and bound to protein and other substances in the plasma. The other half is ionized and is responsible for neuromuscular activity. Disturbances of calcium metabolism is not a problem in the uncomplicated postoperative patient and therefore, administration of calcium is not required in such cases. Decrease in the ionized portion of calcium in blood gives rise to tetany.

### Hypocalcemia

Hypocalcemia is said to be present, if serum level is less than 8mg/dl or 2mmol/liter. The common causes are:

- Hypoparathyroidism
- Vit. D deficiency
- Chronic renal failure (due to raised level of plasma phosphate and a reciprocal lowering of plasma calcium and a deficient formation of  $125(OH)_2D_3$ .)
- Acute pancreatitis (Due to deposition of calcium salts in the foci of fat necrosis, i.e. Dystrophic calcification).
- Mg–deficiency in diet or due to chronic alcoholism. The explanation is uncertain. Impaired function of parathyroid glands is one suggestion.
- Excessive transfusion of citrated blood.

### Treatment

Consists of correction of the underlying cause along with repletion of the deficit.

Acute symptoms can be relieved by Intravenous calcium gluconate. Patients requiring prolonged replacement may be given calcium lactate by mouth.

NB — The three main regulators of plasma ionized calcium are PTH or parathyroid hormone, vitamin D and calcitonin.

### Hypercalcemia

The main causes of hypercalcemia include:

1. Malignancy (commonest cause)—Due to osteolytic metastasis, e.g. in breast cancer, multiple myeloma or Hodgkin's disease.
2. Hyperparathyroidism
3. Hypervitaminosis D
4. Hypercalcemia in immobilization (In a patient confined to bed there is both increased bone resorption and diminished bone formation)
5. Compulsive milk drinking – subjects with this neurosis absorb excess calcium from

the bowel and the consequent hypercalcemia leads to nephrocalcinosis.

### Treatment

Treatment is urgent. The ECF volume is depleted in these states. The deficit is rapidly made good and this immediately lowers the serum  $Ca^{++}$  by dilution. In case of metastatic cancer, the treatment is only prophylactic. The patient is placed on a low calcium diet and measures are taken to ensure adequate hydration.

### Magnesium Abnormalities

Magnesium deficiency occurs infrequently. Plasma ( $Mg^{++}$ ) ranges between 1.5 to 2.5 meq/liter. The body has about 1000 mmol of magnesium, half of which is present in bones. The average daily intake is 10 mmol.

It is a predominately intracellular cation (20mmol/L-ICF). Most of the magnesium is excreted in the feces and the remainder in the urine.

### Magnesium Deficiency

#### Causes

This occurs in starvation, prolonged administration of IV fluids with magnesium-free solutions. Excessive loss of GI fluids as in GI fistulae or ulcerative colitis. Other causes are acute pancreatitis, diabetic acidosis and the late stages of major burns. The  $Mg^{++}$  ion is essential for the proper functioning of most enzyme systems.

#### Clinical Features:

Mg-depletion is characterized by neuromuscular and CNS hyperactivity. The symptoms are similar to those of calcium deficiency, including muscle tremors and tetany, progressing to delirium and convulsions in severe cases.

#### Diagnosis

The diagnosis of Mg-deficiency cannot be made without awareness of the syndrome. In the surgical patient, who exhibits disturbed neuromuscular or cerebral activity in the postoperative period, magnesium deficiency must be kept in mind.

#### Treatment

Treatment is by parenteral administration of magnesium sulfate or chloride. Dose 40 mmol of  $MgSO_4$  dissolved in 5 percent dextrose or isotonic saline per day.

### Magnesium Excess

Magnesium excess is seen in massive trauma because large numbers of body cells are damaged and the magnesium contained inside them is liberated into the ECF. However the most common cause of hypermagnesemia (as of hyperkalemia) is severe renal insufficiency, when the magnesium which is liberated during the normal process of metabolism can- not be excreted. Magnesium also moves out of the cells in acidosis.

#### Clinical Features

There is drowsiness at a plasma level of 4 mmol/l and coma at a level of 7 mmol/l. Peripheral vasodilatation, hypotension and muscular flaccidity like that produced by curare are other features. Death is due to cardiac arrest.

#### Treatment

- Acute symptoms may be controlled by the slow IV administration of calcium chloride or gluconate, 5 to 10 mEq.
- If elevated levels persist, peritoneal dialysis or hemodialysis is required.

- No risk of overloading of circulation. The risks of thrombophlebitis and sepsis are also avoided.

#### Disadvantage

- Enteral route is not available, e.g. in case of paralytic ileus following surgery.
- Intravenous (IV): When rapid correction of hypovolemia and other electrolyte abnormalities are indicated an IV route is preferred.

#### Rate

The rate of infusion is controlled by adjusting the number of drops per minute. A good practical guide is to multiply the number of liters of the requisite fluid to be given in 24 hours by eleven (II). This provides the number of drops of the fluid to be administered per minute.

#### Types of Parenteral Fluid

Parenteral fluid can be broadly divided into (i) Crystalloid (ii) Colloid (iii) Blood.

- Crystalloid** — This is an electrolyte solution in water. Crystalloids form a true solution. They diffuse out quickly into the interstitial space, e.g. Ringer's lactate solution.
- Colloid** — These are regarded as plasma substitutes; colloids do not dissolve into a true solution and cannot pass through a semipermeable membrane, e.g. capillary wall. They contain high molecular weight molecules and remain in the intravascular compartment longer than crystalloids. They provide oncotic pressure.

- Blood** — Whole blood should be used for transfusion when there is significant bleeding leading to hypovolemia. Over 90 percent of donated blood is separated into its cellular components and plasma to allow prescription of individual components as and when necessary. See the chapter on Hemorrhage and Blood Transfusion.

### Common Fluid Preparations

#### Crystalloid Solutions

All are isotonic with body fluid . The composition of various crystalloid solutions is given in the Table 5.4.

1. Normal saline (0.9%)— Contains 154mmol/L Na<sup>+</sup> and 154mmol/l Cl. If excess vomiting has taken place, with resultant loss of chloride this is a more suitable fluid than Ringer's lactate.
2. 5 percent dextrose in water — Contains 278mmol/l dextrose. This solution contains no electrolytes. The purpose of the 5 percent dextrose is to render the fluid, exactly isotonic with plasma, so that there is no hemolysis on its administration. Af the same time the glucose provides instantly available energy. This fluid is used where plain water is required.
3. Lactated Ringer's solution, (Hartmann's solution) — As can be seen in the table below this fluid closely approximates the composition of tissue fluid. Therefore, when tissue fluid is lost during operations, whether on the surface or into the third space Hartmann's solution constitutes the appropriate replacement. At the same time, this is a more physiological solution, than normal saline, which contains

## FLUID THERAPY

- Routes of administration
- Common fluid preparations
- Fluid replacements
  - Basal requirements
  - Continuing abnormal losses over and above basal requirements
  - Correction of pre-existing dehydration.

### Fluid Administration

#### Routes (Enteral and parenteral/ intravenous)

##### Enteral

Oral fluid replacement is suitable if the G.I. tract is functioning and the deficiency is not excessive.

##### Advantages

- It gives the patient a sense of satiety and is more convenient to take compared to IV infusion.

**Table 5.4: Electrolyte content of parenteral fluids (in mmol/liter)**

Solution	Cations					Anions	
	Na	K	Ca	Mg	NH <sub>4</sub>	Cl	HCO <sub>3</sub>
1. Extracellular fluid	142	4	5	3	0.3	103	27
2. Lactated Ringer's - solutions (Hartmann's solution)	130	4	3	-	-	110	28*
3. Isotonic saline - (0.9% saline)	154	-	-	-	-	154	-
4. Darrow's solution	124	36	-	-	-	104	56*
5. M/6 sodium lactate	167	-	-	-	-	-	167*
6. Dextrose saline (1/5 isotonic saline + 4.3% dextrose)	30.6	-	-	-	-	30.6	-

\* Present as lactate which is converted into bicarbonate.



much more chloride than tissue fluid. In Ringer's lactate some of this chloride is replaced by lactate, which acts as a useful buffer to neutralize the excess acid, produced in infection, trauma, etc.

4. M/6 Sodium or Molar lactate — Used to buffer excess acid produced in cases of metabolic acidosis, e.g. diabetes extensive trauma and fulminant infections. If acidosis is severe, full strength molar lactate is used if more moderate, M/6 molar lactate to be used.
5. Darrow's solution — Contains sufficient potassium to combat hypokalemia. In surgical practice, it is a safe and convenient method of supplying this cation, provided alkalosis is not present. The rate of infusion should not exceed 60 drops a minute.

## Colloid Solutions

### Albumin

It is a natural blood product. It is valuable in patients with burns in whom there has been severe loss of protein.

Human albumin is a naturally occurring colloid and solutions are prepared from human plasma.

#### Disadvantages:

- Limited availability and expensive.
- There is no clear evidence that the use of human albumin has any advantages over less expensive, semisynthetic alternatives or crystalloids. However, this is applied to all colloids.

#### Gelatins: (e.g. Hemaccele/Gelofuscine): Features:

- Half life 8 to 10 hours.
- Low incidence of allergic reaction.
- Commonest plasma expander used in clinical practice.
- It contains electrolytes in a concentration very similar to plasma. (Na – 145, Cl – 145, K – 5, Ca – 6.25 all in mmol/liter and traces of phosphates and sulfates).
- Gelatins are derived from proteins formed by hydrolysis of bovine collagen.

#### Dextrans Features

- They are glucose polymers of varying molecular weight producing an osmotic pressure similar to that of plasma.

- Half life 16 hours.
- High Mol. wt. (70000 Da) Dextran (dextran 70) is not filtered by the kidney and therefore stays in circulation longer.
- Low Mol. wt. (40000 Da) Dextran (dextran 40) passes through the kidney and has a relatively transient effect.
- Dextran interferes with hemostasis by reduced factor VIII activity, increased fibrinolysis, and impairment of platelet function and simple hemodilution of clotting factors.
- In patients whose hemostatic function is normal prior to infusion, a maximum dose limit of 1.5g/Kg is often recommended to avoid increased risk of bleeding complications.
- The anticoagulant effect of dextrans can be utilized preoperatively as a prophylaxis against thromboembolism.

#### Hydroxyethyl Starch (HES)

HES produced from Sorghum or Maize are increasingly popular as plasma expanders. The duration of intravascular retention is more than 6 hours even for the 130 K Da tetra starches. Starch preparations are stable at room temperature and have long shelf-lives.

**Advantage:** Low incidence of anaphylaxis and no interference with blood cross matching. It is expensive.

## FLUID REPLACEMENT

When prescribing fluid regimes for patients we need to take three things into account.

1. Basal requirements
2. Continuing abnormal losses over and above basal requirements, i.e. ongoing losses, and
3. Preexisting dehydration and electrolyte loss.

### Basal Requirements (Table 5.5)

This is meant to maintain fluid input under normal circumstances when the patient is nil by mouth following any operation or trauma. Maintenance requirement is just what the name implies: the fluid required to mimic normal intake, maintaining the steady state. In the adult the recommended rate is 30 to 40 ml/kg. of water and 1 mmol/kg.Na<sup>+</sup>. In children the fluid replacement is according to weight using 4,2,1 rule as mentioned earlier.

In the first 24 hours after noncardiac surgery, potassium is often omitted from the IV fluid regime. There is a tendency for potassium to rise during and after surgery because of cell injury, blood transfusions, opposed action of 'Insulin' by stress hormones and decreased renal K<sup>+</sup> clearance.

## Ongoing Losses

Patients with continuing losses above the basal requirements need extrafluid. This is calculated by prediction, quantification and estimation.

- i. **Prediction** — Prediction is according to the type of surgery. A simple guidance for assessing third-space losses after major surgery is as follows: for each quadrant of the abdomen either affected by acute illness or involved in surgical dissection, e.g. appendectomy, a quarter of the maintenance volume of fluid will be required as an additional increment for volume replacement of third space shifts. This fluid is preferably Ringer's lactate as it closely resembles the ECF which is lost.
- ii. **Quantification**—Quantification is done by measuring the fluids coming out of the body, e.g. urine output, vomit, fistula drainage, diarrhea, blood loss, etc.
- ii. **Estimation**—Estimation is the insensible loss, e.g. the insensible losses can be doubled for every degree rise in temperature in a pyrexial patient. Excessive insensible loss also occurs in case of burns.

It is essential for an accurate fluid chart to be kept. This records all fluid intakes (oral and intravenous) and all output records, drain fluid, GI contents, etc. and provides a balance for each 24 hours, once insensible loss has been estimated.

### How to replace the ongoing losses?

The easiest way to ensure that ongoing losses are replaced is to establish two channels—one for the maintenance fluid and the other for loss-replacing fluids adjusted according to hourly losses. Any patient on intravenous fluids should have a daily balance, daily electrolyte measurements and a new regimen calculated everyday. The instruction 'and repeat' is never used in fluid management as it has led to disasters in the past.

### Correction of Pre-existing Dehydration

Patients who arrive in a dehydrated state clearly need to be resuscitated with fluid over and above their basal requirements.

Fluid deficit may be difficult to estimate. clinical examination may reveal.

- Reduced skin turgor and dry mucous membranes.
- Tachycardia and orthostatic hypotension indicating intravascular fluid depletion.
- Persistent oliguria.

Laboratory tests

- a. The hematocrit which is a guide to the degree of hemoconcentration.
- b. Urinary sodium concentration and osmolality—The normal response to dehydration is for the body to preserve sodium and water, by producing only small volumes of concentrated urine. Osmolalities greater than 400 mosmol/kg and Na<sup>+</sup> concentration below 20 mmol/liter indicate significant dehydration.

It is not possible to measure the exact fluid deficit, so replacement is carried out on

Solution	Volume (ml)	Na <sup>+</sup> (mmol)	K <sup>+</sup> (mmol)
5 percent dextrose (0.9% saline)	2000	–	–
5 percent dextrose (R-Lactate)	500	75	–
5 percent dextrose (R-Lactate)	2000	–	–
5 percent dextrose (R-Lactate)	500	65.5	2.5
4 percent dextrose (0.18% saline)	2500	75	–

a trial and error basis. The success of fluid replacement may be monitored by:

- Fall in pulse rate
- Rise in blood pressure
- Restoration of urine output
- Sustained rise in CVP to normal levels (if it is being measured).

### THE FLUID RULE

1. The composition and volume of the fluid given should be similar to that which has been lost. From the knowledge about the movement of fluid between

compartments, already mentioned and the patients history and clinical examination, one can usually decide from where the losses are coming and the extent of loss, i.e. volume of loss. As we have seen bowel losses come from the ECF, while pure water losses are from the total body water. Protein containing fluid is lost from the plasma and there may sometimes be a combination of all three types of loss.

2. The rate of administration should equal the rate of loss (ongoing losses plus maintenance rate) plus a rapid replacement of any pre-existing deficit.

# Chapter 6

## Acid-base Balance

- Introduction
- Body fluid buffer systems
- Role of the lungs
- Role of the kidneys
- Definition of acid-base terms
- Metabolic acidosis
- Metabolic alkalosis
- Respiratory acidosis
- Respiratory alkalosis

### INTRODUCTION

#### Blood Hydrogen Ion Concentration: (H<sup>+</sup>)

Life is an acidogenic process and from birth to death body is under a constant obligation of hydrogen ion output against hydrogen ion intake and production due to various metabolic activities.

The diet normally contains H<sup>+</sup> ion mostly in the form of sulfur containing amino acids of proteins and the urine is the sole channel of hydrogen ion excretion. The average intake is 50 to 80 mmol/day much the same as sodium and potassium.

An acid is a hydrogen ion (Proton) donor and a base accepts hydrogen ions. The body with its various chemicals and enzymes can function optimally only if the pH  $\text{pH} = \text{Log } 1/\text{H}^+$  concentration in nmol/L =  $-\text{Log H}^+$  concentration. of blood is maintained within a narrow physiological range of 7.36 to 7.44. It is the testament to the importance of hydrogen ions that they are regulated on a nanomolar level rather than millimolar as are most of anions and cations in the blood.

#### Regulation of pH

Blood pH is regulated within a narrow range of 7.36 to 7.44 as already mentioned by the following control systems:

1. Buffer systems of the body fluids viz.

- a. Body water
  - b. Plasma Buffer — Bicarbonate/carbonic acid system.
  - c. Other buffers in the blood — Phosphates, hemoglobins and plasma proteins.
2. Role of the lungs.
  3. Role of the kidneys.

The buffer systems of the body fluids can act within a fraction of a second to prevent excessive changes in (H<sup>+</sup>) concentration. On the other hand it takes 1 to 12 minutes for the respiratory system to make acute adjustments and another day or so to make still additional chronic adjustments. Finally, the kidneys, although providing the most powerful of all the acid - base regulatory systems, require many hours to several days to readjust the hydrogen ion concentration.

### BODY FLUID BUFFER SYSTEMS

#### Body Water

Any acid or base administered to the body gets diluted in an ocean of about 40 liters of body water.

#### Bicarbonate/Carbonic Acid System

This is one of the most effective and readily available buffers in the ECF. CO<sub>2</sub> is constantly produced from metabolism of carbohydrates and fats. In presence of the carbonic

anhydrase, CO<sub>2</sub> combines with H<sub>2</sub>O to form carbonic acid which is a weak acid and is very unstable, quickly dissociating into H<sup>+</sup> and HCO<sub>3</sub><sup>-</sup>.

Thus,  
$$\text{H}_2\text{O} + \text{CO}_2 \xrightleftharpoons{\text{CA}} \text{H}_2\text{CO}_3 \rightleftharpoons \text{H}^+ + \text{HCO}_3^-$$

Since, the reaction is bidirectional and the rate of forward or backward reaction is determined by the product of ionic concentrations, this system serves as a good buffering mechanism.

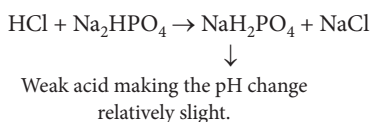
If excess H<sup>+</sup> ions are added, to the medium, the product of [H<sup>+</sup>] × [HCO<sub>3</sub><sup>-</sup>] increases, Hence backward reaction is enhanced, resulting in utilization of more HCO<sub>3</sub><sup>-</sup> and production of H<sub>2</sub>CO<sub>3</sub>. The excess H<sub>2</sub>CO<sub>3</sub> thus produced, breaks into water and CO<sub>2</sub>. This extra CO<sub>2</sub> is exhaled through lungs and the water produced, is of course neutral. In this way, excess H<sup>+</sup> ions are disposed off without a change in the pH of the system.

In alkalosis, the reverse of this happens. A fall in H<sup>+</sup> concentration, favors forward reaction with greater dissociation of H<sub>2</sub>CO<sub>3</sub> into H<sup>+</sup> and HCO<sub>3</sub><sup>-</sup>. More H<sup>+</sup> ions, thus produced try to correct the alkalosis. Alkalosis, through the chemoreceptors of carotid body and other sites induces hypoventilation causing retention of CO<sub>2</sub> in blood. This in turn produces more H<sub>2</sub>CO<sub>3</sub> which dissociates to yield required H<sup>+</sup> ions to correct the alkalosis.

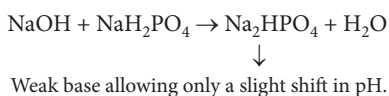


**Other buffers in blood**

i. The phosphate buffer system—It is composed of  $H_2PO_4^-$  and  $HPO_4^{2-}$  when HCl (a strong acid) is added, the following reaction occurs,



When NaOH (strong base) is added, the following reaction occurs



However, the concentration of phosphate buffer is only 1/12th that of the bicarbonate buffer in the ECF. Therefore, its total buffering power is far less than that of the bicarbonate system. On the other hand, phosphate buffer is especially important in the tubular fluid of the kidneys and also in the ICF because of high concentration of the phosphate compared to that in the ECF.

ii. Protein buffers—Depending on the  $p^H$  proteins can act both as a proton acceptor (i.e. base) and as a proton donor (i.e. acid). They serve as a good buffer in both ECF and ICF.

as mentioned above. The normal concentration of dissolved  $CO_2$  in body fluids is fixed around 1.2 mmol/liter ( $PaCO_2 = 40$  mm Hg and solubility coefficient of  $CO_2$ ,  $S$  is 0.03 so that  $S \times PaCO_2 = 0.03 \times 40 = 1.2$ ). At this concentration, pulmonary excretion equals metabolic production.

The respiratory mechanism is a rapid response system that allows carbon dioxide to be transferred from pulmonary venous blood to alveolar gas and excreted in expired gas. Any dysfunction of the mechanism or control of ventilation will lead to retention of  $CO_2$  and a rise in  $H^+$  ion (Respiratory acidosis) or overexcretion of  $CO_2$  and a fall in  $H^+$  ion (Respiratory alkalosis). In effect, respiratory regulation of acid base balance is a physiological type of buffer system. The overall buffering power of the respiratory system is one to two times as great as that of all the chemical buffers combined.

**Reabsorption of filtered bicarbonate**—Bicarbonate is reabsorbed in the proximal and distal tubular segments via secretion of hydrogen ions into tubular lumen by counter transport with sodium.

The hydrogen ion within the tubular cell is generated from carbonic acid breakdown to hydrogen ion and bicarbonate. The carbonic acid is formed in the presence of carbonic anhydrase when water combines with carbon dioxide which diffuses into the cell from peritubular plasma.

The secreted hydrogen ion combines with the filtered bicarbonate to form carbonic acid, which then breaks down to form water and carbon dioxide in the presence of carbonic anhydrase in the tubular membrane. Carbon dioxide either diffuses into the plasma or combines with water in the renal tubular cell to generate hydrogen ion and bicarbonate (Fig. 6.1).

**ROLE OF THE KIDNEYS**

The kidneys maintain hydrogen ion balance via two different mechanisms:

1. By varying the amount of reabsorption of filtered bicarbonate and
2. By adding new bicarbonate to the peritubular plasma. Of these two mechanisms, the first is quantitatively more important in maintaining acid-base balance.

However, both variation in bicarbonate reabsorption and addition of new bicarbonate to plasma are actually determined by the extent of tubular hydrogen ion secretion.

**Addition of New Bicarbonate**

The addition of new bicarbonate to plasma occurs as a result of hydrogen ion excretion via two different urinary buffer systems. Viz.

1. Phosphate buffer system and
2. Ammonia buffer system.

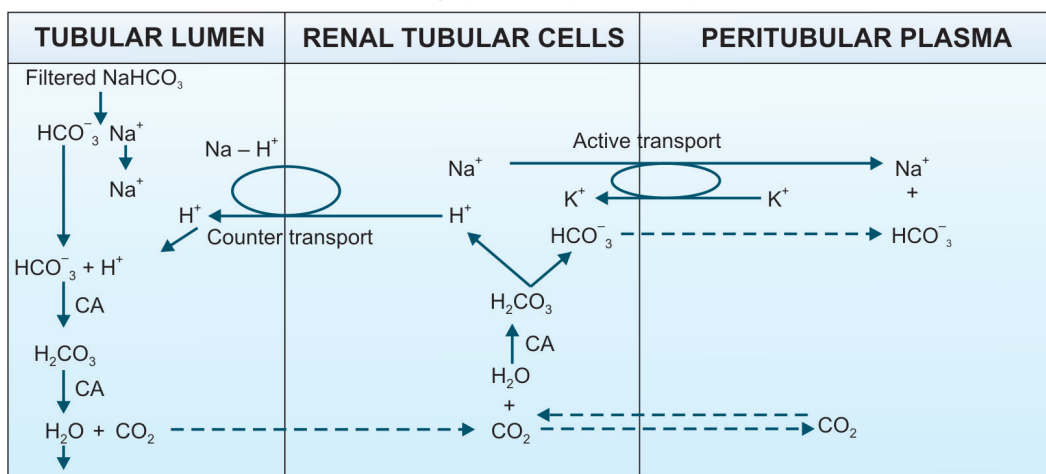
**Phosphate Buffer System**

The phosphate buffer is composed of a mixture of  $HPO_4^{2-}$  and  $H_2PO_4^-$ . Both become considerably concentrated in the tubular fluid because of their relatively poor reabsorption and because of removal of water from the tubular

**ROLE OF THE LUNGS**

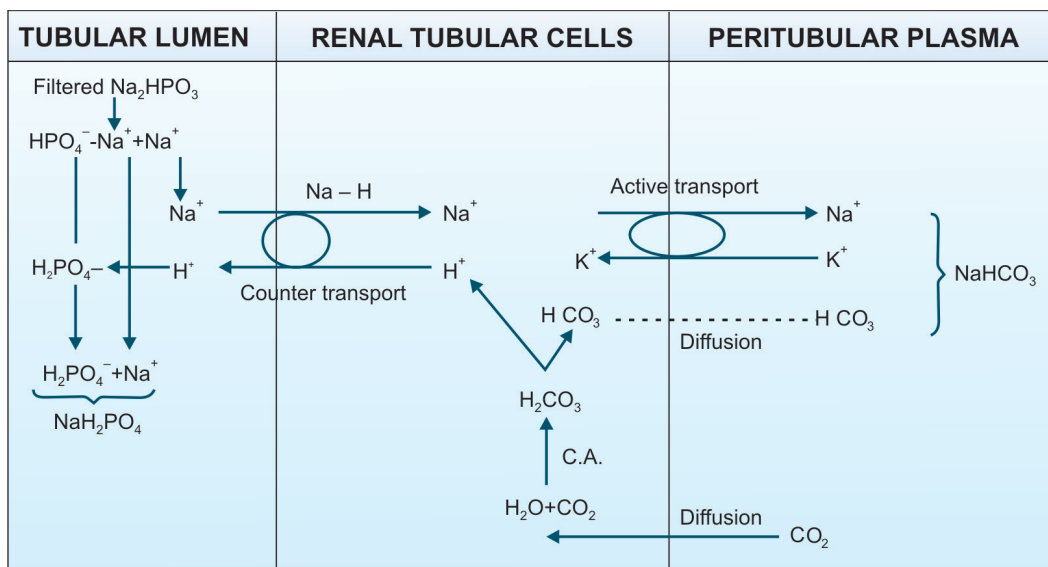
The principal acid product of metabolism is  $CO_2$  equivalent to potential carbonic acid,

**Reabsorption of filtered bicarbonate**

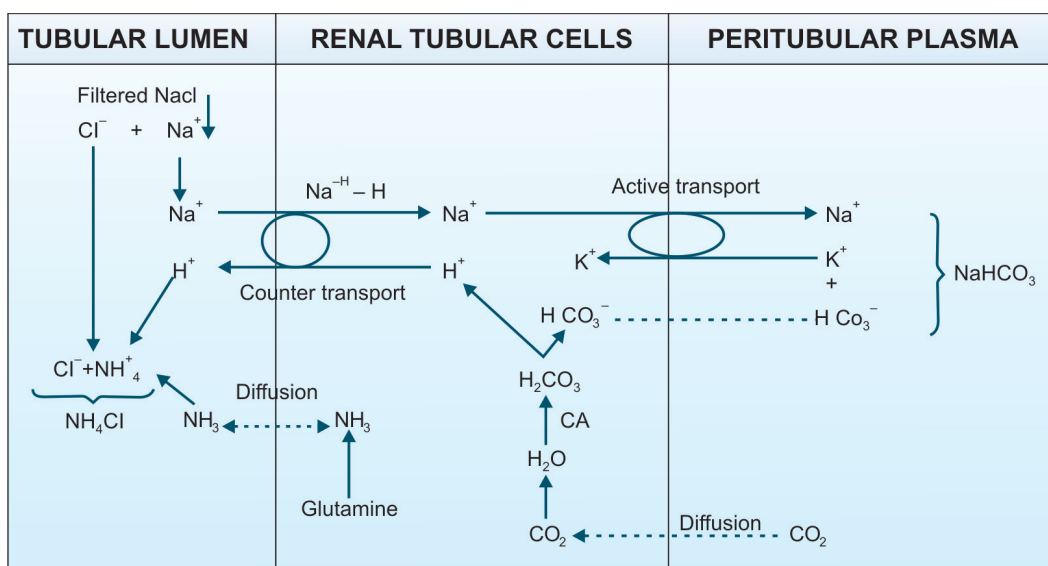


**Fig. 6.1:** Reabsorption of filtered bicarbonate in the renal tubular cells with secretion of hydrogen ions. Solid lines — active transport, Dotted lines — passive transport

CA—Carbonic anhydrase situated at the brush border of the cells at proximal convoluted tubule but not in the distal tubule.



**Fig. 6.2:** Chemical reactions in the tubules involving hydrogen ions, sodium ions and the phosphate buffer system



**Fig. 6.3:** Secretion of ammonia by the tubular epithelial cells and reaction of the ammonia with hydrogen ions in the tubules. CA - carbonic anhydrase – solid lines – active transport, dotted lines – passive transport

fluid. Therefore, even though the phosphate buffer is very weak in the blood, it is a much more powerful buffer in the tubular fluid.

Figure 6.2 illustrates the manner in which hydrogen ions are removed from the tubular fluid by the phosphate buffer system. It will be seen that for each hydrogen ion bound by the phosphate buffer, a new carbonate ion is formed by the epithelial cell and transported into the blood. This contributes to the correction of acidosis when excess hydrogen ions are secreted.

### Ammonia Buffer System

The ammonia buffer system is composed of  $\text{NH}_3$  and the  $\text{NH}_4^+$  ion. The epithelial cells of all the tubules besides those of the thin segment of the loop of Henle continually synthesize ammonia and this diffuses into the tubular urine. Sixty percent of the  $\text{NH}_3$  secreted by the tubular epithelium is derived from Glutamine and the rest 40 percent from other amino acids or amines. The ammonia (which is lipid soluble and

so moves freely across the tubular membrane), then reacts with hydrogen ions to form ammonium ions which are charged and lipid insoluble. Therefore,  $\text{NH}_4^+$  ions are trapped in the tubular lumen and excreted into the urine in combination with chloride ions or other tubular anions (Fig. 6.3)

Thus, it is seen that the net effect of these reactions is to increase the bicarbonate concentration in the blood.

**DEFINITION OF ACID-BASE TERMS**

**Disorders in Blood**

1. Acidemia – A low blood  $P^H < 7.36$ .
2. Alkalemia – A high blood  $P^H > 7.44$ .
3. Hypocapnia - A low  $PaCO_2 < 36$ mm Hg.
4. Hypercapnia – A high  $PaCO_2 > 44$ mm Hg.

**Disorders in the Patient**

1. Acidosis—It is a disturbance which tends to add acid or remove alkali from body fluids.  
In metabolic acidosis, there is quantitative decrease in plasma bicarbonate concentration and when not complicated by other acid-base disorders, it lowers the blood pH.  
In respiratory acidosis, there is quantitative increase in blood  $PCO_2$  and when not complicated by other acid-base disorders, it will also lower the blood pH.
2. Alkalosis—It is any disturbance which tends to remove acid or add base.  
In metabolic alkalosis there is quantitative increase in plasma bicarbonate concentration and when not complicated by other acid base disorders it raises the blood pH.  
In respiratory alkalosis, there is quantitative decrease in blood  $PCO_2$  and when not complicated by other acid-base disorders, it raises the blood pH.

**Compensatory Process**

It is not a primary acid-base disorder but a change that follows a primary disorder.

A compensatory process attempts to restore the blood pH to normal and is not appropriately termed acidosis or alkalosis.

The compensatory process for each primary disorder is given below:

- Metabolic acidosis → Hyperventilation (which lowers  $PCO_2$ ).
  - Metabolic alkalosis → Hypoventilation (which raises  $PCO_2$ ).
  - Respiratory acidosis → Renal bicarbonate retention.
  - Respiratory alkalosis → Renal bicarbonate excretion is increased.
- Primary event and compensatory response for acid-base disorders can also be represented as follows (Table 6.1)

N.B.: Positive base excess occurs in metabolic alkalosis and negative base excess or base deficit indicates metabolic acidosis. It tells about the metabolic status of the patient.

The terms acidosis and alkalosis, therefore have to be qualified whenever they are used if they are to have any meaning.

It is clear that a metabolic acidosis can occur in the presence of alkalemia, e.g. salicylate poisoning and that metabolic alkalosis can occur in the presence of acidemia, when there is an associated rise in  $PCO_2$ .

**Henderson – Hasselbalch Equation**

The bicarbonate - carbonic acid is the major buffer component of the ECF (extracellular fluid). Acid-base disturbances are often represented in terms of changes in either the bicarbonate (base) or dissolved  $CO_2$  (acid) component of this buffer pair.

The classic expression of acid-base state is based on the Henderson-Hasselbalch equation which relates three variables pH,  $PCO_2$  ( $CO_2$  tension in blood) and plasma bicarbonate concentration,  $[HCO_3^-]$  and two constants 'PK' and 'S' as:

$$pH = pK + \text{Log} (HCO_3^-)/S \times PCO_2 \text{ or}$$

$$pH = pK + \text{Log} (HCO_3^-)/0.03 \times PCO_2$$

Where  $pK$  = the negative logarithm of the dissociation constant for carbonic acid (6.1), and  $S$  = Solubility constant for  $CO_2$  in plasma which is 0.03 mmol/L/mm Hg.

Normally the plasma ( $HCO_3^-$  is 24 mmol/l and the arterial  $PCO_2$  is 40 mm Hg. Thus,  $pH = 6.1 + \text{Log} 24/1.2 = 6.1 + \text{Log} 20 = 6.1 + 1.3 = 7.4$ .

**METABOLIC ACIDOSIS**

**Definition**

Metabolic acidosis is a condition in which there is a deficit of base or an excess of any acid other than  $H_2CO_3$ .

**Etiology**

The causes of metabolic acidosis can be divided into those associated with a normal anion gap and those associated with an increased anion gap.

**Anion Gap**

The anion gap is a calculated estimation of the undetermined or unmeasured anions in the blood. In the body to maintain electrical chemical neutrality the number of cations equals the number of anions. The main cations in the body are sodium and potassium. The main anions in the body are chloride, bicarbonate, proteins, e.g. albumin, phosphates, sulfate and organic acids, e.g. lactic and pyruvic acid. But anions other than chloride and bicarbonate are not usually measured in the routine biochemistry department.

The anion gap can be calculated by subtracting the sum of plasma ( $Cl^-$ ) and ( $HCO_3^-$ ) from plasma ( $Na^+$ ) and ( $K^+$ ).

So, Anion gap =  $(Na + K) - (HCO_3 + Cl)$ . The normal anion gap is 10 to 16 mmol/liter.

A normal anion gap in the presence of low bicarbonate ion concentration indicates the presence of hyperchloremic metabolic acidosis. An increase in anion gap indicates that the retention of anions other than chloride, e.g. albumin, ketoacids, lactic acid or in acute renal failure - phosphates and sulfates has occurred.

A. Metabolic acidosis with an increased anion gap is seen in:

1. Addition of excess acid, e.g. poisoning due and salicylates (salicylic acid), paraldehyde prodding acetic acid.

**Table 6.1: Primary event and compensatory response in acid base disorders**

Type	pH	PaCO <sub>2</sub>	HCO <sub>3</sub>
1. Metabolic acidosis uncompensated	↓↓	N	↓↓
2. Metabolic acidosis compensated	↓	↓	↓
3. Metabolic alkalosis uncompensated	↑↑	N	↑↑
4. Metabolic alkalosis compensated	↑	↑	↑
5. Respiratory acidosis uncompensated	↓↓	↑↑	N
6. Respiratory acidosis compensated	↓	↑↑	↑
7. Respiratory alkalosis uncompensated	↑↑	↓↓	N
8. Respiratory alkalosis compensated	↑	↓↓	↓

2. Increased acid production, e.g. Diabetic ketoacidosis producing B-OH Butyric and acetoacetic acids and Acetone. ii) Lactic acidosis seen due to drugs like phenformin, metformin and sodium nitroprusside, acute circulatory failure, etc.
  3. Impaired renal acid excretion
    - a. Acute renal failure—There is excess retention of sulfuric or phosphoric acids in blood.
    - b. Chronic renal failure due to decreased excretion of buffer organic acids from decreased GFR and decreased  $\text{NH}_3$  production because of loss of functioning nephrons. There is also decreased reabsorption of bicarbonate.
- B. Metabolic acidosis with a normal anion gap
1. Loss of bicarbonate
    - i. In urine—Due to:
      - a. Proximal tubular acidosis (loss of bicarbonate and associated  $\text{Na}^+$  due to reduced  $\text{Na}^+/\text{H}^+$  exchange in proximal tubule. Accumulating acid is HCl).
      - b. Distal tubular acidosis – as in (a) occurring in the distal tubule.
      - c. Carbonic anhydrase inhibitors causing reduced  $\text{Na}^+/\text{H}^+$  exchange throughout the nephron.
    - ii. From the GI Tract: Due to diarrhea, fistulae, ureterosigmoidostomy. Accumulating acid is HCl. There is associated  $\text{Na}^+$  and  $\text{H}_2\text{O}$  depletion in GI secretions.
  2. Gain of chloride, e.g. Administration of  $\text{NH}_4\text{Cl}$  given orally or IV.

### Clinical Features

- Related to the underlying disorder.
- The most obvious clinical consequence is stimulation of respiration by the raised  $[\text{H}^+]$ . In severe cases respiration becomes deep and sighing (Kussmaul's respiration). When blood  $[\text{H}^+]$  exceeds 70 nmol/liter (Normal is 40 nmol/liter with  $\text{P}^{\text{H}}$  of 7.4), that is, a pH of 7.15, myocardial function is compromised and cardiac output falls. A pH of less than 6.8 is not compatible with life.

### Diagnosis

It is facilitated by the awareness of those conditions in which it is likely to develop. It should be confirmed by determining the pH,  $\text{PCO}_2$  and  $[\text{HCO}_3^-]$  in blood.

- The presence of concomitant  $\text{Na}^+$ ,  $\text{K}^+$  and water depletion to be assessed.
- Except in renal acidosis the urine is strongly acidic. The standard bicarbonate level is lowered and there is base deficit.

### Treatment

It should be directed at correcting the basic cause like diabetes or shock. Metabolic acidosis is commonly associated with  $\text{Na}^+$  and  $\text{H}_2\text{O}$  depletion. The size of the deficit is assessed and it should be corrected using IV Isoionic (0.9 %) NaCl solution.

- $\text{NaHCO}_3$  Solution—It should be given only in severe acidosis (i.e. pH is < 7.15). The dose is calculated from the formula –  $1/3 \times \text{base deficit and body wt in kg}$ . 8.4 percent  $\text{NaHCO}_3$  solution contains 1 mmol/ml. Treatment with bicarbonate solutions will correct the measured metabolic acidosis but not treat the problem. Indeed as bicarbonate is rapidly converted to  $\text{CO}_2$ , intracellular acidosis, may, in fact get worse. The administration of bicarbonate solutions should be reserved solely for situations in which bases have been lost or the degree of acidosis is severe.
- In the presence of renal disease or markedly reduced renal function, resulting from severe Na and  $\text{H}_2\text{O}$  depletion, renal regeneration of bicarbonate is impaired and approximately 1/3 of the total requirements of  $\text{Na}^+$  and  $\text{H}_2\text{O}$  should be given in the form of isotonic  $\text{NaHCO}_3$  or 1.26 percent  $\text{NaHCO}_3$ , rather than isotonic NaCl solution.

Infusion of  $\text{NaHCO}_3$  is stopped when  $[\text{H}^+]$  is normal. If there is still evidence of  $\text{Na}^+$  and  $\text{H}_2\text{O}$  depletion, infusion of NaCl solution should be continued.

- Where metabolic acidosis is due to chronic renal disease  $\text{NaHCO}_3$  supplements must be continued on a long-term basis.

## METABOLIC ALKALOSIS

### Definition

Metabolic alkalosis is a condition of base excess or a deficit of any acid other than  $\text{H}_2\text{CO}_3$ .

Simple disorders are characterized by an increased serum  $\text{HCO}_3^-$  concentration, a compensatory increase in  $\text{PaCO}_2$  and a resultant increased arterial  $\text{P}^{\text{H}}$ .

- An arterial  $\text{P}^{\text{H}}$  exceeding 7.65 is potentially life-threatening.
- In a simple disorder, a 10 mEq/liter increase in serum ( $\text{HCO}_3^-$ ) from a normal value of 24 mEq/L is accompanied by a 6 to 7 mm Hg increase in  $\text{PaCO}_2$ . If this is not present, a mixed disorder is to be considered.

### Causes

1. Excess alkali intake
  - a. Alkali abuse
  - b. Over treatment of acidosis.
2. Excess loss of acid—For example in vomiting associated with volume and chloride depletion.
3. Increased urinary acidification
  - a. Excess aldosterone
  - b. Hypokalemia
  - c. Diuretics, e.g. loop diuretics like frusemide and thiazides.

### Pathogenesis

1. In volume and chloride depletion, maintenance of metabolic alkalosis is most often due to stimulation of bicarbonate reabsorption by the kidney. Because during volume depletion renal conservation of sodium takes precedence over other homeostatic mechanisms such as correction of alkalosis.

Alkalosis is sustained until volume depletion is corrected by administration of NaCl. This diminishes tubular avidity for sodium and provides chloride as an alternate anion for reabsorption with sodium. Excess bicarbonate can be excreted with sodium.

2. Diuretics—Alkalosis due to loop diuretics or Thiazides is due to ECF volume contraction and inhibition of NaCl reabsorption in the loop of Henle or distal convoluted tubule which increases

delivery of tubular fluid, to more distal nephron segments. The volume deficit and consequent hyperaldosteronism stimulate proton secretion in these segments, generating and maintaining the alkalosis.

3. Hyperaldosteronism — Mineralocorticoids like aldosterone stimulate renal hydrogen secretion by  $K^+$ - $H^+$ / $Na^+$  exchange in the distal tubule. In patients with excess mineralocorticoid activity, elevation of plasma bicarbonate is initiated by urinary loss of protons as ammonium and titrable acidity. Stimulation of tubular acid secretion also enhances bicarbonate reabsorption thereby sustaining the metabolic alkalosis.

Patients with excess mineralocorticoid activity are not volume or chloride deficient. Hence this type of metabolic alkalosis does not respond to sodium chloride administration.

4. Hypokalemia — Most patients with metabolic alkalosis have some hypokalemia. When cellular potassium is depleted sodium and hydrogen enter the cell. This produces an intracellular acidosis and extracellular alkalosis.

Alkalosis due to administration of alkali cannot be sustained unless large amounts are given or renal function is compromised, in which case alkalosis may be sustained with small exogenous loads.

### Clinical Features

There are no specific clinical signs or symptoms. Severe alkalosis may cause apathy, confusion and stupor.

- Hypokalemia may produce ventricular arrhythmia and fibrillation.
- Hypoxia due to shift of oxyHb dissociation curve to the left. This hemoglobin cannot easily unload oxygen at the tissue level and hypoxia may result.

### Tetany

Alkalosis directly enhances neuromuscular excitability, this effect rather than the modest decrease in ionized plasma calcium induced by alkalosis, is probably the major cause of tetany.

### Diagnosis

- Plasma ( $HCO_3^-$ ) is increased.  $PCO_2$  increases by about 0.01 KPa or 0.6 mmHg for each mmol/l increase of bicarbonate. But elevation of  $PCO_2$  is insufficient to prevent alkalemia.
- Plasma ( $K^+$ ) is reduced with typical ECG changes.
- Urinary chloride concentration may be a useful guide in differential diagnosis. It is low (<10 mmol/l), when alkalosis is due to volume contraction and diuretic therapy. Whereas it is higher (>20 mmol/liter) in cases of hyperadrenal-corticism or severe  $K^+$  depletion causing alkalosis.

### Treatment

- Mild to moderate metabolic alkalosis rarely requires specific treatment.
- In patients with pyloric stenosis, persistent vomiting or gastric suction produces a hypochloremic, hypokalemic metabolic alkalosis. Proper management requires replacement of ECF volume deficit with isotonic sodium chloride solution along with replacement of potassium. Volume restitution should be started first and a good urine output obtained before potassium is administered, otherwise dangerous hyperkalemia could result.
- In hyperfunction of the adrenal, the underlying cause is to be corrected.

## RESPIRATORY ACIDOSIS

### Definition

Respiratory acidosis is characterized by an increased blood  $PCO_2$  (>40 mm Hg) and a decrease blood pH.

In practice, this problem most commonly occurs;

- When there is inadequate ventilation of the anesthetized patient or when effects of muscle relaxants have not worn off or been fully reversed at the end of the anesthetic.
- Patients having preexisting pulmonary disease like chronic bronchitis or emphysema also suffer from respiratory acidosis

which gets accentuated by thoracic and upper abdominal incisions.

### Etiology

Hypoventilation brings about retention of  $CO_2$  in blood, which combines with water to produce more  $H_2CO_3$ . This excess  $H_2CO_3$  then dissociates to yield more  $H^+$  ions causing acidosis. The causes of respiratory acidosis include:

1. Depression of the respiratory center: viz.
  - i. Brainstem trauma, hemorrhage and infarction.
  - ii. Cerebrovascular accident or CVA
  - iii. Cerebral tumor
  - iv. Drugs like morphine, pethidine, etc.
  - v. Encephalitis.
2. Defective respiratory neuromuscular system viz.
  - a. Spinal cord, peripheral nerves
    - i. High cervical trauma
    - ii. Motor neuron disease
    - iii. Peripheral neuropathy.
  - b. Respiratory muscles, e.g.
    - i. Myasthenia gravis
    - ii. Muscular dystrophy.
3. Impaired ventilatory apparatus, e.g.
  - a. Defect in chest cell movement like
    - i. Kyphoscoliosis
    - ii. Obesity.
  - b. Airways and lungs defect, e.g.
    - COPD or chronic obstructive pulmonary disease
    - Laryngeal and tracheal stenosis
    - Pneumonia.

### Clinical Features

Hypercapnia ( $CO_2$  retention) may manifest with drowsiness, confusion, headache, flapping tremors and coma. Usually semicoma occurs at a  $PCO_2$  of 60 mmHg and coma at  $PCO_2$  of 80 mmHg. These changes are collectively referred as  $CO_2$  narcosis.

It is often difficult to separate the manifestations of respiratory acidosis ( $PaCO_2$  and  $P^H$ ) from those of associated hypoxia ( $PO_2$ ) viz.

- a. Cerebral vasodilatation which is characteristic of hypercapnia causes morning headache. Dilatation of conjunctival and



superficial facial blood vessels may be noted.

- b. Hemoglobin desaturation and increased erythropoiesis causing cyanosis and polycythemia.
- c. Pulmonary vasoconstriction causing pulmonary hypertension and CCF (Congestive cardiac failure).

### Biochemical Changes

- a. Acute respiratory acidosis  
Acute  $\text{CO}_2$  retention —  $\uparrow \text{PCO}_2$  with minimal  $\uparrow$  of plasma  $[\text{HCO}_3^-]$  and a decrease in  $\text{Cl}^-$  concentration — Decrease in  $\text{P}^{\text{H}}$   
For each 10 mm Hg increase of  $\text{PCO}_2$  there is 1 mEq/L increase of plasma  $[\text{HCO}_3^-]$  and  $\text{P}^{\text{H}}$  decreases by 0.08.
- b. Chronic respiratory acidosis—Occurs in 2-5 days.

The kidneys compensate by increasing  $\text{H}^+$  and  $\text{Cl}^-$  excretions in urine and increased reabsorption of bicarbonate from the tubules. It is seen that for 10 mm Hg increase of  $\text{PCO}_2$ , there is increase of  $[\text{HCO}_3^-]$  by 3-4 mEq/L  $\rightarrow$  and decrease of pH by 0.03.

### Treatment

- i. Correction of the underlying disorder is the only worthwhile approach to the treatment of respiratory acidosis.
- ii. Most patients with chronic hypoventilation related to impairment of respiratory drive or neuromuscular disease eventually require mechanical ventilatory assistance for effective management.
- iii. Administration of supplemental oxygen is effective in attenuating hypoxia, polycythemia and pulmonary hypotension but can aggravate  $\text{CO}_2$  retention and the associated neurologic symptoms. For this reason, supplemental oxygen must be prescribed judiciously and the results monitored carefully.

## RESPIRATORY ALKALOSIS

### Definition

Respiratory alkalosis is a condition when  $\text{CO}_2$  removal by lungs exceeds  $\text{CO}_2$  production in the body and  $\text{PCO}_2$  falls (hypocapnia).

### Cause

Causes include any disorder that is associated with hyperventilation and increased  $\text{CO}_2$  clearance. Viz.

1. Hypoxia due to lung atelectasis, CCF, high altitude, pneumothorax.
2. Hypermetabolic states, eg. fever, thyrotoxicosis, exercise
3. Salicylate poisoning
4. Anemia.

### Clinical Features

Are the same as in metabolic alkalosis viz. Hypoxia, hypokalemia and tetany.

### Treatment

- The primary goal is to correct the underlying disorder.
- Use of controlled ventilation if  $\text{P}^{\text{H}}$  is  $>7.6$ .
- Use of potassium chloride in propepridine in case of hypokalemia and calcium gluconate 10 percent, 10 ml IV slowly in presence of convulsions due to hypocalcemia.



## Nutrition in Surgery

- Introduction
- Assessment of nutritional status
- Indications of nutritional support
- Nutritional requirements
- Nutrient mixing
- Routes for nutritional support
- Enteral nutrition
- Total parenteral nutrition
- Complication

### INTRODUCTION

Nutritional status is an important determinant of outcome after surgical treatment and the adverse influence of malnutrition on recovery has been recognized for almost a century. Nutrition plays a vital role in wound healing and collagen maturation and it boosts the energy reserves of the body.

With the advent of intravenous alimentation and better understanding of the principles of enteral nutrition, the nutritional assessment and management have become part of standard surgical practice. It is wellknown and well-accepted that majority of patients undergoing elective surgical operations withstand the brief period of catabolism and starvation without noticeable difficulty. In contrast, managing an adequate nutritional regimen may be of critical importance in managing seriously ill-patients with preexisting weight-loss and depleted energy reserves. Between these two extremes are patients for whom nutritional support is not essential for life but may serve to shorten the postoperative recovery phase and minimize the number of complications. Not infrequently a patient may become ill or even die from complications secondary to starvation rather than underlying disease.

### ASSESSMENT OF NUTRITIONAL STATUS

Protein calorie malnutrition often goes unrecognized in surgical patients, despite its frequency and association with poor outcome. This assessment of nutritional status should form a part of every physical examination. Gross malnutrition should be obvious clinically, but lesser degrees of malnutrition will require more objective measurements using anthropometric and biochemical measurement.

#### Nutritional Status Parameters

- History: Presence of weight loss and dietary history.
- Physical examination includes testing of muscle power, peripheral edema, angular stomatitis, glossitis. Muscle power is assessed by handgrip strength and respiratory muscle function.
- Body weight and anthropometric measurements:
  - Body weight— Unintentional weight loss of greater than 10 percent of a patient's weight in the preceding 6 months is a good prognostic indicator of poor clinical outcome.
  - Body Mass Index (BMI)— Body weight is frequently corrected for height and the usual measure chosen is the Body

Mass Index (BMI). BMI is defined as body weight in kilograms (kg) divided by height in meters squared.

Thus,  $BMI = \text{Body wt (kg)} / (\text{Height in meters})^2$

Normal – 20 to 25

Obese > 25

Morbid obesity > 35

Mild malnutrition < 20

Moderate malnutrition < 18

Severe malnutrition < 16

#### Anthropometric Measurement

Dietitians frequently use calipers and tape measures to estimate triceps skinfold thickness (TSF) and mid-arm muscle circumference (MAC), which provide rough estimates of body fat mass and muscle mass.

- i. Triceps skinfold thickness (TSF)—Subcutaneous fat accounts for about 50 percent of the body fat stores and accurately reflects the total body fat content. Triceps skinfold thickness is measured with a large skinfold caliper while the patient is standing or sitting with the right arm hanging loosely at the side.
  - Site of measurement—The skin and subcutaneous tissues are pinched just below the midpoint between acromial and olecranon processes.
  - A skinfold thickness below 10th percentile or a visible loss of subcutaneous

**Table 7.1 Immune dysfunction in malnutrition**

- Reduction in the number of T cells, T helper and T – suppresser/cytotoxic cells.
- Decreased natural killer (NK) cell activity.
- Reduced B-cell function.
- Reduced circulating level of compliment components.
- Impaired monocyte and polymorph function.
- Impaired responsiveness of lymphocytes to mitogens

tissue on physical examination indicates fat store depletion.

- ii. Mid-arm muscle circumference (MAC)—Skeletal muscle represents 60% of total body protein and in times of stress and starvation it is assessed by visual inspection and measuring mid-arm muscle circumference at the same level as the triceps skin fold thickness. Muscle circumference below the tenth percentile is considered clinically significant.

**Biochemical Assessments**

- Serum albumin is, however not a reliable indicator of nutritional state. It often reflects the underlying illness, e.g. malignant disease, trauma, sepsis, etc. all of which result in a lowering of plasma albumin level of less than 30g/l.
- Other plasma proteins, e.g. transferrin, retinal binding protein, prealbumin have been evaluated as markers of nutritional status but are not commonly used.

**Immune Assessments**

Malnutrition is associated with a reversible dysfunction of the immune system Table 7.1

- A correlation between inhibition of host-defences and postoperative morbidity and mortality in patients with cancer has been demonstrated. A reduced total lymphocyte count is associated with a worse prognosis.
- Immunity is not however, a precise or reliable indicator of nutritional status nor is it easy or practical to study.
- It has been shown that clinical assessment based on history and physical examination carried out by an experienced

clinician can be as good as or better than laboratory measurements in identifying malnourished patients.

**INDICATIONS OF NUTRITIONAL SUPPORT**

There are no hard and fast rules regarding indications for nutritional support. In general however nutritional support should be considered in any patient who is unable to take or resume an adequate dietary intake for more than 5 days.

Nutritional support should be considered early in patients who are already malnourished or who are subjected to significant metabolic stress.

**Who Needs Nutritional Support?**

1. Patient who cannot eat, e.g.
  - i. Esophageal/gastric outlet obstruction.
  - ii. Head and neck surgery or injury.
  - iii. Stroke or other neurological problem.
2. Patient who cannot eat enough, i.e. hyper-metabolic states.
  - i. Severe burns
  - ii. Major trauma
  - iii. Sepsis.
3. Patient who won't eat viz.
  - i. Patient with anorexia due to malignant disease.

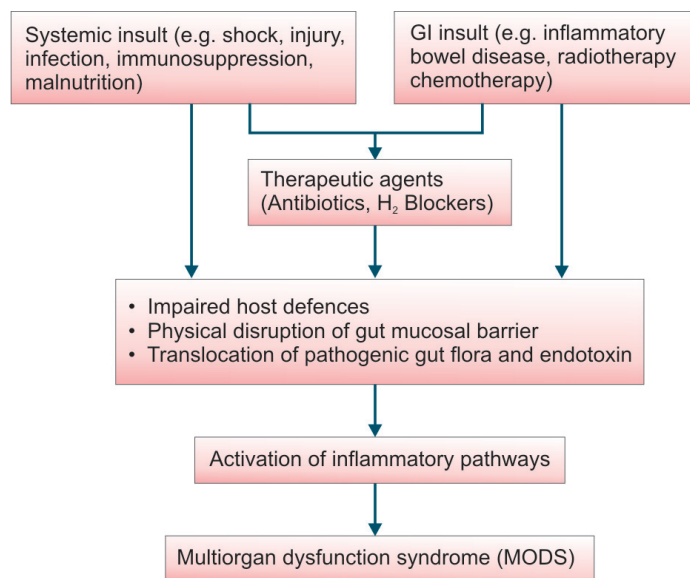
- ii. Depression, eating disorders.
4. Patient who should not eat viz.
    - i. Inflammatory bowel disease
    - ii. GI fistulae
    - iii. Bowel obstruction
    - iv. Prolonged paralytic ileus
    - v. Radiation enteritis
    - vi. Intestinal failure.

**Preoperative Nutritional Support**

There is no clear evidence of benefit from preoperative nutritional support unless the preoperative weight loss is >20 percent . Such feeding for < 7 days is entirely ineffectual and rarely should the surgery be delayed to allow for nutritional support.

**Postoperative Nutrition**

1. Postoperative nutrition is considered for any patient with an inadequate intake after 5 days.
2. Parenteral nutrition is given if oral or enteral nutrition is not anticipated within 7 days after operation in a previously well-nourished patient and as early as possible in a previously malnourished or critically ill patient.
3. Access is created to the GI tract via a gastrostomy or jejunostomy or a central venous feeding line at the time of major oropharyngeal, maxillofacial or upper gastrointestinal operation.



**Fig. 7.1:** Relationship between gut derived endotoxin and MODS

### Consequence of Malnutrition in the Surgical Patient

1. **Reduced Gut Barrier Function**—It is now recognized that GI tract may atrophy without the intraluminal nutrition and the normal barrier to the translocation of endotoxin and bacteria is lost. It is thought that higher proportion of septic episodes that accompany treatment with TPN (Total parenteral nutrition) may be related to gut rest with consequent atrophy and loss of gut barrier function.

Gut derived endotoxin may be the link between gastrointestinal failure and multiple organ failure without overt clinical evidence of infection (Fig. 7.1)

- Poor wound healing and collagen maturation.
- Poor immune function — As mentioned above in Table 7.1
- Reduced muscle strength—(a) Respiratory muscle – Atelectasis and pneumonia.
- Psychological — Apathy and depression.

- Na<sup>+</sup>—1 to 1.5 mmol/kg/day
  - K<sup>+</sup> — 1 mmol/kg/day
  - Fat — 3gm/kg/day
  - Carbohydrate — 2g/kg/day
  - Vitamins — Variable daily allowance.
  - Minerals — Zinc, magnesium, phosphate, selenium
  - Nitrogen — 0.15 – 0.2 gm/kg/day
- 6.25 gm protein = 1gm Nitrogen.

- Maximum intake 2g/kg/day
- Clearance is assured by keeping triglycerides <250mg/dl.

### NUTRIENT MIXING

**Optimum macronutrient mix** is as follows:

#### Carbohydrate

Provides 4 kcal/g and constitutes 55 to 60 percent of total kcal provided.

- Maximum intake tolerated is 7 to 8 gm/kg/day.
- Best provided as complex carbohydrates, not simple sugars.
- Insulin is given for glucose >250 mg/dl.
- Intake is decreased in case of severe hyperglycemia.

#### Protein (4 kcal/g)

Provides 4kcal/g and 20 to 25 percent of total kcals is supplied as protein.

- Adult requirement is 1.5 to 2 g/kg/day
- Child requirement is > 2g/kg/day

#### Micronutrients

The micronutrients include key amino acids such as Glutamine and Arginine, organic compounds (Vitamins) and inorganic compounds (Trace elements like Zinc, Selenium, Manganese, etc.) These compounds are both utilized and excreted at a more rapid rate after injury, leading to well-documented deficiencies. However, because measurement of levels is difficult if not impossible prevention of a deficiency is accomplished only by providing increased intake.

### NUTRITIONAL REQUIREMENTS

- Water — 35 ml/kg/day
- Energy — 30 kcal/kg/day

#### Fat

Provides 9 kcal/g and 20 to 25 percent of total kcals is supplied as lipid.

### ROUTES FOR NUTRITIONAL SUPPORT – ENTERAL OR PARENTERAL NUTRITIONAL SUPPORT

This is represented in Fig. 7.2

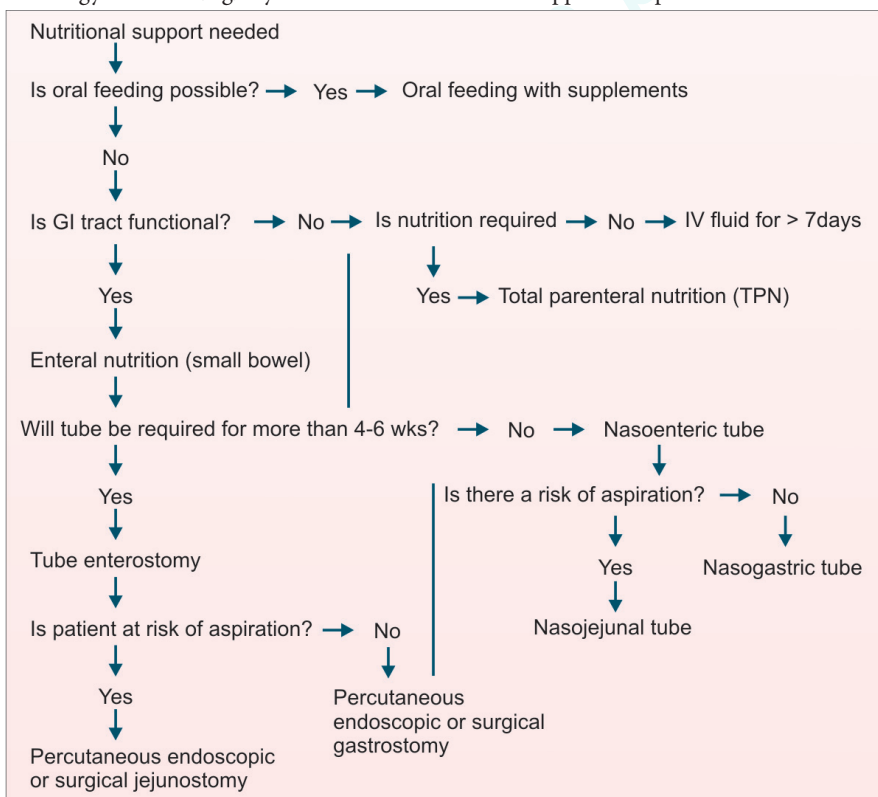


Fig. 7.2: Routes of nutritional support – enteral & parenteral.

### ENTERAL NUTRITION

- If gastrointestinal tract is functional and access can be obtained, enteral nutrition should be preferred, as it is cheaper, safer and has physiological advantages.
- Luminal nutrition is the main stimulus for mucosal growth by a combination of mechanical desquamation, provision of specific nutrients (especially glutamine), stimulation of trophic hormones and increase in splanchnic blood flow.

On the contrary, starvation leads to mucosal atrophy, increased gut permeability, a decrease in gut associated lymphoid tissue (GALT), changes in gut flora and reduced gut barrier function. This may lead to translocation of bacteria and endotoxin into the portal and systemic circulation and consequent fuelling of the inflammatory process leading to multiple organ dysfunction syndromes (Fig. 7.1 above).

- Enteral nutrition has been shown to maintain mucosal integrity, the immune

function of the GI tract, reduce bacterial translocation and increase gut blood flow.

- Total parenteral nutrition (TPN) has been shown to increase bacterial translocation, is immunosuppressive (because of inhibition of GALT and leads to a greater incidence of septic complications.

**Routes of Enteral Nutrition**

- a. Oral — Patients who can eat normally may still benefit from oral supplementation.
- b. Nasogastric — Best for short-term nutritional supplementation via a fine-bore nasogastric (NG) tube.
- c. Nasoenteric route is used if there is impaired gastric emptying or jejunal feeding is required, e.g pancreatitis. It can be used at laparotomy, endoscopically or radiologically. There are an increasing number of well-designed nasojejunal tubes for endoscopic placement, both single lumen and double lumen for simultaneous gastric drainage and Jejunal feeding.
- d. Percutaneous endoscopic gastrostomy (PEG) — It is an innovation in therapeutic endoscopy in the last decade. It is achieved by incising over the illuminated tip of the endoscope while it is in the stomach and then railroading a feeding tube through the gastric and abdominal puncture hole. Indications: Mostly neurological, e.g. stroke, motor neuron disease, head injury, bulbar palsy, etc.

Contraindication— Complete esophageal obstruction. Complications are few (3%) but may be serious, e.g. sepsis or perforation of another viscus, e.g. colon.

e. Feeding jejunostomy—Placement of the feeding tube is done at laparotomy when oral intake is not likely for seven or more days, e.g. major upper GI resections like esophagectomy, gastrectomy, pancreaticoduodenectomy. Major abdominal trauma, when having postoperative chemotherapy or radiotherapy. See chapter 93 and figure 93.4.

**Technique**

*Site*

- 10 to 15 cm beyond the ligament of Treitz.
- Minimum 15cm of feeding tube is kept in bowel lumen.
- The feeding tube (12-14FG Foley’s catheter) usually is inserted into the proximal

jejunum through its antimesenteric border after creating a 4 cm submucosal tunnel.

- The catheter is fixed to the jejunum with a purse string suture which in turn is fixed to the parietal peritoneum. The catheter is also secured to the skin and feeding is started 48-72 hours after insertion.

**Types of Enteral Diet**

- a. Polymeric diet—Contains intact protein and hence requires digestion. This is used for majority patients with normal or near normal GI function.
- b. Monomeric/elemental feed—Contains nitrogen in the form of free amino acids or in some cases, peptides. It is used in patients with impaired intraluminal hydrolysis from severe exocrine pancreatic insufficiency or intestinal failure from short bowel syndrome.
- c. Disease specific diet—Used in, for example, patients with respiratory failure on ventilators. These patients need low carbohydrate diets to reduce CO<sub>2</sub> production, therefore, the majority of energy requirements is from fat.
- d. Immunonutrition— May have some effect in enhancing immunofunction in critically ill. It contains mixtures of Glutamine, Arginine, RNA nucleotides and omega – 3 fatty acids, although they are expensive and their benefit remains controversial.

**Complications of Enteral Feeding**

*Related to Feeding Tube*

- i. Malposition of NG (Nasogastric) or nasoenteric tubes, e.g. into lungs.
- ii. Blockage — Mostly occurs when the giving set is disconnected and the residual diet solidifies. It is prevented by flushing out the tube with water after disconnecting it. The tube is unblocked by instilling pancreatic enzyme or cola.
- iii. Leak and peritonitis.
- iv. Abscess or fistula formation.
- v. Intestinal obstruction.
- vi. Tube displacement.

In case of feeding jejunostomy

*Diet Related*

- i. Diarrhea in 10 percent cases is multifactorial, often associated with concomitant antibiotic treatment or hypoalbuminemia. Codeine phosphate or loperamide is usually effective and feeding is rarely discontinued.

- ii. Nausea and vomiting may develop because of slow gastric emptying. Treatment is by antiemetics.
- iii. Bloating and abdominal pain because of too rapid administration or bolus feeding.
- iv. Regurgitation and pulmonary aspiration often occur.
- v. Vitamins, mineral and trace element deficiencies.
- vi. Drug interactions such as methyl dopa, theophylline, digoxin, etc.

**Enteral Feeding—Indications and Contraindications**

Enteral nutrition is appropriate if spontaneous oral intake is not adequate for nutritional requirement.

*Indications*

- Protein energy malnutrition with inadequate oral intake.
- Major trauma including surgery when return to dietary intake is prolonged.
- Inflammatory bowel disease.
- Distal low output (<200 ml) enterocutaneous fistula.
- To enhance adaptation after massive enterectomy.

*Contraindications*

- Small bowel obstruction or ileus
- Proximal small intestinal fistulas
- Severe diarrhea
- Severe pancreatitis.

Non-functioning small intestine

**TOTAL PARENTERAL NUTRITION (TPN)**

The successful use of intravenous parenteral nutrition (PN) was first demonstrated three decades ago. Total parenteral nutrition is defined as the intravenous provision of all nutritional requirements viz. all the macronutrients and micronutrients such as vitamins minerals and trace elements, without the use of the gastrointestinal tract.

**Indications**

It is required for any patient with intestinal failure (Defined as disease, dysfunction or resection of the intestinal tract resulting in

an inability to meet nutritional requirements by enteral means). The indications are:

- Small bowel ileus.
- Proximal intestinal fistula.
- Massive intestinal resection (Particularly if < 100 cm of small bowel remains).
- Intestinal failure.

There is good evidence that TPN is of no benefit (and may be delirious) if given for less than 10 days. It should not be given therefore, unless it is anticipated that it will be used for at least 10 days. Incidence of TPN is reducing because of increasing preference for the enteral route.

### Route of Delivery

TPN can be administered either via a catheter inserted in a central vein or via a peripheral line.

### PPN (Peripheral Parenteral Nutrition)

There is little evidence demonstrating any benefit at all from peripheral parenteral nutrition. TPN solutions have high osmolalities and can therefore, result in thrombophlebitis if given into a peripheral vein. In order to reduce the osmolality of PPN, the lipid content is increased as glucose-based solutions have high osmolality. Again it is the lipid which is immunosuppressive.

Central venous route, when chosen, the catheter should be inserted via either the subclavian, internal or external jugular vein and is tunneled subcutaneously to minimize the risk of infection. Catheters used for delivering

TPN should be employed for that sole purpose and single lumen catheters used, if possible. TPN should always be administered using an electronically controlled volumetric infusion pump.

### Components

- Calorie — 25 to 30 kcal/g/day
- Carbohydrate — Hypertonic glucose (10-50% solution).
- Fats—10 to 20 percent emulsion – sunflower or soyabean oil stabilized by egg-protein.
- Amino acids — Essential and nonessential.
- Vitamins, mineral and trace elements.

### Checks during Nutritional Support

- Daily – Full blood count (FBC), urea and electrolytes, blood sugar (Random).
- Weekly – Liver function tests including albumin, trace elements.
- Fortnightly – Vitamin B<sub>12</sub>, Zinc, M<sub>n</sub>, Selenium, Copper, Iron, Transferrin.

## COMPLICATIONS

### Related to Feeding Catheter

- Catheter related sepsis – is the most common potentially fatal complication associated with parenteral nutrition and the incidence can be maintained at less than 6 percent. This requires a skilled and dedicated nursing team, rigid adherence to aseptic protocols and avoidance of catheter types that predispose to the

development of infection, e.g. multiple lumen, untunnelled and femoral venous catheters. The organisms most commonly found (90%) is *staphylococcus aureus* and coagulase negative staphylococci developed due to bacterial contamination of the catheter hub from the skin. Treatment usually involves I.V. antibiotic therapy.

- Infective endocarditis.
- Thrombotic complications include central venous and atrial thrombosis and thrombotic occlusion of the catheter.
- Cardiac complications, e.g. perforation of the right atrium (when catheter is positioned in the Rt. atrium) and cardiac tamponade.
- Thoracic duct injury.
- Pneumothorax.
- Hemothorax due to laceration of intrathoracic vein wall.

### Related to Feeding Regimen (Metabolic Complications)

In descending order of frequency these are:

- Hyperglycemia
- Hypoglycemia
- Hypercalcemia
- Hyperkalemia
- Hypokalemia
- Hyponatremia
- Hypnatremia
- Deficiency of folate, zinc, phosphate, Mg, Se, other trace elements and vitamins.
- Deranged liver function and fatty liver due to excess calorie administration.
- Gall Bladder stasis and biliary sludging.



# Chapter 8

## Endocrine and Metabolic Response to Injury

- Introduction
- Systems controlling the response
- Metabolism after injury
- Factors determining the magnitude of metabolic response
- Factors reducing the metabolic response and quick recovery

### INTRODUCTION

Injury to the body triggers a stress response which comprises alterations in fluids and electrolytes, substrates and hormones. The net effect is to contain and heal the tissue damage and to protect the body while it is injured. The response is remarkably similar whether the trauma is a fracture, burn, sepsis or a planned surgical operation and the extent of the response is usually proportional to the severity of the trauma.

### Initiation of the Response

The stress response is initiated by afferent nerve stimulation leading to neuroendocrine response and release of inflammatory mediators and cytokines at the site of injury. Some of the changes are considered to be homeostatic, e.g. preservation of body fluid, and circulating volume, stimulation of the blood clotting system, etc. while others are considered deleterious, e.g. catabolism and immunosuppression. Moreover, severe trauma can lead to excessive cytokine release resulting in progressive organ dysfunction with lethal consequences.

### SYSTEMS CONTROLLING THE RESPONSE

Following injury, the afferent nervous impulses (including pain) arising from damaged tissues

and also from the hypovolemia associated with fluid loss, is carried through spinothalamic pathways to activate the brainstem, thalamic and cortical centers which in turn stimulate the hypothalamus. The control centers for the sympathetic nervous system and the trophic nuclei of the pituitary are located in the hypothalamus. So, stimulation of the latter results in a combined neural and endocrine discharge.

A number of inflammatory mediators and peptides known as cytokines are released at the site of injury which modulate the response to injury and give rise to acute phase response.

The damaged vascular endothelium produce a number of substances, e.g. NO, which affects vasomotor tone and vessel permeability. So, it affects perfusion, circulating volume and blood pressure.

Thus there are four principal systems which produce the response viz.

1. Sympathetic nervous system
2. Endocrine response
3. Acute phase response including increased synthesis of acute phase reactant proteins by the liver.
4. Vascular endothelial cell response.

### Sympathetic Nervous System

Activation of the sympathetic nervous system by pain and hypovolemia causes stimulation of the adrenal medulla and thereby the release

of epinephrine and norepinephrine. Most of the adrenaline comes from the sympathetic nervous system terminals rather than from the adrenal medulla.

It is this surge of catecholamines that is responsible for the traditionally named 'fight or flight' response by cardiovascular, visceral and metabolic actions. (Both  $\alpha$  and  $\beta$  receptors effects occur) viz.

- a. *Cardiovascular effects* — Vasoconstriction, increased heart rate ( $\alpha$  effects) and contractility ( $\beta$  effects).
- b. *Visceral effects*
  - Bronchodilatation and uterine relaxation ( $\beta$ , effects).
  - Mydriasis (contraction of iris) and uterine contraction –  $\alpha$  effects.
- c. *Metabolic effects*
  - Glycogenolysis, lipolysis and calorigenic –  $\beta$ -effect.
  - Gluconeogenesis and suppression of insulin secretion ( $\alpha$  effect).

### Endocrine Response

This includes not only the stimulation of Hypothalamo-Pituitary-Adrenal (HPA) axis but also release of growth hormone, ADH, thyroxin, insulin glucagon and aldosterone causing some metabolic effects, particularly changes in carbohydrate and fat metabolism.



Cortisol, the catecholamines and glucagon are collectively known as the catabolic or counter-regulatory hormones. Insulin and growth hormones are the anabolic hormones.

This response appears to protect not so much against the stress but more against the body's acute phase response from overreacting.

### ACTH

This is released from the anterior pituitary by neurological stimuli reaching the Hypothalamus or by hormones such as ADH, Angiotensin II or catecholamines. The ACTH response to stress is not inhibited by administered steroids. ACTH stimulates the adrenal cortex to release glucocorticoids and also potentiates the action of catecholamines on cardiac contractility.

### Cortisol

Cortisol is the glucocorticoid secreted from the adrenal cortex along with other steroids. Its serum level usually returns to normal 24 hrs after uncomplicated major surgery but may remain elevated for many days in extensive burns or if infection supervenes.

#### Actions

- Metabolic— It stimulates the conversion of proteins to glucose (catabolic action) and storage of glucose as glycogen. It is an antagonist of insulin and this assists gluconeogenesis to increase plasma glucose (Diabetogenic action).
- CVS— It helps to maintain blood volume by decreasing the permeability of the vascular endothelium and enhancing vasoconstriction by catecholamines.
- Anti-inflammatory— It suppresses the synthesis of prostaglandins and leukotrienes.
- Immunosuppressant action — It inhibits the secretion of IL-1, and IL-2, antibody production and mobilization of lymphocytes.

The normal glucocorticoid response may be reduced or absent (due to previous long-term administration of steroids, adrenalectomy or adrenal infarction). This presents with hypovolemia, hyponatremia and refractory hypotension.

### Aldosterone

The inevitable release of ACTH after trauma stimulates a short-term release of aldosterone from the adrenal cortex but this rise,

may be prolonged if other stimuli such as hypovolemia or vasomotor changes (which activate the renin-angiotensin system in the kidney) occur. A rise in plasma potassium concentration can also stimulate aldosterone release. Aldosterone causes increased reabsorption of sodium and potassium secretion in the distal convoluted tubules and collecting ducts and hence, a reduced urine volume.

### ADH or Arginine Vasopressin (AVP)

ADH is produced by the supraoptic nucleus in the hypothalamus and stored in the posterior pituitary or neurohypophysis where it is controlled by the osmoreceptors in the hypothalamus.

After injury, levels of ADH rise. Hypovolemia is a potent stimulus for ADH release. It is also released from the posterior Pituitary by pain, a rise in plasma osmolality (via osmoreceptors in hypothalamus) & anesthetic agents.

#### Actions

- Its actions in the distal tubules and collecting ducts in the kidney lead to increased reabsorption of solute-free water.
  - It causes peripheral vasoconstriction especially in the splanchnic bed and stimulates hepatic glycogenolysis and gluconeogenesis.
- Like cortisol, its level remains increased 24 hrs after surgery but there may be continued secretion of ADH after head injury, burns or prolonged hypoxia resulting in oliguria and hyponatremia.

### Insulin

In the ebb phase after injury plasma insulin concentration falls because catecholamines and cortisol make the  $\beta$ -islet cells of the pancreas less sensitive to glucose. Glucagon also inhibits insulin release and cortisol reduces the peripheral actions of insulin; less carbohydrate is transported into cells and blood sugar rises. In the flow phase, plasma insulin rises but blood sugar remains elevated because various intracellular changes make the tissues resistant to insulin.

### Glucagon

Release of glucagon during stress is secondary to sympathetic stimulation acting directly on  $\alpha$  - cells of the pancreatic islets. It stimulates hepatic ketogenesis and lipolysis in adipose tissue, cortisol prolongs its actions. It

plays a small part in increasing blood sugar by stimulating hepatic glycogenolysis and gluconeogenesis.

### Growth Hormone

Growth hormone is released from the anterior pituitary as a result of neurological stimulation of the hypothalamus or by a rise in circulating levels of catecholamines, ACTH, AVP, Thyroxin or glucagon.

**Effects:** The growth hormone has multiple direct actions on metabolism, while other metabolic actions are mediated indirectly by somatomedins or insulin-like growth factors (IGF) produced by the liver in response to the growth hormone. Their direct effects include promotion of protein synthesis in the liver and muscle and lipolysis of fat stores.

### Acute Phase Response

The wound becomes a 'cytokine organ', whose metabolism and local healing responses are controlled by cytokines and other mediators that are produced locally and also released from activated inflammatory cells, including neutrophils and monocytes. In severe trauma proinflammatory cytokines produce a systemic 'acute phase' response with profound changes in protein metabolism and immunological activation. These effects are mostly beneficial but in severe trauma can be lethal.

### Cytokines

Previously known as lymphokines and now as cytokines, the major groups of cytokines are the interleukins (IL<sub>1</sub>, IL<sub>6</sub>, etc.) and tumor necrosis factor. They are mainly macrophage products viz. splenic macrophages, hepatic Kupffer cells, pulmonary alveolar macrophages, and renal mesangial cells.

Cytokines are peptides produced by a variety of cells, e.g. circulating monocytes, macrophages, and local fibroblasts and endothelial cells and produce mainly paracrine (direct cell-to-cell) effects.

**Local Effects:** Their actions help to contain tissue damage by contributing to the inflammatory reaction through vasodilatation and increased permeability of vessels, migration of neutrophils and monocytes to the wounds, activation of the coagulation and complement cascades and proliferation of endothelial cells and fibroblasts.

**Systemic Effects:** If cytokine production is large enough systemic effects occur such as fever, malaise, headache and myalgia.

**Acute Phase Reactant Proteins (APRS)**

Acute phase reactant proteins are the protein components of plasma whose concentration is significantly increased in acute phase of trauma or inflammation. All these are synthesized in the liver and the best known examples are C-reactive protein, Haptoglobin, alpha-antitrypsin, ceruloplasmin, complement C<sub>3</sub> and fibrinogen.

IL<sub>6</sub> is the main mediator of this altered hepatic protein synthesis.

While total protein synthesis may decline, the synthesis of APRS by the hepatocytes may be markedly enhanced in sepsis and trauma.

The hormone environment is also important in hepate protein synthesis. Cortisol is required for acute phase protein synthesis to occur in the presence of IL<sub>6</sub>. If Corticosteroids are absent, hepatocytes are unresponsive to the effects of IL<sub>6</sub> and no increases in acute phase protein synthesis occurs.

Although IL<sub>1</sub> and TNF are not the major regulators of acute phase protein synthesis, they may lead to depressions of albumin synthesis and elevations in the synthesis of complement C<sub>3</sub> by the liver. Diminution of Albumin synthesis will make amino acids more available for acute phase protein synthesis. This shunting represents a reprioritization of protein synthesis by the liver.

**Interactions between APRS and the Endocrine Response**

IL<sub>1</sub> and IL<sub>6</sub> can activate the hypothalamo-pituitary - adrenal (HPA) axis by increasing the ACTH secretion and also directly stimulating glucocorticoid release from the adrenal gland. Glucocorticoids initially help cytokines to regulate APRS, but if glucocorticoid levels remain elevated they inhibit cytokine production.

**The Vascular Endothelial Response**

It consists of the following

**Neutrophil – endothelium interaction**

After tissue injury vascular endothelium is activated locally resulting in the appearance

of glycoprotein secretions (Adhesion molecules) on the endothelial cell surface along with intercellular adhesion molecules (ICAMS). Neutrophils recognize these surface molecules begin to stick and then migrate out into the interstitium with a concurrent increase in endothelial permeability particularly in the postcapillary venules.

**Nitric oxide**

Nitric oxide (NO) is a powerful vasodilator produced mainly by endothelial cells but also by macrophages, neutrophils, Kupffer cells and renal cells. It is inactivated by hemoglobin and opposed by endothelin. Its other action is to increase production of APRS.

**Endothelins**

Endothelins are a family of potent vasoconstricting peptides with mainly paracrine actions. They are released by thrombin, catecholamines, hypoxia and endotoxins. It has ten times the potency of Angiotensin II. Its actions are opposed by prostacyclin and nitric oxide.

**Platelet activating factor**

Platelet activating factor (PAF) is released from the endothelial cells by the action of TNF, IL<sub>1</sub>, ADH and Angiotensin II. When platelets come in contact with PAF they release thromboxane which causes platelet aggregation and vasoconstriction. PAF also reduces the permeability of endothelial cells to albumin.

**Prostacyclin**

Prostacyclin (PGL<sub>2</sub>), though an arachidonic acid product, is another endothelium derived

vasodilator or like NO which produces vasodilatation and reduced platelet aggregation.

**METABOLISM AFTER INJURY**

**Phases of Metabolic Response After Injury (Fig. 8.1)**

There are two phases viz.

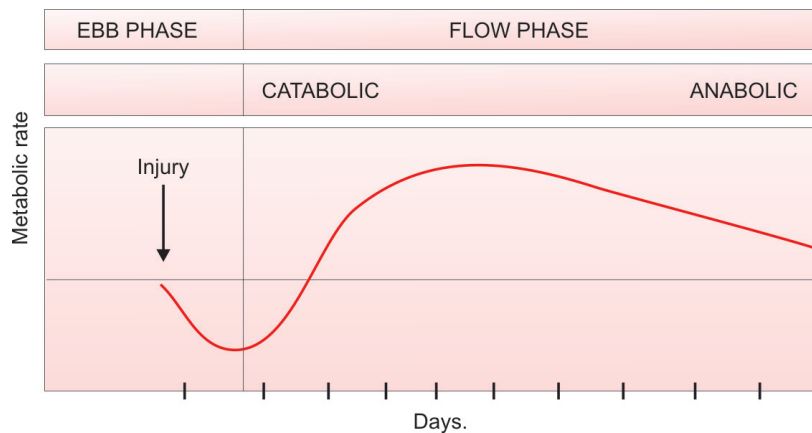
1. Initial ‘Ebb’ phase usually lasting for 24 hrs. It is the phase of reduced energy expenditure. This is followed by the next phase called the ‘flow’ phase.
2. The flow phase has a catabolic phase lasting for 3-8 days followed by the anabolic or ‘recovery’ phase lasting for several weeks or months.

The anabolic phase is characterized by increased metabolism, hyperglycemia, lipolysis, negative nitrogen balance, increased heat production and oxygen consumption. The increase in metabolic rate ranges from about 10 percent in elective surgical operations to 50 percent in multiple trauma and 200 percent in major burns.

The anabolic phase, on the other hand is characterized by protein and fat synthesis and associated with weight gain.

**Increased Metabolism After Injury (Fig. 8.2)**

Resting energy expenditure is increased after tissue injury, the degree of increase being proportional to the magnitude of trauma. There is marked tissue wasting and weight loss. This is partly due to a limited oral intake and partly to extreme catabolism which occurs in the post-injury period.



**Fig. 8.1:** Change in metabolic rate following injury (operation or trauma)

With acute injury muscle and liver glycogen are used as energy fuel (glycogenolysis). The muscle and liver glycogen, however, cannot continue to supply glucose all the time, as its total store would be exhausted in a day or two. After this, protein and fat stores are mobilized to meet the energy requirement.

Fat is the principal energy store of the body. Protein can also be used as an energy source but it cannot be mobilized beyond a certain level. It is important to spare proteins since their excessive breakdown would lead to muscle wasting, ineffective coughing, impaired wound healing and a diminished synthesis of enzymes. Therefore, the calorie distribution of protein to the fuel mixture of the injured is small and the main energy requirement is met from fat.

### Carbohydrate Metabolism After Injury

Hyperglycemia occurs immediately after injury because glucose is mobilized from stored glycogen in the liver by catecholamines, and glucocorticoids, and because insulin resistance of peripheral tissues impairs their uptake of glucose (the 'diabetes' of injury or traumatic diabetes). Glucose provides energy for obligate tissue such as the CNS, leukocytes in the wound and red cells (cells not requiring insulin for glucose transport). In major injuries, the inflammatory cell infiltrate can account for 70 percent of the glucose uptake.

### Fat Metabolism After Injury

Fat is the main energy source in trauma and starvation. Lipolysis involves hydrolysis

of triglycerides to fatty acids and glycerol. Glycerol provides a substrate for gluconeogenesis. Fatty acids are burnt in the liver to supply energy for gluconeogenesis and in the periphery to supply energy directly. Catecholamines produce lipolysis of adipose tissue.

The overall effect of injury on fat metabolism is to increase fatty acid oxidation and formation of ketone bodies. The brain after a period can make use of ketone bodies as an energy resource.

### Protein Metabolism After Injury

In an uninjured person there is equilibrium between a whole body protein synthesis and whole body protein breakdown. After injury this balance is disturbed with a net protein loss.

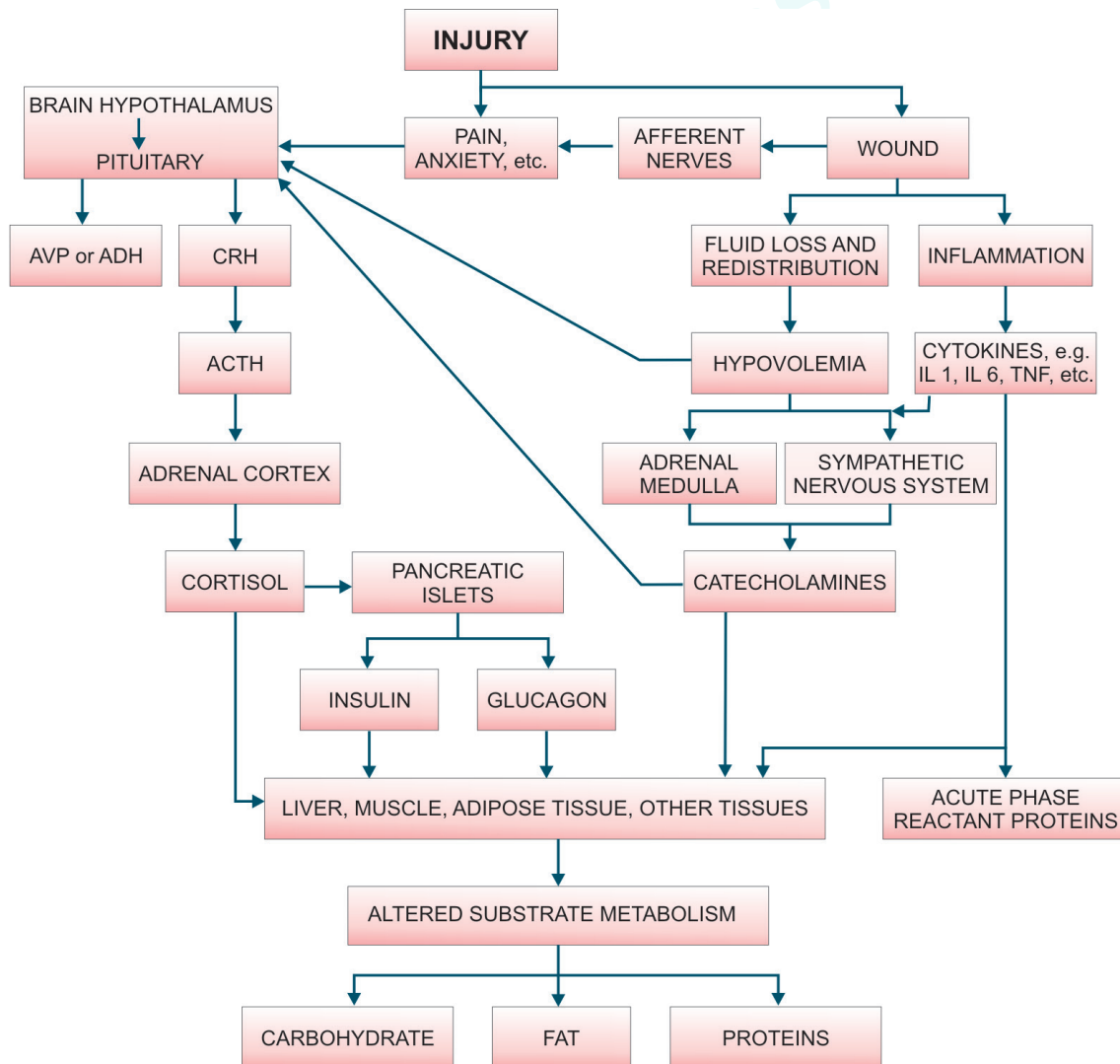


Fig. 8.2: Factors involved in the metabolic response to injury leading to alterations in fluid and electrolytes, substrates and hormones.

The protein loss after injury does not result from impaired protein synthesis. The protein loss occurs primarily from muscle, there being no decrease in the protein content of the liver and the kidneys.

Increased cortisol and glucagon and decreased insulin all limit the ability of muscle to take up amino acids. As catabolism of muscle continues, while anabolism is limited by the hormonal changes, there is a net release of amino acids from muscle cells. Alanine is the principal amino acid released from muscle, and is the principal gluconeogenic precursor in the liver. It has been suggested that a cycle similar to the Cori cycle of glucose to lactate to glucose may be achieved through glucose to alanine to glucose. This cycle then provides a source for gluconeogenesis.

Most of the proteins, which are largely derived from skeletal muscle, are converted to glucose in the liver by the process of gluconeogenesis. Most of this endogenously produced glucose is used by the brain. The remainder is used by red blood cells and leukocytes, which convert the glucose to lactate and pyruvate. These are returned to the liver and resynthesized into glucose (Cori cycle).

### Biochemical and Fluid Balance Disturbance

1. Salt and water retention: This results from the mineralocorticoid effects of both aldosterone and cortisol. This is compounded by the raised levels of ADH, further hindering excretion of free water and resulting in lower volumes of high osmolality urine. Any reduction in renal

perfusion from hypotension secondary to hypovolemia or from the administration of nonsteroidal antiinflammatory drugs also worsens oliguria and can lead to acute renal failure.

2. Hyponatremia ( $\text{Na}^+$ ) – It occurs partly due to a dilutional effect from retained water (due to ADH) and partly because sodium drifts into cells (impaired Na-pump). It does not indicate sodium deficiency, as it occurs at a time when total body sodium is elevated. Serum  $\text{K}^+$  may rise due to cell death, impaired potassium excretion and liberation of potassium by protein catabolism. However, it is more usual to see increased urine potassium excretion which can lead to overall potassium deficit.
3. Acid-base abnormalities: The commonest change is the metabolic alkalosis due to intense reabsorption of sodium in distal tubules of the kidney, accompanied by excretion of  $\text{K}^+$  and  $\text{H}^+$  ions.

In more severe injuries, a metabolic acidosis supervenes due to poor tissue perfusion and anaerobic metabolism with accumulation of lactic acid.

### FACTORS DETERMINING THE MAGNITUDE OF METABOLIC RESPONSE

These include:

1. Magnitude of surgical trauma
2. Smoking
3. Concurrent diseases, e.g. Inflammatory bowel disease, Rheumatoid arthritis, Pancreatic cancer (which augments the metabolic response to surgery)

4. Ischemia and reperfusion injury and
5. Sepsis.

### FACTORS REDUCING THE METABOLIC RESPONSE AND QUICK RECOVERY

1. Reducing the stimuli's causing the response during surgical trauma by:
  - Gentle tissue handling
  - Sharp dissection along anatomical planes
  - Careful hemostasis to reduce blood loss and the risk of hematoma formation.
  - Peritoneal lavage to remove tissue debris and clots
  - Careful suturing without strangulation – All these will help towards reducing the metabolic response and a quicker recovery.
2. Nutritional support, e.g. with amino acid glutamine and arginine supplementation of enteral diets and omega - 3 fatty acids helps to overcome the immunodepression after surgical trauma.
3. Control of pain with analgesics like NSAIDs, local regional blockade.
4. Correction of metabolic acidosis or alkalosis.
5. Correction of Hypoxemia by administration of  $\text{O}_2$ , and attention to airway and breathing.
6. Correction of hypovolemia by prompt replacement of fluids and electrolyte lost and transfusion for hemorrhage if Hb is  $<8$  gm/dl.

Figure 8.2 shows the factors initiating the metabolic response which is a stereotyped reaction to any form of injury leading to alterations in fluid and electrolytes, substrates, and hormones.

## Chapter 9

## Surgical Infections

- Definition
- Determinants of infection
- Sources of infection
- Folliculitis, furuncle, carbuncle
- Hydradenitis suppurativa
- Abscess
- Cellulitis
- Lymphangitis and lymphadenitis
- Erysipelas
- Dog and cat bite wounds
- Drug injection abscess
- Necrotizing fasciitis
- Gas gangrene
- Tetanus
- Hand and foot infections
- Fibrous flexor sheaths
- Foot infections
- Fungal Infections
- Hospital acquired (nosocomial) infections
- Surgical infections of abdomen
- Surgical infections of thorax
- Pathogens in surgical infection
- Antibiotics
- Antibiotic policy

**DEFINITION**

Surgical infections can be defined as infections most effectively treated by surgery or an infection in the surgical wound or operating site.

Infection means invasion of the body by pathogenic organisms, which may be bacterial, fungal or viral.

A pathogenic organism establishes itself in host tissue, multiplies and results in tissue damage, usually due to release of toxic substances. The classification of microorganisms into pathogenic and nonpathogenic is, however, arbitrary, as pathogenicity depends on an imbalance in the relationship between the host and the microorganism. In a host with reduced body resistance, a less harmful organism may produce severe disease.

**DETERMINANTS OF INFECTION**

The determinants of surgical infections are

- i. Microbial pathogenicity
- ii. Host defences
- iii. Local environment and
- iv. The surgical technique.

**Microbial Pathogenicity**

There are three types of pathogens viz

- a. Conventional pathogens—They cause infections in previously healthy individuals and possess high pathogenicity. (see below)
- b. Conditional pathogens—Cause clinical infection only when a predisposing factor is present, e.g. abdominal surgery, catheterization, etc. They are mainly the resident flora (see endogenous infection below).
- c. Opportunistic pathogens—Cause infections when the host is immuno-compromised, e.g. in case of AIDS infections caused by atypical mycobacteria, CM virus, etc. See also pathogens in surgical infection later in this chapter.

**Conventional Pathogens**

The following are the examples with their toxins and pathologic lesions:

- Lancefield group A and B—Hemolytic streptococci and *Staphylococcus aureus* exotoxin: wound sepsis, septicemia
- *Neisseria meningitidis* → Endotoxin → Meningitis
- *Clostridium tetani* → Highly toxic exotoxin → Tetanus.

**Host Defences**

Surgical infection occurs when the balance between the host resistance and the virulence of the organism is jeopardized. Host defences are of two types viz.

**Local Host Defences**

- i. Physical barriers such as skin and mucous membrane.
- ii. Flushing action of tears and bronchi.
- iii. Cilia in trachea and bronchi.
- iv. Low gastric pH (kills bacteria).
- v. Saliva possesses IgA and lysozyme which kill bacteria.

**Systemic Host Defences**

Comprising of

- Cellular components viz. Macrophages, T - lymphocytes, B — Lymphocytes, natural killer cells (NK cells), neutrophils.
  - Humoral components, e.g. antibodies, complements and opsonins (a protein in plasma which can coat relatively avirulent organisms rendering them more easily phagocytosed by polymorphs), interferon, etc.
- Reduced host resistance to infection has several causes viz.



- Metabolic — Malnutrition, diabetes, uremia, jaundice.
- Disseminated disease like cancer and AIDS.
- Iatrogenic — Radiotherapy, chemotherapy, steroids, etc.  
All the local and systemic host defences may be compromised by surgical intervention and treatment.

### Local Environment

- Wound containing devitalized tissue or foreign body (delayed healing).
- Lowered tissue PO<sub>2</sub>, e.g. in shock, peripheral vascular disease—Diminished PO<sub>2</sub> inhibits function of phagocytes and promotes the growth of anaerobes.

### Surgical Technique

The following factors should be considered during surgery to diminish the chances of postoperative infection viz.

- Gentle handling of tissues.
- Removal of devitalized tissues, if any
- Not using cautery excessively.
- Performing intestinal anastomosis without tension.
- Appropriate use of drains.

### SOURCE OF INFECTION

Two types of sources are there: (1) Endogenous source of infection, (2) Exogenous source of infection.

#### Endogenous Infection

Sometimes referred to as autogenous infection, this is acquired from the individual's own commensal microbes. Endogenous infections are particularly common after trauma, surgery and instrumentation and in conditions of lowered local or systemic host defences. The skin and all mucous membranes bear a rich commensal flora and with the exception of the skin, this flora is predominantly anaerobic. The major bacterial species found as commensal flora are as follows:

- Skin—Axilla and perineum-anaerobic-cocci nose, toe webs, axilla, perineum – *Staphylococcus aureus*.
- GI tract — The small intestine has a scanty commensal flora, similar to oropharynx. The large intestine bears a vast microbial load viz. *Bacteroides fragilis* (Anaerobes),

Aerobes include the coliforms—*E. coli*, *Klebsiella* and *proteus*.

- Urogenital tract—Vagina-anaerobes, Doderlein's lactobacilli, Urethra – *Staphylococcus*, *Diphtheroids*.
- Upper respiratory tract—*Streptococcus*, *Haemophilus*, *S. aureus*, *Diphtheroids*.

#### Prevention of Endogenous Infection

- Disinfection of skin
- Bowel preparation.
- Appropriate antibiotic prophylaxis.

#### Exogenous Infection

This is acquired from a source outside the patient – mostly from other humans, but also from other animal (zoonoses) and environmental sources, e.g. soil, water, etc.

#### Human Sources

These include patients with overt clinical infections, those with inapparent or subclinical infections as well as carriers and excretors of pathogenic organisms. Organisms may be transmitted from one person to another by direct contact, by inhalation, by sexual intercourse or transplacentally. This type of transmission is also called cross infection.

#### Types of Surgical Infection

- Skin and soft tissue infections.
  - Spontaneous
    - Folliculitis, furuncle and carbuncle.
    - Hydradenitis suppurativa
    - Perianal and ischiorectal abscess.
    - Breast abscess.
  - Following operation or trauma
    - Cellulitis, erysipelas, lymphangitis.
    - Drug injection abscess.
    - Necrotizing fasciitis.
    - Gas gangrene
    - Tetanus
    - Infections of the hand and foot.
- Hospital acquired (Nosocomial) infections
  - Wound infection (surgical site infection, SSI).
  - Urinary tract infection.
  - IV line infection.
  - Pneumonia.
  - Pseudomembranous enterocolitis.
- Surgical infections of abdomen
  - Biliary infection
  - Liver abscess
  - Peritonitis

- Primary
  - Secondary
  - Tertiary or postoperative peritonitis
- Acute pancreatitis and pancreatic abscess.
  - Acute appendicitis.
- Surgical infections of thorax
    - Lung abscess
    - Empyema (Pleural).

### FOLLICULITIS, FURUNCLE, CARBUNCLE

#### Folliculitis and Furuncle

- Folliculitis means infection of a single hair follicle, whereas furuncle means infection of a group of hair follicles by *Staphylococcus aureus*.
- Boils or furuncles tend to be recurrent and the common sites include face, neck, axilla and buttocks.
- Systemic antibiotics are not indicated, they do not affect resolution. Individual boils that are large and painful should be treated by incision and drainage under local or even general anesthetic.  
In recalcitrant cases, antibiotics like cloxacillin are given. Diabetes if present is treated.

#### Carbuncle

This is a superficial infective gangrene involving the subcutaneous tissue by *Staphylococcus aureus*. Very often the patient is diabetic.

#### Site

Axilla in female and nape of the neck in male are the commonest sites, others sites are back and the shoulder region. Skin of these sites is coarse and has poor vascularity.

#### Clinical Features

- Pain and stiffness over the area on palpation, there is induration of the skin and subcutaneous tissues.
- The skin over the area is red and dusky, multiple vesicles appear on it, which burst on the surface, one after another bringing out a purulent discharge. Thus the surface looks sieve – like.
- At the base of the ulcer lies a grayish slough. If healing is favorable, the slough separates and the cavity gradually fills up with healthy granulation tissue.



### Treatment

- Treatment of diabetes if present.
- Antibiotics—Appropriate parenteral antibiotics are given till complete resolution.
- Hot compresses, preferably with SS. Magsulph is applied to reduce the edema.

### Operation

- Operation is to be undertaken when the carbuncle has softened (if no softening or there is evidence of healing it is not incised complete resolution may take place within 10 – 15 days). Severe pain, toxemia and big size are the other indications for operation.
- A cruciate incision is made and liberally extended to the margins. All sloughs are removed with gauge swabs or scissors. The apices of the four skin flaps are cut making, the opening circular and large. Postoperatively, antibiotics are continued.

## HYDRADENITIS SUPPURATIVA

Hydradenitis suppurativa is an infection of the apocrine sweat glands of the skin. It is common in the axilla, groin, perineum, anal and periumbilical regions. Irritations by deodorants and excessive sweating have been implicated as precipitating factors.

Organisms causing the infection are *Staphylococcus aureus*, streptococci and a variety of skin commensals.

The patient presents with multiple tender swellings under the arm or in the groin, These enlarge and discharge pus.

### Treatment

- To maintain good hygiene.
- Initially warm compress and antibiotics.
- If fails, then complete excision of the infected tissue down to deep fascia with subsequent grafting or delayed closure.

## ABSCESS

An abscess is a localized collection of pus.

### Types

1. Pyogenic abscess—This is caused by the pyogenic organisms. Precursors of pyogenic abscess are cellulitis and acute lymphadenitis.

2. Pyemic abscess—This is a metastatic abscess due to circulation of pyemic emboli in the blood (pyemia).
3. Cold abscess — Usually refers to tubercular abscess either due to involvement of lymph nodes or involvement of spine. Unlike pyogenic abscess, pyemic and cold abscesses are nonreacting in nature and do not show the features of inflammation.

### Bacteremia

It is a condition where organisms circulate in the bloodstream with no clinical manifestation. It is usually transient as the reticuloendothelial system localizes and destroys these organisms.

### Septicemia

It is a condition where organisms not only circulate in the bloodstream, but also proliferate therein and produce toxins which cause toxic illness viz. febrile illness, often with rigors and shock due to toxic.

### Toxemia

Toxemia is a state in which toxins bacterial or chemical circulate in the bloodstream and produce characteristic toxic symptoms.

### Pyemia

Pyemia is a stage of septicemia in which pyogenic microorganisms, most notably *Staphylococcus aureus* and their toxins are carried in the bloodstream, which initiate multiple foci of abscesses in various parts of the body. Pyemic abscess may affect the viscera, e.g. kidney, spleen, heart, brain, etc. On the surface, they are the commonest in the subfascial plane.

### Pyogenic Abscess

It is usually produced by staphylococcal infections. The organisms enter soft tissues by an external wound, minor or major. It can also be due to hematogenous spread from a distant focus such as tonsillitis or caries tooth, etc.

It is the body's reaction to an invading microorganism that produces the classical inflammatory response resulting in the clinical features of infection. Viz. Rubor (redness), tumor (swelling), dolor (pain) and calor (heat).

In acute infection, these clinical features may be accompanied by swinging pyrexia, leukocytosis, raised C-reactive protein and

if the infection spreads, bacteremia and septicemia.

### Pathology

- i. Increased permeability of vessels especially capillaries → exudation of protein and fibrin formation → pyogenic membrane. (See below)
- ii. Increased vascular permeability → outpouring of macrophages and polymorphs → release of lysosomal enzymes → liquefaction of tissue → pus formation.
- iii. Release of toxins and enzymes from the bacteria → Tissue destruction → Pus formation.

Thus, the end result is production of pus which is composed of dead leukocytes, bacteria and necrotic tissue.

The area around the abscess is encircled by fibrin products and is infiltrated with leukocytes and bacteria. It is called pyogenic membrane.

### Clinical Features

The patient feels ill and complains of throbbing pain at the site. Throbbing pain is indicative of pus formation and is due to pressure on the nerve endings by pus.

The signs are those of acute infection mentioned above, i.e. rubor, tumor, dolor, etc.

### Treatment

Incision and drainage (I and D), preferably under general anesthesia as local anesthesia may not act and all the loculi may not be broken without causing pain.

### Procedure

A stab incision is made over the most prominent (pointing) part of an abscess. The pus which comes out is collected and sent for culture and sensitivity. A sinus forceps or finger is introduced within the abscess cavity and all the loculi are broken down. Fresh bleeding which is seen is an indication of completeness of the procedure. The abscess cavity is irrigated with antiseptic agents like povidone iodine.

= Antibiotic of choice is cloxacillin for *aureus*.

= **Hilton's method of drainage of abscess**

It is drainage with the help of sinus forceps. Sinus forceps with blades closed is

introduced inside the abscess cavity, the blades are separated and closed, then the forceps is rotated 90°, again blades are opened and closed.

This method is not popular now-a-days because it failed to break all the loculi. It is useful in case of a small abscess, especially at depth, where finger manipulation is difficult.

In the Hilton's method, skin and superficial fascia are incised, instead of a stab incision, so as to avoid damage to vital structures like vessels and nerves, e.g.

Site	Anatomical structure
1. Axilla	Axillary vessels
2. Midpalmar space	Median nerve
3. Neck	Subclavian vessels and brachial plexus
4. Parotid region	Facial nerve

### Differential Diagnosis

- Soft tissue sarcoma in the thigh. However, throbbing pain, high grade fever with chills and short duration of the swelling clinches the diagnosis of an abscess.
- Aneurysm, e.g. popliteal aneurysm, vertebral artery aneurysm in the posterior triangle can present as subcutaneous abscess with pain, redness and local rise of temperature. Therefore, whenever, in doubt aspiration is done with a wide bore needle before incising the abscess.

### Anorectal Abscess

It is due to pyogenic infection of the anal gland. It starts at the base of anal crypt in between sphincters and then it spreads. The 10 – 12 anal glands are simple glands with a duct draining into the crypts of Morgagni. The gland bodies lie at varying depths from submucosa to the tissue space between the external and internal sphincters.

As the abscess expands, pus may track longitudinally in various directions to present as a perianal, ischioanal or supralevator abscess.

### Perianal Abscess

It occurs due to infection of anal glands in the perianal region. It may be due to a boil or due to anal gland infection or due to thrombosed external pile.

It produces severe pain, throbbing in nature and on examination a soft tender, warm swelling is found.

On rectal examination—There is a tender boggy swelling under the mucosa.

### Treatment

Antibiotics, incision and drainage with excision of part of the skin, i.e. roof.

### Ischioanal Abscess

- Occurs due to spread of anal abscess or due to blood borne infection in diabetic patients. Culture usually shows *E. coli* in 70 to 80 percent cases. *Staphylococcus*, *Streptococcus* and *Bacteroides* are other organisms.
- There is collection of pus in the ischioanal fossa which is lateral to the rectum and medial to pelvic wall. It is bounded above by the levator ani and inferiorly by pad of fat in the ischioanal fossa.
- Ischioanal fat is poorly vascularized. Hence it is more vulnerable for infection.

### Clinical Features

- High grade fever with chills and rigor
- Severe throbbing pain is characteristic.
- Induration in the ischioanal fossa.
- Frank evidence of abscess—soft cystic fluctuation, may not be seen.

### Treatment

Under general anesthesia, a cruciate (+) incision is made and the four flaps are raised. All the pus is evacuated and the wound is packed with providone iodine soaked roller gauge and left open. Edges of the skin are trimmed to leave an opening so that drainage of pus occurs freely. It heals with granulation tissue within 10 to 15 days. Appropriate antibiotics are given for 10 to 15 days.

### Breast Abscess

(Syn – Acute bacterial mastitis – Pyogenic mastitis).

See infective disorders of the breast in Breast Surgery, Section 11.

### CELLULITIS

- It is the nonsuppurative, invasive infection of the skin and subcutaneous tissues.

In addition to cardinal signs of inflammation, there is poor localization.

- A surgical wound, skin puncture or ulcer is identifiable as a possible portal of infection.
- Organisms are  $\beta$ -hemolytic streptococci, *Staphylococcus aureus* and *Clostridium perfringens*.

### Pathology

Tissue destruction and ulceration may follow due to release of exotoxins like streptokinase, hyaluronidase and other proteases.

### Clinical Features

Signs of toxemia like fever with chills and rigor are common following release of exotoxins and cytokines but blood cultures are often negative.

### Treatment

Consists of rest and antibiotics. If there is no response in 48 to 72 hours and an abscess has developed, it calls for incision and drainage.

### Cellulitis at Special Sites

- Face—Facial cellulitis* involving the danger area (upper lip, nasal septum and adjacent area) can lead to cavernous sinus thrombosis via the emissary veins.
- Ludwig's angina*—Involves the submandibular region and can cause edema glottis and respiratory difficulty.
- Pelvic cellulitis*—Due to cervical tear during difficult labor. It can extend along the broad ligament and appear above the inguinal ligament.

### LYMPHANGITIS AND LYMPHADENITIS

Nonsuppurative infection of the lymphatic vessels that drain an area of cellulitis is called lymphangitis. It produces red, tender, warm streaks, 1 to 2 cm wide leading from the area of cellulitis towards the regional lymph nodes.

Lymphadenitis is infection and enlargement of the regional lymph nodes as a result of cellulitis and lymphangitis.

### ERYSEPELAS

It is the acute spreading lymphangitis of the skin with cellulitis caused by Group A,  $\beta$  – hemolytic streptococci.

**Treatment**

- The affected part is immobilized and elevated.
- Antibiotic therapy is based on Gram-stain and culture sensitivity.

**DOG AND CAT BITE WOUNDS**

- The wound is débrided, irrigated and splinted.
- Antibiotics like amoxicillin plus metronidazole or erythromycin are suitable.

**DRUG INJECTION ABSCESS**

This may occur following therapeutic or addictive injection of a drug. Anaerobic organisms are isolated predominantly.

Clinical features include pain, tenderness, lymphadenopathy, erythema, leukocytosis and fever.

**Treatment**

Appropriate antibiotics with incision and drainage.

**NECROTIZING FASCITIS**

Synergistic spreading gangrene or necrotizing fasciitis is caused by a mixed pattern of organisms viz. coliforms, staphylococci, *Bacteroides*, Anaerobic, Streptococci and *Peptostreptococcus*.

Abdominal wall infections are known as Meleney's synergistic gangrene and scrotal infection as Fournier's gangrene. Patients are almost always immunocompromised with conditions such as diabetes mellitus. The wound initiating the infection may have been minor but severely contaminated wounds are more likely to be the cause.

Gangrene sets in as the toxin induced thrombosis cuts the blood supply of the epifascial tissues.

**Clinical Features**

Severe wound pain, signs of spreading inflammation with crepitus and smell are all signs of the spreading infection. Untreated, it will lead to widespread gangrene and MSOF (multi-system organ failure). The subdermal spread of gangrene is always much more

extensive than what appears from initial examination.

**Treatment**

- Wide-spectrum antibiotic with aggressive circulatory support.
- Locally wide excision of the necrotic tissues and laying open of affected areas.

The debridement may need to be extensive and patients who survive may need large areas of skin grafting.

*Differential diagnosis:* Gas gangrene.

**GAS GANGRENE**

Gas gangrene is caused by *Clostridium perfringens* (welchii). These gm positive spore-bearing bacilli are widely found in nature, particularly in soil and feces. Of the 83 species of clostridium, about one-fourth can cause illness and infections in humans. *C. perfringens* is responsible in the majority of trauma related infections. *C. septicum* is more aerotolerant and is associated with spontaneous myonecrosis.

Immunocompromised patients are especially vulnerable.

**Clinical Features**

- Severe local wound pain and crepitus (gas in the tissues may be located in the plain radiographs).
- Edema and spreading gangrene due to release of collagenase, hyaluronidase, other proteases and  $\alpha$ -toxin.
- Disruption and fragmentation of muscle cells and capillaries by toxin produces massive necrosis, hemorrhage and edema. Systemic complications with circulatory collapse and MSOF follow if prompt action is not taken.

**Treatment**

The treatment consists of wide excision of all necrotic and Ischemic tissue with free drainage and high dose antibiotics therapy including penicillin and metronidazole. The use of hyperbaric oxygen is controversial. Antitoxin has been used in military practice but with little benefit. In late cases amputation may be required. Mortality ranges from 25 to 70 percent.

**TETANUS**

Tetanus is caused by *Clostridium tetani*, a gm positive anaerobic bacilli.

**Incubation Period**

Starts from 2 to 15 days after injury. The shorter the incubation period, the poorer the prognosis.

**Clinical Features**

Dysphagia, jaw stiffness and severe pains in neck, back and abdomen, precede the tonic muscle spasms. The sardonic smile of tetanus is the beginning of tonic muscle spasm (*Risus sardonicus*).

Opisthotonus or backward curvature is due to spasm of the extensors of the back, neck and legs.

The bacteria are confined to the wound but produce the ill effects via the exotoxin which is absorbed at the motor nerve endings and travels via the nerves to the anterior horn cells.

The exotoxin is composed of two elements viz.

- a. A neurotoxin which acts on neuromuscular end-organs producing spastic contractions. Death, when it occurs, is due to asphyxia from spasm of the respiratory muscles and cardiovascular complications.
- b. A hemolytic toxin that lyses red blood cells.

**Differential Diagnosis**

Back strain, tonsillitis or acute upper abdominal conditions. Therefore, examinations of the wound are of paramount importance.

**Treatment**

The patient is treated in a quiet room in an intensive care unit.

1. Anti tetanus human immunoglobulin: 3000 units IM stat, then 1000 units injected into and immediately proximal to the wound. Then reinjection of 1000 units of immunoglobulin daily, Repeat injection of Ig (Immunoglobulin) 1000 – 3000 units if symptoms persist.
2. Wide debridement of the wound.
3. Tracheostomy and early respiratory support.
4. Sedation to control the muscle spasms.

5. Antibiotics—Broad spectrum antibiotics, e.g. 3rd generation cephalosporin is given to destroy the bacteria and to prevent further toxin production.
6. Inj-Tetanus toxoid and catheterization done.
7. IV fluid to control insensible and other fluid losses.

### Tetanus Prophylaxis

- Prevention is the ideal and active immunization with tetanus toxoid is administered to all children as part of the triple vaccine during the first year of the life, with a booster dose at 5 year and at the end of schooling.
- If a patient presents to a casualty department with a potentially contaminated wound and has previously been fully immunized, then a booster dose of tetanus toxoid is administered. If a patient has not been vaccinated or is unsure of a status, passive immunization with human antitetanus immunoglobulin is given and a full course of active immunization with tetanus toxoid is commenced.

## INFECTIONS OF HAND AND FOOT

### Hand Infections

Hand infections are commonly encountered in manual laborers and are precipitated by injuries such as a thorn prick, cut injury, etc.

In 80 to 90 percent cases, the causative organism is *Staphylococcus aureus*. In remaining cases, streptococci, Gm negative bacilli, anaerobic organisms also may play a role. Irrespective of the site of infection, edema is commonly encountered on the dorsal aspect because of the following reasons.

1. Lymphatics from the palmar aspect of the hand travel through the dorsal aspect to the corresponding lymph node.
2. Presence of the loose areolar tissue in the dorsum of the hand.

Edema is the chief cause of stiffness of the fingers.

#### Types

- I. Superficial infections:
  1. Paronychia (Nail fold infection)
  2. Cuticular subcutaneous infections

3. Infections of dorsal space
4. Acute lymphangitis.
- II. Deep infections:
  1. Terminal pulp space infection
  2. Deep space infections
    - a. Midpalmar space abscess
    - b. Thenar space abscess
    - c. Hypothenar space abscess.
  3. Web space infection
  4. Suppurative tenosynovitis.

### Paronychia

It means near the nail. It is the commonest type of hand infection. There are two types of paronychia, acute and chronic.

#### Acute Paronychia

- It occurs due to careless nail trimming or picking the skin around the nail fold.
- After an initial inflammatory phase, pus is trapped beside the nail. Throbbing pain suggests development of pus. Even collection of half ml pus produces severe pain. Low grade fever may be present.
- *Treatment*—Using a digital block with 2 percent plain lignocaine 5 ml of the solution is injected into the root of the digit, incision and drainage is done by incising the eponychium (skin overlying the nail base). In the finger, penis and ear lobule. Adrenaline should not be used as it is a vasoconstrictor and can cause gangrene. Antibiotics are given.

#### Chronic Paronychia

- It is not due to bacterial infection. It is due to fungal infection called moniliasis or candidiasis in those whose hands are constantly immersed.
- Microscopic examination of the scrapings and special fungal cultures will confirm the diagnosis.
- If produces a dull nagging pain and the nail is ridged.
- It may resolve if the hands are kept dry and the nail fold is regularly dressed with antifungal agents such as Nystatin or Tolnaftate solution.

### Cuticular and Subcutaneous Infection

- a. Intraepidermal abscess — It is also called purulent blister. It occurs due to cuts, pricks and burn injury.

- b. Intradermal abscess — This variety does not produce dome-shaped elevation.
- c. Subcutaneous abscess—This type of lesion is like that of cellulitis.
- d. Collar-stud abscess — It results when the epidermal component is connected to the dermal component.

#### Treatment

Incision and drainage under antibiotic cover. Care should be taken to drain the deeper cavity.

### Terminal Pulp Space Infection

It is otherwise known as a felon. A felon is an abscess in the fibrous septae closed space of the fingertip pad. This closed space is formed by fusion of digital flexion skin crease with the deep fascia attached to the periosteum of distal phalanx, just distal to the insertion of flexor digitorum profundus. The digital artery which is an end artery runs into this closed space.

#### Clinical Features

It causes severe pain in the finger pulp. Touch, movement or dependent position worsens the pain.

#### Treatment

Incision and drainage under digital block. The incision may be transverse, hockey stick or horseshoe-shaped over the point of maximum tenderness (Fig. 9.4).

### Deep Space Infections (Fig. 9.1)

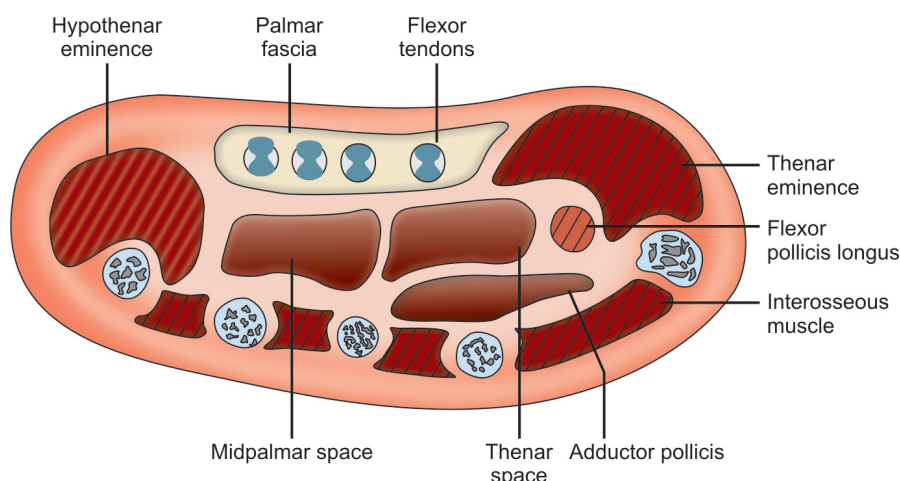
#### Midpalmar Abscess

- Infection of the midpalmar space results in deep palmar abscess.
- Midpalmar space is the space behind the palmar aponeurosis and in front of the metacarpal bones.
- Clinical features — pus collects deep to the palmar fascia running down to the 3rd metacarpal.
- The whole hand is swollen and the palm is intensely tender.

#### Treatment

The infection is drained through a longitudinal web incision or distal palmar crease incision (Fig. 9.4), great care being taken to avoid damage to the tendons, nerves and blood vessels.





**Fig. 9.1:** Transverse section of hand showing sites of deep space infections in the palm

### Thenar Space Abscess

Thenar space abscesses develop in the space superficial to the adductor pollicis muscle and 2nd and 3rd metacarpals and deep to the level of the flexor digitorum superficialis and flexor digitorum profundus tendons of the index finger (Fig. 9.1).

The incision is placed on the free margin of the web of the thumb (Fig. 9.4).

### Hypothenar Space Infection

The hypothenar space is not important surgically since it contains no long flexor tendons but only the hypothenar muscles.

### Web Space Infection

#### Web Space

The three web spaces of the palm lie between the four slips of attachment of the palmar aponeurosis. From the skin edge they may be said to extend proximally as far as the metacarpophalangeal joints, a distance of about 4cm. Between the palmar and dorsal layers of the skin lie the superficial and deep transverse ligaments of the palm, the digital vessels and nerves and the tendons of the interossei and lumbricals on their way to the extensor expansions. The web is filled in with a packing of loose fibrofatty tissue. The deep transverse metacarpal ligaments join the palmar ligaments of the metacarpophalangeal joints and lies 3 cm proximal to superficial transverse ligament.

#### Causes

- Penetrating injuries

- Spread of proximal volar (Palmar space) infection
- Lumbrical canal infection.

#### Clinical Features

- Pain in the region of web space.
- Extremely tender and hot swelling.
- Finger separation sign – Adjacent fingers are separated due to edema.
- Gross edema of the dorsum of hand.
- Untreated pus from one web space can spread to the other web space and to the other proximal volar space.

#### Treatment

Under anesthesia a transverse skin incision is made and the pus is drained.

The cavity is treated like any other abscess cavity. The skin edge is trimmed in such a way as to leave a diamond-shaped opening to get better drainage.

### Suppurative Tenosynovitis

Syn. Tendon sheath infection

#### Surgical Anatomy of Flexor Tendon Sheath Arrangements

### FIBROUS FLEXOR SHEATHS (FIGS 9.2A AND B)

- The fibrous sheaths of the flexor tendons are specialized parts of the palmar fascia.
- From the metacarpal heads to the distal phalanges all five digits are provided

with a strong unyielding fibrous sheath in which the flexor tendons lie.

In the thumb, the fibrous sheath is occupied by the tendon of the flexor pollicis longus alone. In the four fingers, the sheaths are occupied by the tendons of the superficial and deep flexors, the superficial splitting to spiral around the deep within the sheath.

The proximal ends of the fibrous sheaths of the fingers receive the insertion of the four slips of the palmar aponeurosis.

The sheaths are strong and dense over the phalanges, weak and lax over the joints (Fig. 9.2)

### Synovial Flexor Sheaths (Fig. 9.3)

(Syn-Synovial sheaths of the flexor tendons)

Two synovial sheaths envelope the flexor tendons as they traverse the carpal tunnel, one for the flexors digitorum superficialis and profundus (the ulnar bursa) and the other for flexor pollicis longus (radial bursa). These sheaths extend into the forearm for 2.5 cm proximal to the flexor retinaculum and occasionally communicate with each other deep to it. The sheath of the flexors digitorum tendons reaches about halfway along the metacarpal bones where it ends in blind diverticula around the tendons to the index, middle and ring fingers. It is prolonged around the tendons to the little finger and is usually continuous with their digital synovial sheath.

As the radial and ulnar bursae often communicate with each other, deep to flexor retinaculum, there is a potential risk of infections in the tendon sheaths of the little finger and thumb spreading proximally to the palm and forearm.

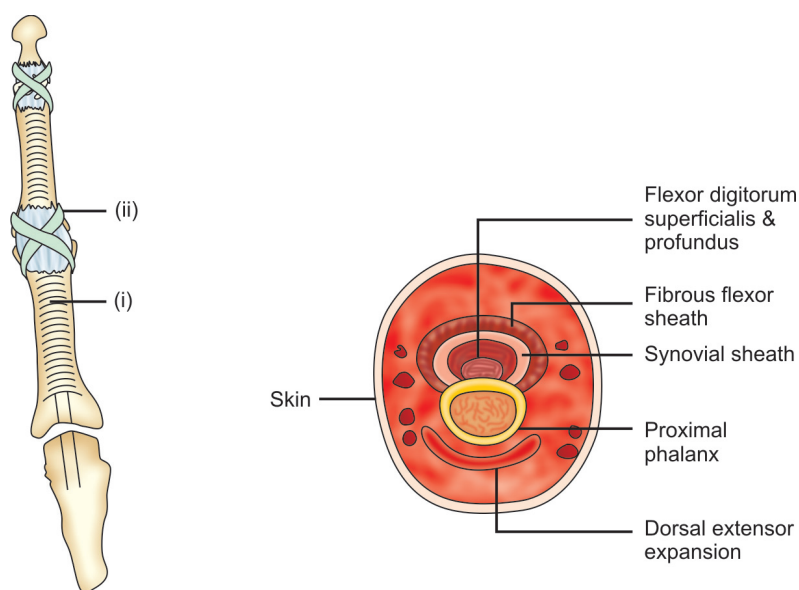
### Etiology

The synovial sheath of the flexor tendon is usually infected by direct puncture wounds, particularly where the skin is in close contact with the sheath at the skin creases but infection may also spread into it from adjacent lesions.

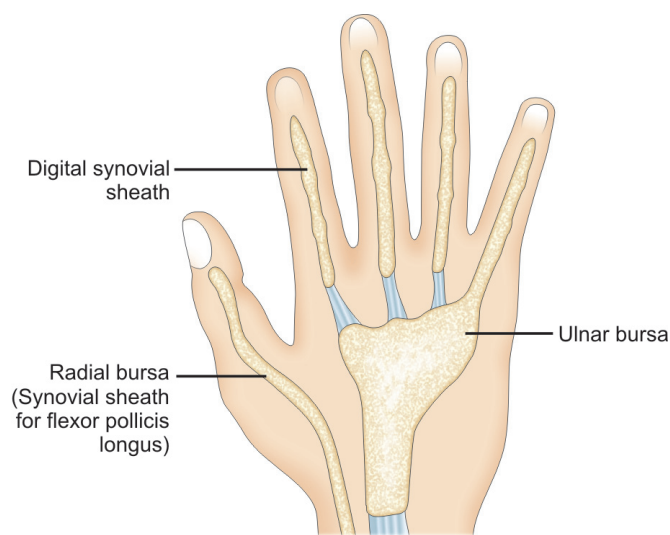
### Clinical Features

Suppurative tenosynovitis is an infection of the flexor tendon sheath of the fingers or thumb; mostly caused by *S. aureus*.

- There is symmetrical painful enlargement of the finger.
- Finger is bent — Hook sign.



**Figs 9.2A and B:** (A) Fibrous flexor sheath (i) Its fibers are transverse and strong across the phalanges (ii), but oblique and slender across the interphalangeal joints (B) Cross-section of a finger showing the arrangement of fibrous flexor sheath



**Fig. 9.3:** Anterior aspect of palm of the hand showing the flexor synovial sheaths

- IP joints movements are very painful.
- MP joint movements are not painful, which differentiates suppurative tenosynovitis from deep palmar abscess.
- When there is infection of the ulnar bursa, the maximum tender spot, is in between the transverse palmar creases on the ulnar side. This sign is described as Kanavel sign.
- Similarly there is tenderness on the lateral side, over the flexor pollicis longus sheath when radial bursa is involved.

**Treatment**

- Under anesthesia, multiple incisions may have to be made to decompress the flexor tendon sheaths, so as to relieve the pus, exudate, etc. (Fig. 9.4).
- The cavity is irrigated with normal saline.
- Postoperative antibiotics is continued for 2 weeks.
- Hand is kept in elevated position to reduce edema.

- The finger must be moved as soon as the signs of inflammation begin to resolve.

**Complications**

- Stiffness of the fingers.
- Osteomyelitis.
- Suppurative arthritis of joints.
- Loss of digit.
- Spread of infection to the space of Parona, a space deep to flexor retinaculum and superficial to pronator quadratus in the lower end of forearm.

**FOOT INFECTIONS**

**Introduction**

Infections in the foot are usually minor. With a significant proportion of the world's population remaining barefoot, minor skin trauma is a frequent cause of local infection.

The rising incidence of diabetes means that this is now a potent cause of major infections.

Even with relatively minor bacterial infections, lymphatic spread is not uncommon. This leads to lymphangitis and involvement of regional lymph nodes.

Local investigation with wound swabs, culture of discharged material and skin scrapings or nail clippings can be helpful in identifying the organism. Blood investigations such as full blood count, blood sugar and blood cultures can be helpful in determining the exact diagnosis and monitoring the benefit of treatment.

Imaging – should be used to determine the extent of infection and the structures involved. Plain X-ray remains the baseline investigation of deeper infection but magnetic resonance imaging (MRI) can give helpful information on the spread of infection through the soft tissues.

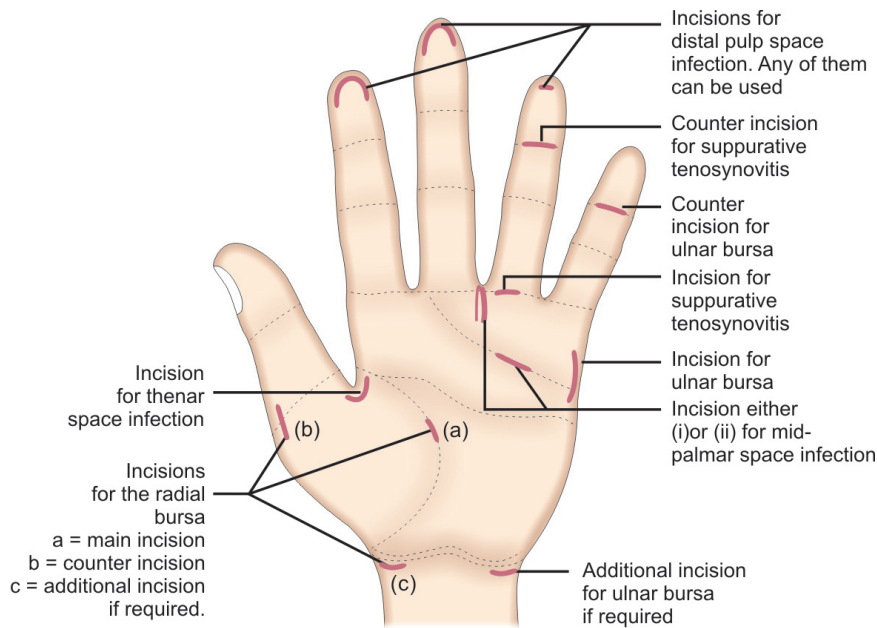
**Treatment**

The basic principles of management involve rest, elevation of foot, antibiotics and where necessary, surgical debridement. Regular dressings are needed. Dressings should keep the recovering granulation tissue moist.

**Ingrowing Toe Nails**

It is also called embedded toe nail. Exact etiology is not clear. Trimming the nail too





**Fig. 9.4:** Incisions for hand infections

excessive amounts of keratin and other debris around the nail plates.

### Pathogenesis and Pathology

The presence of poor vascularity (ischemia) and neuropathy are the two major predisposing factors for the development of diabetic foot infections.

### Vasculopathy

- Microvascular occlusion is due to vasoconstrictors, e.g. endothelins and thrombogenesis and leads to endothelial damage.
- Other factors include formation of reactive oxygen species and growth factors stimulation, e.g. TGF $\beta$  and vascular endothelial growth factors (VEGF). The growth factors are released by ischemic tissues and cause endothelial cells to proliferate.

### Peripheral Neuropathies

This clearly predisposes the patients to unrecognized injury, which potentiates the risk of bacterial invasion and infection. The incidence of neuropathies increases with the duration of disease. The end result is decreased plantar sensation, intrinsic muscle atrophy, and lack of autonomic, glandular and vasomotor responses. Skin insensitivity limits the patients ability to respond to foot trauma. Intrinsic muscle atrophy produces tendon imbalances that expose the metatarsal heads to excessive trauma. This then leads to ulceration. There is a progression from this superficial form of infection through deep infection and abscess formation to osteomyelitis.

If this situation is not brought under rapid control the foot will become gangrenous.

### Treatment

- Superficial ulceration—By desloughing the ulcer and removing the hyperkeratotic skin, the ulcer is dressed locally. The application of a skin tight plaster of Paris cast, changed on a weekly basis, will allow the vast majority of ulcers to heal. It also allows the patient to be mobile.
- Deeper infection without abscess formation can be treated by strict rest, foot elevation, soft tissue support and antibiotics.

much and chronic or repetitive trauma may result in ingrowing toe nail.

The nail appears to be digging under the skin producing an inflamed tender lesion. The corner of the nail on the affected side cannot be seen as it is buried in the surrounding soft tissue.

### Treatment

In the initial stages the condition can be controlled by footwear that does not press on the affected toe. During routine trimming the nail is cut straight and no attempt should be made to clip the corners.

Unfortunately this treatment is not effective in many cases and surgical intervention becomes necessary once an ingrowing toe nail has been infected a few times to prevent recurrence.

- If infection is severe, simple nail removal may be sufficient to settle the infection but recurrence is common.
- Wedge resection of the border of the nail and the associated nailbed is the treatment of choice in most cases.
- In some cases complete resection of the nail and nailbed (Zadek's procedure) may be necessary.

### Diabetic Foot

#### Diabetes

Diabetes accounts for a substantial number of the major foot infections. If superficial they may be associated with ulceration. Deeper infection may involve soft tissue only or can involve bones (osteitis or osteomyelitis). This type of infection can also involve local joints (pyogenic arthritis).

Common diabetic foot infections include

- Acute infections viz.
  - Localized cellulitis.
  - Septic arthritis of metatarsophalangeal joints.
  - Necrotizing cellulitis or fasciitis.
  - Deep space infections.
  - Gangrene, non clostridial and clostridial.
- Chronic infections
  - Neurotropic ulcers.
  - Osteomyelitis.

Majority of infections start in the web spaces, around the nails and sometimes, secondary to puncture wounds.

The high incidence of web space and toe infections is related to the increased moisture level in the web space and the presence of

Any form of abscess needs to be drained urgently and the deeper tissues thoroughly débrided.

- Infection in bone may require amputation.

### FUNGAL INFECTIONS

Fungal infections of foot (Fig. 9.5) are relatively common and can be important as they can cause generalized discomfort that can be mistaken for mechanical causes of pain. They commonly infect the nails leading to thickening and distortion (onychogryphosis) which itself can lead to mechanical symptoms.

#### Madura Foot (Syn. Mycetoma)

Probably the most common serious “primary” infection is Madura foot caused by *Nocardia madurae*, a filamentous organism, similar to actinomycetes (Fig. 9.5).

The organism almost certainly gains access to the foot through minor penetrating injuries or splits in the skin. Subsequently the foot forms multiple painless nodules, which ultimately form vesicular eruptions. These ulcerate and form sinuses which then become, secondarily infected.

#### Treatment

Consists of rest, elevation and antibiotics for secondary infection and protracted treatment with dapsone or similar agents.

Ultimately if the infections persists and heads to disability then amputation can be considered.

Other types of major infections include tuberculosis, and infestation such as guinea worm.

### HOSPITAL ACQUIRED (NOSOCOMIAL) INFECTIONS

#### Definition

Nosocomial infections are a potential threat to all hospitalized patients. They increase morbidity and mortality, prolong hospital stay, increase hospital care costs and occur in almost all body sites.

At any time during hospitalization but especially postoperatively, the onset of fever or an elevated white blood cell count may signal an infectious process. Patients may acquire infection through contact with personnel or from a nonsterile environment or infection may develop from bacteria harbored by the patient before operation.

The most common type of nosocomial infections are as follows.

1. Postoperative wound infection or surgical site infection (SSI).
2. Urinary tract infection.
3. Lower respiratory tract infection.
4. Enteric infections, e.g. pseudomembranous enterocolitis.
5. Intravenous access site infection.

#### Postoperative Wound Infection

It is also referred to as surgical site infection (SSI) resulting from bacterial contamination during or after a surgical procedure.

#### Subclassification

- i. Incisional SSIs—Superficial incisional (involving skin and subcutaneous tissues only) and deep incisional infections (involving fascial and muscle layers of the incision).

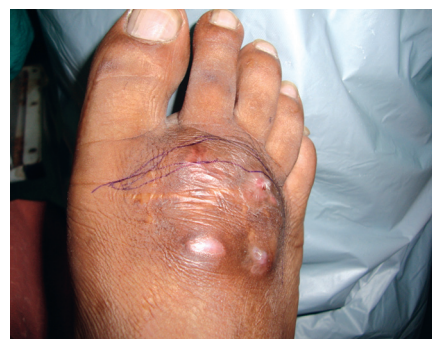

Fig. 9.5: Chronic fungal infection (Mycetoma) of foot

- ii. Organ/space SSIs—It involves any part of the anatomy, e.g. organs or spaces, other than the incision that was opened or manipulated during the surgical procedure, e.g. intraabdominal abscess, empyema, etc.

Altemeier demonstrated that the risk of wound infection varies according to the formula:

Dose of bacterial contamination X Virulence divided by resistance of host

#### Factors Influencing SSI (surgical site infection)

1. Patient factors:
  - For example Diabetes mellitus, smoking, steroids, malnutrition nares colonized with *Staphylococcus aureus*, poor skin hygiene, immunosuppression—all favor the development of SSI.
2. Environmental factors:
  - Preoperative preparation of the patient, i.e. operative site shaving the night before surgery reduces the risk of SSI

Table 9.1: Wound infection rates by class

	Clean	Clean - contaminated	Contaminated	Dirty
a. Features and definition	Elective <ul style="list-style-type: none"> <li>• Non-traumatic</li> <li>• No drains</li> <li>• Primary closure</li> <li>• Respiratory, alimentary or genitourinary tract not entered.</li> </ul>	<ul style="list-style-type: none"> <li>• Nonelective</li> <li>• Lightly contaminated</li> <li>• Opening a viscus with minimal spillage</li> </ul>	<ul style="list-style-type: none"> <li>• Acute purulent inflammation or penetrating trauma &lt;4 hrs old.</li> <li>• Major breach in sterile technique.</li> </ul>	Gross pus or perforated viscus or penetrating trauma > 4 hours old.
b. Example	Hernia repair, varicose vein surgery	Gastric or biliary surgery	Opening the colon, open fractures	<ul style="list-style-type: none"> <li>• Bullet wound</li> <li>• Peptic perforation</li> </ul>
c. Infection rate	<1.5%	<7%	Approx. 15%	As high as 40%

- Breaks in operative sterile technique favors SSI.
  - Poor operating room air quality (Contaminated ventilation) and
  - Colonized operating room instruments will favor SSI.
3. Surgical technique favoring SSI:
- Poor tissue handling.
  - Poor wound care postoperatively.
  - Incomplete removal of foreign bodies/ devitalized tissues from heavily contaminated wound.

### Incisional SSI

The incidence of wound infection depends on whether the wound was initially clean, clean – contaminated, contaminated or dirty as follows (Table 9.1).

#### Clinical Features

Fever usually begins or persists after the 4th postoperative day. Incisional SSI is suggested by erythema, swelling, drainage and increased local pain and tenderness.

Palpation of the wound may disclose an abscess.

#### Treatment

The basic treatment of wound infection is to open the wound and allowed to drain.

- For mild infection → only dressing change will suffice, no antibiotics.
- For clean wound → Cephalosporin like cefazolin 1 gm IV 8 hourly may be given.
- If infection is aggressive → treatment is to give a 3rd generation cephalosporin or a quinolone plus clindamycin or metronidazole or piperacillin – tazobactam alone.
- Invasive and necrotizing infection requires aggressive debridement. Antibiotics are stopped as soon as local inflammation and systemic signs of infection have resolved.

### Organ/Space SSI: Intra-abdominal Infections

Postoperative intra-abdominal infection may present in one of the two ways viz.

- a. Generalized peritonitis due to suture line dehiscence following GI surgery. This is a mixed infection (Polymicrobial) caused by *E. coli*, *Klebsiella*, *Proteus*, *S. faecalis* and *Bacteroides*.

#### Clinical features

Include pain, rigidity and absence of bowel sounds. Fever and leukocytosis are present and septic shock rapidly supervenes.

#### Treatment

Consists of IV fluids for resuscitation, elimination of the source of infection, e.g. laparotomy and closure of perforated viscus, removal of necrotic material and appropriate antibiotic therapy.

b. Intra-abdominal abscess—Intra-abdominal abscess can arise in the following groups of patients.

- Critically ill patients—Abscess due to failure of intraperitoneal host defences and gut barrier function with translocation of intraluminal bacteria into the peritoneal cavity (Tertiary peritonitis).
- Patients with acute abdominal conditions requiring emergency operations, e.g. trauma, perforated viscus. Severe gangrenous perforated appendicitis. These patients have a 6 to 10 percent risk of developing intraabdominal abscess.

#### Clinical Features

Include localized tenderness, intermittent fever and absent bowel sounds, 5 to 10 days after operation. In some instances, abscess is palpable abdominally or rectally (pelvic collection).

Patients with intra-abdominal abscess may develop signs of sepsis such as hypotension, hyperdynamic circulation respiratory distress and other features of multiple organ failure/systemic inflammatory response syndrome (SIRS).

#### Diagnosis

Confirmed by USG scanning and especially CT scan of abdomen. Both are usually performed successively. CT provides more detail information on the precise location and anatomy of the abscess cavity.

#### Treatment

CT guided drainage is now used as the first line of treatment in these patients, with surgery being reserved for large multiloculated abscess containing a large amount of slough.

### Urinary Tract Infection

- The commonest nosocomial infection is that of the urinary tract. It is commonly related to the presence of urethral catheters.
- Catheterization of the urinary bladder should be employed only when necessary and should be discontinued as soon as possible.
- A strict sterile technique should be observed during catheterization and a closed system is used for drainage.

#### Treatment

Culture of the urine and appropriate antibiotics therapy should be employed when infection occurs.

*Symptomatic bacteriuria*, i.e. Presence of  $10^5$  organisms per ml of urine. The most common organisms are *E. coli*, *pseudomonas* and coagulase –ve *Staphylococcus*. Common symptoms are dysuria, frequency and sometimes the onset of incontinence. Loin pain and tenderness are only found in case of severe infection. *Asymptomatic bacteriuria*: Treatment with appropriate antibiotic for one day after catheter removal. Culture of urine is done after 1 week, if bacteriuria persists, appropriate antibiotics are given for 7 to 10 days.

### Respiratory Tract Infection

Factors that predispose postoperative respiratory infection (RTI) include the following.

- Preexisting pulmonary disease, e.g. chronic obstructive airways disease.
- Smoking—Causes thick mucus production and ciliary dysfunction.
- General anesthesia or ventilation paralyzes respiratory epithelial ciliary activity.
- Postoperative pain—Makes deep breathing and coughing difficult and predisposes to atelectasis.

Common organisms causing the RTI are *S. pneumoniae* and *H. influenzae* in patients in previous good health and *E. coli*, *Pseudomonas*, *Klebsiella*, Anaerobic streptococci in patients with previous chronic chest disease. Pneumonia is suggested by increased WBC count, fever, purulent sputum and lung infiltrate.

#### Treatment

Appropriate antibiotics and supportive care. Physiotherapy is the key not only to the prevention but also to the management of many of these infections.

### Infection of Intravenous Access Site

All intravenous access devices like cannulas, catheters attract bacteria and can become infected. Common organisms are *S. aureus* and coagulase negative *S. epidermidis*.

Once the infected device is removed, the infection generally resolves, often without antibiotics.

Prevention of these infections can only be achieved by scrupulous attention to antisepsis, not only at the time of insertion of the cannula or catheter but also thereafter.

Prophylactic antibiotics are no substitute for asepsis and should not be used.

### Enteric Infections

Pseudomembranous enterocolitis is an infection caused by *Clostridium difficile*. It is seen in postoperative patients who have received antibiotics (cephalosporins, ampicillin, etc.) and is characterized diarrhea, abdominal discomfort, leukocytosis and the presence of a typical pseudomembrane in the colon. The infection develops because the antibiotics alter the normal gut flora, allowing the overgrowth of *C. difficile* which produces an enterotoxin responsible for most of the gut symptoms.

#### Treatment

Consists of withdrawing current antibiotics and giving oral vancomycin or metronidazole to which *C. difficile* is sensitive.

## SURGICAL INFECTIONS OF ABDOMEN

### Biliary Infections

Almost all cases occur with gallstones. Infections include acute cholecystitis, cholangitis, empyema and chronic cholecystitis. Uncomplicated gallstones are associated with a 30 to 50 percent incidence of positive bile cultures. The most important bacteria are *E. coli*, *Clostridia* and *Pseudomonas aeruginosa*.

Cholangitis following choledocholithiasis requires stone removal and T – tube drainage. Once the biliary system is drained and gallbladder removed, infection will resolve

without additional antibiotic therapy. In immunocompromised patients, 750 mg ciprofloxacin 12 hourly, or third generation cephalosporin is indicated.

### Hepatic Infections – Liver Abscess

A variety of agents can infect liver including bacteria, viruses, protozoa and helminths.

#### Liver Abscess

See also Liver (36) in section 9.

This may be due to echinococci, amoebas, salmonellae and mixed bacterial populations. The most common aerobic organisms are *E. coli*, *Klebsiella* and *enterococcus*, streptococci and *fusobacterium*.

From 75 to 90 percent of abscesses are found in the right lobe. Right lobe lesions are more likely to rupture intraperitoneally whereas left lobe lesions rupture into the pericardium or pleural space.

#### Diagnosis

The primary symptoms are fever, chills, anorexia, weight loss, abdominal pain and nausea. If suspected, it is readily diagnosed by USG or CT with contrast enhancement. CT is the most sensitive imaging modality. MRI offers no advantage over CT scanning.

### Acute Pancreatitis and Pancreatic Abscess

Acute pancreatitis begins as a chemical inflammation but about half of the related fatalities are due to infection.

Pancreatic abscess develops within necrotic pancreatic tissue and requires drainage. Staged abdominal repair (STAR) has been advocated for severe cases.

**Therapy**—Antibiotics include a 3rd generation cephalosporin alone or in combination with tazobactam.

### Acute Appendicitis

Acute appendicitis requires appendectomy. An antibiotic given prior to appendectomy is directed mainly to prophylaxis of infection in the wound and are not continued postoperatively. Therapeutic antibiotics are indicated if the disease has progressed to

an abscess or if diffuse peritonitis has developed. An abscess may be drained percutaneously with the help of USG or CT or may be drained by laparotomy. Obligate anaerobes are always present. *E. coli* may cause lethal septicemia.

A 3rd generation cephalosporin above or in combination with tazobactam and metronidazole 500 mg 12 hourly have been useful.

### Diverticulitis

Diverticulitis is common in the Western world. More than 50 percent of patients over the age of 50 have colonic diverticula. Diverticula can occur at anytime. Treatment is usually nonoperative (Bowel rest and antibiotics). Because of the anaerobic nature of the disease 500 mg metronidazole 12 hourly is the treatment of choice. If septicemia develops, a 3rd generation cephalosporin may be included.

### Peritonitis

Infective peritonitis may be primary or much more common secondary to some intra-abdominal process.

#### Primary Peritonitis

This is more common in children and women – in the latter, the contamination occurs via the fallopian tubes.

- Children with nephrotic syndrome or who have undergone splenectomy are more susceptible.
- Adults with ascites from liver disease like cirrhosis have increased incidence.

The route of entry of the organism into the peritoneal cavity cannot usually be determined but transmural spread as well as bloodstream spread has both been postulated.

#### Secondary Peritonitis

May occur following a variety of pathological conditions such as peptic ulcer perforation, pancreatitis, bowel ischemia due to strangulation or vascular compromise, large bowel perforations and perforation of any intra-abdominal abscess.

Treatment is operative. The source of infection must be closed or exteriorised and the abdominal cavity must be cleaned of



bacteria, toxins and adjuvants such as bile, mucus, blood and necrotic tissue – STAR (staged abdominal repair) may be required for severe and advanced cases.

### Postoperative or Tertiary Peritonitis

Starts from 15 to 20 percent of all intra-abdominal infections occur following operation. The diagnosis is usually delayed upto 7th postoperative day.

See also ‘The Peritoneum’ in section 10.

## SURGICAL INFECTIONS OF THORAX

### Lung Abscess and Empyema

They are considered together since empyema (pus in pleural cavity) results from lung infection (if not from a detectable abscess) and since the pathogens in lung abscess and empyema are similar.

- Common organisms are anaerobes viz. *Bacteroides*, anaerobic cocci and Fusobacteria.
- Location — More common on the right side than on the left.

### Clinical Features

Similar to those of chronic pneumonia like fever, cough, leukocytosis, pleuritic pain and sputum production. Chest X-ray and CT scan of chest may demonstrate a rounded area of consolidation early and an air – fluid level on upright decubitus.

**Therapy**—includes open drainage and antibiotic therapy for anaerobic coverage with metronidazole. Although antibiotics (Amoxicillin + Metronidazole) help resolution of lung abscess, they confer no benefit in the treatment of empyema.

### Mediastinitis

This infection carries a high mortality. Most commonly it is seen following esophageal resection, perforation and penetrating trauma.

**Therapy**—Adequate drainage and antimicrobials fully active against gm<sup>-ve</sup> organisms and obligate anaerobes. Cefotaxime in combination with metronidazole will cover most pathogenic bacteria.

## PATHOGENS IN SURGICAL INFECTION

### Gram+ve Cocci

The cocci are dot shaped cells

- Gram +ve cocci of importance to surgeons include staphylococci and streptococci.
- Staphylococci (cells in clusters):
  - i. Presence of coagulase enzyme is the virulence factor.
  - ii. Coagulase positive staphylococci (*S. aureus*) are most commonly associated with exogenous wound infection.
  - iii. Coagulase negative is the skin flora, the conditional pathogen called *S. epidermidis*.
- Streptococci (chains/pairs): Aerobic and facultative an aerobic streptococci: virulence is determined by the ability to lyse red blood cells, e.g.
  - i. Alpha hemolytic streptococci—Produce partial lysis of RBCs, called *S. viridans*.
  - ii. Beta hemolytic streptococci cause complete lysis of RBCs. Lancefield group A beta hemolytic streptococci is called *streptococcus pyogenes*.
  - iii. Gamma hemolysis—No lysis of RBC, e.g. *S. faecalis*.
- Anaerobic streptococci, e.g.
  - i. Gut flora, e.g. peptococci
  - ii. *Enterococcus faecalis*.

### Gram –ve Cocci

- *N. meningitidis* (Meningococcus)—Causes meningitis and septicemia.
- *N. gonorrhoeae* (Gonococcus)—Causes gonorrhoeae.

### Aerobic and facultative anerobic Gram Negative Bacilli

– The bacilli are rod shaped cells.

A variety of gram –ve bacilli are associated with surgical infections, most fall into the family Enterobacteriaceae.

Facultative anaerobic bacilli include *E. coli*, *proteus* and *klebsiella* while obligate aerobes are pseudomonas and Acinebacter, organisms most commonly found in

nosocomial pneumonias as well as in severe soft tissue and intraabdominal infections.

### Anaerobic Bacilli

- The most common anaerobes from surgical infections is *Bacteroides fragilis*, while the other one is clostridium, the spore bearing gm +ve rod.
- Anaerobic bacteremia should always prompt a search for an abscess or enteric lesion that requires surgical intervention.

## ANTIBIOTICS

Antibiotics are used in the treatment and prophylaxis of surgical infections.

### Mode of Action

A. Bactericidal, e.g. Beta lactams (like penicillin, ampicillin, cephalosporins), vancomycin, aminoglycosides, etc.

Indications

- Life-threatening sepsis.
- Opportunistic infections in immunocompromised hosts.
- Infective endocarditis.

B. Bacteriostatic, e.g. tetracyclin macrolides, chloramphenicol, etc.

### Penicillin

Various penicillins have been combined with one of the beta lactamase inhibitors viz. clavulanic acid, sulbactam or tazobactam, to extend the activity of amoxicillin and other penicillins.

### Carbapenems

They are semisynthetic β-lactams and include imipenem and meropenem. They act by inhibiting bacterial cell wall synthesis, like penicillin.

### Cephalosporins

They are chemically related to penicillins.

The various cephalosporins with their activity and use are given below in Table 9.2

### Aminoglycosides

Acts by interrupting bacterial protein synthesis by inhibiting ribosomal function (m and tRNA), e.g. streptomycin gentamicin

or tobramycin. They are polycationic compounds of amino sugars.

### Quinolones

Ciprofloxacin, norfloxacin, ofloxacin and levofloxacin are oral broad spectrum antibiotics related structurally to nalidixic acid. They act by inhibiting bacterial DNA synthesis by inhibiting topoisomerase IV and DNA gyrase, and bactericidal in nature.

### Tetracyclines

They inhibit bacterial protein synthesis by interrupting ribosomal function (tRNA). Their use is now limited partly owing to increasing bacterial resistance. Members are oxytetracycline, doxycycline, demeclocycline and minocycline.

### Macrolides

For example erythromycin, clarithromycin, roxithromycin and azithromycin.

### Oxazolidinones

For example linezolid, effective in a variety of hospitalized patients with severe to

life-threatening infections, e.g. Bacteremia, skin and soft tissue infections, nosocomial pneumonia, etc.

### Nitroimidazoles

The most widely used drug is metronidazole. Others include tinidazole and nimorazole. Major use is in anaerobic bacterial infections, also used prophylactically in colonic surgery. It is the treatment of choice for amebiasis, giardiasis and infection with *Trichomonas vaginalis*.

### ANTIBIOTIC POLICY

- Antibiotics are avoided in self-limiting infections.
- Choice is made according to the nature and sensitivity of the infecting organisms.
- Single agent therapy is preferred to combination therapy and narrow spectrum agents preferred to broad spectrum agents whenever possible.
- Adequate doses are given by correct route and at correct time intervals.
- Antibiotics used systemically must not be used topically.

- Antibiotics are not used to treat abscesses unless adequately drained with a few exceptions like lung abscess.
- Body fluids of patients receiving antibiotics disposed off carefully to avoid development of antibiotics resistance.

### Prophylactic Use of Antibiotics

Ever since antibiotics become available they have been used to prevent infection in surgical practice. A number of well-designed trials have established that antibiotics prophylaxis is justified and it should be short – often a single dose will suffice.

Most prophylactic antibiotics used in surgery are given to prevent wound infection and not to prevent other infectious sequelae of the operation such as respiratory or urinary tract infections.

### Indications

The use of newer wide-spectrum antibiotics for prophylaxis should be avoided. The following Table 9.3 gives some examples of prophylaxis which can be used in elective surgical operations.

**Table 9.2: Various cephalosporins with their activity and use**

	Activity	Use
<b>1st generation</b> • Cephalexin • Cefaclor • Cefadroxil	Gram +ve cocci and Gram –ve organisms.	Urinary tract infection Penicillins allergy
} Oral		
<b>2nd generation</b> • Cefuroxime (Oral and parenteral) • Cefoxitin • Cefamandole	Extended spectrum. More effective than first generation against <i>E. coli</i> , <i>Klebsiella</i> and <i>Proteus</i> but less effective against gram +ve organisms	Prophylaxis and treatment of gram –ve infection and mixed aerobic and anaerobic infections
<b>3rd generation</b> • Cefotaxime • Ceftriaxone • Ceftazidime • Cefpirome • Cefixime • Cefpodoxime	Broad spectrum more potent, against gram –ve bacteria than 1st or 2nd generation.	Especially severe infection Enterobacteriaceae and <i>Pseudomonas</i>
} Oral		



**Table 9.3: Use of prophylactic antibiotics in various elective surgical operations**

Type of surgery	Organisms encountered	Prophylactic regimen suggested
1. Vascular	<ul style="list-style-type: none"> <li>• <i>S. epidermidis</i> or MRCNS (Multiply resistant coagulase -ve staph)</li> <li>• <i>S. aureus</i> or MRSA</li> <li>• Aerobic gram -ve bacilli (AGNB)</li> </ul>	Three doses of flucloxacillin with or without gentamicin
2. Orthopedics (Amputation, etc.)	<i>S. epidermidis/aureus</i>	One to three doses of a wide spectrum cephalosporin
3. Esophagogastric	<ul style="list-style-type: none"> <li>• Enterobacteriaceae</li> <li>• Enterococci (including anaerobic/viridans streptococci)</li> </ul>	One to three doses of 2nd generation cephalosporin and metronidazole in severe contamination.
4. Biliary	<ul style="list-style-type: none"> <li>• Enterobacteriaceae mainly <i>E. coli</i></li> <li>• Enterococci including <i>S. faecalis</i></li> </ul>	One dose of a 2nd generation cephalosporin.
5. Small bowel	<ul style="list-style-type: none"> <li>• Enterobacteriaceae</li> <li>• Anaerobes (mainly <i>bacteroides</i>)</li> </ul>	One to three doses of 2nd generation cephalosporin with or without metronidazole.
6. Appendix/Colorectal	<ul style="list-style-type: none"> <li>• Enterobacteriaceae</li> <li>• Anaerobes (mainly <i>bacteroides</i>)</li> </ul>	Three doses of a 2nd generation cephalosporin or gentamicin with metronidazole.

# Chapter 10

## Burns

- Definition
- Classification of Burns
- Pathophysiology
- Systemic effects of burn
- Treatment
- Other types of burn injury
- Complications of burn injury
- Post burn contracture

### DEFINITION

A burn injury is a coagulative type of necrosis of varying depth of skin and deeper tissues.

### CLASSIFICATION OF BURNS

#### According to Agent

- Thermal burn (90%) — The injuries are named burns or scalds according to the type of heat. Dry heat like flames, fire, bomb injuries cause burns. Scalds are due to hot liquids.
- Others (10%)
  - Chemical burn—Due to any strong acid or alkali.
  - Electrical burn—May be caused by high voltage or low voltage current.
  - Radiation burn—Due to X-rays or radium. This occurs when tissue has been irradiated beyond tolerance limit.

#### According to Depth

- Superficial or partial thickness burn
  - 1st degree—It involves only the epidermis.
  - 2nd degree—The depth of involvement is epidermis and superficial dermis upto the reticular layer (Fig. 10.1).
- Deep or Full thickness burn
  - 3rd degree—It involves the epidermis as well as full thickness of dermis.

4th degree—It extends beyond the skin into deeper tissues like the muscles, bone, etc.

#### According to Severity

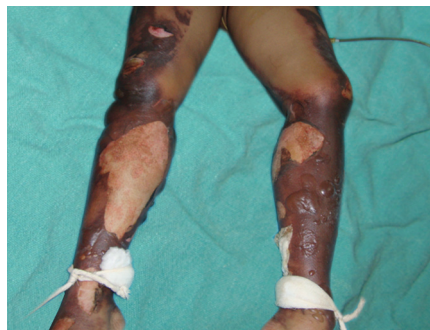- Minor burn—It is partial thickness burn <15 percent in adults, or <10 percent in children.  
Full thickness or deep burn <2 percent.  
These patients can be treated on outpatient basis.
- Major burns— These are.
  - Partial thickness burns >15 percent in adults or 10 percent in children.
  - All deep burns more than 2 percent.
  - All inhalation and electrical burns.
  - Burns with fractures or major mechanical trauma.
  - Burns involving eyes, ears, feet, hands and perineum (Fig. 10.2).

*Estimation of the extent of burn* — It is calculated by the rule of 9, also called the Rule of Wallace (Fig. 10.3).

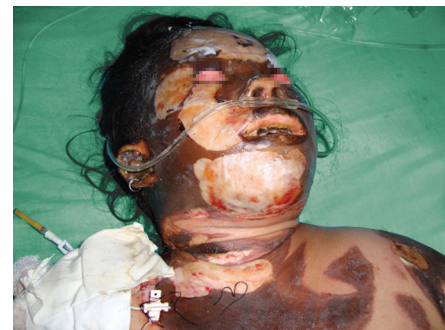Patients own hand represents 1 percent of his total body surface area (TBSA).

The calculations are:

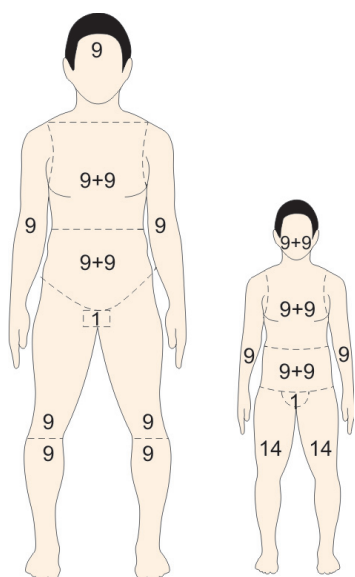
- In adults— Burns of head and neck 9 percent, each superior extremity 9 percent, each inferior extremity 9 percent  $\times 2$ ,  
Front of trunk 9 percent  $\times 2$ , Back of trunk 9 percent  $\times 2$ , and genitalia 1 percent.
- In children— Surface area of head and neck is proportionality larger than that of adult, and that inferior extremity is proportionately smaller. Hence, the formula is modified as follows:
  - Each inferior extremity 14 percent, each superior extremity 9 percent, front



**Fig. 10.1:** Second degree burn with blisters



**Fig. 10.2:** Major burn involving head, neck, face and upper chest



**Fig. 10.3:** Rule of 9 applied to the adult and child.

and back trunk each 18 percent, Head and neck 9 percent  $\times 2$ .

### Assessment of the Depth of Burn

Depth of burn wound can be estimated by the following:

#### History

The first indication of burn depth comes from the history as described below.

- Scald — Superficial burn, but will be deep in a young infant.
- Flame burns — Full thickness burn.
- Alkali burns — Full thickness burn.
- Electrical contact burn — Full thickness burn.
- Acid burns — Weak concentration will cause superficial and strong concentrations, full thickness burn.

The burning of human skin is temperature and time dependent, e.g. exposure to a surface temperature of 70°C for only 1 second is needed to produce epidermal destruction. Exposure to hot water at 65°C for 45 seconds will produce a full thickness burn, for 10 seconds will produce a partial thickness burn.

#### Pin-prick Test

Superficial burn is painful on pin-pricking, whereas full thickness is not. But the test is valuable if it is done within 2-3 hours of post-

burn period; otherwise edema will obscure the findings.

#### By Detecting Physical Changes like Edema by MRI

The estimation of the extent and depth of burn is valuable for the following reasons.

- Resuscitation therapy including necessity for blood transfusion. For more than 40 percent burn about 20 percent of the blood volume should be given as blood in the first 12 hours and between 20-40 percent burn blood transfusion is optional.
- Assessment of burn shock.
- Evaluation of surgical procedures in the postburn period.
- Prevention of infection.

### PATHOPHYSIOLOGY

#### Burn Shock

As burn injury is a type of coagulative necrosis important changes occur over the burnt area.

- There is dilatation of small vessels due to direct injury to the vessel wall which leads to the release of various inflammatory mediators following stimulation of a web of inflammatory proteolytic cascades. Viz. the compliment, kinin and the coagulation system.
- Associated with this dilatation, there is a greatly increased permeability of the injured capillaries. Due to this there is escape of fluid rich in protein and electrolytes especially sodium into tissue spaces causing edema.

This exudative fluid collects in blisters or begins to dry to form a dry brown crust which protects the wound.

The extensive loss of fluid is an important factor in producing the burns shock. The volume loss is greatest in the first 8 hours, and then gradually returns to normal by 24-48 hours.

The various factors which add to the gravity of burn shock which is mainly hypovolemic are as below:

- Neurogenic factor, caused by severe pain.
- Psychogenic resulting from the horror of burning.
- Release of toxic metabolic products from the burnt area.

- Tissue anoxia and metabolic acidosis secondary to the fall of blood pressure.
- Sepsis — Eschar of burn wound acts as a good culture media for bacterial growth. Both gm positive and gm negative bacteria are found. Common organisms are *Staphylococcus aureus*, *Psuedomonas aeruginosa*, *B Proteus*, *E. coli*. In early postburn period upto the first week, there is preponderance of gm positive organisms like *S. aureus*, whereas in subsequent weeks, gm negative organisms take the upper hand. In the postburn period uncontrolled infection leads to the condition known as septic or endotoxic shock.

### SYSTEMIC EFFECTS OF BURN

- Burn injury is progressive in nature, causing various local and systemic effects.

Systemic inflammatory response syndrome (SIRS) along with presence of infection increases morbidity and mortality.

It may also lead to multiorgan dysfunction syndrome (MODS).

- On a cellular level, complement causes degranulation of mast cells and coats the proteins, altered by the burn. This attracts neutrophils, which also degranulate with the release of large quantities of *free radicals and proteases*. These can in turn cause further damage to the tissues.

Mast cells also release primary cytokines such as TNF-alpha. These act as chemotactic agents to inflammatory cells and cause the subsequent release of many secondary cytokines.

In a small burn, the inflammatory reaction is small and localized, but once the burnt area involves 25 percent of TBSA (Total Body Surface Area), the inflammatory reaction causes fluid loss in vessels, remote from the burn injury.

- Organ changes:
  - Liver* — In majority of cases of burn liver necrosis can be detected.
  - Kidney* is often involved due to low blood perfusion. There may be renal tubular damage.
  - Adrenals* — Become slightly enlarged and deeply congested. In severe cases, there may be bilateral necrosis of adrenal cortex due to thrombosis.

- d. *Gastrointestinal tract*—Acute ulceration of the stomach and duodenum called Curling’s ulcer has been noticed as a complication of major thermal injury. Such ulcers are prone to cause gastrointestinal bleeding. Decreased blood flow to intestine cause’s focal necrosis and bacterial translocation.
- e. *Multiple endocrine aberrations lead to hypermetabolism.* There is elevated glucagon, cortisol and catecholamines. Insulin and T<sub>3</sub> hormone levels are depressed.
- f. *Neurogenic changes* in the form of delirium and disorientation are seen due to less blood flow to the brain and electrolyte imbalance.
- g. *Immunologic impairment* — Cell mediated immunity is significantly reduced in large burns, leaving the victims more susceptible to bacterial and fungal infections. The cellular immunity is depressed by burn related byproducts and mediators.
- h. *Pulmonary function* — There may be hyperventilation and pulmonary insufficiency so much so that it may require mechanical ventilatory support.

managed in the burn centers, minor burns are usually managed in the outpatient department.

The need for intravenous fluids is also determined by these criteria.

Children with more than 10 percent burns and adults with more than 20 percent burns usually require IV fluids.

The treatment of burned patient is conveniently described under three headings viz.

1. Treatment of burn shock
2. Local treatment of burn wound
3. General and additional aspects of treating the burned patient.

**Treatment of Burn Shock**

*(i) Fluid resuscitation:* This is the mainstay of management in burns and is vital for preserving organ function.

- Venous access is best obtained with IV catheters or venflons using veins in unburned skin.
- Lactated Ringer’s solution without dextrose is the fluid of choice except in children younger than 2 years; who should receive 5 percent dextrose and Ringer lactate.
- The amount of fluid necessary to maintain adequate perfusion is easily monitored in burned patients with normal renal functions by following the volume of urine output, which should be at least 0.5 ml/kg/hour in adults and 1ml/Kg/hour in children.
- In the first 24 hours, the fluid administered is divided into two equal portions, half of the requirement being given in the first 8 hours following burn injury and the rest in the next 16 hours. This is because capillary permeability is maximum in the initial 8 hours. After the first

24 hours, capillary permeability improves, thereby reducing the subsequent fluid requirement.

- The fluids can be administered according to various formulae given below. (Table 10.1)

The fluid estimate for adults varies from 2-4 ml/kg/percent of burn. Some studies recommend that the amount be only 2 ml/kg/percent burn as this minimizes fluid overload. In children the recommended amount is 3 ml/kg/percent burn as they have a larger body surface area.

*(ii) Sedation and analgesia:* This is accomplished with intravenous opiates. Intramuscular injection should not be given as absorption is unpredictable and dangerous.

Powerful short acting analgesia should be administered before dressing changes.

*(iii) Maintenance of airway:* Airway injury must be suspected with facial burns, carbonaceous sputum and tachypnea.

**Local Treatment of Burn Wound**

- a. *Escharotomy and fasciotomy:* When full thickness burn wounds encompass the circumference of an extremity, peripheral circulation to the limb can be compromised. Clinical sings are cyanosis, impaired capillary refill and deep muscle pain. Arterial flow can be assessed by determination of Doppler signals.
  - Compromised extremities require escharotomies which are release incisions made with a scalpel or electrocautery unit at the bedside over the lateral and medial aspects of the extremity.

**TREATMENT**

The principles of treatment of acute burn injury are the same as any acute trauma case.

*Criteria for Hospital Admission of Burn Patients*

All patients with major burns as described above have to be hospitalized and are best

**Table 10.1: The different formulae for fluid resuscitation in a burn patient.**

	First 24 hours	Second 24 hours
<i>Formula</i>	<i>Crystalloid, e.g. Ringer lactate, normal saline, etc.- colloid- 5 percent glucose</i>	<i>Crystalloid-colloid-5 percent glucose</i>
Parkland	Ringer’s lactate – 4 ml/kg/% burn. No colloid or 5 percent glucose.	Estimation of plasma deficit is 0.3-0.5 ml/kg/% burn, 20-60 percent of calculated plasma volume replaced by colloids – 5 percent glucose is administered as required maintaining adequate urinary output.No crystalloid.
Brooke	Ringer’s lactate – 01.5 ml/kg/% burn, colloid - 0.5 ml/kg/%burn and 5 percent glucose-2000 ml.	Crystalloid-½ to ¾ of first 24 hours requirement – colloid-½ - ¾ of first 24 hrs requirement and 5 percent glucose 2000 ml.
Evans	Normal saline – 1 ml/kg/% burn, colloid-1 ml/kg/% burn and 5 percent glucose- 2000 ml.	Crystalloid-½ of first 24 hours requirement, colloid – ½ of first 24 hours requirement and 5 percent glucose-2000 ml.

- Increased muscle compartment pressures may necessitate fasciotomies.
- b. Burn wound excision:  
Burn wounds of full thickness and deep partial thickness should be excised as soon as possible with a scalpel. The excision should be restricted to less than 20 percent of total body surface area, and 2 hours operating time, as the blood loss can be considerable. The advantages are reduced infection rate, less hospital stay, and reduced stress response to the burn in burns over 40 percent .
- c. Wound closure:  
By closure wound desiccation and evaporative losses are minimized. The pain and protein loss get reduced and exposed vessels, tendons and nerves are protected.  
This can be done by various methods
  - i. Autografts are preferred. Thickness should be 0.012 to 0.015 inches. If donor sites are few due to extensive burns, then meshing of the graft is done to increase its size.
  - ii. In the absence of autografts, other alternatives are cadaveric cutaneous allograft, cutaneous xenograft, synthetic membranes like Biobrane and culture derived epidermal sheets.
- Release of myoglobin due to damage of the muscles can cause renal tubular damage and renal failure.
- Mannitol is used to prevent myoglobin induced renal damage.
- Electrical injuries are divided into low and high voltage injuries, the threshold being 1000V.
- Low voltage injuries cause small localized deep burns. They can cause cardiac arrest through normal pacing interruption without significant direct myocardial damage.
- High voltage injuries cause damage by flash (external burn) and conduction (internal burn). Myocardium may be directly damaged without pacing interruption.

### Chemical Injury

- These burns occur by strong acid or alkalis which produce burns as long as the contact continues.

The severity depends on the amount and concentration of the agent and the period of contact. There may be superficial or deep burns.

Alkalies are usually the more destructive and especially dangerous if they come in contact with the eyes.

- The initial management of any chemical injury is copious lavage with water. The only exception is phenol burns where water may accelerate absorption. So, burn caused by phenol is washed with polyethylene glycol or glycerol to remove residual phenol.
- In case of extensive tissue damage in chemical burns early excision and skin grafting should be done.

### Ionizing Radiation Injury

These injuries can be divided into two groups — localized injury which is much more common and whole body radiation injury.

Whole body irradiation may be lethal or nonlethal depending on the dose of irradiation. When it is lethal there is acute desquamation of the skin leading to a particularly slow and unpleasant death.

In nonlethal radiation injury, there is immune system dysfunction and damage to the gut mucosa. Management of these injuries is mainly supportive.

### Cold Injuries

Cold injuries are mainly of two types viz.

- a. Injuries from industrial accidents.
- b. Frost bite.

*Cold injuries from industrial accident* may occur from exposure to liquid nitrogen or other such liquids which will cause epidermal and dermal destruction.

It is to be remembered that the human tissue is more resistant to cold injury than to heat injury.

*Frost bite* – This mainly affect the extremities exposed to very cold object or climate.

The initial treatment is rapid rewarming in a bath at 42°C. Surgery is usually not required.

## COMPLICATIONS OF BURN INJURY

### Early Complications

#### A. General

- a. Gastrointestinal system
  - Curling's ulcer, gastric hemorrhage.
  - Acute pancreatitis in about 30 percent cases of extensive burns.
- b. Respiratory tract—Pneumonia, Pulmonary edema, ARDS (Adult Respiratory Distress Syndrome).
- c. Acute renal failure, hematuria.
- d. Anemia, bone — Marrow depression.
- e. Toxemia, septicemia, pyemia.
- f. Psychosis, loss of morale.

#### B. Local complications — Eschar formation, gangrene.

### Late Complications

- a. Keloids and hypertrophic scar.
- b. Contractures and deformities.
- c. Marjolin's ulcer, a slowly growing squamous cell carcinoma arising from scars.

## POSTBURN CONTRACTURE

This occurs with full thickness burns, usually on the flexor surfaces of joints, following defective management (Figs 10.4A and B).

### Prevention

- a. Prevention of infection — Infection not only delays healing but also adds to additional scar formation.

## General and Additional Aspects of Burn Care

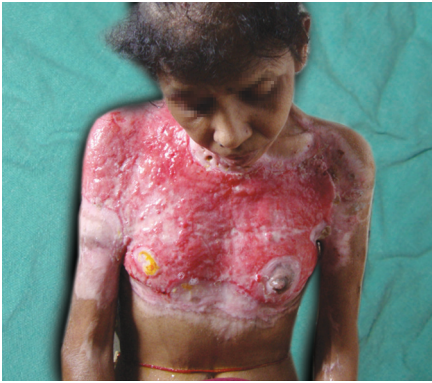- i. Nasogastric suction to treat ileus which is usually present in burns over 25 percent TBSA.
- ii. Tetanus prophylaxis is administered based on the previous immune status of the individual.
- iii. Routine antibiotics as a prophylactic measure against infection.
- iv. Intravenous H<sub>2</sub> blocker is given as a prophylactic measure against stress ulcerations.

## OTHER TYPES OF BURN INJURY

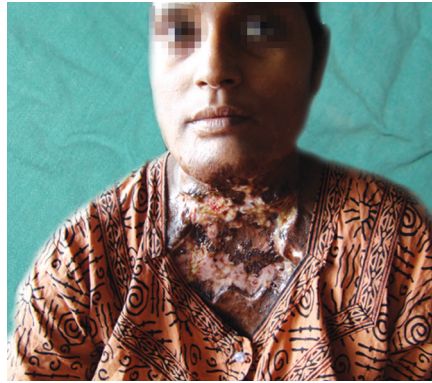### Electrical Burn

- It is always a deep burn and needs hospitalization.
- There is a wound of entry and wound of exit.





**Fig. 10.4A:** Postburn contracture of the neck (Recent)



**Fig. 10.4B:** Postburn contracture of neck (Old)

- b. Adequate splintage of the limb in extension during the process of healing.
- c. Early skin grafting — A full thickness burn can rarely heal by itself and requires skin grafting. Delay in grafting promotes excessive scarring and development of contractures.

### Treatment

The scar tissue has to be totally excised, releasing all tensions on the surrounding tissues. The raw area is grafted with skin. Different plastic procedures (e.g. Z-plasty, V-Y plasty) are available to minimize loss of skin.



# Chapter 11

## Keloid and Hypertrophic Scar

➤ Hypertrophic scar

➤ Keloid

### HYPERTROPHIC SCAR

#### Definition

It is a type of scar characterized by hypertrophy or proliferation of mature fibroblast or fibrous tissue without proliferation of blood vessels.

#### Predisposing Factor

Excessive tension on suture line or infection during healing.

#### Clinical Features

- The scar is raised above the surface.
- Does not encroach the normal skin and
- No claw-like processes, increased vascularity, itching or spread.
- It may regress gradually after 6 months.
- It does not recur after excision if the causative factors are eliminated. Stocking, armlets, elastic bandage may help.

### KELOID

#### Definition

This is a clinical condition characterized by proliferation of immature fibroblasts, collagen fibrils and immature blood vessels, on the top of a scar caused by a pin-prick, burn or incision.

It is usually associated with itching, oozing and blanching.

#### Predisposing Factors

1. Pin-prick, burn or incision scar as mentioned above.
2. Males are affected more than females.
3. Familial diathesis.
4. Hereditary influence.
5. Immunological factor — Patients suffering from tuberculosis are more prone to suffer from keloid.

#### Common Sites

- Over the sternum.
- Vaccination sites.
- Ear lobe (Figs. 11.1A and B).
- Neck.
- Joint surface.

#### Pathology

During wound healing (incision, burn, etc.)

↓  
Tension or infection

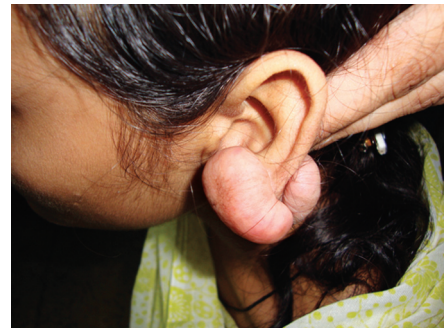↓  
Irritation of mesenchymal cells at the base of the sebaceous and sweat glands

↓  
Immature fibroblasts, blood vessels and collagen fibrils proliferate in the subpapillary layer of the dermis (corium)

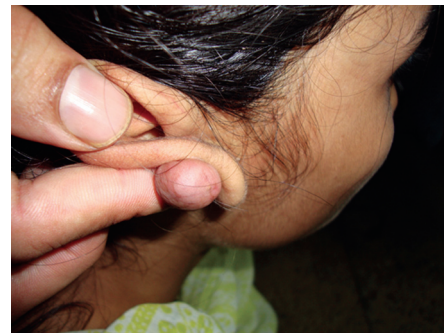↓  
Majority of the cells proliferate in claw-like processes to the surrounding tissue, hence the name keloid (Keloid from Greek chele meaning 'Crab's Claw')

#### Types

1. Spontaneous variety
2. Acquired variety – No history of injury is there.



**Fig. 11.1A:** Keloid of left pinna following repeated ear piercing



**Fig. 11.1B:** Keloid of right pinna of the same patient due to ear piercing.

**Diagnosis**

- The swelling is raised from the surface.
- Lobulated and firm in feel.
- Itching and oozing from the surface.
- Presence of claw-like processes.
- Bluish or pinkish in color.

**Complications**

Cosmetically ugly looking, infection, ulceration, recurrence and malignant change, e.g. Marjolin's ulcer (some authorities believe that keloids never undergo malignant change).

**Treatment**

The following treatment can be adopted:

1. *Excisional Surgery*

This is done in case of single posttraumatic keloid in patients who have no family history.

- These lesions can be safely excised intra or extralesional, followed by approximation of the margins of the wound or application of skin graft.

- Postoperative pressure therapy by the use of custom tailored

pressure garments helps in averting a recurrence.

**Precaution**

Multiple keloids and lesions in keloid prone individuals should never be excised as a recurrence is inevitable.

2. *Excisional Surgery and Radiotherapy*

In keloids of ear lobules excision followed by DXRT (Deep X-ray therapy) proves good over time.

3. Intralesional Triamcinolone injection (5 to 10 mg biweekly upto 10 injections) produces good results.

# Chapter 12

## Tumors of the Skin

- Classification
- Papilloma
- Basal cell carcinoma
- Squamous cell carcinoma
- Melanoma
- Marjolin's ulcer
- Hemangioma
- Lipoma
- Neurofibroma
- von Recklinghausen's disease
- Plexiform neurofibromatosis
- Cutaneous neurofibromatosis

Structurally skin has two different layers –the epidermis and the dermis. Histologically epidermis is composed of several layers viz. stratum corneum or horny layer, stratum lucidum, stratum granulosum (Granular cell layer), stratum spinosum or Malpighi or Prickle cell layer and stratum basale from superficial to deep, (Fig. 12.1).

Basically there are three types of cells viz. keratinocyte, melanocytes, and Langerhans cells.

*Keratinocytes* are arranged in several layers of polygonal cells forming the stratum spinosum.

*Melanocytes* are situated at the junction of epidermis and dermis and derived from the neural crest cells. These cells are responsible for the synthesis of the pigment, melanin.

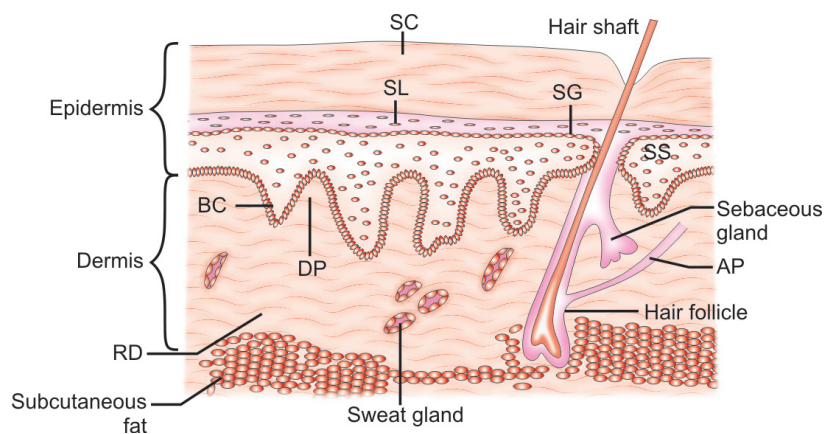
*Langerhans* cells or dendritic cells of Langerhans belong to the mononuclear phagocytic system and are located in the stratum spinosum.

The dermis comprises of papillary dermis and reticular dermis. It contains sweat glands, sebaceous glands and hair follicles. It also contains blood vessels in fine plexuses, intricate network of nerve fibers and sensory nerve endings for pain, touch and temperature. The sebaceous glands secrete sebum which keeps skin soft.

### CLASSIFICATION

The different tumors that arise from the skin are as follows:

1. From epidermis
  - i. Benign — Squamous cell papilloma.
  - ii. Malignant
    - Basal cell carcinoma.
    - Squamous cell carcinoma.
    - Malignant melanoma.
2. From dermis — All the tissue elements of dermis such as fibrous tissue, neural tissue, histocytes, endothelium, adipose tissue and smooth muscle, etc. are capable of transforming into benign and malignant tumors.
  - i. Melanocytes –
    - a. Benign — Nevus.
    - b. Malignant — Malignant melanoma.
  - ii. Histiocytes – Histiocytoma, malignant fibrous histiocytoma (MFH).



**Fig. 12.1:** Section through the skin SC – Stratum Corneum, SL – Stratum Lucidum, SG – Stratum Granulosum, SS – Stratum Spinosum, BC – Basal Cell layer, DP – Dermal Papilla AP – Arrector pili muscle, RD – Reticular dermis

- iii. Peripheral nerves – Neurofibroma, neurofibrosarcoma.
- iv. Adipose tissue – Lipoma, liposarcoma.
- v. Fibrous tissue – Fibroma, fibrosarcoma, etc.
- vi. Tumors of dermal appendages:
  - a. From sweat glands (Eccrine tumors, apocrine tumors, sweat gland carcinoma).
  - b. From sebaceous glands (Sebaceous adenoma and carcinoma).
  - c. From hair follicles (Trichoepithelioma, Trichofolliculoma).

### Tumor-Like Conditions

1. Verrucae (viral wart).
2. Seborrheic keratosis or senile wart.
3. Keratoacanthoma.
4. Actinic keratosis.

### Premalignant Conditions of Skin

1. Solar keratosis – It is the common variety of squamous cell carcinoma *in situ* in sun exposed areas of fair skinned elderly adults. The epidermis shows hyperkeratosis (Thickening of horny layer), acanthosis (Hyperplasia of stratum Malpighi) and dyskeratosis (Dysplastic cells in stratum Malpighi). Squamous cell carcinoma may arise in 20 percent. It may give rise to horn formation.
2. Bowen's disease is the common variety of squamous cell carcinoma *in situ* involving whole thickness of epidermis.

### Etiology

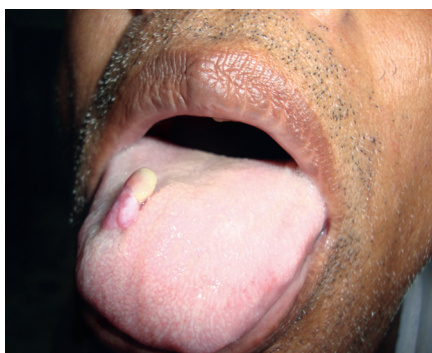Skin exposure to sunlight or arsenic ingestion. Grossly, there is irregular erythematous patch with sharp outline and scaling or crusting. On the penis, it is called erythroplasia of Queyrat.

Squamous cell carcinoma develops in 10 percent of cases.

### PAPILLOMA

A papilloma is a benign epithelial neoplasm producing microscopically or macroscopically visible finger-like or warty projections from epithelial surfaces ((Fig. 12.2).

It may arise either from epidermis or from mucous membrane and always contains a core of connective tissue element with blood vessels and lymphatics. The various examples are:



**Fig. 12.2:** Papilloma of tongue

- i. From the skin — Papilloma of the skin.
- ii. From mucous membrane –
  - a. Squamous cell type — Tongue, mouth, esophagus, vagina.
  - b. Transitional cell type — Bladder, pelvis of ureter, etc.
  - c. Columnar cell type — Colon and rectum (commonest), stomach, small intestine, etc.
- iii. From the wall of the duct, e.g. Breast.
- iv. From the wall of the cyst, e.g. ovary.

### Papilloma of The Skin

A cutaneous papilloma may be either of the following two types viz.

1. Squamous cell type
2. Basal cell type.

### Squamous Cell Papilloma

There are four varieties of such papilloma:

- a. Congenital papilloma — Single or multiple, seen at or immediately after birth.
- b. Infective papilloma or infective wart (*verruca vulgaris*) — It is the common papilloma which probably arises from virus infection.

Infective wart may regress by itself but may recur after removal. When it occurs in the sole of the foot (plantar wart) it may be difficult to differentiate from a corn (Localized hyperkeratosis of the skin).

- c. Soft papilloma — Which is often seen on the eyelids of elderly people.
- d. Keratin horns, also seen in the elderly people, are due to excess keratin formation.

### Basal Cell Papilloma

(Syn— Seborrheic wart or senile wart).

These commonly occur on the face, trunk, arms and arm pits.

The lesion is present for months or years. They may suddenly fall off uncovering a pale pink patch of skin.

The size varies from a few millimeters to 2 cm.

### Treatment

Papillomas are usually excised for cosmetic reasons. In case of plantar wart.

- i. Socks may be changed to cotton variety.
- ii. Application of formaldehyde at nights on the wart may cure the condition.
- iii. Excision or curettage should be carried out if the above measures fail.

### BASAL CELL CARCINOMA

#### Introduction

Basal cell carcinoma (BCC) is a locally malignant condition arising from the basal cell layer of the epidermis also called *rodent ulcer* because it burrows deep like a rat. Another nomenclature is tear cancer because it is commonly found along the region on the face when *tears* roll down.

#### Pathology

- a. *Microscopic* — The lesion consists of uniform cells with no prickle cells or Keratin. The stromal components are composed of inflammatory cells and benign fibrovascular tissue.
- b. *Macroscopic* — Pearly gray papule with telangiectasia and subsequent *ulceration*.
- c. *Etiology* — Mostly occur on sun exposed skin, especially face, or after arsenic exposure. It also occurs in two rare inherited disorders viz Xeroderma pigmentosa and basal cell nevus syndrome.
- d. *Prognosis* — May infiltrate deeply but rarely metastasize.

#### Characteristics of Rodent Ulcer

- Edge of the ulcer — Raised and rounded but not everted — Initially circular but as the growth spreads, the shape becomes irregular.
- Floor — First superficial, then deep and even proceeds upto bone.
- Base of the ulcer – This is indurated but less pronounced or barely perceptible and may be fixed to the deeper structures.

## Treatment

1. Surgery and radiotherapy – The lesion can either be treated with radiotherapy or by excision.

### Contraindications to radiotherapy:

- Adherence to bone or cartilage (because of subsequent necrosis).
- Lesions very close to eye.

Excision should be done with a clear healthy margin of 3-5 mm or more around the lesion.

2. Other methods:
  - a. Curettage followed by diathermy.
  - b. Cryosurgery.
 

Disadvantage of the above methods – Destruction of more tissues and delayed healing, provides no diagnosis.
  - c. Local chemotherapy – with 5 Fu cream, especially in case of flatter lesions. It is a simple and safe procedure.
  - d. Laser beam destruction.

- d. Lupus vulgaris (a type of skin tuberculosis).
- e. Xeroderma pigmentosa.
- f. Chronic ulcer, e.g. Marjolin's ulcer .
- g. Radiation dermatitis.
- h. Prolonged contact with hydrocarbons, e.g. tar, shoot, dyes, etc.

## Sites

- a. Face, dorsum of the hands, palm, sole, etc.
- b. Junctional region of the skin and mucous membrane, e.g. lip, penis (corona glandis), anal region, vulva, etc.
- c. Mucous surface covered by stratified squamous epithelium, e.g. upper air passage or food passage, e.g. tongue, buccal cavity, esophagus, pharynx, larynx.
- d. Often it arises from columnar cells undergoing squamous metaplasia, e.g. in gallbladder. Bronchus, cardiac end of stomach, etc.

## Pathology

- a. Macroscopic: To start with there is a small nodule which breaks down to form an ulcer, which refuses to heal.

### Characteristics of the ulcer:

- Edge of the ulcer — Rolled out and everted.
  - Floor — There is fungation or cauliflower appearance.
  - Base — Indurated and may be fixed to the deeper structures.
- b. Microscopic: It is composed of irregular strands and columns of invading epithelium which invade the subjacent connective tissue with formation of cell nests or epithelial pearls.

**Cell nests**—Epithelial cells of epidermis proliferate into the dermis in columns. In course of time, the central cells undergo degenerative

changes and finally get converted into a hyaline structureless mass of keratin (looks red after eosin stain). This is surrounded by peripheral cells in a concentric manner giving an onion peel appearance. The peripheral cells may show signs of malignancy, e.g. hyperchromatic nuclei, loss of polarity, mitotic figures, etc.

### Presence of cell nests in a squamous cell Carcinoma (Fig. 12.4) indicate

- a. A slowly growing, differentiated tumor and
- b. Poor sensitivity to radiotherapy while their absence indicate a poorly differentiated and rapidly growing tumor, sensitive to radiotherapy.

Cell nests are usually absent in the esophagus and bladder where keratin formation does not occur. Cell nests are also formed in some other tumors (other than squamous cell CA) e.g. pleomorphic adenoma of the parotid gland, teratoma of the testis.

## Spread

Less than 2 percent metastasize to lymph nodes but this occurs in upto 30 percent of those arising in scars. Blood spread occurs only in very advanced cases.

## Treatment

Indications of surgery are as follows:

1. Surgery
  - Involvement of muscle or bone.
  - For lesions larger in size.
  - For lesions close to the eye.
  - For lesions in the scalp.
  - Recurrence after radiotherapy and where radiotherapy is not available.
2. Radiotherapy — Applied in the form of DXRT (Deep X-ray Therapy). It is avoided in case of pinna to avoid radiation necrosis

## SQUAMOUS CELL CARCINOMA (FIG. 12.3)

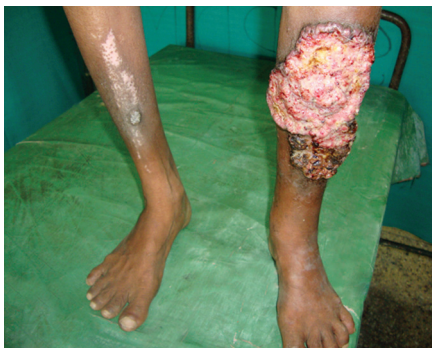(Syn— Epithelioma, Epidermoid carcinoma)

## Introduction

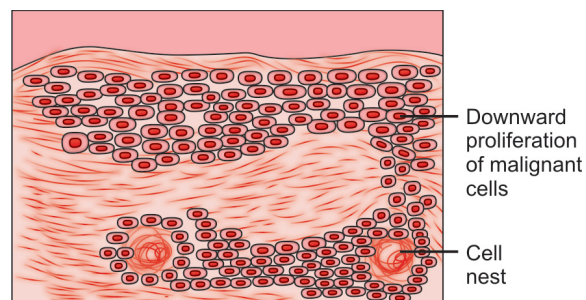
Squamous cell carcinoma (SCC) is a malignant tumor arising from the squamous cells. In case of skin, it is the prickle cell layer from where squamous cell carcinoma arises.

## Etiology

- i. It may arise *de novo* – in a previously normal area exposed to sunlight.
- ii. On some premalignant skin lesions, e.g.
  - a. Senile or solar keratosis.
  - b. Bowen's disease.
  - c. Leukoplakia.



**Fig. 12.3:** Squamous cell carcinoma of left leg



**Fig. 12.4:** Squamous cell carcinoma showing cell nests.



and scalp to avoid depilation. It cures 80 percent of early lesions.

*Treatment of secondary nodes (Mobile):* Radical block dissection performed after biopsy. If lymph nodes are hard and fixed palliative radiotherapy is given.

## MELANOMA

Melanomas are melanin containing tumors arising from the melanocytes lying in the basal layer of epidermis and thought to be derived from the neural crest.

*Melanin*—Sulfur containing, iron-free, black pigment, and in man it protects the skin against sunlight.

### Formation of Melanin

Amino acid Tyrosine is converted to DOPA or Dihydroxy Phenyl Alanine by Tyrosinase, present within the melanocyte. DOPA is converted to melanin by the enzyme DOPA oxidase, also present in the melanocyte.

*Melanophores* are phagocytes. They only carry the melanin pigment but cannot produce it, as they do not possess the enzyme DOPA oxidase like the melanocytes (which both synthesize and carry the pigment). So melanophores are Dopa negative.

### Role of Hormone

Synthesis of melanin is hormone-dependent. Hormones responsible are:

1. MSH (Melanocytes Stimulating Hormone) secreted by the anterior lobe of pituitary.
2. ACTH — It has melanocyte stimulating activity.
3. Sex hormones
  - a. Estrogen and Progesterone in female and
  - b. Androgen in male.

Types:

- a. Benign
- b. Malignant

### Benign Melanoma or Pigmented Nevus

(Syn-Mole)

Nevus = Birth mark.

### Site

An increase in the number of melanocytes may give rise to a mole or a benign naevus. The naevi can occur anywhere in the skin.

Besides the skin, naevi can occur in the nail-bed, conjunctiva and rarely in the mucous membrane.

### Pathology

- a. Histogenesis — Melanocytes normally lie among basal epidermal cells in the ratio of 1:5 to 1:10.

Most naevi begin in infancy as foci of melanocyte proliferation (junctional activity) in the epidermis and are called *junctional nevus*.

↓

Melanocytes begin to grow into the dermis and the lesion with both intraepidermal and dermal components is called a *compound nevus*.

↓

Eventual loss of epidermal component gives rise to the development of *intradermal nevus*. The process can be arrested at any stage.

- b. Macroscopical
  - Junctional nevi are small, flat, brown or black lesions.
  - Compound and intradermal nevi are similar but usually elevated, occasionally hair bearing and papillomatous.
- c. Microscopical
  - Junctional naevi are composed of groups of melanocytes appearing as rounded cells with clear or eosinophilic cytoplasm with granular brown melanin pigmentation. Compound nevi show a similar pattern but with nevus cells containing round or ovoid nuclei and scanty melanin in the dermis.
  - In intradermal nevi, the nevus cells are limited to the dermis and may be multinucleate.
- d. Prognosis
 

Transformation to malignant melanoma is only a risk in naevi with junctional activity after puberty 20 percent of malignant melanomas show evidence of a preexisting benign nevus but the overall risk of malignant change is small since pigmented naevi are very common and malignant melanoma is uncommon.

### Evidence of Malignant Change in a Nevus

The following are the evidences of malignant change in a nevus.

- Persistent itching, bleeding, increase in size and elevation and darkening of skin.
- Regional lymphadenopathy and microscopically if there is hyperchromasia, mitotic figures, pleomorphism and sub-epithelial spread.

### Management

#### Indications

- a. Nevus at a site prone to repeated trauma, e.g. a nevus on the face, traumatized by shaving.
- b. Cosmetic reasons.
- c. Clinical features suggestive of malignant change.

#### Treatment

Local excision with a healthy margin of at least 0.5 cm is sufficient. Naevi appearing at birth or before puberty can be excised close to their margins.

Any excised naevus should be sent for histopathological study.

### Malignant Melanoma

(Syn— Melanocarcinoma).

#### Incidence

The incidence of malignant melanoma is increasing every decade, highest being in Queensland, Australia.

#### Etiology

Common in white skinned people exposed to the sun.

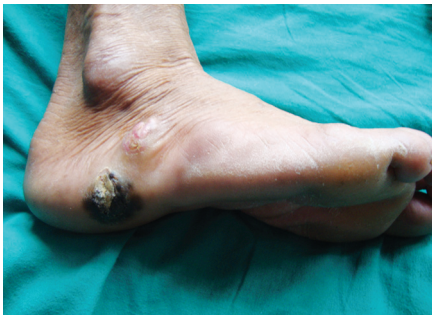Arises *de novo* in 10 percent of cases and the rest from the preexisting mole, e.g. junctional nevus, compound nevus, etc.

#### Pathology

##### Macroscopical

- Types: (i) Two principal types viz. superficial spreading and nodular melanoma (ii) Two less common varieties, e.g. lentigo maligna and acral lentiginous melanoma.
- Superficial spreading type: (70%) most common but less aggressive usually found on lower legs, chest or back, presents as a flat, irregular pigmented plaque with variable pigmentation. The lesion is usually palpable and nodule may develop within the tumor (Fig. 12.5A).





**Fig. 12.5A:** Malignant melanoma of right foot within transit cutaneous metastasis

- Nodular melanoma presents as elevated dark nodule at any site. It is the most malignant type.
- Lentigo maligna is a flat slowly growing lesion on the exposed skin of the elderly. It is the least common and least malignant.
- Acral lentiginous melanoma – a variety of superficial spreading type with a worse prognosis, commonly found in palms and soles.

**Microscopical**

The essential feature of each subtype of malignant melanoma is invasion of the dermis by proliferating malignant melanocytes with large nuclei, prominent nucleoli and frequent mitoses.

- Superficial spreading melanoma shows vertical dermal invasion and horizontal intraepidermal spread.

- Nodular melanoma by contrast has no significant horizontal intraepidermal component.

**Histological classification (Clark's level of invasion)**

Depends on the anatomic level of invasion (Table 12.1).

**Classification by tumor thickness (Breslow):**

This classification is more important for therapy and determinant of prognosis. Tumor thickness is measured with an ocular micrometer in mm. (Table 12.3)

A comparison of Clarke's level of invasion and Breslow's tumor thickness measurement can be assessed to predict the virulence of the lesion. (Table 12.2)

Both methods are complementary and have their drawbacks. Ulcerated lesions may be relatively thin, yet have a poor prognosis, similarly a thick lesion on the sole or back may only reach Clark's level 1.

Table 12.3: Breslow's stage	
Stage	Thickness
Stage - 1	0.75 mm or less
Stage - 2	0.76 - 1.49 mm
Stage - 3	1.50 - 2.49 mm
Stage - 4	2.50 - 3.99 mm
Stage - 5	4.00 - 7.99 mm

Table 12.1: Clark's level of invasion		
Clark's level of invasion	Description	5 year survival
Level 1	Epidermal involvement only	100%
Level 2	Papillary dermis only is involved	90-100%
Level 3	Involves the junction of papillary and reticular dermis	80-90%
Level 4	Tumor extends to reticular dermis	60-70%
Level 5	Subcutaneous fat is involved	15-30%

Table 12.2: Comparison of Clark's level of invasion and Breslow's staging		
Clark's level	Tumor thickness	Virulence
Level 1	0.75 mm from the surface of skin	Low risk Primary tumor, do not metastasise.
Level 2	0.76 - 1.50 mm	Intermediate risk
Level 3		25% incidence of metastasis
Level 4	1.51 mm or deeper below the skin surface	High risk
Level 5		60% incidence of metastasis

**TNM Staging**—See the short case of 'malignant melanoma', chapter 79.

**Spread**

**Local** — Horizontally in the epidermis and vertically into the dermis. The deep fascia acts as a strong barrier.

**Lymphatic spread** — By emboli to regional lymph nodes and by permeation of lymphatic channels giving rise to secondary deposits or satellite nodules between the primary growth and the regional nodes (Fig. 12.5B).

**Blood spread** — It occurs very late to liver, lung brain, etc.

**Prognosis**

Depends on the depth of invasion (Clarke levels) and thickness of tumor, site, type of melanoma and presence of metastasis, etc. as mentioned above. BANS (Back, Arm, Nerve, Scalp) region melanoma has a poor prognosis.

**Amelanotic melanomas:** Most malignant melanomas are brown and black but a small no. lack the pigment called amelanotic melanoma.

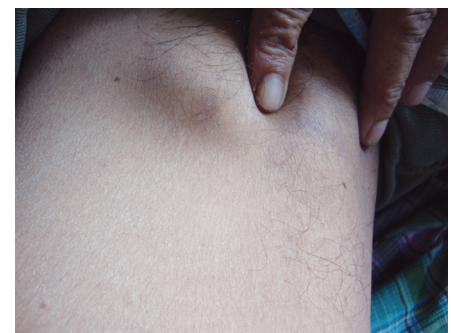**Clinical Features**

The patient usually presents with a change in a pigmented lesion. Symptoms typical of malignant change are an enlarging lesion with itching or pain, bleeding or a change in color.

**Investigations**

There is no method of diagnosis of malignant melanoma except the histological examination (biopsy).

Also at present there are no methods of establishing metastasis. USG and CT have low specificity and sensitivity.



**Fig. 12.5B:** Right inguinal lymph node metastasis of the same patient shown in Figure 12.5A.

**Table 12.4: Characteristics of Marjolin's ulcer and squamous cell carcinoma**

<i>Marjolin's ulcer</i>	<i>Squamous cell carcinoma</i>
1. Grows very slowly because of scar tissue.	Grows slowly.
2. It is painless as scar does not contain nerves.	It can be painful if it infiltrates the nerve fibers.
3. Lymphatic metastasis does not occur as they are destroyed in a scar.	Lymphatic metastasis is the chief method of spread.
4. It is less malignant.	Comparatively more malignant.
5. Surgery cures the disease. Radiotherapy is not very useful.	Both surgery and radiotherapy are used.

### Clinical Staging

Stage I — No evidence of regional spread.

Stage II — Clinical involvement of lymph nodes by embolism or satellite nodules.

Stage III — Blood borne distant metastasis lungs, liver, brain, etc.

### Treatment

- a. Treatment of the lesion:
  - i. Surgical excision is the treatment of choice for almost all melanomas in stage I and II. Radiotherapy has no place and chemotherapy is only considered in stage III.
  - ii. Margin of excision: Resection margin beyond 3 cm of healthy skin confers no survival advantage. Usually the subcutaneous tissue is excised with the lesion but it is not necessary to excise the deep fascia or muscle underneath the lesion.
  - iii. These smaller excisions allow primary closure of the wounds in the majority of patients.
- b. Management of regional lymph nodes: In a patient in whom, there is clinical evidence of regional lymph node involvement a lymph node dissection of that area, is appropriate.
- c. Isolated limb perfusion:
 

*Indications:*

  - i. For local recurrence within 2 cm of primary excision.
  - ii. For in transit metastasis.
  - iii. To convert an advanced inoperable lesion to operability.

The single drug melphalan is used. The perfusion is carried out at a temperature of > 40°C. It is effective in reducing the lesion size and on occasion, healing them completely.

- d. Immunotherapy: It is done using BCG intralesionally.

## MARJOLIN'S ULCER

### Definition

Low grade epidermoid or squamous cell carcinoma arising from the epithelium covering the scar tissue or keloid, is called Marjolin's ulcer.

Common causes of Marjolin's ulcer are:

Burn scar is the commonest cause followed by scar due to varicose ulcer, chronic osteomyelitis scar, lupus vulgaris scar, etc.

Marjolin's ulcer differs from squamous cell CA by the following characteristics (Table 12.4).

### Treatment

1. If the site permits — Wide tridimensional excision with a margin of at least 1cm is performed followed by skin grafting.
2. If the ulcer is a big one involving the distal part of the limb and excision is not possible — the treatment is amputation.
3. Radiotherapy has no role.

## HEMANGIOMA

This is a swelling due to congenital malformation of blood vessels. It is an example of hamartoma.

*Types*

- Capillary
- Venous or cavernous
- Arterial or plexiform

### Capillary Hemangioma

*Types*

- Strawberry angioma (Syn. Strawberry nevus)

- Salmon patch
- Portwine stain

### Port wine Stain

#### Features:

- Diffuse telangiectasia, usually seen on the face, lips and buccal mucosa.
- No swelling is present.
- Treatment is for cosmetic reason.
  - a. Excision and skin grafting (in a boy).
  - b. Skillful use of cosmetics (in a girl).
- Sturge-Weber syndrome—Portwine stain of the face with ipsilateral hemangioma of cerebral hemisphere and choroids angioma, often with secondary glaucoma.

### Strawberry Angioma (Syn— Strawberry Nevus)

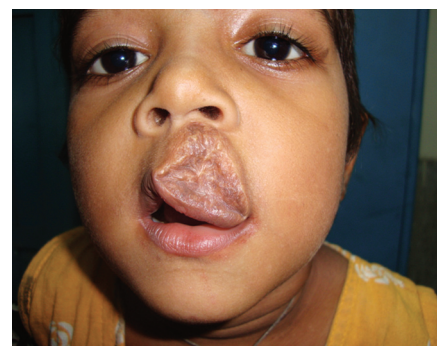#### Features:

- This produces swelling which is compressible and consists of immature vascular tissue.
- By 5 to 7 years of age, the swelling regresses and color fades.
- Mostly seen on the head and neck.
- Treatment
  - a. Natural involution.
  - b. Conservative — Injection of hot water, hypertonic saline or steroids.
  - c. Operative — Excision with or without skin grafting.

### Salmon Patch

- Commonly present over the forehead in the midline.
- Present at birth and disappears by 1 year of age.

Hence no treatment is required.



**Fig. 12.6:** Hemangioma of upper lip

## Cavernous Hemangioma

This condition occurs in places where venous space is abundant, e.g. lips (Fig. 12.6), cheek, tongue, posterior triangle of neck, organs like kidney, liver, brain, etc.

### Clinical Features

- Bluish in color.
- Sign of compressibility — Also called sign of emptying or sign of refilling. It is the diagnostic sign, when the swelling is compressed between the fingers, blood diffuses under the vascular spaces and when pressure is released, it slowly fills up.
- The swelling is warm but not pulsatile.
- Soft cystic, fluctuant but transillumination negative.

### Differential Diagnosis

1. Lymphangioma (not compressible, brilliantly transilluminates).
2. Lipoma (not compressible).

### Treatment

1. Sclerosant Injection— Is the first line treatment, which makes the swelling fibrotic. Sclerosing agents used are boiling water, hypertonic saline, Na tetradecyl sulfate, steroids, etc.
2. Excision — Large hemangiomas should be excised only after preliminary sclerotherapy.

### Complications

1. Ulceration — Usually with capillary hemangioma.
2. Bleeding.
3. Infection.

Nevolipoma: It is the cavernous hemangioma associated with a lipoma.

## Arterial Hemangioma

This is a congenital arteriovenous fistula resulting from an abnormal communication between artery and vein.

*Structural defect* — These are secondary varicose veins. Since high pressure blood from an artery flows into the veins, they get dilated, tortuous and elongated.

### Features

- Increased venous pressure – Pulse rate and CO.

- A continuous bruit or murmur is characteristic.
  - Branham sign or Nicoladoni sign – on compressing the feeding artery the pulse rate diminishes due to decrease in venous return. Also the continuous murmur may disappear.
  - Local gigantism — The affected part is swollen because of high pressure. Thus overgrowth of limb or toe can occur.
  - Ischemic ulcers — Distal to the AV fistula, there are ischemic ulcers due to comparative reduction in blood supply.
  - Cirroid aneurysm — Plexiform hemangioma of the scalp over the forehead and/or temporal region in relation to superficial temporal artery.
- a. Muscle — Intermuscular lipoma.
  - d. Periosteum — Subperiosteal lipoma.
  - e. Synovial membrane — Subsynovial lipoma.
  - f. Serous membrane — Subserous (Retroperitoneal) lipoma.
  - g. Meninges — Extradural or subdural lipoma.
  - h. Gland — Intraglandular lipoma.

### Histology

1. Neurolipoma—Mixture of nervous and adipose tissue, often painful. When multiple, it is called neurolipomatosis or Darcums disease.
2. Fibrolipoma — Mixture of fibrous and adipose tissue.
3. Nevrolipoma — Mentioned above, in cavernous hemangioma.

### Treatment

- a. Therapeutic embolization of feeding artery is the treatment of choice.
- b. Ligations of the feeding vessel, e.g. superficial temporal artery in cirroid aneurysm and excision of the lesion.
- c. Sclerosant injection treatment.

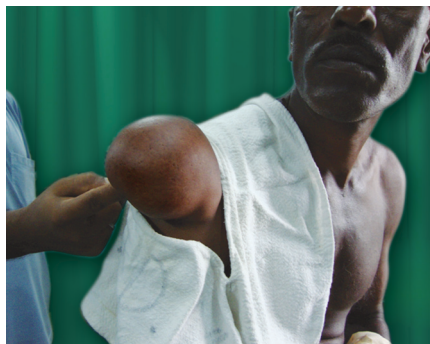## LIPOMA

- It is the commonest benign tumor arising from the fat cells and Can occur in any situation where there is fat, hence known as universal tumor. Common sites are trunk, the nape of neck and the limbs (Fig. 12.7).

### Types

#### Anatomical

- a. Skin — Subcutaneous lipoma.
- b. Aponeurosis or fascia — Subaponeurotic or subfacial lipoma.



**Fig. 12.7:** Lipoma over the right shoulder

### Subcutaneous Lipoma

#### Clinical features

- Most common variety.
- Slipping sign — Edge slips under palpating fingers.
- Freely mobile on both axes.
- Surface is lobulated — Lobules can be seen and felt on the surface and at the edge of the lump.
- Common sites — Shoulder, trunk.
- Differential diagnosis — Neurofibroma.

### Subfascial Lipoma

Site: Limbs, palm, sole

- Presentation – Difficult to appreciate the edge and lobulation.
- Differential diagnosis – Implantation dermoid, TB synovitis.
- Subfacial lipoma of the scalp erodes bone.

### Subsynovial and Intra-articular Lipoma – Rare

Site — Knee joint, elbow.

*Clinical features* — Swelling in relation to elbow joint, knee joint, etc. arising from the fatty pad, deep to the synovial membrane.

*Differential Diagnosis*—Semimembranosus bursa, Baker's cyst.

### Intermuscular Lipoma

Chances of developing liposarcoma is more. *Common site:* Thigh, shoulder region. On contraction of the muscle, it is more firm due to transmitted pressure.



*Differential diagnosis* — Fibrosarcoma, hematoma.

### Submucous Lipoma

*Common sites* — Intestine, larynx, can cause respiratory obstruction (Larynx) or intussusception (Alimentary tract).

*Differential diagnosis* — Intestinal tumour, laryngeal tumor.

### Intraglandular

The glands are the breast and pancreas.

*Differential diagnosis* — Cystic lesions, very rare.

### Extradural Lipoma

It is a very rare variety of spinal tumor. Intracranial lipoma does not occur as there is no fat in extradural tissue inside the skull.

### Subserous Lipoma

Rare, found beneath the pleura or peritoneum. *Differential diagnosis* — Hydronephrosis, retroperitoneal cyst, teratoma. Retroperitoneal lipoma is more common in children than adults.

### Parosteal Lipoma

It is a very rare lies under the periosteum of bone, and feels hard.

*Differential diagnosis* — Bony tumor.

*Treatment* — Excision.

### Complications

- Liposarcoma—Common sites where lipoma undergo malignancy.
  - Retroperitoneal lipoma.
  - Lipoma of the thigh.
  - Lipoma of the shoulder region.

The swelling grows rapidly becomes painful and vascular with red color and dilated veins over the surface, skin fungation or fixation occurs. Mobility gets restricted.

*Treatment* — Wide excision.

- Calcification.
- Myxomatous degeneration.
- Intussusception-an abdominal emergency.

## NEUROFIBROMA

It is not a true tumor but hamartoma, arising not from the nerves proper but from the endoneurium (the supporting connective tissue for the nerve fibrils).

*Cause*—It is due to autosomal gene defect transmitted as a Mendelian dominant.

Neurofibroma if multiple, congenital and familial, the condition is known as von-Recklinghausen's disease.

### Types

- Localized or solitary neurofibroma.
- Generalized neurofibromatosis. or von - Recklinghausen's disease.
- Plexiform neurofibromatosis (pachydermatocele).
- Elephantiasis neurofibromatosis.
- Cutaneous neurofibromatosis (Molluscum contagiosum).

### Rare Varieties

- Amputation neuroma.
- Dumb-bell shaped tumor.
- Acoustic neuroma.

### Solitary Neurofibroma

- This commonly affects a peripheral nerve e.g. ulnar nerve, cutaneous nerve, etc.
- Clinical features
  - Tingling, numbness and paresthesia in the distribution of the nerve.
  - Round to oval swelling in the direction of the nerve.
  - Site - Found usually in the subcutaneous tissue. Other special sites include.
    - Dorsal nerve roots and ganglion - Dumb bell neurofibroma.
    - 8th cranial nerve (Acoustic neuroma).
    - Intramuscular.
    - Inside the bone.

### Differential Diagnosis

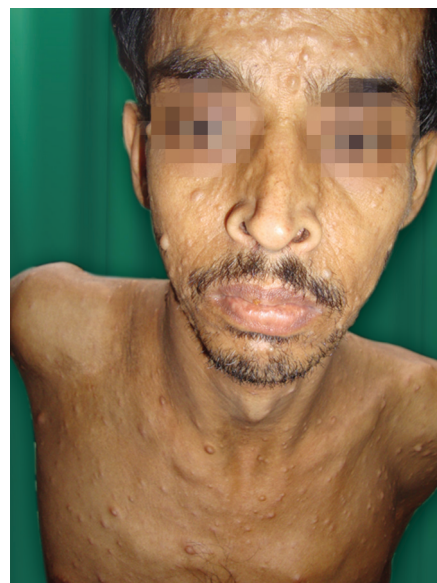- Fibroma.
- Lipoma.
- Enlarged lymph node
- Hemangioma
- Cystic lesions — Neurofibroma to sometimes undergo cystic degeneration.

### Treatment

Complete excision taking care so that the nerves are not injured—Incomplete removal may result in sarcomatous change.

## VON RECKLINGHAUSEN'S DISEASE (FIG. 12.8)

It is an autosomal dominant disorder, transmitted by both sexes.



**Fig. 12.8:** Multiple neurofibromatosis or von Recklinghausen's disease

### Diagnosis

- Café-au lait spots — patches of light brown discoloration > 3 in no and >1.5 cm in diameter (Diagnostic).
- It may diffusely involve peripheral nerves, cranial nerves (Acoustic neuroma), spinal Nerves (Dumb-bell neuroma).
- It may be associated with pheochromocytoma.
- Sarcomatous changes occur in 5 percent cases.

### Note

von Recklinghausen's disease of bone, also called osteitis fibrosa cystica, is found in hyperparathyroidism and characterized by parathyroid adenoma, pathological fracture and recurrent renal calculi.

### Treatment

Swellings are so numerous that excision of all the tumors is impossible and unwarranted.

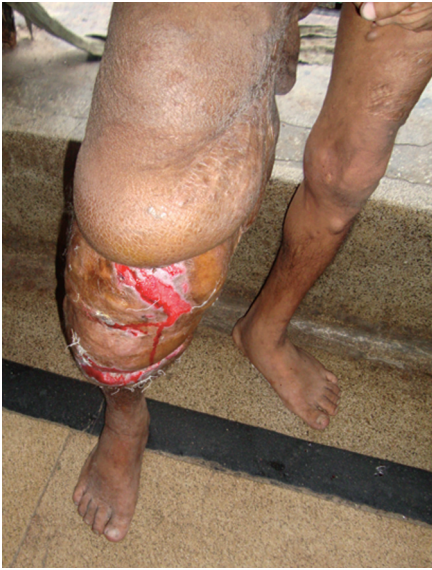Excision of lumps are indicated as below:

- If they are painful and/or tender.
- Cosmetic disfigurement
- Suspicion of malignant change.

## PLEXIFORM NEUROFIBROMATOSIS (FIG. 12.9)

(Syn— Pachydermatocele)

- Excessive overgrowth of endoneurium in the subcutaneous tissue.



**Fig. 12.9:** Pachydermatocele involving right thigh and leg

- Branches of 5th cranial nerve are commonly affected.
- The severe form of plexiform neurofibromatosis is known as elephantiasis neurofibromatosa.

- Diagnosis is only confirmed by histology.
- Differential diagnosis:
  1. Lymphoedema
  2. Filariasis
  3. Nodular leprosy (Elephantiasis grecorum)
  4. Congenital A–V fistula.

### CUTANEOUS NEUROFIBROMATOSIS

- It occurs in connection with the terminal filament of cutaneous nerves.
- Nodules are multiple, small, discrete, sessile or pedunculated. But there is no hypertrophy of skin.
- Common sites — Chest, abdomen or back.

### Rare Types

#### Acoustic Neuroma

- It arises from the auditory nerve sheath at the internal auditory meatus.
- The first symptom is unilateral deafness often first detected by the patient on the telephone. There may be vertigo and severe headache.

Gradually the tumor enlarges and presses upon the adjacent nerves, e.g. Seventh nerve causing fascial weakness. Sixth nerve causing squint. Fifth nerve causing loss of corneal reflex. There may also be trigeminal neuralgia or anesthesia.

### Treatment

Removal of the tumor through the posterior fossa craniotomy.

#### Amputation Neuroma

This is a fusiform swelling that occurs at the end of divided nerve after amputation of a limb.

- These neuromas are painful which may be burning in character.
- The swelling consists of fibrous tissue and coiled nerve fibers.

### Treatment

1. Preventive—During amputation the nerves should be divided, above the level of the proposed bone division.
2. Curative—Excision of the tumor.

## Skin Grafting

### ➤ Types of skin graft

Skin grafting is a useful technique in plastic surgery, for covering those areas of the body which are denuded either partially or totally of skin.

Any area with skin loss is a potential site for pain due to exposure, damage to underlying structures, like nerves, tendons and vessels, loss of fluids, protein and energy, invasion of pathogenic bacteria and scarring.

To get rid of the above problems, skin grafting is so valuable.

### Indications

1. Where a large area of skin has been lost e.g. deep burn, injuries, callous ulcers including varicose ulcers.
2. Skin loss from surgically removed malignant growths.
3. Contracted scars in the vicinity of joints require excision and skin grafting.

### TYPES OF SKIN GRAFT

Various types of skin graft are available and include.

- i. Autograft — It is the patient's own skin. If taken as a partial thickness graft, it can be stored in saline soaked gauze for a period of upto 3 weeks at a temperature of 4°C.
- ii. Homograft — It is a partial thickness graft taken from a cadaver or a volunteer. Tissue typing is done and the graft is stored at a temperature of 4°C for a period

### ➤ Procedure of partial thickness graft

- of 3 weeks. If liquid nitrogen is used, the graft can be stored for about a year.
- iii. Xenograft — It is partial thickness porcine skin.

### Autograft

Autografts are of different types viz.

- Partial thickness graft is the commonest type used. It contains the epidermis and a variable thickness of the dermis.

Partial thickness graft is further divided into thin grafts containing epidermis alone and thick grafts containing superficial one-third to two-third of the dermis.

*Thin grafts (Thiersch graft)* — It is indicated where graft take is important and chance of contracture formation is less. This is because the thinner the graft, the more it contracts but has a better chance of take, common donor sites are the skin of the thigh and the forearms.

Thick grafts are preferred in the *fingers* where, contractures should be avoided.

- Full thickness graft: Composed of full thickness of skin and hence the donor site has to be closed primarily or left open to granulate and contract. Full thickness grafts are preferred for the face where the best cosmetic result is desirable. This graft contracts the least but has a poorer chance of success than a partial thickness graft. Donor sites used for this graft include postauricular, supraclavicular and the nasolabial areas.

### Graft Survival

Graft survival is dependent on its revascularization by the recipient bed.

During the first 48 hours, the nutrition of the graft is by a process of plasmatic imbibition. By this process, nutrients diffuse through the extracellular fluids into the capillaries and cells of the graft. During this period fibrin bonds fix the graft to the bed.

At 48 hours, capillary outgrowths from the bed, communicate with those of the graft and circulation is established by a process called inosculation.

This delicate process can be interfered with if there is gross infection, with streptococcus, irradiated area or application of graft on a denuded bone, tendon or cartilage.

### PROCEDURE OF PARTIAL THICKNESS GRAFT

The hand held Humby Knife or a drum dermatome (Reese dermatome), are commonly used. The donor site is cleaned, draped and held taut, while the graft is taken. This site should be covered with paraffin gauze, soaked in local anesthetic and elastoplast dressing, which is left in place till it heals.

The recipient site is cleaned and the graft may be applied immediately or at a later date.

Graft application has to be done meticulously on a recipient bed where complete hemostasis has been achieved. It is secured in place by sutures or may be draped over the



wound, following which a tie over dressing is done.

Occasionally the graft is meshed with the advantage that large areas of the body can be covered, e.g. in extensive burns. Mesh grafts

contour well on the body surfaces and due to meshing allow egress to any fluid collection.

They are however associated with more graft contraction and give a poorer esthetic result.

Nowadays, the new area in skin grafting is the cultured autograft. These do away with the painful donor site in a patient. However, their problem is the poorer take in comparison to conventional skin grafts.

## Cysts

- Cyst
- Dermoid cyst
- Sebaceous cyst
- Mesenteric cysts

### CYST

#### Definition

A cyst is a collection of fluid in a sac lined by endo- or epithelium, which usually secretes the fluid. The term cyst means bladder in Greek.

#### Types

Broadly there are two varieties — True cyst and the false cyst.

#### True Cyst

The cyst wall is lined by epithelium or endothelium. If infection occurs, cyst wall will be lined by granulation tissue. Fluid is usually serous or mucoid derived from the secretion of the lining cells.

The contents of the cyst may be thick toothpaste like as a result of accumulation of desquamated epithelium in the fluid, e.g. sebaceous cyst, dermoid cyst, etc.

#### False Cyst

It does not have epithelial lining. Fluid collection occurs as a result of exudation or degeneration, e.g. pseudocyst of pancreas, wall of cystic swelling in tuberculous peritonitis, cystic degeneration of tumor, etc.

#### Classification

Cysts are classified as congenital and acquired.

#### Congenital Cysts

- a. Dermoid cysts, e.g.
  - Sequestration dermoid.
  - Tubulodermoids like thyroglossal cyst, ependymal cyst, etc.
  - Teratodermoid in the testis, ovary, etc.
- b. Cysts of embryonic remnants, e.g. urachal cysts, cyst arising from the central part of vitelline duct (vitellointestinal cyst), cysts from the paramesonephric and mesonephric duct remnants.

#### Acquired Cysts

- a. Retention cysts — Due to blocking of a glandular or excretory duct, e.g. sebaceous cyst, ranula (salivary gland), cysts of the parotid, breast and epididymis.
- b. Distension cyst — Due to distension of closed cavities as a result of exudation or secretion, e.g. lymphatic cysts, thyroid or ovarian cysts, etc. which result from dilatation of normal acini or follicle.
- c. Exudation cyst are ganglia, hydrocele, bursae, etc. These are all false cysts.
- d. Degeneration cyst — Due to degeneration in a malignant tumor due to hemorrhage or colliquative necrosis. This is also a false cyst.
- e. Cystic tumors, e.g. dermoid cyst of ovary, cystadenomas.
- f. Parasitic cysts, e.g. hydatid cysts.
- g. Traumatic cysts — They usually occur in the muscles of loin, thigh, etc. To start

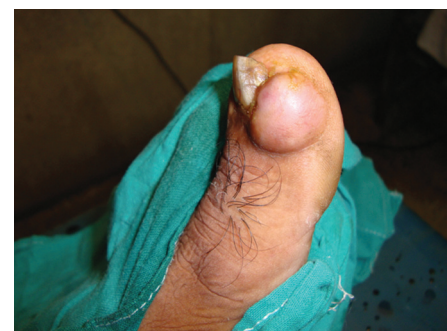with these are hematomas which eventually get lined by endothelium and the fluid inside is brownish containing cholesterol crystals.

### DERMOID CYST

(Syn. Epidermal cyst)

#### Diagnosis

- Site
  - In the midline of the body.
  - On the scalp.
  - At the inner and outer angles of the eye (angular dermoids).
- Absence of punctum.
- Fluctuation positive.
- Painless
- Skin can be lifted up (c.f. sebaceous cyst)



**Fig. 14.1:** Implantation dermoid over the big toe

- Not compressible
- Transillumination negative.

### Types of Dermoid

Four Types:

1. Sequestration dermoid, e.g. external angular, scalp dermoid, cervical and sublingual dermoid.
2. Implantation dermoid (Fig. 14.1) (post-traumatic dermoid), e.g. in the pulp or tips of the fingers, palm and sole, etc.
3. Tubulodermoid, e.g. thyroglossal cyst, postnatal dermoid.
4. Teratodermoid, e.g. sacrococcygeal teratoma, testicular and mediastinal teratoma, ovarian dermoid.

### Sequestration dermoid

- Lining of the cyst and contents like squamous epithelium and contain paste like desquamated material with or without hairs.
- Scalp dermoid
  - May be fully extracranial
  - May be fully intracranial
  - Partly intra and partly extracranial (Hourglass dermoid).
- *Complications*—Infection suppuration, ulceration, cosmetically looks ugly.
- *Treatment*—Excision scalp dermoids should be X-rayed before operation to see any intracranial extension.

### Implantation dermoid

An acquired cyst, lined by squamous epithelium but hair follicles, sweat and sebaceous glands are absent.

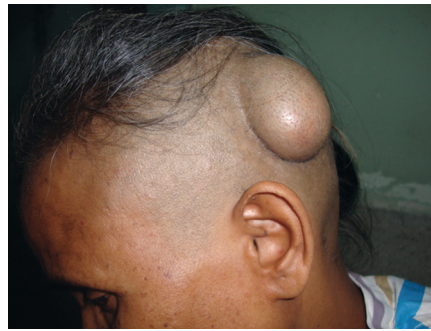The cyst is tense and hard, sometimes stony hard. It may be, painful and tender. History of old injury is an important part of history.

*Treatment:* Excision (for cosmetic reason, to avoid inconvenience at work and to prevent infection).

### Tubulodermoid

Tubulodermoid, e.g. Thyroglossal cyst — see neck swellings.

- Postnatal dermoid arises from remnant of neuroenteric canal.
- Ependymal cyst in the brain — Remnant of neuroectoderm.



**Fig. 14.2:** Sebaceous cyst of scalp

### Teratodermoid

sites as mentioned above.

Contents usually contains derivatives of mesodermal elements such as cartilages bone, tooth, hair and also cheesy material.

### SEBACEOUS CYST (SYN. EPIDERMOID CYST)

- This is a retention cyst due to accumulation of sebum resulting from obstruction to the duct of the sebaceous gland.
- *Common sites*—Scalp, scrotum, face, vulva etc. but it can occur anywhere in the body except palm and sole as there are no sebaceous glands in these regions.
- *Lining of the cyst* — Squamous epithelium.
- *Contents*—Yellowish white paste-like material which is a mixture of sebum, fat and desquamated epithelial cell debris.

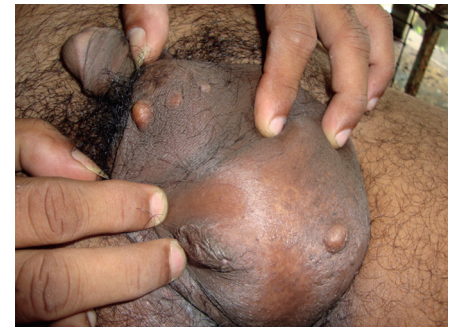### Diagnosis

- Presence of a bluish spot, called punctum which is adherent to the cyst.
- Skin cannot be lifted up (cf. dermoid cyst, lipoma).
- Not compressible.
- Globular or spherical in shape, A few mm to 4 to 5 cm in size.
- Transillumination — Negative.

### Scalp Sebaceous Cyst (Fig. 14.2)

- Skin is attached to the swelling.
- No punctum is usually visible.
- No impulse on coughing or straining.
- The swelling can itself be indented by a finger tip pressure.

This is diagnostic.



**Fig. 14.3:** Multiple sebaceous cysts of the scrotum

**Scrotal sebaceous cysts** — They are usually multiple, no punctum is usually visible. (Fig. 14.3)

### Complications

- Cosmetically looks ugly.
- Infection, ulceration, calcification.
- Cock's peculiar tumor is ulcerated sebaceous cyst of the scalp with excess granulation tissue formation.

Differential diagnosis

- Squamous cell CA.
- Sebaceous horn – slow discharge of sebum from a wide punctum gets inspissated and forms this horny projection.

### Treatment

Total excision under local anesthesia.

### Sebaceous Gland

It is a holocrine variety of exocrine gland producing secretions by fatty degeneration of its central cells. Exocrine glands are of three varieties:

- i. Holocrine, e.g. sebaceous glands—Here the whole of the cell disintegrates and dies to produce its secretion.
- ii. Apocrine, e.g. mammary gland where only the luminal part of the cell disintegrates leaving the nucleus and the basal portion from which the cell disintegrates.
- iii. Merocrine — Where the secretion is discharged without any destruction of the cell. Most of the glands belong to this type.

### MESENTERIC CYSTS

The three main types of cysts which are seen in the mesentery are.

1. Lymphatic cyst.
2. Enterogenous cyst.
3. Dermoid cyst.

### Lymphatic Cyst

This is the commonest type of mesenteric cyst, arising from the misplaced lymphatic tissue which has lost communication with the lymphatic system during development.

- The cysts are thin-walled and contain a cloudy fluid resembling chyle. They most often arise from the mesentery of the ileum.
- The cyst can be adequately treated by enucleation because of its separate blood supply from that of the neighboring bowel.

### Enterogenous Cyst

This is lined by intestinal mucosa and the fluid inside is colorless or yellowish. The cyst

and the adjacent intestine have a common blood supply. Hence removal of the cyst necessitates resection of the adjacent bowel.

It develops from a diverticulum in the mesenteric border of the intestine which has become detached from the intestinal canal during embryonic life.

### Dermoid Cyst

This contains derivatives of all three germ layers viz. ectoderm, mesoderm and entoderm. This is very rare. It is more often found as a retroperitoneal cyst.

### Clinical Features

- These cysts usually occur in the second decade of life.
- The usual feature is a painless lump near the umbilicus which is mobile at right angles to the mesenteric attachment but does not move along the line of

attachment. This mobility is characteristic of mesenteric cysts or masses.

### Differential Diagnosis

- Cysts of mesocolon.
- Omental cyst.
- Ovarian cyst.

### Investigations

- a. Barium meal X-ray coils of intestine may be found displaced by the cyst.
- b. Ultrasound examination differentiates a solid from a cystic lesion.
- c. CT scan gives the best delineation of a mesenteric cyst.

### Treatment

Enucleation of the cyst is the treatment of choice for a lymphatic cyst while an enterogenous cyst has to be excised with the neighboring bowel due to the common blood supply.

# Chapter 15

## Principles of Anesthesia

- Preoperative evaluation and premedication
- Techniques of anesthesia
- General anesthesia
- Monitoring during anesthesia
- Recovery from general anesthesia
- Regional anesthesia
- Local anesthetic agents
- Types of regional anesthesia
- Spinal anesthesia
- Epidural anesthesia
- Extradural sacral block or caudal block
- Some common postoperative complications

### PREOPERATIVE EVALUATION AND PREMEDICATION

#### Introduction

Preoperative evaluation and preparation for anesthesia begins when the anesthesiologist reviews the patient's medical record and visits the patient one or more days before elective surgery. Important aspects of the preoperative evaluation include a history, review of current drug therapy and a physical examination.

The planned management of anesthesia and methods available for relief of postoperative pain are discussed with the patient and informed consent is obtained. The apprehension allaying effect on the patient produced by the preoperative visit is an important aspect of preoperative medication.

After the preoperative visit a summary of pertinent findings, including details of the history, current drug therapy, physical examination and laboratory data should be written in the patient's medical record. A physical status classification is assigned (Table 15.1). Finally orders for the preoperative medication are written.

On occasion, based on the preoperative evaluation, it may be the anesthesiologist's opinion that the patient is not in optimal medical condition before elective surgery.

This judgment should be discussed with the surgeon concerned and unless urgent, elective surgery deferred till the patients medical condition improves.

#### History

- In taking the preanesthetic history special emphasis should be placed on the cardiorespiratory system.
- Adverse events related to the administration of previous anesthetics should be specifically sought.
- Current drug therapy must be carefully reviewed during the preoperative evaluation because adverse interactions of these medications with drug administered in the perioperative period must be considered.

- Questions relating to major organ system function serve to elicit the presence and impact of coexisting diseases.

#### Specific Areas to Investigate in Preoperative History

##### *Previous Adverse Responses Related to Anesthesia*

- Allergic reactions.
- Prolonged skeletal muscle paralysis.
- Delayed awakening.
- Nausea and vomiting.
- Myalgia.
- Hemorrhage
- Jaundice
- Postspinal headache.

**Table 15.1: American Society of Anesthesiologists classification of physical status**

Class	Definition
1.	A normal healthy patient.
2.	A patient with a mild systemic disease.
3.	A patient with severe systemic disease that is not incapacitating.
4.	A patient with an incapacitating systemic disease that is a constant threat to life.
5.	A moribund patient who is not expected to survive for 24hrs. with or without operation.
6.	Emergency operation, the letter "E" is appended to the appropriate classification.

### Cardiovascular System

- Exercise tolerance.
- Angina pectoris.
- Prior myocardial infarction.
- Hypertension.
- Rheumatic fever.
- Dysrhythmias and different conduction blocks.
- Uncontrolled hypertension and angina, arrhythmias and cardiac failure are common reasons for postponement of elective procedures. correction of hypertension and ischemic heart disease is essential and therapy needs to be continued through the operative period. Despite preoperative fasting patients are instructed to take their usual cardiovascular medications on the day of surgery.
- Recent myocardial infarction is a strong contraindication to elective anesthesia. There is a significant mortality from anesthesia within 3 months of infarction and elective procedures should ideally be delayed until at least 6 months have elapsed.
- Patients with valvular heart disease should receive corrective treatment for any preoperative infections and appropriate perioperative prophylactic antibiotic cover, to avoid subacute bacterial endocarditis.
- Electrolyte abnormalities, especially hypokalemia or anemia should be corrected and the circulatory volume should be maintained at normal level. Preoperatively, the presence of an adequate urine output is a useful indicator of adequacy of the circulating volume.
- Optimization of oxygenation preoperatively is important in cardiac risk patients, as operative procedures create an increased demand for oxygen as a result of pain, surgical stress and hypothermia.

### Respiratory Disease

- Bronchial asthma
  - Recent upper respiratory tract infection
  - Pneumonia
  - Cough and sputum production
  - Smoking.
- In general surgical practice, respiratory infection and asthma are the common problems requiring treatment before anesthesia. In patients with chronic respiratory failure, careful attention should be given to preoperative physiotherapy early mobilization,

treatment of infection and optimization of bronchodilator therapy.

- Measurement of oxygen saturation and blood gas tensions preoperatively provide a useful guide and perspective to interpret values during recovery. The need for postoperative monitoring and ventilatory support should be anticipated.

In the presence of respiratory disease, it is advantageous to use local anesthesia as an alternative to general anesthesia, provided that there is a nerve block appropriate for the site of surgery. Upper abdominal and thoracic procedures are unsuited to regional anesthesia alone as positive pressure ventilation under general anesthesia is necessary.

### Metabolic Disorders

- Diabetes mellitus.
- Adrenal gland dysfunction.
- Preanesthetic evaluation should focus on the duration and type of diabetes as well as on the current medical regimen.
- A review of end organ functions with an emphasis to cardiovascular disease, renal insufficiency, retinopathy, and neurologic complications is mandatory.
- Perioperative plasma glucose levels should be as reasonably well-controlled as possible.
- In diabetic patients undergoing surgery several principles of management are generally accepted.
  - i. Patient is admitted 3 days before operation and goes first in the operation list.
  - ii. Catheterization done to make urine available for sugar estimation as and when necessary.
  - iii. The two goals in the management are to prevent hypoglycemia by providing exogenous glucose, e.g. 5 percent dextrose injection and to prevent ketoacidosis by assuring an adequate supply of exogenous insulin.
  - iv. Soluble insulin is substituted for oral hypoglycemic drugs and a reduced dose of insulin is given on the morning of surgery.
  - v. Blood sugar is measured before induction of anesthesia and then regular 3 to 4 hrly estimations in the postoperative period for 24 hrs.

Patients who are receiving adrenocortical steroids or who have received them in the past 2 months will have suppressed adrenal glands, unable to respond to the increased steroid requirement after surgery. Supplementation with regular hydrocortisone is given to avoid acute adrenal insufficiency (Addisonian crisis).

### Renal and Hepatic Disease

- Renal and hepatic dysfunction alters the metabolism and disposition of many anesthetic agents and can cause impairment of many systemic functions.
- Chronic renal insufficiency provides many perioperative management challenges including acid-base abnormalities, electrolyte disturbances and coagulation disorders.
- Dialysis should be performed 18 to 24 hrs before surgery to avoid fluid and electrolyte shifts that occur immediately after dialysis.
- The patient with chronic liver disease poses many perioperative challenges; Hypoalbuminemia increases the free fraction of many drugs, making the patients sensitive to both short-and-long term effects of many anesthetic drugs.
- The perioperative evaluation should focus on hepatic synthetic and metabolic function, presence of coagulopathy, encephalopathy, ascites and the nutritional status of the patient. Experience shows that even minor surgery on cirrhotic patients results in high postoperative mortality.

### Neurological Disease

- Cerebrovascular disease.
  - Seizures.
- Cerebrovascular accidents, delirium and cognitive dysfunction are the commonest neurological sequelae to surgery under general anesthesia.
- Risk factors with an increased incidence of postoperative cerebrovascular accidents include age, cerebrovascular disease, hypertension, atrial fibrillation, etc.
- Patients older than 75 yrs. have a three fold increase in risk of delirium.
- Anticonvulsant drugs are continued preoperatively for surgery in epileptic patients and this may necessitate IV administra-



tion if the patient is 'nil by mouth' for a prolonged period.

- In patients with peripheral neuropathies and myopathies the need for prolonged periods of postoperative ventilation should be anticipated.

### Coagulation Disorders

- Bleeding tendency
- Easy bruising.

Coagulation disorders need to be assessed carefully before surgery using a coagulation screen or clotting factor and platelet measurements. Anticoagulated patients taking warfarin are instructed to cease treatment several days preoperatively and their prothrombin time should be measured before surgery.

### Gastrointestinal Disease

- Regurgitation in the presence of full stomach
- Presence of jaundice.

Regurgitation occurs in the presence of full stomach in emergency (nonstarved) patients and in patients with intestinal obstruction, paralytic ileus or hiatus hernia.

In the anesthetized patient, as the airway reflexes have been lost, there is a risk of pulmonary aspiration of regurgitated gastric contents with the potential consequences of acid pneumonitis, severe bronchospasm, pneumonia and death.

### Prevention

- A rapid sequence induction, during which the patient is preoxygenated and cricoid pressure is applied to compress and occlude the esophagus from the time of loss of consciousness until the lungs are protected by tracheal intubation.
- H<sub>2</sub> receptor blocker, e.g. Inj. ranitidine to decrease gastric secretion and hence regurgitation.
- Preoperative nasogastric drainage and aspiration reduces abdominal distension and discomfort but do not abolish the risk of aspiration.

Anesthesia and surgery in the presence of jaundice, carry a high risk of renal deterioration and damage. A good preoperative urine output should be ensured by intravenous infusion of crystalloid solutions.

### Psychiatric Disease

Tricyclic antidepressants and MAO inhibitors potentiate sympathomimetic agents,

so adrenaline and cocaine must be avoided. Pethidine can also cause hypertension in association with these agents.

### Current Drug Therapy

Concurrent drug therapy must be reviewed, since many drugs can interact with anesthetic drugs, e.g. long-term use of an antihypertensive drug can reduce anesthetic requirements and ethanol use can either increase (long-term use) or decrease (acute intoxication), the requirements.

- Antiarrhythmics (quinidine), local anesthetics (lidocaine) and especially antibiotics (aminoglycosides) may enhance the neuromuscular blockade from neuromuscular blocking drugs.
- Barbiturates enhance the metabolism of anesthetic drugs and thereby increase the possibility of a toxic reaction.

Potential drug interactions however do not dictate the need to discontinue preoperatively the drugs that are producing desirable therapeutic responses. Indeed drug therapy with antihypertensives, digitalis, diuretics, antianginal drugs, anticonvulsants and hormone replacement should be continued throughout the perioperative period.

### Starvation Before Surgery

Standard practice for many years has been a 6 hour abstinence from food and a 4 hour abstinence from fluids. Recently there has been a shift to permit clear liquids (not milk which curdles with stomach acid) upto 2 hours preoperatively. These rules apply to elective healthy patients. Small children are usually given a glucose drink about 4 hrs. preoperatively to prevent preoperative hypoglycemia. Guidelines are outlined in Table 15.2.

**Table 15.2: American Society of Anesthesiologist fasting guidelines**

Ingested material	Minimum fast (hours)
Clear liquids	2
Breast milk	4
Infant formula milk	4-6
Nonhuman milk	6
Light meal	6

### Physical Examination

The physical examination should focus on the cardiovascular system, lungs and upper airway. It should include measurements of heart rate and arterial blood pressure obtained in both the supine and standing positions and auscultation for cardiac murmurs or abnormal breathing. If abnormalities found, additional tests like ECG, pulmonary function tests, etc. may be indicated.

### Airway Examination

The airway head and neck should be examined for factors that could make endotracheal intubation difficult, e.g. fat or short neck, limited temporomandibular joint mobility. The most common scoring of the airway as a prediction of difficult endotracheal intubation is the "Mallampati classifications", when the patients uvula is visible with the mouth open the score is grade 1 (easy intubation), in contrast grade IV, exists when the hard palate is visible but not the soft palate. Grade IV suggests a technically difficult endotracheal intubation.

If regional anesthesia is planned the proposed site of injection should be examined for abnormalities and signs of infection and a limited neurologic examination should be performed.

### Laboratory Tests

A system of routine preoperative investigations prior to elective surgery is suggested in the Table 15.3.

### Selection of Anesthetic Agents and Techniques

Many factors are considered in deciding what type of anesthesia will be used.

- Patient factors: Patient's preferences and prejudices and patient's condition.
- Surgical requirements: Individual skill and experience of the anesthetist with the agents and equipment at his disposal, speed and skill of the surgeon, site of surgery and use of electrocautery and need for muscle relaxation.

### Premedication (Preoperative Medication)

Management of anesthesia begins with the preoperative psychological preparation of the patient and administration of a drug or drugs selected to elicit specific pharmacologic

responses. This initial psychological and pharmacologic component of anesthetic management is referred to as preoperative medication.

### Aims

The principal goals of preoperative medication are:

1. To relieve anxiety and provide sedation.
2. To decrease secretion of saliva (antisialagogue effect) and gastric juices.
3. To induce amnesia.
4. To elevate gastric fluid pH.
5. To prevent allergic reactions to anesthetic drugs (i.e. Prophylaxis against allergic reactions).

### Psychological Premedication

Psychological premedication is provided by the anesthesiologist's preoperative visit and interview with patient and family members. A thorough description of the planned anesthetic and events to anticipate in the perioperative period serves as a nonpharmacologic antidote to anxiety.

Perioperative events to be discussed with the patient include the following:

- Time of anticipated transport to operating room for surgery.
- Anticipated duration of surgery.
- Awakening after surgery in the recovery room.
- Likely presence of catheters (Tracheal, gastric, bladder, venous, arterial).
- Time of expected return to hospital room.
- Incidence of postoperative nausea and vomiting, pharyngitis, myalgia.
- Magnitude of postoperative discomfort and methods available for treatment.
- Time, route of administration and expected effects from the preoperative medication.

### Pharmacologic Premedication

Pharmacologic premedication is typically administered orally or IM in the patient's hospital room 1 hour to 2 hours before the anticipated induction of anesthesia. For outpatient surgery premedication is usually administered IV in the immediate preoperative period (15min before induction).

Ideally, all patients should enter the preoperative period free from apprehension, sedated but easily arousable, and fully cooperative.

**Table 15.3: Routine preoperative investigations**

Investigations	Patient Group
1. Full blood count	<ul style="list-style-type: none"> <li>• All females</li> <li>• Men over 40 years of age</li> <li>• All patients undergoing major surgery</li> <li>• Patients in whom anemia is suspected</li> </ul>
2. Creatinine and electrolytes	<ul style="list-style-type: none"> <li>• Patients over 60 years of age.</li> <li>• All patients undergoing major surgery</li> <li>• Patients receiving diuretic drugs</li> <li>• Patients in whom renal disease is suspected</li> </ul>
3. Blood glucose	<ul style="list-style-type: none"> <li>• Diabetic patients</li> <li>• Patients with glycosuria</li> </ul>
4. Coagulation screen	<ul style="list-style-type: none"> <li>• Patients with a history of bleeding tendency</li> <li>• Patients undergoing major surgery</li> </ul>
5. Chest X-ray	<ul style="list-style-type: none"> <li>• Patients with acute cardiac or chest disease that has worsened in the last year</li> <li>• Patients with a risk of pulmonary tuberculosis (History of contact or immunocompromise)</li> <li>• Patients with malignant disease</li> </ul>
6. ECG	<ul style="list-style-type: none"> <li>• Patients over 50 years or age</li> <li>• Patients with a history of heart disease, hypertension or chronic lung disease</li> </ul>
7. Urinalysis for sugar, blood and protein	<ul style="list-style-type: none"> <li>• All patients</li> </ul>
8. Pregnancy test	<ul style="list-style-type: none"> <li>• All women for whom there is any chance of pregnancy.</li> </ul>

### Drugs for Preanesthetic Medication (Table 15.4)

The common drugs used and their doses should be modified according to age (elderly and less than 1 year of age require little or no premedication), physical condition mental status and choice of anesthetic agent.

### TECHNIQUES OF ANESTHESIA

After the preoperative evaluation, the anesthesiologist selects the technique of anesthesia either a general anesthetic, regional anesthetic or peripheral nerve block.

The technique of anesthesia is determined by several considerations. In many instances more than one technique of anesthesia may be acceptable. It is the responsibility of the anesthesiologist to evaluate the medical condition and unique needs of each patient and to select an appropriate technique of anesthesia.

### GENERAL ANESTHESIA

General anesthesia describes a triad of three major and separate effects: unconsciousness and amnesia, analgesia and muscle relaxation.

Intravenous anesthetic drugs usually produce a single discrete effect, unconsciousness while most inhaled anesthetics produce elements of all three.

General anesthesia is achieved with a combination of intravenous and inhaled drugs, each used to its maximum benefit. The science and art of anesthesia is a dynamic process. As the amount of stimulus to the patient changes during surgery the patient's vital signs are used as a guide and the quantity of drugs is adjusted, maintaining an equilibrium between stimulus and dose.

### Intravenous Agents

The intravenous agents that produce unconsciousness and amnesia are frequently used for the induction of general anesthesia. They include Barbiturates (thiopentone), benzodiazepines (midazolam), propofol, etomidate and ketamine. Except ketamine others have neither analgesic properties nor do they cause paralysis or muscle relaxation.

### Thiopentone

Thiopentone is the most commonly used barbiturate and the drug against which all other

**Table 15.4: Drugs and doses used for preanesthetic medication.**  
IM – intramuscular, IV – intravenous.

Drug	Dosage	Route of Administration
<b>A. Barbiturates</b>		
• Pentobarbital (Nembutal)	50 – 150 mg	Orally, IM
• Secobarbital (Second)	50 – 150 mg	Orally, IM
<b>B. Benzodiazepines</b>		
• Diazepam (Valium)	5 – 10 mg	Orally, IM
• Midazolam	2.5 – 5 mg	IM
<b>C. Narcotics</b>		
• Morphine sulfate	5 – 15 mg	IM
• Meperidine (pethidine)	50 – 100 mg	IM
<b>D. Antihistamines</b>		
• Promethazine	25 – 50 mg	Orally, IM
• Diphenhydramine	25 – 75 mg	Orally
• Belladonna	0.3 – 0.6 mg	IM
<b>E. Alkaloids</b>		
• Atropine	0.2 – 0.3 mg	IM
• Glycopyrrolate	0.1 – 0.3 mg	IM
<b>F. H<sub>2</sub> receptor antagonist, e.g. Ranitidine</b>	150 mg	Orally, IM
<b>G. Stimulants of gastric motility, e.g. Metoclopramide</b>	10 – 20 mg	Orally, IM or IV

drugs used for induction of anesthesia are compared.

It is the ultrashort acting barbiturate who's pneumonic is nembutal (N-Ethyl Methyl butyl Thiobarbiturate). It was first used in clinical practice in 1934 by Lundy and Waters.

Thiopentone sodium occurs as a pale yellow powder with a bitter taste resembling Hydrogen sulphide. The freshly made solution with water (2.5%) has a pH of 10.6. In solution it is not very stable.

### Clinical Effects

1. *Central nervous system (CNS):* General depression of the CNS is observed within 15 to 20 seconds of IV injection of thiopentone. It is a potent anticonvulsant.

It is not an analgesic, rather antianalgesic and consciousness is regained within 5 to 10 minutes because of redistribution of the agent from the brain to peripheral tissues especially muscle and fat.

2. *Cardiovascular system:* It causes myocardial depression and peripheral vasodilation, especially when large doses are administered rapidly.

Arterial pressure decreases and profound hypotension may occur, especially

in a patient with hypovolemia or cardiac disease. It may induce tachycardia.

3. *Respiratory system:* Barbiturates depress medullary respiratory center. Indeed a short period of apnea is common following induction of anesthesia with barbiturates which may require controlled ventilation of the lungs.

4. *Skeletal muscle:* There is poor muscle relaxation with thiopentone.

5. *Eye:* It reduces intraocular pressure. The corneal, conjunctival, eyelash and eyelid reflexes are abolished.

### Dose

- 4 to 5 mg/kg IV
- 30 to 40 mg/kg rectally (5 – 10% solution) for children.

### Metabolism

Thiopentone is eliminated almost entirely after its metabolic degradation in liver, less than 0.5 percent being excreted unchanged in the urine.

### Contraindications

- A. Absolute
- Hypersensitivity.
  - Acute intermittent porphyria, as it precipitates the condition.

iii. If equipment's for resuscitation and ventilation are not available.

### B. Relative

- Bronchial asthma.
- Hypovolemic shock.
- Fixed cardiac output states, e.g. MS. A S, constrictive pericarditis.

### Indications

- For the induction of anesthesia.
- As a sole anesthetic in short surgical procedures.
- For the relief of acute convulsion.
- For sedation.

### Complications

- Perivenous injection*—Cause pain, redness, swelling even necrosis and ulceration, as the solution is highly alkaline. Treatment includes injection of 10 ml of 1 percent procaine to dilute the thiopentone and to promote vasodilation as well as absorption.
- Intraarterial injection*—Inadvertent intra-arterial injection of thiopentone is dangerous as there is precipitation of solid crystals of thiopentone resulting in endothelial damage and arterial thrombosis.

### Treatment

- Intraarterial injection of procaine HCl 10 to 20 ml of 0.5 percent solution or papaverine 40 to 80 mg in 10 to 20 ml of saline.
- Anticoagulant therapy if thrombosis occurs.
- Anaphylactoid reactions—very rare, about 1 on 15000 administrations.

### Ketamine

It is a phencyclidine derivative, introduced by Corssen and Domino in 1965. It was released for clinical use in 1970 and still enjoys use in a variety of clinical settings.

It is a white crystalline powder. In solution form it is available in concentration of 10, 50 and 100 mg ketamine base per ml of sodium chloride containing the preservative benzenethonium chloride.

The drug produces a state of dissociative anesthesia (Complete dissociation between thalamus and limbic system).

### Clinical Effects

- Central nervous system*—It induces anesthesia within 30 to 60 seconds of IV

injection because of high lipid solubility and the action lasts for 5 to 10 min. It is effective within 3 to 4 min. after IM injection and lasts for 15 to 25 min.

It is a potent analgesic. Inductions are smooth but emergency delirium can occur. Vivid and unpleasant hallucinations are known with Ketamine and can be prevented by premedications with injection of droperidol or benzodiazepines like midazolam, lorazepam or diazepam.

It increases cerebral metabolism, blood flow and intracranial pressure.

2. *Cardiovascular system*—The heart rate, blood pressure and cardiac output will increase.
3. *Respiratory system*—Transient apnea may occur but respiration is well maintained thereafter. It is also a good bronchodilator.
4. Skeletal muscle tone is increased and spontaneous movements may occur.
5. *Eye*—Intraocular pressure increases.

### Dose

- 2 mg/kg intravenously.
- 5 to 10 mg/kg intramuscularly.

### Metabolism

It is metabolized by the hepatic microsomal enzyme to form no ketamine, which is then hydroxylated to form hydroxynorketamine. Less than 4 percent of ketamine can be recovered from the urine and less than 5 percent of injected ketamine undergoes fecal excretion.

### Clinical Uses

1. As a sole anesthetic agent, e.g. dressing of burns, endoscopy, etc.
2. As an induction agent.
3. For induction in shock and poor risk patients with severe dehydration, anemia, cardiovascular instability, etc.
4. For postoperative *analgesia* in recovery room and in intensive care units.
5. In patients with reactive airway disease, e.g. asthmatics with acute bronchospasm and COPD with bronchospasm.

### Contraindications

1. In patients with hypertension and psychiatric illness, e.g. schizophrenia.
2. CNS disorders, e.g. cerebral trauma, intracerebral hemorrhage or mass.
3. Open globe injury to eye.

4. ENT procedures involving pharynx, larynx and trachea.

5. Eclampsia.

### Benzodiazepines

Three benzodiazepines commonly used in anesthesia are midazolam (short acting) Lorazepam (intermediate-acting) and diazepam (long-acting). They produce their actions by occupying the benzodiazepine receptor.

All benzodiazepines have hypnotic, sedative, anxiolytic, amnesic anticonvulsant and centrally acting muscle relaxant properties.

### Clinical Uses

1. Preoperative medication.
2. Intraoperatively during regional or local anesthesia.
3. Suppression of seizure activity:
4. Induction of anesthesia: Midazolam is the agent of choice for its faster onset of action. Dose 0.1 – 0.2 mg/kg IV. Diazepam 5 mg to 10mg or midazolam 1 to 2.5 mg administered IV is useful for sedation during regional anesthesia.

### Propofol (Phenol derivative)

This drug became commercially available in 1986. It is comparable to thiopentone but is five times more expensive. It is highly lipid-soluble and is formulated in a white, aqueous emulsion containing soybean oil and egg phosphatide.

Propofol depresses central nervous system within 20 - 40 seconds of injection. Loss of verbal contact is used as an end point. Recovery is rapid and there is minimal hangover effect even in the immediate postanesthesia period.

- Dose: 1.5 to 2.5 mg/kg. The effect lasts for 5 to 10 min. It is the agent of choice for outpatient anesthesia (minimum hangover).
- Propofol causes more respiratory depression than thiopentone.
- Hypotension and fall in peripheral vascular resistance are more marked with propofol as compared with thiopentone.

### Clinical Use

Propofol is suitable both for induction as well as maintenance. Maintenance dose is

50 to 150 mcg/kg/min IV combined with N<sub>2</sub>O or opioids.

### Side Effects

1. Cardiorespiratory depression
2. Pain on injection
3. Allergic reactions.

### Etomidate (Imidazole Derivative)

This is also a rapidly acting intravenous anesthetic agent. Dose is 0.1 to 0.4 mg/kg IV Spontaneous awakening occurs in 7 – 14 min. So it is useful for outpatient procedures, e.g. Bronchoscopy and other short operations.

Etomidate depresses the synthesis of cortisol by the adrenal gland and impairs the response to ACTH. Hence long-term infusions are not advisable.

It is frequently associated with postoperative nausea and vomiting, rapidly metabolized in the liver and decomposed products are excreted in urine and bile.

### Inhalation Induction Agents

More commonly volatile or inhalational agents provide the basis of general anesthesia. The differing physicochemical properties of the different volatile agents will affect their pharmacological effects (Table 15.5) Thus agents with low blood/gas solubilities, e.g. N<sub>2</sub>O, desflurane and sevoflurane will cause rapid onset and recovery of central nervous system effects. The oil/gas solubility reflects one index of potency, defined in terms of the minimum alveolar concentration (MAC) which is the alveolar concentration preventing a response to a surgical incision in 50 percent of subjects, i.e. ED<sub>50</sub>.

Blood/gas coefficient indicates relative affinity of an anesthetic for blood compared to gas at equilibrium. The larger the coefficient, the greater the affinity of the drug for blood and hence the greater the quantity of drug contained in the blood.

Oil/gas partition coefficient indicates lipid solubility and correlates closely with anesthetic potency.

### Ideal Inhalational Anesthetic Agent

An ideal inhalational anesthetic agent would be characterized by:



**Table 15.5: Important physical characteristics of volatile anesthetics**

Agent	Oil/gas coefficient	* MAC (% at Sea level)	Blood/gas coefficient
1. Halothane	224	0.74	2.5
2. Enflurane	96.5	1.68	1.8
3. Isoflurane	90.8	1.15	1.4
4. Desflurane	18.7	6.00	0.45
5. Sevoflurane	47.2	2.00	0.65
6. N <sub>2</sub> O	1.4	104	0.47
7. Diethyl ether	65	1.92	12

\* MAC – Minimum Alveolar Concentration. Potency  $\propto$  1/MAC.

1. Rapid and pleasant induction of and recovery from anesthesia.
2. Adequate relaxation of skeletal muscles.
3. Absence of toxic effects or other adverse properties in normal doses.
4. Minimum or no depression of the cardiovascular and respiratory systems.
5. The agent producing rapid changes in the depth of anesthesia.
6. Nonflammable and nonexplosive.
7. No serious interactions with drugs such as adrenaline or MAO inhibitors.
8. Rapid elimination in an unchanged manner via the lungs.

It is a matter of regret that none of the inhalational anesthetic agents fulfill the properties of an ideal agent.

### Classification

- a. Halogenated hydrocarbons viz.
  - Halothane
  - Chloroform
  - Trichloroethylene
- b. Anesthetic ethers viz.
  - Diethyl ether, enflurane, isoflurane, methoxyflurane (not used nowadays), desflurane, sevoflurane.
- c. Anesthetic gases – N<sub>2</sub>O and cyclopropane. The important agents are described below in brief.

### Diethyl Ether

This is probably the most extensively used volatile anesthetic agent in terms of quantity. The reason for this is its wide safety margin, low cost and ease of administration.

It was first used by WTG Morton in 1846. It is kept in amber colored bottle, wrapped in black paper, as it forms peroxide and toxic aldehyde in presence of light.

Physical properties—described in the table above.

### Pharmacologic Properties

- It causes an increase in sympathoadrenal activity liberating the catecholamines which results in bronchodilatation and increased muscle blood flow.
- Ether causes good skeletal muscle relaxation and there is progressive dilatation of pupils. Nausea and vomiting are common after ether anesthesia (50%).
- Drug interactions (i) with  $\beta$  blockers, severe hypotension precipitates. (ii) It potentiates the nondepolarizing neuromuscular block.

### Ether Convulsion

Occurs in children and in disease states like sepsis with high temperature.

- It is treated by administration of O<sub>2</sub> thiopentone or diazepam and artificial respiration.
- Unlike halothane, respiratory depression precedes cardiac depression, with ether.
- Stages of ether anesthesia.

There are four stages viz. (a) Stage of analgesia (b) Stage of excitement or delirium (c) Stage of surgical anesthesia having four planes and (d) Stage of medullary paralysis leading to respiratory and cardiac arrest.

### Halothane

- It was first prepared by Suckling in 1951 and first used clinically by Johnston of Manchester in 1956.
- Physical properties have been described in the above table.
- Pharmacologic properties: It is a potent anesthetic (MAC – 0.75) but a poor analgesic agent. It produces dose dependent depression of the cardiovascular system, including hypotension and bradycardia. Dysrhythmias are common in presence of hypercarbia.

Halothane sensitizes myocardium to the dysrhythmic effects of catecholamines.

- It increases cerebral blood flow and intracranial pressure. It depresses the central nervous system, vasomotor centre and sympathetic ganglion.
- It is less irritating to the respiratory tract than ether but may produce laryngospasm in children. It potentiates the action of muscle relaxants.
- The hepatotoxic action of halothane is well-documented but the exact mechanism is still not clear.

### Method of Administration

Halothane should always be used through specialized vaporizer, known as Goldman vaporizer.

Like all inhalational anesthetics, apart from N<sub>2</sub>O it is associated with malignant hyperpyrexia.

### Contraindications

Pyrexia following administration of Halothane and history of jaundice are absolute contraindications.

### Enflurane

It is a halogenated ether and a volatile liquid anesthetic. It was introduced in clinical practice by Dobkin and associates in 1968. It is a clear, colorless liquid with a pleasant smell.

*Physical Characteristics* – As described in the table above.

### Pharmacological Properties

It depresses the central nervous system and at a concentration above 3 percent, there may be epileptiform EEG changes. Hence it is best avoided in epilepsy patient. It produces dose-dependent reversible myocardial depression. It may cause hepatotoxicity and hypothermia but less commonly than halothane.

It produces moderate muscular relaxation and excreted unchanged through the lungs. About 3 percent of it is metabolized and excreted through the kidney.

### Isoflurane

It is an isomer of enflurane, first synthesized in 1965 and introduced in clinical anesthesia in 1971. Hepatotoxicity is rare. Induction and recovery with isoflurane are rapid. It has no effect on liver and kidney and is virtually

unmetabolized and excreted unchanged from the body.

### Sevoflurane

A low blood/gas solubility coefficient facilitates rapid induction and emergence. This means that postoperative pain relief must be planned well. It is well-suited for outpatient surgery.

### Desflurane

This is fluorinated Methyl–Ethyl ether. Its effect on the cardiovascular and respiratory systems are similar to isoflurane. Myocardium is not sensitized to catecholamines. Its high cost, may, however be a negative factor.

### Nitrous Oxide

- Nitrous oxide provides only partial anesthesia at atmospheric pressure.
- It is a potent analgesic but only a weak anesthetic. It does however, potentiate the effect of other inhalational anesthetic agents allowing a reduction in the dose required.
- A mixture of 50 percent N<sub>2</sub>O and oxygen (Entonox) is used for analgesia especially in obstetrics and emergency departments.
- It produces no muscular relaxation.
- After prolonged anesthesia, N<sub>2</sub>O accumulate in the cavities of the body, e.g. bowel, middle ear, etc.
- At the end of anesthesia, inspired oxygen concentration is reduced due to the outward movement of expired nitrous oxide (diffusion hypoxia).

## Neuromuscular Blocking Agents

### Why used?

The addition of muscle relaxants affords the opportunity to deliver only sufficient inhalational and intravenous agents to achieve hypnosis, amnesia and analgesia while still providing satisfactory operating conditions.

### Types

There are two types of muscle relaxants viz. Depolarizing and nondepolarizing muscle relaxants.

### I. Depolarizing Muscle Relaxants

They act by causing depolarization block and maintaining the muscle in the depolarized or

relaxed state. It is typically produced by suxamethonium or decamethonium.

*Duration of action:* 3 to 5 min.

### Suxamethonium

It is the only depolarizing agent still in use. It has a structure similar to two acetylcholine molecules and acts in the same way at the neuromuscular junction. The rate of hydrolysis, by plasma cholinesterase, is however much slower, thus depolarization is prolonged resulting in blockade. Its action therefore, cannot be reversed. Because it acts on the acetylcholine receptor there is an initial period of muscle fasciculation which may be painful and distressing to the patient.

### Clinical Use

1. Crush induction—It is the most rapid acting of all the muscle relaxants and is therefore, useful when rapid tracheal intubation, called crush induction is required.
2. For electro convulsive therapy.
3. In repeated doses for longer abdominal operations.

**Dose:** 1 to 1.5 mg/kg body wt. IV

### Disadvantages

1. Prolonged apnea—Some people have deficiency of plasma cholinesterase and thus have prolonged response, called scoline apnea.
2. Dual block—or phase II block occurs if the total dose of suxamethonium is > 500 mg in 1 hr.
3. Hyperkalemia—Occurs if it is given in patients with burn, tetanus and spinal cord injury.
4. Raised intraocular pressure—so contraindicated in patients with penetrating eye injury.
5. Malignant hyperpyrexia.
6. Muscle pain.
7. Anaphylactic response.

## II. Nondepolarizing Muscle Relaxants

They compete with acetylcholine for the end plate receptors at the postjunctional membrane thereby causing nondepolarizing or competitive type of block. Once a significant number of receptors are blocked the end plate potential (EPP) fails to reach the triggering

threshold leading to the block of neuromuscular transmission.

- They are long-acting muscle relaxants.
- Their action is opposed by increasing the local concentration of acetylcholine, e.g. by giving anticholinesterase agents like neostigmine.
- Their action is potentiated by certain antibiotics, e.g. aminoglycosides and volatile anesthetics like ether, halothane, Enflurane and isoflurane and Mg<sup>++</sup>.

### Characteristics of Nondepolarizing Block

1. Absence of fasciculations.
2. There is unsustained response to tetanic stimulation also called the ‘fade’ response.
3. Presence of posttetanic potentiation or stimulation.
4. Antagonized by anticholinesterase agents.
5. 75 percent of receptors must be blocked to see neuromuscular blockade reflected by twitch response and greater than 90 percent for failure in transmission.

Commonly used nondepolarizing agents are:

- d – tubocurarine,
- Gallamine
- Pancuronium
- Vecuronium
- Atracurium
- Mivacurium
- Rocuronium

The characteristics of nondepolarizing muscle relaxants are given in table 15.6

### Clinical Uses

1. To facilitate intubation when succinylcholine is contraindicated.
2. For maintenance of paralysis during anesthesia and in ICU.

### Reversal of Neuromuscular Blockade

At the end of anesthesia, the muscle relaxation produced by nondepolarizing muscle relaxant is usually reversed. This is to ensure good recovery of muscle power to maintain airway and respiration.

Anticholinesterase agent, neostigmine is used for this purpose but the resulting muscarinic action may induce a profound, bradycardia, bronchoconstriction, etc. and is therefore given with atropine or glycopyrrolate.



**Table 15.6: Characteristics of nondepolarizing muscle relaxants**

Agent	Dose (mg/kg)	Duration (min)	Metabolism	Elimination	Comments
1. Pancuronium	0.08 – 0.1	30 – 40	Hepatic 10 – 20%	Renal 85% Hepatic 15%	It causes histamine release, hypertension and tachycardia.
2. Vecuronium	0.08 – 0.1	15 – 20	Hepatic 30 – 40%	Renal 40% Hepatic 60%	Least cardiovascular and respiratory side-effects Minimum histamine release.
3. Atracurium	0.3 – 0.5	10 – 20	Hoffman elimination, nonspecific ester hydrolysis.	Renal 10 – 40% Hepatic 0%	Dose – related histamine release. Used in renal failure
4. Mivacurium	0.15 – 0.2	15 – 20	Plasma cholinesterase	Renal 5% Hepatic 0%	Histamine release. Prolonged action in presence of atypical pseudocholinesterase
5. Rocuronium	0.6 – 1.2	15 – 20	None	Renal <10% Hepatic >70%	Minimal histamine release
6. Gallamine	1 – 1.5	20 – 30	None	Renal 95% Hepatic 0%	It is not a popular drug nowadays, as better drugs are available.
7. d-Tubocurarine	0.2 – 0.5	20 – 25	None	Renal 45% Hepatic 10 – 40%	Hypotension and tachycardia Not used nowadays.

### Dose

Neostigmine – 0.05 – 0.08 mg/kg IV

Atropine – 0.025 – 0.04 mg/kg IV

Glycopyrrolate – 0.01 mg/kg IV

## Management of General Anesthesia

### Induction

General anesthesia can be induced by giving drugs intravenously, by inhalation or by a combination of both methods.

### Rapid Sequence Induction

Anesthesia is most commonly induced by the method of rapid sequence induction in which rapid administration of an ultrashort acting barbiturate (e.g. Thiopentone) is followed by a depolarizing muscle relaxant, e.g. succinylcholine. While other drugs can be used like ketamine, propofol, etomidate for rapid sequence induction of anesthesia, the combination of thiopental and succinylcholine is the standard against which others must be compared. This approach allows anesthesia to be induced within 30 seconds and trachea to be intubated within 60 to 90 seconds. Oxygen is usually given by mask before hand (Preoxygenation) to allow maximum time for intubation while the patient is apneic.

Rapid sequence induction is the method of choice in emergency surgery in patients who have eaten recently.

### Inhalation Induction

Inhalation of nitrous oxide, oxygen plus a potent volatile anesthetic, e.g. halothane, sevoflurane, desflurane or isoflurane can produce anesthesia within 3 – 5 min. After induction, a depolarizing or nondepolarizing neuromuscular blocking drug can be given intravenously to facilitate tracheal intubation. If there is some question about the difficulty of intubation, it can be attempted while the patient is breathing spontaneously, without giving a muscle relaxant.

Inhalation induction is useful in young children or 'Needle – phobic' adults and may also be used for patients at risk of developing airway obstruction.

Analgesic agents are also frequently injected at the time of anesthetic induction to reduce the cardiovascular response to tracheal intubation and to be effective by the time of surgical incision.

### Combined Intravenous – Inhalation Induction

Short-acting anesthetic drugs such as thiopental, propofol or midazolam are often administered intravenously before inhalation

of a volatile anesthetic. This is done to minimize the discomfort of wearing the anesthetic mask and to facilitate inhalation of anesthetic agent, which many people consider to have an offensive odor. This technique combines the advantages of both the intravenous and inhalation approaches.

Anesthesia is induced rapidly and anesthetic drug dosage can be titrated according to the patient requirements.

### Maintaining The Airway

General anesthesia reduces the tone of the muscles that preserve the airway patency and hence there is a requirement for methods such as manual techniques, e.g. jaw-thrust, or devices such as the face mask or laryngeal mask or endotracheal tube to preserve the airway. Sir Ivan Magill developed the endotracheal tube during the First World War to facilitate plastic surgery around the mouth without a face mask. The addition of a cuff to the tube allowed a seal of the trachea to protect the lungs from aspiration of blood or secretions and later to facilitate mechanical positive pressure ventilation.

### Indications of Endotracheal Intubation

1. To provide positive pressure ventilation, e.g. when neuromuscular blocking drugs are given.

2. To provide adequate ventilation when position of the patient is other than supine and when ventilation provided by mask or laryngeal mask airway is not sufficient.
3. When disease of upper airway is present.
4. To provide tracheal or bronchial suctioning.
5. To prevent aspiration of gastric contents.
6. To provide a patent airway.

### Complications of Endotracheal Intubation

Although endotracheal intubation is generally straight forward complications do occur, e.g

- Accidental and unrecognized esophageal intubation.
- Accidental intubation of a main bronchus.
- Trauma to larynx, trachea or teeth.
- Aspiration of vomitus during intubation.
- Disconnection or blockage of the tube.

### Complications Following Extubation

- a. *Early*—Laryngospasm, aspiration of gastric contents, pharyngitis (sore throat), laryngitis and laryngeal or subglottic edema.
- b. *Late*—Laryngeal ulceration with or without granuloma formation, tracheal stenosis, etc.

Careful observation of physical signs and constant vigilance aided by pulse oxymetry, capnography of the expiratory gases, inspiratory oxygen concentration, measurement and ventilator disconnection alarms, are mandatory to minimize these risks.

### Maintaining General Anesthesia

Following the induction of anesthesia, inhalational or intravenous anesthetic agents are administered to maintain an adequate depth of anesthesia.

Adding N<sub>2</sub>O contributes analgesic and weak anesthetic effects which reduce the concentration of volatile anesthetic agent required for maintenance. To provide a safety margin at least 30 percent oxygen is added to the inspired mixture.

Although still employed in some parts of the world, ether has generally been replaced by halothane, enflurane and isoflurane. Desflurane and sevoflurane are the most recently introduced agents, conferring the advantages of fewer side effects and more rapid recovery.

IV anesthesia avoids atmospheric pollution and is usually conducted by infusing thiopentone or propofol and a short-acting opioid analgesic agent fentanyl or Alfentanil in combination with neuromuscular block and pulmonary ventilation with a mixture of N<sub>2</sub>O and oxygen. With a combined opioid nitrous oxide anesthetic, muscle relaxants are more frequently needed to facilitate skeletal muscle relaxation.

### MONITORING DURING ANESTHESIA

Accurate monitoring of vital functions is now regarded as obligatory in all parts of the world. Even for procedures under sedation, basic monitoring is essential.

The basic parameters monitored are inspiratory oxygen concentration, O<sub>2</sub> saturation by pulse oxymetry, expiratory CO<sub>2</sub> measurement, blood pressure and electrocardiogram.

### Clinical Monitoring

#### Inspection

- Skin—Color, capillary refill.
- Eyes—Lacrimation occurs when depth of anesthesia decreases, pupils—size, reactivity.
- Nailbeds—Color, capillary refill.
- Mucous membranes—Color, moisture.

#### Palpation

- Pulse—Fullness, rate and regularity.
- Skin—Temperature and texture.

#### Auscultation

- Chest—Ventilation and cardiac sounds.

### Routine Monitors in Anesthetized Patients

1. Blood pressure
2. Precordial or esophageal stethoscope.
3. Electrocardiogram.
4. Pulse oximeter – Provides continuous assessment of the patient's oxygenation.
5. Oxygen supply failure alarm.
6. Ventilator disconnection alarm.

### Common but not in routine

7. Capnography—Measurement of CO<sub>2</sub> concentration in the inhaled and exhaled gases of the patient.

8. Urine output
9. Body temperature especially in children.
10. A peripheral nerve stimulator should be readily available for evaluation of neuromuscular blockade.

The presence of an anesthetist during the entire procedure is mandatory.

### RECOVERY FROM GENERAL ANESTHESIA

Recovery from general anesthesia should be closely supervised by trained nursing staff and an anesthetist in an area equipped with the means of resuscitation and with adequate monitoring devices. For the seriously ill patient a high dependency unit or an intensive care unit may be necessary until the patient's condition is satisfactory.

The transition from tracheal intubation with ventilatory support to spontaneous breathing with an unprotected airway is a time of increased risk when respiratory arrest or obstruction may occur. The common causes of failure to breathe after general anesthesia are:

- i. Postoperative hypoxia of any cause.
- ii. Hypocarbica from mechanical over-ventilation.
- iii. Persistent neuromuscular block.
- iv. Circulatory failure leading to respiratory arrest.
- v. Alveolar hypoventilation from opioid drugs, or anesthetic agents.

### REGIONAL ANESTHESIA

Spinal, epidural and caudal blocks are commonly referred to as regional or conduction block anesthesia. A regional anesthetic is used when it is desirable that the patient remains conscious during the operation.

Locoregional anesthesia using local anesthetic agents reduces the nociceptive impulses from reaching the central nervous system during and after surgical procedures.

Skeletal muscle relaxation is excellent, especially with spinal and epidural anesthesia. Thus muscle relaxants are unnecessary.

Regional anesthesia is used most often for surgery of the lower abdomen or lower extremities since the effect of sympathetic blockade of these areas is minimal.

*Advantages* of regional anesthesia include reduced physiological derangement associated with surgery, less risk of pulmonary aspiration, as airway reflexes are not obtunded and the provision of postoperative analgesia.

*One disadvantage* of regional anesthesia is the occasional failure to produce adequate depth of anesthesia, another is hypotension due to sympathetic blockade.

For some operative procedures, regional anesthesia is preferred over general anesthesia, e.g. transurethral resection of prostate (TURP).

## LOCAL ANESTHETIC AGENTS – PHARMACOLOGY

### Definition

Local anesthetics are drugs that reversibly block the conduction of impulses in the peripheral nerves.

### Types

These agents can be classified as esters and amides.

*Esters*—(Coo<sup>-</sup>)—Cocaine, procaine, Chlorprocaine. They cannot be autoclaved and are associated with a high incidence of hypersensitivity reactions.

*Amides* (NHCo<sup>-</sup>)—Lignocaine, bupivacaine, ropivacaine, mepivacaine and etidocaine. They are preferred to esters because of disadvantages associated with the use of the latter mentioned above.

### Use

Local anesthetic agents are used for local infiltration, peripheral nerve blocks, obstetric analgesia, acute and chronic pain relief, spinal, epidural and caudal anesthesia.

### Ideal Local Anesthetic Agent

Should have a quick onset of action, long duration of action, should not cause motor blockade, and should be free from cardiac toxicity.

### Mechanism of Action

Local anesthetics act by blocking the receptors within the sodium channels from inside thereby stabilizing the membrane, which

results in a decreased rate of depolarization and nerve conduction.

### Lignocaine

- It was introduced into clinical practice in 1948.
- It has a quick onset and short duration of action compared to bupivacaine. It is effective by all routes of administration.
- The concentration varies according to method of administration, e.g. local infiltration 0.5 percent, nerve blocks – 1.5 percent, epidural anesthesia – 2 percent, 2 percent jelly for urethral dilatation, 4 percent spray for tracheal intubation, 5 percent heavy for spinal block.
- Maximum dose—In most cases the maximum dose in 3 mg/kg (200 mg for an adult) without adrenaline or 6 mg/kg (400 mg for an adult) with adrenaline.
- Lignocaine is cheap and sterilization, done by autoclaving.
- It produces anesthesia lasting for 60 to 90 minutes.

### Bupivacaine

- There is delayed onset and longer duration of action as compared to lignocaine.
- Causes less motor blockade.
- 0.25 percent solution is used for local infiltration, 0.125 percent for continuous epidural analgesia, and 0.5 percent for spinal and epidural anesthesia.
- Maximum safe dose is 2 mg/kg with or without adrenaline.
- Its advantage is that anesthesia lasts for 3 to 6 hrs, about 3 times as long as with lignocaine. So it is the best drug for regional blocks.
- Recently introduced, the levobupivacaine isomer is claimed to have an improved cardiovascular safety profile.

### Ropivacaine

Structurally, the propyl group of bupivacaine is replaced with a butyl group to produce ropivacaine.

### Dose

Maximum safe dose—3 mg/kg without adrenaline and 8 mg/kg with it. A higher dose can be used because of lack of cardiotoxicity.

It provides relatively greater sensory than motor blockade.

## TYPES OF REGIONAL ANESTHESIA

### General Considerations

- NPO (Nothing per oral) status—Because any regional anesthetic may progress to general anesthetic NPO requirements for regional and general anesthetics are identical.
- Monitoring requirements—are no different from those for general anesthesia. oxygen saturation measurement by pulse oxymetry is required for monitoring during regional anesthesia.

In emergency surgery, regional anesthesia carries the advantage of preservation of the protective laryngeal reflexes, particularly in emergency obstetric anesthesia. It is better to administer regional anesthesia for patients who have debilitating respiratory disease.

In cardiovascular disease, however, general anesthesia with support of the circulation and pulmonary ventilation is often more advantageous than risking hypotension and tachyarrhythmia exacerbating ischemic heart disease and resultant angina, which may occur with regional anesthesia.

### Types

1. Local infiltration
2. Tropical anesthesia
3. Plexus blocks
4. Field blocks
5. Intrathecal anesthesia.
6. Epidural anesthesia
7. Intravenous blocks.

### Local Infiltration

This is the method most commonly used by both surgeons and physicians. It is not necessary to starve the patient preoperatively.

It is used during wound debridement, central venous catheter placement or repair of minor lacerations. The agent of choice is lidocaine 1 to 2 percent due to its quick onset and low toxicity.

Epinephrine should not be used in areas at risk of vascular compromise from arterial spasm, e.g. nose, ears, fingers, toes or penis.

*Contraindications:* Local infection and clotting disorder.

### Tropical Anesthesia

Tropical anesthetic agents are used on the skin, the urethral mucosa, nasal mucosa and the cornea. The agents used are amethocaine, lignocaine and prilocaine.

### Plexus Blocks

- Brachial plexus block—This is done for surgery on the arm or hand. Injection of local anesthetic solution is given into the sheath surrounding the brachial plexus.
- Cervical plexus blockade—This indicated for carotid endarterectomy and is the anesthetic method of choice.

### Field Blocks

- For hernia repair—Iliohypogastric and ilioinguinal nerves are blocked immediately inferomedial to the anterior superior iliac spine. The genitofemoral nerve is infiltrated at the midinguinal point and at pubic tubercle. The line of skin incision should be infiltrated with local anesthetic. Local anesthetic lignocaine with adrenaline 1:200000 prolong the duration of action and reduce toxicity by producing vasoconstriction.
- Regional block of the ankle—This is used for surgery on the toes and minor surgery of the foot.

### Intrathecal Anesthesia and Epidural Anesthesia

The knowledge of anatomy of the spinal cord and vertebral column is essential for the correct observation of the above two methods.

#### Spinal Cord

This is the extension of the central nervous system and has the following features.

- The cord extends to various levels depending on the age of the individual. In the fetus the cord is at the level of S<sub>2</sub> vertebra, by the age of 20yrs, it is at its permanent level, i.e. at the level of lower border of L1 vertebra.
- The length of the cord is 45cm.
- The level of the line connecting the highest point of the iliac crest corresponds to the spine of L<sub>4</sub> vertebra. This is an important landmark in the procedure of lumbar puncture.
- Below the level of L1 vertebra, the nerve roots pass vertically downwards in the subarachnoid space forming the cauda

equina. Thus any injection given at a level below L<sub>2</sub> is likely to touch the nerve roots, but unlikely to damage them.

- The subarachnoid space contains CSF but is not one continuous space as is often thought of. It is frequently broken up into many subspaces by the presence of denticulate ligament, trabecula and the nerve roots themselves. This creates a possibility of uneven distribution and may account for the occasional erratic effects seen in spinal anesthesia.

### Vertebral Column

It comprises of the vertebrae with the intervening intervertebral disk. Its special features are:

- When the spinal anesthesia needle is inserted, its direction depends on the direction of the spinous processes. The spinous processes of certain vertebrae are opposite their respective vertebral bodies, including all cervical vertebrae, first two thoracic and last four lumbar vertebrae. The other vertebrae have their spinous processes directed downwards and opposite its lower vertebral body.
- The stability of vertebral column is dependent on a number of ligaments which interlink the various vertebrae. They are:
  - Supraspinous ligament—It joins the tips of the adjacent spinous processes.
  - Interspinous ligament—They are relatively weaker and unite the spinous processes along their adjacent borders.
  - Ligamentum flava—They join the contiguous borders of adjacent laminae.
  - Posterior longitudinal ligament—It is present on the posterior surface of the bodies of the vertebra.
  - Anterior longitudinal ligament—It is present on the anterior surface of the vertebral bodies.

Midline spinal needle puncture pierces the following from outside inwards. Supraspinous ligament, interspinous ligament, and the ligamentum flava.

### Anatomical Landmarks

Various anatomical landmarks that have to be kept in mind in spinal and epidural analgesia are:

- Vertebra prominens – C<sub>7</sub>

- Spine of scapula – T<sub>3</sub>
- Inferior Angle of scapula – T<sub>7</sub>
- Highest point of iliac crest is the L<sub>4</sub> spine / L<sub>4</sub> – L<sub>5</sub> interspace.
- Posterior superior iliac spines (Clinically seen as the sacral dimples) – S<sub>2</sub> level.

### Physiology of Neural Blockade

There is a zone of differential blockade for the motor and the sensory nerves.

#### Motor Block

In spinal anesthesia, there is a difference in motor and the sensory block by two segments. In the extradural block, there is a much greater difference in the block.

Also in spinal anesthesia, the sympathetic fibers are blocked, two to three segments higher than the sensory fibers. In the extradural block there may be a variable block of the sympathetic fibers with persistence of some reflex activity.

### Order of Neural Blockade

It is in the following order – Autonomic pre-ganglionic β fibers, temperature, pain, touch, pressure, somatic motor, vibration and lastly proprioception. During recovery the order is reversed.

### SPINAL ANESTHESIA

This is a commonly used technique in which the drug is injected into the subarachnoid space.

The needle commonly used in 25G but a 29G needle is preferable, especially so in young individuals. The thinner the needle used, the less the incidence of postspinal headache.

- Automatic sympathetic blockade results in hypotension necessitating prior intravenous fluid loading and titration of vasoconstrictor drugs.
- The height of the block is dependent on many factors, including volume and dose of drug, posture of patient and site of injection.

Drugs used commonly are bupivacaine 0.5 percent, lignocaine 2 percent plain and 5 percent with glucose 7.5 percent. Adrenaline added to the hyperbaric solutions of bupivacaine and lignocaine does not prolong their effect.

**Advantages**

1. Avoids the need for tracheal intubation, this is of benefit in patients with chronic respiratory disease.
2. Reduction of surgical hemorrhage, e.g. at prostatectomy.
3. Cheap.
4. Profound muscle relaxation.
5. Excellent postoperative analgesia.
6. Patient is on spontaneous ventilation without becoming asleep and there is no necessity of muscle relaxant drugs.
7. Good cardiovascular stability in peripheral vascular surgery, with reduced stress response and myocardial protection.

**Disadvantages**

1. Hypotension.
2. Postspinal headache in 20 percent of patients usually within first three postoperative days.
3. Meningitis.
4. Backache.
5. Paralysis of 6th cranial nerve.
6. Some patients prefer to be asleep during surgery.

**Indications**

1. Operations in lower half of the body.
2. In cases of difficult intubation.
3. For postoperative and obstetric analgesia.
4. Avoidance of use of muscle relaxants.
5. Operations in patients with significant respiratory disease.

**Contraindications of Spinal Block**

1. Patient refusal.
2. Local infection – as it may introduce bacteria to the intradural or epidural space.
3. Shock.
4. Uncorrected coagulopathy or anticoagulation.
5. Fixed cardiac output states, e.g. severe AS, heart block.
6. Inadequate facilities.
7. Raised intracranial pressure.

**EPIDURAL ANESTHESIA**

- In this technique the drug is injected into the extradural space which lies between the dura mater and the vertebral canal.

- Agents commonly used are bupivacaine (0.25%), or ropivacaine (0.2-0.5%), & lignocaine (0.5-1%). The current trend is to combine weak solutions of local anesthetic with opioid agents such as the lipid-soluble diamorphine or fentanyl which produce analgesia by their action on opioid receptors in the spinal cord.
- Blockade of the somatic and the sympathetic nerves occur. Four segments on each side of the injection are usually affected.
- The block may be given static or as a continuous epidural form in which an epidural catheter is inserted. This continuous block is commonly used for postoperative pain relief and in obstetrics for the first and second stage of labor.

Tuohy needle is used for this procedure and the injection can be made in the cervical, thoracic and the lumbar extradural spaces.

**Advantages**

Compared to spinal analgesia, there is no postoperative headache, the neurological effects are rarer and continuous administration is possible.

**Disadvantages**

Slower in onset.

Indications and contraindications are the same as mentioned in case of spinal analgesia.

**Indications**

1. For hemorrhoidectomy and other perianal operations.
2. Operations on the lower limbs and transurethral operations.
3. Analgesia for circumcision and herniorrhaphy.

Recently the technique of combined spinal-epidural anesthesia has been used. It provides the intense block from spinal anesthesia intraoperatively but also allows the advantages of epidural analgesia to occur postoperatively.

**EXTRADURAL SACRAL BLOCK OR CAUDAL BLOCK**

This method of analgesia was introduced by Cathelin and Sicard of Paris in 1901.

Caudal anesthesia is produced by injecting the local anesthetic into the sacral canal through the sacrococcygeal membrane covering the sacral hiatus. The sacral hiatus a triangular opening, caused by failure of the fifth (and sometimes of the fourth) lamina arch to fuse with rounded apex formed by the fourth sacral spine and a sacral cornu on each side below and laterally. It is situated 4-5 cm from the tip of the coccyx or directly beneath the upper limit of the intergluteal cleft. The average capacity of sacral canal is 34ml in males and 32 ml in females. Its average length is 10-15 cm volume of solution required to produce could block ranges from 10 ml to 30 ml.

It is usually given in children. The advantage is excellent postoperative analgesia is obtained. Bolus dose of bupivacaine 0.25 percent, 0.5 ml/kg is given.

**Combined General and Regional Anesthesia**

Combining the two methods of anesthesia in well-balanced measure that enables a patient to receive a lighter general anesthesia and to have the advantage of good postoperative analgesia.

At its simplest the infiltration of an abdominal wound with local anesthetic agent will facilitate comfortable breathing in the recovery room.

**SOME COMMON POSTOPERATIVE COMPLICATIONS**

- Postoperative pain
- Aspiration of gastric contents.
- Postdural puncture headache (PDPH)
- Postoperative nausea and vomiting (PONV)
- Malignant hyperthermia.

**Postoperative Pain and Its Management**

Optimal perioperative pain management reduces postoperative complications and hospital stay. The international association for the study of pain defines pain as an unpleasant sensory and emotional experience associated with actual or potential tissue damage or described in terms of such damage. This definition reflects the complex nature of pain, which is modulated by many factors (biological, psychological and sociological) and explains why assessment is difficult.



**Simple vs Complex Pain**

Pain can be classified in a number of ways:

- Physiological, clinical, nociceptive or neuropathic.
- Somatic or visceral.
- Acute or chronic.

The traditional division of pain into acute and chronic is not helpful. It may be more useful to view pain as a continuum (See below Table 15.7). One end of the continuum may be termed complex pain and may be a mixture of nociceptive (inflammatory) pain and neuropathic pain, exacerbated or improved by psychosocial factors. The other end of the continuum may be termed simple pain, being predominantly nociceptive pain, again exacerbated or improved by psychosocial factors. That being said, the factors predisposing patients to develop persistent pain states are not yet fully understood.

**Assessment of Acute Postoperative Pain**

Poor pain assessment is a major barrier to good pain management while regular pain assessment using pain charts has been shown to increase the quality of analgesia.

For daily clinical practice, a much simpler assessment is followed as shown in Table: 15.8

**Basic Principles of Acute Postoperative Pain Management**

There is good evidence of the benefits of employing multimodal analgesia after surgery. This involves combining analgesic drugs that work by different mechanisms. NSAIDs, paracetamol, local anesthetics, other non-opioid analgesics and opioids given in combination improve analgesia and reduce side effects. In this scheme the nonopioid drugs contribute significantly to the recovery of the patient by minimizing opioid side effects, e.g. ileus by reducing the total opioid consumption. Evidence suggests that multimodal

analgesia after major surgery can hasten recovery and reduce costs. Thus the basic principles include.

- Regular assessment of pain as part of standard ward observations.
- To use one opioid at a time, prescribed appropriately.
- To use a multimodal approach – a combination of paracetamol, plus NSAIDs plus opioid and local anesthesia – when there are no contraindications.
- To prescribe analgesia regularly rather than as required.
- To plan the technique preoperatively and discuss this with the patient, especially with patient controlled analgesia.
- To ensure that staff caring for the patient have the knowledge and skills (including clinical guidelines), required to manage postoperative pain.
- Nonpharmacological techniques such as relaxation techniques, education and positioning are important in helping to reduce pain and may reduce the dose of drugs required.
- Unexpected pain or increasing pain should be investigated.

**Individual Drugs**

**Paracetamol**

Systemic review has found that paracetamol is effective when taken alone or in combination with NSAIDs for mild to moderate pain or as an adjunct to opioids. It is a drug with a good safety record when used in recommended doses.

**Nonsteroidal Anti-inflammatory Drugs**

Studies have found that NSAIDs are effective for mild to moderate pain and are useful adjuncts with opioids for severe pain. However, NSAID use is restricted by side effects viz.

**Table 15.8: Pain score chart**  
Simple scores that should be included on the ward patient observation chart

Score	Definition
<i>Pain severity (scored by patient)</i>	
0	None
1	Mild
2	Moderate
3	Severe
<i>Sedation</i>	
0	Awake
1	Can be roused
2	Mostly sleeping
3	Difficult to awaken
<i>Nausea and vomiting</i>	
0	None
1	Nausea
2	Vomiting

peptic ulceration, antiplatelet actions, aspirin induced asthma and renal dysfunction. Patients with a tendency to peptic ulceration may need cover with a proton pump inhibitor during treatment with NSAIDs.

**Opioids**

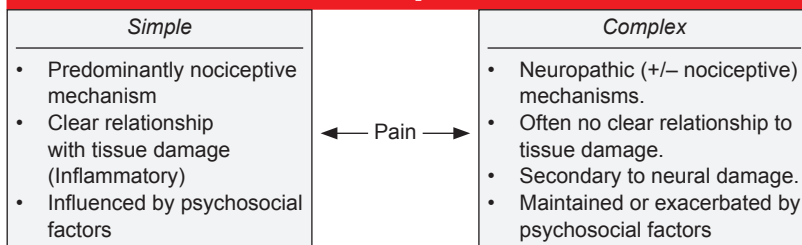
Opioids are the mainstay of management of moderate to severe pain but they have significant side effects. Sedation, respiratory depression, nausea and vomiting, depression of gastrointestinal motility and disruption of sleep patterns to name but a few. Perhaps, the most serious limitation of opioid use is inability to control movement associated pain after surgery. Generally patients given systemic opioids after major surgery, achieve adequate analgesia at rest but not during movement, when they may suffer severe discomfort.

Tramadol is a synthetic analgesic with both opioid agonist and central nervous system effects through noradrenergic and serotonergic pathways. It has been reported to produce minimal sedation, respiratory depression and gastrointestinal stasis and does not appear to have any abuse potential. Treatment has been shown to be as effective as Morphine in providing postoperative analgesia while permitting more rapid psychomotor recovery.

**Patient Controlled Analgesia**

Patients may self-administer opioid analgesia by IV injection or epidurally. The patient

**Table 15.7: The pain continuum**



is trained to give a bolus dose of drug by pressing a control button on a machine consisting of a microprocessor controlled syringe pump. The strength, frequency and total dose of drug in a given time are all limited by computer. Intravenous patient controlled analgesia satisfies the needs of both patients and staff because it provides a perception of patient autonomy, eliminates time delays in providing analgesia, avoids painful intramuscular injections, and increases ease of nursing.

Morphine remains the most popular opioid administered by this route. Patient controlled analgesia opioids may also be administered by the subcutaneous route using the same equipment but with a more concentrated solution of the drug to minimum the volume required.

The effectiveness of the system depends on the dose of drug given and the lockout period. Too low a dose may result in poor pain control and loss of confidence by the patient, too high a dose produces unacceptable side effects. Too long a lockout period result in poor pain control, while too short a period may lead to overdose.

### Local Anesthetic Blocks

Local anesthetic blockade provide excellent short-term analgesia but their administration requires skill and there is a small failure rate. Continuous catheter techniques provide prolonged pain relief but are generally only appropriate for in patients. Particular postoperative care is needed when epidural opioids have been given. A continuous intravenous lignocaine drip (2 mg/min) has been used with success and absence of signs of toxicity.

### Ketamine

Ketamine reduces postoperative morphine requirements. Low dose ketamine is also effective for the relief of neuropathic pain. Low dose (5 – 15 mg/h) continuous intramuscular infusion of ketamine has been successfully used.

- Inhalation of analgesic gases and vapors Entonox can be used for dressing changes.
- Nonpharmacological methods: Transcutaneous Electrical nerve stimulation (TENS)
- Acupuncture
- Hypnosis – when the skills are available.

### Aspiration of Gastric Contents

Risk factors for the pulmonary aspiration of gastric contents are as below.

- Full stomach
- Known reflux
- Raised intragastric pressure, intestinal obstruction, laparoscopic surgery, pregnancy.
- Recent trauma.
- Diabetes mellitus.
- Topically anesthetized airway.
- Perioperative opioids.

The clinical presentation may vary but chest signs include a wheeze and crackles chest X-ray may show diffuse infiltrative pattern, especially in the right lower lobe distribution.

### Prevention

- In high-risk situations, avoidance of general anesthesia is the preferable option.
- If general anesthesia is unavoidable a rapid sequence induction is done using a very short-acting neuromuscular blocker (usually suxamethonium) immediately following preoxygenation of lungs and induction of anesthesia with posterior pressure on the cricoid cartilage to occlude the upper esophagus.

### Treatment

1. 100 percent oxygen.
2. Suction of the oro- or nasopharynx and the patient is placed in the left lateral head down position (Recovery position).
3. If patient is unconscious and breathing spontaneously patient is placed in the recovery position, tracheal intubation if bronchial lavage is indicated.
4. If the patient is unconscious and apneic, trachea is intubated immediately and artificial ventilation is commenced.

### Subsequent Management

- The stomach is emptied with a large bore nasogastric tube prior to attempting tracheal extubation.
- Monitoring of respiratory function, X-ray chest and measurement of arterial blood gases.
- If signs of respiratory failure appear, the patient should be managed in an intensive care unit.

### Postdural Puncture Headache

#### Cause

Postdural puncture headache is a complication of inadvertent breach of the dura mater and subarachnoid mater by an epidural or spinal needle.

Its incidence is less than 1 percent.

The proposed mechanism is cerebrospinal fluid loss, at a rate greater than its rate of production, through a dural tear. The pressure in the subarachnoid space thus falls and the brain 'sinks' within the skull, stretching the meninges and causing a typical 'low pressure' headache.

The symptoms may not develop for several days. If untreated the headache is not only very unpleasant, but on rare occasions can be life-threatening, usually as a result of intracranial hemorrhage or coning of the brainstem.

#### Clinical Features

- Typical onset 24 to 48 hrs after dural puncture.
- Usually lasts 7 to 10 days if untreated.
- Characteristically worse on standing and often absent after overnight bed rest but returns after mobilizing.
- Usually frontooccipital in distribution, radiating to the neck with associated neck stiffness.
- Photophobia, diplopia and difficulty in accommodation.
- Hearing loss, tinnitus and cranial nerve (VIth) palsy are possible.
- Nausea in upto 60 percent cases.

#### Symptomatic Management

- Bed rest.
- Simple analgesia care rarely completely relieve severe postdural puncture headache.
- Fluid intake is encouraged, although evidence of its clinical effectiveness is lacking.
- Caffeine or theophylline reduce intracranial vasodilatation and improve symptoms.
- Sumatriptan (a cerebral vasoconstrictor) is reserved for those in whom blood patching is contraindicated.
- Adrenocorticotrophic hormone can alleviate symptoms.
- Abdominal binders probably increase epidural vein blood flow, compressing dural sac, and raising CSF pressure.
- Autologous epidural blood patching.

### Postoperative Nausea and Vomiting (PONV)

Both of these are common and distressing and the result of combination of many factors. Anesthetic agents and analgesics are often implicated. A past history of PONV is a common feature. Treatment is done with the following agents.

- a. Metoclopramide and domperidone act at dopamine receptors in the midbrain.
- b. Anticholinergic agents (e.g. Hyoscine) affect the so-called vomiting center, also in the midbrain.

- c. Antihistamines, e.g. cyclizine are effective but can cause sedation.
- d. 5HT<sub>3</sub> antagonists: A relatively new group of drugs is the 5HT<sub>3</sub> antagonists, e.g. ondansetron.

### Malignant Hyperpyrexia/Hyperthermia

Rarely induction of anesthesia with halothane or any other halogenated inhalational anesthetic triggers an uncontrolled hypermetabolic reaction in the skeletal muscle of susceptible patients. It is inherited as an autosomal dominant condition and worldwide 50

percent of malignant hyperthermia families have been shown to be linked to the ryanodine receptor on chromosome 19q. This controls a Ca<sup>++</sup> efflux channel on the sarcoplasmic reticulum.

The resultant syndrome of malignant hyperthermia is characterized by a rapid rise in body temperature and a massive increase in oxygen consumption and production of carbondioxide and metabolic acidosis.

Death may result unless the anesthetic is discontinued and treatment with dantrolene sodium is begun promptly.

# Chapter 16

## Clinical Oncology

- Neoplasm
- Sarcoma
- Carcinoma
- Disorders of growth
- Etiology of cancer
- Growth and spread of malignant neoplasms
- Treatment of cancer

### NEOPLASM

#### Definition

Willis defined neoplasm as an abnormal mass of tissue, the growth of which exceeds and is uncoordinated with that of the normal tissues and persists in the same excessive manner even after cessation of the stimuli, which evoked the change. Neoplasm is also progressive, purposeless and persistent. A malignant neoplasm is composed of cells that invade other tissues and spread.

Currently malignancy is considered to be the final result of the interplay of several factors or stimuli, ranging from diet, lifestyle, genetics, radiation chemicals, etc. No human tissue is immune to malignancy.

#### Classification

Neoplasms are classified as (a) Benign and (b) Malignant.

#### Benign Neoplasm

This type of neoplasm is localized, capsulated and well-differentiated. It does not infiltrate surrounding normal tissues and shows no metastasis. Histology is similar to the tissue or cell of origin. In most cases treatment is curative simple excision. Few benign tumors may turn into malignancy after a long time

#### Malignant Neoplasm

All malignant neoplasms arising from the epithelial as well as mesenchymal tissues are loosely denoted by the term 'Cancer'. It shows lack of differentiation, abnormal mitotic activity and erratic rapid growth. These neoplasms infiltrate the surrounding tissues and metastasize through lymphatics or blood.

Treatment of a malignant neoplasm may not be completely curable and involves multimodality of therapy including surgery and /or

radiotherapy, chemotherapy and hormonal therapy in various combinations. Malignant neoplasms are of two types viz. sarcoma and carcinoma.

### SARCOMA

It is the malignant neoplasm arising from the mesenchymal or connective tissues. Greek word 'sar' means 'flesh' and 'oma' means tumor. Carcinomas and sarcomas are solid

**Table 16.1: Nomenclature of connective tissue neoplasms**

<i>Tissue</i>	<i>Benign</i>	<i>Malignant</i>
Bone	Osteoma	Osteosarcoma
Cartilage	Chondroma	Chondrosarcoma
Fat	Lipoma	Liposarcoma
Smooth muscle	Leiomyoma	Leiomyosarcoma
Voluntary muscle	Rhabdomyoma	Rhabdomyosarcoma
Blood vessel	Angioma	Angiosarcoma
Fibrous tissue	Fibroma	Fibrosarcoma

**Table 16.2: Nomenclature of lymphoid and hemopoietic neoplasms**

<i>Tissue of origin</i>	<i>Malignancy</i>
Lymphocytes	Lymphoma
Granulocytes	Myeloid leukemia
Marrow lymphocytes	Lymphocytic leukemia
Plasma cells	Multiple myeloma

'tumors'. Hematologic malignancies, such as leukemia, are liquid tumors of mesenchymal origin.

It is usually a smooth firm or hard swelling, warm and vascular with dilated veins over the surface. Sarcoma spreads mainly through blood commonly to lungs, e.g. liposarcoma, fibrosarcoma, etc. The nomenclature of various connective tissue neoplasms are given in Tables 16.1 and 16.2.

## CARCINOMA

Carcinoma is a malignant neoplasm arising from the epithelial cells. 'Carc' means 'crab-like'. Thus, it is usually a hard, proliferative growth with everted edge.

It spreads through lymphatics as well as blood, e.g. adenocarcinoma, squamous cell carcinoma, transitional cell carcinoma, etc.

Carcinomas which are curable include basal cell carcinoma, papillary carcinoma of thyroid, carcinoma colon, verrucous carcinoma, Marjolin's ulcer, etc.

The nomenclature of epithelial neoplasms is given in the following Table 16.3.

These lists are incomplete and many other special types of neoplasms exist which should be learned while studying various organ systems.

Malignant tumors associated with an organ of the body may be primary or metastatic. It is always worthwhile to consider the possibility that a neoplasm is metastatic particularly, if it is located in the lung, liver, brain or bones. In general secondary tumors, carry the same biologic characteristic and response to treatment as the primary tumor from which they arose.

## DISORDERS OF GROWTH

It is essential to understand the following terms with regard to neoplasia.

### Hyperplasia

Hyperplasia means an increase in the number of cells in an organ or tissue, in response to a stimulus. When the stimulus is removed, the hyperplasia regresses.

### Hypertrophy

Hypertrophy is an increase in the size of cells within an organ in response to a stimu-

<i>Epithelium</i>	<i>Benign</i>	<i>Malignant</i>
Squamous	Squamous papilloma	Squamous cell carcinoma
Glandular	Adenoma	Adenocarcinoma
Transitional	Transitional papilloma	Transitional cell carcinoma
Liver	Adenoma	Hepatocellular carcinoma
Skin	Papilloma Benign nevus	<ul style="list-style-type: none"> <li>• Squamous carcinoma</li> <li>• Basal cell carcinoma</li> <li>• Malignant melanoma</li> </ul>

<i>Name of chemical</i>	<i>Organ in which associated neoplasm occurs</i>
1. Soots and Tars	Skin, lung
2. Tobacco smoke	Lung, mouth, pharynx, esophagus and urinary bladder
3. Nickel compound	Lungs, nasal cavity
4. Arsenic	Lungs, skin
5. Asbestos	Lungs, pleura
6. Cadmium oxide	Prostate
7. Aflatoxin	Liver
8. N-Naphthylamine	Urinary bladder

lus. When the stimulus is removed, the cells return to normal size.

### Atrophy

Atrophy is a reduction in either the size or number of cells within a tissue. This can be reversible when it represents part of a response to an external stimulus or it can be part of the normal aging process.

### Dysplasia

Dysplasia is a premalignant change in cells (usually epithelium) characterized by loss in the uniformity of cells with pleomorphism and hyperchromatism.

### Anaplasia

Anaplasia is characterized by lack of cellular differentiation, abnormal mitotic activity, pleomorphism, hyperchromatism, anisocytosis and anisonucleosis.

## ETIOLOGY OF CANCER

The etiology of cancer is multifactorial in nature. It is divided into genetic, chemical, viral and physical causes. Although one type of carcinogenic factor may be predominant for some cancers, most cancers are probably the result of multiple interacting carcinogenic and anticarcinogenic effects.

Strong evidence shows shared etiology and even synergism, among causative agents, for several human cancers, e.g. smoking acts synergistically in the production of lung cancer with both ionizing radiation and asbestos. Also smoking acts synergistically with alcohol in the etiology of cancer of the oral cavity, pharynx, and esophagus.

Evidence also suggests that some anticarcinogenic factors may reduce the risk of tumor induction by known carcinogens, e.g. increased dietary consumption of beta carotene may reduce the risk of various cancers including cancer of the lungs in smokers.

### Chemical Carcinogenesis

Chemical agents are apparently the most important in the induction of human cancers. The known chemical carcinogens include polycyclic hydrocarbons, azo dyes, Nitrosamines and inorganic compounds such as nickel and chromium (Table 16.4).

The important step in the induction of cancer by chemicals appears to be the interaction of the chemical or its metabolite with proteins and other macromolecules particularly DNA.

### Viral Carcinogenesis

Human malignancies that appear to be etiologically associated with viruses include



Burkitt's lymphoma and nasopharyngeal carcinoma (Epstein-Barr virus), cervical cancer (papilloma virus and herpes virus), and Hepatoma (hepatitis virus).

EB (Epstein-Barr) virus antigen has been demonstrated in the cells of Burkitt's lymphoma. Also the EB virus which is a DNA virus has been formed in cultured Burkitt cells.

Recently strong evidence has shown that retroviruses are probably the most important etiologic agents in some human cancers.

### Genetic Factors

Genetic factors in cancer causation are associated with colon cancers, neurofibromatosis and the various cancers associated with it, e.g. MEN type II. These are cancers related to inheritance of a Mendelian dominant trait.

A second class of hereditary predisposition to cancer results from recessive tumor suppressor genes, with one normal allele being adequate to protect against a particular cancer. Cancers related to recessive genes are retinoblastoma and Wilm's tumor. Knudson has termed these recessive genes antioncogenes.

The genetic trait alone is not sufficient for the development of a tumor. Two or more mutational events must occur before there is oncogenesis. In the inherited cancers, the first mutation is present in all cells derived from the germline, but an additional somatic mutation must occur before a cancer develops.

Some genetically inherited predispositions to cancer appear to be related to either increased chromosomal fragility or defects in the ability to repair damage to the DNA, the so-called chromosomal breakage syndromes, e.g. patients with xeroderma pigmentosum have a markedly increased risk of developing skin cancers on exposure to sunlight. The fibroblasts of these patients have been found to have deficient DNA repair enzymes *in vitro*. They repair UV - induced DNA damage either very slowly or not at all.

### GROWTH AND SPREAD OF MALIGNANT NEOPLASMS

1. Direct spread—May infiltrate and destroy immediately adjacent structures.

2. Lymphatic inversion—To regional lymph nodes and beyond.
3. Blood vessel spread—Usually to the lungs or liver or both.
4. Spread across serosal surfaces, to pleura, pericardium and peritoneum.

### Grading and Staging of Tumors

Prognosis of the course of the disease and the determination of the efficacy of various forms of cancer treatment require a high degree of similarity among the tumors being considered.

Systems have been developed to express the level of differentiation or Grade and extent of spread of a cancer within the patient or stage as parameters of the clinical gravity of the disease.

#### Grading

Grading of a cancer is based on the degree of differentiation of the tumor cells and the rate of growth.

Thus cancers are classified as grades I to IV with increasing anaplasia. Although histologic grading is useful, the correlation between histologic appearance and biologic behavior is less than perfect. In general with few exceptions, such as soft tissue sarcomas, grading of cancers has proved of less clinical value than has staging.

#### Staging

The staging of cancers is based on the primary lesion, its extent of spread to the regional lymph nodes and the presence or absence of blood borne metastases. Two major staging systems are currently in use, one developed by the Union Internationale Cancer Control (UICC) and the other by the American Joint Committee on cancer (AJCC) staging. The UICC employs a classification called the TNM system - T for primary tumor, N for regional lymph node involvement and M for metastasis. The TNM staging varies for each specific form of cancer but there are general principles. With increasing size, the primary lesion is characterized as T<sub>1</sub> to T<sub>4</sub>. T<sub>0</sub> is added to indicate an *in situ* lesion. No would mean no nodal involvement whereas N<sub>1</sub> to N<sub>3</sub> would denote involvement of an increasing number and range of nodes. M<sub>0</sub> signifies no distant metastases whereas M<sub>1</sub> indicates presence of distant metastasis.

The AJCC employs a somewhat different nomenclature and divides all cancers into stages 0 to IV incorporating within each of these stages the size of the primary lesion as well as the presence of nodal spread and distant metastasis.

Staging of neoplastic disease has assumed great importance in the selection of best form of therapy for the patient.

### TREATMENT OF CANCER

The multidisciplinary approach in cancer treatment:

It is now recognized that cancer management is best offered by the multidisciplinary approach, comprising surgeons, pathologists, radiologists, oncologists and often specialist nurses.

The main modalities of treatment of cancer are surgery, radiotherapy and chemotherapy. Hormone treatment is important in certain tumors and newer therapies viz. immunotherapy, gene therapy; biological modifiers, etc. are being investigated to improve the outcome of cancer patients.

### Surgery

The main aim of cancer surgery is local control. Local control equates to cure when disease is localized. Surgery has several roles in cancer treatment including diagnosis, removal of primary disease, removal of metastatic disease, palliation, prevention and reconstruction as described below:

#### Diagnosis and Staging

The surgeon's main role in diagnosis is to provide tissue for exact diagnosis. Various techniques for obtaining tissue suspected of malignancy include aspiration cytology, needle biopsy, incisional and excisional biopsy and laparoscope biopsy.

#### Aspiration Cytology (FNAC - Fine Needle Aspiration Cytology)

It means cytological study of tumor cells to find out the disease and also to confirm whether it is malignant or not. It is done using 23 to 25 gauge needles that has been guided into suspected tissue. It is done in thyroid, lymph node, breast and all other surface lesions.

USG or CT guided FNAC are popular at present. It is absolutely contraindicated in

testicular tumor because tunica albuginea usually prevent tumor spread and once it gets disrupted by FNAC, spread can occur.

Advantages of FNAC include high sensitivity, least invasive, safer, no requirement of anesthesia and an OPD procedure.

### Incision Biopsy

It is taken from the edge of the lesion as in ulcer, not from the center as there is necrosis.

Incision biopsy is contraindicated in a case of melanoma where excision biopsy is preferred.

### Needle Biopsy

It involves obtaining a core tissue through a special needle. The core tissue obtained is usually sufficient for the diagnosis of most tumors.

### Excision Biopsy

In small lesions, excision biopsy is done, e.g. lymph node biopsy is done in case of lymphoma.

### Laparoscopic Biopsy

In malignant ascites, Laparoscopy has an important role for obtaining tissue for diagnosis. Laparoscopy is also widely used for the staging of intra-abdominal malignancy, particularly esophageal and gastric cancer. By this means it is often possible to diagnose widespread peritoneal disease and small liver metastases that have been missed on cross-sectional imaging. Laparoscopic ultrasound is particularly helpful for the diagnosis of intrahepatic metastasis.

### Removal of Primary Disease

Radical surgery for cancer involves removal of the primary tumor and as much of the surrounding tissue and lymph node drainage possible to ensure not only local control but also to prevent the spread of tumor through the lymphatics. It is important to appreciate that high quality meticulous surgery taking care not to disrupt the primary tumor at the time of excision is of utmost importance in obtaining a cure in localized disease and preventing local recurrence.

### Removal of Metastatic Disease

In some cases surgery for metastatic disease, may be appropriate, e.g. liver metastasis arising from colorectal cancer. Successful

resection in such a case of all detectable disease can result in long-term survival in about one-third of patients. Another situation in which surgery may be of value is pulmonary resection for isolated lung metastases, particularly from renal cell carcinoma.

### Palliation

In many cases, surgery is not appropriate for cure but may be extremely valuable for palliation, e.g. removal of a symptomatic primary tumor from a patient, also having distant metastasis will increase the patient's quality of life. Of course it will have little effect on the ultimate outcome.

Other instances where surgical palliation is appropriate include bypass procedures such as an ileotransverse anastomosis to alleviate symptoms of obstruction caused by an inoperable cecal cancer or bypassing an irresectable carcinoma head of the pancreas by means of anastomosing the gallbladder or the bile duct to the jejunum in order to alleviate jaundice.

### Prevention

- Panproctocolectomy with or without an ileal pouch, will prevent the development of colorectal cancer, in a patient with familial adenomatous polyposis.
- A colectomy is advised in a patient with ulcerative colitis who has high grade dysplasia on biopsy.
- Bilateral mastectomy is sometimes requested by the patient with a strong family history of breast cancer.

### Reconstruction

Reconstruction surgery is often an integral part after removal of a solid cancer, e.g. after removal of any gastrointestinal tumor, the continuity of the GI tract must be restored.

Reconstruction may also be important for cosmetic reasons, e.g. after mastectomy and in burns.

### Radiotherapy

#### Mechanism of Action of Radiation Therapy

Radiation therapy uses high energy X-rays to damage the DNA of cells, thereby killing the cancer cells, or at least stopping them from reproducing.

Radiation also damages normal cells but because normal cells are growing more slowly they are better able to repair this radiation damage than are cancer cells. In order to give normal cells time to heal and to reduce a patients' side-effects, radiation treatments are typically given in small daily doses, usually five days a week, over a six or seven week period.

### Types of Radiation Therapy

Radiation therapy is considered to be a local therapy, as it treats a specific localized area of the body. This is in contrast to systemic therapies, such as chemotherapy, which travel throughout the body.

There are two main types of radiation therapy.

- External radiation therapy—Where a beam of radiation is directed from outside the body.
- Internal radiation therapy—It is also known as brachytherapy or implant therapy, where a source of radiotherapy is surgically placed inside the body near the tumor.

External radiation therapy is administered using a machine called linear accelerator. Treatments are given 5 days a week for several weeks depending on the total final dose of radiation that is planned. Patients are given a break from treatment on weekend days to give normal cells sometime to heal, thus reducing side effects.

A person receiving external radiation therapy is not radioactive or dangerous to the people around him or her.

Internal radiation therapy allows a higher total dose of radiation to be given in a shorter time than is possible with external treatments. The radiation sources used here typically include radium, cesium, iodine and phosphorus. Depending on the substance, the implant may be temporary or permanent, although the effect wears off over time in all cases. Depending on the type of radiation source, patients with radiation implants may need to be isolated from visitors for a period of time, so as not to expose others to radioactivity.

### Side-effects of Radiation Therapy

The side-effects are directly related to the area of the body being treated, e.g. radiation that

includes the abdomen can cause diarrhea because of the radiation effect on the wall of the bowel.

Most side-effects are temporary; disappearing gradually after therapy is complete.

Some of the most common side-effects of radiation therapy include hair loss or alopecia, fatigue, neutropenia, skin reaction (like sunburn), dysphagia, nausea, diarrhea and altered taste of food – all due to the effect of radiation on the membranes and /or the gastrointestinal tract. Neutropenia puts the patient at a higher risk of getting infections.

### Response to Radiation Therapy

This varies with the type of cancer being treated. Many patients will have radiological studies (CT scans, MRI, etc.) periodically to see if the tumor has responded (shrunk, stayed the same or grown). In some cases, a decrease in patient's symptoms may be able to signal if the treatment is shrinking the tumor or not.

### Chemotherapy

Chemotherapy includes medications that are used to treat cancer.

Tumor is made up of cells that are reproducing at abnormally high rates, unlike the normal cells; the stop mechanism is missing here. DNA or RNA of a cell directs how to replicate itself and chemotherapy works by destroying this RNA or DNA. The more rapidly tumor cells are replicating; the better chemotherapy is able to kill the cells.

### Cell Cycle

Cell replication occurs in a series of phases called the cell cycle. The cell cycle phases are: resting phase or  $G_0$ , nothing is happening,  $G_1$  or Gap 1, a growth phase, S or synthesis phase when replication of DNA occurs,  $G_2$  or Gap 2, another growth phase, and M or Mitosis phase, when actual division from cell 1 to 2 occurs (Fig. 16.1).

Cell cycle nonspecific chemotherapeutic agents are able to kill a cell during any phase of the cycle including the resting phase. They are most effective when given in bolus doses.

Cell cycle specific chemotherapeutic agents are unable to work at the resting phase and only able to kill during a specific phase.

Specific and nonspecific therapies are often combined to make a regimen, e.g. CHOP for the treatment of lymphoma (non-Hodgkins).

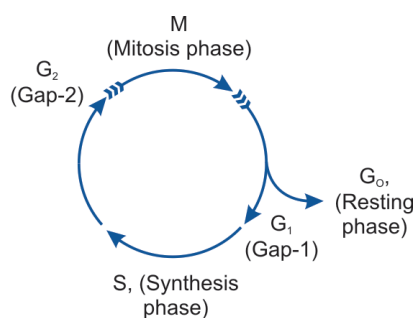


Fig. 16.1: Cell cycle

Where C = Cytosin (cyclophosphamide), H = Hydroxydaunorubicin (adriamycin), O = Oncovin (vincristine), P = Prednisolone.

This combination is given in cycles (Blocks of time), e.g. cytosin, adriamycin and Oncovin are given on day 1, Prednisolone on days 1 to 5, followed by 16 days off (no treatment) for a total of 21 days.

Then it starts over again with the next cycle, for a usual total of 6 to 8 cycles.

Chemotherapy is a systemic therapy while radiation and surgery are local therapies.

*Adjuvant therapy*—It is the chemotherapy given after surgery to reduce recurrence.

*Neoadjuvant therapy*—It is chemotherapy given before surgery to shrink the tumor to make the surgery more successful.

*Concurrent therapy*—When two or more therapies are given together such as chemotherapy and radiotherapy.

### Routes of Administration

1. Orally
2. Intravenously – Either as a short infusion or continuously for 1 or more days.
3. Directly into the body cavity, e.g. urinary bladder or abdominal cavity.

### Side-Effects

These are determined by the medications inability to differentiate between the tumor cells and healthy cells. Some common side - effects are hair loss or alopecia, mouth sores like stomatitis and dysphagia, nausea and/or vomiting, loss of appetite and fatigue, constipation, infection, anemia, etc.

### Response to Chemotherapy

Response to chemotherapy is assessed by radiologic studies, e.g. CT scan, MRI scan and PET scan periodically to see if the tumor has responded as in case of radiation therapy.

Some types of tumors can be followed by checking a tumor marker, which will decrease with successful chemotherapy. A tumor marker is a substance produced by the tumor or by the body in response to the tumor and can be measured by a blood test.

A major advantage of chemotherapy is its ability to treat widespread metastatic cancer, while surgery and radiation therapy are limited to treating cancers that are confined to specific areas.

Administration of chemotherapy become precarious if the liver or the kidneys are damaged as they are the principal organs of excretion of drugs. Unfortunately kidneys and liver damage often result due to cancer invasion, possibly limiting the patients, chemotherapeutic options.

### Chemotherapeutic Agents

1. Alkylating agents are the oldest anticancer drugs. They are latent or active nitrogen mustards, and work by attacking negatively charged sites on DNA (oxygen, nitrogen, phosphorus and sulfur atoms) which stops cellular activity and cause cell death.

These drugs include cyclophosphamide, melphalan, chlorambucil, dacarbazine, procarbazine, etc.

2. Antimetabolites. Methotrexate is the most commonly used antifolate agent in cancer therapy. It has activity against leukemia, lymphoma, breast and head – neck cancers, colon and bladder cancers, choriocarcinoma, etc.

5FU – Prevents DNA synthesis by interfering with the nucleotide production. 5FU is metabolized with dihydropyrimidine dehydrogenase (DPD), as naturally occurring enzyme in the body. If DPD is lacking, severe 5FU toxicity appears.

Other agents causing decreased DNA synthesis are cytarabine, 6 - mercaptopurine and fludarabine, etc.

3. Anthracyclines, e.g. Doxorubicin and Daunorubicin.

Daunorubicin has been isolated from streptomycetes, a soil dwelling fungus, while Doxorubicin is isolated from a mutated strain of the same fungus.

4. Antitumor antibiotics, e.g. Bleomycin is isolated from the fungus streptomycetes verticillus. Its mechanism of action is similar

to anthracyclines. Free oxygen radicals are formed which break the DNA and cause cancer cell death.

5. Plant alkaloids, e.g. (a) Vinca alkaloids—vincristine and vinblastine. (b) Taxanes—paclitaxel and docetaxel—They are specific for the M—phase of the cell cycle and effective in breast, lung, and head-neck, ovary, bladder prostate, esophagus and gastric cancers. Paclitaxel came into use in 1993 (c) Topoisomerase inhibitors.
6. Platinums—Cisplatin is used most often in lung cancer.
  - Carboplatin, 2nd generation platinum has fewer renal side-effects.
  - Oxaliplatin, 3rd generation platinum, used in colon cancer. It has side-effects like neuropathy.

### Other Forms of Cancer Therapy

#### Hormone Therapy

Cancers of the breast, prostate, endometrium are hormone sensitive. Tumors that are hormone sensitive bear appropriate hormone receptors and these are often over expressed.

#### Types of Hormone Therapy

- a. Ablative therapy—This type of therapy was used previously and included oophorectomy and adrenalectomy in the treatment of breast cancer and orchidectomy in the treatment of cancer prostate.
- b. Drugs—Ablative therapy though used occasionally nowadays has given way to drug treatment.

The most widely used class of drugs is the hormone antagonists such as tamoxifen, which is an estrogen receptor blocker widely used in breast cancer. Other examples include cytoproterone acetate which competes with testosterone and goserelin which is an analogue of LHRH or leuteinizing hormone releasing hormone.

#### Gene Therapy

If a gene becomes damaged, this damage is called a mutation. This can lead to a gene not functioning properly and a cell growing uncontrollably leading to cancer formation. The tumor suppressor gene, known as P<sub>53</sub>, suppresses tumor formation.

Oncogenes are genes capable of causing either development of a new cancer or the spread of an existing one (metastasis).

#### Strategies for Gene Therapy

- i. Inserting genes to cancer cells, to make them more susceptible to or prevent resistance to chemo-, radio or hormone therapy.
- ii. To create “suicide genes” that enter cancer cells and cause them to self-destruction.
- iii. Genes to prevent blood vessel formation within the tumor causing it starved to death, called antiangiogenesis.
- iv. To use genes to protect healthy cells from the side-effects of therapy, allowing higher doses of radiation therapy and chemotherapy to be given.

Common cold viruses are used as vectors for gene therapy. At present gene therapy is not curative and is given along with other therapies.

#### Immunotherapy

The aim of immunotherapy is to induce or potentiate antitumor immunity that can destroy the cancer cells.

#### Antitumor Strategies

1. Nonspecific immunotherapy—Exogenous immunostimulation by administration of bacterial agents or their products like BCG. It is thought to activate the antitumor response effectors like natural killer cells and macrophages. Another approach to non-specific immunotherapy is the administration of cytokines such as IL-2, interferons  $\alpha$  and  $\gamma$ ,

IL-2 stimulates cytotoxic. T-Lymphocytes and maturation of effectors such as NK cells into lymphokine activated killer cells. Interferons on the other hand, exert anti-tumor effects by inhibiting tumor cell proliferation.

2. Antigen specific immunotherapy—Can be active, achieved through antitumor vaccines or passive. In passive immunotherapy antibodies to specific tumor associated antigens, can be produced by hybridoma technique and then administered to patients whose cancers express these antigens, inducing antibody-dependent cellular cytotoxicity.

Recent trials suggest that immunotherapy is a potentially useful approach in the adjuvant setting. How to best select patients for this approach and how to mingle immunotherapy with other therapies are not well-understood for most cancer types.

#### Biologic Therapy

The basic concept of biologic therapy is to exploit the molecular differences between normal cells and cancer cells. Several protein kinases have been shown to have oncogenic properties and many other protein kinases have been shown to be aberrantly activated in cancer cells. Therefore, protein kinases involving these aberrantly activated pathways are being aggressively pursued in molecular therapeutics. Some of the kinase inhibitors in clinical development include inhibitors of EGFR (Epidermal Growth Factor Receptor), Cyclin Dependent Kinase (CDK), Protein Kinase (PKC), etc.

Most biologic agents are cytostatic and not cytotoxic. Thus rational combination therapy of new biologic agents with either established chemotherapeutic agents that have synergy or with other biologic agents is more likely to lead to cancer cures.

## Imaging in Surgery

- Plain Radiograph
- Mammography
- Special radiological techniques using contrast media
- Ultrasonography
- CT scan and MRI
- Radioisotope scan

The different modes of imaging are:

1. Plain radiograph
2. Mammography
3. Special radiological techniques using contrast media viz.
  - Contrast studies using iodine containing agents, e.g. oral cholecystography, intravenous urography (IVU), arteriography, venography, myelography, sinography, and arthrography, etc.
  - Barium studies—Barium swallow, barium meal follow through small bowel enema, barium enema, etc.
4. Ultrasonography.
5. CT scanning.
6. Magnetic resonance imaging (MRI)—contrast enhancement is done with salt of gadolinium and
7. Radioisotope scans.

### PLAIN RADIOGRAPH

#### Indications

1. Preoperative—X-ray chest is done if patient has acute respiratory symptoms, suspected metastasis or if the patient has established or suspected cardiorespiratory disease and patient has not had a chest X-ray in the last 12 months.
2. Postoperative chest X-rays are done for diagnostic reasons.

3. Abdominal X-ray—It is done in the following conditions.

- i. For the diagnosis of intestinal obstruction—It is the most important procedure to confirm the clinical diagnosis. Multiple gas–fluid levels are the most important criteria of diagnosis of intestinal obstruction. X-rays are taken in both supine and erect posture.
    - Diagnostic accuracy of plain X-ray in all types of intestinal obstruction is 75 percent.
  - ii. Accumulation of air under the right dome of diaphragm is diagnostic of a suspected case of hollow viscus perforation.
  - iii. It can show the shadow of a renal, gallbladder or pancreatic calculus.
4. Diagnosis of a fracture—When a fracture is suspected on clinical grounds, it is confirmed by radiography.
  5. Diagnosis of bone tumors—Malignant bone tumors like osteoclastoma (soap bubble appearance), osteosarcoma (sun ray spicules, Codman's triangle). Ewing's sarcoma exhibit characteristic features on plain X-ray.
  6. Diagnosis of congenital conditions, e.g. congenital dislocation of hip, talipes equinovarus, etc.
  7. Diagnosis of osteochondritis—e.g. Perthes disease, bone tuberculosis, etc.

8. Diagnosis of degenerative bone and joint diseases, e.g. rheumatoid arthritis, osteoarthritis, cervical spondylosis, vertebral disk protrusion or prolapse.

9. In trauma patients, there may be evidences of rib fracture, pelvic or long bone fractures.

10. X-ray of kidney, ureter and bladder (KUB)—may show the urinary calculi or soft tissue masses in the renal areas or pelvis. Other causes of calcification, e.g. pelvic phleboliths, calcified lymph nodes may also be visualized.

### MAMMOGRAPHY

Soft tissue radiographs of the breasts are taken by placing the breast in direct contact with the ultra sensitive film. The dose of radiation is only 0.1 Gy and is therefore very safe and can be repeated. The cranio-caudal and mediolateral views are taken for each breast.

### SPECIAL RADIOLOGICAL TECHNIQUES USING CONTRAST MEDIA

The natural contrasts in different body tissues due to their contained liquids and air can be augmented by introducing air, Ba-sulfate, or iodine containing media into body cavities and hollow viscera.



Route of administration—Oral or parenteral by which the radiopaque materials are secreted or excreted in body fluids.

### Barium Study

- i. Ba–swallow—Barium suspension is swallowed to outline the esophagus and esophagogastric junction.
- ii. Ba–meal X-ray of stomach and duodenum. The patient takes Ba– suspension and the radiologist concentrates on the esophagogastric junction, stomach and proximal duodenum. It is indicated in cases of gastric ulcer and carcinoma causing gastric outlet obstruction.
- iii. Ba meal follow through—Barium is followed down the small intestine. It is indicated in cases of suspected ileocecal tuberculosis and recurrent appendicitis.
- iv. Small bowel enema—Barium is instilled directly into the small bowel through a tube placed in the duodenum thus avoiding the need to await gastric emptying.
- v. Double contrast Barium X–ray—In this test, relatively small amount of Barium is used, and fine mucosal abnormalities are detected if air is insufflated to distend the organ and spread the barium thinly. Ba–studies are contraindicated if there is any clinical evidence of obstruction or perforation as there is dense adhesions when it escapes into the peritoneal cavity.

### Contrast Studies with Iodine Containing Agents

This is used for the contrast radiology of hollow viscera, ducts and blood vessels (arterio- and venography).

Iodine containing water soluble compounds, e.g. 76 percent urograffin (Na-diatrizoate) is excreted by the kidney after IV administration and used in excretion urography. The same can be injected to outline the vascular tree (arterio- and venography), sinus tracts (sinography) and duct systems (pancreatography).

Iodine containing compounds e.g. Telepaque which are excreted by the liver are also available. The fat-soluble compound Telepaque is given orally to outline the gall bladder (oral cholecystogram) whereas the water-soluble compound Biligradin is injected IV to outline the bile ducts (IV cholangiogram).

Both the above tests cannot be performed in patients with Jaundice because of impaired liver excretion and USG is the investigation of choice in them.

### ERCP and PTC

High quality cholangiograms can now be obtained by direct injection of contrasts into the biliary tree following endoscopic cannulation through the ampulla of Vater (ERCP) or through a needle inserted percutaneously into the intrahepatic bile ducts (PTC).

## ULTRASONOGRAPHY

### Principle

Ultrasonography uses high frequency sound waves transmitted through a probe or transducer. These sound waves are reflected back from tissues of varying acoustic impedance and this information is used to generate an image.

Thus fluid in a simple cyst does not reflect any ultrasound beam and appears grey.

In 'A' scan only static images are produced while in 'B' or real time scan, dynamic images are obtained.

### Advantages

- It is noninvasive and carries no radiation risk.
- It is an excellent modality to investigate the soft tissues.
- Can be used in children without any sedation.
- Portable.

### Disadvantages

- It needs expert interpretation.
- Gas containing structures, e.g. lungs and structures enclosed within bone, e.g. brain cannot be imaged, as sound waves are reflected back at the interfaces with air and bone.

### Applications

1. Gallbladder and biliary tract—Diagnosis of gallstone, pancreatic calculi dilatation and caliber of common bile duct, etc.
2. Vascular surgery—Assessment of blood flow using doppler principle - color

doppler scan can detect site of occlusion in a vessel due to thrombus or embolism.

3. Gastrointestinal surgery:
  - a. Liver—The following pathological conditions can be detected viz.
    - Presence of an abscess or cyst.
    - Hemangioma
    - Tumors like hepatoma or metastatic growth
    - Polycystic lesions
    - Pyogenic abscess
    - Hydatid cyst, etc.
  - b. Spleen
    - Detection of hematoma, subcapsular or deeper.
    - Abscess or tumor
    - Postsurgical collection
    - Acute swelling or infarction.
4. Cardiac surgery—Echocardiography, i.e. USG of heart shows time based tracing movements of heart valves and chamber walls. It can detect the presence of intracardiac lesions.
5. Urology:
  - i. Acute abdomen.
  - ii. Detection of early ascites (very sensitive).
  - iii. Differentiation of abdominal masses (solid, cystic or mixed).
  - iv. Detection of postoperative collection.
  - v. Posttraumatic organ scanning – It is the first line investigation of choice.
  - vi. Posttransplant organ scanning to see whether the organ is functioning properly from the vascular status.

Indications for ultrasonography examination of whole abdomen – USG is indicated in the following conditions.

- i. Acute abdomen.
- ii. Detection of early ascites (very sensitive).
- iii. Differentiation of abdominal masses (solid, cystic or mixed).
- iv. Detection of postoperative collection.
- v. Posttraumatic organ scanning – It is the first line investigation of choice.
- vi. Posttransplant organ scanning to see whether the organ is functioning properly from the vascular status.

4. Cardiac surgery—Echocardiography, i.e. USG of heart shows time based tracing movements of heart valves and chamber walls. It can detect the presence of intracardiac lesions.

5. Urology:
  - Kidney*
    - Stone showing the shadowing effect.
    - Hydronephrosis—very early changes can be detected.
    - Intra or perinephric abscess.
    - Trauma, lacerations and presence of any space occupying lesion.
    - Acute renal vein thrombosis.

#### Bladder

- Calculus
- Sol (space occupying lesion)
- Cystitis.

#### Prostate

- Benign hypertrophy of prostate
- Calcification.

**Table 17.1: Comparison in between CT scan and MRI**

<i>CT scan</i>	<i>MRI</i>
1. It involves ionizing radiation	1. It does not involve ionizing radiation and is harmless
2. CT is most sensitive for detection of focal hepatic lesions.	2. It is the best noninvasive technique for their detection
3. It is more useful for detection of kidney lesions like renal trauma, tumors, etc.	3. Less useful
4. Very useful for evaluation of complications of pancreatitis	4. The characteristics of pancreatitis on MRI are similar to those with CT. However, unlike CT, MRI is unable to detect small pancreatic calcifications
5. It is relatively nonexpensive requires less time	5. It is relatively expensive, time consuming and cannot be used in patients with pacemakers or metallic implants

### CT SCAN AND MAGNETIC RESONANCE IMAGING (MRI)

CT (computerized tomography) scan was introduced by Sir Godfrey Hounsfield in 1970's and since then it has become established as a powerful diagnostic tool in many branches of surgery.

However, MRI is the best method of assessment of soft tissue structures of the brain, spine and extremities.

The comparison between the two modes of imaging is given in Table 17.1.

At present MRI is not superior to other modalities but it is an important adjuvant.

### RADIOISOTOPE SCAN

#### Principle

Scintiscans are used to visualize organs which selectively concentrate injected or ingested radioactive isotopes and to study blood flow through an organ or region.

Isotopes with a short half-life and rapid excretion are used to prevent radiation damage.

#### Applications

a. Liver scan—The isotope used is  $^{99m}\text{Tc}$  - labeled sodium pertechnetate which are

removed by the Kupffer cells from the circulation after injection.

In metastatic carcinoma, there is diminished uptake by the tumor tissue. CT and MRI are superior to this type of scan in detecting metastasis.

b. Lung scan—Ventilation and perfusion scans are done in case of suspected pulmonary embolism.

- In perfusion scan albumin micro-aggregates labelled with  $^{99m}\text{Tc}$  is injected IV to outline pulmonary circulation.

- In ventilation scan,  $^{133}\text{Xe}$  is inhaled to outline the bronchi and alveoli.

- An area of diminished uptake on the perfusion scan with a normal ventilation scan indicates pulmonary embolism.

c. Thyroid scan—is done with  $^{99m}\text{Tc}$  Na - pertechnetate. A nodule is hot if it takes up the isotope to a greater degree than the surrounding gland, cool or warm if the concentration is the same and cold, if it is less.

A hot nodule is most likely to be a benign adenoma, whereas a cold nodule is likely to be a cyst, degenerated benign nodule or cancer.

d. Bone scans—are done with  $^{99m}\text{Tc}$ - labeled diphosphonate which detects osteoblastic activity surrounding bone metastases months before any radiological change.

## **PART II**

# Systemic Surgery Including Orthopedics



Chapter **18****Salivary Glands**

- Surgical anatomy
- Parotid swellings
- Parotid fistula
- Submandibular calculi
- Carcinoma of submandibular salivary gland

**SURGICAL ANATOMY****Salivary Glands**

There are three pairs of major salivary glands viz. the parotid, submandibular and sublingual glands. Besides these main salivary glands, small accessory glands are found scattered over the palate, lips, cheek, tonsil and tongue.

These glands are occasional sites for development of mixed salivary tumor.

**Parotid Gland**

It is the largest of the three paired salivary glands, weighing about 25 gm and is situated in the parotid mould. The mould presents the following boundaries (Fig. 18.1)

- Anteriorly — By the posterior border of the ramus of the mandible.
- Posteriorly — By the mastoid process and the attached sternocleidomastoid muscle.
- Above — By the zygomatic arch.
- Below — By the posterior belly of digastric muscle.

Some parts of the gland extend beyond the mould and produce various processes of the gland, e.g. facial process, pre- and post styloid process, accessory parotid gland, pterygoid process, etc.

**Coverings**

The gland is invested by inner true and outer false capsules.

True capsule is formed by the condensation of the fibrous stroma of the gland.

False capsule or parotid sheath is formed by the splitting of the investing layer of deep cervical fascia.

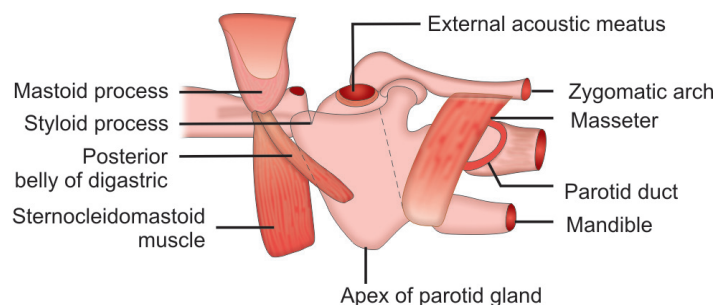
Disposition of parotid fascia (sheath) — The investing layer of the deep cervical fascia splits at the lower pole of the parotid gland and invest the gland, forming the false capsule. The superficial layer of this sheath gets attached to the zygomatic arch above and anteriorly it extends forward over the masseter muscle to form the tough parotidomasseteric fascia.

The deep layer is thin and is attached to the tympanic plate and styloid process of the temporal bone and is thickened to form the stylomandibular ligament. The ligament extends from the tip of the styloid process to the angle of the mandible and separates

the parotid gland from the submandibular glands.

**Presenting Parts (Fig. 18.1)**

- a. Apex — directed below, overlaps the posterior belly of digastric and appears in the carotid triangle.
- b. Base is concave and related to the external acoustic meatus.
- c. Superficial surface is covered by the skin and superficial fascia.
- d. Anteromedial surface is deeply grooved by the ramus of the mandible.
- e. Posteromedial surface is moulded on the mastoid process, sternomastoid muscle, the styloid process and styloid group of muscles.
- f. Borders — anterior, posterior and medial borders.



**Fig. 18.1:** Temporomandibular area, the parotid region and the structures related to it



## Structures Passing through the Gland

The structures within the gland, from outside inwards are basically three – (1) Facial nerve and its branches, (2) Retromandibular vein and (3) External carotid artery.

Within the parotid gland, the facial nerve and the retromandibular vein, divide the parotid gland into two parts – the superficial part and the deep part by the faciovenous plane, known as Patey's faciovenous plane.

1. The facial nerve emerges from the stylo-mastoid foramen about 2.5 cm deep to the middle of the anterior border of the mastoid process and passes downward and forward for about 1 cm before piercing the posteromedial surface of parotid gland. Within the gland, the nerve runs forward for another 1 cm superficial to the retromandibular vein and then divides into temporofacial and cervicofacial branches. The temporofacial branch turns abruptly upward and subdivides into temporal and zygomatic branches.

The cervicofacial passes downward and forward and subdivides into buccal (upper and lower), mandibular and cervical branches.

2. The retromandibular vein — Occupies the intermediate zone and is formed by the union of superficial temporal and maxillary veins. It ends below by dividing into anterior and posterior divisions. The anterior division joins with the facial vein to form the common facial vein. The posterior division joins with the posterior auricular vein to form the external jugular vein.
3. The external carotid artery occupies the deep zone and as it ascends it divides into terminal branches — superficial temporal and maxillary arteries. Sometimes the posterior auricular artery arises within the gland from the external carotid.

## Parotid Duct

It is about 5 cm in length and 3 mm in width. The duct emerges through the anterior border of the gland and passes at first forward on the masseter muscle between the upper and lower buccal nerves. At the anterior border of the masseter it abruptly turns medially and pierces the buccinator muscle. Finally, the duct opens in the vestibule of the mouth on a papilla opposite the crown of upper second molar tooth.

## Vessels

Arteries supplying the gland are derived from the branches of external carotid and the veins drain into the tributaries of external jugular vein.

## Lymphatics

Lymph vessels drain into the superficial and deep group of parotid lymph nodes. The efferent vessels from these nodes terminate into jugulodigastric group of deep cervical nodes.

## Nerve Supply

Secretomotor supply is via the auriculotemporal nerve carrying the parasympathetic fibers from the inferior salivatory nucleus of the medulla via the otic ganglion. The sympathetic fibers provide vasomotor supply to the gland.

## PAROTID SWELLINGS

These are swellings in the parotid region or mould.

## Peculiarities

1. Site—The Swelling lies in the parotid region or mould behind and in front of the lobule of ear.
2. It obliterates the furrow behind the ramus of the mandible.
3. Shape — It may look like the shape of the parotid gland.

## Causes

1. Acute suppurative parotitis (parotid abscess).
2. Acute parotitis.
3. Recurrent subacute and chronic parotitis (sialoadenitis).
4. Parotid tumors.
5. Preauricular lymphadenitis — Swelling is very mobile.
6. Swelling in connection with masseter muscle—Fibroma, Lipoma, Rhabdomyoma Idiopathic hypertrophy of masseter muscle.

### Diagnostic Point

The swelling becomes fixed and hard beneath the fingers when the masseter is contracted by clenching the teeth and free but relatively soft when the masseter is relaxed.

7. Swelling in relation to the overlying skin e.g. sebaceous cyst, lipoma.

8. Neuroma of facial nerve.
9. Adamantinoma of the mandible.

## Parotid Tumor

Approximately 80 percent of neoplasms of salivary glands occur in the parotid glands.

80 percent of parotid tumors are benign and of these 80 percent are pleomorphic adenomas. The remaining 20 percent are malignant.

About 15 percent of salivary gland tumors occur in the submandibular salivary glands, 60 percent of which are benign (95% pleomorphic adenoma) and 40 percent malignant.

All these tumors have a characteristic capacity of local recurrence.

10 percent tumors occur in minor salivary glands including sublingual gland – 10 percent benign (almost all are pleomorphic adenoma) and 50 percent malignant. Tumors of sublingual gland are commonly malignant.

## Classification

Classification into benign, low grade, high grade and nonsalivary tumors is convenient for prognostic purpose.

1. *Benign*
  - a. Pleomorphic adenoma (Mixed parotid tumor)
  - b. Papillary cystadenoma lymphomatous (Warthin's tumor)
2. *Low grade neoplasms*
  - a. Mucoepidermoid carcinoma
  - b. Acinic cell carcinoma
3. *High grade neoplasms*
  - a. Adenoid cystic carcinoma (relatively radiosensitive)
  - b. Adenocarcinoma.
  - c. Undifferentiated carcinoma.
  - d. Epidermoid carcinoma.
  - e. Carcinoma in pleomorphic adenoma.
4. *Nonsalivary tumors*
  - a. Lymphoma — Parotid only.
  - b. Metastatic carcinoma from carcinoma breast, kidney, lungs, etc.
  - c. Lipoma, neurofibroma, hemangioma, etc.

## Mixed Parotid Tumor

### Introduction

It is the most common tumor of the parotid gland, benign in nature. It is called pleomorphic salivary adenoma because there is pleomorphic appearance (myxoid, mucoid and

chondroid, i.e. cartilaginous and adenomatous elements) of this tumor.

The tumor surface exhibits many bulbous protrusions which causes thinning of the surrounding fibrous capsule and in some places complete capsular disruption with penetration into the normal salivary gland.

Thus simple enucleation of the tumor may leave behind these extensions resulting in local recurrence.

### Clinical Features

- Middle-aged women around 40 yrs. are commonly affected.
- The usual complaint is a painless, slow growing tumor over the angle of the jaw.

### Examination

- The tumor has a predilection to develop at the lower part of the gland.
- The overlying skin looks normal and not warm.
- Consistency — Soft, cystic.
- Mobility — The tumor can be moved little in all directions and is not fixed to skin or deeper structures.
- Facial nerve — It is not involved as it is a benign tumor.
- Lymph nodes — Not enlarged.

### Differential Diagnosis

1. Adenolymphoma
2. Carcinoma parotid
3. Chronic sialoadenitis
4. Cervical lymphadenopathy due to tuberculosis, metastasis or lymphoma
5. Lipoma
6. Fibroma
7. Rhabdomyoma.

### Complications

1. Malignant change—After a few years, pleomorphic adenoma shows features of transformation into malignancy.

It should be suspected when :

- Sudden or rapid increase in the swelling occurs which was so long growing very slowly.
- The swelling becomes painful, hard and fixed to the skin or masseter muscle.
- Concomitant facial nerve palsy.
- Cervical lymph nodes may become enlarged.

- Presence of prominent veins over the swelling.
  - Surface ulceration of skin.
2. Recurrence: Causes are:
    - a. Incomplete surgical excision.
    - b. Implantation of tumor cells during manipulation.
    - c. Multicentric growth potentiality of the tumor.

### Treatment

- FNAC from the swelling is done for confirmation of diagnosis.
- The tumor is radioresistant. So treatment of choice is surgery. The operation of choice is superficial parotidectomy or removal of superficial part of the parotid gland along with the tumor.

### Adenolymphoma

Syn. Warthin's tumor, Papillary Cystadenoma Lymphomatosum. Adenolymphoma is not a lymphoma, hence, a misnomer. It is a benign tumor. Constituting 10 percent of all parotid tumors. *Origin:* During development some parotid tissue gets included, within lymph nodes (preparotid) which are present within the parotid sheath.

### Pathology

Gross appearance is soft and frequently cystic. The cysts usually contain glairy brown mucus (Cloudy fluid).

### Microscopic Appearance

- It is quite different from any other tumor in the salivary glands.
- Cystic glandular spaces lined by double layered columnar epithelium.
- Presence of lymphatic tissue in the stroma, lymph follicles (hence the name) is characteristic of adenolymphoma.

### Clinical Features

*Age* — Commonly after 40 yrs.,

*Sex* — More common in men M:F = 4:1.

- a. Symptoms—The patient presents with a slowly growing painless swelling on the side of the face. It is bilateral in some cases.
- b. Signs:
  - It has smooth surface, round border with soft cystic consistency.

- Situation — At the lower pole of parotid elevating the ear lobule.
- Overlying skin is free and looks normal. No venous prominence seen, and not fixed to the deeper structures, i.e. Masseter, so mobile in both axes.
- Lymph nodes— Cervical lymph nodes are not enlarged.

### Differential Diagnosis

1. Mixed parotid tumor — Differentiated by the 99m Tc scan which produces a hot spot in case of adenolymphoma unlike other neoplasms including mixed parotid tumor.
2. Branchial cyst
3. Enlarged cervical lymph nodes
4. Parotid cyst
5. Lipoma

When the swelling is situated below the angle of the mandible

### Treatment

Superficial parotidectomy.

### Carcinoma of Parotid Gland

#### History

*Age:* Usually occurs in elderly persons.

*Sex:* Male and females are equally affected.

#### Symptoms

- Rapidly growing swelling on the side of the face is the most common complaint.
- The swelling may be painful, pain may radiate to the ear, to the face or to the neck.
- Pain is more felt if there is involvement of the jaw.

#### On Examination

*Temperature and tenderness* — The overlying skin may be somewhat warm. When the skin is infiltrated, it may look reddish blue. *Tenderness* is usually not present.

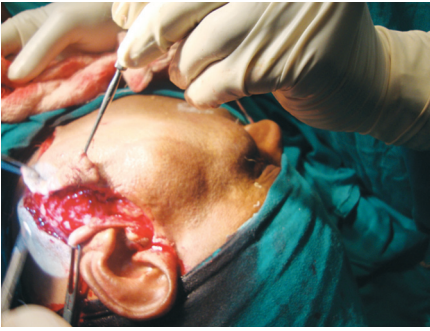*Surface* – Irregular,

*Consistency* – The mass is usually hard but may be firm.

*Margins* – Rounded.

Lymph nodes are involved in 15 percent cases.

Facial nerve is often involved in CA of the parotid. (inability to close the eyes, Asymmetry of the face, difficulty in chewing, Drooling of saliva from angle of mouth).



**Fig. 18.2:** Total parotidectomy in progress for carcinoma of the parotid gland.

The tumor is radioresistant.

Types of malignant tumor see page 126 in classification of parotid tumors.

### Treatment

The tumor is almost radioresistant, so treatment of choice is surgery (Fig. 18.2)

Before surgery:

- FNAC is done to confirm the diagnosis.
  - A CT scan is done to assess the tumor extent.
1. Total parotidectomy with sacrifice of the facial nerve should be the treatment of choice particularly in cases of low grade malignant lesion such as actinic cell tumor, mucoepidermoid carcinoma, etc.
  2. In a few cases of low grade malignant lesion, one may try to save the facial nerve along with total parotidectomy though technically it is difficult. This operation is called conservative total parotidectomy).
  3. Local recurrences should be treated by radiotherapy.
  4. When complete removal is not possible, superficial parotidectomy along with radium implantation should be the treatment of choice.
  5. In case of high grade malignant lesions, e.g. undifferentiated carcinoma, high grade mucoepidermoid carcinoma radical neck dissection should be accompanied by complete parotidectomy.
  6. When the lesion is completely fixed and irremovable only palliative deep X-ray therapy may be advised.

### Chemotherapy

Chemotherapy has very limited role in parotid CA. Chemotherapy has been tried in advanced inoperable disease. A combination

of Methotrexate and 5-FU has been used with some success.

## PAROTID FISTULA

### Definition

A parotid fistula may arise from the parotid gland or the parotid duct. Such fistula may be internal or external when it opens to the exterior.

### Causes

1. Following incision and drainage of parotid abscess.
2. Penetrating injury particularly by glass splinters.
3. As a complication of superficial parotidectomy.
4. Congenital parotid fistula.

### Types

1. Gland fistula — From the gland parenchyma, fistula discharge is minimal.
2. Duct fistula — When there is a fistula opening into a major duct discharge is profuse.

### Clinical Features

Main complaint is an opening on the cheek with discharge which comes out only during meals. There may be excoriation of the neighborhood skin.

### Investigation

Fistulogram is performed with watery solution of lipiodol to know whether the fistula is in relation to the main duct, ductule or to the gland.

### Treatment

1. If the fistula is from the main duct, the duct may be reconstructed by Newman and Seabrook's operation.  
If reconstruction of the duct fails — Total parotidectomy with preservation of the facial nerve will be curative.  
Drug treatment — Initially hyoscine bromide Tab, (Probanthine 15 mg Tab) – ½ Tab twice daily is given to reduce salivary secretion. In case of gland fistula, it closes spontaneously.
2. If there is stenosis at the terminal part of the parotid duct a papillectomy may allow good drainage and fistula may heal spontaneously.

## SUBMANDIBULAR CALCULI

### Diagnosis

#### History

*Age* – Most common in young and middle-aged adults.

*Sex* – Both sexes equally affected.

### Presentation

Patient complains of pain and swelling at the submandibular region, i.e. beneath and in front of the angle of the jaw, aggravated by food classically by sucking a lemon (Fig. 18.3) The gland gets tense and tender.

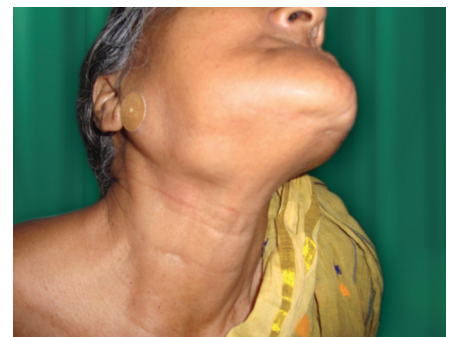Initially the swelling used to disappear in between meals but later on, the swelling is persistent and gets aggravated during intake of meals.

### On Examination

- A swelling is palpable in the submandibular region.
- The swelling is slightly tender, surface is usually smooth, all the margins are palpable and rounded, firm in consistency, free from skin and underlying structures.
- The swelling is bidigitally palpable. A stone in the submandibular duct is palpable at the floor of mouth.

### Investigation

X-ray of the floor of mouth (intraoral occlusal view) is taken to look for any radioopaque calculus in the line of submandibular duct. Sometimes the stone may be nonopaque due to poor mineral content.



**Fig. 18.3:** Submandibular salivary gland swelling due to calculus

## Treatment

### Stone in the Submandibular Duct

The stone is removed by making an incision directly over it through the mucous membrane of the mouth.

#### Operation

- i. Anesthesia — General or local.
- ii. Tissues immediately behind the stone are grasped by the forceps which steady the stone and thus prevent it, from slipping backwards in the gland substance.
- iii. An incision is made on the mucous membrane and duct directly over the stone in the long axis of the duct.
- iv. The stone is removed.
- v. The cut ends of the mucous membrane and the duct wall are all left unsutured.

### Stone in the Submandibular Gland

Excision of the salivary gland is advised.

**Ques:** What are other indications for excision of the submandibular salivary gland?

- Ans:**
- i. Chronically inflamed gland.
  - ii. Any tumor of the gland.
  - iii. Secondary carcinoma of the submandibular lymph nodes.
  - iv. As a part of radial neck dissection.

### Operation of Excision of the Submandibular Gland

1. General anesthesia with endotracheal intubation.
2. Position of patient — supine with neck extended and sand — bag placed beneath it and the face turned towards the opposite side.
3. Antiseptic dressing and draping.

4. Incision — A curved incision, 5 cm long in the line of the skin crease (Langer's line) is made 2 cm below and in front of the angle of the mandible to avoid injury to the cervical branch of the facial nerve.
5. The facial vein and artery are ligated and divided in between ligatures.
6. The lingual nerve and the hypoglossal nerve (XII nerve), lying between the deep surface of the gland and mylohyoid muscle and hyoglossus muscle — should be identified and preserved.
7. The superficial part of the gland is mobilized to raise it from the mylohyoid muscle.
8. The deep part of the gland is dissected from the hyoglossus muscle, mobilized and removed by ligating and dividing the submandibular duct.
9. Hemostasis secured and the wound closed with a drain.

Thus the three steps of dissection of the gland are incision, mobilization and excision.

### Submandibular Salivary Gland Excision – Rule of 2

1. 2" (inches) long incision — Curved incision over the swelling
2. Protect 2 superficial nerves — Cervical and mandibular branches of facial nerve.
3. Protect 2 deep nerves — Lingual and hypoglossal nerves.
4. Ligate facial artery 2 times — First at deeper plane and then at superficial plane.
5. Divide 2 muscles — Superficial – platysma, deep – fibers of mylohyoid.
6. Remove 2 lobes — Superficial and deep.
7. 2 Common indications — Stone and as a part of radical neck dissection.

## CARCINOMA OF SUBMANDIBULAR SALIVARY GLAND

### History

Usually found in elderly (> 50 yrs.) patients.

- The patient usually presents with a swelling in the upper part of lateral side of neck.
- Pain is felt over the swelling. There is no alteration in the size of the swelling during meals.

### On Examination

- There is swelling in the submandibular triangle.
- The swelling is nontender, surface — irregular.
- Margins — Rounded, mobile, free from skin and underlying structures.
- Lymph nodes are involved in 15 percent cases.

### Differential Diagnosis

1. Mixed tumor involving the submandibular salivary gland.
2. Submandibular lymph node enlargement due to Koch's infection.
3. Metastatic submandibular lymph node.
4. Malignant lymphoma.

### Diagnosis

Diagnosis is confirmed by doing a FNAC.

**CT Scan** — If the swelling is large and the deeper extent is not palpable bidigitally a CT scan can delineate the deeper extent of the mass.

### Treatment

Total excision of the submandibular gland followed by postoperative radiotherapy.

Lymph node dissection – If lymph nodes are not palpable, no elective lymph node dissection (Radical block dissection) is needed.

# The Gums and Jaws

- Jaw tumors
- Epulis
- Odontomes
- Dental cyst
- Dentigerous cyst
- Adamantinoma
- Tumors of the jaw bones

## JAW TUMORS

### Classification

Tumors arising from the jaw are of three types viz.

1. Those arising from the mucoperiosteum called epulis.
2. Those arising from the tooth germ called odontomes. The tooth germ consists of the enamel organ and the dental papilla, constituting the developing tooth (See below) and
3. Those arising from the jaw bones.

## EPULIS

### Definition

Epulis is a nonspecific term applied to a localized swelling of the gum. This may be:

- a. Granulomatous or false epulis—This is a heaped up mass of granulation tissue in relation to infected gum or carious tooth or at the site of irritation by a false tooth. It peculiarly occurs in pregnancy following minor trauma and chronic infection.
- b. True epulis
  - i. Benign
    - a. Fibrous or fibroid.
    - b. Giant cell or myeloid.
  - ii. Malignant
    - a. Fibrosarcomatous
    - b. Carcinomatous (rare).

### Fibrous Epulis

It is the most common of all varieties of epulis. It arises from the periosteum at the neck of an incisor or premolar tooth. As it grows, it separates the teeth and ultimately loosens them.

### Clinical Features

- It presents as a firm nodule at the junction of the gum and tooth. It is a slow growing tumor and not tender. The draining lymph nodes are not enlarged.
- A rapidly growing fibrosarcomatous change may occur.
- Excision is the treatment of choice.

### Giant Cell or Myeloid Epulis

- It is an osteoclastoma arising from the underlying bone. Microscopically, the tumor consists of fibrous tissue with abundant vascularity and giant cells of foreign body type.
- It is painless and has a smooth surface.
- X-ray may be performed to show typical soap bubble appearance of osteoclastoma.
- Complications like ulceration and serious hemorrhage may occur.

### Treatment

- i. In case of small swelling, the treatment is curettage and filling the cavity with cancellous bone chips.

- ii. In case of large tumors radical excision of the bone should be performed requiring graft in case of mandible. The graft may be taken from a rib.

## ODONTOMES

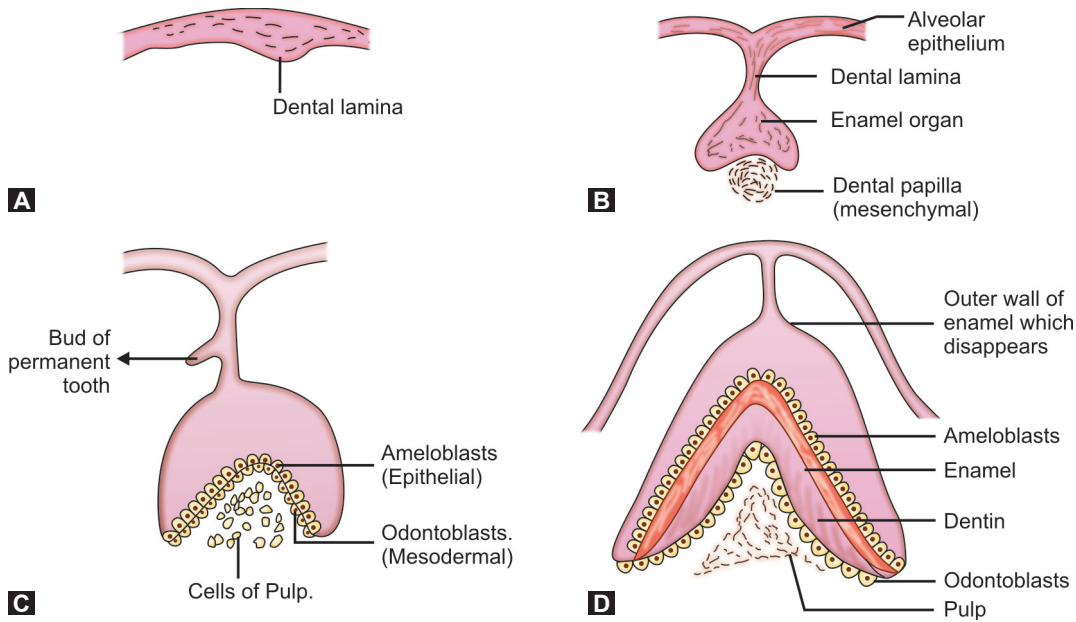
For an understanding of the origin of the odontogenic cysts and also the rarer odontogenic tumors of the jaws, a brief outline of tooth development is necessary (Figs. 19.1A to D & 19.2).

The enamel part of crown of the tooth develops from a downgrowth of the alveolar epithelium and represents the toughest tissue in the human body. The rest of the tooth (pulp, dentine and cement) forming the crown and root embedded in the tooth socket in the Jaw bone (Mandible or Maxilla) differentiates from the underlying mesodermal connective tissue.

The different varieties of odontomes are:

1. Epithelial odontomes arising from the epithelial elements
  - a. Dental cyst
  - b. Dentigerous cyst or follicular odontome.
  - c. Adamantinoma or ameloblastoma.
2. Connective tissue odontomes arising from connective tissue elements.
  - i. Fibrous odontome
  - ii. Cementome
  - iii. Sarcomatous odontomes.





**Figs. 19.1A to D:** Development of tooth. (A) Formation of dental lamina by alveolar epithelial thickening, (B) The enamel organ (local thickening of dental lamina) grows over dental papilla, (C) Apposition of ameloblasts and odontoblasts forming enamel and dentine, (D) Parts of the developing tooth

3. Composite odontomes arising from the epithelial and connective tissue elements viz.
  - i. Compound follicular odontome
  - ii. Composite odontome arising from the whole tooth germ.

Extremely rare

association of such a tooth in relation to a localized swelling in a jaw gives the diagnosis of the cyst.

- Most commonly it develops in relation to the incisors or canines of the maxilla. When it attains large size, it extends into the maxillary air sinus and causes bulging of the cheek. Usually it occurs in adult life and is painless.
- The contents are fluid, usually crystal clear and containing cholesterol crystals.
- Treatment is excision of the cyst with its epithelial lining through intraoral

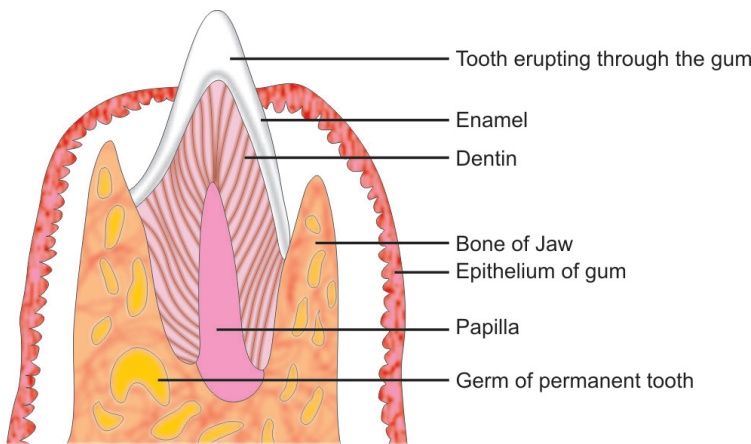
approach. After excision of the epithelium the cyst wall is curetted and the soft tissue is pushed in.

### DENTAL CYST

A dental cyst is found in relation to a normally erupted but pulpless carries tooth. The

### DENTIGEROUS CYST

- It is a squamous epithelial lined cyst containing the unerupted crown of a tooth most commonly an upper or lower-third molar tooth.
- This unerupted tooth constantly irritates the cells that produces degeneration of the cells resulting in a dentigerous cyst. Within the cyst, the tooth lies obliquely or sometimes, embedded in the wall of the cyst.



**Fig 19.2:** Erupting tooth and its relationship to the jaw

### Clinical Features

- Absence of molar tooth.
- As the cyst grows larger it expands the outer aspect of the mandible. The bone gets thinned out resulting in egg shell crackling.

### Diagnosis

- X-ray mandible –
- a. Tooth within the cyst
  - b. Soap bubble appearance due to multiple trabeculations of the bone.



**Treatment**

Excision of the cyst by intraoral approach, when the cyst is small. Large cysts are managed by marsupialization.

**ADAMANTINOMA**

This tumor arises from the ameloblasts or enamel forming cells. Hence it is also called ameloblastoma.

It is a slow growing locally malignant tumor.

**Pathology**

Macroscopic—It is a soft, fleshy tumor, having a maroon color because of hemorrhage. There are often areas of cystic degeneration, hence called multilocular cystic tumor.

**Clinical Features**

The tumors usually occur in the 4th or 5th decade and nearly always located at the angle of the mandible in relation to the molars.

- It is more prominent from the skin than from inside the mouth because it causes more expansion of the outer cortex of the mandible.
- Patient may present with the complain of falling teeth.

**Diagnosis**

X-ray shows a large cyst or small multiple cysts due to the trabeculations, called honey-comb appearance.

**Treatment**

The treatment of choice is wide excision with 1 cm of healthy normal tissue should be removed. It may amount to segmental excision of the mandible or hemimandibulectomy.

**TUMORS OF THE JAW BONES**

About 90 percent of the Jaw tumors are the secondary spread from oral carcinoma. The other uncommon tumors are as below.

**Classification***Benign Tumors*

1. Osteoclastoma
2. Fibroma dysplasia
3. Giant cell reparative granuloma.

*Malignant Tumors of the Maxilla*

- Osteosarcoma.
- Columnar cell carcinoma of the maxillary antrum
- Squamous cell carcinoma from the epithelium overlying the hard palate, tooth socket or the gum.
- Burkitt's tumor or malignant lymphoma.

*Malignant Tumors of the Mandible*

- Primary malignant tumor is extremely rare.
- Secondary malignant neoplasm may occur from (i) carcinoma of the tongue (ii) floor of the mouth and (iii) carcinoma of the lip.

# Chapter 20

## Cleft Lip and Cleft Palate

➤ Embryology

➤ Cleft lip

➤ Cleft palate

### EMBRYOLOGY

At about the 6th week of intrauterine life, the stomodeal depression develops at the cephalic end of the fetus. Around this depression, there are five elevated processes viz. (Figs 20.1A to C)

1. Single frontonasal process
2. Two maxillary processes — One on either side.
3. Two mandibular processes—One on each side.

The two mandibular processes fuse in the midline and form the lower lip and the lower jaw.

### Changes in the Frontonasal Process and Development of Lips

The frontonasal process arises from the capsule of the forebrain vesicle and descends like a curtain. The frontonasal process divides into two lateral nasal processes and one median nasal process by the two olfactory pits which are so called as they are destined to form the future nostrils.

The lateral nasal process moves up and on either side the median nasal process fuses with the maxillary process forming the upper lip. The central part or philtrum of upper lip develops from the median nasal process.

The median nasal process develops a bulge on each side known as the globular process. The maxillary process fuses with the globular process on each side forming the lateral part of the upper lip. So the defect in fusion of the median nasal process with the maxillary

process will lead to the development of cleft lip. The median nasal process will also form the nasal septum.

The fused mandibular processes of the two sides give rise to the lower lip and the lower jaw.

### Development of Palate

The palate develops from three components viz.

- i. Two palatine processes that appear from the maxillary process and grow beneath the olfactory pits and ultimately fuse to form the part of the hard palate behind the premaxilla.
- ii. Premaxilla which is developed from the median nasal process and fills up the triangular gap anteriorly between the two palatine processes. It carries the incisor teeth.

So the defect in fusion of the palatine processes and premaxilla will lead to the development of cleft palate.

### CLEFT LIP (FIG. 20.2)

Developmental error in the formation of the upper lip will give rise to the cleft lip.

### Classification

- A. *Cleft lip may be*
  1. Unilateral — It is the commonest variety and due to the failure of fusion between the globular process and the maxillary process on one side.
  2. Bilateral is rare.

B. *A cleft lip may be*

1. Incomplete—When the cleft has not extended upto the nostril.
2. Complete — The cleft lip extends to the floor of the nose.

C. *A cleft lip may be*

1. Uncomplicated
2. Complicated, that is associated with
  - a. Cleft alveolus or
  - b. Cleft alveolus and cleft palate.

### Problems with Cleft Lip

1. Cosmetically looks ugly.
2. Difficulty in sucking—There may be some difficulty in sucking and bottle feeding.
3. Deformed nostril.
4. Teeth come out through the gap and dental irregularity results.
5. Defective speech particularly with the labial letters B, F, M, P, V.

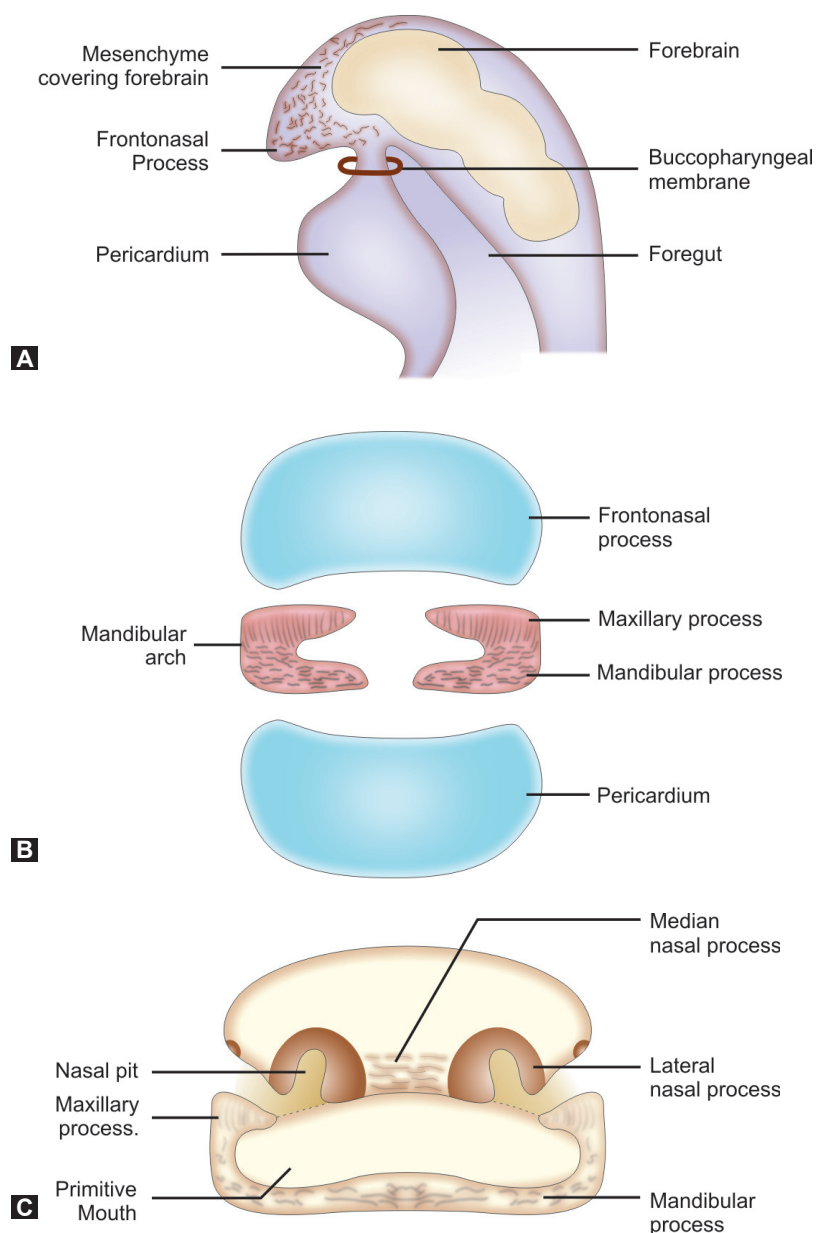
### Treatment

#### *Optimum Time for Repair*

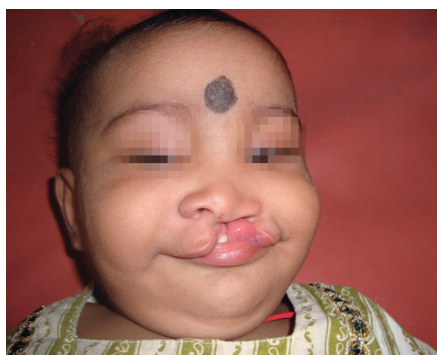Majority of surgeons follow “Rule of 10” as a guide for timing of lip and anterior palate repair. At the time of repair hemoglobin should be more than 10gm%, age approximately 10 weeks, weight more than 10lbs (4.5 kg) and total leukocyte count less than 10000/cmm, i.e. no infection.

#### *Operation*

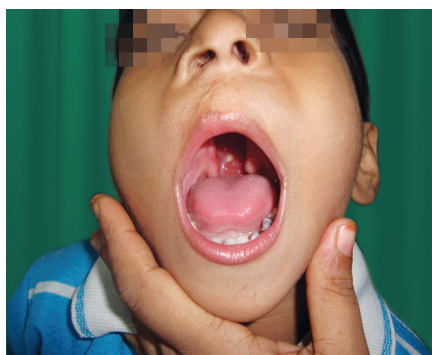- For unilateral cleft lip repair the most commonly done operation is Millard’s rotation advancement repair.



**Figs 20.1A to C:** Development of face. (A) Formation of frontonasal process, (B) Formation of maxillary and mandibular process, (C) Formation of nasal pit and median and lateral nasal processes



**Fig. 20.2:** Cleft lip



**Fig. 20.3:** Cleft palate

- Bilateral cleft lip repair can be done in a single stage or in two stages at the interval of 3 to 6 months using the Millard's technique of repair.

The underlying principles of operation are as follows:

1. There should be three layers of sutures viz. mucosa-to-mucosa, muscle-to-muscle (orbicularis oris which is the mainstay), and skin-to-skin. Alternately, suturing may be done in two layers viz. mucosa with deeper part of the muscle in one layer and skin with superficial part of the muscle in another.
2. The gap on the floor of the nostril must be repaired. Correction of the deformity of the nostril, as well, should always be done.
3. The margins must be made raw by cutting the whole thickness of the lip so that they can unite.
4. The vermillion border of the lip must be made regular.
5. It is to be remembered that there is no loss of tissue, which are only developmentally misplaced. Hence adjustment of the tissues should be so made that the repaired lip is of normal height and thickness without any depression.

### Postoperative Care

1. Infection must be prevented, cleanliness is maintained and antibiotics administered.
2. A Logan's bow is fixed to relieve the tension on the suture line. The sutures are removed on the 5th postoperative day.
3. The patient's hands should be fixed in splints so that the child will not be able to touch the operation site.

### CLEFT PALATE (FIG. 20.3)

Cleft palate is due to failure of fusion of the two palatine processes and the premaxilla. The line of fusion is in the form of Y.

### Classification

Cleft palate may be:

- i. Complete—There is a gap between the two halves of the palate in its entire length so that nose and mouth become interconnected. In front this gap may pass on one side of the premaxilla or on both sides. In the latter case, the premaxilla is not

- attached to the palate, but hangs down from the septum of the nose.
- ii. Incomplete — The two halves of the palate fuse together from before backward. The last parts to fuse are the two halves of the uvula. Incomplete fusion therefore may be
    - a. Bifid uvula.
    - b. The whole length of the soft palate is bifid.
    - c. The whole length of soft palate and the posterior part of the hard palate are involved.
- In incomplete cleft palate, the anterior part of the palate is always normally formed.
3. There is chance of aspiration bronchopneumonia.
  4. Difficulty in hearing: If palatal repair is not done, acute or chronic otitis media may develop. This may lead to hearing problems.
  5. Chance of repeated respiratory tract infection.
  6. Cosmetically looks ugly.
  7. Defect in smelling: This is due to contamination of the nasal mucous membrane with the oral organisms through the cleft palate.

### Treatment

#### Optimum time for operation

Repair should be carried out at the age of 1 to 1.5 years. Early repair results in retarded maxillary growth due to surgical trauma to growth center and periosteum. Delay in repair results in speech defect, i.e. nasal speech.

Like cleft lip, rule of 10 is also applied for cleft palate.

Age: More than 10 months.

Body weight should be more than 10kg.

Hemoglobin level more than 10gm% and total leukocyte count less than 10000/cmm.

Preoperatively culture and sensitivity of the mouth swab to be done.

*Operation:* Wardil's four flap operation is commonly done.

### Principles of Operation

- Palate is infiltrated with 1:2 lacs adrenaline solution.
- Two mucoperiosteal flaps are elevated, one from either side of palatal shelves. Then nasal layers are mobilized.
- Palate is closed in three layers—Nasal layer, muscle layer and oral layer.
- Speech therapy is done at 2 years.
- In combined cleft lip and palate, usually palate is done first, the reason being the function of palate is more critical viz. speech, respiratory tract infection, etc.

#### Postoperative Feeding

In uncomplicated cases, liquid diet is allowed after operation, in 4 hours and continued upto 10 days. Oral cleanliness is maintained. Systemic broad spectrum antibiotic is administered.

### Problems with Cleft Palate

1. Difficulties in sucking: The negative pressure which is required for sucking cannot be produced, so spoon feeding is to be resorted to.
2. Difficulty in speech: A person with cleft palate is unable to pronounce palatal consonants, e.g. B, D, K, P, T. There is nasal intonation due to the fact that air comes out through the nose while talking.

# Chapter 21

## The Tongue and Lip

- Surgical anatomy
- Ulcers of tongue

- Glossitis
- Tumors of tongue

- Lip

### SURGICAL ANATOMY

The tongue is a muscular organ lying on the floor of the oral cavity (Fig. 21.1).

#### Parts

- Tip—It is the anterior free end.
- Root—It is attached to the mandible above and hyoid bone below.
- Body—It is divided into dorsal and ventral surface. Dorsal surface is rough due to the presence of papillae or projections of the mucous membrane. This surface consists

of a oral and a pharyngeal portion separated by a V-shaped groove known as sulcus terminalis. At the apex of this groove is a shallow depression, the foramen cecum marking the embryological origin of the thyroid.

Ventral surface is smooth, has a median fold called frenulum linguae and deep lingual vein on either side which can be seen through the thin mucosa. More laterally can be seen the fimbriated fold containing the deep artery of the tongue and the lingual nerve.

The posterior 1/3rd of tongue (pharyngeal part) has no papillae but carries numerous lymphoid nodules which with the tonsils and adenoids make up the lymphoid ring of Waldeyer.

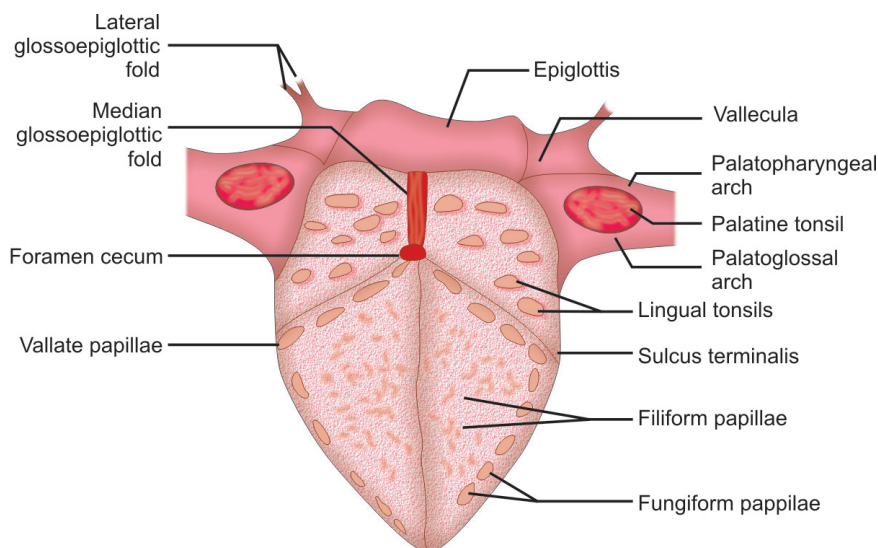
#### Papillae

The papillae are numerous projections of the mucous membrane in front of sulcus terminalis. There are three types of papillae viz.

1. Vallate—Large, arranged in a row in front of sulcus terminalis.
2. Fungiform—Lies over the tip and along its lateral margins.
3. Filiform—These are the most numerous papillae of the tongue lying over the dorsal surface and responsible for its velvety appearance.

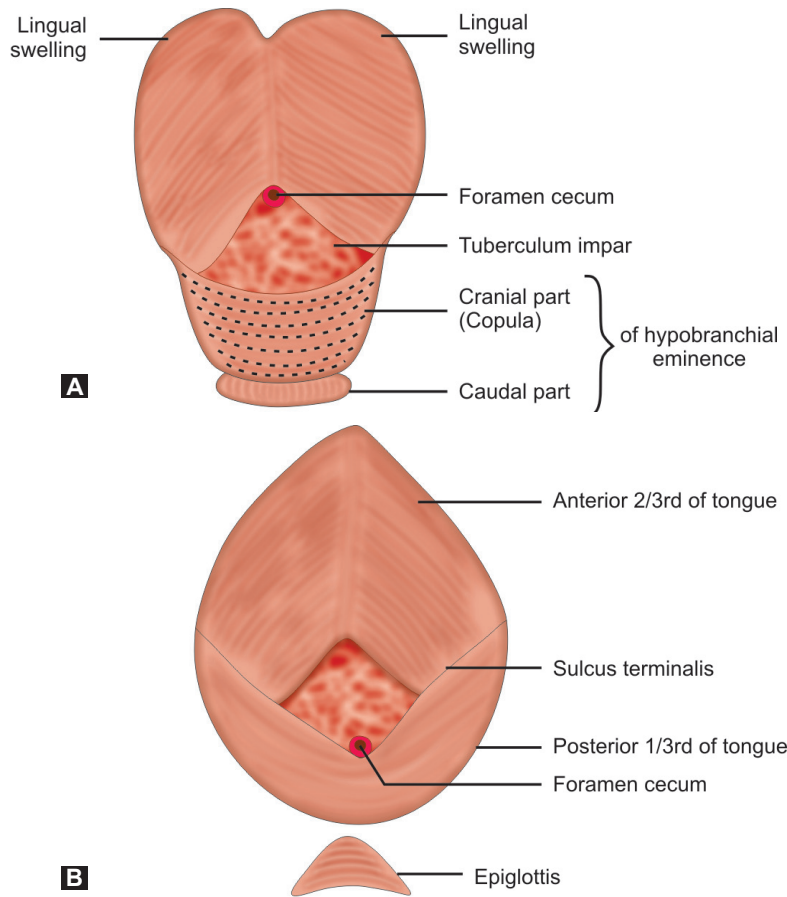
#### Muscles of Tongue

- The intrinsic muscles are disposed in vertical, longitudinal and transverse bundles. They alter the shape of the tongue.
- The extrinsic muscles move the tongue as a whole. They pass to the tongue from the symphysis of the mandible, the hyoid, the styloid process and the soft palate, to be named respectively as genioglossus, hyoglossus, styloglossus and palatoglossus. Blood supply is from the lingual artery, a branch of the external carotid artery, venous drainage by deep lingual vein which drains into facial vein or internal jugular vein.



**Fig. 21.1:** Anatomy of tongue showing the dorsal surface





**Figs 21.2A and B:** Stages in the development of tongue. (A) 1st stage, (B) 2nd stage.

**Development and Nerve Supply (Figs 21.2A and B)**

- Anterior 2/3rd of tongue develops from the first branchial arch (two lingual swellings and tuberculum impar) is supplied by the lingual branch of 5th nerve which also transmits the gustatory fibers of chorda tympani (VII).
- Posterior 1/3rd develops from the 2nd and 3rd arch swelling called copula of His. The copula is the cranial part of the midline swelling known as hypobranchial eminence developed in relation to the medial ends of the 2nd, 3rd and 4th branchial arches. The caudal part of hypobranchial eminence forms the epiglottis. It is supplied by glosso-pharyngeal nerve for general and taste sensations.
- Posterior most part develops from the fourth arch. It is supplied by vagus nerve (internal laryngeal branch).

- All muscles of tongue except palatoglossus are supplied by the hypoglossal nerve. The tongue muscles are developed from the migration of the occipital myotome carrying its own nerve supply, that is the hypoglossal nerve. Palatoglossus, a muscle of the soft palate is innervated by the spinal accessory via pharyngeal plexus.

**Lymphatic Drainage**

It has been described below in spread of the carcinoma of tongue.

**ULCERS OF TONGUE**

**Classification**

- A. Nonspecific
1. Traumatic or dental ulcer due to sharp tooth or dentures.
  2. Infective, e.g.
    - a. Simple ulcer due to glossitis.
    - b. Herpetic ulcer.
    - c. Postpertussis ulcer.
3. Aphthous ulcer.
- B. Specific
- Tubercular ulcer.
  - Syphilitic ulcer.
  - Malignant ulcer.



**Aphthous Ulcer**

These ulcers are common at the tip of the tongue and often multiple. Aphthous (Greek) means mouth ulcer. They are found on the tongue, as well as the lips and mouth in persons suffering from intestinal disorders like inflammatory bowel disease.

The etiology is not clear but susceptibility for development of these ulcers increases in stress, fever and autoimmune disorders.

They start as small blisters which burst and produce painful superficial ulcers, surrounded by a hyperemic zone.

**Tubercular Ulcer**

- Tongue is not a common site for tubercular ulcer as it is covered with squamous epithelium. They do not develop in untreated patients but only in undiagnosed and established pulmonary tuberculosis.
- It commonly occurs in young adults. The ulcers are usually multiple, situated on the margin, dorsum or near the tip. These are extremely painful, when they are situated on a mobile portion of tongue.
- Histologically, the presence of caseation and epithelioid cells are confirmatory.
- Systemic antitubercular treatment cures the ulcers.

**Malignant Ulcer**

This means ulcerative type of carcinoma. As elsewhere the ulcer is raised from the surface, with rolled out everted margins and induration at the base. Significant neck nodes may be present.

Treatment is done in the line of carcinoma of tongue.

**Syphilitic Ulcer**

Through rare nowadays, syphilitic ulcers may be found in any of the three stages of syphilis.

1. In primary stage—Painless chancre occurs at the tip of the tongue. There is enlargement of submental lymph nodes.

The organism *T. pallidum* can be detected in the scraping from the ulcer.

2. In secondary stage, multiple painless, shallow “Snail track” ulcers are found on the margins and under surface of tongue.
3. In the tertiary stage, gummatous ulcers occur. The ulcer has a typical appearance – clear punched out margins, wash leather slough on the floor and no induration at the base.

### GLOSSITIS

This is a term used to describe a red, smooth (depapillated) and sore tongue.

There are two types of glossitis viz.

1. Acute—Acute superficial glossitis which follows superficial injuries and scalds. Herpes of tongue may be included in this type. Acute parenchymatous glossitis sometimes develops following deep wounds in the tongue.
2. Chronic—Chronic superficial glossitis.

### Chronic Superficial Glossitis (Leukoplakia)

The most important feature of leukoplakia is a slowly progressive hyperkeratosis. There is proliferation and heaping up of cornified epithelium with the formation of milk white patches.

This condition may occur anywhere in the mouth but most commonly seen on the tongue.

Other sites of the body where leukoplakia can be seen include glans penis, vulva and perianal region.

#### Etiology

The six well known etiological factors, known as 6S's of chronic superficial glossitis are:

- i. Smoking
- ii. Sharp tooth
- iii. Sepsis
- iv. Spices
- v. Spirits and
- vi. Syphilis.

#### Pathology

#### Macroscopic Features

- The condition is confined to the anterior 2/3rd of the tongue.

- It usually starts at the edges and gradually spreads on to the dorsum.
- The surface may become fissured and cracked due to contraction of the underlying scarred tissue caused by chronic inflammation.
- The affected area of the tongue shows milk white patches.
- In course of time atrophy tends to succeed hypertrophy, the thickened papillae disappear and the white membrane is worn off. The surface becomes smooth and red.

#### Microscopic Features

- The epidermis is greatly thickened and cornified. The prickle cell layer hypertrophies and shows parakeratosis.
- The underlying dermis is infiltrated with chronic inflammatory cells of small round type to be replaced later by fibrous tissue.
- The practical importance of leukoplakia is the danger of its developing into squamous cell carcinoma in 5 to 15 percent of cases, depending on location.

#### Clinical Features

**Age**—Usually occurs after 50 years of age.

**Sex**—Men are affected more than women.

The main complaint is that the tongue becomes white at places and develops fissures and cracks.

#### Examination

Clinically leukoplakia may be seen in one of the following four stages viz.

**Stage 1**—Appearance of a thick gray transparent film on the affected part.

**Stage 2**—The thin film turns opaque and white. In the beginning it looks soft but later cracks and fissures develop.

**Stage 3**—Hyperkeratosis produces warty outgrowths. Simultaneously there is shedding of the cornified layer which leaves smooth and red shiny areas surrounded by whitish condensations.

**Stage 4**—This is the stage of clinically detectable carcinoma. The lesion possesses all the characteristic features of primary carcinoma. It should be suspected if there is local thickening, bleeding or pain.

#### Treatment

- i. Small patches of leukoplakia should be removed.

- ii. The known chronic irritants should be eliminated if possible.
- iii. Large patches should be biopsied. The patients should be examined every month to note the progress of the disease. Appearance of warty growths or lump should arouse suspicion and then portions should be excised and examined histologically.

### TUMORS OF TONGUE

1. Benign—Rare, e.g.
  - Hemangioma
  - Lipoma
  - Neurofibroma
  - Papilloma
  - Lingual thyroid.
2. Malignant tumors
  - Carcinoma
  - Sarcoma.

### Carcinoma of Tongue

#### Predisposing Factors

1. Chronic irritations caused by:
  - a. Sharp tooth or ill fitting denture.
  - b. Oral sepsis.
  - c. Spirit—excess alcohol intake.
  - d. Smoking.
  - e. Spices.
2. Syphilis.
3. Chronic superficial glossitis.
4. Sessile papilloma of tongue.

#### Site

1. Anterior 2/3rd of tongue at or near the lateral margin—25% × 2.
2. Ventral surface of anterior 2/3rd of tongue – 10 percent.
3. Dorsal surface of anterior 2/3rd of tongue – 10 percent.
4. Posterior 1/3rd of tongue—20 percent.
5. Tip of tongue—10 percent.

#### Pathology

Macroscopically carcinoma tongue may be of the following types.

1. Ulcerative type.
2. Papillary or wart type.
3. Nodular type.
4. Fissured type.
5. Frozen type—Tongue becomes an indurated mass.

### Microscopic Features

1. Anterior 2/3rd—Squamous cell carcinoma with characteristic cell nest formation.
2. Posterior 1/3rd—Basal cell carcinoma or lymphoepithelioma.
3. Rarely adenocarcinoma.

### Spread

#### Direct Spread

- i. By continuity—The carcinoma spreads along the substance of the tongue and this is helped by the rich lymphatic plexus in the tongue. Growths in the anterior 2/3rd cannot spread across the midline because of the median raphe. A growth in the anterior 2/3rd seldom encroaches on the posterior 1/3rd and *vice versa*.
- ii. By contiguity:
  - a. From the anterior 2/3rd, to the floor of the mouth, alveolar process, mandible and cheek.
  - b. From the posterior 1/3rd—to the tonsils, epiglottis and the soft palate.

#### Lymphatic Spread

The lymphatic spread is mostly by permeation and not by embolism. The spread is quick and occurs first to ipsilateral regional nodes. The rapid spread is due to the presence of inter-spaces in the tongue musculature, rich lymphatics and excessive mobility of the tongue.

The tongue is drained by four main sets of lymph vessels viz.

- a. Apical vessels—Draining the tip of the tongue into the submental lymph nodes of both sides.
- b. Basal vessels which drain the posterior 1/3rd of tongue drain bilaterally into jugulodigastric and juguloomohyoid nodes.
- c. Lateral or marginal vessels drain the lateral borders of anterior 2/3rd of the tongue homolaterally to the submandibular nodes from where efferents run to the deep cervical nodes.
- d. Central vessels drain the parts on either side of the median raphe and may run from one side to the other. They drain into the deep cervical groups in the jugulodigastric and juguloomohyoid nodes.

Thus in general, lymphatic metastasis from growth on the margins of anterior 2/3rd is homolateral while that from the posterior 1/3rd and tip of tongue are bilateral.

#### Hematogenous Spread

Hematogenous Spread is not commonly manifested and when occurs, it is exclusively with the posterior third growths.

#### Clinical Features

- The patient is usually an elderly one, more than 50 years of age.
- Pain—In the tongue due to ulceration, infection and involvement of lingual nerve.
- Odynophagia or painful deglutition occurs in cancer of posterior 1/3rd of tongue.
- Dysphagia due to ankyloglossia and mechanical disadvantage.
- Salivation—Due to difficulty in swallowing, pain and the presence of mass.
- Dysarthria caused by ankyloglossia and pain.
- Voice change—Especially in case of a mass in the posterior 1/3rd causing obstruction.
- Bronchopneumonia due to inhalation of infected material.
- Asphyxia due to pressure on the air passages by the mass.

#### Investigations

1. Wedge biopsy from the edge of the ulcer. In case of proliferative growth, punch biopsy is recommended.
2. X-ray chest—To rule out aspiration or inhalation pneumonia.
3. X-ray of mandible to exclude its involvement.
4. Routine investigations such as complete blood picture, fasting and postprandial sugar, ECG should be done for anesthetic fitness.

#### Treatment

It consists of (A) Management of the primary growth, (B) Management of the neck nodes and (C) Management of advanced cases.

#### Management of the Primary Growth

1. Preliminary measures
  - To maintain oral hygiene with regular mouthwash with antiseptic lotions.
  - Treatment of the infected gums and carious teeth.
2. Either surgery or radiotherapy is the treatment of choice. However, radiotherapy is contraindicated in the following situations viz.

- i. Any growth involving the mandible as radiation causes bone necrosis.
- ii. Presence of gross sepsis in the mouth or jaw as bone necrosis invariably occurs.

Radiation is given in two forms viz.

- a. Interstitial or direct radiation—This is done for growths in the anterior 2/3rd, i.e. the site accessible for implantation of radium. Total dose 6000 – 8000 rads.
- b. Telecobalt therapy—This is usually done with cobalt 60 unit and indicated for growths in the posterior 1/3rd or large growths (more than 2 cm in diameter or 1 cm in depth).

For any growth in the posterior 1/3rd of tongue, radiotherapy is the treatment of choice.

#### 3. Surgery:

- In the anterior 2/3rd of tongue
  - i. If a growth is less than 1 cm excision of the growth with a wide margin of healthy mucosa not less than 1 cm is done.
  - ii. If the growth is more than 1 cm initially radiotherapy is given. If radiotherapy fails to cure within 2 months of completion of treatment, surgery is indicated.

The types of surgery are as follows depending on the site of lesion.

- a. Partial glossectomy—for growths on the lateral margin, close to the tip.
- b. Hemiglossectomy—This means excision of half of the anterior two-thirds of the tongue. This is done for growths on the lateral margin.
- c. Subtotal glossectomy—This means excision of the whole of anterior 2/3rd of tongue.

- When the growth involves or reaches within 2 cm of the mandible, hemimandibulectomy is done in addition to glossectomy.
- Commando operation—This means glossectomy with hemimandibulectomy and block dissection of the cervical nodes. This is done for large growths with palpable mobile nodes. This operation is so named because of its extensive nature.

### Management of the Neck Nodes

- i. Patients with no palpable neck nodes, no treatment is required but kept on regular monthly check up.
- ii. Nodes palpable but mobile. This may be due to presence of infection. So a course of antibiotics is given for 3 weeks. If there is no response, block dissection is done.
- iii. Fixed and hard palpable nodes—Only palliative treatment is advised.

### Palliation for Advanced Cases

1. In case of large and fixed primary growth, radiotherapy is helpful. However, radiotherapy is of little value for the unresectable nodes.
2. In case of severe pain due to advanced growth trigeminal nerve block with 5 percent phenol is done.
3. In case of recurrence after radiotherapy or surgery cryosurgery is performed. The tissues are exposed to extreme cold (less than  $-20^{\circ}\text{C}$ ) to cause irreversible cell damage.

### Prognosis

If lymph nodes are involved 5 years survival rate is about 15 percent, while in the absence of nodal involvement, it is about 60 percent.

## LIP

### Neoplasm of Lip

#### Classification

- A. Benign—Benign tumors may arise from any of the tissues forming the lips – the skin, fat, fibrous tissue, muscles, blood vessels, lymphatics, nerves and specialized glands. The benign tumors are:
  - i. Lipoma
  - ii. Fibroma
  - iii. Papilloma
  - iv. Hemangioma
  - v. Naevi

- vi. Pyogenic granuloma
  - vii. Leukoplakia
  - viii. Lymphangioma
  - ix. Minor salivary gland, tumors which are common in upper lip, are usually pleomorphic adenomas.
  - x. Keratoacanthoma.
- B. Malignant tumors
    - i. By far the commonest malignant tumor is the squamous cell carcinoma of the lip.
    - ii. Melanoma.

### Carcinoma Lip

#### Predisposing Factors

- i. Exposure to sunlight
  - ii. Recurrent cheilitis
  - iii. Smoking
  - iv. Papilloma
  - v. Leukoplakia
  - vi. Chronic fissures.
- The last three conditions are precancerous lesions.

#### Pathology

*Macroscopic:* It may present as a malignant ulcer, papillary growth, an infiltrating type or as a nodule.

In the ulcerative type, the ulcer presents hard and raised edges characteristic of malignancy. *Microscopically,* 99 percent of all lip cancers are of the squamous cell type. They are usually well-differentiated with grades I and II.

#### Spread

- Mainly local and lymphatic spread occurs. Blood spread is rare.
- Lymphatic spread –
- i. From lower lip to the submental nodes and
  - ii. From the upper lip, to the submental and submandibular nodes ultimately, they metastasize to the deep cervical nodes (Juguloomohyoid and Jugulodigastric nodes).

### Clinical Features

#### Symptoms

- Usual presentation is a nodule or an ulcer which fails to heal.
- The lesion may bleed or may have offensive discharge.
- It is usually painless.

#### On Examination

- There may be a nodule or nonhealing ulcer with hard and raised edges.
- Growth moves with the lip.
- Submental, submandibular and upper deep cervical nodes may get enlarged.

#### Differential Diagnosis

- Keratoacanthoma
- Pyogenic granuloma in early cases
- Basal cell carcinoma
- Minor salivary gland tumors.

#### Treatment

- A. Treatment of the primary lesion
 

Carcinoma of lips is slow growing and can be cured by surgery or radiotherapy.

  - i. In early cases without glandular metastasis, wedge resection with a margin of 0.5 cm of normal tissue is done. Radiotherapy (External beam) has equally good results in this stage with cure rates of about 90 percent. Advanced lesions require combined surgery and radiotherapy.
  - ii. For larger lesions, excision of more than half of the lip may be required. Plastic reconstruction is needed in such case, e.g. rotation flaps from the cheek or neck.
- B. Management of lymph nodes – This is managed in the same line as in case of carcinoma of tongue.
 

Prognosis is good. 5 year survival rate is 80 percent if the lymph nodes are not involved.

# Chapter 22

## Neck Swellings

- Surgical anatomy
- Classification
- Ranula
- Sublingual and cervical dermoid
- Branchial cyst
- Branchial fistula
- Cystic hygroma
- Cold abscess
- Cervical lymphadenopathy
- Carotid body tumor
- Sternomastoid tumor
- Pharyngeal pouch

### SURGICAL ANATOMY

#### Triangles of the Neck (Fig. 22.1)

The anterolateral part of the neck is conventionally divided into anterior and posterior triangles by the diagonally running sternocleidomastoid muscle.

The anterior triangle is bounded posteriorly by the anterior border of the sternocleidomastoid, anteriorly by the midline from the chin to the manubrium and above by the lower border of the mandible. It can be

subdivided by the digastric and the omohyoid muscles into the suprahyoid—submental and submandibular triangles, and the infrahyoid – carotid and muscular triangles.

The posterior triangle is bounded anteriorly by the posterior border of the sternocleidomastoid, posteriorly by the anterior border of the trapezius and below by the middle third of the clavicle.

During clinical examination a neck swelling can be described in relation to one or more of these easily definable triangles.

### CLASSIFICATION

The swellings of the neck, for ease of description, may be divided into midline and lateral swellings (Figs 22.2 and 22.3).

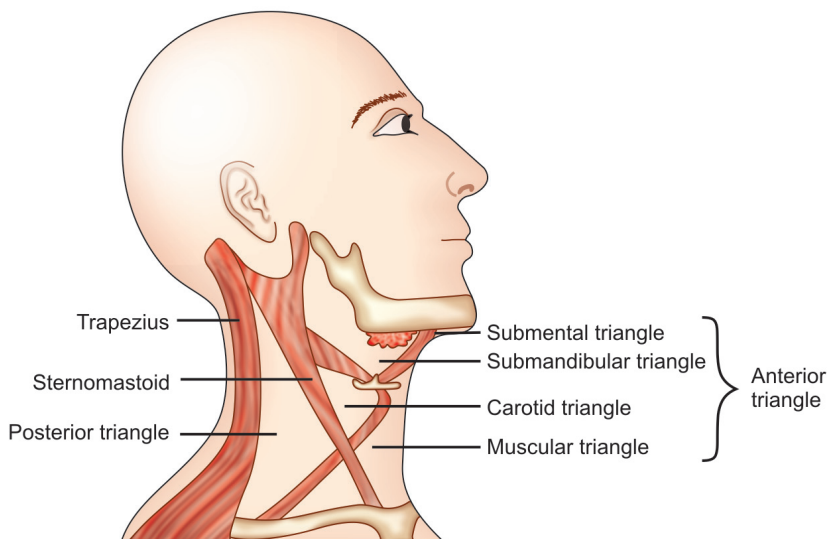
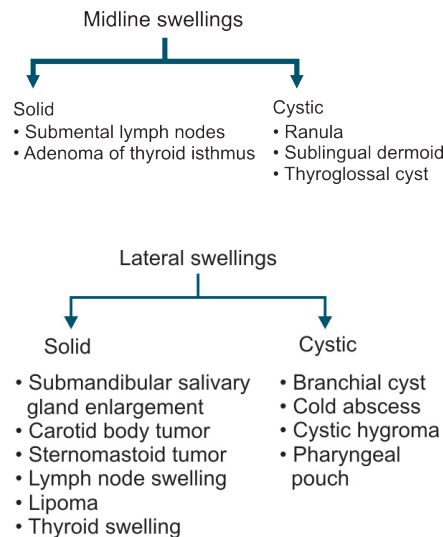


Fig. 22.1: Triangles of the neck

### RANULA

Ranula is Latin for a small frog. It arises from a damaged sublingual gland (These sublingual glands are called glands of Blandin and Nuhn). The *lining wall* is composed of delicate capsule of fibrous tissue, and the *content* is viscid, jelly-like fluid.



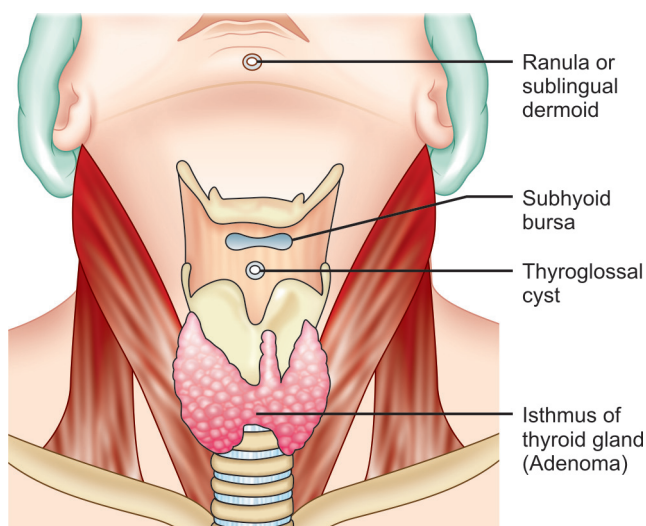


Fig. 22.2: Midline swellings of the neck

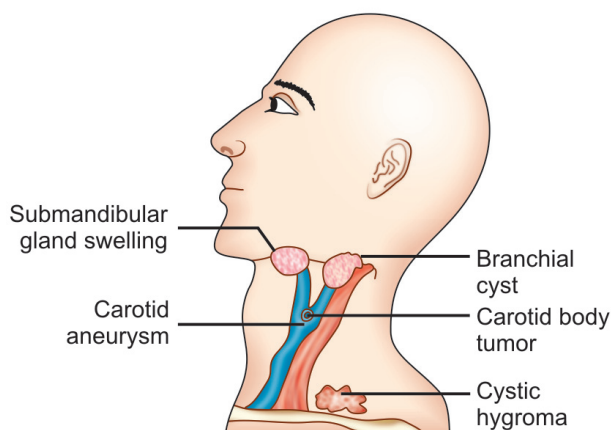


Fig. 22.3: Lateral swellings of the neck

### Diagnosis

The patient is usually a child or young adult of either sex, presents with a swelling (Bluish in color like a frog belly) in the floor of the mouth which is soft, fluctuant and transilluminant, noncompressible and nonreducible.

### On Examination

*Shape and size*—1 to 5 cms in diameter, surface – smooth with diffuse borders.

The ranula is not attached to the overlying mucosa, mylohyoid or muscles of the tongue. The submandibular duct either overlies the lesion or is displaced to one side.

### Complication

- Bursting and reformation
- Infection
- Difficulty in speech or eating if the tongue is pushed upwards.

### Differential Diagnosis

- a. Sublingual dermoid—Transillumination -negative
- b. Hemangioma—Compressible (Other compressible swellings—Lymphangioma and meningocele).

### Treatment

Excision or marsupialization (when complete excision is difficult).

### Plunging Ranula

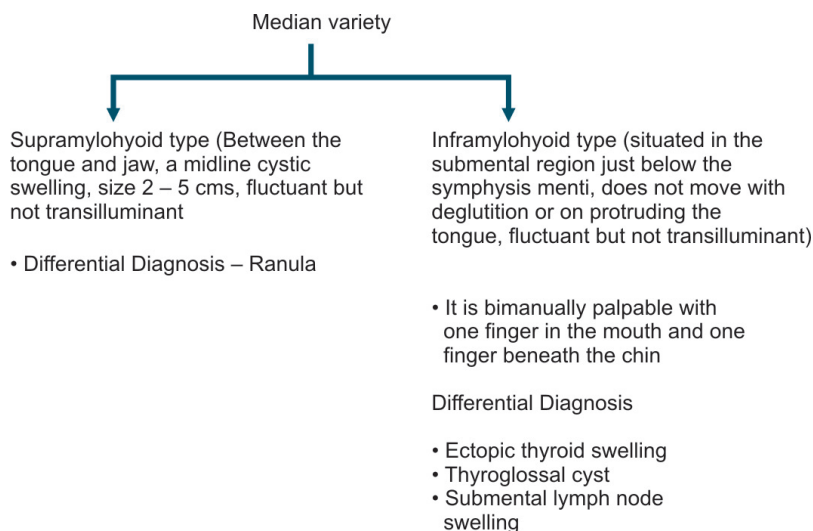
When the oral variety of ranula (described above) extends into the neck, passing beyond the floor of mouth and appears in the submandibular region, then it is called plunging ranula.

*Diagnosis*—by bidigital palpation (one finger in the oral cavity and the other on the neck). The cross fluctuation will be positive.

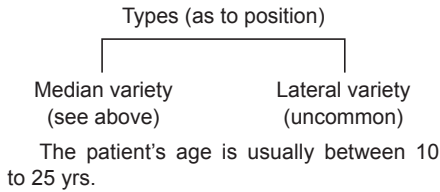
### SUBLINGUAL AND CERVICAL DERMOID

It is a congenital sequestration dermoid, lined by stratified squamous epithelium, and contains doughy mass of keratin. It hardly ever contains hairs as in other dermoids.

*Origin*—During fusion of two halves of the mandible, some ectodermal cells may be sequestered into the underlying mesoderm,



which proliferate and ultimately liquify in future to form the cystic swelling. According to projection of the swelling, it may be supra or inframylohyoid type.



**Lateral Variety**

- a. *Supramylohyoid or sublingual type*—Cystic swelling in the floor of mouth placed laterally, transillumination– Negative. Differential diagnosis – Ranula
- b. *Inframylohyoid or cervical type*—Cystic swelling in the region of the submandibular salivary gland. Transillumination – Negative.

**Differential Diagnosis**

- Plunging Ranula
- Submandibular salivary gland swelling
- Submandibular lymph node swelling – solid swelling.

**Treatment**

- Complete excision.
- Sublingual (supramylohyoid types) dermoids are approached through the floor of the mouth while.
  - Cervical (inframylohyoid type) dermoids are approached via a curved incision along the Langer's line over the submental or submandibular region.

**Thyroglossal Cyst (Tubuloembryonic Dermoid Cyst)**

**Common Sites**

- From above ↓ downwards
- Beneath the foramen cecum
  - In the floor of the mouth
  - Above the hyoid bone
  - Beneath the hyoid
  - On the thyroid cartilage
  - At the level of cricoid cartilage

**Definition**

It is the cystic swelling arising from the remnant of the thyroglossal duct, the other name being median thyroid diverticulum which arises from the floor of the pharynx behind the tuberculum (see below fate of thyroglossal duct) impar of the developing tongue.

- Structures which move up with *deglutition*
1. Thyroid swellings
  2. Subhyoid bursitis.
  3. Pretracheal and prelaryngeal lymph nodes.
  4. Thyroglossal cyst.

**Lining**

The cyst is lined by pseudostratified ciliated columnar or squamous epithelium which produces desquamated epithelial cells or mucus at times.

**Clinical Features**

- Though congenital thyroglossal cyst appears around 15 to 30 yrs.
- Content—Thick jelly like fluid.
- Present as painless, midline swelling, and more common in female.

- The cyst is soft, cystic, fluctuant and transillumination test is negative.
- Mobility
  - Moves with deglutition.
  - Moves with protrusion of tongue.

**Complications**

1. Recurrent infections
2. Abscess and fistula formation
3. Papillary carcinoma.

**Treatment**

*Sistrunk's Operation*

Excision–Fistula with entire thyroglossal tract is excised. Central portion of hyoid bone and lingual muscle are removed. Removal is facilitated by pressing the posterior 1/3rd of tongue. Care should be taken not to perforate the thyrohyoid membrane. Incomplete removal results in recurrence.

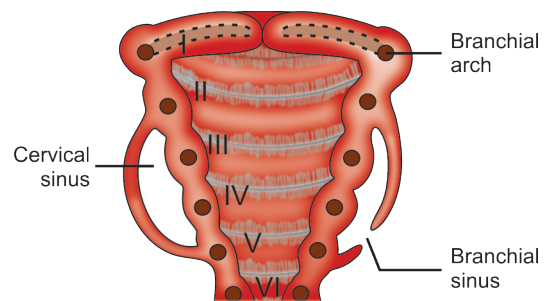
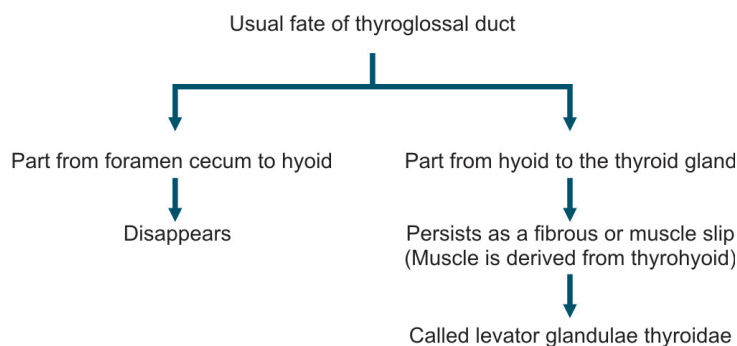
**Thyroglossal Fistula**

(Also called median fistula of the neck, situated below the hyoid bone).

- The fistulas opening moves up on protrusion of the tongue.
- Characteristic feature is the hooding of the skin above the opening, i.e. a crescentic fold of skin overlying the fistulas opening.

**Treatment**

Complete excision of the fistulas tract.  
*Preoperative measure*—For better visualization of the tract, methylene blue may be injected into the fistulas opening on the sight before operation and the opening



**Fig. 22.4:** Formation of branchial cysts and branchial sinus or so called incomplete branchial fistula I-VI the six branchial arches

of the fistula is closed with a purse string suture. This helps in better visualization of the tract during operation.

### BRANCHIAL CYST

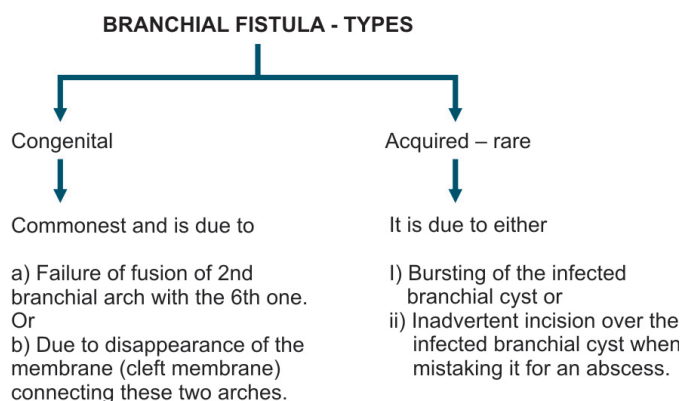
It is a cystic swelling arising in connection with the *persistent cervical sinus* which is formed due to the fusion of overgrowing 2nd branchial arch, with the 6th branchial arch (Fig. 22.4).

Normally the cervical sinus disappears, but if it persists, accumulation of fluid occurs inside the sinus and gives rise to the branchial cyst. The fluid is usually secreted by the appendages, i.e. the sweat and sebaceous glands of the ectodermal lining of the enclosed space.

*Branchial sinus or fistula:* Sometimes the 2nd arch fails to fuse with the 6th arch and thus either a branchial sinus or fistula results.

### Clinical Features

- Lining—The cyst is lined by squamous epithelium.
- Contents—Cheesy, toothpaste-like material.
- Age—Although congenital, it first appears around 20 to 25 yrs. or more as the fluid it contains, accumulates slowly.
- Swelling—The swelling has smooth surface and round borders. It is soft, cystic, fluctuant and transillumination negative.
- Mobility—Not very mobile because of its adherence to the sternomastoid muscle. Fluctuation is often difficult to elicit as the swelling is firm due to thick inspissated content.
- Sternomastoid contraction test—The swelling becomes less prominent.
- Other cysts containing cholesterol crystals are cystic hygroma, thyroglossal cyst, hydrocele, dental and dentigerous cysts. If contents are aspirated it contains cholesterol crystals.
- Local lymph nodes (Deep cervical)—They are not enlarged. If so one should reconsider the diagnosis in favor of cold abscess.
- Site—In the anterior triangle of the neck, partly under cover of the upper 1/3rd of anterior border of sternomastoid. This can be explained because of the development of the sternomastoid muscle from the myotome of second branchial arch.



### Differential Diagnosis

1. Cold abscess—A caseating tuberculous lymph node may simulate a branchial cyst. Aspiration from the cold abscess does not show any cholesterol crystals.
2. Cervical dermoid (inframylorhyoid variety).
3. Carotid body tumor (Solid swelling).
4. Submandibular salivary gland swelling – solid swelling, bidigitally palpable.
5. Solitary enlarged cervical lymph node.

### Treatment

Excision of the cyst with entire epithelial lining with a curved incision centered over the swelling.

If the epithelial lining remains, recurrence will follow.

### Precautions during Operation

- a. The cyst wall is thin and delicate, so not to be held by any tissue forceps.
- b. One should avoid injury to
  - i. The XII and XI nerves.
  - ii. Carotid artery.
  - iii. Wall of the pharynx.

## BRANCHIAL FISTULA

**Types:** See above

### Features

#### Site

- a. Congenital variety—The external opening is at the anterior border of sternomastoid muscle at the junction of lower and middle 1/3rd.
- b. Acquired variety—The opening is at the level of the branchial cyst.

Usually seen in growing adults, but can occur at any age.

*Nature of discharge:* Mucooid or Mucopurulent with or without excoriation of the surrounding skin.

*Treatment* – Complete excision.

*Preoperative measure* – Fistulogram, which may be of some help during excision of the tract.

### Steps of Operation

- Incision—Along the Langer's line encircling cutaneous opening of the fistula.
- After cutting superficial fascia, platysma, the tract is dissected from below up as high as possible.
- Sometimes a second incision is needed above the upper border of the thyroid cartilage which is made parallel to the first one and the dissected tract is taken out through the second incision. This is known as 'step ladder pattern' of dissecting a branchial fistula.
- It is generally possible to trace the fistula upto the lateral wall of the pharynx, where it is ligated and excised.

*N.B.:* Two other terms in relation to branchial cyst and fistula.

- Branchial cartilage—Elongated piece of cartilage deep to the cutaneous dimple at the position of external orifice of a branchial fistula.
- Cervical auricle—It is the cutaneous projection at the position of the external orifice of a branchial fistula.

### Precaution during Operation

- As the tract passes through the bifurcation of common carotid artery, the vessel should be protected.

- To avoid injury to XII nerve.
- Complete removal is necessary; otherwise persistence of the tract will cause recurrence.

## CYSTIC HYGROMA

### Definition

It is a collection of lymphatic sacs, which contain clear colorless lymph.

### Origin

They are congenital and consist of a cluster of lymph channels that failed to connect into the normal lymphatic pathways, i.e. jugular lymph sacs situated between the internal jugular and subclavian veins.

### Site

At the base of the neck, in the posterior triangle. It may extend upto the jaw above and down over the anterior chest wall and axilla.

*Lining:* Lined by columnar epithelium.

*Contents:* Clear watery or straw-colored fluid consisting of cholesterol crystals and lymphocytes.

*Age:* It appears very early and may be found at birth or within the first few years of life. Of all the congenital swellings, it is the earliest to develop, even before sternomastoid tumor.

### Other Sites of Cystic Hygroma

- Axilla
  - Groin or inguinal region
  - Mediastinum
  - Tongue and buccal mucosa of the cheek.
- So these sites are to be examined during examination of a cystic hygroma.

### Atypical Presentation

- During birth, a big cystic hygroma may cause obstructed labor.
- Due to recurrent infection it may present as a pyogenic abscess.
- Cystic hygroma in the mediastinum may present as a growth with mediastinal syndrome characterized by dyspnea, dysphagia, etc.

The swelling is

- Soft cystic fluctuant and brilliantly translucent, surface is lobulated.
- Regional lymph nodes not enlarged.

### Can spontaneous recovery take place?

Yes, and when it occurs, it will take about 2 years.

### Differential Diagnosis

- Branchial cyst
- Cold abscess in the neck
- Solitary lymph cyst—Usually it appears in the adult life and is commonly found in the supraclavicular region.

### Complications

- Recurrent infections as the cyst is surrounded by a shell of lymphoid tissue.
- Sudden increase in size of the cyst may cause respiratory distress, when the treatment is aspiration of the cyst with or without tracheostomy.

### Treatment

- If there is no urgent indication, operation can be delayed upto 2 years, because there is a chance of spontaneous recovery.
- Before commencing any treatment X-Ray chest to be done to see any evidence of mediastinal cystic hygroma.
- Conservative:
  - Aspiration alone, especially when the cyst is big enough to cause pressure symptoms.
  - Aspiration followed by injection of hot water or hypertonic saline. Due to injection of sclerosing agents, fibrosis occurs which gives rise to the following
    - The size diminishes.
    - The cyst becomes more localized.
    - During operation Dissection is easier.
- Operative: Complete excision of the cyst.

### Precautions to be Taken During Operation

- Cyst wall should not be held with tissue forceps.
- There are finger-like projections from the cyst wall invading the surrounding structures. So every care should be taken for complete excision.

### Radiotherapy

Cystic hygroma is relatively radioresistant.

## COLD ABSCESS

### Definition and Nomenclature

It develops as a result of caseation necrosis of cervical lymph nodes.

### Causes

- Tuberculosis – most common.
- Actinomycosis.
- Leprosy.
- Madura foot.

Why called cold abscess?

- Cold abscess means an abscess which has no signs of inflammation. Usually, it is due to TB lymphadenitis or TB spine (cold abscess in the posterior triangle of neck).
- It is one of the commonest causes of cervical lymphadenitis and the commonest cause of cystic swelling in the carotid triangle.

### Pathology

Tuberculous lymphadenitis has 3 stages.

1. Stage of lymphadenitis.
2. Stage of periaadenitis or matting.
3. Stage of cold abscess.

### Stage of Lymphadenitis

Lymph nodes are enlarged, nontender or slightly tender, commonly upper deep cervical nodes are involved. They are discrete and palpable. Age usually 20 to 30 years, i.e. young adults.

### Stage of Periaadenitis or Matting

- Due to involvement of capsule, the nodes move together, become firm and nontender.
- Matting is pathognomonic of tuberculosis.
- Other rare causes of matting are chronic lymphadenitis, anaplastic variety of lymphoma.

### Stage of Cold Abscess

- It occurs due to caseation necrosis of the lymph nodes. The caseating materials liquefies and breaks through the capsules of the lymph nodes to form a 'cold abscess'.
- In the beginning, the abscess remains deep to the deep cervical fascia. Ultimately the fascia is eroded at one point and the pus



**Table 22.1: Stagewise treatment of tuberculous lymphadenitis**

Stage	Investigation	Treatment
1. Lymphadenitis	Lymph node biopsy	Anti TB treatment (ATT)
2. Periadenitis/Matting	Lymph node biopsy	Anti TB treatment (ATT)
3. a. Cold abscess as such	Aspiration for AFB	Nondependent aspiration with ATT
3. b. Collar — stud abscess	Aspiration for AFB	Nondependent aspiration followed by ATT
3. c. Chronic discharging sinus	Edge biopsy from the sinus	ATT

tracks into the superficial space. Now it is called collar-stud abscess. The superficial abscess gradually enlarges and becomes obvious on inspection. In untreated cases, the skin at the center undergoes necrosis and gives rise to the chronic discharging sinus.

### Clinical Features

History of evening rise of temperature  
Loss of weight  
Anorexia  
Sweating  
Lump in the neck  
Tenderness in the cervical spine.

### Investigations

- CBC (Complete Blood Count) may show low Hb%. ESR is increased in most cases.
- Chest X-ray is usually -ve, sputum is examined for AFB (acid fast bacilli).
- FNAC gives diagnosis in 75 percent cases.
- Lymph node biopsy reveals central caseation surrounded by epithelioid cells with Langhan type of giant cells.
- If there is a cold abscess, one can aspirate the content which is cheesy, and may be +ve for AFB.

### Differential Diagnosis

- Branchial cyst—Contains cholesterol.
- Cystic hygroma.

### Treatment

#### Antitubercular treatment (ATT) for Lymphatic TB (Tuberculosis)

WHO recommendation for extrapulmonary TB is as follows:

The three drug regime INH, Rifampicin, Pyrazinamide (HRZ) for two months followed

by INH and Rifampicin for another four months. Stagewise treatment is given in Table 22.1 above.

#### Role of Surgery in TB Lymphadenitis

- Biopsy—Lymph node biopsy, edge biopsy from the edge of the sinus.
- Aspiration—Non dependent aspiration of cold abscess.
- Excision of the lymph nodes, if they persist in spite of ATT.
- Excision of the sinus along with the tract.

### CERVICAL LYMPHADENOPATHY

It is the commonest swelling in the neck.

#### Causes

- Acute
  - Acute pyogenic lymphadenitis.
  - Acute lymphatic leukemia.
  - Acute infectious mononucleosis. (E.B. virus)
- Chronic
  - Inflammatory
    - Nonspecific—Chronic pyogenic lymphadenitis.
    - Specific—TB, syphilis, sarcoidosis.
  - Neoplastic
 

Almost always malignant

    - Primary
      - Lymphoma – Hodgkin's disease
      - Lymphosarcoma.
      - Reticulum cell sarcoma.
    - Secondary – Metastatic lymph node from a primary growth. Primary carcinoma giving rise to metastatic lymph node in the neck are carcinoma scalp (via the preauricular nodes), tongue, mandible, tonsils, oropharynx, submandibular gland, larynx and laryngopharynx, lips, thyroid, breast, lungs, stomach and

other abdominal viscera, skin of neck (melanoma), etc.

- Autoimmune disorders, e.g. SLE, juvenile rheumatoid arthritis (Still's disease).

### Causes of Generalized Lymphadenopathy

- Acute—Infectious mononucleosis, septicemia.
- Chronic—TB, syphilis (see), sarcoidosis.
- Reticuloses—Hodgkin's disease, lymphosarcoma, lymphatic leukemia.

### Differential Diagnosis of Chronic Cervical Lymphadenopathy

The common conditions are:

- Chronic pyogenic lymphadenitis.
- TB lymphadenitis.
- Secondary metastatic lymph node.
- Hodgkin's disease.
- Lymphosarcoma and reticulum cell sarcoma.
- Chronic lymphatic leukemia.

### Examination of Enlarged Lymph Node

Enlarged lymph nodes usually present with a lump in any particular area, e.g. neck or groin.

When a lump is suspected of lymph node origin, the following are also seen in addition to the examination of the lump proper.

- To see the drainage area for any possible primary lesion, e.g.
  - For enlarged lymph node in the neck—To examine scalp, ear, nose, mouth, tongue, larynx, pharynx, etc.
  - For lymph nodes in groin—To examine skin of leg (melanoma) buttock, external genitalia, lower abdomen below the umbilicus and anus.
- Examination of other lymph node areas — For example axilla, groin, abdomen, etc. In generalized lymphadenopathy, lymph nodes are also found at other sites.
- Examination of the abdomen for
  - Liver and spleen if enlarged, suggest a reticulosis, sarcoid or glandular fever.
  - Any mass—For example retroperitoneal nodes in seminoma testis. Also the testis is examined.
- Per rectal and per vaginal examination to see any growth in prostate or ovary.



### Special Investigations

- Blood—Complete blood count, chest X-ray.
- FNAC and biopsy of the enlarged lymph nodes.

### CAROTID BODY TUMOR

(Syn. Chemodectoma, Potato Tumor)

It is a slow growing tumor which arises in the carotid body at the carotid bifurcation. The carotid body is a chemoreceptor organ which is stimulated by the rise in  $PCO_2$  or  $H^+$  ion concentration of arterial blood or a decline in its  $PO_2$ .

### Pathology

#### Macroscopic

The size of tumor varies from 2 – 10 cm. The tumor is well-capsulated, considered to be a benign tumor and remains localized for years.

#### Microscopic

It shows the same histologic pattern of a normal carotid body.

### Clinical Features

This is a firm, homogeneous and compact tumor, almost looks like a potato. Hence the name 'Potato tumor'.

### Age

Highest incidence is between the ages 40 and 60 years of life.

The main symptom is a slow growing painless swelling at the bifurcation of the common carotid artery. Occasionally pressure on the carotid sinus from the tumor produces attacks of faintness.

### Differential Diagnosis

1. Cervical lymph node enlargement.
2. Sternomastoid tumor.
3. Branchial cyst.
4. Aneurysm of carotid artery.

### Special Investigation

Arteriography—Shows the carotid bifurcation to be splayed open by the mass. The rich vascularity of the tumor is also demonstrated.

### Treatment

- It is often possible to dissect the tumor away from the carotid sheath.

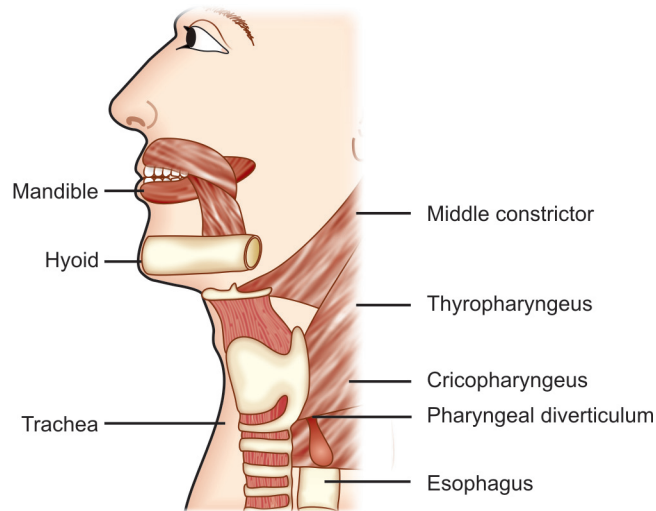


Fig. 22.5: Lateral view of pharynx showing Killian's dehiscence

- If the carotid vessels are firmly involved, resection can be performed with graft replacement of the artery with Dacron graft or autogenous vein graft.

### STERNOMASTOID TUMOR

It is a misnomer as it occurs due to birth injury to the sternomastoid muscle and is not a tumor.

During childbirth, injury to the sternomastoid muscle causes hematoma in the muscle which gets organized to form the swelling.

### Clinical Features

- It is seen in infants of 3 to 4 weeks of age.
- The swelling is smooth, hard, nontender and adherent to the muscle.
- Head points towards the muscle of same side and chin towards the opposite side producing torticollis.
- Delay in correction may produce facial deformity.

### Differential Diagnosis

Other causes of torticollis, e.g.

- Trauma
- Lymphadenitis due to either tuberculosis or suppurative infection
- Rheumatic disorder
- Burns
- Spasmodic.

### Treatment

Division of the lower end of the sternomastoid muscle or excision of the muscle.

### PHARYNGEAL POUCH

#### Definition

It is a laterally placed swelling of the neck located behind the sternomastoid muscle below the thyroid cartilage. It occurs as a result of protrusion or herniation of the mucosa of pharyngeal wall through the Killian's dehiscence. The latter is a weak area of pharyngeal wall between the oblique fibers of thyropharyngeus and the sphincter like transverse fibers of cricopharyngeus part of the inferior constrictor muscle (Fig. 22.5).

### Clinical Features

The patient is usually a male and elderly.

- Patient complains of gurgling sounds in neck at the time of swallowing.
- Dysphagia.
- Regurgitation of food after turning from one side to another leading to features of aspiration pneumonitis, lung abscess and mediastinitis.
- The swelling is soft and cystic with audible gurgling.
- The contents may be emptied on pressure into the pharynx and mouth.

### Diagnosis

Thin Barium Swallow – Evidence of pouch, Esophagoscopy – not indicated.

### Treatment

Excision of the pouch is done through the cervical approach followed by repair of the pharynx in two layers, cricopharyngeal myotomy and closure with drain.

Chapter **23****Thyroid Gland**

- Surgical anatomy
- Physiology
- Investigations—Tests of thyroid function
- Congenital anomalies
- Goiter
- Non-toxic goiter
- Toxic goiter (Thyrotoxicosis)
- Solitary thyroid nodule
- Neoplastic goiter
- Autoimmune thyroiditis
- Subacute thyroiditis
- Riedel's thyroiditis

**SURGICAL ANATOMY**

The thyroid gland is a highly vascular endocrine gland and is composed of two lateral lobes connected by an isthmus. This gland weighs between 20 to 30 gms.

Each lateral lobe extends vertically from middle of the thyroid cartilage to the 6th ring of the trachea. The isthmus covers the second, third and fourth rings of trachea.

A third lobe of conical shape, called the pyramidal lobe, frequently arises from the upper part of isthmus or from the adjacent portion of either lobe but not commonly the left.

A fibrous or muscular band is sometimes found attached above to the body of

the hyoid bone and below to the isthmus of the gland or its pyramidal lobe. When muscular it is termed the levator glandulae thyroidae.

Each lateral lobe is roughly triangular on section. The superficial surface is covered by the infrahyoid muscles (sternothyroid and sternohyoid), the sternocleidomastoid overlapping (Figs 23.1 and 23.3).

The medial surface is related to two tubes—esophagus and trachea, two nerves – recurrent laryngeal and external laryngeal and two muscles—cricothyroid and inferior constrictor.

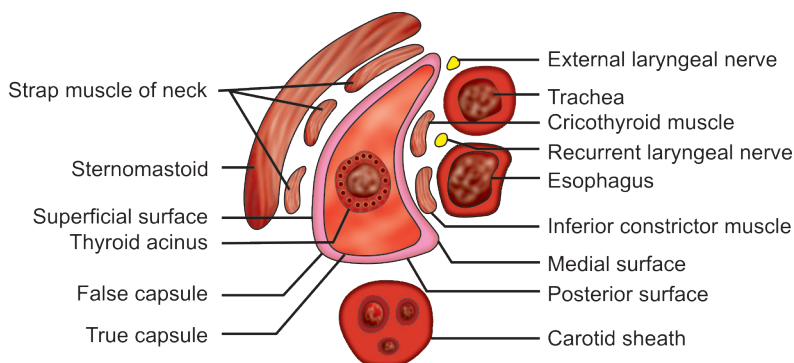
The posterior surface overlaps the carotid sheath containing the common carotid

artery, internal jugular vein and the vagus nerve.

**Coverings**

The thyroid gland is covered by two capsules – the true capsule and the false capsule.

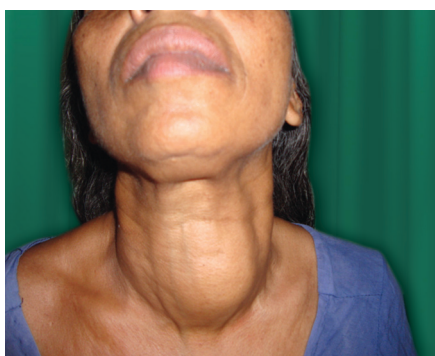1. True capsule is a fibrous capsule which covers the gland and sends numerous fibrous septae within it.
2. False capsule is a fascial sheath derived from the pretracheal layer of the deep cervical fascia. On the posteromedial aspect of each lobe this sheath is thickened to form the ligaments of Berry extending from the posteromedial border of thyroid lobes to the lower border of the cricoid cartilage.



**Fig. 23.1:** The thyroid gland and its relations



**Fig. 23.2A:** Thyroid swelling moves upwards with deglutition often better seen while drinking a glass of water



**Fig. 23.2B:** Thyroid swelling involving the left lobe

### Movements of the Thyroid with Deglutition (Figs 23.2A and B)

The thyroid gland moves with deglutition due to its attachments with the larynx and trachea as follows:

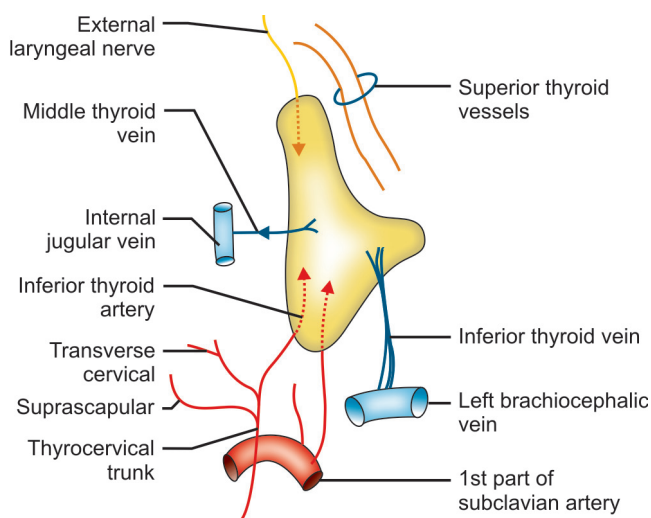
- i. The posterior lamina of the pretracheal fascia which is closely adherent to the rings of the trachea on the back and the isthmus of the thyroid in front.
- ii. The ligaments of Berry on either side.
- iii. Sometimes the presence of levator glandulae thyroideae.

### Blood Supply

The arteries of the thyroid gland are (Fig. 23.2C).

1. Superior thyroid artery, a branch of external carotid artery, goes to the upper pole of each lobe accompanied by external laryngeal nerve.
2. Inferior thyroid artery – A branch of thyrocervical trunk which arises from the 1st part of the subclavian artery, lies posterior to the gland at the level of the cricoid cartilage. The recurrent laryngeal nerve crosses either in front or behind the artery or may pass between the branches.
3. The thyroidea ima, if present, arises from the brachiocephalic artery or the arch of aorta. It ascends in front of trachea, to the isthmus.
4. A variable number of small tracheal arteries enter the deep surface of the gland. After partial thyroidectomy they maintain the blood supply of the remaining glandular tissue.

The veins form a plexus on the surface of the gland and on the front of the trachea. From this plexus superior, middle and inferior thyroid veins arise. The superior and middle thyroid veins drain into the internal jugular vein while the inferior thyroid vein receives tributaries from the isthmus and the lower poles of the thyroid gland and usually drains into the brachiocephalic vein.



**Fig. 23.2C:** Blood supply of thyroid gland

### Lymphatics

The lymphatics of the thyroid are especially important in surgery for malignancy. From the superior aspect the lymph drains medially to the prelaryngeal nodes and laterally to the upper deep cervical nodes.

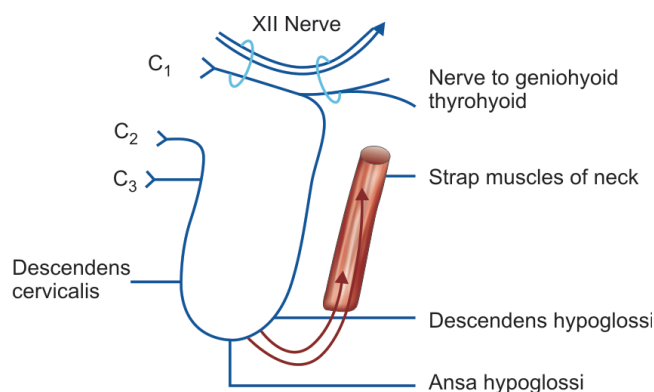
From the inferior aspect, the lymph drains medially to the pretracheal and paratracheal lymph nodes and laterally to the lower deep cervical lymph nodes.

### Development

The thyroid gland is developed from a median diverticulum which appears about the fourth week from the floor of the pharynx between the tuberculum impar and the cupola. It grows down in the midline into the neck as a tubular duct which bifurcates and subsequently divides into a series of cellular cords from which the isthmus and the lateral lobes of the thyroid gland are developed.

Neural crest cells from the ultimobranchial bodies are entangled in the thyroid to form the parafollicular 'C' cells, which secrete the hormone calcitonin.

The connection of the diverticulum with the pharynx is termed the thyroglossal duct which subsequently undergoes degeneration, its upper end being represented by the foramen cecum of the tongue and lower end by the pyramidal lobe of thyroid gland.



**Fig. 23.3:** The ansa hypoglossi – showing nerve supply to the strap muscle of neck

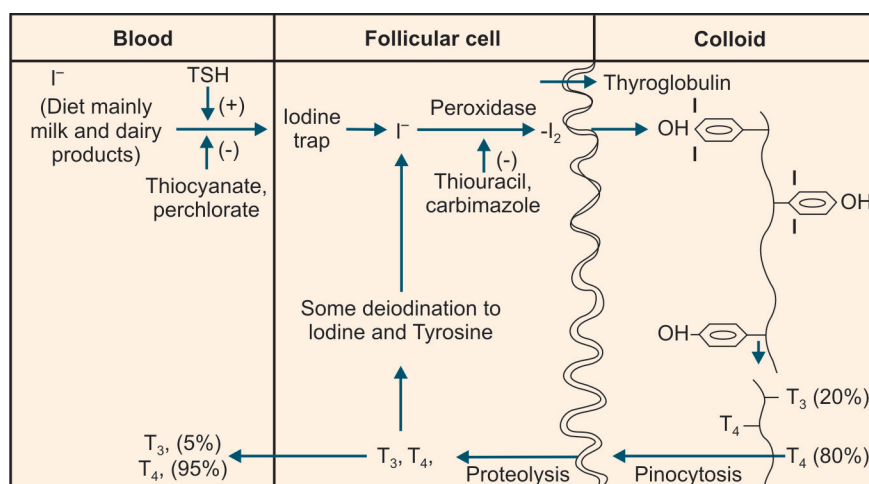


Fig. 23.4: Thyroid hormone synthesis, secretion and release

### Microscopic Structure

The microscopic structure of the thyroid gland consists of the following:

- i. **Follicles**—The unit of the thyroid gland is a follicle or vesicle. Thousands of follicles are aggregated together in the gland supported by connective tissue that contains numerous blood vessels, lymphatics and aggregation of lymphocytes. The follicles have no basement membrane and their lining cells are, therefore, in direct contact with the connective tissue stroma.
- ii. **Follicular cells**—The follicles are surrounded by a single layer of thyroid epithelial cells which subservise three functions viz.
  - a. Synthesis of thyroglobulin which is stored as colloid, consisting mainly of iodinated thyroglobulin. The colloid material serves as a reservoir of thyroid hormone production and to a lesser extent the reservoir of the hormones themselves.
  - b. They collect and transport iodine from blood to colloid where hormones  $T_4$  and  $T_3$  are synthesized and
  - c. Removal of thyroid hormones from thyroglobulin and secretion into the circulation.
- iii. **Parafollicular 'C' cells** which are scattered into the interstitial tissue between the follicles secrete the hormone calcitonin, the calcium lowering hormone.

### PHYSIOLOGY

Functionally, the thyroid gland is considered to be two endocrine glands compressed into one. The thyroid gland produces, thyroxin ( $T_4$ ) and triiodothyronine ( $T_3$ ) and the parafollicular cells produce calcitonin.

### Synthesis, Secretion and Transport of Thyroid Hormones (Fig. 23.4)

#### Synthesis

Occurs in three stages within the thyroid follicle.

- i. **Iodine trapping**—About 100–120 mcg of iodine is required daily. The iodine in the gut is absorbed and enters the iodine pool in the blood. Approximately two-thirds of the absorbed iodide is excreted via the kidneys and one-third is trapped in the thyroid, where 95 percent of body stores of iodine are found.
- ii. **Oxidation**—Hormone synthesis takes place only after the iodine has been oxidized to an active form by the enzyme thyroid peroxidase (TPO).
- iii. **Organification and coupling**—The activated iodine is bound in a matter of seconds to tyrosine molecules attached to thyroglobulin, a glycoprotein, also synthesized by the follicular cell. Monoiodotyrosine (MIT) is next iodinated to form diiodotyrosine or DIT. This process of formation of MIT and

DIT is known as organification. MIT and DIT couple to form Triiodothyronine ( $T_3$ ) and Tetraiodothyronine ( $T_4$ ). This coupling reaction is also catalyzed by the peroxidase enzyme. This  $T_4$  and  $T_3$  is still within the follicular cell which now extrudes the thyroglobulin (containing  $T_4$  and  $T_3$ ) into the follicular space. TSH facilitates both organification and coupling.

Iodide trapping is an active process and is stimulated by TSH. It is competitively inhibited by antithyroid drugs like thiocyanate and perchlorate.

Drugs like carbimazole and thiouracil block thyroid hormone synthesis by inhibiting coupling of iodotyrosines, MIT and DIT and formation of MIT, i.e. organification.

### Thyroid Hormone Secretion or Release

Thyroglobulin is first taken up by the follicular cells prior to its hydrolysis. Under the influence of TSH, a protease acts on thyroglobulin (TG) to release  $T_4$  and  $T_3$  as well as MIT and DIT.  $T_3$  and  $T_4$  enter the blood-stream via thyroid capillaries while MIT and DIT are deiodinated by the enzyme deiodinase. As a result iodine and tyrosine get separated from each other and again reutilized for the synthesis of thyroid hormones.

It is to be noted that all processes involved in the synthesis and secretion of thyroid hormone take place continuously and simultaneously that is, while there is synthesis of glycoprotein in the follicular cells, there is also its secretion into the colloid, its iodination there, and finally, the breakdown of the iodinated thyroglobulin. The next result is a continuous release of thyroid hormone.

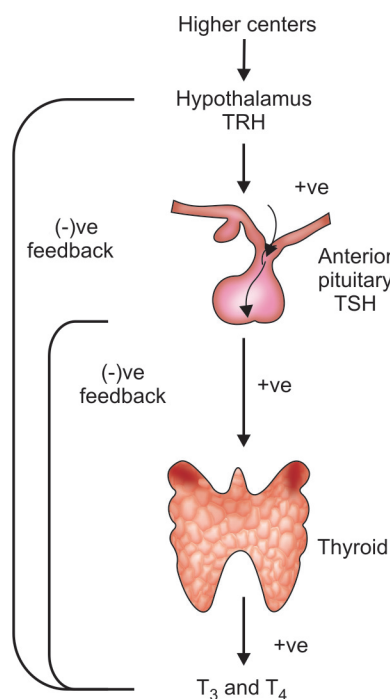
### Transport of $T_4$ and $T_3$ in Blood

Thyroid hormones transport in blood mostly bound to proteins as protein bound hormones (PBH) while a small amount exists in the free form (0.02%  $T_4$  to 0.2%  $T_3$ ) and physiologically active.  $T_3$  is the active form of  $T_4$ .

### Control of Thyroid Hormone Secretion (Fig. 23.5)

It is achieved by the thyroid stimulating hormone secreted by the anterior pituitary. It controls the complex enzymatic reactions





**Fig. 23.5:** Hypothalamic-pituitary thyroid axis

that trap iodine, convert it to  $T_3$  and  $T_4$  and release them into the circulation.

On the other hand, two feedback mechanisms control the TSH secretion – the central positive and the peripheral negative.

1. The hypothalamus secretes thyrotropin releasing hormone (TRH), e.g. exposure to cold, which exerts a positive feedback on the pituitary causing release of TSH and thereby increased formation of  $T_3$  and  $T_4$ .
2. A peripheral level of circulating free  $T_4$  constitutes a negative feedback mechanism on the pituitary TSH secreting capacity.

Low circulating levels of  $T_4$ , e.g. in Hashimoto's disease induce increased TSH secretion and high circulating levels as in oral thyroxin therapy will depress TSH secretion. Serum  $T_3$  has a minimal effect on TSH secretion.

### Thyroid Autoregulation

This term is used to indicate the maintenance of the thyroidal organic iodine stores constant by the thyroid itself, without the mediation of the negative feedback mechanism.

An acute increase in the supply of iodide to the thyroid tends to increase its organic

iodine content. This is resisted by immediate local inhibition of the iodide trapping mechanism. Further the thyroid responsiveness to a constant circulating TSH level diminishes in these circumstances. Therefore, this autoregulation is the first homeostatic defence mechanism of the thyroid against acute changes in the supply of iodine.

### Effects of Thyroid Hormones

1. *Calorigenic action*—Thyroxin increases oxygen consumption of almost all metabolically active tissues. It increases the basal metabolic rate (BMR) and makes the patient more sensitive to warm environments. It also increases nitrogen excretion. If food intake is not increased, endogenous protein and fat stores are catabolized and weight is lost.
2. *Growth and development*—Thyroxin is essential for normal development of the fetus. Growth abnormalities including stunting occur in congenital hypothyroidism.
3. *Cardiovascular system*—Cardiac output and blood flow is increased. Heart rate increases considerably and constitutes one of the most important clinical indices of thyroid function. Mean arterial pressure usually remains unchanged.
4. *Hemopoiesis*—Thyroxin is thought to be necessary for normal hemopoiesis.
5. *Nervous system*—Thyroid insufficiency at any stage of life is associated with depression and slowing of cerebral cortical function whereas in hyperthyroidism, there is irritability and restlessness, which responds to appropriate adjustment of the circulating level of thyroid hormone.

In the peripheral nervous system, the reaction time of stretch reflexes like the ankle jerk is shortened in hyperthyroidism and prolonged in hypothyroidism.

6. *Relation to catecholamines*—Many of the actions of thyroxin are similar to those of catecholamines. Thyroxin is believed to cause increased sensitivity of receptors to catecholamines or an increase in the number of receptors. Thyroxin has the opposite effect of insulin.

### INVESTIGATIONS—TESTS OF THYROID FUNCTION

A large variety of tests are available to evaluate thyroid function. Of course, there is no substitute for good history taking and careful clinical examination in the assessment of thyroid disorders.

The number of tests required should be kept to the minimum to reach a diagnosis and plan the management. Only a small number of parameters require to be measured as a routine, although this may require supplementation or repeat when inconclusive.

### Serum Thyroid Hormones

- i. *Serum TSH*—The serum concentration of TSH is measured by immunoassay technique. The normal level is 0.5 to 5  $\mu\text{u/ml}$ . Older radioimmunoassays for TSH were able to detect elevated TSH levels in hypothyroidism, but were not sensitive enough to detect suppressed levels of TSH, characteristic of hyperthyroidism. Newer 'second' generation sensitive TSH assays can measure levels less than 0.1  $\mu\text{u/ml}$  and third generation or 'supersensitive or ultrasensitive' assays can detect TSH levels as low as 0.01  $\mu\text{u/ml}$ .

In the euthyroid,  $T_3$ ,  $T_4$  and TSH levels will all be within the normal range. Florid thyroid failure results in depressed  $T_3$  and  $T_4$  levels with gross elevation of the TSH. In toxic states, the TSH level is suppressed and undetectable. Thus when the

**Table 23.1: Serum TSH, free  $T_4$  and free  $T_3$  levels in different thyroid functional states**

Thyroid functional state	TSH (0.5-5 $\mu\text{u/ml}$ )	Free $T_4$ (10-30 nmol/l)	Free $T_3$ (3.5-7.5 $\mu\text{mol/l}$ )
1. Euthyroid	Normal	Normal	Normal
2. Thyrotoxic	Undetectable	High	High
3. Suppressive $T_4$ therapy	Undetectable	High	High
4. $T_3$ toxicity	Low/undetectable	Normal	High
5. Myxedema	High	Low	Low



serum TSH level is in the normal range, it is redundant to measure the  $T_3$  and  $T_4$  levels. (Table 23.1)

- ii. *Serum Thyroxin ( $T_4$ ) and Triiodothyronine ( $T_3$ )*—These are transported in plasma bound to specific protein (TBG or thyroxin binding globulin). Only a small fraction of the total (0.02% of  $T_4$  and 0.2% of  $T_3$ ) is free and physiologically active. Assays of total hormone for both are now obsolete because of the confounding effect of circulating protein concentrations, influenced by the level of circulating estrogen and nutritional state. Highly accurate radioimmunoassays of free  $T_3$  and free  $T_4$  are now routine.  $T_3$  Toxicity with a normal  $T_4$  and a high free  $T_3$  level is a distinct entity. (Table 23.1)

### Isotope Scanning

The uptake by the thyroid gland of a low dose of either radiolabeled iodine ( $^{123}\text{I}$ ) or Technetium ( $^{99\text{m}}\text{Tc}$ ) will demonstrate the distribution of activity in the whole gland.

Routine isotope scanning is unnecessary and inappropriate for distinguishing benign from malignant lesions because 80 percent of cold lesions are benign (20% are malignant) and some 5 percent of functioning or 'warm' swellings will be malignant.

Its principal value is in the toxic patient with a nodule or nodularity of the thyroid. Localization of overactivity in the gland will differentiate between a toxic nodule with suppression of remainder of the gland and toxic multinodular goiter with several areas of increased uptake with important implications for therapy.

### Thyroid Antibodies

Thyroid antibodies include antithyroglobulin (anti - Tg), antimicrosomal or antithyroid peroxidase (anti - TPO) and thyroid stimulating immunoglobulin (TSI). Anti - Tg and anti - TPO antibody levels do not determine thyroid function, instead they indicate the underlying disorder, usually an autoimmune thyroiditis. Approximately 80 percent of patients with Hashimoto's thyroiditis have elevated thyroid antibody levels but levels may also be increased in patients with Graves' disease, multinodular goiter and occasionally with thyroid neoplasms.

### Ultrasound

Ultrasound is an excellent noninvasive and portable imaging method for studying the thyroid gland. It is helpful in the evaluation of thyroid nodules, distinguishing solid from cystic ones and providing information about size and multicentricity.

- USG can also be used to guide the fine needle aspiration (FNA) biopsy and trucut biopsy.
- Unsuspected lymph node enlargement may be picked up with USG.

### Fine Needle Aspiration Cytology

FNAC has become the sheet anchor of tissue diagnosis. Benign and malignant lesions of the thyroid can be confidently diagnosed by an experienced cytopathologist.

The lesions are aspirated using a fine gauge (24 - 28G) needle and 10ml disposable syringe. The aspirate is smeared onto a glass slide which is then stained using hematoxylin and eosin. The whole procedure is simple and can be done in the outpatient department and results can be made available within half an hour.

When a FNAC diagnosis is doubtful, a wide needle or a frozen section biopsy is arranged at the time of surgery. Thyroid conditions that may be diagnosed by FNAC include colloid nodules, thyroiditis, papillary, medullary and anaplastic carcinomas and lymphoma. However, FNAC cannot distinguish between a benign follicular adenoma and follicular carcinoma as this distinction is dependent on histological criteria viz. capsular and vascular invasion.

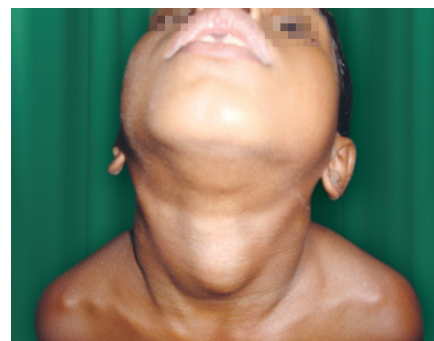## CONGENITAL ANOMALIES

### Lingual Thyroid

A lingual thyroid forms a rounded swelling at the back of tongue at the foramen cecum and it may represent the only thyroid tissue present.

It may cause dysphagia, impairment of speech, respiratory obstruction or hemorrhage. Physiological stresses like puberty, pregnancy and lactation may be the precipitating factors. Patients may be euthyroid or borderline hypothyroid.

Radioisotope scanning will show the lump in the tongue to be hot.



**Fig. 23.6:** Thyroglossal cyst in a boy which moves upwards on protrusion of the tongue

### Treatment

- i. Since the disorder presents itself under physiological stress, it is logical to suppress the TSH with thyroxin in a hope that lingual thyroid will regress in size. However, regular follow up is required to assess the thyroid size and its functional status.
- ii. A lingual thyroid is susceptible to all pathological process seen in the normal thyroid besides having chronic TSH excess. Hence, excision or ablation with radioiodine followed by life long thyroxine supplementation is sometimes necessary.

### Thyroglossal Cyst (Fig. 23.6)

It is a cystic swelling in the remnant of the thyroglossal tract. The common situations in order of frequency are beneath the hyoid, in the region of the thyroid cartilage and above the hyoid bone.

The swelling moves upwards on protrusion of the tongue as well as on swallowing because of the attachment of the duct to the foramen cecum. Aspiration of the cyst shows clear fluid with plenty of cholesterol crystals.

### Treatment

A thyroglossal cyst over 1 cm size should be excised because infection is inevitable. An infected cyst is often mistaken for an abscess and incised, which may result in a thyroglossal fistula. During surgery, it is essential to identify, dissect and excise the entire thyroglossal duct a tract upto the tongue to avoid recurrence.

## GOITER

Goiter may be defined as any enlargement of the thyroid gland, irrespective of its cause. The term goiter is originally derived from the Latin word 'guttur' which means throat.

In clinical practice a working classification based on whether the gland is toxic or not and the nature of the enlargement is helpful. This enables a diagnosis to be made and appropriate action taken in the majority of patients.

### Classification of Goiters

Goiter is classified as follows:

- I. Nontoxic goiter (Euthyroid)
    1. Diffuse or simple goiter
      - a. Physiological
      - b. Endemic goiter/primary iodine deficiency
      - c. Secondary iodine deficiency
        - Dietary
        - Drugs
        - Genetic defects/Dyshormonogenetic goiter.
    2. Multinodular goiter
    3. Solitary nodule
    4. Recurrent goiter
  - II. Toxic goiter
    - Diffuse Toxic goiter or Graves' disease
    - Multinodular goiter (Plummer's disease)
    - Solitary toxic nodule (Toxic adenoma)
    - Recurrent toxic goiter
  - III. Special goiter
    1. Neoplastic goitre
      - Benign, e.g. follicular adenoma
      - Malignant
        - Primary
        - Metastatic or secondary.
- A. *Primary*
- i. Arising from the follicular epithelium.
    - a. Differentiated —
      - Papillary carcinoma
      - Follicular carcinoma.
    - b. Undifferentiated
      - Anaplastic carcinoma
  - ii. Arising from the parafollicular cells — Medullary carcinoma.
  - iii. Arising from the lymphoid cells —Lymphoma.
- B. *Metastatic or Secondary Carcinoma*  
Very rarely breast, renal, ovarium and gastrointestinal cancers metastasize to the

thyroid due to blood spread, where they present as a solitary nodule.

2. Inflammatory goiter
  - a. Autoimmune Goiter—This term denotes a group of conditions having in common the presence of circulating antithyroid antibodies with or without a causal relationship viz.
    - Hashimoto's disease (Lymphadenoid goiter),
    - de Quervain thyroiditis( subacute thyroiditis) and
    - Riedel's Thyroiditis (Fibrosing)
  - b. Infective goiter, e.g acute suppurative thyroiditis, and chronic thyroiditis, e.g. tuberculosis.

## NON-TOXIC GOITER

### Diffuse or Simple Goiter

Simple goiter is the result of hyperplasia of the thyroid to meet physiological demands for thyroxine. The hyperplasia occurs either because a normal gland must meet increased demands for thyroxine as in puberty, pregnancy and lactation or because the production of thyroxine is impaired (Fig. 23.7).

Inadequate levels of circulating thyroxine then increase TSH production which in turn stimulates thyroid hypertrophy until an increased volume of gland becomes available to produce the necessary quantity of thyroid hormone.

### Endemic Goiter

The majority of endemic goiters are due to low dietary intake of iodine (less than 100mcg a day). Endemic goiter is noticed in several parts of India—mainly the sub-Himalayan-belt, where the iodine content of drinking water is particularly low.

Administration of iodine, usually as iodized salt is the cheapest and best prophylaxis in this condition.

### Secondary Iodine Deficiency Goiter

- a. *Dietary*—Some endemic goiters are due to substances in the diet (goitrogens) which interfere with the trapping of iodine or the synthesis of thyroxine. These include thiourea in vegetable of the Brassica family like cabbage, cauliflower soya beans, etc.

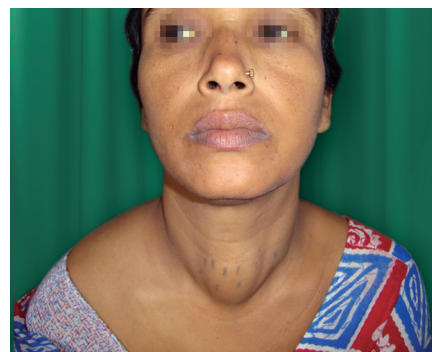


Fig. 23.7: Nontoxic goiter

- b. *Drugs*—The drugs most commonly responsible for thyroid enlargement of this type are the thiourea, especially when over - used in the treatment of thyrotoxicosis. Other drugs, e.g. thiocyanates, iodine, PAS, may all cause goiter if administered over a long period.
- c. *Dyshormonogenetic goiter*—It results from an inherited enzymatic defect that may cause impairment of iodine accumulation, organification or coupling of iodotyrosine in the thyroid gland. This is a rare cause of goiter.

### Multinodular Goiter

The multinodular goiter is seen in older women and is believed to be due to circumscribed involutionary changes taking place in a simple goiter.

### Evolution of Multinodular Goiter from Simple Goiter

It occurs through the following stages:

*Stage I*—In the first stage due to TSH stimulation there is increase in the number of follicles and reduction in the amount of colloid. It is also called the stage of diffuse hyperplasia.

*Stage II or stage of involution*—When TSH stimulation ceases by ingestion of iodine this stage appears forming large follicles filled with colloid (Colloid goiter).

*Stage III - Stage of multinodular goiter*—As a result of alternating periods of iodine sufficiency and iodine want, a mixed pattern develops with areas of active lobules and areas of inactive lobules. Active lobules become more vascular and hyperplastic until hemorrhage and central necrosis appears. Necrotic lobules coalesce to form nodules filled either with iodine-free colloid or a mass of new but

inactive follicles. Continual repetition of this process results in the development of multinodular goiter. Thus in brief the stages in evolution are diffuse hyperplastic goiter → colloid goiter → multinodular goiter.

### Solitary Nodular Goiter

A clinically solitary nodule is often a cluster of nodules of nontoxic goiter usually between 1 and 4 cm in total size but occasionally much larger. In more than 50 percent patients, when the gland is exposed during surgery or scanning, it is evident that the process is generalized with subclinical nodularity elsewhere in the affected lobe or in the other lobe.

A solitary nodule may be an adenoma, a carcinoma or may be secondary to thyroiditis.

### Recurrent Nodular Goiter

This may occur after surgery for multinodular goiter or solitary nodule and usually represents progression of the original underlying process. It may be modified or prevented by administration of thyroxine to stop TSH release and suppress gland function.

### Clinical Features

The cardinal feature is that the patient is euthyroid. Females are more often affected in the ratio of 9:1. Patients usually present with thyroid enlargement that may be diffuse or multinodular. The gland is initially soft but over a period of time becomes firm and progressively increases in size.

### Substernal Goiter

In long-standing multinodular goiter the enlargement may assume monstrous size and may extend inferiorly to present as a substernal goiter. Retrosternal extension and compression may lead to impaired venous return in the jugular veins with flushing of the face. The engorgement of neck veins and superficial veins become more prominent when the hands are raised above the head and the arm touch the ears – “Pemberton sign”.

### Pain

Sudden pain is rare but is generally due to hemorrhage into a cyst and is accompanied with rapid enlargement of the thyroid gland.

### Compressive Symptoms

In long-standing goiters patients may develop pressure symptoms. Dysphagia is not so common but respiratory distress is often seen.

### Malignant Change

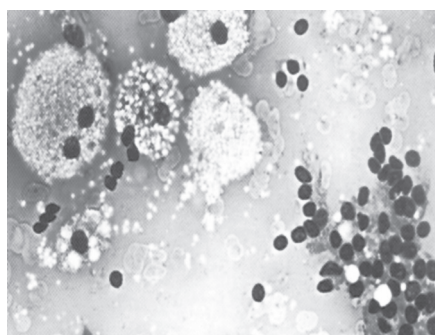
Paralysis of recurrent laryngeal nerve is rare and hoarseness of voice occurs due to malignant change.

### Complications of Multinodular Goiter

1. *Secondary thyrotoxicosis*—This may complicate 30 percent of multinodular goiters.
2. *Pressure effects*—The trachea may be hypoplastic due to chronic compression (scabbard trachea) or obstructed. Hemorrhage into a nodule may produce acute respiratory obstruction.
3. *Carcinoma*—Its incidence has been quoted as below 5 percent and mostly follicular type of carcinoma is seen in those cases. Incidence of cancer has been reported more in endemic areas.

### Investigations

1. Assessment of thyroid function is essential to exclude mild hyperthyroidism.
2. Straight X-ray of the neck and chest may show tracheal deviation or compression and sometimes calcification of the goiter. It also helps to rule out retrosternal extensions.
3. Fine needle aspiration cytology (FNAC)—Dominant or rapidly growing nodules in long-standing goiters should always be subjected to aspiration cytology (Fig. 23.8).
4. Thyroid ultrasound—A thyroid USG reveals nodules of varying size, invariably



**Fig. 23.8:** Diffuse nontoxic (colloid) goiter. Cystic degeneration: Involutinal follicular epithelium, foamy macrophages and abundant thin colloid

many more than those visible or palpable. It can also differentiate between solid and cystic nodules.

### Treatment

#### Thyroxin Suppressive Therapy

Using 150 to 200 µg/day of Thyroxin to suppress TSH to below normal level has been used with varying degrees of success in reducing the goiter size. A nodular goiter is usually unresponsive to thyroxin. So majority of these patients require thyroidectomy.

#### Thyroidectomy

The indications of thyroidectomy, in patients with multinodular goiter are cosmetic in most patients, presence of compressive symptoms, secondary thyrotoxicosis and suspicion of malignant change.

Some surgeons put the patients on 200µg of thyroxin daily for a minimum period of 2 years or even for the rest of patient's life to suppress the TSH stimulation.

#### Prophylaxis in Endemic Areas

Addition of iodine to table salt (iodization) is adequate prophylaxis against the development of simple goiter and prevention of neonatal hypothyroidism and endemic cretinism.

### TOXIC GOITER (THYROTOXICOSIS)

It is a complex disorder which results from the action of excessive thyroid hormones on the tissues.

Usually there are two types of thyrotoxicosis, primary toxic goiter (Syn—Graves' disease, exophthalmic goiter, Basedow's disease) and secondary toxic goiter. They are to be regarded as variations of the same disease, modified according to age of the patient and preexisting state of the gland.

Thus primary toxic goiter occurs in young patients with no previous disease of the gland while secondary toxic goiter occurs in older persons with a long history of nontoxic multinodular goiter.

Sometimes the increased secretion of thyroid hormones is confined to a single nodule, called *toxic adenoma*.



### Recurrent Toxic Nodular Goiter

This may occur after thyroidectomy suggesting that the causal factors are still prevailing.

### Other Causes of Thyrotoxicosis

- Factitious (Iatrogenic) thyrotoxicosis—This occurs due to overdose of thyroxin given for puberty goiter.
- Jod Basedow's Thyrotoxicosis—Jod means iodine in German language. Basedow means toxic goiter. This is a form of iodine induced thyrotoxicosis, iodine being given for hyperplastic endemic goiters.
- Thyroid Cancer—Very rarely malignant goiters can be toxic.
- Neonatal thyrotoxicosis occurs in babies born to thyrotoxic mothers.
- Struma ovarii.
- Hydatidiform mole.
- TSH secreting pituitary adenoma.

### Primary Toxic Goiter

#### Graves' Disease

The disease is known after Robert Graves, an Irish physician. It is an autoimmune disease of unknown cause and the most common form of thyrotoxicosis. It has a familial predisposition with female preponderance (5:1).

It is characterized by an enlarged hyperfunctioning thyroid gland, ophthalmopathy and sometimes infiltrative dermatopathy (Pre-tibial myxedema or edematous swelling of soft tissues of the front of the leg).

#### Pathogenesis

Graves' disease, an autoimmune disorder is caused by abnormal thyroid stimulating antibodies (TSH – RAb) that bind to TSH receptor sites on follicular cells. This was previously called long-acting thyroid stimulator (LATS). Stimulation of the thyroid by TSH – RAb circumvents the normal feedback loop of the hypothalamic pituitary thyroid axis resulting in thyroid autonomy.

#### Pathology

Macroscopically the thyroid gland is diffusely and smoothly enlarged with a concomitant increase in vascularity.

Microscopically the gland is hyperplastic and the epithelium is columnar with minimal colloid present. There may be aggregate of lymphoid tissue in the gland.

### Clinical Features

In Graves' disease the classical triad of goiter, exophthalmos and thyrotoxicosis is seen. Occasionally one of these features may occur singly or in combination. It is hardly seen before 10 yrs of age and in the elderly.

#### Goiter

The enlargement of thyroid is diffuse and symmetric. It may be large or small, firm or soft and a thrill and a bruit may be present. Bruit, when present is best heard on the superior pole on either side.

#### Thyrotoxicosis

There are groups of symptoms in thyrotoxicosis. The cardinal features include loss of weight in spite of good appetite, tachycardia (Figs 23.9 and 23.10), tremor. In addition to these there may be thirst and disturbed menstrual function. Oligomenorrhea, amenorrhea, abortions and failure to conceive are often present.

The basal metabolic rate is increased to even 100 percent. Proximal muscle weakness is present.

#### Exophthalmos

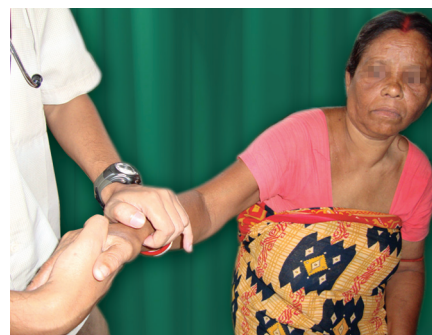This means protrusion of the eyeball. Certain signs are attached to this condition, e.g.

- von Graefe's sign—Lagging behind of upper eyelid when the patient looks downward.
- Joffroy's sign—Absence of wrinkling of the forehead on looking upwards with the face inclined downwards.
- Möbius sign—Failure of convergence of eyeballs.
- Stellwag's sign—Absence of normal blinking. Excessive watering and photophobia may occur.

#### Cause

Graves' ophthalmopathy is an autoimmune disease in which there are antibody mediated effects on the ocular muscles. The eyeball is pushed forward by an increase in retro-orbital contents due to an increase in fat and bulkiness of the extrinsic muscles secondary to deposition of water and mucopolysaccharides combined with lymphocytic infiltration. The eyes may be affected asymmetrically.

Lid retraction is the result of spasm of the levator palpebrae superioris muscle, which causes the white sclera to appear between the



**Fig. 23.9:** Examination of pulse is necessary in a patient with thyroid swelling

upper lid and upper limbus of the cornea in all positions of gaze. It prevents apposition of the eyelids during sleep and is a cause of conjunctival irritation and ulceration.

#### Investigations

- Serum  $T_3$ ,  $T_4$  and TSH estimation is done. In Graves disease TSH levels are decreased or undetectable and the  $T_3$  and  $T_4$  levels are elevated. In a very rare patient with a TSH secreting pituitary tumor, the serum TSH levels are elevated or inappropriately normal. If eye signs are present other tests are not generally needed.
- Radioactive iodine uptake ( $^{123}I$ ) and scan should be performed if the eye findings are absent. An elevated uptake with a diffusely enlarged gland confirms the diagnosis of Graves' disease.
- Thyroid antibodies: Anti-Tg and Anti-TPO are elevated in upto 75 percent of patients but are not specific. Elevated TSH – RAb are diagnostic of Graves' disease and are increased in nearly 90 percent patients.
- MRI scans of the orbits are useful in evaluating Graves' ophthalmopathy.

#### Treatment

There are three main approaches to the treatment of this condition.

- Antithyroid drugs
- Radioactive iodine and
- Surgery.

Besides these, nonspecific measures like rest, sedation and  $\beta$ -adrenergic blockers are helpful to treat this condition.

In patients with multinodular goiter (MNG) or toxic nodule, medical therapy is useful, only for alleviation of symptoms. Subsequently

definitive treatment, either radioiodine ablation or surgery is mandatory for cure.

### Medical Therapy

#### Antithyroid Drugs

##### Indications

- It is almost mandatory in children and adults under the age of 20 to 25 years.
- They may be used at any age to bring about remissions.
- To attain euthyroid status prior to ablative therapy.

##### Drawbacks

- Long duration of treatment (1 – 2 years).
- Recurrence of disease after discontinuation of therapy.
- Side-effects, e.g. agranulocytosis.

#### Treatment

##### Antithyroid Drugs

Drugs in common use are carbimazole (CBZ) and propylthiouracil (PTU). In addition to antithyroid action, PTU also blocks the conversion of  $T_4$  to  $T_3$  in the peripheral tissues.

PTU is started at a dose of 100mg and CBZ at a dose of 10 – 20 mg thrice daily. Most patients become euthyroid within 4 to 8 weeks of therapy. The dose is then reduced to a maintenance dose.

**Iodides**—are the fastest acting thyroid inhibitor. It reduces iodide transport, oxidation and organification and blocks the release of  $T_4$  and  $T_3$ , from the thyroid gland. The preparations used include Lugol's iodine (3 - 5 drops thrice daily). The major use of iodide is in preoperative preparation and in the management of thyrotoxic storm.

**Beta-Blockers**—For example propranolol, atenolol, nadolol block beta - adrenergic receptors and provide relief from symptoms like tremors palpitations, anxiety and heat intolerance. They decrease the heart rate, cardiac output, and oxygen consumption in thyrotoxicosis. Propranolol is used in the dose to 40 – 180 mg/day and atenolol 25 – 100 mg/day. These drugs are contraindicated in patients with congestive cardiac failure, asthma and diabetes.

#### Radioiodine Therapy

##### Indications

Radioiodine is simple and economical therapy. It is indicated in patients above 40 years, especially, those who fail to respond to antithyroid drugs and are failures of surgery.

##### Contraindication

1. Pregnancy, lactation and severe thyrotoxicosis.
2. Patients with large or malignant thyroids. A dose that will deliver 5000 to 8000 rads to the thyroid will be effective in ameliorating the hyperthyroidism in Graves' disease. The patients should be euthyroid prior to radioiodine therapy to prevent thyroid storm. Thyroid function gradually declines beginning in 2 to 3 weeks.

##### Drawbacks

- a. Chance of hypothyroidism.
- b. Risk of carcinogenesis and teratogenicity, though the precise likelihood of this remains contentious.

#### Surgery

The objective of thyroidectomy is complete and permanent control of thyrotoxicosis.

Subtotal thyroidectomy is commonly performed leaving 4 to 8 gms of residual thyroid tissue. Total thyroidectomy should be performed in patients with infertility and Graves disease with coexisting eye disease.

##### Indications

1. Big diffuse toxic goiter and toxic multinodular goiter
2. Autonomous toxic nodule. Ofcourse one may try with radioiodine in patients above 40 years of age.
3. Noncompliance with medical therapy.
4. Children and adolescents with recurrence of disease.
5. Pregnant women in their second trimester.

##### Advantages

1. Surgery provides immediate cure.
2. No prolonged follow up is required. The patients can leave hospital by 5 days and resume work within 1 month.

##### Disadvantages

1. Risk of hypothyroidism.
2. Recurrent laryngeal nerve injury (1 – 4%)
3. Postoperative hypoparathyroidism.
4. Wound problems—Infection and keloid formation.

**Recurrent thyrotoxicosis after surgery:** Here further surgery has almost no place. So radioiodine is the preferred treatment. In case of young women intending to have children, antithyroid drugs should be used.

#### Secondary Toxic Goiter

When toxicity is superimposed on a previously pathological goiter, it is called secondary toxic goiter. Toxic multinodular goiter and toxic adenoma are examples of secondary toxic goiter.

The differences between primary and secondary toxic goiter is given below in a tabular form in Table 23.2.

#### General Choice of Treatment in Toxic Goiter

##### Untreated Cases

1. Primary toxic goiter
  - a. Over 40 years—Radioiodine treatment.
  - b. Below 40 years.
    - i. If goiter is small—Antithyroid drugs.
    - ii. If goiter is large—Surgery (subtotal thyroidectomy).
2. Secondary toxic goiter
 

Surgery is probably the best treatment of this condition.

  - a. Multinodular goiter—Surgery (subtotal thyroidectomy).
  - b. Autonomous toxic nodule—Surgery (excision of the nodule).

##### Treated Cases

1. Recurrence after adequate surgery.
  - a. Over 40 years—Radioiodine treatment.
  - b. Under 40 years—Antithyroid drugs.
2. Failure with antithyroid drugs—Surgery.
3. Failure with radioiodine treatment—Surgery.

#### SOLITARY THYROID NODULE

A solitary thyroid nodule (STN) is confined to one lobe of the thyroid and the contralateral lobe is impalpable. A dominant nodule in a multinodular goiter (MNG) also behaves like a STN. Solitary thyroid nodule is a common problem seen in a thyroid clinic. The majority of solitary thyroid nodules are benign. However, correct diagnosis is essential



**Table 23.2: Difference between primary and secondary toxic goiters**

Primary	Secondary
1. Goiter appears along with toxic symptoms	1. Goiter appears first and toxic symptoms appear much later.
2. Exophthalmos and eye signs are quite common	2. Exophthalmos and eye signs are virtually never seen.
3. Nervous system manifestations (Nervousness, insomnia, sweating, etc.) dominate	3. Cardiovascular manifestations, e.g. auricular fibrillation, heart failure, etc. are dominant (Fig. 23.10).
4. Symptoms appear suddenly and are seldom mild	4. Symptoms appear gradually and are usually mild.
5. The patient is usually young	5. Occurs in elderly subjects, rarely before the age of 35 yrs.
6. The goiter is small to moderate in size, uniform and firm	6. The goiter is often big, always nodular

because of their propensity of harboring malignancy. Reportedly 15 to 50 percent of STNS are malignant. A malignancy should be strongly suspected in the presence of past history of irradiation of neck, family history of thyroid cancer, hyperparathyroidism or pheochromocytoma. A solitary thyroid nodule may be an early presentation of a multinodular goiter.

### Differential Diagnosis of STN

- Benign thyroid neoplasms
  - Adenoma
  - Teratoma
  - Lipoma
  - Dermoid cyst.
- Malignant thyroid neoplasms
  - Papillary carcinoma
  - Follicular carcinoma
  - Medullary carcinoma
  - Lymphoma
  - Metastatic.
- Other thyroid abnormalities

- Thyroiditis
- MNG (part of)
- Thyroid cyst.

### Clinical Features

Most of the patients present with a nodule for months or occasionally years. Thyroid nodules in children and elderly are more likely to be malignant. Symptoms such as rapid growth, recent hoarseness or change in voice, dysphagia, and pain may indicate a malignant tumor. A large size, hard consistency, fixity to surrounding structures, regional lymphadenopathy all raise the suspicion of malignancy (Table 23.3).

### Evaluation of Solitary Thyroid Nodule

Most of the solitary thyroid nodules are benign comprising of colloid nodules, cysts or adenomas. A STN must be evaluated to rule out malignancy.

Apart from clinical features, evaluation of thyroid nodules includes thyroid function

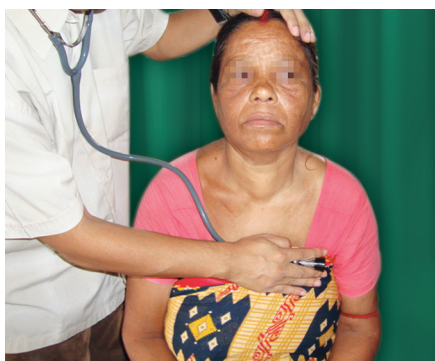test, radionuclide scan, ultrasonography and fine needle aspiration cytology (FNAC).

- Thyroid function tests**—Are not very useful as diagnostic tests since most patients with thyroid cancer and benign thyroid swellings are euthyroid. But these tests if show toxicity indicate a nodular toxic goiter.
- Thyroid scan**—A thyroid scan is usually done with  $^{99m}\text{Tc}$  pertechnetate. It is very helpful to differentiate ‘hot’ from ‘cold’ nodule. Hot nodules are unlikely to be carcinoma and indicate toxic nodules, ‘Cold’ nodules are more suspicious. They may be cystic or solid. Incidence of carcinoma in cold solitary swelling is about 15–20 percent. 80 percent or more are benign.
- Ultrasonography**—This can characterize a nodule as cystic or solid thyroid nodule. Most cystic lesions are benign except a few papillary carcinomas which may be cystic. The ultrasound can also be a guide for FNAC from a particular pathologic area of a cyst or solid thyroid swelling.
- Fine needle aspiration cytology**—It should be the first line of investigation for solitary thyroid nodules. FNAC also helps to differentiate cystic from solid nodules and may be therapeutic for a purely cystic nodule. The FNAC is diagnostic in papillary, medullary and anaplastic carcinomas. It is not able to differentiate between follicular adenoma and carcinoma. The results of FNAC are generally categorized as benign, suspicious or malignant. About 20 percent (Range 10 to 50%) of solitary thyroid nodules with suspicious FNAC turn out to be malignant on histopathology.

### Management of Solitary Thyroid Nodule

The treatment of solitary nodules of the thyroid depends on the FNAC result.

- In a case of simple nodular goiter treatment is mainly for cosmetic reason. If there is no pressure symptoms or acute increase in swelling due to hemorrhage the nodule may be left alone particularly in patients over 40 years of age.
- Patients with malignant aspirates on FNAC, should undergo total or near total thyroidectomy.



**Fig. 23.10:** Examination of cardiovascular system in secondary thyrotoxicosis.

**Table 23.3: Suspicious clinical features of malignancy**

- Age – less than 20 years or more than 60 years.
- Male sex
- Rapid growth
- Pain
- Hoarseness of voice
- Hard consistency
- Fixation to adjacent structures
- Regional lymphadenopathy

- Patients with suspicious cytology should be managed with hemithyroidectomy. Such patients may require a completion thyroidectomy if the histology of the excised specimen reveals malignancy.

### Recurrent Nodular Toxic Goiter

Nodules associated with hormone overproduction may occur after thyroidectomy suggesting that the causal factors are still prevailing.

## NEOPLASTIC GOITER

### Benign Tumors

#### Adenoma

This presents as a solitary nodule in the thyroid and is a slow growing one. It is generally seen in young women. A follicular adenoma can be differentiated from a follicular carcinoma only on the basis of histology. A follicular adenoma is confined to the thyroid and does not show capsular or vascular invasion that may be present in a follicular carcinoma.

#### Treatment

- Ordinarily excision of the adenoma is sufficient, the tumor must be sent for biopsy in order to exclude malignancy.
- If there is any doubt as to whether the nodule is an adenoma or a carcinoma, a hemithyroidectomy should be preferred to simple excision of the nodule.

### Carcinoma of the Thyroid

Carcinoma of thyroid frequently develops as a solitary nodule; a diffuse swelling is very rare except the anaplastic variety.

#### Etiology

- The thyroid is clearly a radiosensitive organ and radiation exposure at a young age predisposes to the development of thyroid cancer.
- The incidence of follicular carcinoma is high in endemic goitrous areas possibly due to continued TSH stimulation.
- The other documented risk factor is a prior nodular thyroid disease like a multinodular goiter.
- Malignant lymphomas may develop in autoimmune thyroiditis or Hashimoto's disease.

### Molecular Biology of Thyroid Cancer

Protooncogenes are genes that usually control the growth of normal cells. Their expressions are regulated, so that cells can grow only when appropriate. Protooncogene become oncogenes, when they are activated and lose normal control. This activation can occur by a number of mechanisms. Most commonly activation is generated by a mutation in the coding sequence of the gene that results in an altered protein product with enhanced function.

In contrast to oncogenes tumor suppressor genes are inactivated to produce a tumorigenic effect or are said to undergo loss of function. Abnormally low activity of tumor suppressor gene can cause inappropriate cell growth. P<sub>53</sub> is a tumor suppressor gene whose mutations are found in thyroid cancers. The Ret oncogene has a role in the development of papillary thyroid cancer and medullary carcinoma of thyroid.

#### Papillary Carcinoma

Papillary carcinoma is the most common thyroid cancer accounting for 60 – 70 percent of all thyroid carcinomas. It is the least aggressive and often has a prolonged course prior to presentation.

**Age** – It is commonly seen in the third and fourth decades of life.

**Sex** – Three times more common in women. It is also the predominant thyroid cancer in children.

#### Pathology

Papillary carcinoma contains columnar epithelium arranged in papillary projections and characteristic empty nuclei, called 'Orphan Annie nuclei'.

The tumor may contain deposits of calcium arranged in concentric layers, called psammoma bodies.

The tumor is multicentric in origin but usually affects only one lobe of the thyroid, in 20 percent of cases both lobes are involved.

This variety of cancer has a special tendency to spread by lymphatics into the regional nodes, i.e. the juxtathyroid lymph nodes and the deep cervical nodes.

#### Clinical Features

As mentioned above, it is the most slow growing malignant tumor of the thyroid. The age

has a special bearing on the prognosis as it shows a peculiar tendency to become more malignant with advancing age.

Dysphagia, dyspnea and hoarseness indicate locally invasive disease. Occasionally, the lymph nodes are enlarged but the thyroid gland is entirely normal on palpation.

#### Micropapillary Carcinoma

It is a tumor of less than 1cm size and may or may not be detected clinically. It is seen following removal of benign nodules or subtotal thyroidectomy. It is not associated with any increased mortality or morbidity. Surgery that has been performed is usually adequate.

#### Investigations

FNAC is diagnostic for papillary carcinoma. The ultrasound generally demonstrates a solid lesion.

A thyroid scan usually identifies the nodules as a 'cold' one. Plain X-ray of neck may reveal calcium flecks suggesting psammoma bodies.

#### Treatment

1. For tumors, larger than 2cm in diameter, a near total or total thyroidectomy should be carried out.
2. For tumors less than 2cm in diameter, an adequate operation is hemithyroidectomy (Thyroid lobectomy and isthmusectomy).

#### Modified Neck Dissection

A modified neck dissection is performed in patients with lymph node metastasis in the neck. The lymph node chain along the internal jugular vein is removed preserving the sternocleidomastoid muscle, internal jugular vein and the spinal accessory nerve.

#### Berry Picking

This is carried out for discrete palpable nodes in the neck. However, this is an inadequate dissection.

Life long L-thyroxin is necessary after hemithyroidectomy and total thyroidectomy as it suppresses the residual tumor. The dose is 0.2 to 0.3 mg/day to inhibit TSH production to which the tumor is very much dependent.

#### Irradiation

This is always a palliative measure indicated for:
 

- a. A large unresectable tumor.

- b. No radioiodine uptake.
- c. Residual metastatic disease after radioiodine.

### Radioiodine Treatment

This is also a palliative measure used for metastatic lesions like pulmonary or multiple bone metastases.

### Prognosis

The prognosis of papillary carcinoma depends on the size of the tumor at presentation, local invasion and the presence of lymph nodes. The AGES (Age of the patient, Grade of the tumor, Extent of disease and size of the tumor) is a postoperative scale for determining prognosis.

In general, 10 year survival rate is nearly 90 percent.

### Follicular Carcinoma

This group comprises 15 to 20 percent of all thyroid cancers.

### Pathology

Macroscopically it is often indistinguishable from follicular adenoma and is well-encapsulated.

On microscopic examination, the follicles are crowded with cells with hardly any colloid. Capsular and vascular invasion, are prominent features. Follicular carcinoma is much more aggressive and dangerous. The tumor is not multicentric like papillary carcinoma and spread to the lymph nodes is uncommon. It spreads hematogenously to distant sites like lungs, bones and liver.

### Clinical Features

The patient usually presents with a solitary nodule or multiple painless nodules. It tends to occur in the older age group with a peak incidence at the 5th decade. Pain and invasion to adjacent structures are late manifestations. This tumor shows good response to radioiodine.

### Investigations

- FNAC cannot differentiate follicular adenoma and carcinoma since follicular cells from adenoma and cancer look similar on cytology.
- Radiology—An X-ray of neck, a chest X-ray and a CT scan may be required

for complete diagnosis or planning management.

### Treatment

- Surgery is the treatment of choice. The operation done is total or near total thyroidectomy.
- Lymph node dissection is not necessary in the absence of palpable lymph nodes.
- Radioiodine therapy is indicated in the postoperative period if secondaries are detected by whole body isotope scanning. Dose – 100-300mci of  $^{131}\text{I}$ .
- External beam irradiation—used in inoperable cancers that have invaded the trachea or for the treatment of metastases that does not pick up radioiodine.
- Life long replacement therapy with L-thyroxin to suppress TSH production as in case of papillary carcinoma.  
*Prognosis:* 10 year survival is about 50 percent.

### Hurthle Cell Carcinoma

It is a variant of follicular carcinoma, consisting of abundance of oxyphilic cells and tends to occur in patients of 60–75 years of age. It is more likely to metastasize than follicular cancer. A hemithyroidectomy is usually sufficient treatment but in presence of capsular or vascular invasion, a total thyroidectomy should be performed.

### Follow-up Protocol for Differentiated Thyroid Carcinoma

- a. In the 1st week after surgery, whole body scan with  $^{131}\text{I}$  is done. If there is no residual thyroid in the neck or any metastatic lesion, patient is kept on full suppressive dose of L-thyroxin.
- b. After 6 months, again whole body scan is done with  $^{131}\text{I}$ . Before scan, L-thyroxin is stopped for one month.
  - Estimation of serum thyroglobulin (TG), —It should be undetectable after surgery.
  - If both are normal, suppressive therapy with L-Thyroxin is continued.
- c. Follow-up is done at yearly interval with clinical evaluation, thyroglobulin estimation and whole body radioiodine scanning.

### Anaplastic Carcinoma

This constitutes about 5 - 10 percent of malignant tumors of thyroid.

### Pathology

The carcinoma may develop in a previous nodular goiter or from preexisting well-differentiated thyroid carcinoma. Macroscopically, the tumor is not encapsulated and extends into the remaining thyroid tissue and even the adjacent structures.

Microscopically, cells are variable from spindle-shaped small cells to multinucleated giant cells. Presence of mitosis is very characteristic in this carcinoma.

These lesions grow rapidly and by the time the patient comes to the surgeon, there is already invasion to trachea or esophagus or adjacent structures of the neck. Regional lymph nodes are frequently involved.

### Clinical Features

It usually involves the elderly patients of the age group 60–70 years. Compressive symptoms like hoarseness of voice, Dyspnea and dysphagia may be present.

On examination, there is hard irregular enlargement of the thyroid gland, which is immobile being fixed to the underlying structures. Carotid pulse is not palpable (Berry's sign). Lymph nodes may be palpable.

### Diagnosis

This is confirmed by FNAC.

### Treatment

- A curative resection is not possible in majority of patients because of its aggressive nature.
- An isthmusectomy is done to relieve tracheal obstruction and obtain tissue for histopathological examination.
- Radiotherapy in all cases and combination chemotherapy with Doxorubicin (adriamycin), vincristine and chlorambucil may provide a worthwhile period of palliation. Radioiodine is ineffective.

### Prognosis

Few patients survive 1 year.

### Medullary Carcinoma of Thyroid (Mct)

### Origin

This type of cancer arises from the parafollicular 'cells' derived from the neural crest

(APUD cells). High levels of serum calcitonin are produced and the levels fall after resection of the tumor or rise again in case of recurrence.

Some tumors are familial (10 – 20%) and may occur with or without other features of MEN (Multiple Endocrine Neoplasia) IIA and IIB others are sporadic (70%). While MEN IIA comprises MCT, pheochromocytoma and hyperparathyroidism MEN IIB, is associated with multiple neuromas of the lips, tongue and inner aspect of the eyelids along with other features of MEN IIA.

### Pathology

Microscopically there is presence of characteristic 'cell balls' (tumor cells) and amyloid stroma.

Macroscopically, the tumor appears as a circumscribed nonencapsulated white mass. In sporadic form, it is mostly solitary but in familial form, bilateral and multicentric.

### Clinical Features

The familial form of the disease frequently affects children and young adults, while the sporadic cases occur at any age with no sex predominance.

Diarrhea is a feature in 30 percent cases and this may be due to 5HT or prostaglandins produced by the tumor cells.

Lymph nodes are involved in 50 - 60 percent cases and hematogenous spread is common. As would be expected, the tumor is not TSH dependent and do not take up radioactive iodine.

Other than calcitonin, the tumor cells also secrete CEA (Carcinoembryonic Antigen), and a range of other peptide hormones, e.g. katalcalcin, CRH regulating peptides etc.

### Treatment

Treatment is by total thyroidectomy and resection of involved lymph nodes with either a radical or modified radical neck dissection.

Pheochromocytoma is to be excluded by measuring urinary catecholamine levels in all cases before embarking on to thyroid surgery, because operation in a patient with undiagnosed pheochromocytoma may result in hypertensive crises and death.

### Prognosis

- 5 year survival rate is 90 percent in node negative and 50 percent in node positive

disease respectively. Life expectancy is good as long as metastases is confined to cervical lymph nodes and poor once blood borne metastasis is present.

- MEN IIA has better prognosis than MEN IIB and sporadic form.
- Other prognostic factors include tumor stage, plasma calcitonin and plasma CEA levels.

### Malignant Lymphoma

This tumor usually arises from the interstitial lymphoid tissue. On FNAC diagnosis may be made or suspected as sufficient material is seldom available. Ultimately diagnosis is settled by large needle (Trucut) or open biopsy.

After the diagnosis is made, radiation is the treatment of choice. Radical surgery is unnecessary.

The prognosis is good if there is no involvement of cervical lymph nodes. Occasionally this tumor may be a part of widespread malignant lymphoma disease, when the prognosis is worse.

### Relative Incidence of Primary Malignant Tumors of Thyroid

1. Papillary carcinoma – 60%
2. Follicular carcinoma – 20%
3. Anaplastic carcinoma – 10%
4. Medullary carcinoma – 5%
5. Malignant lymphoma – 5%

### AUTOIMMUNE THYROIDITIS (HASHIMOTO'S DISEASE)

It is also called lymphadenoid goiter or chronic lymphocytic thyroiditis. This is an autoimmune disease in which antibodies are formed which is reactive to antigens derived from thyroglobulin and the microsomal constituents of the acinar cells. Antimicrosomal and antithyroglobulin antibodies can be measured in the patient's serum.

### Pathology

The gland is enlarged and firm in feel. Afterwards it turns hard and nodular.

Microscopically, there is widespread atrophy of the parenchyma with diffuse fibrosis. The follicles which remain are small and lack colloid. The acinar cells are enlarged and rounded with granular eosinophilic cytoplasm (Askanazy cells).

A characteristic feature is the presence of diffuse lymphocytic infiltrations and localized collections of lymphocytes with germinal centres. This is why the condition is named as lymphadenoid goiter (i.e. resembling lymph gland).

### Clinical Features

More common in females (M:F = 1:10 – 20) Age 30–50 years. The most common presentation is that of a minimally or moderately enlarged firm gland. 20 percent of the patients present with hypothyroidism and 5 percent with hyperthyroidism.

An enlarged pyramidal lobe is often palpable. Thyroid associated ophthalmopathy is rare in patients with autoimmune chronic thyroiditis.

### Diagnosis

When Hashimoto's thyroiditis is suspected, clinically an elevated TSH, reduced T<sub>4</sub> and T<sub>3</sub> levels and the presence of thyroid autoantibodies confirm the diagnosis.

### Treatment

- a. Thyroid hormone replacement therapy is indicated in overt hypothyroid patients, with the aim of maintaining normal TSH levels.
- b. The management of patients with sub-clinical hypothyroidism (Normal T<sub>4</sub> and elevated TSH) is controversial because these patients invariably progress to overt hypothyroidism. Treatment is generally recommended for male patients with TSH greater than 10mU/L.
- c. Treatment is also indicated in euthyroid patients to shrink large goiters.

### Surgical

- a. If diagnosis from a carcinoma is not certain, a total thyroidectomy followed by biopsy is indicated.
- b. If the diagnosis is certain and there are pressure symptoms or discomfort due to a large goiter, a subtotal thyroidectomy is done.

### SUBACUTE THYROIDITIS

(Syn- de Quervain's or granulomatous thyroiditis).

Subacute thyroiditis occurs in adults, usually following a viral illness like influenza or viral pneumonia. This is also known as

granulomatous or de Quervain's thyroiditis. There is a painful swelling of the thyroid, associated with fever.

The condition lasts usually for a few weeks and gradual recovery occurs.

Prednisone 10 to 20 mg daily for 7 days and then in reduced dosage for a month is the treatment.

### **RIEDEL'S THYROIDITIS**

This is a rare disorder in which thyroid tissue is replaced by fibrous tissue. The fibrosis extends through the capsule of the glands into the muscles and adjacent structures including parathyroids, recurrent nerve and the carotid sheaths. It may occur in association with mediastinal and retroperitoneal

fibrosis and is believed to be a collagen disease.

The disease occurs predominantly in women between the ages 30 and 60 years. It typically presents as a painless, hard anterior neck mass, which progresses over weeks to years to produce symptoms of compression including dysphagia, dyspnea, choking and hoarseness.

Hypothyroidism is almost always evident in thyroid function tests. It is often mistaken with anaplastic carcinoma from which it can only be differentiated by open thyroid biopsy.

### **Treatment**

Surgery is the mainstay of treatment when pressure symptoms are present. The chief

goal of operation is to decompress the trachea by wedge excision of thyroid isthmus and to make a tissue diagnosis.

Hypothyroid patients are treated with life long thyroid hormone replacement. Some patients who remain symptomatic have been reported to achieve dramatic improvement after treatment with corticosteroids and tamoxifen.

### **Inflammatory Goiter**

Infective thyroiditis is quite rare and is of the following types.

1. Acute thyroiditis—It is an acute bacterial infection, commonly secondary to a throat infection and sometimes giving rise to abscess formation.
2. Chronic thyroiditis—Tubercular or syphilitic.



# Chapter 24

## Parathyroids

- Anatomy
- Physiology
- Hyperparathyroidism
- Hypoparathyroidism

### ANATOMY

The parathyroid glands normally lie behind the lateral lobe of the thyroid gland, and may be either within or outside the thyroid capsule of pretracheal fascia. There are usually four glands two on each side with a total weight of not more than 200 mg.

The superior gland, often called parathyroid IV as it develops from the fourth pharyngeal pouch, is more constant in position. The inferior gland is parathyroid III, developed from the third pouch. It is more variable in position, usually behind the lower pole below the inferior thyroid artery. The superior one is located on the posterior surface of the lateral lobe at about its middle, above the inferior thyroid artery. The blood supply to all the parathyroids is mainly derived from the inferior thyroid artery.

In histological section, the gland is homogeneous and very vascular. The gland consists of three types of cells.

1. Basophilic or chief cells. Also called principal cells which secrete the parathyroid hormone (PTH).
2. Eosinophilic cells or oxyphil cells of unknown function.
3. Water clear cells – derived from the chief cells.

### PHYSIOLOGY

The parathyroid glands secrete parathyroid hormone (PTH) directly into the blood stream. This hormone acts on the kidney and bones

directly and on the gastrointestinal tract indirectly.

In the kidney PTH causes:

- a. Reduction of urinary excretion of calcium by increasing the reabsorption of calcium by renal tubules.
- b. Promotion of phosphaturia by reducing the renal tubular absorption of phosphate.

In the bones, there is stimulation of osteoclastic activity increasing bone resorption and mobilization of calcium and phosphate. There is evidence that both calcium mobilization and phosphaturic actions of parathyroid hormone are modified through formation of cyclic AMP.

In the gastrointestinal tract, this hormone has a stimulatory effect on intestinal absorption of calcium. This takes place only in presence of active vitamin D<sub>3</sub> (1, 25 dihydroxycholecalciferol), which acts as a hormone after its formation in the kidney from 25 hydroxycholecalciferol with the help of parathormone.

### Regulation of PTH Secretion

This occurs mainly by the serum level of ionized calcium. When the calcium level is high secretion is diminished and calcium is deposited in the bones.

When calcium level is low, the secretion is increased and calcium is mobilized from the bones. Elevated plasma phosphate level is said to stimulate parathyroid secretion.

There is no trophic hormone, which influences the secretion of parathormone.

In chronic renal disease, when the plasma calcium is chronically low, feedback

stimulation of parathyroid glands causes compensatory parathyroid hypertrophy and secondly hyperparathyroidism.

### Calcitonin

Calcitonin is secreted by the parafollicular cells of the thyroid gland and has opposite action to PTH. It lowers the serum calcium and increases calcium storage in bones.

### HYPERPARATHYROIDISM

#### Primary Hyperparathyroidism

Primary hyperparathyroidism is an idiopathic disorder due to autonomous function of one or more affected parathyroid glands.

The majority of cases of primary hyperparathyroidism (90%) are sporadic cases that is, with no familial inheritance. The main pathology is a single adenoma (85%), or rarely hyperplasia of the gland (14%) or very rarely carcinoma of the gland (1%).

Familial causes of primary hyperparathyroidism are seen in multiple endocrine neoplasia (MEN) syndromes viz. MEN—Type I and Type II.

#### MEN-Type I

This consists of tumors or hyperplasia of parathyroid glands, pituitary, adrenal cortex and pancreas together with peptic ulcerations and gastric hypersecretion. This is also known as Wermer's syndrome.

### MEN-Type II

Type—II MEN, also known as sipples' syndrome is characterized by medullary carcinoma of thyroid, parathyroid hyperplasia or adenoma and pheochromocytoma, but no pancreatic islet cell tumor or peptic ulceration. This type II syndrome has been further subdivided into type IIA and IIB.

In type IIB, there are additional mucocutaneous neuromas involving lips, eyelids, tongue, intestine, etc.

### Secondary Hyperparathyroidism

Secondary hyperparathyroidism is the condition in which increased parathyroid hormone (PTH) is secreted to compensate for a chronically low calcium level. There is initially no abnormality inherent to the parathyroid glands:

Chronic renal failure is the most common cause and the pathophysiology of the process includes:

- i. Decreased production of 1, 25 (OH)<sub>2</sub>, vitamin D<sub>3</sub>, probably owing to diminished renal 1- $\alpha$  hydroxylase activity and thereby diminished intestinal absorption of calcium.
- ii. Hyperphosphatemia due to impaired renal excretion leads to a reciprocal fall in the serum calcium level in a compensatory effort to maintain a constant serum calcium phosphate product.
- iii. Decreased clearance of PTH, as renal failure progresses. Early in its course, secondary hyperparathyroidism is quite amenable to medical management, using dietary phosphate restriction, phosphate binding agents, calcium supplements and vitamin D. Later in the course of the disease, these medical measures become less effective, so operation may be required. In many cases, renal transplantation leads to resolution of hyperparathyroidism in 6 to 12 months.

### Tertiary Hyperparathyroidism

A minority of patients with secondary hyperparathyroidism go on to develop this condition, in which parathyroid hyperplasia, results in autonomous hypersecretion such that hyperparathyroidism continues despite correction of the underlying renal disease.

### Clinical Features

- Hyperparathyroidism is common in females, female : male = 2:1
- Age – The incidence of primary hyperparathyroidism peaks in the sixth decade of life in both men and women.
- Incidence—1 in 1000 patients.
- The most common presentation is asymptomatic hypercalcemia. Eighty percent of patients are either asymptomatic or with mild symptoms such as fatigue, weakness, polydipsia, polyuria, arthralgia and constipation. Although about 5 percent of outpatients evaluated for hypercalcemia will be diagnosed as hyperparathyroidism, other causes of hypercalcemia must be considered.

These include:

- i. Hypercalcemia of malignancy (multiple myeloma, squamous cell carcinoma of head and neck).
- ii. Granulomatous disease, e.g. sarcoidosis.
- iii. Vitamin D toxicity.
- iv. Endocrine disorders like thyrotoxicosis, adrenal insufficiency.
- v. Drugs like thiazide diuretics, lithium.
- vi. Immobilization hypercalcemia as in Paget's disease.

Normal PTH values are reported between 10 and 65pg/ml. Intact PTH values for patients with primary hyperparathyroidism will be in the high normal range or frankly elevated.

In contrast the majority of patients with hypercalcemia of malignancy have suppressed PTH values (< 1pg/ml). Thus discrimination between hypercalcemia patients with hypercalcemia of malignancy and hyperparathyroidism is quite good.

The symptoms and signs of hyperparathyroidism can be grouped into four varieties.

- The first group of symptoms are due to raised level of calcium in blood and urine, e.g. nausea, vomiting, polyuria, dehydration, increased thirst and constipation. There is muscle weakness followed by inability to concentrate. Patient may complain of drowsiness. Finally cardiac arrest may occur, the heart being in systole.
- The second group comprises the clinical features due to abnormal deposition of calcium in soft tissues. Mainly kidneys are

affected producing nephrocalcinosis due to calcium deposition in the renal tubules. Symptomless calculi have been formed in the pancreas and salivary glands.

- The third group comprises the effects of bone resorption and is seen in its most florid form in the generalized cystic bone disease known as osteitis fibrosa cystica or von Recklinghausen's disease.
- The fourth group comprises the various bizarre forms of presentation viz. gastroduodenal ulcer, pancreatitis, hypertension, etc. In short hyperparathyroidism is a disease of bones, stones, abdominal groans (peptic ulcer, pancreatitis) and psychic moans (behavioral abnormalities).

Interestingly, clinical examination may not reveal any parathyroid enlargement and the patient is referred to mental institutions, orthopedic and gynecologic departments and shunted from doctor to doctor.

Hence, high index of suspicion is necessary to arrive at a diagnosis.

### Investigations

1. Serum calcium level—The serum calcium level often rises to 12 to 20 mg from the normal level of 9 – 11 mg per 100 ml.
2. Serum PTH level is measured by immunoradiometric assay. It is the hallmark of hyperparathyroidism but its estimation is difficult, costly and needs sophisticated set up.
3. Serum phosphorus levels are decreased.
4. X-ray of hand — Subperiosteal resorption of bone especially in the middle phalanges of the index and middle fingers in the adult is the earliest and most consistent finding, other bones commonly involved are tibia, distal ulna, neck of femur, pubis and outer third of clavicle.

### Preoperative Localization

Localization techniques include:

- i. Ultrasonography of the neck may be helpful in localization of the gland in the hands of an experienced sonologist in about 75 to 80 percent cases.
- ii. CT scanning is particularly helpful when the gland is situated in the mediastinum than in the neck.
- iii. MRI is potentially the most useful for localization of parathyroid. Initial studies

suggest about 85 percent detection rate with lesions smaller than 0.5cm diameter.

iv. Thallium—Technetium subtraction scan is however more helpful in localizing parathyroid adenomas. First the thyroid is outlined with  $^{99m}\text{Tc}$ . Thallium 201 is then administered. This isotope is taken up by both thyroid and parathyroid. Both the images  $^{99m}\text{Tc}$  and Thallium 201 are taken by a gamma camera. These two images are now subtracted by computer and the parathyroid adenoma is localized as hot spot.

## Treatment

### Medical Treatment

Medical treatment has been advocated for primary hyperparathyroidism. This includes use of estrogen supplements or diphosphonate therapy to lower the serum calcium level. This is supported by adequate hydration and avoidance of calcium intake. If the patient is on thiazide diuretic, it should be stopped.

Presently calcium receptor agonists are being experimented in the treatment of this condition, the therapeutic potential of which is still under consideration.

### Surgery

The treatment of choice for symptomatic primary hyperparathyroidism is surgery. The asymptomatic patient may be followed up intermittently without operative intervention.

The surgery of the parathyroid glands needs patience, skill and expertise. The neck is explored with a collar neck incision similar to subtotal thyroidectomy. The upper parathyroid glands are more easily found and are usually located on the posterior surface of the thyroid lobe at the middle or just above this level. The lower glands are larger than the upper ones but less constant in position.

Frozen section of parathyroid glands is essential to confirm whether it is an adenoma or hyperplasia because depending upon the pathological nature of the gland, the treatment has to be carried out as follows:

- i. Single adenoma — excision.
- ii. Diffuse hyperplasia —  $3\frac{1}{2}$  parathyroids are removed and a small piece is autotransplanted into the forearm muscle. In case, there is hyperactivity of this parathyroid tissue, surgical exploration becomes easy. At the same time, if this functions normally patient will not develop hypoparathyroidism.
- iii. Carcinoma — All four glands should be removed along with thyroid tissue.

### Follow-up

Estimation of serum calcium should be done in the postoperative period to assess the functioning of the parathyroid tissue. Very often after surgery for adenoma, there is sudden drop of serum calcium level because of absorption of calcium by the bones. This is known as 'hungry bone syndrome'.

Absorption of calcium can be enhanced by oral administration of 1, 25 dihydroxy cholecalciferol, the metabolite of vitamin D.

## HYPOPARATHYROIDISM

### Cause

- The most common cause of hypoparathyroidism is damage to the parathyroid gland during thyroid surgery.
- Neonatal hypoparathyroidism—Hyperparathyroidism in pregnant women can lead to hypoparathyroidism in neonates from suppression of fetal parathyroid tissue.
- Congenital absence of parathyroid glands and thymus is seen in the DiGeorge syndrome. These patients therefore suffer from lack of thymus dependent lymphoid system.

### Clinical Features

Acute hypocalcemia results in decreased ionized calcium and increased neuromuscular excitability producing tetany. The features of tetany set in when blood calcium level comes down below 6 mg per 100 ml. It takes a few days for this level to be reached, so postoperative tetany takes about 2 to 5 days to appear.

The earlier the features appear, the delayed is the recovery.

- The earliest symptoms are numbness and tingling of the fingers, toes and circum oral area.
- Mental symptoms in the form of anxiousness and depression are also common.
- This is followed by cramps in the hands and feet, carpopedal spasm and spasm of muscles of respiration leading to dyspnea and stridor—Laryngeal spasm and convulsions can occur.

The signs to demonstrate latent tetany are as follows:

- i. Chvostek's signs — Abnormal contraction of the facial muscle, elicited by tapping on the facial nerve anterior to the tragus.
- ii. Trousseau's sign — It is elicited by occluding blood flow to the forearm for 3 minutes with sphygmomanometer cuff applied to the arm and raising the pressure above systolic level (200 mm Hg). This will induce carpal spasm i.e. metacarpophalangeal joints are flexed with extension of interphalangeal joints and adduction of the thumbs causing obstetrician's hand. Similar technique may be applied in the foot to appear the pedal spasm which causes extension of the ankle joint and flexion of the toes.

### Diagnosis

- Estimation of serum calcium level which is usually  $< 6$  mg/100 ml.
- ECG changes include prolonged QT interval.

### Treatment

#### Calcium Therapy

- Oral calcium such as calcium lactate and gluconate may relieve mild symptoms.
- In acute cases, injection of calcium gluconate 10 ml 10 percent solution should be given slowly intravenously (to avoid cardiac arrhythmia).
- In addition vitamin D supplement like calciferol (vitamin  $\text{D}_2$ ) 10 mg twice daily orally may be given. IV Calcium infusion is rarely required.

# Chapter 25

## The Adrenal Glands

- Development
- Anatomy
- Histology
- Tumors of adrenal medulla
- The adrenal cortex
- Adrenal incidentaloma
- Adrenal insufficiency

### DEVELOPMENT

Each suprarenal gland develops from two sources at about 4 to 6 weeks of gestation – the cortex from the elongated suprarenal ridge of mesoderm between thoracic sixth and twelfth segments in the angle between the developing gonad and the attachment of the dorsal mesentery of the primitive gut and the medulla from the neuroectoderm of the neural crest. The suprarenal ridge is formed by the proliferation of the mesothelial cells of the celomic cavity.

The cells arising from the celomic epithelium may be divided into two groups:

- The large acidophil cells which are first formed and surround the cells of the medulla and form the fetal cortex. The fetal cortex begins to involute at about the time of birth and completes this process in 6 to 8 months.
- Subsequently the celomic epithelium gives origin to the smaller basophil cells that surround the fetal cortex and are destined to become the definitive adult cortex.

Each adult adrenal gland is about 4 gm in weight.

### ANATOMY

Each adrenal gland lies along the anteromedial border of the superior pole of kidney. The triangular-shaped right adrenal gland lies close to the inferior vena cava while the left

adrenal gland is crescentic in shape and lies between the kidneys and the aorta. The adrenal cortex is bright yellow and much thicker than the medulla, which is reddish brown.

The adrenals are highly vascular and the arterial supply comes from 3 sources:

- The superior adrenal artery, a branch from the inferior phrenic artery.
- The middle adrenal artery, a branch from the abdominal aorta and
- The inferior adrenal artery, a branch from the renal artery.

There is usually one large vein for each adrenal gland. The vein from the right adrenal gland drains into the inferior vena cava and that from the left one drains into the left renal vein, though infrequently it may drain into the inferior vena cava.

The lymphatics form subcapsular plexus at the adrenal cortex and these along with lymphatics from adrenal medulla drain into the adjacent paraaortic and renal lymph nodes. Nerve supply is not apparent for the adrenal cortex though the adrenal medulla is supplied richly by sympathetic nerves.

### HISTOLOGY

The adrenal cortex in the adult consists of 3 zones:

- A peripheral zona glomerulosa
- An intermediate zona fasciculata and
- An inner zona reticularis adjacent to the medulla.

Each of these zones has characteristic light and electron microscopic features which distinguish one from the others. There are also functional differences viz.

- Aldosterone, a mineralocorticoid is produced exclusively in the zone glomerulosa.
- Glucocorticoids or cortisols are produced in the zona fasciculata and
- Sex steroids like androgens and estrogens are produced in the zona reticularis.

Adrenal medulla constitutes 10 percent of the total gland weight. Adrenal medullary cells are polyhedral in shape and are arranged in cords. They contain catecholamines and on electron microscopy vesicles containing epinephrine and norepinephrine can be identified. In health 80 percent of medullary secretion is epinephrine and only 20 percent is norepinephrine, the precursor of epinephrine.

Adrenaline causes peripheral vasoconstriction but muscular vasodilatation. Noradrenaline causes an overall vasoconstriction. Epinephrine or adrenaline has an additional effect of glycogenolysis.

The cells of adrenal medulla are often referred to as chromaffin cells because they stain specifically with chromaffin salts.

### TUMORS OF ADRENAL MEDULLA

There are three common tumors viz. pheochromocytoma, neuroblastoma and ganglioneuroma.

## Pheochromocytoma

This tumor originates from the chromaffin cells of the adrenal medulla. Rarely a tumour may originate from the extraadrenal chromaffin tissue at ectopic sites, e.g.

- Retroperitoneal tissues along the aorta, at the base of the mesentery.
- Sympathetic ganglia.
- Mediastinum.

Pheochromocytomas are often called 10 percent tumor because 10 percent are bilateral, 10 percent are malignant, 10 percent occur in pediatric patients, 10 percent are extra-adrenal and 10 percent are familial.

Pheochromocytomas occur in families with MEN 2A and MEN 2B in approximately 50 percent patients. Both syndromes are inherited in an autosomal dominant fashion and are caused by mutations in the ret protooncogene.

### Clinical Features

- The most common presenting feature is paroxysmal or persistent hypertension. It is associated with headache, palpitations and diaphoresis which constitute the 'classic triad' of pheochromocytomas. Symptoms such as nausea, vomiting, paresthesias, anxiety, flushing, chest pain and shortness of breath are nonspecific and episodic in nature.
- Cardiovascular complications such as myocardial infarction and cerebrovascular accidents may ensue.
- These symptoms may be incited by a range of stimuli including micturition, defecation, exercise, late pregnancy, palpation of the mass.
- Persistent hypertension occurs in 50 percent of cases. Even in these cases, attacks of paroxysmal increase may occur from time to time.
- Sudden death may occur in patients with undiagnosed tumors who undergo other operations or biopsy.
- Pheochromocytoma should be suspected in patients with malignant hypertension not responding to antihypertensives.

### Investigations

- Diagnosis of pheochromocytoma is confirmed by documenting increased excretion rates of urinary epinephrine and norepinephrine or their metabolites viz. metanephrine, nonmetanephrine and

vinyl mandelic acid (VMA). VMA level above 7 mg/24 hours is diagnostic. 90 percent of the cases can be accurately diagnosed by this technique.

- Localization studies — Once the diagnosis is confirmed by biochemical tests, the localization and extent of disease should be determined. Most often the disease is localized in the abdomen (97%), the thorax (2-3%) and in the neck (1%).
  - CT scanning has 90 percent accuracy in detecting pheochromocytoma.
  - MRI scans are almost 100 percent specific for pheochromocytoma. MRI is also the study of choice in pregnant patients as there is no risk of radiation exposure.
  - Radionuclide imaging — <sup>131</sup>I radiolabeled MIBG (Metaiodobenzylguanidine) has recently been used successfully for localizing pheochromocytoma especially in ectopic positions.

### Treatment

Surgical removal is the only satisfactory treatment. Preoperative use of alpha and beta adrenergic blocking agents, meticulous intraoperative monitoring and modern anesthesia has made surgery safe.

### Preoperative Preparation

It should begin 48 hours before surgery or invasive diagnostic procedures.  $\alpha$  – receptor antagonist, phenoxybenzamine 20 to 40 mg per day orally is used in all patients with severe hypertension. Propranolol is added when severe tachycardia is a problem. It should never be used without a prior alpha blockade or else severe hypertension may result.

### Intraoperative Management

Continuous monitoring of ECG, arterial pressure and CVP are essential.

The common medications used for intraoperative blood pressure control include nitroprusside, nitroglycerin and phentolamine. During simultaneous handling of bilateral tumors a hydrocortisone drip is required.

### Operative Strategy

A transabdominal incision is usually adequate though large tumors may require a thoracoabdominal approach. The chief goal of surgery is to resect the tumor completely

with minimal tumor manipulation or rupture of the tumor capsule.

Most patients are normotensive by the second day. Persistent hypertension indicates either residual tumors or irreversible vascular changes. Urinary VMA is checked at 6 monthly intervals for 3 years and then annually life long.

Laparoscopic adrenalectomy is also being tried recently for many pheochromocytomas less than 5 cm diameter and operated successfully.

## Neuroblastoma

This tumor arises from the immature nerve cells of the sympathetic nervous system (Neuroblasts) contained in the adrenal medulla occasionally; it arises from the neuroblasts located at extra-adrenal sites, e.g. retroperitoneal tissues, mediastinum and along the sympathetic chain.

This is a malignant adrenal tumor often associated with the production of catecholamines and their metabolites.

### Pathology

Macroscopically the tumor usually attains a huge size like the Wilms' tumor. The surface is nodular with a maroon color and there are big areas of necrosis and hemorrhage.

*Microscopically*—The tumors consists of small round cells which are highly immature and undifferentiated type.

Metastasis to liver bone and lung occur frequently.

### Clinical Features

This is the most common adrenal neoplasm in children, more than 80 percent occurring below the age of 5 years. Sometimes an infant may be born with a neuroblastoma. Both sexes are equally affected.

The most common presentation is with an abdominal mass or local pressure symptom.

In almost all cases there is pallor, weight loss and anorexia. More than 60 percent cases present with metastatic features at the time of diagnosis like bone pain, cutaneous metastatic nodules, anemia, etc.

Peptide hormones released by the tumor include VIP and ACTH.

### Investigations

- Urine VMA levels are elevated in 75 percent of patients.



- Chest X-ray.
- Aspiration of bone marrow may show malignant cells.
- CT scan and MRI—MRI is better than CT scan in detecting the mass as well as bony metastasis.
- A biopsy of the tumor is obtained to confirm the diagnosis.

### Treatment

- Early cases respond very well to surgical excision.
- In advanced cases with metastasis, patients receive initial chemotherapy with cyclophosphamide, cisplatin and doxorubicin followed by surgery and adjuvant radiotherapy.
- The younger the child better is the prognosis.
- Spontaneous regression of neuroblastoma is recognized.

### Ganglioneuroma

It originates from the mature nerve cells of the sympathetic nervous system and reproduces ganglion cells of adult type. It is a benign tumor and least harmful among the 3 varieties of the adrenal medullary tumors.

It produces no hormonal secretion, is often asymptomatic and detected accidentally.

Like pheochromocytoma the tumor occurs in adults and usually presents with pressure

symptoms or pain. Tumor calcification seen on plain X-ray is a common finding.

Treatment is by surgical excision.

## THE ADRENAL CORTEX

### Physiology

Cholesterol is the major precursor of all steroid hormones produced by the adrenal cortex. The adrenal cortex contains relatively large quantities of cholesterol mostly as cholesteryl esters. Conversion of cholesteryl ester to free cholesterol is a necessary step in steroid synthesis and is regulated by ACTH (Fig. 25.1).

### Glucocorticoids

These hormones are so named as they exhibit profound influences on glucose metabolism. They directly stimulate intrahepatic synthesis of glucose from noncarbohydrate sources viz. fat and amino acids and glycogen.

Cortisol or hydrocortisone is the chief of these hormones and is responsible for 95 percent of all glucocorticoid activity.

Cortisone is a synthetic preparation and is corrected to cortisol in the body exerting same effects.

The secretion of glucocorticoids is enhanced under stress and trauma and is

inhibited by the negative feedback effects of cortisol.

ACTH secreted by the anterior pituitary is responsible for the control of secretion of cortisol. The secretion of ACTH in turn is controlled like other pituitary hormones, by a releasing hormone or factor from the hypothalamus, known as corticotropin releasing hormone or CRH.

Under physiological conditions, about 75 percent of plasma cortisol is bound to cortisol binding globulin, CBG, transcortin 15 percent is bound to plasma albumin and about 10 percent is unbound. The unbound protein represents the physiologically active steroid.

Hyperplasia or tumors of those cells producing glucocorticoids results in what is known as Cushing's syndrome.

### Mineralocorticoids

These are concerned in the maintenance of water and electrolyte balance. Aldosterone is the most important of these hormones. It causes sodium retention by the kidneys and expansion of the extracellular fluid volume. The secretion of aldosterone is regulated by the renin-angiotensin system, ACTH and the serum concentrations of sodium and potassium. Roughly 30 percent of aldosterone secretion is influenced by ACTH. The remainder depends mainly on the renin – angiotensin system.

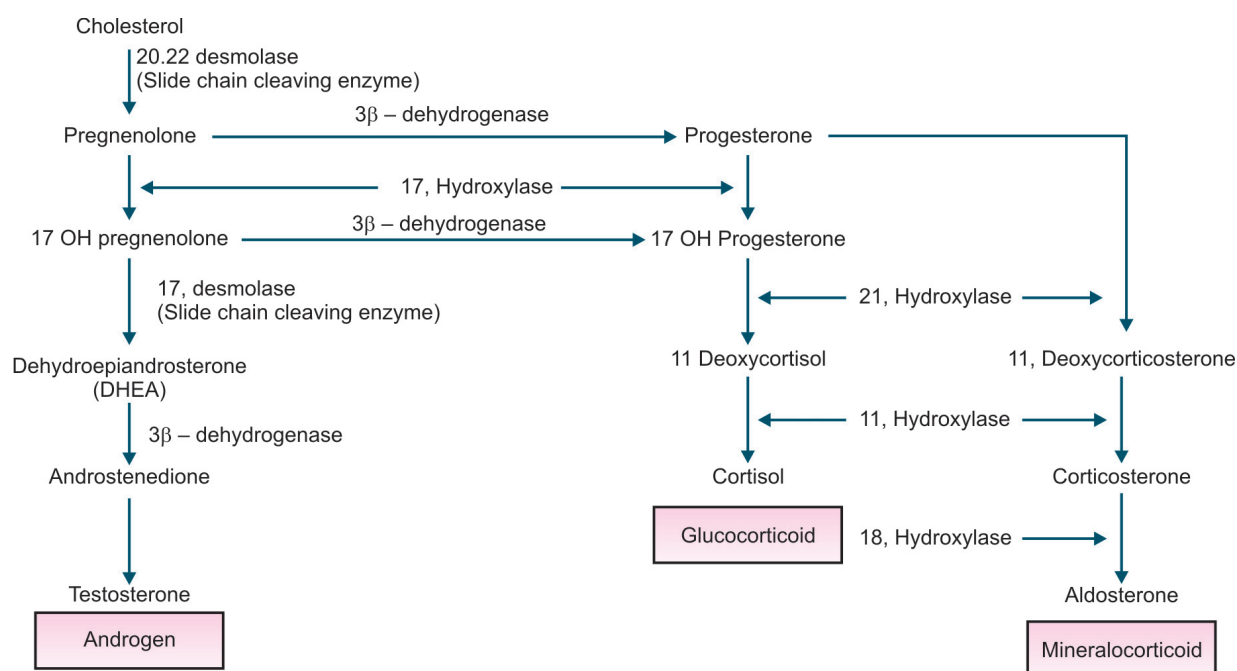


Fig. 25.1: Major steps in the biosynthesis of three principal adrenal steroids

Renin is produced and secreted by the juxtaglomerular cells (JG cells) in the afferent renal arteriole close to the macula densa in response to a fall in blood volume and subsequent fall in pressure in the afferent arteriole. The renin acts on angiotensinogen, an alpha two globulin, synthesized in the liver to form angiotensin I which is converted by a converting enzyme in the pulmonary circulation to angiotensin II. Angiotensin II stimulates zona glomerulosa to release aldosterone. Sodium retention and expansion of blood volume by aldosterone turns off the production of renin.

Clinical states associated with elevated aldosterone production can be subdivided into two types viz. (i) Primary aldosteronism and (ii) Secondary aldosteronism.

- Primary aldosteronism results from glomerulosa cell tumors, which secrete aldosterone in an autonomous manner.
- Hypovolemia from any cause will affect the release of renin which ultimately causes excessive aldosterone production by the adrenal cortex. This is known as secondary aldosteronism.

### Sex Steroids

After puberty the adrenals secrete the sex steroids viz. dehydroepiandrosterone (DHEA), androstenedione, testosterone and estrone.

Excess of androgens will produce virilism in females and enhanced growth of axillary and pubic hairs and increased muscle mass in males.

## Cushing's Syndrome

### Definition

In this syndrome, an excessive secretion of cortisol leads to potentially lethal metabolic derangements.

### Pathology

Nearly 70 percent adult hypercorticism is due to bilateral adrenocortical hyperplasia secondary to chromophobe adenoma of the anterior pituitary. About 20 to 25 percent cases are due to adrenal adenomas or carcinomas. Less than 10 percent cases are seen because of ectopic ACTH producing tumors of nonpituitary, nonadrenal origin, e.g. oat cell carcinoma of the lung, renal cell carcinoma.

Patients on prolonged cortisone therapy may also present with features of Cushing's syndrome.

### Clinical Features

It is four times more common in women, occurring between 30 to 40 years.

They present with obesity which is limited to the head, neck and trunk, an atrophic skin, purplish striae on the abdomen, hips, breast and the axillae, a plethoric face with acne and hirsutism.

Easy and nonhealing bruising occurs due to increased capillary fragility.

Oligomenorrhea and virilism occur in females; while males have gynecomastia and decreased libido. Proximal muscle weakness and osteoporoses are common. Pathological fractures may occur.

Other features are hypertension, glucose intolerance, mental disturbances and psychosis.

### Investigations

#### Plasma Cortisol Level

Nine am and 9 pm plasma cortisol estimations reveal high levels and loss of diurnal variation. The hydrocorticoids and free cortisol levels are increased in the urine. Free cortisol level in urine (> 100mg/24hrs) is the most useful screening test.

#### High Dose Dexamethasone Suppression Test

This test may distinguish between Cushing's disease due to pituitary adenoma and adrenal tumors and ectopic production of ACTH.

This test is carried out by administering 2 mg q i d of dexamethasone for 2 days.

Suppressed levels are seen in patients with pituitary dependent Cushing's disease but not in a patient with adrenal tumor or an ectopic ACTH source.

### Localization Studies

CT scan of pituitary and adrenal to localize the tumors. However, MRI is the best modality for evaluation of the sella. CT scan is also reliable in detecting nodules in the lungs mediastinum, kidney and pancreas which are potential sites of ectopic ACTH production.

### Treatment

- In Cushing's disease, where a pituitary tumor is the cause, hypophysectomy is the treatment of choice. If this fails, bilateral total adrenalectomy should be attempted.

- For the adrenal tumor surgery is the definitive treatment. Substitution cortisone therapy is needed during the early postoperative phase.
- In ectopic ACTH syndrome, surgery of the primary tumor and radiochemotherapy of secondaries will take care of the syndrome. Aminoglutethimide and metyrapone will block the cortisol synthesis and thus may provide symptomatic relief.

## Primary Hyperaldosteronism

(Conn's syndrome).

In this condition, there is excess aldosterone secretion causing sodium retention, potassium depletion, arterial hypertension and suppression of plasma renin activity.

### Pathology

About 90 percent of patients with primary aldosteronism have benign solitary adrenocortical adenoma (Conn's syndrome).

Bilateral adrenal glomerulosa cells hyperplasia also causes primary aldosteronism.

Rarely primary aldosteronism is produced by adrenocortical carcinoma.

A typical aldosterone producing adenoma (APA) is 4 to 26 mm in diameter, solitary, well-capsulated and golden yellow in color, microscopically there are large lipid laden cells arranged in cords and acini.

### Clinical Features

- It is twice common in women aged 30 to 50 years.
- Muscle weakness, polydipsia, fatigue and nocturnal polyuria occur due to excessive potassium loss.
- Hypertension though present is mild.

### Investigations

- All hypokalemic hypertensives should be suspected of this disorder and investigated accordingly.
- ECG changes are characteristic of hypokalemia.
- Localization studies include CT scan or MRI (Fig. 25.2).

### Treatment

- When the cause is an adenoma, adrenalectomy is the treatment of choice.
- When there is hyperplasia results are good with the use of an aldosterone antagonist

like spironolactone (upto 300 mg/day) in combination with antihypertensive drugs. Surgery is reserved for the refractory cases and involves bilateral adrenalectomy.

### Adrenogenital Syndrome

This syndrome is seen due to the excessive production of adrenal sex hormones and it clinically manifests at three stages of life – at birth, during childhood and in adult life.

The congenital infantile variety is by far the most common and is seen mostly in females who present with features of pseudohermaphroditism. This is an autosomal recessive disorder caused by deficiency of enzymes, mostly 21 hydroxylase (95%) in the synthetic pathways of cortisol. The deficiency of cortisol stimulates ACTH activity, which produces adrenal hyperplasia and increased production of sex hormones.

The treatment is mainly medical by lifelong administration of cortisol. The only indication for surgery is a plastic operation on the genitalia to reduce the size of clitoris to ensure normalcy.

In childhood and adult types, the common cause is adenoma or carcinoma of the adrenal cortex. The adult or growing female

becomes masculinized with amenorrhea and hirsutism. The condition is rare in males and virilism attracts little attention.

Treatment is adrenalectomy after tumor localization.

### ADRENAL INCIDENTALOMA

Incidentaloma is an incidentally discovered adrenal mass found during imaging performed for an unrelated indication. This will be found in 3 to 5 percent of patients undergoing abdominal CT examination. The incidence increases with age and in patients with hypertension.

Nonfunctioning adrenocortical adenomas are the most common cause of an incidentaloma (Table 25.1).

- The adrenal is a common site of metastasis of lung and breast tumors, melanoma, renal cell carcinoma and lymphoma.
- Myelolipomas are benign lesions composed of mature adipose tissue and hemopoietic elements.

### Investigations

Investigations are aimed at identifying patients who would benefit from adrenalectomy that

**Table 25.1: Differential diagnosis of incidentaloma**

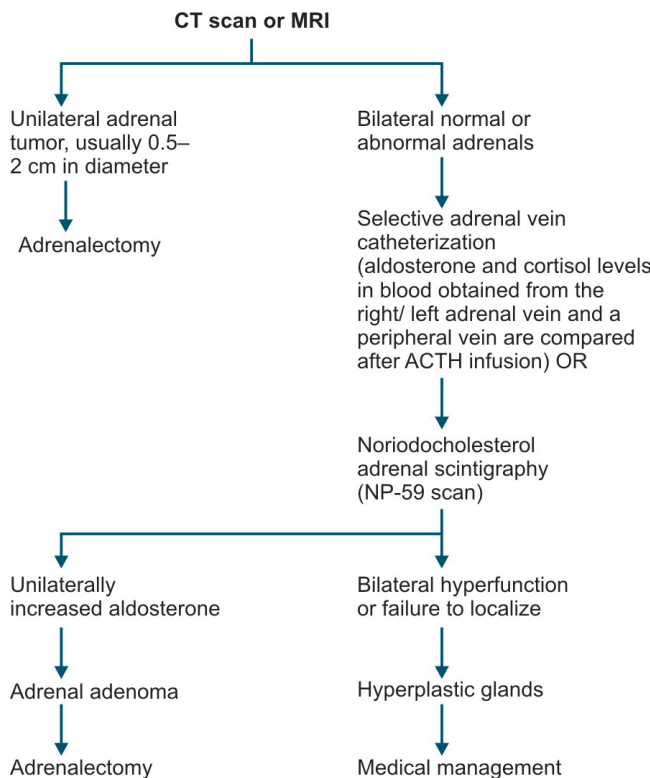
I. Nonfunctioning lesions:
i. Benign
– Cortical adenoma – most common
– Myelolipoma
– Cyst
– Ganglioneuroma
ii. Malignant – Metastasis
II. Functioning lesions:
i. Benign
– Aldosteronoma
– Cortisol producing adenoma
– Sex steroid producing adenoma
– Pheochromocytoma
ii. Malignant
– Adrenocortical cancer
– Malignant pheochromocytoma

is, patients with functioning tumors. These include:

- 2 × 24 hour urine collection for catecholamines and metanephrine and VMA to rule out pheochromocytoma.
- Plasma electrolytes, aldosterone and renin to rule out an aldosteronoma.
- If a patient has a history of malignancy the most likely adrenal abnormality will be metastasis. Fine needle aspiration cytology (FNAC) is performed when pheochromocytoma has been excluded to confirm the diagnosis.
- Incidentaloma of 4 cm or more in diameter carry an increased risk of malignancy.

### Treatment

- Patients with functional tumors as determined by biochemical testing or with obvious malignant lesion, should undergo adrenalectomy.
- A unilateral nonfunctioning adrenal mass > 4 cm in diameter is an indication for adrenalectomy. The patient with a mass smaller than 4 cm in diameter should undergo repeat CT or MRI 4 to 6 months after the previous examination. An increase in size is an indication for adrenalectomy.
- Metastasis — Resection of solitary adrenal metastases of nonadrenal cancers from lungs or kidney has been demonstrated to lead to prolonged patient survival. Suspected adrenal metastases may also be resected for diagnosis or for palliation if large and symptomatic.



**Fig. 25.2:** Localization study of conn's syndrome

**ADRENAL INSUFFICIENCY****Types of Adrenal insufficiency**

1. Primary adrenal insufficiency (Addison's disease) — It occurs as a result of disease processes that destroy the adrenal cortex, e.g. Tuberculosis, metastatic, malignancy (breast, lung), Autoimmune (Polyglandular autoimmune disease), Hemorrhage (Spontaneous, e.g. Waterhouse–Friderichsen syndrome and secondary to stress trauma, infections, coagulopathy, etc.), Infiltrative disorders like amyloidosis, hemochromatosis, drugs like metyrapone, aminoglutethimide, mitotane, etc.
2. Secondary adrenal insufficiency—It is caused by deficient pituitary ACTH secretion, associated with hypopituitarism, e.g. pituitary hemorrhage (Sheehan's syndrome),

exogenous glucocorticoid therapy, pituitary or hypothalamic tumors.

**Clinical Features**

Acute adrenal insufficiency resulting from hemorrhage septicemia, birth injury, etc. Usually presents with shock, nausea, vomiting, abdominal pain, fever, hypoglycemia and electrolyte imbalance. It may also result from sudden deterioration of chronic adrenal insufficiency.

Symptoms of chronic adrenal insufficiency include malaise, weakness, weight loss, nausea and vomiting.

**Treatment**

Acute adrenal insufficiency demands immediate treatment without waiting for the results of diagnostic tests. A strong clinical suspicion is enough to start the treatment.

Blood samples may be sent for urea and electrolytes, blood glucose, basal cortisol and ACTH estimations.

Normal saline 2 to 3 liters is rapidly infused and hydrocortisone 100 mg IV 6 hourly. Any underlying infection is treated aggressively.

Patients with chronic adrenal insufficiency are treated with maintenance oral hydrocortisone in divided doses and fludrocortisone. They must be educated with regard to their life long need for glucocorticoid and mineralocorticoid therapy and the importance of dose adjustment or parenteral administration when stress or minor illness occurs.

Patients on long-term steroid therapy for whatever reason must be given appropriate steroid cover when subjected to severe stress, illness or surgery.

Chapter **26****Arterial Disorders**

- Arterial occlusion
- Intermittent claudication
- Atherosclerosis
- Critical limb ischemia
- Arterial dilatation aneurysm
- Abdominal aortic aneurysm
- Gangrene
- Pressure sores
- Raynaud's syndrome
- Thoracic outlet syndrome
- Buerger's disease

Arterial disorders will manifest as aneurysms and arterial stenosis or occlusion causing interruption of blood supply to any part or organ of the body. In various places the symptoms produced by arterial occlusion are different, e.g. in lower limb, it causes intermittent claudication, rest pain and gangrene, in the heart it causes angina pectoris and myocardial infarction, in the brain, transient ischemic attacks, in the kidney, hypertension, in the intestine, abdominal pain and infarction.

**ARTERIAL OCCLUSION****Classification**

Arterial occlusion is of two types – acute and chronic.

**Acute**

Causes are:

- i. Embolism (Embolus GK—something thrown in). Two types of embolization is seen viz.
  - (a) Cardioarterial and (b) arterioarterial.
  - Cardioarterial embolization—In about 90 percent of patients emboli in the lower extremity originate in the heart. The main causes are mitral stenosis, myocardial infarction and atrial fibrillation. Bacterial endocarditis may rarely cause this type of emboli.

- Arterioarterial embolization—This embolization originates from atherosclerotic plaque which has become ulcerated. Such ulcerated surface becomes covered by platelets and fibrin which are dislodged intermittently. These emboli may lodge anywhere, either near the atherosclerotic artery or some distance away from it. Thus emboli at the ends of anterior or posterior tibial arteries may originate from the atherosclerotic plaques in the abdominal or thoracic aorta.
- ii. Trauma
- iii. Others—Cold and chemicals causing vessel injury.

The clinical presentation of acute arterial occlusion is best remembered by 5 P's viz. pain, paresis, paresthesia, pallor and pulselessness. Pain, paresthesia and paresis or paralysis is due to ischemia of the peripheral nerves which are very sensitive to oxygen deprivation.

**Chronic**

Causes are:

- i. Atherosclerosis.
- ii. Traumatic, e.g. injury to the arterial wall by fractures, adjacent missiles or continuous rubbing may cause thrombosis and narrowing of the arterial lumen.
- iii. Vasospastic, e.g. Raynaud's phenomenon.
- iv. Buerger's disease.
- v. Diabetes.

The most common and significant symptom of chronic arterial occlusion or ischemia is intermittent claudication which may progress on to rest pain and gangrene.

The other features which may draw attention to the ischemia early are loss of hair, dry, wrinkled and atrophied skin, cessation of sweating and sebaceous secretion, and decreased or absent nail growth.

**INTERMITTENT CLAUDICATION (Ischemic Muscle Pain)**

Intermittent claudication is a cramp-like pain felt by the patient when a muscle with inadequate blood supply is put into exercise or working strain.

The pain is probably due to ischemia of the nerves and accumulation of metabolites like substance P and others of anaerobic metabolism.

When this pain occurs on muscular strain or exercise it is called intermittent claudication. When the pain occurs even at rest, it is called rest pain.

Claudication distance—It is the distance which the patient can walk before the onset of intermittent claudication. This is an index of severity of arterial occlusion. The longer is the distance, the better is the prognosis.

**Gradations of Claudication**

Intermittent claudication can be classified into three grades viz.



*Grade I* — This is the mildest type. The patient feels pain for transient period and claudication passes off on slowing down the walking speed or on continued walking.

*Grade II* — This is the usual type, patient walks with effort in spite of claudication because it is unpleasant but not unbearable.

*Grade III* — Pain compels the patient to stop walking.

### Rest Pain

Rest pain is characterized by a continuous aching pain and is indicative of critical ischemia which is defined as the arterial insufficiency threatening the viability of the affected part.

Rest pain usually occurs at sites most distal of the arterial supply, e.g. the toes, foot, fingers and hand. The rest pain is worse at night and aggravated by elevation of the extremity whereas it is relieved to some extent by hanging the foot out of the bed or sleeping in a chair. This rest pain is due to ischemic changes in the somatic nerves. Thus it is the cry of the dying nerves.

## ATHEROSCLEROSIS

This generic term includes the following conditions.

1. Atheroma — A disease characterized by patchy deposits of lipid material in the intima.
2. Arteriosclerosis, which means diffuse fibrosis of the arterial wall and
3. Annular calcification, also called Mönckeberg's sclerosis.

Main effects of atherosclerosis are:

- i. Narrowing and rigidity of the affected vessel because of fibrosis, calcification and atheroma formation.
- ii. Weakening of the arterial wall due to atheromatous ulcer formation, which predisposes to the formation of an aneurysm.
- iii. Thrombosis over the atheromatous patches, causing further narrowing at the site and leading to the risk of distal embolization.

### Prevention of Atherosclerosis

This primarily consists of modifying the risk factors responsible for development of atherosclerosis viz.

- a. Control of hypertension.
- b. Cessation of smoking.

- c. Moderation of alcohol intake.
- d. Lowering of total and LDL cholesterol and increasing HDL level of cholesterol in blood.
- e. Reduction of obesity in obese patients.

### Treatment

The principles of treatment of atherosclerotic vascular disease are:

- i. To relieve the pain.
- ii. Modification of risk factors as described above to arrest the progression of the disease and
- iii. Surgery — Intermittent claudication alone is not an indication for surgery. Rest pain and preangrenous changes in the limb, e.g. color changes, edema and hyperesthesia with or without ischemic ulcer are definite indications for reconstruction with accepted mortality and morbidity.

Different sites of atherosclerosis and their surgical treatment.

### Atherosclerosis of Aortoiliac Segment

- a. *Thromboendarterectomy*—It is the removal of thrombus along with diseased intima through an arteriotomy. Endothelium of the affected part of the vessel is removed, hence the name.

This operation is indicated when the occluded segment is short, i.e. involving the terminal 5cm of the aorta and the proximal part of the common iliac arteries.

- b. *Arterial bypass grafting* — When the disease is more extensive than the above, bypass graft procedure should be the operation of choice. In this technique the diseased segment is bypassed with a synthetic graft, e.g. Dacron knitted graft and PTFE (Polytetrafluoroethylene Graft) or with reversed autogenous long saphenous or internal mammary artery graft.

- c. *Transluminal balloon angiography and stenting* — This is particularly effective to inflate a narrow short occlusion.

The procedure is not as good as reconstructive surgery and is only used when the latter is not possible.

However, the advantage of the procedure is that it can be repeated if stenosis recurs.

### Atherosclerosis of Femoropopliteal Segment

- i. *Bypass grafting* — Bypass operation with autologous saphenous vein is the standard technique.
- ii. *Profundoplasty* — This operation consists of removal of atheromatous stenosis from the origin of the profunda femoris and then to widen the endarterectomized segment by insertion of a vein patch.

Profundoplasty may be carried out in conjunction with bypass graft operation. Even with no demonstrable stenosis, widening of the caliber of apparently normal profunda artery gives better results comparable to only bypass operation.

## CRITICAL LIMB ISCHEMIA (CLI)

Critical limb ischemia may be defined as (European working group).

- i. Persistent rest pain of over 2 weeks duration requiring regular analgesia, with an ankle systolic blood pressure of < 50 mm Hg or a toe pressure of < 30 mm Hg.
- ii. Patient with ulceration or gangrene of the feet with the same reduction of ankle blood pressure.

### Investigations

A hand held Doppler probe should be used to estimate the ankle brachial pressure index (ABPI).

### Treatment

- Nonoperative endovascular intervention involves angioplasty and stenting.
- Surgical options include bypass procedures depending on the site of lesion and if everything fails, the last option is amputation.

## ARTERIAL DILATATION ANEURYSM

### Definition

Dilatations of the localized segments of the arterial system are called aneurysms. Precisely it can be defined as a permanent localized dilatation of an artery to more than twice the diameter of the normal vessel.

## Sites

Aneurysms commonly affect the abdominal aorta, the iliac, femoral and popliteal arteries. Cerebral (Berry's aneurysm) and thoracic aneurysms are less common.

The majority of abdominal aortic aneurysm (AAA) (95%) extend from just below the renal arteries to the bifurcation of the aorta.

## Types

There are two types viz.

1. *True aneurysm* — Where the aneurysmal sac contains all the three layers of the arterial wall.
2. *False aneurysm or pseudoaneurysm* — It is an expanding pulsating hematoma, in contact with an arterial lumen and develop following trauma.

## Classification

Aneurysms can be classified as follows.

- A. According to shape
  - Fusiform.
  - Saccular.
  - Dissecting.
- B. According to etiology
  - Degenerative, e.g. atherosclerosis.
  - Inflammatory, e.g. syphilis, mycotic (which is a misnomer because it is not due to a fungus but due to bacterial infection).
  - Traumatic—During operation or direct trauma during an accident or gun-short injury.
  - Congenital — For example Marfan's syndrome (due to cystic medial necrosis, a degenerative lesion of tunica media in a collagen disorder).

## ABDOMINAL AORTIC ANEURYSM

### Incidence

Abdominal aortic aneurysm (AAA) is 2 to 3 percent in men aged between 65 and 80 years.

### Etiology

- Atherosclerosis.
- Familial—There is a marked familial tendency for the aneurysmal disease. An AAA will be found in 10-20 percent of first degree relatives of patients with AAA.

- Bacterial aortitis – (Mycotic aneurysm) – Biochemical studies have shown that AAA is characterized by abnormalities in collagen and elastin concentration associated with increased proteolysis and a marked inflammatory infiltrate within the aortic wall.
- Risk factors
  - i. Cigarette smoking.
  - ii. Hypertension.
  - iii. Hyperlipidemia.

## Pathophysiology

Once an aneurysm develops, regardless of its cause, its enlargement is governed by a simple physical Law of Laplace, as depicted below:

$$T = R P \text{ where}$$

T = Tension on the arterial wall.

R = Radius of artery.

P = Blood pressure.

This law states that the tension on the wall of the artery is proportional to the radius of the artery and the blood pressure. Put another way, the higher the blood pressure, the wider the lumen, the more likely the aneurysm to rupture.

- Serial USG examination shows AAA's increase in size by 0.3 to 0.5 cm per annum. It is only a matter of time before most aneurysms rupture.
- Thrombosis developing in an AAA may act as a source of peripheral embolus and frequently popliteal aneurysms undergo complete thrombosis and the patient presents with an acutely ischemic limb.

## Clinical Features

Age — 60 to 80 years.

Sex — More common in males.

History of atheromatous disease, e.g. myocardial infarction, hypertension.

### Asymptomatic Group

The vast majority of AAA (75%) is asymptomatic when discovered. They are often detected incidentally during routine physical examination or during an USG or radiological procedure for other reasons.

- The distinctive feature of an aneurysm on physical examination is expansile epigastric pulsation, i.e. it expands outwards, when digital pressure is applied gently to each side of the mass. This finding differentiates it from transmitted pulsation.

### Symptomatic Group

- Symptoms can be due to expansion, thrombosis, emboli or rupture.
- Expansion—Rapid expansion in an AAA causes severe flank or back pain. Expansion is usually the herald of rupture.
- Back pain is a common symptom as the aneurysm presses on and in some cases erodes the spine.
- Rupture—Anterior rupture results in bleeding into the intraperitoneal cavity and is characterized by sudden abdominal pain, collapse and rapid death.
- Posterior rupture produces the retroperitoneal hematoma, when a combination of hypotension and the resistance of the retroperitoneal tissues stop the hemorrhage. The patient remain conscious but in severe pain. If no operation is performed, the mortality is 100 percent.
- More rarely an aneurysm may rupture into the IVC, producing a characteristic clinical picture-- congestive cardiac failure, CCF, a loud abdominal bruit, lower limb ischemia and gross edema.
- An aneurysm may also erode into the duodenum, although this is more often seen as a long-term complication of aneurysm repair. This is an ominous symptom associated with exsanguinating hemorrhage within 24 to 48 hours.

## Investigations

A. For detection of AAA, the investigations are:

1. Plain abdominal X-ray (aortic calcification).
2. Current diagnostic methods to confirm AAA include USG, CT and MRI scan.
  - Real time or B-mode USG, is a non-invasive investigation, which gives anatomical detail of the vessel wall and provides an accurate measurement of aneurysm size. It is the modality of choice for initial evaluation.
  - CT with or without contrast enhancement provides more information than USG regarding the relationship between renal arteries and the AAA. It is also useful to detect retroperitoneal hematoma and contained rupture.

*Disadvantage of CT* — Expense and radiation exposure.

- MRI employs radiofrequency energy and a strong magnetic field to produce images. It does not expose the patient to radiation.

3. Angiography — Not a routine investigation for AAA.

B. Investigations to determine fitness for surgery.

## Management

Surgical repair is the treatment of choice for AAA.

### Indications

- a. Symptomatic aneurysm—Surgery is indicated if the patient is otherwise fit medically.
- b. Asymptomatic aneurysm — If the aneurysm is >5 cm in diameter on ultrasound.

Preoperative counseling and evaluation.

- The relatives should be told the dangers of untreated aneurysm and the patient should be told that it will be necessary to insert prosthesis to replace it.
- In the preoperative work up, patient's cardiac, pulmonary and renal functions are assessed.
- Antibiotics are given along with premedication. A catheter is passed.

### Operation

#### Elective Repair of AAA

Extensive monitoring is required during aortic surgery as clamping and unclamping the aorta are associated with profound hemodynamic changes. These include measurement of:

- Urine output, CVP, PCWP and cardiac output (with the help of swan – ganz catheter).

A large bore IV cannula is placed and autotransfusion facility is utilized to minimize the transfusion hazards.

#### Approach

- The aorta can be approached through a transperitoneal (via a midline longitudinal incision) or a retroperitoneal approach.
- The aim of operation is to open the aneurysm along its length, remove any contained thrombus and inlay a synthetic graft (Dacron) into the aorta. occasionally, as with aortoiliac occlusive disease, a bifurcated graft has to be placed.

#### Endovascular Aneurysm Repair

It is the recently tried method of repair and involves the introduction of an intraluminal stented graft into an aortic aneurysm from a remote arterial site, e.g. via femoral arteriotomy, the graft is manipulated over a guide-wire and is deployed under fluoroscopic control.

#### Advantages

- i. Fewer complications than conventional procedures (due to absence of intraperitoneal manipulation and absence of aortic cross clamping).
- ii. Suitable for elderly patients unfit for conventional surgery.

#### Disadvantages

- i. A complex procedure that requires close cooperation between vascular surgeons and interventional radiologists.
- ii. Initial trials have demonstrated a high incidence of complications. It requires further trials for being introduced into widespread clinical practice.

#### Repair of ruptured AAA

It is a surgical emergency. The patient is taken to operation theater, where resuscitation continues while monitoring lines are being inserted.

- The operative approach is through a midline abdominal transperitoneal incision.
- Once a clamp has been placed on the aorta, the operation continues as for an elective repair.

#### Postoperative Complications

The most frequent complications following AAA repair are cardiac, pulmonary and renal.

- a. Respiratory (commonest) — Shock lung, atelectasis and lower lobe consolidation.
- b. Renal failure.
- c. Infection of the graft.
- d. Sexual dysfunction (not uncommon in aortic surgery).
- e. Aortoenteric fistula.
- f. Hemorrhage.
- g. Clotting abnormalities especially after repair of ruptured AAA (8-10 units of blood required).
- h. Spinal cord ischemia, acute ischemic limb or colonic ischemia.

#### Prognosis

- Most patients do well after repair of AAA.
- In case of ruptured AAA, perioperative mortality is 50 percent but 70 percent of

patients die before they get to hospital so that overall mortality is 85 percent. Elective repair carries a mortality of 5 percent.

## GANGRENE

### Definition

Gangrene is an old descriptive clinical term applied to any black foul smelling area that is in continuity with living tissue. More precisely it is the necrosis of tissue with super-added putrefaction.

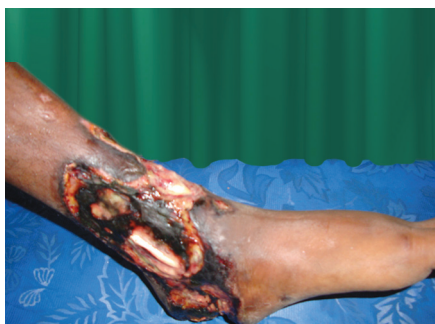The foul smell is due to putrefaction and the black color is due to slow drying and oxidation of hemoglobin and myoglobin in the tissues and formation of iron sulphide.

### Sites

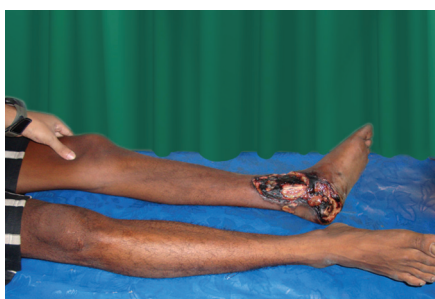The commonest external sites are toes and feet and the internal ones are appendix and strangulated intestine.

### Causes of Gangrene

1. Gangrene secondary to
  - a. Arterial occlusion: Mnemonic (RESTED)
    - Raynaud's disease.
    - Embolism (Embolic gangrene).
    - Senile gangrene due to atherosclerosis.
    - Thromboangiitis obliterans or Buerger's disease.
    - Ergot poisoning.
    - Diabetic gangrene in the elderly.
  - b. Venous occlusion—Deep vein thrombosis.
  - c. Nerve diseases, e.g. peripheral neuritis (including diabetes), hemiplegia, paraplegia, leprosy, etc.
2. Traumatic gangrene
  - i. Direct trauma (Figs 26.1 and 26.2)
    - a. Physical, e.g. crushing of tissues, pressure sores.
    - b. Chemical — Acids and alkalis.
    - c. Thermal burns and scalds.
    - d. Electrical injury.
    - e. Irradiation.
  - ii. Indirect trauma — For example crushing of the tissues or fractures when bone fragments press on the main artery, e.g. in case of supracondylar fracture of the humerus.
3. Infective gangrene
  - Carbuncle.
  - Gas gangrene.



**Fig. 26.1:** Traumatic gangrene of foot



**Fig. 26.2:** Traumatic gangrene of left foot with wasting of the left leg

- Fournier's gangrene.
- Postoperative synergistic gangrene, which usually follows the drainage of deep abscess like empyema thoracis, is usually caused by microaerophilic nonhemolytic streptococci along with *Staphylococcus aureus*.

### The Classical Criteria of Gangrene

There are five classical criteria of gangrene viz.

1. Loss of arterial pulsation
2. Loss of temperature
3. Loss of color
4. Loss of function and
5. Loss of sensation.

### Clinical Types

Clinically there are two types of gangrene.

1. Dry gangrene.
2. Moist gangrene.

#### Dry Gangrene

The characteristic features are:

- i. It is caused by slow occlusion of arteries.
- ii. The involved area is dry shriveled and mummified.
- iii. Infection is not usually present.
- iv. The conditions which produce dry gangrene are atherosclerosis, senility, Buerger's disease, frostbite, etc.

- v. Crepitus is absent and there is no odor.
- vi. Line of demarcation is usually present.
- vii. Conservative amputation is done as treatment.

#### Moist Gangrene

The characteristic features are:

- i. The principal difference between dry and moist gangrene is that in the latter there is bacterial infection as well as venous occlusion. The venous occlusion increases the exudate which cannot be dried up.
- ii. The involved area is swollen and edematous.
- iii. There is presence of infection.
- iv. The conditions which produce moist gangrene are diabetes, bed-sores, gas gangrene, strangulated hernia, etc.
- v. Crepitus may be present and there is foul smell due to hydrogen sulphide produced by putrefactive bacteria.
- vi. The line of demarcation is absent due to infection.
- vii. Treatment is major amputation.

### Separation of Gangrene

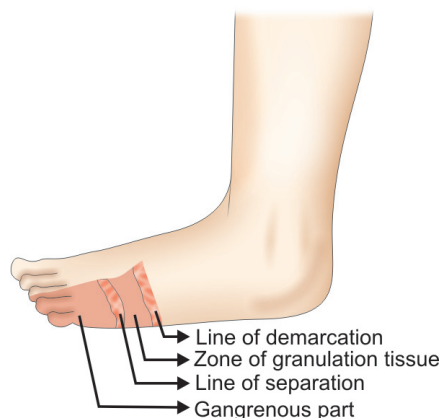
It is the natural attempt of the living tissue to get rid of the dead tissue. Thus there is development of a layer of granulation tissue between the living and dead or gangrenous part (Fig. 26.3).

#### Line of Demarcation

It is the line of division between the living tissue and the granulation tissue.

#### Line of Separation

It is the line separating the granulation tissue from the dead or gangrenous tissue.



**Fig. 26.3:** Dry gangrene of foot showing the lines of demarcation and separation

### Special Investigations

1. *Blood examination*
  - a. Estimation of blood sugar (diabetes)
  - b. Estimation of serum cholesterol (atherosclerosis).
2. *Straight X-ray*
  - a. May show gas bubbles (gas gangrene).
  - b. May show calcification of arteries (atherosclerosis).
  - c. May show the cervical rib.
3. *Doppler ultrasound*—A hand held Doppler ultrasound probe is most useful in the assessment of patients with occlusive arterial disease. It can be used even at sites where arterial pulse cannot be palpated. The ankle brachial pressure index (ABPI) is the ratio of the systolic pressure at the ankle with that at the arm. The resting ABPI is normally 1. Values below 0.9 indicate some degree of arterial obstruction and a value less than 0.3 suggests imminent gangrene.

It should be remembered that retesting after exercise is useful to detect intermittent claudication, as ABPI may be normal at rest. This Doppler probe is also useful to get at idea about the site of stenosis.

4. *Duplex scanning*—This implies two forms of ultrasound viz. B – mode which typically creates a gray scale anatomic image and Doppler ultrasound, which allows moving structures like red blood with in a vessel to be imaged. The modern duplex scanners display the moving structures as a color map proportional to the flow velocity and as an auditory signal. Duplex arterial mapping is being used as a preferred technique to angiography.
5. *Arteriography*—This is the most reliable method of determining the state of the main arterial tree. This procedure gives information about the size of the lumen of the artery, the course of the artery, constriction and dilatation present and the condition of the collateral circulation. Hypaque 45 or sodium diatrizoate is the contrast medium used in arteriography.
6. *Digital subtraction angiography (DSA)*—This technique is preferred nowadays in a specialized center. In this technique, the contrast image is subtracted from the nonrequired surrounding images in a computer system. The result is a greater clarity. DSA is carried out by



arterial or venous injection of the contrast media.

The most sophisticated is the magnetic resonance angiography without the need of the direct arterial puncture.

## Treatment

### General Treatment

This includes nutritious diet, control of diabetes and relief of pain.

#### Care of the affected part

1. The part should be kept dry and every effort is made to convert moist gangrene into dry gangrene. Exposure of the part and use of fan may help in keeping the part dry.
2. The part should be protected from local pressure, especially the malleoli, toes, heel, etc. otherwise patches of gangrene may develop in these areas.
3. The affected part is kept elevated to reduce pain.

### Surgical Treatment

1. *Lumbar sympathectomy* — Done in case of Buerger's disease or thromboangiitis obliterans. Alternatively destruction of the lumbar sympathetic chain with phenol injection (chemical sympathectomy) may increase the blood flow to the skin.
2. *Amputation*
  - As a life saving measure — In case of a body crushed limb or a rapidly spreading moist gangrene and gas gangrene, amputation is required to save the life of the patient.
  - As a limb saving measure — Amputation may be required when gangrene has developed. But a conservative approach should be adopted.
3. *Direct arterial surgery* — It has a place when gangrene has developed chronic occlusion of artery due to atherosclerosis. Revascularization may heal the gangrene or at least considerably limit the level of amputation.

Also it has a definite place in embolism or thrombosis in the form of embolectomy or thrombectomy.

However, in Buerger's or Raynaud's disease, it has no place.

## Diabetic Gangrene

This occurs as a consequence of the following three factors viz.

1. Trophic changes due to peripheral neuropathy. Sensation is impaired and patient cannot realize or neglect minor trauma which invites infection.
2. Angiopathy — This affects both large and small vessels (macro and microangiopathy) leading to ischemia and necrosis.
3. The sugar laden tissues serve as a medium for the bacteria to grow.
4. Increased susceptibility to infection — Due to the factors mentioned above, the infection has a rapid course and involves all the tissues, including bones.

### Special Investigations

1. Blood and urine sugar estimation.
2. X-ray of the local part to exclude osteomyelitis.
3. Pus for culture and sensitivity test.

### Treatment

1. Wound debridement by draining the pus and removal of dead tissue.
2. Diet and/or insulin for control of diabetes.
3. Broad spectrum antibiotics are given on the basis of culture and sensitivity.
4. Amputations may be required. The presence of palpable dorsalis pedis or posterior tibial pulse is a good predictor of healing and hence the amputations should be conservative like digital or transmetatarsal type.

In case of moist gangrene where peripheral pulsations are absent, high up amputation is necessary.

## PRESSURE SORES

Pressure sores are a common cause of morbidity in bed ridden patients and in those with paraplegia.

### Predisposing Factors

- Anemia.
- Malnutrition.
- Moisture is particularly damaging in a patient with urinary and fecal incontinence.
- Increased pressure—This is an important factor. Normally the end arterial pressure is 32 mmHg and when the patient is

supine or sitting the pressure on areas like the sacrum ischium, occiput and heel is about 60 mm Hg.

Normally an individual feels pain and shifts the position thereby relieving the pressure. This does not occur in a paraplegic or bed ridden patient and unrelieved pressure more than 2 hours results in necrosis.

Muscle is more sensitive to ischemia than skin. Hence the area of muscle necrosis is always wider and deeper than the overlying skin.

### Clinical Features

The common sites affected are sacral area, Ischial tuberosity, greater trochanters, heels, malleoli and occiput. The pressure sore initially appears as an area of erythema which does not change color on applying pressure. Progression is rapid with ulceration and deep muscle necrosis upto the bone.

### Prevention

1. The skin is to be kept clean and dry.
2. To relieve pressure by change of posture every 2 hours.
3. Air flotation beds or ripple beds can be used to avoid pressure on bony prominences.

### Treatment

- Necrotic tissue is removed.
- Silver sulphadiazine cream is applied locally.
- Parenteral antibiotics are given for bacteremia.
- Surgical treatment—If the ulcers are more than 2 cm diameter, the defect may be covered after excision of necrotic tissues by split skin graft, rotational flap and now popularly the myocutaneous flap.

## RAYNAUD'S SYNDROME

This is a condition characterized by episodic attacks of small arteries and arterioles of the distal part of the extremities in response to cold exposure or emotional stimuli. They are two types.

- Raynaud's phenomenon — This a benign idiopathic form of intermittent digital ischemia occurring in association with systemic diseases, most commonly scleroderma and collagen vascular diseases.



- Raynaud's disease – this is a similar condition occurring in the absence of any disease process.

The affected digits may go through a classic sequence of color changes including.

- a. Pallor due to severe vasospasm in the dermal vessels.
- b. Cyanosis — As the hand is warmed and the capillaries are slowly filled up with blood. This blood is quickly deoxygenated and so the part becomes cyanosed.
- c. Rubor or redness—As the arteriolar spasm completely passes off, blood enters more quickly and the part becomes red and swollen.

### Clinical Features

Typically the patient is a female in her adolescence and in 50 percent of cases there is a family history.

The patient suffers from the classic attack of vasospasm in the upper limbs on exposure to cold.

Relief is brought on by warmth. The affection may be bilateral and in 10 percent cases, the lower limbs are primarily involved.

### Treatment

- To avoid cold exposure, hands should be protected by gloves or hand warmers in extremely cold weather.
- Stopping of smoking.  
The above two measures will suffice for most of the patients and about 10 percent of patients with Raynaud's syndrome require further treatment.  
Various drugs have been used but presently the drug of choice is the calcium channel blockers like nifedipine 10mg three times a day.
- Cervical sympathectomy is not considered to be of much benefit. The indications are:
  - Symptoms not relieved by medical therapy.
  - Lower limb Raynaud's phenomenon.
- Cervical sympathectomy can now be done by using endoscopic methods.

### THORACIC OUTLET SYNDROME (TOS)

The thoracic outlet syndrome is the term used to cover a spectrum of neurological, arterial and venous disorders resulting from

compression of the neurovascular bundle as it leaves the chest to enter the upper limb via the scalene triangle. This triangle is bounded by scalenus anticus anteriorly, scalenus medus posteriorly and the first rib inferiorly.

### Causes of TOS (Thoracic Outlet Syndrome)

1. Cervical rib—It is the anterior tubercle of the transverse process of the 7th cervical vertebra which attains excessive development and results in cervical rib. It occurs in 1 percent of the population and produces symptoms in only 10 percent of cases.
2. A wide scalenus anticus muscle may narrow the space in the interscalene triangle and cause symptoms.
3. Congenital abnormality of the first rib — A wider first rib may give rise to symptoms.
4. Fracture of the clavicle or the first rib may produce bony callus which may lead to small subclavian aneurysm, peripheral emboli and ischemia of hand.

### Clinical Features

The symptoms of thoracic outlet syndrome vary depending on whether nerves or blood vessels or both are compressed. Majority of patients are middle-aged females, although younger group may be involved.

- i. The neurological symptoms include pain and paresthesia in the neck, shoulder, arm and hand.
- ii. The symptoms of arterial compression are pallor or intermittent cyanosis of the hand and fingers. Embolic episodes give rise to pain, pallor, cyanosis or even gangrene of the fingers. Of course these symptoms are seen less frequently in about 1/4th of the cases.
- iii. Venous compression will produce cyanosis of the skin of the hand and arm. Impaired venous and lymphatic return gives rise to edema.

### Differential Diagnosis

- a. Cervical spondylosis.
- b. Cervical cord compression.
- c. Cervical disk protrusion.
- d. Raynaud's syndrome.
- e. Carpal tunnel syndrome or vessels in the neck.
- f. Pancoast's tumor pressing over the nerves.

### Special Investigation

- i. X-ray of the neck and cervical spine.
- ii. Doppler ultrasound.
- iii. Subclavian angiogram.

### Treatment

#### A. Conservative

In mild cases, treatment is conservative.

- i. Exercise program to strengthen the muscles of the shoulder girdle, particularly the elevators,
- ii. To avoid weight lifting.
- iii. Drugs like analgesics, muscle relaxants and antidepressants for relief of neurological symptoms.

#### B. Surgery

Patients with refractory symptoms require surgery. Operative treatment includes:

- i. Excision of the cervical rib.
- ii. Division of the scalenus anticus muscle and
- iii. Often resection of the first rib to increase the thoracoaxillary channel and to reduce the neurovascular compression.

### BUERGER'S DISEASE

This disease was first described by Leo Buerger in 1908 and is characterized by the following.

- Low grade inflammation of the small and medium size arteries, mostly of the lower limb.
- Thrombophlebitis of the superficial or the deep veins.
- Raynaud's phenomenon.
- Almost all patients are young males below 30 years of age and smokers.

### Pathology

The mechanism by which smoking causes Burger's disease is not known but is postulated to be possibly due to direct endothelial injury by a tobacco product, vasoconstriction, increased sensitivity to tobacco products and a hypercoagulable state leading to thrombosis. There is dense infiltrate of polymorphonuclear leukocytes in the thrombus.

Perivasculitis is present but the elastic lamina is intact and there is no necrosis of the vessel wall. Fibrosis may occur in chronic lesions and will lead to fibrous encasement which may also involve the accompanying vein and the adjacent nerves.

### Clinical Features

- The patient is usually a younger man who smokes or chews tobacco and complains of intermittent claudication in the foot.
- There may be a history of recurrent migratory superficial thrombophlebitis.
- Progression of the disease is related to the smoking habit and may culminate in rest pain, ulceration and gangrene. Remission of the disease is linked to abstinence from smoking. The gangrene is usually of dry type and slowly progressing. A minor trauma may precipitate gangrene.

On examination, the most frequent finding is absence of posterior tibial and dorsalis pedis pulses in the feet. Absence of the posterior tibial pulse especially when bilateral is highly suggestive of the disease.

### Special Investigations

Arteriography is the most important investigating procedure. It shows segmental obliteration of the middle and small size arteries. Digital arteries are characteristically involved. The collaterals which develop due to the occlusion give a characteristic corkscrew appearance.

### Treatment

#### A. Conservative

Conservative treatment has a great role to play in this disease.

- Stoppage of smoking is very important.
- Various drugs have been tried with questionable value. This includes vasodilator drugs, anticoagulants, dextran and steroids.

#### B. Surgical treatment

- Direct arterial surgery is not usually possible due to the distal nature of the disease. It can sometimes be done for proximal segmental occlusions.
- Amputations should be as conservative as possible.
- Lumbar sympathectomy has a limited role to play and is only indicated for:
  - Nonhealing arterial ulcer and
  - For rest pain.

Lumbar sympathectomy does not have any role in the treatment for intermittent claudication.

The operation of lumbar sympathetically is described in the operative surgery section.

- Prostaglandin E<sub>2</sub> infusion may help the patient during an exacerbation.

# Chapter 27

## Varicose Vein, DVT, Pulmonary Embolism

➤ Varicose vein

➤ Deep vein thrombosis

➤ Pulmonary embolism

### VARICOSE VEIN

#### Definition

Varicose veins may be described as elongated, dilated, tortuous and sacculated veins. Varicosity is common with the superficial veins of the lower limbs. It is also seen in the lower end of rectum (piles), esophagus (varix) and spermatic veins (varicocele). The discussion here is confined to the varicose veins of the lower limb.

#### Surgical Anatomy

The venous system of the lower limb consists of three types of veins viz.

a. *Superficial system of veins* comprising the long and short saphenous veins and their tributaries.

The long saphenous vein (Fig. 27.1A) drains the medial part of the venous plexus on the dorsum of the foot and passes upwards immediately in front of the medial malleolus. Here the branches

of the saphenous nerve lie in front of and behind the vein. The vein then ascends over the posterior parts of the medial condyles of the tibia and femur to the groin where it pierces the deep fascia at the saphenous opening situated one and a half inches (3.8 cm) below and lateral to the pubic tubercle, to enter the femoral vein.

At the groin the following tributaries draining the lower abdominal wall, thigh and the scrotum usually join the long saphenous vein:

- i. The superficial epigastric vein,
- ii. The superficial circumflex iliac vein and
- iii. The superficial external pudendal vein.

The short saphenous vein (Fig. 27.1B) commences at the ankle behind the lateral malleolus where it drains the lateral part of the dorsal venous plexus of the foot. It then passes over the back of the calf, perforates the deep fascia over the popliteal fossa and terminates in the popliteal vein. The sural nerve accompanies this vein in most cases.

b. *Deep veins*—These are muscular veins consisting of anterior tibial, posterior tibial and popliteal vein, femoral and peroneal veins.

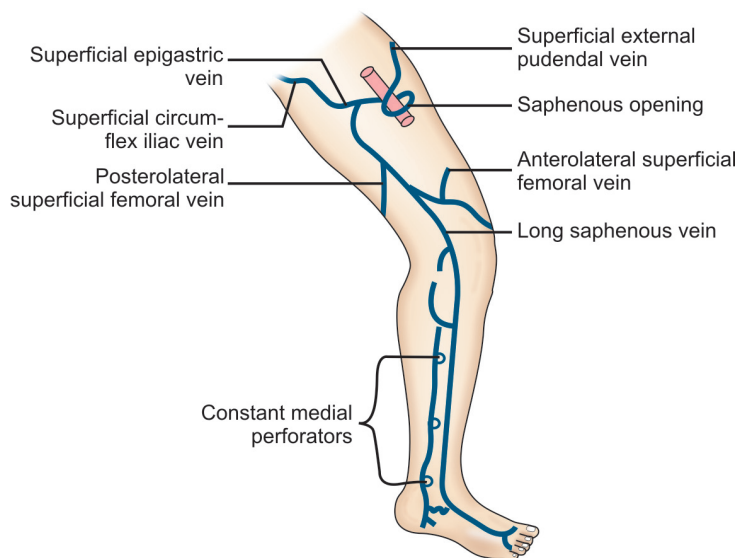
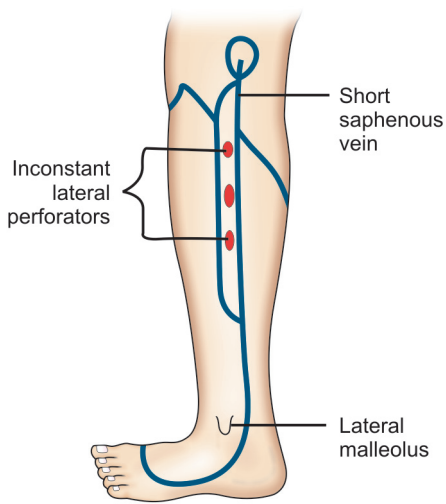
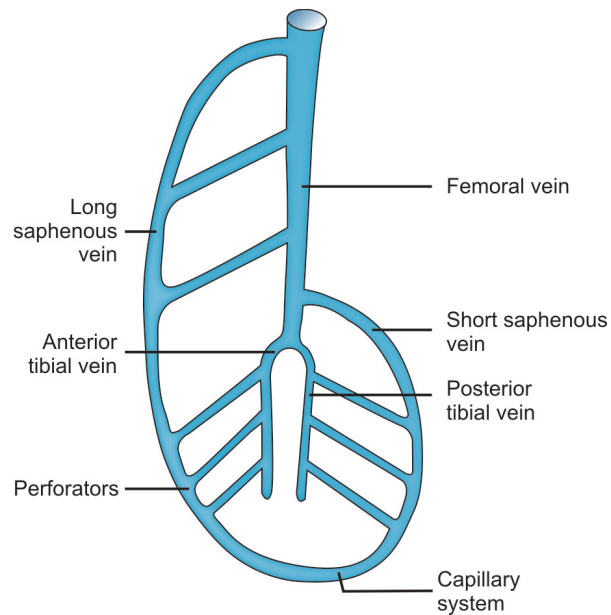


Fig. 27.1A: Long saphenous vein and its tributaries



**Fig. 27.1B:** Short saphenous vein and its tributaries



**Fig. 27.1C:** Plan of venous system of leg

c. *Perforating veins*—These are veins connecting the superficial system of veins to the deep veins (Fig. 27.1C).

There are five constant perforators in the lower limb on the medial side through which the long saphenous vein communicates with the deep venous system viz.

- Medial perforating veins 5 cm, 10 cm and 15 cm, above the medial malleolus. These are three constant medial perforators, also known as Cocklet and Dodd's perforators.
- Knee perforator—It is situated just below the knee (Boyd's perforator).
- Thigh perforator—It is situated a palm's breadth above the knee, also known as adductor canal or Hunterian perforator at midthigh.

### Venous Pump of the Lower Limb

The return of blood to the heart from the lower limb is ensured by several local mechanisms in addition to the general ones such as (a) negative pressure in the thorax and (b) the vis-a-tergo produced by arterial pressure.

These local factors are:

- Muscular
  - Facial and
  - Valvular
- In the lower limbs the muscles surround the deep veins and act as strong pumps for the blood in these veins. Of these the calf muscles (calf pump) is the most effective.

- The calf muscles are surrounded by dense unyielding deep fascia so that the muscular contractions can be effective on the veins.

- Moreover, the valves located in the deep veins force the blood to flow only in an upward direction. Also, the valves present in the perforating veins allow the flow of blood only from the superficial to the deep veins. This again is highly essential. The pressure in the deep veins is higher than that in the superficial veins and becomes much higher during muscular contractions. In the absence of the valves blood would flow from the deep to the superficial veins, which would be hazardous.

See also the long case on varicose vein in chapter 76.

### Etiology

Etiology is not definitely known, but can be considered under two headings viz. primary and secondary.

#### Primary or Idiopathic

This is due to congenital incompetency of the valves with or without weakness of the muscular coat of the veins.

*Exciting causes:*

- Prolonged standing.
- Violent muscular efforts.

- Obesity as fatty tissue offers poor support to veins.

- Aging due to atrophy and weakness of the vein wall.

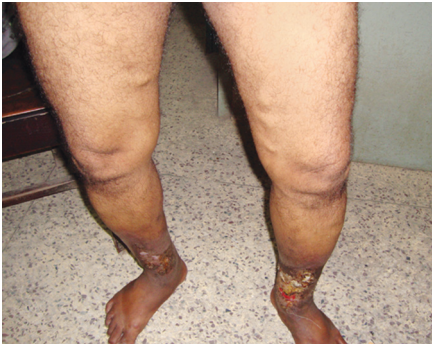### Secondary

- Following a venous thrombosis with resultant valvular damage.
- Pregnancy – Due to pressure over the vena cava by gravid uterus and dilatation of veins by hormonal effects (progesterone and relaxin) making the valvular mechanism incompetent.
- Any abdominal or pelvic tumors.
- Chronic constipation with loaded colon.
- A–V malformations, e.g. congenital A–V fistula, extensive cavernous hemangioma, etc.

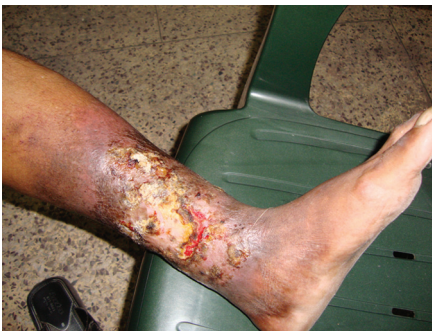### Pathology

At rest there is little difference between the pressures in the superficial and deep venous systems. However, on exercise in the normal limb, the muscle pump propels blood centrally, so that pressure falls in the deep venous system and blood is sucked in from the superficial venous system leading to fall in pressure in that system.

By contrast if the valves at the saphenofemoral and/or saphenopopliteal junctions are incompetent, the muscle pump forces blood into the superficial system, preventing the



**Fig. 27.2A:** Bilateral varicose vein with ulcer formation in both legs



**Fig. 27.2B:** Varicose ulcer of left leg of the same patient

normal fall in pressure. Thus the superficial veins become engorged and varices appear.

## Clinical Features

### Symptoms

1. Disfigurement—The patient is bothered by the appearance of the varices.
2. Pain—characteristically varicose veins give rise to aching in the calves on standing, which is worse at the end of the day and absent in the early morning.  
The pain is relieved by lying down, leg elevation and elastic support stockings.
3. Itching.
4. Swelling.
5. Pigmentation—due to deposition of hemosiderin from lysed red cells.
6. Eczema which may occur over the areas of pigmentation. The hemosiderin causes itching that results in scratching and abrasions giving rise to the eczematous condition.
7. Varicose ulcers—It is usually found at or near the medial malleolus as there is very little soft tissue over the bone here and so little blood supply (Figs 27.2A and B).

## Tests

The aim of these tests is to localize the valve or valves whose incompetence has led to the varicosity. See the long case on varicose vein for figures.

### Brodie–Trendelenburg's Test

- a. With the patient lying, the limb is elevated to drain out the veins. A finger is placed on the saphenous opening so as to occlude the saphenofemoral junction. The patient is then made to stand up quickly and the venous filling is observed with the finger in place.
- b. If the veins fill up from below, then it indicates incompetence of the perforators.
- c. Now the occluding finger is removed and if there is a rapid filling of the vein from above it is indicative of incompetence of the valve at the saphenofemoral junction. In both the above situations the Trendelenburg's test is said to be positive.

### Multiple Tourniquet Test (Oschner's Mahoner's test)

This test is but a variation of the Trendelenburg's test. The patient is placed in the recumbent position and the veins are emptied as above. After this multiple tourniquets are applied at various levels on the limb as described below:

- a. There are mainly ankle, knee and thigh perforators. Hence four tourniquets are applied as below:  
First tourniquet below the level of saphenofemoral junction.  
Second tourniquet below the level of the perforator at Hunter's canal.  
Third tourniquet just below the below knee perforator.  
Fourth tourniquet is applied a palm's breadth above the medial malleolus and just below the 5cm ankle perforator. Additional tourniquets may be applied below the 15 cm and 10 cm ankle perforators.
- b. The patient is then asked to stand keeping the tourniquets tied and appearance of veins observed. If any of the perforator is incompetent, that segment lying between the two tourniquets will become varicose. Hence by this test one can identify the level of incompetence in the various perforators.

### Fegan's Test

- a. This test is done to localize the perforators in the deep fascia.
- b. The varicose veins are marked by a skin marking pencil with the patient in the standing position. The veins are then emptied by elevating the leg in the supine position and the sites of known perforators are palpated along the marked varicose vein with a finger.
- c. The sites where perforators are incompetent and dilated, circular openings with sharp edges are felt in the deep fascia.

### Schwartz's Test

In an advanced case of varicosity, a thrill can be felt by one hand placed over the fossa ovalis when a tap is made on the long saphenous varicose vein in the lower part of the leg by the other hand.

### Perthe's Test

- a. This test is very useful in determining whether the deep veins are patent or not. A tourniquet is applied round the upper thigh, sufficiently tight to occlude the long saphenous vein. With the tourniquet in position, the patient is asked to walk for 5 minutes.
- b. If the deep venous system is competent then the varicose veins will shrink or disappear, however in a blocked system, the varicose veins increase in size and the patient may experience bursting pain in the limb.
- c. If the test shows a blocked deep venous system, it is a contraindication to surgery on the superficial veins which are then the only pathway for venous return from the limbs.

### Pratt's Test

- a. This test is done to map out the level of incompetent perforators.
- b. Esmarch bandage is applied from toes to the groin in supine position.
- c. A tourniquet is applied just above the bandage. This causes emptying of varicose veins.
- d. The patient is asked to stand and the bandage is gradually removed.
- e. Site of 'blow out' is noted and marked, which indicates the site of a perforator.



Apart from these tests, the peripheral arterial pulses should be palpated to exclude any accompanying arterial disease. An abdominal and per rectal examination is done to exclude any underlying disease.

### Complications

1. Due to venous hypertension:
  - Edema.
  - Skin pigmentation.
  - Eczema.
  - Venous ulceration.
  - Lipodermatosclerosis.
2. Due to varicose veins
  - Hemorrhage.
  - Thrombophlebitis.

It is to be remembered that size of the varicose veins is not probably related to the degree of venous hypertension and ulcer formation.

About 40 percent of the limbs with ulceration due to superficial venous incompetence do not have visible varicose veins.

### Investigations

1. *Doppler ultrasound*—This test determines patency of veins and valvular incompetence.
2. *Duplex scanning*—This is one of the best tests for testing the flow patterns and imaging the venous system. It can provide accurate localization of the site of the perforating veins.
3. *Ascending phlebography*—May be required when the varicose veins are secondary to deep vein thrombosis.

### Treatment

There are three modes of treatment.

1. Conservative treatment.
2. Injection sclerotherapy and
3. Surgery.

#### Conservative Treatment

##### Indications

1. Elderly patient.
2. Pregnancy.
3. Patients unfit for operation.
4. Patients with mild disease.
 

The treatment consists of the following

  - i. To avoid prolonged standing and constricting garments.
  - ii. A crepe bandage or elastic stockings are applied from the toes to the thigh. It should be worn all throughout the day and is only taken off before going to bed.

- iii. Leg exercise like frequent elevation of the legs above the heart to strengthen the calf muscles.
- iv. Elevation of the limb while sitting or sleeping as far as practicable.

#### Injection Sclerotherapy (Fegan's Technique)

By injecting sclerosant into the vein, complete sclerosis of the venous walls can be achieved.

Sclerosants used are 3 percent sodium tetradecyl sulfate (STDS) or Ethanolamine oleate (5%). These agents cause aseptic inflammation and perivenous fibrosis leading to sclerosis of the venous walls.

##### Indications

- i. Small varices below the knee.
- ii. Recurrent varices after surgery.
- iii. Uncomplicated perforator incompetence.
  - The varicosities are marked in the standing position and injection is done in lying position, with the leg elevated to make the veins empty
  - Injection must always be intravascular otherwise skin ulceration may occur.
  - Each varicosity is injected with 0.5 to 1ml not exceeding a total of 10ml per session otherwise hemolysis will occur.
  - All injection sites are covered with cotton wool balls and maintained in position by a crepe bandage and a full length elastic stocking for 6 weeks.
  - The recurrence rate is higher than that with surgery.

#### Surgery

##### Indication

When there is saphenofemoral or saphenopopliteal incompetence, surgery is the only effective treatment.

There are two types of operations: (See operations on varicose vein in the operative surgery section in chapter 98)

1. Ligation.
2. Ligation with stripping.

##### Ligation

- a. Saphenofemoral incompetence an inguinal incision is made, long saphenous vein identified and all the three tributaries are ligated. Long saphenous vein is ligated close to the femoral vein. This is called juxtafemoral flush ligation. Now, the long saphenous vein is ligated distal to flush ligation and it is divided between ligatures.

- b. In case of saphenopopliteal incompetence, a ligature is applied at the short saphenous vein flush with the popliteal vein and another ligature distal to it. The short saphenous vein is divided between the ligatures.

##### Ligation with Stripping

This is particularly useful for those cases where incompetence of the long saphenous vein is associated with that of perforators as well. Short saphenous vein stripping is not practiced as incompetent perforators are rarely found with it and there is chance of long-standing edema and damage to the sural nerve.

Stripping of the long saphenous vein using Myer's vein stripper can be done from just below the knee to the groin.

Stripping is not done further below the knee as it gives no additional benefit, but the problems of postoperative discomfort and damage to the saphenous nerve.

Hemostasis is easily achieved by firm bandaging of the limb.

## DEEP VEIN THROMBOSIS

### Syn- Phlebothrombosis

It is an acute thrombosis of the deep veins. Deep vein thrombosis (DVT) is very common in the western countries, the exact cause of which is not known.

The main predisposing factors are:

- i. Stasis or alteration in blood flow, e.g. Bed rest, immobilization, prolonged operations, like major abdominal surgery, neurosurgery, total hip replacement obesity, heart failure, etc.
- ii. Endothelial injury viz. trauma, inflammation, infection and surgery.
- iii. Hypercoagulability viz. polycythemia, thrombocytopenia, sepsis, major trauma, smoking, malignancy.
 

Predisposing factors (i), (ii) and (iii) above constitute the Virchow's triad.
- iv. Varicose veins.

The thrombus may commence in the venous tributary of a main vein. The calf vein is the most frequent site of thrombosis. From here thrombus extends into the main deep vein, where a portion may break off to cause pulmonary embolus, other veins are also involved less frequently. Pulmonary embolism occurs in 5 to 20 percent cases of calf deep vein thrombosis.

## Pathology

- There is aggregation of platelets in valve pockets, the area of maximum stasis or injury. This will lead to activation of clotting cascade producing fibrin.
- Fibrin production overwhelms the natural anticoagulant or fibrinolytic system.
- Natural history: A deep vein thrombosis may have the following fates.
  - a. Complete resolution.
  - b. Pulmonary embolism.
  - c. Postphlebotic limb (PL) – This is a syndrome of bursting pain in the limb on exercise and occurs only in 5 percent cases of asymptomatic DVT within 5 years.

## Clinical Features

- Asymptomatic in most cases.
- Pain
- Swelling or edema of leg.
- Cord-like veins.

The above symptoms are detectable only in 20-25 percent patients.

## Signs

Homan's test

- Forcible dorsiflexion of foot results in severe pain in the calf region.
- Tenderness over the calf muscle, popliteal space or thigh, particularly the adductor canal.

## Investigations

1. Doppler ultrasonography—It is the gold standard for diagnosis. It has a sensitivity of 95 percent for proximal DVT but 75 percent for calf DVT.
2. Duplex ultrasound examination—Both anatomical and functional informations can be obtained by this single test. Filling defects in flow and lack of compressibility indicate the presence of a thrombosis.
3. Ascending venography—It is not routinely done nowadays as it is an invasive as well as expensive test.
4. D-dimer, a fibrin degradation product is increasingly being used as a screening adjunct. Patients who present in the emergency departments with an idiopathic thrombosis usually undergo a D-dimer measurement. If the D-dimer level is increased, a duplex ultrasound examination of the deep veins is performed.

Differential diagnosis: The differential diagnosis of a deep vein thrombosis includes the following:

- A calf muscle hematoma
- A ruptured Baker's cyst
- A thrombosed popliteal aneurysm
- Arterial ischemia.

## Treatment

### Prophylaxis against DVT

- To avoid smoking, control of diabetes and weight reduction in case of obesity.
- Injection Heparin 5000 units S.C. 2 hours before surgery and 24 hours after surgery and then every 12 hours for 5 days.
- Mechanical compression stockings.
- Early mobilization, walking and adequate hydration following surgery.

### Definitive Treatment

1. Bed rest and elevation of leg.
2. Simple analgesics and sedation.
3. Anticoagulation:

#### a. Unfractionated Heparin (UFH):

Heparin exerts its anticoagulant effect by inhibiting thrombin (Factor II) after combining with antithrombin III, which acts as heparin cofactor. Its effectivity can be determined by measuring the clotting time and activated partial thromboplastin time (APTT).

*Dose:* Injection Heparin – 10000 units IV bolus with continuous infusion of 30,000 to 45,000 units/day. During Heparin therapy activated partial thromboplastin time should be double the normal value to prevent the propagation of thrombi. Heparin is given for 7 to 10 days.

#### b. Low molecular weight heparin (LMWH) viz. – Enoxaparin 1mg/kg. subcutaneously twice daily. LMWH is as effective as or even better than unfractionated heparin.

#### c. Oral anticoagulation:

Warfarin, as oral anticoagulant is started 2-3 days before heparin is withdrawn because of the slow onset time of warfarin.

Anticoagulation with warfarin is continued for 3-6 months or even longer for 2 years or indefinitely in some patients with coagulation abnormalities such as antithrombin deficiency or recurrent

venous thrombosis. The dosage of warfarin is maintained by weekly or twice weekly international normalized ratio (INR) estimations.

## PULMONARY EMBOLISM

Thrombi originating mostly in the deep veins of the lower limbs and pelvis get detached, pass through the right atrium and ventricle and lodge in the pulmonary arteries. This is known as pulmonary embolism. It remains undiagnosed in 80 percent cases. There is gross ventilation – perfusion inequality.

### Clinical Features

The patient will complain of dyspnea, chest pain and hemoptysis.

On examination the most consistent finding is tachycardia and tachypnea. Shock and cyanosis are ominous signs and only seen in massive embolus.

### Special Investigations

- X-ray chest—Shows diminished pulmonary vascular markings in 50 percent cases when done within 24-48 hours of attack.
- ECG—The most common abnormality is ST segment depression and T – wave inversion.
- CT scan and MRI—Can detect pulmonary embolism.
- Radioisotope ventilation–Perfusion (V/Q) scan of lung—This is very important and evidence of V/Q mismatch is highly suggestive of pulmonary embolism.

### Differential Diagnosis

Pulmonary embolism is a great masquerader and can mimic acute myocardial infarction, pneumonia and musculoskeletal disorders.

### Treatment

- Anticoagulation with LMWH viz. enoxaparin for 3 to 6 months.
- Thrombolysis with streptokinase 6 lakh units to begin with and later one lakh unit hourly. Heparin should not be combined with thrombolytics.
- Pulmonary embolectomy – done in case of failure of thrombolytic treatment for a massive pulmonary embolus.
- Ventilation support.

# Lymphatics and Lymph Nodes

➤ Diseases of the lymphatics

➤ Disease of lymph nodes

The lymphatic system is composed of:

1. The lymphatic channels which commence blindly in the tissue spaces from which they collect up the interstitial fluid and return it to the circulation after being filtered through lymph nodes.
2. Lymph nodes and
3. Epitheliolymphoid tissues which are collections of lymphoid tissues in the walls of the alimentary canal, the spleen and thymus.

## **DISEASES OF THE LYMPHATICS**

### **Lymphedema**

Obstruction to the flow of lymph through the lymph channels produces a chronic edema. Causes may be grouped as follows.

#### *Types of Lymphedema*

##### **Primary Lymphedema**

It is due to deficient lymphatic channels due to congenital causes such as absent or hypoplastic lymphatics or deficient lymphatic valves.

This can be divided into three clinical subgroups according to the age of onset of the swelling.

- i. Lymphedema congenita—Starts at birth.
- ii. Lymphedema precox—Starts at puberty and constitutes 75 percent of patients with primary lymphedema.

- iii. Lymphedema tarda—Starts in adult life, usually after the age of 35 yrs.

##### **Secondary Lymphedema**

This is due to obstruction of the flow of lymph – either in the vessels or in the glands by an external cause such as:

- a. Fibrosis, e.g. following infection or radiotherapy.
- b. Infestation, e.g. filariasis.
- c. Infiltration by secondary malignant neoplasm, e.g. malignant melanoma.
- d. Trauma, e.g. following block dissection of axilla in radical mastectomy.

Secondary lymphedema can occur at any age when the relevant cause is present.

#### *Clinical Features*

The patient notices swelling of one or both limbs. Primary lymphedema always presents in the legs. The swelling is worse at the end of the day. Occasionally the condition presents with a secondary cellulitis, in which case, the leg is actually painful.

*Examination:* The edema is brawny and typically nonpitting. It is necessary to exclude other causes of edema such as hypoproteinaemia, renal failure or venous insufficiency.

#### *Investigations*

- a. Laboratory tests are done to rule out renal and hepatic causes. Serum creatinine and liver function tests should be obtained in all cases.

- b. Lymphoscintigraphy or lymphangioscintigraphy—Normally radioactivity is noticed in the groin after injection of radioactive labelled antimony sulfate in the web space of second and third toes within 1 hour. Delay in appearance of radioactivity may show a failure of progression, indicating proximal obstruction.
- c. Ultrasound—Useful in detecting a cause of compression due to tumor in unilateral or bilateral lymphedema.
- d. CT scan or MRI—Can show the enlarged lymph nodes and guided biopsies of the node can be taken if malignancy is suspected.

#### *Treatment*

Initially medical management is instituted. This consists of (1) Bed rest (2) Elevation of the limb at night by raising the foot end of bed on blocks of at least 1 foot high, and the following:

##### **Elastic Support**

This may be given by old fashioned 'crepe bandage' or custom made pressure gradient elastic stockings, while on their feet. During night they may be removed and legs kept elevated as mentioned above.

Control of lymphedema requires higher pressures, e.g. 30 to 40 mm Hg for arm and 40 to 60mm Hg for leg.

### Exercise

Exercise has got some effect in reducing lymphedema. Slow, rhythmic, isotonic movements like swimming will increase venous and lymphatic return through the production of movement between skin and underlying tissues and augmentation of the muscle pumps. Exercise also helps to maintain joint mobility. Patients who are unable to move their limbs benefit from passive exercises.

### Drugs

A benzopyrone compound, coumarin (Lympeidin) is found to be very effective in increasing the number and activity of tissue macrophages, disintegrating the macromolecules and reducing the viscosity of interstitial fluid, for better absorption. It has no anticoagulant property like dicumarol.

Diuretics are of no value in pure lymphedema. Their chronic use is associated with side-effects including electrolyte disturbance and should be avoided.

If eczema is present this is treated by triamnisolone solution 0.05 to 0.1 percent.

### Surgery

Main indications are:

1. Functional impairment of the limb for its weight and bulk.
2. Recurrent cellulitis.
3. Physical and cosmetic reasons.

Two operations in common use are:

1. Homan's procedure and
2. Charle's operation.

#### Homan's Procedure

This is also called reduction plasty of Homan and involves raising skin flaps to allow the excision of a wedge of skin and a large volume of subcutaneous tissue down to the deep fascia.

Surgery to medial and lateral aspects of leg must be performed at least 6 months apart to avoid skin flap necrosis.

#### Charle's Operation

Involves total excision of skin and subcutaneous tissue followed by skin grafting (split thickness). Adequate elastic compression is applied over the foot and leg to prevent undue bleeding which is maintained for 72 – 96 hours, when the wound is inspected. External

compression also helps neovascularization of the grafted skin.

### Lymphangitis

Acute lymphangitis is the inflammation of the lymphatic vessels. It is commonly seen in the limbs and often a focus of infection is present.

Ascending infection passes along the lymphatic vessels towards the lymph nodes, which may be enlarged. It presents as red-streaks in fair complexioned individuals along the course of the lymphatics.

#### Treatment

- Strict bed rest with elevation of the affected limb.
- The infection is usually caused by staphylococci or streptococci which are responsive to cloxacillin.
- Rapid resolution of symptoms and signs occurs with treatment. If pus is formed, it is to be drained.

### Neoplasms of Lymphatics

#### Lymphangioma

Lymphangiomas are analogous to hemangiomas of blood vessels.

Types:

Three types are usually seen:

- a. Simple (capillary) lymphangioma
- b. Cavernous lymphangioma and
- c. Cystic hygroma.

#### Simple (Capillary) Lymphangioma

These lesions are also known as lymphangioma circumscriptum. They tend to occur as circumscribed masses subcutaneously in the head and neck region as well as in the axilla.

Histologically they are composed of a network of endothelium lined lymph spaces.

#### Cavernous Lymphangioma

Comparable to cavernous hemangioma, may occur on the lip or tongue, which becomes bulky and known as macrochilia and macroglossia respectively.

#### Cystic Hygroma

This is the most common form of lymphangioma comprising large cyst-like cavities containing clear warty fluid (See also the short case 'cystic hygroma').

### Lymphangiosarcoma

This is a rare malignant tumor of the lymphatics, seen in long-standing cases of primary or secondary lymphedema of the extremities, e.g. postmastectomy lymphedema of the upper limb or lymphedema of the lower limb.

The tumor appears as a nodules in the skin around which satellite nodules may appear. The nodules ulcerate and hematogenous spread occurs.

The cell of origin is the endothelial cell of dilated lymphatics of the dermis and subcutaneous tissue. Amputation is recommended because of the aggressive nature of the tumor.

## DISEASES OF THE LYMPH NODES

### Lymphadenopathy

Lymphadenopathy indicates significant disease more often in adults than in children, because children are more likely to react to minor stimuli with lymphoid hyperplasia. Lymphadenopathy in young adults results in most cases (80%) from benign causes whereas in persons more than 50 years benign causes are responsible in only 40 percent cases.

The various causes of lymphadenopathy are as follows:

#### Inflammatory

1. **Acute:** Acute pyogenic lymphadenitis, Toxoplasmosis, Infections mononucleosis (Cytomegalovirus, EB virus), AIDS, etc.
2. **Chronic:**
  - i. Nonspecific chronic pyogenic lymphadenitis
  - ii. Specific – Tuberculosis
    - Syphilis
    - Brucellosis.

#### Neoplastic

1. **Primary:**
  - Hodgkin and non hodgkin's lymphoma.
  - Malignant histiocytosis
  - Chronic lymphatic leukemia.
2. **Metastatic:** It can occur from many types of carcinomas, e.g. carcinoma of lung, breast, prostate, thyroid, kidney, stomach, colon, etc.

### Immune Disorders

- Systemic lupus erythematosus
- Still's disease.

### Tuberculous Lymphadenitis

Lymph node tuberculosis is the commonest form of extrapulmonary tuberculosis. It commonly affects children and young adults but no age is exempted. The sites of affection in order of frequency are the cervical lymph node, axillary and then inguinal lymph nodes. The nodes are initially discrete but soon get matted because of periadenitis.

### Pathology

The disease runs through the following stages: (Fig. 28.1)

*Stage I:* The glands are enlarged, discrete, firm and slightly tender.

*Stage II:* The nodes are fixed to one another and the surrounding tissue. There is periadenitis and caseation.

*Stage III:* If the disease is not arrested by fibrosis and calcification in stage II, the caseation extends and forms a cold abscess.

*Stage IV:* The cold abscess bursts out of the lymph node mass, and pierces the deep fascia and manifests in the subcutaneous tissue as a collar-stud abscess.

*Stage V:* The abscess bursts through the skin and manifests as a persistently discharging sinus.

### Clinical Features

There may or may not be history suggestive of tuberculosis in these patients. The disease is common among the children and young adults, especially of the poorer community.

Some patients may have systemic symptoms such as low-grade fever, night sweats or weight loss, but these symptoms are not diagnostic and can be seen in patients with lymphoma also.

### Clinical Examination

Local examination reveals enlarged matted glands with cold abscess and /or sinus formation.

### Differential Diagnosis

All causes of lymphadenopathy but one should specially exclude lymphomas and malignancy.

Investigations:

- Fine needle aspiration cytology (FNAC)—It is the investigation of choice for diagnosis of cervical lymphadenopathy in general and tuberculosis in particular. Cytologically epithelioid cells and granulomas are seen in majority of cases. However, granulomas are often absent in patients with HIV.
- Lymph node biopsy—It may be required for diagnosis if FNAC fails to suggest the cause.
- HIV status—Serological investigations for HIV may be carried out if a possibility of HIV/AIDS is suspected.
- Mantoux test is positive, in case of tuberculosis
- ESR—raised, in tuberculosis.

### Treatment

- Treatment of tuberculous lymphadenitis is primarily by antimycobacterial drug therapy. The primary treatment is started with

a four drug combination viz HRZE comprising of INH, Rifampicin, Pyrazinamide and Ethambutol for 2 months followed by 2 drugs viz. INH and Rifampicin treatment for 4 months. Modification of the therapy is required for reasons such as intolerance to a drug, resistance to first line drugs, etc.

- Cold abscesses are aspirated from a non-dependent part with instillation of INH several times till the abscess resolute.

### Lymphomas—Malignant Tumors of the Lymphoid Tissues

#### Hodgkin's Lymphoma

Hodgkin's disease was first described by Thomas Hodgkin in 1832 and constitutes one of the common malignancies in young adults.

#### Pathology

The lymph nodes in lymphoma is usually firm, sometimes described as rubbery and discrete. Matting can sometimes occur in lymphomas also.

The presence of large, firm lymph nodes, limited to one side of neck, without any systemic symptoms and no other lymph node enlargement or hepatosplenomegaly in a relatively younger age group is more suggestive of Hodgkin's disease.

The presence of systemic symptoms, lymph node enlargement, bilaterally in the neck or other lymph node fields such as axilla, inguinal, mediastinal or retroperitoneal region, hepatosplenomegaly are more suggestive of non Hodgkin's lymphoma.

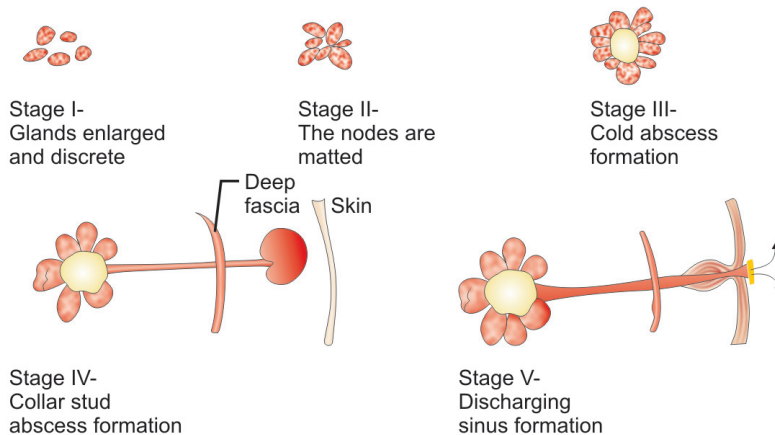
#### Microscopic Examination

These is destruction of the nodal architecture and replacement by a mixture of lymphocytes and plasma cells with large, pale staining histiocyte-like cells. Some of these are multinucleate or binucleate with prominent nucleoli and a 'mirror image' configuration. These Reed-Sternberg giant cells (RS cells) are essential for the diagnosis of Hodgkin's disease. These cells are large malignant lymphoid cells of B cell origin.

*Reye's classification:*

Depending on the type of cells, four distinctive patterns have been defined viz.

- Lymphocyte predominance—5 to 10 percent
- Mixed cellularity—30 to 40 percent



**Fig. 28.1:** Various stages of lymph node tuberculosis



3. Lymphocyte depletion—5 to 10 percent
4. Nodular sclerosis—50 to 60 percent

The number of lymphocytes represents the host response and consequently the lymphocyte depletion type is the most ominous form of Hodgkin's disease. Each group is further subdivided into two subtypes according to the absence (Type A) or presence (Type B) of general symptoms viz. weight loss, fever, pruritus, anemia and bone pain.

### Clinical Features

1. **Age:** Hodgkin's disease has a bimodal age incidence curve, with one early peak at 15 – 34 years and a second peak after the age of 45 years.
2. **Sex:** In younger patient's male to female ratio is equal while in older patients increased incidence is found in males.
3. The most common presentation is painless and progressive enlargement of the lymph nodes first detected in the cervical group of one side and then on the other. This is followed by axillary and inguinal lymph nodes enlargement.
4. Superior vena caval obstruction indicates enlarged mediastinal nodes. This is tested by asking the patient to raise the hand above the head. Engorgement of the veins indicates obstruction and the test is said to be positive (Pemberton's Test).

### Ann Arbor Clinical Staging of Hodgkin's Disease

**Stage 1:** Disease in a single lymph node region.

**Stage 2:** Disease in two or more anatomical group of lymph nodes confined to the same side of diaphragm.

**Stage 3:** Disease in two or more regions on both sides of the diaphragm.

**Stage 4:** Diffuse or disseminated disease in extralymphatic sites including liver and bone marrow.

Various suffixes are added to each anatomical stage:

- A—No systemic symptoms
- B—Systemic symptoms present
- E—Extranodal disease.

### Investigations

1. Complete blood count to rule out leukemia. Anemia indicate widespread metastasis.

2. Chest X-ray—To rule out mediastinal lymph nodes and pleural effusion.

3. Abdominal USG:

- a. To rule out secondaries in the liver
- b. To look for splenomegaly and para-aortic nodes.

However CT scan of abdomen is better to define paraaortic nodes.

4. CT scan of thorax, abdomen and pelvis.

5. Lymph node biopsy—Incision biopsy is done and a neck node is usually removed. FNAC can give the diagnosis but the definitive histologic pattern cannot be ascertained.

### Treatment

Stage I and II are treated by radiotherapy considering that the disease is still curable, the 5 year survival rate being as high as 80 percent. Dose of radiotherapy—3500 – 4500 centigray (CGY) units.

Stage IIIA, IIIB, IV and all patients with B symptoms are treated by chemotherapy because it is considered a systemic disease. Combination chemotherapy is in the form of MOPP.

(Mechlorethamine: 6mg/m<sup>2</sup> IV and Oncovin 1 – 4 mg/m<sup>2</sup> IV - on days 1 and 8, Procarbazine 100 mg orally 1 – 10 days, Prednisolone—15 mg TDS orally 1 – 10 days).

Minimum of 6 cycles or at least 2 extra cycles after attaining complete remission should be given.

10 year disease-free survival to is about 80 percent with successful chemotherapy.

### Nonhodgkin's Lymphoma (NHL)

Non Hodgkin's lymphoma represents a monoclonal proliferation of lymphoid cells and may be of B – cell (70%) or T – cell (30%) origin.

**Age:** Median age 65 – 70 years.

**Sex:** Slight male excess.

### Etiology

- No single causative abnormality described.
- Lymphoma is a late manifestation of HIV infection.
- The development of gastric lymphoma can be associated with *H pylori* infection.
- Specific lymphoma types are associated with EBV, human herpes virus 8 (HMV

8) and HIV infection in 90 percent of endemic T – cell leukemia or lymphoma.

- Lymphoma occurs in congenital immunodeficiency states and in postorgan transplantation immunosuppressed patients.
- Some lymphomas like follicular lymphoma are associated with t (14:18) translocation.

### Classification

The diversity of different classification and terminologies reflects current uncertainty as to the histogenesis of many subtypes of NHL.

### Microscopic Classification

Classification is based on two factors:

- Growth pattern: Follicular (good prognosis) or diffuse (poor prognosis). In the former there is loss of lymph node architecture while in the latter type the hallmark is effacement of normal lymph node architecture and there may be infiltration of neoplastic cells outside the capsule of the involved lymph node.
- Constituent cell type, i.e. T or B cell type. Lukes-Collins divided all malignant lymphomas into either B-cell or T-cell origin. Clinically, the most important factor is grade which is a reflection of proliferation rate.
- High grade NHL has high proliferation rates, rapidly produces symptoms and is fatal if untreated but is potentially curable.
- Low grade NHL has low proliferation rates, may be asymptomatic for many months before presentation, runs an indolent course but is not curable by conventional therapy. Other forms of NHL, including mantle cell lymphoma and MALT type (GI tract, thyroid, lung, breast, skin) lymphomas are less common. (MALT= Mucosa associated lymphoid tissue)

### Clinical Features

- Compared to Hodgkin's lymphoma, which is more often localized to a single axial group, multiple peripheral nodes are more frequently involved in NHL.
- Extranodal disease is more common in NHL, with involvement of the bone – marrow, gut, thyroid, lung, skin, brain and more rarely bone.

- The same staging system viz. Ann Arbor classification is used for both HL and NHL but NHL is more likely to be stage III or IV at presentation.
- Compression syndromes may occur—gut obstruction, ascites, superior vena caval obstruction and spinal cord compression may all be the presenting features.

**Investigations**

These are as for HL but in addition, the following should be performed.

- Routine bone marrow aspiration.
- Immunophenotyping of surface antigens to distinguish T and B – cell tumors. This may be done on blood, marrow or nodal material.
- Measurement of uric acid levels: Some very aggressive NHLS are associated with very high urate levels, which can precipitate renal failure when treatment is started.
- HIV testing: This may be appropriate if risk factors are present.

**Management**

*Low Grade NHL*

Asymptomatic patients may not require therapy. Indications for treatment include masked systemic symptoms, lymphadenopathy causing discomfort or disfigurement, bone – marrow failure or compression syndromes. The options are:

- Radiotherapy—This can be used for localized stage I disease, which is rare.
- Chemotherapy—This is the mainstay of therapy. Most patients will respond to oral therapy with chlorambucil, which is well-tolerated.
- Monoclonal antibody therapy—Humanized monoclonal antibodies can be used to target surface antigens on tumour cells and induce tumor cell apoptosis directly. The anti-CD 20 antibody rituximab has been shown to induce durable clinical responses in upto 60 percent of patients.

*High Grade NHL*

Patients with high grade NHL need treatment at initial presentation.

- **Chemotherapy:** The majority (> 90%) will need IV combination chemotherapy.

The CHOP regimen (Cyclophosphamide, Doxorubicin, Vincristine and Prednisolone) remains the main stay of therapy.

- **Radiotherapy:** It is indicated for a few patients with stage I disease, for spinal cord and other compression syndromes and for a residual localized site of back disease after chemotherapy.
- **Monoclonal antibody therapy:** When combined with CHOP, rituximab (R) increases the complete response rates and improves overall survival. The combination of R – CHOP is currently recommended for those with stage II or greater diffuse large cell lymphomas as first line therapy.
- **Transplantation:** Autologous stem cell transplantation benefits patients with relapsed chemosensitive disease.

*Comparison of Hodgkin's and Non Hodgkin's Lymphoma*

	<i>Non Hodgkin's lymphoma</i>	<i>Hodgkin's lymphoma</i>
1. Cellular derivation	90% B-Cell, 10% T-cell	Unresolved
2. Nodal spread	Discontinuous	Contiguous
3. Localized	Uncommon	Common
4. Abdominal disease	Common	Uncommon
5. Bone marrow involvement	Common	Uncommon
6. Chromosomal translocation	Common	Yet to be described
7. Curability	< 25%	> 75%

## Chapter 29

## Esophagus and Diaphragm

- Esophagus
- Dysphagia
- Achalasia of the cardia
- Plummer – Vinson syndrome
- Tumors of the esophagus
- Carcinoma of the esophagus
- Diaphragmatic hernia
- Congenital diaphragmatic hernia
- Eventration of diaphragm
- Acquired diaphragmatic hernia

**ESOPHAGUS****Surgical Anatomy (Fig. 29.1)**

The esophagus is 10 inches or 25cm long and extends from the lower border of cricoid cartilage to the cardiac orifice of the stomach.

In the neck, it commences in the median plane and deviates slightly to the left as it approaches the thoracic inlet.

The trachea and thyroid gland are its immediate anterior relations, the lower cervical vertebrae and prevertebral fascia are behind it and on either side it is related to the common carotid arteries and the recurrent laryngeal nerves.

In the thorax, anteriorly from above downwards it is crossed by the trachea, the left bronchus which constricts it, the pericardium

(separating it from left atrium) and the diaphragm.

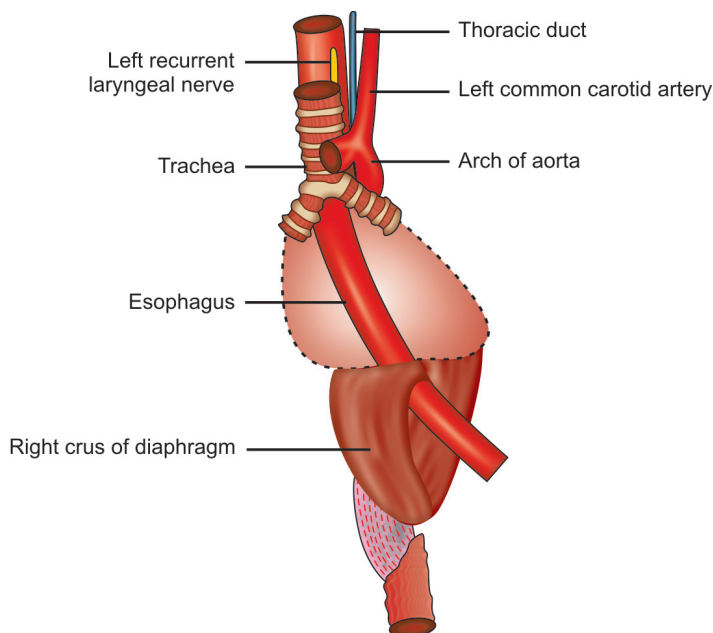
Posteriorly lie the thoracic vertebrae, the thoracic duct, the azygos vein and its tributaries and near the diaphragm, the descending aorta.

On the left side it is related to the terminal part of the aortic arch, the left recurrent laryngeal nerve, left subclavian artery and the thoracic duct.

On the right side there is pleura and the azygos vein.

Below the root of the lung the vagi form a plexus on the surface of the oesophagus, the left vagus lying anteriorly, the right posteriorly.

In the abdomen, esophagus passes through the opening in the right crus of diaphragm and comes to lie on the esophageal groove on the posterior surface of the left lobe of the liver, covered by peritoneum on its anterior and left aspects. Behind it is the left crus of the diaphragm.



**Fig. 29.1:** The esophagus and its relations

**Histology**

It contains no serosal covering unlike the rest of the gastrointestinal tract.

*Blood supply:* Blood supply is from the inferior thyroid artery, branches of the descending thoracic aorta and the left gastric artery.

The veins from the cervical part drain into the inferior thyroid veins and from the thoracic and abdominal portions, into the azygos and left gastric veins.

## Lymphatics

The lymphatic drainage is from a peri-esophageal lymph plexus into the posterior mediastinal nodes which drain both into the supraclavicular nodes and into nodes around the left gastric vessels.

## Innervation

The parasympathetic supply is by the vagus. The peculiarity is that there is only Auerbach's plexus (Myenteric plexus), Meissner's plexus is either absent or sparse.

## Physiology

There are three constrictions in the esophagus situated at the beginning ( $C_6$ ), where it is crossed by the aorta and left bronchus ( $T_5$ ) and at diaphragmatic opening ( $T_{10}$ ). Their locations from the incisor teeth are 15cm, 25cm and 40cm respectively.

The foreign bodies are liable to be arrested in these situations and endoscopes should be passed cautiously through these sites.

## Sphincters of Esophagus

There are two sphincters. The upper one 3-5cm in length at the upper border of esophagus, is derived from the inferior constrictor.

Peristalsis in the central portion of esophagus consists of wave-like movements that pass down the body of oesophagus and becomes stronger towards the lower portion. Esophageal peristaltic pressures range from 25-80 mm Hg.

The lower esophageal sphincter is a high pressure zone, 3-5 cm in length at the lower portion of the esophagus and functions to prevent gastroesophageal reflux.

## DYSPHAGIA

### Definition

Dysphagia can be defined as the difficulty in swallowing.

### Etiology

The causes of dysphagia may be listed as follows:

1. Local causes
  - i. In the wall:
    - a. Organic disease, e.g.

- Benign stricture secondary to reflux esophagitis and caustic stricture.
  - Carcinoma esophagus.
- b. Motility disorders like achalasia, diffuse esophageal spasm.
  - c. Congenital atresia.
  - d. Secondary to Plummer-Vinson syndrome (esophageal web).
    - ii. In the lumen – Foreign body.
    - iii. Outside the wall, e.g.
      - a. Big goiters and retrosternal goiters.
      - b. Acute cellulitis of neck, e.g. Ludwig's angina.
      - c. Cervical lymphadenopathy.
      - d. Bronchogenic carcinoma.
2. General causes
 

These are mainly of neurological origin, e.g.

    - a. Myasthenia gravis.
    - b. Bulbar poliomyelitis.
    - c. Cerebrovascular accident.
    - d. Trauma.
    - e. Parkinson's disease.
  - f. Globus hystericus (functional)—It is a neurotic symptom in patient with emotional instability. 'Of course it requires thorough examination to exclude organic disease.'

### Investigation of Dysphagia

#### History

There may be a history of swallowed caustic in the past.

A previous history of reflux esophagitis suggests peptic stricture.

In esophageal motility disorders, dysphagia may be intermittent or of variable intensity with exacerbations and periods of relative remission. Whereas in carcinoma esophagus, dysphagia is persistent and progressive in relatively older patients.

History of loss of weight suggests malignancy.

#### Examination

- Often this is negative.
- In Plummer-Vinson syndrome, there will be presence of a smooth tongue, anemia and koilonychia.
- Enlarged cervical lymph glands may be detected in carcinoma esophagus.

### Special Investigations

These are done to confirm the diagnosis.

- a. Barium swallow—It may show narrowing of esophagus which is smooth in achalasia and associated with irregular margin (rat tail appearance) in carcinoma.
- b. Esophagoscopy and biopsy in suspected cases of malignancy. This test has become much safer with the advent of flexible fiberoptic instruments.

## ACHALASIA OF THE CARDIA (CARDIOSPASM)

### Definition

This condition can be defined as the neuromuscular failure of relaxation at the lower end of the esophagus with progressive dilatation and often hypertrophy of the esophagus above. Hence, the other name is mega-oesophagus

The Auerbach's plexus connected to the vagus and located between the longitudinal and circular muscle fibers is present but defective. It may be mentioned here that this plexus is totally absent in case of congenital megacolon or Hirschsprung's disease.

### Clinical Features

1. *Age*—The condition commonly occurs in young adults and in the middle aged. It can also affect children rarely.
2. *Sex*—The ratio of female to male is 3:2.
3. The main symptoms are dysphagia, regurgitation and chest pain.

The dysphagia is more marked with liquids and less to solids as the weight of the food helps its passage.

The chest pain may be severe and simulate angina pectoris.

Patients may seek medical advice due to halitosis and persistent eructations of foul air.

4. There may be an associated hiatus hernia and occasionally, malignant change occurs in the dilated esophagus.

### Investigations

1. Barium meal examination—Shows gross dilatation of the esophagus, leading to an unrelaxing narrowed segment at the lower end.

2. Esophagoscopy—Shows an enormous sac of esophagus containing stagnant dirty fluid and food.

### Treatment

The treatment of choice is surgery (Heller's operation).

This operation consists of disrupting the constricting fibers at the cardia.

It is indeed a cardiomyotomy dividing the muscle of the lower end of the esophagus and the upper stomach down to the mucosa in a similar manner to Ramstedt's operation for congenital hypertrophic pyloric stenosis.

In some centers, disruption of the constricting fibers is performed with forcible dilatation of the esophagogastric junction by means of Plummer's hydrostatic bag. Although this avoids open operation, it is accompanied by the risk of rupture of the esophagus.

### Odynophagia

Odynophagia means pain on swallowing. It becomes particularly severe in chemical injury of the esophagus.

### PLUMMER-VINSON SYNDROME (Paterson and Kelly Syndrome)

This syndrome comprises dysphagia, iron deficiency anemia and koilonychia, usually in the middle aged or elderly females.

The dysphagia is due to the presence of a web in the upper part of esophagus.

The condition is premalignant and is associated with the development of a carcinoma in the cricopharyngeal region.

### Treatment

- Correction of anemia with iron.
- Dilatation of the web with esophageal bougies.
- A careful follow up is necessary to detect any malignant transformation.

### TUMORS OF THE ESOPHAGUS

- Benign—Leiomyoma
- Malignant
  - Primary
    - Carcinoma
    - Leiomyosarcoma
  - Secondary—From the lungs and stomach by direct invasion.

### CARCINOMA OF ESOPHAGUS

#### Etiology

The exact cause is not known. Predisposing factors are:

- Increased addiction to alcohol and smoking.
- Poor dental hygiene.
- Barrett's esophagus due to untreated or silent gastroesophageal reflux.
- Secondary involvement from gastric carcinoma at cardiac end.
- Esophageal disorders like achalasia, esophagitis (long-standing), Plummer-Vinson syndrome.

#### Pathology

##### Types

- Squamous cell carcinoma—It is the most common form (95%). It usually occurs in upper two-thirds of the esophagus.
- Adenocarcinoma—It occurs in patients with Barrett's esophagus. Site: Usually in the lower third of esophagus. Grossly, esophageal carcinomas have either polypoid, infiltrative or ulcerative appearance.

##### Spread

Like other carcinoma in the body, esophageal carcinoma also spreads by:

- Local infiltration
- Blood and
- Lymphatics.
  - Local infiltration*—The lack of esophageal serosal layer tends to favor local tumor extension. The tumors of the upper and middle-thirds infiltrate the tracheobronchial tree while lower third tumors may infiltrate the diaphragm, pericardium or stomach.
  - Lymphatic spread occurs along the two sets of lymphatics located in the mucus and muscular layers to regional lymph nodes viz.
    - Tumors located at the upper third of esophagus to cervical lymph nodes.
    - Tumors in the middle third to the mediastinal, paratracheal and tracheobronchial lymph nodes.
    - Tumors in the lower third to the gastric and celiac group of lymph nodes.

Celiac node involvement indicates bad prognosis.

- Hematogenous spread occurs to liver, lungs, bone and brain.

#### Clinical Features

- Age: Usual age is more than 50 years.
- Sex: Male: Female ratio 3:1.
- Onset is insidious, which gradually produces dysphagia and obstruction to solid food.
- Extreme weight loss, anorexia, fatigue and weakness from impaired nutrition usually result in malignant cachexia.
- Hoarseness is due to left recurrent laryngeal nerve palsy and is a bad prognostic sign.
- There may be cervical lymphadenopathy.

#### Special Investigations

- Contrast study—Barium swallow examination shows a persistent irregular filling defect or a persistently stenotic segment. In cancers of the lower third, there is irregular narrowing typically described as a 'rat tail deformity'.
- Esophagoscopy and biopsy is done for confirmation of the diagnosis.
- CT scan of chest and abdomen is done to evaluate metastasis.
- USG of liver is done to rule out any metastatic spread.

#### Treatment

- Surgical treatment provides the only cure if lymph nodes are not involved.
- Radiotherapy—Though squamous cell carcinoma is radiosensitive, radiotherapy alone has hardly succeeded as the only treatment and has a 5 years survival rate of 10 percent.

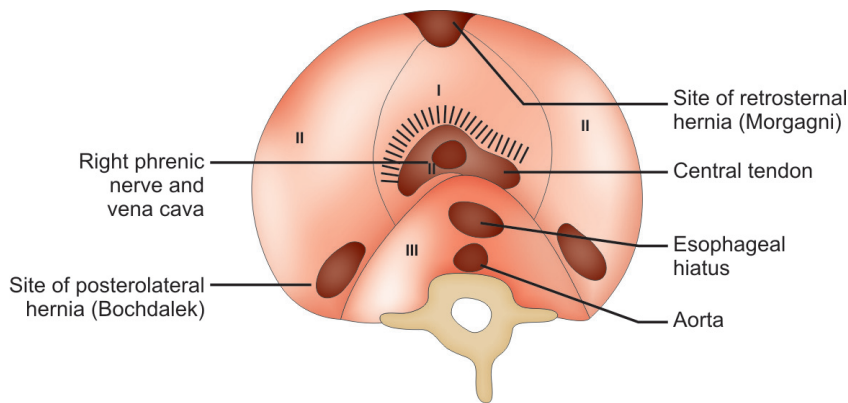
#### Surgical Procedures

- Transhiatal esophagectomy through a laparotomy and cervical incision, followed by anastomosis of the stomach with the esophageal remnant.
- Ivor-Lewis esophagectomy through a right thoracotomy and laparotomy and then esophagogastric anastomosis is done inside the thorax.

#### Palliative Treatment

This is appropriate when patients are too debilitated to undergo surgery or have a tumor





**Fig. 29.2:** Congenital diaphragmatic herniae (shaded areas) I, II, III are developmental parts of diaphragm I-Ventral area II-Lateral area III-Dorsal portion

that is unresectable because of extensive metastasis.

It includes the following:

**Intubation:** Introduction of a tube in the esophagus is a universally accepted procedure. It keeps the passage open and allows the patient to eat or drink as long as he or she survives. There are two types of tubes:

- i. Celestin tube—A flexible polythene tube.
- ii. Souttar's tube—This is made of German silver and may be pushed blindly or through an esophagoscope. Its use is restricted to terminal cases only.

### Chemotherapy

Usually combination chemotherapy is used for inoperable growths in the lower third of esophagus. The usual regime comprises MOCA (Methotrexate, Oncovin, Cyclophosphamide and Adriamycin).

### DIAPHRAGMATIC HERNIA

The diaphragm is of principal importance as the site of hernia. A diaphragmatic hernia can be defined as the displacement of abdominal viscera through a congenital or an acquired gap in the diaphragm.

Almost 98 percent of the diaphragmatic herniae are the esophageal hiatus herniae.

### Classification

1. Congenital
2. Acquired
  - i. Traumatic
  - ii. Hiatal.

### CONGENITAL DIAPHRAGMATIC HERNIA

These herniae can best be understood with reference to the development of the diaphragm. The diaphragm is developed by fusion of five structures as described below (Fig. 29.2):

1. The ventral portion of the diaphragm is developed from the septum transversum. It is attached to the xiphisternum, forming the central tendon and the central part of the muscle back to the esophagus. During folding of the embryo, this mesodermal mass is carried ventrally and caudally to lie in its definite position at the anterior part of the diaphragm. During this migration, the cervical myotomes and cervical nerves contribute muscle and nerve supply respectively, accounting for the long course of the phrenic nerve (C<sub>3,4,5</sub>) from the neck to the diaphragm.
2. The two dorsal portions forming the crura is developed from the mesoderm of the posterior abdominal wall.
3. The two lateral portions grow in from a ridge on the side wall of the celom which is connected with the septum transversum. It forms that part of the diaphragm which is attached to the ribs. It constricts the celom in its growth and ultimately separates pleural from peritoneal cavities.

Types of congenital diaphragmatic hernia:

- a. *Retrosternal hernia:* Hernia through the foramen of Morgagni, between the xiphoid and costal origins.
- b. *Posterolateral hernia:* Hernia through the foramen of Bochdalek. This is called the

posterolateral diaphragmatic hernia due to failure of fusion of the dorsal and lateral parts of the diaphragm. This occurs 3 to 5 times more on the left than on the right side.

- c. *Central hernia:* Hernia through a deficiency of the whole central tendon.
- d. *Esophageal hiatal hernia:* Hernia through a congenitally large esophageal hiatus.

### EVENTRATION OF DIAPHRAGM

It is not a true hernia but extreme elevation of a half or part of the diaphragm which is usually atrophic and abnormally thin. It may result from:

- i. Congenital defect.
- ii. Paralysis of phrenic nerve.
- iii. Anterior poliomyelitis.

### Diagnosis

Hernia through the foramen of Morgagni is usually small and unimportant.

Those through the foramen of Bochdalek or through the central tendon are large and present as respiratory distress soon after birth.

The congenital hiatal herniae present with regurgitation, vomiting, dysphagia and progressive loss of weight, in small children. They usually respond to conservative treatment, nursing the child in a sitting position.

If this fails, surgical repair is necessary.

### Treatment

- Surgical repair is done through the abdominal route. The defect can usually be closed with interrupted nonabsorbable sutures.
- For eventration, the redundant diaphragm may be excised and then plicated or reinforced with prosthesis.

### ACQUIRED DIAPHRAGMATIC HERNIA

#### Traumatic Diaphragmatic Hernia

These are comparatively rare and may follow after gun-shot injuries or crush injuries which involve the diaphragm.

The left diaphragm is far more often affected than the right, which is protected by the liver and is accompanied by herniation of the stomach into the thoracic cavity.

Treatment comprises urgent surgical repair.

## Esophageal Hiatal Hernia

These are divided into

1. Sliding (90%) type and
2. Rolling (10%) type.

### Sliding Hernia

In the sliding variety, the stomach slides through the hiatus and is covered in its anterior aspect with a peritoneal sac, the posterior part is extraperitoneal. It thus resembles the sliding inguinal hernia (Fig. 29.3A).

This type of hernia produces both the effects of a space occupying lesion in the chest and also disturbances of the cardioesophageal sphincter mechanism.

In the rolling or paraesophageal hernia, the cardioesophageal junction is normal but the fundus of the stomach rolls upwards into the chest through the esophageal hiatus alongside the cardia into a preformed peritoneal sac, hence the alternative term of paraesophageal hernia. Thus there are no features of reflux esophagitis but the sac containing the stomach in the thorax causes compression on the heart and lung.

### Clinical Features

These herniae occur in the obese, middle aged and elderly and are four times common in women than men.

Most are symptomless, but when occur, they fall into the following three groups.

- Reflux**—Results from incompetence of the cardiac sphincter. It is manifested by burning retrocecal or epigastric pain, aggravated by lying down or stooping and may be referred to the arms or jaw, thus simulating cardiac ischemia.
- Mechanical**—Symptoms are produced by the presence of the hernia within the thoracic cavity, cough, dyspnea, palpitations, hiccup, etc.
- The effects of esophagitis**—Acid refluxes in the lower esophagus produces diffuse inflammation with multiple ulcers later, fibrosis and stricture formation will develop.

### Diagnosis

- Barium swallow in the Trendelenburg's position (Head down position) will

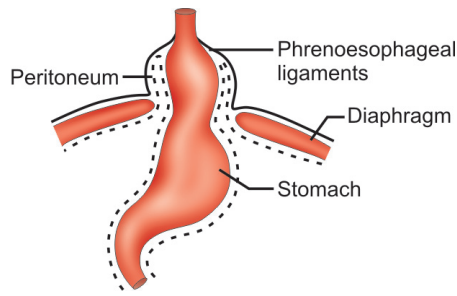


Fig. 29.3A: Sliding hiatus hernia

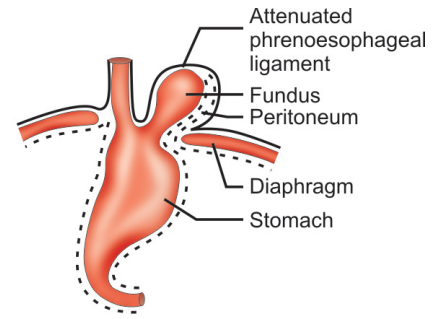


Fig. 29.3B: Rolling or paraesophageal hernia

demonstrate a dilatation above the diaphragm.

- Esophagoscopy may reveal red angry looking mucosa in the lower end of esophagus.

### Differential Diagnosis

The pain of hiatus hernia may be confused with cholecystitis, peptic ulcer or angina pectoris. Sometimes these conditions coexist.

The obstructive symptoms of an associated stricture are to be differentiated from carcinoma of the esophagus or of the cardia.

### Treatment

#### Medical

- Small frequent meals should be taken preferably nonbulky.
- Reduction of weight if patient is obese.
- To avoid stooping or lying down. Elevation of head of bed by 6 inches.
- H<sub>2</sub> receptor antagonist to reduce gastric acidity.

Many patients with mild symptoms obtain considerable relief from this regime.

#### Surgical repair

Surgical repair is undertaken, when

- Medical treatment fails.
- Onset of complications like stenosis, bleeding, etc. occur.
- When an abdominal operation has to be undertaken, e.g. for gallstones, peptic ulcer, etc.

### Operation

#### Nissen Fundoplication

In this operation following a laparotomy fundus of the stomach is mobilized by dividing

the short gastric arteries. Fundus is brought behind the esophagus and wrapped in front of esophagus and sutured.

Diaphragmatic defect is repaired by using nonabsorbable sutures. This prevents the reflux as well as recurrence of the hernia.

The other two procedures viz. HILL repair (Posterior gastropexy) and Besley Mark IV (270° Fundic wrap) are also popular.

### Rolling Hernia

In this type of hiatal hernia, the esophago-gastric junction remains in the normal position and the fundus of the stomach herniates through the hiatus to the left of the esophagus with time, increasing amount of stomach are included in the hernia (Fig. 29.3B).

### Clinical Features

Reflux is uncommon in paraesophageal hiatal hernia and the clinical manifestations are due to obstruction of the herniated stomach.

Eructation and postprandial pain in the lower chest are typical symptoms. If untreated, the stomach may ulcerate, bleed or strangulate.

The diagnosis is often unsuspected in a patient with nonspecific complaints.

Chest X-ray shows a gas fluid level.

Barium meal establishes the diagnosis showing the sac in the thorax.

### Treatment

Unlike sliding hernia, paraesophageal hiatal hernia should be repaired surgically in nearly every instance.

# Chapter 30

## Stomach and Duodenum

- Anatomy
- Congenital hypertrophic pyloric stenosis
- Gastritis
- Peptic ulcers
- Duodenal ulcer
- Perforated gastric or duodenal ulcer
- Peptic ulcer hemorrhage
- Pyloric stenosis
- Gastric ulcer
- Gastric carcinoma
- Zollinger – Ellison syndrome

### ANATOMY

Stomach is roughly J-shaped and the most dilated organ of the digestive tract.

It has two openings—the cardiac and pyloric orifices, two curvatures—greater and lesser curvatures, two surfaces—anterior and posterior surface. The stomach is relatively fixed at both ends but is very mobile in between.

The main parts of the stomach are the fundus, body and the pyloric part, with the greater and lesser curvatures forming the left and right borders respectively (Fig. 30.1).

The stomach is completely invested by peritoneum which passes in a double layer from the lesser curvature to the liver forming the lesser omentum and hangs down from the fundus and greater curvature as the greater omentum.

The fundus is the part which projects upwards above the level of the cardia and is usually full of swallowed air.

The largest part of the stomach is the body extending from the fundus to the notch, angularis incisura at the lower end of the lesser curvature on the right and the more curved greater curvature on the left.

The pyloric antrum begins from the angularis incisura to the pylorus.

The pylorus is the tubular part of the stomach lying in the transpyloric plane. It has a thick muscular wall formed by the circular muscle fibers called the pyloric sphincter. The cavity of the pylorus is the pyloric canal.

### Relations

Anteriorly—the abdominal wall, the diaphragm and the left lobe of liver.

Posteriorly—the lesser sac which separates the stomach from the pancreas, left kidney, left suprarenal, transverse mesocolon, the spleen and the splenic artery.

### Blood Supply

The arterial supply to the stomach is extremely rich and comprises the following.

- The left gastric artery—from the celiac axis.
- The right gastric artery—from the common hepatic artery.
- The right gastroepiploic artery from the gastroduodenal branch of the hepatic artery.
- The left gastroepiploic artery—from the splenic artery.
- The short gastric arteries from the splenic artery.

The corresponding veins drain into the portal system.

### Lymphatic Drainage (Fig. 30.2)

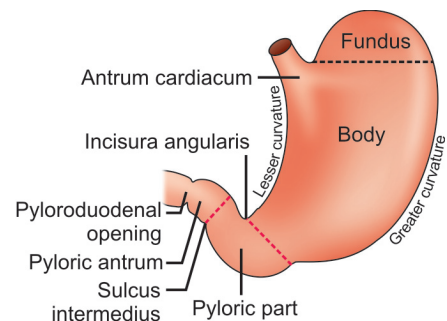
The lymphatic drainage of the stomach accompanies its blood vessels. The stomach can be divided into three drainage zones.

#### Zone-I

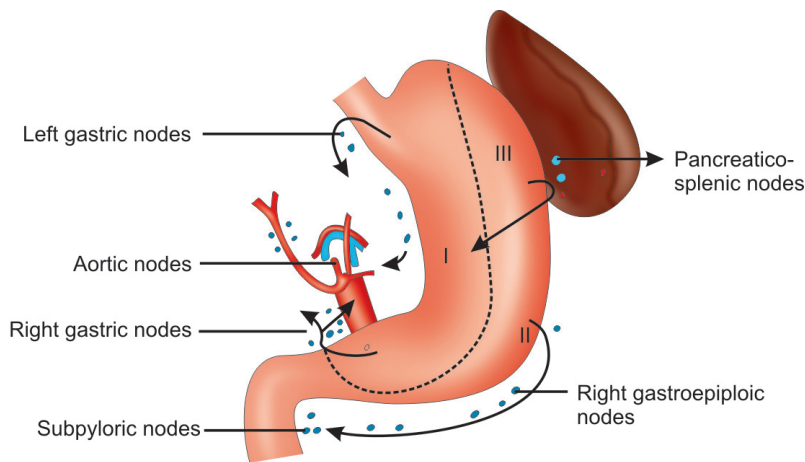
Superior two-thirds of the stomach drains along the left and right gastric vessels to the aortic nodes.

#### Zone-II

The right two-thirds of the inferior one-third of the stomach drain along the right gastroepiploic vessels to the subpyloric nodes and thence to the aortic nodes.



**Fig. 30.1:** The stomach and its subdivisions



**Fig. 30.2:** The lymphatic drainage of stomach

### Zone-III

The left one-third of the greater curvature of the stomach drains along the short gastric and splenic vessels lying in the gastrosplenic and lienorenal ligaments then via the suprapancreatic nodes to the aortic group.

Involvement of the nodes in stomach cancer, along the splenic vessels can be dealt with by removing spleen, gastrosplenic and lienorenal ligaments and the body and tail of the pancreas.

Lymph nodes along the gastroepiploic vessels are removed by excising the greater omentum.

However involvement of the nodes around the aorta and the head of the pancreas may render the growth incurable.

### Nerve Supply

The anterior and posterior vagi enter the abdomen through the esophageal hiatus.

The sympathetic supply is derived mainly from the celiac ganglia.

## CONGENITAL HYPERTROPHIC PYLORIC STENOSIS

### Etiology

The exact etiology of this condition of pyloric obstruction in infants due to gross hypertrophy of pyloric musculature is not known.

It may result from an abnormality of the ganglion cells of the myenteric plexus. Failure

of the pyloric sphincter may then produce an intense work hypertrophy of the adjacent circular muscle of the pylorus.

### Incidence

Mostly the first born male child is affected

Sex: Males: Females = 9:1

The condition often occurs in siblings.

### Clinical Features

The child usually presents at 3 – 4 weeks of age. It is extremely uncommon for a healthy infant to develop this condition after 12 weeks of age.

The presenting symptom is projectile vomiting; the vomit does not contain bile. There is failure to gain weight and as a result of dehydration, the baby is constipated.

### Physical Signs

Visible peristalsis is seen in the epigastrium due to the dilated stomach.

95 percent patients have a palpable pyloric tumor which is felt as a firm bobbin in the right upper abdomen.

### Diagnosis

Diagnosis is usually made on clinical examination. In case of difficulty a barium meal examination may be done which will show a dilated stomach, retention of meal in the stomach for more than 6 hours and the pyloric canal shows an elongation and persistent gross narrowing – ‘the string sign’.

### Treatment

In the majority of cases treatment is surgical. The universally accepted surgical procedure is Ramstedt's operation.

A longitudinal incision is made through the hypertrophied muscle of the pylorus down to the mucosa and the cut edges are separated. The operation is preceded by gastric aspiration. The infant is given glucose water 3 hours after the operation and this is followed by 3 hourly milk feeds which are steadily increased in amount.

Results are excellent and mortality is extremely low.

### Postoperative Complications

1. Gastroenteritis—Rare nowadays with modern aseptic feeds and good nursing techniques.
2. Peritonitis and burst abdomen if there is injury to the gastric mucosa which has been left unrepaired.

### Medical Treatment

This consists of gastric lavage together with 5 ml of 1/10000 Eumydrin (Atropine methyl nitrate) given as an antispasmodic 15 minutes before frequent feeds.

Medical treatment is used only when the diagnosis is in doubt and should not persist for more than 48 hours if symptoms continue.

### Adult Pyloric Hypertrophy

This is occasionally seen. In these cases it may be that the congenital pyloric hypertrophy has persisted and only become manifest in adult life.

The condition is usually misdiagnosed as the far commoner carcinoma of the pylorus.

## GASTRITIS

Gastritis may occur either in an acute or chronic form.

### Acute Gastritis

#### Etiology

Acute gastritis may be precipitated by the following.

- i. Chemicals, e.g. salicylates, nonsteroidal antiinflammatory drugs, acid and alkali.

- ii. Ionizing radiation.
- iii. Generalized stress.
- iv. Shock following gm negative septicemia.

### Pathology

There will be damage to the gastric mucosal barrier due to acute inflammation with edema and polymorphonuclear infiltration of the mucosa, submucosa and lamina propria.

In severe cases, this process can lead to ischemia, sloughing of necrotic mucosa and erosive gastritis.

### Clinical Features

Acute gastritis often produces no symptoms but may cause dyspepsia, anorexia, nausea or vomiting and hematemesis or melena. Many cases resolve quickly and do not require any investigation. In others endoscopy and biopsy may be necessary to exclude peptic ulcer or cancer.

### Treatment

Short-term symptomatic therapy with antacids and acid suppression using proton pump inhibitors or antiemetics, e.g. metoclopramide may be necessary.

## Chronic Gastritis

### Types

1. Type A or autoimmune gastritis.
2. Type B or antral gastritis.
3. Rarer forms, e.g. eosinophilic gastritis, granulomatous gastritis.

### Type A Gastritis

It is characterized by the presence of antibody to parietal cells. The antrum is spared and gastrin secretion is frequently elevated. It is this form that may progress to pernicious anemia.

It is common in the elderly people and may be associated with other organ specific autoimmunity, e.g. Hashimoto's thyroiditis.

The gastritis itself is usually asymptomatic, but there is a fourfold increase in the risk of gastric cancer.

### Type B Gastritis

*Helicobacter pylori* (*H. pylori*), previously known as *Campylobacter pylori* is the most common cause. Parietal cell antibody is not detectable and extensive antral involvement is characteristic. Serum gastric levels are

often low. This is the more common form and has been referred to as antral gastritis.

Antral gastritis may be a precursor lesion for gastric ulcer.

Most patients are asymptomatic and do not require any treatment but patients with dyspepsia may benefit from *H. pylori* eradication.

### Granulomatous Gastritis

It is associated with tuberculous infection, sarcoid or Crohn's disease characterized by antral and duodenal involvement with mucosal inflammation and ulceration that may lead to gastric outlet obstruction.

### Eosinophilic Gastritis

Eosinophilic gastritis is a rare condition in which eosinophils infiltrate the distal stomach and the proximal small bowel to a variable extent, resulting in enlargement of antral folds and simulating Ménière's disease (Massive enlargement of rugal folds in the body and fundus of stomach).

Although this condition may lead to obstruction, it is generally amenable to medical therapy alone.

## PEPTIC ULCERS

### Applied Physiology of Gastric Secretion

Hydrochloric acid is secreted by the parietal cells (oxyntic cells) interspersed along the course of mucosal glands of the body and fundus of the stomach.

Total number of parietal cells is about 1 billion. It is almost doubled in duodenal ulcers and fourfold in Zollinger-Ellison syndrome but it is normal or decreased in number in gastric ulcer.

The parietal cells also secrete the intrinsic factor while peptic or zymogenic cells (also present in the body glands) secrete pepsinogen. A number of endocrine cells are found between the peptic cells but their function is uncertain.

### Regulation of Acid Pepsin Secretion

Occurs by neural (neurocrine), endocrine and paracrine (local) factors.

- Acetylcholine is the neurocrine factor released by the vagus.

- Gastrin is the endocrine regulator which is carried by the blood from the antrum (G cells) and
- Histamine is the paracrine regulator released from cells in the immediate vicinity of the parietal and peptic cells.
- Somatostatin is another paracrine regulator that inhibits secretion by inhibiting mucosal histamine release.

### Applied Importance

Truncal vagotomy reduces acid pepsin secretion by abolishing the direct vagal drive and to a minor degree by reducing antral gastrin secretion by the G – cells.

Truncal vagotomy impairs gastric motility by abolishing receptive relaxation (i.e. accommodation of increased volumes of food without increase in pressure) of the gastric corpus and diminishes the power of antral contractions which grind, mix and expel food.

Because of its effect on gastric motility and emptying truncal vagotomy is usually combined with a drainage procedure. (e.g. Pyloroplasty or Gastrojejunostomy).

Highly selective vagotomy (HSV) denervates only the body of the stomach. Acid pepsin secretion is reduced but antral motility is unaffected, so that a drainage procedure is not needed and gastric incontinence is avoided.

### Evolution of Peptic Ulcer Surgery

1. Billroth I operation - In 1881 Billroth first successfully removed the pyloric end of the stomach and restored the Gastrointestinal continuity by Gastroduodenostomy.
2. Billroth II operation - In 1885, Billroth performed a pylorotomy, closed the Duodenum and restored the continuity of bowel by anastomosing the jejunum to the stomach remnant. This is known as Billroth II operation
3. Only Truncal vagotomy (TV) was first done by Exner in 1911 without a drainage procedure.
4. TV + D—Truncal Vagotomy(TV) with a drainage procedure (D) was first done by Dragstedt in 1945.
5. Selective vagotomy and drainage— Selective vagotomy with drainage procedure was first done by Frankson in 1948.



6. HSV—Highly selective vagotomy was first done by Holle and Hart in 1967.

### Definition of Peptic ulcer

Peptic ulcer is defined as ulceration of the gastrointestinal tract bathed by acid-peptic juice. It results from the interplay of aggressive acid-pepsin and the protective mucosal resistance to ulceration. Whilst acid attack is a marked feature of duodenal ulcer (DU), impaired mucosal resistance appears to be more important for gastric ulcer (GU). The discovery of *H. Pylori* has dramatically changed the management of uncomplicated peptic ulcer disease.

## DUODENAL ULCER

### Risk Factors

Cigarette smoking, stress, NSAIDs, corticosteroids and infection with *H. Pylori* are risk factors for duodenal ulcer development.

- NSAIDs—Deplete endogenous mucosal prostaglandins making the mucosa more susceptible to ulceration.
- Smoking—Increases acid secretion, impairs ulcer healing, accelerates gastric emptying and decreases pancreatic bicarbonate secretion.
- *H. pylori*—The exact mechanism by which *H. pylori* produces ulceration is not known. Over 90 percent patients with a duodenal ulcer have this organism present. Most people with *H. pylori* however, do not develop ulcers.

### Physiology

Duodenal ulceration is associated with higher BAO (Basal Acid Output) and MAO (Maximal Acid Output). Gastric emptying is usually rapid and the total parietal cell mass is enlarged.

### Clinical Features

1. Epigastric pain—Most frequent symptom, appears in empty stomach and relieved by taking food.
2. Appetite is good.
3. Malignancy almost never occurs.
4. Vomiting not so common.
5. Periodicity comes and goes in a 4 to 6 months cycle.
6. Duration of attack—A month or two.

**Table 30.1: Mortality and recurrence ulcer rates after different operations on duodenal ulcer**

	Mortality (%)	Recurrence (%)
1. Vagotomy and gastrojejunostomy	Less than 1	5
2. Vagotomy and pyloroplasty	Less than 1	5
3. Partial gastrectomy	2	1-4
4. Vagotomy + Antrectomy (Hemigastrectomy)	1	1
5. Proximal gastric vagotomy or highly selective vagotomy (HSV)	Less than 1	15

On examination: Duodenal point is tender. Duodenal point is sited in the transpyloric plane on the outer border of right rectus.

### Diagnosis

1. *Endoscopy*—This has replaced Ba-meal examination as the mainstay of diagnosis. In addition to confirming the presence of peptic ulceration, endoscopy allows esophageal disease to be excluded, may reveal unsuspected pathology and allows gastric ulcers to be biopsied to exclude malignancy.
2. *Acid secretory studies*—These are not performed routinely. Surgeons no longer select the type of operation to be performed on the basis of acid output and the ZES (Zollinger-Ellison syndrome) is diagnosed by measuring serum gastrin levels rather than acid secretion.
3. *USG*—This is advisable to exclude gallstones as cholelithiasis and peptic ulceration often coexist and share common symptoms.

### Differential Diagnosis

1. Chronic gastric ulcer.
2. Chronic cholecystitis.
3. Chronic amebiasis and worm infestation.
4. Chronic pancreatitis.
5. Chronic appendicitis.
6. Intestinal tuberculosis.

### Treatment

#### Medical Measures

1. Cessation of smoking and intake of NSAIDs, steroids, etc.
2. A period of bed rest and a change to less stressful life style and small frequent meals without spices (i.e. No hurry, curry and warry).
3. Drug therapy:
  - a. Antacid (liquid)—1, 2 and 3 hours after meal.

- b. H<sub>2</sub> Blocker—Famotidine 40mg/day.
- c. Proton pump inhibitor—e.g. omeprazole 20mg/day.
- d. Cytoprotective agent, e.g. sucralfate, colloidal bismuth, etc.

### Surgical Treatment

#### Indications

1. Failure of medical treatment, i.e. failure of the ulcer to heal or recurrence, after rigid medical treatment (6 months for duodenal ulcer and 3 to 4 weeks for gastric ulcer).
2. Appearance of complications, e.g. pyloric stenosis, repeated hemorrhage.
3. Ulcer of > 5 years standing.
4. Very large ulcers (> 5 cm size).

#### Type of operation (Table 30.1)

1. Truncal vagotomy with a drainage procedure (TV + D), e.g. pyloroplasty or gastrojejunostomy.
2. Partial gastrectomy (PG) (Distal 65–70 percent of stomach removed).
3. Truncal vagotomy and antrectomy (TV + A) - The terms antrectomy and hemigastrectomy (50%) are loosely synonymous. Following antrectomy bowel continuity is maintained by Billroth I or Billroth II anastomosis. Billroth II gastrectomy has higher mortality and morbidity.
4. Highly selective vagotomy (HSV) without any drainage procedure.

### Selecting the Operation for Duodenal Ulcer

Selection of the operative method is largely a matter of the surgeon's preference and the operative findings. The mortality rates and recurrent ulcer rates following different operations for duodenal ulcer are as follows: (Table 30.1)

The operative risks are increased in elderly patients, in patients with concomitant

disease and undergoing emergency operations. In contrast all elective operations carry low risks in young, fit patients.

### Complications

These may be acute or chronic

- |  |           |
|--|-----------|
| 1. Perforation.  | } Acute   |
| 2. Haemorrhage – Hematemesis and/or melena.                        |           |
| 3. Penetration into the neighboring viscera, notably the pancreas. | } Chronic |
| 4. Pyloric stenosis.   |           |

### PERFORATED GASTRIC OR DUODENAL ULCER

**Age:** Highest incidence is between 45 and 55 years.

**Sex:** M : F = 2:1

**Site:** In most cases the ulcer is situated on the anterior surface of the duodenum.

**History:** In 80 percent cases there is a long-standing history of peptic ulceration. In 20 percent cases, there is no such history. It is a silent chronic ulcer that perforates.

### Clinical Features

Clinically three stages are represented.

#### Stage of Peritonism

The contents of the stomach and duodenum enter the peritoneal cavity and cause chemical irritation of the peritoneum. So there is sudden onset of severe and constant pain in the epigastrium. There is no bacterial infection at this stage which lasts for 2–4 hours.

All movements including respiration make the pain worse, so the patient remains immobile on his bed.

Signs of peritonism –

- Extensive rigidity, called cardboard-like rigidity.
- Obliteration or lowering of liver dullness in the midaxillary line as the escaping gas tends to collect under the diaphragm.
- Intestinal sounds are not heard (as the irritant fluid causes intestinal paresis).
- Temperature and pulse are within normal range.

#### Stage of Reaction

This stage persists for 3 – 6 hours. The peritoneum reacts to chemical irritation by pouring

out large quantities of effusion in an attempt to dilute the irritating fluid.

The acid in the peritoneal cavity becomes diluted and the pain and guarding decreases. The patient thinks he is getting better. But he is not, he is getting worse. His peritonitis is progressing and he is becoming hypovolemic.

The most valuable signs indicating these circumstances are an increasing tachycardia and absent bowel sounds.

#### Stage of Peritonitis

The peristomal fluid is secondarily infected by bacteria at this stage, either from bloodstream or from lymphatics.

### Clinical Features

The patient rapidly deteriorates. Incessant vomiting starts and the temperature shoots high. There is a toxic look (peritonitic facies), a rapidly deteriorating quick pulse, rapid shallow respiration and gradual fall of blood pressure.

Abdominal rigidity is replaced by gross distension of the abdomen. Peristaltic sound is nil.

### Investigation

Straight X-ray of the abdomen in erect posture shows subdiaphragmatic gas shadow beneath the right cupola of diaphragm in 70 percent of cases.

### Treatment

- Immediate exploration and repair of the perforation is the treatment of choice.
- A conservative treatment is indicated only in the few cases of leaking perforation (small perforation without features of general peritoneal irritation).
- As soon as the patient has been admitted, diagnosis confirmed and operation decided, the following treatment is instituted.
  1. Rest and inj pethidine.
  2. Nasogastric suction with a Ryle's tube.
  3. IV fluid—Approximately 2.5 liters plus the amount lost in gastric suction.
  4. A parenteral antibiotic.

In some cases, a definitive surgery instead of a simple repair is indicated, e.g.

1. Perforation associated with hemorrhage.
2. Recurrent perforation.
3. Suspicious of malignancy in a perforated gastric ulcer when partial gastrectomy.

May be indicated.

Nowadays, laparoscopic closure of peptic perforation is being done using 10mm access port.

### Operation

Repair of peptic perforation:

1. Under general anesthesia abdomen is opened with an upper midline incision.
2. A hissing sound on nicking the peritoneum due to escape of gas from the peritoneum, confirms perforation. All peritoneal collections are sucked, and the stomach is drawn out to locate the perforation.
3. Site of perforation is reached as follows:
  - i. Following the body of stomach, pylorus, then to first part of duodenum.
  - ii. Presence of phlegmon (Whitish precipitate of mucus secretion and inflammatory exudate).
4. As the perforation is identified it is isolated by mops.
5. Perforation is repaired by three sutures in the axis of the gut using 2/0 polyglactin (Vicryl).
6. The suture area is covered by a tag of omentum called Graham's patch.
7. Peritoneal toileting is done thoroughly.
8. The abdomen is closed in layers after putting a drain in the right paracolic gutter, which is brought out through a separate stab incision in the loin.

### PEPTIC ULCER HEMORRHAGE

Upper GI bleeding commonly manifests as hematemesis and bleeding from peptic ulcer is the most common cause of upper GI bleeding. Hematemesis is blood vomiting blackish red in color and acidic in reaction. It must be differentiated from hemoptysis, which is coughing out of blood, bright red in color – frothy and alkaline in reaction. The differential diagnosis of upper GI bleeding is detailed below:

### Causes

#### Causes in the Esophagus

1. Ruptured esophageal varices.
2. Reflex esophagitis leading to an ulcer of lower end of esophagus.
3. Carcinoma esophagus.
4. Rarely foreign body in esophagus.

### Causes in the Stomach

1. Gastric ulcer.
2. Acute gastric erosion, especially due to intake of drug like aspirin.
3. Gastric carcinoma.
4. Mallory-Weiss syndrome—A vertical tear in the mucous membrane at the esophagogastric junction resulting from repeated vomiting.

### Causes in the Duodenum

1. Duodenal ulcer.
2. Acute hemorrhagic duodenitis (Cushing's ulcer)—commonly associated with head injury.
3. Acute duodenal ulcer resulting from stress e.g. Curling's ulcer found in a case of burn.

### Miscellaneous Causes

1. Angiomatous malformation anywhere in the upper GI Tract.
2. Blood dyscrasias, e.g. purpura, hemophilia etc. of the above long list of causes, the following are important clinically.
  - i. Bleeding peptic ulcer (Gastric and duodenal ulcer)—90 percent.
  - ii. Bleeding from ruptured esophageal varices—4 percent.
  - iii. Bleeding from gastric carcinoma—5 percent.
  - iv. Rest 1 percent is occupied by miscellaneous causes.

### Clinical Features

1. Majority of the cases have a definite history of ulcer related pain, but there are several in whom, the ulcer remained, silent till the time of the hemorrhage.
2. As soon as the bleeding starts, the patient sweats, faints or collapses.
3. In most cases, it is the duodenal ulcer which bleeds (because on the whole duodenal ulcer is commoner than gastric ulcer) and the presenting feature is melena. Only when the duodenal bleeding is massive or when it is a gastric ulcer that bleeds hematemesis occurs first. Melena follows after a variable interval.

### On Examination

- Cold, clammy skin (in severe hemorrhage).
- Weak and thready pulse and tachypnea.

### Differential Diagnosis

See above, causes of upper GI bleeding.

### Management

The three priorities in the management of patients with upper GI bleeding are:

1. Prompt resuscitation
2. Defining the source of bleeding by endoscopy and
3. Institution of appropriate measures to arrest bleeding and prevent further hemorrhage.

90 percent of patients stop bleeding on conservative management. This consists of the following: (Treatment of hypovolemic shock due to blood loss).

1. Absolute bed rest.
2. Sedation—Morphine or pethidine.
3. Immediate fluid transfusion.
4. Ryle's Tube for suction of stomach – it evacuates the collected blood and gives an idea about the continuance of bleeding.

It is important guide to assess whether bleeding stops or not. Moreover, ice-cold milk drip may be started. This provides nutrition and also acts as local hemostatic.

5. Esophagogastrosopy: If a fiberoptic endoscopic is available, this provides very valuable information. If the bleeding is from esophageal varices the condition is detected. Otherwise, the size and nature of the bleeding ulcer can be made out.
  - Endoscopic control of bleeding can also be done (injection, sclerotherapy, laser or heat coagulation).

### Indications for Surgery

1. Failure of conservative treatment, i.e. in spite of all conservative measures, bleeding cannot be arrested.
2. Patient rebleeds in quick successions.
3. Presence of factors associated with rebleeding, e.g. patient. aged >45 years, with evidences of atherosclerosis, endoscopic stigmata, e.g. visible vessel, black/red spots.

### Nature of Surgery

- a. Surgery for bleeding duodenal ulcer, usually involves opening the pylorus, under running of the bleeding vessel and performing truncal vagotomy and pyloroplasty.
- b. Bleeding gastric ulcer can be treated similarly or by partial gastrectomy.

### PYLORIC STENOSIS

Pyloric stenosis is a misnomer but time honoured. It is actually duodenal stenosis in the first part of the duodenum caused by extensive fibrosis on the wall of the ulcer.

Other causes of gastric outlet obstruction include:

- a. Growth in the antrum or pylorus.
- b. Foreign body obstruction.
- c. Adult hypertrophic pyloric stenosis.
- d. Annular pancreas.

### Clinical Features

When stenosis sets in the clinical features of duodenal ulcer changes as depicted below:

1. Periodicity is lost.
2. Pain changes its character. It becomes less severe and lose relationship to food. There is sensation of fullness in the epigastrium, which is continuous but is exaggerated after taking food.
3. Vomiting becomes a constant feature – It is projectile, copious, self-induced and contains old food.
4. Constipation becomes more severe.
5. There is loss of weight due to inanition.

### On Examination

The Stomach is Visible, Palpable and Audible

1. Inspection—A cricket ball size lump is seen moving across the epigastrium from left to right. It is particularly seen after the patient is asked to drink something.
2. A succussion splash, due to the presence of large quantities of fluid together with gas in the stomach is heard on vigorously shaking the abdomen (Audible stomach).
3. On auscultopercussion, the stomach is found to be grossly dilated.

### Biochemical Abnormality (Due to vomiting)

Vomiting depletes the patient of  $\text{Na}^+$ ,  $\text{K}^+$  and  $\text{Cl}^-$ , the latter is lost in excess of  $\text{Na}^+$  and  $\text{K}^+$ , as HCl. There is hyponatremic, hypokalemic and hypochloremic alkalosis with intracellular acidosis (loss of  $\text{K}^+$  from inside the cells) and the patient is severely dehydrated. (Cause of alkalosis is loss of  $\text{H}^+$  in HCl).

Gastric HCl loss causes extracellular bicarbonates to rise and renal bicarbonate excretion rises in an attempt to maintain pH.

Initially the urine is alkaline but as body  $K^+$  stores get depleted, the kidney begins to excrete  $H^+$  ions rather than  $K^+$ . The resulting paradoxical aciduria is a sign of profound biochemical upset.

### Diagnosis

From history, clinical examination and investigations:

- Ba-meal shows a large and low-lying stomach. There is much delay in the passage of Barium and simultaneous finding of the meal in the stomach and transverse colon.
- Endoscopy is usually indicated to rule out the presence of an obstructive neoplasm.

### Management

A careful preoperative preparation is essential. Surgical relief of pyloric stenosis is not an emergency procedure and operation is usually undertaken after several days of preparation to correct dehydration, electrolyte upsets and acid - base imbalance.

### Preoperative Preparation

- Gastric lavage is given with saline through a wide bore tube for 4–5 days prior to operation. This is done to evacuate the stagnant mucus and food material. Atrophic gastritis is thus corrected and the secretory status improves.
- Liquid diet rich in protein.
- IV glucose and electrolytes (to maintain nutrition and correct electrolyte loss and dehydration).
- Supplementation of adequate iron, vitamin and minerals.
- Blood transfusion (to correct anemia and hypoproteinemia).
- Antibiotics.

A normal urine output indicates adequate hydration.

### Operation

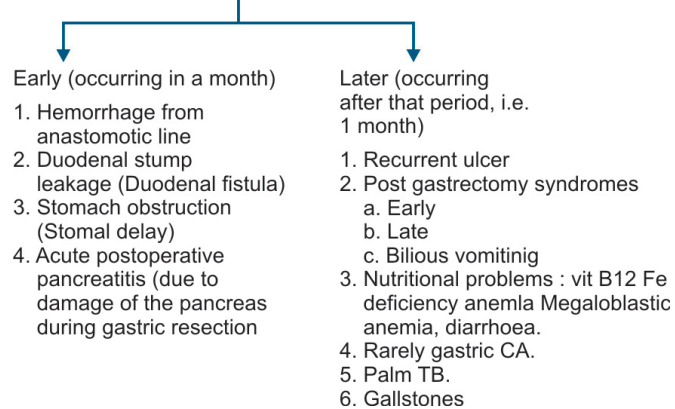
It consists of truncal vagotomy and gastrojejunostomy. See the operative surgery section for details of the operation.

## GASTRIC ULCER

### Introduction

It is the second commonest form of peptic ulceration.

### Complications following gastric operations



**Fig. 30.3:** Complications of gastric operations: (vagotomy, drainage operations, Billroth I & II operations)

### Risk Factors

- Tobacco, alcohol and *H. pylori* infection. 10 percent of people taking NSAIDs, suffer from acute gastric ulcer.
- Gastric ulcer frequently develops in degenerate and aged gastric mucosa.

### Site

Gastric ulcer is most frequently seen near the incisura, a constant notch in the lower part of lesser curvature.

### Age/Sex

Gastric ulcers occur most commonly in elderly women with the highest incidence between 55 and 60 years of age.

### Types of Gastric Ulcer

In 1965, Johnson observed the different behaviors of ulcers in different portions of the stomach and classified them into three groups. *Type 1 ulcer* – located in the body of the stomach have low gastric acid secretion, as determined by secretory tests.

*Type 2 ulcers (25%)* are those combined with a present or past duodenal ulcer. *Type 3 ulcers* – These are located in the prepyloric area.

They behave more like duodenal ulcers and here the effect of acid production appear to be more important

### Clinical Features

- Pain occurs soon (15–30 min) after eating, which is the precipitating factor unlike duodenal ulcer.
- Relieving factor—vomiting.

- There may be loss of weight and hematemesis is more common than melena.

### Diagnosis

Diagnosis cannot be considered adequate until the results of endoscopy and biopsy are known. A benign ulcer must be distinguished from an ulcerating cancer and a good clinical rule is to suspect initially that every gastric ulcer is malignant.

### Treatment

- Combined gastric ulcer + Duodenal ulcer, i.e. Type 2 and 3 ulcers – Treatment of choice is partial gastrectomy that includes the entire antrum and the ulcer plus truncal vagotomy of both vagus nerves.
- For Type 1 ulcer—Treatment is only partial gastrectomy (Billroth-I) that includes the entire antrum and the ulcer without vagotomy. Billroth-I is preferred to Billroth-II operation if the duodenum is not badly deformed.

### Complications

- Complications are same as in case of chronic duodenal ulcer. But bleeding occurs more commonly and perforation less frequently than duodenal ulcers.
- An unusual complication of perforation is a gastroduodenal fistula, when ulcers on the greater curvature penetrate into the colon. Here surgical intervention is necessary.

See also the clinical discussion on the long case of chronic duodenal ulcer

Complications following different gastric operations – See Fig. 30.3 above



**GASTRIC CARCINOMA****Etiology and Risk Factors**

- Sex—Gastric cancer is two to three times more common in men.
- Age—Peak incidence occurs between 50 and 70 years.
- Gastric carcinoma is seen to be associated with blood group A individuals.
- Social class—More frequent among lower social class people.
- Others—Definite premalignant conditions include
  - a. A gastric polyp, e.g. adenomatous polyp.
  - b. Atrophic gastritis or pernicious anemia.
  - c. Prior gastric surgery (postgastrectomy and post-truncal vagotomy stomach).
  - d. Autoimmune and environmental gastritis.
  - e. Cigarette smoking.
  - f. Patients with long-standing dyspepsia.
- Dietary factor – Nitrates in dried smoked and salted food. Nitrate is converted to carcinogenic nitrates by endogenous bacteria such as *H. pylori* or exogenous bacteria through contaminated food.
- A gastric ulcer can rarely undergo malignant change.

**Presentation**

- Irrespective of site the most common presentation is upper abdominal discomfort.
- Loss of appetite with weight loss is a cardinal symptom in gastric cancer.
- The common antral lesions (64%) may cause outlet obstruction with vomiting and a succussion splash.
- Cardiac lesions may cause dysphagia or regurgitation.
- Fundal lesions are often silent. Gastric carcinoma often presents with recurrent superficial thrombophlebitis.

**On Examination**

- A knobby liver or carcinoma itself may be palpable as epigastric lump.
- A left supraclavicular lymph node (Virchow's node) may be palpable (Troisier's sign).
- Jaundice may be caused by the nodal compression at the porta hepatis, involvement of the duct or liver metastasis.

**Pathology****Macroscopic**

There may be four types of growth viz.

1. Proliferative or Cauliflower type. (See fig. 101.8 in Chapter 101, specimens.
2. Ulcerative type—secondary to gastric ulcer.
3. Infiltrative type
  - Localized
  - Generalized leading to linitis plastica or leather bottle stomach.
4. Colloid type—Highly malignant and results from a gelatinous degeneration of one of the above varieties.

**Microscopic**

1. Columnar cell carcinoma—Commonest.
2. Cubical cell carcinoma.
3. Squamous cell carcinoma—Present at esophagogastric junction.

The first two types comprise about 95% of all gastric cancers.

**Spread**

1. Lymphatic—Commonest, both by embolism and permeation.
2. Hematogenous spread.
3. Direct spread—The pancreas, transverse colon, mesocolon, esophagus or liver may be involved.
4. Transperitoneal implantation—
  - a. Carcinoma cells are freely discharged into the peritoneal cavity and give rise to carcinomatosis peritonei. Malignant cells may gravitate to the pelvis and may involve the ovaries giving rise to Krukenberg's tumor.
  - b. Sister Mary Joseph node occurs due to spread to periumbilical region.

**Diagnosis****Diagnostic Test**

Diagnosis is reached by the use of a double contrast Ba-meal as a screening test coupled with endoscopy and biopsy in suspected cases.

**Other Tests**

- i. Hemoglobin—Anemia is present in 45 percent cases.
- ii. Gastric secretory studies—Most have either achlorhydria or hypochlorhydria.

- iii. Laparoscopy—If there are still reasonable doubt after all these tests, it is wise to explore the abdomen.
- iv. CT scan/MRI—To know enlargement of the lymph glands and operability.
- v. Endoscopic ultrasound—To assess the depth of involvement of the gastric wall and lymph nodes in the vicinity.
- vi. Laparoscopy—has proved useful for assessing metastatic spread to liver and peritoneum.
- vii. Chest X – ray and liver ultrasound—are the basic minimum imaging investigations to define metastatic spread and inoperability. With the help of investigations IV, V and Vi one can escape unnecessary laparotomy.

**Treatment**

The treatment of choice is surgical excision if the tumor is operable.

Signs of inoperability is best decided after exploring the abdomen, preoperative decision can be taken on the basis of clinical examination, sonography and CT scan findings.

The signs are:

- a. Fixation to the pancreas or posterior abdominal wall or involvement of the mesentery.
- b. Presence of secondaries in the liver and/or peritoneum.
- c. Evidence of retrograde spread downwards involving the preaortic lymph nodes.

**Curative Resection**

- a. Subtotal radical gastrectomy (>80 percent stomach is removed) for lesions in the distal two-thirds of the stomach.
- b. Total radical gastrectomy—for lesions in the proximal one-third of the stomach.

In both the above cases, there is en bloc removal of the stomach containing the lesion with at least 5 cm clearance on either side, N<sub>1</sub> and N<sub>2</sub> nodes, greater and lesser omentum and spleen. See the long case on gastric carcinoma for definition of N<sub>1</sub> & N<sub>2</sub> nodes (TNM staging).

**Palliative/Conservative Surgery**

This is done in case of inoperable growths to relieve obstruction, bleeding and pain.

In general, resection provides better palliation than does mere bypass of the tumor viz. anterior gastrojejunostomy, which leaves the patient still vulnerable to the complications



of bleeding and pain through penetration of adjacent structures.

### Anastomosis

- Gastrointestinal continuity after subtotal radical gastrectomy is restored by Billroth II (poly a) or a Roux – en – Y anastomosis. A Billroth I is ill advised, as the anastomosis will be sited on the original tumor bed.
- Continuity after total radial gastrectomy is with a Roux – en – Y or an omega loop of jejunum with a side-to-side enteroenterostomy. These anastomoses are protected with a nasojejunal tube until radiological evidence of anastomotic integrity is established. Oral feeding can then be reinstated.
- R<sub>0</sub>, R<sub>1</sub> and R<sub>2</sub> resections: (See also the long case on gastric carcinoma).  
R<sub>0</sub> resection—Removes no lymph nodes. It implies removal of the tumor along with no residual disease.  
R<sub>1</sub> resection—Removes N<sub>1</sub> lymph nodes i.e. perigastric nodes (Supra/infrapyloric, Right/left cardiac greater/lesser curve nodes) within 3 cm from the edge of the primary tumor.  
R<sub>2</sub> resection—Removes N<sub>2</sub> lymph nodes i.e. perigastric nodes > 3cm from the edge of the primary tumor and sited along the three named branches of the celiac axis (left gastric, common hepatic and splenic artery nodes).  
N<sub>3</sub> nodes—Nodes in the lesser omentum, in the root of small bowel mesentery, along middle colic artery and paraaortic nodes above left renal vein.  
R<sub>3</sub> resection—Gastric resection with removal of N<sub>1</sub>, N<sub>2</sub> and N<sub>3</sub> nodes.

The nomenclature of R<sub>1</sub>, R<sub>2</sub> and R<sub>3</sub> resections are presently called D<sub>1</sub>, D<sub>2</sub> and D<sub>3</sub> resections. In general a D<sub>1</sub> resection involves the removal of the perigastric nodes and D<sub>2</sub> resection involves the clearance of the major arterial trunks. The Japanese D<sub>2</sub> gastrectomy commonly preserves the spleen and pancreas.

### Postgastrectomy Symptoms

- Found in 20 percent cases and include biliary reflux, diarrhea, osmotic (early) and hypoglycemic (late) dumping, anemia and malnutrition. A Roux–en–Y anastomosis can lessen the chances of biliary reflux.
- Vitamin B<sub>12</sub> injections and oral FeSO<sub>4</sub> are often needed supplements.

### Prognosis

5 year survival rate in various gastric resections are as follows:

- R<sub>0</sub> resection → 26%
- R<sub>1</sub> resection → 42.4%
- R<sub>2</sub> resection → 49.5%

Chemotherapy and radiotherapy in Gastric carcinoma.

- a. Radiotherapy almost has got no role as gastric carcinoma is relatively radioresistant
- b. Chemotherapy—There is partial response with combination chemotherapy with 5FU, doxorubicin and mitomycin C or cisplatin.

### ZOLLINGER-ELLISON SYNDROME

This is a rare disorder characterized by the triad of severe peptic ulceration, gastric acid hypersecretion and a non – beta cell islet tumor of the pancreas (Gastrinoma). It is most common between 30 and 50 years of age.

### Pathology

The gastrinoma produces enormous amounts of the hormone gastrin, due to which the parietal cell mass increases 3 – 6 folds and secrete to their maximal capacity. The pancreatic lipase is inactivated and bile acids get precipitated, which results in diarrhea and steatorrhea.

In 90 percent cases gastrinoma is situated in the pancreatic head. The size varies between 1 mm to 20 cm. Approximately half to two-thirds of the cases are malignant. Multiple endocrine neoplasia (MEN), Type I is associated in 20 – 60 percent of patients.

### Diagnosis

This is done by the demonstration of hypergastrinemia and concurrent gastric hyperacidity.

The tumor localization may be performed by endoscopic ultrasound. It is seen that 80 – 90 percent of gastrinomas would be found within the gastrinoma triangle.

This triangle is bounded by the junction of second and third parts of the duodenum inferiorly, the junction of the neck and body of the pancreas medially and the confluence of the cystic duct and the common bile duct superiorly.

### Treatment

Surgical resection of the tumor is undertaken. Omeprazole is given in the dose of 60 to 80 mg/day. If a single tumor is found and excised, the patient is cured. Total gastrectomy is advised only, if medical therapy fails.

# Chapter 31

## Small Intestine

- Small intestine
- Intestinal tuberculosis
- Ulcerative tuberculosis
- Hyperplastic ileocecal tuberculosis
- Crohn's disease
- Diverticular disorders
- Short bowel syndrome
- Typhoid enteritis
- Neoplasms
- Enterocutaneous fistula

### SMALL INTESTINE

#### Anatomy

The small intestine lies in coils which are found in all parts of the abdominal cavity below the stomach and liver, and bear no fixed relationship to one another.

The coils are covered to a varying extent by the greater omentum, which hangs down in front of them.

The jejunum begins at the duodenojejunal flexure at the left side of the body of L<sub>2</sub> vertebra and is about two meters in length.

The ileum, which is 3 to 4 meters long, is continuous with the jejunum and ends in the right iliac fossa by joining the medial side of the cecum.

The jejunum which has a thicker and more vascular wall than the ileum lies mainly to the left and above but there is no definite line of demarcation between the two.

The small intestine has a complete peritoneal covering and being attached to the posterior abdominal wall by a long mesentery it is freely movable except at its two ends.

The mesentery contains between its two layers the blood vessels viz. jejunal and ileal branches of the superior mesenteric artery, the lymphatics and nerves of the small intestine. Its root or line of attachment to the posterior abdominal wall is about 15cm

long. It extends obliquely downwards and to the right from the duodenojejunal flexure. Distally the mesentery fans out to its attachment along the whole length of the small gut.

#### Physiology

The major functions of the small intestine are digestive, absorptive and motor. In addition, it has endocrine and immunologic function.

About eight liters of fluid flows into the small bowel each day. Salivary, gastric, biliary, pancreatic and intestinal secretions make up the bulk of this amount. The amount of secretion above the pylorus is 4 liters (saliva 1.5 liter and gastric juice 2.5 liters) and below the pylorus is 4 liters (bile and pancreatic juice 1 liter and succus entericus or small intestinal secretion, 3 liters).

Most of the digestion occurs in the duodenum. The absorption of sugars and peptides occur primarily in the jejunum while amino acid absorption occurs in the ileum.

Fat digestion requires the action of pancreatic lipase and bile salts for emulsification. Pancreatic lipase acts on the emulsified fat to produce fatty acids and glycerol. Most lipids are absorbed in the proximal jejunum, vitamin B<sub>12</sub> combines with intrinsic factor secreted in the stomach and is absorbed by specific receptors in the terminal ileum. Fat soluble vitamins A,

D E and K appear to be absorbed by passive diffusion.

#### Immune Function

The lamina propria contains a variety of immune cells (plasma cells, mast cells and lymphocytes). They produce immunoglobulins and cytokine mediators. The intestinal component of the immune system known as the gut associated lymphoid tissue (GALT), contains more than 70 percent of the body's immune cells.

The B-cells, T-cells and the macrophages are present in the lamina propria. These three types of cells are responsible for the cellular immune response particularly phagocytosis and secretion of cytokines.

#### Hormonal Secretion

Important gastrointestinal hormones are gastrin from the antrum, secretin and cholecystokinin CCK (duodenum and jejunum), pancreatic polypeptide or, PP (Pancreas) having anti CCK function and neurotensin from ileum.

#### Intestinal Motility

Two types of movements occur in small intestine the pace setter being located in the proximal duodenum viz.

- Propulsive that moves enteric contents distally and
- Segmenting which helps to mix and churn the contents.

Feedback inhibition of gastric emptying to jejunal propulsion occurs by the ileal brake.

### INTESTINAL TUBERCULOSIS

In tuberculosis of the small intestine ileocecal region (terminal ileum and cecum) is the most common site (85%) of involvement, possibly due to the presence of abundant lymphoid tissue in this area.

The other sites in order of frequency are colon, jejunum, rectum, anal canal, appendix and duodenum. In contrast to intestinal involvement, esophagus and stomach are far less affected.

#### Types

Depending on the route of infection the lesion may be either primary or secondary.

1. **Primary**—This is due to ingestion of milk infected with bovine strain of *Mycobacterium tuberculosis*. It is less common nowadays (<10%) due to pasteurization of milk. In India, human strain may also cause such primary tuberculosis. This produces hyperplastic tuberculosis and occurs in individuals with a high resistance to tuberculosis.
2. **Secondary**—This may be due to swallowing of infected sputum containing human strain when there is active pulmonary tuberculosis. This produces the more common form, ulcerative tuberculosis and occurs in individuals with low resistance to tuberculosis.

### ULCERATIVE TUBERCULOSIS

#### Pathology

It usually affects the terminal part of ileum as this is the most active absorption part of the gut and is rich in lymphoid tissue (Peyer's patches).

The ulcers start on the Peyer's patches and extend along the transverse axis of the gut (c.f. typhoid ulcer which is longitudinally placed). They have all the characters of tubercular ulcers. As the ulcers are shallow they perforate only rarely and may cause extensive fibrosis leading to single or multiple strictures.

As the small gut contents are liquid intestinal obstruction may set in at a later date in the subacute or acute form.

#### Clinical Features

The commonest mode of presentation is diarrhea and weight loss. The patient may also present with recurrent or continuous abdominal pain, subacute or acute intestinal obstruction, lump in the right iliac fossa and rarely features of peritonitis due to perforation.

#### Special Investigations

1. Stool examination – Pus and occult blood present.
2. X-ray chest and ESR.
3. Barium meal examination fails to detect any abnormality in the lower ileum as the meal passes quickly through this segment due to hypermotility of the affected segment of the ileum.

#### Treatment

- Conservative antitubercular treatment is the rule.
- Surgery is to be undertaken for:
  - a. Strictures causing obstruction
  - b. Perforation (rare).

### HYPERPLASTIC ILEOCECAL TUBERCULOSIS

#### Pathology

The terminal inch or two of the ileum, and the cecum are affected.

The affected gut shows gross thickening of its wall due partly to tubercular granulation tissue and edema but is mostly due to deposits of excess of fibrous tissue which is maximum in the submucosa and subserosal planes.

Unlike other tubercular lesions, there is no ulceration and no breakdown of tissues. Also unlike Crohn's disease, abscess and fistula formation are rare.

#### Clinical Features

- As the patients have good resistance against tuberculosis, constitutional symptoms of tuberculosis are often minimum.
- The patient usually presents with a lump in the ileocecal region.

- Other modes of presentation include alternate constipation and diarrhea, features of subacute or acute intestinal obstruction.

#### Special Investigation

- Ba-meal radiography—It is very suggestive of this condition and will reveal
  - (i) Persistent narrowing of the affected segment
  - (ii) The cecum is pulled up and may become subhepatic.
  - (iii) As the cecum is pulled up the ileocecal angle is widened to 180° from the normal of 90°.
- X-ray chest is usually negative.
- ESR may not be high.

#### Treatment

1. If there is no intestinal obstruction conservative antitubercular treatment is advised.
2. If obstruction is present, surgery is advised under cover of antitubercular treatment. Right hemicolectomy with removal of the diseased segment is the treatment of choice.

### CROHN'S DISEASE

#### Definition

This is a chronic granulomatous inflammatory condition that can involve any part of the gastrointestinal tract; the most common site affected being terminal ileum.

#### Etiology

1. Though a granulomatous infection, no causative infective organism has been found. Many agents including *Mycobacterium paratuberculosis*, viruses and pseudomonas have been proposed but not proved.
2. Immunological factor—Whatever be the initiating factor, immunological mechanisms play a part in the pathogenesis of the disease.
3. Genetic factor—The familial incidence of Crohn's disease is around 10 to 15 percent.
4. Smoking—It appears to accelerate after resection.

#### Pathology

##### Macroscopic

The bowel wall is grossly thickened and enveloped in mesenteric fat (fat wrapping).

### Microscopic

- The histological hallmark is a noncaseating granuloma.
- There is transmural (involving all the layers of colon) chronic inflammation with local lymphadenopathy.

### Clinical Features

- Peak incidence—15 to 20 years.
- Continuous or episodic diarrhea in 90 percent patients.
- Blood in the stools is unusual if only the small bowel is diseased, more common with colonic involvement.
- Large and complex anal lesions (abscess, fissure, fistula) may precede the appearance of intestinal symptoms.
- With progression of disease adhesions and transmural fissuring, intraabdominal abscess, and fistula tracts can develop, e.g.
  - Enterocutaneous fistula—Rarely occurs spontaneously and usually follows previous surgery.
  - Enteroenteric fistula—Between adjacent bowel loops or the pelvic colon.

### Investigations

- Ba-enema*—The best investigations of the small intestine is small bowel enema. This will show up areas of delay and dilatation, characterizing partial obstruction. The involved areas tend to be narrowed, irregular and sometimes when a length of terminal ileum is involved, there may be the string sign of Kantor. Sinograms are useful in patients with enterocutaneous fistula.
- Colonoscopy*—Due to discontinuous nature of Crohn's disease there will be areas of normal colon in between the areas of inflamed mucosa, which is irregular, ulcerated with a mucopurulent exudate.
- Sigmoidoscopy*—Ulceration in the anal canal will be readily seen.

### Complications

- Extraintestinal manifestations are the same as in ulcerative colitis, e.g. erythema nodosum, aphthous ulcers of mouth, iritis, fleeting arthritis, etc.
- Acute colonic dilatation can occur.
- Abscesses and internal fistulas are present routinely.

- Bowel obstruction, resulting from a stricture is common in Crohn's disease, particularly in the small intestine.
- Carcinoma of the colon or small bowel may be associated with chronic Crohn's disease.

### Differential Diagnosis

- Ulcerative colitis (See Table 31.1).
- Tuberculous enteritis.
- Lymphoma.
- Intestinal ischemia.

### Treatment

- Medical—Steroids are the mainstay of treatment. The regimen is the same as for ulcerative colitis. Total parenteral nutrition is an useful adjunct.
- Surgery is required for complications of the disease, e.g.
  - Failure of medical therapy
  - Recurrent intestinal obstruction
  - Perforation
  - Intestinal fistula
  - Anal manifestations, e.g. abscesses, strictures and fistula
  - Malignant change.

### Surgical Options

- Emergency surgery—The usual indication is acute fulminating Crohn's colitis with bleeding, toxic dilatation or perforation. The procedure of choice is usually a subtotal colectomy with formation of an end ileostomy (Permanent end ileostomy in right iliac fossa). Rectum is preserved in many cases.  
Crohn's disease is an absolute contraindication for the formation of an ileoanal pouch.
- Elective surgery
  - Segmental colectomy when a single localized segment is affected, causing either a stricture, fistula or abscess. Colocolic anastomosis is done following segmental colectomy.
  - Subtotal colectomy and iliorectal anastomosis done in patients with diffuse colonic disease and rectal sparing.
  - Total proctocolectomy—Indicated for extensive colonic disease involving the rectum, with or without perianal disease.

- Stricturoplasty—Preferred in case of small bowel Crohn's disease so as to preserve as much small bowel as possible. It is preferred to resection in multiple small strictures.
- Anal disease is usually treated by conservative methods, e.g. drainage of abscesses, dilatation of stricture and fistulae are left alone (spontaneous healing occurs in 50 percent cases). However, low fistulae could be laid open safely.

### DIVERTICULAR DISORDERS

A diverticulum is a blind sac from a hollow viscera viz. the alimentary tract lined by mucosa and communicating with the lumen.

### Types

- True or congenital—Diverticulum contains all the layers of the luminous organ.
- False or acquired—Diverticulum consists of mucosa and submucosa protruding through a defect in the muscle coat.  
Duodenal diverticula of duodenal cap, secondary to stenosis caused by an ulcer is the most common acquired diverticula while Meckel's diverticulum is the most common congenital diverticulum of the small bowel.

### Meckel's Diverticulum

Meckel's diverticulum is the persistence of the proximal or intestinal end of vitellointestinal duct. It is found in 2 percent individuals and is situated on the antimesenteric border of the ileum approximately 60cm (2feet) from the ileocecal valve (2%, 2 feet, 2 inches in length, rule of 2). Sometimes the diverticulum contains ectopic gastric, pancreatic or colonic mucosa.

Other anomalies of the vitellointestinal duct:

- The whole duct may be patent producing umbilical fistula.
- Completely obliterated duct persisting as a band or cord extending from ilium or Meckel's diverticulum to the umbilicus.
- The distal part of the duct may persist as umbilical sinus. The epithelial lining of the sinus may become everted producing an adenoma, enteroteratoma or raspberry tumor.

**Table 31.1: Clinical and pathological differences between Crohn's disease and ulcerative colitis**

	<i>Ulcerative colitis</i>	<i>Crohn's disease</i>
1. <i>Symptoms</i>		
• Diarrhea	Severe	Less severe
• Rectal bleeding	Very common	Uncommon
• Abdominal pain	Sometimes	Common
2. <i>Signs</i>		
Abdomen		
• Abdominal mass	Rare	Sometimes
• Spontaneous fistula	Never	Sometimes
Anal region lesions ulceration, infection, etc.	Occasional	Frequent and complex
3. <i>X-ray findings</i> (Ba-enema)	– Only colon is involved – Pseudopolyps – Internal fistulas very rare	– Colon and/or small bowel involved – Skip lesions present – Internal fistulas common
4. <i>Endoscopy</i>		
• Rectal involvement	– 95%	– 50%
• Appearance	– Uniform, continuous, granular friable lesions.	– Edema, ulcers and normal patches
5. <i>Pathology</i>		
<i>Macroscopic</i>	– Rectum and left colon more involved  – Diffuse superficial continuous ulceration – Thin mesentery – Bowel wall thin – Pseudopolyps common	– Rectum often spared but any part of GI tract involved – Skip lesions present – Thickened mesentery – Bowel wall greatly thickened – Pseudopolyps uncommon
<i>Microscopic</i>	– Inflammation limited to mucosa and submucosa – Crypt abscess common – Granulomas rare	– Transmural inflammation.  – Crypt abscesses uncommon – Granulomas (noncaseating) frequent
6. <i>Prognosis</i>		
Medicine	80% successful cure	Inadequate in 80%
Surgery	Cure possible	Liable to recurrence
Cancer	Increased incidence	Slight

See ulcerative colitis in chapter 32 – Large intestine.

d. Sometimes the intermediate part may remain patent as a cyst known as enterocystoma and the proximal and distal parts persist as fibrous cords connecting the cyst with the intestine and the umbilicus.

### Clinical Features

- The vast majority is entirely symptomless and is incidentally discovered during other abdominal operations.
- The most common presentation is GI bleeding especially in children aged 2 years or younger.
- Diverticulitis produces features simulating those of acute appendicitis. There may be gangrene or perforation and is more common in adults.
- Intestinal obstruction—When a band connects the diverticulum to the umbilicus

a coil of intestine may get twisted around it.

- Herniation—Meckel's diverticulum may become a content of inguinal or femoral hernial sac, called Littre's hernia. If it is a femoral hernia, chance of obstruction and strangulation is very common.
- Peptic ulcer syndrome—The heterotopic gastric mucosa may produce peptic ulcer and its complications in the diverticulum itself or in the adjacent intestine. The usual features are periumbilical pain, hemorrhage, (rectal bleeding) and perforation.

### Diagnosis

1. By small bowel enema.
2. By scintigraphy with sodium  $^{99m}\text{Tc}$  pertechnetate – In children this is the most accurate diagnostic test.

### Treatment

When Meckel's diverticulum is associated with any complication, treatment is resection of the diverticulum or resection of the segment of ileum bearing the diverticulum. End to end anastomosis of the intestine is then performed.

When discovered incidentally, it should be removed only if the neck is narrow.

### SHORT BOWEL SYNDROME

Massive resection of the small bowel will produce this syndrome.

Conditions which may require this type of resection include.

- i. Recurrent Crohn's disease.
- ii. Traumatic disruption of superior mesenteric artery.



iii. Mesenteric occlusion, etc.

70 percent of resection of small bowel can be tolerated if the ileocecal valve and the terminal ileum are preserved. Otherwise nutrition will be hampered severely by even 50 percent resection.

### Clinical Features

In this syndrome there are mainly problems of absorption of fat, water, electrolytes and vitamin B<sub>12</sub>.

Absorption of bile salts occurs in the ileum and help in fat absorption. If ileum is missing there will be bile salt deficiency and a defective fat absorption.

Vitamin B<sub>12</sub> deficiency will produce megaloblastic anemia.

### Treatment

Drugs such as codeine will lessen the intestinal motility and will help more absorption.

Dietary fat is restricted to 30 to 50gm daily to minimize steatorrhea.

Electrolyte depletion, especially of sodium and potassium should be replenished.

The hope for the future is probably allotransplantation of a segment of intestine.

### TYPHOID ENTERITIS

Typhoid fever is caused by the bacillus *Salmonella typhi*.

The following are the complications of this disease which the surgeon is concerned with.

a. Perforation of the typhoid ulcer which occurs in 2 percent cases during the third week of illness.

It usually occurs through ulcerated Peyer's patches in the terminal ileum.

Surgical repair is the treatment of choice.

b. Paralytic ileus—It is probably the commonest complication, conservative treatment is advised.

c. Intestinal hemorrhage occurs in 10-20 percent of hospitalized patients. This occurs from multiple ulcers which make the bowel wall friable.

d. Cholecystitis—Chronic typhoid cholecystitis may result in the patient becoming a typhoid carrier.

The main danger of this type of cholecystitis is the risk of perforation.

e. Genitourinary complications include typhoid pyelitis, cystitis and epididymoorchitis.

### NEOPLASMS

Tumors of small bowel are not common. Colonic neoplasms occur forty times more frequently than small intestinal neoplasms.

### Types

1. Benign—According to the order of frequency they are:

- Leiomyoma
- Lipoma
- Adenoma
- Polyp
- Hemangioma
- Neurogenic tumors.

2. Malignant—Very rare

- Adenocarcinoma – Commonest.
- Carcinoid tumor.
- Lymphoma and
- Sarcoma, especially leiomyosarcoma.

The peculiarity of small intestinal tumors is that benign and malignant neoplasms occur with equal frequency and the two interesting clinical syndromes are:

- i. Peutz–Jeghers syndrome.
- ii. Carcinoid syndrome.

### Peutz–Jeghers Syndrome

This syndrome consists of

- a. Multiple intestinal polyposis and
- b. Melanin spots in the lips, oral mucosa, palms and soles.

Of course there may be pigmentation without polyposis or polyposis without pigmentation.

This is a hereditary disease and inherited through a dominant gene.

Polyposis are mostly seen in the jejunum and next in the ileum.

Colon and rectum have been involved in 1/3rd of cases, whereas stomach in about 1/4th of cases.

These polyps are actually hamartomas and hence, without any malignant potentiality.

### Clinical Features

As malignant transformation is uncommon, excision is only indicated if polyposis is associated with complications such as intussusception and/or bleeding. Though polyposis involves large areas of small and large bowel,

yet excision is done of those polyps, concerned with complications.

### Carcinoid

These tumors are also called vasculocardiac syndrome of hyperserotoninemia and originate from the argentaffin or enterochromaffin cells, hence argentaffin tumor is the other name. Cytoplasm of these cells contain granules rich in 5 hydroxytryptamine. These cells are derived from the neural crest cells.

Carcinoid tumors can occur anywhere in the gastrointestinal tract from the stomach to anus.

The appendix is most frequently involved (50%) followed by ileum (25%) and rectum (15%).

This tumor can also develop outside the GI tract in the bronchus or ovary. Appendicular carcinoids are solitary tumors while 30 percent of intestinal carcinoids are multiple. Majority of these tumors are less than 1cm in diameter and in about 5 percent cases they are more than 2cm in diameter.

### Clinical Features

Flushing is the commonest early symptom, which may be precipitated by emotional stress, ingestion of food or alcohol.

The neck, face, upper trunk show a dusky red hyperemia.

Diarrhea is a significant complaint and characterized by audible borborygmi and cramping abdominal pain.

Asthmatic attacks along with flushing are also common.

Cardiac involvement (pulmonary and tricuspid valve stenosis) is a late development in the syndrome.

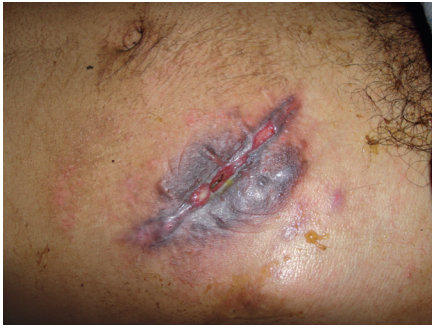### Special Investigation

Estimation of 5–HIAA is the most important test. Serotonin is broken down to 5 – hydroxy indoleacetic acid (5-HIAA) which is excreted in urine.

Normal excretion is <5mg/day whereas in carcinoid syndrome, it is more than 40mg/day.

### Treatment

If primary tumor is less than 1cm in diameter and no extension or metastasis is demonstrable, local excision is advised. In case of lesions more than 1cm wide local excision is done.



**Fig. 31.1:** Enterocutaneous fecal fistula following appendicectomy in a young male patient. He was suffering from tuberculosis.

## ENTEROCUTANEOUS FISTULA

### Definition

A fistula is an abnormal passage or communication from a hollow organ to the surface or from one organ to the other.

Enterocutaneous fistula is a fistulous communication between the intestine and the skin.

### Causes

1. Anastomotic leakage which may be due to:
  - i. Poor blood supply.
  - ii. Tension to the suture line.
  - iii. Distal obstruction.
  - iv. Associated malnutrition or sepsis.
2. Inflammatory bowel disease mainly due to Crohn's disease. Other causes include intestinal tuberculosis (Fig. 31.1) and diverticular disease.
3. Malignancy—By direct invasion of the abdominal wall.
4. Radiotherapy—Especially pelvic irradiation may lead to damage of small or large bowel.
5. Trauma—Penetrating wound of the abdomen can cause fistula, especially if the

trauma results in multiple intestinal perforations, with subsequent sepsis and abscess formation.

### Problems with Fistula

1. Fluid electrolyte loss.
2. Skin excoriation.
3. Nutritional deficiency.
4. Sepsis.
5. Hemorrhage—Sudden hemorrhage may occur due to eroded vessels.

### Investigations

1. Fistulogram: This is done with barium.
2. Ba-meal examination in gastric and duodenal fistulas give more information.

### Treatment

#### Fluid Electrolyte Replacement

An accurate evaluation of the drainage volume, its electrolyte content and an appropriate IV replacement is essential. A high output fistula (>500ml/day) can lead to large fluid and electrolyte losses with eventual circulatory collapse. Serum level of electrolytes need to be tested frequently until fluid balance is achieved. Thereafter twice weekly estimations of hematological and biochemical parameters should be sufficient.

#### Skin Excoriation

This is prevented by adhesive plastic bags (ileostomy or colostomy bags) so that the intestinal content do not come in contact with the skin surface.

#### Nutrition

The oral intake of fluids and foods should be stopped to reduce both fistula output and intestinal secretions. Feeding should be intravenous in the initial management of all fistulae.

Calculation of composition of solution for TPN (Total parenteral nutrition) in duodenal fistula (In an adult of 70Kg.)

Total = 3 liters in a bag/day.

Water = 2500ml (daily requirement)

Fistula loss = 500ml.

Na<sup>+</sup> = 70 mmol (Daily requirement) + 80 mmol (Fistula loss).

K<sup>+</sup> = 60mmol (Daily requirement) + 40mmol (Fistula loss).

N<sub>2</sub> = 14gm/day.

Calorie = 2200 kcal.

Provided by:

1. 1 liter of Amino acid—Containing 14gm nitrogen, 70mmol Na<sup>+</sup> and 60 mmol K<sup>+</sup>.
2. 1 liter of 30 percent glucose—Producing 1200 Kcal.
3. 0.5 liter of 20 percent lipid emulsion—1000 Kcal.
4. 0.5 liter of 0.9 percent saline containing 75 mmol of Na<sup>+</sup> to which is added 40 mmol K<sup>+</sup>, trace elements and vitamins.

### Control of Sepsis

In case of an abscess cavity associated with fistula, antibiotics should be given and the abscess cavity is surgically drained to provide free egress of its contents.

### Surgical Treatment

Approximately 60 percent of fistula close within 1 month of conservative treatment after control of sepsis. Closure will not occur if there is:

- a. Disruption of anastomosis with discontinuity of bowel ends.
- b. Distal obstruction.
- c. A chronic abscess cavity.
- d. Mucocutaneous epithelial continuity.

Closure is less likely if the involved bowel is diseased, e.g. Crohn's disease, malignancy malnutrition, etc.

The basis of surgery is to remove the diseased bowel and the fistula and carry out a restorative end to end anastomosis.

## Large Intestine

- Anatomy
- Blood supply
- Lymphatic drainage
- Nerve supply
- Hirschsprung's disease
- Ulcerative colitis

### ANATOMY

The colon (large intestine) is about 1.5 meter long and is subdivided into:

- Cecum with the appendix—The cecum is 6 cm long and 7.5 cm wide. The length of the appendix varies from 2 to 20 cm with an average of 9 cm.
- Ascending colon – 20 cm.
- Transverse colon – 50 cm.
- Descending colon – 25 cm.
- Sigmoid colon – 40 cm. The length of sigmoid colon varies widely from 12 – 75 cm.
- Rectum – 12 cm.
- Anal canal – 4 cm.
- The large intestine is wider in caliber than the small intestine.
- The greater part of large intestine in fixed except the appendix, transverse colon and the sigmoid colon.
- The outer longitudinal muscle coat forms only a thin layer and is mostly condensed to form three equidistant bands called 'taeniae coli', commencing at the base of the appendix upto the rectosigmoid junction.

The colon but not the appendix, cecum or rectum bears characteristic fat filled peritoneal tags called appendices epiploicae.

The taeniae coli are about 1/6th shorter than the potential length of the colon, which is therefore, puckered upto 3 rows of saccules or haustrations. The taeniatic coli, appendices epiploicae and the haustrations constitute the three cardinal features of the large intestine.

The terminal end of ileum opens into the large gut at the junction between the ascending colon and the cecum. The opening is guarded by the ileocecal valve which prevents reflux from the cecum.

When the food enters the stomach, contraction of duodenum and small intestine starts, followed by propulsion of ileal contents into the large gut (gastroileal reflex).

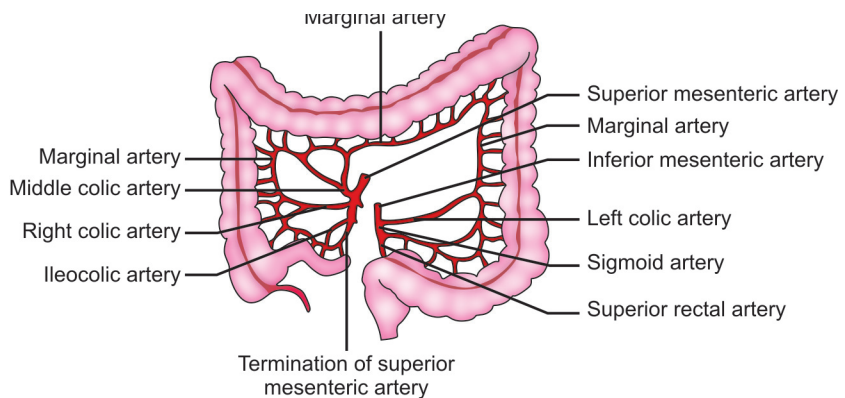
### BLOOD SUPPLY (FIG. 32.1)

- Ileocolic, right colic, and middle colic arteries which are branches of superior mesenteric artery supply the colon from cecum to the splenic flexure.
- Left colic, sigmoid and superior rectal arteries which are branches of the inferior mesenteric artery supply the descending colon, sigmoid colon and the rectum.

Each branch of the superior and inferior mesenteric artery anastomoses with its neighbor above and below so that there is in fact, a continuous vascular arcade along the whole length of the gastrointestinal canal known as the marginal artery.

It is this arterial anatomy which makes many large bowel resections possible with only infrequent compromise to the colonic perfusion. This artery can maintain the vitality of the left colon even after the inferior mesenteric has been ligatured at its origin.

Venous drainage occurs into the i)superior mesenteric vein which joins the splenic vein to form the portal vein behind the neck of the pancreas and ii) the inferior mesenteric vein draining into the splenic vein behind the pancreas in the vicinity of the duodenojejunal flexure.



**Fig. 32.1:** Blood supply of large gut

## LYMPHATIC DRAINAGE

Mucosa contains no lymph channels so mucosal cancers rarely metastasize. Nodes are arranged in four groups viz: epicolic (on the colonic wall), paracolic (located along the medial borders of the ascending and descending colon and the mesenteric borders of the transverse and sigmoid colon), intermediate (located along the right, middle and left colic arteries) and terminal or principal (near the main trunks of superior and inferior mesenteric arteries). The terminal nodes are continuous with the corresponding para-aortic nodes. Lymph from these nodes empties into the intestinal lymph trunk and continues into the cisterna chyli.

## NERVE SUPPLY

Colonic motility is under control of autonomic nervous system: Parasympathetic via vagi and pelvic nerves and sympathetic via superior and inferior mesenteric ganglia.

## HIRSCHSPRUNG'S DISEASE

This is also called congenital megacolon. It is caused by absence of ganglionic cells of the pelvic parasympathetic system in both Auerbach's plexus between the circular and longitudinal muscle layers of the colon and Meissner's submucous plexus. There is failure of migration of neuroblasts into the gut from the vagal nerve trunks.

In approximately 80 percent cases, aganglionosis involve the rectosigmoid junction and in 15 percent cases it extends proximally as far as the hepatic flexure.

## Pathology

The bowel proximal to the aganglionic segment becomes gradually dilated and hypertrophied for a variable length. The mucus lining of the dilated segment is chronically inflamed and frequently ulcerated.

In most cases the pelvic mesocolon is elongated and thickened and its blood vessels are large and prominent. This is due to the fact that the aganglionic segment stops at sigmoid colon; the grossly dilated portion involves the upper sigmoid colon and lower descending colon.

There is an area of transitional zone 1-5cm in length just proximal to the aganglionic segment. Here ganglion cells are present but fewer than normal.

## Clinical Features

This condition is more common in males and shows a familial tendency.

- In 90 percent cases symptoms appear in the early neonatal period within three days of birth.

The child is unable to pass meconium. Toothpaste like stool comes out on introducing finger into the rectum.

- Abdominal distension becomes obvious by the 3rd day with features of intestinal obstruction.
- Sometimes the patient comes in early childhood and occasionally in the adult life.
- In children, there is passage of goat pellet like stools, malnutrition and constipation.
- Rectal examination reveals normal anal sphincter and empty rectum.

## Diagnosis

- History of passage of meconium.
- Plain X-ray abdomen shows gas-filled intestinal loops throughout the abdominal cavity and an absence of gas in the pelvis.
- Barium enema is less accurate in the neonatal period than at any other time as the transition zone narrowing and proximal megacolon may not be found. However the most distinctive feature is retention of barium for 24 hours or more. Thus in the neonates delayed films after 24 hours are obligatory.
- Rectal biopsy remains the gold standard for the diagnosis. The biopsy specimen must include the submucosa to allow evaluation of the presence or absence of ganglion cells. Absence of ganglion cells is pathognomonic for Hirschsprung's disease.
- Exploratory laparotomy—This is to be undertaken when:
  - a. Patient presents with an acute on chronic obstruction in the emergency and
  - b. As a cold procedure when diagnosis is doubtful even after rectal biopsy.

## Treatment

The main aim of treatment of this condition is excision of the entire aganglionic segment and continuity is restored with normal sphincteric control of the anus.

The upper limit of resection must include the transitional zone and a little of healthy dilated colon above it. The lower limit is designed to preserve the anal canal with its sphincter.

## Primary Treatment

As the majority of patients are neonates or infants, presenting either seriously ill or in a state of acute intestinal obstruction emergency colostomy is performed as a life-saving procedure for the relief of obstruction.

The definitive procedure of resection is done at a later date after the child attains at least 1 year of age and normal weight.

## Colostomy

Two types of colostomy can be performed viz.

1. Right transverse colostomy.
2. Loop colostomy placed just above the transition zone.

Right transverse colostomy is better if one wants to protect anastomosis, but it requires a third operation, closure of the colostomy.

In case of loop colostomy, the definitive procedure (i.e. resection and anastomosis) is not protected by a defunctioning colostomy.

## Definitive Procedure

Three types of operations are done viz.

- a. Swenson's operation.
  - b. Duhamel operation.
  - c. Soave's operation.
- a. Swenson's operation—It is combined abdominal and anal approach. Aganglionic segment is resected and coloanal anastomosis is done.
  - b. Duhamel operation—In Swenson's operation the rectal sensation is lost in the absence of the rectum. In Duhamel's operation only the aganglionic segment of the colon is excised per abdomen and the rectum is preserved. The cut end of rectum is closed. The upper cut end of the colon is brought down behind the rectum and in front of the sacrum.

It is then made to traverse through the posterior wall between the fibers of the internal splinter, so that it finally emerges



at the anus posteriorly in the submucous plane and not in the anal lumen.

After an interval of 3 weeks an enterotribe (crusher) is used to crush the partition between the two lumens.

As the nerve supply of the rectum remains undisturbed, the defecation reflex is retained.

- c. Soave's operation: This operation like the Duhamel procedure preserves the rectum, excising only the aganglionic part of the colon from the abdomen.

The rectum is denuded of its mucous membrane. Thereafter, the proximal colon is pulled through the lumen of the rectum and anal canal and is sutured to the anus. Thus, it preserves the rectal sensation but avoids the blind loop of Duhamel's operation.

## ULCERATIVE COLITIS

### Definition

This is an inflammatory condition of the colon of unknown cause that affects any age group, peak incidence being in the 3rd and 4th decades. The colon is affected in continuity and skip lesions, characteristic of Crohn's disease, are almost never seen.

### Etiology

1. **Genetic factors** — Prevalence is 15 times that of the general population among the first degree relatives of patients of ulcerative colitis.
 

There is no clear Mendelian pattern of inheritance.
2. **Immune mechanisms** — Immune mechanisms can be demonstrated both in the circulation and in the mucosa. Immune complexes in the lamina propria may cause activation of the complement pathology with attraction of leukocytes and local tissue damage. An autoimmune etiology in response to bacteria have been suggested.
3. **Microbiology** — No organisms or groups of organisms have yet been identified. However, a first attack of ulcerative colitis can follow a bowel infection, e.g. bacterial dysenteries supporting the idea that contact with bacterial antigens due to damage of normal mucosal defenses can play a role in the development of the condition.
4. **Environmental factors** — Ulcerative colitis is rare in Africa and far East while it is common in the Western World.

### Pathology

#### Macroscopic

- The disease is confined to the rectum and distal sigmoid in 60 percent of cases, extension to the sigmoid is seen in a further 25 percent and in the remaining 15 percent the disease extends beyond the splenic flexure. This last group is at greater risk of developing severe acute colitis, possibly with toxic dilatation (See below).
- Mucosa and superficial submucosa only are affected. There is erythema and ulceration with adjacent areas of regenerating mucosa which appear as pseudopolyps.
- The muscle layer is thickened due to contraction producing shortening and narrowing of the affected colon with loss of normal haustral folds.

#### Microscopic

- A diffuse infiltration of acute and chronic inflammatory cells limited to the mucosa is found.
- The glandular pattern is distorted with goblet cell depletion and crypt abscesses are numerous.
- Long-standing disease may be associated with dysplasia of the epithelium, which may be mild, moderate or severe (precancer).

### Clinical Features

- i. Bloody diarrhea in an otherwise fit patient is the most common presenting symptom. Age 20 to 40 years.
- ii. In most cases, the disease is chronic and characterized by relapses and remissions.
- iii. The well-recognized extra intestinal manifestations of ulcerative colitis are as follows.
  - Skin — Erythema nodosum, pyoderma gangrenosum.
  - Mucous membrane — Aphthous ulcers of mouth and vagina.
  - Eyes — Iritis.
  - Joints — Flitting arthritis.

The above features occur transiently during disease activity.

  - Liver—Chronic active hepatitis, cirrhosis.
  - Bile duct — Sclerosing cholangitis, bile duct carcinoma.
  - Joints — Ankylosing spondylitis.

These features are persistent irrespective of disease activity.

### Complications of Severe Disease

1. Acute colonic dilatation (Toxic megacolon) - Occurs in 3 to 5 percent of cases. Patients are seriously ill (toxic) and plain abdominal films show dilatation of the transverse colon, to greater than 6cm diameter. Perforation is a risk.
2. Perforation occurs with or without preceding acute dilatation and is often lethal. The appearance of this complication is masked by corticosteroids.
3. Massive hemorrhage is uncommon but life-threatening.

### Investigations

1. Barium enema shows the following:
  - a. The earliest sign is the loss of normal colonic haustrations.
  - b. The colon is narrow and contracted (pipe stem colon).
  - c. Pseudopolyps, characterized by small filling defects.
  - d. Strictures raise the suspicion of malignancy.
2. Colonoscopy and biopsy is the most useful investigation. It is helpful in chronic disease to detect cancer, or to assess extent of involvement or response to treatment. Great care should be taken in conducting either a Ba-enema or colonoscopy in patients with severe colitis to avoid perforation.
3. *Laboratory tests* — Anemia and leukocytosis are typical. Severe illness results in derangements of fluid and electrolyte balance, hypoalbuminemia, etc.

### Management

#### Medical

- a. Mild attacks often respond to outpatient management. The aims of therapy are to control the inflammatory process and replace nutritional losses.
 

In the less severe ill patients, use of elemental oral diets may be beneficial while milk is not contraindicated in ulcerative colitis, Diarrhea will be exacerbated, if there is an associated lactase deficiency.
- b. In the severely ill patient, even clear liquids orally may stimulate colonic activity and it is wise to give the patients nothing by mouth (vide below). Parenteral nutrition is required.
 

Antidiarrheal agents—Agents to control diarrhea (diphenoxylate, loperamide,



codeine, anticholinergics) are used with extreme caution for fear of precipitating colonic dilatation and toxic megacolon.

**Drugs (to control the inflammatory process)**

1. Sulfasalazine consists of a sulfonamide (sulfapyridine) combined to a salicylate (5 - amino salicylate, 5ASA which is the active moiety).  
Dose: 4 to 6 gm/day. Initially 500 mg BD and then increased daily or every other day by 1 gm till the therapeutic dose is achieved.

New oral aminosalicylate drugs such as Mesalamine (mesacol) and balsalazide have become first line treatment for mild or moderate ulcerative colitis.

2. Steroids—If response is not prompt with sulfasalazine topical hydrocortisone (100mg) should be self-administered as a retention enema at bed time in a mild attack.

The new glucocorticosteroid budesonide may be used for distal colitis as a rectal preparation.

In the more extensive disease (moderate attack) oral prednisolone 45 to 60 mg/day is given over a 3 to 4 week period.

**Severe Attacks**

These patients must be regarded as medical emergencies and require immediate hospital admission.

- i. Nothing is given by mouth and nasogastric suction started.
- ii. Anemia is corrected with blood transfusion, fluid and electrolyte balance is maintained.
- iii. IV Hydrocortisone 100–200 mg four times daily is preferable to avoid uncertainty of oral absorption.  
Improvement is usually noted after 7 to 10 days of such therapy by a reduction in fever, decreased bloody diarrhea and an improvement in appetite.
- iv. This can be supplemented with a rectal infusion of prednisolone.
- v. There is no evidence, that antibiotics modify the course of a severe attack.  
If there is failure to gain an improvement in 5 to 7 days then surgery must be seriously considered.

**Surgery**

**Indications for Surgery**

1. Failure to respond to intensive medical management in severe or fulminating disease.
2. Chronic—Severe dysplasia on review colonoscopy.
3. Acute—Complications like toxic megacolon, perforation, severe hemorrhage and stenosis causing obstruction.
4. Extraintestinal manifestations.
5. Intractability or persistence of chronic symptoms in spite of medical treatment.

Of the above 1 and 3 require immediate surgery and others elective surgery.

**Surgical Options**

1. Total proctocolectomy with permanent ileostomy (Panproctocolectomy) is the most widely used operation.
2. Total abdominal colectomy with ileostomy and rectal mucus fistula is performed in emergency situations as first aid procedure. It retains the options of a subsequent restorative procedure such as ileorectal anastomosis.
3. Restorative proctocolectomy with an ileoanal pouch, thus preserving the sphincter function. The pouch may be a simple reversed 'J' or 'S' pouch or a 'W' pouch. Probably it is the most promising operation of the future.

The advantages and disadvantages of the above procedures are given below in Table 32.1.

**End Ileostomy Care**

1. During the first few days, fluid and electrolyte balance must be adjusted with great care.
2. The skill and advice of a stoma care specialist are essential.  
*Complications of ileostomy:* Prolapse, retraction, stenosis, bleeding and paraileostomy hernia.  
*Loop ileostomy* is used to defunction a pouch ileoanal procedure or even a low anterior resection.  
*Site:* In the right iliac fossa.

**Table 32.1: Comparison of the three operations most commonly used in the treatment of ulcerative colitis**

	<i>Panproctocolectomy and Ileostomy</i>	<i>Colectomy with ileorectal anastomosis</i>	<i>Total proctocolectomy with ileal pouch anal anastomosis</i>
Advantages	Curative, one operation	Sphincter unchanged. Evacuation 2-4 times per day. No stoma.	Curative, continent
Disadvantages	Incontinence, need to empty 4–8 times a day, external ileostomy appliances	Not curative, cancer risk persists	Failure rate 10 percent, need to evaluate 4-8 times per day
Complications	<ul style="list-style-type: none"> <li>• Stoma revision</li> <li>• Intestinal obstruction</li> </ul>	<ul style="list-style-type: none"> <li>• Small bowel obstruction</li> <li>• Anastomotic leak</li> </ul>	<ul style="list-style-type: none"> <li>• Sepsis, stenosis</li> <li>• Pouchitis.</li> <li>• Bladder dysfunctions</li> <li>• Small bowel obstruction</li> </ul>
Contraindications	• None	<ul style="list-style-type: none"> <li>• Sphincter incontinence</li> <li>• Severe rectal disease</li> <li>• Rectal dysplasia, rectal cancer</li> </ul>	<ul style="list-style-type: none"> <li>• Crohn's disease</li> <li>• Rectal cancer in distal half</li> </ul>

## The Appendix

- Surgical anatomy
- Anatomical positions
- Blood supply
- Appendicitis
- Laparoscopic appendicectomy
- Neoplasms of the appendix
- Carcinoid tumor
- Adenocarcinoma
- Malignant mucocele

### SURGICAL ANATOMY

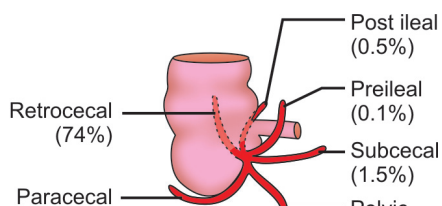
The appendix arises from the posteromedial aspect of the cecum about 2.5 cm below ileocecal valve. Its length ranges from 2 cm to 20 cm.

In the fetus it is a direct outpouching of the cecum but differential overgrowth of the lateral cecal wall results in its medial displacement.

### ANATOMICAL POSITIONS (FIG. 33.1)

The position of the base of the appendix is constant at the base of the cecum where the three *taeniae coli* meet but the position of the appendix itself is extremely variable.

Most frequently (74 percent of the cases) the appendix lies behind the cecum. The organ may be partly or entirely retroperitoneal and sometimes may be in front of the kidney.



**Fig. 33.1:** Different anatomical positions of the appendix

In 20 to 22 percent of the cases, the appendix lies just below the cecum or hangs down into the pelvis less commonly it passes in front of or behind the terminal ileum.

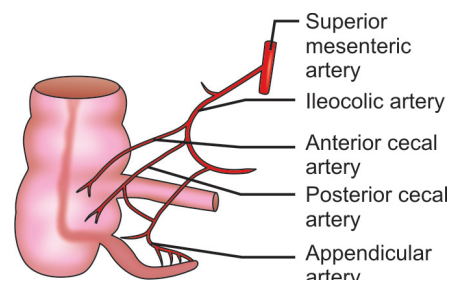
The muscular coat of the appendix resembles that of the small intestine, but the mucous membrane resembles that of the large intestine containing the goblet cells, which secrete mucus in case of mucocele of the appendix.

The submucous coat is well-developed and contains large number of lymphoid tissue, especially in childhood and young, known as abdominal tonsil. The appendiceal orifice is partially occluded by a valve like fold of mucous membrane, called the valve of Gerlach. The lumen of the appendix is relatively wide in the infant and is frequently completely obliterated in the elderly.

Since obstruction of the lumen is the usual cause of acute appendicitis, it is relatively uncommon in these two extremes of life.

### BLOOD SUPPLY (FIG. 33.2)

- The appendicular artery, a branch of the lower division of ileocolic artery, is the main arterial supply to the appendix.
- Accessory appendicular artery, a branch of the posterior cecal artery supplies the base of the appendix.



**Fig. 33.2:** Blood supply of the appendix and cecum

Appendicular artery is an end artery. So inflammatory thrombosis of the artery which sometimes occurs in acute appendicitis will lead to gangrenous changes and perforation in the distal part of the appendix, which has no other source of blood supply.

This is in contrast to acute cholecystitis where the rich collateral vascular supply from the liver bed prevents the gangrenous changes and perforation of gallbladder in case of thrombosis of the cystic artery.

The appendicular vein drains into the ileocolic vein, which is a tributary of the superior mesenteric vein.

The congenital anomalies of the appendix include (i) Agenesis, (ii) Duplication, (iii) High up and (iv) Left sided appendix (Situs inversus).

## APPENDICITIS

Acute appendicitis is the most common cause of acute abdomen. They may occur at any age but most commonly seen in the second and third decades of life. It is rare in infants.

### Etiology

1. *Racial and dietary factors* — Acute appendicitis is more common in the Western World and more commonly seen in whites.  
*Diet* – High protein and low residue diet have some relation, probably because of formation of hard fecal concretions or fecolith. These fecoliths can enter the appendix and cause obstruction.
2. *Socioeconomic status*—Appendicitis is common in the middle class and rich people.
3. *Familial cause*—There may be some familial predisposition.
4. *Bacterial infection* — It is due to bacteria like *E. coli*, *proteus*, *pseudomonas*, *klebsiella* and anaerobes which produce diffuse inflammation of the appendix and cause appendicitis of nonobstructive type.
5. *Obstruction*—Any factor causing obstruction of the lumen can produce obstructive appendicitis, e.g. fecoliths, worms, ova, foreign body, strictures, growth of cecum, lymphoid hyperplasia, carcinoid tumor of the appendix, etc.

### Pathology

#### Types

1. *Acute nonobstructive or catarrhal appendicitis*—Where the entire length of the lumen can drain into the cecum.
  - A mild attack may completely resolve or mucosal or submucosal edema can occur.
  - It is usually infective in origin as mentioned above.
2. *Acute obstructive appendicitis*—In this type of appendicitis, symptoms are abrupt and more severe. The appendix becomes a closed loop and continuing secretion by appendicular mucosa results in distension and pain first in the periumbilical region according to nerve supply of the appendix. Once the serosa is involved pain is migrated from the periumbilical region

to the right iliac fossa. Here the pain becomes more intense and manifests as local peritonitis.

3. *Recurrent appendicitis* — Repeated attacks of nonobstructive appendicitis produce adhesions and fibrosis causing recurrent appendicitis.
4. *Subacute appendicitis*—It is the milder form of acute appendicitis.

### Pathologic Changes

Macroscopic:

- In early acute appendicitis the organ is swollen and serosa shows hyperemia.
- In well-developed acute inflammation called acute suppurative appendicitis the serosa contains engorged vessels on the surface with fibrinopurulent exudates.
- In further advanced cases, called acute gangrenous appendicitis there is necrosis and ulceration of mucosa and the appendix becomes soft and friable.

Microscopic:

- The most important diagnostic criteria is the neutrophilic infiltration of the muscularis propria.
- There is congestion and edema of the appendiceal wall in the early stage. In the later stages the mucosa is sloughed off and the wall becomes necrotic.
- An impacted foreign body, fecolith or concretion may be seen in the lumen.

### Clinical Features

#### Symptoms

##### Pain

The pain commonly starts at the epigastrium or periumbilical region (10th segment) as referred pain and ultimately shifts to right iliac fossa.

In obstructive type this pain is colicky due to spasm and increased intraluminal tension.

Sudden subsidence of pain is due to perforation, releasing the tension.

This is usually followed by diffuse abdominal pain due to generalized peritonitis.

In nonobstructive type the pain is constant aching.

- Nausea and vomiting are due to reflex action induced by rise in intraluminal tension in appendix. However, vomiting is never frequent like intestinal obstruction.
- Fever is usually of low grade which depends on bacterial status.

#### Murphy's Triad or Syndrome

- This is a symptom complex in acute appendicitis, comprising pain in right iliac fossa, first, vomiting next and fever last.
- Constipation is the usual feature except in preileal and postileal appendicitis, where they produce diarrhea due to irritation of ileum.
- Hematuria is uncommon and is due to inflammation of retrocecal appendix which irritates the ureter in the retroperitoneum.

#### Signs

1. *Cough tenderness*—It indicates inflammation of parietal peritoneum. This is an important physical sign which differentiates acute appendicitis from right-sided enteric colic.
2. *Tenderness and rebound tenderness* — They are present at McBurney's point. Rebound tenderness is called Blumberg sign. It is due to inflammation of the parietal peritoneum and can be elicited in all cases of peritonitis.
3. *Rovsing's sign*—The finding of pain in the right iliac fossa on applying pressure on the left iliac fossa is known as the Rovsing's sign and is highly suggestive of acute appendicitis.
4. *Guarding and rigidity* — Muscle guarding correspond to the severity of the inflammatory process. As peritoneal irritation progresses, voluntary muscle guarding increases and is eventually replaced by involuntary rigidity.
5. *Cutaneous hyperesthesia* — It may occur on the right side of the abdomen in the Sherren's triangle bounded by the anterior superior iliac spine, symphysis pubis and umbilicus.
6. *Cope's psoas test* — Pain on hyperextension of the patient's right thigh, thereby stretching the iliopsoas muscle, indicates that the inflamed appendix is in close proximity to the psoas muscle. This may be seen in retrocecal appendicitis.
7. *Cope's obturator test* — Pain on passive internal rotation of right thigh points to pelvic appendicitis. This is due to the fact that the inflamed appendix is in contact with the obturator internus muscle.
8. *Generalized peritonitis* — Features of generalized peritonitis are seen only when

there is rupture of appendix. It occurs rarely nowadays.

9. *Rectal examination* — There is tenderness in the right rectal wall – differential tenderness.

### Alvarado Score

It is the clinical and laboratory based scoring system, most widely used for diagnosis of acute appendicitis. It is also called MANTRELS score and is follows.

Symptoms	Score
Migratory RIF pain	1
Anorexia	1
Nausea and vomiting	1
<i>Signs</i>	
Tenderness over McBurney's point	1
Rebound tenderness	2
Elevated temperature	1
<i>Laboratory tests</i>	
Leukocytosis	2
Shift to left	1
<b>Total</b>	<b>10</b>

A score of 7 or more is strongly predictive of acute appendicitis and immediate operation is required. When the score is 5 or 6, these are borderline cases and further tests like abdominal ultrasonography, etc. are required to avoid normal appendectomy.

### Investigations

1. Blood—Total leukocyte count is almost always elevated above 10000/cm.
2. Plain X-ray abdomen in erect posture is taken to rule out perforation.
3. Abdominal ultrasound is done to rule out other causes including gynecological causes, of acute abdomen.
4. CT scan — It is not required to diagnose a case of simple appendicitis but to detect an appendicular mass, appendicular abscess or pelvic abscess. This investigation is of great help.

### Differential Diagnosis

- A. Abdominal causes
1. Acute cholecystitis.
  2. Perforated peptic ulcer.
  3. Acute intestinal obstruction.

4. Acute pancreatitis.
  5. Meckel's diverticulitis.
  6. Mesenteric vascular obstruction.
- B. Gynecological disorders
1. Acute salpingitis.
  2. Ruptured ectopic pregnancy
  3. Twisted ovarian cyst.
- C. Retroperitoneal causes
1. Right ureteric colic.
  2. Right sided acute pyelonephritis.
- D. Thoracic diseases, e.g.
- Basal pneumonia and pleurisy.
- E. Medical causes
1. Porphyria.
  2. Diabetic abdomen.

### Complications of Acute Appendicitis

#### Rupture of the Appendix

Rupture of the appendix causes generalized peritonitis. Emergency laparotomy, appendectomy, peritoneal wash, followed by drainage of peritoneal cavity is the treatment to be done.

#### Appendicular Mass

- Following an attack of acute appendicitis infection is sealed off by greater omentum, cecum, terminal ileum which results in a tender, soft to firm mass in right iliac fossa.
- Presence of a mass is a contraindication for appendectomy because it is very difficult to remove appendix from such a mass and an attempt to remove may result in a fecal fistula.

#### Treatment

It is treated conservatively by Oschner and Sherren's regime: followed by elective appendectomy after 6 to 8 weeks.

#### Conservative Treatment

1. Ryle's tube suction to give rest to the gut.
2. Stoppage of oral feeding.
3. Intravenous fluid — 2 to 2.5 liters a day to supply the daily requirement.
4. A careful watch is kept on the general condition, temperature and pulse.
5. The mass is marked to identify the progression or regression.
6. Broad spectrum antibiotics started initially parenterally, then orally.

7. Catheterization to maintain the intake output chart.

8. Antispasmodics to relieve pain.

If the temperature does not come down and the toxicity increases, even after 48 hours of conservative treatment immediate surgical exploration is indicated.

Usually the mass resolves in 3 to 4 days in 80 percent of the cases. The abdomen becomes soft and tenderness decreases. Thus Ryle's tube is removed and clear oral fluids followed by soft diet are given. By one week the patient is back to normal.

#### Appendicular Abscess

In untreated cases or when the patient does not respond to the conservative treatment, an appendicular mass may turn into an appendicular abscess.

Clinically there is high fever and tender, smooth, dull (on percussion), soft swelling in the right iliac fossa (lateral part).

Ultrasonography confirms the diagnosis.

#### Treatment

Broad spectrum antibiotic started under general anesthesia, incision is made in the lower lateral aspect of the swelling. Abscess cavity is opened, pus is drained and wound is closed putting a drain in the abscess cavity.

#### Differential Diagnosis of a Mass in Right Iliac Fossa

This is best thought of by considering the possible anatomical structures in this regions viz.

1. Appendicular mass or abscess.
2. Carcinoma cecum.
3. Crohn's disease.
4. Ileocecal tuberculosis.
5. Mesenteric lymphadenitis.
6. Ovarian or tubal mass.
7. Retroperitoneal tumor.
8. Pelvic kidney.

#### Treatment

Acute appendicitis — The treatment of choice is appendectomy. The purpose of immediate operation is to avoid the possibility of rupture of appendix and spreading peritonitis.

*Treatment of subacute and recurrent appendicitis* — The treatment of choice is early appendectomy.

### LAPAROSCOPIC APPENDICECTOMY

In recent years, laparoscopic appendicectomy has been introduced in the management of patients with acute appendicitis. There is no doubt that in experienced hands, the endoscopic operation is safe even in the presence of perforation as much as the traditional procedure. Of course benefit from the laparoscopic approach remains to be confirmed by more trials. The operation of appendicectomy is described in the operative section.

### NEOPLASMS OF THE APPENDIX

85 percent of all appendiceal tumors are carcinoids other types of tumors are rare and include adenocarcinoma, mucinous neoplasms and lymphoma.

### CARCINOID TUMOR

The tumor is small, firm and bright yellow in color due to the contained lipoid. Majority of the tumors occur in the distal third of the appendix and only less than 10 percent occur at the base. These are without symptoms and are usually discovered at the time of operation. Metastasis of carcinoid tumor is rare.

#### Treatment

Appendicectomy is the treatment of choice unless the lymph nodes are involved. If there is nodal metastasis or cecum is involved, right hemicolectomy is indicated.

### ADENOCARCINOMA

This is the second most common tumor of appendix and mostly presents as acute appendicitis or intestinal obstruction.

The treatment is right hemicolectomy.

### MALIGNANT MUOCOCELE

Benign mucocele may occur in the process of acute appendicitis.

Malignant mucocele is mucous papillary adenocarcinoma.

Treatment is simple appendicectomy. There is chance of developing pseudomyxoma peritonei if there is rupture of mucous-filled appendix during operation. In this condition, there is accumulation of a large quantity of mucinous fluid or more gelatinous material in the peritoneal cavity. It also occurs after rupture of a pseudomucinous cyst of the ovary. It is suggested that metaplasia of the peritoneal cells may produce local spread and further production.

Surgical removal of the pseudomucin and the underlying tumor followed by peritoneal toilet offers the best prospects of cure.



# Chapter 34

## Intestinal Obstruction

- Intestinal obstruction
- Paralytic ileus
- Neonatal intestinal obstruction
- Intussusception
- Volvulus

### INTESTINAL OBSTRUCTION

#### Definition

Aboral arrest of propulsion of intestinal contents is known as the intestinal obstruction.

#### Classification

Intestinal obstruction may be divided into two main groups viz.

1. Mechanical or dynamic obstruction – There is physical occlusion of the lumen preventing the intestinal contents from passing along the intestine.
2. Paralytic ileus or adynamic obstruction – is a disorder in which there is neurogenic failure (i.e. failure in the myenteric plexus of Auerbach and submucous plexus of Meissner) of peristalsis to propel the intestinal contents.

#### Mechanical Obstruction

Mechanical obstruction is further classified according to:

1. Its speed of onset.
  2. Its site.
  3. Its nature of vascular compromise.
  4. Its etiology.
1. The speed of onset determines whether the obstruction is acute, chronic or acute on chronic.
    - In acute obstruction, the onset is sudden and the signs and symptoms appear within hours. Usually it affects

small bowel, e.g. volvulus, obstructed hernia.

- In chronic obstruction the symptoms are insidious and slowly progressive appearing within weeks, e.g. carcinoma of the large bowel.
  - A chronic obstruction may develop acute symptoms as the obstruction becomes suddenly complete. When a narrowed lumen gets totally occluded by inspissated bowel contents this is termed acute on chronic obstruction.
2. According to the site of obstruction, it may be
    - i. High or small gut obstruction.
    - ii. Low or colonic obstruction.
  3. According to the nature of obstruction, the obstruction may be:
    - i. Simple or non strangulated when the bowel is occluded without any vascular compromise and
    - ii. Strangulated – When the blood supply of the involved segment of intestine is cut off, e.g. in strangulated hernia, volvulus, or where a loop of intestine is occluded by a band. In case of volvulus closed loop obstruction occurs when both ends of the involved intestinal segment are obstructed.
  4. According to etiology

Whenever we consider obstruction of a tube anywhere in the body, this should be classified into:

1. Causes in the lumen.
  2. Causes in the wall.
  3. Causes outside the wall.
- Applying this to the intestinal obstruction, the causes are:
1. In the lumen
    - Fecal impaction.
    - Gallstone ileus.
    - Food bolus.
    - Pedunculated tumor.
    - Foreign body.
    - Parasite (roundworms)
    - Bezoar.
  2. In the wall
    - i. Congenital
      - Congenital atresia.
      - Imperforate anus.
      - Meckel's diverticulum.
    - ii. Acquired
      - Postanastomotic.
      - Tuberculosis.
      - Regional enteritis.
      - Neoplastic stricture.
      - Radiation.
      - Endometriosis.
  3. Outside the wall
    - Strangulated hernia (external or internal)
    - Bands and adhesions—These are the commonest causes in previously operated patients and account for 40% of all causes.
    - Volvulus.
    - Intussusception.

It is also useful to think of the common causes of intestinal obstruction in various age groups, e.g.

1. Neonatal
  - a. Congenital atresia (Jejunal and ileal).
  - b. Meconium ileus.
  - c. Hirschsprung's disease.
  - d. Volvulus neonatorum (Syn: Midgut malrotation).
2. Infants
  - a. Intussusception.
  - b. Hirschsprung's disease.
  - c. Meckel's diverticulum.
3. Young adults and middle age group
  - a. Strangulated hernia (most common)
  - b. Adhesions and bands.
  - c. Crohn's disease.
4. Elders
  - a. Carcinoma colon.
  - b. Impacted feces.
  - c. Strangulated hernia.
  - d. Diverticulitis.

### Pathophysiology—Distension, Absorption and Secretion

The exact pathophysiology of bowel obstruction is not yet fully understood.

- The older view maintains that a decrease in blood flow is responsible for most of the pathophysiologic changes. More recent work suggests that many of the pathophysiologic changes are in part related to the increases in blood flow seen during the early phases of bowel obstruction, with an inflammatory reaction which play a key role.
- Dilatation and inflammation of the bowel wall may cause activated neutrophils and macrophages to accumulate within the muscular layer of the bowel wall inhibiting or causing damage to secretory and motor processes by release of cytokines, reactive proteolytic enzymes and other locally active substances, e.g. nitric oxide, a potent inhibitor of smooth muscle tone further aggravating dilatation.
- Experimental data also suggest that mucosal production of reactive oxygen metabolites modulate not only gut motility but also gut permeability.
- During the first 12 hours of an obstruction of small bowel water and electrolytes accumulate within the lumen secondary to a decrease in net absorption. Most

of the gas distending the small bowel is derived from i) swallowed air, ii) gas due to bacterial activity releasing  $H_2S$  and  $NH_3$  and iii) Diffusion of oxygen and  $CO_2$  from the blood. Distension due to fluids results from accumulation of various digestive juices viz. saliva, gastric juice, bile, pancreatic juice and succus entericus within the obstructed bowel.

- By 24 hours intraluminal water and electrolytes accumulate more rapidly secondary to a further decrease in absorption and a concomitant increase in net intestinal secretion apparently secondary to mucosal injury and increased permeability. Intraluminal leakage of plasma electrolytes and extracellular fluid occurs. The role of associated neural or systemic humoral/hormonal mechanisms in this increased secretory activity remains poorly understood.
- Intraluminal bacteria derived toxins, bile acids, prostaglandins and vasoactive intestinal peptide — all exacerbate this fluid secretion into the lumen of the obstructed bowel. The decrease in absorptive capacity and increase in secretion leads to fluid losses and subsequent dehydration if not recognized and treated.

### Intestinal Ischemia

- The possibility intestinal wall ischemia is a very real concern in large bowel obstruction especially the closed loop one. When the ileocecal valve is competent (present in about 40 percent of people) the distended colon can not decompress retrograde into the small bowel and a closed loop type of obstruction occurs. Such type of obstruction is most commonly seen in the ascending colon (Fig 34.1). For simple (nonclosed loop) obstruction this scenario rarely occurs.
- Transmigration of resident bacteria through the ischemic or gangrenous bowel results in septic peritonitis and gram-negative or endotoxic shock.

### Clinical Features

#### Symptoms

The cardinal symptoms of intestinal obstruction are four viz. abdominal pain, abdominal distension, absolute constipation and

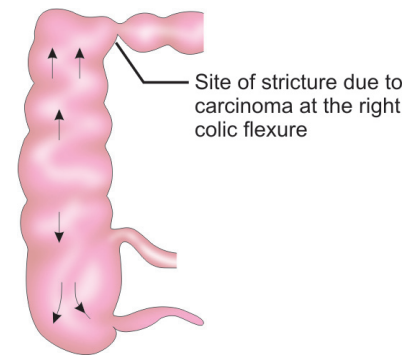


Fig. 34.1: Schematic diagram of a closed loop obstruction.

vomiting. It is important to note that not all of these four features need necessarily be present in a case of intestinal obstruction.

1. Pain abdomen—Colicky in nature, lasts for 5 to 10 min., comes and goes, central abdominal pain is a feature of small intestinal obstruction and peripheral pain is a feature of large intestinal obstruction.
2. Abdominal distension — There is central abdominal distension in ileal obstruction and peripheral distension in large bowel obstruction. It may be localized in one or two quadrants as in sigmoid volvulus.
3. Constipation occurs because the distal bowel does not act. Failure of passing feces as well as flatus is called absolute constipation or obstipation.
4. Vomiting — It is due to reverse peristalsis first stomach contents, then bile followed by feculent vomiting occurs in ileal obstruction. Feculent is not fecal matter but the terminal ileal contents which undergo bacterial decomposition having the smell of fecal matter. Vomiting of altered blood indicates hemorrhage and gangrene. It is often late or even entirely absent in large bowel obstruction.

#### Signs

1. General signs of dehydration — Dry skin, dry tongue, sunken eyes with low urine output.
2. Abdominal findings:
  - a. Distension, tympanic note on percussion.
  - b. Step ladder peristalsis in terminal ileal obstruction.

- Hernial orifices have to be looked for any strangulated hernia, especially a small femoral hernia in females.
- Hypotension and tachycardia.
- Tenderness or rebound tenderness indicates peritonitis. Rebound tenderness is also called Blumberg's sign.

### Rectal Examination

- In small bowel obstruction it is empty and often ballooned out.
- Finger may be stained with blood.
- There may be fecal loading (impacted feces) in colonic obstruction.

### Investigations

- Hb% and PCV — Elevated due to dehydration. Low Hb indicates malignancy.
- Urea and electrolytes — Urea elevated, Na and Cl low.
- Chest X-ray — Elevated diaphragm due to abdominal distension.
- Abdominal X-rays — (Erect and supine):
  - Erect film demonstrates multiple air-fluid levels in a ladder pattern of dilated loops suggesting small bowel obstruction.
  - The supine film shows central distension and valvulae conniventes shadows crossing the entire width of lumen which are produced by the circular mucosal folds in small bowel obstruction, while in large bowel obstruction, there is peripheral distension and haustral shadows do not cross entire width of the bowel.
- Sigmoid volvulus appears as a large dilated loop.
- Cecum has no haustrations. However, it appears as a round gas shadow in the right iliac fossa. A dilated cecum is a dangerous radiological sign in large gut obstruction and indicates impending perforation and fecal peritonitis.

### Management

Although the treatment of specific causes of intestinal obstruction is considered under the appropriate headings, certain general principles can be enunciated here.

- Chronic large bowel obstruction can be investigated in some detail including sigmoidoscopy and Ba – enema and treated electively.

- Acute obstruction of sudden onset is invariably an urgent problem requiring emergency surgical intervention, e.g.
  - External hernial strangulation.
  - Internal intestinal strangulation (constant pain for 2 hours in spite of gastroduodenal aspiration).
  - Failure of improvement with conservative treatment even after 6 hours.

### Preoperative Preparation in Acute Obstruction

- A nasogastric tube is inserted to relieve vomiting and to avoid further distension of bowel by swallowed air.
- Intravenous replacement of fluid and electrolytes together with blood or plasma if the patient is in shock.
- Antibiotic is advisable. It is essential in strangulation which is always a possibility until operation proves otherwise.

### Operation

Operation is begun when the patient has been rehydrated and vital organs are functioning properly.

On opening the abdomen if the cecum is found distended, it is large gut obstruction and if cecum is collapsed, it is small gut obstruction.

Junction of the distended and collapsed part is reached and the site of obstruction, assessed.

Operative details depend on the cause of obstruction viz.

- In obstruction outside the wall, frank adhesions are excised, if present.
- Obstruction inside the lumen is removed by enterotomy.
- Obstruction in the wall is relieved by resection and anastomosis or stricturoplasty.
- If a groin hernia is the cause of obstruction, it is treated accordingly.

At operation, the affected bowel is examined carefully to determine its viability.

Hot mops are applied and anesthesiologist, is asked to administer pure O<sub>2</sub> for at least 3 to 5 minutes. The signs of viability are:

- Color improves (greenish or black bowel is non viable)
- Luster of peritoneum comes back
- Peristaltic movement sets in
- Pulsations of vessels in the involved mesentery appear.

Viable gut is kept inside and abdomen is closed.

For a nonviable gut, there are two options.

- If the general condition of the patient is good and blood is available, resection and anastomosis is done for small bowel obstruction.
- If the condition is not suitable for major operation, e.g. large gut obstruction which has a meagre blood supply, the affected segment is excised, the proximal cut end is brought out as colostomy, and the distal end is also brought out as mucous fistula, (Paul-Mikulicz operation).

### PARALYTIC ILEUS

#### Definition

It is the generalized dilatation and distension of the intestine due to paralysis of the nerve plexuses (Auerbach's and Meissner's plexuses) over the part.

Mechanical obstruction may terminate into paralytic ileus.

#### Causes

- Postoperative
- Infective condition that is associated with peritonitis.
- Reflex, e.g. after spinal surgery, tight plaster jacket, retroperitoneal hemorrhage etc.
- Hypokalemia.
- Uremia or hepatic failure due to toxemic paralysis.

#### Clinical Features

- Absolutely silent abdomen.
- No pain.
- Regurgitant vomiting.

#### Treatment

In 99 percent cases conservative treatment is useful.

If it fails surgical intervention in the form of exploratory laparotomy is needed.

### NEONATAL INTESTINAL OBSTRUCTION

**Incidence:** 1 in 2000 births.

**Causes:**

- Intestinal atresia.
- Volvulus neonatorum.

3. Meconium ileus
4. Hirschsprung's disease (see chapter 32 'Large intestine').
5. Anorectal atresias.

### Intestinal Atresia

- It is the most common cause of intestinal obstruction in neonates.
- Commonly the duodenum is affected, followed by ileum and jejunum.

#### Duodenal Atresia

##### Diagnosis

- a. Abdominal X-ray shows double bubble sign due to gastric and duodenal distension.
- b. Total absence of gas distal to duodenum indicates atresia rather than stenosis.

*Treatment:* Duodenoduodenostomy.

#### Jejunal and Ileal Atresia

##### Features

- Abdominal distension occurs within 24 hours of birth.
  - Plain abdominal X-rays demonstrate dilated loops of bowel usually centrally placed in the abdomen and with air fluid levels.
- Treatment:* Resection of the stricture and anastomosis.

### Volvulus Neonatorum (Syn— Midgut Malrotation)

This is due to a defect of normal rotation of the bowel. The cecum remains high, often with a congenital band, known as transduodenal band of Ladd, passing from it across the second part of duodenum to the posterior abdominal wall.

The cecum and the midgut are suspended on a narrow attachment of mesentery which readily undergoes volvulus. Volvulus tenses the Ladd's band and can cause intermittent obstruction or kinking of the duodenum. It occurs in a clockwise direction.

Malrotation is frequently present in patients with diaphragmatic hernia and anterior abdominal wall defects.

Treatment comprises untwisting the volvulus and dividing the transduodenal band at laparotomy.

### Meconium Ileus

This is a neonatal manifestation of infants with cystic fibrosis (Mucoviscidosis), which is a generalized defect of mucus secretion of

the intestine, pancreas (Fibrocystic pancreatic disease) and the bronchial tree. The lower ileum becomes blocked with inspissated sticky meconium.

- Infants present with bilious vomiting and failure to pass meconium.
- Plain X-ray shows distended bowel loops and soap bubble appearance of meconium in right iliac fossa.

#### Treatment

1. Conservative treatment—It is done in case of uncomplicated meconium ileus that is, in the absence of peritonitis or partial obstruction.

The meconium is cleared by dilute gastrograffin enema per rectum under X-ray control.

2. Surgical treatment—If the above treatment fails or if there is complete obstruction, surgery is indicated.

Bishop Knoop operation is done.

- Ileum is divided at the proximal healthy part and anastomosed to the ascending colon to relieve obstruction – by end to side anastomosis.
- Distal ileum containing thick meconium is brought outside as a fistula and regular saline washes are given to dilute the meconium. Mucous fistula needs to be closed after a few weeks.

### Anorectal Atresia

Any degree of severity of this condition may occur from imperforate anus to complete absence of anus and rectum.

In half of the cases, there is presence of a fistula, in the female into the vagina and in the male into the bladder or urethra.

#### Clinical Features

The anus may be entirely absent or represented by a dimple or by a blind canal. The extent of the defect is judged by X-raying, the child (Invertogram), held upside down with a metal marker at the site of the anus.

The distance between the gas bubble in the lower bowel and the marker thus can be measured.

#### Treatment

1. If the septum is thin, the treatment is division of the septum with suture of the edges of the defect to the skin.

2. In case of an extensive gap between the blind end and the anal verge, a colostomy is performed with later attempt at a pull through operation at about 2 years of age.
3. If a vaginal fistula is present, operation is not urgent, since the bowel decompresses through the vagina. Elective surgery is performed, when the girl is older.
4. If a rectovesical or urethral fistula is present, as evidenced by passage of meconium in the urine, the fistula must be closed urgently, either with colostomy or reconstruction of the anus in order to prevent ascending infection of the urinary tract.

## INTUSSUSCEPTION

### Definition

Invagination of one segment of intestine within the other, immediately adjacent to it is known as intussusception.

It is most common in children between sixth and ninth months.

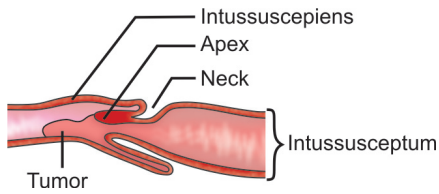
### Etiology

- More than ninety percent cases are idiopathic. It is believed that hyperplasia of Peyer's patches in the terminal ileum may be the initiating event. The swollen lymph follicle protrudes into the lumen of the bowel and acts as a foreign body which is then forced distally along the gut.
- In adults and in some children, a carcinoma, a polyp or an inverted Meckel's diverticulum may form the apex of intussusception.

### Parts

The parts of an intussusception are the following (Fig. 34.2):

1. Intussusceptum – It is the proximal bowel that is, the inner tube which enters inside.
2. Intussuscipiens – It is outer tube or distal bowel which receives the intestine.
3. Apex — The part which advances is the apex.
4. Neck is the narrowest portion of intussusception which marks the junction of the entering layer with the mass. The whole mass that develops is called intussusception. See also figure. 101.6 — The Specimen of intussusception



**Fig. 34.2:** Intussusception with pedunculated tumor

## Types

According to the segment of gut involved:

1. Only small gut is involved producing ileoileal intussusception where ileum is invaginated into ileum.
2. Only large gut is involved giving rise to colo-colic intussusception, where colon is invaginated into colon.
3. Combination of small and large guts leading to:
  - a. Ileocecal and
  - b. Ileocolic intussusception.

These (a & b) constitute more than 80 percent of the cases.

In ileocecal type, the ileocecal valve is the apex of the intussusception, whereas in ileocolic type, the ileoileal intussusception extends through the ileocecal valve into the colon.

An intussusception is an example of strangulating obstruction as the inner layer has its blood supply cut off by direct pressure of the outer layer and by stretching of its supplying mesentery. Hence, if left untreated gangrene of the intussusception may occur.

## Clinical Features

- First born male infants between 6 to 9 months of age are commonly affected.
- Child screams with abdominal pain with drawing up of the legs.
- The attacks of pain last for a few minutes, recur every 10 – 15 minute and become progressively severe.
- The edema and congestion of the gut walls produced as a result of compression of the mesentery between the entering and returning layers, pours out into its lumen a mixture of blood and mucus which is termed the 'red currant jelly stools'.
- Bleeding is due to mucosal ulceration.
- Mucus is due to irritation of intestine. This is followed by total intestinal obstruction.
- Vomiting occurs 3–4 times initially due to pylorospasm, later due to obstruction.

## Signs

- Palpation of the abdomen reveals a sausage-shaped tumor, usually in and around the umbilical region.
- There is emptiness in the right iliac fossa. This is called 'signe de dance' and is caused by the shifting of the contents of the right iliac fossa.
- Rectal examination reveals blood stained mucus on the examining finger.

## Diagnosis

Ba–enema–Claw (pincer) ending is diagnostic of intussusception. If there is any suspicion of gangrene, this test should not be done. In many cases, the diagnosis is established on clinical grounds.

## Treatment

### Nonoperative

- Hydrostatic reduction can be attempted in early intussusception. It is successful in 50 to 70 percent of cases. The intussusception is reduced by the pressure of the column of barium and this is confirmed radiologically.

### Operative reduction

The intussusception is reduced at laparotomy by squeezing its apex towards the neck, through the intussuscepiens.

In late cases reduction may be impossible or the bowel may be gangrenous, resection and anastomosis may then be necessary.

In the usual types, i.e. ileocecal and ileocolic, a right hemicolectomy has to be performed in late cases.

## VOLVULUS

### Definition

Volvulus is defined as the twisting of a loop of bowel around its mesenteric axis which results in a combination of bowel obstruction together with ischemia due to occlusion of the main vessels at the base of the involved mesentery.

### Sites

Most commonly it affects the sigmoid, cecum and small intestine, but volvulus of the gall-bladder and stomach may occur.

## Etiology

The predisposing factors are:

1. An abnormally loaded loop, e.g. the pelvic colon of chronic constipation.
2. An abnormally mobile loop of intestine, e.g. congenital failure of rotation of mid-gut, or a long sigmoid loop.
3. A loop of bowel fixed at its apex by adhesions.

## Sigmoid Volvulus

This usually occurs four times more commonly in men than in women. The patient is usually an elderly one with constipation.

The loop of sigmoid colon usually undergoes twisting in an anticlockwise direction from one half to three turns.

## Clinical Features

There is a sudden onset of pain with characteristic gross and rapid dilatation of the sigmoid loop.

A plain X-ray abdomen shows an enormously dilated oval gas shadow on the left side to give the typical 'bent inner tube' sign. If left untreated, the strangulated bowel undergoes gangrene resulting in death from peritonitis.

## Treatment

1. Conservative: A rectal tube is passed through a sigmoidoscope, which often untwists an early volvulus and is accompanied by the passage of a large amount of flatus.
2. Operative treatment: If the above conservative method fails, the volvulus is untwisted at laparotomy. If the gut is viable, resection of the redundant sigmoid loop and end to end anastomosis done to prevent recurrent volvulus.

If gangrene has set in, the affected segment is excised and the two ends are brought out as double – barreled colostomy, which is later, closed (Paul–Mikulicz procedure). Alternately the proximal end is brought out as a colostomy and the distal loop is closed which is called Hartmann procedure.

## Volvulus of Cecum

This is usually associated with a congenital defect of rotation of bowel and the cecum



instead of being fixed to the posterior abdominal wall in the right iliac fossa (RIF), has a persistent mesentery. Clinically there is an acute onset of pain in the RIF with rapid abdominal distension. It is more common in females.

X-ray of the abdomen shows a grossly dilated cecum, which is rotated clockwise upon its mesentery and frequently located

in the left upper quadrant of the abdomen. Acute gastric dilatation can be mistaken for cecal volvulus radiologically.

### Treatment

The mainstay of treatment of this condition is surgery. At operation, the volvulus is untwisted and the safest method of preventing recurrent episode is to perform a right

hemicolectomy, although this opinion is subjected to controversy.

The definitive treatment of cecal volvulus even when the bowel is viable is cecal resection and ileocolic anastomosis.

Cecopexy and cecostomy are both advocated in the older patients.

Volvulus of the transverse colon can also occur.

# Chapter 35

## Rectum and Anal Canal

- Rectum
- Anal canal
- Prolapse of rectum
- Colorectal carcinoma
- Anorectal anomalies
- Hemorrhoids (piles)
- Anorectal abscess
- Fistula in ano
- Anal fissure (Fissure in ano)

### RECTUM

#### Surgical Anatomy

The rectum has an ill-defined anatomical beginning but surgically the rectosigmoid junction lies opposite the sacral promontory.

The rectum is 12cm in length. Although it is a part of the large gut, it is devoid of taeniae coli, sacculations, appendices epiploicae and mesentery.

The rectum presents a series of three lateral curvatures; two are convex to the right side and one to the left side. The curvatures contain three transverse folds of mucous membrane and circular muscle, called valves

of Houston, projecting left, right and left from above downwards.

#### Relations (Fig. 35.1)

Posteriorly the rectum is in contact with the sacrum and coccyx and the middle sacral artery, which are separated from it by extra-peritoneal connective tissue containing the rectal vessels and lymphatics.

Anteriorly the upper two-thirds of the rectum are covered by peritoneum and relate to coils of small intestine. In front of the lower one-third lies prostate, bladder base and seminal vesicle in the male or the vagina in the female.

A layer of fascia, called the fascia of Denonvilliers separates the rectum from the anterior structures and forms the plane of dissection, which must be sought after in excision of the rectum. Laterally, the rectum is supported by the levator ani.

#### Blood Supply

- The superior rectal artery, continuation of the inferior mesenteric artery, is the principal artery of the rectum.
- The inferior rectal artery, a branch of the internal pudendal artery, anastomoses with the middle rectal artery at the anorectal junction.
- Middle rectal artery, a branch from the anterior division of internal iliac artery.

#### Veins

The veins correspond to the arteries. The superior rectal vein drains into the inferior mesenteric vein (portal system). The middle and inferior rectal veins drain into the internal iliac and internal pudendal veins respectively.

#### Lymphatic Drainage

The lymphatics of the mucosal lining and the muscular layers interchange freely and pass to the pararectal nodes lying in the pararectal tissue.

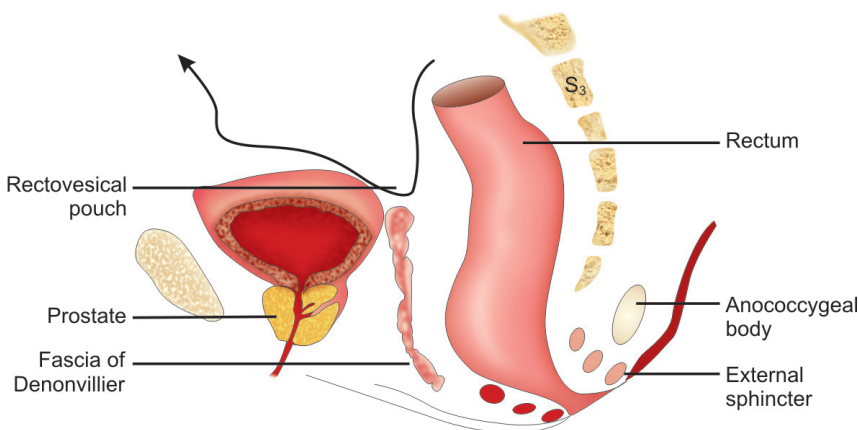


Fig. 35.1: Relations of the rectum

Efferents from the pararectal nodes (upper and middle members) accompany the superior rectal artery to the inferior mesenteric nodes.

Lymph vessels from the lower part of rectum pass to the internal iliac nodes along the middle rectal artery.

The usual drainage flow is upwards along the superior rectal nodes of Gerota to the inferior mesenteric nodes. For this reason, surgical ablation of malignant disease consists of wide clearance of these proximal lymph nodes.

### Development

Rectum is developed from the dorsal part of the entodermal cloaca.

### ANAL CANAL

The anal canal is about one and half inches long (3.8 cm) and is directed downwards and backwards. It extends from the anorectal junction to the anus.

### Relations

It is related in front with the perineal body which separates it from the membranous part of the urethra and the bulbs of the penis in the male and from the lower part of the vagina in the female.

Laterally it is related to the ischiorectal fossa. Behind it is in relation with the anococcygeal ligament which separates it from the tip of the coccyx. For the whole length it is surrounded by sphincter muscles the tone of which keeps it closed.

### Anatomical Anal Canal

It extends from the pectinate line to the anal verge (lower 15 mm + 8 mm). The pectinate line indicates the site of attachment of the anal membrane in fetus. It is also the junction of the entodermal and the ectodermal parts.

### Surgical Anal Canal

Surgical anal canal – starts at a higher level from the anorectal ring or junction to the anal verge.

Interior of the anal canal is divided into three parts (Fig. 35.2).

The upper part is about 15 mm long, the middle part about 15 mm long and the lower part about 8 mm long.

### Upper Part

It shows the following:

- Anal columns of Morgagni—These are longitudinal folds of mucous membrane with submucous coat and macularis mucosae, 10 to 12 in number.
- Anal valves of Morgagni are short transverse folds of mucous membrane that connect the lower ends of the anal columns. The opening of the anal glands is related to many of these anal valves.
- Anal sinus crypt—Above each anal valve there is a depression in the mucosa which is called the anal sinus.
- Pectinate line or dentate line is the imaginary line along which the anal valves are situated.

### Middle Part

It is also lined by mucous membrane but anal columns are not present here. The mucosa

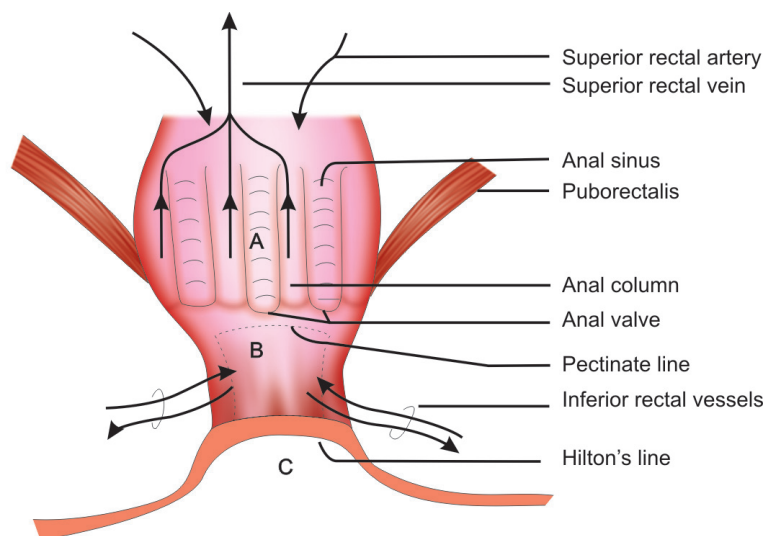
is less mobile than in the upper part of the anal canal. This region is referred to as the pecten or transitional zone. The lower limit of the pecten often has a whitish appearance because of which it is referred to as the white line of Hilton.

### Lower Part

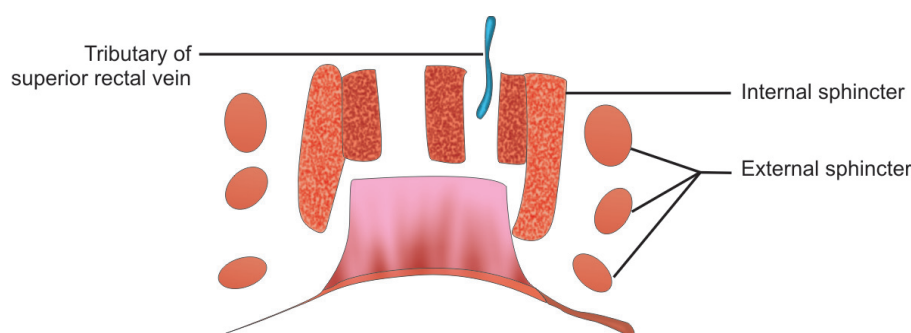
It is lined by true skin containing the sweat and sebaceous glands.

### Anal Musculature (Fig. 35.3)

- Internal sphincter—It is the condensation of the circular muscle of the lower part of the rectum and anal canal.
- Anorectal ring—At the anorectal junction puborectalis, deep part of sphincter ani externus and sphincter ani internus collectively forms the anorectal ring.
- Sphincter ani externus or external sphincter—It is a voluntary muscle along the



**Fig. 35.2:** Interior of the anal canal (A,B,C = upper, middle and lower parts of anal canal)



**Fig. 35.3:** Anal sphincters

whole length of the anal canal, divided into three parts viz. superficial, subcutaneous and deep part.

### Arterial Supply

- Above the pectinate line – superior rectal artery.
- Below the pectinate line – inferior rectal artery.

**Venous drainage** – Corresponds to the arterial supply.

### Lymphatics

From above the pectinate line lymph vessels drain to the internal iliac nodes and vessels from below the pectinate line drain to the superficial inguinal nodes.

### Nerve Supply

Above the pectinate line by antinomic nerves both sympathetic (inferior hypogastric plexus) and parasympathetic by pelvic splanchnic nerves  $S_2, S_3, S_4$ .

Below the pectinate line by the somatic (inferior rectal branch of internal pudendal nerve  $S_2, S_3, S_4$ ) nerves.

### Development

- Part above the pectinate line—from the caudal portion of endodermal cloaca.
- Part below the pectinate line—From the ectodermal cloaca or proctodeum. Failure of fusion of the two parts results in imperforate anus.

## PROLAPSE OF RECTUM

It is the protrusion of the mucous membrane or the entire rectum outside the anal verge. This is common in children and elderly patients.

### Types

#### Partial or Mucosal Prolapse

In this variety palpation of the prolapse reveals that it consists of no more than a double layer of mucosa.

The protrusion is between half and one and a half inches.

#### Complete Prolapse or Procidentia

The prolapse consists of the entire thickness of the rectal wall. Its length is more than one and a half inches and may be as much as 6 inches.

Palpation of the prolapse reveals that it consists of double thickness of the entire rectal wall.

### Partial Prolapse

#### Causes

1. In infants and children – It is due to undeveloped sacral curve and habitual constipation.
2. Excessive straining due to an attack of diarrhea or whooping cough.
3. In adults it is common in females probably due to torn perineum.

#### Treatment

1. In infants and children—The mother is advised digital reposition of the prolapse after lubricating with lignocaine jelly.
2. In adults, submucous injection of ethanolamine oleate is given. It causes aseptic fibrosis and mucosa gets adhered to other layers.

### Complete Prolapse

#### Causes

1. It is common in multiparous elderly women due to repeated birth injuries and lax perineum.
2. Lack of rectal fixation to the bed of the sacrum.
3. Many workers believe that prolapse of the rectum starts as an intussusception.

#### Clinical Features

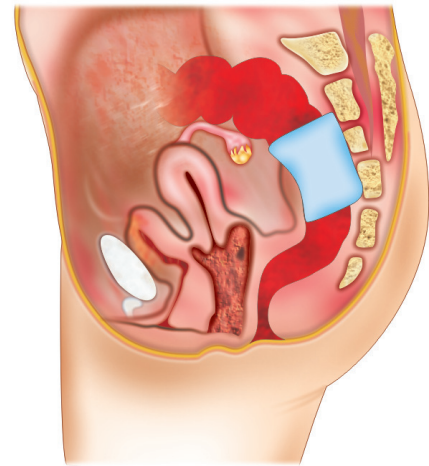
- Constipation is the important feature of rectal prolapse.
- Excessive mucus discharge causing irritation to the perianal skin.
- On asking the patient to strain in squatting position, the rectum descends down which clinches the diagnosis.
- Per rectal examination reveals – Lax anal sphincter and wide gaping on straining.

#### Treatment

A number of operations have been designed for complete prolapse but none is full proof. The more commonly practiced procedures are:

#### Abdominal Procedures

1. *Well's procedure (Ivalon sponge wrap operation)*—This operation, first described by Wells in 1959 is done through the



**Fig. 35.4:** Polypropylene (Marlex) mesh rectopexy for rectal prolapse

abdominal approach. The rectum is separated from the sacrum. A sheet of Ivalon sponge (polyvinyl alcohol) sponge is then sutured to the presacral fascia and periosteum of the sacrum. The mobilized rectum is drawn up to make it taut. The Ivalon sponge is wrapped over it and sutured. The anterior surface of the rectum is left uncovered to prevent constriction of the lumen. Ivalon sponge will initiate fibrosis and fix the rectum in place.

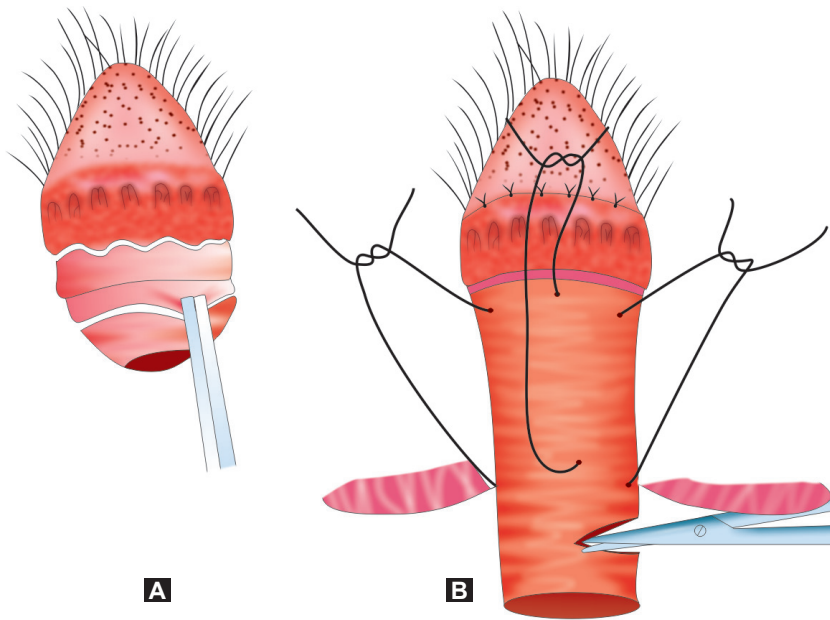
2. *Mesh rectopexy* (Fig. 35.4)—Instead of polyvinyl sponge, a Marlex (polypropylene) mesh can be kept behind the rectum. This is sutured in the middle to the presacral fascia with 3 or 4 interrupted 2-0 prolene sutures. The mesh is then folded over the rectum to wrap about two-thirds of the circumference. Excess mesh is excised. The edges of the mesh are sutured to the rectal wall with interrupted 2-0 prolene.

#### Perineal Procedures

1. *Thiersch's wiring*—This operation is suitable for any age and is simple. Its aim is to reinforce the internal sphincter with a stainless steel wire at the same time narrowing the anal opening.

A steel wire or a thick silk suture is applied all around the anus after reducing the prolapse. The knot is tightened around a finger.

2. *Delorme's procedure* (Figs 35.5A and B) – The prolapsed rectum is pulled down as far



**Figs 35.5A and B:** Delorme's procedure for repair of rectal prolapse, (A) Circumferential mucosal resection started 1.5 to 2 cm above the dentate line, (B) Plication of muscular layer and resection of the excess stripped mucosa. This is followed by reanastomosis of mucosa over the plicated rectal wall

as possible. The whole of the rectal mucosa is removed and the muscle coat is plicated with a series of absorbable sutures. After muscular plication is finished the stripped mucosa is resected and mucosal continuity is maintained by suturing the anal mucosa below to the rectal mucosa above with 4-0 absorbable sutures. So the prolapse is reduced and a ring of muscle surrounds the anal canal which narrows its orifice. This prevents recurrence.

## COLORECTAL CARCINOMA

### General Information

- Most common histological type of colorectal carcinoma is adenocarcinoma.
- Most common site is rectosigmoid.
- It occurs in high socioeconomic populations.

### Etiology

#### Genetic Factors

Accounts for 10 percent of colorectal cancers.

- Familial Adenomatous Polyposis (FAP)** –
  - The gene responsible has been identified on the short arm of chromosome 5.

- The condition is diagnosed when a patient has more than 100 adenomatous polyps in the colon. It is autosomal dominant in character.
- Associated conditions:
  - Gardner's syndrome—Colonic polyps with osteomas of bone and desmoid tumor (musculoaponeurotic fibromatosis). Epidermoid cysts can also occur.
  - Turcot's syndrome—Consists of colonic polyps and brain tumors especially gliomas or medulloblastomas.

#### Clinical Features

- Polyps are usually visible on endoscopy by the age of 15 years.
- Carcinomatous change occurs 10 to 15 years after the onset of polyposis.

Screening policy—Current recommendation is endoscopy from 10 years of age until the age of 40.

#### Treatment

Best treatment of FAP syndrome is total proctocolectomy with ileal reservoir and ileoanal anastomosis.

Drugs used for tumor regression and prevention of new polyp formation are sulindac (NSAID) and vitamin C.

- HNPCC (Hereditary nonpolyposis colorectal cancer)** – The genetic abnormality is usually on chromosome 17 or 18 and autosomal dominant in nature.

It is also known as Lynch syndrome.

### Environmental Factors

- Diet—Unsaturated fats induce progression from adenomas to carcinoma.
- Exposure to food additives, alcohol, ionizing radiation, bile acids promotes development of carcinoma.

### Premalignant Conditions

- Ulcerative colitis.
- Crohn's disease.

### Pathology

#### Macroscopic Types (See fig. 101.9. specimen of carcinoma colon.)

- Nonstenosing type
  - Proliferative or cauliflower type
  - Ulcerative type.
- Stenosing type
  - Annular—The stenosed segment is short in length like a ring.
  - Tubular—The stenosed segment is rather long.

### Microscopic Types

- Almost always it is a columnar cell adenocarcinoma.
- Sometimes a colloid cancer that is, colloid degeneration in a massive adenocarcinoma is seen.
- Anaplastic cancers are rare.

### Spread

- Local spread—
  - By continuity along the bowel wall.
  - By contiguity to adjacent structures, e.g. retroperitoneal structures, liver, pancreas, small intestine, etc.
- Lymphatic spread—In colonic cancer, lymph nodes are rapidly involved. Lymph nodes draining the colon are arranged in three groups viz. paracolic nodes lying in the immediate vicinity of the bowel wall. Intermediate nodes along the ileocolic, right colic, middle colic and sigmoid arteries and the apical nodes around the origins of superior and inferior mesenteric arteries.



- c. Bloodstream spread—Metastasis may occur, quite early in the liver via the portal system before clinical or operative evidence is detected. This is called occult hepatic metastasis.

### Dukes Clinical Staging

Stage A – Tumor confined to bowel wall.

Stage B – Tumor involving serosa.

Stage C – Lymph nodes involved.

C<sub>1</sub> – Apical node clear.

C<sub>2</sub> – Apical node involved.

### Prognosis as Per Dukes Staging

Stage	5-year survival
Stage A	80%
Stage B	60%
Stage C	30%

### Clinical Presentation

- Right colon (Cecum and ascending colon) – 20 percent
  - Mass or lump in the right iliac fossa.
  - Appendicitis when carcinoma occludes the appendicular orifice.
  - Anemia due to protracted occult blood loss.
  - Pyrexia of unknown origin.
  - Weight loss.
- Left colon – (Descending and sigmoid colon) – 70 percent
  - Patient complains of pain in the left iliac fossa, which is referred to the suprapubic area.
  - Alteration of bowel habit (constipation/Diarrhea) is the most common and important symptoms.
    - Palpable lump in the left iliac fossa.
    - Loss of weight.
- Rectal cancer (Rectosigmoid junction and rectum)—45 percent
  - Blood and mucus per rectum—Most common and earliest symptoms.
  - Tenesmus.
  - Sacral or perineal pain.

### Investigations

- Stool for occult blood.
- Sigmoidoscopy—Both rigid and flexible sigmoidoscopies can be used in the left lateral position.

If the history suggests that the problem lies more proximal to rectum, flexible sigmoidoscopy is more practical.

The advantage of the rigid instrument is that it can be used in an unprepared rectum.

- Colonoscopy—If the main symptom is bleeding or anemia, colonoscopy is the investigation of choice.

Treatment of polyp as well as laser therapy is possible during colonoscopy. Full bowel preparation and sedation is necessary.

- Ba-enema—It is reasonable to start with a Barium enema when patients present with a change in bowel habit and abdominal pain with or without abdominal distension. The Ba-enema gives good anatomical and topographical information, which not only diagnoses a polyp or carcinoma but demonstrates the site and configuration of the lesion, thereby helping the planning of operation.
- Intrarectal ultrasound also called endosonography is now an established means of assessing the depth of penetration of the bowel wall by the tumor. This improved diagnostic information is essential when considering local treatment for a rectal cancer.

### Treatment

#### Principles

- Treatment of choice is surgery – either a curative or palliative resection which is worth doing even in presence of metastasis.
- Although surgery is the main modality, radiotherapy and chemotherapy are beneficial.

#### Preoperative Preparation

Colorectal operations are clean contaminated (nonsterilized). So, preoperative gut preparation is necessary which include.

- Mechanical cleansing of bowel and
- Antibiotic prophylaxis.

#### Mechanical Cleansing

- Fluid diet for 48 hours before surgery.
- Nothing per oral after midnight.
- Polyethylene glycol (PEGLEG) Purgation 4 liters in 2 hours on the preoperation day. It is the most commonly used purgation nowadays.

#### Antibiotic Prophylaxis

Injection Cefuroxime 1.5gm IV in combination with injection metronidazole 1gm IV given at the time of induction of anesthesia

and later on 1 or 2 doses may be given 6 hours and 16 hours in the postoperative period.

### Thromboembolism Prophylaxis

It is necessary in elderly patients because they are particularly liable to venous thrombosis and pulmonary embolism. Additional risk factors are obesity, varicose veins and a previous history of thrombosis or embolism.

Subcutaneous heparin 5000 IU TDS until the patient is mobile is the most common method of prophylaxis. The first dose of Heparin is given along with premedication.

### Operation

- The objective of operation is to remove:
  - The cancerous segment of bowel
  - Its mesentery that contains the lymphatic drainage and
  - Any organ that has been invaded by the tumor.
- If multiple colon carcinomas are present or if a colon carcinoma is associated with multiple neoplastic polyps, a subtotal colectomy (total abdominal colectomy) with iliorectal anastomosis should be considered.

### Regionwise Treatment

- Carcinoma right colon—Treatment of choice is right hemicolectomy.
- Carcinoma of mid transverse colon – transverse colectomy ligating only the middle colic artery followed by colocolic anastomosis between ascending and descending colon.
- Carcinoma hepatic flexure or right transverse colon—extended right hemicolectomy is done. Almost the whole area supplied by the right branch of middle colic artery is excised.
- Carcinoma left colon—Treatment of choice is left hemicolectomy which involves removal of left one-third of transverse colon, splenic flexure, whole of descending colon and upper part of pelvic colon followed by end to end anastomosis between transverse and pelvic colon.
- Carcinoma pelvic colon—Wedge resection of the pelvic colon along with the growth followed by pelvicrectal anastomosis.
- Rectal carcinoma –
  - Carcinoma upper 1/3rd of rectum—The operation of choice is high anterior

resection which includes removal of growth along with the nodes followed by colorectal anastomosis. It is indicated when the growth is 11–15 cm from the anal verge.

- ii. Carcinoma lower 1/3rd of rectum— This refers to growth within 7cm from the anal verge. The operation of choice is abdominal perineal resection or APR

In APR, the following structures are removed:

- Growth with entire rectum and anal canal.
- 2/3rd of sigmoid colon and meso – colon with lymphatics and lymph nodes.
- Wide area of perineal skin with part of ischiorectal fossa, muscles and peritoneum of pelvic floor.

This is followed by permanent end colostomy done by bringing the sigmoid colon outside in the left iliac fossa.

- iii. Carcinoma of middle 1/3rd of rectum—This refers to growth between 7 to 11 cm from the anal verge. The decision to save the sphincter can be taken at laparotomy. In case of well – differentiated carcinoma, 2 cm margin of clearance is adequate.

In anaplastic carcinoma 5 cm clearance is necessary. If the sphincter can be preserved, low anterior resection is done. Sutures can be applied by hand or with staples.

If sphincter cannot be preserved, APR is done.

### Hartmann's Operation

This is indicated in old and debilitated patients who may not withstand APR. The growth is excised, the lower end of rectum is closed and a colostomy is performed. When the growth is slow growing, this operation gives good palliation.

### Signs of Inoperability

- When the growth is widely fixed to the posterior abdominal wall.
- Liver and peritoneal deposits present.
- Lymph nodes fixed to the posterior abdominal wall.

**Table 35.1: Types of fistulae in various anorectal anomalies in males and females**

	Males	Females
I. High fistulae	Either to the bladder (Rectovesical) or the prostatic urethra (Rectourethral)	Usually to the vagina (Rectovaginal)
II. Low fistulae	Either to the scrotum at the median raphe or the skin of the perineum	This may extend to the vestibule (Rectovestibular or shotgun perineum)

### Palliative Surgery for Nonresectable Growths

- Ileotransverse anastomosis for right sided growths.
- Permanent colostomy proximal to the growth, e.g. transverse colostomy in case of growth in the left colon.
- End colostomy in left iliac fossa in case of growth in pelvic colon.

### Follow-up

Most tumors recur in the first 2 years after curative resection.

- Colonoscopy and Ba – enema are done in the postoperative period to establish a base line.
- Colonoscopy is repeated annually for at least 4 years, then every 2 to 3 years.
- Routine physical examination, complete blood count and liver function tests should be performed every 3 months for 2 years, then every 6 months for 2 years, and then annually.
- A chest film should be obtained every 6 months for 3 years, then annually.
- CEA level is done every 2 months for 2 years, every 4 months for 2 years, then annually. While the absolute level is important trends must also be noted. A gradual increase in CEA level is usually a sign of recurrence.

### ANORECTAL ANOMALIES

In the fifth week of intrauterine life, there is a common chamber known as cloaca, which is later divided into two chambers, anteriorly allantois gives rise to urinary bladder and posteriorly post allantoic gut gives rise to rectum and upper 2cm of anal canal.

The postallantoic gut fuses with proctodeum, thus giving rise to anal canal. If there

is a defective fusion, it gives rise to various anorectal malformations.

### Types

The anomalies may be divided into two broad groups viz.

- High or Rectal**—The rectum ends above the pelvic floor that is supralevator anomaly. The sphincter mechanism is either ineffective or absent.
- Low or anal**—The gut has developed to a point below the pelvic floor, that is, infralevator anomaly. This is less serious and usually an effective sphincter mechanism is present.

All the above types may be associated with a fistula. The sites of communications varies accordingly whether the defect is high or low and also varies whether the baby is male or female (Table 35.1).

### Clinical Features

Failure of passage of meconium is the main complaint of the patients in both high and low anomalies. On examination low anomalies like anal stenosis, microscopic anus and covered anus (normally located anus but covered by a thin layer of skin) should be easily diagnosed by close inspection, if necessary with a magnifying glass. The patient may have some degree of intestinal obstruction.

In high anomalies the patient is mostly a male infant with acute intestinal obstruction. In the majority of cases, meconium is passed per urethra or there is a speck of meconium at the tip of the penis.

In about 10 percent cases, there is a blind agenesia, no gas or meconium comes out of urethra.

### X-ray Examination

- Invertogram**—This is the straight X-ray of the child inverted to know whether the

anomaly is of high variety or low variety. This has become obsolete because one has to wait till the rectal gas appears and sometimes it takes about a day or more for rectal gas to appear.

2. USG—The ultrasonography of anorectum may be done immediately after birth and the clinician will not have to wait for the gas to appear in the anorectum.

### Treatment

- I. High anomaly—More difficult to treat than low anomalies, usually this is repaired by a three stage procedure.
  1. Preliminary transverse colostomy to relieve intestinal obstruction.
  2. When the child is about 10kg weight at 6-12 months of age, an abdominoperineal pull through operation is done with division of the fistula.
  3. After 2 month's pull through operation colostomy is closed.
- II. Low anomaly—It is relatively easy to treat as the rectum has transgressed the levator ani and only a perineal operation is sufficient and continence is not a problem, unless associated with sacral agenesis, where both facial and urinary continence is in jeopardy.

The general principle of treatment is division of membrane or skin followed by dilatation with some amount of plastic reconstruction or anoplasty.

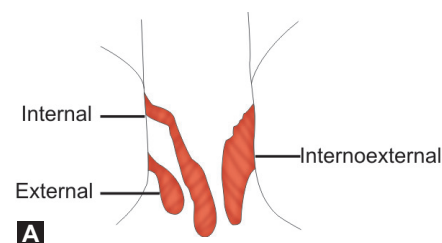
## HEMORRHOIDS (PILES)

(Hema = Blood, Rheos - Flowing)

### Definition

Piles is derived from Pila (Latin) which means a mass looking like a ball.

Hemorrhoid is a condition, where there is varicosity in the veins of anorectal region which subsequently leads to hemorrhage.



### Etiology

1. Idiopathic or primary—The predisposing factors are pregnancy, prolonged standing, etc.
2. Secondary
 

*Causes:*

  - Carcinoma of rectum—By blocking the veins, produces back pressure and manifest as piles.
  - Persistent straining at micturition, e.g. enlarged prostate.
  - Prolonged constipation.

### Classification (Fig. 35.6A)

Depending upon the location of hemorrhoids

1. Internal hemorrhoids—Situated above the pectinate line.
2. External hemorrhoids—Situated below the pectinate line.
3. Internoexternal piles—Situated both above and below the pectinate line.

It is to be remembered that external hemorrhoids is a term, applied to a conglomeration of quite different entities including.

- Perianal hematoma
- The sentinel pile of fissure in ano
- Perianal skin tags.

Strictly speaking, internal piles which prolapses through the anal opening, is termed internoexternal hemorrhoids but this term is seldom employed nowadays.

### Location (Fig. 35.6B)

Classically situated in the 3, 7 and 11 o'clock position. This is due to the peculiarity of the venous drainage of the anus where there are two subdivisions of the right branch of the superior rectal vein but the left branch remains single.

In between these three major piles there may be smaller secondary piles.

### Arterial Pile

A branch of superior rectal artery may enter the pedicle of an internal piles and rarely

there is a hemangiomas condition of this artery, called an arterial pile which may produce severe bleeding at operation.

### Degree of Piles

Internal piles are traditionally classified into four degrees viz.

- First degree hemorrhoids are confined to the anal canal. They bleed but do not come out of the anal orifice.
- Second degree hemorrhoids—During defecation, the pile mass comes out but gets reduced spontaneously.
- Third degree hemorrhoids—The pile mass comes down during defecation, does not get reduced at its own, but requires manual reduction.
- Fourth degree—The pile mass remains permanently prolapsed. There is mucus discharge. The mass may undergo ulceration, infection and give rise to pruritus ani.

### Clinical Features

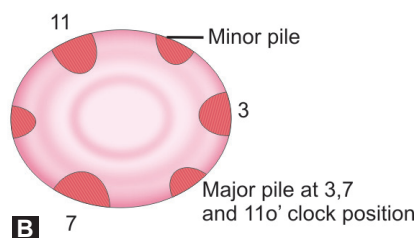
- Bleeding per rectum—Bleeding is painless and bright red which usually appears as a fresh smear on the toilet paper.
- Pain: Pain is not characteristic of hemorrhoid, unless it is associated with fissure in ano or thrombosis. Strangulated piles are extremely painful.
- Mucus discharge
- Pruritus ani—This results from excessive mucus discharge, secreted from the congested mucosa.

### Investigations

1. A digital examination should always be done. A pile mass cannot be palpated, because it collapses to digital pressure. It can be palpated only when it is thrombosed. A digital examination may sometimes detect a carcinoma or a polyp.
2. Proctoscopy—As the proctoscope is removed, the piles prolapses into the lumen of proctoscopy as cherry red masses.

### Complications

1. Anemia—Following severe or continued bleeding.
2. Strangulation—This occurs when the prolapsed piles are gripped by the internal sphincter and get irreducible.
3. Thrombosis – In strangulated piles, venous return is occluded and thrombosis occurs.



**Figs 35.6A and B:** Schematic presentation of classification of piles

The thrombosis is accompanied by considerable pain.

4. Suppuration or ulceration may occur in a thrombosed piles.
5. Fibrosis—After 2 to 3 weeks, thrombosed piles become fibrosed, often with spontaneous cure.

## Treatment

### Nonoperative

- a. Sitz bath—The patient is asked to sit in warm water with the anal region and buttocks dipped in water for about 20 minutes, 2 to 3 times a day. This reduces pain edema and promotes healing.
- b. Antibiotics, laxatives (stool softener) and antiinflammatory drugs are beneficial.
- c. Regulation of bowel habit with a high fiber diet.
- d. Local application of astringent ointments.
- e. Injection of Sclerosant—The agent commonly used is 5 percent phenol in almond oil. The idea is to cause thrombosis of the piles as well as the vessels draining them, and to create fibrosis in the submucous coat so that the lax mucous membrane retracts. This is done in case of first and second degree hemorrhoids.

### Operative Treatment

First and second degree hemorrhoids are treated by Lord's procedure, Barron's band application and cryosurgery.

Third and fourth degree hemorrhoids require hemorrhoidectomy.

1. **Lord's procedure**—Under general anesthesia the internal sphincter is widely stretched. It results in dilatation and disruption of the fibers of internal sphincter. Thus venous congestion is relieved to improve the piles.
2. **Barron's Band Ligation**—Bands are applied at the neck of hemorrhoids which undergo healing by fibrosis.
3. **Cryosurgery**—Liquid nitrogen at  $-196^{\circ}\text{C}$  is applied to pile masses which coagulate the tissues. The procedure is painless but there will be continuous mucus discharge for 3 to 4 weeks.
4. **Hemorrhoidectomy**—This is the ligation and excision of the pile mass under spinal or general anesthesia. (see operative section for details of the operation).

## ANORECTAL ABSCESS

These are abscesses, around the anal canal and rectum. These are important as many of them may culminate in fistula in ano.

Figure 35.7 shows various locations of anorectal abscesses. See also surgical infections in chapter 9.

### Causative Organisms

The usual organism is *E. coli*, less commonly *Staphylococcus aureus*, *streptococcus*, *B. proteus*, etc. In 90 percent cases, the abscess starts as an infection of the anal gland. In the rest, it may be blood borne, e.g. extension of a cutaneous boil.

### Classification

1. Perianal abscess—It is the most common anorectal abscess and lies immediately beneath the perianal skin.
2. Ischiorectal abscess—It lies in the ischio-rectal fossa containing a lot of fat. Both the above anorectal abscess has been described in the chapter of surgical infections.
3. Submucous abscess—It lies in the submucosa above the dentate line. A small incision on the overlying mucosa provides easy drainage.
4. Pelvirectal abscess—It lies above the levator ani and below the peritoneum. It is rare and usually spreads from a pelvic abscess, secondly to appendicitis or salpingitis.

## FISTULA IN ANO

### Definition

A fistula in ano is a track lined by unhealthy granulation tissue that opens internally into the anal canal or rectum and externally onto the skin around the anus.

This is the commonest type of external fistula. A sinus is a granulating track leading from a source of infection to a surface.

### Etiology

The term fistula in ano is loosely applied to both fistula and sinuses in relation to the anal canal.

The great majority result as a sequelae to a perianal abscess, which has either been allowed to rupture spontaneously or has been incised late or in an inadequate or incorrect manner.

Rarely fistulas may appear secondary to infections due to trauma, tuberculosis, Crohn's disease, carcinoma of rectum and radiation, etc.

### Classification

- I. *Anatomical classification*
  1. Subcutaneous.
  2. Submucous.
  3. Low anal—The fistulae open into the anal canal below the anorectal ring.
  4. High anal—The fistulae open into the anal canal at or above the anorectal ring.
  5. Pelvirectal—The fistulous opening lies higher than that in high anal type.
- II. *Park's classification*—Infection of an anal crypt leads to an abscess in the anal glands that lie between the external and internal sphincter muscles. Pus may track in different directions from this source of sepsis. Accordingly the fistulae may be of the following types:
  1. Intersphincteric—The fistulous track runs through the lower part of the internal sphincter.
  2. Trans-sphincteric—The fistulous track crosses both sphincters.

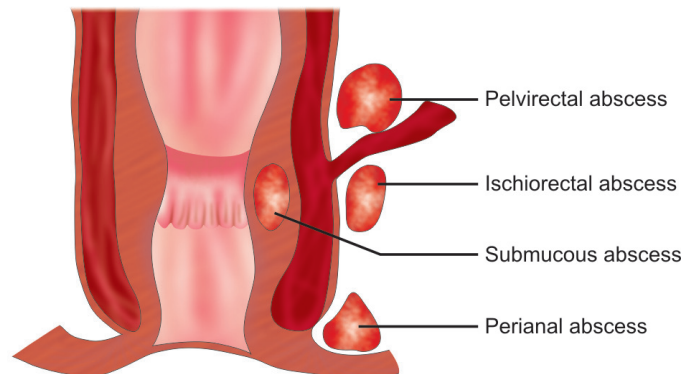


Fig. 35.7: Types of anorectal abscess

3. Supralelevator or Suprasphincteric—The internal opening of the fistulous track is situated above the anorectal ring. The track passes down through the ischio-rectal fossa to the skin.

### Clinical Features

- There is a history of perianal abscess, which following rupture or incision, fails to heal and leaves behind a discharging opening.
- In neglected cases, there may be repeated attacks of perianal abscess formation. The new abscesses may burst out through the old opening or make fresh external openings. This is how multiple fistulae are formed.

**Goodall's rule** – A fistula with an external opening in the anterior half of anus tends to be direct type or straight and in the posterior half indirect type or curved. This rule helps to determine the location of the internal opening. Exceptions to this rule occasionally occur. That is why it is no substitute for an accurate operative evaluation.

### Treatment

#### Low Anal Fistula

Excision of the fistula (Fistulectomy) is the treatment of choice. Under general or spinal anesthesia probe is passed through the external opening upto the internal opening. The fistulous track with unhealthy granulation tissue is excised. The excised specimen is sent for histopathology examination for evidence of any Crohn's disease or tuberculosis.

Postoperatively, sitz bath, antibiotics, analgesics and laxatives are given.

Fistulectomy for low level fistula do not cause rectal incontinence.

#### High Anal Fistula

- The treatment requires staged procedure—Initially protective colostomy is done followed by the definitive procedure. This prevents sepsis and promotes faster healing. Later closure of colostomy is done.
- Seton (Threading) technique: A sick or nonabsorbable stout ligature is passed

across the fistula and left *in situ* with a tie for 2 to 3 weeks. Continuous irritation of the ligature leads to scarring. A ligature used in this manner is called a Seton.

- 'Kshaarsootra'—An Ayurvedic preparation on a cotton thread is used as a medicated seton in high fistulas. It causes cutting of the fistulous tract with scarring induced by the ayurvedic chemicals.

### ANAL FISSURE (FISSURE IN ANO)

This is a longitudinal tear at the anal margin which usually follows the passage of a constipated stool.

#### Site

Fissures are the commonest in the midline posteriorly. In males 90 percent occur posteriorly and 10 percent anteriorly in the midline. In females, the incidence is 70 percent and 30 percent respectively.

The posterior position of majority of the fissures is explained by the anatomical arrangement of the external anal sphincter. Its superficial fibers pass forward to the anal canal from the coccyx leaving a relatively unsupported V-shaped area posteriorly.

Anterior fissures in females may be associated with weakening of the perineal floor following tears at childbirth. Multiple fissures may complicate Crohn's disease of the colon.

#### Types

- Acute—This is a superficial crack with thin margins.
- Chronic—It is a deeper ulcer sometimes exposing the internal sphincter at its base. The fibers of the internal sphincter are found running transversely in the floor of the fissure.

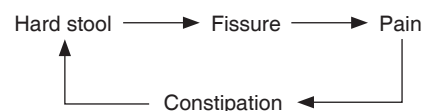
At the lower part of a typical chronic fissure there is a tag of hypertrophic skin, which is called a sentinel pile (Sentinel means guard).

#### Clinical Features

- Pain is severe and burning in character in the acute type. It is less severe in chronic type. The pain occurs during

and after defecation and lasts for about ½ to 1 hour for which defecation is postponed.

- Constipation—Hard stool aggravates pain which again favors constipation. Thus a vicious cycle is established.



- Rectal examination – When buttocks are spread apart a longitudinal tear and a sentinel pile may be seen.

It is cruel to perform a rectal examination in the acute stage. Proctoscopy is also contraindicated.

### Treatment

- In acute cases, a conservative treatment is often successful.

Conservative treatment includes:

- Stool softener to make the stool soft enough to be passed without anal spasm.
- 5 percent Xylocaine ointment for local application. Self anal dilatation with fingers or a small anal dilator (St. Marks) is done after 5 minutes of application of the local anesthetic ointment.
- Sitz bath.
- If the above fails then Lord's stretching is done under general anesthesia to relax the sphincter.

- In chronic cases, operative treatment has to be undertaken. The commonly practiced operations are:

- Sphincterotomy – The lateral internal sphincterotomy is the procedure of choice for anal fissure. Here the internal sphincter is divided away from the fissure either on the right or left lateral position. This abolishes the spasm and allows the fissure to heal promptly.
- Anal dilatation (Lord's procedure) – The four finger dilatation causes fracturing of the internal sphincter and provides relief. Rarely it may be followed by recurrence or incontinence.



# Chapter 36

## Liver

- |   |                          |                        |
|---|--------------------------|------------------------|
| ➤ Surgical anatomy                        | ➤ Functions of liver     | ➤ Liver neoplasm       |
| ➤ Functional anatomy:<br>Hepatic segments | ➤ Amebic liver abscess   | ➤ Portal hypertension  |
| ➤ Microscopic anatomy                     | ➤ Pyogenic liver abscess | ➤ Budd-Chiari syndrome |
|   | ➤ Hydatid cyst of liver  |                        |

### SURGICAL ANATOMY

The liver is the largest organ in the human body and lies immediately below the diaphragm mainly on the right of the median plane its thin left lobe being on the left.

It is divided anatomically into two lobes separated anteriorly and above by the attachment of the falciform ligament and postero-inferiorly by an H-shaped arrangement of fossae (Figs 36.1A and B).

- Anteriorly and to the right—The fossa for the gallbladder.
- Posteriorly and to the right—The groove for the inferior vena cava.

- Anteriorly and to the left—The fissure containing the ligamentum teres.
- Posteriorly and to the left—The fissure for the ligamentum venosum.

The cross bar of the H is the porta hepatis. Two subsidiary lobes lie between the limbs of this H viz. the quadrate lobe in front and the caudate lobe behind.

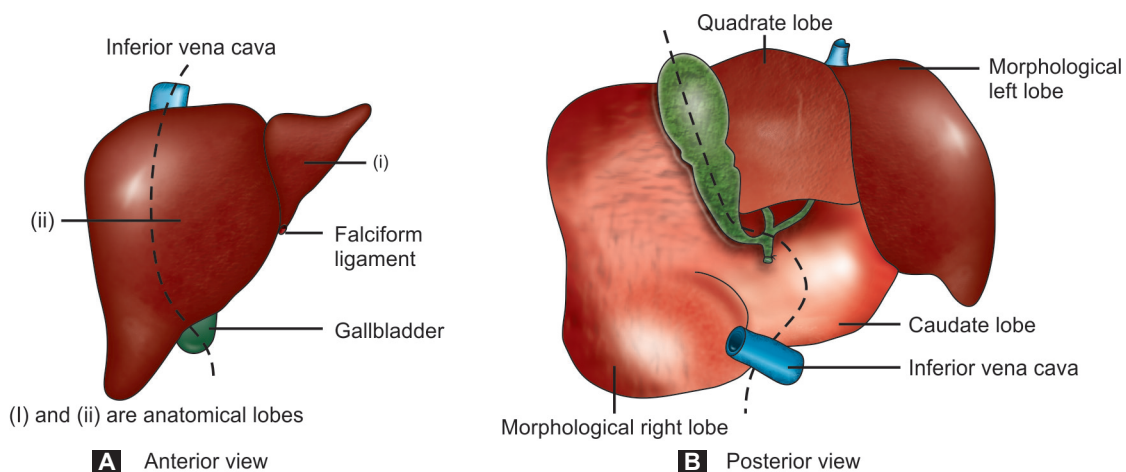
### FUNCTIONAL ANATOMY: HEPATIC SEGMENTS (FIGS 36.2A AND B)

On the basis of the intrahepatic distribution of the hepatic artery, the portal vein and the biliary ducts, the liver can be divided into

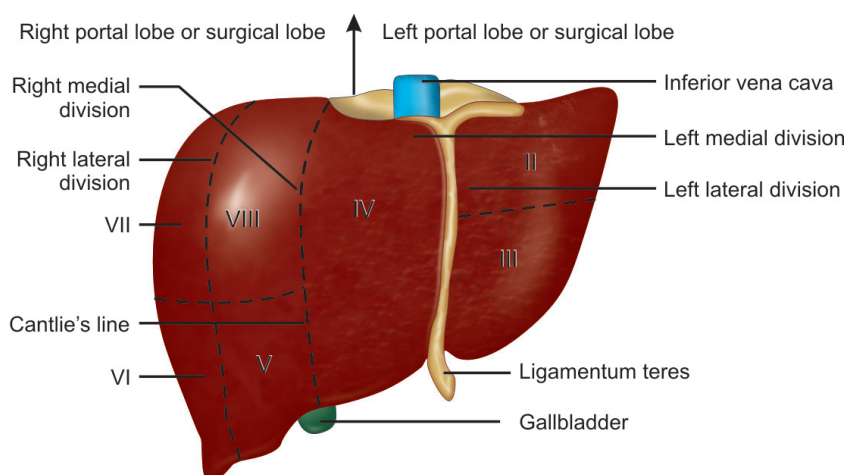
the right and left functional lobes, the physiological lobes are separated by a plane passing through the anterosuperior surface along a line joining the cystic notch for the fundus of the gall bladder to the groove for the inferior vena cava.

This imaginary line, known as Cantlie's line divides the liver into the right (60 – 70% of the liver) and left (30–40%) hemilivers.

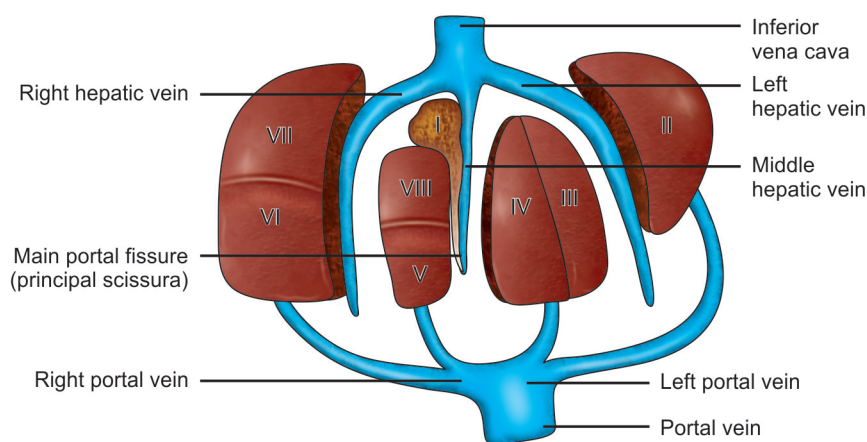
The right and left hemilivers are further subdivided into hepatic sectors or sections based on the divisions of the portal pedicles and the location of the hepatic veins. Thus the right lobe is divided into medial (often called



**Figs 36.1A and B:** Anatomical and functional lobes of liver. The morphological or functional lobes are divided by the dotted line



**Fig. 36.2A:** Anterior view of hepatic segments



**Fig. 36.2B:** Segmentation of the liver based on hepatic veins and portal vein. The main portal fissure is called cantlie's plane

anterior) and lateral (often called posterior) sectors and the left lobe into medial (anterior) and lateral (posterior) sectors. So there are four sectors in the liver right anterior, right posterior, left anterior and left posterior sectors.

These four sectors are further subdivided into eight segments which are conventionally numbered using roman numerals.

The segment is the smallest anatomic unit of liver resection.

The caudate lobe, which is functionally autonomous, receives blood from both the right and left portal pedicles and is classified as segment I. Segment IX is a recent subdivision of segment I and describes that part of the segment that lies posterior to segment VIII.

The left lateral sector contains segment II posteriorly and segment III anteriorly, with the left hepatic vein being between them.

Segment IV (the left medial division) is recognized on the visceral surface as the quadrate lobe.

Segments V and VI are the inferior segments of the right anterior and right posterior sectors respectively. Segments VII and VIII are the superior segments of the right posterior and right anterior sectors respectively.

Each of the segments II to VIII has a named hepatic artery branch, portal venous radicle and drains into its individual segmental bile duct. The hepatic veins are intersegmental, draining the portions of the multiple segments adjacent to them.

The nomenclature used for various types of anatomical hepatic resections (Table 36.1)

### Blood Supply

The liver is unique in its blood supply via the hepatic artery and the portal vein. 20 percent of its blood supply comes via the hepatic artery and the rest 80 percent through the portal vein. The amount of blood entering the liver is 1500ml/min. The blood in the sinusoids comes both from the hepatic artery and the portal vein.

The hepatic artery carries blood at a great velocity and high pressure. The portal vein carries blood at a low velocity and low pressure.

The flow of blood in the portal vein has two streams. The left stream carries blood to the left lobe from upper part of gastrointestinal tract, spleen and parts of the colon.

The rest of the portal blood passes to the right lobe via the right stream. About one fifth of the portal blood comes from the spleen.

The blood from the liver is drained by three hepatic veins – right, middle and the left hepatic veins into the inferior vena cava.

### MICROSCOPIC ANATOMY

The structural unit of liver is the lobule containing hepatocytes arranged radially like the spokes of a wheel around a central vein, a tributary of the hepatic vein.

In spaces between the lobules lie the hepatic artery branches, the portal vein radicles and the bile ductules forming the portal tracts.

**Table 36.1: Nomenclature for various types of anatomical hepatic resections**

Segments removed	Surgical terminology
II, III, IV	Left hepatectomy
II, III, IV, V, and VIII	Extended left hepatectomy
V, VI, VII and VIII	Right hepatectomy
IV, V, VI, VII and VIII	Extended right hepatectomy
II and III	Left lateral segmentectomy

## FUNCTIONS OF LIVER

1. Metabolism of carbohydrates, fats and proteins.
2. Synthesis of bile, prothrombin, albumin and fibrinogen.
3. Excretion of drugs, toxins, poisons, cholesterol, bile pigments and heavy metals.
4. Storage of glycogen, iron, fat, vitamins A and D.
5. Protective by phagocytosis, antibody formation and excretion and destruction of infective organisms.

## AMEBIC LIVER ABSCESS

The causative organism is *Entamoeba histolytica*. It is almost and always secondary to amebic ulcers on the colonic wall. The organisms ultimately reach the liver via the inferior mesenteric vein and then portal vein.

### Pathology

#### Macroscopic

- The abscess involves the right lobe in 70 percent cases, the posterosuperior surface being the most favorite site.
- In 70 percent cases the abscess is solitary; in 30 percent more than one abscess is present.
- The pus is formed by the degenerating liver substance, chocolate-colored and is known as 'anchovy sauce' pus. The pus may also look green because of its bile content, very rarely pus is creamy.
- The wall of abscess cavity is composed of necrotic liver tissue; later fibrous tissue may be deposited on it.

The scrapings from the abscess wall always contain entamoebae.

#### Microscopic

- The pus consists of broken down liver cells and leukocytes.
- In 50 percent cases the pus contains only entamoebae and in the remaining 50 percent the pus also contains streptococci, *B. coli* and staphylococci.
- Rarely the pus is sterile.

#### Fate

The abscess gradually enlarges in an upward direction, if left untreated. The abscess wall ruptures in order of frequency into the right lung, peritoneal cavity, right pleural cavity, and colon and on the skin surface.

Sometimes a small abscess may undergo complete resolution with early medical treatment.

### Clinical Features

- The patient complains of pain over the right hypochondrium, worsened by movements.
- There is rapid loss of weight and a characteristic earthy complexion appears.
- There is progressive anemia, tenderness and rigidity over the right hypochondrium area.
- Enlarged liver is detected on palpation.

### Special Investigations

1. Blood—Often a polymorphonuclear leukocytosis with eosinophilia is found. Anemia may be present.
2. Stool—For detection of entamoebae.
3. X-ray—Straight X-ray abdomen shows tenting (i.e. fixed and elevated) right dome of diaphragm. Both anteroposterior and lateral views are taken.
4. Ultrasound—Useful for both diagnosis and aspiration of the liver abscess. Serial ultrasound examinations can be used to monitor the collapse of the cavity following treatment.

### Complications

The common complications of amebic liver abscess include secondary infection, rupture, basal pneumonia and pleural effusion. The rupture may occur into the pericardial, thoracic or peritoneal cavity.

### Treatment

- **Drugs:** Metronidazole—is the treatment of choice.

**Dose:** Orally 800 mg thrice daily or 400 IV thrice daily × 10 days.

The constitutional signs resolve in 3–4 days time after institution of treatment.

- **Percutaneous drainage**—When the abscess does not resolve on medical treatment, percutaneous drainage or repeated aspiration should be performed under ultrasound guidance.

After aspiration a full course of specific antiamebic drug therapy should be prescribed.

### Open Drainage

When US guided aspiration fails, a laparotomy should be performed. After evacuation

of the pus, the incision must be completely closed.

## PYOGENIC LIVER ABSCESS

It commonly occurs in older patients (>60 years) and the most common cause is biliary tract disease, with sepsis (Cholangitis) due to calculi or a malignant tumor such as carcinoma of gallbladder or pancreas.

### Pathology

The common organisms are *E. coli*, *proteus*, *pseudomonas*, *streptococcus faecalis* and *staphylococcus*. Anaerobic organisms like clostridia, *Bacteroids* and *actinomyces*.

The gross and microscopic features of these lesions simulate the features of pyogenic abscess at other places.

The cavities contain yellow brown pus which may be bile stained.

### Clinical Features

- High grade fever often accompanied by chills and rigor.
- Nausea and vomiting.
- Marked anorexia is present.
- Jaundice—May be present in patients with large abscess, causing compression or erosion of biliary ducts or due to causative pathology, e.g. CBD stone and cholangitis.

### Investigations

- **Blood**—Total leukocyte count is elevated between 15000 to 30000/cmm.
- **Chest X-ray and fluoroscopy**—Straight X-ray chest may show elevated right dome of diaphragm with basal atelectasis or pleural effusion.
- **CT scan and ultrasound**—Accurately indicate the presence, size, number and location of the abscesses. CT scan is of better diagnostic value than ultrasound. Of course, ultrasound guided aspiration may be performed for diagnostic and therapeutic purposes.

### Treatment

#### Antibiotics

Intravenous antibiotics are given immediately and should include coverage for gram-negative and anaerobic organisms such as cefotaxime 1 to 2 gm daily with amikacin and metronidazole.

The antibiotic coverage is usually required for 1 to 2 weeks for optimal results.

### Percutaneous Drainage

The solitary or macro abscess may be drained percutaneously under ultrasound or CT guidance.

The pus from the cavity is aspirated followed by irrigation with saline. The catheter is allowed to drain continuously.

Percutaneous drainage may fail due to:

- Presence of multiloculated cavity containing thick pus.
- Incorrect placement of the catheter within the abscess cavity.
- Thickened walls of the abscess which do not collapse following drainage.

### Open Drainage

It is indicated in patients with failure of percutaneous drainage or in patients with rupture of the abscess into the peritoneal cavity.

### Prognosis

The overall mortality may be high due to a delay in diagnosis and the presence of multiple abscesses (Microabscesses).

A falling serum albumin level and presence of jaundice are bad prognostic signs.

## HYDATID CYST OF LIVER

### Definition

Hydatid cyst of liver is caused by the parasite known as *Echinococcus granulosus* (EG) or dog tapeworm.

### Life Cycle

Offal (carcasses) of sheep infested by *Echinococcus granulosus*



Eaten by dogs (definitive host) *Echinococcus granulosus* develops in the dog's intestine. Each parasite is 1cm long with head and three segments, the last segment of which contains about 500 ova.



Ova from the dog's intestine pass on to grass and vegetables.



Human beings as intermediate host ingest the eggs and the liver is most frequently infected with hydatid cysts.

### Pathology

The hydatid cyst consists of three layers viz.

- Pericyst (Adventitia or pseudocyst) consists of fibrous tissue and is inseparable from liver.

It is due to reaction of the liver to the parasite.

- Ectocyst or laminated membrane—It is formed of the parasite itself, whitish and elastic which can be readily peeled off from the adventitia.

- Endocyst—It consists of single layer of cells (Germinal epithelium) lining the cyst and is the only living part of a hydatid cyst.

The endocyst secretes hydatid fluid internally and ectocyst externally. Brood capsules (Future worms) develop from the germinal layer.

### Clinical Features

- Most of the hydatid cysts are solitary and located in the right lobe. Hydatid cyst remains symptomless for quite a long time and it is often diagnosed incidentally during an operation or investigation. Symptoms are usually produced by pressure to the adjacent organs.
- A visible and palpable swelling may be detected in the right upper abdomen.
- There may be mild pain in the right hypochondrium due to pressure on adjacent organs.
- When it ruptures in the biliary tree, biliary colic, jaundice and urticaria may occur.
- When associated with secondary infection, there is fever with chill and rigor.

### Diagnosis

- CT scan and ultrasonography (USG) can accurately localize the cyst.

In USG, a multivesicular cyst with cart wheel sign is pathognomonic. In long-standing cases the walls calcify and a completely calcified cyst indicates a non-active parasite.

- Casoni's test is rarely used because of its low sensitivity and specificity.

### Differential Diagnosis

- Hepatoma.
- Amebic liver abscess.
- Cystic disease of liver.

### Treatment

- For small cysts no treatment is necessary.
- For larger cysts.

### Indications

#### Medical

- Prior to surgical treatment to decrease accidental peritoneal seeding during surgery.
- In recurrent and surgically unresectable disease.

Albendazole – 400 mg twice daily × 28 days, 2 weeks rest, then the cycle is repeated upto 3 cycles.

#### Surgical

- The cyst is enucleated after adequate medical treatment.

The intact cyst together with the laminated membrane is dissected from the adventitial lining and removed with sponge forceps. There is usually a comparatively easy plane of cleavage here. The adventitial layer need not be removed.

Care must be taken that the cyst does not rupture during the operation because the liberated scolices may form new cysts.

To prevent rupture, the cyst is first aspirated carefully to reduce the tension inside and the surrounding structures are kept separated with packs soaked with hypertonic saline (20 – 30%), sodium hypochlorite solution or savlon.

- Minimal access surgery by PAIR—see long case Hydatid cyst of liver in chapter 73.

### Complications

- Rupture—The hydatid cyst may rupture into the bile ducts (commonest), alimentary tract, (cyst can be vomited) or one of the pleural cavities.
- Suppuration and infection.
- Jaundice either due to cysts pressing the biliary passage or cysts within the passage.

### Malignant Hydatid Disease

This is caused by *Echinococcus multilocularis* and presents with multiple cysts all over the liver. The peculiarity of this cyst is that there is absence of capsule of the hydatid cyst which makes it liable to metastasise. Though benign it mimics clinically and prognostically malignancy as it is difficult to treat and hence the name. The patients usually die of liver failure.



See also long case hydatid cyst of liver, chapter 73.

## LIVER NEOPLASMS

### Benign (Rare)

- i. Hemangioma
- ii. Adenoma.

### Malignant

#### Primary (Rare)

- Hepatocellular carcinoma (HCC) or primary hepatoma.
- Cholangiocarcinoma
- Hepatoblastoma in infants and children.

#### Secondary

These are most common malignant tumors of the liver. Liver is second only to lymph nodes as the most frequent site of metastatic carcinomas.

- Systemic blood spread from carcinoma of the breast, lung, testis and melanoma, etc.
- Portal venous spread occurs from carcinoma of the bowel, spleen and pancreas.
- Lymphatic spread occurs from the breasts and lungs.
- Direct spread from carcinoma of stomach, gallbladder and right colic flexure. Metastasis may be of the following types according to its time of appearance after detection of the primary tumor.
  - Precocious metastases are present before the primary tumor has been detected, e.g. a carcinoid tumor of the ileum.
  - Synchronous metastases are detected at the same time as the primary tumor.
  - Metachronous metastases appear after the primary tumor has been removed, e.g. ocular melanoma.

#### Primary Hepatoma/(Hepatocellular Carcinoma—HCC)

##### Etiology

- Primary hepatoma arises from liver cells. It accounts for 80 – 90 percent of primary liver tumors.
- The three most important etiological factors are HBV infection, hepatocarcinogens in food and chronic liver disease.
- Hepatitis B virus (HBV) is not directly a carcinogen but it produces cirrhotic

changes and increases acceptability of liver cells to carcinogens and more than 60 percent of HCC occur in cirrhotic liver.

##### Pathology

##### Gross

- a. Usually a single large mass is there but satellite nodules due to spread by portal venous radicles may be present.
- b. The tumor usually looks yellow white color with frequent foci of necrosis and hemorrhage.
- c. There is increased vascularity and the tumor cells have tendency to invade the blood vessels to cause obstructive features viz.
  - i. Obstruction of hepatic veins will lead to Budd-Chiari syndrome,
  - ii. That of portal vein, to portal hypertension and
  - iii. Inferior vena cava (IVC) may be invaded upto the right heart.

##### Microscopic

The tumor consists of masses of liver cells that show evidences of malignancy.

##### Clinical Features

HCC is more common in males between 20 to 40 years of age. The clinical features are usually malaise, weakness, jaundice, ascites, and variceal bleeding due to portal hypertension, encephalopathy and upper abdominal lump. The rate of growth is frequently rapid.

In advanced cases, weight loss is present. Mortality increases due to liver failure and sepsis.

##### Spread

1. By continuity to surrounding liver tissue.
2. By contiguity involves peritoneum to cause hemorrhagic ascites.
3. Lymphatic spread occurs to the hilar, hepatic and celiac group of lymph nodes. The mediastinal and cervical nodes may also be involved.
4. Blood spread causes malignant pleural effusion, vertebral involvement follows soon.

##### Diagnosis

As the symptoms simulate those of a chronic liver disease in the absence of a lump, a number of investigations may be necessary. viz. USG,

CT scan, Radioisotope Scan and celiac axis angiography.

The alpha fetoprotein is elevated in about 90 percent of patients and is a useful marker.

##### Treatment

Primary hepatomas affecting one lobe may be treated by hepatic lobectomy. Hepatic transplantation is occasionally carried out if there is no extra hepatic spread.

Chemotherapy and radiotherapy are of no value.

##### Prognosis

Mean survival is four months after diagnosis.

##### Secondaries in Liver

Liver is the second commonest site of metastasis because of its double blood supply.

##### Pathology

**Grossly** most metastatic carcinomas form multiple, spherical nodular masses of variable size. Liver is enlarged and heavy, weighing 5 kg or more. Necrosis at the center of nodular masses metastasis lead to typical umbilication.

**Histologically**, The metastatic tumors generally reproduce the structure of the primary lesions.

##### Route of Spread

Metastatic tumors reach the liver by four possible routes viz. Systemic blood spread, lymphatic spread, portal vein and direct invasion. See above.

##### Clinical Features

- a. Jaundice—Due to liver destruction and intrahepatic duct compression.
- b. Portal vein obstruction producing esophageal varices and ascites.
- c. Inferior vena cava obstruction producing leg edema.
- d. Hepatomegaly.
- e. Hepatic failure.

##### Investigations

- USG abdomen.
- CT scan.
- Liver function tests.
- Upper and lower GI endoscopy and contrast X-ray for identification of the primary.



## Treatment

In majority of cases surgical treatment is only palliative in order to alleviate symptoms viz.

- a. Carcinoma stomach with secondaries palliative anterior gastrojejunostomy if vomiting is present.
- b. Periampullary carcinoma with secondaries—cholecystojejunostomy to relieve jaundice. Resection of secondary tumors is seldom of value.

## Chemotherapy

Combined with hepatic irradiation has provided palliation to a certain extent. Agents like 5FU and mitomycin C, when infused through the hepatic artery has caused reduction in the size of hepatic metastases.

## Prognosis

Mean survival time is six months after diagnosis.

## PORTAL HYPERTENSION

### Definition

The normal portal pressure is between 8 and 15cm of water, in no case it exceeds 25cm in a healthy person. Any rise in portal venous pressure above this level is said to be portal hypertension.

### Etiology

Portal hypertension results from an obstruction in the portal tree. In the majority (80%) of the cases, the cause of obstruction is within the liver, i.e. intrahepatic. The various causes are

1. Prehepatic (About 20%)—There is obstruction of the portal venous inflow into the liver, e.g.
  - a. Congenital malformation like portal vein atresia.
  - b. Portal vein thrombosis due to:
    - Spreading portal vein thrombosis in the neonate due to umbilical sepsis.
    - Pyelophlebitis after acute appendicitis.
    - Trauma.
  - c. Occlusion by tumor or pancreatitis.
2. Intrahepatic (80%)—There is obstruction of portal flow within the liver.
  - a. Cirrhosis—Commonest cause.
  - b. Metastatic tumors.

3. Posthepatic (rare —There is obstruction of the hepatic veins).
  - a. Budd-Chiari syndrome—Due to obstruction of the hepatic veins or their tributaries due to tumor growth, polycythemia and contraceptive pills in women.
  - b. Constrictive pericarditis.

### Pathological Effects

There are four important effects of portal hypertension.

1. Dilatation of portasystemic collaterals leading to esophageal varices, hemorrhoids, collateral veins around the umbilicus (caput medusae), retroperitoneal varices (silent). Esophageal varices can produce massive bleeding.
2. Splenomegaly – Probably resulting from the venous stasis and splenic congestion.
3. Ascites – In hepatic and posthepatic hypertension only.
4. The manifestations of hepatic failure in severe cirrhosis.

### Collateral Channels

These are:

- a. At the lower end of esophagus—Esophageal branches of left gastric vein (portal) and lower esophageal veins (systemic).
- b. Lower end of rectum—Superior rectal vein (portal) and inferior and middle rectal veins (systemic).
- c. Umbilicus—Paraumbilical veins accompanying the round ligament of the liver (portal) and superficial veins of the anterior abdominal wall (systemic) draining into the superior and inferior epigastric veins. The distended tributaries of systemic veins around the umbilicus is known as caput medusae.
- d. Retroperitoneal and diaphragmatic anastomoses between tributaries of splenic and colic veins and the portal radicals with the left renal vein, other tributaries of inferior vena cava and the diaphragmatic veins (systemic). The effect of this anastomosis is silent but presents technical hazards to the surgeon at the time of operation.

### Ascites

This is due to a combination of factors:

- a. Portal hypertension increases transudation of fluid into the peritoneal cavity but

this alone will not produce ascites which is therefore not seen in the prehepatic obstruction.

- b. Reduction in plasma proteins, especially albumin, which is synthesized in the liver. This results in low plasma osmotic pressure and consequent low reabsorption of ascitic fluid.
- c. Hyperaldosteronism due to failure of the damaged liver to inactivate aldosterone, which results in sodium and water retention.
- d. Increased lymphatic pressure in the cirrhotic liver results in lymph transudation from the liver surface.

### The Effects of Liver Failure

1. Jaundice
2. CNS-effects—Mental changes, flapping tremor and hepatic coma. This hepatic encephalopathy is brought about by a shunt of nitrogenous breakdown products from the intestine via the portal tract into the systemic circulation without hepatic detoxication.

### Clinical Features

The portal hypertension patient may present with the following problems to the surgeon:

- a. Jaundice or Hepatomegaly.
- b. Gastrointestinal hemorrhage due to esophageal varices or hemorrhoids.
- c. As one of the causes of ascites.

### Investigations

- a. Blood examination—Anemia, leukopenia and thrombocytopenia.
- b. Liver function tests—Together with liver biopsy if necessary.
- c. Fiberoptic endoscopy will demonstrate varices and will differentiate between bleeding from this source and that from a peptic ulcer or multiple gastric erosions, both of which are common in patients with cirrhosis.
- d. Splenoportogram: This can outline the anatomy of the splenic vein, portal vein, and its intrahepatic radicals and demonstrate the site of obstruction, the direction of portal flow and the presence of hepatic parenchymal lesions.
- e. Ultrasound with Doppler scan—This can demonstrate the patency and size of portal and splenic veins and evaluation of portal

vein anatomy, thrombosis and collateral formation. It is also useful in assessing shunt patency.

### Management

Portal hypertension cannot be cured. Sclerotherapy is the standard treatment for portal hypertension with bleeding.

Treatment should be done only when there is hematemesis because mere presence of varices does not mean that they will bleed and prophylactic surgery or sclerotherapy carries significant morbidity and some degree of mortality also.

The only indication to do surgery when there is no hematemesis is hypersplenism.

Thus treatment of portal hypertension may be discussed under the following three headings.

- Treatment of acute variceal bleed
- Definitive procedures for acute or recurrent bleeds
- Control of ascites and liver failure.

### Treatment of Acute Variceal Bleed

- The immediate treatment of hemorrhage is blood replacement by transfusion.
- Pulse rate, blood pressure, central venous pressure and urine output should be monitored frequently.
- Rapid clearing of the blood from the bowel should be done with mild purgatives and enema. This will reduce ammonia and uric acid levels so as to prevent encephalopathy.
- Drugs to reduce variceal bleed:
  - Intravenous pitressin (vasopressin)—20 units in 200ml of saline over a period of 20 minutes.

This produces a marked fall in portal venous pressure and temporary cessation of bleeding by mesenteric arteriolar constriction.

- Metoclopramide 20 mg IV arrests the bleeding by constricting gastroesophageal sphincter.

- If the bleeding continues, emergency sclerotherapy is done.

This technique is analogous to the injection treatment of piles.

- 2 percent Ethanolamine oleate or sodium tetradecyl sulfate (STD), 3–5ml is injected into each varix

**Table 36.2: Child's criteria, points awarded for abnormality**

	1	2	3
1. Serum albumin (gm/liter)	35	28 - 35	Less than 28
2. Serum bilirubin mg%	<2.0	2 - 3	> 3.0
3. Ascites	Nil	Easily controlled	Not controlled
4. Encephalopathy	Absent	Mild	Severe
5. Prothrombin time (Prolongation)	1 - 4	4 - 6	Above 6

Grade A = 5 - 6 points, suitable for shunt, prognosis good.

Group B = 7 - 9 points, marginally suitable for shunt, prognosis fair.

Group C = above 10 points, unsuitable for shunt. Jaundice, Ascites and low albumin are contraindications for shunt surgery.

- Bleeding can be controlled in 80 to 90 percent cases, by these measures
- If bleeding continues, repeat injections can be given.
- In case of failure of the above measures, balloon tamponade is done.

### Balloon Tamponade

It exerts direct pressure over the varices and is effected by using the Sengstaken tube or its modification, the Minnesota tube. The tube is passed through the nose; Gastric balloon is distended with upto 250 - 300ml air and esophageal balloon with 50 - 60ml of air or to get a pressure of 25 - 30mm of Hg.

### Definitive Procedures

#### Nonshunt Procedures

- Porta azygos disconnection - In this operation the varices around the lower end of esophagus and upper stomach are divided at the cardio esophageal junction with anastomoses using the circular stapling gun, in order to interrupt the communications between the two systems within

the wall of the lower esophagus. It is also effective in 60 percent of cases of acute bleed. However rebleed rates are high at two years.

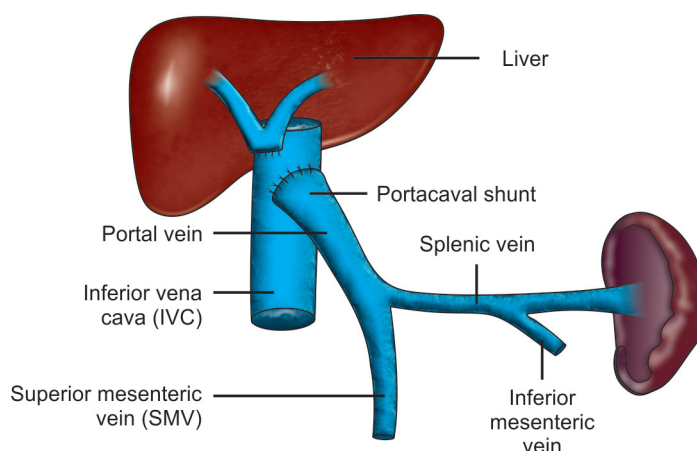
- Sigura procedure—Sigura extended the devascularization to include not only the lower esophagus but also a much more extensive periesophageal clearance through a thoracotomy. The advantage of these procedures is that hepatic encephalopathy is almost nonexistent.

### Shunt Procedures (Figs 36.3 to 36.7)

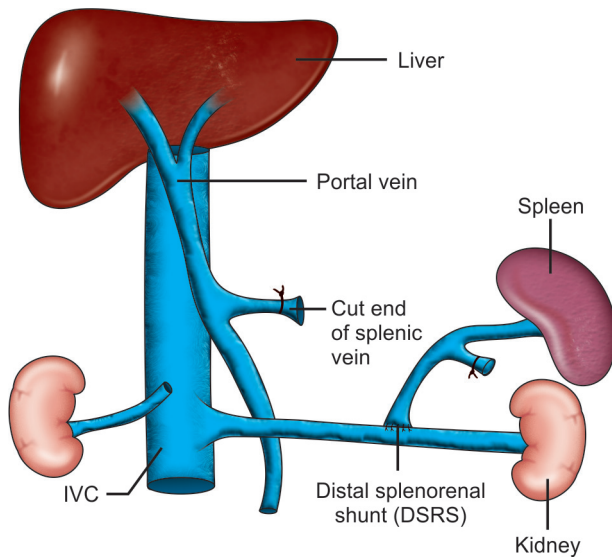
A variety of portal systemic shunt procedures have been described. The best results are seen in patients with compensated liver disease. Child's criteria are a useful guide for deciding the suitability of a patient for shunt surgery and for prognostication (Table 36.2).

#### Indications

- Continuing variceal bleeding in spite of sclerotherapy with compensated liver disease, i.e. child's grade A and B as mentioned above.



**Fig. 36.3:** End to side portacaval shunt



**Fig. 36.4:** DSRS or Warren's shunt

2. As an elective procedure in patients who had bleeding in the past.

**Types**

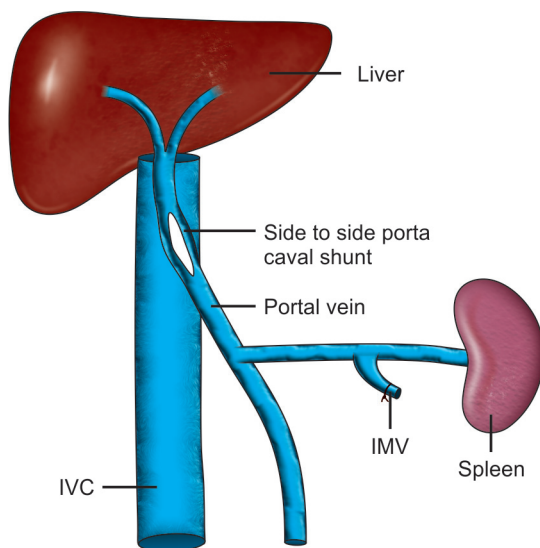
Portal systemic shunts include the following:

1. The classic portacaval shunt (Fig. 36.3) results in a loss of portal blood flow to the liver because portal vein is divided from the liver and the end is anastomosed to the side of IVC (Inferior Vena Cava).  
This controls the bleeding in more than 90 percent cases but chances of encephalopathy is 30 percent because of sudden deprivation of liver blood flow.

2. Selective shunts – In selective shunts some portal flow is preserved to liver so that the rates of encephalopathy are lower. Distal splenorenal shunt (Warren's shunt) (Fig. 36.4) In this operation, the splenic vein is transected, the portal end ligated and splenic end is anastomosed to the left renal vein.

It controls variceal hemorrhage and almost there is zero incidence of encephalopathy.

3. Partially selective shunts—It employs an anastomosis less than 8 mm size to provide for partial portal inflow. These can



**Fig. 36.5:** Side to side portacaval shunt  
IMV = Inferior mesenteric vein  
IVC = Inferior vena cava

be side to side portacaval (Fig. 36.5) or H mesocaval shunts (Fig. 36.6).

4. Transjugular intrahepatic portal systemic stenting (TIPSS)—It employs a catheter through internal jugular vein into the hepatic vein radicle and then into the portal vein radicle through the hepatic parenchyma. (Fig. 36.7)

If provides effective control of acute bleeding episode and is useful as a bridge to liver transplantation in Child's C-class patients.

The complications include postshunt encephalopathy in about 30 to 40 percent cases and intraperitoneal bleeding due to perforation of the liver capsule.

**Liver Transplantation**

Liver transplantation can be considered in Child's 'C' class cirrhotics with variceal bleeding, decompensated liver disease and persistent encephalopathy. The absolute 1 year survival is 90 percent.

The problems of liver transplant include scarcity of donor organs and the expense.

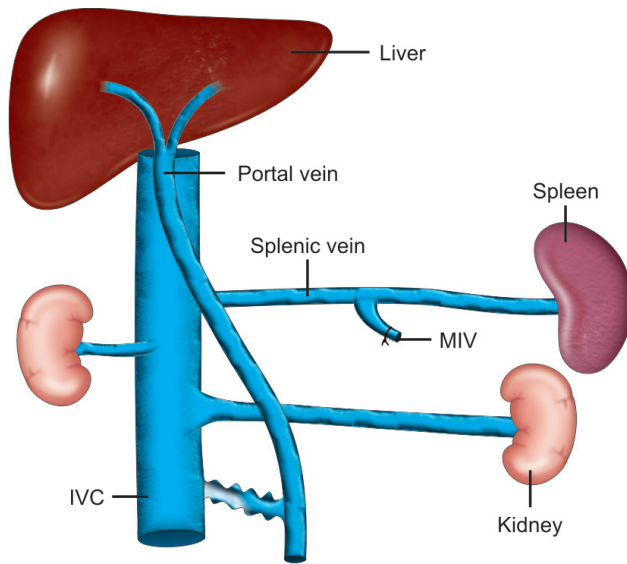
**Control of Ascites**

- Dietary salt restriction.
- Potassium sparing diuretics like spironolactone 100 to 400 mg/day.
- Correction of hypoalbuminemia with albumin infusion.
- Paracentesis gives immediate relief if discomfort is intense but the disadvantage is that the patient loses protein.
- Peritoneovenous shunt (Le Veen or Denver). The shunt has a unidirectional pressure activated valve which shunts ascitic fluid from the peritoneal cavity back into the venous system via the internal jugular vein.
- Surgery—A side to side portacaval shunt is a good surgical option. TIPSS is considered if associated variceal bleed is present.

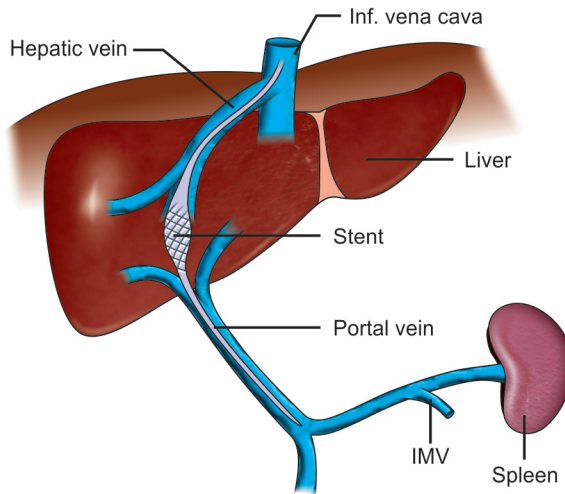
**Control of Porta-Systemic Encephalopathy**

Porta systemic encephalopathy may be precipitated by acute hemorrhage, electrolyte imbalance or sepsis in cirrhotic patients.

The patient usually presents with personality changes, delirium, altered behavior, oliguria and kidney failure and flapping tremor.



**Fig. 36.6:** Side to side H-shaped mesentericocaval shunt using a graft  
 IMV = Inferior mesenteric vein  
 IVC = Inferior vein cava



**Fig. 36.7:** Transjugular intrahepatic porta-systemic stenting (TIPSS)  
 IMV = Inferior mesenteric vein.

The treatment consists of:

- i. Correction of the precipitating factors like GI bleed, hypokalemia and infection.
- ii. Reduction of dietary protein initially no protein and later on 20-40 gm/day.
- iii. Antibiotics administration – oral neomycin to reduce bacterial load inside the bowel lumen, 1 gm 4-6 hourly.
- iv. Oral lactulose 30-50 ml 4 times a day for 2 soft motions per day.

### **BUDD-CHIARI'S SYNDROME**

It is a syndrome due to obstruction of the hepatic veins.

#### **Causes**

- i. Idiopathic hepatic venous thrombosis in young adults of both sexes.
- ii. Blockage of hepatic vein by tumor invasion.
- iii. Polycythemia.
- iv. Contraceptive pills.
- v. Congenital obliteration.

#### **Clinical Features**

1. Acute form—It is the dangerous type and results in severe abdominal pain, vomiting, hypotension and often death.
2. Chronic form—Resembles cirrhosis.
  - Hepatomegaly.
  - Dilated veins over the abdominal wall.
  - Signs of hepatocellular failure and ascites.

#### **Treatment**

All patients require surgical correction as early as possible. In hepatic vein obstruction a mesoatrial shunt is recommended.

Here the superior mesenteric vein is drained into the right atrium using a long Dacron graft.

# Chapter 37

## Gallbladder

- Surgical anatomy
- Congenital disorders of gallbladder
- Gall stone
- Cholecystitis
- Stones in the common bile duct
- White bile
- Courvoisier's law
- Surgical jaundice
- Carcinoma gall bladder

### **SURGICAL ANATOMY (FIG. 37.1)**

It is a pear-shaped organ developed from the cystic bud arising from the trunk of the hepatic bud which grows from the foregut and situated in the gallbladder fossa.

It is 8 to 12 cm long and has a capacity of 50 ml. It acts as a reservoir of bile, after concentrating it 10 times and expels the same by

contraction into the duodenum aided by the hormone cholecystikinin secreted by duodenum in presence of fatty food.

#### **Parts**

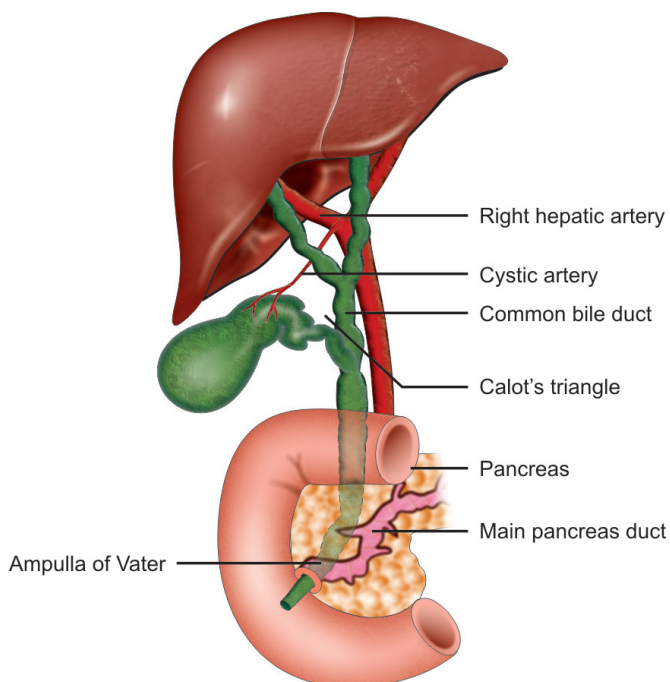
a. Fundus—It is the portion which projects just below the sharp lower border of liver at the tip of 9th costal cartilage intersecting the transpyloric plane.

b. Body—The body is in contact with the first part of duodenum. It passes backwards and upwards towards the right end of porta hepatis.

c. Neck—The upper end of the body narrows into the neck which lies at a higher level than the fundus and against the free edge of the lesser omentum. The wall of the neck where it joins the cystic duct may show a small diverticulum called the Hartmann's pouch—A common site where stones occur and tend to stay for a long time.

d. Cystic duct—The neck continues into the cystic duct which is 2 to 3 cm long and 2 to 3 mm in diameter. It joins the common hepatic duct to form the common bile duct (CBD). This junction is known as the junction of three.

A series of crescentic mucosal folds, 5 to 12 in number exist in the upper part of the cystic duct due to prominent circular muscle fibers. This produces a valve called the spiral valve of Heister, which prevents regurgitation of stone into the CBD.



**Fig. 37.1:** The gallbladder and its duct system

#### **Blood Supply**

1. Cystic artery, a branch of right hepatic artery, given behind the CBD. Cystic vein drains directly into the portal vein which explains early spread of gallbladder malignancy to liver.
2. Many small vessels from the hepatic bed.



### Cholecystohepatic Triangle or Triangle of Calot

#### Boundary

Base—Common hepatic duct.

Sides—Cystic duct and right lobe of liver (inferior border).

Contents—Cystic artery and cystic lymph gland of Lund.

Caterpillar turn or Moynihan's hump—It is the very tortuous hepatic artery running in front of origin of the cystic duct.

**Hepatorenal pouch of Morison**—It is a part of subphrenic space which opens into the general peritoneal cavity and lies between anterior surface of the kidney and inferior surface of liver. After cholecystectomy, the pouch is drained to avoid any collection.

**Ducts of Luschka**—These are the ducts that drain bile directly from the liver into the gallbladder.

### CONGENITAL DISORDERS OF GALLBLADDER

1. Congenital absence of gallbladder is very rare. An intrahepatic gallbladder may sometimes be mistaken for congenital absence.
2. Floating gallbladder—A gallbladder with a large mesentery is called a floating gallbladder and carries the risk of torsion.
3. Cystic duct anomalies:
  - a. Absence of cystic duct—Cholecystectomy becomes difficult in this situation and chance of injury to the CBD is increased.
  - b. Low insertion of cystic duct—The cystic duct opens into the common duct near the ampulla.
  - c. Several small ducts may drain directly from the liver into the gallbladder. They can give rise to significant bile leakage postoperatively.
4. Anomalies of blood supply:
  - a. The cystic artery may pass in front of the common hepatic duct rather than to the right or posterior to this duct.
  - b. Caterpillar hump—As mentioned earlier, the right hepatic artery may course parallel to the cystic duct in a peculiar caterpillar or Moynihan's hump and is mistaken for the cystic artery.

### Biliary Atresia

It means fibrosis of extra and intra-hepatic biliary tree either due to viral

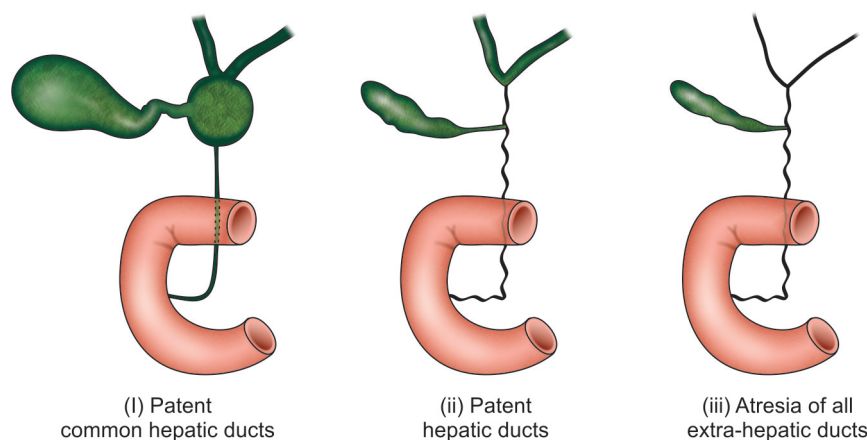


Fig. 37.2: Different types of biliary atresia

infection or defective embryogenesis. There is progressive jaundice in the newborn with steatorrhea.

#### Types (Fig. 37.2)

Type I—Atresia of CBD – 10%.

Type II—Atresia of CBD and common hepatic duct.

Type III—Atresia of CBD, common hepatic duct and right and left hepatic ducts – 88%.

The condition is correctable in 10 percent cases and noncorrectable in the rest.

In correctable cases Roux-en-Y jejunal anastomosis is done. In noncorrectable cases hepaticojejunostomy (Kasai procedure) is performed.

Liver transplantation is becoming more popular in this condition.

#### Choledochal Cyst

It is defined as the cystic enlargement of the common bile duct and more common in females. Todani et al in 1977 divided choledochal cysts into five types as described below:

#### Types (Fig. 37.3)

Type I—Cystic or fusiform dilatation of common bile duct (CBD) – Commonest type (75%).

Type II—A lateral saccular diverticulum of the CBD.

Type III—Dilatation of only the intraduodenal segment of CBD (Choledochoceles).

Type IV—Dilated CBD with dilatation of intrahepatic biliary radicals.

Type V—Isolated intrahepatic cysts. When this is associated with hepatic fibrosis, it is known as Caroli's disease.

#### Triad of Choledochal Cyst

It consists of jaundice, palpable abdominal mass and pain in the right upper abdomen.

#### Complications

These are:

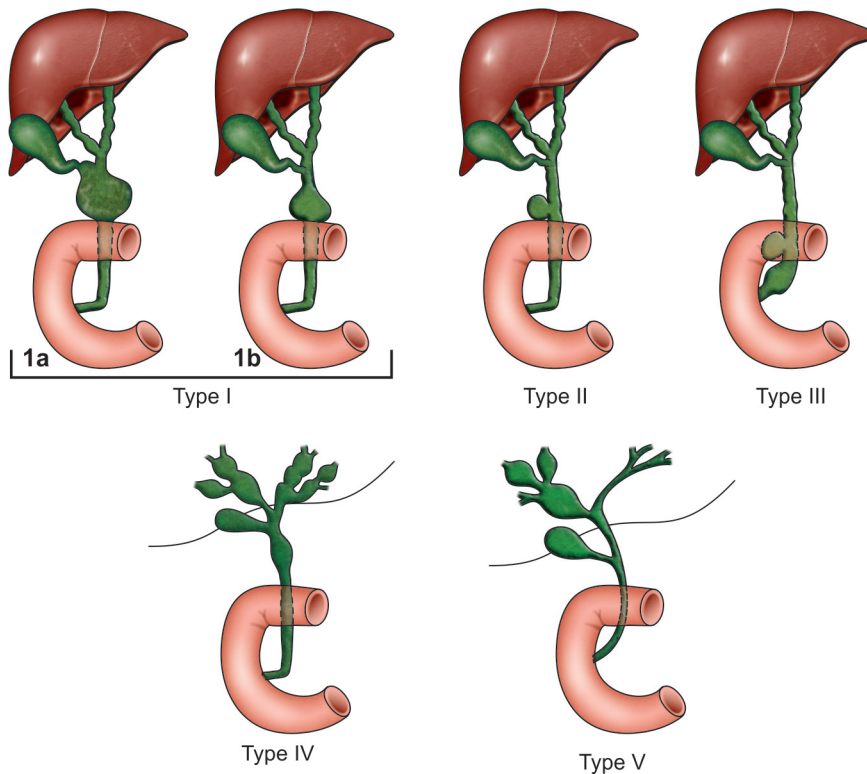
- Suppurative cholangitis.
- Pancreatitis.
- Gallstone and CBD stone formation.
- Biliary cirrhosis.
- Cholangiocarcinoma of CBD in about 30 percent cases.

#### Treatment

1. Type I—Excision of the cyst and reconstruction with Roux-en-Y anastomosis with a loop of jejunum.
2. Type II—Excision of the diverticulum and suturing of the CBD wall is done.
3. Type III—Endoscopic sphincterotomy is done. however excision may be necessary in symptomatic patients.
4. Type IV—Intrahepatic dilatation is difficult to treat. If it is localized, hepatectomy is sufficient but if it is diffuse, liver transplantation may be required.
5. In Caroli's disease, hepatic lobectomy is considered when the condition is limited to one lobe of liver. When diffuse, liver transplantation may be required. Antibiotics are prescribed for associated cholangitis.

### GALLSTONE

The most common biliary pathology is gallstone. Gallstone disease is common in the Northern India including Punjab, Haryana,



**Fig. 37.3:** Types of choledochal cysts. Type Ia—Diffuse type or fusiform type – dilatation of both CBD and the common duct. Type Ib—Cystic type (Small cystic dilatation of the distal CBD). Types II – See text

Jammu and Kashmir, Bihar and Uttar Pradesh. It is rare in Southern India.

Diet rich in fat and cholesterol may be one of the etiological factors.

It is common in fat, fair, fertile, fatty, forty, flatulent female.

### Types

According to their chemical composition and gross appearance, there are three types of stones.

#### Cholesterol Stones (6%)

##### Features

- Mostly solitary (cholesterol solitaire)
- Dirty white in color and radiolucent.

##### Pathogenesis

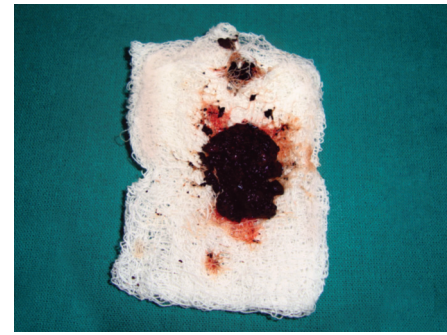
It occurs due to error in cholesterol metabolism. Normal ratio of bile salts to cholesterol is 25:1. If it is less than 13:1, cholesterol precipitates and stone formation occurs. This may happen if the level of bile salts declines or cholesterol gets precipitated.

#### Pigment Stones (4%)

- They are mostly multiple small concretions, jet black in color and radiolucent (Fig. 37.4).
- Composition—Either pure bilirubin or calcium bilirubinate mixed with calcium phosphate and carbonate.
- Pathogenesis: These are associated with excessive hemolysis with increased production of unconjugated bilirubin, e.g. thalassemia, malaria, sickle cell anemia. The unconjugated bilirubin precipitates leading to biliary sludge and stone formation. They may form either in the gallbladder or in the bile ducts (primary ductal stones).

#### Mixed or Infected Stones (90%)

- These are multiple, faceted and dirty white in color (Fig. 37.5).
- It is heavier than bile.
- 10 to 20 percent stones are radiopaque.
- Pathogenesis: Usually these stones are produced by infection of the gallbladder by organisms like *E. coli*, *Klebsiella*,



**Fig. 37.4:** Pigment stones, jet black in color and radiolucent



**Fig. 37.5:** Mixed gall stones

*Streptococcus*, *Staphylococcus*, etc. The stone consists of concentric layers of calcium bilirubinate and cholesterol around the central nucleus of dead bacteria and epithelial debris. Since these stones are mixtures of cholesterol and bile pigments they are called mixed stones.

### Pathological Effects and Complications of Gallstones

- Effect on the gallbladder—
  - Silent or asymptomatic stone which is discovered accidentally during imaging studies such as plain X-ray abdomen and pelvis or spine, ultrasonography of upper abdomen, etc.
  - Acute cholecystitis with its complications like mucocele, empyema, gangrene and perforation, internal fistula like cholecystocolic and cholecystoduodenal fistula.
  - Chronic cholecystitis which may again lead to acute cholecystitis.
  - Carcinoma of gallbladder.

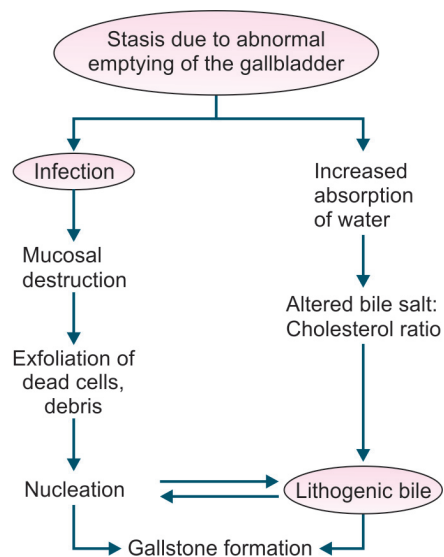
- b. Effect in the CBD:
- Obstructive jaundice
  - Biliary colic
  - Cholangitis
  - Hydrohepatosis
  - White bile
  - Cholangiocarcinoma.
- c. Effect on the intestine—Acute intestinal obstruction, known as gallstone ileus.
- d. Gallstones and other disorders—Saints triad consists of (i) Gallstones (ii) Colonic diverticulosis and (iii) Hiatus Hernia.
- e. Effects on the pancreas—Gallstone pancreatitis due to the presence of stone in the ampulla.
- Acute pancreatitis.
  - Chronic pancreatitis.

### Causative Factors

It is believed that there are three principal factors which predispose to gallstone formation. Certain individuals secrete lithogenic bile and lithogenicity of bile is increased by stasis and infection (Fig. 37.6).

### CHOLECYSTITIS

Inflammation of the gallbladder may be acute (Calculus or acalculus), chronic and acute on chronic, that is, the gallbladder already affected by chronic inflammation is acutely inflamed.



**Fig. 37.6:** Effects of stasis and infection in gallstone formation. The three main causative factors have been circled.

### Acute Calculus Cholecystitis

- In majority of cases (95%) a gallstone is found impacted in Hartmann's pouch or obstructing the cystic duct.
- Gall bladder with chronic cholecystitis is often acutely inflamed.

### Clinical Features

- Pain**—There is pain in the right hypochondrium of sudden onset, often precipitated by fatty food, heavy meal or certain vegetables like cabbage.

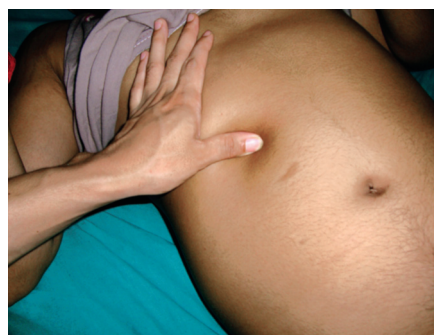Pain often radiates to the inferior angle of the right scapula, an area which has the same segmental supply (T<sub>7</sub>) as the gallbladder.

Sometimes pain radiates to the tip of the right shoulder because of irritation of the diaphragm by the fundus of inflamed gallbladder. This occurs by way of C<sub>4</sub> component of the phrenic nerve which also supplies the tip of right shoulder.

- Nausea and vomiting**—There is reflex nausea and vomiting.
- Temperature**—There is high and hectic temperature if associated with empyema.
- Jaundice**—May occur in a few cases due to associated cholangitis.

### Local Signs

- Rigidity and tenderness are present in the right hypochondrium.
- Murphy's sign is usually positive. There will be catch in the breath at the height of inspiration when pressure is put over the gallbladder point, i.e. tip of the 9th costal cartilage (Fig. 37.7).
- Boas's sign—It is elicited in some cases. This is an area of hyperesthesia between the 9th and 11th ribs posteriorly, on the right side.



**Fig. 37.7:** Murphy's sign

### Diagnosis

Ultrasonography will confirm the diagnosis showing a distended gallbladder with thick walls.

HIDA scan may be helpful when the distended gallbladder obscures the view.

### Differential Diagnosis

- Acute appendicitis.
- Perforated peptic ulcer.
- Acute pancreatitis.
- Right sided pyelonephritis.

### Treatment

Unlike acute appendicitis, the treatment of acute cholecystitis is usually conservative. This is as follows:

- Nasogastric suction and IV fluid. IV fluid is stopped when inflammation subsides and fat-free diet is advised.
- Analgesics**—Morphine is avoided as it causes spasm of the sphincter of Oddi thus increasing tensions and pain.
- Antibiotics**—Broad spectrum antibiotics like third generation cephalosporin, is administered parenterally to start with and thereafter orally.
- Subsequent management:**
  - When the inflammation subsides usually by the third day, diagnosis is confirmed by USG in doubtful cases. With the diagnosis confirmed cholecystectomy is performed 8 to 10 weeks after acute symptoms have subsided (interval cholecystectomy).
  - If no improvement occurs with conservative treatment and toxicity increases, even after 2 to 3 days, decision is taken in favor of immediate surgery.

### Indications of Surgery

- When the diagnosis is doubtful, e.g. from acute appendicitis or peptic perforation.
- Perforation of the gallbladder.
- Empyema not responding to conservative treatment.

### Nature of Surgery

- In majority of cases cholecystectomy is done.
- In some cases where neck of gallbladder is very edematous and friable cholecystostomy is done to drain the gallbladder

and release the tension. Cholecystectomy is undertaken at a later date.

The clinical features and management of acute acalculous cholecystitis is the same as the acute calculus cholecystitis.

Acalculous cholecystitis mostly occurs in patients after major trauma including burns.

### Chronic Acalculus Cholecystitis (Cholecystoses)

Chronic acalculous cholecystitis or cholecystoses occur in the following conditions.

- a. Cholesterosis or strawberry gallbladder. In these conditions, the mucosa of the gallbladder is studded with tiny yellow flecks giving a typical picture of ripe strawberry. The flecks consist of cholesterol crystals and cholesterol esters.
- b. Adenomyomatosis or cholecystitis glandularis proliferans—The adenomatous elements encroach into the muscular wall of the gallbladder which can be local or diffuse. There are chronic inflammatory changes in the gallbladder with hyperplasia of the muscle and mucosa of the gallbladder. Sometimes this can be detected by USG. Clinical features simulate those of chronic cholecystitis.

The treatment of choice in chronic acalculous cholecystitis is cholecystectomy.

### Chronic Calculus Cholecystitis

Chronic cholecystitis is characterized by a small shrunken and distorted gallbladder secondary to repeated attacks of biliary colic or acute cholecystitis which culminate in the fibrosis of the gallbladder wall.

#### Clinical Features

- Pain—There is severe colicky pain in the right upper quadrant of abdomen, epigastrium or under right costal margin. Pain is often precipitated by fatty food and radiates between the shoulder blades associated with nausea and vomiting. Such pain lasts for several hours (< 12 hours).

If pain lasts for more than 12 hours, the diagnosis of acute cholecystitis should be considered.

- Flatulent dyspepsia—A feeling of fullness following heavy or fatty food in association with heart burn and belching.

#### Signs

- Tenderness over the right hypochondrium.
- Classical subject (Five F's) –The patient is usually fat, female, fair, fertile and forty years of age.
- Murphy's sign—Usually positive.

#### Investigations

Ultrasonography—This is the best investigation to detect gallstones and thickened gallbladder wall (normal thickness of gallbladder wall is 5mm).

#### Differential Diagnosis

1. Chronic duodenal ulcer.
2. Chronic pancreatitis.
3. Hiatus hernia.
4. Carcinoma stomach or pancreas.
5. Acute myocardial infarction.

#### Treatment

- I. During colic
  - Nothing per mouth and IV fluid administration.
  - Administration of analgesics.
  - Administration of antibiotics, e.g. cefuroxime or gentamicin.
  - Antiemetics may be needed.
  - Low fat diet until cholecystectomy is done.
- II. Subsequent management – Cholecystectomy is the treatment of choice, provided the patient is fit and the diagnosis has been established.

Dissolution of gallstones—This has no role in the present day management of gallstones.

Newer techniques for gallstones are worth mentioning here viz.

1. Laparoscopic cholecystectomy.
2. Minilap cholecystectomy – This is open cholecystectomy through a small 5cm cosmetic incision for a rapid recovery.
3. Percutaneous cholecystolithotomy.
4. Lithotripsy by ESWL (Extra Corporeal Shock Wave Lithotripsy).

#### Complications of Chronic Cholecystitis

1. CBD stone or choledocholithiasis.
2. Pancreatitis.
3. Cholangitis.
4. Mirizzi's syndrome.

### STONES IN THE COMMON BILE DUCT

Syn—Choledocholithiasis.

#### Classification

- a. Primary bile duct stones—The stones that form in the bile duct itself are called primary bile duct stones. These are usually pigment stones and rarely seen.
- b. Secondary bile duct stones—These are stones that form in the gallbladder and then migrate into the bile duct via the cystic duct.

#### Behavior

Unlike the gallbladder the bile ducts have no muscle in their wall that can effectively contract to expel the stone through the sphincter of Oddi.

In case of a pathological gallbladder or a gallbladder already removed, the flushing action on the common bile duct normally executed by a healthy gallbladder is absent.

Thus a stone in the duct has only remote chances to be expelled by natural process unless it is very small in size.

#### Fate

1. Asymptomatic—Many stones do not cause any symptoms and discovered incidentally during routine palpation of the common bile duct at cholecystectomy.
2. Intermittent obstruction—The stone may move up and down like a ball valve and this gives rise to intermittent obstructive jaundice. The obstruction is due to edema of the adjacent duct wall, caused by the stone. As the stone moves proximally and floats, obstruction is relieved and symptoms subside.

**Charcot's triad:** Intermittent obstruction typically produce the Charcot's triad characterized by:

- Intermittent pain (Biliary colic),
  - Intermittent fever with chill and rigor and
  - Intermittent jaundice.
3. Impacted stone—Sometimes the stone gets fixed or impacted in the CBD most commonly just above the sphincter of Oddi. The impacted stone will cause persistent pain, persistent fever and persistent jaundice.



Pathological effects of an impacted stone are:

- Obstructive jaundice
- Hydrohepatosis
- White bile
- Gradual hepatic failure
- Acute pancreatitis.

### WHITE BILE

This is a misnomer because the content is neither bile nor it is white in color (it is opalescent). The mucous glands of the CBD produce this secretion as the bile formation by hepatocytes ceases when the pressure within the CBD rises above 300mm water.

### Hydrohepatosis

When the obstruction in the CBD is complete and of long duration, there is gross dilatation of the intrahepatic biliary canaliculi which are filled up with white fluid.

### Clinical Features

1. Asymptomatic group.
2. Stones producing ball-valve obstruction will typically produce Charcot's triad.
3. Impacted stone will give rise to severe biliary colic and progressive jaundice.

### COURVOISIER'S LAW

According to this law, in a patient with obstructive jaundice, if the gallbladder is palpable, it is not due to an impacted duct stone but usually due to carcinoma head of the pancreas.

It may be stated the other way round – if the gallbladder is not palpable, the jaundice is due to stone.

### Exceptions to Courvoisier's Law

1. Double pathology—One stone impacted in cystic duct causing gallbladder distension and another stone blocking the common duct causing obstructive jaundice.
2. Primary pigment stone forms in the CBD, and the gallbladder itself is normal and distensible.
3. Carcinoma head of the pancreas in a previous sufferer of chronic cholecystitis.

### Differential Diagnosis

Obstructive jaundice due to other causes:

- Carcinoma head of the pancreas.

- Carcinoma of periampullary region.
- Carcinoma of biliary tree.
- Biliary stricture.

### Investigations

1. USG abdomen.
2. ERCP—Gold standard for diagnosis.
3. MRCP—This is preferred to ERCP if available as a diagnostic tool
4. Liver function tests.
5. CT scan of abdomen if USG is non-conclusive.

### Treatment

1. When the stone is detected during a cholecystectomy, choledocholithotomy and T-Tube (Kehr's) drainage is done and kept for 14 days.

After 14 days a postoperative T-Tube cholangiogram is done to see free flow of dye into the duodenum, so that T-Tube can be removed.

2. When the patient presents with obstructive jaundice, management is as below:

Immediate surgery to perform choledocholithotomy with cholecystectomy is contraindicated due to the following risk factors:

- a. Obstruction in the duct causes back pressure in the liver and the liver function deteriorates quickly.
 

Altered metabolism following surgery and anesthesia and toxic effects of anesthetic drug will yield a poor postoperative outcome.
- b. There is poor absorption of vitamin K a fat-soluble vitamin from the gut in the absence of bile salts. This tends to produce a considerable risk of hemorrhage at and after operation due to diminished coagulability of blood.
- c. Risk of infection due to lowered resistance.

These patients are therefore, subjected to conservative treatment prior to operation to correct the risk factors:

- i. Injection vitamin K – 10mg IM once a day for 5 days to correct prothrombin time.
- ii. IV antibiotics like cefuroxime or cefoperazone.
- iii. Correction of dehydration to ensure urine flow of 30ml per hour.
- iv. Support to liver by:
  - a. High calorie, high carbohydrate, low protein and no fat diet.

- b. Administration of glucose – to start with intravenously 25 percent solution 100ml BD and thereafter orally.
- c. Administration of vitamin B complex and vitamin C.

### Types of Surgery

A. If the gallbladder contains calculi the options are as follows:

1. Cholecystectomy with choledocholithotomy and T – Tube drainage.
2. The alternative procedures include.
  - a. Laparoscopic cholecystectomy and endoscopic sphincterotomy with extraction of stones.
  - b. Cholecystectomy and choledocholithotomy with choledochoduodenostomy when CBD is > 1.5cm in diameter.

B. If the gallbladder contains no calculi the options are as follows:

- i. ERCP extraction.
- ii. ESWL (Extracorporeal shock wave lithotripsy).

C. Retained stone (Syn. Overlooked calculi) – These are stones detected after a choledocholithotomy.

- i. T – Tube *in situ* – Stone may be extracted by:
  - Flushing with normal saline
  - Burhenne technique – Instrumental extraction of CBD stone through the T-Tube tract using radiologic guidance.
- ii. T-Tube not in place – Options are:
  - Endoscopic sphincterotomy and stone extraction by a dormia basket catheter introduced through the endoscope.
  - Laparoscopic or open choledocholithotomy.
  - Extracorporeal shockwave lithotripsy.

### SURGICAL JAUNDICE (OBSTRUCTIVE JAUNDICE)

#### Definition

It is defined as a state of conjugated hyperbilirubinemia due to extrahepatic biliary obstruction.

#### Etiology

The common causes include:

1. Biliary atresia.
2. Choledochal cyst.



3. Stone in CBD
4. Strictures
  - a. Benign
  - b. Malignant
5. Rare causes
  - Parasites
  - Hilar lymphadenopathy
  - Papillary stenosis
  - Biliary dyskinesia.

## Diagnosis

### History

- Repeated attacks of cholangitis are seen in choledocholithiasis. There is intermittent pain, intermittent fever with chills and rigor and intermittent jaundice (Charcot's triad).
- Passage of clay-colored stool.

### Laboratory Tests

1. Liver function test
  - a. Serum bilirubin → More than 80 percent is conjugated bilirubin.
  - b. Alkaline phosphatase – Raised.
  - c. Prothrombin time – Prolonged.
2. USG
3. MRCP.

Both USG and MRCP are noninvasive and very accurate in identifying extrahepatic obstruction. MRCP, nowadays is preferred to ERCP and PTC which are invasive.

## Preoperative Management

This has already been described above in the treatment of CBD stones.

## Problems of Anesthesia

- High risk of ARF (acute renal failure), hepatorenal syndrome and coma.
- Inhalational anesthetic agents are hepatotoxic. So, it is better to avoid them.
- Intraoperative hypotension and anoxia carries grave prognosis.

## Proper Surgical Management

- The treatment of biliary atresia, choledochal cyst and CBD stone has been already described.
- Biliary stricture: This may be benign or malignant.

## Benign Stricture

### Causes

1. Postoperative – 80 percent of strictures are following surgery on the biliary tree.
2. Inflammatory – 20 percent of strictures are due to inflammatory pathology like sclerosing cholangitis, *Ascaris lumbricoides* and recurrent attacks of cholangitis due to CBD stone.

## Malignant Stricture

This is due to periampullary carcinoma or carcinoma head of the pancreas, cholangiocarcinoma, carcinoma of gallbladder, etc.

### Treatment

1. Benign structure
  - i. Low CBD obstruction
    - a. Choledochoduodenostomy or choledochojejunostomy.
    - b. ERCP stenting.
  - ii. High CBD obstruction
    - Left hepaticojejunostomy with jejunojejunostomy.
    - ERCP stenting.
2. Periampullary carcinoma
  - Whipple's operation.
  - Stenting and palliative radiotherapy. This has a better prognosis in comparison to carcinoma head of the pancreas.
3. Sclerosing cholangitis
  - Steroids in large doses.
  - Cholestyramine.
  - Stenting.
4. Cholangiocarcinoma
  - Stenting for relief of jaundice
  - Chemotherapy—Not much helpful

Klatskin tumor—It is cholangiocarcinoma at the confluence of the hepatic ducts. Treatment is similar to cholangiocarcinoma.
5. Carcinoma gallbladder
  - Stenting
  - Radical cholecystectomy.

## CARCINOMA GALLBLADDER

It is the most common malignant lesion of the biliary tract.

### Etiology

- Gallstones are found in 65 to 90 percent patients with carcinoma gallbladder.

- Gallbladder polyp.
- Obesity.
- Estrogens.

## Pathology

### Macroscopic

It may occur in the papillary, tubular and nodular form.

### Microscopically

- Adenocarcinoma in 80 to 95 percent cases.
- Anaplastic carcinoma in 2 to 7 percent.
- Squamous cell carcinoma and adenosquamous carcinoma in 1 to 6 percent cases.

### Spread

- Either direct or lymphatic spread occurs to the liver and hilar lymph nodes.
- Hematogenous spread to segment IV is by direct communicating veins. So removal of a portion of liver is done in carcinoma gallbladder.

## Clinical Features

- Pain in right hypochondrium
- Jaundice
- Nausea and vomiting
- Weight loss.

## Investigations

- USG abdomen
- CT scan abdomen
- CT or USG guided FNAC
- Liver function tests.

## Treatment

1. Extended cholecystectomy that is en bloc removal of gallbladder, a 2cm or greater wedge resection of the gallbladder bed (segment IV and V) and portal lymph nodes.
2. With liver metastasis or distant metastasis, palliative stenting is done for relief of obstructive jaundice.

## Prognosis

5 year survival – 2 to 5 percent. The prognosis is poor due to early spread and aggressive nature of the tumor.

See also the long case obstructive jaundice in chapter 73.

## Pancreas

- Surgical anatomy
- Physiology
- Pancreatitis
- Surgery
- Pancreatic cysts
- Pseudopancreatic cyst
- Tumors of the pancreas

### SURGICAL ANATOMY

Pancreas is a relatively inaccessible retroperitoneal organ weighing about 50 gm with intimate relations to surrounding structures. The pancreas is divided into a head, neck, body and tail (Fig. 38.1).

**The head** of the pancreas is disk-shaped and lies within the C-loop of duodenum. The CBD passes posterior to the head of the pancreas in a groove between the pancreas and second part of duodenum.

A portion of head, known as the uncinete process extends to the left behind the superior mesenteric vessels.

**The neck** is the narrow band of pancreatic tissue, 2 cm long that lies in front of beginning of the portal vein and the origin of superior mesenteric artery from the aorta.

**The body** is somewhat triangular in cross section having anterior, posterior and inferior surfaces. The anterior surface forms a part of the stomach bed being separated from the latter by the omental bursa. The posterior surface is in contact with the left crus of diaphragm, left psoas muscle, left suprarenal and the left kidney. The splenic vein is closely applied to its posterior surface and separates it from the structures mentioned. The splenic artery passes to the

left along the upper border of the body and tail.

**The tail** passes forward in the splenicorenal ligament and comes in contact with the hilum of the spleen. Care should be taken not to injure it during splenectomy.

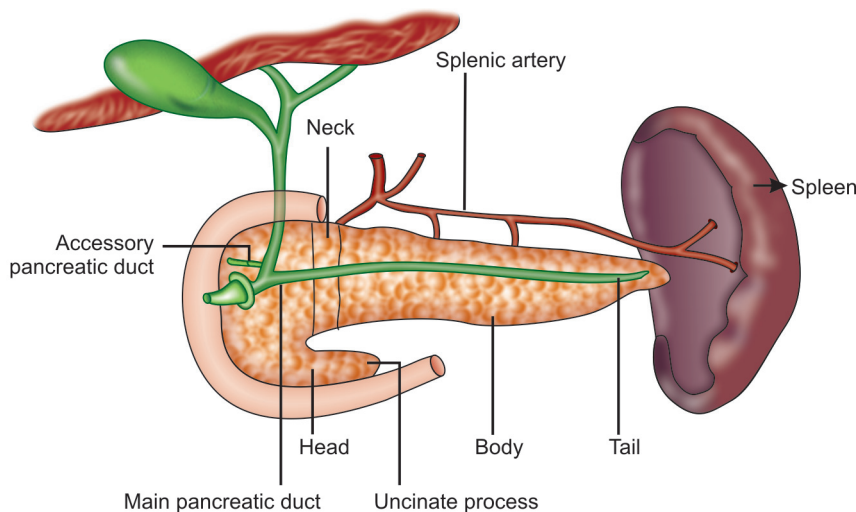
### Pancreatic Ducts

The **main duct** of the pancreas (Duct of Wirsung) is a continuous tube beginning from the tail to the head with gradual increase in diameter. It opens into the second part of duodenum at about its middle after joining with the bile duct on the major duodenal papilla which is surrounded by the sphincter of Oddi. The normal caliber of the main pancreatic duct is 1 to 2 mm in the tail, 2 to 3 mm in the body and 3 to 4 mm in the head region.

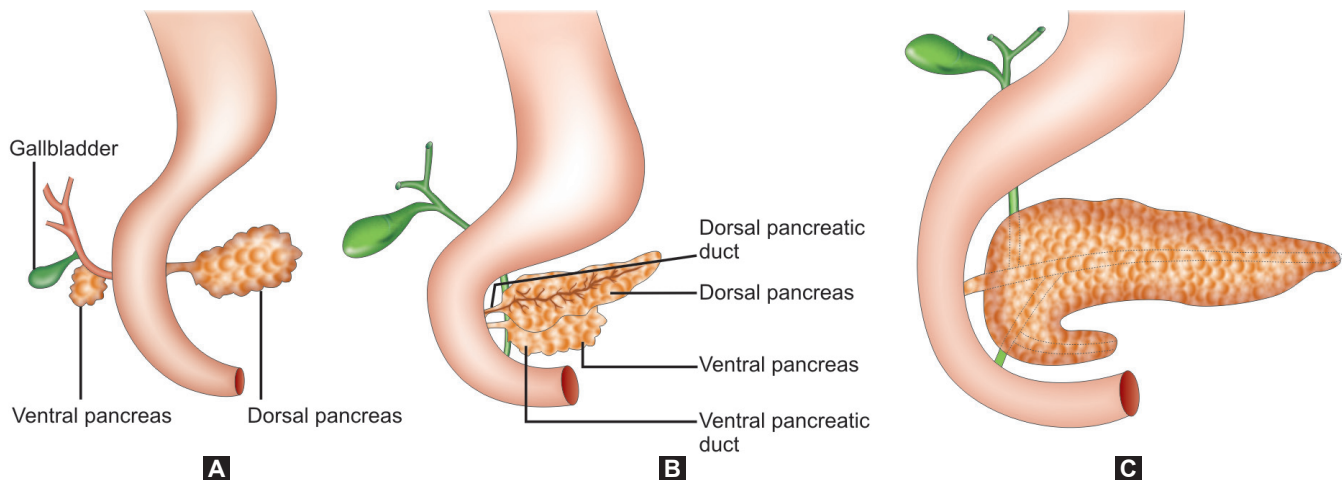
The **accessory duct** of the pancreas (Duct of Santorini) when present drains the uncinete process and lower part of the head and then opens into the duodenum about 2cm above the main duct on the minor duodenal papilla.

### Blood Supply

1. Neck, body and tail — Supplied by the splenic artery venous return occur through numerous branches into the splenic vein.
2. Head — is supplied by the superior and inferior pancreatoduodenal arteries. Venous return occurs through the corresponding veins into the portal vein and the superior mesenteric vein respectively.



**Fig. 38.1:** Gross anatomy of the pancreas



**Figs:** 38.2A to C: Development of pancreas. (A) Dorsal and ventral pancreatic buds arising from the dorsal and ventral borders of the 2nd part of duodenum during 4th week of gestation. (B) Ventral bud rotates behind the foregut to be posterior to the dorsal pancreas. (C) The duct systems fuse during the 6th week of gestation

### Development (Figs 38.2A to C)

The pancreas is developed by the fusion of two buds viz. the larger dorsal pancreatic bud and the smaller ventral pancreatic bud, growing in the dorsal and ventral mesogastrum respectively.

The ventral pancreatic bud forms the uncinuate process and an inferior part of the head of pancreas.

The dorsal pancreatic bud forms the part of the head, whole of neck, body and tail of pancreas.

The duct of ventral bud unites with the duct of dorsal pancreatic bud near its neck and opens into the duodenum as the main pancreatic duct (Duct of Wirsung).

The proximal part of the duct of dorsal pancreatic bud forms the accessory pancreatic duct (Duct of Santorini). The main pancreatic duct fuses with the bile duct to open in the duodenum at the site of major duodenal papilla while the site of entrance of the accessory pancreatic duct, when present is the minor duodenal papilla.

As the duct systems of the two buds anastomose there is eventually some inter change of drainage areas. Thus the accessory pancreatic duct when present, drains the uncinuate process, and lower part of the head and the main pancreatic duct, the rest of the gland.

### PHYSIOLOGY

The pancreas has both exocrine and endocrine functions.

### Exocrine Function

The exocrine part of pancreas is a compound racemose gland consisting of numerous lobules separated by interlobular septa. Each lobule consists of numerous serous acini that produce the exocrine secretion and are connected to the main duct via the intralobular and interlobular ducts. Pancreatic secretion is a clear watery, alkaline secretion (pH = 8) measuring about 1 liter per day. It contains 20 different digestive enzymes which act on the starch, fat and protein viz.

- a. Lipase for fat digestion.
- b. Amylase for carbohydrate digestion.
- c. Trypsinogen for protein digestion.

The pancreatic juice is a combination of acinar cell and duct cell secretions. It is released in response to stimulation by:

- i. Secretin and cholecystokinin (CCK), secreted by the duodenal mucosa when it comes in contact with the fatty acids and/or amino acids and
- ii. Vagal stimulation—It is to be noted that vagal stimulation has very little effects on the ductular secretion. Trypsin, the active form of trypsinogen is the most important proteolytic enzyme of the GI tract as it converts other proteolytic enzymes like chymotrypsinogen, procarboxypeptidase A and B into their active forms.

Trypsin inhibitor is a substance which is present in the pancreas and inhibits trypsin.

### Endocrine Function

The endocrine part of pancreas is composed of numerous islets of Langerhans dispersed throughout the entire organ as ovoid masses of cells. There are 4 types of cells in the islet viz:

1. Beta cells (70%) secrete insulin.
2. Alpha cells (20%) secrete glucagon.
3. Delta cells (5 – 10%) secrete somatostatin and gastrin.
4. PP cells or pancreatic polypeptide secreting cells are found scattered all over the pancreas in addition to islets. Tumor of these cells cause WDHA (Watery diarrhea, hypokalemia, achlorhydria) syndrome. The islet cells appear from the terminal parts of the branching ducts like the acini, but get separated from them and undergo a complete change of secretory function.

Congenital anomalies of development of pancreas include:

#### Annular Pancreas

The ventral pancreatic bud consists of two component parts which normally fuse and then rotate around the duodenum to lie behind the dorsal pancreatic bud.

Occasionally the right portion of the ventral bud migrates along its normal route while the left portion migrates in the opposite direction. This results in the duodenum being surrounded by a ring of pancreatic tissue. This is what is called an annular pancreas.

Annular pancreas is a cause of neonatal intestinal obstruction. There is bile stained vomiting if the obstruction is below the major papilla with abdominal distension. Plain X-ray abdomen shows the double bubble sign.

Treatment of choice is either duodenojejunostomy or a duodenoduodenostomy.

### Ectopic Pancreas

Pancreatic tissue may occur in ectopic sites in the gastrointestinal tract, the most common locations being the wall of the stomach, duodenum or jejunum and in a Meckel's diverticulum.

## PANCREATITIS

Presently pancreatitis is classified into two types – Acute and chronic.

The older terms acute relapsing, chronic relapsing are not advocated. They are regarded as recurrent episodes of the process of inflammation.

In case of acute pancreatitis, the function of pancreas usually returns to normal status, when primary cause is removed.

In case of chronic pancreatitis, structural and functional damage persists, even if the cause is removed.

The former has a high mortality and the latter is a greatly morbid condition.

The pathogenesis, classification, prognosis and management of pancreatitis is still a mystery.

### Acute Pancreatitis

This is an acute condition due to autodigestion of the pancreas caused by raised activated pancreatic enzymes and its interstitial liberation. This is almost always associated with acinar cell injury and clinically manifested by severe upper abdominal pain of recent onset and elevated serum amylase levels.

### Etiology

The two major causes are gallstones and alcohol abuse which account for roughly 80 percent of the cases. The remaining 20 percent comprise a wide variety of conditions. (Table 38.1)

### Pathogenesis

#### Alcohol

Acute pancreatitis occurs as a result of prolonged alcohol abuse of 6 – 8 years duration. This is thought to be caused by the following:

- Alcohol has a direct toxic effect on pancreatic acinar cells allowing escape of enzymes into surrounding tissues and also into the systemic circulation.
- Alcohol causes stimulation of pancreatic secretion and contraction of the sphincter of Oddi. This results in increased intraductal pressure and permeability of the pancreatic duct with activation of proenzymes within pancreatic duct acinar cells. Release of a cascade of mediators then results in inflammation and predisposes to necrosis. The reason why necrosis

develop in some patients and not in others remains obscure.

### Biliary Pancreatitis (Gallstone Pancreatitis)

There are three theories:

1. *Common channel theory:* In 1901, Opie proposed the common channel theory for biliary pancreatitis. If the biliary and pancreatic ducts join to share a common channel before ending at the ampulla, then gallstone migration and obstruction of this passage may lead to impairment of pancreatic secretion and reflux of bile into the pancreatic duct, which activates the proenzymes and triggers the inflammation.

2. *Incompetent sphincter of Oddi*

Due to repeated passage of gallstone the sphincter of Oddi becomes incompetent resulting in reflux of duodenal secretions containing activated pancreatic enzymes, the enterokinase in duodenal juice being the activator of proenzymes. and bile that triggers the inflammation.

3. *Obstruction of the pancreatic duct*

Gallstones cause transient obstruction of the pancreatic duct which in the presence of continuous pancreatic secretion and increased intraductal pressure causes activation of proenzymes within pancreatic duct acinar cells. This results in release of a number of mediators of inflammation.

4. *Other causes*

An episode of acute pancreatitis may be precipitated by several other factors like trauma, tumors, surgery, drugs, infections and metabolic causes. Sometimes there are no identifiable causes. (Idiopathic pancreatitis)

Viral infections like mumps, drugs and trauma probably cause damage to the acinar cells. In pancreatic tumors, pancreatitis possibly results from blockage of the secreted juice.

Hypercalcemia from hyperparathyroidism most likely involves pancreatic hypersecretion and formation of calcified stones intraductally.

In hyperlipidemia, lipase can liberate large amounts of toxic fatty acids into the pancreatic microcirculation producing the consequent ischemic states and inflammation.

**Table 38.1: Minor causes of acute pancreatitis**

1. Idiopathic pancreatitis is common and accounts for about 15% of all cases. 70% of the cases are attributed to microlithiasis.
2. Metabolic – Hyperlipidemia  
– Hypercalcemia.
3. Toxic, e.g. scorpion venom.
4. Drugs, e.g. azathioprine, sulfonamides, estrogens, etc.
5. Infective — Mumps, coxsackie virus.
6. Vascular — Ischemia, vasculitis (SLE, polyarteritis nodosa).
7. Traumatic
  - Blunt and penetrating abdominal trauma.
  - Postoperative (major thoracic and abdominal surgery) or iatrogenic.
8. Miscellaneous
  - Cystic fibrosis.
  - Hypothermia.
  - Tumors (pancreatic carcinoma, periampullary tumor).

Whatever be the cause there is co-localization of intracellular proenzymes and lysosomal hydrolases following acinar cell damage. The hydrolases cause activation of various enzymes. One of the most important step of such activation is formation of trypsin from trypsinogen which is the initiating or trigger mechanism in causing acute pancreatitis as described in Figure 38.3.

### Pathology

In acute pancreatitis the pancreas is damaged by the digestive action of its own juices. It occurs in all grades of severity.

**Macroscopically**, in the mildest form the main objective feature is edema of the pancreas and the condition is called acute interstitial or edematous pancreatitis.

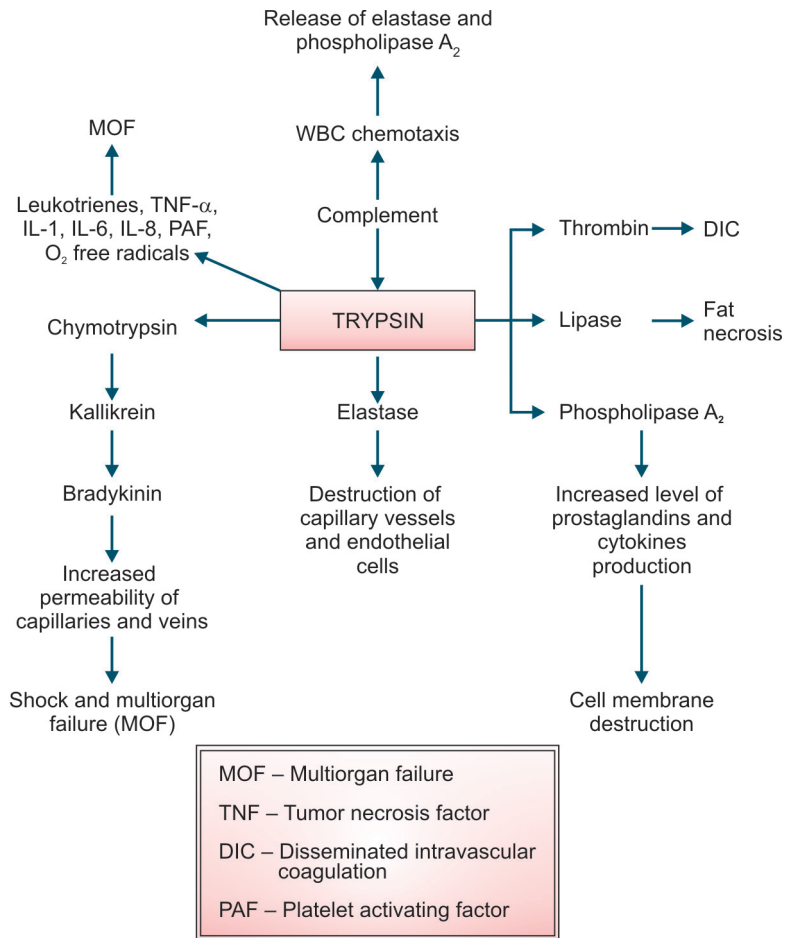
At the other extreme, there is extensive necrosis of the pancreas with hemorrhagic extravasations in its vicinity and multiple points of fat saponification scattered through the abdomen or even more widely. This later condition is known as acute fulminating or necrotizing pancreatitis. In typical case, the peritoneal cavity contains blood stained ascetic fluid and white flecks of fat necrosis in the omentum, mesentery and peripancreatic tissue.

**At cellular level**, the main factor is the activation of trypsinogen into trypsin as mentioned above

Cathepsin B, a lysosomal hydrolase activates trypsinogen to trypsin, which in turn catalyses the conversion of other pancreatic proenzymes to active forms such as chymotrypsin, elastase and phospholipase A<sub>2</sub>, lipase, resulting in a cascade with production of inflammatory mediators and cytokines. (Fig. 38.3) specifically interleukin IL-1, IL-6, IL-8 and TNF- $\alpha$ .

Trypsin does the following:

- Activation of kallikrein through chymotrypsin leads to bradykinin formation which causes increased capillary permeability and vasodilation resulting in shock and multiorgan failure.
- Phospholipase A<sub>2</sub> activation leads to production of prostaglandins which will cause cell membrane destruction like elastase.
- Activation of thrombin may cause disseminated intravascular coagulation (DIC).



**Fig. 38.3:** Pathogenesis of acute pancreatitis following activation of trypsin leading to the production of various inflammatory mediators responsible for the systemic complications

- Activation of the complement system through activation of Hageman factor leads to increased leukocyte chemotaxis which releases elastase and phospholipase A<sub>2</sub>.

**Microscopically**, the following features are seen in varying proportions:

- Necrosis of pancreatic lobules and ducts.
- Fat necrosis.
- Necrosis of arterioles and arteries with areas of hemorrhages.
- Inflammatory reaction, chiefly by polymorphs, around the areas of necrosis and hemorrhages.

### Clinical Features

- Sudden onset of upper abdominal pain which is referred to back. Pain may be relieved or reduced by leaning forward.
- Features of shock and dehydration.
- Oliguria.

### Signs

- Low grade fever, hypotension and tachycardia.
- Mild jaundice may be present due to cholangitis.
- Rebound tenderness, rigidity and abdominal distension.

### Diagnosis

There is no pathognomonic test for acute pancreatitis. The diagnosis rests on the interpretation of clinical and laboratory informations.

### Serum Amylase

- A serum amylase level four times above normal is indicative of the disease. Serum amylase > 1000units/liter may suggest pancreatitis. However, there is no correlation between the serum amylase level and the etiology, prognosis or severity of the disease.



- Serum lipase is more useful and sensitive than amylase.
- Chest and abdominal X-rays — X-rays may help to detect the complications seen in pancreatitis, e.g. a pleural effusion on chest X-rays. Abdominal X-rays may show a sentinel loop or colon cut off sign in pancreatitis.
- Ultrasound scanning: It is the best way to confirm the presence of gallstones in suspected biliary pancreatitis. It also reveals pancreatic edema, swelling and peripancreatic fluid collections.  
However in 20 percent cases, ultrasound examination does not produce satisfactory results because of the presence of bowel gas.
- CT scan — It is a more accurate test for visualization of the pancreas. If any doubt remains after an USG examination CT scan must be performed in order to determine the diagnosis.
- Serum calcium may be lowered. In these cases the prognosis is bad.

### Differential Diagnosis

The less severe episode of acute pancreatitis simulates acute cholecystitis, the more severe attack with a marked degree of shock is usually mistaken for a perforated peptic ulcer, Mesenteric ischemia, high intestinal obstruction or other causes of severe peritonitis.

### Treatment

Treatment is almost always conservative. Acute pancreatitis is a disease with wide spectrum of severity. Over 90 percent patients have a mild self-limited pancreatitis that resolves over short period of time. About 10 percent of patients may develop a severe form of the disease, which is associated with significant morbidity or mortality.

### Assessment of Severity

This is done by multifactor scoring system advocated by Ranson in 1974 as described in Table 38.2.

Patients that present with two or fewer criteria have no mortality, with three to four prognostic signs, have a mortality of 15 percent and with five to six, they have mortality of 50 percent and above,

A C-reactive protein level greater than 210mg per liter in the first 4 days of the attack

**Table 38.2: Ranson's prognostic signs – Markers of bad prognosis in acute pancreatitis**

#### On admission to hospital:

1. Age > 55 yrs.
2. WBC > 1600/cmm.
3. Fasting blood glucose > 200 mg/dl.
4. Serum LDH > 350 IU/liter.
5. SGOT > 250 IU/dl

#### Within the initial 48 hours of admission

6. Fall of hematocrit > 10 points.
7. Blood urea nitrogen rise > 5 mg%.
8. Serum calcium less than 8 mg%.
9. Arterial PO<sub>2</sub> (oxygen tension) < 60 mmHg.
10. Base deficit > 4 mEq/liter.
11. Estimated fluid sequestration > 6 liters.

or 120mg per liter at the end of the first week has a predictive performance similar to the above method and has the added advantage of simplicity.

### Conservative Treatment

1. Intravenous fluids and electrolyte replacement: Aggressive fluid and electrolyte therapy is the key factor in the treatment of acute pancreatitis.
2. Aspiration with Ryles tube to give rest to the pancreas.
3. Pain relief by injection. pethidine and other analgesics.
4. Antibiotics should only be used when pancreatitis is associated with biliary tract disease or sepsis.
5. Injection Ranitidine 50mg IV 8 hourly or omeprazole 40 mg IV BD.
6. Somatostatin or octreotide is often used to reduce pancreatic secretion.
7. Respiratory support — Patients with severe pancreatitis may need respiratory support in the form oxygen supplementation or Venti mask.

### Operative Treatment

It is indicated in the following circumstances:

1. Uncertainty of diagnosis — Needs exploratory laparotomy.
2. Progressive deterioration in spite of conservative measures.
3. Pancreatic abscess.
4. Pancreatic pseudocyst.

### Surgery

After opening the abdomen, all necrotic pancreatic tissue, pus and infected fluid are removed.

After pancreatic necrosectomy with debridement drain is placed in the lesser sac and abdomen is closed with tension sutures.

### Complications

1. Shock and multiorgan dysfunction syndrome (MODS).
2. Hypocalcemia.
3. Abscess formation with pancreatic necrosis.
4. Pseudocyst.
5. Renal failure associated with shock and pancreatic necrosis.
6. Persistent diabetes mellitus.
7. Pancreatic ascites and pleural effusion.

### Chronic Pancreatitis

This is characterized by repeated bouts of mild or moderate inflammation resulting in irreversible damage of pancreatic parenchyma due to progressive fibrosis.

Chronic pancreatitis leads to both exocrine (steatorrhea) and endocrine (diabetes mellitus) insufficiency.

### Etiology

The etiology of chronic pancreatitis has not yet been demonstrated, with the exception of the very rare hereditary chronic pancreatitis of which the gene (Trypsinogen gene) has been identified on chromosome 7.

The probable etiological factors are described in Table 38.3

**Table 38.3: Causes of chronic pancreatitis**

1. Excessive alcohol intake or chronic alcoholism
2. Idiopathic
3. Tropical pancreatitis
4. Metabolic disorders
  - Hypercalcemia
  - Hyperlipidemia
5. Hereditary pancreatitis
6. Obstruction of the pancreatic duct
  - Gallstones
  - Papillary stenosis
  - Carcinoma
  - Pancreas divisum

- Alcohol abuse accounts for more than 90 percent cases of chronic pancreatitis in adults in United States. In the eastern hemisphere this is not more than 30 percent.
- In 10–20 percent cases, the cause is entirely unclear.
- In India, the disease is known as tropical pancreatitis (40%). Most patients are non-alcoholic and associated with poor nutritional status.
- Gallstones, although a very frequent cause of acute pancreatitis, rarely lead to chronic pancreatitis.

### Pathology

**Macroscopically**, pancreas is usually hard and shrunken but may be enlarged. Often there are visible foci of calcification.

**Microscopically**: There is destructive inter- and intralobular fibrosis, epithelial atrophy with duct dilatation, foci of squamous metaplasia and calculi formation.

Islets of Langerhans are often well-preserved in early chronic pancreatitis but as the disease progresses there are broad coalescing areas of fibrosis and the islet size and number are reduced.

The pathogenesis of this process of fibrosis involves the activation of periacinar stellate cells of the pancreas which are converted to myofibroblast like cells following an insult to the pancreas viz. mild or moderate inflammation. These cells synthesize and secrete type I and III collagen leading to subsequent fibrosis.

The role of proinflammatory macrophages, cytokines and stellate cells in models of acute and chronic pancreatitis represent an important area of current research.

### Clinical Features

**Abdominal pain** – Pain is felt in the epigastric region as a major and early symptom in the majority of cases. It occurs most often as relapsing attacks lasting 1 to 7 days. Intensity of pain varies from mild discomfort to severe distress and radiation occurs to the back in about 50 percent cases.

Pain is often exacerbated 15 to 30 minutes after meals. The cause of pain may be alcoholic neuritis, irritation of the retropancreatic nerves or increased parenchymal and ductal pressure.

**Exocrine dysfunction**: Deficiency of lipase and protease to well less than 10 percent of normal cause steatorrhea and weight loss. Weight loss found in 30 percent cases, most often results from the fear of pain following meals.

**Endocrine dysfunction** Diabetes mellitus occurs late in the disease, usually 10 to 15 years after the first symptom of the disease.

### Investigations

- Chronic pancreatitis is usually suspected on clinical findings.
- Plain abdominal X-ray — The finding of pancreatic calcification or calculi is about 95 percent specific for chronic pancreatitis.
- USG is also able to detect calcifications and has the advantage of being widely applied in adults and children complaining of abdominal pain.
- MRCP or magnetic resonance cholangiopancreatography is the latest non-invasive imaging technique to detect the ductal changes as well as the complications like pseudocyst, biliary stricture and should be performed before any decision of therapy (conservative, endoscopic or surgical).

### Differential Diagnosis

- Peptic ulcer disease.
- Carcinoma of head of the pancreas.
- Disorders of small intestine associated with steatorrhea.

### Complications

- Pseudocyst of pancreas.
- CBD strictures due to edema or inflammation.
- Carcinoma pancreas.
- Pancreatic ascites and pleural effusion.

### Treatment

- Mild cases
  - Low fat diet.
  - Pancreatic enzymes orally with vitamins and minerals.
  - Prohibition of alcohol.
  - Removal of associated factors, e.g. cholecystectomy if gallstones are present.
  - Anemia should be corrected.
  - Analgesics in the form of opiates are frequently necessary.

II. In severe cases, surgical treatment is advocated.

## SURGERY

### Indications

- Obstructive jaundice.
- Persistent pain.
- When malignancy cannot be excluded. The following procedures are undertaken.
  - Puestow's operation (Pancreatojejunostomy) – As the duct is dilated more than 8mm it is opened along its whole length and all stones are removed. After this the duct is anastomosed to the first loop of jejunum side to side as Roux –en – Y anastomosis.
  - Total pancreatectomy is indicated when the entire gland is diseased and patient has to take insulin and oral pancreatic enzymes permanently.
  - Distal pancreatectomy with removal of spleen is done in case of chronic pancreatitis involving tail of the pancreas.

## PANCREATIC CYSTS

### Classification

- True (20%)
  - Congenital polycystic disease of the pancreas.
  - Hydatid cyst.
  - Neoplastic
    - Cystadenoma
    - Cystadenocarcinoma.
  - Retention cyst

True cysts require surgical excision.
- False (80%) — There is a collection of fluid in the lesser sac. This is also called pseudocyst of pancreas or pseudopancreatic cyst.

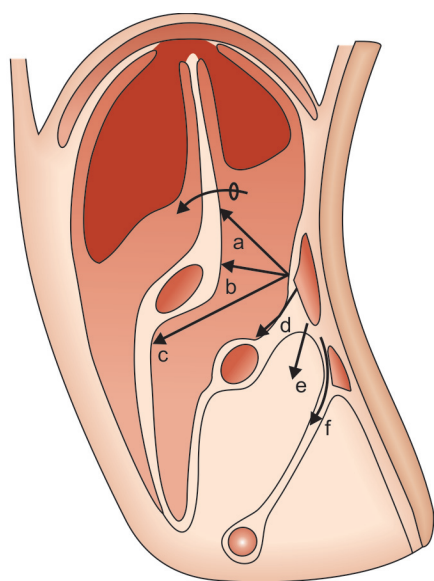
## PSEUDOPANCREATIC CYST

### Causes

- After trauma to the pancreas.
- Following acute and chronic pancreatitis.
- Rarely perforation of a posterior gastric ulcer.

### Clinical Features

Pseudopancreatic cyst presents as a firm, large, rounded upper abdominal swelling. Initially



**Fig. 38.4:** Different sites of pseudopancreatic cyst formation. a—between the liver and stomach, b—behind stomach, c—between stomach and transverse colon d—between the two layers, e—below transverse mesocolon, f—between layers of mesentery

the cyst is resonant because of loops of gas-filled bowel in front of it, but as it increases in size the intestine is pushed away and the mass becomes dull to percussion (Fig. 38.4).

### Treatment

Operation is the only available treatment and should be done early.

Pseudocysts smaller than 6cm in diameter resolve spontaneously in about 6 weeks time after its formation.

Excision of the cyst is impracticable because of intimate relationship of the cyst wall to the stomach, colon, mesocolon, pancreas and liver from which structures it can not be separated.

### Surgery

The surgical options are:

1. **Cystogastrostomy:** This is the most commonly practiced procedure. The stomach is opened through an incision on its anterior wall.

The posterior wall of the stomach and the anterior wall of the cyst which are closely adherent to each other are now incised together for about 5cm. The contents of the cyst are sucked out, several interrupted stitches are applied between the

anterior cyst wall and the posterior gastric wall around the stoma.

The opening on the anterior gastric wall is closed.

This operation is highly favored as the convalescence is short and patient has no discomfort.

2. Cystojejunostomy.
3. Cystoduodenostomy.
4. Laparoscopic cystogastrostomy is becoming popular, effective and less invasive nowadays.

## TUMORS OF THE PANCREAS

### Classification

- A. Exocrine tumors
  1. Benign
    - a. Adenoma.
    - b. Cystadenoma
  2. Malignant
    - Adenocarcinoma
    - Cystadenocarcinoma
 Secondly metastasis from carcinoma of the stomach or bile ducts.
- B. Tumors of endocrine pancreas
  1. Insulinoma from  $\beta$  – cells
  2. Gastrinoma – (Zollinger – Ellison syndrome) from G cells or non  $\beta$  cells.
  3. Glucagonoma from  $\alpha$  – cells.
  4. Vipoma (Verner Morrison syndrome WDHA syndrome, i.e. watery diarrhea, hypokalemia and achlorhydria, pancreatic cholera – from PP cells.
  5. Somatostatinoma from delta cells.

### Carcinoma of the Pancreas

About 70 percent of pancreatic cancers arise in the head region and the rest in the body and tail.

The malignancy most commonly arises from the duct epithelium (75–80%) and rarely from acini.

2/3rd of pancreatic head cancers are of ductal tissue origin and 1/3rd are of periampullary origin. Periampullary refers to carcinoma arising from ampulla of Vater, the duodenal mucosa or the lower end of common bile duct.

### Etiology

- It is one of the commonest malignant tumors occurring in old age. The average age is 60 years and males are more commonly affected.
- The most important etiological associations are smoking and chronic pancreatitis, especially tropical and hereditary pancreatitis.
- Other possible etiological factors include diet rich in fat, alcohol consumption, diabetes. Diabetic patients are 10 times more vulnerable compared to the normal population.

### Pathology

Macroscopically, the growth is infiltrating, hard and irregular.

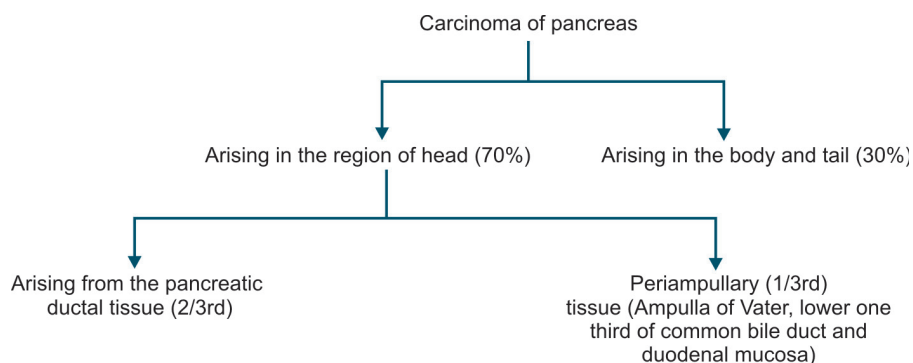
Microscopically – Adenocarcinoma is the predominant lesion, accompanied by fibrous tissue stromal proliferation.

The tumors may be:

- i. Mucus secreting (of duct origin).
- ii. Nonmucus secreting (of acinar origin).
- iii. Undifferentiated or anaplastic and
- iv. Rarely cystadenocarcinoma.

### Spread

- Regional lymph node metastasis is present in 90 percent cases (peripancreatic nodes). Gastric, hepatic, mesenteric and omental nodes are also involved.
- Hematogenous spread occurs to liver, lungs and bones.



- Transcelomic implantation with peritoneal seeding and ascites.
- Direct spread – occurs to the adjacent structures and viscera like duodenum, bile duct, portal vein, inferior vena cava, etc.

**Clinical Features**

**Carcinoma of the Head of the Pancreas**

- Pain and obstructive jaundice – The patient usually presents with painless, progressive jaundice. Pain radiating to the back may result from posterior infiltration of the tumor and is relieved on bending forward.
- There is usually significant loss of weight.
- Palpable gallbladder — In jaundice due to carcinoma of the head of the pancreas, the gallbladder is palpable whereas in patients with jaundice due to stones, it is not (Courvoisier’s law).
- Migratory thrombophlebitis (Trousseau’s sign) may be seen in 10 percent patients.
- Chills and fever are not uncommon due to associated cholangitis.

**Carcinoma of the Ampulla of Vater**

Its presentation is similar to carcinoma of the head of the pancreas.

However, it is a slow growing tumor, metastasises more slowly and hence carries a better prognosis. Jaundice may be intermittent

due to ulceration of the tumor and relief of jaundice.

Patients with ampullary growth with duodenal infiltration will have occult blood in the stools and often melena.

**Carcinoma of the Body and Tail**

The patient usually presents with pain, weight loss and often a mass in the upper abdomen.

Jaundice is usually not common in these tumors (Table 38.4).

The pain is usually boring into the back between L<sub>1</sub> and L<sub>2</sub> vertebrae and relieved by stooping forward.

**Investigations**

**A. Laboratory tests**

1. Liver function tests — Serum alkaline phosphatase (SAP) and conjugated bilirubin levels are elevated. Serum transaminase levels are only slightly elevated.
2. Tumor markers — Pancreatic adenocarcinomas are associated with elevated level of carcinoembryonic antigen (CEA) and pancreatic oncofetal protein (POP) that may be useful in monitoring recurrence after resection.

**B. Radiology**

1. USG — May show the mass in head of the pancreas and distended biliary tree, lymph node status and ascites.

2. CT scan is very useful in diagnosing even small pancreatic tumors and facilitates needle biopsy. The ultrasound examination may be obscured by gas in the overlying intestines.
3. Barium meal study shows widened duodenal “C” loop – pad sign in carcinoma head of the pancreas. Reverse 3 sign is seen in carcinoma of periampullary region.
4. ERCP may demonstrate common bile duct obstruction.

**Treatment**

- I. Palliation: 80 to 90% cases are inoperable at the time of diagnosis.
  - Jaundice is relieved by placing a stent through the tumor either transhepatically or via ERCP.
  - A bypass between the distended gallbladder and a loop of jejunum (cholecystojejunostomy) can also be performed for relief of jaundice.
  - Duodenal obstruction is relieved by gastrojejunostomy.
- II. Curative treatment
 

Small tumors (< 3cm) of the head of the pancreas is curative if lymph nodes are not involved. In the presence of jaundice vitamin K must be given preoperatively.

The operation of choice is excision of the head of the pancreas and duodenum, i.e. pancreatoduodenectomy or Whipple’s operation for operable cases that is, cases without any disseminated disease or local spread to the liver, peritoneum, IVC, superior mesenteric vessels, portal vein or celiac axis.

**Table 38.4: Clinical differences in carcinoma in different regions of the pancreas**

Presentation	Periampullary carcinoma	Carcinoma of head of pancreas	Carcinoma of body and tail of pancreas
1. Jaundice	Fluctuating	Progressive	Absent
2. Pain	Painless	Painless	Back pain
3. Melena	Present	Absent	Absent
4. Cholangitis	Common	Frequent	Absent
5. Palpable gallbladder	Present	Present	Absent
6. Weight loss	Present	Present	Present

**Prognosis**

90 percent of patients with pancreatic adenocarcinoma die within 1 year.

Periampullary growths, however, which present early, have a reasonably good prognosis after resection (50%, 5 years survival).

# Chapter 39

## Spleen

- Surgical anatomy
- Blood supply

- Functions
- Splenomegaly

- Splenectomy
- Rupture spleen

### SURGICAL ANATOMY

The spleen is a wedge-shaped organ lying mainly in the left hypochondrium between the 9th and 11th ribs. It measures 1 inch in thickness, 3 inches in breadth and 5 inches in length and weighs 7 ounces approximately, although considerable variations may occur.

It forms the left lateral extremity of the lesser sac and has two ligaments of attachment viz.

1. Gastrosplenic ligament which passes from it to the greater curvature of stomach carrying the short gastric and left gastroepiploic vessels.
2. Lienorenal ligament which passes from it to the posterior abdominal wall carrying the splenic vessels and tail of the pancreas.

The spleen presents two ends—medial and lateral, two borders—superior and inferior and two surfaces—diaphragmatic and visceral. The visceral surface is related to the fundus of the stomach, anterior surface of left kidney, left colic flexure and the tail of the pancreas. The superior border is characteristically notched near its lateral end or anterior extremity.

### Structure

The spleen has a thin fibrous capsule, to which the peritoneum is adhered intimately. The fibrous tissue of the capsule extends into the spleen to form a series of trabeculae

between which lies the splenic pulp (white pulp and red pulp). These trabeculae subdivide the structure into poorly defined lobules. The lymphoid follicles of the spleen collectively form its white pulp. The white pulp is scattered among the splenic venous sinusoids called the red pulp. The stroma of both red and white pulp is reticular fibers and cells. The organ acts as a blood filter as it contains a large number of macrophages.

### BLOOD SUPPLY

The splenic artery, branch of the celiac axis, has a blood flow of 300ml/min and divides at the hilum in T – or Y-shaped manner. Veins accompany the arteries and unite to form the splenic vein.

### Development

It develops in the 6th week of intrauterine life as several condensations of mesodermal cells in the dorsal mesogastrium.

### Splenunculi or Accessory Spleen

Accessory spleens are the result of lack of fusion of the mesodermal cells.

It may occur near the hilum (50%), tail of the pancreas (30%), the omentum, the small bowel mesentery, and near the splenic vessels.

The incidence is about one in ten subjects and if left behind it may result in persistence

of symptoms following splenectomy, e.g. in case of thrombocytopenic purpura.

### FUNCTIONS

It is the largest lymphoid organ with various functions. Though not essential for life, it has important role in normal physiological processes.

The functions are

1. Phagocytic activity—It removes abnormal or senescent red blood cells and platelets selectively from the circulation. It also removes cellular and non cellular unwanted materials in the blood or plasma viz. bacteria, cell debris, etc. This is done by macrophages in the reticulum (Red pulp).
2. Role as a secondary immune organ—The white pulp consisting of periarteriolar lymphoid sheath contains both T-cells peripherally and B-cells near the center. So, it contributes both to cell-mediated and antibody-mediated immunity.
3. Source of lymphoreticular cells—The spleen (white pulp) produces lymphocytes and monocytes throughout life. In fetal life it also produces erythrocytes.
4. Reserve pool and storage site—It stores 30 to 40 percent of total platelet mass in the body. With splenomegaly, this may increase to 90 percent. Spleen is the major storage site for red cell iron.



## SPLENOMEGALY

### Common Causes of Enlargement of Spleen

According to etiology

- Infections:
  - Bacterial—Septicemia, Typhoid, Paratyphoid, Tuberculosis, Infectious mononucleosis.
  - Parasitic infestations: Malaria, Kala-azar, Tropical splenomegaly, Hydatid cyst, Schistosomiasis.
- Congestion: Congestive cardiac failure (CCF), Portal hypertension.
- Collagen disease:
  - Felty's syndrome.
  - Still's disease.
- Space-occupying lesions:
  - True solitary cysts.
  - Hodgkin's and other lymphomas.
  - Lymphosarcoma.
- Cellular proliferation (mainly blood diseases)
  - Spherocytosis.
  - Thrombocytopenic purpura.
  - Leukemia.
- Infarction: Emboli from bacterial endocarditis.

Splenomegaly is said to be mild when the weight is less than 500 gm, moderate, when weight is 500 to 1000gm and massive, when more than 1000 gm.

## SPLENECTOMY

### Indications

- Rupture of spleen.
- Blood dyscrasias viz.
  - Hereditary spherocytosis.
  - Idiopathic thrombocytopenic purpura (ITP)—most common indication.
  - Hemolytic anemias viz. hereditary spherocytosis, autoimmune hemolytic anemia, sickle cell disease, beta thalassemias.
- Hypersplenism, that is increased normal splenic function with anemia, thrombocytopenia and leukopenia.

It occurs in congestive splenomegaly and neoplastic disorders (leukemias and lymphomas).

- Cysts (hydatid cyst), tumors (lymphomas) and abscesses of spleen.

The operation of splenectomy has been described in the operative surgery section.

## SPLENIC INJURY (RUPTURE SPLEEN)

The spleen is the most commonly injured organ in road traffic accidents. The injury is often associated with fracture of the left lower ribs and rupture of the liver, the left kidney, the diaphragm or tail of the pancreas.

### Nature of Injury

Rupture of spleen falls into one of the following groups.

- Splenic hilar injury—This results from severe fragmentation of the spleen with avulsion of the hilar vessels. There is massive bleeding with rapid death from shock within a few minutes. Fortunately this is rare.
- Injury to splenic parenchyma or lacerated wound—This is the usual type following injury. There are symptoms and signs of progressive blood loss with evidence of intraperitoneal bleeding. The clinical features include:
  - Hypotension, cold, clammy skin.
  - Tachycardia (pulse > 100/min).
  - Clot collected under the left side of diaphragm irritates it and the phrenic nerve causing referred pain in the left shoulder called Kehr's sign.
  - Dullness in the left flank which does not shift, as the fresh blood in the vicinity of spleen is coagulated. This is known as Balance's sign.
- Clean incised wound over the surface—This can be treated by splenorrhaphy.
- Delayed type—This is due to delayed rupture of splenic subcapsular hematoma. In this type after an interval of a few days to weeks after injury, the subcapsular hematoma increases in size due to hemolysis and eventually ruptures the thin overlying peritoneal capsule with a resultant sudden sharp hemorrhage.
- Spontaneous rupture—A spleen diseased by malaria, glandular fever, leukemia, etc. may rupture even after the trivial trauma.

- CT scan is probably the most accurate method available for diagnosis.

### Treatment

- Immediate treatment of shock with IV fluids, blood transfusions, sedation and antibiotics.
- In the majority of cases, the treatment of choice is splenectomy because it is quick and easy to perform.

If not extensively damaged, one should try to preserve the spleen, especially in children by repair (Splenorrhaphy) or partial splenectomy.

### Postoperative Complications

- Hematemesis may occur due to congestion of stomach mucosa as a result of ligation of short gastric vessels.
- Left sided basal atelectasis.
- Infection—People who have had a splenectomy are at increased risk of overwhelming postsplenectomy infection or OPSI. After splenectomy the antibody production is reduced. There is deficiency in antibodies like IgM, opsonins, properdin, etc. Thus, phagocytosis of encapsulated bacteria is defective.

The septicemia is usually caused by *Streptococcus pneumoniae*, (commonest), *H. influenzae*, *N. meningitidis* and the malaria parasite.

The characteristic features are fever with chills and rigor, hypotension, massive bacteremia and septicemia followed by MOSF (Multiorgan system failure) and death.

### Treatment

- Antibiotics like 3rd generation Cephalosporins and Amikacin.
- Ventilatory support.
- Blood transfusion.
- Nutrition and to maintain urine output.

### Prevention

To minimize risk, all patients should receive *Streptococcus pneumoniae* and *Haemophilus influenzae* vaccines 2 weeks prior to or after splenectomy. In addition adults should receive oral penicillin for a minimum period of 2 years and children should take the same till they attain 16 years.

## Chapter 40

## Umbilicus and Abdominal Wall

- Embryology
- Anomalies of development
- Diseases of the umbilicus
- Abdominal wall

**EMBRYOLOGY**

The caudal end of the embryonic area before the formation of the tail fold is anchored to the trophoblast by a connecting stalk.

The formation of tail folds carries the connecting stalk on to the ventral aspect of the embryo so as to occupy the permanent position of the umbilical cord.

- Prior to the formation of tail fold an endodermal diverticulum; called allantois develops into the mesoderm of the body stalk forming the umbilical cord.
- At first the midgut communicates freely on its ventral surface with the yolk sac but the continued development of head, tail and lateral folds results in narrowing of the connection forming the vitellointestinal duct.
- The mesoderm of the folds, mentioned above, which converge to form the umbilical cord, forms the abdominal wall surrounding the umbilicus.
- Thus the umbilical cord consists of an outer covering of amnion, continuing in its interior the vitellointestinal duct, the remains of extraembryonic celom, the allantois and umbilical vessel embedded in a mass of primary mesoderm (Wharton's jelly).

**ANOMALIES OF DEVELOPMENT****The Vitellointestinal Duct**

The vitellointestinal duct may persist completely or partially to give rise to the following anomalies (Figs 40.1A to E).

1. The whole length of the duct may persist resulting in an umbilical fistula, known as vitellointestinal fistula. Such a fistula usually brings out mucus and only rarely stool.
  - The treatment of vitellointestinal fistula is excision of the whole tract together with the umbilicus and repair of the rent in the ileum.
2. Sometimes the major part of the duct obliterates and only a small portion near the umbilicus remains patent forming a sinus that discharges mucus.
  - The epithelial lining of the sinus usually becomes everted and prolapses through the umbilicus in the form of a tumor. This is called umbilical polyp, enteroteratoma or Raspberry tumor all of which are misnomers.
  - Treatment: This consists of excision of the tumor along with the umbilicus and the whole length of the tract.
3. Both the proximal and the distal ends of the duct may be obliterated with the central part remaining patent. This part with its secretion in the closed space forms an

intraperitoneal cyst, called enterocystoma or enterotoma.

Treatment is excision of the cyst.

4. The distal part obliterates while the proximal part remains patent. This results in a Meckel's diverticulum.

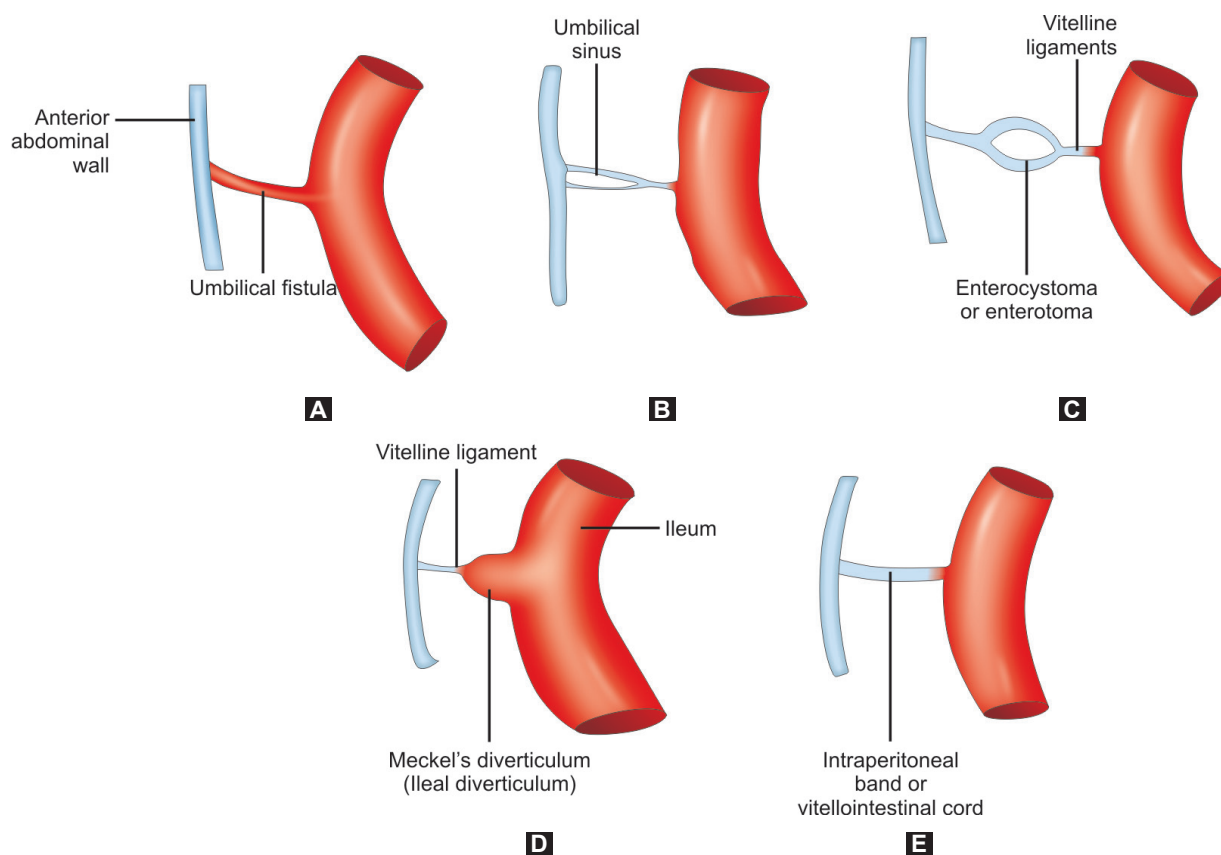
Sometimes the tip of this diverticulum remains attached to the umbilicus with a fibrous cord, which represents the obliterated portion of the vitellointestinal duct. This cord may be the potential danger for intestinal obstruction, When a vitellointestinal cord connected to Meckel's diverticulum but not attached to the umbilicus, becomes adherent to or knotted around another loop of small intestine, it causes intestinal obstruction.

5. Sometimes the whole of the vitellointestinal duct becomes obliterated but a band persists which may cause intestinal obstruction, because the small gut coils may get twisted around the band.

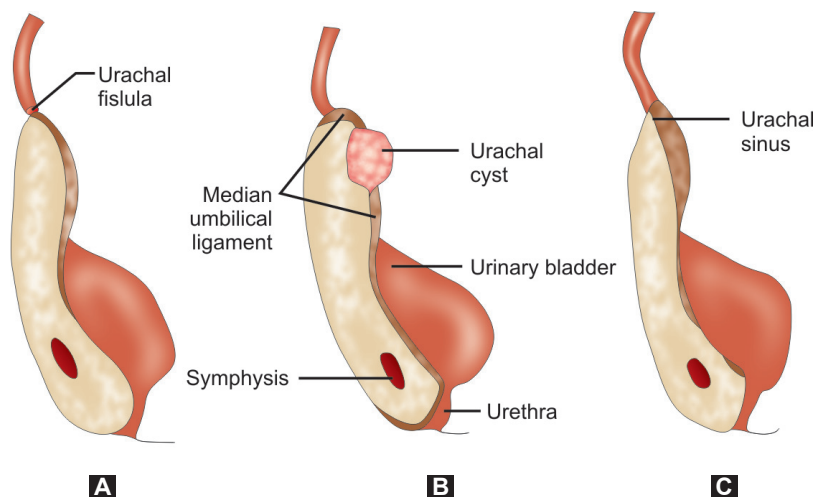
This band is called the vitellointestinal cord.

**Allantois**

1. Normally the lumen of the allantois gets obliterated to form the urachus, connecting the apex of the bladder to the umbilicus. The median umbilical ligament is the fibrous remnant of urachus.



**Figs 40.1A to E:** Anomalies in connection with the vitellointestinal duct



**Figs 40.2A to C:** Anomalies with the allantois. (A) Urachal fistula, (B) Urachal cyst, (C) Urachal sinus. The sinus may or may not be in communication with the urinary bladder

Sometimes the urachus remains patent so that a fistula exists between the apex of the urinary bladder and umbilicus. This is the urinary fistula of the umbilicus. (Fig. 40.2A)

2. Another rare condition is an urachal cyst. This is due to patent midportion of the urachus, with obliterated umbilical and vesical sides. Treatment is excision of the cyst. (Fig. 40.2B)

3. Occasionally the umbilical end of the urachus does not obliterate giving rise to urachal sinus of the umbilicus. Such sinuses discharge small amount of mucus from the umbilicus and may be infected. Treatment is excision of the sinus along with the umbilicus. (Fig. 40.2C) The urachal sinus is usually continuous with the urinary bladder.

### DISEASES OF THE UMBILICUS

#### Classification

1. Umbilical herniae.
2. Umbilical inflammations—Omphalitis, umbilical granuloma, umbilical dermatitis, pilonidal sinus.
3. Umbilical fistula—(a) Fecal fistula – patent vitellointestinal duct, (b) Urinary fistula – patent urachus, (c) Tuberculous peritonitis.
4. Neoplasms:

- a. Benign—Adenoma (Raspberry tumor), endometrioma.
  - b. Malignant—Primary carcinoma. Secondly carcinoma (Sister Joseph's nodule) from stomach, colon, pancreas, ovary, breast, etc.
5. Anomalies of the vitellointestinal duct.
  6. Anomalies of the urachus.
  7. Umbilical calculus (umbolith).

### Omphalitis

Umbilical sepsis can occur both in adults and babies, basically from bad hygiene.

Following birth there is rapid colonization of the severed umbilical stump by bacteria. In more than 50 percent cases the causative organism is *staphylococcus*. Less commonly streptococci, *E. coli* and *Clostridium tetani* have been isolated from the infected stump of the umbilical cord.

### Clinical Features

The umbilicus becomes red and tender. There is a purulent discharge. The complications of omphalitis are:

- i. Parietal abscess
- ii. Septicemia
- iii. Portal vein thrombosis
- iv. Jaundice may occur due to infection reaching the liver via the umbilical vein.

### Treatment

- Prophylaxis is the main treatment because once it happens, it is a dreadful condition.
- Proper care and asepsis should be maintained during severance of the umbilical cord. The stump may be cleaned with povidone iodine.
- Antibiotics like erythromycin may be started in established infection.

### Umbilical Granuloma

It is the condition developed following chronic inflammation of the stump of the umbilical cord following its severance.

There is formation of excess granulation tissue which is bright red, moist and friable.

The treatment is destruction of the umbilical granuloma by application of silver nitrate stick followed by dry dressings.

The important differential diagnosis is umbilical adenoma, which soon recurs in spite of this treatment.

## ABDOMINAL WALL

### Burst Abdomen

Burst abdomen or abdominal dehiscence is the gaping open or disruption of the abdominal wound in the postoperative period. It usually occurs at the end of first week or early second week after operation.

Factors responsible for wound dehiscence are as follows:

### Factors Related to Surgery

- a. Surgery done for grossly contaminated cases, e.g. peritonitis, biliary fistula or fecal fistula.
- b. Method of closure—Several studies have now shown that a technique of mass closure with a running suture is the best method for closure of midline wounds.

The sutures may cut through the tissues either because of too close placement to the wound edge or excessive weakening of tissues.

Another frequent technical error is improper knot tying which may lead to opening of the wound.

- c. Type of suture material—Use of non-absorbable suture material, e.g. Prolene, 0 or 1 caliber lessens the chance of burst abdomen.
- d. Tissue handling—Meticulous dissection, proper hemostasis and proper handling of tissues will have reduced incidence of burst abdomen.
- e. Choice of incision—Midline vertical incisions have decreased chance of wound dehiscence than paramedian incision.

### Factors Related to Patient

- a. Patients with advanced age and coexisting disease like malnutrition, jaundice, anemia, hypoproteinemia, malignancy, diabetes mellitus have poor wound healing and a greater chance of wound disruption.
- b. Straining factors—In the postoperative period, presence of straining factors like violent cough, persistent vomiting,

abdominal distension due to paralytic ileus, predisposes to burst abdomen.

### Clinical Features

- Patients who are recovering reasonably well in the postoperative period suddenly complain of something given way or unusual soaking of abdominal dressing with serosanguinous discharge. It is the pathognomonic sign of burst abdomen.
- It is twice as common in men as in women.
- It usually occurs between 6th and 10th postoperative day and is painless. However the patient may present with tachycardia and signs of gross dehydration.

### Treatment

It is a surgical emergency the abdominal wound should be immediately covered with a sterile towel soaked in warm normal saline. This in turn is covered with cotton wool and firm binder.

When the patient has been taken to the operation theater general anesthesia is administered and a nasogastric tube is placed to decompress the stomach.

### Principles of Surgery

- Bowel is washed with saline and gently replaced into the peritoneal cavity.
- Edges of the wound or incision are trimmed by snipping away necrotic tissue and edematous skin tags.
- If only a small area of the wound has been disrupted, this portion alone should be sutured. However, if more than half of the wound has been disrupted, it is justified to open the remaining portion of the wound and suture the whole wound afresh.
- A single layer closure by taking bites through whole thickness of the abdominal wall using strong monofilament nonabsorbable suture such as polypropylene is performed. The stitches are placed 2.5 cm from the margin and about 2.5 cm apart.

## Neoplasms of the Abdominal Wall

### Classification

1. Benign tumors: Benign tumors may arise from any of the elements contained in it, e.g.

- Lipoma
- Neurofibroma
- Hemangioma
- Desmoid tumor.

They are treated in the same way as in other locations.

2. Malignant tumor—Very rare. One may rarely come across fibrosarcoma of the abdominal wall. This is radioresistant and wide excision is the treatment of choice.

## Desmoid Tumor

### Definition

It is the most important benign tumor of the anterior abdominal wall arising from the musculoaponeurotic structures of the rectus sheath, especially below the level of the umbilicus. Though benign, it is known for its recurrence. That is why, it is also called “recurrent fibroid of Paget”.

### Etiology

- Eighty percent cases occur in multiparous women.
- It may occur in previous abdominal scars.
- Trauma due to repeated pregnancy or a small hematoma of the abdominal wall may be an etiological factor.
- Desmoid tumor may be associated with familial polyposis coli (Gardner’s syndrome).

### Pathology

- It is a slow growing benign fibroma.
- Nonencapsulated and locally invasive.
- Cut surface—Onion-like whorled fibroma.
- Histopathology consists of mature fibrous tissue with multinucleated plasmoidal masses resembling foreign body giant cells.
- It may undergo myxomatous degeneration in which case it increases rapidly.
- Unlike fibroma elsewhere, no sarcomatous change occurs.

### Clinical Features

The patient, usually a middle-aged woman presents with an abdominal lump in relation to the rectus sheath or external oblique aponeurosis. Occasionally it may occur in other sites, e.g. the plantar or the palmar fascia.

### On Examination

The mass is firm to hard in consistency, with irregular surface.

With leg-raising test, it is confirmed that the swelling is parietal.

The diagnosis is confirmed by excision biopsy.

### Treatment

- USG of the abdomen is done to ascertain the nature of the swelling.
- Baseline preoperative investigations are performed.
- Wide local excision of the tumor with a 2.5cm margin of healthy tissue is done. The defect in the abdominal wall is made good by placement of a Prolene mesh.

## Rectus Sheath Hematoma

Rectus abdominis muscle is supplied by superior epigastric artery from above and inferior epigastric artery from below. Injury to one of these vessels will cause bleeding and hematoma in rectus sheath. Commonly the inferior epigastric artery is involved.

### Causes

1. Trauma—A sudden blow to the abdominal wall.
2. Severe straining and exercises.
3. Tetanus and other convulsions.
4. Patients on anticoagulants.
5. Pregnancy—Rarely the cause of hematoma can be pregnancy in the last trimester. The exact cause is not known.

### Clinical Features

- Common in females.
- Sudden onset of a warm, tender swelling just below and to the side of umbilicus at the level of arcuate line where posterior rectus sheath is absent.
- There is bluish discoloration over the swelling.
- Ultrasonography and aspiration confirms the diagnosis.

### Differential Diagnosis

- Spigelian hernia
- Other parietal masses.

### Treatment

- The condition is self-limiting.
- If it persists or progresses or if there is doubt about the diagnosis, exploration and evacuation of hematoma should be done and the bleeding vessels are ligated. The results and recovery are very good.

## Abdominal Wall Abscess

### Causes

1. Infected hematoma.
2. Umbilical sepsis spreading to the abdominal layers causing the abscess.
3. Blood spread from a distant focus.

### Clinical Features

- Tender, soft or firm swelling, which is well-localized, adherent to skin and abdominal muscles underneath.
- Aspiration will show pus.
- It should be differentiated from intra-abdominal mass, cold abscess and parietal hernia.
- Ultrasonography and needle aspiration usually confirm the diagnosis.

### Treatment

Antibiotics and drainage of the abscess under general anesthesia.



# Chapter 41

## The Peritoneum

- Surgical Anatomy
- Peritoneal cavity

- Peritonitis
- Subphrenic abscess

- Pelvic abscess
- Special types of peritonitis

### **SURGICAL ANATOMY**

The peritoneum consists of two layers of serous membranes namely visceral and parietal layers. It is lined by a single layer of flat mesothelial cells, called the mesothelium on a layer of fibroelastic tissue containing macrophages, fat cells, and some collagen and elastic fibers.

The visceral peritoneum surrounds the abdominal viscera completely or partially while the parietal peritoneum lines the rest of the abdominal cavity and is in close contact with the anterior abdominal wall.

The parietal peritoneum is richly supplied with nerves and when irritated, causes severe pain especially localized to the affected area. The visceral peritoneum is, however poorly supplied with nerves and the pain arising there from is vague and ill-defined.

Stimuli which elicit pain in the viscera or visceral peritoneum are:

- Increased intraluminal tension such as over-distension of hollow viscera or stretching of capsule, e.g. adenocarcinoma of kidney.
- Spasm of visceral muscle viz. intestinal obstruction.
- Ischemia as in strangulation.

### **PERITONEAL CAVITY**

The peritoneal cavity is a potential space containing the abdominal viscera. The peritoneum provides a frictionless surface over which the abdominal viscera can freely move and peristalsis occurs. The mesothelial lining

secretes fluid that serves to lubricate the peritoneal surfaces. The peritoneal cavity contains less than 100 ml of fluid which is like lymph containing lymphocytes, few polymorphs and eosinophils.

The peritoneum is a semipermeable membrane. So the fluid can directly pass into the bloodstream and severe toxemia can result from rapid absorption of bacterial toxins and other toxic products.

This feature of semipermeability of the peritoneal membrane and its vast surface area (about 2 m<sup>2</sup>) which is almost equal to that of the skin, has been utilized for peritoneal dialysis in acute renal failure.

The functions of peritoneum are:

- Secretion of peritoneal fluid.
- Absorption—The peritoneum has the capacity to absorb a large amount of fluid and this property is utilized in peritoneal dialysis as mentioned above.
- Facilitation of movement of viscera and peristalsis.
- Fixation of viscera by folds.
- Regeneration and repair by the mesothelial cells.
- Neutralization and localization of inflammation.

### **PERITONITIS**

#### **Etiology**

Nearly all varieties of peritonitis are due to bacterial infection of the peritoneum.

Most commonly, peritonitis results from the perforation of a viscus.

Bacteria may enter the peritoneal cavity via the following four portals viz.

- From intra-abdominal viscera
  - Perforation of a viscus, e.g. perforated duodenal ulcer, perforated appendicitis, rupture of intestine from trauma.
  - Direct extension from a neighborhood inflamed organ, e.g. acute appendicitis, acute cholecystitis, diverticulitis or migration through the devitalized gut wall, e.g. strangulated hernia, infarction of the intestine.
  - Postoperative leakage of an intestinal suture line.
- From the exterior, e.g. open surgery, trauma.
- Via the female genital tract—Acute salpingitis or puerperal infection.
- Via the bloodstream (rare), e.g. as part of a septicemia (pneumococcal, streptococcal or staphylococcal). This has been mistakenly termed primary peritonitis; in fact it is secondary to some initial source of infection.

#### **Pathology of Acute Bacterial Peritonitis**

Bacterial peritonitis is usually polymicrobial, both aerobic and anaerobic organisms are present.

The exception is the rare variety of blood borne peritonitis in which a pure infection

with pneumococcal, streptococcal or *hemophilus* bacteria occurs.

The pathological effects of peritonitis are:

1. Widespread absorption of toxins from the large inflamed surface.
2. The associated paralytic ileus is perhaps due to toxic paralysis of the intrinsic nerve plexus which makes the bowel atonic.
 

As a result of ileus, there will be loss of fluid, electrolytes and proteins.
3. Gross abdominal distension with elevation of diaphragm which provides a liability to lung collapse and pneumonia.

### Clinical Features

It depends upon whether it is localized or generalized peritonitis.

Anatomical, pathological and surgical factors may favor the localization of peritonitis.

### Anatomical Factors

The peritoneal cavity is divided into various compartments (supracolic, infracolic, greater sac, lesser sac, etc.), so that the pus can not go from one compartment to the other unless the involved compartment has been filled with pus.

### Pathological Factors

- Adhesion usually forms around the affected organ as the flakes of fibrin appear in the exudate from the inflamed peritoneum.
- Moreover, greater omentum wraps the inflamed organ or area so as to localize the peritonitis as far as possible.
- Peristalsis also becomes sluggish to help in localization of peritonitis.

### Surgical Factors

Postoperative drains helps to drain the pus or infected bile from the local collection instead of allowing it to spread all over the abdomen.

### Localized Peritonitis

It is related to the causative lesion. The signs and symptoms will vary according to location, e.g. different positions of appendix usually there is associated tachycardia and fever.

The most important sign is guarding and rigidity of the abdominal wall over the area of the abdomen which is involved with positive rebound tenderness.

There may be referred pain, e.g. pain may be referred to right or left shoulder when that half of the diaphragm is irritated.

Most of the localized peritonitis resolves with conservative treatment but about 10 – 15 percent progress to pelvic abscess and very infrequently to generalized peritonitis.

### Generalized or Diffuse Peritonitis

The clinical features of this condition can be conveniently described in the three stages.

i. The first stage is known as the stage of peritonism.

This is due to irritation of the peritoneum caused by perforation of inflamed viscus nearby.

The pain is severe and made worse by breathing and movement. It is first experienced at the site of lesion and gradually spreads all over the abdomen.

The pulse rate increases along with rise of temperature.

Two features are important for diagnosis at this stage viz. sudden onset of pain and presence of muscle guard and rebound tenderness.

ii. The second stage is known as the stage of reaction or stage of illusion (apparent well being). At this stage the irritant fluid becomes diluted with the peritoneal exudate. The peritonitis may resolve so the pulse rate diminishes and the pain and tenderness get apparently relieved.

The abdomen may be comparatively soft. Bowel sounds may be absent as the paralytic ileus sets in.

iii. The third stage is the stage of bacterial or septic peritonitis:

There is increasing abdominal distension and the patient becomes toxic with tachycardia, hypotension, poor sensorium, confusion and shrunken eyes. The inflamed peritoneum readily absorbs both bacteria and bacterial toxins, e.g. *E. coli*, bacteroides.

Circulatory failure ensues with cold clammy skin, dry tongue, drawn and anxious face, called Hippocratic facies.

Nowadays with early diagnosis and adequate treatment this condition is rarely seen.

### Investigations

A number of investigations may be necessary in a doubtful case and the helpful ones are:

1. Peripheral blood count including total leukocyte count (TLC), Hb%, plasma proteins along with prothrombin time.

Estimation of serum electrolytes, bicarbonate, urea, glucose, along with serum amylase estimation.

High levels of serum amylase (above 1000somoogyi units) confirm diagnosis of acute pancreatitis.

2. Straight X-ray abdomen may detect perforation of hollow viscus by a crescentic shadow of intraperitoneal gas. Other helpful findings are distended coils of intestine and multiple fluid levels.

3. Peritoneal diagnostic aspiration may be necessary in case of abdominal trauma. Bile stained fluid indicates perforated peptic ulcer or gallbladder, the presence of pus indicates bacterial peritonitis.

When aspiration fails, then introduction of physiological saline followed by aspiration of peritoneal cavity after a few minutes may produce fluid of diagnostic value. Microscopy of the fluid may show neutrophils (indicative of acute inflammation) or bacteria confirming infection.

4. Ultrasound and CT scanning—When available may be helpful in identifying the cause of peritonitis, e.g. acute pancreatitis, perforated appendicitis, etc.

### Treatment

The essentials of treatment are:

- i. Resuscitation.
- ii. Treatment of infection and toxemia and
- iii. Removal or repair of the causative lesion with appropriate surgery.

i. Resuscitation includes:

a. IV fluids—are given before, during and after surgery. Plasma or plasma expander is given quickly to restore the blood pressure to normal.

b. Nasogastric aspiration with Ryle's tube – it reduces abdominal distension by decreasing gastrointestinal secretion and also by removing swallowed air. It prevents vomiting and gives rest to the gut.

c. Analgesics should not be administered to patients until diagnosis is made because analgesia may obscure the abdominal findings to attain a firm diagnosis.

d. Moist oxygen inhalation and ventilatory support—Oxygen inhalation at the rate of 5 liters per minute with a nasal catheter or Venti-mask may be sufficient prior to induction of anesthesia.

- ii. Treatment of infection and toxemia with IV antibiotics like aminoglycoside, cephalosporin with metronidazole 8 hourly.
- iii. Definitive surgery—This should not be delayed, once the patient is fit for operation. Along with surgery there should be meticulous peritoneal toilet and removal of all necrotic material.

The source of peritonitis is located and appropriate surgical procedure is done e.g.

- Appendectomy for acute appendicitis.
- Repair of perforation for perforated peptic ulcer.
- Closure of perforation for ileal perforation.
- Resection and anastomosis of bowel for gangrene.

### Prognosis

With modern treatment, diffuse peritonitis carries a mortality of about 10 percent and the causes of death are:

- Endotoxic shock
- Bronchopneumonia
- Paralytic ileus
- Electrolyte imbalance and
- Multisystem organ failure (MSOF).

### Complications

1. Paralytic ileus—There is usually little pain with distension of the abdomen. Straight X-ray shows multiple gas-filled loops with fluid levels.
2. Residual or recurrent abscess—Two places are quite common for residual abscess following generalized peritonitis. These are subphrenic abscess and pelvic abscess.
3. Acute intestinal obstruction due to peritoneal adhesions.

## SUBPHRENIC ABSCESS

### Surgical Anatomy

The subphrenic region lies between the diaphragm above and the transverse colon with mesocolon below and is further divided by the liver and its ligaments. The right and left subphrenic spaces lie between the diaphragm and the liver and are separated from each other by the falciform ligament.

- The right and left subhepatic spaces are Morrison's pouch and the lesser sac. The two spaces communicate with each other through the foramen of Winslow. The right

extraperitoneal space lies between the bare area of the liver and the diaphragm.

- About two-thirds of the subphrenic abscesses occur on the right side.

### Etiology

Usually the underlying cause is a peritonitis involving the upper abdomen, e.g. a perforated peptic ulcer, leakage following biliary or gastric surgery, etc.

Rarely infection occurs from hematogenous spread or direct spread from a chest lesion like empyema.

### Clinical Features

Subphrenic abscess usually follows generalized peritonitis after 10 days to 3 weeks.

However if antibiotics have been used, an abscess may be disguised and may manifest weeks or even months after the original episode.

### Symptoms

- There may be no localizing symptoms, the patient presenting with malaise, nausea, loss of weight, anemia, and pyrexia hence the aphorism 'pus somewhere, pus nowhere else, pus under the diaphragm.
- Shoulder pain is due to irritation of under surface of the diaphragm by the pus.

### Signs

- Tenderness in the epigastrium on deep palpation.
- Hepatomegaly.
- In late cases a palpable mass may be felt especially in lesser sac swelling.

### Investigations

- An absolute leukocytosis is the rule.
- X-ray will show tenting of the diaphragm with poor movement on fluoroscopy or there may be pleural effusion.
- Ultrasonography confirms sites and number of abscesses, loculations, etc. Abscess is surrounded by sharp echogenic wall.
- CT scan is very helpful, particularly in obese patients.

### Treatment

Surgical intervention is indicated to drain the abscess.

Percutaneous drainage can be done with the help of ultrasound or CT scan provided the abscess cavity is unilocular.

More than 90 percent subphrenic abscesses are managed by percutaneous drainage successfully.

### Open Drainage

If the ultrasound or CT guarded drainage fails or if the abscess is loculated, surgical drainage is performed.

Posterior approach is no longer advocated as it often traverses the pleural space.

Currently anterior or lateral subcostal approach is more favored and it is wise to put a drain after all the loculi have been broken down. The closure of cavity should be assessed by subsequent ultrasound assessment or sinogram.

## PELVIC ABSCESS

It is the commonest intraperitoneal abscess and the sources are acute appendicitis (75%), gynecological infections (fallopian tubes and ovaries), diverticulitis and as a sequel to generalized peritonitis from any cause.

### Clinical Features

- History of surgery or peritonitis.
- The patient may complain of dull acting poorly localized lower abdominal pain.
- Irritation of the urinary bladder may produce frequency or urgency while that of the rectum will give rise to diarrhea and tenesmus in some cases.

### Diagnosis

Diagnosis is confirmed by per rectal examination. A tender boggy swelling is felt in the anterior wall of rectum. Ultrasound can define and detect the size of the abscess.

### Treatment

Pus is drained through the anterior wall of rectum (in male) and vagina (in female) with a sinus forceps under general anesthesia. The cavity collapses after a few days Postoperatively the patient is given, broad spectrum antibiotics.

## SPECIAL TYPES OF PERITONITIS

Abdominal tuberculosis occurs in three forms viz.

1. Tuberculous peritonitis.
2. Tuberculous mesenteric lymphadenitis—Glandular tuberculosis and
3. Intestinal tuberculosis.

## Tuberculous Peritonitis

The incidence of tuberculosis has declined over the past several decades. This is now a rare disease.

### Source of Infection

Tuberculous peritonitis is always secondary to tuberculosis elsewhere although the primary focus may no longer be active. The possible sites of primary are:

- i. Pulmonary tuberculosis
- ii. Intestinal tuberculosis
- iii. Tuberculous mesenteric lymph nodes
- iv. Tuberculosis of kidney
- v. Tuberculous pyosalpinx.

In most of the cases tuberculous peritonitis results from reactivation of latent primary peritoneal form.

### Pathology

The peritoneum is studded with tubercles with an accompanying serous effusion. It produces the following pathological changes.

1. Intense exudation which causes the ascitic form.
2. Exudation with minimal fibroblastic reaction – loculated form.
3. Extensive fibroblastic reaction – plastic or fibrous peritonitis.
4. Fibroblastic with secondary infection – purulent form.

### Clinical Features

#### Ascitic Form

- It is common in children and young adults who usually present with abdominal distension.
- Omentum can be left as a rolled up transverse mass which is nodular due to extensive fibrosis. Abdomen has a doughy feel with fluid giving rise to shifting dullness.

- Umbilical hernia or congenital hydrocele appears in children due to increased intraabdominal pressure.

#### Loculated or Encysted Form

In this variety ascitic fluid is present in one quadrant of the abdomen which is sealed off by matted intestinal coils surrounded by omentum.

Other cystic swellings in the abdomen such as pseudocyst of the pancreas, mesenteric cyst, and retroperitoneal cyst are the differential diagnoses.

#### Fibrous Peritonitis

In this variety, there is no ascites but there is extensive fibrosis, which results in dense adhesions between the coils of intestine. The coils become dilated and act as blind loop giving rise to wasting, abdominal pain and steatorrhea.

#### Purulent Type

- It is seen in females as a complication of genitourinary tuberculosis like tuberculous salpingitis.
- The spread occurs through the female genital tract and there is always a secondary infection.

#### Treatment

This consists of antituberculous chemotherapy. Surgery is needed for the relief of intestinal obstruction from adhesions.

#### Bile Peritonitis

##### Etiology

The common causes of biliary peritonitis are:

- i. Following perforation of the gallbladder.
- ii. Following biliary surgery—Damage to the CBD, slipping of ligature of the cystic duct, divided cholecystohepatic duct, etc.

- iii. Traumatic rupture of the gallbladder or its ducts due to gunshot, wound or closed injury.
- iv. Following injury to the duodenum due to
  - a. Nephrectomy (Right)
  - b. Right hemicolectomy
  - c. Traumatic injury.

#### Clinical Features

- The patient usually presents with signs and symptoms of diffuse peritonitis with a degree of shock.
- Mild jaundice may or may not be present.

#### Treatment

- Laparotomy is required to deal with the underlying condition following resuscitation.
- Mortality is approximately 50 percent and it is the elderly patient with late disease who responds badly as with all other causes of peritonitis.

#### Postoperative or Tertiary Peritonitis

Such peritonitis occurs following leakage from a suture line.

It should be suspected following surgery on intestines or biliary tract, when a patient who is recovering from paralytic ileus, starts deteriorating.

The condition is often difficult to diagnose as the symptoms and signs are vague, abdominal pain may be absent and tenderness is masked by presence of recent wound.

Oliguria may be an early indicator of postoperative peritonitis.

#### Treatment

- Danger lies in delay not in reoperation.
- Leak or abscess cavity is confirmed by ultrasound.
- Resuturing or drainage of abscess cavity is done at laparotomy.

# Chapter 42

## Hernia

- Definition
- Inguinal hernia
- Nyhus classification of groin hernia
- Differential diagnosis of groin swelling
- Special varieties of inguinal hernia
- Recurrent inguinal hernia
- Strangulated inguinal hernia
- Laparoscopic inguinal hernia repair
- Femoral hernia
- Femoral sheath
- Epigastric hernia
- Umbilical hernia
- Adult umbilical hernia
- Incisional hernia
- Some rare external herniae

### DEFINITION

A hernia is an abnormal protrusion of the whole or a part of a viscus through an opening in the wall of the cavity in which it is contained.

An external abdominal hernia is protrusion of a viscus from the peritoneal cavity through a weak part of the abdominal wall.

Common external hernias are 1. Inguinal 2. Femoral 3. Umbilical 4. Incisional 5. Epigastric hernia

Less common hernias include 1. Lumbar 2. Obturator 3. Gluteal and 4. Spigelian hernia.

### INGUINAL HERNIA

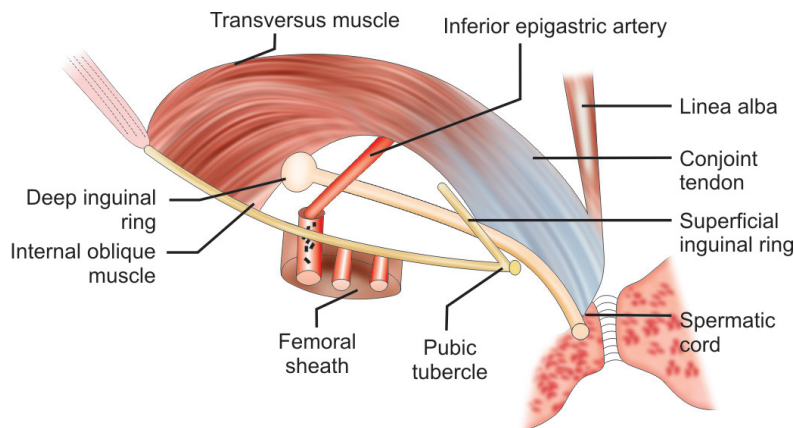
Inguinal hernia occurs either through the deep inguinal ring (indirect) or through

the posterior wall of inguinal canal (direct hernia).

### Inguinal Canal

Surgical anatomy: (Fig. 42.1)

- i. Inguinal canal is about 4cm in length extending from deep inguinal ring to the superficial inguinal ring.
- ii. Superficial inguinal ring is a v-shaped defect in the external oblique aponeurosis immediately superior to the pubic tubercle, with the apex of the V-superolaterally (1/2" or 1.25cm above the pubic tubercle). It is in between the lateral crus attached to the pubic tubercle and the medial crus attached to symphysis pubis, derived from the external oblique aponeurosis and the base is formed by the pubic crest.
- iii. Deep inguinal ring: It is 1/2" or 1.25cm above the midinguinal point, that is, the midpoint between the symphysis pubis and anterior superior iliac spine. It is U-shaped condensation of transversalis fascia being incomplete above.
- iv. Inguinal canal
  - Boundary of inguinal canal
    - (a) Anterior—Skin, superficial fascia, external oblique aponeurosis and



**Fig. 42.1:** Surgical anatomy of the inguinal canal. The deep inguinal ring is lateral to the inferior epigastric artery



fleshy fibers of the origin of internal oblique in its lateral 1/3rd.

- (b) Posteriorly—Fascia transversalis along the whole length of the canal separating it from extraperitoneal fatty tissue and peritoneum. In the medial half there are conjoined tendon and reflected part of the inguinal ligament.
  - (c) Superiorly—There are arched fibers of internal oblique and transversus abdominis before they fuse to form the conjoint tendon.
  - (d) Inferiorly—Inguinal ligament and the lacunar ligament on the medial side (Gimbernat's ligament).
- Contents of the inguinal canal
    1. Spermatic cord
    2. Ilioinguinal nerve
    3. Genital branch of genitofemoral nerve
    4. Vestigial remnant of processus vaginalis sac
    5. Round ligament in females.
  - Defence/shutter mechanism of inguinal canal.
    1. Obliquity of inguinal canal (in children it is straight)—This favors the apposition of the anterior and the posterior walls of the inguinal canal during the rise of intraabdominal pressure thereby preventing the herniation of the abdominal contents.
    2. During straining or coughing, the conjoint tendon contracts and as it forms the anterior, superior and posterior boundaries; it closes the inguinal canal producing a shutter or sphincter like effect.
    3. The ball valve action of the cremaster muscle pulls up the spermatic cord into the canal and plug it during rise of intraabdominal pressure.
  - v. Hasselbach's triangle
    - Boundary:
    - Laterally—Inferior epigastric artery.
    - Medially—Lateral border of rectus abdominis
    - Base – Inguinal ligament.
    - Applied importance
      - Direct hernia occurs through the Hesselbach's triangle.
      - Neck of indirect hernia lies lateral to the inferior epigastric artery.

- Neck of direct hernia is medial to the inferior epigastric artery.

### Indirect Inguinal Hernia

#### Definition

It is a herniation of abdominal contents through the deep inguinal ring into the inguinal canal.

It is the most common type of hernia in the body. As it traverses the inguinal canal, it is invested by the following coverings from outside within viz.

1. Skin
2. Superficial fascia/dartos muscle in scrotum.
3. External spermatic fascia derived from external oblique muscle.
4. Cremasteric fascia derived from the internal oblique muscle.
5. Internal spermatic fascia derived from fascia transversalis and
6. The peritoneum which forms the sac.

#### Types

According to the extent of hernia three types are found

- i. Bubonocoele—When the hernia is limited to inguinal canal. The patient is usually young and presents with an inguinal swelling of short duration.
- ii. Funicular hernia—Here the processus vaginalis closes just above the epididymis. So the contents of the hernia can be felt separately from the testis which lies below the hernia. This usually occurs in adults and a long-standing history is received in these cases.
- iii. Complete (scrotal type) hernia—Here the hernial contents descend upto the bottom of scrotum. The testis is felt posterior to the hernial sac with great difficulty. The processus vaginalis is patent throughout being continuous with tunica vaginalis of the testis. It is a congenital hernia, commonly seen in children but it may appear in adult or adolescent life.

#### Parts of the Hernia

Hernia consists of three parts viz. (a) The Sac, (b) Contents of the sac, (c) Coverings of the sac. The sac and its coverings has been described above.

### Hernial Contents

Hernias are named variously according to the nature of the hernial content, e.g.

- a. Omentum—When the hernia is called omentocele.
- b. A loop of intestine—When the hernia is called enterocele.
- c. Meckel's diverticulum—This is called Littre's hernia.
- d. A part of circumference of the small gut—This is known as Richter's hernia.
- e. Two loops of intestine in the manner of 'W'—This is called Maydl's hernia.
- f. A part of bladder wall/cecum, when the hernia is called a sliding hernia.

### Clinical Types

1. Reducible hernia—The hernia is said to be reducible when the contents can be returned to the abdomen.
2. Irreducible hernia—In this case the contents cannot be returned to abdomen but there are no other complications like obstruction, strangulation, etc.

Irreducibility may be due to:

- i. Adhesion of intestinal loops to the sac or to one another.
  - ii. Omentocele as the omental fat gets adhered to the sac.
  - iii. Adhesion of one part of the sac to another part.
  - iv. A huge hernia, often called scrotal abdomen.
  - v. Presence of solid fecal mass (incarceration) in the lumen of the colon occupying a hernial sac.
3. Obstructed hernia—This is an irreducible hernia containing intestine which is obstructed from outside or within but there is no interference of blood supply to the bowel.
  4. Strangulated hernia—A hernia is said to be strangulated when the blood supply of its contents is seriously impaired, rendering the contents ischemic. Usually there is no clear distinction clinically between obstruction and strangulation and it is safe to assume that strangulation is imminent and treat accordingly. Gangrene can occur within 5 to 6 hours after the onset of first symptoms. A strangulated hernia is usually tense, tender and there is no impulse on coughing.

- 5. Inflamed hernia—Inflamed hernia means Contents of sac have become inflamed.

**Direct Inguinal Hernia**

- It represents 15 percent of inguinal hernias.
- Usually bilateral and acquired.
- Causes: Coughing, straining, obesity, intra-abdominal malignancy.
- The hernia passes through weakness or defect of transversalis fascia, in the posterior wall of inguinal canal.
- The neck of the direct hernial sac is wide due to which strangulation is extremely rare.
- This type of hernia is treated by inversion of the sac (no herniotomy), repair of fascia transversalis in front of the sac and reconstruction of the posterior inguinal canal, e.g. Prolene darning or meshplasty.

*Coverings of direct hernia* (from within outwards).

1. Peritoneum forming the sac
2. Fascia transversalis
3. Cremasteric muscle and fascia
4. External spermatic fascia
5. Superficial fascia/dartos muscle in scrotum
6. Skin.

**Diagnosis**

(See also the long case on hernia chapter 74)

**History**

- Swelling in the inguinal region, this is gradually increasing in size.
- History of dragging pain indicates omentocele.

- *Age*—It occurs in all ages from birth to elderly. Direct hernia is more common in the elderly people while indirect hernia is more common in younger and adult life.

**Clinical Examination**

Clinical examination is done in the standing position, while the examiner sits on a stool, then in the lying position, if necessary (e.g. Ziemann’s test).

**Inspection**

- i. Inguinal or inguinoscrotal swelling—The swelling may be unilateral or bilateral.
- ii. Expansile impulse on coughing is present. This is diagnostic of hernia.
- iii. Presence of a scar indicates recurrent hernia. Ragged scar indicates infection.
- iv. Direct hernia pops out as soon as patient stands.

**Palpation**

- Swelling is soft and gargles if it is enterocele.
- It may be firm or granular if omentocele.

  1. The patient is asked to cough—An expansile impulse is felt at the root of scrotum.
  2. Getting above the swelling is not possible unlike a scrotal swelling where it is possible. This test has no usefulness in bubonocele. It is a test to differentiate a scrotal swelling from an inguinoscrotal swelling.
  3. Reducibility: The patient is asked to lie down. All hernias are reducible unless complicated. The direct hernia usually reduces immediately and spontaneously but indirect hernia may require manipulation.

- 4. Internal or deep ring occlusion test: After the reduction of hernia deep ring is occluded by the pressure of the thumb and the patient is asked to cough.

The swelling does not reappear in case of indirect hernia and the test is said to be positive.

The swelling reappears immediately in case of direct hernia and the test is said to be negative.

- 5. Ziemann’s Test: (Three fingers test)
  - Index finger is kept at the deep ring,
  - Middle finger, at the superficial ring and
  - Ring finger, at fossa ovalis.

Depending on the type of hernia, indirect, direct and femoral, impulse is felt by the index, middle and ring fingers respectively.

- 6. Examination of respiratory system is done to rule out chronic bronchitis, tuberculosis, etc.

- 7. Leg raising test (Head raising test): Weakness of the oblique muscles is manifested by Malgaigne’s bulgings above the iliac crest and inguinal ligament found usually in the people of poor physique but it has no cough impulse. It may be the precursor of a direct inguinal hernia. Malgaigne’s bulge is an absolute indication for hernioplasty.

The differences between direct and indirect hernia are given in table 42.1.

**Treatment**

- Surgery is the treatment of choice.
- Basically three types of operations are performed.

**Table 42.1: Difference between direct and indirect hernia**

	<i>Indirect</i>	<i>Direct</i>
1. Etiology	Preformed sac	Weakness of posterior wall of inguinal canal
2. Precipitating factor	—	Bronchial asthma, chronic bronchitis, enlarged prostate
3. Bilateral	20%	50%
4. Protrusion on coughing	Oblique	Straight
5. Appearance on standing	Does not reach full size immediately	Reaches full size immediately
6. Reduction on lying down	May not reduce immediately	Reduces immediately
7. Internal ring occlusion test	Swelling is not seen	Swelling is seen
8. Malgaigni’s bulge	Absent	May be present
9. Complications (obstruction/strangulation)	Common as the neck is narrow	Not common as neck is wide
10. Relation to inferior epigastric vessels	Lateral	Medial

1. **Herniotomy** (Ligation and exision of the sac only)
  2. Herniotomy and repair of the posterior wall of the inguinal canal, called **herniorrhaphy**.
  3. Herniotomy and reconstruction of the posterior wall of the inguinal canal, known as **hernioplasty** (Prolene darn-ing or Meshplasty).
- In case of direct hernia, herniotomy is not performed.
  - In women it is advisable to remove the round ligament.

#### Which operation and when?

- a. Uncomplicated hernia
  - Herniotomy in children.
  - Herniorrhaphy in adults.
  - Hernioplasty in elderly people with Malgaigne's bulge or weakness of anterior abdominal wall muscles. See operative section for details of operation on hernia-chapter 96.
- b. Strangulated hernia—Emergency exploration and repair is indicated. Resection and anastomosis is performed if gangrenous changes occur in the bowel.
- c. Truss if operation is contraindicated in elderly unfit patient.

#### Complications of Hernia

1. Irreducibility—It occurs due to adhesions formed between sac and the contents.
2. Obstructed hernia—Irreducible hernia with obstruction to the lumen of the gut gives rise to obstructed hernia. Clinically there is vomiting, abdominal distension, severe colicky abdominal pain and step ladder peristalsis.
 

Factors responsible for obstructed hernia – Narrow neck, irreducibility, sudden straining, too many contents, long duration of hernia.
3. Strangulation—Obstructed hernia with impairment of blood supply to intestine. There will be features of intestinal obstruction with shock and toxemia.
4. Incarcerated hernia—It is an obstructed hernia caused by solid fecal matter in the obstructed portion of the colon.
5. Inflamed hernia—It occurs when the contents of hernia get inflamed, e.g. Appendicitis

in a hernia sac, Meckel's diverticulitis in hernial sac.

#### NYHUS CLASSIFICATION FOR GROIN HERNIA

This is a common method of classifying the inguinal hernias. The use of this classification helps to standardize the assessment of the degree of herniation. The classification is as follows:

- Type I—Indirect hernia with a normal deep ring.
- Type II—Indirect hernia with a dilated deep ring and intact posterior wall.
- Type III—Posterior wall defect.
- a. Direct hernia.
  - b. Pantaloon hernia, i.e. both direct and indirect hernias present, hence called double hernia.
  - c. Femoral hernia.
- Type IV—Recurrent hernia
- a. Direct
  - b. Indirect
  - c. Femoral
  - d. Combined.

#### DIFFERENTIAL DIAGNOSIS OF GROIN SWELLINGS

- A. Inguinal swellings
  1. Inguinal hernia restricted to inguinal canal.
  2. Undescended testis.
  3. Inguinal lymphadenitis.
  4. Lipoma of the spermatic cord.
- B. Differential diagnosis of femoral hernia
  1. Saphena varix
  2. Inguinal lymphadenitis below inguinal ligament.
  3. Ectopic testis in femoral region.
  4. Femoral artery aneurysm.
  5. Adductor longus hematoma.

#### SPECIAL VARIETIES OF INGUINAL HERNIA

1. Dual hernia (Syn. Saddle bag hernia, pantaloon hernia).
 

It is both direct and indirect hernia in the same patient.

There are two sacs –

  - a. One sac lying medial to the inferior epigastric artery (Direct Hernia).

- b. Another sac lying lateral to the inferior epigastric artery (Indirect Hernia).
2. Sliding Hernia (Syn. Hernia-en-glissade).
 

Here posterior wall of the sac is formed by sigmoid colon and its mesentery on the left and cecum on right side and sometimes on either side by a portion of bladder.

It mostly occurs in males and most common content is sigmoid colon. Left sided hernia is five times more common than right sided one.

Treatment is operation on similar lines to an inguinal hernia but no attempt should be made to separate the cecum or sigmoid colon from the peritoneum as this will result in devascularization and fecal fistula formation.

#### RECURRENT INGUINAL HERNIA

Recurrent inguinal hernia rate varies from 1 to 3 percent in specialty hospitals but in general hospitals it may be as high as 10 to 15 percent. The causes of recurrence are:

1. Persistence of preoperative factors:
  - Presence of chronic cough
  - Smoking
  - Constipation
  - Old age
  - Hypoproteinemia
  - Benign prostatic hyperplasia.
2. Operative
  - Tension in the sutures
  - Failure to reinforce the sutures.
3. Postoperative
  - Infection and hematoma formation.
  - Missed hernia during primary surgery.
  - A direct hernia is repaired but the spermatic cord is not explored for a coexisting indirect sac.

The incidence of recurrence is more with direct than with indirect hernia.

The clinical features are same as those for inguinal hernia.

#### Treatment

Any preexisting cause of recurrence is corrected and then hernioplasty is done. Hernioplasty is done by operations like Lichtenstein mesh repair.

For recurrent bilateral hernias, Stoppa's operation of giant prosthesis for reinforcement of the visceral sac (GPRVS). In this

operation, prosthetic reinforcement of the peritoneum is done by using a large polypropylene mesh by a midline abdominal incision. The mesh covers all the potential hernial sites in the lower abdomen and prevents herniation.

### STRANGULATED INGUINAL HERNIA

Strangulation is one of the most serious complications of inguinal hernia. It is seen in large indirect inguinal herniae in an elderly patient.

#### Pathology

Strangulation is a type of acute intestinal obstruction where blood supply of gut wall gets jeopardized.

As strangulation sets in, initially there is venous obstruction, because they are superficial, then arterial obstruction starts.

Due to venous obstruction there is edema and transudation of fluid into the sac. If this fluid gets infected by the translocation of bacteria from the gut, toxicity appears.

Following arterial obstruction, the gut becomes friable and flabby. This is followed by discoloration of gut wall which will lead to the development of gangrene. Gangrene may progress to perforation and peritonitis.

Finally there is hypovolemia and shock with loss of electrolytes.

#### Clinical Features

- There is history of inguinal hernia which suddenly becomes irreducible.
- The onset of strangulation is heralded by sudden pain over the site of hernia. This is followed by colicky generalized pain abdomen and vomiting.

On examination, the strangulated hernia is tense, tender, irreducible and there is no expansile impulse on coughing.

- There are features of toxicity and shock.

#### Treatment

Preoperative resuscitation followed by operation is the treatment of choice and is most urgent.

#### Preoperative Resuscitation

1. Prophylactic parenteral antibiotic against the bowel organisms.

**Table 42.2: Difference between the two techniques of inguinal hernia repair**

<i>Open inguinal hernia repair (OIHR)</i>	<i>Laparoscopic inguinal hernia repair (LIHR)</i>
1. Done by either Shouldice or Lichtenstein repair.	1. Done by either TAPP or TEPA technique.
2. Cheaper	2. Costlier.
3. Can be done under local anesthesia.	3. Needs general anesthesia.
4. Used by majority of surgeons till now in our country and UK.	4. Used by less number in both India and UK
5. Comparatively more pain.	5. Less postoperative pain.
6. Delayed return to work.	6. Early return to work.

2. Relief of pain with injection pethidine HCl.
3. A nasogastric tube is passed.
4. Bladder is catheterized
5. Blood requisition done.
6. The operation is done under general anesthesia.

#### Operation

The incision is made as for an inguinal hernia. After cutting the external oblique aponeurosis, the layers covering the sac are dissected off and the sac is opened. The fluid inside the sac is highly infected and is carefully mopped away.

The constricting band which is the neck of the sac is now cut and the intestine is checked for viability. It is helpful to cover the intestine of doubtful viability with a warm and moist swab for 10 minutes. If viable, the gut is returned to the peritoneal cavity if non-viable, resection and anastomosis of the gut is done.

Repair of the posterior wall is done by a tissue repair as use of synthetic mesh will invite infection.

### LAPAROSCOPIC INGUINAL HERNIA REPAIR

This is a new technique in which mesh is stapled over the defect. It is useful for the bilateral hernias, multiple hernias and recurrent hernias.

There are two techniques of laparoscopic hernia repair viz.

- Transabdominal preperitoneal repair (TAPP)—Under general anesthesia pneumoperitoneum is created. The peritoneum is then incised above the hernia and a prosthetic mesh is stapled over the defect.

- Total extraperitoneal approach (TEPA) – Here, one does not enter the abdominal cavity. Surgical balloons are used to inflate the extraperitoneal space along the anterior surface of the posterior rectus sheath upto the symphysis pubis.

A prosthetic mesh is now stapled over the defect under laparoscopic control. The mesh is secured to the posterior rectus musculature, Cooper's ligament, lacunar ligament, the transversus abdominis aponeurotic arch, and laterally to the lateral extension of this arch.

The mesh is placed across the back of the inguinal canal to cover the hernial defect completely. It extends laterally beyond the deep inguinal ring and medially beyond the pubic tubercle.

A comparison of open vs. laparoscopic inguinal hernia repair is given in table 42.2.

### FEMORAL HERNIA

#### Definition

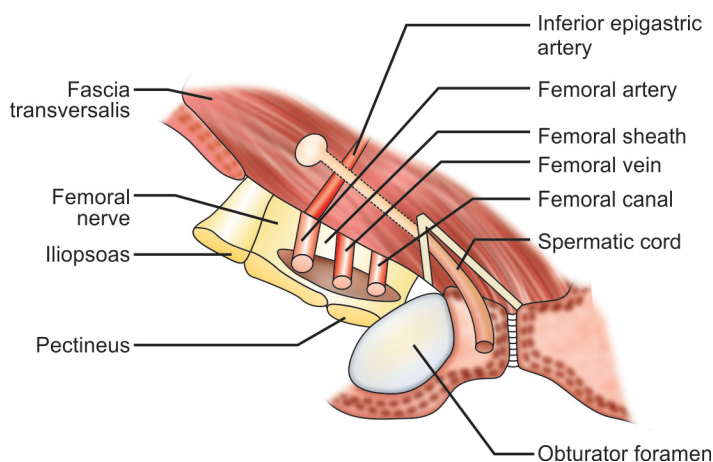
Herniation of intra-abdominal contents through the femoral canal is called Femoral hernia.

- It is the third most common type of hernia (Incisional Hernia comes second).
- Women are more affected than men (2:1) and right side is more affected than the left. It is bilateral in 15 to 20 percent cases.

#### Surgical Anatomy – Femoral Canal and Femoral Ring

##### *Femoral Canal (Fig. 42.2)*

It extends from the femoral ring above to the saphenous opening (fossa ovalis) below,



**Fig. 42.2:** Femoral canal—Boundaries and relations

being the innermost compartment of the femoral sheath.

Length – 2cm, shape: It looks like the inverted truncated cone, the upper end being the femoral ring.

#### Contents of the femoral canal

1. Fibrofatty tissue
2. Lymph nodes and lymphatics. Lymph node situated at the ring is known as Cloquet's node.

#### Femoral Ring: Boundary

1. Anterior—Inguinal ligament.
2. Posterior—Iliopectineal ligament and pubis.
3. Medially—Crescentic edge of the lacunae ligament.
4. Laterally—Fibrous septum separating the canal from the femoral vein (Silver fascia).

The ring is closed above by the septum crurale – a condensed extraperitoneal tissue pierced by the lymphatic vessels.

### FEMORAL SHEATH

A funnel-shaped fascial prolongation around the femoral vessels below the medial half of inguinal ligament.

The anterior wall of the sheath is formed by the fascia transversalis and the posterior wall by the fascia iliaca. The sheath has got three compartments separated by fibrous septae.

1. Lateral compartment contain femoral artery and femoral branch of genitofemoral nerve (femoral nerve is outside the femoral sheath).

2. Intermediate compartment contains femoral vein.
3. Medial compartment is the femoral canal.

#### Coverings of the Sac of Femoral Hernia

1. Skin
2. Sup. fascia
3. Cribriform fascia covering the saphenous opening
4. Fascia transversalis – representing anterior femoral sheath.
5. Extraperitoneal fat and
6. Peritoneum.

#### Course of Femoral Hernia

The hernial sac enters the femoral ring descends vertically courses forward and when enlarging, it courses upward over the inguinal ligament and external oblique aponeurosis, occupying the inguinal region. The shape of the sac thus becomes retort-shaped.

The sac can not pass down into the thigh as the sup fascia of the abdomen (fascia of Scarpa) is attached to the fascia lata of thigh at the lower border of the fossa ovalis.

#### Causes

Femoral hernia is almost always acquired in nature.

1. Pregnancy: Repeated pregnancy causes increased abdominal pressure which is probably an initiating factor. The maximum incidence is around 30 – 40 yrs.
2. Wide femoral canal: This is due to narrow insertion of iliopubic tract into the pectineal line of the pubis and may

be responsible for a few cases of femoral hernia.

#### Symptoms

The symptoms are less pronounced than those of inguinal hernia.

- a. Pain—Dragging type and is caused by adherence of greater omentum.
- b. Swelling – Below and lateral to the pubic a tubercle. In the later stage—however it may extend above the inguinal ligament.
- c. Strangulation—An obese lady may present with the features of intestinal obstruction or strangulation of an unnoticed femoral hernia.

Strangulation is common due to the unyielding nature of the femoral ring.

#### Differential Diagnosis (Fig. 42.3)

1. Incomplete inguinal hernia or Bubonocoele.
2. Saphena varix.
3. Femoral artery aneurysm.
4. Ectopic femoral testis.
5. Psoas abscess.
6. Lipoma.
7. Enlarged lymph node.

#### Treatment

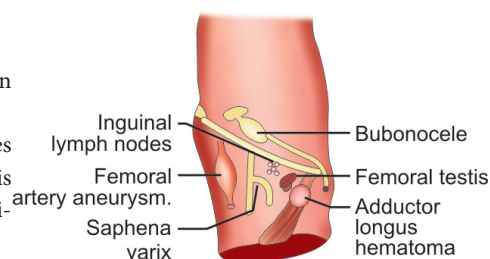
Operation is the treatment of choice. Conservative treatment has no role in femoral hernia, because no truss can be fitted to control the femoral ring.

#### Principle of Operation

Herniotomy and closure of the femoral ring either by suturing inguinal ligament to the pectineal ligament or the conjoint tendon to the pectineal ligament.

There are three approaches to the femoral hernia repair.

1. High approach—From above the inguinal ligament, (Lotheissen's operation).



**Fig. 42.3:** Differential diagnosis of femoral hernia schematically.



2. Low approach—From below the inguinal ligament, (Lockwood's operation).
3. Combined approach—Inguino femoral approach – (High operation of McEvedy).  
A vertical incision is made over the swelling and extended above the inguinal ligament and the sac can be dissected from both above and below. This approach has the advantages of both operations mentioned above.  
See also the operative section on herniae chapter 96.

### EPIGASTRIC HERNIA

(Syn.— Fatty hernia of linea alba) epigastric lipoma).

#### Definition

It is the protrusion or herniation of extraperitoneal fat through a defect in the linea alba anywhere between the xiphoid process and the umbilicus, usually midway between these structures.

#### Etiology

The condition is always acquired, common in manual laborers between the ages of 30 and 45yrs often precipitated by sudden strain causing tearing of the interlacing fibers of the linea alba.

#### Pathology

Initially there is protrusion of extraperitoneal fat through the same opening where the linea alba is pierced by a small blood vessel. At this stage, there is no well-formed sac and so it is known as preperitoneal lipoma or false epigastric hernia.

In the next stage, as the hernia grows bigger and bigger, it drags a pouch of peritoneum after it and becomes a true epigastric hernia often a small tag of omentum gets adherent to the sac when the patient complains of dragging pain, discomfort or pain after food, not unlike that of a peptic ulcer.

#### Clinical Features

There are three clinical types:

1. Symptomless—At the initial stage it is symptomless and often discovered by the patient himself as a swelling during washing his body.
2. Painful swelling—Localized pain exactly at the site of hernia as the fatty content of

**Table 42.3: Comparison of umbilical and paraumbilical hernias.**

Table 42.3: Comparison of umbilical and paraumbilical hernias.		
<i>Umbilical Hernia of Infants</i>	<i>Paraumbilical Hernia of Adults</i>	
1. Age	0 – 3	50 – 60
2. Sex	Common in male child	Common in females
3. Causes	Neonatal sepsis	Obesity, weak muscles, multiple pregnancy
4. Defect	A small defect in the umbilical scar	Defect is above or below the umbilicus
5. Symptoms	Symptomless	Symptoms are present
6. Strangulate	Rare	Common
7. Treatment (Rare)	Conservative surgery	Mayo's repair

the hernia is pressed by the tight margins of the gap in the linea alba to produce partial strangulation. Pain is also felt on wearing tight clothing.

3. Symptoms of peptic ulcer—As stated above. Pain may also be due to associated peptic ulcer or gallstone disease.

#### On Examination

There is a firm globular swelling, varying from a pea size to 2cm diameter, does not have cough impulse (usually) and can not be reduced. The gap in the linea alba cannot be felt clearly. For this reason epigastric hernia is difficult to distinguish from lipoma. Abdominal examination is normal.

#### Treatment

If small and symptomless, the lump can be overlooked.

If there are symptoms, operation is done. Before operation patient is advised for an upper GI endoscopy to exclude an underlying peptic ulcer disease.

See operative section for details of operation chapter 96.

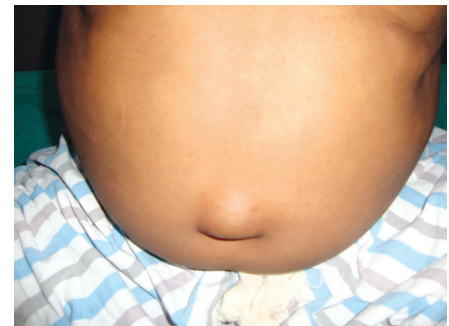### UMBILICAL HERNIA

Comparison of umbilical hernia of infants and paraumbilical hernia of adults (Table 42.3) is given below.

Umbilical hernia occurs as a complication of umbilical sepsis, which causes weakness of the umbilical scar.

#### Clinical Features

- This is common in male child (2:1), who is usually brought to the doctor with the complaint of swelling in the umbilical region, whenever the child cries.



**Fig. 42.4:** Paraumbilical hernia of adult

- Most cases are symptomless but parents are anxious about the swelling. Strangulation is rare.

#### Treatment

- I. Conservative—Most of the hernia close spontaneously without any treatment within two years of age. So the methods are:
  - i. Masterly inactivity.
  - ii. Reassurance to the parents
  - iii. Customary strapping after reduction of the hernia—A coin covered with a pad is placed over the umbilicus, which is then fixed by adhesive strapping.
- II. Operative—Herniorrhaphy is indicated when the hernia is still present after 2 years of age. The umbilicus is preserved. See operative section for details of operation (chapter 96).

### ADULT UMBILICAL HERNIA

(Syn – Paraumbilical hernia) (Fig. 42.4).

#### Introduction

In adults, hernia does not protrude through the umbilical cicatrix. It is a protrusion

through the linea alba just above the umbilicus (supraumbilical) or occasionally below the umbilicus (infraumbilical). That's why it is called paraumbilical hernia.

### Causes

Commonly occurs in middle-aged or elderly women (M:F = 1:5). Contributing factors are obesity, multiparous women, persistent source of straining, e.g. chronic cough, constipation, bladder neck obstruction, etc.

### Content

- The usual content is the greater omentum, often accompanied by small intestine or a portion of the transverse colon.

Owing to adhesions between the contents and the sac, the sac becomes loculated in most cases and the hernia is usually irreducible.

### Clinical Features

- There is a swelling in the umbilical region. Initially the swelling is small but gradually it increases and attains a big size. Dragging pain may be present due to adherent omentum.
- The swelling
  - Firm in consistency as it contains mostly omentum.
  - Dull on percussion.
  - Cough impulse is present when the contents are not adherent but absent, when the hernia becomes irreducible.
- After reducing the swelling, the defect can be made out in the linea alba.

### Complications

- Irreducibility.
- Obstruction with colicky abdominal pain and vomiting, distension follows soon. Untreated cases develop strangulation.
- As the sac enlarges, it sags down resulting in friction of skin and this causes intertrigo (Dermatitis between the skin folds).

### Treatment

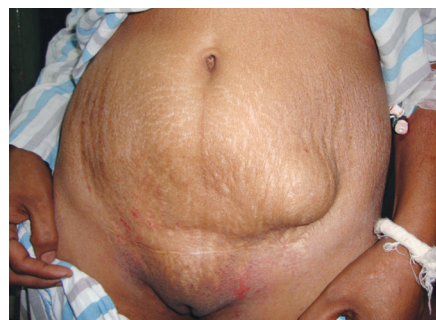Operation is the treatment of choice and no attempt should be made for conservative treatment. Reduction of weight is advisable if the patient is obese. Mayo's operation is usually practiced.

### Mayo's Operation

- Under general anesthesia a transverse elliptical incision is made encircling the umbilicus.
- Upper and lower skin flaps are raised for about three inches. The subcutaneous tissues are dissected off the rectus sheath to expose the neck of the sac.
- The sac is opened at its neck as adhesions are least here. The contents are freed from adhesions at the fundus of the sac and returned to the abdomen.
- The whole circumference of the neck is gradually incised and the fundus of the sac along with the redundant skin is removed.
- The peritoneum of the neck of the sac is closed with absorbable suture such as polyglactin.
- The gap in the linea alba is extended on both sides laterally for one inch or more and then upper and lower aponeurotic flaps are sutured together by using double breasting technique.
- Skin closed with a subcutaneous vacuum suction drain at each end of the wound, which is kept for 48 to 72 hours.

The traditional Mayo's technique is less commonly utilized nowadays since overlapping fascial closures have been shown to weaken the overall wound strength in hernia repair.

In large defects that may close with a significant degree of tension a cone of prolene mesh can be fitted to fill the umbilical defect instead of tissue repair. The mesh is then sutured circumferentially to the surrounding fascia to prevent displacement.



**Fig. 42.5:** Incisional hernia over the left iliac fossa following hysterectomy

### Postoperative Measures

1. Gastric suction to avoid distension.
2. IV infusion of fluid and electrolytes.
3. Adequate antibiotic therapy, nutrition and vitamins.
4. To avoid strenuous work for 3 months.
5. Early ambulation is discouraged.
6. To avoid urinary retention and cough.

### INCISIONAL HERNIA (FIG. 42.5)

(Syn—Postoperative hernia, ventral hernia).

### Definition

An incisional hernia is one where the peritoneal sac herniates through an acquired scar in the abdominal wall usually caused by a previous surgical operation or an accidental trauma. Scar tissue is inelastic and can be stretched easily if subjected to constant strain.

It is very common in females. Contents of such hernia are usually bowel and/or omentum.

### Precipitating Factors

Many factors singly or in combination are responsible for the development of incisional hernia viz.

1. Poor surgical technique:
  - a. Nonanatomic incision, e.g Battle's pararectal incision, damaging number of nerves, has high incidence of incisional hernia.
  - b. Method of closure—Layered closure has higher incidence of developing incisional hernia than wound closed in single layer.
  - c. Inappropriate suture material. The wound gains about 85 percent of normal strength in 6 months. Wound closed with nonabsorbable suture material has far lesser incidence of postoperative hernia than wound closed with absorbable suture.
  - d. Suturing technique—Closing the abdomen with sutures under tension causes pressure necrosis of intervening tissues and is an important cause for development of incisional hernia.
  - e. Drainage tube—When brought out through the main wound, the chance of developing incisional hernia is increased.

2. Postoperative complications: Postoperative wound infection, cough, and respiratory distress due to pneumonia or lung collapse.
3. General factors, e.g. patients with severe anemia, hypoproteinemia, diabetes, advanced malignant disease, jaundice, chronic renal failure, steroid or immunosuppressive therapy and alcoholism favors development of incisional hernia.
4. Tissue failure: Late development of hernia after 5, 10 or more years after operation is usually associated with tissue failure that is abnormal collagen production and maintenance.

### Clinical Features

#### History

A previous operation or trauma is noticed. There may be history of wound infection.

#### Age

Incisional hernia may occur at any age but more commonly in elderly females.

#### Symptoms

- Swelling and pain are the commonest symptoms.
- Rarely features of intestinal obstruction may be present.

#### On Examination

- There is expansile impulse on coughing and reducibility of the hernia is usually present.
- After reduction of the contents, a defect can be palpated through the scar.

### Types of Incisional Hernia

*Type I*—It occurs through, the midline upper or lower abdominal incision where the muscular defect is wide with smooth and regular margins. Hence this hernia gets reduced spontaneously as soon as the patient lies down. Risk of strangulation is almost negligible.

*Type II*—The hernia is situated in the lateral part of abdomen. Here the risk of strangulation is more.

### Treatment

#### Conservative Approach

If the neck of the incisional hernia is wide shows no signs of increase in size

and patient has no symptoms, it may be observed.

#### Operative Treatment

The indications are:

- a. Symptomatic hernia which is showing signs of increase needs repair.
- b. Large hernia with a small opening. Such hernia has a high chance of strangulation and needs to be repaired early. Subacute intestinal obstruction, irreducibility and strangulation are definite indications for repair of incisional hernia.

#### Operation

The following methods are used.

1. Anatomical repair
2. Keel operation
3. Mesh repair.

### Operation for Incisional Hernia

- An elliptical incision is made enclosing the area of unhealthy skin and is prolonged sufficiently to get adequate access. The incision is then deepened to the aponeurosis and the dissection is continued inwards towards the margins of the defect.
- The outer edges are undercut and are reflected beyond the limits of the hernial protuberance; since they are often adherent to the sac the reflection must be carried out with great care.
- Dealing with the sac—If the sac is no more than a redundancy of peritoneum and if it is not too adherent to the skin, it may be possible to free it and to replace it unopened within the abdomen.

More often, however, it is loculated and very adherent. It is then better to open it around its neck and to free the contents. The fundus of the sac along with the redundant skin is removed.

The subsequent repair depends on the size of the sac as follows:

- i. Small sac
  - a. Anatomical repair.
  - b. Keel operation.
- ii. Larger sac—Mesh repair.

#### Anatomical Restoration

By careful dissection, the surrounding abdominal wall is separated into its constituent

layers – usually peritoneum, fleshy muscle and aponeurosis. Each layer is freed sufficiently to allow it to be sutured individually and without tension.

#### Mesh Repair (See also chapter 96 in operative surgery section)

These are becoming increasingly popular, particularly for large incisional hernias with a wide gap, or when the aponeurotic gap can not be properly apposed or tissue is thinned out.

- i. After dealing with the sac and the contents, the peritoneum is sutured as in anatomical restoration.
- ii. The prolene mesh is then bridged across the defect in the abdominal wall by creating a preperitoneal space between the rectus muscles anteriorly and the posterior rectus sheath blended with the hernial sac posteriorly.

The prolene mesh is sutured all around with fine prolene sutures without tension.

- iii. Under no circumstances the intestine should be allowed to come in contact with the mesh to avoid formation of dense adhesions.
- iv. The recti muscles and anterior rectus sheath should then cover the mesh completely. Hemostasis is carefully secured. A suction drain (Redivac) should always be placed to aspirate the oozing fluid and thus to prevent infection.
- v. Local antibiotics and postoperative parenteral antibiotics should be used.

#### The Keel Operation

##### Principle

In this operation the hernial sac is not opened and the repair is done by wide inversion of the sac. So it is an extraperitoneal operation.

##### Essentials of operation

After dissecting and cleaning neck of the sac the sac is pushed back into the abdominal cavity by a series of investing and pleating layers of unabsorbable sutures (3 to 4 layers of sutures). Lastly, the anterior sheath and skin are repaired.

##### Advantages

1. Chance of postoperative ileus and peritonitis is nil.
2. Early feeding may be started.

**Disadvantages**

1. It is a blind operation (sac not opened) and any adhesions of the bowel and omentum with the sac can not be corrected. So there may be a chance of intestinal obstruction in future.
2. During suturing of the sac after inversion there is a chance of injuring the bowel and omental vessels.

**SOME RARE EXTERNAL HERNIAE****Spigelian Hernia**

This is actually an interparietal hernia which occurs through the spigelian fascia, which is the aponeurotic part of the transversus abdominis muscle between the medial border of its muscular part and its insertion into the posterior rectus sheath.

Most of the herniae are seen at the arcuate line that is the lower end of the posterior rectus sheath. Commonly the hernial sac passes through the transversus abdominis and internal oblique muscles to lie in the interstitial space just deep to the external oblique muscle.

The patient presents with dragging pain. This type of hernia is prone to strangulation. Ultrasound is the best diagnostic test.

Treatment is by operative repair of the defect by using a continuous suture of polypropylene.

**Obturator Hernia**

It occurs through the obturator canal alongside the obturator vessels and nerve. This is found in elderly females who have lost much fat.

**Gluteal Hernia**

This type of hernia occurs through the greater sciatic foramen and may be above or below the piriformis.

**Sciatic Hernia**

This occurs through the lesser sciatic foramen.

**Lumbar Hernia**

Two types of lumbar hernia are well-recognized.

1. Primary lumbar hernia: It occurs through the anatomical defect in the superior and inferior lumbar triangles. (Fig. 42.6)

The patient usually presents with a swelling in the lumbar region which is reducible and shows impulse on coughing.

- i. Inferior lumbar hernia: This occurs through the inferior lumbar triangle or the lumbar triangle of Petit.

Boundary of inferior lumbar triangle is as below:

- Inferiorly: Iliac crest.
- Laterally: External oblique muscle.
- Medially: Latissimus dorsi muscle.

- ii. Superior lumbar hernia: This is rarer than inferior lumbar hernia and occurs through the superior lumbar triangle which is bounded as follows:

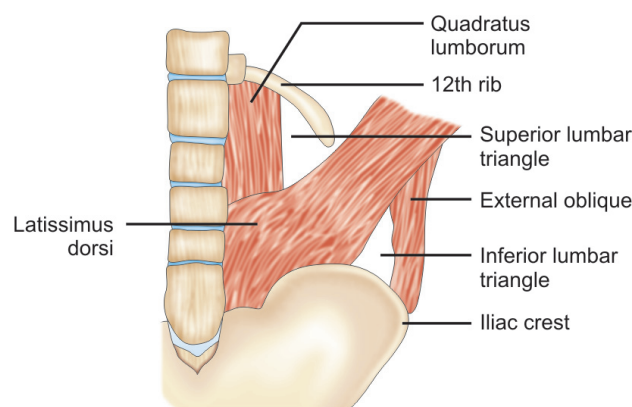
- Above: 12th rib
- Medially: Sacrospinalis muscle
- Laterally: Internal oblique muscle.

2. Secondary or incisional lumbar hernia: It occurs after renal operation done through a loin incision.

Differential diagnosis of lumbar hernia — (a) Lipoma (b) Neurofibroma (c) A cold abscess.

**Treatment**

Treatment is surgical. It is difficult to close the gap by apposing the local tissue. So a repair using a prolene mesh is preferred.



**Fig. 42.6:** Anatomy of the superior and inferior lumbar triangles

# Chapter 43

## The Breast

- Surgical anatomy of the breast
- Benign breast disease
- ANDI
- Infective disorders
- Miscellaneous conditions
- Presentation of breast disease

### SURGICAL ANATOMY OF THE BREAST

#### Definition

The breast is a specialized accessory (modified sweat gland) gland of skin capable of milk secretion.

#### Development

It develops from the mammary ridge. Before puberty, it is small both in male and female. At puberty, it grows due to the influence of

ovarian hormones. The major bulk is produced by adipose tissue.

#### Situation

Breast extends from the 2nd to 6th ribs and from lateral border of sternum to the anterior axillary line. It is situated in the superficial fascia only. The axillary tail (of Spence) formed by upward prolongation of superolateral part of the breast towards the axilla, pierces and opens in the deep fascia. A well-developed axillary tail is sometimes mistaken for a mass of enlarged lymph nodes or a lipoma.

#### Structure

Each mammary gland consists of 15 – 20 lobes. The nipple projects from the lower half of the breast. The main duct from each lobe opens separately on the summit of the nipple and is provided with a terminal ampulla (lactiferous sinus)—a reservoir for milk or abnormal discharges (Fig. 43.1).

Each lactiferous duct is lined by a spiral arrangement of contractile myoepithelial cells.

#### Nipple

The nipple is covered by thick skin with corrugations. The nipple contains smooth muscle fibers arranged concentrically and longitudinally. Thus it is an erectile structure which points outwards.

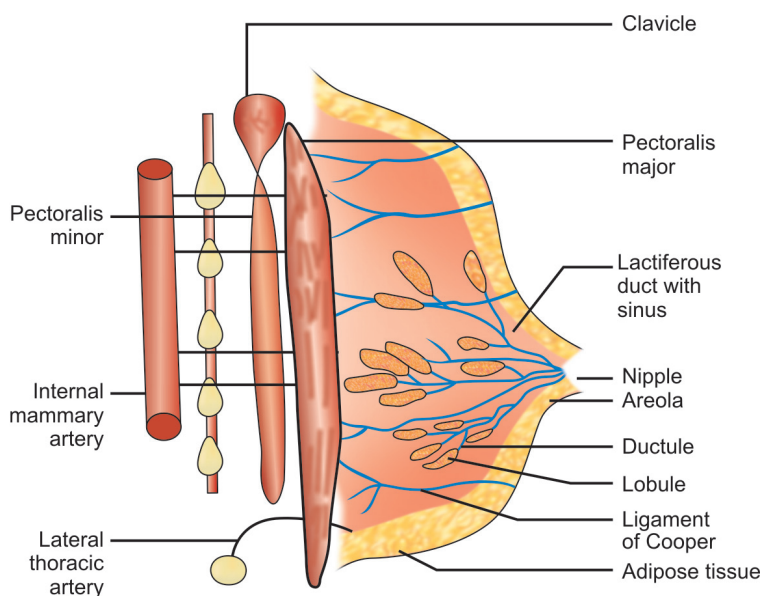
#### Areola

The base of the nipple is surrounded by a circular area of pigmented skin called the areola. The areola contains involuntary muscle arranged in concentric rings as well as radially in the subcutaneous tissue.

The areolar epithelium contains numerous sweat and sebaceous glands, which enlarge during pregnancy producing tiny tubercles known as Montgomery's tubercles.

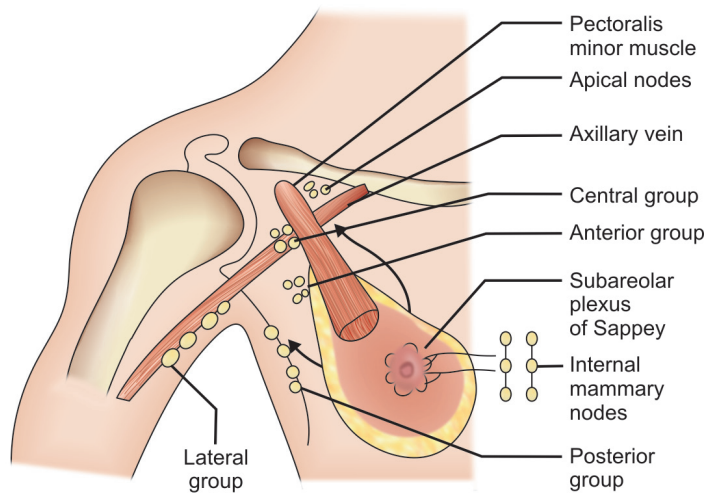
#### Ligament of Cooper

Ligaments of Cooper are hollow, conical projections of fibrous tissue filled with breast tissue, the apices of the cones being attached



**Fig. 43.1:** Structure and blood supply of mature breast in the female





**Fig. 43.2:** Lymph nodes of the axilla and the pathways of lymphatic drainage of the breast

firmly to the superficial fascia and thereby to the skin overlying the breast (Fig. 43.1). These ligaments account for the dimpling of the skin overlying a carcinoma or other lesions of the breast accompanied by cutaneous edema.

### Arterial Supply

1. Lateral thoracic artery—A branch from the second part of axillary artery.
2. Perforating branches of the internal mammary artery a branch from the 1st part of subclavian artery.
3. Lateral branches of the 2nd, 3rd and 4th intercostal arteries.

### Venous drainage

Venous drainage occurs to axillary and internal mammary veins.

### Lymphatic Drainage (Fig. 43.2)

The knowledge of lymphatic drainage is essential since carcinoma of the breast metastasizes early through this route.

Lymphatic drainage occurs through lymphatic vessels and lymph nodes.

- The lymphatic vessels originate in a plexus in the interlobular connective tissue and in the walls of lactiferous ducts.
- This join with the subareolar plexus of Sappey which collects the lymph from the nipple and areola.

- Some lymphatics from the deep surface of the gland communicate with the plexus on underlying deep fascia. They open up when usual channels are blocked.

The lymph drainage of the breast, as with any other organ, follows the pathway of its blood supply and occurs as below:

- a. More than 75 percent of the lymphatics drain to the axillary lymph nodes, about 20 to 30 in number along the tributaries of axillary vessels.
- b. Some 25 percent of the lymphatics drain to internal mammary nodes (4 to 5 in number), following the tributaries of internal mammary vessels.

The axillary nodes are arranged in five groups viz

1. Lateral or humoral group along the axillary vessels.
2. The anterior group along the lateral thoracic vessels. These glands are usually the first to become involved in breast cancer (Level-1 nodes).
3. Posterior group along the subscapular vessels in the posterior wall of axilla.
4. Central group (Level-2 nodes) lies in the fat of the axilla receiving lymph from the above three groups.
5. Apical group, lying in the apex of the axilla receives lymph (Level-3 nodes) from all the above groups. Apex of axilla is bounded by the clavicle, scapula and the

outer border of the 1st rib. It is the channel of communication between the axilla and posterior triangle of neck. The three levels of axillary nodes are described in relation to pectoralis minor muscle.

The apical nodes are in continuity with the supraclavicular glands and lower group of deep cervical glands in the posterior triangle which also receive afferents from the internal mammary glands and drain into the subclavian lymph trunk, which enter the great veins directly or via the thoracic duct or jugular trunk.

## BENIGN BREAST DISEASE

### Presentation

Benign breast disease may present with the following features singly or in combination.

- Lump.
- Nipple discharge or retraction.
- Pain (Mastalgia).

### Classification

#### Congenital Abnormalities

- i. Absence of a breast (amastia) is accompanied by pectoral muscle aplasia or hypoplasia in 90 percent cases. Breast hypoplasia (amazia) is commoner and minor asymmetry is quite normal.
- ii. Accessory breasts and nipples are due to failure of full regression of the primitive breast line.

#### Development Abnormalities

- i. Excessive breast enlargement—There is uncontrolled juvenile hypertrophy due to excessive growth of the periductal connective tissue and ducts but not of lobules.
- ii. Gynecomastia or male breast enlargement occurs in neonates, at puberty (30 – 70% of boys) and old age due to androgen deficiency state.

It is benign and usually regresses spontaneously. There is combined increase of glandular and stromal elements while only a few ductal structures enlarge, branch and elongate occasionally. Subcutaneous mastectomy may be necessary.

Pathological gynecomastia can be induced by hypogonadism, hormone secreting neoplasms, drugs, etc.

**Table 43.1: Classification of benign breast disease based on the concept of ANDI**

Age and physiological state of the breast	Normal process	Aberrations
Less than 25 years, breast development and early reproductive life.	<ul style="list-style-type: none"> <li>• Stromal development</li> <li>• Lobular development</li> </ul>	<ul style="list-style-type: none"> <li>• Adolescent hypertrophy</li> <li>• Fibroadenoma</li> </ul>
25 to 35 years, mature reproductive life	Cyclical activity	<ul style="list-style-type: none"> <li>• Cyclical mastalgia</li> <li>• Cyclical nodularity</li> </ul>
35 to 50 years, involution	<ul style="list-style-type: none"> <li>• Lobular involution</li> <li>• Stromal involution</li> <li>• Ductal involution</li> </ul>	<ul style="list-style-type: none"> <li>• Cysts</li> <li>• Sclerosing lesions</li> <li>• Duct ectasia and periductal mastitis</li> </ul>

### ABERRATIONS OF NORMAL DEVELOPMENT AND INVOLUTION (ANDI)

The alternative names are fibrocystic disease, fibroadenosis, chronic mastitis and mastopathy. The breast is a dynamic organ undergoing periods of development and involution throughout a woman's reproductive life similar to the uterine endometrium.

Of the various aberrations, the following conditions are commonly encountered, viz.

- Fibroadenosis
- Fibroadenoma
- Cysts and
- Duct ectasia.

The classification of benign breast disease based on ANDI is represented in table 43.1 below:

#### Fibroadenosis

Fibroadenosis (Syn— Fibrocystic disease, benign mammary dysplasia, cystic mastopathy) affects premenopausal women and is characterized by cyst formation, hyperplasia of duct epithelium (epitheliosis), enlargement of lobules (adenosis) and fibrosis, which may vary in extent and degree in any one breast.

#### Pathology

Commonest disorder of female breast between puberty and menopause.

#### Cause

Probably this condition is the result of abnormal response to hormonal changes and can be associated with menstrual irregularities, nullipara and estrogen administration.

#### Macroscopically

There is ill-defined area of induration or firm swelling, often painful prior to menstruation. (cyclical mastalgia) Cut surface shows variable fibrosis and cystic changes.

#### Microscopically

It consists of the following four features as mentioned above:

1. Cyst formation (dilatations of terminal ductules, lined by flattened epithelium often with apocrine metaplasia, surrounded by myoepithelial cells).
2. Epitheliosis—Hyperplasia of duct epithelium.
3. Adenosis—Proliferation of lobular epithelium.
4. Fibrosis—It represents involutinal change, localized areas may present as distinct lumps.

#### Treatment

- Reassurance, simple analgesia and a supportive bra often help.
- Linoleic acid (oil of evening primrose) is sometimes beneficial for breast pain.
- Occasionally Danazol or Tamoxifen is required, and found very helpful.

#### Fibroadenoma

##### Definition

Fibroadenoma is a benign tumor of breast consisting of glandular and connective tissue elements.

##### Incidence

It is the commonest benign breast tumor.

#### Pathology

*Macroscopically*—It is a well-circumscribed, elastic round or ovoid mass with homogeneous pale gray cut surface.

*Microscopically*—Two growth patterns are seen.

- i. Pericanalicular (Hard fibroadenoma) – found in teenage group, where lobular epithelial elements are surrounded by loose connective tissue. The tumor is freely mobile.
- ii. Intracanalicular (soft fibroadenoma) – There are curved and branching epithelial lined clefts into which proliferating connective tissue appears to push. The skin temperature is raised with venous prominence which may simulate encephaloid carcinoma.

*Diagnosis* is confirmed by fine needle aspiration cytology (FNAC).

*Treatment*—Excision is curative. See operative section, chapter 87.

#### Cystosarcoma Phyllodes

- It is a variety of soft fibroadenoma (intracanalicular) occurring in the age group of 30 to 40 years.
- It is vascular. Rise of skin temperature and venous prominence simulates a sarcomatous (fleshy) growth.
- Histology—There are multiple cysts into which tumor cells are projected like the pages (leaves) of a book. Hence known as cystosarcoma phyllodes. The tumor may metastasize in < 5 percent of cases.
- *Treatment*—Simple mastectomy is the treatment.

#### Cysts

Cysts are found in the last decade of reproductive life due to nonintegrated involution of stroma and epithelium.

Diagnosis can be confirmed by aspiration and/or USG.

#### Treatment

1. Aspiration—For a solitary cyst or small collection of cysts.
2. Excision biopsy—If a mass is felt after aspiration or the aspirated fluid shows presence of blood, malignancy should be suspected and excision biopsy is the treatment of choice.

3. Other cysts –
  - a. Galactocele—Contain milk. It can become enormous in size.
  - b. Lymphatic cyst.
  - c. Hydatid cyst found in endemic areas.

### Duct Ectasia and Periductal Mastitis

See nonlactational breast abscess below.

### INFECTIVE DISORDERS

- i. Mastitis neonatorum
- ii. Lactational breast abscess
- iii. Nonlactational abscess
- iv. TB, syphilis, actinomycosis.

### Mastitis Neonatorum

- Neonatal breast enlargement usually appears during the 3rd or 4th day of life and disappears during the third week. It is due to stimulation of fetal breast by maternal prolactin and thus is essentially physiological.
- It may be complicated by infection and abscess formation. Antibiotics may help in the early stages, but if fluctuation develops, incision and drainage is necessary.

### Lactational or Puerperal Breast Abscess

This is the commonest infection during the first month after delivery and is caused by *Staphylococcus aureus* or a *Streptococcus* entering through a cracked nipple.

#### Clinical Features

In the first or cellulitic stage the breast becomes tense, tender and very painful. Gradually as the abscess develops the pain and tenderness become localized to the area of abscess formation. Fluctuation is very difficult to elicit in the breast. Edema, brawny induration and local tenderness are the three features one should look for to be sure about abscess formation.

#### Treatment

- During the cellulitic stage the patient should be treated with an appropriate antibiotic which may resolve the infection if given early.
- Support of the breast, local heat and analgesia will help to relieve pain.

- Incision and drainage is to be done if the infection does not resolve within 48 hours without waiting for fluctuation to be positive. If the antibiotic is used continuously even after pus formation 'antibioma' may form. Antibioma is a large sterile, edematous swelling which takes many weeks to resolve.
- The presence of pus is confirmed with a needle aspiration. This has the additional advantage of diagnosing on a smear of a rare inflammatory carcinoma.
- When in doubt, USG may define an area ripe for drainage.

#### Drainage of Breast Abscess – Steps of Operation

1. General anesthesia.
  2. Patient is supine and arm, abducted.
  3. Antiseptic dressing of the arm, axilla, breast and adjoining area.
  4. Incision: Radial incision or a circumareolar incision (better cosmetically) if adequate access is allowed. All loculi are broken first with a hemostatic forceps, then with the finger.
  5. A counter incision is made and a corrugated rubber drain inserted in the most dependent part (Fig. 43.3).
- Hilton's method of drainage of breast abscess with sinus forceps—Not popular nowadays as it cannot break all the loculi but useful in case of small abscess at a depth.
- Other things in the name of Hilton.
- Hilton's line in rectum and anal canal.
  - Hilton's law—When a nerve supplies a joint, it also supplies the muscle and skin of the joint area, e.g. circumflex nerve.

### Nonlactational Abscess

This mostly results as a complication of duct ectasia and preductal mastitis and affects most commonly the nonbreast feeding multiparous women. This is to be differentiated from inflammatory cancer by FNAC.

It is more common in those who smoke, which suggests that arteriopathy is a contributing factor.

#### Pathology

There is inspissation of breast secretion (Brown or green colored the pathogenesis of which is obscure). This is followed by discharge of the secretion due to dilatation and rupture of one or more of the lactiferous ducts with irritant reaction and inflammation in the surrounding tissue leading to periductal mastitis, abscess and fistula formation.

Macroscopically the subareolar ducts are dilated with cheesy material.

#### Microscopic

- The ducts contain debris and foamy macrophages with ulceration and atrophy of epithelium.
- There is chronic inflammatory infiltrate with plasma cells and foreign body giant cells.

#### Clinical Features

Chronic nipple discharge of any color, a subareolar mass, abscess, mammary duct fistula and/or nipple retraction are the commonest symptoms. Mastalgia may be present.

#### Treatment

- i. Conservative—Antibiotics and metronidazole if the condition results from periductal mastitis.
- ii. Surgery—Cone excisions of all the major ducts (after Hadfield) if due to duct ectasia.

### Tuberculosis

Tuberculosis usually presents with multiple chronic abscesses.

Diagnosis rests on the bacteriological and histological examination.

Treatment is done with anti-TB drugs, healing is usual though often delayed.

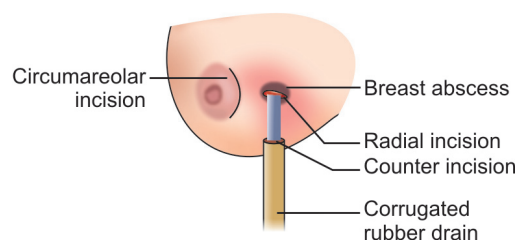


Fig. 43.3: Schematic diagram showing drainage of breast abscess

Mastectomy is restricted to patients with persistent residual infection.

Syphilis—A syphilitic chancre may occur on the nipple with axillary lymphadenopathy.

Syphilis and actinomycosis is treated with penicillin or other antibiotics.

## MISCELLANEOUS CONDITIONS

### Fat Necrosis

#### Etiology

This is most commonly seen after a road traffic accident as a result of seat belt trauma to the breast, hence often called traumatic fat necrosis.

It presents clinically as a firm mass, which is difficult to differentiate from malignancy.

#### Macroscopic

A dense fibrous scar forms causing skin tethering and retraction of nipple. This may mimic a carcinoma and biopsy is required for diagnosis.

#### Microscopic

Necrotic area is replaced by acute inflammatory exudate, foamy lipid-laden macrophages and foreign body giant cells with cholesterol crystals, hemosiderin and granulation tissue.

#### Treatment

Excision is curative.

### Mondor's Disease

Mondor's disease is thrombophlebitis of the superficial veins of the breast and anterior chest wall. In the absence of injury or infection the cause of thrombophlebitis is obscure. It may mimic the lymphatic permeation from an occult carcinoma of breast.

#### Treatment

Only treatment is restricted arm movements and the condition subsides within a few months, without recurrence, complications or deformity.

### Intraduct Papilloma

It is a benign epithelial tumor arising from major ducts or lactiferous sinuses. It often causes nipple discharge or hemorrhage.

#### Pathology

*Macroscopic*—This is a pedunculated, rounded or papillary tumor distending affected duct or sinus.

*Microscopic*—The tumor is composed of branching fibrovascular stroma covered by a double layer of outer cuboidal or columnar epithelium lying on myoepithelial cells.

#### Clinical Features

Age – 35 to 50 years.

The commonest and main symptom is the blood stained nipple discharge.

There may be a cystic swelling beneath the areola and pressure upon it, causes a discharge from the mouth of the affected duct on the nipple.

It is to be differentiated from intraduct carcinoma by contrast mammography. There is irregular filling defect in case of carcinoma while smooth filling defect in case of papilloma.

#### Treatment

Excision in the form of microdochectomy or total duct excision is curative.

### Galactocele

It is encysted milk secretion and is treated by aspiration.

### Sebaceous Cyst

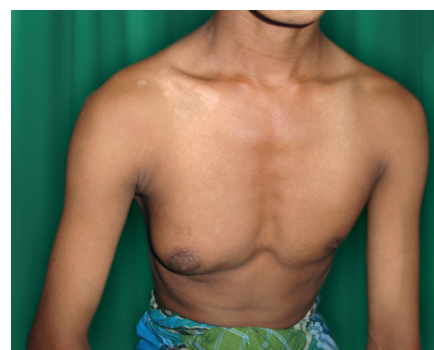Sebaceous cyst may occur on the skin overlying the breast.

### Silicone Granulomas

Silicone used in breast augmentation may escape from the silastic capsule inducing the formation of granuloma and foreign body giant cells. Evidence is lacking of an association with breast cancer.

### Eczema of the Nipple

A biopsy is frequently necessary to differentiate this from Paget's disease. Other differential diagnoses are periductal mastitis and duct ectasia.



**Fig. 43.4:** Right sided gynecomastia in a boy of 14 years

Paget's disease is unilateral, does not itch. The nipple may be destroyed and occurs at menopause.

Eczema of nipple is bilateral, itches and commonly occurs at lactation. The nipple remains intact.

### Gynecomastia

#### Definition

Gynecomastia implies the presence of a female type mammary gland in the male (Fig. 43.4).

#### Physiologic Gynecomastia

Most examples of gynecomastia are physiological and occurs in three phases of life viz:

- i. Neonatal period—Due to the presence of placental estrogens acting on neonatal breast parenchyma.
- ii. Adolescence—Due to an excess of estradiol relative to testosterone.
- iii. Senescence—With aging the plasma testosterone falls and senescent gynecomastia is caused by a relative hyperestrinism.

Therefore, common to each of the above is an excess of estrogens in relation circulating testosterone.

#### Pathology

- There is a combined increase in glandular and stromal elements with regular distribution of each element throughout the enlarged breast.
- In the nonobese patient at least 2 cm of subareolar breast tissue must be present before gynecomastia can be confirmed.

### Causes

According to the pathophysiologic mechanisms the causes are

#### Estrogen Excess States

- A. Gonadal origin—Testicular tumors
  1. Nongermlinal neoplasms of testis.
    - a. Leydig cell tumor.
    - b. Sertoli cell tumor.
  2. Germ cell tumors
    - a. Choriocarcinoma
    - b. Seminoma
    - c. Teratoma.
- B. Nontesticular tumors
  - Lung carcinoma
  - Hepatocellular carcinoma
- C. Liver disease
  - Nonalcoholic and alcoholic cirrhosis.

#### Androgen Deficiency States

- A. Old age may initiate gynecomastia.
- B. Hypoandrogen states (Hypogonadism) e.g.
  1. Primary testicular failure.
    - a. Klinefelter's syndrome (47XXY) Karyotype and azoospermia,
    - b. Kallmann syndrome.
  2. Secondary testicular failure due to
    - a. Trauma.
    - b. Orchitis (Mumps, leprosy, TB)
    - c. Irradiation.
    - d. Hydrocele.
    - e. Varicocele
    - f. Spermatocele.

C. Renal failure.

#### Drugs

- a. Estrogenic—Digoxin, anabolic steroids, cannabis.
- b. Antiandrogens which will inhibit the action and/or synthesis of testosterone, e.g. cimetidine, spironolactone, diazepam, antineoplastic agents like vincristine, etc.
- c. Drugs with idiopathic mechanism, e.g. reserpine, theophylline, verapamil, Tricyclic antidepressant, etc.  
Biopsy is necessary if cancer is a suspicion.

#### Treatment

**Surgery**—The only indication for excision is cosmetic.

Gynecomastia involving the whole breast is removed by Gaillard Thomas's inframammary incision but if it is underlying the nipple only it can be removed through a circumareolar incision.

Drainage for 24 hours should always be employed.

### PRESENTATION OF BREAST DISEASE

1. Lump
  - Painless
  - Painful
2. Pain and tenderness but no lump.
3. Nipple discharge.

4. Changes in the nipple and/or areola.
5. Changes in breast size—This occurs in pregnancy, carcinoma, giant fibroadenoma, phylloides tumor and sarcoma.
  1. Causes of painless lump
    - Carcinoma
    - Cyst
    - Fibroadenoma
    - Fibroadenosis (Nodularity).
  2. Causes of painful lump
    - Cyclical nodularity (Fibroadenosis)
    - Cyst
    - Abscess (usually lactational)
    - Periductal mastitis.
  3. Pain and tenderness but no lump—the causes may be
    - Cyclical mastalgia (including premenstrual tension)
    - Noncyclical mastalgia
    - Pregnancy mastitis.
  4. Nipple discharge
    - Duct ectasia/periductal mastitis.
    - Duct papilloma
    - Duct carcinoma.
    - Cysts.
  5. Changes in the nipple and/or areola
    - i. Congenital inversion
    - ii. Duct ectasia with periductal mastitis
    - iii. Carcinoma
    - iv. Paget's disease
    - v. Eczema
    - vi. Mammary duct fistula.



## Malignant Disease of the Breast

- Carcinoma of the female breast
- Treatment of breast cancer

### CARCINOMA OF THE FEMALE BREAST

This is the commonest cancer among the women.

#### Etiological Factors

1. **Age:** Incidence is rare below the age 20 but thereafter, the incidence steadily rises so that by the age of 90, nearly 20 percent women are affected.
2. **Sex:** Incidence of male breast cancer is 1 percent.
3. **Genetic:** Occurs in women more commonly with a strong family history. Oncogenes BRCA 1 and 2 are responsible for about 75 percent of all hereditary breast cancers.
4. **Dietary factor:** Diets rich in saturated fatty acids, cigarette smoking and alcohol are associated with increased risk

of breast cancer. Vitamin C may be protective.

5. **Endocrine:** Risk is increased by early menarche and late menopause. More common in multiparous women. Breast feeding appears to be protective.
6. **Benign breast disease:** Especially in two conditions viz. fibroadenoma and fibroadenosis with atypical epithelial hyperplasia are associated with increased risk of breast cancer (Fig. 44.1).

#### Pathology

Over 90 percent of breast cancers arise in the ductal epithelium and only 10 percent in the mammary lobules. When the carcinoma infiltrates the basement membrane it is called infiltrating and when it does not, it is called noninfiltrating type of carcinoma.

#### Classifications

- I. Carcinoma of duct origin
  1. Ductal carcinoma *in situ* (Noninfiltrating).
  2. Infiltrating duct carcinoma (accounts for 75% of all breast carcinomas)
    - i. Adenocarcinoma with productive fibrosis (scirrhous carcinoma). These cancers have no specific microscopic appearance.
    - ii. Invasive duct carcinomas with specific histological features, e.g.
      - Colloid (mucinous) carcinoma.
      - Medullary (contains plenty of lymphocytes) carcinoma.
      - Tubular carcinoma

- Paget's disease of nipple
- Papillary carcinoma
- Cribriform carcinoma.

- II. Carcinoma of mammary lobules
  - Noninfiltrating
  - Infiltrating

#### Paget's Disease of Nipple

This condition arises from an underlying carcinoma of the mammary duct which gradually grows towards the nipple and invades the surrounding skin. It constitutes 1 percent of all breast carcinomas and is associated with a lump in 50 percent of cases.

Microscopically there are malignant epithelial cells (Paget's) cells in lower epidermis with dermal inflammation and fibrosis.

Treatment is simple mastectomy when there is no associated lump. If a lump is present, the condition is treated as per the stage of breast cancer.

The better prognosis of this condition is probably related to early diagnosis.

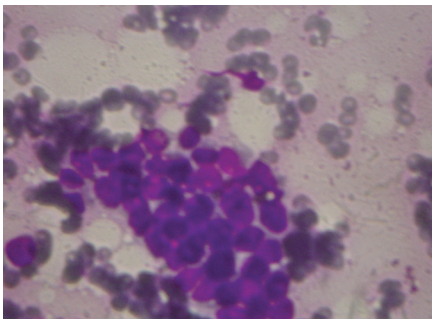
#### Scirrhous Carcinoma

It accounts for 65 percent of all invasive breast cancers.

#### Microscopic

- Contains islets of malignant cells in the ocean of fibrous tissue.
- Age usually more than 50 years.
- No venous prominence, hard in feel.
- Nipple is raised up and retracted.

Atrophic scirrhous carcinoma is the exaggerated form of scirrhous carcinoma especially in an old lady (>65 years).



**Fig. 44.1:** FNAC from a breast lump showing fibroadenosis with cellular atypia

Prognosis: Overall 50 percent 5 years survival.

### Encephaloid (Medullary) Carcinoma

- Age – Middle-aged lady (30 – 40 years)
- Affected side may be bigger than the healthy one.
- The tumor is neither soft nor hard. It is known as encephaloid because of its softness, simulating the consistency of brain.

#### Macroscopic

- Looks like large, soft fleshy mass with foci of necrosis.

#### Microscopic

- There is marked infiltration of lymphocytes and plasma cells.
- 10 years survival is >80 percent.

### Mucinous Carcinoma (Colloid Carcinoma)

Large soft pale gray mass.

Microscopically there are small islands of tumor cells floating in masses of pale blue staining amorphous mucin.

Prognosis is favorable with lower incidence of nodal metastases. 10 years survival is 90 percent.

### Inflammatory Breast Carcinoma

Syn—Mastitis carcinomatosa, Acute cancer of pregnancy and lactation or lactating Carcinoma

- It frequently occurs in a lactating mother with history of recent childbirth.
- Breast is well-enlarged, painful and soft with presence of venous prominence.
- There is rise of skin temperature with erythema and peau-d-orange.
- It may simulate breast abscess and is sometimes drained inadvertently. Hence it is always important to put a needle, not a knife to confirm if there is pus or not.
- Microscopically there is no specific histologic character. Subdermal lymphatics and vascular channels are permeated with microscopic foci of highly undifferentiated tumor cells.
- Prognosis – Very poor.

### Staging

Manchester staging

Stage I – Mobile lump in the breast.

Stage II – Mobile lump in the breast with mobile axillary lymph nodes.

Stage III – Either lump or node is fixed.

Stage IV – There is distant metastasis.

### TNM Classification

T = Tumor

T<sub>IS</sub> – Carcinoma *in situ*.

T1 – Tumor upto 2 cm in its greatest dimension.

T2 – Tumor > 2 cm but < 5 cm in its greatest dimension.

T3 – Tumor >5 cm in its greatest dimension.

T4 – Any size invading skin or chest wall, or both.

### N – Lymph Node

N0 – No nodal metastasis.

N1 – Metastasis in ipsilateral mobile axillary nodes.

N2 – Metastasis in fixed ipsilateral axillary nodes.

N3 – Metastasis in ipsilateral supra- or infra-clavicular nodes.

### M = Distant Metastasis

(Liver, Lung, Bone, Brain, etc.)

M0 – No Metastasis.

M1 – Distant metastasis present.

Manchester staging applied to TNM classification.

Stage I – T1, N0, M0

Stage II – T2, T3, N1, M0

Stage III – T3, T4, N2, M0

Stage IV – Any T any N with M1

### Borders Grading

It is the histological method of assessing malignancy.

Grade I – upto 25% cells are undifferentiated.

Grade II – upto 50% cells are undifferentiated.

Grade III – upto 75% cells are undifferentiated.

Grade IV – > 75% cells are undifferentiated.

### Clinical Features

#### Symptoms

- The patient typically presents with a painless lump mostly in the upper and outer quadrant of the breast.
- Pain is present only in about 10 percent cases.
- Nipple discharge is uncommon but may be the only symptom.

- There may be enlargement, shrinkage or asymmetry of the affected breast.

- Sometimes the patient presents with metastatic symptoms like backache, chest pain, jaundice, etc.

#### Signs

- The lump is usually hard, nontender, minimally mobile with indistinct borders.
- In locally advanced carcinoma there may be erythema, peau-d-orange, ulceration of the skin or fixation to the chest wall.
- Axillary and/or supraclavicular lymphadenopathy.
- Signs of metastatic disease – e.g. hepatomegaly, bone tenderness.
- Nipple changes – Destroyed, deviated, displaced, depressed, discharging blood or discolored.

### Special Investigations

a. Mammography: Mammography should be done in women over 35 years both as a diagnostic test on the symptomatic breast and as a check on the other breast.

Infiltrating radiopaque mass with irregular edges, called spiculation and microcalcifications indicate malignancy. Thickening may be evident in the skin over the quadrant having the cancer.

A mammogram may detect a lesion that is too small to palpate.

b. Ultrasonography: Ultrasonographic examination is also used especially in younger women to define and guide abnormalities of palpable or impalpable abnormalities.

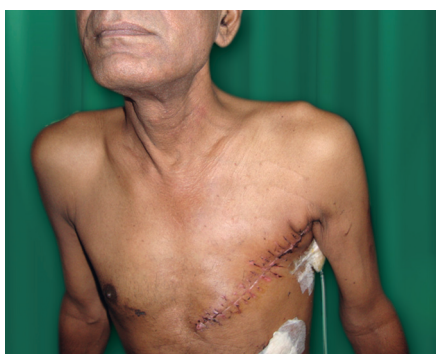c. Magnetic resonance imaging (MRI): Magnetic resonance imaging is not used routinely for the assessment of breast cancers but it can be more accurate than USG and mammography in the local staging of primary breast cancer, diagnosis of local recurrence and assessment of response to neoadjuvant chemotherapy.

d. Excision biopsy / FNABC usually confirm the diagnosis.

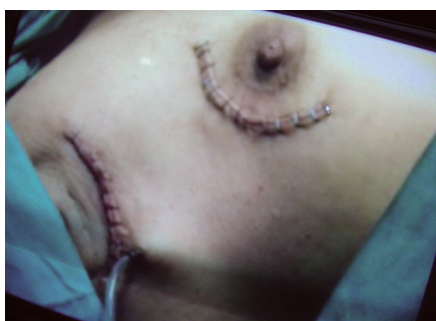e. Chest X-ray is done to detect lung metastasis.

f. Radioisotopic bone scan, CT scan may be done to detect the extent of metastasis.

g. Estrogen progesterone and her-2 neu receptor assay from the excised biopsy specimen. This is important for planning of treatment and prognosis.



**Fig. 44.2:** MRM (Modified radical mastectomy) done in a male patient with breast cancer



**Fig. 44.3:** Conservative breast surgery done in a patient with early breast cancer

- h. Investigations like full blood count, serum alk. phosphatase, SGOT, SGPT and  $Ca^{++}$  are done to know about liver or bone metastasis.

## TREATMENT OF BREAST CANCER

### Early Breast Cancer

(See also the long case on early breast carcinoma).

Early breast cancer is defined as the disease that can be extirpated by surgery. It comprises the  $T_{1-3}$ ,  $N_{0-1}$ ,  $M_0$  tumors. The management of this disease consists of:

- Breast surgery and treatment of the axilla.
- Pathological staging to direct adjuvant therapy.
- Adjuvant therapy – Hormone therapy, chemotherapy, radiotherapy.
- Follow-up.

### Breast Surgery

All patients require removal of the primary tumor with either wide local excision (conservative breast surgery) or mastectomy.

### Mastectomy—Surgical Procedures of the Past and Present

- An abrupt change in surgical procedure took place in mid-1970's with a shift from radical mastectomy to modified radical mastectomy.
- In radical mastectomy the breast and underlying pectoral muscles as well as regional axillary nodes are removed.
- Modified radical mastectomy means total or simple mastectomy and axillary dissection with preservation of pectoralis major muscle and its neurovascular bundle (Fig. 44.2).
- Breast reconstruction can be done either at the time of primary surgery or a later date—TRAM flap, Latissimus dorsi flap and implants all have a role.

**Conservative breast surgery** (Fig. 44.3) usually refers to the following:

- Lumpectomy or segmental mastectomy.
- Wide local excision – 1 cm margin of breast tissue around the cancer is removed.
- Quadrantectomy – 2 to 3 cm of breast tissue around the tumor is removed.

Any of the above procedure is combined with whole breast radiation and a separate axillary dissection and/or sentinel node biopsy as detailed below.

### Treatment of the Axilla

This is necessary because clinical assessment is inadequate and 30 percent of involved nodes are impalpable. It consists of the following:

- Axillary node sampling if >4 nodes are involved it is diagnostic of metastasis and adjuvant chemotherapy is suggested.
- Axillary clearance involves removal of Level I, II and III nodes, in the node positive axilla.
- Sentinel lymph node (SLN) biopsy—It is indicated in all patients of early breast cancer with clinically node negative axilla. The rationale of SLN biopsy is that if SLN does not show metastasis, axillary node sampling or clearance is not required.

This technique is becoming the standard of care nowadays.

### Adjuvant Therapy

#### I. Radiotherapy

Radiation is given if axillary nodes are involved. 1000 cGy radiation to lymph node fields and 5000 cGy to the whole breast.

#### II. Chemotherapy

The aim is to reduce the recurrence rate not the overall survival. It is indicated in premenopausal women with positive nodes and to postmenopausal women with ER negative status. The regimen is either CMF (Cyclophosphamide, Methotrexate 5 FU) or CAF (Cyclophosphamide, Adriamycin and 5 FU).

#### III. Hormonal Therapy

Tamoxifen 10 mg BD for 3 to 5 years is given to postmenopausal women who are ER positive.

### Follow-up Plan in Breast Cancer

Life long follow-up should be done as follows:

- Every 3 months for 3 years. Postoperative, then.
- Every 6 months until 5 years. Postoperative, then.
- Every 6 to 12 months life long.

**Prognosis** – 80 percent patients have 10 year survival rate.

### Treatment of Late/Advanced Breast Cancer (Stage III and IV)

Cure is not possible; the aim is palliation of symptoms.

Here spread to regional nodes or distant spread is present at the time of diagnosis.

#### I. Surgery – Simple or toilet mastectomy is done for the primary tumor.

- Internal fixation for a pathological fracture or vertebral instability.
- Ovarian ablation in premenopausal women as second line hormonal therapy.

#### II. Radiotherapy is done only to relieve pain from bony metastasis

#### III. Chemotherapy – Tamoxifen, Aminoglutethimide (Medical adrenalectomy causing decrease of adrenal hormone synthesis).

**Prognosis** – Poor, only 30 to 40 percent respond to treatment with mean survival of 2 years, by which time nonresponders have died.

# Chapter 45

## Symptoms of Urinary Disease

- Symptoms
- Nonspecific symptoms
- Physical examination of the genitourinary system
- Investigation of the urinary tract

### SYMPTOMS

#### Hematuria

Hematuria is the passage of blood in the urine. Frank hematuria is the presence of blood on macroscopic examination while microscopic hematuria indicates that red blood cells are only seen on microscopy. Hemoglobinuria is defined as the presence of free hemoglobin in the urine.

- Hematuria whether microscopic or macroscopic is always abnormal.
- Timing of hematuria with micturition—Blood appearing at the beginning of the urinary stream indicates a lower urinary tract disease, while uniform staining throughout the stream points to a cause higher up.

Terminal hematuria is typical of severe bladder irritation by stone or infection.

- Hematuria is commonly painless but if there is pain, the characteristics of pain may help to identify the source of the bleeding as described below.

#### Pain

- Renal pain—It is typically felt deep in the loin resulting from inflammation and acute obstruction to the flow of urine from the renal pelvis. It is probably the result of stretching of the capsule of the kidney.
- Slow growing masses such as tumors or cysts are not usually painful unless they are very large.

- Ureteric colic—Pain arising from the ureter is colicky with sharp exacerbations against a constant background and felt in the loin with radiation to ipsilateral groin and genitalia. Ureteric colic is usually caused by the passage of a stone but blood clot or shouged renal papilla may give rise to identical pain.

The pain is often so severe and intolerable that the patient rolls around in agony. Local tenderness is much less than would be expected from the severity of the pain. The colic usually lasts for 4 to 6 hours and is relieved by anti spasmodics and narcotic.

- Bladder pain is felt as a suprapubic discomfort made worse by bladder filling. Pain due to cystitis has a typical burning or scalding character felt in the urethra on micturition.

#### Disordered Micturition

Dysuria is defined as a pain that arises from an irritation of the urethra and is felt during micturition.

Frequency of micturition indicates increased passage of urine during day time while nocturia indicates increased passage of urine during the night. It may result from increased urine formation or decreased bladder capacity.

Urgency is an uncontrollable desire to micturate and may be associated with urge incontinence.

Hesitancy refers to a delay in initiating a urinary stream while intermittency refers to

repeated starting and stopping of the urine stream during voiding.

Hesitancy and intermittency are obstructive symptoms related to voiding and seen in case of benign prostatic hyperplasia and urethral strictures.

Dysuria, frequency and urgency are the irritative symptoms related to voiding and are commonly seen in inflammation of the urethra, prostate or bladder.

#### Incontinence

- Urinary incontinence means inability to prevent the passage of urine.
- Stress incontinence refers to incontinence associated with increase in intra-abdominal pressure. Patients often report leaking of urine, while coughing, laughing or during physical exertion.
- Urge incontinence is secondary to an involuntary contraction of the bladder usually resulting from inflammation or irritation of the bladder or from neurologic disorders such as stroke or spinal cord injury.
- Total incontinence refers to a continuous leakage of urine from a fistula between the skin or vagina and the urinary tract proximal to the sphincter mechanism, e.g. a vesicovaginal fistula.

### NONSPECIFIC SYMPTOMS

Non specific symptoms include fever, anorexia, weight loss, malaise, nausea and vomiting.



## PHYSICAL EXAMINATION OF THE GENITOURINARY SYSTEM

General survey is done for the presence of anemia, jaundice, cachexia, pulse, blood pressure, neck glands, etc.

### Examination of Abdomen

- Renal mass—It is present in the loin, bimanually palpable, ballotable and moves up and down with respiration.
- Distended bladder—It is a mass arising from the pelvis and dull on percussion.
- External genitalia—To see any abnormality in the skin of penis, scrotum and the surrounding inguinal region.
- Testicles are palpated to see the presence of any mass or tenderness.

The epididymis is palpated on the posterolateral aspect of the testicles.

- Varicocele may be palpable in the scrotum. The presence of a hydrocele sac is confirmed by transilluminating the sac with a penlight.
- Per rectal examination is done to see the anal tone and the size, contour and consistency of the prostate.

## INVESTIGATIONS OF THE URINARY TRACT

### Examination of Urine (Urinalysis)

- a. Dipstix—Dipstix is a strip coated with chemicals for measuring the urine pH, glucose, protein, blood, bilirubin ketones and nitrites. When the urine is macroscopically clear and negative on dipstix testing, the chances of finding an abnormality on microscopy and culture of a midstream clean catch specimen are small.

The presence of protein and nitrites which are a product of the activity of organisms in the urine indicates the likelihood of infection.

The amount of protein in the urine is normally less than 100mg/24 hours. Dipstix will only detect levels greater than 0.3g/liter.

- b. Microscopy—The presence of RBC, WBC, casts, crystals and bacteria may indicate the presence of infection or renal disease.

- c. Urine culture—The presence of greater than  $10^5$  organisms per ml of urine is deemed to indicate the presence of infection.

### Blood Tests

- i. Renal function studies—Level of blood urea creatinine and electrolytes are raised in patients with renal failure.
- ii. Estimation of Hb%, WBC and platelets may detect anemia or polycythemia.
- iii. Serum  $Ca^{++}$ , phosphates, uric acid and albumin estimations are used for screening of metabolic disorders in patients with renal calculi.
- iv. Prostate specific antigen (PSA) has now largely superseded acid phosphatase as a tumor marker in patients with suspected or proven prostatic carcinoma.
- v. Estimation of alpha-fetoprotein and human chorionic gonadotropin (hCG) are used as tumor markers in testicular cancer.

### Imaging

- i. Plain X-ray KUB (Kidneys, ureters and bladder)—It is useful to detect soft tissue masses in the renal areas or pelvis, urinary calculi (90% are radiopaque) and bony metastasis.
- ii. Intravenous urography (IVU)—Intravenous contrast media are organic chemicals to which iodine atoms are attached to absorb X-rays. When injected, usually into a vein in the antecubital fossa, the substance is filtered from the blood by the glomeruli and does not undergo tubular absorption.

As a result it rapidly passes through the renal parenchyma into the urine, which it renders radiopaque. Generally hypaque (Na diatrizoate) or urograffin is injected.

The first film is taken 5 minutes after injecting the dye when a clear image of the renal outline is obtained (nephrogram). Subsequent excretion of the contrast media outlines the collecting systems, renal pelvis, ureters and bladder showing any structural abnormalities or filling defects.

In the normal individual the whole urinary tract should be visualized after 20 minutes. The patient is then asked to pass urine and a final postmicturition film taken to assess bladder emptying and detect any residual urine.

IVU is particularly valuable to demonstrate tumors and calculi within the urinary tract. However, with the availability of more sophisticated ultrasonography and other forms of scanning, the indications for the urogram have been fewer.

Besides, IVU may be complicated by allergic reactions to the ionic contrast medium, ranging in severity from a mild urticarial rash that responds to antihistamines to anaphylactic shock requiring IV hydrocortisone and circulatory support. Newer nonionic contrast media like omnipaque are now being used more widely because of their low morbidity and mortality.

- iii. Ultrasonography—It is very useful in the assessment of renal and scrotal masses. Ultrasound imaging has proved of particular value in distinguishing between solid and cystic lesions especially in the kidney and in assessing obstruction in the urinary tract, e.g. hydronephrosis, residual bladder urine.

Transrectal ultrasound is of particular value in the assessment of prostatic carcinoma.

- iv. Computed tomography (CT scanning)—CT scan is particularly useful to assess structures in the retroperitoneum. It allows differentiation between fluid-filled and solid lesions.

CT scanning is now the investigation of choice for staging testicular tumors in which the presence of retroperitoneal lymph node masses is a feature of advanced disease.

- v. Magnetic resonance imaging (MRI) and positron emission tomography (PET) scan—These technologies produce stunning images of the urinary tract and give functional information as well. If the above tests are widely available they will replace many of the routine imaging techniques.

- vi. Radioisotope scanning – Diethyl triamine pentaacetic acid (DTPA) behaves in the kidney like inulin. It is filtered by the glomeruli and not absorbed by the tubules.

Using a gamma camera DTPA labelled with technetium 99m can be followed during its transit through individual kidney to give dynamic representation of renal function. This process is divided into three phases viz. (Fig. 45.1)



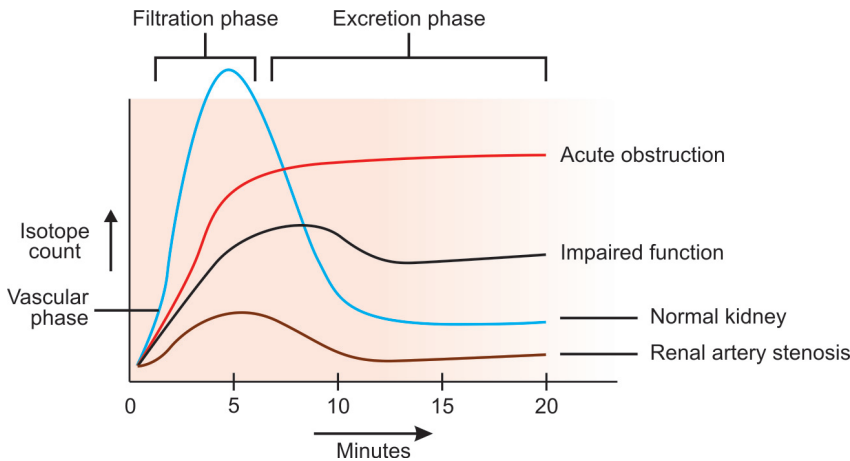


Fig. 45.1: Radioisotope renogram

- a. Vascular phase—Due to arrival of isotope in the kidney from the bloodstream, with a rapidly rising curve of activity lasting for about 30 seconds.
- b. Filtration phase—It is the next phase when the rate of rise slows as isotope is concentrated and passed into the collecting system, lasting for 2 to 5 minutes.
- c. Excretion phase—A peak is reached when the isotope passes down the ureter. Then activity falls as isotope is no longer being delivered to the kidney but continues to be transported down the ureter.

Alternations to this occur in certain disorders, e.g.

- In renal artery stenosis, there is impairment of the vascular phase so that the curve rises slowly.
- In acute obstruction and impaired renal function, the third phase is abnormally prolonged. Thus the function of kidney is well-assessed with this technique.

Other substances like dimercaptosuccinic acid (DMSA), Hippuran labeled with suitable radioisotopes have similarly been used to investigate renal function.

### Endoscopy

In many disorders of the lower urinary tract, direct examination of the urethra and bladder using a cystoscope is required.

- a. Cystoscopy
  - Urinary bladder is visualized for diagnosis of bladder cancer, papilloma and cystitis with modern flexible fiberoptic cystoscopes available since early 1980s, this diagnostic examination is performed under local anesthetic in the outpatients department with minimal patient discomfort.
  - Cystoscopy can also be used to introduce catheters into the ureteric orifices. This may be performed to obtain samples of urine from each kidney to localize

infection or to instill contrast medium to take X-rays of the upper urinary tracts, called ascending ureteropyelography.

- b. Urethroscopy is done to exclude a urethral stricture or tumor.
- c. Nephroscopy—The interior of the kidney can be inspected with a modified cystoscope or nephroscope, introduced either through an incision in the renal pelvis at open operation or via a percutaneous tract dilated to a sufficient diameter to accommodate the instrument. This is usually performed to remove a large renal calculi.

### Urodynamics

Most of the investigations described above, provide information mainly about anatomy of the urinary tract.

Several specialized tests, collectively known as urodynamic studies are available for assessing disorders of function.

- a. Urine flow rate measurement is useful in assessing the degree of obstruction to micturition, e.g. enlargement of prostate. The urine flow rate decreases in bladder outflow obstructions (BOO).

For a voided volume of 200ml a peak flow rate of > 15ml/sec is normal, flow rate of 10 to 15 ml/sec is equivocal and a flow rate of <10ml/sec is said to be low.

In bladder outflow obstruction voiding pressures increase. Voiding pressures of >80cm H<sub>2</sub>O are called high, pressures between 60 and 80cm H<sub>2</sub>O are equivocal and pressures of <60 cm H<sub>2</sub>O are normal.

- b. Cystometry (static and ambulant) – differentiates between urge and stress incontinence. Cystometry is the recording of pressure volume relationship of the bladder during its artificial filling via a catheter.

# Chapter 46

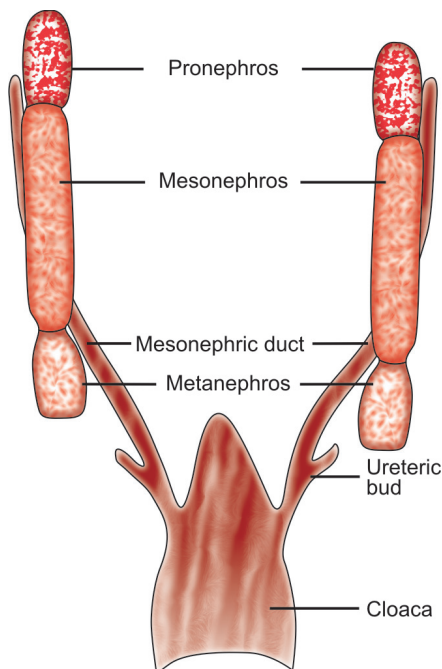
## Kidney and Ureter

- Embryology
- Surgical anatomy
- Relations
- Congenital anomalies of kidneys and ureters
- Horseshoe kidney
- Polycystic kidney
- Solitary renal cyst
- Hydronephrosis
- Renal stone
- Ureteric stone
- Renal infection
- Acute pyelonephritis
- Pyonephrosis
- Perinephric abscess
- Renal carbuncle
- Chronic pyelonephritis
- Renal neoplasms
- Nephroblastoma
- Adenocarcinoma
- Tumors of renal pelvis and Ureter
- Squamous cell carcinoma of renal pelvis

### EMBRYOLOGY

The embryonic origin of kidney is from two sources (Fig. 46.1) viz.

- The excretory part (the nephron with glomerulus, convoluted tubules and loop



**Fig. 46.1:** Development of kidney from the ureteric bud and the metanephros

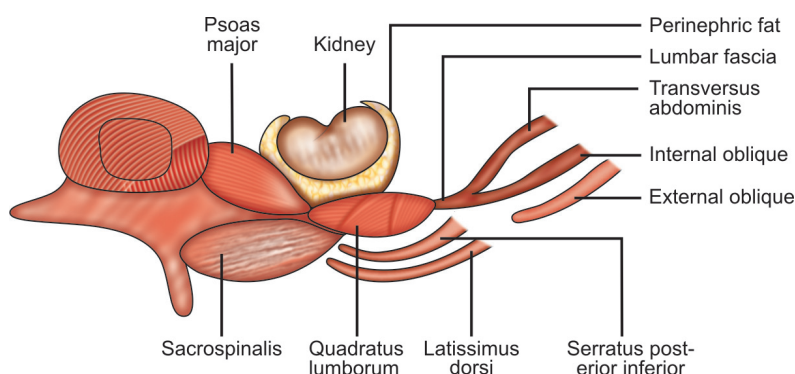
of Henle) is derived from the lowest part of the nephrogenic cord, the cells of which form the metanephric blastema or metanephrogenic cap. The nephrogenic cord develops from a bulging of the intermediate mesoderm on the posterior abdominal wall lateral to the attachment of the dorsal mesentery of the gut (Fig. 46.1). Its surface is covered by the epithelium lining the peritoneal cavity (celomic epithelium). The nephrogenic cord is associated with the development of a number of important structures at varying stages of development viz. a) the mesonephric tubules which take part in forming the duct system of testis, b) the mesonephric duct, c) the paramesonephric duct and d) the gonad (testis or ovary). Initially the excretory ducts of both the urinary and genital system open into a common cavity, called the cloaca from which develops the rectum, urinary bladder and the whole of the female and most part of the male urethra.

- The collecting part of the kidney is derived from a diverticulum called the ureteric bud which arises from the lower part of the mesonephric (wolffian) duct at about the 5th week of intrauterine life. The stalk of the bud forms the ureter and the dilated

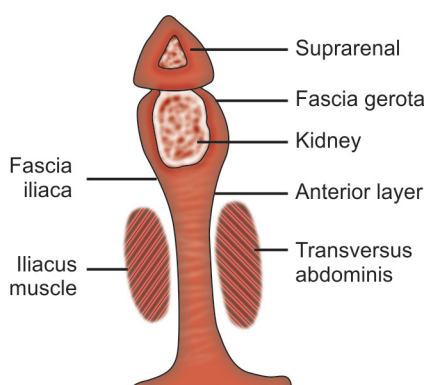
upper part of the ureteric bud forms the renal pelvis. The primitive pelvis bifurcates repeatedly from 6 weeks to 8 months to form first the calices major and minor and after several subsequent divisions, the collecting tubules, which establish connections with the nephrons and the partition between the excretory and collecting parts disappear so that a continuous channel is developed for the excretion of urine. During development, the kidney at first lies in the pelvis. In subsequent development of the embryo, differential growth of the abdominal wall causes the kidney to ascend to the lumbar region, between 5th and 8th week of gestation. Finally it rotates so that the forward facing hilum is placed medially.

### SURGICAL ANATOMY (FIGS 46.2A AND B)

The kidney is relatively larger in newborn than in adults. The length, breadth and anteroposterior thickness of kidneys in an adult are 11cm, 6cm and 3cm respectively. The weight of the kidney in males is about 150gm and in females about 135gm. By USG and MRI, normal anatomical measurements can be done.



**Fig. 46.2A:** Structures encountered during exposure of kidney



**Fig. 46.2B:** Vertical disposition of renal fascia

## RELATIONS

The kidneys lie retroperitoneally and surrounded by peritoneal fat and Gerota's fascia.

The posterior aspect of the kidney lies against the quadratus lumborum and the renal hilum lies against the psoas muscle.

Anteriorly the right kidney is adjacent to the duodenum and hepatic flexure of the colon. The left kidney is bounded anteriorly by the splenic flexure.

The medial aspect of the kidney presents a deep vertical slit called the hilum, which transmits from before backwards the renal vein, the renal artery and pelvis of ureter.

Lymphatics and nerves also enter the hilum, the latter being sympathetic, mainly vasomotor fibers.

In the kidney the arteries are end arteries, while the veins anastomose freely. The left adrenal and gonadal vein drain into the left renal vein, while on the right side they drain directly into the inferior vena cava.

The ureter along its course in the retroperitoneum presents three constrictions – at the pelviureteral junction (PUJ), at the pelvic brim, where it crosses the common iliac vessels and at the ureterovesical junction. In patients passing a kidney stone, these areas represent the common sites of impaction.

## CONGENITAL ANOMALIES OF KIDNEYS AND URETERS

### Congenital Anomalies of the Kidney

1. Absence of one kidney—In 1 in 2400 births, there is complete failure of development of one kidney. In such cases the present single kidney becomes hypertrophied and functions almost double the normal to make good the absence of one kidney.
2. Fetal lobulation— In the early stage the kidney is a lobulated organ and in each lobule there is a secretory and excretory unit. Such lobulated appearance persists

throughout fetal life but disappears in the first year of life by moulding. If lobulated appearance persists, the condition is called fetal lobulation.

3. Ectopic kidney— Occasionally the kidney will fail to migrate cranially resulting in an ectopic kidney. The left kidney is more often seen to be ectopic than the right one. The ectopic kidney may lie on its own side forming the pelvic kidney or it may cross over to the other side (crossed ectopia).
4. Horse-shoe kidney—The two metanephric masses may fuse during development forming a horse-shoe kidney. The connecting isthmus may lie either in front of or behind the aorta and inferior vena cava.
5. Congenital polycystic kidney — This is believed to result from failure of the excretory tubules of the metanephros to establish contact with the collecting tubules. The condition is almost always bilateral. Isolated cysts are commonly seen, but sometimes the whole kidney is a mass of such cysts. The cysts press upon normal renal tissue and destroy it.
6. Aberrant renal vessels— There may be an aberrant renal artery supplying the kidney. Such aberrant artery is usually small and insignificant but occasionally it may be large and significant due to the fact that it supplies the entire segment of the kidney. Such artery is more often seen supplying the lower pole of the kidney and is in intimate contact with the pelviureteral junction, where there is often a fibrous thickening around the vessel pressing on the ureter. Hydronephrosis is sometimes found in these cases. It is more common on the left side.

### Congenital Anomalies of Ureters

1. Absence of one ureter — It is also associated with the absence of the kidney of that side. It is due to failure of development of the ureteric bud on that side.
2. Duplication:
  - a. Duplication of renal pelvis— In this condition the ureter is divided at its upper part to form two renal pelvis. This anomaly is more often found on the left side. The upper renal pelvis

is smaller and drains only the upper group of calices, whereas the lower renal pelvis is bigger in size and drain the middle and lower groups of calices.

- b. Partial duplication of ureter—A ureter may be double in its entire length except in its lower third where they fuse to form a single ureter.
- c. Double ureter—The ureter may be double in its entire length with two separate openings in the bladder on that side. This is less common than the previous anomaly.
3. Congenital megaureter—The ureter is dilated and its wall is also thickened. However, the ureteric orifice is normal.
4. Postcaval ureter: The right ureter instead of lying lateral to it, lies behind it. Pressure by the vein on the ureter may lead to hydronephrosis.
5. Ureterocele— This is a cystic dilatation of the intramural part of the ureter due to congenital atresia but in 1/10th of the cases, it is bilateral. Females are more often affected than males.
6. Ectopic ureteric orifice— The condition is usually associated with complete double ureters. The ectopic opening may be located in the apex of trigone, prostate urethra, vas deferens, rectum or vagina in the female.

tissues of both sides lie very close to each other. As the fusion occurs very early, normal rotation and ascent of the kidney cannot occur. So the result is a pair of ectopic kidneys below the umbilicus with each pelvis lying on the anterior surface of the organ.

The ureter rides over the isthmus to traverse the anterior surface of the fused portion which produces some degree of ureteral obstruction. There may be associated aberrant renal vessels.

Due to the above two factors, incidence of hydronephrosis is high. Infection and stone formation are other complications.

It is to be noted that the isthmus usually joins the lower poles of the kidneys, very rarely it may join the upper poles.

### Clinical Features

- Majority of the patients are asymptomatic.
- There may be infection and calculus formation. The ureters are angulated as they pass over the isthmus. This may lead to infection and nephrolithiasis.

IVU is usually diagnostic. The ureters are often curved like a flower vase.

### Treatment

No treatment is usually necessary. Treatment is required for infection, obstruction and calculus disease. The prognosis is excellent.

## HORSESHOE KIDNEY

This is caused by fusion of lower poles of both kidneys by renal tissue of varying thickness or by a fibrous band. The connecting isthmus may lie either in front of or behind the aorta and inferior vena cava. (Fig. 46.3)

### Pathology

Fusion usually occurs when the embryo is about 30 to 40 days old when the metanephric

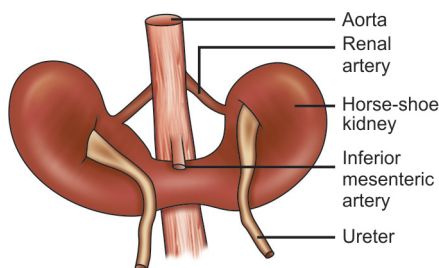


Fig. 46.3: Horseshoe kidney.

## POLYCYSTIC KIDNEY

Polycystic kidney is an autosomal dominant condition and can be transmitted by either parent. This condition is often associated with cysts of the liver, spleen and pancreas. The disease does not usually manifest itself clinically before the age of 30 years.

### Pathology

The condition is almost always bilateral.

- The kidneys become enormously enlarged due to the presence of cysts of different sizes in the substance of the kidney, giving it the appearance of a bunch of grapes.
- Some of the cysts are white while others are brown due to hemorrhage inside. The cysts press upon the normal renal tissue and destroy it. This results in gradual renal failure, as the pathology is bilateral.

### Clinical Features

- Bilateral renal lump may be the presenting feature. Characteristically there is a knobby feel due to the large cysts on the surface.
- Loin pain — A dull aching pain is caused by the weight of the organ dragging upon its pedicle or by stretching of the renal capsule by the cysts. Rarely this condition may present with colicky pain due to stone formation or hemorrhage into the cyst with clot retention.
- Hematuria — Rupture of a cyst into the renal pelvis may cause hematuria which is typically moderate and lasts for a few days.
- Hypertension is present in 75 percent of patients with polycystic kidneys, the actual cause of which is not known.
- Infection — Repeated attacks of pyelonephritis is quite common in this condition.
- Uremia—As the loss of renal tissue progresses a preuremic stage and uremia sets in.

### Special Investigations

- Imaging: Ultrasound and CT scan will show multiple cysts in both kidneys and sometimes cysts in the liver and other organs.
- IVU – There is a typical appearance on excretory urography, called spider leg deformity of the calices as they are spread over the cysts.

### Treatment

1. Conservative—The patient is advised high intake of fluid and a low protein diet.

Iron may be advised to prevent anemia and antibiotics to prevent infection.

2. Surgery—The standard operative treatment is Rovsing's operation. It is not curative but prolongs the patient's life.

It consists of decompressing the cysts thereby the remaining healthy tissue gets relieved of pressure necrosis by the enlarged cysts. The operation is done on one kidney first and then on the second kidney after 3 to 4 weeks.

3. Treatment of renal failure—When renal insufficiency becomes life-threatening, chronic dialysis or renal transplantation may be necessary.

## Prognosis

Patients usually live for 5 to 10 years after the diagnosis is made.

## Infantile Polycystic Disease

This is different from the adult polycystic disease and is inherited as an autosomal recessive disease. Many patients are stillborn and most of the others die from renal failure early in life.

## SOLITARY RENAL CYST (Syn-Simple Cyst)

Simple cyst of the kidney is usually unilateral and single but may be multiple or multilocular.

Its origin may be similar to that of polycystic kidney the difference being one of degree. It may be an acquired one due to tubular obstruction and ischemia.

Simple cysts usually involve the lower pole of the kidney. A solitary cyst may be so placed as to compress the ureter causing progressive hydronephrosis.

If the cyst is infected, the patient usually complains of pain in the flank, malaise and fever.

Physical examination is usually normal, although occasionally a mass in the region of kidney may be palpated.

CT scan appears to be the most accurate means of differentiating renal cyst and tumor. USG can also differentiate between a cyst and a solid mass.

Treatment consists of excision of the cyst or a partial nephrectomy together with the cyst.

## HYDRONEPHROSIS

### Definition

Hydronephrosis is defined as an aseptic dilatation of renal pelvis and calices, accompanied by destruction of renal parenchyma caused by continuous incomplete or intermittent complete obstruction to the flow of urine.

### Causes

The condition may be unilateral or bilateral depending on the site of obstruction.

### Unilateral Hydronephrosis

Unilateral hydronephrosis occurs, when the obstruction is somewhere in the ureter, above

the level of the urinary bladder. The causes may be:

1. Extramural obstruction
  - Involvement of the ureter by malignant neoplasms of the cervix, prostate, rectum, colon and cecum.
  - Pressure on the ureter by loaded rectum, gravid uterus, uterine and ovarian tumors.
  - Postcaval ureter.
  - Idiopathic retroperitoneal fibrosis.
  - Aberrant renal vessels.
2. Intramural obstruction
  - Congenital stenosis, kink or achalasia of the pelviureteral junction – This is the commonest cause of unilateral hydronephrosis and is probably due to neuromuscular incoordination.
  - Ureterocele and congenital small ureteric orifice.
  - Inflammatory stricture following removal of ureteric calculus, repair of a damaged ureter or tuberculous infection.
  - Neoplasms of the ureter or bladder cancer involving the ureteric orifice.
3. Intraluminal obstruction
  - Calculus in the pelvis of ureter.

### Bilateral Hydronephrosis

Bilateral hydronephrosis occurs when the obstruction is below the level of the urinary bladder. However it may also be caused rarely by one of the lesions described above, occurring on both sides. The causes are:

1. Due to urethral disease viz.
  - Posterior urethral valves.
  - Congenital stricture of the external urethral meatus.
  - Phimosis.
2. Due to prostatic disease viz.
  - Benign prostatic hypertrophy (BPH).
  - Carcinoma of prostate.
3. Due to bladder disease viz.
  - Bladder cancer involving both ureteric orifices.
  - Bladder neck obstruction (stenosis, hypertrophy, functional obstruction due to neuropathic conditions).

### Pathology

The essential change in hydronephrosis is dilatation of the renal pelvis and calices.

The normal pelvis has an average capacity of 7 to 10 ml of urine. The dilatation of the

pelviccaliceal system may contain 400ml to 500 ml of urine.

Grossly, the kidneys may have moderate to marked enlargement. Initially there is extrarenal hydronephrosis, characterized by dilatation of renal pelvis medially in the form of a sac. As the obstruction persists, there is progressive dilatation of pelvis and calices and pressure atrophy of renal parenchyma. Eventually, the dilated pelviccaliceal system extends deep into the renal cortex so that a thin rim of renal cortex is stretched over the dilated calices and the external surface assumes lobulated appearance. This advanced stage is known as intrarenal hydronephrosis.

An important point of distinction between the cut surface of advanced hydronephrosis and polycystic kidney disease is the direct continuity of dilated cystic spaces that is, dilated calices with the renal pelvis in the former.

Microscopically, there is progressive atrophy of the tubules and glomeruli, along with interstitial fibrosis.

The wall of the hydronephrotic sac is thickened due to fibrous scarring and chronic inflammatory cell infiltrate.

Stasis of urine in hydronephrosis causes, infection (pyelitis) resulting in filling of the sac with pus, a condition called pyonephrosis.

### Clinical Features

The usual presentation is a dull aching pain in the loin. There may be colic and Dietl's crisis. The crisis is characterized by paroxysmal lumbar and abdominal pain with nausea and vomiting. A swelling is palpable in the loin and some hours later there is passage of large quantity of urine with resolution of swelling and pain.

Dietl's crisis is due to intermittent hydronephrosis and is also seen in kinking of the ureter due to wandering kidney.

On examination, hydronephrotic lump can be palpable in the loin.

There may be local and systemic features of calculus disease and urinary tract infection. Some patients are completely asymptomatic.

### Investigations

#### Laboratory Findings

1. Blood — Serum urea and creatinine ratio will be well above the normal of 10:1 in



cases of significant bilateral hydronephrosis with compromised renal functions.

2. Straight X – ray:
  - a. Enlarged renal shadow.
  - b. Radiopaque renal or ureteric calculi in unilateral and bladder calculus in bilateral hydronephrosis patients.
3. Excretory urogram (IVP): Shows the dilated pelvicaliceal system. The calices are clubbed and the renal parenchyma is thinned out.
4. Renal scan is the most useful investigation and is done by using <sup>99m</sup>Tc labeled DTPA. It will show depression of both the vascular and filtration phases and a rising rather than a falling excretory phase due to retention of the radiopaque urine in the renal pelvis.
5. Ultrasound can easily confirm the diagnosis of hydronephrosis.
6. Instrumental examination:
  - a. Cystometry is helpful in diagnosis of neurogenic bladder.
  - b. Cystoscopy and panendoscopy may reveal the primary obstructive agent. Retrograde ureteropyelograms can also be obtained.
7. Contrast CT scan — provides both anatomical and functional information.

### Treatment

The kidney is to be conserved whenever possible. Nephrectomy is done only if the renal parenchyma is largely destroyed and the other kidney is functioning well.

### Surgery

- i. A pyeloplasty is done in case of hydronephrosis due to pelviureteral junction obstruction. Pyeloplasty may be either.
  - a. Dismembered pyeloplasty, e.g. Anderson – Hynes pyeloplasty (see operative section, chapter 97) or
  - b. Nondismembered pyeloplasty (Foley's Y–V pyeloplasty).
- ii. Endoscopic pyelolysis — Nowadays endoscopic pyelolysis is done. It is the procedure of dilatation of the pelviureteral junction by using a balloon passed either through a nephroscope or by passing the balloon up through ureteric orifice into the pelviureteral junction under fluoroscopic control. The long-term benefits

of this procedure, however, are not yet certain.

### Complications

- Infection leading to pyonephrosis.
- Hematuria.
- Chronic renal failure.
- Stone formation.

### RENAL STONE

#### Incidence

Urinary calculi are four times more common in men than in women. They are rare in children.

#### Etiology

The exact etiology is not fully understood, but the following factors are currently suggested.

1. Crystalloid colloid imbalance—The urinary crystalloids are calcium, ammonium, oxalates, phosphates urates and uric acid and the colloids are mucin and chondroitin sulphuric acid. The presence of colloids in urine allows the crystalloids to be kept in solution by the process of adsorption. If the proportion between them changes e.g. crystalloids increase or the colloids decrease, or if the colloids lose their dissolving property, the crystalloids get precipitated and stone formation occurs.
2. Urinary infection— This is the commonest secondary cause of stone formation especially in women.

Typically infective stones are large staghorn calculi made of calcium, magnesium, ammonium phosphate or triple phosphate, known as struvite.


These are formed by the action of enterobacteriae, usually *E. coli* and proteus, which produce an enzyme urease that splits urinary urea to form ammonium ions that combine with calcium, magnesium and phosphate to form struvite.

Due to formation of ammonium ions, there is a rise in urinary pH, urea splitting organisms are frequently found in the interstices of infective stones and are difficult to eradicate even with prolonged courses of antibiotics.

3. Prolonged immobilization commonly leads to decalcification and increase

in the concentration of calcium in the urine. Also urinary stasis in prolonged recumbency helps deposited calcium to aggregate to form a nidus for urinary stone.

4. Obstruction to urinary outflow leads to stasis, infection and stone formation— A stone in such condition may show several layers of uric acid followed by deposits of phosphates.
5. Hyperparathyroidism— This occurs in 5 percent cases and results from the excess mobilization of calcium from the bones. There is recurrent stone formation in the kidney and urinary tract if the pathology is not removed.
6. Dietary factors:
  - a. Increased vitamin D intake leads to hypercalcemia and stone formation. Increase ingestion of diets rich in calcium has the same effect.
  - b. Vitamin A deficiency — There is desquamation of epithelium, which acts as a nidus for stone formation.
7. Other postulations:
  - i. Randall's plaque theory— Urinary metabolites excreted in the renal tubules accumulate in the renal papilla at the apex of renal pyramid forming a white plaque, called the Randall's plaque. The epithelium over the plaque breaks and the raw area is exposed over which urinary salts are deposited producing papillary calcification. Later on the plaque falls into the lumen of the calyx and acts as a nidus for a large stone.
  - ii. Carr concretion theory— Carr postulates that minute concretions or microliths which occur regularly in renal parenchyma are drained by intrarenal lymphatics. If there is damage or obstruction of the lymphatics by these microliths, they(microliths) ulcerate into the collecting tubules, come in contact with urine and act as a nidus for stone formation.
  - iii. Idiopathic stone formation— In 5 to 10 percent of all stone formers, no abnormality can be found to account for the stone forming tendency. Most of these patients have calcium oxalate calculi and a tendency to excrete alkaline urine. These patients

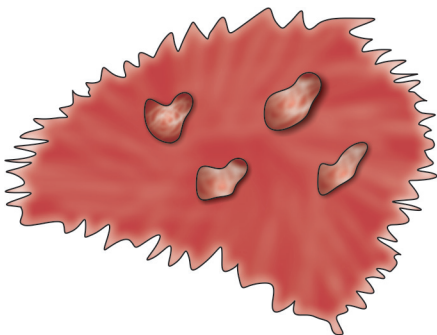


**Fig. 46.4:** Staghorn calculus. Even a large such calculus remain asymptomatic for years due to its smooth surface.

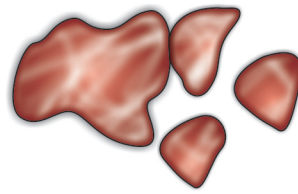
often continue to form stones over a period of years.

### Types of Stones

1. Phosphate stones (10 – 15%)
  - It is either calcium phosphate or calcium magnesium, ammonium phosphate stone usually occurring in infected urine, as mentioned above.
  - Single, dirty white in color.
  - Commonly occurs in renal pelvis and as it grows within the major and minor calices, the **staghorn calculus** is formed. (Fig. 46.4)
  - It presents with obstructive uropathy.
  - It is easily seen in the plain X-ray of abdomen.
2. Oxalate stones (75%) – Calcium oxalate
  - It is also called mulberry stone as it is dark in color with sharp projections.
  - The stone is single, radiopaque rough and spiky producing early hematuria leading to early diagnosis. (Fig. 46.5)
  - Thus it is prognostically better.



**Fig. 46.5:** Oxalate stone. Early hematuria occurs due to its spiky projections.



**Fig. 46.6:** Multiple, small faceted uric acid stones.

3. Uric acid stone (Fig. 46.6)
  - Multiple, small, faceted and radiolucent (pure uric acid stones). Xanthine stones are also radiolucent.
  - If calcium oxalate is present, the stones become radiopaque.
  - Commonly occurs due to error in uric acid metabolism.
4. Cystine stones
  - These occur in the urinary tract of patients of cystinuria which results from error in cystine metabolism.
  - These are usually multiple, soft like bees wax, pink or yellow-colored which changes to greenish hue on external exposure.
  - These are radiopaque due to their sulphur content.

### Clinical Features

- Nonobstructive stones are asymptomatic in most cases.
- Pain is the leading symptoms in 75 percent of patients with urinary stones.
- Fixed renal pain — This type of pain is felt in the loin at the renal angle formed by the sacrospinalis and the 12th rib. It is usually dull aching in nature and may sometimes be felt anteriorly in the hypochondrium. It gets worse on movement especially walking up the stairs.
- Ureteric colic — Classically this type of colic is caused by a stone migrating down the ureter or impacted at the pelviureteric junction. It is severe colicky pain originating at the loin and radiating to the groin, testicles or vulva and medial side of the thigh. This may be associated with nausea, vomiting and strangury. Strong parenteral antispasmodic drugs are required for relief.
- Hematuria is common with renal stones because majority of the stones are oxalate stones. Hematuria usually occurs in small

amount to make the urine dirty or smoky during or after an attack of pain.

- Recurrent UTI — Fever with chills and rigors, burning micturition, pyuria may occur along with frequency of micturition.

### Complications

1. Calculous hydronephrosis — Occurs due to back pressure producing renal enlargement. Due to stretching of the capsule, it results in renal pain and associated palpable renal mass.
2. Calculous pyonephrosis— Infected hydronephrosis may convert the kidney into a bag of pus, called pyonephrosis.
3. Renal failure — Bilateral staghorn calculi may not be symptomatic until they present with end stage renal disease or uremia.

### Investigations

1. Urinalysis — For all cases of stones for hematuria, pyuria and crystalluria.
2. Urinary biochemistry:
  - 24 hours urinary excretion of calcium. It is normally less than 300mg in male and 350mg in female. Higher levels indicate hypercalciuria, either idiopathic or secondary. This is an important diagnostic test for every case of urolithiasis.
  - Tests for cystinuria and oxaluria.
  - pH of urine — If it is more than 7.6, presence of urea splitting organisms is assured.
3. Blood tests for calcium, phosphate, uric acid and proteins as there is proteinuria in hematuria.

### Special Investigations

- Plain X-ray KUB
  - 90 percent of all renal stones are radiopaque.
  - Enlarged renal shadow can be made out.
- USG
  - Diagnosis of the stone and size can be made out.
  - Can confirm the enlarged kidney and the exact location of the stone.
  - It is also useful to distinguish between opaque and nonopaque stones.
- IVU—It is done to locate the stone exactly in relation to kidney and ureter

and to assess renal function. A nonradiopaque stone is seen as a filling defect. Hydronephrotic changes can be made out.

- Contrast Enhanced CT (CECT) Scan – has become the mainstay of investigation in acute ureteric colic.

### Treatment

Treatment is divided into:

- Conservative or nonoperative treatment.
- Operative treatment and prophylactic medical therapy to prevent recurrence.

#### Conservative or Nonoperative Treatment

- Not all patients with renal stones are in need of surgery. Stones less than 5mm often pass with the urine spontaneously unless they are impacted.
- Extracorporeal shock wave lithotripsy (ESWL):—It is the modern method of nonoperative treatment of renal stones. The earlier generation of ESWL machines required the patient to be kept in a water bath. The newer generation machines does not require a water bath. The ultrasound is focussed on the stones which results in fragmentation of the stones. These fragmented stones are cleared subsequently.

Most oxalate and phosphate stones less than 2cm size fragment well by this method, while cystine and xanthine stones do not fragment well and is difficult to treat with ESWL.

#### Complications

- Pain due to blockage of the ureter by the fragments.
- Infection by the organisms released from the stones when broken.
- Recurrent calculus from the retained fragments acting as a nidus.

#### Operative Treatment

- Percutaneous nephrolithotomy (PCNL): This is a minimally invasive technique for extraction of renal stones. A hollow needle is passed percutaneously into the renal collecting system through the renal parenchyma. A guidewire is inserted through the needle and the needle is then withdrawn. Following the guidewire the track is dilated using a series of dilators. The nephroscope is then inserted, through this dilated tract. Smaller stones can be

extracted under vision. The larger stone needs to be fragmented by an ultrasound or by an electrohydraulic probe and the fragmented pieces are removed by using a nephroscope.

#### Indications

PCNL is useful for calculi more than 2.5cm in diameter which are not suitable for ESWL, hard stones and ESWL failure cases.

#### Complications

- Injury to the colon, spleen and pleura.
  - Bleeding during stone removal.
  - Sepsis.
- Open surgery
    - Pyelolithotomy—When there is extrarenal pelvis containing the stone it is removed through an incision on the pelvis of the kidney.
    - Nephrolithotomy—Here the pelvis is intrarenal and the stone is taken out through the kidney parenchyma.
    - Pyelonephrolithotomy—Stone is extracted through an incision in the pelvis as well as the renal parenchyma.
    - Partial nephrectomy—When the stone is impacted in the lowermost calyx, a lower pole nephrectomy can be done.
    - Nephrectomy—When the kidney is destroyed by pyonephrosis following obstruction by stone, nephrectomy is performed.

#### Bilateral Kidney Stones

- Kidney with better function is operated first.
- The opposite side is operated 1 to 2 months later.
- If there is pyonephrosis with high temperature, pain and tenderness, nephrostomy is done and a tube drain is placed in the pelvis of the kidney for drainage of pus and urine. Kidney function is assessed afterwards. If the kidney is functioning, ESWL/PCNL/open procedure is done otherwise nephrectomy is performed for a nonfunctioning kidney.

#### Prevention of Recurrence

##### General Measures

- Large amount of fluid intake is to be ensured obeying the advice of Hippocrates.
- Avoidance of milk, cheese and calcium rich food should be advised.

Bendroflumethiazole (5mg) reduces urinary calcium.

#### Specific Measures

- Patients with hyperuricemia should avoid red meat and fish which are rich in purines and should receive treatment with allopurinol.
- Patients with cystinuria should have restricted fish, meat and eggs containing high sulphur containing proteins.
- Patients with oxalate stones should avoid foods high in oxalate, e.g. strawberry, spinach, plums, etc.

### URETERIC STONE

Ureteric stone almost always originates in the kidney. Stones coming down from pelvis of kidney may get impacted at any site of anatomical narrowing of the ureter viz.

- Pelviureteric junction.
- At the site of crossing of the iliac artery.
- Crossing of the vas deferens or broad ligament.
- At the ureterovesical junction.
- Ureteric orifice.

The impaction may lead to hydroureteronephrosis, renal parenchymal atrophy, infection and pyonephrosis.

#### Clinical Features

- Pain — This may occur in two forms viz. ureteric colic and fixed pain. Ureteric colic occurs, when the stone tries to pass down the ureter while fixed pain occurs when the stone gets impacted at some site.
- An attack of hematuria or pyuria.
- Guarding and abdominal rigidity which may mimic acute appendicitis on the right side.

#### Investigations

Same as in a case of renal stone.

#### Treatment

Most of the ureteric stones pass spontaneously with the urine. Patient is asked to take a lot of water and antispasmodics.

The methods of treatment of ureteric stone include:

- ESWL or PCNL as in case of renal stones. These techniques are applied for stones in the middle or upper part of the ureter. The

stone is flushed back into the kidney using a ureteric catheter and a j-stent secures the repositioned calculi in the kidney for subsequent removal with ESWL or PCNL.

2. URS or ureterorenoscopy for mid and lower third stones removal.
3. Laparoscopic removal in cases of failure of ESWL or URS or as primary treatment if the stone is large (usually more than 1.5cm).
4. Open surgery — ureterolithotomy.

### Ureteroscopic Stone Removal

An ureteroscope is a long endoscope that can be passed transurethrally across the bladder into the ureter.

The ureteroscope is used to remove stones which are impacted in the ureter.

Stones that cannot be caught in baskets or endoscopic forceps under direct vision are fragmented by electrohydraulic or ultrasonic lithotripsy.

### Open Surgery

#### Ureterolithotomy

A plain radiograph should be taken to confirm the position immediately before surgery.

The approach for ureterolithotomy is muscle cutting and extra peritoneal.

For a stone in the upper two-third of the ureter the incision is made along a line, drawn from the renal angle to a point a few cm above the mid inguinal point. For stones in the upper third, upper part of this line is incised and for the middle third, the lower part. The muscles are cut along the line of incision and the peritoneum is displaced medially by gauge dissection and the ureter is found adhering to it.

The ureter is incised over the stone and the stone is extracted. The incision in the ureter is closed by 4/0 catgut or Vicryl, a drain placed in the retroperitoneum and the wound closed in layers.

In case of stone in the lower third of the ureter, a subumbilical midline or Pfannenstiel's incision is commonly employed.

## RENAL INFECTION

### Renal Tuberculosis

Renal tuberculosis arises from hematogenous infection from a distant focus, either lung or

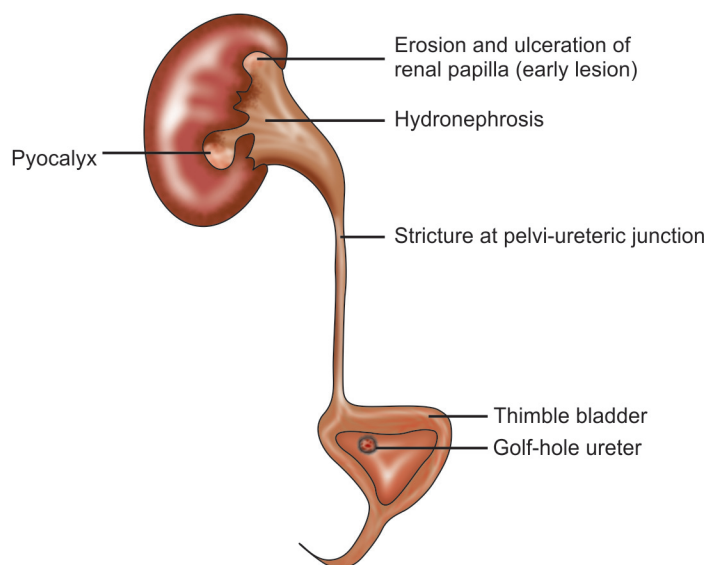


Fig. 46.7: Pathological changes in renal and bladder tuberculosis

less commonly a lymph node and the primary lesion often remains unrecognized.

### Pathology (Fig. 46.7)

The tuberculous lesion starts as a group of tuberculous granulomas in a renal pyramid that coalesces and forms an ulcer. The ulceration extends into the calyx and towards the renal cortex.

If untreated the lesions enlarge and a tuberculous abscess may form in the parenchyma. The necks of the calices and the renal pelvis stenosed by fibrosis confine the infection so that there is tuberculous pyonephrosis which is sometimes localized to one pole of the kidney.

Extension of pyonephrosis or tuberculous renal abscess outside the kidney leads to perinephric abscess and the kidney is progressively replaced by caseous material (putty kidney) which may be calcified (cement kidney).

Renal tuberculosis is usually unilateral; less commonly the kidneys may be affected bilaterally as part of the generalized process of miliary tuberculosis.

Fibrosis and stricture at the pelvi-ureteric junction may lead to hydronephrosis.

Renal tuberculosis is often associated with tuberculosis of the bladder and typical tuberculous granulomas may be visible in the bladder wall.

In the male tuberculous epididymo-orchitis may occur without apparent infection of the bladder.

### Clinical Features

- Renal tuberculosis usually occurs between 20 and 40 years of age and twice as common in men as in women.
- Right kidney is affected slightly more than the left one.
- Frequency is often the earliest and only symptom. The frequency is noticed both in the day and at night. Causes of frequency are the following.
  - a. Tuberculous cystitis is the main cause of frequency.
  - b. Irritation of the bladder wall by caseous debris reaching via the ureter.
  - c. Progressive diminution in the capacity of the bladder due to fibrosis in its wall.
- Sterile pyuria — It is the presence of pus cells of more than 10 per HPF in urine without organisms in acid urine. (HPF = High Power Field)
- Renal pain is minimal but there may be a dull ache in the loin.
- Hematuria is a less common symptom and painless. It occurs due to bleeding from the ulcer in the renal papilla.
- Constitutional symptoms are common weight loss and evening rise of temperature are typical. A high temperature is suggestive of secondary infection or dissemination, that is, miliary tuberculosis.
- A tuberculom kidney is edematous and friable and is more prone to damage than a normal kidney due to trauma.



- The patient may present with a renal lump. The prostate, seminal vesicles, and scrotal contents should be examined for nodules or thickening.

### Investigations

1. Urine examination — Shows sterile pyuria in acid urine
  - Staining of urine sediment for Ziehl-Neelsen stain shows the presence of mycobacteria.
  - Culture of mycobacteria in Lowenstein-Jensen medium.
2. Plain X-ray of abdomen will show the calcified lesion in the kidney if present.
3. IVU – The earliest change is hydronephrosis in one or more calices. Later there may be gross damage of the renal parenchyma progressing to a nonfunctioning kidney.

### Cystoscopy

- a. Ureter — It is thickened, shortened and straight due to extensive periureteric fibrosis. The ureteric openings are pulled upwards and take on the shape of a golf hole, hence the name golf hole ureter.
- b. Bladder becomes small, contracted and ineffectively functioning. Micturition is painful and is called strangury. There is also severe pain in the suprapubic region which is referred to the tip of penis. Such a small nonfunctioning urinary bladder is called thimble bladder. (See chapter 47)

### Treatment

Conservative treatment with antitubercular drugs is started. If the therapy is started early, surgery may not be needed for many patients.

### Operative Treatment

The aim of operative treatment should be as conservative as possible. The optimum time for surgery is between 6 and 12 weeks of the start on antituberculous chemotherapy.

The following operative procedures are undertaken.

- i. Pyeloplasty — When there is a pelvic type of hydronephrosis due to stricture at the pelviureteral junction, a procedure similar to Anderson – Hynes operation is performed.

- ii. Boari operation or a bowel interposition— This is done for ureteric stenosis and shortening.
- iii. Augmentation cystoplasty — This is performed in case of thimble bladder. The aim is to increase the capacity of the bladder with the help of an isolated loop of bowel (either a loop of terminal ileum or pelvic colon) which is anastomosed to the bladder and thus made a part of it.
- iv. Nephroureterectomy — If the kidney is totally nonfunctioning, it is best to perform a nephroureterectomy.

### ACUTE PYELONEPHRITIS

The kidney may be infected either via the bloodstream or by an ascending infection from the lower urinary tract. Acute pyelonephritis is an acute infectious inflammatory process involving the renal parenchyma and the pelvis.

In 75 percent of patients this condition results from an ascending infection. It is especially common when there is a congenital abnormality of the kidney, e.g. Horse-shoe kidney or double kidney or when an incompetent ureterovesical valve allows ureteric reflux during micturition.

The other predisposing factors for ascending infection include:

- Catheterization.
- Secondary to urinary infection associated with a bladder stone.
- Prostatic obstruction.
- Pregnancy causing ureteric relaxation and urinary obstruction by the gravid uterus.

### Pathology

Macroscopically, the lesion may affect one or both kidneys, which are enlarged, hyperemic and show scattered small abscesses.

Microscopically, the kidney is actually inflamed, infiltrated by polymorphs and later shows necrosis and abscess formation.

### Clinical Features

1. The urine is examined for pus cells and bacteria.
2. Culture of urine grows *E. coli* in most cases other causative organisms include proteins, *pseudomonas* and fecal streptococci.
3. An IVP shows blunting of the calices and dilatation of ureter. An underlying

cause such as calculus, diverticulum of bladder or enlarged prostate may also be seen.

### Differential Diagnosis

- Acute appendicitis.
- Acute cholecystitis.
- Acute pancreatitis.

### Treatment

Once urine has been obtained for culture, an wide spectrum antibiotic is commenced usually a combination of Ampicillin and an aminoglycoside like gentamicin suffices. The therapy should be prompt and prolonged upto 3 weeks.

General measures are IV fluids, analgesics, antipyretics and bed rest.

Prognosis is good if the patient is treated promptly.

### Complications

Complications of acute pyelonephritis are encountered more often in patients with diabetes mellitus or with urinary tract obstruction. The complications are:

1. Pyonephrosis
2. Perinephric abscess
3. Septicemia
4. Chronic pyelonephritis.

### PYONEPHROSIS

This is a unilateral disease in which the kidney is converted into a bag of pus. The condition may result from the following

- Complication of renal calculus.
- Complication of acute pyelonephritis.
- Infection of a hydronephrosis.

### Clinical Features

The classic symptoms are anemia, fever, and a easily palpable loin swelling.

When the tuberculous caseous material accumulates, the condition is known as tuberculous pyonephrosis.

An IVP shows little or no function and the enlarged renal shadow is usually obvious. There may be delayed excretion of dye.

Imaging may show a colculus.

### Treatment

Pus is drained under antibiotic cover by either percutaneous nephrostomy or open



surgery. Nephrectomy may be occasionally required.

### PERINEPHRIC ABSCESS

This usually results from the rupture of an intrarenal abscess and lies between the renal capsule and the fascia of Gerota.

Causative organisms are the same as for intrarenal abscess viz. staphylococci, *E. coli*, proteins, and pseudomonas and mycobacterium tuberculosis.

The classic features are abdominal tenderness, high fever and a mass in the loin.

### Investigations

Diagnostic investigation of choice is CT scan and USG abdomen. CT guided aspiration of pus is done and sent for culture.

### Treatment

This is done by antibiotics and drainage.

Traditionally, drainage is done by open surgery but now percutaneous drainage is also being used. A specimen of pus is sent for culture.

Nephrectomy may be required occasionally.

### RENAL CARBUNCLE

This is better termed a renal cortical abscess and represents a hematogenous infection, usually caused by coliforms or *staphylococcus aureus*, coming from a primary focus such as a cutaneous boil.

### Clinical Features

There is pyrexia, abdominal pain and a palpable mass in the loin. The abscess can rupture into the perinephric tissue and result in a perinephric abscess.

Diagnosis is established by either ultrasound or preferably CT scan. Percutaneous aspiration can be done under CT guidance.

### Treatment

This consists of surgical drainage under antibiotic cover either percutaneously or open surgery if the former fails.

### CHRONIC PYELONEPHRITIS

Chronic pyelonephritis usually refers to small shrunken kidney or a coarsely scarred kidney is due to bacterial infection.

This may follow very often vesicoureteric reflux (hence called 'reflux nephropathy') and infection in childhood or may develop in adult life as a result of persistent bacteriuria in between repeated episodes of acute pyelonephritis.

### Pathology

The brunt of the attack falls on the renal tubules that become atrophic, dilated and sometimes cystic.

In contrast the glomeruli retain their structure till late in the disease.

There is interstitial inflammation and scarring in the scattered areas of renal parenchyma. The nonscarred areas show compensatory glomerular and tubular hypertrophy.

### Clinical Features

The condition is three times more common in women and produces few symptoms until it ends up in renal insufficiency when the symptoms are similar to those of chronic renal failure.

Clinical examination is unremarkable and the only findings are hypertension and anemia.

### Investigations

Urinalysis may be normal or show evidences of infection. An USG will show loss of cortical thickness, calyceal dilatation and cortical scars with an irregular contour.

An IVU may confirm the ultrasonographic findings as well as poor excretion of the contrast.

A micturating cystourethrogram (MCU) is done to look for evidence of vesicoureteral reflux.

### Treatment

Consists of:

- Prompt treatment of urinary tract infection if present and monitoring and preserving the renal function.
- Children with recurrent urinary tract infection require long-term prophylactic antibiotics.
- Investigations should be carried out to detect the underlying cause which is to be corrected.
- Nephrectomy is required if renal function is poor and the opposite kidney is normal.

In late cases, when patients present with renal failure, maintenance hemodialysis or renal transplantation is required.

## RENAL NEOPLASMS

### Classification

Tumors of the kidney are divided into those arising from the kidney substance and those originating from the renal pelvis.

The latter is derived from a transitional cell epithelium and identical pathologically with the tumors of the ureter and bladder.

### Tumors of the Kidney Itself

#### Benign

- Adenoma — It is usually a small pea size tumor occasionally discovered incidentally during radiological examination and is symptomless.
- Hemangioma — Is a rare cause of hematuria.

#### Malignant neoplasms

- Primary
  - Nephroblastoma (Wilms' tumor in children)
  - Adenocarcinoma (Hypernephroma, Grawitz tumor).
- Secondary — The kidney is a rare site for secondary deposits of carcinoma although it may be involved in advanced cases of lymphoma and leukemia.

### Tumors of the Renal Pelvis

- Papilloma.
- Transitional cell carcinoma.
- Squamous cell carcinoma.

The two principal tumors of the kidney are the nephroblastoma in children and adenocarcinoma which usually occurs after the age of 40 years.

## NEPHROBLASTOMA (WILMS' TUMOR OR EMBRYOMA OF THE KIDNEY)

Wilms' tumor originates from the mesenchyme of the metanephros, containing epithelial and connective tissue elements.

It occurs predominantly in children in the first 4 years of life, although it occasionally affects older children and adolescents.

### Pathology

The tumor is located in one or other pole of one kidney but bilateral tumors occasionally pose a difficult clinical problem. This is an extremely anaplastic tumor.

**Grossly**, the tumor is large, soft and heterogenous on cut section and is very vascular.

**Microscopically**, the tumor contains both epithelial and mesenchymal elements with connective tissue components such as muscle, fat, fibrous tissue and cartilage.

### Clinical Features

- Rapid growth produces a large palpable mass in the loin so much so that it may be visible on simple inspection of the abdomen.
- Other features are abdominal pain and fever. Hematuria is uncommon as the involvement of the renal pelvis is late. Metastasis occurs early by the bloodstream to the lungs. Liver and bone metastasis are rare. Lymphatic spread is uncommon.

### Investigations

1. Ultrasonography reveals a solid mass in the abdomen and may detect the tumor in the vena cava or right atrium.
2. Plain X-ray abdomen can differentiate the tumor from neuroblastoma which is usually calcified.
3. Contrast enhanced CT scan establishes the diagnosis.

### Treatment

- Nephrectomy is performed as soon as possible followed by radiotherapy with or without chemotherapy with actinomycin - D.
- Partial nephrectomy may be possible in patients with bilateral disease.
- These children are best treated in specialist pediatric oncology units.

### Prognosis

Under 1 year age, 80 percent survive for 5 years but the prognosis is less good in older children.

## ADENOCARCINOMA (HYPERNEPHROMA)

This tumor accounts for 80 percent of all renal growths. It is twice as common in men as in women. The incidence is 3 to 7 per 100000 population.

### Etiology

The following are considered as the predisposing factors for the development of the tumor.

1. Diet—High intake of fat, oil and milk.
2. Toxic agents—Exposure to lead, cadmium, asbestos, petroleum by-products and smoking.
3. Genetic factors—Oncogene on short arm of chromosome 3 and human leukocyte antigen BW - 44 and DR - 8, are involved.
4. Associated disease - There is an association between renal cell carcinoma and (a) von Hippel Lindau syndrome, (b) Adult polycystic renal disease.

### Pathology

**Macroscopically** renal cell cancers are bright yellow masses with apparent capsule, with areas of cyst formation, hemorrhage and calcification. Cystic degeneration gives the appearance of a honeycomb.

**Microscopically** the most common cell type resembles the cells of the proximal renal tubule having large clear cells containing glycogen and lipid. About 10 percent show other cell types like granular cells with eosinophilic granules, spindle cells (carrying a poor prognosis) resembling sarcoma.

### Robson's Staging of Renal Cell Carcinoma

Stage I — Tumor confined to the kidney.

Stage II — Tumor extending into perinephric fat but confined within Gerota's fascia.

Stage III — Tumor shows spread to regional lymph nodes, renal vein or inferior vena cava.

Stage IV — Distant metastasis or involvement of adjacent organs.

### Grading

Frequency of mitosis is used as the basis of Grading of renal adenocarcinoma.

G<sub>1</sub> — highly differentiated tumor.

G<sub>2</sub> — moderately differentiated tumor.

G<sub>3</sub> — poorly or undifferentiated tumor.

### Spread

- a. Direct spread to perirenal fat and adjacent organs, e.g. colon, pancreas, liver, duodenum, etc.

b. Lymphatic spread — When the tumor breaks through the renal capsule and invades the perirenal tissues, lymph nodes in the hilum and then paraaortic lymph nodes are affected.

c. Hematogenous spread — occurs along renal vein by permeation and to lungs, bones and liver by embolism.

In the lungs, these form cannon ball metastasis. Metastasis to bones may cause pathological fracture and may be the first sign of presentation.

### Clinical Features

- Males are more affected than females (2:1)
- The cardinal symptoms of renal cell carcinoma are hematuria, pain and a mass in the loin. Hematuria occurs in only 60 percent of cases and all three are present in less than 10 percent of patients.
- Paraneoplastic manifestations are due to ectopic hormone production by the tumor and are as under:
  - i. Hypercalcemia due to parathormone.
  - ii. Hypertension due to renin production.
  - iii. Polycythemia with high ESR due to production of erythropoietin.
  - iv. Cushing's syndrome due to excess production of glucocorticoids.
  - v. Others :
    - Persistent fever of unknown origin is a deceiving symptom caused by a pyrogen secreted by the tumor.
    - Stauffer's syndrome—There is hepatomegaly with disordered liver function without metastasis. It is reversed by nephrectomy.
    - Pathological fracture due to secondary deposit.
    - Anemia and lassitude.
      - Some tumors are diagnosed incidentally on an IVU or ultrasound performed for another reason.
      - Varicocele of spermatic cord in case of left sided involvement.

### Investigations

- Blood tests may reveal anemia or polycythemia and elevated ESR and abnormal liver function tests.
- IVU is the screening investigation of choice for a suspected renal tumor. Typically it shows a space occupying

lesion which distorts the collecting system and the renal outline.

- Ultrasound scanning is normally used to distinguish between a solid tumor and a benign cyst. It can also assess the tumor extension into the renal vein and inferior vena cava.
- Contrast enhanced CT scanning is helpful to evaluate complex lesion which have not been diagnosed with certainty by IVU and ultrasound alone. It can assess the renal mass, fixity and the nodal status.
- MRI — It shows more clearly than any other method the exact extent of tumor thrombosis in the vena cava.

### Management

1. **Surgery:** In the absence of distant metastasis, the treatment of choice for renal adenocarcinoma is radical nephrectomy. This involves removal of the kidney, adrenal gland and surrounding perinephric fat within Gerota's fascia together with the upper ureter and any enlarged paraaortic nodes.

A transperitoneal approach is preferred so that the renal vessels can be ligated before mobilizing the kidney. This reduces the operative blood loss and dislodgement of tumor thrombus from the renal vein.

2. **Palliation:** The treatment of metastatic disease is very unsatisfactory.
  - Isolated lung metastasis, removed surgically along with radical nephrectomy can sometimes be curative.
  - Palliative radiotherapy may help controlling symptoms from isolated deposits but systemic chemotherapy has proved very disappointing.
  - Immunotherapy – This is currently under review and most exciting. The following methods of immunotherapy are available.

- a. Interferon.
- b. Lymphokine activated Killer cells (LAK cells).
- c. Tumor infiltrating lymphocytes.

### Prognosis

Overall survival is 40 percent at 5 years.

## TUMORS OF RENAL PELVIS AND URETER

### Incidence

Patients who develop a transitional cell carcinoma of the pelvis or ureter have a 30–50 percent chance of developing a transitional cell tumor of the bladder, in future. On the other hand, transitional cell carcinoma of bladder is associated with only 2 to 3 percent chance of future development of a tumor in the upper urinary tract.

### Etiology

The exact etiology is unknown. The predisposing factors are:

- Balkan nephropathy — It is an environmental tubulointerstitial renal disease of unknown cause endemic to certain areas of the Balkan Peninsula (Yugoslavia, Romania, Bulgaria and Greece). Affected patients are at high risk for the development of renal pelvic cancer.
- Smoking
- Analgesic nephropathy— Persons who consume for years, the analgesics containing aspirin or phenacetin, have a nine fold greater risk of developing papillary necrosis and transitional cell carcinoma of the renal pelvis.
- Chronic inflammation and irritation due to renal stone.

### Clinical Features

Hematuria is the presenting symptom in 80 percent of patients.

Pain with or without obstruction is seen in 40 percent patients.

Other features are anorexia and weight loss. A palpable mass is rare.

### Investigations

- Urine cytology shows the presence of malignant cells in urine.
- IVU – displays a radiolucent filling defect that can be confirmed by retrograde pyelography.
- USG – The initial evaluation of filling defect is performed by ultrasonography.
- CT or MRI is essential; for staging and evaluating regional lymph nodes.
- Ureteroscopy – The recent advent of ureteroscopy has allowed direct visualization and biopsy of suspected lesions especially in cases of unexplained hematuria or positive cytology.

### Treatment

Conventional surgical treatment is nephroureterectomy. The ureter is disconnected with a cuff of bladder wall.

In the presence of metastatic disease, chemotherapy, similar to that used in bladder cancer is helpful.

## SQUAMOUS CELL CARCINOMA OF RENAL PELVIS

A squamous cell carcinoma of renal pelvis may occur when there has been squamous metaplasia of the epithelium, usually due to stones.

Macroscopically the growth is flat and infiltrative.

Microscopically, there are features of squamous cell carcinoma simulating those found elsewhere.

These tumors are radiosensitive but metastasize at an early stage and the prognosis is poor.

# Chapter 47

## Urinary Bladder

- Embryology
- Surgical anatomy
- Common congenital anomalies of urinary bladder
- Cystitis
- Schistosomiasis of the bladder
- Thimble bladder
- Tumors of the bladder
- Carcinoma of the bladder
- Urinary incontinence
- Retention of urine
- Vesical fistula
- Urinary diversion
- Ileal loop conduit
- Neurogenic bladder

### EMBRYOLOGY

The urinary bladder is developed from two sources –

1. The trigone is developed from the Wolffian (mesonephric) ducts, that is, mesodermal in origin, and
2. The rest of the bladder is developed from the endodermal cloaca.

The endodermal cloaca is divided into two parts by the development of urorectal septum, the posterior part forms the rectum, whereas the anterior part known as primitive urogenital sinus, is divided into three parts. (Fig. 47.1)

- a. The cephalic and the largest vesicourethral part develops into the urinary bladder except the trigone.
- b. The middle narrow pelvic part which gives rise to the prostatic and membranous parts of the urethra in male and
- c. The lower dilated phallic part which forms the penile urethra in male.

The second and third parts constitute the definitive urogenital sinus.

It is seen that the ureteric bud originates from a little above the actual end of the Wolffian duct.

With the gradual absorption and descent of the openings of the mesonephric ducts, the trigone is formed.

Eventually the ureteric buds open directly into the bladder and the ureteric openings migrate headwards and laterally probably due to growth of the bladder wall.

- The terminal parts of the mesonephric ducts will give rise to the ejaculatory ducts.
- The upper part of the posterior wall of the prostatic urethra is also formed the incorporation of the lower most portions of the mesonephric ducts while the ventral wall of prostatic urethra is developed from the endoderm of the vesicourethral part of cloaca upto the opening of the prostatic utricle.

Below the opening of the ejaculatory ducts, the prostatic urethra is developed from the endoderm of the pelvic part of the urogenital sinus.

The membranous part of the urethra is also derived from the pelvic part of urogenital sinus.

### SURGICAL ANATOMY

Urinary bladder is a hollow ovoid muscular organ, which has the shape of a three sided pyramid with the apex pointing to the top of the symphysis pubis and triangular base towards the rectum. It is a pelvic organ in adults but when fully distended, becomes easily palpable in the abdomen.

The ureters enter the bladder posteroinferiorly in an oblique manner and these points are 5cm apart.

Both the oblique direction of the ureter within the bladder musculature and the flap valve action of the bladder mucosa prevent the vesicoureteric reflux.

The mean capacity of bladder is 200 ml. Individuals normally feel to micturate when the bladder contains about 300 ml of urine.

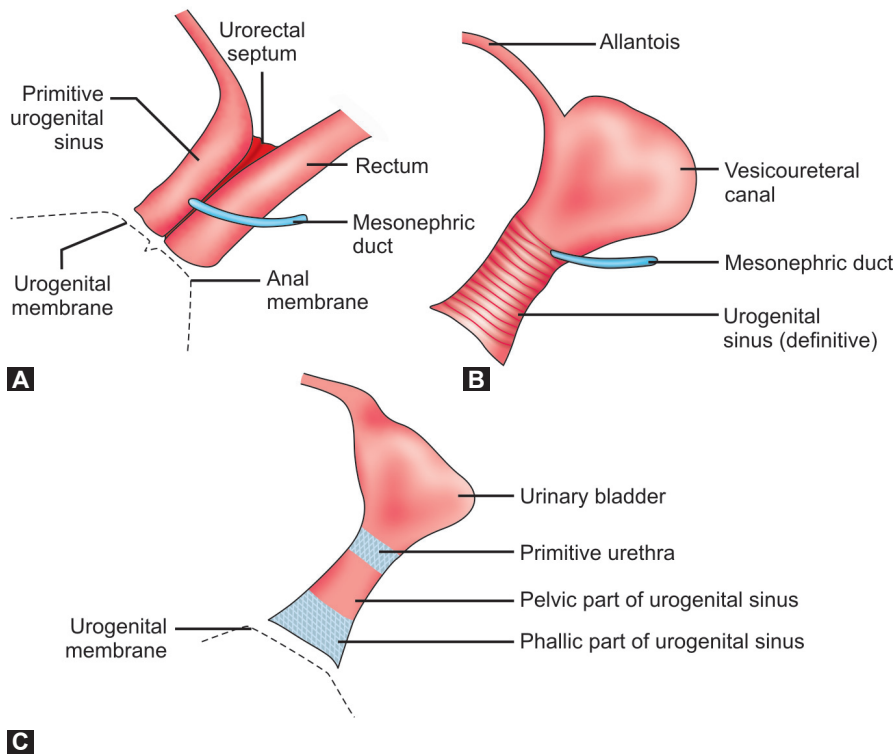
### Structure

The bladder has three coats viz.

- Serous or peritoneal coat covering only the superior surface.
- Muscular coat known as the detrusor muscle. There are external and internal layers of longitudinal muscle and a middle layer of circular muscle.
- The circular muscle is thickened around the internal urethral orifice forming the sphincter vesicae but it is thin and scattered elsewhere.
- The mucous coat is pale rose in color and is of transitional variety.

### Blood Supply

Superior and inferior vesical arteries from the anterior division of internal iliac artery. The bladder also receives contributions from



**Figs 47.1A to C:** Development of urinary bladder. (A) Division of cloaca into rectum and urogenital sinus. (B) Division of primitive urogenital sinus into vesicourethral canal and definitive urogenital sinus (UGS). (C) Definitive UGS divides into a cranial pelvic part and a caudal phallic part.

inferior gluteal, obturator, uterine and vaginal arteries.

Venous drainage is via a plexus of veins which drain into the internal iliac vein.

Lymphatics – drain into the internal and external iliac nodes. There is a rich lymphatic plexus within the detrusor muscle.

### Nerve Supply

- Parasympathetic nerves reach in the Nervi erigentes  $S_{2-4}$  carrying motor fibers to the detrusor muscle and inhibitory fibers to sphincter vesicae. They also carry the sensation of bladder distension.
- Sympathetic nerve supply is via the superior hypogastric and pelvic plexuses. They are vasomotor and inhibitory to the detrusor muscle and will cause contractions of the sphincter vesicae. The somatic innervation to the external sphincter (sphincter urethrae) is derived through the pudendal nerves ( $S_{2-4}$ ).

### COMMON CONGENITAL ANOMALIES OF URINARY BLADDER

The anomalies are:

- Diverticula
- Ectopia vesicae or extrophy of bladder
- Patent urachus
- Vesicoureteric reflux (VUR)—It is a common cause of urinary tract infection in children and may require long-term prophylactic antibiotics. Milder grades of reflux often improve with age but spontaneous resolution is less likely with more severe grades. For severe degrees of reflux, reimplantation of the refluxing ureters may be appropriate.

### Diverticula

Only a small number of diverticula of the bladder are congenital while the majority are acquired and secondary to bladder outflow obstruction.

Congenital diverticula may develop near the line of fusion along the interureteric bar which delineates the parts of bladder developed from the endoderm and mesoderm or at the apex of the bladder.

Diverticulum at the line of fusion occurs due to congenital weakness of the bladder wall while that at the apex usually arises from the unobliterated vesical end of the urachus.

These are usually single and almost exclusively occur in males.

The complications are infection and stone formation when the diverticulum should be excised.

### Ectopia Vesicae (Syn—Extrophy of Bladder)

It is a condition in which the bladder fails to develop properly and the ureters together with the trigone open directly on to the anterior abdominal wall below the umbilicus.

In the male there is an associated epispadias and in both sexes there is wide separation of the symphysis pubis. Typically there is a widened pelvis with a waddling gait.

The infant is completely incontinent of urine and there is excoriation of the abdominal skin and a permanent unpleasant ammoniacal smell of infected urine.

If the condition remains untreated, the child may die of pyelonephritis or else frequently develops adenocarcinoma of bladder after initial metaplastic change.

### Treatment

- The most satisfactory treatment is reimplantation of the ureters either into the colon or on to an ileal loop (ureteroileostomy), combined with excision of the bladder itself as a prophylaxis against malignant change.
- This is followed by reconstruction of anterior abdominal wall.
- Surgical correction of the genitalia can be deferred until the child is older and is usually performed in stages.

### Patent Urachus

Developmentally, the allantois which connects the urogenital sinus with the umbilicus becomes the urachus.



Normally the urachus is obliterated and is represented by a fibrous cord which is called the median umbilical ligament, connecting the apex of the bladder to the umbilicus.

### Anomalies of Urachus (See Figs 40.2A to C)

1. Patent urachus—The cavity of whole length of the urachus remains patent and a fistula exists between the apex of bladder and umbilicus. This is the urinary fistula of the umbilicus.
2. Urachal diverticulum occurs when the vesical end of urachus persists at the apex of the bladder forming the diverticulum.
3. The central part of the urachus persists forming a midline infraumbilical cyst.
4. Urachal sinus—When the umbilical end of the urachus fails to obliterate giving rise to urachal sinus of the umbilicus. Treatment is excision in all cases.

### Vesical Stone

Bladder calculi may be the result of stones passed down the ureter after its origin in the kidney but more usually the stones form *de novo* in the bladder.

The usual reason for the later is bladder outflow obstruction, although stones may form in diverticula or on foreign bodies including catheters in the bladder. Chemically this is made up of either triple phosphate (ammonium, magnesium and calcium phosphate) or calcium oxalate.

### Clinical Features

Males are more commonly affected and the male to female ratio is 8:1.

Clinically three types of bladder stones are found 1. The usual type, 2. Silent type and 3. The masked type.

### Usual Type

- Frequency is the earliest symptom and there may be a feeling of incomplete evacuation.
- Pain—Most marked in oxalate calculi due to the presence of spikes. The pain is referred to the tip of penis or to the labia majora at the end of micturition; such pain passes off as the patient lies down and the stone falls back from the trigone into the pouch behind the interureteric bar.

- Terminal hematuria—It is characterized by passage of few drops of blood at the end of micturition especially seen with oxalate stones.
- Acute retention of urine may occur very rarely in a few adults. Per rectal or per vaginal examination sometimes reveals a large vesical calculus.

### Silent Type

When the vesical calculus lies in a postprostatic pouch or diverticulum of bladder, it remains asymptomatic for a long time. These stones are usually discovered during cystoscopy or plain X-ray abdomen done for some other purpose.

### Masked Type

In some cases of vesical calculus, the symptoms of cystitis predominate and the stone is masked. Thus if a patient frequently presents with symptoms of cystitis thorough investigations should be done to exclude vesical calculus.

### Investigation

1. Straight X-ray of KUB region (kidney, ureters and bladder) reveals vesical calculus in about 95 percent cases.
2. Cystoscopy—it should be done as a routine, especially to eliminate other pathology like diverticulum, tumor of bladder, enlarged prostate, etc. associated with the calculus. This examination also detects the stones which are nonopaque to X-ray.
3. Urine examination—Pus cells, RBC and typical crystals of the stone may be present, e.g. hexagonal crystals of cystine and envelope shaped crystals of calcium oxalate.

### Treatment

1. Very small stones pass out spontaneously with the urine.
2. Usually suprapubic cystolithotomy has to be performed by a suprapubic incision if the stone is a large one.
3. Endoscopic removal – Endoscopically small stones may simply be washed out of the bladder through the cystoscope. Larger stones, however, need to be broken into fragments before removal.

The time honored method is litholapaxy. The stone is crushed endoscopically with lithotrite, the crushing instrument which is introduced into the bladder via the urethra. The fragmented stone is then washed out of the bladder via a cystoscope.

Contraindications of litholapaxy are contracted bladder, urethral stricture and a large stone.

### CYSTITIS

Cystitis is the inflammatory condition of the bladder wall and is commoner in women than in men because of shortness of female urethra and its proximity with the vagina teeming with organisms.

It is of the following types:

1. Acute cystitis.
2. Chronic cystitis
3. Special forms of cystitis.
  - a. Acute abacterial cystitis or acute hemorrhage cystitis due to trauma, toxic drugs and chemicals, viruses (adenovirus) and irradiation.
  - b. Chronic intestinal cystitis (Hunner's ulcer).
  - c. Cystitis cystica.
  - d. Encrusting cystitis.
  - e. Malakoplakia
  - f. Specific cystitis due to.
    - i. Bacteria—*Mycobacterium tuberculosis*, *T. pallidum*.
    - ii. Parasite—Schistosomiasis or Bilharziasis.
    - iii. Fungus, e.g. *Candida albicans* (Monilia) – very rarely.

### Acute Cystitis

The mucous membrane of the bladder is remarkably resistant to infection. Thus mild degrees of cystitis are common but more severe forms occur only in presence of a predisposing factor. The commonest of these is partial retention or stasis of urine due to the following causes.

1. Cystocele in connection with prolapse of uterus and this will give rise to recurrent episodes of cystitis in multiparous women.
2. Prostatic enlargement—Most common predisposing factor in men.
3. Vesical stone or diverticulum.

4. Carcinoma of bladder—Here the ulcerated surface and necrotic debris will cause the most severe type of cystitis.
5. Spinal injury.
6. Stricture of urethra.

### Infecting Organisms

Most cases of cystitis are due to ascending infection via the urethra by the gm negative bacilli, the normal inhabitants of the intestinal tract, which contaminate the vulva and reach the bladder.

Most common is *E. coli* followed by proteus, Klebsiella and Enterobacter.

Less common offenders are *Streptococcus faecalis* and staphylococci. Thus in great majority of cases the causative agents of cystitis are the patients own fecal flora. Hence this is a form of endogenous infection.

### Clinical Features

Typically there is frequency and urgency of micturition with dysuria. There may be suprapubic discomfort or pain in between voids and the urine often has a fishy smell or may be blood stained.

Associated loin pain suggests spread of infection to the kidney (acute pyelonephritis).

Systemic upset in the form of fever with chills and malaise may be present in severe cases accompanying bacteremia.

### Diagnosis

The midstream specimen of urine is sent for microscopy and culture. A colony count of  $>10^5$ /ml of urine indicates significant bacteriuria and infection.

The sensitivity of the organisms is assessed.

### Treatment

This should be commenced forthwith and modified if necessary, when the bacteriological report is available.

The patient is urged to drink plenty of fluids and alkalinizing agents such as sodium bicarbonate or potassium citrate.

If the initial course of antibiotics produces resolution of symptoms, the midstream urine examination is repeated at 2 weeks and again at 3 months to ensure that infection has been eradicated.

Further investigations like cystoscopy and IVU are carried out after the acute phase to measure the postvoid residual volume of

urine and to find out the cause of hematuria if present.

### Fate of Acute Cystitis

1. Resolution
2. Chronic cystitis
3. Gangrenous cystitis occasionally.

### Chemical Cystitis

Chemical cystitis can be induced by certain agents excreted in the urine. The best known example is cyclophosphamide. Chemicals are at times instilled in the urinary bladder for therapeutic purposes, e.g. intravesical chemotherapy for bladder cancer and may cause chemical injury.

The usual manifestations are irritative lower urinary symptoms and hematuria. Late fibrosis can occur from drug induced cystitis. One curious late complication of cyclophosphamide cystitis is leiomyosarcoma of the bladder. Acetone, formaldehyde are other chemicals that can cause cystitis.

It can be prevented by diuresis and if necessary keeping the bladder empty with a catheter, so that the offending agents cannot come in contact with the urothelium.

### Chronic Interstitial Cystitis (Hunner's Ulcer)

Guy Hunner first described this condition as early as 1914. It is a form of chronic abacterial cystitis, practically confined to women.

This may be a form of autoimmune disease but essentially the cause is obscure.

### Pathology

There is nonspecific chronic inflammation affecting mainly the submucous and muscular layers of the bladder wall which is infiltrated with small round cells, fibrotic and scarred.

The main effect is reduction of bladder capacity to about 100ml or less, so that intense pain is felt when the bladder distends.

Cystoscopy reveals characteristic ulcers (Hunner's ulcers) in the vault of the bladder but it may be absent. This area bleeds when the bladder is decompressed.

### Treatment

Treatment is difficult and unsatisfactory.

1. Steroids—The dramatic response to steroids in some cases have suggested

that a collagen disturbance may be responsible.

2. Hydrodistension of urinary bladder followed by intravesical instillation of dimethyl sulphoxide (DMSO) is the current choice in early cases.
3. Cystectomy with urinary diversion is the only option for severe recurrent cases.

### Chronic Cystitis

It is caused by the same pathogens as for acute cystitis. Persistence of the infection leads to chronic cystitis, which differs from the acute form only in the character of this inflammatory infiltrate.

Chronicity of infection gives rise to fibrous thickening of the subepithelial layer and consequent thickening and inelasticity of the bladder wall, resulting in reduced bladder capacity.

Symptoms vary from minor frequency to recurrent episodes of severe acute cystitis.

Chronic inflammation may lead to problems in the long term.

Histologically, the chronically inflamed bladder may show cystic changes (cystitis cystica) and the development of squamous metaplasia.

Squamous cell carcinoma may develop in areas of squamous metaplasia in long-standing inflammation.

### Treatment

If infection persists despite adequate treatment of any predisposing factors, the patient should be treated with long-term low dose antibiotics, e.g. trimethoprim 100mg twice daily, cotrimoxazole 1 tab twice daily) to suppress multiplication of bacteria in the bladder.

This regime should be continued for 6 – 12 months and in many patients the infection does not recur after stopping treatment.

### Acute Abacterial Cystitis

Cystitis may also be due to trauma chemicals, toxic drugs, irradiation or viruses and related organisms such as *Chlamydia trachomatis*.

Although pus cells may be present in the urine there are no organisms on standard culture.

The condition is to be differentiated from genitourinary tuberculosis and other irritative lesions like calculi or tumors.

### Irradiation Cystitis

Radiotherapy given for tumors of the pelvic viscera can give rise to overt cystitis with typical symptoms. Subsequent fibrosis may lead to shrinkage of the bladder and persistent frequency of micturition. The contracted bladder may require augmentation cystoplasty. In mild cases, symptomatic treatment and reduction in the dose of radiation are all that is required.

### Cystitis Cystica

Normally glands are not found in the bladder mucosa. But in long-standing chronic inflammation, small islands of epithelium become buried and form minute cysts filled with clear fluid, most abundant over the trigone. This is frequently found in patients with recurrent frequency and dysuria.

Very rarely, cases of adenocarcinoma of the bladder may arise in these areas of glandular metaplasia. Of course, cystitis cystica as such is completely a benign condition.

### Encrusted Cystitis

Encrusted cystitis results from infection of the bladder by urea splitting organisms, particularly *B. proteus* and *Ps. pyocyanea* which render the urine alkaline (hence also called alkaline encrusted cystitis) and promote the deposition of phosphatic material on the bladder wall.

There are symptoms of chronic UTI.

The treatment is by antibiotics and attempting to acidify urine which is usually resisted by the ammonia produced by the proteus.

The end result is usually a small contracted bladder requiring urinary diversion or cystoplasty.

### Malakoplakia

It is associated with chronic cystitis of unknown etiology characterized macroscopically by yellow slightly raised mucosal plaques, 3 to 4 cm in diameter. The surrounding mucosa is edematous, hyperemic and inflammatory.

Histologically, the plaques are made up of large foamy macrophages with occasional multinucleate giant cells and interspersed lymphocytes. In addition mineralized laminated concretions known as Michaelis Gutmann (MG) bodies are typically present both within the macrophages and between

cells and composed of bacterial debris which reflect defective macrophage function. When malakoplakia involves the ureter, it can cause obstruction, resembling a urothelial cancer.

This is not a premalignant condition.

Treatment is empirical but a combination of trimethoprim and sulphonamide may be the treatment of choice.

### Tuberculous Cystitis

Tuberculosis of the bladder is virtually always associated with renal tuberculosis. From the kidney, it is carried in the stream of urine to the bladder.

#### Pathology

The earliest involvement of the bladder is located in the vicinity of the ureteral orifice which is drawn upwards by fibrosis and infiltration of the ureteral wall and held permanently wide open like a golf hole (golf hole ureter).

Superficial tuberculous ulcers then spread across the trigone and eventually may involve the whole bladder wall, causing great pain and frequency of micturition.

#### Clinical Features

There is persistent frequency and painful voiding resembling cystitis from any cause.

The urine shows many pus cells but is sterile on routine culture.

#### Treatment

Treatment should ideally be given in consultation with a chest physician with experience in dealing with tuberculosis. However it responds rapidly to antituberculous drugs but occasionally in cases of advanced renal changes, the infection may not subside until the involved kidney and ureter have been removed.

As the granulomas in the bladder respond to treatment, they heal with fibrous tissue, and the bladder shrinks until it may have a small capacity. Augmentation cystoplasty works very well for such a patient. Bladder augmentation may be done either by ileocystoplasty or cecocystoplasty. The fibrosed supratrigonal bladder is removed and the bladder is augmented with a segment of bowel (an intact segment of cecum, a detubularized segment of ileum or a detubularized ileocecal segment).

### SCHISTOSOMIASIS OF THE BLADDER (Syn—Endemic hematuria, urinary bilharziasis)

This is an infestation of the bladder by a trematode, *Schistosoma hematobium*, through the cutaneous route, while taking bath in infected water.

#### Pathology

The life cycle of *S. hematobium* involves two hosts. 1. Definitive host – man and 2. The intermediate host – fresh water snail.

The cercariae (fork tailed larval form) released from the snail swim freely in fresh water, pierce the skin of man and ultimately lay their ova in venules in the bladder and ureters.

In the bladder and lower third of the ureters the extruded ova from the venules damage the overlying mucosa causing terminal hematuria and later stimulate fibrosis and calcification, causing contraction of the bladder and ureteral stenosis.

Hydronephrosis and pyonephrosis may follow, often bilateral leading to renal failure.

Squamous cell carcinoma of bladder is a common sequel to bladder Schistosomiasis.

#### Clinical Features

The earlier stages of the infestation go unnoticed and later on hematuria brings the patient to the doctor. Physical signs are almost nil.

#### Diagnosis

1. A microscopic examination of urine will show the presence of eggs of *S. hematobium*.
2. The presence of eggs can be demonstrated in the vesical mucosa removed by cystoscopic biopsy.
3. Cystoscopy may show sandy patches of calcified dead ova with degeneration of the overlying epithelium.

#### Treatment

The modern chemotherapy for bilharziasis consists of a single dose of praziquantel, which for safety may be repeated after a month. Dose is 60mg/kg. local treatment of bilharzial ulcers and granulomas may be performed by light diathermy coagulation.

Bilharzial papillomas and carcinomas require the same surgical measures as the non-bilharzial ones.

### THIMBLE BLADDER (Syn— Systolic Bladder)

It is the inability of the bladder to retain adequate amount of urine as a result of reduction of bladder capacity due to fibrosis and contraction and clinically manifested by frequency of micturition, dysuria and recurrent episodes of cystitis.

The common causes are:

1. Tuberculous cystitis
2. Chronic intestinal cystitis
3. Radiation cystitis
4. Malignancy
5. Bilharziasis
6. Previous surgery on the bladder.

#### Investigations

- Cystoscopy
- Cystography
- IVU
- Urine for culture and sensitivity
- Specific diagnostic tests.

#### Treatment

1. The cause is treated.
2. Augmentation of bladder capacity by doing ileocystoplasty or cecocystoplasty.
3. Steroids
4. Hydrostatic dilatation.

### TUMORS OF THE BLADDER

#### Classifications

- I. Epithelial tumors—These constitute 95 percent of the bladder tumors originating from the mucous membrane.
  1. Benign
    - Papilloma
    - Adenoma
  2. Malignant
    - i. Transitional cell carcinoma (commonest).
    - ii. Squamous cell carcinoma following squamous metaplasia.
    - iii. Adenocarcinoma following columnar cell metaplasia. This is rare (2%).
- II. Connective tissue (Mesenchymal) tumors
  1. Benign
    - Hemangioma.
    - Neurofibroma
    - Leiomyoma
    - Rhabdomyoma

2. Malignant—commonest is rhabdomyosarcoma less common tumors are leiomyosarcoma and fibrosarcoma.
- III. Miscellaneous group—Pheochromocytoma, carcinoid tumor, lymphoma, etc.
- IV. Secondary neoplasms
  - From the kidneys—papilloma and papillary carcinoma may spread to the bladder by implantation.
  - From the prostate cancers and
  - From the rectum, sigmoid colon and uterus direct spread may occur.

### CARCINOMA OF THE BLADDER

The bladder is the second most common site of genitourinary tumors after the prostate.

Bladder cancer is more common in males and usually occurs after the age of 50. In men it is the fourth most common cancer after prostate, lung and colorectal carcinomas.

#### Predisposing Factors

1. Chemicals—Aniline dye workers and those working in the leather, paint and rubber industry are more susceptible to bladder cancers. In aniline dye workers, 2 Naphthylamine is the chief carcinogenic agent.
2. Schistosomiasis or bilharziasis of bladder makes it more susceptible to develop squamous cell carcinoma.
3. Smoking increases the risk of developing bladder carcinoma.
4. Pelvic irradiation
5. Chemotherapeutic agent like cyclophosphamide
6. Balkan nephropathy
7. Chronic cystitis – This may lead to squamous cell metaplasia leading and squamous cell carcinoma.

#### Pathology

Like cancer anywhere bladder cancer may take one of three macroscopic forms viz. a papillary growth, a solid nodule and an ulcer.

Carcinoma *in situ*, at cystoscopy, may appear entirely normal or as flat plaques resembling ordinary bacterial cystitis.

#### Microscopically

There are three types:

- i. Transitional cell carcinoma—90 percent.

- ii. Squamous cell carcinoma—about 5 percent.
- iii. Adenocarcinoma—1 to 2 percent arises either from the urachal remnant or from areas of glandular metaplasia.

#### Grading

There are three Grades  $G_1$ ,  $G_2$  and  $G_3$ .

$G_1$  = well-differentiated.

$G_2$  = moderately differentiated

$G_3$  = poorly differentiated

#### Staging

Staging is determined by depth of bladder wall invasion, extent of pelvic and lymph node spread and presence of distant metastases.

#### TNM Staging

##### T = Primary tumor

$T_a$  = Noninvasive papillary carcinoma

$T_{is}$  = Carcinoma *in situ* flat tumor.

$T_1$  = Tumor invades subepithelial connective tissue.

$T_2$  = Tumor invades muscle.

$T_{2a}$  = Tumor invades superficial muscle (inner half).

$T_{2b}$  = Tumor invades deep muscle (outer half).

$T_3$  = Tumor invades perivesical tissue

$T_{3a}$  = Microscopically

$T_{3b}$  = Macroscopically (extravesical mass).

$T_4$  = Tumor invades any of the following: Pelvic wall, prostate, uterus, vagina, abdominal wall.

$T_{4a}$  = Tumor invades prostate or uterus or vagina.

$T_{4b}$  = Tumor invades pelvic wall or abdominal wall.

##### N = Regional lymph nodes

$N_0$  = No regional lymph node metastasis.

$N_1$  = Metastasis in a single lymph node 2cm or less in greatest dimension.

$N_2$  = Metastasis in a single lymph node > 1 cm but < 5cm in greatest dimension or multiple lymph nodes none more than 5cm in greatest dimension.

$N_3$  = Metastasis in a lymph node > 5cm in greatest dimension.

##### M = Metastasis

$M_0$  = No distant metastasis.

$M_1$  = Distant metastasis present.

#### Spread

- a. Direct spread into the pelvic viscera, e.g. prostate, uterus, vagina, colon and rectum.

- b. Lymphatic spread – to internal iliac nodes then to paraaortic nodes.
- c. Hematogenous spread occurs to liver, lungs and less commonly to brain.

### Clinical Features

- Painless hematuria (95%) is the most common symptom, dysuria or frequency occurs in 10 percent cases.
- Suprapubic pain if tumor extends beyond bladder wall.
- Abdominal examination is negative unless the bladder outlet is obstructed (palpable bladder), the ureteric orifice is occluded (palpable kidney) or large bladder mass.
- Nonspecific symptoms are weight loss, anemia and pyrexia.

### Investigations

1. The three cardinal investigations in patients with hematuria are urine analysis, Intravenous urography and cystoscopy.
  - a. Urine examination shows presence of blood and demonstration of cancer cells is confirmatory.
  - b. IVP shows the growth as a persistent filling defect.
  - c. Cystoscopy shows the growth and permits a biopsy.
2. USG and CT scan—will diagnose and stage the invasive tumors.
3. To detect distant metastasis chest X-ray and skeletal survey with CT scan bone, liver and brain scan may be necessary.

### Treatment

The different modalities of treatment available are:

1. Surgery—Transurethral resection of bladder tumor (TURBT) and radical cystectomy.
2. Radiotherapy.
3. Intravesical chemotherapy and immunotherapy with BCG.

### Principles of Management

The most important aspect in the management of bladder tumors is to evaluate the stage and grade of the tumor as the treatment and prognosis depends on it.

- Carcinoma *in situ* (T<sub>is</sub>) and superficial nonmuscle invasive tumors (T<sub>1</sub>) are usually managed with transurethral resection of bladder tumor (TURBT) with or

without intravesical chemotherapy or immunotherapy.

- Muscle invasive tumors (T<sub>2</sub>, T<sub>3</sub>) are treated by radiotherapy and total cystectomy either alone or in combination.
- Partial cystectomy (partial bladder resection) can be done for localized lesions situated away from ureteral orifices and the base.
- Palliative radiotherapy and chemotherapy can only be applied in case of advanced fixed tumors (T<sub>4a</sub> and T<sub>4b</sub>).
- Metastatic cancer – The aim is palliation and patient is given multiagent chemotherapy viz. M-VAC (Methotrexate, vinblastine, doxorubicin and cisplatin).

### Surgery

#### Radical Cystectomy

Once the tumor has invaded the superficial muscle it is unlikely to be satisfactorily controlled endoscopically.

Worldwide most patients presenting with muscle invasive bladder cancer are treated by radical cystectomy with formation of a conduit drainage system (by ileal conduit or ureterosigmoidostomy) or orthotopic bladder substitution (a type of bladder reconstruction). In this operation, the bladder with the overlying peritoneum, the prostate, seminal vesicles, all the fascial and surrounding areolar tissues and all the pelvic lymph nodes are removed. The anterior trunk of internal iliac artery and its branches should also be removed.

These are the same patients who are expected to respond to radiotherapy with an excellent chance of tumor cure and preservation of a functioning bladder.

#### Radiotherapy

Patients unfit for surgery or unwilling to accept the consequences of surgery are treated by radiotherapy. These patients are usually older and frailer and possibly have more advanced disease than a comparable cystectomy group.

#### Chemotherapy

The use of chemotherapy as either neoadjuvant or adjuvant treatment along with definitive therapy has often resulted in a 5 year survival rate of 60 to 70 percent.

Combination chemotherapy using CMV (Cisplatin, Methotrexate and Vinblastine) and M-VAC (Methotrexate, Vinblastine, Adriamycin and Cisplatin) appear to show extremely good response rates.

### Prognosis

- i. Superficial tumors—75 percent 5 year survival.
- ii. Invasive tumors—10 percent 5 year survival.
- iii. Fixed tumors and metastasis—Median survival is 1 year.

## URINARY INCONTINENCE

### Definition

Urinary incontinence is defined as the involuntary loss of urine. Extraurethral incontinence is loss of urine through a channel other than the urethra, e.g vesicovaginal and ureterovaginal fistulae.

### Physiology of Micturition

The normal bladder capacity is 300 – 400ml. As the bladder fills with urine, the detrusor muscle relaxes to accommodate the rise in volume without a rise in pressure.

When the bladder is full, stress receptors in the bladder wall will initiate a reflex contraction via the nervi erigentes (S<sub>2-4</sub>) of the detrusor muscle and relaxation of the sphincter urethrae through the pudendal nerves.

Although micturition is primarily a spinal reflex, coordination between contraction of detrusor and the relaxation of the distal sphincter occurs in the pons for normal micturition. Fibers also come from the frontal cortex (Fig. 47.3).

Thus the spinal reflex is controlled by an inhibitory cortical and pontine mechanism which allows conscious control over micturition. The conscious control develops during early childhood.

If the integration pathway from the pons is interrupted, the function of sacral spinal segment is preserved and the detrusor contracts but the distal sphincter does not relax and remains toxically contracted. This disorder is known as detrusor – sphincter dyssynergia and may produce urge incontinence. (See neurogenic bladder later in this chapter).



## Etiology

### Incontinence in Male

1. Stress incontinence or incontinence due to sphincter weakness. There is involuntary loss of urine during activities which produce a rise of intra-abdominal pressure, e.g. coughing, straining or lifting, etc. It may occur in the postoperative period, e.g. post-prostatectomy incontinence. Incontinence may occur after repeated urethral dilatation or urethroplasty, and in chronic illness or debility or after pelvic fracture.
2. Urge incontinence is not due to sphincter weakness and is accompanied or immediately preceded by a sudden compelling desire to pass urine which is difficult to defer. It occurs either due to motor dysfunction, e.g. detrusor hyperreflexia (Uninhibited bladder seen in patients with neurological disease) or detrusor instability (secondary to bladder outflow obstruction or idiopathic) or sensory dysfunction of the bladder. Sensory urgency may be associated with intravesical pathology (Interstitial cystitis, bladder calculi, bladder tumor, etc.)
3. Overflow incontinence – There is involuntary leakage of small amounts of urine from time to time from a distended bladder in cases of neglected chronic retention. The bladder is thin-walled and hypotonic.

### Incontinence in Female

1. Stress incontinence usually occurs after repeated childbirths.
2. Urge incontinence occurs following urinary infection, e.g. cystitis which is common in women.
3. Continual or extraurethral incontinence, e.g. vesicovaginal fistula often occurs following radiotherapy in carcinoma cervix. This type of incontinence also occurs in Congenital ectopic ureter opening into vagina and ectopia vesicae (Extrophy of the bladder).

## Clinical Features

- In stress incontinence, there is loss of urine during coughing, sneezing, straining, weight lifting, etc. These symptoms are quite specific for stress incontinence. The vesical pressure becomes greater than

urethral pressure transiently with resultant urine leakage. This is very common in women, especially following childbirth. The urine losses usually range from 10 to 50 ml.

- In urge incontinence, there is abnormal detrusor contraction which results in raised vesical pressure. If the raised vesical pressure exceeds the urethral pressure, urinary leakage occurs.
- Symptoms of continuous dribbling (as in fistula), operation like abdominoperineal resection, hysterectomy, neurological disease may point to an underlying cause.

## Investigations

1. Urine culture to exclude infection.
2. IVP—is indicated in most patients. It may be diagnostic in congenital abnormalities, e.g. ectopic ureter or urinary fistula.
3. Urodynamics—Specific information about detrusor and sphincter function is best obtained from urodynamic studies.
  - Uroflowmetry measures flow rate.
  - Cystometry is the recording of pressure volume relationship of the bladder during its artificial filling via a catheter. It can differentiate between urge and stress incontinence.
  - Videocystometry – shows leakage of urine on straining in patients with stress incontinence.
4. Cystoscopy – if bladder stone or neoplasms are suspected.
5. Vaginal speculum examination with or without cystogram if vesicovaginal fistula is suspected.

## Treatment

### Stress Incontinence

- Medical treatment:
  - i. Pelvic floor exercises and weight reduction if the patient is obese.
  - ii. Alpha-adrenergic drugs like phenylpropranolamine may help by increasing urethral tone.
  - iii. Estrogen cream in case of atrophic vaginitis with stress incontinence. Local or systemic estrogen reduces urine leakage by proliferation of urethral mucosa.
- Surgery: If the above measures fail, surgical correction is required.

- Retropubic or endoscopic urethropexy is done.
- Colposuspension operation is done in females with stress incontinence.

### Urge Incontinence

- a. This is mainly treated medically by the following measures:
  - Treatment of any underlying cause like infection, tumor, stone, etc.
  - Anticholinergic and smooth muscle relaxants, e.g. propantheline, flavoxate hydrochloride.
  - Bladder training.
- b. Surgical treatment
  - i. Augmentation cystoplasty by doing either ileocystoplasty or colocolocystoplasty.
  - ii. A small number of patients require urinary diversion, e.g. ileal conduit or Koch pouch.

### Urinary Fistula

Always requires surgical treatment.

### Overflow Incontinence

- a. Treatment of the cause of bladder outflow obstruction, e.g. By TURP (Transurethral resection of prostate) for BPH (Benign prostatic hypertrophy).
- b. CISC (Clear intermittent self-catheterization)—This is the treatment of choice for neurogenic overflow incontinence.

## RETENTION OF URINE

Urinary retention is defined as the inability to pass urine.

### Types

It is of two types: Acute retention and chronic retention.

- Acute retention is the sudden inability to micturate in the presence of a painful bladder.
- Chronic urinary retention is the presence of an enlarged painless bladder with or without difficulty in micturition.

Overflow incontinence is an uncontrollable leakage and dribbling of urine from the urethra in a case of chronic retention. Lower motor neuron or flaccid bladder (diabetes mellitus, tabes dorsalis, posterior spinal cord lesion, etc.) usually

produces chronic retention with overflow incontinence.

- Acute on chronic retention is a condition in which acute retention superimposes on chronic retention. This usually occurs due to cold weather, drinking of alcohol or idiopathic suppression of the act of micturition.
- Spastic or upper motor neuron bladder causes chronic retention with reflex incontinence (Automatic bladder).

### Causes

1. Mechanical
  - a. In the lumen of the urethra, e.g. UTI, foreign body, stones.
  - b. In the wall of the urethra, e.g. benign enlargement of prostate and carcinoma prostate, stricture urethra in the male. (BPH is the most common cause of chronic retention), rupture of the urethra.
  - c. Outside the wall of urethra, e.g. fecal impaction, in the female retroverted gravid uterus, fibroid of uterus, ovarian cyst, etc.
2. Neurological
  - i. Injury or disease of the spinal cord.
  - ii. Diabetes—progressive lower motor neuron pattern (flaccid bladder).
  - iii. Idiopathic—detrusor sphincter dyssynergia.
  - iv. Postoperative due to pain and pelvic nerve damage.
  - v. Drugs like narcotics, anticholinergics and antipsychotics.

### Investigations

- Blood urea and electrolytes estimation to assess renal function.
- Full blood count.
- Urine is tested for RBC and signs of infection.
- Prostate specific antigen if carcinoma is suspected.
- Plain abdominal X-ray to see bladder calculi and other stones.
- IVU—For stones and tumors.
- Urodynamics—allows identification and assessment of neurologic bladder dysfunction and bladder outflow obstruction.
- Ultrasound examination to assess BPH and residual urine volume.

### Management

1. Conservative measures: Before a catheter is introduced to relieve the retention of urine, the following conservative measures are tried.
  - Change of posture from recumbency to sitting or standing particularly in the postoperative patients.
  - Privacy and sound of running water often helps.
  - Application of heat and cold alternatively over the hypogastrum often helps the patient to pass urine by diminishing congestion at the bladder neck.
2. Catheterization:
 

If all the above measures fail, the bladder must be catheterized taking all aseptic precautions and care otherwise urinary infection or damage may result.
3. If urethral catheterization is not possible with all possible attempts, then suprapubic puncture or cystostomy is done to relieve the retention of urine.

### VESICAL FISTULA

A fistula is an abnormal communication between two epithelial surfaces – usually between one hollow viscus and another or with the skin.

### Types

- I. Urogenital
  1. Vesicovaginal fistula—(commonest) following neglected obstructed child-birth and also secondary to carcinoma of the cervix or following its irradiation.
  2. Vesicouterine fistula—due to neoplastic disease and postirradiation necrosis.
- II. Vesicoenteric: A fistula into the ileum is seen in Crohn's disease. Vesicoenteric fistula also occurs in tuberculosis and malignancy. This may also be iatrogenic.

### Clinical Features

There is escape of urine in both vesicovaginal and vesicouterine fistula from the vaginal orifice. In vesicoenteric fistula, the most striking feature is the passage of turbid urine, containing recognizable fecal contents and fecal organisms.

### Diagnosis

A cystogram may show the communication but the pressure in the sigmoid is usually

much greater than that in the bladder so that the fistula is better seen with a contrast enema.

### Treatment

- Vesicoenteric fistula—The affected bowel is resected and end to end anastomosis done. The hole in the bladder is closed with absorbable sutures and a catheter is left indwelling for 5 to 6 days.
- Vesicovaginal fistula can be repaired through the transvaginal or transvesical approach.

### URINARY DIVERSION

It is the diversion of urine temporarily or permanently proximal to the site of obstruction.

- Temporary type is done in benign conditions and distal obstructions to promote healing.
- Permanent diversion is done in case of malignant lesions.

### Indications

1. Benign conditions
  - a. Congenital conditions like bladder extrophy, urethral agenesis.
  - b. Acquired—Neuropathic bladder – end stage incontinence that is not otherwise treatable.
  - c. Ureteric injury.
2. Malignant disorders
  - i. After radical cystectomy.
  - ii. As a palliative procedure in advanced bladder cancer.

### Methods of Urinary Diversion

1. Nephrostomy (open and percutaneous method).
2. Transureteroureterostomy – done in case of ureteric injuries.
3. Cutaneous ureterostomy.
4. Ureterosigmoidostomy.
5. Suprapubic cystostomy
6. Intestinal conduit using either ileum or colon.

### Suprapubic Cystostomy

It is commonly indicated for:

- Urethral trauma or surgery on the urethra.
- Retention of urine where a urethral catheter is difficult to pass.

Presently suprapubic cystostomy sets are available which has simplified the

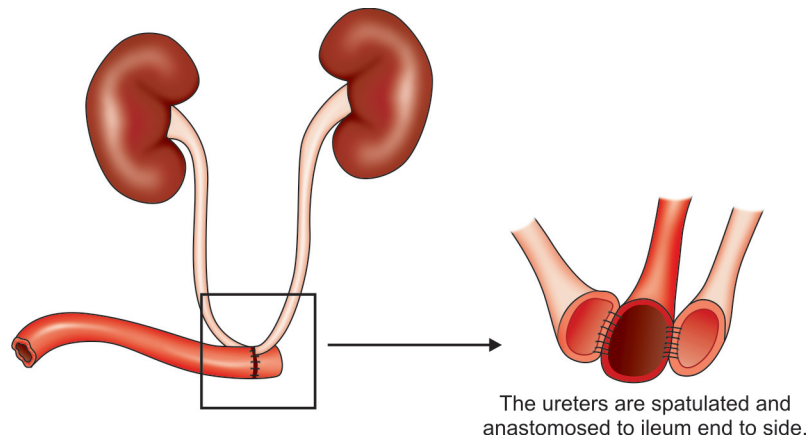
procedure. The catheter is connected to a closed drainage system and is changed every 4 weeks due to occurrence of encrustation and obstruction by phosphate debris.

- Ureterosigmoidostomy—This technique was previously popular but nowadays ileal conduit is preferred.

Its disadvantages are:

- a. Reflux of urine with pyelonephritis.
- b. Anastomotic leak especially in post-radiation cases.
- c. Hyperchloremic acidosis.

The technique involves division of the ureters which are pulled into the sigmoid colon and stitched mucosa to mucosa.



**Fig. 47.2:** Diversion of urine by ileal conduit

### ILEAL LOOP CONDUIT

Here the ureters are mobilized and a loop of ileum with intact vascularity is isolated. Ureteroileal anastomosis is done either end to end or end to side or both ureters are anastomosed together and then to the end of the ileal segment.

The distal loop is brought out through a preselected site. Excess ileum is then everted for about 2 cm (Fig. 47.2).

### Continent Urinary Diversion

This can be done by many methods of which the Koch's pouch is frequently used.

In this method avascularized loop of ileum is isolated and ureteroileal anastomosis is carried out at one end and the other end forms the stoma. The ileum at each end is intussuscepted to form an antireflux nipple. The middle portion is formed into a reservoir.

The technique provides a device in which urine collects and can be removed periodically.

### NEUROGENIC BLADDER

A neurogenic or cord bladder is one in which the normal vesical function is disturbed by interruption of the neural pathways of the bladder.

The understanding of this impaired function requires knowledge of normal neural connections that control bladder function.

- Voluntary micturition is under the control of the brain (prefrontal cortex),

connections pass from here to the main controlling and coordinating center in the pons, the pontine micturition center and from here down into the spinal cord, where they are found in the lateral columns bilaterally.

- The parasympathetic supply to the bladder leaves from S<sub>2</sub>, S<sub>3</sub> and S<sub>4</sub> segments of the spinal cord by way of the pelvic nerves (Nervi erigentes). These fibers pass through the hypogastric plexus without interruption, to reach bladder wall. In the wall of the bladder they form synapses with short postganglionic fibers.
- The sympathetic fibers are derived from spinal segments T<sub>10</sub>, T<sub>11</sub>, T<sub>12</sub>, L<sub>1</sub> and L<sub>2</sub> synapse in the hypogastric plexus from where postganglionic fibers reach the bladder wall.
- The somatic innervation of the sphincter urethrae (external urethral sphincter) is derived from the perineal branch of internal pudendal nerve (S<sub>2</sub>, S<sub>3</sub> and S<sub>4</sub>). This controls the voluntary part of micturition. Thus, the bladder is analogous to the skeletal muscle in that neural control can be divided into upper and lower motor neuron components.

The features of neurogenic bladder dysfunction depend upon the level of involvement of the micturition center.

### Upper Motor Neuron, Unstable or Uninhibited Bladder (Spastic Bladder) (Fig. 47.3A)

This is due to lesions above the sacral micturition center. The higher motor centers

fail to exert their usual inhibitory influences on the sacral center. As a result this center becomes excited and the desire to pass urine occurs when the bladder holds less, often considerably less than 300ml urine.

The causes of uninhibited bladder are:

- Stroke
- Multiple sarcosis
- Parkinsonism
- Spinal cord injury (trauma, prolapsed intervertebral disk, etc.)

The patient complains of frequency, urgency and sometimes urge incontinence.

When the bladder fills to a certain limit the detrusor muscle contracts reflexly and the bladder empties – hence this is also known as reflex or automatic bladder. These automatic contractions of the bladder occur usually at intervals of one to four hours.

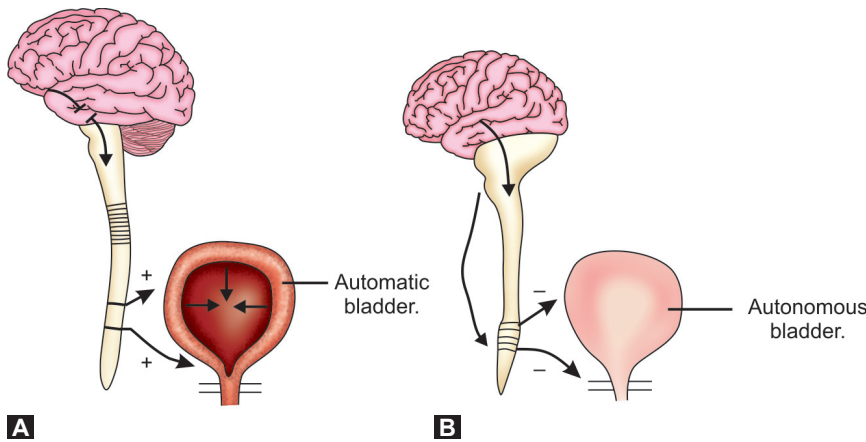
### Treatment

- Intermittent self-catheterization.
- Indwelling catheterization.
- Anticholinergic drugs like oxybutynin, propantheline bromide, etc.

### Flaccid (Lower Motor Neuron) Bladder (Fig. 47.3B)

Damage to the lower motor neuron component, i.e. the sacral micturition center gives rise to flaccid bladder and sphincter with overflow incontinence. The causes are:

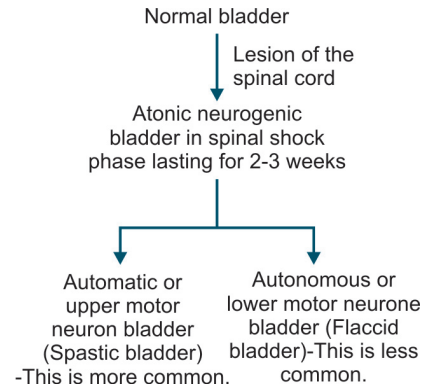
1. Spinal cord injury.
2. Tumors
3. Poliomyelitis
4. Spina bifida



**Fig. 47.3(A to B):** Neurogenic bladder dysfunction. (A) Upper motor neuron (spastic) bladder due to lesions above the sacral micturition center. (B) Lower motor neuron (flaccid) bladder due to lesions of sacral micturition center or peripheral nerves.

limb from the bladder. The stage of spinal shock lasts for a variable period commonly 2 to 3 weeks. Following this phase the bladder may become either spastic or remains flaccid depending on the level of spinal cord injury as mentioned above.

During the stage of spinal shock, the bladder has to be drained preferably by intermittent catheterization.



Thus following spinal cord injury the various stages of bladder dysfunction may be as follows.

**Complications**

- Recurrent urinary tract infections.
- Calculus formation.
- Hydronephrosis.
- Pyonephrosis.

**Treatment**

- Intermittent self-catheterization (ISC).
- Indwelling catheterization.

Long-term catheterization (urethral or suprapubic) may be necessary in either spastic or flaccid bladders, but this is avoided if at all possible as it is associated with increased infection as well as blockage.

**Atonic Bladder in Spinal Shock**

If there is severe spinal cord injury, there is a stage of flaccid paralysis, below the level of injury, regardless of the stage of trauma. There is bladder overfilling with overflow incontinence due to involvement of afferent

5. Radiation
6. Pelvic surgery.

Therefore, the micturition center in the spinal cord is completely destroyed and contraction of the detrusor is dependent only on the nerve plexus and ganglia situated in the bladder wall.

Such contractions are often inefficient resulting in a continuous dribbling. This has been referred to as autonomous bladder.

There is accumulation of huge residual urine which causes back pressure on the kidneys producing hydronephrosis or even pyonephrosis.

# Chapter 48

## Renal Failure and Transplantation

➤ Acute renal failure

➤ Chronic renal failure

➤ Renal transplantation

### ACUTE RENAL FAILURE

#### Definition

Acute renal failure (ARF) is defined as the acute suppression of renal function developing over a period of hours to days resulting in the failure to maintain fluid, acid base and electrolyte balance, produce hormones like renin, prostaglandins, and erythropoietin and excrete nitrogenous waste products like urea and creatinine. It is often accompanied by oliguria (urine output of 400ml/24hrs or less) and rarely anuria.

#### Causes

There are many possible causes of ARF which can be broadly divided into three categories viz. prerenal, renal and postrenal.

1. Prerenal causes:
  - i. Loss of blood from any cause, e.g. trauma, hemorrhage from surgery.
  - ii. Loss of plasma as in burns and crushing injuries.
  - iii. Loss of fluid and salt
    - a. From the gut in severe vomiting, diarrhea, acute intestinal obstruction, pancreatitis, paralytic ileus, peritonitis and fistulous drainage.

- b. From the skin due to sweating and severe exfoliative dermatitis.
- iv. Hypotension due to cardiogenic shock (Myocardial infarction, constrictive pericarditis, etc.) and bacteremic shock.
2. Renal causes: (intrinsic renal failure)
  - i. Acute tubular necrosis (ATN) — Two types are recognized.
    - a. Ischemic ATN — Ischemia is caused by a low blood pressure and this is often accentuated by renal vasoconstriction. Prolonged renal ischemia with prerenal azotemia leads to the development of ischemic ATN.

Causes:

1. Following a sudden decrease in blood volume due to hemorrhage, severe plasma loss as in burns, great decrease in extra cellular fluid volume, e.g. in prolonged vomiting and diarrhea, etc. These conditions all fall into the category of shock.
2. The renal failure of crush syndrome in which there is severe contusion of the muscles of the leg and release of free myoglobin on the circulation, leading to a degree of vasoconstriction.

3. Incompatible blood transfusion— This may lead to renal failure with hemoglobinemia and antibodies against red cells.
4. Postoperative renal failure – multiple factors are involved viz. traumatic shock, blood loss, infection, etc.
5. Sepsis syndrome.
- b. Nephrotoxic ATN: This may be caused by a wide variety of agents, e.g. salts of heavy metals (mercury and gold), carbon tetrachloride, radiographic contrast media, insecticides and drugs particularly aminoglycoside antibiotics. The kidney shows extensive necrosis of the proximal tubules but unlike the changes seen in ischemia, the basement membrane is undamaged.
- ii. Acute renal disease—for example acute glomerulonephritis, acute intestinal nephritis and pyelonephritis.
- iii. Disease of large renal vessels, e.g. renal arterial thrombosis, emboli or stenosis, bilateral renal vein thrombosis.
3. Postrenal causes. They are related to obstruction which may result from blockage of the ureter, e.g.



by stones and tumor, or bladder outflow obstruction due to prostatic hypertrophy or carcinoma.

Immediate relief of such obstructive lesions by the appropriate means may result in rapid resolution of the acute renal failure.

### Pathology

Almost 80 percent of acute renal failure is due to acute tubular necrosis or vasomotor nephropathy (VMN) but the clinician must be aware of the possibility of other etiologies.

In case of ARF, grossly the kidney is large, edematous and pale.

Microscopically, there is mitochondrial disruption, nuclear changes and shedding of the brush border of proximal convoluted tubules.

### Clinical Course of Intrinsic Renal Failure

It has three distinct phases:

- Oliguric phase which lasts for about 10 days but is extremely variable.
- The diuretic phase heralds the recovery of renal tubular function.
- The recovery phase may last (postdiuretic phase) from 3 to 12 months during which glomerular filtration rate (GFR) and tubular function gradually improve to nearly baseline levels.

### Diagnosis

Acute renal failure usually comes to the attention of the physician either because of a raised serum creatinine or blood urea nitrogen level or because of oliguria.

### Clinical Evaluation

A clinical evaluation is of utmost importance to make the diagnosis of acute renal failure.

The background factors and the etiology of oliguria with azotemia should be ascertained through a careful history, thorough clinical examination and other relevant investigations.

- A plain abdominal film may exclude calculi in the urinary tract.
- Ultrasound can detect dilatation of the ureter and kidneys that might suggest an obstructive lesion, while abdominal CT scan and antegrade or retrograde

pyelography may help in assessing the nature and site of the obstruction.

- Renal scintigraphy is useful in determining arterial patency to the kidneys and gives information about excretion and differential function between the two kidneys.
- IVU — With high dose or infusion pyelogram, some excretion may be seen especially in the early phase despite azotemia. A dense nephrogram progressing to a negative pyelogram is very suggestive of obstruction.

### Treatment

Postrenal failure cases are amenable to surgical drainage either endoscopically or by open surgery, e.g. nephrostomy or ureterostomy. Prerenal failure detected clinically and by biochemical parameters should be treated by hydration and diuretics. They rapidly reverse and recover function.

### Intrinsic Renal Failure

It requires elaborate treatment.

### Conservative Treatment

It consists of supportive measures to keep the patient alive till recovery of the renal lesion takes place.

- Fluid replacement — Intake of fluid is restricted to replacing the lost volumes only, i.e. 500 to 800ml (Insensible loss) plus previous days urine output.
  - Fever increases fluid loss. Preexisting over hydration should be taken note of. Fluid is best given orally. In case of nausea or vomiting IV route has to be used.
- A low protein diet with additional calories (daily intake of 3000kcal) is generally recommended and should be ordered in consultation with the dietitian.
- Nephrotoxic drugs should be discontinued or avoided.
- Electrolytes—Hyperkalemia should be corrected by IV glucose – insulin or non-exchange resins (calcium resonium).

Acidosis correction with  $\text{NaHCO}_3$  should be resisted for fear of Na retention. sodium restriction is necessary to prevent fluid over load.

- Intravenous  $\text{H}_2$  receptor antagonist is very useful since upper GI hemorrhage is very common in ARF patients.

- Antibiotics may be needed to avert infection — Pre-existing or related to catheter or IV fluids.
- Improved urine output may be obtained by infusion of dopamine (2–5  $\mu\text{g}/\text{kg}/\text{min}$ ) and frusemide (10–15  $\text{mg}/\text{kg}/\text{hour}$ ) and there is good evidence that this may be useful in improving renal blood flow by reversing renal vasoconstriction.

### Dialysis

Dialysis may be indicated if conservative measures fail to control the situation.

### Indications

- Clinical
  - Fluid overload.
  - Pulmonary edema.
  - Poor clinical condition.
  - Pericarditis.
  - Before surgery.
- Biochemical
  - Serum potassium > 7 mmol/liter.
  - Serum urea > 35 mmol/liter.
  - Arterial pH < 7.15 and bicarbonate < 15mmol/liter.
  - Daily rise of urea over 50 mg%.

### Peritoneal Dialysis Versus Hemodialysis

Peritoneal dialysis is the simplest form of treatment, although hemodialysis may be necessary.

### Dialysis

Both forms of dialysis are effective when properly used.

Peritoneal dialysis is preferred in patients who cannot tolerate hypotensive episodes or the heparinization required to perform hemodialysis.

Hemodialysis, on the other hand, achieves more rapid clearance of the plasma and is especially useful in treating hyperkalemia, fluid overload and drug overdoses.

### CHRONIC RENAL FAILURE

Chronic renal failure is defined as an established slowly progressive decrease in GFR and tubular function. Generally the term chronic renal failure is applied in cases of renal failure of more than several months duration.

The most common causes are diabetic nephropathy, hypertension and glomerulonephritis.

### Causes

1. Hypertension (Nephrosclerosis)
2. Diabetic nephropathy
3. Glomerulonephritis
4. Obstructive uropathy
5. Interstitial nephritis
6. Chronic pyelonephritis
7. Hereditary renal disease, e.g.
  - Polycystic kidney disease
  - Alport's syndrome.

In this condition, the kidney progressively fails to perform, its function of excretion of waste products, maintenance of regulatory functions of the body, erythropoiesis and control of normal blood pressure usually the disease is progressive, leading to end stage renal failure.

### Clinical Features

1. Anemia—Normochromic normocytic anemia occurs in almost all patients with CRF with creatinine concentration greater than 3.5 mg/dl. Hb concentration remains in the range of 5 to 8 gm/dl.
2. Coagulopathy—due to decreased platelet adhesiveness. Hemodialysis is the most effective treatment of platelet dysfunction.
3. Electrolyte disturbance – The most serious electrolyte abnormality is hyperkalemia. Hazards of hyperkalemia are cardiac conduction abnormalities and dysrhythmias.
  - Hypermagnesemia — Increased plasma magnesium levels may accompany chronic renal failure especially when GFR falls below 10ml/min. Hypermagnesemia results in CNS depression, depression of ventilation and coma.
  - Hypocalcemia in CRF reflects the presence of hyperphosphatemia and decreased intestinal absorption of calcium secondary to decreased activity of vitamin D. Decreased vitamin D activity is due to the fact that kidneys are responsible for the final conversion of this vitamin (25, OH cholecalciferol) to 1, 25 dihydroxy cholecalciferol, a highly active metabolite.
 

Chronic hypocalcemia will lead to hyperparathyroidism with resulting bone decalcification, development of

osteodystrophic abnormalities and pathological fractures.

- Plasma sodium concentration is usually normal in patients with chronic renal failure.
- Metabolic acidosis results as the hydrogen ion excretion (40 – 60 mcg/day) is impaired in CRF.
 

Hemodialysis is effective in restoring the arterial pH to nearly normal values.
- Systemic hypertension – caused by renal ischemia leading to increased angiotensin activity or Na retention activating aldosterone mechanism or both.
- Infection is due to use of immunosuppressive drugs like corticosteroids and decreased activity of phagocytes.

### Treatment

Conservative treatment—In case of established chronic renal failure conservative treatment consists of the same concerns about fluid and electrolyte balance, prevention or adequate treatment of infections and nutrition as for acute renal failure.

More aggressive measures like dialysis or transplantation are used when conservative treatment fails.

## RENAL TRANSPLANTATION

Transplantation means implanting a tissue or organ in one part taken from another part or another person as in grafting. Renal transplantation means transplantation of a kidney from a compatible donor to restore kidney function in a recipient suffering from renal failure.

Renal transplantation is the treatment of choice for many patients with end stage renal disease as it provides a better quality of life than that with chronic dialysis. It is also more cost-effective than dialysis.

### Definitions

- Isograft means a transplant between two identical twins.
- Allograft is an organ or tissue transplanted from one individual to another.
- Heterotopic graft is a graft placed at a site different from that where the organ is normally located.

- Orthotopic graft is the graft placed in its normal anatomical site.
- Xenograft means a graft performed between different species.
- Structural grafts act as a non living scaffold and can be of biological origin, e.g. arterial and heart valve grafts or synthetic, e.g. Dacron vascular prosthesis.

### Preparation of the Recipient

Recipient is prepared by hemodialysis to optimize coagulation and hydration and to improve electrolyte and acid-base balance and blood transfusions to correct anemia in the pretransplant phase. The following are the contraindications to renal transplantation.

1. Severe diabetes with large vessel disease.
2. Active malignant disease.
3. Active tuberculosis or other systemic infection.
4. Extremes of age (Elderly people > 65 years or very young children).
5. Bladder outflow obstruction.
6. Some types of glomerulonephritis, e.g. focal glomerular sclerosis, mesangiocapillary glomerulonephritis.

The last three are relative contraindications.

### Donor Selection

The majority of donated kidneys come from cadavers, although a small proportion of transplants are taken from live related donors.

- Cadaveric donor— Cadaveric donors are usually patients with irreversible brain-stem damage who are dependent on artificial ventilation but have no evidence of malignant disease.

Both kidneys are removed from the donor en bloc with a patch of aorta and inferior vena cava through a cruciate or subcostal incision. The kidneys are then perfused via the renal artery with cold hypertonic citrate solution and packed in ice.

- Living related donors
  - An identical twin
  - Father or mother
  - Son or daughter is ideal
  - Brother or sister.

### Preoperative Management

1. Tissue typing
  - i. The behavior of organs and tissues transplanted, within a species depend

initially on surgical technique and subsequently on biological factors.

The biological destruction of allografts is an immune process. The graft behaves as an antigen, which specifically sensitizes the lymphoid tissues (CD<sub>4</sub> or helper T cells and CD<sub>8</sub> or cytotoxic T cells) of the recipient. Antibodies and cellular immune mechanism destroy the grafts.

The most important transplantation antigens responsible for initiating rejection are called HLA or human leukocyte antigens. Although HLA antigens are found on the surface of most cells of the body, they were first studied in white cells, hence the name.

The HLA antigens are glycoproteins which are expressed by a group of genes on the short arm of chromosome 6 which make up the human major histocompatibility complex (MHC).

- ii. There are other minor histocompatibility factors which can lead to graft rejection. This is evidenced by the fact that even when grafts are matched for all HLA antigens, immunosuppression may still be required to prevent rejection.
- iii. ABO blood group antigens— The ABO blood group antigens are very important in transplantation because they are expressed not only by red blood cells but by most other cell types as well. Hence it is vital for all types of organ allograft to ensure that the recipients receive a graft that is ABO blood group compatible.

### Test Done Before Transplantation

1. Tissue typing.
2. ABO blood group compatibility.
3. Complete blood picture.
4. Renal function tests.
5. To exclude diabetes, hypertension, HIV, Hepatitis B and C infections.

6. Bilateral renal angiography to study vascular pattern.
7. Other biochemical investigations.

### Operation Technique

#### Donor Operation

- Removal of kidney from a living donor is similar to a nephrectomy for other reasons. It is important to preserve as much length of the artery, vein and ureter as possible. It is preferable that the donor is looked after by a separate team of surgeons from the recipient.
- When a living donor kidney is not available a cadaveric kidney is used as mentioned earlier.

#### Recipient Operation

- The kidney is transplanted in the retroperitoneal tissues of the right iliac fossa. The renal artery is anastomosed with internal iliac artery end to end and the renal vein with external iliac vein end to side.

The ureter is implanted into the bladder through the submucosal tunnel.

### Postoperative Management

1. Immunosuppression with the exception of kidney grafts between identical twins, some method of inhibiting the immune system of the recipient is always necessary.

The most valuable immunosuppressive agents are azathioprine, cyclosporine – A and corticosteroids.

The best form of immunosuppression is a triple therapy, regimen of azathioprine, cyclosporin A and corticosteroids each given in relatively low nontoxic doses so that bone marrow depression for azathioprine, nephrotoxicity for cyclosporin A and Cushing's syndrome for corticosteroids are avoided with the simultaneous achievement for good immunosuppression.

2. If necessary dialysis is maintained until the kidney function is satisfactory.

3. A full blood count, electrolytes, urea, creatinine levels are measured each day.
4. Long-term immunosuppression and follow up are mandatory.

### Complications Following Transplantation

1. Infection due to immunosuppression
2. Rejection
  - a. Acute rejection — This occurs between 1 and 8 weeks after transplantation. This responds to high doses of IV steroids, e.g. Methylprednisolone 90 mg IV/day × 3 days.
  - b. Chronic rejection — This may occur at any time after transplantation. It involves the vascular element and does not respond to steroids.
3. Surgical complications
  - a. Vascular complications
    - Renal artery thrombosis occurs in 1 percent of cases. Renal vein thrombosis is more common which occurs in approximately 5 percent of cases.
    - It presents during the first week after transplantation with sudden pain and swelling at the site of the graft. The diagnosis is confirmed by Doppler ultrasonography.
    - Urgent surgical exploration is indicated and in most cases transplant nephrectomy is required.
    - Renal artery stenosis can develop later on even years after transplantation and treated by angioplasty. When angioplasty fails or is not technically possible the condition can be treated successfully by open surgery and vascular reconstruction.
  - b. Urinary leak giving rise to urinoma It usually results from technical error at the ureteric anastomosis or ureteric ischemia.
  - c. Lymphocele can develop due to perivascular dissection. Such lymphocele can lead to ureteric obstruction. Asymptomatic collection needs to be observed, large ones need drainage.

# Chapter 49

## Urethra and Penis

- Urethra
- Phimosis
- Paraphimosis
- Carcinoma penis
- Peyronie's disease

### URETHRA

#### Development

The urethra consists of the prostatic, membranous and spongy parts.

#### Prostatic Part (3cm)

- Part of the prostatic urethra above the colliculus seminalis or verumontanum, i.e. above the opening of the ejaculatory ducts is developed as follows:
  - Posterior wall is developed from the vesicourethral part of endodermal cloaca incorporated with the caudal parts of the two wolffian ducts.
  - Anterior or ventral wall is formed from the endoderm of the vesicourethral part of the cloaca. Upper part of the prostatic urethra upto the colliculus, corresponds in development with the entire female urethra.
- Part below the colliculus — All walls are developed from the endoderm of pelvic part of urogenital sinus.

#### Membranous Part (2cm)

It is the part lying within the deep perineal pouch and developed from the endoderm of the pelvic part of the urogenital sinus.

#### Spongy Urethra (15cm)

- Penile part—Upto the base of glans penis is developed from the phallic part of

urogenital sinus by the meeting of the two genital folds.

- Glandular part—the proximal portion develops from the prolonged urogenital sinus while the distal portion is developed from the ectodermal invagination.

#### Applied Importance

- Hypospadias— If the ectoderm from the genital tubercle forming the glans penis which is a solid column of ectodermal cells does not canalize and there is accompanying failure of complete fusion of the genital folds the result is hypospadias - a midline opening on the ventral surface of penis.
- Epispadias— It is a condition in which the urethra opens on the dorsal surface of penis close to anterior abdominal wall. The cause of epispadias is obscure.

#### Surgical Anatomy

##### Prostatic Urethra

The prostatic urethra as the name implies, traverses the prostate. Its posterior wall contains a longitudinal elevation called the urethral crest, on each side of which is a shallow depression, the prostatic sinus into which 15 to 20 prostatic ducts empty.

At about the middle of the crest is an elevation termed the colliculus seminalis

or verumontanum, into which opens the prostatic utricle, the male equivalent of the vagina.

On either side of the orifice of the prostatic utricle open the ejaculatory ducts formed by the union of the duct of seminal vesicle by the terminal part of the vas deferens.

Figure 49.1 shows inside of prostatic urethra.

#### The Membranous Part

It is the shortest portion of the urethra and runs from the prostate to the bulb of the penis. It perforates the perineal membrane after which it becomes spongy urethra about one inch below and behind the symphysis pubis.

#### The Spongy Part

The spongy urethra (15cm) traverses the corpus spongiosum of the penis. It first passes upwards and forwards to lie below the pubic symphysis and then in its flaccid state bends downwards and forwards.

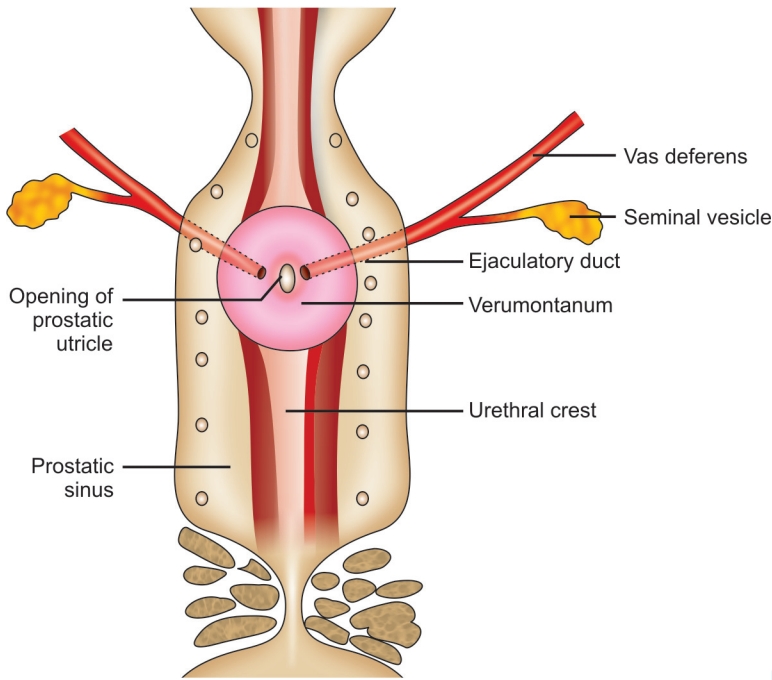
#### The Female Urethra

The female urethra is about 4cm in length and lies embedded in the anterior wall of vagina.

Its external meatus opens 1 inch behind the clitoris.

Surgical anatomy of penis – See figures 84.2 and 84.3 and short case, carcinoma of penis in chapter 84

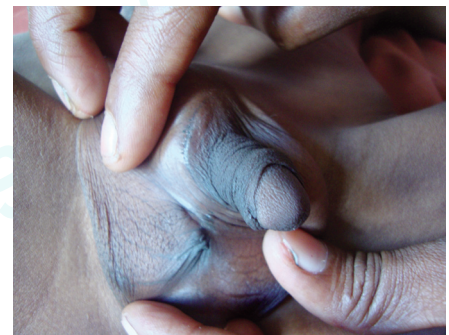



**Fig. 49.1:** Schematic diagram showing inside of prostatic urethra.



**Fig. 49.2:** Distal penile hypospadias



**Fig. 49.3:** Penoscrotal hypospadias

## Hypospadias

This is the commonest congenital malformation of the urethra. In this condition the external urethral meatus is situated at some point on the under surface of the penis or perineum.

### Types

1. Glandular variety—Here the external urinary meatus is situated a few mm away from the normal site within the glans. It is the commonest variety.
2. Coronal varieties — It occurs due to failure of development of urethra within the glans penis. Thus the urethra opens at the corona glandis. Both the above types do not give major functional problems. It can be left alone without treatment.
3. Penile variety — Here the external meatus is situated at any part on the under surface of the body of penis (Fig. 49.2).
4. Penoscrotal — The urethral opening is situated at the junction of the penis and the scrotum (Fig. 49.3).
5. Perineal type — In this case the scrotum is split and the urethra opens, between its two halves.

Apart from the glandular variety the other varieties are due to failure of fusion of the genital folds in varying degrees.

### Clinical Features

- Incidence is 1:350 males.
- Chordee —Many of the cases are associated with bending of the penis on erection. The chordee is the fibrous cord distal to the ectopic meatus.

Hence, the more proximal the ectopic meatus is, the more prominent is the bending or chordee.

- The inferior aspect of the prepuce is poorly developed and the upper aspect of prepuce looks like a hood.

### Treatment

In case of glandular hypospadias, no treatment is required, only meatotomy and dilatation of the external urethral meatus, when it is too small.

In case of the other varieties, operative treatment has to be undertaken. The operation is done either in two stages or as a single stage procedure.

Two stage procedure consists of:

1. Straightening of the penis or chordee correction, when the child is 1.5 to 2 years of age.
2. Reconstruction of the urethra is done when child is 5-6 years old. By using locally available skin either from the prepuce or from penile shaft. This is called

urethroplasty. Hence circumcision should not be done in hypospadias.

One stage procedure: Nowadays one stage operation is done between 6 months to one year of age due to advances in pediatric anesthesia and techniques in surgery.

### Injuries to the Urethra

This has been discussed in the chapter of genitourinary trauma.

### Urethral Stricture

#### Causes

1. Congenital, e.g.
  - Meatal stenosis associated with coronal hypospadias.
  - Bulbar stricture.
2. Acquired
  - a. Traumatic
    - Perineal trauma
    - Urethral instrumentation
    - Ruptured urethra (bulbus or membranous part).
  - b. Inflammatory, e.g.
    - Balanitis xerotica obliterans (meatal stricture).



- Tuberculosis.
  - Nonspecific urethritis.
  - Postgonococcal urethritis.
- c. Neoplastic, e.g.
- Transitional cell carcinoma of urethra
  - Adenocarcinoma of urethra.
- d. Postoperative
- Prostatectomy
  - Repair of ruptured urethra.

### Clinical Features

- History of instrumentation or perineal injury is usually present. In many patients of course, no precipitating cause is found
- Common in young age 20 - 40years.
- Suprapubic pain and swelling due to distended bladder.
- There is slow urinary stream.

### Special Investigations

- Uroflowmetry— Urine flow-rate shows a characteristic prolonged plateau appearance.
- If a urethral stricture is suspected an ascending urethrogram should be performed to demonstrate its length, site and caliber.
- Many strictures are, however, detected only during cystourethroscopy.

### Treatment

#### Treatment of Passable Strictures

1. Dilatation: The traditional treatment of urethral stricture is periodic dilatation under local anesthetic with metal sounds or plastic bougies and using strict aseptic technique. To start with the dilatation is done frequently but gradually, the interval is increased. Finally, dilation is advised, only once a year, throughout the life of the patient. This is popularly known as birthday dilatation.
2. Internal urethrotomy: This is achieved by cutting the stricture with an endoscope knife under direct vision (optical urethrotomy) which minimizes the chance of false passage formation. The roof (12 o'clock position) of the stricture is divided by a sharp thrust of knife. The procedure can be repeated if necessary and cure rates of 50 to 80 percent can be expected. Some centers advocate the use of specially lubricated ('Lofric') catheters for self dilatation of the urethra for several

months after urethrotomy to reduce the risk of stricture recurrence.

#### Treatment of Impassable Stricture

**Urethroplasty** or surgical reconstruction is indicated for dense fibrotic strictures or recurrent strictures after urethrotomy.

- a. If the stricture is short, it can be excised and an end to end anastomosis performed.
- b. In case of a long segment stricture the narrowed area of urethra is opened longitudinally and penile or scrotal skin on a vascular pedicle is used to cover the defect.

**Meatoplasty:** Strictures at the external urethral meatus can be treated by reconstruction of the meatus (Meatoplasty).

See also operative surgery section, chapter 97

#### Complications of Stricture Urethra

The major complication of stricture of urethra is obstruction to the outflow of urine. This gradually causes dilatation of the urethra proximal to the stricture and compensatory hypertrophy of the bladder musculature. Thus the complications are:

1. Urinary tract infection due to stasis of urine.
2. Paraurethral abscess. It may rupture through the skin causing urinary fistula.
3. Stone formation due to urinary stasis and infection.
4. Hernia, hemorrhoids and rectal prolapse due to abdominal straining to void urine.
5. Hydronephrosis and hydroureter due to back pressure.

### PHIMOSIS

Phimosis is defined as the inability to retract the foreskin fully over the glans penis.

An infant's foreskin is normally adherent to glans penis until the age of 3 years. Thereafter it separates progressively from the glans and is nonadherent by the age of 6 years.

#### Causes

1. Congenital — In these cases the preputial orifice is narrow since birth. In extreme cases there is ballooning of the preputial sac.
2. Acquired:
  - a. Inflammatory — Long-standing inflammation of the glans (balanitis), or of the prepuce (posthitis), or a combination of both (balanoposthitis).

- b. Traumatic — Phimosis may result from forceful stretching.
- c. Neoplastic — Carcinoma of penis may present as a recent phimosis.

### Clinical Features

#### Age

Congenital phimosis present in the first few years of life. Acquired phimosis may present later in life according to the causes of phimosis.

Difficulty in micturition is the main symptom. The mother complains that when the child micturates, the prepuce balloons out and the urine comes out in thin stream.

On examination, the opening of the prepuce is so small that it cannot be retracted over the glans penis.

#### Complications

- Paraphimosis — When a phimotic prepuce is forcibly retracted over the glans penis, it is stuck, behind the glans producing this condition.
- Carcinoma of penis.

#### Treatment

Circumcision — It is the removal of part or all of the prepuce.

For the technique of circumcision see the operative surgery section, chapter 97

### PARAPHIMOSIS

This is a complication of phimosis and is caused by pulling a tight foreskin over the glans penis.

It cannot be returned back to position and remains as a constricting band behind the corona glandis.

There is gross edema and swelling of the prepuce as well as the glans. Gangrene may ensue in neglected cases.

There is great discomfort and pain.

#### Treatment

1. In early cases reduction may be done one ml of hyaluronidase is injected into each lateral aspect of the swollen prepuce. The swelling reduces considerably due to absorption of the edema fluid and reduction is often possible.

Alternately multiple punctures may be made in the oedematous prepuce to drain the fluid out and then reduction is done.

2. If the above method is unsuccessful, the constricting band is dorsally slit under general anesthesia. Thereafter the narrow cuff of skin which forms the constricting band is excised. Reduction is now easy. Circumcision may be performed immediately or at a later date after 6 to 8 weeks.

## CARCINOMA PENIS

### Definition

Carcinoma of penis develops from the squamous epithelium of glans or prepuce, from a premalignant lesion or *de novo*.

### Etiology

- a. Factors associated with increased incidence of carcinoma penis.
  - i. Poor personal hygiene.
  - ii. Recurrent balanitis or balanoposthitis.
  - iii. Phimosis: It is virtually unknown among Jews, who are circumcised soon after birth. Irritation due to retention of smegma is probably a factor. Regular washing under the prepuce and glans penis probably offers protection equal to that of circumcision.
- b. Premalignant conditions are:
  - i. Leukoplakia — This is an area of hyperkeratosis on the inner surface of the prepuce almost always caused by balanitis and balanoposthitis. It is similar to the condition seen on the tongue.
  - ii. Erythroplasia of Querelet (syn—Paget's disease of the penis) — It appears as an area of chronic red eczema of the glans penis or inside of the prepuce. The lesion oozes and forms crust. Paget's disease is the intraepithelial stage of squamous cell carcinoma, very similar to the Paget's disease of nipple.
  - iii. Bowen's disease— This is also a variant of carcinoma *in situ* which appears as elevated red papules on the shaft of penis.
 

This disorder may also occur in mucosa at other places viz. Oral cavity, vulva.
  - iv. Long-standing genital warts (syn—Condyloma acuminata) may rarely be the site of carcinoma of penis.

- v. Balanitis Xerotica Obliterans (BXO)
  - A history of BXO is found in about one in five cases of cancer of the penis.

### Pathology

The most frequent site of the tumor is in the sulcus between the glans and the prepuce.

### Macroscopically

Carcinoma of penis may present either as a papillary growth on the glans or as an ulcerating and infiltrating tumor. The latter type is more common.

### Microscopically

These lesions are squamous carcinomas with epithelial pearl formation and mitotic activity.

Invasion of the urethra or corpora cavernosa is a poor prognostic sign.

### Spread

1. Local— The tumor may fungate through the prepuce to present as an ulcerating lesion on the penile skin. Proximal spread along the shaft may destroy the substance of the penis.
2. Lymphatic — The inguinal lymph nodes are frequently involved, often bilaterally.
3. Blood borne spread occurs late and is unusual.

### Staging

The following is the Jackson's clinical staging of carcinoma penis.

Stage I — Tumor confined to the glans or prepuce.

Stage II — Tumor involves the shaft (corpora cavernosa) of penis.

Stage III — In addition to stage II, enlarged mobile inguinal lymph nodes are present.

Stage IV — Inguinal nodes are fixed and/or there is distance metastasis.

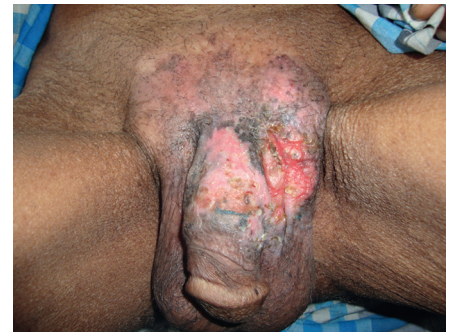For TNM staging see the short case on 'carcinoma penis', chapter 84

### Clinical Features

#### Age

About 40 percent of the patients of carcinoma of penis are under 40 years of age. It commonly affects individuals of middle or old age (Fig. 49.4).

Majority of patients present with non-healing ulcer on the glans or a purulent or



**Fig. 49.4:** Squamous cell carcinoma over the shaft of penis in an old patient

blood stained discharge from below the non-retractile prepuce.

Curiously enough, carcinoma of penis never seems to occlude the urethra to produce retention of urine.

Carcinoma as such is a painless condition but if there is too much of associated secondary infection, the lesion may be painful.

### Diagnosis

Diagnosis is confirmed by incisional biopsy from the periphery of the lesion at its junction with normal tissue.

### Investigations

For staging of the disease – USG and CT scan of abdomen are done to assess lymph node enlargement in the pelvis when the inguinal lymph nodes are palpable.

### Treatment

#### Stage I

1. Growth confined to prepuce — Circumcision is the treatment of choice.
2. Growth confined to the glans (stage I) –Treatment is either radiotherapy or surgery.
  - i. Radiotherapy—With external beam or local moulds especially iridium.
 

Advantage—Penis is preserved and suitable for young patients. If there is local recurrence, partial amputation is done.
  - ii. Partial amputation of penis with at least 2cm above the upper edge of the tumor if radiotherapy fails or is not available. In stage I cancer, radiation gives a 5 year cure rate of almost 100 percent but careful follow-up is

essential because late recurrence will develop in about 25 percent cases which will require partial amputation.

### Stage II

- i. Surgery is the treatment of choice and total amputation of penis with perineal urethrostomy is done if adequate shaft (minimum 2.5 cm to carry out sexual function and to direct the urinary stream) cannot be obtained, otherwise partial amputation should be done.
- ii. Radiotherapy should be done in cases unfit for surgery.

### Stage III and IV

- i. Treatment of the penile growth by circumcision, partial amputation or total penectomy depending on the site and extent of lesion. Radiotherapy is done in cases unfit for surgery.

- ii. Management of inguinal lymph nodes.

It is treated in one of the two ways.

1. Inguinal block dissection on both sides if the nodes are mobile and operable. Block dissection should however, be delayed for at least 3 weeks after treatment of the penile lesion. Enlargement if due to infection, will usually subside with antibiotic treatment during this period. Block dissection is indicated if there is persistent enlargement and needle aspiration proves the tumor metastasis.
2. Radiotherapy and chemotherapy is done as a palliative measure if the nodes are matted together and fixed.

### Prognosis

For localized disease without metastasis (Stage I and II) the 5-year survival rate is 60 to 90 percent.

With inguinal node involvement it is 30 to 50 percent and with iliac node involvement it is 20 percent.

There are no known survivors amongst those with distant metastasis.

### PEYRONIE'S DISEASE

This is a condition associated with fibrosis of one or both cavernosum, which gives rise to the curving of the penis in erect position.

The exact etiology is not known, past trauma, has been incriminated as the initiating factor. It is sometimes associated with Dupuytren's contracture.

Examination reveals an indurated mass felt on the dorsum of penis.

*Treatment* is difficult. Injection of hydrocortisone into the indurated area may be tried with some success.

# Chapter 50

## Prostate

- Surgical anatomy
- Histology
- Relations
- Blood supply
- Physiology
- Development
- Benign Enlargement of Prostate
- Carcinoma Prostate

### SURGICAL ANATOMY (Figs 50.1A to C)

It is a fibromusculoglandular organ, about 3 cm long, which surrounds the prostatic urethra. It resembles the size and shape of a chestnut and weighs about 18gm.

#### The Prostatic Capsules

These are normally two but pathologically three in number.

1. The true capsule—A thin fibrous sheath which surrounds the gland.
2. The false capsule—Outside the true capsule there is condensation of pelvic fascia forming the false capsule which continues with the fascia of Denonvilliers posteriorly

and into the fascia surrounding the bladder. Between the true and false capsules lies the prostatic venous plexus.

3. The pathological capsule—When benign adenomatous hypertrophy of prostate takes place, the normal peripheral part of the gland becomes compressed into a capsule around this enlarging mass. This is also called the surgical capsule of the prostate (Fig. 50.1).

#### Lobes

The majority of the prostate lies on the lateral and posterior aspects of the urethra. There is little prostatic tissue anteriorly.

Anatomically, the prostate is divided into three lobes – median and two lateral lobes.

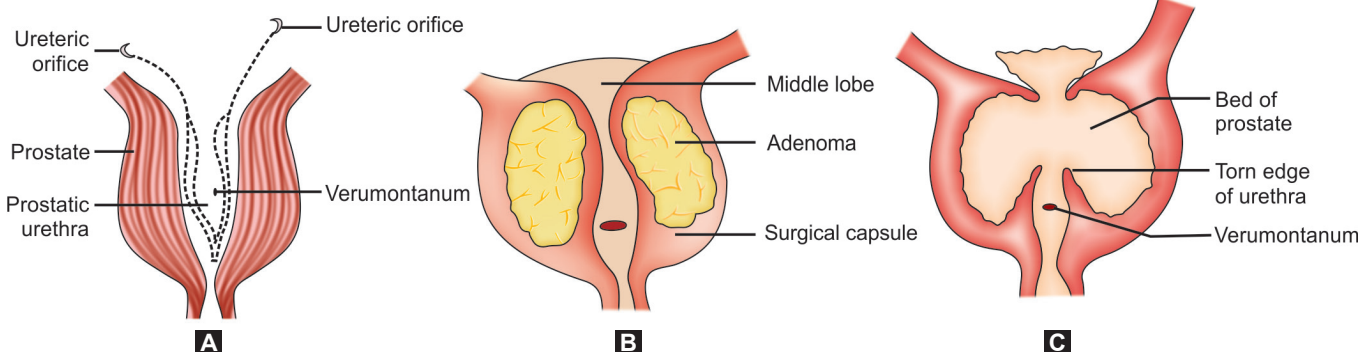
Surgically it is divided into five lobes— median, anterior, posterior and two lateral lobes.

Both views are equally correct because subdivisions of the prostate are arbitrary.

#### HISTOLOGY

Embedded in a fibromuscular stroma there is an inner group of mucosal glands derived from the mesodermal part of the prostatic urethra (central zone) and an outer group of glands (peripheral zone) derived from the rest of the prostatic urethra (endodermal).

This subdivision is of practical importance because the majority of prostatic carcinomas arise in the peripheral zone while benign hypertrophy tends to affect the central zone.



**Figs 50.1A to C:** Surgical anatomy of prostate (A) The normal prostate in vertical section (B) The prostatic adenoma compresses the normal prostatic tissue (C) Prostatectomy removes the adenoma leaving the surgical capsule

## RELATIONS

- Cranial to the prostate are the trigone, ureters and base of the bladder. The ejaculatory ducts enter the upper posterior part of the gland to open into the urethra at the verumontanum. The urethra enters the upper aspect of the prostate near its anterior border. (See Fig. 49.1)
- Inferiorly—The apex of the prostate rests on the external sphincter of the bladder which lies within the deep perineal pouch.
- Anteriorly—Lies the symphysis pubis separated by the fat of the retropubic space of Retzius. Close against the prostate in this space lies the prostatic venous plexus.
- Posteriorly—Lies the rectum separated by the fascia of Denonvilliers.
- Laterally lies the levator ani.

## BLOOD SUPPLY

Arterial supply is mainly from the inferior vesical and middle rectal branches of the internal iliac artery. Venous drainage is to the prostatic venous plexus which drains into the internal iliac vein.

Some venous blood from the prostate passes directly to the valveless prevertebral venous plexus, so affording an easy route of spread of infection or cancer to the spine.

## PHYSIOLOGY

The testicular hormones regulate the development and function of the prostate.

Testosterone is secreted by Leydig cells. In the absence of both testes, the prostate fails to develop.

Prostatic secretion provides 10 to 20 percent of the volume of ejaculate. It contains prostaglandins and the enzyme acid phosphatase. It has also antibacterial activity which may help to prevent urinary infection in men.

Prostate elaborates and secretes prostate specific antigen (PSA), which is a glycoprotein and a tumor marker of prostatic malignancy.

Its normal serum level is 4ng/ml, measured by immunoassay. This level is increased to more than 30ng/ml in metastatic prostatic cancer and in locally confined prostatic cancer, it is 15ng/ml or lower.

## DEVELOPMENT

The glandular part of prostate is developed as solid outgrowths from around the whole circumference of the prostatic urethra. The outgrowths are subsequently canalized to form the follicles and ductules of the gland. The glands are arranged into peripheral zone and central zone as mentioned earlier.

Some glands in front of the urethra degenerate and a fibromuscular isthmus or the so called anterior lobe is formed. Benign glandular hypertrophy, therefore, never affects this part of the organ.

The fibromuscular part is developed from the splanchnic mesoderm which surrounds the urogenital sinus.

## BENIGN ENLARGEMENT OF PROSTATE (BENIGN PROSTATIC HYPERTROPHY)

### Definition

Benign prostatic hypertrophy (BPH) is a condition of unknown etiology characterized by an increase in size of the inner zone of glands of the prostate. It usually occurs in men over 50 years of age. The term BPH is a misnomer as the change is hyperplasia rather than hypertrophy.

### Etiology

The exact etiology of BPH is unknown but the following theories are suggested.

#### a. The hormone theory:

According to this theory, there is decline in the level of androgen, e.g. testosterone with advancing age slowly but significantly. However, the levels of estrogenic steroids are not decreased equally.

A plausible hypothesis suggested is that there is synergistic stimulation of the prostate by both hormones – the estrogen acting to sensitize the prostatic tissue to the growth promoting effect of dihydrotestosterone (DHT) derived from testosterone by the enzyme 5 $\alpha$  - reductase.

The importance of DHT is underlined by the fact that in 5 $\alpha$  - reductase deficiency, the prostate is vestigial and these patients do not develop BPH.

#### b. The neoplastic theory:

This theory postulates that BPH is a benign neoplasm. As the prostate is

composed essentially of fibrous tissue, muscle tissue and glandular tissue, the neoplasm is adenofibromyoma.

Recently prostatic growth factors have been isolated that stimulates the growth of fibroblasts and epithelial cells.

## Pathology

Grossly, the prostate is enlarged, nodular firm and weighs 2 to 4 times the normal weight, i.e. it may weigh up to 40 to 80gm.

- The appearance on cut section varies depending upon whether the hyperplasia is predominantly of the glandular or fibromuscular tissue.
- In primary glandular BPH, the tissue is soft, honeycombed, and milky fluid exudes, while in mainly fibromuscular BPH, the cut surface is firm, homogeneous and does not exude milky fluid.
- Microscopic stromal nodules develop around the periurethral glands; glandular hyperplasia originates around these nodules.
- Eventually their overgrowth compresses the peripheral zone glands forming the 'surgical capsule'. A plane of cleavage is readily set up between the nodular mass and the surgical capsule.

## Histology

There is hyperplasia of all three tissue elements in varying proportions glandular, fibrous and muscular.

## Clinical Features

BPH results in bladder outlet obstruction (BOO). Symptoms of bladder outflow obstruction are of two types viz.

Obstructive and irritative symptoms

#### 1. Obstructive symptoms

- Poor stream of urine due to urethral compression which does not improve, rather, worsens by straining.
- Hesitancy due to longer time taken by the detrusor to overcome the urethral resistance.
- Terminal dribbling and incomplete emptying due to a weak detrusor which cannot sustain the pressure till the end of voiding. There is increased residual volume of urine in the bladder which ultimately gives rise to acute or chronic urinary retention.



- Pain is not a symptom of bladder outflow obstruction.
2. Irritative symptoms: (due to detrusor irritation):
    - Frequency and nocturia—There is incomplete voiding, so the patient has to pass urine more frequently.
 

Later the causes of frequency are cystitis, residual urine and stones.

Nocturia occurs because at night, the cortical inhibition of the bladder is reduced and the sphincter tone is low.
    - Urgency—This is due to the following factors:
      - i. A part of prostatic urethra which is very sensitive is exposed to the bladder urine as the prostate enlarges intravesically.
      - ii. The internal sphincter being stretched up, drops of urine come down to the prostatic urethra giving rise to urgency and urge incontinence.
  3. Other features:
    - Hematuria can result due to a friable prostate or from the rupture of a dilated vein in the bladder base.
    - Hernia and hemorrhoids are frequently associated due to increased intra-abdominal pressure.
    - Urinary infection and vesical calculi are prone to develop due to an increasing volume of residual urine. In advanced cases there may be vesicoureteral reflux, hydronephrosis and renal failure due to back pressure.
 

On digital rectal examination, there is enlarged smooth prostate.
- accuracy. USG can also detect coexistent prostatic cancer.
6. Other investigations like cystourethroscopy and IVP are not routinely done in a case of BPH.

### Differential Diagnosis

From other causes of bladder outflow obstruction, e.g.

- Bladder neck stenosis or hypertrophy
- Urethral stricture
- Functional obstruction
- Prostatic cancer.

### Treatment

#### Indications

- a. Retention of urine—Acute or chronic.
- b. Secondary complications, e.g. Stones, urinary infection.
- c. Large residual urine volume (>150ml) and a poor flow rate (<10ml/sec).
- d. Severe symptoms which interfere with the patient's normal lifestyle. No treatment is required for the patient with an enlarged prostate who has few symptoms, good bladder emptying and normal renal function.

#### Treatment Options

The treatment can be surgical or nonsurgical.

#### Surgery

Prostatic resection is done by any of the following methods.

1. Endoscopic operations:
  - i. Transurethral resection of prostate (TURP)—TURP is preferred in a gland weighing less than 60gm.
 

Advances in fiberoptic technology have resulted in greatly improved visualization of the prostate per urethra.

A resectoscope sheath (24-26F) with its obturator is passed into the bladder. The obturator is then removed and the working element is passed which contains the loop electrode. Resection is done by means of the loop electrode which is connected to the diathermy.

Injury to the external sphincter is avoided by keeping the resection proximal to the verumontanum.

Irrigation fluid is used throughout the procedure and 1.5 percent glycine is preferred. As the irrigating fluid is under pressure, it gets absorbed by the venous sinuses and the TUR syndrome (Hypervolemia and hyponatremia) can result.

- ii. Transurethral incision of prostate (TUIP)—This procedure is indicated for younger patients with small prostate and mild symptoms in whom TURP is considered excessive.
 

The technique involves bilateral endoscopic incisions at 5 O'clock and 7 O'clock position in the prostatic urethra.

The advantages of the procedure are shorter operating time, faster recovery and lower incidence of retrograde ejaculation and bladder neck contracture.

#### 2. Open prostatectomy:

The indications for open prostatectomy are:

- Prostate gland weighing more than 60gm.
- If an additional procedure like cystolithotomy is required.

This is done either by the transvesical route (Freyer, 1901) or the retropubic route (Millin, 1945).

- a. Transvesical prostatectomy (See also Freyer's method of prostatectomy in the operative surgery section chapter 97).

This is done with the patient in a slight Trendelenburg position. A transverse suprapubic incision is made and the bladder is exposed. Any vesical pathology is checked. The index finger is used to break the anterior commissure following which the adenoma is enucleated.

Hemostasis is initially maintained by packing the prostatic bed with a roller gauge for 5 min. Bleeding vessels are dealt with by diathermy or under running with an absorbable suture.

A three way Foley's catheter is then inserted and the bulb is inflated to provide hemostasis. This is removed 7 to 10 days after the operation.

Suprapubic drainage is provided with a Malecot catheter to prevent clot retention. The abdominal wound is closed with a drainage in the retropubic space.

### Investigations

1. Urinalysis is done to rule out infection.
2. Urine culture with antibiotic sensitively is done to identify the organism.
3. Blood urea, serum creatinine and electrolytes are done routinely.
4. Uroflowmetry—Urine flow rate of 15 ml per sec. is normal with increasing obstruction, due to BPH, the flow rate decreases.
5. Ultrasonography (USG)—USG of kidneys and bladder is done to detect residual urine volume and other urinary tract pathology like stones, tumor and diverticula, etc. Transrectal ultrasound (TURS) is the referred method because of its greater

b. Retropubic prostatectomy: Exposure of the bladder is made in the same way as above. The bladder is separated from the posterior aspect of pubis. The anterior capsule of the prostate is incised with diathermy and hemostasis secured.

The adenoma is then enucleated with a finger.

A wedge of tissue is taken out from the bladder neck so as to prevent stricture formation in this region.

Hemostasis is secured and a Foley's catheter is introduced per urethra.

Prognosis: Majority of patients have good quality of life after prostatectomy.

## Nonsurgical Treatment

### 1. Medical treatment

- $\alpha_1$  Blockers—For example Prazocin which relaxes the prostatic smooth muscle. Prazocin improves symptoms and urinary flow rates.
- $5\alpha$  reductase inhibitors—For example Finasteride which inhibits the conversion of testosterone to DHT (Dihydrotestosterone), the androgen active in promoting prostate growth. The drug taken for one year can cause 25 percent shrinkage of the prostate gland.

2. Hormones: Androgens play an important role in the causation of BPH. Thus androgen blocking drugs are found to be useful. These drugs are GnRH analogs (Leuprolide), antiandrogens (Flutamide) and  $5\alpha$  reductase inhibitors (Finasteride).

3. Laser prostatectomy using Nd - YAG laser has been introduced recently.

4. Microwave hyperthermy is a new technique in which thermal damage is produced to the prostatic tissue.

5. Other newer methods include high energy ultrasound and intraurethral stents. The latter is used in men with retention of urine and who are grossly unfit (ASA grade IV) for surgery.

## Complications after Open Prostatectomy

- Immediate (within 48 hours) – these are primary hemorrhage, septicemia.
- Intermediate (within 14 days) – secondary hemorrhage, urinary tract infection.

c. Late complications

- Urethral stricture at
  - Meatus
  - Penoscrotal junction
  - Membranous urethra.
- Bladder neck contracture due to presence of a shell of tissue at the bladder neck. This complication is prevented by doing trigonectomy.
- Retrograde ejaculation.
- Recurrent adenoma—After 8 years 5 percent of patients after open prostatectomy have recurrent adenoma.

## Special Complications after TURP

- TUR syndrome – hypervolemia and dilutional hyponatremia.
- Perforation—of the bladder or prostatic capsule may occur at the time of TURP.
- Incontinence—occurs due to damage of the external urethral sphincter when resection is extended downwards beyond the verumontanum.
- Recurrence 15–18 percent after 8 years.

## CARCINOMA PROSTATE

It is the most common cancer in men over 65 years and the second most common cause of death due to cancer only surpassed by cancer of lung.

### Etiology

The etiology is not definitely known but all evidence suggests that there are hormonal, genetic, and environmental factors.

- Prostate cancer growth is enhanced by testosterone and inhibited by estrogens or antiandrogens.
- Familial susceptibility—It is three times more common in parents or siblings of men who died of it.
- It may be linked to the loss of tumor suppressor genes.

### Pathology

#### Macroscopically

- Carcinoma arises most commonly in the peripheral zone in atrophic areas rather than in hypertrophic areas.
- The gland becomes hard, dense and nodular and when bisected a gritty sensation is

felt as in scirrhous carcinoma of breast. The cut surface looks dense, dry and without any lobulation which differentiates it from benign hyperplasia.

### Microscopically

In 95 percent cases, the tumor is an adenocarcinoma, located in the peripheral zone especially in the posterior lobe. Four histologic types are described – adenocarcinoma, transitional cell carcinoma, squamous cell carcinoma and undifferentiated carcinoma.

### Spread

- Direct spread into the remainder of the gland and to the seminal vesicles.
- Lymph node metastasis occurs to the external iliac and internal iliac nodes. When periurethral lymphatics are involved, the patient complains of pain.
- Hematogenous spread occurs to the bones and characteristically secondaries are osteoblastic. Frequent sites of involvement are pelvic bones, lower lumbar vertebrae, the rib cage and skull.

### Staging

For clinical staging, TNM system is considered the international standard.

#### T (Primary Tumor)

T<sub>1</sub> – No tumor palpable, incidental carcinoma in a clinically benign gland after histological examination of a prostatectomy specimen

T<sub>1a</sub> – Tumor involving less than 5 percent of tissue resected.

T<sub>1b</sub> – Tumor involving more than 5 percent of tissue resected.

T<sub>1c</sub> – Tumor identified by needle biopsy, e.g. because of elevated PSA.

T<sub>2</sub> – Tumor confined within the prostate.

T<sub>2a</sub> – Tumor involves one lobe.

T<sub>2b</sub> – Tumor involves both lobes.

T<sub>3</sub> – Tumor extends through the capsule.

T<sub>3a</sub> – Unilateral or bilateral extension through the capsule.

T<sub>3b</sub> – Tumor extends to the seminal vesicle.

T<sub>4</sub> – Tumor which is fixed or invading adjacent structures other than seminal vesicles, e.g. bladder neck, external sphincter, rectum or pelvic wall, etc.

**N (Regional Lymph Nodes)**

- N<sub>0</sub> – No evidence of involvement of regional lymph nodes.
- N<sub>1</sub> – Involvement of a single regional lymph node.
- N<sub>2</sub> – Involvement of multiple regional (iliac) lymph nodes.
- N<sub>3</sub> – Fixed mass of regional lymph nodes.
- N<sub>4</sub> – Involvement of juxtaregional lymph nodes which are common iliac or para-aortic nodes.

**M (Distance Intestacies)**

- M<sub>0</sub> – No evidence of distant metastasis.
- M<sub>1</sub> – Distant metastasis present.

**Clinical Features**

- Symptoms include those of bladder outflow obstruction, e.g. poor flow, hesitancy and nocturia.
- Symptoms of advanced disease include bone pain which is worse at night, ureteric obstruction and hydronephrosis.

**On Examination**

- Local extent of tumor (T-stage) is detected on rectal examination.
- There may be anemia, enlarged liver, palpable hydronephrosis, vertebral tenderness or palpable bladder.

**Special Investigations**

1. Blood—Blood urea, NPN, serum creatinine estimations done to detect renal function.
2. Urinalysis is done to exclude any infection or hemorrhage.
3. Biopsy—diagnosis is established by either a FNAC or core biopsy.
4. Other investigations are:
  - i. Prostate specific antigen—Normal level 0 – 4ng/ml. PSA level more than 10ng/ml is suggestive of cancer and if PSA is

more than 35ng/ml, it is diagnostic of advanced prostate cancer.

- ii. Transrectal ultrasound (TRUS)—It is one of the most useful staging investigations. Malignant nodules appear hypoechoic.
- iii. Liver function tests will be abnormal if there is metastatic invasion of liver.
- iv. X-ray chest may reveal metastasis in either the lung fields or the ribs.
- v. Bone scan is done as a part of the staging procedure if the PSA is more than 20ng/ml.

**Treatment**

This depends on the stage of the disease. The age and clinical condition of the patient also play an important part in any decision on treatment.

1. Carcinoma confined to the prostate (T<sub>1</sub> – T<sub>2</sub>, N<sub>0</sub> – N<sub>1</sub>, M<sub>0</sub>):

The treatment can be either radical prostatectomy (Removal of prostate and seminal vesicles) or radical radiotherapy (7000 rads over 7-8 weeks). Both treatment modalities give comparable results.

Pelvic lymph node dissection can be carried out immediately prior to radical prostatectomy.

In lymph node negative cases 5 year survival is almost 100 percent with radical radiotherapy.

2. Locally advanced disease (T<sub>3</sub> – T<sub>4</sub>, N<sub>0</sub> – N<sub>1</sub>, M<sub>0</sub>).

External beam radiotherapy is usually suggested for this group of patients.

As the disease has spread to the nodes, it is difficult to remove them surgically.

Side-effect of radiotherapy is radiation cystitis and proctitis.

3. Advanced or metastatic disease (Any T<sub>1</sub>, any N, M<sub>1</sub>):

The treatment of choice is androgen deprivation as the prostate gland is very androgen sensitive.

The main treatment options are orchidectomy or the administration of hormones viz.

- Bilateral orchiectomy (Total or subcapsular) is the simplest form of treatment and produces a response in 70–80 percent of patients.
- Stilbestrol—1mg TDS in patients with bony metastasis. This agent is rarely used now because of unpleasant side-effects like stroke, venous thrombosis, etc.
- Antiandrogens, e.g. Flutamide, cyproterone acetate, etc. They produce pharmacological orchidectomy thus avoiding surgical castration.
- LH–RH agonists – (Leuteinizing hormone releasing hormone) inhibits gonadotrophin production and thereby testosterone levels. LH–RH agonists initially stimulate the hypothalamic LH–RH receptor and then down-regulate it resulting in cessation of pituitary LH production and hence a decrease in testosterone production. In the first 10 days testosterone level may rise and it is wise to give flutamide or cyproterone acetate for this period.

Drugs used include goserelin and leuprolide. It may be given as monthly or three monthly depot injections. These drugs are expensive.

**Prognosis**

- a. Localized tumors—Eighty percent 5 year survival.
- b. Tumors with local spread—Forty percent 5 year survival.
- c. Tumors with distant metastasis—Twenty percent 5 year survival.

# Chapter 51

## Testis and Scrotum

- Embryology
- Descent of testis
- Undescended testis
- Testicular torsion
- Testicular tumor
- Hydrocele
- Varicocele
- Epididymal cyst
- Spermatocele
- Degeneration cysts
- Epididymo-orchitis
- Elephantiasis of scrotum
- Fournier's gangrene

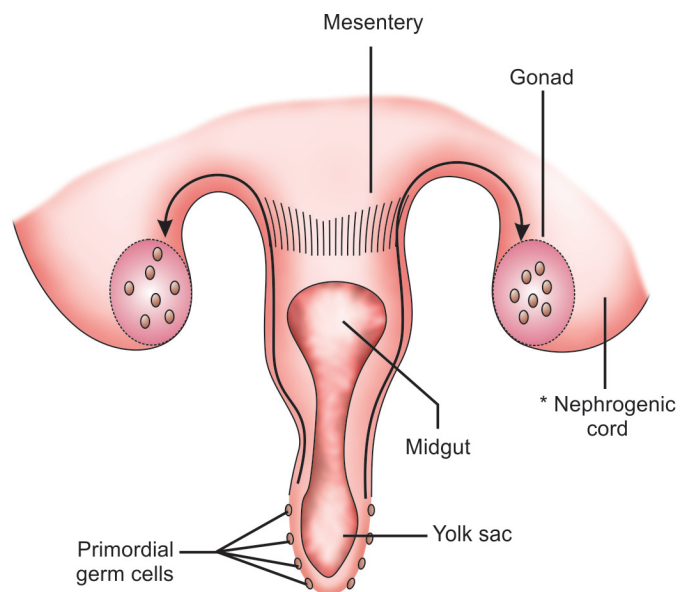
### EMBRYOLOGY (Fig. 51.1)

Each testis develops in the posterior abdominal wall in the lumbar region between 5th and 6th week of intrauterine life, from the genital ridge formed by the proliferation of the celomic epithelium that covers the medial side of the mesonephros of the corresponding side.

- Numerous solid sex cords appear from the surface of the genital ridge into the mesoderm of the mesonephros.
- Primordial germ cells migrate from the wall of the yolk sac into the genital ridge and get incorporated into the sex cords (testes cords). The inner ends of sex cords join to form a cellular plexus, called the rete cord, which is situated close to the blind ends of the mesonephric tubules. Meanwhile the sex cords and the rete cord are canalized to form the seminiferous tubules and rete testes.
- Some of the cells of the testes cords instead of forming seminiferous tubules persist to form the interstitial cells of Leydig.
- The mesoderm of the mesonephros cuts off the connection of the testes cords from the genital ridge and forms the tunica albuginea as well as mediastinum testes and the fibrous septae separating the lobules of testes.

- Efferent ductules of testis are derived from the 12 to 15 persistent mesonephric tubules which establish connections between the rete testis and the mesonephric duct.

The cranial part of the mesonephric (Wolffian) duct becomes highly coiled on itself to form the epididymis while its distal part becomes the vas deferens.



**Fig. 51.1:** Migration of primordial germ cells to the gonad during development of testis

\* The nephrogenic cord develops as a bulging of the intermediate mesoderm on the posterior abdominal wall lateral to the attachment of the dorsal mesentery of the gut. Apart from the gonad (testis or ovary), it also takes part in the development of the mesonephric duct, paramesonephric duct and the metanephrogenic cap (see chapter 46 - development of kidney).

## DESCENT OF TESTIS

From about 8th week of intrauterine life as the testis enlarges it undergoes a caudal migration from its original lumbar position towards the groin. It enters the scrotum at or immediately after birth as follows:

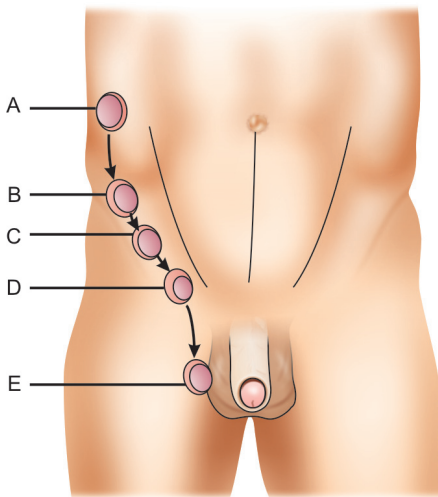
### Chronology of Descent (Fig. 51.2)

- The testes reaches the iliac fossa during the third month of fetal life.
- At 7th month it reaches the deep inguinal ring.
- During the 8th month it traverses the inguinal canal.
- At 9th month it lies at the superficial inguinal ring and
- At or immediately after birth it reaches the scrotum.

### Factors Helping in the Descent of Testis

The exact cause is still unknown but the following factors may be conjointly responsible for descent.

1. Pull of the gubernaculum—A mesenchymal strand, the gubernaculum



**Fig. 51.2:** The time table for testicular descent. (A) Intra-abdominal testis 3rd month; (B) Deep inguinal ring 7th month; (C) Inguinal canal 8th month (D) Superficial inguinal ring 9th month; (E) Scrotum at birth. Position from (A) to (D); also indicate the different positions of undescended testis

testis, extends from the caudal end of the developing testis along the course of its descent to blend into the scrotal fascia. It is suggested that it acts as a guide (gubernaculum = rudder) or that its swelling dilates the inguinal canal and scrotum.

2. Higher temperature inside the abdomen.
3. Intraabdominal pressure – increased intraabdominal pressure helps in rapid descent along the inguinal canal.
4. Hormonal influence
  - i. Androgen secretion by Leydig cells. This is the most important driving force.
  - ii. Hypothalamic pituitary gonadal axis.
  - iii. MIS (müllerian duct inhibitory substance) secreted by Sertoli cells.
5. Active contraction of the arched fibers of internal oblique muscle squeezes the slippery convex surface of testis and helps its rapid descent along the inguinal canal.

### Factors Preventing Descent of Testis

1. Short vas deferens.
2. Short testicular artery.
3. Coiling of the vas deferens and artery.
4. Adhesion of the vas and the artery with the surrounding structures.

### Defects in the Descent of Testis

1. Undescended (arrested descent) testes: This is the commonest anomaly. The testis fails to reach the bottom of the scrotum and lies arrested at some place in the normal pathway of its descent.

- Canalicular testis is the testis lying in the inguinal canal.
- Emergent testis is the testis near the superficial inguinal ring and it peeps out on straining.

2. Maldescended testis (Ectopic or deviated testis)

This is less common than the undescended testis. The testis may take any one of the abnormal positions along four gubernacular fails (iliac, perineal, pubic and femoral) other than that at the scrotum (Fig. 51.3). The positions in order of frequency are iliac, perineal, pubic and femoral. The testis is fully developed and liable to injury.

3. Anorchism (cryptorchism)—Both testes are retained in the abdomen and the individual is sterile.

4. Monorchism—One testis is intra-abdominal and the other is in its normal position.

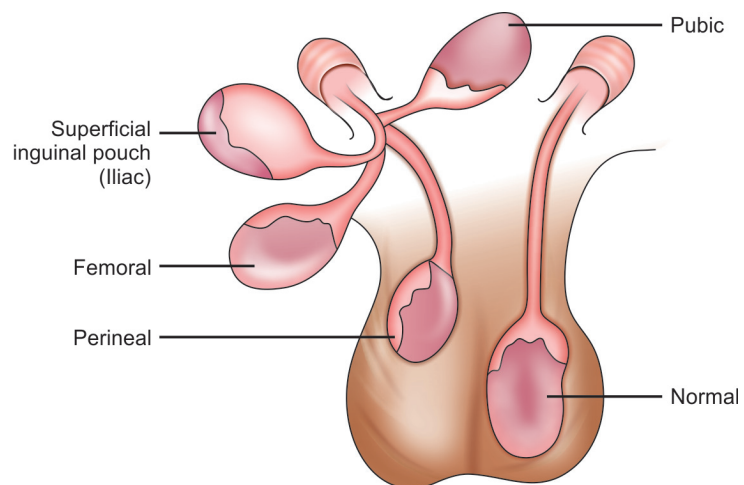
5. Retractable testes: The retractile testis is a normal testis with an excessively active cremasteric reflex resulting in the testes being drawn up to the external inguinal ring. This condition is found only in children.

No treatment is necessary for this condition as the testis comes down to normal position when cremasteric hyperactivity subsides around puberty.

## TESTES

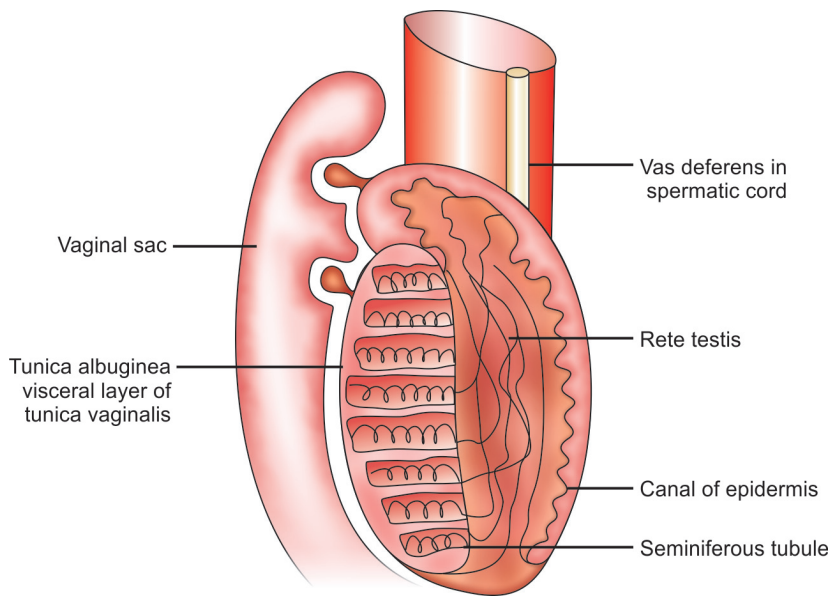
### Surgical Anatomy

The testes are the reproductive glands in the male weighing about 11 to 15 gm. The average



**Fig. 51.3:** Ectopic positions of testis





**Fig. 51.4:** Structure of testis in sagittal section

measurements are 5cm in length, 2cm breadth and 3cm in anteroposterior diameter.

### Macroscopic Anatomy

The testis lies anteriorly in the scrotum and has the epididymis attached to its posterior surface. Each testis is contained by a white fibrous capsule, the tunica albuginea and each is invaginated laterally and anteriorly into a double serous covering the tunica vaginalis. There is normally a small amount of serous fluid between the parietal and visceral layers of tunica vaginalis.

### Blood Supply

The testicular artery arises from the aorta. It anastomoses with the artery to the vas supplying the vas deferens and epididymis, which arises from the inferior vesical branch of the internal iliac artery. This anastomosis is important because ligation of the testicular artery is not necessarily followed by testicular atrophy.

Venous drainage is via a venous plexus in the spermatic cord, the pampiniform plexus to the testicular vein. On the right this vein drains into the inferior vena cava and on the left side, into the left renal vein.

Lymphatic drainage follows the usual rule. It accompanies the venous drainage and thus passes to the para-aortic lymph nodes.

Nerve supply—T<sub>10</sub> sympathetic fibers via the renal and aortic plexus.

### Histology (Fig. 51.4)

The testes is divided into 200 to 300 lobules each containing one to three seminiferous tubules.

Each tubule has a basement membrane and contains several layers of developing germinal cells, supported by Sertoli cells. The basal layer of cells consist of spermatogonia which divide to form primary spermatocysts, which again undergo meiotic division to form secondary spermatocytes. These in turn divide to form spermatids which eventually mature into spermatozoa.

In between the seminiferous tubules lie the interstitial cells of Leydig which secrete the hormone testosterone.

The seminiferous tubules each about 2 feet (62cm) in length anastomose posteriorly into a plexus termed rete testis from which about a dozen efferent ducts arise, pierce the tunica albuginea at the upper part of the testis and pass into the head of epididymis which is actually formed by these efferent ducts coiled within it.

The efferent ducts fuse to form a considerably convoluted single tube which constitutes the body and tail of the epididymis.

### The Epididymis

The epididymis consists of head, body and tail applied to the back of testis. The head of the epididymis is connected to the testes by the vasa efferentia (efferent ductules

of testis), whilst the tail gives rise to the vas deferens. The blood supply is from the intrascrotal branches of the testicular artery.

### Vas Deferens

This is 18 inches (45cm) long tube. The vas passes from the tail of the epididymis to traverse the scrotum, inguinal canal and comes to lie upon the side wall of the pelvis. It then turns medially to the base of the bladder and joins the more laterally placed seminal vesicle to form the ejaculatory duct which traverses the prostate to open into the urethra at the verumontenum or colliculus seminalis.

### Seminal Vesicles

These are coiled sacculated tubes 5cm long which can be unraveled to three times that length.

They lie on each side extraperitoneally at the bladder base lateral to the termination of the vas deferens. Each has common drainage with its neighboring vas via the ejaculatory duct as mentioned above.

The vesicles can be felt on per rectal examination if enlarged, e.g. in tuberculous infection. The seminal vesicles act as stores for semen and receive their nerve supply from the 1st lumbar sympathetic ganglion through the presacral plexus.

A bilateral high lumbar sympathectomy results in sterility as ejaculation is prevented.

### UNDESCENDED TESTIS (Syn—Incomplete Descent of Testis)

The normal process of descent, the factors helping and preventing descent, the chronology of descent and the abnormalities of descent have already been described.

### Pathology of an Undescended Testis

- An undescended testis fails to develop normally.
- The scrotum is an effective temperature regulator for the testis which are kept about 1°C (1.8°F) cooler than body temperature.
- The spermatogenic cells are sensitive to body temperature and deleterious changes occur in the first year of life.

By the age of 4 years massive collagen deposition is evident and by the age of 16 years, irreversible destructive changes will occur, which will halt spermatogenesis and limit the production of androgens to around half the normal level.

- An incompletely descended testis brought down before puberty often develops and functions satisfactorily.

## Clinical Features

### Symptoms

- The cardinal symptom with which the patient presents is the absence of one or both testis from the scrotum. The adult patient with bilateral cryptorchism may present with a complaint of infertility.
- In small number of cases, patients present with indirect inguinal hernia, i.e. a swelling in the groin along with undescended testis.

### Signs

- In true incomplete descent, the scrotum on the affected side is atrophic. If the scrotum is normally developed, retractile testis should be suspected. A retractile testis can always be brought to the bottom of the scrotum, by gently milking it from its position in the inguinal region. A diagnosis of undescended testes should be made only if this is not possible.
- Occasionally one may feel a lump in the line of testicular descent along with an empty scrotum.

## Complications (can be remembered as SATHI)

- S 1. Sterility—In cases of bilateral undescended testis.
- A 2. Atrophy of the testis if descent does not occur by puberty.
- A 3. Other associated anomalies—for example renal agenesis, ectopia vesicae, Klinefelter's syndrome.
- T 4. Torsion—An undescended testis is prone to torsion because of absence of anchorage to the scrotum unlike a normal one.
- T 5. Tumor—Cancer is 35 to 40 times more common in misplaced testes than in the normally descended organ. Seminoma

is the most common tumor. It is rare before the age of 10.

- T 6. Trauma—A testis located in the inguinal region is liable to repeated trauma.
- H 7. Hernia—A congenital hernia is associated with 50 percent of cases.
- I 8. Inflammation, e.g. epididymoorchitis is very rare but is of interest on the right side as it mimics acute appendicitis.

## Treatment

1. There is no scope for hormone treatment. The treatment is always operative and the operation is orchidopexy (See operative section – chapter 97).  
Ideal age for operation: Age by 12 to 24 months of age.  
Operation—The testis is explored in the inguinal canal. It is mobilized by dividing the adhesions and brought down into the scrotum and fixed there in a dartos pouch between the dermis and the dartos.
2. Orchidectomy—It is done after the age of 14 years because of the risk of malignancy.

## TESTICULAR TORSION (Syn—Torsion of the Spermatic Cord)

Torsion is more common in childhood, around puberty but can occur at any age.

## Underlying Abnormalities

- High investment of tunica vaginalis on the cord giving rise to intravaginal torsion. This is the most common abnormality.
- Torsion of testis, together with its covering layers – This type of torsion is found in neonates and is called extravaginal torsion. It is less common.
- Torsion of the testis without involving the cord – This occurs in case of congenitally long mesorchium, separating it from the epididymis. The testis twists on this long mesorchium.
- There may be no underlying abnormality.

## Predisposing Factors

- Trauma
- Cycling
- Cold weather
- Pubertal growth spurt.

## Clinical Features

There are two types of clinical presentation viz.

- i. 50 percent patients have a clear history of warning attacks of testicular pain relieved spontaneously.
- ii. In the other half of patients, there is warning attack and the patient wake up from sleep with pain and swelling in the testes, sometimes accompanied by vomiting and shock.

## Diagnosis

Diagnosis should be suspected in any patient with acute scrotal pain and swelling of the testis. It is mainly clinical.

Diagnosis can be made accurately by Color Doppler but the time lost in the investigation should be kept in mind.

## Differential Diagnosis

1. Epididymoorchitis—Differentiated by:
  - i. Elevation test – If the testicle is elevated pain increases in case of torsion as the twisting is more, while elevation relieves pain in epididymoorchitis.
  - ii. Tender rectal examination with fever is present in epididymoorchitis but not in torsion.
2. Traumatic hematocele—There will be history of trauma.
3. Mumps orchitis—This is rare before puberty and is often preceded by mumps parotitis.
4. Strangulated inguinal hernia—A torted testis may mimic this condition but the affected hemiscrotum is empty.

## Treatment

- In the first few hours of torsion, the testes may be untwisted manually.
- If this is not successful then urgent exploration of the scrotum is done, torsion is corrected and the viable testis is fixed to the scrotum to prevent recurrence.
- Gangrenous testes, which is black-colored is removed.
- Opposite testes is fixed at an early date to prevent torsion.
- In case of doubtful diagnosis of torsion it is better to perform immediate exploration as waiting for making the correct

diagnosis may lead to complete death of the testis.

## TESTICULAR TUMOR

### Incidence

Testicular tumors are responsible for 1 percent of all malignant tumors in the male and 99 percent of testicular tumors are malignant.

### Classification

- A. Germ cell tumors (GCT)—95 percent
- Seminoma or seminomatous germ cell tumors (SGCT) (40 to 45 percent) - These are adenocarcinomas arising from the lining cells of the seminiferous tubules.
  - Teratoma (40 percent)—These tumors arise from primitive totipotent cells. When the cells keep their totipotent character a teratoma develops. Where they differentiate partly, a mixture of seminoma and teratoma is formed.
  - Combined seminoma and teratoma (14 percent).

Germ cell tumors are also found in the ovary, retroperitoneum and mediastinum.

- B. Nongermin cell tumors (2 - 5 percent)
- Sex cord stromal tumors
    - Leydig cell tumor.
    - Sertoli cell tumor (Androblastoma).
    - Mixed forms.
  - Combined germ cell—Sex cord stromal tumors—Gonadoblastoma.
  - Other tumors
    - Malignant lymphoma
    - Metastatic tumors (leukemia).

### Pathology

#### Seminoma

It is the carcinoma of the seminiferous tubules. When germ cells (one cell type) are the only element present; the tumor is called a seminoma.

This is the most common form of testicular tumor in the adult (30 - 40 years) and almost never occurs in infancy.

Macroscopically, there is uniform, smooth swelling of testis. The cut surface has a cream-colored uniform homogeneous appearance.

Microscopically, seminoma cells generally lie in cords, sheets or columns forming lobules. Typically in a classic seminoma the tumor cells are fairly uniform in size with clear cytoplasm and the nuclei are large, hyperchromatic and centrally located.

Seminomas are part of a continuum, at one end is the well-differentiated spermatocytic seminoma found in older men whose cells resemble spermatocytes. They rarely metastasize and highly chemosensitive, at the other extreme, is the anaplastic seminoma, with nuclear pleomorphism with giant cells resembling syncytiotrophoblast which stain for  $\beta$  hCG.

These tumors spread mainly by the lymphatic route.

*Teratoma (Nonseminomatous germ cell tumor or NSGCT):*

The teratoma contains totipotent germ cells and can have ectodermal, mesodermal and endodermal elements within it.

Microscopically it is the second commonest tumor group after seminoma. These tumors form a spectrum of well-differentiated to anaplastic highly malignant growths. The testicular tumor panel has classified teratomas as follows:

- Malignant teratoma differentiated (MTD)* — It is uncommon. The best known variety is a dermoid cyst, which may contain tooth, hairs, cartilage and the glandular elements.
- Malignant teratoma intermediate (MTI)*— It is the most common variety. The cells are mixture of differentiated and anaplastic cells.
- Yolk sac tumor and malignant teratoma trophoblastic (MTT)*—This type of teratoma occurs due to extra embryonic differentiation and secretes HCG. It is similar to choriocarcinoma in a female.
- Malignant teratoma undifferentiated (MTU)*—The tumor cells are highly anaplastic carcinomatous cells with frequent mitotic figures and tumor giant cells.

Grossly most teratomas are large gray white masses making the involved testis enlarged. Cut surface is variegated with solid glandular and hemorrhagic areas.

### Predisposing Factors

- Undescended testis—Ten percent of men with a tumor have a history of testicular maldescent.

- Carcinoma *in situ*—Fifty percent risk of developing invasive cancer after 5 years.
- Infertility—There is increased incidence of carcinoma *in situ* and invasive cancer.

### Spread

- Local spread of testicular cancer is exceptionally rare because of encapsulation within tunica albuginea.
- Lymphatic spread occurs to iliac para aortic, mediastinal and supraclavicular nodes.
- Hematogenous spread is rare and may occur in lungs. Stromal tumors rarely metastasize.

### Clinical features

- Age usually 30 to 40 years, a decade earlier than other germ cell tumors.
- The usual presentation in 65 to 75 percent cases is a painless testicular lump, which may feel heavy.
- Testis is enlarged, rubbery and smooth in seminoma whereas lumpy and nodular in teratoma.
- In 10 to 20 percent cases secondary hydrocele appears due to collection of blood stained fluid. Transillumination is negative.
- Infertility is not uncommon.
- Gynecomastia is seen in about 10 percent patients.

### Staging of Testicular Cancer

Stage I—Tumor confined to the testis only.

Stage II—Tumor and enlarged lymph nodes below the diaphragm of size less than 2cm in greatest dimension.

Stage III—Tumor and enlarged lymph nodes above the diaphragm - Mediastinal and/ or supraclavicular lymph node involvement.

Stage IV—Blood spread to lungs, liver or elsewhere.

### Investigations

- USG of testis, where differentiation from hematocele is difficult or diagnosis is in doubt, USG gives a clear indication of the tumor.
- Imaging for RPLN (Retroperitoneal lymph nodes)—CT scan is the ideal diagnostic tool for the detection of metastasis in RPLN and this has now replaced lymphography in most oncology units.

- X-ray chest to detect pulmonary metastasis.
- Tumor markers—Both hCG and AFP are elevated in teratomas while low hCG levels are found in seminoma.

### Treatment

- Plan of surgery and adjuvant therapy: Seminomas are highly radiosensitive while the teratomas are not.  
Teratomas are highly chemosensitive.
- Inguinal exploration of testis (Chevasseau's procedure)—This is a time honored technique in cases of doubtful malignant neoplasm of the testis.

### Procedure

Testis is explored through an inguinal incision. It is delivered out and a soft clamp is applied to the testicular vessels at the level of deep inguinal ring while doing the procedure, so that tumor embolization does not occur. The testis is split open longitudinally, the suspicious area is biopsied and sent for frozen section.

If the frozen section is positive, the spermatic cord is doubly transfixed and divided at the level of deep inguinal ring and testis is removed.

This is called high orchiectomy.

If the frozen section is negative, the testis is sutured and replaced back into the scrotum.

This procedure is known as Chevasseau's procedure.

### Surgery

Once malignant testicular tumor is confirmed the first step is high orchiectomy as described above. Further treatment is

dependent on the type of tumor and the stage.

### Seminoma

All stage I and II tumors are treated by retroperitoneal and mediastinal radiotherapy.

Stage III and IV—Chemotherapy is the treatment of choice. Common agents are PVB, i.e. cisplatin, vincristine and bleomycin.

### Teratoma

Stage I—is treated by high orchidectomy and subsequent follow up of tumor markers (AFP and hCG levels in serum) and serial CT scans. Stage II, III and IV—Treatment of choice is chemotherapy. Some advocate a RPLND (Retroperitoneal lymph node dissection) after completion of chemotherapy. Serial rise of tumor markers is an indication of tumor recurrence.

### Prognosis

#### Seminoma

- Seminoma with no metastasis—5 year survival is 90 percent.
- Seminoma with metastasis—5 year survival is 75 percent.

#### Teratoma

- Stage I and II—5 year survival is 85 percent.
- Stage III and IV—5 year survival is 60 percent.

#### Lymphoma

The prognosis of lymphoma is considerably worse than that of seminoma or teratoma with a 5 year survival of 25 to 40 percent.

## HYDROCELE

### Definition

A hydrocele is an abnormal collection of serous fluid in the tunica vaginalis of the testis or within some part of the processus vaginalis.

According to etiology, hydrocele is divided into two types viz.

- Primary or idiopathic hydrocele—The cause is unknown and no associated disease of the testis or the epididymis is present.
- Secondary hydrocele—Here hydrocele is secondary to a disease of the testis and/or the epididymis.

### Primary or Idiopathic Hydrocele (Figs 51.5A to E)

The following varieties of primary hydrocele can be seen viz.

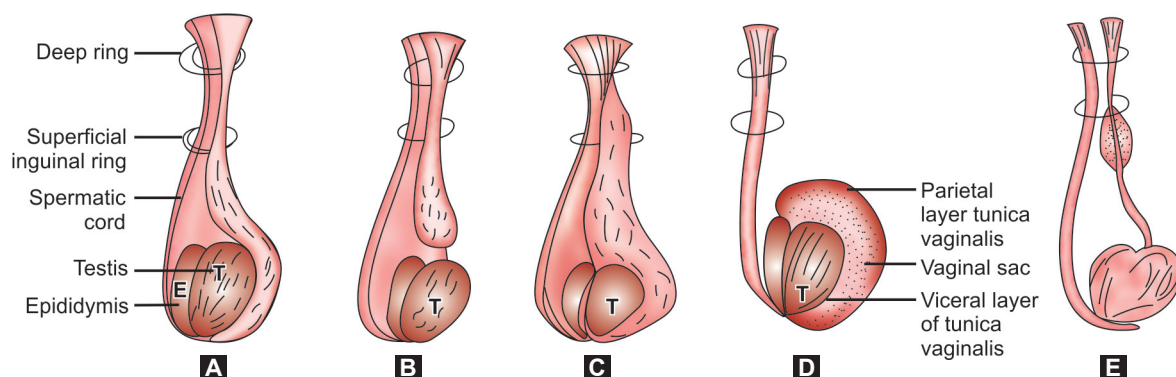
- Vaginal hydrocele – the commonest type.
  - Encysted hydrocele of the cord.
  - Congenital hydrocele
  - Funicular hydrocele
  - Infantile hydrocele.
- These are unusual types
- Other rare types:
    - Bilocular hydrocele
    - Hydrocele of the hernial sac.

### Vaginal Hydrocele

In this condition there is abnormal collection of serous fluid between visceral and parietal layers of tunica vaginalis.

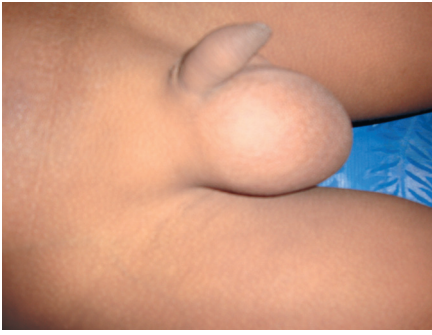### Composition of Hydrocele Fluid

- Color—Straw or amber colored.
- Composition—Water, fibrinogen, inorganic salts, albumin and cholesterol crystals.



**Figs 51.5A to E:** The anatomical classification of hydrocele. (A) Congenital hydrocele; (B) Funicular hydrocele; (C) Infantile hydrocele; (D) Vaginal hydrocele; (E) Encysted hydrocele of the cord





**Fig. 51.6:** Congenital hydrocele

It is interesting to note that the following swellings contain cholesterol crystals viz. hydrocele, branchial cyst, and dental and dentigerous cysts.

### Clinical Features

- The patient presents with a scrotal swelling which may cause social embarrassment.
- The swelling may be uni- or bilateral and getting above the swelling is possible.
- The swelling is not reducible and transillumination test is positive, as the hydrocele fluid is clear.
- Fluctuation test is positive as it is a cystic swelling.

### Differential Diagnosis

Other causes of scrotal swelling, e.g.

- Inguinal hernia.
- Filariasis of scrotum
- Epididymal cyst
- Encysted hydrocele of cord.
- Hematocele
- Pyocele, etc.

### Complications

- Calcification
- Pyocele
- Hematocele
- Hernia of the hydrocele sac—It occurs following a tear in the sac which results in accumulation of fluid in the subcutaneous plane.

### Treatment

Operation is the treatment of choice. The following procedures are done.

1. Lord's plication is indicated in small hydrocele.
2. Jaboulay's operation (Eversion of sac) is done for medium size hydrocele.

3. Partial excision and eversion of the sac is indicated in a large hydrocele.

See also operative surgery section, chapter 97.

### Encysted Hydrocele of the Cord

- In this condition, the processus vaginalis remains patent in the middle being shut off from the tunica vaginalis below and peritoneum above.
- It presents as a soft, cystic, fluctuant and transilluminant swelling, separate from the testis in the inguinoscrotal or scrotal region in relation to the spermatic cord.
- Diagnosis is established by 'Traction test'. The swelling has got free mobility but when traction is applied to testes gently, the swelling becomes fixed and it moves down, when testes is pulled down.
- Treatment—Excision of the sac.

### Congenital Hydrocele

In this condition the processus vaginalis remains patent and there is direct communication of the tunica vaginalis with the peritoneal cavity. Of course the communicating orifice at the deep inguinal ring is too small for the development of a hernia (Fig. 51.6).

This condition may be associated with tuberculous peritonitis in children.

### Funicular Hydrocele

This is also congenital but largely incomplete as the processus vaginalis is shut off from the tunica vaginalis just above the testis.

### Infantile Hydrocele

This is just opposite of the above (Funicular) variety. Here the tunica vaginalis is continuous with the processus vaginalis but is shut off from the peritoneal cavity at the deep inguinal ring. So, unlike the congenital or funicular variety, it does not disappear when the patient lies down.

### Bilocular Hydrocele

Here the hydrocele has two communicating sacs one above and one below the neck of the scrotum. A cross fluctuations may be elicited.

### Hydrocele of the Hernial Sac

Sometimes hydrocele may be associated with the hernial sac. The reason is that some fluid

gets stagnated within the hernial sac when a tag of omentum blocks the opening of the sac at the deep inguinal ring.

### Secondary Hydrocele

The usual causes in order of frequency are:

1. Acute and chronic epididymo-orchitis (e.g. tuberculosis, filariasis, etc.)
2. Testicular tumor
3. Trauma
4. Postherniorrhaphy hydrocele.

The last two are rarely seen.

A secondary hydrocele hardly attains big size and it is lax. So that palpation of the testis and epididymis is not difficult.

### Treatment

Treatment of the primary cause would cure it.

Causes of hydrocele having transillumination test negative are:

- If the sac is thick or calcified
- Hematocele
- Chylocele
- Pyocele
- Malignant testicular tumor with blood stained effusion.

### VARICOCELE

Varicocele is defined as the varicosity of the pampiniform plexus of veins.

It is mostly found in young adults and in more than 90 percent cases, occurs on the left side due to the following reasons.

- a. The left testicular vein drains into the left renal vein at right angle so that there is more chance of blockage of drainage from the left testicular vein. But the right testicular vein opens obliquely into the inferior vena cava and this drainage occurs freely.
- b. Sometimes the left renal vein may be sandwiched between the abdominal aorta and the trunk of superior mesenteric artery which may culminate into varicosities of the left pampiniform plexus.
- c. The left testicular artery may arch over the left testicular vein and this may cause compression over it.
- d. The left testicular vein is crossed by the pelvic colon which may compress it when loaded. This may cause varicocele due to obstruction in drainage.
- e. The total length of the left testicular vein is more than that of the right testicular vein.



## Surgical Anatomy

Pampiniform plexus of veins (15 – 20) draining the testis and epididymis makes the major bulk of the spermatic cord. As they ascend, the number is reduced to 12 and on reaching the superficial inguinal ring they unite to form 4 veins. At the level of deep ring they are 2 in number and in retroperitoneum, it forms the single testicular vein.

## Etiology

- No definite cause is known in majority of cases (idiopathic), though congenital absence of valves has been incriminated.
- A rapid onset varicocele in an elderly patient suggests renal cell carcinoma invading the renal veins.

## Clinical Features

- The patient may have aching or dragging pain particularly after prolonged standing.
- It can be differentiated from an omentocele by the peculiar feel of the bag of worms.
- It is more common on the left side for reasons stated above.
- Many a varicocele are asymptomatic and found incidentally.
- Infertility: Varicocele is often associated with infertility. The scrotal temperature is usually higher in the presence of varicocele and this may impair spermatogenesis.

## Treatment

1. Asymptomatic varicocele—No treatment is required, only scrotal support and reassurance.
2. Symptomatic varicocele—Excision of the pampiniform plexus in the inguinal canal after ligating them. Testis still has a venous drainage via the cremasteric veins.

## EPIDIDYMAL CYST

These are cysts in connection with the epididymis divided into the following types:

1. Retention cysts, e.g. spermatocele due to obstruction of the sperm conducting mechanism.
2. Degeneration cysts occur due to cystic degeneration of the appendages of epididymis viz paradidymis, superior and inferior aberrant ductules and appendix of epididymis which are vestigial remnants of the mesonephric tubules and the duct.

The remnant of the paramesonephric duct also produces the degeneration cysts, the degeneration cysts are of two types viz.

- a. Solitary cysts.
- b. Multiple cysts. } See below

## SPERMATOCELE

This is a unilocular acquired retention cyst due to obstruction of the sperm conducting duct of the epididymis.

Aspiration yields barley water-like fluid and transillumination test is negative.

It is usually situated behind the testis and the testis is distinctly separate from the swelling.

## Treatment

Small spermatocele does not require any treatment. Big spermatocele requires complete excision through a scrotal incision.

## DEGENERATION CYSTS

### Multiple Cysts

#### Origin

The origin of the cyst is debated. It is believed to be due to dilatation of the tubules of the epididymis (inferior aberrant ductules).

They are brilliantly transilluminate because they contain crystal clear fluid. The cysts feel like a bunch of tiny grapes, located behind the testis.

Treatment is required only if the swelling is troublesome. It consists of excision of the cysts.

### Solitary Cysts

#### Origin

It may be due to degeneration of either of the following embryonic remnants around the epididymis.

- a. Remnants of the Wolffian duct system (i.e. mesonephric tubules and mesonephric duct).
  - i. The paradidymis or organ of Germalde which represents the mesonephric tubules that lie between the testis and the epididymis but are not connected to either of them. This is the commonest cause.

ii. Appendix of epididymis (pedunculated hydatid cyst of Morgagni) – which represents the cranial end of the mesonephric duct is a small rounded structure attached to the head of epididymis.

- b. Remnant of the paramesonephric or Müllerian duct—The appendix of the testis or sessile hydatid cyst of Morgagni – This is a small rounded body attached to the testis and represents the cranial end of the müllerian duct.

## Features

- Solitary cysts are commoner than multiple cysts.
  - They are located between the body of the testis and head of epididymis.
  - They also contain like multiple cysts the crystal clear fluid and are therefore brilliantly transilluminant.
- Treatment is excision of the cyst.

## EPIDIDYMO-ORCHITIS

The epididymis and testis are often involved together in infections due to their unusual proximity.

## Acute Epididymo-orchitis

The condition commonly occurs in association with infection of the urinary tract such as cystitis, urethritis and prostatitis or may follow instrumentation of the urinary tract. *E. coli* and *pseudomonas* are the commonest organisms. The route of infection is along the vas deferens or its associated lymphatics.

## Clinical Features

The epididymis is swollen tense and tender. The spermatic cord is also tender and thickened. The scrotal skin becomes red and edematous.

Severe pain in the testes and groin along with fever is usually present.

## Investigations

Blood examination will reveal leukocytosis. Culture of urethral discharge and urine can reveal the offending organism.

## Treatment

- Strict bed rest and scrotal support is advised.

- A broad spectrum antibiotic is started while awaiting the results of culture and continued for 2 weeks or until the inflammation has subsided.
- Anti-inflammatory drugs are given if necessary.
- Drainage is required if pus has formed.

### Chronic Epididymo-orchitis

This usually follows repeated attacks of or partially treated acute epididymo-orchitis.

In the tropics, the commonest cause is filaria; the next common cause is tuberculosis.

### Tuberculous Epididymo-orchitis

The onset is nearly always gradual. It is more often due to a hematogenous spread than descending infection, affecting first the tail of the epididymis.

Caseation leads to formation of cold abscess, which may burst outside and gives rise to a sinus posteriorly on the scrotum. Sinus on the anterior aspect is found in syphilis.

On examination, multiple nodules may be felt in the thickened epididymis. The testes may be entirely normal.

### Investigations

- In every case, urine must be examined for tubercle bacilli, if necessary repeatedly.
- Even when the smear for AFB (acid fast bacilli) of the urinary sediment is negative, a culture may be positive and should be performed.
- An IVP and chest X-ray should also be performed to rule out urinary and pulmonary tuberculosis respectively.

### Treatment

The epididymitis will usually resolve on antitubercular therapy. If there is no sign of resolution within 2 months, epididymectomy or orchidectomy is advised. A full course of antituberculous chemotherapy should be completed following operation.

### ELEPHANTIASIS OF SCROTUM

Elephantiasis of scrotum is almost always due to filariasis, caused by the parasite *W. bancrofti*. Nonfilarial elephantiasis is

encountered very rarely and caused by lymphogranuloma venereum but in the later case, the elephantiasis is not as massive as in case of filariasis.

### Pathology

Elephantiasis is due to obstruction of the pelvic lymphatics by *W. bancrofti* with super added infection, usually streptococcal and associated lymphangitis.

### Causes of Lymphangitis

1. Mechanical irritation caused by movements of the adult worms along the lymphatic vessels.
2. Allergic—Due to liberation of toxic products from dead worms, undergoing degeneration and liberation of toxins by the fertilized females at the time of infection.
3. Secondary bacterial infection.

### Effects of Lymphangitis

- a. Obliterative endolymphangitis due to endothelial proliferation and inflammatory thickening of the wall of lymph vessels and
  - b. Fibrosis of lymph vessels caused by recurrent attacks of lymphangitis.
- Both the above factors will cause **lymphatic obstruction** and imprisonment of dead worms in the lymph vessels and the lymph nodes.

### Effects of Lymphatic Obstruction

- Lymphatic obstruction brought about over a span of several years causes exudation of lymph in the connective tissue of the scrotum. In long-standing cases the penis may be completely buried in it.
- The testis may undergo atrophy due to pressure and lack of blood supply.
- The subcutaneous tissue of penis may also be replaced by fibrous and blubbery tissue and may be greatly enlarged and curved.

### Clinical Features

- Filarial fever 103 to 104°F usually associated with chill and rigor occurs characteristically during the new - moons and full moons.

### On Examination

- Scrotal skin is thickened, rough and hyperkeratotic with loss of hairs.
- The testes, epididymis and spermatic cord are often impalpable due to unyielding nature of the scrotal wall.
- There may be vesicular eruptions over the surface of skin of scrotum, which may ulcerate and discharge clear or milky lymph.
- Associated findings
  - i. Secondary hydrocele or chylocele in the tunica vaginalis.
  - ii. Elephantiasis of the lower limb or breast.

### Investigations

- a. Eosinophilia 5 to 15 percent in early cases, no such finding in late cases.
- b. The demonstration of microfilariae in the night blood smear is diagnostic.

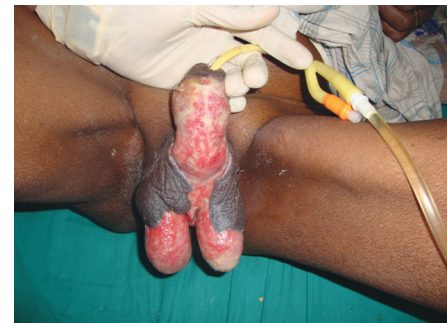### Treatment

The treatment of choice is surgery. The patient is however, prepared preoperatively as follows.

- a. A course of antifilarial drug, e.g. Diethyl carbamazine 100mg TDS × 3 weeks.
- b. A course of antibiotic to guard against streptococcal infection.
- c. Local dressing with povidone iodine (Betadine) if lymphorrhoea is present.

### Principles of Operation

1. Excision of the hypertrophied and edematous scrotal and/or penile skin and subcutaneous tissue.
2. Resurfacing of the decorticated penis. The raw shaft of the penis is covered with either the free skin graft taken from the thigh or the preserved inner layer of prepuce.



**Fig. 51.7:** Fournier's gangrene of the scrotum

3. Management of the exteriorized testes can be dealt within two ways:
  - a. The testis can be covered either by the remnant of scrotal skin or by approximating the skin from the two sides of the perineum.
  - b. If there is lack of scrotal or perineal skin pockets in the subcutaneous are made in the medial side of the upper part of each thigh superficial to fascia lata and the testes are then placed in the pockets of the respective sides.
4. A Foley catheter is kept *in situ* for a few days to prevent contamination of the wound with urine.

### Difficulties

1. Injury to the urethra—It can be avoided by passing a dilator or catheter during operation.

2. Excess blood loss—Blood transfusion to be arranged during operation.
3. Shortage of skin to accommodate the testes, when they are placed in the subcutaneous pouch in the upper part of each thigh.

### IDIOPATHIC (FOURNIER'S) GANGRENE OF SCROTUM

This is a synergistic spreading gangrene or necrotizing fasciitis of scrotum affecting men in their 4th and 5th decades, caused by a mixed pattern of organisms viz. coliforms, staphylococci, bacteroids, anaerobic streptococci and peptostreptococcus.

Patients are almost always immunocompromised with conditions such as diabetes mellitus.

The wound initiating the infection may have been minor but severely contaminated wounds are more likely to be the cause.

Gangrene sets in as the toxin induced thrombosis cuts the blood supply of the epifascial tissues.

### Clinical Features

- Severe wound pain, swelling and crepitus in the scrotum with fever and a bad smell.
- If remains untreated it will lead to widespread gangrene and multiorgan failure.
- The skin sloughs out, exposing the testes covered with tunica (Fig. 51.7)

### Treatment

1. A wide spectrum antibiotic is started IV with aggressive circulatory support.
2. Locally, wide excision of the necrotic tissue and laying open of the affected areas need to be done.

The debridement may be extensive and patients may need large areas of skin grafting.

## Chapter 52

# Evaluation and General Management of Trauma

## ➤ Injury control

Injury is a major global health problem. It has become a leading cause of death in developed as well as developing countries in the age group 1 to 44 years. In the age group between 15 and 44 years, road traffic deaths are second only to HIV-AIDS as a cause of death.

It is also a leading cause of disability and a major contributor to health costs.

### **INJURY CONTROL**

The spectrum of injury control consists of surveillance, prevention and treatment, comprising of prehospital and hospital care Fig. 52.1.

#### **Surveillance**

There is a need to have ongoing data regarding the extent and characteristics of the injury problem in each country. This allows better

targeting of interventions and assessment of their success or failure.

The World Health Organization (WHO) has made progress on promoting surveillance by published guidelines for collecting, coding and processing injury data.

#### **Prevention**

It is a scientific field like that used to control any other health problem and consists of:

- a. Primary prevention which may be educational such as antidrunk efforts or legislative, e.g. enforcement of speed limits.
- b. Secondary prevention attempts to lessen the consequences of injury and can be active or passive.
  - i. Passive strategy—The most important is designing safer cars and installing smoke detectors that work automatically.

- ii. Active strategy—Wearing helmets and seat belts are the important active strategies.

- c. Tertiary prevention—Aims to minimize the effect of injury on a person by prompt delivery of healthcare by individuals and systems.

#### **Treatment**

Treatment of injury is divided into two parts viz.

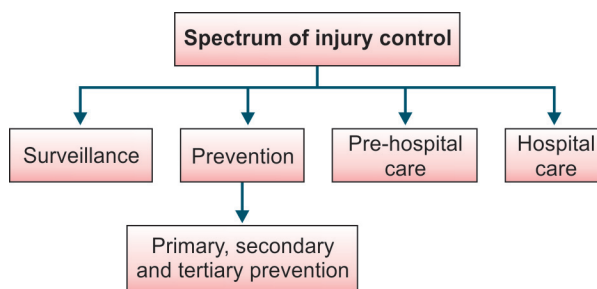
- a. Care at the site of accident or prehospital care and
- b. Hospital care.

#### **Prehospital Care**

The prehospital trauma life support (PHTLS) consists of two levels of prehospital care viz. the basic and the advanced level. The basic level includes airway control, oxygen administration, breathing support, cervical spine immobilization by collar, straps etc. and hemorrhage control by simple splinting and manual pressure. The advanced level of PHTLS includes the techniques of venous access and endotracheal intubation.

The PHTLS was introduced in 1983-1984 in USA. Since then program has become internationally implemented as advanced trauma life support (ATLS) program for training of emergency physicians and surgeons.

- i. Airway control involves:



**Fig. 52.1:** Spectrum of injury control

- Triple maneuver—viz. extension of neck, forward displacement of mandible and opening the mouth.
  - Suction of secretions and clearing the oropharynx.
  - Endotracheal intubation failing which cricothyrotomy or minitracheostomy may be required to give 100 percent oxygen if necessary.
- ii. Breathing support is given by:
- Mouth-to-mouth ventilation or
  - Mouth-to-airway ventilation after an airway has been introduced.
- iii. Two intravenous lines are secured in the hypotensive patient and Ringer's lactate is administered to provide circulatory support.

### Prehospital trauma triage

The next step after PHTLS is to sort out the casualties into priorities for the purpose of treatment. This is termed as triage (French word triage = to sort) which is a dynamic process and may change with time.

Triage involves grouping the casualties into three priorities and different color flaps are given depending on their requirement of emergency care and evacuation. The effective, quick and safe transport to the hospital by trained paramedical personnel is crucial to lessen further insults to the accident victim.

The three priorities are:

- Immediate priority, e.g. obstructed airway, hypovolemic shock, red color flap is put for these patients.
- Urgent priority, e.g. multiple long bone fractures, significant burns. A yellow flap is placed for these patients.
- Delayed priority, e.g. a walking wounded patient. A green color flap is used to code for these patients.

### The Golden Hour

The golden hour is the first 1 hour period following injury in which the patient may appear physiologically stable but may have a life-threatening injury.

Rapid triage, resuscitation, diagnosis and effective treatment can save the lives of many critical trauma patients during this period.

### Hospital Care

#### Trauma resuscitation

Once the patient reaches the hospital information from paramedical personnel can be vital and the MIST handover should be used, as below:

- Mechanism of injury
- Injuries identified
- Signs at the site of accident
- Treatment administered.

Trauma resuscitation consists of the following and is known as advanced trauma life support (ATLS).

- Primary survey
- Secondary survey
- Definitive care.

**Primary Survey:** During primary survey life threatening conditions are identified in the order ABCDE and their simultaneous management is commenced.

- A-Airway management
- B- Breathing
- C-Circulation with hemorrhage control
- D-Disability (neurologic status) assessment.
- E-Exposure with control of the environment (prevention of hypothermia) for thorough examination and assessment of the patient.

During this phase the airway control, oxygenation and ventilation are reassessed and management of shock and hemorrhage control as done in PHTLS are reevaluated.

#### Disability assessment or assessment of dysfunction of the nervous system.

A brief neurologic examination should be performed to determine the level of consciousness as follows: AVPU schedule

- A for alert
- V for response to verbal command
- P for respond to painful command. P is roughly equal to a score of 8 on Glasgow coma scale(GCS).
- U for unresponsive. U is equivalent to a GCS score of 3.

The size of the pupils are tested to assess the neurologic status.

**Secondary Survey:** The secondary survey does not begin until primary survey(ABCDE)

is completed and resuscitation phase including management of other life-threatening conditions like pneumothorax, flail chest, etc. is over so that the patient is stabilized.

Secondary survey is a head to toe evaluation of the trauma patient, that is, a complete history, physical examination and check of all vital signs. A full history should be obtained from the patient if possible or from the ambulance crew or relatives. The mnemonic 'AMPLE' (A - allergies, M - medication, P - past medical history, L - time of last food or drink, E - events and environment leading to the injury) is a good way to remember what one should ask about the history. Each area of the body should be completely examined and a full neurological examination performed including a Glasgow Coma Scale (GCS) determination. The secondary survey has been summarized as "tubes and fingers in every orifice."

The following things are done in secondary survey.

- i. Intravenous line is secured with a wide bore cannula (16 Fr), preferably in the upper limb if not already secured.
- ii. Blood is drawn and sent for the following urgent investigations.
  - Hemoglobin, packed cell volume.
  - Blood grouping and cross matching of blood. If this is a problem, then one can administer O negative blood.
  - Blood sugar, urea and electrolytes (Na, K), Renal failure can occur early in hypovolemic shock.
- iii. Nasogastric tube aspiration to empty the stomach.
- iv. Foley catheter, CVP line, pulse oximeter and continuous ECG monitoring are indispensable in the severely injured patient.
- v. Peritoneal lavage is a technique that enables the clinician to investigate the possibility of intraperitoneal bleeding. Warm saline is instilled into the peritoneal cavity. More than 100000 red blood cells per cu mm of the fluid removed is an indication for exploratory laparotomy.
- vi. Investigations:
  - a. X-rays of skull, cervical spine, chest, pelvis and the limbs are commonly required.



- b. CT scan, MRI, USG abdomen are other imaging studies.
- vii. Other general measures which should be taken for any injured patient include:
- Nil by mouth and consent if the patient has to be taken up for surgery.
  - Strict intake output chart is maintained. There should be a urine output of 30ml/hour in an adult and 1ml/kg/hour in children.
  - Vital parameters are recorded every 15 minutes.
  - Pain relief—Morphine and pethidine are effective drugs; nowadays diclofenac sodium injections are also used. They do not produce sedation and quite effective in relieving moderate pain.
  - Tetanus prophylaxis with toxoid and tetanus immunoglobulin is required almost in all cases with dirty wounds.

- Prophylactic broad spectrum antibiotics are started immediately especially in the polytrauma case and in patients with compound fracture. Third generation cephalosporins are popular.
- H<sub>2</sub> blockers are given intravenously as a prophylactic against gastrointestinal bleeding induced by major trauma.

### *Definitive Care Phase*

During this phase, the comprehensive care of the patient is planned according to the site and type of injury, e.g. laparotomy for doubtful diagnosis or visceral injury in case of abdominal trauma, fracture stabilization, transfer of the patient to a referral trauma center, e.g. neurosurgical unit, if required after head injury, etc.

The patient should only be transferred if stable with appropriate medical escort, usually an anesthetist.

### Documentation

Medical record keeping is an essential part of good medical practice. Documentation of trauma should be clear and concise. It must be chronological and include time of arrival.

### Re-evaluation

Vital signs can change rapidly. Throughout the assessment of a trauma patient, one should remember to reevaluate the findings. Some new finding may be discovered, which was missed initially. Impaired consciousness is the most common cause of a diagnosis being missed.

### Rehabilitation

The consequences of injuries to the individual that result in physical impairment are minimized by appropriate rehabilitative services, e.g. supply of artificial limbs, change of the nature of occupation, etc.

## Head Injury

- Classification
- Pathology
- Management
- Intracranial hemorrhage
- Fracture of skull bone

Head injuries affect many people in the prime of their life and are of composite nature as the injury to the skull bones, intracranial vessels and the brain occur either singly or in different combinations.

However, injury to the brain is almost always a constant factor and the other injuries may or may not be associated with it.

### CLASSIFICATION

- a. By mechanism
  - i. Closed head injury—Here there is no communication between the intradural contents and the environment. It is of two types viz. high velocity, e.g. auto accidents and low velocity, e.g. falls and assaults.
  - ii. Open or penetrating head injury—Here the dura is breached and CSF leakage may be present and there is communication between the intradural contents and the environment. It may be due to gun-shot wounds or other open injuries.
- b. By severity
  - i. Mild when Glasgow coma scale (GCS) is 13 to 15.
  - ii. Moderate when Glasgow coma scale is 9 to 12.
  - iii. Severe when Glasgow coma scale is 8 or less.
- c. By morphology
  - i. Skull fractures—May be a vault fracture or a basilar fracture.

ii. Intracranial lesions—It may be of two types viz.

- Focal injury—When the injury is limited to a localized area of the brain and can be:
  1. Contusion.
  2. Laceration and
  3. Intracranial hematoma

Which may be a intracerebral or extracerebral hematoma.

- Diffuse injury involving a diffuse brain area and can be a concussion or a diffuse axonal injury (DAI). In diffuse axonal injury there is acute disruption of the axons in the corpus callosum and the brainstem. It is an important cause of persistent coma or a vegetative state occurring after head injury.

### PATHOLOGY

The pathological changes due to trauma to the brain can be classified into primary and secondary changes.

#### Primary Brain Injury

Primary brain injury is the injury caused at the time of impact, e.g. contusion and lacerations which are irreversible.

#### Cerebral Contusion

This is a severe degree of brain injury manifested by areas of hemorrhage in the brain

parenchyma but without any surface laceration. There may be associated cerebral edema and defects in blood brain barrier.

Contusion may resolve after a variable time period with persistent neurological deficit.

#### Cerebral Laceration

This is a severe degree of brain injury associated with a breach in the surface parenchyma. The tearing of brain surface may be due to skull fracture or shearing forces. There is tearing of pia and arachnoidmater and may be a associated with intracerebral hemorrhage.

#### Secondary Brain Injury

- Secondary brain injury results from a chain of events triggered by the primary injury. The cranial vault acts as a closed box, within which blood or swelling soon results in raised intracranial pressure and compression of healthy brain.

Secondary brain injury consists of:

- i. Intracranial hematomas which may be of four types viz. intracerebral, extradural, acute subdural and chronic subdural,
  - ii. Cerebral swelling or edema,
  - iii. Cerebral ischemia and
  - iv. Cerebral herniation.
  - v. Infections and seizures,
- The most important aspect of the management of head injuries is the prevention or

early recognition and treatment of secondary brain injury.

- Raised intracranial pressure (ICP) is damaging both directly to the cerebral cortex and by producing downward pressure on the brainstem and indirectly by reducing cerebral perfusion pressure (CPP), thereby threatening cerebral blood flow and oxygen delivery.  
CPP = Mean BP - ICP. Normal upper limit of ICP is 15mmHg. Treatment should be directed to keep ICP below 20mmHg. Sustained pressures above 30mmHg are associated with a poor prognosis.
- A minimum of 40mmHg of CPP is required for adequate brain function. A CPP less than this causes first electrical, then structural damage.

## MANAGEMENT

The management of head injury will be according to ATLS (Advanced Trauma Life Support) protocol of management which includes,

- Primary survey and resuscitation
- Secondary survey and
- Definitive care.

### Primary survey and resuscitation

The elements or primary survey and resuscitation are:

- a. Maintenance of airway with cervical spine control.
- b. Maintenance of breathing and ventilation.
- c. Maintenance of circulation and stoppage of bleeding.
- d. Assessment of dysfunction of the nervous system.
- e. Exposure in a controlled environment. All clothings are removed to look for any other obvious injury to other parts of the body. If environment is too cold, the patient is covered with a blanket to avoid hypothermia.

### Secondary Survey

This involves reassessment and through clinical examination from the head to foot.

History is obtained following the AMPLE rule as described earlier.

- a. Assessment of the level of consciousness is the most important part of the

examination in the head injury patient. This is performed by determination of the Glasgow coma scale (GCS) as follows:

Eye opening (E) –

- Spontaneously - 4.
- To speech - 3.
- To pain - 2.
- None - 1.

Best verbal response (V) –

- Oriented - 5.
- Confused - 4.
- Inappropriate words - 3.
- Incomprehensible sounds - 2.
- None - 1.

Best motor response (M) –

- Obeys commands - 6.
- Localizes pain - 5.
- Withdraws to pain - 4.
- Flexor response to pain - 3.
- Extension to pain - 2.
- None - 1.

Total score is 15. Minimum score is 3. GCS 8 or less means patient in coma GCS > 8 → patient is not in coma.

- b. Pupil size and reaction should be noted. Failure of the pupil to react to both direct and consensual light implies a 3rd nerve lesion which is the most useful indicator of an expanding intracranial lesion.
- c. An ipsilateral dilated pupil is a sign of extradural hemorrhage.
- d. Bilateral pinpoint pupils are either due to drug overdose or pontine hemorrhage.

### Investigations

1. X-ray skull and cervical spine if injury to the neck is also suspected. AP chest X-rays are essential in all coma cases. Indications of skull X-ray in recent head injury.
  - i. Loss of consciousness or amnesia at any time.
  - ii. Alcohol intoxication.
  - iii. Difficulty in assessing the patient, e.g. the young patient, history of epilepsy.
  - iv. CSF or blood leak from the nose or ear.
  - v. Suspected penetrating injury or fracture.
2. CT scan—This is done after resuscitation is complete in selected cases, when the patient is stabilized. Indications for CT scan and neurological referral in acute head injury are:

- i. Skull fracture with confusion.
- ii. Skull fracture with seizures.
- iii. Penetrating injury or CSF leakage.
- iv. Depressed fracture.
- v. Persistent or severe headache.
- vi. Vomiting.

### Definitive Care

#### Minor Head Injury

Patients with no fracture, who are walking and talking (oriented), can be allowed home provided the relations are warned to return the patient to hospital, if headache, vomiting, drowsiness, visual disturbance or coma occurs.

Hospital admission after recent head injury is indicated in presence of one or more of the followings.

1. Skull fracture.
2. Neurological signs viz. headache and vomiting.
3. Difficulty in assessing the patient, e.g. alcoholics and epileptics.
4. Absence or low GCS.
5. Coexisting medical problem, e.g. diabetes.

#### Severe Head Injury (GCS is 8 or less)

Aim of treatment is to prevent secondary brain injury by controlling the increase of intracranial pressure (ICP).

1. The following measures are taken to control the ICP.
  - Intubation and ventilation is done to protect the airway and prevent hypoxia.
  - Sedation, analgesia and paralysis to prevent coughing with Fentanyl, propofol or Atracurium.
  - Nursing the patient with 30° head up tilt which facilitates venous drainage from the head and lowering of ICP.
  - Mannitol—Most commonly used osmotic diuretic, used as a 20 percent solution, 200ml IV given over 30min and repeated every 6 to 8 hours. If it fails to produce diuresis, frusemide is given IM 40 to 80mg.
  - Hyperventilation to reduce PCO<sub>2</sub> to 4 to 4.5 kPa (30 - 40mmHg) can temporarily reduce ICP and is useful in the first 24 hours.
  - Control of seizures with appropriate anticonvulsant therapy and for this

EEG may be needed to ensure this is achieved.

- IV fluids are given to avoid dehydration or fluid overload which will increase the ICP. Five percent Dextrose is best avoided as it increases cerebral edema.
  - Blood Na level is maintained > 140mmol/liter using IV normal saline.
  - The core body temperature should be between 36°C and 37°C.
  - Strict glycemic control between 70 – 140 mg/dl should be ensured.
  - Prompt surgery to drain the intracranial hematoma which is life saving and treatment of fracture skull bone if present.
2. Other supportive therapy
- H<sub>2</sub> Blocker like IV pantoprazole 40mg daily to prevent the stress ulcer (Cushing's ulcer) formation in stomach.
  - Broad spectrum antibiotic is given if there is CSF leak, pulmonary complications or compound fracture.
  - Ryle's tube feeding.
  - Urinary catheterization.
  - Care of the back, skin and eyes.
  - Regular monitoring of vital parameters.
  - Stabilization of neck.
  - Treatment of associated fractures of pelvis and long bones.
  - To maintain the intake output chart.

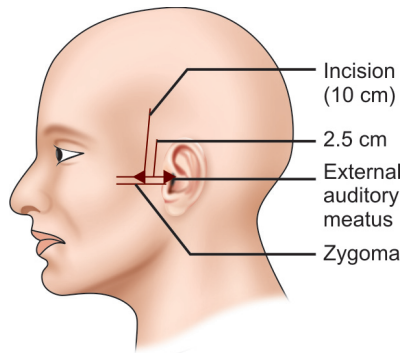
## INTRACRANIAL HEMORRHAGE

### Extradural Hematoma

- This is mostly due to tear of the middle meningeal artery.
- Hematoma is located between the skull and the dura mater.
- Often there is a lucid interval before signs of raised intracranial pressure ensue.

Treatment is prompt evacuation of hematoma via a trephine hole or burr-hole made on the skull right at the site of the artery.

The standard incision of a temporal burr hole is a vertical incision placed just above the



**Fig. 53.1:** Incision for extradural hematoma

zygomatic arch, midway between the external angular process and the external auditory meatus (Fig. 53.1).

A burr-hole is made 2 inches behind and 2 inches above the external angular process which is the surface marking of the anterior division of the middle meningeal artery. The burr-hole is enlarged with a bone nibbler (craniectomy), all blood clots are removed and the bleeding point is detected. If it is from the bony canal in the pterion, the canal is plugged with bone wax. If the bleeding is from the dural surface, the bleeding point is secured either by underrunning with a fine needle or by diathermy. If required a drain is placed in the extradural space.

If on opening, blood is found to come from the back, it is the posterior division of the artery which is bleeding. A second incision and a second burr-hole is made a little posteriorly and the bleeding is secured.

### Acute Subdural Hematoma

- This is due to tearing of veins between the arachnoid and dura mater. It is usually seen in the elderly. There is progressive neurologic deterioration.
- Mortality increases threefold, when evacuation of an acute subdural hematoma is delayed more than 4 hours.

### Treatment

The treatment of choice is evacuation either by craniectomy or craniotomy flap, burr-holes are of no value, because in spite of all investigations it is difficult to localize the site of the hematoma.

Craniotomy flap is a better technique and involves making multiple burr-holes and connecting them by using a Gigli-saw.

A vascularized flap of bone is raised and the clot is evacuated under vision. Any bleeding vessel is ligated. Following this the flap is replaced and the scalp incision is closed.

Even if the hematoma is evacuated, the patient may succumb to the widespread brain damage present as an associated injury.

### Chronic Subdural Hematoma

It results from tearing of the veins in the subdural space which enlarges slowly.

Often the precipitating injury is trivial. This usually occurs in the elderly people due to cerebral atrophy which increases the subdural space resulting in a greater tendency to rupture the veins.

Clinical features include drowsiness, confusion, headache and hemiplegia.

### Treatment

The treatment of choice is evacuation of the hematoma through a burr-hole along with a washout using warm saline.

## FRACTURE OF SKULL BONE

- In a linear fracture, without displacement, local cleaning and suturing of the laceration would suffice.
- A depressed fracture of skull requires elevation if more than 1cm depressed. The site is exposed and a burr-hole is made through the undamaged bone, at the periphery of the depressed fracture. Through this an elevator is passed to lift the fragments up.

# Chapter 54

## Thoracic Trauma

- Types
- Management
- Investigations
- Specific injuries
- Traumatic hemothorax
- Pulmonary contusion
- Tracheal and bronchial injury
- Cardiovascular injury
- Cardiac contusion and rupture
- Diaphragmatic injury
- Esophageal injury

Approximately 25 percent of trauma deaths are due solely to thoracic injuries and 50 percent of patients who die from multiple injuries have significant thoracic injury.

The spectrum of thoracic injuries can be represented as follows (Fig. 54.1).

### TYPES

There are two types according to mechanism of injury:

- a. Penetrating injury and
- b. Blunt injury.

### Penetrating Injuries

- These are usually caused by gunshot, knives and other weapons.

- Stab wounds tend to cause less severe injury and damage only the tissues in the path of the stab. The stabbing object should only be removed in the operation theater otherwise there may be devastating intrathoracic bleeding.
- Missile wounds are more severe and their effects depend upon the velocity of the missile. Bullets with a velocity of less than 300m/sec cause the least damage, while with a velocity of more than 300m/sec, there is a cavitation effect, resulting in tissue destruction 20 to 30 times the size of the bullet. Bullets with a velocity of more than 770m/sec have a blast-like effect. Tissues with a low specific gravity like the lung sustain, less

damage, while high specific gravity tissues like bone and the liver have more damage.

Any penetrating chest wound should be checked for visceral and vascular injury. Pneumothorax is observed in almost all cases of penetrating chest injury with hemothorax occurring in about 80 percent cases.

### Blunt Injuries

These are usually a consequence of crush injury or road traffic accidents. Rib fracture is the commonest manifestation of this type of injury.

The flexibility of the thorax in children makes them more vulnerable to injury to the thoracic structures from pulmonary contusion to rib fracture compared to adults.

### MANAGEMENT

The management of thoracic injury patient will be according to advanced trauma and life support (ATLS) protocol of management which consists of:

- Primary survey and resuscitation.
- Secondary survey and
- Definitive treatment or care.

### Primary Survey

Primary survey and resuscitation is done as mentioned earlier in head injury.

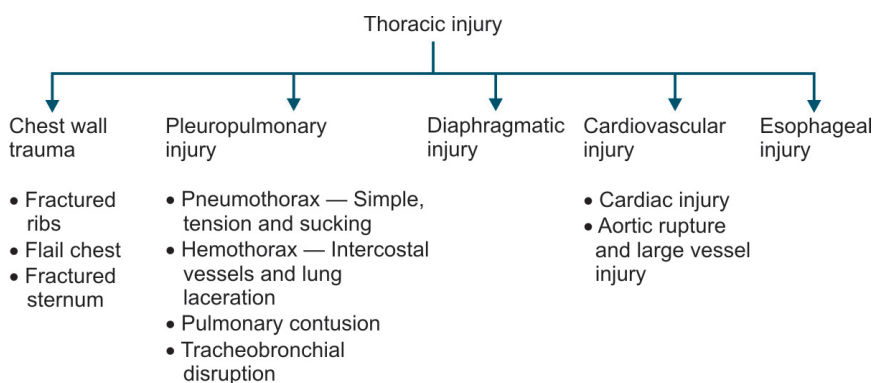


Fig. 54.1: Spectrum of thoracic injuries.



During primary survey one should exclude life threatening injuries like:

- i. Tension pneumothorax which is relieved immediately by inserting a wide bore needle at 2nd intercostal space lateral to the sternum.
- ii. Pericardial tamponade—It is relieved urgently by inserting a wide bore needle to left of xiphisternum into the pericardial cavity. An open chest wound should be covered with Vaseline gauze dressing.

### Secondary survey

After stabilization of the patient a detail secondary survey is done from the history, clinical examination from the head to foot and investigations.

### History

A brief history is taken from the patient or witness about time of injury, weapon type and its direction, the patients position at the time of injury and the patients progress during transport.

### Examination

Apart from examination of other parts of the body, a detailed chest examination is undertaken.

### Inspection

- Respiratory rate
- Paradoxical respiration (Flail chest).

### Palpation

- Palpable crepitus in surgical emphysema.
- Position of trachea and apex beat along with mediastinal shift to opposite side found in traumatic pneumothorax and hemothorax.

### Percussion

- Hyperresonance (Pneumothorax)
- Dullness on percussion (Hemothorax)

### Auscultation

- Absence of breath sounds in hemothorax and pneumothorax.

## INVESTIGATIONS

1. Urgent X-ray chest to see any rib fracture, pneumothorax and hemothorax.
2. Arterial blood gas analysis.

3. CT scan of chest in selected cases.
4. Other investigations if the patient has associated injuries.
5. Bronchoscopy if there is suspected disruption of upper airway.

### Definitive Care

- The main problems associated with thoracic injury are hypoxemia, hypovolemia and cardiac failure. Treatment should aim to improve oxygenation.
- Emergency thoracotomy is needed only in 10 to 15 percent cases of blunt and open chest injuries. The indications are:
  - a. Massive bleeding from chest drains (> 100ml/hour).
  - b. Cardiac tamponade causing circulatory shock and if needle aspiration is unsuccessful.
  - c. Rupture of the bronchus, esophagus, aorta or diaphragm.

## SPECIFIC INJURIES

### Rib Fractures

- First rib fracture is a hallmark of severe thoracic trauma and multiple system injuries in road traffic accidents carrying a mortality exceeding 30 percent.
- Locally it can produce injury to the brachial plexus or subclavian artery, Horner's syndrome or thoracic outlet syndrome. The aorta is injured in about 8 percent cases of first rib fractures.
- A simple isolated rib fracture commonly affects the 4th to 9th rib and more often occurs on the left than on the right side. It usually results from road traffic accidents, falls or beatings.
- Pain is the presenting symptom and there is local tenderness, bruising and crepitus.

### Treatment

This consists of:

- Analgesias like NSAIDs.
- Intercostal nerve block and
- Vigorous chest physiotherapy.

### Flail Chest

Flail chest occurs when four or more ribs are fractured in at least two locations either on one side of the chest or either side of the sternum.

The flail (Floating) segment moves paradoxically that is, inwards during inspiration and outwards during expiration and may occasionally be sufficient to compromise ventilation.

- Patients with flail chest frequently have an underlying pulmonary contusion which with or without rib fractures may compromise oxygenation or ventilation to an extent that requires intubation and mechanical ventilation.
- If the flail segment is small, does not interfere with respiration and cause alteration of arterial blood gas analysis, it is called a minor flail chest.
- A major flail chest patient in addition to intensive care and pain control requires intermittent positive pressure ventilation for 2 to 3 weeks.
- General care involves intermittent suction, antibiotics, skin care, bowel and bladder care and maintenance of nutrition.
- Routine fixation of flail segment is not required. However, if there are other underlying injuries requiring thoracotomy, the flail segment can be fixed simultaneously.

### Traumatic Pneumothorax

This means an accumulation of air in the pleural space and it can be of the following types.

1. Open pneumothorax, also called sucking wound of the chest – This occurs in case of a penetrating injury.
2. Closed pneumothorax – It occurs in case of fracture of ribs.
  - a. Simple pneumothorax.
  - b. Tension pneumothorax.

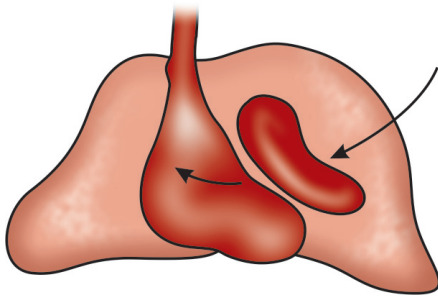
### Open Pneumothorax

During open pneumothorax collapse of the lung on the side of the injury follows and ventilation of the opposite lung is also impaired due to mediastinal shift to that side (Fig. 54.2).

As a result of mediastinum moving paradoxically during breathing, the venous return to the heart is reduced.

Diagnosis is made from the respiratory distress, absent breath sounds and hyperresonant percussion note on the affected side of hemithorax.

Plain X-ray chest shows the pneumothorax and mediastinal shift.



**Fig. 54.2:** Open pneumothorax

Treatment: The sucking wound should be sealed with an occlusive dressing and then surgical repair is arranged.

### Closed Pneumothorax

- Here air leaks from the damaged lung.
- Simple pneumothorax results when the source of air leak in the lung is a small one which rapidly seals off.
- Tension pneumothorax arises when a tear in the visceral pleura acts like a valve allowing air, into the pleural cavity in inspiration but preventing escape of air in expiration. This results in progressive collapse of the ipsilateral lung, mediastinal shift, collapse of contralateral lung and cardiac or respiratory arrest, hence this is a life-threatening situation.

### Treatment

- Immediate relief at emergency is obtained by inserting a wide bore needle at the second intercostal space lateral to the sternum.
- Subsequently a chest drainage tube with water seal drainage system is inserted through the second intercostal space or the fifth intercostal space in the midaxillary line.
- A simple pneumothorax, unless large is treated conservatively with analgesias, antibiotics and chest physiotherapy.

### TRAUMATIC HEMOTHORAX

Traumatic hemothorax is usually due to laceration of one of the vessels of the chest wall (intercostal or internal mammary artery) and can often be managed by intercostal drainage alone.

Thoracotomy becomes increasingly likely if there is an initial blood loss, in excess of 1 liter followed by contained bleeding greater

than 200ml/hour over the next four consecutive hours. Antibiotics and bronchodilators are given in the postoperative period.

### PULMONARY CONTUSION (CONTUSION - BRUISE) (LUNG INJURY)

It occurs with blunt trauma and in most cases of flail chest.

Following lung contusion the capillaries rupture and fluid with blood fills the alveoli, interstitial spaces and the bronchi resulting in airway obstruction.

The patient is breathless, apprehensive and cyanosed and coughing produces sputum tinged with blood. Adult respiratory distress syndrome (ARDS) may develop as there is a progressive reduction in the pulmonary compliance and ventilation gets compromised.

### Diagnosis

- Chest X-ray—A dense pulmonary filtrate will become evident over the injured area.
- Blood gas analysis will show hypoxia and hypercarbia.

### Treatment

- Supplemental oxygen.
- Prevention of infection of the underlying lung, by early mobilization if the patient's condition permits prophylactic antibiotics, suction drainage and physiotherapy.
- IV fluids are given to avoid overhydration as well as under resuscitation.

### TRACHEAL AND BRONCHIAL INJURY

The injury to the trachea requires considerable force and may be from direct trauma or due to blunt trauma causing airway compression between the sternum and the vertebral column. Esophageal injury must be excluded.

- Manifestations include hemoptysis, pneumothorax and surgical emphysema.
- Persistent air leak and failure of the lung to reexpand despite chest tube drainage is commonly found in major airway injury.
- Diagnostic bronchoscopy should be done if possible before intubation and the tube should be passed beyond the site of injury.

- Chest tube drainage is used for any pneumothorax.
- If bronchoscopy reveals the site of injury then primary repair is carried out.

### CARDIOVASCULAR INJURY

#### Pericardial Tamponade

It is a hemopericardium due to penetrating chest trauma which compromises diastolic filling and results in a reduced cardiac output.

150ml of blood is enough to produce this condition which is classically described by Beck's triad hypotension, muffled heart sounds and venous distension. This is seen in 40 percent cases and the often described pulsus paradoxus is even less frequent.

#### Diagnosis

Radiograph shows a globular heart and echocardiography is diagnostic.

#### Treatment

- An immediate relief can be obtained by aspiration of the pericardium by advancing a wide bore needle to the left of the xiphisternum towards the heart.
- But exploratory thoracotomy through the 5th intercostal space is safer for the following reasons.
  - a. Without exploration associated injuries may be over looked.
  - b. The site and extent of cardiac injury can be adequately determined by exploration.
  - c. Intrapericardial blood clots may later lead to constrictive pericarditis.

### CARDIAC CONTUSION AND RUPTURE

Cardiac contusion and rupture usually result due to blunt cardiac trauma. Myocardial contusion is suggested by ST segment elevation and sometimes Q wave with arrhythmias and the patient has chest pain.

They are rarely fatal and treated like myocardial infarction.

#### Injury to Aorta

This is the most lethal injury following blunt chest trauma.

The usual site of injury is immediately distal to the left subclavian artery that is, the aortic isthmus between the relatively fixed distal aortic arch and mobile descending aorta.

Thoracic aortography either by the femoral or brachial route is the diagnostic investigation. Treatment is surgical repair either by direct suture or by a tube graft.

### DIAPHRAGMATIC INJURY

- This occurs more commonly with penetrating injuries than blunt trauma. The left hemidiaphragm is affected more than the right as the later is protected by the liver.
- Colon, stomach, omentum or spleen can herniate into the thorax displacing the lung. Bowel sounds may be heard in the chest and the chest X-ray may reveal bowel gas in lung fields. A contrast study will confirm the diagnosis.

Treatment is reduction of hernia and repair of the tear in the diaphragm with nonabsorbable sutures. The access may be

obtained through lower thoracotomy or thoracoabdominal incision.

### ESOPHAGEAL INJURY

Although rare this is a rapidly progressive and fatal injury because of mediastinal contamination by saliva and gastrointestinal contents. There is a high incidence of associated injuries, e.g. trachea and vessels.

The causes generally are:

- Iatrogenic injury during endoscopy or dilatation.
- Full thickness rupture during emesis, called Boerhaave's syndrome, leading to mediastinitis and left pleural effusion. It may be mentioned here that a longitudinal mucosal tear of the gastroesophageal junction during emesis is called Mallory-Weiss syndrome.
- Ingestion of a foreign body with immediate perforation or erosion.
- Blunt or penetrating external trauma.

Esophageal injury results in either:

- Fulminating mediastinitis if mediastinal pleura is intact and

- Fulminant pleuritis with massive pleural effusion, if mediastinal pleura have ruptured. The effusion results in hypovolemia, sepsis and cardiopulmonary embarrassment due to mediastinal shift.

The most common site of injury is at the tracheal bifurcation – rarely traumatic tracheoesophageal fistula results.

### Clinical Features

- Fever, tachycardia, hypotension, leukocytosis and pain.
- Deep subcutaneous emphysema confined to deep cervical fascia from mandible to the clavicle.
- Mediastinal emphysema on chest X-ray is highly suggestive.

### Treatment

- Early recognition with urgent operative intervention is mandatory.
- Two layer closures, continuous non-absorbable mucosal suture followed by continuous nonabsorbable muscular suture with drainage is essential.

# Chapter 55

## Abdominal Trauma

- Classification
- Management
- Laparotomy
- Specific injuries
- Retroperitoneal hematoma
- Damage control surgery in major trauma
- Abdominal compartment syndrome

### CLASSIFICATION

According to mechanism of injury, abdominal trauma may be of three types:

1. Blunt injury
2. Penetrating injury
3. Instrumentation injury (Iatrogenic).

#### Blunt Injury

This type of injury leads to higher mortality rates than penetrating injury and presents greater problems in diagnosis.

- Blunt injury causes solid organ trauma viz. liver, spleen and kidneys more often than hollow viscera, resulting in hemorrhage and hemorrhagic shock.
- Injury to upper abdomen is more dangerous than that of lower abdomen. Multiorgan system injury is also more common in blunt injury than in other types.

#### Penetrating Injury

Penetrating injury is usually caused by sharp instruments like a knife or by various types of firearms. Sharp penetrating injury in the midline is more serious than in the flanks as it may lead to injury to the great vessels.

Sepsis is more common in penetrating injury. Injury to the spine is common in gunshot wounds from side or back.

#### Instrumentation Injury

Instrumentation injury or iatrogenic injury may occur during gastroduodenoscopy, colonoscopy, sigmoidoscopy, esophagoscopy in the form of perforation of the gut wall. Sometimes an enema nozzle may cause a rectal tear.

### MANAGEMENT

The advanced trauma life support (ATLS) protocol of management is followed for the management of abdominal trauma which consists of:

1. Primary survey and resuscitation as mentioned earlier.
2. Secondary survey, i.e. a full history, clinical examination and investigations and
3. Definitive care.

#### Primary Survey

In **primary survey** airway control, breathing and circulatory support are ensured. Cervical spine immobilization and hemorrhage control are done. Life-threatening injuries like tension pneumothorax and cardiac tamponade should be excluded and appropriate measures taken.

The aim of resuscitation is to correct and maintain oxygenation and tissue perfusion.

When patient is stable, secondary survey is made.

#### Secondary survey

##### History

History of shoulder tip pain suggests splenic injury.

- One should ask about the AMPLE history as described earlier.
- Possibility of pathological visceromegaly should be enquired of, e.g. history of malaria, hepatitis or Kalaa-zar as well as drug treatment.
- In penetrating injuries, the nature and direction of penetration as well as the patient position at the time of injury is important.

##### Clinical Examination

- Vital signs are noted to identify revealed or concealed hemorrhage and shock.
- One should look for the signs of peritonitis, e.g. localized tenderness, guarding or rigidity. Even minimal tenderness and guarding are significant.
- Failure to pass urine may imply genitourinary trauma.
- In case of doubt, repeated clinical examination at ½ or 1 hourly interval is most revealing. Presence of patterned bruising

is suggestive of severe pressure. Per rectal examination is done to see the presence of any bleeding.

### Investigations

When history and clinical examination are doubtful, proper investigations are helpful.

An unstable patient may have to be directly taken to the operation theater for damage control surgery allowing no time for performing investigations. In a stable patient the following investigations are done.

1. Complete blood picture—A low hematocrit or a fall in hematocrit may indicate bleeding.
2. Plain X-ray abdomen (erect and supine)—Free air under the diaphragm or extraluminal air in the retroperitoneum may indicate hollow visceral perforation.
 

Location of foreign body or missile is facilitated by the radiograph.
3. Chest X-ray (erect if possible)—may show subphrenic air suggestive of ruptured viscus and rib fracture near the spleen.
4. Serum amylase—may be elevated in pancreatic injury. However a normal amylase level does not exclude major pancreatic trauma.
5. Urine microscopy—microscopic hematuria may be found in renal injury.
6. Ultrasound examination (USG)—It can pick solid organ injury, e.g. liver, pancreas, spleen and kidney. It is noninvasive and easily available. Disadvantage is that it is operator dependent and has a low sensitivity due to presence of gas-filled bowel loops. The objective of US examination is to search for free intraperitoneal fluid.
7. CT Scan.

In the stable patient this investigation is being increasingly used in blunt as well as penetrating abdominal trauma. A standard trauma scan with a modern spiral scanner can be acquired in 3-5 min and should include intravenous contrast.

The indications of doing CT scan are:

1. Doubtful abdominal examination.
2. Hematuria.
3. Pelvic fracture with significant bleeding.
4. Associated head injury and spinal cord injury.

The advantages of CT scan are:

- i. Can quantify the amount of free blood in the peritoneal cavity.

ii. IV contrast can be given and the genitourinary tract can be visualized, thus avoiding the necessity of doing an IVU.

iii. Determines excellently the extent of injury of the solid visceral organs, e.g. liver, spleen, kidneys and pancreas as well as the retroperitoneal structures.

However CT scan is costlier and unreliable in detection of rupture of bowel, and diaphragmatic injuries.

In the hemodynamically unstable patient the scan takes too much time and is not used, instead immediate laparotomy is the preferred option.

### Diagnostic Peritoneal Lavage (DPL)

This is rarely practiced nowadays as better facilities like ultrasound, CT scan are available.

### Definitive Care

- Resuscitation, clinical assessment and monitoring are all that is required in the majority of cases.
- Laparotomy: The indications are:
  - i. All gunshot wounds.
  - ii. All eviscerations even with a small tag of protruding omentum.
  - iii. Subphrenic gas.
  - iv. Continuing shock despite resuscitation.
  - v. Stab wounds with significant blood loss and peritonitis.
  - vi. Frank blood detected on four quadrant tap and/or peritoneal lavage.
  - vii. Urinary damage as revealed in urgent IVU or CT scan.

### LAPAROTOMY

- The abdomen is opened with a quick mid-line incision.
- A transverse supraumbilical incision is useful in children under the age of 5 years.

Exploration is made methodically with examination of the organs in the supracolic compartment viz. the spleen, liver, gallbladder, the diaphragm in that order. Then the stomach and greater omentum, together with the adherent transverse mesocolon and transverse colon are lifted up and the infracolic compartment is explored, e.g. duodenum, D-J flexure, jejunum, ileum, the mesentery, the appendix, cecum, ascending

colon, transverse colon, descending colon and sigmoid colon.

Finally pelvic organs, e.g. bladder, uterus and ovaries in female and hernial orifices are examined. The retroperitoneal organs and structures like the kidneys, pancreas, aorta, should also be looked for recording the findings of each organ.

Quick mass closure leaving a drain behind is the best.

See also operative surgery section, chapter 88.

## SPECIFIC INJURIES

### Spleen

It is the most commonly injured solid organ in abdominal trauma.

Spleen is removed if it is shattered. If it is not extensively damaged it is preserved by repair, partial splenectomy or enclosing the organ in a mesh sac. See the operative section for the operation of splenectomy.

### Liver

It is the second most common organ injured in abdominal trauma after the spleen.

### Classifications

- Minor lacerations.
- Moderately sized tears.
- Extensive lacerations.

### Treatment

- Stable patients with minor injuries are treated conservatively at first instance. These patients are best followed up by serial CT scanning to monitor resorption of hemoperitoneum and the pattern of healing of intrahepatic lesions.

Surgical exploration is necessary if there is evidence of continued blood loss.

- Moderate injuries—These are managed with simple sutures and resectional debridement to control bleeding.
- Major injuries—If there is massive bleeding from the liver and the patient becomes hypothermic and acidotic then it is better to pack the liver with gauge rolls and return the patient to the intensive care. The patient is operated again after 36–72 hours when the injury is debrided and the packs can be safely removed with no fresh



bleeding. This is called damage control surgery.

### Gallbladder

- Injury to the gallbladder is relatively uncommon and is usually due to penetrating abdominal trauma.
- For perforations or avulsion injury of the gallbladder the recommended treatment is cholecystectomy.
- If the patient is unstable, then a tube cholecystostomy is done through the site of perforation. The tube is removed only after a cholangiogram shows a normal gallbladder and bile ducts with a free flow of dye into the duodenum.

### Extrahepatic Biliary Tree

Penetrating injuries are the usual causes. Injuries due to blunt trauma are infrequent and difficult to diagnose.

Isolated extrahepatic biliary tree injury may be present but the accompanying hepatic artery and the portal vein are frequently involved and the resulting bleeding is difficult to control. If bleeding is present, then Pringle maneuver is used and the hepatoduodenal ligament with all its contained structures is clamped proximally and distally after which repair is carried out.

If the major bile ducts are incompletely divided the defect is repaired primarily with absorbable sutures. When the duct is completely transected repair by end to end anastomosis invariably leads to stricture formation. Therefore, some form of biliary enteric anastomosis like choledochojejunostomy or cholecystojejunostomy is done.

### Portal Vein

Portal vein injury usually occurs following a penetrating injury and the recommended treatment is lateral venorrhaphy with 5 – 0 Prolene by vascular surgical technique.

### Stomach

Most penetrating wounds of the stomach are treated by means of debridement of the wound edges and primary closure in two layers. It is rarely injured in a blunt trauma as it is relatively mobile and in a protected position.

### Pancreas

- Penetrating trauma is responsible for 70 percent of the pancreatic injuries and blunt abdominal trauma, for the rest.
- Combined severe injuries to the pancreas and duodenum represent a minority of cases of pancreatic trauma.
- Blunt injury to the upper abdomen may compress the pancreas against the vertebral column leading to traumatic pancreatitis and even transection.

### Diagnosis

- Diagnosis is made by having a high index of suspicion based on history, mechanism of injury and associated clinical findings.
- New generation CT scan is an excellent way to clinch the diagnosis.
- Endoscopic retrograde cholangiopancreatography (ERCP) can diagnose transection of the pancreatic duct and finds use for further evaluation in a stable patient or when CT scan is not available or shows ambiguous findings.

### Treatment

- If there is any evidence that the pancreas has been contused, independent of the location, it should be drained.
- If a distal ductal injury is detected, during the operation distal resection with splenic preservation if possible, is the treatment of choice.
- A Whipple procedure is preserved for severe combined pancreatoduodenal injuries.

### Duodenum

A motor vehicle accident causing a steering wheel blow to the epigastrium is the most common mechanism of blunt duodenal injuries. Like pancreatic injury, duodenal injuries are more often due to penetrating abdominal trauma and involve the second part of duodenum.

### Diagnosis

- Plain abdominal X-ray shows retroperitoneal air in the upper abdomen silhouetting the lateral aspect of the duodenum, accumulation of air around the right kidney, obliteration of the psoas shadow on

the right side and air in front of the first lumbar vertebra on a lateral film.

If findings are equivocal, then air injected through the nasogastric tube will make the retroperitoneal air more visible.

- CT scan done with oral and intravenous contrast medium is diagnostic.

### Treatment

- During exploration, the complete duodenum must be inspected, especially so when there is retroperitoneal hematoma or bile stained fluid in the vicinity of the duodenum. An extensive Kocher's maneuver is required.
- Treatment options depend on the severity of injury and the time passed from injury to treatment. The size of duodenal perforation is probably the most important consideration in the management.
- 75 percent cases of duodenal perforations are treated by debridement and simple suturing.
- Options for duodenal perforations which cannot be tackled by simple suturing are end to end anastomosis and Roux–en–y duodenojejunostomy.
- Most cases of intraluminal hematoma are treated conservatively with nasogastric suction, nil orally and IV fluids.

### Mesenteric Trauma

This type of trauma occurs in decelerating injuries while riding in a vehicle known as the seat belt syndrome.

There is mesenteric laceration and associated rupture of the small intestine. If the mesenteric laceration is transverse, the intestine gets devascularized and should be resected. On the other hand, if the laceration is parallel to the mesentery, then it can be sutured.

### Small Intestine

- Commonly injured in both penetrating and blunt abdominal trauma.
- Intestinal injury following blunt trauma may be due to crushing of the intestinal loops between the vertebrae and the anterior abdominal wall, and a sudden increase in the intraluminal pressure of the bowel.

- Tears usually occur at relatively fixed points along the attachment of the intestinal mesentery.
- Associated intra-abdominal injury mostly of spleen or liver is present in 40 percent of patients.
- For all rectal injuries, fecal diversion is a must and is achieved by double barreled colostomy. Retrorectal drainage should be done for all rectal injuries.
- Colostomy closure is done after 2 – 3 weeks if the patient is well.

### Treatment

Early diagnosis and prompt surgical intervention are the most important determinants of a successful outcome.

Surgical treatments consist of resection of devitalized segments of bowel and primary anastomosis.

This is followed by thorough saline lavage of the peritoneal cavity before closure of the abdomen.

The skin and subcutaneous tissues are left unsutured and packed with acriflavine gauze. Delayed primary suture is undertaken 5 to 7 days later.

### Colon and Rectum

- Colonic injury usually occurs due to penetrating trauma and rarely in blunt trauma.
- Transverse colon is most commonly affected segment followed by right colon, left colon and rectum.
- The lesions may consist of incomplete lacerations (seromuscular tears), hematoma or contusion with variable degrees of involvement of the adjacent mesentery or omentum, complete lacerations with fecal spillage or avulsion from the mesentery with full thickness necrosis.

### Treatment

- Minor injuries – are closed with primary suture with or without proximal defunctioning colostomy.
- In case of severe colonic injuries of the left colon with extensive tissue destruction, fecal contamination and associated injuries, the surgical options are:
  1. Wound exteriorization as a colostomy.
  2. Primary closure and a proximal colostomy.
  3. Proximal end colostomy and distal mucous fistula (Hartmann procedure).
- Extensive injury of the right colon is best treated by right hemicolectomy.

## RETROPERITONEAL HEMATOMA

### Surgical Anatomy of Retroperitoneum

- Retroperitoneum is the actual space between the peritoneal cavity and the posterior bodywall. It is bounded superiorly by the diaphragm, inferiorly by the levator ani muscles, anteriorly by the posterior parietal peritoneum and by spaces between leaves of the small and large bowel mesenteries and posteriorly by the vertebral column, psoas and quadratus lumborum muscles.
- Contents of the retroperitoneum include
  - a. Solid organs and major blood vessels viz. kidneys, ureters, adrenal glands, the duodenum, pancreas, abdominal aorta and the inferior vena cava and
  - b. Soft tissues viz. autonomic and peripheral nerves, small blood vessels, lymphatics and lymph nodes, fatty and fibrous connective tissue.

### Features

- The retroperitoneal hematoma is mostly caused by a pelvic fracture. It takes a serious injury to produce a retroperitoneal hematoma.
- Typically the patient presents with pelvic fracture with complaints of abdominal pain, hematuria, hypovolemic shock and anemia.
- Upto 4000ml of fluid may accumulate inside the retroperitoneum especially under pressure to produce the hypovolemia and shock.

### Investigations

1. Plain X-ray abdomen shows a pelvic fracture, obliteration of psoas shadow, site of the missile in penetrating injury.
2. CT scan is the preferred investigation of choice to diagnose the injury.

### Treatment

For treatment purposes, retroperitoneum is divided into three zones viz.

- Zone 1 or central zone is the midline retroperitoneum which extends from the diaphragmatic hiatus to the sacral promontory. Treatment is surgical exploration as the bleeding is from the branches of the aorta and the inferior vena cava.
- Zone 2 or perinephric zone – Consisting of both abdominal flanks. A hematoma in zone 2 is the result of injury to the renal vessels or parenchyma. Treatment is conservative in most cases.
- Zone 3 or pelvic zone – Hematomas resulting from the blunt trauma is best treated nonsurgically. If bleeding persists due to major vessel injury surgical intervention is needed.
- All retroperitoneal hematomas due to penetrating injury are explored.

## DAMAGE CONTROL SURGERY IN MAJOR TRAUMA

- The traditional approach to major trauma is not applicable in devastating injuries.
- Most severely bleeding and polytrauma patients die from hypothermia, coagulopathy and acidosis.
- Hence the principles of damage control surgery are:
  - a. Control of bleeding / hemorrhage.
  - b. Prevention of contamination from perforated hollow viscus.
  - c. Core warming.
  - d. Correction of coagulopathy with infusion of FFP (Fresh frozen plasma) and
  - e. Correction of acidosis.
- Damage control surgery includes primary resuscitation and abbreviated laparotomy. The hemoperitoneum is evacuated and the abdomen is packed in four quadrants. Life saving procedures, e.g. repair of perforation of hollow viscus or ligation of a bleeding vessel is performed very rapidly and the abdomen is closed temporarily. The aim is to restore the physiology rather than anatomy.
- When the patient is stable and organ function is maintained, usually 45 to 72 hours after the initial operation, the patient is taken back to the operating room for pack

removal, debridement of nonviable tissue and definitive repair.

### **ABDOMINAL COMPARTMENT SYNDROME**

- Abdominal compartment syndrome (ACS) is characterized by a sudden increase in intra-abdominal pressure leading to decreased urinary output, hypoxia, hypercarbia and hypotension due to decreased venous return to the heart.
- Diagnosis is confirmed by measurement of bladder pressure.
- ACS can occur in patients following blunt or penetrating trauma, abbreviated laparotomy and elective surgery.
- Normal intraabdominal pressure (Bladder pressure) is 10 to 15 cm H<sub>2</sub>O (7 – 11 mmHg). When the abdominal pressure raises to more than 25cm of H<sub>2</sub>O significant cardiovascular, respiratory, cerebral and renal dysfunction occurs.
- Treatment includes a rapid decompression of the elevated intra-abdominal pressure by opening the abdominal wound and performing a temporary closure of the abdominal wall with mesh or a plastic bag.
- Hypovolemia should be corrected prior to abdominal decompression.

# Chapter 56

## Genitourinary Tract Trauma

- Kidney injury
- Ureteric injury
- Bladder injury
- Injuries to the urethra

### KIDNEY INJURY

Renal injuries are the most common cause of genitourinary tract trauma. Most injuries are related to sporting mishaps or automobile accidents chiefly in men and boys.

#### Mechanism of Injury

- i. Blunt trauma is responsible in 70 to 80 percent cases.
- ii. Penetrating trauma is responsible for the rest of the cases.

#### Classifications

Pathologic classifications of renal injuries is as follows (Fig. 56.1):

**Grade 1**—It is the most common type. Renal contusion and subcapsular hematoma without parenchymal laceration.

**Grade 2**—Nonexpanding perirenal hematoma and cortical laceration less than 1cm deep.

**Grade 3**—Renal parenchymal laceration more than 1cm deep, no urinary extravasation.

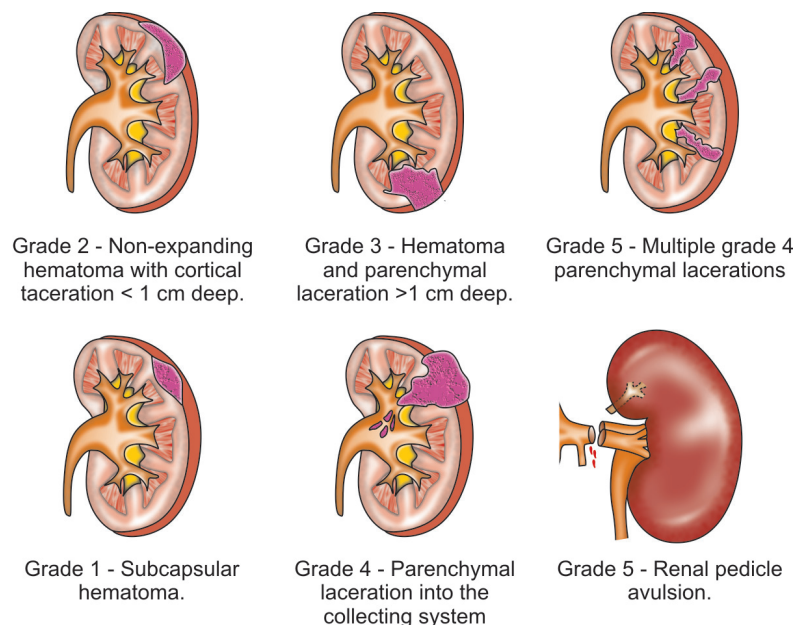
**Grade 4**—Renal parenchymal laceration extending into the renal collecting system or thrombosis of a segmented renal artery.

**Grade 5**—Multiple Grade 4 parenchymal lacerations, avulsion of the renal vessels or a shattered kidney.

Of the above, Grade 1 and 2 are regarded as minor injury and Grade 3, 4 and 5 as major injury.

### Clinical features

- Hematuria—Microscopic or gross hematuria following trauma to the abdomen indicates injury to the urinary tract.
- History of stab or gunshot wounds to the flank area should alert the physician to possible renal injury.
- The degree of renal injury however does not correspond to the degree of hematuria since only mild hematuria may occur in major trauma and gross hematuria in minor renal trauma.
- Hematuria after a trivial injury should suggest an underlying disorder, e.g. calculus hydronephrosis or tuberculosis which has made it more prone to trauma than a normal kidney.
- In 90 percent cases it is self-limiting though it may be prolonged upto a fort night.



**Fig. 56.1:** Pathological grades of renal injury.

- Pain: Loin pain is a significant finding in almost all cases.
- Shock: The presence of shock indicates either major injury, e.g. pedicle injury or shattered kidney or associated injuries of other abdominal viscera.
- Retroperitoneal bleeding may cause abdominal distension, ileus, nausea and vomiting.
- A palpable mass may represent a large retroperitoneal hematoma or urinary extravasation.

### Investigations

- Laboratory tests show hematuria and a low hematocrit.
- Intravenous urogram (IVU): Renal injury is best investigated by doing an IVU and a CT scan. In IVU, 5, 15 and 30 minute films are taken. The following may be the findings:
  - a. There may be distortion of the calices.
  - b. Extravasation of the contrast.
  - c. It will show the presence and function of the contralateral kidney.
  - d. Nonfunctioning kidney in case of pedicle injury. This is an indication for immediate arteriography to identify possible avulsion of renal pedicle or renal arterial thrombosis.
- CT scan—It is best noninvasive investigation in renal injury. It can detect minor extravasation and evaluate associated intra-abdominal and retroperitoneal injuries. It is used to grade the injury and hence, the line of management. Of course it is not available in all centers. In absence of CT scan, an IVU is done.
- Ultrasound, however is widely available and has proved useful in initial assessment, especially when combined with doppler assessment of renal blood flow.

### Treatment

1. Minor injury—Conservative treatment with bed rest, hydration and antibiotics for 7 to 14 days. Objective of treatment is to allow absorption of hematoma without infection. It is cured in more than 80 percent cases.
2. Major injury (Ruptured kidney, shattered kidney and pedicle avulsion).
  - Primary survey and resuscitation of the patient is performed following the

ATLS protocol of management as mentioned earlier in chapter 52,

- Indications of surgery
  - i. Expanding retroperitoneal hematoma with signs of progressive blood loss.
  - ii. Proven renal pedicle avulsion.
  - iii. Penetrating renal trauma.
  - iv. Severe urinary extravasation on CT scan or IVU.
- Surgery involves
  - i. Nephrectomy in case of shattered kidney.
  - ii. Repair of vascular injury with 6/0 Prolene in case of avulsion of renal pedicle.
  - iii. For ruptured kidney, abdomen is opened through a long midline incision so that other abdominal viscera can be examined.
- Devitalized kidney tissue is excised while lacerations can usually be sutured directly with appropriate attention to the bleeding vessels.

### URETERIC INJURY

#### Causes

1. Iatrogenic—This is the commonest cause and occurs during the course of pelvic surgery, e.g. hysterectomy, abdominoperineal resection, etc. Injury may be due to clamping or ligation, devascularization or partial division of ureter.
2. Blunt trauma.
3. Gunshot injuries—commonest site is midposition of ureter. Majority of iatrogenic injuries occur in the last 4 to 6 cm of its length.

#### Clinical Features

- Patient is usually a female of 30 to 45 years of age.
- Pain, swelling and fever of 101 to 102°F.
- Dribbling of urine through the abdominal or vaginal wound by development of fistula from 3 days to 3 weeks after operation.

#### Investigations

1. Indigo carmine test—IV injection of indigo carmine will produce vaginal leakage of colored dye.
2. USG—Urinoma (collection of urine) may be seen.

3. IVU—Extravasation may be seen in an early case, hydroureteronephrosis after a few weeks of nonfunctioning kidney in late cases, on the affected side.
4. Plain X-ray KUB—Soft tissue shadow may be seen.

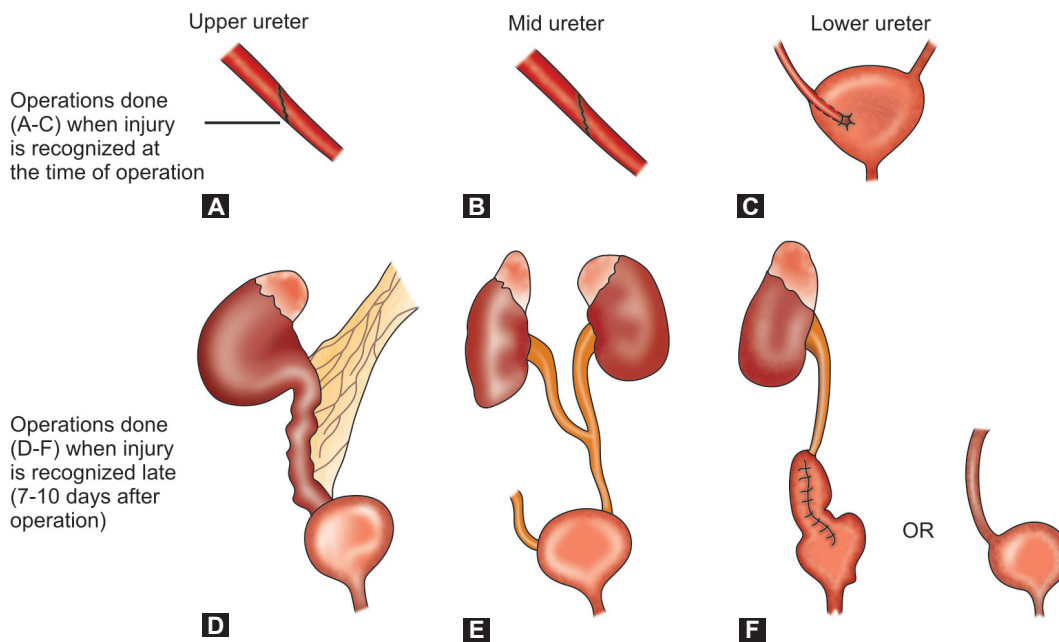
### Treatment

- Prompt treatment of ureteral injuries is required. Best repair is at the time of operation if recognized.
- If the injury is recognized 7 to 10 days after the event and no infection, abscess or complications exist, immediate reexploration and repair is indicated. Type of repair—This depends on the time of detection of injury (Fig. 56.2)
  - a. If recognized at the time of operation then for—
    - i. Upper ureter injury—End to end anastomosis with splintage by a ureteric stentor T-Tube emerging below the anastomosis is done.
    - ii. Lower ureter injury—Ureteroneocystostomy whereby the upper end of a transected ureter is implanted into the bladder is performed.
  - b. If the injury is recognized late (7 – 10 days after operation), then for—
    - i. Upper ureter injury—usually primary ureteroureterostomy (which is the anastomosis between two segments of the same ureter) or ileal replacement is done.
    - ii. Mid ureter injury—Best is primary or transureteroureterostomy (anastomosis of the transected end of one ureter into the side of the intact contralateral ureter).
    - iii. Lower ureter injury:
      - Spatulation and end to end anastomosis (primary ureteroureterostomy) if there is no loss of length.
      - Boari bladder flap (ureteric reimplant into tubed bladder flap) if there is little loss of length.
      - If the above fails, i.e. there is marked loss of length, transureteroureterostomy is done.

### BLADDER INJURY

The bladder is in an anatomically protected position in the bony pelvis and is commonly injured where there is a fracture of the pelvis.





**Figs 56.2A to F:** Operations for repair of ureteric injuries. (A & B) End to end anastomosis; (C) Ureteroneocystostomy or ureteric reimplantation; (D) Ileal replacement; (E) Transureteroureterostomy; (F) Boari bladder flap or spatulation and end to end anastomosis.

About 15 percent of all pelvic fractures are associated with concomitant bladder or urethral injuries.

### Types

There are two types:

1. Intraperitoneal rupture and
2. Extraperitoneal rupture.

### Pathology

1. Intraperitoneal rupture is more common in male usually secondary to blow, kick or fall on a fully distended bladder. More rarely it is the result of surgical damage, e.g. during transurethral resection of bladder tumor (TURBT).
2. Extraperitoneal rupture is usually caused by a fracture pelvis due to blunt trauma when fragments from the fracture site perforate the bladder. Pelvic fracture accompanies bladder rupture in 90 percent of cases.

If the urine is infected, extraperitoneal bladder perforations may result in deep pelvic abscess and severe pelvic inflammation.

### Clinical Features

- Intraperitoneal rupture
  - Patient becomes unable to void,
  - Progressive distension of abdomen with loss of bowel sounds.

- IVU will demonstrate leakage of urine in peritoneal cavity.
- Diagnosis is confirmed by a cystogram.
- Extraperitoneal rupture
  - The patient presents with suprapubic swelling which becomes painful and red with signs of toxemia in neglected cases.
  - Diagnosis is confirmed by cystogram.

### Treatment

- a. Minor degrees of rupture are treated by simple catheterization for a week or so. The rupture usually seals off rapidly and is not associated with long-term problems.
- b. Major rupture needs exploration and drainage. The laceration is repaired in two layers with 2/0 polyglycolic acid (Vicryl).
  - The perivesical space is drained and suprapubic catheterization done for 10 to 14 days.
  - Peritoneum should be opened to look for intraperitoneal rupture of bladder or other visceral injury.

### Prognosis

Early recognition and treatment of bladder rupture are crucial. Untreated major perforations of the bladder are associated with 100

percent mortality. If recognized and treated within 24 hours mortality falls to 55 percent and, if within 12 hours, to 11 percent.

### INJURIES TO THE URETHRA

Urethral injuries are rare in women. They occur most often in men following pelvic fractures or falling on buttocks from a height.

Management varies according to the level of injury. The urethra is divided into two broad anatomic divisions viz.

- Anterior urethra consisting of bulbar and penile urethra and
- Posterior urethra consisting of prostatic and membranous urethra.

### Anterior Urethral Trauma (Spongy Urethra)

#### Causes

- Instrumentation with cystoscopes, dilators or catheters are the common causes.
- Straddle perineal injury can also cause this type of injury.

#### Pathology

The injury may vary from a simple contusion to urethral laceration as in straddle trauma.

In the latter type of injury the urethra gets crushed against the inferior edge of symphysis pubis. Most commonly the Buck's fascia is torn and the extravasating urine is then confined by the Colles fascia. The urine tracks down into the scrotum and on to the anterior abdominal wall and can be infected. The extravasation cannot extend into the thigh due to the firm attachment of the fascia to ischiopubic rami.

### Clinical Features

- Patient gives history of some instrumentation into the urethra or straddle injury.
- Blood is present at the urethral meatus.
- Perineal swelling may be present due to periurethral collection of blood and urine.

### Diagnosis

Diagnosis is confirmed by urethroscopy or retrograde urethrography which reveals extravasation at the site of injury. No extravasation is seen in a contused urethra.

### Treatment

- Minor injuries – Simple urethral catheterization for a week. They should reevaluate

after 6 to 12 months to exclude any stricture formation.

- Major injury – Immediate repair is done if extensive debridement of devitalized tissue is not required.

If primary repair is not possible, suprapubic catheterization is done and the damage is repaired at a later date when local conditions are favorable.

### Injury To Posterior Urethra (Prostatomembranourethra)

The prostatic urethra becomes the membranous urethra when it passes through the urogenital diaphragm which forms the voluntary external sphincter. The urogenital diaphragm is attached to the pubic bone.

This type of injury is commonly associated with pelvic fractures and gross disruption of the pelvic ring.

### Clinical Features

The patient presents with a history of pelvic fracture and complains of lower abdominal pain and inability to pass urine.

Blood at the urethral meatus is diagnostic of urethral injury.

Per rectal examination reveals a pelvic hematoma and the prostate may be impalpable as it is displaced upwards.

### Investigations

- IVU shows a tear drop bladder displaced upwards in the pelvis and compressed at its base by hematoma.
- An ascending urethrogram will reveal a partial or complete rupture.

### Treatment

- Suprapubic catheterization should be done as soon as possible.
- If there is associated intra or extraperitoneal rupture of bladder lower midline laparotomy is done, bladder rupture repaired, suprapubic catheter inserted and the retropubic space is drained.

### Complications of Urethral Injury

1. Urethral stricture—The main complication is urethral stricture formation, the treatment of which is urethrotomy or urethroplasty in severe cases.
2. Urinary incontinence due to damage of external urethral sphincter.
3. Impotence.

## Chapter 57

Fractures and Dislocations—  
General Considerations

- Definitions
- Classification of fractures
- Healing of a fracture
- Treatment of fracture
- Reduction
- Complications of fractures

**DEFINITIONS**

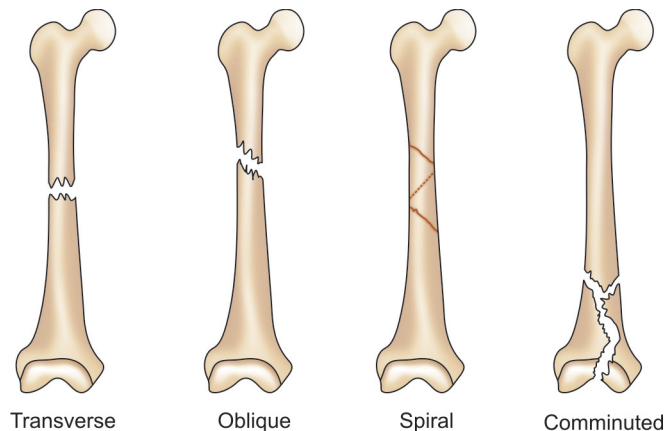
1. **Fracture:** A fracture is a partial or complete break in the continuity of bone.
2. **Dislocation:** Dislocation means a complete disruption of a joint while subluxation is a partial dislocation.

In dislocation, there is complete loss of congruity between the articulating surfaces of a joint so that the bones forming the joint are displaced relative to one another, e.g. in anterior dislocation of shoulder the head of the humerus loses all contact with the glenoid cavity and lies anterior to it below the coracoid process.

3. **Sprain:** Sprain is an incomplete tear of a ligament or a group of ligaments around a joint. This is not associated with instability of the joint, e.g. ankle sprain.

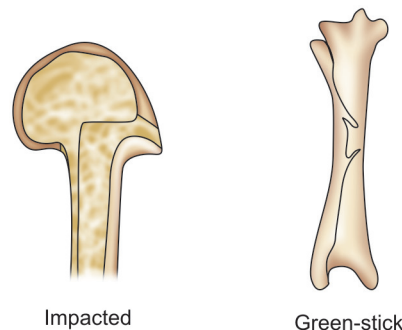
- iii. Spiral fracture—The fracture surface is spiral in shape.
- B. According to the cause of fracture, it may be:
  - i. Traumatic fracture.
  - ii. Pathological fracture—It is the fracture at an area of bone weakened by a pathologic

- process, e.g. secondary metastasis, infection, metabolic bone disease, etc.
- iii. Stress or fatigue fracture—When fracture occurs due to repeated stress, none of which by itself is sufficient to cause a fracture.

**CLASSIFICATION OF FRACTURES**

Fractures can be classified in different ways as described below. (Fig. 57.1)

- A. According to the plane of fracture surface, a fracture may be:
  - i. Transverse fracture—Here the plane of fracture surface is perpendicular to the long axis of the bone.
  - ii. Oblique fracture—When the fracture surface forms an angle with the long axis of the bone.



**Fig. 57.1:** Types of fractures.

- C. Fractures may be classified as:
- i. Simple or closed fracture—In which the fracture surface does not communicate with the exterior through the skin or mucous membrane.
  - ii. Compound or open fracture—In which the fracture surface communicates with the exterior through a break in the skin or mucous membrane.
- D. According to number, fracture may be:
- i. Single.
  - ii. Multiple—When there are more than one fracture either in the same bone or in different bones.
- E. Fractures may be:
- i. Complete—When the whole thickness of bone has been disrupted. A complete fracture may be:
    - a. Impacted—When one fragment gets impacted into another.
    - b. Nonimpacted—When the fragments keep separate. In the majority of

cases there is displacement between the two fragments. When displacement of a fracture is described, it is usually the position of the lower fragment, in relation to the upper one.

- ii. Incomplete—When some thickness of the bone still keeps intact, e.g. Green stick fracture in children where only one side of the bone is fractured, the other simply bends.

A few peculiar fractures require special mention, e.g.

1. A comminuted fracture is one in which there are more two fracture fragments.
2. Complex or complicated fracture—When a fracture is accompanied by damage to major neighboring structures, e.g. nerves or vessels or viscera, it is known as a complicated fracture, e.g. the brachial artery injury in case of supracondylar fracture of humerus, injury to the bladder and urethra associated with pelvic fracture.

### HEALING OF A FRACTURE

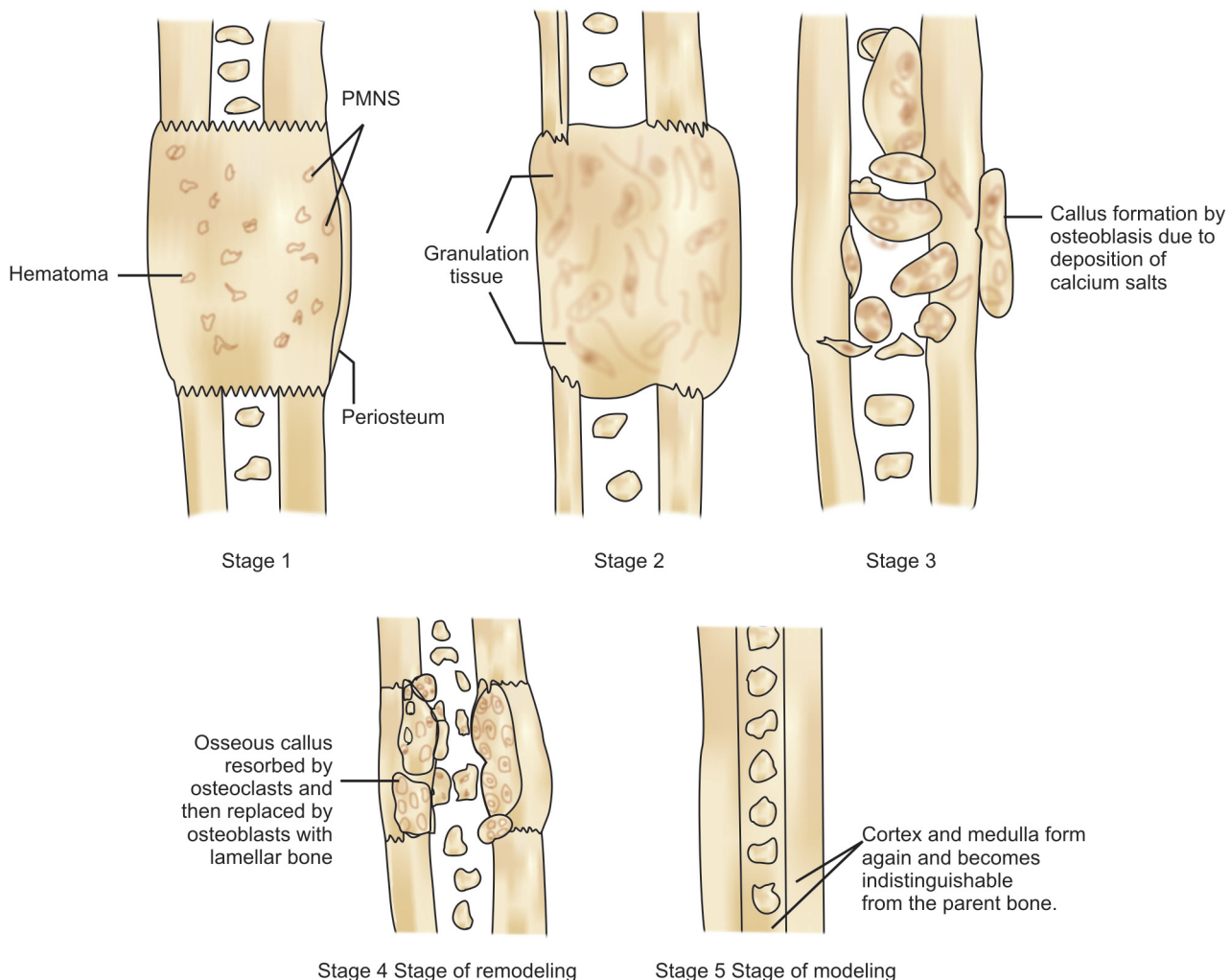
The healing of a fracture occurs through a number of stages described below. The process of healing is similar in many ways to that of soft tissue wounds except that the end result is mineralized mesenchymal tissue, i.e. bone.

#### Stages of Fracture Healing (Frost, 1989) (Fig. 57.2)

1. Stage of hematoma formation (1 week).
2. Stage of granulation tissue formation (upto 2-3 weeks).
3. Stage of callus (hard bone-like substance between the fracture ends) formation (4-12 weeks).
4. Stage of remodeling (1-4 years).
5. Stage of modelling (many years).

#### Stage of Hematoma Formation

When a bone is fractured, blood accumulates around the fracture to form a hematoma.



**Fig. 57.2:** The stages of healing of fracture, (PMNS – Polymorphonuclear leukocytes)

A loose meshwork is formed by blood and fibrin clot which acts as framework for subsequent granulation tissue formation.

The periosteum is elevated from the fracture ends resulting in ischemic necrosis of the fracture ends, usually over a length of a few millimeters.

Local inflammatory response occurs at the site of injury with exudation of fibrin, polymorphs and macrophages and an outflow of chemical mediators and growth factors (TGF, PDGF, etc). See wound healing chapter 2. Fragments of necrosed bone are scavenged by macrophages and osteoclasts.

Deprived of the blood supply some of the osteocytes die while others are sensitized to respond subsequently by differentiating into daughter cells.

### Stage of Granulation Tissue Formation

This stage lasts for about 2 to 3 weeks. In this stage the sensitized daughter cells or osteocytes and mesenchymal cells from the periosteum and endosteum stimulate the formation of new blood vessels (neovascularization), fibroblasts and osteoblasts. Collectively they form a soft granulation tissue between the fracture fragments. The blood clot is eventually removed by macrophages, giant cells, and other cells arising in the granulation tissue.

### Stage of Callus Formation

This stage lasts for about 4 to 12 weeks. In soft tissue healing granulation tissue is replaced by fibrous tissue while in bone healing, the osteoblasts within the granulation tissue stimulate the bone growth.

So bone healing differs from soft tissue healing at this stage.

The osteoblasts lay down intercellular matrix which soon becomes impregnated with calcium salts. This results in the formation of callus or woven bone (immature bone). The callus is the first sign of union of fracture ends visible on X-rays.

### Stage of Remodeling

Stage of remodeling was formerly called the stage of consolidation. In this stage the woven bone is replaced by mature bone with typical lamellar structure. It is a slow process extending from one to four years.

### Stage of Modeling

In the stage of modeling, formerly called the stage of remodeling, the bone is gradually strengthened over many years. The modeling of endosteal and periosteal surfaces occur so that the fracture site becomes indistinguishable from the parent bone. This stage is more conspicuous in children but occurs to a very limited extent in fractures in adults.

### Clinical Features

- Pain
- Loss of function
- Deformity
- Tenderness and swelling
- Discoloration or bruising.

### Investigations

1. Radiographs—This is done in two planes (anteroposterior and lateral views) to see which bone has been fractured, the line of fracture and the type of displacement.
2. CT scan and MRI—These are done rarely.
3. USG—may be done to detect an effusion.

## TREATMENT OF FRACTURE

### Treatment of Closed Fracture

It should be remembered that one should treat the patient as a whole and not only the fracture.

Therefore, it should follow similar lines to any emergency management viz. advanced trauma and life support (ATLS) protocol (see chapter 52, Evaluation and general management of trauma) which comprises.

- Primary survey and resuscitation.
- Secondary survey and
- Definitive care which includes the reduction of fracture.

**Primary survey and resuscitation includes (ABCDE)**

- Airway
- Breathing
- Circulation
- Assessment of dysfunction of central nervous system.
- Exposure and search for other associated injuries of head and spine, ribs, pelvis, etc. apart from the fracture itself.
- Other measures: The following measures are also taken during primary survey.

- i. Estimation and correction of blood loss: In an area of fracture there is always a significant internal hemorrhage. This is particularly severe in fracture of pelvis, femur and multiple fractures. Any external bleeding if present should be stopped by local pressure.

Blood is sent for grouping and cross-matching to combat the blood loss and treatment of oligemic shock.

- ii. Relief of pain with.
  - a. Local splintage of the fracture.
  - b. Intravenous opiates.
  - c. Nerve block, e.g. femoral nerve block in fracture of femur.

Splintage of the fracture: This should be done urgently after the detection of fracture. Before splinting, any ring or bangle worn by the patient is removed. Almost any available object, e.g. a rigid cardboard or wooden plank, folded newspaper, stick, etc. can be used at the site of accident for splintage of the fracture.

In secondary survey history taking and a complete examination from head to foot is performed.

Treatment of fracture is included in the definitive care.

The treatment of fracture can be best described under three headings viz.

- Reduction which means to bring the fractured segments in alignment without any displacement by closed or open method.
  - Retention—This is to keep fracture fragments immobilized in the reduced position till union occurs and
  - Rehabilitation—means restoration of function of the fractured bone.
- This is classically described as 3R's.

### REDUCTION

There are two methods of reduction: closed and open.

#### Closed Reduction

Closed reduction is again achieved in two ways:

- a. Manipulation: It is the most commonly practiced method and is done under general anesthesia as muscle relaxation is necessary to bring the fracture fragments in position.

It basically consists of realigning a displaced fracture by feeling it through the soft tissue and requires some experience.



It is not necessary that perfect anatomical reduction is achieved in all cases. Displacements compatible with normal functions of the limb are considered as acceptable.

Most fractures reduced by closed manipulation need some kind of immobilization.

- b. Continuous traction: This is used in case of fractures where the muscles attached to either of the fragments apply a strong force which either does not allow reduction or causes redisplacement.

Once a fracture has been reduced by traction, it can be immobilized by other methods such as the plaster cast or the traction itself may be continued to maintain the reduction until the fracture unites.

### Open Reduction

Operative reduction of the fracture under direct vision is indicated when:

1. Closed reduction fails either because of difficulty in controlling the fragments or because soft tissues are interposed between them.
2. When fractures involve joint surfaces.
3. Where internal fixation is obligatory to keep the fragments in position.

### RETENTION (Immobilization of Fractures)

Immobilization of a fracture is done for the following reasons:

1. To relieve pain—This is the most important reason for immobilization of a fracture.
2. To prevent movement that might interfere with the union of the fracture. Persistent movement may cause tearing of the capillaries bridging the fracture. Strict immobilization is necessary for some fractures, e.g. scaphoid fracture, fracture of the neck of femur, etc.

The following are the methods of immobilization of a fracture.

1. Plastering
2. Splintage and
3. Internal fixation.

### Plastering

Plastering may be done in two ways viz.

- a. Complete plastering – Here the whole circumference of the limb is encased in plaster. Some fundamental principles are to be followed while applying the plaster as below.
  - The plaster should include the joint above and the joint below the fracture.
  - The joint is immobilized in a functional position, e.g. knee joint in a slightly flexed position and ankle joint at right angle. In the upper limb elbow is kept 90° flexed.
  - Padding the limb adequately, especially on bony prominences.
  - The patient is advised for active mobilization of joints not included in the plaster to prevent their stiffness, e.g. metacarpophalangeal joints in the upper limb.
- b. Plaster cast—Here only half the circumference of the limb is covered with the plaster, the remaining part being bandaged to keep the cast in position. The plaster cast is used for the immobilization of soft tissue injuries and for reinforcing plaster casts.

### Splintage

Splints are devices meant for supporting a limb that has been inflamed, injured, deformed or paralyzed.

In case of fractures they are used either temporarily during transportation or for definitive treatment, e.g. Thomas's splint for fracture femur anywhere along its length.

The disadvantage of this method of treatment is prolonged hospitalization and confinement to bed. It is hazardous especially for elderly people who may develop bed sores and chest infection due to prolonged recumbency.

### Internal Fixation

#### Indications

1. Inability to keep the fragments in acceptable position even with the best of plastering and splintage. This is the most frequent indication.
2. When an open reduction has to be done. As the bone is exposed, advantage of internal fixation is taken of.
3. As a method of choice in certain fractures to secure early mobilization, e.g. intracapsular fracture of femoral neck.

### Methods

1. Bone plating—The plate is fixed with the help of screws.
2. Steal wire—The wire is passed through tunnels made in the fragments, e.g. fracture of the olecranon or patella.
3. Kirschner wire—This is used for the fixation of small bones of hands and feet.
4. Intramedullary nailing, e.g. Smith Peterson nail. It is a hollow rod made of stainless steel, which is introduced into the medullary cavity of long bones.

### Advantages

1. It allows early mobility of the patient out of bed and hospital.
2. Joints do not get stiff and muscle functions remain good, unlike plastering.

### Disadvantage

These include infection and nonunion. The results of internal fixation may be disastrous due to wound infection.

### Rehabilitation

While treating fractures, all attempts must be made to bring the function of the limb back to normal.

Soft tissue damage is presented by elevation and active exercises.

Elevation: The fractured limb should be kept elevated whether it is the lower or the upper limb to prevent edema formation and subsequent joint stiffness.

### Exercises

- a. Active exercises of all unsplinted joints must be advised to patients during the stage of retention. This will prevent stiffness and weakness of these parts. The muscles within the plaster should be exercised in order to prevent wasting.
- b. After removal of immobilization physiotherapy, is advised to bring back the muscle power and movements.

### Treatment of Compound Fracture (Open Fracture)

A fracture is called open or compound when there is a break in the overlying skin and soft tissue, thus establishing communication between the fracture and the external environment.

### Consequences of Open Fracture

- a. Infection of bone (osteomyelitis) due to contamination of bacteria from the outside environment. Hence tetanus prophylaxis as well as broad spectrum antibiotic should be started immediately.
- b. In case of major skin loss grafting may be necessary. Operative fixation is avoided due to the presence of the open wound.
- c. Problems of union: Nonunion and malunion are common due to open fractures. This is due to the following reasons:
  - i. A piece of bone may be lost from the wound at the time of fracture.
  - ii. The bone may get infected secondarily and thus affect union.
  - iii. The fracture hematoma, which is supposed to have osteogenic potential, is lost from the wound.

Due to the facts stated above open fractures deserve the utmost care throughout their management.

Depending upon the extent of soft tissue injury, open fractures have been divided into three types as follows by Gustillo and Anderson:

Type I—Open fracture with small clean wounds less than 1cm long.

Type II—Open fractures with a laceration of more than 1cm long usually upto 10cm with only moderate soft tissue damage.

Type III—There is extensive damage to skin, soft tissues and the neurovascular structures with considerable contamination of the wound.

There are three grades of severity.

Type III A—The fractured bone can be adequately covered by soft tissue.

Type III B—The fractured bone cannot be adequately covered by soft tissues. There is also periosteal stripping and severe contamination of the fracture.

Type III C—There is an arterial injury, which needs to be repaired.

The value of classification lies in the fact that it enhances communication, directs evaluation of the injury and assists planning of treatment.

### Management

The principle of treatment is to convert an open fracture into a closed one by meticulous wound care. Thereafter the treatment is in the line of closed fracture.

The management may be discussed under the following headings:

1. General treatment
2. Wound debridement
3. Wound closure and
4. Stabilization of fracture or fracture management.

### General Treatment

- This is done in the same line as in case of treatment of closed fracture, following the ATLS protocol.
- Additionally prophylactic antibiotic and tetanus toxoid are administered.
- The injured limb is rested in a splint or cast.
- Treatment of shock, if present.
- X-rays are taken to evaluate the fracture in order to plan further treatment.

### Wound Debridement or Wound Excision

This should be undertaken under strict aseptic precautions in an operation theater.

The injured part is thoroughly cleansed with a mild antiseptic solution such as Cetavlon (Savlon) and the wound is irrigated with saline, wound margins are shaved and all foreign bodies and dirt removed.

The wound is extended to allow adequate inspection and excision of the deeper layers. Small spiky bone chips are removed but a big piece of bone is not removed as bone shortening may occur.

Main arteries and nerves are identified and safeguarded.

### Wound Closure

Once the wound is débrided, decision regarding its closure is to be made very cautiously.

Primary closure by suturing the skin edges or by raising a flap can be acceptable for clean wounds where debridement is done within 6 to 8 hours of injury.

It is best to leave the wound open, whenever in doubt about its cleanliness or if the debridement is done after 6 to 8 hours of injury. The wound is covered with gauze or biological dressings, e.g. synthetic skin, etc. The wound can be subsequently treated by delayed primary closure after an interval of 4 to 6 days or be allowed to heal by secondary intention.

### Fracture Management

Nonoperative method of treatment as in closed fracture usually give good results because an open fracture is a potentially infected fracture in spite of best debridement.

In case an operative reduction is planned, it is safer to wait for the wound to heal before intervening.

In cases where there is extensive damage to soft tissues (Type III) external fixation provides fixation of the fracture as well as allows good care of the wound.

Some of the common methods of stabilizing the open fractures are as described below:

- a. Immobilization in plaster—In cases where a stable fracture reduction can be achieved with moderate wound dimensions, a plaster of Paris cast for immobilization is as appropriate as for a closed fracture.
- b. Skeletal traction—In cases where there is circumferential loss of skin or the wound is big and the fracture unstable, skeletal traction can be used to keep the fracture in good alignment until the wound heals. After healing of the wound, one can continue traction until the fracture unites or changeover to some other form of immobilization such as plaster cast.
- c. External fixation—It provides stability to the fracture and permits access to virtually the whole circumference of the limb.
- d. Internal fixation—Approach to the management of open fractures has become very aggressive in recent years. In advanced trauma centers more and more open fractures received early are treated with primary internal fixation.

### Rehabilitation

This is done along the lines of a simple fracture. It consists of exercises during immobilization of the fracture, after removal of immobilization and advice regarding mobilization of the injured limb.

In lower limb injuries, it consists of graduated weight bearing and gait training.

### COMPLICATIONS OF FRACTURES

Complications of fractures can be described under two headings viz. (A) General complications and (B) Local complications.

### General Complications

1. Shock
2. ARDS (Adult respiratory distress syndrome)
3. Deep vein thrombosis and pulmonary embolism.
4. Crush syndrome
5. Fat embolism.

### Local Complications

1. Complications related to the fracture itself
  - i. Infection – osteomyelitis.
  - ii. Delayed union
  - iii. Nonunion
  - iv. Malunion
  - v. Avascular necrosis
  - vi. Shortening
  - vii. Compartment syndrome.
2. Complications due to associated injury
  - i. Injury to nerves
  - ii. Injury to blood vessels
  - iii. Injury to tendons and muscles
  - iv. Injury to viscera
  - v. Injury to joints.
3. Other complications, e.g.
  - i. Joint stiffness
  - ii. Sudeck's atrophy (Painful posttraumatic osteoporosis)
  - iii. Myositis ossificans
  - iv. Volkmann's ischemic contracture
  - v. Osteoarthritis.

### General Complications

#### Shock

Hypovolemic or oligemic shock is very common following fractures of major bones such as femur and pelvis and may lead to death if not treated promptly.

In major fractures there is significant amount of blood loss, e.g. in pelvis fracture 1500 to 2000ml and in fracture femur 1000 to 1500ml.

The patient becomes apathetic and thirsty with deadly pallor, rapid thready pulse, and cold clammy skin; shrunken eyes and dry tongue. Blood pressure falls. Eventually the renal function is impaired and urinary output falls.

#### Treatment

This should be urgent and consists of replacement of lost blood and stoppage of further bleeding.

An urgent intercostal drainage is required for chest bleeding with dyspnea.

Administration of oxygen is important. Two large bore IV cannulas (No 14 or 16) are to be established and about 2 liters of crystalloids, preferably Ringer's lactate should be infused rapidly followed by colloids (Hemacel) and blood.

Pneumatic antishock trouser, called MAST, i.e. Military antishock trousers is often used. They work by compressing the capillaries and increasing vascular resistance.

The patient's heart rate, blood pressure and CVP, urinary output and acid-base balance are to be monitored.

If improvement does not occur any concealed hemorrhage into the chest and abdomen are to be excluded by investigations such as ultrasonography and CT scan.

In an emergency situation, group O Rh-negative blood may be used until cross-matched blood is available.

For pelvic fracture, temporary stabilization with an external fixator has been found useful in reducing the hemorrhage.

#### Acute Respiratory Distress Syndrome

Acute respiratory distress syndrome (ARDS) is a common sequelae of multiply injured patient. Other conditions acting as predisposing factors include gm-ve sepsis, pancreatitis, peritonitis, gastric aspiration, inhalation toxicity with smoke chemicals and gases. Ionizing radiation hematological conditions like multiple transfusions, DIC, etc.

ARDS is a condition of acute respiratory failure, usually occurring 24 hours after the injury, characterized by a decreased  $PO_2 < 50\text{mmHg}$  and noncardiac pulmonary edema.

The exact mechanism is not known but it is supposed to be due to release of inflammatory mediators, which cause disruption of microvasculature of the pulmonary system.

X-ray chest shows diffuse pulmonary infiltrates with ground glass appearance.

#### Treatment

- The most important aspect of management is early and effective treatment of shock.
- Administration of 100 percent oxygen and assisted ventilation are the sheet anchor of treatment. It takes about 4 - 7 days for the

chest to be clear and the patient returns to normal.

- If not detected early, the patient's condition deteriorates rapidly progressing to cardiorespiratory failure and death.
- v Early stable fixation of a long bone fracture helps to reduce the risk of developing this condition.

#### Deep Vein Thrombosis and Pulmonary Embolism (DVT and PE)

Deep vein thrombosis is a common complication associated with lower limb and spinal injuries.

It may be due to pressure on the calf against the operating table or mattress or due to slowing of circulation due to immobility.

Calf vein thrombosis may give rise to pulmonary embolism following dislodgement of the thrombus which usually occurs in the 3rd week after the injury.

#### Treatment

Prophylaxis is very important. This may be done by:

- i. Avoidance of pressure to the calf and stasis.
- ii. Active ankle and calf muscle exercises should be regularly practised by the patient.

Treatment of DVT is elevation of the limb, elastic bandage and anticoagulant therapy.

For pulmonary embolism, assisted ventilation and heparin therapy has to be done.

#### Crush Syndrome

In crush syndrome, a large bulk of muscle is crushed following natural disasters like earthquakes, air-raids, mining and other such accidents.

Crushing of muscles results in entry of myohemoglobin into the circulation which precipitates in renal tubules leading to acute tubular necrosis.

There is scanty urine, restlessness and delirium. It may take 2 to 3 days for these features to appear.

#### Treatment

In case of crushed limb, a tourniquet is applied as first aid which will allow gradual release of deleterious substances. If a limb is crushed severely for several hours, it should be amputated.

If oliguria develops, the patient is treated in the line of acute renal failure.

### Fat Embolism

The essential feature of fat embolism is occlusion of small vessels by fat globules.

The fat globules may originate from bone marrow or adipose tissue. Fat embolism is common following fractures of major bones and in severe injuries with multiple fractures. It usually occurs 48 to 72 hours after the injury and primarily affects three organ systems viz. the lungs, the brain and the skin.

- i. The respiratory symptoms begin insidiously with tachypnea then dyspnea and cyanosis develops.
- ii. Cerebral signs are confusion, agitation, stupor and coma.
- iv. Cutaneous signs are petechiae over the upper extremities especially in the axillary areas, the chest, conjunctiva and the uvula.

Examination of sputum and urine may reveal the presence of fat globules. Blood PO<sub>2</sub> less than 60 mm Hg indicates the need for assisted ventilation.

### Treatment

It consists of

- i. Respiratory support.
- ii. Anticoagulant therapy (Heparin 10000 IV intravenously 12 hourly). It probably helps by emulsifying the fat globules and thereby reducing obstruction in capillaries and
- iii. Hydrocortisone is given IV in high doses.

### Local Complications

#### Infection

In open fractures microorganisms can gain entrance and settle in bone to produce osteomyelitis, closed fractures can also rarely get infected by hematogenous infection.

Infection can also occur during open reduction of fractures.

Presence of infection delays union and can also lead to nonunion.

Treatment is along the lines of chronic osteomyelitis.

The following measures are taken to combat infection:

- i. Adequate drainage of infected area.

- ii. Removal of all devitalized tissue and dead bone.
- iii. Continued immobilization of fracture.
- iv. Wide spectrum antibiotics depending on the culture and sensitivity test.

#### Delayed Union

No fixed time limit exists beyond which the union can be called delayed union. In general if the fracture is clinically mobile three months after injury, it is called delayed union.

The fracture in a state of delayed union may unite in a longer period or may pass into the state of nonunion. The causes of delayed union are same as that of nonunion but acting in lesser degree.

The treatment of delayed union is continued immobilization for longer period, till the fracture unites or develops signs of nonunion (Sclerosis at the bone ends on X-ray) when operative intervention is required.

#### Nonunion (Fig. 57.3)

Nonunion of a fracture is a state in which the process of union has come to a standstill and union will not occur without surgical or any other additional intervention. Usually it is not before six months that a fracture can be so labeled.

#### Causes of Nonunion

1. Infection—Is usually seen in open fractures. Presence of infection stops the progress of healing process. As long as infection remains uncontrolled, healing remains held up and progresses again after infection has been controlled.

2. Interposition of soft tissue between the bone fragments, e.g. quadriceps muscle in fracture shaft of femur. As the bone ends are not in contact union will not occur.

3. Inadequate immobilization—If there is significant relative motion between bone fragments process of union stops at the stage of fibrocartilage formation and the fracture goes into nonunion.

Therefore, as a general rule, the joint above and below the fracture should be immobilized in plaster or splints so that the fractured bone ends are held quite still. Similarly, immobilization should be continued until bony union has occurred otherwise healing process will stop at the stage of cartilage formation and nonunion will develop.

4. Destruction of bone, e.g. by a tumor in pathological fracture also delays or stops union.

5. Loss of a fragment of bone as in an open fracture will leave behind a gap between the fractured bone ends and lead to non-union.

6. Poor blood supply to one or both fragments delays union or even leads to non-union, e.g.

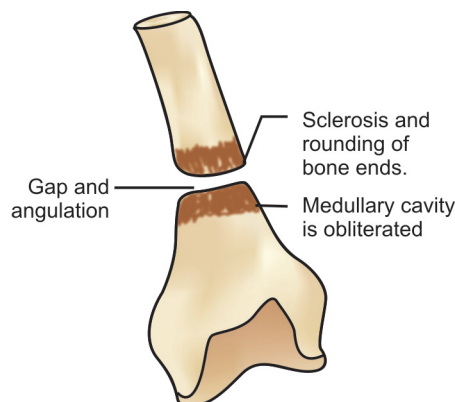
- a. In fracture scaphoid the proximal fragment becomes avascular as the only blood supply to the bone enters through a ridge on the distal fragment.
- b. Fracture distal third of tibia—The distal fragment is relatively avascular as it is in a subcutaneous plane and muscles are not attached here.

#### Clinical Features

- There is abnormal mobility on stressing the fracture.
- Increasing deformity at the fracture site.
- On X-ray –
  - i. There is presence of sclerosis and rounding of bone ends.
  - ii. Callus formation is either absent or minimal.
  - iii. The medullary cavity may be obliterated.

#### Treatment

Treatment of nonunion depends upon the site of nonunion and the disability caused by it. The following treatment options should be



**Fig. 57.3:** Radiological features of nonunion

considered depending upon the individual cases.

1. Bone grafting—This is the most important and essential treatment of nonunion. The grafts are taken from the iliac crest and internal fixation is required in most cases.
2. Excision of one fragment and its replacement by a prosthetic device, e.g. in nonunion of intracapsular fracture of femoral neck in an elderly patient, whole of head and neck are excised and replaced by a metallic prosthesis (Replacement arthroplasty).
3. No treatment—In certain situations like clavicle and scaphoid, nonunion may not cause any functional impairment and it can be left alone without any treatment.
4. Illizarov method Prof. Illizarov from the former USSR designed a special external fixation apparatus for treating nonunion.

### Malunion

When a fracture unites in a deformed position, it is called malunion. Malunion may be primary or secondary.

- i. When a fracture was not reduced properly and it has united in a deformed position, it is called primary malunion.
- ii. Sometimes the fracture was reduced properly, but redisplacement occurs within the plaster or splintage later on. This is called secondary malunion.
  - Malunion may cause overlapping or angulation. Overlapping is less important in the upper limb but in the lower limb it will lead to shortening of the limb.
  - Angulation is more important. Even slight angulation may not be acceptable as it interferes with the function of the neighboring joint and may give rise to osteoarthritis later on.

### Treatment

1. Conservative—Sometimes slight malunion is acceptable and may not require any treatment, as the neighboring ball and socket joint compensates for the deformity. In case of shortening of the lower limb, a raised shoe is the treatment.
2. Operative—When unacceptable malunion has occurred, the treatment is osteot-

omy and correction of deformity followed by immobilization.

### Avascular Necrosis

This is defined as the necrosis of bone due to deficient blood supply. It is a frequent complication of fracture near articular end of bone or following dislocation, both of which disrupt the blood supply to a segment of bone.

Common sites of avascular necrosis are the following:

1. Head of femur following fracture of femoral neck and dislocation of hip.
2. Proximal fragment of scaphoid in fracture through the waist of scaphoid.
3. Lower third of tibia is liable to avascular necrosis following fracture.
4. Whole of lunate bone following dislocation of lunate.

### Diagnosis

Diagnosis is usually obvious by skiagraphy after about three months of injury when the avascular segment appears dense.

### Treatment

1. Prevention: Fractures which are likely to undergo avascular necrosis should be immobilized rigidly for a longer period of time.
2. Treatment options: Once avascular necrosis has occurred, the following treatment options remain.
  - i. Excision followed by replacement arthroplasty is done in majority of cases, e.g. in fracture neck femur, the dead head of the femur is replaced by Austin-Moore prosthesis.
  - ii. Only excision of the avascular segment of bone, e.g. dead proximal fragment of scaphoid.
  - iii. Total joint replacement or arthrodesis may be required once the patient is disabled because of pain from osteoarthritis secondary to avascular necrosis.

### Shortening

This is a common complication of fractures and results from the following causes:

- i. Fracture fragments unite with overlap or marked angulation, i.e. due to malunion.
- ii. A piece of bone is lost.

iii. Epiphyseal growth plate is crushed and undergoes premature closure.

### Treatment

- a. Shortening in the upper limb goes unnoticed, hence no treatment is required.
- b. For shorter lower limbs, the treatment depends upon the amount of shortening.
  - i. Shortening upto 2cm can be managed with high heel shoe.
  - ii. In case of shortening more than 2cm reconstructive procedures are to be thought of.

### Compartment Syndrome

#### Definition

This is a symptom complex manifested when there is increased pressure within a closed osteofascial compartment. The limbs contain muscles within such compartments enclosed by bones, fascia and interosseous membrane.

A rise in pressure within these compartments due to any reason will jeopardize the blood supply to the muscles and nerves to the compartment giving rise to the syndrome.

The rise in compartment pressure may be due to trauma (commonest) leading to muscle edema and fracture hematoma within the compartment, thermal injury snake bite, etc.

#### Diagnosis

Diagnosis is made by high index of suspicion. An excessive pain, not relieved by usual doses of analgesic, in a patient with an injury known to cause compartment syndrome should raise the suspicion. It has been observed that blood flow ceases when intracompartmental pressure is 55 mm Hg in the forearm and 65 mmHg in the leg. Normal compartmental pressure is 10 to 12 mm Hg and when it is more than 40 mm Hg urgent treatment is required. Injuries with a high risk of developing compartment syndrome include supracondylar fracture of humerus and fracture of both bones forearm, crush injuries to the leg and forearm.

#### Treatment

- Prevention is important and consists of limb elevation and active finger or toe movements.



- Surgery—Early surgical decompression is necessary in established cases. This can be performed in two ways.
  - a. Fasciotomy—The deep fascia of the compartment is slit longitudinally, e.g. in forearm.
  - b. Fibulectomy—The middle third of fibula is excised in order to decompress all compartments of the leg.

### Injury to Nerves

The nerves that are likely to be injured are:

- i. The axillary nerve in case of shoulder dislocation producing paralysis of deltoid muscle.
- ii. Radial nerve in fracture shaft of humerus causing wrist drop.
- iii. Ulnar nerve in fracture medial epicondyle of humerus resulting in claw hand.
- iv. Median nerve in case of supracondylar fracture of humerus.
- v. Common peroneal nerve in fracture neck of fibula or knee dislocation resulting in foot drop.
- vi. Sciatic nerve in case of posterior dislocation of the hip causing foot drop.
- vii. Spinal cord or Canada equina in fracture dislocations of the spine producing quadriplegia or paraplegia depending on the level of lesion.

### Treatment

This varies with the type of fracture whether closed or open.

In a closed fracture, the type of damage is either neurapraxia or axonotmesis and nerve recovery is good with conservative treatment.

In open fracture, a complete lesion or neurotmesis is more likely. The nerve is explored during wound debridement and repaired either immediately or 3 weeks later.

### Vascular Injury

The blood vessels that are likely to be injured are:

- i. Popliteal artery—This is the most frequently damaged vessel in musculoskeletal injuries. This may be injured in supracondylar fracture of the femur.
- ii. Femoral artery—May be injured in fracture lower third of femur.
- iii. Axillary artery—May be injured in fracture dislocation of the shoulder.
- iv. Brachial artery—May be injured in supracondylar fracture of the humerus.

- v. Subclavian artery—May be injured in fracture of the clavicle.

### Effects of Injury

Vascular injury will lead to gangrene in severe cases and ischemic injury to nerves and muscles, e.g. Volkmann's ischemia in less severe cases.

### Diagnosis

- a. At the fracture site: Vascular injury is detected by:
  - i. Massive external bleeding in open fractures
  - ii. Rapidly increasing swelling.
  - iii. A wound in the normal anatomical path of the vessel.
- b. Signs in the limb distal to the fracture: The classic signs of ischemia are represented by five P'S viz. pain (cramps like), paresthesia, pallor, paralysis and pulselessness. As a matter of fact, pulselessness in an injured limb should be considered to be due to vascular damage unless proved otherwise.

The confirmation of obstruction to blood flow in a vessel and its site can be easily made by Doppler study.

But in the absence of such facility, it is needless to waste time and emergency treatment must be started.

### Treatment

1. All bandages and splints should be removed.
2. If the fracture is displaced it should be reduced and where practicable the fracture, should be fixed internally.
3. The vessel is explored. A torn vessel can be sutured or a segment may be replaced by a vein graft. If there is thrombosis, endarterectomy will restore the blood flow.

### Injury to Muscles and Tendons

Some degree of damage occurs to muscles and tendons with most fractures. It may result from the object causing the fracture, e.g. an axe or from the sharp edge of the fractured bone.

### Treatment

- Rest to the injured muscle and analgesics are all that is required with partial rupture. A complete rupture requires repair.

- Rarely if rupture of tendon or muscle is detected late, reconstruction may be required.

### Injury to Viscera

Internal organs damaged in fractures are:

- i. Urinary bladder, urethra, rectum or vagina in case of fracture of pelvis.
- ii. Lungs in fractures of the ribs producing pneumothorax and
- iii. Brain in fracture of the skull.

All the above injuries require emergency treatment.

### Injury to Joints

Fracture near a joint may be associated with subluxation or dislocation of that joint. These are commonly found in high velocity traffic accidents.

Early open reduction and stabilization of the fracture to permit early joint movements has improved the results.

### Joint Stiffness

This is a common complication of fracture treatment. It is to be remembered that some joints like the shoulder, elbow, knee and finger joints become more easily stiff than others.

The common causes of stiffness are:

- i. Intraarticular and periarticular adhesions secondary to immobilization.
- ii. Contracture of the muscles around a joint because of prolonged immobilization.
- iii. Adhesion of muscle at the fracture site, e.g. quadriceps adhesion in fracture of femoral shaft.
- iv. Myositis ossificans.

Stiff joints hamper the normal physical activity of the patient and results in late osteoarthritis.

### Treatment

- The treatment is physiotherapy in the form of hot fomentation, wax bath, diathermy, etc.
- Sometimes the joint is manipulated under general anesthesia to correct the intraarticular adhesions followed by continuous passive motion. This may allow free movement of the joint.
- Occasionally, adherent or contracted tissues need to be released by operation, e.g. when knee flexion is prevented by adhesion of the quadriceps.

### *Sudeck's Atrophy*

(Syn— Algodystrophy, Painful post traumatic osteoporosis, Post traumatic osteodystrophy). This is a form of reflex sympathetic dystrophy seen in the foot or hand after Colles' fracture or fracture around the ankle.

There will be marked joint stiffness, associated with pain with vasomotor changes like local swelling, redness and warmth. Movements are grossly restricted and X-rays show characteristic patchy rarefaction.

#### Treatment

- With prolonged physiotherapy (elevation and graduated exercises) there is usually slow but steady recovery, especially if treatment is started early.
- If the above measure fails, sympathetic block or sympatholytic drugs like IV guanethidine may bring relief. In some cases beta-blockers have been shown to produce good response.

### *Myositis Ossificans*

This term is a misnomer as there is no associated inflammatory lesion of the muscle.

It should better be called post-traumatic ossification.

#### Pathology

There is ossification of hematoma around a joint resulting in the formation of a mass of bone restricting joint movements often completely.

Hematoma forms after injury to bone, e.g. supracondylar fracture or posterior dislocation at the elbow along with stripping of the capsule and the periosteum.

Instead of being absorbed the hematoma is invaded by osteoblasts and gradually becomes ossified. The muscle tissue itself is not affected. It is more common in children because the periosteum is loosely attached to the bones in them.

Diagnosis of post-traumatic ossification is suspected when after immobilization is discontinued, the joint movements do not improve or the movement already gained is lost.

Careful palpation will reveal a firm lump in the area.

#### Treatment

- Massage following injury is strictly avoided.
- In the early active stage of myositis, the limb should be rested.
- In the late stages, after immobilization is discontinued, it is possible to regain movement by physiotherapy.
- In some cases, once the myositic mass matures, it may be helpful to excise the mass.

### *Volkman's Ischemic Contracture*

This is a flexion deformity of the wrist and fingers, from fixed contracture of the flexor muscles in the forearm. The condition is a sequel to Volkmann's ischemia, which is an ischemic injury to the muscles and nerves of the flexor compartment of the forearm following the supracondylar fracture of the humerus. There is occlusion of the brachial artery either by the sharp edge of the proximal fragment or by thrombosis or spasm of the vessel wall. It may also be caused by too tight plaster bandaging.

The muscles most commonly affected are the flexor pollicis longus and flexor digitorum profundus as they are supplied by the anterior interosseous branch of ulnar artery which is an end artery. The muscle ischemia leads to compartment syndrome.

#### Diagnosis

- a. The patient, usually a child complains of severe pain in the forearm and is unable to move the fingers fully. Ischemic pain is much severe than the pain due to the fracture.
- b. Other signs of impaired circulation in the hand and fingers are absence of the radial pulse, and stretch pain, i.e. the child complains of pain in the flexor aspect of forearm when the fingers are extended passively.
- c. There is tenderness on pressing the forearm muscles.

#### Treatment

1. Prophylactic treatment in the incipient stage is the best, e.g. removal of tight plaster bandaging and fasciotomy.
2. In established cases the following options are available.
  - a. Mild deformities can be corrected with intensive exercises guided by a physiotherapist and passive stretching of the contracted muscles with Volkman's splint.
  - b. For moderate deformities, muscle slide operation or Maxpage's operation is done—Here the flexor muscles are released from their origin at the medial epicondyle and ulna. The common flexor origin thus slides down and develops a new attachment lower down.
  - c. For a severe deformity, bone operations such as shortening of the forearm bones, carpal bone excision, etc. may be required.

### *Osteoarthritis*

Osteoarthritis in a nearby joint can occur after fractures. The causes are:

1. Avascular necrosis following fractures, e.g. osteoarthritis of hip following avascular necrosis of femoral head in fracture neck femur.
2. Malunion of long bone fracture causing mechanical alteration in weight bearing axis of the limb and irregular joint surfaces.
3. When fracture has involved a joint, incongruity of the articular surface or resultant callus of the fracture may produce this condition.

#### Treatment

1. Prevention should be the aim which is done by:
  - i. Accurate anatomical restoration of joint surfaces in case of fracture through a joint and
  - ii. By making sure that long bone fractures heal in proper alignment.
2. In an established case, osteotomy, arthrodesis or arthroplasty should be the treatment depending on the age of the patient, occupation and the joint involved.

# Chapter 58

## Fractures and Dislocations of Upper Limb

- Fracture clavicle
- Dislocation of shoulder
- Fracture through the proximal humerus
- Fracture of the shaft of humerus
- Supracondylar fracture of humerus
- Dislocation of the elbow
- Fracture both bone forearm
- Fracture dislocations of the forearm
- Pulled elbow
- Colle's fracture
- Fracture of scaphoid

### **FRACTURE CLAVICLE**

Fracture of the clavicle usually occurs due to fall on the outstretched hand. It is the most frequently injured bone in the body.

Fracture can also occur due to direct violence on the clavicle.

Commonest site of fracture is the middle third of the clavicle (about 80%). Occasionally fracture may occur at the lateral or medial end of the clavicle.

After fracture the lateral fragment of clavicle gets displaced downwards due to weight of the limb, while proximal fragment is held up by the sternomastoid muscle.

### **Diagnosis**

Following injury the patient complains of difficulty to move the shoulder and raise the arm. There is pain around the shoulder in case of fracture of the lateral third of clavicle.

A swelling is visible at fracture site due to displacement at bone ends. There is also tenderness at the site of fracture.

In undisplaced fracture, careful palpation of this subcutaneous bone to elicit tenderness is the only method to diagnose the fracture.

X-ray confirms the fracture showing the site of fracture and the degree of displacement of fragments See Fig. 103.21 in the section on X-rays.

### **Treatment**

The treatment is primarily conservative as fractures of the clavicle unite readily. Rarely operation is required.

1. Conservative: Anatomical reduction is not required. A well fitting figure of '8' bandage is applied while the patient is sitting and shoulders are braced backwards. In addition a triangular sling is given to support the weight of arm.

The bandage is tightened every week and is kept for three weeks in children and six weeks in adults.

2. Operative: Open reduction and internal fixation with plate is rarely required in cases of fracture of the outer third of the clavicle, nonunion or when damaged neurovascular structures have to be repaired.

### **Complications**

1. Malunion—It is common due to excessive callus formation. This usually improves with time and does not cause any functional disability.
2. Nonunion is very rare.
3. Injury to subclavian vessels and brachial plexus. This is also rare.
4. Shoulder stiffness of the affected side.

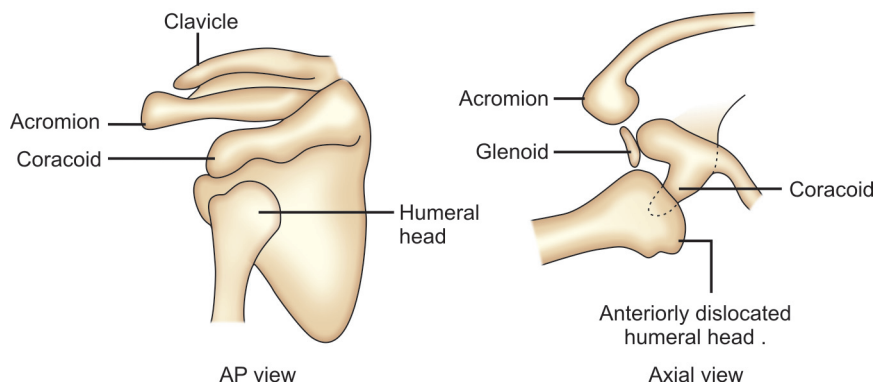
### **DISLOCATION OF SHOULDER**

Shoulder joint is most commonly dislocated in the human body. It occurs more commonly in adults and anterior dislocation is much more common than the posterior one.

### **Anterior Dislocation (Fig. 58.1)**

#### *Mechanism of Injury*

Usually the dislocation occurs following a fall on the outstretched hand. The injury is also produced by forced abduction and external rotation of the shoulder.



**Fig. 58.1:** Anterior shoulder dislocation

The head of the humerus is driven forward tearing the capsule or avulsing the glenoid labrum and usually ends up just below the coracoid process (subcoracoid dislocation). There may be an associated fracture of the proximal end of the humerus.

**Clinical Features**

- There is severe pain, limitation of movements and tenderness in the affected joint.
- The rounded contour of the shoulder is lost. The shoulder is flattened with a prominence of the acromion process.
- Clinical tests for the confirmation of dislocation are:
  - a. Hamilton’s ruler test: A straight ruler can touch the acromial end and the lateral epicondyle simultaneously. Normally, this is not possible because of fullness of the shoulder.
  - b. Dugas test: The patient cannot touch the opposite shoulder with the elbow touching the side of the body.
  - c. Bryant’s test: The anterior and posterior folds of axilla are at different levels.

The above tests are mostly of academic significance.
- X-ray will confirm the diagnosis. It shows (AP view), the overlapping shadows of the humeral head and glenoid fossa, with the head usually lying below and medial to the socket.

**Treatment**

Treatment consists of reduction under general anesthesia, followed by immobilization of the shoulder in a chest-arm bandage for three weeks.

**Techniques of Reduction**

**Kocher’s maneuver** – (To remember the steps of reduction, remember, TEA-I).

This is the most commonly used method. The steps are:

- (1) Traction is applied with the elbow bent at right angle along the long axis of the humerus.
- (2) External rotation – The arm is rotated externally.
- (3) Adduction – The externally rotated arm is adducted by carrying the elbow across the body towards the midline.
- (4) Internal rotation - The arm is rotated internally so that the hand falls across to the opposite shoulder.

**Hippocrates Method**

In this method the surgeon applies firm and steady pull on the semiabducted arm. He keeps his foot in the axilla against the chest wall. The head of the humerus is brought back into position using the foot as a fulcrum.

A fracture of the greater tuberosity often associated with an anterior dislocation, usually comes back to its position as the head is reduced and needs no special treatment.

**Complications**

1. Early
  - i. Injury to the axillary nerve and brachial plexus.
  - ii. Associated fracture of humeral neck or greater tuberosity.
2. Late
  - i. Recurrent dislocation.
  - ii. Shoulder stiffness.

**Posterior Dislocation (Fig. 58.2A)**

This rare type of dislocation occurs due to forcible medial rotation of the arm or by direct blow on to the anterior aspect of head of humerus. It may also occur during epileptic convulsions.

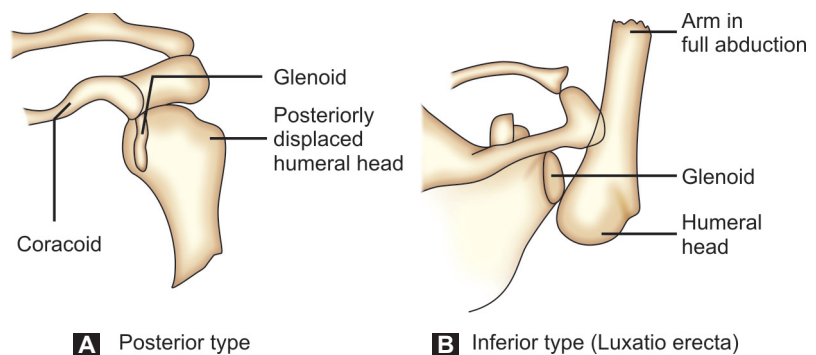
The diagnosis is often missed as the clinical features are not as striking as in anterior dislocation.

**Diagnosis**

Clinically there is pain, deformity and local tenderness. X-ray—The anteroposterior projection is often normal and calls for an axial view which shows the posteriorly displaced head of humerus.

**Treatment**

Reduction is performed under general anesthesia by Hippocratic method, but after traction, instead of internal rotation arm is rotated externally and slightly abducted.



**A** Posterior type **B** Inferior type (Luxatio erecta)

**Figs 58.2A and B:** Posterior and inferior type of shoulder dislocations

### Complications

1. Unreduced dislocation—May require operative correction.
2. Recurrent dislocation.

### Inferior Dislocation Of Shoulder (Luxatio Erecta) (Fig. 58.2B)

This is a rare variety of dislocation where the head comes to lie in the subglenoid position. It usually occurs due to hyperextension injury.

### Treatment

Reduction under general anesthesia is usually obtained by applying traction in abduction and swinging the arm into adduction position.

With another hand the surgeon should push the head of the humerus up into the glenoid cavity.

Once reduced the shoulder is kept in reduction with broad arm sling and bandaging the arm by the side of the chest as for anterior dislocation.

### Recurrent Dislocation

The shoulder is the commonest joint to undergo recurrent dislocation. This results from the following causes:

- i. Inadequate treatment for the first episode of dislocation.
- ii. Anatomically unstable joint, e.g. Marfan's syndrome.
- iii. In an epileptic patient.

### Treatment

Operation is the treatment of choice. The following operations may be considered.

- a. Putti-Platt operation: Shoulder joint is approached from the anterior aspect and exposed. The subscapularis muscle and joint capsule are shortened by overlapping or reefing in order to restrict lateral rotation. For recurrent posterior dislocation the operation is done from the posterior aspect and infraspinatus tendon is reefed.
- b. Bankart operation: At this operation the anterior edge of glenoid fossa is roughened and detached glenoid labrum is reattached by staples or nonabsorbable sutures passed through drill holes in glenoid margin.

After any of the above operations, the arm is bandaged to chest in full internal

rotation and adduction for six weeks after which physiotherapy is started to mobilize the shoulder.

### FRACTURE THROUGH THE PROXIMAL HUMERUS

In the proximal humerus, fractures mostly occur at surgical neck. Fractures through the anatomical neck are rare. They are sometimes associated with fracture dislocations of the shoulder.

Most of the patients are elderly with osteoporotic bones and there is history of fall on the outstretched hand. The same injury will produce fracture separation of proximal humerus epiphysis and in young adult's dislocation of shoulder, rather than fracture of humerus as the bone is quite strong.

In old individuals there may be as many as four segments fracture involving the proximal humerus. The four segments are articular segment (head), greater tuberosity, lesser tuberosity, and the shaft. If any segment has 45° of angulation and displaced more than 1cm the fracture is said to be displaced.

### Clinical Feature

There is pain and swelling at the fracture site. The patients cannot move the shoulder joint. In case of impacted fracture through the surgical neck limited movement is possible.

X-ray is confirmatory and shows the degree of comminution and displacement.

### Treatment

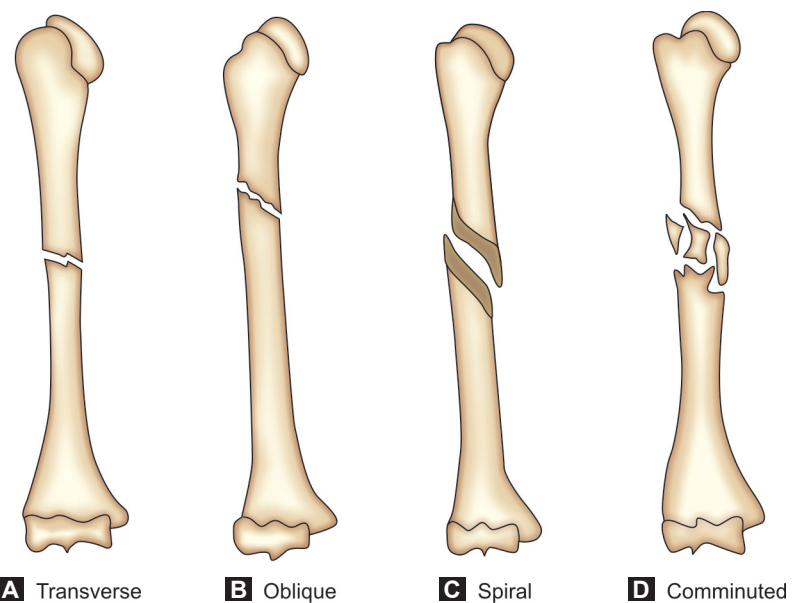
1. Minimally displaced fracture—The arm is held by a sling. Active exercises start by six weeks by which time fracture heals.
2. Two-part fracture—Closed manipulation is usually adequate. If closed reduction fails then internal fixation may be required with T-Plate and screws. Movements of the elbow and fingers should be started from the beginning while the shoulder exercises are started at 4 weeks.
3. Three part fracture—Open reduction and internal fixation with wire loop and repair of rotator cuff injury.
4. Four part fracture—Prosthetic replacement of the head is performed.

### Complications

1. Shoulder stiffness—Common. This is prevented by early mobilization.
2. Neurovascular injury.
3. Malunion / Nonunion.
4. Avascular necrosis—Especially with four part fracture.

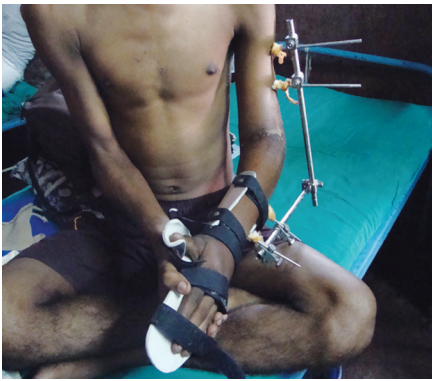### FRACTURE OF THE SHAFT OF HUMERUS (Fig. 58.3)

This fracture can occur due to the following causes:



**Figs 58.3A to D:** Different types of fractures of humeral shaft





**Fig. 58.3E:** External fixator applied in a case of comminuted fracture of lower end of humerus with infection

1. Fall on the outstretched hand producing transverse fracture.
2. Fall on the elbow with arm abducted – oblique or transverse fracture.
3. Direct injury in the form of a blow or angulatory stress produces transverse, spiral, oblique or comminuted fracture (Figs 58.3A to E).

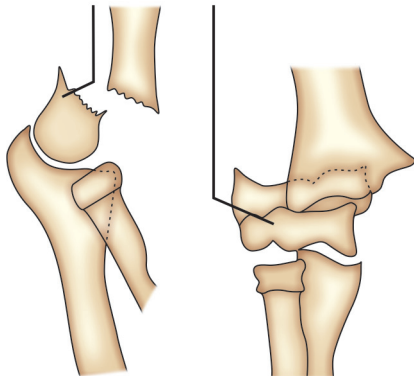
**Displacement**

If the fracture occurs proximal to the insertion of the deltoid, the proximal fragment is adducted due to the pull of the pectoralis major. With fractures below the deltoid insertion, the proximal fragment is abducted by the deltoid.

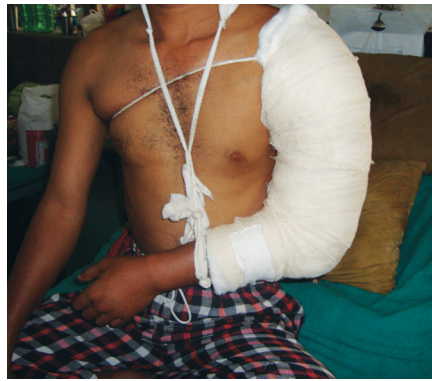**Clinical Features**

- Following injury the patient develops pain and is unable to move the arm.
- Examination shows deformity and abnormal mobility at fracture site.

The distal fragment is displaced posteriorly, laterally and proximally



**A** Extension type fracture



**Fig. 58.3F:** U-Slab plaster applied in a patient with fracture shaft humerus

- Injury to radial nerve is quite common and its function is always tested at the time of initial examination. X-ray confirms the diagnosis and shows the site, degree of comminution and displacement of fracture, as well as the orientation of fracture line.

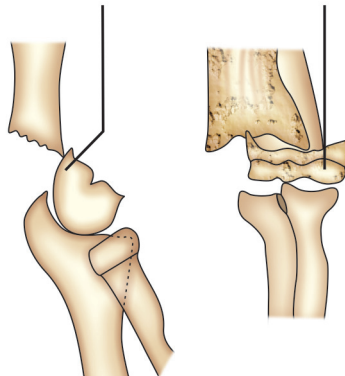
**Treatment**

Anatomical reduction is not necessary. Fracture is immobilized in a U-slab (Fig. 58.3F) supported with a triangular sling. Weight of the arm corrects angulation to nearly perfection. In 8-12 weeks most fractures are united and immobilization is discarded followed by physiotherapy to regain shoulder and elbow movements.

**Complications**

1. Radial nerve injury – seen typically in spiral fractures of distal third of humerus.

The distal fragment is displaced anteriorly, medially and proximally



**B** Flexion type fracture

**Figs 58.4A and B:** Two types of supracondylar fracture of humerus

2. Delayed union.
3. Malunion.
4. Nonunion
5. Injury to brachial artery.
6. Stiffness of the shoulder joint.

**SUPRACONDYLAR FRACTURE OF HUMERUS (Fig. 58.4)**

This is a common childhood injury accounting for 65 percent of fractures around the elbow in the child, between 5 to 8 years because of ligamentous laxity at this age. After 9 years elbow dislocation is more common. It is more common in boys than girls and left side is predominant.

It is relatively uncommon in adults.

**Mechanism and Type of Injury**

The injury usually occurs due to fall on the outstretched hand and the fracture line runs transversely across the distal metaphysis of the humerus.

The fracture is complete in 50 percent cases and green stick in rest 50 percent cases.

**Displacement:** The distal fragment is displaced posteriorly, while the proximal fragment projects anteriorly and may injure the brachial artery or median nerve.

**Types of Supracondylar Fracture**

1. Extension type—This is the commonest (99%) type with posterior displacement and results from fall on the outstretched hand.
2. Flexion type—Incidence is 1percent with anterior displacement resulting from fall on a flexed elbow.

**Clinical Features**

1. Immediately after injury the patient complains of severe pain and is unable to move the elbow.
2. The elbow swells up rapidly. However a quick palpation of the bony prominence reveals the normal relationship of the olecranon with the medial and lateral epicondyles, of humerus viz. an equilateral triangle.

This distinguishes the condition from posterior dislocation of the elbow.

It is vital to check the radial pulsation which may be absent due to edema and

contusion or laceration of the brachial artery. The hand is examined for injury to median nerve. It is also necessary to diagnose early the volar compartment syndrome.

**X-ray:** Standard anteroposterior and lateral views of the elbow should be taken. It is wise to take the radiographs of the normal elbow to compare for any fractures because in a child, radiographs are quite difficult to interpret due to complex ossification pattern of the distal end of humerus. (See Fig. 103.23).

### Treatment

There are two types of treatment as described below.

1. Nonoperative treatment—This is indicated for nondisplaced or minimally displaced fracture or for severely comminuted fracture in elderly patient with limited functional ability.

Posterior plaster slab is applied with the elbow at 90° Flexion and the forearm in neutral position for 3 weeks in a collar and cuff sling.

2. Operative treatment: This is indicated in
  - i. Displaced fracture
  - ii. Vascular injury
  - iii. Open fracture
  - iv. Failure of closed reduction.
 Open reduction and internal fixation with two Kirschner wires are done.

### Complications

- Brachial artery injury may give rise to Volkmann's ischemic contracture in some patients.
- Median nerve injury.
- Elbow stiffness.

- Malunion
- Myositis ossificans.

### DISLOCATION OF THE ELBOW

This usually occurs due to fall on the outstretched hand with the elbow slightly flexed.

In this injury there is considerable damage to the joint capsule, brachial muscle is torn and the collateral ligaments are ruptured or stretched.

### Types

Elbow mostly (90 percent) dislocates posteriorly. Anterior dislocation of the elbow may rarely occur as a complication of the olecranon fracture. (10 percent)

### Clinical Features

The elbow is held supported by the opposite arm in an attitude of slight flexion. There is disruption of the normal relationship between the olecranon and the medial and lateral epicondyles of humerus.

This clinically distinguishes a dislocation of the elbow from supracondylar fracture (Fig. 58.5). Neurovascular injury should always be assessed.

X-ray confirms the diagnosis. This reveals the dislocation as well as other associated fractures like:

- Fracture of the olecranon process.
- Fracture of the medial epicondyle.
- Fracture of the coronoid process.

### Treatment

Closed reduction under general anesthesia followed by immobilization of the elbow in a plaster back slab and sling for 3 weeks. Subsequently elbow movements are begun gently and never forced.

### Complications

These are same as in supracondylar fracture of humerus.

### FRACTURE OF THE RADIUS AND ULNA

This is often termed as the fracture of both bones of the forearm.

The cause of fracture may be:

- i. Either an indirect force such as a fall on the outstretched hand causing spiral fracture at different levels of the radius and ulna.
- ii. A direct blow causing transverse fractures at the same level.

### Clinical Features

The deformity and swelling are usually obvious. The hand must be examined for circulatory and neurological abnormality.

**X-Ray:** In children the fracture is often greenstick, i.e. minimally displaced. But in adults they are very much prone to severe displacement.

### Treatment

1. Children—Closed reduction is usually successful and the fragments can be immobilized in a full length plaster cast from axilla to metacarpal shafts with elbow at 90 degrees and forearm in neutral position. Union takes about 6-8 weeks time.
2. Adults—They usually need open reduction and internal fixation (Fig. 58.6). The fragments are held by plates and screws or intramedullary rods. A full length cast is applied and the bones take about 12 weeks time to attain strong union.

### Complications

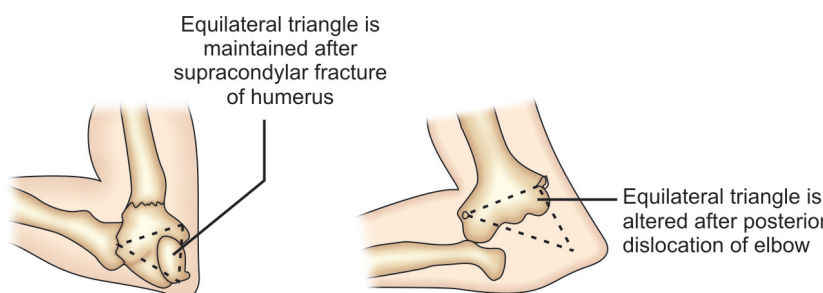
1. Compartment syndrome.
2. Delayed union and nonunion.
3. Malunion—With closed reduction there is always a chance of malunion.

### FRACTURE DISLOCATIONS OF THE FOREARM (Fig. 58.7)

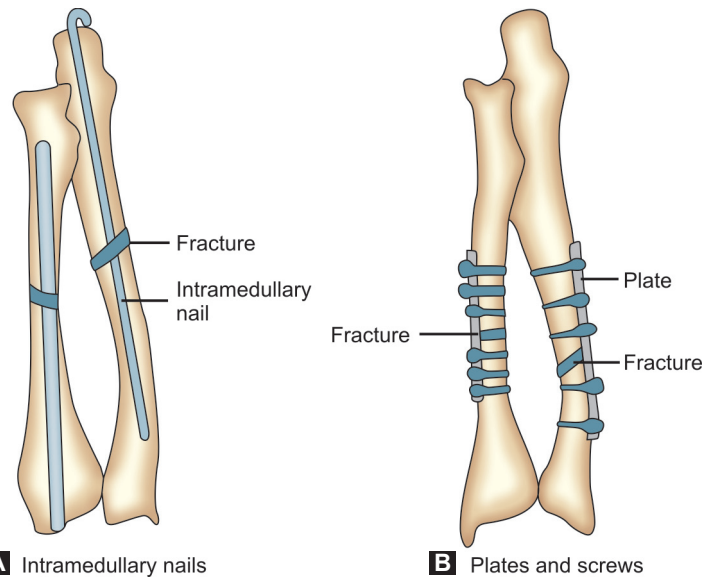
The fracture of a single forearm bone is often associated with dislocation of either the superior or inferior radioulnar joint.

There are two types:

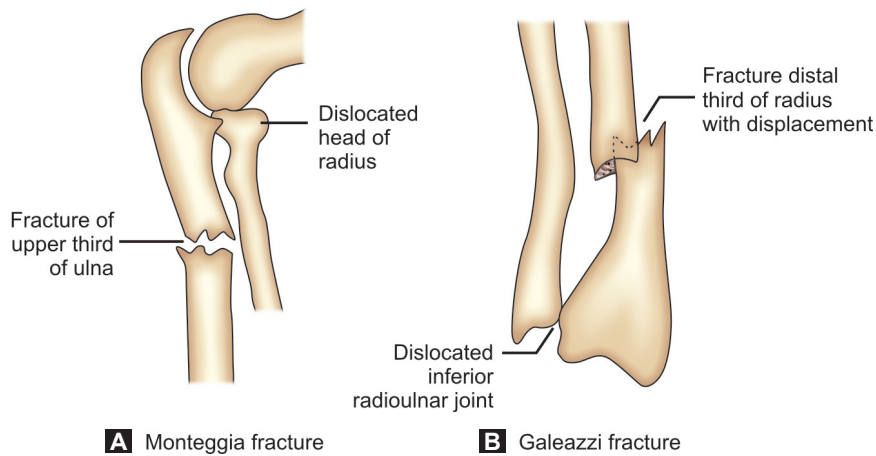
- i. Monteggia fracture dislocation and
- ii. Galeazzi fracture dislocation.



**Fig. 58.5:** Relationship of olecranon, medial and lateral epicondyles on the posterior aspect of elbow



**A** Intramedullary nails **B** Plates and screws  
**Fig. 58.6:** Methods of internal fixation in fractures of forearm bones.



**A** Monteggia fracture **B** Galeazzi fracture  
**Fig. 58.7A and B:** Fracture dislocations of the forearm.

**Monteggia Fracture Dislocation (Fig. 58.7A)**

To remember in Monteggia fracture dislocation, medial bone, i.e. ulna is fractured.

- This is a fracture of the upper third of ulna with dislocation of the superior radioulnar joint.
- It is caused by a fall on the outstretched hand with the forearm forced into excessive pronation (hyperpronation injury). It may also result from a direct blow on the back of the upper forearm.

**Diagnosis**

In a case with isolated fracture of the ulna in its upper half or a dislocation of the head of the radius should be carefully looked for.

**Treatment**

This is a very unstable injury. Therefore treatment is open reduction and internal fixation using a plate. The arm is held in plaster for 6-12 weeks until union occurs.

However in children, conservative treatment may be possible.

**Complications**

- Malunion occurs in cases treated conservatively.
- Injury to radial nerve.

**Galeazzi Fracture Dislocation (Fig. 58.7B)**

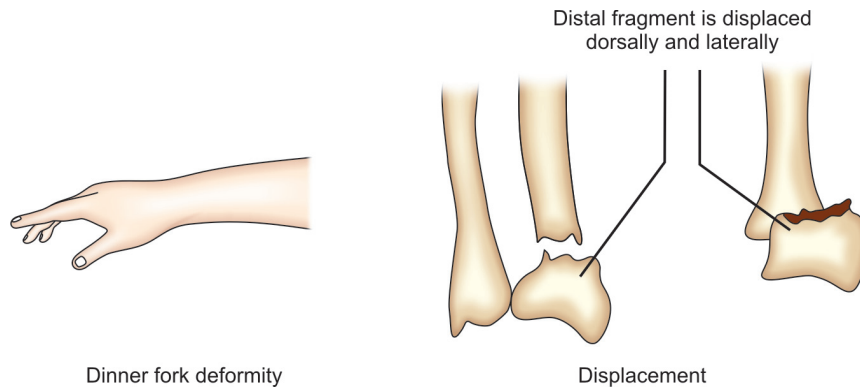
- This is a fracture of the lower third of the radius with dislocation or subluxation of

the inferior radioulnar joint. So this injury is the counterpart of the Monteggia fracture dislocation.

- This also results from a fall on the outstretched hand and is more common than Monteggia fracture dislocation.
- There may be associated ulnar nerve injury.
- Treatment is in the same line as the Monteggia fracture.

**PULLED ELBOW**

This is subluxation of the head of radius which usually occurs in children, when the forearm is suddenly pulled to save the child from falling. As the head of the radius is not fully developed, it slips from the grasp of the annular ligament.



**Fig. 58.8A:** Colles' fracture with typical deformity and displacement

### Diagnosis

There is no definite sign but the history of a sudden jerk followed by inability to use the arm is very suggestive.

### Treatment

- Spontaneous recovery sometimes occurs if the arm is rested in a sling for a few days.
- The head is reduced by fully supinating the forearm and applying direct pressure over the head of radius. A sudden click is heard or felt as the head goes back to its place. The child becomes comfortable and starts moving his elbow almost instantly.

### COLLES FRACTURE (Fig. 58.8)

It is the most common fracture of the upper extremity and more common in elderly patients. It was described by Sir Abraham Colles in 1814, hence the name.

### Site

The fracture usually occurs at the distal end of the radius at its corticocancellous junction about 2cm from the distal articular surface with typical displacement (Fig. 58.8A).

It nearly always results from a fall on an outstretched hand.

### Displacement

There is classic 'dinner fork deformity' (Fig. 58.8A) with characteristic dorsal displacement of the distal fragment.

### Clinical Features

The wrist has a typical dinner fork deformity. There is prominence of the back of the wrist and the hand is radially deviated.

Normally the radial styloid process is distal to the ulnar styloid process, but they are at the same level after the Colles fracture, which reflects the radial shortening.

**X-Ray:** This is important to differentiate from other fractures at the same site, e.g. Smith's fracture, Barton's fracture, etc. The dorsal tilt is the most characteristic displacement, best seen in the lateral X-ray. A lateral tilt can be detected on an anteroposterior X-ray.

### Treatment

Treatment of Colles' fracture is usually conservative.

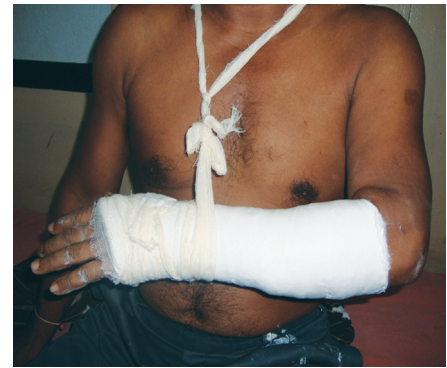- For an undisplaced fracture immobilization in a below elbow plaster cast for six weeks is sufficient (Fig. 58.8B).
- For displaced fractures: The treatment is manipulative reduction followed by immobilization with complete plaster or with a plaster cast from below the elbow to the metacarpal heads, maintaining the wrist in palmar flexion and ulnar deviation.

### Technique of Closed Manipulation

This is done under regional or general anesthesia with good relaxation of forearm muscles.

The surgeon grasps the injured hand as if he were shaking hands.

- The first step is disimpaction of the fragments by firm longitudinal traction to the



**Fig. 58.8B:** POP cast applied in a patient with Colles' fracture (left)

hand against the counter traction by an assistant who grasps the arm above flexed elbow. Some displacements are corrected by traction alone.

- The surgeon now presses the distal fragment into palmar flexion and ulnar deviation using the thumb of his other hand. As this is done patient's hand is drawn into pronation, palmar flexion and ulnar deviation. An X-ray is taken to check the success of the closed reduction.

The patient is advised to move his fingers, the elbow and shoulder joints through their full range several times a day.

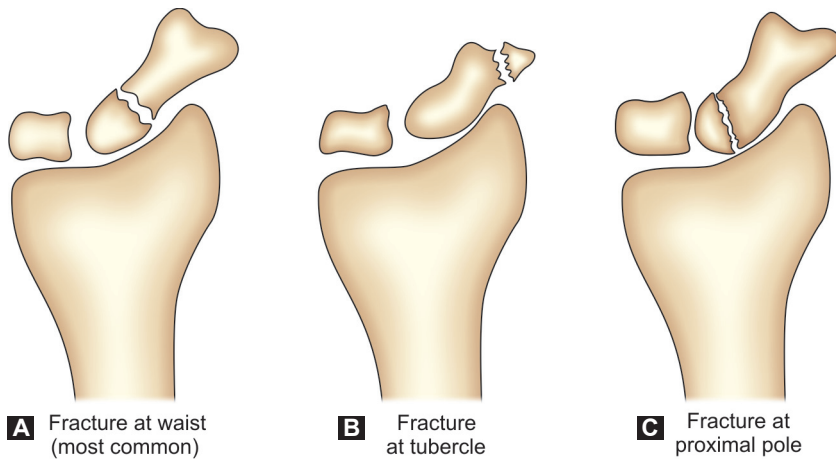
It is essential to check the position again after 10 days. Often the fracture is redisplaced in the cast and if this happens remanipulation may be needed.

The plaster is removed after 6 weeks and joint mobilizing and muscle strengthening exercises are started for the wrist and fingers. Shoulder joint movements are also continued to avoid the development of frozen shoulder.

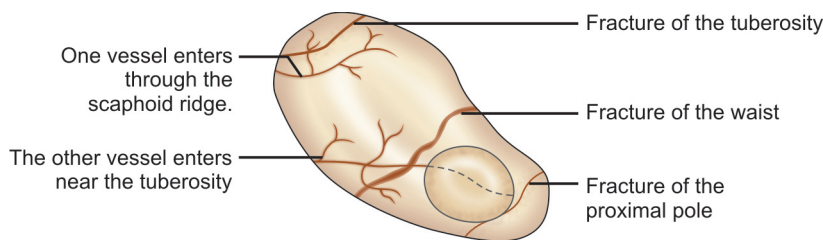
### Complications

- Malunion:
- Sudeck's atrophy—The hand is stiff, painful and hypersensitive and rarely responds to treatment.
- Shoulder, wrist and finger stiffness.
- Carpal tunnel syndrome.
- Rupture of extensor pollicis longus—This occurs very rarely a long time after the fracture has united. Treatment is tendon transfer (extensor indicis to extensor pollicis longus)





**Figs 58.9A to C:** Different types of fractures of scaphoid



**Fig. 58.10:** The blood supply to the scaphoid. The vessels arising from the superficial branch of radial artery enter the bone distally and run proximally

### FRACTURE OF SCAPHOID (FIGS 58.9 AND 58.10)

The scaphoid fracture is common in young adults but rare in the elderly and children.

#### Site and Type of Fracture

The fracture usually occurs through the waist of the scaphoid. Rarely does it occur through the tuberosity.

The fracture may be a crack fracture or a displaced fracture.

#### Clinical Features

The history of the fall on the outstretched hand with pain and swelling over the radial aspect of the wrist should make one suspect this type of fracture.

On examination, there is tenderness in the scaphoid fossa or anatomical snuff box

lying between the tendons of extensor pollicis longus and brevis and at the wrist.

**X-Ray:** Anteroposterior, lateral and oblique views of the wrist are taken.

In a suspected crack fracture, the X-rays should be repeated after 2 weeks. Sometimes the fracture becomes visible at this stage because of resorption of fracture ends in two weeks time. If no fracture is seen even at 2 weeks, no further treatment is required.

#### Treatment

1. Undisplaced fracture: Treatment is usually conservative in a scaphoid cast for 3-4 months.

The scaphoid cast extends from below the elbow to the metacarpal heads and includes the thumb upto the interphalangeal joint.

2. In widely displaced fractures open reduction and internal fixation using a special compression screw (Herbert's screw) is required.

#### Complications

1. Avascular necrosis—In fractures through the waist, there is high probability of the proximal fragment becoming avascular as the blood supply enters the bone from the distal fragment. The patient complains of pain and weakness of the wrist. (Fig. 58.10)

Treatment is excision of the avascular segment of the bone.

2. Delayed and nonunion—It may result from either the impaired blood supply or imperfect immobilization.

3. Wrist osteoarthritis—It occurs due to avascular necrosis or nonunion.



# Chapter 59

## Fractures and Dislocations of the Lower Limb

- Dislocation of the hip
- Fracture of the neck of the femur
- Fracture shaft of femur
- Condylar fractures of femur
- Fracture patella
- Traumatic dislocation of patella
- Soft tissue injuries of the knee
- Meniscal injury
- Fractures of the shafts of tibia and fibula
- Fractures of single leg bone
- Ankle fractures
- Fracture calcaneum
- Ruptured tendoachilles

### DISLOCATION OF THE HIP

There are three types of dislocations of the hip viz.

1. Posterior dislocation—commonest type.
2. Anterior dislocation.
3. Central dislocation.

Majority of these injuries occur in road traffic accidents, associated with other injuries which may need priority treatment.

As the hip joint is a ball and socket joint with inherent stability largely due to the bony configuration of the articulating surfaces of the acetabulum and femoral head to each other as well as the joint capsule and strong ligaments, it requires a great force to dislocate the joint.

In presence of fracture of femoral shaft hip dislocation is quit often overlooked. Therefore it is always wise to take an X-ray of pelvis to rule out dislocation of hip in the presence of other serious injuries and especially if femoral shaft is broken.

#### Posterior Dislocation of Hip (Fig. 59.1)

This is the commonest type of hip dislocation. The injury occurs due to force acting along the long axis of femur when the hip is flexed and adducted, e.g. when the knee hits

the dashboard in an automobile accident. The femoral head is forced out of its socket, often a small or large piece of bone is broken at the back of the acetabulum as well (fracture – dislocation).

#### Clinical Features

An isolated posterior dislocation is easy to diagnose from the history of severe trauma and the characteristic deformity of the lower limb which is adducted, internally rotated and slightly flexed.

This is associated with apparent shortening of the leg (Fig. 59.1A).

*X-Ray:* In the anteroposterior film the femoral head is seen out of its socket and above the acetabulum. Multiple views may be needed to exclude a fracture of the acetabular rim or the femoral head. CT scan is the best way to delineate suspected acetabular injury.

#### Treatment

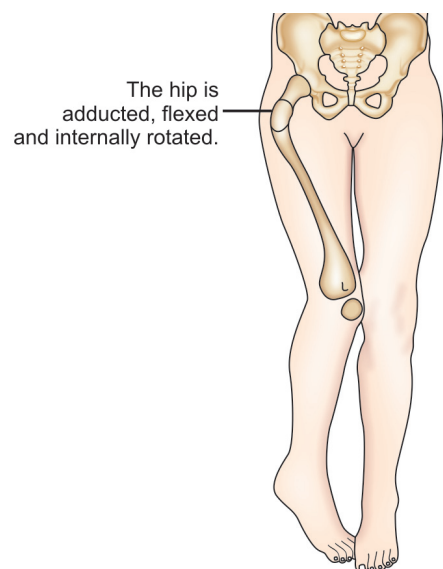
##### Closed Reduction

The dislocation is reduced under general anesthesia.

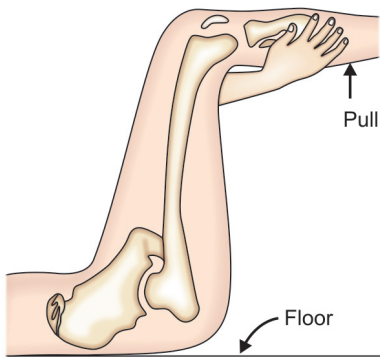
The assistant steadies the pelvis, while the surgeon flexes the patient's hip and knee at 90 degrees and pulls the thigh vertically upwards (Fig. 59.1B).

X-ray is essential to confirm reduction.

Following reduction skin traction is applied and the hip is kept fully extended, and slightly abducted. Traction in bed is maintained for six weeks followed by gradual active hip mobilization. Weight bearing is allowed after three months of injury.



**Fig. 59.1A:** The clinical deformity in posterior dislocation of hip



**Fig. 59.1B:** Mechanism of reduction of posterior dislocation of hip

### Open Reduction

This is often required in the following cases:

- i. When closed reduction fails and
- ii. If the acetabular fragment is large and comes from the weight bearing part of the acetabulum.

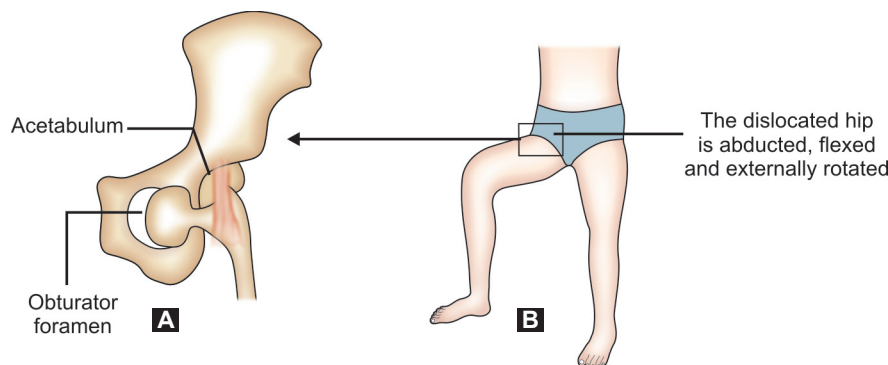
### Complications

1. Sciatic nerve injury—The sciatic nerve lies immediately behind the acetabulum and may get damaged when femoral head moves posteriorly.
2. Avascular necrosis of femoral head.
3. Secondary osteoarthritis.
4. Myositis ossificans traumatica around the hip very rarely.

### Anterior Dislocation (Fig. 59.2)

This type of dislocation occurs when the legs are forcibly abducted and externally rotated in a road accident or fall from a tree.

Clinically the limb is in an attitude of external rotation.



**Figs 59.2A and B:** Anterior dislocation of hip. (A) Clinical displacement and position of lower limb (B) Displacement of femoral head

There may be apparent lengthening with the head palpable in the groin.

Treatment and complications are similar to that of posterior dislocation.

### Central Dislocation

- In this type of injury the femoral head is driven through the medial wall of the acetabulum towards the pelvic cavity.
- Joint stiffness and osteoarthritis are inevitable.

### Treatment

Treatment is basically conservative. If femoral head is driven into the pelvis; heavy skeletal traction from a Steinmann pin in proximal tibia is applied for six weeks. Weight bearing should be deferred for three months.

In some young patients if the fragments do not fall back in place by traction, surgical reconstruction of the acetabular floor may be necessary.

## FRACTURE OF THE NECK OF THE FEMUR

Most patients who sustain this injury are elderly females. However, no age or sex is exempted. Average age of patient affected is 75 to 80 years and female to male ratio is 4:1. The common underlying cause is osteoporosis.

### Anatomy

The proximal femur consists of head, neck, greater and lesser trochanters. The capsule of the hip joint is the key to understand the fracture of neck of the femur.

It is attached anteriorly from the acetabular labrum to the intertrochanteric line

and posteriorly it is 1.5 cm proximal to the intertrochanteric crest.

This attachment of the capsule divides fracture neck of the femur into:

- a. Intracapsular type and
- b. Extracapsular type.

There are three important ligaments viz. iliofemoral, ischiofemoral and pubofemoral ligaments which are thickenings of the joint capsule.

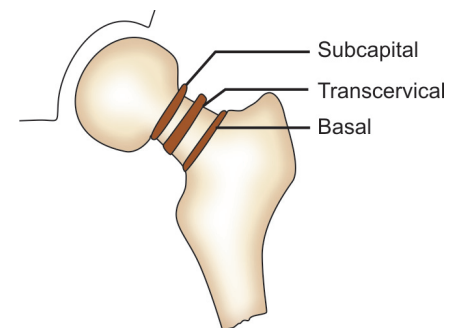
Intracapsular fractures have two special features viz.

- i. The proximal fragment, i.e. femoral head cannot be manipulated or immobilized by conservative means.
- ii. The blood supply of the proximal fragment is often damaged producing avascular necrosis of a part or whole of the femoral head.

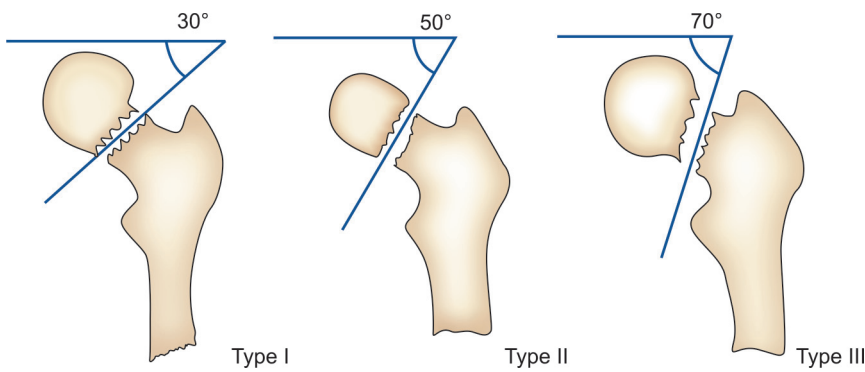
There are mainly three sources of blood supply to the head of femur. (See Fig. 63.1)

- a. The main blood supply is from the extracapsular arterial ring formed by branches of medial and lateral circumflex femoral arteries, arising from the deep femoral artery. The retinacular branches arise from the extracapsular arterial ring and pass proximally along the neck of the femur sub synovially.
- b. Terminal branches of the ascending nutrient arteries.
- c. Arteries of the ligamentum teres femoris. This supply is insignificant.

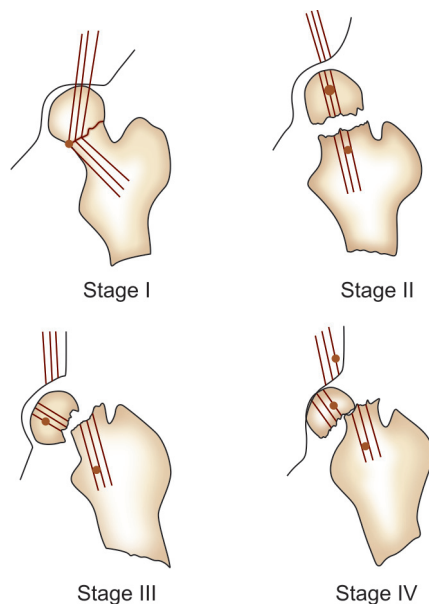
From the above description one can easily assess that in intracapsular fracture, the ascending nutrient arteries and the retinacular arteries which are the major source of blood supply are invariably damaged giving rise to avascular necrosis, more so if the fracture is displaced.



**Fig. 59.3A:** Anatomical classification of the fracture of the neck of the femur



**Fig. 59.3B:** Pauwel's classification of the fracture of neck of the femur. The more the angle, the worse is the prognosis



**Fig. 59.3C:** Garden classification of the fracture of the neck of the femur. Stage I—Incomplete fracture, Stage II—Complete undisplaced fracture, Stage III—Complete and partially displaced fracture, Stage IV—Complete and fully displaced fracture. The straight lines indicate change in direction of the medial trabecular stream of the neck in relation to the bony trabecular stream in the head and the corresponding part of the acetabulum

### Classification (Figs 59.3A to C)

Fractures of the neck of femur can be classified in different ways as described below.

- a. Anatomical classification – on the basis of anatomical location of the fracture (Fig. 59.3A) viz.
  - i. Subcapital, i.e. a fracture just below the head.
  - ii. Transcervical, i.e. a fracture in the middle of the neck.
  - iii. Basal fracture, i.e. a fracture at the base of the neck.
- b. Pauwels classification (Fig. 59.3B): This classification is based on the angle of

inclination the fracture line makes in relation to the horizontal plane (Pauwels angle). There are three types – Type I (30° angle), Type II (50° angle) and Type III (70° angle).

The more the angle (Higher type), the more unstable is the fracture and worse the prognosis.

- c. Garden's classification (Fig. 59.3C): This classification is used nowadays and is based on the degree of displacement and progressive severity as follows.

Stage I—This is an incomplete impacted fracture. The inferior cortex remains

intact, while the superior cortex is impacted.

Stage II—Complete fracture of the femoral neck including the inferior cortex without displacement.

Stage III—Complete fracture with partial displacement. The distal fragment rotates laterally, while the proximal fragment rotates medially and is abducted.

Stage IV—Complete fracture with full displacement.

The prognosis worsens and the complication rate increases through stages I to IV.

### Clinical Features

- There is a history of fall followed by pain in the hip.
- A patient with an impacted fracture may sometimes come walking the complaint being a little pain in the groin.

On examination, there is shortening and external rotation of leg due to the action of the psoas on the distal fragment.

There may be tenderness at the site of femoral neck.

*X-Ray:* Both anteroposterior and lateral views of pelvis with both hips are taken. This not only diagnoses the fracture but also suggests the exact site and type of fracture.

Some impacted femoral neck fractures may be missed in X-ray as the fracture line is invisible.

### Treatment

There is hardly any role of nonoperative treatment surgery is the treatment of choice.

#### Intracapsular Fracture

Operative treatment is almost mandatory because the proximal fragment cannot be immobilized by conservative means.

Two types of procedures are available:

1. Internal fixation—This is done in case of children and adults.
2. Excision of head of femur with prosthetic replacement—This is done in old people who should get over and be active without delay if pulmonary complications and bedsores are to be prevented.

Impacted fracture can be left to unite but there is always a risk that it may become displaced even while lying in bed, so fixation is safer.

**Internal fixation**

Internal fixation is preferred for younger and fit patients with Garden stage I and II.

Attempt is made to unite the fracture under portable X-ray control or image intensifier. Any of the following implants may be used for internal fixation.

- Multiple cancellous screws – most commonly used.
- Sliding (dynamic) hip screw (DHS).
- Multiple Knowles pins or Moore's pins used in children.

**Disadvantage:** High failure rate in case of displaced fractures.

**Replacement Arthroplasty (Hemiarthroplasty)**

This is the procedure of choice in elderly patients > 60 years and fractures with Garden stages III and IV, and particularly in those with severe osteoporosis in whom the bone is too weak to support internal fixation devices. *The Austin Moore* prosthesis is used most commonly. Sometimes *Thompson* prosthesis is used. It cannot be used in younger patients as the prosthesis becomes loose over a period of time, approximately 8 to 10 years.

- Total hip replacement may be used in fit elderly patients and in patients with rheumatoid arthritis or on steroid therapy.
- This is also done when the treatment is delayed and in patients with Paget's disease and suspected acetabular damage.

**Extracapsular Fracture**

This is best treated by open reduction and internal fixation. The operative intervention helps to:

- Ensure best possible position and
- Mobilize the patient quickly so as to avoid the complications of recumbency.

**Complications (See also non-united fracture neck of femur, chapter 78)**

- Nonunion—It occurs in approximately 30 to 40 percent of intracapsular fractures. The two main causes are.
  - Inadequate immobilization even with internal fixation.
  - Poor blood supply of the proximal fragment.

Treatment is done depending on the age of the patient –

- Elderly patient – Total hip replacement.
  - In the young – Internal fixation with fibular bone grafting.
- Avascular necrosis—There is high incidence of avascular necrosis in garden III and IV fractures as there is significant vascular damage due to the nature of blood supply of the proximal fragment mentioned earlier.
 

Whether the fracture unites or not, collapse of the femoral head will cause pain and progressive loss of function.

Treatment is total joint replacement.
  - Delayed osteoarthritis—This may result from avascular necrosis or an associated trauma to the hip joint.
 

See also the long case nonunited fracture neck femur, chapter 78

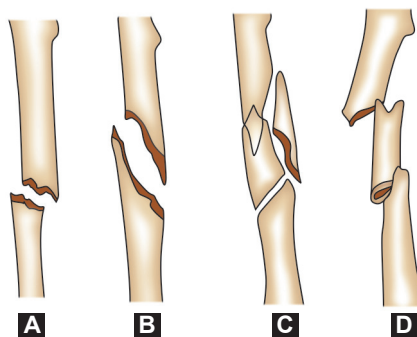
**FRACTURE SHAFT OF FEMUR (Figs 59.4A-D)**

Fracture shaft femur may occur by a severe violence as may occur in a road traffic accident. The portion of the bone extending from about 3 inches below the lesser trochanter to about 2 inches proximal to the supracondylar portion of the femur is known as the shaft of the femur.

The fracture may occur at any site and is equally common in the upper middle and lower thirds of the shaft.

**Types of Fracture**

The fracture may be an oblique, transverse, spiral or comminuted depending upon the nature of the fracturing force (Figs 59.4A-D).



**Figs 59.4A to D:** Different types of femoral shaft fracture (A) Oblique (B) Spiral (C) Comminuted (D) Segmental fracture

**Displacements**

In children, there is no marked displacement but in adults there is a great deal of displacement in most cases.

The proximal fragment is flexed, abducted and externally rotated due to the pull by the iliopsoas, gluteal muscles and external rotators respectively.

The distal fragment is adducted due to pull by adductor muscles.

These fractures are associated with blood loss in excess of a liter, so blood grouping and cross matching is done to replenish the blood loss.

**Clinical Features**

Following injury, the affected thigh is deformed, swollen and patient cannot lift the leg. Hypovolemic shock and vascular injury may be present.

**X-Ray:** X-ray should include the whole femur and pelvis because there may be associated hip dislocation. The X-rays will show the site and type of fracture with degree of displacement and comminution. (See Fig. 103.27)

**Treatment**

Fracture of the shaft of the femur occurs in so many different forms that almost all methods of fracture treatment may be applicable.

The treatment methods include:

- Closed reduction and spica cast immobilization.
- Skeletal traction
- External fixation only in case of open fractures.
- Internal fixation with
  - Intramedullary nail (after open/closed reduction)
  - Interlocking intramedullary nail after closed reduction
  - Plate fixation after open reduction.

The closed methods are preferred to open methods.

Nowadays, the most popular method of treating these fractures is by interlocking intramedullary nailing.

In children, treatment is mainly by non-operative methods.

- From birth to 2 years, the fracture is treated by Gallows' traction. In this method the legs of the child are tied to an overhead beam. The hips are kept a little



raised from the bed so that the weight of the body provides the countertraction and the fracture is reduced. This is continued till sufficient callus is formed, usually in 3 to 6 weeks.

- b. From 2 years to 16 years—Conservative treatment is done.

Different methods of traction are used to keep fragments in proper alignment. Once the fracture becomes 'Sticky' further immobilization can be provided by a 'hip spica'.

### Complications

1. Early
  - Shock
  - Fat embolism
  - Injury to femoral artery
  - Injury to sciatic nerve
  - Infection.
2. Late
  - i. Delayed union—if union is insufficient to allow unprotected weight bearing after 5 months.
  - ii. Nonunion—It occurs when the fracture surfaces are rounded and sclerotic. Treatment is by internal fixation and grafting.
  - iii. Malunion—More likely to occur with conservative treatment.
  - iv. Knee stiffness.

### CONDYLAR FRACTURES OF FEMUR

These are of three types (Fig. 59.5) viz.

- a. Supracondylar fractures—These are extra articular fractures occurring just above the femoral condyles, hence called supracondylar.
- b. Intercondylar fracture—T and Y Types.
- c. Unicondylar fractures—Medial or lateral, condylar fracture.

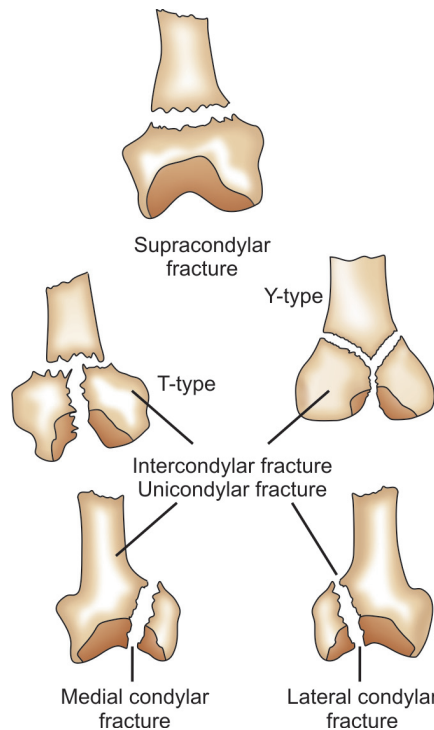
Types b and c are intraarticular fractures.

### Diagnosis

There is pain, swelling and bruising around knee. All movements at the knee are lost. X-ray confirms the diagnosis.

### Treatment

- a. Unicondylar fracture—If undisplaced, long leg caste is applied for 3 to 6 weeks followed by protected weight bearing.



**Fig. 59.5:** Different types of condylar fracture of the femur

If displaced, open reduction with internal fixation with multiple cancellous screws is performed.

- b. Intercondylar fracture—Open reduction and internal fixation is done. In some cases conservative treatment with skeletal traction may give good results.
- c. Supracondylar fracture—It is best to treat displaced supracondylar fractures with internal fixation. This could be done by closed or open techniques. Nail or plate may be used.

In general open reduction and internal fixation is the treatment of choice in condylar fractures of the femur.

### FRACTURE PATELLA

Patella is an important sesamoid bone which gives shape to the knee and protects anterior aspect of the knee joint.

Fracture patella can occur as a result of:

- a. Direct trauma, e.g. fall on the knee or the knee hitting the car dashboard. The fracture is typically comminuted and displaced called stellate fracture.
- b. Indirect trauma to patella occurs due to sudden forceful quadriceps contraction

while trying to regain balance after a stumble. The patella fractures transversely, the so called two part fracture.

Most often both the above mechanisms are at play simultaneously so that once the fracture occurs by a direct violence, a simultaneous contraction of the quadriceps pulls the fragments apart.

The result is a separated fracture of the patella with some comminution.

### Clinical Features

Following injury, to front of knee or a stumble, knee becomes swollen and painful.

In case of transverse fracture (indirect injury), a gap is palpable between the fragments and knee cannot be extended actively due to tear and discontinuity of the quadriceps mechanism.

In cases of stellate fracture, no gap is palpable.

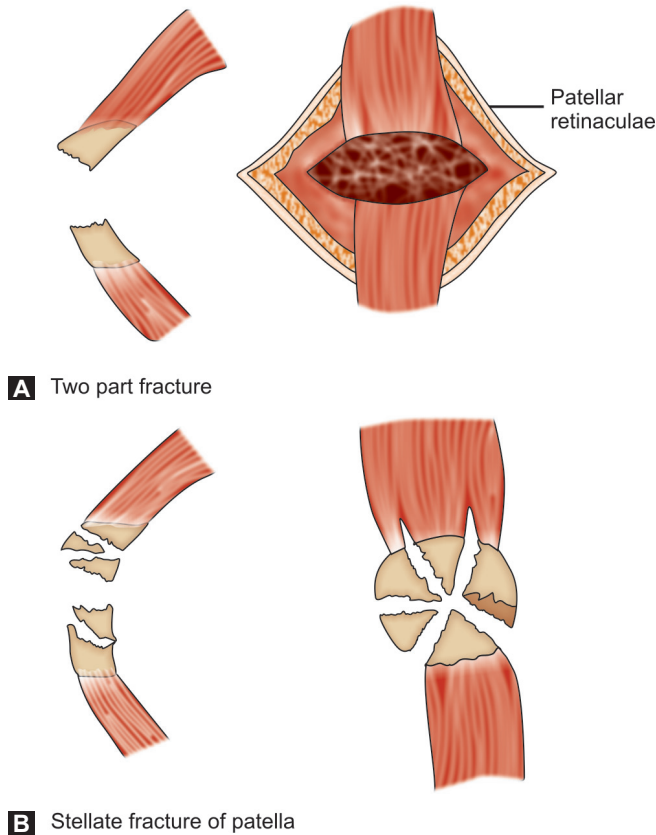
X-ray will confirm the diagnosis and show the exact nature of injury and displacement of fragments.

### Treatment

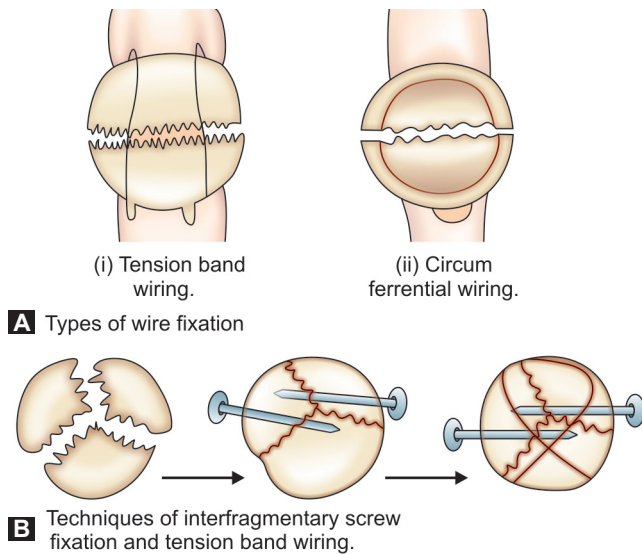
Patellectomy is rarely done nowadays. Open reduction and internal fixation is the treatment of choice.

- a. Undisplaced fracture: A plaster cast extending from the groin to just above the malleoli, with the knee in full extension (cylinder cast), should be given for 3 weeks, followed by physiotherapy.
- b. Two-part fracture (Fig. 59.6):
  - i. In transverse displaced fractures when both fragments are large enough an attempt is made to reduce the fragments at operation and they (fragments) are fixed together by wire (either tension band or circumferential wiring). (Fig. 59.7A) Reduction must be perfect so that articular surface is quite smooth.
  - ii. In transverse, displaced fractures, when one fragment is very small, it is excised and quadriceps expansion or ligamentum patella can be sutured to the remaining larger fragment of patella. After operation the knee is immobilized in plaster for 4 to 6 weeks to allow healing of attachment of tendon to bone.
- c. Comminuted fracture: In comminuted fractures with displacement, it is difficult to restore a perfectly smooth articular surface. So, excision of patella





**Figs 59.6A and B:** Two types of displaced fracture of the patella



**Figs 59.7A and B:** Different methods of fixation of fracture patella.

(total patellectomy) is the treatment of choice, if inter fragmentary srew fixation and tension band wiring fails. (Fig. 59.7B)

**Complications**

1. Knee stiffness is due to intra- and periarticular adhesions. Treatment is physiotherapy.

2. Extensor weakness results from in-adequate repair of the extensor apparatus or due to quadriceps weakness.
3. Osteo arthritis occurs a few years after injury.

**TRAUMATIC DISLOCATION OF PATELLA**

Patella almost always dislocates laterally. Following injury, knee becomes painful and cannot be extended.

Displaced patella can be seen and palpated on outer aspect of knee joint.

X-ray confirms the diagnosis showing laterally displaced patella (See Fig. 103.28).

**Treatment**

Under general anesthesia or adequate sedation knee is gradually extended and patella is pushed medially, reduction is easy and following reduction, an above knee plaster slab is applied for three weeks. Knee mobilization is started after three weeks and recovery is usually complete.

**SOFT TISSUE INJURIES OF THE KNEE**

These mainly consist of injuries to the ligaments and the menisci. (Fig. 59.8)

**Ligament Injury**

The following ligaments may be injured due to trauma.

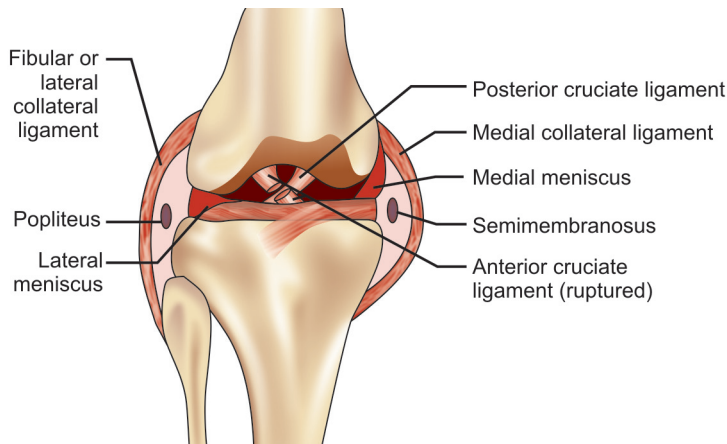
- A. Injury to collateral ligaments
  1. Medial
  2. Lateral.
- B. Injury to cruciate ligaments
  1. Anterior
  2. Posterior.

**Mechanism of Injury**

1. Medial collateral ligaments—This is usually caused by blow on the lateral side of the knee. There is associated medial meniscus injury as it is attached to the medial collateral ligaments.

Injury to the medial collateral ligaments is much commoner than injury to the lateral collateral ligaments.

2. Lateral collateral ligament—This is caused by a blow on the medial side of knee. It is an uncommon injury.



**Fig. 59.8:** Schematic diagram showing rupture of anterior cruciate ligament.

3. Anterior cruciate ligament injury:
  - i. Is usually caused by forceful abduction of tibia along with external rotation. The violence must be forceful enough to tear the medial collateral ligament. The unhappy triad of O'Donoghue consists of tear of the medial collateral ligament, medial meniscus and anterior cruciate ligament. (Fig. 59.8)
  - ii. Forced hyperextension may rupture the posterior capsule and anterior cruciate ligament.
4. Posterior cruciate ligament—The injury to posterior cruciate ligament usually occurs when the anterior aspect of the tibia is violently struck backwards with the knee in 90° flexion. This injury is common to the front-seat passenger in a motor car when the individual is thrown against the dash-board.

### Clinical Features

- History of mechanism of injury is important.
- Pain and swelling of the knee are the usual complaints. The pain may be localized over the torn ligament in cases of injury to the collateral ligaments, but there is diffuse or vague pain in cruciate ligament injuries.
- Cruciate ligaments prevent anteroposterior gliding of the tibia. The anterior cruciate prevents anterior glide, and the posterior cruciate prevents posterior glide. This property is made use of in detecting injury to these ligaments.

### Investigations

- X-ray – A plain X-ray may be normal or a chip of bone avulsed from the ligament attachment may be visible.
- MRI is a noninvasive method of diagnosing ligament injuries and may be useful in doubtful cases.
- Arthroscopy may be needed in doubtful cases.

### Treatment

Treatment depends on the type of injury.

- i. Partial tears or simple strains just
  - a. Need limitation of activity and quadriceps exercises for 3 to 6 weeks.
  - b. A crepe bandage should be applied. A temporary plaster back slab may be required to relieve pain.
- ii. Complete tear
  - a. Conservative treatment—This is the usual method and consists of:
    - Aspiration of the hemarthrosis.
    - Complete plaster is applied from the upper thigh to the toes with the knee in 10° flexion. This plaster is kept for 6 weeks.
    - Active quadriceps exercises.
  - b. Operative—Repair of the ligament followed by immobilization is indicated. Many surgeons prefer to do operation for all complete tear cases.

### MENISCAL INJURY

These usually result from sporting injuries. Menisci are important as they increase knee

stability, control the gliding motion of the joint and distribute loads during movement.

Medial meniscus distribute about 90% of the body weight and consequently tear of the medial meniscus is much more common than the lateral meniscus in the ratio of 15 to 20:1.

### Mechanism of Injury

The injury is sustained when a player, standing on a semi flexed knee, twists his body to one side.

### Pathology

The tears can be classified into:

- Posterior horn tear,
- Anterior horn tear and
- Bucket handle tear.

Of the above, bucket handle tear is the commonest variety. Some underlying pathological changes in the meniscus make it prone to tear. These are discoid meniscus, i.e. the meniscus instead of normal semilunar shape is like a disk, degenerated meniscus as in osteoarthritis and a meniscal cyst.

### Clinical Features

- The patient is usually young engaged in sports like football.
- An accurate history of injury (twisting injury in semiflexed and weight bearing knee) is very important.
- The patient may present with locked knee, i.e. full extension is limited by 5° to 10° and attempts to forced extension are painful, while flexion is free and relatively painless.
- A meniscus is avascular, so there is no hemarthrosis when it is torn. However, a synovial effusion occurs, which results in swelling of the knee.

### Investigations

- X-rays are normal but should always be obtained to exclude any bony injury or loose body.
- Arthroscopy or direct visualization of inside of joint confirms the diagnosis in 95 percent cases.

### Treatment

Torn meniscus in addition to causing disability from pain and locking will slowly damage the articular cartilage of femur and tibia and lead to degenerative arthritis.

When the diagnosis is certain, treatment is excision of the damaged meniscus.

In bucket handle type of tear, partial meniscectomy (removal of the central part) and for any other type of tear, total meniscectomy is done.

During meniscectomy, there may be iatrogenic damage to the articular cartilage, which should be taken care of.

Meniscectomy through an arthroscope is nowadays possible which avoids long incision and hospital stay.

See Figs 100.2A to C and 100.3A and B for surgical anatomy of the menisci and the operation of meniscectomy in operative section.

## FRACTURES OF SHAFTS OF TIBIA AND FIBULA

The bones tibia and fibula frequently fracture together like fractures of forearm bones. Fractures of the shafts of tibia and fibula are one of the commonest long bone fractures.

### Mechanism of Injury

The tibia and fibula may be fractured by a direct or indirect injury.

1. Direct injury: Road traffic accidents are the commonest cause of these fractures. The fractures tend to be transverse and at the same level.
2. Indirect injury: A bending or twisting force, e.g. falling in a ditch may result in an oblique or spiral fracture. The sharp edge of the fracture fragment may pierce the skin resulting in an open fracture. In fact, this is the commonest site for a compound fracture.

### Displacement

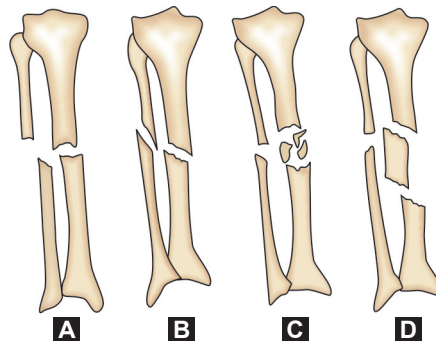
The fracture may be closed or open and may occur at different levels, upper, middle or lower thirds.

Displacements may be sideways, angulatory or rotational occasionally the fracture remains undisplaced (Fig. 59.9A-D).

### Clinical Features

There is usually history of injury to the leg followed by the classic features of fractures viz. pain, swelling, deformity, etc.

X-ray will confirm the diagnosis.



**Figs 59.9A to D:** Different types of fractures of tibia and fibula. (A) Transverse, (B) Spiral, (C) Comminuted, (D) Segmental fracture

### Treatment

Treatment depends on whether the fracture is closed or open.

#### I. Closed fractures

- Treatment of the closed fracture is by closed reduction under anesthesia, both in children and in adults followed by an above knee POP cast. In children it is possible to achieve good alignment in most cases and the fracture unites in about 6 weeks. In adults the fracture unites in 16 - 20 weeks time.
- Sometimes the reduction is not achieved by closed method or the fracture displaces in the plaster. In such case, open reduction and internal fixation is required

#### II. Open fractures

The aim in the treatment of open fractures is to convert it into a closed fracture by judicious care of the wound and maintain the fracture in good alignment while this is being done.

The following methods are used depending on the grade of the open fracture.

Grade I – Wound debridement and an above knee POP cast with dressing through a window in the cast.

Grade II – Wound debridement and primary closure, if less than 6 hours old and above knee plaster cast application. The wound may need dressing through window in the plaster cast.

Grade III – Wound debridement, dressing and external fixator application. The wound is left open.

### Role of Operative Treatment

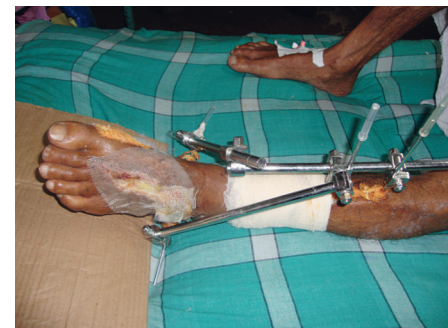- Operative treatment is more often indicated in cases of delayed union, malunion and nonunion.
- Open reduction and internal fixation is necessary when it is not possible to achieve a satisfactory alignment of a fracture by non operative methods. External fixation is useful where internal fixation cannot be carried out due to risk of infection and plaster application makes dressing the wound difficult (Figs 59.9E and F).
- The internal fixation device may be a plate or an intramedullary nail depending upon the configuration of the fracture.

### Complications

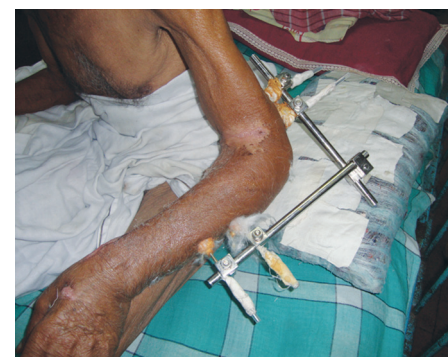These can be early or late. Early complications include:

- i. Infection
- ii. Compartment syndrome
- iii. Vascular injury, e.g. popliteal artery.

Late complications are:



**Fig. 59.9E:** External fixator applied in a 90-year-old patient with fracture both bone left leg



**Fig. 59.9F:** Fracture both bone left forearm fixed with external fixator in the same patient

1. Malunion
2. Delayed union
3. Nonunion
4. Sudeck's atrophy
5. Joint stiffness of ankle and subtalar joints.

### FRACTURES OF SINGLE LEG BONE

Fractures of only tibia or fibula are uncommon. Tibial fracture is treated in the same way as described for both bone fractures.

In displaced tibial fracture, closed manipulation usually fails as the intact fibula acts as splint and fractured fragments of tibia cannot be moved. In such cases open reduction and internal fixation is usually required.

If fibula alone is broken, it is most likely a part of ankle fractures and therefore the ankle should be examined clinically and radiologically.

When isolated fibular fracture is the only injury, basically no treatment is required. Crepe bandage or plaster slab is given to reduce the pain initially and as soon as comfortable, patient can start walking and plaster is discarded.

### ANKLE FRACTURES

Different varieties of fractures occur around the ankle and the group as a whole is known as Pott's fracture, after Percival Pott who first described it in 1768.

#### Mechanism of Injury

1. The ankle is usually injured by indirect violence, as a result of forcible movement of the foot in relation to tibia.

Although the mechanism is described as if the foot moved on a fixed tibia, but in practice ankle fractures always occur whilst the tibia moves along with the body with foot fixed.

The momentum of the body may impose one of the variety of forces upon the ankle to cause fracture, the most important being external rotation, abduction and adduction. Two things should be noted in this connection viz.

- a. The foot is inherently more stable in eversion than inversion. So inversion

(Adduction) injuries are commoner than those due to eversion (Abduction).

- b. During normal walking the feet are placed in a slight external rotation. A sudden arrest of foot while the tibia continues to move forward has the effect of externally rotating the foot on the tibia. Hence external rotation injury is the commonest.

2. Ankle fracture may also occur by an upward thrust if the patient has fallen from a height.

#### Classification

1. The Lauge – Hansen classification of ankle injuries is most widely used. This is based on the position of the foot (supinated or pronated) and the direction of the deforming force (abduction, adduction, or external rotation) at the time of injury. The patterns are as follows:
  - i. Adduction (supination) injuries, so that the sole faces medially.
  - ii. Abduction (pronation) injuries, so that the foot is everted and the sole faces laterally.
  - iii. Pronation – external rotation injuries.
  - iv. Supination – external rotation injuries.
  - v. Vertical compression injuries.

2. The Danis–Weber classification: This is based on the level of fibular fracture relative to the syndesmosis, the distal tibi-fibular joint.

The three types are:

1. Type A—A fracture below the syndesmoses.
2. Type B—A fracture at the syndesmoses often associated with disruption of the anterior fibers of the tibiofibular ligament.
3. Type C—The fibular fracture is above the syndesmoses, the tibiofibular ligament must be torn, resulting in an unstable fracture subluxation.

#### Clinical Features

- The patient may have stumbled over an unexpected obstacle or stair or may have fallen from a height. The ankle is twisted severely under the leg.
- Pain, swelling and deformity appear rapidly and may be marked.
- The site of tenderness is important, if both sides are tender, an injury (bony or

ligamentous) must be suspected on both sides.

- X-ray—This should include AP, lateral and mortice (internal rotation 15 degrees) views.
- X-ray study will reveal the type of injury and hence the treatment.

#### Treatment

Open injuries are managed on similar lines to any compound fracture. For closed injuries, the soft tissue management and limb swelling need close monitoring.

Timing of surgery is also important.

It should either be done within a few hours of injury or once the swelling subsides.

The definitive management of fracture is as follows:

- a. Undisplaced fracture – Fracture of the lateral malleolus alone without talar tilt are stable and can be managed with cast immobilization for 6 weeks.

Fractures which are undisplaced but potentially unstable, e.g. those involving both malleoli can be managed conservatively but need close monitoring.

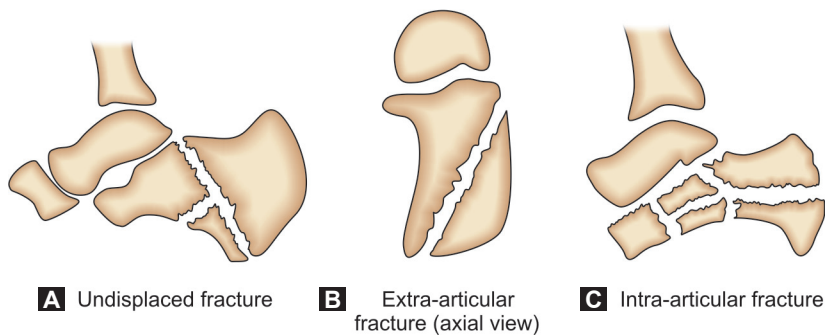
- b. Displaced isolated lateral malleolar fracture – It does not need anatomical reduction of the fibula and are managed non-operatively with a cast.
- c. Displaced isolated medial malleolar fracture – This will need proper reduction and internal fixation with two cancellous lag screws or a tension band wire.
- d. Displaced bimalleolar or trimalleolar fracture – Posterior fragment of the lower end of tibia is often called the third malleolus. These are unstable fractures and need operative intervention, in the form of internal fixation with compression screws. All major ligament injuries e.g. those of the deltoid ligament, lateral ligament should be repaired.

External fixation: This is required for open fractures with crushing of the muscles and tendons with skin loss around the ankle.

#### Complications

- Wound infection
- Malunion
- Joint stiffness and pain
- Osteoarthritis.





**Fig. 59.10A to C:** Types of fracture calcaneum

### FRACTURE CALCANEUM

This occurs due to fall from a height. The calcaneum is driven against the talus and is crushed.

Other injuries due to fall from a height, e.g. fractures of hip, pelvis, ankle should be excluded.

Calcaneal fractures can be divided into two groups (Fig. 59.10).

- Extra-articular fractures (75%)—Involve the calcaneal process or the posterior part of the bone. They are easy to manage and have a good prognosis.
- Intra-articular fractures (25%) are complex and may have an unpredictable outcome.

#### Clinical Features

The foot is swollen, painful and bruised. The heel may look broad and squat and the normal concavity below the lateral malleolus is lacking.

X-Ray: Extra-articular fractures are quite obvious. However, intra-articular fractures require a CT scan for accurate definition. X-ray of spine and pelvis are important as in any severe injury.

#### Treatment

- Extra-articular fractures are managed conservatively. Undisplaced or minimally displaced intra-articular fractures are managed similarly.
- Displaced intra-articular fractures are best treated by open reduction and internal fixation.

#### Complications

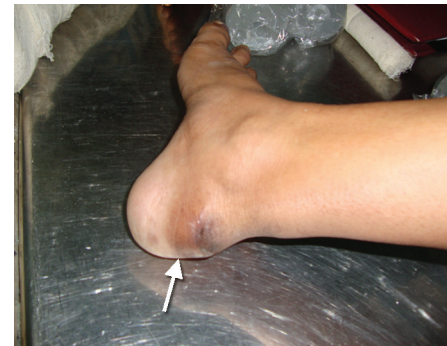- Broadening of the heel.
- Osteoarthritis of talocalcaneal joint.

### RUPTURED TENDOACHILLES

This is a pathological tear of tendoachilles about 5 cm above the insertion of the tendon. Such tear occurs through an area of avascular degeneration during vigorous physical activity. The patient is able to walk but with a limp.

#### Clinical Features

- This injury usually affects middle-aged individuals.
- The patient gives history of sudden agonizing pain at the back of the ankle while running or jumping.



**Fig. 59.11:** Ruptured tendoachilles (traumatic) of right ankle, as indicated by the arrow

- Patient walks with a limp. On examination there is tenderness at the site of rupture. A gap is felt in the course of the tendon 5 cm above its insertion. The gap is more prominent on dorsiflexion of the ankle (Fig. 59.11).

#### Simmonds Test

This is a useful test to diagnose the condition. With the patient lying in prone position the calves are squeezed – on normal side the foot is seen to plantar flex but on the ruptured tendon side the foot remains still.

#### Treatment

1. Conservative—This is preferred especially in sedentary or elderly patients and is done with (i) plaster immobilization for 8 weeks and (ii) wearing of shoes with heel raised.
2. Operative—This is done in fresh cases especially in athletes.

The tendon is repaired with nonabsorbable sutures followed by plaster immobilization in equinus position of foot for 6 weeks. If the rupture is neglected for 4 weeks, conservative treatment is preferred.



# Chapter 60

## Osteomyelitis

- Definition
- Types

- Acute pyogenic osteomyelitis

- Chronic osteomyelitis

### DEFINITION

Osteomyelitis can be defined as the infection of bone with all its components viz. periosteum, cortex and medulla.

### TYPES

There are two types:

1. Acute (pyogenic) osteomyelitis.
2. Chronic osteomyelitis which may be:
  - i. Nonspecific, e.g.
    - a. Chronic pyogenic
    - b. Brodie's abscess
  - ii. Specific, e.g.
    - Tubercular osteomyelitis
    - Syphilitic osteomyelitis.

### ACUTE PYOGENIC OSTEOMYELITIS

#### Definition

It is an acute pyogenic inflammation of all parts of the bone, viz. cortex, medulla and the periosteum. In one word it is boil in a bone.

#### Etiology

1. Predisposing factors:
  - a. Age—Children aged between 2-10 years are more commonly affected, site of affection being the metaphysis.
  - b. Sex—It is more common in males.

- c. A septic focus often acts as a source of infection, e.g. acute tonsillitis, acute otitis media, acute umbilical sepsis, acute skin infections, like boils, carbuncles, etc.
- d. Lowered general resistance.
2. Precipitating or exciting factors:
  - a. Trauma, e.g. open fractures, operations on bone.
  - b. Organisms—In 80 percent cases the organism responsible is *Staphylococcus aureus*. Other organisms that may be responsible include the *Streptococcus haemolyticus*, *pneumococcus*, *H. influenzae*, *Staphylococcus albus* and the *salmonellas*.

#### Pathology

Organisms reach the bone through the bloodstream from a septic focus elsewhere in the body as mentioned above.

They enter into the bone through the nutrient artery and finally settle in the metaphyseal region because of the following reasons:

- a. Metaphysis is highly vascular.
- b. It is the growing end of bone and soft.
- c. Due to hairpin arrangement of the metaphyseal arteries, there is stagnation and slowing of circulation so that the organisms get more opportunity to settle here. After settling, the organisms induce an acute inflammatory reaction characterized

by edema with inflammatory exudate and pus formation (Fig. 60.1A).

#### Fate of Inflammation

- i. The inflammation may be resolved completely if the patient has a good resistance or has been subjected to early and efficient treatment.
- ii. Pus may spread downwards along the length of medulla causing venous and arterial thrombosis resulting in widespread destruction of bone.

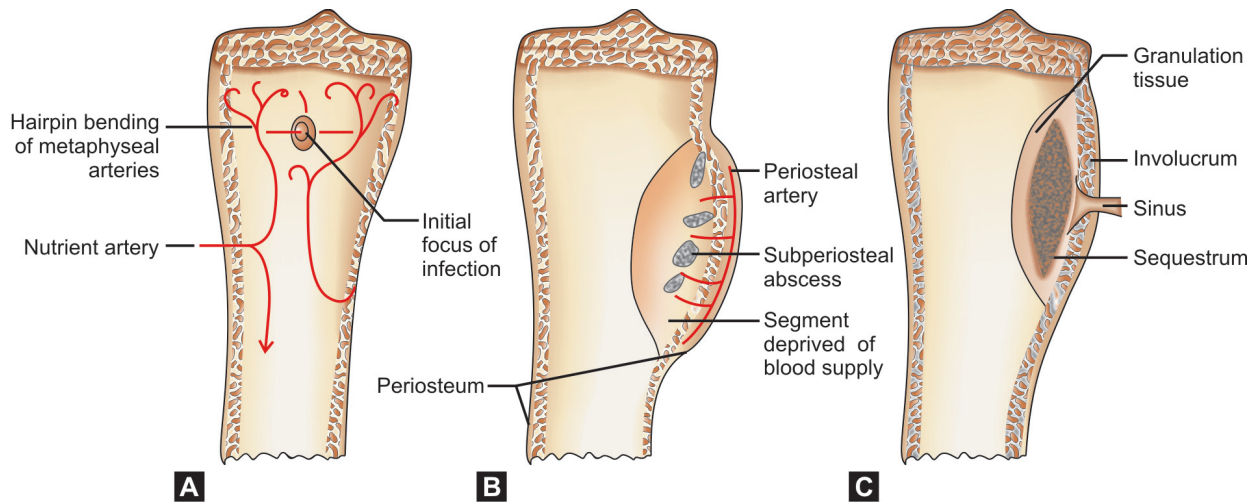
The infection process rarely crosses the growth plate as it contains no blood vessels and the periosteum is firmly attached to the plate at this level.
- iii. Pus goes towards the surface to lie under the periosteum and forms a subperiosteal abscess (Fig. 60.1B).

If the metaphysis is intracapsular, e.g. in the hip and shoulder joints, an acute suppurative arthritis results.

Later the abscess may burst into the soft tissues and eventually reach the surface to form a sinus (Fig. 60.1C).

Often the blood supply to a part of bone is cut off by toxic thrombosis (due to bacterial toxin) of the vessels. The ischemic bone dies and eventually separates from the living bone as a sequestrum (Fig. 60.1C).

Meanwhile new bone is laid down beneath the stripped up periosteum forming an investing layer known as the involucrum.



**Figs 60.1A to C:** Pathology and fate of inflammation in osteomyelitis.

The development of sequestrum and involucrum are all well-established in chronic osteomyelitis. In acute osteomyelitis there is only beginning of sequestrum formation.

### Clinical Features

- Children, especially boys are the usual sufferers.
- The bones most commonly involved are the tibia, femur and humerus.
- Onset is rapid and pain is the presenting symptom.
- There may be history of recent boils or a minor injury.

### Local Examination

- Swelling and local rise of temperature.
- Skin overlying the area is glossy, reddish with venous prominence.
- Lack of movements – Both active and passive movements are painful. There may be swelling of the adjacent joint, because of either sympathetic effusion or concomitant arthritis.

See also the long case osteomyelitis, chapter 78

### Investigations

1. Blood –
  - a. There may be polymorphonuclear leucocytosis and raised ESR.
  - b. Culture must be done along with sensitivity of the organisms which is positive in >50% cases.
2. X-rays—Show no abnormality for the first 7-10 days. After this period, the earliest sign is periosteal new bone

formation (periosteal reaction) at the metaphysis.

3. Bone scan—A bone scan using technetium-99 may show increased uptake by the bone in the metaphysis. This is positive before the changes appear on the X-ray. This may be required in an early case where the diagnosis is in doubt.

### Treatment

- A patient of acute osteomyelitis is generally ill and requires hospital admission.
- Immediate and proper steps are taken to ensure symptomatic relief of pain, fever and restlessness.
- An intravenous line is secured and nonsteroidal anti-inflammatory drugs (NSAIDs) are advised for relief of pain.
- Empirically wide spectrum antibiotic is started till the culture report of blood or pus is available. Other antibiotics may be substituted if they are indicated by the sensitivity tests. The duration for which antibiotics to be administered is debatable. In practice it is usually given for a period of 3 to 6 weeks.
- Intravenous fluids and dietary supplementation help to combat dehydration and nutrition.

### Local Treatment

This consists of:

- a. Rest to the part either with soft pillows or by a suitable splint.
- b. No movement of the affected limb is encouraged.

### Surgical Treatment

If the patient does not respond, i.e. temperature does not subside and no clinical improvement occurs, surgical treatment is indicated.

Under general anesthesia, the affected site is explored and pus is drained. The abscess is usually found deep to the periosteum or within the bone. A drill hole is made in the bone in the region of the metaphysis. If pus comes out from the drill hole, the hole is enlarged until free drainage is obtained. A swab is taken for culture and sensitivity. The wound is closed over a sterile suction drain.

Rest, antibiotics and hydration are continued postoperatively. Antibiotics are continued for 6 weeks.

### Complications

- i. Septicemia and pyemia which may give rise to metastatic abscesses.
- ii. Acute pyogenic arthritis—This occurs in joints, where the metaphysis is intraarticular, e.g. the hip (the upper femoral metaphysis), the shoulder (the upper humeral metaphysis), etc.
- iii. Pathological fracture—It is the commonest complication of acute osteomyelitis. A delay in diagnosis and inadequate treatment will lead to this complication.

### Differential Diagnosis

1. Acute suppurative arthritis—Acute osteomyelitis is differentiated from this condition by:

- a. The point of greatest tenderness is over the bone rather than the joint.
  - b. A good range of movement is retained. In septic arthritis joint movement is painful and restricted.
  - c. Although the joint is distended with fluid due to sympathetic effusion, it does not contain pus in septic arthritis.
2. Acute rheumatic arthritis—The features are similar to acute septic arthritis. Of course, the fleeting character of the joint pains, elevated ASO titer and CRP values may help in diagnosis. (CRP – C-reactive protein)
  3. Scurvy: There is subperiosteal hematoma formation which mimics acute osteomyelitis on X-ray but the absence of pain, tenderness and fever points to the diagnosis of scurvy.
  4. Hemarthrosis.
  5. Ewing's tumor.

## CHRONIC OSTEOMYELITIS

Chronic osteomyelitis generally denotes chronic pyogenic osteomyelitis. The other causes are tuberculosis, syphilis, fungal infection, etc. as mentioned earlier.

There are three types of chronic osteomyelitis viz.

- i. Chronic osteomyelitis secondary to acute osteomyelitis
- ii. Brodie's abscess.
- iii. Nonspecific osteomyelitis of Garre. (ii) & (iii) are special types

### Chronic Pyogenic Osteomyelitis

#### Pathology

Two factors are responsible for the chronicity of the disease viz.

- a. The presence of dead infected bone or sequestrum, which cannot be absorbed. (See the specimen sequestrum in chapter 101)
- b. The intraosseous abscess cavity which can not be obliterated because of its rigid bony walls.

It is often confined to one end of the bone but it may affect the whole length. The bone is generally thickened and is generally denser than normal often honeycombed with granulation tissue, fibrous tissue or pus.

Often a sinus track leads to the skin surface, the sinus tends to heal and breakdown

recurrently but in presence of sequestrum, it never heals permanently.

#### Clinical Features

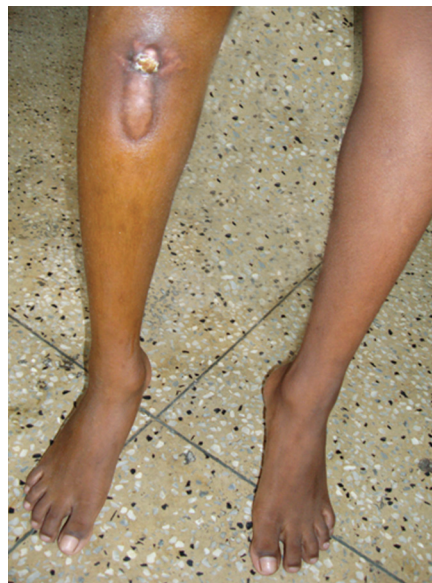- Purulent discharge from a sinus over the affected bone is the main symptom (Fig. 60.2).
- Pain is predominant in some cases.
- Discharge of pus may be continuous or intermittent and may contain bone chips.

#### Examination

- Bone is palpably thickened and there are nearly always a number of overlying scars or sinuses.

#### Investigations

1. X – ray shows
  - Thickening and irregularity of the cortices.
  - Sequestrum—This is seen as a dense loose fragment with irregular but sharply demarcated edges lying within a cavity in the bone.
2. Radioisotope scanning shows increased uptake in the vicinity of the lesion.
3. CT scan—In diffuse disease it may be of value for localization of abscess cavity and sequestrum, thus allowing accurate planning of operative treatment.



**Fig. 60.2:** Chronic osteomyelitis of the upper end of right tibia in a boy aged 11 years, with discharging sinus.

#### Complications

1. Pathological fracture may occur through the weekend area of the bone.
2. Squamous cell carcinoma may develop in a sinus of many years duration.
3. Growth abnormalities – This occurs due to growth abnormalities at the adjacent growth plate. There may be:
  - i. Shortening when the growth plate is damaged.
  - ii. Deformities appear when a part of the growth plate is damaged and the rest keeps growing.
  - iii. Lengthening due to increased vascularity of the growth plate due to the nearby osteomyelitis.
4. Amyloidosis – This is late complication of osteomyelitis.

#### Treatment

Treatment of chronic osteomyelitis is primarily surgical. The aim of surgery is the removal of the infected granulation tissue and sinuses as well as the dead bone or sequestrum.

- The operative procedure done is known as sequestrectomy with saucerization (shallowing) of the osteomyelitic cavity.

In saucerization the bone cavity is made shallow by removing the wall which allows free drainage of the infected material.

- An useful advance in the treatment is the use of gentamicin impregnated beads made of polymethyl methacrylate (PMMA) following debridement of the affected area to get a high concentration of the antibiotic, which cannot be achieved by systemic therapy. The beads are then gradually pulled daily after 4 to 6 weeks of stay.

The dead space left after removal of the beads is subsequently filled by a flap of muscle or bone chips.

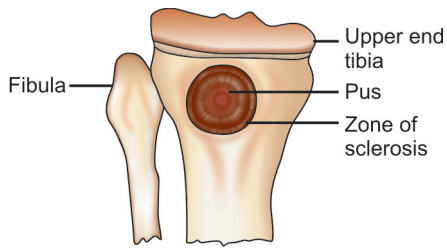
### Brodie's Abscess (Syn—Chronic Bone Abscess)

This is a special form a chronic osteomyelitis, which arises insidiously without a preceding acute attack.

There is a localized abscess within a bone, near the metaphyses (Fig. 60.3).

- A deep boring pain is the predominant symptom and the common sites are upper end of tibia and lower end of femur.

The pain may become worse at night.



**Fig. 60.3:** Brodie's abscess

- X-ray shows a circular or oval cavity surrounded by a zone of sclerosis. The rest of the bone is normal.

### Treatment

Treatment is operative. Surgical evacuation and curettage is performed under antibiotic cover. The residual cavity is filled with cancellous bone chips.

### Nonspecific Osteomyelitis of Garre

This is a sclerozing nonsuppurative osteomyelitis as a result of low grade infection and ensuing irritation. The shafts of the femur and tibia are the most commonly affected sites.

Unlike chronic pyogenic osteomyelitis, there is no discharging sinus.

Thus Garre's osteomyelitis is to be differentiated from the bone tumors which may present with similar features viz. local pain, pyrexia and swelling.

### Treatment

Acute symptoms subside with rest and broad spectrum antibiotics. Sometimes making a hole in the bone brings relief of pain.

See also the long case osteomyelitis in chapter 78.

# Chapter 61

## Bone Tumors

- Benign tumors
- Malignant tumors
- Secondary carcinoma of bone
- Tumor-like conditions of bone

Bone is a mesenchymal tissue. Thus tumors of bone may arise from different tissue components—osseous, e.g. bone, cartilage, periosteum and nonosseous, e.g. fat, fibrous tissue, nerve tissue, vascular tissue, etc. indigenous to the bone (Table 61.1).

Tumors of bone are commonly benign and metastatic deposits in bone are commoner than primary bone tumors. Of the primary bone malignancies, multiple myeloma is the commonest.

Most primary malignant bone tumors occur in children and young adults.

### **BENIGN TUMORS**

#### **Osteoma**

This is a benign tumor composed of sclerotic, well-formed bone protruding from the cortical surface of a bone.

**Table 61.1 Classification of bone tumors**

	<i>Benign</i>	<i>Malignant</i>
1. Bone forming tumor	<ul style="list-style-type: none"> <li>- Osteoma (from osteoblasts)</li> <li>- Osteoblastoma</li> </ul>	Osteosarcoma
2. Cartilage forming tumors	<ul style="list-style-type: none"> <li>- Chondroma</li> <li>- Chondroblastoma (from cartilage cells)</li> <li>- Osteochondroma</li> </ul>	Chondrosarcoma
3. Giant cell tumor (GCT) from osteoclasts	<ul style="list-style-type: none"> <li>- Benign GCT</li> </ul>	Malignant GCT
4. Marrow tumors		<ul style="list-style-type: none"> <li>- Ewing's tumor (from reticuloendothelial cells of marrow)</li> <li>- Multiple myeloma (from plasma cells)</li> <li>- Malignant lymphoma (NHL-Non Hodgkin Lymphoma)</li> </ul>
5. Vascular tumors	Hemangioma	Angiosarcoma
6. Others (other connective tissue and nerve tissue tumors)	<ul style="list-style-type: none"> <li>- Lipoma</li> <li>- Fibroma</li> <li>- Neurilemmoma (from nerve sheath)</li> </ul>	<ul style="list-style-type: none"> <li>- Liposarcoma</li> <li>- Fibrosarcoma</li> <li>- Malignant fibrous histiocytoma</li> <li>- Undifferentiated sarcoma</li> <li>- Neurofibrosarcoma</li> </ul>
7. Tumor-like lesions	<ul style="list-style-type: none"> <li>- Bone cysts – simple or aneurysmal</li> <li>- Fibrous dysplasia</li> <li>- Reparative giant cell granuloma (e.g. Epulis)</li> </ul>	



### Types

1. Ivory osteoma — Arises from the membrane bone of skull.
2. Osteoid osteoma — It can arise in any bone except the skull bone, the commonest bones affected are the femur and tibia. X-ray will confirm the diagnosis. X-ray shows a small round or oval radiolucent area with sclerosis at the margin.

These tumors do not undergo malignant transformation.

### Treatment

Excision of the osteoma.

### Chondroma

This tumor arises from precartilaginous cells of the bone, which fails to become ossified. It usually involves the short long bones viz. metacarpals, metatarsals and proximal phalanges of hands and feet.

### Pathology

It is usually solitary.

### Types

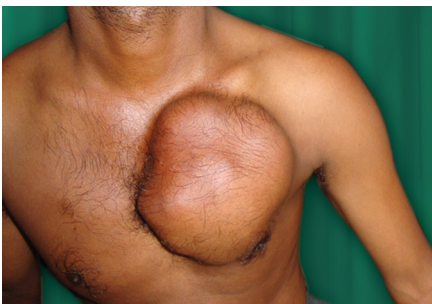
There are two types –

- a. Enchondroma – Growing within the bone and
- b. Ectochondroma – Growing outwards on the surface of the bone.

In enchondroma, fracture is common due to thinning of the cortex. Occasionally chondroma undergoes malignant change becoming a chondrosarcoma (Fig. 61.1).

### Clinical Features

- The tumor usually presents with painless expanded swelling of the affected bone.
- An ectochondroma may interface with joint and tendon movement.



**Fig. 61.1:** Bony tumor (chondrosarcoma) involving the anterior chest wall

- The patient may present with a fracture after a trivial injury.
- X-ray shows a rarefied area on the cortex with a clear outline.

Treatment is excision of the tumor.

### Osteochondroma

#### (Syn—Exostosis)

This tumor consists of normal bone covered by a cap of cartilage. It is one of the most common benign tumors.

It is truly a hamartoma, arising from the growth plate of the developing bone. As the bone grows in length, the tumor gets left behind and thus appears to migrate along the shaft towards its center.

It grows outwards from the bone like a mushroom. The lesion stops growing when the growth of the skeleton ceases.

### Clinical Features

- Age—Usually present in teenage and adult life.
- The most common site of osteochondroma is the growing ends of bone including the distal femur, proximal tibia and proximal humerus.

### Examination

The tumor is bony hard in consistency and fixed to the bone but not the muscle or skin. X-ray shows mushroom like bony tumor but not the cartilaginous cap.

### Treatment

Excision of the tumor if it causes pain or pressure symptoms on the adjacent structures, but one should wait until the cessation of skeletal growth, i.e. after epiphyseal union. See also short cases in orthopedics, chapter 85.

## MALIGNANT TUMORS

### Osteosarcoma

Excluding multiple myelomas these are the most common primary malignant tumors of bone, derived from the pluripotent mesenchymal cell with bony propensity.

### Classification

Osteosarcoma has been subclassified as follows:

1. Depending on the presence of preexisting lesion –
  - i. Primary osteosarcoma—No pre-existing lesion present.
  - ii. Secondary osteosarcoma developing in presence of a pre-existing lesion (see below).
2. Depending on the dominant histomorphology the following are the subtypes:
  - a. Osteoblastic osteosarcoma – with a lot of new bone formation.
  - b. Osteolytic type or Telangiectatic osteosarcoma – which is predominantly a lytic tumor. Hence pathological fracture is common.
  - c. Fibroblastic osteosarcoma, the basic cell being the fibroblast.
  - d. Chondroblastic osteosarcoma, the basic cell being a cartilage cell. It is common in the pelvis.

### Primary Osteosarcoma

There are no known premalignant conditions related to it. It is commoner and occurs in the age group of 10 – 20 years. It is much more malignant than the secondary one.

### Secondary osteosarcoma

This occurs in the older age group (45 years onwards). It arises from preexisting lesion or in bone that has been irradiated.

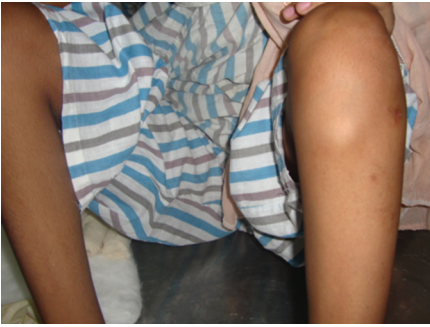Pre-existing lesions are Paget's disease, multiple enchondromatosis, fibrous dysplasia, irradiation, multiple osteochondroma, etc.

### Spread

All osteosarcomas are aggressive lesions and metastasize widely through the bloodstream, usually to the lungs. Lymph node involvement is unusual. Osteolytic type is more malignant than the osteoblastic type.

### Clinical features

- Pain is usually the first symptom, soon followed by swelling. The pain is constant boring and becomes worse, as the swelling increases in size.
- The bones commonly involved in order of frequency are distal femur, proximal tibia, proximal humerus, pelvis and fibula. Over 70 percent of all osteosarcoma as occur in the lower limbs. (Fig. 61.2)



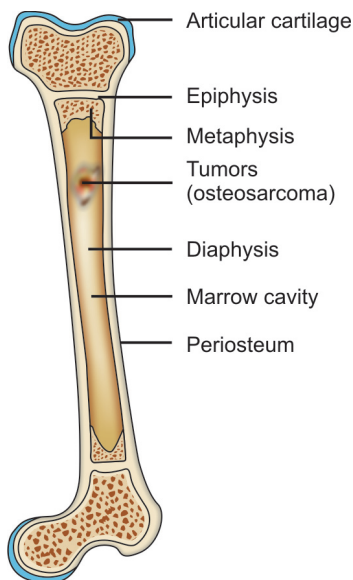
**Fig. 61.2:** Osteosarcoma of the upper end of left tibia in a young female patient

- There may be a history of trauma but more often it is incidental and draws attention of the patient to the swelling. Sometimes the patient presents with a pathological fracture.

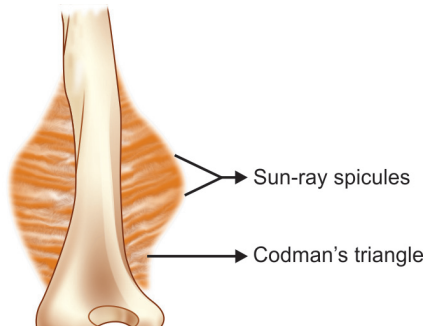
#### On examination

The swelling is usually located in the region of metaphysis, firm to soft in feel and highly tender (Fig. 61.3).

Local temperature is raised due to high vascularity and the skin over the swelling is red, tense and glossy with prominent veins on it.



**Fig. 61.3:** Origin of osteosarcoma from the metaphysis of a long bone. It is to be noted that osteoclastoma is epiphyseal and Ewing's sarcoma is diaphyseal in origin.



**Fig. 61.4:** X-ray appearance of osteosarcoma.

#### X-Ray

- Local X-Ray shows the following features (Fig. 61.4)
  - a. The growth is at the metaphysis.
  - b. Usually but not always there is evidence of new bone formation. Tumor bone is laid below the periosteum especially along the stretched blood vessels and at the junction of bone and lifted periosteum. These are prominent in X-ray plates as sunray spicules and Codman's triangle respectively.
  - c. There is a big soft tissue shadow.
- X-ray chest – Metastasis may be present in the form of multiple deposits or as a solitary cannon ball deposit.

#### CT Scan and MRI

These are important investigation modalities to know the extent of tumor spread within the medullary cavity. The soft tissue involvement is best delineated with the MRI.

#### Biopsy

Either a core biopsy or a biopsy is done to confirm the diagnosis. Sometimes, the fine needle aspiration cytology (FNAC), a relatively quicker and easier method may establish the diagnosis.

#### Treatment

The aim of treatment is to confirm the diagnosis from the clinical features, X-ray findings and biopsy, to evaluate the spread of tumor from CT scan and MRI of the affected bone and chest X-ray and to execute adequate treatment.

The different modalities of treatment include:

1. Surgery
2. Chemotherapy and
3. Radiotherapy.

#### Surgery

A limb ablation or a limb salvage surgery may be done depending on the spread of the tumor.

- a. *Early presentation of tumor:* When the tumor is diagnosed in the early stage neoadjuvant chemotherapy is given to down-size the tumor and its vascularity. Limb salvage surgery is performed subsequently.

The bone defect of the excised tumor is filled with bone grafts. Custom made prosthesis or intramedullary nail can also be used depending on the situation.

- b. *Locally advanced tumor:* In patients with locally advanced disease, amputation has to be performed with complete removal of the tumor. Pain relief is also obtained with amputation and is an important indication for palliative amputation.

#### Chemotherapy

Preoperative neoadjuvant chemotherapy decreases the size of the tumor and also ablates the micrometastases that have already occurred. It has made possible the concept of limb salvage surgery.

Drugs that yield best response include methotrexate, endoxan and cisplatin.

#### Radiotherapy

This may be indicated in cases where the tumor is surgically inaccessible or patient refuses surgery.

#### Ewing's Sarcoma

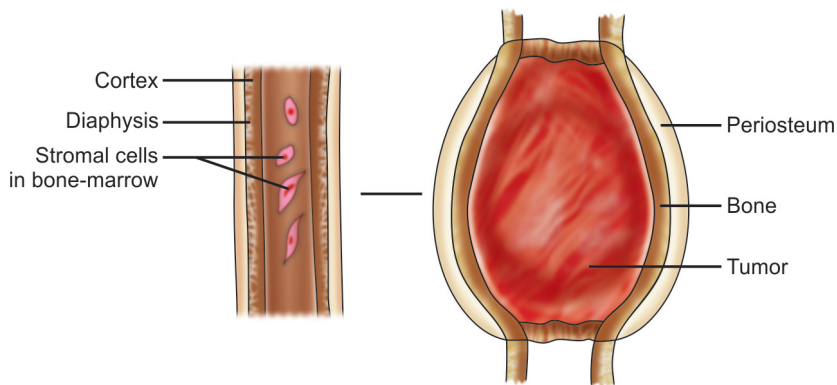
It is one of the most lethal primary malignant bone tumors in the pediatric age group.

The tumor usually involves the diaphysis of long bones as well as flat bones such as scapula and pelvis.

It arises from the stromal cells of the bone marrow be round cells and the spindle cells (Fig. 61.5).

#### Pathology

- Femur is the most common bone involved followed by tibia, fibula, humerus, pelvis and scapula.
- The tumor is soft and may resemble brain tissue cut surface is grayish white.



**Fig. 61.5:** Origin of Ewing's sarcoma from the stromal cells (round and spindle cells) in bone marrow. The tumor spreads very rapidly.

Histologic features are:

- i. Undifferentiated round cells in sheets
- ii. There are hyperchromatic cells with scanty cytoplasm. So this tumor is also called round cell tumor.

There is alternate deposition of tumor tissue and new bone giving rise to onion peel appearance, best appreciated in X-ray.

- Spread—Hematogenous spread to lungs and other bones is very quick and more common than in osteosarcoma.
- Prognosis is worse—If untreated, death is usual within 2 years.

### Clinical Features

Age – 5 to 15 years.

Sex – It is more common in males.

There is pain and swelling in relation to the affected bone, associated with local heat and tenderness.

This may be accompanied by fever and malaise so that osteomyelitis is suspected. Moreover, incision on the swelling, based on this diagnosis often brings out semisolid gray material looking like pus and this further confuses the diagnosis.

Thus, as for all bone tumors, the importance of jointly considering the clinical, radiological and pathological evidence cannot be overemphasized.

### Investigations

1. Local X-ray shows:
  - a. Onion peels appearance due to alternate layers of reactive new bone formation and the tumor tissue.
  - b. Extensive destruction of the bone as shown by widening of the medulla as well as gross rarefaction of the cortex.

2. Tissue diagnosis is obtained by needle or open biopsy.
3. MRI scanning is very useful to determine the extent of intramedullary and soft tissue involvement and aids in surgical planning.
4. X-ray chest and CT scan of abdomen and chest are additional imaging studies to determine metastasis.

### Treatment

There are three modalities of treatment:

- a. Radiotherapy
- b. Chemotherapy
- c. Surgery.

Ewing's sarcoma is a highly radiosensitive tumor. In most cases, distant metastasis has occurred by the time diagnosis is made.

Thus treatment consists of:

- i. Control of the local tumor by radiotherapy (6000 rads) and control of the metastasis by chemotherapy.
- ii. The chemotherapy consists of VAC or vincristine, adriamycin and cyclophosphamide in cycles repeated every 3 to 4 weeks for about 12 to 18 cycles.

After radiotherapy, the tumor is excised and the gap is filled with bone and the segments are supported with plate and screws or nail.

Amputation is done in selected cases only.

### Osteoclastoma (Syn—Giant Cell Tumor, Gct)

These neoplasms probably arise from the mesenchymal stromal cell and may be benign, locally malignant or malignant. Malignancy may be a transformation of benign tumor or it may arise *de novo*.

This tumor is also called osteoclastoma because of the presence of multinucleate giant cells in the tumor which resemble osteoclasts.

### Pathology

Giant cell tumor is a neoplasm found mainly in the epiphysis of long bones most commonly at the lower end of femur. Other flat bones like ribs, scapula, mandible, etc. and fibula, lower end of radius may also be involved.

Grossly, the lesion is soft gray to red and hemorrhagic in appearance and produces thinning and expansion of the cortical bone. These are bony trabeculae, passing through the soft tumor mass. On the X-ray these give a 'soap bubble appearance' which though diagnostic of osteoclastoma is not necessarily a constant feature.

Microscopically two types of cells are found viz.

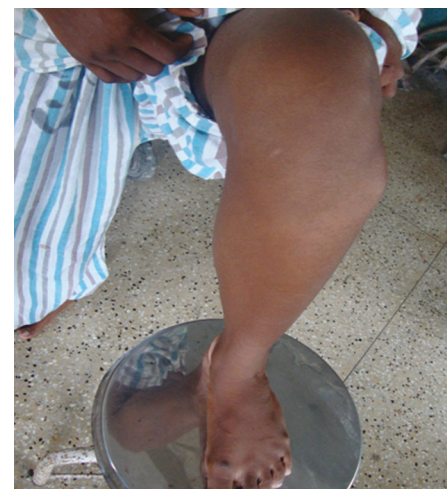- a. Spindle cells — These are basic mononuclear stromal cells, the exact nature of which is still unknown.
- b. Giant cells of foreign body type— These are either products of basic mononuclear cells, or derived from osteoclasts or modified megakaryocytes.

### Clinical Features

Age — 20 to 40 years.

Sex — It is more common in females. (Fig.61.6)

- Swelling is usually located at the end of a long bone gradually increasing in size and duration may be more than a year.



**Fig. 61.6:** Osteoclastoma over the head of left fibula in a girl aged 20 years

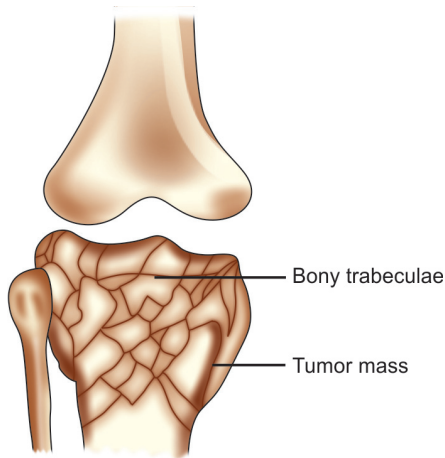
- Pain at the site of lesion is not unbearable and is much less than that of osteosarcoma.

### On Examination

- Surface is smooth, skin temperature – not raised and usually there is no venous prominence over the swelling.
  - Tenderness – mild
  - Pathological fracture of the affected bone is common as the cortex gets thinned out.
  - Joint involvement is more as the tumor arises from the epiphysis.
- Features of the malignant variety are akin to those of osteosarcoma.

### Investigations

1. Local — X-rays shows the following features: (Fig. 61.7)
  - i. It occurs at the end of a long bone and is usually eccentric in situation.
  - ii. The long axis of the tumor is along the transverse axis of the bone.
  - iii. There is destruction of bone substance so that the cortex is expanded and thinned out over the tumor.
  - iv. There is often a 'soap bubble appearance' due to the presence of trabeculae of the remnants of bone traversing the tumor.
2. Biopsy — This must be done in all cases to confirm the diagnosis. Fine needle aspiration cytology (FNAC) may show the multinucleated giant cells.
3. X-ray chest — To detect any metastasis.



**Fig. 61.7:** X-ray appearance of osteoclastoma—loculated lytic lesion (soap bubble appearance)

### Treatment

- Treatment is essentially surgical. The ideal surgical treatment is total excision of the tumor which is readily applicable to dispensable bones like the fibula or ribs.
- For lesions at juxtaarticular sites, e.g. knee joint, the choice rests between through curettage and filling of the cavity with bone chips or the more major procedure of prosthetic replacement.
- Amputation is occasionally required for a frankly malignant GCT or a recurrent GCT of the limbs.
- Radiotherapy has been tried for lesions either nonoperable or at inaccessible sites such as spinal GCT.

### Multiple Myeloma

Multiple myeloma is the most common primary malignant neoplasm of bone in the older age group > 50 years.

The tumor arises from the plasma cells present in the bone marrow. Hence it is also known as plasmacytoma when it occurs as a solitary lesion, it is known as solitary plasmacytoma, and when multiple, it is known as multiple myeloma. (Fig. 61.8).

### Pathology

Grossly, the tumor is soft, gray and friable. The bone is simply replaced by tumor and there is no reactive new bone formation.

Microscopically, there is dull monotony of plasma cells and intercellular matrix is little or nil.

### Spread

There is hematogenous spread to lungs, liver, spleen and other bones.

### Pathologic Physiology

- There is hyperproteinemia, with an increase in the globular fraction, known

as M-protein or Bence Jones protein in the serum or urine. In 60percent cases, the M – protein is IgG type.

- Abnormal proteins are excreted through the kidney and may cause renal failure due to tubular block.
- Bone is decalcified, so that there is rise of serum  $Ca^{++}$  and fall in serum phosphate.
- Due to bone marrow depression, there is anemia and intercurrent infection.
- There may be collapse of the vertebral bodies to cause neurological manifestations, e.g. paraplegia.

### Clinical Features

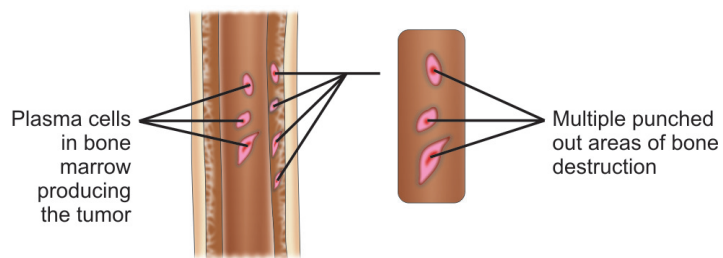
- Age — 50 years or more.
- Sex — It is more common in men than in women.
- The common presentation is increasingly severe pain in the lumbar and thoracic spine.
- There may be general weakness, anemia and infection.
- Occasionally pathological fracture occurs and presents with a deformity.
- Renal failure.

### Investigations

1. Local X-ray—Multiple punched out areas of destruction in the skull and other flat bones. (Fig. 61.8)
2. Other tests to support the diagnosis of multiple myeloma are:
  - a. Urine—Bence Jones proteins are found in 30percent cases.
  - b. Blood—Low hemoglobin with very high ESR, increased total protein and Albumin / Globin ratio is reversed.

Increased serum calcium and serum alkaline phosphatase is characteristically normal.

- c. Open biopsy—An open biopsy from the lesion may sometimes be required to confirm the diagnosis.



**Fig. 61.8:** Origin and X-ray appearance of multiple myeloma



### Treatment

- The main modality of treatment is chemotherapy and the drug of choice is melphalan. Other drugs used are vincristine, prednisolone and cyclophosphamide. The treatment cycles are repeated every 4 weeks for 6 to 12 cycles.
- Radiotherapy in addition to chemotherapy is given to relieve pain.
- Complication like pathological fracture is prevented by splinting the affected part. In case of pathological fracture, surgical fixation may be advised.
- Antibiotics are given to control infection.
- Blood transfusion and hematinics are given to correct anemia.

## SECONDARY CARCINOMA OF BONE

Secondary metastasis account for the majority of malignant bone tumors and far more common than primary malignant tumors of bone.

The sources are from primary malignant tumors with affinity to metastasize to bone, e.g. carcinoma of breast, prostate, lung, kidney and thyroid.

In some cases no primary site can be found at the time when the secondary lesion presents.

### Types of Bone Lesion

The majority is osteolytic but a few, mostly arising from the prostate stimulate new bone formation and are then called osteosclerotic.

### Routes of Spread

- Most commonly metastasis occurs through hematogenous spread.
- There is a direct communication between the pelvic venous plexus and the vertebral veins. So carcinoma from pelvic organs may directly reach the pelvic bones and vertebrae.
- Tumors of the oral cavity may involve the jaw bones and those of the rectum may involve the sacrum by direct contiguity.
- In thyroid cancer, whatever is the histological type of the primary tumor, the

metastatic lesion is always of the follicular variety.

### Sites of Affection

- Bones rich in red marrow are commonly affected, e.g. vertebrae, skull, pelvis, sternum, ribs, upper end of femur and humerus.
- Unusual sites are below elbow and knees. If there is such lesion, possibility of multiple myeloma should be excluded.

### Clinical Features

- Pain, swelling and often a pathological fracture are the usual presenting features.
- A vertebral metastasis may present with back pain, compression fracture, root pain or paraplegia.

### Investigations

1. Local X – ray.
2. Biopsy in doubtful cases.
3. Bone scan with radioactive isotope. It is the optimal investigation for bone pain and detection of early lesions.
4. All investigations are done to detect the primary tumor. The breast, prostate, kidney, bronchus and thyroid should be especially investigated.

### Treatment

- a. Curative: This is out of question excepting when the primary growth is suitable for radical surgery and there is a solitary bone metastasis, e.g. hypernephroma, thyroid carcinoma, etc.
- b. Palliative
  1. Drugs
    - a. Analgesics — Are given for relief of pain. Habit forming drugs are avoided as far as possible.
    - b. Chemotherapy—Combination chemotherapy is preferred. Hypercalcemia of malignancy requires rehydration and IV bi phosphonate therapy.
    - c. Endocrine treatment, e.g. in case of prostate cancer.
  2. Radiation: It is one of the best ways of palliation. External beam radiation is the treatment of choice for localized bone pain.
  3. Surgery: The role of surgery is limited. A fungating growth from a bone may

require amputation. For pathological fractures, internal fixation provides good results.

## TUMOR-LIKE CONDITIONS OF BONE

### Simple Bone Cyst

It occurs in children and adolescents. The ends of the long bones are the favorable sites, the commonest site being the upper end of the humerus.

The cyst itself may not produce symptoms and the patient often presents with a pathological fracture through the cyst.

X-ray shows a well-defined radiolucent zone in the metaphysis or diaphysis of a bone.

A lesion close to the epiphyseal plate is considered 'active' as against the one away from it, e.g. in the diaphysis.

### Treatment

It is treated with curettage and bone grafting in selected cases.

Asymptomatic bone cysts need no treatment.

### Aneurysmal Bone Cyst

It is an expansile lytic lesion usually occurring before the age of 20 years. It consists of a blood filled space enclosed, in a shell, ballooning up the overlying cortex – hence its name.

A gradually increasing swelling is the usual presentation. There may be mild pain often it presents with a pathological fracture.

X-ray shows the following features.

- Eccentric well-defined radiolucent area at the ends of long bones and dorso-lumbar spines.
- Expansion of the overlying cortex.
- Trabeculation within the substance of the tumor.

Treatment is by curettage and bone grafting. In some cases surgical intervention is needed for the treatment of pathological fracture.

### Fibrous Dysplasia

This is a disorder in which normal bone is replaced by fibrous tissue – hence the name.



The mass of fibrous tissue thus formed grows inside the bone and erodes the cortices of the bone from within.

### Types

There are two types viz.

1. Monostotic type—Only single bone involvement is seen. This form affects the femur, tibia, ribs or the craniofacial bones. Children in 5 to 15 years of age

are commonly affected. Pain, deformity or fractures are the usual presenting features.

2. Polystotic type—Multiple bone involvement is seen in this variety. This type of presentation is seen with precocious puberty (Albright's syndrome) and other endocrine disorders such as acromegaly, Thyrotoxicosis or Cushing's syndrome.

Craniofacial bones are almost always involved in this form.

X-ray will show sharply defined, centrally placed lytic areas with homogeneous ground glass appearance. Diagnosis is confirmed by biopsy.

### Treatment

The fibrous defect is thoroughly curetted out and the gap is filled with bone grafts.

# Tuberculosis of Bones and Joints

➤ Tuberculosis of spine

➤ Tuberculosis of hip

➤ Tuberculosis of Knee

The spine is the commonest site of bone and joint tuberculosis, consisting of about 50 percent of the total number of cases. Tuberculosis is still a common infection in developing countries like India.

After the lung and lymph nodes, bone and joint is the next common site of tuberculosis in the body.

The joints most commonly affected in order of frequency are the hip, the knee and the elbow.

## **TUBERCULOSIS OF SPINE (SYN—POTT'S DISEASE AND CARIES SPINE)**

Tuberculosis of the spine is secondary to a primary lesion in the lungs, intestine, neck glands, etc. It involves mainly the portions of the vertebral bodies adjoining the intervertebral disk. The dorsolumbar region is the most commonly affected area.

Developmentally, the lower half of the cephalad vertebra and the upper half of the caudal vertebra along with intervertebral disk develop from one pair of sclerotome and have a common blood supply. Therefore infection via the arteries involves the embryological section just mentioned in the commoner para discal tuberculosis of the spine. (see below).

### **Types of Vertebral Tuberculosis**

Tuberculous lesions in the vertebra may be of the following types:

- a. Parakiscal—This is the commonest type and involves the contiguous areas of two adjacent vertebrae along with the intervening disk.
- b. Central—In this type central part of a single vertebra is involved. There may be concentric or wedge type of collapse of vertebra.
- c. Anterior—In this type, the infection is localized to the anterior part of the vertebral body. The infection spreads up and down under the anterior longitudinal ligament.
- d. Posterior—In this type, the posterior complex of the vertebra, i.e. the pedicle, lamina, spinous process or transverse process are affected.

### **Pathology (Figs 62.1A to D)**

In the commoner paradiscal type, the organism *Mycobacterium tuberculosis* lodge in the contiguous areas of two adjacent vertebrae. The granulomatous inflammation results in erosion of the margins of these vertebrae.

The nutrition of the intervening disk which comes from the end plates of the adjacent vertebra is compromised. This results in disk degeneration, gradually progressing to complete destruction.

Soon there will be destruction and collapse of the vertebra due to the weight of the vertebral column. In the dorsal spine the line of weight bearing passes anterior to the vertebra, so that the anterior part of the weakened vertebra is more compressed than the posterior resulting in wedging.

In the cervical and lumbar spines, because of their lordotic curvature (round forwards), wedging is less. Thus an angular deformity in the form of kyphus (due to gradual collapse) or Gibbus (hunchback) due to sudden collapse results following the wedging of the vertebra (Fig. 62.1D).

The main complications of caries spine are (a) Cold abscess and its spread and (b) Pott's paraplegia.

- a. Cold abscess—This is a collection of pus and tubercular debris from a diseased vertebra. It is called a cold abscess because it is not associated with usual signs of inflammation viz. heat, redness, etc. found with a pyogenic abscess.

It is also much less painful than pyogenic abscess.

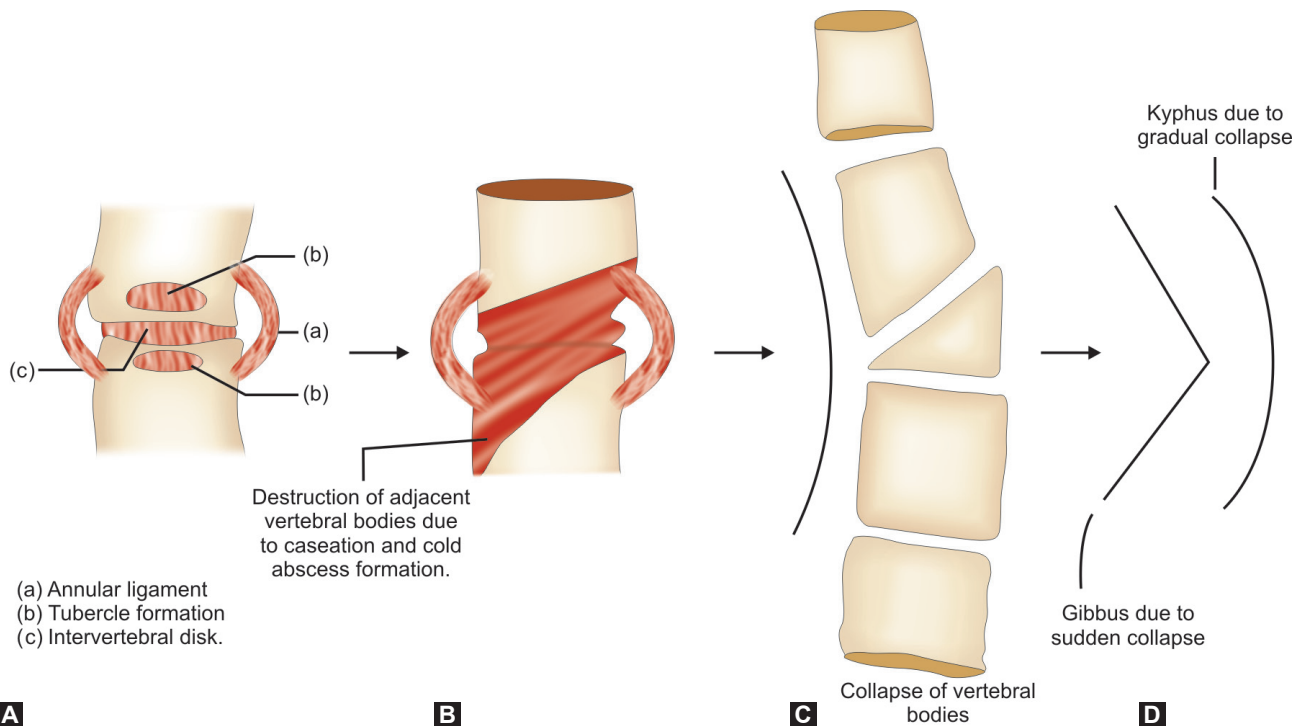
#### *Spread of cold abscess:*

The tubercular pus can track in any direction from the affected vertebra.

If it travels backwards, it may press upon the important neural structures in the spinal canal.

The pus may come out anteriorly forming the prevertebral abscess or on the sides of the vertebral body forming paravertebral abscess.

Once outside the vertebra the pus may travel along the musculofascial planes or neurovascular bundles to appear superficially at places far away from the site of lesion, e.g. retropharyngeal abscess, abscess in the neck and axilla, psoas abscess, gluteal abscess, etc.



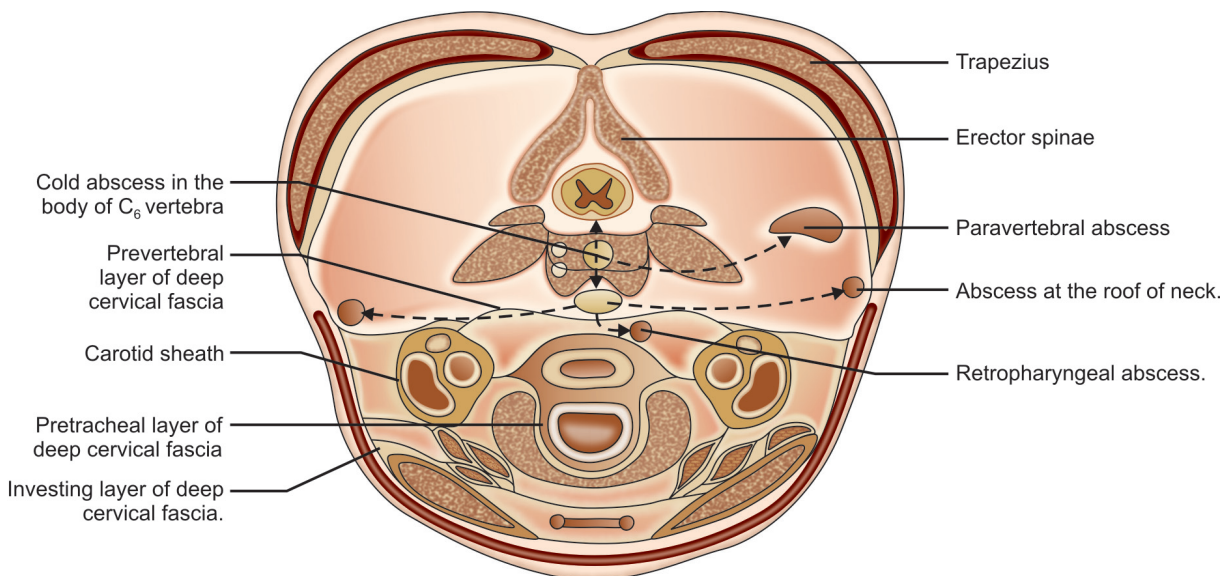
**Figs 62.1A to D:** Pathology of caries spine—Mechanism of formation of Gibbus and Kyphus

The details of the spread of abscess in relation to the level of vertebral involvement are as follows.

- I. In the cervical region the cold abscess may rupture either anteriorly or posteriorly. (Fig. 62.2A)
  - i. Anterior rupture—The pus may follow one of the following tracks deep to the prevertebral fascia.

- Upper cervical region, pus collects behind the pharynx as retropharyngeal abscess.
- Lower cervical region, cold abscess is formed behind the esophagus or trachea.
- Laterally, pus follows the course of anterior rami of spinal nerves to appear in the posterior triangle. The

- abscess forms at the posterior border of sternomastoid.
- Downwards, the pus collects behind the prevertebral fascia in the posterior mediastinum.
- The pus may travel along the axillary sheath, which is a tubular sheath of prevertebral fascia carrying the brachial plexus and subclavian artery



**392 Fig. 62.2A:** A - Pathway of spread of cold abscess developed in the cervical vertebra (C<sub>6</sub>) as indicated by arrows (dashed lines)

into the axilla forming an abscess there.

- ii. Posterior rupture—Pus enters the spinal canal and follow the anterior primary division of cervical spinal nerve to reach the posterior triangle to form an abscess there.

II. In the thoracic and lumbar region: (Fig.62.2B)

1. Pus may follow a thoracic nerve and presents in the thoracic wall as parasternal abscess anteriorly or paravertebral abscess posteriorly.
2. Pus may gravitate downwards and enter either of the three gaps behind the lateral, medial and median arcuate ligaments respectively.
  - a. Behind the lateral arcuate ligament it may reach the inguinal region along the subcostal and ilioinguinal nerves.
  - b. Behind medial arcuate ligament, pus enters the psoas sheath and forms a psoas abscess.

The psoas abscess may be huge and may come to the surface over a variety of places viz. over the lumbar region, in the iliac fossa, in the thigh below the inguinal ligament. Rarely may it extend along the

sciatic nerve of the thigh to appear in the popliteal fossa.

- c. Behind the median arcuate ligament pus comes in contact with the abdominal aorta and may follow its iliac branches producing the gluteal and ischiorectal abscess.

b. Pott's paraplegia: This is found in 20 percent of the cases and due to the following factors either alone or in combination.

1. Soft inflammatory material may compress the cord. This may be:
  - a. Cold abscess emerging from the back of the vertebral body.
  - b. Tuberculous granulation tissue.
  - c. Caseous mass.
2. Solid material may compress the cord or the cord may be stretched on it, e.g.
  - i. Bony ridge at the kyphus.
  - ii. Sequestered bone or disk or both.
  - iii. True pathological dislocation rarely.
3. Thrombosis of the anterior spinal artery by the inflammatory reaction causing infarction of the spinal cord.

### Clinical Types of Paraplegia

There are two types of Pott's paraplegia:

- a. Early onset: This type of paraplegia occurs during the active phase of disease and is

usually caused by tubercular pus, debris, bony sequestrum or caseous material pressing on the cord. This usually occurs within two years of onset of the disease.

- b. Late onset: Paraplegia occurring several years after the disease has become quiescent, usually at least two years after the onset of the disease. The cause of such paraplegia may be recurrence of the disease, internal gibbus, i.e. prominent anterior wall of the spinal canal in case of severe kyphosis or spinal cord ischemia. Prognosis of this type of paraplegia is bad.

### Clinical Features

This can be best remembered by the mnemonic DR. PAN.

D – Deformity—Gibbus and kyphosis due to collapse of the vertebral bodies.

R – Rigidity or restricted flexion of the spine. This is the earliest clinical sign. In the early stage, it is due to reflex muscular spasm. In later stages, fibrous or osseous ankylosis is the cause of rigidity.

P – Pain—Back pain is the commonest presenting symptom. There is both local and referred pain according to the nerve roots involved, e.g. pain in the arm (cervical roots), pain abdomen (dorsolumbar roots), sciatic pain (lumbosacral roots).

A – Abscess, i.e. cold abscess—The patient may first present with a swelling (cold abscess) in various parts as mentioned earlier. A detailed examination in such cases will reveal tuberculosis of the spine.

N – Neurological symptom, i.e. paraplegia. The patient may present with early or late onset paraplegia.

Besides the above, constitutional symptoms like fever, weight loss are rarely the only presenting symptoms.

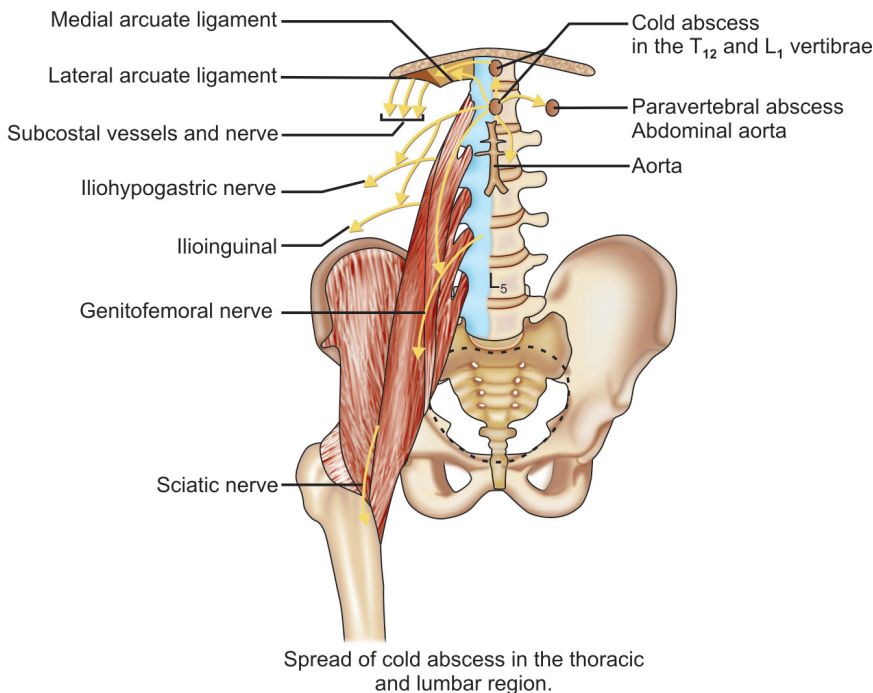
See also chapter 78 for long case on caries spine

### Investigations

#### Radiological Examination

1. Local X-ray—Both anteroposterior and lateral views should be taken. The features are:

- i. Diminution of the intervertebral space, the earliest and most constant sign in caries spine.



**Fig 62.2B:** Pathway of spread of cold abscess in the thoracic and lumbar region. (see text for description.)

- ii. Wedge shaped (Triangular) deformity of the vertebra with collapse above and below.
- iii. Presence of pre and paravertebral abscess.
2. CT scan—It may detect small paravertebral abscess not seen on a plain X-ray. Some prefer CT scan to X-rays to determine the clinical progress.
3. MRI—MRI helps in further delineation of the disease and helps to detect the cord compression.
4. Biopsy—A CT guided needle biopsy or open biopsy may be required in cases with doubtful diagnosis.
5. Other general investigations like X-ray chest, ESR, Mantoux test, ELISA test for detecting antitubercular antibodies may be carried out whenever required.

### Differential Diagnosis

1. Back pain
  - Traumatic—History of trauma present
  - No fever or abscess.
  - Prolapsed disk—Straight leg raising test will be positive.
  - Ankylosing spondylitis—Diffuse morning stiffness.
2. Neurological deficit
  - Spinal tumor
    - No back pain.
    - Present with gradually increasing neurological deficit.
  - Secondary metastasis in the spine
    - Presence of primary elsewhere
    - Back pain present.

### Treatment

#### Conservative treatment

- a. Chemotherapy – Previously three drugs viz. injection streptomycin 1gm1m daily for 3 months, 1NH orally 300mg daily and PAS (paraaminosalicylic acid) 15gm daily orally were given for 12 to 18 months.
- Nowadays with the introduction of rifampicin, ethambutol and pyrazinamide the duration of treatment has been reduced to 9 months.

Treatment with triple drug therapy consists of 1NH 5mg/kg/day, rifampicin 15mg/kg/day and ethambutol 25mg/kg/day orally for 9 months. If required one of the drugs may be substituted by pyrazinamide to have better

effect. Chemotherapy controls 90 percent of caries spine cases.

- b. Proper nutrition is to be maintained as malnutrition and ill health are two main predisposing factors for initiation of this disease.
- c. Rest to the spine – It serves two purposes viz.
  - i) Relieves pain and
  - ii) Provide favorable conditions for healing.

Rest to the spine is provided either by using a spinal brace or in the early stage the patient is asked to lie on a hard bed.

Immobilization by plaster of Paris (POP) caste is no more practised as it is very troublesome to the patient and immobilization without plaster gives the same result.

Immobilization has to be continued till the disease has been arrested which is confirmed when 3 consecutive monthly X-rays do not show any evidence of further destruction.

#### Surgical treatment

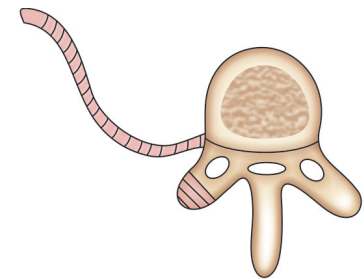
##### Indication

- a. Cold abscess or any other cause like severe pressure from a mechanical accident producing paraplegia.
- b. Resistance to chemotherapy.
- c. Kyphosis with several vertebral involvement, severe kyphosis, progressive kyphosis, etc.

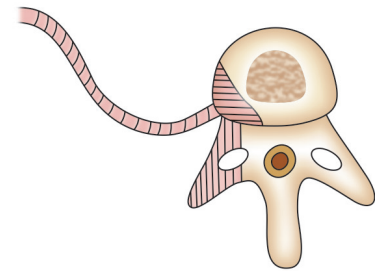
#### Types of Surgery

1. Costotransversectomy (Fig. 62.3A)—This is indicated for a tense paravertebral cold abscess. As the name suggests excision of the transverse process of the affected vertebra and about an inch of the adjacent rib to facilitate the drainage of abscess is done.
2. Anterolateral decompression (ALD) Fig. 62.3B – This is indicated when the compression on the cord is by solid agents. The structures removed in this procedure are posterior part of the rib, transverse process, pedicle and part of the vertebral body, anterior to the cord.

This is the surgery of choice for Pott's paraplegia. In this operation, the spine is opened from its lateral side and access is made to the front and side of the cord, thus it is called anterolateral decompression.



**A** Costotransversectomy



**B** Anterolateral decompression

**Figs 62.3A and B:** Operative procedures for Pott's paraplegia. The shaded areas indicate the structures to be removed

The cord is laid free of any granulation tissue, caseous material, bony space or sequestrum pressing on it. Bone graft may be inserted if needed.

### TUBERCULOSIS OF HIP

Hip is the most commonly affected part after the spine. Usually it occurs in children and adolescents but patients at any age can be affected.

#### Pathology

Tuberculosis of the hip is secondary to a primary lesion either in the lungs, intestine, or lymph glands.

- Organisms travel either through the hematogenous route or lymphatics to settle in
- i. Acetabular cartilage.
  - ii. Cartilage of head of femur.
  - iii. At the posteroinferior aspect of neck of femur and
  - iv. Greater trochanter.

Synovial membrane is the one most commonly affected. Here the tubercle formation causes synovial hypertrophy resulting in pannus (Granulation tissue) formation. This pannus destroys the articular cartilage resulting in the development of fibrous ankylosis of the hip.



Microscopy shows tubercle formation, giant cells and lymphocytes.

### Stages of Tuberculosis of the Hip

Tuberculosis of the hip has been arbitrarily divided into three stages in its clinical course.

Stage I – Stage of synovitis.

Stage II – Stage of arthritis.

Stage III – Stage of erosion.

1. *Stage of synovitis:* In this stage the synovial membrane is edematous and grossly hypertrophied. An infected effusion collects in the synovial cavity, which demands maximum capacity within the joint. This is obtained by the position of flexion, abduction and external rotation. It is also called the stage of apparent lengthening as the pelvis is tilted down. On measuring the true limb lengths, the two limbs are found to be equal but the apparent length is more than true length.
2. *Stage of arthritis:* In this stage, synovial fluid is gradually absorbed and articular cartilage is destroyed by tubercular granulation tissue. This produces frictional pain which is relieved by nature's protective spasm of the adductors and flexors (iliopsoas) of hip.

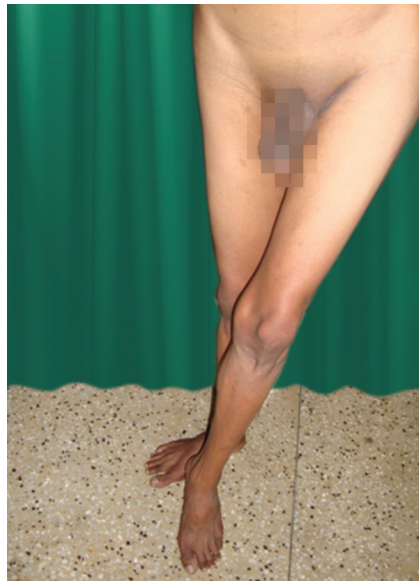The joint space becomes minimum and the hip assumes the position of flexion, adduction and internal rotation.

At night during sleep, the spasm is relieved, frictional pain appears and the child cries. This phenomenon is known as night cry. Very often pain is referred to the knee via the obturator nerve.

It is also called the stage of apparent shortening as the pelvis is tilted upwards, to compensate for the adduction. On measuring the true limb lengths the two limbs are found to be equal, but the apparent length is less than the true length.

3. *Stage of erosion:* In this stage, the attitude of the second stage is exaggerated. The cartilage is destroyed and the head and / or the acetabulum is eroded. There may be a pathological dislocation or subluxation of the hip. Due to these effects there is a true shortening with considerable restriction of hip movements. (Fig. 62.4)

See also the long case of tuberculosis of Hip, chapter 78.



**Fig. 62.4:** Stage of erosion (True shortening of the left lower limb due to tuberculosis of left hip)

### Associated Changes in the Pelvis and Spine

Stage I : To correct abduction pelvis is tilted downwards and there is scoliosis with convexity towards the sound side.

Stage II : To correct abduction, pelvis is tilted upwards, and there is scoliosis with convexity towards the sound side.

### Clinical Features

- Tuberculosis of the hip is common in the first three decades of life and more prevalent in males.
- The patient presents with painful limp and is the most common earliest symptom. The gait is called antalgic or painful gait.
- There is cough, loss of appetite, weakness and apathy.
- Discharging sinus—In advanced stage there is evidence of cold abscess and discharging sinus.
- Movement—Practically all movements of the affected hip are restricted.
- Trendelenburg test and gait—May be present in advanced cases.

### Investigations

1. Local X-ray:
  - In the stage of synovitis, no radiological abnormality is seen.

- In the established case, the findings are:
  - i. The joint space is diminished because of destruction of articular cartilage.
  - ii. Head is not flattened as in Perthes, disease. It maintains its rounded contour.
  - iii. There may be irregularity of acetabular margin.
  - iv. In advanced stage of posterior dislocation of hip, Shenton's line on X-ray is broken.
- 2. Other investigations: These are the same as described in tuberculosis of spine viz. X-ray chest, ESR, Mantoux test, ELISA test.

### Treatment

Tuberculosis is no more a dreadful disease as it was before because the diagnosis is made earlier, the treatment begins early and the results are also good.

Antituberculosis drugs viz. 3 drug regimes, i.e. isoniazid, rifampicin and ethambutol are started from the very beginning.

### Immobilization

The affected hip, if in the stage of synovitis, is put to rest by immobilization using below knee skin traction or Thomas splint. In addition to providing pain relief, this also corrects any deformity by counteracting the muscle spasm.

Repeated radiological check up is done. Traction is continued for 6-10 months, then the patient is asked to move on a crutch, weight bearing may be allowed after a year.

### Surgery

The operative treatment is indicated when articular cartilage (stage II and III) is involved producing significant joint damage or subluxation. The following surgical procedures are undertaken.

- a. Synovectomy—If the synovial membrane is markedly thickened, and inflamed, synovectomy and joint toilet may be helpful.
- b. Arthrodesis—This means operative fusion of the joint to provide the patient, with a painless, stable although stiff joint. See also chapter 78 (Examination of hip joint and long case on tuberculosis of hip).

## TUBERCULOSIS OF KNEE

The knee is a common site of tuberculosis after the spine and hip. The knee joint being superficial pain and swelling appears early and diagnosis is frequently made before much destruction of the joint.

This swelling is known as “white swelling” of the joint as it does not show redness as seen in acute inflammatory lesion.

### Pathology

Like tuberculosis of hip, it is also secondary to a primary lesion either in the lungs, intestine or lymph glands.

The disease usually begins in the femoral or tibial condyles or more commonly in the synovial membrane leading to hypertrophy of the synovium.

In the early stages the disease may be confined to the synovium, without significant damage to the joint. In later stages, the articular cartilage and bone are destroyed irrespective of the site of origin. In long-standing cases, destruction of the ligaments produces subluxation of the tibia. The tibia flexes, slips backwards and rotates externally on the femoral condyles (Triple displacement). In the

late stage one may feel cold abscess and even later sinuses can be seen.

### Clinical Features

The disease is insidious in onset, showing systemic and local features of tuberculosis. The patient, usually in the age of 10-25 years, presents with complaints of pain and swelling in the knee. Subsequently the pain increases in intensity and the knee takes an attitude of flexion. The child starts limping.

On examination there is swelling and effusion of the joint. There is atrophy of the thigh muscle and the movements of the joint are restricted.

In the advanced stage of the disease, triple displacements are seen.

### Investigations

1. Local X-ray—In a case of synovial tuberculosis it is essentially normal, except a soft tissue shadow corresponding to the distended knee.

In the arthritic stage, the joint surfaces may be eroded; joint space may be diminished or completely lost. In advanced stages triple displacement will be evident in X-ray.

2. Biopsy is required in doubtful cases and gives the definitive diagnosis. Other investigations are done in the lines already discussed in tuberculosis of hip.

### Treatment

I. *Conservative*: This is indicated in the stage of synovitis and consists of chemotherapy traction and joint aspiration.

Skin traction helps to prevent triple displacements.

II. *Operative treatment*: The following operative procedures may be required in suitable cases.

a. Synovectomy—It may be required in the synovial stage when the disease is not responding favorably. Arthrotomy and partial synovectomy are done.

b. Joint debridement—In the stage of early arthritis, synovectomy joint debridement and curettage of the juxta-articular foci are carried out.

c. Arthrodesis—In advanced arthritis arthrodesis is the treatment of choice and the indications are triple displacement, gross instability and painful ankylosis after earlier synovectomy.

## Perthes Disease

### ➤ Perthes disease

#### **PERTHES DISEASE** (Syn—Coxa Plana, Pseudocoxalgia, Osteochondritis of the Femoral Capital Epiphysis)

#### Definition

It is crushing osteochondritis of the epiphysis of femoral head. It was first described by **Legg Calve Perthes** in 1910, hence the name.

Epiphyseal head of femur bears the weight of the body and accepts the crushing force. There is no inflammation. Hence, the term osteochondritis is a misnomer. Better term should be osteochondrosis (Developmental error or destruction of epiphysis).

The femoral head changes its shape and becomes flattened instead of being round.

#### Surgical Anatomy

Vascular supply of femoral head (Fig. 63.1).

1. For the first 3 to 4 years of life, the main blood supply to the femoral head comes from metaphyseal vessels which cross the future epiphyseal growth plate.
2. A portion of blood supply comes from the capsular or retinacular arteries. There is virtually no blood supply through the ligamentum teres femoris.
3. At about the age of 7 to 8 years, the blood vessels in the ligamentum teres femoris develop.
4. Between the ages of 4 and 8 years, the blood supply from the metaphysis is curtailed, because the femoral neck is

developing at this stage and the major part of the blood is exhausted in it.

At this age, the epiphysis is nourished only by the retinacular vessels mainly lateral epiphyseal vessels which are the branches from the medial circumflex femoral artery and run in the retinaculæ, longitudinal folds of articular capsule. These vessels are therefore obviously susceptible to obliteration by increased intracapsular pressure, e.g. effusion in the joint.

#### Etiology

Vascular Jeopardy— This is the most important factor. There is avascular necrosis of the ossific nucleus of femoral head, which results from the already existing deficient blood flow due to anatomic reasons (mentioned above) and a precipitating factor which cuts off even

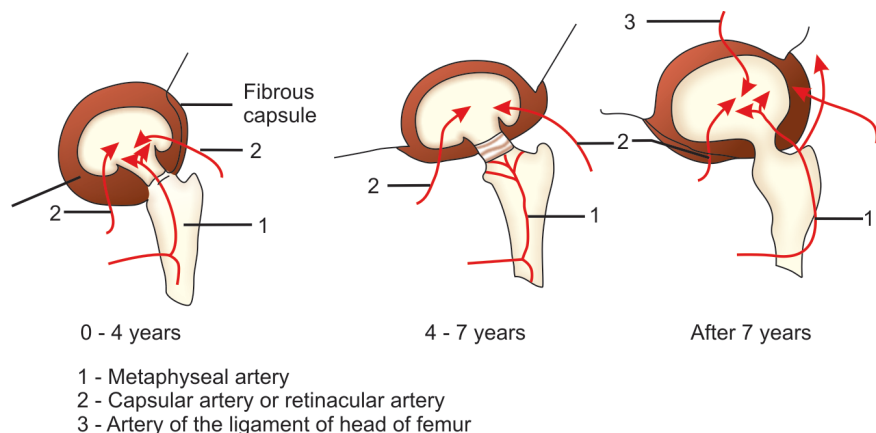
this deficient flow. The precipitating factors are:

- a. Traumatic effusion—History of trauma can be elicited in more than half of the cases of Perthes disease.
- b. Inflammatory condition—Any inflammatory condition of the hip, e.g. septic arthritis, synovitis may lead to this condition.
- c. Epiphyseal dysplasia—Irregular ossification as happened in epiphyseal dysplasia may cause this condition.
- d. A few medical conditions like rickettsial infections have been blamed with little definite evidence.

#### Pathology

Pathology of Perthes disease is best described under two stages viz.

Stage I – Stage of avascular necrosis.



**Fig. 63.1:** Blood supply of head of femur in childhood

Stage II – Stage of regeneration.

### Stage I—Stage of Avascular Necrosis

In this stage the ossific nucleus undergoes avascular necrosis. So the head of the femur fails to grow and on the X-ray, it looks flat and smaller than that of the opposite side. However the cartilaginous part of the head continues to grow, as it is nourished by the synovial fluid. So the small dense head is covered with the well-developed cartilage. In X-ray this is evident by increase in joint space.

### Stage II—Stage of Regeneration

During this stage, blood vessels from the neck of the femur begin to grow into the dead head. As a result, necrosed bone is washed off and new soft bone is laid down. As new blood vessels virtually creep into the dead head the process is called regeneration by creeping substitution.

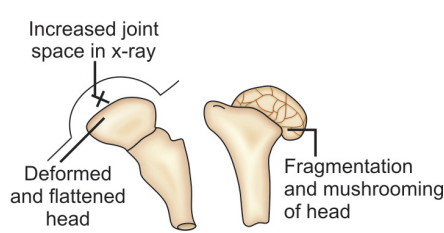
As the neck and head become hypervascular, they become soft and the neck shaft angle diminishes due to weight bearing which results in a coxa vara.

The process of regeneration starts at the periphery and proceeds to the center and ultimately the whole of the bony head are regenerated.

Perthes disease as such, is therefore, harmless because complete regeneration of the head occurs in about 3 to 4 years time. But the permanent flattening of the head will definitely cause an early osteoarthritis of the hip in future, which is in fact the real danger.

### Clinical Features

- The disease occurs most commonly between 5 and 10 years of age and is more frequent in children who had a low birth weight. It is common in boys.
- Unlike tuberculosis, the constitutional symptoms like fever, malaise, loss of



**Fig. 63.2:** Radiological features in Perthes disease

appetite, etc. are absent and the child remains playful.

- Movements—As there is coxa vara deformity, abduction is restricted.
- Pain in the hip may be present but it is mild and intermittent and there is no night cry as in tuberculosis.

### X-Ray

The X-ray findings are quite characteristic (Fig. 63.2).

- a. Transverse diameter is bigger than the vertical diameter of head, which remains partially uncovered.
- b. There is flattening of the head and Shenton's line is broken.
- c. Joint space is increased and neck of femur is broad.

### Investigations

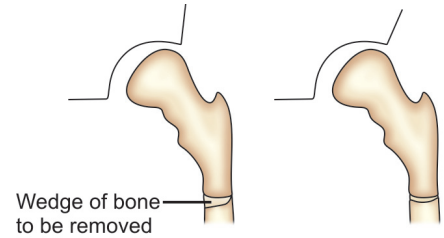
Investigations are important, to differentiate this disease from tuberculosis of the hip. In tuberculosis of hip.

1. Mantoux test—is often positive and ESR is raised.
2. X-ray—the joint space is diminished. The head is rarefied but its shape and size remain unaltered.

### Treatment

#### Aim of Treatment

As the disease is self-limiting, the whole idea behind treatment is to keep flattening and distortion of the head to a minimum



**Fig. 63.3:** Adduction osteotomy of femur for containment of head of femur.

and thereby to prevent early and severe osteoarthritis.

When the child complains of pain, he should be put to bed and skin traction is applied to the affected leg in the position of flexion, abduction and external rotation for 6 to 10 months. Repeated X-rays are done to assess the development of head.

Containment may also be achieved surgically by means of osteotomy (containment osteotomy) just below the greater trochanter and the shaft is so angled that it is adducted about 20 degrees in relation to the proximal fragment. Union occurs in 5 to 6 weeks (Fig. 63.3) see also the long case Perthes Disease in chapter 78.

### Some Other Forms of Osteochondritis

#### Definition

Osteochondritis is a disease of epiphysis beginning as necrosis and followed by healing.

Some common examples of osteochondritis other than Perthes disease are as follows.

1. Kohler's disease—Primary aseptic necrosis of the tarsal navicular bone.
2. Kienbock's disease—Primary aseptic necrosis of lunate bone.
3. Osgood—Schlatters disease – Primary aseptic necrosis of Tibial tubercle.
4. Freiberg's disease—Primary aseptic necrosis of the head of second metatarsal.
5. Calve's disease—Primary aseptic necrosis of central bony nucleus of vertebral body.

## Congenital Dislocation of Hip

- Definition
- Etiology
- Pathological anatomy
- Clinical features
- Investigations
- Treatment

### DEFINITION

Congenital dislocation of hip (CDH) is a congenital condition, where the hip is dislocated posteriorly. One in four cases, the dislocation is bilateral. If recognized and treated early in the neonatal period most hips will develop normally.

### ETIOLOGY

The exact etiology is not known but the following factors appear to be important.

#### Bony Dysplasia

Acetabulum develops at the junction of triradiate cartilage. The growing head impinges at this point to form the cavity.

If the head is rudimentary and ill-developed and the fusion of the triradiate cartilages improper, then the cavity does not develop properly.

Head is pushed upwards to lie on the dorsum ilii, whenever any weight transmits upwards through the shaft.

Thus, the term developmental dysplasia of hip (DDH) is preferred to congenital dislocation of hip (CDH).

#### Joint Laxity

CDH is five times more common in females. This may be due to the hormone 'relaxin' which enters the fetus crossing the placental barrier from the mother. It is usually secreted

shortly before delivery by the mother. When the fetus is a female, relaxin acts on the fetal joints in the same way as it does on those of the mother. This produces joint laxity and thus dislocation.

#### Breech Malposition

The incidence of an unstable hip is about 10 times more in newborns with breech presentation than those with vertex presentation. In one series 16 percent of CDH were breech born. In another study 50 percent of breeches had CDH.

#### Familial

Ten times higher incidence of CDH than general population is seen in siblings of affected children. There may be familial joint laxity.

### PATHOLOGICAL ANATOMY

This may be described under two headings viz.

1. Changes in the bones.
2. Changes in the soft tissues.

#### Changes in the Bones

- a. Acetabulum
  - The acetabular cavity is shallow that is, not able to contain the cartilaginous femoral head.
  - Inverted limbus—The fibrocartilaginous labrum of the acetabulum (limbus) may be folded into the cavity of the acetabulum (inverted limbus).

- Fibrofatty tissue lies in the floor of the acetabular cavity to make it more shallow.
- b. Head of the femur is small and rudimentary.
- c. Neck of femur is anteverted even to 90°. Normally the neck is 20° anteverted.
- d. Dorsum ilii—There may be a shallow depression known as wandering acetabulum on the dorsum ilii in the advanced stage.

#### Changes in the Soft Tissues

- a. Capsular ligament—The capsule is stretched and elongated. The margin of the capsule is attached to the fibrofatty tissue instead of bony attachment.
- b. The muscles around the hip, especially the adductors are thrown into spasm, and finally undergo adaptive shortening.

### CLINICAL FEATURES

Girls are affected five times more commonly than boys. In one fourth of all cases both hips are affected.

Diagnosis of CDH is easy in an older child but may be very difficult in young children, especially during infancy. This is because of subtle clinical findings and difficulties in interpreting X-rays of these children.

The following are the salient clinical features at different positions viz.



- When the patient lies on bed.
- When the patient stands.

### Patient Lying on Bed

The features are

- The baby cries during change of napkin when the thigh is abducted, because the hip is adducted and internally rotated by the spasm of the muscles, especially the adductors.
- There is asymmetry of the labiofemoral fold in unilateral cases.

### Ortoloni Test

There is a clicking sound when the 90° flexed hip is gently abducted, because the head slips into the acetabular cavity and makes the sound.

### Telescopic Test

The head can be manually reduced and taken out repeatedly.

### When the Patient Stands

The clinical features are:

- Limping.
- Trendelenburg sign is positive, when the patient stands on the affected leg, the inferior gluteal fold of the healthy side sags down. In normal cases, when one stands on one leg both inferior gluteal folds are at the same level (Fig. 64.1A).
- Trendelenburg gait: This is a lurching movement typical of the disease and the patient lurches on the healthy side. In bilateral cases there is waddling gait, i.e.

alternate lurching on both sides, simulating the movement of a duck.

## INVESTIGATIONS

### X-rays

In a child below the age of one year, it is difficult to diagnose a dislocated hip on plain X-rays because the epiphysis of femoral head is not ossified. Von Rosen's view may be helpful in diagnosis.

In an older child, the following are the important findings:

- Acetabular angle is increased. Acetabular angle is the angle between the roof of acetabulum and the transverse line passing through the center of the triradiate cartilage. Normally the angle is about 22°. In CDH the angle is 45° or more (Fig.64.1B).
- Perkin's line (Fig.64.1C): On each side a line is dropped vertically downwards from the upper outer end of the acetabulum. A transverse line is now drawn, joining the central points of the triradiate cartilage of the two sides and this is prolonged outwards.
  - In a normal case, the epiphysis of femoral head lies medial to the vertical line and below the transverse line.
  - In case of CDH
    - In earlier cases, the head lies lateral to the vertical line but still below the transverse line.
    - In more advanced cases, the head lies lateral to the vertical line and above the transverse line.

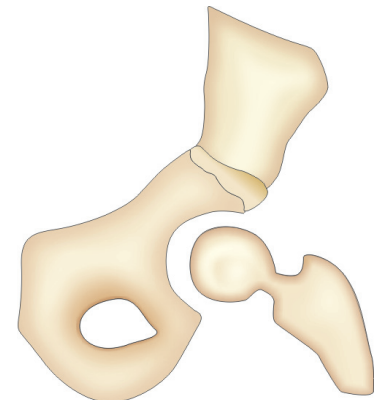


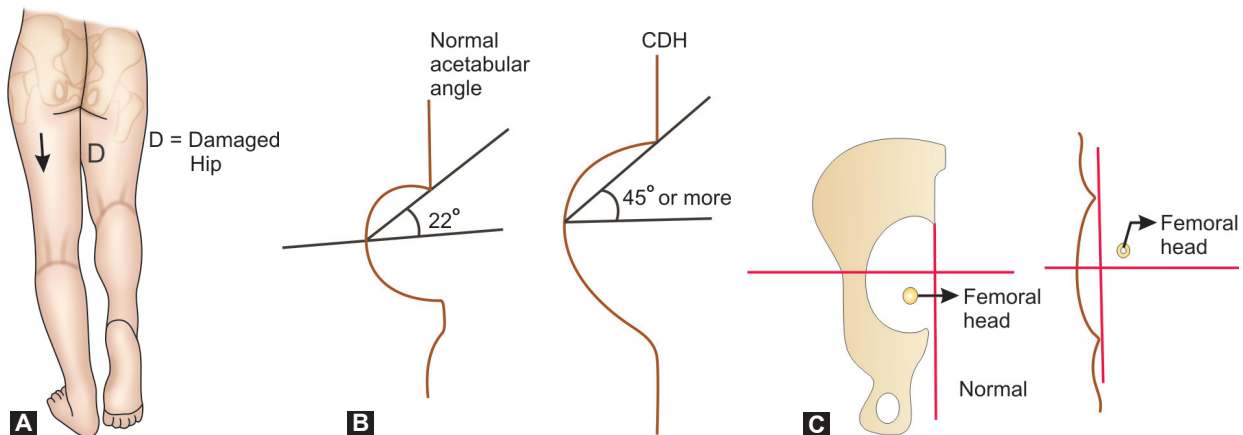
Fig. 64.2: Innominate osteotomy

- There is a break in Shenton's line. This line consists of a continuous curve, produced by the inferior margin of the superior pubic ramus and the medial cortex of the femoral neck and shaft.

## TREATMENT

The treatment of CDH varies according to the age at which the patient presents as described below:

- Birth to 6 months—The diagnosis is made before weight bearing. Here weight bearing means when the child begins to crawl at the age of 6 months.
  - The femoral head is reduced into the acetabulum by closed manipulation and maintained with plaster cast or the Denis – Brown splint may be used to keep the thighs in abduction.
- 6 months to 6 years—It may be possible upto 2 years to reduce the head into



Figs 64.1 A to C: (A) Trendelenburg sign, (B) Increased acetabular angle in CDH, (C) Perkin's line

the acetabulum by closed methods. After 2 years it is unwise to attempt closed reduction because the soft tissues around the hip become tight and forcible reduction of such a hip will produce avascular necrosis of the femoral head. In these cases reduction is achieved by open methods and an additional corrective osteotomy of the femur may be required. If the head though reduced, is poorly covered it should be provided with a bony roof by innominate osteotomy.

Innominate osteotomy (Fig. 64.2)—An osteotomy is made just above the acetabulum running transversely. The lower fragment is levered down to form the acetabular roof.

A wedge-shaped graft from the anterior part of the iliac blade is inserted into the osteotomy. Postoperative immobilization in a hip spica for 6 weeks, followed by long leg plaster for 4 weeks is required. Once union has been achieved in the area of osteotomy and bone graft, full weight bearing is permitted.

- After the age of 6 years:
  - a. For unilateral cases operative reduction is feasible at least up to the age of 10, as in the former group. It may be necessary to combine this with corrective osteotomy of the femur or innominate osteotomy of pelvis.

In older children no treatment is required till osteoarthritis develops in later life as the untreated hip is mobile and painless.

- b. With bilateral dislocation the deformity is symmetrical and therefore, less noticeable. The risk of operative intervention is also greater because failure on one or other side results in asymmetrical deformity. Therefore most surgeons avoid operation unless pain or deformity is severe. The untreated patient waddles throughout life and may be uncomplaining. However if disability becomes severe hip replacement may be justified.

# Chapter 65

## Congenital Talipes Equinovarus and Other Deformities of Foot

➤ Deformities of foot

➤ Talipes equinovarus

➤ Congenital talipes equinovarus

### DEFORMITIES OF FOOT

#### Surgical Anatomy

Foot is formed by articulations of tarsals viz. calcaneus, cuboid, talus, navicular and the cuneiforms (medial, intermediate and lateral), metatarsals and phalanges (Fig. 65.1).

For descriptive purposes, the foot is often divided into hind foot, midfoot and forefoot.

The hindfoot is the part consisting of talocalcaneal (subtalar) and calcaneocuboid joints. Midfoot comprises of talonavicular and naviculocuneiform joints. The forefoot is cuneiform-metatarsal and other joints beyond it.

The ligaments related to the various deformities are: (Fig. 65.1)

- Deltoid ligament — This is the medial collateral ligament of the ankle. It has a superficial and a deep part.
- Spring ligament — This is the plantar calcaneonavicular ligament which joins the anterior end of the calcaneum to the navicular bone.
- Capsular ligaments — These are formed by the thickened portions of the capsule of the talonavicular, naviculocuneiform and cuneiform-metatarsal joints. These ligaments are important structures in the pathology of CTEV (Congenital talipes equinovarus).
- Interosseous ligament — This ligament is between the talus and calcaneum joining their apposing surfaces.
- Plantar ligaments (long and short) — These are ligaments extending from the plantar surface of the calcaneum to

the cuboid giving support to the lateral longitudinal arch of the foot.

The important tendons related to the pathology of CTEV are those of tibialis posterior, flexor digitorum longus and flexor hallucis longus of which the tendon of tibialis posterior has its main insertion on the navicular and is the most important one.

The various deformities of foot are:

- Pes cavus or claw foot.
  - Pes planus or flat foot.
  - Talipes or clubfoot.
  - Splay foot—The transverse arch is flattened.
- a. *Pes cavus*: When the longitudinal arch of foot is exaggerated or high up, it is known as pes cavus.

The condition is homologous to claw hand and is similarly caused by paralysis of interossei and lumbrical muscles as in poliomyelitis, Friedreich's ataxia, etc. Many cases are, however idiopathic.

The deformity consists of dorsiflexion of the metatarsophalangeal joints and plantar flexion of the interphalangeal joints.

- Pes planus*: This is a condition in which there is flattening of the longitudinal arch of the foot. It is usually associated with a valgus deformity of the foot that is, twisting outwards.

At birth the foot is always flat; the arches of the foot develop only when the child stands. The arches are maintained by:

- Shapes of the bones — Bones are shaped at different angles to form and maintain the arch.
- Ligaments—Spring ligament, plantar ligaments and transverse metatarsal ligaments.
- Muscles of the sole and calf, especially the tibialis posterior and peroneus longus.
- Plantar fascia.

#### Types

- Congenital flat foot occurs when the arches have failed to develop.
- Infantile flat foot — This is physiological and all infants have flat foot for a year or two.
- Traumatic — This is caused by fractures which abolish the arch, e.g. Pott's fracture, fracture of the calcaneum, etc.
- Idiopathic — This is the commonest type to cause strain.
- Spastic flat foot — Caused by spasmodic contraction of the peroneal muscles

#### Effects

- Neuralgic pain due to pressure upon the nerves.
- A shuffling gait.
- Development of tarsal osteoarthritis due to loss of shock absorbing function and malalignment of the tarsal bones.

#### Treatment

- Arch supports and special shoes with medial heel wedges are worn.
- Exercises to improve function of the muscles of the sole and calf.

- c. *Talipes*: In normal condition, when the foot remains plantigrade, the sole of the foot remains parallel to the ground. When it does not remain plantigrade the condition is known as talipes deformity. This may be of the following types:
1. Talipes equinus (derived from equine, i.e. a horse that walks on toes) — Heel is raised.
  2. Talipes varus — Foot is inverted.
  3. Talipes valgus — Foot is everted.
  4. Talipes calcaneus — (Reverse of equinus) — Toes are raised and the foot rests on the heel.
  5. Talipes equinovarus — Combination of equinus and varus deformities (commonest).
  6. Talipes equinovalgus — Not common.
  7. Talipes calcaneovalgus — This is a combination of calcaneus and valgus deformities.
  8. Talipes calcaneovarus — Not common.

- Injury to lateral popliteal nerve.
- ii. Muscular
  - Dystrophy of peroneal muscles, in which unopposed action of the invertors and flexors causes this deformity.
  - Spastic type.
- iii. Traumatic — Postburn contracture.

2. *Joints*
  - a. Ankle joint — There is plantar flexion.
  - b. Talocalcaneonavicular joint undergoes inversion (varus).
  - c. Midtarsal and tarsometatarsal joints — there is adduction.
3. *Bones*
  - a. Subluxation of the navicular bone medially on the head of talus is the crucial component in the pathology of CTEV.
  - b. Head and neck of talus deviated medially.
  - c. Calcaneum is small and rudimentary and is rotated medially.

### CONGENITAL TALIPES EQUINOVARUS (CTEV)

#### Etiology

The exact etiology is not known but the following factors are important.

- a. Genetic predisposition—It may occasionally be familial.
- b. Mechanical factors, e.g. malposition *in utero*.
- c. Dysplasia — Developmental defect affecting the ligaments on the medial side of the foot.
- d. Drugs, e.g. thalidomide.

#### Pathological Anatomy (Figs 65.1A and B)

Changes occur in muscles, bones and joints as described below.

1. *Muscles* — The invertors tibialis posterior and anterior are contracted. Evertors like peroneus longus and brevis are stretched (paralyzed or weak). Tendoachilles is contracted, so the heel is raised.
  - Medial ligaments are more contracted than lateral ones.
  - Subcutaneous tissues on the medial side adjoining the heel are contracted.

### TALIPES EQUINOVARUS

It is deformity of the foot where the heel is raised (equinus) and there is inversion (varus) of foot. The combination of two deformities gives the name equinovarus.

#### Causes

- I. Congenital — Majority of talipes equinovarus are of congenital variety. The etiology is described below.
- II. Acquired:
  - i. Paralytic
    - Anterior poliomyelitis

#### Clinical Features

- Boys are affected twice as often as girls.
- In 1/3rd of cases, the condition may be bilateral.
- The patient presents with the deformity of foot which itself is diagnostic (Fig. 65.2).

#### Treatment

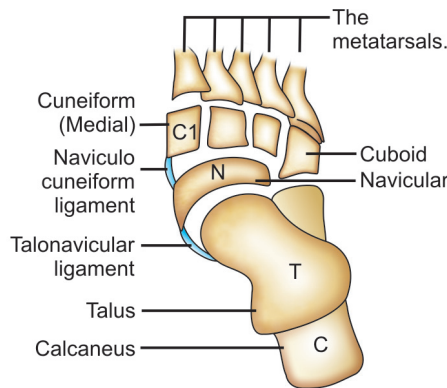
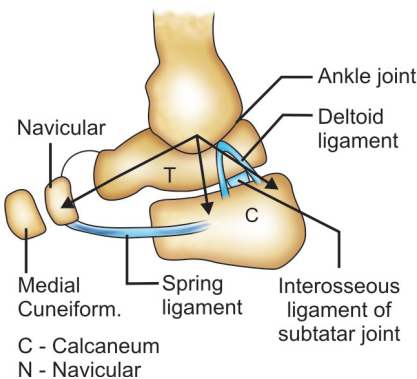
Before any treatment, it must be assessed if the foot is pliable or rigid.

If the foot is pliable, the deformity can be corrected easily without resistance.

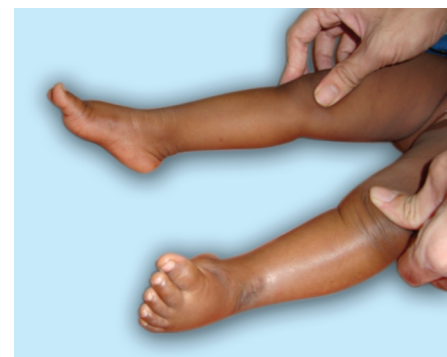Rigidity means there is difficulty in correction and great resistance is felt during correction.

Treatment also depends on the age of presentation. Ideally the treatment should start within one week of birth. The earlier the treatment is started, the easier it is to correct the deformity.

The patients are divided into the following groups for treatment.



**Figs 65.1A and B:** Joint and ligaments of foot



**Fig. 65.2:** Congenital talipes equinovarus (CTEV)

a. 0 to 2 months age

i. Correction of deformity: Each component of the deformity is corrected in the following order.

First – Adduction of forefoot relative to the hindfoot is corrected, then inversion correction, i.e. inversion of foot with sole directed medially is corrected, finally the equinus (plantar flexion) deformity is corrected.

It may require three to six manipulations without anesthesia as the foot is almost always pliable.

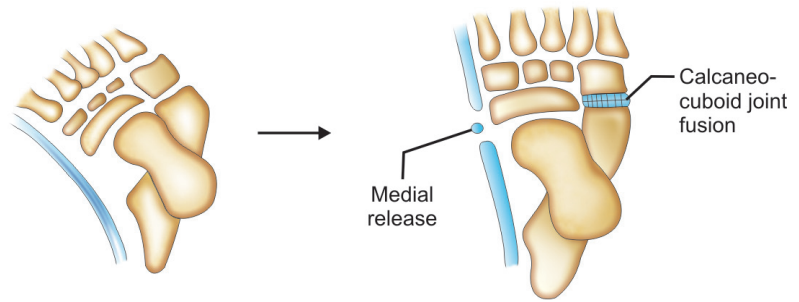
ii. Maintenance of correction: The corrected position of the foot is held preferably by a plaster of Paris (POP) caste in between manipulations.

The plaster cast must extend to the upper thigh with the knee flexed at right angles, otherwise the infant is able to draw the foot up inside the plaster cast (Fig. 65.4). The POP caste is kept for 3 to 6 weeks or more and it must be changed every week at first but may be extended two to three weeks later on for 6 months.

Success rate of serial manipulation and casting ranges from 15 to 80 percent.

If correction is achieved in first 6 months of age, it can be maintained by

Denis-Brown night splints and some modified shoes, known as CTEV shoes during walking in day time.



**Fig. 65.4:** Medial release operation in CTEV with fusion of calcaneus cuboid joint (Evan's operation)

Splintage may need to be continued till puberty.

b. After 2 months to below 5 years: Correction is done under general anesthesia in all cases. The scheme of treatment is as follows:

i. Footispliableoreasy–Immobilization is done in POP cast after correction of deformity and it is maintained in over corrected position. The other conditions for maintenance are the same as mentioned above (Fig. 65.3).

ii. If the foot is rigid that is, the calf muscles are wasted, the heel is very small and rudimentary and correction cannot be achieved within three weeks of manipulation, early operation is justified rather than violent manipulation, e.g. medial soft tissue release by Brochman's operation.

Brochman's operation: Under general anesthesia, soft tissues on the medial side of foot are excised. Along with this

posterior capsulotomy (cutting the posterior capsule of ankle joint) is done.

Foot is kept in corrected or over corrected position for 3 to 6 weeks.

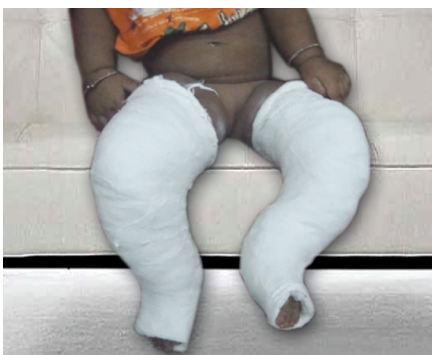c. 5 to 10 years: At this age this deformity is almost always associated with bony deformity. So some sort of bone operation is usually required in case of rigid foot.

I. If the foot is pliable the following soft tissue operations can be done either singly or in combination depending upon the severity of each case.

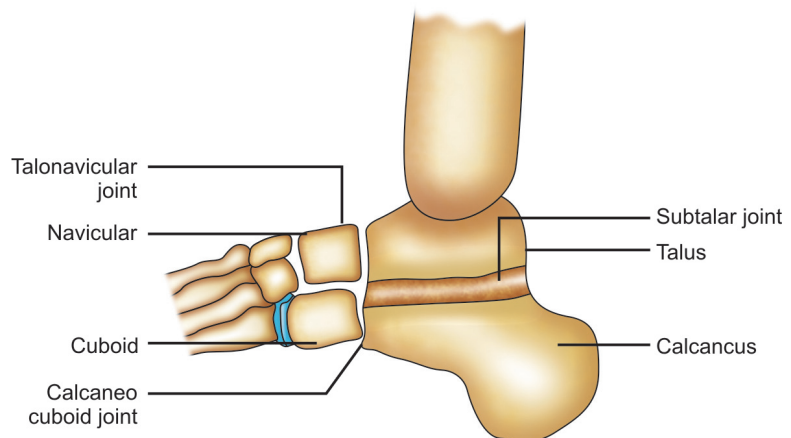
- a. Brochman's operation as above.
- b. Transfer of tibialis anterior tendon to the outer side of the foot.
- c. Lengthening of a short tendoachilis by Z plasty

II. In case of rigid foot, the following operations are done.

- a. *Evan's operation*: This is the main operation required in this group. It consists of arthrodesis of calcaneocuboid joint with thorough soft tissue release on the posteromedial



**Fig. 65.3:** POP cast applied in a child with bilateral CTEV.



**Fig. 65.5:** Triple arthrodesis



aspect of foot with fusion of the calcaneocuboid joint, the lateral side of the foot thus, resulting in gradual correction of the deformity. (Fig 65.4)

b. *Dwyer's osteotomy*: This consists of osteotomy of the calcaneum performed in order to correct varus (inversion) deformity of the heel. A wedge or bone graft is inserted to the medial aspect of the calcaneum.

d. *Above 10 years*

i. Triple arthrodesis is done. In this operation, suitable wedges are taken out from subtalar, calcaneocuboid and talonavicular joints to correct the deformity (Fig. 65.5).

This operation is done after 12 years of age as the bones remain cartilaginous before this age and it is difficult to get arthrodesis successful.

ii. External fixator — By Illizarov's technique or JESS method as popularized by Dr BB Joshi from Bombay based

on the same principles as the former technique.

Illizarov technique, the different components of the deformity are corrected by gradual stretching with the help of an external fixator. Once correction is achieved, it is maintained by plaster casts.

This technique is indicated in neglected and recurrent (after operation) cases of clubfoot. The treatment plan of CTEV can be summarized as follows (Fig. 65.6).

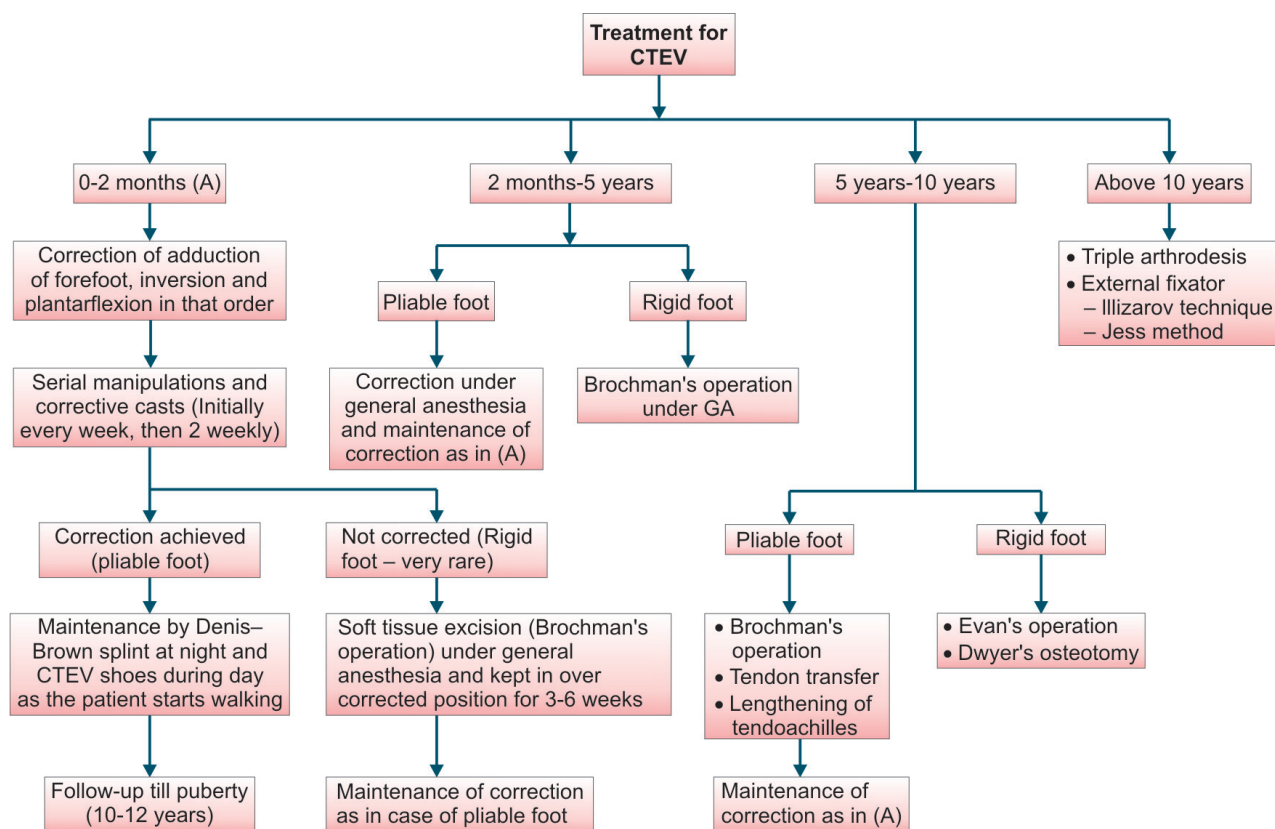


Fig. 65.6: Treatment plan for CTEV

# Chapter 66

## Miscellaneous Affections of the Soft Tissues

- Bursitis
- Tenosynovitis
- Dupuytren's contracture
- Mallet finger
- Trigger finger
- De Quervain's disease
- Ganglion
- Compound palmar ganglion
- Carpal tunnel syndrome
- Tennis elbow
- Golfer's elbow
- Plantar fasciitis
- Marrant Baker's cyst
- Ruptured biceps tendon
- Frozen shoulder

### BURSITIS

A bursa is a fibrous sac lined with synovial membrane and containing a small quantity of synovial fluid. Bursa is found between.

1. Tendon and bone
2. Skin and bone
3. Muscle and muscle.

Their function is to facilitate movement without friction between these surfaces.

Bursitis means inflammation of a bursa, which may be an anatomical or adventitious one.

Anatomical bursae—These are normally situated bursae.

Adventitious bursa—These are bursae developing from connective tissue secondary to prolonged pressure over bony prominences, where no bursae previously existed, e.g. dorsum of foot in neglected CTEV; a bursa between gluteus maximus and ischial tuberosity (weaver's bottom).

Some commonly seen bursitis are given below.

1. Infrapatellar bursitis (Clergyman's knee).
2. Prepatellar bursitis (Housemaids knee).
3. Olecranon bursitis (Students elbow).
4. Ischial bursitis (Weaver's bottom).
5. Semimembranous bursitis.

### Types

1. Irritative bursitis: This is caused by excessive pressure or friction with long continued inflammation, the sac gets thickened and may cause pressure erosion on the adjacent bone.
2. Infective bursitis: It is the less common type and commonly occurs in the prepatellar or trochanteric bursa. A bursa may be infected with pyogenic, tubercular or syphilitic infection.

### Treatment

- a. Most cases of irritative bursitis respond to analgesics, rest to the part and removal of the causative factor i.e. friction or pressure. In more resistant cases, the sac is infiltrated with hydrocortisone. Rarely excisions of the bursa are required.
- b. Treatment of infective bursitis consists of surgical drainage and antibacterial drugs.

### TENOSYNOVITIS

This is defined as the inflammation of the synovial lining of a tendon sheath. It may be of two types viz. irritative tenosynovitis and infective tenosynovitis.

These are usually seen in the flexor tendons of the hand and forearm.

- a. Irritative tenosynovitis—This results from mechanical irritation and is treated by rest, analgesia and ultrasonic therapy. Some cases need local hydrocortisone infiltration.
- b. Infective tenosynovitis—May result from infection by pyogenic bacteria or *Mycobacterium tuberculosis*.

Suppurative tenosynovitis has been described in the chapter of surgical infections. Tubercular tenosynovitis involving the sheaths of the flexor tendons of the forearm at the level of the wrist occurs commonly and is known as compound palmar ganglion which has been described later in this chapter.

### DUPUYTREN'S CONTRACTURE (SYN—CONTRACTURE OF THE PALMAR APONEUROSIS, DUPUYTREN'S DISEASE, PALMAR FIBROMATOSIS)

In this condition, there is thickening and shortening of the palmar aponeurosis resulting in flexion contractures of the fingers of the hand with particular involvement of the ring and little fingers.

The cause is unknown but there is an increased hereditary disposition (autosomal dominant). An increased incidence is also

found among alcoholics, diabetics and epileptics, treated with phenytoin.

### Pathology

The palmar aponeurosis, a thin but tough membrane beneath the skin of the palm is continuous proximally with the palmaris longus tendon and distally, with the fibrous flexor sheaths covering the flexor tendons of the fingers.

The term fibromatosis means tumor-like lesions of fibrous tissue.

The characteristic early lesion is a collection of fibroblasts and contractile myofibroblasts in the longitudinal fibers of the aponeurosis in the palm or between the aponeurosis and the skin, forming a nodule.

The nodules thus formed, coalesce to form cords of fibrous tissue extending into the soft tissues. Shortening of these cords causes flexion contractures of the fingers.

### Clinical Features

- The condition is more common in elderly males.
- There is flexion deformity of the fingers involving the metacarpophalangeal (MP) and proximal interphalangeal (PIP) joints. The contracture is generally limited to medial three fingers. Sometimes it may be associated with a thickening of plantar fascia (plantar fibromatosis) or that of the penile fascia (Peyronie's disease).

Dupuytren's contracture is to be differentiated from a similar deformity due to contracture of the flexor tendons, e.g. Volkmann's ischemic contracture (VIC).

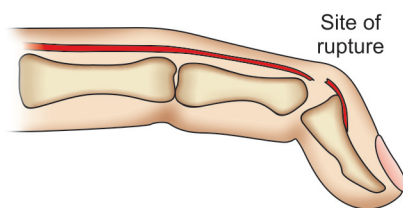
In the former, only the MP and PIP joints are flexed, unlike the latter, where the DIP joints are also flexed. (DIP—Distal interphalangeal)

### Treatment

- An elderly patient with mild contracture does not need any treatment.
- If the deformity is significant and hampers the activity of the patient, excision of the affected segment of palmar aponeurosis may be required.

### MALLET FINGER

This is a condition in which there is avulsion of extensor tendon from distal phalanx of a finger (Fig. 66.1).



**Fig. 66.1:** Mallet finger (Baseball finger) – The extensor tendon is avulsed from its insertion. The terminal joint (DIP) cannot be extended fully.

It usually occurs by sudden forced flexion of the distal interphalangeal joint (DIP) by a blow on the tip of a finger by a ball. Hence, it is also called the base ball finger.

### Clinical Features

The peculiar deformity is obvious. The patient fails to extend the terminal phalanx passive extension is possible but the terminal phalanx falls back into flexed position again when it is released, due to the influence of the long flexor tendon.

### Treatment

The condition is treated with a splint known as Oatley splint or Mallet finger splint for 6 weeks.

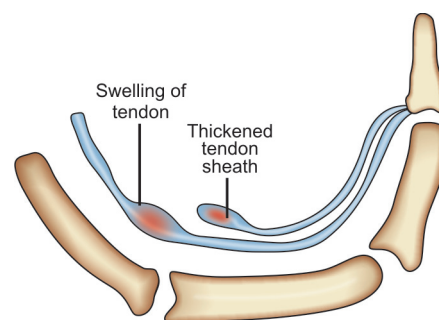
### TRIGGER FINGER (SYN—DIGITAL TENOVAGINITIS, SNAPPING FINGER)

In this condition, stenosis of finger flexors occur at the entrance to the fibrous flexor tendon sheath at the metacarpophalangeal joints. It is due to a localized disparity between the size of the tendon and its sheath, i.e. local enlargement of the tendon or constriction of its sheath or both.

The tendon cannot enter the sheath easily (locking). When sufficient force is exerted, it enters with a snap, hence called snapping finger (Fig. 66.2).

### Clinical Features

- Middle aged women are the usual sufferers.
- Patient herself describes the characteristic locking and snapping.
- There may be tenderness at the base of middle and ring fingers which are most commonly affected.



**Fig. 66.2:** Mechanism of trigger finger. When an attempt is made to extend the finger, the swollen part of the tendon is reluctant to enter the constricted mouth of the fibrous sheath. With sufficient force it enters with a snap.

### Treatment

- In early cases, local injection of hydrocortisone is given.
- In established cases, the treatment is to incise the mouth of the fibrous flexor sheath.

### DE-QUERVAIN'S DISEASE (SYN—TENOVAGINITIS OF THE ABDUCTOR POLLICIS LONGUS AND EXTENSOR POLLICIS BREVIS) (FIG. 66.3)

This is a common and well-recognized condition characterized by pain over the styloid process of the radius and a palpable nodule in the course of abductor pollicis longus and extensor pollicis brevis.



**Fig. 66.3:** de Quervain's disease (Right side)—Pain over the radial styloid process is aggravated by adducting the thumb across the palm

### Etiology and Pathology

The exact etiology is not known. It may be due to frequent repetitive movements such as wringing clothes, typing, etc.

The common fibrous sheath of the first dorsal compartment of the extensor retinaculum containing the abductor pollicis longus and extensor pollicis brevis tendons is thickened, where it crosses the tip of the radial styloid process.

The condition is possibly analogous to trigger finger, the other common form of tenovaginitis.

### Clinical Features

- It usually occurs in middle-aged women.
- Patient complains of pain on the radial side of the wrist (Fig. 66.1).
- On examination: A localized firm nodule can be felt just above the radial styloid process.
- Ulnar deviation of the wrist is painful.

### Treatment

1. Conservative treatment: In early cases, local injection of hydrocortisone along with rest and physiotherapy may cure and reverse the process.
2. Operative treatment: Longitudinal slitting open of the fibrous sheath of the involved tendon effects complete cure.

### GANGLION

It is the commonest cystic swelling on the back of the wrist formed as a result of myxomatous degeneration of the synovial tendon sheath. Some schools claim that it is the benign neoplasm of the tendon sheath or the joint capsule.

It contains clear gelatinous fluid.

Other common sites include dorsum of foot and ankle and palmar aspect of the wrist and fingers.

### Clinical Features

The patient is usually a young adult presenting with a painless lump.

On examination, the lump is well-defined; cystic swelling but often it is felt firm or even hard. The swelling is mobile across but not along the axis of the tendon.

### Treatment

- Complete excision of the cyst is the treatment of choice.
- The excised specimen should be sent for biopsy as very rarely there may be some neoplastic change, especially synovioma.

### COMPOUND PALMAR GANGLION

It is the chronic inflammation of the ulnar bursa, the common synovial sheath that surrounds the flexor tendons of the fingers viz. flexor digitorum superficialis and profundus in front of the wrist. It gives rise to a swelling which extends both above and below the flexor retinaculum resembling an 'hour glass' so known as compound ganglion.

### Cause

In most cases it is caused by infection with tubercle bacillus. A similar condition may complicate rheumatoid arthritis, without demonstrable bacterial infection.

### Pathology

The affected synovial membrane is greatly thickened. In most cases there is histological evidence of tuberculosis.

The swelling often contains an excess of fluid and there may be collections of small fibrinous bodies, called melon seed bodies which look like sago grains.

### Clinical Features

- Age—Usually below 40 years.
- Pain is unusual and the patient usually presents with an hour glass swelling in the region of the affected tendon sheaths.

- On examination, cross fluctuation test is positive.
- This means that fluid from one part can be pushed to the other part which proves that the two swellings are continuous.
- Fluctuation test is also positive but transillumination test is negative.
- There may be wasting of the muscles of the hand and fingers.
- There may be evidence of tuberculosis elsewhere in the body, e.g. chest, other joints, etc.

### Treatment

1. Conservative treatment: This consists of
  - Immobilization of the involved tendon sheaths in a plaster cast.
  - If the condition is tuberculous, antitubercular treatment is started.
2. Operative treatment: This is indicated, if no improvement is noticed after 3 or 4 months of conservative treatment.

The entire flexor sheath is dissected out with excision of all the diseased synovial membrane.

If there is rheumatoid disease, the treatment is complete excision of the ulnar bursa keeping the flexor tendons intact.

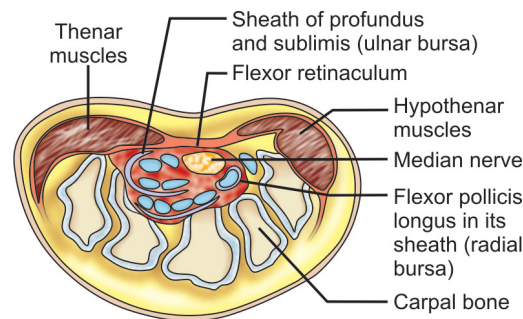
### CARPAL TUNNEL SYNDROME

In this condition, the median nerve is compressed as it pass through the carpal tunnel – the space between the flexor retinaculum and the carpal bones. (Fig. 66.4)

The flexor tendons with their covering sheaths also pass through this tunnel.

### Causes

Any space occupying lesion within the carpal tunnel can give rise to this syndrome, e.g.



**Fig. 66.4:** The carpal tunnel showing the median nerve and the flexor tendons of the fingers and thumb.



1. Idiopathic—The commonest cause.
2. Posttraumatic—Bone thickening after a Colles' fracture.
3. Inflammatory—Rheumatoid or tuberculous tenosynovitis, e.g. compound palmar ganglion, osteoarthritis of wrist, etc.
4. Endocrine causes—
  - Myxedema
  - Acromegaly.

### Clinical Features

- Age and sex—Middle-aged women are the usual sufferers.
- Pain—Pain is classically localized along the distribution of the median nerve that is radial three and a half fingers.
 

The pain is usually worse at night. The patient notices that pain is relieved by hanging the hand over the edge of the bed (diagnostic). Pain is increased if the fingers and wrist are kept flexed for sometime.
- There may be paresthesia and numbness along the distribution of the median nerve.
- In severe cases there is wasting and weakness of the median nerve innervated small muscles of the hand viz. the three thenar muscles and first two lumbricals resulting in inability of abduction and opposition of the thumb.
- Evidence of pregnancy, myxedema, osteoarthritis, rheumatoid arthritis, etc. should be looked for.

### Treatment

Simple decompression of the tunnel by incising the flexor retinaculum longitudinally gives excellent results.

### TENNIS ELBOW (SYN—LATERAL EPICONDYLITIS)

Tennis elbow is a common and well-defined clinical entity. It is an extraarticular affection characterized by pain and acute tenderness at the origin of the extensor muscles of the forearm.

### Etiology and Pathology

It is believed to be caused by strain of the forearm extensor muscles at the point of their origin from the bone, that is, lateral epicondyle of humerus.

Although it sometimes occurs after playing tennis, overactivities are more often responsible. The elbow joint remains unaffected.

### Clinical Features

- There is tenderness over the lateral epicondyle of the humerus.
- Pain is felt at the lateral aspect of elbow often radiating to the back of forearm and is aggravated by putting the extensor tendons to a stretch, e.g. by palmar flexing the wrist and fingers with the forearm pronated.
- Elbow movements are normal.
- X-ray does not reveal any abnormality.

### Treatment

1. If left alone symptoms may subside spontaneously.
2. The patient may be treated initially with analgesias and anti-inflammatory drugs for a week or so.
3. If there is no response, a local injection of hydrocortisone at the point of maximum tenderness generally brings relief.
4. Operation: The origin of the common extensor muscle is stripped from the lateral epicondyle in persistent or recurrent cases.

### GOLFER'S ELBOW (MEDIAL EPICONDYLITIS)

This is analogous to tennis elbow except that the common flexor origin into the medial epicondyle is affected.

### PLANTAR FASCITIS

This is a common cause of pain in the heel and occurs as a result of inflammation of the plantar aponeurosis at its attachment on the tuberosity of the calcaneum.

The pain is worst early in the morning and often improves in the later part of the day.

On examination, there is marked tenderness on the medial aspect of calcaneal tuberosity at the site of attachment of the plantar fascia (Fig. 66.5).

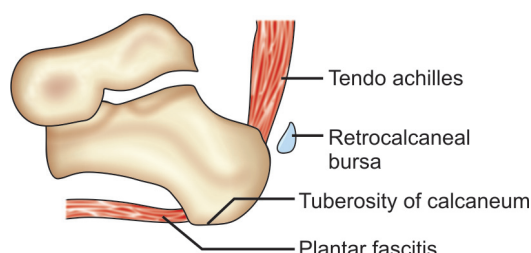


Fig. 66.5: Plantar fasciitis—An inflammation of the plantar aponeurosis.

### Treatment

Analgesics, the use of heel pad and local injection of steroids bring relief in most cases.

### MORRANT BAKER'S CYST (POPLITEAL CYST)

A Baker's cyst is a herniation of the synovial cavity of the knee in the popliteal fossa. It is not a primary condition and is always secondary to disease of the knee with persistent accumulation of synovial fluid as in osteoarthritis or rheumatoid arthritis.

The sac extends backwards and downwards and in a long-standing case may extend for a considerable distance downwards even to the calf.

### Clinical Features

- There is a swelling situated near the midline in the popliteal fossa, below the level of the joint line and deep to the gastrocnemius muscle. Some of the cyst may bulge out between the heads of the gastrocnemius.
- The condition is often bilateral and knee movements are painful and restricted.
 

On examination, the swelling is cystic in feel and fluctuation test is positive. Knee joint shows evidence of arthritis.

### Differential Diagnosis

- i. Popliteal aneurysm, which pulsates.
- ii. Calf vein thrombosis.
- iii. Semimembranosus bursa which usually presents as a painless lump in the medial part of the popliteal fossa between the semimembranosus and the medial head of gastrocnemius.

### Treatment

- Aspiration and injection of hydrocortisone followed by application of crepe bandage.



- Treatment of the associated joint pathology, e.g. osteoarthritis should be done.
- If the conservative treatment fails, the cyst should be excised.

### **RUPTURED BICEPS TENDON**

This is a tear of the tendon of the long head of biceps at the bicipital groove of the humerus. The long tendon of biceps is one of several tendons in the body that are prone to rupture, without violent stress or injury.

Other tendons that are prone to injury include the supraspinatus tendon and the tendon of extensor pollicis longus.

Predisposing factors are relative avascularity in elderly patients and weakness of the tendon due to osteoarthritis of the shoulder.

#### **Clinical Features**

The patient is usually a middle-aged male and gives history of sudden pain and snap at the shoulder while lifting or pulling with the same arm. Soon the pain disappears and patient forgets it. Later he may notice

unusual bulge of the muscle in front of the arm.

#### **On Examination**

- Mild tenderness over the bicipital groove of the humerus soon after the rupture.
- Later, when the patient is asked to flex his elbow against resistance, the belly of the long head of biceps is seen to bunch up into a short round mass like a ball.

#### **Treatment**

- The disability is usually so mild that no treatment is required.
- When repair is demanded by the patient the distal stump of the tendon, is sutured to the walls of the bicipital groove. The proximal stump is ignored.

### **FROZEN SHOULDER (SYN—PERIARTHRTIS SHOULDER AND ADHESIVE CAPSULITIS)**

This is a condition where the glenohumeral joint becomes painful and stiff resulting in

marked restriction of all movements, especially the abduction and external rotation. The exact etiology is not known. There is loss of resilience of the joint capsule, possibly with adhesions between its folds.

#### **Clinical Features**

The patient aged 40 to 60 years may give a history of trauma, often trivial followed by pain which gradually increases in severity and becomes worse at night so that it may prevent sleeping on the affected side.

There is no abnormality on X-ray.

#### **Treatment**

- This is a self limiting disease lasting for 12 to 18 months after which in most cases the inflammation subsides, leaving a stiff but painless shoulder.
- Conservative treatment consists of physiotherapy, analgesias and hot fermentation.
- An intraarticular injection of hydrocortisone may speed up the recovery.
- Once acute pain has subsided, manipulation under anesthesia may help to region normal joint movements.

## Amputations

- Indications
- Types
- General principles – closed type
- Complications of amputation
- Recommended ideal length of the stump
- An ideal amputation stump

Amputation is a procedure where a part of the limb is removed through one or more bones. Amputations of lower limbs are more commonly performed than that of upper limb. However, partial amputation of fingers of the hand is common mainly as a sequelae to farm and machine injuries.

The term disarticulation means amputation of a limb through a joint without cutting a bone.

### INDICATIONS

Injury is the commonest cause of amputation in developing countries. The injury may be sustained in traffic accidents, train accidents or in agriculture fields in harvesting season, etc.

Indications for amputation vary in different age groups. In the young adults the amputation is most often secondary to injury or its sequelae. In children, injury and malignancy top the list, while in the elderly patients aged more than 50 years, peripheral vascular disease with or without diabetes is the main cause.

Some common indications are:

1. Crushed Injury.
2. Peripheral vascular disease, e.g. Buerger's disease, diabetes.
3. Infections, e.g. gas gangrene.
4. Tumors, e.g. osteosarcoma.
5. Deformities, e.g. pressure sores, huge lymphedema, and poliomyelitis.

### TYPES

#### Guillotine or Open Amputation

In this type of amputation, the skin is not closed over the amputation stump and all tissues are divided at the same level. Open amputation is usually done when the wound is not healthy.

#### Indications

- i. Presence of gross sepsis, e.g. gas gangrene, street accidents, etc.
- ii. When the distal part of the limb is trapped by machinery or in mining accidents. The operation is followed after some period by one of the following procedures for constructing a satisfactory stump.
  - Revision of the stump—After removal of the terminal granulation tissue, scar

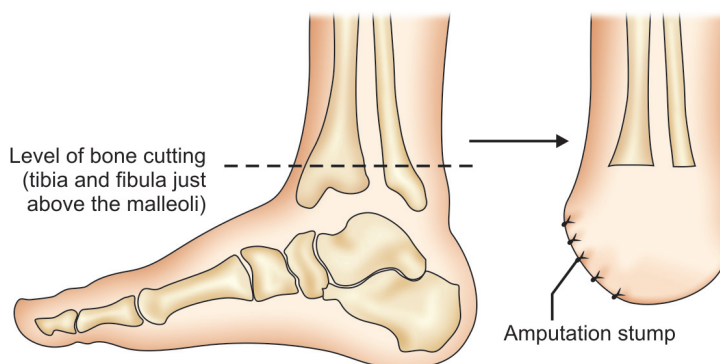
tissue as well as a moderate amount of bone, the stump is reconstructed.

- Re-amputation—This is an amputation at a higher level, as if an amputation is being performed for the first time.
- Secondary closure—of the skin flaps after a few days.

#### Closed Amputation

Closed amputation is where the skin is closed primarily, e.g. most elective amputations, like

- i. Below and above knee amputations,
- ii. Below and above elbow amputations.
- iii. Disarticulation of hip, knee, etc.
- iv. Symes amputation where the foot is disarticulated from the ankle. A special prosthetic shoe is necessary after this amputation so that weight bearing function is preserved (Fig. 67.1).



**Fig. 67.1:** Syme's Amputation

## GENERAL PRINCIPLES – CLOSED TYPE

- **Level of amputation:**  
This indicates the level of a limb at which a stump is most suitable for an artificial limb. With modern techniques of fitting artificial limbs the strict levels adhered to in the past are no longer tenable.

The principles guiding the level of amputation are as follows.

- Anatomical principles**—A joint must be saved as far as possible. Nowadays it is possible to fit artificial limbs to stumps shorter than ideal length as long as the stump is well healed, nontender and properly constructed.
- Suitability for the efficient functioning of the artificial limb**—Sometimes length is compromised for the efficient functioning of the artificial limb to be fitted on a stump, e.g. a long stump of an above knee amputee may hamper with optimal prosthetic fitting.
- The disease**—The nature and extent of the disease or trauma for which amputation is being done, is the important consideration. One tends to be conservative with dry gangrene (vascular) and trauma but liberal with acute life-threatening infections and malignancies.
- Tourniquet:** The use of a tourniquet is highly desirable except in case of an ischemic limb.
- Skin flaps:** The skin over the stump should be mobile and normally sensitive so that movements of the artificial limb on the stump do not cause pain.

The scar should be transversely placed. The modern artificial limbs are side-bearing so that they do not cause pressure at the end of the scar. Hence, a terminal scar is preferred nowadays.

A terminal scar has also the advantage that a long flap with the lack of vascularity and chance of necrosis is avoided.

- **Muscles:** Muscles should be cut distal to the level of bone. The following two methods are found advantageous for muscle suture:
  - Myoplasty**—Here the opposing groups of muscles are sutured to each other.
  - Myodesis**—i.e. the muscles are sutured to the end of the stump.
 These are contraindicated in peripheral vascular diseases.
- **Major blood vessels:** Should be isolated and doubly ligated using nonabsorbable

sutures. The tourniquet should be released before skin closure and meticulous hemostasis should be secured.

- **Nerves:** Each nerve is gently pulled distally into the wound and divided with a sharp knife so that the cut end retracts well proximal to the level of bone section.
- **Bone:** Level of bone resection is decided as discussed earlier, excessive periosteal stripping is avoided as it may lead to the formation of ring sequestrum from the end of the bone. The sharp edges of the cut bone should be made smooth and bony prominences which are not well-padded by soft tissues should be cut.
- **Drain:** A corrugated rubber drain should be used for 48 to 72 hours. Prophylactic antibiotic is required with properly applied bandage to protect the stump from microbial contamination.
- **POSTOPERATIVE CARE**  
It includes:
  - Dressings—Postoperatively for a few days the stump together with the proximal joint is immobilized in a plaster of Paris cast. This helps in wound healing and maturation of the stump. In addition, the patient can be fitted with a temporary artificial limb with a prosthetic foot for almost immediate mobilization.
  - Elevation of stump to prevent contracture and promote healing.
  - Stump exercise is necessary for maintaining the range of motion of the proximal joint and to strengthen the muscles controlling the stump.

— Prosthetic fitting and gait training is started usually three months after the amputation.

## COMPLICATIONS OF AMPUTATION

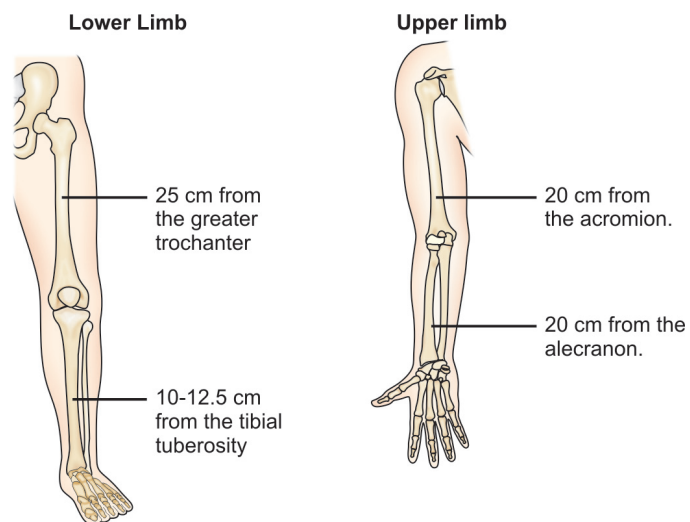
1. Hemorrhage—Reactionary or secondary.
2. Infection
  - i. In soft tissues.
  - ii. At the bone ends.
3. Skin flap necrosis—It can be avoided by taking as much subcutaneous tissue as possible with the skin while designing the skin flaps. Small areas of flap necrosis may heal with dressings but redesigning of the flap is required for larger area of flap necrosis.
4. Neuroma—A neuroma always forms at the end of a cut nerve; painful neuroma is prevented by cutting the nerve sharply at a proximal level and allowing it to retract well proximal to the end of the stump to lie in the normal soft tissues.
5. Phantom sensation—All individuals in the postoperative period after amputation experience some form of phantom sensation as if the amputated part is still present.

Phantom pain is the awareness of pain in the amputated limb. Treatment is difficult.

6. Stiffness of the proximal joint.

## RECOMMENDED IDEAL LENGTH OF THE STUMP (FIG. 67.2)

- In above knee amputations, 25 cm from the greater trochanter.



**Fig. 67.2:** The ideal length of the stump in the upper and lower limbs.

- In below knee amputations, 10 to 12.5cm from the tibial tuberosity.
- In above and below elbow amputations 20cm from the acromian process and olecranon process respectively. These stump lengths are not, however constant as mentioned above in general principles. Basically it gives

a rough idea as to how much length of the stump is desirable for fitting a prosthesis.

### **AN IDEAL AMPUTATION STUMP**

It should fulfil the following criteria:

- Long enough to fit a prosthesis

- Good sensation
- Good power
- Good soft tissue cover
- No neuroma
- No infection
- Conical shape
- Proximal joint should be normal
- No bad scarring.





## **PART III**

# Practicals and Viva in Surgery



# Chapter 68

## Writing a Surgical Long Case

- Introduction
- General plan of writing a surgical long case

### INTRODUCTION

Each student is given a long case in the practical examination. Separate marks are allotted for writing good history and recording the findings of physical examination.

A proper history and physical examination often give so much information that very few investigations are needed to reach the diagnosis.

### GENERAL PLAN OF WRITING A SURGICAL LONG CASE

This consists of the following parts.

- a. History or interrogation of the patient.
- b. Physical examination.
- c. Summary of the case.
- d. Provisional diagnosis.
- e. Investigations suggested.
- f. Differential diagnosis.

### History

#### *Particulars of the patient*

1. Name
2. Age
3. Sex
4. Religion
5. Occupation
6. Residence.

#### *Chief Complaints or Presenting Symptoms*

Here the presenting symptom or the complaint is recorded in the patients own words. If there is more than one complaint they are listed in a chronological order of their appearance. If the symptoms appear simultaneously, they are written in order of severity. Chief complaints should not be more than three or four in number.

#### *History of Present Illness*

This includes the full details from the appearance of first symptom to the present time. This is also recorded in the patients own words. The mode of onset, progress of the disease and the treatment which the patient might have received are recorded.

If the patient had chief complaints of pain and vomiting the details are written in two paragraphs maintaining the chronological order.

Once the chief complaints are elaborated, symptoms pertaining to different systems should be asked and recorded, if relevant, e.g.

- Respiratory symptoms: Cough, hemoptysis, chest pain, breathlessness.
- Alimentary system: Pain, vomiting, hematemesis, melena, acidity, heart-burn, flatulence, jaundice, details of bowel habit, bleeding per rectum, etc.

- Cardiovascular system: Palpitations, chest pain, paroxysmal nocturnal dypnea, breathlessness on exertion.
- Urinary symptoms: Hematuria, any renal or ureteric colic, dysuria, hesitancy urgency.
- Neurological symptoms: Headache, tremor, fainting attacks, muscle weakness, sensory loss, of consciousness.

#### *Past History*

The diseases suffered by the patient in the past are noted. This will include previous illness like diabetes tuberculosis, AIDS, tropical diseases (malaria, kala-azar), asthma, accident operations, etc.

#### *Drug History*

Like intake of antihypertensives anticoagulants, anticonvulsants, steroid, insulin, diuretics, etc.

#### *History of Allergy*

History of allergy is very important patient should be enquired about allergy to any diet and drugs.

#### *Personal History*

The following points should be enquired about:

- a. Smoking, (cigarette, Tobacco chewing)
- b. Drinking of alcohol

- c. Marital status
- d. Number of children
- e. Menstrual and reproductive history in women
- f. Status of health of spouse and children.

### Family History

Here one should inquire about the existence of any familial disease present or not, e.g. Hemophilia, breast cancer, piles, fissures, etc. History of immunization is taken in case of children.

### Physical Examination

Physical examination is done under three headings viz.

- General survey
- Local examination
- Systemic examination.

### General Survey

This involves the following:

1. **Mental state:** This includes initial assessment of patient's intelligence, anxiety, apathy, depression, Lack of co-operation or depression.
2. **Build:** Means skeletal structure of an individual in relation to age and sex. Build may be short, average or tall in comparison to normal individual of the same age and sex.
3. **Facies:** Some typical facies are thyrotoxic facies, moon facies of Cushing's syndrome, acromegaly, etc.
4. **Nutrition:** Cachexia is a feature of malignancy.
5. **Decubitus:** That is position in bed, e.g. lying in bed with the injured limb extremely rotated is seen in fracture neck of femur.
6. **Anemia:** Anemia is defined as a qualitative or quantitative reduction of the red cell mass or hemoglobin or both in relation to standard age and sex. This results in reduction in oxygen transport capacity of blood.

Anemia is assessed by the presence of pallor, i.e. paleness of skin and mucous membrane and other structures described below:

- a. Lower palpebral conjunctiva
- b. Tip and dorsum of the tongue
- c. Soft palate
- d. Nail bed

- e. Skin of the palms and sole.

Depending on the degree of pallor, anemia may be mild, moderate or severe.

7. **Jaundice:** Jaundice is defined as yellowish discoloration of the skin and mucous membrane due to hyperbilirubinemia.

Sites: Jaundice is looked for in the following sites:

- a. Upper bulbar conjunctiva
- b. Soft palate
- c. Under surface of tongue
- d. Palms, soles and
- e. General body skin.

Normal serum bilirubin is 0.2 to 0.8 mg percent and clinically jaundice is seen when bilirubin level is more than 2 mg percent.

Latent jaundice is said to be present when bilirubin level is between 9 mg percent to 1.9 mg percent.

8. **Cyanosis:** It is the bluish discoloration of the skin and mucous membrane due to excessive amount of reduced hemoglobin (usually more than 5 gm%) in blood.

Cyanosis may be of two types namely:

- a. Central cyanosis and
- b. Peripheral cyanosis.

Central cyanosis occurs when the defect lies in the cardiopulmonary circulation, e.g. heart failure and some lung diseases.

It characteristically affects the tongue as well as the limbs. Thus the cyanosis is general and cyanosed extremities are warm.

Peripheral cyanosis is due to excessive reduction of oxyhemoglobin in the capillaries which may happen in exposure to cold. The cyanosed extremity or extremities are cold and the tongue is unaffected.

Sites to look at:

- i. Peripheral cyanosis: Ear lobule, tips of fingers, toes, palms and soles.
- ii. Central cyanosis is looked for in the tongue inner surface of the lips in addition to the sites of peripheral cyanosis.

9. **Neck glands:**

There are two lymph node groups in relation to the investing layer of deep cervical fascia viz.

- a. Superficial lymph nodes lying superficial to the fascia and
- b. Deep lymph nodes lying deep to the fascia.

An enlarged cervical lymph node is the commonest cause of a lump in the neck. It is usually secondary to acute infection,

but when due to malignant spread, the primary lesion is sited in the head and neck in 90 percent cases.

10. **Neck veins:** Prominent neck veins are seen in superior vena caval obstruction by mediastinal masses or less commonly fibrosis, thrombosis or invasion of the vein. There is venous engorgement and edema of the face, neck and arms.

11. **Edema:** This is excessive accumulation of fluid in the extravascular compartment.

Sites to look for edema:

- i. In ambulant patient it is detected by pressing on the medial surface of the tibia one inch above the medial malleolus for 5 to 10 seconds. If edema is present, a dimple will appear in the skin.
- ii. In nonambulant patient, it is tested over the sacral region in the same manner as above.

12. **Pulse:** Its rate, regularity and volume are noted. Bradycardia means heart rate below 60 per minute. Tachycardia means heart rate more than 100 per minute.

13. **Blood pressure:** May be raised in case of polycystic kidney disease or adrenal tumors (Adrenocortical adenoma or pheochromocytoma).

14. **Respiration:** Normal respiration is abdominothoracic and rate is 18 to 20 /min.

It is to be noted whether the respiration is thoracoabdominal or abdominothoracic.

15. **Temperature:** Temperature is measured by clinical thermometer.

- Normal body temperate – 98 to 99°F.
- Pyrexia – Above 99°F.
- Hyperpyrexia – more than 106°F.
- Hypothermia below 95°F

Types of fever:

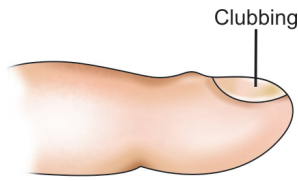
- a. Continuous: Fluctuation of temperature is less than 1.5°F and the temperature does not touch the base line.

- b. Intermittent fever: Fever continues for several hours and returns to normal during the day. This may be:

- Quotidian – The paroxysm of intermittent fever occurs daily.
- Tertian – Intermittent fever occurs on alternate days.
- Quartan – Intermittent fever occurs every three days.

16. **Clubbing:** (Fig. 68.1)

In clubbing there is obliteration of the angle, known as Lovibond's angle between



**Fig. 68.1:** The nail loses its longitudinal ridges and becomes convex from above downwards and from side to side

the nail and the nailbed. Also the longitudinal and transverse curvatures of the nail are increased. These changes are due to diffuse enlargement of the terminal phalanges as well as proliferation of sub-ungual connective tissues.

In extreme cases the terminal segment of the finger is bulbous, like the end of a drumstick. The toes may also be affected. Clubbing is found in a number of abdominal and cardiopulmonary disorders, e.g.

- a. Chronic abdominal disorders
    - Polyposis of the colon
    - Ulcerative colitis
    - Crohn's disease.
  - b. Carcinoma of the bronchus
  - c. Pulmonary tuberculosis
  - d. Subacute bacterial endocarditis.
17. Any obvious deformity, e.g. limping.
  18. Skin pigmentation, e.g. in case of varicose vein.

### Local Examination

Local examination of a particular area of the body, e.g. thyroid, Abdomen, etc. is discussed under the following headings viz.

- Inspection (Look)
- Palpation (Feel)
- Percussion (Tap) and
- Auscultation (Listen).

Of the above the first two are very important and the last two are not so important.

During examination of abdomen, per rectum and per vagina examination and examination of hernial orifices are of special importance. Draining lymph nodes are also examined in the local examination.

### Systemic Examination

Systemic examination is important for the following reasons:

- i. For making a diagnosis, e.g. examination of the chest and spine may reveal caries

- spine or basal pleurisy in a patient with obscure pain abdomen.
- ii. To determine the prognosis, e.g. in a patient with gastric carcinoma if the left supraclavicular lymph node (Virchow's node) is palpable, prognosis is worse.
- iii. For selecting the type of anesthesia to be administered, e.g. regional anesthesia is preferred in presence of heart and lung disease.

Each system should be examined in brief as follows:

1. Nervous system:
  - a. Higher functions:
    - State of consciousness, co-operative or not
    - Speech
    - Cranial nerve, if any palsy.
  - b. Motor function, e.g.
    - Upper limbs tone, power, co-ordination.
    - Lower limbs – Power, tone, co-ordination.
  - c. Sensory function
    - Superficial sensation.
    - Pain, touch, temperature.
  - d. Reflexes
    - Superficial – Plantar response and abdominal reflex.
    - Deep reflexes – Jerks.
  - e. Cerebellar sign
  - f. Gait.
2. Examination of spine.
3. Examination of cardiovascular system.
  - a. Apex beat, parasternal heave or thrill.
  - b. Heart sounds and murmur.
4. Examination of the respiratory system.
  - Inspection: Shape of the chest, respiratory rate, movement of chest.
  - Palpation: Movement of chest, position of trachea.
  - Percussion note over the chest.
  - Auscultation: Breath sounds, any added sound – crepitus or ronchi
5. Examination of abdomen:
  - a. Inspection: Shape of abdomen, position of umbilicus, skin over the abdomen, any scar mark present or not hernial sites, external genitalia.
  - b. Palpation:
    - Temperature, tenderness, any muscle guard, swelling.
    - Palpation of liver, kidneys and spleen, fluid thrill.
    - Percussion

- Shifting dullness
- Upper border of liver dullness.
- General note over abdomen.
- Auscultation
  - Bowel sounds.
  - Any added sound.
- Per rectal examination.
- Per vaginal examination.

### Summary of the Case

Summary of the case is stated mentioning the important points which also include significant negative points in the history and observations on examination.

This will give some clue to come to a diagnosis of the probable disease the patient is suffering from. One should remember that clinical diagnosis of a rare disease is rarely correct.

### Provisional Diagnosis

The law of probability should be observed while considering the diagnosis, that is, common disease should be commonly diagnosed.

### Investigations Suggested

Investigations are considered under the following headings:

- a. Investigations to assess anesthetic fitness.
- b. Investigations for confirmation of diagnosis.
- c. Investigations to stage the disease in case of malignant disease.
 

Investigations may also be mentioned under the following two headings.

  - a. Base line investigations
    - Blood for Hb percent TC, DC, ESR, bleeding time and clotting time.
    - Blood for sugar (Fasting and postprandial) urea, creatinine.
    - Urine for routine examination.
    - Stool for routine examination of ova, parasite and cyst.
    - Chest X-ray (P-A view).
    - ECG in all 12 leads.
  - b. Special investigations:

These are done according to the nature of provisional diagnosis.

### Differential Diagnosis

A list of differential diagnosis is considered for exclusion of disease of less probability.



# Chapter 69

## Examination of a Swelling or Tumor

- General plan of examination of a swelling or tumor

### GENERAL PLAN OF EXAMINATION OF A SWELLING OR TUMOR

#### History

History is recorded in the same way as discussed earlier with special stress to the following:

1. **Duration:** The date of noticing the swelling should be enquired of:
  - If the swelling is of longer duration without pain, it is likely to be a benign lesion, while a long-standing swelling with slight pain indicates chronic inflammation. On the other hand, swellings of shorter duration with pain are suggestive of inflammation and those without pain indicate malignant lesions.
2. **Mode of onset:**
  - i. Since birth – e.g. sacrococcygeal tumor, meningocele.
  - ii. Swelling following trauma – e.g. Hematoma.
  - iii. Swelling noticed casually is more likely to be neoplastic.
3. **Reduction or loss in body weight:** Weight loss after appearance of the swelling is common in a malignant tumor. Reduction in size of the swelling during the course of illness is common in chronic inflammatory swelling.
4. **Progress of the swelling:** Rapid growth usually means malignancy. A change in growth rate from slow to rapid may mean transformation of a benign lesion into a malignant one.

5. Site and size of the swelling, secondary changes like softening, ulceration, fungation, inflammatory changes, etc. are noted. Past history, personal history, family history, treatment history, history of allergy is recorded as discussed earlier.

#### Physical Examination

1. General survey as in chapter 68.
2. Local examination.

#### Inspection

The following are inspected - Site, size (extent of the swelling), shape, surface, skin over and around the swelling, side or edge, sessile or pedunculated.

#### Palpation

- a. Corroboration of the findings of inspection in relation to site, size, shape and surface, local temperature and tenderness.

- b. Consistency, i.e. feel of the lump including fluctuation and fluid thrill. If consistency is firm, it may be a fibroma, if soft, a lipoma, if cystic, cysts or chronic abscess, if bony hard, an osteoma, if stony hard, a carcinoma.

Fluctuation test is done with two fingers in two planes at right angles to each other (Figs 69.1A and B).

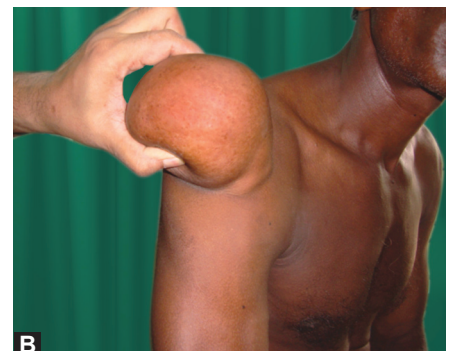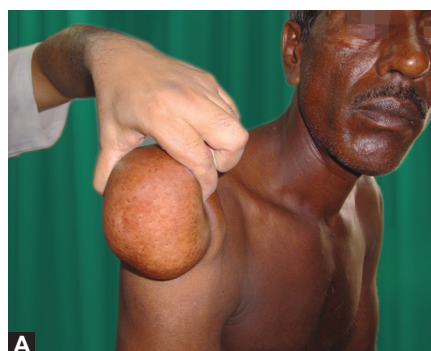Paget's test is done to differentiate between a small solid and cystic swelling (Fig. 69.2).

A cystic swelling is softer at the center while a solid swelling is harder in the center compared to the periphery.

- c. Translucency (Transillumination test) (Fig. 69.3).

Transillumination test is positive if the swelling contains clear fluid, e.g. water, serum, lymph, or plasma.

Darkness is essential to perform this test. The important brilliantly transilluminant swellings are vaginal hydrocele, cystic



**Figs 69.1A and B:** Eliciting fluctuation in two directions

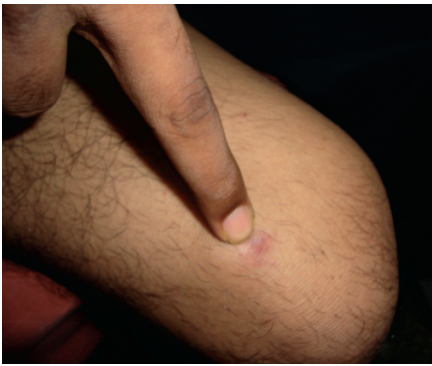


Fig. 69.2: Paget's test for a small swelling

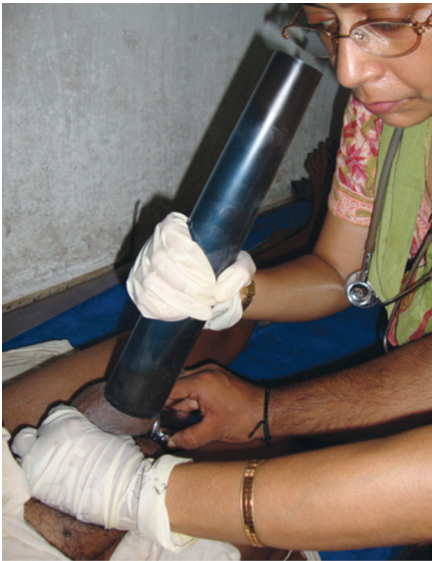

Fig. 69.3: Transillumination test in hydrocele

hygroma, encysted hydrocele of the cord, and congenital hernia in infants.

- d. **Compressibility:** When the swelling is compressed, with the fingers, it diminishes in size and may disappear completely but when the pressure is released, it reappears again. Hemangioma, lymphangioma and cystic hygroma are all compressible swellings.

- e. **Reducibility:** A reducible lump is pushed and moved away in another place (change of place) and will not reappear spontaneously with out cough or gravity with-release of compression. This differentiates a reducible lump from a compressible one.

Common reducible swellings are hernia, saphena varix, lymph varix, meningocele, varicocele, etc.

- f. **Impulse on coughing (straining):** This test is done to confirm the finding on inspection by palpation of the impulse. The swelling is held between finger grip and the effect of straining on the swelling is noted when the patient coughs or the child strains.

Impulse (expansile) on straining or coughing is tested to prove or disprove the intracavitary communication of a swelling, e.g. abdominal cavity and external hernia, chest cavity and empyema necessitans and spine or cranium and spinal or cranial meningocele.

- g. **Pulsatility:** Some lumps pulsate as they are in close association with an artery.

Two finger test – This test is done to know the type of pulsation namely (a) expansile or (b) transmitted. The pulsation is expansile in case of a swelling arising from the wall of an artery and is transmitted if the swelling is very close to an artery.

The index and middle fingers are placed over the swelling. If the pulsation is transmitted the fingers move up parallel to each other with each pulsation. If the pulsation is expansile the fingers are lifted up and also move up with each pulsation.

- h. Fixity of the swelling to skin.  
 i. Fixity of the swelling to deeper structures
- Muscle – Mobility is tested with muscle relaxed and contracted.
  - Tendon – Mobility is tested with tendon relaxed and after the tendon is made taut with contraction of muscle.

- Bones – The swelling is fixed as such and is bony hard.
- j. Regional lymph nodes should always be noted with its consistency and mobility.

### Percussion

A fluid filled or solid lump is dull but gas filled lump is resonant on percussion.

Fluid thrill: It is detected by smartly tapping on one side of the lump and feeling the transmitted wave or vibration with the finger placed on the opposite side.

In a large cystic swelling, a percussion wave can be transmitted along its wall which is avoided by placing the edge of the patients or assistants hand on the lump between the palpating and percussing hands of clinician.

Fluid thrill cannot be elicited across small cystic swelling because of quick movement of waves.

The presence of fluid thrill is a valuable diagnostic sign to indicate fluid filled swelling, e.g. hydatid cyst, ascites, ovarian cyst, etc.

### Auscultation

A pulsatile swelling is always auscultated for any bruit.

### Diagnosis of a Swelling

- a. From the history and clinical examination, the anatomical structure or the plane from which the swelling is arising is first determined.
- b. The clinicopathological nature, e.g. congenital or acquired (Traumatic, inflammatory, neoplastic or otherwise) is next diagnosed.
- c. Supporting investigation like FNAC, ultrasonography, X-ray, CT scan, etc. are next carried out on the basis of history and clinical examination to confirm the clinical diagnosis.

# Chapter 70

## Examination of an Ulcer

### ➤ General plan of examination of an ulcer

#### GENERAL PLAN OF EXAMINATION OF AN ULCER Physical Examination

##### History

Mnemonic 'DROPS' for points to be recorded in history.

D =

- Duration – Means how long the ulcer is present.
- Discharge – If any, its nature whether serous, purulent or serosanguinous.
- Associated disease like diabetes, nephritis, generalized tuberculosis, AIDS, present or not.

R =

- Reduction or loss of weight present or not.

O =

- Mode of onset – How the ulcer developed - following trauma or spontaneously.

P =

- Pain –
  - Inflammatory ulcers are painful.
  - Tuberculous ulcers are slightly painful.
  - Syphilitic ulcer, trophic ulcer, carcinomatous and rodent ulcers are painless.
- Progress of the ulcer, past history and past treatment history are noted.

S =

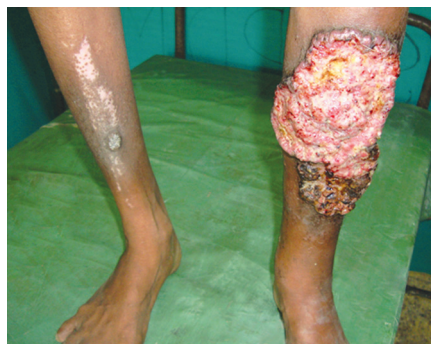- Swelling before ulcer, e.g. tuberculous cervical lymphadenitis causing ulcer or sinus in the neck.

1. General survey (as in chapter 68)
2. Local examination.

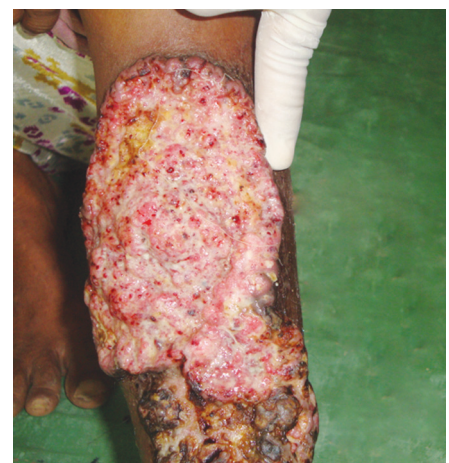##### Inspection (Fig. 70.1)

- a. Site: Rodent ulcer occurs in the upper face, varicose ulcer, over medial malleolar area or in lower medial third of leg, ischemic ulcers at the ends of the limbs.
- b. Number: Solitary or multiple.
- c. Size and shape: Carcinomatous ulcers are irregular in shape.
- d. Edge or margin: It is the junction between healthy surrounding tissue and ulcer.
  - Undermined edge is seen in tuberculosis.
  - Sloping or shelving edge in healing ulcer.

- Punched out or square cut edge – here the edge drops down at right angles to the skin surface. It is seen in case of deep trophic ulcer or gummatous ulcer.
  - Raised or rampart like edge is seen in rodent ulcer.
  - Everted and rolled out edge is seen in squamous cell carcinoma (Figs 70.1 and 70.2).
- e. Floor of ulcer: It is the exposed surface of ulcer.
    - Presence of pale and smooth granulation tissue at the floor indicates poor healing.
    - A black mass at the floor suggests malignant melanoma.
    - Red granulation tissue indicates the ulcer is healthy and healing.
  - f. Discharge: Purulent discharge is seen in acute pyogenic infection, blue or green

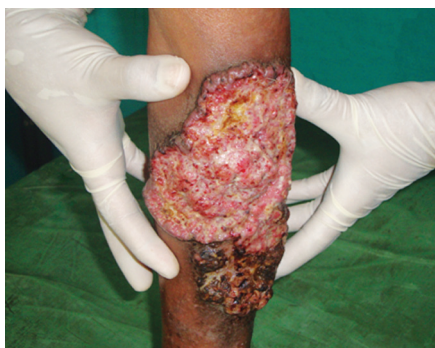

**Fig. 70.1:** Inspection of the ulcer (left leg) for its site, size, shape, surface, floor, margin and surrounding area, it was a squamous cell carcinoma in a middle aged woman

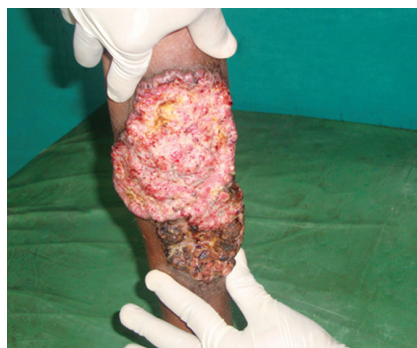

**Fig. 70.2:** Palpating the edge of ulcer for induration and tenderness

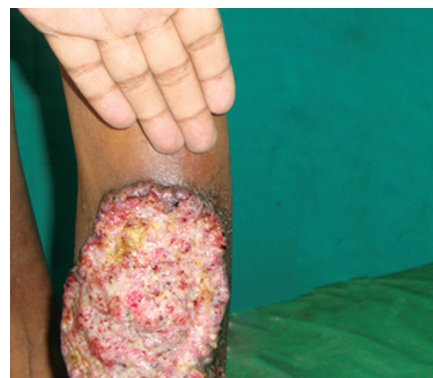



**Fig. 70.3A:** Palpating the base of the ulcer in horizontal axis



**Fig.70.3B:** Palpating the base of the ulcer in vertical axis



**Fig.70.4:** To feel the temperature in the surrounding area and comparing with the opposite side

discharge in *Ps. pyocyaneus* infection, serous or watery discharge is typical of tuberculous ulcer.

Blood stained (serosanguinous or sanguinous) discharge in nonspecific and malignant ulcers.

- g. Surrounding area: If glossy edematous and red, the ulcer is acutely inflamed.
- h. The whole limb containing the ulcer should be examined for the presence of deep vein thrombosis and varicose vein.

### Palpation

- a. Tenderness:
  - Inflamed ulcer – acutely tender.
  - Varicose ulcer – may or may not be tender.
  - Neoplastic ulcer is almost always non-tender.
  - Chronic ulcers (tuberculosis, syphilis) are slightly tender.
- b. Base: It is the area on which the ulcer rests. The base of the ulcer is palpated by making an attempt to pick up the ulcer between finger grips (Figs 70.3A and B).

Slight induration is present in chronic ulcer, but marked induration or hardness is a feature of malignant ulcer.

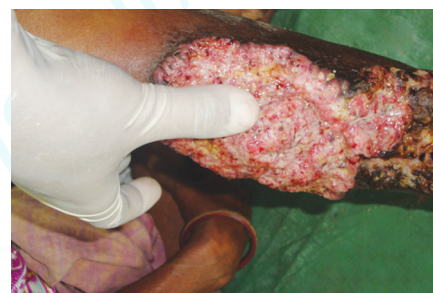- c. Temperature (Fig. 70.4): Examination of regional lymph nodes — The lymph nodes become enlarged and tender in an acutely inflamed ulcer. In tuberculosis, the lymph nodes are enlarged, matted and tender and in rodent ulcer, lymph nodes are not affected.

In malignant ulcer, the lymph nodes are stony hard and may be fixed to the neighboring structures.

- d. Examination of vascular insufficiency: When the ulcer is situated on the lower part of leg, search is made for varicose veins.
- e. Arterial pulsation is examined as an ulcer may result from poor blood supply, e.g. in arteriosclerosis, Buerger's disease, Raynaud's disease, etc.

Bleeding: Malignant ulcer and healthy granulation tissue will bleed during palpation (Fig. 70.5).

The student may remember the mnemonic "DRESSINGS" to record the various findings of clinical examination of an ulcer.



**Fig.70.5:** The ulcer may bleed on touch in case of healthy granulation tissue or carcinoma

D - Discharge and depth of ulcer, R - Relation to underlying structure. E - Edge or margin S - Site, size, shape, surface, surrounding area, solitary or multiple in number. I - Induration at the base and impairment of circulation, N - Nodes - enlarged or not, Neurological deficit present or not G - General examination to note the evidence of malnutrition, tuberculosis, cardiac failure, etc. S - Slide (Biopsy), Smear or swab for culture and sensitively to antibiotic, special investigations as deemed necessary, e.g. X-ray chest or underlying bone, blood sugar, biopsy of tissue from margin of the ulcer.

# Chapter 71

## Thyroid Swelling

- General plan of examination of thyroid swelling
- Primary thyrotoxicosis
- Thyroid carcinoma
- Nontoxic multinodular goiter (colloid goiter)
- Hypothyroidism
- Retrosternal goiter

### GENERAL PLAN OF EXAMINATION OF THYROID SWELLING

#### History

**I. Particulars of the patient – as stated earlier.**

#### II. Chief complaints

The patient may present with one or more of the following complaints viz.

1. A girl at menarche presenting with a diffuse enlargement in front of the neck.
2. A pregnant or lactating mother with a diffuse enlargement in front of the neck.

Physiological goiter is more often seen in women at puberty or during pregnancy when the metabolic demands are high and the production of  $T_3$  and  $T_4$  are comparatively low. Due to feedback mechanism TSH levels increase, which stimulate thyroid gland and causes diffuse hypertrophy and hyperplasia.

3. A woman from an endemic area of thyroid disease presents with a diffuse swelling in front of neck.
4. Swelling in front of neck with pressure symptoms on the trachea (dyspnea), esophagus (dysphagia), recurrent laryngeal nerve (hoarseness of voice).

5. Swelling in front of neck associated with tremor, eye signs in young female means a toxic goiter.
6. Swelling with palpable lymph nodes in the neck indicates malignancy.
7. Swelling in front of neck with palpitation and weight loss is found in a toxic goiter.
8. Swelling in front of neck with sudden increase in size and pain may be due to hemorrhage within the goiter.
9. A nodular swelling in front of neck in a middle-aged person for years with palpitation, precordial pain and exhaustion on strain indicates secondary thyrotoxicosis affecting mainly the cardiovascular system.

#### III. History of present illness:

- i. Pain: A goiter is usually painless. Appearance of pain in a painless goiter suggests the following.
  - a. Hemorrhage within a nodule.
  - b. Carcinoma supervening on a preexisting nodule.
  - c. Onset of inflammation.
  - d. Pyrexia.
  - e. Pressure symptoms.
- ii. Pressure symptoms – Present or not.
  - Dyspnea – Common causes of dyspnea in relation to goiter are compression or

erosion of trachea, retrosternal goiter and bilateral recurrent laryngeal nerve injury during surgery.

- Dysphagia is a late feature.
  - Dysphonia or hoarseness of voice is due to recurrent laryngeal nerve infiltration by anaplastic carcinoma and myxedema.
- iii. Rate of growth of goiter
    - Gradually increasing in size is usually a benign swelling while a rapidly increasing one is probably malignant.
    - Sudden increase in size with appearance of pain indicates hemorrhage within goiter.
    - Initially slowly growing later rapidly increasing in size is suggestive of a benign growth turning malignant.
  - iv. Reduction or gain in weight:
    - Weight gain with decreased appetite – Hypothyroid state.
    - Loss of weight with increased appetite – Hyperthyroid state.
  - v. Others symptoms of hyper- or hypothyroidism present or not.
    - a. Hyperthyroidism: Thin built, intolerance to heat, menorrhagia, restlessness, tremor, hot and moist skin, palpitations, dyspnea, and tiredness, ophthalmoplegia and goiter.



b. Hypothyroidism: Everything will be slow like walking, talking, mobility, etc. The features are obesity, bradycardia, oligomenorrhea, intolerance to cold, jerks – sluggish, tremors – absent, lethargic, loss of outer ends of the eyebrows, thinning of the hair. The hands are cold and skin is coarse with a goiter.

#### IV. Past history:

- Previous surgery suggests a recurrent goiter.

- Any history of irradiation in the neck.

#### V. Family history:

- Medullary carcinoma of thyroid can run in families.

- Pendred syndrome is a condition where the patient presents with congenital deafness associated with goiter and hypothyroidism. The goiter is due to absence of the enzyme thyroid peroxidase (dyschromogenetic goiter).

#### VI. Personal history/obstetrical history/menstrual history.

#### VII. Past treatment:

History of any drug treatment in the past, e.g. antithyroid drugs, eltroxin, beta-blockers, etc.

## Physical Examination

### General Survey

- I. Stature: Thin built in thyrotoxicosis and obese in myxedema.
- II. Pulse: In myxedema there is bradycardia (40–60 per minute), increased sleeping pulse rate (90 or more per minute) in thyrotoxicosis.
- III. Blood pressure: High systolic and low diastolic pressure, i.e. wide pulse pressure in primary thyrotoxicosis.
- IV. Cervical lymph nodes may be palpable in papillary carcinoma.
- V. Leg and foot: For pretibial myxedema of thyrotoxicosis.
- VI. Skin: Hot and moist in thyrotoxicosis while cold and coarse in myxedema.
- VII. Facies: Thyrotoxic facies/ myxedema facies.

### Local Examination

(A) **Inspection:** The gland is inspected from the front.

- i. A normal thyroid gland is not visible. If visible it is pathological.

If an obvious thyroid swelling is present, it is examined in line with ‘examination of a swelling’ as described earlier.

A thyroid swelling if uniformly enlarged takes the position and form of the thyroid gland.

- ii. Movement with deglutition: This is the most important physical sign of a thyroid swelling. Such movement may be greatly restricted when it is fixed by malignant infiltration or inflammation.
- iii. In a short neck person, thyroid gland is made prominent by Pizzillo’s method. The patient is asked to press the head against the hands placed at the back of the head to make the thyroid gland prominent (see below).
- iv. Movement on protrusion of tongue: Suggests thyroglossal cyst. This test is done in case of a nodule or a cyst in the region of isthmus of thyroid gland. It is of no value in cases of multinodular goiter or other thyroid swellings. A thyroid swelling does not move upward on protrusion of the tongue.

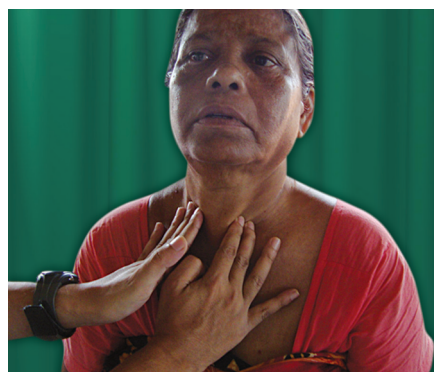#### (B) Palpation:

- i. The thyroid gland may be palpated from the front or behind (Fig. 71.2). Patient’s neck is slightly flexed for this purpose.

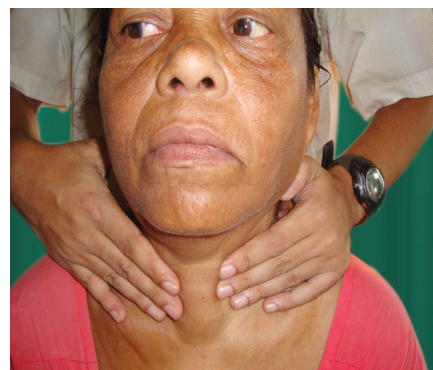*Lahey’s method:* (Fig. 71.1)

The examiner stands in front of the patient. In order to palpate the right lobe, the thyroid gland is pushed to the right from the left side. The lobe is thus made prominent and palpated with the other hand.

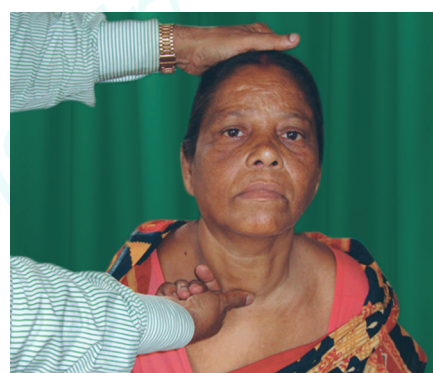- During palpation, size (extent), shape, surface, consistency are noted. Local



**Fig. 71.1:** Palpation of thyroid gland from the front (Lahey’s method)



**Fig. 71.2:** Palpation of thyroid gland from behind



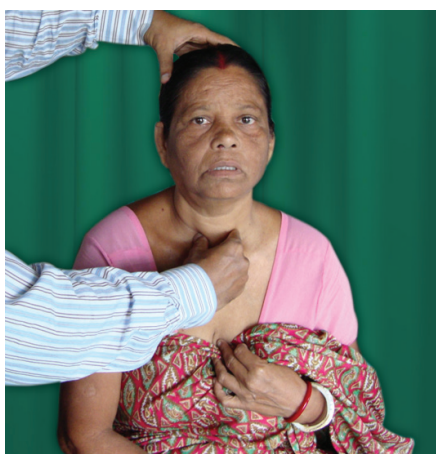**Fig. 71.3:** Crile’s method of palpating small thyroid swelling with the pulp of the thumb

rise of temperature is a feature of toxic goiters.

- The movement of the gland with deglutition is confirmed.
  - Consistency
    - Stony hard consistency is felt in case of carcinoma, Riedel’s thyroiditis or calcification in a multinodular goiter.
    - Firm – Adenoma, multinodular goiter.
    - Soft – Graves’ disease, colloid goiter.
- ii. Crile’s method is indicated, when there is a doubtful nodule. The thumb is kept over the suspected area of the nodule and the patient is asked to swallow. The nodularity is better appreciated with this test (Fig. 71.3).
  - iii. Pizzillo’s method of palpation – This is indicated in short neck obese patients as described above. As the gland is made prominent, palpation becomes easier (Fig. 71.4).

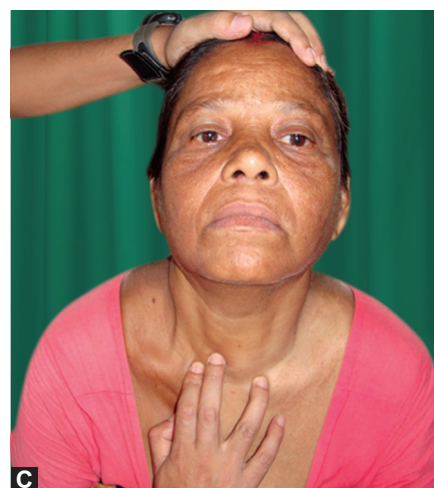
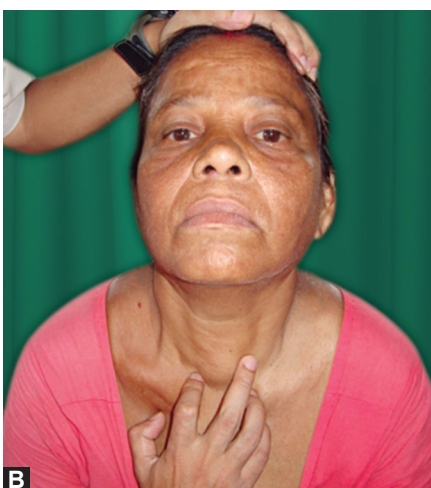
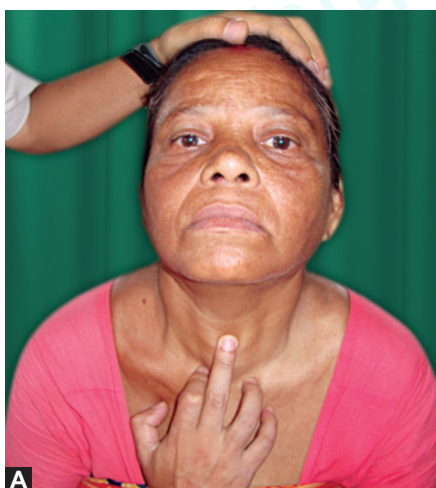**Fig. 71.4:** Pizzillo's method for palpation of the thyroid gland



**Fig. 71.5:** Kocher's test

iv. Kocher's test: This test is positive when mild pressure on the lateral lobe produces stridor due to tracheomalacia caused by: Long-standing multinodular goiters or carcinoma with infiltration into the trachea (Fig. 71.5).



**Figs 71.6A to C:** Method of examination of trachea to find out deviation using three fingers

- v. Sternomastoid contraction test: This test is done to see the relation of the swelling with sternomastoid muscle, when only one lobe is enlarged. Here the examiner keeps the hand on the side of the chin opposite the side of the lesion and the patient is asked to push the hand against resistance. If the swelling becomes less prominent, it indicates the swelling is deep to the sternomastoid muscle.
- vi. Palpation of trachea: This is checked by palpation using three fingers—The index, middle and ring fingers. The middle finger is run upwards along the trachea to feel the position—Central or deviated, the index and ring fingers being placed over sternal heads of sternomastoid muscles.
 

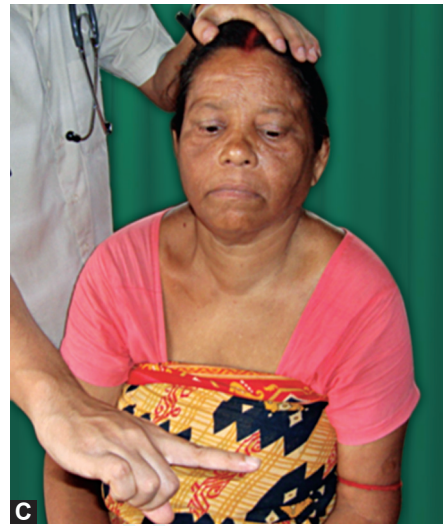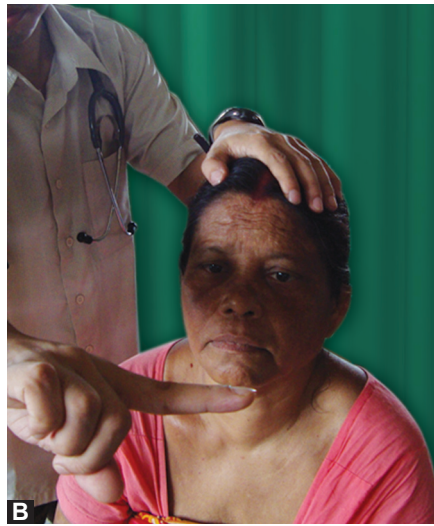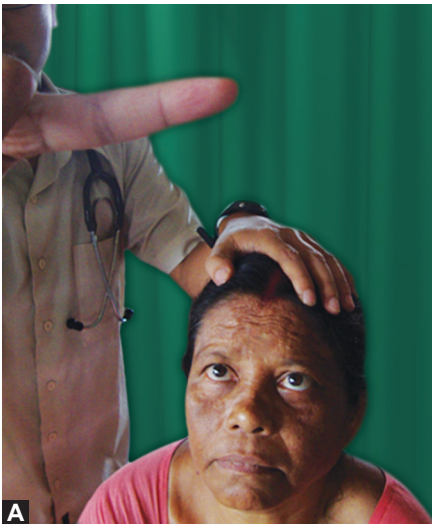In case of solitary nodule confined to one lobe, trachea is deviated to the opposite side. However, in multinodular goiters, trachea need not be deviated, because of symmetrical enlargement of both lobes (Figs 71.6A to C).
- vii. Pulsation of the common carotid artery: It is normally felt at the level of thyroid cartilage where it bifurcates. In multinodular goiters, it may be pushed laterally so that pulsations are felt in the posterior triangle. Carcinoma of the thyroid infiltrates the carotid sheath and pulsations may be absent. Absent carotid artery pulsation is called Berry's sign positive.
 

Since the lumen is not narrowed, superficial temporal artery pulsations are felt normally.
- viii. Evidence of toxicity: Present or not.
  - a. Toxic eye signs (Figs. 71.7 to 71.10)—
    - Lid lag or von Graefe's sign. (Figs 71.7A to C).
    - Möbius sign—Loss of convergence on accommodation at a near object from a distant object. (Figs 71.8A and B).
    - Joffroy's sign—Loss of wrinkling of forehead on looking up. (Fig. 71.9).
    - Stellwag's sign—Infrequent blinking – a staring look. These are mostly present in primary thyrotoxicosis or Graves' disease. (Figs 71.10).
    - Naffziger's sign (Fig. 71.11)—With the patient in sitting position and neck fully extended the examiner looks along the superior orbital margin. Exophthalmos is said to be present when eyeball is seen beyond the superior orbital margin.
  - b. Tremor in hands and tongue
  - c. Thrill over the thyroid gland.
- viii. Evidence of involvement of sympathetic trunk producing Horner's syndrome characterized by enophthalmos, pseudoptosis, anhidrosis and miosis.
- c. Percussion—Normally percussion over the sternum is resonant. In retrosternal goiters it gives a dull note.
- d. Auscultation—In thyrotoxicosis, the bruit is audible near the upper pole of thyroid lobes (Fig. 71.12).

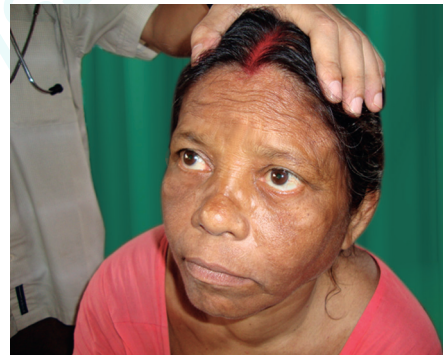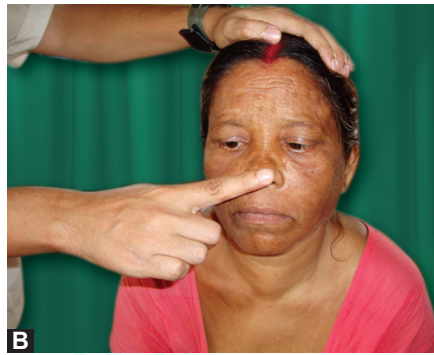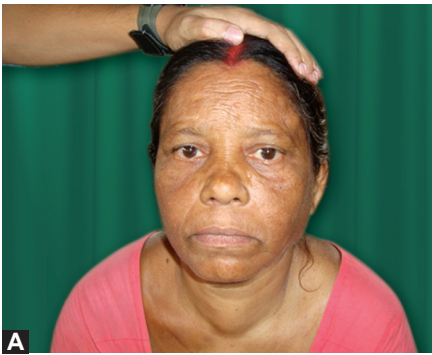### Systemic Examination

All systems to be examined as discussed earlier.



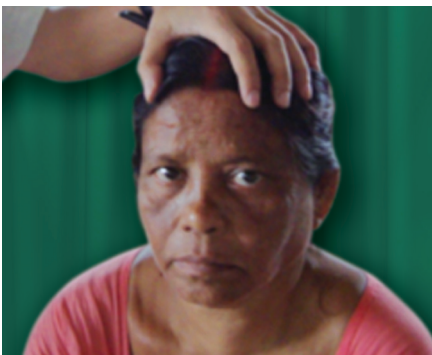

**Figs 71.7A to C:** Lid lag or von Graefe's sign—Inability of the upper eyelid to keep pace with eyeball when looking downwards

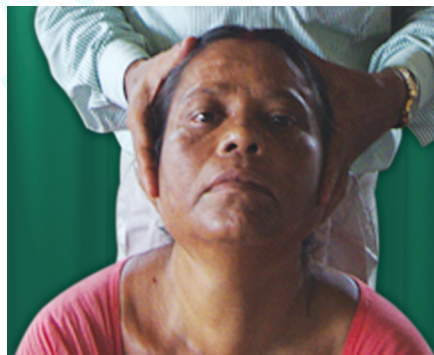

**Figs 71.8A and B:** Möbius sign—To check the lack of convergence of eyeball

**Fig. 71.9:** Joffroy's sign



**Fig. 71.10:** Stellwag's sign



**Fig. 71.11:** Naffziger's sign



**Fig. 71.12:** Auscultation of thyroid to detect the presence of bruit

## Summary of the Case

### Provisional Diagnosis

From the above examination one can conclude any one of the following about the gland and its activity, e.g.

The gland may contain:

- A solitary nodule.
- A multinodular goiter.
- A diffuse homogeneous enlargement of the whole gland.

Activity of the gland:

- Normal or Euthyroid.
- Hyperfunctioning.
- Hypofunctioning.

It is easier to classify the swelling according to pathology whereas classification according to activity is hopelessly confusing.

Thus,

- A solitary nodule may be due to the following causes:

- Dominant nodule of a multinodular goiter.
- A cyst (caused by hemorrhage into a necrotic nodule).
- An adenoma which may be hyperfunctioning.
- A carcinoma (papillary, follicular or medullary).

- Multinodular goiter may be due to the following causes:

- Multinodular simple goiter where more than one lump is palpable.
- Hashimoto's thyroiditis both (1) and (2) may present with hyper- or hypofunctioning thyroid gland.
- An anaplastic carcinoma especially if the mass is fixed to the surrounding tissues.

- Diffuse homogeneous enlargement of the whole gland: The causes may be:

- Graves' disease (primary thyrotoxicosis).
- A hyperplastic (colloid) goiter.
- Thyroiditis (Hashimoto's, de Quervain, or Riedel's).

Therefore, the thyroid swelling may have a provisional diagnosis of a solitary/multinodular/diffuse homogeneous goiter with normal, hypo- or hyperfunctioning status.

Investigations suggested

- Investigations to confirm diagnosis.

II. Other investigations anesthetic fitness. Differential diagnosis.

## Clinical Discussion

- What other swellings apart from thyroid moves up and down with deglutition?

- Thyroglossal cyst.
- Subhyoid bursal cyst.
- Pretracheal or prelaryngeal lymph node.
- Any swelling arising from larynx or trachea.

- Why the thyroid swelling moves up and down with deglutition?

The thyroid gland is ensheathed by pretracheal fascia, which is condensed posteromedially to form the ligament of Berry attached to the cricoid cartilage.

The pretracheal fascia is also attached to the larynx and trachea.

During deglutition, the larynx and the cricoid cartilage move up and down. Thus, thyroid swelling also moves up and down with deglutition due to its attachment to the larynx and the cricoid cartilage.

- Enumerate the conditions when movement with deglutition is not seen?

- Large goiters
- Anaplastic carcinoma.
- Riedel's thyroiditis.

- How do you ascertain retrosternal prolongation of goiter?

- From history, patient may have dyspnea, and swelling of face and neck.
- Local examination: The lower limit of thyroid gland is not visible. There may be prominent and engorged subcutaneous veins over neck and upper anterior part of chest wall due to superior vena caval obstruction in severe cases.
- Pemberton's sign is positive



**Fig. 71.13:** Demonstration of Pemberton's sign

- Lower limit of the swelling cannot be palpated.
- Trachea cannot be felt in the suprasternal notch.
- On percussion over manubrium sterni, the area is dull.

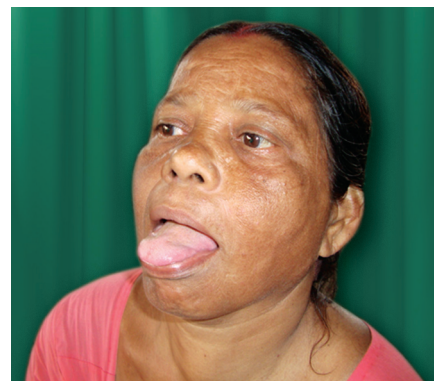
- What is Pemberton's sign?

Arms are elevated and held in contact with ears – after a few minutes the neck and face become congested and edematous due to pressure on the great veins at the root of the neck (Fig. 71.13).

- How will you demonstrate tremor?

The patient is asked to stretch out both the upper limbs in front and spread out the fingers. The fingers are looked at for presence of tremor (Fig. 71.14A).

Patient is asked to put out tongue resting on lower lip. Fine tremor may be observed in the tongue. In a severe case, the whole body may tremble (Fig. 71.14B).



**Figs 71.14A and B:** (A) Examination of tremor of the hands and fingers in the outstretched position (B) Examination of tremor of the tongue



7. What are the different levels of lymph nodes in the neck?

There are six different levels (Level I to VI) of lymph node groups in the neck. They are as follows:

- Level Ia lymph nodes are palpated at the submental triangle with the pulp of the fingers directed upwards with the neck slightly flexed and turned to the same side.
- Level Ib nodes are palpated similarly in the submandibular triangle.
- Level II, III and IV nodes are palpated along the line of internal jugular vein with the pulp of the fingers.
- Level V nodes are palpated at the posterior triangle and level VI nodes at the pre- and paratracheal region.

The number of lymph nodes, size, surface, margin, consistency and fixity to the skin or underlying structures are noted.

If the lymph nodes are enlarged, the drainage area is to be examined for any evidence of infection or any malignant tumor.

## PRIMARY THYROTOXICOSIS (GRAVES' DISEASE)

### Case Summary

The female patient aged 40 years has been admitted with the complaint of swelling in front of the neck mainly on the right side for last 2 years.

Along with the swelling, patient complained of bulging of her both eyes for last one and a half years. She complains of insomnia, decrease in weight, tremors, irritability, heat intolerance for last 1 year. Patient is taking antithyroid drugs for last 1 year. Her symptoms have improved to some extent but is still persisting.

On examination, patient has a typical thyrotoxic facies, pulse rate 105/min, thyroid gland is enlarged, margins well-defined, surface smooth, toxic eye signs viz. exophthalmos, von Graefe's sign, Möbius sign, Joffroy's sign, Stellwag's sign are all positive.

There is palpable thrill and audible bruit near the upper pole of the gland.

### Clinical Discussion

1. What is your case?

It is a case of primary thyrotoxicosis or Graves' disease.

2. Why do you say so?

- a. The patient gives history of irritability, insomnia, loss of weight, in spite of good appetite, palpitations, intolerance to heat and tiredness.
- b. She presents with a swelling in front of neck which moves with deglutition. There is exophthalmos, ophthalmoplegia, tachycardia and tremors in the hands and tongue, also palpable thrill and audible bruit near the upper pole of the swelling.

3. What is thyrotoxicosis?

It is a clinical syndrome that results due to excessive levels of active thyroid hormones viz. serum  $T_3$  and  $T_4$  in the circulation. Graves' disease (80%), toxic multinodular goiter (10%) and toxic adenoma (5%) account for 95 percent of causes of thyrotoxicosis. Other causes include iatrogenic, Jod-Basedow thyrotoxicosis, neonatal thyrotoxicosis and struma ovarii, etc.

4. What is exophthalmos and why does it occur?

In exophthalmos, both upper and lower eyelids move away from center, with the sclera visible below or all around the iris, due to forward protrusion of the eyeball.

### Causes of Exophthalmos

1. Exophthalmos is caused by the eyeball being pushed forward by an increase in retro-orbital contents. The extrinsic ocular muscles become bulky pushing the eyeball forward due to deposition of water and mucopolysaccharides combined with lymphocytic infiltration
2. The etiology of exophthalmos is not completely known. However, the orbital fibroblasts and muscles are thought to share a common antigen with thyrocytes, the TSH receptor. Ophthalmopathy results from inflammation caused by sensitized killer T-lymphocytes and cytotoxic antibodies. It may be an autoimmune process with antibody mediated effect on ocular muscles.

5. What are the levels of  $T_3$ ,  $T_4$  and TSH in Graves' disease?

$T_3$  and  $T_4$  levels are elevated with very low level of TSH.

6. What are the causes of exophthalmos?

1. Endocrine – Primary thyrotoxicosis.

2. Nonendocrine

- Superior vena caval obstruction.
- Unilateral or bilateral cavernous sinus thrombosis.
- Orbital cellulitis
- Severe glaucoma (Buphthalmos).
- Optic nerve glioma.
- Cushing's syndrome.

7. What is the etiology of primary thyrotoxicosis?

Graves' disease is an autoimmune disorder caused by abnormal thyroid stimulating antibodies (TSH-RAB) that bind to TSH receptor sites on follicular cells. This was previously called long-acting thyroid stimulator or LATS. Binding of these antibodies to the receptors imparts thyroid autonomy and excess thyroid hormone secretion.

8. What is the gross and microscopic pathology of the gland?

- Macroscopically
  - Thyroid gland is diffusely and smoothly enlarged.
  - There is high vascularity.
- Microscopically,
  - The gland is hyperplastic.
  - Epithelium is columnar with minimal colloid.
  - Aggregates of lymphoid tissue in the gland.
  - Increased vascularity.

9. What are the manifestations of Graves' disease?

- a. Thyroid enlargement or goiter.
- b. Extrathyroid features viz.
  - Exophthalmos
  - Dermopathy
  - Thyroid acropathy
  - Gastrointestinal, cardiovascular and neurological manifestations of thyrotoxicosis.

10. What is the course of exophthalmos?

- a. Proptosis.
- b. Proptosis with edema of eyelids, chemosis of conjunctiva.
- c. Corneal ulceration and papilledema.
- d. Malignant exophthalmos.

11. What are the eye signs in exophthalmos?

- a. von Graefe's sign: This is the earliest sign. The upper lid lags behind as the patient looks down.
- b. Stellwag's sign: Infrequent blinking.



- c. Joffroy's sign: Lack of wrinkling of the forehead due to immobility of the facial muscles when eyeballs are rolled upward.
- d. Möbius sign: Lack or difficulty of convergence of the eyeballs. See figures given earlier in this chapter.
12. What is progressive exophthalmos? Increase in exophthalmos in spite of removal of major portion of thyroid is known as progressive exophthalmos. It is associated with chemosis and impairment of corneal sensitivity and ulceration.
13. What is malignant exophthalmos? It is a form of progressive exophthalmos leading to optic nerve damage, chemosis, and ophthalmoplegia causing diplopia, corneal ulceration and visual loss.
14. What are the different grades of exophthalmos?  
Grade 0 – No sign, No symptom.  
Grade 1 – Only sign (Lid retraction or Lid lag), No symptom.  
Grade 2 – Soft tissue involvement.  
Grade 3 – Proptosis > 22 mm as measured by exophthalmometer.  
Grade 4 – External ophthalmoplegia (Diplopia, etc.)  
Grade 5 – Corneal ulceration.  
Grade 6 – Loss of vision.
15. How to show von Graefe's sign (Lid lag)? The patient is asked to look downward following the examiner's finger. The eyeball moves downward but the upper eyelid lags behind due to spasm of the Muller's muscle, i.e. the smooth muscle part of levator palpebrae superioris (Figs. 71.7A to C).
16. What is dermatopathy? This consists of:  
a. Pretibial myxedema  
b. Pruritus  
c. Thinning of hairs  
d. Palmar erythema.
17. What is pretibial myxedema? It is the thickening of the pretibial skin by a mucin like deposit in the subcutaneous tissue, often bilateral and symmetrical in distribution. It is a misnomer as it is not seen in myxedema.
18. What is thyroid acropathy? It is the clubbing of fingers and toes in association with features of thyrotoxicosis and pretibial myxedema (severe).
19. What are the GI manifestations of thyrotoxicosis? These are increased appetite, weight loss and diarrhea.
20. What are the cardiovascular manifestations in thyrotoxicosis? These are:  
• Palpitation, tachycardia and exertional chest pain,  
• Dyspnea on minimal exertion.  
• Arrhythmias i) Pulse – Ectopic beats, extrasystoles and water-hammer pulse (pulse pressure > 80 mm Hg).  
ii) Paroxysmal atrial fibrillation.
21. What are the neurological manifestations in thyrotoxicosis?  
• Tremor of the fingers and tongue.  
• Irritability, insomnia, increased sweating and nervousness.  
• Exaggerated deep reflexes.  
• Undue fatigue and muscle weakness.
22. What is thyrotoxic myopathy?  
a. Weakness of proximal limb muscle.  
b. May resemble myasthenia gravis.  
c. Severe degree is called myopathy.
23. What is secondary thyrotoxicosis?  
a. Secondary thyrotoxicosis is toxicity superimposed on a previously diseased gland, more commonly a multinodular or a solitary nodular goiter.  
b. The brunt of attack falls on the cardiovascular system – palpitation, precordial pain and later on auricular fibrillation and heart failure may occur.  
c. Neurological and eye signs are usually absent or mild.
24. How to confirm the diagnosis of primary thyrotoxicosis?  
a. By clinical examination.  
b. Investigations:  
1.  $T_3$ ,  $T_4$  and TSH levels— $T_3$  and  $T_4$  levels are elevated and TSH level is decreased or undetectable.  
2. Radioactive iodine ( $^{123}\text{I}$ ) uptake and scan with  $^{123}\text{I}$  or  $^{99\text{m}}\text{Tc}$ —An elevated uptake with diffusely enlarged gland confirms the diagnosis of Graves' disease, normal uptake being 16 – 48 percent in 24 to 48 hours.  
3. Thyroid antibodies—Antithyroglobulin (Anti Tg) and antithyroid peroxidase (Anti TPO) antibodies are elevated in 75 percent patients but are not specific. Elevated TSH-RAb is diagnostic of Graves' disease and is increased in 90 percent patients.
25. What is the differential diagnosis in this case?  
i. Anxiety state.  
ii. Pulmonary tuberculosis.  
iii. Malnutrition.  
iv. Diabetes mellitus.  
v. Pheochromocytoma.
26. What are the different modalities of treatment of thyrotoxicosis?  
• General measures  
• Surgery  
• Antithyroid drugs  
• Radioiodine therapy.
27. What are the general measures?  
• Rest  
• Sedation  
• Provision of adequate nutrition and use of beta-blockers.
28. What are the indications of surgery?  
• Failure of medical treatment continued for 2 years.  
• Low socioeconomic class patient.  
• Large diffuse toxic goiter and toxic multinodular goiter.  
• Autonomous toxic nodule in a patient below 40 years of age.
29. What are the advantages of surgery?  
• Surgery provides immediate cure.  
• No prolonged follow up is required. The patient can leave hospital by 5 days and resume work within one month.  
• Failure rate is minimal.
30. What are the disadvantages of surgery?  
• Risk of hypothyroidism in 20 to 45 percent cases.  
• Postoperative complications like hypoparathyroidism, recurrent laryngeal nerve injury, wound infection and keloid formation.  
• Recurrent thyrotoxicosis in 5 to 10 percent cases.  
• If total thyroidectomy is done; life long supplement with L-thyroxine is required.
31. What surgery is planned for the patient?  
a. Subtotal thyroidectomy – i.e. removing the thyroid leaving behind 1/8th of the gland (3-4 gm) on each side in the tracheoesophageal groove is usually done.  
b. Near total or total thyroidectomy can be done in patients with toxic eye signs to

provide total control of thyrotoxic features and better regression of eye signs.

However, complications like recurrent nerve injury and hypoparathyroidism are more common following total thyroidectomy. Besides, the patient will need life long l-thyroxine replacement.

32. What is the preoperative preparation?

Drug treatment is done to make the patient euthyroid as follows:

- Carbimazole 10 mg at 6 to 8 hourly intervals daily (30-40mg daily), till the patient is euthyroid (after 8-12 weeks usually), then the dose may be reduced to 5mg 8 hourly. The last dose is given on the evening before surgery.
- Lugol's iodine (5% iodine in 10% (KI) solution) – 10 drops TDS × 2 weeks before operation to reduce vascularity.
- Thyroxine 0.1 mg daily to prevent TSH stimulation which may increase size and vascularity of the gland.

33. What are the steps of operation of subtotal thyroidectomy?

It is discussed in the operative surgery section.

34. What is the postoperative advice to the attending nurse?

- To remove the stitches, if there is dyspnea.
- Endotracheal intubation set is kept ready.
- Tracheostomy set is to be kept ready especially in a peripheral hospital.

35. What are the complications of subtotal thyroidectomy?

- Hemorrhage.
- Respiratory obstruction.
- Recurrent laryngeal nerve injury.
- Hypoparathyroidism.
- Hypothyroidism.
- Thyroid storm or crisis.

36. What is thyroid crisis?

Acute exacerbation of hyperthyroidism in the postoperative period is called thyroid crisis or storm. It usually occurs in a poorly prepared patient for surgery.

The features are hyperpyrexia, sweating, tachycardia, restlessness and convulsions. If not treated vigorously the patient may die.

The treatment consists of oxygen administration, IV fluids, intravenous beta blockers and hydrocortisone, cooling of the patient, sedation, digitalization of the

patient, antithyroid drugs and Lugol's iodine 10 drops TDS.

37. What are the indications of antithyroid drugs?

- In children and adults under the age of 20 to 25 years.
- May be used at any age to bring about remissions.
- To attain euthyroid status prior to ablative surgery.

38. What are the advantages of medical management?

- No complications of surgery.
- No exposure to radioactive material and its side effects.

39. What are the drawbacks of medical treatment?

- Long duration (1-2 years) of treatment is required.
- Failure rate is about 50 percent.
- Side effects of the drugs include agranulocytosis, aplastic anemia, etc.

40. What is the principle of treatment by antithyroid drugs?

- Antithyroid drugs like propylthiouracil and carbimazole act by inhibiting thyroid hormone synthesis, they inhibit both the oxidative processes required for iodination of tyrosyl groups and the coupling of iodotyrosines to form  $T_3$  and  $T_4$ .

Propylthiouracil also blocks the conversion of  $T_4$  to  $T_3$  in the peripheral tissues.

- Antithyroid drugs also have immunosuppressive action on thyroid stimulating antibody (TSH-Rab) production.
- Beta-blockers like propranolol are effective in blunting the widespread sympathetic stimulation (tremors, anxiety, palpitation, heat intolerance, etc.) that occurs in hyperthyroidism.
- Iodides (e.g. Lugol's iodine) acts by reducing vascularity of the gland.

41. What is the dosage of carbimazole?

For initial control, 15mg TDS (5mg Tab available) or 30 to 60 mg per day. This is continued till the patient becomes euthyroid which usually requires 4 to 8 weeks. The dose is then reduced to half 5mg TDS or 5 to 20 mg/day as a maintenance therapy.

The exact duration of therapy is difficult to predict in the individual patient.

In general 12 to 24 months course is employed.

42. What is Lugol's iodine?

- It is the preparation of 5 percent iodine in 10 percent KI solution.
- Dose is 10 drops thrice daily orally for 2 weeks prior to surgery.
- It is also used in the treatment of thyroid storm.

43. What is the role of sedation?

It reduces anxiety and improves sleep. Drugs used are diazepam and alprazolam.

44. What are the indications of radioiodine therapy?

The indications are:

- All patients after the age of 35 years and not pregnant.
  - Recurrent thyrotoxicosis after surgery.
  - Severely ill thyrocardiacs.
- Beta-blockers should not be used in patients with significant myocardial disease as it may precipitate cardiac failure and bronchospasm.

45. What are the advantages of radioiodine therapy?

- No surgery and prolonged drug therapy is required.
- Very simple treatment as it is given as an oral drink as a solution of  $Na^{131}I$ .

46. What are the disadvantages of radioiodine treatment?

- The center should have isotope facility.
- Danger of radioactive exposure.
- Genetic damage when used in pregnancy.
- Patient develops hypothyroidism in 40 to 70 percent cases in 10 years time.
- Danger of carcinogenesis and slow in producing the effect (effect starts in 3-4 weeks).

47. How does radioiodine act?

It destroys thyroid cells and reduces the functioning thyroid mass to below the critical level.

48. What are the contraindications of radioiodine therapy?

- Age below 35 years
- Pregnancy
- Children
- Ophthalmopathy.

49. What is the dose of radioiodine?

- 300 to 600 MBq – response in 8 to 12 weeks.

- Further dose if no improvement occurs after 12 weeks.
  - Multiple doses may be required in 20 to 30 percent cases.
50. Will you like to combine some drugs along with radioiodine?  
Yes, propranolol 40mg OD orally with radioiodine to alleviate the sympathetically mediated manifestations of thyrotoxicosis.
51. What is Plummer's disease?  
It is secondary thyrotoxicosis in a multinodular goiter. Hyperthyroidism is milder and cardiac manifestations are common. The patient is usually an elderly female not accompanied by extrathyroidal manifestations of ophthalmopathy, pretibial myxedema and thyroid acropathy.
52. What is thyrotoxicosis factitia?  
Thyrotoxicosis factitia is iatrogenic thyrotoxicosis and occurs due to overdose of l-thyroxin given for puberty goiter. It is also seen in people who take thyroid extract as tonic.
53. What is Jod-Basedow thyrotoxicosis?  
Jod means iodine in German language and Basedow means toxic goiter. This is a form of iodine induced temporary thyrotoxicosis, iodine being given for hyperplastic endemic goiter.
54. What are other causes of thyrotoxicosis?  
a. Thyroiditis: Acute phase of Hashimoto's disease, subacute thyroiditis or de Quervain's.  
b. Neonatal thyrotoxicosis: In babies born to thyrotoxic mothers.  
c. TSH secreting pituitary adenoma.  
d. Struma ovarii.

## THYROID CARCINOMA

### Case Summary

This 35-year-old female patient presents with a swelling in the front and sides of the neck for last 2 years which was initially

increasing slowly in size but for last six months patient noticed the swelling was increasing rapidly.

She complains of dull aching pain over the swelling and hoarseness of voice for last 4 months. There are no symptoms suggestive of hypo-or hyperthyroidism.

On examination, general survey is essentially normal. On local examination there is diffuse enlargement of the whole gland. The right lobe is more enlarged than the left lobe. Surface is hard and nodular. The swelling is mobile and moving with deglutition. Multiple lymph nodes are palpable but mobile in the right cervical group. There is no dysphagia and carotid artery pulsation is palpable on both sides.

### Clinical Discussion

1. What is your case?  
It is a papillary carcinoma of the thyroid.
2. Why do you say so?
  - a. Young patient.
  - b. Surface is uneven and nodular.
  - c. Presence of palpable cervical lymph nodes.
  - d. Recent history of rapid growth – earlier for 1½ years growing slowly.
3. What are the types of carcinoma of thyroid? The types are:
  1. Primary
    - a. Arising from follicular epithelium:
      - i. Differentiated
        - Papillary: 60 to 80 percent
        - Follicular: 20 to 25 percent.
      - ii. Undifferentiated: Anaplastic carcinoma—5 to 10 percent.
    - b. Arising from interstitial lymphoid tissue: Malignant lymphoma—5 percent.
    - c. From para-follicular cells: Medullary carcinoma—5 percent.
  2. Secondary metastasis from carcinoma of breast, kidney, stomach, colon, etc. 2 to 4 percent.

4. What is the pathology of papillary carcinoma?

Papillary carcinoma is the most common thyroid cancer. It is the least aggressive and has a prolonged course prior to presentation.

Grossly, there is complex mass of papilliferous projections lying in cystic spaces.

Papillary tumors are divided (Woolmer) into three subgroups according to the size and extent – occult (less than 5 mm), intrathyroidal and extrathyroidal.

Microscopically,

- Presence of characteristic pale empty nuclei – called orphan Annie nuclei.
- Presence of psammoma bodies which are laminated calcified spherules. (Psammo-sand).

5. What is the mode of spread of papillary carcinoma?

- Lymphatic spread is the commonest to regional lymph nodes.
- Hematogenous spread is rare.

6. What is micropapillary carcinoma?

It is a tumor of less than 1cm size. It is seen following removal of benign nodules or subtotal thyroidectomy and not associated with any increased mortality or morbidity. Surgery that has been performed is usually adequate.

7. What is the clinical presentation of papillary carcinoma?

- a. Slowly growing swelling of the thyroid.
- b. Recent history of rapid growth.
- c. Initially painless, but dull aching pain of recent onset.
- d. Regional cervical lymph nodes are enlarged.
- e. Berry's sign may be positive.

8. What is follicular carcinoma?

It is a type of differentiated carcinoma arising from the follicular epithelial cell.

9. What is the pathology of follicular carcinoma?

Grossly, it is often indistinguishable from follicular adenoma and is well encapsulated.

Microscopically, the follicles are crowded with cells with hardly any colloid. Capsular and vascular invasions are prominent features. Follicular carcinoma is much more aggressive and dangerous compared to the papillary type.

	Papillary	Follicular
i. Subject	Young female	Elderly male
ii. Multicentric foci	Frequently seen	Seldom seen
iii. Hematogenous spread	Less common	More common
iv. Lymphatic spread	Common	Uncommon
v. Capsule	Seldom encapsulated	Commonly encapsulated
vi. Prognosis	Very good	<ol style="list-style-type: none"> <li>a. Noninvasive type—good</li> <li>b. Invasive type—bad.</li> </ol>

10. What are the types of follicular carcinoma?  
Depending upon the microscopic invasion of the capsule and the pericapsular blood vessels, there are two types.
- Invasive type.
  - Noninvasive type.
11. What are the differences between papillary and follicular carcinomas? See below
12. What are Hurthle cell tumors?  
Hurthle cell tumors are a variant of follicular carcinoma, in which oxyphil (Hurthle, Askanazy) cells predominate histologically. There is higher incidence of lymph node metastasis (25%) and occur in higher age groups (60 – 75 years).
13. How will you proceed to manage this case?  
Apart from routine investigations done for anesthetic fitness, I would like to do some investigations to confirm my diagnosis viz.
- FNAC from the lymph nodes and the thyroid swelling.
  - USG of thyroid gland to assess the extent of thyroid enlargement as well as the lymph node enlargement.
  - Thyroid hormone profile – T<sub>3</sub>, T<sub>4</sub> and TSH.
14. What are the other possibilities?
- Nontoxic multinodular goiter.
  - Follicular adenoma or solitary nodule (nontoxic).
  - de Quervain's thyroiditis.
  - Riedel's thyroiditis.
15. How do you treat this case?  
After confirmation by FNAC, I will do a total thyroidectomy and modified radical neck dissection on the right side.
16. What is Berry's picking.  
It is the removal of palpable discrete lymph nodes in the neck. However, this is an inadequate dissection.
17. What is near total thyroidectomy?  
This consists of total thyroid lobectomy on the affected side with conservation of 1 to 2 gm of thyroid tissue on the contralateral side, which preserves the blood supply to one or both parathyroids. Surgeons who have less experience in total thyroidectomy may choose to near total thyroidectomy.
18. Why total thyroidectomy is done in papillary carcinoma?  
A total thyroidectomy is carried out because of multiple foci of disease in the whole thyroid.
19. What is the status of hormone replacement therapy after differentiated thyroid cancer surgery?  
Following thyroidectomy, all individuals with papillary as well as follicular carcinoma should be placed on suppressive dose of thyroid hormone l-thyroxin for life-long whether or not the entire thyroid has been removed. This will reduce the recurrence rate. Papillary carcinoma responds the most because the tumor is usually TSH dependent.  
Dose – 0.3 to 0.4 mg/day of l-thyroxin for complete suppression of TSH production, i.e. a suprathreshold dose is given.
20. What is the treatment of follicular carcinoma?
- If minimally invasive: Hemithyroidectomy and follow-up.
  - If frankly invasive: Treatment is total thyroidectomy with life-long l-thyroxin replacement therapy.
- If lymph nodes are palpable; it is combined with modified radical neck dissection.
- Radioiodine therapy is indicated in the postoperative period if secondaries are detected by whole body isotope scanning. Dose: 100 – 300 mci of <sup>131</sup>I.
  - External beam irradiation is used in inoperable cancers that have invaded the trachea and for the treatment of metastases that does not pick up radio-iodine.
21. What is the follow up protocol for differentiated thyroid carcinoma?
- In the first week after surgery, whole body scan with <sup>131</sup>I is done. If there is no residual thyroid tissue in the neck or any metastatic lesion, patient is kept on full suppressive dose of l-thyroxin.
  - After 6 months physical examination of the neck and whole body scan with <sup>131</sup>I is done. Before scan, l-thyroxin is stopped for 1 month.
    - Estimation of serum thyroglobulin (Tg) – It should be undetectable after surgery.
    - Cervical ultrasound to confirm the findings, if any of palpation during physical examination of the neck.
 If the above tests are normal, suppressive therapy with l-thyroxin is continued.
- Follow-up is done at yearly intervals, with clinical evaluation, thyroglobulin estimation and whole body radioiodine scanning.  
It radioiodine scanning shows any metastasis, this is treated with ablative doses of radioiodine.
22. What are the prognostic scales in carcinoma thyroid?  
These are:
- AGES scale and
  - AMES scale.
23. What is AGES scale?  
It is also known as Mayo's group scale.
- A – Age of the patient.  
G – Grade of the tumor.  
E – Extension of the tumor: Intrathyroidal or extrathyroidal.  
S – Size of the tumor.
24. What are the patients with good prognosis according to AGES scale?
- A – Age less than 40 years in female and 50 years in male.  
G – Well-differentiated tumor.  
E – Intrathyroid tumor and  
S – Size less than 1 cm in papillary and 4cm in case of follicular carcinoma.  
These patients are designated as low risk group and consist of 85 percent of the patients.
25. What are the patients with poor prognosis (High risk group)?
- A – Age > 40 years in female and > 50 years in male.  
G – Poorly differentiated tumor.  
E – Extrathyroidal extension of tumor.  
S – More than 1cm in papillary and 4cm in follicular carcinoma.  
High risk group consists of 15 percent of cases.
26. What is AMES scale?  
It is from Laley's clinic
- A = Age  
M = Metastasis  
E = Extent of tumor  
S = size of tumor  
High risk = 85 percent  
Low risk = 15 percent
27. Why thyroglobulin assay is done in the postoperative period?  
Thyroglobulin (Tg) estimation in the postoperative period is used as a tumor marker to detect any recurrent disease in the neck or metastatic disease.

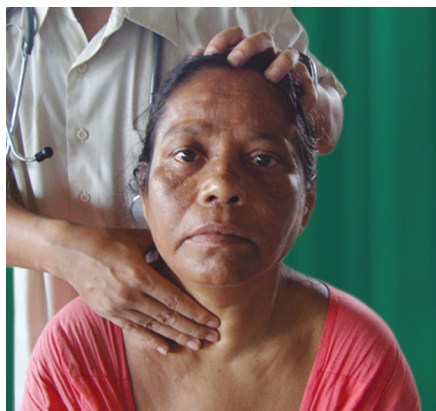

Normally the thyroglobulin level is less than 3ng/ml in a patient after total thyroidectomy.

Serial thyroglobulin estimations may rule out the need for whole body radioiodine scanning ( $^{131}\text{I}$ ), if thyroglobulin level is normal.

If the thyroglobulin level is raised, radioiodine scanning may be done to localize the metastatic disease.

28. What is the clinical presentation of anaplastic carcinoma?
- Anaplastic carcinoma usually involves the elderly patients of the age group 60 – 70 years.
  - Compressive symptoms like dysphagia, dyspnea and hoarseness of voice may be present.
  - On examination there is hard irregular enlargement of thyroid gland, which is immobile being fixed to the underlying structures.
  - Carotid pulsation is not palpable (Berry's sign positive) and lymph nodes in the neck are palpable (Fig. 71.15).
29. How do you treat anaplastic carcinoma of thyroid?
- The diagnosis is first confirmed by FNAC or true cut needle biopsy.
  - A curative resection is not possible because of its aggressive nature.
  - An isthmusectomy is done to relieve tracheal obstruction and obtain tissue for histopathology examination.
  - Radiotherapy is given in all cases.
  - Radioiodine is ineffective.
  - Combination chemotherapy has been tried but not very effective.



**Fig. 71.15:** Demonstration of Berry's sign, i.e. absence of the carotid pulse

30. What is the prognosis of anaplastic carcinoma?

Very few patients survive one year.

31. What is a medullary carcinoma of thyroid (MTC)?

It is the thyroid carcinoma arising from the cells of the ultimobranchial bodies (parafollicular or C - cells) which secrete calcitonin, a tumor marker and a calcium lowering hormone.

32. What is the clinical presentation of medullary carcinoma of thyroid?

- Family history of carcinoma of thyroid in 30 percent cases.
- The patient may present with features of thyroid carcinoma viz. neck mass and features of compression-- dysphagia, dyspnea and hoarseness.
- Diarrhea may be present in 30 percent cases.
- History of hypertension or other features of multiple endocrine neoplasia (MEN).

33. What is the genetic basis of medullary thyroid carcinoma?

It has an autosomal dominant inheritance, RET protooncogene in chromosome no 10 is the genetic marker.

34. What are the pathological features of medullary thyroid carcinoma?

Grossly, the tumor appears as a circumscribed, nonencapsulated white mass. In sporadic form, it is mostly solitary, but in familial form, bilateral and multicentric. Microscopically, there is presence of characteristic 'cell balls' (tumor cells) and amyloid stroma, with no papillary or follicular structure.

35. What are the secretory products of tumor cells in MTC?

These are calcitonin, carcinoembryonic antigen (CEA), histamine, serotonin, prostaglandins, substance P, ACTH, etc.

36. What are the different forms of MTC?

- Sporadic form – 70 percent
- Associated with MEN IIa
- Associated with MEN IIb
- Familial MTC without other endocrinopathies.

37. What are MEN IIa and IIb?

MEN IIa or Sipple's syndrome comprises hyperparathyroidism (50%), multicentric medullary carcinoma thyroid and pheochromocytoma.

MEN IIb comprises pheochromocytoma, medullary carcinoma of thyroid and mucosal neuromas producing lumpy eyelids or lips.

38. What is MEN I.

MEN I or Wermer's syndrome consists of parathyroid hyperplasia (80%), pancreatic islet cell tumor (65%), pituitary adenoma (75%), thyroid and adrenocortical adenomas.

The abnormal gene in MEN type I has been mapped to chromosome 11.

39. What is the treatment of medullary carcinoma?

Treatment of choice is total thyroidectomy and resection of involved lymph nodes with either a radical or modified radical neck dissection.

40. What is the tumor marker in MTC?

It is 'calcitonin'. High levels of calcitonin > 0.08ng per ml are produced in MTC. This level falls after resection of the tumor and will rise again if the tumor recurs. So, it is an important marker for follow-up.

## NONTOXIC MULTINODULAR GOITER (COLLOID GOITER)

### Case Summary

A 40-year-old female patient presents with a bilobed swelling occupying the front and sides of the neck for last 5 years.

The swelling was increasing very slowly over the last 5 years without any pain or constitutional symptoms related to the gastrointestinal, cardiovascular or nervous system.

On examination, the swelling is butterfly-shaped and moves with deglutition, soft elastic in feel, surface is nodular, no toxic signs present and neck nodes are not palpable. No fixity with the surrounding structures is present and carotid pulsation, palpable. The margins of the swelling are rounded and pass beneath the sternocleidomastoid muscle on the lateral sides. There is no evidence of retrosternal prolongation.

### Clinical Discussion

1. What is your case?

It is a case of nontoxic multinodular goiter involving both lobes of thyroid gland.



2. Why do you say so?
  - a. The swelling is butterfly-shaped and moves up and down with deglutition.
  - b. No toxic signs like exophthalmos, tremor, tachycardia, and palpitation present.
  - c. No neck nodes palpable.
  - d. The swelling is soft elastic in feel and surface is nodular.
  - e. No fixity to surrounding structures and carotid pulsation is palpable.
3. What is the differential diagnosis of a non-toxic multinodular goiter?
  - a. Colloid goiter
  - b. Chronic thyroiditis
  - c. Carcinoma of thyroid.
4. What are the etiological factors for the development of a simple or diffuse goiter?
  - a. Physiological due to increased demand for thyroid hormones, e.g. puberty, pregnancy and lactation.
  - b. Primary iodine deficiency states or end-emic goiter, e.g. mountainous regions, great lakes of America, North India.
  - c. Secondary iodine deficiency states, e.g.
    - i. Dietary, e.g. cabbage, cauliflower, soybeans which contain thiourea which interfere with trapping of iodine or the synthesis of thyroxine.
    - ii. Drugs – e.g. overdose of thiocyanates, iodine in the treatment of thyrotoxicosis.
    - iii. Dysshormonogenetic goiter due to inherited deficiency of enzymatic defects, e.g. thyroid peroxidase, causing impairment of iodine accumulation, organification or coupling of iodo-tyrosines in the thyroid gland. This is very rare and also called familial goiter. This is inherited as autosomal recessive gene.
5. What is Pendred's syndrome?  
It is the dysshormonogenetic goiter associated with congenital deafness. The enzyme deficient is the thyroid peroxidase which is responsible for organification of trapped iodine.
6. What is the natural history of a simple goiter or evolution of multinodular goiter?

The following stages are seen in the evolution of multinodular goiter.

### Stage I or Stage of Diffuse Hyperplasia

- i. Relative lack of iodine (due to increased demand or diminished ingestion or defective utilization) causes fall in the level of circulating thyroxine.
- ii. Consequently anterior pituitary produces more TSH due to loss of inhibitory feedback effect of thyroxine which in turn causes hyperplasia of the thyroid gland. There is increase in the number of follicles and reduction in the amount of colloid.

### Stage II or Colloid Goiter

Correction of iodine lack is followed by normal production of thyroxine and TSH level falls. There is formation of large follicles filled with colloid. Thyroid undergoes involution.

Stage I and II together forms the hyperplasia involution cycle.

### Stage III or Stage of Multinodular Goiter

As a result of alternating periods of iodine sufficiency and iodine lack due to causes mentioned above, a mixed pattern develops with areas of active and inactive lobules.

Active lobules become more vascular and hyperplastic until hemorrhage and central necrosis appears. Necrotic lobules coalesce forming a nodule filled either with iodine-free colloid or a mass of new but inactive follicles.

Continual repetition of this process results in the development of multinodular goiter.

7. What are the complications of multinodular goiter?
  1. Secondary thyrotoxicosis known as Plummer's disease.
  2. Follicular carcinoma, especially in endemic areas.
  3. Tracheal compression.
  4. Retrosternal prolongation.
  5. Respiratory distress due to complications 3 and 4 above.
8. What are the normal levels of thyroid hormones?
 

T<sub>3</sub> – 1.5 to 3.0 nmol/liter  
T<sub>4</sub> – 75 – 150 nmol/liter

TSH – 0.3 – 3.3 m Iu/liter  
Free T<sub>3</sub> – 3.5 – 7.5 pmol/liter  
Free T<sub>4</sub> – 10 – 30 pmol/liter.

9. How do you treat this case of multinodular goiter (MNG)?  
I would like to confirm my diagnosis first by:
  - a. Ultrasonography of thyroid gland.
  - b. FNAC from different sites of thyroid gland.
  - c. Thyroid profile: T<sub>3</sub>, T<sub>4</sub> and TSH
 As this multinodular goiter involves both lobes of thyroid subtotal thyroidectomy is the treatment of choice.
10. Does all patients with thyroid nodule need thyroid profile study?  
TSH level estimation is required in all patients with thyroid nodule to detect hypo- or hyperthyroidism. If TSH is normal; T<sub>3</sub>, and T<sub>4</sub> level estimations are not required. But in suspected hypo- or hyperthyroidism thyroid profile (T<sub>3</sub>, T<sub>4</sub> and TSH) is to be done.
11. If a single nodule is palpable, can it be still a multinodular goiter?  
Yes, it may be dominant nodule of a multinodular goiter which is detected by ultrasonography.
12. How do you treat multinodular goiter?  
Surgery is the treatment of choice – the following operations are done:
  - a. Hemithyroidectomy – when nodules are localized to one lobe.
  - b. Subtotal and near total thyroidectomy: When both the lobes are studded with nodules. Total lobectomy is done on the more affected side with subtotal resection on the less affected side.  
Postoperatively l-thyroxine 0.2 mg/day is given to suppress TSH secretion with the aim of preventing recurrence for a minimum period of 2 years or even for rest of the patients' life.
13. What are the indications of thyroidectomy (Hemi- or subtotal)?
  - a. Cosmetic reason (unsightly goiter).
  - b. Retrosternal prolongation or tracheal compression producing respiratory distress.
  - c. Suspicion of malignancy.
  - d. Secondary thyrotoxicosis.

**HYPOTHYROIDISM**

## 14. What is hypothyroidism?

It is a clinical syndrome resulting from deficiency of circulating thyroid hormones.

## 15. What are the causes of hypothyroidism?

- a. Congenital – cretinism.
- b. Acquired –
  - i. Primary
    - a. Thyroiditis
      1. Autoimmune thyroiditis
        - Nongoitrous – primary myxedema.
        - Goitrous – Hashimoto's thyroiditis
      2. Riedel's thyroiditis
    - b. Iatrogenic
      - Thyroidectomy
      - $^{131}\text{I}$  Therapy
      - Antithyroid drugs
    - c. Endemic – iodine deficiency.
    - d. Dysrhormonogenetic – defective synthesis of hormones.
  - ii. Secondary
    - Hypopituitarism
    - Hypothalamic hypothyroidism.

## 16. What is cretinism?

When hypothyroidism gets manifested in neonates it is known as cretinism. It is due to complete or near complete failure of thyroid development (sporadic) or maternal and fetal iodine deficiency (endemic). A cretin infant is pot-bellied with umbilical hernia, puffy face, protruded tongue and pale appearance. The boy is physically and mentally retarded due to impaired development of skeletal and central nervous system.

## 17. What is myxedema?

It is the severe form of thyroid deficiency developing in the older children and adults. Clinically the features are bradycardia, lethargy, tiredness, cold intolerance, weight gain, slow speech and movement (bradykinesis), constipation, carpal tunnel syndrome, facial and periorbital puffiness due to deposition of glycosaminoglycans in the subcutaneous tissues which may be expressed in various combinations.

There are also malar flush, cardiomegaly, enlarged tongue and deep voice. Pericardial and pleural effusions may occur.

## 18. How do you confirm the diagnosis?

- a. Low circulating  $\text{T}_3$  and  $\text{T}_4$ .
- b. Raised TSH in primary thyroid failure.
- c. Low TSH level in secondary hypothyroidism and do not respond to TRH stimulation.
- d. ECG – low voltage with flattened or inverted T-wave.
- e. Hyponatremia.
- f. Thyroid antibodies – Antimicrosomal and anti  $\text{T}_4$ ,  $\text{T}_3$  antibodies.

## 19. How it is managed?

- a. Administration of l-thyroxine 0.05 to 0.2 mg (50 – 200mg)/day.
- b. Myxedema coma – Emergency, IV thyroxine 400mg IV then 100mg/day. Correction of hyponatremia.

**RETROSTERNAL GOITER**

## 20. What are retrosternal goiters?

When a portion or whole of the thyroid swelling extends into the superior mediastinum it is known as retrosternal goiter.

## 21. What are the types of retrosternal goiter?

- There are three types:
- Substernal
  - Intrathoracic
  - Plunging.

## 22. What are the predisposing factors?

- a. Short neck
- b. Strong strap muscles
- c. More common in males
- d. Negative intrathoracic pressure.

## 23. What are the clinical features?

- a. Often asymptomatic
- b. Nocturnal dyspnea
- c. Harsh cough and stridor.
- d. Examination –
  - i. Prominent and engorged subcutaneous veins over the neck and upper anterior part of chest wall, superior vena caval obstruction in severe cases.
  - ii. The trachea cannot be palpated with finger tip in the suprasternal notch.

iii. One cannot get the lower limit of the swelling on palpation.

iv. Pemberton sign – is positive. Arms are elevated and held in contact with ears. After a few minutes, the neck and face becomes congested and edematous due to pressure on the great veins at the root of the neck.

v. Percussion elicits dull note over manubrium sterni. (Fig. 71.16)

vi. X-ray of chest – soft tissue shadow in the superior mediastinum and deviation and compression of trachea.

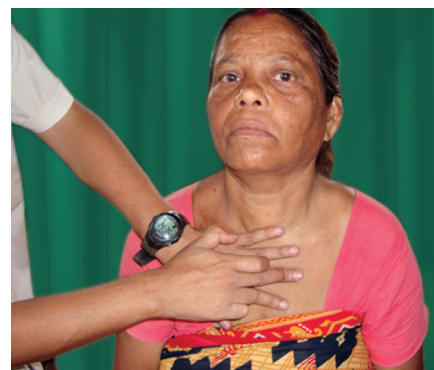## 24. How do you confirm the diagnosis?

- a. Clinical examination.
- b. X-ray chest and thoracic inlet.
- c. Radioiodine uptake study.
- d. CT scan of chest.

## 25. How do you treat retrosternal goiter?

Surgery is the treatment of choice. Basic surgical steps are:

- a. Adequate mobilization by ligating and dividing the superior thyroid, middle thyroid and inferior thyroid vessels.
- b. Placement of 1/0 or 2/0 sutures placed deeply into the goiter for traction.
- c. Traction and blunt dissection.
- d. Evacuation of colloid if it is a colloid goiter.
- e. Piecemeal delivery of a multinodular goiter.



**Fig. 71.16:** Percussion over the sternum shows dullness in case of retrosternal extension

# Chapter 72

## Breast Carcinoma

- General plan of examination of a case of carcinoma breast
- Early carcinoma of breast
- Locally advanced carcinoma of breast (LABC)
- Breast carcinoma with distant metastasis
- Breast Reconstruction

### GENERAL PLAN OF EXAMINATION OF A CASE OF CARCINOMA BREAST

#### History

- Particulars of the patient as discussed earlier.
- Chief complaints.
  - Swelling in the breast.
  - Pain in the breast / pain over the swelling.
  - Ulceration over the swelling / breast.
  - Change in the breast size, skin retraction, nipple retraction, present or not.
  - Swelling in the axilla.
- History of present illness:
  - Detailed history about the swelling is taken, e.g.
    - Duration
    - Rate of growth
    - Any swelling in the opposite breast.
  - Pain—Duration, site, character, relation with the swelling and menstrual cycle are noted.
  - Nipple discharge if present, type of discharge (serous / milky/ serosanguinous) should be enquired of.
  - Any metastatic symptoms present or not like bone pain, cough, hemoptysis, dyspnea, etc.

- History of appetite and weight loss.
  - If any ulcer is present, details about the ulcer are noted.
- Past history.
  - Family history—Whether a close relative like mother, aunt, daughter, etc. has suffered from carcinoma breast or not.
  - Personal history:
    - Age at menarche.
    - Number of pregnancies, abortion.
    - Age at 1st pregnancy.
    - History of OC pill and hormone replacement therapy.
  - Treatment history
  - History of allergy.

#### Physical Examination

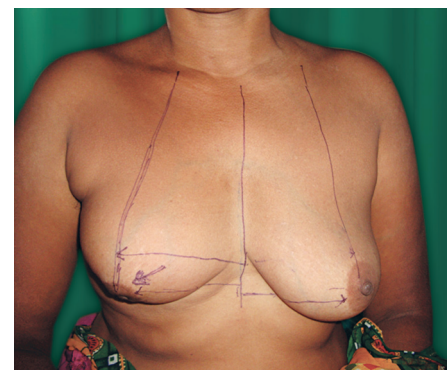
##### a. General survey.

**b. Local examination:** Examination of breasts. The body above the waist is stripped and both breasts are completely exposed before inspection is commenced. Patient position – sitting with the arms by her side.

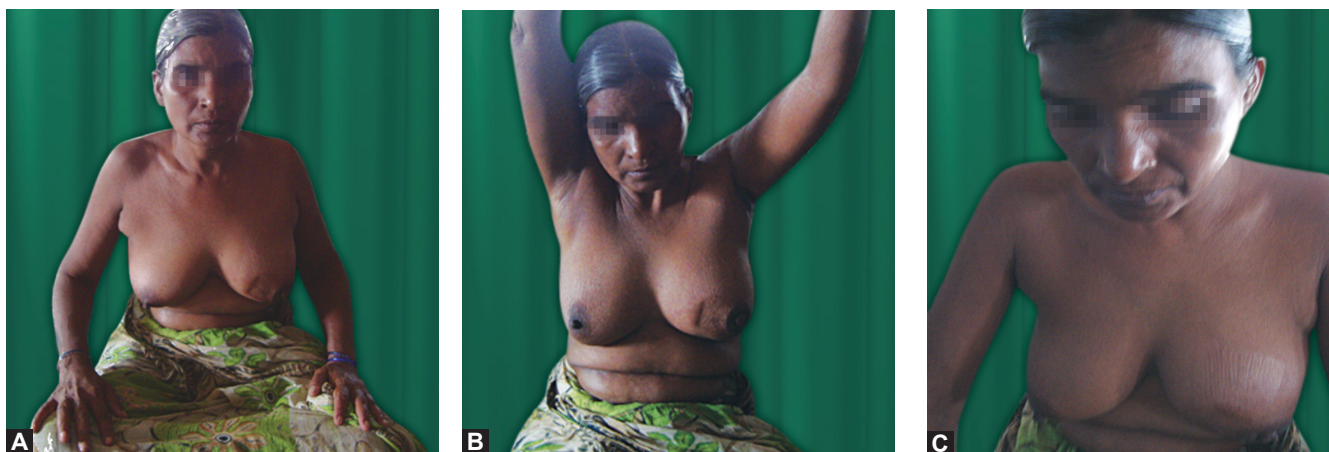##### 1. Inspection:

- Breast as a whole—Normal breast is examined first, then examination of the diseased breast—Right / left.
  - Size and shape—Altered by the growth / not.

- Swelling – If present the following are noted number, size, shape, surface, venous prominence, skin retraction, any dimpling.
- Nipple:
    - Any retraction.
    - Discharge.
    - Ulceration.
    - Position in comparison to normal side (Fig. 72.1)
  - Areola:
    - Any diminution in size due to retraction.
    - Any cracks, fissure, ulcer or eczema.



**Fig. 72.1:** Deviation of the right nipple in advanced carcinoma of right breast



**Figs 72.2 A to C:** The three positions of the patient for examination of the breast as mentioned above (A) Sitting with arms by the side, (B) Sitting with arms raised, (C) Sitting and leaning forward.

- Any edema of the arm.
- Inspection with the patient sitting and leaning forward to see whether both the breasts fall forward equally.
- Inspection of the breasts with the arms raised over the head to look for nipple deviation or any skin changes.

2. Palpation: Normal breast is palpated first and described as normal. Diseased breast (right / left).

- Local temperature and tenderness.
- Swelling if present, the details are palpated, viz. quadrant in which it is situated, size, shape, margin and consistency, fixity to skin, pectoral fascia and muscle, and to the chest wall, fixity to serratus anterior and breast tissue.

If swelling is cystic—Fluctuation and transillumination is tested.

- If ulcer is present, examination of its site, size and shape, margin, edge, floor, any discharge, surrounding area, etc.

- Examination of regional lymph nodes:
  - Examination of axillary nodes Anterior, central, apical, lateral and posterior nodes.
  - Examination of supraclavicular nodes.

c. **Systemic examination** as discussed earlier.

- **Summary of the case**
- **Provisional diagnosis**

- **Differential diagnosis**
- **Investigations suggested.**

### Clinical Discussion

1. What are the different positions for local examination of the breast?

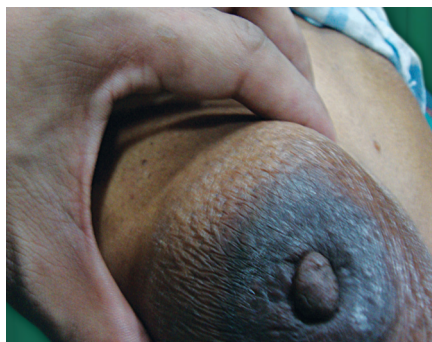There are three positions (Figs 72.2 A to C).

- Patient is undressed upto the waist and sitting with the arms by the side of the body.
- Patient sitting and arms raised over the head and
- Patient sitting and bending forward so that the breasts fall away.

The above positions are necessary for evaluation of the different physical signs.

2. How do you palpate the breasts?

The normal breast is palpated first. The lump in the affected breast is palpated by the flat of the fingers and to some extent between finger grips.



**Fig. 72.3:** Dimpling of skin in carcinoma of the breast by moving the lump

3. How will you demonstrate skin fixity?

Skin fixity implies infiltration of the skin by the underlying malignant tumour. This is tested by moving the lump from side to side – skin dimpling occurs (Fig. 72.3).

Alternately, skin fixity is demonstrated by trying to lift the skin from the underlying lump in between fingers.

If the skin is fixed to the lump, the overlying skin cannot be lifted from the lump.

4. How will you demonstrate fixity to the pectoral muscle and fascia?

- The lump is moved in the direction of the fibers of the pectoralis major and at right angles to it with the muscle relaxed (the arms hanging beside) (Fig. 72.4A).

- Next, the patient places her hands on the hips and presses her hands over the hips as firmly as possible to make the pectoralis major taut which is verified by feeling the taut anterior axillary fold.

- The lump is moved along and across the contracted fibers of pectoralis major.

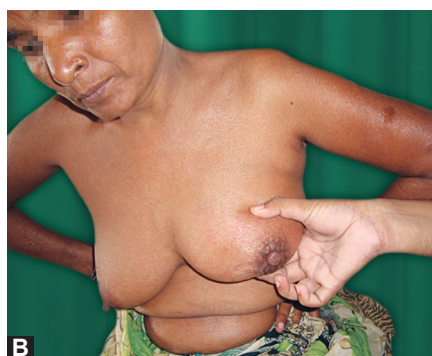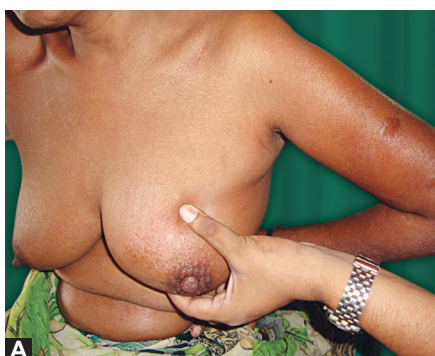Any restriction in mobility indicates fixity to the pectoral fascia or muscle. (Fig. 72.4B).

Contraction of the muscle excludes the movement of muscle as a whole.

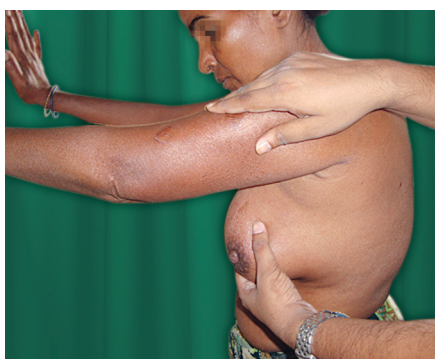5. How do you demonstrate fixity to the chest wall?

The lump with the breast is moved in all directions with relaxed muscles. Immobility of the lump irrespective of contraction of the muscle indicates fixity of the lump to the chest wall.

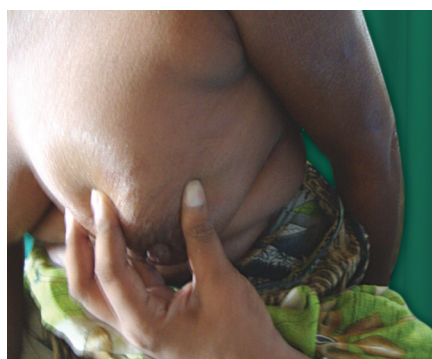




**Figs 72.4 A and B:** Demonstration of fixity to pectoralis major muscle in relaxed and contracted state of the muscle



**Fig. 72.5:** Demonstration of fixity to the serratus anterior muscle.



**Fig. 72.6:** Demonstration of peau d'orange

6. How will you demonstrate fixity to the serratus anterior muscle?
  - a. When the lump is located in the outer and lower quadrant, fixity to this muscle is tested.
  - b. The mobility of the lump over the chest wall is tested. Next, the patient is asked to press the outstretched hands against a wall and the lump is moved over the taut serratus anterior muscle. Any restriction in mobility compared to that in the relaxed state indicates fixity to the muscle (Fig. 72.5)
7. How will you demonstrate peau d'orange?
  - a. When subdermal lymphatics are blocked by the malignant process, cutaneous edema results. At the sites where the skin is tethered by sweat ducts and hair follicles it cannot swell imparting the "orange peel appearance" of the skin. This is known as peau d'orange.
  - b. Peau d'orange is demonstrated by squeezing a segment of skin over the breast, which will show the cutaneous lymphedema in the skin with prominent sweat ducts and hair follicles in

between, as they are more firmly fixed to the subcutaneous tissue than the rest of the skin (Fig. 72.6).

8. What are the different groups of axillary lymph nodes?
 

The axillary lymph nodes, 20 to 30 in number, drain not only the lymphatics of the breast but also those of the pectoral region, upper abdominal wall and the upper limb and are arranged in five groups viz.

  - a. Lateral or humeral group along the axillary vein.
  - b. Anterior group lying deep to pectoralis major along the lower border of pectoralis minor.
  - c. Central group in the axillary fat.
  - d. Posterior group along the subscapular vessels.
  - e. Apical group immediately behind the clavicle at the apex of axilla above pectoralis minor and along the medial side of axillary vein. This node receives lymph from all the above groups.

From the apical node emerges the subclavian lymph trunk which enters directly

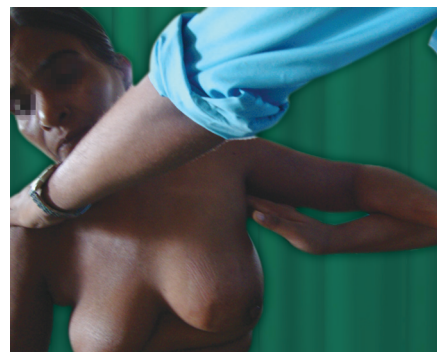into the subclavian vein or else joins the right jugular trunk on the right side and on the left side, it usually drains directly into the thoracic duct.

9. How will you palpate the different groups of axillary nodes?
  - a. Examination from the front – Anterior, apical central and lateral groups.
  - b. Examination from behind—Posterior and supraclavicular groups. The supraclavicular nodes are located above the clavicle in the supraclavicular fossa in the posterior triangle. These are examined as spread can occur from the axillary nodes.

The left axilla is palpated with the right hand and *vice versa* except for posterior and lateral groups which are palpated with the corresponding hand.

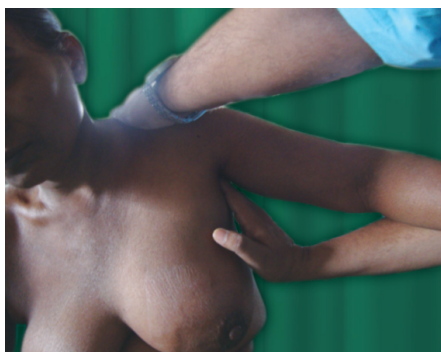### Palpation of Left Axilla

- a. Patient will be in sitting position.
- b. Clothes are removed from neck to waist.
  - i. Palpation of the central (medial) group (Fig. 72.7A):
    - Patient's left hand is raised with the left hand of the clinician.
    - The extended fingers of right hand of the examiner are placed in the axilla directing the palm towards the lateral chest wall.
    - The patient's arm is then brought down to her side and rested on the right forearm of the examiner.
    - The left hand of the examiner is now placed on the right shoulder of the patient to steady it.
    - The central lymph nodes are then palpated by sliding the fingers of right hand against the chest wall.

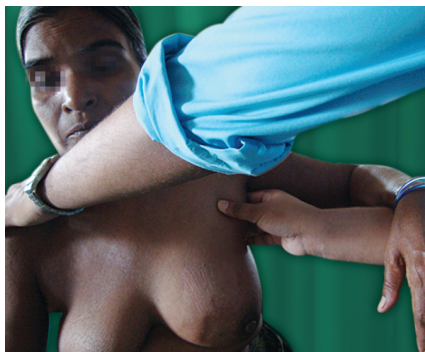

**Fig. 72.7 A:** Palpation of central group of nodes

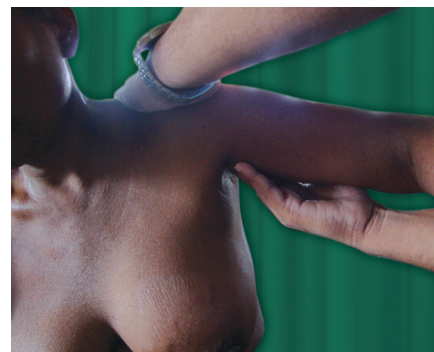



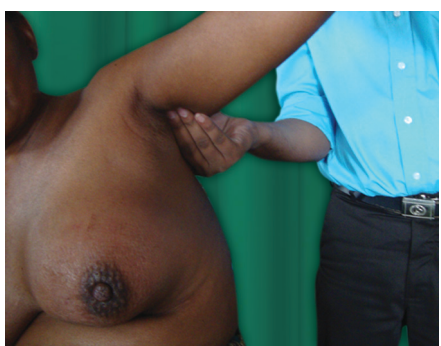**Fig. 72.7 B:** Palpation of apical group of nodes



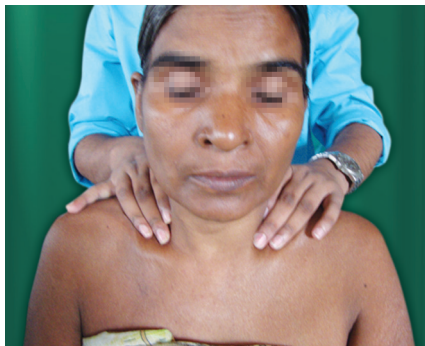**Fig. 72.7 C:** Palpation of anterior group of nodes



**Fig. 72.7 D:** Palpation of lateral group of nodes



**Fig. 72.7 E:** Palpation of posterior group of nodes



**Fig. 72.7 F:** Palpation of the supraclavicular group of nodes

- ii. Palpation of the apical nodes (Fig. 72.7B): In the above way, the fingers are insinuated higher up in the axilla and the apical nodes are palpated keeping right hand in the supraclavicular fossa.
- iii. Palpation of the anterior or pectoral group (Fig. 72.7C): The same procedure is followed as in case of central group. The pectoral nodes are felt between the forefingers placed beneath the pectoralis major, i.e. anterior axillary fold and thumb in front.
- iv. The lateral group (Fig. 72.7D): This group is palpated with the right hand against the upper end of humerus between two axillary folds. The left hand of the clinician steadies the left shoulder of the patient.
- v. Palpation of the posterior group (Fig. 72.7E): The examiner stands on the back of the patient. Patient's left hand is supported with the left hand of the clinician and posterior group of lymph nodes are palpated with the fingers of the right hand.

- vi. Palpation of the supraclavicular group (Fig. 72.7F): The clinician stands on the back of the patient and the supraclavicular nodes are palpated with the pulp of the fingers.

### EARLY CARCINOMA OF BREAST

#### Case Summary

This 45-year-old female patient, married with two children presents with a lump in the upper and outer quadrant of left breast for last 9 months which was painless to start with but recently she feels pain and discomfort for last 2 months. There is a little elevation but no retraction of the left nipple. There is no ulceration, nodules or venous prominence on the skin of the breast.

On physical examination, general survey is essentially normal.

On local examination, the right breast is normal. The lump in the left breast is felt at the upper and outer quadrant, globular in shape, nontender and free from pectoralis major and the overlying skin. Size is 4

cm × 3cm and consistency, hard and margins, ill-defined. Left axillary nodes are enlarged, discrete, nontender, mobile and hard.

There is no clinical evidence of metastasis elsewhere.

Systemic examination is normal.

#### Clinical Discussion

1. What is your case?  
It is an early carcinoma of left breast, stage II ( $T_2 N_1 M_0$ ).
2. Why do you say so?
  - a. The lump is the size of a lemon 4 cm × 3cm, hard, ill-defined and nontender.
  - b. No nipple retraction.
  - c. The lump is not fixed to the pectoralis major and the overlying skin.
  - d. The left axillary nodes enlarged, discrete, nontender and mobile.
3. What are the other possibilities in this case?
  - a. Fibroadenoma
  - b. Fibroadenosis with nodularity
  - c. Chronic abscess
  - d. Tuberculosis of breast
  - e. Antibioma.
4. How will you confirm the diagnosis?
  - a. By FNAC (Fine needle aspiration cytology) and
  - b. Imaging:  
FNAC is safe and easy method in which a cytological diagnosis can be made.  
The accuracy is 95percent in an experienced hand.
5. What will you do if FNAC is inconclusive?  
Imaging procedures especially mammography and ultrasound are used to clinch the diagnosis.  
The lesion is first localized using a mammographic technique and under

radiographic control, FNAC is done. If there is doubt about malignancy even after this, ultrasonography is used to guide the needle into the lesion and a core of tissue around the needle tip is excised out. The tissue is then subjected to histopathological examination and the patient is treated accordingly. This also allows the tumor to be stained for receptor status.

6. What is triple assessment?  
This consists of:
  - a. Clinical examination
  - b. FNAC and
  - c. Mammography with or without ultrasound imaging.
7. How FNAC is done?
  - a. It is a method of obtaining tissue for cytological diagnosis.
  - b. A fine needle of 22G along with a syringe is used.
  - c. The swelling is fixed after local preparation.
  - d. The needle is introduced and aspirated.
  - e. The aspirate in the lumen of the needle and the syringe is pushed on to glass slide and immediately fixed in fixing solution.
  - f. The slide is examined for cellular details.
8. What are the disadvantages of FNAC?
  - a. Skilled pathologist is required.
  - b. False negative rate of about 15 percent mostly because of sampling error or due to a very scirrhous acellular carcinoma.
  - c. Deep lesions may be missed.
9. What is mammography?  
Mammography is soft tissue radiography of the breast. It forms part of the screening procedure for carcinoma of breast along with self-breast examination (SBE) and FNAC.
10. How does mammography help in the diagnosis of carcinoma breast?
  - a. Screening mammography is used to detect high risk groups and unexpected breast cancer in asymptomatic women after 35 years.
  - b. It is used to guide interventional procedures including needle localization and needle biopsy.
  - c. Diagnostic mammography is used to evaluate women with abnormal findings such as a breast mass or nipple

discharge. Usually craniocaudal and mediolateral views are taken.

11. What is magnification mammography?
  - a. 1.5 times magnifications.
  - b. Increases diagnostic accuracy.
  - c. Microcalcification better appreciated.
  - d. Enhances the sharpness of detail.
  - e. May reduce the referrals for biopsy.
12. What is the role of ultrasound scan?
  - a. It is used for the diagnosis of breast cancer in women below 35 years, with dense breasts.
  - b. In women more than 35 years with a breast lump with equivocal mammography finding, ultrasound examination and biopsy are used to avoid a delay in diagnosis.
  - c. It has no proven role in the primary screening of breast cancer but it is practised in centers where mammography is not available.
  - d. Ultrasound guided fine needle aspiration cytology improves the accuracy of diagnosis.
13. What are the characteristics of breast cancer in mammography?  
These are the following:
  - a. A mass of high density with peripheral spiculation.
  - b. Architectural distortion.
  - c. Microcalcifications.
  - d. Increased thickness of skin due to lymphedema and
  - e. Nipple inversion.

One or more of these features may be present, the most reliable being a combination of mass effect with localized macrocalcification.
14. What is the cause of fixity of breast cancer to surrounding structures?  
It is due to local invasion or spread by continuity of the malignancy.
15. What are the other modes of spread?  
By lymphatics and by blood.
16. Where do the lymphatics drain?  
Mostly to the axillary group of lymph nodes (75%), the rest (25%) drains into the internal mammary group of nodes along the internal mammary vessels.  
Some lymphatics cross the midline and go to the other axilla.
17. What does fixity suggest?  
Fixity to surrounding structures, e.g. overlying skin, pectoral fascia and muscle,

chest wall, etc. suggests advanced malignancy and poor prognosis.

18. What are the risk factors of breast carcinoma?
  - a. Age—carcinoma of breast is rare below the age of 20 years. There is steep rise from 30 to 70 years.
  - b. Early menarche and late menopause make women more prone to carcinoma breast.
  - c. Nulliparity and first baby at more than 30 years of age – more chance of carcinoma breast.
  - d. Radiation exposure in thorax before 30 years.
  - e. Fibrocystic disease, particularly lesions with dysplasia.
  - f. Hormone replacement therapy if taken more than five years, there is more chance of breast cancer
  - g. History of breast carcinoma in first degree relatives, e.g. mother, sister, daughter, etc.
  - h. Genetic factors—Patients carrying BRCAI and BRCA II genes are at increased risk of breast cancer. So genetic and mammographic screening will increase the early rate of detection and decreased rate of mortality in breast cancer.
  - i. Social status—more common among the white and affluent women due to dietary factors.
  - j. Life style factors, e.g. smoking, alcohol, obesity, etc. are associated with increased risk.
19. What is the percentage of occurrence of carcinoma in various quadrants of breast?
  - a. About 60 percent arise in the upper and outer quadrant.
  - b. 10 percent in the lower and outer quadrant.
  - c. 12 percent in the upper and inner quadrant.
  - d. 6 percent in the lower and inner quadrant.
  - e. 12 percent in the central or subareolar region.
20. What are the histopathological types of carcinoma breast?  
There are mainly two types viz.
  - I. Ductal carcinoma arising from the ductal epithelium – 85 to 90 percent.
  - II. Lobular carcinoma arising from the mammary lobules – 5 to 10 percent.

Ductal carcinoma:

- a. Ductal carcinoma *in situ* (DCIS) or non-infiltrating ductal carcinoma – 5 percent. Here the basement membrane of the duct is not invaded.
- b. Invasive or infiltrating duct carcinoma – 80 to 85 percent – Subtypes of invasive duct carcinoma are:
- Infiltrating duct carcinoma not otherwise specified – 65 percent - These cancers have no specific microscopic appearance. This is also called scirrhous carcinoma.
  - Invasive carcinomas with specific histological features, e.g.
    - Medullary carcinoma – 5 percent
    - Tubular carcinoma – 3 percent
    - Mucinous carcinoma – 3 percent
    - Papillary carcinoma – 3 percent
    - Cribriform carcinoma – 3 percent
    - Others like signet ring, clear cell, carcinoid, adenocystic carcinomas – 3 percent
- Lobular carcinoma may be of two types:
- Lobular carcinoma *in situ* (LCIS) or noninfiltrating type – 1 percent.
  - Invasive or infiltrating type – 5 to 9 percent.
21. What is scirrhous carcinoma?
- It is the infiltrating duct carcinoma with productive fibrosis.
  - It cuts like an unripe pear.
  - Histologically there are spherical malignant cells with variable gland formation and mitosis in a dense collagenous stroma.
  - Occurs in middle aged and elderly.
  - Accounts for more than 60 percent of all invasive breast cancers.
  - Cut surface shows stellate tumor with chalky white or yellow streaks radiating into the surrounding parenchyma.
22. What is medullary carcinoma?
- Macroscopically, it tends to be soft fleshy well-circumscribed and possesses a uniform consistency.
  - Most characteristic histologic feature is the prominent lymphocyte infiltration.
  - Less frequently associated with lymph node metastasis. So prognosis is better.
23. What is colloid or mucinous carcinoma?
- 2 to 3 percent of all invasive cancers.
  - Usually occurs in older women.
  - Cut surface is glistening and gelatinous.
  - Contains more mucin, in which there are small islands of tumor cells.
  - Better prognosis.
24. What is lobular carcinoma?
- Accounts for 5 to 10 percent of all breast cancers.
  - Grossly small poorly defined rubbery mass.
  - Multicentric and is more often estrogen receptor positive than ductal carcinoma.
  - Arise from cells of acini and terminal ducts.
  - Bilateral in more than 40 percent cases.
25. What is the most malignant type of carcinoma breast?
- It is the inflammatory carcinoma of the breast or mastitis carcinomatosa.
26. What is inflammatory carcinoma?
- It is a variety of medullary or encephaloid carcinoma, in which the stroma is very vascular and hot, with worst prognosis.
  - There is slightly increased incidence in pregnancy and lactation.
27. What is Paget's disease of nipple?
- It is the weeping eczematous lesion of nipple and areola from extension of underlying intraductal carcinoma.
  - Microscopically contain Paget's cells which are malignant epithelial cells in the Malpighian layer of the epidermis with dermal inflammation and fibrosis.
  - It does not respond to usual treatment of an inflammatory lesion.
  - Nipple erosion occurs and finally nipple is destroyed.
28. What is the atrophic scirrhous carcinoma?
- It is the scirrhous carcinoma occurring in atrophic breasts in aged women.
  - Incidence is about 5 percent
29. What is duct carcinoma *in situ* (DCIS)?
- It is seen in mammographically detected lesions.
  - This is a preinvasive form of breast cancer seen in premenopausal women.
  - Confined to the ducts and does not invade the basement membrane but can present as a lump.
  - It is not associated with axillary metastasis or distant occult invasion.
  - Treatment is total mastectomy.
30. What is lobular carcinoma *in situ* (LCIS)?
- It is usually discovered on biopsy performed for other reasons.
  - Usually seen in younger women.
  - It is typically impalpable and undetectable mammographically.
  - Multicentric foci present in 90 percent cases and contralateral LCIS is found in 25percent cases.
  - Treatment is bilateral mastectomy with or without immediate reconstruction.
31. What is Manchester staging?
- It is a clinical staging of carcinoma breast evolved in city Hospital, Manchester UK in midfifties. It includes:
- Stage I
- Tumor confined to the breast.
  - No axillary glands.
  - Tumor not fixed to deeper structures.
  - Skin involvement, if present, less than the tumor.
- Stage II
- Same as stage I with mobile ipsilateral axillary lymph nodes.
- Stage III
- Tumor fixed to pectoral fascia and muscle or
  - Skin involvement more than the tumor or
  - Fixed ipsilateral axillary nodes – IIIA
  - Tumor of any size with extension to the chest wall or skin (peau d'orange, ulceration or satellite skin nodules in the same breast) or ipsilateral supra-clavicular lymph node involvement – IIIB.
- Stage IV
- Presence of distant metastasis.
  - Extension to opposite breast.
  - Extension to opposite axilla.
32. What is T, N, and M classification?
- It is the tumor, node, metastasis staging. It is important prognostically and in making treatment plan.
- Tumor (T) size measurements are done with scale or measuring tape and *in situ* carcinoma is assessed with mammography.
- T = Primary tumor**
- T<sub>0</sub> – No evidence of primary tumor
- T<sub>IS</sub> – Carcinoma *in situ*,  
– Intraductal carcinoma  
– Paget's disease of nipple
- T<sub>1</sub> – Tumor 2cm or less in its greatest dimension.
- T<sub>2</sub> – Tumor > 2cm but < 5cm in greatest dimension.
- T<sub>3</sub> – Tumor > 5cm in its greatest dimension.

T<sub>4</sub> – Tumor of any size invading skin or chest wall.

T<sub>4a</sub> – Extension to the chest wall.

T<sub>4b</sub> – Edema (including peau d'orange), ulceration of the skin of the breast or satellite skin nodules confined to the same breast.

T<sub>4c</sub> – Both (T<sub>4a</sub> + T<sub>4b</sub>)

T<sub>4d</sub> – Inflammatory carcinoma.

N – Regional lymph nodes.

N<sub>0</sub> – No regional lymph node metastasis.

N<sub>1</sub> – Mobile ipsilateral axillary nodes.

N<sub>2</sub> – Fixed ipsilateral axillary nodes.

N<sub>3</sub> – Enlarged ipsilateral supraclavicular nodes.

M – Distant metastasis.

M<sub>0</sub> – No known distant metastasis.

M<sub>1</sub> – Distant metastasis present.

33. What are stage groupings?

STAGE	T	N	M
<b>O</b>	T <sub>1S</sub>	N <sub>0</sub>	M <sub>0</sub>
<b>I</b>	T <sub>1</sub>	N <sub>0</sub>	M <sub>0</sub>
<b>II IIA</b>	T <sub>0</sub>	N <sub>1</sub>	M <sub>0</sub>
	T <sub>1</sub>	N <sub>1</sub>	M <sub>0</sub>
	T <sub>2</sub>	N <sub>0</sub>	M <sub>0</sub>
<b>IIB</b>	T <sub>2</sub>	N <sub>1</sub>	M <sub>0</sub>
	T <sub>3</sub>	N <sub>0</sub>	M <sub>0</sub>
<b>III IIIA</b>	T <sub>0</sub>	N <sub>2</sub>	M <sub>0</sub>
	T <sub>1</sub>	N <sub>2</sub>	M <sub>0</sub>
	T <sub>2</sub>	N <sub>2</sub>	M <sub>0</sub>
	T <sub>3</sub>	N <sub>1</sub>	M <sub>0</sub>
<b>IIIB</b>	T <sub>3</sub>	N <sub>2</sub>	M <sub>0</sub>
	T <sub>4</sub>	Any N	M <sub>0</sub>
<b>IV</b>	Any T	N <sub>3</sub>	M <sub>0</sub>
	Any T	Any N	M <sub>1</sub>

34. What is early malignancy?

- Tumor confined to breast.
- No regional glands.
- No distant metastasis.
- No deep fixity.
- Skin involvement nil or less than the size of the tumor.

35. What are the sites of distant metastasis and how it occurs?

Distant metastasis occurs by hematogenous spread as follows:

- Through general circulation to viscera like lungs, liver, brain and occasionally to adrenals and ovaries.
- Through vertebral venous plexus of Batson to lumbar vertebrae, femur, thoracic vertebrae, ribs and skull.

36. What are the effects of lymphatic obstruction in breast carcinoma?

a. Peau d'orange—This is a form of cutaneous lymph edema due to blockage of cutaneous lymphatics by the malignant process.

The edematous skin is tethered by the hair follicles and sweat ducts as they are more firmly fixed to the subcutaneous tissue than the rest of the skin. This tethering by sweat ducts imparts an orange peel appearance to the edematous skin, known as peau d'orange.

b. Early lymphedema of the arm—This is postoperative edema occurring in a few days and is infective in origin.

c. Late lymphedema of the arm—Swelling of the arm may be evident at a time several months to years after operation. Obese patients are more susceptible.

The obstruction may occur after complete axillary clearance or following axillary clearance and radiotherapy.

d. Cancer-en-cuirasse—This is a feature of much locally advanced stage but may also occur in case of recurrence after mastectomy.

The skin of the thoracic wall and breast is infiltrated with cancer cells which becomes thick indurated hard and studded with carcinomatous nodules simulating the rigid coat or shield of soldier. (Cuirasse = leather or metal breast plate worn by soldiers).

This is usually associated with lymphedema of the arm or a brawny arm, it usually responds to systemic palliative treatment.

e. Lymphangiosarcoma—This is a rare but late complication of lymphedema and has a poor prognosis. Treatment is cytotoxic therapy or irradiation. Forequarter amputation is sometimes indicated.

37. According to stage grouping what is early breast cancer? – Stage I and stage IIA and T<sub>2</sub>N<sub>1</sub>M<sub>0</sub>.

38. What is the treatment plan of carcinoma breast?

It is local manifestation of a systemic problem. Hence less and less radical treatment and more of conservative treatment are planned.

39. What are the conservative surgical procedures in carcinoma breast?

- Lumpectomy
- Quadrantectomy

c. Tumorectomy or segmental resection.

40. What is lumpectomy?

Where the tumor along with a rim of at least 1cm of normal breast tissue is removed, it is known as lumpectomy – presently called wide local excision.

41. What are the criteria for breast conservation surgery?

- A small breast cancer <4cm in its greatest dimension.
- Clinically negative axilla.
- Breast of adequate size to allow uniform dosage of radiation.
- Facility of radiation therapy available.
- Patients consent for breast conservation surgery.
- Patient should be willing to accept 10 percent chance of local recurrence.

42. What is quadrantectomy?

In quadrantectomy 2-3cm of normal breast tissue along with the tumor is removed.

43. What is sampling of axillary nodes.

- To study a group of lymph nodes in the axilla to find out any metastatic deposit, at least four nodes are removed for such sampling.
- For planning of axillary treatment with breast conservation surgery.

44. What is QUART?

- It is a method of treatment popularized by Veronesi of Italy.
- It consists of QA – Quadrantectomy A – Axillary clearance, and RT – Radiotherapy.

45. How radiotherapy is given after BCT (Breast conservation therapy)?

It is done by implanting radium needles to remaining breast tissue and is known as brachytherapy.

46. What is the role of axillary sampling?

This is done to assess adjuvant chemotherapy. Clinically negative nodes may be pathologically positive in 20 to 30 percent cases.

47. What are the advantages of lumpectomy with or without brachytherapy over modified radical mastectomy?

- Long-term disease control and disease-free survival data similar to modified radical mastectomy.
- Less disfigurement and emotional upset.
- Local tumor recurrence higher in non-irradiated group.



48. What are the risk factors for local recurrence following conservative breast surgery?
- Young patient
  - Inadequate margins
  - Lymphovascular invasion
  - Extensive intraductal component.
49. What adjuvant therapy is given to positive axillary nodes after breast conservation therapy or surgery?
- Radiotherapy—1000 cGy of radiation to lymph node fields and 5000 cGy to the whole breast.
  - Chemotherapy—The regimen is either CMF (Cyclophosphamide, Methotrexate and 5FU) or CAF (cyclophosphamide, adriamycin and 5FU).
  - Hormone therapy—If the tumor is ER +ve, tamoxifen is given in the dose of 20mg daily ×5 years.
50. What is Patey's modified radical mastectomy?
- This involves en bloc removal of breast and axillary lymph nodes.
  - The pectoralis minor muscle is divided for adequate axillary dissection.
  - The line of resection is 4 to 5 cm beyond the tumor margin to ensure adequate clearance.
  - The limits of excision are:
    - Superiorly upto the clavicle.
    - Inferiorly upto 1" below the inframammary fold that is, upto the caudal extension of breast.
    - Medially upto the midline and
    - Laterally upto the anterior border of latissimus dorsi.
51. Describe the steps of modified radical mastectomy?  
It is discussed in the operative section.
52. What structures are preserved during modified radical mastectomy?  
(One can remember the mnemonic ABC)
- A – Axillary vein.
  - B – Long thoracic nerve of Bell supplying serratus anterior.
  - C – Cephalic vein.
- Along with the above nerve to latissimus dorsi is also preserved.
53. What are the indications of modified radical mastectomy in early breast cancer?  
Although breast conserving surgery is preferred modified radical mastectomy is, however still the most common operation performed for carcinoma of breast.
- The indications are:
- Poorly differentiated tumor.
  - If resection lines are not free of tumor after quadrantectomy or lumpectomy.
  - Multicentric disease.
  - Patient's choice.
54. What is Border's histological grading?  
This is the histological method of assessing malignancy
- Grade I – Upto 25 percent cells are undifferentiated.
- Grade II – Upto 50 percent cells are undifferentiated.
- Grade III – Upto 75 percent cells are undifferentiated.
- Grade IV – More than 75 percent cells are undifferentiated.
55. When will you consider adjuvant chemotherapy in node negative patients?  
Adjuvant chemotherapy is considered when other prognostic factors indicate a high risk of recurrence. These are:
- Tumor size >1cm
  - Tumor grade - Moderately or poorly differentiated tumor.
  - Negative ER/PR status
  - Positive Her-2 neu receptor
  - Premenopausal women.
- On the other hand, postmenopausal women with tumor <1cm size and positive ER/PR status does not require adjuvant chemotherapy.
56. What is the role of hormone therapy in early breast cancer patients?  
Tamoxifen is effective in both pre-and postmenopausal patients in most cases except ER negative tumor in premenopausal women. It reduces the incidence of contralateral breast cancer and annual recurrence rate.
57. How does tamoxifen act?  
Tamoxifen is an antiestrogen. It blocks the uptake of estrogen by the tumor cells due to its binding with the estrogen receptor situated on the nucleus.
58. What are the side-effects of tamoxifen therapy?
- Nausea, vomiting.
  - Fluid retention.
  - Slight increase of thrombotic events.
  - Transient hypercalcemia.
  - Increased incidence of endometrial cancer.
59. What other hormonal agents used in hormone therapy?
- Oral aromatase inhibitors like tetrazole, anastrozole which block estrogen synthesis by the adrenals. These are effective in postmenopausal women.
  - Surgical oophorectomy causes decreased local recurrence and improved disease-free survival period.
  - LHRH agonist like Goserelin induced chemical castration in premenopausal women due to increased progesterone synthesis by corpus luteum and consequent termination of the effect of estrogen which is reversible.
60. What newer drugs have been introduced after tamoxifen?  
These include raloxifen, toremifene having effects similar to tamoxifen.
61. Why radiation therapy is required after breast conservation surgery?  
It has been shown in different trials that patients treated by breast conservation surgery alone, e.g. Lumpectomy and not receiving radiotherapy have higher incidence of local recurrence.
62. What is sentinel lymph node (SLN) biopsy?
- Sentinel lymph node (SLN) is the first lymph node to be affected in malignancy in the drainage area.
  - It is indicated in all patients with early breast cancer ( $T_2N_1M_0$ ) and is done along with conservative breast surgery.
  - It is localized preoperatively by injection of blue dye and  $^{99m}Tc$  labeled colloid albumin near the tumor. Dissection is performed to localize the node with dye. The marker can be identified with a hand held gamma camera, probe. The node is sent for frozen section.
63. What is the rationale of SLN biopsy?  
If the sentinel node does not show metastasis, axillary dissection is not required.
64. What are the drawbacks?
- This is still under evaluation.
  - 3 percent of patients can have skipped lesions.
65. What is Achin Closs modified radical mastectomy?
- It is same as Patey's operation but pectoralis minor is left intact. It is retracted for dissection of level II lymph nodes.



- b. There is incomplete dissection of level III nodes and preservation of the Pectoralis minor muscle.
66. What are the toxic effects of combination chemotherapy?
- Alopecia
  - Bone marrow suppression
  - Megaloblastic anemia
  - GI disturbances, e.g. nausea, vomiting
  - Nephritis
  - Cardiac toxicity (Adriamycin).
67. What is Nottingham prognostic index (NPI)?  
The Nottingham prognostic index (NPI) includes not only tumor size and lymph node status but also tumor grade.  
 $NPI = (0.2 \times \text{size}) + \text{Grade} + \text{Nodes}$ .  
The size is in cm, the grade is on a 1 to 3 score and the nodes are also scored on 1 to 3. Where score of 1 = no nodal involvement, 2 = 1 to 3 nodes involved and 3 = four or more nodes involved.  
Based on the overall index, patients can be divided into an excellent prognosis group, a moderate prognosis group and a poor prognosis group.  
The lower the score, the better is the prognosis.
68. What are the different levels of axillary nodes?  
There are three levels viz.  
Level I – Nodes below pectoralis minor  
Level II – Nodes behind pectoralis minor.  
Level III – Nodes above pectoralis minor.  
It is thought that tumor spread occurs from level I to level II and from level II to level III nodes.

## LOCALLY ADVANCED BREAST CARCINOMA

### Case Summary

The 50-year-old postmenopausal patient presents with a moderately large ulcerated breast lump in her right breast for last 2.5 years which has gradually increased in size for last one year. The ulcer has appeared 3 months back.

There is a swelling in her right axilla for last five months.

There is no history of anorexia, loss of weight, bowel and bladder habits are normal.

On examination, there is pallor and the lump (12cm × 8cm) is fixed to the chest wall and overlying skin. There is peau d'orange and skin retraction. Right axillary nodes are palpable and fixed to one another.

The right breast is drawn up right supraclavicular nodes are not palpable.

Systemic examination is normal.

### Clinical Discussion

- What is your diagnosis?  
It is a locally advanced carcinoma of right breast ( $T_{4c}N_2M_0$ ) stage IIIB.
- Why do you say so?
  - Tumor is fixed to the chest wall and overlying skin.
  - Ipsilateral axillary nodes are palpable and fixed to one another.
  - No distant metastasis present.
- What do you mean by locally advanced breast cancer?  
It includes stages IIIA and IIIB stage groups with the following TNM characteristics.
  - Stage IIIA –  $T_3N_2M_0$
  - Stage IIIB –  $T_4$ , any N,  $M_0$  or any T,  $N_3$ ,  $M_0$
- What is the principle of management?  
The aim of treatment is palliation. The treatment planning depends on whether the tumor is operable or not.
- What are the inoperable cases of LABC?
  - A large tumor with extensive skin involvement and satellite nodules.
  - Tumor fixed to the chest wall.
  - High tumor / Breast ratio.
- How do you investigate the patient with LABC?
  - Tests to confirm the diagnosis.
    - By FNAC.
    - Mammography of both breasts.
  - Evaluation of distant metastasis as there is high chance of distant metastasis in LABC by.
    - X-ray chest –PA view.
    - Liver function tests.
    - USG / CT scan of abdomen.
    - Whole body bone scan with  $^{99m}Tc$  phosphonate to detect otherwise occult osseous metastasis.
- What is the treatment protocol in LABC?
  - Confirmation of diagnosis.
  - Neoadjuvant combination chemotherapy with CAF to make the tumor oper-

able. 3 to 6 cycles are given depending on the response.

- Once the lesion is operable simple mastectomy is done.
  - Postoperative radiotherapy to the breast flap and axilla.
  - Hormonal therapy, e.g. tamoxifen to ER positive tumors.
  - The remaining cycles of chemotherapy if not given earlier.
- What is the 5 year and 10 year survival rate after the multimodality treatment of LABC?  
5 year survival rate is 45 percent and 10 year survival rate is 28 percent.
  - What is inflammatory carcinoma?  
It usually occurs in lactating mother simulating acute mastitis but there is absence of fever and presence of peau d'orange as there is early invasion of subdermal lymphatics with highly undifferentiated tumor cells. The vascular channels are also invaded by the malignant cells giving rise to venous prominence. Axillary lymph nodes are involved early. It is also called lactational carcinoma and included in LABC.
  - What is the treatment of inflammatory carcinoma?
    - Systemic chemotherapy with CAF for 3 to 6 cycles after confirmation of diagnosis followed by:
    - Simple mastectomy with removal of level I nodes.
    - Postoperative chemotherapy (remaining cycles, if any) and radiotherapy.
    - Tamoxifen in case of ER positive tumors.
  - What is toilet mastectomy?  
In LABC with foul smelling fungating ulcer, palliative mastectomy is done to get rid of the bad smell. This is called toilet mastectomy.

## BREAST CARCINOMA WITH DISTANT METASTASIS

- What is the aim of treatment?
  - To provide palliation only.
  - Symptomatic relief due to metastasis and to control micrometastasis.
- What are the different modalities of treatment in breast carcinoma with distant metastasis?
  - Hormonal therapy
  - Chemotherapy

**Table 72.1: Hormonal agents used in metastatic breast carcinoma.**

Order	Premenopausal	Postmenopausal
1st line	Anti-estrogen or ovarian ablation (surgical, chemical or radiation)	Anti-estrogen (Tamoxifen)
2nd line	Ovarian ablation	Aromatase inhibitors, e.g. Letrozole
3rd line	Progestins	Progestins
4th line	Androgens	Androgens / Estrogens

- c. Radiotherapy  
d. Surgery.
3. What is the role of hormonal agents in metastatic breast carcinoma (MBC)?  
Tumors with positive ER and PR receptors respond to endocrine treatment in 80 percent cases. The various hormonal agents are as follows: (Table 72.1)
4. What is the role of chemotherapy in MBC (Metastatic breast disease)?  
Combination chemotherapy is given in patients with failure of hormone therapy. Regimes of chemotherapy are:
- CMF (Cyclophosphamide, methotrexate and 5FU).
  - CAF (Cyclophosphamide, adriamycin, 5FU).
  - Usually 6 to 12 cycles are given.
5. What are the newer chemotherapeutic agents used in MBC?  
Taxanes—Paclitaxel and docetaxel. They act by causing arrest of G2 / M phase of cell cycle.
6. What is the dosage schedule of CMF regime?
- Cyclophosphamide—600mg/m<sup>2</sup> on day 1 and 8.
  - Methotrexate—40mg/m<sup>2</sup> on day 1 and 8.
  - 5 Fluorouracil (FU)—600mg/m<sup>2</sup> on day 1 and 8.
- The above scheduled is repeated after 3 weeks at each month.
7. What is neoadjuvant chemotherapy?  
It is the use of systemic chemotherapy before surgery also called primary chemotherapy.
8. What is the role of radiotherapy in MBC?  
It is indicated for:
- Relief of metastatic bone pain.
  - Whole brain irradiation provides some palliation of symptoms.
  - For spinal cord compression early radiotherapy is very effective.
9. What is the role of surgery in MBC?
- Primary lesion—Simple or toilet mastectomy.
  - Pathological fracture—Internal fixation.
  - Vertebral instability—Internal fixation.
  - Lung metastasis—Resectable disease confined to one lobe—Resection is of some value.
  - Ovarian ablation as second line hormonal therapy in premenopausal women.
10. What is the cause of skin retraction in carcinoma breast?  
This is due to puckering and retraction of the ligaments of Cooper following infiltration by tumor cells.
11. What is the cause nipple retraction?  
The lactiferous or milk ducts are invaded by malignancy. Which pull the ducts inside giving rise to retraction of nipple.
12. Why does the tumor ulcerates?  
The neoplastic cells grow along the endolymphatic spaces to reach the dermis of skin. As the tumor cells continue to grow, it gives rise to the ulceration.  
As new areas of skin are invaded, small satellite nodules appear near the ulcer crater.
13. What are the prognostic factors in carcinoma breast?
- Lymph node status – This is the most important prognostic factor. The greater the number of lymph nodes, involved, the worse the prognosis.
  - Tumor size – the greater the size, the poorer the prognosis.
  - ER/PR receptor status – prognosis is good for ER/PR +ve tumors.
  - Histological grade – prognosis is bad in case of poorly differentiated (High grade) tumors and inflammatory carcinoma.
  - Growth factors, e.g. EGF, TGF α and β, PGE, etc.
14. What are the investigations for staging in carcinoma breast?
- History and physical examination.
  - Bilateral mammography.
  - Investigations to know about distant metastasis, e.g. X-ray chest, liver function test. whole body bone scan USG abdomen, etc.
15. What is the line of treatment of breast cancer in pregnancy?
- If breast cancer diagnosed in first trimester, pregnancy is allowed to continue.
  - In a patient with stage III disease or LABC, requiring irradiation and adjuvant chemotherapy, pregnancy is terminated.
  - An operation can be undertaken only in the second trimester for local control of disease.
  - In the last trimester standard treatment should be given, adjuvant chemotherapy and radiation being delayed until after delivery.
16. What is the follow up protocol in CA breast?
- Most recurrences occur within 5 years after primary therapy. However recurrence may occur even after 20 years.
  - Follow-up includes history and physical examination together with biochemical and radiological investigations.
  - Follow-up examination is done every 4 months for first 2 years, every 6 months from 3rd to 5th year and yearly thereafter.
17. What is the effect of pregnancy on carcinoma of breast?  
Recent trials suggest that breast cancer in pregnancy irrespective of stage is associated with a prognosis similar to that in the non-pregnant state.
18. What is revision mastectomy?  
It is the completion mastectomy after an incompletely performed mastectomy with significant residual breast tissue.

### BREAST RECONSTRUCTION

- What is the indication?  
It is done in about 50 percent women following breast conservative surgery. The patient gets benefited by improved quality of life.

2. What is the timing of breast reconstruction?
  - a. Immediate breast reconstruction (IBR) is done at the time of mastectomy. Its advantages are reduced cost, easier axillary dissection, patient's convenience and better reconstruction. However, it is unsuitable for high risk patients and the procedure is lengthy (3-6 hours) which needs preoperative counseling.
  - b. Delayed reconstruction – this is done 3-6 months following mastectomy.
3. What are the methods of breast reconstruction?
  - a. Use of autologous tissue:
    - By latissimus dorsi (LD) myocutaneous flap.
    - By transverse rectus abdominis myocutaneous (TRAM) flap.
  - b. Silicon gel implant under pectoralis major muscle. Nipple reconstruction may be done later or prosthetic nipple may be fitted. The subcutaneous technique of placement of the implant is not preferred as it frequently causes skin necrosis and extrusion.

# Chapter 73

## Abdomen

- General plan of examination of an abdominal case
- Gastric carcinoma
- Pyloric stenosis
- Chronic duodenal ulcer
- Chronic cholecystitis
- Mucocele of the gallbladder
- Obstructive jaundice due to periampullary carcinoma
- Obstructive jaundice due to carcinoma of gallbladder
- Obstructive jaundice due to postcholecystectomy; stricture of CBD
- Hydatid cyst of liver
- Pseudocyst of pancreas
- Carcinoma of colon

### GENERAL PLAN OF EXAMINATION OF AN ABDOMINAL CASE

#### History

- I. Particulars of the patient.
- II. Chief complaints with duration.  
The patient may present with one or more of the following complaints in different combinations.
  1. Pain abdomen.
  2. Sensation of fullness or discomfort over the epigastrium after meals.
  3. Nausea and vomiting.
  4. Yellowish discoloration of eyes and urine.
  5. Alteration of bowel habits.
  6. Abdominal distension.
  7. Loss of appetite.
  8. Weight loss.
  9. Vomiting of blood.
  10. Passage of black tarry stool.
  11. Fever.
- III. History of present illness:
  - a. Pain – Detailed history is to be taken regarding different aspects of pain, e.g.
    1. Onset – sudden/insidious.
    2. Duration of pain, any periodicity of the attack of pain.
    3. Site – in relation to different quadrants of abdomen.
    4. Radiation.
    5. Nature of pain – persistent/colicky.
    6. Aggravating factors and relieving factors.
    7. Relationship to food.  
The various aspects of pain can be remembered by the mnemonic 'DROPS': D = Duration, R = Relationship to food, Relieving or aggravating factors, Radiation, O = Onset, P = Persistent or colicky in nature, periodicity, S = Site, swelling or any associated abdominal lump.
  - b. Nausea and vomiting.
    - i. Frequency, character (Projectile or effortless).
    - ii. Vomitus – Amount, color, smell, old food particles present or not, any blood present or not.
    - iii. Any relation to pain.  
If there is hematemesis, the number of bouts, color, amount, whether associated with melena or not, should be enquired of.
  - c. Jaundice – The following are enquired of.
    1. Onset – sudden/insidious.
    2. Duration – long-standing (benign)/ shorter duration (malignancy).
    3. Past history of cholecystectomy – benign stricture of CBD.
    4. Family history of hemolytic anemia.
    5. Associated symptoms like clay-colored stool, pruritus, fever with chill and rigor (cholangitis).
  - d. Abdominal distension, duration, progress of the distension.
  - e. Bowel habit – Constipation, diarrhea, alternate constipation and diarrhea is seen in carcinoma of colon.
  - f. Details of urinary symptoms.
- IV. Past history – e.g. Past history of tuberculosis may be present in a case of abdominal tuberculosis.
- V. Family history – Peptic ulcer may be found in several members of the same family.
- VI. Personal history.
- VII. Treatment history.
- VIII. Any history of allergy.

## Physical Examination

### General Survey

Pallor, build, supraclavicular nodes, pulse, BP, to be seen.

### Local Examination

Examination of abdomen.

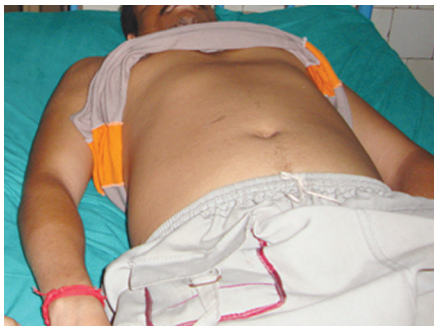### Position of Patient

Supine with arms by the side. The patient is undressed from the nipples upto the knees. This may be embarrassing to the female patient. So female attendant must be present during examination of women. The hips and knees are kept in 45° and 90° flexed positions respectively.

### Position of Examiner

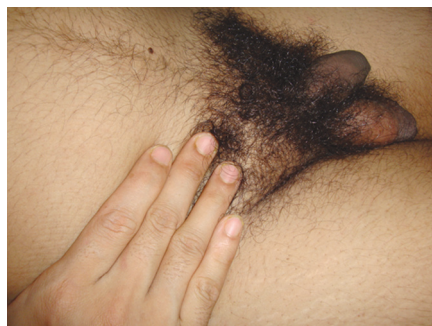Seated by the right side of the patient.

1. Inspection: (Fig. 73.1)
  - Shape of the abdomen – Normal/scaphoid/distended.
  - Skin of the abdomen
    - Any scar mark (length, previous operation, site)
    - Striae
    - Pigmentation.
  - Venous prominence
  - Abdominal movements.
    - Respiratory
    - Visible – peristalsis (and its direction).
    - Pulsatile movement (vascular tumor).
  - Umbilicus
    - Position
    - Inverted/everted
    - Sinus/discharge (umbilical sinus/fistula)
  - Hernial orifices (Fig. 73.2).



**Fig. 73.1:** Inspection of abdomen is done at the level of the patient's abdomen

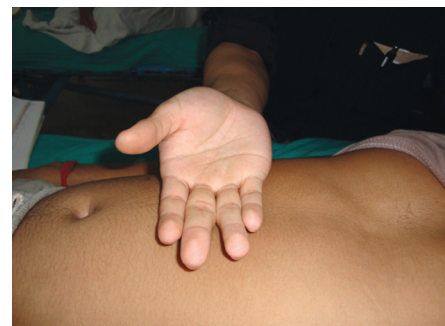- External genitalia.
2. Palpation:
  - a. *Superficial palpation*
    - Temperature – Temperature of abdomen is compared with that of chest with the dorsum of fingers (Fig. 73.3).
  - b. *Obvious lump*—The position of an abdominal lump is usually described in relation to the nine regions of abdomen divided by two horizontal and the two vertical lines (Fig 73.4).
    - Muscle guard
    - Venous filling
    - Any superficial tenderness.
  - c. *Deep palpation*
    - i. Feel of the abdomen – soft elastic (normal/rigid/doughy).
    - ii. Deep tender spots at the following sites are palpated:
      - a. Gastric point – a point in the mid epigastrium.
      - b. Duodenal point – A point in the transyloric plane 2.5 cm to the right of the midline.
      - c. Gallbladder point – A point at the junction of lateral border of rectus abdominus and tip of the 9th costal cartilage.
      - d. McBurney's point—A point at the junction of lateral one-third and medial two-third of the spinoumbilical line.
      - e. Renal point – A point at the junction of erector spinae and the 12th rib.
      - f. Amebic point – Point on the left spinoumbilical line analogous to McBurney's point on the right side.
    - iii. Visceral palpation
      - a. Liver – not palpable/palpable



**Fig. 73.2:** To see and feel the expansile impulse on coughing to confirm a hernia

If palpable, one should note the following:

- Size – The extent of enlargement is measured by the number of centimeters below right costal arch on midclavicular line.
  - Margin – sharp/rounded.
  - Surface (smooth/irregular).
  - Consistency (soft/firm/hard).
  - Tenderness (present/absent).
  - Whether pulsatile or not.
- b. Spleen: Palpable/not palpable, if palpable, one should note the following:
    - Size
    - Surface
    - Margin
    - Consistency
    - Notch and
    - Tenderness.
  - c. Gallbladder – palpable/not palpable, if palpable one has to note
    - The consistency—cystic/hard
    - Mobility and
    - Murphy's sign.
  - d. Kidneys: Palpable/not palpable.
  - e. Succussion splash sign of pyloric obstruction is elicited if there is evidence of visible peristalsis in the epigastric region.
  - f. Bladder – full/empty.
  - g. Testes
    - Present/absent
    - Testicular swelling
    - Testicular sensation.
  - h. Any other mass, if present, the following are recorded.
    - i. Site
    - ii. Size
    - iii. Shape
    - iv. Tenderness



**Fig. 73.3:** To feel the temperature of the abdomen using dorsum of the hand



- v. Mobility
  - vi. Pulsation
  - vii. Consistency.
- Percussion
    - General note - resonant (tympanic)
    - Fluid thrill: (Present / absent) -
    - Shifting dullness – Present / absent
    - Upper border of splenic dullness
    - Percussion over a mass, if any
    - Urinary bladder – Full or empty.
  - Auscultation
    - Peristaltic sounds (IPS): Normal/hyperperistalsis/diminished/absent.
    - Gastric splashing sound.
    - Bruit over abdomen, aorta, liver, spleen.
    - Venous hum around umbilicus in portal hypertension.
  - Auscultopercussion
 

This is done in case of gastric outlet obstruction to delineate the greater curvature of the stomach.

    - Per rectal examination
    - Per vaginal examination.

### Systemic Examination

All systems are to be mentioned.

#### Summary of the case

#### Provisional diagnosis

#### Differential diagnosis

#### Investigation suggested.

### Clinical Discussion

1. What are the different quadrants of abdomen?

Abdomen is divided into four quadrants for clinical examination by drawing two lines at right angles to each other – one vertical line in the midline and the other horizontal line through the umbilicus. The four quadrants are:

- a. Right upper quadrant (RUQ),
  - b. Right lower quadrant (RLQ),
  - c. Left upper quadrant (LUQ) and
  - d. Left lower quadrant (LLQ).
2. How abdomen is divided into different regions?

Abdomen is divided into nine regions for clinical examination by four lines—two vertical and two horizontal lines (Fig. 73.4).

The two vertical lines are right and left midclavicular lines.

#### Horizontal lines:

The upper horizontal line passes through the transpyloric plane, which is midway between the suprasternal notch and the symphysis pubis. It also corresponds to the line drawn one hands breadth (of patient) below the xiphisternal junction.

The lower horizontal line passes through the transtuberular plane, which is drawn by joining the tubercle of the iliac crest on either side. The iliac tubercle is located about 5 cm behind the anterior superior iliac spine.

The nine regions are:

1. Right hypochondrium
  2. Epigastrium
  3. Left hypochondrium
  4. Right lumbar
  5. Umbilical
  6. Left lumbar
  7. Right iliac fossa
  8. Hypogastrium and
  9. Left iliac fossa.
3. What are the landmarks of the transpyloric plane?
 

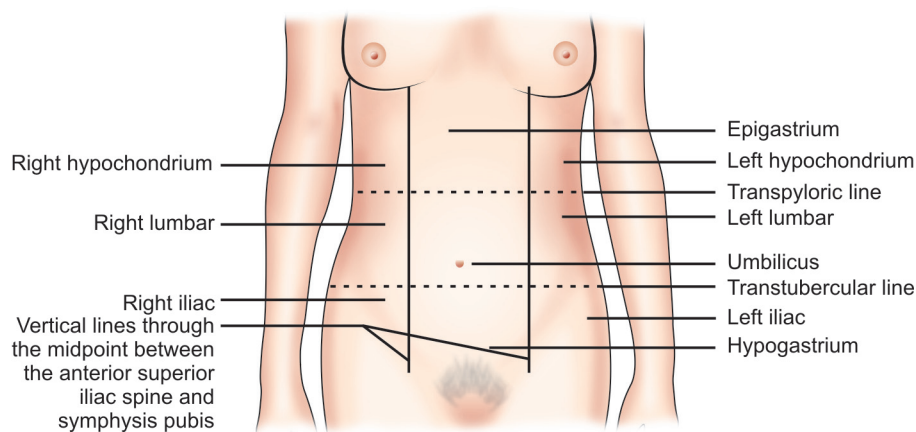
The landmarks are:

    1. Pylorus of stomach, hence called transpyloric plane.
    2. Fundus of the gallbladder.
    3. Neck of the pancreas, behind which there is formation of portal vein.
    4. Origin of the superior mesenteric artery.

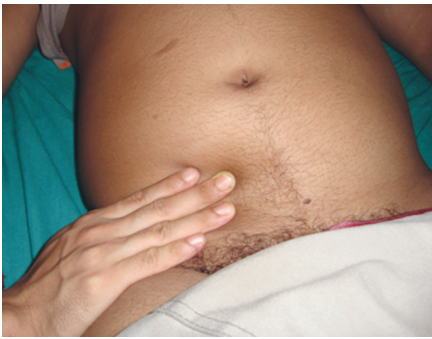5. End of the spinal cord.

6. Hilum of the kidney. This plane cuts the lower part of left hilum and upper part of right hilum.

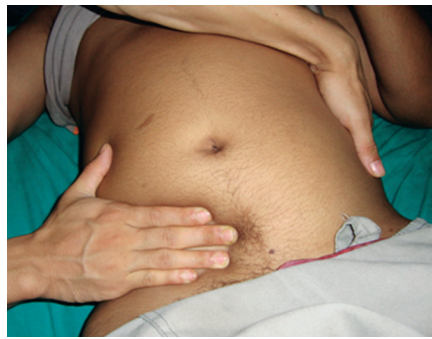4. How will you palpate liver? (Figs 73.5A and B)
  - a. Patient lies supine with legs flexed at the hips and knees.
  - b. Patient is asked to take deep breaths with open mouth.
  - c. Palpation is started from right iliac fossa towards the right costal margin keeping the radial border of index finger parallel to the right costal margin.
  - d. With each expiration the hand is moved near the right costal margin.
  - e. The enlarged liver border is palpated with the radial border of the index finger.
  - f. The enlargement of liver is described in number of centimeters below the right costal margin on the midclavicular line. Liver is not palpable in normal individual.
5. How will you palpate gallbladder? (Fig. 73.6)
  - a. The normal gallbladder is not palpable. The method of palpation is the same as that for liver.
  - b. The swelling projects downwards and forwards from below the liver just lateral to the outer border of right rectus muscle.
  - c. Its upper limit cannot be felt as it lies under the liver.



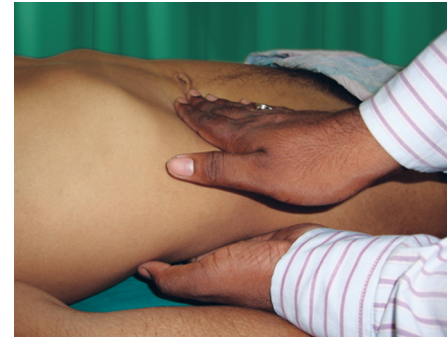**Fig. 73.4:** Division of abdomen into nine regions, by two horizontal and two vertical lines. The horizontal lines are the transpyloric and the transtuberular lines and the vertical lines are as described in the diagram above



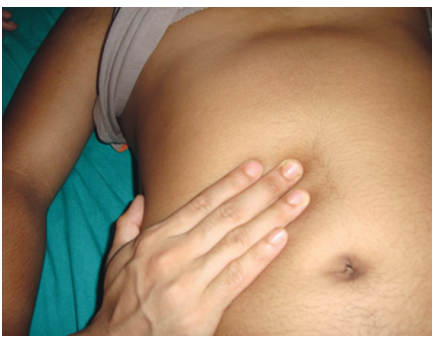**Fig. 73.5A:** Palpation of liver starts from the right Iliac fossa



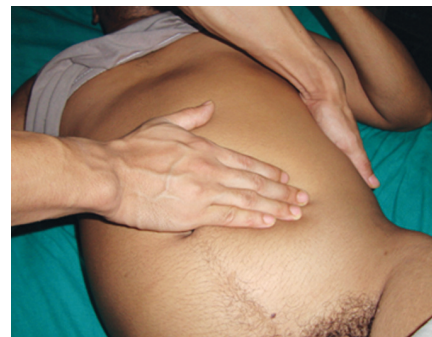**Fig. 73.7A:** Palpation of spleen starts from the right iliac fossa towards the left hypochondrium



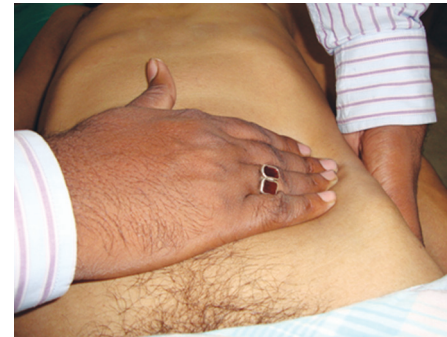**Fig. 73.8A:** Palpation of the right kidney



**Fig. 73.5B:** Palpation of liver just below the right costal arch



**Fig. 73.7B:** Palpation of spleen near the left costal arch



**Fig. 73.8B:** Palpation of the left kidney

6. How will you palpate spleen? (Figs 73.7A and B)
  - a. Patient lies spine with legs flexed at the hips and knees.
  - b. Patient is asked to take deep breaths with open mouth.
  - c. The spleen is made more prominent by lifting the lower ribs forwards with the left hand.
  - d. Palpation is started from the right iliac fossa with the finger tips pointing towards the left costal margin.

- e. If the spleen is enlarged, its tip will hit the tips of the index and middle fingers when the patient breathes in. The normal spleen is not palpable. To be just palpable, spleen should be at least 2 to 3 times its normal size. When enlarged, it extends from the left costal margin towards the right iliac fossa. The superior border usually presents one or two notches close to the lateral end.
7. How will you palpate kidney? (Figs 73.8A and B)
  - a. Right kidney

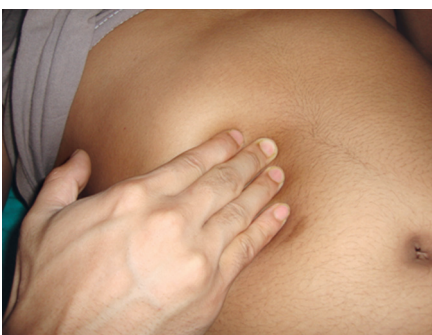The kidney is palpated bimanually with the patient lying on his back with a pillow under the knees.

- a. Right kidney
  - Clinician's left hand is placed posteriorly between the ribs and iliac crest.
  - The right hand is placed over the right lumbar region horizontally.
  - Patient is asked to breath in and out.
  - An enlarged kidney is palpable by pressing the left hand forward and the right hand backward (Bimanually palpable).
  - A kidney is normally not palpable.

- b. Left kidney
 

Left kidney is palpated in the same way as the right kidney by placing the left hand posteriorly in the left loin and the right hand horizontally anteriorly in the left lumbar region.

8. How do you elicit rebound tenderness?
  - a. Pressure exerted during palpation elicits a painful response in the region of an inflamed organ.
  - b. If the hand is suddenly taken off, an expression of agony is observed on the patient's face due to aggravation of the painful response. This is called rebound tenderness.
  - c. Sudden movement of the deeply inflamed or ischemic organ aggravates the pain.
9. How will you elicit fluid thrill? (Fig. 73.9)
  - a. Position of patient – Supine with the side of his hand kept firmly over the midline in abdomen.
  - b. Clinician's one hand is placed flat over the lumbar region of one side.
  - c. The opposite lumbar region is tapped with the other hand.



**Fig. 73.6:** Palpation of the gallbladder



- d. A fluid thrill is felt as wave in the palpating hand laid flat in the lumbar region. It is felt in huge ascites.
10. How will you elicit shifting dullness? (Figs 73.10A to F)
- The presence of free fluid in the abdominal cavity can be determined by eliciting shifting dullness (Fig. 73.10A).
  - Percussion is commenced from center of the abdomen and carried down to one flank till the resonant note becomes dull (Fig. 73.10B).
  - The patient is then turned to the opposite side (Figs 73.10C and D).
  - The clinician waits for a few seconds to allow the fluid to gravitate and again percusses the flank.
  - Presence of free fluid is confirmed if the note now becomes relatively resonant (Fig. 73.10E).
  - The same process is repeated on the other side (Fig. 73.10F).

11. What is succussion splash? How do you elicit it?

It is the splashing sound over the stomach area by shaking the patient gently in gastric outlet obstruction, e.g. pyloric stenosis.

Test:

- The patient should not take any fluid 3 to 3.5 hours prior to the test.
- The bell of stethoscope is placed over the left hypochondrium and gentle shake is given to the abdomen holding the patient at the hips.
- Splash of fluid is heard if there is gastric outlet obstruction. Normally splashing sounds are heard soon after the intake of fluid.

12. By what tests will you differentiate a parietal from an intraabdominal lump?

- Rising tests – (Raising shoulders or leg lifting tests) (Fig 73.11).
  - The patient is asked to raise his shoulder from the bed keeping his hands over the chest or to raise both the extended legs from the bed.
  - If the swelling is invisible or disappears, then it is intraabdominal swelling.

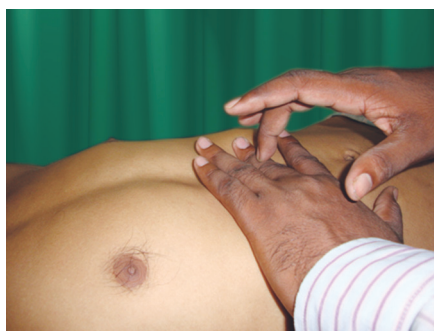- If the swelling becomes more prominent, then it is a parietal swelling.

Leg raising test is more applicable for lower abdominal swellings.

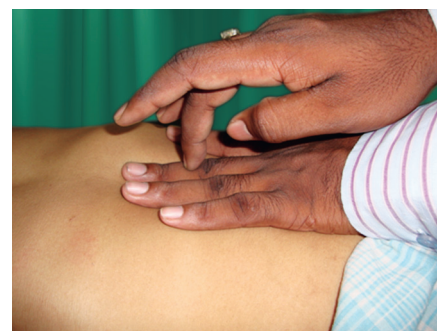- Another differentiating point is that a swelling moving up and down with respiration is obviously intraabdominal.

13. How do you distinguish an intraperitoneal from retroperitoneal swelling?

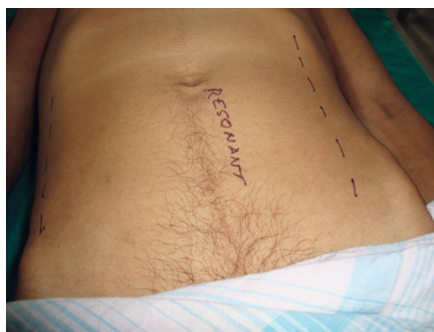This is done by examination of the lump in the knee elbow position.



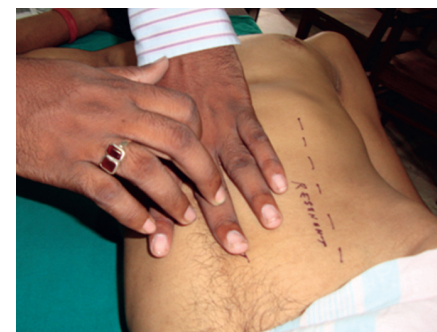**Fig. 73.10A:** Demonstration of shifting dullness. Percussion in the midline to exclude any swelling



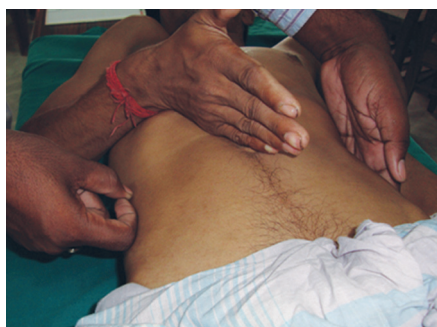**Fig. 73.10B:** Percussion in the left flank from the center



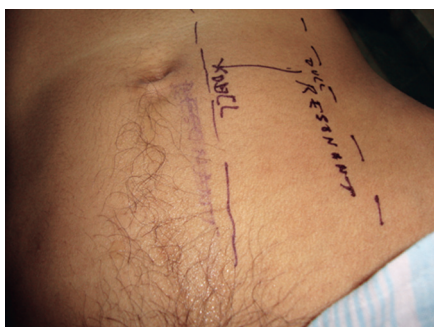
**Fig. 73.10C:** Dullness area marked



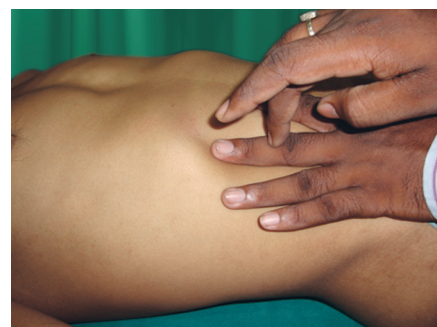**Fig. 73.10D:** Patient is turned to the right and percussion done from left to right flank



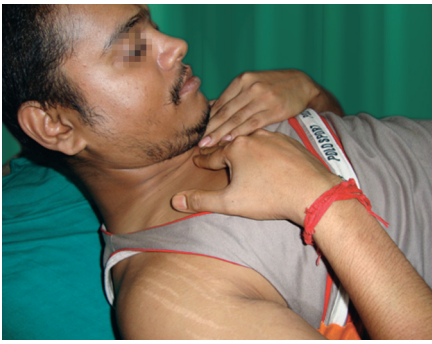**Fig. 73.9:** Demonstration of the fluid thrill



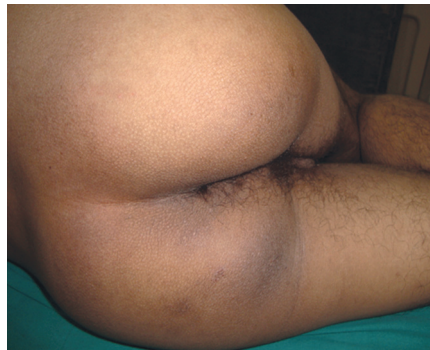**Fig. 73.10E:** Left flanks area of dullness has shifted towards the right



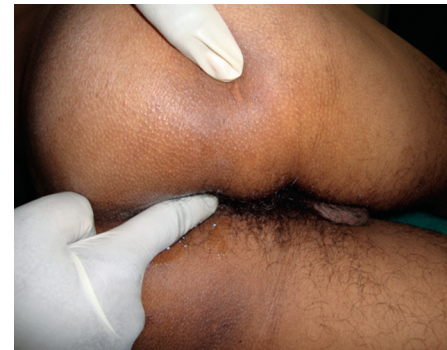**Fig. 73.10F:** Percussion process repeated in the right flank



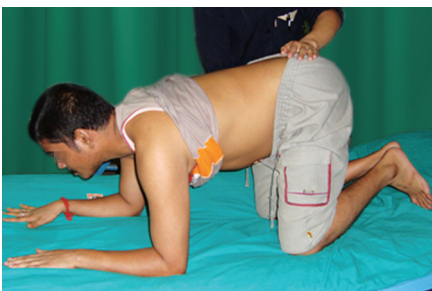**Fig. 73.11:** Head raising test



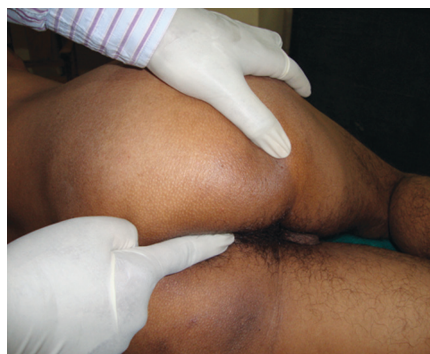**Fig. 73.13A:** Per rectal examination – positioning of the patient



**Fig. 73.13C:** The right index finger is pushed gently into the anorectum pointing towards the umbilicus



**Fig. 73.12:** Knee elbow test



**Fig. 73.13B:** Gloved right index finger is placed at the anus

Test: (Fig. 73.12)

- a. The patient is asked to assume the knee elbow position.
  - b. The lump is examined. If the lump disappears or becomes less prominent, then it is a retroperitoneal swelling.
  - c. If the lump becomes more prominent or remains the same, then it is said to be intraperitoneal.
14. What are the structures that move with respiration?  
These are structures in relation to the diaphragm viz. liver, gallbladder, stomach, spleen, kidney, greater omentum, hepatic and splenic flexures and the duodenojejunal flexure.
15. How would you perform the per rectal examination?  
Abdominal examination is not complete without per rectal examination which is done as below after explaining the procedure to the patient and taking the consent (Figs 73.13A to C).
- i. It is done in left lateral position of the patient with right leg completely flexed and left leg remaining straight.

- ii. The anus is inspected for any discharge, skin changes and swelling after separating the buttocks.
- iii. Xylocaine jelly is applied over the anus and pulp of the gloved right index finger is gently pushed into the anorectum in the direction of the umbilicus. Rectum is palpated for any growth or stricture. The size, texture and median groove of the prostate are felt. Finger tip should be inspected for any staining with blood, mucus or pus.

## GASTRIC CARCINOMA

### Case Summary

A 65-years-old male patient presents with persistent epigastric pain and sensation of fullness after meal for last 6 months. He had anorexia and loss of weight for last 4 months. There is no history of peptic ulcer disease in the past.

Epigastric pain is unrelated to food, does not respond to treatment and is often associated with vomiting.

On physical examination, patient has marked wasting and pallor, no palpable left supraclavicular node and jaundice, pulse – 80/min.

On examination of abdomen, it is scaphoid in shape, there is an irregular, hard lump 6cm × 4cm over the epigastrium which moves with respiration. Visible peristalsis is seen in the upper abdomen moving from left to right.

There is no abdominal distension and ascites. Auscultopercussion revealed dilated stomach.

- Per rectal, examination normal.
- Systemic examination revealed no abnormality.

### Clinical Discussion

1. What is your case?  
This is a case of gastric outlet obstruction due to carcinoma of stomach.
2. Why do you say so?
  - a. There is persistent upper abdominal pain, with an irregular hard lump over the epigastrium moving with respiration.
  - b. Anorexia, pallor and loss of weight.
  - c. Vomiting.
  - d. No history of peptic ulcer disease.
3. What are other possibilities?
  - a. Gastric outlet obstruction due to chronic duodenal ulcer.
  - b. Gastric outlet obstruction due to bezoar.



- c. Gastric outlet obstruction due to leiomyoma and lymphoma of stomach.
- d. Gastrointestinal stromal tumors (GIST) causing gastric outlet obstruction.
- e. Adult hypertrophic pyloric stenosis.
- f. Other causes of epigastric lumps, e.g. hepatic, colonic, gallbladder, omentum, etc.
4. What are the effects of gastric outlet obstruction?
- Huge dilatation of stomach.
  - Metabolic effects – There is hypokalemic hyponatremic and hypochloremic metabolic alkalosis due to loss of  $K^+$ ,  $Na^+$  and chloride by vomiting.
5. What are different types of presentation in gastric carcinoma?
- Sudden dyspeptic symptoms after the age of 40 years.
  - Dysphagia (growth at the cardiac orifice).
  - Gastric outlet obstruction when growth is at the pylorus simulating pyloric obstruction in chronic duodenal ulcer.
  - Bleeding manifestations
    - Hematemesis – More common.
    - Melena – Less common
  - Lump in the epigastrium.
  - Silent or latent group usually growth at the body of stomach grows in silence. The patient presents with features in other organ or at remote site without any features in relation to stomach, e.g.
    - Troisier's sign – Visible and palpable left supraclavicular node (Virchow's gland).
    - Obstructive jaundice due to metastasis in the liver.
    - Ascites – Peritoneal deposits or carcinomatosis peritonei.
    - Krukenberg's tumor – Often tumor cells grow in the ovaries producing large cystic or solid tumors.
    - Hemoptysis – Sometimes the patient presents with pulmonary metastasis producing hemoptysis.
6. What are the predisposing factors?
- Gastric polyp – a higher incidence with polyp of >2 cm diameter.
  - Pernicious anemia.
  - Atrophic gastritis.
  - Smoking.
  - Genetic factor – Gastric carcinoma is more common in blood group A people.
  - Postgastrectomy and Post-truncal vagotomy stomach.
  - Autoimmune gastritis.
  - Intake of raw alcohol in Scandinavian countries.
  - Long-standing gastric ulcer.
  - H. pylori* infection.
7. What are the macroscopic types?
- According to Borrmann's classification based on gross appearance, there are four types viz.
- Ulcerative type
  - Proliferative type
  - Colloid type – Highly malignant variety. Transcelomic spread may occur to ovaries producing Krukenberg tumor.
  - Scirrhus or infiltrative type – The process especially involves the submucous and subserous layers. It occurs in two forms viz.
    - Localized form – Occurring in the prepyloric region causing early pyloric stenosis and
    - Diffuse or generalized form – Here the whole stomach is involved and the wall becomes rigid and thickened giving the name, leather bottle stomach or 'Linitis plastica'.
8. What is the incidence of carcinoma in various parts of stomach?
- Pylorus – 50 – 60 percent.
  - Body (more common at greater curvature) and fundus – 15 – 25 percent.
  - Cardia - 25 percent.
9. What are the histopathologic types of carcinoma stomach?
- Mainly columnar cell adenocarcinoma.
  - Cubical cell adenocarcinoma in some cases.
  - Rarely squamous cell carcinoma at the esophagogastric junction.
10. What is Lauren's pathologic classification?
- According to Lauren's classification there are two types of gastric carcinoma viz.
- Intestinal type with glandular pattern of pleomorphic cells and scanty mucin. It occurs in the elderly and is usually well-defined.
  - Diffuse type – Consists of small uniform cells with plentiful mucin but few glandular lumina. It represents the infiltrative form (linitis plastica) of gastric carcinoma. Prognosis is worse, compared to the intestinal type.
11. What is early gastric cancer?
- Early gastric cancer is defined as small, discrete, single or multiple lesions confined to the mucosa and submucosa.
  - Lymph node metastases are uncommon and occur only in 5 to 10 percent cases.
  - 5-year cure rates are 85 percent or greater.
12. What are the subtypes of early gastric cancer?
- There are three subtypes viz. I, IIa, IIb, IIc and III.
- Type I – Exophytic or polypoid lesion extending into the gastric lumen.
- Type II – Superficial type
- Elevated lesions
  - Flat lesions
  - Depressed lesions
  - Excavated or ulcerated type extending into muscularis propria without invasion of this layer by actual cancer cells.
13. What is advanced gastric cancer?
- These are tumors invading the muscularis propria or beyond.
  - They are frequently associated with contiguous organ involvement or distant spread and have a higher stage (stages III and IV).
  - Less amenable to curative surgery.
  - Comprise 80 – 90 percent of all gastric cancer cases.
14. How staging is done in gastric carcinoma?
- There are two types of staging.
- TNM staging – developed by American Joint Committee on Cancer (AJCC) and the International Union against Cancer (UICC) and based on the depth of tumor invasion, extent of lymph node metastases and presence of distant metastasis.
  - Japanese staging.
15. What is TNM staging?
- The T-stage and N-stage are determined by endoscopic ultrasound (EUS) and CT scanning. The EUS T-stage and N-stage correspond fairly with the pathologic T-stage and N-stage.



Here, T = Depth of tumor invasion.  
 N = Lymph node metastasis  
 M = Distant metastasis

**TNM staging by AJCC and UICC**  
*(International Union against Cancer)*

T<sub>is</sub> – Carcinoma *in situ*, intraepithelial tumor without invasion of lamina propria.

T<sub>1</sub> – Tumor invades lamina propria or submucosa.

T<sub>2</sub> – Tumor invades muscularis propria or subserosa.

T<sub>3</sub> – Tumor penetrates serosa, i.e. visceral peritoneum without invasion of adjacent structures.

T<sub>4</sub> – Tumor invades adjacent structures (liver, pancreas, spleen, kidney, retroperitoneum, etc.)

**N (Lymph nodes)**

N<sub>0</sub> – No regional lymph node metastasis.

N<sub>1</sub> – Metastasis in 1-6 regional lymph nodes.

N<sub>2</sub> – Metastasis in 7-15 regional lymph nodes.

N<sub>3</sub> – Metastasis in more than 15 regional lymph nodes.

**M (Distant metastasis)**

M<sub>0</sub> – No distant metastasis.

M<sub>1</sub> – Distant metastasis.

**Stage Grouping –**

This is given below in Table 73.1

Table 73.1: The stage grouping of TNM system of classification				
Stage	T	N	M	
0	T <sub>is</sub>	N <sub>0</sub>	M <sub>0</sub>	
I	IA	T <sub>1</sub>	N <sub>0</sub>	M <sub>0</sub>
	IB	T <sub>1</sub>	N <sub>1</sub>	M <sub>0</sub>
		T <sub>2</sub>	N <sub>0</sub>	M <sub>0</sub>
II		T <sub>1</sub>	N <sub>2</sub>	M <sub>0</sub>
		T <sub>2</sub>	N <sub>1</sub>	M <sub>0</sub>
		T <sub>3</sub>	N <sub>0</sub>	M <sub>0</sub>
III	IIIA	T <sub>2</sub>	N <sub>2</sub>	M <sub>0</sub>
		T <sub>3</sub>	N <sub>1</sub>	M <sub>0</sub>
		T <sub>4</sub>	N <sub>0</sub>	M <sub>0</sub>
	IIIB	T <sub>3</sub>	N <sub>2</sub>	M <sub>0</sub>
IV		T <sub>4</sub>	N <sub>1-3</sub>	M <sub>0</sub>
		AnyT	AnyN	M <sub>1</sub>

For all practical purposes, N<sub>3</sub> is considered equivalent to M<sub>1</sub>, hence any T with N<sub>3</sub> is considered stage IV disease.

16. What is Japanese system of classification and staging of gastric carcinoma?

This is known as PHNS system of classification and is based on the following factors:

1. P = Peritoneal metastasis

P<sub>0</sub> – No evidence of peritoneal metastasis.

P<sub>1</sub> – Peritoneal metastasis above the transverse colon.

P<sub>2</sub> – Peritoneal metastasis below the transverse colon, including ovarian metastasis.

P<sub>3</sub> – Multiple distant, peritoneal metastases.

2. H = Hepatic metastasis

H<sub>0</sub> – No liver involvement.

H<sub>1</sub> – Metastasis limited to one lobe.

H<sub>2</sub> – Few scattered metastasis to both lobes.

H<sub>3</sub> – Multiple deposits in both lobes.

3. L = Lymph node involvement

N<sub>1</sub> – Epigastric nodes within 3 cm of the primary

N<sub>2</sub> – Nodes around the celiac axis and along its branches (left gastric, common hepatic and splenic) and epigastric nodes beyond 3 cm of the primary.

N<sub>3</sub> – Hepatoduodenal nodes, retropancreatic nodes and those at the root of the mesentery.

N<sub>4</sub> – Paraaortic lymph nodes.

4. S = Serosal involvement by the cancer

S<sub>0</sub> – No observed invasion of the serosa by the cancer.

S<sub>1</sub> – Invasion of the serosa suspected by surgeon.

S<sub>2</sub> – Definite serosal involvement by cancer.

S<sub>3</sub> – Invasion of other organ present.

Stage Grouping: This is shown in Table 73.2

Table 73.2: Stage grouping of the PHNS system of classification				
Stage	Peritoneal metastasis	Liver metastasis	Lymph node metastasis	Serosal invasion
Stage I	P <sub>0</sub>	H <sub>0</sub>	N <sub>0</sub>	S <sub>0</sub>
Stage II	P <sub>0</sub>	H <sub>0</sub>	N <sub>1, N2</sub>	S <sub>1</sub>
Stage III	P <sub>0</sub>	H <sub>0</sub>	N <sub>3</sub>	S <sub>2</sub>
Stage IV	> P <sub>1</sub>	> H <sub>1</sub>	N <sub>4</sub>	S <sub>3</sub>

17. What factors influence the prognosis of gastric carcinoma?

1. Depth of tumor invasion – Serosal involvement is associated with negligible 5 years survival. This is the most important prognostic factor.

2. Lymph node metastasis.  
 i. No involvement – 80 percent 5 years survival.  
 ii. Nodal metastasis – 0 to 40 percent, 5 years survival according to level of involvement.

3. Histological grade of the tumor and the histological type, e.g. intestinal type has good prognosis while diffuse type has worse prognosis.

18. What is Trousseau’s sign?

It is also known as superficial migrating thrombophlebitis, commonly seen in carcinoma of stomach and pancreas.

19. What are the neoplasms of stomach?

*Benign tumors and polyps (5-10%).*

1. Hyperplastic polyps
2. True neoplasms
  - i. Epithelial – Adenoma
  - ii. Mesenchymal
    - Lipoma, leiomyoma.
    - Hemangioma
    - Neurilemmoma

*Malignant tumors (90 – 95%),*

1. Carcinoma (85 – 90%).
2. Lymphoma
3. Malignant GIST.

20. How does gastric carcinoma spread?

This can spread through the following routes:

1. Direct
  - a. By continuity – It spreads through the submucous layer at a distance from the growth margin. So, wide excision of the normal gastric wall is needed.
  - b. By contiguity – It spreads to adjacent structures viz. liver, pancreas, colon, kidney, omentum, etc. early and easily.

## 2. Lymphatic spread

- a. From pylorus – Spread occurs to suprapyloric and subpyloric glands.
- b. From lesser curvature – Spread occurs to right and left gastric lymph nodes.
- c. From greater curvature to short gastric, splenic and gastroepiploic nodes.

Ultimately all lymph nodes drain into celiac group of lymph nodes. From celiac group it can spread to supraclavicular lymph nodes.

The Japanese have introduced the concept of lymph node levels N<sub>1</sub>, N<sub>2</sub>, N<sub>3</sub> in relation to lymphatic spread. The nodal station defined as level N<sub>1</sub>, N<sub>2</sub> and N<sub>3</sub> vary depending on the location of the tumor.

N<sub>1</sub> – Lymph nodes are perigastric within 3 cm of the primary tumor.

N<sub>2</sub> – Lymph nodes around celiac axis and its trifurcation viz. left gastric, splenic, and common hepatic and nodes beyond 3 cm of the primary.

N<sub>3</sub> – Hepatoduodenal and retropancreatic nodes and nodes situated at the root of the mesentery. These are distant nodes outside the normal lymphatic pathways from the stomach.

In D<sub>1</sub> lymphadenectomy or D<sub>1</sub> resection all N<sub>1</sub> lymph nodes are removed en bloc with the stomach.

In D<sub>2</sub> lymphadenectomy or D<sub>2</sub> resection, all the N<sub>1</sub> and N<sub>2</sub> lymph nodes are removed en bloc with the stomach.

3. Hematogenous spread occurs to liver, lungs and bones.
4. Transcolonic spread to ovaries may produce Krukenberg's tumor. There may be peritoneal seeding (carcinoma peritonei) and umbilical deposits (Sister Mary Joseph's nodules) occurring due to spread along the lymphatics in the falciform ligament.
21. What is rectal shelf of Blumer?
 

In advanced cases of gastric carcinoma, peritoneal deposits, felt in rectovesical or rectouterine pouch on per rectal examination as a shelf is known as rectal shelf of Blumer.
22. How do you investigate the case?
  - a. Investigations for anesthetic fitness – Examination of blood, stool and urine, X-ray chest – PA view, blood sugar, urea, creatinine and ECG.

## b. Special investigations:

- i. Stool for occult blood – if positive, there is a lesion with chronic hemorrhage in the growth.
- ii. Upper GI Endoscopy – Diagnosis is confirmed in most cases with this investigation because–
  - a. It can show the entire stomach including the fundus and cardiac orifice.
  - b. Biopsy from the growth can be taken.
  - c. Gastric juice may be aspirated and examined for malignant cells by Pap stain.
  - d. Endoscopic ultrasound (EUS), if available, may be done which will clearly show the depth of invasion of the tumor in the stomach wall
- iii. Barium meal X-ray of stomach and duodenum – This is helpful for the diagnosis of linitis plastica. Endoscopy may not find any pathology as mucosa may appear normal.
- iv. CT scan/MRI – Growth of lymph nodes and operability are better assessed.
- v. Laparoscopy – Can detect the presence of any peritoneal metastasis and liver metastasis.

## 23. What is the treatment of this case?

The treatment of choice is surgery after proper preoperative preparation. Adjuvant chemotherapy has been found to be beneficial in a few patients only. After exploratory laparotomy if the growth is localized and resectable (see below), a lower radical gastrectomy as curative resection, is performed otherwise, a palliative bypass or other procedures (see below) are done in advanced cases of gastric carcinoma.

## 24. What is the aim of surgery?

- a. Radical curative resection, whenever possible.
- b. Bypass procedure to relieve vomiting in advanced cases.
- c. Palliative gastrectomy in cases of fungating, ulcerative bleeding mass. It gives better palliation in inoperable cases.

## 25. What is operability?

- a. A tumor is said to be operable, when it is confined to the organ of origin and a curative resection is possible.

- b. There is no local fixity and lymph node metastasis, no distant metastasis or ascites.

## 26. What are the signs of inoperability?

- a. Local fixity to pancreas or posterior abdominal wall.
- b. Liver metastasis.
- c. Left supraclavicular nodal metastasis.
- d. Presence of ascites.
- e. Peritoneal seeding – local or pelvic

## 27. What is resectability?

The word resectable means the growth can be removed irrespective of its spread. Thus a growth may be inoperable but resectable as there is no local fixity.

## 28. What are the types of radical surgeries?

The following radical surgical procedures are done depending on the site of the primary tumor in operable cases.

- a. Lower radical gastrectomy for carcinoma at the pyloric region.
- b. Upper radical gastrectomy for carcinoma in the upper third of stomach.
- c. Total radical gastrectomy for diffuse growth (linitis plastica) involving the whole stomach.
- d. Subtotal radical gastrectomy for growth in the middle third of stomach. If growth involves a greater area, total gastrectomy may be necessary.

## 29. What structures are removed in lower radical gastrectomy?

- a. 75 percent of stomach including the growth with a margin of at least 5-6 cm from the palpable tumor mass of unstretched stomach.
- b. Lesser and greater omentum.
- c. 2cm of the first part of duodenum.
- d. Removal of all related lymph nodes.
- e. Spleen and distal pancreas – These organs were removed earlier but presently they are not included in the resection in view of the increased morbidity and mortality.

## 30. How continuity is maintained after lower radical gastrectomy?

Continuity is restored by Billroth II gastrojejunostomy or by Roux-en-Y gastrojejunostomy.

31. What are R<sub>0</sub>, R<sub>1</sub>, R<sub>2</sub> and R<sub>3</sub> resections?

- a. These terms are based on the groups of nodes removed along with the gastric resection.

- b.  $R_0$  resection – Removal of the tumor alone with no residual disease.
- c.  $R_1$  resection – Gastric resection with removal of level 1 nodes. ( $N_1$  nodes).
- d.  $R_2$  resection – Gastric resection with removal of level 1 and 2 ( $N_1$  and  $N_2$ ) nodes.
- e.  $R_3$  resection – Gastric resection with removal of level 1, 2 and 3 ( $N_1$ ,  $N_2$  and  $N_3$ ) nodes.
32. What is the present nomenclature of these resections?
- There are presently called as  $D_1$ ,  $D_2$  and  $D_3$  resections.
  - The term R is presently used as  $R_0$  for curative resection and  $R_1$  for palliative resection with residual tumor.
33. What structures are removed in upper radical gastrectomy?
- It involves removal of upper part of stomach, lower end of esophagus with regional lymph nodes and spleen. Continuity is maintained by esophagogastronomy to a vagotomized gastric remnant. Anastomosis of the distal stomach to the esophagus produces a poor functioning result because alkaline reflux can be troublesome and very difficult to control.
- This is why some surgeons perform total radical gastrectomy in case of proximal third cancer.
34. How continuity is restored after total radical gastrectomy?
- This is done either by:
- Roux-en-Y esophagojejunostomy or
  - Jejunal pouch esophageal anastomosis.
35. What palliative procedures are done in inoperable gastric carcinoma?
- These are:
- Anterior gastrojejunostomy.
  - Partial gastrectomy if lump is locally resectable.
  - Divine's antral exclusion operation.
  - Feeding jejunostomy.
  - Intubation of gastric carcinoma at cardioesophageal junction for relief of obstruction.
36. Why anterior and not posterior gastrojejunostomy?
- Malignancy tends to spread posteriorly; hence the stoma gets infiltrated with posterior gastrojejunostomy.
37. What is Divine's antral exclusion operation?
- Stomach is divided proximal to the growth and both ends are sutured.
  - A side to side or end to side gastrojejunostomy is performed. Thus, the tumor is excluded from the food passage.
38. At what distance jejunojunostomy should be performed after esophagojejunostomy? Jejunojunostomy is done at about 50cm from the esophagojejunostomy site to avoid bile reflux.
39. What are the roles of chemotherapy and radiotherapy in the treatment of gastric cancer?
- Radiotherapy has no role in the management of adenocarcinoma of stomach.
  - Chemotherapy has been associated with partial response (>50 percent tumor mass regression).
- The recent drug regimen used in combination chemotherapy includes 5FU, Adriamycin and mitomycin C, i.e. the FAM regimen.
40. What are the postgastrectomy complications?
- These include biliary reflux, diarrhea, osmotic (early) and hypoglycemic (late) dumping, anemia and malnutrition and are seen in 20 percent cases.
41. How do you prevent the above complications?
- Oral iron tablet and vit  $B_{12}$  injection are often needed supplements.
  - The Roux loop should be 50 cm long to avoid bile reflux.
  - To prevent early and late dumping patient is advised to take small amount of food at repeated intervals and to avoid intake of water during food as it increases the bulk of food.
- Patient is also asked to lie down for some-time after taking food to prevent, postural hypotension.

### GASTRIC OUTLET OBSTRUCTION (PYLORIC STENOSIS) DUE TO COMPLICATION OF CHRONIC DUODENAL ULCER

#### Case Summary

The 50-years-old male patients with vomiting for last six months and pain in the upper abdomen for last 5 years.

Vomiting is the chief complaint. It occurs in the evening mainly, very large in amount, foul smelling, frothy, nonbile stained and vomitus contain undigested food particles taken one or more days previously. Vomiting usually offers considerable relief.

Regarding pain, patient gives the following history. He used to suffer from pain in the epigastrium 2-3 hours after meal.

Pain occurs in the middle of night and relieved by meal, e.g. taking biscuits. Pain is aggravated by missing a meal or anxiety states.

Periodicity of pain was marked and occurs for 2-3 months with a pain free interval of 3-4 months.

Water brash and heart burn were present throughout this period but no vomiting.

For last six months patient is having constant dull aching pain in the central upper abdomen with vomiting and periodicity of pain lost.

Vomiting used to take place once or twice a week previously but now it occurs almost daily. There is lack of appetite.

On examination, on general survey, patient is emaciated with poor nutrition and pallor. On abdominal examination, abdomen is scaphoid, visible peristalsis is seen moving from left to right. Succussion splash is present over the epigastrium and auscultopercussion revealed a dilated stomach.

#### Clinical Discussion

- What is your case?  
This is a case of gastric outlet obstruction due to chronic duodenal ulcer.
- Why not pyloric stenosis?
  - Both gastric outlet obstruction and pyloric stenosis are the same. Pyloric stenosis is the popular nomenclature yet the term outlet obstruction is more scientific.
  - In chronic duodenal ulcer, due to cicatrization (repeated cycles of inflammation and healing) there is narrowing of the lumen of 1st part of duodenum, acting as the outlet of stomach.
  - There is no stenosis in the pylorus, so pyloric stenosis is a misnomer.
- What are other causes of gastric outlet obstruction?
  - Growth in the antrum of pylorus.
  - Annular pancreas.

- c. Foreign body obstruction or bezoars.  
 d. Adult hypertrophic pyloric stenosis.  
 e. In children and newborn – Congenital hypertrophic pyloric stenosis, duodenal atresia and congenital band passing over duodenum.
4. Why vomiting occurs?  
 Antral contraction fails to expel gastric contents into the duodenum. So reverse peristaltic waves set in to cause vomiting.
5. Why is there lack of appetite?  
 As the stomach always remains full, due to stagnation, there is lack of appetite.
6. Why there is mental confusion and weakness?  
 a. Patient does not take adequate food, so nutrition is poor.  
 b. Due to vomiting there is loss of  $\text{Na}^+$  and  $\text{K}^+$ , which produces muscular weakness.  
 c. Due to hypochloremic metabolic alkalosis, there may be mental confusion.
7. Why there is metabolic alkalosis?  
 Metabolic alkalosis is due to loss of chloride by vomiting.
8. What is the reaction of urine?  
 It is acidic due to paradoxical aciduria.
9. Why is there paradoxical aciduria?  
 Due to vomiting serum potassium falls. Normally potassium is excreted through the distal renal tubules. Due to hypokalemia, the distal tubules and the collecting ducts do not excrete  $\text{K}^+$  ions and instead excrete more amounts of  $\text{H}^+$  ions, while reabsorbing  $\text{Na}^+$  due to aldosterone effect, so urine becomes acidic.  
 This is called paradoxical aciduria, as on the background of metabolic alkalosis, kidney should have excreted alkaline urine.
10. How will you confirm your diagnosis?  
 The diagnosis is confirmed by doing an upper GI endoscopy.
11. What information can be obtained by upper GI endoscopy?
12. What is the role of Ba-meal study?
13. What other investigations are indicated?  
 Vide carcinoma of stomach Q. 22
14. How will you prepare the patient for surgery?  
 The patient with gastric outlet obstruction needs some specific preparation which includes:
- a. Correction of dehydration – either by oral fluid or by intravenous normal saline infusion. Adequate urine output suggests proper hydration.  
 b. Correction of electrolyte imbalance – Patient suffers from hyponatremia and hypokalemia due to vomiting and increased renal loss.  
 Hyponatremia is corrected by intravenous infusion of normal saline. Once adequate urine output is established, potassium should be supplemented for correction of hypokalemia.  
 c. Correction of hypoproteinemia by oral high protein diet, fresh frozen plasma or human albumin transfusion.  
 d. Anemia is corrected by blood transfusion.  
 e. Gastric lavage is done before each feed 4-5 days before surgery. Gastric lavage removes the food residue, decreases the mucosal edema, and also brings back the gastric tonicity.
- f. Correction of hypocalcemia – secondary to metabolic alkalosis, ionized calcium may fall which may result in tetany and altered consciousness.
15. How will you do gastric lavage?  
 a. Gastric lavage is done before each feed 4-5 days before surgery. It is the thorough washing of stomach with normal saline to get rid of stagnant mucus and food materials.  
 b. A Ryle's tube of 16 or 18 Fr. Size is inserted into the stomach and gastric juice is aspirated.  
 c. Normal saline is allowed to run through the Ryle's tube and aspirated back.  
 d. This is repeated till the returned fluid is clear. This requires about three to four 500 ml bottles of normal saline.
16. How will you manage this patient?  
 a. First diagnosis is confirmed by upper GI endoscopy.  
 b. Other investigations like complete hemogram, blood sugar, urea, creatinine, X-ray chest PA view, ECG, bleeding and coagulation time, liver function tests, stool for occult blood and serum Na, K and Cl estimations.  
 c. Surgical intervention after preoperative preparation.
17. What operation will you do in this case?  
 • Truncal vagotomy and gastrojejunostomy.
18. What are other options for surgical treatment?  
 a. Highly selective vagotomy and gastrojejunostomy.  
 b. Only gastrojejunostomy in elderly frail patient.
19. What is the drawback of gastrojejunostomy alone?  
 Gastrojejunostomy alone is not the sufficient treatment because after gastrojejunostomy, acid secretion status of stomach improves and there is chance of stomal or anastomotic ulcer.
20. Why do you use normal saline instead of sodium bicarbonate?  
 Though sodium bicarbonate is a better mucolytic agent, it will produce more alkalosis. Hence it is avoided.
21. What are the changes in serum electrolytes in pyloric stenosis?  
 These are hyponatremia, hypokalemia and hypochloremia.
22. What is the cause of these changes?  
 These changes are due to excess vomiting which depletes the patient of  $\text{Na}^+$ ,  $\text{K}^+$  and  $\text{Cl}^-$ , the latter is lost in excess of  $\text{Na}^+$  and  $\text{K}^+$  as HCl.  
 Gastric HCl loss causes extracellular  $\text{HCO}_3^-$  to rise and renal excretion of  $\text{HCO}_3^-$  increases to maintain  $\text{P}^{\text{H}}$ . Large amount of  $\text{Na}^+$  are excreted in urine with  $\text{HCO}_3^-$ .
23. What is the electrolyte content of gastric juice?  
 Na – 45 mmol/liter  
 K – 10 mmol/liter  
 Cl – 120 mmol/liter  
 Hydrogen (H) – 65 mmol/liter
24. What is saline load test?  
 It is simple test to assess the degree of pyloric obstruction.
25. How do you do it?  
 a. Through a nasogastric tube about 700 ml of normal saline is infused into the stomach over three to five minutes and the tube is clamped.  
 b. After half an hour, the stomach is aspirated and the residual volume of saline is measured.  
 c. A residual volume of more than 350 ml indicates obstruction.

26. How can you assess emptying of solids?  
Solid emptying can be measured with Technetium ( $^{99m}\text{Tc}$ ) labeled chicken liver.

## CHRONIC DUODENAL ULCER

### Case Summary

The 45-year-old male patient presents with pain in the central upper abdomen, for last 5 years.

The pain is burning in character with no radiation. He gives history of hyperacidity and hypereructation. Pain is aggravated in empty stomach 2-3 hours after meal and relieved by taking food and antacids.

Periodicity of pain is well-marked. Pain occurs for 2-3 months with a pain-free interval of 3-4 months.

There is no history of vomiting, hematemesis and melena and appetite is good.

Bowel and bladder habits are normal. No other systemic symptoms are present. There is no major medical or surgical illness in the past.

Personal history – He belongs to low socioeconomic class and takes 15 to 20 bidis a day for last 15 years.

On examination, general survey is normal. Abdominal examination is also normal except deep tenderness over the duodenal point. No visible peristalsis, liver, spleen, kidney are not palpable. No free fluid in the abdomen and bowel sounds audible.

### Clinical Discussion

1. What is your case?

It is a case of uncomplicated chronic duodenal ulcer.

2. Why do you say so?

It is uncomplicated because there is no history suggestive of any complication, e.g. vomiting, hematemesis or melena.

Chronic duodenal ulcer is suggested by the presence of hunger pain, well-marked periodicity, and tenderness over the duodenal point.

3. What are other possibilities?

- Chronic cholecystitis
- Chronic pancreatitis
- Chronic intestinal tuberculosis
- Chronic gastric ulcer
- Chronic appendicitis.

4. Why it is not a case of chronic cholecystitis?  
a. There is no history of radiation of pain to right shoulder.  
b. Pain is related to food.

5. Why it is not a case of chronic pancreatitis?  
a. There is no radiation of pain to the back.  
b. No history of alcohol addiction.

6. Why it is not a case of intestinal tuberculosis?  
a. There is absence of constitutional symptoms, e.g. evening rise of temperature, loss of weight, anorexia, night sweating, etc.  
b. No history of intermittent diarrhea.

7. How does chronic duodenal ulcer differ from chronic gastric ulcer?

- Pain – The following are the characteristics of pain in chronic gastric ulcer which differ from those of chronic duodenal ulcer.
  - Onset of pain – Soon after eating (15 – 30 or 60 minutes after taking food).
  - Relieving factor – Lying down flat and vomiting.
  - Periodicity of pain – Vague and not well-marked.
  - Water brash and heart burn absent.
  - Loss of weight due to less food intake for fear of pain.
  - Vomiting is frequent and often relieves pain.
  - Aggravating factor – Food
- Hemorrhage – Hematemesis more common than melena in gastric ulcer.
- Anemia – More common in gastric ulcer.
- Tenderness – Present over the gastric point located in the mid epigastrium.
- Malignancy – A giant gastric ulcer may undergo a malignant change.

8. What is the duodenal point?

It is deep tender spot in the transpyloric plane 2.5 cm to the right of the midline, sometimes felt in active duodenal ulcer.

9. What are the complications of peptic ulcer? There are three types of complications:

- Acute –
  - Perforation
  - Hemorrhage – Hematemesis in gastric ulcer and melena in duodenal ulcer.
- Subacute

i. Perigastric and periduodenal adhesion with or without abscess formation.

ii. Penetration into the pancreas (back pain present).

c. Chronic

i. Pyloric stenosis in chronic duodenal ulcer.

ii. Hourglass contracture in gastric ulcer.

iii. Tea pot deformity in gastric ulcer.

iv. Malignancy in gastric ulcer.

10. What do you mean by peptic ulcer?

Peptic ulcer is defined as a breach of surface epithelium of the gastrointestinal tract by an interaction of acid and pepsin on the mucosa.

11. How will you confirm the diagnosis of peptic ulcer disease?

a. Endoscopy – Esophagogastroduodenoscopy is done to visualize the ulcer directly and multiple biopsies are taken from different quadrants to rule out malignancy.

b. Rapid urease test is done with the aspirated gastric juice to detect *H. pylori* infection.

c. Pap stain is done with the aspirated gastric juice after it is centrifuged to exclude malignant lesion.

12. What is the pathogenesis of peptic ulcer?

A. *Gastric ulcer*: The key factor in the genesis of gastric ulcer is breakdown of gastric mucosal barrier by various factors like nonsteroidal antiinflammatory drugs (NSAIDs), *H. pylori* infection, alcohol, trauma and shock (hemorrhagic and endotoxic). This allows back diffusion of  $\text{H}^+$  ions resulting in mucosal damage. Gastric mucus, a viscid layer of mucopolysaccharides has considerable buffering capacity which is enhanced by the presence of bicarbonate within the mucus. Gastric mucus secreted by the mucus producing cells of the stomach and the pyloric glands, acts as a physiological barrier to protect the gastric mucosa from mechanical damage.

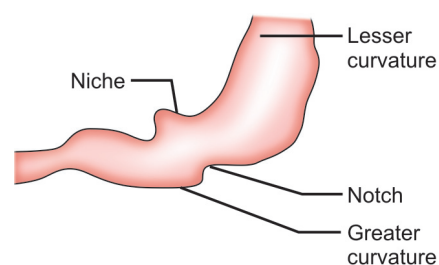
B. *Duodenal ulcer*: In this case, acid hypersecretion is the main cause of mucosal damage. The factors causing acid hypersecretion are:



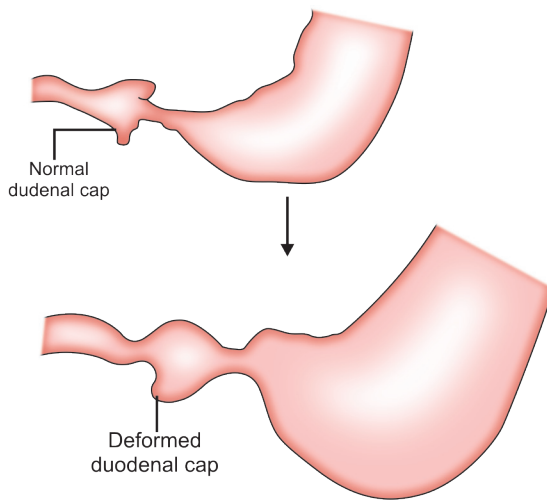
- i. Parietal cell hyperplasia due to increased vagal activity.
  - ii. *H. pylori* infection.
  - iii. Hypergastrinemia, e.g. Zollinger Ellison syndrome.
  - iv. Other predisposing factors like smoking, stress, cirrhosis, and Blood group O individuals also increase gastric acid secretion.
13. What is the role of *H. pylori* infection in the causation of peptic ulcer?  
*Helicobacter pylori* (*H. pylori*) is a gram-negative spirochetal bacterium with multiple flagellae, which allow it to burrow and live deep beneath the mucus layer closely adherent to the epithelial surface. It is seen that around 90 percent of duodenal ulcer patients and 70 percent of gastric ulcer patients are infected with *H. pylori*, the remaining 30 percent of gastric ulcers are due to NSAIDs and other factors. *H. pylori* exclusively colonizes in gastric type epithelium and in the duodenum in association with patches of gastric metaplasia. Normal duodenal mucosa is resistant to *H. pylori* infection but *H. pylori* induced inflammation causing duodenitis and gastric metaplasia act as precursor of duodenal ulcer.  
 In most people *H. pylori* causes antral gastritis associated with depletion of somatostatin (D cells) and gastrin release from G cells. The subsequent hypergastrinemia stimulates acid production by parietal cells.  
 In the majority of cases this has no clinical consequences but in a minority of patients (perhaps smokers) this effect is exaggerated leading to duodenal ulceration.  
 The role of *H. pylori* in the pathogenesis of gastric ulcer is more complex and impaired mucosal defense resulting from a combined effect of *H. pylori* infection, NSAIDs and smoking may have a more important role.  
*H. pylori* also secretes cytotoxins viz. cytotoxin associated protein (Cag A) and vacuolating cytotoxin (Vac-A) which can damage the gastric epithelial cells and lead to peptic ulceration.
14. What lesions may be caused by *H. pylori* infection?
- a. Chronic gastritis and pangastritis.
  - b. Peptic ulceration (Gastric ulcer and duodenal ulcer).
  - c. Carcinoma of stomach.
15. How to detect *H. pylori* infection?
- a. Gastric biopsy – Histological detection is done by Giemsa stain.
  - b. Serological test – ELISA test for *H. pylori* antibody (IgG and IgA).
  - c. Microbiological culture – This is the gold standard for diagnosis and defines antibiotic sensitivity.
  - d. Rapid urease test (RUT) – This is cheap, quick and specific but lacks sensitivity.
16. What are the types of gastric ulcer?
- a. Type I or primary of gastric ulcers which occur due to damage of mucosal defences.
  - b. Type II – Gastric and duodenal ulcers coexist. It is seen in 10 percent patients. Usually duodenal ulcer is the primary lesion and gastric ulcer follows as a result of stasis and gastritis due to fibrous stenosis or pylorospasm.
  - c. Types III – Ulcers occurring in the pyloric channel or prepyloric area and have features more in common with duodenal than gastric ulceration.
17. What are the common sites of gastric ulcer?
- a. Middle or lower part of lesser curvature – 90 percent within 5 cm of pylorus.
  - b. Near the cardia.
  - c. Pyloric canal.
  - d. Greater curvature – The ulcer here runs the risk of malignant change.
18. What is the common site of duodenal ulcer?  
 Chronic duodenal ulcer usually occurs in the first part of the duodenum just distal to the junction of pyloric and duodenal mucosa.
19. What are the Ba-meal signs in gastric and duodenal ulcers?
- a. Gastric ulcer – The Ba-meal shows the presence of ulcer crater or niche usually projecting from the lesser curvature with a notch or incisura opposite the niche on the greater curvature (Figure 73.14A).
  - b. Duodenal ulcer: A duodenal ulcer produces distortion of the duodenal cap, which is normally triangular in shape. The distortion is due to inflammatory

edema and subsequently due to scarring (Fig. 73.14B).

20. What are the disadvantages of Ba-meal X-ray?
- a. It gives only an indirect evidence of ulcer.
  - b. It cannot identify the early and superficial lesions.
  - c. It does not have provisions for tissue biopsy.
21. What is the diagnostic accuracy of Ba-meal?  
 About 80 percent.
22. What other investigations are done?
- a. Stool for occult blood which can be positive in some patients.
  - b. Acid output studies – Basal acid output (BAO) and maximal acid output (MAO) are measured and expressed as H<sup>+</sup> ion secretion in mEq/hour.
  - c. Serum gastrin level estimation – gastrin level more than 200 pg/ml is abnormal. It is abnormally high in Zollinger – Ellison syndrome (>1000 pg/ml). Normal gastrin level is 20 to 25 pg/ml.
- Gastrin level is also raised in atrophic gastritis and pernicious anemia as the absence of acid in the stomach results in the absence of normal inhibition of gastrin release by the antral G cells.
23. What is basal acid output?  
 It is the measurement of acid production by unstimulated stomach under basal fasting conditions. The normal value ranges between 2 and 5 mEq/hour.
24. What is maximal acid output?  
 It measures the acid production during stimulation by pentagastrin injection (a synthetic gastrin analog) given in a dose that is maximal for this effect.



**Fig. 73.14A:** Ba-meal signs in gastric ulcer

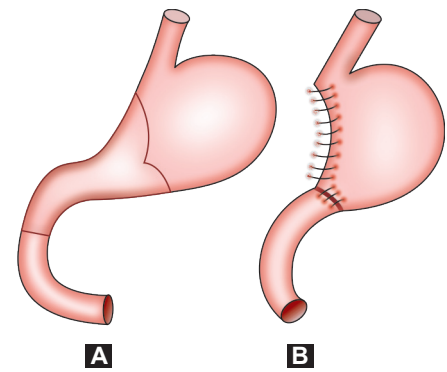


**Fig. 73.14B:** Ba-meal sign in duodenal ulcer

The normal value ranges between 20 and 30 mEq/hour. In duodenal ulcer this is >35 mEq/hour.

25. What is the medical treatment for peptic ulcer?
- Medical treatment is similar for gastric and duodenal ulcer.
  - Treatment includes use of specific medications viz. antacids, H<sub>2</sub> blockers, mucosal coating agents, PPI or proton pump inhibitor like omeprazole and antibiotics to eradicate *H. pylori* infection.
  - Lifestyle modification, e.g. changes of irregular habits of eating, working and sleeping.
  - To avoid smoking and other gastric irritants like alcohol, caffeine, NSAIDs like aspirin, ibuprofen, indomethacin and others.
26. What are the indications for surgical intervention?
- Intractable ulcer – If the ulcer fails to heal within 6 months, or recurrence occurs following stoppage of treatment.
  - Perforation of the ulcer with peritonitis.
  - Gastric outlet obstruction.
  - Hemorrhage – When repeated episodes occur in the form of hematemesis or melena and remains uncontrolled with medical measures.
27. What are the surgical options in gastric ulcer?
- For type I and type II ulcers, the following operations are done:

- Partial gastrectomy (distal two-thirds of stomach is removed) with gastroduodenal anastomosis (Billroth type I operation) (Figs. 73.15 A and B).
  - Partial gastrectomy with gastrojejunal anastomosis (Billroth type II operation) (Fig. 73.16).
- Type III ulcer – It is treated in line with duodenal ulcer and truncal vagotomy and gastrojejunostomy is done. Highly selective vagotomy is not recommended for gastric ulceration.
28. What are the results of surgical treatment? The recurrence rate is low about 2 percent and long-term results are excellent.
29. What are the surgical options in chronic duodenal ulcer?
- Truncal vagotomy with gastrojejunostomy – Most widely practiced procedure.
  - Truncal vagotomy and antrectomy – It has very low rates of recurrent ulcer.
  - Partial gastrectomy or subtotal gastrectomy.
  - Highly selective vagotomy.
30. What are the complications of gastrectomy?
- Early complications:
    - Hemorrhage
    - Paralytic ileus
    - Duodenal fistula
    - Duodenal blow out.
  - Delayed complications:
    - Recurrent ulcer.
    - Early and late dumping syndromes.



**Figs 73.15A and B:** Billroth I operation – The cut end of the duodenum is directly anastomosed, end to end with the gastric opening left towards the greater curvature side

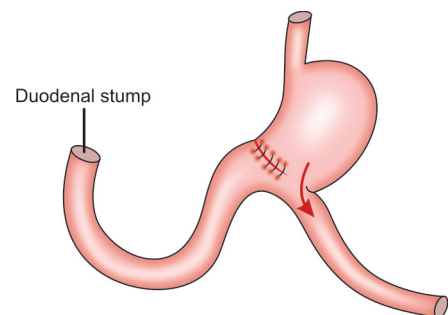
- Gastrojejunocolic fistula.
- Nutritional problems, e.g. weight loss, steatorrhea, diarrhea, iron deficiency, hypocalcemia, anemia.
- Bilious vomiting.

31. Why does bilious vomiting occur?

Bilious vomiting is due to stagnation of bile in the afferent loop. Following a kink, when the obstruction is released or kinking is overcome, there is sudden rush of bile from afferent loop into the stomach and instantaneous bilious vomiting occurs.

32. What is early dumping syndrome?

This occurs about ½ to 1 hour after food. Due to sudden entry of food rich in carbohydrate into the jejunum fluid is shifted from blood vessel or veins into



**Figs 73.16:** Billroth II operation consisting of partial gastrectomy, closure of the cut ends of the duodenum and lesser curvature side of the stomach, followed by a posterior gastrojejunostomy

the lumen of jejunum for maintaining the osmotic equilibrium thus resulting in hypovolemia.

The syndrome is manifested by tachycardia, hypotension, sweating, epigastric fullness and sensation of warmth.

It can be prevented by

- i. Taking meals which are small in amount and dry.
- ii. Milk and carbohydrate meals should be avoided.

*Treatment*

- It subsides naturally with the passage of time.
- When the syndrome persists conversion of a Billroth II anastomosis to Billroth I is the operation of choice.

33. What is late dumping syndrome?

Here symptoms appear 2.5 to 3 hours after taking food. This is due to reactive hypoglycemia. Immediately after taking food, increased absorption of carbohydrate from the small bowel causes a rise in plasma glucose and a consequent rise in plasma insulin level leading to secondary hypoglycemia.

It is clinically manifested by faintness, nausea, hypotension, epigastric emptiness and tremor. Symptoms are relieved by intake of glucose. Octreotide is very effective.

34. What are the incidences of postcibal or dumping syndrome?

- a. Early dumping syndrome – 5 to 10 percent.
- b. Late dumping syndrome – 5 percent.

35. What are the causes of postgastrectomy anemia?

- a. Defective iron absorption in polya or Billroth II gastrectomy.
- b. Vit B<sub>12</sub> deficiency after total gastrectomy as no intrinsic factor is available.
- c. Malnutrition.

36. What is a gastrojejunal fistula? How is it produced?

A gastrojejunal fistula is an internal communication between stomach, jejunum and transverse colon. It occurs when a recurrent ulcer after gastrojejunostomy, penetrates into the transverse colon. It should arouse the suspicion of Zollinger-Ellison syndrome or malignancy.

It is manifested by severe diarrhea due to enteritis, caused by colonic content

passing directly into the small bowel, resulting very soon in dehydration, K<sup>+</sup> loss, acidosis and anemia.

*Treatment:* Excision of gastric, jejunal and colic components of fistula and construction of higher gastrectomy.

In frail and poor risk patient this is done in three stages.

- a. Proximal colostomy, then
- b. Excision of fistula and construction of higher gastrectomy followed by
- c. Closure of colostomy.

37. What is recurrent peptic ulcer?

It is the recurrence of peptic ulcer following effective surgical treatment. The usual sites are:

- a. Anastomotic ulcer at gastroduodenal stoma.
- b. Anastomotic ulcer in the jejunum near the gastrojejunostomy stoma.
- c. Ulcer in the duodenum.

38. What are the causes of recurrent ulcer?

- a. Incomplete surgery, e.g. incomplete vagotomy or inadequate resection of stomach.
- b. Cigarette smoking.
- c. Endocrine disorder like gastrinoma or Zollinger-Ellison syndrome.

39. How do you diagnose and treat the recurrent ulcer?

- a. Gastroduodenoscopy is the most accurate way of making the diagnosis.
- b. *Treatment:*
  - i. This problem is easier to treat. It responds well to antisecretory agents, e.g. H<sub>2</sub> blockers or proton pump inhibitors in most cases.
  - ii. Revagotomy is done in case of incomplete vagotomy.
  - iii. If gastrinoma is present; the tumor is to be removed. If not due to gastrinoma, then revision gastrectomy is necessary.

40. What do you do in truncal vagotomy?

Truncal vagotomy consists of resection of 1 to 2 cm segment of each vagal trunk as it enters the abdomen, on the distal esophagus.

41. What is the disadvantage of truncal vagotomy?

- Postvagotomy diarrhea occurs in 10 percent patients.

42. Why a drainage operation is required with truncal vagotomy?

Vagus is the secretomotor nerve of stomach. Hence after vagotomy gastric emptying is inadequate due to decreased motility resulting in persistent gastric distension, foul eructations, nausea, vomiting and abdominal pain.

It is therefore, mandatory to do a drainage operation combined with truncal vagotomy.

43. What is selective vagotomy?

In this operation, only the branches of the vagus that supply the stomach are transected, preserving the celiac and hepatic branches.

A drainage procedure is still required because the gastric nerves (anterior and posterior nerves of Latarjet) are divided producing pyloric denervation.

44. What is highly selective vagotomy?

This operation preserves the terminal branches of gastric nerves that is, the nerves of Latarjet, denervating only the acid secreting portion of the stomach.

This makes a gastric drainage procedure unnecessary as the antral innervation remains intact.

45. How vagotomy helps in the treatment?

It diminishes acid secretion.

46. What are the complications of vagotomy?

- a. Hemorrhage from periesophageal veins.
- b. Splenic injury.
- c. Pancreatic injury.
- d. Incomplete vagotomy.
- e. Gastric atony.
- f. Postvagotomy diarrhea probably due to increased gastric emptying following drainage procedure.
- g. Cholelithiasis due to impaired gallbladder motility.

47. What is the treatment of postvagotomy diarrhea?

- a. Mild cases – Kaolin pectin compounds.
- b. Severe cases – Codeine phosphate, Diphenoxylate with Atropine (Lomotil) or Loperamide may be needed.

48. What is the difference between antrectomy and hemigastrectomy?

The terms antrectomy and hemigastrectomy are more or less synonymous.

49. What is the most effective surgery for reducing gastric acid output?

Vagotomy combined with antrectomy. Vagotomy removes the vagal cholinergic 'drive' while antrectomy abolishes gastrin

production from antrum, thus the two principal stimuli of gastric secretion are removed.

50. What are the disadvantages of vagotomy with antrectomy?
  - a. Increased time and effort is required to perform the operation.
  - b. More chance of anastomotic leakage.
51. What do you do in subtotal gastrectomy?
 

This involves resection of 80 percent of the distal stomach followed by gastrojejunanal anastomosis.
52. How does this operation help?
 

It removes the major source of gastrin and about more than half of the parietal cell area of the stomach.
53. What is the most common cause of death after Billroth II operation?
 

Blow out of duodenal stump which usually occurs on the 3rd to 6th day after operation.
54. How do you treat it?
  - a. Fluid and electrolyte replacement and total parenteral nutrition.
  - b. Suction of duodenal discharge if the drain is *in situ*, if the drain is not present near the stump, immediate reoperation is carried out and drain, inserted.
  - c. Barrier cream like zinc oxide is applied to protect the skin.
  - d. Healing usually takes place in 4-6 weeks provided there is no distal obstruction in the afferent limb of the gastrojejunostomy.
55. What is Zollinger-Ellison syndrome?
 

In 1955 Zollinger and Ellison described this syndrome consisting of—

  - a. Upper gastrointestinal ulcer disease (stomach, esophagus, jejunum and duodenum up to the 3rd part).
  - b. Marked increase in gastric acid secretion.
  - c. Nonbeta cell islet tumor of pancreas (gastrinoma).

There will be diarrhea and hypokalemia with hypergastrinemia and massive acid hypersecretion even up to 500 ml/hour. The CT scan locates the tumor in the pancreas.
56. How do you treat this condition?
 

Total gastrectomy is the definitive treatment. Removal of gastrin producing lesion will rarely cure the condition. Omeprazole in the doses of 20-40 mg BD may control the acid hypersecretion

initially. Laparotomy is carried out after controlling the ulcer.

## CHRONIC CHOLECYSTITIS

### Case Summary

A 45-year-old fatty, female patient, mother of 4 children, presents with the complaints of

- a. Pain in the right upper abdomen especially after fatty and heavy meals for the last two years and
- b. Flatulent dyspepsia for last two years. Regarding pain patient gives the following history.
  - The pain is of sudden onset, colicky in nature, severe in intensity, radiates to the right shoulder and inferior angle of right scapula and relieved by analgesics.
  - The patient also complains of heart burn, acidity and flatulence for the last 6 months.
  - Bowel and bladder habits normal. No signs and symptoms of any systemic disease present. No significant past and family history present.
  - On examination: On general survey, patient is of average build, pulse – 80/min, BP – 130/90 mm Hg. No jaundice and no neck glands present.
  - On abdominal examination shape is normal. Abdomen moves normally with respiration, no venous prominence and umbilicus is normal in position and inverted.
  - On palpation, mild tenderness is present over right hypochondrium and no lump palpable.
  - On percussion abdomen is tympanitic and there is no free fluid in the abdomen. On auscultation, normal bowel sounds present. External genitalia normal, systemic examination normal, per rectal and per vaginal examination not done.

### Clinical Discussion

1. What is your case?
 

It is a case of chronic cholecystitis.
2. Why do you say so?
  - a. The patient is female, fertile and 40 years old.
  - b. History of biliary dyspepsia.

- c. The nature of upper abdominal pain is suggestive of gallbladder colic.
  - d. There is no lump in the right hypochondrium.
3. What are the other possibilities in this case?
    - a. Chronic gastric ulcer.
    - b. Chronic duodenal ulcer.
    - c. Chronic pancreatitis.
    - d. Recurrent appendicitis.
    - e. Hiatus hernia.
    - f. Right sided renal calculus.
  4. What are the presentations in chronic cholecystitis?
    - a. Biliary colic is the most common presentation.
    - b. Features of biliary dyspepsia – A feeling of fullness following heavy or fatty food in association with heart burn and belching.
    - c. Silent stones – Patient is asymptomatic and stones are detected in routine check up.
    - d. Features of acute cholecystitis and its complications like empyema, perforation, biliary peritonitis, etc.
    - e. Features of acute pancreatitis.
  5. What is biliary colic?
 

Biliary colic is a sharp, intermittent pain in the right hypochondrium, with radiation to the back or right shoulder, usually following a fatty meal. The pain is caused by contraction of the gallbladder against a stone impacted in the cystic duct.
  6. What is Murphy's sign?
    - a. This sign is positive in acute cholecystitis.
    - b. The patient is asked to take a deep breath.
    - c. Pressure is applied over the gallbladder point (a point beneath the right costal margin in the midclavicular line where lies the fundus of gallbladder).
    - d. There is a catch in breath at the height of inspiration and the patient complains of stabbing pain.
    - e. This sign is not found in chronic cholecystitis and uncomplicated cases of gallstones.
  7. What is Boas' sign?
 

It is an area of hyperesthesia between 9th and 11th ribs posteriorly on the right side. It is positive in some cases of acute cholecystitis.

8. What is the triangle of Calot?  
This is a triangular space bounded by the inferior surface of the liver, the common hepatic duct and the cystic duct.
9. What are the contents of the triangle of Calot?  
a. Cystic artery, branch of right hepatic artery.  
b. Cystic lymph gland of Lund.
10. What are the ducts of Luschka?  
These are the hepatocholecystic ducts that drain bile from the liver, directly into the gallbladder.
11. How do you confirm the diagnosis?  
Diagnosis is confirmed by doing an ultrasonography of upper abdomen.
12. How USG helps in the diagnosis?  
It tells about:  
a. The presence of stone (linear acoustic shadow).  
b. Gallbladder wall thickness – Normal / thickened.  
c. Size of the gallbladder–Normal size, contracted or distended.
13. What other investigations you like to do?  
Investigation for fitness of the patient for general anesthesia, viz.  
1. Hb%TC, DC, ESR, BT, CT.  
2. Blood sugar, urea, and creatinine.  
3. Liver function tests,  
4. Chest X-ray–PA view.  
5. ECG.
14. When will you consider ERCP or MRCP in gallstone disease?  
a. If ultrasonography shows dilatation of common bile duct.  
b. If LFT shows elevation of serum enzymes–ALT, AST and alkaline phosphatase.  
c. If there is history of jaundice or patient is having jaundice.
15. What are the advantages and disadvantages of ERCP?  
*Advantages*  
a. Biopsy from the periampullary region or brush cytology from the bile duct may be taken.  
b. Bile aspirated may be used for exfoliative cytology.  
c. Therapeutic intervention like sphincterotomy and stone extraction or biliary stenting is possible.  
*Disadvantages*  
a. An invasive investigation.  
b. There is chance of postoperative cholangitis or pancreatitis.
16. What are the advantages and disadvantages of MRCP?  
*Advantages*  
a. It is a noninvasive investigation.  
b. Biliary tract dilatation, any obstruction due to stone or growth may be ascertained.  
c. It gives a very good picture of the biliary tree.  
*Disadvantages*  
It has only diagnostic value. No therapeutic intervention is possible.
17. How do you treat this case?  
Treatment is cholecystectomy. If facilities for laparoscopic cholecystectomy are available, laparoscopic cholecystectomy is done.
18. What are the advantages of laparoscopic cholecystectomy?  
a. Short hospital stay and early return to work.  
b. More acceptance by the patient.  
c. Surgery is safe in the hands of an experienced surgeon.  
d. Less pain and cosmetic.
19. What preoperative counseling would you do with the patient before laparoscopic cholecystectomy?  
Counseling is to be done regarding conversion to open procedure in the following situations.  
a. If there is gross adhesion and the anatomy in the Calot's triangle is not clear.  
b. If there is excessive bleeding  
An informed consent is to be taken from the patient regarding the above.
20. What is minicholecystectomy?  
It is the open cholecystectomy done through a small right subcostal incision of about 5 cm. The advantages of this procedure include little postoperative pain and shorter hospital stay.  
It has been claimed to be comparable to laparoscopic cholecystectomy.
21. If cystic duct is found densely adherent with the common bile duct, what will you do?  
a. In such situation, the gallbladder is opened and the stones are removed as there is chance of injury to the bile duct, while dissecting the cystic duct.  
b. Gallbladder is removed leaving a portion of neck which is oversewn with silk suture.
22. What are the indications for exploration of CBD while doing cholecystectomy?  
a. Preoperative indications:  
i. If there is history of jaundice or cholangitis.  
ii. If liver function test is abnormal with elevated ALT/AST and alkaline phosphatase.  
iii. If preoperative USG, ERCP or MRCP has shown stone in the CBD  
b. Intraoperative indications:  
i. Palpable stone in the CBD is the absolute indication for opening the CBD.  
ii. Intraoperative cholangiogram shows a stone in CBD.  
iii. Common bile duct is dilated >1 cm.
23. What is extended or radical cholecystectomy?  
When gallbladder is removed along with adjoining segments of liver, it is known as extended cholecystectomy.
24. What are the steps of operation of open cholecystectomy?
25. What are the steps of operation of laparoscopic cholecystectomy?  
See operative surgery section.
26. What are the complications following cholecystectomy?  
a. Hemorrhage due to injury to right hepatic artery.  
b. Bile duct injury and stricture of CBD, a late complication.  
c. Biliary leak leading to acute biliary peritonitis (Waltman-Walters syndrome).  
d. Wound infection.  
e. Subphrenic abscess.  
f. Anesthesia related chest complications.
27. What is Waltman-Walters syndrome?  
This syndrome is due to sudden accumulation of bile following cholecystectomy in the right sided subdiaphragmatic or subhepatic space due to biliary leak and is manifested by a state of collapse with  
a. Tachycardia.  
b. Persistently low BP.  
c. Chest pain and  
d. Upper abdominal discomfort simulating coronary thrombosis.  
Treatment is immediate reexploration and evacuation of bile otherwise condition of the patient deteriorates rapidly.



28. What are the contraindications of laparoscopic cholecystectomy?  
Cirrhosis of liver – is perhaps the absolute contraindication.  
The relative contraindications are:
- Acute cholecystitis.
  - Choledocholithiasis.
  - Cholangitis.
  - Pancreatitis.
  - Previous upper abdominal surgery.
  - Coagulopathies.
  - Severe cardiac or pulmonary disease.
29. What is the rate of conversion of laparoscopic to open cholecystectomy?
- About 4 percent.
30. What are the types of gallstone?
- Mixed or infected stone (90%).
  - Pigment stones (4%).
  - Cholesterol stones (6%).
31. What are the characteristics of mixed gallstones?
- These are multiple, faceted and dirty white in color.
  - It is heavier than bile.
  - 10-20 percent stones are radiopaque.
  - The stone consists of concentric layers of calcium bilirubinate and cholesterol (predominant component) around the central nucleus of dead bacteria and epithelial debris.
32. What are the characteristics of pigment stones?
- Jet black in color, called black pigment stone.
  - Composition – either pure bilirubin or calcium bilirubinate mixed with calcium phosphate and carbonate.
  - Commonly formed in the gallbladder as multiple small concretions.
33. What are the characteristics of cholesterol stone?
- Cholesterol stone is mostly solitary (cholesterol solitaire).
  - It is lighter than bile, hence called floating stone.
  - Dirty white in color.
  - It occurs due to error in cholesterol metabolism. Normal ratio of bile salts to cholesterol is 25:1. If it is less than 13:1, cholesterol precipitates and stone formation occurs.
34. Which factors are responsible for formation of gallstones?
- Metabolic – Altered concentration of bile salts and cholesterol forms cholesterol stone as mentioned above.
  - Infection within the biliary tree.
  - Stasis within the biliary tree.
  - Hemolysis leading to increased bile pigments in bile.
35. What factors responsible for reduction of bile salts concentration in bile?
- Estrogen
  - Diseases affecting terminal ilium which interferes with the enterohepatic circulation of bile.
  - Cholestyramine therapy.
36. What factors increase cholesterol secretion in bile?
- Increasing age.
  - Obesity.
  - Clofibrate.
  - Women on oral contraceptive pill.
4. What is the fate of mucocele of the gallbladder?
- Surgical removal or cholecystectomy – commonest.
  - May be secondarily infected and change into an empyema.
  - Spontaneous regression occasionally, if the stone falls down.
5. How does a mucocele of gallbladder look like?
- A mucocele has a thin healthy transparent wall without congestion.
  - No adhesion with the surrounding structures.
6. What are the clinical presentations?
- Palpable gallbladder – which sometimes is very big (ram horn), even extending upto the right iliac fossa.
  - Biliary dyspepsia suggestive of chronic cholecystitis.
  - History of biliary colic.
7. How do you confirm your diagnosis?  
By USG of the upper abdomen
8. What is the treatment of choice?  
Cholecystectomy – either open or laparoscopic.
9. What are the gallstones?  
These are stones formed in the gallbladder, also known as biliary stones, developed in bile.
10. What is acalculous cholecystitis?  
Acute or chronic inflammation of the gallbladder in the absence of gallstones is known as acalculous cholecystitis.  
Acute acalculous cholecystitis occurs in the patients in intensive therapy unit, and following major surgery, trauma or burns.
11. What is cholecystoses?  
Cholecystoses is defined as chronic acalculous cholecystitis due to the following conditions viz.
- Cholesterosis or strawberry gallbladder.
  - Adenomyomatosis or cholecystitis glandularis proliferans.
  - Cholesterol polyposis.
- wall is healthy and the virulence of the organism is low.
- b. The bile is absorbed and replaced by mucus secreted by the gallbladder epithelium.
- c. A mucocele also occurs in those cases of malignancy which occlude the cystic duct.

## MUCOCELE OF GALLBLADDER

### Case Summary

In case of mucocele of gallbladder, the history and examination part is the same as in chronic cholecystitis. Except on abdominal examination, on palpation a lump is palpable in the right upper abdomen, which is pyriform in shape and moves up and down with respiration.

It is dull on percussion and the dullness is continuous with liver dullness. The lump has smooth surface, firm but elastic in feel with no tenderness. Liver and spleen are not palpable.

### Clinical Discussion

#### 1. What is your case?

It is a case of mucocele of the gallbladder.

#### 2. Why do you say so?

- Pain in the right upper abdomen in a middle-aged female patient.
- Patient is having pyriform swelling in the right hypochondrium which moves up and down with respiration.
- The lump is dull on percussion and the dullness is continuous with that of the liver.

#### 3. How does it occur?

- Usually it occurs as a sequel to acute obstructive cholecystitis due to a stone impacted either in the cystic duct or in Hartman's pouch, when the gallbladder

12. What is strawberry gallbladder?
- In this condition, the interior of the gallbladder is studded with tiny yellow flecks giving a typical picture of ripe strawberry.
  - The flecks consist of cholesterol crystals deposited in the submucosa.
13. What are the effects and complications of gallstones?
- Effects on the gallbladder:
    - Silent stones or asymptomatic stone – discovered accidentally during investigations for other conditions.
    - Biliary colic or gallstone colic.
    - Mucocele of the gallbladder.
    - Acute cholecystitis with its complications like perforation, peritonitis, internal fistula, e.g. cholecystocolic and cholecystoduodenal fistula, empyema and gangrene.
    - Chronic cholecystitis.
    - Carcinoma of gallbladder.
    - Flatulent dyspepsia.
  - Effects on the common bile duct:
    - Obstructive jaundice.
    - Cholangitis.
    - Pancreatitis (acute and chronic).
    - Hydrohepatosis and liver failure – due to back pressure the hepatocytes stop secreting bile and the biliary canaliculi are grossly dilated.
    - White bile – It is a misnomer as it is neither bile (actually mucin secreted by the mucous glands in the wall of the ducts) nor white. It is opalescent.
  - Effects on the intestine – Acute intestinal obstruction known as gallstone ileus.
14. What difficulties are faced during cholecystectomy in case of mucocele of gallbladder?
- The distended gallbladder producing a large lump.
  - The stone impacted in the neck may cause difficulty in defining and dissecting the cystic duct.
15. How do you overcome the above difficulties?
- The lump gets reduced in size following aspiration of the mucoid material.
  - The stone impacted in the neck should be manipulated or massaged from the neck into the gallbladder.

16. What is hepatorenal pouch of Morison?
- It is a space lying between the anterior surface of right kidney and the inferior surface of the liver.
  - After cholecystectomy this pouch is drained to avoid any collection.

### OBSTRUCTIVE JAUNDICE DUE TO PERIAMPULLARY CARCINOMA

#### Case Summary

A male patient aged 60 years presents with yellowish discoloration of eyes and urine for last 9 months, anorexia, loss of weight, vague abdominal discomfort for the same duration.

The yellowish discoloration of eyes was fluctuating in character. Initially the yellowish discoloration was deepening for first 6 months, then there was diminution for one month and again it was increasing for last two months.

He complains of itching over whole body and passage of clay-colored stool.

Along with anorexia, he complains of sensation of fullness after meal for the last 3 months.

He gives history of passage of black tarry stool 3 months back which lasted for 10 days. No history of vomiting and hematemesis and no alteration of bowel habit.

Patient complains of a mass in the right upper abdomen for last 6 months but no other systemic symptoms. No previous history of acute or chronic cholecystitis, is present.

On examination, on general survey, pallor is present, nutrition is poor and deep jaundice is there. No palpable neck glands present.

On abdominal examination, shape of abdomen → normal, umbilicus: → normal in position and inverted, liver and spleen → not palpable.

A lump is palpable in the right hypochondrium, the lateral, medial and lower margins palpable; the upper margin passes deep to the right costal margins. The lump appears to be palpable gallbladder.

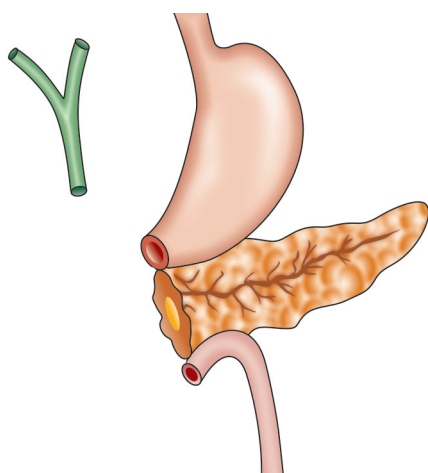
Bowel sounds audible.

Per rectal examination – No significant finding (A hard fixed lump in the rectovesical pouch may or may not be revealed in advanced cases).

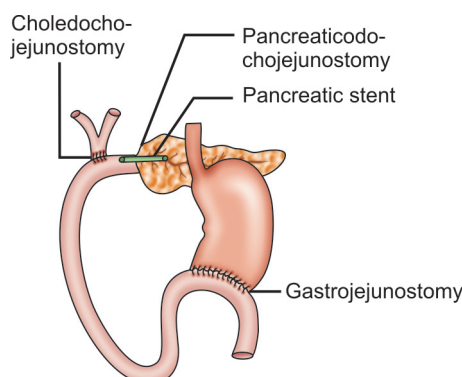
#### Clinical Discussion

- What is your case?  
This is a case of obstructive jaundice due to periampullary carcinoma.
- Why do you say so?
  - Yellowish discoloration of eyes and urine which is fluctuating in nature.
  - Itching over whole body and passage of clay-colored stool.
  - History of melena and loss of weight.
  - Palpable gallbladder.
 (It the jaundice is progressively rising with no fluctuating character and there is no history of melena, the provisional diagnosis may be given as obstructive jaundice due to carcinoma head of the pancreas).
- Why it is not a case of medical jaundice?
  - Absence of prodromal symptoms.
  - Passage of clay-colored stool.
  - Itching all over the body.
- Why it is not a case of obstructive jaundice due to stone in CBD?
  - No history of severe pain.
  - No history of fever with chills and rigor i.e. cholangitis.
  - The gallbladder is palpable.
  - There is no past history suggestive of calculus cholecystitis.
- Why gallbladder is distended?  
Due to back flow of bile which collects in the gallbladder which is still soft and distensible.
- What is Courvoisier's law?  
The law states that in a patient with obstructive jaundice if the gallbladder is palpable, the cause of obstruction is not choledocholithiasis as the gallbladder would have been fibrosed by chronic cholecystitis but is usually a carcinoma head of the pancreas.
- What are the fallacies to Courvoisier's law?
  - Palpable gallbladder in obstructive jaundice may be due to double impaction viz. (i) stone in the CBD and (ii) stone in the cystic duct producing a mucocele.
  - If carcinoma head of the pancreas is associated with chronic cholecystitis; gallbladder would not be palpable.
- What do you mean by periampullary carcinoma?  
This includes a group of malignant tumors at or near the ampulla viz.

- Adenocarcinoma arising from head of the pancreas adjacent to the ampulla – 40 - 60 percent.
  - Carcinoma arising from ampulla of Vater – 20 to 40 percent.
  - Distal bile duct carcinoma – 10 percent.
  - Duodenal carcinoma adjacent to the ampulla – 10 percent.
9. What are the differences in clinical presentation between carcinoma head/periamпуляр growth and that of body and tail?
- (i) *CA head/ periamпуляр growth* (ii) *CA body and tail*
- a. Jaundice (i) Present (either persistent or fluctuating) (ii) Absent
- b. Cholangitis (i) Present (ii) Absent
- c. Palpable gallbladder (i) Present (ii) Absent
10. How does jaundice of a periamпуляр growth differs from carcinoma head?
- In periamпуляр carcinoma, jaundice is fluctuating due to tumor slough. In carcinoma head of pancreas jaundice is persistent and progressive.
11. What investigations will you suggest for this patient?
- A. Investigations for confirmation of diagnosis which are:
- a. Liver function test:
    - Serum bilirubin – Total conjugated and unconjugated.
    - Serum enzymes – ALT, AST and alkaline phosphatase.
    - Serum albumin: globulin ratio.
    - Prothrombin time.
  - b. Ultrasonography of hepatobiliary system.
  - c. ERCP – To visualize the common bile duct obstruction.
  - d. CT scan of upper abdomen.
  - e. Ba-meal examination may show widened C-loop in carcinoma head of pancreas; while a reverse 3 sign in periamпуляр carcinoma.
- B. Investigations for anesthetic fitness which are complete hemogram, BT, CT, blood sugar, urea and creatinine, chest X-ray, ECG, urine for routine examination.
12. Why prothrombin time is prolonged in obstructive jaundice?
- In obstructive jaundice there is defect in absorption of fat-soluble vitamins viz. vit. A, D, E and K from the gut. Vitamin K is required for the synthesis of prothrombin in the liver.
13. How do you correct prothrombin time in obstructive jaundice?
- The prolonged prothrombin time is corrected by administration of injection of vitamin K for 3 to 5 days prior to operation in the dose of 10 mg IM/day.
14. What operation will you plan for this patient?
- Clinically, if there is absence of distant metastasis and if CT scan reveals no sign of local spread, curative surgery that is Whipple's pancreatoduodenectomy is planned.
15. What preoperative preparation will you do for this patient?
- Patients with obstructive jaundice are at increased risk for the development of renal failure (Hepatorenal syndrome), bleeding tendency due to deficiency of vitamin K, infections as a result of depressed immune system, malnutrition and hypoproteinemia and wound complications. Therefore, adequate preoperative preparation as described below is to be taken to avoid the development of postoperative complications.
1. Antibiotic coverage – e.g. combination second or third generation cephalosporin, e.g. cefuroxime or ceftriaxone and metronidazole are given before, during and after surgery. Nephrotoxic drugs like aminoglycosides are avoided.
  2. Control of bleeding tendency – Inj. vit. K 10 mg IM daily is given 3-5 days prior to operation to correct the prolonged prothrombin time and the bleeding tendency.
  3. Maintenance of renal function: The perioperative use of mannitol, which results in an osmotic diuresis and adequate hydration with IV fluid and plenty of fluids by mouth, have been successful in preventing renal failure (Hepatorenal syndrome) in cases of obstructive jaundice.
  4. Correction of anemia – By blood transfusion.
  5. Correction of malnutrition and hypoproteinemia with:
    - a. Increased dietary protein.
    - b. Transfusion of aminoacid or human albumin.
    - c. Transfusion of fresh frozen plasma.
16. What are the signs of inoperability in a case of periamпуляр carcinoma?
- a. Multiple liver metastases.
  - b. Ascites.
  - c. Peritoneal metastasis.
  - d. Invasion of growth to IVC, superior mesenteric vessels or portal vein.
  - e. Extensive lymph node metastasis.
17. What structures are removed in Whipple's operation?
- The following structures are removed in Whipple's operation (Fig. 73.17A).
- a. Head and neck of the pancreas including the uncinate process.
  - b. Distal 40 to 50 percent of stomach with whole of duodenum upto 10 cm of proximal jejunum.
  - c. Lower end of common bile duct (CBD).
  - d. Gallbladder.
  - e. Paraduodenal, peripancreatic and pericholedochal lymph nodes.
18. How will you maintain continuity following resection for Whipple's operation?
- The continuity is maintained by performing the following triple bypass (Fig. 73.17B)
- a. Choledochojejunostomy (end to side).
  - b. Pancreaticojejunostomy 10 to 15 cm beyond choledochio jejunostomy.
  - c. Gastrojejunostomy, 10 to 15cm beyond choledocojejunostomy (vide figure)
19. What is pylorus conserving pancreaticoduodenectomy?
- a. Here the distal third of stomach is not removed.
  - b. The line of resection is 2 cm distal to the pylorus.
- Duodenum along with other structures are removed as described above.
20. What is extended Whipple's operation?
- It involves:
- a. Wider soft tissue clearance.
  - b. Resection of superior mesenteric vessels and adjacent lymph nodes.
21. If on exploration the growth is found to be inoperable, what to do?



**Fig. 73.17A:** Appearance after pancreaticoduodenectomy



**Fig. 73.17B:** Appearance of pancreaticoduodenectomy after reconstruction

In this case palliative bypass surgery is to be done as follows:

- i. For relief of jaundice, any of the following operations may be done
    - a. Roux-en-Y cholecystojejunostomy or
    - b. Roux-en-Y choledochojejunostomy or
    - c. Choledochoduodenostomy if no duodenal obstruction is present.
  - ii. For gastric outlet obstruction and vomiting gastrojejunostomy is done.
  - iii. Celiac plexus block is done for relief of intractable pain.
22. What surgical procedures are available in periampullary carcinoma?
    - a. Pancreatoduodenectomy
    - b. Pylorus preserving resections
    - c. Extended Whipple's procedure
    - d. Palliative procedures.
  23. What is the prognosis of carcinoma of pancreas?
    - a. 5-year survival after curative resection of carcinoma head of pancreas is 3 percent while that for periampullary carcinoma is 30 percent.
    - b. Median survival is 6 months.
  24. What is the operative mortality rate for Whipple's operation?
 

Earlier it was 8 percent with improvement of technique and intensive care nowadays it is 1 to 2 percent.
  25. What are the different tumor markers in carcinoma of pancreas?
    - a. CA 19 - 9 is the most encouraging.
    - b. Other tumor markers include CEA and CA 494.
  26. What is the treatment of chronic pancreatitis with jaundice and pancreatic ductal obstruction?
 

Whipple's procedure.
  27. When do you suspect that carcinoma of pancreas is advanced?
    - a. Presence of a palpable mass in the abdomen.
    - b. Troisier's sign (left supraclavicular lymph node enlarged) or Trousseau's sign (superficial migrating thrombophlebitis) is positive.
    - c. Presence of liver metastasis.

### OBSTRUCTIVE JAUNDICE DUE TO STONE IN CBD

#### Case Summary

A female patient aged 45 years presents with upper abdominal pain for last 1½ years. There is yellowish discoloration of the sclera and itching for last six months along with intermittent attacks of fever with chill and rigor.

The patient states that she had recurrent attacks of severe colicky pain in the right upper abdomen, often radiating to the back or interscapular region, onset is sudden and during pain she doubles up in bed often keeping a pillow against abdomen and pain is often associated with vomiting, retching

and constipation but no appreciable loss of appetite. The pain gets relieved by the gentle local pressure or analgesic drug.

During each attack pain persists for half an hour or so and during 24 hours there are three to four attacks. Following acute pain, patient noticed yellowish discoloration of the eyes, dark urine and clay-colored stool. This yellowish discoloration gradually increased day by day and thereafter started fading often disappearing completely by few days.

Bowel and bladder habits are normal and there are no other systemic symptoms.

On examination, on general survey patient is of average built, mild pallor and moderate jaundice, no palpable neck nodes, scratch marks are present over different parts of the body as evidence of itching.

On abdominal examination, gallbladder is not palpable. Liver is two fingers enlarged (due to cholangitis), firm, nontender, and smooth surface, spleen not palpable.

Hernial sites and external genitalia are normal.

#### Clinical Discussion

1. What is your case?
 

It is a case of obstructive jaundice due to stone in the CBD.
2. Why do you say so?
  - a. Sudden onset of severe colicky pain is suggestive of stone.
  - b. Jaundice is fluctuating in nature.
  - c. No melena or loss of appetite.
  - d. Itching marks present all over the body and clay-colored stool.
  - e. Gallbladder is not palpable.
3. What is Courvoisier's law?
4. What are the fallacies?
 

Described earlier.
5. What are the effects of stone in the CBD?
 

Discussed earlier in "Mucocele the gallbladder".
6. What are the sites of impaction of stone in the CBD?
  - a. Supraduodenal
  - b. Retroduodenal
  - c. Infraduodenal.
7. What are the other possibilities?
  - a. Carcinoma head of pancreas or periampullary carcinoma.
  - b. Stricture of CBD - benign and malignant.

- c. Lymph node mass at the porta hepatis causing biliary obstruction (Metastatic, lymphoma, Tuberculosis).
  - d. Cholangiocarcinoma involving the bile duct.
  - e. Carcinoma of gallbladder.
  - f. Sclerosing cholangitis.
  - g. Chronic pancreatitis.
8. What investigations will you do in this patient?
- A. Investigations for confirmation of diagnosis.
    - i. Liver function tests – serum bilirubin (conjugated and unconjugated), serum proteins (Total Albumin and Globulin), Liver enzymes (ALT, AST and Alkaline Phosphatase), and prothrombin time.
    - ii. Ultrasonography of upper abdomen is the mainstay of diagnosis.
    - iii. CT scan of abdomen if USG is non-conclusive about carcinoma head of the pancreas.
    - iv. ERCP – is the gold standard for diagnosis.
    - v. MRCP or magnetic resonance cholangiopancreatography is a non-invasive newer imaging modality which provides very good delineation of both bile and pancreatic ducts. But no therapeutic intervention as in ERCP is possible during MRCP.
  - B. Investigations to assess patient's fitness for general anesthesia viz.
    - Complete hemogram, bleeding time, clotting time.
    - Blood for sugar, urea, creatinine.
    - Chest X-ray.
    - ECG.
9. What are the types of stones in CBD?
- Two types of stones may develop:
- a. Primary – Also called brown pigmented stone.
  - b. Secondary – Stone coming from the gallbladder via the cystic duct.
10. How will you treat this patient?
- Treatment is divided into two groups:
- Group I – Treatment of CBD stone with gallbladder *in situ* with or without containing stone.
- Group II – Treatment of retained stone in CBD.

### Treatment of Group I Cases

- a. If gallbladder contains calculi  
Treatment is:
  1. Cholecystectomy with exploration of CBD and T - tube drainage or choledochoduodenostomy if CBD is > 1.5 cm in diameter.
  2. If endoscopic facilities are available, laparoscopic cholecystectomy with ERCP extraction of stones in one sitting or in different sittings.
- b. If gallbladder contains no calculi, the options are
  1. ERCP extraction
  2. ESWL or extracorporeal shock wave lithotripsy.

### Treatment of Group II Cases

- Retained stones or overlooked calculi are stones detected soon after a choledochotomy. Treatment options are:
1. If the T – Tube is *in situ*, stones may be extracted by:
    - a. Flushing with normal saline or
    - b. Burhenne technique—which is instrumental extraction of CBD stone through the T-tube tract using radiologic guidance.
  2. If T-tube is not in place, options are ERCP extraction or ESWL as in Group Ib cases above.
  3. Open choledocholithotomy if the above measures fail.
11. What are the steps of operation of choledocholithotomy?  
See operative surgery.
12. What is Charcot's triad?  
This is the classical triad of symptoms suggestive of cholangitis and consists of intermittent pain, intermittent fever and intermittent jaundice.
13. What are the recurrent bile duct stones?  
These are stones formed within the bile duct two years after the initial operation having the characteristics of primary duct stones.
14. What is transcystic exploration of bile duct?  
The exploration of common bile duct and removal of stones from there after approaching through the cystic duct with the help of choledochoscope.  
However stones more than 1cm in diameter cannot be removed by this method.

## OBSTRUCTIVE JAUNDICE DUE TO CARCINOMA OF GALLBLADDER

### Case Summary

A 60-year-old male patient presents with pain in the right upper abdomen for last 4 years. Initially, patient had colicky pain in the right upper quadrant of abdomen but in the last 6 months the patient is having dull aching continuous pain in the same area.

The patient has anorexia and loss of weight for last 8 months. There is yellowish discoloration of the eyes and skin and an abdominal lump in the right hypochondrium.

On examination on general survey patient has pallor jaundice is present but no neck glands palpable.

On abdominal examination, a hard, non-tender irregular lump is felt in the right hypochondrium and the lump moves up and down with respiration.

There is history of chronic cholecystitis.

No other mass is palpable. Normal bowel sounds are present.

### Clinical Discussion

1. What is your case?  
This is a case of obstructive jaundice due to carcinoma of gallbladder.
2. Why do you say so?
  - a. History of chronic cholecystitis.
  - b. Patient is elderly with a hard irregular, non-tender lump in the right upper abdomen, which moves with respiration.
  - c. Presence of jaundice.
  - d. Anorexia and weight loss.
3. What is the etiological relationship between carcinoma gallbladder and gall stone disease?  
Gallstones are present in 70 – 90 percent cases of carcinoma of gallbladder.
4. What investigations do you suggest in this case?
  - a. Ultrasonography of abdomen to assess the extent of involvement of liver and nodes as well as CBD.
  - b. Liver function tests.
  - c. CT scan of abdomen – to assess the operability and to stage the disease. CT guided FNAC can be done to confirm the diagnosis.



- d. ERCP is done if the patient presents with jaundice with a serum bilirubin level of more than 10 mg% and if a preoperative biliary stenting is contemplated.
- e. Baseline investigations as mentioned earlier to assess the patients' fitness for general anesthesia.
5. What are the histological types of carcinoma of gallbladder?
- Adenocarcinoma in 80 to 95 percent cases.
  - Anaplastic carcinoma - 2 to 7 percent cases.
  - Squamous cell carcinoma and adenosquamous carcinoma in 1 to 6 percent cases.
6. What is the TNM classification of carcinoma gallbladder?
- T - Primary tumor*
- T<sub>0</sub> - No evidence of primary tumor.
- T<sub>1</sub> - Tumor invades lamina propria or muscle layer.
- T<sub>1a</sub> - Tumor invades lamina propria.
- T<sub>1b</sub> - Tumor invades muscle layer.
- T<sub>2</sub> - Tumor invades perimuscular connective tissue, no extension beyond serosa.
- T<sub>3</sub> - Tumor invades serosa or liver or only other adjacent organ like duodenum, stomach, omentum, pancreas, extrahepatic bile ducts, etc.
- T<sub>4</sub> - Tumor invades portal vein, hepatic artery or invades two or more extrahepatic organs or structures.
- N - Regional lymph nodes*
- N<sub>0</sub> - No regional lymph node metastasis.
- N<sub>1</sub> - Regional lymph node metastasis present.
- M - Metastasis*
- M<sub>0</sub> - No metastasis.
- M<sub>1</sub> - Distant metastasis present.
7. What are the different presentations of carcinoma gallbladder?
- Symptoms of acute cholecystitis like pain in right upper abdomen, vomiting and positive Murphy's sign.
  - With features of chronic cholecystitis and jaundice.
  - With features of malignancy, e.g. anorexia, weight loss and generalized weakness.
  - With metastatic features, e.g.
    - Gastric outlet obstruction.
    - Palpable gallbladder hard nodular liver and ascites.
8. How does the carcinoma gallbladder spread?
- Direct invasion to porta hepatis and liver.
  - By lymphatics to hilar lymph nodes.
  - By veins to liver segment IV.
  - Distant metastasis is uncommon.
9. How do you treat carcinoma gallbladder?
- If carcinoma has not invaded the muscle (T<sub>1</sub>) simple cholecystectomy is enough.
  - If carcinoma has invaded the serosa or liver (segment IV and V), extended cholecystectomy is done. This is en bloc removal of gallbladder, 2 cm or greater wedge resection of liver tissue and portal lymph nodes.
  - For jaundice, biliary enteric bypass or stenting is done.
  - For gastric outlet obstruction - gastrojejunostomy is done.
  - For pain relief, celiac plexus block is done with alcohol.
10. What is the prognosis?
- 5 years survival rate is 2-5 percent but it is > 50 percent if the tumor is confined to the mucosa only.
11. Which tumor markers are important in carcinoma of gallbladder?
- CA 19 - 9 and CEA are elevated in CA of gallbladder but these markers are also elevated in other GI malignancies.
12. What is the sequence of changes in the development of carcinoma gallbladder?
- This is as follows:
- Normal epithelium → Epithelial metaplasia as a result of chronic irritation, e.g. due to stones, etc. → Dysplasia → Carcinoma *in situ* → invasive carcinoma.

### OBSTRUCTIVE JAUNDICE DUE TO POSTCHOLECYSTECTOMY; STRICTURE OF CBD

A 45-year-old male patient presents with painless and progressive jaundice with history of cholecystectomy done 1 year back.

He complains of intermittent attacks of cholangitis characterized by episodic pain and fever with chills and rigor.

The liver is enlarged, smooth, soft and tender.

### Clinical Discussion

- What is your case?  
It is a case of obstructive jaundice due to postcholecystectomy biliary stricture.
- Why do you say so?
  - Cholecystectomy done 1 year back.
  - Intermittent attacks of cholangitis.
  - Painless and progressive jaundice.
- What are the causes of biliary stricture?
  - Benign
    - Surgical trauma producing postoperative stricture (Bismuth type I to V) - 95 percent.
    - Inflammatory stricture
      - Sclerosing cholangitis
      - Chronic pancreatitis
      - Parasitic infestation
    - Congenital stricture.
  - Malignant stricture due to carcinoma of bile duct or cholangiocarcinoma.
- What are the causes of operative injury to the bile duct?
  - Blind plunge application of a hemostat to a bleeding cystic, accessory cystic or to the right hepatic artery - commonest cause.
  - Failure to identify the anatomy in Calot's triangle, when there is much inflammation.
  - Failure to appreciate the anatomical variations, ductal and/or vascular.
  - Excessive dissection and devascularization of the common bile duct during choledochotomy.
  - Injury during other operations, e.g. partial gastrectomy.
- How many injuries are recognized intraoperatively and in the postoperative period?
  - Intraoperatively recognized about 15 percent of injuries.
  - Postoperatively recognized 85 percent of the injuries.
- What is Bismuth classification of the benign biliary stricture?  
There are five anatomical types (Bismuth 1982)
  - Type I - Low common bile duct stricture, stump > 2 cm.
  - Type II - Middle common hepatic duct stricture stump < 2 cm.
  - Type III - Hilar stricture - confluence of right and left duct intact.

- Type IV – Right and left hepatic ducts separated.  
 Type V – Involvement of intrahepatic ducts.
7. What are the complications of biliary stricture?
    - a. Recurrent cholangitis
    - b. Biliary cirrhosis
    - c. Portal hypertension.
  8. What investigations do you suggest?
    - a. Liver function tests – shows elevated serum bilirubin (mainly conjugated type), and alkaline phosphatase level.
    - b. Ultrasonogram.
    - c. Cholangiography via T-tube, if present.
    - d. Transhepatic cholangiography.
    - e. Percutaneous transhepatic cholangiography (PTC).
    - f. Fistulogram of biliary fistula if present.
    - g. ERCP–(Endoscopic retrograde cholangiopancreatography).
    - h. MRCP (Magnetic resonance cholangiopancreatography) – This is newer noninvasive method of investigation of the biliary tree and can accurately define the extent of injury.
  9. How will you treat this case?
    - I. Low CBD obstruction – The options are:
      - a. Choledoduodenostomy or choledochojejunostomy.
      - b. ERCP stenting.
      - c. Recent advance is endoscopic balloon dilatation of stricture.
    - II. High CBD obstruction – The options are:
      - a. Left hepaticojejunostomy with jejunojunctionostomy.
      - b. ERCP stenting.
      - c. Roux-en-Y hepaticojejunostomy if duct is available.
  10. How do you treat the malignant stricture of CBD?
    - a. Periapillary carcinoma
      - i. Whipple's operation.
      - ii. If patients general condition is poor, then stenting and palliative radiotherapy is given.
    - b. Cholangiocarcinoma – palliative treatment only for relief of jaundice by:
      - i. Endoscopic stenting or
      - ii. Biliary enteric bypass or
      - iii. Percutaneous transhepatic biliary drainage (PTBD).
  11. What is the treatment of sclerosing cholangitis?
    - a. Steroids in large doses.
    - b. Cholestyramine
    - c. Stenting for relief of jaundice.
  12. What is Klatskin tumor and how do you treat it?
    - a. It is cholangiocarcinoma at the confluence of the hepatic ducts.
    - b. Treatment is like cholangiocarcinoma.
  13. What are the difficulties of operation in case of stricture of bile duct?
    - a. Commonly the stricture is high in the hilum area.
    - b. It is surrounded by major blood vessels.
    - c. Presence of scar tissue.
  14. What are the results of treatment of benign stricture?
 

Surgical correction is successful in 90 percent cases.
  15. What is the prognosis of this disease?
    - a. If the disease is not treated, there will be recurrent attacks of cholangitis and secondary liver disease like biliary cirrhosis.
    - b. Mortality is about 10 percent.
- HYDATID CYST OF LIVER**
- Case Summary**
- A 40-year-old female patient presents with painless, slowly growing swelling in the right upper abdomen for last 4 years. She complains of occasional dull aching pain for last 1 year. The patient used to keep pet dogs at home for a long time.
- On examination on general survey, she is of average build and nutrition, pulse 76/min BP – 130/80 mm Hg, no neck glands palpable.
- On abdominal examination, liver is enlarged 3 fingers below the right costal margin in the midclavicular line. A cystic swelling measuring 6 cm × 5 cm is palpable in relation to liver. It is nontender and moves with respiration.
- No free fluid is present in the abdomen and normal bowel sounds audible. Systemic examinations are normal.
- Clinical Discussion**
1. What is your case?
 

It is a case of hydatid cyst of the right lobe of liver.
  2. Why do you say so?
    - a. The swelling is cystic in nature and non – tender.
    - b. It is continuous with liver.
    - c. It is not possible to insinuate the finger between the swelling and the costal margin.
  3. What are other cystic swellings of liver?
    - a. Amebic liver abscess.
    - b. Pyogenic liver abscess.
    - c. Post-traumatic cyst in liver containing blood and bile.
    - d. Solitary liver cyst.
    - e. Congenital polycystic disease of liver (Hepatoma or metastatic tumor).
  4. What is a hydatid cyst?
 

It is a parasitic cyst developing in liver and other organs caused by *Echinococcus granulosus*.
  5. Why it is called hydatid?
 

Because of the nature of the cyst contents which is watery in nature.
  6. What is the definitive host?
 

Carnivorous animals like dogs, foxes, rodents, etc.
  7. What do you mean by definitive host?
 

The host in which sexual reproduction of the parasite occurs is known as the definitive host.
  8. What is an intermediate host?
 

The host in which asexual form of reproduction takes place.
  9. What is the organwise involvement in hydatid disease?
    - a. Liver – most common, about 70 to 75 percent cases, then in order of frequency.
    - b. Lungs
    - c. Kidneys
    - d. Brain
    - e. Bone, etc.
  10. What is the composition of a hydatid cyst?
 

A hydatid cyst is made up of three layers viz. (Fig. 73.18A)

    - i. Pericyst or pseudocyst which consists of fibrous tissue inseparable from the liver.
    - ii. Ectocyst or laminated membrane which is whitish and elastic and can be readily peeled off from the pericyst.
    - iii. Endocyst – Consists of single layer of germinal epithelium lining the cyst. It secretes hydatid fluid internally and ectocyst externally.
  11. What is hydatid fluid?
    - a. Watery in color.
    - b. Slightly alkaline.

- c. Bile stained when connected to biliary radicals.
- d. No albumin.
- e. Contains hooklets and scolices.

12. What are brood capsules or hydatid sand?

These are future worms generated from the germinal epithelium (vide Fig. 73.18B)

13. What is malignant hydatid disease?

It is caused by *Echinococcus multilocularis*.

14. Why it is called malignant?

It presents with multiple cysts all over the liver. Though benign it is very difficult to eradicate the disease like malignancy. The patients usually dies of liver failure.

15. What is the fate of a hydatid cyst?

- a. Rupture – Most common.
- b. Suppuration and infection.
- c. Jaundice.

16. What are the clinical presentations?

- a. Right upper quadrant mass
- b. Asymptomatic
- c. Abdominal pain
- d. Dyspepsia
- e. Fever with chills
- f. Jaundice
- g. Arthritis.

17. What investigations would you like to do in this case?

I. I will do the following investigations to confirm my diagnosis:

1. Laboratory evaluations:

- a. Eosinophilia – Absorption of products from the parasites act as antigenic stimulus leading to eosinophilia in 25 to 35 percent cases.
- b. Bilirubin level.

2. Radiological tests:

- a. Plain X-ray of abdomen – calcification which is well-circumscribed in the region of liver with the cyst.
- b. Ultrasound scan – A multilocular cyst with cartwheel sign is pathognomonic.
- c. CT scan – shows floating layers of germinal membrane. It is complementary to ultrasound scan and helpful in assessing the extent of the cysts and the presence of any complications like rupture, infection, etc.

3. Serological tests:

a. ELISA test for *Echinococcus* antigen.

b. Casoni's test – It is rarely used nowadays because of low sensitivity and specificity.

II. Investigations to be done for fitness of the patient for general anesthesia include blood sugar, urea, creatinine, X-ray chest PA view, ECG, liver function tests and complete hemogram.

18. How will you treat this patient?

As it is a reasonably large cyst surgical treatment is required. Before surgery a course of albendazole for 3 weeks is to be given. Dose – 10 mg/kg/day in divided doses 4-6 weeks prior to surgery.

19. What is the role of Albendazole before surgery?

- a. The cyst regresses to some extent.
- b. Albendazole has scolicial activity which prevents peritoneal seedling in case of accidental spillage of hydatid cyst fluid during operation.

20. What operation will you do in this patient?

I will do complete excision of the cyst followed by omentoplasty to tackle the cavity of the cyst.

21. What are the principles of surgical treatment?

- a. Removal of the intact cyst with the laminated membrane.
- b. Prevention of spillage.
- c. Closure of biliary communications.
- d. Sterilization of the cavity and closure.

22. What is the preoperative management?

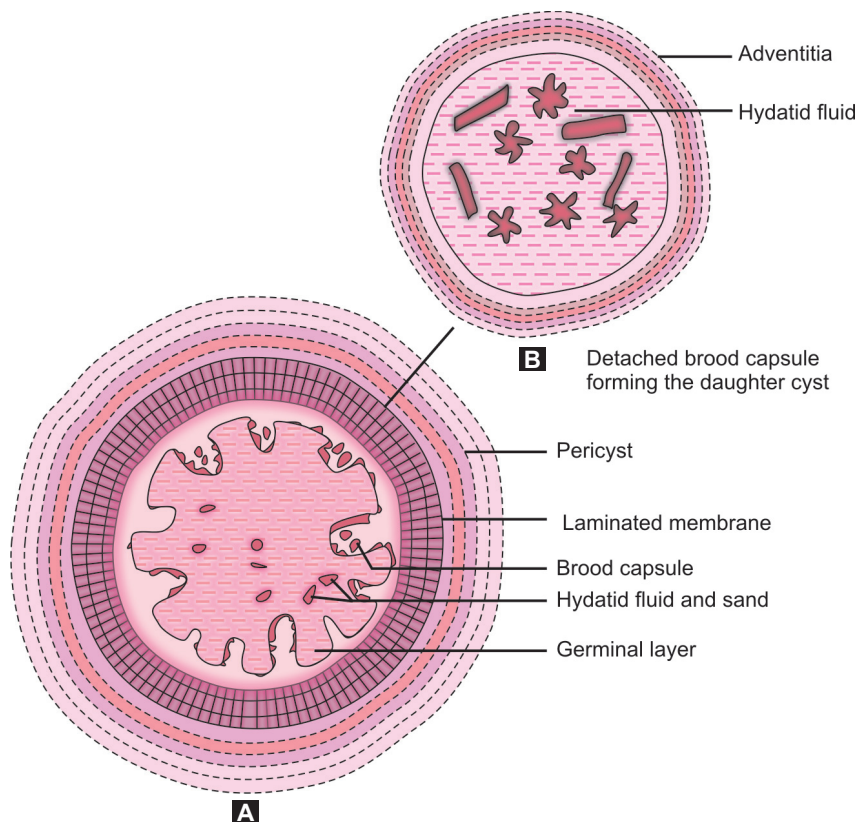
- a. IV corticosteroid and Inj. adrenaline are kept ready.
- b. Preoperative administration of Inj. antihistamine.
- c. Providone isdine 1% some use a 10% solution.

23. How do you prevent spillage at the time of surgery?

- a. Aspirating the fluid and injecting sporicidal agent into the cyst.
- b. Packing the abdomen with packs soaked in 20 percent hypertonic saline or 0.5 percent cetrimide solution.

24. What scolicial agents are used?

- a. Hypertonic saline 15 - 20 percent.
- b. Cetrimide solution 0.5 - 1 percent.
- c. Povidone-iodine (1%) solution.
- d. Ethanol 80 percent.



**Figs 73.18A and B:** (A) A typical hydatid cyst. (B) A daughter cyst

25. Why formalin is not used as scolecoicidal agent?  
Formalin damages the bile ducts in case they communicate with the cyst and produces sclerosing cholangitis.
26. How do you remove the cyst?  
a. Laparotomy done through the right subcostal incision.  
b. Isolation of the area of liver bearing the cyst from the peritoneal cavity and subphrenic spaces by abdominal packs (black or any dark-colored pack so as to visualize the whitish looking scolices and brood capsules easily) soaked in hypertonic saline.  
c. Aspiration of at least half of the fluid of the cyst followed by injection of scolical solution to render the cyst about 3/4th filled up.  
d. Liver and adventitia overlying the cyst is opened along the needle track, bringing into view the white slimy laminated membrane.  
e. The laminated membrane is grasped by a sponge forceps and is separated from the adventitia with a finger and removed.  
f. The residual cavity is obliterated by deep stitches, if it is a small one or by omentoplasty if it is a large one.
27. How do you tackle the cavity of hydatid cyst following excision of the cyst?  
a. Can be left open.  
b. Small cavity is obliterated by deep stitches.  
c. Obliterated by omentum, called omentoplasty.  
d. Cystoenteric anastomosis (Roux-en-Y cystojejunostomy) – Particularly in case of a cyst with a major biliary communication.  
e. Marsupialization.  
f. External drainage – The cavity is closed keeping a drain inside.
28. What is done for biliary communication or biliary fistulas?  
a. Identifying the communication and suturing it followed by omentoplasty.  
b. Cystojejunostomy (Roux-en-Y type).
29. What radical surgical procedures are done for hydatid disease?  
a. It involves removal of the pericyst and parasitic cyst contents – cystopericystectomy and wedge resection of liver.  
b. Hepatic resection – Segmental lobar resection is performed in case of very big cyst located in the peripheral part of liver. There is no risk of spillage of cyst contents into peritoneal cavity.
30. What are the complications of hydatid cyst?  
The complications are:  
a. Rupture into the bile ducts (most common), in the alimentary tract when the cyst can be vomited, into the pleural cavity producing empyema, into the lungs when the cyst contents and bile may be coughed out, into the peritoneal cavity.  
b. Infection and suppuration – Pain, rigor and fever.  
c. Pressure effects:  
i. Pressure on the bile ducts – Obstructive jaundice.  
ii. Pressure over the portal vein – portal hypertension.  
d. Anaphylactic shock following rupture of the cyst.
31. What are the features of intraperitoneal rupture of cyst?  
a. The patient may present with acute abdomen with signs of shock viz. rapid thready pulse, pallor, hypotension and cold clammy skin.  
b. Signs of diffuse peritonitis, e.g. rebound tenderness and rigidity all over abdomen, absence of bowel sounds.  
c. Skin manifestations – Itching and urticaria.
32. How do you treat intraperitoneal rupture?  
a. Treatment of shock with O<sub>2</sub> inhalation, IV fluid and IV hydrocortisone, Inj. antihistamine.  
b. Exploratory laparotomy, peritoneal lavage with scolical solution as well as excision of hydatid cyst and tackling of the cyst cavity as described earlier.
33. How will you manage anaphylaxis?  
a. Prevention is the best.  
b. Injection antihistaminic prior to surgery.  
c. IV hydrocortisone.  
d. Injection epinephrine/adrenalin.  
e. Prevention of spillage.
34. What are the causes of jaundice in patients with hydatid cyst?  
a. Rupture of the cyst into the duct and its blockage by the daughter cysts.  
b. External compression of the bile duct by a large cyst.  
c. Associated cholangitis may cause jaundice.
35. How do you manage rupture into the bile duct?  
a. Bile duct exploration and T-tube drainage.  
b. Sphincteroplasty.
36. What are the indications of medical treatment in hydatid cyst?  
a. Small hydatid cyst.  
b. Disseminated hydatid disease.  
c. Inaccessible deep seated cyst in liver.  
d. Patient unfit for surgery.  
e. Intraperitoneal and endothoracic rupture.  
f. Prior to surgery.
37. What drug is given?  
Tab Albendazole is used in the dose of 400mg twice daily × 28 days, then 2 weeks rest, and then the cycle is repeated upto three cycles.
38. What is percutaneous aspiration of cyst, PAIR that is puncture, aspiration, injection and reaspiration.  
a. Under ultrasound guidance percutaneous puncture and aspiration of the cyst is done after adequate medical treatment with albendazole, although praziquantel has also been used.  
b. 20 percent hypertonic saline or 80 percent alcohol is instilled into the cyst cavity as scolecoicidal agent.  
c. After 5 minutes, the scolical agents are reaspirated.  
d. This procedure has to be done on a number of occasions.  
e. Systemic therapy with albendazole is given along with this.  
f. This gives a success rate of 70 percent in some trials.
39. What are the contraindications of PAIR?  
a. Infected cyst.  
b. Multilocular cysts.  
c. Cysts with biliary communication.
40. What is hydatid thrill?  
Three fingers are placed over the swelling and tapped on the sides. Sometimes impulse is felt in the middle finger, due to displacement of daughter cysts. However,



this is not very reliable method of clinical examination.

41. What is the prognosis?
  - a. In case of *E. granulosus* 5-year survival 95 percent, Recurrence 10 percent after 5 years.
  - b. In case of *E. multilocularis* 5-year survival is 50 percent.

## PSEUDOCYST OF PANCREAS

### Case Summary

A 45-years-old male patients with the history of severe abdominal pain 10 weeks back with vomiting. The pain was sudden in onset, started in the central part of abdomen and then radiated to whole abdomen and back.

About 2 weeks following the onset of pain patient noticed a small swelling in the central part of abdomen which was gradually increasing in size for the last 2 months. There is a sense of discomfort and dull aching pain over the swelling now.

Bowel and bladder habits normal and there is no other systemic symptom.

On examination: On general survey patient is of average build and nutrition, P-70/min BP - 120/70 mm Hg, neck glands not palpable, no jaundice present.

On examination of abdomen an epigastric swelling is visible occupying the epigastric, umbilical and hypochondriac regions of the abdomen. On palpation, the lump is about 7 inches in diameter. The lump is intraabdominal and globular in shape. Margins are rounded, upper margin could not be felt and the lower margin is indistinct. Surface is smooth, consistency tense cystic, nontender.

The swelling is resonant to percussion

Liver and spleen – Not palpable. Systemic examination is normal.

### Clinical Discussion

1. What is your case?  
This is a case of pseudopancreatic cyst.
2. Why do you say so?
  - a. There is an acute attack of pain in upper abdomen 6 weeks back which radiates to back associated with vomiting.
  - b. Swelling appears 2 weeks after the attack of pain.
3. Character of the swelling is tense cystic, occupies the central upper abdomen, surface is smooth, and nontender, globular in shape.
3. What are the other possibilities?
  - a. Cystic neoplasm of the pancreas, e.g. cystadenoma and cystadenoma carcinoma.
  - b. Mesenteric cyst.
  - c. Hydatid cyst of spleen.
  - d. Hydatid cyst of liver.
  - e. Hydronephrosis of left kidney.
  - f. Retroperitoneal cyst.
  - g. Simple cyst of liver.
  - h. Cyst of greater omentum (omental cyst)
4. How will you confirm the diagnosis?  
I will confirm my diagnosis by ultrasonography of upper abdomen. It will give the following informations:
  - a. Site of collection.
  - b. 98 percent specific and 90 percent accurate.
  - c. Associated chronic pancreatitis can be excluded.
  - d. Intraductal calculi may be seen.
 Percutaneous aspiration may be done under ultrasonic guidance.
5. What is the role of CT scan?
  - a. CT scan has got increased sensitivity and specificity in diagnosis of pseudocyst of pancreas.
  - b. It can also visualize retroperitoneal extension of fluid collection.
  - c. It can show relationship between the cyst and adjacent viscera.
6. What is the role of ERCP?
  - a. It will demonstrate well if there is any pancreatic duct abnormality like dilatation or any intraductal calculi.
  - b. Any communication of the pancreatic duct with the cyst may be seen.
7. How do you treat this case?  
Surgery is the only available treatment. This is a large cyst of > 2 months duration. So, the cyst wall is likely to be mature. I will plan to do a cystogastrostomy cysts adherent to the stomach and located in the epigastric region is best treated by cystogastrostomy.
8. What additional procedures are done during internal drainage of cyst?
  - a. The cyst wall is sent for histopathological examination to exclude malignancy.

b. The cyst fluid is sent for cytological examination.

c. The cyst cavity is irrigated with normal saline before internal drainage of the cyst.

9. When do you consider a cystojejunostomy? This operation is done in case of a large cyst extending beyond the epigastric region to the umbilical, hypochondriac and lumbar region.

Cystojejunostomy with a Roux-en-Y loop of jejunum is the preferred option.

10. What operation is done for a cyst in the head of pancreas?

Cystoduodenostomy is the operation of choice.

11. What operation will you do in case of a cyst in the body and tail of pancreas?

The cyst in the body and tail is best drained by cystojejunostomy to a Roux-en-Y loop of jejunum.

12. What are the different methods of treatment of a pseudocyst?

A pseudocyst may be treated by any of the following methods viz.

1. Internal drainage which may be of three types.
  - a. Transgastric cystogastrostomy.
  - b. Transduodenal cystoduodenostomy and
  - c. Cystojejunostomy to a Roux- loop of jejunum.
2. External drainage – This is done with tube drainage or marsupialization. But the disadvantage is formation of pancreatic fistula and recurrence of pseudocyst. The incidence is 4 times greater than when internal drainage is done. This is indicated in case of critically ill patients, immature cysts (< 4 - 6 weeks duration) and infected pseudocyst or pancreatic abscess.
3. Excision – Total excision of the cyst is done only in case of small cysts of the body or tail with minimal attachment to adjacent organs.
4. Cyst aspiration under ultrasonographic guidance. But it has many problems like:
  - a. Pancreatic fistula formation.
  - b. Needs repeated aspiration.
  - c. Chronic pseudocyst associated with ductal obstruction and dilatation cannot be treated by this method.



5. Endoscopic cystogastrostomy or cystoduodenostomy. The cyst is localized and punctured endoscopically through the stomach or duodenal wall using a diathermy.  
An opening of 1 to 2 cm size is made in the cyst wall.  
Problems with this technique are:
  - i. Chance of bleeding from the cut margin.
  - ii. Chance of leakage of cyst fluid into the peritoneal cavity.
  - iii. Debridement of the pseudocyst cannot be done.
13. What are the complications of pseudocyst?
  1. Infection – Manifested by high fever with chills, which ultimately results in the formation of pancreatic abscess.
  2. Hemorrhage – The cyst may erode some adjoining visceral vessels producing severe hemorrhage, e.g. erosion of gastroduodenal and splenic vessels.
  3. Rupture into the stomach, duodenum or colon, so hematemesis or melena may occur.
  4. Obstruction – may compress the stomach, duodenum or colon.
  5. Obstructive jaundice due to compression of common bile duct.
14. What is a pseudopancreatic cyst?  
This is a fibrous encapsulated fluid filled cyst arising from the pancreas, lacking true epithelial lining and containing pancreatic juice and enzymes.
15. What are the principal causes for the formation of pseudopancreatic cyst?  
The principal causes are:
  - a. Acute pancreatitis
  - b. Chronic pancreatitis
  - c. Trauma and
  - d. Unknown in some cases.
16. Is acute pancreatitis always followed by pseudopancreatic cyst?
  - a. No, it occurs only in 5-15 percent cases of acute pancreatitis.
  - b. About 2 to 3 weeks are required for well formation of a cyst.
  - c. About 40 percent of acute pseudocyst resolves within 4-6 weeks. After this period spontaneous resolution is difficult because of well-formed fibrous wall.
17. What is the pathogenesis of pseudopancreatic cyst?
  - a. The fluid collection may be a sympathetic effusion or may develop due to rupture of a major branch of the pancreatic duct after an acute episode of pancreatitis.
  - b. Fluid extravasates, localizes and becomes walled off by fibrosis.
  - c. Some reabsorption of fluid occurs in early part. When fibrosis occurs in 4 - 6 weeks time, reabsorption of fluid stops and it persists.
  - d. Pseudocysts formed after chronic pancreatitis is unlikely to resolve, as they are already well-fibrosed (matured).
  - e. If the cyst is less than 5 cm in diameter and asymptomatic, it may not require surgery.
18. What are the indications of treatment of a pseudocyst?
  - a. Mature pseudocysts more than 5cm in diameter.
  - b. Cyst with complication.
  - c. Cyst showing increase in size.
19. How does a patient presents with pseudopancreatic cyst?
  - a. History of blunt trauma to upper abdomen.
  - b. Features of acute pancreatitis (commonest presentation) – Patients with acute pancreatitis should be suspected of pseudocyst formation when symptoms fail to resolve in 7 - 10 days time, palpatory evidence of an abdominal lump and other radiological features, e.g. X - ray chest, pleural effusion, USG and CT scan findings, etc.
  - c. Persistent hyperamylasemia following an attack of acute pancreatitis suggests development of pseudocyst.
20. What are the pathological types of pseudocysts?
  - a. Acute pseudocysts following acute pancreatitis.
  - b. Chronic pseudocysts following chronic pancreatitis.
21. What is the nature of post-traumatic pseudocyst of pancreas?
  - a. They are due to ductal disruption following trauma.
  - b. The duct is usually injured at the site of crossing the vertebral column.

## CARCINOMA OF COLON

### Case Summary

A 60-year-old male patient presents with the complaints of pain and lump in the left lower abdomen for last 9 months. The patient have attacks of constipation followed by diarrhea for last 6 months. He is passing blood with stool for the last 3 months.

The lump is gradually increasing in size for last 6 months with anorexia and loss of weight for the same period.

There are no urinary symptoms and no other systemic symptoms.

On physical examination, on general survey he has mild pallor. On abdominal examination, contour of abdomen and position of umbilicus are normal. There is no visible peristalsis or pulsation.

The lump is palpable in the left lumbar region extending into the left iliac fossa, surface smooth, size 12 cm × 8 cm, margin rounded, consistency firm.

The lump is mobile from side to side and up and down. Liver, spleen and kidneys are not palpable.

No other mass is palpable in the abdomen and no free fluid or ascites present.

Systemic examination is normal.

### Clinical Discussion

1. What is your case?  
This is a carcinoma of descending colon.
2. Why do you say so?
  - a. The patient has complaints of pain and lump in the left lower abdomen for 9 months which is gradually increasing in size.
  - b. There is alteration of bowel habit viz. attacks of constipation followed by diarrhea for last 6 months.
  - c. Presence of anorexia and loss of weight for last 6 months.
  - d. History of bleeding P/R for last 3 months.
  - e. On palpation of the lump, it is found to be firm in consistency occupying the left lumbar region and left iliac fossa.
3. What are other possibilities?
  - a. Tuberculosis of left colon
  - b. Lymphoma
  - c. Retroperitoneal tumor
  - d. Crohn's disease affecting left colon.

4. How will you confirm your diagnosis?
1. Colonoscopy and biopsy from the lesion – It is the investigation of choice. Full bowel preparation and sedation is necessary for colonoscopy.
  2. Ba-enema – The Ba-enema gives good anatomical and topographical information, which not only diagnoses a polyp or carcinoma but demonstrates the site and configuration of the lesion, thereby helping the planning of operation. Ba-enema is however, contraindicated if there is evidence of impending colonic obstruction.
5. How do you assess the extent of the disease?
- a. Chest X-ray PA view to rule out metastasis.
  - b. CT scan of abdomen – This is a very good investigation to assess the extent of invasion by the primary tumor.
  - c. USG abdomen to assess any lymph node or liver metastasis.
  - d. Liver function test (LFT) - Elevated levels of liver enzymes viz. ALT, AST, Alkaline phosphatase and LDH suggest liver metastasis.
6. What other investigations will you do in this case?
- Investigations for fitness for general anesthesia are to be done in this patient.
7. How will you treat this patient?
- Exploratory laparotomy followed by left hemicolectomy if operable is the treatment of choice.
8. If the growth is not resectable, what will you do?
- a. In case of left colonic growth, a transverse colostomy is done.
  - b. In right colonic growth, an ileotransverse anastomosis is done.
  - c. In sigmoid or rectal growth, a sigmoid colostomy proximal to the growth is done.
9. How will you prepare the patient for surgery?
- Colorectal operations are clear contaminated (nonsterilized). So, preoperative gut preparation is necessary. This includes the following:
- i. Bowel preparation by:
    - a. Mechanical cleansing and
    - b. Antibiotic prophylaxis.
  - ii. Thromboembolism prophylaxis.

- iii. Blood or packed cell transfusion for pallor.

### Mechanical Cleansing

- Liquid diet 24 hours before surgery.
- Gut irrigation with polyethylene glycol (PEGLEG) which is a balanced salt solution and a sachet of 100 gm is administered by dissolving it in 2 liters of water on previous evening. A dose of metachlorpramide may be given beforehand to reduce nausea. It is the most commonly used purgation nowadays.

### Antibiotic Prophylaxis

Inj. cefuroxime 1.5 gm IV in combination with inj. metronidazole 1gm IV and Inj. Amikacin (500mg) IV is given at the time of induction of anesthesia. The prophylactic antibiotic is given for 24 hours.

### Thromboembolism Prophylaxis

Heparin 5000 IU sc tds until the patient is mobile is the most common method of prophylaxis. The first dose of heparin is given along with premedication.

10. What is the ideal proximal and distal line of resection?
- a. The proximal line of resection is 5cm away from the tumor margin.
  - b. Distal line of resection – Usually 5 cm but may be as small as 2 cm from the tumor margin.
11. What are the macroscopic types of carcinoma colon?
- There are four macroscopic types viz.
- Type 1 – Annular  
Type 2 – Tubular  
Type 3 – Ulcerative  
Type 4 – Proliferative.
12. What are the histological features?
- This is almost always a columnar cell adenocarcinoma arising from the epithelium lining the mucous membrane.
  - Sometimes, a colloid degeneration in a massive adenocarcinoma is seen.
  - Anaplastic cancers are rare.
13. What is Duke's staging for carcinoma of colon?
- Stage A – Tumor confined to bowel wall.  
Stage B – Tumor involving serosa.  
Stage C – Bowel wall invasion of any extent with lymph node metastasis

C<sub>1</sub> – Epicolic and paracolic nodes involved.

C<sub>2</sub> – Intermediate and proximal lymph nodes involved.

14. What is the lymphatic drainage of the colon?

The lymph nodes draining the colon are grouped as described below:

1. Epicolic nodes, located in the immediate vicinity of bowel wall.
2. Paracolic nodes – lying just beside the bowel wall.
3. Intermediate lymph nodes arranged along the right colic, ileocolic, middle colic, left colic and sigmoid arteries.
4. Main or proximal or apical lymph nodes aggregated around the origin of superior and inferior mesenteric arteries.

15. What is Aster Collar's modification of Duke's staging?

Stage A – Tumor confined to mucosa.

Stage B – Tumor involving serosa

B<sub>1</sub> – Tumors invading upto the muscularis propria.

B<sub>2</sub> – Transmural invasion of bowel wall.

B<sub>3</sub> – Lesion involving adjacent organs.

Stage C – Bowel wall invasion of any extent with lymph node metastasis.

C<sub>1</sub> – Lesion of B<sub>1</sub> depth and with lymph node metastasis.

C<sub>2</sub> – Lesion of B<sub>2</sub> depth and lymph node metastasis.

C<sub>3</sub> – Lesion of B<sub>3</sub> depth and lymph node metastasis.

Stage D – Presence of distant metastasis.

16. What is TNM staging for carcinoma of colon?

*T = Primary tumor*

T<sub>0</sub> – No evidence of primary tumor.

T<sub>1</sub> – Tumor invades submucosa.

T<sub>2</sub> – Tumor invades muscularis propria.

T<sub>3</sub> – Tumor invades to the subserosa or to the paracolic tissue in areas not covered by serosa.

T<sub>4</sub> – Tumor invades through the serosa and/or involves the adjacent organs.

*N – Regional lymph nodes*

N<sub>0</sub> – No regional lymph nodes involved

N<sub>1</sub> – Metastasis in 1-3 pericolic nodes

N<sub>2</sub> – Metastasis in 4 or more pericolic nodes

- $N_3$  – Metastasis in any lymph node along the course of a named vessel.  
 $M$  = Distant metastasis  
 $M_0$  – No distant metastasis  
 $M_1$  – Presence of distal metastasis.
17. How does the carcinoma of colon spread?
- Local spread
    - By continuity along the bowel wall.
    - By contiguity to adjacent structures e.g. liver pancreas, small intestine, retroperitoneal structures, etc.
  - Lymphatic spread – In colonic cancer, lymph nodes are rapidly involved. Lymph nodes draining the colon are arranged in the following groups.
    - Epicolic and paracolic nodes in the immediate vicinity of the bowel wall.
    - Intermediate nodes along the ileocolic, middle colic, right colic and sigmoid arteries.
    - Proximal or apical nodes along the origin of superior mesenteric and inferior mesenteric arteries.
  - Blood spread: Metastasis may occur quite early in the liver via the portal system, before clinical or operative evidence is detected. This is called occult hepatic metastasis.
18. What are the features of nonresectability of the carcinoma of colon?
- Fixity to pelvic walls, abdominal wall or urinary bladder.
  - Multiple liver metastases.
  - Disseminated peritoneal seedling, ascites and omental deposit suggests advanced disease and only palliative resection is advisable.
  - Fixed metastatic lymph nodes preclude a curative resection.
19. What is Turnbull's technique?
- This is a technique to prevent dissemination of tumor cells by bloodstream due to handling.
  - Before the tumor is handled the blood vessel draining the site of growth is ligated.
  - The intraluminal spread of tumor is prevented by blocking the lumen on both sides by tapes.  
This is called Turnbull's no touch technique of colonic resection.
20. What structures are removed in Right hemicolectomy?
- The tissues removed are a segment of 8 to 10 cm of terminal ileum, cecum, appendix, ascending colon, right colic flexure and right half of transverse colon. The ileocolic artery, the right colic artery and the right branch of middle colic artery are ligated and divided. Ileotransverse anastomosis is done to maintain gut continuity.
21. During right hemicolectomy what structures are liable to be injured?
- Duodenum, ureter and gonadal vessels.
22. What is the treatment of growth in the right colic flexure or right half of transverse colon?
- The treatment of choice is extended right hemicolectomy. Here the trunk of middle colic artery is tied and resection is extended upto the proximal descending colon and an ileo descending anastomosis is done for gut continuity.
23. What is the extent of resection for growth in midtransverse colon?
- Extended right hemicolectomy resection being extended further down upto the mid descending colon.  
Alternately, whole of transverse colon with both right and left colic flexures are removed followed by anastomosis between ascending and descending colon.
24. What is the extent of resection for growth in the descending colon?
- Here the treatment of choice is standard left hemicolectomy. The trunk of left colic artery and upper sigmoid arteries are ligated.
25. What structures are removed in left hemicolectomy?
- The structures removed are distal half of transverse colon, splenic flexure, descending colon and the fixed upper part of pelvic colon. Anastomosis is done between transverse colon and pelvic colon.
26. What is the extent of resection for growth in sigmoid colon?
- The operation of choice is an extended left hemicolectomy or wedge resection of sigmoid colon.
27. What are the functional effects following colectomy?
- Right hemicolectomy
    - Stools are softer.
    - 750 ml of stool is passed instead of normal 250 ml. This is however, compensated later on as ileum absorbs more water.
  - Left hemicolectomy – Several small stools are passed everyday. The volume is usually not increased.
  - Total colectomy with ileorectal anastomosis.
    - About 1000 ml of ileal contents enter the rectum.
    - 4 to 10 bowel movements/day occur. However, with time the ileum compensates and the number of bowel motions becomes less with lessening of the stool volume.
28. What is the role of adjuvant chemotherapy?
- This is given in advanced colorectal malignancies.
  - Agents used are 5 fluorouracil, systemic folinic acid – leucovorin and immunotherapy with monoclonal antibodies to CEA (Carcinoembryonic antigen).
29. What is the protocol for colorectal malignancy follow-up?
- Most tumors recur in the first 2 years after curative resection.
  - Routine physical examination, complete blood count and liver function tests should be performed every three months for 2 years, then every 6 months for 2 years, and then annually.
  - A chest film should be obtained every 6 months for 3 years, then annually.
  - CEA level is done every 2 months for 2 years, every 4 months for 2 years, then annually. While the absolute level of CEA is important, trends must also be noted. A gradual increase in CEA level is usually a sign of recurrence.
  - Colonoscopy and Barium enema are done in the postoperative period to establish the base line. Colonoscopy is repeated annually for at least 4 years, then every 2 – 3 years.
30. What is CEA?
- Carcinoembryonic antigen (CEA) is a glycoprotein, found in the cell membrane of many tissues, including the tumors in the colon and rectum.  
It is detected by radioimmunoassay. It is nonspecific for colonic carcinoma and high levels of CEA are found in colorectal carcinoma, other gastrointestinal cancers and many benign diseases.

31. What is the role of CEA estimation?
- Failure of serum CEA to fall to normal levels after resection implies a poor prognosis.
  - Progressive increasing levels of CEA level indicate recurrence in the postoperative period.
32. What are the etiological factors for the development of carcinoma of colon?
- Environmental factors like:
    - Diet – low fiber diet, alcohol.
    - Exposure to food additives, bile acids, ionizing radiation promote the development of carcinoma.
  - Premalignant conditions, e.g. ulcerative colitis and Crohn's disease.
  - Genetic factors – accounts for 10 percent of colorectal cancers.
    - Familial adenomatous polyposis (FAP).
    - Hereditary nonpolyposis colon cancer (HNPCC).
33. What is FAP?
- This is an inherited autosomal dominant disorder.
  - There is diffuse adenomatous polyposis of colon.
  - The condition is diagnosed when a patient has more than 100 adenomatous polyps in the colon. The gene responsible for the syndrome is situated in chromosome 5.
34. What is the treatment of FAP?
- The best treatment of FAP syndrome is total proctocolectomy with ileal reservoir and ileoanal anastomosis. Drugs used for tumor regression and prevention of new polyp formation are sulindac (NSAID) and Vitamin C.
35. What is HNPCC (Hereditary nonpolyposis colonic cancer)?
- The genetic abnormality is usually on chromosome 17 or 18 and autosomal dominant in nature. It is also known as Lynch syndrome. Both synchronous and metachronous cancers occur in the colon.
36. What is synchronous cancer?
- The occurrence of two or more carcinoma in colon simultaneously is known as a synchronous tumor. It occurs in 5 percent cases.
37. What is metachronous cancer?
- Metachronous carcinoma is a new primary lesion in a patient who has had a previous resection of cancer. It occurs in 2 percent cases.
38. What are the types of colonic polyps?
- Polyps are sessile or predominated growths of pathological mucosa projecting into the lumen. The word polyp is derived from Greek word polypous which means many footed (poly = many; pous = foot). The following are the types of polyp.
- Inflammatory polyp – e.g. pseudopolyps of ulcerative colitis and granulomatous colitis.
  - Neoplastic polyp –
    - Adenomatous polyp, e.g. familial adenomatous polyposis or FAP which includes Gardner's syndrome and Turcot's syndrome. According to histologic appearance, adenomatous polyps may be of three types viz. tubular (75%), villous adenoma (10%) and tubulovillous adenoma.
    - HNPCC.
    - Hamartomatous polyp, e.g. juvenile polyps and Peutz-Jeghers syndrome.
    - Hyperplastic or metaplastic polyp.
39. What is Gardner's syndrome?
- It consists of colonic polyps with osteomas, desmoid tumor and epidermoid cysts as associated lesions.
40. What is Turcot's syndrome?
- It consists of colonic polyps with brain tumors as associated lesion.
41. What is Peutz-Jeghers syndrome?
- It consists of hamartomatous polyps with mucocutaneous pigmentation and tumors of the ovary, breast, pancreas and endometrium. The polyps are mostly in the small intestine.
42. What is juvenile polyp?
- It is the most common cause of bleeding per rectum in infants and young children. The polyp usually arises from the posterior wall of rectum as a pedunculated red mass and is easily felt on rectal examination. It is removed by operation under general anesthesia. Histologically they are proliferations of lamina propria enclosing dilated cystic glands.
43. What is Cowden's syndrome?
- It is an autosomal dominant condition consisting of:
- Tricholemmomas.
  - Breast carcinoma
  - Gastrointestinal polyposis (Hamartomatous polyp) in only 35 percent cases
  - Thyroid disease.
44. What are hyperplastic polyps?
- These are the most common type of polyps, ten times more common than adenomas. They may occur anywhere in the colon but mostly located at the rectosigmoid junction. They have no malignant potential and size is as small as 5mm in diameter.
45. What is Cronkhite Canada syndrome?
- It consists of nonfamilial juvenile polyposis with ectodermal changes like alopecia, onychodystrophy and hyperpigmentation.
46. What is the prognosis of colorectal carcinoma?
- | Duke's stage | 5-year survival |
|--------------|-----------------|
| Stage A      | 80 percent      |
| Stage B      | 60 percent      |
| Stage C      | 30 percent      |

# Chapter 74

## Hernia

➤ General plan of writing a case of hernia

➤ Reducible indirect inguinal hernia

➤ Incisional hernia

### GENERAL PLAN OF WRITING A CASE OF HERNIA

#### History

1. Particulars of the patient – as mentioned earlier.
2. Chief complaints.
  - Swelling in the right groin for 2 years.
  - Pain over the swelling for last 8 months.
3. History of present illness.
  - a. *Swelling*
    - Duration of the swelling.
    - Site of appearance of the swelling – when the swelling appears in the groin and extends into the scrotum, it is usually a hernial sac while a swelling appearing in the scrotum and extending up towards the abdominal cavity may be a testicular growth, varicocele or an infantile hydrocele.
    - Mode of onset – If spontaneous, it may be a varicocele if it appears during straining or lifting heavy weight it is a hernia.
    - Disappearance of the swelling on lying down – if spontaneous, it may be a direct or incomplete indirect inguinal hernia or a varicocele. A complete indirect inguinal hernia requires some manipulation for reduction.
  - b. *Straining factor*: Presence of any straining factor like cough, chronic

constipation, difficulty in passing urine should be enquired of. The straining factor, if present plays an important role in the development of hernia.

- c. *Pain*: The pain is usually dull aching in nature not a persistent one. Whether pain is associated with vomiting, abdominal distention and constipation that is, features of intestinal obstruction.
4. Past history: History of any previous operation, e.g. appendectomy, lower ureteric stone removal, etc. which may cause weakness of the abdominal wall by division of nerves by an incision and may lead to development of a direct inguinal hernia.
  5. Personal history.
  6. Family history.
  7. History of any allergy to drugs.

#### Physical Examination

- i. *General survey*: Build and nutrition, blood pressure and pulse, respiratory rate (any distress present or not) are recorded.
- ii. *Local examination*: The patient is examined both in standing and lying down position. Per rectal examination is done in an elderly person to see the prostatic enlargement.

##### *In standing position*

##### *Inspection*

##### *Swelling*

- Site – Inguinal region and femoral region.

- Size and shape – A direct inguinal hernia is spherical in shape and has little tendency to extend towards the scrotum while an indirect inguinal hernia is pyriform in shape and usually extends down into the scrotum.
- Skin over the swelling – There may be wrinkling and pigmentation if the patient has used a truss.
- Surface.
- Extent of the swelling
  - Confined to the inguinal region (Bubonocoele).
  - Extending upto mid scrotum or root of the scrotum (Funicular type).
  - Extending upto the bottom of the scrotum (complete hernia).
- Position of the penis – Any deviation. A large hernia may push the penis to the other side.
- Visible impulse on coughing present or not.

##### *Palpation*

- Temperature and tenderness over the swelling.
- Whether it is possible to get above the swelling – In case of an inguinoscrotal swelling it is not possible to get above the swelling. This is tested by using the fingers and thumb across the neck of the scrotum and to feel the cord.

If one can get above the swelling that is, upper end of the swelling, the normal



spermatic cord, above the swelling is felt (intrascrotal swelling).

*In lying down position*

#### 1. **Reducibility**

- The swelling disappears spontaneously on lying down (direct inguinal hernia).
- Reduced on manipulation by surgeon called taxis (indirect inguinal hernia).
- Which part of swelling is easy to reduce – first part or last part? If first part is reduced easily and last part is difficult, it is omentocele. If first part is difficult to reduce and last part is reduced easily, it is enterocele.

2. **Invagination test:** After reducing the hernia, index or little finger is introduced, through the scrotum into the superficial inguinal ring and rotated so that pulp of the finger is directed posteriorly, the patient is asked to cough and an impulse is felt.

We get the following informations:

- i. If impulse is felt at the tip there is indirect inguinal hernia.
- ii. If impulse is felt on the pulp there is direct inguinal hernia.
- iii. Size of the external ring can be assessed. But this test is subjective and depends upon the feeling of the examiner. So it is not reliable.

3. **Deep ring occlusion test:** It is examined after reducing the hernia.

- Positive test, i.e. no swelling on coughing indicates indirect hernia.
- Negative test, i.e. swelling appears on coughing indicates a direct inguinal hernia.

*Percussion*

- Resonant note over the swelling suggests enterocele.
- Dull note over the swelling suggests omentocele.

*Auscultation:* Bowel sounds are present in case of enterocele.

iii. Systemic examination

- Summary of the case.
- **Provisional diagnosis:** A complete diagnosis should be mentioned, e.g. a right sided indirect incomplete reducible uncomplicated inguinal hernia containing intestine.

- Investigations suggested.
- Differential diagnosis to be mentioned.

## REDUCIBLE INDIRECT INGUINAL HERNIA

### Case Summary

The male patient aged 45 years having the occupation of cultivation, presents with swelling over the right groin and scrotum for last 2 years. He complains of dull aching pain over the swelling for last 6 months.

The swelling appeared gradually over the last 2 years. It becomes more prominent on coughing and disappears on lying down. Patient has history of chronic cough but his bladder and bowel habits are normal and there is no history of chronic constipation or difficulty in micturition.

On general survey pulse 80/m, BP – 13/90 mm Hg, mild pallor, average build and nutrition, no palpable neck glands.

### On local examination

On inspection, there is a swelling in the right inguinoscrotal region extending from the right inguinal canal to the bottom of the scrotum.

The swelling is pyriform in shape and there is expansile impulse on coughing.

On palpation, temperature is not raised and there is no tenderness over the swelling.

It is not possible to get above the swelling and there is palpable impulse on coughing over the swelling.

On lying down the swelling is easily reducible and is located above and medial to the pubic tubercle.

On invagination test, the superficial inguinal ring is patulous and on coughing the impulse touches the tip of finger. The deep ring occlusion test is positive and the swelling is resonant on percussion.

Bowel sounds are audible over the swelling on auscultation.

The left inguinoscrotal region is normal and systemic examination is also normal.

### Clinical Discussion

1. What is your case?

It is a case of right sided complete, reducible, indirect inguinal hernia containing intestine without any complication.

2. Why do you say so?

- a. A 45-year-old male patient complains of swelling in the groin and scrotum for 2 years.
- b. The swelling has expansile impulse on coughing and reduces partially or completely on lying down.
- c. Deep ring occlusion test is positive.
- d. On invagination test, the swelling touches the tip of the finger.

3. What is the pubic tubercle?

- a. From the anterior superior iliac spine, if one goes medially along the inguinal ligament, the first bony point felt is the pubic tubercle.
- b. Alternately, the adductor longus muscle is made taut by adducting the thigh against resistance. The origin of the adductor longus is traced and the bone little above is the pubic tubercle.

4. What is the deep ring?

Deep inguinal ring is situated 1.25 cm (½”) above the midinguinal point (mid point between the symphysis pubis and anterior superior iliac spine). It is ‘U’ shaped condensation of transversalis fascia being incomplete above.

5. How do you perform the deep ring occlusion test?

It is performed after reducing the hernia. With the patient in lying down position, the deep ring is occluded by pressure of thumb. The patient is then asked to stand and cough.

### Observation

- The test is positive in case of an indirect inguinal hernia when no swelling appears on coughing.
- It is said to be negative, in case of direct inguinal hernia. When the swelling reappears at the external ring on coughing in spite of deep ring occlusion. Thus it is the confirmatory test to differentiate an indirect from a direct hernia, clinically.

6. How will you do the invagination test?

This is done after reducing the hernia clinically.

The index or little finger is introduced into the superficial inguinal ring through a tag of scrotal skin, the tip looking towards the deep ring and the pulp towards the posterior wall of inguinal canal.

- The patient is asked to cough and the following are noted.
- a. Impulse on coughing felt at the tip in case of indirect inguinal hernia.
  - b. Impulse felt on the pulp in case of direct inguinal hernia.
  - c. How many fingers does the ring admit.
7. What is Zeeman's test?  
This test is done to differentiate the three types of hernia viz. direct and indirect inguinal hernia and femoral hernia. Hernia is reduced.  
Now the index finger, middle finger and the ring fingers are placed over the deep ring, superficial ring and the fossa ovalis respectively and the patient is asked to cough.
- If the impulse touches the index finger, it is indirect inguinal hernia.
  - If impulse touches the middle finger, it is direct inguinal hernia.
  - If the impulse touches the ring finger, it is femoral hernia.
8. What is Malgaigne's bulge?  
a. This is a sign of poor tone of the oblique muscles of the abdominal wall.  
b. The rising test will demonstrate the bulging just above the iliac crests and the inguinal ligaments.  
c. The rising test is performed by asking the patient to lift the trunk or the legs without support.
9. What are the common inguinoscrotal swellings?  
a. Complete inguinal hernia.  
b. Congenital hydrocele.  
c. Varicocele  
d. Encysted hydrocele of cord presenting both in the inguinal and scrotal region.  
e. Funiculitis.
10. What are common inguinal swellings?  
a. Inguinal hernia restricted to inguinal canal.  
b. Undescended testis.  
c. Lipoma of spermatic cord.  
d. Inguinal lymphadenitis.  
e. Undescend testis.
11. What are the common femoral swellings?  
a. Femoral hernia.  
b. Saphena varix.  
c. Ectopic testis in femoral region.  
d. Femoral artery aneurysm.  
e. Adductor longus hematoma.  
f. Psoas abscess.
12. What are the common scrotal swellings?  
a. Hydrocele.  
b. Varicocele.  
c. Testicular tumor.  
d. Encysted hydrocele of cord.
13. How do you clinically differentiate a scrotal from an inguinoscrotal swelling?  
Get above the swelling is present in case of scrotal but not in case of inguinoscrotal swelling.
14. How will you differentiate inguinal and femoral hernia?  
a. This is done by noting the relation of the hernia with the pubic tubercle.  
b. Inguinal hernia lies above and medial to the pubic tubercle.  
c. Femoral hernia lies below and laterals to the pubic tubercle.
15. How do you treat the patient?  
The treatment of choice is surgery. Before surgery is undertaken all baseline investigations are done for fitness for general anesthesia viz. blood for complete hemogram, bleeding time, clotting time, sugar, urea, creatinine, urine and stool for routine examination, X-ray chest PA view and ECG.
16. What operation do you perform in this patient?  
Herniorrhaphy operation is done for this patient 45 years old with good musculature of the abdominal wall.
17. What is herniotomy?  
a. This means excision of the hernial sac only.  
b. Done in case of hernia in children.  
c. It is the basic requirement of all hernia operations except the inversion herniorrhaphy done for a direct hernia.
18. What is herniorrhaphy?  
a. It is herniotomy plus repair of the posterior wall of inguinal canal by suturing the conjoint tendon with inguinal ligament.  
b. It is done in case of hernias of young adults with relatively good musculature.
19. What is hernioplasty?  
In hernioplasty, the posterior wall of inguinal canal is strengthened by bridging the gap between the conjoint tendon and inguinal ring with the help of natural tissues like fascia lata or synthetic mesh like Prolene mesh or Dacron mesh.
20. What is hernia?  
It is an abnormal protrusion of the part or whole of a viscus through an opening in the wall of its containing cavity.
21. What are the parts of a hernia?  
It consists of three parts viz.  
• Sac  
• Coverings of sac.  
• Contents of the sac.
22. What is the hernial sac?  
It is the peritoneal pouch having a neck, body and fundus.
23. What are the coverings of the indirect inguinal hernia?  
a. When the hernia is in the inguinal region, the coverings are:  
• Skin, superficial fascia,  
• External spermatic fascia derived from external oblique aponeurosis,  
• Cremasteric muscle and fascia derived from internal oblique,  
• Internal spermatic fascia derived from the fascia transversalis .  
• Deep to this is the hernial sac, derived from the parietal peritoneum.  
b. When the hernia descends into the scrotum, the coverings are the same except, the superficial fascia which contains the dartos muscle.
24. From where the sac gets its blood supply?  
The blood supply comes from the coverings of the sac.
25. What are the complications of hernia?  
a. Irreducibility.  
b. Obstruction.  
c. Strangulation.  
d. Gangrene of gut.  
e. Fluid collection in hernial sac called hydrocele of a hernial sac.
26. What are the causes of irreducibility?  
a. Adhesions between the contents and the sac.  
b. Intercontent adhesions.  
c. Narrow neck of the sac.  
d. Retention of feces in the large bowel contained in the sac.
27. How do you diagnose obstructed hernia?  
a. Clinically there is vomiting, abdominal distension, severe colicky abdominal pain, i.e. signs of intestinal obstruction.  
b. Cough impulse is usually absent.  
c. The swelling is irreducible but painless.

28. What are the signs of strangulation?
- The swelling is tense, tender and there is no impulse of coughing.
  - It is irreducible and painful.
  - Signs of intestinal obstruction may be present in case of enterocele.
29. What is Gilbert classification of hernia?  
Gilbert in 1987 described the following anatomical classification of hernia.
- Type I : Hernia has got snug internal ring through which a peritoneal sac passes out as indirect sac. Inguinal canal intact.
- Type II : Moderately large internal ring which admits one finger. Inguinal canal otherwise intact.
- Type III : Large internal ring with defect more than two fingers breadth. Inguinal canal weak.
- Type IV : Typical direct hernia with full blow out of the posterior wall of inguinal canal. Internal ring is intact.
- Type V : It is a direct hernia protruding out through a punched out hole in fascia transversalis. Internal ring is intact.
30. What is superficial inguinal ring?
31. What is Hasselbach's triangle?
32. What is the boundary of the inguinal canal?
33. What is Nyhus classification of hernia?
34. What are the different hernias according to the nature of contents?
35. What is the difference between direct and indirect hernia?
36. What is dual hernia?  
Vide the chapter 42 on Hernias for answer to questions 30 to 36.
37. If a patient suffers from both Hernia and enlarged prostate which operation will you do first?  
Prostate operation is to be done first, because if hernia repair is done first, there is chance of recurrence.
38. What are the characteristics of direct inguinal hernia?
- Direct inguinal hernia represents 15 percent of all inguinal hernias.
  - It is usually bilateral and acquired.
  - Neck of direct hernial sac is wide so that chance of strangulation is less.
  - Commonly found in elderly male patient.
  - This type of hernia is usually incomplete.
39. What will you do with the direct hernial sac at operation?
- As the direct hernia is usually incomplete and neck of the sac is wide, excision of sac is not required. It is just inverted into the peritoneal cavity.
  - In case of a large hernial sac, the fascia transversalis is plicated to keep the sac reduced.
  - The redundant portion of the sac is dissected, ligated at neck and excised only in case of a huge diverticulum like sac of a direct hernia.
40. How will you treat a direct hernia?  
By hernioplasty with a nylon darn technique.
41. What are the other techniques?
- Lichtenstein mesh repair.
  - Shouldice repair.
  - Stoppa's GPRVS (giant prosthetic replacement of visceral sac) repair.
  - Rives preperitoneal mesh repair.
42. In which hernia repairs, GPRVS is more suitable?
- Elderly patient with bilateral hernias.
  - Recurrent hernias.
  - Large hernias.
43. What is the approach for placement of the mesh?  
The mesh is placed in the preperitoneal space of Bogros by either a midline abdominal incision or Pfannenstiel incision. Unilateral mesh placement may also be done by an inguinal incision.
44. How is the mesh anchored in place?  
The prosthesis is fixed with a single suture to umbilical fascia only.
45. Where is the mesh placed in GPRVS?
- The large sheet of mesh (polypropylene or Dacron) is placed between the peritoneum and anterior, inferior and lateral abdominal wall.
  - The mesh stretches in the lower abdomen and pelvis from one end to the other enveloping the lower half of parietal peritoneum.
  - It gets incorporated with the parietal peritoneum by fibrous tissue.
46. What is Fruchand's myopectineal orifice?  
It is an osseomyoaponeurotic tunnel through which all the groin hernias come out. It is bounded as follows.
- Laterally by iliopsoas muscle.
  - Medially by the lateral border of rectus muscle.
  - Above by the arched fibers of internal oblique and transverse abdominis muscle.
  - Below by the pecten pubis and fascia covering it.
47. What is Shouldice repair for inguinal hernia?
- This repair was first practiced at shouldice clinic at Toronto, Canada.
  - It is done under local anesthesia.
  - Fascia transversalis is divided from the deep ring to the pubic tubercle. The lower flap is sutured behind the upper flap of fascia transversalis.
  - The upper flap is sutured to the inguinal ligament from deep ring to the pubic tubercle.
  - The posterior wall of inguinal canal is further strengthened by apposing conjoint tendon to inguinal ligament from pubic tubercle to the deep ring and back in two layers.
  - Recurrence rate following this type of repair is less than 1 percent.
48. What is Lichtenstein repair?
- Repair of the posterior wall with Prolene mesh is called Lichtenstein's repair.
  - A new deep ring is created.
  - Recurrence rate is very low.
49. What is laparoscopic hernia repair?  
Vide the chapter 42 on hernias.
50. What are the complications of hernia surgery?
51. What are the steps of operation of herniotomy and herniorrhaphy?  
Vide operative surgery section, chapter 96.

## INCISIONAL HERNIA

### Case Summary

A 45-year-old female patient presents with a swelling in the lower abdomen for last one year.

She had undergone abdominal hysterectomy 2½ years back. There was postoperative wound infection and delayed healing of the wound.

The swelling began to appear in the middle of the lower midline scar about 1½ years

after the operation. It was small initially but gradually increased to its present size in one year.

The swelling appears with strain and on coughing but disappears fully on lying down.

Bowel and bladder habits are normal, no systemic symptoms present patient underwent cholecystectomy 10 years back.

On physical examination on general survey, the patient is obese, P – 80/mm, BP 130/90 mm Hg, no jaundice, no palpable neck glands but there is mild pallor.

On local examination, the skin over the swelling is thin and atrophic; size is about 10 cm × 8 cm.

Surface is smooth, soft and nontender.

There is expansile impulse on coughing. No other lump is palpable in the abdomen. No other signs on systemic examination.

### Clinical Discussion

- What is your case?  
This is a case of incisional hernia through lower midline incision following abdominal hysterectomy.
- What is an incisional hernia?  
It is defined as protrusion of abdominal contents through an old operation scar.
- What are the predisposing factors for the development of incisional hernia?  
The following factors singly or in combination are responsible for development of incisional hernia.
  - Poor surgical technique
    - Vertical incision has more chance of developing hernia than the transverse incision.
    - Closing the abdomen with sutures under tension.
    - Drainage tube brought out through the main wound instead of a separate wound.
  - Improper suture material – e.g. cat-gut instead of polyglycolic acid.
  - Rough handling of tissues and improper hemostasis.
  - Layered closure instead of single layer closure.
- Postoperative complications
  - Wound infection.
  - Pneumonia or atelectasis causing cough and respiratory distress.
- Patient factors like
  - Malnutrition
  - Obesity.
  - Diabetes mellitus
  - Advanced malignancy
  - Presence of jaundice
  - Prolonged steroid therapy.
- Why incisional hernia is more common in lower abdominal scar than upper abdominal scar?
  - Lower abdomen has to bear maximum pressure in erect posture.
  - As the posterior rectus sheath is deficient in the lower abdomen, it is weaker than upper abdominal scar.
  - No linea alba below the level of linea semicircularis.
- Why incisional hernia is less common in transverse incision?  
Abdomen bulges transversely during increase of intraabdominal pressure due to coughing straining, etc.  
This causes lateral separation of the longitudinal scar causing its disruption.
- What are the different types of operation for incisional hernia?
  - If the gap is large – mesh repair is done.
  - If the gap is small – anatomical repair is done.
  - If the gap is very large in lower abdomen muscle pedicle graft is done with fascia lata or rectus femoris.
- How will you treat this case?  
In this patient muscle tone is good and the hernial gap is about 1½" in size. So anatomical or layered repair is ideal.
- How will you do anatomical repair?
- How will you do mesh repair?  
Vide chapter 42 on "Hernias".
- What are the types of incisional hernia?
  - Midline incisional hernias through midline abdominal incisions.
  - Lateral incisional hernias through lateral abdominal incisions.
- What is shoelace darn repair of incisional hernia?
  - In this operation, a new linea alba is reconstructed.
  - The anterior rectus sheath of both sides is fixed to the new linea alba so that the rectus muscle is allowed to straighten and lie alongside the midline.
  - The new linea alba is reconstituted by suturing a strip of fascia from the medial side of each anterior rectus sheath.
- What is the incidence of recurrence following repair on incisional hernia?  
Following mesh repair the recurrence rate is low – about 10percent but the rate is about 30 to 40 percent in repairs without mesh.
- What is the role of laparoscopic repair on incisional hernia?
  - Laparoscopic repair is suitable for small reducible incisional hernias.
  - The mesh is placed either in the preperitoneal space or in the gap of hernia inside the peritoneum.  
Intraperitoneal mesh placement is associated with increased incidence of adhesion.

## Renal Case

- General plan of writing a renal case
- Renal cell carcinoma (Hypernephroma)
- Hydronephrosis

### GENERAL PLAN OF WRITING A RENAL CASE

#### History

1. Particulars of the patient.
2. Chief complaints:
  - a. Passage of blood in urine for..... months.
  - b. Pain in the loin / abdomen for..... months.
  - c. Swelling in the loin / abdomen for .....months.
  - d. Difficulty in passing urine.
  - e. Constitutional symptoms like fever, anorexia, weight loss, etc.
3. History of present illness.
  - a. Pain – The following types of pain are experienced in the urinary tract.
    - i. Renal pain – Constant dull aching pain well localized, felt at the renal angle due to stretching of the renal pelvis or capsule. Sometimes pain is felt in front of abdomen about an inch below the tip of ninth costal cartilage. This is called anterior renal pain.
    - ii. Ureteric colic – This is miscalled renal colic. Truly it should be termed as loin to groin pain associated with passage of stone or blood clot along the ureter.
    - iii. Bladder pain is felt in the hypogastrium and gets worsened by filling or emptying. Pain from the trigone of the bladder is referred to the tip of the penis.
    - iv. Prostatic pain is the deep seated pain either in the perineum or rectum.
    - v. Urethral pain occurs during the act of micturition along the urethra.
  - b. Hematuria
    - Painless (tuberculosis, bladder tumor) or painful (calculus, trauma, cystitis).
    - Relation with urinary stream, e.g.
      - Initial hematuria (urethral).
      - Total hematuria (renal)
      - Terminal hematuria (vesical).
    - Associated pain during hematuria (clot colic).
    - Shape of clot passed (long tube like— ureteric origin, flat like soaked tea leaves – bladder origin).
  - c. Frequency of micturition
    - Normal frequency is 5 to 6 times in 24 hours.
    - Any history of increased frequency diurnal, nocturnal or both is noted.
  - d. Difficulty in passing urine.
    - Hesitancy
    - Urgency
    - Any narrowing of the stream (enlarged prostate, stricture urethra).
  - e. History of incontinence.
  - f. Details of general symptoms like anaemia, weight loss, anorexia, etc. Other systemic symptoms.

4. Past history
5. Personal history
6. Family history
7. History of allergy.

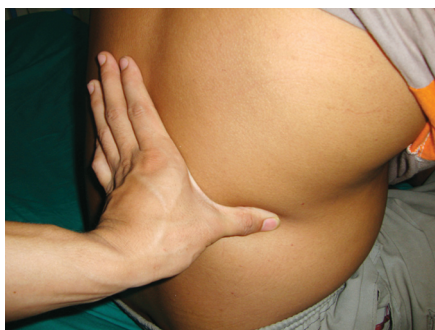#### Physical examination

1. General survey – Build, pallor, pulse, BP etc. are noted.
2. Local examination.
 

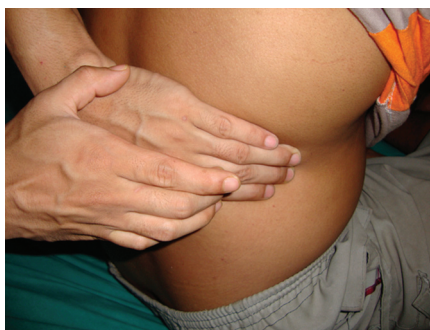Examination of the kidney: In sitting position:

  - a. Inspection of fullness in the loin and its palpation with comparison with the other side. Palpation of the renal angle on both sides for any tenderness (Fig.75.1).
  - b. Palpation of kidney is done in lying down position: Bimanual palpation is done. A normal kidney is not palpable unless the subject is very thin. Palpation of the urinary bladder – normal urinary bladder is not palpable, distended urinary bladder is palpable in the hypogastric region as a cystic swelling.
  - c. Percussion
    - i. Anteriorly there may be a band of colonic resonance which is of doubtful value as the ascending colon on the right side and descending colon on the left side are displaced away from their normal positions with the enlargement of the kidney.
    - ii. Posteriorly the area over the renal angle is resonant but in case of renal enlargement, this area becomes dull (Fig. 75.2).





**Fig. 75.1:** Palpation of the renal angle



**Fig. 75.2:** Percussion over the renal angle

d. Auscultation – Generally noncontributory.

Per rectal examination – Any rectal lesion or prostatomegaly is examined.

3. **Systemic examination** – as discussed earlier.

- **Summary of the case**
- **Provisional diagnosis**
- **Differential diagnosis.**

## RENAL CELL CARCINOMA (HYPERNEPHROMA)

### Case Summary

The male patient aged 45 years, presents with a lump in the right lumbar region, with loin pain and hematuria for last 8 months.

The swelling was initially small but gradually increasing in size during this period.

The patient also complains of passage of blood in urine for last 5 months, which is intermittent and lasted for about 3 – 4 days each time.

The pain is dull aching in nature and persistent with no specific aggravating and relieving factors.

On examination, on general survey patient has pallor. On local examination, the right kidney is enlarged and palpable occupying the right lumbar, epigastric, right hypochondriac and umbilical region.

Surface is irregular, nontender and moving slightly with respiration.

Liver and spleen are not palpable; no other mass is present in the abdomen external genitalia is normal, per rectal examination is normal.

### Clinical Discussion

1. What is your case?

It is a case of right sided renal cell carcinoma.

2. Why do you say so?

- a. The patient aged 45 years presents with the triad of swelling in the right lumbar region with painless hematuria and loin pain.
- b. Pain is persistent and dull aching in nature.
- c. No specific aggravating or relieving factor for pain is present.
- d. The lump is irregular nontender, and moving slightly with respiration.

3. How do you classify renal tumors?

Renal tumors are divided into two types viz. tumors arising from the kidney substance and tumors arising from the renal pelvis.

- a. Tumors of the kidney itself –
  - i. Benign
    - Adenoma
    - Hemangioma.
  - ii. Malignant
    - Primary, e.g. Nephroblastoma or Wilms' tumor in children, adenocarcinoma or hypernephroma.
    - Secondary – Very rare, kidney is involved in advanced cases of lymphoma and leukemia.
- b. Tumors of the renal pelvis
  - Benign – papilloma
  - Malignant, e.g. transitional cell carcinoma and squamous cell carcinoma.

4. What are the peculiarities of renal cell carcinoma?

- a. In spite of being malignant tumor, it is encapsulated (pseudocapsule).

b. Usual mode of distant spread is by hematogenous route instead of lymphatic spread.

c. The cancer cells look benign though they are highly malignant.

5. What is the gross appearance of the tumor?

a. The tumor is encapsulated and usually located to one or the other pole of the kidney.

b. Cut surface looks golden yellow due to the presence of intracellular lipids, with areas of hemorrhage and necrosis. Cystic degeneration imparts honey-comb appearance of the cut surface.

6. What is the microscopic appearance?

a. The most common cell type resembles the cells of the proximal renal tubule having large clear cells containing glycogen and lipid.

b. About 10 percent of the tumors show other cells viz. granular cells and spindle cells.

7. What is the most common site of origin? Proximal convoluted tubule.

8. What is the differential diagnosis?

- a. Polycystic kidney.
- b. Tuberculous pyonephrosis.
- c. Retroperitoneal cyst.
- d. Hydatid cyst of kidney.
- e. Simple cyst of kidney.

9. How will you investigate to confirm the diagnosis?

The following investigations are done to confirm the diagnosis

a. Ultrasonography – This helps as follows.
 

- Differentiates between a solid tumor and a benign cyst.
- Any lymphadenopathy and liver enlargement may be seen.

b. Intravenous pyelogram (IVU) may help in the following ways.

- i. It is the screening investigation of choice for a suspected renal tumor.
- ii. It shows the space occupying lesion with spider leg deformity of the calices.
- iii. It shows the functions of the opposite kidney as well as the diseased kidney.

c. CT scan/MRI scan: It helps in the following way.

- i. A small cortical mass may be missed by IVU but CT scan can diagnose it.
- ii. It can diagnose with certainty, the involvement of perinephric tissue, hilar lymph nodes, renal vein and vena cava. Staging is done depending on these findings.
- MRI scan shows the inferior vena caval involvement more clearly.
10. What other investigations you like to do?  
I will do investigations for fitness of the patient for general anesthesia.
11. What is the staging system of hypernephroma?  
There are two types of staging:
- Robson's staging – more popular.
  - TNM staging.
12. What is Robson's staging?  
Stage I – Tumor confined to the kidney.  
Stage II – Tumor invasion to perinephric fat but confined within Gerota's fascia.  
Stage III – Tumor shows spread to regional lymph nodes, renal vein or inferior vena cava.  
Stage IV – Distant metastasis or involvement of adjacent organs like colon, pancreas, etc.
13. What is TNM staging?  
T = Primary tumor.  
T<sub>0</sub> – No evidence of primary tumor.  
T<sub>1</sub> – Tumor 7 cm or less in greatest dimension, limited to kidney.  
T<sub>1a</sub> – Tumor 4 cm or less in greatest dimension.  
T<sub>1b</sub> – Tumor more than 4 cm but not more than 7 cm in greatest dimension.  
T<sub>2</sub> – Tumor more than 7 cm in greatest dimension but limited to kidney.  
T<sub>3</sub> – Tumor extends into major veins, adrenal gland or perinephric tissues (renal sinus fat) but not beyond Gerota's fascia.  
T<sub>4</sub> – Tumor invades beyond Gerota's fascia.  
N = Regional lymph nodes.  
N<sub>0</sub> – No regional lymph node metastasis.  
N<sub>1</sub> – Metastasis in a single regional lymph node.  
N<sub>2</sub> – Metastasis in more than one regional lymph node.  
M = Distant metastasis  
M<sub>0</sub> – No distant metastasis  
M<sub>1</sub> – Distant metastasis present.
14. How will you treat this patient?  
CT scan report is reviewed with particular attention to tumor spread beyond renal capsule and to renal vein and inferior vena cava. For stage I and II – Radical nephrectomy is done.  
Stage IV – Palliative nephrectomy is done.  
Stage III – Radical nephrectomy with the help of a vascular surgeon for removal of vascular thrombus.
15. How do you manage extension of the tumor into the renal vein or inferior vena cava?
- If tumor extends into the renal vein, only, it is ligated proximal to the site of tumor extension.
  - If tumor involves inferior vena cava, the following are done
    - Satinsky clamping of the vena cava.
    - Cavotomy and extracting the thrombus.
    - If tumor involves the vena cava above the diaphragm – cardiopulmonary bypass is required to remove the thrombosis.
16. What structures are removed in radical nephrectomy?  
This involves en bloc removal of the kidney with the tumor, ipsilateral adrenal gland, perinephric fat and fascia, proximal two-thirds of the ureter, lymph nodes up to the area of transection of renal vessels.
17. What is the approach for radical nephrectomy?  
Transperitoneal approach.  
Early ligation of the renal pedicle.
18. What are the paraneoplastic syndromes associated with renal cell carcinoma?  
These syndromes are due to liberation of various hormones by the tumor cells as follows.
- Hypercalcemia due to PTH (parathyroid hormone) production.
  - Stauffer's syndrome—Hepatic cell dysfunction (abnormal LFT), in renal cell carcinoma. It is reversed after nephrectomy.
  - Cushing's syndrome due to secretion of ACTH.
  - Enteropathy and diarrhea due to secretion of glucagon.
  - Anemia, weight loss and pyrexia of unknown origin caused by pyrogens secreted by the tumor. The patient of renal cell carcinoma may present with one or more of the above syndromes which are called atypical presentations of renal cell carcinoma.
19. What is the role of adjuvant therapy in renal cell carcinoma?
- Renal cell carcinoma is radioresistant and chemoresistant.
  - Recently immunotherapy has been tried. The cytokine interleukin II has shown promising results in clinical trials.
20. What is the prognosis?
- For stage I, II and III, 5 years survival is 70 percent.
  - For stage IV, 5 years survival is less than 10 percent.
  - Most patients with multiple distant metastasis die of the disease within 1 – 2 years.
21. What are the predisposing factors for renal cell carcinoma?
- Diet – High intake of fat, oil and milk.
  - Toxic agents, e.g. exposure to lead, cadmium and petroleum products.
  - Smoking.
  - Associated diseases, e.g.
    - Adult polycystic disease.
    - von Hippel-Lindau syndrome (cerebellar hemangioma, retinal angioma and renal cell carcinoma).

## HYDRONEPHROSIS

### Case Summary

The 40-year-old male patient presents with pain in the left loin for last 2 years and swelling in the same region for 2 years.

The pain is dull aching and persistent in nature throughout this period. Sometimes patient has pain relief with analgesics and passage of urine.

There is no history of dysuria or hematuria and retention of urine.

Patient passes urine 5–6 times in 24 hours. No history of increased frequency or fever. There are no other systemic symptoms.

### On Examination

On general survey slight pallor is present, BP 130/80 mmHg, pulse 80/min.

On local examination, there is fullness in the left lumbar region.

On palpation, temperature is normal and there is no local tenderness. The left kidney is palpable 8 cm × 5 cm in size, nontender and moves with respiration.

Surface is smooth, consistency tense cystic. The hand can be insinuated between the swelling and the left costal margin. The swelling is dull on percussion.

Liver and spleen – not palpable, no free fluid is present in abdomen, systemic examination is normal.

### Clinical Discussion

1. What is your case?  
It is a case of left sided hydronephrosis.
2. Why do you say so?
  - a. The swelling is in the loin and moves up and down with respiration.
  - b. Bimanually palpable.
  - c. Ballotable.
  - d. The swelling is cystic in feel and retroperitoneal.
3. What are the differential diagnoses?
  - i. Polycystic kidney
  - ii. Renal cell carcinoma
  - iii. Hydatid cyst of kidney.
  - iv. Simple renal cyst
  - v. Retroperitoneal cyst
  - vi. Neuroblastoma in children
  - vii. Nephroblastoma
  - viii. Splenomegaly.
4. What investigations will you do in this patient to confirm your diagnosis?
  - a. Ultrasonography – Nowadays, it is the most useful noninvasive investigations
    - It localizes pathology in the kidney such as stone or growth.
    - Gives an idea about the hydronephrotic sac.
  - b. Intravenous urography (IVU):  
After ultrasound confirms a kidney mass and hydronephrotic sac, an IVU is done. It will help as follows:
    - It reveals function of the affected kidney as well as that of the opposite kidney.
    - In case of total loss of function there will be no shadow. If some function is present, the picture comes late.
  - c. Retrograde pyelography – This is done when IVP shows the affected

kidney is nonfunctioning and the site of obstruction cannot be delineated.

- d. Isotopic renogram:  
99mTc labelled DTPA (Diethylene tri-amine penta acetic acid) scan is done. DTPA is filtered by glomeruli and not absorbed. The dye DTPA collects in the pelvicaliceal system in a case of obstruction either at the pelviureteral junction or at the ureter. It will not be cleared even after administration of frusemide. The accumulated dye is visualized in a gamma camera.  
Thus, it can assess the renal function better. Even 5 – 10 percent of excretory function can be assessed which is not possible with IVP.

5. What other investigations are done?  
Other investigations are done for fitness of the patient for general anesthesia.
6. What is the principle of treatment of hydronephrosis?  
The principle of treatment of hydronephrosis is to conserve the kidney whenever possible even if, little amount of functioning kidney tissue is present. Nephrectomy is done when kidney function is totally lost or when there is pyonephrosis.
7. What conservative operation is done in hydronephrosis?  
The operation is known as Anderson Hynes pyeloplasty.
8. What are the ideal conditions for Anderson Hynes operation?
  - a. Extrarenal or pelvic type of hydronephrosis.
  - b. Infection should be absent.
9. What are the modern techniques of treatment?
  - a. Endoscopic pyelolysis.
  - b. Laparoscopic pyeloplasty.
10. What is hydronephrosis?  
Hydronephrosis is defined as an aseptic dilatation of renal pelvis and calices, accompanied by destruction of renal parenchyma caused by continuous incomplete or intermittent complete obstruction to the flow of urine.
11. What are the important causes of hydronephrosis?  
There are two types of hydronephrosis
  - Unilateral and
  - Bilateral hydronephrosis.

Causes of unilateral hydronephrosis

- Obstruction in the lumen – calculus in the pelvis of ureter.
- Intramural obstruction, e.g.
  - a. Congenital stenosis.
  - b. Inflammatory stricture after removal of ureteric calculus.
  - c. Tuberculous infection.
  - d. Neoplasm of ureter or bladder cancer involving the ureteric orifice.
- Extramural obstruction:
  - a. Tumors
    - Carcinoma cervix
    - Carcinoma prostate
  - b. Postcaval ureter
  - c. Idiopathic retroperitoneal fibrosis.

12. What are the causes of bilateral hydronephrosis?  
This occurs when the level of obstruction is below the level of urinary bladder.

- a. Urethral disease, e.g.
  - Phimosis
  - Congenital stricture of external urethral meatus.
  - Posterior urethral valve.
- b. Prostatic disease, e.g.
  - Benign prostatic hypertrophy (BPH).
  - Carcinoma prostate.
- c. Bladder disease, e.g.
  - Bladder cancer involving both ureteric orifices.
  - Bladder neck obstruction, e.g. stenosis, hypertrophy.

13. What are the pathological types of hydronephrosis?

Three types are there:

- a. Pelvic type – Pathology is more limited to dilatation of pelvis, which is extrarenal type.
- b. Renal type – This occurs when the pelvis is intrarenal. Renal parenchyma is destroyed and stretched like parchment paper.
- c. Pelvirenal type – Combination of the above two types.

14. What is Dietl's crisis?

It is the pelvic ureteric kinking in case of a mobile kidney leading to acute colicky pain and swelling in the loin. The swelling gets reduced with passage of large quantity of urine, as the kinking is somehow

corrected. This phenomenon is known as Dietl's crisis (Dietl's – Professor of pathology of Poland).

15. Is the accumulated urine in hydronephrotic sac a static fluid?

No, it is being constantly exchanged into the body fluids.

16. How is the fluid exchanged?

In hydronephrosis the fluid goes out of the renal pelvis by extravasation into the perineal space by pyelovenous back flow, when pressure is high.

When pressure is low, it goes back by pyelolymphatic back flow.

The rate of urine going out of renal pelvis is 0.04 to 0.16 ml/min.

17. What is the cause of hydronephrosis during pregnancy?

It may be due to:

- i. Atony of ureteric musculature due to progesterone.
- ii. Pressure of the enlarging uterus on the ureters (more on the right side).

# Chapter 76

## Varicose Vein

- General plan of writing a case of varicose vein
- Varicose vein

### GENERAL PLAN OF WRITING A CASE OF VARICOSE VEIN

#### History

1. Particulars of the patient.
2. Chief complaints: The long or short saphenous venous system is usually affected.
  - a. Dull aching pain in the lower limb.
  - b. Swelling along the veins in the right / left lower limb.
  - c. Skin pigmentation. Edema or ulceration of the leg.
3. History of present illness:
  - a. Swelling
    - Onset (sudden or insidious) and duration.
    - Relation of the swelling to standing and walking.
    - Site, size and course of varicose veins.
  - b. Pain
    - Character of pain—Dull aching/cramping.
    - Time of occurrence—Towards the end of the day.
    - Aggravating factors—Walking/standing.
    - Relieving factors – lying down.

The characteristic pain of varicose vein consists of dull aching pain in calves and lower legs which usually occurs towards the end of the day and is relieved on lying down for 15 – 30 min.
  - c. Ulcer – Also known as gravitational ulcer.

- Duration
- Site
- Any discharge or bleeding.
- Edema and induration of surrounding tissues.
- Painful or not.
- History of skin pigmentation or eczema.

Varicose ulcer is usually a painless ulcer, typically located on the medial aspect of lower leg. Pigmentation and eczema are the precursors of ulcer formation.

The presence of varicose vein in the leg or thigh helps in the diagnosis.

4. Past history: Any history of deep venous thrombosis, prolonged immobilization or hospitalization.
5. Personal history: Occupation – Varicose veins are more common in conductors and drivers whose work demand prolonged standing.
6. Family history – Varicose veins are mostly idiopathic but may be familial.
7. History of allergy.

#### Physical Examination

1. General survey.
2. Local examination
  - Patient is first examined in standing position then, in lying down position to perform certain tests.
  - a. Inspection:
    - Presence of any pigmentation or ulceration at lower part of leg.

- To see whether long saphenous (media side) or short saphenous (lateral side) venous system is affected.
- Any impulse on coughing present at the saphenous opening.

#### b. Palpation

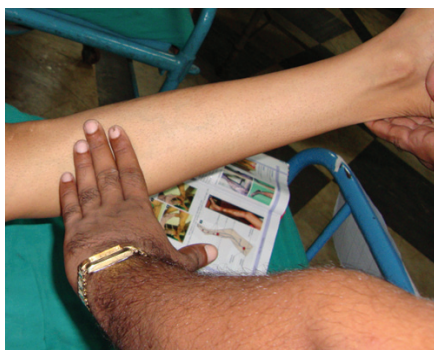Tests for varicose vein

- i. Brodie-Trendelenburg test – For saphenofemoral incompetence and incompetence of perforating veins.
  - ii. Oschner's – Mahorner's triple or more tourniquets at adductor canal and at 10 and 15 cm above the medial malleolus.
  - iii. Pratt's test for perforator incompetence.
  - iv. Perthes test – To know the patency of deep veins.
  - v. Fegan's test to see the site of perforator vein which is dilated.
- c. Examination of abdomen – to see any presence of a tumor or lump which may pass upon the veins to produce stasis and varicosity.
  - d. Examination of the other limbs.
  - e. Systemic examination.
    - Summary of the case.
    - Provisional diagnosis
    - Investigations suggested.

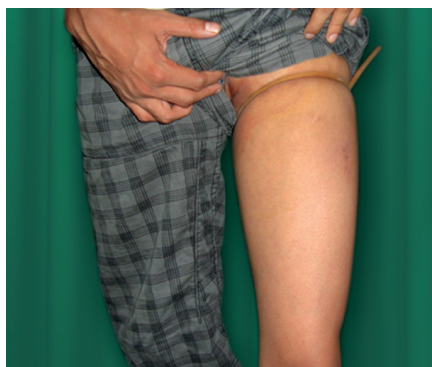#### Clinical Discussion

1. How will you do Brodie-Trendelenburg test? (Figs 76.1 to 76.3)  
The test is done in two parts—Trendelenburg I and Trendelenburg II.





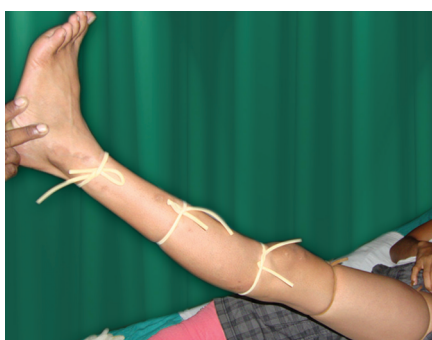**Fig. 76.1:** Emptying of varicose vein by elevation and milking before the tourniquet test



**Fig. 76.3:** The patient stands with the tourniquet at the SF junction



**Fig. 76.2:** Occlusion of saphenofemoral (SF) junction with the thumb



**Figs 76.4:** Demonstration of multiple tourniquet test

The patient is asked to lie on the couch in supine position (Fig. 76.1). The leg is elevated and the vein emptied. Saphenofemoral junction is occluded with the help of the thumb or a tourniquet and the patient is asked to stand (Figs 76.2 and 76.3).

Trendelenburg I—Thumb/Tourniquet is released. Immediate filling of the veins by a column of blood from above downwards indicates saphenofemoral incompetence. Trendelenburg II – The pressure at the saphenofemoral junction is maintained without releasing the thumb or tourniquet and the patient is asked to stand. If the veins start getting dilated below the tourniquet, it indicates that there is some more perforator incompetence below the saphenofemoral junction.

2. How will you do Perthes' test?

This test is done to know the patency of deep veins.

A tourniquet is tied below the saphenous opening with the veins being full. The patient is asked to walk for about 3 to 5 min.

If the deep veins are patent and dilated, superficial veins will collapse. However, if the deep veins are occluded by thrombosis, the superficial veins will become more distended and patient will complain of bursting pain in the leg and the test is said to be positive Perthes test.

In the absence of deep vein patency, the superficial venous system is the only channel to drain the blood from the leg. So operation is contraindicated.

3. What are the tests done to know the level of incompetent perforation veins?

- a. Multiple tourniquet test
- b. Pratt's test
- c. Fegan's test

4. What is multiple tourniquet test?

This test is done to find out the exact site of perforators.

### Method

- a. The patient is asked to lie down and the veins are emptied by elevating the leg and by milking.

- b. There are mainly ankle, knee and thigh perforators. Hence the tourniquets are applied as below: (Figs 76.4A and B)

First tourniquet below the level of saphenofemoral junction.

Second tourniquet below the level of perforator at Hunter's canal.

Third tourniquet – just below the knee perforator.

Fourth tourniquet – just below the 5 cm ankle perforator.

Additional tourniquets may be applied below the 5 cm and 10 cm ankle perforators.

- c. The patient is asked to stand keeping the tourniquets tied and appearance of veins observed. If any of the perforator is incompetent, that segment lying between the two tourniquets will become varicose. The individual perforator may also be tested by using two tourniquets. After emptying the veins the two tourniquets are tied one above and one below the perforator to be tested.

When the patient is asked to stand the segment of the vein between the two tourniquets will become varicose if the particular perforator is incompetent (Fig. 76.5).

5. How will you do Pratt's test?

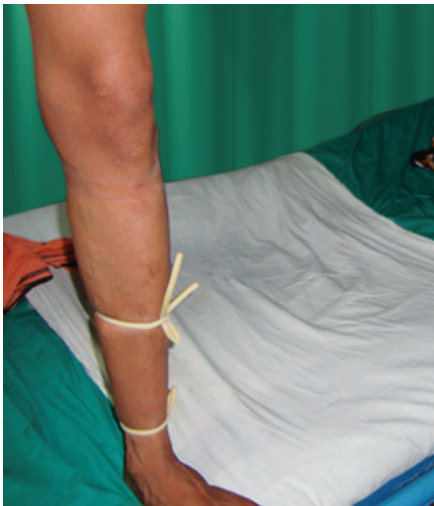- a. This test is done to map out the level of incompetent perforators.
- b. Esmarch bandage is applied from toes to the groin in supine position.
- c. A tourniquet is applied just above the bandage.
- d. The patient is asked to stand and the bandage is gradually removed.
- e. Site of 'blow out' is noted and marked as the incompetent perforator.

6. What is Fegan's test?

- a. This test is done to localize the perforators in the deep fascia.
- b. The veins are emptied and the sites of known perforator's area are palpated with a finger.
- c. The sites where perforators are incompetent and dilated, circular openings with sharp edges are felt in the deep fascia.

7. What is Morrissey's cough impulse test?

- a. This test is done in standing position.
- b. The examiner keeps the finger at saphenofemoral junction and the patient is asked to cough.



**Fig. 76.5:** Two tourniquet test for testing the 5 cm above ankle perforator

- c. Fluid thrill / an impulse felt by the fingers indicates saphenofemoral incompetence.

## VARICOSE VEIN

### Case Summary

A 46-year-old male patient presents with gradual onset of swelling of veins along the inner aspect of right leg for 5 years.

There is pain in the right lower limb and ulceration on the medial aspect of right ankle for last two years.

The swelling gets aggravated after prolonged standing and walking while it is reduced and sometimes disappear on lying down.

The pain is dull aching in nature and felt in the calf region. The pain is experienced near the end of the working day.

There is serous discharge and pain in the ulcer area.

On examination, on general survey mild pallor is present, P-80/min BP – 130/80 mm Hg.

On local examination: on the right side Trendelenburg test as well as cough impulse test is positive which indicates saphenofemoral in competence.

Multiple tourniquet tests reveal perforator incompetence at adductor canal and at 10 and 15 cm above the ankle perforators

- Perthes test is negative on the right side.
- The left lower limb is normal.
- Systemic examination is normal.

### Clinical Discussion

1. What is your case?  
This is a case of varicose vein affecting great saphenous system of veins in right lower limb with perforator incompetence at saphenofemoral function, adductor canal, 10 cm and 15 cm above the medial malleolus.
2. What are varicose veins?  
Dilated, elongated and tortuous veins are called varicose veins.
3. What are the sites of varicosities?
  - a. Lower limb veins
  - b. Esophageal varix
  - c. Hemorrhoidal veins – piles
  - d. Pampiniforms plexus of veins – varicocele.
4. What are the components of the venous system of lower limb?  
It consists of three types of veins. (See also chapter 27)
  - a. Superficial system of veins comprising the long and short saphenous veins and their tributaries.
  - b. Deep veins – Muscular veins and anterior tibial, posterior tibial and popliteal vein, femoral and peroneal veins.
  - c. Perforating veins – These are veins connecting the superficial system of veins to the deep veins.
5. Why does a varicose vein occur?  
Varicose veins may be primary or secondary.
  - a. Primary – Varicose vein is due to incompetent valves in the superficial veins producing reversed gravitational flow, possibly because of an inherited defect.
  - b. Secondary varicose veins occur as a result of enforced reverse flow in collateral branches. Superficial veins then act as bypass and become varicose in course of time. This may be due to:
    - i. Venous obstruction – tumor, pregnancy, thrombosis of the deep veins.
    - ii. Increased blood flow, e.g. arteriovenous fistula, hemangioma.
    - iii. Loss of venous valves following deep vein thrombosis.
6. What are the predisposing factors for primary varicose vein?
  - a. Prolonged standing
  - b. Obesity
  - c. Old age – Valves become incompetent.

7. What are the sites of perforating veins?  
There are five constant perforators in the lower limb on the medial side.
  - a. Medial perforating veins 5 cm, 10 cm and 15 cm, above the medial malleolus. These are three constant medial perforators, also known as Cockett and Dodd's perforators.
  - b. Knee perforator – It is situated just below knee (Boyd's perforator).
  - c. Thigh perforator – It is situated a palm's breadth above the knee, also known as adductor canal or hunterian perforator at mid thigh.
8. What is the normal physiology of venous drainage from the lower limbs?  
Blood is propelled from the lower limbs to the heart against gravity by the following mechanisms:
  - a. Vis-a-tergo or the pumping action of the heart allows the blood flow through the capillary bed to the venous side.
  - b. Competent valves in the veins of the limbs direct the flow of blood in one direction towards the heart.
  - c. Muscle pump or calf pump – This act as a peripheral heart increasing the venous return to the heart by the alternate contraction and relaxation of the surrounding muscles of the leg.
  - d. Negative intrathoracic pressure.
  - e. Venae comitantes.

In the resting position, blood returns to the heart mainly by a vis – a – tergo and during walking mainly by calf pump.
9. What are the complications of varicose vein?
  - a. Hemorrhage
  - b. Thrombophlebitis
  - c. Complications due to venous hypertension e.g.
    - i. Edema
    - ii. Skin pigmentation
    - iii. Eczema
    - iv. Venous ulceration
    - v. Lipodermatosclerosis.
10. What investigations will you do to confirm the diagnosis?
  - a. Doppler ultrasound – This test determines the patency of the veins and valvular incompetence.
  - b. Duplex scanning – This is one of the best tests for testing the flow patterns and imaging the venous system. It can

provide the accurate localization of the perforating veins.

11. What other investigations you like to do?  
Routine investigations are done to know the fitness of the patient for general anesthesia.
12. What are the different modalities of treatment of varicose vein?
  - a. Conservative treatment – which consists of avoiding.
    - i. Prolonged standing and constricting garments.
    - ii. A crepe bandage or elastic stockinette applied from the toes to the thigh and
    - iii. Leg exercise.
  - b. Injection sclerotherapy and
  - c. Surgery.
13. How will you treat this patient?
  - Surgical treatment is considered in this patient as there is saphenofemoral incompetence.
  - The operation of choice is saphenofemoral flush ligation, or Trendelenburg operation, stripping of the long saphenous vein up to the upper calf and ligation of all incompetent perforators below knee.
14. What is sclerotherapy?  
Sclerotherapy is the method of treatment, where the lumen of the vein is obliterated by injecting chemicals or sclerosant.
15. What are the methods of sclerotherapy?
  - a. Paravariceal, e.g. hemorrhoids.
  - b. Intravariceal, e.g. varicose veins and esophageal varix.
16. What agents are used?
  - a. Sodium tetradecyl sulphate 3 percent.
  - b. Ethanolamine oleate 5percent.
  - c. Phenol in olive oil or almond oil.
17. What is the mechanism of action of sclerosant?  
The sclerosant solution destroys the endothelial lining and results in fibrotic occlusion of the vein.
18. What is indication of sclerotherapy?
  - a. Small varices below the knee.
  - b. Recurrent varices after surgery.
  - c. Uncomplicated perforator incompetence.
19. What is the technique of sclerotherapy?
  - a. Varicose vein is marked in standing position.
  - b. Injection is given in lying position with the leg elevated. 0.5 to 1 ml of the solution is injected in the vein.
    - c. Each injection site is covered with a cotton wool ball and maintained in position by a crepe bandage and a full length elastic stocking for 6 weeks.
    - d. A maximum of 10ml sclerosant may be injected in one sitting, otherwise there will be hemolysis.
20. What are the complications of sclerotherapy?
  - a. Skin pigmentation.
  - b. Ulceration of the skin if injected in the extravascular space.
  - c. Rarely deep vein thrombosis.
  - d. Superficial thrombophlebitis over small region.
21. What are the indications for surgery?
  - a. Saphenofemoral or saphenopopliteal incompetence.
  - b. Very large varices, even if asymptomatic.
  - c. Severe symptoms.
  - d. Cosmetic reasons.
22. What are the types of operation available?
  - a. Ligation (saphenofemoral or saphenopopliteal).
  - b. Ligation and stripping.
  - c. Phlebectomy.
23. What is the technique of ligation?  
Either the saphenofemoral or saphenopopliteal junction is done. The saphenous vein is ligated flush with the femoral or popliteal vein.  
Another ligature is passed distal to the flush ligature and the vein is divided between ligatures.  
There must be no tributary left between the flush ligature and the femoral or popliteal vein.
24. What are the tributaries of long saphenous vein near its termination?
  - a. Superficial circumflex iliac vein.
  - b. Superficial epigastric vein.
  - c. Superficial external pudendal vein.
25. What is Trendelenburg operation?  
It is the treatment of choice for long saphenous vein incompetency and consists of saphenofemoral ligation with stripping of the long saphenous vein due to the presence of incompetent perforators. This is followed by crepe bandage application and elevation of the affected limb.
26. Why stripping operation is not done for short saphenous system?
  - a. It may cause long-standing edema.
  - b. Incompetent perforating veins are not found in relation to short saphenous vein.
  - c. Chance of injury to sural nerve.
27. When do you do subfacial ligation?  
It is done for treating incompetent perforating veins. Incompetent perforation sites are explored subfascially and then ligated and divided (Cockett and Dodd operation).
28. How do you manage small residual varicosities following surgery?  
They are managed either by compression bandage or injection sclerotherapy.
29. What will you do on the day of surgery before the patient is anesthetized?  
The main trunk of the varicose vein along with the communicating vein should be marked with gentian violet for identification during surgery.
30. What are the contraindications of injection sclerotherapy and operative treatment?
  - a. Deep vein thrombosis with edema of the limb.
  - b. Pregnancy.
  - c. Thrombophlebitis.
  - d. Women taking and contraceptive pills because there are chances of deep vein thrombosis and fatal thromboembolism.
31. What are the results of surgical treatment?  
The overall results are good. Recurrence rate is about 10 percent.
32. What is phlebectomy?  
When the dilated segment is a short one, with multiple small incisions, the dilated vein is removed and is known as phlebectomy.
33. How small dilated veins are removed?  
By hook phlebectomy. A small incision of 1 to 2 mm is made and a small section of varicosity is picked up with a small hook and removed after ligating it. Incision is closed by adhesive tapes.
34. What is a venous ulcer?  
It is the venous ulcer developing on the lower third of medial aspect of the leg.
35. How the venous ulcers develop?
  - a. Venous ulcer always develops in association with incompetent valves in the superficial or deep veins with reverse flow of blood.
  - b. The basic defect is venous stasis and venous hypertension especially during

- standing or walking resulting in local tissue anoxia.
- c. This occurs particularly in the region of medial aspect of leg with constantly placed perforators.
  - d. Due to stasis the pressure in the veins is about 30mmHg higher than that in the arteries. So there is extravasation of RBC's and deposition of hemosiderin pigment underneath the skin leading to its pigmentation.
  - e. The skin in this area is usually thin. Local anoxia combined with pigmentation causes disruption of skin and ulceration often after a trivial trauma.
36. What is the treatment of venous ulcer?
- a. Venous ulcer due to superficial varicosity heals well after surgical treatment of varicose veins.
  - b. Venous ulcer due to deep vein thrombosis, conservative treatment of the ulcer is the only option (Bisgard's method).
37. What is the conservative treatment? It consists of:
- a. Elevation of the limb.
  - b. Local cleaning of the ulcer and dressing.
  - c. The most effective treatment is the use of elastic stockinette to provide high level of compression at the site of ulcer, which will hasten the healing process. A pressure of 30 to 45 mm Hg is good for healing.

# Chapter 77

## Buerger's Disease

- General plan of examination of a case of Buerger's disease
- Buerger's disease

### GENERAL PLAN OF EXAMINATION OF A CASE OF PERIPHERAL VASCULAR DISEASE AND GANGRENE (BUERGER'S DISEASE)

#### History

1. Particulars of the patient.
2. Chief complaints
  - a. Pain in the right or left lower limb – Intermittent claudication, rest pain.
  - b. Ulceration.
  - c. Black discoloration of toes.
3. History of present illness  
Pain—Site, character and radiation of pain. Pain due to arterial insufficiency of the lower limb is of two types viz. intermittent claudication and rest pain. Intermittent claudication is the earliest symptom of ischemia due to chronic arterial obstruction and is characterized by cramp-like pain felt usually in the calf muscle. Pain is induced by walking and relieved by rest or standing still. Claudication distance: It is the distance the patient can walk (say 500 yards or more) before the onset of cramp-like pain. The claudication distance may reduce to 100 yards or less over a period of months or years and signifies the progress of ischemia. Rest pain—This is a more serious symptom of arterial insufficiency, consisting of

- incapacitating pain due to severe ischemia felt in the calf or foot even at rest. Rest pain signifies impending gangrene (pregangrene). Ulceration—Detail history is to be taken regarding onset, any history of trauma. Gangrene—Duration, unilateral or bilateral, site and extent, coldness, numbness, paresthesia – present or not. Type of gangrene – dry/moist.
4. Past history—History of hypertension and diabetes mellitus should be enquired of.
  5. Personal history—History of smoking, duration of smoking. Total no. of cigarettes he takes per day. Whether the patient is still smoking.
  6. Family history—whether any member of the family suffers from atherosclerosis.
  7. History of allergy.

#### Physical Examination

##### General Survey

- Decubitus—Patient feels comfortable with the affected legs hanging below the level of the bed. Pulse—Details of pulses are to be described in local examination.

##### Local Examination

- Examination of the lower limbs.
- a. Inspection:  
The limbs are placed side by side.

- Signs of ischemia—For example, diminished growth of hairs, loss of subcutaneous fat, brittle nails, shiny and thin skin.
- Color of the affected limb is compared with that of the unaffected side. If both limbs are affected, then it is necessary to compare with clinician's own skin.

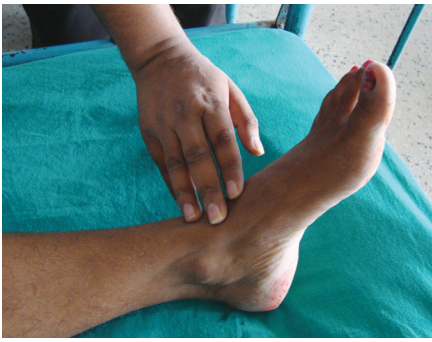In case of established gangrene the following are noted.

- Color change in the gangrenous area.
- Presence of any discharge, blebs and bullae.
- Type of gangrene and site.
- Line of demarcation—The level and depth of demarcation is noted. The line of demarcation is seen at the junction of the dead and living areas. In senile gangrene this is poorly marked.
- Skip lesions (black patches) above the gangrenous parts are looked for. These black patches indicate future spread of the gangrene.

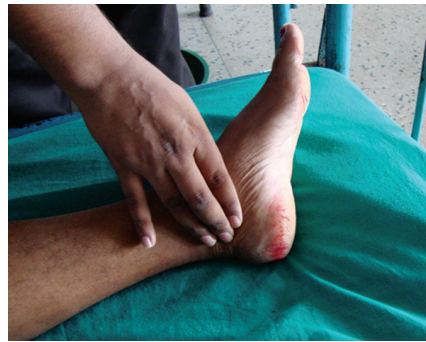##### b. Palpation

- Skin temperature—The ischemic limb is cold. The limb is palpated from the foot and is seen at what level the temperature becomes normal in comparison to the normal side.
- Gangrene
  - Sensation
  - Tenderness
  - Any local crepitus

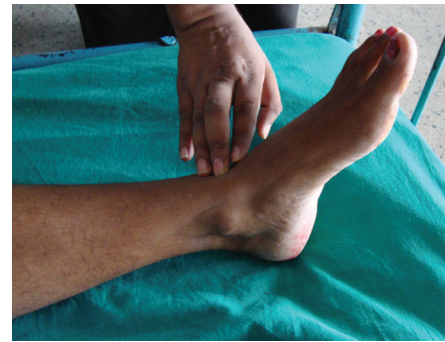



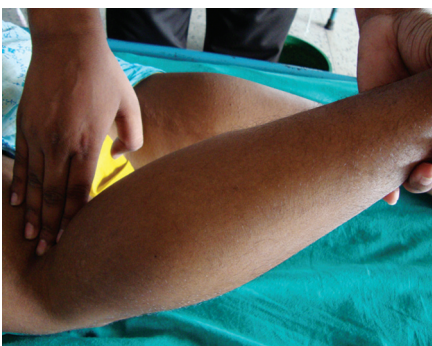**Fig. 77.1:** Palpation of arteria dorsalis pedis



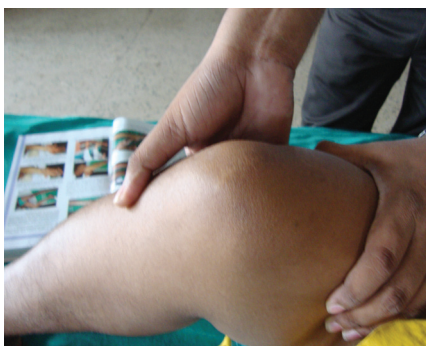**Fig. 77.2:** Palpation of posterior tibial artery



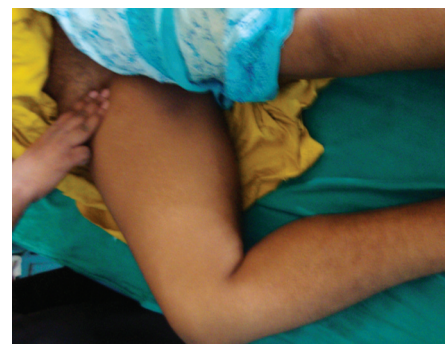**Fig. 77.3:** Palpation of anterior tibial artery



**Fig. 77.4:** Palpation of popliteal artery in prone position



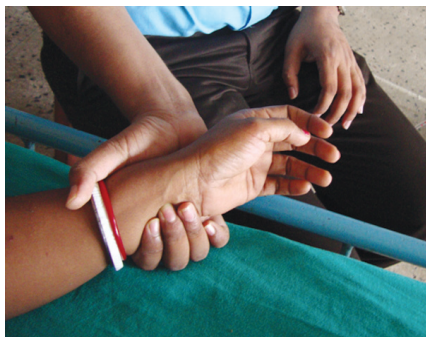**Fig. 77.5:** Palpation of popliteal artery in supine position



**Fig. 77.6:** Palpation of femoral artery



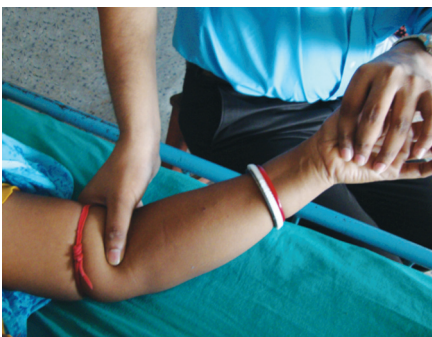**Fig. 77.7:** Palpation of radial artery



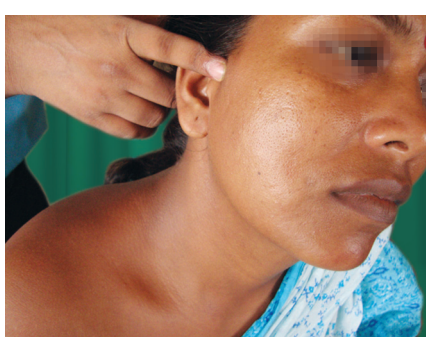**Fig. 77.8:** Palpation of ulnar artery



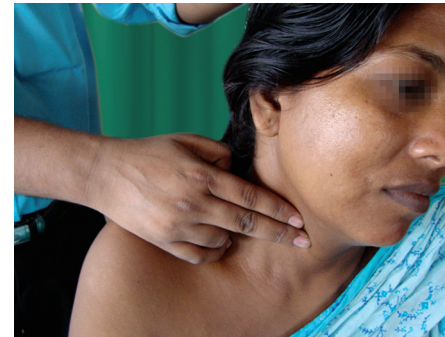**Fig. 77.9:** Palpation of axillary artery



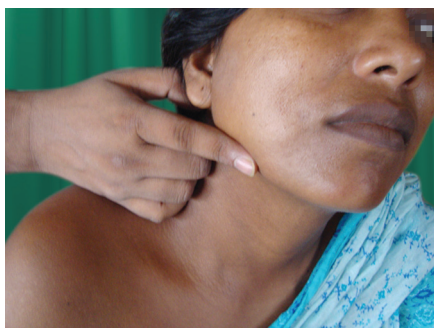**Fig. 77.10:** Palpation of brachial artery



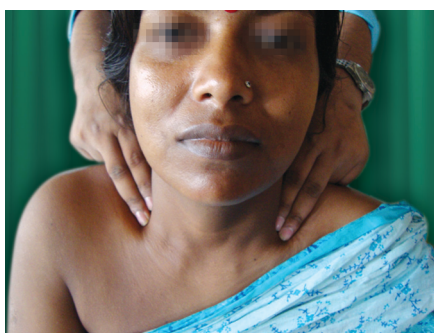**Fig. 77.11:** Palpation of superficial temporal artery



**Fig. 77.12:** Palpation of common carotid artery



**Fig. 77.13:** Palpation of facial artery



**Fig. 77.14:** Palpation of subclavian artery

- Palpation of the area adjacent to the gangrenous area for tenderness and edema.
- Buerger's test for circulatory insufficiency—In a normal person, the leg can be kept at 90° angles above the horizontal without appearance of any pallor. In Buerger's disease when the affected leg is raised vertically upwards, a marked pallor develops in 2 to 3 minutes. The angle between the limb and the horizontal, at which such pallor appears, is known as Buerger's angle of circulatory insufficiency.
- Palpation of the peripheral pulses—The following pulses are felt and compared with the normal side. Arteria dorsalis pedis, posterior tibial, anterior tibial, popliteal, femoral, radial, ulnar, brachial, axillary, subclavian, carotid and superficial temporal and facial artery (Figs 77.1 to 77.14).

### Systemic Examination

Examination of abdomen and all other systems.

- Summary of the case

- Provisional diagnosis.
- Investigations suggested.

### BUERGER'S DISEASE

#### Case Summary

The 35-years-old male patient presents with pain in the right leg during walking for the last three years.

He is a heavy smoker and used to smoke 25 bidis per day.

He has some relief of pain keeping the right leg below the level of the bed. There is black discoloration of his great toe for last 3 months following a minor trauma.

On examination, on general survey, he has mild pallor, pulse 80/min, BP – 130/80 mm Hg.

On local examination of lower limbs, there are signs of ischemia on the right side, (skin is thin and shiny, nails brittle with transverse ridges).

There is dry gangrene involving the right great toe. Arteria dorsalis pedis and posterior tibial pulses are absent on the right side. Systemic examination revealed no abnormality.

#### Clinical Discussion

1. What is your case?  
This is a case of peripheral vascular disease affecting the right lower limb with gangrene of right great toe due to Buerger's disease.
2. Why do you say so?
  - a. There is history of intermittent claudication.
  - b. Gangrene of the right great toe.
  - c. The patient is a smoker.
  - d. Younger age group.
  - e. Male patient
  - f. No atheromatous changes of radial artery on palpation.
3. What is the other important cause of chronic limb ischemia?  
Atherosclerosis—It is the commonest cause of ischemia in the limb.
4. What are the points in favor of diagnosis of atherosclerosis?
  - a. Age – Usually after 50 years.
  - b. Presence of hypertension.
  - c. Diabetes
  - d. Hyperlipidemia
  - e. History of ischemic heart disease.

5. What is intermittent claudication?
6. What is claudication distance?  
Already mentioned above.
7. What is rest pain?
8. What are the different grades of claudication?  
Vide the chapter 26 “arterial disorders”.
9. Why the patient likes to sit with legs hanging?  
Due to gravity there is more blood supply.
10. What is Buerger's angle of circulatory insufficiency?  
Mentioned earlier in this chapter.
11. What is Buerger's disease?  
It is thromboangiitis obliterans involving low grade inflammation of the small and medium sized arteries mainly of the lower limbs, first described by Leo Buerger, an urologist, in 1908.
12. What is gangrene?  
It is the macroscopic death of tissues with super added putrefaction. The five signs of gangrene are:
  - a. Loss of color (color change)
  - b. Loss of temperature (coldness)
  - c. Loss of sensation
  - d. Loss of pulsation
  - e. Loss of function or movement.
13. What is pregangrene?
  - a. It is the symptom complex of rest pain, color changes, edema and hyperesthesia. Ischemic ulcer may or may not be present.
  - b. Clinically there may be disappearing pulse, that is, there is normal pulse during clinical examination but on exercising the patient upto the point of claudication, the normal pulse becomes impalpable. The disappearing pulse indicates arterial occlusion.
14. What are the common sites of gangrene?  
The commonest external sites are toes and feet and the internal ones are strangulated loop of intestine and appendix.
15. What are necrosis, slough and eschar?
  - a. Necrosis—Death of a group of cells.
  - b. Slough—Dead soft tissue, e.g. skin, fascia or tendon.
  - c. Eschar—It is dried up slough.
16. What are the clinical types of gangrene?
  - a. Dry gangrene
  - b. Wet gangrene
17. What is dry gangrene?



It is the gangrene without putrefaction and occurs due to gradual occlusion of arteries, e.g. Buerger's disease, atherosclerosis.

In dry gangrene:

- The affected part is dried shriveled up and mummified.
- No putrefaction hence, no discharge or offensive smell.
- Line of demarcation and separation are well-delineated.

18. What is wet gangrene?

- It is the gangrene with super added putrefaction.
- Commonly occurs in diabetes, bed-sores and gas gangrene.
- Presence of discharge and offensive smell.
- Line of demarcation and separation are not well-marked.

19. What is line of demarcation and separation?

A gangrenous part is separated from healthy part by granulation tissue.

- Line of demarcation—It is the junction of healthy part and granulation tissue.
- Line of separation—It is the junction of gangrenous part and granulation tissue.

20. What are the different sites of pain in relation to vascular obstruction?

Level of obstruction	Site of pain
a. Aortoiliac	Buttock
b. Femoral	Thigh
c. Popliteal	Calf
d. Posterior tibial and dorsalis pedis	Foot and toes

21. What is critical limb ischemia?

- It is defined as persistent rest pain of over 2 weeks duration requiring regular analgesia.
- Ulceration or gangrene of foot or toes with
- Ankle pressure < 50 mm Hg and
- Toe systolic pressure < 30 mm Hg.

22. What are the causes of gangrene?

Vide the chapter 26 on arterial disorders.

23. How will you palpate the popliteal artery?

- Patient is asked to lie in prone position.
- The knee is flexed and popliteal artery is palpated in the middle of the popliteal fossa.

24. How will you palpate posterior tibial artery?

It is palpated behind the medial malleolus midway between medial malleolus and tendoachillis.

25. How will you palpate dorsalis pedis artery?

Dorsalis pedis artery is palpated just lateral to the tendon of extensor hallucis longus.

26. How will you differentiate Buerger's disease from atherosclerosis?

- Patient is usually below 30 years.
- Arterial wall is not thickened.
- History of thrombophlebitis of superficial or deep veins.
- Patient is usually a heavy smoker and remission of disease is linked to abstinence from smoking.

27. Why it is not a case of Raynaud's disease?

- Raynaud's phenomenon is absent.
- Lower limbs are involved.
- Intermittent claudication and rest pain are present.

28. Why it is not a case of diabetic gangrene?

- History of diabetes mellitus absent.
- History of intermittent claudication and rest pain.
- Dry gangrene.
- Dorsalis pedis and posterior tibial pulses are absent.

29. What are the signs of ischemia?

- Loss of hair
- Loss of subcutaneous fat
- Skin—shiny and thin
- Nails brittle
- Interdigital cracks
- Local temperature decreased
- Wasting of small muscles of foot.

30. How does the gangrene develop in diabetes?

Gangrene is formed in diabetes as a consequence of the following factors:

- Infection—This is the main cause. There are trophic changes due to peripheral neuropathy. Sensation is impaired and patient cannot realize or neglect minor trauma, which invites infection.
- Diabetic angiopathy—This affects both large and small vessels (macro and microangiopathy) leading to ischemia and necrosis.
- The sugar laden tissues serve as a medium for the bacteria to grow.

d. Due to the above mentioned factors, infection has a rapid course and involves all the tissues including bones.

31. How will you treat diabetic gangrene?

- Control of diabetes.
- Regular dressing of the affected part by draining the pus and removal of dead tissue.
- Broad spectrum antibiotics.
- If uncontrolled, conservative amputation is done, e.g. digital or transmetatarsal amputation.

32. What investigations you like to do for confirmation of diagnosis of Buerger's disease?

- Doppler study.
- Arteriography, nowadays this has been replaced by digital subtraction angiography.

33. How Doppler ultrasound help us?

a. Listening to audible signal—When the Doppler ultrasound probe is placed over an artery, ultrasonic beam passes to the artery and is reflected back after being converted into audible sounds.

At the site of obstruction, the sound will disappear. This gives an idea about the site of blockage.

b. Measuring segmental blood pressure: By applying cuff at the thigh, calf and ankle and by listening with the Doppler probe, it is possible to measure blood pressure at the thigh calf and ankle. By measuring the ankle blood pressure and blood pressure at the arm, it is possible to find the ratio of ankle and brachial blood pressure, called ankle-brachial pressure index (ABPI). In a normal person ABPI is > 1. ABPI < 0.3 indicates critical ischemia.

34. How does arteriography help us?

It can show the site, size and number of arterial obstruction. It can also show the collateral circulation. It is done by direct arterial puncture or arterial catheterization. Complications like dissecting aneurysm, hemorrhage and embolism may occur.

So, nowadays it is done by digital subtraction angiography, where no arterial puncture is needed and contrast medium is injected into the vein. Hence there is no chance of complications and it gives more clarity.

35. What is arteriography or angiography?

It is the radiological visualization of the arterial tree.

36. What is Brown's vasomotor index?

It gives an idea about the spasm of collaterals. If the index is > 3.5, there is vasospasm.

37. How is it measured?

- a. Skin and mouth temperature are recorded separately.
- b. Body is heated mechanically, e.g. stimulation by electrical pad.
- c. Again skin and mouth temperatures are recorded.

Formula for vasomotor index:

Rise in skin temperature—Rise in mouth temperature divided by rise in mouth temperature.

38. How will you treat a case of Buerger's disease?

- a. Conservative treatment has a great role to play in this disease.
  - Stoppage of smoking is very important.
  - Nonaddictive analgesic drugs for pain relief.

- Buerger's exercise—The limb is elevated for 2 min and lowered for 2 min this exercise is repeated several times.

b. Surgery

- If there is no improvement with conservative treatment, then bilateral lumbar sympathectomy is done. In this operation, second, third and fourth lumbar sympathetic ganglia with intervening trunk are removed. The first lumbar ganglia of one side is spared otherwise there will be impotency.

However, the disease process can not be prevented through this operation, as it causes vasodilation of arteries of skin, so it only prevents ischemic changes and there is no relief of intermittent claudication as muscle ischemia persists.

- c. Amputation of the gangrenous part—amputation should be as conservative as possible depending on the level of obstruction as evident by Doppler ultrasound study.

39. How do you find lumbar sympathetic trunk?

The sympathetic chain is identified medial to the psoas muscle on the sides of the lumbar vertebral body. On the right side, this is overlapped by the inferior vena cava and on the left side by the aorta.

40. How would you differentiate between sympathetic trunk and lymphatic vessels? By the presence of distinct ganglia and the rami communicantes in the sympathetic trunk.

41. What are the rami communicantes?

- a. These are white and gray rami communicantes which connect the sympathetic trunk with the spinal cord and the peripheral nerve.
- b. The gray rami communicantes carries the preganglionic sympathetic fibers from the spinal cord to the sympathetic ganglia.
- c. The white rami communicantes carry postganglionic fibers from the sympathetic ganglia to the peripheral nerve.

# Chapter 78

## Orthopedic Long Cases: Hip Joint

- General plan of examination of hip joint
- Tuberculosis of hip
- Perthes disease
- Caries spine
- Osteomyelitis
- Nonunited fracture neck femur

### GENERAL PLAN OF EXAMINATION OF HIP JOINT

#### History

1. Particulars of the patient
  - Age is important in different hip conditions, e.g. congenital dislocation of hip occurs at 0 to 2 years, tuberculosis of hip 2 to 5 years, Perthes disease 8 to 10 years and osteoarthritis occurring from 40 years onwards.
  - Sex: Tuberculosis of hip and Perthes disease are more commonly seen in males while rheumatoid arthritis is more common in females.
2. Chief complaints
  - a. *Pain*: This is the most common complaint of a patient with a hip disorder. The pain is usually experienced in the groin or in front of thigh. The nature and duration of pain as well as the aggravating and relieving factors are enquired.
  - b. *Limp*: This is the second commonest complaint. It could be painful, e.g. in arthritis, trauma or painless, e.g. in congenital dislocation of hip.
  - c. General symptoms like fever, malaise, loss of weight.
  - d. Deformity.
3. History of present illness like limping and other systemic symptoms if present are described.

The detailed history of pain is noted as mentioned above.

4. History of past illness, e.g. osteoarthritis can occur many years after a joint is damaged due to injury or infection. An old tubercular lesion in the body may present as tuberculosis in the bone or joint.
5. *Family history*: It may be important in case of tuberculosis.
6. Personal history.
7. History of allergy.

#### Physical Examination

1. *General survey*: Built, pallor, nutrition, etc. noted.
2. *Local examination*:
  - a. *In standing position*: The predominant examination method is inspection. The following are noted.
    - Gait.
    - Wasting of the muscles on the affected side.
    - Lordosis.
    - Deformity.
    - Trendelenburg test.
  - b. *Lying down position*.
    - **Inspection**
      - Position of anterior superior iliac spine (ASIS) on the affected side: It ASIS is shifted up, it indicates fixed adduction deformity, whereas

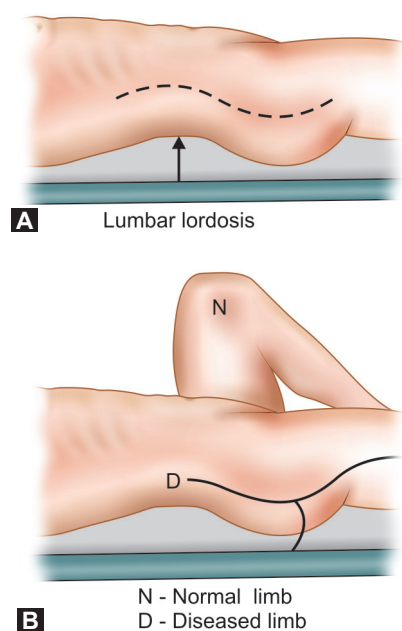
if ASIS is tilted down, it indicates fixed abduction deformity.

- Lumbar lordosis may be a result of fixed flexion deformity.

#### Palpation

- Temperature—Over the groin and over the swelling if any.
  - Tenderness—Over the groin.
  - Local lymph nodes in the groin palpable or not.
  - Deformity—Fixed flexion deformity.
    - Fixed adduction deformity
    - Fixed abduction deformity.
  - Limb length measurement
    - Apparent length of the whole limb.
    - Actual or true length of the limb. Measurement of lengthening or shortening of the limb—apparent or true.
  - Greater trochanter
    - Thickening
    - Proximal migration.
  - Bryant's triangle.
  - Telescoping test for hip stability.
3. *Systemic examination*: – Examination of abdomen, respiratory, cardiovascular and nervous systems are done to exclude any abnormality.
    - Summary of the case.
    - Provisional diagnosis.
    - Differential diagnosis.





**Figs 78.1A and B:** The thomas test  
(A) Lumbar lordosis (B) Lumbar lordosis obliterated

### CLINICAL DISCUSSION

1. What information will you get from examination of the hip joint?
  - a. Apparent or true shortening or lengthening of the affected limb.
  - b. Hip is stable or not.
  - c. Restriction of any movement.
  - d. Presence of any fixed deformity.
2. How will you identify fixed flexion deformity?
  - a. By seeing the lumbar lordosis.
  - b. By Thomas' test.
3. How do you perform Thomas' test?
 

The test consists of three steps (Figs 78.1A and B):

  - a. The patient lies supine and the clinician passes the hand beneath the spine with the palm of the hand facing upwards.
  - b. The normal hip is flexed till the thigh touches the abdomen. Now the hand can feel the spine which suggests obliteration of the lumbar lordosis.
  - c. The affected hip now shows flexion and the concealed deformity stands revealed. The angle formed by the back of thigh and the bed is the angle of fixed flexion deformity.

4. What is the limitation of Thomas' test?
 

This test is not useful in bilateral fixed flexion deformity.
5. What precaution is to be taken during the test?
 

The normal hip should not be over flexed beyond the point of obliteration of lumbar lordosis, especially in children, as this will raise the pelvis and the deformity appears exaggerated.
6. What test is done in bilateral fixed flexion deformity?
 

*Prone test:* This is done as follows: (Fig. 78.2)

  - The patient remains in prone position with the body at the edge of the bed and the legs hanging out.
  - The hand of clinician supports the lumbar spine.
  - The angle between the body and thigh is measured and this is the angle of fixed flexion deformity.
7. What does fixed flexion deformity signify?
 

It signifies loss of hip extension.
8. How do you test fixed adduction deformity?
 

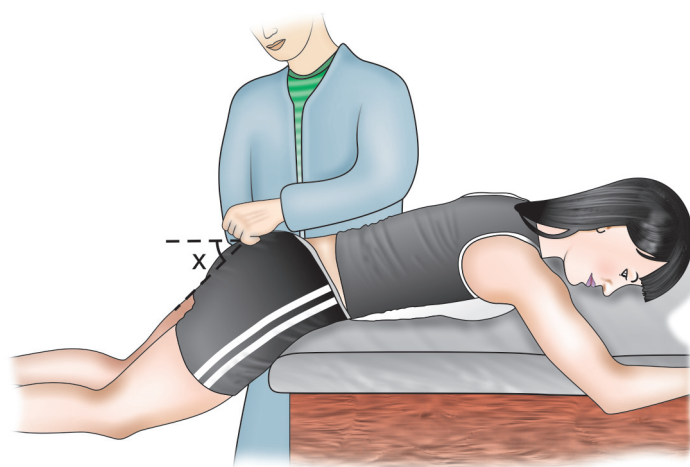
This can be tested by either of the two methods:

  - a. *Decompensation method*
    - This method aims at revealing the concealed deformity.
    - Here the affected limb is adducted till both the anterior superior iliac spine come to lie in the same horizontal line and at right angles to the midline of the body. (Fig. 78.3A and B)
  - b. *Now the angle of adduction is estimated.*
  - b. *Kothari's method:*
    - The angle formed between the interspinous line connecting the two ASIS and the horizontal line drawn through the sound ASIS is measured.
    - This angle formed at the sound side above the horizontal line is the angle of fixed adduction deformity.
9. What is the significance of fixed adduction deformity?
 

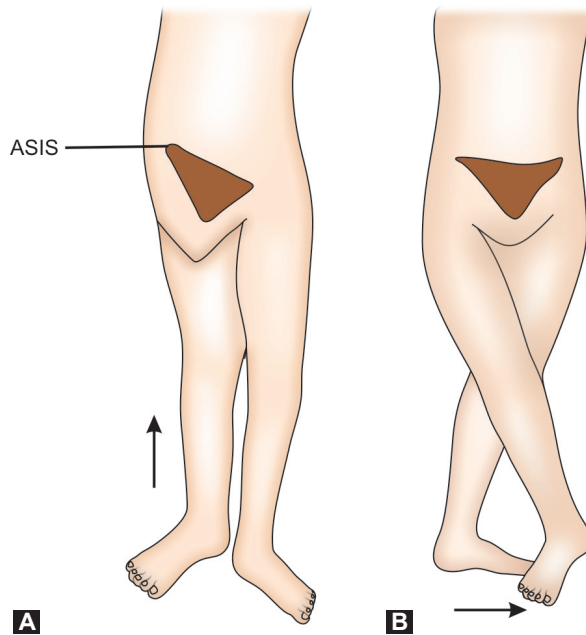
It signifies that there can be further adduction in the line of the deformity but there can be no abduction.
10. How do you test fixed abduction deformity?
 

This can be tested by either of the two methods.

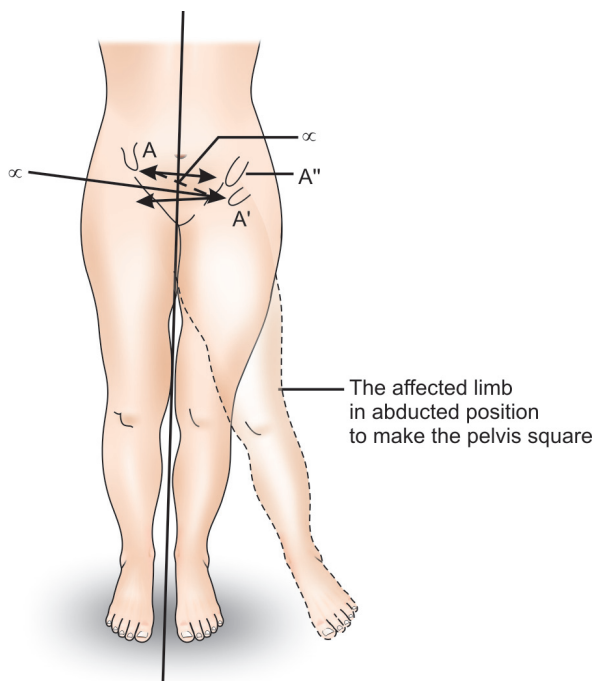
  - a. *Decompensation method:*
    - Here the 'concealed deformity' is 'revealed'.
    - The affected limb is abducted till the interspinous line becomes horizontal and at right angles to the body.
    - Now the angle of abduction is estimated. (Fig. 78.4)
  - c. *Kothari's method:*
    - The angle between the interspinous line and the horizontal line is drawn from the sound ASIS.
    - The angle formed at the sound side below the horizontal line, indicates the fixed abduction deformity.



**Fig. 78.2:** The method of doing prone test in bilateral fixed flexion deformity  
X = Angle of fixed flexion deformity of hip (left)



**Figs. 78.3A and B:** The method of squaring of the pelvis (making ASIS both sides at the same level) by the decompensation method in fixed adduction deformity in which the anterior superior iliac spine (ASIS) of the affected side (right) lies at a higher level than that of the sound side (Arrow in A) the opposite feature is seen in fixed abduction deformity.



**Fig. 78.4:** Assessment of pelvic tilt in fixed abduction deformity.  
 $\alpha$  = Angle of fixed abduction deformity. A, A', A'' = Anterior superior iliac spines

11. What is the significance of fixed abduction deformity?

It signifies no adduction movement, but only further abduction is possible.

12. What is Trendelenburg test?

This test is done to know the stability of the hip joint.

13. How will you do Trendelenburg test?

The test is done as follows:

a. The patient is asked to stand on the normal limb. The pelvis on the opposite side rises. Alternatively, the iliac crest will be low on the standing side and high on the side of the elevated leg due to the intact abductor mechanism of the hip on the normal side.

b. The patient is now asked to stand on the affected limb. Due to the faulty abductor mechanism, the opposite side of the pelvis sinks. In other words, the iliac crest will be high on the standing side and low on the side of the elevated leg.

The test in this case is said to be positive (Fig.78.5).

14. What does the positive Trendelenburg test signify?

The positive test signifies insufficiency of the hip abductor mechanism, which consists of the head of femur (fulcrum), neck of femur (lever) and the gluteus medius abductor (power).

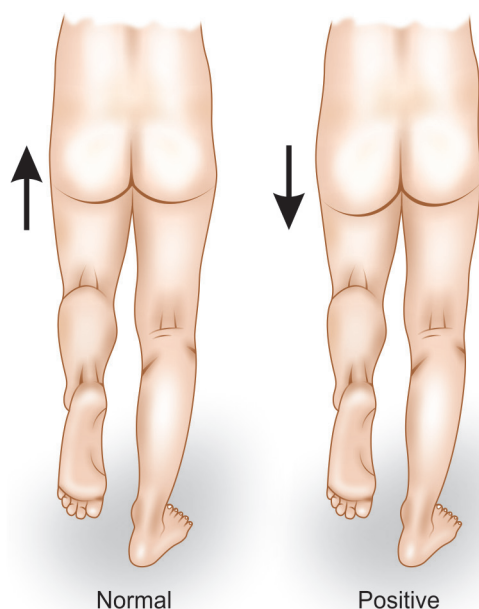
15. What are the causes of positive Trendelenburg test?

- Failure in power, e.g weakness of gluteus medius due to polio.
- Failure in fulcrum, e.g. arthritis due to tuberculosis and rheumatoid lesion, dislocation of hip.
- Failure of lever, e.g. fracture neck femur, trochanteric fracture.

Sometimes two or more factors operate at a time.

16. What is the principle of Trendelenburg test?

When a person stands on one limb the other side of the pelvis drops due to gravity. To balance this, the abductor muscle of the hip (mainly gluteus medius on the side of standing contracts and makes the pelvis higher on the opposite side (Fig.78.5).



**Fig. 78.5:** Trendelenburg test

17. What are the abductors of the hip joint?  
These are gluteal muscles (Gluteus medius and minimus) and tensor fascia lata, sartorius and piriformis.

18. How will you measure the apparent length of the limb?

The apparent length of the limb is recorded by measuring from any fixed point in the midline of the trunk, e.g. xiphisternum suprasternal notch, etc. to the tip of the medial malleolus without correcting any of the existing fixed deformities.

19. How will you record the real length of a limb?

a. The patient lies supine. The two limbs are brought to the same identical position by squaring the pelvis, i.e. bringing the two ASIS in the same line.

b. The true length is measured from the anterior superior iliac spine (ASIS) to the tip of the medial malleolus.

20. Which segment of the limb is shortened in hip diseases?

There is supratrochanteric shortening in hip diseases.

21. How do you measure supratrochanteric shortening?

Supratrochanteric shortening is accurately measured by drawing Bryant's triangle.

22. How will you draw Bryant's triangle?

a. The patient lies supine with the pelvis square and the limbs in identical position.

b. The tips of the greater trochanters and ASIS's on both the sides are marked.

c. Three lines are drawn on each side.

$a_1$  – A perpendicular from the ASIS on to the bed.

$b_1$  – The tip of the greater trochanter is joined to the ASIS.

$c_1$  – Another perpendicular is dropped from the tip of the greater trochanter to  $a_1$ .

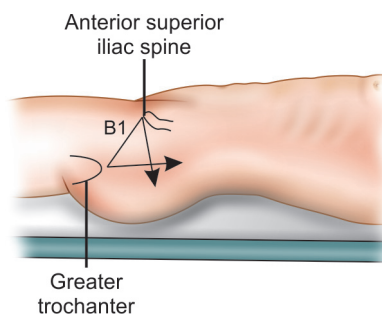
Diminution of  $c_1$  limb indicates shortening above the greater trochanter. (Fig. 78.6)

23. What are the normal ranges of movement at the hip and the muscles causing the movement?

- Flexion: 0 to 120° with the thigh flexed.

- 0 – (75 – 90)° – with the thigh extended.

Muscles causing flexion are Iliacus and psoas.



**Fig. 78.6:** Bryant's triangle

- Extension: 0 to 15°, Muscles – Gluteus maximus and hamstring muscles.
- Adduction: Normal angle 0 to 30°, Muscles-Adductor longus, magnus and brevis, pectineus and gracilis.
- Abduction: Normal range 0 to 45°, Muscles – Gluteus medius, Gluteus minimus and tensor fascia lata.
- Internal rotation: Normal range – 30 to 40°, Muscles – Gluteus minimus, tensor fascia lata.
- External rotation: Normal range – 45°, Muscles – Obturator, piriformis gemelli and gluteus maximus.

24. What is telescoping test?

This is a test of hip stability in lying down position.

25. How do you perform it?

a. The patient lies in supine position and the patient's hip and knee are flexed to 90°.

b. One hand is placed over the side of the pelvis just touching the greater trochanter.

c. The femur is now pushed down into the examination table. The femur and leg are then lifted up.

d. In a normal hip, little movement occurs during the action. In a dislocated hip, there will be a lot of relative movement felt by the hand.

This excessive movement is called the telescoping of the hip (Fig. 78.7).

26. What are the limitations of Telescopy test?

a. It is difficult to perform in fat or obese people but mainly useful in neonates and children.

b. It is not useful in painful conditions of the hip.

27. In which conditions telescopy test is useful?

a. Congenital dislocation of hip.

b. Old and neglected posterior dislocation of hip.

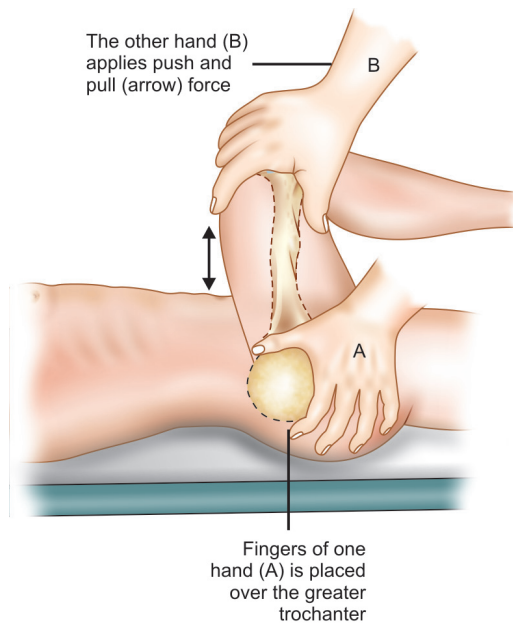
c. Nonunited fracture neck femur.

d. In neonates and children, it is easy to perform.

## TUBERCULOSIS OF HIP

### Case Summary

A 10-year-old female child presents with complaints of pain, stiffness and limp on right hip for last 2 years. She also gives history of occasional fever, ill health and loss of weight.



**Fig. 78.7:** Telescopy test to examine hip stability in lying down position

Family history reveals tuberculosis of her father. There is no history of trauma.

General survey shows pallor, BP – 110/70 mm Hg; P – 84/min.

Local examination reveals:

- There is swelling near the hip joint (cold abscess).
- All movements, both active and passive are limited in all directions.
- Hip is unstable (Trendelenburg test positive).
- There is apparent shortening of the limb on the right side.
- Limb attitude is flexion, adduction and internal rotation.
- There is wasting of thigh and gluteal muscles.

Systemic examination does not reveal any abnormality.

### Clinical Discussion

- What is your case?  
This is a case of tuberculosis of hip on the right side, stage II.
- Why do you say so?
  - There is pain, stiffness and limp on the right hip.
  - General symptoms like fever, anorexia pallor present.
  - Family history of tuberculosis.

d. Examination of local part shows wasting of the muscles, fixed flexion deformity, apparent shortening of the limb restriction of all movements and Trendelenburg test +ve.

- What is the incidence tuberculosis of hip?  
It is the second most common type (after spine TB) of osseous tuberculosis.
- What is the nature of infection?  
This is always a secondary involvement, acquired by hematogenous spread from a primary source, usually the lungs or lymph nodes.
- What is the initial site of involvement?  
Commonly it begins as an osseous focus. Purely synovial tuberculosis as seen in the knee joint is uncommon in the hip. The following are the bony sites of affection of the hip in order of frequency.
  - Acetabular roof.
  - Epiphysis.
  - Metaphysis (Babcock's triangle).
  - Base of greater trochanter.
- What is the pathology?  
For convenience it is described in three stages (Fig.78.8):  
*Stage 1:* (Stage of synovitis or Stage of apparent lengthening) — characterized by
  - Accumulation of synovial fluid due to inflammation of synovial membrane.
  - Joint cavity accommodates synovial fluid as much as possible.
  - Maximum space is available when joint is flexed, abducted and externally rotated.
 If infection is diagnosed and treated at this stage, full function of the joint may be restored.

*Stage 2:* (Stage of arthritis or Stage of apparent shortening) — characterized by

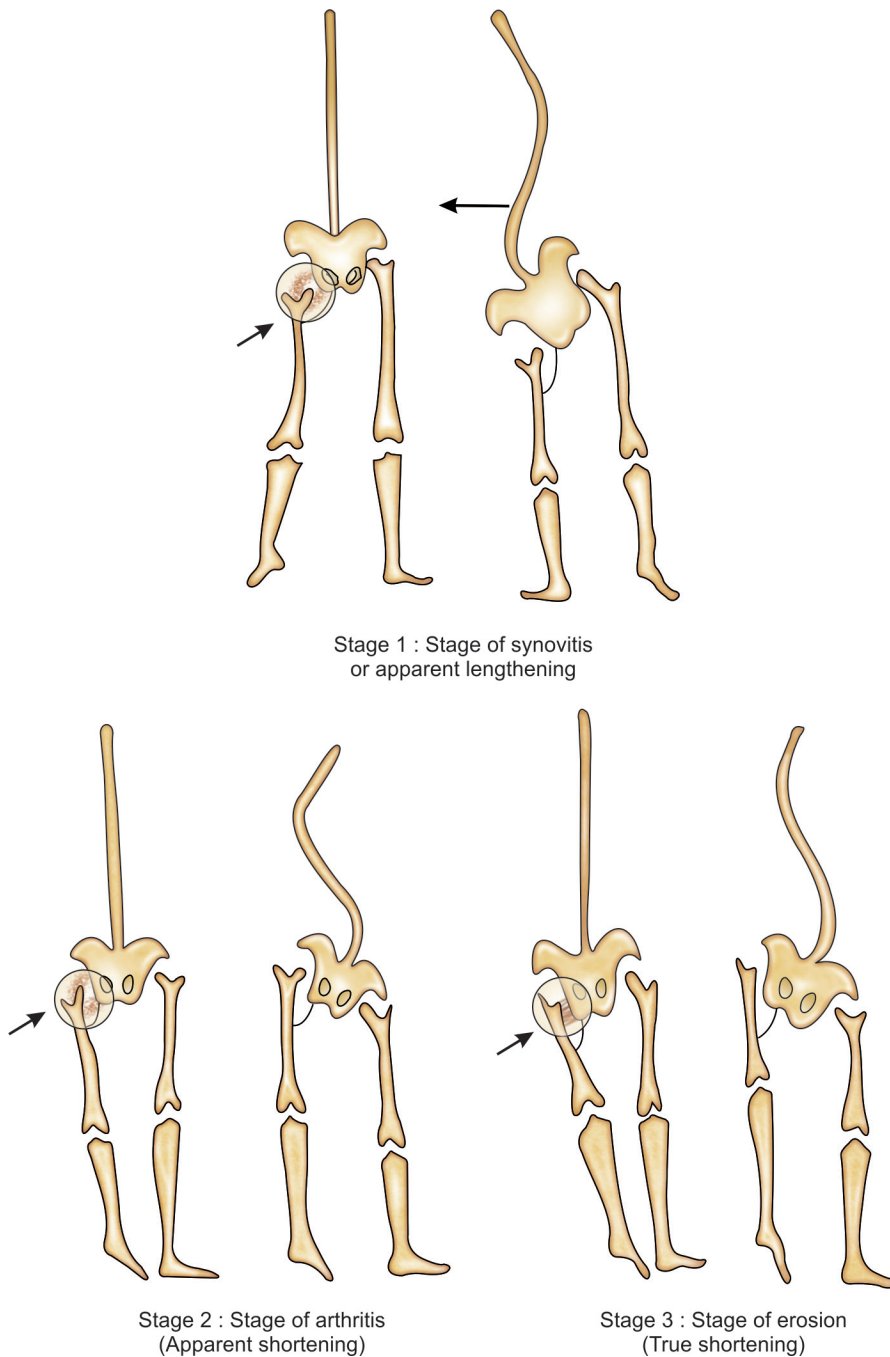
- Synovial fluid is gradually absorbed and there is spread of tuberculous granulation tissue underneath the articular cartilage leading to its destruction.
- Damage of articular cartilage produces friction pain which is relieved by nature's protective spasm of the powerful flexors and adductors of thigh (Adductor spasm).
- Joint space becomes minimum and hip assumes the position of flexion, adduction and internal rotation.
  - At night when spasm is relieved during sleep, friction pain appears and the child cries, which is called "Night cry".
  - If treatment is started at this stage, there is some loss of function, since healing leaves fibrous ankylosis of joint.

*Stage 3:* (Stage of erosion and bone destruction or stage of true shortening)

- There is further destruction of acetabular cartilage and head of femur so much so that head may be dislocated to dorsum illi (posterior dislocation of hip).
- Deformity of second stage is exaggerated.
- There may be formation of wandering acetabulum which is nothing but a shallow depression on dorsum illi due to constant friction of the head as patient walks.
- In an advanced case, there is formation of cold abscess, discharging sinus and wasting of muscles.

- What is the earliest clinical feature?  
Limping is the earliest clinical feature.





**Fig. 78.8:** Stages of tuberculosis of the right hip joint with primary (arrow) and compensatory (corrected) deformities. *Stage 1:* The affected hip is in a position of flexion, abduction and external rotation. Abduction is corrected by tilting the pelvis downwards and scoliosis with the convexity towards the affected side. *Stage 2:* The affected hip is in a position of flexion adduction and internal rotation. Adduction is corrected by tilting the pelvis upwards and scoliosis with convexity towards the sound side. *Stage 3:* The affected hip has the same deformity as in stage 2 but in an exaggerated form.

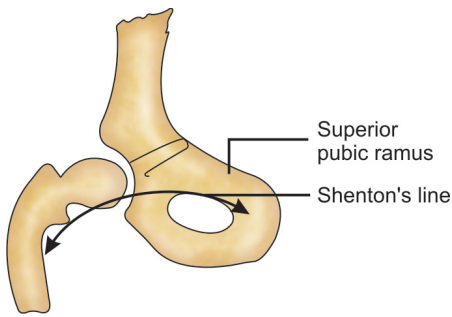
8. What is night cry?
  - a. It is the pain felt during the night by children affected with tuberculosis.
  - b. It is due to friction between the damaged articular surfaces of acetabulum and head of femur following disappearance of protective muscle spasm during sleep.
9. Where does tuberculosis infection start?
  - a. In primary or synovial type, the bacilli in the bloodstream are deposited in the synovium. It is commoner in the knee joint.
  - b. In secondary or osseous type, the infection starts in the bony part (Metaphysis) of the joint and then involves synovial membrane.
10. Which one is common?
 

Osseous type is common. Purely synovial tuberculosis is only found in the knee. In other cases it is secondary.
11. What is Shenton's line?
 

It is an imaginary semicircular line joining medial cortex of femoral neck to lower border of the superior pubic ramus. Normally, this is a smooth arc. Any break in continuity of this indicates dislocation or subluxation of femoral head (Fig.78.9).
12. What are the causes of true shortening of the limb in Tuberculosis of hip?
  - a. Severe disease resulting on gross destruction of bone.
  - b. Wandering acetabulum.
  - c. Damage to the proximal femoral epiphysis.
  - d. Frame knee: Premature fusion of distal femoral epiphysis in patients who are on plaster for a long time (usually more than a year).
13. What is frame knee?
 

Prolonged plastering of the limb, usually more than a year, may result in fusion of epiphysis around the knee, which results in marked shortening of the limb with restriction of movement. This condition is called the frame knee.
14. What investigations will you do to confirm your diagnosis?





**Fig. 78.9:** Shenton's line

- a. X - ray examination of pelvis including both hips (Both AP and lateral views): The findings may be:
  - Haziness of bones around hip — Earliest sign.
  - Irregular acetabular margin.
  - In advanced stage, when there is dislocation of hip, Shenton's line is broken.
  - Diminished joint space due to destruction of cartilage.
- b. Blood examination — Lymphocytosis, high ESR.
- c. Mantoux test
- d. Serum ELISA test for detecting antimycobacterial antibodies.
- e. CT scan or MRI scans of hip joint.
- f. Arthroscopic biopsy.

15. Can other joints be affected with TB Hip?

Tuberculosis is usually monoarticular like traumatic and septic arthritis.

16. Name some polyarticular arthritis.

- a. Rheumatoid arthritis.
- b. Osteoarthritis.

17. How will you treat this case?

- a. *Conservative:* This consists of
  - Rest and general care.
  - Antituberculous drugs.
- b. *Operative treatment:*
  - General care includes improvement of nutrition, correction of anemia.
  - *Chemotherapy:* The antitubercular drug regimen which is being used at present is as follows: (Table 78.1)

18. What are the dosages of different drugs? (See table 78.1)

19. What drugs are used in cases of multidrug resistant tuberculosis (MDR)?

In cases of drug resistance, that may be either primary or secondary, there are some reserved drugs which are as follows:

- a. Capreomycin — 15 to 30 mg/kg up to 1 gm/day.
- b. Kanamycin — 10 to 20 mg/kg, up to a maximum of 1 gm.
- c. Cycloserine — 10 to 20mg/day upto a maximum of 1 gm/day.
- d. Ethionamide — 15 to 30mg/day upto a maximum of 1gm/day.
- e. Prothionamide dose—Same as ethionamide.

The drug combination usually used in MDR Tuberculosis is kanamycin + cycloserine + ethionamide + INH.

20. What is the local treatment in TB of hip?

- a. *During acute symptoms:* Traction and antitubercular treatment (ATT) gives maximum relief of symptoms. The aim is to restore movement and protect the joint from stress.
- b. *Stage of cure:* When pain and deformity has been corrected, achieving a painless joint movement is the goal. X - ray helps at this stage (showing minimal or no destruction of hip).
  - When the disease is synovial or the osseous focus is in the neck of femur or trochanter treatment is continued assuming that a mobile joint will result.

- In case of gross destruction of acetabulum or the femoral head, shown in X-ray painless movement will not be possible. So arthrodesis is the aim of treatment. Chemotherapy is continued for adequate period giving no chance for reactivation or flaring up.

c. Stage of convalescence – when disease is arrested ambulation is started.

- Prior to weight bearing patient is allowed movement in bed.
- Ambulation is allowed after 4 to 6 months of treatment (Traction or plaster).
- The first 6 weeks of ambulation is nonweight bearing, next 1½ to 2 months partial weight bearing, next 3 to 6 months full weight bearing walking with crutches.
- Unprotected full weight bearing walking is allowed around 1½ to 2 years from the onset of disease.

21. What are the different options of operative treatment?

- a. Synovectomy or clearance operation.
- b. Arthrodesis.
- c. Osteotomy.
- d. Girdle stone arthroplasty.
- e. Total hip replacement.

**Table 78.1: The antitubercular drug regimen**

Category	Type of patient	Duration	Drugs
Cat I	New sputum positive case	<ul style="list-style-type: none"> <li>• Intensive phase — 2 months.</li> <li>• Continuation phase — 4 months.</li> </ul>	INH + ETB + RMP + PZA INH + RMP
Cat II	Retreatment group (previously treated). Either replage or treatment failure patients.	<ul style="list-style-type: none"> <li>• Intensive phase — 3 months.</li> <li>• Continuation phase — 5 months</li> </ul>	INH + RMP + SM + ETB + PZA INH + RMP + ETB
Cat III	<ol style="list-style-type: none"> <li>i. Extrapulmonary</li> <li>ii. New serum negative but with pulmonary TB.</li> </ol>	<ul style="list-style-type: none"> <li>• Intensive phase 0 2 months.</li> <li>• Continuation phase — 4 months</li> </ul>	INH + RMP + PZA INH + RMP
		<b>Dose/kg B.Wt</b>	<b>Side effects</b>
INH (Isoniazid)	5mg (Adult - 300mg/day)		Hepatitis, peripheral neuritis
Rifampicin (RMP)	10mg (Adult - 450 - 650 mg/day)		Hepatitis
PZA (Pyrazinamide)	25mg (Adult - 1.5 - 2gm/day)		Arthritis
Ethambutol (ETB)	15mg (Adult - 800 - 1000 mg/day)		Optic neuritis
Streptomycin (SM)	15mg (Adult - 1000mg)		Ototoxicity and renal toxicity

## 22. What is synovectomy?

In TB hip when the disease is not responding to general treatment, excision of the diseased synovium as much as possible is indicated.

The diseased focus in the acetabular region is approached and thoroughly irradiated. The cavity so produced is packed with cancellous bone chips. This is called joint debridement.

Posterior approach is preferred. The diseased synovium, necrotic tissue, pus and dead cartilages are removed from the joint. The joint is then thoroughly washed with saline.

- A long period of follow up is necessary to know whether cure has been permanent or not.
- Chemotherapy is continued long enough giving no chance for reactivation or flaring up.
- A certain proportion of hips may require arthrodesis later, but many will have mobility at the end of such treatment.

## 23. What are the indications and types of arthrodesis?

- a. When the patient comes in a late stage with irreversible damage of articular cartilages, bony fusion or arthrodesis must be considered.
- b. The indications are:
  - i. Failure of conservative treatment to arrest the disease after one year.
  - ii. Recurrence or relapse of pain and deformity after conservative treatment.
  - iii. Presence of sequestrum in the head or neck of the femur or in the acetabulum.

**Types:**

- a. Intra-articular arthrodesis.
- b. Extra-articular arthrodesis.
- c. Combined arthrodesis.

The aim of arthrodesis operation is to obtain a bony ankylosis of the joint.

- a. Intra-articular arthrodesis with modern chemotherapeutic drugs, this is the preferred method of arthrodesis.

This joint is opened, diseased tissue removed, the head of femur and acetabulum are made raw to expose bleeding bony surface and then bone graft is used to fill up the defect.

Joint is kept immobilized in plaster with apposition of bone surfaces in optimum position of joint, bony union takes place.

- b. *Extra-articular arthrodesis:* Prior to advent of modern day chemotherapy, extraarticular arthrodesis was the treatment of choice as surgeons did not dare to expose the joint cavity for fear of development of tubercular sinus.

Bone grafts were used to bring about iliofemoral or ischiofemoral fusion.

- c. *Combined procedure:* Majority of surgeons presently prefer the combination of intra-and-extra articular arthrodesis.

## 24. What is the optimal position of arthrodesis?

The optimal position is 30° flexion, 0 to 5° adduction, 10 to 15° external rotation.

## 25. When do you plan corrective osteotomy?

This is done when bony ankylosis of hip has occurred in an unacceptable position. A subtrochanteric osteotomy, an extra-capsular procedure is usually performed.

## 26. What is excision arthroplasty or Girdlestone arthroplasty?

- a. The hip joint is exposed through posterior approach.
- b. The head and neck of femur are excised and the dead and necrotic tissues are removed.
- c. The gluteal muscles are put on the floor of the acetabulum and the upper end of the femur is allowed to move on this floor, thus making a pseudoarthrosis.
- d. Postoperatively bilateral skeletal traction is applied for 4 weeks, followed by mobilization of the hip.
- e. It is possible to regain reasonable movement of the hip by this procedure even in severely damaged joints.

**PERTHES DISEASE****Case Summary**

A male child aged 7 years, was admitted with a limp on the right side and pain in the right hip. There is no history of trauma. onset is gradual.

There is no history of fever, loss of weight and anorexia. No history of tuberculosis in the family is present.

On local examination of right hip:

- a. There is apparent shortening.

- b. Some movements are painless but abduction and internal rotation are limited.

**Clinical Discussion**

## 1. What is your case?

This is a case of crushing osteochondritis of right femoral head epiphysis or Perthes disease.

## 2. Why do you say so?

- a. The boy's age is 7 years,
- b. No history of trauma.
- c. Pain and limping present.
- d. Limitation of all movements except abduction and internal rotation.
- e. No general features of fever, loss of weight, night sweats, etc.

## 3. How will you differentiate from tuberculosis of hip?

- a. Absence of general features like fever, loss of weight, anorexia, night sweats.
- b. Dramatic response to bed rest and skin traction for relief of pain during irritability. In tuberculosis of hip this has no effect.

## 4. What is the full name of the disease?

Legd-Calvé-Perthes disease.

## 5. What are the different types of epiphysis in the body?

There are three types, viz.

- a. *Pressure epiphysis or crushing epiphysis:* It transmits the body weight and protects the epiphyseal cartilage, e.g. heads of femur and humerus and condyles of femur and tibia.
- b. *Traction epiphysis:* It is produced by the pull of some muscles, e.g. trochanters of femur and tubercles of the humerus.
- c. *Atavistic epiphysis:* It grows like a parasite and receives its nutrition from the host bone, e.g. coracoid process of scapula.

## 6. What is the pathogenesis and pathology of Perthes disease?

This is a form of crushing osteocondritis where the disease affects the femoral head. The head undergoes avascular necrosis.

**Pathogenesis**

Vascular jeopardy is the most important factor in the pathogenesis of Perthes disease (Fig. 63.1).

- a. Up to the age of 4 years, head is supplied mainly by the metaphyseal arter-

ies and partly by the retinacular or capsular arteries.

- b. Between 4 and 8 years, as the metaphysis grows, head receives its blood supply only from the capsular arteries. Hence avascularity develops at this stage. The precipitating cause is usually an effusion into the hip joint following trauma (in 50% cases) or a nonspecific synovitis.
- c. After 8 years head enjoys increased vascularity because metaphyseal artery and artery from ligament of the head of femur give additional supply.

#### Pathology

The pathological process takes 2 to 4 years to be complete, passing through the following three stages.

- a. *Stage 1:* Bone death — due to avascularity, part of the bony femoral head dies. Though the head looks normal in plain X-ray, it stops enlarging.
- b. *Stage 2:* Revascularization and repair — New blood vessels invade the necrotic area and new bone is laid down on the dead trabeculae producing increased density on X-ray.

If a small part of epiphysis is involved and there is rapid repair, the bony architecture is completely restored.

- c. *Stage 3:* Distortion and remodelling — If a large portion of bony epiphysis is involved or the repair process is slow, the epiphysis collapses, with distorted growth at the head and neck in future. The epiphysis may get flattened (coxa plana) but enlarged (coxa magna) and the femoral head is incompletely covered by the acetabulum.

7. How will you confirm the diagnosis?

- X-ray of the local part.
- CT scan/MRI scan of right hip. At present, this can show changes in a better way. It also helps in radiological prognostic staging devised by Catterall.

8. What are the radiological features?

The radiological picture varies with the age of the child, the stage of the disease and the amount of head which has been ischemic. The usual findings are:

- a. Increase in joint space.
- b. Increased density of head.
- c. Fragmentation and mushrooming of head.

- d. Deformed and flattened head, short neck and coxa vara (late feature) (see Fig. 63.2).

9. What is Catterall prognostic staging?

A prognostic staging (by CT scan / MRI scan) has been devised by Catterall in which increasing amounts of femoral head involvement are related to a worsening outcome.

It is as described below.

Stage I — Less than half of the head is necrotic and no collapse occurs.

Stage II — More than half of the head is involved but still there is no collapse.

Stage III — Two-thirds of the head is involved and there is collapse.

Stage IV — Whole of the head becomes ischemic and necrotic and there is severe collapse.

While stage I and II require no treatment or simple bed rest and traction is enough.

Grade III and IV indicate worse prognosis and must need containment treatment (see below).

10. How do you treat the case?

- a. As the disease is self-limiting, the whole idea behind treatment is to keep flattening and distortion of the head to a minimum, and therapy to prevent early and severe osteoarthritis.

- b. When half or less than half of the head is involved by the disease, prognosis is good and treatment is simple traction, as mentioned above.

- c. When there is more than two-thirds of the head is involved containment treatment is required.

#### Traction

If the hip is irritable and the child complains of pain, hip is rested in Thomas bed knee splint with traction for 6 to 10 months. Repeated X-rays are done to assess the development of head.

#### Containment Treatment

It has been seen that for better vascularization, femoral head should be well contained within the acetabulum. This can be achieved by conservative methods (plaster, splints, etc.) or by operation (containment osteotomy or adduction, i.e. varus osteotomy).

The varus osteotomy is done just below the greater trochanter and the shaft is so

angled that it is adducted about 20 degrees in relation to proximal fragment. Union occurs in 5 to 6 weeks (See Fig. 63.3).

11. What will happen if the patient is not treated?

Osteoarthritis will occur.

12. What are other causes of avascular necrosis of head of femur?

- a. Idiopathic—commonest.
- b. Fracture of femoral neck.
- c. Dislocation of hip.
- d. Steroid therapy.
- e. Sick cell disease.

### CARIES SPINE (TUBERCULOSIS OF SPINE)

#### General Plan for Writing a Case of Caries Spine

##### History

1. *Particulars of the patient:*

- Age — Caries spine is most common in children and adolescents but it can also occur in adults.
- Sex — Males are more affected than females.

2. *Chief complaints:*

- a. Pain over the spine.
- b. Difficulty in bending forward due to muscle spasm in the early stage and in later stages fibrous or osseous ankylosis causing rigidity of the spine.
- c. Evidence of cold abscess (swelling).
- d. Neurological manifestation like root pain and paraplegia of sudden or gradual onset.

3. *History of present illness:*

Detailed history of pain is recorded.

- a. Site—May be cervical, dorsal or lumbar.

- b. Onset

- i. Gradual aching — Tuberculosis.
- ii. Acute and sudden pain following a strain, e.g. lifting a heavy weight indicates prolapsed intervertebral disk.

- c. Type

- i. Dull aching pain — Tuberculosis.
- ii. Sharp pain — Nerve compression.

- d. Aggravating factor — Pain gets aggravated by movements in tuberculosis.

- e. Radiation to chest or abdomen present or not.

4. Past history — tuberculosis in the lungs.
5. Family history — tuberculosis.
6. Personal history.
7. History of allergy.

### Physical Examination

1. General survey: Presence of generalized wasting may be present in tuberculosis of spine.
  2. Local examination:
    - *Inspection:*
      - a. *Gait:* Patient walks with short steps in caries of dorsal spine to avoid jerks.
      - b. *Attitude:*
        - i. Cervical spine—The child supports his head with both hands under the chin and twists his whole body to look sideways.
        - ii. Dorsal spine—The patient provides support placing his hands on lower part of thigh.
      - c. *Deformity:*
        - i. Kyphosis—It is gradual backward bending.
        - ii. Gibbus—It is the sudden backward bending of spine with a prominent backward projection.
      - d. *Swelling:* In caries spine there may be a lateral thoracic, presternal or paravertebral abscess.
    - *Palpation:*
      - a. *Tenderness:* It may be roughly located by applying gentle blows on either side of spine. A better method to elicit tenderness is to apply pressure on the side of the spinous process with the thumb.
      - b. *Swelling:* A cold abscess may be present by the side of vertebra, neck, chest and thigh.
      - c. Erector spinae muscles are felt for wasting or rigidity.
    - *Percussion:* Over the spine is often performed to elicit tenderness.
    - *Range of movements:* Movements of the spine includes flexion, extension, lateral flexions and rotations.
- Flexion movement is the first to be affected. All movements become painful due to muscle spasm.
3. Systemic examination
    - a. Neurological examination of lower limbs to detect Pott's paraplegia or root pain.

- b. Examination of chest, abdomen, kidney, thyroid, etc. to see the presence of any primary malignancy. If present, spine involvement may be due to secondaries.
- c. Summary of the case.
- d. Provisional diagnosis.
- e. Differential diagnosis.

### CARIES SPINE (Tuberculosis of Spine)

#### Case Summary

An 11-year-old male child presents with pain in the back and deformity (gibbus) for last two years. There is family history of tuberculosis.

Pain was gradual in onset, with occasional fever and loss of weight and anorexia.

No significant personal, past and drug history is present.

General survey shows pallor and wasting of muscles. Local examination reveals that the child walks with short steps. A gibbus is present in the dorsolumbar spine and cold abscess in the lumbar region. All movements of the spine are restricted but movements of the hip joints are normal.

No neurological or other systemic symptoms are present.

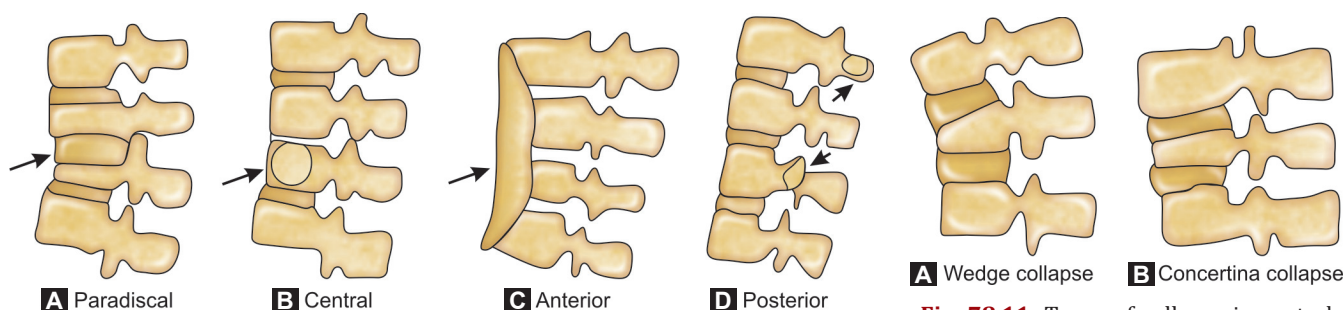
#### Clinical Discussion

1. What is your case?  
This is a case of tuberculosis of spine.
2. Why do you say so?
  - a. Adolescent male child with pain in the back and deformity, i.e. gibbus.
  - b. Constitutional symptoms of fever, anorexia and loss of weight present.
  - c. Family history of tuberculosis present.
  - d. Movements of the spine are restricted.
3. What are the different deformities found in caries spine?
  - *Kyphosis:* This is excessive posterior convexity of the spinal column. This is most prominent in the thoracic part of vertebral column since there is a natural posterior curvature in this area. Cervical and lumbar regions having a normal lordosis, seldom shows evidence of kyphosis.
  - *Gibbus:* It is the sudden backward bending with a prominent backward protection. It is a type of kyphosis.

- *Scoliosis:* It means lateral curvature of the spine.
- *Lordosis:* It means excessive anterior curvature of the spine. It is most prominent in the lumbar region since there is a natural lordosis here.

4. What are the normal curvatures of spine?
  - a. Cervical and lumbar spine – Lordosis.
  - b. Dorsal spine – Kyphosis.
5. What is the commonest site of skeletal tuberculosis?  
Spine is the commonest site of skeletal tuberculosis.
6. What is the commonest site of involvement of spine?  
The thoracolumbar spine is the commonest site of involvement.
7. Why?
  - a. Thoracolumbar spine is the most mobile part of spine and so richly supplied by blood vessels.
  - b. More susceptible to trauma due to its maximum mobility.
  - c. There is possibility of direct spread of infection from the kidney.
8. What are the different sites of involvement in caries spine?
  - a. Paravertebral type is the most common. In this type adjoining parts of two vertebrae with intervertebral disk are involved.
  - b. *Central type:* Here the central part of vertebral body is involved, sparing the disk. This leads to early collapse of the weakened vertebrae giving rise to 'wedge' (commoner) or concertina collapse (Fig. 78.11).
  - c. *Anterior type:* Here the anterior surface of the vertebral body is involved and the infection, spreads up and down underneath the anterior longitudinal ligament.
  - d. *Appendicular or posterior type:* In this type the posterior complex of the vertebra viz. the pedicle, lamina, spinous process or transverse process are affected (Fig. 78.10).
9. What are the clinical features in caries spine?
  - a. Caries spine is more common in the first three decades of life without any predilection for sex.
  - b. *Pain:* Back pain is the commonest presenting symptom. There is a nagging pain over the spine which is very often





**Figs 78.10A to D:** Different sites of involvement (indicated by arrows) in caries spine.

**Fig. 78.11:** Types of collapse in central type of caries spine.

- pinpointed by the patient. Sometimes pain is radiated to the lower limb.
- c. Rigidity of the spine which is manifested by difficulty in bending forward. This occurs due to spasm of the back muscles in early stages and later on there is fibrous or bony ankylosis of the vertebrae.
  - d. Cold abscess: There may be presence of cold abscess according to the site of lesion, e.g. iliopsoas abscess, lateral thoracic abscess, presternal abscess, etc.
  - e. Deformity in the form of kyphosis, Gibbus (sharp angular kyphosis) and scoliosis.
  - f. Neurological manifestations like root pain and paraplegia. The student can remember the clinical features by the mnemonic “DR PAN” where D = Deformity, R = Rigidity, P = Pain, A = Abscess (cold), N = Neurological symptoms.
10. What is the pathology of caries spine?
    - a. Tuberculosis of spine is always secondary. Bacteria reach the vertebra through blood from lungs or the lymph nodes.
    - b. *Tubercle formation:* Central area of caseation surrounded by epithelioid cells and Langhans giant cells and the peripheral rim of lymphocytes and fibroblasts.
    - c. *Joint pathology:* Synovial membrane gets thickened and studded with tubercles.
    - d. Cold abscess formation and finally fibrous ankylosis.
    - e. *Panus formation:* Granulation tissue which grows over the articular cartilage and destroys it is known as pannus.
  11. Where does the disease start?
    - a. Vertebral body – 90 percent.
    - b. Appendages – 10 percent.
  12. What is the most dreaded complication in caries spine?
 

The development of neurological complication, i.e. paraplegia.
  13. What is the incidence?
 

About 10 to 30 percent of patients with caries spine will develop neurological complication.
  14. What are the types of tuberculous paraplegia?
 

Two types are there:

    - a. Early onset paraplegia – This comes during the active phase of the disease, usually within 2 years.
    - b. Late onset paraplegia – This appears after 2 years.
  15. What are the causes of early onset paraplegia?
    - a. *Inflammatory causes:* The spinal cord may be compressed by the soft inflammatory material, e.g. cold abscess, posterior spinal disease, caseous mass, tubercular granulation tissue, infective thrombosis of the spinal vessels.
    - b. *Mechanical causes:*
      - Sequestrum in the canal.
      - Pathological dislocation—A ridge of bone pressing on the cord.
  16. What are the causes of late onset paraplegia?
    - a. Recurrence of the disease.
    - b. Internal gibbus.
    - c. Fibrous septae following healing.
  17. Which fibers are last involved?
 

Position and vibration sense are last to be involved.
  18. Why motor involvement is more pronounced than sensory involvement?
    - a. Caries spine mostly affects the vertebral body which remains close to the anterior cord through which the motor tract passes; hence motor involvement occurs first and to a greater extent.
    - b. The motor tract is more sensitive to compression than the sensory tract.
  19. What is the first sign of neurological improvement?
 

Vibration and joint sense is the first to recover although this was the last neurological involvement.
  20. What is the last feature to recover?
 

Muscle wasting.
  21. How does the cold abscess produce pathological effects?
 

The pus may take any of the following courses from the vertebra, viz.

    - a. It forms prevertebral abscess anteriorly.
    - b. Presses upon the spinal cord posteriorly leading to paraplegia.
    - c. If it passes on the sides, it produces paravertebral abscess.
    - d. The pus can pass along musculofascial planes or neurovascular bundles, and can present as superficial abscesses at distant places from the spine.
  22. How does the cold abscess spread to distant areas in the cervical, thoracic and lumbar regions?
 

The cold abscess spreads to distant areas along musculofascial and neurovascular bundles (See Fig. 62.2).

    - a. In the cervical region:
      - i. Along the musculofascial plane— It passes to the posterior border of sternocleidomastoid to produce abscess in the posterior triangle. It passes downwards behind the prevertebral fascia come to the posterior mediastinum.
      - ii. The pus may travel along the axillary sheath, which is a tubular sheath of prevertebral fascia carrying the brachial plexus and subclavian artery into the axilla forming an abscess there (axilla).



- b. In the thoracic region:
- Pus may gravitate down from posterior mediastinum behind the medial and lateral arcuate ligaments to become psoas and lumbar abscess respectively.
  - Paravertebral, lateral or anterior thoracic abscess may develop following the intercostal vessels and nerves.
- c. In the lumbar region:
- Along musculofascial plane – psoas or lumbar abscess develops.
  - Along the lumbar nerve abscess forms in the loin or along femoral or obturator nerve in the thigh.
23. What investigations will you do to confirm the diagnosis?
- X-ray of spine—Both anteroposterior and lateral views are taken. There is diminution of the intervertebral space and destruction of opposite surfaces of the vertebrae.
  - CT scan of spine and / or MRI scan.
  - MRI, though costly, clearly shows the cord compression canal stenosis and cold abscess.
  - CT guided biopsy may be done to get the material for culture and histopathological examination to confirm the diagnosis.
  - Blood for Mantoux test, X-ray chest in a child.
24. How will you manage the case?
- There is no cold abscess formation or neurological complication in this case. So conservative treatment with rest, immobilization and antitubercular drugs are to be undertaken.
- For kyphosis, the patient may require special extension apparatus.
  - Repeated chest X-rays are done to assess the progress.
25. What are the indications of operative intervention?
- Cold abscess or any other factor causing neurological complications.
26. How will you treat cold abscess?
- A small cold abscess subsides with antitubercular treatment.
  - Aspiration*: The abscess is aspirated with a thick needle as the caseous material is difficult to take out with a narrow bore needle.

The aspiration should be antigravity entering through a zigzag tract to avoid sinus formation.

- Evacuation*: Here the cold abscess is drained, its walls curetted and the wound closed without a drain. This is unlike drainage of a pyogenic abscess, where a postoperative drain is almost always left.
27. How will you treat a patient with neurological involvement (Pott's paraplegia)?
- Conservative treatment*: Antituberculous chemotherapy is the mainstay of treatment. The spine is put to absolute rest by sling traction for cervical spine and bed rest for dorsolumbar spine. Besides, care of the skin, bladder and bowel are taken. Repeated neurological evaluation is necessary.
  - Operative treatment*: If paraplegia does not improve at a satisfactory rate or if it deteriorates in spite of conservative treatment surgical intervention is indicated.
 

The operative method aims at removal of agents causing compression. The following operations are commonly performed.

    - Costotransversectomy
    - Anterolateral decompression.
  - Costotransversectomy*: As the name implies the operation consists of removal of a section rib and transverse process.
 

If the paralysis is due to compression by soft inflammatory material like cold abscess, tubercular granulation tissue or caseous mass, this operation is sufficient for the drainage.

*Indications*: Paraplegia with tense paravertebral abscess.
  - Anterolateral decompression*: If the compression of the cord is by solid agents, like sequestered bone, disk or both, true pathological dislocation, bony ridge at the kyphos, etc. this operation is performed to remove the compressing agent.
 

Structures removed in order to achieve adequate exposure of the cord are the rib, transverse process, pedicle and part of the body of the vertebra.

Granulation tissue lying in front of the cord and posterior to the vertebral body is scrapped out. Dura is not opened.

## OSTEOMYELITIS

### General Plan of Writing a Case of Chronic Osteomyelitis

#### History

- Particulars of the patient*:
 

*Age*: Acute osteomyelitis is common in children.
- Chief complaints*:
  - Pain in the bone.
  - Discharging sinus.
- History of present illness*:
  - Pain is usually throbbing in character in acute osteomyelitis. Pain and swelling appear almost simultaneously.
  - In case of discharging sinus, the nature of discharge is enquired of. History of expulsion of bone chips through the sinus is strongly suggestive of osteomyelitis.
- Past history of infections like otitis media, furunculosis pneumonia, typhoid is significant.
- Personal history.
- Family history.
- History of any allergy.

#### Physical Examination

- General survey—pallor, BP, pulse, palpable lymph nodes are to be looked for.
- Local examination*:
  - Inspection*:
    - Swelling*: The site, size, shape, surface and pulsation are observed.
    - Skin*: congestion and edema.
    - Sinus*: If present, its position, nature of discharge (Bone chips, thick pus or tissue) and number (usually single) are noted.
  - Palpation*:
 

Local temperature and tenderness.

    - Corroboration of inspection findings regarding the swelling and sinus.
    - The bony swelling with sinuses adherent to the bone is pathognomonic of osteomyelitis.
    - Neighboring joints*: There is stiffness due to sympathetic effusion.
- Measurement of long bones*: Bone may be shortened if epiphyseal cartilage is destroyed or lengthened if epiphyseal cartilage is included in hyperemia in chronic osteomyelitis.

3. **Systemic examination:** It includes examination of chest, abdomen (GI tract) and the nervous system as mentioned earlier.
- Summary of the case
  - Provisional diagnosis.
  - Differential diagnosis.

**Summary of a Case of Chronic Osteomyelites**

A male patient aged 10 years presents with pain and discharging sinus in the lower part of left leg for last 8 months.

He gives history of pain in the bone 1 year ago which subsided taking analgesic drugs.

He also gives history of recurrent attacks of pain, fever and discharges through the sinus at intervals of 2½ to 3 months. He does not give history of trauma, typhoid, otitis media or furuncle.

General survey reveals mild pallor and malnutrition.

Local examination shows: A sinus in the lower part of left leg, which is single in number and contains sprouting granulation tissue.

Underlying bone is thickened at the site of sinus with irregular surface. There were no systemic symptoms.

**Clinical Discussion**

1. What is your case?  
This is a case of chronic osteomyelitis involving left lower tibia.
2. Why do you say so?
  - a. Presence of chronic discharging sinus with history of discharging bone chips.
  - b. The sinus is fixed to the bone.
  - c. The bone is thickened.
3. What is chronic osteomyelitis and how does it differ from an acute type?
  - a. Chronic osteomyelitis is usually used to denote chronic pyogenic osteomyelitis.
  - b. The other causes of chronic osteomyelitis are tubercular and fungal.
  - c. Chronic osteomyelitis results from ineffective treatment of the acute type leading either to formation of dead bone or formation of an abscess.
  - d. Formation of sequestrum or dead bone indicates that acute disease has turned into a chronic one.
4. What are the organisms?
  - a. The usual organisms are *Staphylococcus aureus*, *E coli*, *Staphylococcus pyogenes*, *Proteus* and *Pseudomonas*.

- b. In the presence of foreign implants, *Staph. epidermidis* which is usually non pathogenic, is the commonest of all.
5. What are the predisposing factors?
    - a. Trauma.
    - b. Reduced host resistance, e.g. malnutrition, malaria, influenza, etc.
    - c. Hematogenous spread to bone from areas of septic focus.
  6. What is a sequestrum?  
It is a dead piece of bone in the osteomyelitic cavity either separated or in the process of separation.
  7. What is involucrum?
    - a. It is the dense sclerotic bone overlying a sequestrum.
    - b. There may be some holes in the involucrum for pus to drain out. These holes are known as cloacae.
  8. How do you clinically know that sequestrum has formed?  
Sprouting granulation tissue at the mouth of sinus indicates formation of sequestrum.
  9. How will you confirm the diagnosis?
    - a. Straight X – ray of the local part.
    - b. Pus for culture and sensitivity.
  10. What are the X – ray findings?
    - a. Thickening and irregularity of the cortices.
    - b. Bone cavity – This is seen as an area of rarefaction surrounded by sclerosis.
    - c. Sequestrum – This appears denser than the surrounding normal bone as the decalcification which occurs in normal bone does not occur here.
    - d. Involucrum and cloacae may be visible.
  11. What is the differential diagnosis?
    - a. Soft tissue infection with discharging sinus. X–ray does not show bone involvement.
    - b. *Ewing’s sarcoma:* Radiological findings may be similar. Biopsy will help in differentiation.
    - c. Tubercular osteomyelitis.

12. How tuberculous osteomyelitis differs from chronic pyogenic osteomyelitis? (Table 78.2)
13. How will you treat the case?
  - a. Treatment of chronic osteomyelitis is primarily surgical. Antibiotics are used during acute exacerbation and in the postoperative period.
  - b. Aim of surgical treatment is: (i) Removal of dead bone as well as pus and granulation tissue from the abscess cavity. (ii) Elimination of the dead space.
14. What is saucerization?  
In saucerization the bony cavity containing pus and granulation tissue is made shallower by removing its wall. This allows free drainage of the infected material.
15. What is sequestrectomy?
  - a. It is the removal of the sequestrum.
  - b. After exposure of the bone, periosteum is separated and involucrum is chiseled away.
  - c. Removal of sequestrum is done.
  - d. Sequestrum should not be removed until it is fully separated from the living bone and the involucrum has formed completely.
16. What is Garre’s osteomyelitis?  
This is a sclerosing nonsuppurative chronic osteomyelitis. Straight X-ray shows thickened bone with sclerosis. There is no abscess cavity, sequestrum or sinus formation.
17. What are the complications of chronic osteomyelitis left untreated?
  - a. Pathological fracture.
  - b. Amyloidosis
  - c. Squamous cell carcinoma and at the sinus tract.
  - d. Growth abnormality as the growth plate is involved.
18. What is Brodie’s abscess?
  - a. It is a special type of osteomyelitis, called subacute hematogenous osteomyelitis in which the body defence

**Table 78.2: Comparison of tubercular and pyogenic osteomyelitis**

Tubercular osteomyelitis	Pyogenic osteomyelitis
a. Discharge is thin and watery	a. Discharge is thick
b. History of pulmonary tuberculosis	b. No history of pulmonary tuberculosis
c. Sinus shows undermined margin and bluish surrounding margin	c. Sinus shows sprouting granulation tissue

mechanisms contain the infection to create a chronic bone abscess, usually in the tibial or femoral metaphysis.

- b. The abscess cavity is surrounded by a halo of sclerosis in X-ray. (Fig. 60.3)
  - c. Treatment is surgical evacuation and curettage under antibiotic cover and package of cavity with cancellous bone chips.
19. What is the treatment of Garre's osteomyelitis?  
Treatment is operative. The abnormal area is excised and the exposed surface is thoroughly curetted. Bone grafts may be needed.
  20. What may be the other method of treatment of osteomyelitis?  
In osteomyelitis of bones like fibula, metacarpal or metatarsal bones, amputation may be done.
  21. What is the postoperative management of the osteomyelitis cavity?
    - a. After surgery the wound is closed over a continuous suction irrigation system. The suction tube and irrigation tube are put in the osteomyelitic cavity. Irrigation is done with normal saline or Ringer lactate. Antibiotics are continued for 4 to 7 days.
    - b. Immobilization of the limb for at least 2 to 3 months.

## NONUNITED FRACTURE NECK OF FEMUR

### General Plan of Writing a Case of Nonunited Fracture Neck of Femur

#### History

1. *Particulars of the patient:*  
*Age:* This type of fracture usually occurs in older people above 60 years of age due to accidental fall in the bathroom.  
In young people, it usually occurs due to direct collisions.  
*Sex:* It is more common in females the underlying cause being osteoporosis and female to male ratio is 4:1.
2. *Chief complaints*
  - a. Pain in the groin.
  - b. Inability to walk with the affected right or left lower limb.
  - c. Shortening of the affected lower limb.

#### 3. *History of present illness:*

*Pain:* The patient, usually a female gives history of a trivial injury like slipping on the floor or a fall in the bathroom after which she feels pain in the groin (right / left) and inability to walk or bear weight. Attempted hip movements are also painful and associated with severe spasm.

4. Family history.
5. Past history.
6. Personal history.
7. History of allergy.

### Physical Examination

1. *General survey:* One should look for any pallor, muscle wasting, BP, pulse, etc. Local examination: Exposure – The patient is seated comfortably with both limbs exposed and supported.
2. *Inspection:* The following features are to be noted:
  - a. Gross deformity and shortening – a comparison is made with the opposite limb.
  - b. Swelling which may be due to malposition of the fracture fragments or due to callus formation.
  - c. Wasting of the muscles and deformity of the joints may be present.
2. *Palpation:* The following features are noted on palpation:
  - a. Temperature.
  - b. Tenderness at the site of fracture which is an important sign of an ununited fracture.
  - c. Palpation of bone ends – any bony irregularity in the form of a gap, a sharp elevation or a bend indicates an improper position of bone.  
This is a definite sign of old fracture.
  - d. Abnormal mobility at the fracture site.  
This is a pathognomonic sign of non-union of a fracture.
  - e. Limb length measurement:
    - i. Without correcting the deformity or making the pelvis square – From xiphisternum to the tip of medial malleolus.
    - ii. After correcting the deformity or making pelvis square – from anterior superior iliac spine to medial malleolus.
  - f. Stability of hip – This is examined by Trendelenburg's test.

3. Examination of adjacent joints to detect any deformity swelling or limitation of movements.

#### 4. *Systemic examination:*

- Summary of the case.
- Provisional diagnosis.
- Differential diagnosis.

### Case Summary

A 62-year-old female patient presents with complaints of pain and inability to walk with her right limb for last 5 months.

She gives history of fall in the bathroom 5 months back.

After the accident she could not walk. She was treated by a local doctor with traction and still now she is not able to walk.

On examination, she has mild pallor, average built and nosystemic symptoms or disease. Local examination shows:

- a. The affected right limb externally rotated and shortened.
- b. Tenderness over the right groin.
- c. Inability to raise her right leg.
- d. Limb measurement shows shortening of right limb.

### Clinical Discussion

1. What is your case?  
This is a case of nonunited fracture of the neck of right femur.
2. Why do you say so?
  - a. Old age.
  - b. Tenderness over the right groin.
  - c. Inability to raise the right leg.
  - d. Right lower limb is externally rotated.
  - e. Shortening of the right lower limb.
3. Why does the fracture nonunited?
  - a. History of improper treatment by traction only by local doctor.
  - b. Patient's lower limb is still externally rotated.
  - c. The patient still cannot walk using her right foot.
4. Why nonunion is common in fracture neck femur?
  - a. Inadequate immobilization even after internal fixation.
  - b. Interruption of blood supply to head by fracture and capsular injury.
  - c. No soft tissue is present over the neck, so osteogenesis cannot occur.
  - d. Synovial fluid prevents hematoma formation.

5. How does the head of femur receive the blood supply?  
Head of femur receives blood supply from the following sources:
  - a. *Main source:* Capsular or lateral epiphyseal artery which may be easily torn in fracture neck of femur.
  - b. *Minor source:*
    - i. Nutrient artery and
    - ii. Artery of the ligamentum teres. These two minor vessels cannot maintain adequate blood supply in the absence of capsular vessels.
6. What are the different types of fractures of neck femur?  
Vide the chapter on 'Fractures and dislocation of the Lower Limb'.
7. What is Bryant's triangle?
8. What is Trendelenburg's test?  
Vide the long case Tuberculosis of hip.
9. What is Nélaton's line?
  - a. It is a line drawn from the most prominent part of ischial tuberosity to anterior superior iliac spine.
  - b. Normally it touches the tip of the greater trochanter.
  - c. Upward displacement of trochanter is easily detected, and confirms the supratrochanteric shortening of femur.
10. What is Chiene's test?
  - a. Normally, a tape joining, the tips of the greater trochanters is parallel to the line joining the two anterior superior iliac spines.
  - b. When a trochanter is raised, these two lines converge towards the affected side.
11. How will you confirm your diagnosis?
  - a. Straight X-ray of pelvis with both hips (anteroposterior and lateral views) will confirm the diagnosis.  
It shows the following features:
    - i. Upward displacement of greater trochanter.
    - ii. Break in the cortex of neck.
    - iii. Lesser trochanter is more prominent.
  - b. MRI scan or CT scan of hip will show the avascular changes of head.
12. Why lesser trochanter becomes more prominent?  
Because the limb is externally rotated, so the lesser trochanter becomes more medial than its normal posteromedial position.
13. How will you treat this case?  
The patient is 62-year-old, and X-ray does not show, any pathology in the acetabulum.  
Hemiarthroplasty with Austin Moore prosthesis will be done in this case of non-united fracture.
14. What will you do if the patient is young?  
In young patient, internal fixation is done with multiple cancellous hip screws under X-ray control or image intensifier.
15. What will you do if the patient comes with avascular necrosis of head?
  - a. The patient is treated by hemiarthroplasty if there is no evidence of osteoarthritis.
  - b. In presence of osteoarthritis, total hip replacement will be done.
16. How will you treat a young patient with nonunited fracture neck with avascular necrosis of head?
  - a. *Osteotomy:* Intertrochanteric osteotomy with displacement of lower fragment medially and slightly abducted and immobilized—McMurray's osteotomy.
  - b. *Arthrodesis:*
    - For working class people.
    - Intra- or extra-articular arthrodesis is done so as to get a stable and painless joint.
  - c. Girdlestone arthroplasty.

# Chapter 79

## Skin and Subcutaneous Tissue

- Introduction
- Sebaceous cyst
- Dermoid cyst
- Hemangioma
- Lipoma
- Neurofibroma
- Keloid
- Basal cell carcinoma
- Squamous cell carcinoma
- Malignant melanoma
- Marjolin's ulcer

### INTRODUCTION

- Time given for a short case examination usually ranges from 5 to 10 minutes.
- The candidate should take a short history of the case and mainly a short local examination during this period.
- The history and examination findings are mentioned in brief.
- In viva, questions are usually asked regarding the following:
  - a. Reasons in favor of the diagnosis.
  - b. Other possibilities or differential diagnosis.
  - c. Confirmation of the diagnosis.
  - d. Treatment.

### Skin and Subcutaneous Tissue

#### SEBACEOUS CYST

##### Case Summary

The 25-year-old male patient presents with a swelling on the right side of face for last 2 years. Patient complains of occasional discharge of grayish-white material having a peculiar odor.

##### On Examination

There is a punctum on the surface of the swelling and on squeezing grayish cheesy material is expressed through the punctum with offensive smell. The swelling is indented on pressure.

The swelling is globular in shape, surface smooth and margins well defined, soft cystic in feel. Hairs are sparse over the swelling.

1. What is your diagnosis?  
This is a case of sebaceous cyst on the right side of face.
2. What else can it be?
  - a. Dermoid cyst.
  - b. Lipoma.
  - c. Fibroma.
  - d. Neurofibroma.
3. What are the points in favor of your diagnosis?
  - a. Presence of punctum.
  - b. Loss of hairs over the swelling.
  - c. Skin is fixed in the central part.
  - d. Soft cystic in feel.
  - e. The swelling is not compressible and transillumination test is negative.
4. What is a sebaceous cyst?  
This is a retention cyst in relation to sebaceous gland due to blockage of sebaceous duct and accumulation of secretion within the gland.
5. What is a sebaceous gland?  
It is a holocrine variety of exocrine gland producing secretion by fatty degeneration of its central cells.
6. What are the types of exocrine glands?  
There are three types viz.
  - Holocrine.

- Apocrine.
- Merocrine gland.
  - i. Holocrine gland, e.g. sebaceous gland. Here the whole of the cell disintegrates and dies to produce its secretions.
  - ii. Apocrine gland, e.g. mammary gland, where only luminal part of the cell disintegrates leaving the nucleus and the basal portion from which the cell regenerates..
  - iii. *Merocrine gland*: Here the secretion is discharged without any destruction of the cell. Most of the glands belong to this type.
- 7. What are the complications?
- 8. What is Cock's peculiar tumor?
- 9. What is sebaceous horn?
- 10. What is the treatment?
- 11. What are the characteristics of scrotal sebaceous cyst?
- 12. What are the characteristics of scalp sebaceous cyst?  
Vide the Chapter "Cysts" in General Surgery section.
- 13. Why is it called epidermoid cyst?  
Because it is lined superficial squamous epithelial cells.
- 14. What is the content of sebaceous cyst?  
It contains epithelial debris and grayish white cheesy material with an unpleasant smell consisting of sebum and fat.



15. What are the common sites for sebaceous cysts?

The common sites are scalp, scrotum, face and vulva.

It can occur anywhere in the body except the palms and sole where sebaceous glands are absent.

16. What organism is commonly found in the sebaceous cyst?

The organism is *Demodex folliculorum*.

17. Where are the sebaceous glands located?

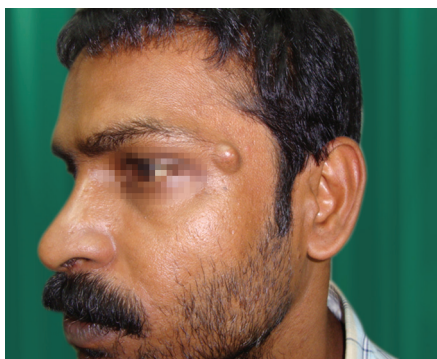These glands are situated in the dermis and their ducts open either into a hair follicle or directly on to the skin surface and secrete the sebum.

## DERMOID CYST

### Case Summary (Fig. 79.1)

The 42-year-old male patient presents with a painless slow growing swelling near the external angle of left eye for last 3 years. On examination there is a soft cystic swelling 4 cm × 3 cm size near the outer aspect of left eye. The overlying skin is not adhered. Transillumination test is negative but fluctuation test is positive. The swelling is noncompressible.

1. What is your diagnosis?  
This is a case of external angular dermoid on the left side.
2. Why do you say so?
  - a. Painless slow growing swelling.
  - b. Situated at the line of embryonic fusion.
  - c. Skin over the swelling is free.
  - d. Swelling in noncompressible and soft cystic in feel.



**Fig. 79.1:** External angular sequestration dermoid (Left)

3. What are other possibilities?

- a. Sebaceous cyst.
- b. Lipoma.
- c. Meningocele.
- d. Fibroma.
- e. Neurofibroma.

4. Why it is not a sebaceous cyst?

- a. Punctum is absent.
- b. Overlying skin is free.
- c. Deeper tissues like bone are involved.

5. Why it is not a meningocele?

- a. No impulse on coughing.
- b. Not reducible or compressible.

6. What are the types of dermoid cyst?

There are four types, viz.

- a. Sequestration dermoid formed by the sequestration of some ectodermal cells into the deeper layers during embryonic development, e.g. external angular and postauricular dermoid.
  - b. Implantation dermoid or post-traumatic dermoid, e.g. in the pulp or tips of the fingers, palm and sole (Fig. 84.1).
  - c. Tubulodermoid, e.g. thyroglossal cyst, postanal dermoid arising from the nonobliterated portion of a congenital ectodermal duct.
  - d. Teratodermoids, e.g. sacrococcygeal teratoma, testicular and mediastinal teratoma. This type of cyst develops from totipotent cells containing different structures arising from, ectodermal, mesodermal and endodermal elements like hairs, bones, teeth and other elements.
7. What is the complication of dermoid cyst?
    - a. Infection
    - b. Hemorrhage.
    - c. Suppuration.
    - d. Ulceration.
    - e. Pressure on deeper structures.
  8. What are the common sites of sequestration dermoid?
    - a. Postauricular dermoid.
    - b. Forehead or root of nose.
    - c. External angular dermoid.
    - d. At the anterior triangle of neck (cervical dermoid).
  9. How will you treat the case?
    - a. One X-ray of skull both AP and lateral view is done to look for any bony gap through which the cyst may extend

intracranially. In such case, an expansile impulse on coughing will be present.

- b. In the absence of intracranial extension, excision of cyst is the treatment of choice.

10. What is the content of dermoid cyst?

The content of dermoid cyst consists of desquamated epithelial cells with or without hairs.

See also Chapter 14, Cysts

## HEMANGIOMA

### Case Summary

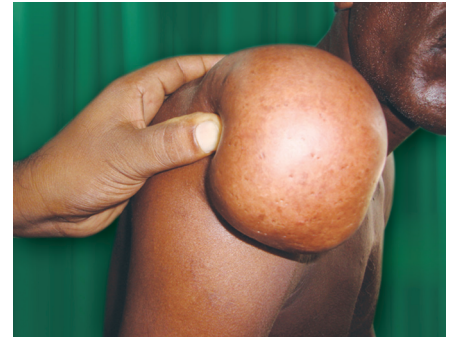The 5-year-old female child presents with a swelling on the left side of neck for last 2 years.

The swelling is gradually increasing in size and there is gradual discoloration of swelling during this period.

On examination the swelling is compressible, surface smooth, soft cystic feel, margins ill-defined. Size is 5 cm × 3 cm on the left side of neck. No pulsation is present.

1. What is your diagnosis?  
This is a case of hemangioma of left side of neck.
2. Why do you say so?
  - a. The swelling is bluish in color and soft cystic in feel.
  - b. It is compressible.
  - c. The swelling is not pulsatile.
3. What is a hemangioma?  
This is a swelling due to congenital malformation of blood vessels and is an example of hamartoma.
4. What are the common site?
  - a. Skin—Face, cheek, ears, neck.
  - b. Mucous membrane—Lips (Fig. 12.6) tongue, mouth.
  - c. Internal organs—Liver, brain.
5. What are the different types of hemangiomas?
  - a. Capillary hemangioma—Arising from the capillary.
  - b. Plexiform or arterial hemangioma arising from the artery.
  - c. Cavernous hemangioma—Arising from the vein.
6. What are characteristics of the above three types of hemangioma?
  - a. *Capillary hemangioma*: It is a red or purple patch.

- b. *Cavernous hemangioma*—It is raised from the surface, nonpulsatile, bluish in color and compressible.
- c. *Arterial hemangioma*—It is raised from surface, pulsatile and compressible swelling with a feeling of bag of worms.
7. What type of hemangioma is this one?  
This is a case of cavernous hemangioma, as it is bluish in color, compressible and nonpulsatile.
8. What are the common differential diagnoses of cavernous hemangioma?  
a. Sebaceous cyst.  
b. Dermoid cyst.  
c. Neurofibroma.  
d. Lipoma.  
e. Lymphangioma.
9. How will you treat the case?  
Treatment is conservative by injection of a sclerosing agent. The idea is to produce fibrosis in the lesion and thereby obliterate the vascular spaces.
10. What sclerosing agents are used?  
a. Boiling water.  
b. Hypertonic saline solution.  
c. Steroids.  
d. 3 percent sodium morrhuate.
11. How long will you do the sclerosing treatment?  
This is done once a week for 4 to 6 weeks if necessary.
12. What is role of surgery?  
a. If the lesion is small and localized it can be excised wholly after sclerosing treatment.  
b. If the lesion is large, arteriography is done to know the feeding arteries. These feeding vessels may be ligated or obliterated by therapeutic embolization if the facility is available, before excision of the lesion.
13. What are the complications of hemangioma?  
a. Ulceration usually with capillary hemangioma.  
b. Bleeding following trauma.  
c. Infection.  
d. Phleboliths (calcifications).
14. What is nevilipoma?  
It is the lipoma containing dilated capillaries.
15. What is the peculiarity of capillary hemangioma?  
Majority of capillary hemangiomas unlike cavernous and arterial hemangiomas disappear by 5 to 7 years of age.
16. What are the different types of capillary hemangioma?  
a. Strawberry angioma.  
b. Salmon patch.  
c. Port-wine stain.
17. What is Salmon patch?  
This is commonly present over forehead in the midline at birth and disappears by one year of age. Hence no treatment is required.
18. What is strawberry angioma?  
a. It produces a swelling which is compressible and consists of immature vascular tissue.  
b. Mostly seen on the head and neck.  
c. The swelling usually regresses by 5 – 7 years of age.  
d. Treatment  
i. Natural involution.  
ii. *Conservative*: Injection of hot water, hypertonic saline or steroids.  
iii. *Operative*: Excision with or without skin grafting.
19. What is Port-wine stain?  
a. It is a deep or purple discoloration with no swelling on the face, lips and buccal mucosa.  
b. The lesion does not show any change during the rest of life.  
c. Treatment.  
i. May be left as such.  
ii. Laser therapy.  
iii. Excision with skin grafting may be considered in some cases.
20. What is cirroid aneurysm?  
a. It is the plexiform hemangioma of the scalp over the forehead and/or temporal region in relation to superficial temporal artery.  
b. *Treatment*:  
i. Ligation of the feeding vessel and excision of the mass.  
ii. Therapeutic embolization of the feeding artery may render the excision easier.
21. What is Sturge-Weber syndrome?  
It consists of:  
a. Port-wine stain of the face.  
b. Hemangioma of ipsilateral cerebral hemisphere.



**Fig. 79.2:** Slip sign in lipoma. Lipoma slips by the palpating finger

- c. Eye complications like loss of vision, glaucoma and buphthalmos.

## LIPOMA

### Case Summary (Fig. 79.2)

The 35-year-old male patient presents with a gradually increasing swelling over the deltoid region of right shoulder for the last 5 years. There is no pain over the swelling and no other swelling is present in the body.

On examination, a soft globular swelling of about 6 cm diameter is present in the deltoid area of right shoulder. The surface is smooth lobulated with well-defined margins which slips under the finger during palpation.

The overlying skin is free and the swelling is freely mobile on the underlying structures. The swelling becomes more prominent on contraction of the underlying muscle suggesting that it is superficial to the muscle.

1. What is your case?  
This is a case of subcutaneous lipoma over the deltoid area of right shoulder.
2. What are the points in favor of your diagnosis?  
a. Slow growing painless swelling.  
b. The well-defined margin slips under the finger.  
c. Surface is smooth and lobulated and skin is free.  
d. Soft in feel and mobile lump.
3. What are other possibilities?  
a. Fibroma.  
b. Neurofibroma.  
c. Sebaceous cyst.  
d. Dermoid cyst.

4. What is a lipoma?  
This is a well-encapsulated benign tumor arising from the fat cells.
5. What are the types of lipoma?  
Depending on the anatomical location, lipomas may be of the following types:
- Subcutaneous.
  - Subfascial—Lipoma from fat cells lying deep to deep fascia.
  - Intermuscular—From fat cells lying in between two muscles.
  - Intramuscular—Lipoma from fat cells in between muscle fibers.
  - Submucosal.
  - Subsynovial.
  - Intraglandular—From fat cells lying within the gland, e.g. salivary glands, breast.
  - Extradural.
  - Subperiosteal.
6. Why is it called a universal tumor?  
Lipoma is called the universal tumor as it is the commonest benign soft tissue tumor and can occur anywhere in the body, i.e. universal occurrence.
7. What is Dercum's disease?  
a. It consists of multiple painful nodular deposits of fat, called neurolipomatosis.  
b. There are no capsules around these fatty deposits. So they are also called pseudolipomas.
8. What are the complications of lipoma?  
a. *Liposarcoma*: Common sites where lipoma undergoes malignancy are retroperitoneal lipoma, lipoma of thigh and subcutaneous lipoma in the shoulder region.
  - Malignancy is suspected, when the swelling grows rapidly, becomes painful and vascular with dilated veins over the surface.
  - Mobility gets restricted.
  - Treatment is wide excision.
- Calcification.
  - Myxomatous degeneration.
  - Intussusception – rarely which is an abdominal emergency.
9. What is differential diagnosis?  
a. Sebaceous cyst.  
b. Dermoid cyst.  
c. Cold abscess.  
d. Any cystic tumor.  
e. Baker's cyst.
10. What is the treatment?  
Surgery is the treatment of choice. Either enucleation or excision is done.
11. What is enucleation?  
When capsule is incised and tumor removed, leaving behind the capsule, it is known as enucleation.
12. What is excision?  
When tumor is removed along with the capsule, it is called excision.
13. What are the common sites?  
a. Nape of neck.  
b. Shoulder.  
c. Back.  
d. Gluteal region.  
e. Retroperitoneum.
14. What is the slip sign?  
Slipping edge of the lipoma on palpation is known as the slipping sign. (Fig. 79.2)  
See also Lipoma in chapter 12.
5. What is the differential diagnosis of a neurofibroma?  
a. Fibroma.  
b. Lipoma.  
c. Hemangioma.  
d. Cystic lesions like sebaceous cyst, dermoid cyst or bursa.  
e. Enlarged lymph nodes especially when present in the neck.
6. What are the different types of neurofibroma?  
a. Localized or solitary neurofibroma.  
b. Generalized neurofibromatosis or von Recklinghausen's disease.  
c. Plexiform neurofibromatosis or pachydermatocele.  
d. Elephantiasis neurofibromatosa.  
e. Cutaneous neurofibromatosis or Molluscum contagiosum.  
f. Rarer types, viz. amputation neuroma, acoustic neuroma and dumb-bell-shaped tumor.
7. What is the treatment of solitary neurofibroma?  
Complete excision taking care that the nerve is not injured.
8. What are the complications of neurofibroma?  
a. Cystic degeneration.  
b. Infection.  
c. Sarcomatous changes.  
d. Mediastinal syndrome when found in the mediastinum.
9. What are the common sites of neurofibroma?  
a. Majority arises from the peripheral nerves and present in the subcutaneous tissues.  
b. From the dorsal nerve roots and ganglion (Dumb-bell neurofibroma).  
c. 8th cranial nerve (Acoustic neuroma) tumor.  
d. Intramuscular  
e. Inside the bone.
10. What is acoustic neuroma?  
a. It is the neurofibroma arising from the auditory nerve sheath at the internal auditory meatus.  
b. It produces compression effect in the form of tinnitus, vertigo and severe headache.
11. What is von Recklinghausen's disease of bone?

### NEUROFIBROMA

The 32-year-old male patient presents with a globular swelling and dull aching pain on the left arm for last 3 years.

On examination, the swelling is firm globular in shape and tender, size 5 cm × 3 cm. Over the front of mid left arm in relation to the median nerve with pain and paresthesiae along the course of the nerve.

There is no other swelling in other parts of the body.

- What is your diagnosis?  
This is a case of solitary neurofibroma in the front of left arm.
- Why do you say so?
  - The swelling is firm and tender.
  - It is subcutaneous.
  - Pain and paresthesia in the course of the nerve (median nerve).
- What is a neurofibroma?
  - It is not a true tumor but a hamartoma and arises not from the nerve proper but from the endoneurium, which is the supporting connective tissue for the nerve fibril.
  - It is due to autosomal gene defect transmitted as a 'Mendelian dominant'.
- What is von Recklinghausen's disease?  
Neurofibroma if multiple, congenital and familial, the condition is known as Von Recklinghausen's disease. (see fig. 12.8)

It is called *ostitis fibrosa cystica*, found in hyperparathyroidism and characterized by parathyroid adenoma, pathological fracture and recurrent renal calculi.

12. What is *pachydermatocele*?
  - a. This is plexiform neurofibromatosis due to excessive overgrowth of endoneurium in the subcutaneous tissue.
  - b. A severe form of *pachydermatocele* affecting the cutaneous nerves of the limbs is known as elephantiasis neurofibromatosa. Here the subcutaneous tissue is thickened, coarse and dry resembling elephants' skin.
13. What is turban tumor?
  - a. This is the neurofibroma arising from the cutaneous nerves of the scalp.
  - b. It may achieve a massive swelling which covers the head like a turban, hence the name turban tumor.
14. What are the common sites of *pachydermatocele*?
  - a. In the face in relation to branches of trigeminal nerve.
  - b. In the arm or thigh along the distribution of cutaneous nerves. (Fig. 12.9). See also Neurofibroma in chapter 12.

### KELOID

The 45-year-old female patient presents with a butterfly-shaped scar in front of her chest wall with gradually increase in size for last four years. She gives history of a pinprick over the area.

- She complains of itching over the scar, which is raised from the surface and bluish or pinkish in color.
  - The swelling is tender and local temperature is raised.
1. What is your diagnosis?  
This is a case of butterfly keloid in the region of manubrium sterni.
  2. Why do you say it keloid?
    - a. Butterfly-shaped.
    - b. Itching is present.
    - c. No regional glands.
    - d. Elevated scar.
    - e. Spreading into the surrounding area.
  3. What is a keloid?

The term keloid comes from the Greek word 'kele' which means tumor. However keloid is not a tumor and it never turns malignant. So, keloid is a misnomer.

Pathologically, a keloid is an excessive overgrowth of a scar but it differs from the hypertrophic scar in the following respects.

- a. A keloid spreads to normal tissues.
  - b. Itching is present.
  - c. It continues to grow even after one year and sometimes many years, while hypertrophic scar almost never grows after 6 months.
4. What are the common sites for keloid formation?
    - a. Over the sternum (Butterfly keloid).
    - b. Ear lobule.
    - c. Neck.
    - d. Vaccination site.
    - e. Joint surface.
  5. What are the predisposing factors?
    - a. Pin pick, burn or incision scar.
    - b. Females are more affected than males.
    - c. Patients suffering from tuberculosis are more prone to suffer from keloid.
    - d. Racial factor—keloid is more common in colored races than the whites.
  6. What are the pathological characteristics of keloid?
    - a. Histologically keloid consists of immature fibroblasts, blood vessels and collagen fibrils on the top of a scar.
    - b. It is a self-limiting process and after some years stop growing.
  7. How will you treat this patient?  
Treatment is very difficult.
    - a. Conservative treatment:
      - i. Intrakeloidal injection of steroid is very helpful, e.g. injection triamcinolone at weekly intervals for 4 to 6 weeks.
      - ii. Other injections used are injection hyaluronidase, vitamin A and methotrexate intrakeloidal.
    - b. Surgery has limited role.
      - i. Intrakeloidal excision and approximation of margin is done.
      - ii. Excisional surgery and radiotherapy—In keloids of ear lobules excision followed by deep X-ray therapy proves good over time.
  8. What are the complications of keloid?
    - a. Cosmetically ugly looking.
    - b. Infection and ulceration.
    - c. Recurrence after excision.
  9. What are the characteristics of hypertrophic scar?

- a. Scar raised above the surface.
  - b. It does not extend into the normal skin.
  - c. It rarely grows after 6 months.
- Hypertrophic scars are more cellular and vascular than the mature scars. (See also Chapter 11, Keloid and hypertrophic scar)

### BASAL CELL CARCINOMA (BCC) (Syn- Rodent Ulcer)

#### Case Summary

The 50-year-old male patient presents with a insidiously progressing ulcerative lesion on the left side of face in the infraorbital region for last three years.

He has no other complaint besides this.

On examination, the edge of the ulcer is raised and rolled up, floor is covered with a scab. On removal of the scab, there is bleeding. The lesion is not fixed to bone.

The base is indurated and regional lymph nodes are not palpable.

1. What is your diagnosis?  
This is a basal cell carcinoma of skin in the left infraorbital region.
2. Why do you say so?
  - a. Ulcerative lesion with rolled up edge located on the face above a line joining the ear lobule to angle of mouth.
  - b. Regional lymph nodes not enlarged.
  - c. Local bleeding on removal of the scab from the floor of the ulcer.
3. What is the cell of origin of basal cell carcinoma?  
It arises from basal cells of epidermis.
4. Why is it called rodent ulcer?  
As it burrows deep into the surrounding tissues like rodent, so it is called rodent ulcer. Lymphatic spread is not seen.
5. What are the common sites of this tumor?
  - a. Inner and outer canthus of eye.
  - b. Nose.
  - c. Nasolabial fold.
  - d. Forehead.
6. What is the pathology of this tumor?
  - a. Grossly, there is pearly gray papule with telangiectasia and subsequent ulceration.
  - b. Microscopic features: The lesion consists of uniform round cells with no prickle cells or keratin.

The stroma is composed of chronic inflammatory cells and benign fibrovascular tissue.



7. What is the differential diagnosis?
- Squamous cell carcinoma—margin is everted not rolled up as in rodent ulcer, lymphatic involvement is early.
  - Malignant melanoma
    - Dark-colored lesion.
    - Regional lymphadenopathy.
    - Satellite nodules are present.
8. How will you confirm the diagnosis?  
Diagnosis is confirmed by doing a biopsy from the ulcer margin.
9. How will you treat the case?  
This is treated by radiotherapy as the lesion is not close to eye and not fixed to bone.
10. When will you do surgical treatment?
- If the lesion is very close to the eye.
  - If it is fixed to the bone.
  - Recurrence after radiotherapy.
11. What is the principle excision?  
Three dimensional excision of the lesion with 5 mm of healthy tissue margin followed by closure of defect with any of the following:
- Direct suture.
  - Skin grafting.
  - Pedicle grafts.
  - Rotation flaps.
12. What is the recent treatment option?  
Laser beam destruction of the growth.
13. What is the role of cryosurgery?
- Done in case of small lesions in elderly patient.
  - Cosmetically good result.
  - Liquid nitrogen is applied with a cotton tipped applicator over the tumor and 5mm area of normal healthy tissue for 30 seconds.
14. What is the role of curettage?
- This is indicated for a small superficial lesion less than 1cm in diameter and diathermy ablation to achieve a cure.
  - It is not suitable for a lesion situated over a bone or cartilage.
- On local examination, the swelling shows growth with rolled out everted margin, size 5 cm × 4 cm. There is ulceration in the center, floor is covered with necrotic slough and base is indurated and fixed to the underlying structure. The swelling is not fixed to the underlying bone. The axillary lymph nodes are not palpable.
- What is your diagnosis?  
This is a case of squamous cell carcinoma of the dorsum of right hand.
  - Why do you say so?
    - The patient is male and the lesion is found on the exposed surface of the body.
    - History of exposure to sunlight for a long period as the patient is a daily laborer.
    - Typical characteristics of the ulcer:
      - Ulcerative growth with rolled out everted margin.
      - Floor is covered with necrotic slough.
      - Base is indurated.
  - What is the differential diagnosis?
    - Basal cell carcinoma.
    - Malignant melanoma mainly amelanotic type.
    - Infected wart.
  - What is a squamous cell carcinoma?  
It is the malignant tumor arising from the squamous cells. In case of skin, it is the prickle cell layer from which squamous cell carcinoma arises.
  - What are the common sites?
    - Face, dorsum of hands, palm, sole, etc.
    - Junctional region of skin and mucous membrane, e.g. lips, penis (corona glandis), anal region, vulva, etc.
    - Vagina.
    - Following columnar cell metaplasia, e.g. gallbladder, bronchus, cardiac end of stomach, etc.
    - From mucous surface covered by stratified squamous epithelium, e.g. tongue, buccal cavity, esophagus, pharynx, larynx, etc.
  - What are the predisposing factors?
    - Prolonged exposure to sunlight.
    - On a premalignant condition of skin, e.g.
      - Bowen's disease.
      - Leukoplakia.
      - Radiation dermatitis.
      - Lupus vulgaris (a type of skin tuberculosis).
    - Prolonged contact with hydrocarbons, e.g. tars, soot, dyes, etc.
7. What is the pathology of squamous cell carcinoma?
- Grossly the lesion starts as a nodule which breaks down to form an ulcer, which refuses to heal.  
The ulcer has a rolled out, everted edge, base is indurated and floor is covered with necrotic slough.
  - Microscopically, it is composed of irregular strands and columns of epithelium, which invade the surrounding connective tissue with formation of cell nests or epithelial pearls.
8. What is the cell nest?
- Epithelial cells of epidermis proliferate into the dermis in columns. In course of time, the central cells undergo degenerative changes, into a hyaline structure less mass of keratin. This is surrounded by peripheral cells in a concentric manner giving an onion peel appearance.
  - Cell nests are absent in the squamous cell carcinoma of esophagus and bladder, where keratin formation does not occur.
  - Cell nests are also formed in some other tumors like pleomorphic adenoma of the parotid, teratoma of the testis, etc.
9. What is the TNM staging of squamous cell carcinoma and basal cell carcinoma?
- T* – Primary tumor  
*T<sub>X</sub>* – Primary tumor cannot be assessed.  
*T<sub>0</sub>* – No evidence of primary tumor  
*T<sub>IS</sub>* – Carcinoma *in situ*.  
*T<sub>1</sub>* – Tumor < 2 cm in greatest diameter  
*T<sub>2</sub>* – Tumor > 2 cm but < 5 cm in greatest diameter.  
*T<sub>3</sub>* – Tumor > 5 cm in greatest dimension.  
*T<sub>4</sub>* – Tumor invading the deeper structures like muscle bone or cartilage.
- Lymph node involvement – N*  
*N<sub>X</sub>* – Regional lymph nodes cannot be assessed.  
*N<sub>0</sub>* – No regional lymph node metastasis.  
*N<sub>1</sub>* – Regional lymph node metastasis present.
- M – Distant metastasis*  
*M<sub>X</sub>* – Distant metastasis cannot be assessed.  
*M<sub>0</sub>* – No distant metastasis.  
*M<sub>1</sub>* – Presence of distant metastasis.
10. What are the different stages groupings?
- Stage 0 –  $T_{IS}/N_0/M_0$   
 Stage I –  $T_1/N_0/M_0$

## SQUAMOUS CELL CARCINOMA

### Case Summary

The 50-year-old male patient, a daily laborer in occupation presents with a swelling on the dorsum of right hand for last three years. The swelling was growing in size for last two years but the increase in size was more in the last three months with ulceration.



Stage II – T<sub>2</sub>, T<sub>3</sub>/ N<sub>0</sub>/M<sub>0</sub>  
 Stage III – T<sub>4</sub>/ N<sub>0</sub>/M<sub>0</sub> or any T/N<sub>1</sub>/M<sub>0</sub>  
 Stage IV – Any T/any N/M<sub>1</sub>

11. How does squamous cell carcinoma spread?
  - a. Local spread by continuity and contiguity.
  - b. Lymphatic spread – both by lymphatic permeation and embolization.
  - c. Blood spread occurs only in very advanced cases.
12. How will you confirm the diagnosis?  
 Diagnosis is confirmed by an incisional biopsy taken from the junction of tumor and the normal skin.
13. What are the modalities of treatment?
  - a. Surgery.
  - b. Radiotherapy.
14. What is the role of surgery?
  - a. Once the diagnosis is confirmed, wide local excision is the treatment of choice. Excision of the growth along with 2cm of the normal tissue surrounding the tumor is performed.
  - b. Surgery is done if there is recurrence of growth after radiotherapy.
  - c. In case of tumor involving penis, finger, toes, amputation is indicated.
15. What is the role of radiotherapy?
  - a. Indications
    - i. Poorly differentiated tumor, i.e. anaplastic carcinoma.
    - ii. Tumors of the head and neck.
    - iii. When the patient does not agree for surgical excision.
  - b. Methods of radiotherapy
    - i. Deep X-ray therapy.
    - ii. Radium needles.
    - iii. Radium moulds.
16. What is the indication of postoperative radiotherapy?  
 If the resection lines are not free of tumor then postoperative radiotherapy is indicated.
17. How do you follow up this patient?  
 Follow up is done as per the following schedule:
  - a. For first 3 years at every 3 months interval that is 4 times yearly, then for next 2 years, every 6 months interval.
  - b. If lymph node enlargement and metastasis is detected, ipsilateral lymph node dissection of the axilla is performed.

**Table 79.1: Difference between squamous and basal cell carcinoma.**

	<i>Squamous cell carcinoma</i>	<i>Basal cell carcinoma</i>
a. Common site	Anywhere on the skin or mucous membrane	Upper part of face
b. Edge of the lesion	Raised and everted	Raised and rolled up
c. Base	Indurated	Not indurated
d. Microscopic picture	Cell nest or epithelial pearl is present	Cells are arranged in palisade pattern (fence or guard wall)

18. What is the difference between squamous cell carcinoma and basal cell carcinoma?  
 Table 79.1
19. What is overall prognosis?  
 5 years survival rate is about 95 percent.  
 See also chapter 12, Squamous Cell Carcinoma.

- b. They are actually neuroectodermal cells derived from the neural crest.
- c. Immature melanocytes are called melanoblasts.
5. How melanin is produced by the melanocyte?  
 Amino acid tyrosin is converted to dihydroxyphenylalanine (DOPA) by tyrosinase, present within the melanocyte. DOPA is converted to melanin by the enzyme DOPA oxidase, also present in the melanocyte.
6. What are the sites where melanin is found?
  - a. Skin—90 percent.
  - b. Choroid of eye.
  - c. Substantia nigra.
  - d. Adrenal medulla.
7. What are the different layers of skin?
  - a. Skin consists of epidermis and dermis. (Fig. 12.1)
  - b. Epidermis is composed of the following layers of epithelium from base to surface:
    - Stratum germinativum or basal cell layer.
    - Stratum spinosum or prickle cell layer.
    - Stratum granulosum or granular cell layer.
    - Stratum lucidum—A thin homogeneous layer
    - Stratum corneum or horny layer.
  - c. Dermis again consists of 2 parts—the superficial papillary dermis and the deeper reticular dermis containing bundles of collagen fibers. The dermis contains the blood vessels, lymphatics and nerves.
  - d. The dermis also contains cutaneous appendages or adnexal structures, viz. sweat glands, sebaceous glands, hair follicles, arrectores, pilorum and nails.

### MALIGNANT MELANOMA

#### Case Summary

The 52-year-old female patient presents with a pigmented lesion about 1 cm in diameter, with irregular borders on the anterior aspect of right leg for last 1 year. Initially the swelling was slow growing but it has increased rapidly during last 3 months.

On examination, the swelling is darkly pigmented nodular lesion of size 3 cm × 2 cm on the anterior aspect of right leg, firm in consistency and base is indurated. There is change of color but no lymph node enlargement in the popliteal fossa or inguinal region.

1. What is your diagnosis?  
 This is a case of malignant melanoma over right leg.
2. Why do you say so?
  - a. An ugly looking black-colored asymmetrical swelling over the right leg of a female patient.
  - b. The swelling is about 3 cm × 2 cm in size, with change in color.
  - c. The lesion has irregular borders.
  - d. Recent rapid growth of the lesion.
  - e. Regional lymph nodes are not involved.
3. What are melanomas?  
 Melanomas are tumors arising from the melanocytes.
4. What are melanocytes?
  - a. Melanocytes are melanin pigment producing cells located in the basal layer of the epidermis.

- e. The epidermis also contains dendritic cells of Langerhans, which belong to mononuclear phagocytic system.
- 8. What is the importance of knowing the structure of skin?
  - a. Benign melanoma or pigmented nevus is classified according to its position, e.g. epidermal, junctional and intradermal nevus.
  - b. Clark's staging depends on the level of invasion of different layers of epidermis and the dermis.
  - c. Breslow's staging involves measuring maximal vertical thickness of the lesion from the basal layer of epidermis.
- 9. What are the different types of benign nevus?
  - a. *Lentigo*: Basal layer of epidermis is replaced by melanocytes.
  - b. *Junctional nevus*: It is the one in which nevus cells lie at the dermoepidermal junction forming well-circumscribed nests. It is more prone to malignant change.
  - c. *Compound nevus*: It is the commonest type having junctional activity as in junctional nevus as well as nests of nevus cells in the dermis.
  - d. *Intradermal nevus*: It shows mild or no junctional activity. Aggregation of melanocytes takes place entirely in the dermis.
- 10. What are the features of malignant change in a benign nevus?
  - a. Persistent itching.
  - b. Bleeding.
  - c. Increase in size.
  - d. Elevation and darkening of skin.
  - e. Regional lymph adenopathy.
  - f. Microscopically, there is hyperchromasia, mitotic figures, pleomorphism and subepithelial spread.
- 11. What is malignant melanoma?

Clark's level	Breslow's tumor thickness	Risk of metastasis
Level 1	0.75 mm	No risk of metastasis
Level 2 and 3	0.76 – 1.5 mm	Intermediate risk, 25 percent incidence of metastasis
Level 4 and 5	1.51 mm or deeper	High-risk, 60 percent incidence of metastasis

- It is the malignant tumor arising from the melanocytes.
- 12. How will you confirm the diagnosis of malignant melanoma?
  - The diagnosis is confirmed by incisional biopsy.
- 13. How the pathologic staging is done?
  - 1. *Clark's staging* (Table 79.2)
    - Clark et al in late seventy classified melanoma into five levels depending on the level of invasion of different layers of skin. The deeper the levels of invasion, more is the chance of having regional and distant metastasis.
  - 2. *Breslow's staging*: This involves measuring the maximal vertical thickness of the lesion from the basal layer of the epidermis by an ocular micrometer.
    - Stage 1 – Thickness 0.75mm or less.
    - Stage 2 – Thickness 0.76 to 1.50mm.
    - Stage 3 – Thickness 1.51 to 3.00mm.
    - Stage 4 – Thickness more than 3.00mm.
- 14. How will you compare Clark and Breslow's staging with prognosis? (Table 79.3).
- 15. What is (American Joint Committee of Cancer (AJCC) staging?
  - This is the most current staging system, called TNM classification.
    - T – Primary tumor
    - T<sub>X</sub> – Primary tumor cannot be assessed, i.e. either removed earlier or unknown primary.
    - T<sub>0</sub> – No evidence of primary tumor.
    - T<sub>IS</sub> – Melanoma *in situ* (Clark level 1).

- T<sub>1</sub> – Tumor 1 mm or less in thickness.
- T<sub>2</sub> – Tumor thickness of 1.01 to 2.0 mm.
- T<sub>3</sub> – Tumor thickness of 2.01 to 4.0 mm.
- T<sub>4</sub> – Tumor thickness of > 4.0 mm.
- Each T is subdivided into
  - a – Without surface ulceration
  - b – With surface ulceration
- N – Lymph node involvement
  - N<sub>X</sub> – Lymph nodes status could not be assessed.
  - N<sub>0</sub> – No regional lymph node involvement.
  - N<sub>1</sub> – There is only one metastatic lymph node.
  - N<sub>2</sub> – 2 – 3 metastatic lymph nodes.
  - N<sub>3</sub> – 4 or more metastatic lymph nodes.
- M – Distant metastasis.
  - M<sub>X</sub> – Distant metastasis cannot be assessed.
  - M<sub>0</sub> – No distant metastasis.
  - M<sub>1</sub> – Distant metastasis present.
    - M<sub>1a</sub> – Involvement of skin and subcutaneous tissue beyond the site of primary lymph node drainage.
    - M<sub>1b</sub> – Lung metastasis
    - M<sub>1c</sub> – Other visceral metastasis.
- 16. What is stage grouping and prognosis?
  - Stage I – T<sub>1</sub> and T<sub>2</sub>/N<sub>0</sub>/M<sub>0</sub>—5 year survival is >90 percent.
  - Stage II – T<sub>3</sub>, T<sub>4</sub>/N<sub>1</sub>, N<sub>0</sub>/M<sub>0</sub>—70 percent. 5 year survival.
  - Stage III – Any T/N<sub>2</sub>/M<sub>0</sub>—35 percent. 5 year survival.
  - Stage IV – Any T, Any N, M<sub>1</sub> (M<sub>1a</sub>, M<sub>1b</sub>, M<sub>1c</sub>) – <2 percent. 5 year survival.
- 17. What are the clinical types of malignant melanoma?
  - There are four common types of malignant melanoma, viz.
    - a. Superficial spreading melanoma.
    - b. Nodular melanoma.
    - c. Lentigo maligna melanoma.
    - d. Acral lentiginous melanoma.

**Table 79.2: Clark's staging**

Level of invasion	Description	5 year survival
Level 1	Epidermal involvement only	100%
Level 2	Papillary dermis only is involved	90 – 100%
Level 3	Involves the junction of papillary and reticular dermis	80 – 90%
Level 4	Tumor extends to reticular dermis	60 – 70%
Level 5	Subcutaneous fat is involved	15 – 30%

18. What are the features of superficial spreading melanoma?
- It is the most common type (70 percent).
  - Less aggressive.
  - Usually found on lower legs, chest or back.
  - The lesion is usually flat, with irregular margin and variegated color. It is usually palpable and nodule may develop within the tumor.
19. What are the features of nodular type?
- It is the most malignant type.
  - Incidence 15 to 30 percent.
  - Uniform color.
  - Clinically presents as a raised nodule. Surface ulceration and bleeding may occur.
  - Lymph node involvement is common.
20. What are the features of lentigo maligna melanoma?
- This is also called Hutchinson's melanotic freckle.
  - It is the least common and least malignant.
  - It is the flat, slowly growing lesion on the exposed skin of the elderly.
21. What are the features of acral lentiginous melanoma?
- It is a variety of superficial spreading type.
  - Worse prognosis.
  - Commonly found in the palm and sole.
22. How does malignant melanoma spread?
- Local spread:** It spreads horizontally within the epidermis and vertically into the dermis. The deep fascia acts as a strong barrier.
  - Lymphatic spread:**
    - By emboli to regional lymph nodes.
    - By permeation of lymphatic channels, there is formation of satellite nodules between the primary growth and the regional nodes.
  - Blood spread occurs very late to liver, lungs and brain.
23. What is amelanotic melanoma?
- Generally, the malignant melanoma and its metastatic deposits are black-colored due to the presence of melanin pigment but sometimes they contain very little or no pigment. This is called amelanotic melanoma. The cells lose their capacity to produce melanin, though they contain the precursor or melanin pigment, i.e. DOPA reaction is positive.
24. How will you treat malignant melanoma?
- Surgical excision of the primary lesion with adequate margin is the mainstay of treatment.
25. What should be the margin of excision?
- Earlier a wide excision margin of 5 cm was thought to be adequate. However, subsequent study has shown that tumor thickness is the main determinant factor for margin of excision of the tumor.
- For lesion < 1 mm thickness, a margin of excision of 1 cm is adequate.
  - For lesions 1 to 4 mm thickness, a margin of excision of 1 to 2 cm is adequate.
  - For lesions > 4 mm, a margin of excision of 2 cm is safe.
- These smaller excisions allow primary closure of the wound in the majority of patients.
26. What is the management of regional lymph nodes?
- In a patient in whom clinical evidence of lymph node involvement is present, a lymph node dissection of that area is appropriate.
27. What is isolated limb perfusion?
- Indications:**
    - For local recurrence within 2cm of primary excision.
    - For in transit metastasis (multiple skin deposits).
    - To convert an advanced inoperative lesion to operable one.
  - The technique involves clinical isolation of limb and cannulation of the major artery and vein supplying the limb with extracorporeal circulation through an oxygenated circuit in addition to a heat exchanger to enable hyperthermic (temperature >40°C) perfusion, delivering a high concentration of cytotoxic drug. Drug commonly used is melphalan.
  - Introduction of TNF- $\alpha$  and interferon to the limb perfusion may increase the tumor response rate.
28. What is the role of immunotherapy?
- Immunotherapy is done by intralésional BCG vaccination.
  - Levamisole is also used as a nonspecific immunostimulant.
29. What are the prognostic factors in malignant melanoma?
- Clark's level of invasion:** Survival rates get worsened with increasing level of invasion of the tumor.
  - Site:** Malignant melanomas located at the back, arm, neck and scalp (BANS) have poor prognosis.
  - Ulceration of the tumor is an important prognostic factor and prognosis is poor when the tumor is ulcerated.
  - Presence of lymph node metastasis: Prognosis worsens with more number of lymph node involvements.
  - Breslow's tumour thickness:** Prognosis worsens with increasing thickness of the tumor.
30. How do you follow-up the patient with malignant melanoma?
- First 2 years – follow-up at an interval of 3 – 4 months.
  - Next 3 years – every 6 months.
  - Afterwards – yearly follow-up.
  - Follow-up evaluation includes physical examination, chest X-ray, serum LDH estimation, USG and CT scan of abdomen, pelvis, chest and brain in selected cases.
31. Which hormones control melanin production?
- MSH or Melanocyte stimulating hormone from the anterior pituitary.
  - ACTH.
  - Sex hormones—estrogen and androgen. See also Malignant Melanoma in chapter 12.

## MARJOLIN'S ULCER

### Case Summary

The 50-year-old male patient presents with a gradually increasing ulcer over a burn scar for last three years in the left arm.

The patient had a burn injury of left upper limb 8 years back. There is no axillary lymphadenopathy.

On examination, the lesion (ulcer) has a size of 8 cm  $\times$  6 cm, margins are rolled out, floor is covered with necrotic tissue. Axillary lymph nodes are not palpable.

1. What is your diagnosis?  
This is a case of Marjolin's ulcer of the left arm developing in a postburn scar with no evidence of lymph node metastasis.
2. What is Marjolin's ulcer?  
It is a low grade squamous cell carcinoma developing on a chronic benign ulcer or a long-standing scar tissue.
3. What are the common causes of Marjolin's ulcer?
  - a. Postburn scar.
  - b. Varicose ulcer.
  - c. Postradiation ulcer.
  - d. Chronic ulcer due to trauma.
  - e. Lupus vulgaris scar.
4. What are the characteristic features of Marjolin's ulcer?
  - a. It grows slowly as the scar tissue is avascular.
  - b. It is painless as the scar tissue contains no nerves.
  - c. Lymphatic metastasis does not occur as they are destroyed in a scar.
5. How will you treat the case?
  - a. At first diagnosis is confirmed by incisional biopsy from the margin of the ulcer.
  - b. Wide local excision is done with 1cm margin of healthy normal tissue.
6. What is the role of radiotherapy?  
As scar tissue is relatively avascular, Marjolin's ulcer is relatively resistant to radiotherapy.

# Chapter 80

## Neck Swellings

- Ranula
- Cystic hygroma
- Branchial cyst
- Branchial sinus
- Thyroglossal cyst
- Tubercular cervical lymphadenopathy

### RANULA

#### Case Summary

The 2-year-old female patient presents with a swelling in the floor of mouth for last 1 year. The swelling was very small at the outset but is slowly increasing in size.

On examination, the swelling is soft cystic, size 5 cm × 3 cm, right sided, bluish in color, situated between the under surface of tongue and the symphysis menti. It is brilliantly transilluminant.

(For plunging ranula, cross fluctuation is positive between the neck swelling and swelling in the floor of mouth).

1. What is your diagnosis?  
This is a case of ranula on the floor of mouth.
2. Why do you say so?
  - a. Unilateral bluish cystic swelling.
  - b. Situated in the floor of mouth between under surface of tongue and symphysis menti.
  - c. It is brilliantly transilluminant.
3. What is ranula?  
It is a mucous retention cyst arising from the mucous glands situated on the floor of mouth. The name of the glands are glands of Blandin and Nuhn.
4. Why this cyst is called ranula?

As this swelling looks like the belly of a frog (Rana in Latin = frog), it is called ranula.

5. What is plunging ranula?  
When the ranula extends into the neck along the posterior border of mylohyoid muscle and appears in the submandibular region, it is called plunging ranula.
6. What are other possibilities?
  - a. Sublingual dermoid in which transillumination is negative.
  - b. Hemangioma – Compressible.
  - c. Lymphangioma – Also compressible.
7. How do you treat the case?
  - a. Complete excision of the cyst.
  - b. Marsupialization (excision of the roof) is done if complete excision is not possible. The cyst wall with overlying mucous membrane is excised. Cut margin of cyst wall and mucous membrane are sutured. So the cyst becomes open mouthed preventing any further mucous retention.
8. What are the complications of ranula?
  - a. Repeated bursting of the ranula and reaccumulation.
  - b. Infection
  - c. A big ranula may cause difficulty in speech and swallowing.

### CYSTIC HYGROMA

#### Case Summary

The 3-year-old female child presents with a gradually increasing swelling on the right side of neck since birth.

On examination, the swelling is soft cystic occupying whole of the right side of neck. The swelling is brilliantly transilluminant and fluctuation is positive, surface lobulated, margins not well-defined on all sides.

The swelling is free from skin and underlying structures and increases in size when the child cries.

1. What is your diagnosis?  
This is a case of cystic hygroma on the right side of neck.
2. What are the points in favor of your diagnosis?
  - a. Swelling is present since birth.
  - b. Increase in size when the child cries.
  - c. Surface is lobulated and fluctuation, positive.
  - d. Swelling is brilliantly translucent, which is the classical feature.
3. What are other possibilities?
  - a. Branchial cyst.
  - b. Cold abscess.
  - c. Solitary lymphatic cyst.
4. What is cystic hygroma?  
This is a congenital malformation of lymphatic channels that fail to connect into the main lymphatic pathways that is jugular lymph nodes situated between the internal jugular vein and subclavian vein.
5. What are other sites of cystic hygroma?
6. What is the content of cystic hygroma?
7. What are the atypical presentations?
8. What are the complications?



9. What is the treatment?  
Vide 'Cystic Hygroma' in the chapter 22 on 'Neck Swellings'.
10. Which are cysts that contain cholesterol crystals?
  - a. Branchial cyst.
  - b. Thyroglossal cyst.
  - c. Hydrocele.
  - d. Cystic hygroma.
  - e. Dental cyst.

## BRANCHIAL CYST

### Case Summary

The 40-year-old male patient presents with a painless swelling on the right lateral aspect of upper part of neck for last three years. The swelling is gradually increasing in size. No other swelling is present in other parts of the body.

On examination, the swelling is soft, cystic 5 cm × 3 cm in size, situated medial to the sternocleidomastoid muscle in its upper third.

The swelling has smooth surface, rounded margin, free from the skin and underlying structures, fluctuation positive but transillumination is negative.

On sternomastoid contraction test, the swelling becomes less prominent. Cervical lymph nodes are not enlarged.

1. What is your diagnosis?  
This is a case of branchial cyst in the right side of the neck.
2. What are the points in favor of your diagnosis?
  - a. Painless swelling in upper right lateral part of neck for last three years.
  - b. It is situated medial to the right sternocleidomastoid muscle in its upper third.
  - c. Regional lymph nodes are not enlarged.
  - d. Swelling is 5 cm × 3 cm, soft cystic, fluctuation and transillumination, negative.
3. What are other possibilities?
  - a. Chronic cervical lymphadenitis.
  - b. Cold abscess in the neck.
  - c. Cervical dermoid—lateral variety.
  - d. Carotid body tumor which is a solid swelling.
  - e. Submandibular salivary gland swelling.
4. What are the cysts that contain cholesterol in their contents?  
Vide earlier in cystic hygroma.

5. What is the origin of branchial cyst?
6. What is the treatment?
7. What precautions are taken during excision?  
Vide the 'Branchial cyst' in the chapter 22 on Neck Swellings.

## BRANCHIAL SINUS (OR FISTULA)

### Case Summary

The 2-year-old male child presents with a discharging sinus in the lower part of the neck on the left side which sometimes discharges mucous like material since birth.

On examination, the opening of the sinus is situated in the lower third of neck at the anterior border of sternomastoid. Surrounding skin shows excoriation.

Cervical lymph nodes are not palpable and the opening does not move up on protrusion of tongue.

1. What is your diagnosis?  
This is a case of branchial sinus on the left side of neck.
2. Why do you say so?
  - a. The child has the discharging sinus since birth.
  - b. The opening is situated in the lower third of the neck at the anterior border of sternocleidomastoid.
  - c. Surrounding skin shows excoriation and the discharge is mucoid or watery.
  - d. The lymph nodes are not palpable and the opening does not move up on protrusion of tongue.
3. Is it congenital or acquired?  
It may be congenital or acquired. This can be diagnosed by its situation.
  - a. Congenital – The external opening is at the anterior border of sternomastoid muscle at the junction of lower and middle 1/3rd
  - b. Acquired – The opening is at the level of the branchial cyst. It is the rarer type.
4. How does the acquired sinus develop?  
It develops either due to
  - a. Bursting of the infected branchial cyst.  
Or
  - b. Inadvertent incision over the infected branchial cyst while mistaking it for an abscess.

5. Is it sinus or fistula?  
In most of the cases, the internal opening is not found so this is better called a branchial sinus rather than a fistula.
6. Where does the fistulous tract open?  
The tract pierces the deep fascia at the upper border of the thyroid cartilage. It passes through the fork of the common carotid bifurcation.  
It passes deep to the posterior belly of digastric and opens into the anterior aspect of the posterior pillar of the fauces just behind the tonsil.  
But in most of the cases, it cannot reach the pharynx.
7. How do you assess the sinus tract preoperatively?  
By doing a sinogram.
8. How do you treat the case?  
Complete excision of the sinus tract.
9. What is the tract lined by?  
It is lined by stratified squamous epithelium.
10. What is the mechanism of formation of branchial sinus or fistula?  
Vide 'branchial fistula' in the chapter 22 of 'Neck Swellings'.

## THYROGLOSSAL CYST

### Case Summary

The 15-year-old female patient presents with a painless, globular swelling, 1.5 × 1.5 cm size, situated just below the hyoid bone in the midline for last two years.

On examination, the swelling moves up on deglutition and on protrusion of the tongue. Transillumination test is negative.

1. What is your diagnosis?  
This is a case of thyroglossal cyst at the subhyoid region.
2. What are the points in favor of your diagnosis?
  - a. The swelling is globular and small, situated below the hyoid bone in midline.
  - b. Moves up with deglutition.
  - c. Moves up on protrusion of the tongue.
  - d. Transillumination test is negative.
  - e. It is painless.
3. What are other possibilities?
  - a. Cervical dermoid cyst.
  - b. Ectopic thyroid gland.
  - c. Subhyoid bursal cyst.
  - d. Enlarged cervical lymph node.

All the above swellings move up with deglutition but do not move up on protrusion of tongue.

4. How thyroglossal cyst is formed?
5. What is thyroglossal cyst?  
A tubuloembryonic dermoid cyst.
6. What is the lining of the cyst?
7. What is the treatment?  
Vide 'thyroglossal cyst' in the chapter 22 on 'neck swellings'.
8. What is Sistrunk's operation?
  - a. Excision of the cyst along with the tract with few fibers of posterior part of the base of tongue.
  - b. Hyoid bone is divided at the body to facilitate tract dissection.
9. What is the location of the cyst?
  - a. Suprahyoid.
  - b. Subhyoid
  - c. Over thyrohyoid membrane.
  - d. At thyroid cartilage
  - e. At foramen cecum.
10. What is thyroglossal fistula?
  - a. It is always acquired.
  - b. Follows incision and drainage of an infected thyroglossal cyst or incomplete removal.
  - c. It is usually covered with a hood of skin.
  - d. Moves with protrusion of tongue.
  - e. Differential diagnosis is tubercular sinus.
  - f. Treatment is excision of the sinus along with the tract from base of the tongue – Sistrunk's operation.

## TUBERCULAR CERVICAL LYMPHADENOPATHY

### Case Summary

The 5-year-old male patient presents with a swelling in the left upper part of neck for last one year. The swelling was initially small but is rapidly growing in size for last 4 months. There is family history of tuberculosis.

On examination, there is a swelling in the left side of neck at the level of upper border of thyroid cartilage, 4 cm × 3 cm in size, well-defined margin, firm in consistency, free from skin and underlying structures. Thyroid gland is not palpable.

1. What is your diagnosis?  
It is a lymph node swelling.
2. Why do you call it a lymph node mass?
  - a. Common site.
  - b. Firm in consistency.
  - c. There is family history of tuberculosis.
  - d. The swelling is partly deep to the sternocleidomastoid muscle.
3. What are other possibilities?
  - a. Chronic pyogenic lymphadenitis.
  - b. Lymphoma (Hodgkin's leukemia),
  - c. Chronic lymphatic leukemia.
  - d. Carotid body tumor.
  - e. Metastatic cervical nodes.
4. What are the causes of cervical lymphadenopathy?
  5. What are the stages of tuberculous lymphadenitis?
  6. What investigations would you like to do to confirm your diagnosis?
  7. What is the treatment of tubercular lymphadenitis?
  8. What is the role surgery in tubercular lymphadenitis?  
Vide 'Cervical Lymphadenopathy' in the chapter 22 on Neck Swellings.
  9. What is Hodgkin's disease?  
This is a type of malignant lymphoma involving the lymph nodes.
  10. What are changes in lymph nodes?
    - a. Lymph nodes become enlarged and pink in color.
    - b. There is no differentiation between cortex and medulla.
    - c. The nodes become rubbery in feel.
    - d. Lymphocytic infiltration of lymph nodes or other extralymphatic organs destroys the normal architecture.
  11. What are the characteristic microscopical features?  
Microscopically, there is cellular infiltration of nodes with lymphocytes, histiocytes, eosinophils, Reed-Sternberg giant cells and fibrous tissue.
  12. What are Reed-Sternberg giant cells?
    - a. Here nucleus divides but cytoplasm does not, so that nucleus is bilobed.
    - b. It is also found in infections mononucleosis and other lymphomas.

## Salivary Glands

- Parotid swelling
- Carcinoma of parotid gland
- Parotid fistula
- Chronic submandibular sialoadenitis due to submandibular duct calculus
- Carcinoma of submandibular salivary gland

### PAROTID SWELLING (MIXED PAROTID TUMOR)

#### Case Summary

The 45-year-old male patient presents with a swelling occupying the area below, in front of and behind the lobule of right ear, obliterating the furrow behind the ramus of the mandible for last 5 years.

The swelling is painless and slowly increasing in size. There are not other swellings in the body.

On examination, there is a firm swelling in the right parotid region 7cm × 5cm in size. Surface is smooth, rubbery hard in consistency, margins well-defined and rounded, free from skin and underlying structures.

There is no evidence of facial nerve palsy and palpable lymph nodes in the neck.

1. What is your diagnosis?  
This is a case of mixed parotid tumor on the right side.
2. Why do you say so?
  - a. Swelling is in the parotid region.
  - b. It is slow growing, painless, present for long 5 years.
  - c. It is rubbery hard in consistency and free from the underlying structures and the overlying skin.
  - d. Facial nerve is not involved.
  - e. Mixed parotid tumor is the most common benign parotid tumor.

3. How do you palpate the parotid gland?
  - a. The superficial lobe of the parotid gland is palpated with the palmar aspect of the fingers over the parotid region.
  - b. The deep part of the gland is palpated by bidigital palpation with one finger inside the mouth behind the tonsillar fossa and the other finger outside in the parotid region.
4. Where does the parotid duct open?  
The parotid duct (Stensen's duct) opens on the buccal aspect of cheek opposite the crown of upper second molar tooth.
5. What are the symptoms of facial nerve palsy?
  - a. There is deviation of the angle of mouth while laughing, talking, etc. and difficulty in lip movement, blowing and whistling due to paralysis of orbicularis oris.
  - b. Difficulty in closing the eyes due to paralysis of orbicularis oculi.
  - c. Absence of corrugations in the forehead as the patient tries to frown suggests paralysis of corrugator supercilii.
  - d. Absence of furrows in the forehead as the patient looks up suggests paralysis of frontal belly of occipitofrontalis.
  - e. The patient is asked to blow with the mouth closed. Inability to do so indicates paralysis of buccinator muscle.
6. What is the differential diagnosis?
  - a. Adenolymphoma or Warthin's tumor.
  - b. Chronic sialoadenitis.
  - c. Carcinoma of parotid gland.
  - d. Cervical lymphadenopathy due to tuberculosis, lymphoma or metastasis.
  - e. Neurofibroma.
  - f. Lipoma.
7. Why the tumor is called mixed parotid tumor or pleomorphic adenoma?  
It is so called because of its mixed histologic appearance viz. myxoid, mucoid, chondroid or cartilaginous and adenomatous elements in the tumor.
8. What complications can occur?
  - a. Malignant transformation.
  - b. Facial nerve involvement.
  - c. Spread to local lymph nodes.
9. What are the signs of malignant transformation?
  - a. Rapid growth.
  - b. Appearance of pain.
  - c. Tumor getting fixed to deep structures.
  - d. Involvement of local lymph nodes.
  - e. Consistency hard.
  - f. Facial nerve involvement.
10. How facial nerve is related to the parotid gland?
  - a. The facial nerve emerges from the stylomastoid foramen and enters the gland at the upper part of posteromedial surface.
  - b. Within the gland the nerve divides and rejoins to form a plexus known as plexus anserinus ultimately 5 branches come out of this plexus through the upper

pole, anterior border and lower pole of the gland. These branches are:

- i. Temporal.
  - ii. Zygomatic.
  - iii. Buccal.
  - iv. Mandibular and
  - v. Cervical.
11. How will you treat this patient?
    - a. FNAC is done from the swelling to confirm the diagnosis.
    - b. If the report is benign, superficial parotidectomy is done.
  12. Can FNAC cause tumor implantation?
 

Evidences suggest that FNAC using 18G needle does not cause implantation of tumor cells in the needle tract.
  13. Would you like to do an incisional biopsy?
 

No, as there is chance of tumor cell implantation and parotid fistula.
  14. What is superficial parotidectomy?
 

Removal of superficial part of the parotid gland lying superficial to fasciovenous plane is known as superficial parotidectomy.
  15. What is Patey's fasciovenous plane?
 

It is the plane between the superficial and deep lobe formed by retromandibular vein and the fascial nerve.
  16. How retromandibular vein is formed and how does it end?
    - a. The retromandibular vein is formed by the union of superficial temporal and maxillary veins, within the parotid gland.
    - b. It ends below by dividing into anterior and posterior divisions.
 

Anterior division joins with the fascial vein to form the common facial vein, while the posterior division joins with the posterior auricular vein to form the external jugular vein.
  17. What is the arrangement of structures in the fasciovenous plane?
 

The structures within the gland from outside inwards are arranged as below:

    - a. Facial nerve and its branches.
    - b. Retromandibular vein.
    - c. External carotid artery.
  18. What are the commonest benign and malignant tumors of the parotid gland?
    - a. 80 percent of parotid gland tumors are benign and 20 percent are malignant.
    - b. Mixed parotid tumor or pleomorphic adenoma is the commonest benign tumor.
    - c. Mucoepidermoid carcinoma is the commonest malignant tumor.
  19. What are the different tumors of the parotid gland?
 

There are mainly three types of tumors viz.

    - a. Epithelial tumors.
    - b. Nonepithelial tumors
    - c. Metastatic carcinoma
    - I. Epithelial tumors – 90 percent.
      1. Benign (80%) – Adenomas which are of three types viz.
        - i. Pleomorphic adenomas (80%).
        - ii. Monomorphic adenomas, e.g. adenolymphoma or Warthin's tumor, oxyphilic adenoma, etc.
        - iii. Other types like myoepithelioma, clear cell adenoma.
      2. Malignant tumors
        - i. Mucoepidermoid carcinoma.
        - ii. Pleomorphic adenocarcinoma.
        - iii. Adenocystic carcinoma.
        - iv. Acinic cell carcinoma.
        - v. Adenocarcinoma.
        - vi. Epidermoid carcinoma.
        - vii. Undifferentiated carcinoma.
      - II. Nonepithelial tumors, e.g. fibroma, neurofibroma hemangioma, sarcoma, etc. These are very rare.
      - III. Metastatic carcinoma – Secondary to epidermoid carcinoma, malignant melanoma, etc.
    20. What is the incidence of mixed parotid tumor turning malignant?
 

In about 2–3 percent cases, the tumor may turn malignant.
    21. What is the incision for superficial parotidectomy?
 

The incision starts below the zygomatic process just in front of the tragus, then curves round the ear lobule and then descends downwards along the anterior border of the upper third of sternocleidomastoid muscle.
    22. How to recognize the facial nerve at the time of surgery?
      - After incising the deep cervical fascia, the lower pole of the parotid gland, is dissected and lifted up.
      - The digastric muscle (posterior belly) is traced upto the mastoid process. Facial nerve is in between the muscle and tympanic plate.
      - To use nerve stimulator.
      - Gentle handling, good suction, perfect hemostasis helps in the clear recognition of the nerve.
    23. What is the treatment of malignant pleomorphic adenoma?
 

Radical parotidectomy (removal of whole gland, facial nerve, parotid duct, fibers of masseter, buccinator, pterygoids and radical block dissection of the neck).
    24. What is the Frey's syndrome?
 

This is a condition of gustatory sweating and flushing in the parotid region following parotidectomy and may occur in upto more than 50 percent of patients. It occurs as a result of partial injury to the auriculotemporal nerve.

Other causes of the syndrome – Injury due to:

      - a. Birth trauma.
      - b. Accidental injury.
      - c. Inadvertent injury following incision and drainage of parotid abscess.
    25. What is the explanation of this syndrome?
 

Following injury to the auriculotemporal nerve postganglionic parasympathetic fibers from the otic ganglion, become united to the sympathetic nerves from the superior cervical ganglion, which are to supply vessels and sweat glands of that region. This causes flushing and sweating of skin.
    26. What is the treatment?
      - Surgical intervention is not helpful.
      - Patient manages to live with this as there may be spontaneous recovery in some cases.

Some local antiperspirant may help.

### **CARCINOMA OF PAROTID GLAND**

The 52-year-old male patient presents with a swelling over the right parotid region for last 2 years. Initially the swelling was increasing slowly but for the last 6 months it had a rapid increase in size associated with dull aching pain.

On examination, on general survey the patient has pallor. The swelling is 7cm × 5cm size, surface lobulated, margins rounded, hard in consistency. The skin is adherent near the center of the swelling. Testing of the facial nerve reveals a lower motor neuron type of palsy on the right side.

There are no palpable lymph nodes in the neck.

1. What is your diagnosis?  
This is a case of carcinoma of right parotid gland with facial nerve palsy.
2. What are the points in favor of your diagnosis?
  - a. Rapid growth of the swelling.
  - b. Hard in consistency.
  - c. Facial nerve palsy is present.
  - d. Skin is adherent near the center of the swelling.
3. What are the malignant tumors of the parotid gland?
  - a. Mucoepidermoid carcinoma – commonest.
  - b. Acinic cell carcinoma.
  - c. Adenoid cystic carcinoma or cylindroma.
  - d. Undifferentiated carcinoma.
  - e. Carcinoma in pleomorphic adenoma.
4. What are the slow growing malignancies? Mucoepidermoid carcinoma and acinic cell carcinoma.
5. What are the rapidly growing malignancies? Adenocarcinoma, anaplastic carcinoma, adenoid cystic carcinoma and carcinoma in pleomorphic adenoma.
6. What is the TNM classification of parotid tumors?
 

T – Primary tumor.

T<sub>X</sub> – Primary tumor cannot be assessed.

T<sub>0</sub> – No clinical evidence of primary tumor.

T<sub>1</sub> – Tumor < 2 cm in greatest dimension, without extraparenchymal extension. Extraparenchymal extension is clinical or macroscopic evidence of invasion of soft tissues or nerve except those listed under 4a and 4b. Microscopic evidence alone does not constitute extraparenchymal extension.

T<sub>2</sub> – Tumor > 2 cm but not more than 4 cm, without extraparenchymal extension.

T<sub>3</sub> – Tumor > 4 cm and / or extraparenchymal extension.

T<sub>4a</sub> – Tumor invades skin, mandible, ear canal or facial nerve.

T<sub>4b</sub> – Tumor invades base of skull, pterygoid plates or encases carotid artery.

N – Regional lymph nodes.

N<sub>X</sub> – Regional lymph nodes cannot be assessed.

N<sub>0</sub> – No regional lymph node metastasis.

N<sub>1</sub> – Metastasis is a single ipsilateral lymph node 3 cm or less in greatest dimension.

N<sub>2</sub> – Metastasis in single ipsilateral lymph node 3 – 6 cm in greatest dimension.

N<sub>2b</sub> – Multiple ipsilateral lymph nodes, none greater than 6 cm in greatest dimension.

N<sub>2c</sub> – Metastasis in a lymph node, more than 6 cm in greatest dimension.

M – Distant metastasis.

M<sub>0</sub> – No distant metastasis.

M<sub>1</sub> – Distant metastasis to bone, lungs, etc.

7. What is the role of radiotherapy?
  - a. The tumor is radioresistant, so surgery is the treatment of choice.
  - b. Local recurrences should be treated by radiotherapy.
  - c. When complete removal is not possible, superficial parotidectomy along with radium implantation is the treatment of choice.
8. What is role of radical neck dissection?
  - a. Low grade malignancies like mucoepidermoid carcinoma, acinic cell carcinoma do not require radical neck dissection.
  - b. In case of high grade malignant lesions like undifferentiated carcinoma, high grade mucoepidermoid carcinoma radical neck dissection should be accompanied by complete parotidectomy.
9. What is the role of chemotherapy?
  - a. Chemotherapy has very limited role in parotid carcinoma.
  - b. It has been tried in the treatment of advanced inoperable disease.
  - c. A combination of methotrexate and 5Fu has been used with some success.
10. When will you consider incisional biopsy in parotid carcinoma?  
Incisional biopsy is contraindicated in parotid tumor. Incisional biopsy is only justified when there is skin ulceration due to malignant parotid tumor when biopsy from the margin of the ulcer will help in diagnosis.
11. How will you manage facial nerve injury during operation?

When nerve is divided inadvertently it may be sutured. If a segment of nerve is sacrificed during radical surgery primary grafting by using great auricular nerve or hypoglossal nerve may be done. Hypoglossal nerve may be transposed for anastomosis to the peripheral branches of facial nerve.

12. How will you identify facial nerve during surgery?

The facial nerve emerges through the stylomastoid foramen and following are the important landmarks for the identification of the nerve during surgery.

- There is a palpable groove between the bony external auditory meatus and the mastoid process which is filled with fibrofatty tissue. The facial nerve lies deep in this groove.
- The styloid process itself can be palpated superficial to the stylomastoid foramen and nerve is identified just lateral to the styloid process.
- The posterior belly of digastric muscle is inserted into the mastoid process, just behind the stylomastoid foramen. By dissection at the medial border of the posterior belly of digastric near its insertion, facial nerve may be identified.

13. What will happen if great auricular nerve is injured during parotidectomy?

This results in an area of anesthesia around the angle of mandible and ear lobe. This is troublesome in female who finds it difficult to wear ear rings. Spontaneous recovery may occur in 18 months.

14. How will you approach the deep lobe of the parotid gland?

Approach is by a standard parotidectomy incision. A normal superficial parotidectomy is done with preservation of facial nerve branches.

- The facial nerve branches are mobilized and lifted in nylon slings.
- The deep part of the gland is then dissected all around and removed. It is easy to dissect the deep lobe by finger or a sharp dissection with scissors.
- Only rarely it is necessary to do a mandibulectomy to guide access to the deep lobe.

15. What is dumb-bell parotid tumor?

Tumor arising from the deep part of the parotid gland enlarges medially passing



between the styloid process and mandible to present as a swelling of the soft palate on the lateral wall of the pharynx behind the posterior pillar of tonsil.

There is no visible swelling in the preauricular region.

This tumor with the component in the neck and the lateral pharyngeal budge is called the dumb-bell parotid tumor.

16. What are the characteristics of adenoid cystic carcinoma?

- Adenoid cystic carcinomas are extremely slow growing tumors.
- Histology shows characteristic cribriform appearance.

### Spread

- The peculiarity is that the tumor has relentless perineural lymphatic spread along the facial nerve into the brain.
- Invasion into the base of the skull is a common mechanism of death.
- 20 percent of patients survive 5 years.
- Thus adenoid cystic carcinomas are more extensive than the clinical signs or radiographic appearance suggest.

17. How will you treat patients with adenoid cystic carcinoma?

Radical parotidectomy followed by radial postoperative radiotherapy. The radiotherapy should include the skull base in order to control the perineural tumor extension.

18. What are the characteristics of mucoepidermoid carcinoma?

These tumors are the commonest parotid malignancy. It is usually a radiation induced salivary gland tumor.

Clinical features – female predominance.

Macroscopic—Poorly defined, partially encapsulated, solid-cystic or semi-cystic tumor.

Microscopic—There are cords, sheets or cystic configurations of squamous and mucus secreting cells. The grade of squamous component determines the prognosis. Facial nerve involvement is usually present.

Prognosis—75 percent of patients survive 5 years Prognosis is poor if histological evidence of lymphatic invasion or capsule infiltration is there.

19. What are the characteristics of acinic cell tumor?

Uncommon, incidence-1 to 3 percent of parotid tumors.

Macroscopic – Encapsulated, lobulated tumor with areas of hemorrhage and necrosis.

Microscopic – Arrangement of tumor cells resembles cords, sheets or glandular pattern of rounded cells similar to normal acinar cells.

Prognosis – 75 percent 5 years survival after adequate resection.

## PAROTID FISTULA

### Case Summary

The 15-year-old male child presents with watery discharge from the right parotid region for last 1½ months.

Patient gives history of a very painful swelling and fever 2 months back for which an incision and drainage operation was done 10 days after the onset of swelling.

Following the operation, the swelling disappeared but the patient complained of watery discharge from the site of incision. The discharge increases during intake of food.

On examination, there is a cruciate scar over the right parotid region and there is a small opening at the upper part of the parotid area through which the discharge comes out.

1. What is your diagnosis?

This is a case of parotid fistula on the right side following incision and drainage of the parotid abscess.

2. What are other causes of parotid fistula?

3. What is the type of parotid fistula?

4. What is the treatment of fistula from the main duct?

5. What is the drug treatment of gland fistula? Vide 'parotid fistula' in the chapter 18 on salivary glands.

## CHRONIC SUBMANDIBULAR SIALOADENITIS DUE TO SUBMANDIBULAR DUCT CALCULUS

### Case Summary

The 35-year-old female patient presents with a swelling in the right submandibular region for last 1 year.

The swelling gets aggravated and painful during intake of food especially while sucking the lemon.

Initially the swelling used to disappear in between meals but for last 3 months, the swelling is persistent and becomes aggravated during intake of meals.

On examination, a swelling is palpable in the submandibular region. A stone is palpable in the submandibular duct in the floor of mouth.

1. What is your diagnosis?

This is a case of right sided submandibular chronic sialoadenitis due to calculus in the submandibular duct.

2. What are the points in favor of your diagnosis?

- Swelling increases during meals.
- Patient complains of pain during meals.
- The stone is palpable in the submandibular duct in the floor of mouth.
- The swelling is palpable by bidigital examination.

3. What is the common differential diagnosis? Submandibular lymph node enlargement.

But in bidigital examination the lymph gland is not palpable while the submandibular gland enlargement is palpable as the deep part of the gland is deep to myelohyoid and lymph node is superficial to it.

4. How will you confirm the diagnosis?

It is confirmed mainly by clinical examination. Straight X-ray of floor of mouth (intraoral occlusal view) shows the calculus. Sometimes the stone may be radiolucent due to poor mineral content.

5. What is salivary calculus?

- It resembles dental tartar.
- The salivary calculus consists of phosphates and carbonates of calcium and magnesium mixed with cellular debris and mucus.

6. Why calculus formation is common in submandibular gland?

- The secretion is viscid in nature due to higher mucin content.
- Secretion moves against gravity as the duct moves upwards, so stasis is common.
- The secretion is rich in salts.

7. What is the size and shape of stone? Size varies from a millet to a pea.

Shape – oval or elongated.

8. What is Sjögren's syndrome?

- This consists of symmetrical enlargement of all the salivary and lacrimal glands.

- b. There may be systemic manifestations of generalized arthritis, scleroderma or polyarteritis nodosa.
9. How will you treat this patient?
- Stone in the submandibular duct is removed by making an incision directly over it through the mucous membrane of the mouth under local or general anesthesia.
  - Stone in the submandibular gland – excision of the gland is done under general anesthesia.
10. What are other indications of excision of the submandibular gland?
11. What are the steps of operation of excision of the submandibular salivary gland?  
Vide submandibular calculi in the chapter 18 on salivary glands.
12. What structures may be injured during excision of the submandibular gland?
- Hypoglossal and lingual nerve.
  - Facial artery and vein.
  - Cervical branch of facial nerve.
- There is no lymph node enlargement in the neck.
- What is your diagnosis?  
This is a case of carcinoma of right submandibular salivary gland, without any lymph node metastasis.
  - What are the points in favor of your diagnosis?
    - The swelling is in the right submandibular triangle.
    - It is palpable bidigitally and hard in consistency.
    - There is no alteration of size during the meals.
  - What is the differential diagnosis?
    - Mixed tumor of the submandibular gland.
    - Metastatic submandibular lymph node.
    - Malignant lymphoma.
    - Tuberculosis of submandibular gland.
  - How do you confirm the diagnosis?  
By doing a fine needle aspiration cytology or FNAC.
  - How will you treat this case?  
Excision of the submandibular gland followed by postoperative radiotherapy.
  - What nerves may be injured during excision of the submandibular salivary gland?
    - The mandibular branch of facial nerve.
    - The hypoglossal nerve.
    - The lingual nerve
    - The cervical branch of facial nerve.
  - What are the anatomical parts of submandibular gland?
    - The submandibular gland situated in the submandibular triangle is divided into superficial and deep parts by the mylohyoid muscle.
    - The deep part of the gland lies between the mylohyoid and hyoglossus muscle.
  - Both parts are continuous around the posterior border of mylohyoid muscle.
  - The superficial part of the gland lies on mylohyoid, hyoglossus and the middle constrictor muscle of pharynx and is covered by the skin, platysma and deep cervical fascia.
  - Which artery lies in relation to the submandibular gland?  
The facial artery.
  - Where does the submandibular duct open?
    - The submandibular duct (Wharton's duct) emerges from the deep surface of superficial part of the gland and runs in the floor of the mouth along the side of tongue to open in the sublingual papilla on either side of frenum.
    - The sublingual gland lies just lateral to the submandibular duct.
  - What is the nerve supply of the gland?
    - The gland is supplied by both parasympathetic and sympathetic nerves, both of which are secretomotor to the gland.
    - The parasympathetic stimulation produces watery secretion, whereas sympathetic stimulation produces sticky mucus rich fluid. The sympathetic also provides vasomotor supply.
    - The preganglionic parasympathetic fibers arise from superior salivary nucleus in the pons and pass successively through the facial, chordatympani and lingual nerves to terminate in the submandibular ganglion, relay here and the postganglionic fibers reach the submandibular gland through lingual nerve.
    - The sympathetic fibers reach the gland around facial artery and convey postganglionic fibers from superior cervical ganglion of the sympathetic trunk.

## CARCINOMA OF SUBMANDIBULAR SALIVARY GLAND

### Case Summary

The 60-year-old male patient presents with a swelling in the right upper lateral side of neck for last one year.

Initially the swelling was gradually increasing in size but attained this large size due to rapid increase in the last three months.

There is no alteration in size during meals.

On examination, the swelling is palpable in the right submandibular triangle.

The swelling is nontender, hard in feel, surface irregular, margins rounded, bidigitally palpable.

## Mouth and Oral Cavity

- Cleft lip
- Cleft palate
- Carcinoma tongue
- Carcinoma lip

### CLEFT LIP

1. What is your case?  
This is a case of congenital left sided incomplete uncomplicated cleft lip without any other congenital abnormalities.
2. Why do you say so?
  - a. It is present since birth and there is no history of upper lip injury, so it is congenital.
  - b. Cleft has not reached upto nostril, so it is incomplete.
  - c. It is not associated with cleft palate, so it is uncomplicated.
3. Why does it develop?  
It is developed due to failure of fusion between left sided median nasal process and maxillary process, at the time of development of the upper lip.
4. What is the development of upper lip?
  - a. At about the 6th week of intrauterine life, the stomodeal depression develops at the cephalic end of fetus. Around this depression there are five elevated processes viz.
    - i. Single frontonasal process.
    - ii. Two maxillary processes – one on either side.
    - iii. Two mandibular processes – one on each side.
  - b. The two mandibular processes fuse in the midline to form the lower lip and lower jaw.
  - c. The frontonasal process – This arises from the capsule of the forebrain vesicle and descends like a curtain. The frontonasal process divides into two lateral nasal processes and one median nasal process by the two olfactory pits which are future nostrils.
  - d. The lateral nasal process moves up and the median nasal process on either side fuses with the maxillary process to form the upper lip.
5. How do you classify cleft lip?
6. What are the problems with cleft lip?
7. What is the optimum time of repair of cleft lip?
8. What operation is done for unilateral cleft lip repair?
9. What are the underlying principles of operation?
10. What is the postoperative care?  
Vide the chapter 20 on cleft lip and palate.

### CLEFT PALATE

1. What is your case?  
This is a case of cleft of soft and hard palate with intact premaxilla in an one year old baby. There is no associated cleft lip.
2. How does the palate develop?
  - a. Palate is developed from three components viz. two palatine processes and the premaxilla.
  - b. Two palatine processes appear from the maxillary process, grow beneath the olfactory pits and ultimately fuse to form the part of the hard palate, known as primary palate.
  - c. Premaxilla which is developed from the median nasal process fills up the triangular gap anteriorly between the

- two palatine processes. It is also called the secondary palate.
3. What are the types of cleft palate?
  - a. Complete – When there is a gap between two halves of the palate in its entire length so that the nose and mouth are interconnected. In front this gap may pass on one side of premaxilla or on both sides.
  - b. Incomplete – This is due to defective fusion of the palatine processes and may be of the following types.
    - i. Bifid uvula.
    - ii. Cleft in the whole soft palate.
    - iii. Cleft in the whole soft and posterior part of hard palate.
4. What are the problems with cleft palate?
5. What is the optimum time of operation and the rule of 10 applied for cleft palate?
6. What operation is done and what are the principles of operation for cleft palate?  
Vide the chapter 20 on cleft lip and cleft palate.

### CARCINOMA TONGUE

#### Case Summary

The male patient aged 55 years presents with an ulcer on the left lateral margin of tongue for last 2 years. The ulcer was initially small but for last 8 months it has a rapid increase to attain the present size.

Patient complains of excessive salivation for last 6 months. He is a chronic smoker for last

20 years and used to chew tobacco for last 10 years. There is no lump palpable in the neck.

On examination, the ulcer is 3 cm × 2 cm size, the base is indurated, margin, irregular and everted and floor is covered with necrotic tissue which bleeds to touch. The cervical lymph nodes are not palpable.

1. What is your diagnosis?

This is a case of ulcerative type of carcinoma tongue on left lateral aspect of the tongue without any lymph node metastasis.

2. Why do you say so?

a. Elderly male patient.

b. Patient is a chronic smoker and used to chew tobacco for a long 8 years.

c. Locally ulcer shows features of malignancy, e.g.

- Margin irregular and everted.
- Base is indurated.
- Floor covered with necrotic tissue which bleeds to touch.
- Located in the anterior 2/3rd of tongue.

3. What are the predisposing factors?  
5 'S'

a. Oral sepsis and Chronic superficial glossitis

b. Sharp tooth or ill fitting denture.

c. Spirit or excess alcohol intake.

d. Smoking.

e. Spices.

4. What are the premalignant factors?

a. Leukoplakia of tongue.

b. Sessile papilloma of tongue.

5. What are the causes of pain in carcinoma tongue?

a. Involvement of lingual nerve – pain is referred to ear.

b. Infection with sloughing.

c. Pain during swallowing when growth is located in the posterior 1/3rd of tongue.

6. What are the common sites of carcinoma tongue and percentage?

7. What are the clinical features?

8. What are the macroscopic types of carcinoma tongue?

9. What is the histology in carcinoma tongue?

10. How does a carcinoma tongue spread?

Vide carcinoma tongue in the chapter 21 the tongue.

11. What are the different lymph nodes in the neck?

a. The lymph nodes in the neck are situated either superficial or deep to the investing layer of deep cervical fascia. Accordingly they are grouped as superficial and deep cervical lymph nodes.

b. The cervical lymph nodes are also classified into 6 levels as below:

- Level I – Submental (IA) and submandibular (IB) lymph nodes.

- Level II, Level III and level IV are lying in relation to upper, middle and lower thirds of the internal jugular vein.

- Level V – Lymph nodes lying in the posterior triangle of neck.

- Level VI – Lymph nodes in the pre- and paratracheal area.

12. What is the TNM staging of oral carcinoma including tongue?

T – Primary tumor.

T<sub>x</sub> – Primary tumor cannot be assessed.

T<sub>0</sub> – No evidence of primary tumor.

T<sub>IS</sub> – Carcinoma *in situ*.

T<sub>1</sub> – Tumor 2 cm or less in greatest dimension.

T<sub>2</sub> – Tumor more than 2 cm but not more than 4 cm in greatest dimension.

T<sub>3</sub> – Tumor more than 4 cm in greatest dimension.

T<sub>4</sub> – Tumor invading adjacent structures.

N – Regional lymph nodes (cervical lymph nodes).

N<sub>x</sub> – Regional lymph nodes cannot be assessed.

N<sub>0</sub> – No regional lymph node metastasis.

N<sub>1</sub> – Metastasis in a single ipsilateral lymph node 3 cm or less in greatest dimension.

N<sub>2a</sub> – Metastasis in single ipsilateral lymph node 3 to 6 cm in greatest dimension.

N<sub>2b</sub> – Multiple ipsilateral lymph nodes none greater than 6 cm in greatest dimension.

N<sub>2c</sub> – Bilateral or contralateral lymph node, none greater than 6 cm in greatest dimension.

N<sub>3</sub> – Metastasis in a lymph node more than 6 cm in greatest dimension.

M – Distant metastasis.

M<sub>0</sub> – No distant metastasis.

M<sub>1</sub> – Distant metastasis to bone, lungs etc.

13. What structures are removed in radical neck dissection?

The radical neck dissection as described by Crile in 1906 involves removal of the following:

a. Sternocleidomastoid and omohyoid muscle.

b. Spinal accessory and cervical plexus of nerves.

c. All levels of cervical lymph nodes (level I to level VI).

d. Internal jugular vein.

e. Submandibular salivary gland.

f. All intervening areolar tissue.

14. What is the differential diagnosis of carcinomatous ulcer in tongue?

a. Traumatic ulcer.

b. Tubercular ulcer – Ulcer with an undermined edge and may be associated with tuberculosis elsewhere in the body.

c. Infective ulcer – due to nonspecific bacterial infection.

d. Aphthous ulcer – usually multiple shallow painful ulcers.

e. Syphilitic ulcer – very rare nowadays.

15. How will you confirm the diagnosis?

By taking biopsy.

16. What are the complications of carcinoma tongue?

a. Infection.

b. Dysphagia from growth in the posterior 1/3rd of tongue.

c. Feter oris.

d. Bleeding – Due to erosion of carotid artery or internal jugular vein by metastatic lymph nodes.

e. Aspiration.

17. How will you treat this case?

18. How the primary growth is managed?

19. What is the management of lymph nodes?

20. What is the management in advanced cases?

21. What is the prognosis?

See 'carcinoma of tongue' in the chapter 21, section 5.

22. What are the causes of death in patients with carcinoma tongue?

Advanced carcinoma of tongue may lead to death due to:

a. Hemorrhage from the primary growth or vascular erosion (carotid artery or internal jugular vein).

- b. Starvation and malignant cachexia.
- c. Asphyxia due to pressure upon the air-passages by metastatic lymph nodes.
- d. Inhalation bronchopneumonia due to inhalation of infected material from necrotic neoplasm.

indurated and floor is covered with infected granulation tissue.

The submental and submandibular lymph nodes are enlarged.

1. What is your diagnosis?  
It is the ulcerative type of carcinoma of the lower lip.
2. What are the points in favor of diagnosis?
  - a. Ulceroproliferative lesion in the lower lip.
  - b. Elderly male patient.
  - c. Habit of chewing tobacco.
  - d. Base of ulcer is indurated, margin is rolled out and everted and floor is covered with infected granulation tissue.
3. What are the sites of carcinoma lip?
  - a. Lower lip – 95 percent.
  - b. Upper lip – 5 percent.
  - c. Angle of mouth – 2 percent.
4. What are the predisposing factors for carcinoma lip?
5. What are the gross types of carcinoma lip?
6. How does carcinoma of lip spread?

7. What are the histological types of carcinoma lip?

8. What is the histological diagnosis?  
See carcinoma of lip in the chapter 21 'the tongue' and lip, section 5.

9. How will you confirm the diagnosis?  
By taking an incision biopsy from the margin of ulcer.

10. How will you treat this case?

- a. As the lesion is large, wide excision of the growth with 2cm healthy tissue is done.
- b. Primary reconstruction of the defect and modified radical neck dissection on the right side is done.

11. How will you reconstruct the defect?  
By rotation flaps from the cheek or neck.

12. How will you manage lymph nodes in carcinoma of lip?

This is managed in the same line as in case of carcinoma of tongue.

13. What is the prognosis?  
5 year survival rate is 80 percent if lymph nodes are not involved.

## CARCINOMA LIP

### Case Summary

The 55-year-old male patient presents with an ulceroproliferative lesion in the lower lip for last 2 years extending to the right angle of mouth.

Initially the growth was small but for the last 4 months the lesion was increasing rapidly in size. The patient is in the habit of chewing tobacco for last 20 years.

On examination, there is a large ulceroproliferative lesion of the lower lip. The margin of the ulcer is rolled out and everted, base



# Chapter 83

## Hernias, Breast and Abdominal Wall

- Congenital hernia
- Epigastric hernia
- Umbilical hernia
- Femoral hernia
- Lumbar hernia
- Desmoid tumor
- Raspberry tumor
- Vitellointestinal fistula or persistent vitellointestinal duct (VID)
- Urachal fistula
- Breast

### CONGENITAL HERNIA

#### Case Summary

The patient's mother says that the patient aged 7 years has right inguinoscrotal swelling.

The swelling increases during straining like crying, coughing, etc.

On examination, there is expansile impulse on coughing.

1. What is your diagnosis?

This is a case of right-sided congenital inguinal hernia in 7-year-old male child.

2. Why early operation is indicated in children?

Because of high chance of strangulation.

3. What is the peculiarity of inguinal canal in children?

In the child below 2 years of age, the superficial and deep inguinal rings lie superimposed on each other.

After 2 years, the deep ring moves laterally and proper inguinal canal can be identified.

4. What operation will you do in this case? Simple herniotomy is to be done.

5. What are the indications of herniorrhaphy in children?

Children having high risk of recurrent hernia should have a formal herniorrhaphy. These conditions or risk factors include:

- a. Malnutrition.
  - b. Growth failure.
  - c. Connective tissue disorders like Ehlers Danlos syndrome, Marfan's syndrome, etc.
6. What is the chance of developing hernia on the opposite side? About 10 percent of the patients develop contralateral hernia.
7. What are the essential steps of operation of herniotomy?
- a. Under general anesthesia, a transverse skin crease incision is made overlying the deep inguinal ring.
  - b. The external oblique aponeurosis is incised in the same line.
  - c. The hernial sac is dissected, identified and isolated from the cord structures.
  - d. The sac is twisted and ligated with transfixation suture at the neck and the redundant sac is excised.
  - e. External oblique aponeurosis is closed with absorbable suture and skin apposed by subcuticular suture.

### EPIGASTRIC HERNIA

#### Case Summary

The 50-year-old male patient, daily laborer in occupation, presents with a swelling midway

between umbilicus and xiphisternum for last three years.

Initially, the swelling was very small pea size. It has gradually increased to its present size.

The patient complains of a dull aching pain over the swelling for last 6 months.

On examination, the swelling is 5 cm below the xiphoid, globular 3 cm in diameter, firm in feel without any expansile impulse on coughing, surface smooth. Abdominal examination is normal.

1. What is your case?

This is a case of epigastric hernia.

2. What are the points in favor of your diagnosis?

a. Small midline lump.

b. Firm in consistency.

c. Elderly male patient, daily laborer in occupation (straining factor is present).

d. Surface is smooth, impulse on coughing absent.

3. What is epigastric hernia?

This is also called fatty hernia of the linea alba and is due to protrusion of extraperitoneal fat through a defect in the linea alba somewhere between xiphisternum and umbilicus, usually at midway.

In most of the cases, the hernial sac is absent so that classical features of hernia viz. reducibility and impulse on coughing are absent.

4. What may be the cause of pain in epigastric hernia?
  - a. Usually epigastric hernias are asymptomatic.
  - b. Dull aching pain over the swelling may be due to traction on the parietal peritoneum.
  - c. The pain may be due to strangulation of the contained omentum.
5. What operation will you do in this case?
  - a. Anatomical repair of the defect in linea alba is done.
  - b. Under general anesthesia, the hernial mass is dissected all around, the gap in the linea alba. The neck of the sac is closed with absorbable suture.
  - c. The facial defect in the linea alba is closed with nonabsorbable suture.
  - d. If the defect is large (>4 cm), a prolene mesh (preperitoneal) repair is done.
5. What is paraumbilical hernia?
6. What are the usual contents of paraumbilical hernia?
7. What are the predisposing factors for paraumbilical hernia?
8. What are the complications?
9. How will you treat paraumbilical hernia?
10. What postoperative measures will you take to prevent recurrence?
 

See 'paraumbilical hernia' in the chapter 42 'hernia'.

### FEMORAL HERNIA

The 40-year-old female patient presents with a small swelling in her right groin for last 2 years which is gradually increasing in size.

The swelling appears on straining like coughing, walking, lifting weights, etc.

On local examination, the swelling in the right groin shows expansile impulse on coughing, lies below and lateral to the pubic tubercle, is reducible and small globular in shape.

There is no swelling in the left groin. Examination of chest and abdomen is normal.

1. What is your case?
 

This is a case of reducible, uncomplicated right, sided femoral hernia.
2. What are the points in favor of your diagnosis?
  - a. Patient is a female.
  - b. The swelling is below and lateral to the pubic tubercle.
  - c. There is expansile impulse on coughing.
  - d. Small globular in shape.
3. What are the coverings of femoral hernia?
4. What is the course of femoral hernia?
5. Why femoral hernia cannot pass down into the thigh?
6. What is the differential diagnosis?
7. How will you treat this case?
 

See 'femoral hernia' in the chapter 42 on 'hernia'.
8. What is the boundary of femoral ring?
9. What are the contents of femoral canal?
10. What is extent and boundary of femoral canal?
 

See 'femoral hernia' in the chapter 42 on 'hernia'.
11. How does a femoral hernia patient present?
  - a. Lump in the groin.
  - b. Acute intestinal obstruction.

- c. Strangulated hernia with pain and irreducible tender swelling in the groin.

### LUMBAR HERNIA

#### Case Summary

The 45-year-old female patient presents with a swelling in the lower part of left loin for the last three years.

The swelling appears on strenuous activities like lifting weight, walking. There is often a dull aching pain over the swelling for last one year.

On examination, there is expansile impulse on coughing, over the swelling. The swelling is easily reducible on lying down.

A gap felt in the right lateral abdominal wall just above the iliac crest.

1. What is your diagnosis?

This is a case of left lumbar hernia through the inferior lumbar triangle of Petit.

2. What is the boundary of inferior lumbar triangle?
3. What is the boundary of superior lumbar triangle?
4. What is the differential diagnosis?
5. How will you treat this case?
 

See 'lumbar hernia' in the chapter 42 on 'hernia'.

### DESMOID TUMOR (Syn— Recurrent Fibroid of Paget)

#### Case Summary

The 40-year-old female patient presents with a swelling in her lower abdomen for last 5 years.

The swelling was growing slowly but in the last 1 year, it has grown rapidly to attain the present size. The patient has no other complaints.

On examination, the swelling occupies the infraumbilical and hypogastric region.

The swelling is parietal as seen in the head lifting test and firm in feel with irregular surface. Liver and spleen are not palpable and there is no other mass in the abdomen.

1. What is your diagnosis?
 

This is a case of desmoid tumor of the anterior abdominal wall.

### UMBILICAL HERNIA

The 5-year-old male child presents with a swelling in his umbilicus since birth.

The swelling is aggravated with straining, e.g. running, walking and crying and is reduced spontaneously on lying down. The swelling is painless and there is no history of irreducibility. The child has history of neonatal umbilical sepsis.

On examination, the umbilicus is stretched and everted due to a swelling in the umbilicus.

A gap of about 3 cm is palpable in the umbilical cicatrix.

1. What is your case?
 

This is a case of uncomplicated umbilical hernia in male child aged 5 years.
2. What are the points in favor of your diagnosis?
  - a. History of umbilical sepsis in the neonatal period.
  - b. Umbilical scar at the tip of the hernia and hernia is reducible.
  - c. The patient is a male child of 5 years age.
3. How will you treat this case?
 

As the child is 5-year-old, spontaneous closure is unlikely. So, surgical treatment is advised.

Herniorrhaphy is done with the preservation of the umbilicus.
4. How the operation is done?
 

See the 'umbilical hernia' in the chapter 96 in operative surgery section.

2. What is desmoid tumor?  
This is also known as desmoid fibromatosis or musculoaponeurotic fibromatosis, arising from the musculoaponeurotic structures of the rectus muscle. They are composed of uniform looking fibroblasts arranged in bands and fascicles.
3. What are the extraabdominal desmoids?  
Unlike abdominal desmoids (common in women), extraabdominal desmoids are more common in men and are widely distributed in areas such as upper and lower extremities, chest wall, back, buttocks and head and neck region.
4. What are the pathological features?
5. What are the important etiological factors?
6. How will you treat this case?  
See desmoid tumor in chapter 40.
7. Why wide excision of the tumor is required?  
Desmoid tumors frequently undergo recurrences. So wide margin of excision is necessary to prevent recurrences.

### RASPBERRY TUMOR (Syn— Umbilical Polyp, Umbilical Adenoma, Enteroteratoma)

#### Case Summary

The 7-year-old female child presents with a swelling in the umbilicus for last 1 year. There is mucous discharge from the swelling.

On examination, there is soft pinkish mass in the umbilicus, 2cm × 1cm size. The mass is red and bleeds on touch.

No other mass is palpable in the abdomen.

1. What is your case?  
This is a case of raspberry tumor of umbilicus.
2. What is raspberry tumor?  
This is a misnomer because it is not a neoplastic lesion. It arises from the unobliterated distal portion of the vitellointestinal duct (VID).  
The mucosa of the unobliterated part of the VID prolapses through the umbilicus and gives the appearance of a raspberry like tumor.
3. How does it differ from umbilical granuloma?

It differs from umbilical granuloma by the fact that it does not respond to silver nitrate application.

4. What is endometrioma?
  - a. Endometrioma is defined as the presence of ectopic endometrial glands in the umbilicus, appearing as a fleshy mass which becomes painful and discharges blood during each menstrual cycle.
  - b. It may be associated with endometriosis of ovary and / or uterus.
  - c. It is treated by umbilectomy with excision of the endometrioma.
5. What is the treatment of raspberry tumor?  
Umbilectomy with excision of the raspberry tumor.
6. What other condition may be associated with raspberry tumor?  
Meckel's diverticulum.
7. How will you detect the presence of Meckel's diverticulum?
  - a. <sup>99m</sup>Tc scan.
  - b. Barium meal follow through examination or small bowel enema examination.

### VITELLOINTESTINAL FISTULA OR PERSISTENT VITELLOINTESTINAL DUCT (VID)

#### Case Summary

The 2-year-old male child presents with intermittent mucus discharge and sometimes feces (fecal fistula at the umbilicus).

On examination, there is slight feculent discharge through the umbilicus. There is also prolapse of the mucous membrane through the umbilicus.

1. What is your diagnosis?  
This is a case of vitellointestinal fistula or persistent vitellointestinal duct.
2. What is vitellointestinal duct?  
In the embryo the vitellointestinal duct or yolk stalk joins the midgut to the umbilicus.  
Normally, the duct extending from the umbilicus to the gut is obliterated early in intrauterine life.
3. What are the different anomalies of development of vitellointestinal duct?
4. How will you treat this fistula?

See the chapter 40 on umbilicus and abdominal wall.

5. What are other causes of fecal discharge through the umbilicus?
  - a. Crohn's disease.
  - b. Carcinoma of colon or small gut infiltrating the umbilicus.
  - c. Abdominal tuberculosis.

### URACHAL FISTULA

#### Case Summary

The 10-year-old male child presents with intermittent watery discharge from the umbilicus for last 1 year, which smells of urine.

The patient has no other complaint.

On examination, there is urinerous discharge from the umbilicus. No lump is present in the abdomen.

1. What is your diagnosis?  
This is a case of urinary fistula due to patent urachus.
2. What is allantois?
  - a. The allantois is the endodermal diverticulum passing through the umbilicus from the cloaca to the placenta.
  - b. In future the allantois forms the bladder except the trigone area.
3. What is the fate of allantois?
  - a. Normally the lumen of the allantois gets obliterated to form the urachus, connecting the apex of the bladder to the umbilicus.
  - b. The urachus also disappears and turns into a fibrous remnant, known as median umbilical ligament.
  - c. The urachus occasionally remains patent so that a fistula exists between the apex of urinary bladder and umbilicus. This is the urinary fistula of the umbilicus or the urachal fistula.
  - d. The patent urachus does not result in urinary fistula in all cases. It results only in cases associated with lower urinary tract obstruction, e.g. posterior urethral valve, stricture urethra, bladder neck obstruction, etc.
4. What is urachal cyst?
5. What is the treatment?  
See 'allantois' in the chapter 40 'umbilicus and abdominal wall'.

**BREAST****Fibroadenoma***Case Summary*

The 26-year-old female patient presents with a swelling in the upper and outer part of her left breast for last 2 years. Initially it was of small size like a marble, and then increased slowly to its present size of an orange.

There is no nipple discharge and pain in the breast. The right breast is normal.

On examination, the swelling is located in the upper and outer quadrant, size 5cm × 4cm, smooth surface and well-defined margins and firm in consistency. The lump is free from the skin and underlying tissues, it sleeps under the fingers when pressed. There is no palpable node in the axilla.

1. What is your diagnosis?  
This is a case of fibroadenoma of the left breast in the upper and outer quadrant.
2. What are the reasons to say this diagnosis?
  - a. Young female patient.
  - b. Absence of clinical symptoms.
  - c. On examination – The swelling is freely mobile, firm in feel with well-defined margins, smooth surface, and no axillary glands palpable.
3. What is a breast mouse?
  - a. A fibroadenoma of the breast is known as a breast mouse.
  - b. This is because, the lump has intrinsic mobility and can be moved within the breast from one place to another.
4. What is fibroadenoma?
  - a. This is a benign tumor of the breast consisting of glandular, fibrous and epithelial elements. It is the most common benign tumor of the breast.
  - b. Microscopically there are two types viz.
    - i. Pericanalicular or hard fibroadenoma – found in the teenage group, highly mobile (breast mouse) and consists of encircling masses of fibrous tissue around the patent or dilated ducts. Here, the proliferation of fibrous tissue is more prominent than the glandular element.
    - ii. Intracanalicular or soft fibroadenoma is one in which the stroma compresses the ducts so that they become slit-like clefts lined by

ductal epithelium. There is venous prominence and raised skin temperature. It simulates encephaloid carcinoma.

Cystosarcoma phyllodes is a type of soft fibroadenoma. Here the proliferation of glandular element is more than the fibrous tissue.

5. How will you confirm your diagnosis?  
By FNAC from the swelling.
  6. How do you treat the case?  
Excision of the fibroadenoma under general anesthesia.
  7. What is giant fibroadenoma?  
Fibroadenomas more than 5 cm diameter is called giant fibroadenoma.
- Cystosarcoma Phyllodes or Phyllodes Tumor of Breast**
8. What are the characteristics of phyllodes tumor?
    - i. It is a variety of soft fibroadenoma (Intracanalicular type).
    - ii. The tumor rapidly increases in size and occupies the whole breast.
    - iii. It is vascular. The rise of skin temperature and venous prominence simulate a sarcomatous growth.
    - iv. Histology – There are multiple cysts into which tumor cells are projected like the pages (leaves) of a book, hence the name cystosarcoma (sarcoma fleshy) phylloides.
    - v. Simple mastectomy is the treatment of choice.
    - vi. Following excision there is increased chance of local recurrence.
    - vii. About 10 to 20 percent of phyllodes tumor is histologically malignant and less than half of them metastasize.

**Gynecomastia***Case Summary*

The 14-year-old male patient presents with swellings in his both breasts for last two years. Initially the swellings were small like a marble, and then gradually increased in size for last 8 months to reach the present big size.

On examination, the swelling in each breast measures 7cm × 4cm, occupying all the quadrants of the breast. Surface is smooth, margins are well-defined. The swelling is

painless, firm in consistency, mobile and free from the skin and underlying pectoral muscle.

No axillary lymph nodes are palpable. Both the testes are normally palpable. Liver is not enlarged.

1. What is your diagnosis?  
This is a case of bilateral gynecomastia.
2. What are the reasons in favor of your diagnosis?
  - a. The boy is aged 14 years with complaints of gradual enlargement of breasts.
  - b. The swelling is painless, firm in consistency, mobile and free from the skin and underlying pectoral muscle. Axillary lymph nodes are not enlarged.
3. What is gynecomastia?  
Gynecomastia implies the presence of a female type mammary gland in the male person.
4. What are the causes?
  - a. Primary or idiopathic – Commonest cause.
  - b. Secondary –
    - i. Drugs, e.g. digitalis, spironolactone, calcium channel blocker, vincristine, ketoconazole, diazepam, tricyclic antidepressants.
    - ii. Liver disease like alcoholic and non-alcoholic cirrhosis.
    - iii. Testicular tumors, e.g. Leydig and Sertoli cell tumors, seminoma, teratoma, etc.
    - iv. Nontesticular tumors like lung carcinoma, hepatocellular carcinoma.
5. Is gynecomastia due to glandular enlargement of breast?  
No, there is no glandular enlargement, only there is proliferation of fibrofatty tissue.
6. Is preoperative biopsy necessary?  
In adolescents it is not necessary but if an adult or elderly patient presents with unilateral gynecomastia, carcinoma of male breast is suspected. So, preoperative cytology should be done.
7. How will you treat this case?
  - a. Gynecomastia involving the whole breast as in this case is treated by subcutaneous mastectomy making a submammary (Gaillard – Thomas) incision.
  - b. Gynecomastia underlying the nipple only, is removed through a circumareolar incision.
  - c. Drainage for 24 hours should always be employed.

**Carcinoma Male Breast****Case Summary**

The 46-year-old male patient presents with swelling in his left breast for last one year.

Initially the swelling was small like a marble then it was increasing rapidly for last 6 months to attain the present size.

On examination, the swelling in the left breast measures 5 cm × 3 cm occupying all the quadrants of the breast.

Surface is smooth, margins are well-defined. The swelling is painless, firm in consistency, mobile and free from the skin and underlying pectoral muscle.

One axillary lymph node is palpable in the left axilla, which is mobile and firm in consistency.

1. What is your diagnosis?

This is a case of carcinoma of left breast in a male patient aged 46 years.

2. What are the reasons to say this?
  - b. Lymph node is palpable in the left axilla.
  - c. Rapid increase in size in the last 6 months.
3. What are the risk factors?
  - a. Gynecomastia.
  - b. Klinefelter's syndrome.
  - c. BRCA – 2 genes.
4. How will you treat the case?
  - a. The diagnosis is confirmed by doing a FNAC from the lump.
  - b. Other investigations for anesthetic fitness are done.
  - c. Then the operation of modified radical mastectomy is done followed by adjuvant therapy.
5. What adjuvant therapy do you suggest?
  - a. Postoperative radiotherapy to the breast flap and lymph node fields for locoregional control of the tumor.
  - b. As the tumor is large (>1cm), and there is axillary lymph node metastasis, postoperative 6 cycles chemotherapy is given with either of the two regimes:
    - i. CAF (Cyclophosphamide, adriamycin and 5 fluorouracil)
    - or
    - ii. CMF (Cyclophosphamide, methotrexate and 5 fluorouracil).
6. What is the role of hormone therapy?
  - a. Male breast cancer is estrogen receptor positive in 70 to 80 percent cases and progesterone receptor positive in about 65 percent cases. Hormone therapy is effective in such cases.
  - b. Firstline hormone therapy—Orchidectomy or tamoxifen therapy).
  - c. Second line hormone therapy—LHRH analogues (Goserelin) or Aromatase inhibitors (Anastrozole or letrozole).



# Chapter 84

## External Genitalia and Urethra

- Testicular tumor
- Undescended testis
- Hydrocele
- Encysted hydrocele of the cord
- Varicocele
- Filariasis of scrotum
- Phimosis
- Hypospadias
- Carcinoma penis

### TESTICULAR TUMOR

#### Case Summary

The 28-year-old Hindu male patient presents with a swelling in the right side of scrotum for last 1 year.

Initially the swelling was increasing gradually, but for the last 6 months there was a rapid increase in size. There is no swelling in the groin, neck or abdomen. The patient complains of a sensation of hernias in the right side of scrotum. There is no history of trauma.

On examination, there is a right-sided scrotal swelling as it is possible to get above the swelling.

The swelling is firm in feel, globular in shape, 8 cm × 6 cm size, painless with the loss of testicular sensation.

The right spermatic cord is normal, the left testis and spermatic cord are also normal.

Abdominal examination reveals no abnormality.

1. What is your diagnosis?  
This is a case of right-sided testicular tumor.
2. Why do you say it a testicular tumor?
  - a. It is possible to get above the swelling. So it is a scrotal swelling.
  - b. Testicular sensation is lost.
  - c. The swelling is firm in feel, surface smooth, enlarged in size but epididymis is normal.
  - d. There is no history of trauma.

- e. There is a sensation of heaviness of right side of scrotum.
3. What are other possibilities?
  - a. Old hematocele.
  - b. Chronic epididymoorchitis.
  - c. Vaginal hydrocele.
  - d. Inguinal hernia.
4. How will you differentiate from old hematocele?  
By ultrasonography of scrotum which will help to find out the clot as well as the testicular structure.
5. How do you differentiate between chronic epididymoorchitis and testicular tumor?
 

*Testicular tumor*

  - a. Epididymis normal.
  - b. Testis is enlarged.
  - c. The swelling is painless.

*Chronic epididymoorchitis*

  - a. Epididymis thickened and nodular.
  - b. Testis is normal.
- c. History is severe pain in the scrotum.
6. How do testicular tumors present clinically?  
Testicular tumor presentation can be:
  - i. Typical.
    - Testicular swelling.
    - Sensation of heaviness of scrotum on the affected side.
    - Loss of testicular sensation.
    - Painless.
  - ii. Atypical – Hurricane type – this is a highly malignant tumor which progresses very rapidly killing the patient in a few months. There may be associated gynecomastia.
  - iii. Metastatic –
    - Abdominal lump – Retroperitoneal due to enlarged pre- and paraaortic lymph nodes.

**Table 84.1 Seminoma vs. non-seminomatous germ cell tumor**

	<i>Seminoma</i>	<i>NSGCT</i>
1. Primary tumor	Larger, confined to testis for sufficient time	Smaller
2. Metastasis	Mainly lymphatic spread	Mainly hematogenous spread
3. Response to radiation	Highly radiosensitive	Radioresistant
4. Response to chemotherapy	Less chemosensitive	Highly chemosensitive
5. Serum markers	hCG, low levels	hCG, AFP or both, high levels
6. Prognosis	Better	Poor

- Enlarged left supraclavicular lymph nodes (Virchow's node).
7. How do you classify testicular tumors?
  8. What are the predisposing factors?
  9. How will you investigate the case?
  10. How will you do staging of testicular tumor?
  11. How will you treat this case?
  12. What is the prognosis?  
See 'testicular tumor' in the chapter 51 on 'testis and scrotum'.
  13. What is the difference between seminoma and nonseminomatous germ cell tumors (NSGCT) or teratomas? See Table 84.1.
  14. How will you do postoperative follow up?
    - a. Seminoma: CT scan of abdomen every 6 months till no sign of disease is present.
    - b. Teratoma
      - i. Tumor markers every two months for 12 months. Then every 3 months for 12 months, then every 6 months for 12 months, then yearly for 10 years.
      - ii. CT scan at 3rd and 6th months after treatment.
  2. What is imperfect descent of testis?  
When the descent of testis is arrested in some part of its pathway to scrotum, it is called imperfect descent or undescended testis.
  3. What is cryptorchidism?
    - a. Literally means hidden testis.
    - b. Commonly employed when it is bilateral.
  4. How does the testis develop?
  5. What is the chronology of descent of testis?
  6. What are the factors that help in the descent of testis? What factors hinder testicular descent?
  7. What is ectopic or Maldescended testis?
  8. What is retractile testis?
  9. How will you differentiate retractile from undescended testis?  
See 'descent of testes' in the chapter 51 testis and scrotum.
  10. What are the complications of undescended testis?
  11. What type of malignancy develops in undescended testis?  
See "undescended testis" in the chapter 51 on testis and scrotum.
  12. How will you manage the case?  
Management comprises of establishing the location of testis by:
    - i. US scan in case of clinically palpable testis and if
    - ii. Testis is not palpable, location is established by combination of the following: (see also Q. 34 below).
      - US scan
      - CT scan and
      - MRI
      - Laparoscopy, especially in cryptorchidism.
  13. What is the ideal age for the placement of undescended testis in scrotum?
    - a. 12 months to 2 years.
    - b. The degenerative changes in the seminiferous tubules begin to start at this age.
    - c. A testis which has not descended by the end of first year will probably remain so.
  14. What is the treatment?  
There is no scope for hormone treatment. The treatment is always operative and the operation is orchidopexy.
  15. What is orchidopexy?  
Orchiopexy or orchidopexy is the operation of bringing down the testis and fixing it in the scrotal sac.
  16. What are the principles of the operation?  
The operations involves
    - a. Mobilization of cord.
    - b. Repair of associated hernia and
    - c. Adequate scrotal fixation without tension.
  17. What are the methods of fixation of testis in the scrotum?
    - a. Subdartos pouch
    - b. Ombredanne's technique
    - c. Keetley-Torek procedure
    - d. Denis Browne's procedure
    - e. Fowler Stephens procedure
    - f. Silbar procedure.
  18. What is subdartos pouch?
    - a. About 2.5 cm incision is made over the scrotum and a subdartos pouch is created by dissecting between the scrotal skin and dartos muscle.
    - b. The testis is brought into the subdartos pouch by making a small incision in the dartos muscle. The skin is closed over it.
  19. What is Keetley-Torek procedure?
    - a. Testis is brought out through the scrotum and is placed in the subcutaneous tissue of the inner side of thigh and is secured by stitches to fascia lata.
    - b. Disadvantages are:
      - i. Requires good length of cord.
      - ii. Requires second stage procedure of separation of testis and placement in scrotum.
  20. What is Ombrédanne's procedure?
    - a. Here the mobilized testis is placed in the opposite scrotum after making a small opening in the median septum.
    - b. Disadvantages include:
      - i. Difficulty in making the opening.
      - ii. Testis is not properly anchored.
  21. What is Denis Browne's procedure?
    - a. Narrowing of the neck of scrotum.
    - b. Followed by external anchorage to the thigh.
  22. What is Fowler Stephens procedure?
    - a. It is based on the principle that testicular artery is not an end artery and one of the factors hindering mobilization of testis is the short length of the testicular vessels.

## UNDESCENDED TESTIS

### Case Summary

The 5-year-old male child presents with a history of absence of right testis in the scrotum since birth.

Patient's mother noticed a small swelling in the right groin for last 1 year when the patient stands up, walks or strains. The swelling disappears on lying down.

On examination, the right scrotal sac is underdeveloped. The right testis is not palpable in the inguinal canal or in other ectopic sites.

On standing a swelling is found which is confined to the right inguinal canal. There is an expansile impulse on cough over the swelling and the swelling reduces easily on lying down.

The left hemiscrotum is normal and the left testis is palpable in the scrotum.

1. What is your diagnosis?

This is a case of right-sided undescended testis. Testis is impalpable in the inguinal canal but there is an associated right inguinal hernia.

- b. In this procedure testicular vessels are divided high up so that the testes could be mobilized well and brought down into the scrotum. The blood supply to the testis is maintained by artery to the vas and the cremasteric vessels.
23. What is Silbar procedure?
- It is orchidopexy with microvascular anastomosis.
  - The testis is mobilized well. The testicular vessels are divided and the testis is placed in the scrotal pouch.
  - The testicular artery is anastomosed to inferior epigastric artery and testicular vein to inferior epigastric vein.
24. What are the indications of orchidectomy in undescended testis?
- If the testis is atrophic and nonfunctioning.
  - If the testis cannot be mobilized in spite of all maneuver.
  - If there is any complication, e.g. torsion, or tumor.
25. What are the tails of Lockwood?
- Lockwood has explained location of ectopic testis by describing 5 tails of gubernaculum of testis viz.
- Scrotal tail (normal site).
  - Pubic tail.
  - Perineal tail.
  - Femoral tail.
  - Superficial inguinal tail. (Iliac tail)
- Differential growth of any of the tails b, c, d or e may lead to deviation of testis to an ectopic site.
26. What are the sites where the ectopic testis may lie?
- The sites in order of frequency are (see the Figure 84.1):
- Superficial inguinal pouch which is a space between the external oblique aponeurosis and fascia of scarpa (Membranous layer of superficial fascia).
  - In the perineum.
  - In the suprapubic area or at the root of penis (pubic tail).
  - In the femoral triangle near the fossa ovalis.
27. What is canalicular testis?
- It is a type of undescended testis lying in the inguinal canal.
  - It may be palpable within the inguinal canal.
28. What is emergent testis?
- It is a type undescended testis near the superficial inguinal ring and may sometimes project beyond the ring on straining, but again slips back into the inguinal canal.
29. How to differentiate between an ectopic testis in the superficial inguinal pouch and the canalicular testis?
- Abdominal muscles are made taut by leg raising test.
  - The ectopic testis in the superficial inguinal pouch becomes more prominent as it is superficial to external oblique aponeurosis.
  - The canalicular testis being deep to external oblique aponeurosis becomes less prominent.
30. How does ectopic testis differ from the undescended testis?
- An ectopic testis is fully developed in contrast to undescended testis.
  - Spermatogenesis is normal in ectopic testis.
  - Scrotum is fully developed in case of ectopic testis.
  - An ectopic testis is more prone to injury.
31. What are the pathological changes in undescended testis?
- The testis is flabby and poorly developed.
  - Size is small.
  - The undescended testis is exposed to higher (1.8°F) body temperature compared to scrotum and deleterious changes occur to spermatogenic cells in the first year of life.
  - By the age of 4 years massive collagen deposition is evident and by the age of 16 years, irreversible destructive changes will occur.
32. What is the effect of undescended testis on fertility?
- In case of bilateral undescended testis, the patient suffers from sterility.
  - In case of unitateral undescended testis, there may be subfertility due to defective spermatogenesis in the normally descended testis.
33. What does an impalpable testis imply?
- Impalpable testis implies that the testis cannot be detected on physical examination. The causes may be:
- Agenesis.
  - Atrophic.
  - Intraabdominal (hidden testis).
  - Missed on clinical examination.
34. How do you evaluate a patient with bilateral impalpable testis?
- A detailed history and clinical examination including palpation along the route of normal descent and the ectopic sites.
  - If basal gonadotropin levels are high and there is no rise of testosterone following hCG stimulation test, it will indicate bilateral anorchia (absence of testis).
  - Ultrasonography.
  - Laparoscopy – helps in locating the intraabdominal testis. It is the standard method of localization of intraabdominal testis. CT scan and MRI are not reliable investigations for this.
35. What is the risk of malignancy of undescended testis?
- Undescended testis has 35 – 40 times greater risk of developing tumors than in normally descended testis.
  - The risk is 1 in 80 in inguinal testis and 1 in 20 in abdominal testes.

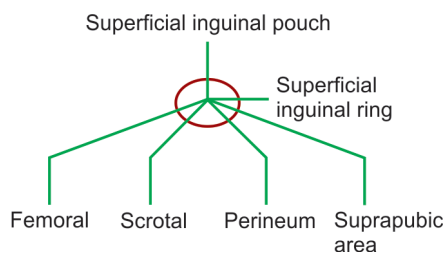


Fig. 84.1: Sites of ectopic testis.

## HYDROCELE

### Case Summary

The 35-year-old male patient presents with a swelling on the left side of scrotum for last 2 years. The swelling was small to start with, then it was slowly increasing in size.

There is no pain in the swelling and patient has no other complaint.

On examination, the swelling shows no expansile impulse on coughing and there is get above the swelling. Surface is smooth, margins rounded, nontender, cystic in feel. Fluctuation positive and transillumination

is also +ve. The testis can not be felt separate from the swelling.

1. What is your diagnosis?  
This is a case of left-sided vaginal hydrocele.
2. What are the points in favor of your diagnosis?
  - a. Getting above the swelling is possible.
  - b. Transillumination test is positive.
  - c. No impulse on coughing is present.
  - d. Cystic in feel.
  - e. The testis cannot be felt separate from the swelling.
3. What are other possibilities?
  - a. Testicular tumor.
  - b. Hematocele.
  - c. Inguinal hernia.
  - d. Filariasis of scrotum.
  - e. Encysted hydrocele of the cord.
4. What is hydrocele?  
This is a collection of serous fluid in the tunica vaginalis testis or any part of processus vaginalis.
5. What are the causes of vaginal hydrocele?
  - a. Primary hydrocele: Here the testis and epididymis are normal and the cause is not clear.
  - b. Secondary hydrocele: Here the hydrocele is secondary to a disease of the testes and epididymis.
6. What is the source of fluid in primary hydrocele?
  - a. Endothelium of tunica vaginalis.
  - b. Deficient absorption of fluid by tunica.  
This is the most important factor.
7. What are the types of primary hydrocele?
  - a. Vaginal hydrocele—In this condition there is abnormal collection of serous fluid between the visceral and parietal layers of tunica vaginalis.
  - b. Infantile—When processus vaginalis is obliterated at the deep inguinal ring and accumulation of fluid takes place upto that level, it is called infantile hydrocele.
  - c. Congenital hydrocele—When processus vaginalis communicates with the peritoneal cavity and fluid accumulates in it, it is called congenital hydrocele.
  - d. Encysted hydrocele of cord—When only a small portion of processus vaginalis remains patent, it is called encysted hydrocele of cord.
  - e. Funicular hydrocele—It is the opposite of infantile hydrocele (see Fig. 51.5B)

8. What is the difference between congenital and vaginal hydrocele?  
In congenital hydrocele, fluid comes from the peritoneal cavity but in vaginal hydrocele; fluid is secreted by epithelial covering of the tunica vaginalis testis.
9. How do you treat congenital hydrocele?  
The treatment of congenital hydrocele is the same as congenital hernia that is, herniotomy through an inguinal approach.
10. What are the complications of hydrocele?
11. What operations are done for hydrocele?  
See 'hydrocele' in the chapter 51 on 'testis and scrotum'.
12. What are steps of operation of eversion of sac?  
See the operative surgery section, chapter 97.
13. Would you like to put a drain following hydrocele operation?
  - a. In case of small hydrocele with good hemostasis no drain is required.
  - b. In large hydrocele, where there is chance of oozing, a drain is kept in dartos pouch for 24 – 48 hours.
14. When do you excise the tunica vaginalis sac?  
When the sac is very large and thick, e.g.
  - a. Hematocele.
  - b. Chylocele.
  - c. Infected hydrocele.
15. How do you test transillumination?
  - a. Scrotum is made tense by pressing the neck with fingers. A pencil torch is held on the lateral wall. A red glow is seen over scrotum which indicates a +ve test.
  - b. The light should not be thrown from the back of the swelling as the testis will come on the way and the test will be negative.
16. In what conditions the transillumination test in scrotum become negative?
  - i. In the presence of hydrocele
    - a. Calcified sac.
    - b. Chylocele.
    - c. Thickened sac.
  - ii. Hematocele
  - iii. Testicular tumor.
17. How will you test for fluctuation?
  - a. The upper pole of the swelling is held between the thumb and forefingers of one hand to make the swelling tense and steady.

- b. Steady pressure is applied at the lower pole with the thumb and fingers of the other hand.
  - c. Observation: Thumb and fingers at the upper pole are passively raised and / or appreciably separated.
18. What is hydrocele of hernial sac?  
It is a condition in which there is a collection of fluid in the hernial sac, after the neck of the sac gets closed by a tag of omentum.
  19. What is postherniorrhaphy hydrocele?  
It is the hydrocele developed following herniorrhaphy due to lymphatic injury in the cord. It is seen in less than 2 percent cases.
  20. What is bilocular hydrocele or hydrocele en bissac
    - a. It denotes a hydrocele having two intercommunicating sacs.
    - b. It causes inguinoscrotal swelling but one can get above the swelling and there is no expansile impulse on coughing.
    - c. The upper sac lies above and the lower sac below the neck of the scrotum.

### ENCYSTED HYDROCELE OF THE CORD

#### Case Summary

The 25-year-old male patient presents with a swelling in the upper part of the right side of scrotum for last 3 years. There is no increase in the size of the swelling on straining.

On examination, the swelling measures 4 cm × 3 cm, soft, cystic, fluctuant and transilluminant.

The swelling has got free mobility but when traction is applied to testis gently, the swelling becomes fixed. Testis is felt separate from the swelling.

1. What is your diagnosis?  
This is a case of right sided encysted hydrocele of the cord.
2. What is encysted hydrocele of cord?  
In this condition, the processus vaginalis remains patent in the middle being shut off from the tunica vaginalis below and peritoneum above.
3. What is the differential diagnosis?
  - a. Spermatocele.
  - b. Cyst of the epididymis.
  - c. Lipoma of the cord.
  - d. Varicocele.

4. What is traction test?  
In case of encysted hydrocele of cord, when traction is applied to testis gently, the swelling becomes fixed as it is related to the cord. When the testis is pulled downward, the swelling also moves downward.
5. How will you treat this patient?  
By excision of the sac under local or general anesthesia.
6. What are the layers of the scrotum?  
Mnemonic: Some dirty fool called it testis
  - a. Some – Skin
  - b. Dirty – Dartos
  - c. Fool – External spermatic fascia
  - d. Called – Cremasteric fascia
  - e. It – Internal spermatic fascia
  - f. Testis – Tunica vaginalis
7. What is hydrocele of the canal of Nuck?
  - a. It resembles encysted hydrocele but occurs in female in relation to round ligament.
  - b. It is wholly or partially located in the inguinal canal.
4. Why it is more common on the left side?
5. What is pampiniform plexus of veins?
6. What is the treatment of varicocele?  
Vide ‘varicocele’ in the chapter 51 on ‘testis and scrotum’.
7. What is bow sign?
  - a. The varicocele mass is held between fingers and thumb.
  - b. The patient is asked to bow.
  - c. Tension in the varicocele becomes appreciably less.
8. What is the differential diagnosis?
  - a. Congenital hydrocele.
  - b. Lymph varix.
  - c. Vaginal hydrocele.
  - d. Epididymal cyst.
  - e. Inguinal hernia.
  - f. Encysted hydrocele of cord.
9. What are the types of varicocele?
  - a. Primary varicocele-- In more than 90 percent cases no cause is found and the varicocele is called the primary varicocele.
  - b. Secondary varicocele – It occurs secondary to obstruction of the testicular vein due to retroperitoneal tumor or kidney tumor.
10. What are the indications of operation in varicocele?
  - a. Dragging pain especially after prolonged standing.
  - b. Large swelling.
  - c. As a part of medical fitness for new job.
  - d. Semen analysis shows subfertility.
11. What are the beneficial effects of operation?
  - a. Spermatogenesis returns to normal and there is improvement of fertility.
  - b. Dartos contracts and supports the testis relieving pain.
  - c. There is no stagnation of blood in the pampiniform plexus and testis is exposed to cooler temperature.
12. What is Palomo’s operation?
  - a. This is a method of high ligation of the testicular vein done for the treatment of varicocele.
  - b. Under regional anesthesia an oblique incision is made 3cm above the level of deep inguinal ring.
  - c. After incising the skin, subcutaneous tissue, external oblique muscle and aponeurosis, internal oblique and transverses abdominis muscle, the retroperitoneum is exposed.
- d. Testicular vein is dissected in the retroperitoneum lateral to the external iliac artery. The testicular vein is then ligated and divided.
13. What is triangle of doom?
  - a. This is a triangular area bounded by the testicular vessels laterally and the vas deferens medially and the line joining these two structures above.
  - b. This triangle is considered as dangerous for laparoscopic approach for varicocele or hernia because the external iliac vessels lie on its floor, covered only by peritoneum and the transversalis fascia. Hence sharp instrument dissection and application of electrocautery is dangerous in this triangle.
14. What are the complications of varicocele operation?
  - a. Hydrocele this is due to lymphatic obstruction.
  - b. Recurrence of varicocele.
  - c. Injury to testicular artery.

## VARICOCELE

### Case Summary

The 22-year-old male patient presents with a swelling in the left side of scrotum for last 5 years. The swelling disappears on lying down position but reappears on standing and walking.

Patient complains of dull aching pain in the left side of scrotum for last 8 months. There is no pain in abdomen and urinary complaints.

On examination, the left testis is lying at a lower level than the right.

There is no expansile impulse on coughing. On palpation there is a mass of dilated veins which feels like the bag of worms, on the left side of scrotum. Abdominal examination reveals no abnormality.

1. What is your diagnosis?  
This is a case of varicocele of left scrotum.
2. Why do you say this?
  - a. Left-sided scrotal swelling.
  - b. Bag of worms feel on palpation.
  - c. There is dull aching pain in the left side of scrotum for 8 months.
3. What is varicocele?  
It is defined as the varicosities of the pampiniform plexus of veins.

## FILARIASIS OF SCROTUM

### Case Summary

The 45-year-old male patient presents with thickened, rough and hyperkeratotic skin of the scrotum with loss of hairs for last 6 years. There is also occasional watery discharge from the skin of the scrotum.

There are recurrent attacks of fever with chill and rigor for last 2 years.

On examination, the skin of scrotum is highly thickened rough and hyperkeratotic, the penis buried.

1. What is your diagnosis?  
This is a case of filariasis of scrotum.
2. What are the points in favor of your diagnosis?
  - a. The skin of scrotum is thickened, rough and hyperkeratotic.
  - b. Periodic fever.
  - c. Penis is buried.
3. What is filariasis?  
It is a lymphedema caused by blockage of lymphatic channels due to infection by the parasite *W. bancrofti*.
4. Why does the scrotal skin get thickened?
  - a. The skin of the scrotum is loose and lax. So lymph stasis can occur in this tissue to a great extent.



- b. The lymph is a protein; it produces inflammation and forms a blubbery tissue.
- c. Thickening is maximum at the bottom of the scrotum.
5. How lymphedema is produced?
  - a. Microfilariae produces repeated inflammation in lymphatics and lymph nodes. This leads to fibrosis of lymph vessels and obstruction.
  - b. Imprisonment of dead worms in the lymph vessels and nodes also helps to produce fibrosis and obstruction.
6. What is Ramhorn penis?  
It is the filarial involvement of penis. The penis becomes thickened and distorted, resembling the horn of a ram.
7. What are definitive and intermediate hosts for *W. bancrofti*?  
Man is the definitive host and mosquito (*Culex fatigans*) is the intermediate host for the parasite causing filariasis.
8. Which is the infective form?  
It is the adult worm living or dead, which produces the pathological effect.
9. What is the life cycle of the parasite?
  - i. Adult worms of *Wuchereria*, both male and female reside in the lymphatic system of human being.
  - ii. The male and female worms mate in the lymphatic system.
  - iii. After sporulation, the female worm dies and liberates large number of microfilariae (embryos of filarial nematode).
  - iv. The microfilariae enters into systemic circulation more commonly at night.
  - v. When a mosquito bites a man, it sucks the microfilariae along with blood.
  - vi. This microfilariae undergoes several changes in the gut of mosquito to get matured.
  - vii. The matured microfilaria enters the human being again by the bite of the mosquito and reaches the lymph nodes through the lymphatics.
  - viii. The matured microfilariae then develop into adult worms and the cycle continues.
10. What are other sites affected by filariae apart from elephantiasis of scrotum and penis?

- a. Lower limbs.
- b. Breast.
- c. Vulva.
- d. Arm.
11. How will you manage the case?
  - a. Firstly I would like to confirm my diagnosis by blood examination for microfilariae. Usually a nocturnal blood smear is taken for examination. Complete hemogram is done which may show eosinophilia.
  - b. Surgery – Treatment of choice is operative. The patient is however prepared preoperatively as follows.
    - i. A course of antifilarial drug e.g. Diethyl carbamazine 100mg TDS × 3 weeks.
    - ii. A course of antibiotic to guard against secondary streptococcal infection.
    - iii. Local dressing with povidone iodine if lymphorrhea is present.
12. What are the principles of surgery?
13. What are the difficulties of surgical treatment?  
See 'elephantiasis of scrotum' in the chapter 51 'testis and scrotum'.
14. What is chyluria?
  - a. Passage of milk-colored urine in filariasis is known as chyluria.
  - b. It is due to obstructed and dilated lymphatic channels communicating with urinary tract as pyelolymphatic, ureterolymphatic, vesicolymphatic and venolymphatic channels.
  - c. The communication may be associated with colicky pain.
15. What is chylocele?  
Chylocele is collection of chylous fluid in the tunica vaginalis testis. This is usually secondary to filarial epididymo-orchitis. One of the lymphatic varix ruptures and discharge chyle into the tunica vaginalis sac.
16. What is lymphedema?  
It is the abnormal collection of interstitial lymph fluid, mostly in the subcutaneous tissue plane due to either developmental anomaly of lymphatics or secondary lymphatic obstruction.
17. What is primary lymphedema?
  - a. It is the congenital lymphedema.
  - b. It can present at birth (congenital lymphedema), puberty (lymphedema precox) or adult life (lymphedema tarda)

congenital lymphedema is also called Milroy's disease.

18. What is secondary lymphedema?  
This is lymphedema secondary to:
  - a. Infection (bacterial and fungal).
  - b. Neoplasia.
  - c. Radiation.
  - d. Parasitic infestation – filariasis.

## PHIMOSIS

### Case Summary

The 5-year-old male child presents with the complaint of difficulty in micturition. The mother complains that when the child micturates, the prepuce balloons out and urine comes out in thin stream.

On examination the opening of the prepuce is very small and it cannot be retracted over the glans penis.

1. What is your diagnosis?  
This is a case of congenital phimosis.
2. What do you say so?
  - a. The child is 5-year-old.
  - b. Foreskin cannot be retracted over the penis since birth.
  - c. There is ballooning of prepuce at the time of passing urine.
  - d. Urine comes out in thin stream.
3. What is phimosis?
4. What are the causes of phimosis?  
See chapter 49 'urethra and penis'.
5. Is congenital phimosis physiological or pathological?
  - a. In fact, phimosis is physiological upto four years of age. After 4 years, the loose adhesion between the prepuce and the glans can easily be separated and can easily be retracted.
  - b. It is said to be pathological when there is narrow stream of urine and ballooning of prepuce at the time of micturition.
6. What are the complications of phimosis?
  - a. Recurrent balanitis and balanoposthitis.
  - b. Paraphimosis.
  - c. Formation of preputial stone from the retained smegma.
  - d. Obstruction to urinary flow leading to hydronephrosis and hydronephrosis.
  - e. Malignancy usually in adults.
7. What is paraphimosis?
8. What is the treatment of phimosis?
9. What is the treatment of paraphimosis?

See phimosis and paraphimosis in the chapter 49 on 'urethra and penis'.

10. What are the indications of circumcision?
11. What are the steps of operation of circumcision?
12. What are the complications of circumcision operation?  
See circumcision operation in the operative section, chapter 97.

### HYPOSPADIAS

The mother of the 4-year-old male child complains that the urethral orifice is situated on the under surface of penis since birth.

The patient also soils his clothes while passing urine.

On examination, the penis appears hypoplastic, the external urethral orifice is situated on the under surface of penis near the distal part of the body.

The distal part of penis is bent due to the presence of chordee.

1. What is your diagnosis?  
This is a case of distal penile type of hypospadias.
2. What are the points in favor of your diagnosis?
  - a. Urethral meatus is situated on the under surface near the distal part of the body.
  - b. Chordee is present.
  - c. Prepuce is not developed inferiorly and it looks like a hood.
  - d. Size of penis is relatively small.
3. What are the different types of hypospadias?
4. What is the incidence?
5. How will you treat the case?
6. What is chordee?  
See hypospadias in the chapter 49 on 'urethra and penis'.
7. How does normal urethra develops?  
See 'developing of urethra' in the chapter 49 on 'urethra and penis'.
8. What are the indications for operation in hypospadias?
  - a. Cosmetic or psychological problems in school going child.
  - b. Patient cannot pass urine in erect posture.
  - c. Severe chordee so that the penis remains bent during erection.
  - d. In perineal type, infertility may occur.

9. What is the ideal age of operation?  
Previous ideal age was 4 to 6 years. With the improvement of pediatric anesthesia and techniques in surgery; the present day consensus is to repair at 6 months to 1 year of age.
10. What are the principles of repair?
  - a. Correction of chordee, called orthoplasty.
  - b. Construction of a neourethra, called urethroplasty.
  - c. Meatoplasty and glanuloplasty – correction of meatal stenosis and reconstruction of glans penis.
11. What are the complications of hypospadias repair?
  - a. Urethrocuteaneous fistula – The most common complication.
  - b. Urethral stricture.
  - c. Urethral diverticulum.
  - d. Bleeding and hematoma.
  - e. Meatal stenosis.
12. What are the advantages of one stage procedure?
  - a. Less hospital stay.
  - b. Penis looks normal like a circumcised one.
  - c. Less chance of fistula formation.
13. When will you consider a two stage repair?  
In case of scrotal or perineal hypospadias, with severe chordee or short penis, a two stage procedure is preferred.
  - In the first stage, orthoplasty is performed.
  - In the second stage, 6 months after the first stage, a neourethra is constructed.
14. What are the common congenital anomalies associated with hypospadias?
  - a. Undescended testis.
  - b. Upper urinary tract abnormality.
  - c. Inguinal hernias.
15. Why the penis is small?
  - a. The growth of phallus and urethral groove occurs simultaneously.
  - b. If urethra is not formed, phallus ceases to grow and results in the small size of the penis.
16. What is epispadias?  
Epispadias designates the presence of urethral orifice on the dorsal aspect of the penis.
17. What congenital malformation is associated with epispadias?

Epispadias is commonly associated with bladder extrophy, (Ectopia vesicae), a congenital malformation of the bladder.

18. What is the pathogenesis of chordee?
  - a. The chordee is due to foreshortened ventral skin devoid of dartos fascia, along with splaying and fibrosis of the incompletely formed corpus spongiosum.
  - b. Significant degrees of chordee are present in about 35 percent of patients with hypospadias.

### CARCINOMA PENIS

#### Case Summary

The 50-year-old male patient presents with an ulcer in the glans penis for last 1 year. The ulcer was small to start with but it gradually involved almost whole of the glans penis.

The patient complains of a foul smelling discharge and occasional bleeding from the ulcer. The patient is unable to retract the prepuce since the onset of the lesion. He has no difficulty in passing urine.

On examination, there is an ulceroproliferative indolent lesion, involving almost whole of glans penis. The ulcer has an indurated base and everted edge. The shaft of penis is normal.

Inguinal lymph nodes are not palpable.

1. What is your diagnosis?  
This is a case of carcinoma penis involving the glans penis without any clinical involvement of inguinal lymph nodes.
2. What are the points in favor of your diagnosis?
  - a. Elderly male patient with an ulceroproliferative lesion at the glans penis.
  - b. The ulcer grows slowly and painlessly.
  - c. Presence of foul smelling discharge and occasional bleeding from the ulcer.
3. What are the other possibilities?
  - a. Condyloma acuminata or long standing genital wart.
  - b. Ulcers – Chancre or chancroid.
  - c. Leukoplakia – Caused by balanitis and balanoposthitis.
  - d. Buschke – Lowenstein tumor, also known as giant condyloma acuminata.
  - e. Balanitis xerotica obliterans (BXO) – a sclerotic lesion of unknown etiology.

4. What are the premalignant lesions of penis?
5. What factors are associated with increased incidence of carcinoma penis?
6. What are the macroscopic types of carcinoma penis?
7. What are the microscopic types of carcinoma penis?
8. How does carcinoma penis spread?
9. What is modified Jackson's staging of carcinoma penis?  
See 'carcinoma penis' in the chapter 49 on 'urethra and penis'.

10. How will you confirm your diagnosis?  
By incisional biopsy from the growth.

11. What is TNM staging?

*P* - Primary tumor.

T<sub>0</sub> - No primary tumor.

T<sub>IS</sub> - Carcinoma *in situ*.

T<sub>1</sub> - Tumor less than 2 cm. Size and superficial (no deep extension).

T<sub>2</sub> - Tumor 2 - 5 cm size.

T<sub>3</sub> - Tumor > 5 cm size.

T<sub>4</sub> - Large lesion involving adjacent organs.

*N* - Regional lymph nodes (*Inguinal lymph nodes*)

N<sub>0</sub> - No regional lymph node involvement.

N<sub>1</sub> - Mobile unilateral inguinal nodes.

N<sub>2</sub> - Mobile bilateral inguinal nodes.

N<sub>3</sub> - Fixed inguinal nodes.

*M* - Distant metastasis.

M<sub>0</sub> - No distant metastasis.

M<sub>1</sub> - Presence of distant metastasis.

12. What is the outline of treatment of carcinoma penis?

13. How do you manage inguinal lymph nodes?

See carcinoma of penis in the chapter 49 on urethra and penis.

14. What is the role of chemotherapy in carcinoma penis?

Combination chemotherapy or monotherapy involving methotrexate, bleomycin and cisplatin is advised in advanced cases that is, M<sub>1</sub> or N<sub>3</sub> case stages where other forms of treatment is not possible or effective.

15. What is the treatment in this patient?

a. As the growth has involved only the glans penis and inguinal lymph nodes

are not palpable, the treatment of choice will be partial amputation of penis.

b. The line of resection should be 2cm proximal to the proximal margin of the growth.

16. How do you perform partial amputation of penis?

a. Under local or general anesthesia a long ventral skin flap is raised. The corpora cavernosa is divided at the proposed line of resection and is overrun with sutures.

b. The corpus spongiosum is also divided ½ inch distal to the line of section of corpora cavernosa.

c. A small opening is made on the ventral flap and the corpus spongiosum is brought out through the opening.

d. The two flaps are now sutured together at the dorsum of the penis.

e. The end of the emerging urethra is split for a distance of 1cm and each half is sutured to the skin of the flap to prevent future stricture formation.

Thus a neourethra is formed on the ventral aspect of the penis.

f. A self-retaining catheter is introduced and kept *in situ* for a few days till the wound heals. See also steps of operation and figs 97.9A to E in operative section.

17. What structures are removed in total amputation of penis?

a. The two corpora, cavernosa with ischiocavernosus is excised upto their origin from ischiopubic rami.

b. The corpus spongiosum along with the penile and glandular part of the

urethra is excised keeping 1.5 to 2.0 cm margin projecting beyond the perineal membrane.

c. The stump of the urethra is brought out through the posterior part of the incision (racket-shaped incision made previously) and a perineal urethrostomy is done.

d. A self-retaining catheter is kept *in situ* for a few days till the wound heals, after which the catheter is taken out.

e. Along with total amputation bilateral orchidectomy should also be done to abolish the sexual desire and the psychological upset resulting therefrom.

Also with bilateral orchidectomy, the patient can easily pass urine as the testis does not overhang perineal urethrostomy.

See also the total amputation of penis in chaptre 97, operative section.

18. What is the structure of penis?

a. The penis has three parts viz. glans, body and root and consists of three longitudinal columns of erectile tissue, covered by fibrous tissue (Buck's fascia) and skin.

b. The ventral corpus spongiosum is expanded proximally as the bulb and distally as the glans penis and transmits the urethra.

c. Two dorsolateral corpora cavernosa attach to each side of the inferior pubic arch as the crura. They form the crura of the penis and stop anteriorly just short of the glans (Fig. 84.2).

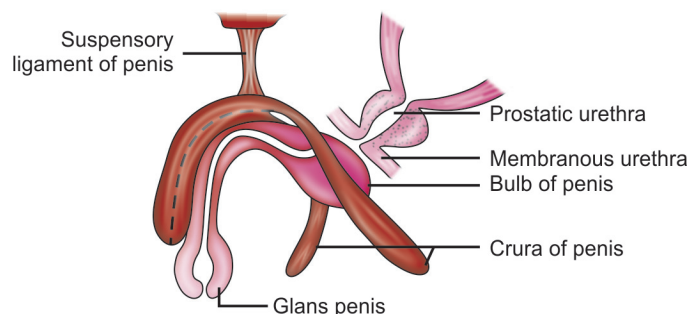


Fig. 84.2: Gross anatomy of penis and urethra.

19. What is the blood supply of penis?

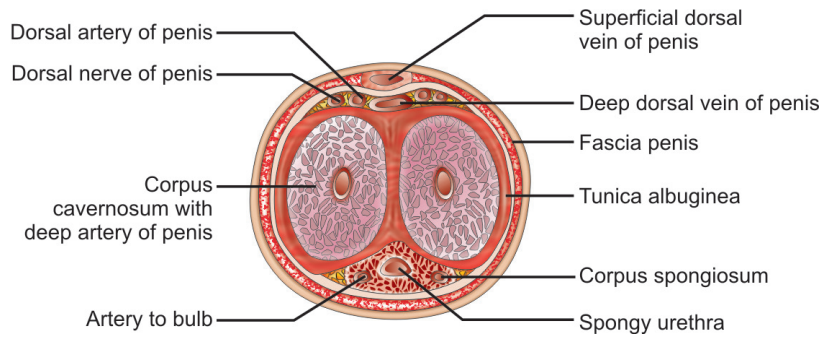
Arterial supply:

- a. Two dorsal arteries lying superficial to corpora cavernosa.
- b. Two deep arteries of penis within the corpora cavernosa.
- c. Two arteries to the bulb lying within the corpus spongiosum.

All the above six are branches from the internal pudendal artery.

Venous drainage: Occurs through two unpaired veins viz.

- a. Superficial dorsal vein runs superficial to fascia penis (Buck's fascia) and drains into the great saphenous vein.
- b. Deep dorsal vein lies deep to Buck's fascia and drains into the prostatic venous plexus see (Fig. 84.3).



**Fig. 84.3:** Transverse section through body of penis.

20. What is the lymphatic drainage of the penis?

- a. The lymph vessels from the skin drain into the superficial inguinal group of lymph nodes.

- b. The lymph vessels from the glans and corpora drain into the deep inguinal nodes and partly to external iliac nodes.
- c. The penile lymphatics usually drain into both inguinal areas.

# Chapter 85

## Orthopedics – Short Cases

- Cubitus valgus
- Cubitus varus
- Wrist drop
- Claw hand
- Ganglion
- Genu varum
- Genu valgum
- Semimembranosus bursitis
- Recurrent dislocation of patella
- Congenital talipes equinovarus (CTEV)
- Exostosis
- Osteosarcoma

### CUBITUS VALGUS (Fig. 85.1)

#### Case Summary

The 15-year-old boy presents with outward deviation of the right forearm from arm mainly on extension. He gives history of right lateral condylar fracture a few years back.

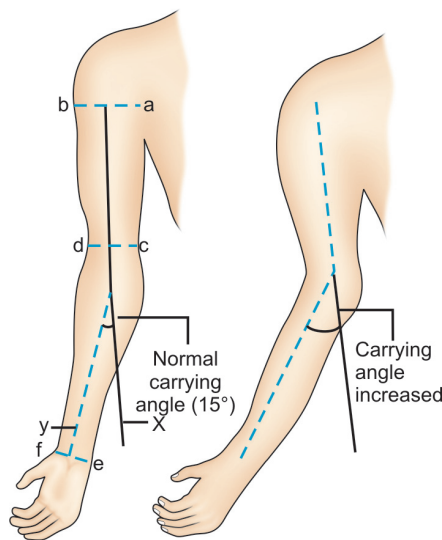
On examination, the carrying angle is seen increased on the right side.

1. What is your case?  
This is a case of cubitus valgus deformity of right elbow joint.
2. Why do you say so?
  - a. History lateral condylar fracture of right humerus.
  - b. Outward deviation of right forearm from the arm.
  - c. Carrying angle is increased.
3. What is the carrying angle?
  - a. The carrying angle is the outward deviation of the extended and supinated forearm from the axis of the arm.
  - b. Normally it is more (15°) in females than in males (10°).
  - c. The angle disappears on pronation or on full flexion of the forearm.
4. What problem may appear with this deformity?  
This deformity as such does not create any problem but late or tardy ulnar nerve palsy may occur.

5. What is the cause of tardy ulnar nerve palsy?
  - a. Ulnar nerve undergoes ischemic and fibrotic changes due to friction neuritis by prominent medial epicondyle when flexion and extension occurs.
  - b. The progress of palsy may be arrested by transposition of the nerve from its

normal position behind the medial epicondyle to the front of the joint.

6. How will you treat the case?
    - a. Mild deformity does not require any treatment.
    - b. If tingling and numbness appears in hand due to tardy ulnar nerve palsy, then ulnar nerve transposition is done.
- As this case shows mild deformity and there is no feature of ulnar nerve palsy, no treatment is required.



**Fig. 85.1:** Cubitus valgus a- Tip of anterior axillary fold. b-Most prominent part of deltoid bulge. c-Medial epicondyle. d-Lateral epicondyle. e-Ulnar styloid. f-Radial styloid. x-Axis of the right arm. y-Axis of the right forearm.

### CUBITUS VARUS (FIG. 85.2)

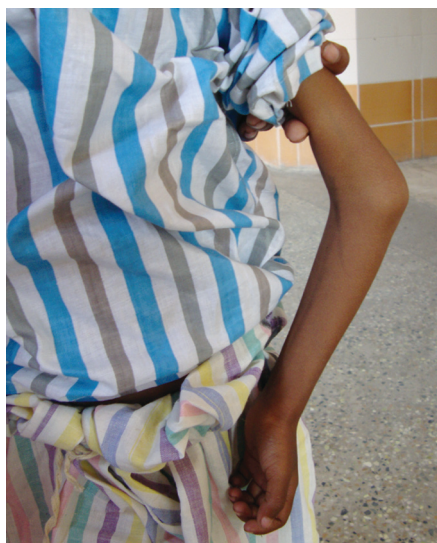#### Case Summary

A 4-year-old male child presents with inward deviation of left forearm from arm on extension. He gives history of trauma to left elbow 6 months back due to fall on the outstretched hand, followed by pain and swelling at elbow.

He was treated with plaster cast immobilization for three weeks. On plaster removal patient gradually noticed the deformity –

On examination, there is reduced carrying angle. Relationship of 3 bony points (i.e. tip of olecranon, medial epicondyle and lateral epicondyle) is unaltered (This relationship is altered in case of fracture lateral condyle of humerus, unlike malunited supracondylar fracture).





**Fig. 85.2:** Cubitus varus

1. What is your cases?  
This is a case of cubitus varus deformity of left elbow joint.
2. Why do you say so?
  - a. History of fall on the outstretched hand
  - b. The long axis of the forearm is inward (Medially) deviated with respect to the long axis of the arm.
  - c. Carrying angle is reduced.
3. How the axis of forearm is drawn?  
Axis of forearm is drawn by joining mid-points of the line joining radial and ulnar styloid and the line joining lateral and medial epicondyles of humerus on the anterior surface of forearm (Fig. 85.1).
4. How the axis of arm is drawn?  
The axis of arm is drawn by joining mid-point of a line drawn from the tip of the anterior axillary fold to most prominent part of the deltoid bulge as seen from the front to midpoint of interepicondylar line (Fig. 85.1)
5. How do you define the carrying angle?  
It is the angle between the extended long axis of the arm and that of the forearm in fully extended elbow and fully supinated forearm, i.e. The anatomical position.
6. What are the causes of cubitus varus?
  - a. Malunited supracondylar fracture (commonest cause)
  - b. Lateral condyle fracture of humerus (rarely)
  - c. Infective, e.g. growth plate damage

- d. Neoplastic, e.g. Secondary to osteochondroma or exostoses near elbow.
  - e. Congenital, e.g. epiphyseal dysplasia.
7. How will you manage the case?  
Investigation: X-ray—
1. Both elbows in one film, in full extension and forearm supinated – A-P view (To compare and assess the exact degree of correction that is required)
  2. Lateral view of the affected elbow to assess the posterior tilt/shift.

### Treatment

Mild deformity in a male child may not require any treatment but an ugly elbow in a female child should be corrected for cosmetic reasons.

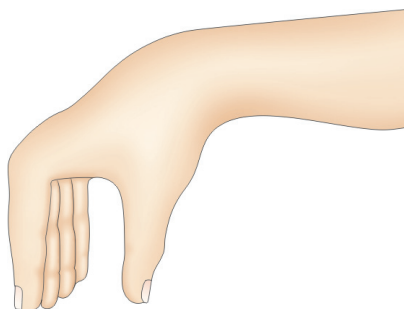
Treatment is supracondylar corrective osteotomy (French osteotomy).

### WRIST DROP (RADIAL NERVE PALSY) (Fig. 85.3)

1. What is the case?  
This is a case of left sided wrist drop.
2. What is wrist drop?  
It is due to weakness or paralysis of extensors of the wrist joint.
3. What are the extensors of the wrist?
  - a. Extensor carpi ulnaris.
  - b. Extensor carpi radialis longus and brevis.

The above muscles are the prime mover and they are associated by the following muscles.

  - a. Extensor pollicis longus and brevis.
  - b. Extensor digitorum and extensor indicis.
  - c. Extensor digiti-minimi.
4. What are the muscles supplied by radial nerve in the forearm?



**Fig. 85.3:** Wrist drop

- a. In front of lateral epicondyle, radial nerve divides into two branches – one deep or posterior interosseous nerve and one superficial or cutaneous branch.
  - b. The posterior interosseous nerve supplies all the extensors of the back of forearm.
  - c. The cutaneous branch is purely sensory and supplies the dorsum of forearm and dorsum of lateral three fingers.
5. What are the common sites of radial nerve injury?
- a. At the axilla in case of fracture and dislocation of upper end of humerus.
  - b. Radial groove – Fracture of humerus.
  - c. Elbow – Fracture neck or dislocation of head of radius.
6. How do you differentiate the radial nerve injury at radial or spiral groove or above?  
If the radial nerve injury occurs at radial groove patient can extend his elbow, as supply to triceps or extensors of elbow comes from the nerve higher up.
7. Can the patient of wrist drop extend his fingers?  
In radial nerve injury, extensors of wrist and metacarpophalangeal joints are paralyzed. So the patient cannot extend the wrist and the metacarpophalangeal joints.  
The patient can extend the interphalangeal joints as this is performed by the interossei, supplied by the ulnar nerve.
8. How do you test for radial nerve?  
Radial nerve is assessed by the following tests.
- i. Test for triceps – Patient is asked to extend the flexed elbow against resistance.
  - ii. Test for brachioradialis – Patient is asked to flex his elbow in mid prone position against resistance.
  - iii. Test for extensors of the wrist – Patient with paralyzed wrist extensors, has wrist drop. This is tested by asking to extend the wrist against resistance.
  - iv. Test for extensor digitorum – The patient is asked to extend his flexed finger at metacarpophalangeal joint against resistance.
9. How will you treat this patient?  
Treatment may be conservative or operative.

## A. Conservative treatment:

- Splintage of the wrist with cock up splint.
- Every joint of the affected limb is put through the full range of movement at least once a day for preserving mobility of the joints.
- Care of skin – Since the skin is anesthetic, it should be protected from trauma and pressure sores.
- Physiotherapy – consists of massage of the paralyzed muscles and passive exercises to the limb.
- Relief of pain with suitable analgesics.

B. Operative treatment – If there is no improvement with conservative treatment within three months, operative treatment is performed.

Nerve injury will be treated by:

- Nerve suture.
- Nerve graft and
- Tendon transfers and arthrodesis

These are reconstructive procedures and performed when there is no hope of recovery of a nerve, usually after 18 months. Even though the nerve recovers after this time the neuromuscular junction has degenerated making the transmission of impulses impossible. Rarely an amputation may be justified for an anesthetic limb or the one with causalgia. Nerve suture and nerve graft are the techniques of nerve repair (neurorrhaphy) usually done within a few days of injury.

10. Which tendons are transferred in wrist drop?

- Pronator teres to extensor carpi radialis longus.
- Flexor carpi ulnaris to long extensor of fingers.
- Palmaris longus to extensor pollicis longus.

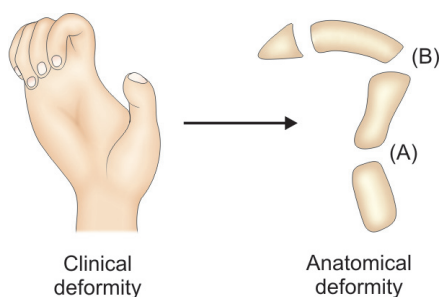
### CLAW HAND (Fig. 85.4) (Syn— Simian hand)

1. What is your case?

This is a case of claw hand deformity of right side probably arising from sharp glass cut injury in front of wrist.

2. What is claw hand deformity or main en griffe?

- This is a deformity in which the metacarpophalangeal joints are hyperextended



**Fig. 85.4:** Claw hand showing (A) Hyperextension of metacarpophalangeal joint and (B) Flexion of interphalangeal joint

and proximal and distal interphalangeal joints are flexed.

- The hyperextension of the metacarpophalangeal joint is due to unopposed action of the extensor digitorum and paralysis of the lumbricals which cause flexion of these joints.
  - The flexion of the proximal and distal interphalangeal joints is mainly due to paralysis of the interossei which are really the sole, extensors of these joints, extensor digitorum playing little part in the movement.
3. Injury to which nerves is responsible for claw hand deformity?
- Claw hand deformity is due to combined injury of the ulnar and the median nerves.
  - The deformity is due to paralysis of the interossei and lumbricals all of which are supplied by the ulnar nerve except the first two lumbricals which are supplied by the median nerve.
  - The muscles are supplied by the first dorsal segment of spinal cord through the ulnar and median nerves.
  - Any lesion of this segment of spinal cord or the nerves that supply these muscles will give rise to this deformity.
4. What is partial claw hand deformity?
- Partial claw hand deformity results from ulnar nerve palsy.
  - Here all the interossei (four dorsal and four palmar) and the third and fourth lumbricals are paralyzed. The first and second lumbricals are spared as they are supplied by the median nerve.
5. What are other causes of claw hand?
- Leprosy involving both ulnar and median nerves.
  - Klumpke's paralysis (lower brachial plexus lesion involving C<sub>8</sub> and T<sub>1</sub> nerve roots.)
  - Cervical rib causing friction of the lowest trunk of the brachial plexus.
  - Progressive muscular atrophy including amyotrophic lateral sclerosis, syringomyelia, etc.
6. What are the conditions that can initiate a claw hand?
- Volkman's ischemic contracture with or without associated nerve damage.
  - Postburn contracture.
  - Dupuytren's contracture
  - Fibrosis secondary to suppurative tenosynovitis.
7. What are the features of median nerve injury at wrist?
- Atrophy of the thenar prominence.
  - Pen test – This is the test for abductor pollicis brevis which draws the thumb forwards at right angle to the palm. The patient is asked to touch the pen held above the palm with tip of his thumb. The thumb cannot touch the pen due to paralysis of abductor pollicis brevis.
  - Inability to touch the ends of fingers with tip of thumb is due to paralysis of opponens pollicis.
  - There is sensory loss on the palmar aspect of the lateral three and a half fingers.
8. What are the features of ulnar nerve injury at wrist?
- Wasting of hypothenar eminence.
  - Card test – This test is done for palmar interossei of fingers. The fingers will not be able to grip a card due to loss of adduction by the palmar interossei paralysis.
  - Test for first dorsal interosseous muscle – This is examined by asking the patient to abduct the index finger against resistance.
  - Book test (Froment's sign)
    - This test is used to detect paralysis of the adductor pollicis and the first dorsal interosseous muscle.
    - Normally a person will grasp a book firmly between thumb and index finger, with the thumb remaining extended due to the actions of adductor pollicis and the first dorsal interosseous muscles.

- c. If the ulnar nerve is injured, the adductor pollicis will be paralyzed, and the patient will hold the books by using the flexor pollicis longus supplied by median nerve in place of the adductor. This produces flexion of the interphalangeal joint of the thumb.
  - d. The above effect (flexion) becomes more pronounced if the examiner tries to pull the book out while the patient tries to hold it.
9. What is Volkmann's ischemic contracture? This is defined as the fibrosis of the flexor muscles of the forearm following ischemia, as a result of injury to the brachial artery, most commonly due to supracondylar fracture of humerus. Unlike the claw hand Volkmann's sign (extension of interphalangeal joint on flexion of wrist joint) will be present in case of Volkmann's ischemic contracture.
  10. How will you treat this case? Treatment is either conservative or operative in the same line as in case of wrist drop (radial nerve palsy).
5. What are the common sites?
    - a. Dorsum of the wrist is the commonest site.
    - b. Palmar aspect of wrist or hand.
    - c. Dorsum of foot and ankle.
  6. What is compound palmar ganglion?
    - a. It is the chronic inflammation (either tubercular or rarely rheumatoid affection) of the ulnar bursa which is the common synovial sheath surrounding the flexor digitorum superficialis and profundus in front of the wrist.
    - b. It gives rise to an hour glass swelling, the constriction being produced by the flexor retinaculum.
    - c. That the two swellings are continuous is proved by the presence of cross fluctuation between the two.
    - d. The affected synovial membrane is greatly thickened.
  7. Why it is called compound? As it is a combination of two swellings one above and one below the flexor retinaculum, it is called a compound ganglion.
  8. How will you treat a ganglion?
  9. How will you treat compound palmar ganglion? Vide ganglion and compound palmar ganglion in the chapter 66 miscellaneous affections of the soft tissues.

### GANGLION

A 26-year-old female patient presents with a painless globular swelling on the dorsum of right wrist for last 2 years. Initially it was pea size but it gradually increased to the present size.

On examination, the lump is well-defined and firm in feel. Surface is smooth, size 4 cm × 3 cm. It is fixed to the underlying tendon as the swelling becomes fixed making the tendon taut.

1. What is your case? This is a ganglion on the dorsum of right wrist joint.
2. What are the points in favor of your diagnosis?
  - a. The lump is painless, firm in feel and located on the dorsum of right wrist joint.
  - b. Surface is smooth, and fixed to the underlying tendon.
3. What is a ganglion? It is a cystic swelling in relation to joint capsule or tendon sheath.
4. How does it develop? It is developed due to myxomatous degeneration of the fibrous tissue of the joint capsule or tendon sheath.

### GENU VARUM (Fig. 85.5)

1. What is your case? This is a case of bow legs or genu varum.
2. What is genu varum? In this deformity the knees and legs are separated outwards and the ankles are approximated.
3. How do you measure the angle of deformity?
  - a. There is usually a valgus angulation of about 6 degrees in an adult knee. Medial deviation of the foot so as to obliterate this angle gives rise to genu varum.
  - b. The angle of deformity can be determined by the angle formed between two lines as follows:
    - i. One line is drawn joining the anterior superior iliac spine and center of the patella in a fully extended knee.
    - ii. The other line is drawn joining the center of the patella to the midpoint

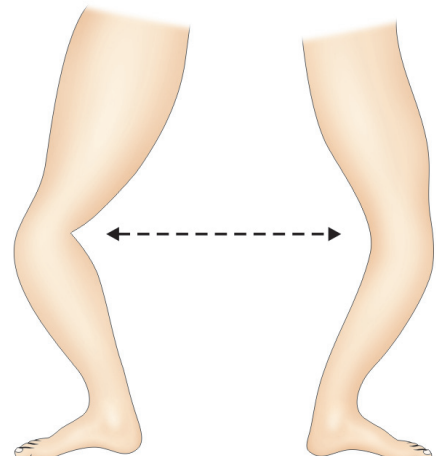


Fig. 85.5: Genu varum

- between the two malleoli, in front of the ankle.
4. What is the other way of determining the varus?
    - a. Normally in fully extended knee, when the medial malleoli of both legs are touched, the two knees also touch each other.
    - b. In genu varum, when the two malleoli are touched the knees remain separated.
    - c. This intercondylar distance measured indicates the amount of the varus deformity.
  5. How do you measure varus angle radiologically?
    - a. This is measured by intersection of the axis of the tibia and that of the femur.
    - b. The axis of the individual bones is obtained by joining two points in the center of the bone 1cm and 6cm from the knee.
  6. What position do you prefer for accurate measurement – supine or weight bearing position? Weight bearing position gives actual measurement, as the ligamentous laxity exaggerates the nonweight bearing varus angulation.
  7. What is physiological genu varum?
    - a. Around the age of 1-1½ years, the infants normally have a genu varum.
    - b. Gradually the stress of weight bearing makes the normal valgus angle of 6 degrees at about 6 years of age.
    - c. So, no treatment except reassurance is required for the physiological varus deformity.

8. What are the causes?
  - a. Physiological or developmental which undergoes spontaneous correction.
  - b. Pathological: This results from damage of epiphyseal cartilage or condyle of lower femur or upper tibia on the medial side.
    - i. Idiopathic.
    - ii. Traumatic, malunited fracture in adults.
    - iii. Blount's disease – Medial side of tibial epiphysis remains underdeveloped during first 3 years of life.
    - iv. Osteoarthritis.
    - v. Rheumatoid arthritis.
    - vi. Rickets.
    - vii. Others – Achondroplasia, cerebral palsy, myelomeningocele.
9. How will you treat the case?
  - i. Physiological type – Conservative treatment is done upto 6 years. Spontaneous recovery usually occurs.
  - ii. Pathological type – Upper tibial osteotomy is performed when the child attains 10 years of age.

### GENU VALGUM (Fig. 85.6)

1. What is your case?  
This is a case of genu valgum.
2. What are the points in favor of your diagnosis?
  - a. The knees are angled inwards.
  - b. Intermalleolar distance is increased.
  - c. There is exaggeration of the normal valgus angle of 6 - 8 degrees.
3. How do you measure the valgus angle?  
It is measured by the angle of deformity as in case of genu varum both clinically and radiologically.
4. What is its common name?  
Knock knee.
5. What is physiological knock knee?
  - a. During the growth of a child, the knee undergoes changes.
  - b. Before 1 year of age, there is varus deformity, called physiological genu varum.
  - c. Between 1½ to 3 years, the knee goes into valgus, called physiological genu valgum.
  - d. Spontaneous correction of this valgus occurs and the normal valgus angle of

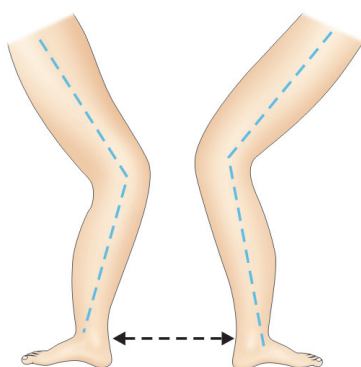


Fig. 85.6: Genu valgum

6 - 8 degrees is achieved by 6 - 8 years of age.

6. What are the causes?
  - i. Physiological.
  - ii. Pathological:
    - a. Trauma, e.g. fractures of condyles.
    - b. Infection like osteomyelitis.
    - c. Bone softening like rickets, osteomalacia.
    - d. Degenerative conditions, e.g. osteoarthritis, rheumatoid arthritis.

Each of the above causes may affect either the tibia or the femur.

7. How does infection causes genu valgum?
  - a. Infection interferes with the epiphyseal growth plate.
  - b. If medial growth plate is involved, genu varum results.
  - c. If lateral growth plate is involved, genu valgum results.
8. Why should genu valgum be treated?
  - a. Genu valgum is an ugly cosmetic deformity so it has to be corrected.
  - b. Genu valgus predisposed to degenerative changes especially of the lateral compartment of the knee.
9. What is the indication of operation?  
If the intermalleolar distance is more than 10cm at the age of 10 years.
10. What operation is done?  
Supracondylar wedge osteotomy of femur is done.
11. Will you prefer a femoral or tibial osteotomy?  
Femoral osteotomy is preferred, especially if the magnitude of the deformity is large.

### SEMIMEMBRANOSUS BURSITIS (FIG. 85.7)

#### Case Summary

The 10-year-old male patient presents with a swelling on the posteromedial aspect of left knee for last 3 years. Initially the swelling was small but it gradually increased to the present size. The swelling is painless and becomes more prominent with the knee straight.

The knee joint movements are normal and there is no other swelling in the body.

On examination, the swelling is cystic in feel and fluctuation is positive. It is irreducible.

The patient has no systemic symptoms.

1. What is your case?  
This is a case of semimembranosus bursitis on the left side.
2. Why do you say so?
  - a. Painless lump on the posteromedial aspect of left knee.
  - b. Fluctuation is positive.
  - c. It is irreducible.
  - d. It becomes more prominent with the knee straight.
3. Where does the bursa lie?
  - a. The bursa lies between the medial head of gastrocnemius and the semimembranosus tendon.
  - b. It is adherent to both the muscles.
4. What is the other possibility?
  - a. Popliteal cyst or Morsant Baker's cyst.
  - b. It is simply a herniation of the synovial cavity of the knee.

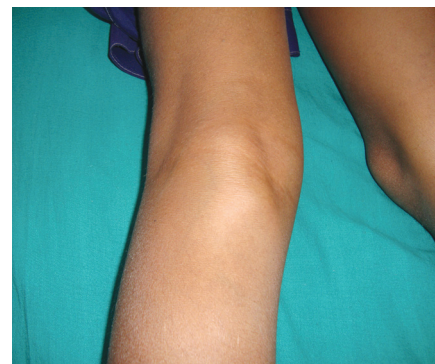

Fig. 85.7: Semimembranosus bursitis



5. How will you differentiate between semimembranosus bursitis and Baker's cyst?

(See Table 85.1 below)

6. What are the other cystic swellings behind the knee?

- Lymphangiectasis.
- Popliteal artery aneurysm – a pulsatile swelling.
- Neuromyxofibroma.
- Knee joint effusion.

7. How will you treat semimembranosus bursitis?

- Excision is usually done.
- Rarely aspiration and injection of hydrocortisone may be done.

8. What is the incision used?

A lazy 'S' incision is used making sure to avoid crossing the transverse crease at right angles.

9. Why not a longitudinal incision?

Scar formation may lead to contracture of the knee.

10. Do you use a tourniquet?

Yes.

11. When do you remove tourniquet?

Before the deep fascia is stitched, the tourniquet is removed and complete hemostasis is achieved.

12. What happens if deep fascia is not sutured?

Herniation of the popliteal pad of fat may occur.

13. Why do you call it bursitis?

Normally bursa is not palpable. Until and unless it is inflamed a bursa cannot be palpated, hence called bursitis.

14. What is the postoperative complication?

Recurrence of the cyst.

15. How do you prevent it?

A few fibers of semimembranosus must be removed to ensure complete removal and hence prevent recurrence.

16. What is the treatment of Baker's cyst?

See 'Morrant Baker's cyst in the chapter 66 miscellaneous soft tissue affections'.

## RECURRENT DISLOCATION OF PATELLA

### Case Summary

A 20-year-old female patient presents with locking of left knee in flexed position. She gives history of similar episodes in the past. The patella got dislocated laterally to the outer side of the knee but the dislocation reduced spontaneously.

On examination, the patella is small, high lying in the shallower part of intercondylar groove. The Q-angle (Quadriceps angle) is increased and apprehension test is positive.

There is associated genu valgum. No other deformity is present in the limbs.

1. What is your case?

This is a case of recurrent dislocation of left patella.

2. What are the points in favor of your diagnosis?

- Young adult female.
- Locking of knee in flexed position.
- Patella is small and high lying.
- Q-angle is increased.
- Genu valgum.
- Apprehension test is positive.

3. What is Q-angle?

The Q-angle is the angle between the line of action of the quadriceps and the ligamentum patellae. It is similar to the

tibiofemoral angle. The normal Q-angle is 10 to 15°. Excessive Q-angle leads to patellar dislocation.

4. Why it is common in genu valgum?

Because in genu valgum the Q angle is increased and predisposes to recurrent dislocation of patella.

5. What are the factors causing this?

- Excessive joint laxity.
- Weakness of the oblique fibers of Vastus medialis that acts as a dynamic sling to hold the patella. This in turn may be caused by hypoplasia, poliomyelitis and trauma.

c. Absence of bony ridge on lateral femoral condyle, which checks the lateral displacement of patella.

d. Genu valgum deformity as mentioned above.

6. What are the causes of locking of knee joint?

- Meniscus injury.
- Loose bodies in knee joint.
- Recurrent dislocation of patella.

7. What is apprehension test?

a. Lateral pressure is applied over the patella in an extended knee and the knee is gradually flexed.

b. The patient has an apprehension that the patella is going to be dislocated and will try to stop the test, generally by pushing the examiner's hand away.

c. It is done in the quiescent stage.

8. What is habitual dislocation of patella?

a. This is a condition where patella is dislocated each time the knee is flexed.

b. There is wasting of thigh.

c. Treatment is difficult.

9. What is acute dislocation of patella?

Acute dislocation of patella results from a sudden contraction of the quadriceps muscle while knee is flexed or semiflexed.

10. How will you treat recurrent patellar dislocation?

- Operation is the treatment of choice.
- Shifting of patellar tendon from tibial tuberosity to medial and lower position (Hauser's operation).
- If patella is small and chondromalacia is present, patellectomy is done.

11. How will you treat habitual dislocation?

- Release of shortened quadriceps (Vastus lateralis component) on the lateral side.

**Table 85.1: Difference between semimembranosus bursitis and Baker's cyst**

<i>Semimembranosus bursitis</i>	<i>Baker's cyst</i>
1. Age – Usually adolescent age group	Elderly age group
2. Pain – Painless swelling.	Pain is the main complaint with swelling
3. On knee flexion – It is less marked but can be felt easily.	It disappears on knee flexion.
4. No association	Classically associated with osteoarthritis or tuberculosis of knee.
5. Site – Situated posteromedially	Situated in the midline.
6. X-ray – Normal	Shows features of osteoarthrosis or tuberculosis of knee.



- b. Repair of lax structures on the medial side.

## CONGENITAL TALIPES EQUINOVARUS

### Case Summary

The mother of a 10-week-old baby presents her child with bilateral club foot or talipes with the following deformities.

- i. The foot is plantar flexed, inverted and adducted.
  - ii. The foot as a whole is small.
  - iii. The heel is small and raised.
  - iv. Muscles – The inverters, e.g. tibialis anterior and posterior are contracted, while everters like peroneus longus and brevis are stretched.
  - v. The defects are present since birth.
1. What is your case?  
This is a case of congenital talipes equinovarus (CTEV).
  2. Why do you say so?
    - a. The foot is plantar flexed, inverted and adducted.
    - b. Bilateral and present since birth.
    - c. The foot as a whole is small.
    - d. Heel is small and raised.
    - e. The inverters of foot are contracted, while the everters are stretched.
  3. What is talipes?
    - a. In normal condition, the sole of the foot is parallel to the ground and is said to be plantigrade.
    - b. When it does not remain plantigrade, the condition is known as talipes. (Talus + pes – literally meaning walking on talus).
  4. How do you classify talipes?  
Talipes is classified as follows:
    - a. Etiological – See the chapter on ‘congenital talipes equinovarus’ chapter 65.
    - b. Clinical –
      - i. Mobile and correctable.
      - ii. Rigid and noncorrectable depending upon whether correction is possible by manipulation or not.
  5. How will you confirm your diagnosis?  
The diagnosis in a newborn infant is definitely clinical.
  6. What is the incidence of talipes?
    - a. Talipes is the commonest congenital abnormality of foot, the incidence being 1 in 1000.

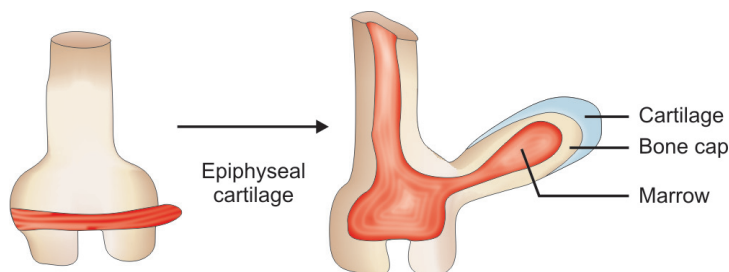


Fig. 85.8: Exostosis

- b. Males are more commonly affected than females and unilateral involvement is more common than bilateral involvement.
7. In CTEV, what are the bony changes?
8. What soft tissue changes occur in CTEV?  
See the chapter 65 on ‘congenital talipes equinovarus’.
9. When should you start treatment of CTEV?
  - a. It should be started immediately after birth by manipulation, without anesthesia.
  - b. The mother is taught the procedure which is performed for a few seconds, 6 times a day.
  - c. If correction occurs, it is maintained by adhesive strapping.
10. What is the order of correction?  
Adduction is corrected first followed by inversion and plantar flexion last of all.
11. How will you treat this case?  
As the baby is 10 weeks old, correction is done as started above.
12. How do you treat CTEV if the child is older than 2 months?  
See the chapter on ‘congenital talipes equinovarus’ Chapter 65.
13. After treatment what will suggest recurrence of deformity?  
Contracture of tendoachillis is the earliest feature of recurrence.
14. Will development of calf muscle come to normal following correction?  
It never comes to normal. Correction at an early age gives better result.
15. How long will you follow up a case for recurrence?  
For five years after operation.
16. For tendoachillis lengthening which is the preferred method?  
Open lengthening is always preferred to subcutaneous tenotomy.

## EXOSTOSIS (Fig. 85.8) (Syn— Osteochondroma)

### Case Summary

An 18-year-old male patient presents with a bony outgrowth from the lower end of left femur for last 2 years. The hard lump is painless and grows away from the growing end of bone.

On examination, the lump is bony hard in consistency about 10cm long, fixed to the bone, i.e. left femur but not the muscle and skin. Movement of left knee joint is normal.

1. What is your case?  
This is a case of exostosis at the lower end of left femur.
2. What is exostosis?
  - a. An exostosis is a benign cartilage capped outgrowth attached by a bony stalk to the underlying skeleton.
  - b. It arises as an outgrowth from the epiphyseal cartilage. As it grows away from bone it is called exostosis.
3. Why do you say so?
  - a. The lump is painless and bony hard in a 18-year-old boy.
  - b. It is situated near the knee joint.
  - c. It is fixed to the underlying bone and points away from the growing end of bone.
  - d. Movement of joint is normal.
4. Is it always painless?  
No, pain may occur if:
  - a. Pressure on a nerve occurs.
  - b. There is inflammation of the overlying bursa.
5. How will you confirm your diagnosis?  
Straight X-ray of bone will show the mushroom like bony tumor but not the cartilaginous cap.
6. When does the growth of exostosis stop?  
It (exostosis) tends to stop growing once the normal growth of the skeleton is completed.

7. What is the treatment?

See 'osteochondroma' in the chapter 61 on bone tumors.

## OSTEOSARCOMA

### Case Summary

The 15-year-old boy presents with a hard fusiform swelling at the lower end of right femur for last 1 year. Initially it was small, but for the last 6 months it increased rapidly to attain the present size with the appearance of pain. There is no history of trauma.

Patient has pallor and anorexia.

On local examination, there is a large fusiform (10 cm × 8 cm size) lump at the lower end of right femur. The overlying skin is stretched and shiny with prominent engorged veins. Local temperature is elevated with tenderness and the lump is fixed to the bone. Surface is smooth, consistency, bony hard and the muscle over the lump is mobile.

The right knee joint is normal. The inguinal lymph nodes on the right side are not involved. There is no evidence of other systemic disease.

1. What is your case?

This is a case of osteogenic sarcoma of the lower end of right femur.

2. What do you say so?

a. Young male patient aged 15 years.

b. The swelling, at the metaphyseal end of right femur has a rapid growth in the last 6 months.

c. The swelling is bony hard in consistency, tender with temperature raised.

d. The overlying skin is stretched and shiny with prominent engorged veins.

e. No history of trauma with rapid growth.

3. What is osteogenic sarcoma?

It is a malignant tumor arising from the osteoblast.

4. Why it is called osteogenic?

This tumor is osteogenic as the tumor cells or osteoblasts give rise to new bone formation instead of destroying it.

5. What is the most common malignant tumor of bone?

Metastatic bone tumors are the most common malignant bone tumors.

6. What are the other possibilities?

a. Ewing's sarcoma.

b. Posttraumatic swelling.

7. What are the different types of osteogenic sarcoma?

8. How does the tumor spread?

9. How will you confirm your diagnosis?

10. What is Codman's triangle and sunray spicules in local X-ray?

See osteosarcoma in the chapter 61 on 'bone tumor'.

11. How will you treat this case?

a. Though sarcoma, it is sensitive to chemotherapy. It is treated by combined therapy viz. surgery and chemotherapy.

b. In this case of there is no distant metastasis and X-ray chest is normal, either midhigh amputation followed by application of artificial limb or limb saving surgery with arthrodesis or joint replacement is performed.

c. Radiotherapy is reserved for inaccessible tumors and patients refusing operation.

12. What drugs are used in chemotherapy?

a. Drugs that yield best response include methotrexate, endoxan and cisplatin.

b. Preoperative neoadjuvant chemotherapy decreases the size of the tumor and also ablates the micrometastasis. It has made possible the concept of limb saving surgery.

13. Who was Codman?

Earnest Codman (1869 – 1940), was a surgeon attached to Massachusetts's General Hospital, Boston, USA.

14. What is the prognosis of this tumor?

a. If no treatment is done, death occurs within 6 months of diagnosis.

b. If only amputation is done – 5 year survival is about 20 percent.

If amputation is combined with pre- and postoperative chemotherapy, 5 year survival is about 60 percent.

# Chapter 86

## The Thyroid

- Introduction
- Thyroidectomy
- Operations of the thyroid
- Steps of operation of total thyroidectomy
- Postoperative complications
- Important preoperative management

### INTRODUCTION

- In the practical examination, questions in operative surgery may be asked in two ways, viz. indications and steps of operation and related topics like relevant surgical anatomy, preoperative care, postoperative care and complications.
- Operations may also be asked along with instruments, long case and short case.
- Hence, it is of vital importance to get clear knowledge about the common surgical operations.

Some important terms:

According to time and extent, the operation may be:

- i. Minor operation (upto 30 minutes), e.g. excision of lipoma, dermoid cyst or a small swelling under local anesthesia.
- ii. Intermediate or semimajor operation (30-45 minutes), e.g. herniorrhaphy, appendicectomy under regional or general an-esthesia.
- iii. Major operation (45-50 minutes to 2 hours), e.g. cholecystectomy, gastrectomy, etc. under general anesthesia.
- iv. Extramajor operation (2-4 hours), e.g. pancreatoduodenectomy, under general anesthesia.

### Indications of Operation

An operative procedure is performed depending on a clear indication which may be absolute or relative.

- i. Absolute indications—This includes conditions where surgery is the only curative option, e.g. acute appendicitis, symptomatic gallstones, etc.
- ii. Relative indications—This includes conditions where surgery is the better option, e.g. thyrotoxicosis, hernia, etc.

### THYROIDECTOMY

- A. Surgical anatomy—See 'surgical anatomy' in the chapter 23 on the thyroid gland.
- B. Indications:
  - a. Thyrotoxicosis—Subtotal thyroidectomy
  - b. Solitary thyroid nodule—Lobectomy (Hemithyroidectomy)
  - c. Multinodular goiter and diffuse colloid goiter—Partial thyroidectomy
  - d. Carcinoma thyroid—Near total or total thyroidectomy.

### OPERATIONS OF THE THYROID

#### Partial Thyroidectomy

This is done in cases of nontoxic metabolic goiters, i.e.

(i) Diffuse colloid goiter (ii) Multinodular goiter. In this operation, thyroid tissue amounting to normal size thyroid is left behind and the excess is resected.

#### Subtotal Thyroidectomy

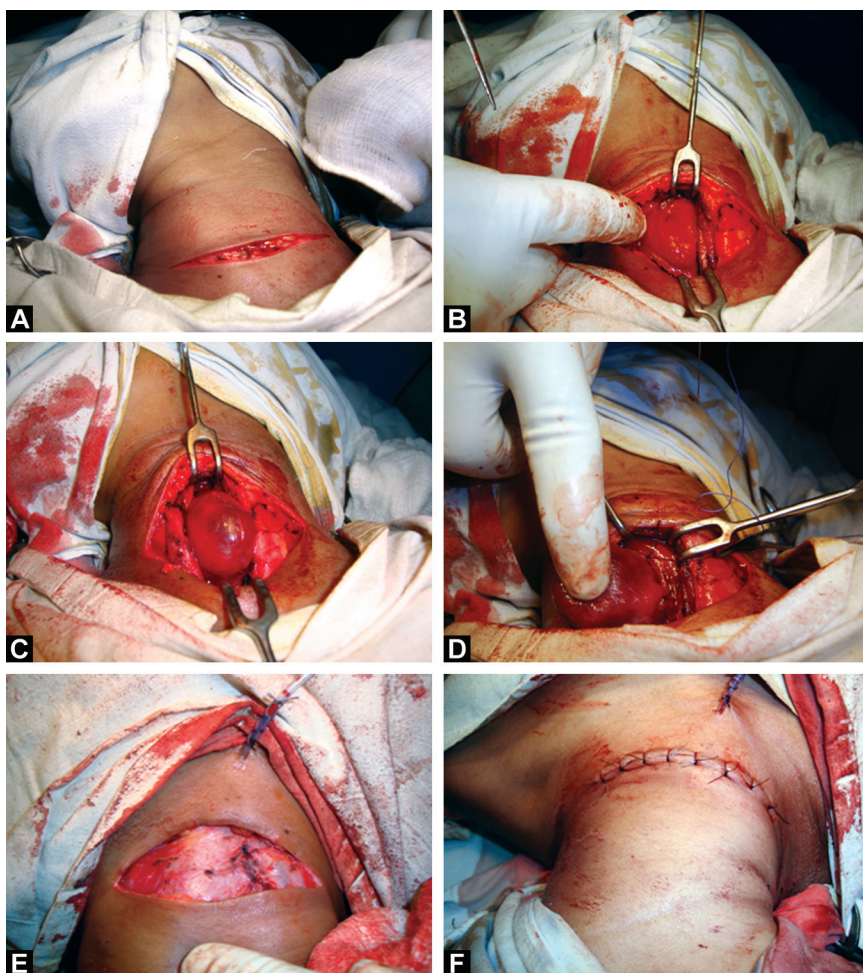
This is done for cases of toxic goiter—primary or secondary. Almost the whole of the thyroid is removed leaving behind only a small strip (3–4 gm) on either side in the tracheoesophageal cleft. It is safe to keep this part intact because it is the part which lies in close relation to the important structures like the recurrent laryngeal nerves, parathyroid, etc. As the thyroid tissue is hyperfunctioning these small strips left behind are sufficient to produce the requisite amount of thyroxin.

#### Total Thyroidectomy

This means 2 × total lobectomy plus isthmusectomy. This is done in cases of carcinoma of thyroid.

#### Hemithyroidectomy (Lobectomy)

This means removal of one lobe of thyroid along with the entire isthmus, i.e. total lobectomy plus isthmusectomy. It is done in case of (a) Adenoma where there is a suspicion of malignancy and (b) A dominant nodule in a multinodular goiter.



**Fig. 86.1A-F:** Steps of operation of total left lobectomy. (A) Incision (B) Deep cervical fascia cut (C) Thyroid gland exposed after cutting the pretracheal fascia (D) Ligation of left middle thyroid vein (E) Closure of deep cervical fascia putting a drain beside the trachea (F) Skin closure is complete

Various steps of operation of left lobectomy are shown in Figures 86.1A to F

### Excision of a Nodule

A solitary nodule or a cyst may be excised and sent for biopsy.

## STEPS OF OPERATION OF TOTAL THYROIDECTOMY

### Position of Patient

General anesthesia with endotracheal intubation is done. The patient is supine on the operating table with the table tilted up 15° at

the head end to reduce venous engorgement. A sandbag is placed transversely under the shoulders and the neck is extended to make the thyroid gland more prominent and apply tension on the skin, platysma and strap muscles which make dissection easier.

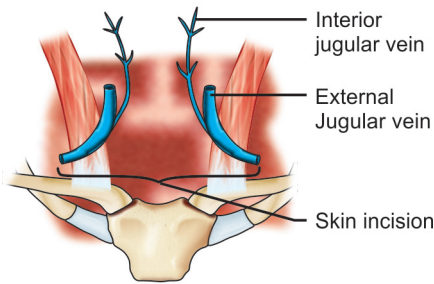
### Incision: Kocher's Collar Incision

This incision is made one inch above the sternal ends of the clavicles starting from lateral margin of one sternomastoid to the lateral margin of the other sternomastoid. In the operation of excision of a nodule or of hemithyroidectomy, however, the incision need not be so long but at the same time it

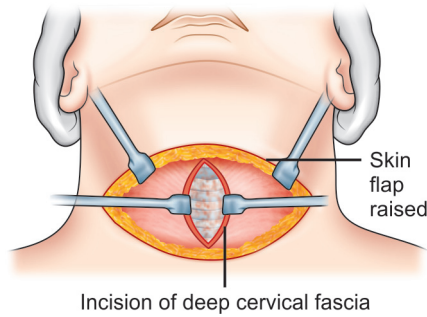
must be adequate enough to allow palpation of the rest of the thyroid to exclude presence of other nodules (Fig. 86.2).

- The skin, subcutaneous tissue and platysma are cut. It is better that the platysma is cut at a different level from the skin as this can minimize the scar.
  - The skin flaps are mobilized up and down to upper border of thyroid cartilage and to the suprasternal notch respectively.
  - The investing layer of the deep cervical fascia is incised vertically in the midline (Fig. 86.3). The infrahyoid muscles are retracted. The anterior surface of the gland covered with pretracheal fascia is exposed. (Fig. 86.4) This fascia is incised and a finger is insinuated to know the whole extent of the goiter. In case of big thyroid swelling, the strap muscles have to be cut, to get proper exposure. The muscles, if cut, should be incised as high as possible because, the nerves are coming from below upwards (Fig. 23.3).
  - The superior pole of the gland is first delivered at the wound, where the superior thyroid vessels are clamped as close to the gland as possible to prevent injury to the external laryngeal nerve and then divided.
  - The middle thyroid vein is ligated and cut at posterolateral border of thyroid.
  - The inferior thyroid artery is ligated away from the lower pole to prevent injury to the recurrent laryngeal nerve.
  - Inferior thyroid veins are ligated and cut at the lower pole (Fig. 86.5).
  - Same steps are repeated on the other side.
  - After the vessels have been ligated, resection of the thyroid is done as is required, i.e. partial, subtotal or total.
- The cut surface of the remaining thyroid tissue, which often bleeds considerably, even after long vessels have been ligated, is sutured with mattress stitches to achieve hemostasis, which must be perfect.
- A corrugated rubber drain is put on each side of the trachea and the wound is closed in layers.
  - The platysma is stitched after the sandbag is removed.
  - The skin is closed with interrupted stitches or with a subcuticular suture.

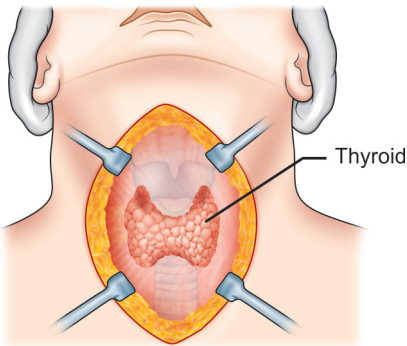




**Fig. 86.2:** Incision in thyroidectomy



**Fig. 86.3:** Incision of deep cervical fascia



**Fig. 86.4:** Thyroid gland is exposed beneath the pretracheal fascia

## POSTOPERATIVE COMPLICATIONS

### Hemorrhage

This is a reactionary type of hemorrhage occurring from the cut surface of the gland or due to slipping of ligature from a main vessel, most commonly the superior thyroid artery.

A tension hematoma may develop deep to the cervical fascia causing dyspnea for which the wound should be opened up immediately in the ward. All the stitches are

cut and the trachea is exposed to relieve the pressure exerted on it by the accumulated blood clots.

Thereafter, proper exploration should be made in the operation theater, hemostasis achieved and the wound closed with adequate drainage.

### Respiratory Obstruction

This may occur due to:

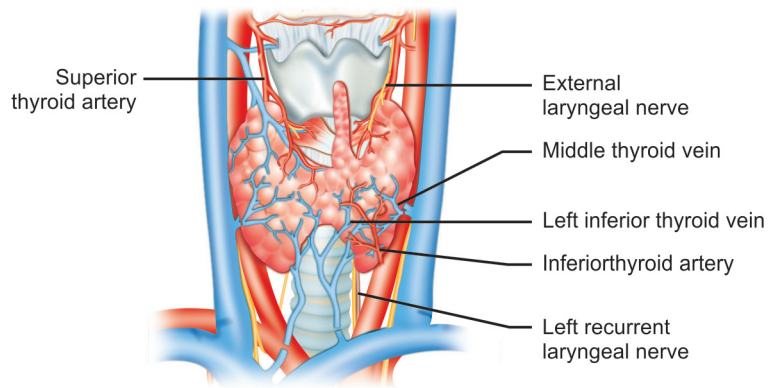
- Laryngeal edema in most cases following prolonged intubation.
- Collapse or kinking of the trachea rarely as a complication of very large goiters.
- Pressure on the trachea by blood as mentioned above.

Unilateral or bilateral recurrent laryngeal nerve paralysis will not cause immediate postoperative respiratory obstruction, unless associated with laryngeal edema but they will aggravate the obstruction.

### Recurrent Laryngeal Nerve Palsy

The nerve may be either contused or cut on one side or both. Most important clinical feature of recurrent nerve injury is hoarseness of voice.

- In unilateral nerve injury, the vocal cord of the affected side is adducted and drawn to the midline by the unparalyzed cricothyroid. In the majority of cases, accommodation occurs and the difficulties pass off in a few months.
- Bilateral nerve injury is ominous. Both the vocal cords are adducted causing complete closure of the glottis.



**Fig. 86.5:** Ligature of vessels completed

Immediate asphyxia may develop as soon as the endotracheal tube is withdrawn. Immediate tracheostomy is a life-saving measure in these cases.

### Thyroid Crisis

A thyroid crisis can occur in a patient postoperatively whose thyrotoxicosis was inadequately controlled preoperatively.

It is manifested by hyperpyrexia, tachycardia, restlessness, irritability, delirium, convulsions, etc. Management is medical by sedation, ice-sponging, beta-blockade with propranolol 20mg 6 hourly, antithyroid drugs, etc.

### Hypoparathyroidism

Hypoparathyroidism causing tetany may occur as a result of removal of parathyroids with the thyroid or impairment of blood supply to the parathyroids. The arteries to the parathyroids are end arteries.

If two of the four parathyroids are intact, tetany does not develop. The incidence of this condition is less than 0.5 percent and most cases present 2 to 5 days after operation.

Calcium (Ca-gluconate 10 percent 10-20 ml IV) and if necessary 1, 25 dihydroxycholecalciferol should be given to control tetany resulting from hypocalcemia, a feature of insufficient parathormone secretion.

### Hypothyroidism

Hypothyroidism is inevitable after a total thyroidectomy and replacement thyroxin should be commenced. Many patients who have



undergone subtotal thyroidectomy will eventually develop hypothyroidism.

### Wound Infection

A subcutaneous or deep cervical abscess should be drained.

### Hypertrophic or Keloid Scar

This may occur following wound infection. Intradermal injections of corticosteroid should be given at once and repeated monthly if necessary.

### IMPORTANT PREOPERATIVE MANAGEMENT

1. A laryngoscopy must be done to assess the condition of vocal cord which is

put on record in history sheet properly countersigned for medicolegal protection.

2. In a case of thyrotoxicosis, the patient must be prepared with antithyroid drug and propranolol to make him/ her euthyroid clinically and biochemically otherwise there is chance of thyrotoxic crisis.

Drugs used are:

- a. Carbimazole—5 to 10 mg TDS is administered for 8 to 12 weeks prior to operation to make the patient euthyroid.
- b. Propranolol—40mg TDS to decrease the pulse rate. It also inhibits the peripheral conversion of T4 to T3. Clinical response to  $\beta$ -blockers is quick and operation is arranged in a few days rather than weeks.

- c. Iodine (Lugol's 5% of iodine dissolved 10% KI solution) may be given with carbimazole or  $\beta$ -blocker for ten days before operation to reduce the size and vascularity of the gland which are increased by treatment with carbimazole.

### Questions

1. What is partial thyroidectomy?
2. What is subtotal thyroidectomy?
3. What is total thyroidectomy?
4. What is lobectomy?
5. What are the steps of operation of thyroidectomy (partial, subtotal or total)?
6. What are the postoperative complications?
7. What are the important preoperative measures to be taken in a thyrotoxic patient before operation?

# Chapter 87

## The Breast

- Surgical anatomy
- Simple mastectomy
- Radical mastectomy
- Modified radical mastectomy
- Drainage of breast abscess
- Fibroadenoma

### Surgical Anatomy

The following points are to be noted in surgical anatomy:

- Definition
- Course of development
- Situation
- Structure—nipple, areola, ligaments of Cooper
- Blood supply
- Lymphatic drainage.

See the chapter 43 on 'the breast' for details.

### What Operations are done on the Breast?

- Excision of fibroadenoma
- Simple mastectomy
- Radical mastectomy
- Drainage of breast abscess.

### SIMPLE MASTECTOMY

#### Indications

- Benign conditions:
  - Cystosarcoma phyllodes
  - Tuberculosis of the breast with multiple discharging sinuses not responding to conservative therapy
  - Intractable chronic breast abscess with discharging sinuses where previous attempts of drainage have failed.
- Malignant condition: As a curative procedure simple mastectomy with axillary clearance followed by radiotherapy and chemotherapy.

### Steps of Operation

- Position of patient—Supine with arm of the affected side abducted.
- General anesthesia with endotracheal intubation.
- Antiseptic dressing over the root of neck, both the breasts, axilla of the affected side, lower part of the chest and abdomen upto the umbilicus.
- Draping.
- Incision: An elliptical incision is made about 1" (one inch) away from the margin of the growth not excluding the nipple and areola. Upper end of incision is extended to the anterior fold of axilla and lower end to the xiphisternum (Fig. 87.1).
- The skin flaps are raised on either side.
- The breast tissue is dissected out from the pectoral fascia by sharp dissection with the scalpel.
- Hemostasis is secured.
- Skin incision is closed by interrupted stitches keeping a suction drain 14G which is brought out through a separate stab wound in the midaxillary line.
- Entire specimen is sent for histopathological examination.

### RADICAL MASTECTOMY

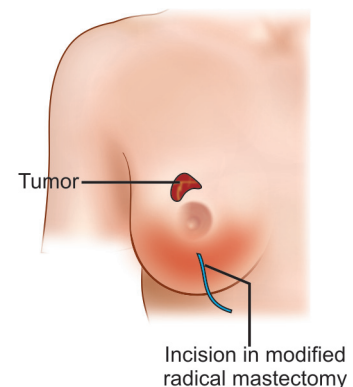
#### Indications

As curative treatment of carcinoma breast stage I and II (Recall stages I to IV of carcinoma breast. See the long case in chapter 72)

- What are the types of radical/curative surgeries in carcinoma breast?
  - Radical mastectomy of W. Halsted
  - Patey's modified radical mastectomy
  - Simple mastectomy with axillary clearance followed by radiotherapy
  - Lumpectomy with axillary clearance followed by radiotherapy
- What is Patey's operation?

The steps of operation are the same as radical mastectomy except that in radical mastectomy both pectoralis major and minor are removed.

In Patey's mastectomy, only the pectoralis minor is removed but the major is preserved.



**Fig. 87.1:** Showing the incision in modified radical mastectomy

3. What are the advantages of Patey's operation?
  - a. It maintains the contour of the chest as the pectoralis major muscle is preserved.
  - b. It is easier to place a skin graft over the pectoralis major muscle.
  - c. The artificial breast can be placed over the pectoralis muscle.
4. What structures are removed in radical mastectomy?
  - a. Breast containing the tumor.
  - b. Axillary fat with lymphatics and lymph nodes
  - c. Pectoralis major, pectoralis minor and clavipectoral fascia.
5. What are the structures that must be preserved?
  - a. Nerve to serratus anterior
  - b. Nerve to latissimus dorsi
  - c. Axillary vein
  - d. Cephalic vein.
6. Upper flap is raised in the subcutaneous plane between the superficial fascia of the breast and the subdermal fat using electrocautery—Superiorly upto the clavicle, medially up to the sternum and laterally up to the lateral border of latissimus dorsi muscle.
7. The lower flap is then raised similarly in the subcutaneous plane till the rectus sheath is reached inferiorly. The entire breast along with axillary lymph nodes and fat is thus excised. The pectoralis minor and clavipectoral fascia are removed but the cephalic vein is protected. While dissection is performed in the axilla, the intercostobrachial nerve and the nerves to latissimus dorsi and serratus anterior are preserved. The nerve to latissimus dorsi is found superficially near the subscapular vessels (Fig. 87.2). Sometimes, the nerve to latissimus dorsi is sacrificed if involved glands are found adhered to it. Hemostasis is secured and a thorough wound lavage is performed.
8. Wound is then closed in a single layer with interrupted stitches after placing 14 G suction drains under the mastectomy flaps and in the axilla. The drains are brought out laterally at the mid-axillary line.
9. The entire specimen is sent for histopathological examination.
- d. Postoperative edema—The arm of the affected side is swollen and heavy. It may be of two types:
  - i. Early postoperative edema—It occurs within a month and is caused by infection. This is treated with antibiotics and elevation of the hand
  - ii. Late postoperative edema—It occurs due to obstruction caused by enlarged lymph glands in the axilla either due to incomplete removal or further secondary deposits.
- e. Cancer *en cuirasse* (armour's coat)—Skin of the chest is thickened and edematous on which there appears nodular secondary deposits simulating an armour's coat
- f. Lymphangiosarcoma—Rare.

### MODIFIED RADICAL MASTECTOMY (PATEY'S OPERATION)

#### Steps of Operation

1. General anesthesia with endotracheal intubation.
  2. Position of patient—Supine with abduction of the arm of the affected side, resting on a platform.
  3. Antiseptic dressing as in case of simple mastectomy.
  4. Draping.
  5. Incision is made in the same way as in case of simple mastectomy.
1. What are the complications of Patey's operation?
    - a. Wound infection
    - b. Local recurrence
    - c. Adduction deformity

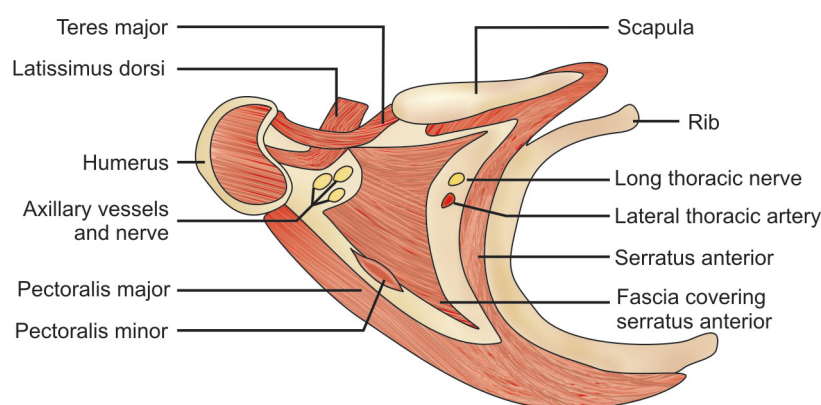


Fig. 87.2: Dissecting of axilla in modified radical mastectomy

### DRAINAGE OF BREAST ABSCESS

See "Drainage of breast abscess" in the chapter 43 on breast.

### Breast Conservation Surgery or Therapy (BCT)

#### Definition

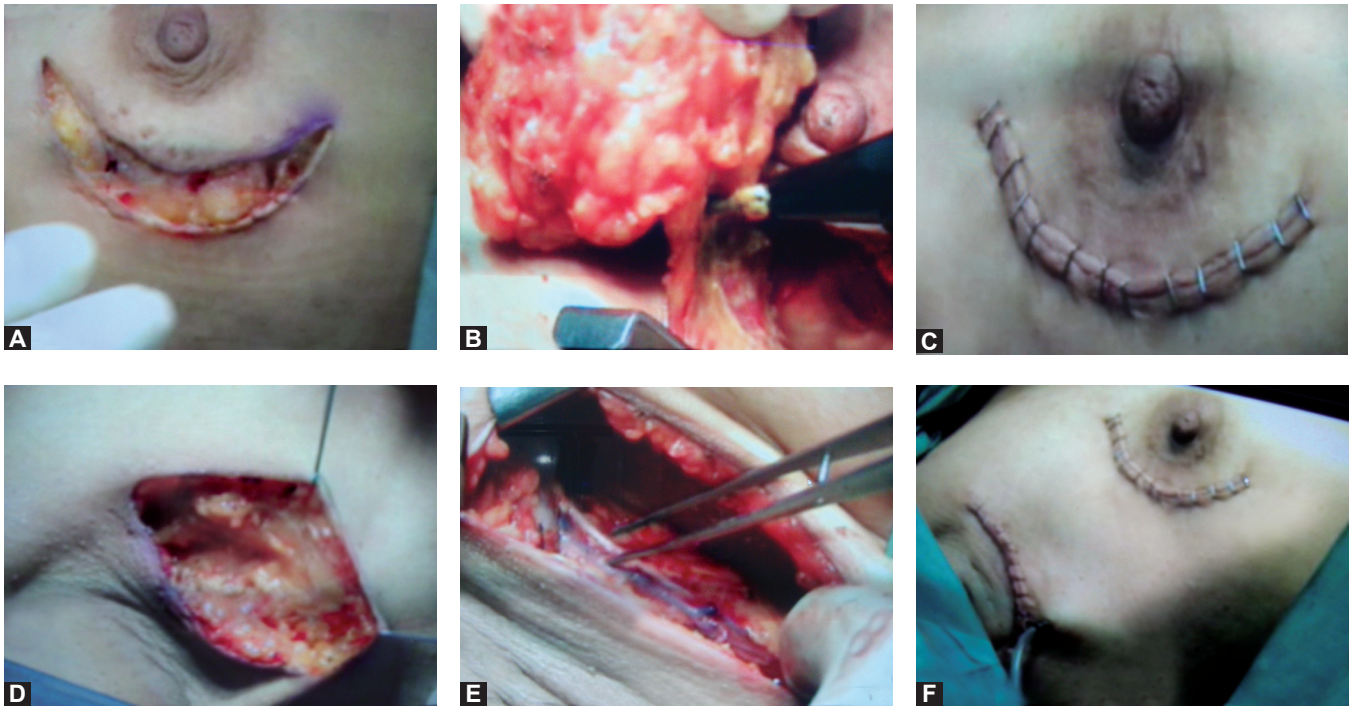
Breast conservation surgery consists of wide local excision of the tumor (Lumpectomy) with (node positive cases) or without (node negative cases) axillary dissection. Presently, BCT followed by radiotherapy has become the standard of care in early breast cancer.

#### Indications of BCT

1. Early breast cancer (Stage I and II, i.e. T<sub>1</sub> and T<sub>2</sub>, N<sub>0</sub>, N<sub>1</sub> and M<sub>0</sub>)
  2. Mammographically detected lesion
  3. Selected cases of LABC (Locally advanced breast cancer) which include T<sub>3</sub> tumors with N<sub>1</sub> and N<sub>2</sub> nodes without distant metastasis after downsizing with neoadjuvant chemotherapy.
- BCT is gaining popularity as it provides less physical disfigurement and emotional upset when compared to MRM (Modified radical mastectomy) as the alternative therapy, although local recurrence rate and disease-free survival are similar in both forms of surgery.

#### Contraindications

BCT is contraindicated in the following situations:



**Figs 87.3A to F:** (A) Incision; (B) Breast lump almost dissected out; (C) Closure of incision done; (D) Incision for axillary dissection; (E) Axillary vein exposed; (F) Axillary wound closed with 14G suction drain

- i. Poorly differentiated tumor
- ii. Paget's disease
- iii. High tumor/breast ratio
- iv. Difficulty in follow-up
- v. Centrally placed tumor
- vi. Pregnancy.

**Procedure**

**Case**

In a 50-year-old female patient presented with T<sub>2</sub> (3cm), N<sub>1</sub>, M<sub>0</sub> tumor, wide local excision with axillary dissection is performed.

**Wide Local Excision of the Tumor (Figs 87.3A to C)**

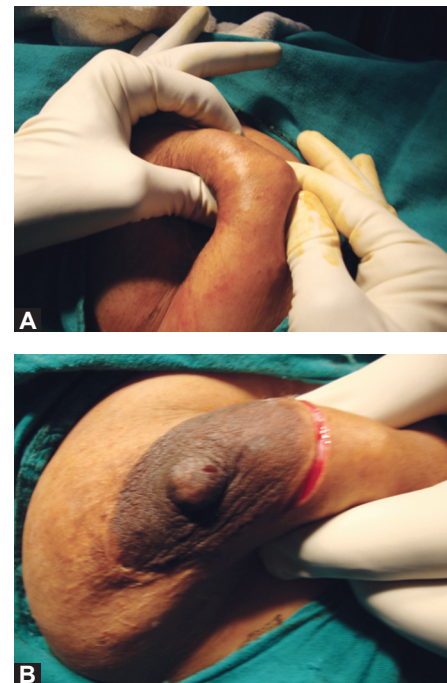
1. Position of patient—Supine with ipsilateral arm abducted at 90°.
2. Anesthesia: GA with endotracheal intubation.
3. Antiseptic dressing and draping.
4. Incision: About 5 cm curvilinear (non radial) incision is made directly over the lump parallel to the Langer lines.
5. The dissection is extended down to the pectoralis major with excision of the fas-

cia. The lump along with 1–1.5 cm rim of breast tissue is removed.

6. Wound is closed after meticulous hemostasis without any drain.
7. The lumpectomy specimen is sent for HP examination, after proper labelling of all margins.

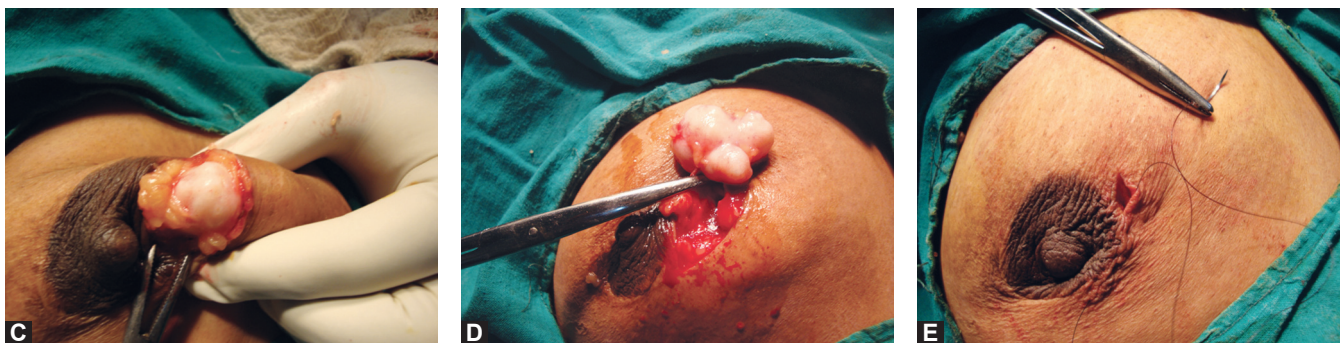**Axillary Dissection (Figs 87.3D to F)**

1. A transverse 5–6 cm incision is made at the lower axillary hairline from the lateral pectoral fold to the fold raised by lateral border of latissimus dorsi.
2. Anterior dissection is continued up to the lateral border of pectoralis major and posterior dissection, up to the lateral border of latissimus dorsi muscle.
3. The axillary vein is exposed along its entire length and the level, I, II, and III nodes are removed. The medial pectoral nerve and the nerve to serratus anterior are preserved.
4. After proper hemostasis and thorough lavage, axillary wound is closed in a single layer putting a 14 G closed suction drain near the inferior end of the incision.



**Figs 87.4A and B:** (A) Fixation of the swelling; (B) Making the circumareolar incision





**Figs 87.4C to E:** (C) Fibroadenoma exposed; (D) Tumor almost dissected out; (E) Skin closure nearing completion

## FIBROADENOMA

What are the steps of operation of excision of fibroadenoma?

### Excision of Fibroadenoma

#### Steps of Operation (Figs 87.4A to E)

1. General anesthesia with endotracheal intubation.
2. Position—Supine with arm of the affected side abducted.
3. Antiseptic dressing; Axilla is shaved before antiseptic dressing is applied with Betadine

from the root of the neck to the upper part of abdomen and from the sternum to the middle of the arm including the axilla.

4. Draping.
5. Incision: The swelling is fixed by the assistant and a curvilinear incision is made over the tumor. Instead of curved incision, radial incision may be made (Figs 87.4A and B).
6. Incision is deepened to cut through the skin, superficial fascia and the capsule (compressed breast tissue) of the fibroadenoma (Fig. 87.4C).

The fibroadenomatous nodule is dissected out with the tip of the scissor

(Fig. 87.4D). Hemostasis is secured and the space is obliterated with multiple stitches.

Skin closure is done with fine monofilament nylon (Fig. 87.4E).

1. What is preferred incision for a fibroadenoma on the lateral quadrant of the breast?

Gaillard Thomas Incision—A curved incision on the thoracic mammary fold. It is cosmetically better.

2. What is the most important step? To make the tumor fixed or steady so that it does not move.



# Chapter 88

## The Abdomen—General

- Abdominal incisions
- Individual in incisions
- Closure of abdominal wound
- Exploratory laparotomy
- Colostomy
- Loop ileostomy

### ABDOMINAL INCISIONS AND CLOSURE

Abdominal incisions (Fig. 88.1) are divided into three main groups viz.

- I. Vertical incisions:
  - a. Upper midline incision
  - b. Lower midline incision
  - c. Paramedian incision.
- II. Oblique incisions:
  - a. Kocher's subcostal incision
  - b. Roof top (Bilateral subcostal) incision
  - c. McBurney's gridiron incision
  - d. Muscle cutting iliac incision (Rutherford – Morrison incision).

- III. Transverse incisions:
  - a. Upper transverse incision
  - b. The Lanz incision
  - c. Pfannenstiel's infraumbilical curved incision.

### INDIVIDUAL INCISIONS

#### Upper Midline Incision (Epigastric Midline Incision)

- a. Extent—This incision starts from xiphisternum and ends at umbilicus.
- b. Structures cut are skin, subcutaneous fat, linea alba and peritoneum.

Q. What is linea alba?

The linea alba is a dense strong structure half an inch wide, formed by the interlacing fibers of the rectus sheaths. It is relatively avascular, white and linear, hence the name.

- c. Indications: It is the incision of choice where speed is essential, e.g. perforated peptic ulcer.
- d. Advantages:
  - i. Quick entry and most suitable for emergency cases.
  - ii. Both sides of abdomen equally accessible.
  - iii. Simple to open and simple to close.
- e. Disadvantages: More chance of ventral hernia as compared to paramedian incision.

#### Lower Midline Incision

- a. Extent—The incision starts from the umbilicus and ends at symphysis pubis.
- b. Structures cut are same as in upper midline incision. The linea alba here is thin and narrow.
- c. Lower midline incision is better avoided as the linea alba is thin and narrow and posterior sheath is deficient.
- d. Most cases of burst abdomen follow this incision.

#### Paramedian Incision

- a. This is a time honored incision made about 1" (one inch) away and parallel to the midline. It is less used nowadays.
- b. The structures cut include:
  - i. Skin

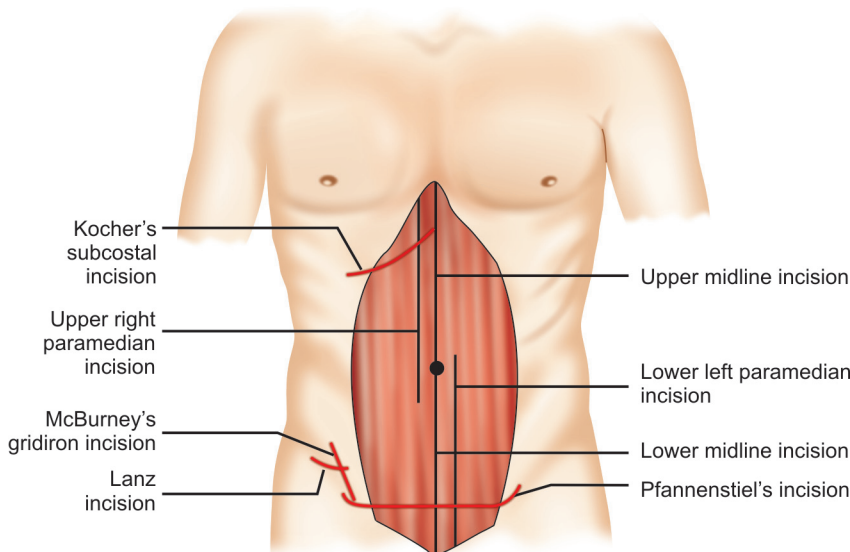


Fig. 88.1: Different types of abdominal incisions

- ii. Anterior rectus sheath
  - iii. Rectus muscle
  - iv. Posterior rectus sheath
  - v. Fascia transversalis
  - vi. Extraperitoneal fat
  - vii. Peritoneum.
- c. It may be upper or lower paramedian incision on the right or left side.
- d. Indications:

**Upper paramedian incision**

Right side

- Cholecystectomy
- Partial gastrectomy
- Pancreatic operations.

Left side

- Splenectomy

**Lower paramedian incision**

Right side

- i. Right hemicolectomy
- ii. Acute intestinal obstruction, unless there is sigmoid volvulus.

Left side

- i. Operation on volvulus
- ii. Left hemicolectomy.

e. Advantages:

- i. Incision can be extended downwards and transversely
- ii. Suitable for exploratory laparotomy for proper diagnosis
- iii. Chances of incisional hernia are less.

f. Disadvantages:

- i. In fatty patient, cholecystectomy sometimes becomes difficult by this incision
- ii. Access to the superior surface of liver is difficult with this incision.

**Kocher's Subcostal Incision**

- a. Extent: It starts below the xiphisternum and extends to the right about 2.5 cm (1") below and parallel to costal margin for about 12.5 cm (5") downwards and outwards.
- b. The structures cut are:
  - i. Skin and superficial fascia
  - ii. Anterior rectus sheath
  - iii. Rectus muscle medially and a part of external oblique, internal oblique and transverses abdominis laterally.
  - iv. Fascia transversalis, extraperitoneal fat and peritoneum.
- c. Indication: This incision is commonly used for cholecystectomy in obese patients.
- d. Advantages:

- i. Adequate and direct access to the biliary tract and liver

- ii. Freedom from wound dehiscence.
- e. Disadvantages:
- i. Laparotomy is not possible. So difficulty arises in detecting a second pathology, like diseases of the colon or small gut
  - ii. Appendix is not easily approachable
  - iii. Greater blood loss.
- Left subcostal incision—indicated for splenectomy.

**Rooftop or Bilateral Subcostal Incision**

- a. This provides better exposure for pancreas, liver and adrenals.
- b. A curved skin incision is made below and parallel to both costal margins. The incision is deepened through recti and part of the oblique muscles of the anterior abdominal wall on either side.

**McBurney's Gridiron Incision**

- a. Extent: This incision is made perpendicular to spinoumbilical line at McBurney's point for about 3" (1" or 2.5 cm above and 2" or 5cm below the point).  
McBurney's point is located at the junction of medial 2/3rd and lateral 1/3rd of spinoumbilical line.
- b. Structures cut from superficial to deep are:
  - i. Skin and subcutaneous tissue.
  - ii. External oblique muscle and aponeurosis cut along the line of skin incision. Fibers of internal oblique and transversus abdominis together are split perpendicular to the skin incision and retracted.
  - iii. Peritoneum is exposed and cut in the line of skin incision.

c. Indications:

- i. On the right side—For appendicectomy.
  - ii. On the left side—For pelvic colostomy.
- d. Advantages:
- i. No muscle is cut, all are split along their fibers. So there is no chance of incisional hernia.
  - ii. The opening and closure are quick, easy and almost bloodless.
- e. Disadvantage: The exposure may sometimes be inadequate especially in obese patients.

**Rutherford Morrison Incision**

It is a muscle cutting incision.

- a. Extent: The skin incision is the same as for McBurney's incision. Thereafter, all the

muscles are divided along the line of skin incision.

b. Structures cut are:

- i. Skin
- ii. Subcutaneous tissue
- iii. Fibers of external oblique (split)
- iv. Fibers of internal oblique and transversus abdominis are cut across instead of splitting as in case of grid-iron incision
- v. Peritoneum.

c. Indications:

- i. Exposure of lower ureter
  - ii. Exposure of colon and iliac arteries
  - iii. Appendicectomy—Usually a grid iron incision is converted into this incision in cases of difficult appendix
  - iv. Drainage of appendicular abscess.
- So the approach can be extraperitoneal or intraperitoneal.

**Upper Transverse Incision (Syn.— Transverse Epigastric Incision)**

- a. Extent: This incision is placed three fingers breadth above the umbilicus extending up to the costal margin on either side.
- b. Indications:
  - i. Pyloromyotomy in infants
  - ii. Exposure of biliary tree and adrenals.
- c. Structures cut are:
  - i. The skin and subcutaneous tissues
  - ii. Anterior rectus sheath
  - iii. Rectus muscles
  - iv. Posterior rectus sheath and peritoneum.

**The Lanz Incision**

This incision offers better cosmetic result following appendicectomy.

- a. Extent: This is a modified grid iron incision. Here a transverse incision is made centering the McBurney's point along interspinous crease.
- b. The rest of the steps are similar to grid-iron incision.

**Pfannenstiel's Incision**

- a. Extent: This incision is made along the interspinous crease with its center 5 cm (2") above the symphysis pubis. It is about 12.5 cm (5") in length.

- b. Structures cut from superficial to deep are:
  - i. Skin and subcutaneous tissue.
  - ii. Anterior rectus sheath divided in the line of skin incision and reflected upwards and downwards. Hemostasis is achieved with diathermy. The recti are separated and retracted laterally.
  - iii. The peritoneum is incised vertically to open the abdomen.
- c. Indications: This incision is suitable for operations on the bladder, prostate and female pelvic organs.

### CLOSURE OF ABDOMINAL WOUNDS

1. Mass closure:
  - a. This is a continuous full thickness closure except skin of abdominal wounds with nonabsorbable sutures like no. 1 Prolene or loop Ethilon.
  - b. This is ideal for midline incisions.
  - c. The skin is closed with 1/0 Ethilon.
2. Layered closure: Studies have revealed that:
  - a. Layered closure has no definite advantage over mass closure.
  - b. A layered closure may be used for traditional paramedian incision.
  - c. The peritoneum is closed with continuous catgut (1/0 chromic) sutures.
  - d. The anterior rectus sheath is closed with 1/0 Prolene sutures.
  - e. The cut muscles are sutured with interrupted catgut stitches.
  - f. The skin is closed with interrupted or Ethilon sutures.

### EXPLORATORY LAPAROTOMY

#### Definition

Exploratory laparotomy means exploration of the peritoneal cavity (Fig. 88.2).

#### Indications

##### Elective Exploratory Laparotomy

- a. To come to a definite diagnosis when it is not ascertained preoperatively.
- b. To detect a second pathology, a thorough exploration of abdomen is often necessary.

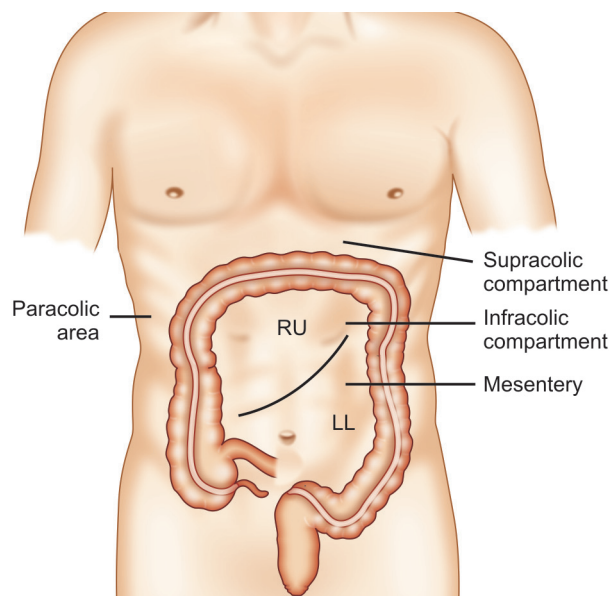
##### Emergency Exploratory Laparotomy

- a. Blunt trauma abdomen — Laparotomy is indicated for the following conditions:
  - i. Persistent and progressive shock despite resuscitation.
  - ii. Clinically established peritonitis.
  - iii. Progressive pallor and tachycardia with falling blood pressure suggestive of internal hemorrhage.
  - iv. Positive diagnostic peritoneal lavage (DPL).
- b. Penetrating injury of the abdomen.
- c. Various emergencies which constitute the acute abdomen are as follows:
  - i. Acute intestinal obstruction after failure of conservative treatment
  - ii. Acute appendicitis
  - iii. Intestinal obstruction with strangulation
  - iv. Colonic obstruction requires early exploration after exclusion of fecal impaction by enema and/or manual measure
  - v. Peptic perforation.

#### Steps of Operation

1. Position of patient: Supine.
2. Anesthesia: General anesthesia with endotracheal intubation.
3. Incision: A liberal midline incision is made.

4. The incision is deepened through skin and subcutaneous tissue and hemostasis is secured.
5. Linea alba is exposed and incised vertically.
6. On opening the peritoneum, exploration of whole of abdomen is carried out systemically as described below:
  - a. The peritoneal cavity is divided into supracolic and infracolic compartments by the transverse colon and mesocolon. (Fig. 88.2)
  - b. The infracolic compartment is again divided into right upper and left lower parts by the attachment of the mesentery. On the sides of the colon, paracolic gutters are present. Infracolic compartment below opens into the pelvis.
  - c. Structures present in the supracolic compartment are examined first in the following order: stomach and first part of duodenum, liver, gallbladder with biliary tree and liver.
  - d. Then colon is lifted up and infracolic compartment is examined as follows: 2nd and 3rd part of duodenum, duodenojejunal flexure, jejunum, ileum, appendix, cecum, ascending transverse and descending colon, sigmoid



**Fig. 88.2:** Different parts of the peritoneal cavity. RU and LL symbolize the right upper and left lower parts of the infracolic compartment

colon and pelvic organs, especially in female patients—the uterus and ovary.

**Q. How do you palpate the pancreas?**

The lesser sac is opened to explore the pancreas. The kidneys are also examined at their anatomical sites.

## COLOSTOMY

### Definition

External drainage of colon is called colostomy. The purposes of colostomy include the following:

- i. Diverting fecal stream for some distal pathology, e.g. colonic perforation.
- ii. To decompress the obstructed colon.
- iii. Replacement of anus, e.g. carcinoma rectum.

### Indications

1. Congenital—High anorectal anomalies where the child is born with obstruction.
2. Traumatic—Injuries to the rectum and anal canal. Here sigmoid colostomy is done.
3. Inflammatory, e.g.
  - i. In some complicated cases of fistula in ano
  - ii. Diverticulitis.
4. Neoplastic:
  - i. Carcinoma rectum and anal canal sigmoid colostomy is done
  - ii. Carcinoma descending colon transverse colostomy is done.
5. Miscellaneous:
  - i. Colonic obstruction
  - ii. Rectovesical or rectovaginal fistula.

### Types

- I. According to the period of diversion, a colostomy may be: 1. Temporary 2. Permanent.
  1. Temporary colostomy is done as an interim measure for:
    - a. Relief of distal obstruction, e.g. carcinoma sigmoid colon.
    - b. Protection of low colorectal anastomosis after anterior resection or after resection of sigmoid colon for tumors or volvulus to prevent fecal peritonitis.
    - c. Injury to colon and rectum.
  2. Permanent: This is done for life long period and is never closed, e.g. after

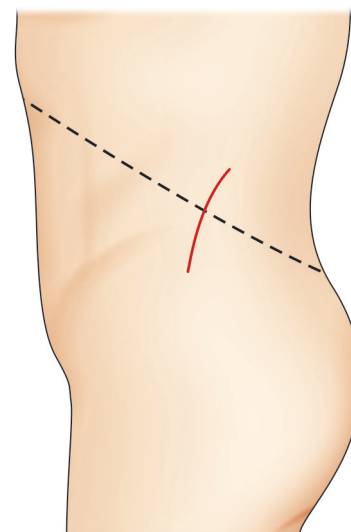
abdominoperineal resection operation in case of carcinoma rectum.

II. According to the way of fashioning of colostomy:

- i. Terminal or end colostomy—This is done at the sigmoid colon and opening is made at the left iliac fossa. It is a type of permanent colostomy having a single stoma.
- ii. Loop colostomy—Here a loop of colon is taken out and colostomy is performed. It may be in the sigmoid or transverse colon. It is a temporary colostomy and most commonly practised. It is now usual for these colostomies to be opened (double stoma) at the time of mucocutaneous apposition.
- iii. Divine's defunctioning colostomy: (Syn— A divided stoma colostomy or double barreled colostomy)
  - a. The colostomy is made with a bridge of skin between the two stomas.
  - b. Two limbs of the colon are brought out through separate skin incisions.
  - c. The proximal stoma is thus an end colostomy while distal one is called a mucous fistula.
  - d. This ensures absolute rest to the distal segment of the colon and rectum but restoration of bowel continuity is more difficult.

### Steps of Operation of Pelvic (Loop) Colostomy

1. Position of the patient supine.
2. General anesthesia with endotracheal intubation.
3. Antiseptic dressing from midchest to midhigh.
4. Draping.
5. Incision (Fig. 88.3) — Left gridiron muscle splitting incision is made.
6. Pelvic colon which is mobile, is identified and withdrawn.
7. The stoma is made in the proximal part of the mobile loop of pelvic colon in order to prevent prolapse.
8. The loop is brought out and retained by glass rod and a simple rubber catheter.
9. Opening the colostomy: The colon is opened immediately along a tinea in case of acute obstruction and mucocutaneous sutures are applied with catgut or vicryl.



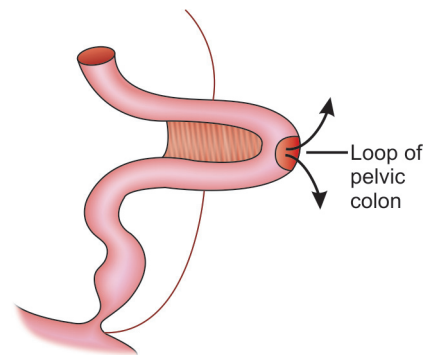
**Fig. 88.3:** Incision for pelvic colostomy

In nonemergency cases, colon is opened 2 or 3 days after operation to allow peritoneal adhesion between bowel and wound margins and negligible stool contamination.

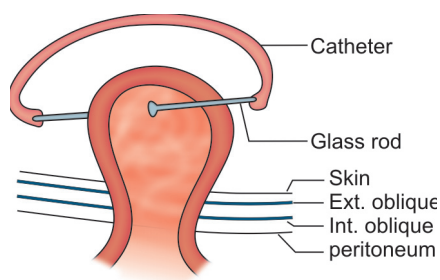
10. After opening the colostomy, the disposable colostomy bag is applied.

### Steps of Operation of Transverse Loop Colostomy (Fig. 88.4)

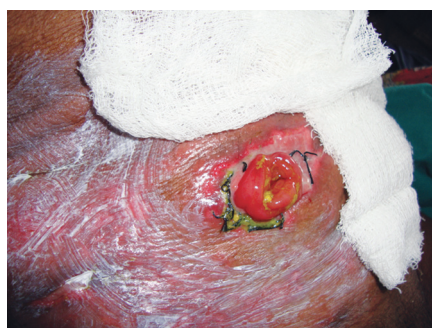1. Position of patient, anesthesia and antiseptic dressing are the same as in case of pelvic (loop) colostomy.
2. Draping.
3. Incision — A transverse incision is made midway between umbilicus and costal margin placed over the rectus abdominis muscle.
4. The incision is deepened to cut the rectus sheath and muscle.
5. The transverse colon is prepared by incising the greater omentum. A small



**Fig. 88.4:** Loop colostomy



**Fig. 88.5:** Securing the loop with a glass rod and catheter



**Fig. 88.6:** The ileostomy stoma

hole is made in the transverse mesocolon by the edge of the bowel wall and a rubber tube is passed through it to hasten the delivery of the colon.

6. The transverse colon is secured in the wound by pressing one glass rod through transverse mesocolon without injuring any vessel. A rubber catheter is passed between two ends of the glass rod so that it cannot be displaced (Fig. 88.5).

7. Colon wall is attached to sheath and peritoneum by a few interrupted sutures.

8. Opening the colostomy — See pelvic (loop) colostomy above. Colostomy bag is applied after opening the colostomy.

Q. How will you take care of colostomy postoperatively?

- Glass rod is removed after 7 days
- Application of colostomy bag after opening the colostomy

c. Bowel should move after 48 hours. If not moved, digital stimulation or removal of faecal mass is done.

Q. What are the postoperative complications of colostomy?

- Immediate:
  - Abdominal distention
  - Fecal impaction
  - Colostomy diarrhea.
- Delayed
  - Prolapse
  - Colostomy herniation
  - Stomal stenosis
  - Retraction
  - Skin irritation.

### **LOOP ILEOSTOMY (FIG. 88.6)**

- Loop ileostomy is preferred to loop colostomy to defunction distal colorectal anastomosis.

- A loop ileostomy is constructed following a colonic resection and distal colorectal or coloanal anastomosis.

### **Steps of Operation**

- Position of patient — Supine.
- General anesthesia with endotracheal intubation.
- Incision and exposure — Initial steps consist of laparotomy and resectional surgery for the primary condition.

To make a loop ileostomy, a 2 cm circle of skin is incised in the right lower quadrant (over rectus muscle) a few centimeters below the umbilicus over a predetermined site.

- The dissection is continued to rectus sheath.
- A cruciate incision is made in the sheath and the rectus muscle is split to expose the peritoneum and open it.
- A loop of ileum is selected to form the stoma without tension and a window is made in its mesentery to pass rubber tubing through it.
- The loop of ileum is brought out with a tissue forceps and ileum is opened by incising the bowel for half its circumference at a point 2 cm from the level of skin in the distal limb.
- A spout can be formed from the longer proximal loop by everting it. Three or four absorbable sutures are inserted to secure the defunctional side and six to eight on the functional side.
- The ileostomy bag is applied.



# Chapter 89

## Stomach and Duodenum

- Surgical anatomy of vagus nerves
- Type of vagotomy
- Gastrojejunostomy
- Operation for peptic ulcer perforation
- Gastrectomy
- Pyloromyotomy (Ramstedt's operation)
- Heller's esophago-cardiomyotomy

Since 1940s, Dragsted and his colleagues at the University of Chicago revolutionized gastroduodenal surgery by bringing vagotomy in the treatment of duodenal ulcer.

### SURGICAL ANATOMY OF VAGUS NERVES

In abdomen the two vagus nerves enter through esophageal hiatus. The left vagus becomes the anterior vagus and the right, becomes the posterior vagus, lying on the anterior and posterior aspect of the esophagus respectively.

The anterior vagus has three main divisions viz. hepatic, gastric and antral. The antral branch is known as the anterior nerve of Latarjet.

The posterior vagus gives off branches analogous to those of the anterior vagus except instead of hepatic branch it gives off the celiac branch which supplies the pancreas and the intestine as far as the splenic flexure.

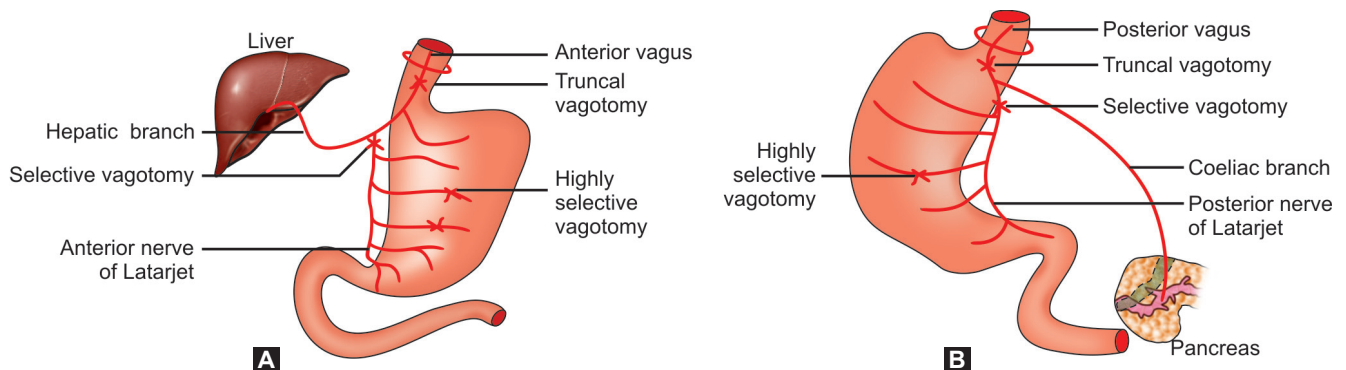
So, the posterior vagus after giving off the celiac and gastric branches is continued as the posterior nerve of Latarjet.

### TYPES OF VAGOTOMY (FIGS 89.1A AND B)

1. Truncal vagotomy — The vagus is cut at trunk above hepatic or celiac branches. It is also known as total vagotomy.
2. Selective vagotomy — Vagus is cut below hepatic or celiac branch. Hence

the functions of liver gallbladder and pancreas are preserved. Thus fatty diarrhea and gallbladder dyskinesia, common complications of truncal vagotomy are avoided.

3. Highly selective vagotomy (syn— Parietal cell vagotomy, or proximal gastric vagotomy).
  - Here only the gastric branches supplying the fundus and body are individually cut.
  - The antral pump mechanism remains intact, as the nerves of Latarjet are not interfered.
  - Hence, there is no need of drainage procedure, which is a must in the above two varieties.



**Figs 89.1A and B:** Showing different types of vagotomy of (A) Anterior and (B) Posterior vagus nerves

- The disadvantage of the procedure is that a few nerves may be spared and acid secretion may continue producing recurrent ulcer.

## Truncal Vagotomy

### Indications

1. Truncal vagotomy is nowadays occasionally performed in the treatment of chronic duodenal ulcer along with gastrojejunostomy or pyloroplasty.
2. Gastric outlet obstruction following chronic duodenal ulcer may require gastrojejunostomy and truncal vagotomy.

### Steps of Operation

1. Position of patient — Supine.
2. General anesthesia with endotracheal intubation.
3. Antiseptic dressing and draping.
4. Incision — An upper midline incision is preferred.
5. Abdomen is opened, pathology, confirmed and vagotomy decided. The chronic duodenal ulcer is evidenced by the white scar on the anterior aspect of the 1st part of duodenum and on rubbing the scar, with a dry gauze, petechial hemorrhage appears.
6. The left lobe of liver is retracted upwards. Spleen and small intestines are packed off.

### Anterior Vagus dissection:

7. The stomach is pulled downwards so that the cardioesophageal junction becomes exposed.
8. The peritoneum over the cardioesophageal junction is incised and anterior vagus is dissected out either by finger dissection or by a right angle forceps.
9. Vagus is cut and ligated. A portion of it is sent for biopsy.

### Posterior Vagus dissection:

10. Posterior vagus is stouter and stronger than the left and lies in the loose areolar tissue behind the esophagus. Esophagus is mobilized by finger dissection and retracted to left, with the help of a simple rubber catheter.
11. The posterior vagus is dissected out by finger dissection, cut and ligated. A portion of it (1" or 2.5 cm) is also sent for biopsy.
12. Drainage procedure is performed.
13. Laparotomy wound is closed in layers.

Q. Why the nerve is ligated?

It is very often accompanied by an artery.

Q. Why sent for biopsy?

It is of medicolegal importance to prove that the structure removed is really the vagus nerve and no other structure.

Q. What are the complications of truncal vagotomy?

1. Gastric stasis
2. Diarrhea
3. Gallbladder dyskinesia and gallstone formation.
4. Perforation of esophagus
5. Subphrenic abscess.
6. Mediastinitis.

## GASTROJEJUNOSTOMY

### Definition

This means an anastomosis between the stomach and the jejunum.

### Types

Gastrojejunostomy may be anterior or posterior depending on whether the anastomosis is made on the anterior or the posterior wall of the stomach.

### Indications

1. Surgical treatment of chronic duodenal ulcer along with truncal vagotomy.
2. Pyloric stenosis or gastric outlet obstruction.

### Preoperative Preparation

(In case of gastric outlet obstruction)

- a. Correction of fluid and electrolyte status with IV fluid and electrolytes.
- b. Nasogastric suction.
- c. Correction of hypoproteinemia by oral high protein diet, amino acid or human albumin infusion.
- d. Gastric lavage with normal saline before each feed for 4 to 5 days prior to surgery to remove food residue, decrease mucosal edema and restore gastric tonicity.
- e. Correction of dehydration to ensure adequate urine output.

### Steps of Operation

#### Posterior Gastrojejunostomy

1. Position of patient supine.
2. General anesthesia with endotracheal intubation.

3. Antiseptic dressing and draping.

4. The abdomen is opened with a midline incision as in case of truncal vagotomy.

5. Vagotomy is completed after which posterior gastrojejunostomy is decided and started.

6. The transverse colon is lifted upwards to expose the transverse mesocolon.

7. A vertical rent is made in the transverse mesocolon with scissors in an avascular area in between middle colic and left colic arteries.

8. Two Babcock forceps are applied about 6cm apart to the selected site on the posterior wall of stomach which is pulled or pushed through the rent in the mesocolon.

9. A loop of jejunum is selected 8 – 10 from the duodenojejunal flexure and held by Babcock forceps.

10. Now the selected portions of the stomach and jejunum are placed side by side, and anastomotic clamps are applied. Forceps are removed. The site is packed with moist packs.

11. Anastomosis is done in 4 layers in the following order from below upwards using 2/0 polyglactin sutures (Vicryl) (Fig. 89.2).

- i. Posterior seromuscular
- ii. Posterior through and through
- iii. Anterior through and through
- iv. Anterior seromuscular.

12. The margin of mesocolon rent is fixed to the stomach wall with interrupted suture 1cm from the suture line.

13. Closure — Transverse colon is put back in normal position and abdomen is closed in layers.

Q. Do you put a drain?

No drain is used here.

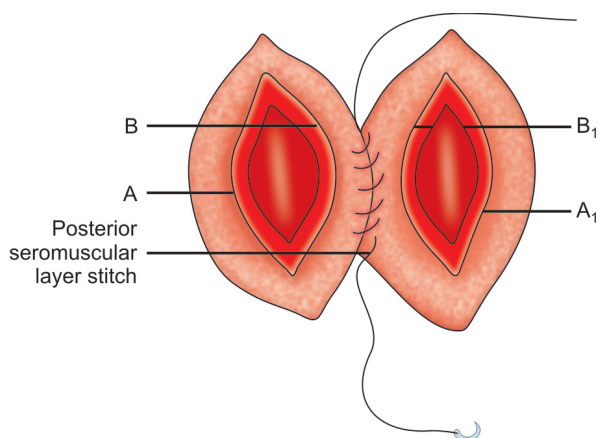
Q. What are the complications of this operation?

- i. Stomal obstruction which is detected by increased gastric suction even after 48 hours.
- ii. Hemorrhage.
- iii. Biliary vomiting.
- iv. Leak.
- v. Gastrojejunal intussusception.
- vi. Gastrojejunocolic fistula.

Q. What is an ideal gastrojejunostomy?

A retrocolic, short loop, no tension, dependent, isoperistaltic gastrojejunostomy with a vertical stoma, is considered as an ideal gastrojejunostomy.

Q. What is antecolic and retrocolic gastrojejunostomy?



**Fig. 89.2:** Showing the layers of stitch in gastrojejunostomy. BB<sub>1</sub> – Posterior through and through layer. AA<sub>1</sub> – Anterior through and through layer

When gastrojejunostomy is done anterior to colon, it is antecolic and when done posterior to colon, it is called retrocolic gastrojejunostomy.

- Q. What are the types of stoma?  
The stoma may be transverse, oblique and vertical. Vertical stoma is the ideal.
- Q. What do you mean by short loop?  
Short loop means a loop of jejunum 8 – 10” away from the DJ flexure.
- Q. What is no tension?  
This means no tension on the suture line.
- Q. What is isoperistaltic anastomosis?  
When lesser curvature of stomach is anastomosed to proximal jejunum, it is called isoperistaltic.
- Q. What is dependent gastrojejunostomy?  
It means gastrojejunostomy at the dependent part of stomach.
- Q. Why the rent in the mesocolon should be closed?  
To prevent internal herniation.
- Q. Why it should be sutured on to stomach and not to jejunum?  
a. To prevent jejuno gastric intussusception.  
b. If there is any anastomotic leak, it collects in greater sac, and may collect in pelvis.
- Q. What is the present status of gastrojejunostomy?  
a. Nowadays, it is seldom performed in the treatment of chronic duodenal ulcer because of the success of medical treatment with antibiotics, H<sub>2</sub> blockers and potent antacids.  
b. It is only indicated in pyloric stenosis or gastric outlet obstruction.

### Anterior Gastrojejunostomy

This is an antecolic anastomosis, which is occasionally indicated for malignant gastric outlet obstruction as a palliative procedure, when posterior gastrojejunostomy is not possible.

### OPERATION FOR PEPTIC ULCER PERFORATION

See perforated gastric/duodenal ulcer in the chapter no 30.

### GASTRECTOMY

Radical subtotal gastrectomy is the most commonly performed operation for gastric cancer. Here more than 80 percent of the stomach is removed along with the tumor and the lymph nodes.

### Radical Subtotal Gastrectomy

#### Indications

Carcinoma of the gastric pylorus, antrum and the distal third of body of stomach.

#### Steps of Operation

1. Position of patient — Supine.
2. General anesthesia with endotracheal intubation.
3. Antiseptic dressing from mid chest to mid thigh.
4. Draping.
5. Incision — Abdomen is opened with long midline incision. The liver is palpated to rule out metastatic disease. A careful examination is made to exclude peritoneal

deposits along the parietal walls and in the pelvis.

The local operability of the tumor is assessed by making a small opening in the gastrosplenic ligament which provides access to the posterior wall of stomach to see whether the tumor is free from the pancreas.

6. The greater omentum is now reflected and mobilized from its colonic attachment and lesser sac is completely opened. The omentum is dissected from the transverse mesocolon carefully till the upper border of pancreas is reached.
7. At the left extremity of greater omentum the left gastroepiploic vessels pass forwards in the gastrosplenic omentum in the hilum of the spleen. The lymph nodes at the origin of left gastroepiploic artery are carefully dissected out, and then the artery and vein are doubly ligated and divided.
8. At the right extremity of the greater omentum, the right gastroepiploic vessels are carefully isolated along with the subpyloric nodes before doubly ligating and dividing them at their origins from the gastroduodenal vessels.
9. Now the stomach is drawn caudally to put on stretch the free edge of lesser omentum. An incision is made carefully in the anterior leaf to expose the right gastric vessels and the suprapyloric lymph nodes. The nodes are dissected and the right gastric vessels are doubly ligated and divided.
10. Kocherization of duodenum is performed to dissect the first part from the head of the pancreas. Duodenum is transected 3 to 4cm beyond the pylorus and its stump, oversewn.
11. Lesser omentum is divided as close to the porta hepatis and liver as possible safeguarding the vital structures in its right free border.
12. The celiac nodes are dissected-free and the left gastric artery is divided as close to its origin as possible.
13. The stomach is turned cranially and a pair of noncrushing gastroenterostomy clamps is applied 5 cm proximal to tumor margin for proximal division of stomach.
14. Reconstruction
  - i. A poly type (Billroth II) retrocolic loop gastrojejunostomy may be done in two layers with 2 – 0 silk and 2 – 0

Vicryl or PDS to re-establish the continuity of the GI tract (Fig. 89.3).

Alternately a Roux-en-Y gastrojejunostomy is performed.

- ii. A feeding jejunostomy may be done for enteral feeding in the early postoperative period.
- iii. Two tube drains of 32 Fr. Size are placed one at the duodenal stump and the second near the gastrojejunal anastomosis.

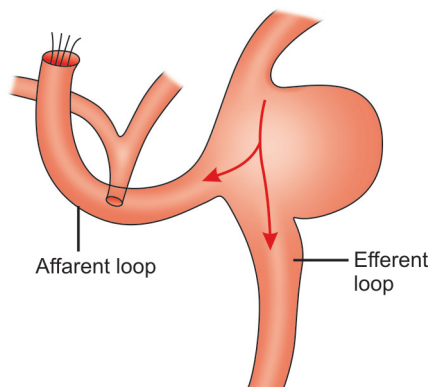
## Radical Total Gastrectomy

### Indications

1. Carcinoma of the proximal body and fundus of stomach.
2. Linitis plastica in which the tumor cells infiltrate the submucosa, subserosa and the muscle coat extensively without protruding into the lumen of the stomach. The whole stomach becomes contracted and rigid.

### Steps of Operation

1. Position of patient, anesthesia and incision are the same as in case of radical subtotal gastrectomy.
2. After opening the abdomen initial inspection and palpation of the liver, parietal and pelvic peritoneum is made to rule out metastatic disease.
3. Local operability is assessed by opening the lesser sac through a small window in the gastrocolic omentum. This maneuver enables one to see whether the major vessels, root of the mesentery, mesocolon and the pancreas are involved or not.
4. The greater omentum is now reflected and mobilized from its attachment on the transverse colon and completely separated from the transverse mesocolon till the anterior surface of the pancreas.



**Fig. 89.3:** Polya type gastrojejunostomy

5. The stomach is then mobilized along its greater and lesser curves. The right gastric artery along the lesser curve and the right gastroepiploic artery along the greater curve are identified, ligated and divided.
6. The short gastric and the left gastroepiploic arteries are ligated and divided at the cardiac end of stomach.
7. Duodenum is mobilized by Kocherization and divided at a point of about 4cm from the duodenopyloric junction. The duodenal stump is closed in two layers.
8. The perigastric lymph nodes within 3cm of the primary tumor as well as the nodes along the celiac trunk and its branches viz. the common hepatic, splenic and left gastric arteries are dissected and removed.
9. The stomach is turned cranially and is divided at the cardiac end.
10. Reconstruction:
  - a. Roux en Y loop of jejunum (Fig. 89.4) is brought up through a window in the transverse mesocolon.
  - b. Single layered esophagojejunal anastomosis is performed with absorbable suture material like 3/0 Vicryl to establish the continuity of the GI tract. Alternately a stapler can be used for the anastomosis.
  - c. Feeding jejunostomy is done to start early enteral feeds.
  - d. Two tube drains are placed — One near the duodenal stump and other near the anastomosis.

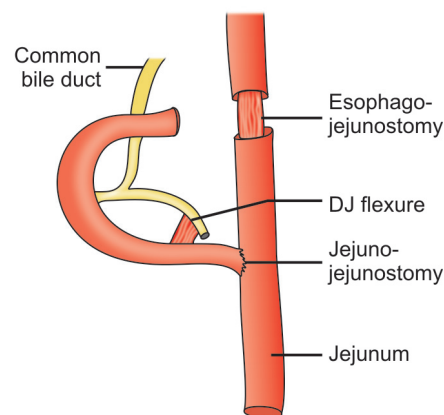
## PYLOROMYOTOMY – RAMSTEDT'S OPERATION

### Indications

Congenital hypertrophic pyloric stenosis. This is a minor gastric operation in babies within the first 5 weeks of life.

### Preoperative Preparation

1. Correction of dehydration, hypochloremia and hypokalemia developed as a result of vomiting with normal saline charged with potassium (10 – 15 mmol KCl/500 ml of 0.9% saline).
2. A nasogastric tube is passed for gastric lavage and free drainage of stomach content.



**Fig. 89.4:** Roux-en-Y anastomosis after radical total gastrectomy

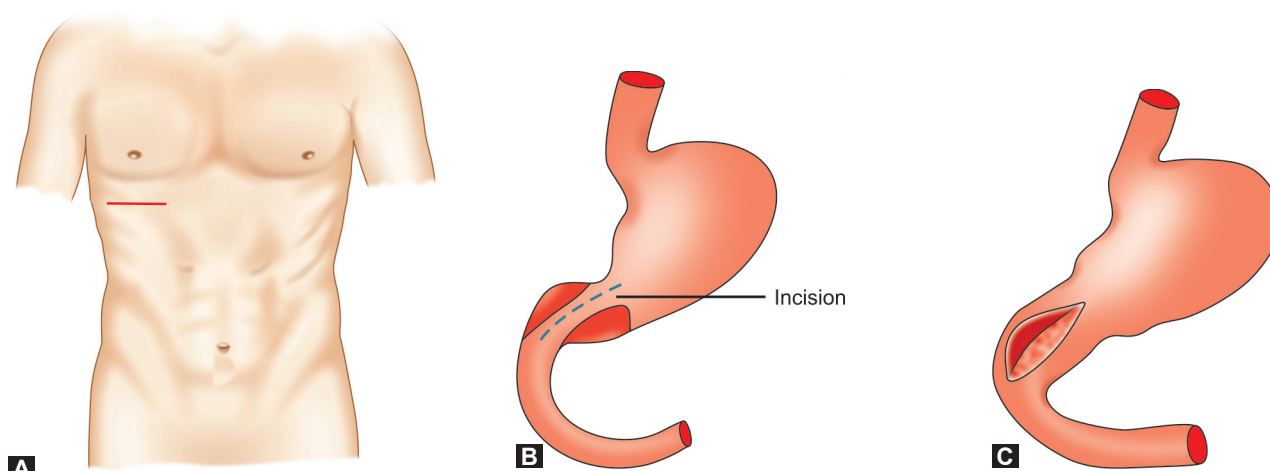
### Steps of Operation

1. Position of patient — Supine.
2. Anesthesia — General anesthesia with endotracheal intubation but local anesthesia is also a practical alternative.
3. Antiseptic dressing and draping.
4. Incision (Fig. 89.5A) — A 3 to 4 cm transverse incision is made in the right upper quadrant of abdomen. The rectus abdominis muscle is divided in the line of the incision and peritoneum is opened.
5. The liver is retracted upwards as it lies well below the costal margin in the neonate to expose the pyloric end of stomach.
6. The thickened pylorus is pinched between the finger and thumb so as to stretch the anterior wall, which is least vascular.
7. A 2 to 3 mm deep incision is made along the full length of the tumor (Fig. 89.5B).
8. The hypertrophied muscle fibers (longitudinal and circular) are split along the incision by a small artery forceps, taking care not to penetrate the mucosa (Fig. 89.5C).
9. Presence of air or bile at the duodenal end of the incision is an indication of perforation. Perforation, if occurs, is repaired with interrupted 4 – 0 chromic catgut and reinforced by omentum.
10. Closure –
  - The muscle and sheath is closed en mass with 3 – 0 Vicryl.
  - Skin is closed with subcuticular stitch.

### Postoperative Care

- a. Oral feeds are started 4 hours after the operation and a normal feeding pattern is established within 24 hours.
- b. IV fluid is administered for 4 to 8 hours.





**Figs 89.5A to C:** Pyloromyotomy for congenital hypertrophic pyloric stenosis. (A) Abdominal incision for pyloromyotomy (B) The dotted line indicates incision over the thickened pylorus (C) Pyloromyotomy completed with budding

- c. The child can be discharged on the 2nd to 4th postoperative day.

### HELLER'S ESOPHAGOCARDIOMYOTOMY

#### Indications

This operation is indicated for cardiospasm.

- When instrumental dilatation with esophageal bougies fail to relieve symptoms.
- When secondary changes like ulceration occurs in the esophagus.

#### Preoperative Preparation

- The patient is admitted a few days before operation.
- Correction of anemia, fluid electrolyte disturbance and pulmonary infection if any.
- Ryle's tube is left in the stomach and gastric contents are aspirated.
- Prophylactic antibiotic is administered.

#### Steps of operation

- Position of patient — Supine.
- Anesthesia — General anesthesia with endotracheal intubation.
- Antiseptic dressing and draping.
- Incision — An upper midline incision is made to open abdomen.
- Exposure of esophagus — The left lobe of liver is mobilized and retracted after division of left triangular ligament as in vagotomy.
  - A transverse incision is made over the peritoneum covering the esophageal

- hiatus and the esophagus is mobilized by finger dissection.
  - The mobilized esophagus is pulled gently by a tape passed around it.
- Procedure:
    - A longitudinal incision is made on the constricted part of the esophagus extending about 5cm proximally and 2cm distally on to stomach.
    - The incision is deepened through the muscle coat (seromyotomy) until submucosa is reached. The muscle fibers are carefully dissected apart with an artery forceps so that intact mucosa buldges out (Fig. 89.6).
    - Hemostasis is achieved.

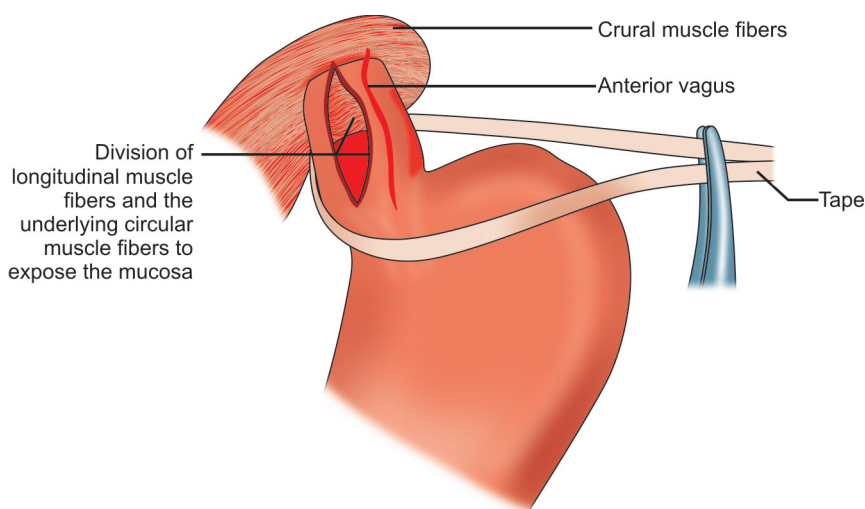
- The stomach is squeezed to demonstrate if there is any leakage of air due to perforation. Any leak of mucosa should be repaired with fine (4/0) catgut.
- Closure — Abdomen is closed en-mass.

#### Postoperative care

- Oral feeding can be started after 48 hours if there is no pain on swallowing.
- Normal diet after 5 to 7 days.
- Systemic antibiotic for 5 days.

#### Postoperative Complications:

- Reflex esophagitis — This may occur in 5 percent cases.
- Persistent dysphagia.



**Figs 89.6:** Heller's Esophagocondiomyotomy



# Chapter 90

## Hepatobiliary and Pancreas

- Cholecystectomy (Open method)
- Laparoscopic cholecystectomy
- Choledocholithotomy
- Choledochoduodenostomy
- Cystogastrostomy

### CHOLECYSTECTOMY (OPEN METHOD)

#### Surgical Anatomy

See “surgical anatomy of the gallbladder in the chapter of gallbladder”.

#### Indications

Removal of the gallbladder is indicated in all pathological conditions of the organ like inflammation, stones, carcinoma, etc. as described below:

- Chronic cholecystitis.
- Mucocele or empyema of gallbladder.
- A calculus cholecystitis.
- Gallstone disease.
- Perforation of gallbladder.
- Carcinoma of gallbladder.
- Traumatic rupture of gallbladder.
- Failed laparoscopic cholecystectomy.
- Presence of contraindications to laparoscopic cholecystectomy.

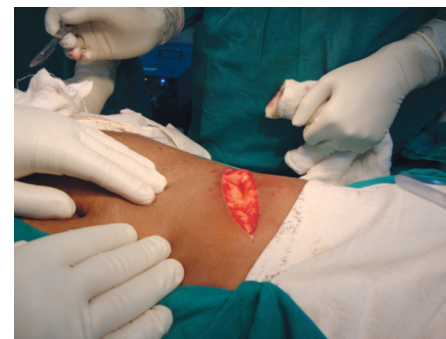#### Steps of Operation (Figs 90.1A to H)

1. Position of patient—Supine.
2. Anesthesia—General anesthesia with endotracheal intubation.
3. Antiseptic dressing and draping.
4. Incision—Either
  - a. Kocher’s right subcostal incision (Figs 90.1A and B) (good access), or
  - b. Right upper transverse incision (good cosmesis) or

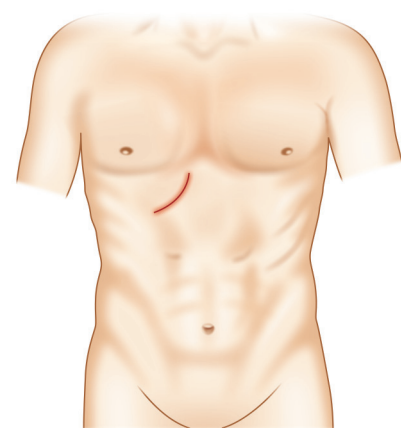
- a. Right upper paramedian incision is made.
5. Exposure:
    - The rectus muscle is divided to expose parietal peritoneum which is cut to open the peritoneal cavity.
    - After preliminary exploration and confirmation of gallbladder pathology cholecystectomy is decided.
    - The gallbladder fundus is held by a Moynihan’s cholecystectomy forceps.
    - Three moist mops are now placed for good exposure of the Calot’s triangle as follows:
      - i. Medial most one to displace the stomach to the left.
      - ii. Second one to displace the colon downwards.
      - iii. Third one in the hepatorenal pouch.
    - Another Moynihan’s cholecystectomy forceps is applied to hold the neck of gallbladder (Hartmann’s pouch).
  6. Procedure
    - a. Retraction and exposure—Retractors are placed and held by the assistants to facilitate further exposure and access. One Deaver’s retractor retracts the right lobe of liver upwards and another Deaver’s retractor retracts the stomach and colon.

A good light is vital for excellent visualization.
    - b. Dissection of Calot’s triangle (Fig. 90.1D):

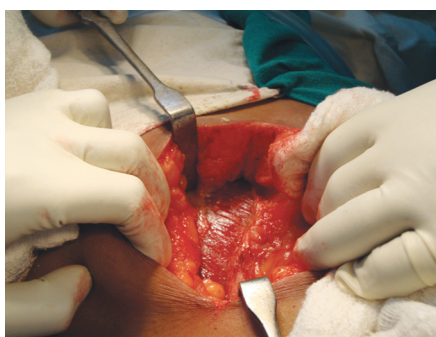- The gallbladder is retracted gently downwards and to the right.
- The cholecystoduodenal fold of peritoneum is cut and dissection



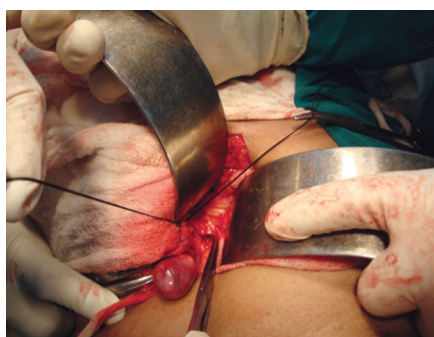
**Fig. 90.1A:** Kocher’s incision made



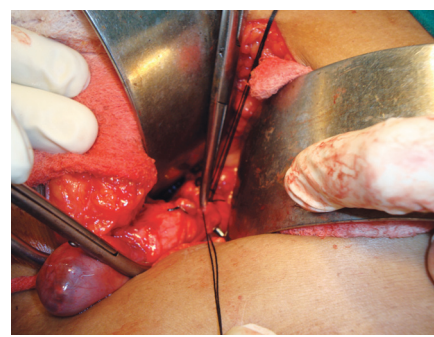
**Fig. 90.1B:** Kocher’s incision (I) for cholecystectomy (schematic)



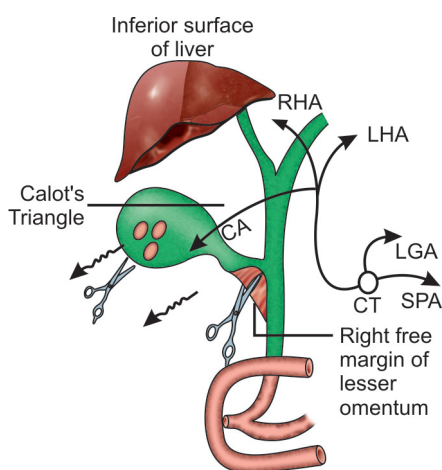
**Fig. 90.1C:** Anterior rectus sheath cut and rectus muscle exposed



**Fig. 90.1E:** Cystic artery dissected and threaded with silk



**Fig. 90.1G:** Cystic duct dissected and ligated



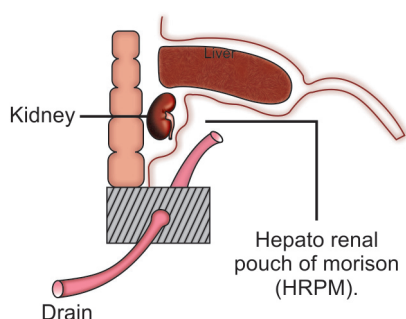
**Fig. 90.1D:** Dissection of Calot's triangle (Schematic), two arrows (→) indicate line of traction

CA - Cystic artery  
RHA - Right hepatic artery  
LHA - Left hepatic artery  
LGA - Left gastric artery  
SPA - Splenic artery  
CT - Celiac trunk.

**Fig. 90.1D:** Dissection of Calot's triangle (Schematic), two arrows (→) indicate line of traction

is continued to expose cystic duct and cystic artery using a peanut swab.

- c. The cystic artery is dissected with a right angled forceps. The ligation and division of cystic artery is preferably done first with 1-0 silk to avoid the risk of tear if the duct is divided first.
- d. The cystic duct is then ligated with 1-0 silk using a right angled forceps at its junction with the bile duct and cut 1cm proximal to ligation.
7. Dissection of gallbladder from liver - The gallbladder is retracted with Moynihan's cholecystectomy forceps and a finger is

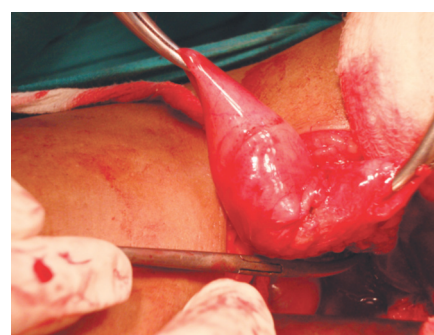

**Fig. 90.1F:** Placing the drain in the Morison's pouch (schematic)

insinuated between the liver and gallbladder which is gently dissected out from its bed.

If the gallbladder is densely adherent to the liver bed, after partial removal of the gallbladder the remaining gallbladder mucosa is fulgurated.

8. Hemostasis—The gallbladder is attached to the liver by two peritoneal folds. As gallbladder is dissected, the peritoneal folds are divided with scissors or diathermy knife. Minor oozing from liver bed can be tackled by application of gel foams or surgical. If bleeding is not controlled a hot mop is applied for 5 to 10 minutes. Bleeding points can be secured by diathermy or by transfixation sutures.
9. Closure:
  - Hemostasis is checked.
  - Mops and instruments are counted.
  - A corrugated rubber drain is placed in the Morison's pouch (Fig. 90.1F).
  - Rectus sheath is closed with 2-0 Vicryl.
  - Skin is closed with interrupted silk sutures.



**Fig. 90.1H:** Gallbladder dissected out from the liver bed

## Postoperative Care

- Oral fluids may be started after 24 hours.
- Drain is removed after 72 hours.
- Systemic antibiotics and analgesics are given.

## Postoperative Complications

### A. Early:

1. Biliary leak—Acute biliary peritonitis (Waltman—Walter syndrome).
2. Hemorrhage.
3. Bile duct injury—Lateral tear or complete transection.
4. Anesthesia related chest complications.
5. Wound infection.

### B. Late—Biliary stricture.

## LAPAROSCOPIC CHOLECYSTECTOMY (LC)

### Indications

- Laparoscopic cholecystectomy is now considered the gold standard for the

treatment of a pathological gallbladder, e.g. stones, inflammation, etc.

- The indications for laparoscopic cholecystectomy are the same as open cholecystectomy mentioned above. At present the only absolute contraindication to LC is the presence of gallbladder cancer or uncorrectable coagulopathy.
- Patients unfit for open surgery or general anesthesia because of severe cardiac or pulmonary compromise are also not good candidates for LC.

### Steps of Operation

1. Anesthesia—General anesthesia with endotracheal intubation.
2. Antiseptic dressing and draping.
3. Position of patient—15° Trendelenburg position.
4. Creation of pneumoperitoneum:
  - a. Either Veress needle insertion (closed method) or open method of insertion of Hasson cannula can be used for creating the pneumoperitoneum (Fig. 90.2A).
  - b. One centimeter incision is made below the umbilicus. Veress needle is inserted into the abdomen almost at right angle (80°) to the abdominal wall with a slight angle towards the pelvis. The safe entry of the needle inside the peritoneal cavity can be confirmed by injecting 5 ml of saline. If the needle is in correct place, the saline could be pushed easily and on aspiration nothing will come.
  - c. Once the needle is in the peritoneal cavity it is connected to an automatic CO<sub>2</sub> insufflator by the insufflation



**Fig. 90.2A:** Hand instruments for laparoscopic cholecystectomy

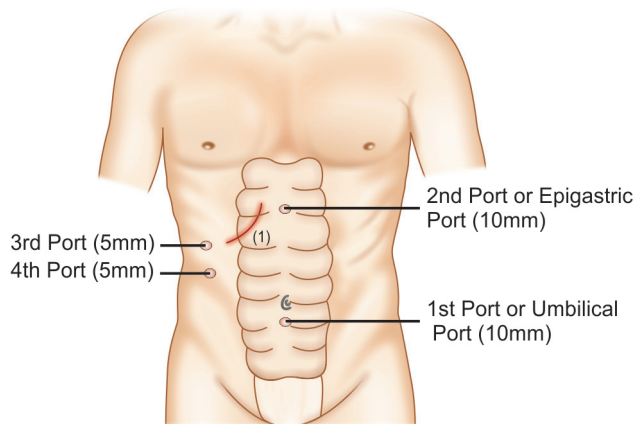


**Fig. 90.2B:** Trocars and cannula for making the ports

5. Insertion of ports (Figs 90.2B and C):
  - a. Placement of first port (umbilical port): A 10 mm trocar and cannula is inserted into the abdomen through the infraumbilical incision and the trocar is removed keeping the cannula in place. This port is for insertion of video laparoscope.
  - b. Inspection of the abdominal cavity is done to rule out any injury from Veress needle or first trocar entry.
  - c. Introduction of 2nd, 3rd and 4th port – After the introduction of the first port, the patient is positioned in a reverse Trendelenburg's position with a left tilt of the table. This maneuver aids the viscera (duodenum and colon) to fall away from the operative field.
    - i. The second 10 mm port for the Maryland dissector is made at the junction of upper

1/3 and lower 2/3rd of a line joining the xiphisternum and umbilicus.

- ii. One 5 mm port through the 5 mm incision is made at the right, midclavicular line 2 cm below the costal margin. This port is for the introduction of grasper to hold the Hartmann's pouch which is manipulated by surgeon's left hand.
  - iii. The second 5 mm port through a 5 mm incision is made in the right midaxillary line at the level of the umbilicus.
5. Dissection of the cystic pedicle and Calot's triangle:
    - This is the most important part of the operation.
    - After removal of adhesions, dissection is started at the neck of the gallbladder with a Maryland dissector.
    - Posterior dissection of the Calot's triangle is the most important initial step to create a wide posterior 'safety window' behind the cystic duct and artery.
    - Anterior dissection of the Calot's triangle is complementary and should be done after the posterior dissection.
    - In laparoscopic cholecystectomy, the vital point is the circumferential dissection of the gallbladder and cystic duct junction.
  6. Application of clips and division of cystic duct and artery:
    - A large window is created between the cystic duct and cystic artery so that the clips may be applied easily.
    - The clips are applied by a 10mm clip applicator inserted through the epigastric port. Three clips are applied on the



**Fig. 90.2C:** Placement of ports in laparoscopic cholecystectomy



cystic duct and the cystic artery each and the duct and the artery are divided by an endoscissors keeping two clips in the cystic duct and artery towards the bile duct side.

7. Dissection of gallbladder from the liver bed: Once the cystic duct and artery are divided, the gallbladder is dissected from the liver bed by using a diathermy hook from the liver bed.
8. The gallbladder bed is irrigated with normal saline and hemostasis is ensured with diathermy coagulation.
9. Extraction of gallbladder—The separated gallbladder is held by a crocodile forceps and removed through the epigastric port.
10. A Ryle's tube drain is placed along the midaxillary line port in the hepatorenal pouch of Morison for 24 to 48 hours.
11. Closure of incision—The cannulas are withdrawn and the incisions are closed.

### Postoperative Care

1. Systemic antibiotic.
  2. Oral feeding can be started once the patient has fully recovered from anesthesia.
  3. The patient can be discharged after 48 hours.
- Q. What are the postoperative complications?
- A. a. Hemorrhage.
  - b. Bile leakage.
  - c. Port site infection: Tubercular infection has been reported at the port site which requires antitubercular drugs.
- Q. What are the advantages and disadvantages of LC?

#### Advantages

1. Short hospital stay.
2. Earlier return to full activity.
3. Decreased total costs.
4. Less pain.
5. Excellent cosmesis.

#### Disadvantages

1. More difficult to control hemorrhage
2. Potential CO<sub>2</sub> insufflation complications.
3. Slight increase in bile duct injuries.
4. Adhesions and inflammations limit use.
5. Lack of depth perception.

## CHOLEDOCHOLITHOTOMY

### Indications

1. Preoperative indication:
  - a. Obstructive jaundice due to a stone in CBD detected preoperatively. This is the principal indication.
  - b. USG shows a stone in CBD or abnormal dilatation of CBD.
2. During operation:
  - a. If stones are palpable in CBD.
  - b. If CBD is hugely dilated.
  - c. If gallbladder contains multiple small stones and cystic duct is dilated.
3. Postoperative indication:
 

If T-Tube cholangiogram shows left over stone.

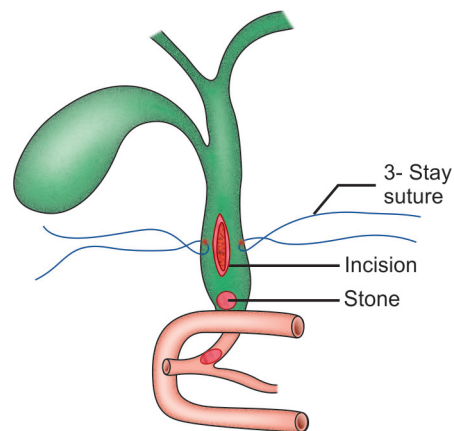
### Steps of Operation

If started fresh either a liberal right subcostal incision or a right upper paramedian incision is made.

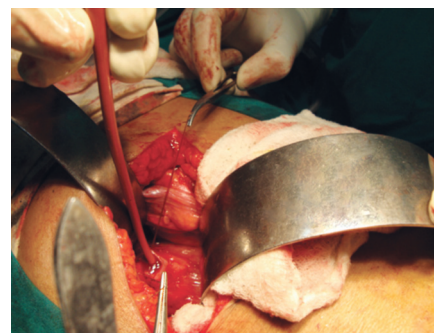
After cholecystectomy following steps are taken:

1. At first the bile duct is identified by:
  - i. Anatomical position at the right free margin of lesser omentum. The hepatic artery is on the left and the portal vein, in between the two.
  - ii. Duct is aspirated and bile comes out.
2. Two stay sutures are applied (Fig. 90.3A).
3. A small nick is made in between stay sutures to open the CBD.
4. The stones are either milked out or removed by Desjardins choledocholithotomy forceps.
5. A dilator or bougie is negotiated both proximally and distally into the duct to confirm that there is no stone.
6. The CBD is washed with plain sterile water. If duodenum balloons out, it suggests that there is no stone (Fig. 90.3B).
7. The T-piece of a latex T-Tube is inserted into the bile duct and the duct is closed with a running 3/0 catgut or Vicryl suture so that the tube emerges from the lower end of the suture line (Figs 90.3C and D). The size of the T-Tube will normally be between 10 and 16F depending on the size of the duct.
8. The T-Tube is brought directly to the surface of the abdominal wall to exit

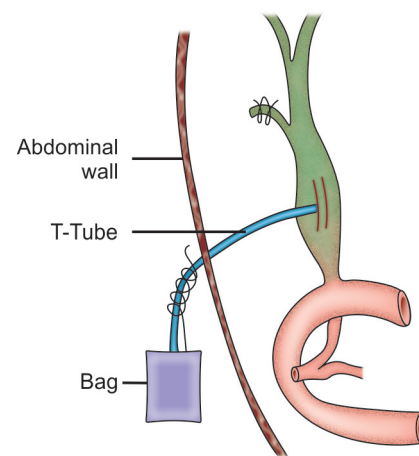
through a separate stab incision. The tube is sutured to the skin and connected to a drainage bag (Figs 90.3E and F).



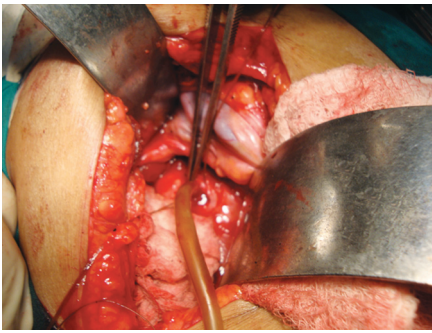
**Fig. 90.3A:** Exploration of common bile duct choledochotomy is done in between stay sutures



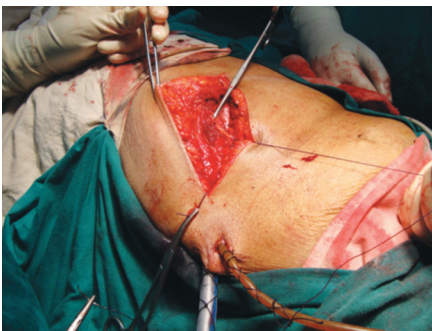
**Fig. 90.3B:** Flushing the CBD with normal saline via a plain rubber catheter



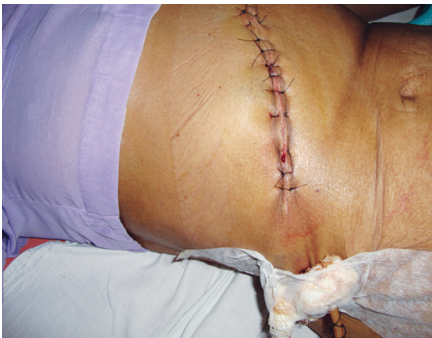**Fig. 90.3C:** T-Tube drainage of bile duct



**Fig. 90.3D:** T-Tube introduced into the CBD



**Fig. 90.3E:** Closure of abdomen after cholecystolithotomy



**Fig. 90.3F:** Cholecystolithotomy completed with T - Tube and parietal drains *in situ*

### CHOLEDOCHODUODENOSTOMY

#### Indications

The operation is a biliary drainage procedure indicated in the management of both benign and malignant disease provided the common bile duct is dilated to 12mm or more.

The indications are:

- a. Impacted stone at the lower end of the common bile duct.

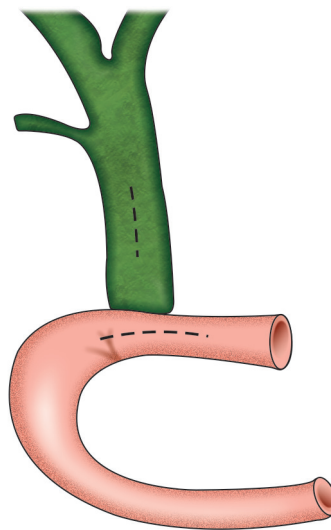
- b. Bismuth type 1 bile duct stricture.
- c. As a palliative procedure in malignant conditions obstructing the CBD, e.g. carcinoma head of the pancreas, cholangiocarcinoma, etc.
- d. Some patients with choledochal cyst. The purpose of this operation is to ensure adequate drainage of bile into the intestine.

#### Preoperative Care

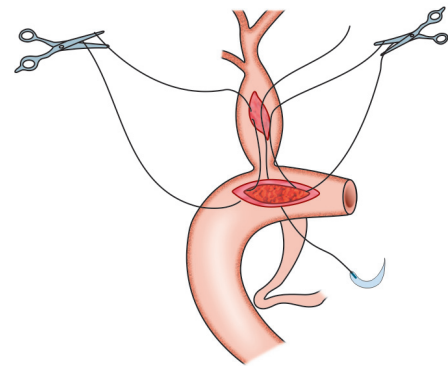
These patients are usually ill, infected and jaundiced. So they require careful preparation as described in “choledocholithiasis” in the chapter on “gallbladder”.

#### Steps of Operation

1. Position of patient—Supine with head higher than the feet.
2. Anesthesia—General anesthesia with endotracheal intubation.
3. Antiseptic dressing and draping.
4. Incision—A right subcostal or upper midline incision is made and abdomen is opened.
5. The identify of common bile duct (CBD) is confirmed by aspiration of bile through a syringe and fine needle.
6. An incision of about 2 to 2.5 cm is made vertically in the middle of CBD (Fig. 90.4A).
7. The duodenum is Kocherized and a slightly smaller transverse incision is made close to the lower end of choledochotomy incision (Fig. 90.4A).



**Fig. 90.4A:** Incisions in the common bile duct and duodenum for choledochoduodenostomy



**Fig. 90.4B:** Corner stitches have been placed between common bile duct and first part of duodenum

8. The anastomosis is performed in one layer of interrupted inverting sutures of 3/0 absorbable materials, e.g. Vicryl, knotted on the inside (Fig. 90.4B).
  9. The anastomosis should be tension-free. A rubber tube drain is placed beneath the anastomosis and abdomen is closed in layers.
- Q. What are the postoperative complications?
- a. Leakage, peritonitis, fistula.
  - b. Postoperative pancreatitis if anastomosis is done in a low duct.
  - c. Sump syndrome—There is recurrent attacks of cholangitis due to stasis in the bypassed duct.

### CYSTOGASTROSTOMY (FIG. 90.5)

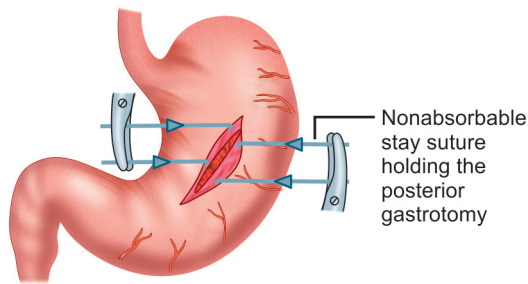
This operation is done in case of pseudocyst of pancreas which is defined as a peripancreatic fluid collection contained by a wall of fibrous granulation tissue that does not have an epithelial lining.

This is in contrary to cystic neoplasms of the pancreas, which is characterized by an epithelial lining. It is in principle a drainage procedure. A cystogastrostomy is ideal when the pseudocyst is adherent to posterior stomach wall and indenting it.

#### Steps of Operation

1. Position of patient—Supine.
2. Anesthesia—General anesthesia with endotracheal intubation.
3. Antiseptic dressing and draping from midchest to midhigh.





**Fig. 90.5:** Cystogastrostomy

4. Incision—Rooftop or upper midline incision is made.
5. Packing—The transverse colon and the coils of small intestine are packed aside using mops to give a clear view of the stomach with the protuberant retrogastric cyst.
6. The anterior wall of stomach is picked up between two stay sutures at the site of maximum bulge produced by the cyst. A longitudinal anterior gastrotomy is made.
7. A needle with attached syringe is introduced into the cyst through the posterior stomach wall and clear fluid is aspirated and sent for bacteriological culture.
8. The posterior wall of the stomach along with the cyst wall is incised over a distance of 3 to 4 cm with a stab knife in between two deep nonabsorbable stay sutures (Fig. 90.5).
9. Any loculi within the collection are broken down and necrotic material is removed.
10. Hemostasis—Bleeding from the posterior gastrotomy is checked by a series of about 10 to 12 through and through interrupted 2/0 vicryl sutures placed all around the stoma.
11. An edge biopsy of the cyst wall is taken to exclude cystic neoplasm of the pancreas.
12. The cyst wall is irrigated with saline till a clear returning fluid is seen.
13. The anterior stomach wall is closed in 2 layers with inner continuous 2/0 Vicryl and outer 2/0 silk.
14. Abdomen is closed in layers.

See also 'pancreatic cyst' in the chapter 38 on 'pancreas'.

# Chapter 91

## The Spleen: Splenectomy

### ➤ Indications

#### INDICATIONS

See “indications of splenectomy” in the chapter 39 on spleen.

#### PREOPERATIVE CARE

- In nearly all patients requiring splenectomy blood transfusion both before and during operation is valuable.
- Pneumovax is given to all patients undergoing elective splenectomy as protection against subsequent pneumococcal infection.
- Antibiotic prophylaxis in the immediate preoperative period.
- DVT prophylaxis since splenectomy results in a rise in circulating platelets.

#### STEPS OF OPERATION

- Anesthesia—General anesthesia with endotracheal intubation.
- Position of patient—Supine.
- Antiseptic dressing and draping.
- Incision:
  - Midline incision of emergency splenectomy for rupture spleen.
  - An oblique left subcostal incision for elective splenectomy.
- The abdomen is explored and a search is made for the splenancule.
- Mobilization of spleen:

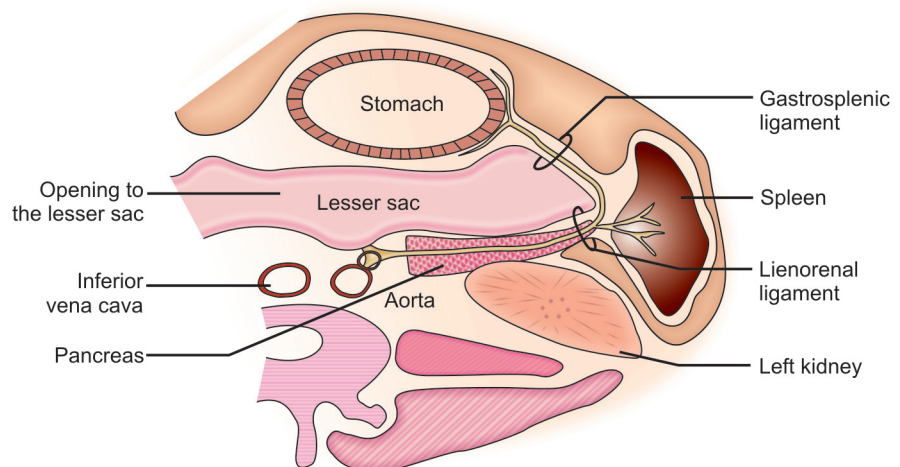
### ➤ Preoperative care

- A hand is passed over the lateral surface of spleen and diaphragm, the organ is lifted forwards and medially and the posterior layer of lienorenal ligament which passes from it to the posterior abdominal wall and holds it in position, is divided under vision, at the inferior pole.
- The gastrosplenic omentum or ligament stretching between the spleen and the upper part of greater curvature of stomach is divided between

### ➤ Steps of operation

clamps at the superior pole. The short gastric vessels within this ligament require to be ligatured (Fig. 91.1) and divided

- Avascular connections between the spleen and the splenic flexure as well as the diaphragm are also divided.
- Dealing with splenic vessels—The splenic vessels are now clearly dissected and identified.
    - The tail of the pancreas is separated from the hilum by gauge dissection.



**Fig. 91.1:** Peritoneal folds or ligaments anchoring the spleen and containing large vessels. (See also surgical anatomy of spleen in chapter 39, section 9). The gastrosplenic ligament contains the short gastric and left gastroepiploic vessels and the lienorenal ligament contains the splenic vessel. The other ligaments of spleen, e.g. splenophrenic and splenocolic ligaments are usually avascular.

- b. The splenic artery and vein are identified and individually ligated and divided.
- c. The artery is doubly ligated with silk before the vein. Veins, if ligated first will cause splenic congestion and subsequent difficulty of operation.
- d. A hot mop is placed in the splenic bed and hemorrhage is checked.
- 8. The abdomen is closed en-mass with non absorbable sutures after inserting a drain to the splenic bed.
- 9. What are the postoperative complications? See 'splenic injury' in the chapter 39 on spleen.

# Chapter 92

## The Appendix: Appendicectomy

➤ Surgical anatomy

➤ Indications

➤ Steps of operation

### SURGICAL ANATOMY

See the chapter 33 on 'the appendix'.

### INDICATIONS

1. Emergency operation: Acute appendicitis.
2. Elective operation:
  - a. Interval appendicectomy—Six weeks after conservative treatment of appendicular lump.
  - b. Chronic or recurrent appendicitis.

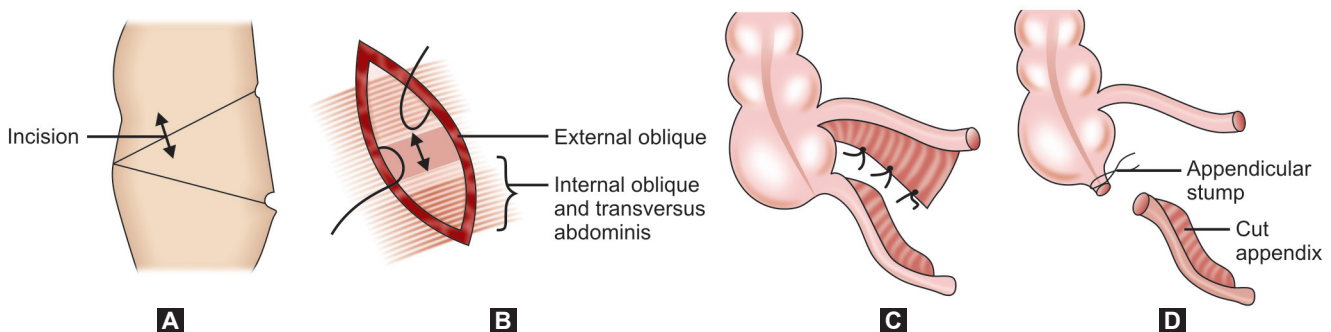
### STEPS OF OPERATION (FIG. 92.1)

1. Anesthesia—General anesthesia with endotracheal intubation.
2. Position of patient—Supine.
3. Antiseptic dressing and draping.

4. Incision—McBurney's incision is made at right angle to the spinoumbilical line at the junction of lateral one-third and medial two-thirds (Fig. 92.1A).
5. The incision is deepened to cut through skin and subcutaneous tissue. Hemostasis is secured with diathermy.
6. The external oblique aponeurosis is exposed. It is muscular in the upper part and aponeurotic in the lower part.
7. An incision is made on the external oblique in line with the skin incision. Fibers of internal oblique and transversus abdominis together are split perpendicular to skin incision and retracted (Fig. 92.1B). The peritoneum is exposed and incised in the line of the skin incision.
8. The abdomen is opened and the cecum is delivered out of the wound with

a Babcock's forceps. Very often it is delivered with finger dissection.

9. Appendix is identified and tip is held with Babcock's forceps. Anterior taenia of cecum ends at the base of appendix.
10. Mesoappendix is cut in between ligatures (Fig. 92.1C). Hence appendicular artery is also ligated.
11. The base of the appendix is ligated with 2/0 chromic catgut after crushing (for better ligature) with a Kocher's artery forceps (Fig. 92.1D).
12. Terminal part of the ileum is inspected for any Meckel's diverticulum.
13. Hemostasis is ensured.
14. Abdomen is closed in layers:
  - a. Peritoneum with continuous catgut sutures.
  - b. Muscles with interrupted catgut sutures.



**Figs 92.1A to D:** (A) McBurney's incision for appendicectomy (B) Separation of internal oblique and transversus abdominis by muscle splitting (C) Segmental ligature and division of mesoappendix (D) Base of the appendix is crushed and ligated, appendix is then amputated distal to the ligature

c. External oblique aponeurosis with continuous catgut stitches.

d. Skin is closed with interrupted silk suture.

Q. What are the postoperative complications?

a. Wound infection.

b. Pelvic abscess.

c. Portal pyemia.

d. Residual abscess.

e. Incisional hernia—A late complication.

f. Fecal fistula due to cecal below out rarely.

Q. How do you identify the cecum after opening the abdomen?

Cecum is identified by:

a. Pale white color in contrast to the maroon color of small intestine

b. Presence of tenia

c. Saccular structure.



## Small Bowel

- Small bowel resection and anastomosis
- Meckel's diverticulectomy
- Feeding jejunostomy
- Strictureplasty
- The Roux loop

### SMALL BOWEL RESECTION AND ANASTOMOSIS

Surgical anatomy of small intestine: see the chapter 31 on small intestine.

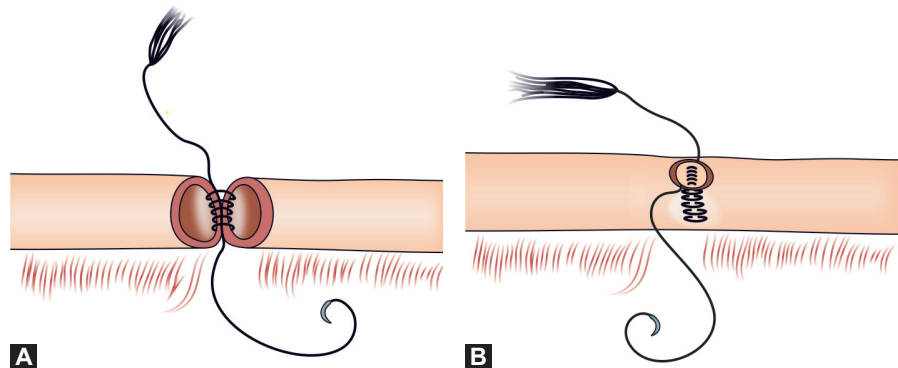
#### Indications

1. Small bowel trauma.
2. Intestinal obstruction with nonviable gut (strangulated inguinal hernia).
3. Tumors of bowel or mesentery.
4. Strictures—Crohn's disease or tuberculosis.

#### Steps of Operation (Fig. 93.1)

1. Anesthesia—General anesthesia with endotracheal intubation.
2. Position of patient—Supine.
3. Antiseptic dressing and draping.
4. Incision—Abdomen is usually opened with midline incision.
5. Technique:
  - a. Following laparotomy the affected loop is withdrawn from the wound until a sufficiently healthy bowel has been delivered and the wound and peritoneal cavity are protected with moist packs.
  - b. An opening is made with the tip of a small hemostatic forceps in an avascular area of the mesentery just beneath the proximal and the distal bowel wall at selected sites for its transection.

- c. The mesentery with its contained blood supply is now divided between these two points as follows:
  - Incision is made on thin peritoneum of the mesentery overlying the vessels in the shape of a broad V, the base being the length of gut to be resected and the apex pointing towards the root of the mesentery.
  - The vessels supplying this segment of the gut are ligated with 1-0 silk and cut in between ligatures after clamping with a series of hemostatic forceps.
- d. Two pairs of intestinal occlusion clamps are applied on each side of intestine which is to be resected. The intestine is then divided in between the occlusion clamps on either side.
- e. The loop of intestine is now removed with two pairs of intestinal occlusion clamps still attached to it.
6. Anastomosis:
  - a. Hand sewn method:
    - i. Two layered anastomosis:
      - a. The occlusion clamps with cut ends of the intestine are approximated so that the cut ends of the bowel lies in close apposition. The anastomosis is done in two layers – a layer of through and through sutures and a layer of seromuscular sutures.
      - b. Two cut ends of the bowel is first united by a continuous through and through suture with 2/0 polyglactin (Vicryl). Starting from the antimesenteric border, the suture is applied



**Figs 93.1A and B:** Small bowel end to end anastomosis. (A) Application of continuous full thickness suture posteriorly (B) Application of continuous full thickness sutures anteriorly

- first posteriorly and then continued anteriorly until the starting point is reached, where it is tied to the short end (Figs 93.1A and B).
- c. Now the second layer of seromuscular interrupted stitches are applied with 2/0 silk all around, the first layer (Lembert suture).
  - d. The gap in the mesentery is apposed with interrupted sutures with 2/0 silk taking care not to take any bite through the mesenteric vessels.
- ii. Interrupted single layer extramucosal anastomosis.
    - a. This is now considered to be the 'gold standard' for intestinal anastomosis and is the preferred hand sewn technique.
    - b. A series of interrupted sutures with 2/0 Vicryl are applied between bowel ends taking submucosa, muscle coat, and serosa but omitting the mucous membrane.
  - iii. Continuous single layer extramucosal anastomosis:
    - a. This technique is favored because of less chance of anastomotic leakage. Moreover, it is quicker than interrupted single layer technique.
    - b. Two stay sutures are applied on the mesenteric and antimesenteric aspect of the gut. Then sutures are applied first posteriorly starting from the antimesenteric border as mentioned earlier and then continued anteriorly till the starting point is reached when it is tied to short end.
- b. **Stapled anastomosis:** The first surgical stapler was invented in 1908 and since then many surgeons use them routinely as an alternative to a hand sewn technique.
    - a. Staplers have become well-established in gastrointestinal surgery. The chief advantage is that they cut down the time taken for bowel anastomosis by about 80 percent.
    - b. They are also useful for anastomosis in inconvenient regions, e.g. low anterior resection of rectum.

**Disadvantage:** They are fairly expensive which makes their use limited in a developing country like India.

**Anastomosis:**

- a. Anastomosis can be made with linear or circular stapling devices used alone or in combination.
- b. Linear stapling devices are used for side to side anastomosis.
- c. Circular stapling devices are required for end to end anastomosis.

**Stapled side to side anastomosis (Fig. 93.2)**

- i. The antimesenteric borders of the bowel to be anastomosed are approximated with traction sutures.
- ii. Small enterotomies are made with a blade or cutting diathermy.
- iii. One limb of linear stapler is inserted into each lumen and the tissue is aligned evenly on each side so that full length of the stapler is used.
- iv. The instrument is closed and the staples are fired. The residual enterotomy is closed using staples or sutures.

**Stapled colorectal anastomosis**

- a. The rectum is cross clamped after mobilization to the desired level. A linear stapler is applied at the level of transection. The rectum is stapled and divided. Alternately a purse string suture is applied into the open end of the distal rectum and drawn around the locking device.
- b. A purse string suture is applied around the end of the proximal colon. The anvil of the circular stapler is inserted

into the proximal colon and the purse string is drawn and secured.

- c. The circular stapling cartridge is placed per anus and the trocar is advanced through the middle of the existing staple line.
- d. The anvil shaft and the instrument shaft are engaged. The gap between them is closed, apposing colon and rectum.
- e. The staples are now fired, the anvil is disengaged and the instrument is withdrawn. The anastomosis is air tested.

### Examples

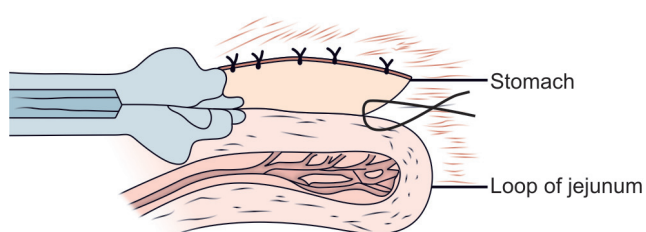
1. A linear cutting stapling device with one blade in stomach and one in jejunum, is used to create a stable gastrojejunostomy (Fig. 93.2).
2. Anastomosing with a circular stapling device for colorectal anastomosis is performed in case of anterior resection of rectum (Fig. 93.3).

### MECKEL'S DIVERTICULECTOMY (FIG. 93.4)

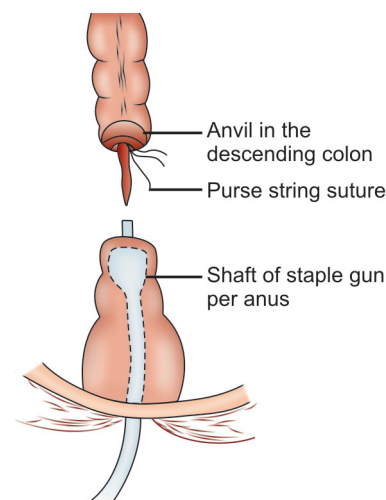
#### Indications

- a. Intestinal obstruction due to a band.
- b. Hemorrhage.
- c. Diverticulitis.

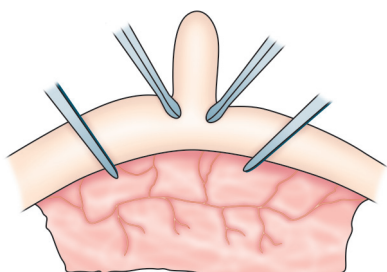
The above conditions are usually diagnosed during laparotomy.



**Fig. 93.2:** A linear cutting stapling device with one blade in stomach and one in jejunum for side to side anastomosis



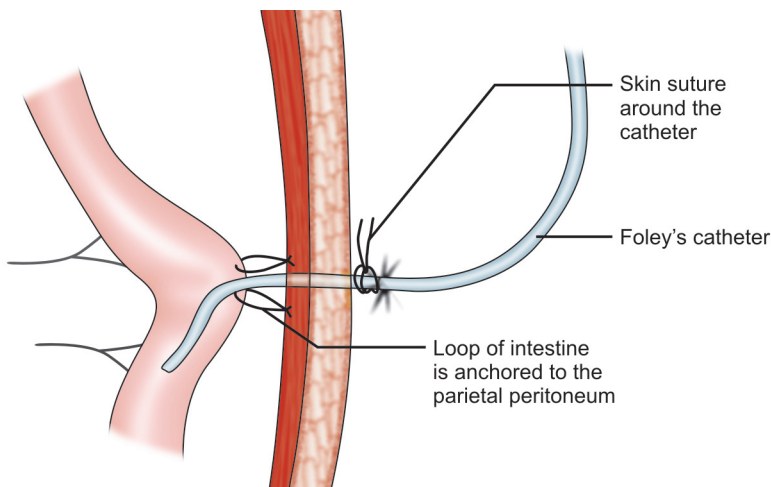
**Fig. 93.3:** Circular stapling device for end to end colorectal anastomosis



**Fig. 93.4:** Meckel's diverticulectomy.

### Steps of Operation

- Position of patient, anesthesia and incision are the same as in case of exploratory laparotomy.
- Abdomen is opened by midline incision and Meckel's diverticulum is detected.
- The loop of bowel bearing the diverticulum is brought out and moist packs are applied to isolate it.
- Two crushing clamps are applied across the diverticulum and two occlusion clamps across the bowel
- The diverticulum is excised and the resulting defect is closed transversely using first an interrupted 2/0 Vicryl suture, followed by a covering seromuscular layer with 2/0 mersilk.



**Fig. 93.6:** Feeding jejunostomy

### STRICTUROPLASTY

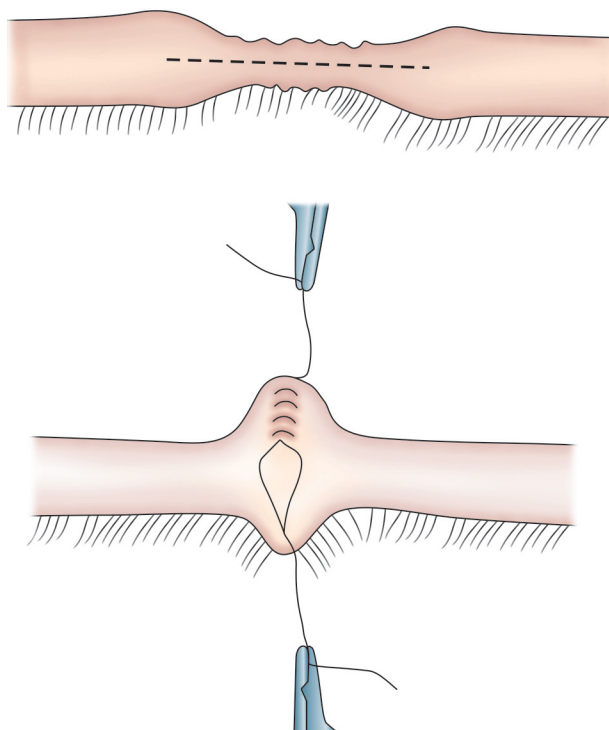
#### Indications

- Tubercular stricture.
- Stricture due to Crohn's disease.

#### Steps of Operation (Fig. 93.5)

- Position of patient, anesthesia and incision are same as in case of exploratory laparotomy.

- A longitudinal full thickness incision is made across the stenotic area extending into the normal bowel on either side for about 1cm (Fig. 93.5A).
- The incision is closed transversely either full thickness, interrupted single layer suture with 2/0 Vicryl or two layers of sutures as in Meckle's diverticulectomy (Fig. 93.5B).



**Figs 93.5A and B:** Strictureplasty of small bowel: (A) A longitudinal full thickness incision along the stenotic area; (B) Single layer transverse closure

### FEEDING JEJUNOSTOMY (FIG. 93.6)

#### Indications

- Benign stricture of esophagus, e.g. following corrosive injury.
- Following major esophageal surgery for cancer.
- As a palliative procedure in carcinoma of stomach.
- Pre- and postoperative nutritional support, e.g. after Whipple's operation.

#### Steps of Operation

- Position of patient—Supine.
- Anesthesia—General or local anesthesia may be used.
- Antiseptic dressing and draping.
- Incision—Abdomen is opened through the upper midline incision.
- The upper jejunum is exposed and a loop of jejunum is selected a few centimeters distal to the duodenojejunal flexure so that it will easily reach the anterior abdominal wall.

6. A Vicryl purse string suture is inserted on the antimesenteric border and a tiny enterotomy is made in the center of the purse string. A tube or a Foley's catheter is introduced through the enterotomy into the lumen of the bowel (Fig. 93.6).
7. Now the knot is applied snugly around the tube or catheter. Which is brought outside the abdomen through a separate stab incision. The jejunum is sutured to the parietal peritoneum. Nowadays' needle catheter jejunostomy tube is also available.

### Ileostomy

See the chapter 88 'the abdomen – general'.

### THE ROUX LOOP (FIG. 93.7)

- A defunctioning loop of jejunum (The Roux-en-Y loop) provides a convenient conduit for connecting various upper abdominal organs to the remaining small bowel.
- The technique was originally described by the Swiss surgeon, César Roux in 1907 for esophageal bypass.

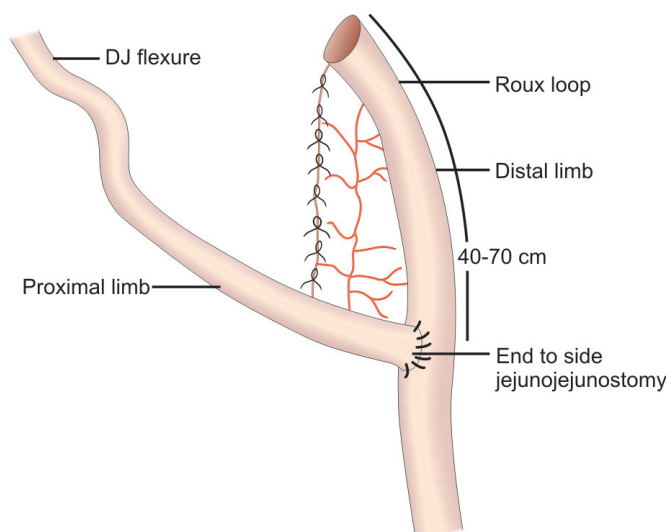
- The method has proved invaluable in gastric, biliary and pancreatic surgery. It can be used to bypass or replace the stomach, the distal bile duct and to drain the pancreatic duct or pseudocyst.

### Advantages of Roux-en-Y Loop Over an Intact Loop

- a. It can stretch further.
- b. It is empty of intestinal contents thus preventing contamination of the organ to be drained, e.g. bile duct.
- c. Active peristalsis down the loop encourages drainage.

### Steps of Operation

1. Position of patient—Supine.
2. General anesthesia with endotracheal intubation.
3. Antiseptic dressing and draping.
4. Incision: Laparotomy is done with a mid-line incision.
5. A loop of jejunum is selected 10 to 15 cm distal to the duodenojejunal flexure. The number of vessels requiring division depends on the length of conduit required.
6. The bowel is divided between clamps. The divided distal end forms the apex of the conduit. Some mesenteric division and sacrifice of jejunal vessels will be required to create adequate length.
7. The proximal end is anastomosed end to side some 40 to 70 cm down the distal limb to prevent the reflux of luminal contents from reaching the optimal anastomosis.



**Fig. 93.7:** A Roux loop created by division of small bowel and the reanastomosis of the proximal end to the side of the distal limb.

# Chapter 94

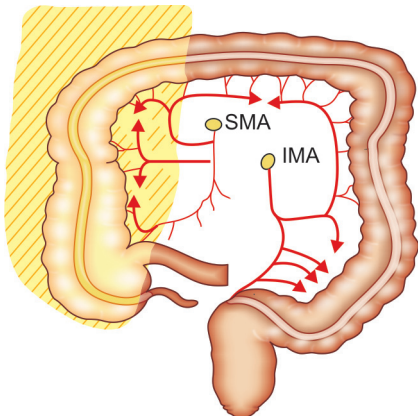
## Large Bowel

- Right hemicolectomy
- Left hemicolectomy
- Sigmoid colectomy
- Colostomy
- Abdominoperineal resection of rectum
- Rectal prolapse operations

Surgical anatomy—See the chapter 32 on ‘large intestine’ and chapter 35 on ‘rectum and anal canal.’

### RIGHT HEMICOLECTOMY

In this procedure the ascending colon with terminal part of ileum (15–20cm), appendix, cecum, right colic flexure and right one-third of transverse colon with peritoneal attachment of the resected portion of colon are removed (Fig. 94.1). The actual length varies from patient to patient due to the location of pathology and other factors. The territory



**Fig. 94.1:** Striplled area shows the structures removed during right hemicolectomy  
SMA = Superior mesenteric artery  
IMA = Inferior mesenteric artery

of ileocolic, right colic and right branch of middle colic vessels are excised.

### Preoperative Preparation

1. Bowel contains stool which is a potential source of infection. So good preoperative preparation is required before colorectal surgery to reduce the incidence of anastomotic leakage and wound infection.
  - a. Mechanical preparation of bowel –
    - i. Low residue diet for 2 to 3 days before surgery.
    - ii. No feed on the day of surgery.
    - iii. Bowel wash—Balanced electrolyte solution with polyethylene glycol, available as ‘peglec’ powder is dissolved in 2 liters of water and taken at half an hour intervals on the day before surgery to empty the colon completely.
  - b. Antibiotic prophylaxis—Sterilization of the gut is not complete with mechanical wash.  
A systemic antibiotic, e.g. ceftriaxone and metronidazole combination is administered at the time of induction of anesthesia to reduce the bacterial count.
2. The patient is catheterized after induction of anesthesia to monitor urinary output during and after surgery.
3. DVT prophylaxis should be used.

See also colorectal carcinoma in the chapter 35 on ‘rectum and anal canal.’

### Indications

1. Carcinoma cecum and ascending colon.
2. Ileocecal tuberculosis.
3. Crohn’s disease of ileocecal region.
4. Injuries of ileocecal region.

### Steps of Operation

1. General anesthesia with endotracheal intubation.
2. Position of patient—Supine.
3. Antiseptic dressing and draping.
4. Incision—Midline incision is made to open the abdomen.
5. After opening the abdomen, pathology is confirmed and right hemicolectomy is decided.

In case of malignant lesions, lymph node involvement, peritoneal and liver metastasis, involvement of adjacent structures is assessed carefully. This assessment is important to decide whether radical surgery would be possible or would radical surgery alter the prognosis without increasing the risks.

6. Mobilization of the right colon:
  - i. A vertical incision is made on the peritoneum in the right paracolic gutter extending from below the cecum to upwards just above the hepatic flexure. If the carcinoma infiltrates the lateral



abdominal wall, a large disk of peritoneum and underlying muscle is excised with the specimen. The right colon is lifted off medially from the posterior abdominal wall.

- ii. Usually no significant blood vessels are encountered during this maneuver.
- iii. Care needs to be taken during mobilization so that duodenum (second part), right ureter and gonadal vessels are not injured.

7. Division of the vessels:

- i. Once the right colon is mobilized the ileocolic, right colic and right division of middle colic vessels can be seen against light and palpated easily. These are ligated and divided individually close to the superior mesenteric vessels to devascularize the whole of the ascending colon, right part of transverse colon and the terminal ileum which are to be resected.

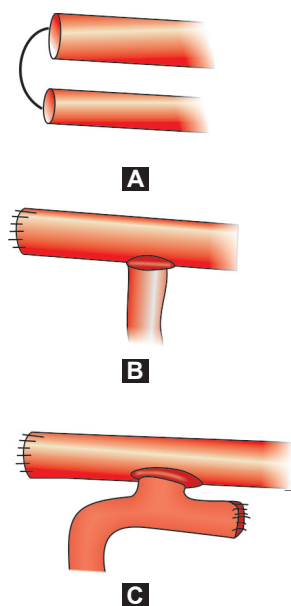
- ii. Excision of segment—Usually two non-crushing clamps and two crushing clamps are used. Noncrushing clamps are applied few inches inside the healthy intestine and crushing clamps towards the devascularized side of intestine.

Transverse colon and ileum are divided between the crushing and the non-crushing clamps.

8. Restoration of bowel continuity:

- a. The terminal ileum is anastomosed with the transverse colon end to end (more popular), if necessary widening the ileum with an antimesenteric slit (cheatle cut) (Fig. 94.2A).
- b. Prior to anastomosis, vascularity of the ends should be meticulously assessed. It is also seen that the anastomosis lies freely without twist or tension.
- c. End to side and side to side anastomosis can also be done (Figs 94.2 B and C). In the latter the closed end of colon looks towards the right and that of ileum towards left. In end to side anastomosis, one should avoid torsion of ileal end.

- d. Anastomosis is done in two layers with 2/0 polyglactin (Vicryl) for the inner layer and 2/0 silk for the outer layer. Some advocate single layer interrupted Vicryl suture.



**Figs 94.2A to C:** Showing different methods of ileotransverse anastomosis, (A) end to end (B) end to side and (C) side to side

- e. Anastomosis can also be done with linear cutter stapling device.
  - f. Closure of the mesenteric rent by apposing the cut edges of ileal mesentery and transverse mesocolon is done to avoid internal herniation.
  - g. After anastomosis, the raw surfaces are examined and bleeding if any particularly in the right flank is stopped. It is wiser to wrap the anastomosis by omentum.
9. Drain—It is better to drain the right flank with a drain of suction or passive type. The use of drain is controversial, some prefer it, some do not.
10. Closure—Mass closure of abdomen with 1/0 Prolene is the method of choice.

### Extended Right Hemicolectomy

#### Indications

Carcinoma at the hepatic flexure or in the right side of the transverse colon.

- In this operation, the splenic flexure is also mobilized; the middle colic vessels are divided close to their origin.
- The terminal ileum is anastomosed to the descending colon or sigmoid colon. The omentum should be excised en bloc with a tumor of the transverse colon or hepatic flexure.

### Conservative Right Hemicolectomy

#### Indications

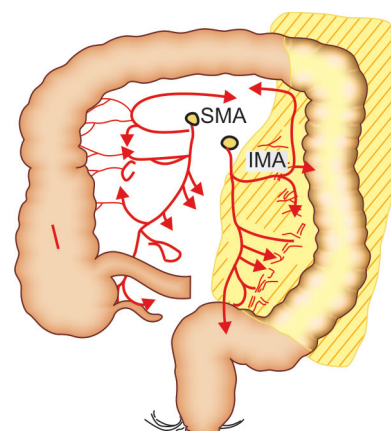
Benign localized lesion like tuberculosis, gangrenous appendicitis with cecal involvement, Crohn's disease.

In this operation, the ascending colon, cecum, appendix and a small part of terminal ileum are removed. The territory of right branch of middle colic artery is spared. The continuity is restored with ileoascending anastomosis.

### LEFT HEMICOLECTOMY

In this operation the left colic flexure, descending colon and the sigmoid colon are excised in continuity with the relevant mesentery (Fig. 94.3).

In standard left hemicolectomy inferior mesenteric artery and the left branch of middle colic artery are excised. In extended left hemicolectomy, right colic flexure, transverse colon, left colic flexure, descending colon and sigmoid colon (upto beginning of rectum) are excised in continuity. The actual length of intestine resection for malignancy is determined by the extent of intestinal devascularization required for proper lymphadenectomy and obtaining a 5 cm margin of normal colon proximal and distal to the malignant lesion is rarely an issue.



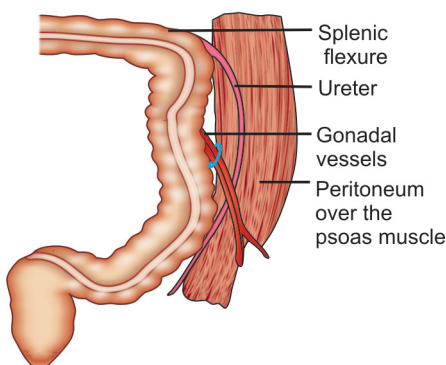
**Fig. 94.3:** The strippled area shows the structures removed in lefthemicolectomy  
SMA = Superior mesenteric artery  
IMA = Inferior mesenteric artery

## Indications

1. Carcinoma of the descending and sigmoid colon.
2. Diverticular disease of colon.
3. Ischemic colitis.
4. Local trauma.

## Steps of Operation

1. Position of patient, anesthesia and incision are the same as in case of right hemicolectomy.
2. On examination of abdomen, assessment is done regarding general peritoneal and liver metastasis, fixity of the part, nodal involvement around the inferior mesenteric artery at its origin and the proximal bowel.
3. Small bowel is exteriorized to the right side and covered with a moist pack.
4. Mobilization of left colon:
  - i. The principles of mobilization of left colon are similar to that of the right. Before the lateral peritoneum is divided developmental or postoperative bands at its outer side.
  - ii. By incising the peritoneum in the left paracolic gutter and by finger and gauze dissection, the whole of the left colon is raised from its bed exposing the quadratus lumborum, psoas muscle, perinephric fat, duodenojejunal flexure, lower part of aorta and left common iliac artery and ovarian / testicular vessels. Care is taken to safeguard the left kidney and ureter, the duodenojejunal flexure and the gonadal vessels (Fig. 94.4).
5. Division of the vessels:  
The inferior mesenteric artery is divided at its origin from the aorta. Smaller branches



**Fig. 94.4:** Showing left ureter over the psoas muscle

from left branch of middle colic artery are also divided depending on the extent of resection. The lymphatic structures are also cleared. Clamps are set at appropriate levels and the intervening bowel is removed.

6. Anastomosis—Anastomosis is done with single layer interrupted Vicryl suture. Some advocate anastomosis in two layers – inner layer with continuous 2/0 Vicryl and outer layer with interrupted 2/0 mersilk.
7. The mesenteric gap is closed.
8. Closure—Abdomen is closed en mass with 1/0 Prolene.

## SIGMOID COLECTOMY

### Indications

1. Traumatic injury or colonoscopic injury.
2. Sigmoid volvulus.
3. Growth of polyp at or near the apex of sigmoid loop.

### Procedure

- a. In this procedure, sigmoid colon is excised. Adjoining part of descending colon or upper rectum may be included.
- b. The territory supplied by sigmoid arteries and superior rectal artery are ligated and divided.  
Alternatively, the inferior mesenteric artery may be divided at its origin and left colic branch is divided proximal to its bifurcation.
- c. After mobilization, and excision of the sigmoid colon bowel continuity is restored by end to end anastomosis between the mobilized left colon and upper rectum at the level of sacral promontory with interrupted 2/0 Vicryl sutures.
- d. The rent in the pelvic mesocolon is sutured.
- e. Abdomen is closed in layers.

- It is to be noted that resection of a lesion of the sigmoid colon or the most proximal rectal tumors and restoration of bowel continuity by anastomosis of proximal colon to the rectum above the peritoneal reflection are termed high anterior resection.

- On the other hand resection of the distal sigmoid or proximal rectum requiring an anastomosis within 10 cm of the anus, i.e. below the peritoneal reflection is called low anterior resection.

- In elective cases of sigmoid colectomy, the colon should be prepared. If it contains stool, primary anastomosis should be avoided. Defunctioning transverse colostomy or Hartmann's operation may be necessary as part of staged procedures.

## Total Colectomy

In this procedure, the terminal ileum along with whole of the colon from ileocecal junction to the rectosigmoid junction is excised. The bowel continuity is restored with ileorectal anastomosis.

The common indications are:

- a. Advanced ulcerative colitis.
- b. Familial adenomatous polyposis (FAP).
- c. Selected cases of Crohn's colitis.

## COLOSTOMY

See chapter 88 on 'the abdomen – general'.

## ABDOMINOPERINEAL RESECTION (APR) OF RECTUM

### Indications

1. Distal rectal cancers with less than 3 cm of normal rectum below the growth. If more than 3 cm remains below the growth then low anterior resection is the operation of choice.
  2. In cancers of middle and lower rectum where rectovaginal septum (in females) and the anal sphincters are involved by the growth.
  3. In large or recurrent cancers of anal verge which cannot be treated locally by wide excision or radiotherapy and chemotherapy.
  4. In uncommon cancers of lower rectum and anal canal like melanoma, sarcoma, etc. which cannot be treated by local excision.
- The incidence of APR has decreased considerably in the last two decades due to improvement in chemotherapy and radiotherapy and use of circular staplers. Sphincter preserving surgery in the form of low anterior resection is on the rise.

### Steps of Operation

1. Anesthesia—General anesthesia with endotracheal intubation.
2. Position of patient—Lithotomy Trendelenburg position.

3. Antiseptic dressing from mid chest to mid thigh and draping.
4. Nasogastric tube inserted and catheterization done in the preoperative preparation.
5. Incision: A lower midline incision is made from the supraumbilical region to the symphysis pubis.

6. Assessment of operability:

- After opening the abdomen a through systematic examination of all organs and peritoneal cavity is made from above downwards.
- The liver, under surface of diaphragm, and paracolic gutters are inspected and palpated.
- Whole of small and large intestine along with the mesentery and omentum are examined.
- A mobile growth without any fixity to pelvic walls or bladder is suitable for resection.

Thus, the resectability and the site for resection of the bowel is decided.

7. Packing—The coils small intestine are packed off into the upper abdomen.
8. Mobilization of colon—The initial mobilization and dissection of colon is identical to that for a left hemicolectomy except a minor modification to avoid mobilization of the splenic flexure. The left ureter is identified by visualizing it to cross over the bifurcation of the common iliac artery or incising the peritoneum over the psoas muscle and finding the ureter on the medial aspect of peritoneum.

9. Ligation of inferior mesenteric pedicle—The inferior mesenteric artery is divided at its origin from the aorta. It is not necessary to ligate the artery flush with the aorta for oncologic reasons.

The inferior mesenteric vein is divided at the inferior border of the pancreas. The vein is ligated first, then the artery.

A double ligature or a transfixation suture is advisable for the artery.

10. Pelvic dissection and total mesorectal excision (TME)—

- The rectosigmoid and its mesentery are lifted upwards away from the sacrum and the presacral plane or cleavage is identified by inserting scissors downwards and backwards behind the mesorectum.

- The hand is swept from side to side to free the rectum completely posteriorly.
- The peritoneum is divided on either side of rectum as far as the peritoneal reflection to join the two peritoneal incisions anteriorly. This incision is deepened in a transverse direction to divide the fascia of Denonvilliers upto the upper border of prostate or the middle of the vagina. Care is taken not to injure the vas deferens.
- The rectum is displaced from one side to the other to make the lateral ligaments taut and each lateral ligament is divided by cautery. The middle rectal artery lies in this ligament and often needs ligation. The lateral dissection is carried upto the levators, where the abdominal part of the dissection ends.
- Total excision of mesorectum both posteriorly and laterally upto the coccyx is considered to be the most important part of this pelvic dissection.

11. Division of colon—The sigmoid colon is divided at the proposed site of resection. Normally if a length of about 5cm of colon protrudes out of the abdominal wall, a tension-free colostomy can be made.

The proximal cut end of sigmoid colon should be wrapped by a mop and retracted upwards over the abdominal wall till the construction of colostomy.

The distal cut end should be covered by a rubber glove or gauge and secured in position by encircling heavy silk ligation at two different levels after removing the clamps.

12. Perineal dissection—

- a. An incision is made encircling the anus and extending over the coccyx.
- b. Posteriorly the strong fascia of Waldeyer is divided transversely to expose and separate the mesorectum from the hollow of the sacrum with finger dissection.
- c. The lateral incisions are deepened until the levator ani is exposed. This muscle is divided with scissors, after introducing two fingers above the muscle from behind.

- d. Anterior mobilization—When levator ani on either side has been divided, anterior mobilization is commenced. By combined scissors and gauge dissection, the rectum is separated from the urethra and prostate or vagina as the case may be. When this is accomplished the entire segment of bowel is removed.

13. Closure of the perineum—Hemostasis secured by ligating the bleeding vessels and the wound is closed keeping a suction drain through a separate stab wound.

14. Closure of the abdomen—

- a. The proximal end of sigmoid colon is brought out, through a site already marked in the left iliac fossa to perform the colostomy.
- b. The surgeon should introduce his index finger into the colostomy to confirm a free lumen without undue constriction in the abdominal wall.
- c. After proper counting, the abdomen is closed without any drain. A layered closure is preferred but single layered closure may be done in some cases.

### Postoperative care

- a. Oral feeds are given after the colostomy starts working.
- b. Broad spectrum antibiotic is continued.
- c. Indwelling catheter is kept for 7 to 8 days.
- d. The suction drain is removed after 3 to 4 days.
- e. Stitches are removed after 7 to 8 days.

### Postoperative complications:

1. Stoma, complications like necrosis due to ischemia, retraction, herniation, stenosis and prolapse.
  2. Reactionary hemorrhage.
  3. Sepsis.
  4. Tumor recurrence.
1. What is Hartmann's operation?
  2. What are the signs of inoperability of colorectal carcinoma?
  3. What palliative surgery will you do for nonresectable growths?
  4. What is postoperative follow-up protocol in colorectal carcinoma?  
See colorectal carcinoma in the chapter 35 on 'rectum and anal canal'.

### **RECTAL PROLAPSE OPERATIONS**

Operations for rectal prolapse are as follows:

1. Abdominal procedures:
  - a. Well's procedure (Ivalon sponge wrap procedure).
  - b. Mesh rectopexy.
2. Perineal procedures:
  - a. Thiersch wiring
  - b. Delorme's procedure.  
See rectal prolapse in the chapter 35 on 'rectum and anal canal' for description about the above procedures, and diagrams for operations.

# Chapter 95

## Anal and Perianal Operations

- Hemorrhoidectomy  
—Indications and steps of operation

- Anal stretching
- Subcutaneous lateral internal sphincterotomy (SLIS)

- Fistulectomy  
—Preoperative preparation and steps of operation

### HEMORRHOIDECTOMY

Surgical anatomy of anal canal and definition, classification and degree of hemorrhoids have been described in the chapter 35 on “rectum and anal canal”.

- First and second degree hemorrhoids are treated by Lords procedure, Baron’s band application and cryosurgery.
- Third and fourth degree hemorrhoids require hemorrhoidectomy.

#### Indications

- As mentioned above surgery offers the best chance of cure in cases of third and fourth degree hemorrhoids.
- Failure of nonoperative treatment of second degree hemorrhoid is also an indication for hemorrhoidectomy.

#### Steps of Operation of Hemorrhoidectomy by Open Method (Milligan and Morgan)

- Anesthesia—General anesthesia with endotracheal intubation or spinal or local anesthesia with 1 percent Xylocaine with adrenaline. Use of general anesthesia is preferred by some surgeons.
- Position of patient—Lithotomy.
- Antiseptic dressing and draping.
- Exposure of the pile masses:
  - The positions of the pile masses are confirmed by proctoscopic examination. Mild anal stretching is done.

- A curved artery forceps is applied to the perineal skin just outside the mucocutaneous junction at 3, 7 and 11 o’clock positions, opposite the primary pile groups and gently pulled outwards. As a result the mucosa covered part of the piles protrudes out.
  - Now a second artery forceps is applied on to the apex of each hemorrhoid mass thus producing the triangle of exposure.
- Ligation and excision:
    - The pile mass at 3 o’clock position is dealt first (Fig. 95.1).
    - A V-shaped incision is made around the pile on mucocutaneous junction with blunt pointed scissors. The incision is deepened towards the anal canal to reveal the fibers of the internal anal sphincter.
    - The pedicle is narrowed as dissection is continued towards the apex. The

pedicle is transfixed doubly with catgut or Vicryl. The hemorrhoidal tissue is excised distal to the ligature with scalpel.

- The procedure is repeated for the remaining major piles. Any bleeding from the perianal skin or submucosal veins is secured with diathermy.
- Dressing—A roller gauge smeared with providone iodine (Betadine) lotion and Xylocaine jelly is applied to the anus and secured with a T-Bandage.

#### Postoperative Care

- Dressing is changed after 24 hours and the patient is put into sitz bath twice or thrice daily.
- Analgesic and stool softener are advised in the postoperative period.
- The patient can be discharged after 3 to 4 days and reviewed after 10 to 12 days.

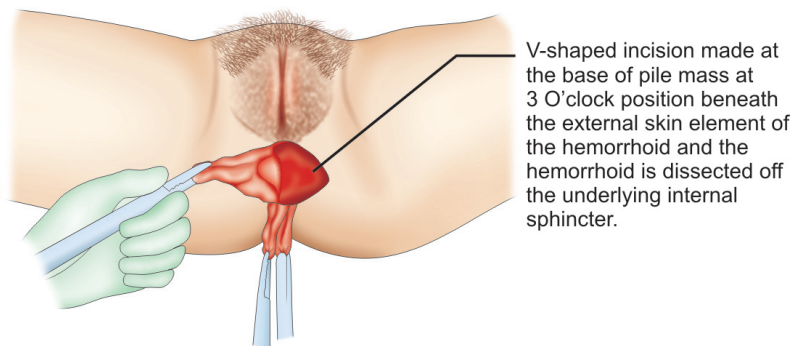


Fig. 95.1: Hemorrhoidectomy (Milligan and Morgan method)



### Postoperative Complications

1. Reactionary hemorrhage—This is avoided by transfixing the pedicle twice.
2. Secondary hemorrhage should be treated by blood transfusion and antibiotics. In most cases the bleeding stops.
3. Pain.
4. Retention of urine.
5. Anal stenosis.
6. Incontinence.

### ANAL FISSURES

An anal fissure is an elliptical ulcer located almost exclusively in the midline both anteriorly and posteriorly.

### Indications of Operative Treatment

1. Failure of conservative treatment in acute anal fissure.
2. Chronic anal fissure with sentinel tag.  
The operations are:
  - a. Anal stretching and
  - b. Subcutaneous lateral internal sphincterotomy.

### ANAL STRETCHING

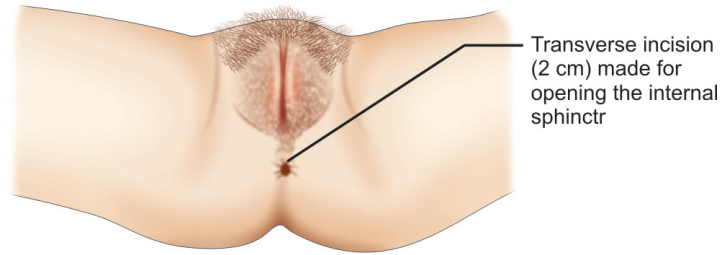
1. Position of patient—Lithotomy.
2. Anesthesia—General or spinal anesthesia.
- 3a. Four finger anal stretching of internal sphincter is carried out slowly and gently over 2 to 3 minutes.
- b. Initially two index fingers are inserted in the anus one by one and internal sphincter is dilated laterally.
- c. Subsequently two middle fingers are introduced one by one to carry out the four fingers dilatation.

### Subcutaneous Lateral Internal Sphincterotomy (SLIS)

This consists of division of distal 2/3rd of the internal sphincter.

### Steps of Operation

1. Position of patient—Lithotomy.
2. Anesthesia—General or spinal anesthesia.



**Fig. 95.2:** Incision for subcutaneous lateral internal sphincterotomy (SLIS)

3. Technique:
  - i. Open method
    - a. Incision – 1 to 2 cm transverse incision is made at the anal verge over the free edge of the internal sphincter (Fig. 95.2).
    - b. Dissection is continued to expose the internal sphincter.
    - c. The free lower border of the internal sphincter is then grasped, drawn into the wound and its distal portion (2/3) is divided.
  - ii. Closed method
    - a. A pointed no. 11 blade is introduced into the intersphincteric plane and the internal sphincter is incised from without.
    - b. The scalpel is withdrawn and on digital palpation the tight band of the distal internal sphincter can be felt to have released.
    - c. Any associated sentinel skin tag at the outer end of the fissure or a fibroepithelial polyp at the inner end is excised.
4. Closure—A lubricated roller gauge pack is left in the anal canal and secured with a T-bandage.

### Postoperative Care

- Sitz bath.
- Analgesic and stool softener.

### OPERATION FOR FISTULA IN ANO (FISTULECTOMY)

### Preoperative Preparation

#### Low Fistula

- A fistulogram may be helpful to define the fistulous tract.

- A proper bowel wash is given to empty anorectal region.

### Operation – Fistulectomy

Fistulectomy means excision of the fistulous tract.

### Steps of Operation

1. Position of patient – Lithotomy.
2. Anesthesia—General anesthesia with endotracheal intubation or spinal anesthesia.
3. Antiseptic dressing and draping.
4. Technique:
  - a. A malleable probe is introduced gently through the external opening of the fistula and the probe is allowed to emerge through internal opening in the anal canal.
  - b. Now the entire track is excised with subcutaneous tissue and some part of internal sphincter.
  - c. Fistulectomy wounds are larger with the broader end facing externally and the time for wound healing is significantly prolonged.
  - d. Closure—The wound is packed with povidone iodine to allow healing by secondary intention.
5. Postoperatively sitz bath, antibiotics, analgesics and laxatives are given.

### High Fistula

Seton placement technique—See fistula in ano in the chapter 35 “rectum and anal canal”.

1. What are the postoperative complications?
  - a. Sepsis.
  - b. Recurrence.

# Chapter 96

## Hernia

- Operations for inguinal hernia
- Inguinal hernia repair in infants and children-herniotomy
- Inguinal hernia repair operations in adults
- (Herniorrhaphy and hernioplasty)
- Strangulated inguinal hernia
- Laparoscopic hernia repair
- Femoral hernia repair
- Operation for epigastric hernia
- Operation for umbilical hernia
- Operation for paraumbilical hernia
- Operation for incisional hernia

### OPERATIONS FOR INGUINAL HERNIA

Operation is the treatment of choice for inguinal hernia.

Basically three types of operations are available viz.

1. Herniotomy:
  - Herniotomy is the cutting of the hernial sac distal to the ligature. Posterior wall of the inguinal canal is not repaired. Herniotomy alone is mainly indicated in children and for small hernia in young adults with good muscular tone.
  - It is also employed as the first step in herniorrhaphy and hernioplasty other than some cases of direct herniae with a diffuse bulge and sliding herniae where the sac is too redundant.
2. Herniorrhaphy: This denotes strengthening of the posterior wall of the inguinal canal by suturing the conjoint tendon with the inguinal ligament in addition to herniotomy.
3. Hernioplasty: This consists of reconstruction of the posterior wall of inguinal canal by placement of some prosthetic materials like prolene mesh or dacron mesh or

natural tissues like fascia lata following herniotomy.

Q. Enumerate the surgical anatomy of the inguinal canal?

See 'surgical anatomy of inguinal canal' in the chapter 42 on 'hernia'.

### INGUINAL HERNIA REPAIR IN INFANTS AND CHILDREN — HERNIOTOMY

#### Steps of Operation

1. Anesthesia: General anesthesia with endotracheal intubation.
2. Position of patient: Supine.
3. Antiseptic dressing and draping.
4. Incision: A transverse 4 to 5 cm skin crease incision is made just above the symphysis pubis (Fig. 96.1A).
5. Exposure of inguinal canal:
  - a. The incision is deepened to cut through skin and superficial fascia having two layers namely the superficial fatty layer, known as the fascia of Camper and the deeper membranous layer known as the fascia of Scarpa. The vessels lying between these two layers of fascia viz.
    - i. Superficial external pudendal.
    - ii. Superficial epigastric and

iii. Sometimes superficial circumflex iliac are ligated or cauterized to secure hemostasis.

b. The superficial ring as well as the cord is exposed.

c. Since superficial and deep rings are superimposed at this age, splitting of external oblique aponeurosis is not necessary.

6. Dissection of the cord:
  - The cord is identified and isolated just distal to the superficial ring.
  - The coverings of the spermatic cord namely, external spermatic fascia,

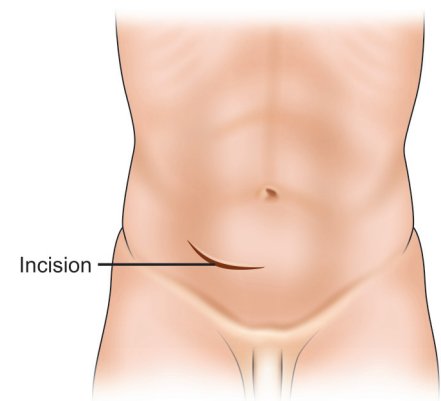
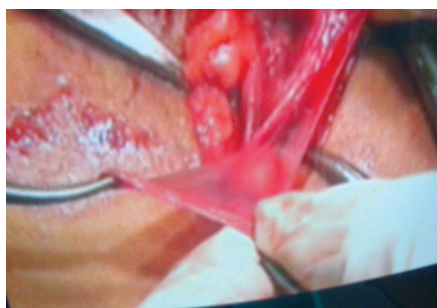

Fig. 96.1A: Skin crease incision for herniotomy in children



**Fig. 96.1B:** Isolation of the sac during herniotomy

cremasteric fascia and internal spermatic fascia are separated by blunt dissection with mosquito forceps to expose the diaphanous sac, the vas and the vessels.

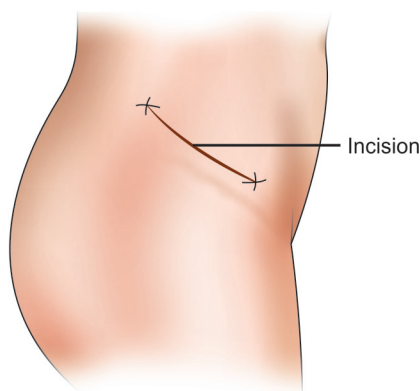
7. Isolation of the sac (Fig. 96.1B).
  - a. The diaphanous sac is isolated from the vas and vessels by careful and gentle dissection because the sac is firmly adhered to the vas deferens.
  - b. By gentle traction and gauge stripping the sac is freed upto its neck.
  - c. The sac is transfixed, ligated and removed.
8. Closure:
 

The subcutaneous tissue is closed with 3/0 chromic catgut stitches. The skin is closed with subcuticular stitches with absorbable sutures.

### INGUINAL HERNIA REPAIR OPERATIONS IN ADULTS (HERNIORRHAPHY AND HERNIOPLASTY)

#### Steps of Operation (Fig. 96.2)

1. Position of patient: Supine
2. Anesthesia: The operation can be performed under general anesthesia, spinal anesthesia or even local infiltration anesthesia (1% lignocaine with adrenaline, 50ml).
3. Antiseptic dressing and draping.
4. Incision: An incision is made ½" above and parallel to the medial two-thirds of inguinal ligament. The pubic tubercle and the anterior superior iliac spine are the important landmarks (Fig. 96.2A).
5. The incision is deepened to cut through the skin and subcutaneous tissue to

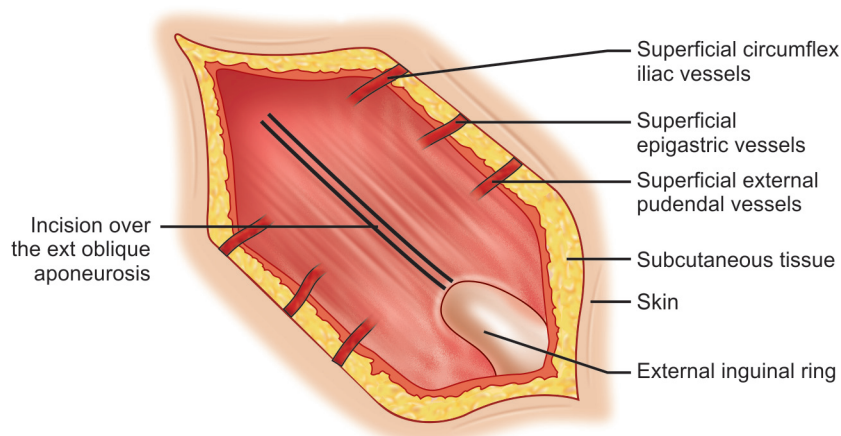


**Fig. 96.2A:** Incision for inguinal hernia repair in an adult

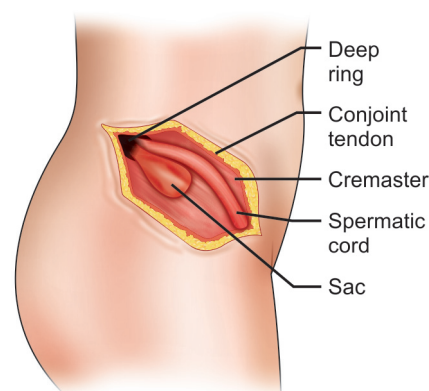
expose the glistening fibers of the external oblique aponeurosis.

6. Exposure of inguinal canal:
  - a. The superficial inguinal ring is identified at the medial end of the external oblique aponeurosis.
  - b. Incision is made over the external oblique aponeurosis along its fibers to expose the deep ring as well as the inguinal canal (Fig. 96.2B).
  - c. Ilioinguinal nerve is identified and safeguarded.
  - d. The cut edges of external oblique aponeurosis are retracted with hemostats to expose conjoint muscle arching over the cord above and glistening inguinal ligament below (Fig. 96.2C).
7. Dissection of the cord:
 

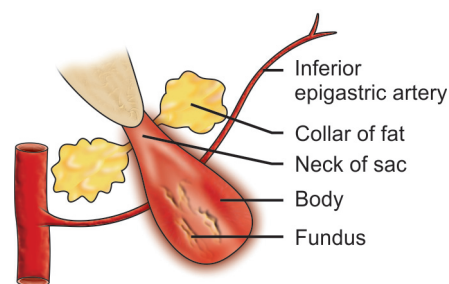
The spermatic cord is elevated from the medial part, coverings are incised and separated by gauge dissection to expose the sac.



**Fig. 96.2B:** Incision over the external oblique aponeurosis shown by the double lines



**Fig. 96.2C:** Structures after cutting the external oblique aponeurosis



**Fig. 96.2D:** Structures for identification of neck of sac

8. Dissection of the sac:
  - a. An indirect sac is easily identified, as a pearly white pyriform structure on the anterosuperior aspect of the cord.
  - b. The fundus of the sac is held with a pair of hemostat and separated from cord structures by gauge dissection upto the neck.
  - c. The neck is identified by (Fig. 96.2D)
    - i. Narrowest portion of the sac.

- ii. A collar of extraperitoneal fat and
  - iii. Presence of inferior epigastric artery which lies medial to the deep ring.
  - d. A direct sac is usually a broad based bulge of peritoneum through the Hesselbach's triangle. It can be seen once the cord is retracted downwards and laterally. In case of direct hernia one should first look for indirect hernia by dissection of the cord.
9. Direct sac — It does not require herniotomy and is simply pushed back.
  10. Repair: (Herniorrhaphy)

The Bassini method: This repair was first done by Edoardo Bassini, an Italian surgeon in 1884. He approximated the conjoint tendon and inguinal ligament by 4 or 5 interrupted, nonabsorbable polypropylene sutures.

11. Closure:
  - a. Cord is replaced into inguinal canal by drawing the testes downwards.
  - b. External oblique aponeurosis is closed with absorbable suture starting laterally and ending medially by reconstructing the superficial ring.
  - c. Skin is closed with 2/0 Ethilon stitches.

### Mesh Repair (Hernioplasty)

1. Lichtenstein prolene mesh repair:
  - At present this is the gold standard for inguinal hernia repair in adults.
  - This is especially indicated for inguinal hernia in the elderly and for recurrent hernia.
  - Recurrence rate following Lichtenstein repair is less than 1 percent.

Technique

- a. After removal of hernial sac, a prolene mesh of appropriate size is taken and fashioned to the shape of the floor of the inguinal canal.
- b. An opening is made on the lateral aspect of the mesh to allow it to pass around the spermatic cord at the level of the deep ring.
- c. The lower end of the mesh is sutured with the inguinal ligament with continuous or interrupted sutures using 2/0 prolene.
- d. The upper end of the mesh is fixed to the conjoint tendon by interrupted sutures with 2/0 prolene. The mesh is

also fixed with the periosteum at the medial overlapping the pubic tubercle.

2. Prolene Hernia System (PHS) repair: This device, currently used for repair of direct and indirect inguinal hernia, consists of:
  - i. An underlay portion lying inside the deep ring.
  - ii. A “connector” of the onlay and underlay portions.
  - iii. An onlay portion which is designed to cover the floor of the inguinal canal.

### Postoperative care

- a. Early ambulation.
- b. Prophylactic antibiotic.
- c. Analgesic.

### Postoperative complications

1. General — Pulmonary complications especially in the elderly.
2. Local — Hemorrhage, vas deferens injury, wound infection, recurrence.

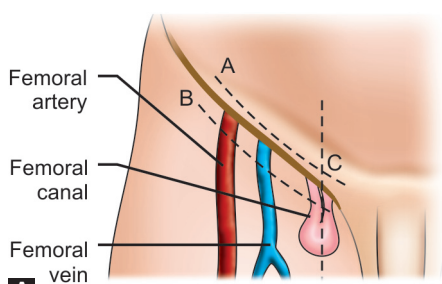
## STRANGULATED INGUINAL HERNIA

This is a surgical emergency. Preoperative resuscitation followed by operation is the treatment of choice.

See ‘preoperative resuscitation and operation’ of strangulated hernia in the chapter 42 on ‘hernia’.

## LAPAROSCOPIC HERNIA REPAIR

See the chapter 42 on ‘hernia’ for techniques of laparoscopic inguinal hernia repair.



**A**

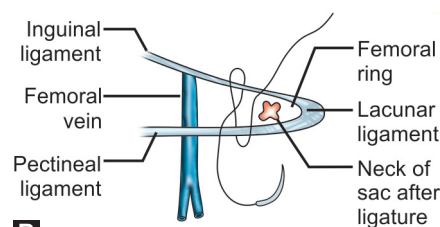
## FEMORAL HERNIA REPAIR

See treatment and principles of operation of femoral hernia in the chapter 42 on hernia.

The approach that enjoys a great popularity is a repair from above the inguinal ligament, that is, Lotheissen's operation (Fig. 96.3A). The advantage of this approach is that it can be used for repairing coexisting inguinal and femoral herniae.

### Steps of Lotheissen's Repair

1. Position of patient — Supine and the bladder is catheterized preoperatively to reduce the preoperative risk of damage.
2. General anesthesia with endotracheal intubation.
3. Antiseptic dressing and draping.
4. Incision — An incision is made about a finger's breadth above and parallel to the inguinal ligament. The incision is deepened to cut through skin and subcutaneous tissue. The external oblique aponeurosis is incised to expose the inguinal canal. The spermatic cord is isolated and taped as in case of inguinal hernia.
5. The lower skin flap is mobilized to expose the femoral hernia.
6. The coverings of the sac viz. the thinned out cribriform fascia and condensed fatty tissue are dissected. If strangulation is present, the surroundings are packed off and the sac is opened from below to drain the infected fluid.
7. The contents of the sac are examined, healthy bowel is returned to abdomen, nonviable gut is resected.
8. The sac is mobilized from below, trans-fixed, ligated and divided near the neck.



**B**

**Figs 96.3A and B:** Broken lines A, B, C indicate the incisions for femoral hernia repair. A-Inguinal incision (Lotheissen's approach) B-Vertical incision (Macevedy's approach) C-Low incision (Lockwood approach); B-Approximation of inguinal and pectineal ligaments with 2/0 prolene suture



9. The triangular gap is repaired with 2/0 prolene sutures approximating the pectineal ligament and the inguinal ligament (Fig. 96.3B).
10. The inguinal canal, subcutaneous tissue and skin are closed as for an inguinal hernia.

### OPERATION FOR EPIGASTRIC HERNIA (FIG. 96.4)

Anatomical repair of the defect:

- Under general anesthesia a small transverse incision is made over the swelling (Fig. 96.4A).
- The skin and subcutaneous tissue is dissected off from the anterior rectus sheath. The hernial mass is dissected all around the gap in the linea alba. The hernial sac is opened and content, if any is reduced (Figs 96.4B and C).
- The neck of the sac is closed with absorbable suture and the fat distal to the ligature is excised. The fascial defect in the linea alba is closed with interrupted non-absorbable suture such as 2/0 Prolene (Fig. 96.4D).
- If the defect is large (>4cm), a Prolene mesh is placed in the preperitoneal space and the fascial defect is closed in front of the mesh.
- Closure: The skin is closed with 2/0 Ethilon stitches.

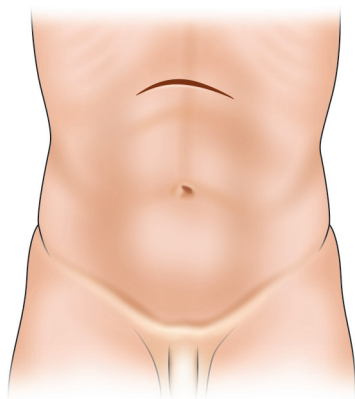


Fig. 96.4A: Incision for epigastric hernia

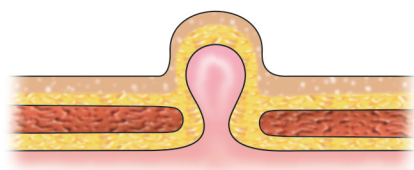


Fig. 96.4B: Small empty sac of epigastric hernia

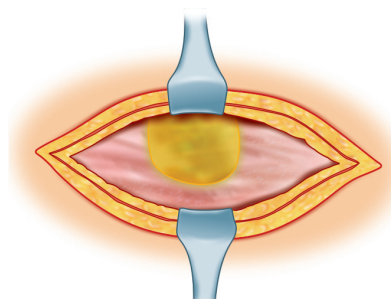


Fig. 96.4C: Herniated fat exposed

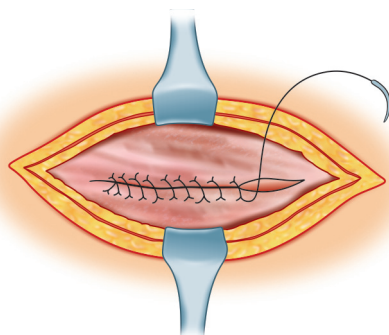


Fig. 96.4D: Repair with continuous fine prolene suture

### OPERATION FOR INFANTILE UMBILICAL HERNIA

A curved incision is made below the umbilicus with convexity towards the pubis (Fig. 96.5A).

↓  
Anterior rectus sheath is exposed and the flap with the umbilicus retracted upwards (Fig. 96.5B).

↓  
The sac is identified and opened at the neck (unlike in inguinal hernia).

↓  
Contents reduced, sac is ligatured and divided at the neck.

↓  
The defect in the linea alba is closed (Fig. 96.5C) and the skin edges are apposed accurately and sutured.

### OPERATION FOR ADULT UMBILICAL HERNIA (Syn— Paraumbilical Hernia)

#### Mayo's Repair

See paraumbilical hernia in the chapter on hernia in chapter 42, section 10.

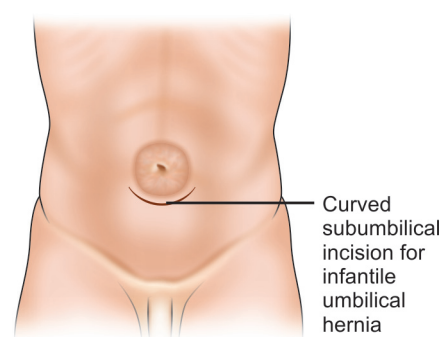


Fig. 96.5A: Incision for umbilical hernia

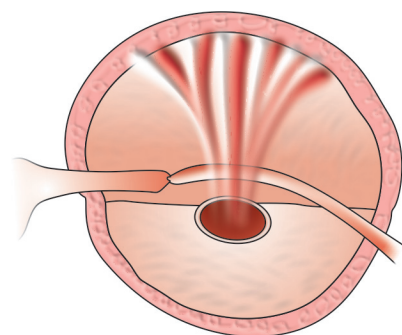


Fig. 96.5B: Skin flap with umbilical cicatrix is dissected upwards, exposing the sac freed all around

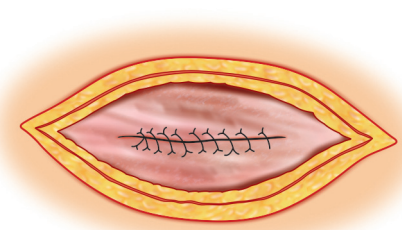


Fig. 96.5C: Repair of the defect with transverse row of sutures

### OPERATION FOR INCISIONAL HERNIA

The peculiarity of incisional hernia is that it is iatrogenic. The incidence of incisional hernias after laparotomy is 2 to 11 percent. It is a chronic wound failure. Hence all surgeons should pay careful and meticulous attention to wound closure and wound care.

An incisional hernia may develop through any abdominal incision but it is usually mid-line infraumbilical and small. Ninety percent of incisional herniae occur within three years of operation.



### Preoperative Measures

1. Reduction of obesity: The decrease in intraabdominal pressure that occurs with weight loss leads to a lower recurrence rate.
2. Correction of blood sugar if any.
3. Correction of anemia.
4. Immediate preoperative:
  - a. Nasogastric tube.
  - b. Catheterization to make the bladder empty.
5. Perioperative antibiotic cover.

### Operation

#### Open Mesh Repair

This is considered the best option for large incisional herniae with a wide gap or when the aponeurotic gap cannot be apposed.

The mesh may be applied at three levels in the abdominal wall as described below:

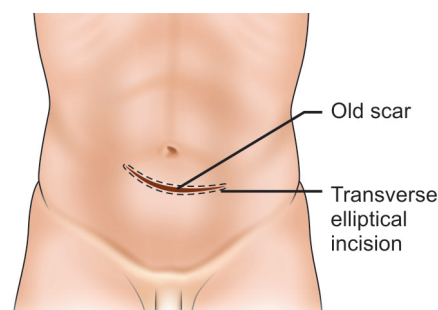
- a. The onlay repair: Here the prolene mesh is placed anterior to the aponeurosis. It should extend 4cm beyond the margin of the defect. The mesh is secured with interrupted 2/0 prolene sutures at 2cm

intervals. The mesh may be further fixed to the margin of the defect by continuous sutures. The skin is closed over the mesh Fig. 96.6A(i).

- b. Extraperitoneal or sublay repair: It is also called Rives–Stoppa–technique. In this technique the mesh is placed beneath the rectus muscle and in front of the posterior rectus sheath and the peritoneum. The anterior rectus sheath is closed in a separate layer. This is the most accepted technique of incisional hernia repair Fig. 96.6A(ii).

- c. The inlay or intraperitoneal repair –

- In this repair, the mesh is sutured to the fascial edges without initially closing the defect.
- The sac is opened and any adhesions for 4cm around the rim are freed before applying the mesh.
- The mesh lies in contact with the bowel, which may lead to adhesions and enterocutaneous fistula formation [Fig. 96.6A.] (iii) However PTFE (Polytetrafluoroethylene or Teflon and Dacron (polyester) mesh have



**Fig. 96.6B:** Incision for incisional hernia repair

been reported to have fewer of these complications.

#### Steps of Operation of Sublay or Extraperitoneal Mesh Repair

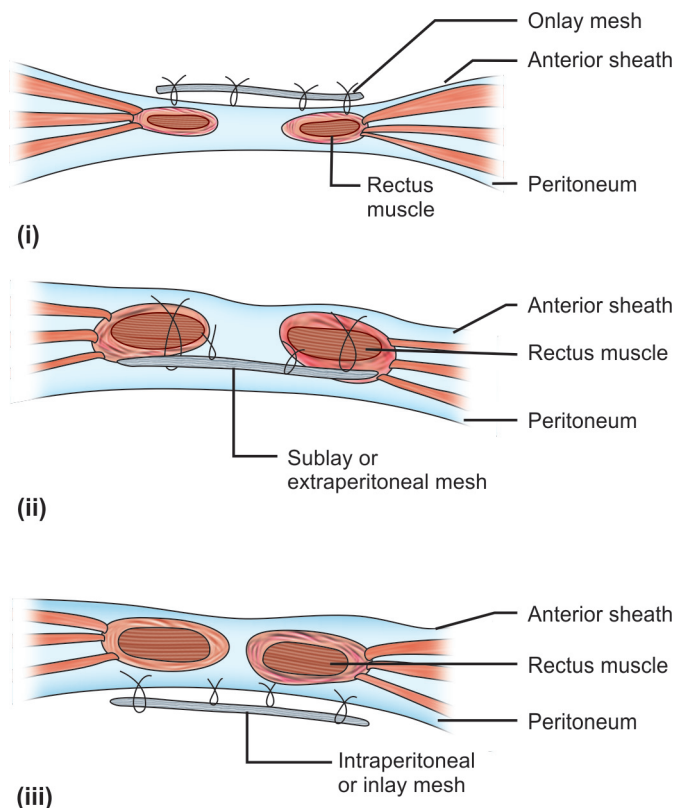
1. Position of patient: Supine.
2. Anesthesia: General anesthesia with endotracheal intubation.
3. Antiseptic dressing from midchest to midthigh and draping.
4. Incision: A transverse elliptical incision is made enclosing the old scar if any and redundant skin is removed (Fig. 96.6B).

5. Exposure: The outer edges containing skin and subcutaneous tissue are elevated and reflected beyond the hernial protuberance with great care, both above and below.

Dissection is continued around the margins of the hernia defect till a wide mobilization has been achieved.

6. Dealing with the sac:
  - a. If the sac is no more than a redundancy of peritoneum and if it is not too adherent to the skin, it may be possible to free it and to replace it unopened by buried mattress sutures.
  - b. More often the sac is loculated and very adherent when it is better to open it near the neck. Adherent loop of gut is freed from the under surface of the sac. Adherent omentum is liberated by ligation and division. The sac is transfixed at the neck and excised. Multiple defects or button hole tears, are managed by uniting them and repairing the resultant larger defect with prolene sutures.

7. Repair: Extraperitoneal or sub lay mesh repair is done as described above.



**Fig. 96.6A:** Three alternate levels viz (i) onlay (ii) sublay and (iii) inlay of placement of mesh in incisional hernia repair

## 8. Closure:

- Meticulous hemostasis is done.
- One or two subcutaneous suction drains are placed. Skin wound is closed with interrupted 2/0 Ethilon sutures.

*Postoperative Care*

1. The drains are left till the daily loss is less than 30ml.
2. Early ambulation is encouraged.
3. Stitches are removed after 7 to 8 days.

*Postoperative Complications*

- a. Hematoma formation.
  - b. Wound infection.
  - c. Recurrence.
- Q. What is incisional hernia?  
 Q. What are the predisposing factors?  
 Q. How does the incisional hernia present?  
 Q. How will you do anatomical repair?  
 See the chapter 42 on 'hernia' and the long case of incisional hernia, chapter 74.
- Q. What is laparoscopic repair of incisional hernia?

- a. It is relatively a new technique and varying degrees of success have been reported.
  - b. The patients undergoing laparoscopic repair have been reported to have fewer postoperative complications than those receiving open repair.
- After creation of pneumoperitoneum and port placement, the hernial contents are reduced and the mesh is placed to overlap the defect and fixed with clips and sutures.

# Chapter 97

## Operations on Urology

- |                                  |                             |                           |
|----------------------------------|-----------------------------|---------------------------|
| ➤ Nephrectomy                    | ➤ Suprapubic cystostomy     | ➤ Amputation of penis     |
| ➤ Open Surgery for renal calculi | ➤ Prostatectomy             | ➤ Orchidopexy             |
| ➤ Anderson – Hynes pyeloplasty   | ➤ Circumcision              | ➤ Orchidectomy            |
| ➤ Ureterolithotomy               | ➤ Meatotomy and meatoplasty | ➤ Operation of hydrocele  |
|                                  |                             | ➤ Operation of varicocele |

### NEPHRECTOMY

1. Surgical anatomy: See chapter 46 on 'kidney and ureter'.
2. Surgical approaches to the kidney: There are two approaches, viz. (a) Posterolateral approach and (b) Anterior approach.

#### Posterolateral Approach

Position of patient:

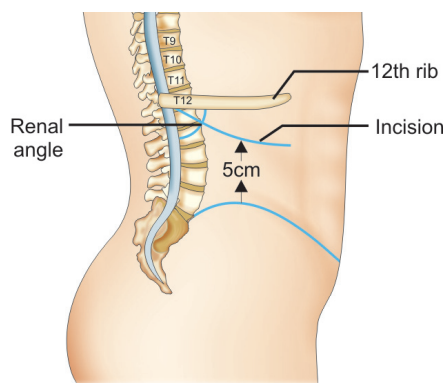
- The patient is placed on his sound side with his back brought over towards the edge of the table.
- The leg next to the table is fully flexed at the hip and knee, the upper leg is extended.
- The patient is maintained in this position by an adhesive tape or strapping.
- To increase access, the trunk should be flexed laterally by raising the kidney bridge.

#### Incisions:

- i. Lumbar subcostal approach is commonly used. The incision starts at the renal angle between the 12th rib and the lateral border of sacrospinalis and is extended parallel to the 12th rib upto a point downwards and forwards in the anterior abdominal wall 4–5 cm above the anterior superior iliac spine. It can be further extended

- forwards to the lateral border of the rectus muscle or beyond (Fig. 97.1).
- ii. 12th rib approach: This approach provides better access to the kidney. The incision is made in the line of 12th rib which is resected. All muscles of the abdominal wall are divided to expose the kidney.
  - iii. Supracostal approach: The incision is made between the 11th and 12th rib. It is known as Turner-Warwick incision. Both the ribs are retracted. The exposure is quiet good. For the practical purpose, any one of the above three incisions is chosen.

- iv. Nagamatsu incision: This incision is the same as the one used for 12th rib resection but the posterior end of the incision



**Fig. 97.1:** Standard lumbar (Loin) incision for kidney exposure

is extended vertically upwards up to the 10th rib or a little above. Necks of 12th, 11th and 10th ribs are cut. This provides a large anterosuperior flap of skin, muscles and ribs which when retracted gives an extensive exposure especially to tackle the upper pole of kidney.

#### Anterior Approach

The approach is used for large kidney tumors (renal cell carcinoma), for exploration of an injured kidney and the treatment of hydronephrosis.

The incision starts at the tip of the 12th rib and is carried below and more or less parallel to the costal margin across the midline to the opposite costal margin. So, this is a transverse muscle cutting incision.

#### Indications

1. Malignant tumors of kidney, renal pelvis or ureter
2. Rupture of kidney with uncontrollable bleeding
3. Malignant hypertension of renal origin, e.g. renal artery stenosis
4. A nonfunctioning kidney due to hydronephrosis, renal tuberculosis and staghorn calculus
5. Donor's kidney for transplantation. The other kidney should be adequately functioning.

### Steps of Operation for Simple Nephrectomy

1. Anesthesia — General anesthesia with endotracheal intubation.
2. Position of patient — The patient is placed in lateral position as in posterolateral approach described above.
3. Antiseptic dressing and draping.
4. Incision: A standard lumbar subcostal incision is made as described above. Many surgeons prefer the 12th rib approach.
5. Exposure:
  - a. The incision is deepened to cut through the skin, subcutaneous tissue and muscles.
  - b. On the posterior part of the incision, latissimus dorsi, quadratus lumborum and serratus posterior inferior are cut.
  - c. In the anterior part of the incision, external oblique, internal oblique, transversus abdominis and the lumbar fascia are divided in the line of skin incision.
  - d. Care must be exercised to avoid injury to the peritoneum as it lies exposed when the fascia transversalis is divided.
  - e. The peritoneum is separated and pushed aside. The renal fascia is identified and incised by a combination of blunt and sharp dissection. The kidney is freed from perirenal fat and is delivered to the wound.
  - f. Care must be taken to see that the pleura, subcostal nerve and colon are not damaged.
6. Dealing with the renal pedicle:
  - a. The upper ureter is identified, divided between clamps and ligated.
  - b. The renal vessels should be secured separately away from the hilum and the artery should be ligated first. The artery is clamped and doubly ligated with 1/0 silk. The renal vein is similarly dealt with subsequently.
7. Closure:
  - Hemostasis is ensured.
  - Muscles are sutured interruptedly with 1/0 chromic catgut or Vicryl after putting a corrugated rubber or tube drain.
  - The skin is closed with interrupted Ethilon sutures.

Q. What are the coverings of kidney?

1. Renal capsule or True capsule
2. Perinephric fat or fatty capsule
3. Renal fascia of Gerota, which keeps the kidney in position. It is a part of fascia transversalis. The anterior layer is continued as fascia transversalis and the posterior layer as fascia iliaca. Above it encloses the suprarenal gland. (See Fig. 46.2B)

### OPEN SURGERY FOR RENAL CALCULI

- Renal stones with diameter less than 5 mm usually pass spontaneously down the ureter and do not require any intervention.
- Larger stones can nowadays be treated with minimally invasive procedures like ESWL and percutaneous nephrolithotomy (PCNL).
- Open surgery is indicated, when minimally invasive procedures are not available or not successful. The open procedures are:
  1. Pyelolithotomy — This procedure is done in case of extrarenal pelvis.
  2. Nephrolithotomy — Here the pelvis is intrarenal and the stone is taken out through the kidney parenchyma.

### Pyelolithotomy — Procedure

- i. A loin approach is made to expose the kidney as above.
- ii. The renal pelvis is cleared of fat and opened posteriorly by making a longitudinal or transverse incision between stay sutures.
- iii. The stones are removed with stone forceps, e.g. Desjardins forceps. In case of intrarenal pelvis, retraction of kidney substance will allow incision on the renal pelvis.
- iv. Closure:
  - The rent in the renal pelvis is closed with 3/0 catgut or Vicryl sutures.
  - A corrugated rubber or tube drain is inserted in the retroperitoneal area.
  - The wound is closed in layers.

### Extended Pyelolithotomy

- This is done for removal of staghorn calculus (GIL – Vernet 1983).
- The kidney is fully mobilized and Gerota's fascia is opened to remove the perinephric fat.

- The renal pelvis is opened transversely and the incision can be extended into the necks of the calices in case of staghorn stone.
- The stone is removed with the help of stone holding forceps.

### Nephrolithotomy

- i. This implies the removal of a stone entirely through the renal parenchyma without opening the pelvis.
  - ii. Procedure:
    - a. The extraperitoneal approach is made to expose the kidney.
    - b. A nephrotomy is made through the Brödel's line which is 5 cm behind and parallel to the convex border of kidney.
    - c. After removal of stones, the open calices are closed with 3/0 catgut stitches.
  - iii. Nephrectomy — This is indicated when renal function has been grossly damaged by the stone and the opposite kidney is normally functioning.
- Q. Postoperative complications?
- DVT (Deep Veins Thrombosis)
  - Hemorrhage
  - Sepsis.

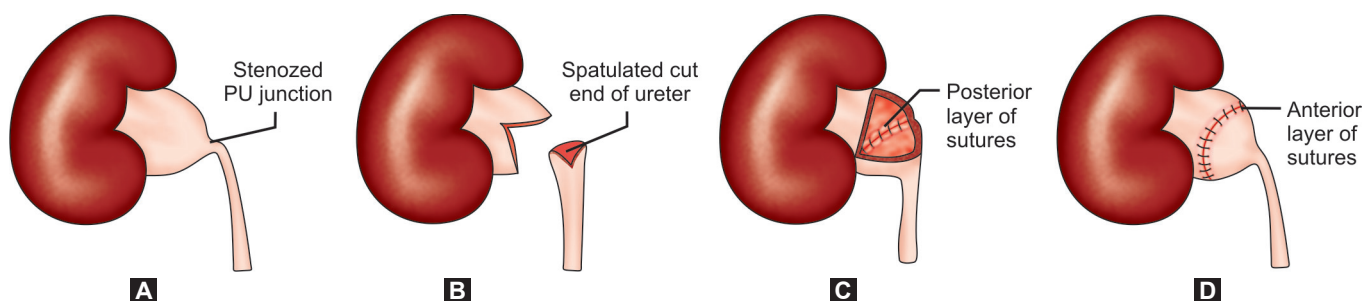
### ANDERSON-HYNES PYELOPLASTY

#### Indications

This operation is done in case of idiopathic pelviureteral junction (PUJ) obstruction with hydronephrosis and at least 15 percent function on DTPA scan.

### Steps of Operation (Figs 97.2A to D)

1. The kidney is exposed through a loin approach as described above in the operation of simple nephrectomy.
2. The pelvis is cleared of fat by gentle gauge dissection.
3. The ureter is mobilized in its upper third.
4. The redundant renal pelvis and the upper end of ureter, a short distance below the stenosed pelviureteral junction are excised (Fig. 97.2A).
5. The cut end of the ureter is spatulated on its posterior aspect for about 2.5cm (Fig. 97.2B).



**Figs 97.2A to D:** Anderson-Hynes pyeloplasty (A) Excision of PU junction; (B) Spatulation; (C) Anastomosis of posterior layer; (D) Anastomosis of anterior layer

- The spatulated ureter is anastomosed to the pelvis using 3/0 polyglactin (Vicryl) sutures (Figs 97.2C and D).
- The anastomosis is stented either by a double J Stent or by a nephrostomy.
- Closure: A 15 FR suction drain is inserted and wound closure is done in layers.

### OPERATION FOR URETERIC STONES — URETEROLITHOTOMY

#### Indications

- When the stone is impacted and produces repeated ureteric colic.
- When there is repeated hematuria.
- In presence of repeated infections.
- When there is evidence of back pressure e.g. hydronephrosis and hydroureter.
- When repeated X-rays (3 times), show that the size of the stone is increasing and the stone remains static in its position without going down.

#### Preoperative Preparation

- A plain X-ray of KUB region immediately before operation to confirm the position of the stone.
- Urine for culture and sensitivity.
- Systemic antibiotic particularly in the presence of infection.

#### Steps of Operation

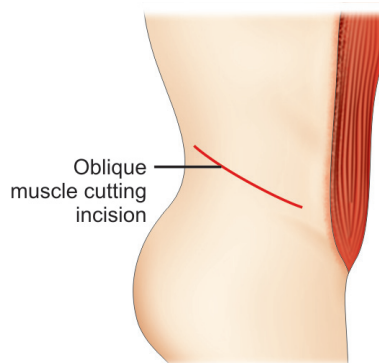
- Stone in the upper third of ureter:
  - Patient position — The patient is placed in the kidney position.
  - General anesthesia with endotracheal intubation.
  - Antiseptic dressing and draping.
  - Kidney is exposed by standard loin incision.

- The upper ureter is gently exposed by sharp and blunt dissection taking care not to dislodge the stone.
- Extraction of stone — After the stone is identified, two stay sutures are applied. Ureterotomy is made directly over the stone which is extracted with stone holding forceps. The incision in the ureter is closed with a few interrupted 4/0 chromic catgut or polyglactin stitches.
- Closure: A tube drain is inserted and the wound is closed in layers.

- Stone in the middle third of ureter:

#### Steps of operation

- Position of patient — Semirecumbent with a sandbag behind the buttock.
- Anesthesia — GA with endotracheal intubation.
- Antiseptic dressing and draping.
- Incision — An oblique muscle cutting incision is made one inch above and parallel to the iliac crest from the level of midaxillary line to the lateral border of rectus (Fig. 97.3).
- The incision is deepened to cut through the skin, subcutaneous tissue and the three oblique muscles of the anterior



**Fig. 97.3:** Incision for ureterolithotomy in the middle third of ureter

- abdominal wall. The peritoneum is pushed medially by gauge dissection.
- Identification of ureter:
  - It is a tubular structure vertically disposed from above downwards.
  - Peristaltic movements can be seen by stimulating the structure with a dissecting forceps.
  - It crosses the bifurcation of common iliac vessels.
  - It is accompanied by genitofemoral nerve.
- The stone is palpated and steadied or fixed with the help of two slings round the ureter — One proximal and the other distal to the stone. A vertical incision is made over the stone which is then extracted with the stone holding forceps.
- Closure: The ureterotomy is usually closed with 3/0 or 4/0 chromic catgut or Vicryl sutures. The wound is closed in layers with a tube drain in the retroperitoneal area.

- Stone in the lower third of ureter.

#### Steps of operation:

- Position of patient — Supine.
- Anesthesia — General anesthesia with endotracheal intubation.
- Antiseptic dressing and draping.
- Incision — A subumbilical midline or a Pfannenstiel incision is commonly employed.
- The incision is deepened to cut through skin, subcutaneous tissue and the rectus sheath. The rectus muscle is now retracted laterally.
- Exposure:
  - The peritoneum is gently raised from the bladder and side wall of pelvis until bifurcation of common iliac vessel is seen.



- b. The ureter is identified and stone is palpated.
  - c. Subsequent steps are identical to those described for stone in the middle third of ureter.
  - d. In case of a stone impacted in the intramural part of ureter, a transvesical approach is used. The bladder is opened in the midline, a meatotomy on the affected side done and stone is extracted with forceps.
7. Closure— The abdomen is closed in layers with a drain in the field of operation.

8. Bladder is recognized by the presence of distended veins and the surface muscles. Aspiration from bladder is done to confirm the organ.
9. Bladder is grasped by two stay sutures and opened by a small stab between the stay sutures.
10. A self retaining catheter is introduced (Malecot or Foley) into the bladder and the bladder is closed tightly around the catheter with chromic catgut (Fig. 97.4D).
11. The catheter is brought through a stab wound above the incision.
12. A corrugated rubber drain is placed in the space of Retzius and the wound is closed in layers.

4. Then the suprapubic catheter with the needle trocar is introduced in the midline two fingers breadth above the pubis.
5. Before introducing the catheter into the bladder urine is aspirated from the bladder with a fine needle.
6. The catheter enters the bladder with a 'give' and urine flows freely on withdrawing the trocar.
7. The balloon on the catheter is inflated and the catheter is sutured to the skin and connected with an urobag.

### SUPRAPUBIC CYSTOSTOMY

It is the drainage of urinary bladder by the suprapubic route.

#### Indications

1. To relieve acute retention of urine in:
  - a. Benign enlargement of prostate in elderly patients.
  - b. When urethral catheterization has failed, e.g. urethral stricture, bladder neck obstruction, etc.
2. In the treatment of rupture urethra and bladder.
3. To provide additional drainage for the bladder.
  - a. After repair of a vesical fistula.
  - b. For excessive bleeding after prostatectomy.
4. Neurologic bladder in paraplegia where continuous catheterization produced acute urethritis.

#### Steps of Operation (Fig. 97.4)

1. Position of patient — Supine.
2. General anesthesia or local anesthesia.
3. Bladder must be distended before operation otherwise there will be peritoneal injury and contamination with urine.
4. Antiseptic dressing and draping.
5. Incision — A transverse suprapubic incision is made 2 fingers breadth above the pubis. The incision is deepened to cut through the skin and subcutaneous tissue (Fig. 97.4A).
6. The rectus sheath is cleaned and incised transversely and is separated upwards and downwards from the underlying rectus abdominis muscles (Fig. 97.4B).
7. The rectus abdominis muscles are separated in the midline to expose the bladder (Fig. 97.4C).

#### Suprapubic Trocar Catheter

##### Procedure

1. Presently suprapubic cystostomy set containing suprapubic catheter with needle trocar is available which has simplified the procedure.
2. With the patient supine the suprapubic area is cleaned and draped.
3. The skin and tissues down the bladder is infiltrated with one percent lignocaine.

### PROSTATECTOMY

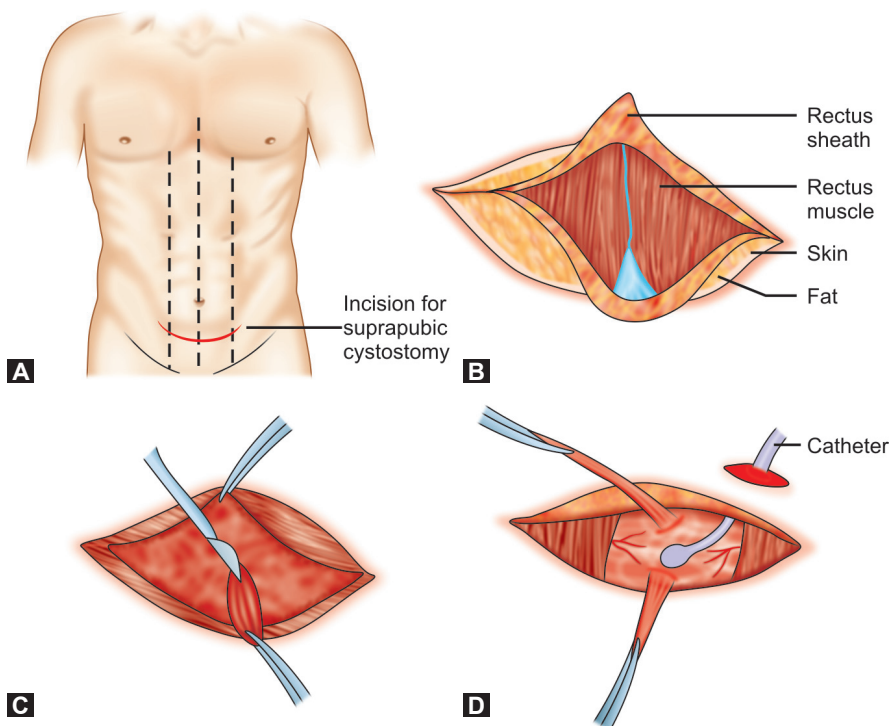
Surgical anatomy and physiology — See the chapter 50 on 'prostate' in urology section.

- Q. What are the methods of prostatic resection?  
See benign enlargement of prostate in the chapter 50 on 'prostate'.

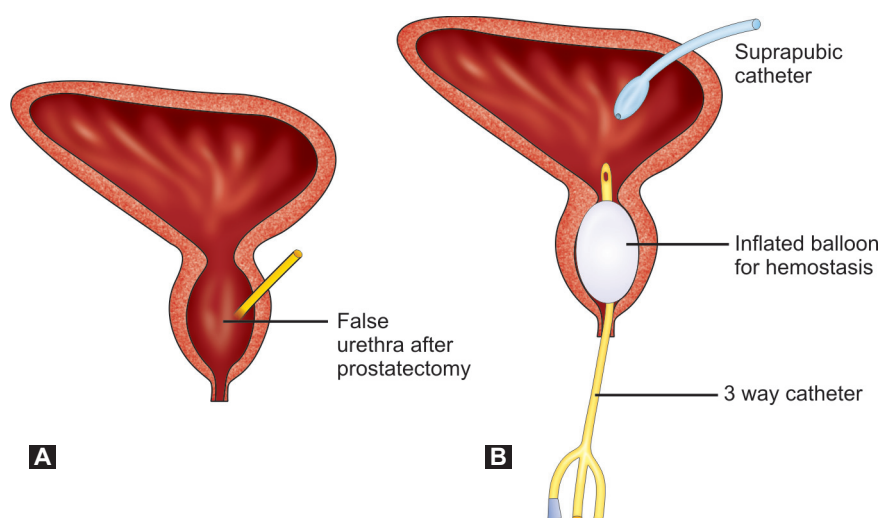
#### Freyer's Transvesical Suprapubic Prostatectomy

##### Steps of Operation (Fig. 97.5)

1. Position of patient— Slight Trendelenburg position.



**Figs 97.4A to D:** Suprapubic cystostomy (A) Incision for suprapubic cystostomy (B) The rectus sheath is reflected upwards and downwards (C) The rectus abdominis muscles are separated in the midline (D) Insertion of suprapubic catheter in between two stay sutures



**Figs 97.5A and B:** Transvesical prostatectomy

- Anesthesia— General anesthesia with endotracheal intubation.
- Antiseptic dressing and draping.
- A catheter is passed and the bladder is filled with sterile water.
- Incision— A Pfannenstiel incision is made. The rectus sheath is divided in the same line and the rectus muscles are separated in the midline to expose the bladder.
- The urinary bladder is opened between two stay sutures.
- Enucleation of prostate:
  - The index finger is forced into the interval urethral opening and by exerting pressure anterior, wall of urethra is torn.
  - A plane of cleavage between the adenoma and the so called surgical capsule is now found by moving the finger laterally on either side and the lobes are separated.
  - Enucleation of adenoma is completed by dividing the urethra and any mucosal attachment posteriorly. The enucleated tissue is examined for two lateral and the middle lobes.
  - After enucleation, the posterior lip of the bladder neck is grasped with volsellum forceps and excised with diathermy (Fig. 97.5A).
- Hemostasis is secured with posterolateral stitches at 5 and 7 o' clock position.
- A three way catheter is introduced per urethra and the balloon is inflated and kept in the prostatic cavity (Fig. 97.5B).
- The bladder is closed in two layers around a Malecot catheter.
- Continuous irrigation is started to prevent clot formation.
- The wound is closed in layers after putting a corrugated rubber drain in the space of Retzius. Postoperatively, suprapubic catheter is removed by about 3rd day when the irrigating fluid is clear. Per urethral catheter is removed by about 7th day.

### CIRCUMCISION

The word circumcise means to cut around. In circumcision, the foreskin is removed by

cutting around its base, where its inner layer is attached to the margin of the glans penis at the coronal sulcus.

### Indications

- Phimosis — A pathological constriction of the foreskin preventing its drawing back over the glans. The operation is done usually after two years.
- Paraphimosis — The retracted foreskin can not be brought forward again.
- Recurrent balanitis — Recurrent infection under the foreskin.
- Squamous cell carcinoma of the foreskin.

### Contraindications

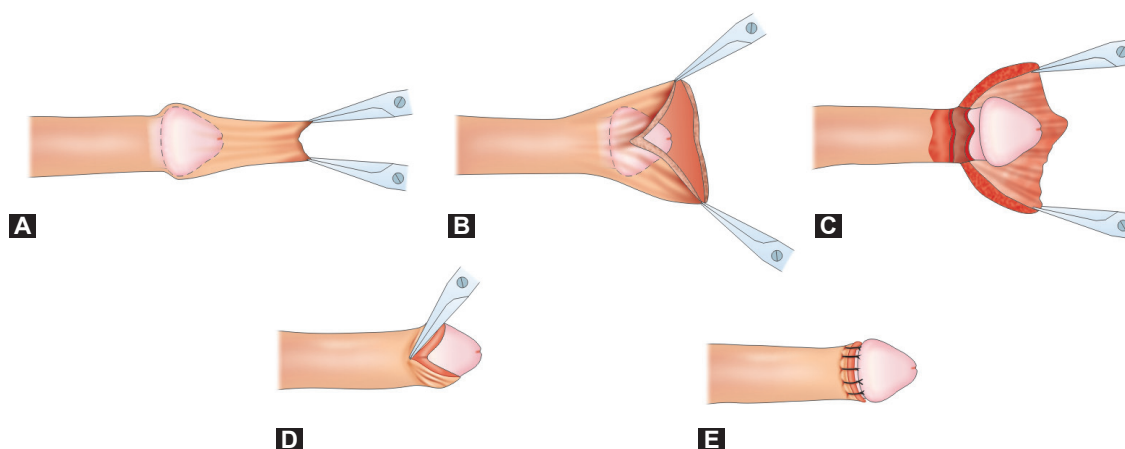
- A bleeding diathesis.
- Hypospadias, in which the hooded foreskin may be needed for repair.

### Steps of Operation (Fig. 97.6)

- Position of patient — Supine.
- Anesthesia — Usually general anesthesia. Local anesthesia has also been used.
- Antiseptic dressing.
- Draping.
- The foreskin is pulled down and two straight artery forceps are applied side by side on the dorsal surface of the foreskin. The adhesion between the prepuce and the glans penis is separated with a probe or mosquito forceps (Fig. 97.6A).
- The foreskin is then divided between these two forceps upto about 4 mm away from the corona. From the apex of this incision, the foreskin is incised laterally and circumferentially towards the frenum (Figs 97.6B and C).
- The frenum is held with the artery forceps and the foreskin is excised (Fig. 97.6D). The frenum is transfixed using 3/0 chromic catgut (Fig. 97.6E).
- Hemostasis is secured by suturing the two layers of skin with 3/0 catgut.
- Dressing— A strip of gauze with anesthesia jelly or a sofratulle is wrapped loosely around. Sometimes dressing is avoided.

### Postoperative Complications

- Bleeding and hematoma formation. Thus meticulous hemostasis is essential.
- Sepsis.
- Acute retention of urine.
- Meatal stenosis.



**Figs 97.6A to E:** Circumcision (A) Pulling the foreskin (B) Cutting the foreskin (C) Cutting the foreskin laterally (D) Artery forceps across the frenulum (E) Sutures across cut edges of foreskin

## MEATOTOMY AND MEATOPLASTY

### Indications

- Pinhole meatus, causing obstruction to the outflow of urine.
- Stricture of the external urethral meatus.

### Steps of Operation

#### Meatotomy (Fig. 97.7)

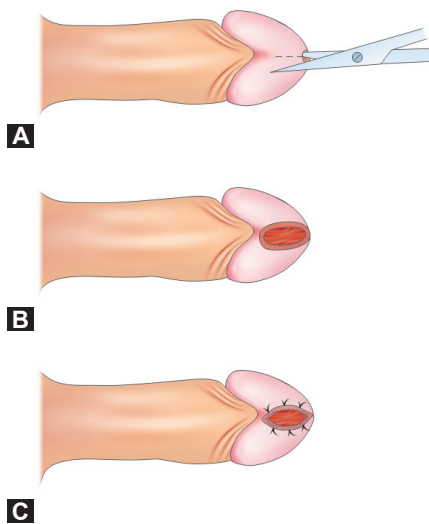
1. Position of patient — Supine.
2. Anesthesia — General or spinal anesthesia.
3. The tightened meatus is widened by cutting down external meatus by introducing a blade of pointed scissors (Figs 97.7A and B).

The cut edge of urethral mucosa and skin are then stitched together with fine absorbable sutures (Fig. 97.7C).

#### Meatoplasty (Fig. 97.8)

1. Position of patient and anesthesia are same as above.
2. A stay suture is inserted through the tip of the glans to invert the penis.
3. An inverted U incision is placed on the ventral surface of penis following the coronal sulcus (Fig. 97.8A).
4. The incision is deepened to expose the underlying corpora and the flap is reflected proximally in this plane beyond its base (Fig. 97.8B).
5. A wide meatotomy is done over a fine probe or bougie (Fig. 97.8C).

6. The apex of the flap is stitched into the proximal end of the incision in the urethra with fine absorbable sutures (Fig. 97.8D).
7. Then one edge of the flap is stitched to the cut edge of the urethra on the same side, bringing the edge of the flap progressively towards the tip of the penis until the apex of the incision in the glans penis is reached. A further stitch closes the lateral defect (Fig. 97.8E).
8. The same procedure is repeated on the opposite side (Fig. 97.8F).



**Figs 97.7A to C:** Meatotomy (A) Cutting the tightened meatus (B) Widened meatus after cutting (C) Cut edge of mucosa and skin stitched together

## AMPUTATION OF PENIS

### Partial Amputation of Penis

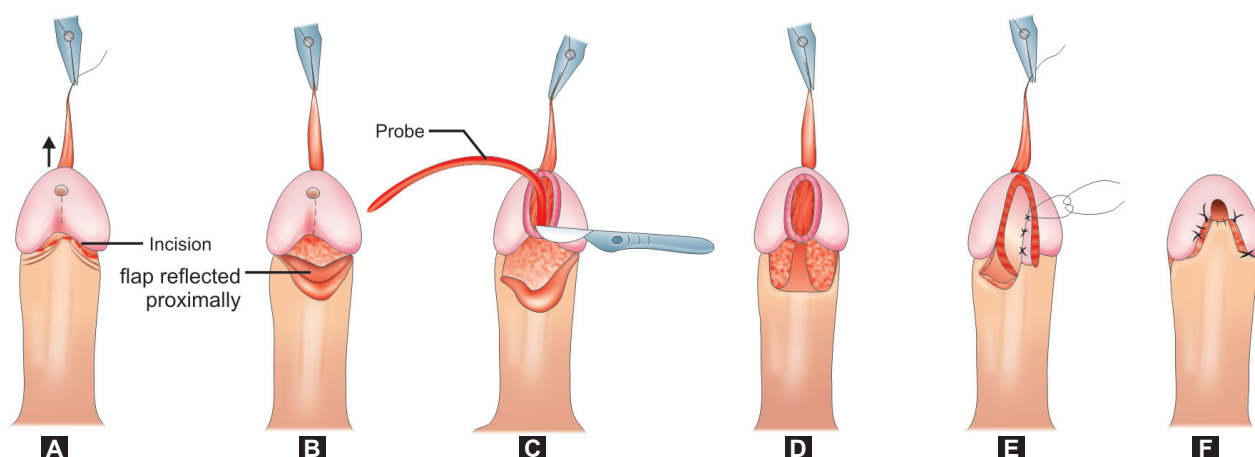
#### Indication

Carcinoma of penis when:

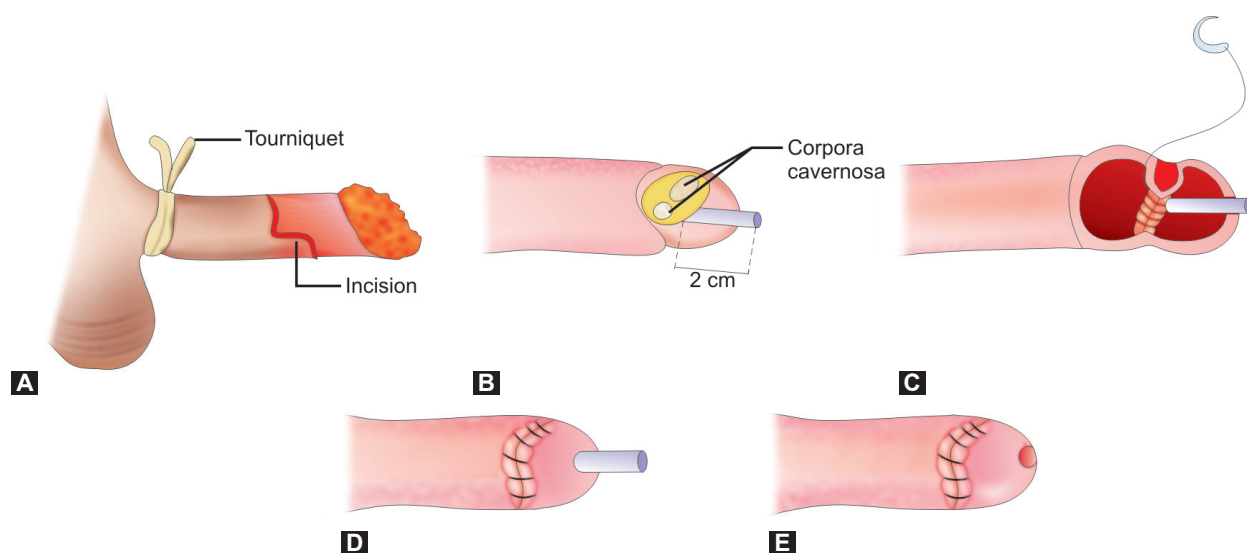
- i. Growth is confined to the glans.
- ii. The patient develops recurrence after radiotherapy.

#### Steps of Operation (Fig. 97.9)

1. Position of patient — Supine.
2. Anesthesia — General or spinal anesthesia.
3. A tourniquet or fine catheter as tourniquet is applied to the base of the penis and the site of amputation is marked 3 cm proximal to the growth (Fig. 97.9A).
4. Incision: An incision is made over the previously marked site to produce a 2 to 3 cm. long U-shaped ventral flap and a short dorsal flap (Fig. 97.9A).
5. The incision is deepened to cut through the subcutaneous tissue upto the fascial sheath covering the corpora cavernosa and corpus spongiosum. The superficial vessels particularly the dorsal veins are ligated with 3/0 catgut.
6. The two corpora cavernosa are now divided at the level of the base of the flaps. The deep vessels in the two corpora are identified and ligated. The corpus spongiosum containing urethra is dissected free and divided half an inch distal to the line of section of corpora cavernosa (Figs 97.9B and C).
7. Fashioning the urethra:



**Figs 97.8A to F:** Meatoplasty (A) Meatoplasty incision (B) The flap is reflected proximally (C) Division of urethra longitudinally over a probe (D) Apex of the flap stitched to proximal end of urethral incision (E) The edge of the flap is brought forwards till the apex of the incision in the glans penis is reached (F) Final appearance



**Figs 97.9A to E:** Partial amputation of penis (A) Incision (B) The corpus spongiosum is divided distal to corpora cavernosa (C) The corpora cavernosa is closed transversely (D) The ventral flap is closed over the dorsum of penis (E) The final appearance after fashioning of urethra

- a. A small opening is made in the ventral flap and the corpus spongiosum is brought out through the opening. The two flaps are now stitched together at the dorsum of the penis (Fig. 97.9D).
- b. The emerging urethra is split transversely and stitched to the skin (mucosa to skin) with fine catgut (Fig. 97.9E).
- c. A Foley's catheter is introduced and left *in situ* for 48 hours.

### Total Amputation of Penis

This is a mutilating operation indicated for carcinoma of penis involving the body of the penis (stage II).

#### Steps of Operation

1. Position of patient — Lithotomy Trendelenburg position.
2. Anesthesia—General anesthesia with endotracheal intubation or spinal anesthesia.

3. Antiseptic dressing and draping. A metal bougie is passed per urethra after draping.
4. Incision—A Racket-shaped incision is made encircling the base of penis and is extended vertically downwards in the midline of the scrotum to the perineum upto a point 1" in front of the anus.
5. Exposure:
  - a. The scrotum is split into two halves by dissecting in the midline.



- b. The penis is now mobilized anteriorly by dividing the suspensory ligament. The dorsal vessels are secured by ligature.
  - c. The perineal part of the incision is deepened and its margins are retracted to expose the bulb of penis and the two crura.
  - d. The bulb is separated from the anterior part of the perineal membrane and the crura are detached from the ischiopubic rami with raspatory. Both the testes are removed. Some surgeons however retain them for normal hormonal production.
  - e. The bougie is now withdrawn and the bulb of the urethra is divided 5cm distal to the perineal membrane after dissecting it from the muscular tissues at the bulb.
6. Closure:
- a. The wound is closed after suturing the two flaps in the midline. The posterior part of incision is closed round the stump of the urethra. A small drain is left in the anterior part.
  - b. The urethral stump is split into two halves which are sutured to the skin as in case of partial amputation described above.
  - c. A self-retaining Foley's catheter is introduced and left several days.
- Q. How do you manage the inguinal lymph nodes?  
See carcinoma penis in the chapter 49 on 'urethra and penis'.

## ORCHIDOPEXY

Orchidopexy consists of mobilization of testis and spermatic cord and retaining the testis in the scrotum.

### Indication

#### *Undescended or Ectopic Testis*

This operation is done to avoid complications like malignant change (about 10%), sterility in bilateral cases, trauma and infection.

Age of operation – should be done before 2 years.

The classical description of orchidopexy was given by Bevan in 1899.

### Steps of Operation

1. Position of patient — Supine.
2. Anesthesia — General anesthesia with endotracheal intubation.

3. Antiseptic dressing and draping.
4. Incision — A skin crease incision is made 1cm above and parallel to the medial two-thirds of the inguinal ligament (Fig. 97.10A).
5. The incision is deepened to cut the subcutaneous tissue with care because the ectopic testis may lie in the superficial inguinal pouch deep to the Scarpa's fascia. If the testis is in the inguinal canal, it is exposed after opening the canal by incising the external oblique aponeurosis (Fig. 97.10B).
6. Mobilization of testis and cord: This is the most important step.
  - a. First, the gubernaculum is clamped, divided and ligated at the lower pole of testis.
  - b. Cremasteric fascia is cleared from the spermatic cord by blunt gauge dissection (Fig. 97.10C).
  - c. Herniotomy: At the anterolateral aspect of the cord, thin-walled hernial sac is identified (Fig. 97.10D). It is freed from the cord upto the deep ring, twisted and transfixed at the neck with 3/0 chromic catgut. The excess sac is excised (Fig. 97.10E).
  - d. Mobilization of vas deferens and the vessels: This is accomplished by division of relatively avascular fibrous bands around the spermatic cord. The testis should now reach as far as the scrotum or beyond without tension.
7. Fixation of testis in the dartos pouch (Fig. 97.10F):
  - a. A finger is pushed through the inguinal wound to breakdown the fascia occluding the neck of the scrotum and to stretch the corrugated skin of the scrotum.
  - b. With the finger still in place, the skin over the lower part of scrotum is incised and a pouch made between the skin and dartos fascia.
  - c. An artery forceps is then pushed through the dartos fascia upto the inguinal wound, where the testis is grasped. By withdrawing the forceps, the testis is pulled down through the dartos fascia into the pouch.
  - d. Fixation of testis – The testis can be anchored to midline tissue of scrotum by 3/0 catgut suture through tunica albuginea.

8. Closure:

- The scrotal skin is closed over the testis with absorbable interrupted sutures.
- The inguinal wound is closed in layers.
- Orchidopexy is performed on the other side if the condition is bilateral.

See also the short case undescended testis' and the chapter 51 on "testis and scrotum".

## ORCHIDECTOMY

### Simple Orchidectomy

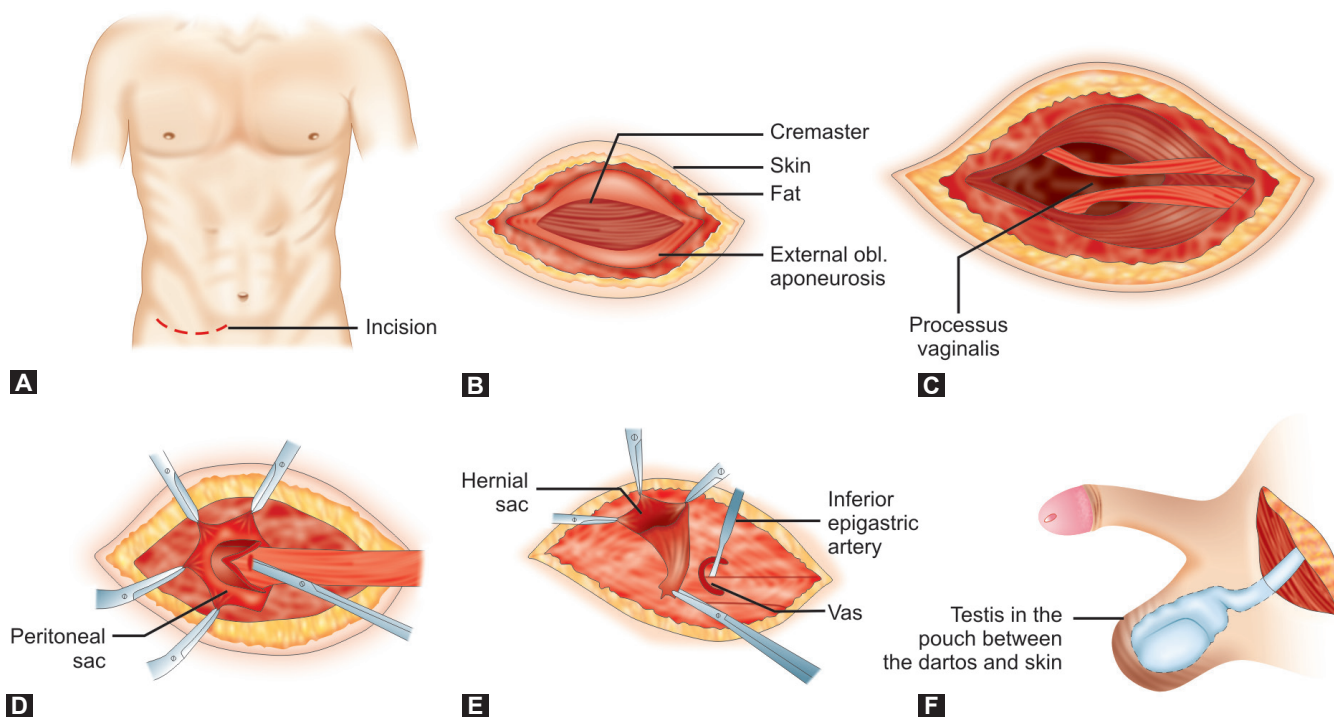
#### *Indications*

1. Severe testicular trauma when testis is not salvagable.
2. Neglected testicular torsion with nonviable testis.
3. Unilateral undescended or ectopic testis after puberty. If the condition is bilateral, orchidopexy should still be attempted.
4. During repair of large indirect or direct hernia in elderly men, the testis is often removed and inguinal canal obliterated. Operation is performed depending on the clinical diagnosis and ultrasonographic evidence.

#### *Steps of Operation (Fig. 97.10)*

1. Position of patient — Supine.
2. Anesthesia — General anesthesia with endotracheal intubation or spinal anesthesia.
3. Antiseptic dressing or draping.
4. Incision — A vertical scrotal incision is made on the scrotal skin of the affected side.
5. Exposure:
  - a. The incision is deepened to cut through dartos and other layers of scrotum with diathermy. The testis is delivered to the wound after incising tunica vaginalis.
  - b. Gentle traction is applied to the testicle and about 4 to 6 cm of the spermatic cord is dissected free.
  - c. The vas deferens and the testicular vessels are clamped, ligated and divided as high as possible separately. If mass ligature is planned, transfixation suture should be applied. The testis is now removed.





**Figs 97.10A to F:** Orchidopexy (A) Orchidopexy incision (B) The external oblique aponeurosis is divided revealing the internal oblique and cremaster (C) The cremaster is split in the direction of its fibers to show the sac of the processions vaginalis on the anterior aspect of the cord (D) The sac is opened and dissected off the cord which it invests closely (E) Lifting the sac off the cord (F) The testis is placed in the Dartos pouch

6. Closure—The dartos is closed with 2/0 chromic catgut sutures.

The skin is approximated with 2/0 non-absorbable Ethilon (Black monofilament polyamide) sutures.

### Radical Orchidectomy (Fig. 97.11)

#### Indication

This operation is performed in case of malignant tumors of testis through an inguinal approach as scrotal surgery may cause scrotal recurrence or spread of tumor to inguinal lymph nodes. Moreover, following scrotal surgery radiotherapy becomes difficult.

#### Steps of Operation

1. Position of patient and anesthesia are same as in case of simple orchidectomy.
2. Incision—An inguinal incision is made 1cm above and parallel to medial two-

thirds of inguinal ligament, as for an inguinal hernia (Fig. 97.11A).

3. The incision is deepened to cut the subcutaneous tissue until the external oblique aponeurosis is exposed.

The external oblique aponeurosis is divided in the line of skin incision to open the inguinal canal.

4. The spermatic cord is identified and freed by blunt dissection upto the deep inguinal ring and then clamped with a noncrushing clamp, transfixed and doubly ligated at the level of deep ring (Fig. 97.11B).
5. The testis is pulled up from the scrotum and the tumor is confirmed. The testis and the cord are then removed together (Fig. 97.11C).
6. Closure—The external oblique aponeurosis is closed with 2/0 chromic catgut and the skin, with interrupted, nonabsorbable suture. A corrugated rubber drain

is inserted in the most dependent part of scrotum.

### OPERATION OF HYDROCELE

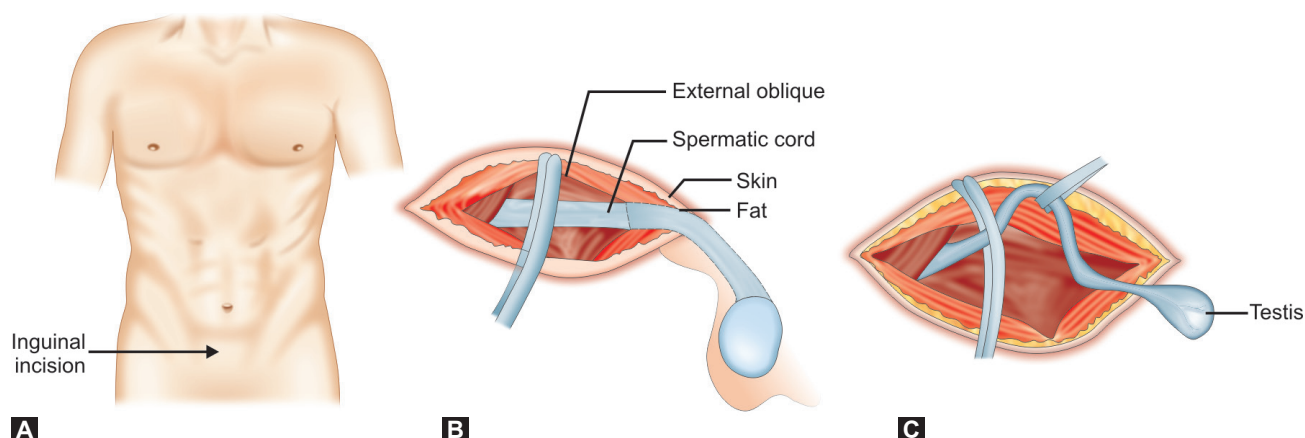
#### Definition

Vaginal hydrocele is an abnormal collection of serous fluid in the tunica vaginalis of the testis.

#### Surgical Anatomy

#### Coverings of Scrotum

1. Skin.
2. Subcutaneous tissue with dartos muscle.
  - Q. Name the subcutaneous muscles of the body. These are:
    - a. Dartos muscle.
    - b. Platysma.
    - c. Palmaris brevis.
    - d. Arrector pili.



**Figs 97.11A to C:** Right sided orchidectomy for testicular tumor (A) Right orchidectomy incision (B) The cord is clamped at internal ring before delivering the testicle (C) The testis is delivered from the scrotum

3. External spermatic fascia — Prolongation of external oblique aponeurosis.
  4. Cremasteric fascia—Prolongation of internal oblique and transversus abdominis muscle.
  5. Internal spermatic fascia — Prolongation of fascia transversalis.
  6. Parietal layer of tunica vaginalis.  
All the above layers must be incised for eversion of sac.
4. Incision:
    - The scrotum is fixed and kept in tense position by the assistant.
    - A vertical incision is made on the anterior aspect of scrotum away from the median raphe.
  5. The incision is deepened to cut through all the layers of scrotum till the parietal layer of tunica vaginalis is exposed.
  6. Opening and eversion of sac:
    - A small nick is made on the tunica vaginalis and the fluid is let out.
    - The nick is extended to make a bigger opening.
    - The tunica vaginalis is everted around the testis. The everted margins are stitched behind the cord and epididymis.
    - Hemostasis is secured.
  7. Testis is placed in the scrotal cavity so that the sinus of epididymis looks laterally.
  8. The wound is closed with interrupted, nonabsorbable stitches.
  9. Same steps are done on the opposite side in case of bilateral hydrocele.
- Q. Do you put a drain?  
Yes, a drain is inserted in a big hydrocele.
- Q. When will you excise the scrotal skin?  
Scrotal skin is excised partly in a big hydrocele.
- Q. What are the postoperative complications?
- a. Wound infection.
  - b. Hematoma.
  - c. Edema of penis which subsides naturally.

### Tunica Vaginalis

It is a part of processus vaginalis. It has a parietal and visceral layer. It secretes a serous fluid from the endothelial surface when the collection is significant, it will manifest as hydrocele.

The purpose of eversion of sac of tunica vaginalis is to keep the endothelial surface out and in contact with the layers of scrotum, so that the endothelial surface becomes rough and cannot secrete any further.

### Steps of Operation

1. Position of patient — Supine.
2. Anesthesia — General anesthesia with endotracheal intubation. Spinal anesthesia or local anesthesia may be used.
3. Antiseptic dressing and draping. Antiseptic dressing is applied from the level of umbilicus to midhigh including the perineum with Betadine lotion.

## OPERATION OF VARICOCELE (VARICOCELECTOMY)

### Surgical Anatomy

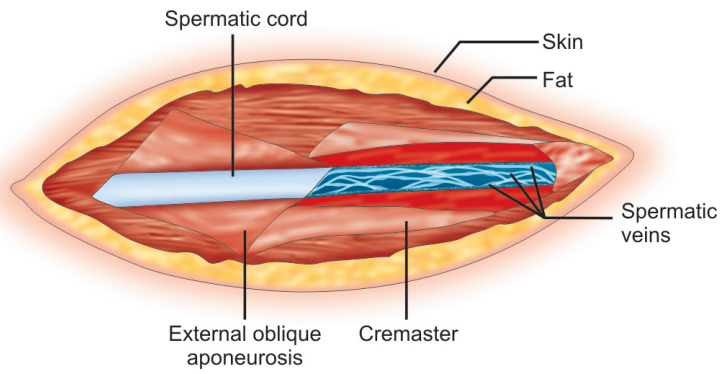
See varicocele in the chapter 51 on 'testis and scrotum'.

### Indication

Symptomatic varicocele.

### Steps of Operation

1. Position of patient — Supine.
2. Anesthesia — General or spinal anesthesia.
3. Incision—The classical operation of varicocele is carried out through an inguinal approach. An oblique inguinal incision is made half inch above and parallel to the medial half of inguinal ligament.
4. Procedure:
  - a. The inguinal canal is opened and spermatic cord delivered.
  - b. The coverings of the cord are incised and the vas deferens, the arteries and the veins (two to three) are separated from the main mass of dilated vessels (Fig. 97.12).
  - c. All the dilated tortuous spermatic veins, thus separated, are freed for a short distance upwards and downwards and excised between ligatures placed some 5 cm apart.



**Fig. 97.12:** Varicocelelectomy after exposure of inguinal canal

- d. Approximation of these ligatures shortens the cord and the testis remains suspended at a higher level.
5. Closure:
  - Hemostasis is secured.
  - External oblique aponeurosis is closed with continuous 1/0 chromic catgut sutures.
  - Skin is closed with interrupted, non-absorbable stitches.
- Q. What are the postoperative complications?
  - a. Hemorrhage.
  - b. Sepsis.

## Vascular Surgery

- Lumbar sympathectomy
- Operations for varicose vein
- Trendelenburg's operation
- and stripping of long saphenous vein
- Ligation of calf perforators
- Saphenopopliteal ligation and stripping
- Multiple phlebectomies
- New alternative treatments

### LUMBAR SYMPATHECTOMY

Lumbar sympathectomy should better be called lumbar ganglionectomy. In this operation, the second, third and fourth lumbar sympathetic ganglia with intervening trunk are removed. If bilateral sympathectomy is planned, the first ganglion of at least one side is preserved to prevent sterility due to paralysis of the ejaculatory mechanism.

#### Indications

1. Buerger's disease affecting the lower limb. Sympathectomy has no role in the treatment of intermittent claudication as muscle

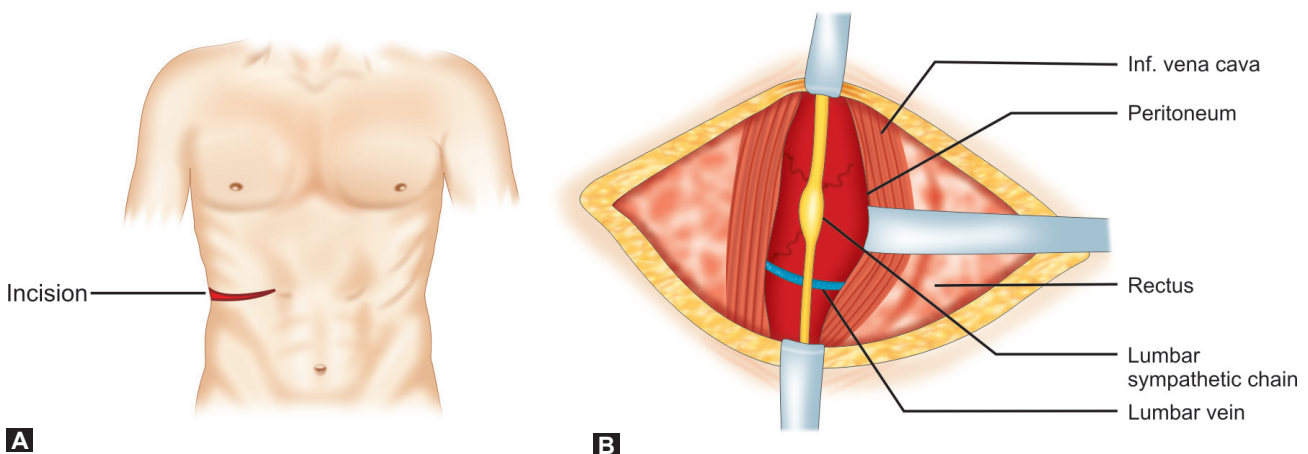
ischemia persists. It only prevents ischemic changes through vasodilatation of arteries of the skin. Patients with rest pain, pregangrene or dry gangrene may show transient improvement with sympathectomy.

2. Hyperhidrosis of the lower limb.
3. Causalgia of lower limb.

#### Steps of Operation (Figs 98.1A and B)

1. Position of patient—Supine with a sand bag behind the loin on the side of operation to produce a 15 to 20° tilt.
2. Anesthesia—General anesthesia with endotracheal intubation.

3. Antiseptic dressing and draping.
4. Incision—An oblique or transverse incision is made in the loin starting midway between the anterior superior iliac spine and costal margin to lateral border of rectus abdominis (Fig. 98.1A).
5. Exposure:
  - a. The incision is deepened to divide the flat muscles of anterior abdominal wall viz. external oblique, internal oblique and transversus abdominis in the line of skin incision to expose extraperitoneal fat.
  - b. The peritoneum is displaced medially and forwards from the posterior



**Figs 98.1A and B:** Right lumbar sympathectomy (A) Incision for right lumbar sympathectomy (B) Exposure of lumbar sympathetic chain

abdominal wall with ureter and genital vessels with it.

- c. Identification of sympathetic chain—The peritoneum is retraced with a large Deaver retractor. The sympathetic chain is identified as a cord-like structure in the groove between the vertebral bodies and psoas muscle. On the right side this is overlapped by the inferior vena cava and on the left side by the aorta (Fig. 98.1B).
6. Division of the ganglia:
  - a. The sympathetic chain is picked up with a right angled forceps and dissected upwards and downwards.
  - b. The first lumbar ganglion lies behind duodenum and the 4th ganglion behind the common iliac vessels. The second lumbar ganglion is large.
  - c. The L<sub>2</sub>, L<sub>3</sub> and L<sub>4</sub> ganglia with their white and gray rami are excised and removed. The tissue is sent for histological confirmation.
  - d. While dissecting the sympathetic chain some lumbar vessels may need ligation and division.
7. Closure—The abdominal wound is closed in layers— muscles, with no 1/0 polyglactin sutures and skin, with interrupted silk stitches.

### Postoperative Complications

1. Retroperitoneal hematoma.
2. Ileus.
3. Neuralgia in the distribution of genitofemoral nerve.

### OPERATIONS FOR VARICOSE VEIN

The following operations are performed for the treatment of varicose veins:

1. High ligation of saphenofemoral junction. (Trendelenburg's operation) and stripping of long saphenous vein (LSV).
2. Incompetent calf perforators or communicating veins ligation (subfascial ligation).
3. Saphenopopliteal ligation and stripping.
4. Multiple phlebectomies.
5. New alternative treatments—i) Radio frequency closure.  
ii. Endovenous laser therapy ( EVLT ).

### TRENDELENBURG'S OPERATION AND STRIPPING OF LONG SAPHENOUS VEIN

#### Indications

This operation is indicated in patients with varicose veins with evidence of long saphenous reflux at the groin on clinical and Doppler examination.

#### Contraindication

If long saphenous veins are a collateral channel for obstructed deep veins.

#### Preoperative Preparation

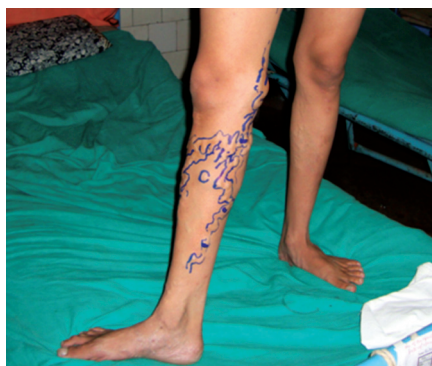All sites of prominent varicosities are marked with a marker (Fig. 98.2). The skin of the groin and leg is shaved before operation.

#### Steps of Operation (Fig. 98.3)

1. Position of patient—Supine with 30° Trendelenburg position and legs slightly abducted.
2. Anesthesia—General or spinal anesthesia.
3. Incision—The incision is made centering the saphenofemoral junction which is 3 to 4 cm below and lateral to the pubic tubercle, 6 to 8 cm in length, in the skin crease below and parallel to the inguinal ligament.
4. Exposure:
  - a. The incision is deepened through the membranaus layer of superficial fascia until the long saphenous vein is encountered.
  - b. The tributaries of long saphenous vein namely superficial epigastric, superficial external pudendal, and superficial

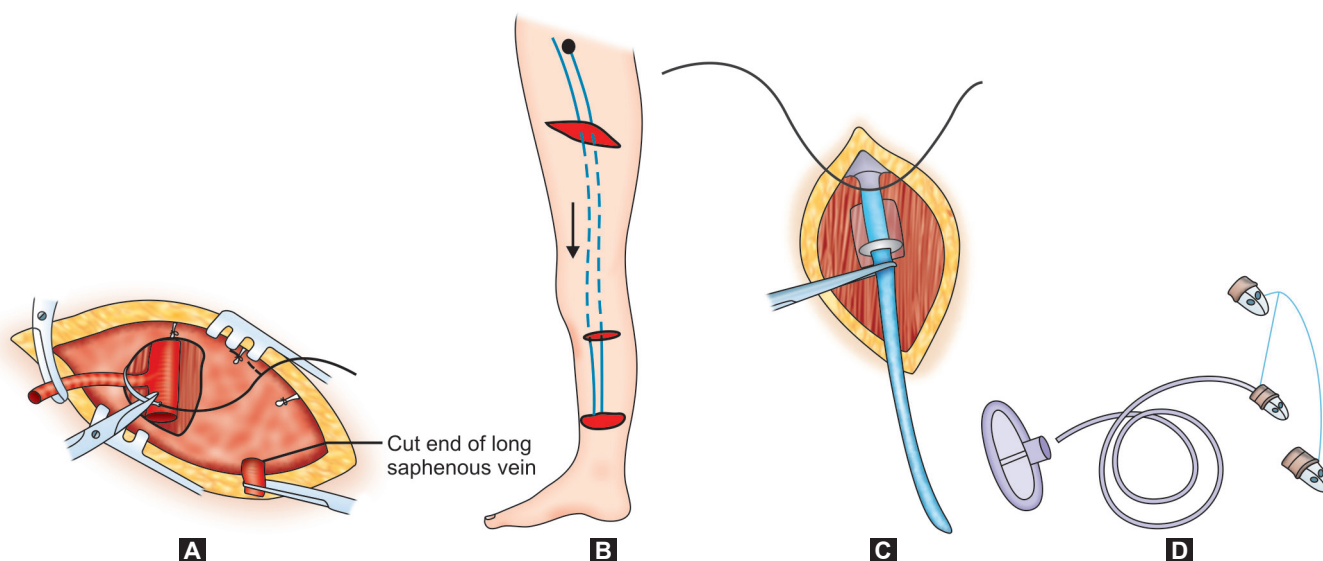
circumflex iliac veins entering the proximal part of long saphenous vein are traced and divided between ligatures.

- c. The long saphenous vein is carefully dissected upto its junction with the femoral vein and the femoral vein is displayed 1cm below and above the junction.
5. High ligation of the long saphenous vein —The long saphenous vein is ligated flush with the saphenofemoral junction with 3/0 polyglactin (Vicryl) (Fig. 98.3A). The saphenous stump is doubly ligated or transected for greater safety. The distal end of vein is clamped with artery forceps.
6. Stripping of long saphenous vein (LSV):
  - a. Most surgeons combine this high ligation with stripping of LSV between the groin and knee because if it is left *in situ*, the chance of recurrent varicose veins is higher.
  - b. A few surgeons preserve the vein if it is of small caliber and the thigh perforators are competent. The decision is based on accurate preoperative assessment including duplex scanning.
  - c. If the stripper is extended much below the knee, the risk of damage to the great saphenous nerve increases significantly.
7. Technique:
  - a. The stripper is inserted through the groin end of the vein and gently manipulated till it reaches below the knee (Fig. 98.3B).
  - b. An oblique incision is made about three fingers breadth below the knee over the tip of the stripper.
  - c. The vein is dissected carefully and a small incision (venotomy) is made on the vein through which the tip of the stripper is delivered and fitted with a T - shaped handle. The vein is clamped distally, divided and ligated (Fig. 98.3C).
  - d. An acorn head of adequate (Fig. 98.3D) size is now applied at the top end of the stripper in the groin which is gently pulled down until it is flush with the upper end of the saphenous vein which is then ligated. The artery forceps is now removed.
  - e. The long saphenous vein is stripped from groin to knee (after ligating it below the knee over the stripper) with steady downward traction over the handle. The process can also be done in a reverse way.



**Fig. 98.2:** Marking the varicose vein with a marker before operation





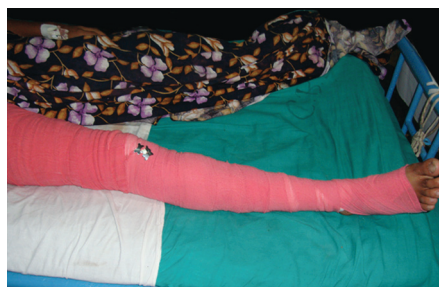**Figs 98.3A to D:** Stripping and ligation of long saphenous vein (A) The long saphenous vein is transfixed flush with the femoral vein (B) The stripper is passed from the groin to the knee (C) long saphenous vein exposed just below knee (D) A plastic disposable stripper with olive or acorn head of different sizes.

8. Closure—The groin wound as well as distal knee wound are closed with interrupted nonabsorbable sutures.
9. Compression bandage—A dressing is applied to the wounds. In addition, an elastic crepe bandage is applied from below upwards to prevent bleeding from the stripper track and subsequent hematoma formation (Fig. 98.4).

### LIGATION OF CALF PERFORATORS (COCKETT AND DODD'S PROCEDURE)

#### Indication

This operation is done for incompetent perforators causing venous ulcers.



**Fig. 98.4:** Crepe bandage is applied after any operation on varicose vein

#### Steps of Operation

1. Position of patient—The patient lies supine with a Trendelenburg tilt of the table. The legs are partially abducted and externally rotated.
2. Anesthesia—General anesthesia with endotracheal intubation or spinal anesthesia.
3. Incision—A long vertical incision is made parallel to the subcutaneous posterior border of tibia 2 cm behind it, in the lower half of the leg.
4. The incision is deepened to divide the deep fascia in the same vertical plane. The flaps are reflected till the perforators can be seen. Passing through the holes in the deep fascia. They are ligated and divided.
5. Closure—The deep fascia is not closed. Only the skin is closed with interrupted stitches.
6. The leg is bandaged with elastic crepe bandage and kept elevated for 48 hours to prevent development of lymphatic edema.

### SAPHENOPOPLITEAL LIGATION AND STRIPPING

#### Indication

Short saphenous vein varicosity with saphenopopliteal incompetence. The saphenopopliteal

junction is identified by a marker before operation.

#### Steps of Operation

1. Position of patient—The patient lies prone on the table with the knee flexed.
2. Anesthesia—General anesthesia with endotracheal intubation or spinal anesthesia.
3. Incision—A transverse incision is made across the lower part of the popliteal fossa at the level of the head of the fibula.
4. Exposure—The incision is deepened through the subcutaneous tissue to expose the short saphenous vein.
5. Flush ligation—The short saphenous vein is ligated and divided at the level where it pierces deep fascia to join the popliteal vein.
6. Stripping –
  - The stripper is introduced into the short saphenous vein in a downward direction and its exit is made by a short incision just below the lateral malleolus.
  - An acorn head is applied at the upper end and handle at lower end.
  - The vein is now stripped in downward direction.
7. Closure—The proximal and distal wounds are closed with interrupted Ethilon sutures.

**MULTIPLE PHLEBECTOMIES****Indication**

Presence of varices away from the saphenous veins.

**Procedure**

- a. A small incision is made over the vein in a marked place.
- b. The vein is grasped with mosquito forceps or special vein hook.

- c. The loop is divided between two forceps and the cut ends are ligated.
- d. The process is repeated in other places already marked.
- e. Closure—Each wound is closed with fine nonabsorbable sutures.

**NEW ALTERNATIVE TREATMENTS**

- Radiofrequency closure: In this method instead of removing great or short saphenous

vein a device is used to obliterate the vein by generating heat through high radiofrequency of a small multipronged catheter, which destroys the endothelium of the vessel. The procedure is effective and has good long-term results but takes longer time than endovenous laser therapy, described below

- Endovascular laser therapy—(EVL) is also an effective means of obliterating the saphenous vein by heat generated from the laser tip that destroys the endothelial lining of the target vein.

# Chapter 99

## Some Minor Surgical Procedures

- Establishing an intravenous line
- Venepuncture
- Venesection
- Insertion of nasogastric tube
- Insertion of intercostal drain
- Lymph node biopsy
- Excision of sebaceous cyst
- Excision of lipoma
- Operation for ingrowing toenail
- Catheterisation
- Urethral dilatation

### ESTABLISHING AN INTRAVENOUS LINE

#### Indication

Intravenous line is established for the administration of fluids, blood and the drugs.

#### Equipments

- An IV cannula of appropriate size (18G or 20G for adults and 22G or 24G for children).
- Alcohol swab.
- A tourniquet.
- Sterile gloves.
- Adhesive tape.

#### Procedure

- Hands are washed with soap water, to wear the sterile gloves (usually the forearm vein).
- Cannulation site is cleaned with the alcohol swab.
- Tourniquet is applied above the elbow.
- The vein to be punctured is steadied with left hand fingers and the cannula is pressed 1cm distal to the site at an angle of 15 to 20°.
- Cannula is advanced into the vein slowly until a flash of blood comes out.
- The needle is withdrawn and cannula is advanced.

- Cannula is fixed to the skin with adhesive tape.

#### Precautions

- Cannula should not be introduced into the vein over a joint.
- Cannula should be introduced into veins of the left upper limb so that the patient can use the right hand.

### VENEPUNCTURE

#### Indication

This is done to obtain blood sample for various tests.

#### Equipments

- Syringe—5ml or 10ml size.
- Tourniquet.
- Sample tubes.
- Alcohol swab.
- Sterile gloves.

#### Procedure

- Hands are washed with soap water and sterile gloves worn.
- Skin over the chosen vein (usually a forearm vein) is cleansed with alcohol swab.
- Tourniquet is applied above the elbow.
- The vein is steadied with fingers of the left hand and the needle is introduced into

the vein and advanced slowly till flash of blood comes into the syringe.

- Required amount of blood is drawn with the tourniquet *in situ*.
- The tourniquet is released and pressure is applied over the puncture site with a cotton swab for 2 to 3 minutes.

#### Precaution

If forearm veins cannot be punctured as in case of a shocked or obese patient, the veins over the dorsum of hand are tried.

### VENESECTION (VENOUS CUT DOWN)

#### Indications

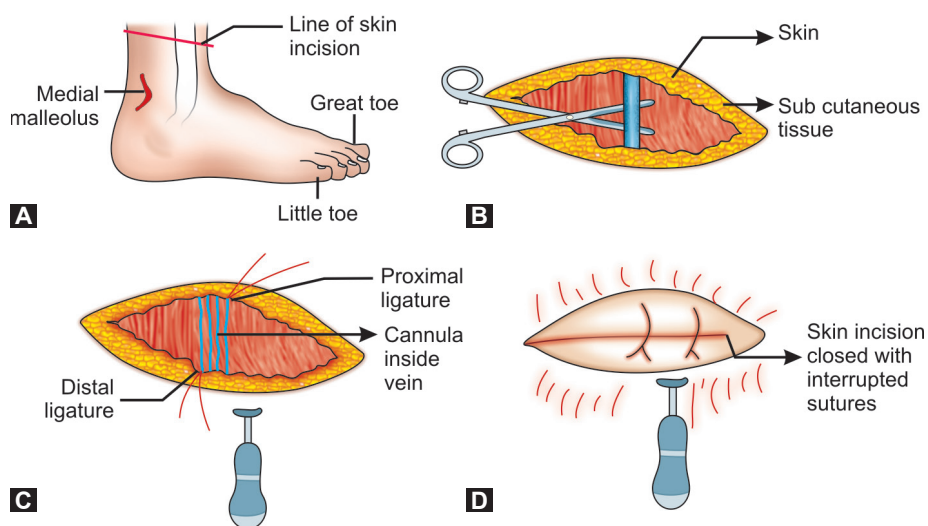
- In a shocked patient due to trauma, burn, etc., when peripheral veins are collapsed and venepuncture is not possible.
- Intravenous fluid therapy for a prolonged period.

#### Sites

- Cephalic vein at forearm.
- Cephalic vein at deltopectoral groove.
- Great saphenous vein at the ankle.

#### Procedure (Fig. 99.1)

- Hands are washed with soap water and rubber gloves worn.



**Figs 99.1A to D:** Steps of venesection—great saphenous vein cannulation

- The area is cleaned with povidone iodine lotion and draped with a towel.
- The area is infiltrated with 1 percent lignocaine.
- A small transverse incision is made across the selected vein. The incision is deepened to cut the subcutaneous tissue and the vein is isolated by blunt dissection (Figs 99.1A and B).
- Two ligatures are passed around the vein. The distal one is tied and held by a hemostatic forceps (Fig. 99.1C).
- A curved needle is passed through the middle of the vein wall and the vein wall in front of the needle is incised.
- No 18 or 16 intracath or venous cannula is passed and the proximal ligature is tied over the cannula.
- The end of the cannula is connected to an IV infusion set.
- The skin incision is closed with interrupted, nonabsorbable sutures (Fig. 99.1D).
- Sterile dressing is applied.

### INSERTION OF NASOGASTRIC (RYLE'S TUBE)

#### Indications

- Intestinal obstruction
- Paralytic ileus.
- Decompression of stomach during upper abdominal surgery.
- For enteral feeding.

#### Equipments

- Nasogastric tube (usually 14F or 16F size).
- Lubricating jelly.
- Sterile gloves.
- Collection bag.
- Stethoscope.
- Adhesive tape.

#### Procedure

The procedure is explained to the patient. There may be some cough during insertion of the tube.

- Position of patient—Lying down position.
  - The Ryle's tube is lubricated with lignocaine jelly.
  - The tube is passed along floor of nasal cavity. When it passes into the pharynx, patient is asked to swallow it. The patient may be asked to take sips of water. During swallowing, the tube will enter into the esophagus.
  - The tube is further advanced till the second ring in the tube lies at the level of nostril when the tip will lie in the stomach.
- Q. How do you confirm the presence of Ryle's tube in the stomach?
- Air is blown through the tube with a 50ml syringe and the epigastrium is auscultated with a stethoscope – audible gurgling sound in the epigastrium will confirm that the tube is in the stomach.
  - If the aspirate is dropped on a blue litmus paper, it will turn red.
- Q. What are the features of Ryle's tube?

- The Ryle's tube is usually one meter long and made of transparent plastic tubing.
- Presence of a number of side holes in the tube near the tip.
- Presence of radiopaque lead shots near the tip of the tube.
- There are three circular markings in the tube viz.
  - First circular marking with a single line is at 40 cm from the tip of Ryle's tube and indicates the gastroesophageal junction.
  - Second circular marking with two lines is at 50 cm from the tip and indicates body of the stomach.
  - Third circular marking with three lines is at 60 cm from the tip and indicates pyloric region of the stomach.

### INSERTION OF INTERCOSTAL DRAIN

#### Indications

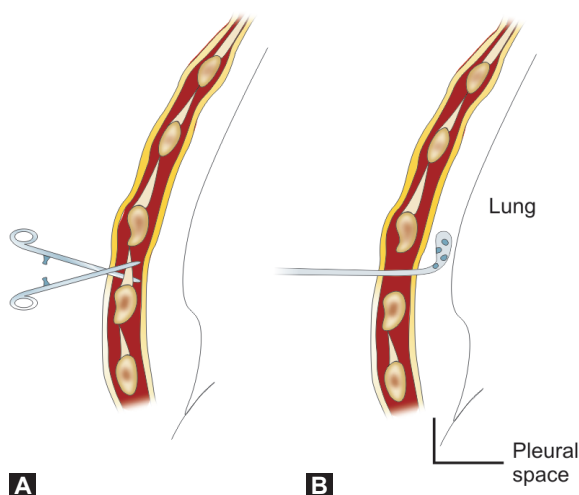
- Traumatic hemothorax and pneumothorax.
- Pyothorax.
- Following thoracotomy.

#### Equipments

- Antiseptic solution—povidone iodine, swabs.
- 20 ml syringe, injection 1 percent lignocaine.
- Artery forceps.
- Chest drainage tube with underwater seal drainage bag containing 20 ml of sterile water.
- Scalpel blade and suture, needle holder, dissecting forceps, scissors.
- Dressing and adhesive tape.

#### Procedure (Fig. 99.2)

- Hands are washed with soap water and sterile gloves put on.
- Position of patient—Supine with the back rest lifted to about 45°, arms, abducted and raised over head to enlarge the intercostal spaces.
- Antiseptic dressing and draping.



**Figs 99.2A and B:** Insertion of intercostals drain (A) Artery forceps inserted to spread the intercostal muscles (B) Chest drain introduced into the pleural space

4. Local anesthesia injection at the site of insertion to skin, subcutaneous tissue down to the pleura.  
*Site of insertion*—A point in the 5th to 7th intercostal spaces between the midaxillary and anterior axillary lines is the most appropriate for chest drain insertion.
  5. *Incision*—A 2 to 3 cm incision is made with a no. 11 knife at the level of upper border of the rib at the selected site. The incision is deepened to cut the subcutaneous tissue.
  6. The intercostal muscles are separated with artery forceps to expose the pleura (Fig. 99.2A).
  7. The pleura is pierced with artery forceps and a finger is introduced to confirm entry into the pleural space with the guiding finger still in place, the chest drain is introduced into the pleural space (Fig. 99.2B).
  8. The drain is connected to water seal drainage bag to ensure the fluid in the tube swings with respiration.
  9. The drain is fixed to the skin by inserting a stitch through the skin but not piercing the drain.
  10. A sterile dressing is applied at the exit of the tube.
- Q. What are the complications of chest drain insertion?
- a. Hemorrhage.
  - b. Damage to intercostal vessels and nerve.
  - c. Lung and mediastinal injury.
- Q. What are the criteria for removal of chest drain?
- a. When fluid drainage is <100 ml per day.
  - b. When the lung is inflated on the chest X-ray.
- Q. How do you remove the chest drain?
- a. The dressing and the sutures holding the drain in place are removed.
  - b. The patient is asked to hold breath in full inspiration as the drain is removed.
  - c. The wound is closed by tying two loose sutures.

## LYMPH NODE BIOPSY

### Site

The enlarged lymph nodes are usually excised from the neck, axilla and groin for histopathological examination.

### Procedure

1. The area is cleaned with antiseptic solution and draped.
2. Injection 1 percent lignocaine is injected all around the lymph node to achieve a ring block.
3. A skin crease incision about twice the size of the lymph node is made across the node. The superficial fascia is incised in the same line. If the nodes are lying deep to the deep fascia, it is also incised in the line of skin incision.
4. The loose tissues around the lymph node are dissected. The lymph node has small blood vessels which are ligated and divided. The lymph node is then excised and sent for biopsy, after placing in 10 percent formal saline.
5. The wound is closed in layers.

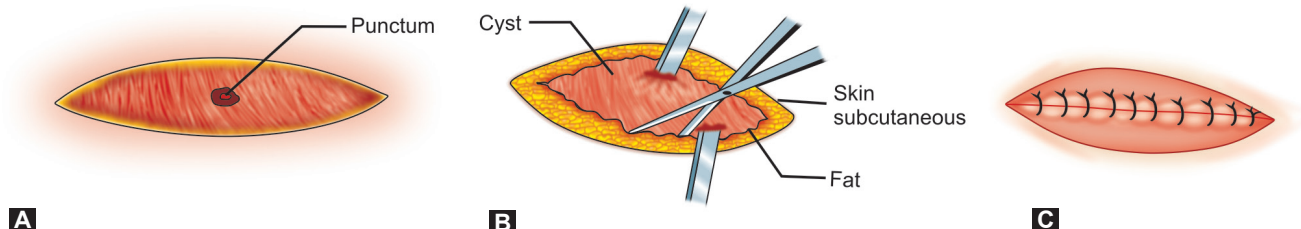
### Precaution

The lymph node capsule should not be grasped as it may distort the histological feature.

## EXCISION OF SEBACEOUS CYST

### Procedure (Fig. 99.3)

1. The area is cleaned with antiseptic solution and draped.
2. 1 percent lignocaine is infiltrated encircling the cyst.
3. *Incision*—An elliptical skin crease incision is made encircling the punctum (Fig. 99.3A).



**Figs 99.3A to C:** Excision of sebaceous cyst (A) Elliptical incision around the punctum (B) Dissection along the plane of cleavage (C) Skin incision closed. Final appearance



4. The incision is deepened carefully upto the edge of the cyst so that the cyst wall is not punctured.
5. Now tissue is separated with hemostatic forceps or fine curved scissors to open the cleavage line.
6. Along this cleavage line, the cyst wall is freed from the tissue all around (Fig. 99.3B).
7. Hemostasis is done.
8. The skin incision is closed with interrupted, nonabsorbable sutures (Fig. 99.3C).
6. Hemostasis is secured and the skin incision is closed with interrupted non-absorbable sutures.

### OPERATION FOR INGROWING TOENAIL

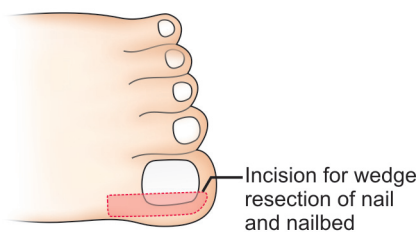
Two types of operations are done viz.

- i. Wedge resection of the border of the nail and associated nailbed for one sided ingrowing toenail.
- ii. Complete resection of the nail and the nailbed (Zadek's operation) when both side of the nail are involved. Alternatively, wedge resection of the nail and the germinal epithelium of the nail may be done on both sides leaving behind a central nail plate.

#### Wedge Resection of the Nail and the Nailbed

*Procedure (Fig. 99.5)*

1. The great toe and the 1st web space is cleaned with an antiseptic solution and draped.
2. Anesthesia—Digital nerve block of the affected great toe is done by injecting 1 percent lignocaine at its base on either side.
3. A rubber tourniquet is applied at the base of the great toe.
4. Incision—A vertical incision is made with a stout blade to remove one third segment of the nail and the nailbed down to the bone (Fig. 99.5).  
A second parallel incision is made through the skin just beyond the sulcus and angled slightly so as to meet the first one in the depth of the wound.
5. The intervening block of tissue comprising  $\frac{1}{3}$ rd of the nail, the sulcus, the nailbed



**Fig. 99.5:** Wedge resection for ingrowing big toenail

and the matrix on the affected side is dissected out and excised.

6. The skin flaps are sutured with non-absorbable sutures.
7. A paraffin gauge and bandage is applied and the tourniquet is removed.

### CATHETERIZATION

#### Indications

1. Retention of urine (acute and chronic).
2. Postoperative use—To maintain intake output chart.
3. Prior to a pelvic operation.

#### Equipments

Sterile gloves, 2 percent xylocaine jelly, povidone iodine solution, 20 ml syringe, distilled water, urobag, draping sheet.

#### Procedure

1. Hands are washed with soap water and sterile gloves put on.
2. Position of patient—Supine with legs apart.
3. The genitalia are cleaned with antiseptic solution and the area is draped.
4. The uncircumcised foreskin is retracted and the glans penis and corona are exposed.
5. 15 ml of 2 percent xylocaine jelly is introduced into the urethra through the external urethral meatus. The under surface of the penis is massaged to make the jelly go further down.
6. The penis is held vertically upwards by encircling a gauge around the penis for 5 minutes to prevent the anesthetic gel from escaping.
7. The lubricated Foley's catheter is then pushed gently through the external urethral meatus and gradually advanced till it reaches the bladder and urine comes out through the catheter.
8. About 15 to 20 ml water is pushed to inflate the balloon of the catheter.
9. The catheter is connected to an urobag and the preputial skin is brought back over the glans, to avoid the development of paraphimosis afterwards.
10. In case of chronic retention, the bladder should be emptied slowly.

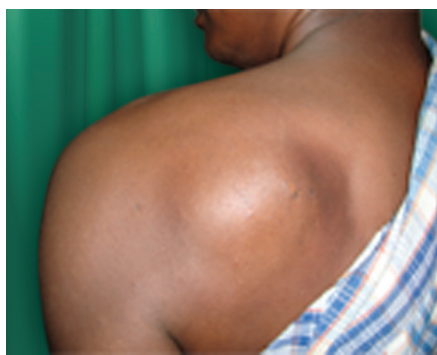### EXCISION OF LIPOMA

Lipoma is the commonest benign tumor arising from the fat cells. According to anatomical location, it can be subcutaneous, subfascial, intramuscular, subperiosteal, etc.

#### Excision of Subcutaneous Lipoma (Fig. 99.4)

##### Procedure

1. The area is cleaned with antiseptic solution and draped.
2. Local anesthetic, 1 percent lignocaine is infiltrated encircling the tumor.
3. Incision—A linear incision is made over the swelling.
4. The incision is deepened to cut the subcutaneous tissue. The plane of cleavage between subcutaneous tissue and the lipoma is identified by blunt dissection with artery forceps or fine curved scissors.
5. The blunt dissection is continued all round the tumor with a finger or the hemostatic forceps to shell out the lipoma.



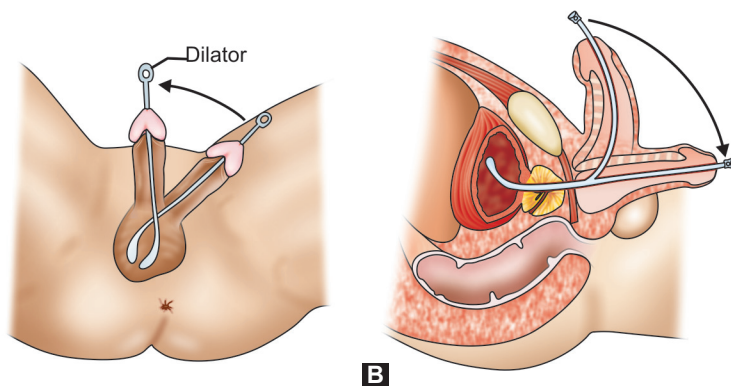
**Fig. 99.4:** Subcutaneous lipoma over the left scapular region of back

**URETHRAL DILATATION****Indication**

The only indication for urethral dilatation is a stricture (a compression or narrowing of the urethral lumen).

**Technique (Fig. 99.6)**

1. Position of patient—Supine.
2. Local area is cleaned with antiseptic solution after shaving.
3. Anesthesia—About 15ml of 2 percent xylocaine jelly is introduced through the external urethral meatus. One has to wait for about 5 minutes to get the action of the local anesthetic.



**Figs 99.6A and B:** Urethral dilatation (A) The dilator is rotated anticlockwise to bring it to the midline as indicated by the arrow (B) The dilator is depressed in between thighs to introduce it into the bladder

4. The surgeon preferably stands on the left side of the patient holding the penis vertically up. This will convert S-shaped curve of urethra into a J-shaped one which adapts to the curve of the bougie.
5. Dilatation is started with 10/14 Clutton's dilator as a thinner instrument is more likely to produce a false passage.
6. The dilator is introduced through the external urethral meatus keeping it parallel to the left inguinal ligament (Fig. 99.6A).
7. The dilator is allowed to pass by its own weight. As the dilator goes in, it is rotated anticlockwise to bring it to the midline over the abdomen.
8. A little resistance is felt as the tip reaches the perineal membrane. The dilator is then depressed in between the two thighs, when it slips into the bladder, traversing the membranous and prostatic parts of the urethra (Fig. 99.6B).
9. Once the dilator goes into the bladder, it can be rotated easily. Usually the adult male urethra should be dilated to size 28F. However, one should stop if the stricture grips a narrower dilator and try to better it next time. Force should never be used. The procedure should not produce any bleeding and pain.

**Frequency of Dilatation**

- a. With a severe stricture weekly dilatation may be needed to prevent retention of urine. However, this is unusual.
  - b. The usual protocol is dilatation every three to four weeks for 6 months, then quarterly for a year, then ½ yearly for 2 years and lastly once a year (birthday dilatation).
- Q. What are the complications of urethral dilatation?
- a. False passage.
  - b. Bleeding.
  - c. Urethral fistula formation.
  - d. Restricture.
- Q. What is the treatment of impassable stricture?
- See urethral stricture in the chapter 49 on 'urethra and penis'.

## Orthopedic Operations

- Patellectomy
- Excision of medial semilunar cartilage
- Intramedullary nailing
- Nerve repair
- Tendon repair

### PATELLECTOMY (Removal of Whole of the Patella)

#### Indications

1. Multiple fractures of the patella.
  2. Transverse fracture of patella with damaged posterior articular surface.
- Q. Name the patella conserving operations?
- a. Suturing of the patella.
  - b. Tension band wiring.
- When the posterior articular surface is intact, the conserving operations are performed; otherwise osteoarthritis develops obviously in a damaged articular surface.
- Q. If patella is removed; does it impair the function of the knee joint?
- No, provided the extensor expansion is properly repaired.

#### Steps of Operation (Fig. 100.1)

1. Anesthesia — General anesthesia with endotracheal intubation or spinal anesthesia.

2. Position of patient — Supine with leg fully extended.
3. Antiseptic dressing with povidone iodine lotion from mid thigh to mid leg and draping.
4. Incision — A curved transverse incision is made from the lateral to medial border of knee (Fig. 100.1A).
5. Incision is deepened to cut through the skin and fascia. The flaps are raised above and below (Fig. 100.1B).
6. Patella is exposed along with the knee joint.
7. Blood clots present in the joint cavity and the fracture fragments are removed keeping the extensor expansion intact as far as practicable (Fig. 100.1C).
8. The extensor apparatus is stitched with nonabsorbable sutures like prolene (Fig. 100.1D).
9. Hemostasis is secured and skin is closed with interrupted, nonabsorbable sutures.
10. Compression bandage and a posterior plaster slab are applied to achieve immobilization. Skin stitches are removed after

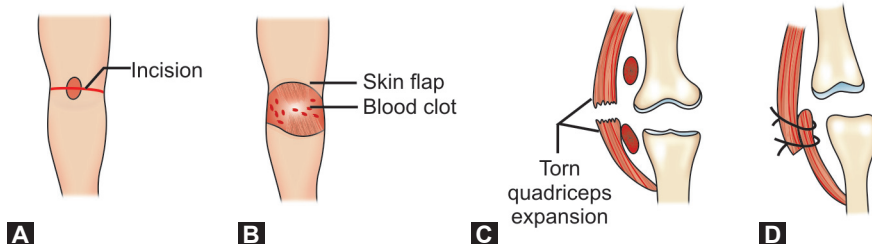
7 days. Immobilization is maintained for 4 weeks. Quadriceps exercise is encouraged after 3 weeks with the posterior plaster slab *in situ*. Weight bearing is allowed after 6 weeks.

- Q. What are the postoperative complications?
1. Improper extension of the knee joint.
  2. Stiff knee (Inability to flex the knee).
- Q. How will you treat the above?
- a. Adequate suturing of quadriceps expansion and
  - b. Proper physiotherapy and quadriceps exercise.

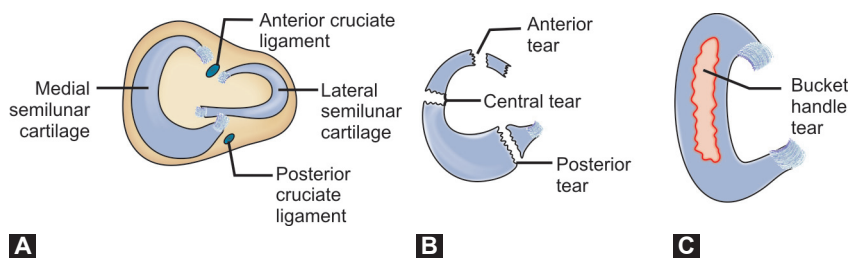
### EXCISION OF MEDIAL SEMILUNAR CARTILAGE (SYN— MENISECTOMY)

#### Surgical Anatomy (Fig. 100.2A)

- a. There are two semilunar cartilages — Medial and lateral in the knee joint.
- b. The medial semilunar cartilage is bigger than the lateral, elongated in shape and is more fixed to the capsule of the joint. The lateral cartilage is smaller and only loosely attached to the capsule.
- c. The cartilages have anterior and posterior horns which are attached to the tibial intercondylar area by fibrous connections.
- d. Injury to the medial semilunar cartilage is more common than the lateral one as it is comparatively big, more fixed to the capsule and the medial condyle is bigger.



**Figs 100.1A to D:** Patellectomy. (A) Transverse incision made; (B) Skin flaps raised; (C) Injured quadriceps expansion; (D) Repair of quadriceps expansion done



**Figs 100.2A to C:** Surgical anatomy and different types of injury to medial semilunar cartilage (A) The knee joint in transverse section; (B) Different types of injury to medial semilunar cartilage; (C) Bucket handle tear

### Types of Injury (Figs 100.2B and C)

The following types of injury may occur:

1. Anterior tear.
2. Posterior tear.
3. Central tear.
4. Bucket handle tear.

### Mechanism of Injury

This type of injury typically occurs in a footballer. When the flexed knee is forcibly abducted and externally rotated, the medial meniscus undergoes tear. The nonshooting limb is affected.

For clinical features and diagnosis see meniscal injury in orthopedics section, chapter 59.

### Indication

When the diagnosis of meniscal injury is certain the treatment is excision of the damaged cartilage.

### Steps of Operation (Fig. 100.3)

1. General anesthesia with endotracheal intubation.
2. Application of tourniquet to exsanguinate the limb.
3. Position of patient — Supine with the knee flexed at right angle over the edge of the table (Fig. 100.3A).

The surgeon sits on a stool facing the knee.

4. Incision: A 5cm long incision is made on the medial aspect of patella in the space between the ligamentum patellae and tibial collateral ligament extending downwards a little below the upper margin of tibia. This incision is especially designed to save the infrapatellar branch of saphenous nerve (Fig. 100.3B).
5. The incision is deepened to open the joint by dividing the capsule, a fatty layer and the synovial membrane.
6. The anterior attachment of the cartilage is divided and the freed anterior end is held with the Kocher's hemostatic forceps.
7. The cartilage is pulled forward and the peripheral attachment is divided. If possible, whole cartilage should be removed.

8. The anterior end is further pulled forward and the posterior attachment is cut. Alternatively, posterior segment of the cartilage is easily removed by making an additional vertical incision behind the tibial collateral ligament.
9. The knee is extended and the wound is closed in layers — the synovial membrane, capsule and skin. The wound is dressed with plenty of cotton padding under pressure to cause hemostasis.
10. The tourniquet is removed and a posterior splint is applied and kept for 10 days.
11. Postoperatively, quadriceps exercise is commenced from the following day and weight bearing is allowed after 2 weeks.

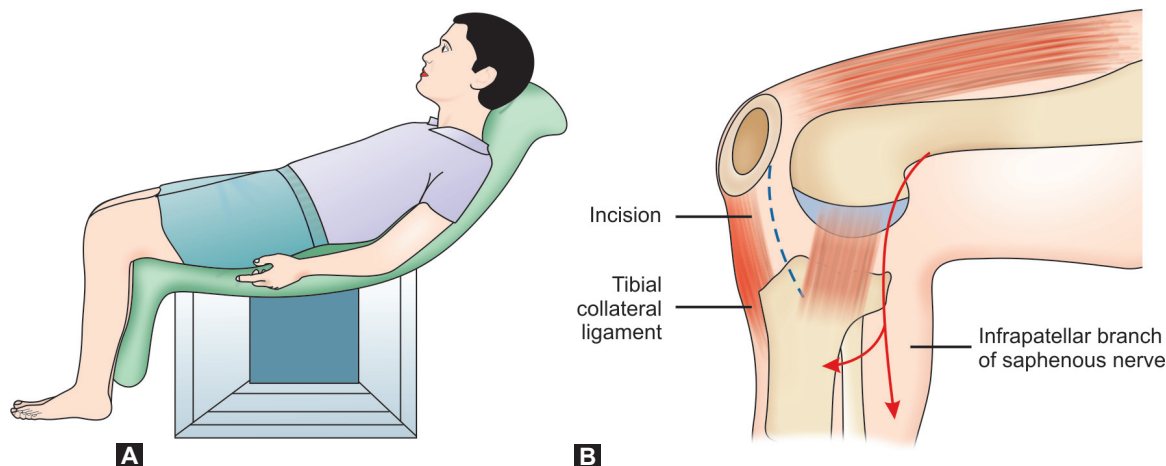
### INTRAMEDULLARY NAILING

#### Indication

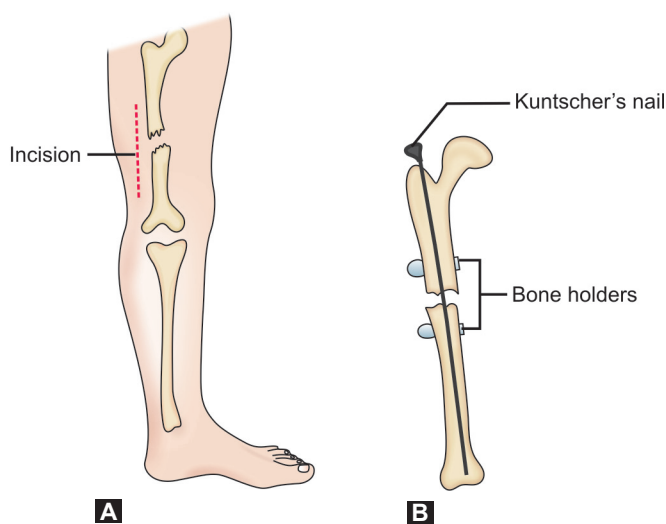
The operation is done to achieve internal fixation of fragments in fracture shaft of the femur.

#### Steps of Operation (Fig. 100.4)

1. Position of patient — Supine and turned to the side by putting a sand bag below the pelvis so that posterolateral aspect of affected thigh is exposed.
2. Anesthesia — General anesthesia with endotracheal intubation or spinal anesthesia.
3. Antiseptic dressing and draping.
4. Incision — A six inches vertical incision is made on the posterolateral aspect of



**Figs 100.3A and B:** Menisectomy (A) Position of patient; (B) Incision for menisectomy



**Figs 100.4A and B:** Intramedullary nailing for fracture shaft of femur

thigh centering the site of fracture (Fig. 100.4A).

5. The incision is deepened through the muscles to expose the fracture site.
6. The medullary cavity of both fragments is explored first with a guide pin, then a cannulated reamer.

The reamer is used to enlarge the medullary cavity to accommodate a nail of appropriate size and caliber.

7. The guide pin is thrust up the medulla of the proximal fragment while the leg is adducted as much as possible.
8. The guide pin when inserted accurately should emerge through the greater trochanter and protrude through the skin.
9. A skin incision is made at this point and a Kuntscher nail is threaded on to the guide pin and is driven down the medulla till it emerges at the fracture.
10. The bone ends are now accurately apposed and held with a bone holder (Fig. 100.4B).
11. The nail is driven downwards into the distal fragment taking care to see that 2cm of the nail is left protruding above the trochanter for extraction of the nail.
12. Hemostasis is secured and the wound is closed in layers.
13. Active movements are encouraged from the outset but unsupported weight bearing is not allowed.

- Q. What is the width of the nail?  
13 to 15mm in an adult.

Q. How do you measure the length of the nail?

By taking an X – ray of the opposite femur, where a measuring rod is placed.

The length amounts from the tip of the greater trochanter to upper border of patella plus 2cm for extraction of the nail.

Q. What are the types of nail?

- a. Kuntscher's nail.
- b. Triangular nail
- c. Rush nail one end of which is slightly bent.

Q. What are the advantages of IM nailing?

- a. Better fixation.
- b. Early recovery thus avoiding prolonged immobilization.

Q. What are the disadvantages?

- a. Sepsis.
- b. Osteomyelitis.

### NERVE REPAIR

- Complete disruption of a peripheral nerve may be associated with both open and closed injuries.
- Magnification is essential. If an operating microscope is not available, simple magnifying loops usually suffice.
- Nerve trunk is covered by fibrous epineurium. This epineurium is important as this layer is just apposed at the time of repair.
- Recovery is good in case of a pure motor nerve as compared to a mixed nerve.

### Operative Steps (Fig. 100.5)

- a. Nerves are explored from the wound.
- b. They are brought near to each other.
- c. False neuroma at the ends (which takes about three weeks to form) are trimmed so that margins become clear cut (Fig. 100.5A).
- d. Suturing is done with 8/0 Nylon by apposing only the epineurium. The sutures are placed at 1.5mm or so apart. The sutures should not pass through the nerve fibers. Usually four (two lateral, one anterior and one posterior) sutures are given (Figs 100.5B to D).
- e. After repair, the limb is immobilized in flexed position to avoid tension over the nerve. Movement is allowed after three weeks.

Q. What is primary repair?

Primary repair is done when the nerve is cut by a sharp object and the patient reports early. If the wound is contaminated, a delayed primary repair is done, once the wound heals, usually after two weeks.

Q. What is secondary repair?

It is indicated in case of:

- i. Nerve lesions presenting late due to lack of detection at the time of injury or poor general condition of the patient.
- ii. Syndrome of incomplete interruption and failure of improvement in 6 weeks and
- iii. Failure of conservative treatment – If conservative treatment yields no result in 3 weeks. Secondary repair is attempted.

Q. Which peripheral nerves are commonly injured and what are the results of their repair?

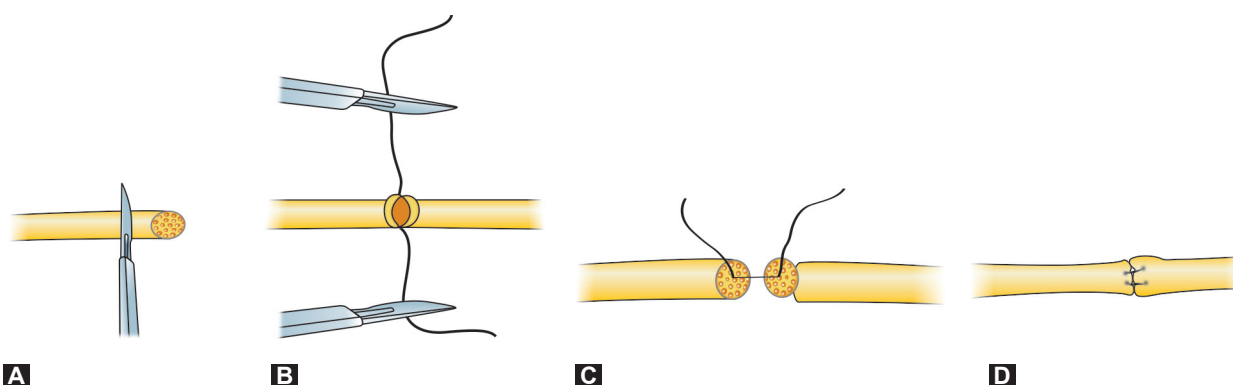
- a. The nerves commonly injured are the radial nerve, ulnar nerve, median nerve, sciatic nerve, etc.
- b. Results of repair
  - i. Radial nerve—Good recovery as it is mainly motor.
  - ii. Ulnar nerve—Recovery is not good.
  - iii. Median nerve—Though a mixed nerve recovery is better than ulnar nerve.
  - iv. Sciatic nerve—Recovery is not good as a whole.

### TENDON REPAIR (FIG. 100.6)

#### Principles of Repair

1. Like nerve repair, tendon repair, may be.





**Figs 100.5A to D:** Nerve suture (A) Cutting the neuroma; (B) First and second sutures in place; (C) Suturing the epineurium; (D) Sutures completed

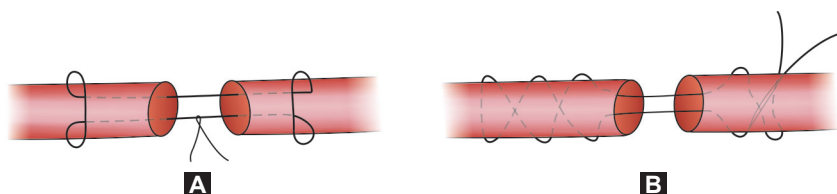
- a. Primary repair — When repair is done immediately after the trauma in a clean wound and
  - b. Secondary repair—When repair is done 3 weeks after healing of the wound without infection or 3 months after if the wound has been infected.
2. A tendon is composed of longitudinal bundles of fibrous tissue so that
3. Repair of tendons which are not enclosed in a sheath, e.g. those in the forearm or

longitudinal sutures will not hold the cut ends of a tendon. Hence the suture is interwoven for some distance on either side and then tied with the knot lying in between the cut ends by either a Kessler stitch or a Bunnell stitch. (Figs 100.6A and B)

dorsum of hand are usually followed by good functional recovery but when a repaired tendon lies in a synovial sheath, e.g. a digital flexor tendon, the results are less satisfactory owing to adhesion of the sheath to the tendon.

### Steps of Operation

1. The wound is explored to identify the cut ends of the tendon, after application of tourniquet.
2. Tendon ends are approximated and trimmed, if ragged.
3. An interwoven suture is made and tied to unite the cut ends as mentioned above.
4. The tourniquet is removed and the part is immobilized in a position of minimum tension for 3 weeks in the upper limb and 6 weeks in the lower limb. Movements of fingers and toes are started after that.



**Fig. 100.6A and B:** Two methods of suture of tendons (A) Kessler's stitch (B) Bunnell stitch

# Chapter 101

## Surgical Pathology (Specimens)

- Introduction
- Gastrointestinal specimens
- Urology specimens
- Orthopedic specimens

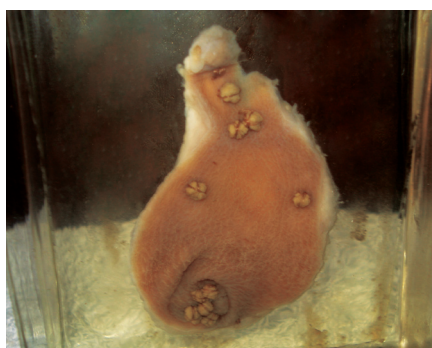### INTRODUCTION

1. Knowledge about the pathological specimens will help the students to memorize various surgical diseases and diagnose them with naked eye seeing the organs as a whole or their cut sections.
2. Usually the student is required to answer questions about one or two specimens in the practical examinations.
3. The questions are usually based on the following points viz.
  - a. Identification of the specimen.
  - b. Macroscopic features for diagnosis.
  - c. Microscopic features.
  - d. Clinical presentation and
  - e. Treatment.

### GASTROINTESTINAL SPECIMENS

#### Gallstones (Cholelithiasis) (Fig. 101.1)

1. What is the specimen?  
This is a specimen of gallbladder cut open containing multiple gallstones.
2. What are the different types of gallstones?
3. What are the characteristics of cholesterol stones?
4. How cholesterol stones are formed?
5. What are the characteristics of pigment stones?
6. What is the pathogenesis of pigment stones?



**Fig. 101.1:** Specimen of gallbladder cut open containing multiple gallstones

7. What are the characteristics of infected or mixed stones and what is the pathogenesis?
8. What are effects of gallstone on the gallbladder, common bile duct and intestine?
9. What are the features of acute cholecystitis?
10. What is the differential diagnosis of acute cholecystitis?  
See gallstones in the chapter on gallbladder.
11. What is acalculous cholecystitis?
12. What is cholecystosis?  
See 'Cholecystitis' in the chapter 37 on gallbladder'.

#### Mucocele of Gallbladder (Fig. 101.2)

1. What is the specimen?  
It is a specimen of mucocele of gallbladder.
2. Why do you say so?
  - a. The size of the gallbladder is enlarged.



**Fig. 101.2:** Specimen of mucocele of gallbladder

- b. The wall is thinned out like parchment paper.
- c. When the specimen is looked at against sunrays then thin wall is evident.
- d. No adhesion with the surrounding structures.
3. What is mucocele?  
It is a condition where the gallbladder is distended with mucin, following obstruction of the cystic duct by stone or tumor (cholangiocarcinoma).
4. Where from the mucin comes?  
The mucin is secreted by the gallbladder epithelium. But there is no bile as cystic duct is obstructed.
5. What is the other name of mucocele?  
It is also called hydrops of the gallbladder.
6. Is there any infection in mucocele?  
Usually there is no infection. If infection is present at all, it is minimum.

7. What is the clinical presentation?
  - a. Palpable gallbladder – pyriform-shaped nontender, gallbladder is palpable in the right hypochondrium.
  - b. Flatulent dyspepsia – suggestive of chronic cholecystitis.
  - c. History of biliary colic.
8. How will you confirm the diagnosis?
 

By ultrasonography of upper abdomen.
9. How do you treat?
 

By cholecystectomy.

### Empyema of Gallbladder (Fig. 101.3)

1. What is the specimen?
 

It is a specimen of empyema of gallbladder.
2. Why do you say so?
  - a. The gallbladder is bigger in size.
  - b. Wall is thick – This is the most important feature.
3. How do you say that the wall is thick?
 

When the specimen is held against sunlight, it does not pass freely through the wall, as in case of mucocele.
4. What is empyema?
 

It is a condition, when the gallbladder is distended with pus. It is caused by super added infection of a mucocele of gallbladder.
5. What are the fates of empyema?
  - a. Resolution by proper treatment.
  - b. Gangrene.
  - c. Perforation – Perforation of gallbladder is less common in comparison to appendix. Hence in acute appendicitis, surgery is the treatment of choice,



**Fig. 101.3:** Specimen of empyema of gallbladder

- whereas in acute cholecystitis, common practice is to treat conservatively.
6. What are the common organisms?
  - a. *Streptococcus*.
  - b. *Staphylococcus*.
  - c. *E. coli*
  - d. *Klebsiella* and even *Cl. welchii*.
7. What is the portal of entry?
  - a. Hematogenous.
  - b. Directly from duodenum along bile duct.
  - c. Lymphatics
8. How do you treat?
 

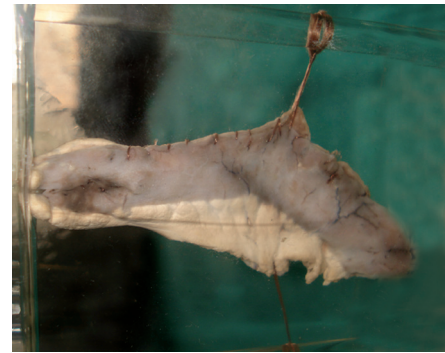Conservatively by IV fluids, broad spectrum, antibiotics and nasogastric suction.
9. Can you go for immediate surgery?
  - a. Surgery is difficult because of surrounding inflammatory edema that makes dissection of Calot's triangle difficult.
  - b. There is chance of injury to CBD.
  - c. Hence, it should be undertaken, if at all by an experienced surgeon.

### Acute Appendicitis (Fig. 101.4)

1. What is the specimen?
 

This is a specimen of appendix.
2. Why do you say so?
 

The organ is appendix because of its shape (cul-de-sac like structure) and presence of mesoappendix attached to the organ.
3. What features of acute inflammation do you find?
  - a. The appendix is bigger and/or distended.
  - b. Presence of congested blood vessels.
  - c. Presence of black patches on the surface, suggestive of gangrene.
  - d. In some specimens there may be site of perforation.
4. What are the pathological types?
  - a. Acute obstructive appendicitis.
  - b. Acute nonobstructive or catarrhal or infective or inflammatory appendicitis.
5. What are the causes of obstructive appendicitis?
  - a. Fecoliths.
  - b. Worms, ova.
  - c. Foreign body, e.g. fruit seeds, etc.
  - d. Carcinoid tumor of the appendix.
6. What is the pathology of acute appendicitis?
  - a. Obstructive type: In this type of appendicitis symptoms are abrupt and



**Fig. 101.4:** Specimen of appendix because of its shape (cul-de-sac like structure) and presence of mesoappendix attached to the organ

more severe. The appendix becomes a closed loop and continuing secretion by appendicular mucosa results in distension and rise of intraluminal tension. This leads to the venous and lymphatic obstruction → Edema and ulceration of mucosa → Proliferation of bacteria inside lumen and their translocation through the wall → Toxic thrombosis of the appendicular vessel which may result in gangrene and perforation of the appendix as well as peritonitis.

- b. Nonobstructive type:
  - i. The inflammation sets in the mucous membrane and progresses rapidly when it reaches the loose submucous tissue.
  - ii. The appendix looks red and turgid.
  - iii. This type is comparatively less severe than the obstructive type. It may remain limited to the mucous membrane only.
  - iv. The results of inflammation may be ulceration, suppuration and gangrene or complete resolution.
7. What are the sites of perforation?
  - a. Tip of the appendix is the least vascular part and appendicular artery is an end artery.
  - b. At the site of impaction.
8. What are the complications of acute appendicitis?
  - a. Gangrene.
  - b. Perforation.
  - c. Peritonitis.
  - d. Appendicular lump formation.
  - e. Appendicular abscess.

- f. Rarely portal pyemia.
9. What is appendicular lump?

It is a swelling consisting of inflamed appendix, edematous cecum, terminal part of ileum and greater omentum all glued together by inflammatory exudate.

10. What is the fate of appendicular lump?
- Complete resolution.
  - Formation of appendicular abscess.
11. What is the average time for lump formation?
- About 48 hours.
12. What is the treatment of appendicular lump or mass
13. What is the treatment of appendicular abscess?
14. What are the important clinical features of acute appendicitis?
15. What is the important differential diagnosis?
16. How will you treat a case of acute appendicitis?
- See 'Appendicitis' in the chapter 33 on 'the appendix'.
17. What are the problems of appendicitis in children?
- Omentum is small, so lump formation is delayed and perforation is more common. Therefore, surgery should be done without delay.
18. What is the problem in older age group?
- The vessels are atherosclerotic. So chance of perforation and gangrene are more common.
  - As abdomen is loose and lax, very often peritonitis is not diagnosed. Therefore if acute appendicitis is suspected, it should be operated without delay.
19. What is the role of appendicectomy in pregnancy?
- In the first and second trimester, operation is easy and done through normal incision.
  - In the third trimester, appendix is shifted up. So, it is operated by a higher incision.
  - Appendicitis may lead to abortion. Hence, appendicectomy should be done even if there is pregnancy because if there is perforation, survival of fetus becomes difficult.

### Meckel's Diverticulum (Fig. 101.5)

- What is the specimen?  
This is a specimen of Meckel's diverticulum.
- Why do you say so?  
This is a small pouch arising from the small intestine at its antimesenteric border.
- Which part of small intestine is it?  
It is ileum.
- How do you know it is ileum?
  - In the ileum, there is abundant fat in the mesentery, so that spaces between vessels are not visible, but in jejunum fat is less and arterial windows are visible.
  - In ileum, the lumen is narrow, in jejunum it is wide.
  - The diverticulum is situated 50–60 cm away from the ileocecal junction; hence it is in the ileum.
- Why it is not a specimen of appendix?
  - The diameter of the diverticulum is more than that of the appendix.
  - Part of the ileum along with the diverticulum is present in the specimen. In appendicectomy specimen, only appendix is present. The gut is not large gut or cecum as there are no taeniae coli, sacculations or appendices epiploicae.
- What is Meckel's diverticulum?
- What are the anomalies of vitellointestinal duct?
- What is clinical presentation of Meckel's diverticulum?



**Fig. 101.5:** Specimen of Meckel's diverticulum with the small pouch arising from the antimesenteric border

- How can Meckel's diverticulum be investigated for diagnosis?
- How do you treat Meckel's diverticulum?  
See 'Meckel's diverticulum' in the chapter 31 on 'small intestine'.
- What is the rule of 2 in Meckel's diverticulum?  
It is present in 2 percent of human beings, 2 inches in length and is located about 2 feet away from the ileocecal junction.
- What is a diverticulum?  
It is an abnormal sac or pouch protruding from the wall of a hollow organ.
- What are the associated congenital anomalies?
  - Anorectal malformation.
  - Esophageal atresia.
  - Cardiovascular and nervous system anomalies.
- Why a segment of ileum is excised along with Meckel's diverticulum?  
The heterotopic gastric or pancreatic epithelium is present near the base of the diverticulum and adjoining wall. So, a portion of ileum on either side needs to be resected.
- What is the vitellointestinal duct?  
It is the connection between the midgut and the yolk sac (extraembryonic part) of the embryo in early fetal life. Normally the duct disappears during development.

### Intussusception (Fig. 101.6)

- What is the specimen?  
This is a specimen of ileocecal intussusception.
- What is intussusception?
- What are the types?
- What are the parts of intussusception?
- What are the etiological factors?
- How does a patient with intussusception usually present?
- How do you investigate a case of intussusception?
- How will you treat a case of intussusception?  
See 'intussusception' in the chapter 34 on 'intestinal obstruction'.

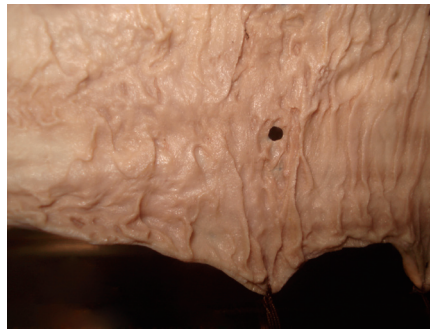### Benign Gastric Ulcer (Fig. 101.7)

- What is the specimen?  
This is a specimen of stomach cut open showing a benign ulcer in the region of lesser curvature.





**Fig. 101.6:** Specimen of ileocecal intussusception



**Fig. 101.7:** Specimen of stomach cut open showing a benign ulcer in the region of lesser curvature

2. Why do you say benign ulcer?
  - a. Ulcers along the lesser curvature are more commonly benign.
  - b. The margin of the ulcer is clear cut and not everted.
  - c. Gastric mucosal folds are converging towards the base of the ulcer. In malignancy, these folds are effaced or taken up around the ulcer.
3. What are the sites of peptic ulcer?
 

Peptic ulcers occur in those parts of the gastrointestinal tract bathed by acid pepsin viz.

  - a. Stomach – Majority occur in the lesser curvature. So gastric ulcer is a type of peptic ulcer.
  - b. Duodenum – 98 percent occur in the first part.
  - c. Lower end of Oesophagus – Due to reflux esophagitis.
  - d. Meckel's diverticulum due to presence of heterotopic gastric mucosa.
  - e. Stoma of gastrojejunostomy towards the jejunum.
4. What are the macroscopic features of chronic gastric and duodenal ulcers?
 

See Table 101.1 below
5. What are the microscopical features of chronic peptic ulcer?
  - a. In a chronic open ulcer, four zones can be distinguished from superficial to deep viz.
    - i. Superficial thin layer of necrotic fibrinoid debris.
    - ii. A zone of active inflammatory infiltration with neutrophils predominating.
    - iii. Zone of granulation tissue.
    - iv. Zone of fibrous collagenous scar.
  - b. Epithelial proliferation is seen at the margins with healing.
  - c. Muscular coat is more destroyed than the mucous membrane during ulceration.
6. What are the complications of chronic peptic ulcers?
  - a. Acute –
    - i. Hemorrhage – Hematemesis and melena.
    - ii. Perforation leading to perforative peritonitis.
  - b. Intermediate – Residual abscess in the subphrenic spaces following perforation.
  - c. Chronic –
    - i. Cicatrization leading to pyloric stenosis, hour glass stomach or tea pot deformity.
    - ii. Penetration of ulcer into adjacent viscera.

**Table 101.1: Chronic gastric ulcer versus chronic duodenal ulcer.**

	<i>Chronic gastric ulcer</i>	<i>Chronic duodenal ulcer</i>
1. Usual size	Less than 2 cm	Seldom greater than 0.5 cm diameter
2. Mucosal folds	Radiate from the ulcer in a spoke like fashion	There is duodenal cap deformity
3. Site	Lesser curvature	Mostly in the first part of duodenum

iii. Malignant transformation – This occurs almost exclusively in case of gastric ulcers.

7. What is the pathogenesis of gastric and duodenal ulcers?
8. What is the role of *H. pylori* infection in the causation of peptic ulcer?
9. What is Basal acid output (BAO) and maximal acid output (MAO)?
10. What is the medical treatment of peptic ulcer?
11. What are the surgical options in gastric ulcer?
12. What are the surgical options in chronic duodenal ulcer?
 

See the long case 'chronic duodenal ulcer' in chapter 73.
13. What are the types of gastric ulcer?
 

Type I – High gastric ulcer. It is a subacid state.

Type II – Normal or hyperacid state. In this type combined duodenal and gastric ulcers exist.

Type III – Prepyloric ulcer (Hyperacid state). The features of prepyloric or pyloric channel ulcers simulates duodenal ulcer.
14. What is Zollinger–Ellison syndrome?
15. How will you treat Zollinger–Ellison syndrome?
 

See long case 'chronic duodenal ulcer' chapter 73 and chapter 30 on 'stomach & duodenum'.
16. What are the pathological changes following perforation of a chronic peptic ulcer?
17. What is the treatment of peptic perforation?
 

See 'perforation of peptic ulcer' in the chapter 30 on 'stomach and duodenum'.

### Carcinoma of Stomach (Fig. 101.8)

1. What is the specimen?
 

This is a specimen of carcinoma of stomach showing a proliferative growth in the pyloric region.
2. What are the important etiological factors for development of carcinoma of stomach?
3. What are the common presentations of a patient with carcinoma of stomach?
4. What are the macroscopic types?
5. What are the histopathologic types of carcinoma stomach?



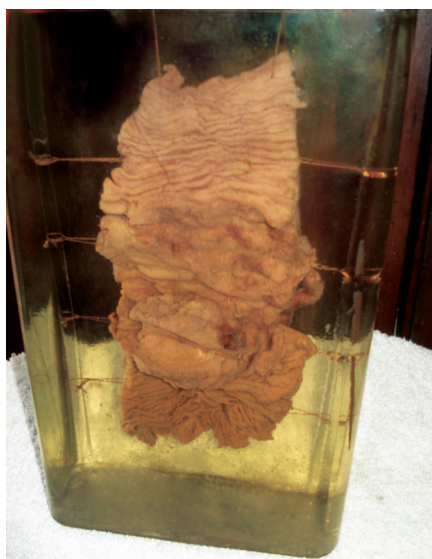

**Fig. 101.8:** Specimen of carcinoma of stomach showing a proliferative growth in the pyloric region

6. What is Lauren's pathologic classification of gastric cancer?
7. What is early gastric cancer and what are its subtypes?
8. What is advanced gastric cancer?
9. What is the TNM staging of carcinoma of stomach?
10. How does gastric carcinoma spread?
11. What is operability?
12. What is resectability?
13. What are the types of radical surgery?
14. What palliative procedures are done in inoperable carcinoma of stomach?
15. What are the postgastrectomy complications?
16. How will you prevent the complications?  
See the long case 'gastric carcinoma' chapter 73 and the chapter 30 on 'stomach and duodenum'.
17. What is the treatment of choice in gastric carcinoma?  
The treatment of choice is radical surgical excision of the tumor if operable.

### Carcinoma Colon (Fig. 101.9)

1. What is the specimen?  
This is a specimen of cecum with appendix and ascending colon which are cut open showing an ulceroproliferative growth arising from the cecum. So, this is a specimen of carcinoma of cecum.
2. How does a patient with right colonic cancer present?
  - a. It is more common in females.
  - b. Carcinoma cecum may present with features of acute appendicitis.
  - c. May present with vague symptoms like anemia, anorexia and esthenia.
- d. May present with a lump or intestinal obstruction due to intussusception.
3. How does a patient with left colon cancer present?  
The patient may present with the following
  - a. May present with alteration of bowel habit that is, alternate periods of constipation and diarrhea.
  - b. May present with a lump or lower abdominal distension.
4. What are the macroscopic types of carcinoma colon?
5. What are the histological features?
6. What is Duke staging for carcinoma of colon?
7. What is Astler Coller modification of Duke staging?
8. What is the lymphatic drainage of colon?
9. What is the TNM staging?
10. What investigation will you do to confirm the diagnosis?  
See the long case 'carcinoma of colon' chapter 73.
11. How will you treat this case?
  - a. The treatment of choice is right hemicolectomy if the growth is operable.
  - b. If the growth is not resectable, palliative bypass in the form of ileotransverse anastomosis is done.



**Fig. 101.9:** Specimen of cecum with appendix and ascending colon which are cut open showing an ulceroproliferative growth arising from the cecum

12. What is the preoperative gut preparation for this patient?
13. How does carcinoma of colon spread?
14. What are the etiological factors for the development of carcinoma colon?
15. What is the protocol for colonic/colorectal cancer follow up?
16. What is the prognosis of colorectal carcinoma?  
See the long case 'carcinoma of colon', in chapter 73 and colorectal carcinoma in chapter 35.

### Carcinoma Rectum (Fig. 101.10)

1. What is the specimen?  
This is a specimen of rectum, anal canal and part of the sigmoid colon which is cut open showing a proliferative growth in the rectum, extending upto the anus. So this is a specimen of carcinoma of rectum extending into the anal canal.
2. How the specimen came into the jar?  
The specimen was preserved in the jar following abdominoperineal resection of rectum.
3. How patients with carcinoma rectum present?
  - a. Blood and mucus per rectum – This is the most common and earliest symptom.
  - b. Tenesmus – Patient complains of painful straining without passage of stool but may pass blood mixed with mucus. Patient has a constant sense of incomplete evacuation.
  - c. Pain – Pain is usually a late symptom. Pain with defecation suggests involvement of the anal sphincters.



**Fig. 101.10:** Specimen of rectum, anal canal and part of the sigmoid colon which is cut open showing a proliferative growth in the rectum extending upto the anus

- d. General symptoms like anorexia, weight loss, etc.
- e. A change in bowel habits or stool caliber.
4. What are the macroscopic types of carcinoma rectum?  
It is the same as those of carcinoma of colon as described earlier.
5. What are the histologic types?  
Same as those of carcinoma of colon.
6. How does carcinoma of rectum spread?  
See 'spread of carcinoma of colon' in the long case of 'carcinoma of colon', chapter 73.
7. How do you confirm the diagnosis of carcinoma of rectum?
8. What is metachronous cancer?
9. What are carcinoembryonic antigen (CEA) and its role in carcinoma of rectum?
10. What are the etiological factors for development of rectal cancers?
11. What is Duke staging?  
See long case on 'carcinoma of colon', chapter 73.
12. What is the TNM staging?  
It is the same as the TNM staging of carcinoma of colon. In case of lymph nodes  
N<sub>1</sub> = Presence of metastasis in 1 – 3 perirectal lymph nodes and  
N<sub>2</sub> = Presence of metastasis in 4 or more perirectal lymph nodes.
13. What is the treatment of rectal carcinoma?  
See 'region-wise treatment of colorectal carcinoma' in the chapter on 'rectum and anal canal', chapter 35.

### Ulcerative Colitis (Fig. 101.11)

1. What is the specimen?  
This is a specimen of colon showing multiple small polyps involving almost the whole segment of colon (pancolitis). So, this is a specimen of ulcerative colitis with pseudopolyp formation.
2. What is the definition of ulcerative colitis?  
Ulcerative colitis can be defined as a disease of unknown etiology, characterized by nonspecific inflammation of the mucosa and superficial submucosa with varying degrees of ulceration and associated with relapses and remissions.
3. What is the usual progression of the disease?  
In 95 percent cases the disease starts in the rectum and spreads proximally towards



**Fig. 101.11:** Specimen of colon showing multiple small polyps

- the cecum. The whole of the colon may be involved. In contrast to Crohn's disease, there is no granuloma formation and presence of skip areas.
4. What are the macroscopic features of ulcerative colitis?
    - a. The characteristic feature is the continuous involvement of rectum and colon without any skip areas as seen in Crohn's disease.
    - b. Mucosa shows linear and superficial ulcers usually not penetrating the muscular layer.
    - c. The intervening intact mucosa may undergo hyperplasia (20%) to form 'inflammatory pseudopolyps' in the chronic stage.
    - d. The muscle layer is thickened due to contraction producing narrowing and shortening of the affected, colon with loss of normal haustral folds giving 'hose pipe' appearance.
  5. What are the microscopic features?
    - a. The inflammation almost always involves the mucosa and superficial submucosa.
    - b. Formation of crypt abscesses.
    - c. There is intense infiltration of mucous membrane with lymphocytes, plasma cells and eosinophils.
  6. How patients of ulcerative colitis present?
    - a. Bloody diarrhea in an otherwise fit patient is the commonest presenting symptom.
    - b. Anemia, ill health and hypoproteinaemia are common.
    - c. Perforation – Once there is perforation, symptoms and signs of peritonitis are the presenting features.

- d. Malignant change – Rarely a stenosing lesion may present with subacute intestinal obstruction.
- e. Toxic megacolon or fulminant colitis – patient is acutely ill and there may be abdominal pain, fever, tachycardia, electrolyte imbalance and shock.
- f. Tenesmus – Patient always feels a sensation of incomplete evacuation.
7. What are the extraintestinal features of ulcerative colitis?  
See ulcerative colitis in the chapter 32 on large intestine.
8. What are the grades on ulcerative colitis?  
Depending on clinical severity of disease, ulcerative colitis may be:
  - i. Mild –
    - Less than 4 motions per day with or without rectal bleeding.
    - No systemic symptoms.
  - ii. Moderate –
    - More than 4 motions per day.
    - Rectal bleeding more frequent than milder form.
    - No systemic symptoms.
  - iii. Severe –
    - More than 4 motions per day.
    - Rectal bleeding is very frequent.
    - Systemic symptoms may be fever, weight loss and hypoalbuminemia.
9. What investigations are helpful for diagnosis of ulcerative colitis?
10. What is the medical treatment of ulcerative colitis?
11. What are the indications of surgical treatment?
12. What are the surgical options for ulcerative colitis?  
See 'ulcerative colitis' in the chapter 32 on large intestine.

### Hydatid Cyst (Fig. 101.12)

1. What is the specimen?  
This is a specimen of hydatid cyst.
2. Why do you say so?  
The specimen shows soap bubble or grape-like daughter cysts containing clear fluid. So, these are nothing but hydatid daughter cysts.
3. Which parasite causes hydatid disease?  
The parasites causing hydatid disease are
  - a. *Echinococcus granulosus* (Dog tapeworm) and

- b. *Echinococcus multilocularis* causing malignant hydatid disease.
- Which one is the definitive host for the *echinococcus*?  
Definitive host is one who harbors the adult parasite. Dog is the definitive host for the *Echinococcus*.
  - Who is the intermediate host for the *echinococcus*?  
The intermediate host harbors the larval forms of the parasite. Man and sheep are the intermediate hosts.
  - What are the common sites of hydatid cyst?  
a. Liver – 80 percent (commonest site).  
b. Spleen and other parts of abdomen – 18 percent.  
c. Lungs – 2 percent.
  - How does man get infected?
  - What are the different layers of the hydatid cyst?
  - What are the presentations of hydatid cyst?
  - How do you accurately diagnose the cyst?
  - How will you treat the hydatid cyst?
  - What are the complications of hydatid cyst if left untreated?
  - What is malignant hydatid disease?  
See Hydatid cyst of liver in the chapter 36 on 'liver' and see the long case 'Hydatid cyst of liver', chapter 73.
  - What are the functions of the endocyst?  
The germinal epithelium lining the endocyst secretes the laminated membrane externally and the hydatid fluid internally.
  - What are the cystic swellings of liver other than hydatid cyst?
  - Why it is called hydatid?
  - What is hydatid fluid?
  - What are the brood capsules?




**Fig. 101.12:** Specimen of hydatid cyst showing soap bubble or grape like daughter cysts containing clear fluid

- What scolical agents are used during operation?
- What are the indications of medical treatment of hydatid cyst?
- What is the prognosis?  
See the long case 'hydatid cyst of liver', chapter 73.

### Carcinoma Breast (Figs 101.13A and B)

- What is the specimen?  
This is a specimen of breast showing an irregular mass within the breast parenchyma. There is no definite capsule around the tumor. The nipple appears retracted. So this is a specimen of carcinoma of breast.
- Why do you say so?  
a. Absence of definite capsule.  
b. Retracted nipple.  
c. Irregular shaped mass within the breast parenchyma.
- What are the histopathological types of carcinoma breast?
- What is medullary carcinoma of breast?
- What is lobular carcinoma?
- What scirrhus carcinoma?
- What is the most malignant type of carcinoma breast?
- What is inflammatory carcinoma?
- What is Paget's disease of nipple?
- What is ductal carcinoma *in situ* (DCIS)?
- What is lobular carcinoma *in situ* (LCIS)?
- What is Manchester staging?
- What is the TNM classification?
- What is Border's histological grading?
- What is the percentage occurrence of carcinoma in various quadrants of breast?
- What are the risk factors for the development of breast carcinoma?
- What are the modes of spread of breast carcinoma?
- What are the effects of lymphatic obstruction in breast carcinoma?
- What is Nottingham prognostic index (NPI)?
- What are the different levels of axillary nodes?  
See the long case 'Early carcinoma of breast', chapter 72
- How does a patient with carcinoma of breast present?

- Lump in the breast – Typically, the patient presents with a painless lump in the breast.
  - Age – Breast carcinoma can occur at any age after puberty but it usually occurs after the age of 40 years.
  - Nipple discharge – is uncommon but may be the only symptom.
  - Enlargement, shrinkage or asymmetry of one breast.
  - With metastatic symptoms, e.g. chest pain, dyspnea, jaundice, ascites, enlarged axillary or left supraclavicular lymph nodes.
- What is the treatment of early breast cancer (Stage I and II)?
  - What is the treatment of late breast cancer?
  - What is the prognosis of early and late breast cancer?
  - What is the follow up plan in breast cancer?  
See 'carcinoma of the female breast' in the chapter 44.

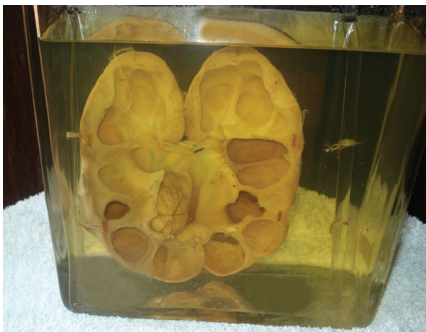

**Figs 101.13A and B:** Specimen of breast showing on irregular mass within the breast parenchyma



**UROLOGY SPECIMENS****Hydronephrosis (Fig. 101.14)**

1. What is the specimen?  
It is a specimen of hydronephrosis.
2. Why do you say hydronephrosis?
  - a. Kidney tissue is thinned out and stretched like parchment paper.
  - b. A little amount of cortical tissue is visible.
  - c. Pelvis is dilated.
  - d. Kidney is converted into multiple sacs. So the diagnosis is hydronephrosis.
3. What is hydronephrosis?  
Hydronephrosis is defined as an aseptic dilatation of renal pelvis and calices, accompanied by destruction of renal parenchyma caused by continuous incomplete or intermittent complete obstruction to the flow of urine.
4. Why aseptic dilatation?  
Originally there is no infection. Fluid may be secondarily infected.
5. Why there is no infection?  
Because of pyelovenous or pyelolymphatic backflow when urine gets infected it is known as infected hydronephrosis or pyonephrosis.
6. What are the important causes of hydronephrosis?
7. What are the pathological types of hydronephrosis?
8. What is Dietl's crisis?
9. What investigations are done to confirm the diagnosis?  
See the long case 'hydronephrosis', chapter 75.



**Fig. 101.14:** Specimen of hydronephrosis with the kidney tissue thinned out and stretched like parchment paper

10. How the patient presents?
  - a. Lump in the loin – unilateral/bilateral.
  - b. Pain – Dull aching or stretching pain but renal colic is present in case of stone.
  - c. Hematuria – may be present when stone is the cause.
  - d. There may be symptoms of the causes of hydronephrosis like enlarged prostate, stricture urethra, etc.
11. What is treatment of hydronephrosis?  
See 'hydronephrosis' in the chapter 'on kidney and ureter', chapter 46.

**Polycystic Kidney (Fig. 101.15)**

1. What is the specimen?  
It is the cut section of kidney showing polycystic disease of kidney.
2. Why do you say so?
  - a. There are multiple cavities in the cut section with intervening cortical tissue.
  - b. Some of the cavities intercommunicate.
  - c. Presence of cysts continuing hemorrhagic fluid.
3. What is the origin?  
It appears due to failure of fusion between the collecting and excretory part of the renal tissue.
4. What is the collecting part?  
The collecting part consists of the collecting tubules, pelvicaliceal system and ureter. It develops from the ureteric bud which arises from the lower part of mesonephric (wolffian) duct at about the 5th week of intrauterine life.
5. What is the excretory part?  
The excretory part consists of the nephron which contains renal capsule, i.e. glomerulus with Bowman's capsule, the



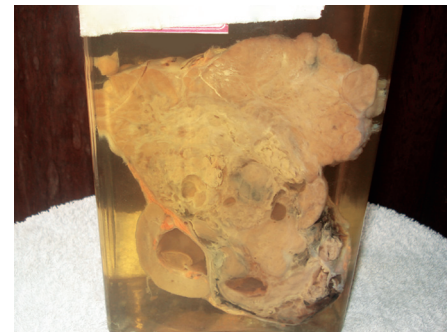
**Fig. 101.15:** The cut section of kidney showing polycystic disease of kidney

proximal and distal convoluted tubules and the loop of Henle. It is derived from the lowest part of the nephrogenic cord, the cells of which form the metanephric blastema or metanephrogenic cap.

6. Is it associated with other cystic disease?  
Yes, cystic disease of the liver, lungs and particularly pancreas.
7. What is the quality of urine?  
The patient passes lots of urine and the specific gravity is very low.
8. What are the presenting features?
9. What are the investigations?
10. How do you treat the patient?
11. What is infantile polycystic disease?  
See 'polycystic kidney' in the chapter on 'kidney and ureter', chapter 46.
12. What is the difference in appearance of polycystic kidney and hydronephrosis?
  - In polycystic kidney, the cysts are of varying sizes and do not communicate with the pelvicaliceal system.
  - In hydronephrosis the cystic spaces are intercommunicating as they are dilations of the pelvicaliceal system.

**Hypernephroma (Fig. 101.16)**

1. What is the specimen?  
It is a specimen of hypernephroma.
2. What is the proper term?  
The proper term is tubular adenocarcinoma of the kidney, that is, adenocarcinoma arising from renal tubular cells.
3. What was the original term and why it is called hypernephroma?  
Von Grawitz first described this tumor. Hence this is known as Grawitz tumor. Grawitz thought it arising from



**Fig. 101.16:** Specimen of hypernephroma

suprarenal 'adrenal cortical rest' which may sometimes be present in the cortex of the kidney. Hence the term hypernephroma.

4. On seeing the specimen why do you diagnose as such?

The cut section of the specimen shows the following:

- Presence of hilum.
  - Shape looks like kidney.
  - In the lower part there is healthy cortical tissue with pelvicaliceal system.
5. What is the naked eye or gross appearance of the tumor?
- The tumor in cut section shows variegated appearance and golden yellow color due to the presence of intracellular lipids.
  - The variegated appearance is due to the following:
    - In some place it is whitish due to the tumor tissue, in some place it is blackish due to hemorrhage and necrosis and
    - Areas of cystic degeneration imparts honeycomb appearance of the cut surface.
6. What is the microscopic appearance?
7. What investigations will you do to confirm the diagnosis?
8. What are the types of staging in hypernephroma?
9. What is Robson's staging?
10. What is TNM staging?  
See the long case 'Renal cell carcinoma', chapter 75.
11. How does the patient of hypernephroma present?
- Age – Usually above 40 years.
  - Sex – Males are more affected than females (2:1).
  - The classical triad of renal cell carcinoma consists of hematuria, pain and a mass in the loin while hematuria is present in 60 percent cases, all three are present in less than 10 percent of patients.  
Pain is dull aching due to stretching of the capsule. It may be colicky due to clot colic due to hematuria.
  - Pyrexia – Due to absorption of toxic materials liberated by the tumor tissue.
  - Patient may present with features of metastasis, e.g. pain chest, cough,

hemoptysis, bone pain, nodular liver, etc. without any local feature.

- Polycythemia – Due to liberation of erythropoietin by the tumor cells.
  - Hypercalcemia – Due to liberation of parathyroid hormone by tumor cells.
12. How will you treat the patient?  
See 'hypernephroma' in the chapter on 'kidney and ureter', chapter 46.
13. What is the prognosis of hypernephroma?  
See the long case 'renal cell carcinoma', chapter 75.

### Benign Enlargement of Prostate (Fig. 101.17) (Benign Prostatic Hypertrophy)

1. What is the specimen?  
It is a specimen of the benign enlargement of the prostate with a catheter/glass rod placed at the site of the urethra.
2. Why do you say so?  
Both the lobes are enlarged, median lobe is prominent. There is no nodule.
3. Why it is not enlarged thyroid?  
a. There is no isthmus connecting the two enlarged lobes.  
b. In thyroid, the two lobes are oblong shaped not globular.
4. What is benign prostatic hypertrophy (BPH)?
5. What are the hormonal theory and the neoplastic theory of development of benign prostatic hypertrophy?  
See 'benign enlargement of prostate' in the chapter on 'prostate', chapter 50.
6. What are the pathological changes produced by BPH?
- Changes in the urethra (prostatic):



**Fig. 101.17:** Specimen of the benign enlargement of the prostate with a catheter/glass rod placed at the site of the urethra

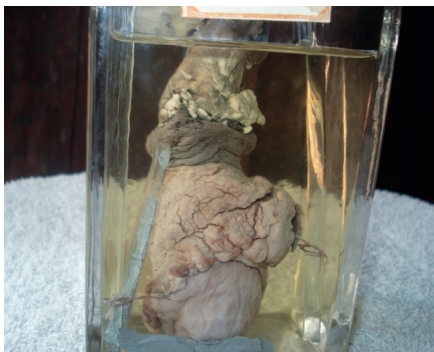- The urethra gets elongated and tortuous.
  - The shape looks like the letter 'S'.
  - The urethra is compressed from side to side.
2. Changes in the bladder:
- Formation of retroprostatic pouch with increased amount of residual urine → stagnation and infection → sometimes stone formation in the pouch.
  - Cystitis.
  - Hypertrophy and dilatation of the bladder.
  - Diverticulum and sacculum of the bladder.
  - Formation of stone in the bladder.
3. Changes in the kidney:
- Hydronephrosis.
  - Hydronephrosis.
  - Pyonephrosis.
  - Chronic renal failure
4. How does a patient with BPH present?
- An old man above 55 years, presents with features of prostatism, characterized by:
    - Hesitancy of micturition (Delay in the start).
    - Frequency of micturition.
    - Diminished flow of the urinary stream (instead of hitting back the pan it splashes the shoes).
  - Acute retention of urine.
  - Hematuria.
  - The patient may also present with hydronephrosis and renal failure.
5. Why does hesitancy occur?  
This occurs due to ball valve action. The enlarged median lobe obstructs the outflow whenever the patient tries to strain. Hence there is a delay.
6. Why does frequency occur?
- The prostatic urethra which is very sensitive gets irritated by the urine as a portion of it is dragged inside the bladder due to enlargement of the median lobe.
  - Due to cystitis and residual urine.
  - Stone in the bladder.
6. What is the microscopic picture in BPH?  
There is hyperplasia of all three tissue elements in varying proportions – glandular, fibrous and muscular.
7. What are the capsules of prostate?



8. What are the lobes of prostate?
9. What are the different zones of glands in the prostate?  
See 'anatomy of the prostate' in the chapter on 'prostate', chapter 50.
10. How would you investigate and treat a case of BPH?  
See benign enlargement of prostate in the chapter on prostate, chapter 50.

### Carcinoma Penis (Fig. 101.18)

1. What is the specimen?  
It is a specimen showing a growth over the penis.
2. Why do you say carcinoma of the penis?  
The growth looks like a cauliflower and is situated over the glans.
3. Can the patient present with acute retention of urine?  
No, because, the growth hardly infiltrates the urethra due to the presence of tough Buck's fascia.
4. What is the common age group?  
50 to 70 years.
5. How does the patient terminate?  
a. Intercurrent infection.  
b. Malignant cachexia.  
c. Hemorrhage due to erosion of femoral vein by the enlarged metastatic lymph nodes.
6. What are the risk factors for the development of carcinoma of penis?
7. What are the premalignant conditions?
8. What are the macroscopic types of carcinoma penis?
9. What are the microscopic types of carcinoma penis?
10. How does carcinoma of penis spread?
11. What is Jackson's staging of carcinoma of penis?

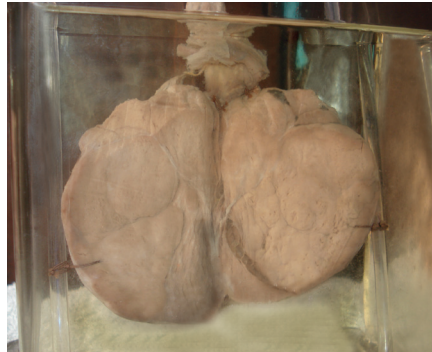


**Fig. 101.18:** Specimen of carcinoma of penis showing a cauliflower like growth

12. What is the treatment of CA penis?  
See carcinoma penis in the chapter 49 on urethra and penis. See also the short case "carcinoma of penis", chapter 84.

### Testicular Tumor – Specimen (Fig. 101.19)

1. What is the specimen?  
It is a cut section of testis and from the features I think it is seminoma of the testis.
2. Why it is seminoma and not a teratoma?  
The cut section shows homogeneous creamy white appearance. Fine septae are visualized.
3. What do you find in teratoma?  
Teratoma shows a variegated appearance, e.g. solid tissues, hemorrhagic areas and rarely ectodermal elements like hairs.
4. What is the origin of seminoma?  
Cells of seminiferous tubules present in rete testis. So by nature it is carcinoma.
5. What is the origin of teratoma?  
Totipotent germ cells often containing a mixture of all the elements ectoderm, endoderm and mesoderm.
6. What is the histological picture of seminoma?  
  - Seminoma cells lie in cords, sheets and columns forming lobules. Tumor cells have clear cytoplasm and large, hyperchromatic and centrally placed nuclei.
  - Grading: A continuum of well to poorly differentiated tumors.
7. What is the histological picture of teratoma?  
They are of four types in order of increasing malignancy:



**Fig. 101.19:** Specimen of cut section of testis showing seminoma of testis

- Malignant teratoma differentiated (MTT): Most cells are differentiated.
  - Malignant teratoma intermediate (MTI).
  - Malignant teratoma trophoblastic and yolk sac tumor: Most common in infants and children.
  - Malignant teratoma undifferentiated or anaplastic: 90 percent cases have elevated AFP or hCG or both.
8. How do you classify testicular tumors?
    - A. Germ cell tumors: 95 percent.
      1. Seminoma – 40 percent.
      2. Nonseminoma germ cell tumor (NSGCT) which includes different types of teratoma – 40 percent.
      3. Combination of seminoma and teratoma – 15 percent.
    - B. Nongermin cell tumors:
      1. Stromal tumors:
        - a. Leydig cell tumors – Masculinizing tumors.
        - b. Sertoli cell tumors – Feminizing tumors.
      2. Lymphoma – Rare.
      3. Metastatic, e.g. Leukemia.
  9. How do these tumors spread?
    1. Seminoma – Lymphatic spread is more common.  
Retroperitoneal nodes are mostly involved.
    2. Teratoma: More prone to hematogenous spread.  
Metastasis to brain, lung, liver and bone more common.
  10. How does a patient present with testicular tumor?
    - Age – teratoma – 25 to 35 years and seminoma – 35 to 45 years.
    - On local examination testis is hard, heavy, enlarged, cricket ball size. Surface – smooth in seminoma, nodular in teratoma. Testicular sensation – absent.
    - Associated hydrocele – present in 10 to 20 percent cases.
    - Cord and epididymis – Thickened.
    - Undescended testis – has a predilection to testicular tumor.
    - Metastatic features: e.g.
      - a. Abdominal lump due to enlarged lymph glands.
      - b. Pulmonary metastasis – cough, chest pain, hematemesis, etc.
      - c. Skeletal metastasis like bone pain.

- Unusual presentation: with gynecomastia and hurricane type killing the patient within a few months.
11. What investigations will you do?
    - a. USG of testis – Very important and differentiates from hematocele.
    - b. CT scan abdomen shows enlarged retroperitoneal lymph nodes – their positions and size.
    - c. X-ray chest to see pulmonary metastasis.
    - d. Tumor markers: hCG, LDH and AFP.
  12. How will you treat this case?
 

Seminomas are highly radiosensitive while teratomas are highly chemosensitive.

### Treatment

High orchidectomy: Once malignant tumor is confirmed the 1st step is high orchidectomy. Further treatment depends on the type of tumor.

- a. Seminoma – Early stage – Retroperitoneal and Mediastinal radiotherapy.  
Advanced stage – Chemotherapy with cisplatin, vincristine, bleomycin.
- b. Teratoma – Early stage – Follow up with serial CT scans and tumor markers.  
Advanced stage – Chemotherapy.

## ORTHOPEDIC SPECIMENS

### Sequestrum (Figs 101.20A and B)

1. What is the specimen?  
This is a specimen of sequestrum.
2. What is sequestrum?  
The sequestrum is a dead piece of bone in a living one either completely separated or in the process of separation from living bone by granulation tissue. It is usually found in chronic pyogenic osteomyelitis.
3. How do you know that it is sequestrum?  
This specimen of bone has smooth surface on one side and rough surface on the other side.
4. Why one side of sequestrum is rough and other side is smooth?  
The smooth side is in contact with pus and the rough side is in contact with the granulation tissue which tries to eat the sequestrum away.
5. Why it is not a rib?



**Figs 101.20A and B:** (A) Feathery sequestrum (B) Ring sequestrum

- In case of rib, unlike the sequestrum, both the surfaces are smooth.
6. What is slough?  
Slough is a necrosed soft tissue.
  7. What is involucrum?  
It is the laying down of dense sclerotic bone from periosteum on the surface of sequestrum.
  8. What is a cloaca?  
The Latin word cloaca means 'a canal'. Cloaca is thus an opening or canal situated in the involucrum through which bone chips and pus gradually come out.
  9. What are the types of sequestrum?  
Basically two types are found viz.
    - a. Pyogenic sequestrum and
    - b. Nonpyogenic sequestrum.
 Nonpyogenic sequestrum is of two types:
    - i. Feathery sequestrum and
    - ii. Ivory sequestrum.
  10. What is feathery sequestrum?  
These are very light and delicate looking simulating the feather of a bird (Fig. 101.20A). It is found in tubercular osteomyelitis.
  11. What is Ivory sequestrum?  
It is white, dense and heavy looking like Ivory. It is found in syphilitic osteomyelitis.
  12. What is ring sequestrum?  
It is a type of pyogenic sequestrum (Fig. 101.20B) developed at the amputation stump. It is small and circular in shape and is caused by:
    - i. Infection at the stump.
    - ii. Too much of elevation of periosteum during amputation thereby jeopardizing the blood supply.
  13. How does the sequestrum look in X-ray?  
It looks more dense and white in comparison to the surrounding healthy bone.

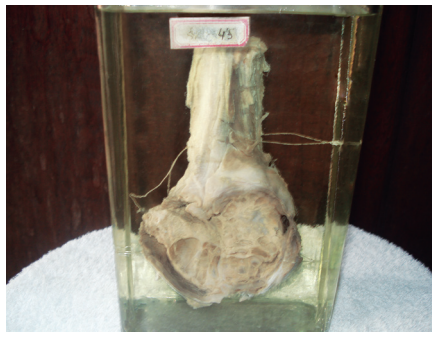14. Why more dense and white?  
Calcium deposited in dead bone, can not be washed away, whereas in healthy bone due to intact circulation, calcium is drained out. So there is no stagnation of calcium in healthy bone as in case of sequestrum.
15. How do you treat a case of sequestrum?  
Removal of sequestrum or sequestrectomy followed by saucerization of osteomyelitic cavity.
16. What is osteomyelitic cavity?  
It is a small infected cavity which harbors the sequestrum. It contains little amount of pus.
17. How do you differentiate it from Brodie's abscess?  
Brodie's abscess is also a cavity containing pus but there is no sequestrum instead it is surrounded by sclerosed bone.

### Osteosarcoma (Fig. 101.21)

1. What is the specimen?  
It is the specimen of osteosarcoma.
2. Why do you say so?
  - a. It arises from the metaphyseal region of the long bone (say the portion of bone involved).
  - b. There is soft tissue involvement, e.g. muscle and skin by the tumor.
  - c. Bone is not expanded or destroyed as in osteoclastoma.
3. Why do you say osteosarcoma not osteogenic sarcoma?  
Because, osteosarcoma may be osteogenic or osteolytic.
4. What are the sunray spicules?  
This is an X-ray finding.  
Tumor bone is laid below the periosteum along the stretched blood vessels which are prominent in X-ray plate as sunray spicules.



**Fig. 101.21:** Specimen of osteosarcoma arises from the metaphyseal region of the long bone with soft tissue involvement



**Fig. 101.22:** Specimen of osteoclastoma

5. What is Codman's triangle?  
Tumor bone is also laid at the junction of bone and lifted periosteum which appears in X-ray plate as a triangular dense shadow known as Codman's triangle.
6. What is the site of origin of osteosarcoma?  
Metaphyseal region.
7. What is the site of origin of osteoclastoma?  
Epiphyseal region.
8. How the tumor spreads?
9. What is the primary and secondary osteosarcoma?
10. How does a patient present with osteosarcoma?
11. How do you confirm the diagnosis?
12. How do you treat the patient?  
See 'osteosarcoma' in the chapter on bone tumors, chapter 61.

### Osteoclastoma (Fig. 101.22)

1. What is the specimen?  
It is the specimen of osteoclastoma arising from the upper end of tibia.
2. Where from does the tumor arise?
  - a. The tumor arises from the epiphyseal end of a long bone, e.g. lower end of femur, upper end of tibia.
  - b. It may also arise in the flat bones like ribs, scapula and mandible.
  - c. Fibula and lower end of radius may also be involved.
3. Is it the true nomenclature?  
No, because it is not arising from the osteoclasts. The correct name should be giant cell tumor as the tumor arises from the multinucleate giant cell situated at the epiphyseal end.
4. What is the common age for the tumor?  
Usually 25 to 35 years.
5. What is the age of occurrence of bone tumors?
  - a. 1st decade – Ewing's sarcoma.
  - b. 2nd decade – Osteosarcoma.
  - c. 3rd decade – Osteoclastoma.
  - d. 4th decade – Multiple myeloma.
6. Is the tumor benign or malignant?  
The tumor may be benign, locally aggressive or malignant.
7. What is the naked eye appearance of the tumor?
8. What is the microscopic feature?
9. How does the patient present?
10. What are the X-ray findings of the tumor?
11. How do you confirm the diagnosis?  
See 'osteoclastoma' in the chapter on 'bone tumors', chapter 61.
12. What is osteoclastoma alba?  
It is the osteoclastoma of the lower end of radius. It is called osteoclastoma alba as it looks white for its relative avascularity.
13. Why pathological fracture is common?  
As the bone is thinned out and there is cortical destruction, pathological fracture commonly occurs.
14. What is the treatment of pathological fracture?  
Operative fixation of the fracture ends followed by bone grafting.
15. How do you treat the tumor?  
See 'osteoclastoma' in the chapter on 'bone tumors', chapter 61.

# Problems

- Introduction
- Gastrointestinal surgery
- Thyroid
- Breast
- Trauma
- Urology
- Preoperative preparations

## INTRODUCTION

1. Problems are asked as part of the viva voce. These consist of surgical emergencies like acute intestinal obstruction, acute abdominal pain, acute retention of urine, trauma, etc. as well as ward procedures like preoperative preparation in patients with diabetes mellitus, obstructive jaundice, thyrotoxicosis, etc.
2. Usually one or two problems are asked.
3. In theory papers also problem-related questions are set.
4. The problems discussed below are commonly asked in the examination.

## GASTROINTESTINAL SURGERY

### Acute Abdominal Pain (Acute Abdomen)

Q. A patient has come to emergency with acute abdominal pain. What will be your approach for management (i.e. diagnosis and treatment)?

As soon as the patient comes one should exclude medical causes of acute abdomen by proper history taking, clinical examination and relevant bedside laboratory investigations and routine examination of blood and urine.

Medical causes of acute abdomen are:

- i. Acute myocardial infarction with epigastric pain, nausea and vomiting. The distinguishing feature is complete absence of any epigastric tenderness.
- ii. Pleurisy and pneumonia may present with acute abdominal pain due to irritation of the lower intercostal nerves, which supply the abdominal wall.
- iii. Diabetic ketoacidosis – Ketonic smell may be present with impairment of consciousness and marked dehydration.
- iv. Herpes zoster.
- v. Drugs like warfarin and digoxin.
- vi. Porphyria.
- vii. Hepatitis due to drugs and viral infections.
- viii. Nonspecific mesenteric lymphadenitis especially in children.
- ix. Intestinal amebiasis/giardiasis or other worm infestations may mimic acute abdomen.

The important surgical causes should be differentiated from one another by their respective important clinical features and relevant investigations available at hand-like plain X-ray abdomen, examination of blood and urine, etc.

Important surgical causes are:

1. Acute cholecystitis.
2. Acute pancreatitis.
3. Acute intestinal obstruction.
4. Acute peptic perforation.
5. Acute appendicitis.

## Diagnostic Features

### 1. Acute cholecystitis –

- i. The patient is usually an adult female patient with pain in the right upper abdomen which radiates to the inferior angle of right scapula or right shoulder.
- ii. The pain is often precipitated by a fatty food, heavy meal or certain vegetables like cabbage.
- iii. History of biliary dyspepsia (indigestion and belching with fatty food) may be present.

Investigations:

- i. Blood – There is leukocytosis.
- ii. Plain X-ray abdomen – It may reveal gallstone in 10 percent cases. It will exclude acute intestinal obstruction and peptic perforation.
- iii. Ultrasonography – It will confirm the presence of stone which is responsible for more than 90 percent cases of acute cholecystitis.

### 2. Acute pancreatitis –

- a. Classically a middle-aged male or female patient presents with acute upper abdominal pain which radiates to the back and gets relieved by leaning forward.
- b. The patient may be addicted to alcohol (alcoholic pancreatitis) or suffer from gallstone disease.



c. Features of shock, dehydration and oliguria are likely to be present.

Investigations:

- Blood – Leukocytosis.
- Serum amylase – Raised
- Plain X-ray abdomen to exclude peptic perforation and intestinal obstruction.

### 3. Acute intestinal obstruction –

- a. The patient typically presents with colicky abdominal pain, vomiting and abdominal distension.
- b. Investigation – Plain X-ray abdomen shows distended intestinal loops with multiple air fluid levels.

### 4. Acute peptic perforation –

- a. The patient presents with previous history of peptic ulcer.
- b. Acute epigastric pain with sweating.
- c. There is muscle guard and rigidity and obliteration of liver dullness.
- d. Plain X-ray of abdomen shows free gas under the right dome of diaphragm.

### 5. Acute appendicitis –

- a. The patient presents with acute abdominal pain, which starts in the periumbilical region and then localizes to the right iliac fossa.
- b. Tenderness present over the McBurney point.
- c. Psoas test is positive which means on extension of the hip joint there is pain.
- d. Rovsing's sign – Pressure over the left iliac fossa will lead to pain in the right iliac fossa in acute appendicitis.

## Treatment

1. Acute cholecystitis – Treatment is conservative with:
  - i. Nasogastric suction.
  - ii. IV fluid.
  - iii. Wide spectrum parenteral antibiotic.
  - iv. Nothing per mouth.
  - v. Operation is done after 6–8 weeks after conservative treatment.
2. Acute pancreatitis:
  - a. Treatment of choice is conservative as in case of acute cholecystitis.
  - b. Moist O<sub>2</sub> inhalation if the patient is in shock.
  - c. Treatment of pain with inj pethidine and other analgesics.
  - d. Injection ranitidine.

e. Somatostatin or octreotide to reduce pancreatic secretion.

Operative treatment is indicated if the above treatment yields no result and in case of pancreatic abscess and pseudocyst.

3. Acute intestinal obstruction – Surgery is the treatment of choice backed by proper preoperative preparation.
4. Acute peptic perforation – Surgery is the treatment of choice. Laparotomy is done and perforation is repaired.
5. Acute appendicitis – Immediate appendectomy is the treatment of choice unless there is lump formation.

## Acute Cholecystitis

Q. A female patient aged 35 years presents with acute pain in the right upper abdomen with history of biliary dyspepsia. How will you manage the case?

The likely diagnosis in this case will be acute cholecystitis. The other possibilities which may cause acute pain in the right upper abdomen include acute pancreatitis. Peptic ulcer perforation, acute retrocecal appendicitis, right-sided pyelonephritis and the medical causes mentioned above in acute abdomen.

The approach to such a patient to arrive at a diagnosis is detailed history taking, physical examination and the relevant investigations.

## History

- a. Pain – Detailed history of pain is to be noted like time of onset, site at onset, mode of onset (sudden in case of perforation, colic and gradual in case of intestinal obstruction), radiation and character of pain, aggravating and relieving factors, history of similar episodes of pain earlier.
- b. Associated symptoms like vomiting, urinary symptoms like frequency, burning sensation hematuria.
- c. Details of menstrual history and history of past illness like peptic ulcer, any mass in abdomen.

## Physical Examination

1. General survey:
  - One should look for features of shock, e.g. rapid thready pulse, cold clammy skin, hypotension, shrunken eyes, dry tongue, etc. in a patient with acute abdomen.

• State of nutrition, jaundice and pallor are examined.

## 2. Examination of abdomen

- Inspection:
  - To look at the hernial orifices.
  - Any visible peristalsis, any fullness or distension of abdomen and presence of any obvious lump.
- Palpation:
  - To look for tenderness and rebound tenderness.
  - Muscle guard and rigidity.
  - Murphy's sign which is elicited in acute cholecystitis.
  - If any lump is palpable, detailed examination of the lump regarding the site, size, shape, tenderness, mobility, pulsation and consistency should be done.
  - Rovsing's sign, psoas test and obturator test (elicited in acute appendicitis).
- Percussion:
  - Obliteration of liver dullness present in case of peptic ulcer perforation.
  - Any organomegaly like liver, kidney, spleen, etc.
- Auscultation – Peristaltic sounds present or absent.
- Per rectal and per vaginal examination done to exclude any pelvic mass, pelvic collection or tenderness.

## Systemic examination:

- Examination of the cardiovascular system to exclude acute myocardial infarction.
- Examination of the respiratory system to exclude pleurisy or basal pneumonia.

## Investigations

- a. Blood – Leukocytosis is found in acute inflammatory conditions.
- b. Serum amylase and lipase – Elevated levels suggest acute pancreatitis.
- c. Chest X-ray PA view.
- d. Straight X-ray abdomen – Helpful in hollow viscus perforation and intestinal obstruction.
- e. Ultrasonography of abdomen.
- f. CT scan of abdomen in selected cases.
- g. Upper GI endoscopy for diagnosis of peptic ulcer disease.



Treatment – It is done according to the underlying cause as already outlined in acute abdomen.

### Acute Peptic Perforation

Q. A 45-year-old male patient presents with pain in the epigastrium which afterwards become generalized. On examination there is cardboard-like rigidity and obliteration of liver dullness. How will you manage this case?

The most likely diagnosis is perforated peptic ulcer causing generalized peritonitis.

The approach is the same as for a case of acute abdomen due to acute cholecystitis described above, that is, detailed history taking, clinical examination and relevant bedside laboratory investigations.

In a suspected perforated peptic ulcer, a chest X-ray PA view in erect posture is done which shows free gas under right dome of diaphragm.

Q. How patients with peptic perforation usually present?

Q. What are the stages of development of peritonitis in peptic perforation?

Q. How do you treat a case of peptic perforation?

See 'perforated gastric or duodenal ulcer' in the *chapter 30* on 'stomach and duodenum'.

### Acute Pancreatitis

Q. A middle-aged male patient who is a chronic alcoholic has come to emergency with acute pain in the epigastrium for 2 days which radiates to the back. How will you proceed to manage the case?

- The most likely diagnosis in this patient is acute alcoholic pancreatitis.
- The approach to such a patient to arrive at a diagnosis is detailed history, physical examination and the relevant investigations as in a case of acute abdomen due to acute cholecystitis described above.

Q. What are the important etiological factors for the development of acute pancreatitis?

Q. What is acute pancreatitis?

Q. How alcohol causes pancreatitis?

Q. How gallstones cause pancreatitis?

Q. What is the pathology of acute pancreatitis?

Q. What is the usual presentation of patients with acute pancreatitis?

Q. How USG and CT scan help in evaluation of a patient with acute pancreatitis?

Q. What are the Ranson's criteria for predicting the severity of acute pancreatitis?

Q. How do you treat a case of acute pancreatitis?

Q. What are the complications of acute pancreatitis?

See acute pancreatitis in the chapter 38 on 'pancreas'.

### Acute Intestinal Obstruction

Q. A 55-year-old male patient has presented to emergency, with pain in abdomen, vomiting, abdominal distension and absolute constipation. How will you manage the case?

The likely diagnosis in this case is acute intestinal obstruction.

The approach to such a patient to arrive at a diagnosis is detailed history taking, physical examination and the relevant investigations as in a case of acute abdomen due to acute cholecystitis described above. Moreover, the following points are to be noted during examination of the abdomen.

1. Inspection:
  - a. Presence of scar indicates band obstruction or adhesion.
  - b. Distension:
    - Central – Small gut, obstruction
    - Peripheral – Large gut, obstruction
    - Left side more distended in case of volvulus.
  - c. Peristalsis – Step ladder peristalsis in terminal ileal obstruction.
  - d. Abdominal movement diminished with respiration.
2. Palpation:
  - a. Presence of tenderness or rebound tenderness indicates peritonitis. Rebound tenderness is also called Blumberg's sign.
  - b. Muscle guard: Presence of muscle guard indicates peritoneal irritation by blood or intestinal contents. In case of intestinal obstruction, it indicates strangulation.

3. Percussion:

- a. Usually tympanic note on percussion.
- b. Obliteration of liver dullness indicates hollow viscus perforation.

4. Auscultation:

- Metallic sounds in mechanical obstruction.
- No sounds – Paralytic ileus.
- Clicks or gurgles – Normal.

5. Hernial sites – Must be examined to avoid laparotomy and false diagnosis.

Treatment will be done accordingly after establishing the diagnosis.

Q. What are the important causes of intestinal obstruction?

Q. What is the pathophysiology of intestinal obstruction?

Q. How will you treat this patient with acute intestinal obstruction?

See 'mechanical intestinal obstruction' in the *chapter 34* on 'intestinal obstruction'.

Q. How will you differentiate between simple and strangulated obstruction?

See table below.

### Acute Appendicitis

Q. A 20-year-old woman has come to emergency with pain in the right iliac fossa. How would you proceed to examine and investigate the case to arrive at a diagnosis? Give an outline of treatment to be adopted?

- The most likely diagnosis in this case will be acute appendicitis.
- The other possibilities which may cause acute pain in the right lower abdomen include:
  - a. Meckel's diverticulitis.
  - b. Psoas abscess and other causes of acute abdomen as mentioned above.
  - c. Right-sided ruptured ectopic pregnancy.
  - d. Acute salpingitis.
  - e. Twisted right ovarian cyst.

The approach to such a patient to arrive at a diagnosis is detailed history taking,

**Table 102.1: Simple intestinal obstruction versus stragulated obstruction.**

Simple obstruction	Strangulated obstruction
1. Pain is intermittent colicky	1. Pain is continuous
2. Rebound tenderness and muscle guard absent	2. Present
3. General conditions are stable	3. General conditions change – There is hypotension, tachycardia, sweating and scanty urine

physical examination and the relevant investigations which are same as described above in acute pain in the right upper abdomen in case of acute cholecystitis.

- Treatment is done accordingly after establishing the diagnosis.
- In Meckel's diverticulitis, Meckel's diverticulectomy with a wedge of ileum is the treatment of choice.
- In ruptured ectopic gestation, resuscitation followed by exploratory laparotomy and right salpingectomy along with removal of the product of conception is the treatment of choice. Similarly in right twisted ovarian cyst, right ovarian cystectomy is performed.

Q. A lady aged 30 years complains of acute pain in right lower abdomen. What are the common possibilities? How would you arrive at a diagnosis? Give the outline of treatment?

The answer to this question will be in the same line as above for acute appendicitis.

### Appendicular Lump

Q. How will you manage a patient presenting with a lump in right iliac fossa?

The important causes of lump in the right iliac fossa are.

- I. Parietal swellings:
  - Lipoma.
  - Desmoid tumor.
- II. Intraabdominal swellings which may arise in connection with:
  - a. Structures normally present there and
  - b. Structures present there abnormally.
  - a. Lump arising from the normal structures
    1. Intestines:
      - a. Appendicular lump (commonest).
      - b. Appendicular abscess.
      - c. Carcinoma cecum.
      - d. Hyperplastic tuberculosis of ileocecal region.
      - e. Crohn's ileitis.
      - f. Acute lymphadenitis.
      - g. Lymphoma.
      - h. Secondaries.
    2. Retroperitoneal swellings, e.g.
      - Retroperitoneal sarcoma.
      - Iliopsoas abscess.
    3. In females – Ovarian cyst, fibroid uterus and tuboovarian mass.
  - b. Lump arising from abnormal structures:
    1. Undescended testis – Seminoma.

2. Unascended or dropped kidney – Hydronephrosis.

To arrive at a diagnosis a detailed history, physical examination and some relevant investigations are required. These are done in the same line as described above in case of acute pain in right upper abdomen, i.e. acute cholecystitis and in the chapter on 'examination of a swelling'.

### Appendicular Lump and Abscess

Q. What is appendicular lump?

Q. What is the conservative treatment (Ochsner-Sherren regime) for treatment of appendicular lump?

Q. What is appendicular abscess?

Q. How will you treat appendicular abscess? See 'complications of acute appendicitis' in the chapter 33 on 'appendix'.

### Upper GI Bleeding or Hematemesis

Q. A patient has come with hematemesis, how do you manage?

OR

Q. What is upper GI bleeding? enumerate the causes. How do you manage such a case?

- Upper GI bleeding is defined as bleeding from the GI tract proximal to the ligament of Treitz and commonly manifests as hematemesis.
- Hematemesis is blood vomiting, blackish red in color and acidic in reaction. It must be differentiated from hemoptysis which is coughing out of blood – bright red in color and alkaline in reaction.

### Causes

- I. Causes in the esophagus:
  1. Ruptured esophageal varices (portal hypertension).
  2. Reflux esophagitis leading to an ulcer of lower end of esophagus.
  3. Carcinoma esophagus.
- II. Causes in the stomach:
  1. Gastric ulcer.
  2. Acute gastric erosion especially due to intake of drugs like aspirin.
  3. Gastric carcinoma.
  4. Mallory – Weiss tear – a vertical tear in the mucous membrane at esophagogastric junction resulting from repeated vomiting.

III. Causes in the duodenum:

1. Duodenal ulcer.
2. Acute hemorrhagic duodenitis – commonly associated with head injury.
3. Acute duodenal ulcer resulting from stress or Curling's ulcer found in case of burn.

IV. Miscellaneous causes, e.g.

1. Angiomatous malformation anywhere in the upper GI tract.
2. Collagen diseases like SLE and polyarteritis nodosa.
3. Blood dyscrasias.

Of the various causes mentioned above, the following are the most important for the practical purpose.

- i. Bleeding from the peptic ulcer (Gastric ulcer and duodenal ulcer combined) – responsible for more than 90 percent cases.
- ii. Bleeding from ruptured esophageal varices – about five percent.
- iii. Bleeding from gastric carcinoma – about three percent.
- iv. Rest 1 percent is due to miscellaneous causes.

### Management

This consists of:

1. Diagnosis from detail history taking, physical examination and relevant investigations like upper GI endoscopy, CT scan, etc. and
2. Treatment which comprises:
  - a. Resuscitation.
  - b. Steps to arrest hemorrhage.
  - c. Final treatment of the cause.
- I. History:
  - a. History of peptic ulcer disease.
  - b. History of recent heavy use of alcohol or antiinflammatory drugs like aspirin which will give rise to erosive gastritis.
  - c. History of repeated vomiting producing hematemesis indicates Mallory Weiss tear or syndrome.
  - d. History of loss of weight, anorexia and vomiting suggest gastric carcinoma.
  - e. History of bleeding from any part of the body with slight provocation makes one suspect the presence of blood dyscrasias.
- II. Physical examination:
  - a. Signs of chronic liver disease like hepatosplenomegaly, jaundice, ascites, spider angioma and gynecomastia

suggest portal hypertension and bleeding from gastric or esophageal varices.

- b. An epigastric hard lump or enlarged neck glands suggest gastric carcinoma.

### III. Investigations:

1. Blood—Hemoglobin, prothrombin time and other coagulation studies.
2. Endoscopy of upper GI tract within first 12 to 24 hours can be very helpful in planning rational therapy by visualizing the bleeding source.
3. Ultrasonography of whole abdomen and CT scan of abdomen are done to know pathology of the organs.

### Treatment

1. Resuscitation—As soon as the patient comes with features of hypovolemic shock, from loss of blood, the following steps of resuscitation are taken:

- i. IV fluid channel is established for:
  - a. IV infusion of fluid and electrolytes.
  - b. Infusion of plasma expanders to make up the volume loss.
  - c. Fresh blood transfusion.
  - d. Injection of Sodibicarb to correct metabolic acidosis, if required.
  - e. Administration of pressure raising drugs like injection dopamine.
- ii. Ryle's tube suction of stomach which evacuates the collected blood and gives an idea about continuation of bleeding.
- iii. Moist O<sub>2</sub> inhalation to correct anoxia.
- iv. Catheterization with self-retaining Foley's catheter to know the intake-output chart.
- v. Wide spectrum antibiotic by parenteral route to combat infection.
- vi. Monitoring of pulse, respiration and blood pressure.

2. Steps to arrest hemorrhage:

- a. For bleeding peptic ulcer:
  - i. Endoscopic control of bleeding by thermocoagulation or clipping or Nd: YAG laser coagulation.
  - ii. If the above fails, operative intervention and ligation of the bleeding point under direct vision is done.
- b. For rupture of esophageal varices:
  - i. Use of Sengstaken tube. This is a temporary measure (48 hours).
  - ii. IV pitressin – 20 units in 200ml of saline over 20 min.

iii. Endoscopic thermocoagulation or Nd: YAG laser coagulation.

iv. Definitive treatment like porta caval shunts in case continued bleeding or an elective procedure in patients with history of past bleeding. See also 'portal hypertension' in the chapter 36 on 'liver'.

3. Final treatment of cause:

- a. For gastric carcinoma – Radical (upper, lower or subtotal) gastrectomy.
- b. For gastric ulcer – Partial gastrectomy.
- c. For duodenal ulcer with outlet obstruction – Vagotomy and gastrojejunostomy is done.

See also 'peptic ulcer hemorrhage' in chapter 30.

### Lower GI Bleeding

Q. What is lower GI bleeding?

It is the bleeding of GI tract distal to the ligament of Treitz. This bleeding cannot pass into the stomach so common presentation is melena and hematochezia.

Q. What are the causes?

1. Benign anorectal conditions, e.g hemorrhoid, fissure, polyps, and injuries to rectum.
2. Inflammatory bowel disease, e.g. ulcerative colitis and Crohn's disease.
3. Neoplasms – Colonic polyps and carcinoma.
4. Colonic vascular malformation – angiodysplasia.
5. Meckel's diverticulitis.

Q. How will you manage the case?

It consists of:

1. Diagnosis of the cause and site of bleeding from detail history taking, physical examination and relevant investigations like colonoscopy, ultrasound and CT scan, etc. and
2. Treatment – comprising resuscitation and definitive operation.

Q. How will you localize the site of bleeding?

The following investigations are done to localize the site of bleeding:

1. Per rectal digital examination, proctoscopy and sigmoidoscopy.
2. Upper GI endoscopy – If blood is present in nasogastric suction, upper GI endoscopy is done to detect the presence of duodenal ulcer.

3. Colonoscopy is a valuable technique for evaluation of patients with small to moderate lower GI bleeding. It can diagnose the site and cause of bleeding in most cases.

4. 99mTc radiolabeled red blood cell scan can localize the hidden site of bleeding.
5. Barium enema – may be helpful for diagnosis of diverticulosis.

Q. How will you treat?

1. If source is known, local resection of the affected bowel or colonoscopic electrocoagulation of angiodysplasia is done.
2. If source of bleeding is not known, total colectomy is done as a last resort.

Q. What is the outcome?

- Bleeding stops spontaneously in 90 percent cases.
- Mortality is 10 to 15 percent.

### Bleeding Per Rectum (Hematochezia)

Q. What are the common causes of bleeding per rectum?

- a. Rectal polyp.
- b. Internal piles.
- c. Carcinoma rectum.
- d. Fissure in ano.
- e. Bleeding from colon and small intestine – ulcerative colitis, carcinoma and Meckel's diverticulitis.
- f. Infectious gastroenteritis.

Q. What is the commonest cause of bleeding per rectum in a child?

Rectal polyp is the commonest cause.

Q. How do you treat internal piles?

Hemorrhoidectomy.

Q. How do you evaluate a patient with hematochezia?

Proper evaluation of the patient to arrive at a diagnosis requires history taking, physical examination and relevant investigations.

I. History –

- History of peptic ulcer disease or recent heavy use of alcohol or antiinflammatory drugs for a possible upper GI source sites.
- History of bleeding at other sites at slight provocation may indicate the presence of blood dyscrasias.
- History of bleeding per rectum in drops at the end of defecation suggests hemorrhoids.

## II. Physical examination

1. Fever with hypovolemia as evidenced by tachycardia and hypotension may represent inflammatory bowel disease or infectious gastroenteritis. Shigella, *E. coli* and salmonella infections often cause bloody diarrhea.
2. Abdominal examination may reveal a mass or tenderness.
  - A right lower abdominal mass may be present in Crohn's disease or carcinoma of cecum.
  - A left lower abdominal mass may be associated with carcinoma of left colon or diverticulitis.
  - Bowel sounds may be hyperactive as blood is a cathartic.
  - Rectal examination may show hemorrhoids, fissures or a growth.

III. Investigations: These are same as described above to localize the site of lower GI bleeding.

**Neonatal Intestinal Obstruction**

- Q. What are the common causes of neonatal intestinal obstruction?  
The common causes are:
- a. Intestinal atresia (From duodenum to colon).
  - b. Volvulus neonatorum.
  - c. Meconium ileus.
  - d. Hirschsprung's disease.
  - e. Imperforate anus.
- Q. What is the commonest cause of neonatal intestinal obstruction?  
Intestinal atresia, commonly duodenum is affected, followed by ileum and jejunum.
- Q. How will you diagnose and treat duodenal atresia?  
*Diagnosis*
- a. Abdominal X-ray – shows double bubble sign due to gastric and duodenal obstruction.
  - b. Total absence of gas distal to duodenum indicates atresia rather than stenosis.
- Treatment* – Duodenojejunostomy.
- Q. What is volvulus neonatorum and how do you treat this condition?
- Q. How will you treat meconium ileus and volvulus neonatorum?  
See 'neonatal intestinal obstruction' in the *chapter 34* on 'intestinal obstruction'.
- Q. When will you suspect neonatal intestinal obstruction?

- a. Bilious vomiting, however small it may be.
- b. Abdominal distension and
- c. Constipation should make one suspect neonatal intestinal obstruction.

**Strangulated Inguinal Hernia**

Q. What is strangulated hernia?

When an inguinal hernia gets obstructed and the blood supply of the gut is jeopardized, it is known as strangulated inguinal hernia.

Q. How does a patient with strangulated inguinal hernia present?

Q. What is the treatment?

See 'strangulated inguinal hernia' in the *chapter 42* on 'hernia'.

Q. What precautions do you take during operation of strangulated inguinal hernia?

- a. Strangulation should never be relieved before letting out the highly infected fluid content of the sac. The fluid is let out by making a nick in the sac otherwise fluid enters the peritoneal cavity.

- b. Gut is examined for viability after relieving the strangulation. If the gut is viable, it is pushed into the abdominal cavity, if not, resection and anastomosis is to be done.

Q. What are the signs of nonviability of gut?

- a. Absence of pulsation in the mesentery.
- b. Absence of peristalsis in the affected loop.
- c. Color is greenish or blackish instead of red.
- d. The fluid in the sac is red in color and foul smelling.

In doubtful cases, hot mop should be applied to the loop of gut for at least ten minutes to see if signs of viability appear.

**THYROID****Postoperative Respiratory Distress After Total Thyroidectomy**

Q. A 40-year-old female patient had undergone total thyroidectomy and developed severe respiratory distress on the same day of operation. How will you manage?  
Important causes of respiratory distress after thyroidectomy are:

1. Hemorrhage.

2. Laryngeal edema following prolonged intubation.
3. Collapse or kinking of the trachea rarely as a complication of large goiter.
4. Bilateral recurrent laryngeal nerve palsy which may cause respiratory obstruction if associated with laryngeal edema.
  1. Hemorrhage – A tension hematoma develops deep to the cervical fascia causing dyspnea. It is a reactionary type of hemorrhage occurring from the cut surface of the gland or due to slipping of ligature from a main vessel, most commonly the superior thyroid artery.

**Treatment**

- a. The wound is opened up immediately in the ward. All the stitches are cut and the trachea is exposed to relieve the pressure exerted on it by the accumulated blood clots.
  - b. Proper exploration is then made in the operation theater, hemostasis achieved and the wound is closed with adequate drainage.
2. Collapse or kinking of trachea (Tracheomalacia) – This condition will need immediate endotracheal intubation or tracheostomy.

**Tetany**

Q. A patient has developed tetany 5 days after total thyroidectomy. How will you manage?  
The tetany is due to hypoparathyroidism as a result of removal of parathyroids or impairment of their blood supply during thyroidectomy. See 'postoperative complications after total thyroidectomy' in the *chapter 23* on 'thyroid'.

**BREAST****Breast Lump**

A 45-year-old female patient has presented with a lump in her right breast. How will you manage?

The important causes of lump in the breast in this age group are:

1. Benign tumors, e.g. fibroadenoma and duct papilloma.
2. Malignant tumors, e.g. carcinoma of breast.
3. Nonneoplastic lesions, e.g.
  - a. Fibroadenosis

- b. Cyst.
- c. Tuberculosis of breast.
- d. Galactocele.
- e. Antibiooma.
- f. Organized hematoma.
- g. Traumatic fat necrosis.

*Mnemonic: FAT*

F – Fibroadenoma, Fibroadenosis, Fat necrosis.

A – Antibiooma,

T – Tumors (Duct papilloma and carcinoma), tuberculosis.

The management consists of detailed history, clinical examination, relevant investigations and definitive treatment.

### History

History about the lump:-

- Onset and progress.
- Any pain present or not. Fibroadenosis may be painful.
- Family history of breast carcinoma.
- Personal history – details of menstrual and obstetric history.

### Examination of breasts

- Shape and symmetry of breasts.
- Areola – Shape, presence of crack, ulcer or fissure.
- Skin over the breast – Scar, venous prominence, etc.
- Any obvious swelling – Site, size, shape, surface, margin, consistency, fixity to skin pectoral fascia and chest wall.
- Examination of axillary lymph nodes.
- Examination of abdomen – Respiratory and cardiovascular system.

### Investigations

- Complete hemogram.
- Liver function tests
- Chest X-ray.
- Mammography or USG of breast to see the nature of lump.
- Biopsy from the lump – FNAC is very sensitive and specific. If FNAC is inconclusive a tru cut needle biopsy or incisional biopsy is indicated.

### Treatment

The treatment is done according to the underlying cause, e.g.

- a. Fibroadenoma – Simple excision.
- b. Duct papilloma – Microdissectomy.

- c. Carcinoma of breast –
  - i. Early carcinoma of breast. (See also the long case ‘early carcinoma of breast’ chapter 72).
    - Breast conservative surgery.
    - Modified radical mastectomy and adjuvant therapy viz. Radiotherapy, hormone therapy and chemotherapy.
  - ii. Advanced carcinoma of breast:
    - Palliative surgery, e.g. toilet mastectomy.
    - Adjuvant therapy, e.g. systemic chemotherapy, hormone therapy and radiotherapy to breast and axilla.
- d. Fibroadenosis:
  - i. Reassurance.
  - ii. Evening primrose oil.
  - iii. Danazol failing primrose oil.

### Nipple Discharge

Q. A 35-year-old female patient presented with abnormal nipple discharge. How will you manage this patient?

The important causes of nipple discharge in such a patient include:

- a. Milky discharge – Hyperprolactinemia.
- b. Blood stained – Duct papilloma, duct carcinoma, duct ectasia, Paget’s disease.
- c. Purulent – Breast abscess.
- d. Various shades (Brown, green or black) – fibroadenosis (Fibrocystic disease).

### Diagnosis

Diagnosis is made from the clinical examination and some relevant investigations.

### History

- a. Detailed history is taken about the character of discharge and its origin from a single or many ducts.
- b. Any lump in the breast, if present onset and progress.
- c. History of any pain and fever.

### Examination of Breast

Symmetry of the breast, and nature of discharge. If a lump is palpable, size, shape margin, consistency, etc. is noted.

### Investigations

- i. Examination of discharge – For blood, Gram stain and Papanicolaou stain.
- ii. Mammography.
- iii. USG of breast.

- iv. If lump is palpable FNAC from the lump.
- v. If milky discharge, serum prolactin assay.
- vi. Ductography if duct pathology is suspected.

### Treatment

Depends on the underlying cause, e.g.

- a. Fibroadenosis –
  - Reassurance.
  - Evening primrose oil.
  - Danazol.
- b. Duct ectasia and duct papilloma without lump formation involving a single duct — Microdochectomy.
- c. If there is duct carcinoma — treatment depends on the stage of the disease as in case, of carcinoma of breast stated above in ‘breast lump’.
- d. Breast abscess — Incision and drainage under general anesthesia.
- e. Paget’s disease
  - i. Simple mastectomy for *in situ* carcinoma without a lump.
 If associated with a lump and invasive ductal carcinoma treatment is done as in case of carcinoma of breast stated above.

## TRAUMA

### Polytrauma

Q. A 40-year-old male patient has come to emergency with multiple injuries following a road traffic accident. How will you manage this patient?

A. The management of multiply injured patient consists of the following protocol:
 

- i Primary survey and resuscitation
- ii Secondary survey and
- iii Definitive care.

Q. What are the components of the primary survey and resuscitation?

A. The elements of primary survey one (ABCDE); are — airway, breathing, circulation, disability (neurologic), and exposure (undress) and environment (temperature control).

These refer to a priority order and should be done immediately as soon as the patient comes before any history taking or other aspects of the physical examination.

Q. How will you manage airway?

Q. How will you give breathing and circulatory support?



See evaluation and general management of the multiply injured patient in trauma section.

Q. How will you manage (neurologic) disability and exposure / environmental control?

A. *Disability* - A rapid neurologic evaluation should be done to assess the initial dysfunction of the nervous system from the following:

- A – Alert V – response to vocal stimuli.
- P – Responds only to painful stimuli.
- U – Unresponsive to all stimuli.

Exposure and environment control:

- The patient should be fully undressed and exposed for examination of any external injury.
- After patients clothing is removed and assessment completed, the patient should be covered with warm blankets or a warming device to prevent hypothermia.

Q. What is secondary survey?

A. The secondary survey consists of a detail history and a head to foot examination. History is taken from the patient if conscious or from the accompanying person or relative if unconscious.

In history the following points are asked – (AMPLE)—Allergies, Medication, Past medical history, Time of last food or drink, Events and environment related to injury the secondary survey in benign once the patient is stabilized during the primary survey and resuscitation.

Q. What general measures are taken for this patient?

Q. What is Triage?

Q. What is the golden hour?

Q. What is done in definitive care phase?

A. See 'evaluation and general management' of multiply injured patient in 'trauma section'.

### Head Injury

Q. What is head injury?

A. Head injury one of composite nature as the injury to the skull bones, intracranial (vessels and the brain occur either singly or in different combinations. However, injury to the brain is almost always a constant factor and the other injuries may or may not be associated with it.

Q. How do you assess the level of consciousness in head injury?

Q. How do you classify head injury?

Q. What is primary brain injury?

Q. What is secondary brain injury?

Q. What investigations will you do in a patient with head injury?

Q. What measures will you take to control the raised intracranial pressure (ICP) in head injury?

Q. What is extradural haematoma (EDH) and how will you treat the condition?

Q. What is acute and chronic subdural haematoma? How do you treat them?

Q. What is the treatment of skull fracture?

A. See 'Head injury' in the chapter on Trauma.

### Thoracic Trauma

Q. Enumerate the spectrum of thoracic injuries?

Q. What are the types of chest injuries?

Q. How do you examine and investigate a case of chest injury?

Q. What are the indications of thoracotomy in chest injury?

Q. How do you treat rib fracture?

Q. What is flail chest and how do you treat this condition?

Q. What are the types of traumatic pneumothorax?

Q. How will you diagnose and treat closed pneumothorax?

Q. How will you treat surgical emphysema?

Q. What is traumatic haemothorax and how do you treat it?

Q. What is pericardial tamponade and what is its treatment?

Q. What is the treatment of diaphragmatic injury?

Q. How will you diagnose and treat the esophageal injury?

A. See thoracic injuries in the chapter on thoracic trauma.

### Abdominal Trauma

Q. A 40-year-old man has sustained blunt trauma abdomen following a road traffic accident. How will you investigate and manage this case?

A. The management plan is the same as in case of a polytrauma patient described earlier that is

- a. Primary survey and resuscitation

b. Secondary survey consisting of a full history, clinical examination and investigations. And

c. Definitive care.

Q. What are the common organs injured in blunt trauma abdomen?

A. The spleen followed by the liver are the common organs injured in blunt trauma abdomen.

Q. What are the clinical features of splenic injury? How will you diagnose and treat a case of splenic injury?

Q. What are the complications of splenectomy?

Q. What are the types of liver injury and how will you treat it?

Q. How will diagnose and treat pancreatic trauma?

Q. What is damage control surgery in major trauma?

Q. What is abdominal compartment syndrome?

A. See the chapter on abdominal trauma.

Q. What are the types of abdominal trauma?

Q. How will manage colon and rectal injuries?

A. See colon and rectum injury in the chapter on abdominal trauma.

### Genitourinary Trauma

#### Renal Injury

Q. A 35-year-old male patient suffered blunt trauma abdomen due to a motor vehicle accident. He was having haematuria and right loin pain. How will you manage the case?

A. The general plan of management is the same as in case of blunt trauma abdomen mentioned above.

Q. What are the pathological grades of renal injury?

Q. What investigations will you do in renal trauma?

Q. What is the treatment of minor renal injury?

Q. What are the indications of surgery in major renal trauma?

Q. What are the surgical options?

A. See 'kidney injury' in the chapter on genitourinary trauma.

#### Bladder And Urethral Injury

Q. A male patient aged 25 years has undergone pelvic fracture due to a road traffic

accident. Since the accident, he is not passing urine with progressive distension of abdomen. How will you manage the case?

- A.
- The most likely diagnosis in this case will be concomitant bladder and/or urethral injuries.
  - The line of management will be same as in case of a multiply injured patient that is
    - a. Primary survey and resuscitation
    - b. Secondary survey with a full history, physical examination and relevant investigations.
    - c. Definitive care.
- Q. What is the pathology in case intra and extra peritoneal rupture of urinary bladder?
- Q. How do you diagnose intra and extra peritoneal rupture of bladder?
- Q. How will you treat a case of bladder injury?
- A. See 'Bladder injury' in the chapter on genitourinary trauma.
- Q. What is the treatment of posterior urethral injury?
- Q. How do you treat the injury to anterior urethra?
- Q. What are the complications of urethral injury?
- A. See injuries to the urethra in the chapter on genitourinary trauma.

### Burn

- Q. A 35-year-old female patient has suffered a 50% burn injury. How will you manage the case?
- A. The management of burn patient is performed following the same line as the trauma management that is, primary survey and resuscitation comprising ABCDE, physical examination and relevant investigations and definitive care consisting of local treatment of burn wound and other aspects of general care like tetanus prophylaxis, H<sub>2</sub> blocker etc.
- Q. How do you classify burns?
- Q. What is the rule of 9 or how will you assess the amount of burn area?
- Q. How do you administer fluid in a burn patient according to Parkland formula in the first and second 24 hours period of burn?
- Q. What are burn shock and its pathogenesis?
- Q. What is the local treatment of burn?

Q. What are the general aspects of burn care?

Q. What are the complications of burn injury?

Q. What is burn contracture? How do you prevent and treat the condition?

A. See the chapter on Burn.

## UROLOGY

### Acute Retention Of Urine

Q. A 65-year-old male patient has come to emergency with acute retention of urine. How will you manage?

A. The causes of retention of urine in a 60 years old male patient are –

i Bladder outlet obstruction

#### Causes

- Benign hyperplasia of prostate commonest
- Carcinoma of prostate
- Carcinoma bladder
- An obstructing calculus at the bladder neck.

ii Urethral causes

- Stricture
- Calculus
- Tumours
- Urethritis

iii Pressure from outside e.g. carcinoma rectum.

iv Others

- Meatal stenosis
- Phimosis
- Drugs like narcotics, anticholinergics etc.
- Injury or disease of the spinal cord.

The management of this patient involves diagnosis of the cause of retention from physical examination and investigations and treatment of the cause and thereby relief of retention.

- Physical examination involves per rectal examination to detect prostate enlargement or rectal growth.
- Genital examination to look for purulent or bloody (traumatic) discharge.
- Abdominal examination may reveal distended bladder.
- Neurologic examination is done to see any herniated disc or other lesions.

### Investigations

1. Urine is tested for RBC and signs of infection.

2. Blood urea and electrolytes to assess renal function.

3. Full blood count.

4. Prostate specific antigen if carcinoma prostate is suspected.

5. Plain x-ray of kidney, ureter and bladder (KUB) to see the presence of calculi.

6. Ultrasonography of KUB, region and prostate,

### Treatment of retention

1. Conservative measures

- Privacy and sound of running water may be helpful.
- Application of heat and cold alternately
- Over the hypogastrum

2. Catheterization

Q. How will you do definitive treatment of retention of urine?

A. This is done according to the cause of retention e.g.

1. Transurethral resection of prostate (TURP) or open prostatectomy in case of BPH.

2. Radical prostatectomy or radical radiotherapy for carcinoma confined to prostate. For advanced or metastatic disease, androgen deprivation (Bilateral orchidectomy, Antiandrogens like Flutamide, cyproterone acetate) is the treatment of choice.

3. Urethral dilatation is done for stricture urethra.

4. Transurethral resection of bladder tumour for non invasive tumours and radiotherapy and total cystectomy alone or in combination is done for muscle invasive tumours.

Q. What are the different types of retention?

A. Two types — Acute and chronic retention. Acute retention is painful while chronic retention is painless.

Q. What are the causes of retention in infants?

- A.
- Phimosis and urethral valve.
  - Stones in bladder in school going children.

### Hematuria

Q. A 50-year-old patient has presented with hematuria. How will you manage?

A. The important causes of hematuria are –

- i In the kidney –
  - Trauma
  - Tumour – Renal cell carcinoma (RCC)
  - Tuberculosis

- Calculus
- Polycystic kidney
- ii Renal pelvis and uerter
  - Tumor – Transitional cell carcinoma
  - Calculus
- iii Urinary bladder
  - Stone – in school going children
  - Carcinoma of bladder
  - Carcinoma prostate
  - Cystitis
  - Tuberculosis
- iv Prostate
  - Benign hyperplasia of prostate
  - Carcinoma of prostate
- v Urethra
  - Tumor
  - Granuloma
- vi Rare causes
  - Patients on anticoagulants and analgesics
  - Bleeding disorders

To arrive at a definite diagnosis, a detailed history, clinical examination and some relevant investigations are required. Treatment depends on the underlying cause.

### History

- i History about haematuria –
  - Quantity – Profuse hematuria occurs in papilloma.
  - Colour – Bright red from lower urinary tract, dark from the kidney.
  - It's relation to maturation – When blood appears at the beginning of the act (urethral), towards the end (vesical) or is intimately mixed throughout the flow (prerenal or renal).
- ii History suggestive of bladder outlet obstruction e.g. frequency, urgency, hesitancy and narrow stream of urine.
- iii Any history of urethral trauma or in take of drugs.
- iv Any history of pain: Painless hematuria is seen in case of new growth like papilloma or carcinoma and painful hematuria, in case of urinary calculi.

### Physical examination

- a General survey to look for any pallor, pulse, blood pressure, cachexia.
- b Local examination for any palpable lump in the loin, or palpable bladder in the hypogastric region.

- c Per rectal examination to assess the prostate size or carcinoma or growth in the rectum involving the bladder.

### Investigations

1. Examination of urine –
  - a Urine is poured in tray containing water and examined.
    - Worm like clots – seen in case of growth in ureter
    - Flat disc like – urethral growth
    - Pieces of tumour – papilloma of bladder.
  - b Microscopic examination
    - Abacterial of sterile acid pyuria suggests renal tuberculosis.
    - Pus cells, seen in urinary tract infection and malignant cells positive, in renal cell carcinoma or papilloma bladder
2. Examination of blood to see the bleeding and coagulation time.
3. Cystoscopy – To see the presence of any growth, inflammation or ulcer.
4. Intravenous Urography (IVU):
  - a Alternated and elongated calices (spider leg deformity) with clubbing or cupping are seen in polycystic kidney and renal cell carcinoma. But the former condition is frequently bilateral.
  - b Papilloma in renal pelvis is shown by a filling defect in the pelvis of the kidney.
5. X-ray of KUB region – may show renal, ureteric or bladder stones.
6. Ultrasound examination will detect renal cell carcinoma and stones.
7. CT scan of abdomen – for diagnosis of kidney tumour and its extent.

### Treatment

Depends on the underlying cause:

- a Carcinoma of kidney – see 'hypernephroma' in the chapter on kidney and ureter.
- b Renal stones and ureteric stones – see the chapter on kidney and ureter.
- c Bladder stones – see vesical stone in the chapter of urinary bladder.
- d For enlarged prostate and carcinoma of prostate – see acute retention of urine above.
- e Renal trauma – see problems in trauma section.

## PREOPERATIVE PREPARATIONS

### Preoperative Management Of Diabetes

Q. Why preoperative control of diabetes is necessary?

A. This is necessary for the following reasons:

- a There is unrecognized hypoglycemia, ketoacidosis and protein depletion in the postoperative period.
- b Uncontrolled diabetes predisposes to increased incidence of infective complications and cardiac problems like acute myocardial infarction or arrhythmias.
- c Impairment of wound healing.

Q. What is the perioperative management of a diabetic patient?

A.

- a The two goals in the management of diabetes are to prevent hypoglycemia by providing exogenous glucose and to prevent hyperglycemia and ketoacidosis by assuring and adequate supply of insulin.
- b The patient is admitted 2 to 3 days before surgery.
- c Long acting insulin or oral hypoglycemic drugs should be stopped and soluble insulin started.
- d The patient should be the first case in the operating list in the morning.
- e Catheterization is done to make urine available for sugar estimation as and when necessary.
- f Oral feeding is started as early as possible after the operation. The preoperative drug regime of oral hypoglycemic drugs or long acting insulin should be started at the earliest opportunity after the surgery.
- g The perioperative management differs according to the nature of operation as follows –
  - i. *For minor operation* – usually no alteration in diabetic management is necessary. If the patient must omit a meal, an i.v. infusion of 5% dextrose is started to run 50 to 100 ml / hour to prevent hypoglycemia.
  - ii. *For major operation* – The operation is carried out only if the blood glucose levels are within normal limits.

**Regimen**

There are many regimens available for the perioperative management of insulin dependent diabetes mellitus (IDDM), one of such is described below:

- i Usual preoperative fasting orders are followed.
- ii Blood glucose levels, serum electrolytes, and urine for sugar and ketones are tested 2 hours before surgery.
- iii If the patient is likely to be fasting for more than 6 hours, an infusion of 5% dextrose water with 5 meq of kcl and 4 to 6 units of soluble insulin (GKI or glucose potassium insulin regimen) is started at a rate of 50 ml per hour. This infusion is continued during the surgery and in the postoperative period.
- iv Hourly blood glucose levels are checked and the infusion rate adjusted to maintain blood sugar levels between 100 to 180 mg% and potassium within 4 to 5 meq/dl. The stress of surgery increases the requirement of insulin so that the blood glucose levels need to be monitored closely during the surgery and in the postoperative period.

**Preoperative Preparation of Case of Gastric Outlet Obstruction**

See the long case "Gastric outlet obstruction" due to complication of chronic duodenal ulcer.

**Preoperative Preparation in a Case of Obstructive Jaundice**

This has been discussed in connection with choledocholithiasis in the chapter on gall bladder.

**Preoperative Preparation for Colorectal Surgery**

See the operation of right hemicolectomy in the operative surgery section.

**Preoperative Preparation in a Case of Toxic Goiter**

- a *Aim* - The aim of preoperative preparation is to make the euthyroid or near euthyroid at operation. The normal thyroid status is determined by clinical assessment e.g. by improvement of clinical symptoms and by objective signs such as lowered pulse rate, weight gain and serial estimations of the thyroid profile.
- b *Preparation* -
  - i Carbamazole in the dose of 30 to 40 mg a day is the preparation of choice. When the gland becomes euthyroid (usually after 8 to 12 weeks) the dose may be reduced to 5 mg 8 hourly. Thyroxin 0.1 mg daily may be given in conjunction with Carbamazole lessening the danger of producing iatrogenic thyroid insufficiency.

ii *Beta Blocker* -

- The alternative method of preparation is by using Beta blocking drugs e.g. propranolol 40 mg TDS or Nadolol (long acting) 160 mg once daily for a week or two.
  - The advantage is that operation can be arranged in a few days rather than weeks. The dose may be increased to achieve the desired response and sometimes larger doses like propranolol 80 mg TDS and Nadolol 320 mg daily are necessary.
  - Beta blockers do not interfere with synthesis of thyroid hormones and hormone levels remain high during treatment and for some days after thyroidectomy. So the drug is continued for 7 days postoperatively.
  - Propranolol inhibits the peripheral conversion of  $T_4$  to  $T_3$ .
- iii *Lugol's iodine* - 8 to 10 drops TDS for 10 days before operation may be given with Carbamazole or beta blocker. It helps to reduce the vascularity of the gland and thereby reduces the operative blood loss.
  - iv Propranolol or nadolol control symptoms very rapidly and may be used in combination with carbamazole in control very severe hyperthyroidism.

## X-rays

- Introduction
- Plain X-ray abdomen
- Radiopaque shadows in plain X-ray
- Chest X-ray
- Contrast films
- Oral cholecystography
- ERCP
- T-tube cholangiography
- Intravenous urogram or pyelogram
- Ultrasonography
- CT scan and MRI
- MRI scan
- Orthopedic X-rays

### INTRODUCTION

1. One or two plain or contrast X-rays are given in the practical examination.
2. The candidate must be able to identify the X-rays and tell the provisional diagnosis.
3. Questions are asked regarding the clinical presentation, pathology and treatment of the condition provisionally diagnosed.
4. The examinee should also have some knowledge about modern radiological investigations like ultrasonography, CT scan and MRI scan.

### PLAIN X-RAY ABDOMEN

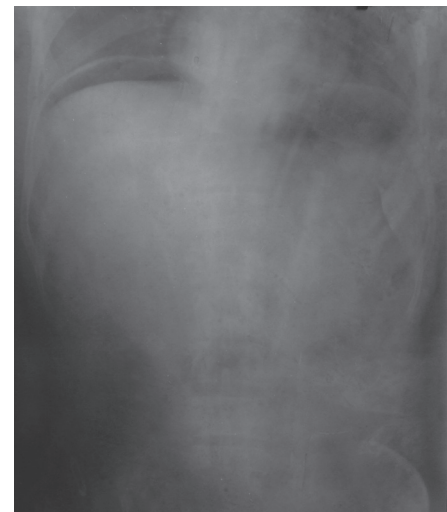#### Free Gas Under Diaphragm (Fig. 103.1)

1. What is the X-ray?  
This is a plain X-ray of the chest PA view along with upper part of abdomen showing free gas (air) under both domes of the diaphragm.
2. What does it indicate?  
It indicates the presence of pneumoperitoneum.
3. What is the commonest cause of pneumoperitoneum?

Hollow viscus perforation, e.g.

- a. Stomach—Peptic ulcer perforation and perforation of malignant gastric ulcer.
  - b. Small gut perforation due to typhoid ulcer, tubercular ulcer and trauma.
  - c. Large gut perforation due to malignancy, diverticulitis, volvulus, trauma and iatrogenic following sigmoidoscopy, colonoscopy, etc.
4. What is the commonest site of peptic perforation?  
The commonest site is the anterior wall of the first part of duodenum.
  5. What may be the cause in this X-ray?  
Peptic ulcer perforation.
  6. Why?  
Because it is the commonest cause—Massive gas is indicative of peptic perforation.
  7. Does the absence of gas exclude peptic perforation?  
No, gas may be absent in 30 percent cases. It may be due to a slow perforation. If ulcers perforate posteriorly, gas is then confined to the retroperitoneum and may not be evident on X-ray.
  8. What are the pathological stages of presentation?  
See 'perforated gastric or duodenal ulcer' in the chapter 30 on 'stomach and duodenum'.

9. What is the clinical presentation of a patient with peptic ulcer perforation?  
The patient most commonly presents in the first stage of development of peritonitis known as stage of chemical peritonitis or stage of peritonism. The features are:
  - a. History of sudden agonizing pain in the upper abdomen usually following a large meal.



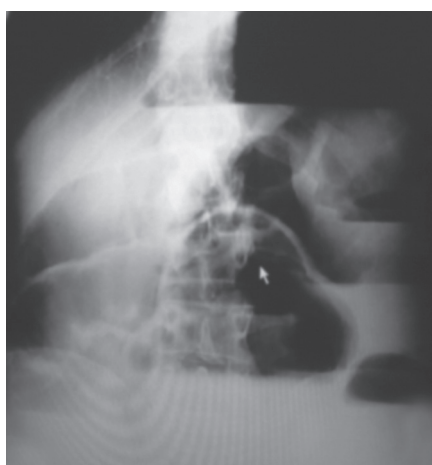
**Fig. 103.1:** Plain X-ray of the chest PA view along with upper part of abdomen showing free gas (air) under both domes of the diaphragm



- b. Patient gives history of peptic ulceration and treatment.
- c. Drug history of ingestion of steroids or NSAIDs.
- d. On abdominal examination, there may be muscle guard or rigidity (cardboard rigidity) all over the abdomen, on percussion, liver dullness may be obliterated and on auscultation bowel sounds may be absent.
10. How will you treat peptic perforation?  
The patient is treated by resuscitation followed by laparotomy, repair of perforation and thorough peritoneal toilet.
11. How will you resuscitate the patient?
- Intravenous fluid—Ringer lactate is infused to replace the fluid deficit.
  - Urinary catheterization is done to monitor the intake output chart.
  - Nasogastric suction.
  - Broad spectrum antibiotic, e.g.
    - A second or third generation cephalosporin, e.g. ceftriaxone – 1gm IV once daily.
    - Injection amikacin 500 mg IV twice daily and
    - Injection metrogyl 500 mg IV twice daily.
  - Monitoring of vitals, e.g. pulse, BP, respiration, etc.
12. What are the steps of repair of perforation?  
See 'repair of peptic ulcer perforation' in chapter 30.
13. What is the most important part of this operation?  
Peritoneal toilet.
14. What is the significance of pneumoperitoneum in a patient with blunt trauma abdomen?  
This indicates injury to either small or large intestine. There may be a simple perforation or complete transection of the gut. The management will be in the same line as that of peptic perforation.
15. What is the postoperative treatment after repair of peptic perforation?
- To continue the nasogastric aspiration, IV fluid, antibiotics and IV ranitidine or omeprazole.
  - Monitoring of vital signs and urine output.
16. What clinical sign is reliable when free gas is not demonstrable?  
Obliteration of liver dullness is fairly reliable.
17. How will you manage gastric perforation?
- Closure with the omental patch.
  - Occasionally partial gastrectomy.
  - Biopsy of the ulcer edges to exclude gastric cancer.
18. What is the name of the omental patch procedure?  
It is called Graham's patch repair.

### Multiple Air—Fluid Levels (Fig. 103.2A)

1. What is this X-ray?  
This is a plain X-ray of abdomen with lower part of chest and upper part of pelvis taken in erect posture showing multiple air fluid levels. The gas-filled intestinal loops are central in location and arranged in a stepladder fashion.
2. What is the provisional diagnosis?  
The appearance is suggestive of acute small intestinal obstruction.
3. In what conditions, multiple fluid levels are seen?
- Dynamic or mechanical small intestinal obstruction.
  - Paralytic ileus.
4. How the fluid levels are developed?
- Gut is distended with gas and fluid in intestinal obstruction.
  - If X-rays are taken in a standing or erect position, gases accumulate above the fluid in different loops of intestines and the gas fluid interface appears as a straight line.
5. What number of fluid levels normally present?



**Fig. 103.2A:** Plain X-ray of abdomen in erect posture showing multiple air fluid levels

About 3 to 4 fluid levels are present in normal patients. If fluid levels are more than 4, intestinal obstruction is suspected.

6. How does the patient present clinically?  
The patient presents clinically with four cardinal features viz.
- Abdominal distension.
  - Vomiting.
  - Intermittent colicky abdominal pain and
  - Absolute constipation.
- It is important to note that not all of these four features need necessarily be present in a case of intestinal obstruction.
7. Why is there intermittent colicky pain?  
Intestine from time to time tries to overcome the mechanical obstruction by vigorous contractions. This produces colicky abdominal pain.
8. Why does abdominal distension occur?  
Abdominal distension occurs due to the accumulation of fluid comprising various digestive juices and gas, mainly nitrogen (90%) and hydrogen sulphide.
9. Why is there vomiting?  
Due to distension of the gut with fluid and gas, patient tries to relieve it by vomiting. So, in high intestinal obstruction, it is early and more prominent but in low or large intestinal obstruction, it may be late.
10. What are the important causes of intestinal obstruction?
11. What are the volumes of different gastrointestinal secretins?  
See the chapter 34 on 'intestinal obstruction'.
12. What will be the findings on abdominal examination?
13. How will you treat the patient with intestinal obstruction?
14. How will you differentiate between simple and strangulated obstruction?  
See the problem 'acute intestinal obstruction'.
15. What is the preoperative resuscitation of a patient with acute intestinal obstruction?
16. How will you perform exploratory laparotomy in a case of acute intestinal obstruction? How will you diagnose the site of obstruction on exploration?
17. How will you differentiate a viable and nonviable segment of gut?  
See the chapter 34 on 'intestinal obstruction'.

**Sigmoid Volvulus (Fig. 103.2B)**

## 1. What is the X-ray?

It is a plain film of the abdomen and upper part of pelvis with features of sigmoid volvulus.

## 2. What are the features?

The features are due to gross distension of the colon with gas shadows and depicted by the following signs:

- Bent inner tube sign.
- Dahl Froment's sign.
- Bird's beak deformity.

## 3. What is bent inner tube sign?

The dilated and distended colon appears twisted like a rubber tube with a cut off distally. This is called bent inner tube sign.

## 4. What is Dahl Froment's sign?

- Three lines are seen in the dilated sigmoid colon.
- The two outer lines indicate the outer margins and the intervening line is formed by two inner wall of gut.
- All these three lines converge over the left sacroiliac joint. This is called Dahl Froment's sign.

## 5. What is bird's beak deformity?

Water-soluble or barium contrast stops at the site of obstruction and tapers to a point like the beak of a bird. This is known as bird's beak deformity.

## 6. What is volvulus?

Volvulus is defined as the twisting of a loop of bowel around its mesenteric axis,

which results in a combination of bowel obstruction together with ischemia due to occlusion of the main vessels at the base of the involved mesentery.

It is a type of closed loop obstruction and may result in strangulation and perforation.

## 7. What is a compound volvulus?

- Sometimes a loop of ileum gets twisted with volvulus of sigmoid colon and there may be gangrene in either ileum, sigmoid colon or both. This is also known as ileosigmoid knotting.
- Plain X-ray shows both distended ileal and sigmoid loops.

## 8. What are the sites where volvulus can occur in the gastrointestinal tract?

- Sigmoid colon—Most common.
- Cecum—When mobile.
- Small intestine.
- Transverse colon.
- Stomach.

## 9. Why volvulus is common in sigmoid colon? This is due to the following factors.

- Band or adhesion at the antimesenteric border.
- An abnormally loaded colon of chronic constipation.
- Long redundant colon.
- Long mesentery with less fat.

## 10. Name some important causes of large gut obstruction?

- Within the lumen—Fecal impaction.
- In the wall
  - Carcinoma of colon.
  - Strictures
    - Tubercular.
    - Anastomotic.
    - Crohn's disease.
    - Ulcerative colitis.
    - Malignant stricture.
- Outside the wall
  - Strangulated hernia.
  - Volvulus.

## 11. How does a patient with sigmoid volvulus present?

- The patient is usually an elderly male complaining of sudden abdominal pain with distension.
- The distended gut feels like a segment of pneumatic tire. Initially the left side, then entire abdomen is distended.
- Constipation.
- History of similar episode of pain and abdominal distension earlier.

## 12. What is the character of rotation?

- The upper loop falls on the lower loop in an-anticlockwise movement.
- At half turn—There is luminal obstruction, at one and half turn twisting, there is venous obstruction and at two and half turns twisting, there is arterial obstruction.

## 13. Is the rotation always anticlockwise?

No, in case of cecal volvulus, rotation is clockwise.

## 14. How do you treat a case of sigmoid volvulus?

## 15. What is the treatment of cecal volvulus?

See 'volvulus' in the chapter 34 on 'intestinal obstruction'.

## 16. What is pseudo-obstruction or Ogilvie's syndrome?

- Clinically and radiologically this condition mimics mechanical obstruction without any apparent cause.
- Neuronal cause may be responsible.
- Treatment is initially conservative but if this fails or peritonitis sets in, surgical treatment is advised.

## 17. What is the treatment of compound volvulus?

- If circulation is impaired one should not try to untwist it.
- The gut is deflated by puncture, and then resection is done.
- The knot of ileum is untied. According to viability, resection and anastomosis of ileum may be required.

**RADIOPAQUE SHADOWS IN PLAIN X-RAY****Kidney Stone (Fig. 103.3)**

## 1. What is the X-ray?

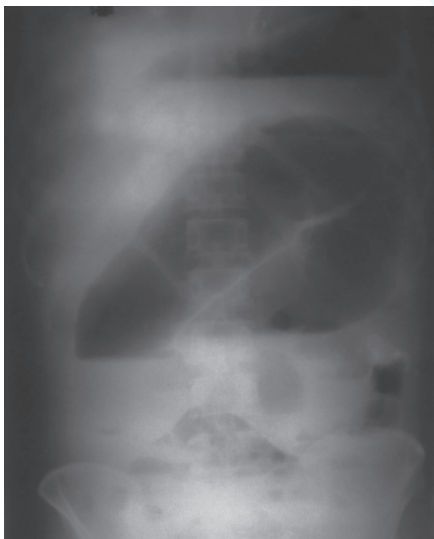This is a plain film of kidney, ureter and bladder region (KUB region) showing radiopaque shadow in the right kidney region suggesting kidney stone.

## 2. What percentage of gallstone and kidney stones are radiopaque?

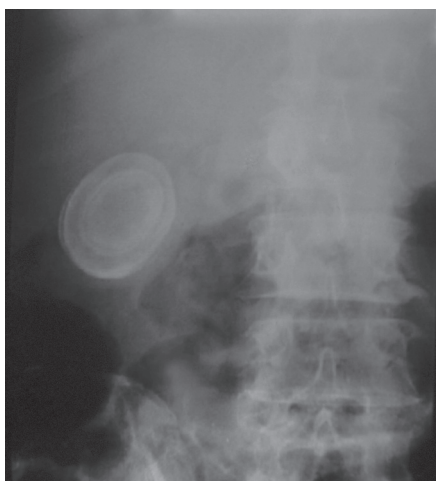About 90 percent of kidney stones are radiopaque but only 10 percent of gallstones are radiopaque.

## 3. What is the differential diagnosis of radiopaque shadows in this region?

- Kidney stone.
- Gallstone.



**Fig. 103.2B:** Plain film of the abdomen and upper part of pelvis with features of sigmoid volvulus



**Fig. 103.3:** Plain X-ray of KUB region showing radiopaque calculus in the right kidney region

- c. Foreign body.
  - d. Fecolith (Dried up fecal matter in the lumen of bowel presenting like a stone).
  - e. Phlebolith.
  - f. Calcified lymph node.
  - g. Calcified adrenal gland.
  - h. Calcified renal tuberculosis.
  - i. Chip fracture of transverse process of vertebra.
  - j. Pancreatic calculi.
4. How will you differentiate between gallstone and kidney stone?
    - a. This is done by taking a lateral view.
    - b. A gallstone is seen well anterior to the vertebral body while kidney stone is seen superimposed on the vertebral body.
    - c. Confirmation will be done by an ultrasonography.
  5. Which type of renal stones is radiopaque?
    - Oxalate stones.
    - Phosphate stones.
    - Cystine stone.
    - Xanthine stones.
  6. Which types of renal stones are radiolucent? Uric acid stones are radiolucent. But if these stones are contaminated with calcium salts, they may be radiopaque.
  7. How the patients with renal stone present?
    - a. Asymptomatic—If the stones are nonobstructive.
    - b. Symptomatic group:
      - i. Pain is the leading symptom in 75 percent of patients.

#### Types

- Fixed renal pain which is dull aching in nature felt in the renal angle and gets worse by movement, e.g. walking up the stairs.
- Renal or ureteric colic—Caused by a stone impacted at the pelviureteral junction or by a stone migrating down the ureter.

ii. Hematuria.

iii. Pyuria.

iv. Recurrent UTI.

v. May present with complications like hydronephrosis, pyonephrosis or renal failure.

8. How renal stones are formed?

9. What are the characteristics of phosphate stones?

10. What are the characteristics of oxalate stones?

11. What are the characteristics of uric acid stones?

12. What are the characteristics of cystine stones?

13. How renal stones are treated by ESWL?

14. What is percutaneous nephrolithotomy (PCNL)?

15. What are the complications and indications of PCNL?

16. What is the indication of open surgery for renal stones?

17. What are the open surgical options for renal stones?

See 'renal stones' in the chapter 46 on 'kidney and ureter'.

#### Gallstones (Fig. 103.4)

1. What are the different types of gallstones?

2. What are the characteristics of mixed stones?

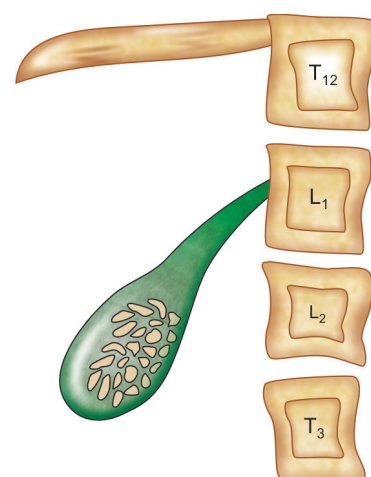
3. What are the characteristics of pigment stones?

4. What are the characteristics of cholesterol gallstones?

5. How cholesterol stones are formed?

6. What is the pathogenesis of pigment stones?

7. What is the pathogenesis of infected or mixed stones?  
See 'gallstones' in the chapter 37 on 'gall bladder'.



**Fig. 103.4:** A gallbladder filled with radiopaque stones which are rare

#### Vesical Calculus (Fig. 103.5) (Schematic)

1. What is the X-ray?

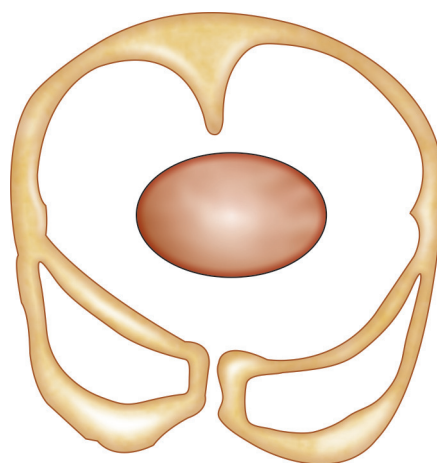
This is plain X-ray of abdomen and pelvis showing a radiopaque shadow in the pelvis, possibly a vesical calculus.

2. What is a primary and secondary vesical calculus?

a. Primary vesical calculus—

i. This type of calculus originates in the kidney and then passes into the bladder where it enlarges. The urine is sterile.

ii. Chemically these are oxalate, cystine and uric acid stones.



**Fig. 103.5:** Vesical calculus as seen in a plain radiograph (Schematic)

- b. Secondary vesical calculus—
  - i. These stones are formed in infected urine and more usually *de novo* in the bladder.
  - ii. Chemically this type of calculus is made up of triple phosphate (ammonium, magnesium and calcium phosphate).
3. What are the modes of presentation?
  - a. Usual type—
    - Frequency—Earliest symptom.
    - Pain—More marked in oxalate calculi.
    - Terminal hematuria that is, passage of few drops of blood at the end of micturition, more commonly seen with oxalate stones.
    - Acute retention of urine—Rarely.
  - b. Silent type—Here vesical calculus lies in a postprostatic pouch or diverticulum of bladder and remains asymptomatic for a long time. These stones are usually discovered during cystoscopy or plain X-ray abdomen done for some other purpose.
  - c. Masked type—In this type the patient presents with symptoms of cystitis and the stone is masked. Thus a patient presenting frequently with symptoms of cystitis should be thoroughly investigated to exclude vesical calculus.
4. What investigations will you do to confirm diagnosis?
5. How will you treat a case of vesical calculus? See 'vesical calculus' in the chapter 47 on 'urinary bladder'.

### CHEST X-RAY (FIG. 103.6A) (SCHEMATIC)

1. What are the views of chest X-ray?
 

There are two views of plain chest radiography viz. a posteroanterior view (PA view), also known as a frontal view and the anteroposterior (AP) view (Fig.103.6A).

  - A lateral view (which is at right angles to PA view) may be needed as a supplementary view.
  - Oblique views (films taken with the patient turned to one or other side) are useful for demonstrating the chest wall and ribs, particularly the fractures and occasionally for better showing of the intrathoracic shadows.
2. What do you mean by a PA view chest radiograph?

In PA view, X-ray exposure is done from the back and provides better view of the heart and lungs.

The PA view is preferable to AP view but may not be practicable in sick patients.

3. What do you mean by AP view chest radiograph?
 

In AP view X-ray exposure is done from the front and gives details of the bony cage.
4. Chest radiographs are taken in which phase of respiration?
  - Both PA and AP views of chest X-ray should be taken on full inspiration with the patient in erect position.
  - The films taken on expiration are difficult to interpret as in expiration, the lung bases appear hazy and the heart shadow increases in size.

### Cannon Ball Metastasis in Chest X-ray (Fig. 103.6B) (Schematic)

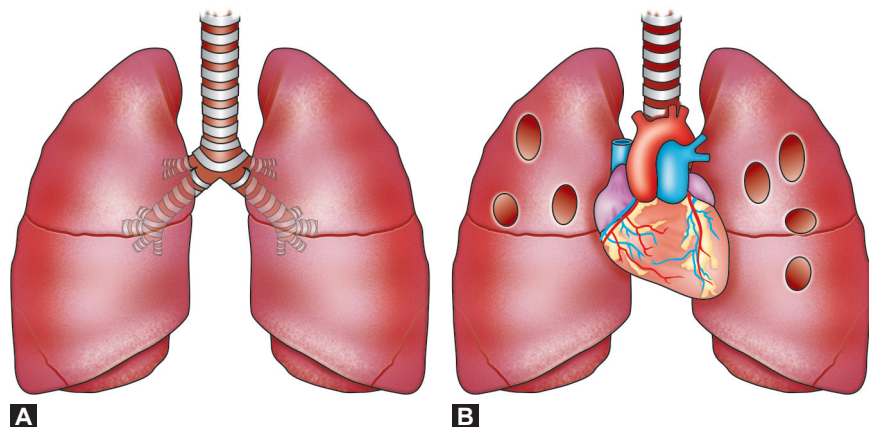
5. What is the X-ray?
 

This is a plain X-ray of chest with normal bony contour showing multiple rounded opacities in both lung fields suggestive of cannon ball metastasis.
6. What does cannon ball metastasis in chest X-ray signify?
 

Cannon ball metastasis to the lungs represents one or more discrete pulmonary nodules and is the hallmark of blood borne metastasis to the lungs. The pulmonary nodules are maximal on the outer portions of the lungs.
7. What are the primary sites?
 

The primary sites are:

- a. Kidney.
  - b. Testis.
  - c. Ovary and uterus.
  - d. Breast.
  - e. Stomach and the intestine.
  - f. Thyroid.
  - g. Soft tissue sarcomas.
  - h. Osteosarcomas.
8. How tumor metastasis to lungs may occur? The different routes of spread to lungs are (LLB – Local Lymphatic and Blood spread).
    - i. Lymphatic spread—The tumor cells reach the lungs through the thoracic duct and superior vena cava to the pulmonary vascular bed.
    - ii. Hematogenous spread.
    - iii. Intrabronchial spread, e.g. tumors from trachea, bronchi and larynx.
    - iv. Direct spread occurs from the carcinoma of esophagus.
  9. How will you treat pulmonary metastasis? Treatment is mainly palliative as pulmonary metastasis indicates advanced malignancy and consists of:
    - a. Treatment of the primary lesion and
    - b. Treatment of the pulmonary lesion:
      - i. Surgery—Segmental lung resection in case of a solitary lesion or multiple lesions confined to one lobe.
      - ii. Chemotherapy.
      - iii. Hormone therapy.
  10. What are other important findings in plain chest radiograph?
    - a. Fracture of ribs.
    - b. Fracture clavicle.
    - c. Pneumothorax.
    - d. Hydrothorax.



**Figs 103.6A and B:** (A) Line diagrams showing normal X-ray chest—PA view (B) Plain X-ray chest with cannon ball metastasis in both lungs



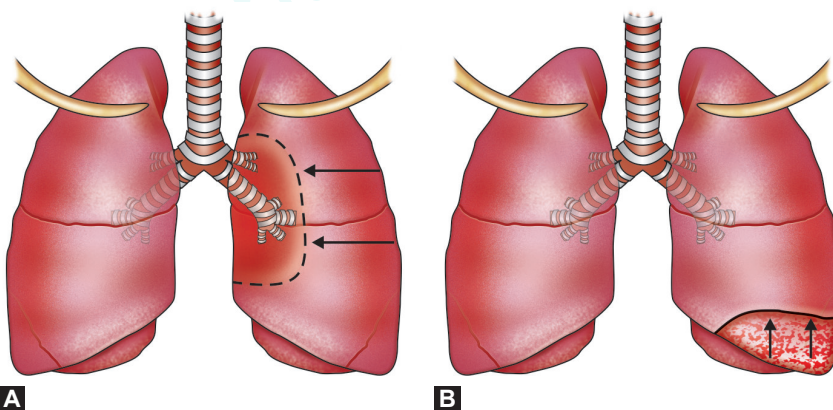
11. How will you diagnose pneumothorax on plain chest radiograph?
    - a. The diagnosis of pneumothorax depends on recognizing the line of the pleura separated by air from the chest wall, mediastinum or diaphragm with no vessels beyond this line.
    - b. Sometimes a pneumothorax is more obvious on a film taken in expiration.
    - c. With tension pneumothorax there is mediastinal shift and the hemidiaphragm is often flattened.
  12. What are the causes of pneumothorax?
    - a. Trauma.
    - b. Tuberculosis.
    - c. Majority of pneumothoraces occur in young patients with no obvious lung disease but having small blebs or bullae at the periphery of their lungs which burst.
  13. How will you recognize hydro, hemo or pyopneumothorax?
    - Fluid in the pleural cavity, whether it be a pleural effusion, blood or pus, assumes a different shape in the presence of a pneumothorax.
    - The diagnostic feature is the air fluid level (Figs 103.7A and B) (Schematic).
2. What is the provisional diagnosis? Achalasia cardia.
  3. What is achalasia cardia? Achalasia is a neuromuscular abnormality resulting in failure of relaxation at the cardiac sphincter which is shown as a smooth tapered narrowing at barium swallow examination. The failure of relaxation at the cardiac sphincter is due to loss of ganglion cells in the Auerbach's myenteric plexus.
  4. What is the other name of achalasia? Mega esophagus.
  5. How does a patient with achalasia usually present?
  6. What investigations are done for evaluation of achalasia?
  7. What is the treatment of choice in achalasia?
  8. What is the role of dilatation in achalasia? See 'achalasia of the cardia' in the chapter 29 on 'esophagus and diaphragm'.
  9. What is presbyesophagus or diffuse esophageal spasm? This is a condition of incoordinate contraction of esophagus associated with high intraesophageal pressure (more than 400 mm Hg due to marked hypertrophy of circular muscle of the esophagus).
  10. How does it differ from achalasia? Diffuse esophageal spasm differs from achalasia as below.
    - a. It is primarily a disease of esophageal body, rather than the sphincter.
    - b. Produces lesser degree of dysphagia.
    - c. Has less effect on patients' general condition.

## CONTRAST FILMS

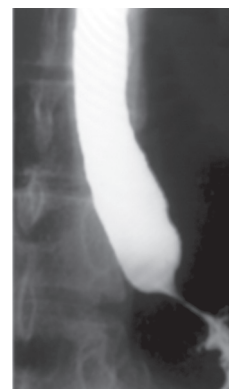
### Barium Series

#### Barium Swallow – Achalasia (Fig. 103.8)

1. What is the X-ray plate? This is a contrast film showing barium swallow X-ray of esophagus with smooth



**Figs 103.7A and B:** Radiological features of left pneumo- and hydropneumothorax following trauma (A) Pneumothorax (left) arrows indicate pleural margin beyond which no vascular markings visible (B) Hydropneumothorax – the arrows indicate air fluid level



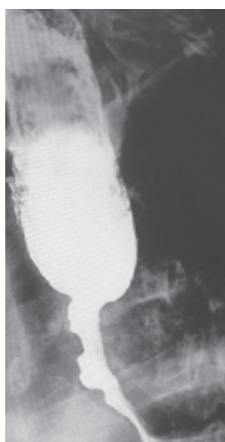
**Fig. 103.8:** Barium swallow X-ray of esophagus with smooth pencil-shaped narrowing at the lower end of esophagus in achalasia cardia

11. What is the finding in barium swallow X-ray? The appearance in barium swallow is called a Corkscrew esophagus.
12. What is the treatment of diffuse esophageal spasm?
  - a. Esophageal dilatation.
  - b. Long esophageal myotomy from the cardia to aortic arch.

#### Barium Swallow – Carcinoma of Esophagus (Fig. 103.9)

1. What is the X-ray? This is a contrast film showing barium swallow X-ray of esophagus with irregular narrowing at the lower end.
2. What is the provisional diagnosis? Carcinoma of esophagus.
3. How does a patient of carcinoma esophagus present?
  - Age—usual age is more than 50 years.
  - Sex—Male: female ratio is 3:1.
  - Dysphagia of insidious onset.
  - Extreme weight loss, anorexia, fatigue and weakness from impaired nutrition.
  - Hoarseness of voice indicates left recurrent laryngeal nerve palsy and is a bad prognostic sign.
  - Neck mass due to lymph node metastasis.
4. What investigations will you do for evaluation of carcinoma of esophagus? See 'carcinoma of esophagus' in the chapter 29 on 'esophagus and diaphragm'.
5. What is Barrett's esophagus?
  - a. This is a condition in which stratified squamous epithelium of the lower





**Fig. 103.9:** Barium swallow showing carcinoma of esophagus

esophagus is replaced by columnar epithelium following reflux esophagitis.

- b. It is a premalignant condition and produces invasive carcinoma in the following order:  
Columnar metaplasia → Dysplasia → Carcinoma *in situ* → Invasive adenocarcinoma (5 – 8% cases).
6. What is pathology and spread of carcinoma of esophagus?
7. What are the predisposing factors for the development of carcinoma of esophagus?
8. How will you treat carcinoma esophagus?
9. What is the palliative treatment for dysphagia in advanced carcinoma of esophagus?  
See 'carcinoma esophagus' in the chapter 29 on 'esophagus and diaphragm'.
10. What is the TNM staging for carcinoma of esophagus?

*Primary Tumor – T*

T<sub>is</sub> – Carcinoma *in situ*.

T<sub>1</sub> – Tumor invaded to lamina propria or submucosa.

T<sub>2</sub> – Tumor invaded to muscularis propria.

T<sub>3</sub> – Tumor extending to the adventitial coat.

T<sub>4</sub> – Tumor extending to the adjacent structures.

*Lymph Nodes – N*

N<sub>0</sub> – No regional lymph node metastasis.

N<sub>1</sub> – Regional lymph node metastasis.

*Distant metastasis – M*

M<sub>0</sub> – No distant metastasis.

M<sub>1</sub> – Distant metastasis present.

CT scan is very helpful to delineate the lymph node as well as distant metastasis.

### Barium Meal X-ray of Stomach and Duodenum

A. Benign Gastric Ulcer (Fig. 103.10) (Schematic)

1. What is the X-ray?

This is a barium meal X-ray of stomach and duodenum showing a benign ulcer crater in the lesser curvature of stomach.

2. Why do you call it benign gastric ulcer?

a. The ulcer crater projects beyond the lumen of the stomach.

b. Ulcers along the lesser curvature are mostly benign.

c. The mucosal folds converge towards the base of the ulcer.

d. A benign ulcer is usually round or oval while a malignant ulcer is irregular.

3. How many hours of fasting is required before barium meal examination and why?

a. The patient fasts for at least 6 hours before barium meal examination.

b. This is because food residues in the stomach can be very confusing and makes it difficult or impossible to recognize significant disease.

4. What is the amount of barium the patient takes during Ba meal examination?

The patient drinks about 150 to 200 ml of barium.

5. What is niche and notch?

• The niche is on the lesser curvature and corresponds to the ulcer crater.

• The notch is on the greater curvature opposite the level of ulcer crater on the lesser curvature, due to persistent spasm of the area.

6. How the double contrast effect is produced and why?

a. The double contrast effect is produced by distension of stomach with a gas producing agent, e.g. CO<sub>2</sub> forming granules. This is given along with high density barium.

b. The double contrast effect is produced to get a better mucosal detail with the stomach distended with gas. Supine, oblique and lateral views are taken to show all parts of the stomach.

7. How to differentiate malignant ulcer from mucosal folds?

Mucosal folds do not reach upto the base of the ulcer.

8. What are the features of chronic duodenal ulcer?

a. Deformed duodenal cap or bulb.

b. Ulcer crater – trifoliate deformity.

9. What is the pathogenesis of peptic ulcer?

10. How the patients with chronic gastric ulcer present?

11. What are the complications of peptic ulcer?

12. What is the medical treatment of peptic ulcer?

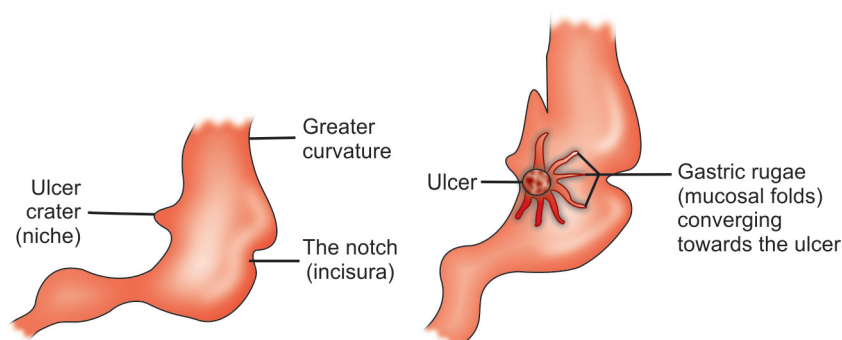
13. What are the surgical options in gastric ulcer?

14. What are the complications of gastrectomy? See the long case 'chronic duodenal ulcer' and surgical pathology section on 'Benign gastric ulcer'.

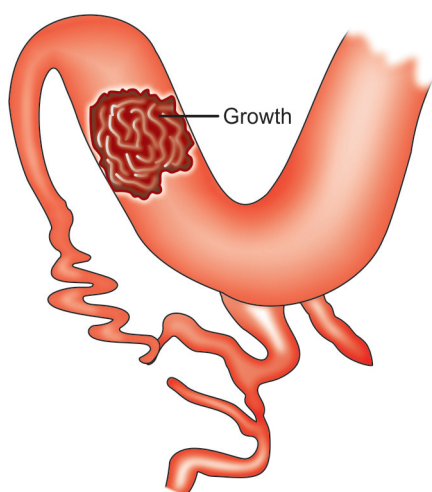
B. Carcinoma of stomach (Fig. 103.11) (Diagrammatic)

1. What is the X-ray?

This is a barium meal X-ray of stomach and duodenum showing a large irregular filling defect in the pyloric region of stomach.



**Fig. 103.10:** Barium meal X-ray features of benign gastric ulcer



**Fig. 103.11:** Diagrammatic outline of barium meal X-ray of stomach and duodenum showing carcinoma of stomach (pyloric growth)

2. What is the provisional diagnosis?  
Carcinoma at the pyloric region of stomach.
3. What are macroscopic types of gastric carcinoma?
4. What are the histopathologic types of gastric carcinoma?
5. What is early gastric cancer?
6. What is advanced gastric cancer?
7. What are the predisposing factors for carcinoma of stomach?
8. How patients with gastric carcinoma usually present?
9. What is operability and resectability?
10. What operation will you do in a patient with a carcinoma at the pyloric antrum?  
See the long case of 'gastric carcinoma' chapter 73 and the specimen 'carcinoma stomach' (Fig. 101.8).

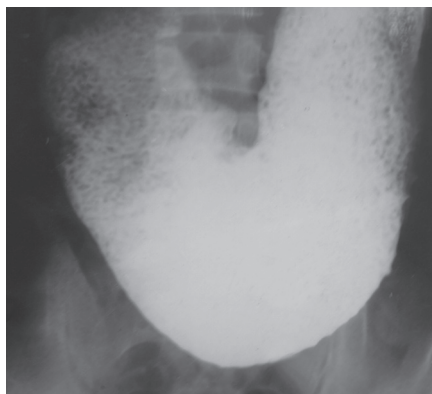
#### C. Gastric Outlet Obstruction (Fig. 103.12)

1. What is the X-ray?  
This is a barium meal X-ray of stomach and duodenum showing a hugely dilated stomach which contains residual fluid and food materials.
2. What is the provisional diagnosis?  
Gastric outlet obstruction.
3. What is the likely cause of gastric outlet obstruction?  
This is likely to be due to complication of chronic duodenal ulcer. In malignant obstruction, such huge distension is unlikely.
4. Why there is paradoxical aciduria?

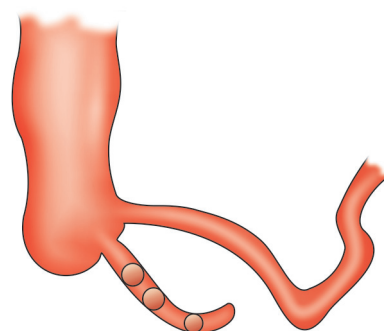
5. How will you confirm the diagnosis of gastric outlet obstruction?
6. How will you prepare the patient for surgery?
7. How will you treat the patient of gastric outlet obstruction?  
See the long case of 'gastric outlet obstruction', chapter 73.

#### Barium Meal Follow Through—Appendicitis (Fig. 103.13) (Diagrammatic)

1. What is the X-ray?  
This is a contrast X-ray of barium meal follow through examination showing the appendix with multiple filling defects in its lumen.
2. What is the provisional diagnosis?  
Pathological appendix.
3. What is the likely cause of filling defects?  
Fecoliths, which are inspissated fecal matter.
4. What treatment will you do in this case?  
Appendectomy.
5. What are the types of appendicitis?
6. How does a patient of acute appendicitis present?
7. What is the Alvarado score for diagnosis of acute appendicitis?
8. What are the complications of acute appendicitis?
9. How will you manage the appendicular lump?  
See appendicitis in the chapter 33 on 'the appendix' and the problem 'appendicular lump', chapter 102.
10. What are the steps of operation of appendectomy?



**Fig. 103.12:** Barium meal X-ray showing gastric outlet obstruction

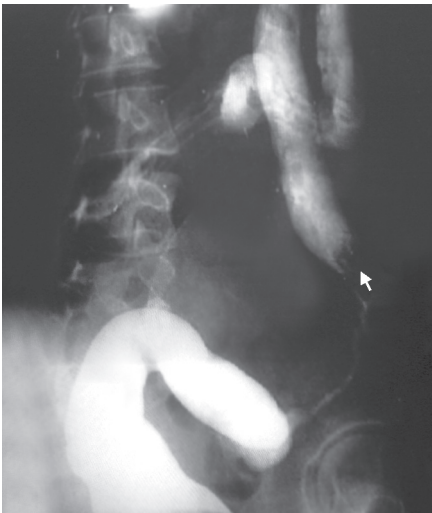

**Fig. 103.13:** Barium meal follow through examination with filling defect in the appendicular lumen (diagrammatic)

See 'appendectomy' in the operative surgery section, chapter 92.

#### Barium Enema—Carcinoma Colon (Fig. 103.14)

1. What is the X-ray?  
This is contrast X-ray of Barium enema showing a filling defect at the junction of right colic flexure and the ascending colon.
2. What is the provisional diagnosis?  
Carcinoma of colon.
3. What may be the other possibilities?
  - a. Tuberculosis.
  - b. Crohn's disease.
  - c. Radiation enteritis.
  - d. Lymphoma.
  - e. Anastomotic stricture.
4. What is enema?  
When a liquid is injected into the rectum it is known as enema. It is derived from Greek.
5. What is a barium enema?  
It is the X-ray study of lower intestinal tract following administration of barium, a radiopaque medium.
6. What structures are visualized in barium enema?
  - a. Rectum and anal canal.
  - b. Sigmoid and descending colon.
  - c. Transverse colon with two flexures.
  - d. Ascending colon.
  - e. Cecum.
  - f. Terminal ileum if ileocecal valve allows the barium.
7. How the patient is prepared for barium enema examination?
  - a. Liquid diet for 24 hours before the examination.
  - b. Enema on the night before examination.



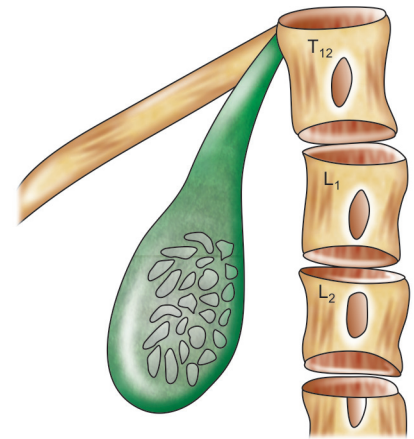
**Fig. 103.14:** Barium enema showing carcinoma of colon

- c. Osmotic purgatives like lactulose for 2 consecutive nights before the date of examination.
8. How will you do double contrast barium enema examination?  
This is done in three phases:
  - a. Filling with barium.
  - b. Gas/air insufflation.
  - c. Radiography.
 The steps are as follows:
  - a. The patient lies on his / her side.
  - b. Rectal catheter is introduced gently and taped.
  - c. Connections are made to the Barium reservoir and to the hand pump for injecting the air.
  - d. An IV injection of buscopan (20mg) is given to relieve any spasm of the colon.
  - e. The infusion of barium is started with intermittent screening.
  - f. Infusion is stopped when barium has reached the splenic flexure.
  - g. Air is gently pumped into the bowel forcing the column of barium towards the cecum and producing the double contrast effect.
  - h. Various films are taken of the entire colon and rectum and the spot films if necessary depending on the pathology.
9. What are the indications of barium enema?
  - a. Mass in relation to colon.
  - b. Patient with change in bowel habit – alternate diarrhea and constipation.

- c. Melena.
- d. Lower abdominal colicky pain.
10. What are the contraindications of barium enema?
  - a. Toxic megacolon.
  - b. Following rectal biopsy within 3 days.
  - c. Incomplete bowel preparation – This is a relative contraindication.
11. What are the methods of barium enema?
  - a. Single contrast study. This is done in children as mucosal pattern demonstration is not necessary in them and for reducing the intussusception.
  - b. Double contrast study. This is indicated as follows:
    - i. To study the mucosal pattern.
    - ii. Polyps and polyposis.
    - iii. Diverticular disease.
12. What are the macroscopic types of colonic carcinoma?
13. What are the histologic features of colon cancer?
14. What is Dukes staging for carcinoma of colon?
15. What are the etiological factors for carcinoma of colon?
16. How does carcinoma of colon spread?
17. What is the preoperative bowel preparation before colonic surgery?  
See the long case 'carcinoma of colon', chapter 73.
18. How does a patient with right colonic carcinoma present?
19. What is the treatment of carcinoma cecum and ascending colon?  
See 'colorectal carcinoma' in the chapter on 'rectum and anal canal', chapter 35.

### ORAL CHOLECYSTOGRAPHY (Fig. 103.15) (Diagrammatic)

1. What is the X-ray?  
This is a plate of oral cholecystography showing multiple filling defects within the gallbladder.
2. What is the provisional diagnosis?  
Gallstones producing the filling defects.
3. How oral cholecystography is done?
  - a. The patient is asked to take 6 tablets of Iopanoic acid (Telepaque) between 8 to 9 pm on the previous night.
  - b. In the next morning at 9 am X-ray of right upper abdomen is taken.



**Fig. 103.15:** Diagrammatic representation of oral cholecystography showing filling defects due to radiolucent gallstones. Nonopaque stones become visible by oral cholecystography

- If the gallbladder is not visualized, this suggests nonfunctioning gallbladder.
- If the gallbladder is opacified, this suggests gallbladder has concentrated the dye well and become opacified.

Once the gallbladder is opacified, the patient is given a fatty meal and further X-rays are taken at 15 minutes, 30 minutes and 1 hour interval. In response to the fatty meal the gallbladder contracts and gets emptied. So the opacified gallbladder will show reduction in size due to emptying. This suggests normal contractile function of the gallbladder.

4. What are the causes of nonvisualization of gallbladder?
  - a. Patient has not taken the oral contrast agent.
  - b. Vomiting after intake of dye.
  - c. Diarrhea which prevents absorption of the dye.
  - d. The liver is grossly damaged and fails to excrete the dye into the bile.
  - e. Nonfunctioning gallbladder.
  - f. Obstruction of the cystic duct.
5. What are the contraindications of oral cholecystography?
  - a. Patient is suffering from jaundice (so, liver can excrete the dye into the bile).
  - b. Allergy to the dye.
6. Questions related to gallstones?

See the long case 'chronic cholecystitis' questions 31 to 36 in chapter 73.

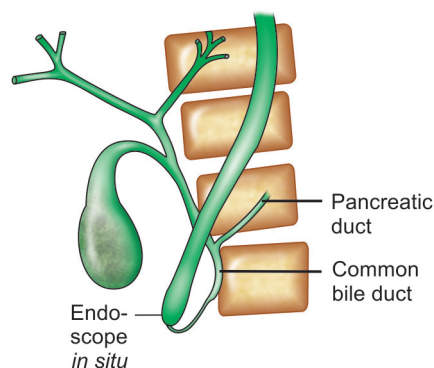
### ENDOSCOPIC RETROGRADE CHOLANGIOPANCREATOGRAPHY (ERCP) (Figs 103.16A and B)

1. What is the X-ray?

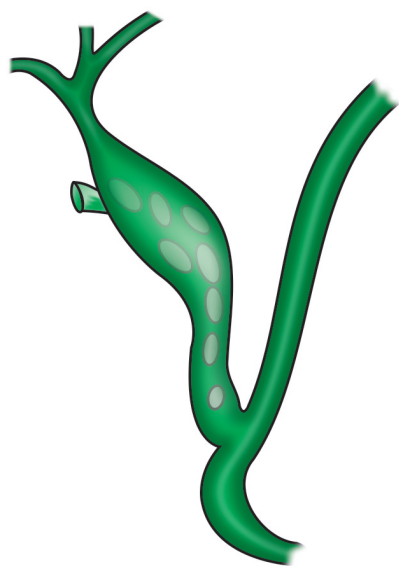
This is a plate of ERCP with the endoscope *in situ* showing a normal biliary system and the pancreatic duct.

2. What is ERCP?

ERCP consists of injecting contrast material (urograffin 60%, 2 – 3ml) directly into the biliary and pancreatic system through a catheter inserted into the ampulla of Vater with the help of a side viewing endoscope positioned in the duodenum.



**Fig. 103.16A:** ERCP showing a normal biliary and pancreatic system (schematic)



**Fig. 103.16B:** ERCP showing multiple stones in a dilated common bile duct following cholecystectomy (schematic)

Pancreatogram and cholangiogram is then obtained.

3. Is prophylactic antibiotic necessary before ERCP?

Yes, because acute cholangitis may follow ERCP when contrast fills a dilated and obstructed duct or gallbladder.

4. What are the indications of ERCP?

There are two types of indications viz. diagnostic and therapeutic.

*Diagnostic indications*

1. Obstructive jaundice—ERCP is done to know the cause of obstruction, e.g. CBD stones, strictures, etc. The stones are seen as negative shadows.

2. Pancreatic disease:

a. Chronic pancreatitis—Pancreatic duct is dilated and contains single or multiple calculi which is visualized clearly by ERCP.

b. Pseudopancreatic cyst—ERCP can show whether pancreatic duct is communicating with the cyst or not.

c. It can show stricture of the pancreatic duct.

3. Precholecystectomy check up in patients with dilated CBD shown in USG especially when laparoscopic cholecystectomy is done.

4. Biopsy or brushings can be obtained if there is obstruction due to tumor.

5. Aspirated bile can be sent for cytological and microbiological examination.

*Therapeutic indications*

1. Endoscopic sphincterotomy and stone extraction.

2. Endoscopic stenting to relieve obstructive jaundice due to stones in CBD or tumor.

3. Nasobiliary drainage for temporary drainage of the bile duct.

Diagnostic ERCP is nowadays less commonly performed as MRCP (see below Q. 9) which is noninvasive provides better informations. But the ability of ERCP to take biopsies, to remove stones and stent the strictures makes it an important therapeutic tool.

5. What are the stones that can be extracted by ERCP?

Stones smaller than 15 mm size can be extracted by ERCP.

6. What are the contraindications of ERCP?

- Presence of coagulation defects.
- Long segment stricture of bile duct.

7. What are the complications of ERCP?

- Bleeding.
- Perforation of duodenum.
- Acute pancreatitis.

8. What type of endoscope is used for upper GI endoscopy?

End viewing endoscope is used for upper GI endoscopy.

9. What is MRCP?

This is magnetic resonance cholangiopancreatography. This is the noninvasive imaging study of the pancreatobiliary system.

10. What are the advantages and disadvantages of MRCP?

See the long case of 'chronic cholecystitis' in chapter 73.

### T-TUBE CHOLANGIOGRAPHY (Fig. 103.17)

1. What is the X-ray?

The X-ray plate is the T – tube cholangiogram showing dye in duodenum and a radiolucent shadow in the common bile duct.

2. What is your provisional diagnosis?

Residual stone.

3. What else can it be?

The air bubble, entering through the tube may also show a radiolucent area.

4. How will you differentiate between air bubble and residual stone?

a. The air bubble shadow changes its position; with change of position of the patient on the table, e.g. it (air bubble) goes up in head up position and goes down in head down position of the patient.

b. A filling defect due to a calculus changes direction opposite to the air bubble with change of posture.

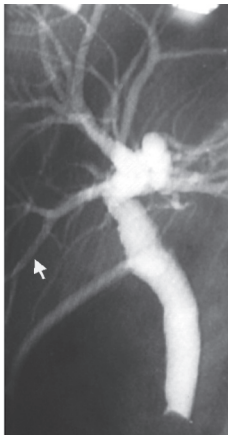If the stone is impacted there will be no change of position of the filling defect with change of posture.

5. What is T – tube cholangiogram?

When common bile duct exploration is done for the removal of stone, a T – tube is introduced into the duct. Dye can be passed through this tube and whole of common duct visualized. This may be done.

a. Preoperatively to ensure that there are no duct stones and



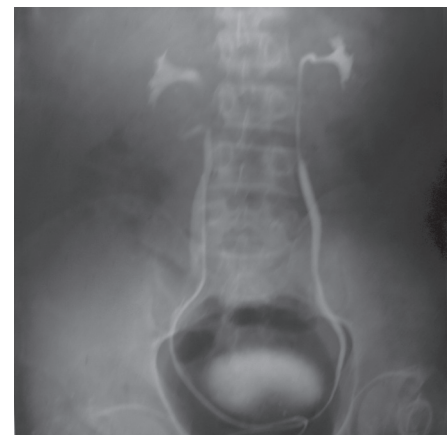

**Fig. 103.17:** T-tube cholangiography

- b. Postoperatively this is done before removal of the tube at 7th to 10th postoperative day. The contrast material used is 10 to 15 ml of 50 percent Hypaque diluted with 30 ml normal saline.
6. Why a T-tube is placed in CBD?
- Primary closure of bile duct is associated with a higher incidence of leakage.
  - To relieve the spasm of the sphincter produced due to passage of bougie through the papilla.
  - Drainage of infected bile.
  - Contrast study through the T-tube reveals residual stone.
7. Why T-tube cholangiogram is done after 7 to 10 days of operation?
- In choledocholithotomy, papillary edema and spasm occur due to passage of bougie through the papilla which persists for at least seven days.
  - If T-tube cholangiogram is done during this period, it may lead to a false diagnosis of papillary stenosis and there will be no free flow of contrast into the duodenum.
  - So T-tube cholangiogram is done after 7 days of choledocholithotomy.
8. How the T-tube is removed?
- T-tube is clamped for 24 hours, if there is no pain and fever, the tube is removed.
  - The T-tube cholangiogram shows free flow of bile into the duodenum.
9. What will be the effect if stone is not removed from the CBD?
- There will be cholangitis, pancreatitis and obstructive jaundice.
10. How will you manage residual stone?
- This is managed by one of the following methods:
- Endoscopic sphincterotomy and extraction of the stone.
  - Contact dissolution by infusing monooctanoin or methyl terbutyl either via the T-tube tract in case of cholesterol stone.
  - Burhenne's technique—Patient is discharged home with T-tube *in situ* and after 4 to 6 weeks when T-tube tract gets matured, T-tube is removed, and the residual stone is extracted through the mature T-tube tract with the help of a Dormia basket catheter or choledochoscope.
11. What is choledochoscopy?
- It is the endoscopic evaluation of CBD.
  - Postexploration, it can be used to see for any residual stone, in the CBD.
12. What are other cholangiograms?
- Intravenous cholangiogram.
  - Percutaneous transhepatic cholangiogram (PTC).
13. What is the indication of PTC?
- It is done for evaluation of proximal duct pathology.
- Nowadays it is rarely performed due to the advent of MRCP.
14. How is it performed?
- The coagulation profile is corrected.
  - Antibiotic.
  - Under fluoroscopic control, Chiba needle is introduced through the 8th intercostal space in the midaxillary line.
  - Intrahepatic biliary radical entered and contrast injected.
  - Cholangiogram is taken.
- b. Injection of contrast agent – 76 percent urograffin (Na – diatrizoate) 50 to 100 ml is injected. 1 ml of the solution is injected slowly to see for any allergic reaction. If no allergic reaction occurs, the remaining contrast agent is injected slowly IV and serial X-rays are taken at 5, 10, 15 and 30 minutes and the delayed films.
3. What are the contrasts employed?
- Iodine containing ionic agent—Sodium diatrizoate (urograffin) – 76 percent and meglumine iothalamate.
  - Iodine containing nonionic agent, e.g. Omnipaque.
4. What are the prerequisites of using the contrast agents?
- Estimation of blood urea and creatinine because passage of contrast medium requires efficacy of glomerular filtration.
  - Emergency drugs—Adrenalin injection, steroids, etc.
  - Oxygen.
5. What is the preparation?
- Oral purgative and antifatulent tablet are taken the night before the procedure to evacuate bowel gas for better visualization.
  - Informed consent.
6. What are the indications?
- Evaluation of renal lumps, e.g.
    - Hydronephrosis—Clubbing of calices in early stage and widely dilated pelvicalyceal system in the advanced stage.

### **INTRAVENOUS UROGRAM OR PYELOGRAM (IVU OR IVP) (Fig. 103.18)**

1. What is the X-ray?
- It is the intravenous contrast X-ray of the urinary system showing normal pelvicalyceal system, ureters and bladder.
2. How intravenous urogram is done?
- A control X-ray of KUB region is done to exclude any radiopaque calculi.



**Fig. 103.18:** Showing intravenous urogram



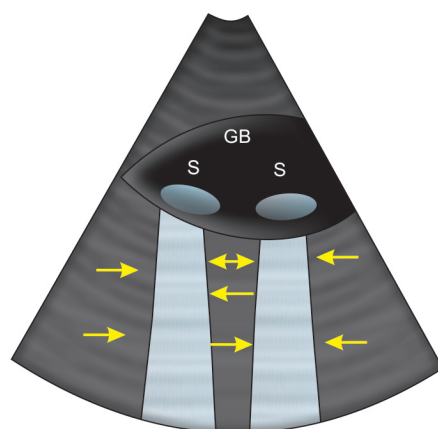
- ii. Hypernephroma—spider leg deformity of the calices (splaying of the calices) usually at one pole.
  - iii. Polycystic kidney disease—There is spider leg deformity of the calices in both the kidneys as the disease is bilateral.
- b. Calculus in the urinary system.
  - c. Diagnosis of congenital abnormality producing prolonged urinary tract infection, e.g. bifid pelvis, bifid ureter, horse shoe kidney and ectopic kidney with recurrent infections.
  - d. Renal trauma—Emergency IVP will show the passage of contrast medium outside the renal outline.
7. What are other uses of iodine containing contrast agents?
    - a. Angiography.
    - b. Intravenous contrast enhancement of computed tomography.
  8. How does it indicate function?
 

Passage of contrast medium depends upon the glomerular filtration function. So, if the pelvicalyceal system is visualized, the kidney is normally functioning. If 90 to 95 percent of parenchymal function is lost, kidney is nonvisualized by IVP and it is termed nonfunctioning.
  9. What are other methods of assessing renal function?
    - a. Biochemical, e.g. serum urea and creatinine.
    - b. Radioisotope scanning or isotope renogram. This is considered better than IVP because with isotopic renogram 5 to 10 percent function of renal parenchyma may be assessed. If 100 percent parenchyma function is lost, then only isotope renogram will not show any density.
  10. What are other types of pyelography other than intravenous?
    - a. Retrograde pyelography—It is the contrast imaging of the urinary system through ureteric catheters.
    - b. Antegrade pyelography—Here the contrast agent is injected into the renal calices or pelvis.

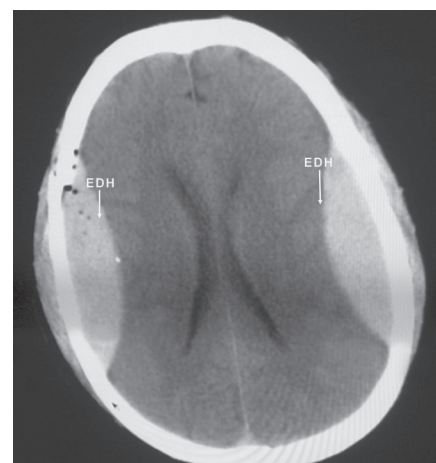
### ULTRASONOGRAPHY (Fig. 103.19) (Diagrammatic)

1. What is the plate?
 

This is an ultrasonography plate showing calculi in the gallbladder.



**Fig. 103.19:** Line diagram of ultrasound scan showing stones (S) in the gallbladder (GB). The arrows point to the acoustic shadow behind the stones



**Fig. 103.20A:** CT scan brain

2. How do you know that it is calculi?
 

Stones cast acoustic shadow behind them. This is present in this plate.
3. What are the advantages of ultrasonography?
4. What are the disadvantages of ultrasonography?
5. What are the applications of ultrasonography?
6. What are the indications of ultrasonography of abdomen?
 

See 'ultrasonography' in the chapter 17 on 'imaging in surgery'.

### CT SCAN AND MRI

1. What is the plate (Fig. 103.20A)?
 

This is CT scan plate of brain showing extradural and/or subdural hemorrhage.
2. What is the principle of CT scan?
  - a. CT scan is actually the attenuated (decreased strength) X-ray passing through cross section of the body. Thus, the entire body can be studied in a series of cross sections. This is called tomogram.
  - b. Resolution is very high and can be increased by using contrast medium.
  - c. It can pass through the bone which is not possible in case of ultrasonography. So the lungs containing air and the brain within the bony cavity cannot be imaged by ultrasonography.
3. How will you compare the two modes of imaging – CT scan and MRI?
 

See 'CT scan and MRI' in the chapter 17 on 'imaging in surgery'.

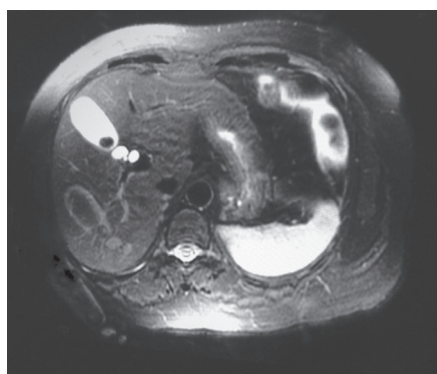
4. What is extradural hematoma?
5. How will you treat intracerebral hematoma?
6. What is subdural hematoma? What are the types of subdural hematoma?
7. How will you treat subdural hematoma?
 

See 'head injury' in the chapter 53 on section 'trauma'.

### MRI SCAN

1. What is the principle of MRI scan (Fig. 103.20B)?
  - a. It does not use X-rays as in CT scan. Instead it uses a magnetic field under which most tissues produce radio waves. These radio waves are produced as an image and studied.
  - b. MRI scan uses the biophysical parameters viz. resonant frequency, proton density and motion, and the resolution is better.
2. What are the advantages?
  - a. It is noninvasive and without hazards of radiation.
  - b. It has better contrast resolution.
  - c. Diminished allergic reactions.
  - d. It can produce images in various planes – sagittal, coronal and in oblique directions.
3. What are the disadvantages?
  - a. Equipments are costly.
  - b. Complete study takes a longer time.
  - c. The strong magnetic field can cause derangement of pacemaker.
4. What contrast agent is used in MRI?
 

Gadolinium intravenously which enhances the lesion.



**Fig. 103.20B:** MRI scan

5. What is the development in the technique?
  - a. MRI – angiogram.
  - b. MRCP or magnetic resonance cholangiopancreatography.

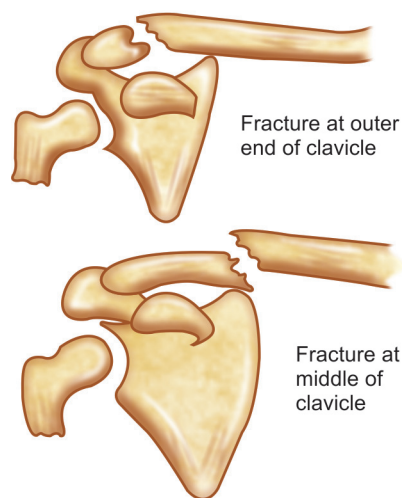
### ORTHOPEDIC X-RAYS

#### Fracture Clavicle (Fig. 103.21) (Schematic)

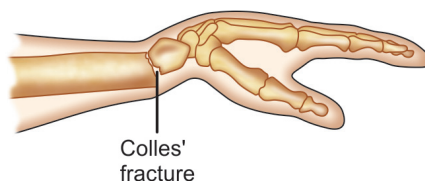
1. What is the X-ray?
 

This is a straight X-ray of clavicle with shoulder joint showing fracture clavicle. (There is no lateral view of fracture clavicle).
2. What are the sites of fracture clavicle?
3. How will you diagnose the fracture?
4. What is the treatment?
5. What is the complication of fracture clavicle?
 

See 'fracture clavicle' in the chapter 58 on 'fractures and dislocations of upper limb'.



**Fig. 103.21:** Fractures of clavicle (Schematic)



**Fig. 103.22:** Line diagram showing, Colles' fracture

#### Fracture Colles' (Fig. 103.22) (Diagrammatic)

1. What is the X-ray?
 

This is the straight X-ray of wrist both anteroposterior and lateral views showing Colles' fracture.
2. What is Colles' fracture?
3. What is the displacement?
4. What is the mechanism of injury?
5. What is the treatment?
6. What is the technique of closed manipulation?
7. What are the complications?
 

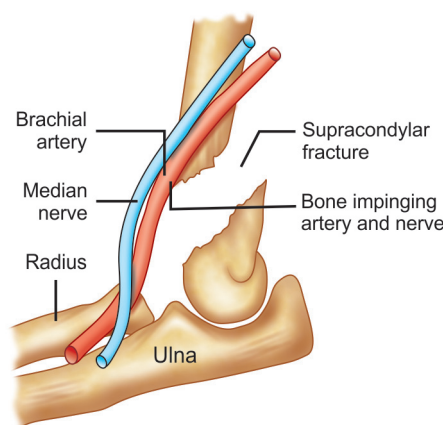
See 'Colles' fracture' in the chapter 58 on 'fractures and dislocations of the upper limb'.

*Note:* All displacements in fractures are expressed in relation to the distal fragment.

#### Supracondylar Fracture of Humerus (Fig. 103.23) (Schematic)

1. What is the X-ray?
 

This is a straight X-ray of elbow both anteroposterior and lateral views showing supracondylar fracture of humerus.



**Fig. 103.23:** Showing supracondylar fracture of humerus (Schematic)

2. What is the supracondylar fracture of humerus?
 

This is the fracture of the lower end of humerus just above the condyles.
3. What is the common age of affection?
4. What is the displacement?
5. What are the types of supracondylar fracture?
6. What is the treatment?
7. What are the complications?
 

See 'supracondylar fracture' in the chapter 58 on 'fractures and dislocations of upper limb'

#### Fracture Shaft Humerus (Fig. 103.24) (Diagrammatic)

1. What is the X-ray?
 

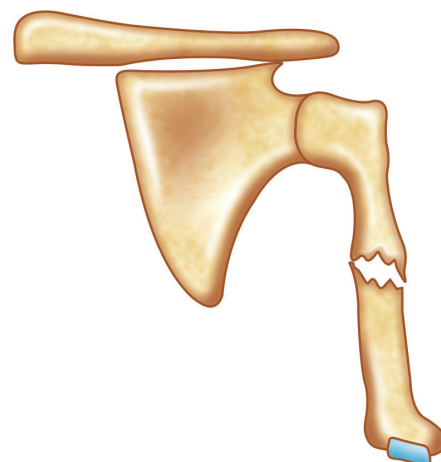
This is the straight X-ray of humerus showing a fracture (oblique or transverse or spiral).
2. What are the causes of fracture of the shaft of humerus?
3. What are the displacements?
4. How does the patient present with this fracture?
5. How will you treat the case?
6. What are the complications?
 

See 'fracture of the shaft of humerus' in the chapter on 'fractures and dislocations of upper limb', chapter 58.

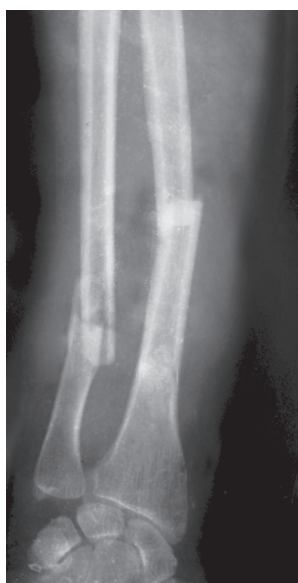#### Fracture of Both Bones of the Forearm (Fig. 103.25)

1. What is the X-ray?
 

This is a straight X-ray of the forearm both anteroposterior and lateral views



**Fig. 103.24:** Line diagram showing fracture shaft humerus



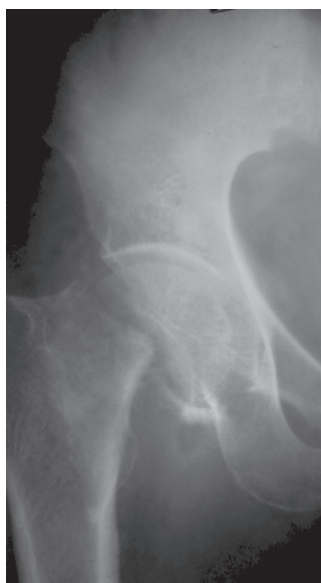**Fig. 103.25:** Straight X-ray of the forearm showing fracture of both bones

showing fracture of both bones of the forearm (at the same or different levels).

2. What are causes?
3. How will you diagnose?
4. How will you treat the case?
5. What is Monteggia fracture dislocation?
6. How will you treat Monteggia fracture dislocation?
7. What is Galeazzi fracture dislocation?
8. How will you treat Galeazzi fracture dislocation? See chapter 58, page 358

### Fracture of the Neck of the Femur (Fig. 103.26)

1. What is the X-ray?  
This is a straight X-ray of right hip joint and pelvis showing fracture of the neck of the right femur.
2. What are the types of fracture neck femur?
3. How will you diagnose the fracture?
4. What is the treatment of intracapsular fracture?
5. What is the treatment of extracapsular fracture?
6. What are the complications of the fracture neck femur?  
See 'fracture of the neck of the femur' in the chapter on 'fractures and dislocations of the lower limb', chapter 59.



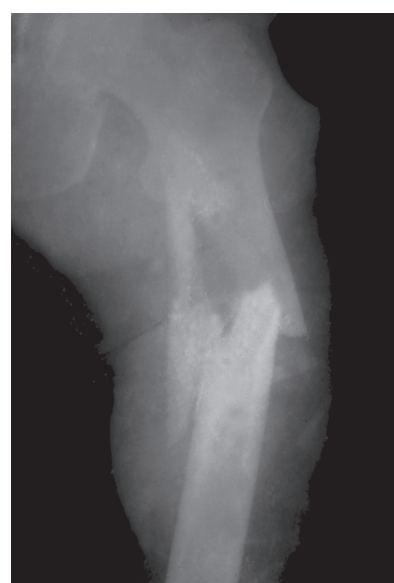**Fig. 103.26:** Straight X-ray of right hip joint and pelvis showing fracture of the neck of the right femur

### Fracture Shaft of the Femur (Fig. 103.27)

1. What is the X-ray?  
This is a straight X-ray of left femur and pelvis showing fracture of the shaft of the left femur in its middle third.
2. Which portion of femoral fracture is known as femoral shaft fracture?  
It is the fracture from 2 cm below the lesser trochanter to approximately 10 cm above the knee joint.
3. What are the types?
4. What are the displacements?
5. How will you diagnose the fracture?
6. What is the treatment?
7. What are the complications?  
See 'fracture shaft of the femur' in the chapter 59 on 'fractures and dislocations of the lower limb'.

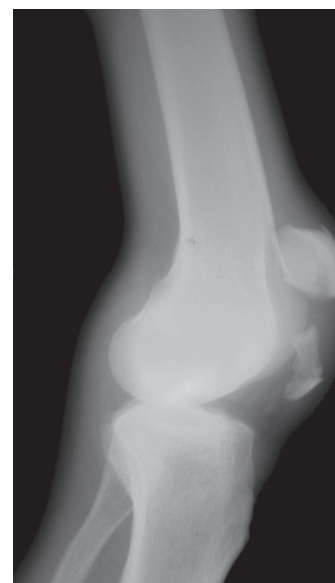
### Fracture of Patella (Fig. 103.28)

1. What is the X-ray?  
This is straight X-ray of the knee (lateral view) showing fracture of patella.
2. What are the types of fracture patella?
  - a. Vertical fracture.
  - b. Transverse fracture.
  - c. Chip fracture of medial border of patella.
  - d. Stellate fracture of patella.
3. What type of trauma will cause fracture patella?

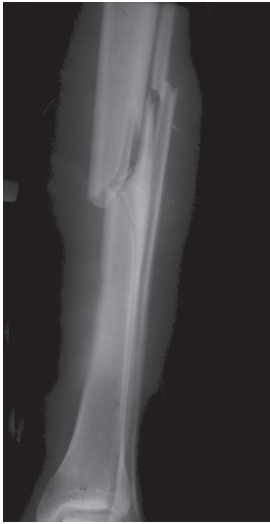

**Fig. 103.27:** Straight X-ray of left femur and pelvis showing fracture of the shaft of the left femur in its middle-third

4. What are the clinical findings of fracture patella?
5. How will you treat fracture patella?
6. What are the complications of fracture patella?
7. What is traumatic dislocation of patella?  
See 'fracture patella' in the chapter 59 on 'fractures and dislocations of the lower limb'.



**Fig. 103.28:** Fracture of patella, lateral view



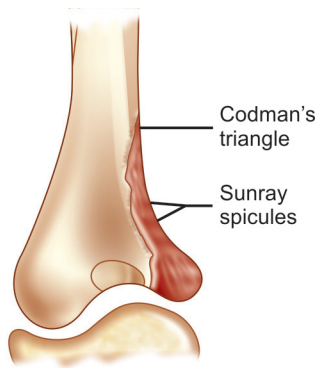
**Fig. 103.29:** Radiograph showing fracture both bones of the leg

**Fracture of Both Bones of the Leg (Fig. 103.29)**

1. What is the X-ray?  
This is a straight X-ray of the leg showing fracture of both bones of the leg.
2. What is the mechanism of injury of both bones of the leg?
3. What are the displacements?
4. How will you treat the case?
5. What are the complications?  
See 'fracture of the shafts of tibia and fibula' in the chapter 59 on 'fractures and dislocations of the lower limb'.

**Osteosarcoma (Fig. 103.30) (Schematic)**

1. What is the X-ray?  
This is straight X-ray of femur showing osteosarcoma at the lower end.

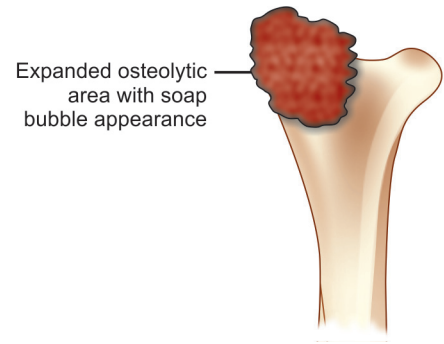


**Fig. 103.30:** Radiological features of osteosarcoma (Schematic)

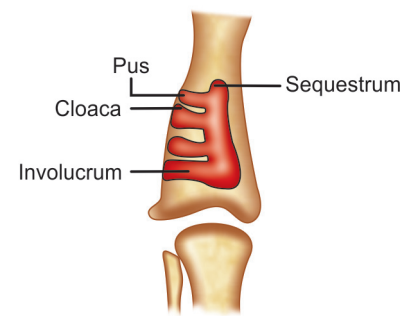
2. How do you say osteosarcoma?
  - a. Presence of sunray spicules and
  - b. Codman's triangle respectively in the X-ray plate.
3. Other questions related to osteosarcoma – see 'the specimen of osteosarcoma' the chapter 61 on 'bone tumors'.

**Osteoclastoma (Fig. 103.31) (Schematic)**

1. What is the X-ray?  
This is a straight X-ray of femur showing the soap bubble appearance at the lower end and the cortex which is expanded and thinned out over the tumor.
2. What is the provisional diagnosis?  
Osteoclastoma.
3. Other questions related to osteoclastoma – see the specimen of osteoclastoma and 'osteoclastoma' in the chapter 61 on 'bone tumors'.



**Fig. 103.31:** Radiological features of osteoclastoma (Schematic)



**Fig. 103.32:** Radiological features of chronic osteomyelitis (Schematic)

**Osteomyelitis (with Sequestrum) (Fig. 103.32) (Schematic)**

1. What is the X-ray?  
This is straight X-ray of leg showing extensive periosteal reaction and sequestrum formation at the lower end of femur.
2. For other questions related to osteomyelitis and sequestrum – see the specimen 'sequestrum' in chapter 101 and the chapter 60 on 'osteomyelitis'.



## Instruments

- Introduction
- Parts of a typical surgical instrument
- Instruments for preparing and draping
- Instruments for skin incision
- Instruments for hemostasis
- Retractors
- Dissecting forceps
- Tissue holding forceps
- Scissors
- Instruments for tissue approximation and wound closure
- Polyglactin sutures
- Gastrointestinal clamps
- Occlusion clamps
- Crushing clamps
- Instruments used in biliary tract surgery
- Instruments used in rectal surgery
- Instruments for Genitourinary surgery
- Ordinary catheters
- Self-retaining catheters
- Bougie or urethral dilator
- Pyelolithotomy forceps
- Suprapubic cystolithotomy forceps
- Special instruments in general surgery
- Orthopedic instruments
- Sterilization

### INTRODUCTION

1. In the practical examination, instruments are asked in the viva voce.
2. Usually one or two instruments are given and the following points are asked.
  - a. Identification of the instrument—proper identification and complete nomenclature is very important.
  - b. Some uses of the instrument—The student should know the name and steps of operation in which the instrument is used.
  - c. Sterilization of the instrument—The candidate should mention one method of sterilization which is most suitable for the instrument. If examiner asks about other methods, then mention about them.
3. Each instrument is described here under the following headings viz. identification features, uses and sterilization.
  - a. Blades—A pair of blades forms the terminal part of the instrument.
  - b. A pair of shaft or body of the instrument.
  - c. Joint—The two parts of the shaft and the blades are kept attached by a joint.
  - d. Two finger bows are provided for holding the instrument.
  - e. A catch or a ratchet—Once the catches are pressed the blades are kept in a closed position. The finger bow, together with the shaft and ratchet constitutes the handle of the instrument.

### INSTRUMENTS FOR PREPARING AND DRAPING

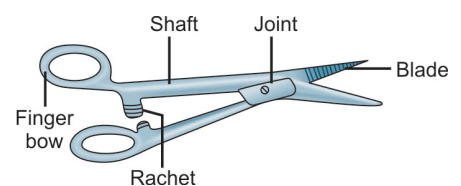
#### Rampléy's Sponge or Swab Holding Forceps (Fig. 104.2)

##### Features

- a. This is a long instrument provided with finger bows and a pair of long shaft.
- b. Distal end of the blade is oval and fenestrated with serrations in the inner aspect, for better grip of the swabs.
- c. It may be straight or curved.

##### Uses

- a. Cleansing the operative field with sponge or swab dipped in antiseptic solution, e.g. povidone iodine.
- b. Can be used for holding a swab to clean blood during dissection of Calot's triangle in cholecystectomy.
- c. Removal of the laminated membrane and daughter cysts during operation of hydatid cyst.
- d. To strip off the peritoneum from the fascia transversalis by holding a swab in the forceps while kidney exposure or lumbar sympathectomy.
- e. To clean the blood in the suture line with a swab held in the forceps while performing gastrojejunostomy and intestinal anastomosis.

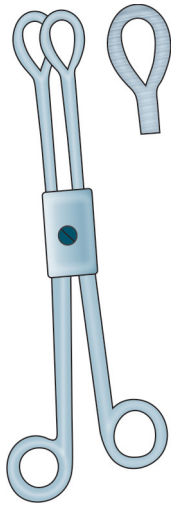


**Fig. 104.1:** Parts of an instrument

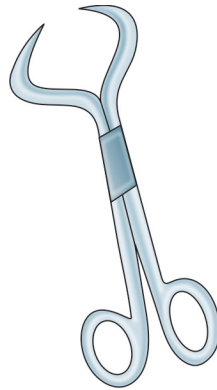
### PARTS OF A TYPICAL SURGICAL INSTRUMENT (Fig. 104.1)

A typical surgical instrument consists of the following parts:

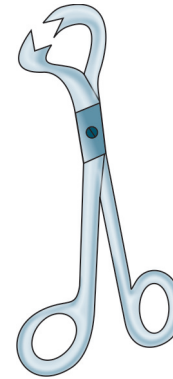




**Fig. 104.2:** Rampléy's swab holding forceps



**Fig. 104.3:** Mayo's towel clip



**Fig. 104.5:** Moynihan's tetra towel clip

- f. It may be used as a tongue holding and ovum forceps.

**Sterilization**

By autoclaving

- Q 1. What area would you clean for an abdominal operation?  
An area extending from midchest to midhigh is to be cleaned with antiseptic solution.

- Q 2. Why the instrument is long?  
The instrument is made long to apply antiseptic dressings from a distance so that sterile gloved hand of the surgeon is not contaminated.

**Mayo's Towel Clip (Fig. 104.3)**

**Features**

- a. This is a light instrument about 5 inches long.
- b. Blades are curved towards inside and are pointed for better grasp of drapes.
- c. Has a catch lock.

**Uses**

- a. For fixing the draping sheets.
- b. May be used for fixing the diathermy cables.
- c. May be used as a tongue holding forceps.
- d. Can be used to hold and elevate ribs in cases of flail chest injuries.

**Sterilization**

By autoclaving.

1. What is draping?

Draping is covering the body with sterile towels to isolate the area of operation from rest of the body.

The idea of draping is to prevent contamination from the adjacent skin areas.

**Doyen's Cross Action Towel Clip (Fig. 104.4)**

**Features**

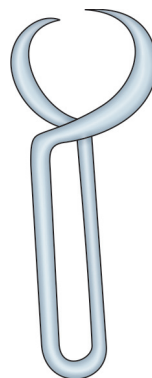
- a. Small instrument without any finger bows and lock.
- b. Tips are pointed and curved.
- c. Tips are held together by outward cross-action of the arms.

**Uses**

Same as Mayo's towel clip.

**Sterilization**

By autoclaving.



**Fig. 104.4:** Doyen's cross-action towel clip

**Moynihan's Tetra Towel Clip (Fig. 104.5)**

**Features**

- a. Longer than Mayo's towel clip.
- b. It has four teeth at the distal end, two in each blade.
- c. Lock and catch present.

**Uses**

- a. Holding drapes.
- b. To cover cut margins of incisions with sterile sponges to decrease chances of contamination.

**Sterilization**

By autoclaving.

**INSTRUMENTS FOR SKIN INCISION**

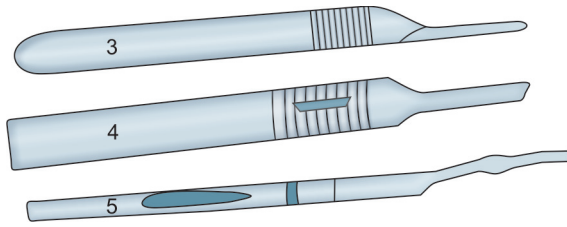
**Bard Parkers Knife with Detachable Blade (Fig. 104.6)**

**Features**

- It consists of straight handle made of stainless steel and a narrow distal end with a socket for the surgical blade.
- A number like 3, 4 or 5 is written on the handle.

**Uses**

- To make the surgical blade handy and easy to use providing adequate grip.
- The whole unit of the handle with the blade is known as a scalpel.



**Fig. 104.6:** Scalpel handles with numbers 3, 4 and 5

**Surgical Blades (Figs 104.7A and B)**

*Features*

- a. Blades bearing numbers 10, 11, 12 and 15 fit handle numbers 3 and 5.
- b. Blades with numbers 18, 19, 20, 21, 22, 23 and 24 fit in handle number 4.

**INSTRUMENTS FOR HEMOSTASIS**

**Hemostatic/Artery Forceps (Fig. 104.8)**

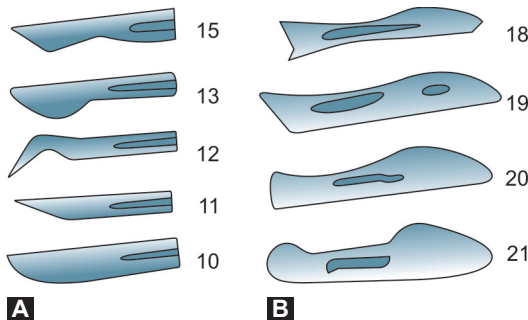
The term hemostatic forceps is more accurate than artery forceps because these forceps are used for both arteries and veins. However the term artery forceps is very commonly used.

*Types*

- a. Small-sized forceps.
  - b. Medium-sized forceps.
  - c. Large-sized forceps.
- Each type can be straight or curved.

*Features*

- Common features of all artery forceps include:
- a. Blades are smaller than handles or shafts (1:2 – 1:3).



**Figs 104.7A and B:** (A) Scalpel blades with numbers 10, 11, 12, 13, 15 (B) Scalpel blades with numbers 18, 19, 20, 21

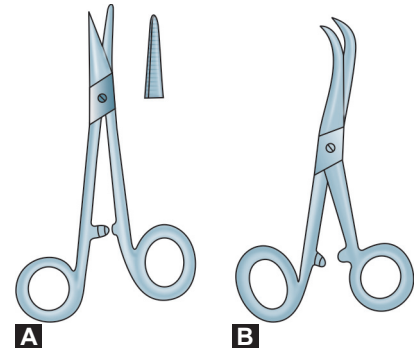
- b. Inner margins of blades are transversely serrated and are well apposed.
- c. Catch lock is present.
- d. Blades are conical and blunt.

1. How will you differentiate artery forceps from a needle holder?
  - a. In a needle holder, the blades have criss-cross instead of transverse serrations and there may be a groove in the center of each blade on the inner side.
  - b. The needle holder is relatively a heavier instrument.

*Uses*

It is the most versatile instrument in surgical practice and used as follows:

- a. As a hemostat to hold bleeding vessels while cutting through different layers of tissues.
- b. To open an abscess cavity by Hilton's method.
- c. To hold cut ends of stay sutures.
- d. May be used as a dressing forceps.
- e. To hold the surgical peritoneum, rectus sheath, linea alba, external oblique aponeurosis while making and closure of abdominal incisions.
- f. To crush the base of appendix in appendicectomy.



**Figs 104.8A and B:** (A) Artery forceps-straight variety (B) Artery forceps-curved variety

- g. To hold free ends of sutures as they are passed one after the other without tying, e.g. intestinal and biliary anastomosis.
- h. To dissect the vein while doing venesection in the arm or in the leg.
- i. Blunt dissection while doing lymph node biopsy, excision of sebaceous cyst, lipoma, etc.
- j. To tie a knot after suturing.

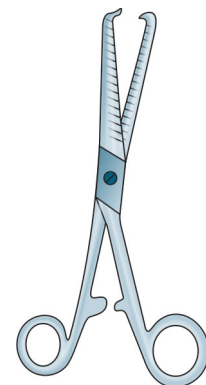
*Sterilization*

By autoclaving.

**Kocher's Artery Forceps (Fig. 104.9)**

*Features*

- a. Features are the same as the artery forceps except that at the tip of the blades there is a tooth in one blade and a groove in the other, where the tip fits when the ratchet is closed.
- b. This type of forceps is suitable for holding vessels in tough structures like palm,



**Fig. 104.9:** Kocher's artery forceps

soles and the scalp, where the vessels tend to retract in the deep fascia.

**Uses**

- a. Original use—To hold superior thyroid pedicle vessels.
- b. To hold the perforating vessels during mastectomy.
- c. To crush the base of appendix during appendectomy.
- d. To hold the meniscus during meniscectomy.
- e. To cause artificial rupture of gestational membranes.
- f. To hold cut ends of vessels in tough fibrous tissues, e.g. palm, soles and scalp.

**Sterilization**

By autoclaving.

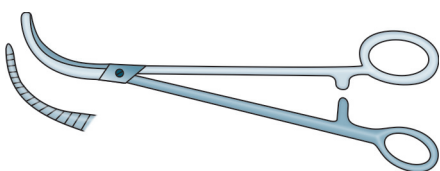
**Right-Angled Artery Forceps (Fig. 104.10)**

**Features**

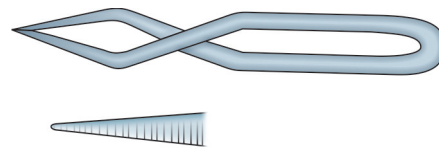
It is a long instrument with blades curved at right angles at distal end.

**Uses**

- a. This is usually used to dissect pedicles of important organs, e.g. spleen, kidney and to pass a ligature around the dissected vessels and ducts especially those at depths, e.g. cystic artery and cystic duct during cholecystectomy.
- b. To dissect anterior and posterior vagus nerves and to pass ligatures around them during vagotomy.
- c. During nephrectomy to dissect renal vessels and to pass ligature around them.
- d. During splenectomy to dissect splenic artery and vein and to pass ligature around them.



**Fig. 104.10:** Right-angled artery forceps



**Fig. 104.11:** Bulldog clamp

**Sterilization**

By autoclaving.

**Bulldog Arterial Clamp (Fig. 104.11)**

**Features**

- a. Small paper clip like instrument.
- b. Action is based on cross closure of jaws.
- c. Serrations are present on the inner margins of the jaws.
- d. Handle of the clamp pressed to open the jaws.

**Uses**

- a. To clamp arteries and veins during their anastomosis.
- b. Clamping of portal vessels (Pringle maneuver).  
The jaws may be additionally covered with a rubber tubing to prevent crushing of artery.

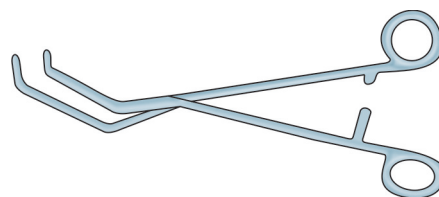
**Sterilization**

By autoclaving.

**Satinski's Arterial Clamp (Fig. 104.12)**

**Features**

- a. It is an angled forceps with a screw joint.
- b. It has double right angled jaws.
- c. Jaws have longitudinal serrations.



**Fig. 104.12:** Satinski's clamp

**Uses**

- a. As a pedicular clamp for nephrectomy, adrenalectomy, pneumonectomy, etc.
  - b. Partial occlusion of major vessels like inferior vena cava, aorta, for their repair.
    1. What is primary hemorrhage?
    2. What is reactionary hemorrhage?
    3. What is secondary hemorrhage?
    4. What do you mean by class I, class II and class III hemorrhage?
    5. How will you estimate the blood loss after trauma or operation?
    6. How will you treat hemorrhage?
    7. What are the surgical means to control hemorrhage?
- Sterilization—By autoclaving  
See the chapter 3 on 'hemorrhage and blood transfusion' in 'general surgery'.

**RETRACTORS**

**Hook Retractor (Figs 104.13A and B)**

**Features**

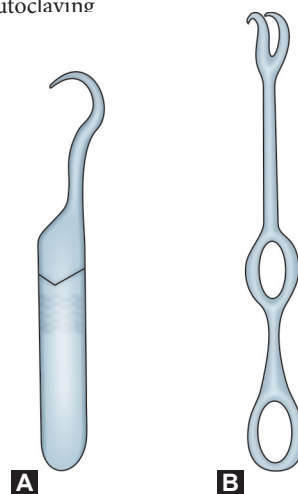
- a. It may be a single or double hook retractor.
- b. There is a shaft with a handle.
- c. The tip may be sharp or blunt.

**Uses**

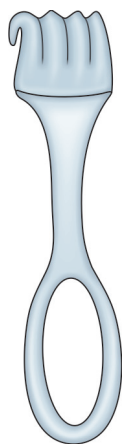
- a. To retract skin edges during excision of sebaceous cyst and lipoma.
- b. To retract the skin during venesection.
- c. To retract tough fascia.

**Sterilization**

By autoclaving



**Figs 104.13A and B:** (A) Single hook retractor; (B) Double hook retractor



**Fig. 104.14:** Cat's paw or volkman's retractor

**Cat's Paw or Volkman's Retractor (Fig. 104.14)**

*Features*

Features are same as the double hooked retractor but the number of hooks are generally 4 or 5, i.e. multi-hooked.

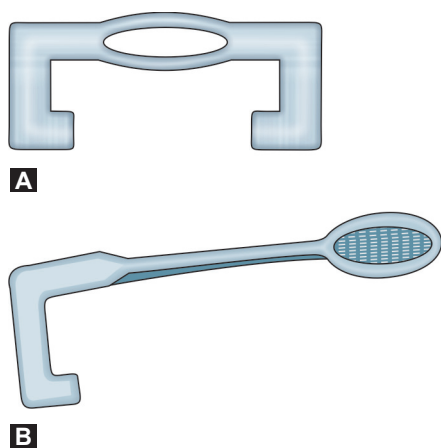
*Uses*

Retraction of skin and tough fascia, e.g. sole, palm and scalp.

**Langenbeck's Retractor (Fig. 104.15)**

*Features*

- a. Solid retractor with a long handle and a blade which is curved at right angle to the handle.



**Figs 104.15A and B:** (A) Double-bladed Langenbeck's retractor (B) Single-bladed Langenbeck's retractor

- b. The tip of the blade is curved at right angle for better retraction of the tissues.
- c. Generally it is single bladed but blades may be present at both ends.
- c. It is available in different sizes depending on its width.

*Uses*

- 1. To minimize tissue handling and for better visualization of the operative field in operations like hernioplasty, thyroidectomy, etc.
- 2. Bleeding may be better seen and controlled with placement of retractors.

*Sterilization*

By autoclaving.

**Morris Retractor (Fig. 104.17B)**

*Features*

- a. The design is like the letter 'L'. The handle is wider and the blade is also wider.
- b. The lower end of the blade is curved inward.

*Uses*

- a. To retract the layers of the abdominal wall during appendicectomy.
- b. To retract skin flaps and sternocleidomastoid muscle during radical neck dissection.


*Sterilization*

By autoclaving.

**Deaver's Retractor (Fig. 104.16)**

*Features*

- a. It is the 'S' shaped large curved retractor.
- b. Its handle is the continuation of the blade.



**Fig. 104.16:** Deaver's retractor

*Uses*

- a. To retract right lobe of liver during cholecystectomy.
- b. To retract left lobe of liver during truncal vagotomy.
- c. To retract the abdominal wall while mobilizing the colon from the paracolic gutter during right or left hemicolectomy.
- d. To retract the bladder in male or uterus in female during pelvic dissection in anterior resection or abdominoperineal resection.
- e. To retract the stomach during Whipple's operation.

*Sterilization*

By autoclaving.

**Self-Retaining Abdominal Retractor (Fig. 104.17A)**

*Features*

- a. It has essentially two blades, one of which is static and the other slides over a long rod.
- b. The sliding blade is fixed to the horizontal bar by means of a screw.
- c. A third blade can be added to some retractor.

*Uses*

Used to retract the abdominal wall in a number of operations requiring good retraction for proper exposure, e.g. Whipple's operation, pancreaticojejunostomy, hemicolectomy, abdominoperineal resection and anterior resection.

*Sterilization*

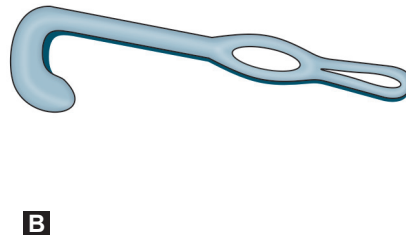
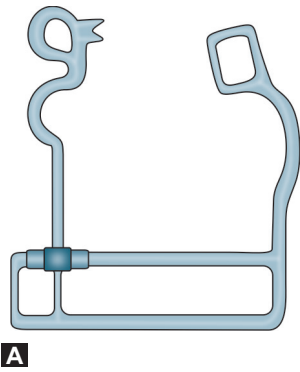
By autoclaving.

**DISSECTING FORCEPS**

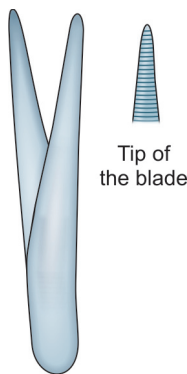
**Plain Dissecting Forceps (Fig. 104.18)**

*Features*

- a. Designed in such a way that on pressing their limbs, the tips are well-apposed and do not slip against each other.
- b. There are transverse serrations at the tip of the blades which help in lifting the tissues and the needle during suturing.



**Figs 104.17A and B:** (A) Self-retaining abdominal retractor (B) Morris retractor



**Fig. 104.18:** Plain dissecting forceps

- c. It is available as small and long plain dissecting forceps.

**Uses**

- a. To hold delicate tissues like peritoneum, vessels, bowel wall, etc.
- b. Can be used to dissect soft friable tissues.
- c. Used in pediatric patients to hold the delicate structures during suturing.

**Sterilization**

By autoclaving.

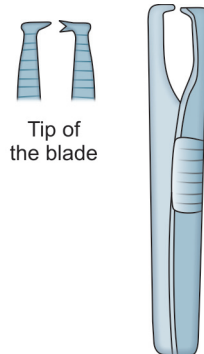
**Toothed Dissecting Forceps (Fig. 104.19)**

**Features**

Same as the plain dissecting forceps but there is a tooth at the tip of one blade and a groove at the tip of other blade.

**Uses**

To hold tough structures like skin, fascia, rectus sheath during suturing.



**Fig. 104.19:** Toothed dissecting forceps

**Sterilization**

By autoclaving.

**TISSUES HOLDING FORCEPS**

**Allis' Tissues Forceps (Fig. 104.20)**

**Features**

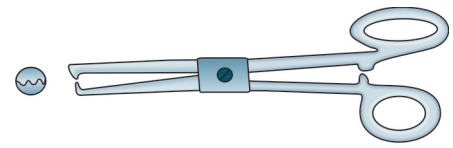
- a. The blades of the forceps are straight along the long axis.
- b. The tips are provided with sharp teeth which interlock on approximation. The teeth are meant for better grip of tissues.
- c. There is a catch lock mechanism.

**Uses**

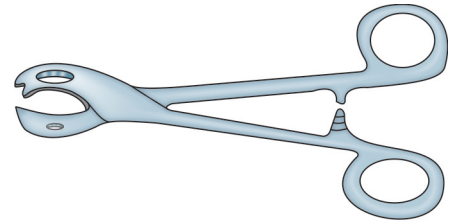
- a. To hold thin and tough structures, e.g. subcutaneous tissue, deep fascia, rectus sheath, etc. for giving traction.
- b. To hold fibrous capsule of a structure.

**Sterilization**

By autoclaving.



**Fig. 104.20:** Allis' tissue forceps



**Fig. 104.21:** Lane's tissue forceps

- 1. Why thin structures are held?  
Because there is little space between the blades.

**Lane's Tissue Forceps (Fig. 104.21)**

**Features**

- a. The blades are curved and stouter than other tissue forceps.
- b. The blades are also fenestrated to make the instrument lighter as well as to provide more space to hold bulky tissues.
- c. The tip of the blades has a single tooth.
- d. The handle has a catch lock mechanism.

**Uses**

- a. To hold the spermatic cord during repair of hernia.
- b. May be conveniently used as a towel clip.

**Sterilization**

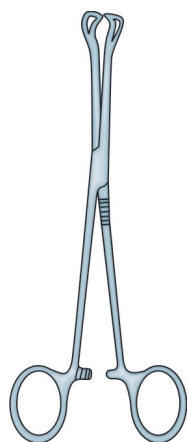
By autoclaving.

**Babcock's Tissue Forceps (Fig. 104.22)**

**Features**

- a. The blades are long and the tip is broad and fenestrated to make the instrument light.
- b. It is a nontraumatizing forceps due to the absence of tooth.
- c. The broad tip is transversely serrated.





**Fig. 104.22:** Babcock's tissue forceps

**Uses**

1. During appendicectomy one pair of Babcock's forceps holds the appendix near its tip; one holds the body of the appendix and a third one, the base of the appendix.
2. During gastrectomy and gastrojejunostomy to hold the margins of the stomach while application of the occlusion clamp.
3. During small and large intestine resection anastomosis to hold the margins of the gut before applying an intestinal occlusion clamp.
4. May be used to hold the cut margins of the bladder during transvesical prostatectomy.
5. During choledochoduodenostomy, to hold the duodenum before making an incision in the first part of duodenum.

**Sterilization**

By autoclaving.

**SCISSORS**

- Scissors are used for blunt as well as sharp dissection.
- They are also used for cutting the sutures, surgical dressings, gauge and various tubings.

**Mayo's Scissors (Figs 104.23A to C)**

**Features**

- a. It may be of two type's straight variety and the curved variety.
- b. May be sharp or blunt pointed.

**Uses**

- a. During appendicectomy to split internal oblique and transversus abdomens muscle.
- b. May be used to cut dressings and sutures.
- c. To cut a corrugated rubber drain.


**Sterilization**

By autoclaving

**McIndoe Scissors (Fig. 104.24)**

**Features**

- a. These are fine scissors.
- b. Blades are delicate and smaller than Mayo's scissors.



**Fig. 104.24:** McIndoe's scissors

**Uses**

- a. It is used for cutting external oblique aponeurosis in appendicectomy.
- b. During thyroidectomy to raise the upper and lower skin flaps by sharp dissection.

**Sterilization**

By autoclaving.

**Heath's Suture Cutting Scissors (Fig. 104.25)**

**Features**

- a. This is a fine scissors curved on angle type.
- b. The serrations at the tip allow gripping of the suture material.

**Uses**

To cut the sutures on the skin or mucosal surface.

**INSTRUMENTS FOR TISSUE APPROXIMATION AND WOUND CLOSURE**

These are:

1. Suture material.
2. Suture needles.
3. Needle holder.

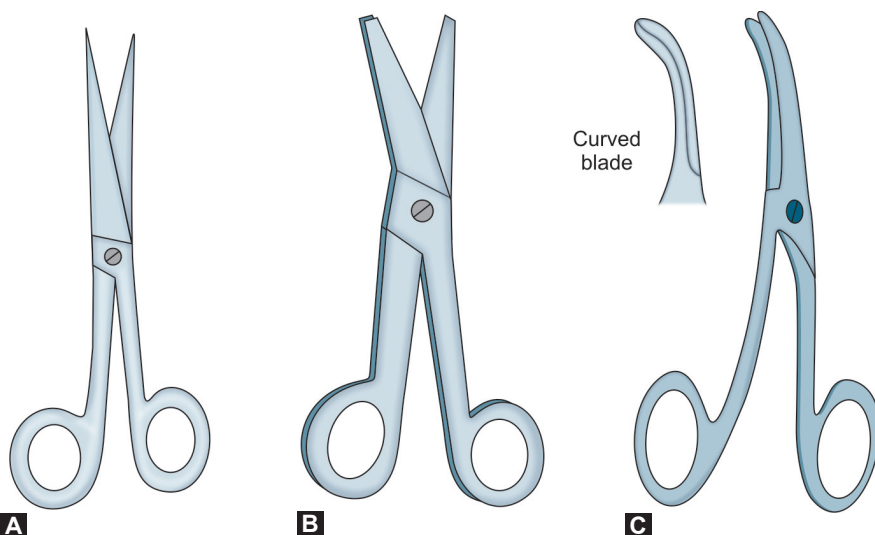
**Suture Material**

**Definitions**

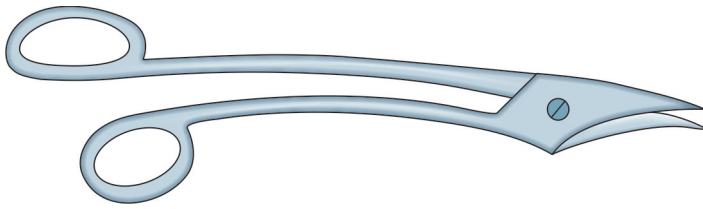
1. Suture material—When two cut edges of wound are approximated, either continuously or interruptedly, it is known as suturing and the material used for it is called suture material.
2. Ligature—Ligatures obliterate the lumen of tubular structures.

**Classifications**

- i. According to the behavior of the suture material in the tissues they are divided into:
  1. Absorbable sutures are those which are absorbed in the tissues either by enzymatic digestion or by phagocytosis.



**Figs 104.23A to C:** (A) Mayo's straight sharp pointed scissors; (B) Mayo's straight blunt scissors; (C) Mayo's curved-on-flat scissors



**Fig. 104.25:** Heath's stitch cutting scissors

Depending on the source these sutures may be:

- a. Natural, e.g. plain and chromic catgut.
- b. Synthetic, e.g.
  - Polyglactin 910 (Vicryl).
  - Polyglactin 910 rapide (Vicryl rapide).
  - Polyglycolic acid (Dexon).
  - Polydioxanone suture (PDS).
2. Nonabsorbable sutures are those which remain in the tissues for an indefinite period without absorption.
- ii. Again depending on the source, sutures may be:
  - a. Natural sutures, e.g. silk, linen thread.
  - b. Synthetic sutures, e.g. polypropylene (Prolene), polyamide (Ethilon and Nylon).
  - c. Metal like stainless steel wire.
- iii. Depending on the number of strands, in the suture materials, sutures may be:
  3. Monofilament sutures consisting of a single strand of fiber, e.g. catgut, PDS, Prolene and Ethilon (polyamide), steel.
  4. Multi-or-poly filament sutures – consisting of multiple strands braided together, e.g. silk, linen, polyglycolic acid (Dexon) and Vicryl.

### Catgut

1. What is catgut?
  - a. It is the natural absorbable surgical suture derived from the submucosa of the sheep's intestine.
  - b. Catgut is a misnomer. The origin of the word is obscure but it might have come from the word 'Kitgut'. The kit means a medieval three stringed violin with strings made of it (catgut).  
To avoid confusion, nowadays it is referred to as surgical gut.
2. How catgut is prepared?
  - a. Sheep's intestine is scraped leaving only the submucosa.

- b. The submucosa is dried and cut into strips.
- c. These strips are then rolled out.
- d. The rolled out strips are made fat free (defatting) by treatment with fat solvents.
- e. Fat-free rolled out materials are then spun into different diameters of catgut.
- f. Plain catgut can be chromicized when needed by treating with chromic acid.
- g. Catgut is wrapped in sterile packs with fluid.
3. What is the fluid in which the catgut is kept?
 

It is kept in a fluid containing isopropyl alcohol which maintains the suppleness or flexibility of the catgut.
4. What is the advantage of chromic catgut?
 

A chromic catgut produces much less tissue reaction than a plain catgut and remains in tissue for longer time.
5. What is the average duration of absorption of catgut?
  - a. Plain catgut loses 50 percent tensile strength in tissues in 3 days and loses all tensile strength in 15 days.
  - b. Chromic catgut loses 50 percent tensile strength in 7 days and loses all its tensile strength in 28 days.
  - c. The chromic catgut gets totally absorbed in tissues in about 100 days while plain catgut in about 60 days.
6. What is numbering of catgut?
  - a. Catgut is numbered from 0 to 10.
  - b. More the number of Zero's, finer the catgut, e.g. 5/0 is thinner than 4/0, 3/0, etc.
  - c. The thickness increases from 0 to 1, 2, etc, e.g. no. 2 catgut is thicker than no. 1.
7. How does the catgut gets absorbed?
 

The catgut being a protein (99% collagen) gets absorbed by a process of enzymatic digestion by proteolytic enzymes contained in the polymorphs and macrophages.

8. What are the uses of catgut?
  - a. During appendectomy, to tie the mesoappendix and base of the appendix with 2/0 chromic catgut.
  - b. During small bowel resection-anastomosis, the posterior and anterior through and through layers are applied with 2/0 atraumatic catgut sutures. The seromuscular (anterior and posterior) layer is usually sutured with 2/0 Mer silk.
  - c. During gastrojejunostomy to suture the posterior and anterior through and through layers with 2/0 atraumatic catgut.
  - d. During cholecystectomy, bleeding from the gallbladder bed is controlled by suturing the gallbladder bed with 1/0 atraumatic catgut mounted on a 40mm needle.
  - e. During closure of subcostal incision, the posterior rectus sheath, anterior rectus sheath, external oblique aponeurosis and muscle may be sutured with 1/0 chromic catgut sutures.  
It is to be noted that nowadays, synthetic absorbable sutures viz. polyglactin (Vicryl) and polyglycolic acid (Dexon) are replacing the catgut for most of its uses.
9. What is an atraumatic suture?
 

When a suture is attached to an eyeless needle it is called an atraumatic suture.
10. How catgut is sterilized?
 

By gamma irradiation.

### Synthetic absorbable suture polyglycolic acid suture (dexon)

1. What is Dexon?
  - a. It is a synthetic absorbable polyfilament suture.
  - b. It is the polymer of glycolic acid.
  - c. Dexon maintains tensile strength for about 30 days and gets absorbed in 80 to 90 days.
  - d. It causes minimal tissue reaction and possesses better knot holding properties than catgut.

### POLYGLACTIN SUTURES (VICRYL)

2. What is Vicryl?
  - a. This is a copolymer of lactide and glycolide in the ratio of 90:10.

- b. It maintains tensile strength in the tissues for about 28 days and gets totally absorbed in about 90 days.
- c. Like Dexon, this is a synthetic absorbable polyfilament suture.
3. What are the uses of dexon and vicryl?
- These are used in all situations, where catgut is indicated as mentioned above.
  - During biliary enteric anastomosis, e.g. choledochoduodenostomy, choledochojejunostomy, hepaticojejunostomy, 3/0 or 4/0 atraumatic sutures are used.
  - Single layered anastomosis in large gut may be done with 2/0 Vicryl or Dexon interrupted sutures.
4. What is Vicryl rapid suture?
- This is a variety of polygalactin suture. The rapid absorption characteristics of Vicryl rapide is obtained by exposure of coated Vicryl to gamma irradiation.
  - It maintains tensile strength for 10 to 12 days and gets absorbed in tissues in 42 days.
  - Uses:
    - For subcuticular sutures.
    - During circumcision for approximation of cut margins of the prepuce.
5. What is polydioxanone suture (PDS)?
- It is a synthetic delayed absorbable monofilament suture formed by polymerizing the monomer paradioxanone.
  - It differs from Dexon and Vicryl.
    - It is monofilament.
    - Losses tensile strength in 56 days.
    - It gets absorbed in 180 days.
6. What are the uses of PDS?
- All situations where catgut, polyglycolic acid and polyglactin sutures are used.
  - No 1 or 1/0 suture may be used for closure of midline and other abdominal incisions.
7. How the synthetic absorbables are sterilized? By ethylene oxide.
- c. It is sterilized by gamma radiation.
2. How silk thread is prepared?
- Viscous fluid secretion from silkworm is kept exposed to air.
  - The thread that is formed is spun to form cocoon.
  - The cocoon is unraveled and silk fibers are produced.
  - The fine fibers are assembled by twisting or braiding to form silk thread.
3. What is mersilk?  
It is the black braided silk mounted on atraumatic needles. Mersilk is available in different sizes from no. 7/0 to 1.
4. What are the uses of silk?
- No 1 or 1/0 silk sutures are used as ligatures in the following situations.
    - During cholecystostomy to ligate the cystic duct and cystic artery.
    - During small and large gut resection to ligate the mesenteric vessels.
    - To ligate the pedicles during nephrectomy and splenectomy.
    - During truncal vagotomy to ligate the anterior and posterior vagus nerves before their division.
    - Used for skin closure with continuous or interrupted sutures.
  - Mersilk –
    - 2/0 or 3/0 Mersilk is used for anterior and posterior seromuscular sutures in small gut anastomosis and in gastrojejunostomy.
    - 4/0 Mersilk may be used for nerve suture.
5. How silk is sterilized?  
By autoclaving. It is never boiled.

### Polypropylene (Prolene)

1. What is Prolene?
- It is the propylene polymer and a monofilament.
  - There are minimal tissue reactions.
  - It maintains the tensile strength for an indefinite period.
  - It is extremely smooth and does not cut through the tissues.
  - Prolene sutures are available in a variety of eyeless needles and in various sizes from 8/0 to 1.
2. What are the uses of Prolene?

- Mass closure of midline abdominal incision.
  - Used for mesh repair of incisional hernia.
  - Repair of posterior wall of inguinal canal during herniorrhaphy with 1/0 or no 1 prolene.
  - Fine sutures like 4/0 or 5/0 Prolene are used for vascular anastomosis and repair of tendon and nerve injuries.
3. How prolene is sterilized?  
By Ethylene oxide.

### Polyamide (Nylon, Ethilon, Sutupak)

1. What is polyamide?
- It is the polyamide polymer and a monofilament.
  - There is extremely low tissue reaction.
  - It maintains the tensile strength for a long time and the loss of tensile strength per year is only 12 to 25 percent.
  - It passes through the tissues very smoothly because of having a very low coefficient of friction.
  - It is available in various sizes and has replaced silk in many surgical procedures.
2. What are its uses?
- For closure of skin incision.
  - For herniorrhaphy.
  - For vascular anastomosis with finer sutures (4/0, 5/0, etc.).
3. How polyamide is sterilized?  
By Ethylene Oxide (EO) sterilization.

### Suture Needles (Fig. 104.26)

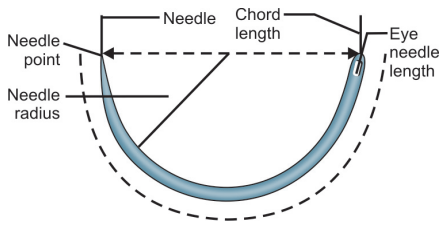
Suture needles are made from stainless steel due to which they do not rust or break easily.

1. What are the parts of a needle?
- Eye—for threading a suture. In atraumatic (Eyeless) needles, there are no eyes.
  - Needle point—The sharp apex of the needle is the needle point.
  - Needle length—This is the circumferential length of the needle.
  - Needle cord length—It is the linear distance between the pointed tip and eye of the needle.
2. What is the weakest part of a needle?  
The part of the needle near the eye is the weakest part.

### Nonabsorbable Suture

#### Silk

1. What is silk?
- It is the natural nonabsorbable polyfilament suture.
  - It knots securely and has got good handling properties.



**Fig. 104.26:** Parts of a surgical needle

3. How surgical needles are classified according to shape, cutting edge and presence of eye?

- a. According to shape
  - Straight needles and
  - Curved needles.
- b. According to cutting edge
  - Round body needles—They are uniformly round on cross section).
  - Cutting needles—They are triangular on cross section.
- c. According to eye
  - Eyed needles or traumatic needles and
  - Eyeless (Atraumatic needles).

Eyed or traumatic needles are rarely used nowadays except for gross works like suturing skin, or fixing drains to skin, etc.

*Advantages of eyeless needles:*

- i. Eyeless needles cause minimal trauma to tissues during their passage.
  - ii. They are supplied in a presterilized pack so, sterilization before use is not required.
  - iii. As the needle is a disposable one, there is no hazard of loss of sharpness.
  - iv. Faster and precise surgery with its use.
4. What is the correct site for holding a needle?

It should be grasped at the junction of posterior 1/3rd and anterior 2/3rd of the needle in the shaft.

5. What are the round body needles?
  - a. The tip of the needle is rounded along with the body.
  - b. It separates the tissue fibers rather than cut them.
  - c. The tissues close tightly round the suture material and form a leak proof suture line.
6. What are the types of round body needles?
  - a. Intestinal needles—These are smooth, delicate and eyeless needles.

b. Heavy needle—for wound closure and hernia repair.

c. Blunt point needle—for suturing liver, kidney and spleen.

7. What is a reverse cutting needle?

a. Here the cutting edge apex is on the outer side of the needle curvature unlike the conventional cutting needle where the cutting edge apex is on the inside of the needle curvature.

b. Advantage is that it reduces the risk of ligature cutting through the tissue when a knot is tied.

8. What is a taper cut needle?

a. A taper cut needle has only 1/16 part reverse cutting while rest is round bodied.

b. It is used to suture tough but important structure like liver, heart, etc.

9. How needles are sterilized?

By keeping the needles dipped in concentrated Lysol for 1 hour or in dilute Lysol for 24 hours.

10. What are the uses of needles?

a. Curved cutting needles – used for suturing skin, and other tough structures like linea alba, anterior rectus sheath, external oblique aponeurosis, etc.

b. Curved round body needles – for suturing muscle, peritoneum and other delicate structures.

c. The atraumatic needles are used for intestinal resection – anastomosis, biliary enteric anastomosis, vascular and nerve sutures.

### Needle Holder (Fig. 104.27)

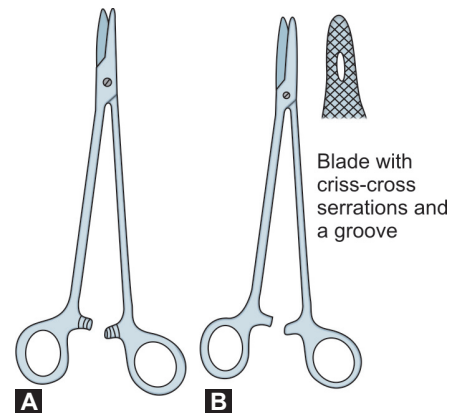
#### Features

- a. The blades are much smaller in comparison to the hemostatic forceps.
- b. The inner surface of the blades are serrated in a criss-cross pattern and may have a groove for better accommodation and grip of the needle.
- c. Types—Straight type and curved type.

The straight variety is used to hold needles during suturing at surface, while the curved variety is used during suturing at depth.

#### Uses

Needle holder is used to hold the needle for suturing in all operations.



**Figs 104.27A and B:** (A) Long straight needle holder (B) Long curved needle holder

#### Sterilization

By autoclaving.

### GASTROINTESTINAL CLAMPS

Gastrointestinal occlusions clamps are used in surgical interventions of the gastrointestinal tract viz.

- i. To occlude or to crush the lumen of the bowel.
- ii. To occlude the supplying blood vessels of the part of the gut held during anastomosis.

#### Types

Gastrointestinal clamps are of two types viz.

1. Noncrushing or occlusion clamps and
2. Crushing clamps.

### OCCLUSION CLAMPS

These are used to occlude the lumen of the gut and supplying blood vessels to prevent spilling of the gut contents and to produce a bloodless field of operation.

#### Types

- a. Moynihan's gastric occlusion clamp.
- b. Lane's twin gastroenterostomy occlusion clamp.
- c. Intestinal occlusion clamp
  - Lane's intestinal occlusion clamp.
  - Doyen's intestinal occlusion clamp.
  - Carwardine's twin intestinal occlusion clamp.

**Difference between crushing clamps and occlusion clamps**

	<i>Crushing clamps</i>	<i>Occlusion clamps</i>
1. Blades	<ul style="list-style-type: none"> <li>• They are stout and heavy.</li> <li>• Blades are well-apposed and a firm pressure effect is obtained.</li> </ul>	The blades are lighter and appose lightly just occluding the lumen
2. Lever arrangement	Present which greatly multiplies the exerted pressure.	No such lever arrangement
3. Serrations	Deeper and lock firmly	Serrations are lighter

1. What are the points of difference between the crushing and occlusion clamps?  
See the table above

**Moynihan's Gastric Occlusion Clamp (Fig. 104.28)**

**Features**

- a. This clamp has long and stout blades to hold a considerable length of the stomach wall and have transverse serrations and central fenestrations on the inner aspects.
- b. The blades may be straight or curved.

**Uses**

It is used to hold and occlude stomach during gastrectomy, gastrojejunostomy, etc.

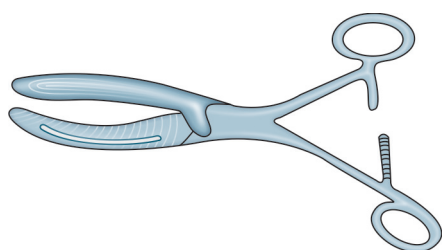
**Sterilization**

By autoclaving.

**Lane's Twin Gastroenterostomy Occlusion Clamp (Fig. 104.29)**

**Features**

- a. This twin clamp has two pairs of blades, one each for stomach and small intestine.



**Fig. 104.28:** Moynihan's curved gastric occlusion clamp

b. Each pair of blades has a separate locking mechanism and handles. The clamps can be detached from each other.

- c. Arrangement of fixing of the two pairs of clamps: Provisions are so made with two rings and a screw that the clamps can be attached together either with their handles on the same side or opposite to each other according to surgeon's convenience.
- d. The blades are serrated longitudinally for a better grip.
- e. On proper apposition, the stomach and jejunum are held close to each other by this instrument.
- f. The instrument may be curved or straight.

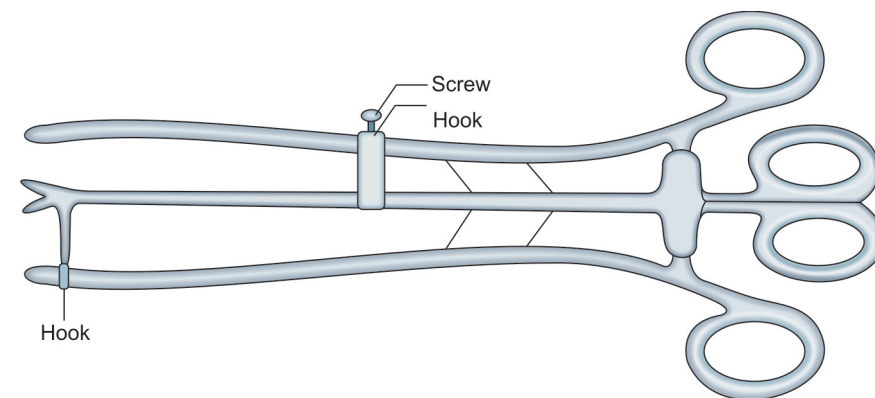
**Uses**

This instrument is used during gastrojejunostomy.

**Sterilization**

By autoclaving.

- 1. What are the indications of gastrojejunostomy?



**Fig. 104.29:** Lane's twin gastrojejunostomy occlusion clamp

- 2. What are the steps of operation of gastrojejunostomy?
- 3. What are the steps of operation of truncal vagotomy?
- 4. What are the types of vagotomy?  
See the operations 'vagotomy and gastrojejunostomy' in the operative surgery section, chapter 89.

**Sterilization**

By autoclaving.

**Doyen's Intestinal Occlusion Clamp (Fig. 104.30)**

**Features**

- a. It is a light instrument with thin and long blades.
- b. The blades have longitudinal serrations on the inner aspect.
- c. There are finger bows and a pair of shaft.
- d. The instrument may be curved or straight.

**Uses**

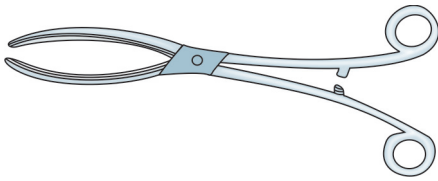
This instrument is used for resection and anastomosis of gut.

**Sterilization**

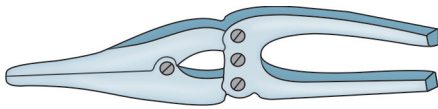
By autoclaving.

- 1. What are the indications of intestinal resection and anastomosis?
- 2. What are the different types of intestinal anastomosis?
- 3. What are the steps of operation of small gut resection and anastomosis?  
See small bowel resection and anastomosis in the operative section, chapter 93.





**Fig. 104.30:** Doyen's intestinal occlusion clamp



**Fig. 104.31:** Payr's gastric crushing clamp

### CRUSHING CLAMPS

#### Types

*Payr's Gastric Crushing Clamps (Fig. 104.31)*

#### Features

- The blades are stout and heavy.
- The handles have a double lever arrangement with four joints, so that a maximal pressure effect can be produced by limited effort.
- The blades have longitudinal serrations which are deep and lock firmly.

#### Uses

It is used in case of partial and total gastrectomies. It should not be used where anastomosis is to be done.

However, surgeons rarely use these clamps nowadays. If used at all, it is applied towards the side of stomach that is to be resected and the proximal stomach (in partial gastrectomy) is held by a gastric occlusion clamp.

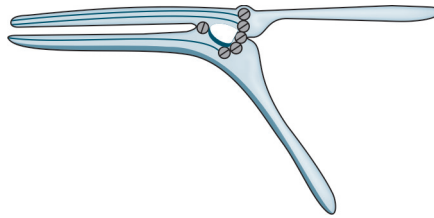
#### Sterilization

By autoclaving.

- What are the indication of partial gastrectomy? See gastric ulcer, chapter 30.
- What are the steps of operation of subtotal gastrectomy?  
See the operative section, chapter 89.  
Subtotal gastrectomy in gastric carcinoma.

#### *Payr's Intestinal Crushing Clamp (Fig. 104.32)*

It resembles, the gastric crushing clamp but the blades are smaller and the instrument is a little lighter.



**Fig. 104.32:** Payr's intestinal crushing clamp

### INSTRUMENTS USED IN BILIARY TRACT SURGERY

Apart from the general set of instruments the following instruments are used in biliary tract surgery:

- Cholecystectomy forceps.
- Desjardin's choledocholithotomy forceps.
- Kehr's T - tube.
- Baker's dilators.

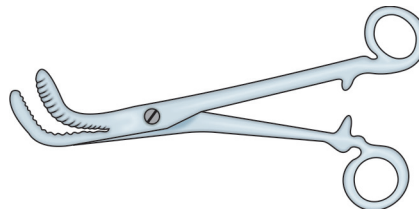
#### Cholecystectomy Forceps (Figs 104.33A and B)

##### Features

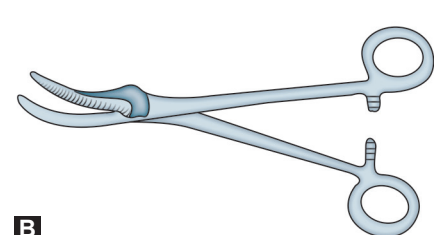
- This instrument has short angled blades with transverse serrations on their inner surface and is provided with catches and finger bows.
  - The handles are long to facilitate working at depth in the gallbladder bed.
- Why the blades are curved?  
The curvature of the blades helps in tying the vessels at depth.
  - The tips of the blades are pointed which helps in easy negotiation of the instrument around the cystic duct and artery.

##### Types

- Henry Gray's cholecystectomy forceps.



**A**



**B**

**Figs 104.33A and B:** (A) Henry-Gray's cholecystectomy forceps; (B) Moynihan's cholecystectomy forceps

- Moynihan's cholecystectomy forceps. They look more or less same, the difference being Henry Gray's forceps is a little lighter and the blades are more angular.

##### Uses

- The first cholecystectomy forceps is used to hold the fundus of gallbladder and a second one is used to hold the neck of the gallbladder at the Hartmann's pouch. A third forceps may be used to hold the body of the gallbladder if it is long.
- Dissection of the cystic duct and artery after the anterior layer of the lesser omentum has been incised and reflected. However a right angled forceps is usually preferred for this purpose.

##### Sterilization

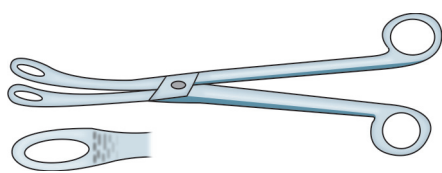
By autoclaving.

- What are the indications of cholecystectomy?
- What are the steps of operation of open cholecystectomy?  
See 'cholecystectomy' in operative surgery section, chapter 90.
- What are the complications following cholecystectomy?
- What is Calot's triangle?
- Gallstones—Types and pathogenesis.  
See the long case – "chronic cholecystitis" chapter 73.

#### Desjardin's Choledocholithotomy Forceps (Fig. 104.34)

##### Features

- This is a long slender forceps with no catches on the handles.
- It has long curved blades, each having a fenestration at its end.



**Fig. 104.34:** Desjardin's choledocholithotomy forceps

### Uses

To remove stones from the common bile duct during choledocholithotomy.

1. Why the instrument is long?  
To facilitate working at depth.
2. Why is it slender and delicate?  
Because the bile duct is a delicate structure within which the instrument is to move.
3. Why the blades are fenestrated?  
To have a good grip of the stone so that it does not slip during removal.

### Sterilization

By autoclaving.

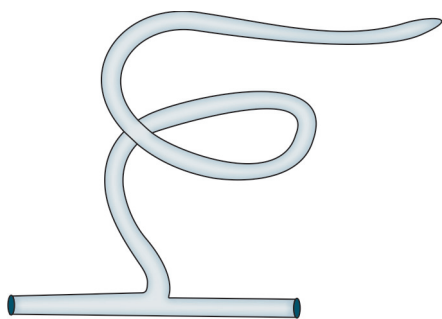
### Kehr's T Tube (Fig. 104.35)

#### Features

- a. This is a flexible tube made of latex or rubber available with numbers 12, 14, 16 and 18.
- b. The tube is so named as it looks like the letter T.

#### Uses

- a. Following choledochotomy, the bile duct is closed over a T-Tube as primary closure of bile duct will give rise to leakage in most cases.
- b. After repair of bile duct injury T-Tube is used to drain the bile duct for 4–6 weeks and then it is removed.
- c. It may be used as a stent following repair of ureteric injury.



**Fig. 104.35:** Kehr's T-Tube

### Sterilization

By autoclaving.

1. What are the indications of choledocholithotomy and choledochotomy?
2. What are the steps of operation of choledocholithotomy?

See the operation of choledocholithotomy chapter 90, in operative surgery section.

3. What are the types of stones in CBD?

See the long case of obstructive jaundice due to stone in the CBD, chapter 73.

4. What is Charcot's triad?

See the long case of obstructive jaundice due to stone in the CBD, chapter 73.

5. How T – Tube is inserted?
  - a. The short limb of the T – Tube is cut to its desired length and is passed inside the common bile duct through the incision made over it, one arm directing towards the liver and the other towards the duodenum.

A slit is made in the short limb before insertion so that the two openings are connected by the slit and a rim of tube is cut away along the slit for better drainage.

- c. The choledochotomy is closed over the T – Tube by interrupted sutures, e.g. 3/0 Vicryl so that the T – Tube fits snugly in the bile duct taking care not to take any bite in the wall of T- Tube.
- d. The long limb of the T – Tube is brought out through a stab wound in the skin in the lateral abdominal wall and is connected to a plastic bag for collection of bile.

6. How the T – Tube is removed?

7. What is T – Tube cholangiogram?

See the T – Tube cholangiography in X-ray section, chapter 103.

### Bakes Dilator (Fig. 104.36)

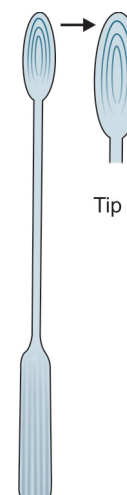
#### Features

- a. This is a long malleable instrument.
- b. It has a wide handle, a slender shaft with a bulbous tip.

#### Uses

- a. It is used during choledocholithotomy. After clearance of stones in the bile duct, this dilator is passed to see any retained stone by sounding with this instrument.

- b. The patency of the ampulla of Vater can be tested with this instrument, when the



**Fig. 104.36:** Bakes dilator

ampulla is patent the metal tip of the dilator is seen in the duodenum. This is called “steel sign”.

### Sterilization

By autoclaving.

## INSTRUMENT USED IN RECTAL SURGERY

### Proctoscope (Fig. 104.37)

#### Features

- a. The instrument has two parts – the outer tube and the inner obturator. The outer tube has a handle attached to it.
- b. It may have an inbuilt lighting arrangement.

#### Uses

- a. It is used to visualize the anal canal and lower end of rectum to diagnose piles, ulcers and growths of rectum.
- b. For minor operations like taking rectal biopsy, polypectomy and sclerosant injection into the pile mass.

### Sterilization


By autoclaving.

### Probe (Fig. 104.38)

It is a metallic malleable olive pointed probe usually with an eye.

#### Uses

- i. To probe into a sinus or fistula to know its direction and length.



**Fig. 104.37:** Proctoscope



**Fig. 104.38:** Probe

- ii. During fistulectomy, it acts as a guide.
- 1. Why the probe is malleable and olive pointed?  
The instrument is made malleable and olive pointed instead of sharp tip so as to avoid making any false passage.

**Sterilization**

By autoclaving.

**Piles Holding Forceps (Fig. 104.39)**

**Features**

There is a circular groove along the inner side of each blade around the fenestration in the blade.

There is no such groove in case of a swab holding or tongue holding forceps though the latter looks like the piles holding forceps.

**Use**

To hold the pile mass during hemorrhoidectomy. However, Allis tissue forceps can also be used for this purpose.

**Sterilization**

By autoclaving.

1. What are piles?
2. What are the types of piles?
3. What are the degrees of piles?
4. What are primary and secondary piles?
5. What are the complications of piles?
6. What are the treatments of piles?  
See 'hemorrhoids' in the chapter on rectum and anal canal, chapter 35.

**Flatus Tube (Fig. 104.40)**

**Features**

This is thick rubber tube with a conical base and the rounded tip.

**Uses**

- i. This tube is used to correct sigmoid volvulus in adults (nonoperative decompression).
- ii. It is used to aid passage of flatus to reduce the distension of gut in paralytic ileus.

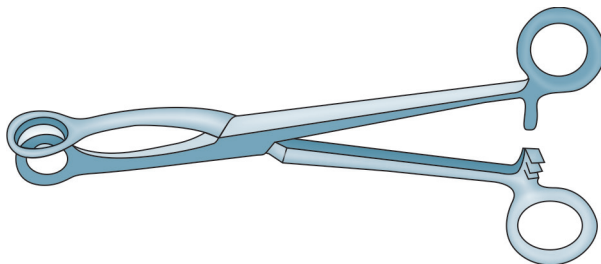
**Sterilization**

By autoclaving.

1. What are the common causes of intestinal obstruction?
2. What are the features of intestinal obstruction?
3. How will you differentiate simple and strangulated obstruction?  
See the X-ray of 'multiple air fluid levels' chapter 103 and the problem 'acute intestinal obstruction', chapter 102.
4. How is the flatus tube inserted?
  - a. The tube is sterilized and well-lubricated with 2 percent xylocaine jelly and then introduced upto the pelvic colon through the anus, with the patient lying either in lateral or in knee elbow position.
  - b. The other end of the tube is kept immersed in a kidney dish containing water.



**Fig. 104.40:** Flatus tube



**A**



Tip of sponge holding forceps



Tip of piles holding forceps

**B**

**Fig. 104.39A and B:** (A) Piles holding forceps (B) Tip of sponge holding and piles holding forceps

## INSTRUMENTS FOR GENITOURINARY SURGERY

### Catheters

A catheter is a tubular instrument for the passage of fluid from or into a body cavity especially one passed through the urethra into the bladder to drain the retained urine.

#### Types

Catheters are broadly divided into two types:

- a. Ordinary catheters—Catheters used for drainage of urinary bladder for a short period or for diagnostic purposes, e.g.
  - i. Simple rubber catheter.
  - ii. Male metallic catheter.
  - iii. Female metallic catheter.
- b. Self-retaining catheters—These are used when there is considerable delay in the return of normal micturition, e.g.
  - i. Foley's catheter.
  - ii. Malecot's catheter.
  - iii. Gibbon's catheter.
  - iv. de Pezzer's catheter.

### ORDINARY CATHETERS

#### Simple Rubber Catheter (Fig. 104.41)

##### Features

- a. It is made of India rubber.
- b. The tip of the catheter is smooth and rounded. There is an opening at the side near the tip.
- c. It is available in various sizes, e.g. 6, 8, 10, etc.
  - This is an English scale regarding the diameter of the catheter.
  - The diameter is expressed in mm as follows:  
Diameter = Number of catheter/2 + 1.

##### Uses

- a. Urological use:
  1. To drain the urinary bladder in case of retention.
  2. To differentiate anuria from retention of urine.
  3. To measure the amount of residual urine after micturition.

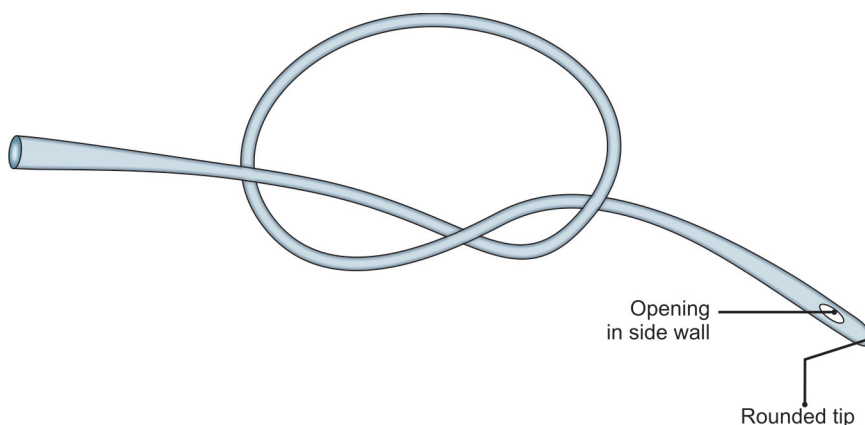


Fig. 104.41: Simple rubber catheter

4. For administration of intravesical chemotherapy or BCG vaccine for treatment of bladder carcinoma.
5. For diagnosis of urinary tract injuries. Catheterization of bladder if reveals hematuria, indicates urinary tract injury.
6. To obtain a specimen of uncontaminated urine for chemical examination.
- b. Nonurological use:
  - a. Can be used as an oxygen catheter.
  - b. May be used during choledocholithotomy for flushing the bile duct with normal saline to remove the sludge and small stones.
  - c. To irrigate an abscess cavity.
  - d. For diagnosis of esophageal atresia in a newborn. The catheter cannot be passed into the stomach.

##### Sterilization

By autoclaving.

1. How will you catheterize a patient presenting with acute retention of urine?
2. What are the complications of catheterization?  
See minor surgical procedures in operative surgery section, chapter 99.

#### Male Metallic Catheter (Fig. 104.42)

##### Features

- a. The terminal part of this catheter is curved like a dilator.
- b. The tip is rounded with side holes near the tip.
- c. There are two rings near the base for holding the catheter.

##### Uses

This is used for relief of urinary retention when a simple rubber, Foley's or Gibbon's catheter cannot be passed through the urethra.

##### Sterilization

By autoclaving.

1. How will you pass the metallic catheter?  
It is passed like a urethral dilator (Clutton or Lister's metallic dilator) – see urethral dilatation in minor surgical procedures in operative surgery, chapter 99
2. How do you know the catheter has gone into the bladder?
  - a. As the catheter goes into the bladder, there is loss of resistance and the instrument can be rotated freely on either side.

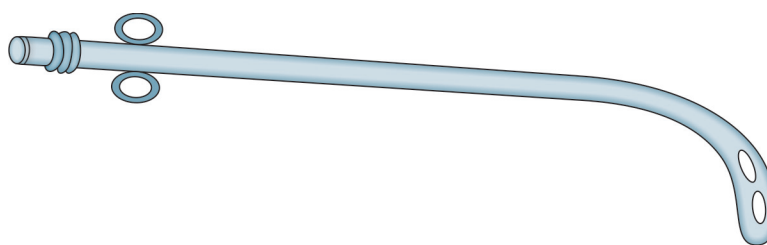


Fig. 104.42: Male metallic catheter

- b. There is no bleeding through the urethra and urine will come out through the catheter.

**Female Metallic Catheter (Fig. 104.43)**

This is a short metallic catheter. The tip is rounded with multiple side holes near the tip.

*Uses*

1. To empty the bladder before pelvic operations to prevent injury to the bladder.
2. May be used to relieve retention of urine if a rubber catheter cannot be passed.

**SELF-RETAINING CATHETERS**

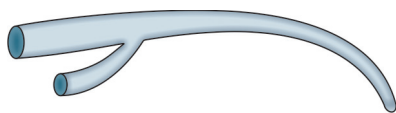
**Foley's Catheter (Figs 104.44A and B)**

*Features*


- a. Foley's catheters are ballooned. In two ways Foley's balloon catheter, the side channel is used to inflate the balloon which keeps it indwelling or self-retaining. The main channel is used for drainage of urine.
- b. In three ways Foley's balloon catheter, there is an additional third channel for bladder irrigation or drainage, e.g. after prostatectomy.



**Fig. 104.43:** Female metallic catheter




**A**



**B**

**Figs 104.44A and B:** (A) Two way Foley's balloon catheter; (B) Three ways Foley's balloon catheter



**Fig. 104.45:** Catheter introducer

- c. Though most commonly used, the disadvantages of Foley catheters are that the lumen is relatively small and the catheters are soft and pliable disfavoring early negotiation through urethral obstruction without the help of metal introducer (Fig. 104.45).

*Uses*

- a. Urologic use:
  1. For drainage of bladder to monitor urine output following major operation or trauma and also in critically ill patient where prolonged catheterization is required.
  2. For drainage of bladder following open prostatectomy. Here the three way catheter is used as bladder irrigation is required.
  3. Urethral catheterization following urethroplasty.
  4. May be used for tube nephrostomy.
  5. To relieve retention of urine by urethral catheterization.
  6. May be used for suprapubic cystostomy.
- b. Nonurologic use
  1. For intercostal drainage in case of empyema, hemothorax or pneumothorax.
  2. May be used for gastrostomy or jejunostomy.
  3. May be used for tube cecostomy.


*Sterilization*

It is available in a presterilized pack which is usually sterilized by gamma irradiation.

1. What do you mean by 14Fr catheter?
 

This is a French scale measurement and indicates the circumference of the catheter in mm.

Diameter of the catheter is measured by = No. of catheter in French scale divided by 3.



**Fig. 104.46:** Malecot's catheter

**Malecot Catheter (Fig. 104.46)**

*Features*

- a. It is retained after introduction by its dilated winged end.
- b. The dilated winged end may be made straight by introducing a Malecot catheter introducer (Fig. 104.47) or by inserting a hemostatic forceps.

*Uses*

Its uses are the same as Foley's catheter, except that it is never used for urethral catheterization.

*Sterilization*

By autoclaving.

**De Pezzer's Catheter (Fig. 104.47)**

This is also a self-retaining catheter and is kept in place after introduction due to dilated bulbous end.

*Uses*

Same as the Foley's catheter, but it is never used per urethra.

*Sterilization*

By autoclaving.

1. How self-retaining catheters are removed?
  - a. Foley's catheter is removed after withdrawing the water from the balloon.



**Fig. 104.47:** de Pezzer's catheter



- b. The Malecot or the de Pezzer catheter is removed by a smart pull.

**Gibbon’s Catheter (Fig. 104.48)**

*Features*

- a. This catheter is nonballooned and used per urethra only.
- b. It is made of polyvinyl chloride (PVC) which is least irritant and more tough in texture. So it is ideal for long-term drainage.
- c. The catheter is provided with a plastic stylet for the ease of introduction. The stylet is removed after the catheter is passed into the bladder.
- d. The catheter has two plastic flaps attached to the tube some 20cm from the tip which are secured to the penile shaft by strapping or in the female to the inner side of the thigh.

*Uses*

For urinary catheterization in case of retention.

*Sterilization*

It is supplied in a presterilized pack which is sterilized by gamma irradiation.

**BOUGIE OR URETHRAL DILATOR**

Bougie or urethral dilator is an instrument used for gradual and periodic dilatation of urethra.

*Types*

There are two common varieties:

- 1. Lister’s bougie.
- 2. Clutton’s bougie.

**Lister’s Metallic Bougie (Fig. 104.49)**

*Features*

- a. It is a solid cylindrical metallic instrument with a definite curvature near the tip.
- b. The tip is olive pointed.
- c. The shaft is more curved.
- d. Handle is round.
  - The number written on the handle has a difference of 3. The denominator number indicates the circumference in mm at the base, and the numerator indicates the circumference in mm at the tip.

- This is available in a set of 12 and the different numbers are 7/10, 9/12, 11/14 ..... 29/32.

**Clutton’s Metallic Bougie (Fig. 104.50)**

This is identical to Lister’s metallic bougie with the following differences:

- a. The tip is blunt.
- b. The shaft is less curved.
- c. The handle is violin-shaped.
  - The numbers written on the handle has a difference of 4 and has the same implication as in Lister’s metallic bougie.
  - This is also available in a set of 12 and the different numbers are 6/10, 8/12, 10/14 ..... 28/32.

*Uses*

- a. For dilatation of urethra in urethral stricture.
- b. Prior to cystoscopy for dilatation of urethra.
- c. During repair of rupture urethra by railroad technique.
- d. Nonurological use—During choledocholithotomy this is used as a sound to

ascertain presence of bile duct stones. This may be passed through the ampulla of Vater to ascertain the patency of ampulla.

*Sterilization*

By autoclaving.

- 1. How will you do urethral dilatation?
- 2. What are the complications of urethral dilatation?
 

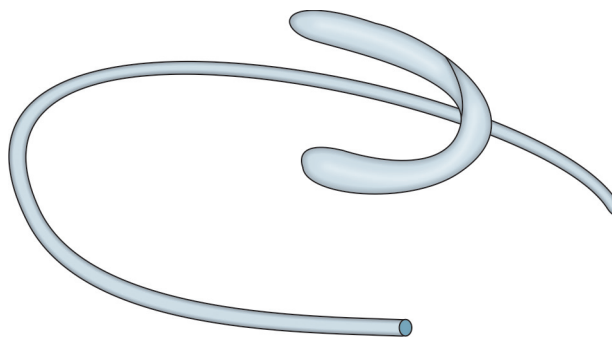
See urethral dilatation in operative surgery section, chapter 99.
- 3. When does a stricture is said to be impassable?
 

The impassable stricture is one where a smallest size filiform bougie (1Fr) cannot be passed.

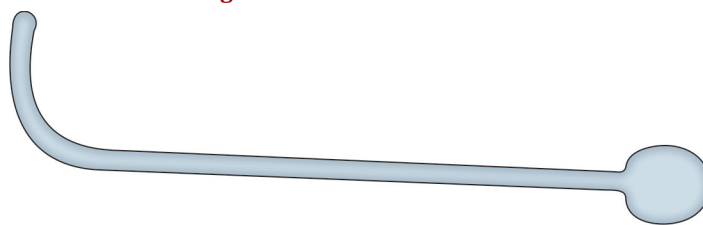
**PYELOLITHOTOMY FORCEPS (FIG. 104.51) (NEPHROLITHOTOMY FORCEPS)**

*Features*


- a. This is long instrument with a pair of blades, a pair of shafts and finger bows.



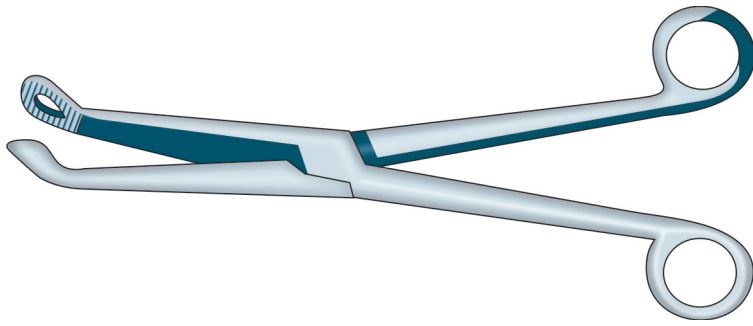
**Fig. 104.48:** Gibbon’s catheter



**Fig. 104.49:** Lister’s bougie



**Fig. 104.50:** Clutton’s bougie



**Fig. 104.51:** Pyelolithotomy forceps

- b. The blades are small and oval with transverse serrations on the inner side of the blades with a central fenestration.
- c. There is no catch in the shaft.

**Use**

This instrument is used to hold the stone during pyelolithotomy, nephrolithotomy or ureterolithotomy.

**Sterilization**

By autoclaving.  
See also 'renal stone' in the chapter on kidney and ureter, chapter 46.

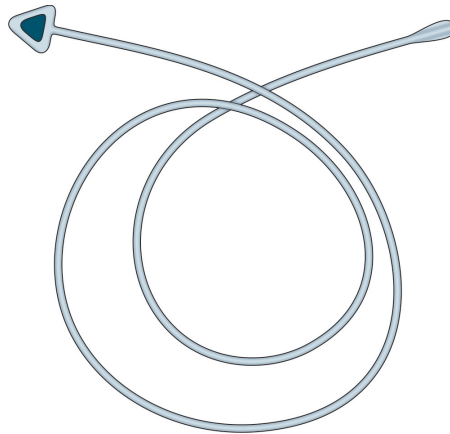
**SUPRAPUBIC CYSTOLITHOTOMY FORCEPS**

**Features**

- a. The forceps consists of a pair of blades, a pair of shafts and the finger bows – one is ring-like for the thumb, the other meant for other fingers is hook-like.
- b. The inner surface of each blade is provided with knobs for better grip of the stone.
- c. There is no ratchet in the shaft.

**Use**

Used for suprapubic cystolithotomy.



**Fig. 104.52:** Myer's Vein stripper

**Sterilization**

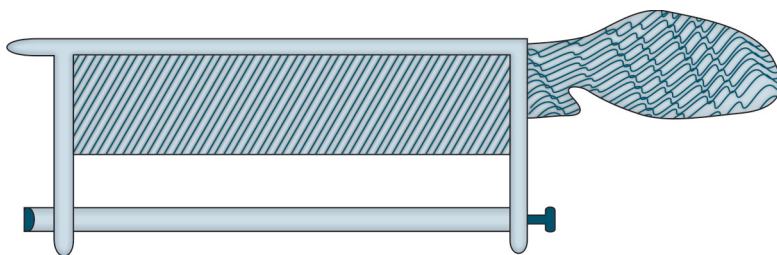
By autoclaving.

**SPECIAL INSTRUMENTS IN GENERAL SURGERY**

**Myer's Vein Stripper (Fig. 104.52)**

**Features**

It is one meter long flexible wire with detachable heads.



**Fig. 104.53:** Humby's skin grafting knife

**Use**

This is used in stripping of varicose veins of the lower extremity viz. the long and short saphenous veins secondary to ligation and division of saphenofemoral and saphenopopliteal junctions respectively.

**Sterilization**

By autoclaving.

See also the long case on 'varicose vein' in chapter 76 to know the various tests for diagnosis, pathogenesis and treatment and the chapter 27 on 'varicose vein, DVT, pulmonary embolism'.

**Humby's Skin Grafting Knife (Fig. 104.53)**

**Features**

- a. It is made of stainless steel and has a handle and stem system.
- b. The disposable blade is mounted on the blade holder.

**Use**

It is used for taking the split thickness skin graft.

**Sterilization**

By autoclaving.

**Volkman's Spoon or Scoop (Fig. 104.54)**

**Features**

- a. It is a metallic instrument with spoon-like ends having sharp edges.
- b. The spoon on one side is larger than that on the other side.
- c. The sharp edges allow easy curettage.

**Uses**

- a. Used to curette a chronic abscess either in bone or the soft tissue.
- b. May be used to curette a sinus or fistulous tract.

**Sterilization**

By autoclaving.

**Sinus Forceps (Fig. 104.55)**

**Features**

- a. It is a straight, long, delicate instrument with a pair of blades, shafts and finger bows without any catch.



**Fig. 104.54:** Volkmann's spoon or scoop

- b. The tip of the blade is serrated transversely.

**Uses**

- a. Exploring a sinus—This is the main use.
- b. Draining or dressing an abscess cavity by Hilton's method.
- c. Placing a nasal or aural dressing in position.

**Sterilization**

By autoclaving.

**Drains**

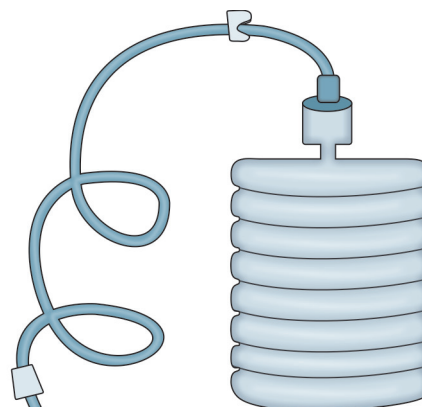
- a. Corrugated rubber drain (Fig. 104.56A):
  - i. It is made of India rubber and constitutes the traditional method of drainage.
  - ii. It drains by capillary action or gravity into the dressings or stoma bag.

**Uses**

It is mostly used in the operation of hydrocele, in the retropubic space after



**A**



**B**

**Figs 104.56A and B:** (A) Corrugated rubber drain (B) Closed suction drain

open prostatectomy and after drainage of breast abscess.

- b. Suction drain (Fig. 104.56B):

**Features**

- i. Suction drain is a closed system drain with one end lying at the operative site and the other end connected to a vacuum forming sterile plastic container.
- ii. It comes in various sizes as per diameter of the drain.
- iii. It can be placed in nondependent drainage.

**Uses**

- i. It is used after modified radical mastectomy and total thyroidectomy.
- ii. It is used after the operation of ventral hernia.

- c. Fixation of drain: A drain should be fixed to skin wound by silk suture so that it does not get displaced.
- d. Removal of drain: A drain should be removed as soon as the discharge is none or minimal. Most drains are removed within 5 days unless the daily volume is large. This is because drains kept for a long period can cause complications

like sepsis, hemorrhage, adhesions and blocked drains.

**Sterilization**

By autoclaving.

**ORTHOPEDIC INSTRUMENTS**

**Chisel, Osteotome, Bone Gouge and Mallet**

These are most commonly used instruments in orthopedic surgery.

**Chisel (Fig. 104.57)**

**Features**

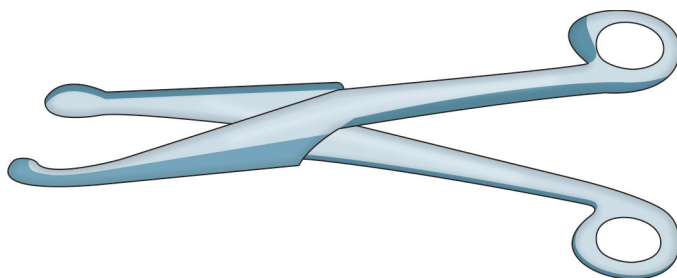
- a. It has three parts viz. head, shaft and the cutting edge.
- b. The head is flat atop where the mallet strikes the instrument.
- c. The shaft is polygonal to provide a comfortable grip.
- d. The cutting edge is sharp and bevelled on one side in contrast to osteotome, which is bevelled on both sides.

**Uses**

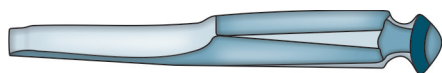
- a. It is used to remove bone chips in operations like bone grafting, saucerization, etc.
- b. Excision of exostosis.
- c. Removal of upper femoral cortex at the site of introduction of Smith Peterson . nail.

**Sterilization**

By autoclaving.



**Fig. 104.55:** Sinus forceps



**Fig. 104.57:** Chisel

**Osteotome (Fig. 104.58)**

This instrument is almost similar to chisel except that the cutting edge is bevelled on both sides.

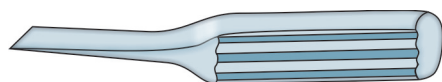
*Uses*

It is used for osteotomy which means operative division of a bone.

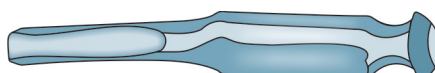*Sterilization*

By autoclaving.

1. How many types of osteotomy are there? Two types.
  - i. Linear or transverse osteotomy.
  - ii. Wedge or cuneiform osteotomy.
2. What are the examples of linear osteotomy?
  - i. McMurray's intertrochanteric abduction osteotomy.
  - ii. Osteotomy to refracture a malunited fracture (corrective osteotomy).
3. What are the indications of McMurray's osteotomy?
  - i. Ununited fracture neck femur.
  - ii. Osteoarthritis.
4. What are the indications of wedge osteotomy?
  - a. To correct genu varum and genu valgum deformity.
  - b. To correct cubitus varus and cubitus valgus deformity.
  - c. To correct an old and neglected case of club foot deformity.
5. What is the principle of wedge osteotomy?
  - Wedge osteotomy consists of removal of a triangular piece of bone, the base being directed on the longer side. After removal of the bone necessary manipulations will correct the angular deformity.
  - Stapling of the bone may be done after correction.



**Fig. 104.58:** Osteotome



**Fig. 104.59:** Bone gouge

**Bone Gouge (Fig. 104.59)**

*Features*

- a. This instrument has a head, a shaft and a cutting edge.
- b. The shaft is grooved and its cutting edge is rounded.

*Use*

It is used like a chisel to cut out small irregular pieces of bones.

*Sterilization*

By autoclaving.

**Mallet (Fig. 104.60)**

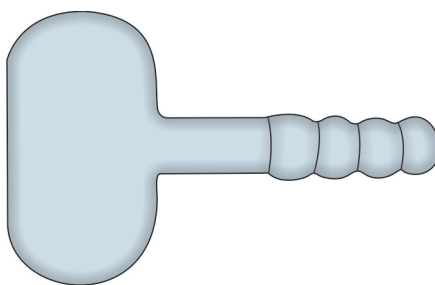
- Mallets are orthopedic hammers made of metals, like lead or steel, wood or Bakelite.
- It has a handle to hold the instrument and a head which is meant to strike over another instrument.

**Bone Cutting Forceps and Bone Nibbler**

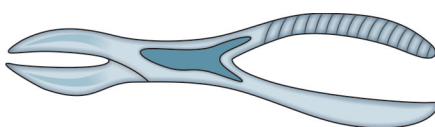
**Bone Cutting Forceps (Fig. 104.61)**

*Features*

- a. It consists of a pair of blades, handles and the joint.



**Fig. 104.60:** Mallet



**Fig. 104.61:** Bone cutting forceps

- b. The blades are sharp and meant for cutting bone.
- c. The joint may be simple or provided with a lever system which multiplies the force applied to the handles, so that less effort is required to cut a bone.
- d. Handles are ridged for a better grip.

*Uses*

This instrument is used to cut small long bones like the metacarpals, metatarsals and phalanges, etc. Bigger bones are cut with saw.

*Sterilization*

By autoclaving.

**Bone Nibbler or Gouge Forceps (Fig. 104.62)**

It is a special type of bone cutting forceps which cuts away the bones by the edges as well as the tip of its blades.

*Uses*

- a. To make the sharp margin of a cut bone end blunt, e.g. in an amputation stump.
- b. To enlarge a burr hole.
- c. To take pieces of bone for biopsy.

*Sterilization*

By autoclaving.

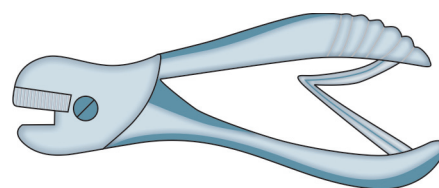
**Periosteum Elevators**

These are also known as raspatory or rugine. These instruments are used for the purpose of elevating periosteum and cutting the ribs. These are:


1. Farabeuf's raspatory.
2. Doyen's raspatory.
3. Rib shear (scissor) with a serrated blade.

1. **Farabeuf's Raspatory (Fig. 104.63)**

*Features*



**Fig. 104.62:** Bone nibbler



**Fig. 104.63:** Farabeuf's raspatory

- a. This instrument consists of three parts viz. handle, thumb rest and blade.
- b. The handle is flat and grooved on both surfaces for efficient grip.
- c. The thumb rest is the corrugated oval area next to the blade.
- d. The blade is rectangular and its sharp edges elevate the periosteum with sliding movement.

1. Why do you elevate periosteum?
  - a. Unless the periosteum is elevated no sharp instrument will work on bones and they will slip off.
  - b. The soft tissue structures and blood vessels are reflected away from the operation field along with the periosteum so that they are not damaged.

*Uses*

Periosteum elevators are used in operations of amputation, SP nailing, IM nailing and bone plating, etc.

*Sterilization*

By autoclaving.

2. **Doyen's Rib Raspatory (Fig. 104.64)**

*Features*


- a. The instrument consists of a handle, shaft and blade.
- b. The handle is polygonal in shape for better grip.
- c. The semicircular blade is attached perpendicular to the shaft of the instrument in the form of a hook. The inner surface of the blade is sharp enough to separate the periosteum from the bone by simple sliding motion.

*Use*

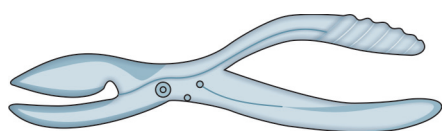
It is used to separate the periosteum from the inner aspect of the rib before its resection.

*Sterilization*

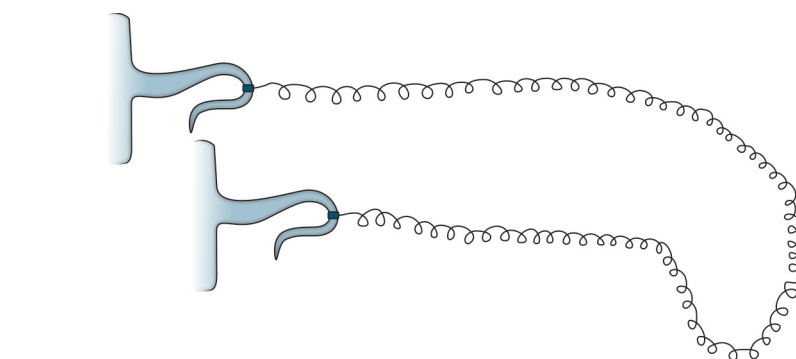
By autoclaving.



**Fig. 104.64:** Doyen's Raspatory



**Fig. 104.65:** Rib shear with a serrated blade



**Fig. 104.66:** Gigli's wire saw

3. **Rib Shear with a Serrated Blade (Fig. 104.65)**

*Features*

- a. This instrument is provided with large handles which are made rough for a good grip.
- b. It has one cutting blade. The other blade has serrations and deep groove instead of a cutting edge.
- c. There is a lever arrangement present between the handles, which give a mechanical advantage of exerting maximal force with slight effort.

*Use*

It is used for rib resection in cases of:

- i. Empyema thoracis.
- ii. To remove an osteomyelitic segment.
- iii. To remove growths arising from the ribs.
- iv. To take rib grafts.

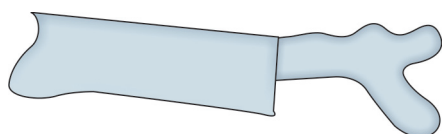
4. **Gigli's Wire Saw (Fig. 104.66)**

*Features*

- a. It consists of 2 to 4 strong flexible metal wires of 14 to 20 inches length, braided closely together for strength and efficiency.
- b. The braided wire ends in a loop at either end to be hooked into the handle with which the surgeon works with the saw.

*Uses*

- a. It is used for cutting the skull between trephine holes, in order to reflect an osteoplastic flap.



**Fig. 104.67:** Amputation saw

- b. To cut the mandible in hemimandibulectomy.
- c. It is used as a substitute to amputation saw.

5. **Amputation Saw (Fig. 104.67)**

The amputation or bone saw may have a fixed or a detachable type of blade.

*Uses*

It is used to cut bone during amputation of long bones.

*Sterilization*

By autoclaving.

6. **Bone Holding Forceps**

There are two common types viz.

1. Ferguson's lion toothed bone holding forceps – the teeth look like those of a lion when viewed from the side (Fig. 104.68A).
2. Farabeuf's bone holding forceps (Fig. 104.68B).

*Uses*

- i. To hold a bone during open reduction of a fracture.
- ii. To hold the bones steadily during bone plating and IM nailing.

7. **Instruments used for Skeletal Traction**

1. Steinman's pin with rotating stirrup
2. Kirschner wire apparatus

1. **Steinman's pin with rotating stirrup (Fig. 104.69)**

- a. This pin has a diameter of about 3mm and is sharpened at one end.
- b. The pin is either drilled or hammered through the bone and traction is applied through the stirrup.

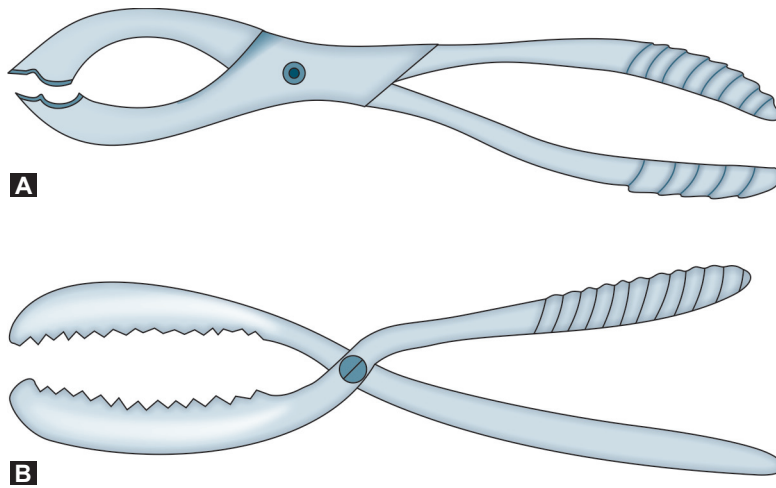
*Use*

To apply skeletal traction in the treatment of fractures mostly of the lower limb and sometimes of the upper limb.

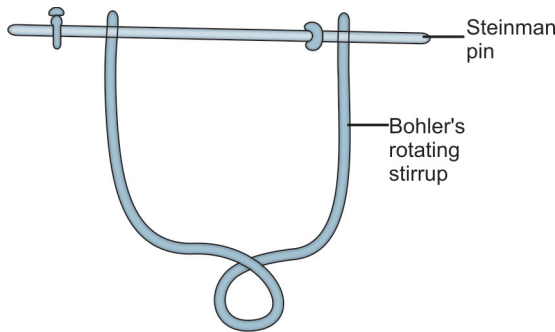
*Sterilization*

By autoclaving.

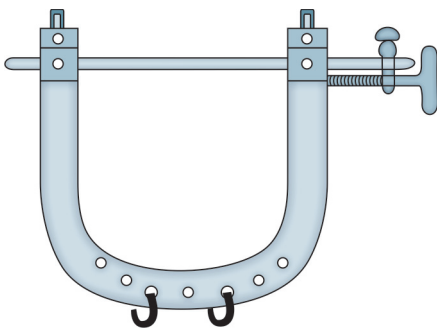




**Figs 104.68A and B:** (A) Fergusson's bone holding forceps (B) Farabeuf's bone holding forceps



**Fig. 104.69:** Steinman pin with Böhler's rotating stirrup



**Fig. 104.70:** Kirschner wire apparatus

2. *Kirschner's wire apparatus* (Fig. 104.70)
  - a. It consists of a steel wire (<1mm in diameter) a stirrup and the stretcher.
  - b. The Kirschner's wire is drilled through the bone.
  - c. The stirrup is 'U' shaped and by means of a 'stretcher' and a 'handle' the ends of the stirrup can be approximated to make the wire taut

- and prevent it from bending under tension.
- d. The traction cord is tied to the hook attached to one of the holes located on the curve of the stirrup.

*Use*

To apply skeletal traction for the treatment of unstable fractures and fractures of limbs with bulky muscles.

1. What is skeletal traction?
 

Traction is employed in the treatment of fractures to correct over riding of fragments and to maintain them in position till union takes place. Skeletal traction is the term used to denote traction applied directly to bone. It is an alternative to surface or skin traction but like the latter it does not cause any skin sore.
2. What are the bones in which skeletal tractions is commonly employed?
  - a. Femur through the condyles.

- b. Tibial tubercle 2cm behind its crest.
  - c. Posterior tuberosity of calcaneum.
  - d. Ulna through the olecranon.
3. What are the complications of skeletal traction?
    - a. Bone infection.
    - b. Joint stiffness.
    - c. Loosening of the pin in the traction apparatus.
    - d. Prolonged and excessive traction may lead to delayed or nonunion.
  4. How a limb is supported during traction?
    - a. Thomas bed knee splint.
    - b. Böhler Braun splint.

**STERILIZATION**

**Definition**

Sterilization is the process of complete destruction or removal of all microorganisms including spores and viruses.

Disinfection is the process that eliminates or destroys all microorganisms except bacterial spores and some viruses.

Both sterilization and disinfection are applied to inanimate objects, e.g. instruments, but not to living tissues, e.g. the skin as they are tissue damaging processes.

**Methods of Sterilization**

1. Steam autoclaving:
  - It is the most commonly used method as dry heat does not damage the common theater instruments.
  - It is done in specially made chambers, known as autoclaves.
  - The combinations of pressure, temperature and time are as described below:
    - a. Temperature should be 121°C at 30 lb/sq inch pressure for 30 min for metallic instruments.
    - b. Temperature is 121°C at 15 lb/sq inch pressure for 15 min for rubber goods like catheters, drains, gloves, etc.
2. Boiling in boiled water for half an hour, would kill the spores of the spore bearing organisms.
3. Flaming—is done by pouring spirit on the instruments and then putting fire. It is not used routinely.

4. Ethylene oxide—This is highly penetrative noncorrosive gas with a broad spectrum cidal action but needs elaborate arrangement.
5. Irradiation—This technique employs gamma rays or accelerated electrons. Sterilization by ionizing radiation is an industrial process and is suitable for single use items, e.g. IV sets, catheters, syringes, sutures, dressing materials, etc.
6. Chemical solutions: e.g. Lysol, phenol, cydex.
  - Commonly used chemical solution is the 2 percent glutaraldehyde solution, known as cidex.
- It is suitable for sterilization of sharp instruments, as it does not damage them.
- The instruments are kept for 15 – 20 min. The solution is highly effective against the fungi, tubercle bacilli and viruses.
7. Low temperature plasma sterilization: It is the newer sterilization technique since 1993. These are suitable for sterilization of both blunt and sharp instruments. Here radiofrequency energy is applied to create hydrogen peroxide plasma. Sterilization is complete within an hour or so.

*Thus is brief*

- a. Blunt instruments are sterilized by autoclaving.
- b. Sharp instruments are sterilized by chemical sterilization with cidex (2% glutaraldehyde).
- c. Both sharp and blunt items are sterilized by plasma sterilization with the exception of linen, powders and liquids.
- d. Single use disposable items, e.g. IV sets, catheters, sutures and dressing materials are sterilized by ionizing radiation as an industrial process.

# Bibliography

## General (Common to All Sections)

1. Al-Fallouji MAR. Postgraduate Surgery, 2nd edition, Butterworth–Heinmann Ltd, 1998.
2. Ahmed HA, RV Srivastava ASI Textbook of Surgery 1st edition, Tata McGraw-Hill, 2003.
3. Brunnicardi F Charles. Schwartz's Principles of Surgery, 9th edition, The McGraw-Hill Companies, 2010.
4. Burnand KG, Young AE, The New Aird's Companion in Surgical Studies, 3rd edition, Churchill Livingstone, 1998.
5. Chumber S. Essentials of Surgery, 1st edition, Jaypee Brothers Medical Publishers (P) Ltd, New Delhi, 2005.
6. Cuschieri A, et al. Essential Surgical Practice, 3rd edition, Butterworth–Heinmann Ltd, 1995.
7. Courtney JR, M, Sabiston, Textbook of Surgery, 18th edition, Elsevier, 2008.
8. Norman S William, et al. Bailey and Love's Short Practice of Surgery, 25th edition, Hodder Arnold, 2008.
9. Peter MJ, Ronald A, et al. Oxford Textbook of Surgery, 1st edition, Oxford Medical Publications, 1994.
10. Way LW, Doherty GM, Current Surgical Diagnosis and Treatment, 13th edition, The McGraw-Hill companies, 2010.

## **PART I: GENERAL SURGERY**

### Section 1: Physiological Basis of Surgery

#### *Shock*

1. Ledingham I, McArdle CS, McDonald RC. Septic Shock. In: Recent Advances in Surgery, 10, Edinburgh, Churchill Livingstone, 1980.
2. Upwadia FE. Principles of Critical Care, 2nd edition, Oxford University Press, New Delhi, 1995.

#### *Wound Healing*

3. Cushieri A, et al. Essential Surgical Practice, 3rd edition, Butterworth Heinmann Ltd, 1995.
4. Hunt TK, et al. Wound Healing and Wound infection. What Surgeons and Anesthesiologists can do? Surg Clin North Aus 1997; 77: 587.
5. Israelsson IA, et al. Closure of Midline Laparotomy Incisions, with Polydioxanone and Nylon: The Importance of Suture Technique. Br J Surg 1994; 81: 1606.

#### *Hemorrhage and Blood Transfusion*

6. Atkinson RS, Rushman GB, Davies N J A. Lee's Synopsis of Anesthesia, 11th edition, Oxford: Butterworth–Heinmann Ltd, 1993.
7. Wright A, et al. Lancet, 1985; 2: 1148.

#### *Hemostasis and Coagulation*

8. Handin RI, LUX SE, Hoesel TP. Blood Principles and Practice of Hematology, 2nd edition, Lippincott Williams and Wilkins, Philadelphia, 2003.
9. Walter HB, Israel MS. General Pathology, 7th edition, Edinburgh, Churchill Livingstone, 1997.

#### *Fluid and Electrolyte Balance*

10. Ganong WF. Review of Medical Physiology, 23rd edition, 2010.
11. Lattimer CR, Wilson NM, Logattolla NR, Key Topics in General Surgery, 1st edition, Bios Scientific Publishers Ltd, 1996.
12. RCG Russel, et al. Bailey and Love's Short Practice of Surgery, 22nd edition, ELBS with Chapman and Hall, 1995.
13. Smith JAR. Fluid Balance and Electrolyte Disturbance, Recent Advances in Surgery, 15, Churchill Livingstone 1992, 209-23,

### *Acid-Base Balance*

14. Mohan H. Textbook of Pathology, 5th edition, Jaypee Brothers Medical Publishers (P) Ltd, 2005.
15. Stoelting RK, Dierdorf SF, McCammon RL, Anesthesia and Coexisting Disease, 2nd edition, New York, Edinburgh, Churchill Livingstone, 1988.

### *Nutrition in Surgery*

16. Clarke PJ, et al. The Total Parenteral Nutrition Service-An update, *Annals of the Royal College of Surgeons of England*; 1998; 70: 296-300.
17. Johnson CD, Taylor I Recent Advances in Surgery, 19: Churchill Livingstone, 1996 149-67.
18. Lattimer CR, Wilson NM, Lagattolla NR. Key Topics in General Surgery, 1st edition Bios Scientific Publishers Pvt. Ltd, 1996.
19. Norman S Williams, et al. Bailey and Love's Short Practice of Surgery, 25th edition, Hodder Arnold, 2008.
20. McLatchie GR Oxford Handbook of Clinical Surgery, 1st edition, Oxford University Press, 1990.

### *Endocrine and Metabolic Response to Injury*

21. Burnand KG, Young AE. The New Arid's Companion in Surgical Studies, 1st edition, Churchill Livingstone, 1992.
22. Kirk RM. Clinical Surgery in General, RCS course Manual, 2nd edition, Churchill Livingstone, 1996.
23. Udwardia FE. Principles of Critical Care, 2nd edition, Oxford University Press, 2005.

## **Section 2: Surgical Infection and Burn**

### *Surgical Infections*

24. Cushieri A, et al. Clinical Surgery, 1st edition, Blackwell Scientific Publication, 1996.
25. Deitch EA. Surgical Infections, *The Surgical Clinics of North Am* Number 3, WB Saunders Co, June 1994; 74
26. Lattimer CR, Wilson NM, Lagatolla NF, Key Topics in General Surgery, 1st edition, Bios Scientific Publishers Ltd, 1996.
27. Lucarotti ME, Virjee J, Thomas WEG, Intraabdominal Abscesses, *Surgery* 1991; 98: 2335-41.
28. Molloy RG, Mannick JA, Rodrick ML. Cytokines, Sepsis and Immunomodulation, *British Journal of Surgery*, 1993; 80: 289-97.

### *Burns*

29. Clarke J. Current Management in Burns, *Current Practice in Surgery* 1990; 2:227-31.
30. Deltch EA. The Management of Burns, *N Engl J Med.* 329, 1249, 1990.
31. Keswani RK, Management of Burns in India, In *Recent Advances of Surgery*, Jaypee Brothers Medical Publishers (P) Ltd., New Delhi, 1987.
32. Rossi LFA, Shakespeare PG recent Advances in Surgery. Churchill Livingstone, 1991, 14, 69-84.

## **Section 3: Skin and Cysts**

### *Tumors of the Skin*

33. McCarthy WH. Malignant melanoma, *Recent Advances in Surgery*, Number 11, Edinburgh, Churchill Livingstone 1982; 85-100, .
34. Scott RN, Makay AJ, Elective Lymph Node Dissection in the Management of Malignant Melanoma, *Br J of Surg* 1993; 80: 284-88.

### *Skin Grafting*

35. Barclay TL, Kernahan DA, Rob and Smiths. Operative Surgery, Butterworth-Heinmann Oxford, 1992.
36. McGregor IA, Fundamental Techniques of Plastic Surgery and their Surgical Applications, Churchill Livingstone, New York, 1989.

## **Section 4: Specialties Related to Surgery**

### *Principles of Anesthesia*

37. Atkinson RS, et al. (Eds), Leiss Synopsis of Anesthesia, 11th edition, Butterworth-Heinmann.
38. Churchill Davidson HC, A Practice of Anesthesia, 5th edition, London.
39. Miller RD, Anesthesia, 4th edition Vol. 1 and 2, Churchill Livingstone.
40. Stoelting RK, Dierdorf SF, Anesthesia and Coexisting Disease, 3rd edition, Churchill Livingstone.
41. Vickers MD (Ed), Medicine for Anesthetist, Blackwell.

## Bibliography

### *Clinical Oncology*

42. Free A III, et al. The Concept of Neoadjuvant Chemotherapy in Salmon SE (Ed), Adjuvant Therapy of Cancer, 5th edition, Orlando, Grune and Stratton, 1987.
43. Hill GJ. Historic Milestones in Cancer Surgery, *Semin, Oncol* 6; 409: 1979.
44. Price P, Sikora K (Eds), Treatment of Cancer, 4th edition, Arnold Publishers, 2002.
45. Wittekind, et al. TNM Atlas, 5th edition, Springer, International edition, 2005.

### *Imaging in Surgery*

46. Haaga JR, et al. Computed Tomography and Magnetic Resonance Imaging of the Whole Body, Vol 2, 3rd edition, Mosby, 1994.
47. Armstrong P, Martin L. Wastic, 1st edition, Chapman and Hall, London, 1997.

## **PART II: SYSTEMIC SURGERY INCLUDING ORTHOPEDICS**

### **Section 5: Head and Neck**

#### *Salivary Glands*

48. Cotran RS, Kumar V, Robbins SL. Robbins Pathologic Basis of Disease, 6th edition, Philadelphia, WB Saunders Company, 1999.
49. Nyhus LM, Baker RJ, Fischer JE (Eds), Mastery of Surgery, 3rd edition, Little Brown and Co Boston, New York, Toronto.
50. Rintoul RF (Ed), Farquharson's Textbook of Operative Surgery, 7th edition Edinburgh, London, Melbourne, 1986.

#### *The Tongue*

51. Macgregor Ian A, Frances M. Macgregor. Cancer of the Face and Mouth, Churchill Livingstone.
52. Wittekind C, et al. TNM Atlas, 5th edition, Springer, International edition, 2005.

#### *Neck Swellings*

53. Cushieri A, Giles GR, Moosa AR, Essential Surgical Practice, 3rd edition, 1995.
54. Gluckman Jack L, Johnson J T, Surgical Management of Neck Metastasis, 1st edition, Martin Dunitz, 2003.
55. Schqartz SI, Tom SG, et al. Principles of Surgery, 6th edition, McGraw-Hill, 1994.

### **Section 6: Endocrine Surgery**

#### *Thyroid Gland*

56. Greenspan FS, Baxter JD (Eds), Basic and Clinical Endocrinology, 4th edition, Lange Medical Book, Prentice Hall, International Inc, 1994.
57. Littimer C R et al, Key Topics in General Surgery, 1st edition, Bios Scientific Publishers Ltd, 1996.
58. Weetman AP, Thyroiditis, *Current Practice in Surgery* 1992; 4:118-22.
59. Young AE. The Thyroid Gland, In: Brunand KG, Young AE (Eds). The New Aird's Companion in Surgical Studies, Edinburgh, Churchill Livingstone, 1992, 633-60.

#### *Parathyroid*

60. Collins REC, Parathyroid Disease, *Surgery*, 1988: 1486-89.
61. Gunn A, Parathyroidectomy, *Current Practice in Surgery*, 1990: 161-67.

#### *Adrenal Glands*

62. Fardon JR, Dunn JM. Adrenal Tumours, *Recent Advances in Surgery*, 1992; 15: 55 – 68.

### **Section 7: Vascular Surgery**

63. Burnand KG. The Arteries, In: Burnand KG, Young AE (Eds), The New Aird's Companion in Surgical Studies, Edinburgh, Churchill Livingstone 1992, 301 – 84.
64. Rutherford RB (Ed), Vascular Surgery, 5th edition, WB Saunders Company, Philadelphia, 2000.
65. Tibbs DJ, Scurr H, Sabiston DC, et al. Varicose Veins, Venous Disorders and Lymphatic Problems in the Lower Limbs, Oxford University Press, Oxford, 1997.



### Section 8: Gastrointestinal Surgery

66. Das S. A Concise Textbook of Surgery, 4th edition, Published by Dr S Das, Kolkata, 2006.
67. Devita, et al. Cancer: Principles and Practice of Oncology, 6th edition. JB Lippincott Co, 2001.
68. Fisher JE, Bland K 9, (Eds), Mastery of Surgery, 5th edition, Lippincott Williams and Wilkins, 2007.
69. Fuchs CS, Mayor RJ, Gastric Carcinoma, N Engl J Med 1995; 332:32.
70. Goligher JC (Ed), Surgery of Anus, Rectum and Colon, 5th edition, London, Balliere Tindal, 1984.
71. Guillem JG, Ellin Sigurdson R. Colorectal Cancer, The Surg Clinic of North Am Vol 82, 5, WB Saunders Co, Oct 2002.
72. Slisenger, Fordtran's: Gastrointestinal and Liver Disease, 7th edition.
73. Zinner MJ, Schwartz SI, Ellis H, Maingot's Abdominal Operations, 10th edition, McGraw-Hill Co, New York, 1997.
74. Zuidem GD, Yeo CJ, Shackelford's Surgery of the Alimentary Tract, 5th edition, WB Saunders, Philadelphia, 2002.

### Section 9: Hepatobiliary Pancreas and Spleen

75. Al-Fallouji MAR, Collins REC, Surgical Relief of Obstructive Jaundice in District General Hospital, Journal of the Royal Society of Medicine, 78: 211-16.
76. Blumgart LH, Fong Y (Eds), Surgery of the Liver and Biliary Tract, 3rd edition, WB Saunders, London, 2000.
77. Braunwald E, et al. Harrison's Principles of Internal Medicine, 15th edition, McGraw-Hill Co, New York, 2001.
78. Pitt henry A. The Surgical Clinical of N. Am, Biliary Tract Surgery, Vol-70, November 6, WB Saunders Company, December, 1990.
79. UD Wadia TE (Ed), Laparoscopic Surgery, Oxford University Press, 1991.

### Section 10: Umbilicus, Abdominal Wall, Peritoneum and Hernia

#### *Umbilicus and Abdominal Wall*

80. Brunicaardi F, et al. Schwartz's Principles of Surgery, 8th edition, McGraw-Hill Co, 2005.
81. Zinner Michael J, Ashley SW, Maingot's Abdominal Operations, 11th edition, McGraw-Hill Co, 2007.

#### *The Peritoneum*

82. Darryl T Hiyama, et al. Benign Peritonitis and Intraperitoneal Abscess, Zinner M J (Ed), Maingot's Abdominal Operations, 10th edition, Prentice Hall Int, UK I.
83. Morris PJ, Wood WC. The Peritoneum and Peritonitis, In: Mcin Whinnie (Ed): Oxford Textbook of Surgery, 2nd edition, Oxford University Press, UK II.

#### *Hernia*

84. Conner CEH (Ed), Chassinis's Operative Strategy in General Surgery, An Expositive Atlas, 3rd edition, 2004.
85. Guy Voeller, Ventral Abdominal Hernia, In Fischer JE (Ed) Mastery of Surgery, 5th edition, Lippincott Williams and Wilkins, 2007;2
86. Lichtenstein IL, Herniorrhaphy: A Personal Experience of 6321 cases. Am J Surg 1987; 153: 553-59.
87. Mudge M, Hughes LE, Incisional Hernia-A 10 Year Prospective Study of Incidence and Attitudes, Br J Surg 1985: 72: 70.
88. Nyhus Loyd M. Hernias. The Surg. Clinics of North America Vol 64, 2, WB Saunders Co, April, 1984.
89. Rathkow IM, Robbins AW, Classification Systems and Groin Hernias, Surg Clinics N Am 1998, 78: 1122 - 44.
90. Robert M, Zollinger Jr, Classification System of Groin Hernias, Surg Cl North America 2003, 83: 1053 - 63.

### Section 11: Breast Surgery

91. Baum M. Carcinoma of the Breast, In: Recent Advances in Surgery, 10, S Taylor (Ed), Churchill Livingstone, Edinburgh, 1980.
92. Devita VT Jr, et al. Cancer: Principles and Practice of Oncology, 6th edition, JB Lippincot Co, 2001.
93. Jatoi I, Singletary SE Breast Cancer: New Concepts in Management. The Surg N Am Vol. 83, 4, Saunders An Imprint of Elsevier, August, 2003.
94. Mannel RG, Fenn MJ, Davies EL. Benign Breast Disease and Its Management. In: Johnson CD, Taylor I (Eds), In Recent Advances in Surgery, 21, 1998.
95. Rath GK, Mohanti DK, Eds, Textbook of Radiation Oncology Principles and Practice, BI, Churchill Livingstone.

## Bibliography

### Section 12: Urology

96. Blandy JP, Lecture Notes on Oncology, Blackwell Scientific Publications, 1989.
97. Blandy John, Fowler C, Urology, 2nd edition, Blackwell Science Ltd., 1996.
98. Burnard KG, Young AE (Eds), The New Aird's Companion in Surgical Studies, Edinburgh, Churchill Livingstone, 1992.
99. Cumming J. Renal Cell Carcinoma, Recent Advances in Surgery, 1992,15,137–51.
100. Glenn's Urologic Surgery, 9th edition, Lippincott Raven Publishers, 1998.
101. Kirk D, The Current Management of Prostatic Adenocarcinoma, Current Practice in Surgery, 1991; 3: 117-7.
102. Tanagho EA, Mc Ananinch JW (Eds), Smiths General Urology, 15th edition, Lange Medical Books, McGraw-Hill Co, New York, 2000.
103. Wassh Patrick C. (Editor in Chief), Campbell's Urology, 8th edition, WB Saunders, 2002.

### Section 13: Trauma

104. Brewes PC, Open and Closed Abdominal Injuries, Br J Hosp Med 29, 402–11.
105. Cetti NE. Trauma to Genitourinary Tract, Surgery 1988, 8. 63: 1492
106. Feliciano DV, et al. Advances in the Diagnosis and Management of Thoracic Trauma, Surg Cl N Am 1999; 79: 1417.
107. Galbraith SL, Teasdale GM, Head Injuries, In: Recent Advances in Surgery, 11, Russel R (Ed), Churchill Livingstone, 1982, 71–84.
108. Huckstep RL, A Simple Guide to Trauma, 4th edition, Churchill Livingstone, 1986.

### Section 14: Orthopedics

109. Duthie, Bently (Eds), Mercers Orthopedic Surgery, 9th edition, Oxford University Press, 1996.
110. Adams JC, Hamblen D (Eds), Outline of Fractures including Joint Injuries, Churchill Livingstone.
111. Solomon, et al. Apley's System of Orthopedics, 8th edition, Arnold Publishers, 2001.
112. Maheswari J. Essential Orthopedics, 3rd edition, Mehta Publishers, 2005.
113. Shenay RM, Essentials of orthopedics, 1st edition, Jaypee Brothers, 2010
114. Wilson JN (Ed), Watson Jones. Fractures and Joint Injuries, 6th edition, Churchill Livingstone, 1982.

## **PART III: PRACTICALS AND VIVA IN SURGERY**

### Section 15A and B: Clinical Surgery (Long and Short Cases)

#### *Short and Long Cases*

115. Bhattacharya SK. Short Cases in Surgery, 4th edition, CBS Publishers, 1993.
116. Browse L, An Introduction to the Symptoms and Signs of Surgical Disease, 2nd edition, Edward Arnold, 1991.
117. Chary AY, Clinical and Operative Surgery, 3rd edition, Paras Publishing, Hyderabad, India, 2007.
118. Das S, A Manual on Clinical Surgery, 5th edition, Published by Dr S Das, 2000.
119. Ghosal SR, Practicals and Viva in Surgery, 1st edition, Elsevier, 2005.
120. Maheswari J, Essential Orthopedics, 3rd edition, Mehta Publishers, 2005.
121. Patel TN, A System of Surgical Diagnosis, Third edition, Jaypee Brothers Medical Publishers (P) Ltd.
122. Scot PR, An Aid to Clinical Surgery, Churchill Livingstone.
123. Sengupta SP, Manual of Long and Short Cases in Surgery, 2nd edition, New Central Book Agency Ltd, 2007.
124. Saha ML, Bedside Clinics in Surgery, 1st edition, Academic Publishers, Kolkata, 2004.

### Section 16: Operative Surgery

125. Banerji Kaushik, Essential handbook of Practical orthopedic examination, 2nd edition, Academic Publishers, 2009.
126. Chowdhury D, General Surgical Operation, 1st edition, Jaypee Brothers Medical Publishers (P) Ltd New Delhi, 2008.
127. Das K, Handbook of Operative Surgery, 5th edition, Published by Dr K Das, 1996.
128. Dudley H, Carter D, et al. Atlas of General Surgery, 3rd edition, Chapman and Hall, London, 1996.
129. Dudley H, Carter D, (Eds) Rob and Smiths Operative Surgery (Various Volumes), 4th edition, Butterworths, London, 1985.
130. Farquharson M, Brenden Farquharson's Textbook of Operative Surgery, 9th edition, Hodder Arnold, 2005.

131. Fischer J E, et al. *Mastery of Surgery*, 5th edition, Lippincot, Williams and Wilkins, 2007.
132. Kirk RM. *Essential Surgical Operations*, 2nd edition, Churchill Livingstone, 2007.
133. Kirk RM *General Surgical Operations*, 4th edition, Churchill Livingstone, 2007.
134. Sengupta SP, *System of Operative Surgery*, 1st edition, Academic Publishers, 1988.
135. Comus W, *Assisting at Surgical Operations*, 1st edition, Cambridge University Press, 2006.

### **Section 17: Viva Voce in Surgery**

#### *Surgical Pathology (Specimens)*

136. Dasgupta S. *Essentials of Surgical Pathology*, 1st edition, New Central Book Agency, Kolkata, 2003.
137. Charles I, Dick BM. *A Textbook of Surgical Pathology*, 12th edition, Churchill Livingstone, 1979.
138. Guthrie W, Fawkes R. *A Color Atlas of Surgical Pathology*, Wolfe Medical Publications London.
139. Watter JB, Israel MS, *General Pathology*, 6th edition, Churchill Livingstone, 1989.

#### *X-Rays*

140. Bhusan N, Lakhkar and CM Shetty. *Concise radiology for Undergraduates*, 1st edition, Arya Publishing, 2006.
141. Ghosal SR, *Practicals and Viva in Surgery*, 1st edition, Elsevier, 2005.
142. Grainger and Allison's, *Diagnostic Radiology, A Textbook of Medical Imaging*.
143. Saha ML, *Bedside Clinics in Surgery*, 1st edition, Academic Publishers, Kolkata, India, 2004.
144. David S, *Textbook of Radiology and Imaging*, 7th edition, Churchill Livingstone, 2003.

#### *Instruments*

145. Banerji Kaushik, *Essential handbook of Practical Orthopedic Examination*, Academic Publishers, 2nd edition, 2009.
146. Bhowmik A, Chatterjea G. *A First Handbook of Medical Instruments*, 2nd edition, Rajendra Brothers, Calcutta, 1980.
147. Chumber Sunil. *Essentials of Surgery*, 1st edition, Jaypee Brothers Medical Publishers (P) Ltd, New Delhi, 2005.
148. Kapur MM, *A Complete Hospital Manual of Instruments and Procedures*, 1st edition, Jaypee Brothers, 2005.
149. Comus W, *Assisting at Surgical Operations*, 1st edition, Cambridge University Press, 2006.

# Index

## A

Abdomen 284  
Abdominal  
  aortic aneurysm 171  
  compartment syndrome 347  
  incisions and closure 565  
  trauma 645  
  wall abscess 259  
Abdominoperineal resection of rectum 591  
ABO grouping 20  
Abrasions and friction burns 14  
Achalasia 654  
Acid pepsin secretion 194  
Acoustic neuroma 90  
Acquired  
  coagulation factor inhibitors 28  
  cysts 93  
  diaphragmatic hernia 190  
  disorders of coagulation 27  
Activation of renin angiotensin system 3  
Acute  
  abdomen 638  
  abdominal pain 638  
  appendicitis 71, 213, 627, 640  
  bacterial peritonitis 260  
  calculus cholecystitis 242  
  cholecystitis 639  
  cystitis 300, 301  
  epididymo-orchitis 330  
  gastritis 193  
  intestinal obstruction 640  
  obstruction 217  
  pancreatitis 248, 640  
  paronychia 65  
  peptic perforation 640  
  phase reactant proteins 57  
  postoperative pain 109  
  pyelonephritis 294  
  pyogenic osteomyelitis 380  
  renal failure 309  
  respiratory distress syndrome 357  
  retention of urine 646  
  subdural hematoma 338  
Adamantinoma 130  
Adenocarcinoma 214, 296  
Adenolymphoma 125  
Adenoma 156  
Adrenal  
  cortex 165  
  incidentaloma 167  
  insufficiency 168  
Adrenogenital syndrome 167  
Adult  
  pyloric hypertrophy 193  
  umbilical hernia 270  
Advanced breast cancer 282  
Albumin 41  
Aldosterone 56  
Allantois 256  
Allis' tissues forceps 669  
Alvarado score 213  
Amebic liver abscess 232  
Aminoglycosides 72  
Ammonia buffer system 45  
Amputation  
  neuroma 90  
  of penis 607  
Anaerobic bacilli 72  
Anal  
  canal 222  
  fissures 229, 595  
  musculature 222  
  stretching 595  
Anaplasia 113  
Anaplastic carcinoma 157  
Anatomical anal canal 222  
Anderson-Hynes pyeloplasty 603  
Androgen deficiency states 279  
Aneurysmal bone cyst 389  
Angiogenesis 8  
Ankle fractures 378  
Annular pancreas 247  
Anomalies of urachus 300  
Anorectal  
  abscess 63, 228  
  anomalies 226  
  atresia 218  
Anterior  
  gastrojejunostomy 572  
  urethral trauma 350  
  vagus dissection 571  
Antibiotic prophylaxis 476  
Antiplatelet therapy 31  
Apthous ulcer 135  
Appendicitis 212  
Appendicular  
  abscess 213  
  lump 641  
  mass 213  
Arginine vasopressin 56  
Arterial  
  dilatation aneurysm 170

  hemangioma 88  
  hemorrhage 16  
Artery forceps 666  
Ascites 235, 237  
Ascitic form 263  
Aspiration  
  cytology 114  
  of gastric contents 110  
Aspirin 31  
Atherosclerosis 170  
  of aortoiliac segment 170  
  of femoropopliteal segment 170  
Atonic bladder in spinal shock 308  
Atrophy 113  
Autoimmune thyroiditis 158  
Autologous transfusion 22  
Avascular necrosis 398  
Axillary dissection 563

## B

Babcock's tissue forceps 669  
Bacteremia 62  
Bakes dilator 676  
Balloon tamponade 236  
Banked whole blood 19  
Bard parkers knife with detachable blade 665  
Barium  
  enema 656  
  meal X-ray of stomach and duodenum 655  
Basal cell  
  carcinoma 83, 518  
  papilloma 83  
Benign  
  breast disease 275  
  enlargement of prostate 319, 634  
  gastric ulcer 628  
  melanoma 85  
  neoplasm 112  
  prostatic hypertrophy 319, 634  
  stricture 245  
  tumors 130, 156, 384  
Benzodiazepines 101  
Berry picking 156  
Bicarbonate/carbonic acid system 43  
Bilateral  
  hydronephrosis 289  
  kidney stones 292  
  subcostal incision 566  
Bile peritonitis 263

- Biliary
    - atresia 240
    - infections 71
    - pancreatitis 248
  - Bilocular hydrocele 329
  - Bladder injury 349
  - Bleeding
    - disorders 30
    - per rectum 642
  - Blood
    - clotting factors 24
    - group antigens 20
    - hydrogen ion concentration 43
    - tests 284
    - transfusion 17
  - Blunt injuries 339
  - Body fluid buffer systems 43
  - Bone
    - cutting forceps 683
      - and bone nibbler 683
    - gouge 683
    - nibbler 683
  - Bony dysplasia 399
  - Branchial
    - cyst 142, 525
    - fibula 142
    - sinus 525
  - Breast 538, 643
    - abscess 63, 562
    - cancer 282
    - carcinoma with distant metastasis 445
    - conservation surgery or therapy 562
    - disease 279
    - lump 643
    - reconstruction 446
    - surgery 282
  - Breath malposition 399
  - Brodie's abscess 382
  - Brodie-Trendelenburg's test 179
  - Budd-Chiari's syndrome 238
  - Buerger's disease 175, 494, 496
  - Buffers in blood 44
  - Bulldog arterial clamp 667
  - Bupivacaine 106
  - Bursitis 406
  - Burst abdomen 258
- C**
- Calcitonin 160
  - Callus formation 354
  - Capillary
    - hemangioma 87
    - hemorrhage 16
  - Carbapenems 72
  - Carbuncle 61
  - Carcinoid tumor 214
  - Carcinoma
    - breast 437, 632
    - colon 656
    - gallbladder 245
    - lip 138, 534
    - male breast 539
    - of ampulla of Vater 253
    - of bladder 303
    - of body and tail 253
    - of colon 475
    - of esophagus 189, 654
    - of female breast 280
    - of gallbladder 469
    - of head of pancreas 253
    - of pancreas 252
    - of parotid gland 125, 528
    - of stomach 629
    - of submandibular salivary gland 127, 531
    - of thyroid 156
    - of tongue 136
    - penis 316, 546, 635
    - prostate 321
    - rectum 630
    - tongue 532
  - Cardiovascular
    - injury 341
    - system 97
  - Caries spine 507
  - Carotid body tumor 145
  - Carpal tunnel syndrome 408
  - Cat's paw 668
  - Caudal block 108
  - Causes of
    - exophthalmos 429
    - gangrene 172
    - generalized lymphadenopathy 144
    - lymphangitis 331
    - thoracic outlet syndrome 175
    - thyrotoxicosis 153
  - Cavernous
    - hemangioma 88
    - lymphangioma 183
  - Cell cycle 116
  - Cellulitis 63
  - Cephalin clotting time 26
  - Cephalosporins 72
  - Cerebral
    - contusion 336
    - laceration 336
  - Cervical lymphadenopathy 144
  - Charle's operation 183
  - Chemotherapy 116, 126, 190, 235, 304, 386
  - Cholecystectomy 575
    - forceps 675
  - Cholecystitis 242
  - Cholecystohepatic triangle 240
  - Cholecystoses 243
  - Choledochal cyst 240
  - Choledochoduodenostomy 579
  - Choledocholithotomy 578
  - Cholelithiasis 626
  - Cholesterol stones 241
  - Chondroma 385
  - Christmas disease 29
  - Chronic
    - acalculus cholecystitis 243
    - bone abscess 382
    - calculus cholecystitis 243
    - cervical lymphadenopathy 144
    - cholecystitis 463
    - cystitis 301
    - duodenal ulcer 457, 459
    - epididymo-orchitis 331
    - gastritis 194
    - interstitial cystitis 301
    - osteomyelites 382, 510, 511
    - pancreatitis 250
    - paronychia 65
    - pyelonephritis 295
    - pyogenic osteomyelitis 382
    - renal failure 310
    - subdural hematoma 338
    - submandibular sialoadenitis 530
    - superficial glossitis 136
  - Chronology of descent 324
  - Classification of
    - burns 75
    - fractures 352
    - goiters 151
    - shock 3
    - wounds 14
  - Claw hand 551
  - Cleft
    - lip 131, 532
    - palate 132, 133, 532
  - Closed
    - amputation 411
    - pneumothorax 341
    - reduction 354, 370
  - Clot retraction 26
  - Clutton's metallic bougie 680
  - Cockett and Dodd's procedure 615
  - Cold
    - abscess 143
    - injuries 78
  - Colles fracture 368
  - Colloid
    - carcinoma 281
    - goiter 434, 435
    - solutions 41
  - Colorectal carcinoma 224
  - Colostomy 208, 568, 591
  - Common bile duct 243
  - Compartment syndrome 359
  - Complications of
    - amputation 412
    - blood transfusion 21
    - burn injury 78
    - chronic cholecystitis 243
    - endotracheal intubation 105
    - enteral feeding 53
    - fractures 356
    - gallstones 241
    - hernia 267
    - multinodular goiter 152
    - severe disease 209
    - stricture urethra 315
    - urethral injury 351
  - Condylar fractures of femur 374
  - Congenital
    - anomalies of ureters 287
    - cysts 93



## Index

- diaphragmatic hernia 190  
disorders of  
    coagulation 29  
    gallbladder 240  
    hernia 535  
    hydrocele 329  
    hypertrophic pyloric stenosis 193  
    talipes equinovarus 403, 555  
Conservative right hemicolectomy 590  
Continent urinary diversion 307  
Contracture of palmar aponeurosis 406  
Control inflammatory process 210  
Correction of pre-existing dehydration 42  
Corticosteroids 12  
Cortisol 56  
Courvoisier's law 244  
Coverings of  
    sac of femoral hernia 269  
    scrotum 610  
Coxa plana 397  
Critical limb ischemia 170  
Crohn's disease 202  
Crush  
    injury 15  
    syndrome 357  
Crushing clamps 675  
Crystalloid solutions 40  
Cubitus  
    valgus 549  
    varus 549  
Cushing's syndrome 166  
Cutaneous neurofibromatosis 90  
Cystic hygroma 143, 183, 524  
Cystitis cystica 302  
Cystogastrostomy 579  
Cystosarcoma phyllodes 276, 528  
Cystoscopy 294
- D**
- Daily electrolyte requirement 35  
De Pezzer's catheter 679  
Deaver's retractor 668  
Deep vein thrombosis 180  
Deformities of foot 402  
Dehydration 36  
Delayed hemolytic transfusion reactions 21  
Dental cyst 129  
Dentigerous cyst 129  
Depolarizing muscle relaxants 103  
De-Quervain's disease 407  
Dermoid cyst 93, 95, 515  
Descent of testis 324  
Desflurane 103  
Desjardin's choledocholithotomy forceps 675  
Desmoid tumor 259, 536  
Diabetes mellitus and uremia 13  
Diabetic  
    foot 68  
    gangrene 174  
Diagnostic peritoneal lavage 344  
Diaphragmatic  
    hernia 190  
    injury 342  
Diffuse peritonitis 261  
Digital tenovaginitis, snapping finger 407  
Direct inguinal hernia 266  
Diseases of  
    lymphatics 182  
    umbilicus 257  
Dislocation of  
    elbow 366  
    hip 370  
    shoulder 362  
Disorders of  
    fluid and electrolyte balance 36  
    growth 113  
    scarring 13  
Distance intestacies 322  
Distant metastasis 281  
Disturbances of  
    sodium balance 37  
    water balance 36  
Diverticula 299  
Diverticular disorders 203  
Diverticulitis 71  
Doyen's  
    cross action towel clip 665  
    intestinal occlusion clamp 674  
Duct ectasia and periductal mastitis 277  
Duodenal  
    atresia 218  
    ulcer 195  
Dupuytren's  
    contracture 406  
    disease 406  
Dysphagia 188  
Dysplasia 113
- E**
- Early  
    breast cancer 282  
    carcinoma of breast 440  
Ectopia vesicae 299  
Ectopic  
    pancreas 248  
    testis 609  
Eczema of nipple 278  
Effects of injury 360  
Elective exploratory laparotomy 567  
Elephantiasis of scrotum 331  
Embryoma of kidney 295  
Emergency exploratory laparotomy 567  
Empyema of gallbladder 627  
Encephaloid carcinoma 281  
Encrusted cystitis 302  
Encysted hydrocele of cord 329, 543  
Endemic  
    goiter 151  
    hematuria 302  
Endogenous infection 61  
Endoscopic retrograde cholangiopancreatography 658  
Endothelins 57  
Enflurane 102  
Enteral 40  
    nutrition 53  
Enterocutaneous fistula 206  
Enterogenous cyst 95  
Eosinophilic gastritis 194  
Epididymal cyst 94, 330  
Epididymis 325  
Epididymo-orchitis 330  
Epigastric  
    hernia 270, 535  
    midline incision 565  
Erysipelas 63  
Esophageal hiatal hernia 191  
Etomidate 101  
Ewing's sarcoma 386  
Examination of  
    breasts 644  
    enlarged lymph node 144  
Excision of  
    sebaceous cyst 619  
    subcutaneous lipoma 620  
Exocrine function 247  
Exogenous infection 61  
Exophthalmos 153  
Exostosis 385, 555  
Extended  
    pyelolithotomy 603  
    right hemicolectomy 590  
Extensor pollicis brevis 407  
External and internal hemorrhage 16  
Extracapsular fracture 373  
Extracellular synthesis 10  
Extradural  
    hematoma 338  
    lipoma 89  
    sacral block 108  
Extrahepatic biliary tree 345  
Extraperitoneal mesh repair 600  
Extrophy of bladder 299
- F**
- Feeding jejunostomy Fegan's test 179  
Fegan's technique 180  
Female  
    metallic catheter 679  
    urethra 313  
Femoral  
    canal 268  
    and femoral ring 268  
    hernia 268, 269, 536  
    repair 598  
    ring 269  
    sheath 269  
Fibrinolytic therapy 31  
Fibroadenoma 276, 538, 564  
Fibroadenosis 276  
Fibrous  
    dysplasia 389  
    epulis 128  
    flexor sheaths 66  
    peritonitis 263  
Filariasis of scrotum 544  
Fine needle aspiration cytology 114, 150  
Fissure in ano 229

Fistula 206  
 in ano 228  
 Fistulectomy 595  
 Flail chest 340  
 Flatus tube 677  
 Fluid  
   electrolyte replacement 206  
   replacement 41  
 Foley's catheter 679  
 Follicular carcinoma 157  
 Foot infections 67  
 Formation of  
   granulation tissue 8  
   prothrombin activator 25  
 Fournier's gangrene of scrotum 332  
 Fracture  
   calcaneum 379  
   clavicle 362, 661  
   Colles' 661  
   dislocations of forearm 366  
   healing 353  
   of both bones of  
     forearm 661  
     leg 663  
   of neck of femur 371, 662  
   of patella 662  
   of radius and ulna 366  
   of scaphoid 369  
   of shaft of humerus 364  
   of skull bone 338  
   patella 374  
   shaft  
     humerus 661  
     of femur 373, 662  
   Free gas under diaphragm 649  
 Fresh frozen plasma 18  
 Freyer's transvesical suprapubic prostatectomy 605  
 Frozen shoulder 410  
 Functions of liver 232  
 Fungal infections 69  
 Funicular hydrocele 329

## G

Galactocele 278  
 Galeazzi fracture dislocation 367  
 Gallstone 240, 626  
   pancreatitis 248  
 Ganglion 408, 552  
 Ganglioneuroma 165  
 Gastrectomy 572  
 Gastric  
   carcinoma 199, 453  
   outlet obstruction 457, 648  
   secretion 194  
   ulcer 198  
 Gastrointestinal  
   disease 98  
   specimens 626  
   surgery 638  
 Gastrojejunostomy 571  
 Gelatins 41

Gelofuscine 41  
 Genitourinary  
   system 284  
   trauma 645  
 Genu  
   valgum 553  
   varum 552  
 Giant cell 128  
   tumor 387  
 Gibbon's catheter 680  
 Glossitis 136  
 Glucagon 56  
 Glucocorticoids 165  
 Gluteal hernia 273  
 Goiter 151, 153  
 Golden hour 334  
 Golfer's elbow 409  
 Gouge forceps 683  
 Gradations of claudication 169  
 Granulation tissue formation 354  
 Granulocyte transfusions 18  
 Granulomatous gastritis 194  
 Graves' disease 153, 429  
 Groin swellings 267  
 Gynecomastia 278, 538

## H

Halothane 102  
 Hand infections 65  
 Hartmann's operation 226  
 Hashimoto's disease 158  
 Head injury 645  
 Healing of  
   fracture 13, 353  
   specialized tissues 13  
 Heath's suture cutting scissors 670  
 Heller's esophagocardiomyotomy 574  
 Hemangioma 87, 515  
 Hematochezia 642  
 Hematoma 14  
   formation 353  
 Hematuria 283, 646  
 Hemiarthroplasty 373  
 Hemithyroidectomy 557  
 Hemoglobin solutions 19  
 Hemophilia 29  
   hemorrhage 16, 559  
 Hemorrhoidectomy 594  
 Henderson-Hasselbalch equation 46  
 Hepatic infections 71  
 Hepatocellular carcinoma 234  
 Hernioplasty 598  
 High  
   anal fistula 229  
   dose dexamethasone suppression test 166  
 Hip joint 499  
 Hippocrates method 363  
 Hirschsprung's disease 208  
 Hodgkin's  
   and non Hodgkin's lymphoma 186  
   disease 185  
   lymphoma 184

Homan's procedure 183  
 Hormone therapy 117  
 Horseshoe kidney 288  
 Hospital acquired infections 69  
 Humby's skin grafting knife 681  
 Hunner's ulcer 301  
 Hurthle cell carcinoma 157  
 Hydatid cyst 631  
   of liver 233, 471  
 Hydradenitis suppurativa 62  
 Hydrated cell 9  
 Hydrocele 328, 542  
   fluid 328  
   of hernial sac 329  
 Hydronephrosis 244, 289, 486, 633  
 Hydroxyethyl starch 41  
 Hypercalcemia 39  
 Hyperkalemia 38  
 Hypernatremia 37  
 Hypernephroma 296, 485, 633  
 Hyperparathyroidism 160  
 Hyperplasia 113  
 Hyperplastic ileocecal tuberculosis 202  
 Hypertrophic scar 13, 80  
 Hypertrophy 113  
 Hypocalcemia 39  
 Hypoparathyroidism 162, 559  
 Hypospadias 314, 546  
 Hypothenar space infection 66  
 Hypothyroidism 436, 559

## I

Ileal loop conduit 307  
 Ileostomy 588  
 Imidazole derivative 101  
 Immediate hemolytic transfusion reactions 21  
 Immobilization of fractures 355  
 Incisional hernia 271, 482  
 Incompatible white cells 21  
 Incomplete descent of testis 325  
 Incontinence in  
   female 305  
   male 305  
 Incubation period 64  
 Indirect inguinal hernia 265, 480  
 Infantile  
   hydrocele 329  
   polycystic disease 289  
 Infections of hand and foot 65  
 Inflammatory  
   breast carcinoma 281  
   goiter 159  
 Ingrowing toe nails 67  
 Inguinal  
   canal 264  
   hernia 264, 267  
     repair operations in adults 597  
 Injection sclerotherapy 180  
 Injury to  
   posterior urethra 351  
   urethra 314, 350  
   viscera 360

## Index

- Insertion of  
intercostal drain 618  
nasogastric 618
- Instruments for  
genitourinary surgery 678  
skin incision 665  
tissue approximation and wound closure 670
- Instruments used in biliary tract surgery 675
- Intermittent claudication 169
- Intermuscular lipoma 88
- Internal fixation 355
- Interpretation of fluid balance 33
- Intestinal  
atresia 218  
ischemia 216  
motility 201  
obstruction 215  
tuberculosis 202
- Intracapsular fracture 372
- Intracellular  
compartment 34  
synthesis 9
- Intracranial hemorrhage 338
- Intraduct papilloma 278
- Intramedullary nailing 623
- Intrathecal anesthesia and epidural anesthesia 107
- Intravenous  
potassium 38  
urogram or pyelogram 659
- Intrinsic renal failure 310
- Ionizing radiation injury 78
- Irradiation cystitis 302
- Ischemic muscle pain 169
- Ischiorectal abscess 63
- Isoflurane 102
- J**
- Jaw tumors 128
- Jejunal and ileal atresia 218
- Joint  
laxity 399  
stiffness 360
- K**
- Keel operation 272
- Kehr's T tube 676
- Keloid 80, 518
- Ketamine 100, 110
- Kidney  
injury 348  
stone 651
- Kocher's  
artery forceps 666  
collar incision 558  
subcostal incision 566
- L**
- Lane's  
tissue forceps 669  
twin gastroenterostomy occlusion clamp 674
- Langenbeck's retractor 668
- Lanz incision 566
- Laparoscopic  
appendectomy 214  
biopsy 115  
cholecystectomy 576  
hernia repair 598  
inguinal hernia repair 268
- Laparotomy 344
- Left hemicolectomy 590
- Leukoplakia 136
- Ligament of Cooper 274
- Ligation of calf perforators 615
- Lignocaine 106
- Lingual thyroid 150
- Lister's metallic Bougie 680
- Liver  
neoplasms 234  
transplantation 237
- Lobectomy 557
- Local host defences 60
- Locally advanced breast carcinoma 445
- Loop ileostomy 569
- Lotheissen's repair 598
- Low  
anal fistula 229  
fistula 595
- Lower  
GI bleeding 642  
midline incision 565  
motor neuron bladder 307
- Lumbar  
hernia 273, 536  
sympathectomy 613
- Lung  
abscess and empyema 72  
injury 341
- Luxatio erecta 364
- Lymph node 281
- Lymph node  
biopsy 619
- Lymphadenitis 63, 143
- Lymphadenopathy 183
- Lymphangioma 183
- Lymphangiosarcoma 183
- Lymphangitis 63, 183, 331
- Lymphatic  
cyst 95  
obstruction 331
- Lymphedema 182
- Lymphoma 328
- M**
- Macrolides 73
- Madura foot 69
- Magnesium  
abnormalities 39  
deficiency 39  
excess 40
- Malakoplakia 302
- Male metallic catheter 678
- Malecot catheter 679
- Malignant  
hydatid disease 233  
hyperpyrexia/hyperthermia 111  
melanoma 85, 520  
mucocele 214  
tumors of  
mandible 130  
maxilla 130  
ulcer 135
- Mallet 683  
finger 407
- Marjolin's ulcer 87, 522
- Massive  
blood transfusion 28  
transfusion 19
- Mastectomy 282
- Mastitis neonatorum 277
- Matrix formation 9
- Mayo's  
operation 271  
repair 599  
scissors 670  
towel clip 665
- McBurney's gridiron incision 566
- McIndoe scissors 670
- Meatoplasty 607
- Meatotomy 607
- Meckel's  
diverticulectomy 586  
diverticulum 203, 628
- Meconium ileus 218
- Medial epicondylitis 409
- Mediastinitis 72
- Medullary carcinoma of thyroid 157
- Melanoma 85
- Meniscal injury 376
- Menisectomy 622
- Mesenteric  
cysts 94  
trauma 345
- Methods of urinary diversion 306
- Micropapillary carcinoma 156
- Micturition 304
- Midgut malrotation 218
- Minor head injury 337
- Mixed  
or infected stones 241  
parotid tumor 124, 527
- Modified  
neck dissection 156  
radical mastectomy 562
- Moist gangrene 173
- Mondor's disease 278
- Monteggia fracture dislocation 367
- Morant baker's cyst 409
- Morris retractor 668
- Motor block 107
- Moynihan's  
gastric occlusion clamp 674  
tetra towel clip 665
- Mucinous carcinoma 281
- Mucocele of gallbladder 465, 626
- Multinodular goiter 151, 435
- Multiple  
cysts 330  
myeloma 388

phlebectomies 616  
 tourniquet test 179  
 Murphy's triad or syndrome 212  
 Muscles of tongue 134  
 Mycetoma 69  
 Myeloid epulis 128  
 Myer's vein stripper 681  
 Myositis ossificans 361

**N**

Neck nodes 138  
 Necrotizing fasciitis 64  
 Needle holder 673  
 Neonatal intestinal obstruction 217, 643  
 Neoplasms of  
     abdominal wall 258  
     appendix 214  
     lip 138  
     lymphatics 183  
 Neoplastic goiter 156  
 Nephrectomy 602  
 Nephroblastoma 295  
 Nephrolithotomy 603  
     forceps 680  
 Neuroblastoma 164  
 Neurofibroma 89, 517  
 Neurogenic bladder 307  
 Neurological disease 97  
 Neuromuscular blocking agents 103  
 Neutrophil-endothelium interaction 57  
 Nipple discharge 644  
 Nitric oxide 57  
 Nitroimidazoles 73  
 Nitrous oxide 103  
 Nondepolarizing muscle relaxants 103  
 Non-Hodgkin's lymphoma 185  
 Nonlactational abscess 277  
 Nonshunt procedures 236  
 Nonspecific osteomyelitis of Garre 383  
 Nonsteroidal anti-inflammatory drugs 109  
 Non-toxic  
     goiter 151  
     multinodular goiter 434  
 Nonunited fracture neck of femur 512  
 Normal  
     distribution of electrolytes in body water 33  
     water and electrolyte balance 35  
 Nyhus classification for groin hernia 267

**O**

Obstructive jaundice 244  
 Obturator hernia 273  
 Odontomes 128  
 Odynophagia 189  
 Omphalitis 258  
 Open  
     amputation 411  
     fracture 355  
     pneumothorax 340  
     prostatectomy 321

Operation for  
     adult umbilical hernia 599  
     epigastric hernia 599  
     fistula in ano 595  
     incisional hernia 272, 599  
     infantile umbilical hernia 599  
     ingrowing toenail 620  
     inguinal hernia 596  
     peptic ulcer perforation 572  
     ureteric stones 604  
     varicose vein 614

Operation of  
     hydrocele 610  
     pelvic colostomy 568  
     thyroid 557  
     total thyroidectomy 558  
     transverse loop colostomy 568  
     varicocele 611

Opioids 109  
 Oral cholecystography 657  
 Orchidectomy 609  
 Orchidopexy 609  
 Order of neural blockade 107  
 Ortaloni test 400  
 Oschner's Mahoner's test 179  
 Osteoarthritis 361  
 Osteochondritis 397, 398  
 Osteochondroma 385, 555  
 Osteoclastoma 637, 663  
 Osteoma 384  
 Osteomyelitis 510, 663  
 Osteosarcoma 385, 556, 636, 663  
 Osteotome 683  
 Oxazolidinediones 73

**P**

Packed red cells 18  
 Paget's disease of nipple 280  
 Palmar fibromatosis 406  
 Palpation of left axilla 439  
 Pancreatic  
     abscess 71  
     cysts 251  
     ducts 246  
 Papillary carcinoma 156  
 Papilloma of skin 83  
 Paracetamol 109  
 Paralytic ileus 217  
 Paramedian incision 565  
 Paraphimosis 315  
 Paraumbilical hernia 599  
 Paronychia 65  
 Parosteal lipoma 89  
 Parotid  
     duct 124  
     fistula 126, 530  
     gland 123  
     swellings 124  
     tumor 124  
 Partial  
     amputation of penis 607  
     thickness graft 91  
     thyroidectomy 557

Parts of  
     hernia 265  
     typical surgical instrument 664  
 Patellectomy 622  
 Paterson and Kelly syndrome 189  
 Patey's operation 562  
 Payr's  
     gastric crushing clamps 675  
     intestinal crushing clamp 675  
 Pelvic abscess 262  
 Penicillin 72  
 Peptic ulcer  
     hemorrhage 196  
     surgery 194  
 Percutaneous drainage 233  
 Perfluorocarbons 19  
 Periapillary carcinoma 466  
 Pericardial tamponade 341  
 Perinephric abscess 295  
 Peripheral  
     parenteral nutrition 54  
     vascular disease 494  
 Peritonism 196  
 Peritonitis 71, 260  
 Persistent vitellointestinal duct 537  
 Perthes  
     disease 506  
     test 179  
 Peutz-Jeghers syndrome 205  
 Peyronie's disease 317  
 Pfannenstiel's incision 566  
 Pharyngeal pouch 145  
 Phenol derivative 101  
 Pheochromocytoma 164  
 Phimosis 315, 545  
 Phosphate buffer system 44  
 Phyllodes tumor of breast 538  
 Pigment stones 241  
 Pigmented nevus 85  
 Piles 227  
     holding forceps 677  
 Pin-prick test 76  
 Plain  
     dissecting forceps 668  
     X-ray abdomen 649  
 Plantar fasciitis 409  
 Plasma and blood substitutes 19  
 Plexiform neurofibromatosis 89  
 Plexus blocks 107  
 Plummer-Vinson syndrome 189  
 Plunging ranula 140  
 Polyamide 672  
 Polycystic kidney 288, 633  
 Polyglactin sutures 671  
 Polypropylene 672  
 Polytrauma 644  
 Popliteal cyst 409  
 Port wine stain 87  
 Portal  
     hypertension 235  
     vein 345  
 Porta-systemic encephalopathy 237  
 Postburn contracture 78  
 Postcholecystectomy 470

## Index

- Postdural puncture headache 110  
Posterior  
  dislocation of hip 370  
  gastrojejunostomy 571  
  vagus dissection 571  
Postgastrectomy symptoms 200  
Postoperative nausea and vomiting 111  
Potassium  
  balance 36  
  depletion 38  
  excess 38  
Pott's disease and caries spine 391  
Pratt's test 179  
Prehospital trauma triage 334  
Pressure sores 174  
Primary  
  brain injury 336  
  hepatoma 234  
  hyperaldosteronism 166  
  hyperparathyroidism 160  
  lymphedema 182  
  osteosarcoma 385  
  peritonitis 71  
  thyrotoxicosis 429  
  toxic goiter 153  
Prolapse of rectum 223  
Propofol 101  
Prostacyclin 57  
Prostatectomy 605  
Prostatic  
  capsules 318  
  urethra 313  
Prostatomembranourethra 351  
Prothrombinase 25  
Proximal humerus 364  
Pseudocoxalgia 397  
Pseudocyst of pancreas 474  
Pseudopancreatic cyst 251  
Psychiatric disease 98  
Puerperal breast abscess 277  
Pulmonary contusion 341  
Pyelolithotomy 603  
  forceps 680  
Pyemia 62  
Pyloric stenosis 197, 457  
Pyloromyotomy 573  
Pyogenic  
  abscess 62  
  liver abscess 232  
Pyonephrosis 294
- Q**
- Qualitative platelet dysfunction 30  
Quinolones 73
- R**
- Radial nerve palsy 550  
Radical  
  cystectomy 304  
  mastectomy 561  
  orchidectomy 610  
  subtotal gastrectomy 572  
  total gastrectomy 573  
Rampley's sponge 664  
Ramstedt's operation 573  
Ranula 139, 524  
Raspberry tumor 537  
Raynaud's syndrome 174  
Rectum 221  
Rectus sheath hematoma 259  
Recurrent  
  dislocation of patella 554  
  fibroid of Paget 536  
  inguinal hernia 267  
  laryngeal nerve palsy 559  
  nodular  
    goiter 152  
    toxic goiter 156  
  toxic nodular goiter 153  
Red blood cells 21  
Regional lymph nodes 322  
Renal  
  carbuncle 295  
  cell carcinoma 485  
  stone 290  
  transplantation 311  
  tuberculosis 293  
Repair of peptic perforation 196  
Replacement arthroplasty 373  
Respiratory  
  disease 97  
  obstruction 559  
  tract infection 70  
Retention of urine 305  
Retroperitoneal hematoma 346  
Retroperitoneum 346  
Retrosternal goiter 436  
Rib fractures 340  
Riedel's thyroiditis 159  
Right  
  angled artery forceps 667  
  hemicolectomy 589  
  iliac fossa 213  
Robson's staging of renal cell carcinoma 296  
Rodent ulcer 83, 518  
Role of  
  hormone 85  
  kidneys 44  
  lungs 44  
  operative treatment 377  
  surgery in TB lymphadenitis 144  
Rolling hernia 191  
Ropivacaine 106  
Roux loop 588  
Rupture of appendix 213  
Ruptured  
  biceps tendon 410  
  tendoachilles 379  
Rutherford Morrison incision 566  
Ryle's tube 618
- S**
- Salivary glands 123  
Salmon patch 87  
Saphenopopliteal ligation and stripping 615  
Satinski's arterial clamp 667  
Scalp sebaceous cyst 94  
Schistosomiasis of bladder 302  
Schwartz's test 179  
Sciatic hernia 273  
Scirrhus carcinoma 280  
Sebaceous  
  cyst 94, 278, 514  
  gland 94  
Secondary  
  brain injury 336  
  carcinoma of bone 389  
  hydrocele 329  
  hyperparathyroidism 161  
  iodine deficiency goiter 151  
  lymphedema 182  
  osteosarcoma 385  
  peritonitis 71  
  toxic goiter 154  
Self-retaining abdominal retractor 668  
Semimembranosus bursitis 553  
Seminal vesicles 325  
Seminoma 327, 328  
Sequestration dermoid 94  
Sequestrum 636  
Serum thyroid hormones 149  
Severe head injury 337  
Sevoflurane 103  
Sex steroids 166  
Shock 3  
Short bowel syndrome 204  
Sigmoid  
  colectomy 591  
  volvulus 219, 651  
Silicone granulomas 278  
Simian hand 551  
Simmonds test 379  
Simple  
  bone cyst 389  
  cyst 289  
  lymphangioma 183  
  mastectomy 561  
  orchidectomy 609  
  rubber catheter 678  
Sinus forceps 681  
Sistrunk's operation 141  
Skin  
  and subcutaneous tissue 514  
  excoriation 206  
Sliding hernia 191  
Small  
  bowel resection and anastomosis 585  
  intestine 201, 345  
Sodium balance 35  
Soft tissue injuries of knee 375  
Solitary  
  cysts 330  
  neurofibroma 89  
  nodular goiter 152  
  renal cyst 289  
  thyroid nodule 154, 155  
Spastic bladder 307  
Spermatocele 330



- Sphincters of esophagus 188  
 Spigelian hernia 273  
 Spinal block 108  
 Splenectomy 255  
 Splenic injury 255  
 Splenomegaly 255  
 Spongy urethra 313, 350  
 Squamous cell  
     carcinoma 84, 519  
     papilloma 83  
 Starling  
     equation 33  
     hypothesis 33  
 Sternomastoid tumor 145  
 Stone in  
     CBD 468  
     submandibular  
         duct 127  
         gland 127  
 Strangulated inguinal hernia 268, 598, 643  
 Strawberry  
     angioma 87  
     nevus 87  
 Strictureplasty 587  
 Stripping of long saphenous vein 614  
 Subacute thyroiditis 158  
 Subcutaneous lateral internal sphincterotomy 595  
 Subfascial lipoma 88  
 Submandibular  
     calculi 126  
     duct calculus 530  
     salivary gland excision 127  
 Submucous lipoma 89  
 Subphrenic abscess 262  
 Subserous lipoma 89  
 Subtotal thyroidectomy 557  
 Sudeck's atrophy 361  
 Supracondylar fracture of humerus 365, 661  
 Suprapubic  
     cystolithotomy forceps 681  
     cystostomy 306, 605  
     trocar catheter 605  
 Surgical  
     anal canal 222  
     infections of thorax 72  
 Suture needles 672  
 Suxamethonium 103  
 Swab holding forceps 664  
 Sympathetic nervous system 55  
 Synovial flexor sheaths 66  
 Syphilitic ulcer 135  
 Systemic host defences 60  
 Systolic bladder 303
- T**
- Talipes equinovarus 403  
 Telescopic test 400  
 Tendon repair 624  
 Tennis elbow 409  
 Tenosynovitis 406  
 Tenovaginitis of abductor pollicis longus 407
- Teratodermoid 94  
 Teratoma 328  
 Tertiary  
     hyperparathyroidism 161  
     peritonitis 72, 263  
 Testicular  
     cancer 327  
     torsion 326  
     tumor 327, 540  
 Tests of thyroid function 149  
 Tetanus 64  
     prophylaxis 65  
 Tetany 48, 643  
 Tetracyclines 73  
 Thenar space abscess 66  
 Thimble bladder 303  
 Thiopentone 99  
 Thoracic  
     outlet syndrome 175  
     trauma 645  
 Thrombin time 26  
 Thrombocythemia 30  
 Thrombocytopenia 29  
 Thromboembolism prophylaxis 225, 476  
 Thrombophilia 31  
 Thyroglossal  
     cyst 141, 150, 525  
     fistula 141  
 Thyroid  
     antibodies 150  
     autoregulation 149  
     cancer 156  
     carcinoma 432  
     crisis 559  
     hormone secretion 148  
     swelling 424  
 Thyroidectomy 152, 557  
 Thyrotoxicosis 152, 153  
 Tissues holding forceps 669  
 TNM  
     classification 281  
     staging 303  
 Toothed dissecting forceps 669  
 Torsion of spermatic cord 326  
 Total  
     amputation of penis 608  
     colectomy 591  
     parenteral nutrition 53  
     thyroidectomy 557  
 Toxic goiter 152, 154, 648  
 Tracheal and bronchial injury 341  
 Transverse epigastric incision 566  
 Trauma resuscitation 334  
 Traumatic  
     diaphragmatic hernia 190  
     dislocation of patella 375  
     hemothorax 341  
     pneumothorax 340  
 Treatment of  
     acute variceal bleed 236  
     axilla 282  
     breast cancer 282  
     burn shock 77  
     cancer 114  
     closed fracture 354  
     compound fracture 355  
     fracture 354  
     impassable stricture 315  
     passable strictures 315  
     retention 646  
 Trendelenburg's operation 614  
 Triangles of  
     Calot 240  
     neck 139  
 Trigger finger 407  
 Tropical anesthesia 107  
 True cyst 93  
 Truncal vagotomy 571  
 Tubercular  
     cervical lymphadenopathy 526  
     ulcer 135  
 Tuberculosis 277  
 Tuberculosis of  
     hip 394, 502  
     knee 396  
     spine 391, 507  
 Tuberculous  
     cystitis 302  
     epididymo-orchitis 331  
     lymphadenitis 184  
     peritonitis 263  
 Tubulodermoid 94  
 Tubuloembryonic dermoid cyst 141  
 Tumors of  
     adrenal medulla 163  
     bladder 303  
     esophagus 189  
     jaw bones 130  
     kidney itself 295  
     pancreas 252  
     renal pelvis 295  
     tongue 136  
 Tunica vaginalis 611  
 Types of  
     adrenal insufficiency 168  
     bone lesion 389  
     burn injury 78  
     collagen 10  
     dermoid 94  
     enteral diet 53  
     fracture 373  
     gastric ulcer 198  
     hemorrhage 16  
     hormone therapy 117  
     incisional hernia 272  
     injury 623  
     lymphedema 182  
     parenteral fluid 40  
     radiation therapy 115  
     regional anesthesia 106  
     skin graft 91  
     stones 291  
     supracondylar fracture 365  
     surgery 244, 394  
     surgical infection 61  
     vagotomy 570

## Index

vertebral tuberculosis 391  
wound 14  
Typhoid enteritis 205

### U

Ulcerative  
  colitis 209, 631  
  tuberculosis 202  
Ulcers of tongue 135  
Ultrasonography 119, 660  
Umbilical  
  adenoma 537  
  granuloma 258  
  hernia 270, 536  
  polyp 537  
Undescended testis 325, 541  
Unilateral hydronephrosis 289  
Upper  
  GI bleeding 641  
  midline incision 565  
  motor neuron 307  
  transverse incision 566  
Urachal fistula 537  
Ureteric  
  injury 349  
  stone 292  
Ureterolithotomy 293, 604  
Ureteroscopic stone removal 293  
Urethra 313

Urethral  
  dilatation 621  
  dilator 680  
  injury 645  
  stricture 314  
Urinary  
  bilharziasis 302  
  diversion 306  
  fistula 305  
  incontinence 304  
  tract 284  
  infection 70

### V

Vaginal hydrocele 328  
Vagus nerves 570  
Varicocele 329, 544  
Varicolectomy 611  
Varicose vein 177, 489, 491  
Vas deferens 325  
Venous  
  drainage 275  
  hemorrhage 16  
  pump of lower limb 178  
Vertebral column 107  
Vesical  
  calculus 652  
  fistula 306  
  stone 300

Viral carcinogenesis 113  
Vitamin K deficiency 27  
Vitellointestinal  
  duct 256  
  fistula 537  
Volkmann's  
  ischemic contracture 361  
  retractor 668  
  spoon or scoop 681  
Volvulus 219  
  neonatorum 218  
  of cecum 219  
Von Recklinghausen's disease 89

### W

Wedge resection of nail and nailbed 620  
White bile 244  
Wide local excision of tumor 563  
Wilms' tumor 295  
Wound  
  excision 14, 356  
  healing 6  
  infection 560  
Wrist drop 550

### Z

Zollinger-Ellison syndrome 200