

15TH
EDITION

HARRISON'S

**PRINCIPLES OF
INTERNAL
MEDICINE**

**SELF-ASSESSMENT
and BOARD REVIEW**

Richard M. Stone

- More than 800 board-type questions
- Fully explained answers
- Current references with each answer



HARRISON'S 15TH
EDITION

PRINCIPLES OF
**INTERNAL
MEDICINE**

SELF-ASSESSMENT AND BOARD REVIEW

NOTICE

Medicine is an ever-changing science. As new research and clinical experience broaden our knowledge, changes in treatment and drug therapy are required. The editor and the publisher of this work have checked with sources believed to be reliable in their efforts to provide information that is complete and generally in accord with the standards accepted at the time of publication. However, in view of the possibility of human error or changes in medical sciences, neither the editors nor the publisher nor any other party who has been involved in the preparation or publication of this work warrants that the information contained herein is in every respect accurate or complete and they are not responsible for any omissions or for the results obtained from use of such information. Readers are encouraged to confirm the information contained herein with other sources. For example and in particular, readers are advised to check the product information sheet included in the package of each drug they plan to administer to be certain that the information contained in this book is accurate and that changes have not been made in the recommended dose or in the contraindications for administration. This recommendation is of particular importance in connection with new or infrequently used drugs.

HARRISON'S 15TH EDITION

PRINCIPLES OF INTERNAL MEDICINE

SELF-ASSESSMENT AND BOARD REVIEW

For use with the 15th edition of HARRISON'S PRINCIPLES OF INTERNAL MEDICINE

EDITED BY

RICHARD M. STONE, MD

Clinical Director, Adult Leukemia Program
Department of Adult Oncology
Dana-Farber Cancer Institute

Associate Professor of Medicine
Harvard Medical School
Boston, Massachusetts

CONTRIBUTING EDITOR

Daniel J. DeAngelo, MD, PhD

Department of Adult Oncology
Dana-Farber Cancer Institute

Instructor in Medicine
Harvard Medical School
Boston, Massachusetts

McGraw-Hill

MEDICAL PUBLISHING DIVISION

New York
Milan

Chicago
New Delhi

San Francisco
San Juan

Lisbon
Seoul

London
Singapore

Madrid
Sydney

Mexico City
Toronto

McGraw-Hill



A Division of The McGraw-Hill Companies

Copyright © 2001 by The McGraw-Hill Companies, Inc. All rights reserved. Manufactured in the United States of America. Except as permitted under the United States Copyright Act of 1976, no part of this publication may be reproduced or distributed in any form or by any means, or stored in a database or retrieval system, without the prior written permission of the publisher.

0-07-138678-5

The material in this eBook also appears in the print version of this title: 0-07-137375-6.

All trademarks are trademarks of their respective owners. Rather than put a trademark symbol after every occurrence of a trademarked name, we use names in an editorial fashion only, and to the benefit of the trademark owner, with no intention of infringement of the trademark. Where such designations appear in this book, they have been printed with initial caps.

McGraw-Hill eBooks are available at special quantity discounts to use as premiums and sales promotions, or for use in corporate training programs. For more information, please contact George Hoare, Special Sales, at george_hoare@mcgraw-hill.com or (212) 904-4069.

TERMS OF USE

This is a copyrighted work and The McGraw-Hill Companies, Inc. ("McGraw-Hill") and its licensors reserve all rights in and to the work. Use of this work is subject to these terms. Except as permitted under the Copyright Act of 1976 and the right to store and retrieve one copy of the work, you may not decompile, disassemble, reverse engineer, reproduce, modify, create derivative works based upon, transmit, distribute, disseminate, sell, publish or sublicense the work or any part of it without McGraw-Hill's prior consent. You may use the work for your own noncommercial and personal use; any other use of the work is strictly prohibited. Your right to use the work may be terminated if you fail to comply with these terms.

THE WORK IS PROVIDED "AS IS". MCGRAW-HILL AND ITS LICENSORS MAKE NO GUARANTEES OR WARRANTIES AS TO THE ACCURACY, ADEQUACY OR COMPLETENESS OF OR RESULTS TO BE OBTAINED FROM USING THE WORK, INCLUDING ANY INFORMATION THAT CAN BE ACCESSED THROUGH THE WORK VIA HYPERLINK OR OTHERWISE, AND EXPRESSLY DISCLAIM ANY WARRANTY, EXPRESS OR IMPLIED, INCLUDING BUT NOT LIMITED TO IMPLIED WARRANTIES OF MERCHANTABILITY OR FITNESS FOR A PARTICULAR PURPOSE. McGraw-Hill and its licensors do not warrant or guarantee that the functions contained in the work will meet your requirements or that its operation will be uninterrupted or error free. Neither McGraw-Hill nor its licensors shall be liable to you or anyone else for any inaccuracy, error or omission, regardless of cause, in the work or for any damages resulting therefrom. McGraw-Hill has no responsibility for the content of any information accessed through the work. Under no circumstances shall McGraw-Hill and/or its licensors be liable for any indirect, incidental, special, punitive, consequential or similar damages that result from the use of or inability to use the work, even if any of them has been advised of the possibility of such damages. This limitation of liability shall apply to any claim or cause whatsoever whether such claim or cause arises in contract, tort or otherwise.

DOI: 10.1036/0071386785



Want to learn more?

We hope you enjoy this McGraw-Hill eBook! If you'd like more information about this book, its author, or related books and websites, please [click here](#).

CONTENTS

<i>Introduction</i>		<i>vii</i>
SECTION I	PRACTICE OF MEDICINE	
	<i>Questions</i>	<i>1</i>
	<i>Answers, Explanations, and References</i>	<i>4</i>
SECTION II	GENETICS AND DISEASE	
	<i>Questions</i>	<i>9</i>
	<i>Answers, Explanations, and References</i>	<i>13</i>
SECTION III	CLINICAL PHARMACOLOGY	
	<i>Questions</i>	<i>21</i>
	<i>Answers, Explanations, and References</i>	<i>23</i>
SECTION IV	NUTRITION	
	<i>Questions</i>	<i>27</i>
	<i>Answers, Explanations, and References</i>	<i>30</i>
SECTION V	ONCOLOGY AND HEMATOLOGY	
	<i>Questions</i>	<i>35</i>
	<i>Answers, Explanations, and References</i>	<i>51</i>
SECTION VI	INFECTIOUS DISEASES	
	<i>Questions</i>	<i>79</i>
	<i>Answers, Explanations, and References</i>	<i>96</i>
SECTION VII	DISORDERS OF THE CARDIOVASCULAR SYSTEM	
	<i>Questions</i>	<i>127</i>
	<i>Answers, Explanations, and References</i>	<i>146</i>
SECTION VIII	DISORDERS OF THE RESPIRATORY SYSTEM	
	<i>Questions</i>	<i>171</i>
	<i>Answers, Explanations, and References</i>	<i>180</i>
SECTION IX	DISORDERS OF THE KIDNEY AND URINARY TRACT	
	<i>Questions</i>	<i>197</i>
	<i>Answers, Explanations, and References</i>	<i>207</i>

SECTION X	DISORDERS OF THE GASTROINTESTINAL SYSTEM	
	<i>Questions</i>	221
	<i>Answers, Explanations, and References</i>	235
SECTION XI	DISORDERS OF THE IMMUNE SYSTEM, CONNECTIVE TISSUE, AND JOINTS	
	<i>Questions</i>	257
	<i>Answers, Explanations, and References</i>	267
SECTION XII	ENDOCRINE AND METABOLIC DISORDERS	
	<i>Questions</i>	287
	<i>Answers, Explanations, and References</i>	303
SECTION XIII	NEUROLOGIC DISORDERS	
	<i>Questions</i>	333
	<i>Answers, Explanations, and References</i>	349
SECTION XIV	ENVIRONMENTAL AND OCCUPATIONAL HAZARDS	
	<i>Questions</i>	375
	<i>Answers, Explanations, and References</i>	377
	<i>Appendix</i>	381
	<i>Bibliography</i>	391

INTRODUCTION

Harrison's Principles of Internal Medicine: PreTest Self-Assessment and Review has been designed to provide physicians with a comprehensive, relevant, and convenient instrument for self-evaluation and review within the broad area of internal medicine. Although it should be particularly helpful for residents preparing for the American Board of Internal Medicine (ABIM) certification examination and for board-certified internists preparing for recertification, it should also be useful for internists, family practitioners, and other practicing physicians who are simply interested in maintaining a high level of competence in internal medicine. Study of this self-assessment and review book should help to (1) identify areas of relative weakness; (2) confirm areas of expertise; (3) assess knowledge of the sciences fundamental to internal medicine; (4) assess clinical judgment and problem-solving skills; and (5) introduce recent developments in general internal medicine.

This book consists of multiple-choice questions that (1) are representative of the major areas covered in *Harrison's Principles of Internal Medicine*, 15th ed., and (2) parallel the format and degree of difficulty of the questions on the examination of the ABIM. Questions have been appropriately updated and chosen to reflect important recent developments in internal medicine, such as the increasing contributions of molecular biology to the understanding, diagnosis, and treatment of many disorders. This edition represents a reorganized version in which the sections correspond to those in the parent textbook. Many questions have been revised. Except-type questions have been eliminated to reflect the changing ABIM certification examination format. New sections in general medicine, pharmacology, nutrition, and genetics have been added. Each question is accompanied by an answer, a paragraph-length explanation, and a reference to a specific chapter in *Harrison's*. In some cases references to more specialized textbooks and current journal articles are also given. A list of normal values used in the laboratory studies in this book can be found in the Appendix,

followed by a Bibliography listing all the sources used for the questions. As in the current edition of *Harrison's*, the system of international units (SI) appears first in the text and the traditional units follow in parentheses. All color plates referred to in the text are found at the back of the book.

We have assumed that the time available to the reader is limited; therefore, this book has been designed to be used profitably a chapter at a time. By allowing no more than two and a half minutes to answer each question, you can simulate the time constraints of the actual board examinations. When you finish answering all the questions in a chapter, spend as much time as necessary verifying answers and carefully reading the accompanying explanations. If after reading the explanations for a given chapter, you feel a need for a more extensive and definitive discussion, consult the chapter in *Harrison's* or any of the other references listed.

Based on our testing experience, on most medical examinations, examinees who answer half the questions correctly would score around the 50th or 60th percentile. A score of 65 percent would place the examinee above the 80th percentile, whereas a score of 30 percent would rank him or her below the 15th percentile. In other words, if you answer fewer than 30 percent of the questions in a chapter correctly, you are relatively weak in that area. A score of 50 percent would be approximately average, and 70 percent or higher would probably be honors.

This book is a teaching device that provides readers with the opportunity to evaluate and update their clinical expertise, their ability to interpret data, and their ability to diagnose and solve clinical problems.

The editor wishes to acknowledge the efforts of his administrative assistant, Cynthia Curti, whose tireless efforts allowed completion of this complicated project. Key individuals at McGraw-Hill Medical Publishing Division, Mariapaz Ramos Englis, Catherine H. Saggese, and Martin J. Wonsiewicz, Publisher, provided critical support, advice, and understanding during the production of this and previous editions of the PreTest.

This page intentionally left blank.

I. PRACTICE OF MEDICINE

QUESTIONS

DIRECTIONS: Each question below contains five suggested responses. Choose the **one best** response to each question.

I-1. Which of the following statements concerning “practice guidelines” is correct?

- (A) Physicians must follow clinical practice guidelines to the letter in order to avoid malpractice lawsuits
- (B) Only guidelines that come from governmental agencies are relevant for the practicing clinician
- (C) Guidelines can protect patients from receiving sub-standard care
- (D) Guidelines are based on the premise that cost must be reduced in the practice of medicine
- (E) Guidelines can be expected to apply only to those patients in a “managed care” setting

I-2. A 51-year-old married father of three presents with epigastric abdominal pain and weight loss. Computed tomography (CT) of the abdomen reveals an extensive mid-pancreatic mass with obvious liver metastases. Needle biopsy of one of the hepatic lesions is consistent with pancreatic adenocarcinoma. At this point the patient’s primary care physician should tell the patient

- (A) that a referral to an oncologist will be made
- (B) the nature of histology and refer the patient to an oncologist and defer discussion of the prognosis
- (C) to get his affairs in order as quickly as possible
- (D) that we now have effective therapy for pancreatic carcinoma
- (E) that he has an extremely serious life-threatening illness, but that all measures will be undertaken to extend the quantity and quality of the patient’s life

I-3. A 35-year-old woman with a severe anxiety neurosis develops acute appendicitis. The primary care physician, the surgical consultant, and the infectious disease consultant all recommend urgent appendectomy. The patient wants to be treated only with antibiotics because she is concerned about the risks of anesthesia. The patient states she understands the reasons for the physician’s recommendations and that she might die if she does not have this operation, yet she feels strongly that this is what is best for her. At this point the most appropriate course of action would be to

I-3. (Continued)

- (A) call a psychiatrist
- (B) tell the patient that you cannot treat her and refer her to another hospital
- (C) declare the patient legally incompetent, restrain her, and perform surgery since it will be life saving
- (D) treat the patient with antibiotics
- (E) call a lawyer

I-4. What is the most important principle in discussions with a surrogate decision maker for a patient who is unconscious and incapable of making an important decision regarding advanced care, especially if there is no documentation of the patient’s desires?

- (A) Without knowing the patient’s specific wishes, prolongation of life must be carried out at all costs
- (B) The physician should make a judgment based on the medical facts
- (C) The physician should decide as the patient would under the circumstances, assuming the patient knew all information
- (D) The surrogate makes the decision based on what he or she thinks is best for the patient
- (E) The hospital ethics board must decide

I-5. Which of the following is the most likely cause of death for a woman between the ages of 45 and 54 in the United States?

- (A) Breast cancer
- (B) Ischemic heart disease
- (C) Lung cancer
- (D) Suicide
- (E) Accidents

I-6. A 52-year-old postmenopausal woman comes for a routine visit to her primary care physician. She asks about the value of hormone replacement therapy. Which of the following statements is correct regarding this situation?

- (A) Use of tamoxifen slows the development of osteoporosis but has no effect on the incidence of breast cancer

I-6. (Continued)

- (B) The use of tamoxifen reduces the risk of breast cancer but has no effect on osteoporosis
- (C) The use of tamoxifen reduces both the risk of osteoporosis and breast cancer
- (D) Calcium and estrogen slow the development of osteoporosis and reduce the frequency of breast cancer
- (E) Alendronate has no effect on the development of osteoporosis

I-7. Which of the following is a correct statement concerning the differences in the etiology and incidence of ischemic heart disease in men and women?

- (A) The incidence of ischemic heart disease is higher in women than in men
- (B) Women are more likely to present with angina as the initial symptom of ischemic heart disease, and men with myocardial infarction
- (C) The risk of morbidity and mortality after a myocardial infarction is lower in women than men
- (D) Women have a lower perioperative mortality rate after coronary artery bypass surgery than men
- (E) Men have more frequent problems secondary to bleeding complications with antithrombotic therapy

I-8. A 35-year-old woman pregnant with her first child develops edema. She presents to her obstetrician, who finds that her blood pressure is 170/115 and that she has bipedal edema and bilateral rales on pulmonary examination. Laboratory studies reveal 6 g protein in a 24-h urine collection, elevated hepatic transaminases, and a platelet count of 80,000/ μ L. The patient is currently at 31 weeks of pregnancy and is admitted to the hospital and put on bed rest. Her blood pressure and the status of the fetus are closely monitored. Which of the following additional measures represents the most appropriate treatment?

- (A) Magnesium sulfate: 6-g bolus over 15 min followed by 1 to 3 g/h by continuous infusion pump
- (B) Intravenous labetalol
- (C) Intravenous diazepam
- (D) Oral losartan
- (E) Oral captopril around the clock

I-9. Which of the following statements concerning the management of deep venous thrombosis in pregnancy is correct?

- (A) Low-molecular-weight heparins are contraindicated in the third trimester of pregnancy
- (B) Warfarin therapy is contraindicated only in the first trimester of pregnancy
- (C) Warfarin therapy is contraindicated throughout pregnancy but safe during breast feeding

I-9. (Continued)

- (D) Warfarin therapy is contraindicated throughout the pre- and postpartum periods
- (E) All therapies and measures appropriate for the nonpregnant individual are appropriate in those women who suffer a deep venous thrombosis during pregnancy

I-10. A 30-year-old Hispanic woman in the second trimester of pregnancy receives a 100-g oral glucose challenge. She has elevated values of serum glucose at each of the 1-, 2-, and 3-h time points. Which of the following statements concerning this clinical situation is correct?

- (A) A trial of caloric restriction and minimal intake of concentrated sweets should be undertaken
- (B) The patient should be given subcutaneous insulin therapy
- (C) The patient should be treated with oral hypoglycemic agents
- (D) The patient should be treated with magnesium sulfate
- (E) The patient should receive insulin by continuous intravenous infusion

I-11. Which of the following strategies will best minimize the risk of mother-to-child transmission of HIV?

- (A) Induction of delivery as early as possible in pregnancy consistent with maintaining good fetal maturity
- (B) Cesarean section
- (C) Use of zidovudine
- (D) Elective cesarean section at term plus zidovudine
- (E) Zidovudine plus protease inhibitor therapy

I-12. Which of the following is the LEAST likely symptom of hyperthyroidism in a 77-year-old man?

- (A) Atrial fibrillation
- (B) Confusion
- (C) Tremor
- (D) Weakness
- (E) Syncope

I-13. An older spouse brings her 75-year-old husband to the primary care physician because he no longer has been working in his basement wood shop. He recently underwent radiation therapy for localized prostate cancer. The patient complains of a prolonged history of inability to fall asleep and arising early in the morning. He has not been eating well lately, and his energy level has really fallen off. He has not been doing his daily crossword; in fact, he is not interested in much of anything anymore. His general physical examination, including tests for cognitive function, is normal. Laboratory studies are also un-

I-13. (Continued)

helpful at establishing the diagnosis. Which of the following would be the most useful systemic therapy?

- (A) Haloperidol
- (B) Amitriptyline
- (C) Methylphenidate
- (D) L-Thyroxine
- (E) Electroconvulsive therapy

I-14. The most common cause of urinary incontinence in an older individual is

- (A) diuretics
- (B) stress incontinence
- (C) detrusor underactivity
- (D) detrusor overactivity
- (E) cognitive impairment

I-15. A 75-year-old widower who lives alone is brought to his primary care physician by his daughter because she feels that he has been confused over the past few days. Prior to this he was quite independent and cognitively intact. The patient has a history of hypertension and is on hydrochlorothiazide. He is due for bilateral cataract extraction in 2 months. Of note, he reports a fall in his living room about two weeks earlier, at which time he sustained a hip bruise and bumped his head.

At this time his general physical examination is unremarkable; his neurologic examination is normal except for the mental status component, which discloses defects in short-term memory. Which of the following diagnostic studies is most likely to explain this patient's condition?

- (A) Neuropsychiatric battery
- (B) CT scan of head
- (C) Electroencephalogram
- (D) Serum chemistry panel
- (E) Urinary screen for toxic substances

I-16. An 80-year-old woman with severe osteoarthritis is wheelchair-bound. She develops a pressure ulcer on her right buttock that involves the dermis; however, subcutaneous tissues and deeper structures do not appear to be involved.

In addition to efforts to increase mobility and to relieve pressure, the most appropriate therapy is

- (A) surgical debridement
- (B) dry dressings
- (C) wet dressings changed when dry

I-16. (Continued)

- (D) wet dressings changed when wet
- (E) topical antibiotics

I-17. A 15-year-old boy is concerned about his lack of pubic hair, deep voice, and muscle growth. On physical examination you confirm that his testicles have not enlarged and he lacks pubic hair. Which of the following statements about this situation is correct?

- (A) The patient will most likely progress through puberty without intervention
- (B) Testosterone should be administered
- (C) Growth hormone should be given
- (D) A hormonally active adrenal tumor is likely
- (E) Prednisone will result in an amelioration of the symptoms

I-18. Which of the following statements concerning primary disease prevention is correct?

- (A) Counseling a patient to stop smoking is unlikely to have a beneficial effect
- (B) Nicotine replacement therapy has not been shown to aid in smoking cessation
- (C) Bupropion therapy has not been shown to aid in smoking cessation
- (D) 50% of Americans are overweight
- (E) Patients should be advised to eat at least six servings of fruits and/or vegetables daily

I-19. Which of the following is a recommendation of the U.S. Preventive Services Task Force?

- (A) Annual mammography beginning at age 40
- (B) Colonoscopy every 5 years beginning at age 50
- (C) Total blood cholesterol measurement for all individuals at age 35
- (D) Annual vision screening beginning at age 50
- (E) Annual blood pressure measurement in all individuals

I-20. For which of the following herbal remedies is there the best evidence for efficacy in treating the symptoms of benign prostatic hypertrophy?

- (A) Saint-John's wort
- (B) Ginkgo
- (C) Kava
- (D) Saw palmetto
- (E) No herbal therapy is effective

I. PRACTICE OF MEDICINE

ANSWERS

- I-1. The answer is C.** (*Chap. 1*) As the complexity of medicine increases, the difficulty of choosing amongst various diagnostic and therapeutic approaches is a daunting challenge for even the most well-read physician. Professional organizations including general medical groups, subspecialty associations, and government agencies have been busily developing formal clinical practice guidelines to help physicians make sensible choices. Guidelines may well prevent patients from receiving substandard care whether or not they are in a fee-for-service, managed care, or indigent setting. Because practice guidelines cannot possibly take into account the uniqueness of each individual and every specific permutation that may occur in the clinical setting, in no way can or should they be followed to the letter. In generally all cases, the purpose of clinical guidelines is not to make physicians more subject to lawsuits but rather to standardize and improve care.
- I-2. The answer is E.** (*Chap. 1*) One of the most important facets of being a physician is the communication of bad news, particularly to a patient whose diagnosis represents great likelihood of premature death. There is no one guiding principle of how to tell patients bad news. However, it makes sense to be honest with the patient, tell as much information as the individual is capable of dealing with at any given time, and to disclose things gradually rather than abruptly. Hope should never be removed, yet ineffective therapies should not be inappropriately glorified. Most of all, the dying patient needs to be treated with respect and dignity. It is vital that the physician reassure the patient that compassionate care will be provided throughout the course of the patient's illness; a fear of abandonment is often a grave concern in these situations.
- I-3. The answer is A.** (*Chap. 2*) In general, patients who are conscious adults are considered legally competent to make decisions affecting their health care. Competent patients must be able to express their choice as well as appreciate the medical situation, the nature of the alternatives, and the risks, benefits, and consequences of each. In a situation where the decision not to have surgery could result in death and where surgery would be curative, the physician is obligated to at least consider that the patient may be suffering from a mental condition impairing her ability to make an informed decision. In a patient with severe anxiety neurosis, it is possible that she is suffering from a psychotic delusion about the risk of surgery. Therefore, it would make more sense to have a psychiatric consultant on such a difficult case. Psychiatrists are skilled at identifying treatable depression or psychosis. The court rarely needs to become involved in such cases.
- I-4. The answer is C.** (*Chap. 2*) In situations in which patients lack decision-making capability, family members are routinely asked to serve as surrogates. If the patient has given a formal advanced directive such as a living will or a health care proxy, decisions made by surrogates may be somewhat more straightforward. However, even in such cases, the most important guiding principle is to do what the patient would do in the circumstances if he or she were fully competent at the time. Such a guiding principle is based on knowing as much information as possible about the patient based on conversation with family members and other relevant parties who can respect the patient's values. Moreover, the physician must have a good grasp of the medical situation in order to provide maximum information to the family so that the patient's best interests can be protected. If there is a

dispute between what the physician or surrogate thinks is in the best interest of the patient, then consultation with a hospital ethics committee might be helpful. Courts should only be used as a last resort in the case of intractable disagreements.

- I-5. The answer is A.** (*Chap. 6*) There are distinct epidemiologic factors governing different illnesses experienced by men and women. Although women are more likely to be disabled and have more days of restricted activity than men at all ages (particularly due to obstetric and gynecologic conditions) and women make more visits to physicians, women live longer than men, with a survival advantage in all age groups. The longer life expectancy of women is due in large part to the difference in mortality caused by a slightly reduced incidence of ischemic heart disease in women. The leading causes of death among young women in the United States are accidents, homicide, and suicide. However, during the middle years, breast cancer is more common than heart disease or lung cancer. For those over age 65, heart disease, lung cancer, and cerebrovascular disease are more important causes of death than breast cancer. Despite heart disease being the greatest cause of death overall, most U.S. women believe that breast cancer poses the greatest threat to their lives.
- I-6. The answer is C.** (*Chap. 6*) In order for a woman's health to be maintained or improved, primary prevention and screening are very important. Certain critical preventive measures include measuring blood pressure at least every other year throughout life and counseling on diet, smoking cessation, exercise, and use of seat belts. Also recommended are counseling about safe sexual practices, alcohol abuse, and violence. Bone mineral testing as a means to screen for osteoporosis is becoming more widely accepted. A bone density test is recommended for all women over age 65 as well as those who have increased risk for developing osteoporosis, such as women who have undergone early menopause. Postmenopausal estrogen therapy may be associated with a reduction in the risk of death from cardiovascular disease, although this is yet not definitively proven. On the other hand, calcium, estrogen, the osteoclast inhibitor alendronate, and the estrogen receptor antagonists tamoxifen and raloxifene reduce the frequency of bone fracture and osteoporosis in postmenopausal women. Both tamoxifen and raloxifene have been shown to reduce the risk of breast cancer in postmenopausal women.
- I-7. The answer is B.** (*Chap. 6*) Women have a lower incidence of ischemic heart disease than men principally due to the protective effect of estrogen, which may be due to improvement in the lipid profile, a direct vasodilatory effect, or other factors. Nonetheless, postmenopausal women have a similar risk of coronary events to men of that age group; ischemic heart disease is the leading cause of mortality in older women. Ischemic heart disease presents differently in men than in women, who are likely to have angina; men tend to present with myocardial infarction as the initial symptom of coronary disease. Traditionally, women, particularly black women, tend to have a higher likelihood of complications after myocardial infarction. Moreover, women have a more difficult time with coronary bypass surgery with higher perioperative mortality, less relief, and less patent grafts. Percutaneous transluminal coronary angioplasty is also less successful in women than men. Finally, women reap less benefit and have a higher likelihood of serious bleeding complications secondary to antithrombotic therapy than do men. Estrogen replacement therapy actually decreases cardiovascular mortality in postmenopausal women and is the subject of ongoing research.
- I-8. The answer is B.** (*Chap. 7*) Although preeclampsia is associated with abnormalities of circulatory autoregulation, the precise factors causing this syndrome are unknown. Preeclampsia is defined by the new onset of hypertension, proteinuria, and pathologic edema in a pregnant woman. It occurs in 5 to 7% of all pregnant females. Risk factors for the development of preeclampsia include first pregnancy, diabetes, renal disease or hypertension, extremes of maternal age, obesity, factor V Leiden mutation, angiotensinogen gene T235, antiphospholipid antibody syndrome, and multiple gestation. The patient in the

question has severe preeclampsia, which may be manifested by central nervous system dysfunction (headaches, blurred vision, seizures, or coma), marked elevation of blood pressure, severe proteinuria (>5 g/24 h), renal failure, pulmonary edema, hepatic injury, thrombocytopenia, or disseminated intravascular coagulation. Since preeclampsia resolves within a few weeks after delivery, rapid delivery should be the most appropriate goal. For those women with severe preeclampsia, delivery should be accomplished after 32 weeks' gestation, which balances the risk to the mother and the fetus. In the meantime, the blood pressure should be controlled carefully without great swings, which would minimize blood flow to the fetus. Angiotensin-converting enzyme inhibitors as well as angiotensin-receptor blockers should be avoided in the second and third trimesters of pregnancy because of their potential adverse effects on fetal development. The drugs of choice are intravenous labetalol or hydralazine. Calcium channel blockers are a reasonable alternative. While magnesium sulfate is the treatment of choice for prevention of eclamptic seizures, this drug should probably only begin once the decision to proceed with delivery has been made.

- I-9. The answer is C.** (*Chap. 7*) Hypercoagulability is characteristic of pregnancy. In fact, pulmonary embolism is the most common cause of maternal demise in the United States. Probably the most important risk factor for venous thrombosis during pregnancy is carriage of the factor V Leiden allele. This mutation, whose gene product accounts for activated protein C resistance, also increases the risk of severe preeclampsia. If the fetus also carries this mutation, the risk of extensive placental infarction is also high. Other mutations associated with an increased risk of thrombosis during pregnancy include the prothrombin G20210A and the methylene tetrahydrofolate reductase C677T mutations. Almost all diagnostic and therapeutic procedures appropriate for the nonpregnant patient may be used in pregnancy, except for the use of warfarin anticoagulation throughout pregnancy. Warfarin is contraindicated in the first trimester, due to the development of fetal chondrodysplasia punctata, and in the second and third trimesters, due to the occurrence of fetal optic atrophy and mental retardation. However, both bolus and continuous heparinization are useful in the management of venous thromboembolism. Warfarin therapy may be given in the postpartum period since it is not contraindicated in breast-feeding women. Although some concerns about low-molecular-weight heparin use with regard to fetal epidural hematoma have been raised, in general these drugs do not cross the placenta and may be substituted for unfractionated heparin in the pregnant woman.
- I-10. The answer is A.** (*Chap. 7*) Unless a person is a member of a low-risk group, screening for gestational diabetes should be carried out in all pregnant women. Low-risk patients for gestational diabetes include those <25 years of age, with a body mass index <25 kg/m², no maternal history of macrosomia or gestational diabetes, no diabetes in a first-degree relative, and not members of a high-risk ethnic group (African-American, Hispanic, or native American). If a patient has an elevated 1-h glucose level after taking 50 g of oral glucose, then a 100-g challenge should follow. If elevated values of serum glucose are noted at either the 1-, 2-, or 3-h time point, measures to control the gestational diabetes should be undertaken. Those with gestational diabetes are at an increased risk of preeclampsia, delivering infants who are large for the gestational age, and birth lacerations. Dietary measures are usually sufficient to control most patients with mild gestational diabetes. However, those who cannot maintain fasting serum glucose concentrations <5.8 mmol/L (<105 mg/dL) or 2-h postprandial glucose concentrations <6.7 mmol/L (<120 mg/dL) should be treated with insulin. Oral hypoglycemic agents are contraindicated in the treatment of gestational diabetes. Importantly, those women in whom the diagnosis of gestational diabetes is made should be followed in the postpartum period for the development of type 2 diabetes, which is common in such patients.
- I-11. The answer is D.** (*Chap. 7. International Perinatal HIV Group, N Engl J Med 325: 1371, 1999.*) Fortunately, recent studies have shown zidovudine treatment of both the mother during the prenatal and intrapartum periods and of the neonate at birth can reduce the risk of vertical transmission to 7.3%. When such therapy is combined with elective

cesarean section, the risk of vertical transmission drops to 2%. The benefit of multiple drug therapy has not yet been established. Risk factors for transmission of HIV infection in the perinatal period include vaginal delivery, preterm delivery, trauma to the fetal skin, and maternal bleeding.

- I-12. The answer is C.** (*Chap. 9*) One of the most important principles of caring for the older patient is the recognition that diseases present in an atypical fashion. For example, hyperthyroidism in a young or middle-aged individual usually manifests as tremor, goiter, or exophthalmos. Instead, this endocrinopathy in an older person is more likely to cause one of the “final common pathway” symptoms such as weakness, fatigue, syncope, confusion, or depression. Atrial fibrillation is also a more typical presentation of hyperthyroidism in this age cohort than any of the classic symptoms or findings. The differential diagnosis of a limited number of presenting symptoms in the elderly is both broad and similar amongst several syndromes: incontinence, falling, syncope, and confusion. Moreover, due to decreased physiologic reserve in the elderly, patients often present at an earlier stage of the disease.
- I-13. The answer is C.** (*Chap. 9*) Significant depression occurs in up to 10% of older adults and is easily overlooked. The diagnosis requires symptoms to persist for a least 2 weeks and for a patient to exhibit at least four of the following: sleep disturbance, lack of interest, feelings of guilt, decreased energy, decreased concentration, decreased appetite, psychomotor agitation/retardation, and suicidal ideation. Methylphenidate in the morning and at noon can often be associated with a rapid response with a cost of few side effects. Sertaline and desipramine are effective for those with primarily psychomotor retardation, whereas nortriptyline or nefazodone are more useful for those who display agitation. Amitriptyline should be avoided due to the problems of anticholinergic and orthostatic side effects. Electroconvulsive therapy is only indicated if a reasonable attempt at drug therapy fails.
- I-14. The answer is D.** (*Chap. 9. Burgio et al, JAMA 280: 1995, 1998.*) Incontinence is a very common symptom in older adults; one needs to consider many nonbladder causes such as delirium, infection, atrophic urethritis/vaginitis, psychologic, excess urine output (diuretics, alcohol, hyperglycemia), restricted mobility, and stool impaction. Stress incontinence is rare in men but is the second most common cause of incontinence in women and is optimally treated with surgery. Urethral obstruction is the second most common cause of incontinence in men, often due to prostatic enlargement. Detrusor underactivity, associated with urinary frequency, nocturia, and frequent leakage of small amounts of urine, is due to a poorly contractile bladder and is the least common cause of incontinence. Involuntary bladder contraction (detrusor overactivity) accounts for two-thirds of geriatric incontinence and is treated primarily by biofeedback and behavioral modification. Drug therapy involves the use of such drugs as oxybutin, dicyclomine, or tolterodine.
- I-15. The answer is B.** (*Chap. 9*) Falls are a common problem in the elderly, occurring in about 30% of community-dwelling individuals annually. The cause of a fall is usually multifactorial and may be due to (1) reduced visual acuity; (2) reduced hearing; (3) proprioceptive dysfunction; (4) dementia; (5) foot and other musculoskeletal disorders; (6) postural hypotension, or (7) use of medicines such as sedatives, antidepressants, and anti-convulsants. The most common complication of falls in the elderly is fracture, hip fractures being particularly ominous; dehydration, electrolyte imbalance, pressure sores, hypothermia, and rhabdomyolysis may also occur. One insidious late complication is subdural hematoma, which may present with a new neurologic sign, such as confusion, even in the absence of headache and focal findings. A CT or magnetic resonance image of the brain is the best way to make the diagnosis of subdural hematoma, which may require surgery for optimal management.
- I-16. The answer is D.** (*Chap. 9*) One of the main problems of immobility in the elderly is the development of pressure ulcers. Obviously, the optimal approach is prevention through the avoidance of bedrest, or at least maximal efforts at frequent change of position and

close inspection at areas of pressure points. The therapy of an ulcer is based on its stage: (1) nonblanchable erythema of intact skin, (2) ulcer of epidermis and/or dermis, (3) involvement of subcutaneous tissues, or (4) extending to deeper tissues such as muscle or bone. Stage 3 or 4 lesions often require surgical debridement. For stage 1 sores, adequate nutrition and good hygiene may be sufficient. In grade 2 through 4 lesions, the wound must be kept clean and moist, generally with the use of wet saline dressings, which should be changed when still wet. Bacterial colonization of ulcers is ubiquitous, but topical antibiotics should be considered only for ulcers that have not healed after 2 weeks of conservative therapy. Associated cellulitis or osteomyelitis, if it occurs, would require systemic antibiotics.

- I-17. The answer is A.** (*Chap. 8*) About 3% of males fail to reach puberty (enlargement of testes with testosterone production, deepening of the voice, growth of facial and pubic hair) by age 15. The vast majority of these individuals with delayed puberty (due to functional hypothalamic-pituitary-gonadal delay) will progress through puberty normally, so reassurance should be the primary treatment. Occasionally, mainly for psychosocial reasons, a trial of androgen, perhaps low-dose oral oxandrolone, is reasonable. Hormonally active tumors may be associated with premature, rather than delayed, puberty. There are rare causes of pubertal delay based on congenital defects in the hypothalamic-pituitary axis, such as Kallmann syndrome, or due to gonadal problems, such as orchitis or bilateral undescended testes.
- I-18. The answer is E.** (*Chap. 10. Hughes et al, JAMA 281: 72, 1999.*) Primary prevention involves counseling patients to reduce behaviors or situations that predispose to illness. Smoking cessation (which definitely can be aided by discussions with the physician) is the most important issue, given the health havoc wreaked by tobacco products. Smoking cessation groups, nicotine replacement, and bupropion therapy have each been shown to improve the success rate. Americans need to decrease their caloric intake (30 to 40% are overweight), especially when the calories come in the form of saturated fat. In order to take in adequate vitamins and minerals without having to resort to dietary supplements, a balanced diet including at least six servings of fruit and/or vegetables each day is recommended.
- I-19. The answer is E.** (*Chap. 10*) In order for a screening test to receive sanctioning as a valid procedure, certain basic criteria need to be met: (1) the disease must be a significant enough public health issue to warrant a screening program; (2) the test itself must be feasible, not too costly, and not be associated with an unacceptably high rate of false-positive or negative results; and (3) the disease must be sufficiently treatable at an early stage so that intervention (during a latency period of goodly length) will improve the outcome. Actually, very few tests in practice have measured up to these stringent criteria, chiefly due to lack of prospective data. Nonetheless, the U.S. Preventive Service Task Force has endeavored to recommend a reasonable battery of screening studies or procedures: annual blood pressure/height and weight/Pap smear; fecal occult blood testing and/or sigmoidoscopy for those >49 years; mammography for women between 50 and 70; total blood cholesterol (men aged 35 to 64; women aged 45 to 64); and a check for vision and hearing impairment for those ≥ 65 years.
- I-20. The answer is D.** (*Chap. 11. Wilt et al, JAMA 280: 604, 1998.*) Since plant products are in widespread use in the well-accepted therapeutic armamentarium of western medicine (e.g., digoxin, taxol, penicillin), it should not be surprising that several "herbal remedies" have been demonstrated via prospective clinical trials to be beneficial. For example, Saint-John's-wort is more effective than placebo for mild to moderate depression; the mechanism is not known, although the metabolism of several neurotransmitters is inhibited by this substance. Kava products have anti-anxiolytic activity. Extracts of the fruit of the saw palmetto, *Serona repens*, have been shown to decrease nocturia and improve peak urinary flow compared with placebo in men with benign prostatic hypertrophy. Saw palmetto extracts impact the metabolism of androgens, including the inhibition of dihydrotestosterone binding to androgen receptors.

II. GENETICS AND DISEASE

QUESTIONS

DIRECTIONS: Each question below contains five suggested responses. Choose the **one best** response to each question.

II-1. In spermatogenesis, at which stage do the sex chromosomes segregate?

- (A) Meiosis II, primary spermatocyte
- (B) Meiosis I, primary spermatocyte
- (C) Meiosis II, secondary spermatocyte
- (D) Meiosis I, secondary spermatocyte
- (E) Meiosis II, spermatid

II-2. In contrast to spermatogenesis, oogenesis is largely completed prior to birth. The ova develop from oogonia, which are cells derived from the ovarian cortical tissue. By the third month of gestation, the primary oocyte begins to develop. At which stage of cell division are the oocytes suspended prior to ovulation?

- (A) First metaphase
- (B) Second metaphase
- (C) First prophase
- (D) Second prophase
- (E) Second telophase

II-3. A neonate is found to have an enzymatic deficiency in the conversion of pyruvate to pyruvate phosphate. The wild-type sequence includes the following:

Lys -Arg -His -His -Tyr -Leu
AAG-AAG-CAC-CAC-UAC-CUC

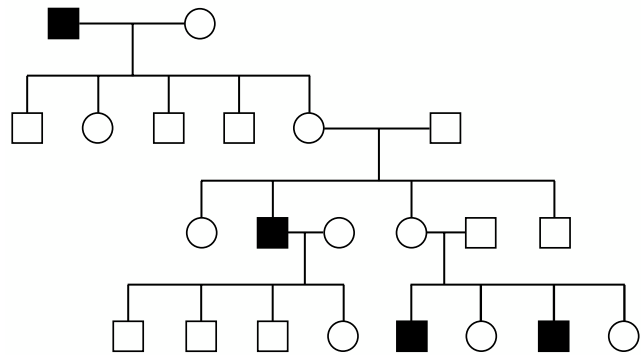
The sequence of the mutated enzyme is

Lys -Glu -Ala -Pro -Leu -Pro
AAG-GAA-GCA-CCA-CUA-CCU

What kind of mutation is illustrated by the above amino acid sequence?

- (A) Point mutation
- (B) Frame shift mutation resulting in a nucleotide deletion
- (C) Chain termination mutation
- (D) Frame shift mutation resulting in the addition of a nucleotide
- (E) Splice mutation

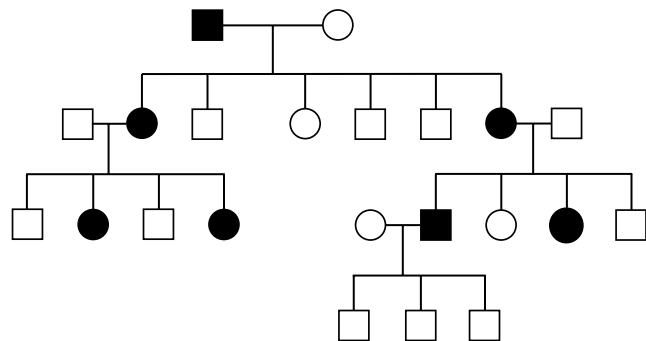
II-4. The following pedigree is an example of what pattern of inheritance?



Solid figure = Affected individual
Open figure = Unaffected individuals

- (A) X-linked recessive inheritance
- (B) X-linked dominant inheritance
- (C) Autosomal recessive inheritance
- (D) Autosomal dominant inheritance
- (E) The inheritance pattern cannot be determined by the limited information provided in the above pedigree

II-5. The pedigree described below is an example of what pattern of inheritance?



Solid figure = Affected individuals
Open figure = Unaffected individuals

II-5. (Continued)

- (A) X-linked recessive inheritance
- (B) X-linked dominant inheritance
- (C) Autosomal recessive inheritance
- (D) Autosomal dominant inheritance
- (E) The inheritance pattern cannot be determined by the above pedigree

II-6. Bob arrives in your office for genetic counseling. Bob's brother Tom died at a young age from Tay-Sachs disease. Both he and his sister Sarah are unaffected. Bob's son Adam and Sarah's daughter Jennifer have recently married and are expecting their first child. What is the chance that the child would have Tay-Sachs disease?

- (A) 1/4
- (B) 1/9
- (C) 1/12
- (D) 1/36
- (E) 1/44

II-7. How many α genes are deleted in hemoglobin H disease?

- (A) 0
- (B) 1
- (C) 2
- (D) 3
- (E) 4

II-8. You are called to see a 23-year-old woman who is suffering from a moderately severe postpartum hemorrhage. She has no other significant medical conditions. On physical examination there is no evidence of any other significant bleeding diatheses. There are no petechial lesions or ecchymoses noted, and there is no bleeding within the oral pharynx. Her past medical history includes a wisdom tooth extraction that was complicated by a severe hemorrhage. In addition, she has had a prior hemarthrosis of her right knee after moderate trauma. Both of her parents are alive and well and neither has a significant bleeding history. Her father had a recent uncomplicated inguinal hernia repair, and her mother had a recent uncomplicated breast biopsy for a benign lesion. Her menses are of normal frequency and duration, but she does complain of heavy menstrual bleeding. All laboratory data are pending. Her brother is 18 years old and has had multiple spontaneous hemarthroses without evidence of trauma. He has also had an episode of a spontaneous psoas hematoma. What is the most likely explanation for this patient's bleeding disorder?

- (A) von Willebrand's disease
- (B) Factor XI deficiency
- (C) Glanzmann's thrombasthenia
- (D) Hemophilia A
- (E) Dysfibrinogenemia

II-9. A 16-year-old adolescent is seen in your clinic. On physical examination you note that he has small testes for his stated age and has poorly developed secondary sexual characteristics. In addition, on physical examination there is notable gynecomastia. He is rather tall, with abnormally long upper and lower limbs. A buccal smear is obtained and examined microscopically. How many chromatin-positive inclusion bodies are seen?

- (A) 0
- (B) 1
- (C) 2
- (D) 3
- (E) 4

II-10. A 3-month-old child arrives in your clinic who has profound hypotonia. On physical examination, in addition to the hypotonia, he is noted to have a brachycephalic head with a flat occiput and a low bridge nasal structure. The hands are short and broad, and a single crease is noted on the fifth finger. The feet show a characteristic wide gap between the first and second toes and the furrow is extending along the proximal plantar surface. A full karyotype is performed and shows an abnormality. However, the total number of chromosomes is normal at 46. What is the most likely explanation for this child's clinical syndrome?

- (A) Fragile X syndrome
- (B) Down's syndrome
- (C) Prader-Willi syndrome
- (D) Cri-du-chat syndrome
- (E) Isochromosome X

II-11. Which of the following is an example of a balanced karyotype?

- (A) 46, X, i(Xq)
- (B) 46, X, X, -14, +t(14;21) (p11;q11)
- (C) 46X, Y, -5, +der5 (5;11) (q21;q21) mat
- (D) 46, X, Y, +t(9;22) (q34;q11.2)
- (E) 46, X, -X, +t(X;21) (p21;p12)

II-12. Sickle cell disease is a result of a homozygous hemoglobin S (hemoglobin SS). States of decreased oxygen tension cause red blood cell sickling, which leads to occlusion of small vessels and results in "sickle crisis." Patients typically present at birth but usually live into early adulthood. Despite the severe manifestations of this disease, the heterozygous frequency in West Africa is approximately 20%. Which of the following explanations best describes the reason for the maintenance of the hemoglobin S polymorphic phenotype in West Africa?

- (A) Recurrent mutations of β^A to β^S
- (B) A selection advantage of both homozygous and heterozygous states

II-12. (Continued)

- (C) A selection advantage of the heterozygous state over both homozygous states
- (D) A selection advantage of β^A/β^S over β^S/β^S
- (E) A selection advantage of β^A/β^S over β^A/β^A

II-13. A patient has blood type AB. She has a sister with blood type O, the father has blood type A, and the mother, blood type O. The maternal grandparents were first-degree cousins. What is the most likely explanation for this patient's blood type?

- (A) There is a question of paternity
- (B) An error was made in the typing of the patient's blood type
- (C) The patient's mother's serum contains anti-A, anti-B, and anti-H antibodies
- (D) An error in the typing occurred in the mother's blood type
- (E) A new mutation in the patient occurred, giving rise to the AB blood phenotype

II-14. A male child presents to your clinic with a history of multiple pulmonary infections. The child's birth was complicated by meconium ileus. The child has had a recurrent cough with thick, difficult-to-mobilize, viscous sputum. There have been multiple episodes of recurrent pulmonary infections and abnormal chest x-rays. The child is also thin for his stated age and seems to be failing to thrive. Which of the following statements is correct concerning the mode of inheritance of this patient's disease?

- (A) Most patients will have an affected parent
- (B) Males are more commonly affected than females
- (C) The recurrent risk is 1 in 4 for each subsequent sibling
- (D) The trait is never transmitted directly from father to son
- (E) The disorder is a result of a new spontaneous mutation

II-15. A 45-year-old man comes to your office with a history of stage I colon cancer. The patient's father was diagnosed at age 49 with colon cancer, and his brother (the patient's uncle) also had colon cancer diagnosed at age 47. The patient's grandmother had endometrial cancer diagnosed at age 51. This patient most likely has a defect in which of the following genes?

- (A) p53
- (B) APC
- (C) MSH-2 gene affecting DNA mismatched repair
- (D) Retinoblastoma gene (Rb)
- (E) A reciprocal translocation involving chromosomes 8 and 14, t(8;14)

II-16. The Prader-Willi syndrome (PWS) is a rare syndrome of progressive obesity, hypotonia, and mental retardation. On physical examination, children with PWS also have small hands and feet and male children also have cryptorchidism. Which of the following statements concerning the mode of inheritance of PWS is true?

- (A) PWS is inherited as an X-linked recessive disorder
- (B) PWS is inherited as an X-linked dominant disorder
- (C) PWS is a result of a gene duplication
- (D) PWS is caused by maternal uniparental disomy
- (E) PWS is inherited as an autosomal dominant disorder

II-17. A specific gene B has two distinct mutant alleles, B_1 and B_2 . Both mutant alleles cause a specific genetic disorder when homozygous. If B_1B_1 patients occur at a frequency of 1/40,000 and B_2B_2 patients occur with a frequency of 1/90,000, what is the frequency of the heterozygous state?

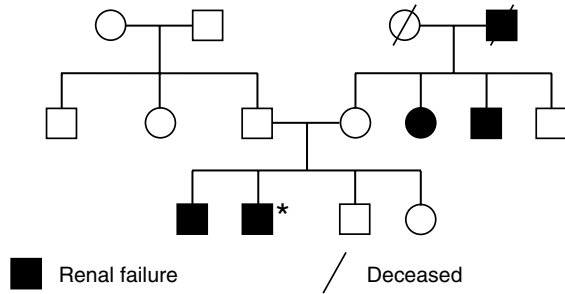
- (A) 1/600
- (B) 1/300
- (C) 1/200
- (D) 1/60,000
- (E) 1/30,000

II-18. A 35-year-old woman comes to your clinic for a consultation. She is 17 weeks pregnant with her second child. She is G2 P1. Her prior pregnancy was complicated by neonatal alloimmune thrombocytopenia (NATP). Analysis of the patient's serum reveals circulating anti- PI^{A1} antibodies. Which of the following statements concerning NATP is true?

- (A) If the gene frequency of PI^{A2} is 0.02, then the likelihood of her second child having NATP is low
- (B) Given the gene frequency of PI^{A2} of 0.02, then the likelihood of her second child having NATP approaches 100%
- (C) The incidence of NATP is approximately 1/20,000 neonates
- (D) NATP is unrelated to the circulating anti- PI^{A1} antibodies because IgG antibodies do not cross the placental barrier
- (E) NATP is unrelated to the entity referred to as post-transfusion purpura

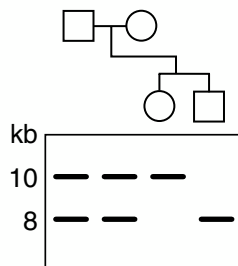
II-19. A 42-year-old man (indicated by the star in the family history below) has renal failure as a result of Alport's syndrome, which consists of nephritis associated with sensorineural deafness and is inherited as an autosomal dominant defect. He is being evaluated for a renal transplant from a living related donor. The best candidate for evaluation as a potential kidney donor for this man would be his

II-19. (Continued)



- (A) mother
 (B) father
 (C) unaffected brother
 (D) sister

II-20. Peripheral blood cells are obtained from the members of a family; the DNA is extracted, treated with restriction endonuclease E run on an agarose gel, transferred to nitrocellulose paper, probed with a 4-kilobase (kb) radiolabeled segment of DNA, and exposed to x-ray film. In the following pattern, solid blocks indicate segments of DNA hybridizing to the probe and numbers indicate DNA length in kilobases. What most likely accounts for the fact that only one band appears in the son and only one (different) band appears in the daughter?



- (A) A gene deletion in each child
 (B) Chromosome segregation in the offspring
 (C) Linkage disequilibrium in the offspring
 (D) Parents who are heterozygotes for restriction fragment length polymorphism
 (E) Loss of the restriction site for endonuclease E in both the children

II-21. Match the following statement with the disease it most aptly describes: A disease in which an affected person will bear, on average, both normal and affected offspring in equal proportion, with children of either sex equally likely to be affected, characterized by a delayed age of onset, and in which patients are >90% likely to have inherited an abnormal gene from a parent.

- (A) Manic-depressive psychosis
 (B) Myasthenia gravis
 (C) Hemophilia A

II-21. (Continued)

- (D) Neurofibromatosis
 (E) Huntington's chorea

II-22. Diseases inherited in a multifactorial genetic fashion (i.e., not autosomal dominant, autosomal recessive, or X-linked) and seen more frequently in persons bearing certain histocompatibility antigens include

- (A) gluten-sensitive enteropathy
 (B) neurofibromatosis
 (C) adult polycystic kidney disease
 (D) Wilson's disease
 (E) cystic fibrosis

II-23. Which of the following statements concerning patients who have Klinefelter syndrome is correct?

- (A) They are 20 times as likely as normal men to develop breast cancer.
 (B) They have normal serum testosterone and testes of average size.
 (C) They have an increased incidence of hypospadias.
 (D) The diagnosis can usually be made after birth.
 (E) Social maladjustment and mental deficiency is a rare finding in patients with Klinefelter syndrome.

II-24. Which of the following statements concerning the ataxia-telangiectasia syndrome is correct?

- (A) It is inherited as an autosomal dominant disorder.
 (B) The cause is adenosine deaminase deficiency.
 (C) Malignancy is a common cause of death.
 (D) Both the immunodeficiency and the chromosomal instability are seen primarily in homozygotes.
 (E) Humoral and not cellular immunity seems to be primarily affected.

II-25. Which of the following statements concerning Marfan syndrome is true?

- (A) Marfan syndrome is an example of genetic heterogeneity.
 (B) All patients should have a slit-lamp examination.
 (C) The skin examination is usually unremarkable.
 (D) Most patients have a mutation in the gene coding for elastase.
 (E) This disorder is generally inherited as an autosomal recessive disorder.

II-26. Which of the following is true in Alport syndrome?

- (A) The presence of hematuria is typically benign.
 (B) The disorder is generally inherited as an autosomal recessive disorder.
 (C) Most patients have mutations in a gene coding for collagen.
 (D) Blue sclerae are a common finding.
 (E) The syndrome is characterized by the presence of profound sensorineural deafness.

II. GENETICS AND DISEASE

ANSWERS

- II-1. The answer is B.** (*Chaps. 65, 66*) Spermatogenesis occurs in the seminiferous tubules of the testes of the male from the time of sexual maturity onward throughout adulthood. Spermatogonia are found at the periphery of the tubules. These spermatogonia are of several cell types, ranging from a self-renewing stem cell to a more specialized cell that is committed to sperm formation. The last stage of the developmental sequence is the primary spermatocyte. This cell undergoes meiosis I: the primary spermatocyte divides to form two secondary spermatocytes, each with 23 chromosomes. These cells rapidly undergo meiosis II, forming two spermatids. The spermatids mature without further division into spermatozoa and are released into the lumen of the tubule. The total time involved for all stages of spermatogenesis from the beginning of meiosis I to the formation of a mature sperm is approximately 64 days, and as many as 200 million sperm are produced per ejaculate.
- II-2. The answer is C.** (*Chaps. 65, 66*) Oogenesis is largely completed prior to birth. The ova develop from oogonia, which are cells derived from the cortical tissue of the ovary. By approximately the third month of prenatal development the oogonia have begun to develop into primary oocytes. The primary oocytes have already entered their first meiotic prophase. This process is not synchronized, however, and both early and late stages coexist within the fetal ovary. Primary oocytes remain in suspended prophase until sexual maturity is reached. As each individual follicle begins to mature, the meiotic division of the primary oocyte resumes. Meiosis I is completed about the time of ovulation. This may be >40 years from the beginning of the initial cell division. When the primary oocyte completes meiosis I, each daughter cell receives 23 chromosomes; one receives most of the cytoplasm and becomes the secondary oocyte, the other becomes a polar body. The second meiotic division commences almost immediately and proceeds as the ovum passes into and down the uterine tube. The second meiotic division usually takes place before the ovum reaches the uterus within the fallopian tube. The second meiotic division produces a mature ovum with virtually all the cytoplasm from the original primary oocyte, and a second polar body is formed.
- II-3. The answer is D.** (*Chap. 65*) Single base mutations change the DNA sequence, alter the code of the triplet base, and cause the replacement of one amino acid by another in the gene product. Since the code is degenerate, not all base substitutions will actually lead to an amino acid sequence alteration. Deletion or insertion of a base alters the whole reading frame. In the example listed, the addition of a single nucleotide alters the reading frame from that point onward. Chain termination mutations result in the presence of a stop codon, therefore causing a premature cessation of protein translation. Splice mutations are common and tend to affect the normal mechanism by which introns are excised and exons spliced together. Such changes typically lead to complete failure of synthesis of the gene product. Other mutations may affect the regulatory sequences and hence the transcription of the entire gene product.
- II-4. The answer is A.** (*Chap. 65*) The information provided in the pedigree is adequate to determine the mode of a single-gene inheritance pattern. The example provided is typical of patients with hemophilia A or with Duchenne muscular dystrophy. Other examples

exist. X-linked recessive inheritance is marked by having the incidence of the trait much higher in males than in females. The genetic trait is passed from an affected male through all of his daughters to, on average, half of their sons. The trait is never transmitted directly from father to son. The trait may be transmitted through a series of carrier females; if so, the affected males are related to each other through the female, as is presented in this case.

- II-5. The answer is B.** (*Chap. 65*) The information provided in the pedigree is adequate to determine the mode of a single-gene inheritance pattern. The example given is characteristic of an X-linked dominant single-gene inheritance, as is common in the X-linked blood group system, Xg. The Xg system is governed by a pair of alleles, Xg^a and Xg. These alleles produce only two phenotypes, Xg (A+) and Xg (A−), respectively. Another example of X-linked dominant inheritance pattern is vitamin D-resistant rickets. The X-linked dominant inheritance pattern is characterized by having affected females exist in the heterozygote state. Affected females are twice as common as affected males, and the affected males are hemizygotes. In vitamin D-resistant rickets, both sexes are affected. However, the serum phosphate level is less depressed; hence, the rickets is less severe in the heterozygous female than in the hemizygous male.
- II-6. The answer is D.** (*Chaps. 65, 68*) In Ashkenazi Jews in North America, the gene for Tay-Sachs disease is very common. Tay-Sachs disease is a neurologic degenerative disorder that typically develops at approximately 6 months of age. Affected children become progressively blind and regress mentally as well as physically. The disease is usually fatal in early childhood. The cause of the disease results in the mutation of a specific lysosomal enzyme, hexosaminidase A (hex A). In classic Mendelian genetics the unaffected siblings, Bob and Sarah, each have a 2/3 chance of being a carrier for the Tay-Sachs disease and hence a 50% chance of passing on the carrier state. Therefore, both Adam and Jennifer have a 1/3 chance of being a carrier. If both Adam and Jennifer are carriers, there is a 1/4 chance that a child would be affected with the Tay-Sachs disease. Therefore, the cumulative probability is $1/3 \times 1/3 \times 1/4$, which equals 1/36.
- II-7. The answer is D.** (*Chap. 65*) α Thalassemia is a result of deletions of the α genes. Other mechanisms are sometimes involved. For example, the variant hemoglobin Constant Spring results in a chain termination mutation that allows for the synthesis of an elongated α -globin gene, which leads to α thalassemia. Chromosome 16 carries two identical tandem α genes; therefore there are four α genes per individual deployed genotype. Each gene results in the synthesis of 25% of the total α -globin synthesis. The deletion of one α gene results in 75% of total α -globin gene production, and patients are typically silent carriers with no obvious hematologic abnormalities. α -Thalassemia trait is caused by the loss of two α -globin genes, resulting in the synthesis of 50% of the total α -globin synthesis. The loss of two α genes can occur by deletions either in *cis* (both α_1 - and α_2 -globin genes are deleted on the same chromosome) [$\alpha\alpha$ /−−] or in *trans* (both α_1 genes are deleted on different chromosomes) [− α /− α]. The α -thalassemia genotype in blacks is typically of the *trans* type, while that of the Southeast Asians is of the *cis* type. Regardless, patients typically have mild microcytosis and a mild anemia. The deletion of three α -globin genes results in hemoglobin H disease. Hemoglobin H is the tetrameric β_4 . Hemoglobin H precipitates within the erythrocytes, causing a moderately severe hemolytic anemia. The total α -globin gene synthesis is only 25% of normal. The homozygous deletion of all four α -globin genes results in hydrops fetalis with hemoglobin Bart's and is almost always restricted to Southeast Asians. In these patients there is no detectable α -globin gene synthesis.
- II-8. The answer is D.** (*Chap. 65*) Hemophilia A is an X-linked recessive inherited disorder. Women who carry the trait are obligate heterozygotes. Females undergo lyonization in which only one X chromosome is active. The second X chromosome is condensed and inactive and appears in interphase cells as the sex chromatin. The X inactivation occurs early in embryonic life. The inactive X chromosome can be either the paternal or maternal

X chromosome. The X inactivation is a random process and clinically can lead to a variable expression of X-linked disorders such as hemophilia A. The variability can lead to a phenotype that is either entirely normal or to full expression of the defect. When the deleterious gene is represented in a majority of the cells, it is regarded as an extreme example of “unfavorable lyonization.” Examples of this include hemophilia A, color blindness, hemophilia B (Christmas disease), and Duchenne muscular dystrophy. Therefore, women are considered to be mosaics with respect to the X chromosome. The clinical phenotype of hemophilia A is expressed when the level of factor VIII is <30% normal. Severe hemophilia A is present when <1% of normal activity of factor VIII is present. Moderate hemophilia A occurs in about 10% of patients, and factor VIII levels range between 2 and 5% of normal. Mild hemophilia A occurs when patients have approximately 20 to 30% of factor VIII activity. In these patients, bleeding generally occurs only after significant trauma or surgery, as is the case of this patient.

- II-9. The answer is B.** (*Chap. 66*) In somatic cells only one X chromosome is active; all other X chromosomes are inactivated. Chromosome inactivation typically begins by methylation of the DNA leading to downregulation of gene transcription. The inactivation of the X chromosome causes chromosome condensation and produces a Barr body. The clinical characteristics of the patient described are consistent with classic Klinefelter’s syndrome, and the karyotype is 47,XXY. Therefore one X chromosome will be inactivated and will be seen on a buccal smear as a Barr body. The normal male has a karyotype 46,XY and there is no Barr body seen; a normal female is 46,XX and again has one Barr body.
- II-10. The answer is B.** (*Chaps. 65, 66, 68*) The clinical characteristics of this child are consistent with Down’s syndrome; however, the child has a normal number of chromosomes. Infrequently a child with a Robertsonian translocation can develop a Down’s syndrome phenotype. For example, a Robertsonian translocation between the long arms of chromosomes 14 and 21 results in a t(14q;21q). In this example, the child has 46 chromosomes; however, the karyotype is effectively trisomic for chromosome 21. The phenotypic consequences of this are indistinguishable from those of the standard 47,XX or 47,XY, +21, which is the standard trisomic 21 genotype. A Robertsonian translocation involves two acrocentric chromosomes, which fuse at the centromere region and lose their short arms. A carrier of a balanced Robertsonian translocation has 45 chromosomes, including the translocation chromosome. The fragile X chromosome is an X-linked mental retardation disorder that typically affects male children, with an incidence as high as 1 in 1000 male births. The clinical characteristics of the fragile X syndrome include large testes, especially after puberty, protuberant ears, and a prominent chin. The children are typically mildly retarded, and speech development is disproportionately delayed. The Prader-Willi syndrome is characterized by diminished fetal activity, obesity, hypotonia, mental retardation, short stature, and hypogonadotropic hypogonadism. This is caused by a microdeletion involving the paternal chromosome 15 and is an example of imprinting. Cri-du-chat syndrome arises from a deletion of part of the short arm of chromosome 5 (5p–). These children have a characteristic cry, which sounds like the mewing of a cat. The facial appearance is also distinctive with hypertelorism, low-set ears, and micrognathia. The most common type of isochromosome X involves the long arm of the X chromosome and is designated i(Xq). Patients with a normal X chromosome and an iso(Xq) are monosomic for genes on the short arm of the X chromosome but trisomic for genes on the long arm. About 20% of women with Turner syndrome have this characteristic karyotype.
- II-11. The answer is E.** (*Chap. 66*) The karyotype listed in E is a result of a balanced translocation and has equal gene copies of all 46 chromosomes. Balanced translocations typically do not lead to an abnormal phenotype; however, translocations can lead to the formation of unbalanced gametes and therefore carry a high risk of abnormal offspring.
- II-12. The answer is C.** (*Chap. 65*) Sickle cell disease arises from a single substitution in the second position of the triplet coding for glutamic acid and alters this to the code for

valine. The carrier state in West Africa is approximately 20%, and it is generally agreed that the sickle cell mutation is a balanced polymorphism in areas with endemic malaria caused by *Plasmodium falciparum*. Deoxygenated erythrocytes with the sickle cell trait containing *P. falciparum* are more likely to undergo sickling than unparasitized cells. Hence this process probably accelerates removal of these cells from the circulation and therefore protects the individual from a malarial infestation. Therefore, patients who carry the sickle cell trait (β^A/β^S) are at a distinct survival advantage over both homozygous states, including patients with the β^A/β^A phenotype.

- II-13. The answer is C.** (*Chaps. 65, 114*) The H antigen is a substrate from which the A and B antigens are made. The A and B genes act on the H antigen, converting it to either the A or B antigen. The O gene is thought to be silent. Therefore, type O cells carry an unaltered H antigen. Anti-H antibodies are found in the serum of patients whose red blood cells lack the H antigen. These patients have an O_h phenotype. This was first identified in Indians living in Bombay and has been referred to as the *Bombay phenotype*. In this clinical situation there was a consanguineous marriage between the patient's grandparents. The mother has the O_h phenotype and therefore was unable to express the B phenotype despite the fact that she likely carries the B gene, which was then passed on to the patient.
- II-14. The answer is C.** (*Chaps. 65, 68*) The patient's clinical syndrome is consistent with cystic fibrosis inherited as an autosomal recessive disorder. Characteristically the trait appears only in siblings and not in their parents, offspring, or other relatives. On average, one-fourth of the siblings are affected. In other words, the recurrence rate for each subsequent child is 1 in 4. The parents of the affected child may be consanguineous. Males and females are equally affected.
- II-15. The answer is C.** (*Chap. 65*) The patient has Lynch syndrome, which is characterized by familial colon cancer typically affecting patients before the age of 50. In addition, a family history of endometrial or ovarian cancer has also been recognized. HNPCC mutations are caused by several different mismatched repair genes, including MSH-2 and MLH-1. These enzymes are involved in the detection of nucleotide mismatches and in the recognition of slipped-strand trinucleotide repeats. Mutations of the p53 gene cause the Li-Fraumeni syndrome, which simply causes cancers involving the soft tissue or bone and, less frequently, leukemia, adrenal cortical carcinoma, or neuroblastoma. Patients are typically affected before age 30. The APC mutation causes familial polyposis syndrome and invariably leads to colon cancer before the age of 30 in affected individuals. Defects of the retinoblastoma gene cause retinoblastoma and, less frequently, osteosarcoma. The reciprocal translocation involving chromosomes 8 and 14 typically involves the *c-myc* that causes Burkitt's lymphoma.
- II-16. The answer is D.** (*Chaps. 65, 66*) Microdeletions involving chromosome 15 can lead to the Prader-Willi syndrome or to Angelman's syndrome. Therefore, this pattern of inheritance is consistent with imprinting. In PWS, for example, nondeletion patients invariably have two maternal copies of chromosome 15 but no paternal copy. This is referred to as maternal uniparental disomy. For some nondeletion Angelman syndrome patients, however, the reverse is true. Patients have two paternal copies but no maternal copy of chromosome 15, referred to as *paternal uniparental disomy*. This indicates that at least some genes on chromosome 15 are differentially expressed, depending on which parent contributed the chromosome.
- II-17. The answer is E.** (*Chap. 65*) Population genetics reviews the association of individual gene alleles. The frequency of genotypes can be described by the algebraic formula $p^2 + 2pq + q^2 = 1$, with p^2 corresponding to the frequency of AA, q^2 corresponding to the frequency of aa, and $2pq$ corresponding to the frequency of the heterozygous state Aa. In this clinical syndrome the gene frequency of the B_1 allele is the square root of 1/40,000, which equals 1/200, and the gene frequency of B_2B_2 is the square root of 1/90,000, which equals 1/300. Therefore, the heterozygous state is $2 \times 1/200 \times 1/300$, which equals

1/30,000. Notice that the heterozygous state is more common than either of the homozygous states.

- II-18. The answer is B.** (*Chap. 65*) Neonatal alloimmune thrombocytopenia (NATP) is a potentially life-threatening disorder limited to fetuses and neonates. It is immunologically mediated as a result of genetic predisposition of the mother. Maternal IgG alloantibodies cross the placenta, resulting in immune destruction of platelets bearing paternal alloantigens. First-born offspring constitute about 50% of the cases, and subsequent affected siblings usually develop worsening degrees of thrombocytopenia. The GPIIb/IIIa receptor complex is the site of the polymorphism. The majority of cases of NATP are caused by anti-PI^{A1} antibodies; <5% are due to less common polymorphisms. Mothers who are PI^{A1-} (i.e., PI^{A2}/PI^{A2}) account for the vast majority of cases of NATP. The gene frequency of PI^{A2} is 0.02, therefore approximately 1 in 2,500 neonates is born with NATP as a direct manifestation of the PI^{A1} polymorphism. This entity is pathophysiologically related to posttransfusion purpura as both diseases involve the development of platelet-specific antibodies directed against the naturally occurring platelet receptor GPIIb/IIIa.
- II-19. The answer is B.** (*Chaps. 65, 274, 276*) Many autosomal dominant disorders vary in the time of onset and the severity of expression. Therefore, persons such as the two apparently unaffected siblings who are at risk for the development of hereditary nephritis, even in the absence of overt evidence of renal impairment, are poor renal donor candidates. In addition, the mother is clearly a carrier and a poor candidate. The father is the best close relative to evaluate as a potential donor.
- II-20. The answer is D.** (*Chap. 65*) One of the most important techniques for identifying the genomic sites responsible for inherited diseases and for prenatal diagnosis is the identification of restriction fragment length polymorphisms (RFLPs). Such RFLP sites are the consequences of variable sequences that may or may not allow a specific restriction endonuclease (an enzyme recognizing a specific, usually four- to seven-base DNA sequence) to cut at that site. In the Southern blots of the depicted family, the parents are heterozygous for a restriction site that is 2 kb away from one nonpolymorphic site and 8 kb away from another nonpolymorphic site in the other direction (which is the section the probe recognizes). In one of each of the parents' chromosomes the polymorphic site is present; in the other chromosome it is not. Thus, upon digestion of the parents' DNA, both a 10-kb fragment, representing the chromosome that lacks the polymorphic site, and an 8-kb fragment, representing the chromosome that has this site, exist. The son has inherited the chromosome with the site present from both his father and his mother, while the daughter has inherited the chromosome without the sequence that does not allow the extra cut from both parents. If the polymorphic sequence that allows cutting were associated with an autosomal recessive disease (by virtue of its being proximate on the genome), then such a marker could be used to predict the presence of the disease in the son or a fetus with a similar pattern on Southern blotting of DNA.
- II-21. The answer is E.** (*Chaps. 65, 363*) Autosomal dominant diseases are manifest in the heterozygous state, when only one abnormal gene is present, with the corresponding allele being normal. Consequently, there is a 50% chance that the offspring of an affected heterozygote will inherit the mutant allele. Furthermore, affected individuals will bear an equal number of normal and affected offspring. There is no sex predilection for such a disease. In many autosomal dominant disorders, the affected person may not have an affected parent. This occurs because the mutations leading to such disorders are often spontaneous. The parent in whose germ cell the mutation arose will be clinically normal, as will the parent's other children. However, since the mutation is now present in the reproductive cells of an affected individual, such a patient will transmit the disease to half of his or her children. Some autosomal dominant diseases, such as tuberous sclerosis and achondroplasia, arise in spontaneous mutations in about 80% of cases; Marfan syndrome and neurofibromatosis do so in about 30 to 40% of cases. By contrast, Huntington's chorea,

adult polycystic kidney disease, and familial hypercholesterolemia have a much lower incidence of occurrence resulting from spontaneous mutations. Other characteristics of many autosomal dominant disorders that are not seen in recessive syndromes are delayed age of onset and variability of clinical expression. For example, the neurologic abnormalities associated with Huntington's chorea frequently do not present until the fourth or fifth decade. Second, the multiple endocrine neoplasia syndromes manifest themselves with abnormalities in various organs within the same kindred. Hemophilia A is an X-linked recessive disorder, and hemochromatosis is autosomal recessive. Myasthenia gravis is inherited in a polygenic fashion but is more common in patients who harbor an HLA-B8 histocompatibility antigen locus.

- II-22. The answer is A.** (*Chap. 65*) Many common diseases are known to “run in families” yet are not inherited in a simple Mendelian fashion. It is likely that the expression of these disorders depends on a family of genes that can impart a certain degree of risk and then be modified by subsequent environmental factors. The risk of the development of disease in a relative of an affected person varies with the degree of relationship; first-degree relatives (parents, siblings, and offspring) have the highest risk, which in itself varies with the specific disease. Many of these multifactorial genetic diseases are inherited in a greater frequency in persons with certain HLA (major histocompatibility system) types. For example, there is a tenfold increased risk of celiac sprue (gluten-sensitive enteropathy) in persons who harbor HLA-B8. This genotype also imparts increased risk for chronic active hepatitis, myasthenia gravis, and Addison's disease. The incidence of diabetes mellitus is much higher in those expressing HLA-D3 and HLA-D4. Spondyloarthropathies, psoriatic arthritis (HLA-B27), hyperthyroidism (HLA-DR3), and multiple sclerosis (HLA-DR2) are other examples of diseases with histocompatibility predispositions. By contrast, Wilson's disease and cystic fibrosis are inherited in an autosomal recessive fashion, and adult polycystic kidney disease and neurofibromatosis are among the disorders inherited in an autosomal dominant manner.
- II-23. The answer is A.** (*Chaps. 66, 338*) Phenotype men who have two or more X chromosomes have Klinefelter syndrome. Although the diagnosis of Klinefelter syndrome may be suspected prepubertally owing to the increased length of the lower body segment, most affected persons first present postpubertally with signs of decreased testosterone production and small testes. The risk of breast cancer is 20 times that of normal men (and one-fifth that of women), presumably as a consequence of long-term estrogen stimulation of the breast. Mosaic chromosome patterns (46,XY/47,XXY) are found in 10% of affected persons, 70% of whom display the mosaicism only in the testes, which may be normal in size. Hypospadias is not increased in incidence in affected persons. Although mental deficiency and social maladjustment occur with increased frequency in persons with Klinefelter syndrome, most patients with the disorder have normal mental and social competence.
- II-24. The answer is C.** (*Chaps. 65, 307. Rosen, N Engl J Med 311:235, 300, 1984.*) Ataxia-telangiectasia is an autosomal recessive primary immunodeficiency disorders associated with abnormal thymic development, progressive cerebellar ataxia, and oculocutaneous telangiectasia. The responsible gene, located on chromosome 11, leads to a generalized defect in the ability to repair damage to DNA. Such a defect accounts for the frequent occurrence of malignancies, particularly lymphomas, and the exquisite sensitivity to therapeutic irradiation. There is evidence for both humoral and cellular immunodeficiency; most patients have depressed IgA and IgE levels as well as cutaneous anergy. Sinopulmonary infections are common with severe resultant respiratory insufficiency, often associated with bronchiectasis. Adenosine deaminase deficiency is associated not with ataxia-telangiectasia but with severe combined immunodeficiency. The features of ataxia-telangiectasia, which include severe immunodeficiency, chromosomal instability, and an increase in the risk of malignancy, apparently apply to both heterozygotes as well as to homozygotes.

- II-25. The answer is B.** (*Chaps. 65, 348*) Marfan syndrome is caused by a mutation in the gene for fibrillin. Severe disease is characterized by the triad of: (1) long thin extremities frequently associated with other skeletal changes; (2) ectopia lentis; (3) aortic aneurysms. Milder forms of the disorder may be more difficult to diagnose. Cardiovascular abnormalities are the major source of morbidity and mortality. Mitral valve prolapse is common and progresses to regurgitation in one-quarter of patients. Dilatation of the aortic root can progress to cause aortic regurgitation, aortic dissection, or frank rupture. All patients should have a slit-lamp examination to check for lens dislocation. Striae may occur over the shoulders and buttocks, but otherwise the skin is normal. The disorder is generally inherited as an autosomal dominant trait, but approximately one-fourth of cases are probably new mutations. Marfan syndrome is an example of a genetic pleiotropy in which one gene has multiple clinical effects. Other examples include single defects occurring early in development that lead to various abnormalities or, in some cases, a single-gene product that participates in a number of unrelated biosynthetic pathways. Marfan syndrome is not an example of genetic heterogeneity in which several genes when mutated can cause the same effect. An example of this is the genetic heterogeneity seen in deafness in which there are approximately 16 to 18 types of autosomal recessive deafness, in addition to the numerous autosomal dominant and X-linked forms of genetic deafness.
- II-26. The answer is C.** (*Chap. 348*) Alport syndrome is an inherited disorder associated with hematuria, sensorineural deafness, and conical deformation of the anterior surface of the lens (lenticonus). A second X-linked form is associated with diffuse leiomyomatosis. Both an autosomal recessive form as well as an autosomal dominant form have been described. These two autosomal forms are associated with renal disease but not deafness or lenticonus. Both the X-linked and autosomal recessive forms are caused primarily by mutations in the genes for type IV collagen. This is a major component of basement membranes. Blue sclerae, which may be present in other inherited disorders of connective tissue such as osteogenesis imperfecta or type VI Ehlers-Danlos syndrome are not seen in Alport syndrome. The hematuria typically progresses to frank nephritis and may cause renal failure in late adolescence in affected males and occasionally older females. The sensorineural deafness is primarily in the high-tone range. It frequently can be detected only by an audiogram and is usually not progressive. The lenticonus rarely occurs without nephritis and is considered to be pathopneumonic for the classic X-linked inheritance form of Alport syndrome.

This page intentionally left blank.

III. CLINICAL PHARMACOLOGY

QUESTIONS

DIRECTIONS: Each question below contains five suggested responses. Choose the **one best** response to each question.

- III-1.** Which of the following antiemetic drugs acts preferentially on the peripheral nervous system?
- (A) Cisapride
 - (B) Meclizine
 - (C) Ondansetron
 - (D) Scopolamine
 - (E) Prochlorperazine
- III-2.** All of the following drugs may be associated with hepatotoxicity. Which is most likely to produce a primarily cholestatic (jaundice) picture?
- (A) Acetaminophen
 - (B) Allopurinol
 - (C) Cyclosporine
 - (D) Nifedipine
 - (E) Zidovudine
- III-3.** A 35-year-old woman develops a generalized seizure and is brought to the emergency room. Your goal is to reduce the chance for additional seizures by therapy that will achieve a therapeutic plasma phenytoin level as soon as possible. However, you infuse the phenytoin at a rate of 50 mg/min over 20 min. What is the reason for not administering the drug more rapidly?
- (A) Rapid administration slows drug clearance
 - (B) High blood levels during a rapid load could produce drug toxicity
 - (C) The equilibrium phase would be reached too quickly
 - (D) High levels can exacerbate the seizures
 - (E) If administered too rapidly, first-pass effect will cause rapid catabolism
- III-4.** If the plasma half-life of lidocaine is 2 h and its metabolism is governed by first-order kinetics, when will the steady-state plasma level be reached if the drug is administered at the maintenance rate without an initial loading dose?
- (A) 2 hours
 - (B) 8 hours
- III-4.** (Continued)
- (C) 1 day
 - (D) 2 days
 - (E) Never
- III-5.** A 75-year-old patient with advanced metastatic prostate cancer and a long history of renal failure has severe bone pain. He is given meperidine. Two days later he develops a generalized seizure. What is the likely mechanism of this complication?
- (A) Buildup of meperidine
 - (B) Buildup of meperidine metabolite levels
 - (C) Brain metastases
 - (D) Hypercalcemia
 - (E) Worsening renal failure
- III-6.** A 72-year-old man with chronic atrial fibrillation presents with bruising. He is otherwise well, although he admits to being concerned about a failing memory and is taking a host of over-the-counter remedies in an effort to deal with this problem. His only medicines are furosemide, digoxin, and warfarin. His physical examination, with the exception of ecchymoses and irregular heartbeat, is normal; there is no evidence of cognitive impairment. His serum chemistry profile and complete blood count are normal. However, coagulation tests reveal an INR of 7. What is the most likely cause of this patient's coagulopathy?
- (A) Warfarin overdose
 - (B) Interaction between digoxin and warfarin
 - (C) Dietary change
 - (D) Interaction between furosemide and warfarin
 - (E) Use of dietary herbal supplements
- III-7.** A 55-year-old man with a history of seasonal allergic rhinitis develops a low-grade fever and cough. He complains to his physician that he is producing copious amounts of greenish sputum and coughing quite a bit. Since the patient is known to be allergic to penicillin, the physician prescribes erythromycin. The patient is also taking terfenadine because of his allergic symptoms. Which of the following is a potential complication in this clinical scenario?

III-7. (Continued)

- (A) Decreased bioavailability of erythromycin with failure to treat pulmonary infection
- (B) Congestive heart failure
- (C) Increased bleeding
- (D) Stevens-Johnson syndrome
- (E) A disulfiram-like reaction if ethanol is ingested

III-8. A 25-year-old man who was recently admitted to a psychiatric hospital with the diagnosis of severe depression complicated by psychosis is brought to the emergency room because of worsening mental status and fever. The patient is unable to give a history because he is profoundly confused and claims to be on Mars. The psychiatrist informs you that the patient has been started recently on haloperidol and amitriptyline. Physical findings include a rectal temperature of 40.6°C (105°F), muscle rigidity, and dry skin. A cooling blanket is ordered, and you administer acetaminophen. Which of the following agents would be most appropriately ordered at this time?

- (A) Bromocriptine
- (B) Atropine
- (C) Levarterenol
- (D) Chlorpheniramine
- (E) Methylprednisolone

III-9. A 35-year-old previously healthy woman was given a 10-day course of erythromycin for a nonproductive

III-9. (Continued)

cough, diffuse interstitial infiltrates, and a presumptive diagnosis of mycoplasma pneumonia. She now has a well-demarcated rash on her fingers (Plate M). She also has fever and severe erosions on the buccal mucous membranes. The most likely diagnosis is

- (A) hypersensitivity vasculitis
- (B) polyarteritis nodosum
- (C) toxic epidermal necrolysis
- (D) erythema multiforme major
- (E) erythema nodosum

III-10. A 70-year-old woman with a history of diabetes, hypertension, and recurrent urinary tract infections is admitted with fever and pyuria. Her urine output is poor. Antibiotics and dopamine are administered; the dopamine dose is progressively titrated from 3 $\mu\text{g}/\text{kg}$ to 30 $\mu\text{g}/\text{kg}$. The patient complains of chest discomfort. An electrocardiogram discloses changes compatible with ischemia in the anterior precordial leads. What is the likely cause for these electrocardiographic changes?

- (A) Interaction with dopamine receptors in coronary arterioles
- (B) Peripheral conversion of dopamine to norepinephrine
- (C) Interaction with cardiac β_1 -adrenergic receptors
- (D) Interaction with cardiac β_2 -adrenergic receptors
- (E) Interaction with peripheral α -adrenergic receptors

III. CLINICAL PHARMACOLOGY

ANSWERS

- III-1. The answer is A.** (*Chaps. 43, 72*) Vomiting is coordinated at the brainstem level and is effected by peripheral neuromuscular responses (in the pharynx, stomach, and chest/abdominal wall). The cerebral cortex or inner ear can send stimuli to the chemoreceptor trigger zone (CTZ) in the medulla, which itself can respond to blood-borne stimuli (e.g., chemotherapeutic agents) to initiate emesis. The CTZ is enervated by serotonin (5HT₃), cholinergic muscarinic (M₁), histaminergic (H₁), and dopaminergic (D₂) receptors. Consequently, blocking these nerves with 5HT₃ antagonists (granisetron, ondansetron), anti-histamines (meclizine, diphenhydramine), anticholinergics (scopolamine), or phenothiazines (which are dopamine blockers, such as prochlorperazine) can help in the management of the patient who is vomiting. Prokinetic agents such as the 5HT₄ antagonists cisapride and metoclopramide work by stimulating gut motility and gastric emptying.
- III-2. The answer is C.** (*Chaps. 71, 296. Lee, N Engl J Med 333:1118–1127, 1995.*) Liver injury is a common side effect of therapeutic agents. Some drugs produce a primarily hepatic response (e.g., phenytoin, enalapril, isoniazid, chlorthiazide, imipramine, ibuprofen, ketoconazole, zidovudine, nifedipine) or fatty infiltration (e.g., tetracycline, amiodarone, valproic acid) due to direct toxicity to the hepatocyte itself. Acetaminophen is directly toxic to the liver and can produce massive hepatic necrosis if ingested in large enough quantities. Other drugs (e.g., allopurinol, quinidine, sulfonamides) produce hypersensitivity reactions with granuloma formation. Finally, erythromycin, oral contraceptives, and cyclosporine may each occasionally lead to jaundice on the basis of intrahepatic cholestasis.
- III-3. The answer is B.** (*Chap. 70*) Drug metabolism consists of a distribution phase and an elimination phase. After a single rapid intravenous bolus, all of the drug is in the central or plasma compartment followed by transfer to an extracellular compartment, termed the *distribution phase*. A phase of slower decline, the *equilibrium phase*, then follows. During the initial and distribution phases the drug levels can be quite high. In the case of phenytoin, such high levels could lead to cardiovascular collapse. Therefore, the loading dose needs to be given slowly to prevent high levels. In certain situations, high initial levels may be desirable. For example, high levels of certain benzodiazepines are required to induce rapid brain uptake to produce quick sedation. On the other hand, if potassium chloride is infused too quickly, cardiac arrest can result.
- III-4. The answer is B.** (*Chap. 70*) First-order kinetics refers to a pattern in which the time required for the plasma level to fall by one half is the same regardless of drug concentration. Elimination of a drug is generally defined as elimination of 90% of the steady-state level, and, therefore, clinically complete at three to four half-lives. The same logic applies to drug build-up during a constant infusion. The time required to reach steady-state levels is also a first-order process; three to four half-lives would then put the level at about 90% of steady state, thus basically clinically complete. Therefore, when a rapid antiarrhythmic effect of lidocaine is needed, a bolus loading dose is required, followed by a maintenance dose to maintain therapeutic levels.
- III-5. The answer is B.** (*Chap. 71*) Narcotics generally are considered to have favorable risk-benefit ratio. However, they should be used cautiously, particularly in the elderly. Patients

on narcotics should always be placed on an adequate bowel regimen and be cautioned against driving or other dangerous activities; other medical issues should be considered. Patients with impaired hepatic function and, to a lesser degree, renal failure may have impaired clearance of the narcotic. In the case of meperidine, byproducts excreted by the kidney can significantly lower the seizure threshold. Parenchymal brain lesions are very uncommon in prostate cancer.

- III-6. The answer is E.** (*Chaps. 9, 11, 71*) Older patients are much more likely than younger ones to experience problems with drugs. For example, drug clearance may be reduced due to decreased glomerular filtration rate and decreased hepatic clearance. Given the relative increase in the ratio of body fat to water in the elderly, water-soluble drugs may have higher levels and fat-soluble agents tend to have longer half-lives. If albumin levels decline due to illness, the plasma level of protein-bound drugs such as warfarin or phenytoin may increase. Pharmacodynamic considerations also suggest that a given dose may have a greater effect in an older patient than in a younger patient. "Polypharmacy," the use of many drugs (which may have myriad drug-drug and other interactions), is a well-recognized problem. It is also important to consider the use of over-the-counter medicines, which is very common in this age cohort. For example, anti-insomniacs can have behavioral consequences, and nonsteroidal anti-inflammatory drugs may affect the kidney in such a fashion as to precipitate renal dysfunction or to cause worsening of hypertension. The physician should also question the patient about dietary supplements such as ginkgo biloba, used to boost memory, which can interfere with an otherwise stable warfarin regimen.
- III-7. The answer is B.** (*Chaps. 71, 137*) Although antibiotics typically have a very high therapeutic index, they may interact with other drugs that are being ingested by the patient, with a potential for deleterious consequences. For example, erythromycin and other macrolide antibiotics that are well tolerated as single agents (except for frequent gastrointestinal toxicity) can inhibit the hepatic metabolism of many concurrently administered drugs, such as theophylline, terfenadine, warfarin, and ergot alkaloids. In any of these cases, the non-antibiotic drug may cause toxicity as a result of increased serum concentrations. Decreased metabolism of terfenadine can lead to severe cardiac dysfunction. Erythromycin can inhibit the metabolism of cyclosporine, consequently leading to a higher likelihood of cyclosporine-induced complications such as renal failure. Clarithromycin has a greater effect on hepatic metabolism than does azithromycin.
- III-8. The answer is A.** (*Chaps. 17, 71. Caroff, Med Clin North Am 77:185, 1993.*) This patient is suffering from the neuroleptic malignant syndrome, which is characterized by muscle rigidity, autonomic dysregulation, and hyperthermia. The patient probably has been exposed to phenothiazines for the first time, given his relatively recent admission to the psychiatric facility. This syndrome represents an idiosyncratic reaction to inhibition of central dopamine receptors that results in increased heat production and failure of heat dissipation. In addition to rapid physical cooling and administration of an antipyretic or acetaminophen (but not aspirin), the use of the dopamine agonist bromocriptine or dantrolene should be strongly considered. Dantrolene reverses the hypothalamic dysfunction caused by major tranquilizers.
- III-9. The answer is D.** (*Chaps. 57, 59. Roujeau, N Engl J Med 331:1272, 1994.*) Patients with erythema multiforme major have typical target lesions, usually on the extremities, which are associated with mucous membrane lesions. This syndrome usually follows mycoplasma or herpes simplex infections, has a benign course, and is not thought to be associated with drug reaction. On the other hand, the Stevens-Johnson syndrome is due to reaction to a systemically administered drug such as a sulfa, phenytoin, allopurinol, penicillin, and nonsteroidal anti-inflammatory drugs. Typical lesions of Stevens-Johnson syndrome are small blisters on dusky purpuric macules. 10 to 30% of cases include fever and lesions of the respiratory and/or gastrointestinal tracts. Another related severe cutaneous reaction to drugs is toxic epidermal necrolysis; individual lesions are similar to those

seen in Stevens-Johnson syndrome, but epidermal separation from the basal layer with lateral pressure (Nikolsky's sign) also occurs. These patients have systemic consequences and widespread injury to the skin, similar to those with extensive burns. Erythema nodosum represents painful tender lesions, usually on the legs, associated with infection or drug ingestion. Stevens-Johnson syndrome and toxic epidermal necrolysis represent two severe cutaneous reactions to drugs in which fatalities have been reported. The skin lesions usually occur 1 to 3 weeks after the initial exposure to the offending drug.

- III-10. The answer is E.** (*Chap. 72*) The catecholamine neurotransmitters norepinephrine, epinephrine, and dopamine exert their physiologic effects by binding to adrenergic receptors. At low (2 to 5 $\mu\text{g}/\text{kg}$) doses dopamine interacts only with dopaminergic (type 1) receptors, which mediate renal and mesenteric vasodilation, with the former effect leading to increased urine output. At higher doses (10 to 20 $\mu\text{g}/\text{kg}$) dopamine exerts a positive inotropic effect on the heart by stimulating cardiac β (type 1) receptors. However, at infusion rates >20 $\mu\text{g}/\text{kg}$ the predominant effect is on α -adrenergic receptors, leading to vasoconstriction (and increased peripheral vascular resistance, causing increased cardiac work) and the ischemia noted in this susceptible patient.

This page intentionally left blank.

IV. NUTRITION

QUESTIONS

DIRECTIONS: Each question below contains five suggested responses. Choose the **one best** response to each question.

- IV-1.** A patient who is being screened for vitamin B₁₂ deficiency undergoes a Schilling test, 1 mg of cobalamin administered intramuscularly 1 h after the administration of radiolabeled cobalamin. A normal Schilling test, excretion of >10% of the labeled cobalamin in a 24-h urine specimen, would be most likely in which of the following situations?
- (A) Intrinsic factor deficiency
 - (B) Chronic pancreatitis
 - (C) Surgically absent terminal ileum
 - (D) Achlorhydria
 - (E) Celiac sprue
- IV-2.** A 23-year-old woman presents for a routine physical examination. The patient gives a history of trying to diet, but she also admits to binge intake and extensive use of laxatives. The physical examination discloses a woman of normal height and weight and is unremarkable except for chipping and erosion of the front teeth. This patient is likely to
- (A) have disrupted menstrual cycles
 - (B) experience a normal life span
 - (C) have osteopenic bones
 - (D) have elevated serum anti-goblet cell antibodies
 - (E) be unconcerned about body shape and weight
- IV-3.** Which of the following personality traits is most likely to describe a young woman with anorexia nervosa?
- (A) Depressive
 - (B) Borderline
 - (C) Anxious
 - (D) Perfectionist
 - (E) Impulsive
- IV-4.** Which of the following therapies is most effective for a patient with anorexia nervosa who is 70% of ideal body weight?
- (A) Tricyclic antidepressant
 - (B) Serotonin uptake antagonist antidepressant
- IV-4.** (Continued)
- (C) Supervised oral re-feeding in the hospital
 - (D) Total parenteral nutrition
 - (E) Oral re-feeding with outpatient psychiatric treatment
- IV-5.** A strain of obese mice homozygous for a mutation in the *ob* gene has a failure to elaborate normal amounts of the peptide leptin. Which of the following statements about leptin is correct?
- (A) Leptin is secreted by cells in the hypothalamus
 - (B) Overproduction causes increased energy expenditure.
 - (C) Aberrant leptin physiology has never been shown to be a cause of obesity in humans.
 - (D) Obese people have normal levels of serum leptin.
 - (E) Patients with nongenetic causes of obesity do not respond to exogenous leptin.
- IV-6.** A 32-year-old obese woman presents to you for advice regarding weight loss. She has no significant medical problems at this time. She requests a pill to help her lose weight. You should
- (A) tell her that a low-calorie diet and exercise are the best ways to lose weight
 - (B) prescribe phentermine
 - (C) prescribe fenfluramine
 - (D) prescribe a combination of phenylpropranolamine plus fenfluramine
 - (E) prescribe L-thyroxine
- IV-7.** A 65-year-old man with a known history of prostatism develops a fever of 39.5°C (103°F), shaking chills, and progressive deterioration. He is brought to the emergency room where his systolic blood pressure is 60 mmHg. He is given intravenous fluids and pressors and is intubated. Although his gram-negative sepsis is brought under control with antibiotics, he remains intubated for another 5 days to recover from diffuse lung injury. During this time he is not given any nutrition. How does the pa-

IV-7. (Continued)

tient cope metabolically with the stress imposed by his acute illness?

- (A) Conversion of body fat into ketones
- (B) Conversion of body fat into protein
- (C) Conversion of glucose to glycogen
- (D) Conversion of skeletal muscle to amino acids
- (E) Conversion of glycogen to glucose

IV-8. You are evaluating a 45-year-old homeless individual with known chronic schizophrenia. He appears to be generally malnourished with decreased temporal and proximal extremity muscle mass. Which of the following immunologic/hematologic abnormalities is most likely to be found in this situation?

- (A) Depressed absolute lymphocyte count
- (B) Depressed absolute monocyte count
- (C) Depressed absolute granulocyte count
- (D) Hypogammaglobulinemia
- (E) Microcytic red cells

IV-9. Dietary deficiency of thiamine produces which of the following clinical syndromes?

- (A) Loss of proprioception
- (B) Peripheral neuropathy
- (C) Color blindness
- (D) Osteoporosis
- (E) Bruising

IV-10. Why do patients with the carcinoid syndrome develop pellagra (loss of appetite, generalized weakness, abdominal pain, vomiting, stomatitis and bright red glossitis, and a skin rash that is pigmented and scaling in sunlight-exposed areas)?

- (A) Failure to elaborate serotonin
- (B) Vitamin B₁₂ deficiency
- (C) Thiamine deficiency
- (D) Niacin deficiency
- (E) Pyridoxine deficiency

IV-11. Why is it necessary to coadminister vitamin B₆ (pyridoxine) together with isoniazid?

- (A) Vitamin B₆ requirements are higher in tuberculosis patients.
- (B) Isoniazid causes decarboxylation of γ carboxyl groups in vitamin K–dependent enzymes.
- (C) Isoniazid interacts with pyridoxal phosphate.
- (D) Isoniazid causes malabsorption of vitamin B₆.
- (E) Isoniazid causes a conversion of homocysteine to cystathionine.

IV-12. A 50-year-old chronic alcoholic has bruising, inflamed and bleeding gums, and painful joints. The platelet

IV-12. (Continued)

count and prothrombin time are normal. The most likely cause for this clinical scenario is deficiency of which of the following vitamins?

- (A) Vitamin A
- (B) Vitamin B₁
- (C) Vitamin B₁₂
- (D) Vitamin C
- (E) Vitamin K

IV-13. A 23-year-old individual who believes in megavitamin therapy develops severe headaches. Ophthalmologic examination discloses papilledema. The cause for this problem is

- (A) vitamin A intoxication
- (B) vitamin B₆ intoxication
- (C) vitamin D intoxication
- (D) vitamin E intoxication
- (E) not likely related to vitamin excess

IV-14. Which of the following patients is LEAST likely to benefit from nutritional support?

- (A) A 50-year-old female malnourished alcoholic about to undergo lumpectomy for lung cancer
- (B) A 23-year-old patient hospitalized for management of severe burn injury
- (C) A 50-year-old man with malnourishment due to pancreatic cancer
- (D) A 38-year-old woman undergoing allogeneic bone marrow transplantation
- (E) A 45-year-old man with advanced liver failure due to autoimmune hepatitis awaiting liver transplantation

IV-15. A 65-year-old woman complains of a 20-lb weight loss over the past 6 months. She is of average build and has not been on a diet. She states that she has just not been very hungry. Physical examination is unrevealing. Complete blood count is normal, as is urinalysis, multiphased chemical screen, thyroid-stimulating hormone, chest x-ray, and stool for blood. The next most appropriate study would be

- (A) abdominal CT
- (B) serum protein electrophoresis
- (C) colonoscopy
- (D) blood cultures
- (E) short ACTH test

IV-16. A 35-year-old obese woman presents with irregular menses. A pregnancy test is negative. What is the most likely cause of oligomenorrhea in this individual?

- (A) Glucagon resistance
- (B) Excess production of tumor necrosis factor α by adipocytes

IV-16. (Continued)

- (C) Polycystic ovarian syndrome
- (D) Elevated leptin levels
- (E) Anatomic impairment of menstrual flow

IV-17. Which of the following endocrinologic abnormalities is typical of patients with anorexia nervosa?

- (A) Increased gonadotropin-releasing hormone levels
- (B) Depressed serum cortisol levels
- (C) Elevated thyroid stimulating hormone levels
- (D) Increased insulin-like growth factor levels
- (E) Increased growth hormone

IV-18. A 45-year-old truck driver is involved in a serious motor vehicle accident. He has fractured multiple bones and sustained a pneumothorax and a hepatic laceration requiring emergency surgery. In order to maintain energy balance, what must this patient receive per day?

- (A) 2000 kcal
- (B) 2500 kcal
- (C) 3500 kcal
- (D) 4500 kcal
- (E) 5500 kcal

IV-19. Which of the following statements concerning the measurement of serum albumin to assess the degree of malnutrition in a patient is correct?

- (A) A low serum albumin indicates malnutrition.
- (B) The half-life of serum albumin is about 3 weeks.
- (C) Circulating tumor necrosis factor α is required for albumin synthesis.
- (D) Measurement of a longer-lived circulating protein such as transferrin gives a better indication of the nutritional state.
- (E) Albumin levels are unaffected by changes in extracellular volume.

IV-20. A 50-year-old man with recent acute pancreatitis receiving his third week of nutritional support via a central venous catheter might be expected to develop which of the following complications at this time?

- (A) Zinc deficiency
- (B) Osteomalacia
- (C) Microcytic anemia
- (D) Hyperosmolar coma
- (E) Hypophosphatemia

IV. NUTRITION

ANSWERS

- IV-1. The answer is E.** (*Chaps. 75, 286*) Absorption of vitamin B₁₂ depends on a number of factors in the stomach, pancreas, and ileum. Cobalamin, present primarily in meat, is bound in the stomach by a glycoprotein called R-binder protein, which is synthesized in both the stomach and salivary glands. The complex requires gastric acidity. Normal pancreatic function is required because protease enzymes split the cobalamin R-binder complex to release cobalamin in the proximal small intestine, where it is then bound by intrinsic factor, another glycoprotein that is synthesized and released by gastric parietal cells. Intrinsic factor promotes the uptake of cobalamin by specific receptors in the brush border of mucosal ileal mucosal cells. Therefore the lack of stomach acid, the lack of secretion of intrinsic factor by gastric parietal cells, chronic pancreatitis with resultant deficiency of pancreatic proteases, bacterial overgrowth syndromes in which bacteria actually utilize the cobalamin, or ileal dysfunction or absence prevents normal excretion of radiolabeled cobalamin in the Schilling test. Celiac sprue does not affect these processes; instead, patients with gluten-sensitive enteropathy will have impaired absorption of carbohydrates manifested by an abnormal D-xylose test. Patients with an abnormal initial Schilling test should have subsequent studies including the administration of radiolabeled cobalamin in conjunction with intrinsic factor, or with pancreatic enzymes, or following a 5-day course of tetracycline to distinguish amongst the causes of abnormal vitamin B₁₂ absorption.
- IV-2. The answer is B.** (*Chap. 78*) This patient has bulimia nervosa, typically seen in females in their mid-twenties who report binge eating and purging five to ten times per week for over 5 years. In an attempt to avoid weight gain after being on a diet, the patient may induce vomiting, take laxatives or diuretics, or engage in some form of compensatory behavior dedicated to minimizing net caloric intake. Patients may induce vomiting by stimulating the gag reflex or by taking syrup of ipecac or may learn to vomit at will. The use of laxatives and/or diuretics is common in this condition. Although patients usually appear normal, they may have salivary gland hypertrophy, a scar on the dorsum of the hand due to repeated trauma from teeth, or chipped and eroded front teeth due to constant exposure to stomach acid. However, serious complications and mortality among patients with bulimia nervosa are rare and the prognosis is good.
- IV-3. The answer is D.** (*Chap. 78*) The most important feature of patients with anorexia nervosa is refusal to maintain even a low-normal body weight. The full syndrome of anorexia nervosa occurs in about 1 in 200 individuals. Patients with anorexia nervosa are always markedly underweight, hardly ever menstruate, and often engage in binge eating. The mortality rate is 5% per decade. The etiology of this serious eating disorder is unknown but probably involves a combination of psychological, biologic, and cultural risk factors. This illness often begins in an obsessive or perfectionist patient who begins a diet. As weight loss progresses, the patient has increasing fears of gaining weight and engages in stricter dieting practices. This disorder essentially occurs only in cultures in which thinness is valued, suggesting a strong cultural influence. Bulimia nervosa, in which patients continue to maintain a normal body weight but typically engage in overeating with binges followed by compensatory purging or purging behavior, has a higher than expected prevalence in patients with childhood or parental obesity. It is totally unclear whether anorexia nervosa is hereditary in nature.

- IV-4. The answer is C.** (*Chap. 78*) Treating patients with severe anorexia nervosa (<75% of expected body weight) requires careful medical and psychiatric care. Patients with such severe weight deficits should be hospitalized, at which time a program of nutritional restoration with oral feeding with food or liquid supplements can be undertaken. However, much support and education are required to reassure the patient that the weight gain will not be permitted to get “out of control.” Psychiatric treatment focuses on emotional support and improving self-esteem. Complications of re-feeding can be as severe as congestive heart failure; abnormal liver function tests and low levels of magnesium and phosphate have been reported. Tricyclic antidepressants are contraindicated due to the possibility of prolongation of the QT interval in the setting of abnormal electrolyte levels. No psychotropic medicine has been shown to be beneficial in this disorder.
- IV-5. The answer is E.** (*Chap. 77. Heymsfield et al, JAMA 282:1568–1575, 1999.*) Studying mutations in obese rodents has provided important insights into the mechanism of obesity in humans. Genetically obese (*ob/ob*) mice have a mutation in the gene that encodes the peptide leptin. Leptin is normally secreted by adipose (fat) cells and acts through the hypothalamus to provide a homeostat for adipose energy stores. Patients who are leptin deficient develop severe obesity, insulin resistance, and hyperphagia as well as overly efficient metabolism. Although high leptin levels in mice are associated with decreased food intake and increased energy expenditure, patients with common obesity do not respond significantly to administration of recombinant leptin. Most obese people do have increased leptin levels and do not have mutations of either leptin or its receptor. Therefore, it is not surprising that administering leptin to such individuals has no benefit. Typical obese people may have “leptin resistance.”
- IV-6. The answer is A.** (*Chap. 77, Connolly et al, N Engl J Med 337:581–588, 1997.*) Although it may be tempting to use drugs to help a severely overweight person lose weight, such an approach is rarely effective. Leptin therapy is not effective in people with a nongenetic cause of obesity. Several amphetamine-type drugs such as phentermine can cause modest weight loss over a short period of time, but rebound weight gain is typically seen upon discontinuation of the agent. Serotonin uptake inhibitors such as fenfluramine also have modest efficacy and perhaps potentiate the weight loss effect of phentermine. However, dual treatment with both these agents yields a twentyfold increase in the likelihood of severe pulmonary hypertension and valvular heart disease. Modest weight loss has been described with the new central neurotransmitter uptake inhibitor, sibutramine, and with an inhibitor of intestinal lipase, orlistat. Since most obese individuals are euthyroid, thyroid hormone replacement has little role in treatment of overweight patients.
- IV-7. The answer is D.** (*Chap. 74*) A normal person stores about 15 kg of energy as fat, 6 kg as muscle, and 0.4 kg as glycogen. During the first 24 h of starvation, energy needs can be met by the conversion of liver stores of glycogen to glucose. During prolonged starvation, body fat is converted into fatty acid–derived ketones. Normal-weight individuals can fast for 2 months, while obese individuals can fast for many more months. However, the response to acute illness such as surgical trauma or sepsis includes a promotion of hypermetabolism in which skeletal muscle and viscera undergo proteolysis to provide the amino acid substrates required for gluconeogenesis. Such rapid proteolysis is promoted by high levels of circulating catecholamines, glucagon, and cortisol, as well as cytokines such as tumor necrosis factor and interleukins 1 and 6. If the starvation process is prolonged, severe protein-calorie malnutrition can be associated with decreased cardiac and renal function, fluid retention, intestinal mucosal atrophy, and loss of cell-mediated immune functions.
- IV-8. The answer is A.** (*Chap. 74*) Nutritional assessment should be undertaken in any patient with a debilitating chronic illness or in homeless individuals. The conditions that promote involuntary diet restriction such as drug abuse, chronic alcoholism, or many psychiatric disorders are often associated with malnutrition. Severe malnutrition, defined

as <70% of ideal body weight, causes diminution of skeletal protein and is evidenced by decreased temporal and proximal extremity muscle mass. Decreased body fat stores are indicated by a decrease in skin-fold thickness (the so-called pinch test). Evidence of vitamin deficiency may abound, including bruising due to vitamin C deficiency or coarse skin with “goose bumps” due to vitamin A deficiency. Vitamin deficiency can cause ophthalmoplegia, confabulation, cerebellar gait, and peripheral neuropathy. While levels of serum immunoglobulins, granulocytes, and monocytes are generally well preserved, lymphopenia, which can be promoted by chronic alcoholism or other chronic infections such as HIV, is the most common hematologic abnormality. Patients may often display anergy in skin testing. More common than the microcytic red cells in iron deficiency is the macrocytosis of coexistent vitamin B₁₂ deficiency.

- IV-9. The answer is B.** (*Chap. 75*) Thiamine (or vitamin B₁), when metabolized to thiamine pyrophosphate, is the coenzyme required for proper energy-producing metabolism of branched-chain amino acids. Thiamine may also play a role in peripheral nerve conduction. Deficiency of this vitamin produces anorexia, irritability, apathy, generalized weakness, as well as pain and numbness in the extremities due to peripheral neuropathy. Vitamin B₁ deficiency may also present with central nervous system problems, especially with the syndrome known as Wernicke’s encephalopathy, which consists of horizontal nystagmus, ophthalmoplegia due to weakness of one or more extraocular muscles, cerebellar ataxia, and mental impairment. Thiamine should be given prophylactically to all chronic alcoholic patients in the emergency room to prevent precipitation of thiamine deficiency after administration of glucose-containing fluids. Unlike in vitamin B₁₂ deficiency, joint position sense is usually maintained in patients with thiamine deficiency.
- IV-10. The answer is D.** (*Chap. 75*) The amino acid tryptophan is converted to the niacin derivatives nicotinic acid and nicotinamide, coenzymes required for numerous oxidative and reductive enzymes. Niacin deficiency causes pellagra, which is a complicated syndrome involving loss of appetite, weakness, irritability, abdominal pain, bright red tongue and stomatitis, and a skin rash characterized by pigmentation and scaling, particularly in areas exposed to sunlight. Pellagra can be seen in those whose diet consists primarily of corn in parts of China, Africa, and India; in chronic alcoholics; in those with congenital defects of tryptophan absorption; and in patients with carcinoid syndrome, in which there is an increased conversion of tryptophan into serotonin.
- IV-11. The answer is C.** (*Chap. 75*) Certain medications, including isoniazid used for tuberculosis, L-dopa used for Parkinson’s disease, and penicillamine used for scleroderma, promote vitamin B₆ (pyridoxine) deficiency by reacting with a carbonyl group on 5-pyridoxal phosphate, which is a cofactor for a host of enzymes involved in amino acid metabolism. Foods that contain vitamin B₆ include legumes, nuts, wheat bran, and meat. Vitamin B₆ deficiency produces seborrheic dermatitis, glossitis, stomatitis, and cheilosis (also seen in other vitamin B deficiencies). A microcytic, hypochromic anemia may also result from the fact that the first enzyme in heme synthesis (amino-levulonic synthetase) requires pyridoxal phosphate as a cofactor. However, vitamin B₆ is also necessary for the conversion of homocysteine to cystathionine. Consequently, deficiency of this vitamin could produce an increased risk of cardiovascular disease due to the resultant hyperhomocystinemia.
- IV-12. The answer is D.** (*Chap. 75*) Scurvy develops when the body pool of vitamin C drops to <33 mg/d and the plasma levels drop to <11 mg/L. Vitamin C is a cofactor for many enzymes involved in connective tissue metabolism and cross-linking. Consequently, the symptoms of vitamin C deficiency reflect diminished formation of connective tissue components such as skin and gums. Impaired connective tissue formation presents with petechiae, ecchymoses, and perifollicular hemorrhages in the skin; bleeding gums; and bleeding into the joints, peritoneal cavity, pericardium, and adrenal glands. The symptoms of scurvy improve within a few days after administration of vitamin C. Whether or not vitamin

C supplementation can prevent cancer due to its effect on the prevention of converting nitrate to carcinogenic nitrosamines is controversial.

- IV-13. The answer is A.** (*Chap. 75*) Vitamin A intoxication may occur in those who ingest >15 mg/d of vitamin A for a period of several months (lower amounts in children). Manifestations of vitamin A intoxication include dry skin, cheilosis, glossitis, vomiting, alopecia, bone pain, hypercalcemia, lymph node enlargement, or hyperlipidemia. Patients will also develop amenorrhea and features of pseudotumor cerebri with increased intracranial pressure and papilledema. Liver fibrosis and bone demineralization have also been described. Patients with liver disease, alcoholics, and the elderly are more prone to this problem, in addition to those who ingest megadoses of vitamins. Vitamin A overload is teratogenic and has been associated with spontaneous abortions.
- IV-14. The answer is C.** (*Chap. 76. Heyland et al, JAMA 280:2013–2019, 1998.*) Nutritional support is risky, depending on the route used, and is expensive. Although nutritional support has been proposed in many situations, it has been proved beneficial through the use of prospective, randomized clinical trials in a subset. Compared with other preoperative patients, only those presurgical patients who have severe protein-calorie malnutrition benefit from parenteral nutrition. Critically ill patients, patients undergoing bone marrow transplantation, and those with liver failure, pancreatitis, and severe inflammatory bowel disease have all been shown to benefit from nutritional support. Patients with cancer cachexia probably achieve no net benefit, except for those about to undergo cancer surgery who have severe protein-calorie malnutrition.
- IV-15. The answer is A.** (*Chaps. 43, 74*) Involuntary weight loss is almost always due to a serious condition. The three mechanisms of weight loss are increased energy expenditure (relatively rare), loss of energy in stool or urine, and decreased food intake. In young persons the most likely causes of weight loss are diabetes, hyperthyroidism, anorexia nervosa, and infection (particularly with HIV). In older persons cancer is the most likely cause of weight loss, with psychiatric illness, including Alzheimer's disease and depression, being the second most important cause. A simple round of screening tests is recommended during the initial evaluation of a patient with significant weight loss. In the current case, the normal CBC and negative stool for occult blood loss suggest that upper or lower gastrointestinal endoscopy probably would not be useful. Since this patient has normal electrolytes, Addison's disease is also less likely, making the short ACTH test an inappropriate initial diagnostic study. Since the patient has no fever, blood cultures or bone marrow biopsy cultures are not likely to be revealing. Serum protein electrophoresis would be appropriate in the setting of anemia or abnormal protein excretion on urinalysis. An abdominal CT, which will provide a reasonable initial screen for pancreatic or gynecologic malignancies, is probably the best initial test in the case of occult weight loss in an older individual.
- IV-16. The answer is C.** (*Chap. 77*) Menstrual abnormalities are often associated with obesity in women. The excessive number of adipocytes allows increased peripheral conversion of the excess levels of androgen to estrogen. There is a decreased level of sex hormone-binding globulin. Such endocrinologic abnormalities are frequently associated with the polycystic ovarian syndrome (PCOS). PCOS, which includes anovulation and hyperandrogenism, is also found in many nonobese women, but many PCOS patients also have insulin resistance, suggesting a link between these two problems. Moreover, the increased incidence of endometrial cancer in obese women is believed to be due to the increased conversion of androstenedione to estrogen, high levels of which promote the proliferation of cells that line the uterine cavity.
- IV-17. The answer is E.** (*Chap. 78*) Patients with anorexia nervosa who develop severe malnourishment may develop a host of endocrinopathies. First, amenorrhea is very common and is attributed to a failure of the body weight-sensitive hypothalamus to elaborate

normal amounts of gonadotropin-releasing hormone (GnRH). The mechanism of hypothalamic-mediated GnRH lack may be the low leptin level in these adipocyte-poor individuals. Although serum cortisol levels are generally elevated, anorexic patients do not display features of hypercortisolism. As might be expected, the thyroid function test pattern in patients with anorexia nervosa resembles the euthyroid sick syndrome in which thyroxine (T_4) and triiodothyronine levels are in the low or low-normal range, reverse T_4 is elevated, and the thyroid stimulating hormone is low or partially suppressed. While levels of the stress-related growth hormone are elevated, hepatically produced insulin-like growth factor secretion is depressed. Some of these abnormalities, particularly decreased sex steroids and elevated cortisol, in combination with nutritional deficiencies can lead to severe osteoporosis.

- IV-18. The answer is E.** (*Chap. 73*) In order to maintain a stable weight, energy intake must match energy output. For an average healthy male, this requires about 2800 kcal/d; this varies upward if the individual is quite active. Moreover, in times of stress, much greater needs must be met. The stress of severe trauma, burn, or hyperthyroidism (if severe) can essentially double the resting energy requirement. Fever itself increases energy requirements by 10 to 15% per degree above normal.
- IV-19. The answer is B.** (*Chap. 74*) The laboratory assessment of a patient's nutritional status could include measurement of serum albumin, a hepatically synthesized protein with a half-life of 2 to 3 weeks. Increased extracellular volume or acute stresses such as trauma or surgery could, via tumor necrosis factor, depress the albumin level and give a false impression of chronic malnutrition. The measurement of shorter-lived "visceral" proteins (e.g., transferrin, prealbumin, or fibronectin) has been considered as an alternative to albumin, but their levels are also affected by acute inflammation. Hepatic diseases such as cirrhosis can lead to a low albumin synthesis, even in the face of adequate nutrition. Similarly, the loss of gut protein due an inflammatory condition such as Crohn's colitis can lower the serum albumin.
- IV-20. The answer is D.** (*Chap. 76*) Total parenteral nutrition (TPN) may be life-saving, but it is expensive, can be logistically difficult, and is associated with several complications, including infection due to the presence of a central venous catheter and anatomic issues related to the catheter itself. Moreover, there are a myriad potential metabolic problems such as immediate fluid overload, hyperglycemia, hypokalemia, or hyperphosphatemia. After TPN has proceeded for several weeks, patients may experience congestive heart failure, refeeding edema, or electrolyte/acid-base imbalances, particularly hyperosmolar nonketotic hyperglycemia coma. Once long-term TPN has been successful in converting the patient to an anabolic state, deficiencies of micronutrients, vitamins, and trace minerals (e.g., zinc, copper, selenium) may develop. Close monitoring and inclusion of essential "extras" in the TPN formula can avoid most of these complications.

V. ONCOLOGY AND HEMATOLOGY

QUESTIONS

DIRECTIONS: Each question below contains five suggested responses. Choose the **one best** response to each question.

V-1. Which of the following statements concerning the musculoskeletal abnormalities in patients with sickle cell disease is correct?

- (A) Hand-foot syndrome characterized by diffuse swelling, tenderness, and warmth of the hands and feet in children under the age of 5 leads to chronic disability in about 10% of patients.
- (B) Acute arthritis seen in patients with sickle cell crisis is often associated with high white cell counts in joint effusions.
- (C) The bone pain in sickle cell crisis is due to bone and bone marrow infarction.
- (D) Acute gouty arthritis is common in patients with sickle cell disease.
- (E) Total hip replacement is contraindicated in patients with sickle cell anemia who sustain avascular necrosis of the femoral head.

V-2. A 70-year-old man of Irish descent returns to his physician for a routine check of his blood pressure. He is a vigorous, retired executive who except for mild hypertension is healthy. After his examination, as he is getting dressed, he states that his wife has been nagging him to mention a spot on his nose (as shown in Plate P). He is certain that this lesion, which has been present for several years, is of no significance. The most likely diagnosis for this lesion is

- (A) dermal nevus
- (B) sebaceous hyperplasia
- (C) clear cell acanthoma
- (D) xanthoma
- (E) basal cell carcinoma

V-3. A 52-year-old woman sees her physician for an “insurance physical.” Physical examination reveals only a pigmented lesion (as shown in Plate Q) present on one foot. The woman states that the lesion apparently was present at birth and does not itch or bleed; it is, however, not as homogeneous in color as it used to be. Which of the following statements about the condition described is true?

V-3. (*Continued*)

- (A) Bleeding and tenderness would be the first signs of malignant degeneration.
- (B) It is unlikely that the lesion, present since birth, is malignant.
- (C) The diagnostic procedure of choice is an incisional biopsy of this lesion.
- (D) Change in color of the lesion is a suspicious sign for potential malignancy.
- (E) Early diagnosis of this lesion would not affect prognosis.

V-4. A 58-year-old man presents with fatigue. His physical examination is normal except for the presence of splenomegaly. CBC discloses hematocrit, 29%; platelet count, 90,000/ μ L; WBC, 2700/ μ L; and an essentially normal red cell morphology (differential 12% monocytes, 12% granulocytes, and 76% lymphocytes). A bone marrow aspirate and biopsy were performed. The aspirate was dry and the biopsy is pending. Based on the available information, the most likely diagnosis in this case is

- (A) chronic lymphocytic leukemia (CLL)
- (B) hairy cell leukemia
- (C) chronic myeloid leukemia (CML)
- (D) myelofibrosis
- (E) multiple myeloma

V-5. A 58-year-old chronic alcoholic and heavy smoker presents with a 3-cm, firm, right midcervical neck mass. An excisional biopsy reveals squamous cell carcinoma. Which of the following is the most appropriate approach at this time?

- (A) Bronchoscopy, esophagoscopy, and laryngoscopy
- (B) CT of the neck
- (C) CT of the brain
- (D) Neck dissection
- (E) Radiation therapy

V-6. A 28-year-old man with newly diagnosed acute myelogenous leukemia spikes a temperature to 38.7°C

V-6. (Continued)

(101.7°F) on the sixth day of induction therapy. He feels well and has no physical complaints. His only medicine is intravenous cytosine arabinoside, 140 mg every 12 h. Physical examination is unrevealing. His white blood count is $900/\mu\text{L}$, of which 10% are granulocytes and the rest mostly lymphocytes; platelet count is $24,000/\mu\text{L}$. Findings on chest x-ray and urinalysis are normal.

After obtaining appropriate cultures, the man's physician should

- (A) observe closely for the development of a clinically evident source of fever
- (B) begin antibiotic therapy with gentamicin and mezlocillin
- (C) begin granulocyte transfusion and antibiotic therapy with gentamicin and mezlocillin
- (D) begin gammaglobulin treatment and antibiotic therapy with gentamicin and mezlocillin
- (E) begin antibiotic therapy with amphotericin, gentamicin, and mezlocillin

V-7. Coumarin-induced skin necrosis is occasionally associated with the institution of oral anticoagulants in patients with

- (A) antithrombin III deficiency
- (B) protein C deficiency
- (C) factor VIII deficiency
- (D) plasminogen deficiency
- (E) dysfibrinogenemias

V-8. A 55-year-old woman presents to the emergency department because her family notes that she has yellow skin. The patient has lost 7 kg (15 lbs) over the past 3 months but states that this is because she has been dieting in preparation for her daughter's wedding. Her past medical history is significant only for vitiligo. Her physical examination is unremarkable except for the presence of scleral icterus and a yellow tinge to the skin. Laboratory evaluation reveals hematocrit of 17%, WBC count of $2500/\mu\text{L}$, and platelet count of $70,000/\mu\text{L}$. Serum chemistries are normal except for direct bilirubin of $51 \mu\text{mol/L}$ (3 mg/dL) and indirect bilirubin of $12 \mu\text{mol/L}$ (0.7 mg/dL). The patient's reticulocyte count is 3%. MCV is 108 fL. Which one of the following additional laboratory findings would most likely be associated with this patient's clinical syndrome?

- (A) Clonal chromosomal abnormalities on karyotypic analysis of the bone marrow
- (B) Positive direct Coombs' test
- (C) Extrahepatic biliary obstruction
- (D) Decreased gastric fluid pH
- (E) Antiparietal cell antibody

V-9. A 43-year-old woman was diagnosed as having an infiltrating ductal carcinoma of the right breast when she**V-9.** (Continued)

was 41. The lesion was 3 cm in diameter. Lymph node examination was negative. Estrogen and progesterone receptors were negative. She underwent a lumpectomy, followed by radiation therapy to the breast and chest wall, followed by six cycles of cyclophosphamide plus doxorubicin chemotherapy. At this time she feels well but has two 2-cm nodules in each lung on chest radiography. These were not present on prior chest radiographs. In discussing the situation with the patient, which of the following statements is correct?

- (A) These nodules are a late manifestation of cyclophosphamide toxicity.
- (B) Tamoxifen therapy should be employed at this time.
- (C) Autologous bone marrow transplantation offers this patient the best chance for long-term disease-free survival.
- (D) An antibody to the *erbB2* proto-oncogene may improve the response to chemotherapy.
- (E) The patient has a median survival of approximately 6 to 12 months.

V-10. A 27-year-old woman presents with stage II (breast and lymph node involvement) right breast cancer. Her family history is markedly positive for other tumors. One of her sisters developed an osteogenic sarcoma at age 17, her brother was diagnosed with acute leukemia at age 5, her mother died of breast cancer, and she has two uncles with soft-tissue sarcomas, both developing this disease when in their thirties. This patient's peripheral blood lymphocytes would be most likely to reveal which of the following abnormalities?

- (A) Retinoblastoma gene mutation
- (B) p53 gene mutation
- (C) Translocation between chromosomes 9 and 22
- (D) Translocation between chromosomes 8 and 14
- (E) Mutations of epidermal growth factor receptor gene

V-11. A patient with a myelodysplastic syndrome (subtype, refractory anemia with ringed sideroblasts) has been transfusion-dependent for the past 2 years. The patient has received a total of 50 units of packed red blood cells. His physical examination is normal except for hyperpigmentation. Laboratory evaluation reveals mild glucose intolerance. A trial of erythropoietin was unsuccessful. Which of the following would be the most important therapeutic approach at this time?

- (A) Granulocyte colony-stimulating factor (G-CSF)
- (B) Phlebotomy
- (C) Ascorbic acid
- (D) Desferrioxamine
- (E) Hypertransfusion (maintain hematocrit at 40%)

- V-12.** A 26-year-old woman has painful mouth ulcers. Six weeks ago, she was started on propylthiouracil for hyperthyroidism. She is afebrile, and physical examination is unremarkable except for several small oral aphthous ulcers. White blood cell count is $200/\mu\text{L}$ (15% neutrophils, 80% lymphocytes, 5% monocytes); hemoglobin concentration, hematocrit, and platelet count are normal. The woman's physician should stop the propylthiouracil and
- schedule a follow-up outpatient appointment
 - arrange for HLA typing of her siblings in preparation for bone marrow transplantation
 - prescribe oral prednisone, 1 mg/kg
 - hospitalize her for broad-spectrum antibiotic therapy
 - hospitalize her for white blood cell transfusion
- V-13.** An 18-year-old black man undergoing a physical examination prior to playing college sports is found to have a normal CBC except that the MCV is 72 fL. Subsequent testing reveals a normal metabisulfite test and a normal hemoglobin electrophoresis. Which of the following conditions most likely accounts for these findings?
- Hemoglobin E trait
 - Sickle C disease
 - Sickle β thalassemia
 - β -thalassemia trait
 - α -thalassemia trait
- V-14.** A 30-year-old black woman with long-standing sickle cell anemia presents with severe pain in the chest and abdomen ~1 week after having an upper respiratory infection. No intrathoracic or intraabdominal pathology was immediately obvious on routine physical examination and laboratory evaluation. The most appropriate therapeutic intervention at this point is
- hypertransfusion
 - hydration and narcotic analgesia
 - hydroxyurea
 - broad-spectrum antibiotics
 - exploratory laparotomy
- V-15.** In persons who have chronic myelogenous leukemia, the translocation that accounts for the Philadelphia chromosome most commonly is found in
- all cells of the body
 - all three hematopoietic cell lines but not in nonhematopoietic cells
 - all cells of the granulocytic cell line but not in nongranulocytic cells
 - all bone marrow stem cells but not in mature cells
 - all bone marrow stem cells and certain mature granulocytes
- V-16.** Which of the following statements describes the relationship between testicular tumors and serum markers?
- V-16.** (Continued)
- Pure seminomas produce α -fetoprotein (AFP) or β -human chorionic gonadotropin (β -hCG) in >90% of cases.
 - More than 40% of nonseminomatous germ cell tumors produce no cell markers.
 - Both β -hCG and AFP should be measured in following the progress of a tumor.
 - Measurement of tumor markers the day following surgery for localized disease is useful in determining completeness of the resection.
 - β -hCG is limited in its usefulness as a marker, because it is identical to human luteinizing hormone.
- V-17.** A 45-year-old man presents with fatigue. Two years ago the patient received six cycles of combination chemotherapy (each cycle consisted of cyclophosphamide, doxorubicin, vincristine, and prednisone) for non-Hodgkin's lymphoma in chest and abdominal sites. The patient entered complete remission and has been followed expectantly since that point. His last prior visit was 3 months ago at which time he had no evidence of recurrent lymphoma, felt well, and had a normal laboratory examination. At this time his physical examination is remarkable for a purple discoloration of the fingertips, ears, and nose. The patient is somewhat pale. There is no evidence for peripheral lymphadenopathy. Laboratory studies include the following: white count $10,000/\mu\text{L}$ (differential 60% neutrophils, 10% bands, 10% lymphocytes, 10% monocytes, 3% eosinophils, 1% basophils, 2% metamyelocytes, 1% myelocytes, and 1% nucleated red blood cell), hematocrit 28% and platelet count $300,000/\mu\text{L}$. The following results are also found: MCV 98 fL, lactic dehydrogenase $6.8 \mu\text{kat/L}$ (400 U/L), total bilirubin $51 \mu\text{mol/L}$ (3.0 mg/dL), and direct bilirubin $5.1 \mu\text{mol/L}$ (0.3 mg/dL). Review of the peripheral blood smear reveals clumped red cells. A routine direct Coombs' test is negative. Additional laboratory testing would most likely reveal
- positive direct Coombs' test (using anti-IgG antisera) if specimen is processed without allowing cooling
 - positive indirect Coombs' test detected with anti-IgG antibodies
 - circulating antibodies against Epstein-Barr virus
 - circulating antibodies against fetal red blood cells
 - circulating antibodies against *Mycoplasma pneumoniae*
- V-18.** A 70-year-old man presents with back pain and fatigue. Workup reveals hematocrit of 30%, white blood cell count of $3.5/\text{mL}$, and platelet count of $220,000/\text{mL}$. Serum calcium and serum creatinine are normal. However, serum protein electrophoresis reveals a monoclonal protein of 42 g/L (4.2 g/dL), proved to be IgG- κ ; based on immunoelectrophoresis. Bone marrow examination dis-

V-18. (Continued)

closes sheets of dysplastic plasma cells, and skeletal survey reveals multiple osteolytic lesions in the skull and spine. The patient is started on melphalan, prednisone, and erythropoietin. Which of the following would be most reasonable to add to the patient's therapeutic regimen at this time?

- (A) G-CSF
- (B) Anti-interleukin (IL)6 antibodies
- (C) Pamidronate
- (D) Fludarabine
- (E) Doxorubicin

V-19. A 25-year-old, previously healthy woman presents with jaundice, confusion, and fever. Initial physical examination is unremarkable except for scattered petechiae on the lower extremities, scleral icterus, and disorientation on mental status examination. Laboratory examination discloses the following: hematocrit, 27%; white cell count, 12,000/ μL ; platelet count, 10,000/ μL ; bilirubin, 85 $\mu\text{mol/L}$ (5 mg/dL); direct bilirubin, 10 $\mu\text{mol/L}$ (0.6 mg/dL); urea nitrogen, 21 mmol/L (60 mg/dL); creatinine, 400 $\mu\text{mol/L}$ (4.5 mg/dL). Red blood cell smear discloses fragmented red blood cells and nucleated red blood cells. Prothrombin, thrombin, and partial thromboplastin times are all normal.

The most effective and appropriate therapeutic maneuver is likely to be

- (A) plasmapheresis
- (B) administration of aspirin
- (C) administration of high-dose glucocorticoids
- (D) administration of high-dose glucocorticoids plus cyclophosphamide
- (E) splenectomy

V-20. A 38-year-old woman presents with redness and burning in the distal extremities. She has no other complaints. She has never been pregnant. Physical examination is normal except for redness of the fingertips and splenomegaly. Laboratory examination reveals hematocrit 40%, WBC count 9000 with a normal differential, and platelet count of 950,000/ μL . Other laboratory studies include reticulocyte count of 1%, bone marrow examination that discloses a hypercellular marrow with megakaryocytic hyperplasia and hyperlobated megakaryocytes, absent collagen deposition, and the presence of normal amounts of bone marrow iron. Cytogenetic studies reveal a normal female karyotype. A red cell mass study is normal. Which of the following statements concerning the patient's condition is true?

- (A) Observation is indicated.
- (B) Splenectomy should be performed.
- (C) Oral administration of chlorambucil, 0.4 mg/kg daily for 5 days, should begin.

V-20. (Continued)

- (D) Aspirin, 2 tablets every 6 h, should be administered.
- (E) Hydroxyurea, 1000 mg daily orally, is indicated.

V-21. A 42-year-old woman presents with epistaxis and gum bleeding. Physical examination is remarkable for a temperature of 38°C (100.4°F) and petechiae on the lower extremities. Laboratory evaluation includes a hematocrit of 29%, platelet count of 15,000/ μL , and WBC of 2100/ μL (differential including 22% blasts, 30% promyelocytes, 20% lymphocytes, 10% monocytes, 2% myelocytes, and 3% metamyelocytes). PT is 15 s and PTT is 55 s. Bone marrow examination discloses a hypercellular marrow infiltrated with myeloblasts and heavily granulated promyelocytes. Myeloperoxidase stain of a bone marrow aspirate smear is markedly positive and demonstrates numerous intracellular rodlike forms. The patient is begun on all-*trans* retinoic acid. Which of the following is the most likely complication of this therapy?

- (A) Worsening of disseminated intravascular coagulopathy
- (B) Infection during neutropenia
- (C) Respiratory distress
- (D) Uric acid nephropathy
- (E) Mucositis

V-22. Which of the following statements regarding toxic effects of chemotherapy is correct?

- (A) Anthracyclines are relatively nonmyelosuppressive.
- (B) Vincristine is a relatively weak myelosuppressive agent and can be administered during periods of low blood counts.
- (C) Cisplatin-induced nausea and vomiting are mild.
- (D) The use of bleomycin has been associated with secondary leukemia.
- (E) Cisplatin can produce hypercalcemia by impairing renal excretion.

V-23. A 45-year-old man develops leukocytosis and fatigue. Workup reveals infiltration of the bone marrow with lymphoblasts. A sample of bone marrow is also sent for immunologic and cytogenetic analysis. Which of the following findings would be associated with the best prognosis?

- (A) Common acute lymphocytic leukemia antigen (CALLA) CD10 positivity, normal cytogenetics
- (B) CALLA CD10 positivity, t(9;22)
- (C) Surface immunoglobulin positivity, t(8;14)
- (D) My10 (CD34) positivity, normal cytogenetics
- (E) My7 (CD13) positivity, t(4;11) translocation

V-24. Two years ago a 68-year-old man was found to have a prostate nodule on routine examination. Biopsy revealed

V-24. (Continued)

poorly differentiated prostatic adenocarcinoma; staging studies failed to reveal any evidence of extraprostatic spread. Because of a desire to maintain potency, the patient opted for radiation therapy as primary treatment. Except for requiring lower extremity revascularization for intractable claudication, he did well until recently, when he developed pain in his right hip. Prostate specific antigen was elevated. Bone scan revealed areas of positive uptake in the pelvis and ribs (not present on the original staging study). The patient expresses a desire not to have a bilateral orchiectomy, “unless it would significantly improve my quality of life or survival compared with other therapies.”

The most appropriate strategy at this point is to

- (A) biopsy one of the bony lesions
- (B) administer cisplatin and 5-fluorouracil
- (C) administer leuprolide and flutamide
- (D) administer diethylstilbestrol (DES) at low dose
- (E) perform an orchiectomy

V-25. A 72-year-old man with known benign prostatic hypertrophy develops fever and flank pain. He rapidly becomes very ill. He presents to the emergency room with a blood pressure of 80/40 mmHg, heart rate of 120, and a temperature of 39.5°C (103°F). His urine shows numerous white cells. His laboratory examination is remarkable for a white count of 2000, hematocrit of 28%, and platelet count of 10,000. The PT and PTT are elevated. The most appropriate way to deal with this patient’s coagulopathy is

- (A) intravenous ϵ -aminocaproic acid
- (B) intravenous heparin
- (C) platelets and fresh-frozen plasma
- (D) antithrombin 3 concentrates
- (E) intravenous antibiotics

V-26. A 65-year-old woman presents with bleeding gums. Except for the presence of petechiae on the ankles, the physical examination is unremarkable. The white blood cell count is 500/ μ L with 10% neutrophils, the hematocrit is 25%, and the platelet count is 10,000/ μ L. Examination of a bone marrow biopsy reveals a cellularity of 10%. The few cells available for scrutiny do not reveal any morphologic abnormalities. The patient has no history of recent drug ingestion or hepatitis and has never experienced any similar problems. The most appropriate therapy for this patient would be

- (A) prednisone
- (B) low-dose ara-C
- (C) plasmapheresis
- (D) antithymocyte globulin, cyclosporine, methylprednisone, and G-CSF
- (E) G-CSF, erythropoietin, and IL-11

V-27. A patient being treated for refractory anemia has required monthly transfusions of 2 units of packed red blood cells over the past several months. Three days after receiving 2 units of packed red blood cells for a hematocrit of 22%, the patient’s hematocrit was 27%. One week after the transfusion the hematocrit is 22%; the patient feels ill, has a low-grade fever, and is mildly jaundiced. Which of the following statements about this situation is incorrect?

- (A) This problem is probably due to autoantibodies.
- (B) Intravascular hemolysis has probably occurred.
- (C) The Rh status of donor and recipient should be rechecked.
- (D) If the patient is Rh-positive, one should look for anti-Kell or anti-Duffy antibodies in the patient’s serum.
- (E) A positive direct Coombs’ test is unlikely.

V-28. Intravenous aprotinin is given to patients undergoing cardiac surgery to reduce blood loss. The mechanism of action is

- (A) primary inhibition of fibrinolysis (prevents dissolution of formed clots)
- (B) prevention of activation of the clotting cascade
- (C) prevention of activation of the clotting cascade and inhibition of fibrinolysis
- (D) enhancement of platelet activity
- (E) enhancement of platelet activity and inhibition of activation of the clotting cascade

V-29. Which of the following statements regarding ovarian cancer is correct?

- (A) A surgical debulking procedure is unhelpful.
- (B) Nulliparity is a risk factor.
- (C) A history of cervical cancer is a risk factor.
- (D) Stromal cell and germ cell tumors of the ovary are the most common histologic subtypes.
- (E) Histologic grade is not an important prognostic factor.

V-30. A 65-year-old woman on hemodialysis for chronic renal failure requires an urgent dental extraction for an abscessed tooth. Of the following, the most appropriate agent to administer to reduce the risk of significant bleeding would be

- (A) desmopressin
- (B) conjugated estrogen
- (C) erythropoietin
- (D) fresh-frozen plasma
- (E) ϵ -Aminocaproic acid

V-31. A 70-year-old woman is well except for a history of hypertension. On a routine physical examination, complete blood count and serum chemistry analysis are all normal except for total protein, which is 80 g/L (8.0 g/

V-31. (Continued)

dL). Subsequent workup reveals an M component on serum protein electrophoresis analysis. This proves to be an IgG monoclonal protein [11.5 g/L (1.15 g/dL)]. Quantitative immunoglobulin levels reveal normal levels of IgA and IgM, but the IgG level is 25% greater than normal. Bone radiographs and bone marrow examination are unremarkable, except the bone marrow biopsy shows several lymphoid aggregates and approximately 5% plasma cells. The most appropriate course of action at this time is

- (A) inform the patient that she has a benign process with a low incidence of conversion to a malignancy
- (B) give therapy with melphalan and prednisone in monthly pulses
- (C) perform an abdominal and pelvic CT scan
- (D) perform a serologic workup to rule out occult systemic lupus erythematosus and rheumatoid arthritis
- (E) perform a chest x-ray and plan a tuberculin skin test

V-32. An otherwise healthy 70-year-old woman undergoes routine mammography. A 1-cm speculated lesion in the upper outer quadrant of the left breast is noted. There are microcalcifications surrounding this lesion. The physical examination in general and of the breast is normal. Needle localization–guided biopsy of the lesion reveals infiltrating ductal carcinoma of the breast, with cancer cells at the margin of the resected specimen. Reexcision of the lesion contains negative margins. Examination of lymph nodes obtained at axillary dissection reveals no evidence of tumor. The patient is referred for radiation therapy to the breast. Hormone receptor status of the lesion reveals both estrogen- and progesterone-receptor positivity. The most appropriate systemic therapy is

- (A) none
- (B) tamoxifen
- (C) tamoxifen plus cytotoxic chemotherapy
- (D) cytotoxic chemotherapy
- (E) tamoxifen, cytotoxic chemotherapy, and intravenous antibody therapy against the *erbB2* proto-oncogene gene product

V-33. Children with acute lymphoblastic leukemia are much more likely to be cured than adults with the same disease. The most important factor accounting for this is

- (A) children are much less likely to have disease outside the bone marrow than are adults
- (B) lymphoblasts from children are more likely to contain a Philadelphia chromosome
- (C) blasts from children with ALL are more likely to contain an occult t(12;21)
- (D) blasts from children with ALL are more likely to contain a t(4;11) chromosomal translocation

V-33. (Continued)

- (E) children are much less likely to die as a consequence of chemotherapy-induced complications

V-34. Which of the following statements concerning the genetics of hereditary hemochromatosis is correct?

- (A) The majority of patients share a specific mutation.
- (B) About 1% of white Americans carry the gene for this disease.
- (C) Heterozygotes are typically affected.
- (D) Penetrance of the disease is near 100%.
- (E) The mutation produces a protein that promotes iron excretion.

V-35. Each condition listed below is associated with an increased risk of cancer of the esophagus. Which one is most closely linked to adenocarcinoma of the esophagus?

- (A) Achalasia
- (B) Smoking
- (C) Barrett's esophagus
- (D) Tylosis
- (E) Alcoholism

V-36. A 59-year-old man presents with fatigue, epigastric pain, early satiety, and iron-deficiency anemia. Upper gastrointestinal endoscopy reveals diffuse thickening throughout the stomach with some extension into the duodenum. Biopsy is undertaken. Review of the specimen reveals infiltration with malignant-appearing lymphocytes. Which of the following statements concerning the current situation is correct?

- (A) The patient has a greater than average likelihood of having blood group A.
- (B) The patient should receive combination chemotherapy with 5-fluorouracil, doxorubicin, and mitomycin C.
- (C) The prognosis would have been better if the biopsy had revealed neoplastic signet-ring cells.
- (D) Chemotherapy is absolutely contraindicated because of the risk of bleeding and perforation.
- (E) Immunoperoxidase studies probably would reveal evidence of B cell derivation.

V-37. Which of the following statements concerning screening for colorectal cancer is correct?

- (A) Patients who have a positive fecal Hemoccult test while on a low-meat diet are likely to have colorectal carcinoma.
- (B) The vast majority of patients with documented colorectal cancers have a positive fecal Hemoccult test.
- (C) No randomized studies of Hemoccult screening have documented a significant reduction in mortal-

V-37. (Continued)

ity from colorectal cancer in annually screened persons.

- (D) Present American Cancer Society recommendations include Hemoccult screening beginning at age 50 and sigmoidoscopic examination every 3 to 5 years beginning at age 50 for persons at average risk.
- (E) Rehydration of Hemoccult slides has no effect on the positivity rate.

V-38. A 53-year-old man with rectal bleeding was found to have adenocarcinoma 2 cm below the peritoneal reflection. After a negative metastatic workup, the patient underwent resection of the tumor with primary reanastomosis. Pathologic examination revealed a moderately well-differentiated adenocarcinoma of the rectum with 2 of 10 adjacent lymph nodes that contained cancer. The patient has no other medical problems. Optimal therapy at this point should include

- (A) pelvic radiation therapy alone
- (B) a chemotherapy regimen containing 5-fluorouracil (5-FU)
- (C) a combination of pelvic irradiation and a chemotherapy regimen containing 5-FU
- (D) a chemotherapy regimen containing 5-FU plus levamisole
- (E) observation alone

V-39. A 36-year-old woman presents with a firm painless mass in her right thigh just superior to her knee. A CT scan reveals a 4- by 5-cm solid mass attached to the muscle. You refer the patient to a surgeon, who performs an incisional biopsy. The pathology indicates high-grade fibrosarcoma with several mitoses per 10 high-power fields. The most appropriate management at this point is

- (A) observation
- (B) radiation therapy
- (C) chemotherapy with a doxorubicin-containing regimen
- (D) radiation therapy plus chemotherapy with a doxorubicin-containing regimen
- (E) complete excision of the mass

V-40. A 50-year-old man with a history of organomegaly and an elevated hematocrit without an apparent secondary cause was well until the sudden onset of pain in the right upper quadrant. On examination the patient is afebrile and has clear lungs, normal cardiac function, an abdominal fluid wave, splenomegaly, and a markedly enlarged liver with a palpable, very tender edge. Liver function tests are normal except for mild elevation of hepatic transaminases. Which of the following is the most appropriate procedure for the purposes of establishing a diagnosis?

V-40. (Continued)

- (A) CT scan of the liver
- (B) Abdominal ultrasound
- (C) Radionuclide liver-spleen scan
- (D) Hepatic venography
- (E) Paracentesis

V-41. A 65-year-old man with long-standing, stable biopsy-proven postnecrotic cirrhosis develops abdominal pain in the right upper quadrant and abdominal swelling. He is afebrile. Palmar erythema, spider telangiectasias, and mild jaundice are noted on physical examination. His abdomen is distended, shifting dullness is present, a tender, firm liver edge is felt 3 finger-breadths below the right costal margin, and a spleen tip is palpable. A faint bruit is heard over the liver. Laboratory values include the following:

Hematocrit: 34%

White blood cell count: 4300/ μ L

Platelet count: 104,000/ μ L

Serum albumin: 26 g/L (2.6 g/dL)

Serum globulins: 46 g/L (4.6 g/dL)

Alkaline phosphatase: 8.0 μ kat/L (480 U/L)

Paracentesis reveals blood-tinged fluid. The serum marker most specifically associated with this man's condition is

- (A) antinuclear antibody
- (B) α fetoprotein
- (C) antimitochondrial antibody
- (D) 5'-nucleotidase
- (E) chorionic gonadotropin

V-42. A 68-year-old man is undergoing adjuvant chemotherapy for completely resected colon cancer that involved several pericolic lymph nodes at the time of his surgical resection. He calls the internist covering for his primary oncologist with a complaint of a few days of diarrhea. He tells the physician that he has experienced approximately three to five loose watery stools per day over the past few days. He is mildly light-headed when walking around. The patient should be told to

- (A) take loperimide and increase oral fluid intake
- (B) begin metronidazole for presumed *Clostridium difficile* colitis
- (C) begin therapy with octreotide
- (D) come to the clinic or emergency room for evaluation
- (E) begin loperimide and metronidazole and increase fluid intake

V-43. A 73-year-old woman with known myelodysplastic syndrome and chronic anemia has required multiple trans-

V-43. (Continued)

fusions over the past several months. She now presents with profound fatigue and a hematocrit of 20%. Two units of blood are ordered, but the blood component lab informs you that they expect at least a day before a product will be ready for the patient. The most likely explanation for this problem in finding appropriate blood for transfusional therapy in this patient is

- (A) presence of allo-antibodies in the patient's serum
- (B) presence of autoantibodies in the patient's serum
- (C) rare blood group
- (D) careful screening necessary in myelodysplasia patients to prevent bloodborne infection
- (E) anti-HLA antibodies in the patient's serum

V-44. A 35-year-old woman develops hirsutism, deepening voice, and clitorimegaly. A pelvic examination reveals a left ovarian mass. Assuming appropriate diagnostic and staging tests are performed, given this clinical presentation, if the patient requires chemotherapy she should be treated in a fashion analogous to the management of

- (A) epithelial ovarian cancer
- (B) lymphoma
- (C) testicular cancer
- (D) soft tissue sarcoma
- (E) carcinoid tumor

V-45. A 65-year-old woman presents with severe pelvic pain with radiation down both legs. There is no evidence of a sensory level. Physical examination is unremarkable except for a colostomy in the right lower quadrant. There is a history of an abdominal-perineal resection for rectal cancer 3 years ago. Postoperatively she received pelvic irradiation and adjuvant chemotherapy with 5-FU. The most likely cause for this patient's pain is

- (A) pelvic recurrence of rectal cancer
- (B) bony metastasis
- (C) secondary leukemia with bone pain
- (D) post-radiation radiculitis
- (E) sciatic nerve inflammation

V-46. Which of the following is correct regarding small cell lung cancer compared to non-small cell lung cancer?

- (A) Small cell lung cancer is more radiosensitive.
- (B) Small cell lung cancer is less chemosensitive.
- (C) Small cell lung cancer is more likely to present peripherally in the lung.
- (D) Small cell lung cancer is derived from an alveolar cell.
- (E) Bone marrow involvement is more common in non-small cell lung cancer.

V-47. A 43-year-old woman presents with a hematocrit of 25%, an MCV of 101, reticulocyte count of 1.2%, platelet

V-47. (Continued)

count of 25,000/ μL , and white count of 2300/ μL with 25% neutrophils.

Non-Hodgkin's lymphoma was diagnosed 6 years ago. At that time she presented with diffuse large cell lymphoma in abdominal and cervical lymph nodes. She underwent six cycles of cyclophosphamide, doxorubicin, vincristine, and prednisone chemotherapy followed by a disease-free interval of 6 months, at which point she relapsed. She then received three additional cycles of identical chemotherapy. Because of persistent abnormal nodes, she then received four cycles of chemotherapy consisting of etoposide, ara-C, cisplatin, and methylprednisolone. She achieved a remission followed by consolidation therapy with high-dose cyclophosphamide and total-body radiation with autologous marrow. She tolerated the transplant well (which was carried out approximately 2 years ago) and was working until her current presentation with fatigue. Serum chemistries at this time are normal. Her blood smear reveals a dimorphic population of red cells, diminished numbers of platelets, and a paucity of white cells; some of the neutrophils are bilobed. A bone marrow examination is performed. Given the above facts, which of the following is the most likely result?

- (A) Hypolobated megakaryocytes, megaloblastic erythroid precursors, and excessive number of immature myeloid cells
- (B) A marked increase in the ratio of fat to cells
- (C) Foci of immature lymphoid cells
- (D) Erythroid hypoplasia
- (E) Normal-appearing bone marrow

V-48. A 65-year-old man presents with cervical adenopathy and night sweats. Further workup reveals a moderately large mediastinal mass and diffuse abdominal periaortic adenopathy on abdominal/pelvic CT. Bilateral bone marrow biopsies fail to disclose tumor. Cervical lymph node biopsy discloses infiltration with moderately immature-appearing lymphoid cells. Immunophenotypic studies performed on these cells obtained from the biopsied node reveal expression of the following antigens: CD19, CD20, and CD5, CD23 is absent. Cytogenetic studies showed a t(11;14) translocation. The patient's CBC is normal. The most likely diagnosis in this case is

- (A) hairy cell leukemia
- (B) small lymphocytic lymphoma
- (C) diffuse large cell lymphoma
- (D) mantle cell lymphoma
- (E) acute lymphoblastic leukemia

V-49. A 28-year-old man with embryonal carcinoma of the testicle is undergoing chemotherapy with a regimen containing bleomycin, etoposide, and cisplatin. Toxicity to

V-49. (Continued)

which one of the following organs bears close scrutiny in this situation?

- (A) Brain
- (B) Eye
- (C) Lungs
- (D) Liver
- (E) Heart

V-50. A patient with stable phase chronic myeloid leukemia is being managed with α -interferon therapy. After having done well for 2 years, he now presents with an increasingly left shifted white cell differential on blood smear. Bone marrow examination shows a hypercellular marrow with increased numbers of basophils. Cytogenetic analysis reveals that there are two Philadelphia chromosomes per cell. The most likely explanation for this cytogenetic change is

- (A) interferon effect
- (B) accelerated or blastic phase
- (C) diagnosis actually agnogenic myeloid metaplasia/myelofibrosis
- (D) error in interpretation of cytogenetic result
- (E) favorable prognostic sign

V-51. A 35-year-old woman presents because of excessive bleeding after a dental extraction. She has a history of frequent prolonged menstrual periods, prolonged bleeding after the delivery of her only child 5 years ago, and easy bruisability. She also notes that her mother had a history of excessive bleeding as well. Physical exam at this time is unremarkable. The following studies are sent: WBC, $6500/\mu\text{L}$; hematocrit, 39%; platelet count, $250,000/\mu\text{L}$; PT, 12 s; PTT, 25 s; bleeding time, 15 min (normal, 5 to 10 min). The patient is taking no medicine and has taken no aspirin or nonsteroidal anti-inflammatory agents in the past month. Based on the available information, the most likely diagnosis is

- (A) hemophilia A
- (B) hemophilia B
- (C) factor XII deficiency
- (D) von Willebrand's disease
- (E) Bernard-Soulier disease

V-52. A 68-year-old woman with metastatic breast cancer with a pleural effusion and multiple bony metastases complains of moderately severe pain in the area of her left clavicle and right femur. She has already received radiation therapy to these areas, and plain x-ray of the leg reveals that there is little danger of a pathologic fracture. The patient's current medicines include amitriptyline, oxycodone 30 mg every 3 to 4 h, and acetaminophen 650 mg every 4 h. Which of the following is the best therapy at this point?

V-52. (Continued)

- (A) Addition of morphine 30 mg every 4 h
- (B) Morphine sulfate intravenous drip 1 mg/h
- (C) Nerve block
- (D) Substitute subcutaneous meperidine 50 mg every 3 h for the oxycodone
- (E) Substitute controlled-release morphine 60 to 120 mg twice a day in place of the oxycodone

V-53. Mutations in the retinoblastoma gene cause cancer by

- (A) constitutively activating G proteins
- (B) acting as a "turned-on" growth factor receptor
- (C) constitutively activating tyrosine phosphorylation
- (D) inability to initiate apoptosis
- (E) failure to regulate transition from G_1 to S phase

V-54. A 32-year-old woman presents to your office concerned about her risk of cancer. Her mother died at age 50 with ovarian cancer. She has one brother and two sisters. The brother and one sister are fine, but her other sister was recently diagnosed with stage II breast cancer at age 39. The most effective strategy at this point would be to

- (A) recommend that the sister be tested for presence of *BRCA-1* or *BRCA-2* mutation
- (B) recommend that the patient be tested for the presence of *BRCA-1* or *BRCA-2* mutation
- (C) recommend bilateral simple mastectomies
- (D) recommend bilateral total mastectomies
- (E) recommend annual mammographic screening

V-55. A 42-year-old man is admitted to the hospital with a fever. Eight days ago he received his third cycle of cyclophosphamide, doxorubicin, vincristine, and prednisone chemotherapy to treat a diffuse large cell lymphoma that had presented in the right cervical area and in the mediastinum. After the first two cycles, the tumor had diminished markedly in size based on physical exam and chest radiography. At this time the patient appears mildly ill, has a temperature of 39°C (102°F) and a non-focal physical examination. His CBC reveals a hematocrit of 32%, white count of 1000 with 20% neutrophils, and a platelet count of $85,000/\mu\text{L}$. The patient is treated with broad-spectrum antibacterial antibiotics, defervesces, and is released in 8 days, at which time his neutrophil count is $>500/\mu\text{L}$.

The most appropriate course of action would be to

- (A) administer the same doses of chemotherapy used in the last cycle within 1 week; administer G-CSF beginning the day after the chemotherapy is completed
- (B) delay readministration of chemotherapy for 2 weeks

V-55. (Continued)

- (C) decrease the dose of cyclophosphamide and doxorubicin by 25%; administer the chemotherapy within the next week
- (D) change therapy to cyclophosphamide, vincristine, and prednisone
- (E) change therapy to etoposide, methylprednisone, cytarabine, and cisplatin

V-56. A 52-year-old man noted a pigmented lesion in the area of his left flank. Excisional biopsy revealed a malignant melanoma 2.5 mm in thickness. The patient then underwent a definitive resection of the tumor with 2-cm margins that were not involved. Chest x-ray and liver function tests are normal. The patient should receive

- (A) interferon- α
- (B) interleukin-2
- (C) dacarbazine
- (D) dacarbazine plus carmustine
- (E) observation

V-57. A 65-year-old man with a long smoking history presents with progressive weakness of both legs. Specifically, he has had difficulty arising from a sitting position. The patient also complains of a cough. Physical examination is remarkable for a mildly chronically ill-appearing male with weakness of the proximal muscles of the arms and legs. Chest x-ray reveals a large right hilar mass. Which tumor-associated pathophysiologic abnormality most likely accounts for the patient's neurologic symptoms?

- (A) Small cell lung cancer and abnormalities in the presynaptic component of neuromuscular transmission
- (B) Non-small cell lung cancer and abnormalities in the presynaptic component of neuromuscular transmission
- (C) Small cell lung cancer and abnormalities of axonal transmission
- (D) Non-small cell lung cancer and abnormalities of axonal transmission
- (E) Non-Hodgkin's lymphoma and abnormalities at the motor neuron

V-58. A 55-year-old woman presents with progressive incoordination. Physical examination is remarkable for nystagmus, mild dysarthria, and past-pointing on finger-to-nose testing. She also has an unsteady gait. MRI reveals atrophy of both lobes of the cerebellum. Serologic evaluation reveals the presence of anti-Yo antibody. Which of the following is the most likely cause of this clinical syndrome?

- (A) Non-small cell cancer of the lung
- (B) Small cell cancer of the lung

V-58. (Continued)

- (C) Breast cancer
- (D) Non-Hodgkin's lymphoma
- (E) Colon cancer

V-59. A 21-year-old man is undergoing intensive chemotherapy for acute lymphoblastic leukemia, having been diagnosed 3 months previously. A bone marrow exam done 1 month ago revealed a complete remission. He now presents with facial swelling and cough. Physical examination reveals facial swelling, dilated neck veins, and a prominent venous pattern on the skin of the upper thorax. A Hickman catheter in the left anterior chest appears normal. The rest of his physical exam is unremarkable. Laboratory examination reveals a normal CBC, and a chest x-ray shows mediastinal widening. The most likely cause of this patient's clinical syndromes is

- (A) recurrence of tumor in the mediastinum
- (B) radiation-induced pulmonary fibrosis
- (C) hypercoagulable state induced by the underlying neoplasm
- (D) catheter-associated superior vena cava thrombosis
- (E) fungal infection of the chest

V-60. The most common cause of high serum calcium in a patient with a known cancer is

- (A) ectopic production of parathyroid hormone
- (B) direct destruction of bone by tumor cells
- (C) local production of tumor necrosis factor and IL-6 by bony metastasis
- (D) high levels of 1,25-hydroxyvitamin D
- (E) production of parathyroid hormone-like substance

V-61. A 35-year-old man with acute myeloid leukemia is 12 days status post-receiving high-dose cytarabine for relapsed disease. He is complaining of severe right lower quadrant pain. His temperature is 39°C (103°F), blood pressure is 100/60, and heart rate is 110. He is moderately ill-appearing. His physical examination is remarkable for rebound tenderness in the right lower quadrant. Laboratory examination reveals a white count of 100/ μ L (differential: 0 polys and 100 lymphs), platelet count is 12,000/ μ L, hematocrit is 28.0%. Liver function tests are normal. KUB is unremarkable. CT scan of the abdomen shows a thickened proximal colonic wall due to a pericolonic mass or infiltrate. The most appropriate therapy or strategy at this time is

- (A) exploratory laparotomy
- (B) continued broad-spectrum antibiotics with good bowel organism coverage
- (C) continued broad-spectrum antibiotics with good bowel organism coverage and do not allow the patient to eat
- (D) administration of reinduction chemotherapy for the pericolonic chloroma

V-61. (Continued)

- (E) placement of a CT-guided catheter for percutaneous drainage of the abdominal abscess

V-62. A 70-year-old woman presents to her internist for routine check-up. She has diabetes and hypertension, both of which are managed with oral therapy. She is chronically fatigued but has no specific complaints. Physical examination discloses several 1- to 2-cm nodes on both sides of the anterior neck and in the axilla. Routine blood counts reveal that her white count is 98,000 mainly due to a preponderance of mature-appearing lymphs, hematocrit is 38.2%, and platelet count is 250,000/ μL . Except for a mildly elevated LDH, her serum chemistries are normal. Serum protein electrophoresis reveals hypogammaglobulinemia. Flow cytometric analysis of the patient's peripheral blood reveals that most of the cells express the CD20, CD23, and CD5 antigens. A CT scan of the chest, abdomen, and the pelvis discloses multiple 1- to 2-cm lymph nodes in the peri-aortic area. The most appropriate therapy at this time is

- (A) observation
 (B) intravenous gammaglobulin
 (C) chlorambucil
 (D) chlorambucil and prednisone
 (E) fludarabine

V-63. A 65-year-old man presents because of fatigue. He has no other specific complaints except for mild left-sided abdominal pain. Physical exam is remarkable for a spleen tip which is palpable 7 finger breadths from the left costal margin. Serum chemistries are remarkable for an LDH which is elevated fourfold. Hematocrit is 26%; white count is 18,000/ μL with 1% blasts, 5% promyelocytes, 4% myelocytes, 10% metamyelocytes, 10% band forms, 25% polys, 25% lymphs, 10% monocytes, and 10% nucleated red blood cells; and platelet count is 245,000/ μL . The red cell smear discloses many tear drop-shaped red cells. A bone marrow examination is undertaken, but the bone marrow aspirate is impossible to obtain. The most likely finding on the bone marrow biopsy is

- (A) myelofibrosis
 (B) hairy cell leukemia
 (C) acute myeloid leukemia
 (D) aplastic anemia
 (E) metastatic prostate cancer

V-64. A 65-year-old former heavy smoker who was diagnosed with small cell cancer of the lung 1 year ago now presents with fever, chills, and cough. His disease originally presented with a right perihilar mass. After the histologic diagnosis was made and distant metastases were excluded, the patient received combination chemotherapy and radiation therapy to his right lung. At this time the patient looks mildly ill, has a temperature of 38°C (101°F),

V-64. (Continued)

and decreased breath sounds at the right base. Chest x-ray shows tracheal deviation to the right, a question of a right lower lobe mass, and dense right lower lobe collapse or consolidation. There is a small right pleural effusion. Which of the following represents the most important next step in management?

- (A) External beam radiation therapy
 (B) Systemic chemotherapy
 (C) Broad-spectrum antibiotics
 (D) External beam radiation therapy plus chemotherapy
 (E) Bronchoscopy

V-65. A 43-year-old man presents with severe mid-thoracic back pain. His past medical history is remarkable for the removal of a malignant melanoma (depth 1.5 mm) approximately 3 years ago. The patient's back pain is severe and has been waking him up at night over the past week. Physical examination is unremarkable. Plain films of the spine reveal loss of the left pedicle in the fifth thoracic vertebra. Magnetic resonance images are obtained, and the patient is begun on steroids. Which of the following treatment modalities is most appropriate in this situation?

- (A) Surgery
 (B) Radiation therapy
 (C) Chemotherapy
 (D) Hormonal therapy
 (E) Immunotherapy

V-66. A 72-year-old man who has become progressively more fatigued is found to be anemic. Hematologic laboratory values are as follows:

Hemoglobin: 100 g/L (10 g/dL)

Hematocrit: 27.5%

Mean corpuscular volume (MCV): 101 fL

Mean corpuscular hemoglobin (MCH): 30 pg

Mean corpuscular hemoglobin concentration (MCHC): 340 g/L (34 g/dL)

Reticulocyte count: 0.5%

White blood cell count: 7300/ μL (65% neutrophils)

Platelet count: 210,000/ μL

The most likely diagnosis is

- (A) acute leukemia
 (B) aplastic anemia
 (C) autoimmune hemolytic anemia
 (D) iron deficiency
 (E) myelodysplastic syndrome

V-67. Which of the following industrial toxins is associated with tumors of the liver?

V-67. (Continued)

- (A) Asbestos
- (B) Benzene
- (C) Mustard
- (D) Chromium
- (E) Vinyl chloride

V-68. A 59-year-old postmenopausal woman underwent radical mastectomy 3 years ago for carcinoma of the breast. All nodes biopsied were negative, and the estrogen receptor status of the tumor was positive at 150 fmol/mg of cytosol protein. No further therapy was ordered. Now the woman presents with right upper leg pain. Plain films reveal a 3-cm lytic lesion in the right upper femur with cortical erosion, and a bone scan shows not only the femoral lesion but also three separate lesions in her ribs, two in her skull, and one in her pelvis. Chest x-ray is unremarkable, and liver function tests are normal.

The most appropriate therapeutic option now would be

- (A) tamoxifen, 10 mg twice daily
- (B) tamoxifen, 10 mg twice daily, plus CMF combination chemotherapy (cyclophosphamide, methotrexate, and 5-fluorouracil)
- (C) tamoxifen, 10 mg twice daily, plus external-beam radiation to the femoral lesion
- (D) tamoxifen, 10 mg twice daily, plus prophylactic internal fixation of the right femur followed by external-beam radiation
- (E) tamoxifen, 10 mg twice daily, plus both CMF and external-beam radiation to the femoral lesion

V-69. A 65-year-old man develops superficial thrombophlebitis in multiple sites including the arms and chest. He has had several episodes in the past couple of months, each of which lasted a few days. Which of the following neoplasms is most closely associated with this patient's clinical problem?

- (A) Prostate carcinoma
- (B) Lung carcinoma
- (C) Pancreatic carcinoma
- (D) Acute promyelocytic leukemia
- (E) Paroxysmal nocturnal hemoglobinuria

V-70. Which of the following statements concerning the difference between hemophilia A and hemophilia B is correct?

- (A) Patients with hemophilia A have a prolonged partial thromboplastin time; patients with hemophilia B have a prolonged partial thromboplastin time and a prolonged prothrombin time.
- (B) Hemophilia A is inherited in a sex-linked fashion, hemophilia B is inherited in an autosomal dominant fashion.
- (C) Patients with hemophilia A can be treated with recombinant factor concentrates; patients with hemophilia B require purified factor concentrates.

V-70. (Continued)

- (D) Hemophilia A patients have a defect in a clotting protein not dependent on vitamin K; hemophilia B patients have a defect in a clotting protein that is vitamin K dependent.
- (E) Hemophilia A patients present with bleeding into the joints; hemophilia B patients present with mucosal bleeding.

V-71. A 65-year-old woman with myelodysplastic syndrome, subtype refractory anemia, has required platelet transfusional therapy intermittently for the past year. She normally receives one bag (approximately 6 units) of irradiated single donor platelets obtained by a pheresis. Her platelet count today is 6000 and she is receiving a bag of platelets. At the conclusion of the transfusion, she develops a temperature to 39°C (102.2°F) and has rigor. She has had several similar reactions in the past several weeks. Her platelet count drawn 1 h after the platelet transfusion is 36,000/μL. Assuming that blood and platelet culture results are negative, which of the following would be the best way to reduce the likelihood of such febrile reactions in the future?

- (A) Premedicate the patient with acetaminophen and diphenhydramine
- (B) Administer cytomegalovirus (CMV)-negative platelets
- (C) Administer HLA-identical platelets
- (D) Administer leukocyte-reduced platelets
- (E) Administer platelets from the patient's sibling

V-72. A 27-year-old man has a testicular mass. Chest x-ray reveals six discrete tumor nodules, and an abdominal CT scan shows enlarged paraaortic nodes. Serum α -fetoprotein level is elevated. He undergoes transinguinal orchiectomy, which reveals teratocarcinoma. Treatment is started with three cycles of combination chemotherapy consisting of bleomycin, etoposide, and cisplatin; he tolerates the chemotherapy well. Four of the six lung nodules resolve completely, the paraaortic nodes disappear, and α -fetoprotein levels return to normal. The two remaining pulmonary nodules, one in each lung, have diminished in size to about 2 cm. The man receives a fourth cycle of the same drugs with no change in his clinical status.

At this stage, his physician should

- (A) continue the same chemotherapy for one more cycle but increase the dosage of drugs by 50%
- (B) switch to a new drug regimen
- (C) perform thoracotomy in order to biopsy and remove the nodule on one side
- (D) administer low-dose, whole-lung radiation
- (E) administer high-dose spot radiation to the individual lung nodules

V-73. A 32-year-old man with acute myeloid leukemia in first remission undergoes an allogeneic bone marrow

V-73. (Continued)

transplant with marrow from his HLA-identical sister. Prior to the administration of his sister's marrow, the patient underwent preparation with high-dose cyclophosphamide and total-body irradiation. About 6 days after the administration of the graft, the patient feels quite ill. He develops a fever to 39°C (102.2°F) and begins to note a maculopapular skin rash over the arms and back. He has severe diarrhea and intermittent abdominal pain. Results of his liver function tests are markedly abnormal with elevation of the serum bilirubin, SGOT, and alkaline phosphatase. The most likely cause for this clinical syndrome is

- (A) graft-versus-host disease
- (B) CMV infection
- (C) autoimmune transfusion reaction
- (D) bacterial sepsis
- (E) venoocclusive disease of the liver

V-74. A 40-year-old woman undergoes her first mammogram. The study reveals a cluster of microcalcifications in the right breast. Needle biopsy reveals a focus of lobular carcinoma in situ (no invasion). At this point the patient should be offered

- (A) quadrantectomy and lymph node dissection on the ipsilateral side
- (B) quadrantectomy with irradiation
- (C) right breast mastectomy with irradiation depending on lymph node status at the time of surgery
- (D) irradiation therapy to the right breast
- (E) resection followed by annual mammography and semiannual physical exam

V-75. A 45-year-old woman with long-standing rheumatoid arthritis is diagnosed as having "anemia of chronic disease." The predominant mechanism causing this type of anemia in persons with chronic inflammatory disorders is

- (A) defective porphyrin synthesis
- (B) impaired incorporation of iron into porphyrin
- (C) intravascular hemolysis
- (D) depressed erythroid maturation due to decreased erythropoietin production
- (E) impaired transfer of reticuloendothelial storage iron to marrow erythroid precursors

V-76. Which of the following statements best characterizes the hemolysis associated with glucose-6-phosphate dehydrogenase (G6PD) deficiency?

- (A) It is more severe in affected blacks than in affected persons of Mediterranean ancestry.
- (B) It is more severe in females than in males.
- (C) It causes the appearance of Heinz bodies on Wright staining of a peripheral smear.
- (D) It most often is precipitated by infection.

V-76. (Continued)

(E) The best time to perform the diagnostic test is during a hemolytic crisis.

V-77. A 65-year-old man with a benign past medical history presents to his internist for a routine medical check-up. His physical examination and laboratory studies are normal except for a serum prostate-specific antigen (PSA) value of 8 ng/mL (normal 0 to 3 ng/mL). Which of the following is a true statement about the man's condition?

- (A) His likelihood of prostate cancer is 75%.
- (B) If he does have prostate cancer, the disease is likely confined to the gland.
- (C) Assuming there is no evidence of metastatic spread, the patient should undergo a radical prostatectomy.
- (D) Assuming there is no evidence of spread, the patient should receive radiation therapy to the prostate.
- (E) The patient should receive therapy with leuprolide and flutamide.

V-78. A 38-year-old premenopausal woman has a 3-cm mass in her left breast. Breast biopsy reveals infiltrating ductal carcinoma, and a left modified radical mastectomy is performed. The pathology report states that the primary tumor is estrogen-receptor-positive and that 4 of 28 lymph nodes identified are involved with tumor. Chest x-ray, bone scan, liver scan, and blood chemistries are all normal. The most appropriate next step in the management of this patient would be

- (A) antiestrogen therapy (e.g., tamoxifen)
- (B) appropriate combination chemotherapy
- (C) postoperative radiation therapy to the left chest wall and axilla
- (D) bilateral oophorectomy
- (E) follow-up in 2 months

V-79. A 55-year-old man complains of numbness in both legs and progressive inability to walk over the past 2 months. Physical examination is normal except for a decreased perception of light touch and pain in the lower extremities as well as bilateral leg weakness. There is no sensory level. Laboratory workup is remarkable for a hematocrit of 30% and elevated total protein. Serum protein electrophoresis reveals an M spike. The etiology of this patient's weakness is most likely

- (A) necrosis of central nervous system gray and white matter
- (B) inflammation of dorsal root ganglia
- (C) loss of cerebellar Purkinje cells
- (D) elaboration of tumor-associated protein that elicits an immune response that is cross-reactive with peripheral nerves
- (E) tumor-elaborated immunoglobulin that is reacting with myelin components

- V-80.** A 45-year-old woman presents with an axillary mass. She has no other complaints. Her past medical history is benign and she is taking no medication. Physical examination is unremarkable except for the presence of a firm, nonmoveable mass of 4×3 cm in the left axilla. Biopsy of the mass reveals poorly differentiated malignant neoplasm without gland formation. Immunoperoxidase staining of the tumor is negative for cytokeratin and positive for the leukocyte common antigen. The most appropriate next step for this patient is
- modified radical mastectomy with axillary radiation therapy
 - axillary radiation therapy
 - administration of cyclophosphamide, methotrexate, and 5-fluorouracil
 - administration of tamoxifen
 - chest and abdominal CT
- V-81.** Evaluation of a person who has pure red blood cell aplasia would be expected to reveal
- markedly hypocellular bone marrow
 - normochromic, normocytic red blood cells
 - increased iron turnover on ferrokinetic studies
 - a reticulocyte count $>2.0\%$
 - decreased urinary erythropoietin content
- V-82.** A 28-year-old man presents with chest pain. Chest x-ray reveals a large mediastinal mass. Abdominal CT reveals periaortic lymphadenopathy. Physical examination, including examination of the testes, is negative. Mediastinoscopic biopsy reveals poorly differentiated carcinoma. Which of the following laboratory tests would be most likely to be positive?
- Prostate-specific antigen (PSA)
 - Beta human chorionic gonadotropin (β -hCG)
 - Carcinoembryonic antigen (CEA)
 - CA-125
 - CA19-9
- V-83.** Which of the following is likely to be a neoplasm of T-lymphocyte lineage?
- Chronic lymphocytic leukemia
 - Follicular lymphomas
 - Burkitt's lymphoma
 - Mycosis fungoides
 - Small lymphocytic (well-differentiated) lymphomas
- V-84.** A 29-year-old woman undergoing an infertility workup presents for a preoperative evaluation prior to a planned laparoscopy. She appears to be healthy and her physical examination is unremarkable. She is not taking any medicines. Preoperative laboratory evaluation is normal except that her prothrombin time is prolonged to a level two times above normal. Which one of the following
- V-84.** (*Continued*) additional tests is most likely to define the reason for this laboratory abnormality?
- Anticardiolipin antibody
 - Serologic test for syphilis
 - Factor VIII levels
 - Factor V mutational analysis
 - Mixing studies
- V-85.** A 21-year-old woman who has had severe menorrhagia is referred by her gynecologist for evaluation of a possible systemic coagulopathy. A younger sister has been noted to bleed excessively after trauma. She takes no medications; physical examination is unremarkable. Initial laboratory results include the following: platelet count, $252,000/\mu\text{L}$; prothrombin time, 23.6 s (control 11.6 s); and partial thromboplastin time, 26.9 s (control 33.3 s). Further laboratory testing should include
- determination of α_2 -antiplasmin level
 - screening for inhibitors
 - determination of bleeding time
 - determination of factor VII level
 - determination of factor VIII level
- V-86.** Why are patients with the factor V Leiden mutation at higher risk for venous thrombosis during pregnancy or after surgery?
- Platelets aggregate abnormally
 - This mutation is associated with an antibody to protein S
 - This mutation is associated with an antibody to protein C
 - Inability of protein C to cleave factor V
 - This mutation results in the production of fibrin that is resistant to clot dissolution
- V-87.** A 65-year-old woman with increasing abdominal pain is found to have a pelvic mass on physical examination. After appropriate staging studies she undergoes a laparotomy and is found to have serous carcinoma of the ovary with involvement of one ovary and several omental implants. She then undergoes a hysterectomy, bilateral salpingo-oophorectomy, liver biopsy, omentectomy, cytologic examination of abdominal washings, and extensive inspection. All evidence of disease is removed.
- Assuming generally good health, an uneventful postoperative recovery, and lack of proximity to a center performing clinical trials, she should now receive
- no further therapy
 - combination chemotherapy
 - combination chemotherapy only if serum CA125 level is elevated
 - intraperitoneal chemotherapy
 - whole abdominal radiation therapy

- V-88.** A 55-year-old man who recently underwent hip surgery develops a pulmonary embolism and is placed on unfractionated heparin. After 3 days of therapy, his platelet count (previously normal) is now 50,000/ μl . What is the mechanism of the thrombocytopenia in this case?
- (A) The induction of an anti-platelet antibody
 - (B) Platelet-heparin binding causing platelet aggregation
 - (C) Splenomegaly causing platelet pooling
 - (D) Heparin-induced bone marrow suppression
 - (E) Platelet aggregation due to the formation of a heparin–platelet factor IV antibody complex
- V-89.** A feature of idiopathic thrombocytopenic purpura common to both children and adults is
- (A) occurrence after an antecedent viral illness
 - (B) presence of antibodies directed against target antigens on the glycoprotein IIb-IIIa complex
 - (C) absence of splenomegaly
 - (D) persistence of thrombocytopenia for more than 6 months
 - (E) necessity of splenectomy to ameliorate thrombocytopenia
- V-90.** Persons with polycythemia vera and a hematocrit $>45\%$ are most likely to display which of the following?
- (A) Increased levels of urinary erythropoietin
 - (B) Increased bone marrow iron stores
 - (C) Decreased carotid blood flow
 - (D) Hypocellular bone marrow
 - (E) Myelophthistic changes in their peripheral blood smear, including teardrop-shaped red blood cells and normoblasts
- V-91.** A young woman presents with bleeding after a dental extraction. She is found to have a bleeding time of greater than 20 min along with a normal prothrombin time and partial thromboplastin time. There is a familial history of bleeding, and the patient's laboratory evaluation reveals a normal platelet count. The factor VIII coagulant activity is 54% of normal, von Willebrand factor (vWF) antigen is 48% of normal, and ristocetin cofactor is 13% of normal. A normal spectrum of vWF multimers in the patient's plasma on SDS-agarose electrophoresis is noted. This patient's coagulopathy is primarily caused by
- (A) defective release of vWF from endothelial cells
 - (B) inappropriate binding of vWF to platelets
 - (C) reduced synthesis of vWF by endothelial cells
 - (D) an inability to assemble high-molecular-weight multimers or premature catabolism of vWF
 - (E) an alteration in the platelet receptor for vWF
- V-92.** A 1-year-old boy bleeds significantly after an inguinal hernia repair. The patient has no siblings, and there
- V-92.** (*Continued*) is no familial history of a bleeding diathesis. Platelet count, bleeding time, prothrombin time, and partial thromboplastin time are all normal. The most likely diagnosis is
- (A) prekallikrein deficiency
 - (B) factor XII deficiency
 - (C) factor XIII deficiency
 - (D) thrombasthenia
 - (E) protein S deficiency
- V-93.** Which statement about doxorubicin (Adriamycin) cardiotoxicity is true?
- (A) Acute cardiotoxicity, which is characterized by arrhythmias and other abnormal electrocardiographic changes, is common and serious
 - (B) Chronic cardiotoxicity occurs in 20% of persons whose lifetime dose of doxorubicin is 300 mg/m²
 - (C) Weekly doxorubicin therapy is less well tolerated than the same total dose given every 3 weeks
 - (D) Doxorubicin cardiotoxicity and cytotoxicity occur via the same pathway
 - (E) Previous cardiac irradiation and exposure to cyclophosphamide or anthracycline antibiotics other than doxorubicin increase the risk of cardiotoxicity
- V-94.** Which statement regarding the treatment of patients with non-Hodgkin's lymphoma is true?
- (A) Radiation therapy is curative for most patients with low-grade non-Hodgkin's lymphoma
 - (B) In those patients with low-grade lymphoma who require chemotherapy, only combinations of agents can change overall survival rate
 - (C) Over 75% of patients with intermediate-grade (e.g., diffuse large cell) lymphoma will achieve complete remission with combination chemotherapy
 - (D) Maintenance therapy (low-dose prolonged therapy after complete remission is achieved) improves survival in patients with diffuse large cell lymphoma
 - (E) Patients with non-Hodgkin's lymphoma who have AIDS have the same rate of response to chemotherapy as stage- and grade-matched patients without AIDS
- V-95.** A 65-year-old man presents because his wife notes that his eyes are becoming yellow. On further questioning, the patient complains of epigastric discomfort, dark urine, light stools, and pruritus. Past medical history and physical examination are unremarkable. Laboratory tests confirm the clinical impression of an elevation in the serum level of conjugated bilirubin. Abdominal ultrasound demonstrates a mass in the head of the pancreas and enlarge-

V-95. (Continued)

ment of the common bile duct. Chest x-ray and abdominal-pelvic CT disclose no additional abnormalities. A CT-guided needle biopsy of the mass obtains tissue that on pathologic examination reveals neutrophils and fibrous elements. Which of the following procedures would be most reasonable at this point?

- (A) Another attempt at CT-guided needle biopsy
- (B) Radiation therapy
- (C) Celiac angiography
- (D) Repeat CT in 2 to 3 months
- (E) Percutaneous placement of biliary stent

V-96. In addition to a checkup including health counseling and examination of the oral cavity, thyroid gland, skin, lymph nodes, testes, and prostate, which, according to the American Cancer Society, of the following should be done annually after age 40 in the asymptomatic, average-risk man in order to promote the early detection of cancer?

- (A) Colonoscopy
- (B) Sigmoidoscopy
- (C) Digital rectal examination with palpation of the prostate
- (D) Digital rectal examination with palpation of the prostate and stool guaiac
- (E) Digital rectal examination with palpation of the prostate, stool blood test, and chest x-ray

V-97. A 21-year-old woman is hospitalized for the treatment of a painful ulcer that has been present on her right lower leg for the last 4 weeks. The lesion began as a painful, reddish-purple nodule, then rapidly broke down and enlarged (see Plate R). Bacterial cultures did not yield a significant pathogen, and a 2-week course of oral dicloxacillin, 250 mg four times daily, was not helpful. The

V-97. (Continued)

lesion border now is undermined with a violaceous rim; biopsy is consistent with pyoderma gangrenosum. The lesion described is most closely associated with which of the following disorders?

- (A) *Pseudomonas* sepsis
- (B) Subacute bacterial endocarditis
- (C) Eosinophilic gastroenteritis
- (D) Systemic lupus erythematosus
- (E) Myelodysplastic syndrome

V-98. A 55-year-old Japanese businessman visiting the United States has been in excellent health until 6 months ago, when he first noted mild upper abdominal fullness after meals. On examination the man is noted to have hyperpigmented, heaped-up velvety lesions (as shown in Plate S) confined to the neck, axillae, and groin. Which of the following conditions is associated with the skin findings?

- (A) Non-Hodgkin's lymphoma
- (B) Anorexia nervosa
- (C) Acute leukemia
- (D) Adenocarcinoma of the stomach
- (E) Addison's disease

V-99. A 76-year-old man has developed over the past 3 months a large number of occasionally pruritic lesions on his trunk (Plate T). These lesions are probably a manifestation of

- (A) hypertriglyceridemia
- (B) systemic vasculitis
- (C) severe drug reaction
- (D) disseminated candidiasis
- (E) malignancy

V. ONCOLOGY AND HEMATOLOGY

ANSWERS

- V-1. The answer is C.** (*Chaps. 106, 325*) Several musculoskeletal abnormalities are associated with sickle cell disease. Children may develop diffuse swelling, tenderness, and warmth of the hands and feet, termed *sickle cell dactylitis* or *hand-foot syndrome*, which is self-limited and not associated with long-term damage. Blood cell formation in the distal extremities decreases with age; this syndrome is rarely seen after age 5. Although sickle cell crisis is often associated with arthritis of the knees and elbows, joint effusions tend to be noninflammatory with low white cell counts and a predominance of mononuclear cells. Osteomyelitis is common, particularly with salmonella, and occasionally septic arthritis can occur. The major problems during sickle cell crisis is sickled red cell-mediated bone infarction, which is quite painful. Radiographic manifestations of such infarction include periosteal elevation and irregular thickening of the bone cortex. In its most extreme form this bony infarction can produce avascular necrosis of the head of the femur, which occurs in about 5% of patients. If this process is severe, total hip replacement may be quite beneficial. Although patients with sickle cell disease are often hyperuricemic, gouty arthritis is uncommon. Bone marrow hyperplasia with associated widening of the medullary cavities and thinning of the cortex can result in cupping of the vertebral bodies (fish-bone deformity on radiographs) and vertebral compression.
- V-2. The answer is E.** (*Chap. 86. Bruce, Brodland, Mayo Clin Proc 75:491–500, 2000.*) Basal cell carcinoma is the most common malignancy in the United States. The typical appearance is that of a slowly enlarging, pearly translucent papule with rolled borders and overlying telangiectasias. As the lesion enlarges, central ulceration may occur (rodent ulcer). Sun-exposed areas are most commonly involved—about 90% of tumors occur on the head and neck—and fair-skinned persons are at greatest risk. Dermal nevi, which occur commonly on the faces of adults, lack the translucency seen in basal cell carcinoma. Sebaceous hyperplasia is usually smaller and has a distinct yellowish color. Diagnosis of basal cell carcinoma is easily established by punch or incisional biopsy.
- V-3. The answer is D.** (*Chap. 86. Bruce, Brodland, Mayo Clin Proc 75:491–500, 2000.*) The characteristics that distinguish superficial spreading malignant melanoma from a normal mole include irregularity of its border and variegation of color. Instead of the homogeneous color and regular borders of a “normal” mole, the lesion shows disorderliness and irregularity. The first changes noted by persons who develop melanoma in a preexisting mole are a “darkening” in color or a change in the borders of the lesion. Irregularity of the borders in an expanding, darkening mole is melanoma until proved otherwise; excisional (not incisional) biopsy should be done promptly because early diagnosis and excision reduce the mortality. It is best not to cut into a lesion for which melanoma is in the differential diagnosis.
- V-4. The answer is B.** (*Chap. 112. Pettitt et al, Br J Haematol 106:2–8; 1999.*) Pancytopenia with a dry marrow aspirate argues against CLL and myeloma. Normal RBC morphology argues against myelofibrosis. The WBC count and differential count argue against CML. Hairy cell leukemia is a neoplasm of mature B lymphocytes typically presenting with pancytopenia, splenomegaly, and a dry bone marrow aspirate. Patients with hairy cell leukemia are prone to infections with unusual microorganisms, such as atypical mycobac-

teria; they tend to be granulocytopenic and have a preponderance of mature-appearing lymphocytes in the peripheral blood that have, on close inspection or on ultrastructural analysis, multiple hairlike projections. Bone marrow biopsies typically yield a “fried egg” appearance in that the cells appear to be separated from one another, due to these projections and fixation artifacts generated from them. Immunophenotypically, hairy cells are characterized by the presence of mature B cell markers as well as the CD25 antigen, which is the low affinity IL-2 receptor. Fortunately, there are many treatment modalities available for patients with hairy cell leukemia. The current treatment of choice is a 7-day intravenous infusion of 2-chlorodeoxyadenosine. This single course of treatment results in complete remissions in ~80% of patients. Other effective modalities include splenectomy, interferon- α , or pentostatin (deoxycoformycin).

- V-5. The answer is A.** (*Chap. 87. Vokes, N Engl J Med 328:184–194, 1993.*) Patients who are heavy smokers and drinkers are at increased risk to develop squamous cell carcinoma of the head and neck. In fact, the risk for those who both smoke and drink is multiplicatively increased compared with those who abuse just one of these substances. A firm neck mass in a patient with these habits should prompt an aggressive search for a primary lesion in the head and neck region and would include panendoscopy (laryngoscopy, esophagoscopy, and bronchoscopy) with biopsy of all suspicious areas. Squamous cell carcinoma in the midcervical chain in the presence of a normal physical examination (thereby excluding large tumors of the mouth or supraglottic region) could represent a metastasis from an infraglottic primary. Therefore, the best way to ascertain the diagnosis in this case is to perform a careful upper aerodigestive examination, which should begin with indirect laryngoscopy. CT of the neck, while helpful in delineating the extent of disease, would likely not reveal the primary. Treatment planning optimally requires delineation of the primary and definition of lymph node metastases. The standard approach to a primary head and neck squamous cell carcinoma with a large lymph node metastasis is radiation therapy or surgery or both. However, use of induction chemotherapy is being investigated as a possible means both to improve survival and to reduce the amount of disfiguring local therapy that would be required in such instances.
- V-6. The answer is B.** (*Chap. 85. Pizzo, N Engl J Med 341:893–900, 1999.*) If not attacked promptly, infection in neutropenic patients can be quickly fatal. Often, these patients display neither the signs nor the symptoms of infection. Fever should be regarded as an indication of infection, and antibiotic therapy should begin immediately after appropriate cultures are obtained. An effective initial antibiotic regimen would consist of an aminoglycoside antibiotic or third-generation cephalosporin and a semisynthetic antipseudomonal penicillin. Gammaglobulin is of little benefit in the treatment of granulocytopenic cancer patients. Granulocyte transfusions are of no benefit. Amphotericin B is appropriate if granulocytopenia persists and defervescence does not occur after 7 days of antibacterial antibiotics, or sooner, if clinical deterioration is noted.
- V-7. The answer is B.** (*Chap. 118*) Several reports have described the association of coumarin-induced skin necrosis in patients with congenital protein C deficiency. The skin lesions occur on the breasts, buttocks, legs, and penis. They appear to be a result of diffuse thrombosis of the venules with interstitial bleeding. This condition is presumed to result from an imbalance in hemostatic mechanism activity favoring thrombosis during the early phases of coumarin administration. Protein C has a relatively short half-life within the circulation (about 14 h) compared with that of some of the vitamin K–dependent procoagulant clotting factors (factor X and prothrombin), and a rapid drop in its effective concentration could produce such a situation. However, only about one-third of cases of coumarin-induced skin necrosis are related to protein C deficiency.
- V-8. The answer is E.** (*Chap. 107. Toh et al, N Engl J Med 337:1441–1448, 1997.*) While pancytopenia is frequently due to an intrinsic bone marrow abnormality, vitamin B₁₂ and folate deficiency may also present with low blood counts. The elevated red cell volume

coupled with a low reticulocyte index suggests a megaloblastic anemia. The history of vitiligo represents one of the several autoimmune-type diseases associated with pernicious anemia (PA). Other such immunologically mediated diseases include Graves' disease, myxedema, thyroiditis, idiopathic adrenocortical insufficiency, and hypoparathyroidism. PA is a failure of gastric production of intrinsic factor due to autoimmune destruction of parietal cells, which prevents B₁₂ absorption in the distal ileum. Antibody-mediated destruction of parietal cells results in achlorhydria (an abnormally high gastric pH). The hematologic abnormalities of PA include elevated MCV, decreased reticulocyte count, hypersegmented neutrophil nuclei, and megaloblastic changes in the bone marrow that can, if severe, be confused with acute leukemia. Extramedullary manifestations of PA include neurologic abnormalities typified by demyelination of the posterior and lateral spinal columns of the spinal cord, resulting in numbness and parasthesia, weakness, and ataxia. Patients with megaloblastic anemia on the basis of deficiency of intrinsic factor respond to cyanocobalamin injections within several days. Hypokalemia may complicate the recovery phase.

- V-9. The answer is D.** (*Chap. 89*) Despite having a negative lymph node exam at the time of her original diagnosis 2 years earlier, this patient is at relatively high risk for recurrence because of the size of her tumor. She received appropriate adjuvant chemotherapy given this risk; unfortunately, this treatment did not eliminate the eventual clinical relapse manifested by the two lung nodules. In this patient the prior probability of these lung nodules being due to her original breast cancer is very high. Whether or not to do a needle biopsy of lesions to confirm the presence of breast cancer would be somewhat controversial. If the patient were a nonsmoker, the chances of the lesions being anything other than breast cancer is very low. Patients with metastatic breast cancer may live with the disease for several years but are not known to benefit from a myeloablative approach. Once a patient has metastatic breast cancer, bisphosphonate therapy may be of benefit in reducing the risk of skeletal complications. In those (~20%) of patients whose tumors overexpress the *erbB2* proto-oncogene, the addition of an antibody to this molecule (herceptin) can improve the results when compared to the use of paclitaxel chemotherapy alone.
- V-10. The answer is B.** (*Chap. 81. Varley et al, Br J Cancer 76:1–14, 1997.*) The most common genetic alteration in human cancer is mutation or deletion of the p53 gene, which is found on the long arm of chromosome 17. Wild type p53 suppresses malignant transformation of cells in tissue culture. It appears to regulate cell cycle progression by holding cells at the G₁ checkpoint. Like the retinoblastoma tumor suppressor gene, p53 may be activated by protein products of transforming viruses. A rare autosomal dominant cancer syndrome, the Li-Fraumeni syndrome, is characterized by families with a very high incidence of a diverse spectrum of childhood and adult tumors, including breast cancer, soft tissue sarcomas, brain tumors, bone sarcomas, leukemia, and adrenocortical carcinoma. Germ line mutations in the p53 gene have been found in several of these families. Since an abnormality of one allele of p53 is inherited, these patients are at risk of developing homozygous p53 loss and a predisposition to neoplastic transformation. Mutations of the p53 gene are also very common in sporadic human tumors.
- V-11. The answer is D.** (*Chap. 109. Hoffbrand, Wonke, J Intern Med 740:37–41, 1997.*) Since each unit of transfused blood contains 200 to 250 mg of iron and normal iron excretion is only 1 mg/d, a patient receiving about 40 units of blood annually will accumulate about 8 g of iron, putting him or her at risk for problems related to transfusional iron overload. In addition to the requirement for many transfusions, the disorder must also have a long natural history to allow for the development of the clinical sequelae of chronic iron overload. Thalassemia major, myeloproliferative disorders, myelodysplastic syndromes (without excess myeloblasts), pure red cell aplasia, and moderately severe aplastic anemia are diseases that may be associated with transfusional iron overload. The spectrum of problems produced by iron deposition in tissues includes cardiac dysfunction (arrhythmias, conduction defects, and restrictive cardiomyopathy), hepatic cirrhosis, glucose in-

tolerance, gonadal dysfunction, and hyperpigmentation due to increased melanin production secondary to dermal iron deposition. The only available treatment for transfusion-associated hemochromatosis (phlebotomy is not an option because of chronic anemia) is chelation with desferrioxamine, which must be given subcutaneously over 12 to 16 h/d by a portable pump. While oral ascorbic acid may enhance iron excretion in patients receiving desferrioxamine, it has no role as a monotherapy and may be associated with dangerous cardiac toxicity.

- V-12. The answer is A.** (*Chaps. 64, 109*) Severe neutropenia is a rare idiosyncratic reaction to certain drugs, including propylthiouracil. In addition to having sore throat and oral and anal mucosal ulcerations, affected persons are susceptible to overwhelming, life-threatening infections. However, in the absence of fever or clinical signs of infection, they should be followed as outpatients, saving them exposures to nosocomial pathogens in the hospital. Empirical use of broad-spectrum antibiotics without fever or other signs of infection is not advisable, and glucocorticoid therapy is not useful. White blood cell transfusion can be accompanied by serious morbidity (i.e., pulmonary leukostasis). Because severe drug-induced neutropenia is generally self-limited once use of the offending drug has been stopped, consideration of bone marrow transplantation is not justified.
- V-13. The answer is E.** (*Chap. 106. Weatherall, Provan, Lancet 355:1169–1175, 2000.*) Hemoglobinopathies are a diverse group of congenital disorders characterized by one or more mutations in one of the genes coding for hemoglobin chains. The clinical consequences can range from no effect to incompatibility with life. Microcytosis occurs in these conditions except for the silent α -thalassemia carrier state in which only one of the four α -globin genes is deleted. Such persons have no hematologic abnormalities. Persons with deletion of two of the four α -chain genes (α -thalassemia trait) tend to have microcytic and slightly hypochromic red cells without significant hemolysis or anemia. Hemoglobin electrophoresis may be normal or may reveal a decreased amount of hemoglobin A₂. Deletion of three of the four α -chain genes, so-called hemoglobin H disease, is associated with significant anemia and with a production of hemoglobin H (β -chain tetramers) on hemoglobin electrophoresis. There are only two genes coding for the β -globin chain. Patients with abnormalities in one such chain have β -thalassemia trait characterized by microcytosis, abnormal-appearing red cells, and an elevated level of hemoglobin A₂ or F or both on hemoglobin electrophoresis. Any patient who inherits at least one allele with a hemoglobin S mutation (sickle hemoglobin, valine to glutamic acid substitution at the sixth amino acid of the β -globin chain) will demonstrate red blood cell sickling under reduced oxygen tension, as is artificially produced by addition of an oxygen-consuming agent such as metabisulfite to the blood. Therefore, any patient with sickle cell trait, sickle cell anemia, or a compound heterozygote such as sickle β -thalassemia or sickle C will have a positive metabisulfite test (and would also have a positive hemoglobin electrophoresis). Hemoglobin E is a very common hemoglobin variant that is highly prevalent in Southeast Asia. Patients with this disorder have an abnormal hemoglobin electrophoresis, slightly macrocytic red cells, and target cells, but no anemia or other clinical manifestations unless they also inherit β thalassemia.
- V-14. The answer is B.** (*Chap. 106. Castro, Br J Haematol 107:2–11, 1999.*) Most clinical problems arising in patients with sickle cell anemia are due to vasoocclusive phenomena caused by sickling of deoxygenated red blood cells in capillaries. Microinfarcts can occur suddenly and cause severe pain in almost any part of the body, although the abdomen, chest, back, and joints are most commonly affected. These crises may be precipitated by upper respiratory infection, cold weather, or dehydration. Unfortunately, it is often difficult to distinguish between a painful sickle abdominal crisis and an actual acute abdominal emergency. Pleuritic chest pain and fever may occur in the absence of an infiltrate. If an infiltrate does occur, distinguishing between pneumonia and pulmonary infarction is difficult, although culture and Gram stain of the sputum might be helpful in this regard. In addition to painful crises, microinfarcts can cause chronic damage in the lungs, kidneys,

liver, skeleton, and skin. Painful crises should mandate the use of adequate analgesia, including narcotics, and hydration. Unfortunately, there is an increased risk of opiate addiction in this patient population. Oxygen is helpful if hypoxemia complicates a painful crisis. The role of transfusional therapy in sickle cell anemia is controversial. There is some evidence to suggest that use of aggressive transfusions may decrease the frequency of painful crises, but such an approach has little role in an ongoing crisis. Hydroxyurea therapy may reduce the incidence of sickle crises by increasing synthesis of fetal hemoglobin. Antibiotics should be administered only in the setting of documented infection.

- V-15. The answer is B.** (*Chap. 111*) In about 95% of persons who have CML, material comprising approximately one-half of the long arm of chromosome 22 is translocated to the end of chromosome 9. This abnormality, called the Philadelphia chromosome, can be found in all hematopoietic cell lines. It is thought to represent an acquired somatic cell mutation in the bone marrow, with preferential survival and proliferation of the affected cell clone. The pathogenesis of chronic myelogenous leukemia is therefore a paradigm for all cancers that are believed to arise from a single cell that gives rise to the malignant clone. Normal stem cells exist in the marrow of patients with CML, but they are suppressed by the malignant cells.
- V-16. The answer is C.** (*Chap. 96*) Ninety percent of persons with nonseminomatous germ cell tumors produce either AFP or β -hCG; in contrast, persons with pure seminomas usually produce neither. These tumor markers are present for some time after surgery—if the presurgical levels are high, 30 days or more may be required before meaningful postsurgical levels can be obtained. The half-lives of AFP and β -hCG are 6 days and 1 day, respectively. After treatment, unequal reduction of β -hCG and AFP may occur, suggesting that the two markers are synthesized by heterogeneous clones of cells within the tumor; thus, both markers should be followed. β -hCG is similar to luteinizing hormone except for its distinctive beta subunit.
- V-17. The answer is D.** (*Chap. 108*) If patients develop circulating anti-IgM antibodies with specificity for polysaccharide antigens on red cell membranes, they may suffer from so-called cold-reactive hemolysis. The clinical manifestations of the presence of such antibodies are hemolysis, which is generally not severe, and a mild elevation of the reticulocyte count, agglutination of red cells, and an increased rate of hemolysis at temperatures $<37^{\circ}\text{C}$ (98.6°F). A second clinical manifestation of cold hemolysis is the presence of acrocyanosis, characterized by marked purple discoloration of the extremities, ears, and nose during cooling. IgM antibodies may be missed if the blood is allowed to cool after it is drawn because of adsorption onto the patient's own red blood cells and subsequent removal as the blood clots. Therefore, the blood should be allowed to clot at a warm temperature. Serologic analysis will reveal a positive direct Coombs' test if anti-C3 antisera is used. The activation of complement by the fixed IgM molecules results in the marked accumulation of the C3dg degradation product on the red cell surface, allowing detection in this fashion. The specificity of the cold agglutinin antibody may be helpful in that a reaction with adult red cells compared with fetal (cord) blood is more common in benign lymphoproliferative disorders. On the other hand, antibodies that react more strongly with fetal cells compared with adult cells are called anti-*i* and are generally seen in lymphomas and in infectious mononucleosis. The patient in this question may well have a recurrence of his lymphoma, which is presenting as a cold hemolytic disease because of the presence of monoclonal IgM antibody. This problem is best treated by successful anti-lymphoma therapy.
- V-18. The answer is C.** (*Chap. 113. Kyle, Ann Intern Med 132:734–736, 2000.*) This patient has classic symptomatic multiple myeloma. Although not in renal failure and not hypercalcemic, the patient has several markers of high tumor burden, including heavy plasma cell infiltration of the bone marrow and multiple osteolytic lesions in the bony skeleton. Initial chemotherapy could reasonably include either high-dose dexamethasone; combi-

nation chemotherapy with vincristine, doxorubicin, and dexamethasone; or a combination of the alkylating agent melphalan and prednisone. Erythropoietin is given because this drug has a reasonable chance to ameliorate the anemia associated with this disease. Bisphosphonates have been shown to reduce the bony destruction caused by the myeloma cells by interference with osteoclastic activity, thereby reducing liberation of bony calcium. Perhaps because of their ability to stabilize the bony matrix, bisphosphonates have been shown in randomized controlled trials to reduce lytic disease compared to placebo. In a randomized study performed by the Eastern Cooperative Oncology Group, the rate of skeletal events was twice as high in the placebo group compared with the pamidronate-treated group. There was also a survival benefit associated with pamidronate use (in those who had received more than one antimyeloma treatment). Oral pamidronate has not been as successful in reducing complications of myeloma as was the intravenous preparation. Bisphosphonates may have a primary anti-myeloma effect, perhaps by induction of *apoptosis* (programmed cell death) in myeloma cell lines. As such, the current standard of care is to administer intravenous bisphosphonates at the beginning of chemotherapy and to continue treatment indefinitely.

- V-19. The answer is A.** (*Chap. 108. George, Blood 96:1223–1229, 2000.*) This young woman is suffering from a combination of hemolytic anemia with fragmented red cells in the absence of disseminated intravascular coagulation (DIC), thrombocytopenia, fever, mental status changes, and renal dysfunction, which is essentially pathognomonic of thrombotic thrombocytopenic purpura (TTP). The pathogenesis is believed to be due to an antibody against a protease that normally cleaves von Willebrand's factor. Pathologically, arteriolar hyalinization, which is also seen in DIC, may be noted. Seventy percent of patients with TTP improve with exchange transfusion or plasmapheresis. Glucocorticoids, antiplatelet agents, splenectomy, and vincristine have been of benefit to subsets of patients, but each is less effective and probably associated with a greater risk than therapeutic plasmapheresis.
- V-20. The answer is E.** (*Chap. 110*) When a patient presents with thrombocytosis, it is important to determine if this abnormality is due to a myeloproliferative disorder or is reactive due to infection, malignancy, hemolytic anemia, the postoperative state, hemorrhage, iron deficiency, drug reaction, chronic inflammatory disease, response to exercise, recovery from myelosuppression, recovery from B₁₂ deficiency, or even myelodysplastic syndrome (either 5q-syndrome or rare cases of sideroblastic anemia). Once secondary causes of thrombocytosis have been satisfactorily excluded, then it is important to delineate the specific myeloproliferative disorder. The normal red cell mass virtually excludes polycythemia vera, and normal cytogenetics makes the diagnosis of chronic myelogenous leukemia most unlikely. Anemia, massive splenomegaly, teardrop red cell forms, or an elevated white count would advance consideration of agnogenic myeloid metaplasia/myelofibrosis. However, the bone marrow examination did not disclose excess collagen fibrosis. As such, the patient in this question has essential thrombocythemia. Patients with this disease may develop hemorrhage or thrombotic complications. Older patients have a higher risk of thrombosis; some younger patients can be observed. However, this patient is symptomatic due to erythromelalgia, the syndrome of redness and painful burning of the distal extremities caused by localized platelet aggregation. Chronic use of alkylating agents should be avoided due to the risk of leukemogenesis. Antiplatelet agents may protect against thrombosis but could lead to severe hemorrhage. Splenectomy would result in an even higher platelet count. The best treatment in this patient is probably the use of hydroxyurea at a dose titrated to lower the platelet count to below 500,000. Interferon- α may be a useful alternative for those patients unable to tolerate hydroxyurea. Anagrelide is also effective at lowering platelet counts, but it must be given continuously to maintain its effects.
- V-21. The answer is C.** (*Chap. 111. Degos, Blood 85:2643–2653, 1995.*) Acute promyelocytic leukemia (APML) [M3 according to the FAB (French-American-British) classifi-

cation system] is characterized by bone marrow infiltration with malignant-appearing promyelocytes. Distinctive features of this entity compared with other subtypes of de novo acute myeloid leukemia include the common presentation with leukopenia, the frequent development of DIC due to release of procoagulant granules from the promyelocytes, and the pathognomonic demonstration of a translocation between chromosomes 15 and 17 on cytogenetic analysis. This translocation juxtaposes sequences from the retinoic acid-receptor alpha gene on chromosome 17 with another DNA binding protein, called PML, on chromosome 17. The resultant fusion protein plays some role in preventing normal differentiation. Interestingly, even before the documentation of the genetic basis for this translocation, it was noted by investigators in China that the use of all-*trans* retinoic acid, an orally administered vitamin A derivative, led to complete remissions in the vast majority of patients with APL. The mechanism of action of this drug appears to be induction of differentiation of the malignant clone. As such, patients enter remission slowly over a period of 30 to 60 days. DIC, typically made worse by chemotherapy, is rapidly ameliorated by all-*trans* retinoic acid. Other cytotoxic effects of chemotherapy, such as mucositis and myelosuppression, do not occur with all-*trans* retinoic acid. Common side effects include dry skin and peeling at the corners of the mouth. A life-threatening complication, occurring in ~20% of patients treated with all-*trans* retinoic acid, is the so-called retinoic acid syndrome, manifested by pulmonary infiltrates and incipient respiratory failure, sometimes associated with a high white count. Glucocorticoids, leukopheresis, and hydroxyurea have each been associated with some improvement. Patients given all-*trans* retinoic acid alone will eventually relapse, so initial induction therapy with all-*trans* retinoic acid should be combined with chemotherapy.

- V-22. The answer is B.** (*Chap. 84*) The most prominent general side effects of chemotherapy relate to the effect of these drugs on dividing cells, including myelosuppression, stomatitis, and alopecia. Certain drugs, such as L-asparaginase and vincristine, can be administered during periods of low white blood cell count because they are relatively nonmyelosuppressive. Alkylating agents, such as melphalan, cyclophosphamide, and nitrogen mustard, damage bone marrow stem cells, an effect associated with the development of secondary myelodysplastic syndromes and acute leukemias. Anthracyclines are myelosuppressive, but they inhibit more committed hematopoietic cells than do the alkylating agents. Cisplatin is quite emetogenic; however, vomiting can be managed successfully with the use of a number of agents, including dexamethasone, ondansetron, and metoclopramide. Massive losses of potassium and magnesium (in turn leading to hypocalcemia) must be anticipated with the use of cisplatin because of drug-induced renal tubular damage.
- V-23. The answer is A.** (*Chap. 111*) Adults with acute lymphocytic leukemia (ALL) do not respond nearly as well to chemotherapeutic programs as do children with the same disease. The reason for the inferior results in adults is not poor tolerance of chemotherapy. Instead, adults with ALL are more likely to present with a disease typified by adverse prognostic factors, usually indicating derivation from a more primitive hematopoietic stem cell. For example, Philadelphia chromosome-positive ALL—t(9;22)—is much more common in adults than in children. Adults are also more likely to have leukemic cells that bear either myeloid antigens or immunophenotypic evidence of derivation from a primitive stem cell (CD34 positivity). Balanced translocations in ALL, such as the t(4;11) associated with biphenotypic leukemia, also portend a poor prognosis. The most favorable subtype of ALL is that derived from a pre-B cell—CALLA (CD10) or B4 (CD19) positivity—with normal cytogenetics. However, for reasons that remain unclear, even this “favorable” prognostic subgroup is not associated with the high cure rate characteristic of children with the same immunophenotype and cytogenetics.
- V-24. The answer is C.** (*Chap. 95. Morris, Scher, Cancer 89:1329–1348, 2000.*) Given the poorly differentiated histology at presentation with the associated high risk of recurrence and the characteristic indicators of metastatic prostate cancer, biopsy is unnecessary. Since the patient has symptomatic disease, he should be started on androgen deprivation therapy,

which is likely to cause a decrease in his pain. An equivalent response rate has been demonstrated with bilateral orchiectomy, DES, and luteinizing hormone–releasing hormone (LHRH) analogues such as leuprolide. Given his desire not to have an orchiectomy and his vascular disease, LHRH analogues would be the best approach. Though providing “total androgen blockade” may be beneficial, whether flutamide should be routinely combined with an LHRH agonist such as leuprolide is unclear. Chemotherapy, perhaps with taxines, may have a role in hormone-refractory disease.

- V-25. The answer is E.** (*Chaps. 62, 117. Levi, Ten Cate, N Engl J Med 341:586–592, 1999.*) This patient has overt DIC, which occurs in 30 to 50% of patients with gram-negative sepsis. Specific constituents of the bacterial cell wall, such as lipopolysaccharide or endotoxin, may induce a generalized inflammatory response that activates the cytokine network as well as the coagulation cascade. Such activation depletes platelets and coagulation factors, thereby leading to bleeding. By far the most important aspect to the management of DIC is the treatment of the underlying disorder, which in this case of obvious bacterial sepsis would be antibiotics. Heparin could interrupt the coagulation cascade and be of some clinical benefit but would be less appropriate in this situation than antibiotics. The administration of platelet concentrates, fresh-frozen plasma, and even antithrombin-3 concentrates to respond to the minimal depletion of this important inhibitor of coagulation may produce some clinical benefit, but again, would not be as useful as rapid treatment of the infection. Antifibrinolytic agents, such as ϵ -aminocaproic acid, have been useful in occasional patients with secondary hyperfibrinolysis, such as those with the coagulopathy of acute promyelocytic leukemia, but would not be useful in the situation of gram-negative sepsis.
- V-26. The answer is D.** (*Chap. 109. Young, Maciejewski, N Engl J Med 336:1365–1372, 1997.*) This patient presents with severe aplastic anemia manifested by profound neutropenia and thrombocytopenia as well as significant anemia. Though hypoplastic myelodysplastic syndrome has been reported, the absence of morphologic evidence of dysplasia as well as normal karyotype argues against this diagnosis and in favor of acquired aplastic anemia. There is no obvious inciting event such as hepatitis or drug ingestion in the recent past. Most believe that acquired aplastic anemia results from an immune-mediated inhibition of hematopoiesis. In fact, especially for patients who cannot tolerate an allogeneic bone marrow transplant due to age or comorbid disease, the treatment of choice is immunosuppression with a combination of antithymocyte globulin, high doses of methylprednisolone, cyclosporine, and G-CSF. This combination regimen carries with it 70 to 80% likelihood of decreasing transfusion requirements, at least for a time. The successful immunosuppressive treatment of aplastic anemia is sometimes marred by late development of a clonal hematologic disorder such as myelodysplasia, acute leukemia, or paroxysmal nocturnal hemoglobinuria.
- V-27. The answer is C.** (*Chap. 114*) The clinical scenario is consistent with a delayed transfusion reaction. Immediate transfusion reactions, which are most commonly due to ABO incompatibility and result from clerical error, are associated with intravascular hemolysis (anti-A and anti-B antibodies fix complement) manifested by lumbar pain, hemoglobinemias, and shock. Fever, malaise, and a drop in hematocrit with findings compatible with extravascular hemolysis (microspherocytes, indirect hyperbilirubinemia) 1 week after red cell transfusion are typical of a delayed transfusion reaction, which is usually mediated by antibodies to Rh (or if the recipient is Rh-negative, by anti-Duffy, anti-Kidd, or anti-Kell antibodies). A previous transfusion may have been the precursor of the clinically relevant anamnestic response. These antibodies likely coat the donor red cells, thereby producing a positive direct Coombs’ test. Less commonly the donor’s plasma could contain antibodies that would react with the recipient’s cells. Sensitization to the alloantigens on donor leukocytes transfused along with the red cells could account for fever, but not hemolysis.
- V-28. The answer is C.** (*Chap. 117. Mannucci, N Engl J Med 339:245–253, 1998.*) Aprotinin is a polypeptide extracted from bovine lung that inhibits several serine proteases,

including trypsin and plasmin as well as tissue and plasma kallikrein. It is through the inhibition of kallikrein, thereby inhibiting the formation of activated factor XII, that aprotinin inhibits the initiation of coagulation. In the absence of normal kallikrein function, aprotinin inhibits the generation of active urokinase, a catalyst of the plasminogen to plasmin reaction required for fibrinolysis (dissolution of clots). Aprotinin also directly inhibits plasmin. Aprotinin must be given intravenously and has no effect on platelet function. This drug has been shown conclusively to reduce blood loss in patients undergoing cardiac surgery and may be the best choice for this purpose. Nonetheless, the prophylactic use of aprotinin in all patients undergoing cardiac surgical procedures is not recommended; it should be reserved for those patients at increased risk for significant blood loss during their procedure.

- V-29. The answer is B.** (*Chap. 97*) Though the incidence of ovarian carcinoma is low, the propensity to present at an advanced stage (only 25% of patients have disease limited to one or both ovaries) helps to explain why this disease is the most common cause of death among all gynecologic malignancies. Due to the advanced stage at presentation, surgical debulking is the initial therapy for most patients. Only ~15% of ovarian cancers arise from nonepithelial elements. Epithelial tumors are most common in peri- or postmenopausal women, especially nulliparous women or those with few children. Prior breast cancer increases the risk of developing ovarian cancer by two- to fourfold. An advanced stage and a larger size of residual tumor after initial surgery carry an adverse prognosis, as do poorly differentiated ovarian carcinomas, which have a 5-year survival of well under 20%.
- V-30. The answer is A.** (*Chap. 117. Mannucci, N Engl J Med 339:245–253, 1998.*) Chronic uremia produces a complex abnormality of hemostasis, but patients generally have a prolonged bleeding time due to abnormal platelet function. Desmopressin given before the planned dental extraction is a reasonably safe and rapid way to decrease the risk of bleeding. Both conjugated estrogens and erythropoietin can also reduce the risk of bleeding in patients with uremia undergoing surgical procedures. However, since the effect is delayed, they would not be appropriate in an acute setting. The use of fresh-frozen plasma will not ameliorate prolongation of the bleeding time. The use of the fibrinolysis inhibitor ϵ -aminocaproic acid may have some utility in primary menorrhagia, genitourinary tract bleeding after prostate surgery, mild hemophilia, or profound thrombocytopenia or to reduce blood loss after cardiac or joint surgery.
- V-31. The answer is A.** (*Chap. 113. Bataille, Harousseau, N Engl J Med 336:1657–1664, 1997.*) This patient has classic features of monoclonal gammopathy of undetermined significance (also called benign monoclonal gammopathy) in that she has a monoclonal protein (modestly elevated IgG) without other evidence of multiple myeloma. Specifically this patient has no anemia, hypercalcemia, bone lesions, renal failure, depression of other immunoglobulin levels, or excessive numbers of plasma cells in the bone marrow (>10% atypical plasma cells in her bone marrow). The lymphoid aggregates noted in this patient's bone marrow are quite common for her age. A workup for lymphoma, connective tissue disorders, or infectious etiology in the absence of other signs or symptoms is not warranted. Therapy is not indicated here because this condition generally has a benign course. The patient should be followed with serial evaluations of her M spike and check-ups to be sure progression to frank myeloma has not occurred. Multiple myeloma will develop in about 16% of patients with monoclonal gammopathy of undetermined significance, with an annual actuarial risk of 0.8%. Whether or not every patient who develops multiple myeloma has an occult history of benign monoclonal gammopathy is not known, but the epidemiologic associations between monoclonal gammopathy of undetermined significance and multiple myeloma are similar.
- V-32. The answer is B.** (*Chap. 89. Osborne, N Engl J Med 339:1609–1618, 1998.*) Lumpectomy plus radiation is an accepted way to minimize the risk of local recurrence while

preserving the breast itself. The question for this older woman with a small hormone receptor–positive lesion and no involvement of axillary lymph nodes is whether or not adjuvant systemic therapy is indicated. There are significantly fewer recurrences and deaths in both pre- and postmenopausal women given tamoxifen for 5 years compared to those given placebo, even for patients with negative axillary lymph nodes. While the overall magnitude of the benefit is relatively small, the reduction in the rate of recurrence and deaths from breast cancer is the same in women with both node-negative and node-positive cancers. Tamoxifen has been beneficial in women age 70 years of age or older, and the drug is tolerated well in this age group. The use of chemotherapy in a patient of this age with node-negative status is probably not worth the risk. Herceptin (monoclonal antibody therapy against the *erbB2* proto-oncogene gene product) has been shown to benefit patients with metastatic breast cancer, but its role in the adjuvant setting, especially for those with limited local disease, is completely undefined.

- V-33. The answer is C.** (*Chap. 111. Pui, Evans, N Engl J Med 339:605–615, 1998.*) Approximately 85% of children with ALL are cured, but only about one-third of adults with the same disease can expect to experience long-term disease-free survival. Although it is true that children tolerate the complicated therapy better than adults, most of the difference in the outcome between these two age groups is accounted for on the basis of the biologic differences in the lymphoblasts. Most importantly, lymphoblasts from older adults with ALL typically display a different spectrum of chromosomal abnormalities (and of course genetic pathophysiology) than do those from children. Lymphoblasts that contain the Philadelphia chromosome (a translocation between chromosome 9 and 22, which juxtaposes the *BCR* and *ABL* genes) are virtually impossible to cure with chemotherapy and require a bone marrow transplant for any hope for good outcome. The Philadelphia chromosome is present in about 25 to 33% of adults with ALL but only in 3–5% of children. Rearrangements involving the *MLL* gene on chromosome 11q23, such as the t(4;11) translocation, are about equally common in both age groups. The so-called tel-1-CBF α fusion mRNA created when there is a t(12;21) chromosomal translocation (often occult on routine karyotype analysis) is present in 22% of children and almost no adults. Virtually every child with this chromosomal abnormality (which disrupts the transcriptional apparatus for genes important in hematopoietic development) is cured.
- V-34. The answer is A.** (*Chaps. 105, 345. Andrews, N Engl J Med 341:1986–1995, 1999.*) Patients with this fairly common monoallelic genetically based disease deposit iron in the liver, heart, pancreas, pituitary, and parathyroid gland. The most typical life-threatening events include hepatic cirrhosis and hepatocellular carcinoma. Endocrinopathies such as diabetes mellitus, hypopituitarism, hypogonadism, and hypoparathyroidism have been noted. Some 60 to 70% of affected individuals carry a unique missense mutation (C282Y) that results in a derangement of relevant protein, designated HFE. Homozygotes are typically but not universally affected; occasionally, heterozygotes (incidence is as high as 1 in 10 in northern Europeans) can be shown to have problems with iron loading as well. The *HFE* gene forms a heterodimer with the β_2 -microglobulin protein, which, when expressed on the surface of duodenal crypt cell, limits normal iron absorption. In the presence of this *HFE* missense mutation, iron absorption can occur to a much greater degree than normal. Phlebotomy is the preferred treatment for this condition. Each unit of blood contains approximately 200 to 250 mg of iron. Patients with hereditary hemochromatosis typically absorb 3 mg (rather than the standard 1 mg) of iron per day.
- V-35. The answer is C.** (*Chap. 90*) Squamous cell cancer of the esophagus accounts for approximately 10,000 deaths annually in the United States. Worldwide, incidences vary greatly, but it is particularly common in a belt from the Caspian Sea to northern China. In the United States, epidemiologic studies have linked smoking and alcohol to squamous cell cancer of the esophagus and may explain the association of this tumor with head and neck carcinoma. Exposure to agents that damage the mucosa (e.g., very hot tea, lye, radiation) or ingestion of carcinogens such as nitrites, smoked opiates, and fungal toxins is

associated with an increased risk of esophageal carcinoma. The long-term stasis associated with achalasia leads to chronic irritation of the esophagus, which is thought to predispose to cancer formation. Tylosis is a genetically acquired disease characterized by thickening of the skin of the hands and feet and is associated with squamous cell cancer of the esophagus. Chronic gastric reflux (Barrett's esophagus) is associated with adenocarcinoma but not with squamous cell carcinoma of the esophagus.

- V-36. The answer is E.** (*Chap. 90*) Malignant neoplasms of the stomach typically present with epigastric pain, postprandial fullness, and weight loss or fatigue. Iron-deficiency anemia may also be seen. Histologically, 90% of stomach cancers are adenocarcinomas and 10% are due to non-Hodgkin's lymphomas or leiomyosarcomas. Risks for the development of gastric adenocarcinoma include decreased gastric acidity, prior antrectomy (latency period of 15 to 20 years), atrophic gastritis, and the presence of blood group A. These risk factors are not associated with the development of primary gastric lymphoma, which is a more treatable disease than adenocarcinoma. The only real chance for a cure with adenocarcinoma is complete surgical removal of the tumor and resection of the adjacent lymph nodes. The use of adjuvant chemotherapy, radiation therapy, or both after complete resections in patients with adenocarcinoma seems to offer some benefit compared with surgery alone. Moreover, the use of these modalities in cases where resection was only partial is controversial, although combination chemotherapy with a regimen such as 5-fluorouracil, doxorubicin, and mitomycin C will lead to partial responses in up to 50% of cases. However, complete removal of the tumor in patients with gastric lymphoma results in a 5-year survival rate of 40 to 60% (compared with 25 to 30% in adenocarcinoma). Combination chemotherapy may even be a useful adjunct in the postsurgical setting and may be able to substitute for surgery. The latter point is a subject of much debate; however, fears that presurgical chemotherapy would lead to an inordinate risk of bleeding or perforation seem unfounded on the basis of recent studies. Gastric lymphomas are nearly always of B cell origin.
- V-37. The answer is D.** (*Chap. 90. Desch et al, J Clin Oncol 17:1312, 1999.*) The goal of screening for colorectal cancer is to detect surgically curable neoplasms. Though rigid or flexible sigmoidoscopy clearly plays a role in early detection of distal colon cancers, the overall benefit or cost/benefit of routine screening in this fashion has not been established. Most efforts have been in the area of Hemoccult testing for occult fecal blood. The following features complicate the use of this modality: (1) Approximately 50% of those with documented colorectal cancers have a negative Hemoccult test; (2) asymptomatic cancers are found in only 10% of those who test positive (although benign polyps will be detected in an additional 20 to 30%); and (3) those with a positive test are subjected to additional uncomfortable and expensive procedures, including sigmoidoscopy, barium enema, and colonoscopy. Nonetheless, a study from the University of Minnesota documented a statistically significant reduction in mortality in a group of patients undergoing annual Hemoccult screening compared with a randomized control group that received routine care. A cost-effectiveness analysis of this study has not been performed. The present American Cancer Society recommendations are somewhat more aggressive than the available data would completely support: annual digital rectal examinations beginning at age 40, annual fecal Hemoccult screening beginning at age 50, and sigmoidoscopy (preferably flexible) every 3 to 5 years beginning at age 50 for asymptomatic persons at average risk. Of course, patients with a positive family history or other high-risk features in whom the probability of colorectal cancer is higher than that in the average population should be screened more aggressively.
- V-38. The answer is C.** (*Chap. 90. Watanabe, Muto; Crit Rev Oncol Hematol 32:5-17, 1999.*) Total resection of the primary tumor is the treatment of choice for both colon and rectal carcinoma. Assuming that metastases are ruled out, the presence or absence of extension into the muscularis mucosa or the presence of carcinoma in regional lymph nodes is an important prognostic feature. For example, those with regional lymph node involvement

have 30 to 60% 5-year survival, whereas those whose cancer extends into the muscularis but not to the serosa and who do not have positive lymph nodes have 85% 5-year survival. 5-FU is the most active single agent in treating advanced colorectal cancer, and when used in combination with leucovorin, the odds for recurrence of colon cancer can be reduced. Furthermore, radiation therapy to the pelvis can significantly lower the probability of local recurrence in patients with high-risk rectal carcinoma. Data from several controlled studies indicate that postoperative radiation therapy combined with chemotherapy (including 5-FU) appears to reduce the likelihood of local recurrences and increases the potential for long-term survival without recurrence. In this setting, chemotherapy may act as a radiation sensitizer.

- V-39. The answer is E.** (*Chap. 98*) Sarcomas are tumors that arise from bone and connective tissue elements. Except for the pediatric tumor rhabdomyosarcoma (a tumor that arises from striated muscle), all the so-called soft tissue sarcomas are non-bone sarcomas, which respond relatively poorly to chemotherapy. The two major types of bone sarcomas, Ewing's sarcoma and osteogenic sarcoma, are more responsive to chemotherapy and are generally treated with tri-modality therapy—surgery, radiation therapy, and multiagent chemotherapy. High-grade or poorly differentiated sarcomas are best managed with wide surgical excision. Although amputation is rarely needed for extremity lesions, it is important that the surgeon remove enough tumor so that the margins are free of neoplastic cells. Sometimes postoperative radiation therapy is given to the tumor bed if the margins are positive or close. The major risk from high-grade soft tissue sarcomas is eventual death from metastatic disease, usually due to spread into the lungs. Preoperative chemotherapy may be useful; postoperative (adjuvant) chemotherapy with a doxorubicin-containing regimen may offer a survival benefit (based on a meta-analysis of 14 randomized trials).
- V-40. The answer is D.** (*Chaps. 110, 117*) Primary erythrocytosis with organomegaly strongly suggests the diagnosis of polycythemia rubra vera. One well-recognized complication of this condition is hypercoagulability, with a particular propensity toward hepatic vein thrombosis. Such an occlusion would lead to the Budd-Chiari syndrome, which is characterized by a grossly enlarged, tender liver with severe ascites. In addition to hepatic vein thrombosis secondary to a hypercoagulable state, such a syndrome could result from idiopathic causes, hepatic invasion by tumor, or the venoocclusive disease associated with chemotherapy or radiation. Once right-sided heart failure is excluded clinically, the diagnosis is best established by hepatic venography or liver biopsy showing sinusoidal dilatation.
- V-41. The answer is B.** (*Chap. 91*) The clinical constellation of tender hepatomegaly, a bruit in the right upper quadrant of the abdomen, bloody ascites, and very elevated alkaline phosphatase occurring in a patient with previously stable cirrhosis is characteristic of primary hepatocellular carcinoma. This disease typically is associated with very high levels of α fetoprotein, a unique and specific fetal α_2 globulin. Rarely, ectopic hormones such as chorionic gonadotropin are found in the serum of patients with hepatocellular carcinoma. The enzyme 5'-nucleotidase may be elevated in a patient with any condition associated with hepatocellular damage. Antimitochondrial antibodies are found in primary biliary cirrhosis and are not typical of primary hepatocellular carcinoma.
- V-42. The answer is D.** (*Chaps. 84, 90*) It has been clearly shown that patients with colon cancer whose tumors exhibit regional spread at the time of original surgical resection (i.e., lymph node–positive disease) have experienced a reduction in their risk of eventual recurrence and death from metastatic disease; therefore, so-called adjuvant chemotherapy is given after recovery from surgery. A regimen using the antimetabolite 5-FU in conjunction with the dihydrofolate reductase inhibitor leucovorin is usually given. Leucovorin, in this case, is used to enhance the binding of a 5-FU metabolite to the target enzyme, thymidylate synthetase, thereby potentiating its antineoplastic as well as toxic effects. Diarrhea is a common yet potentially extremely serious complication of 5-FU/leucovorin therapy and

must be taken seriously. The rapid onset of dehydration may occur. Therefore, every patient who presents with moderate or moderately severe diarrhea should be asked to come to a health care facility for intravenous fluids, evaluation, and possible admission if severe dehydration is documented. It is unlikely that this diarrhea would be caused by anything other than the chemotherapy, and therefore antibiotics to treat infections are not warranted. Antimotility agents such as loperimide can be helpful but should not be used as the sole therapeutic modality. The issue of diarrhea as a symptom in patients with colon cancer is now even more important with the increasing use of the topoisomerase 1 inhibitory chemotherapy agent irinotecan, which also produces diarrhea as a toxic side effect.

- V-43. The answer is A.** (*Chap. 114*) Although patients with myelodysplasia, especially those with normal cytogenetics and no excess myeloblasts in the marrow or blood, can be managed for long periods of time with only supportive care, including transfusion, limitations exist. Fortunately, given careful screening for bloodborne viral infections, the incidence of transfusion-associated infection is now rare. However, the need for chronic transfusional therapy may be associated with iron overload and the requirement to use an iron chelating agent such as desferrioxamine. Furthermore, either due to their disease and associated immune dysregulation or due to exposure to many different blood group antigens, chronically transfused patients, such as the one in question, frequently develop a large panel of serum allo-antibodies. The presence of these antibodies may make it very difficult to find blood that will be negative in a cross-match with the patient's serum. While the presence of these antibodies may or may not produce hemolysis if blood containing a potential target antigen is transfused, blood bank practice requires a negative cross-match except in emergency situations.
- V-44. The answer is C.** (*Chap. 97*) Most ovarian neoplasms are epithelially derived. Typically, ovarian carcinoma presents in an indolent fashion with abdominal fullness at an advanced stage with extensive interperitoneal metastasis. However, a small subset of ovarian neoplasms are germ cell tumors, which are capable of producing sex hormones such as androgens, leading to virilization, as noted in this patient. Such ovarian germ cell tumors should be treated in an analogous fashion to testicular cancer in the male, since they are highly responsive to cisplatin and etoposide.
- V-45. The answer is A.** (*Chap. 90*) Invasive rectal cancer is generally treated with surgical resection followed by adjuvant chemotherapy and radiation therapy to decrease the risk of recurrence and metastasis. The use of combined-modality therapy decreases the risk of recurrence in patients with rectal cancer whose primary lesions penetrate through the muscularis or into the surrounding lymph nodes. However, if rectal cancer recurs, it usually does so locally and can invade through tissue planes in the pelvis to create problematic pain due to nerve root invasion. Such patients typically have radicular-type pain due to local spread of their cancers. Bony metastases are uncommon. With the elimination of nitrosoureas from the adjuvant treatment regimen for rectal cancer patients, the likelihood of secondary leukemia (and concomitant bone pain) is markedly diminished. Pelvic radiation therapy can contribute to adhesion, but would be an unlikely cause of chronic pelvic pain.
- V-46. The answer is A.** (*Chap. 88*) Approximately 20% of all lung cancers are small cell cancers. These tumors tend to present centrally, be derived from neuroendocrine tissues, and be much more chemo- and radiosensitive than non-small cell cancer. Histologic subtypes of non-small cell cancer include adenocarcinoma (which definitely does have a more peripheral presentation), large cell cancer, bronchoalveolar cell cancer, and squamous cell (or bronchogenic) lung cancer. All histologic types of lung cancer are associated with smoking. In the relatively uncommon patient who presents with a small non-small cell primary lesion and no lymph node involvement, surgery alone may be curative. Patients with small cell lung cancer are divided into two staging groups: those with limited disease who have tumors generally confined to one hemithorax encompassable by a single radi-

ation port and all others who are said to have extensive disease. About 20 percent of patients who present with limited stage small cell lung cancer are curable with a combination of radiation therapy and chemotherapy (cisplatin and etoposide being the two most active agents).

- V-47. The answer is A.** (*Chaps. 109, 115. Friedberg et al: J Clin Oncol 17:3128–3135, 1999.*) Myelodysplasia is a bone marrow stem cell disorder usually characterized by hypercellular marrows with peripheral blood cytopenias. Characteristic dysplastic changes seen in the bone marrow include hyperlobated megakaryocytes, megaloblastic nuclear maturation in the erythroid series, and dysplastic myeloid maturation including nuclear to cytoplasmic asynchrony and hyperlobated mature myeloid cells (Pelger-Huet anomaly). There may also be excessive numbers (>5%) of bone marrow myeloblasts. Chromosomal changes frequently include abnormalities of the long arm of chromosome 5 and/or loss of chromosome 7. Myelodysplasia is a disease of the elderly, without a clear-cut etiologic predisposition; however, ionizing radiation, alkylating agent chemotherapy, and industrial solvents are agents that can damage the bone marrow stem cell and lead to the clinical pathologic syndrome of myelodysplasia. An unfortunate complication of autologous bone marrow transplantation for non-Hodgkin's lymphoma is the development of myelodysplastic syndrome. It is unclear whether the myelodysplasia occurs secondary to the preparative regimen, usually consisting of high-dose chemotherapy and total-body radiation, or to the extensive therapy that many of these patients receive prior to the time of their transplant. Autologous bone marrow transplantation for non-Hodgkin's lymphoma is known to be potentially curative in patients who have entered into second remission or at least a minimal residual disease state. These patients were formerly considered incurable with additional standard chemotherapy. Therefore, despite the very serious problem of posttransplant myelodysplasia, for many patients autologous transplantation remains the best means to deal with relapsed non-Hodgkin's lymphoma. In this case, since there is no evidence of myelophthisis there is no reason to suspect infiltration of the marrow. Patients can develop the hemolytic uremic syndrome posttransplant and could have erythroid hyperplasia on that basis; but the presence of a normal blood smear mitigates against that diagnosis. While bone marrow aplasia could be a late complication of bone marrow transplantation, the presence of dysplastic cells in the peripheral blood argues against it.
- V-48. The answer is D.** (*Chap. 112. Weisenburger, Armitage, Blood 87:4483–4494, 1996.*) Mantle cell lymphoma is now a well-recognized clinical entity that was formerly termed *intermediate lymphoma*. Cells are typically of intermediate differentiation, although a blastic variant also exists. Immunophenotypically, the cells express B cell antigens such as CD19 and CD20 but also express the nominal T cell antigen CD5. In addition to chronic lymphocytic leukemia, mantle cell lymphoma is one of the only B cell neoplasms that routinely express this antigen. It may be distinguished immunophenotypically from chronic lymphoid leukemia (or small lymphocytic lymphoma, which is the lymph node–predominant form) by the lack of CD23 expression. The t(11;14) brings cyclin D₁ under the influence of immunoglobulin heavy chain promoters and leads to cyclin D₁ overexpression. It is not clear how this contributes to lymphomagenesis. This translocation is nearly always associated with mantle cell lymphoma. The prognosis for patients with mantle cell lymphoma is poor. Although it is relatively chemotherapeutically resistant, as is the case with other low-grade lymphomas, the natural history is not nearly as indolent, with median survival in the 2- to 3-year range.
- V-49. The answer is C.** (*Chaps. 84, 96*) It is important to be familiar with the unique side effects of chemotherapeutic agents. Most drugs used to treat cancer inhibit cell division in one form or another. Tissues that undergo rapid turnover such as the hair, gastrointestinal tract, and bone marrow are most typically affected. Therefore, hair loss, mouth sores, diarrhea, and cytopenias are very commonly observed side effects after the administration of chemotherapy. However, certain commonly used drugs have a more specific side-effect spectrum. Bleomycin, an anti-tumor antibiotic used to treat patients with Hodgkin's disease

and testicular cancer, can produce interstitial lung disease and pulmonary fibrosis. Patients who receive bleomycin-containing chemotherapy regimens are typically followed with serial lung exams and pulmonary function studies, with a decrement in the diffusion capacity for carbon monoxide being a cause for concern. Since oxygen can potentiate the pulmonary damage mediated by bleomycin, patients receiving such chemotherapy must be damaged with very low inspired concentrations of oxygen, if, for example, they need a surgical procedure.

- V-50. The answer is B.** (*Chap. 111*) The Philadelphia chromosome is the diagnostic hallmark of CML. This cytogenetic abnormality involves the translocation between the *BCR* gene on chromosome 22 and the *c-abl* proto-oncogene on chromosome 9. This results in hematopoiesis that is abnormally regulated. Patients with CML typically experience a chronic phase that lasts for 3 to 4 years in which there is little clinical symptomatology. High platelet count, large spleen, and the presence of excess basophils in the blood or bone marrow at the time of presentation suggest that the chronic phase may be relatively short. Nonetheless, the finding of any additional cytogenetic abnormalities during the course of treatment or follow-up during stable phase is an ominous sign. Specifically, it is likely that accelerated phase (or blast crisis) is impending. The most commonly observed second cytogenetic event is a duplicated Philadelphia chromosome.
- V-51. The answer is D.** (*Chaps. 62, 116*) von Willebrand's disease is the most common inherited coagulopathy. von Willebrand's protein is a complex multimer with many subunits. Patients with von Willebrand's disease have an abnormality of either formation of this protein or appropriate aggregation of the multimers into the full protein, whose function is to bind to factor VIII and to help platelets bind to damaged endothelial surfaces. Clinical manifestations of von Willebrand's disease are similar to conditions in which there is a defect in platelet number or function with a propensity for excessive bleeding after minor surgical procedures and mucosal and skin bleeding. Factor VIII activity levels are low in patients with von Willebrand's disease. Because platelet function is altered in this disease, the bleeding time is elevated. Therefore, the diagnosis of von Willebrand's disease is highly suspected in this patient with a typical clinical history, a family history, and a prolonged bleeding time. The diagnosis of which of several subtypes of von Willebrand's disease this patient might have would depend upon further testing, largely involving protein electrophoresis with analysis of the von Willebrand's protein multimers. For most subtypes of von Willebrand's disease, therapy is required only for bleeding prophylaxis around the time of surgery and could include the use of arginine vasopressin (DDAVP) and/or administration of factor concentrates.
- V-52. The answer is E.** (*Chap. 79. Levy, N Engl J Med 335:1124–1132, 1996.*) Seventy-five percent of cancer patients with advanced disease experience pain which may be caused by tumor invasion, invasive surgical procedures, or radiation or chemotherapy injury. The vast majority of patients will experience pain relief with pharmacologic intervention. It is helpful to use the World Health Organization method for the rational titration of oral analgesia. The goal is to keep the patient ambulatory and pain-free. For mild pain, patients should receive acetaminophen, aspirin, or a nonsteroidal adjuvant with or without an additional adjuvant such as glucocorticoid or antidepressant. The next step consists of adding an opioid such as codeine or hydrocodone. If pain persists despite these steps, the opioid should be replaced with a more potent drug, potentially at higher dose, such as immediate-release morphine 15 to 30 mg every 3 to 4 h, or controlled-release morphine, 60 mg (or higher) twice a day.
- V-53. The answer is E.** (*Chap. 82. Weinberg, Cell 81:323–330, 1995.*) Unbridled proliferation, one hallmark of cancer, may occur due to several mechanisms. Loss of normal control of movement through the cell cycle represents one group of such mechanisms. The G₁-S transition (movement into DNA synthesis phase) and the G₂-M transition (movement into mitotic phase) are tightly regulated. The G₁-S transition is frequently disrupted in

cancer. Cyclin/cyclin-dependent kinase (Cdk) protein complexes are responsible for phosphorylating the retinoblastoma gene product, Rb, at ten different sites. Such modification alters the ability of this protein to associate with other cellular proteins such as E2F, a transcription factor that heterodimerizes with other transcription factors to active genes required to progress on to S phase. If an Rb mutation prevents normal association with E2F, the free E2F can act as a transcription factor and initiate S phase. Mutations in the retinoblastoma gene product are found in many tumors including osteosarcoma, retinoblastoma, breast cancer, and lung cancer.

- V-54. The answer is A.** (*Chaps. 81, 89*) Since several first-degree relatives are afflicted with ovarian or premenopausal breast cancer, there is a high likelihood that these neoplasms are caused by an inherited mutation in either the *BRCA-1* or *BRCA-2* tumor suppressor genes. It is believed that ~10% of all breast cancer arises from an inherited mutation, and about 60 to 80% of all inherited mutations are either in the *BRCA-1* or *BRCA-2* gene. There are several mathematical models in existence, such as the Gale model, that serve to predict an individual woman's risk for developing breast cancer based on the family history. Moreover, it is recommended that analysis for *BRCA-1* and *-2* mutations be carried out in situations where there is a >10% likelihood that breast cancer will develop based on such mathematical analysis. In this situation the chance of an inherited cancer syndrome is quite high, given the fact that two first-degree relatives have been affected early in life with breast and ovarian cancer. If the family can be shown to harbor one of these mutations, then the risk for each individual can be assessed. The most straightforward way to determine this is to test the affected family member, because it is certainly possible that two cancers in the family could have been coincidental or that they could have occurred on the basis of a non-*BRCA-1* or *-BRCA-2* mutation. If the affected relative is positive for one of these mutations, then given the autosomal dominant inheritance pattern, the sibling has a 50% chance to carry this mutation in the germline and thereby have a very high risk for developing breast or ovarian cancer. If the affected sister had a sample of blood sent for germline sequencing of *BRCA-1* and *BRCA-2* genes and a mutation were found, then there would be a 50% chance that her sister would have the same mutation. In such a situation, screening would be required only for that specific mutation. If the mutation were not present, then her risk for breast cancer would be no higher than in the normal population and routine screening could be advised. If the mutation were present, then bilateral simple mastectomies and oophorectomy at the conclusion of child rearing would be an appropriate management strategy. However, the issue of genetic testing is very complex and is almost certainly best done in the setting of a specialized clinic.
- V-55. The answer is A.** (*Chaps. 84, 104. American Society of Clinical Oncology, J Clin Onc 12:2471–2508, 1994.*) Two hematopoietic growth factors are currently approved for use in the management of chemotherapy-induced neutropenia. Granulocyte macrophage colony-stimulating factor (GM-CSF) and G-CSF are now commonly used to ameliorate the myelosuppression associated with chemotherapy use. While the agents, particularly G-CSF, are well tolerated, their use is expensive and not appropriate for each cycle of chemotherapy. The American Society of Clinical Oncology has recommended that G-CSF be administered with the first cycle of planned chemotherapy only if the patient has a $\geq 40\%$ risk of experiencing fever and neutropenia. If the patient has experienced an episode of febrile neutropenia, then administration of the growth factor with a subsequent course is reasonable, especially if dose intensity is important. Clearly in the case of cyclophosphamide, doxorubicin, vincristine, and prednisone chemotherapy for early-stage large cell lymphoma, chemotherapy must be administered at full doses, on time, to ensure that cure is most likely. Consequently, since the patient has recovered within ~2 weeks after the administration of cycle three of chemotherapy, cycle four should be given on time, at full dose with G-CSF support to limit the likelihood that the subsequent cycle would result in another hospitalization for febrile neutropenia. Since the tumor is responding well to chemotherapy, changing to an alternative regimen, particularly a less myelosuppressive one, would be inappropriate. Moreover, colony-stimulating factors are not recommended

for routine use in either afebrile or febrile neutropenic patients unless factors predictive of deterioration are present.

- V-56. The answer is A.** (*Chap. 86. Haluska, Multani, Cancer Chemother Biol Response Modif 18:470–488, 1999.*) The most important prognostic factor for outcome in malignant melanoma is the stage at presentation. Stages I and II refer to tumors in which there is no evidence, either clinically or pathologically, of disease in draining lymph nodes. For these patients, the risk of recurrence is critically dependent upon the depth of invasion; overall survival ranges from >95% in those with primary lesions <0.75-mm thick to <50% in those whose primary lesion is >4mm in thickness. The presence of one or more pathologically involved lymph nodes is associated with a 45% or lower chance of long-term survival. Those with intermediate-risk local disease (lesions between 0.75 mm and 3.5 mm in thickness) may benefit from elective regional lymph node resection. Chemotherapeutic treatment for regional lymph node or distant metastasis is highly unsatisfactory. While dacarbazine and nitrosoureas are active agents, response rates of $\leq 20\%$ make it unlikely that these agents would be useful in the adjuvant setting. However, clinical trials have suggested that adjuvant interferon- α can improve the disease-free and overall survival significantly in patients at extremely high risk for recurrence (those with deep lesions or with clinical or pathologic evidence of nodal metastasis). A study performed by the Eastern Cooperative Oncology Group randomized patients to receive interferon- α 2B at a maintenance dose of 10 mU/m² per day twice weekly (after a higher induction dose) or observation for those with primary lesions >4 mm in thickness and patients with clinical or pathologic evidence of spread to regional nodes. There was a distinctly significant prolongation of both relapse-free and overall survival in the treated group. The effect was greatest in those patients with clinically palpable lymph nodes. Because the interferon was fairly toxic and was stopped in a significant portion of patients, ongoing studies are determining the minimum effective interferon dose.
- V-57. The answer is A.** (*Chap. 101*) The Lambert-Eaton neuromuscular syndrome—weakness of muscles caused by inability to release acetylcholine from the presynaptic fiber of the neuromuscular junction—is one of the most common paraneoplastic neurologic syndromes. However, patients with clinical Lambert-Eaton syndrome harbor a malignancy only about 50% of the time. Small cell lung cancer accounts for the vast majority of those with malignancy-associated Lambert-Eaton syndrome; 3% of all patients with small cell cancer of the lung have this type of paraneoplastic syndrome. Most patients have abnormalities of the peripheral nervous system, but ocular (ptosis, diplopia) and bulbar (dysphasia, dysarthria) symptoms may also occur. The pathophysiology is believed to represent a neoplasm-induced IgG antibody against the voltage-gated calcium channels in the terminus of the motor neuron. The best therapy is control of the primary neoplasm; however, immunosuppression to reduce antibody formation and acetylcholine-enhancing drugs such as pyridostigmine have also been tried, with variable success.
- V-58. The answer is C.** (*Chap. 101. Sillevs Smith et al, N Engl J Med 342:21–27, 2000.*) One of the better characterized paraneoplastic neurologic syndromes is cerebellar ataxia caused by Purkinje cell drop-out in the cerebellum; it is manifested by dysarthria, limb and gait ataxia, and nystagmus. Radiologic imaging reveals cerebellar atrophy. Many antibodies have been associated with this syndrome, including anti-Yo, anti-Tr, and antibodies to the glutamate receptor. Although lung cancer, particularly small cell cancer, accounts for a large number of patients with neoplasm-associated cerebellar ataxia, those with the syndrome who display anti-Yo antibodies in the serum typically have breast or ovarian cancer.
- V-59. The answer is D.** (*Chap. 102*) Superior vena cava syndrome, in which there is either extrinsic compression of the superior vena cava or intrinsic obstruction due to thrombosis, usually occurs in association with malignancy. The most common malignancy associated with superior vena cava syndrome is lung cancer. Typical symptoms include swelling of

the neck and face, with headache and worsening symptoms upon bending forward or lying down. The worrisome complication of progressive compression of the superior vena cava by tumor is tracheal compromise with a need for rapid, albeit difficult, intubation. While patients with solid tumors certainly have a higher incidence of venous thromboses, at this time the most common cause of thrombosis-associated superior vena cava syndrome is certainly central venous catheter-associated clots. In this patient's case, his leukemia is in remission and would not be expected to be associated. Most hematologic neoplasms are not associated with a hypercoagulable state, although exceptions do occur. A nuclear medicine flow study would reveal that injected radiocontrast would require collateral channels to reach the heart because the superior vena cava is blocked by clot. Though occasionally small clots can be dealt with by anticoagulation alone, the general approach is to remove the catheter and administer anticoagulation, usually in the form of heparin followed by warfarin. Some centers routinely place patients on chronic low-dose warfarin therapy to reduce the risk of this complication.

- V-60. The answer is E.** (*Chaps. 100, 102*) Although it was formerly thought that most cases of hypercalcemia of malignancy were due to a direct resorption of bone by the tumor, it is now recognized that 80% of such instances occur because of production of a protein called parathyroid hormone reactive protein (PTHrP) by the tumor. PTHrP shares 80% homology in the first 13 terminal amino acids with native parathyroid hormone. The aberrantly produced molecule is essentially functionally identical to native parathyroid hormone in that it causes renal calcium conservation, osteoclast activation and bone resorption, renal phosphate wasting, and increased levels of urinary cyclic adenosine monophosphate. Only about 20% of cases of the hypercalcemia malignancy are due to local production of substances, such as transforming growth factor and IL-1 to -6, which cause bone resorption at the local level and release of calcium from bony stores. Although aggressive hydration with saline and administration of a loop diuretic are helpful in the short-term management of patients with the hypercalcemia of malignancy, the most important therapy is the administration of a bisphosphonate, such as pamidronate, which will control the laboratory abnormalities and the associated symptoms in a vast majority of patients. Symptoms of hypercalcemia are nonspecific and include fatigue, lethargy, polyuria, nausea, vomiting, and decreased mental acuity.
- V-61. The answer is C.** (*Chaps. 85, 111*) Complications related to chemotherapy-induced myelosuppression and gastrointestinal epithelial dysfunction can be life-threatening. Bacteremias caused by enteric gram-negative rods and gram-positive cocci and disseminated candidemia are common. Patients often experience painful mucositis and discomforting diarrhea as a consequence of antileukemic chemotherapy. One specific complication of chemotherapy is *typhlitis*, also called *neutropenic enterocolitis*, which refers to an inflammation of the bowel wall in the setting of profound neutropenia and gut denudation. Physical examination usually mimics an acute abdomen. CT typically discloses an inflammatory-type mass in the right lower quadrant and/or thickening of the cecal wall. Since the patient is profoundly neutropenic, there is no abscess to drain. Second, exploratory laparotomy would be prohibitively dangerous and not very effective in this setting. The most appropriate therapy is bowel rest, good antibiotic coverage for bowel flora, and waiting for time to elapse until the patient's neutrophils recover. Although very high mortality rates associated with typhlitis were originally reported, with a conservative management strategy most patients will recover, assuming that their leukemia responds to therapy.
- V-62. The answer is A.** (*Chap. 112. Wierda, Kipps, Curr Opin Hematol 6:253–261, 1999.*) Chronic lymphocytic leukemia (CLL), the most common of the acute or chronic leukemias, is a malignancy of mature-appearing B lymphocytes that characteristically occurs in older adults. The diagnosis can be confirmed by flow cytometric means since CLL cells typically co-express B cell antigens such as CD20 and CD23 as well as the nominal T cell antigen, CD5. The prognosis of a patient with CLL is critically dependent on his or her stage: Rai

stage 0 patients have lymphocytosis only, stage I patients have lymphocytosis plus lymphadenopathy, stage II patients have splenomegaly, stage III patients have anemia (not due to autoimmune hemolysis), and stage IV patients have thrombocytopenia. The expected length of survival for those with stage 0 CLL is similar to that of age-matched controls. The survival prognosis for those with stage I CLL is also favorable, with 7- to 10-year mean survival. As such there is no role for chemotherapy in this patient who is doing well, albeit with the knowledge that she does have a chronic malignancy. Although the patient is hypogammaglobulinemic, as is typical for patients with CLL, she has had no infection; it has been clearly shown that prophylactic intravenous gammaglobulin therapy for all patients with CLL is highly costly without clear-cut benefit. If a patient needs systemic therapy because of rapid doubling of the lymphocyte count, symptoms due to bulky nodes, or cytopenias, then fludarabine is often used initially because it offers the best response rate. The drug, however, is myelosuppressive and immunosuppressive and should be administered with caution. Given the indolent nature of the disease and advanced age of this patient, therapy is not warranted at this time.

- V-63. The answer is A.** (*Chap. 110. Tefferi, N Engl J Med 342:1255–1265, 2000.*) The myeloproliferative disorders are characterized by an overproduction of one or more cellular elements with, in general, normal morphologic appearance of the cells. In polycythemia vera the red cell mass is high, in essential thrombocytosis platelets are produced in far greater numbers than normal, and in chronic myeloid leukemia (CML) the white count is generally elevated. Patients with CML typically present with an elevated white count with a left-shifted differential, peripheral blood basophilia and/or eosinophilia, and splenomegaly. However, the platelet count is usually elevated and the hematocrit is normal. The finding of a left-shifted white cell series, nucleated red blood cells, and tear drop-shaped red cells suggests a myelophthitic picture. Although myelophthisis could be due to infiltration with metastatic tumor, the splenomegaly in this case coupled with the dry bone marrow tap strongly suggests that this patient has idiopathic myelofibrosis (also termed *agnogenic myeloid metaplasia*). Median survival of patients with idiopathic myelofibrosis is approximately 5 years and is modified adversely by the size of the spleen, the patient's age, and particularly the degree of the anemia. Treatment is largely supportive, although splenectomy should be considered if symptoms of early satiety or intractable abdominal pain occur in the presence of refractory thrombocytopenia or the need for abundant red cell transfusions.
- V-64. The answer is E.** (*Chap. 88*) Although patients with limited disease small cell carcinoma of the lung may be cured with a combination of chemotherapy and radiation therapy, most patients experience either local or systemic relapse. In this case, the patient is presenting with classic findings of postobstructive pneumonia due to an endobronchial lesion or due to bronchial compression from an extrinsic mass. Tracheal deviation, decreased breath sounds, and a collapsed lobe are all consistent with this diagnosis. While systemic antibiotics are generally administered, successful therapy critically depends on establishing a patent airway. Bronchoscopy can determine whether the lesion is intrinsic or extrinsic and whether laser cautery or brachytherapy (placing radiation seeds in the area of the tumor) could be helpful. It is unlikely that external beam radiation therapy could be delivered safely given the patient's prior extensive treatment for limited stage small cell lung cancer. Chemotherapy and even additional external beam radiation therapy might play a role in the management of this patient, but only after an attempt at an anatomic solution.
- V-65. The answer is A.** (*Chaps. 86, 102.*) Metastases to the spine are extremely common in patients with solid tumors, particularly those with breast cancer, renal cell carcinoma, multiple myeloma, melanoma, prostate cancer, and lung cancer. Back pain in a patient with cancer should always be taken seriously. Any finding suggesting cord compression on physical examination (extensor plantar response or loss of pinprick sensation in a sensory level distribution) or an abnormal routine radiographic exam (particularly loss of pedicles on plain radiography of the spine) should prompt a definitive anatomic study. The

most appropriate definitive study is a magnetic resonance image of the entire spine to define the locus of disease, which most commonly would be metastases to a vertebral body growing into the canal. In this patient's case, there is a high likelihood of disseminated malignant melanoma, given that he had a deep lesion resected several years ago. However, other histologies are also theoretically possible. The uncertainty of the diagnosis coupled with the radio-chemoresistance of this tumor should prompt primary consideration for surgery to resect the tumor, to prevent cord compromise, and to define the histology. A prolonged disease-free interval with subsequent development of aggressive metastatic disease is not unusual for patients with malignant melanoma.

- V-66. The answer is E.** (*Chaps. 61, 109*) A slightly increased MCV and an inappropriately low reticulocyte count are characteristic of a macrocytic, hypoproliferative anemia. Iron-deficiency anemia is accompanied by microcytic red blood cell indices, and autoimmune hemolytic anemia is typically associated with reticulocytosis, unless a coexisting process, such as folate deficiency, interferes with the bone marrow erythropoietic response. Aplastic anemia and acute leukemia are unlikely diagnoses if white blood cell count and platelet count are normal. A macrocytic, hypoproliferative anemia in the older man described in the question would most likely be due to a myelodysplastic syndrome. A bone marrow examination with iron stain would be required to define the precise subtype of this heterogeneous disorder, which is characterized by a stem cell defect leading to disordered hematopoietic maturation. Given the normal platelet count and white blood cell count, either refractory anemia or refractory anemia with ringed sideroblasts is the most likely subtype.
- V-67. The answer is E.** (*Chaps. 80, 91*) It is now well recognized that many environmental and industrial exposures are associated with an increased risk of neoplasia. For example, tobacco smoking is associated with an increased likelihood of developing cancer of the oral cavity, lung, esophagus, kidney, bladder, and pancreas. In fact, due to the increased frequency of cigarette smoking among American women after World War II, beginning in 1988 female deaths from lung cancer exceeded the deaths from breast cancer. Occupational causes of cancer include arsenic-induced lung cancer and skin cancer. Asbestos exposure is a well-recognized cause of mesothelioma of the lung, pleura, and peritoneum. Benzene and perhaps other industrial solvents are associated with an increased risk of leukemia. Chromium compounds and benzidine are industrial carcinogens associated with lung cancer and bladder cancer, respectively. The use of mustard gas in the workplace is associated with an increased incidence of lung and head and neck cancer. Finally, workers in the plastic industry exposed to vinyl chloride have been shown to develop angiosarcoma, a rare tumor of the liver.
- V-68. The answer is D.** (*Chap. 89*) The appropriate systemic therapy for postmenopausal women with estrogen-receptor-positive breast cancer metastatic to bone is tamoxifen, 10 mg twice daily. Radiation therapy can relieve bone pain and may prevent fractures if used prophylactically to treat lesions of weight-bearing bones. For lytic lesions >2.5 cm in diameter in weight-bearing bones, prophylactic internal fixation followed by radiation therapy is the treatment of choice, especially if the lesions involve the cortex. Pamidronate may have a role in stabilizing the bone matrix to lessen the incidence of subsequent pathologic fracture.
- V-69. The answer is C.** (*Chap. 117. Bick, Hematol Oncol Clin North Am 10:875, 1996.*) A unifying pathophysiologic explanation for the association between malignancy and thrombosis has not been developed; however, many factors may play a role in increasing the likelihood of abnormal clotting in cancer patients. Such factors include immobilization and bed rest, dysproteinemias producing hyperviscosity, abnormal platelet function in myeloproliferative disorders, tumor-associated low-grade DIC, production of procoagulants by the tumor, and cancer-mediated thrombocytosis. Unlike the case for patients with coagulopathies, there is no useful laboratory test that will identify the hypercoagulable

state. Different types of malignancies may be associated with specific thrombotic syndromes. For example, migratory superficial thrombophlebitis (Trousseau's syndrome) in the absence of apparent predisposing factors is most frequently associated with gastrointestinal malignancies, particularly pancreatic carcinoma. Hepatic vein thrombosis (Budd-Chiari syndrome) and portal vein thrombosis are associated with myeloproliferative disorders such as paroxysmal nocturnal hemoglobinuria, essential thrombocythemia, and polycythemia vera.

- V-70. The answer is D.** (*Chap. 117. Mannucci, Tuddenham, Semin Hematol 36:104–117, 1999.*) Hemophilia A and hemophilia B are similar diseases in which abnormal levels of the clotting factors VIII and IX, respectively, lead to bleeding in the postsurgical setting as well as into large joints and muscles. Mucosal bleeding characteristic of defects in platelet number and/or function does not occur. The genes encoding factor VIII and factor IX both lie on the X chromosome, leading to sex-linked genetic transmission. These factors are both involved in coagulation via the intrinsic pathway; the partial thromboplastin time is prolonged, yet the prothrombin time is preserved. Hemophilia A and B are both treated with factor replacement therapy. Fortunately, at this time recombinant factors are available for both diseases, as are inactivated purified products, each of which carries a very low risk of transmitting the viral diseases that plagued prior therapy. It is necessary to increase the factor VIII levels above 1% of normal to prevent severe bleeding, about 5% to prevent moderate bleeding, and about 50% to prevent bleeding during surgery.
- V-71. The answer is D.** (*Chap. 114. Heyman, Semin Oncol 17:198–209, 1990.*) Platelet transfusions are a mainstay of the therapy in the chronically thrombocytopenic patient. Automated platelet pheresis yields approximately 6 units of platelets (each unit is 6×10^{10} platelets) from an individual donor, and these may be stored at room temperature for ~5 days. Each unit should raise the platelet count by at least 5000 cells/ μ L. Therefore, this patient has responded appropriately to her transfusion, although she has had a significant febrile reaction. It is important to rule out bacterial contamination of the transfused platelets, but this is a very rare complication. More commonly, febrile reactions after receiving platelets are due to reaction to HLA antigens to which the patient has been sensitized. While such reactions might be circumvented by administering platelets from an HLA-compatible donor or sibling, given the appropriate rise in the platelet count after the transfusion, the easiest way to approach the current problem would be to administer leukocyte-reduced platelets. Currently available filters can reduce the leukocyte content (and thereby diminish the exposure to sensitizing alloantigens) by >99.9%. Another advantage of leukocyte-reduced products is reduction of the risk of CMV transmission. Though transfusion-associated graft-versus-host disease is not eliminated by leukocyte reduction, since there are still a few remaining allogeneic lymphocytes in such products, this dreaded complication can be eliminated by irradiating all blood products at a dose of 25 Gy.
- V-72. The answer is C.** (*Chap. 96. Bosl, Motser, N Engl J Med 337:242–253, 1997.*) Persons with disseminated teratocarcinoma treated with combination chemotherapy achieve complete remission in >90% of cases. Occasionally, residual masses remain after chemotherapy and on biopsy prove to be benign mature teratomas rather than residual malignant disease. In these cases, partial responders can be converted to complete responders—and even cured—by surgical removal of residual masses. If viable cancer is detected in the surgical specimen, then additional chemotherapy should be administered.
- V-73. The answer is A.** (*Chap. 115*) One of the most important complications of allogeneic bone marrow transplantation is acute graft-versus-host disease. This condition is believed to be due to a reaction by engrafted lymphoid cells, particularly T cells, against host tissues. Graft-versus-host disease is essentially not a complication of syngeneic (identical twin) or autologous transplants. Acute graft-versus-host disease typically involves the skin, gastrointestinal tract, and liver. Elevations of the alkaline phosphatase and jaundice are common.

An isolated elevation of bilirubin and alkaline phosphatase and the onset of ascites would raise consideration of venoocclusive disease (VOD) of the liver. Such a problem would probably not be associated with a skin rash and diarrhea. Secondly, hepatic VOD is much more common when therapy with combined alkylating agents is used as the preparative regimen. Efforts to prevent acute graft-versus-host disease have centered upon the use of immunosuppressive agents including glucocorticoids, methotrexate, and cyclosporine. Another approach is the use of T cell–depleted donor marrows. However, while T cell–depleted donor marrows will reduce the risk of severe graft-versus-host disease, the rate of relapse may be lower in patients with graft-versus-host disease than in those without.

- V-74. The answer is E.** (*Chap. 89. Fisher et al, J Clin Oncol 16:441–452, 1998.*) Given the increasing frequency of breast biopsy for patients with suspected breast cancer, the incidence of carcinoma in situ is increasing. There are two histologically distinct types of carcinoma in situ: ductal and lobular. Ductal carcinoma in situ may form palpable tumors and is frequently confined to one breast. This finding would be a marker for an increased risk of developing an invasive cancer. Although controversial, based on a recently published clinical trial, it appears that the optimal treatment for such patients is wide excision followed by radiation therapy. On the other hand, lobular carcinoma in situ does not form palpable tumors and tends to be a diffuse finding in both breasts. Without treatment the cumulative incidence of a breast cancer (in either breast) is about 25% with a latent period of 5 to 20 years. Most doctors recommend resection of the lesion with careful follow-up. Whether tamoxifen is of benefit is unknown. Molecular analysis may one day make it possible to predict which in situ cancers will become invasive. Women whose quality of life is lowered by the lingering risk may opt for bilateral prophylactic mastectomy.
- V-75. The answer is E.** (*Chaps. 61, 105. Means, Int J Hematol 70:7–12, 1999.*) A mild-to-moderate degree of anemia often accompanies chronic infectious, inflammatory, or neoplastic diseases. Typically, the anemia of chronic disease is normochromic and normocytic. Bone marrow examination reveals normal erythroid maturation. Neither significant disturbance of hemoglobin synthesis nor hemolysis occurs in this type of anemia. Affected persons usually have a low serum iron concentration and a low total transferrin level (resulting in essentially normal or only slightly decreased transferrin saturation). Even though storage iron is abundant, there is a decreased amount of iron in erythroblasts, reflecting a defect in the transfer of reticuloendothelial iron to developing red blood cells.
- V-76. The answer is D.** (*Chap. 108. Beutler, N Engl J Med 324:169, 1991.*) The gene for G6PD is located on the X chromosome; thus, G6PD deficiency is a sex-linked trait. Hemolytic anemia occurs much more commonly in males than in heterozygote female carriers, who are usually asymptomatic. Of the more than 100 variants of G6PD, the most commonly encountered variant of clinical significance in the United States is the A-type, which is found in about 15% of black males. It generally causes less severe hemolysis than the Mediterranean variant. Hemolysis is usually precipitated by an environmental oxidant stress, most commonly viral or bacterial infection. Certain drugs, such as anti-malarial agents, sulfonamides, phenacetin, and vitamin K, can also trigger hemolysis. These oxidant stresses cause precipitation of hemoglobin because affected persons are unable to maintain adequate intracellular levels of reduced glutathione. Precipitated hemoglobin forms Heinz bodies that are visualized only with supravital stains; these inclusions cause premature destruction of the red cells. The diagnosis should be considered in any person experiencing a hemolytic episode. However, since decreased G6PD levels are found mainly in older cells, a false-negative test may be obtained during a hemolytic crisis, and the test should be repeated upon recovery.
- V-77. The answer is B.** (*Chap. 95. Carter et al, J Natl Cancer Inst 91:1733–1737, 1999.*) PSA determinations are assuming an increasingly important role in the diagnosis, screening, and staging of men with prostate cancer. Patients with urinary symptoms found to have an elevated level of serum PSA have a 60% percent likelihood of having prostate

cancer. About 16% of patients with prostate cancer have an elevated level of serum PSA as their sole diagnostic abnormality. However, additional studies need to be done to delineate precisely the role of PSA evaluation in screening. Fewer than 10% of ambulatory volunteers older than 50 years have elevated serum PSA values. A serum PSA between 4 and 10 ng/mL indicates that cancer is 25% likely, whereas values >10 ng/mL increase the likelihood of cancer to about 60%. About 20% of those with an elevated PSA (alone) compared with 10% of those with a suspicious digital rectal examination (alone) will have prostate cancer. The vast majority of cancers that are detected by screening for PSA are localized clinically and therefore have an excellent chance of being cured with either radiation or surgery. Moreover, few tumors detected by PSA screening are incidental since most have a high volume or a worrisome Gleason score (indicating a poor prognosis based on histologic grade). On the other hand, additional studies demonstrating a screening-induced decrease in cancer-related mortality are necessary in order to convince all that screening for prostate cancer with PSA determinations is beneficial. A clear use for serum PSA determination is in postoperative evaluation. If the postoperative serum PSA value is detectable, the presence of residual tumor is likely. A rising PSA value after definitive radiation therapy indicates a high likelihood of eventual metastatic spread. The use of systemic hormonal therapy for metastatic prostate cancer should be reserved for those patients with certain evidence of locally advanced or metastatic disease.

- V-78. The answer is B.** (*Chap. 89. Early Breast Cancer Trialists' Collaborative Group, Lancet 352:930–942, 1998.*) For premenopausal women who have node-negative breast cancer (axillary metastases only), chemotherapy, when employed as an adjuvant therapy, leads to a statistically significant reduction in the recurrence rate. It is the treatment of choice following mastectomy in this group of women except in those with very small tumors. Though the risk of recurrence in this stage I group is relatively low, analysis of large randomized trials clearly points to a survival benefit with the use of adjuncts chemotherapy.
- V-79. The answer is E.** (*Chaps. 101, 113. Grisold; Drlicek, Curr Opin Neurol 12:617–625, 1999.*) A relatively common subtype of paraneoplastic neurologic syndromes is that which affects peripheral nerves. Subacute sensory neuronopathy, characterized by paresthesia and pain in the distal limbs with truncal sensory ataxia, is associated with axonal degeneration with relative myelin sparing. The most common type of paraneoplastic neuropathy is a mixed sensory and motor axonopathy. Symptoms may include muscle wasting, weakness, distal paresthesia, and occasionally pain. Pathologically, this disease is characterized by noninflammatory degeneration of axons with mild myelin loss and may be associated with small cell carcinoma of the lung, breast carcinoma, gastric carcinoma, Hodgkin's disease, lymphoma, and multiple myeloma. Another type of neuropathy associated with Waldenström's microglobulinemia or in certain patients with benign monoclonal gammopathy is the elaboration of IgM that reacts with a myelin-associated glycoprotein in peripheral nerves. Such an antibody tends to disrupt sensory rather than motor neurons. Another demyelinating neuropathy associated with IgG myeloma is predominantly motor, indolent, and not associated with an anti-myelin-associated glycoprotein antibody, although demyelination is still the primary pathology. Patients with monoclonal gammopathies who develop neuropathy also include those with the POEMS syndrome, characterized by polyneuropathy, organomegaly, endocrinopathy, M-protein secretion, and skin changes. Any patient with a demyelinating myopathy secondary to monoclonal immunoglobulin protein may respond to immunosuppressive therapy.
- V-80. The answer is E.** (*Chap. 99. Ellerbeek, Cancer 66:1461–1467, 1990.*) In general, women who present with an isolated axillary mass that proves to be adenocarcinoma or poorly differentiated carcinoma should receive treatment appropriate for stage II breast cancer. They should receive either a modified radical mastectomy or breast irradiation for purposes of decreasing local recurrence followed by adjuvant systemic therapy with chemotherapy or tamoxifen or both, depending on menopausal status and the hormone receptor status of the tumor. However, patients whose routine pathology reveals either

poorly differentiated adenocarcinoma or poorly differentiated malignancy deserve a careful pathologic review to determine if there are any findings compatible with a specific organ of origin. In this case, the absence of cytokeratin filaments argues against the diagnosis of breast carcinoma; on the other hand, the leukocyte common antigen positivity is highly consistent with a lymphoid neoplasm. The patient would be expected to respond to therapy as if she had a more straightforward presentation of lymphoma. To determine the optimal therapy for such a patient, the disease should be staged as in any non-Hodgkin's lymphoma. Therefore, CT of the chest and abdomen should be performed to determine whether there are additional sites of disease.

- V-81. The answer is B.** (*Chaps. 61, 104, 109*) Pure red blood cell aplasia is characterized by a normochromic, normocytic anemia and little production of reticulocytes. Erythroblasts are selectively absent from the bone marrow of affected persons. The production of white blood cells and platelets is preserved. In contrast to aplastic anemia, the bone marrow in persons with pure red blood cell aplasia is normocellular or even hypercellular. Iron kinetic studies reveal prolonged clearance of plasma iron and reduced turnover of iron. Levels of erythropoietin are usually markedly elevated.
- V-82. The answer is B.** (*Chap. 99. Lenzi et al, J Clin Oncol 15:2056–2066, 1997.*) Approximately 10% of all cancer patients present in such a manner that assignment of the organ of origin of the tumor is unclear. Most patients who present in this fashion will have neoplasms that are poorly responsive to systemic therapy. However, it is important to recognize certain subgroups in whom a specific approach to treatment might be beneficial or even associated with long-term disease-free survival. One such group has what has been termed the unrecognized extragonadal germ cell cancer syndrome. This includes those patients displaying one or more of the following features: age less than 50; tumor involving midline structures, lung, or parenchymal lymph nodes; an elevated serum α fetoprotein or β hCG level; or evidence of rapid tumor growth. If patients with these features do not have any histologic or immunohistochemical features suggesting a primary site, then strong consideration should be given to treatment with a cisplatin-based chemotherapy regimen (as would be used for germ cell cancer). Approximately 20% of patients presenting in this fashion may be cured with the use of cisplatin, bleomycin, and VP-16 chemotherapy.
- V-83. The answer is D.** (*Chap. 112*) Lymphoid neoplasms may be classified as to their cell of origin by the use of antisera and monoclonal antibodies against certain cell surface phenotypic markers and, more recently, by the use of DNA probes for immunoglobulin genes and genes for the beta chain of the T cell receptor. The malignant cell in CLL is a morphologically normal but functionally abnormal B lymphocyte. Follicular lymphomas arise from the lymphoid follicle, while the diffuse, small lymphocytic lymphomas (identical to CLL) are derived from the secretory compartment of the medullary cords. The Burkitt's lymphoma cell is a malignant cell of B lymphocyte lineage; in many cases it bears a characteristic chromosomal translocation—t(8;14). In contrast to these B cell neoplasms, mycosis fungoides is a peripheral T cell lymphoma in which helper-cell function and phenotype have been identified in some cases.
- V-84. The answer is A.** (*Chap. 117. Greaves, Lancet 353:1348–1353, 1999.*) A deficiency in factor VIII would be likely to elevate the partial thromboplastin time, not the prothrombin time. Mixing studies could identify the rare factor VII deficiency that would lead to an elevation of the prothrombin time. The most likely explanation for this sort of abnormality is a so-called lupus-like inhibitor that binds to phospholipids used in the coagulation test. Patients with such an antibody tend not to bleed but rather to have an increased incidence of venous and arterial thrombosis as well as mid-trimester abortions. Occasionally the platelet count is low or below normal. The presence of an anticardiolipin antibody defines the syndrome. The presence of such an antibody could account for a false-positive test for syphilis. However, those who actually have antitreponemal antibodies usually have

a normal prothrombin time. A lupus anticoagulant can be confirmed by noting the failure of normal plasma to correct the abnormal prothrombin time in the laboratory assay.

- V-85. The answer is D.** (*Chaps. 62, 117*) A marked prolongation of the prothrombin time with a normal partial thromboplastin time localizes the hemostatic defect to the extrinsic limb of the coagulation cascade. Congenital factor VII deficiency is a rare, autosomal recessive disorder. Factor VIII deficiency and the presence of specific inhibitors directed toward a coagulation factor (most commonly factor VIII) would be associated with a prolongation of the partial thromboplastin time. Nonspecific inhibitors (lupus anticoagulants) most commonly are associated with prolongation of the partial thromboplastin time and occasionally with prolongation of the prothrombin time (particularly when hypoprothrombinemia is present). Patients with α_2 -antiplasmin deficiency have a bleeding disorder associated with accelerated clot lysis. Both the prothrombin time and the partial thromboplastin time are normal in these persons.
- V-86. The answer is D.** (*Chap. 117*) The incidence of the so-called factor V Leiden mutation is relatively common (3% are heterozygotes). This mutation, the substitution of a glutamine residue for arginine in position 506 in the factor V molecule, abolishes a protein C cleavage site. Therefore, the mutation causes intrinsic resistance to the anticoagulant effect of protein C, with a corresponding magnification of the thrombogenic effect of factor V activation. Heterozygotes for this mutation will have a sevenfold increased risk of clotting, and homozygotes are at a twentyfold increased risk. It is estimated that $\geq 30\%$ of those who sustain a deep venous thrombosis or pulmonary embolism while taking oral contraceptives harbor a factor V Leiden mutation. Those with homozygous mutations in this gene require lifelong anticoagulation.
- V-87. The answer is B.** (*Chap. 97. Ozols, Semin Oncol 27:47–49, 2000.*) The overall 5-year survival of those with disease that extends beyond the ovaries is 40%; however, some patients who are able to undergo complete or nearly complete initial cytoreductive surgery may be cured with combination chemotherapy. Presumably such therapy eradicates residual subclinical disease, which is invariably present despite the apparently complete resection. Effective drugs include taxol, cisplatin, cyclophosphamide, hexamethylmelamine, and doxorubicin. Paclitaxel plus cisplatin is the standard regimen. Since some patients may have recurrent disease without an elevation of CA125, which is a useful antigen in monitoring response to therapy in those who have elevated levels, the delay of therapy pending a rise in this level would not be prudent. Clear survival benefits have yet to be shown for the fairly toxic regimen of whole abdominal radiation therapy. Intraperitoneal chemotherapy holds promise in the eradication of minimal disease, but its role needs to be defined by further clinical trials.
- V-88. The answer is E.** (*Chap. 118. Ananthasubramaniam et al, Prog Cardiovasc Dis 42: 247–260, 2000.*) An important reason why a relatively pure low-molecular-weight heparin is preferred over standard unfractionated heparin is the reduced incidence of heparin-induced thrombocytopenia. Fractionated heparin is more likely to bind to the anti-heparin protein platelet factor IV, thereby generating antibodies. The platelet factor IV–heparin/antibody complex can cause platelet aggregation via Fc receptor binding and thereby result in thrombocytopenia. Not only is thrombocytopenia a clinical problem, but such aggregation can produce paradoxical arterial thrombosis. Any patient with suspected or proven heparin-induced thrombocytopenia should be switched to low-molecular-weight heparin.
- V-89. The answer is C.** (*Chap. 116*) The onset of severe thrombocytopenia after an antecedent viral illness is common in children with a diagnosis of idiopathic thrombocytopenic purpura (ITP). Unlike childhood ITP, adult ITP tends to be a chronic disease in which spontaneous remissions are rare, and a majority of patients will have a fall in their platelet count after the withdrawal of glucocorticoids, necessitating elective splenectomy. The presence of antibodies directed against target antigens on the glycoprotein IIb-IIIa or Ib-

IX complex has been noted in some adults with chronic ITP but not in children. Splenomegaly is not a feature of ITP; it is a common finding in patients with secondary thrombocytopenia.

V-90. The answer is C. (*Chap. 110*) Persons with polycythemia vera and a hematocrit >45% usually have diminished cerebral blood flow and are particularly at risk for developing thrombotic complications. Functional platelet abnormalities may cause both thrombotic and bleeding problems (the gastrointestinal tract is a common site of bleeding), and affected persons frequently are iron-deficient even at the time of presentation. Erythropoietin production is suppressed in polycythemia vera, a disease characterized by loss of normal control of erythroid stem-cell proliferation. The bone marrow is hypercellular, with hyperplasia of all marrow elements. Therapy is aimed at reducing the hematocrit to <45%, usually with phlebotomy.

V-91. The answer is A. (*Chap. 116*) Electrophoretic analysis has allowed the delineation of three major types of defects in von Willebrand's disease (vWD). The most common abnormality (type I disease) is characterized by a moderate decrease in the plasma level of von Willebrand factor (vWF antigen) resulting from defective release of the protein from endothelial cells. There are usually concordant reductions in antihemophilic factor or factor VIII coagulant activity as well as ristocetin cofactor activity.

The various forms of type II disease are characterized by normal or near-normal levels of dysfunctional protein. In both types IIa and IIb, there is a loss of high-molecular-weight multimers on SDS-agarose electrophoresis. In type IIa patients, the pattern is caused either by an inability to assemble the larger multimers or by premature catabolism in the circulation. In contrast, patients with type IIb have inappropriate binding of the abnormal, larger vWF forms to platelets, which results in the formation of intravascular platelet aggregates. These are rapidly cleared from the circulation, which causes mild, cyclic thrombocytopenia.

A severe recessive form of vWD (type III disease) results from reduced synthesis of vWF by endothelial cells. A hyperactive platelet receptor (glycoprotein Ib) with increased affinity for larger vWF multimers is the defect in so-called platelet-type vWD, or pseudo-vWD. The gene encoding vWF has been cloned and localized to chromosome 12.

V-92. The answer is C. (*Chap. 117*) Factor XIII deficiency may be inherited or acquired and frequently causes severe bleeding problems. In time, prothrombin time, and partial thromboplastin time (PTT) are all normal. The screening test for factor XIII deficiency is a clot solubility in urea assay. Persons with deficiencies of factor XII (Hageman factor) or prekallikrein often have dramatic prolongations of the PTT, but do not have bleeding problems even with surgery or trauma. The presence of a normal bleeding time excludes thrombasthenia, an inherited disorder in which there is defective platelet aggregation in response to agonists that require fibrinogen binding, such as adenosine diphosphate, thrombin, or epinephrine. Protein S is a vitamin K-dependent plasma protein and a cofactor for the expression of the anticoagulant activity of activated protein C. Familial protein S deficiency is associated with a thrombotic diathesis.

V-93. The answer is E. (*Chap. 84. Stone et al, in Braunwald et al (eds) Heart Disease, 6th ed, Philadelphia, Saunders, 2001.*) Two types of cardiotoxicity are associated with doxorubicin (Adriamycin) therapy. Acute cardiotoxicity produces electrocardiographic abnormalities, such as arrhythmias, but rarely is serious. Chronic cardiotoxicity, which rarely develops with total doxorubicin doses <500 mg/m², leads to congestive heart failure; it occurs with increased frequency in persons who also have received cardiac irradiation, cyclophosphamide, or anthracycline compounds other than doxorubicin. Up to half of all cases of cardiotoxicity occur 6 months or more after completion of therapy. Efforts to limit cardiotoxicity and thereby enable the administration of a higher total dose of anthracycline include weekly or continuous intravenous schedules, anthracycline analogues, and cardioprotective agents that limit free radical-induced myocardial damage. While doxo-

rubricin exerts its antineoplastic activity by inhibiting topoisomerase II function, cardiotoxicity appears to be due to oxidant-mediated damage. Dexrazoxone is a chelating agent that may prevent anthracycline-mediated cardiotoxicity.

- V-94. The answer is C.** (*Chap. 112. Hauke, Armitage, Intern Med 39:197–208, 2000.*) Stage (extent of disease) and tumor grade (histologic appearance) are the most important factors for determining treatment of the non-Hodgkin's lymphomas. Since 80 to 90% of patients with low-grade lymphomas—small lymphocytic (diffuse, well-differentiated lymphocytic) or follicular, small cleaved cell (nodular, poorly differentiated lymphocytic)—present with disseminated disease, radiation therapy is rarely curative. On the other hand, such diseases behave in an indolent fashion and can be treated effectively in a palliative manner with single-agent alkylator therapy; the use of more aggressive combination regimens produces a higher complete response rate but has never been conclusively shown to prolong survival. Most patients with diffuse large cell lymphoma, the most common intermediate-grade histology, achieve complete remission and many can be cured with combination chemotherapy regimens, including cyclophosphamide, doxorubicin, vincristine, and glucocorticoids (and possibly also etoposide or methotrexate, among others). Prolonged (>1 year) maintenance therapy is of no value. A lymphoma presenting in a patient with AIDS has a much lower chance (<25% complete response rate) of responding to combination chemotherapy than does a lymphoma of similar histologic appearance in an immunocompetent patient, probably related to the heightened toxicity of treatment in AIDS patients rather than tumor drug resistance.
- V-95. The answer is C.** (*Chap. 92. Warsaw, N Engl J Med 326:455–465, 1992.*) The clinical history is highly suggestive of carcinoma of the head of the pancreas. The failure to obtain diagnostic tissue at needle biopsy is not unusual because of surrounding inflammation, edema, and fibrosis. Even though well over 90% of patients with pancreatic cancer cannot be cured surgically, an attempt at such a procedure is appropriate, particularly for lesions in the pancreatic head, which tend to present earlier because they produce extrahepatic biliary obstruction and because of their frequent confusion with other, more curable lesions in this location (duodenal, ampullary, and distal bile duct tumors). Therefore, such a patient should undergo a preoperative celiac angiogram to rule out vascular invasion by tumor and ensure resectability. It would not be unreasonable to attempt a preoperative diagnosis via ERCP, although the yield would be small. Repeating a needle biopsy is unlikely to achieve diagnostic results. Neither watchful follow-up nor palliative biliary stent therapy is appropriate until a tissue diagnosis of cancer and a determination of unresectability have been made.
- V-96. The answer is C.** (*Chap. 80*) Early detection of cancer is a major focus for the internist in evaluating his or her patients. Such detection depends on an awareness of the epidemiology of cancers and the sensitivity and specificity of any proposed test. It is recommended that each time a patient is seen by his or her physician, cancers of the oral cavity, thyroid, skin, lymph node, testes, and prostate be considered by performance of a careful physical examination. Between the ages of 20 and 39 the American Cancer Society recommends that such a physical examination be performed every 3 years. For men aged 40 to 49 a digital rectal examination with palpation of the prostate is recommended annually. For those aged 50 and older, the annual cancer-related checkup should include a digital rectal examination and palpation of the prostate as well as annual stool blood test plus sigmoidoscopy every 3 to 5 years. Screening for advanced prostate cancer by serologic measurement of the prostate specific antigen (PSA), while sometimes recommended for men over 50, remains controversial. It is important to recognize that for a screening test such as PSA to be effective, it must pick up disease in the curable stage. Chest radiography, for example, is not useful as a screening test for lung cancer in average-risk, asymptomatic patients because cancers that are picked up by this modality tend to be too far advanced for meaningful intervention. On the other hand, PSA detection might well pick up insignificant cancers that are unlikely to progress. Finally, it is important to recognize that a more

aggressive approach to the detection of cancer is appropriate if a patient has a symptom, an abnormal physical examination, or a strong family history.

- V-97. The answer is E.** (*Chap. 57*) Pyoderma gangrenosum is most closely associated with ulcerative colitis and regional enteritis. Its association with rheumatoid arthritis also is well recognized, and it can accompany a variety of neoplastic hematologic disorders, such as acute and chronic myelogenous leukemia, myeloma, myeloid metaplasia, and polycythemia vera. Bacterial cultures and skin biopsies should be done in an evaluation for sepsis, vasculitis, or leukemia cutis. However, diagnosis of pyoderma gangrenosum is based on the lesion's morphology, not histologic analysis.
- V-98. The answer is D.** (*Chap. 57*) Acanthosis nigricans is a skin disease associated with a number of disorders. The skin, which is thrown up into folds, appears velvety and hyperpigmented (brown to black) grossly and papillomatous microscopically. The lesions appear on the flexural areas of the neck, axillae, groin, antecubital fossae, and occasionally around the areolae, periumbilical and perianal areas, lips, buccal mucosa, and over the surfaces of the palms, elbows, knees, and interphalangeal joints. The disorder may be hereditary or appear in association with obesity or an endocrinopathy (acromegaly, polycystic ovary syndrome, diabetes mellitus, Cushing's syndrome, but not adrenal insufficiency). Drugs such as nicotinic acid also can produce the condition. When acanthosis nigricans develops in a nonobese adult, neoplasia, particularly gastric adenocarcinoma, must be suspected.
- V-99. The answer is E.** (*Chap. 57*) These fleshy hyperpigmented papules, seborrheic keratoses, are very common, especially in older adults. They may occasionally be pruritic and tender (but only if secondarily infected). Early "flat" lesions can be confused with solar lentigo, whereas larger pigmented lesions may be mistaken for pigmented basal cell carcinoma or melanoma. Either electrocautery or cryotherapy may be used to remove lesions. Usually they are quite benign and not associated with any systemic condition; however, should seborrheic keratoses appear rapidly and in large numbers, especially if associated with acrochordon (skin tags) and acanthosis nigricans, then a suspicion for internal malignancy is raised (sign of Leser-Trelat).

VI. INFECTIOUS DISEASES

QUESTIONS

DIRECTIONS: Each question below contains five suggested responses. Choose the **one best** response to each question.

VI-1. A 21-year-old woman with relapsed acute lymphoblastic leukemia is treated with a five-drug induction regimen (cyclophosphamide, daunorubicin, vincristine, prednisone, and L-asparaginase). On the sixth day after the initiation of this therapy the patient develops a fever and is started on intravenous ceftazidime. The patient defervesces but develops another fever 5 days later and is started on amphotericin B. Ten days later the patient, still on oral steroids, remains febrile, neutropenic, and thrombocytopenic and is noted to have shortness of breath. Chest x-rays show a densely consolidated pulmonary infiltrate in the left lung zone. A sputum culture demonstrates normal oral flora and several colonies of *Aspergillus*. The most appropriate conclusion to draw is that

- (A) the patient most likely has invasive pulmonary aspergillosis
- (B) the *Aspergillus* is a contaminant; the patient most likely has bacterial pneumonia
- (C) biopsy is not required for a definitive diagnosis
- (D) the patient most likely has viral pneumonitis
- (E) the patient is colonized with *Aspergillus*, but the most likely etiology of the infiltrate is drug toxicity

VI-2. A 28-year-old Egyptian farmer presents with left flank pain. Ultrasonography reveals enlargement of the left ureter and hydronephrosis of the left kidney. Cystoscopy reveals a mass extending from the left ureter into the bladder. Parasitic ova (150 by 50 mm) are noted in the urine and in a biopsy of the ureteral mass. Which of the following statements is correct?

- (A) Renal failure is likely in the absence of treatment.
- (B) The lesion is not reversible by chemotherapy.
- (C) In the absence of treatment, the patient has an increased risk for transitional cell carcinoma of the bladder.
- (D) The patient is suffering from schistosomiasis.
- (E) The organism causing this problem is spread by fecal-oral contact.

VI-3. A 45-year-old man reports to his internist because of fatigue. He gives a history of being treated successfully

VI-3. (Continued)

for testicular cancer 10 years earlier. The physical examination is unremarkable. Routine blood tests reveal a normal complete blood count, normal creatinine, normal α -fetoprotein, and normal β -human chorionic gonadotropin, but his hepatic transaminases are each three times the upper limit of normal. Knowing that the patient had received blood transfusional therapy while receiving cancer chemotherapy, the physician orders serologic studies for hepatitis viruses, which reveals evidence of having had a prior infection with hepatitis C virus (HCV). The next most appropriate diagnostic or therapeutic strategy would be to

- (A) send serum to detect HCV RNA by polymerase chain reaction (PCR) analysis
- (B) refer for liver biopsy
- (C) begin interferon (IFN) therapy
- (D) repeat the serologic test for hepatitis C virus
- (E) order tomographic scanning of the abdomen and pelvis

VI-4. Which of the following patients would be most likely to harbor a *Helicobacter pylori* infection in the stomach?

- (A) A 60-year-old middle-income American
- (B) A 25-year-old American in a low-income group
- (C) A 60-year-old Pakistani
- (D) A 25-year-old Zairian
- (E) A 70-year-old Dane

VI-5. A 55-year-old woman from Oregon presents with diplopia 24 h after eating home-canned fruit. Within a few hours of presentation she is also noted to have dysphonia and arm weakness. Other symptoms include nausea, vomiting, dizziness, blurred vision, and dry mouth. The patient is afebrile, alert, and oriented. Which of the following is LEAST important in managing this patient's illness?

- (A) Intravenous penicillin
- (B) Spirometric monitoring
- (C) Antitoxin therapy

VI-5. (Continued)

- (D) Laxatives
- (E) Enema

VI-6. Which of the following is associated with a low risk for the development of pneumonia in a hospitalized patient?

- (A) Administration of omeprazole
- (B) Administration of ranitidine
- (C) Administration of sucralfate
- (D) Use of an endotracheal tube
- (E) Narcotic administration

VI-7. A 35-year-old patient undergoing initial therapy for acute myeloid leukemia has tolerated the chemotherapy well. However, 6 days after the initiation of chemotherapy and ~10 days after the insertion of an indwelling trans-thoracic intravenous device (Hickman catheter), he develops a fever. Examination is negative except for erythema and tenderness at the insertion site and along the subcutaneous tunnel. Blood cultures and chest x-ray are negative. The most appropriate course of action at this point is to

- (A) remove the line and insert a new one over a guide-wire
- (B) begin intravenous vancomycin
- (C) begin intravenous vancomycin and gentamicin
- (D) remove the line
- (E) begin intravenous vancomycin, gentamicin, and amphotericin B

VI-8. A 70-year-old man with a history of heavy smoking and moderately severe chronic obstructive pulmonary disease (COPD) has been feeling poorly. He reports cough, chills, pleuritic chest pain, and low-grade fever. Chest x-ray reveals a small dense infiltrate in the right lower lobe. Gram's stain of the patient's sputum reveals numerous gram-negative cocci, many of which occur in pairs. The most appropriate therapy would be

- (A) no antimicrobial therapy is required
- (B) tetracycline
- (C) ciprofloxacin
- (D) trimethoprim/sulfamethoxazole (TMP/SMZ)
- (E) penicillin/clavulanic acid

VI-9. Which of the following statements concerning the use of protease inhibitors to treat individuals infected with HIV is correct?

- (A) Initial treatment of HIV-infected patients should include a reverse transcriptase inhibitor, with protease inhibitors being administered after progressive disease
- (B) Inhibition of the human protease has significant clinical consequences

VI-9. (Continued)

- (C) These drugs are metabolized by cytochrome P450 enzymes
- (D) Gastrointestinal side effects are rare
- (E) These agents work chiefly by stabilizing, rather than decreasing, the viral load

Questions VI-10 to VI-11.

A 35-year-old man with a history of abrasion of the right hand presents with acute pain in the right shoulder. His physical examination reveals a temperature of 39.5°C (103°F) and rigor, and he appears to be quite ill. There is dusky erythema and edema of the right shoulder and right upper extremity with marked tenderness. Within a few hours the patient is unresponsive and is found to be hypotensive. Laboratory evaluation reveals an elevated serum, creatinine, thrombocytopenia, and elevated hepatic transaminases. The soft tissues in the left upper extremity have begun to necrose. Blood culture, obtained at the time of initial presentation, has already turned positive.

VI-10. The organism that is most likely to be responsible for this clinical syndrome is

- (A) group A streptococci
- (B) group D streptococci
- (C) *Staphylococcus aureus*
- (D) *Bacteroides fragilis*
- (E) *Clostridium septicum*

VI-11. The most appropriate therapy for this patient is

- (A) penicillin G
- (B) penicillin G/clavulanic acid
- (C) erythromycin
- (D) vancomycin
- (E) surgery

VI-12. Which of the following statements regarding cryptosporidiosis is correct?

- (A) Symptomatic infection in immunocompetent hosts is unusual.
- (B) Serologic techniques are needed for the diagnosis.
- (C) While it is a common cause of diarrhea in patients with AIDS, severe manifestations, including weight loss and pain, are uncommon.
- (D) The disease is transmitted by the fecal-oral route.
- (E) The treatment of choice is praziquantel.

VI-13. Several weeks after eating a meal in rural France that included meat from locally bred horses and pigs, a 35-year-old woman presents with muscle aches and swelling, particularly in both biceps and the neck. Physical examination reveals periorbital edema. Laboratory evaluation reveals eosinophilia, elevated serum IgE, and elevated creatinine phosphokinase levels. The most likely diagnosis is

VI-13. (Continued)

- (A) ocular larva migrans (*Toxocara canis* infection)
- (B) trichinosis
- (C) viral myositis
- (D) polymyositis (autoimmune)
- (E) typhoid fever

VI-14. Which of the following syndromes is LEAST likely to be associated with parvovirus infection?

- (A) A 5-year-old child with a 3-day history of low-grade fevers who presents with ruby red cheeks
- (B) A 35-year-old woman with painful wrist and knees for 3 weeks
- (C) A 20-year-old patient with sickle cell disease who presents with a marked drop in his hematocrit
- (D) A 55-year-old with hemolytic anemia and a normal white count and platelet count
- (E) A 7-year-old boy with nausea, vomiting, and watery diarrhea for 3 days

VI-15. Which of the following is most likely to yield a diagnosis that will detect the specific parasite?

- (A) String test for duodenal sampling to detect amebiasis
- (B) Scotch tape technique on the perianal skin to detect beef tapeworm
- (C) Aspiration of a liver abscess to detect *Entamoeba histolytica*
- (D) Stool sediment examination to detect *Schistosoma haematobium*
- (E) Gram stain on induced sputum to detect *Pneumocystis carinii*

VI-16. Which of the following statements concerning predisposition to parasitic infections is correct?

- (A) Depression of the CD4+ lymphocyte count predisposes to malaria.
- (B) Patients infected with chronic lymphocytic leukemia are prone to infection with *Strongyloides*.
- (C) Splenectomized patients are at risk for babesiosis.
- (D) Patients with multiple myeloma tend to develop leishmaniasis.
- (E) Patients with cystic fibrosis are at a markedly increased risk for toxoplasmosis.

VI-17. Which of the following statements concerning Creutzfeldt-Jakob disease is correct?

- (A) The disease is caused by retroviral infection.
- (B) The disease can be inherited.
- (C) The disease is limited to Northern Europe and North America.
- (D) Intraspecies transmission is not possible.
- (E) Pathologic examination of a brain of a patient with this disease would reveal hemorrhagic necrosis of both cerebral hemispheres.

VI-18. Nonvenereal treponemal infections are best characterized by

- (A) pulmonary infections with a tendency to form nodules
- (B) biliary tract invasion
- (C) infection of the genitourinary tract with episodes of hematuria and eventual renal failure
- (D) primary cutaneous lesions that progress to include lymphadenopathy and bone destruction
- (E) meningeal irritation with occasional parenchymal involvement

VI-19. A 53-year-old black man who received a renal allograft 7 months ago is now receiving azathioprine and prednisone. He presents to the hospital 1 week after developing fever, night sweats, and anorexia. He also complains of coughing and chest pain. Chest film reveals biapical infiltrates with an apparent cavity in the left upper lobe. Auramine-rhodamine staining reveals the presence of microorganisms consistent with tubercle bacilli. The patient's creatinine is 106 $\mu\text{mol/L}$ (1.2 mg/dL). The treatment of choice at this time would be

- (A) isoniazid, rifampin, and pyrazinamide
- (B) isoniazid, rifampin, pyrazinamide, and ethambutol
- (C) isoniazid and rifampin
- (D) rifampin, pyrazinamide, and ethambutol
- (E) isoniazid, rifampin, pyrazinamide, ethambutol, and streptomycin

VI-20. A 25-year-old intravenous drug abuser with fever has blood cultures obtained, and 24 h later a report from the microbiology laboratory indicates the presence of gram-positive cocci in clusters. The identification of the organism and sensitivities are pending. The most appropriate antibiotic choice would be

- (A) penicillin
- (B) nafcillin
- (C) vancomycin
- (D) TMP/SMZ
- (E) ciprofloxacin

VI-21. Four months after having undergone a sibling-donor renal allograft, a 38-year-old man is doing well and has had no evidence of graft rejection or major problems stemming from his chronic immunosuppressive therapy (cyclosporine and prednisone). He now develops a fever to 39°C (102°F), headache, and a stiff neck. MRI of the brain with gadolinium enhancement reveals no abnormalities. The most likely cause of the patient's current clinical problem is infection with

- (A) *Listeria monocytogenes*
- (B) *Mycobacterium tuberculosis*
- (C) *Toxoplasma gondii*
- (D) *H. influenzae*
- (E) Epstein-Barr virus (EBV)

- VI-22.** A 12-year-old girl presents with painful epitrochlear lymphadenopathy associated with low-grade fever and malaise. The patient has a cat and also gave a history of a papillary lesion in the left forearm about 1 week or 10 days ago. The most likely etiologic agent in this situation is
- Bartonella henselae*
 - Staphylococcus aureus*
 - Epstein-Barr virus
 - Sporothrix schenckii*
 - Yersinia pestis*
- VI-23.** Which of the following statements concerning catheter-associated urinary tract infection is correct?
- Most catheter-associated infections are symptomatic.
 - Topical periurethral antibiotics should be applied.
 - Routine antimicrobial prophylaxis is indicated.
 - The majority of patients catheterized for longer than 2 weeks develop bacteriuria.
 - Skin organisms such as *Staphylococcus* and *Streptococcus* are the most common cause of infections.
- VI-24.** What are the clinical consequences of *Bacillus anthracis* endospores coming in contact with an abrasion on the arm of a rancher?
- The endospores germinate in the skin, gain access to the blood, and cause death due to massive sepsis.
 - The endospores germinate in the skin, gain access to the lymphatic system, and cause significant axillary lymphadenopathy.
 - The endospores germinate in the skin, gain access to the blood, and cause fatal pneumonia.
 - The endospores are engulfed by dermal macrophages and are transported by them to the blood, at which point they germinate; the ensuing bacterial proliferation causes death due to massive sepsis.
 - The lesion that forms undergoes central necrosis and surrounding edema.
- VI-25.** A 23-year-old previously healthy female letter carrier works in a suburb in which the presence of rabid foxes and skunks has been documented. She is bitten by a bat, which then flies away. Initial examination reveals a clean break in the skin in the right upper forearm. She has no history of receiving treatment for rabies and is unsure about vaccination against tetanus. The physician should
- clean the wound with a 20% soap solution
 - clean the wound with a 20% soap solution and administer tetanus toxoid
 - clean the wound with a 20% soap solution, administer tetanus toxoid, and administer human rabies immune globulin intramuscularly
 - clean the wound with a 20% soap solution, administer tetanus toxoid, administer human rabies immune globulin intramuscularly, and administer human diploid cell vaccine
 - clean the wound with a 20% soap solution and administer human diploid cell vaccine
- VI-25.** (Continued)
- VI-26.** During the summer, a previously healthy 10-year-old boy living in rural Louisiana presents with a brief illness characterized by 2 days of fever, headache, and vomiting that progresses to lethargy, disorientation, and most recently a grand mal seizure. Laboratory examination is remarkable for peripheral blood leukocytosis and a normal CSF examination except for the presence of 35 monocytes per microliter. An IgM enzyme-linked immunoassay for the LaCrosse virus returns positive. Anticonvulsive medicine has been administered. At this point the physician should
- tell the family that there is a high likelihood of improvement during the coming week and a good chance for discharge within 2 weeks
 - order a brain biopsy to exclude herpes encephalitis
 - administer empirical acyclovir
 - administer empirical chloramphenicol and ampicillin
 - share with the parents your concern that this illness, for which there is no specific therapy, is often fatal
- VI-27.** The most common source of bacterial infection of intravenous cannulas is
- contamination of fluids during the manufacturing process
 - contamination of fluids during insertion of the cannula
 - contamination at the site of entry through the skin
 - contamination during the injection of medications
 - seeding from remote sites as a result of intermittent bacteremia
- VI-28.** A 73-year-old previously healthy man is hospitalized because of the acute onset of dysuria, urinary frequency, fever, and shaking chills. His temperature is 39.5°C (103.1°F), blood pressure is 100/60 mmHg, pulse is 140 beats per minute, and respiratory rate is 30 breaths per minute. Which of the following interventions would be the most important in the treatment of this acute illness?
- Catheterization of the urinary bladder
 - Initiation of antibiotic therapy
 - Infusion of Ringer's lactate solution
 - Infusion of dopamine hydrochloride
 - Intravenous injection of methylprednisolone

- VI-29.** Infection with *Pseudomonas* organisms is frequently associated with which of the following?
- (A) Pneumonia after a nail puncture wound of the foot
 - (B) Pyoderma gangrenosum
 - (C) Both a mild form and an invasive form of otitis externa
 - (D) Meningitis in neonatal infants
 - (E) Endocarditis in patients undergoing dental work
- VI-30.** A 65-year-old Greek woman visiting her children in New York City complains of upper abdominal pain. The patient is brought to the family physician, who notices icteric sclera and a mass in the right upper quadrant. CT reveals a 10-cm multiloculated cyst with mural calcification that is compressing the common bile duct. Which of the following statements is correct concerning this clinical situation?
- (A) Treatment with the antiamebic agent chloroquine is indicated.
 - (B) Treatment with an antiechinococcal agent such as albendazole is sufficient.
 - (C) The adult parasite resides in the patient's intestine.
 - (D) Infection was probably caused by exposure to infected dogs.
 - (E) Surgery is contraindicated because of the risk of anaphylaxis from dissemination of infectious material.
- VI-31.** A 60-year-old man from North Carolina presents with a fever and progressive confusion. His wife reports that he experienced ~1 week of fever, headache, and malaise before the more profound neurologic condition occurred. Just prior to the presentation at the hospital he had a generalized seizure. The IgM capture enzyme immunoassay of the patient's CSF was positive for the eastern equine encephalitis virus. An MRI would most likely reveal
- (A) normal findings
 - (B) meningeal enhancement
 - (C) hydrocephalus
 - (D) lesions in the basal ganglia
 - (E) temporal lobe enhancement
- VI-32.** The most common cause of "traveler's diarrhea" ("turista") in Americans traveling abroad is
- (A) *Staphylococcus aureus*
 - (B) *Clostridium perfringens*
 - (C) *Escherichia coli*
 - (D) *Bacillus cereus*
 - (E) rotavirus
- VI-33.** Which of the following vaccines are not recommended for use in immunocompromised adults?
- VI-33.** (Continued)
- (A) Bacillus Calmette-Guerin (BCG) vaccine (against tuberculosis)
 - (B) Inactivated influenza vaccine for current year
 - (C) 23-Valent pneumococcal vaccine
 - (D) Quadrivalent meningococcal vaccine
 - (E) Inactivated polio vaccine
- VI-34.** A 38-year-old homosexual man known to be infected with HIV presents with a week of fever and tachypnea. Chest x-ray reveals bilateral alveolar infiltrates. Arterial blood gas determination reveals a Pa_{O₂} of 55 mmHg on room air. Bronchoalveolar lavage is positive for methenamine silver staining material. Which of the following statements is correct concerning the current clinical situation?
- (A) Transbronchial biopsy should be carried out to confirm the diagnosis.
 - (B) Glucocorticoids are contraindicated given the risk of other opportunistic infections in Kaposi's sarcoma.
 - (C) Pentamidine therapy by the aerosolized route would be appropriate if the patient had a known allergy to sulfa drugs.
 - (D) TMP/SMZ and pentamidine should be administered in combination.
 - (E) TMP/SMZ alone should be administered.
- VI-35.** A 50-year-old woman emigrated from El Salvador ~10 years ago and currently resides in Washington, DC. She complains of shortness of breath. Chest x-ray reveals biventricular cardiac enlargement. An echocardiographic study shows biventricular enlargement, thin ventricular walls, and an apical aneurysm. The patient has no history of alcohol abuse, thyroid disease, risk factors for atherosclerotic heart disease, or family history of hemochromatosis. In considering a potential etiology for the patient's current problem, which of the following statements is correct?
- (A) The etiologic agent can be demonstrated on Giemsa stain of the peripheral blood.
 - (B) Other manifestations of infection could include involvement of the gastrointestinal tract.
 - (C) The vector for the transmission of this disease is the tsetse fly.
 - (D) Glucocorticoids may be beneficial.
 - (E) Given the progressive and ultimately fatal course, cardiac transplantation should be considered.
- VI-36.** A 35-year-old homosexual man presents with 2 days of fever and watery diarrhea. Over the past 24 h he has also passed bloody stools. The physical exam reveals a moderately ill man with a temperature of 39°C (102.2°F) and is otherwise unremarkable, with normal vital signs. Blood culture reveals infection with *Shigella flexneri*.

VI-36. (Continued)

Which of the following statements about this clinical situation is correct?

- (A) Ingestion of a significant number of organisms of *S. flexneri* rarely produces clinical disease.
- (B) Patients with this infection may develop a reactive arthritis.
- (C) Hemolytic uremic syndrome is a potential complication of infection with this organism.
- (D) Amoxicillin is the appropriate antibiotic therapy.
- (E) Infection is equally common in homosexual men whether or not infected with HIV.

VI-37. Which of the following organisms is most likely to cause infection of a shunt implanted for the treatment of hydrocephalus?

- (A) *Staphylococcus epidermidis*
- (B) *Staphylococcus aureus*
- (C) *Corynebacterium diphtheriae*
- (D) *Escherichia coli*
- (E) *Bacteroides fragilis*

VI-38. Which of the following statements concerning the epidemiology and pathogenesis of infection with *Vibrio cholerae* is correct?

- (A) Widespread use of vaccines has greatly limited the incidence of cholera in the developing world.
- (B) All species within the *Vibrio* genus produce a similar clinical illness: watery diarrhea.
- (C) Pathogenesis of cholera infection requires direct bacterial invasion of the gastrointestinal mucosa.
- (D) Perturbation of the adenylate cyclase enzyme in intestinal epithelial cells is the primary pathologic event in producing diarrhea.
- (E) The natural habitat of *V. cholerae* is in water contaminated with human feces.

VI-39. Which of the following represents an occupational risk for contraction of brucellosis?

- (A) Cotton harvesting
- (B) Coal mining
- (C) Slaughterhouse work
- (D) Poultry farming
- (E) Light bulb manufacturing

VI-40. A 60-year-old insulin-dependent man with diabetes mellitus has had purulent drainage from his left ear for 1 week. Suddenly, fever, increased pain, and vertigo develop. The most likely causative agent is

- (A) *Aspergillus*
- (B) *Mucor*
- (C) *Pseudomonas*
- (D) *Staphylococcus aureus*
- (E) *Haemophilus influenzae*

VI-41. Typhoid fever is characterized by which of the following statements?

- (A) The illness is usually acquired from inhalation.
- (B) Leukocytosis occurs in acutely ill persons.
- (C) Rose spots are usually present at the time when the fever begins.
- (D) Chloramphenicol is effective in preventing relapse.
- (E) Fluoroquinolone antibiotics eradicate the organism even in the presence of gallstones.

VI-42. Exposure to which of the following mandates passive immunization with standard immune serum globulin?

- (A) Rabies
- (B) Hepatitis A
- (C) Hepatitis B
- (D) Tetanus
- (E) Cytomegalovirus

VI-43. A 20-year-old sexually active woman presents with swelling of the vaginal labia. Examination of the perineal area reveals active and enlarged labia covered with sharply defined subcutaneous bleeding nodules that appear to erode through the skin. The most likely etiologic agent in this case is

- (A) *Treponema pallidum*
- (B) *Haemophilus*
- (C) herpes virus
- (D) *Calymmatobacterium*
- (E) *Neisseria gonorrhoeae*

VI-44. To determine whether a child with paroxysmal coughing and gasping has whooping cough, a physician should order

- (A) white blood cell count and differential
- (B) Gram stain of the sputum
- (C) blood cultures
- (D) chest x-ray
- (E) lateral x-ray of the neck

VI-45. Hypersensitivity reactions—such as erythema nodosum, erythema multiforme, arthritis, and arthralgias—are most frequently associated with which of the following infections?

- (A) Histoplasmosis
- (B) Cryptococcosis
- (C) Aspergillosis
- (D) Blastomycosis
- (E) Coccidioidomycosis

VI-46. Imipenem, a newer antibiotic with a broad antibacterial spectrum, is coadministered with cilastatin because

- (A) the combination of these antibiotics is synergistic against *Pseudomonas* spp.

VI-46. (Continued)

- (B) cilastatin aids the gastrointestinal absorption of the active moiety, imipenem
- (C) cilastatin inhibits a β -lactamase that destroys imipenem
- (D) cilastatin inhibits an enzyme in the kidney that destroys imipenem
- (E) cilastatin prevents the hypoprothrombinemic effect of imipenem

VI-47. A 35-year-old man is seen 6 months after a cadaveric renal allograft. The patient has been on azathioprine and prednisone since that procedure. He has felt poorly for the past week with fever to 38.6°C (101.5°F), anorexia, and a cough productive of thick sputum. Chest x-ray reveals a left lower lobe (5 cm) nodule with central cavitation. Examination of the sputum reveals long, crooked, branching, beaded gram-positive filaments. The most appropriate initial therapy would include the administration of which of the following antibiotics?

- (A) Penicillin
- (B) Erythromycin
- (C) Sulfisoxazole
- (D) Ceftazidime
- (E) Tobramycin

VI-48. A previously healthy 28-year-old man describes several episodes of fever, myalgia, and headache that have been followed by abdominal pain and diarrhea. He has experienced up to 10 bowel movements per day. Physical examination is unremarkable. Laboratory findings are notable only for a slightly elevated leukocyte count and an elevated erythrocyte sedimentation rate. Wright's stain of a fecal sample reveals the presence of neutrophils. Colonoscopy reveals inflamed mucosa. Biopsy of an affected area discloses mucosal infiltration with neutrophils, monocytes, and eosinophils; epithelial damage, including loss of mucus; glandular degeneration; and crypt abscesses. The patient notes that several months ago he was at a church barbecue where several people contracted a diarrheal illness. While this patient could have inflammatory bowel disease, which of the following pathogens is most likely to be responsible for his illness?

- (A) *Campylobacter*
- (B) *S. aureus*
- (C) *E. coli*
- (D) *Salmonella*
- (E) Norwalk agent

VI-49. A 52-year-old patient with a history of chronic alcoholism presents with severe sore throat and fever. Examination of the mouth reveals poor dentition. The pharynx demonstrates swollen tonsillar pillars which are red, ulcerated, and covered with a grayish membrane. There is marked swelling of the submandibular tissues. The patient cannot fully open his mouth. Which of the following

VI-49. (Continued)

is the most important therapeutic principal related to treatment of this individual?

- (A) Penicillin should be given.
- (B) Antibiotics active against both aerobic and anaerobic bacteria are indicated.
- (C) Chloramphenicol should be given.
- (D) Metronidazole is appropriate therapy.
- (E) Anatomic therapy is definitively indicated.

VI-50. A 62-year-old gardener who has chronic lymphocytic leukemia develops lymphangitis and a painless, nodular lesion on his wrist. Subsequently, he becomes severely ill with cavitary right-upper-lobe pneumonia; *Sporothrix schenckii* is isolated. He should be treated with

- (A) chloramphenicol
- (B) potassium iodide
- (C) penicillin
- (D) amphotericin B
- (E) flucytosine

VI-51. A 22-year-old female intravenous drug abuser and admitted prostitute is seen in the emergency room with a complaint of vaginal discharge. She is afebrile and has no complaint or physical findings except that she has yellow mucopurulent discharge emanating from the cervical os. Gram's stain of the discharge reveals polymorphonuclear leukocytes, but organisms are not seen. The patient has no primary care doctor. The most appropriate action at this time is to

- (A) await results of cervical swab cultures
- (B) schedule the patient for colposcopy to cauterize the endocervical cells that have migrated onto the visible ectocervix
- (C) treat for chlamydial infection with doxycycline, 100 mg PO bid for 7 days
- (D) treat for gonorrheal infection with ciprofloxacin, 500 mg PO
- (E) treat for both chlamydial and gonorrheal infection with cefixime, 400 mg PO, plus azithromycin, 1 g PO

VI-52. A 19-year-old woman visits the emergency room because of a swollen left knee. She has no past medical problems. She gives a history of several days of feeling feverish and having muscle and joint aches. Specifically, her hands and wrists were painful for a few days, but at this point she is bothered only by her knee. Physical examination is remarkable only for vesiculopustular skin lesions and a mildly swollen left knee. The procedure most likely to yield a diagnosis at this point would be

- (A) cervical culture
- (B) blood culture
- (C) sinovial culture

VI-52. (Continued)

- (D) serum complement assay
- (E) skin biopsy

VI-53. Four days after he and his friends were killing muskrats along a rural creek, a boy becomes ill with headache, fever, and a macular rash. On examination, axillary adenopathy is noted, but otherwise the examination is normal. Which of the following tests would be most helpful in proving that this boy has tularemia?

- (A) Blood culture
- (B) Aspiration and culture of an axillary lymph node
- (C) Determination of serum agglutinins for *Francisella tularensis*
- (D) Bone marrow culture
- (E) Examination of his friends

VI-54. A 10-year-old boy is seen in a rural Arizona clinic because of prostration, fever of 40°C (104°F), and severe headache. Examination is negative for rash, stiff neck, joint tenderness, and chest and abdominal abnormalities. However, several tender, enlarged lymph nodes are palpated in the left axilla, which is very edematous. The test most likely to be of greatest help in the immediate management of this boy would be

- (A) blood culture
- (B) examination of a blood smear
- (C) biopsy of an axillary lymph node
- (D) aspiration and Gram stains of an axillary lymph node
- (E) surgical excision of an axillary node

VI-55. A 10-year-old boy presents with an abnormal appearing face. The boy lives in Rhode Island and has been playing outside a good deal this summer. He has been feeling poorly for a week with complaints of muscle aches and headache. His mother has noticed that her son has a low-grade fever and an oval rash on the back measuring about 10 cm in diameter. Physical examination reveals evidence of the oral erythema on the posterior thorax and evidence of right facial droop. Routine laboratory studies are unremarkable. A lumbar puncture reveals an opening pressure of 80 mmHg, total protein of 0.46 g/L (46 mg/dL), and glucose of 5.0 mmol/L (90 mg/dL) with 10 white cells, all of which are lymphocytes. The most specific diagnostic study would be

- (A) polymerase chain reaction–based DNA detection
- (B) *Borrelia* serology
- (C) blood culture for *Borrelia*
- (D) cerebrospinal fluid culture for *Borrelia*
- (E) western blot detection of *Borrelia* antigen in the cerebrospinal fluid

VI-56. According to the 1993 revised classification system for HIV infection and expanded AIDS surveillance case

VI-56. (Continued)

definition for adolescents and adults, which of the following HIV-infected individuals is considered to have AIDS?

- (A) An asymptomatic individual with a CD4 T cell count of 600/ μ L
- (B) An asymptomatic individual with a T cell count of 100/ μ L
- (C) An individual with thrush and a T cell count of 300/ μ L
- (D) An individual with idiopathic thrombocytopenic purpura and a CD4 T cell count of 600/ μ L
- (E) An individual with fever, diarrhea, peripheral neuropathy, and a CD4 T cell count of 600/ μ L

VI-57. *Listeria monocytogenes* most frequently causes which of the following infections?

- (A) Endocarditis
- (B) Peritonitis
- (C) Hepatitis
- (D) Meningitis
- (E) Conjunctivitis

VI-58. Which of the following statements concerning infections with intestinal nematodes is correct?

- (A) A relatively small number of organisms typically produce severe clinical symptoms.
- (B) *Ascaris* larvae enter the body via migration through dermal capillaries.
- (C) Hookworm infections result from the swallowing of hookworm eggs.
- (D) *Strongyloides* infection is associated with recurrent urticaria.
- (E) Pinworm infection is associated with iron deficiency anemia.

VI-59. Which of the following drugs would be LEAST likely to benefit a patient experiencing an acute attack of malaria?

- (A) Quinine
- (B) Chloroquine
- (C) Primaquine
- (D) Hydroxychloroquine
- (E) Mefloquine

VI-60. Which of the following food- or waterborne bacteria responsible for diarrheal illness has the LONGEST incubation period (time from ingestion to illness)?

- (A) *Clostridium perfringens*
- (B) *Staphylococcus aureus*
- (C) *Bacillus cereus*
- (D) *Campylobacter jejuni*
- (E) *Vibrio parahaemolyticus*

VI-61. A 22-year-old gay man from New Orleans presents with a 2-week history of fever, anorexia, and progressive diffuse lymphadenopathy. Physical findings reveal an emaciated young man who has several tongue ulcers. Hepatomegaly is noted. Laboratory examination reveals pancytopenia, an elevated alkaline phosphatase, and hyperkalemia. A chest radiograph reveals a miliary pattern of diffuse infiltration. A tongue biopsy reveals the presence of hyphae that bear both large and small spores. The correct diagnosis is

- (A) histoplasmosis
- (B) coccidioidomycosis
- (C) cryptococcosis
- (D) blastomycosis
- (E) aspergillosis

VI-62. A 45-year-old man with acute myeloid leukemia in second remission presents with cough, shortness of breath, and fever 3 months after an allogeneic bone marrow transplant. The patient was well before the transplant. At that time, serology revealed antibodies to cytomegalovirus (CMV). The graft was successful, but the patient has required the use of intermittent courses of glucocorticoids to treat moderately severe graft-versus-host disease characterized by a diffusely erythematous skin rash and diarrhea.

VI-63. Which of the following samples of pleural fluid is most suggestive of tuberculous pleuritis?

Fluid sample	Color	pH	Protein, g/L	Glucose, mmol/L	LDH, U/mL	WBC	
						Total (per μL)	% Lymphocytes
(A)	Clear yellow	7.15	35	1.1	600	2000	95
(B)	Thick green	7.00	40	1.1	600	10,000	50
(C)	Clear yellow	7.30	15	4.4	150	200	50
(D)	Pink-tinged	7.40	30	4.4	600	3000	50
(E)	Clear yellow	7.30	35	3.3	150	2000	95

LDH, lactate dehydrogenase; WBC, white blood cell count

VI-64. A 10-year-old child has malaise, a low-grade fever, and submental lymphadenopathy. Biopsy of a cervical lymph node reveals granulomatous inflammation; the culture grows *Mycobacterium scrofulaceum*. The best treatment for this child would be

- (A) excision of the infected nodes
- (B) isoniazid and ethambutol
- (C) streptomycin, isoniazid, and ethambutol
- (D) rifampin, isoniazid, and ethambutol
- (E) observation until the results of sensitivity studies are available

VI-62. (Continued)

On examination the patient appears mildly ill, has a temperature of 38.6°C (101.5°F), blood pressure of 130/80 mmHg, pulse of 110 beats per minute, and respiratory rate of 30 breaths per minute. Skin examination reveals a diffuse erythematous maculopapular rash, particularly on the arms and legs. Diffuse crackles are heard in both lungs. Chest x-ray demonstrates bilateral interstitial infiltrates, worse in the lower lobes. Examination of sputum fails to reveal a causative agent. Bronchoscopy is carried out, but the toluidine blue stain, routine culture, and fungal stains are negative. Because the patient continues to have respiratory deterioration, he undergoes an open-lung biopsy. Examination of the lung tissue reveals the presence of cells that are several times larger than surrounding cells and contain a 10- μm inclusion placed centrally in the nucleus. There is also a plasmacytic and lymphocytic infiltrate in the lung. At this point, the best course of therapy would be to administer

- (A) trimethoprim/sulfamethaxole
- (B) acyclovir plus CMV immune globulin
- (C) ganciclovir
- (D) ganciclovir plus CMV immune globulin
- (E) foscarnet

VI-65. Which of the following statements concerning the use of fluoroquinolone antibiotics (e.g., ciprofloxacin, norfloxacin) is correct?

- (A) Resistance can develop by bacterial plasmid-mediated expression of β -lactamase enzyme.
- (B) They are bacteriostatic rather than bactericidal.
- (C) They have activity against all known bacterial enteric pathogens.
- (D) They are excreted primarily by biliary clearance.
- (E) They are contraindicated in patients with fever and neutropenia because of their inability to eradicate *Pseudomonas* spp.

VI-66. A 40-year-old Canadian who operates a tropical fish store sees his physician because of a nonhealing ulcer on his left arm. He is afebrile and gives no history of night sweats, weight loss, or other constitutional symptoms. Biopsy of the lesion shows granulomatous inflammation and rare acid-fast organisms. A tuberculin test is negative. This man most likely has an infection caused by

- (A) *Mycobacterium tuberculosis*
- (B) *M. ulcerans*
- (C) *M. kansasii*
- (D) *M. marinum*
- (E) *M. fortuitum*

VI-67. Which of the following statements concerning syphilis in HIV-infected persons is correct?

- (A) Syphilis is as common in HIV-infected persons as it is in non-HIV-infected persons, though the course of the disease is more aggressive in the HIV-infected group.
- (B) Serologic testing cannot be used to confirm the diagnosis of syphilis in most patients with HIV infection.
- (C) Failure to respond to single-dose penicillin G therapy is more likely in patients infected with both HIV and syphilis than in those infected with syphilis alone.
- (D) Central nervous system syphilis is rare in HIV-infected patients.
- (E) Syphilis is not an independent risk factor for HIV infection.

VI-68. Which of the following statements concerning transmission of HIV from an infected patient to a health care worker exposed by a skin puncture from a needle contaminated with blood from an HIV-infected individual is correct?

- (A) Risk for HIV infection in such a situation is greater than the risk of hepatitis B infection following a similar exposure.
- (B) Antiretroviral drugs do not reduce the risk of post-exposure infection.
- (C) Risk of transmission from an infected health care worker to a patient is actually greater than in this situation.
- (D) Risk of HIV infection in the health care worker in this situation is approximately 3 in 1000.
- (E) Postexposure prophylaxis should consist of AZT.

VI-69. Which of the following statements concerning antifungal therapy is correct?

- (A) Dose-related hepatotoxicity is a complication of ketoconazole treatment.
- (B) Clotrimazole is the preferred imidazole for the treatment of vaginal candidiasis.

VI-69. (Continued)

- (C) Oral fluconazole may be used as primary therapy in patients with aspergillosis.
- (D) Flucytosine plus amphotericin B is useful in cases of refractory hepatic candidiasis.
- (E) The treatment of candidal hepatitis frequently requires 2 weeks of daily intravenous administration of amphotericin B.

VI-70. A 35-year-old HIV-infected homosexual man presents with fever, pain of the right upper quadrant, and a CT of the liver that shows a 10-cm, oval hypoechoic cyst in the right lobe. An ELISA assay detects the presence of antibodies to *Entamoeba histolytica*; cysts from the same organism are found in a stool specimen. Which of the following is the most appropriate next step in management?

- (A) Administration of metronidazole
- (B) Administration of chloroquine
- (C) Drainage of the hepatic lesion for therapeutic purposes
- (D) Aspiration of the hepatic lesion for diagnosis
- (E) Hepatic resection

VI-71. Which of the following statements concerning viral upper respiratory infections is correct?

- (A) Risk factors for infection with rhinovirus include exposure to cold temperatures, fatigue, and sleep deprivation.
- (B) The incubation period for rhinoviral illness is approximately 1 week.
- (C) Infection with respiratory syncytial virus (RSV) is unusual in older children and adults.
- (D) Ribavirin given by aerosol is effective in treating infants with RSV.
- (E) Pentamidine is a useful prophylactic therapy against adenovirus infections.

VI-72. The characteristic “sulfur grains” of actinomycosis are composed chiefly of

- (A) organisms
- (B) neutrophils and monocytes
- (C) monocytes and lymphocytes
- (D) eosinophils
- (E) calcified cellular debris

VI-73. The best available therapy for disseminated *M. avium-intracellulare* (MAI) infection in patients with AIDS is administration of

- (A) isoniazid, rifampin, and ethambutol
- (B) ciprofloxacin
- (C) streptomycin and pyrazinamide
- (D) clarithromycin
- (E) clarithromycin, ethambutol, and rifabutin

- VI-74.** Antigen testing of blood and cerebrospinal fluid is most useful in the diagnosis of
- (A) histoplasmosis
 - (B) blastomycosis
 - (C) cryptococcosis
 - (D) coccidioidomycosis
 - (E) sporotrichosis
- VI-75.** A 55-year-old homeless man presents with fever and stiff neck several days after an upper respiratory infection. He also notes painful hands and hair loss. Physical examination reveals a disheveled male with a temperature of 40°C (104°F), blood pressure of 120/70, heart rate of 70, and respiratory rate of 20. The remainder of the physical examination is remarkable for an erythematous posterior pharynx, areas of alopecia on the head and body, swollen metacarpophalangeal joints, and a stiff neck. Laboratory evaluation is remarkable for a white blood cell count of 2300/ μ L with 25% neutrophils, 65% lymphocytes, and 10% monocytes; hematocrit is 42% and platelet count is 55,000/ μ L. Other laboratory studies are unremarkable. Examination of the CSF reveals normal opening pressure, total protein of 1 g/L (100 mg/dL), glucose of 1.1 mmol/L (20 mg/dL), and white count of 400/ μ L (80% lymphocytes and 20% neutrophils). Gram stain, acid-fast stain, and India ink stain are all negative. Which of the following statements about this patient is correct?
- (A) Intravenous penicillin G is the treatment of choice.
 - (B) The low CSF glucose is pathognomonic for bacterial meningitis.
 - (C) A routine blood culture will probably establish the diagnosis.
 - (D) The patient probably has come in contact with an infected rodent.
 - (E) Alopecia is unrelated to the current infection.
- VI-76.** A 45-year-old man with acute myelogenous leukemia (AML) is seen 45 days after initial treatment with daunorubicin and cytosine arabinoside. After this therapy he sustained 22 days of neutropenia, during which time he became febrile and received broad-spectrum antibiotics. He was discharged feeling relatively well after a 28-day hospital course with a normal CBC and bone marrow. Within several days after hospital discharge, he developed a fever of 38.5°C (101.3°F) and mild abdominal pain, particularly in the right upper quadrant. Physical examination is unrevealing. His CBC is normal, as is the rest of his laboratory examination except for an elevated alkaline phosphatase. CT of the liver is nonspecifically abnormal. The most appropriate action at this point would be
- (A) admission of the patient for administration of broad-spectrum antibacterial antibiotics
 - (B) MRI of the right upper quadrant
 - (C) abdominal ultrasonography
- VI-76.** (Continued)
- (D) bone marrow aspirate and biopsy
 - (E) liver biopsy
- VI-77.** Which is the major mode of transmission of HIV worldwide?
- (A) Heterosexual sex
 - (B) Homosexual sex (anal intercourse)
 - (C) Homosexual sex (genital-oral contact)
 - (D) Intravenous drug use
 - (E) Contaminated blood products
- VI-78.** Impaired immune competence is the predisposing factor in about half of all persons who develop
- (A) histoplasmosis
 - (B) coccidioidomycosis
 - (C) blastomycosis
 - (D) cryptococcosis
 - (E) sporotrichosis
- VI-79.** In which of the following infections is ribavirin effective?
- (A) Influenza A
 - (B) Influenza B
 - (C) Herpes simplex virus
 - (D) Respiratory syncytial virus
 - (E) Immunodeficiency virus
- VI-80.** The type of endocarditis most commonly found in patients who are intravenous drug abusers is
- (A) *Staphylococcus aureus* infection of the tricuspid valve
 - (B) *S. aureus* infection of the mitral valve
 - (C) α -hemolytic streptococcal infection of the tricuspid valve
 - (D) α -hemolytic streptococcal infection of the mitral valve
 - (E) *Pseudomonas aeruginosa* infection of the pulmonary valve
- VI-81.** A 28-year-old woman who works in a poultry processing factory develops an acute febrile illness. Which of the following signs and symptoms is LEAST suggestive of the diagnosis of psittacosis?
- (A) Shaking chills with fever to 40.6°C (105°F)
 - (B) Severe headache
 - (C) Nonproductive cough
 - (D) Stiff back and neck
 - (E) Diarrhea
- VI-82.** Which of the following is LEAST suggestive of infection with poliovirus?

VI-82. (Continued)

- (A) Low-grade fever and malaise with complete resolution in 2 to 3 days
- (B) Biphasic illness with several days of fever, then meningeal symptoms and asymmetric flaccid paralysis 5 to 10 days later
- (C) Descending symmetric motor paralysis
- (D) Failure to isolate a virus from the cerebrospinal fluid in the presence of marked meningismus
- (E) Recovery of function up to 6 months after initial paralysis

VI-83. A 38-year-old woman has undergone allogeneic bone marrow transplantation for acute myelogenous leukemia in second remission from a matched unrelated donor; she now develops pneumonia proven to be due to cytomegalovirus. The patient is placed on ganciclovir, but the pneumonia progresses. Which of the following drugs may potentially be effective in this situation?

- (A) Acyclovir
- (B) IFN- α -2
- (C) Almuvidine
- (D) Foscarnet
- (E) Ribovirin

VI-84. Which of the following is LEAST likely to be a manifestation of late syphilis?

- (A) Lymphadenopathy
- (B) Aortitis
- (C) Papulosquamous skin rash
- (D) Hemiparesis
- (E) Ataxic gait

VI-85. A 23-year-old woman who will be doing Peace Corps work in Bolivia has had all her routine immunizations and has been vaccinated against hepatitis A and B. Which of the following is the most reasonable recommendation for prophylaxis against common infectious diseases in the country of her destination?

- (A) Chloroquine
- (B) Mefloquine
- (C) Yellow fever vaccine
- (D) Yellow fever vaccine plus chloroquine
- (E) Yellow fever vaccine plus mefloquine

VI-86. A 35-year-old Jamaican emigrant develops diffuse lymphadenopathy, fever, lymphocytosis, hypercalcemia, and nodular skin infiltrates. Biopsy of a skin lesion reveals a monotonous population of lymphocytes that stain with antibody directed at CD4 (T4). Which infectious agent is associated with this disease?

- (A) HIV-1
- (B) HIV-2
- (C) Human T-lymphotropic virus I (HTLV-I)

VI-86. (Continued)

- (D) HTLV-II
- (E) Feline leukemia virus (FeLV)

VI-87. There has been an outbreak of infections caused by methicillin-resistant *S. aureus* in the surgical intensive care unit. The most effective means of limiting the spread is

- (A) treatment with cephalosporins to which most strains are sensitive
- (B) treatment with nafcillin and gentamicin, which have a synergistic effect
- (C) use of high-dose nafcillin alone and isolation
- (D) treatment with vancomycin
- (E) minimization of the use of any antibiotics in affected patients because resistance will develop rapidly in other bacteria

VI-88. A 40-year-old Filipino man has hypopigmented macular lesions and a palpably enlarged ulnar nerve. The diagnosis of leprosy can best be established by

- (A) a positive lepromin skin test
- (B) a culture of material obtained on skin biopsy
- (C) the development of erythema and swelling of the lesions after a trial of dapsone therapy
- (D) the demonstration of acid-fast organisms in skin or nerves
- (E) none of the above; leprosy is a clinical diagnosis

VI-89. A 35-year-old Samoan presents with recurrent fever, headache, photophobia, and painful lymphangitis in the left leg. The best way to diagnose filariasis caused by *Wuchereria bancrofti* is

- (A) biopsy of any inflamed lymph nodes to demonstrate the adult worm
- (B) serologic studies
- (C) observation of intense itching after a single dose of diethylcarbamazine
- (D) demonstration of microfilariae after injection of blood into mice
- (E) demonstration of microfilariae in blood taken between 9 P.M. and 2 A.M.

VI-90. A 45-year-old man presents with fever of 40°C (104°F), myalgia, and headache. The patient was originally treated symptomatically for what was presumed to be a viral upper respiratory infection. However, the symptoms persisted and he became short of breath. A chest x-ray revealed interstitial infiltrates, and he was admitted to the hospital for intensive support. CBC revealed a white count of 2000/ μ L, hematocrit of 38%, and platelet count of 75,000/ μ L. SGOT was 240 μ /L and SGPT was 300 μ /L. The bilirubin and alkaline phosphatase were normal. In questioning family members while the patient was in in-

VI-90. (Continued)

tensive care, a history of travel to Cape Cod and a tick bite was obtained. In addition to supportive care, the appropriate therapy is

- (A) Lyme vaccine
- (B) doxycycline
- (C) penicillin
- (D) acyclovir
- (E) chloroquine

VI-91. An 18-year-old sexually active woman from the innercity presents with fever, pleuritic pain of the right upper quadrant, and lower abdominal pain. Pelvic examination reveals mucopurulent cervicitis and tenderness after the production of cervical motion. The right upper quadrant, uterine fundus, and adnexa are slightly tender. The white blood cell count and erythrocyte sedimentation rate are elevated, but the results of the remainder of the laboratory examination, including liver function tests, are normal. Which of the following agents is the most likely cause of this clinical syndrome?

- (A) Herpes simplex virus
- (B) *Treponema pallidum*
- (C) *Neisseria gonorrhoeae*
- (D) *Chlamydia trachomatis*
- (E) *Mycoplasma hominis*

VI-92. To what molecule or lymphocyte does HIV bind?

- (A) CD4 molecule
- (B) CD8 molecule
- (C) CD4 molecule plus interleukin receptor
- (D) CD4 molecule plus chemokine receptor
- (E) Chemokine receptor only

VI-93. A 65-year-old retired banker who spends the summer on Nantucket Island off the Massachusetts coast returned to his home in Boston early in September. He noted the gradual onset of a febrile illness with chills, sweats, myalgias, and yellow eyes. His doctor palpated the spleen and noted a macrocytic anemia, hyperbilirubinemia, and a high serum level of lactic dehydrogenase on laboratory examination. Which of the following would be the most helpful diagnostic procedure at this point?

- (A) Blood culture
- (B) Examination of leukocytes on blood film
- (C) Examination of erythrocytes on blood film
- (D) Splenic biopsy
- (E) Liver biopsy

VI-94. Which of the following statements concerning the relationship of tuberculosis (TB) and HIV infection is correct.

- (A) Levels of plasma HIV RNA decrease in the setting of active TB.

VI-94. (Continued)

- (B) TB usually develops only when the median CD4 count is $<200/\mu\text{L}$.
- (C) Extrapulmonary disease is more common than pulmonary disease in the HIV-infected individual
- (D) A negative PPD skin test effectively rules out diagnosis of TB in this setting.
- (E) Therapy for TB is the same in the HIV-infected patient as in the HIV-negative patient.

VI-95. A 35-year-old intravenous drug abuser with HIV infection is being managed with combination antiretroviral therapy. The patient was doing well on his current medical regimen, which consists of lamivudine and saquinavir as well as methodone, TMP/SMZ, and fluconazole. Although he has been stable clinically of late, efavirenz has recently been added to his medical regimen in an attempt to decrease a rising viral load. After ~1 week of therapy with efavirenz, the patient develops abdominal cramps, malaise, sweats, and anxiety. The most likely reason for the patient's symptoms is

- (A) primary efavirenz toxicity
- (B) increased fluconazole levels
- (C) infection with *Pneumocystis* due to decreased TMP/SMZ levels
- (D) lamivudine toxicity secondary to decreased albumin binding
- (E) reduced plasma methadone concentration.

VI-96. A 42-year-old man underwent allogeneic bone marrow transplantation from an unrelated donor for acute myeloid leukemia in second remission. He develops hepatomegaly and fever 3 months after the infusion of the allogeneic cells. Radiographic imaging of the abdomen reveals extensive intraabdominal lymphadenopathy as well as an enlarged liver, which appears to be diffusely infiltrated. There is no ascites noted. Which of the following is the likely mechanism for the patient's current deterioration?

- (A) Venooclusive disease of the liver
- (B) Overgrowth of EBV-infected lymphocytes
- (C) Recurrence of acute myeloid leukemia
- (D) Graft-versus-host disease
- (E) Toxoplasmosis

VI-97. Which statements concerning *Acinetobacter* is correct?

- (A) This organism is often confused with *Neisseria* on Gram stain.
- (B) This organism is often mistakenly identified as a diphtheroid on Gram stain.
- (C) This organism is a member of the Enterobacteriaceae family on the basis of its appearance on routine laboratory culture media.

VI-97. (Continued)

- (D) This organism is usually sensitive to penicillin and ampicillin.
- (E) Organisms of the genus *Acinetobacter* are rarely isolated from normal patients.

VI-98. Correct statements concerning melioidosis include which of the following?

- (A) Infection is usually caused by person-to-person transmission.
- (B) Patients with pneumonia usually have relatively few organisms in the sputum.
- (C) The diagnosis usually depends on serologic testing.
- (D) Cavitory lung lesions do not occur.
- (E) Therapy with a combination of two or three antibiotics is recommended for severely ill patients.

VI-99. A 43-year-old nurse whose job requires frequent hand washing has noted a small erosive skin lesion between the third interdigital web of the right hand (Plate A). The best therapy for this condition would be

- (A) topical 5-fluorouracil
- (B) topical clotrimazole
- (C) oral griseofulvin
- (D) topical hydrocortisone
- (E) topical tar derivative

VI-100. For the past 2 days, a 24-year-old woman has had fever and pain in the left wrist, right ankle, and left knee. Nine painful skin lesions are present on the distal extremities, predominantly about the joints (as shown in Plate B). The most likely diagnosis is

- (A) herpes simplex
- (B) meningococcemia
- (C) gonococemia
- (D) erythema multiforme
- (E) anthrax

VI-101. A 26-year-old man from Cape Cod sees his physician because of a 3-week history of an expanding, slightly burning ring of redness (as shown in Plate C) that first surrounded a red papule on the posterior neck. He complains of headaches, generalized muscle aches, anorexia, and malaise. On examination, he is noted to be febrile [38.3°C (101°F)]; his rash is slightly raised and slightly tender and displays central clearing but no scaling, even after vigorous scraping. Which of the following vectors has been strongly associated with the type of rash described above?

- (A) Kissing bug
- (B) Spider
- (C) Flea
- (D) Tick
- (E) Housefly

VI-102. A 24-year-old man is concerned because of the appearance of several light brown spots on his trunk (Plate D). The lesions (limited to the chest, back, abdomen, and upper arms) are flat and sharply margined and have a fine scale that is easily scraped off. The most appropriate diagnostic study is

- (A) Giemsa stain of scraped material (Tzanck preparation)
- (B) bacterial culture of the lesions
- (C) fungal culture of the lesions
- (D) microscopic examination of potassium hydroxide-treated scrapings
- (E) examination of the serum for anticardiolipin antibody

VI-103. A 67-year-old man presents with a history of headache for 5 days and 2 days of swelling of the right part of the forehead and right eye (see Plate E). A Tzanck preparation of the lesion reveals multinucleate giant cells on Giemsa stain. The patient was admitted to the hospital and begun on intravenous acyclovir. The most important next step would be

- (A) ophthalmologic consultation
- (B) administration of systemic glucocorticoids to prevent postherpetic neuralgia
- (C) administration of antistaphylococcal antibiotics to prevent secondary bacterial infection
- (D) application of iodine-containing solution to prevent secondary bacterial infections
- (E) CT scan of the brain

VI-104. Which statement concerning *Klebsiella* infections is correct?

- (A) Most clinical isolates are obtained from the respiratory tract.
- (B) Predisposing factors for *Klebsiella* pneumonia include alcoholism, diabetes mellitus, and chronic bronchopulmonary disease.
- (C) *Klebsiella* is closely related to *Pseudomonas*.
- (D) Detecting *Klebsiella* growth from a sputum culture obtained from an intubated patient mandates treatment with an aminoglycoside or a third-generation cephalosporin.
- (E) Successful treatment of established *Klebsiella* infection requires 3 days of antibiotics.

VI-105. Which statement concerning toxoplasmosis is correct?

- (A) A pregnant woman who has acquired *Toxoplasma* any time before pregnancy is likely to deliver an infected infant.
- (B) A woman who develops acute toxoplasmosis during one pregnancy is more likely than are other women to give birth to an infected child in a subsequent pregnancy.

VI-105. (Continued)

- (C) A woman who acquires toxoplasmosis during the last trimester of pregnancy is more likely to deliver an infected infant than she would be if she acquired the infection during the first trimester.
- (D) Toxoplasmosis in a person with Hodgkin's disease probably is due to newly acquired infection.
- (E) Antibody titres indicate toxoplasmosis in immunocompromised patients.

VI-106. A person with liver disease caused by *Schistosoma mansoni* would be most likely to have

- (A) gynecomastia
- (B) jaundice
- (C) esophageal varices
- (D) ascites
- (E) spider nevi

VI-107. A 25-year-old homosexual man presents with a diffuse maculopapular rash over his trunk, head, neck, palms, and soles. Generalized lymphadenopathy is also present. He has a history of 4 weeks of anal pain. Which of the following tests is likely to identify the etiologic agent?

- (A) Antinuclear antibody
- (B) Blood culture
- (C) Serum rapid plasma reagin (RPR)
- (D) Skin biopsy
- (E) Serum HIV antibody

VI-108. An 18-year-old man (pictured in Plate F) presents because of unsightly facial inflammation. Which of the following statements is correct?

- (A) Closed comedones (whiteheads) are less commonly associated with the inflammatory lesions than are open comedones (blackheads).
- (B) Glucocorticoids, although not indicated except in the most severe cases, would likely result in improvement.
- (C) Vigorous scrubbing of the face, which will eliminate surface oils, is indicated.
- (D) Systemic antibiotic therapy is unlikely to be helpful.
- (E) Patients on systemic retinoic acid may experience very dry skin and hypertriglyceridemia.

VI-109. Which statement concerning the pathogenesis of fever is correct?

- (A) Aspirin inhibits the production of endogenous pyrogens.
- (B) The major endogenous pyrogens in humans include interleukin 4 (IL-4) and transforming growth factor- β (TGF- β).
- (C) Endogenous pyrogens are produced by bacteria, protozoa, and fungi.

VI-109. (Continued)

- (D) Endogenous pyrogens raise body temperature through their effect on skeletal muscle beds.
- (E) Endogenous pyrogens play a role in the cachexia of chronic infections.

VI-110. Which statement concerning pneumococcal infection is correct?

- (A) Pneumococcal bacteremia is prevalent in infants and the elderly.
- (B) Only patients who have had a splenectomy for a hematologic malignancy should receive pneumococcal vaccine.
- (C) Pneumococcal pharyngitis is the most common precipitating event for pneumococcal meningitis in adults.
- (D) The occurrence of the "crisis" in pneumococcal pneumonia generally corresponds to the time of maximum leukocytosis.
- (E) Hypogammaglobulinemia is an important factor contributing to the unfavorable prognosis for pneumococcal pneumonia in alcoholic persons.

VI-111. Which statement about the pathogenesis of streptococcal infections is correct?

- (A) Streptococcal strains with M protein in the cell wall are nonpathogenic.
- (B) Manifestations of infection with group A streptococci are due primarily to direct invasion.
- (C) Penicillin significantly shortens the clinical course of the pharyngitis produced by group A streptococci.
- (D) Nonenterococcal group D streptococci cause endocarditis.
- (E) Streptococcal pyoderma leads to acute rheumatic fever.

VI-112. Leptospirosis may be characterized by which of the following statements?

- (A) Fleas are the most important vector for the transmission of *Leptospira* to humans.
- (B) Leptospirosis usually begins with cough and sputum production.
- (C) Leptospiral hepatitis often causes marked transaminasemias without a high bilirubin.
- (D) A normal glucose concentration and a moderately elevated white blood cell count (100 to 1000 cells/ μ L) are characteristic cerebrospinal fluid findings in leptospiral meningitis.
- (E) The best way to diagnose acute leptospirosis is by dark-field microscopic examination of blood smears.

VI-113. *Neisseria gonorrhoeae* infections can be described by which of the following statements?

VI-113. (Continued)

- (A) Gonococci with pili tend to be avirulent.
- (B) Strains of *N. gonorrhoeae* that produce β -lactamase are resistant to penicillin but usually are sensitive to “third-generation” cephalosporins such as ceftriaxone.
- (C) Gonococcemia occurs infrequently during menstruation.
- (D) The skin lesions of gonococcemia usually appears first on the proximal portions of the extremities.
- (E) Gonococcal arthritis is usually symmetric in distribution.

VI-114. Which statement concerning infectious mononucleosis is correct?

- (A) The most common symptom of infectious mononucleosis is lymphadenopathy.
- (B) In young adults, the incubation period for infectious mononucleosis is 5 to 10 days.
- (C) The atypical lymphocytes associated with infectious mononucleosis are B cells.
- (D) Heterophil antibody titers usually decline within 3 to 6 months from the onset of symptoms.
- (E) Antibodies to EBV generally are short-lived.

VI-115. Which statement concerning malaria is correct?

- (A) Malaria caused by each of the four plasmodial species can relapse after the initial illness.
- (B) Red cells with the Duffy blood group antigen are resistant to *Plasmodium vivax*.
- (C) Renal impairment is a grave prognostic sign in falciparum malaria.
- (D) *P. falciparum* causes immune-mediated nephropathy.
- (E) Massive splenomegaly can result from repeated bouts of infection.

VI-116. Which of the following statements about clostridial infections are correct?

- (A) Early antibiotic therapy is important after the isolation of clostridia from any wound to prevent more serious disease.
- (B) Alpha toxin, a lecithinase, is one of the major clostridial toxins, causes diarrhea.
- (C) *Clostridium perfringens* is one of the most common causes of food poisoning in the United States.
- (D) The diagnosis of clostridial myonecrosis can be difficult to make because few organisms are present in the skin lesions.
- (E) Septicemia with *C. septicum* is usually associated with steroid usage.

VI-117. In which of the following patients should an anaerobic organism be considered as a potential etiologic agent?**VI-117.** (Continued)

- (A) A previously healthy 18-year-old boy with sudden fever, cough, and right lower lobe infiltrate.
- (B) A 50-year-old man with alcoholism who has marked cellulitis, swelling, and pain in the left lower mandible.
- (C) A 50-year-old woman with diabetes, low-grade fever, malaise, and a swollen and inflamed right pinna (of the ear).
- (D) A 50-year-old woman with fever, hypoxia, and pulmonary infiltrates 4 h after having general anesthesia for a cholecystectomy.
- (E) A 38-year-old man with a history of rheumatic fever and severe periodontitis in whom a low-grade fever, malaise, and a new heart murmur develop.

VI-118. Which statement about varicella-zoster infection is correct?

- (A) Once dermatomal herpes zoster develops in a patient, repeated recurrences are the rule.
- (B) Encephalopathy is a serious complication of varicella in children.
- (C) Chickenpox is very contagious, with attack rates estimated at between 70 and 90%.
- (D) Varicella pneumonitis, the most serious complication of chickenpox, occurs more frequently in children than in adults.
- (E) Within 72 h of exposure, varicella-zoster immune globulin should be given, if applicable, to all patients to prevent the development of clinical disease.

VI-119. Which of the following statements accurately describe cytomegalovirus (CMV)?

- (A) Approximately 60% of infants who are breast-fed by seropositive mothers become infected; this represents the majority of cases of cytomegalic inclusion disease in newborn infants.
- (B) About 10% of newborn infants have asymptomatic CMV infection in the United States; <1% have symptomatic disease.
- (C) CMV mononucleosis is the most common cause of heterophil-negative mononucleosis.
- (D) CMV pneumonia, a major cause of morbidity and mortality in bone marrow transplant patients, can be diagnosed only by viral cultures of sputum.
- (E) An elevated anti-CMV antibody indicates current infection.

VI-120. Which statement about viral gastroenteritis caused by rotavirus and Norwalk virus is correct?

- (A) Both alter cyclic nucleotide levels and cause a secretory diarrhea
- (B) Norwalk agent is the most important cause of severe diarrhea in infants

VI-120. *(Continued)*

- (C) Rotavirus infection can be diagnosed only retrospectively by serologic methods since isolation from stool is very difficult
- (D) Norwalk virus has been associated with both food-borne and waterborne epidemics
- (E) Both viruses may sometimes disseminate systemically

VI-121. Which of the following statements correctly characterize tetanus?

- (A) Neonatal tetanus develops after passage through a contaminated birth canal.

VI-121. *(Continued)*

- (B) Human tetanus immune globulin can modify the course of disease significantly once symptoms develop.
- (C) Tetanus does not recur because lasting immunity develops.
- (D) Trismus occurs in <10% of those infected.
- (E) In a patient who is uncertain about his or her immunization status, both tetanus toxoid and immune globulin should be given for serious wounds.

VI. INFECTIOUS DISEASES

ANSWERS

- VI-1. The answer is A.** (Chap. 206) *Aspergillus* spp. are commonly found in the environment, particularly on decaying vegetation. Thus, *Aspergillus* spores are ubiquitous, but invasive infection is rare except in patients subject to immunosuppression. Patients with granulocytopenia and/or lymphopenia resulting from glucocorticoid or cyclosporine administration are at risk. Invasive *Aspergillus* infection is characterized by hyphal invasion of blood vessels with concomitant thrombosis. Invasive *Aspergillus* in an immunocompromised host usually presents as a densely consolidated pulmonary infiltrate that is rapidly progressive and is most common in those with prolonged neutropenia secondary to the treatment of acute leukemia and/or recipients of bone marrow transplants. A definitive diagnosis is difficult and requires biopsy; however, the isolation of even a single colony of *Aspergillus* from the sputum of a neutropenic patient with pneumonia, except for among patients who are smokers, suggests the diagnosis of invasive *Aspergillus*. While the fungus ball may be amenable to surgical resection, more typical invasive disease, such as that evidenced by this patient, requires prolonged therapy with amphotericin B. Itraconazole may play a role in less dramatic presentations. Unless the immunosuppression resolves rapidly, the chance for a cure with this type of infection is poor.
- VI-2. The answer is D.** (Chap. 227) Schistosomiasis represents the clinical manifestation of infection with a trematode (flake). The urinary tract disease noted in this patient is characteristic of *Schistosoma haematobium* infection, which is endemic in parts of Africa and the Middle East. The infective stage of this parasite, termed a *cercaria*, penetrates the unbroken skin of a human who comes in contact with contaminated water. After several days the schistosomules (developing schistosomes) travel to the lungs and then to the portal vein, where they mate and migrate to the ureteral venules (for *S. haematobium*; *S. mansoni* and *S. japonicum* migrate to the venules of the mesentery). Eggs are deposited in the bladder and ureters, with mature ova being released into the water, where they hatch into a meracidium that infects the intermediate host, a snail, eventually releasing thousands of cercaria to renew the cycle. Eggs deposited in the ureters and bladder elicit an intense inflammatory and granulomatous response that may cause functional obstruction. These lesions are reversible with the use of antischistosomal chemotherapy such as praziquantel. As fibrosis ensues, chemotherapy is less effective. The diagnosis is based on the demonstration of the characteristic eggs in the tissues or urine. *S. haematobium* infection is a predisposing factor for the development of an unusual histologic variant of bladder cancer (squamous cell carcinoma).
- VI-3. The answer is A.** (Chaps. 180, 297. Catalina, Navarro, *Hosp Pract* 35:97–108, 2000.) Risk factors for the acquisition of HCV include receiving a blood transfusion before 1992, intravenous drug use, hemodialysis, sexual relations with an infected individual, or history of a sexually transmitted disease. Most patients with HCV infection remain asymptomatic for a long time after initial infection. The biggest concern in chronically infected patients is the development of cirrhosis, along with the complications of portal hypertension and an increased risk of hepatocellular carcinoma. It is best to confirm a positive serology result with the PCR-based test for HCV mRNA. Moreover, quantitative tests for the level of HCV RNA may be useful in measuring response to therapy. Liver biopsy would not be indicated until the PCR test confirms the presence of disease, though such a procedure

would be very helpful in assessing the magnitude of histologic change. In addition to counseling a patient with a confirmed infection to eliminate behaviors that could result in transmission to others, treatment with recombinant IFN- α -2b may result in some degree of benefit. Patients most likely to respond to interferon therapy are those with cirrhosis, a low but present serum HCV mRNA level, and a HCV genotype other than type 1. Interferon in combination with ribavirin may be more effective than therapy with either agent alone.

VI-4. The answer is C. (*Chap. 154*) The most important risk factors for *H. pylori* infection include older age, low income, and residence in a developing country. It is believed that infection generally is acquired in childhood. Although humans are the major reservoir of *H. pylori*, the route of infection is unclear, with fecal-oral and oral-oral spread both being possible. *H. pylori* is endemic in only 30% of Americans, but prevalence rates are as high as 80% in developing countries. Infection with a related species, *H. heilmanii*, is about 1% as common as *H. pylori* infection.

VI-5. The correct answer is A. (*Chap. 145*) Botulism is caused by protein neurotoxins elaborated by the *Clostridium botulinum* anaerobic gram-positive organism. These organisms form spores that are found in soils and marine environments throughout the world. Eight toxin types have been described; each can be inactivated by cooking at high temperatures. In the United States, toxin types A, B, and E are usually associated with food-borne botulism, often from home-canned food, particularly vegetables, fruit, and occasionally meat and fish.

The incubation period after the ingestion of food containing the toxin is usually 18 to 36 h but can vary. The disease is usually heralded by cranial neuropathies and then generally progresses to symmetric descending paralysis that is sometimes associated with nausea, vomiting, abdominal pain, dizziness, blurred vision, dry mouth, and dry sore throat. Although potentially anxious, patients are generally alert and oriented.

The diagnosis must be suspected clinically and should be distinguished from Guillain-Barré syndrome, Lambert-Eaton syndrome, polymyositis, tick paralysis, diphtheria, and chemical intoxication.

Treatment should include hospitalization and close monitoring for a potential decline in respiratory function, which should be treated with intubation and mechanical ventilation. Trivalent (including types A, B, and E) equine antitoxin should be administered immediately. Anaphylaxis and serum sickness may occur. In the absence of ileus, cathartics and enemas should be given to purge the toxin; gastric lavage will help only in cases where the time after ingestion is brief. Antimicrobial therapy plays no role in this situation, since the disease is not caused by a proliferation of bacteria but instead by previously elaborated toxins.

VI-6. The answer is C. (*Chap. 135. Craven, Chest 108:1S–16S, 1995.*) Nosocomial pneumonia, a pulmonary infection acquired during or as a result of hospitalization, is fairly common. Patients in an intensive care unit who have an endotracheal tube in place are at an increased risk from bacteria leaking around the cuff or contaminating humidifiers or the ventilator circuit condensate. Since an increased degree of colonization of the oropharynx or stomach is a very important factor in the development of nosocomial pneumonia, patients who have an increased propensity to aspirate because of a decreased gag reflex, depressed consciousness, poor gastric emptying, or the presence of a nasogastric tube are also at increased risk. Bacteria are more likely to colonize the stomach when the gastric pH is elevated, as is caused by H₂ histamine receptor antagonists such as ranitidine and other antacids. However, sucralfate heals ulcers without altering gastric pH and may produce less of a risk of gastric colonization and the subsequent development of nosocomial pneumonia.

VI-7. The answer is D. (*Chap. 135*) Nosocomial bacteremia and infection of intravascular devices are common causes of morbidity related to hospitalization. Many times bacteria are cultured from a line without the clear presence of infection. The most common organ-

isms causing such incidental bacteremias include coagulase-negative *Staphylococci*, *Candida* spp., *S. aureus*, and *Enterococci*. In the absence of physical findings compatible with infection in the skin, it may be possible to treat the patient with antibiotics while leaving the catheter in place, especially in the case of bacteremia caused by coagulase-negative *Staphylococci*. By contrast, a clinical line infection, manifested by fever and signs of cutaneous involvement such as erythema and induration at the insertion site or subcutaneous tunnel, should mandate blood cultures and removal of the line. Even though broad-spectrum antibacterial coverage could be administered, it is virtually impossible to eradicate these invasive infections around the plastic tubing with antibiotics alone, mandating line removal. Replacing an infected line over a guidewire may result in immediate contamination of the new line.

- VI-8. The answer is E.** (*Chap. 148*) In addition to *Haemophilus influenzae* and *Streptococcus pneumoniae*, the gram-negative coccus *Moraxella (Branhamella) catarrhalis* is a common cause of exacerbations of chronic bronchitis and pneumonia in patients with moderately severe COPD. The symptoms are typically modest in severity, although chills, pain, and malaise often are noted. Low-grade fevers and a lack of leukocytosis are also common. If the patient actually has pneumonia, the radiologic appearance is variable, and clinical parameters do not permit one to determine the organism causing illness in a heavy smoker with COPD. However, the Gram's stain in this case, which depicts the abundant presence of gram-negative cocci in pairs, is typical of *M. catarrhalis*. Cephalosporins, tetracycline, erythromycin, TMP/SMZ and quinolones are all effective. However, since resistance to both TMP/SMZ and tetracycline has been reported, those with pneumonia require treatment with the most effective agent. Therefore, the most appropriate choice is the combination of a penicillin and clavulanic acid, which suppresses the *M. catarrhalis* β -lactamases.
- VI-9. The answer is C.** (*Chaps. 191, 309. Flexner, N Engl J Med 338:1281–1292, 1998.*) The protease inhibitors, albeit with significant expense and side effects, are critical in the increasingly successful medical management of patients with HIV infections. The HIV protease is responsible for cleaving sequences in the GAG viral polyprotein, which allows for physical development and replication of the virus. There are four FDA-approved HIV-protease inhibitors: indinavir (Crixivan), nelfinavir (Viracept), ritonavir (Norvir), and saquinavir (Invirase). Bioavailability after oral dosing is variable; whether or not the drug should be taken with food is unique to each specific agent. These agents are metabolized by the cytochrome P450 enzymes; as such, care should be taken when patients also require therapy with drugs that affect this detoxification system. Side effects are common and include nausea, vomiting, and diarrhea with almost all the agents. Hyperglycemia, fat redistribution, and liver test abnormalities have all been noted. These agents are associated with a rapid and profound decrease in viral load when given as monotherapy. Such reductions in the viral load are associated with an increase in the CD4 count. Current clinical guidelines involve the recommendation that a protease inhibitor should be combined with two reverse transcriptase inhibitors for maximal antiviral effect during initial therapy. Such combination therapy may have long-lasting effects on suppression of HIV proliferation.
- VI-10. The answer is A.** (*Chap. 140*) This patient presents with the classic findings of necrotizing fasciitis, including systemic toxicity associated with minimal to marked skin changes. The site of inoculation, often resulting from simple trauma, is usually somewhat distant from the area of clinical involvement and may be due to simple trauma. Group A streptococci released during abdominal surgery may also cause this type of illness. While staphylococci, *Bacteroides* spp., or anaerobic streptococci can also cause a similar syndrome, group A streptococci account about 60% of these cases.
- VI-11. The answer is E.** (*Chap. 140. Working Group on Severe Streptococcal Infection, JAMA 269:390–391, 1993; Bisno, Stevens, N Engl J Med 334:240–245, 1996.*) As group A streptococcal necrotizing fasciitis progresses, the marked tenderness of involved skin may

progress into anesthesia as a result of infarction of cutaneous nerves. Surgery is required for both diagnosis and therapy. The process usually extends beyond the area of clinical involvement, and therefore extensive debridement is required. Antibiotics are adjunctive therapy; penicillin G 2 to 4 million units IV every 4 h is recommended, although erythromycin 250 mg four times a day may be substituted in case of allergy. This patient also has group A streptococcal toxic shock–like syndrome, which, in contrast to *S. aureus*–associated toxic shock syndrome, is associated with bacteremia. The mortality rate of this syndrome, which results from a pyrogenic exotoxin A produced by the bacteria, is ~30%.

- VI-12. The answer is D.** (*Chap. 218. DuPont et al. N Engl J Med 332:855, 1995.*) Cryptosporidiosis is transmitted by the fecal-oral route by animal-to-person or person-to-person contact. Waterborne transmission may occur since oocytes are hardy and resist killing by routine chlorination. Though symptomatic and asymptomatic infections can occur in an immunocompromised host, followed by 1-week incubation period, immunocompetent individuals typically develop watery nonbloody diarrhea with occasional pain, nausea, anorexia, and weight loss. In such individuals the illness usually subsides in 1 to 2 weeks; however, in those with AIDS the disease can be more prolonged and much more severe. In addition to fluid and electrolyte depletion, weight loss, wasting, and severe abdominal pain may occur with occasional biliary involvement. The diagnosis rests on stool examination to detect oocytes. Since the interpretation of routine smears is difficult, modified acid-fast and direct immunofluorescence stains have been employed to increase the sensitivity. Treatment is supportive, since no antibiotic has been shown to be definitively effective.
- VI-13. The answer is B.** (*Chap. 219*) *Trichinella* spp. are members of the nematode phylum (roundworms). Trichinosis occurs after eating meat containing *Trichinella* nematode oocytes. After the consumption of affected meat, the encysted larvae are released by the action of gastric acid and pepsin. The larvae penetrate the small interstitial mucosa and rapidly mature into adult worms. In 1 week, female worms release newborn larvae that travel via the circulation to striated muscle and then encyst. Clinical symptoms follow each of these phases. Initially gut invasion may be marked by abdominal pain, nausea, and constipation or diarrhea. Larval migration, which occurs during the second week after infection, produces a local and systemic hypersensitivity reaction manifested by fever, hypereosinophilia, and periorbital and facial edema. Myocarditis, encephalitis, and pneumonitis are rare but potentially life-threatening complications that may occur during this phase. After larval encystment in muscle for 2 to 3 weeks, edema and symptoms of myositis, including muscle edema and weakness, develop. The symptoms subside gradually during what may be a prolonged convalescence. Antihelminthic drugs are ineffective against the encysted larvae. Trichinosis, which typically is associated with eosinophilia and an elevated IgE level, may be prevented by cooking pork until it is no longer pink or freezing it at -15°C for 3 weeks. Ocular larva migrans, another nematode infection, is caused by the invasion of *Toxocara* larvae into the eye, typically producing a granulomatous mass, usually in the posterior pole of the retina.
- VI-14. The answer is E.** (*Chap. 187. Takahashi et al, Proc Natl Acad Sci USA 95:8227–8232, 1998.*) Parvovirus subtype B19 is a nonenveloped single-stranded DNA virus. Several clinical syndromes have been found to be associated with parvovirus B19 infection. These syndromes generally occur on the basis of intranasal respiratory infection with the virus. Normal, immunocompetent hosts generally clear the parvoviral infection but may experience a clinical syndrome of aching joints, fever, and chills. Patients may develop an exanthem more common in children, termed *fifth disease*, which is characterized by a facial rash with a “slapped cheek” appearance. Anemia may result from parvovirus infection even in normal hosts. In those with chronic hemolysis such as in patients with spherocytosis or sickle cell disease, parvoviral infection can result in a very serious aplastic crisis, which can produce life-threatening anemia. Immunodeficient patients may also experience profound anemias after infection with this virus. Moreover, B19 infection in adults

may present as a rash or an acute, peripheral, symmetric, nondestructive polyarthritis. Studies have suggested a link between parvovirus B19 infection and rheumatic disease, including rheumatoid arthritis, vasculitis, lupus, and dermatomyositis. Parvovirus is not known to cause primary gastrointestinal infection, which is more likely to be on the basis of infection with a rotavirus or Norwalk agent.

- VI-15. The answer is B.** (*Chaps. 210, 211*) After taking a thorough history in the setting of a suspected parasitic infection, the clinician must have a fairly good idea of the parasite with which infection is likely so that the appropriate diagnostic test can be ordered. Since many helminths and protozoa exit the body in the fecal stream, examination of the stool is critical in parasitic infestations. Microscopic examination of the stool can, if a motile tapeworm is noted, help make a diagnosis of *Taenia saginata*. This organism also could be readily detected by the Scotch tape technique applied to the perianal skin, sometimes revealing the ova even if the motile segments have disintegrated. *Giardia lamblia*, *Cryptosporidium*, and *Strongyloides* often infect the duodenum, and therefore a string test in which the contents of this organism can be examined may be necessary to make the diagnosis. *E. histolytica* has been difficult to diagnose in the setting of a presumed liver abscess because the organism grows primarily in the cavity wall. Aspirated fluid is frequently negative for the organism. The diagnosis of *P. carinii* is routinely made by examination of a silver-stained induced sputum specimen. *S. haematobium*, a common cause of hematuria (and sometimes cancer) in third world patients, can be detected easily by examination of the urine for characteristic forms.
- VI-16. The answer is C.** (*Chaps. 210, 211. Mannheimer, Infect Dis Clin North Am 8:483–498, 1994.*) The approach to a patient with potential parasitic infestation must include a detailed travel and dietary history as well as an understanding of whether any behaviors have predisposed the patient to exposure, such as wading or swimming in fresh water (relevant to the acquisition of schistosomiasis). Residents in institutional settings or child care centers where fecal-oral hygiene may be substandard not infrequently develop giardiasis, cryptosporidiosis, or pinworm infestations. Immune status also determines predisposition to parasitic infection. For example, individuals infected with HIV-1, especially those with depressed CD4+ lymphocyte counts, may develop infections with *Toxoplasma*, *Isospora*, *Cyclospora*, cryptosporidia, *Leishmania*, American trypanosomes, and free-living amoebae. Patients infected with the retrovirus human T-lymphotropic type I are likely to be infected with *Strongyloides*. Persons with asplenism, either anatomic or functional (as in patients with sickle cell anemia), are at risk for developing florid infection from intraerythrocytic protozoa such as malaria and babesiosis. Those with cystic fibrosis or hypogammaglobulinemia (e.g., multiple myeloma or CLL) may develop major infestation with giardiasis.
- VI-17. The answer is B.** (*Chap. 375. Johnson, Gibbs Jr, N Engl J Med 339:1994–2004, 1998.*) Creutzfeldt-Jakob disease is a degenerative disease of the brain caused by prions, which are infectious proteins—the only known disease-causing agent not associated with nucleic acid. This disease typically presents with dementia with myoclonus; death occurs within a year. Genetic or sporadic types may occur, in addition to infectious presentations. The prion stimulates a normal cellular protein called Pr^{PC} to cause its conversion to a disease-causing isoform called Pr^{Sc}. The disease-causing isoform contains a high β -pleated sheet content. The sporadic form of Creutzfeldt-Jakob disease is most common; inherited diseases account for 15% of cases. There is now major concern that a small European epidemic may be occurring on the basis of consumption of animals displaying bovine spongiform encephalopathy (BSE). The best example of an infectious prion disease was the epidemic of Kuru in an indigenous tribe of New Guinea. Spongiform degeneration and proliferation of supporting astrocytes is the characteristic pathologic finding.
- VI-18. The answer is D.** (*Chap. 173*) Nonvenereal treponematoses occur in less developed areas of the world and include yaws, pinta, and endemic syphilis, each caused by *Trepo-*

nema pallidum. These conditions may be distinguished epidemiologically and clinically from venereal syphilis. Pinta involves the skin alone, whereas yaws affects the skin and bones; endemic syphilis involves the skin, bones, and mucus membranes. Yaws is characterized by the development of one or more initial skin lesions followed by relapsing nondestructive secondary lesions of the skin and bones, but with ultimate destruction occurring in the late stages. A manifestation of endemic syphilis is usually an intraoral mucous lesion, resembling that seen in secondary syphilis. Pinta may begin with a small papule that may coalesce with adjacent satellite papules and produce seasonal lymphadenopathy. Treatment for all the endemic treponematoses consists of the intramuscular administration of 2.4 units of benzathine penicillin G.

- VI-19. The answer is B.** (Chaps. 168, 169. *American Thoracic Society and Centers for Disease Control, Am J Respir Crit Care Med 149:1359, 1994.*) Isoniazid, rifampin, pyrazinamide, ethambutol, and streptomycin are considered first-line agents for antituberculous treatment. All except streptomycin are given orally and are well absorbed. They are all bactericidal and are associated with a low rate of drug resistance induction. Multiple second-line drugs are useful in patients who have drug resistance or intolerance to the first-line agents. Such drugs include ofloxacin, cycloserine, and *p*-aminosalicylic acid as well as the injectable agents kanamycin, amikacin, and capriomycin. The backbone of the initial treatment regimen, which is designed to produce maximal antimycobacterial kill, is 2 months of treatment with isoniazid, rifampin, pyrazinamide, and, except for those who seem to have a low likelihood of harboring a drug-resistant strain on epidemiologic grounds, ethambutol. Once the sputum culture reveals drug-sensitive tuberculosis, ethambutol can be dropped from the regimen for the remaining 2 months. Pyridoxine should be added to the regimen to prevent isoniazid-associated neuropathy, which is more common in those at high risk of vitamin deficiency, such as alcoholics, and those with conditions in which neuropathy is likely, such as chronic renal failure, diabetes, and AIDS. It is also important that patients be supervised during the period of drug treatment to ensure compliance. After the initial 2 month treatment phase, a continuation phase of 4 months is recommended during which treatment with isoniazid and rifampin should be sufficient to eradicate the organism.
- VI-20. The answer is C.** (Chap. 139. *Lowy, N Engl J Med 339:520–532, 1998.*) This patient must be considered to have a life-threatening infection with *S. aureus* with possible valvular involvement. Only 5% of isolates are sensitive to penicillin; methicillin-resistance is extremely common. Vancomycin with or without an aminoglycoside is recommended for such suspected community- or hospital-acquired *S. aureus* infections. Though drugs such as TMP/SMZ or clindamycin or fluoroquinolones such as ciprofloxacin are effective, they are not as efficacious as vancomycin and are more likely to induce resistance during therapy. There have been isolated case reports of vancomycin-resistant *S. aureus* strains; however, the mechanism of resistance is not due to the same genes causing vancomycin resistance in enterococci, which is a major clinical problem at this time.
- VI-21. The answer is A.** (Chap. 136. *Fishman, Rubin, N Engl J Med 338:1741–1751, 1998.*) In recipients of solid organs, infections in the immediate posttransplant period are usually due to conventional nosocomial infections such as bacterial or fungal (especially candidal) infestations. Those that occur between 1 and 6 months after transplantation are generally due to so-called unconventional or opportunistic infections, due in part to chronic immunosuppression. Infections with cytomegalovirus (CMV) and EBV and opportunistic infections due to *P. carinii*, *Aspergillus*, and *L. monocytogenes* begin to occur. The use of TMP/SMZ prophylaxis during the first 4 to 12 months after transplantation has effectively limited the incidence of *P. carinii* pneumonia and reduced the risk of infection with respiratory pathogens such as *L. monocytogenes*, *Nocardia*, and *T. gondii*. However, even with the use of such prophylactic therapy, infections can occur. Given the clinical scenario of acute meningitis, the most likely pathogen is *L. monocytogenes*. Chronic meningitis in this setting is usually caused by *Cryptococcus neoformans*. Given the lack of focal findings on the MRI of the patient's brain, infection with *Toxoplasma* or *Nocardia* or EBV-

associated posttransplantation lymphoproliferative disease would be unlikely. Metastatic *Aspergillus* infection can also cause a focal brain lesion. Infections with typical organisms that cause meningitis in nonimmunocompromised individuals, such as *H. influenzae* are unusual. Systemic infections with *M. tuberculosis*, *Histoplasma capsulatum*, or *Coccidioides immitis* can cause a more chronic syndrome consisting of fever and headache, sometimes associated with an altered state of consciousness.

- VI-22. The answer is A.** (*Chap. 163. Zangill, N Engl J Med 329:8, 1993.*) This patient exhibits the typical manifestation of cat-scratch disease, which is a painful regional lymphadenopathy that persists for several weeks or months after a cat scratch. Before the development of the lymphadenopathy, a localized papule or pustule that eventually crusts develops within a few days after the scratch. Since scratches most often occur on the hand or face in children, youngsters account for 60% of cases. The epitrochlear, axillary, pectoral, and cervical lymph nodes are commonly involved. Systemic symptoms and even severe manifestations such as encephalitis, seizures, and coma may occur. Most cases are self-limited and can be diagnosed by microscopic examination of a lymph node biopsy specimen. The cat-scratch disease skin test is no longer used because of fear of the transmission of viral agents. Serologic tests can confirm that the causative organism is the gram-negative bacillus, *B. henselae*. Bacillary angiomatosis, also caused by *B. henselae*, causes skin lesions resembling Kaposi's sarcoma, and occurs in patients with immunocompromised states such as an HIV infection. The Wharthin-Starry silver stain can detect the *Bartonella* spp. in both conditions; it appears that ciprofloxacin and doxycycline have activity in *Bartonella* infections.
- VI-23. The answer is D.** (*Chap. 135. Stamm, Am J Med (Suppl 3B):65S–71S, 1991.*) Bacteriuria is a common problem in institutionalized patients with urethral catheters. Since the risk of infection is about 3 to 5% per day of catheterization, most patients who have a catheter in for >2 weeks eventually develop bacteria in the urine. Infections generally result from migration through the column of urine in the catheter lumen or from organisms moving up the mucous sheath outside the catheter. In either case, the most common organisms causing such infections are *Proteus*, *Pseudomonas*, *Klebsiella*, *Escherichia coli*, and *Serratia*. Other important factors are female sex, severe underlying illness, disconnection of the catheter and drainage tube, and lack of systemic antimicrobial therapy. Despite these facts, prevention with short courses of systemic antimicrobial therapy, topical application of periurethral ointments, and the addition of antimicrobials to the drainage bag is not recommended for general use. Though most catheter-associated infections cause minimal symptoms, gram-negative bacteremia is a complication that may occur in 1 to 2% of those who have catheter-associated bacteriuria. In fact, the most common cause of gram-negative bacteremia in hospitalized patients is a catheterized urinary tract. The best treatment, if possible, is removal of the catheter in conjunction with a short course of antibiotics to which the organism is susceptible. However, if the catheter must be left in place, antibiotic therapy usually engenders resistance and should probably be cause for ignoring the bacteriuria as long as it remains asymptomatic.
- VI-24. The answer is E.** (*Chap. 141. Dixon et al, N Engl J Med 341:815–826, 1999.*) The endospores of *B. anthracis*, a gram-positive organism, are generally hearty and difficult to eradicate. The endospores are introduced into the body via the skin (abrasion or cut), inhalation, or ingestion or they phagocytosed by macrophages and carried to regional lymph nodes. Germination occurs in the lymph node; bacteria released into the blood stream cause massive septicemia, which is almost always fatal. When anthrax endospores are ingested or inhaled or if bacteria reach the meninges, fatality is common. However, 80 to 90% of cutaneous anthrax is self-limited. The primary skin lesion is a pruritic papule that appears 3 to 5 days after the introduction of endospores. One to two days later the lesion forms a vesicle that eventually undergoes central necrosis, giving a typical black eschar. The eschar is surrounded by edema and purplish vesicles. This so-called malignant

edema can, if present in the neck and thoracic region, lead to a tracheal compromise. Antibiotic treatment for cutaneous anthrax is recommended but probably not required.

- VI-25. The answer is D.** (*Chap. 197. Fishbein, Robinson, N Engl J Med 329:1632–1638, 1993.*) The patient in question has been bitten by a member of a species known to carry rabies in an area in which rabies is endemic. Based on the animal vector and the facts that the skin was broken and that saliva possibly containing the rabies virus was present, postexposure rabies prophylaxis should be administered. If an animal involved in an unprovoked bite can be captured, it should be humanely killed and the head should be sent immediately to an appropriate laboratory for rabies examination by the technique of fluorescent antibody staining for viral antigen. If a healthy dog or cat bites a person in an endemic area, the animal should be captured, confined, and observed for 10 days. If the animal remains healthy for this period of time, the bite is highly unlikely to have transmitted rabies. Postexposure prophylactic therapy includes vigorous cleaning of the wound with a 20% soap solution to remove any virus particles that may be present. Tetanus toxoid and antibiotics should also be administered. Passive immunization with antirabies antiserum in the form of human rabies immune globulin (rather than the corresponding equine antiserum because of the risk of serum sickness) is indicated at a dose of 10 units/kg into the wound and 10 units/kg intramuscularly into the gluteal region. Second, one should actively immunize with an antirabies vaccine [either human diploid cell vaccine or rabies vaccine absorbed (RVA)] in five 1-mL doses given intramuscularly, preferably in the deltoid or anterior lateral thigh area. The five doses are given over a 28-day period. The administration of either passive or active immunization without the other modality results in a higher failure rate than does the combination therapy.
- VI-26. The answer is A.** (*Chap. 198*) The presence of IgM antibodies in either the serum or the CSF that are reactive with the LaCrosse (California) arbovirus is highly suggestive of acute infection with this agent. Moreover, the patient resides in an endemic area (the North Central states, New York, wooded areas of eastern Texas and Louisiana, and along the eastern seaboard). The virus is present in the woodland mosquito, *Aedes triseriatus*, chipmunks and squirrels serve as amplifier hosts. Human infections occur most often during the summer months, when the mosquito is active, and usually involve 5- to 10-year-old boys who live in rural areas. The clinical presentation may be the abrupt epileptic type, as in this patient, or the more lethargic form. While EEGs are typically abnormal and imaging studies of the brain may also reveal abnormalities in the temporal lobe, the presence of the specific antibody obviates the need for brain biopsy to exclude herpes encephalitis, which is also typically localized in the temporal lobes. Despite the abrupt clinical onset and severity, there is progressive improvement beginning about the fourth day, with almost all patients becoming afebrile, seizure-free, and able to leave the hospital within several weeks. The mortality is <2%; however, about 15% of affected persons may develop short- or long-term sequelae, including personality and behavioral changes.
- VI-27. The answer is C.** (*Chap. 135*) Infection of cannulas occurs most commonly by contamination during insertion or manipulation. Although the daily application of an antibacterial ointment is recommended by some authorities, the best way to prevent these infections is to change the cannula periodically, no less frequently than every 2 or 3 days. An exception is the use of cuffed catheters, which are inserted surgically into the subclavian vein and can be used for many weeks. Infections of such devices with relatively nonpathogenic organisms, such as coagulase-negative staphylococci, may be treated with intravenous antibiotics; however, gram-negative rod and candidal infections usually mandate removal of the indwelling catheter. Infections of cannulas occur much less frequently as a result of the other factors listed in the question.
- VI-28. The answer is B.** (*Chap. 124. Wheeler, Bernard; N Engl J Med 240:207–214, 1999.*) In the case presented, the history and physical examination strongly suggest gram-negative

sepsis stemming from a urinary-tract infection. In older men, obstruction resulting from prostatic hypertrophy is usually the cause. Prompt initiation of appropriate antibiotic therapy is most important. The choice of antibiotics can be guided by the history and microscopic examination of a Gram-stained urine specimen. In the absence of definitive laboratory information, initial treatment with maximal doses of broad-spectrum antibiotics, such as gentamicin or tobramycin plus ampicillin or a cephalosporin, is indicated. Bladder catheterization may be necessary to relieve the obstruction or monitor urine flow. Intravenous infusion of bicarbonate solutions and Ringer's lactate or dextrose-in-saline solutions is needed acutely to correct acidosis, restore vascular volume, and maintain renal perfusion. Glucocorticoids may protect against the lethal effects of endotoxin in experimental animals, but recent placebo-controlled trials have failed to support their use in most clinical situations. Antiendotoxin antibodies and agents that interfere with the action of cytokines (e.g., tumor necrosis factor α and interleukin 1β) that mediate the manifestations of septic shock are under investigation.

- VI-29. The answer is C.** (Chap. 155) Primary *Pseudomonas* osteomyelitis is very unusual except in intravenous drug addicts, but it should be considered in a nail puncture wound that does not respond to local or oral antibiotic therapy. Ecthyma gangrenosum, an indurated black area approximately 1 cm in diameter with an ulcerated center and surrounding erythema, is highly suggestive of *Pseudomonas* bacteremia. *Pseudomonas* is the most common cause of chronic otitis externa, which usually responds to local measures. In diabetics, however, a rapidly invasive form may develop and require aggressive debridement and antibiotic therapy. *E. coli* is the most common cause of gram-negative meningitis in neonatal infants. The development of *Pseudomonas* meningitis usually occurs only after introduction by surgery, trauma, or foreign objects such as shunts. *Pseudomonas* endocarditis may affect intravenous drug users or patients under-going open-heart surgery.
- VI-30. The answer is D.** (Chap. 223. Ammann, Eckert, *Gastroenterol Clin North Am* 37:655–689, 1996.) This patient hails from an area where echinococcal infection is endemic. It is prevalent in areas where livestock is raised in association with dogs. Dogs, which are the definitive hosts, harbor the adult *Echinococcus granulosus* worm and pass eggs in their feces, which can then be ingested by the intermediate hosts, including sheep, cattle, and humans. After ingestion of the eggs, the hatched embryos enter the portal circulation and frequently travel to the liver or lungs. The larvae develop into fluid-filled hydatid cysts from which secondary cysts develop. A slowly enlarging mass ultimately develops. After 5 to 20 years the mass may enlarge to the point where it may cause symptoms, such as those resulting from compression of the bile duct. Leakage of cyst fluid into the biliary tree can also mimic recurrent cholelithiasis; episodic leakage from the cyst can produce a syndrome of fever, pruritus, and urticaria or possibly even fatal anaphylaxis. The presence of daughter cysts within larger cysts and eggshell calcification in the wall of the cyst is essentially pathognomonic for *E. granulosus* infection and suggests that carcinoma, bacterial or amebic liver abscess, and hemangioma are less likely. Aspiration of the cyst may be conducted carefully for diagnostic purposes. Serology is not specific. Albendazole is not sufficiently effective to be used as monotherapy. Surgery is indicated for such a space-occupying lesion, although the risks of anaphylaxis and dissemination of infectious scolices may be minimized by instilling ethanol into the cyst cavity.
- VI-31. The answer is D.** (Chap. 198. Deresiewicz et al, *N Engl J Med* 336:1867–1874, 1997.) This patient presents with the typical clinical course of eastern equine encephalitis (EEE), which consists of a benign viral-type prodrome followed by progressive neurologic symptoms such as confusion, somnolence, focal weakness, seizures, or meningeal signs. The neurologic syndrome frequently progresses to stupor; the death rate is ~33%. Laboratory findings include leukocytosis and hyponatremia. CSF typically reveals an elevated protein, abnormal glucose, and increased numbers of neutrophils. The MRI findings almost always reveal focal abnormalities in the basal ganglia and thalamus, best seen on T2-weighted images, appearing as an area of increased signal intensity. Definitive diagnosis depends

on isolation of the EEE virus from CSF or brain tissue or by specific antibody tests. Such tests include an IgM capture enzyme immunoassay, which can be performed on CSF, or a fourfold rise in titer of serum antibody against the EEE virus. Serum IgM can also provide presumptive evidence of EEE infection.

- VI-32. The answer is C.** (*Chap. 131. Passaro, Parsonnet, Curr Clin Top Infect Dis 58:217–236, 1998.*) Toxigenic *E. coli* is the major cause of diarrhea (“turista”) for Americans abroad. *S. aureus*, *C. perfringens*, and *B. cereus* cause various types of acute food poisoning owing to bacterial proliferation and elaboration of toxins in improperly stored food. Children throughout the developing world suffer acute diarrhea, similar to traveler’s diarrhea, caused by rotavirus infection. All five of these agents cause watery diarrhea that generally is without blood, mucus, or fecal leukocytes, as opposed to illness caused by *Shigella*, *Salmonella*, or *Campylobacter*, which produces a more invasive, dysenteric type of disease.
- VI-33. The answer is A.** (*Chap. 122*) Since BCG is a live attenuated organism and has been reported to cause disseminated infection in immunocompromised patients, it should not be administered to those with HIV infection or those with suspected immunodeficiency. Though patients with immune dysfunction often do not mount a good response to an administered vaccine, they should still receive certain preparations. Patients about to undergo splenectomy or cancer chemotherapy should, when possible, be vaccinated before therapy. Influenza vaccine should be given in autumn to those with any chronic medical illness in addition to those with an obvious immune deficiency. The chronically ill, the immunosuppressed, and those at risk for infection with encapsulated microorganisms (e.g., anatomic or functional asplenia, multiple myeloma) should receive pneumococcal vaccine. The last group plus those with terminal complement component deficiencies should receive the quadrivalent meningococcal vaccine. Patients with HIV infection, especially those who are potential household contacts of children receiving the oral polio vaccine (attenuated live virus), should receive three doses of the inactivated polio vaccine.
- VI-34. The answer is E.** (*Chap. 209. Maser, N Engl J Med 323:1500–1504, 1990.*) Patients with AIDS, premature malnourished infants, children with primary immunodeficiency diseases, and patients receiving immunosuppressive therapy (particularly glucocorticoids for cancer or organ transplantation) are at risk for developing *P. carinii* pneumonia. Although infection is usually confined to the lungs, disseminated infection can occur in up to 3% of patients. In this patient, sputum obtained at bronchoalveolar lavage has yielded diagnostic material. Toluidine blue, which also selectively stains the wall of the pneumocystis cyst, would have been appropriate, as would immunofluorescent or immunoperoxidase staining. Further diagnostic studies are not required in this setting, and treatment should be undertaken. For patients with severe hypoxemia, glucocorticoids may be effective in mitigating immune-mediated lung damage. Steroids should be administered in conjunction with appropriate antimicrobial therapy, which includes either intravenous TMP/SMZ or intravenous pentamidine. Therapy should continue for 21 days in patients with AIDS. Aerosolized pentamidine is effective as prophylaxis but is not indicated in primary infections. Combination therapy with TMP/SMZ and pentamidine has not been shown to be more effective than either agent alone.
- VI-35. The answer is B.** (*Chap. 216. Kirchoff, N Engl J Med 329:639–644, 1993.*) This patient formerly resided in an area endemic for the protozoan parasite *Trypanosoma cruzi*. So-called American trypanosomiasis, or Chagas’ disease, is found in almost all Latin American countries. Given the increased number of immigrants from these countries to the United States, the domestic prevalence of the infection is increasing. Transmission occurs through the bite of blood-sucking insects known as reduviid bugs, in contrast to African trypanosomiasis (sleeping sickness), which is transmitted to humans by tsetse flies. The acute infection is self-limited and is characterized by a mild febrile illness often associated with lymphadenopathy. Years or even decades later an estimated 10 to 30% of

infected patients will be afflicted with symptomatic Chagas' disease. The heart is most commonly affected; manifestations include dilated biventricular cardiomyopathy, conduction disturbances, arrhythmias, and the development of mural thrombi complicated by thromboembolic phenomena. Dilatation of the esophagus or colon can also be seen. The diagnosis is made by serology; active parasitic forms cannot be found in the peripheral blood. Treatment is supportive. Glucocorticoids or the immunosuppression required for heart transplantation is contraindicated because of the possibility of reactivation and subsequent development of acute Chagas' disease. Prophylactic treatment with antitrypanosomal drugs such as benznidazole and nifurtimox is not effective enough to provide protection against acute infections.

- VI-36. The answer is B.** (*Chap. 157*) *Shigella* infections may produce a limited clinical illness characterized only by minor watery diarrhea but may also manifest as severe dysentery with fever and bloody diarrhea. Various *Shigella* species are associated with different clinical patterns of disease. *S. flexneri* may be the cause of watery diarrhea or dysentery due to anal-oral sexual practices among gay men. Individuals infected with HIV are much more likely to be infected with *S. flexneri*. Studies have shown that normal volunteers who ingest *S. flexneri* (10^4 organisms) are likely to become ill with fever only (25%); fever and self-limiting watery diarrhea (25%); fever, watery diarrhea progressing to dysentery, including bloody diarrhea (25%); with the other 25% remaining clinically well. Extracolonic manifestations of *Shigella* infection include hemolytic uremic syndrome, possibly progressing to dialysis, but generally only with the *S. dysenteriae* type I infection. Seizures and reactive arthritis have been seen in association with *S. flexneri* strains. While it is sometimes difficult to culture, a positive culture for *Shigella* is more common in the setting of fecal leukocytes or bloody diarrhea. Treatment is generally supportive. However, the use of antibiotics in severe cases may reduce the duration of illness and decrease the likelihood of carriage. Ampicillin is effective; amoxicillin is not. In developing countries, strains resistant to multiple antibiotics are common. The best approach is prevention of *Shigella* transmission by appropriate environmental and personal hygiene measures.
- VI-37. The answer is A.** (*Chaps. 139, 372*) Probably because of its ubiquity and ability to stick to foreign surfaces, *S. epidermidis* is the most common cause of infections of central nervous system shunts as well as an important cause of infections on artificial heart valves and orthopedic prostheses. *Corynebacterium* spp. (diphtheroids), just like *S. epidermidis*, colonize the skin. When these organisms are isolated from cultures of shunts, it is often difficult to be sure if they are the cause of disease or simply contaminants. Leukocytosis in cerebrospinal fluid, consistent isolation of the same organism, and the character of a patient's symptoms are all helpful in deciding whether treatment for infection is indicated.
- VI-38. The answer is D.** (*Chap. 159*) Cholera is a severe diarrheal disease caused by gastrointestinal tract infection with *V. cholerae*. Diseases caused by members of the genus vibrio include gastroenteritis, wound infections, cellulitis, and otitis due to organisms such as *V. parahaemolyticus*, *V. vulnificus*, and *V. alginolyticus*. However, the organism *V. cholerae* has lipopolysaccharide O1 antigens on its surface and is associated with the classic illness characterized by profound watery diarrhea and electrolyte imbalance. Treatment, if given in time, can be highly effective and consists of either oral or intravenous rehydration with a sugar/electrolyte solution. Cholera is a toxin-mediated disease in which the toxin binds to the G_{M1} ganglioside glycolipid on the surface of jejunal epithelial cells. An activated subunit of cholera toxin is then transferred intracellularly, which upregulates the catalytic subunit of intestinal epithelial adenylate cyclase enzyme. The resultant accumulation of high levels of cyclic AMP activates the secretory chloride transport system, thereby leading to the accumulation of excessive amounts of sodium chloride, and thus water, into the intestinal lumen. Cholera is therefore toxigenic but not enteropathogenic. The most important measures to prevent cholera infection revolve around improving sanitary facilities for patients and aseptic food preparation. Traditional killed cholera vaccine is ineffective;

there are two types of vaccine under development, but development has not yet proceeded to the point where the epidemiology of the disease has been affected.

- VI-39. The answer is C.** (*Chap. 160*) Brucellosis is a disease transmitted to humans from infected animals and is caused by one of four species: *Brucella melitensis* (goats, sheep, and camels), *B. abortus* (cattle), *B. suis* (hogs), and *B. canis* (dogs). *Brucellae* can survive for many weeks unless the animal product (particularly milk) has been boiled or pasteurized. The organism is most commonly transmitted through the ingestion of untreated milk or milk products and raw meat. Contact with animals, especially at the slaughterhouse, is a risk for infection. Brucellosis is a systemic disease with many clinical manifestations including fever, chills, headache, myalgia, fatigue, anorexia, and bone pain. Arthritis, osteomyelitis, myocarditis, endocarditis, and pericarditis have all been described as a consequence of *Brucella* infection.
- VI-40. The answer is C.** (*Chap. 155*) *Pseudomonas* organisms can cause a rapidly invasive infection of the external ear that results in extensive bony erosion in diabetics. Aggressive surgical debridement and parenteral administration of antibiotics are required. *Aspergillus* organisms can be isolated frequently from external ear swabs but do not cause invasive disease. Mucormycosis must be considered in any seriously ill diabetic patient with sinus or ocular involvement. Infection usually spreads from the nasal cavity and does not involve the ears. Insulin-dependent diabetics are likely to have their skin colonized by *S. aureus*, but this is not associated with external otitis. *H. influenzae* is a frequent cause of otitis media, especially in children, but not of otitis externa.
- VI-41. The answer is E.** (*Chap. 156. Cherubin, Rev Infect Dis 13:343–344, 1991.*) *Salmonella typhi* survives well in food and water and generally causes infection by penetrating the intestinal mucosa and entering the bloodstream. Usually at the time when affected persons present with fever and other signs of an acute illness, the white blood cell count is depressed. In contrast, rose spots usually do not occur until the second week of illness. Therapy with chloramphenicol does not prevent relapses but does alter the course of the acute illness. A chronic carrier state can develop, in large part because of the propensity of *S. typhi* to seed and inhabit the gallbladder, especially in adults with gallstones. The fluoroquinolones are becoming the treatment of choice to eradicate the chronic carrier state.
- VI-42. The answer is B.** (*Chap. 122*) Passive immunization can be used to provide temporary immunity in a person who is exposed to an infectious disease and has not been previously actively immunized. Standard human immune serum globulin does not contain known antibody content for a specific agent, unlike special immune serum globulins that exist for the treatment of susceptible patients exposed to hepatitis B, varicella (which is indicated for postexposure prophylaxis of susceptible immunocompromised persons, susceptible pregnant women, and exposed newborn infants), rabies, tetanus, and CMV (used in bone marrow and kidney transplant recipients). Intramuscular immune globulin can be used for hepatitis A pre- and postexposure prophylaxis as well as hepatitis C postexposure prophylaxis; it is of questionable efficacy in postexposure prophylaxis for hepatitis B and rubella but may play a role in postexposure prophylaxis for immunocompromised persons exposed to measles.
- VI-43. The answer is D.** (*Chap. 164*) This patient is suffering from donovanosis, a chronic progressively destructive bacterial infection of the genital region that was formerly known as *granuloma inguinale* or *granuloma venereum*. This disease is caused by gram-negative pleomorphic encapsulated intracellular bacterium called *C. granulomatis*. Although there may be some patients who develop this disease on the basis of nonintimate contact, it is most likely that this is a sexually transmitted disease. The incubation is usually 1 to 4 weeks but may be longer. Most patients have disease limited to the genital area; extragen-

ital lesions occur in about 6% and may include oral lesions and bleeding and/or bone disease. Diagnosis involves demonstration of intracellular Donovan bodies within the mononuclear cells obtained from a lesion. Syphilitic plaques are usually white rather than the red lesions characteristic of donovanosis. Donovanosis lesions can be so necrotic that squamous cell carcinoma may be considered.

- VI-44. The answer is A.** (*Chap. 152*) Because a marked lymphocytosis characteristically is observed in children (less commonly in older persons) who have *Bordetella pertussis* infection (whooping cough) and is rare in patients with other respiratory illnesses, a white blood cell count with differential would be useful in making the diagnosis. Blood cultures would be negative, and Gram stain of the sputum and chest and neck x-rays would show nonspecific changes unless a lobar pneumonia superinfection had occurred. The diagnosis of pertussis is confirmed in most cases by nasopharyngeal culture, though ELISA and DNA-based detection methods are alternative diagnostic procedures. Supportive care and the administration of erythromycin are the mainstays.
- VI-45. The answer is E.** (*Chap. 202. Schneider et al; JAMA 277:904–908; 1997.*) Coccidioidomycosis, caused by the inhalation of *Coccidioides immitis*, may present clinically with manifestations of hypersensitivity reactions. Arthralgias and frank arthritis (so-called desert rheumatism) as well as skin reactions such as erythema nodosum and erythema multiforme are associated far more frequently with coccidioidomycosis than with the other mycoses listed in the question. Delayed hypersensitivity to *C. immitis* antigens tends to be a good prognostic sign.
- VI-46. The answer is D.** (*Chap. 137*) Imipenem is a novel β -lactam antibiotic in the carbapenem class with activity against most gram-positive organisms, including those which produce β -lactamase. Imipenem's antibacterial spectrum is quite broad and extends to all pathogens except xanthomonas, resistant *Pseudomonas* spp., methicillin-resistant staphylococci, and *E. faecium*. This drug must be given intravenously because of its instability in gastric acid. Since imipenem is hydrolyzed in the renal tubule by dihydropeptidase I, the coadministration of cilastatin, an inhibitor of this enzyme, serves to markedly boost levels of this broad-spectrum antibiotic. Clavulanate is a β -lactamase inhibitor used with partial success when combined with amoxicillin (Augmentin) for the treatment of resistant otitis and urinary tract infections.
- VI-47. The answer is C.** (*Chap. 165*) This patient is chronically immunosuppressed from his antirejection prophylactic regimen, which includes both glucocorticoids and azathioprine. However, the finding of a cavitory lesion on chest x-ray considerably narrows the possibilities and increases the likelihood of nocardial infection. The other clinical findings, including production of profuse thick sputum, fever, and constitutional symptoms, are also quite common in patients who have pulmonary nocardiosis. The Gram stain, which demonstrates filamentous branching gram-positive organisms, is characteristic. Most species of *Nocardia* are acid-fast if a weak acid is used for decolorization (e.g., modified Kinyoun method). These organisms can also be visualized by silver staining. They grow slowly in culture, and the laboratory must be alerted to the possibility of their presence on submitted specimens. Once the diagnosis, which may require an invasive approach, is made, sulfonamides are the drugs of choice. Sulfadiazine or sulfisoxazole from 6 to 8 g/d in four divided doses is generally administered, but doses up to 12 g/d have been given. The combination of sulfamethoxazole and trimethoprim has also been used, as have the oral alternatives minocycline and ampicillin and intravenous amikacin. There is little experience with the newer β -lactam antibiotics, including the third-generation cephalosporins and imipenem. Erythromycin alone is not effective, though it has been given successfully along with ampicillin. In addition to appropriate antibiotic therapy, the possibility of disseminated nocardiosis must be considered; sites include brain, skin, kidneys, bone, and muscle.
- VI-48. The answer is A.** (*Chap. 158*) Campylobacters are motile, curved gram-negative rods. The principal diarrheal pathogen is *C. jejuni*. This organism is found within the gastro-

intestinal tract of many animals used for food production and is usually transmitted to humans in raw or undercooked food products or through direct contact with infected animals. Over half the cases are due to insufficiently cooked contaminated poultry. *Campylobacter* is a common cause of diarrheal disease in the United States. The illness usually occurs within 2 to 4 days after exposure to the organism in food or water. Biopsy of an affected patient's jejunum, ileum, or colon reveals findings indistinguishable from those of Crohn's disease and ulcerative colitis. While the diarrheal illness is usually self-limited, it may be associated with constitutional symptoms, lasts more than 1 week, and recurs in 5 to 10% of untreated patients. Complications include pancreatitis, cystitis, arthritis, meningitis, and Guillain-Barré syndrome. The symptoms of *Campylobacter* enteritis are similar to those resulting from infection with *Salmonella*, *Shigella*, and *Yersinia*; all these agents cause fever and the presence of fecal leukocytes. The diagnosis is made by isolating *Campylobacter* from the stool, which requires selective media. *E. coli* (enterotoxogenic) is not generally associated with the finding of fecal leukocytes, nor is the Norwalk agent. *Campylobacter* is a far more common cause of a recurrent relapsing diarrheal illness that could be pathologically confused with inflammatory bowel disease than are *Yersinia*, *Salmonella*, *Shigella*, and enteropathogenic *E. coli*.

- VI-49. The answer is B.** (*Chap. 167*) This patient is suffering from so-called Ludwig's angina, an anaerobic bacterial process that typically arises from an infection of the third molar. The infection can produce submandibular cellulitis with marked local swelling of the tongue, pain, inability to open the mouth, and posterior displacement of the tongue. Occasionally tracheotomy may be required as a life-saving procedure; in most cases antibiotic therapy will resolve the infection adequately. The best approach for anaerobic infections is to keep in mind that most represent a combination of infection with both anaerobes and other bacteria, including those considered to be aerobic. β -Lactamase is common amongst anaerobic bacteria that cause infections above the diaphragm. Therefore, penicillin is no longer an appropriate therapy. Clindamycin or a combination of penicillin and metronidazole, which has an excellent antianaerobic spectrum, is indicated. Chloramphenicol is appropriate at this time only for anaerobic infections of the central nervous system.
- VI-50. The answer is D.** (*Chap. 208*) Patients who have localized sporotrichosis can be treated successfully with potassium iodide. However, systemic infections, particularly pneumonia in immunocompromised persons, should be treated with amphotericin B. Untreated persons can develop chronic sporotrichosis. Itraconazole may also be effective in treating this condition.
- VI-51. The answer is E.** (*Chap. 132*) The cause of mucopurulent cervicitis, a yellow discharge characterized by the presence of numerous polymorphonuclear leukocytes, is idiopathic at least half the time. However, in clinical situations when the prior probability of a sexually transmitted disease (e.g., chlamydia or gonorrhea) is high and the likelihood of follow-up is low, guidelines call for the administration of a single-dose regimen that represents empirical therapy against both organisms. Even though gram-negative diplococci were not seen on the Gram's stain, this test is less than 50% sensitive for *N. gonorrhoeae*. Cervical ectopy, the protrusion of columnar epithelium onto the visible cervix, may produce a cloudy but not mucopurulent discharge.
- VI-52. The answer is A.** (*Chap. 147*) One of the most common causes of infectious arthritis in young adults, particularly in urban medical centers, is gonococcal infection. Entry occurs via sites of sexual contact: the genitourinary tract, oropharynx, or rectum. Infection at one of these sites, particularly in menstruating females, pregnant women, and those with complement deficiencies, may lead to dissemination. Such an occurrence produces a biphasic illness that is first manifested by constitutional symptoms, migratory arthritis (particularly in the knee, shoulder, wrists, and interphalangeal joints of the hand), tenosynovitis, and vesiculopustular skin lesions. While these symptoms may abate, joint involvement may

progress to a purulent mono- or polyarticular arthritis. Synovial culture and Gram stain are usually negative early in the course of the illness but may be positive at later stages. Blood cultures may be positive, but only in the early stage of the illness. Complement deficiencies are present only in patients who have congenital hypocomplementemia. Gonococci are demonstrable by Gram stain in the skin lesions in about two-thirds of cases. However, diagnosis is best made by observing the intracellular gram-negative diplococci in leukocytes from Gram-stained smears of urethral or endocervical exudates. Because of the presence of other gram-negative diplococci in normal oral flora, Gram stains of pharyngeal smears are not specific. Selective media, such as Thayer-Martin, should be used to culture gonococcus from the urethra, endocervix, pharynx, or rectum. The endocervical culture is positive in 80 to 90% of women with gonorrhea. Treatment for disseminated gonococcal infection includes hospitalization and the administration of ceftriaxone, ceftizoxime, or cefotaxime. If the patient is proved to have gonorrhea, a serologic test for syphilis and confidential testing for HIV infection should also be undertaken.

- VI-53. The answer is B.** (*Chap. 161*) Aspiration and culture of an enlarged axillary lymph node would be most helpful in yielding a diagnosis of tularemia in the case described in the question; however, culture is positive in only 10% of cases. Agglutinin reactions ordinarily are not positive for a least 1 week after infection but are specific. A wide variety of animals and insects can transmit tularemia to humans.
- VI-54. The answer is D.** (*Chap. 162*) In the case presented, the diagnosis of plague (*Yersinia pestis* infection) must be considered. To make this diagnosis, affected lymph nodes should be aspirated and the contents should be Gram-stained. In most cases of bubonic plague, lymph-node aspirates teem with pleomorphic gram-negative bacilli, which can be definitively identified by immunofluorescent staining of the specimen. Blood culture, bone marrow examination, and lymph-node biopsy may be used to diagnose plague, but with unacceptable delay. In this situation, great care should be exercised in handling the infected materials, as there is a significant risk of infection for the laboratory workers.
- VI-55. The answer is C.** (*Chap. 176. Spach, N Engl J Med 329:936–947, 1993.*) Ninety percent of cases of Lyme disease (Lyme borreliosis) have occurred in the northeastern coastal states. The principal vectors for the causative agent of this disease, *B. burgdorferi*, are *Ixodes* ticks. Less than half of patients with Lyme disease recall receiving a tick bite. Most infections occur during the months of May to August, when human outdoor activities are maximal, and coincide with the time when nymphal *Ixodes* ticks are most active. Like syphilis, another spirochete-mediated disease, the affliction occurs in stages. The initial localized stage is frequently characterized by a macular dermatitis, erythema migrans, which develops at the site of the tick bite. The incubation period is 7 to 10 days and is frequently accompanied by constitutional symptoms. Erythema migrans is typically oval, well demarcated, and >5 cm in diameter. Within a few days to weeks after the initial infection, dissemination occurs. The most frequent neurologic manifestation of early disseminated Lyme disease is cranial neuritis, especially facial palsy. Peripheral neuropathy or lymphocytic meningitis may also occur. Nonneurologic manifestations of Lyme disease include atrioventricular block, myopericarditis, and chronic arthritis. The diagnosis is generally made on clinical grounds; however, the most specific diagnostic test for Lyme disease is isolation of the causative organism from blood or erythematous lesions; culture from the CSF is very difficult. An ELISA-based antibody test is frequently plagued by false-positive and false-negative results. Detection of the presence of the organism by a DNA-based method (PCR) remains experimental.
- VI-56. The answer is B.** (*Chap. 309*) In 1993 the CDC revision of the AIDS classification system partitioned HIV-infected adolescents and adults on the basis of clinical conditions associated with HIV infection as well as CD4+ T lymphocyte counts. There are three gradations of CD4 counts and three clinical categories, leading to a matrix of nine mutually exclusive categories. The HIV-infected individual with a T cell count <200/ μ L, even if

asymptomatic, is automatically defined as having AIDS. On the other hand, the presence of any of the following clinical conditions is also an AIDS-defining condition, regardless of the CD4 count: candidiasis of bronchi, esophagus, trachea, or lungs; invasive cervical cancer; coccidioidomycosis (disseminated or extrapulmonary); extrapulmonary cryptococcosis; cryptosporidiosis; cytomegalovirus infection (other than in liver, spleen, or lymph nodes); encephalopathy; chronic herpes simplex or herpes simplex bronchitis, pneumonia, or esophagitis; disseminated histoplasmosis; isosporiasis; Kaposi's sarcoma; Burkitt's lymphoma; CNS lymphoma; infection with *Mycobacterium avium* complex or *M. tuberculosis*; recurrent pneumonia; progressive multifocal leukoencephalopathy; recurrent salmonella septicemia; CNS toxoplasmosis; or wasting syndrome. There are a number of HIV-associated conditions that do not meet the case definition for AIDS; patients with such conditions are said to have AIDS only if they have a CD4 T cell count of $<200/\mu\text{L}$. Such symptomatic conditions include bacillary angiomatosis, thrush, vulvovaginal candidiasis, cervical dysplasia, constitutional symptoms including fever and diarrhea, hairy leukoplakia, herpes zoster, idiopathic thrombocytopenic purpura, listeriosis, pelvic inflammatory disease, and peripheral neuropathy. Although it is useful to have a comprehensive understanding of the various conditions that can be defining of or associated with HIV infection, given the advances in antiretroviral therapy, as well as the knowledge that early therapy is quite beneficial, it is more important to recognize HIV infection than it is to understand who is considered who to have AIDS.

- VI-57. The answer is D.** (Chap. 142) *L. monocytogenes* is a gram-positive motile bacillus that tends to infect infants as well as persons over age 55. Major illnesses in both groups are meningitis and other forms of central nervous system infection. Many of the older patients are immunosuppressed because of disease (e.g., cancer), immunosuppressive drug therapy, or both. Endocarditis, peritonitis, hepatitis, and conjunctivitis can also be caused by *Listeria* infection.
- VI-58. The answer is D.** (Chap. 220) Infection with intestinal nematodes is extraordinarily common worldwide, particularly in tropical developing countries. Usually, large worm burdens are required to elicit clinical manifestations of disease. However, in the case of *A. lumbricoides*, single worms (reaching up to 40 cm in length) can cause biliary obstruction or cholecystitis. *Ascaris* is transmitted by the hand-to-mouth fecal carriage route, with subsequent larval development followed by hematogenous migration to the lungs [possibly resulting in eosinophilic pneumonitis (Loeffler's syndrome)]. By contrast, hookworm larvae are hatched in the soil, where, after a 1-week development period, the infectious filariform larvae penetrate the skin and reach the lungs by way of the bloodstream. They are then swallowed and may reach the small intestine, where they produce epigastric pain, diarrhea, and iron deficiency if the worm burden is high enough. Unlike other nematodes, *Strongyloides* replicates in humans, and this permits many cycles of autoinfection with intestinal production of larvae. These infections can persist for decades. As is the case for hookworms, *Strongyloides* larvae hatch in the soil, penetrate the skin or mucous membranes, and ultimately reach the small intestine. Migrating larvae may elicit a pathognomonic serpiginous eruption, which can cause intense pruritus and may be recurrent over a period of many years. Nausea, diarrhea, bleeding, colitis, and weight loss may also be seen with high-burden *Strongyloides* infection. Many American schoolchildren are infected with pinworm (*Enterobius vermicularis*). Eggs are released only in the perianal region and may be transmitted by hand to mouth to complete the life cycle. Perianal pruritus is the most typical clinical symptom. The diagnosis may be made by applying clear cellulose tape to the perianal region in the morning and transferring the tape to a microscopic slide where the characteristic pinworm eggs may be demonstrated.
- VI-59. The answer is C.** (Chaps. 212, 214) Most antimalarial drugs—including quinine, 4-aminoquinolines (e.g., chloroquine, hydroxychloroquine), and 4-quinoline-methanols (e.g., mefloquine)—concentrate in erythrocytes and thus destroy the intracellular schizonts responsible for the acute manifestations of malarial illness. However, these drugs do not

readily concentrate in the liver and therefore allow survival of hepatic schizonts and re-infection at a later date. In contrast, primaquine, an 8-aminoquinoline, can eradicate hepatic parasites but is not effective in acute illness.

- VI-60. The answer is D.** (*Chap. 131*) Bacteria that cause diarrhea via elaboration of toxins are generally associated with a shorter time from ingestion to illness than are invasive strains. For example, enterotoxigenic *E. coli* (the most common cause of traveler's diarrhea), *C. perfringens* (associated with poorly cooked meat or poultry), *S. aureus* (associated with improperly refrigerated dairy foods), and *B. cereus* (associated with grossly contaminated uncooked rice) all have incubation periods of 24 h or less. Even though the pathogenesis may depend on direct mucosal damage, *V. parahaemolyticus*, which is present in inadequately cooked seafood, can cause a diarrheal illness within 6 to 48 h after consumption of a contaminated food. Ingestion of water contaminated with the intestinal flora of wild or domestic animals may cause infection with *C. jejuni*, a common cause of acute, sometimes bloody diarrhea. The incubation period for this invasive bacterium is 2 to 6 days, longer than that associated with other pathogens. Therapy is usually supportive, though erythromycin will shorten the duration of illness.
- VI-61. The answer is A.** (*Chap. 201. Wheats, Am J Med 98:336–342, 1995.*) The patient in question is presumably an HIV-infected man with acute disseminated histoplasmosis, often mistaken for miliary tuberculosis because of its similar pattern of constitutional findings and diffuse chest x-ray abnormalities. Indurated ulcers of the mouth, tongue, nose, or larynx also occur in about 25% of patients with acute disseminated histoplasmosis. Addison's disease, granulomatous hepatitis, gastrointestinal ulcerations, endocarditis, and chronic meningitis may also be seen. Since patients with HIV infection may present with febrile syndromes on the basis of multiple organisms and since serologic tests for histoplasmosis are plagued by frequent false-negative and false-positive results, a definitive diagnosis requires demonstration of the organism by culture or histology. The classic morphology of hyphae that bear large and small spores in this clinical setting is diagnostic. Treatment requires initial administration of amphotericin B, followed by prolonged administration of itraconazole.
- VI-62. The answer is D.** (*Chap. 185*) CMV, a double-stranded herpes virus, is transmitted by intimate contact. Once infected, a patient carries the virus for life with actual disease occurring only in the setting of immunosuppression. However, congenital CMV infections may result in significant psychomotor, hearing, ocular, or developmental abnormalities. Second, the most common clinical manifestation of CMV infection, CMV mononucleosis, occurs in normal hosts and resembles the mononucleosis syndrome caused by Epstein-Barr virus, although pharyngitis and lymphadenopathy are much less common with CMV infection. The bone marrow transplant recipient described in the question is clearly at increased risk for CMV-associated syndromes, which may include fever and leukopenia, hepatitis, pneumonitis, esophagitis, gastritis, colitis, and retinitis. Risk factors for infection in transplant patients include the presence of graft-versus-host disease, older age, and known CMV seropositivity in the recipient. Pneumonitis is often manifested by tachypnea, hypoxia, and nonproductive cough. Chest x-ray may reveal bilateral interstitial or reticulonodular infiltrates, particularly beginning in the lower lobes. Since the number of organisms that cause such diffuse pulmonary changes in the posttransplant setting is large, it is important to determine the specific diagnosis. Virus isolation from the specimen obtained at bronchoscopy would be the ideal way to make the diagnosis, but cultures may be falsely negative and results may take several days to return. Cytomegalic cells, demonstrated at open-lung biopsy, are the pathologic hallmark of CMV infection. Cytomegalic cells are characterized by large size and the presence of an 8- to 10- μm intranuclear inclusion that is centrally placed and sometimes surrounded by a clear halo ("owl's eye" appearance). Cytoplasmic inclusions may also be found. The use of blood from seronegative donors, deglycerolized packed red blood cells, and leukoreduced transfusions may all reduce the risk of transfusion-associated CMV in the posttransplant period. Other prophylactic mea-

tures include the use of acyclovir (in high doses) and the use of immunoglobulin. The best results for an active infection have been obtained with the use of ganciclovir, a drug similar in structure to acyclovir, but with more activity against CMV than the parent compound. While ganciclovir alone has been most effective for the treatment of CMV retinitis or colitis, in bone marrow transplant patients who develop CMV pneumonia, ganciclovir is more effective when combined with CMV immunoglobulin. Prolonged therapy may be required. Foscarnet inhibits viral DNA polymerase and may be effective in ganciclovir-resistant CMV infections. Foscarnet is considerably more toxic than is ganciclovir; side effects include renal failure, electrolyte wasting, seizures, and fever.

- VI-63. The answer is A.** (*Chap. 169*) The diagnosis of a tuberculous pleural effusion is suggested by the following set of pleural-fluid findings: color, clear yellow; pH, <7.20; protein, > 30 g/L; glucose, < 1.2 mmol/L (25 mg/dL); lactate dehydrogenase (LDH), >450 U/mL; and a lymphocytosis. Tubercle bacilli rarely are identified on a smear of infected pleural fluid, and cultures are positive in no more than one-quarter of cases. Antituberculous treatment should begin as soon as the diagnosis is suspected.
- VI-64. The answer is A.** (*Chap. 171*) Two of the lesser-known species of *Mycobacterium*, *M. scrofulaceum* and *M. avium-intracellulare*, cause lymphadenitis in children. Lymph nodes that drain the buccal mucosa are usually affected. Both *M. scrofulaceum* and *M. avium-intracellulare* respond poorly to chemotherapy. The treatment of choice, therefore, is prompt lymph-node excision before rupture has occurred.
- VI-65. The answer is C.** (*Chap. 137. Hooper, N Engl J Med 324:384–394, 1991.*) The fluoroquinolones are an important class of antimicrobial agents with excellent bioavailability. They are renally excreted, and their concentrations increase in chronic renal failure, but generally not to toxic levels. Adverse effects are rare; gastrointestinal symptoms, headache, sleep disturbances, and allergic reactions occur in <4% of these patients. Theophylline clearance is inhibited by these agents, and care must be taken if coadministration is necessary. Their mechanism of action is novel: they appear to inhibit bacterial topoisomerase II (also known as DNA gyrase), an enzyme involved in the uncoiling of DNA. Their spectrum of activity includes most Enterobacteriaceae, *H. influenzae*, *Neisseria* spp., *P. aeruginosa*, and *S. aureus* (including the penicillin-resistant variety). In addition, activity against *Chlamydia*, *Mycoplasma*, and *Legionella* spp. has been demonstrated. They are bactericidal and play a wide range of potential roles, but they may be preferred in complicated urinary tract infections (because of their excellent concentration in the urine with activity against many otherwise difficult to treat species), chronic *Salmonella* carriage, exacerbation of cystic fibrosis (because of excellent activity against *P. aeruginosa*), gram-negative osteomyelitis, and malignant otitis externa. Finally, fluoroquinolone antibiotics may be the treatment of choice for patients with bacterial gastroenteritis who are ill enough to require treatment. These agents are effective against enterotoxigenic *E. coli*, which often causes traveler's diarrhea, as well as *Shigella*. Unfortunately, resistant *Staphylococci* and *Pseudomonas* spp. have been noted.
- VI-66. The answer is D.** (*Chap. 171*) *M. marinum* is known as the “swimming pool” or “fishtank” bacillus because ulcerative cutaneous infections can be acquired from contact with contaminated swimming pools and aquariums. *M. ulcerans* also causes ulcerative skin lesions but characteristically is confined to tropical regions. Other “atypical” mycobacteria that cause cutaneous infections in humans include *M. avium-intracellulare*, *M. scrofulaceum*, *M. kansasii*, and *M. fortuitum*.
- VI-67. The answer is C.** (*Chap. 172. Hook, N Engl J Med 326:1060–1069, 1992.*) Syphilis, like other diseases associated with genital ulcers, is more common in HIV-infected patients, probably because of the increased efficiency of HIV inoculation via the ulcer itself. It is unclear, however, whether syphilis in patients coinfecting with HIV actually follows an accelerated clinical course. Though the serologic analysis of syphilis in patients with HIV

infection is altered, accurate information is still provided for most patients with HIV infection. Significantly higher serum antitreponemal titers have been reported in patients with HIV compared with those not infected with the virus. Patients with documented secondary syphilis may fail to exhibit positive serology. False-positive serologic studies are also possible in HIV-infected patients who may exhibit polyclonal B cell activation early in the course of their infection. It has been shown consistently that single-dose penicillin therapy for early syphilis is more prone to failure in HIV-infected patients than in those who are not infected with the virus. It is particularly troubling that the central nervous system may be a sanctuary from penicillin.

- VI-68. The answer is D.** (*Chap. 309. Cardo et al, N Engl J Med 337:1485–1490, 1997.*) The risk of HIV infection in a health care worker exposed to the blood of an HIV-infected patient by a needle stick exposure is small but real. The risk, approximately 3 in 1000 such exposures, could be decreased further if workers could adhere to the standard guidelines for dealing with sharp objects. Risk of transmission of hepatitis B from patient to worker in a similar situation is much higher; there are cases of health care workers exposed to the blood of patients infected with both HIV and hepatitis B who contracted only hepatitis B. However, in the face of a known parenteral exposure to HIV, postexposure prophylaxis is recommended (a combination of two nucleoside analogue reverse transcriptase inhibitors given for 4 weeks or a combination of two nucleoside analogue reverse transcriptase inhibitors plus a protease inhibitor given for 4 weeks). Most clinicians choose the second regimen.
- VI-69. The answer is D.** (*Chap. 200*) Successful treatment of antifungal infections is not as straightforward as that for bacterial infections. The topical imidazoles that are available for the treatment of vaginal candidiasis include miconazole, clotrimazole, and butoconazole; the triazole terconazole is also available. No substantial difference in efficacy or toxicity among these agents has been noted. Ketoconazole therapy is useful in the treatment of several fungal infections, including esophageal candidiasis, but is associated with several dose-related toxicities, including anorexia and inhibition of steroidogenesis in the adrenal cortex or gonads; hepatotoxicity is idiosyncratic. Fluconazole is an orally administered triazole that may have activity in candidal infection and is useful in a prophylactic role in allogeneic bone marrow transplant patients. Amphotericin B itself is a difficult drug to administer because of frequent toxicities, including azotemia, anemia, hypokalemia, nausea, anorexia, weight loss, phlebitis, and hypomagnesemia. Nonetheless, amphotericin B is indicated for the treatment of invasive infections such as candidal hepatitis. Given a daily dose of about 0.5 mg/kg and the requirement that at least 2 g of the drug should be given in this situation, prolonged therapy is required. Flucytosine, a synthetic oral drug converted to the antimetabolite 5-FU in the fungal cell, may aid in the treatment of refractory invasive candidal disease that is not responsive to amphotericin B alone. Flucytosine is not substituted for, but instead is added to, amphotericin B. Patients on flucytosine should be monitored carefully, since this drug may be myelosuppressive.
- VI-70. The answer is A.** (*Chap. 213. Petri, Singh, Clin Infect Dis 29:1117–1125, 1999.*) AIDS patients, particularly homosexual men, have a significant incidence of infection with *Entamoeba* spp., though they are frequently asymptomatic. The most common amebic-related syndrome is that of colitis. Extraintestinal infection by the organism *E. histolytica* usually involves the liver. While the symptoms (fever, pain in the right upper quadrant, and pleural effusion) and the radiologic findings (hypoechoic hepatic cysts) are nonspecific and can also be seen in bacterial abscesses and cancer, such symptoms in a patient with positive serology are quite helpful in making the diagnosis of invasive amebiasis. For that reason, no further diagnostic studies are indicated in the patient. Except in patients with threatened imminent rupture of the cyst or failure to respond to medical therapy, drainage or aggressive aspiration is not necessary. The drug of choice is metronidazole, though the less effective agent chloroquine also may be considered.

- VI-71. The answer is D.** (*Chap. 189*) While the clinical syndromes induced by viruses that cause upper respiratory illness are not sufficiently distinct to delineate which virus is the cause of a given clinical syndrome, knowledge of the epidemiologic setting does aid in diagnosis. Rhinoviruses are a common cause of the common cold. They are spread by direct contact with infected secretions and are transmitted efficiently by hand-to-hand contact. Rhinoviral infections are generally uncomplicated; the incubation period is about 2 days. RSV infections are a major cause of lower respiratory disease in infants, but the virus may also infect older children and adults. Reinfection with this agent is common. Though most patients recover in a week or two, occasionally more severe illness may develop and require admission to an intensive care unit. The diagnosis of RSV infection can be made by culturing the agent from nasal swabs or respiratory secretions or by demonstrating the preserved anti-RSV antibodies. While therapy for RSV infection is mainly symptomatic, aerosolized ribavirin will speed resolution in affected infants. Adenoviruses are also a common cause of upper respiratory infection in infants, children, and adults, especially in military personnel. There is no active therapy available for this infection; however, live viral vaccines, which have been administered to military recruits, may be useful.
- VI-72. The answer is A.** (*Chap. 166*) In the examination of purulent material from persons suspected of having actinomycosis, it is important to search the material for the characteristic “sulfur grains” and then examine the grains for organisms. Actinomycetes are gram-positive, branching organisms. If they are detected in a patient who presents with a suggestive clinical picture, such as a chronic draining sinus in the oropharyngeal area, gastrointestinal tract, or pelvic area, the diagnosis of actinomycosis is confirmed. A prolonged treatment course with intravenous penicillin is indicated.
- VI-73. The answer is E.** (*Chaps. 168, 171. Shafran et al, N Engl J Med 335:377–383; 1996.*) MAI infections are often considered to be rapidly fatal in patients with AIDS. The macrolide antibiotic clarithromycin (6-*O*-methylerythromycin) appears to be the best available drug for disseminated MAI infections in those with AIDS. It is similar to erythromycin in its mechanism of action but does not cause the gastrointestinal distress seen after exposure to the parent compound. Because the MAI organism may acquire resistance to clarithromycin, it should be combined with other antimycobacterial agents, such as ethambutol or rifabutin, or both. The standard dose of clarithromycin is 500 mg twice daily. Standard triple-drug therapy with isoniazid, rifampin, and ethambutol may be useful in the treatment of MAI lung disease in HIV-negative patients.
- VI-74. The answer is C.** (*Chap. 204*) The initial diagnosis of cryptococcal meningitis usually is based on finding encapsulated yeast on an India ink preparation. This test, however, is positive in only about half the cases in which the diagnosis is eventually made. Testing of serum and CSF for cryptococcal antigen is a very helpful adjunctive test because antigen is found in about 90% of cases. In pulmonary cryptococcosis, only about one-third of affected persons are antigen-positive.
- VI-75. The answer is D.** (*Chap. 198*) Lymphocytic choriomeningitis (LCM) virus is an RNA virus associated both with an influenza-like illness manifested by rash, arthritis, or orchitis and with aseptic meningitis. These two syndromes may occur simultaneously or consecutively. Mice and other rodents are the major natural hosts for LCM infection. Human infections generally are due to residence in a rodent-infested house, but laboratory animals and pets may also be vectors. The mode of entry is the respiratory tract with subsequent penetration of the blood-brain barrier. An influenza-like illness may resolve but be followed by arthralgias (particularly in the hands), hair loss, testicular pain or orchitis, bradycardia, pharyngeal injection, and occasionally axillary adenopathy. Most patients recover within 1 to 4 weeks, though those who develop encephalitis have a significant risk of long-term neurologic sequelae. Laboratory findings include leukopenia and thrombocytopenia

(during the first week of the illness). In those with meningeal signs, examination of the CSF reveals lymphocytosis (up to 1000 lymphocytes/ μL), as well as elevated CSF protein and a normal or low glucose, a finding unusual in nonbacterial infections. Culturing the virus from blood or the spinal fluid requires a biosafety level 3 facility; antibody detection methods are available. Since there is no specific treatment available, supportive care is the optimum approach.

- VI-76. The answer is E.** (*Chap. 205. Rex et al: Clin Infect Dis 30:662–678; 2000.*) This patient represents a classic case of hepatic candidiasis, which might be better termed *disseminated candidiasis* because in addition to hepatic involvement the disease often involves other tissues, such as the kidneys. Prolonged neutropenia with concomitant administration of broad-spectrum antibacterial antibiotics, especially during induction therapy for AML, is an important risk factor for the development of invasive candidiasis. A fever that develops around the time of neutrophil recovery, especially if it is associated with pain in the right upper quadrant or elevated alkaline phosphatase (which should be proved to be of hepatic origin), is strongly suggestive of hepatic candidiasis. The definitive diagnosis depends on documentation of yeast or pseudohyphae in a granulomatous lesion obtained from infected tissue. Empirical amphotericin B may be indicated. While CT or MRI may reveal “bull’s-eye” lesions, a tissue diagnosis is required. If the liver biopsy was nonspecific and failed to reveal organisms and the patient was persistently febrile, especially if his alkaline phosphatase value continued to rise, a more aggressive attempt at diagnosis, possibly even including an open biopsy, would be required. Prolonged administration of amphotericin B is often needed (up to 2 to 4 g) to effect an improvement in the clinical and laboratory findings.
- VI-77. The answer is A.** (*Chap. 309*) In the United States most patients with AIDS still contract HIV from anal intercourse during homosexual sex. However, in all developed countries, even in the United States, there is now greater prevalence of new cases among heterosexuals. There is no question whatsoever that the major mode of transmission of HIV worldwide is heterosexual sex. In the United States a substantial portion of infected individuals contracted HIV via sharing of contaminated needles during intravenous drug use. In developing countries the number of infected men and women is essentially equal. In Sub-Saharan African countries, including Zimbabwe and Botswana, seroprevalence data indicate that at least 25% of adults and perhaps 50% of people in high-risk settings are infected. However, since different subtypes of HIV are prevalent in different geographic regions, the development of a single vaccine that will protect patients around the world from this devastating infection will not be possible.
- VI-78. The answer is D.** (*Chap. 204*) Fungal and yeast infections, predominantly candidiasis, aspergillosis, and mucormycosis, occur frequently in severely immunosuppressed patients, particularly those who have received broad-spectrum antibiotics for a prolonged period. A number of other types of fungal infection occur in these patients. About 75% of all cases of *Cryptococcus neoformans* infection occur in persons who have AIDS or lymphoma, are taking glucocorticoids, or are otherwise immunocompromised. The association of cryptococcal meningitis and Hodgkin’s disease is important clinically.
- VI-79. The answer is D.** (*Chap. 181. Balfour Jr, N Engl J Med 340:1255–1268, 1999.*) Ribavirin is a synthetic nucleoside analogue. Its mechanism of antiviral activity is not precisely characterized. Ribavirin-5 monophosphate interferes with the synthesis of pyrimidine metabolites and also inhibits capping of virus-specific messenger RNA. Ribavirin is licensed for use as an aerosol to treat respiratory syncytial virus (RSV) infections in infants and is often given in addition to immunoglobulin therapy. Although it has some activity in influenza A and parainfluenza A, it is much less effective in these conditions. In combination with interferon, ribavirin has been approved for the treatment of patients with chronic HCV infections. Aerosolized administration may be associated with bronchospasm, rash, or conjunctival irritation; systemic administration may result in hematologic

toxicity. Because of its potential mutagenicity, health care workers must take appropriate precautions.

- VI-80. The answer is A.** (*Chaps. 126, 139*) *S. aureus* accounts for well over half of all endocarditis infections in intravenous drug users. Unfortunately, a substantial proportion of such infections are due to methicillin-resistant strains, which are now isolated frequently from skin sites of such persons. *S. aureus* frequently is found in association with right-sided lesions, particularly those on the tricuspid valve, which could be a function of its bombardment with injected particulate matter. Tricuspid valve endocarditis is associated with a high fever and frequent pulmonary involvement. There have been epidemics of *Pseudomonas* endocarditis in drug users, but such infections are much less common than are those due to staphylococci. The least pathogenic organisms, such as viridans streptococci and enterococci, are much less common and tend to infect previously damaged or diseased left-sided valves. Diagnosis involves obtaining a positive blood culture. Treatment consists of the administration of the appropriate antibiotic for 4 weeks.
- VI-81. The answer is E.** (*Chap. 179*) Fever, chills, headache, cough, and myalgias are the typical presenting signs and symptoms of psittacosis. Gastrointestinal symptoms also may occur but are much less common. The diagnosis of psittacosis usually depends on serologic tests or cultures of respiratory secretions but is often made clinically on the basis of an appropriate history and nonspecific radiographic findings. A low-titer positive complement fixation antibody test in conjunction with the clinical setting described would strongly suggest the diagnosis of psittacosis and warrant the use of tetracycline.
- VI-82. The answer is C.** (*Chap. 193*) Up to 90% of patients with poliovirus are asymptomatic or have only a self-limited febrile illness. Paralytic polio is characterized by an initial febrile illness that resolves and is followed by the development of aseptic meningitis and asymmetric paralysis. In contrast to polio, the Guillain-Barré syndrome is characterized by symmetric muscle weakness with frequent paresthesia. Motor neurons are primarily affected by poliovirus infection with the resultant loss of reflexes and flaccid paralysis. Return of neuronal function may be possible for up to 6 months after infection.
- VI-83. The answer is D.** (*Chap. 181*) Acyclovir, converted to acyclovir monophosphate and then to the triphosphate form, inhibits viral DNA polymerase with minimal effect on host cell DNA polymerase. However, acyclovir, valacyclovir, and famciclovir are effective against herpes simplex and varicella virus but not against CMV. Cidofovir, a phosphonate nucleotide analogue of cytosine, is effective in CMV retinitis as well as against other herpes viruses. This drug does not require initial phosphorylation by viral-induced kinases. An intravenous form of cidofovir is approved for the treatment of CMV retinitis in AIDS patients, as is fomivirsen, an antisense oligonucleotide that inhibits CMV replication by binding to CMV mRNA. Foscarnet is also effective against CMV and may be used in cases of ganciclovir resistance. Ganciclovir triphosphate, in contrast to acyclovir triphosphate, does inhibit CMV DNA polymerase. Foscarnet is a pyrophosphate-containing compound that inhibits CMV and other herpes viruses by interacting with DNA polymerase at the phosphate-binding site at concentrations that have relatively little effect on cellular polymerase. Foscarnet does not require phosphorylation to exert its antiviral activity (and is therefore active against isolates of herpes simplex and varicella-zoster viruses that are resistant to acyclovir on the basis of deficiencies in the viral thymidine kinase). Foscarnet is poorly soluble and must be administered via a dilute solution over 1 to 2 h. The major foscarnet-associated toxicity is renal dysfunction; hypocalcemia, hypomagnesemia, hypokalemia, and hypophosphatemia may develop. Lamivudine is a nucleoside analogue that is used in combination with other drugs for HIV infection.
- VI-84. The answer is A.** (*Chap. 172*) Lymphadenopathy and a papulosquamous rash that includes the palms and soles characteristically accompany secondary syphilis, which appears about 8 weeks after the healing of the primary chancre. Lymphadenopathy is not a

well-recognized manifestation of late syphilis. The inflammatory lesions of late syphilis are diverse and range from asymptomatic neurosyphilis, which is characterized only by pleocytosis or elevated protein on CSF examination, to the complex intellectual and functional disturbances caused by parenchymal damage of brain tissue (general paresis). Meningovascular syphilis can lead to middle cerebral artery strokes, which produce hemiparesis and dysphasia. Demyelination of the posterior columns leads to the ataxic gait and destroyed joints from loss of position sense characteristic of tabes dorsalis. About 10% of patients with late untreated syphilis experience cardiovascular complications, usually in the form of aneurysms of the ascending aorta. Gummas are nodules of granulomatous inflammation that involve the skin and skeleton. Gummas of the skin may take the form of nodules, a papulosquamous eruption, or ulcers.

- VI-85. The answer is E.** (*Chap. 123*) In giving advice to a patient who will be traveling outside the country for a prolonged period of time, is important to understand the nature of the infectious diseases endemic in the country of destination. So-called routine immunizations that should be up to date regardless of travel must be administered, if not already done [these include diphtheria, tetanus, polio, measles, influenza (seasonal related), and pneumococcal infection in high-risk hosts]. Recommended immunizations include hepatitis A and B. Yellow fever vaccine should be given to those going to sub-Saharan Africa and equatorial South America. Regarding malaria prophylaxis, the incidence of chloroquine-resistant falciparum malaria has been increasing. It is currently recommended that those traveling to South America (except for northern Argentina and Paraguay) receive mefloquine instead of chloroquine. The incidence of malaria is actually highest in sub-Saharan Africa and Oceania and is increasing in Kenya. The risk is intermediate for travelers to Tahiti and the Indian subcontinent, and relatively low for those who travel to Asia and Central and South America. The traveler should always take personal protection measures against mosquito bites, especially between dusk and dawn. These measures will also decrease the incidence of other insect-transmitted illnesses such as dengue fever.
- VI-86. The answer is C.** (*Chap. 191. Hollsberg, N Engl J Med 328:1173–1182, 1995.*) Retroviruses contain an RNA genome that requires reverse transcription into DNA after entrance to the host cell. The DNA copy of the viral genome may then integrate into the host genome, which allows viral gene transcription and ultimately leads to complete viral replication. AIDS, the best known human retroviral disease, is caused by HIV-1, which attaches to CD4 molecules on lymphocytes and monocytes and produces lymphopenic immunodeficiency. HIV-2, isolated in Africa, appears to be an uncommon cause of AIDS. The two retroviruses associated with transformation of human cells are HTLV-I and HTLV-II. The role of HTLV-II in human disease is unclear, although the virus was originally isolated from a patient with a T cell variant of hairy cell leukemia. Between 1 and 3% of those infected with HTLV-I develop a fulminant and refractory malignancy of CD4⁺ lymphocytes called adult T cell leukemia/lymphoma, which is characterized by lymphocytosis, leukemic skin infiltrates, bone lesions, and hypercalcemia. Increased numbers of interleukin 2 (IL-2) receptors can be found on the surface of the malignant cells. A demyelinating disorder termed *tropical spastic paraparesis* and a chronic T cell leukemia represent other diseases associated with HTLV-I infection. FeLV, which is responsible for tumors in cats, does not cause human disease.
- VI-87. The answer is D.** (*Chap. 139*) Methicillin-resistant *S. aureus* has become a major source of morbidity and mortality. In vitro sensitivity testing may demonstrate sensitivity to cephalosporins, but these tests are unreliable and all strains are resistant in vivo. These strains have an altered penicillin-binding protein and are resistant to all penicillinase-resistant penicillins, alone or in combination with an aminoglycoside. Resistance is not plasmid-mediated, and there is no risk of spread to other bacteria. Administration of vancomycin is the most effective treatment.
- VI-88. The answer is D.** (*Chap. 170*) A papular reaction usually develops in patients with tuberculoid leprosy a month after the injection of killed suspensions of *Mycobacterium*

leprae, but it is not diagnostic since positive reactions occur in nearly all adults. Culture of *M. leprae* is exceedingly difficult and can be accomplished only in mice and armadillos. A minimum of 6 months is usually required before the results are available; therefore, cultures are not practical for diagnosis. Erythema of existing skin lesions with dapsone therapy is not diagnostic. Demonstration of the organism on microscopic examination of a biopsy specimen is the only definitive way to make the diagnosis of leprosy. A sensitive serologic assay that is effective in diagnosing lepromatous disease was recently developed.

- VI-89. The answer is E.** (*Chap. 221*) Adult worms reside in lymph nodes, but biopsy is relatively insensitive and problematic because of the potential to exacerbate lymphatic drainage. Serologic testing is available at specialized centers with indirect hemagglutination, but cross-reactions with other filariae are common. Intense pruritus and a rash after the administration of diethylcarbamazine (Mazzotti test) suggest dermal microfilariae; this reaction typically occurs in patients with onchocerciasis. Maintenance of filariae in cultures or animals is extremely difficult. The best animal model is the cat, but this technique plays no role in clinical diagnosis. Diagnosis is best made by demonstrating microfilariae on a Giemsa stain of blood after special techniques to concentrate the parasites. *W. bancrofti* microfilariae usually maintain a nocturnal periodicity and are found in the bloodstream in greatest numbers at night. The exact reason for the periodicity is not known, but it may be related to oxygen tension in the pulmonary vessels.
- VI-90. The answer is B.** (*Chap. 177. Dumler, Bakken, Annu Rev Med 49:201–213, 1998.*) The differential diagnosis of infectious transmitted by tick bite in an endemic area includes ehrlichiosis, Lyme infection (*B. burgdorferi*), and babesiosis. Babesiosis may be diagnosed by a characteristic form on the peripheral blood smear. Ehrlichiosis represents infections caused by *Ehrlichia* spp., small obligate intracellular bacteria with a gram-negative type cell wall. In infected cells cytoplasmic vacuoles form clusters called *morulae*, which can sometimes be seen by examining the peripheral blood smear. There are two distinct types of human ehrlichiosis. One is *human monocytotropic ehrlichiosis*, seen mainly in the south-central, southeastern, and mid-Atlantic states and transmitted by the Lone Star tick, which feeds upon white-tailed deer as well as dogs. The etiologic agent for *human monocytotropic ehrlichiosis* is *E. chaffeensis*, and the disease has an incubation period of 8 days after the tick bite. Clinical manifestations are nonspecific and include fever, headache, myalgia, and malaise. Severe complications can produce a toxic shock–like or septic shock–like syndrome. Leukopenia and thrombocytopenia are common, as are elevations in hepatic aminotransferases. Tetracycline or doxycycline is the treatment of choice. A related but distinct illness, human granulocytotropic ehrlichiosis, occurs in a more northern distribution (similar to that of Lyme disease). White-footed deer mice in the United States and red deer in Europe are the primary reservoir, with the vector being *Ixodes* ticks. The incubation period is 4 to 8 days, and the disease is very similar to that described for human monocytotropic ehrlichiosis, with severe complications common in the elderly. Pancytopenia and transaminitis are also seen. Diagnostic studies can include examination of the peripheral blood smear for evidence of the morulae, or, in more sensitive fashion, use of PCR to detect the genome of the pathogenic microorganism. Therapy should include doxycycline, 100 mg given twice daily. Given the clinical course described with this patient, exposure to ticks in an endemic area should certainly prompt rapid administration of doxycycline.
- VI-91. The answer is C.** (*Chap. 133*) The findings on pelvic examination, coupled with the elevated sedimentation rate in this setting, strongly suggest acute pelvic inflammatory disease (PID). About 5% of women with PID have associated perihepatitis, termed the *Fitz-Hugh–Curtis syndrome*, manifested by pleuritic pain of the right upper quadrant and tenderness on palpation, along with normal liver function tests and ultrasound of the right upper quadrant. *N. gonorrhoeae* is the primary pathogen in this condition, but chlamydial salpingitis is increasing in incidence, particularly in higher socioeconomic groups. Organisms typically found in the vagina, such as peptostreptococci, *E. coli*, and group B streptococci may also play a primary or secondary role in PID.

- VI-92. The answer is D.** (*Chap. 309. Fauci, Science 239:617–622, 1998.*) HIV infection produces profound immunodeficiency consequent to the reduction in the number of helper T cells, which are defined by the presence of the CD4 molecule on the cell surface. While HIV attaches to the CD4 molecule, a co-receptor must also be present to allow efficient entry of HIV-1 into the cell. Co-receptors are also primary receptors for certain chemoattractant cytokines, termed *chemokines*, which are themselves coupled to G proteins. These two receptors are called CCR5 and CXCR4. Disease complications are really defined by the level of CD4+ T cells that remain after infection. Dendritic cells, such as the Langerhans' cell in the skin, may be the initial target of HIV infection prior to CD4 + T cells. Initial infection is believed to be followed by rapid viral replication in the CD4 + T cells, which then leads to an HIV-viremic phase with rapid dissemination of virus to other lymphoid organs as well as the brain. Certain mutations in genes that encode for proteins interacting with the chemokine co-receptors result in a relative difficulty for HIV entry into T cells and are thereby responsible for the rare patient infected with HIV who does not have any clinical sequelae of the disease. Strains of HIV that utilize the CCR5 as a co-receptor are called *R5 viruses*, and those that utilize CXCR4 are called *X4 viruses*. Some can bind to both co-receptors and are called *R5X4 viruses*. Natural chemokine ligand for these co-receptors can actually block entry of HIV. All the manifestations of immunodeficiency may be explained by infection and depletion of CD4+ T cells, but it is also known that HIV infection can result in a variable level of CD8 + T cells, B cells that display abnormal activation, depressed monocytic function (due to coexpression of CD4 and chemokine receptors), and functional abnormalities of natural killer (NK) cells. In fact, rare genetic defects in the CCR5 gene may protect people from HIV infection despite repeated exposure to the virus.
- VI-93. The answer is C.** (*Chap. 214*) This patient was in the right location and has the typical clinical features of a patient infected with *Babesia*, tick-borne protozoa that multiply in red blood cells. The clinical manifestations can be more severe in splenectomized persons. The best way to make the diagnosis is to demonstrate the parasite's presence in erythrocytes in Giemsa-stained peripheral blood smears. Serologic confirmation can also be helpful. The combination of quinine and clindamycin constitutes the most effective treatment.
- VI-94. The answer is E.** (*Chaps. 169, 309*) Tuberculosis has experienced a resurgence associated with the HIV epidemic. In the United States, up to 5% of patients with AIDS has active TB infection, which is more commonly pulmonary than extrapulmonary. It is important to recognize and treat TB early in the course of disease in patients with HIV infection, since TB can increase the level of HIV RNA in the plasma. Skin testing is helpful for predicting who is at risk for TB but is not helpful in the diagnosis of active infection. The epidemic of TB associated with HIV infection is probably the greatest health risk to the general public and the health care profession. Though atypical mycobacterial infection occurs relatively late in HIV infection in patients with low CD4 counts, active typical TB may develop relatively early in the course of the disease. Patients with relatively high CD4+ T cell counts may exhibit typical pulmonary reactivation with the clinical syndrome of weight loss, fever, cough, and dyspnea and with a chest x-ray revealing apical cavitory disease. In patients with lower CD4 + T cell counts, disseminated disease, including extrapulmonary manifestations, is more common. Fortunately, the treatment of active TB in an HIV patient can be quite successful, and the recommended therapy is generally the same as it would be in a patient who does not have HIV infection. However, rifabutin should be substituted for rifampin in patients who are receiving the protease inhibitors or nonnucleoside reverse transcriptase inhibitors because of adverse interactions.
- VI-95. The answer is E.** (*Chap. 309. Piscitelli, Gallicano, N Engl J Med 344:984–996, 2001.*) The mainstay of treatment of patients with HIV infection is combination antiretroviral therapy, or HAART. When to initiate such therapy is controversial, but it is certainly reasonable to treat patients with the acute HIV syndrome, those with symptomatic disease, those with CD4+ T cell counts <500/ μ L, or those with >20,000 copies of HIV RNA/

mL. Combination therapy usually consists of two nucleoside analogues, one of which is usually lamivudine, and a protease inhibitor. Another regimen uses two nucleoside analogues plus a nonnucleoside reverse transcriptase inhibitor. The increase in the plasma HIV RNA load is often considered an indication to change therapy, as is a failure to achieve an improvement in the CD4 counts. It is very important to consider drug-drug interactions in patients taking complicated medical regimens that include antiretroviral drugs in addition to prophylactic antibiotics and/or other medicines. There are numerous such interactions among the antiretroviral drugs themselves. For example, efavirenz, a nonnucleoside reverse transcriptase inhibitor, can decrease the serum levels of the HIV protease inhibitor indinavir, requiring an increase in the indinavir dosage. Second, both efavirenz and another nonnucleoside reverse transcriptase inhibitor, nevirapine, can reduce plasma methadone concentrations by ~50% in those receiving methadone maintenance therapy. Such a decrease in the methadone concentration could precipitate methadone withdrawal, which would yield the symptoms evidenced by this patient. It is therefore very important to consider the effect of any new drugs in HIV patients taking a stable regimen by consulting the appropriate sources in the literature or on an internet-based site.

- VI-96. The answer is B.** (*Chap. 180*) EBV infection is highly prevalent. Acute EBV infection typically results in an infectious mononucleosis syndrome characterized by fever, sore throat, and lymphadenopathy. However, EBV is one of the viruses that may persist for years within the host genome as a latent infection. EBV persists in B lymphocytes; proliferation of such EBV-infected cells is held in check by the immune system. In situations of profound immunodeficiency, such as would occur after a bone marrow transplant in a patient on heavy doses of immunosuppressive therapy to prevent graft-versus-host disease, overgrowth of such cells may occur, yielding a potentially fatal lymphoproliferative disease. So-called EBV lymphoma can occur after bone marrow transplant or in any allogeneic transplant situation where immunosuppression is potent and prolonged. Although many diseases can affect the liver in a patient who has recently undergone an allogeneic bone marrow transplant, the lymphadenopathy and diffusely infiltrative process is characteristic of EBV lymphoma, which often presents in an extranodal fashion. The relatively late onset and lack of ascites argues against venoocclusive disease. Recurrence of acute myeloid leukemia would usually yield abnormal counts; liver enlargement would be relatively unusual in most subtypes of AML. Graft-versus-host disease is a typical cause of fever and abnormal liver function tests but usually would not be associated with hepatomegaly and lymphadenopathy. Toxoplasmosis in this setting would usually present as focal disease, typically in the brain. Therapy for EBV lymphoma includes reduction in the immunosuppressive medications if possible, but often requires formal antilymphoma therapy such as cyclophosphamide, doxorubicin, vincristine, and prednisone.
- VI-97. The answer is A.** (*Chap. 153*) *Acinetobacter* is a ubiquitous commensal organism that is an important cause of bacteremia, pneumonia, and other serious infections. It is a gram-negative rod when grown in broth and can be confused with other members of the Neisseriaceae family (*Moraxella*, *Neisseria*, and *Kingella*) on Gram stain because of its pleomorphic appearance, particularly when it is grown in agar. It is also confused with Enterobacteriaceae species in cultures because of its simple growth requirements. Unlike the Neisseriaceae, it is resistant to penicillin and ampicillin but sensitive to gentamicin and tobramycin; this difference in antibiotic sensitivity makes it very important to distinguish this organism from Neisseriaceae in clinical isolates from patients with serious illnesses.
- VI-98. The correct answer is E.** (*Chap. 155*) Melioidosis is caused by *Pseudomonas pseudomallei*, a gram-negative bacillus that is ubiquitous in many tropical areas of Asia and Africa. Infection occurs from contact with contaminated soil. Pulmonary infections are the most common; in patients acutely ill with pneumonia, many organisms can be detected in sputum. The organisms can be grown on routine culture media. Serologic tests are used largely for epidemiologic studies. Melioidosis, particularly the chronic form, may be mistaken for tuberculosis; granulomas may develop, but calcification of cavitary lung lesions

does not occur. In acute melioidosis, therapy with tetracycline and chloramphenicol or ceftazidime plus TMP/SMZ is recommended. Although the organism is usually sensitive to each of these agents, the high fatality rate of this disease (>50%) has led to the use of a multiple antibiotic regimen.

- VI-99. The answer is B.** (*Chap. 55*) Predisposing factors for cutaneous candidial infection include diabetes mellitus, chronic intertrigo, oral contraceptive use, and cellular immune deficiency syndromes. Candidial infections typically occur in sites that are chronically wet and macerated such as an intertriginous areas in an individual who practices frequent washing. Particularly in those with depressed cellular immunity, the oral cavity may be involved with an infection (thrush) manifested by the appearance of white plaques. Fissured lesions appearing at the corners of the mouth in patients with poorly fitting dentures also occur on the basis of candida infection. The diagnosis can be made clinically or on the basis of demonstration of yeast on KOH preparation. Treatment involves removing predisposing factors such as chronic wetness, antibiotics, or improving glucose control in diabetics and use of effective topical agents such as nystatin or azoles; occasionally, the addition of hydrocortisone cream is required to decrease the associated inflammatory response. Systemic therapy with fluconazole may be required in immunosuppressed patients or individuals whose disease fails to respond to topical therapy.
- VI-100. The answer is C.** (*Chaps. 57, 147*) The skin lesions of disseminated gonococcal infection occur on the distal extremities, usually around joints, and appear within a week of the onset of joint symptoms. The lesions, which may number as many as 20 (average: four or five), are often painful, and each crop of new lesions is associated with a temperature rise. Lesions begin as a red macule or purpuric spot and then develop into a papule, a vesicle, and finally, a pustule. Organisms rarely are cultured from the skin lesions; they can be demonstrated occasionally on Gram stain and more regularly with immunofluorescent techniques. Herpes simplex typically occurs as grouped vesicles. Skin lesions of meningococemia consist of red macules that quickly become petechial or purpuric; migratory polyarthralgias and tenosynovitis are atypical. Erythema multiforme requires “iris” lesions for diagnosis. Anthrax consists of a single pimple or papule on exposed parts of the body; the lesion rapidly enlarges, developing into a vesicle that is surrounded by edema and later undergoes hemorrhagic necrosis, ulceration, and eschar formation.
- VI-101. The answer is D.** (*Chaps. 57, 176. Edlow, Ann Emerg Med 33:680–693, 1999.*) An expanding erythematous rash not associated with scaling is characteristic of erythema chronicum migrans. The disease first appears weeks to months after a tick bite. The lesion begins as a red macule at the site of the bite; the borders of the lesion then expand to form a red ring, with central clearing, as wide as 20 to 30 cm or more in diameter. Occasionally, secondary rings may occur within the original one. The lesion may itch or burn and may be accompanied by fever, headache, vomiting, fatigue, and regional adenopathy.
- VI-102. The answer is D.** (*Chaps. 55, 56*) A very common asymptomatic fungus infection of the skin caused by the dermatophyte *Pityrosporum orbiculare* (tinea versicolor) is often the source of a patient’s concerns regarding cancer or serious infectious disease. However, this infection is easily treated by scrubbing off the scales with soap and water and with short applications of selenium sulfide (2.5%) for 12 nights. Antifungal creams, including imidazoles such as miconazole, can also be used. Lesions are sharply margined macules with fine scaling that is easily scraped off with the edge of a microscopic glass slide. The scrapings, examined microscopically after treatment with potassium hydroxide, will reveal hyphae and spores commonly referred to as “spaghetti and meatballs.” Tinea versicolor has a predilection for sites in the upper trunk and upper arms; lesions rarely appear on the face.
- VI-103. The answer is A.** (*Chaps. 57, 183*) Herpes zoster, caused by the varicella zoster virus, which resides in ganglia after primary infection, usually produces a vesicular eruption

limited to the dermatome innervated by the corresponding sensory ganglia. Frequently the characteristic rash, grouped vesicles on an erythematous base, is preceded by several days of pain and paresthesia in the involved area. The most common site of involvement is in thoracic dermatomes, but trigeminal, lumbar, and cervical regions may also be affected. Immunosuppressed persons may display dissemination of zoster, which certainly mandates systemic therapy. Nasociliary branch involvement is not uncommon in ophthalmic zoster and may be heralded by vesicular lesions on the side or tip of the nose. Given the possibility of associated conjunctivitis, keratitis, scleritis, or iritis, an ophthalmologist should always be consulted. Though the risk of postherpetic neuralgia is significant in patients over age 60, it is unclear if early use of steroids prevents this complication. While it is reasonable to undertake measures to contain bacterial superinfection, including the use of antibacterial compresses, administration of prophylactic systemic antibiotics is not indicated.

- VI-104. The correct answer is B.** (*Chap. 153*) *Klebsiella* and the related *Serratia* and *Enterobacter* are the most important enteric organisms other than *E. coli* to infect humans. Although respiratory disease is important (*Klebsiella* accounts for 1% or less of community-acquired pneumonia), most clinical isolates now come from the urinary tract. All three genera are important pulmonary nosocomial pathogens. However, merely finding these organisms growing in the sputum of a very ill hospitalized patient does not necessarily implicate the bacteria as pathogenic in that particular circumstance and may indicate colonization rather than infection. Clinical context and procurement of the sample in a sterile fashion (transtracheal aspiration, bronchoscopy) will aid in the diagnosis. Chronic alcoholics, diabetics, and those with chronic lung disease are at increased risk for *Klebsiella* pneumonia, a difficult disease to treat because of the frequency of suppurative complications (empyema and abscess) with the associated requirement for prolonged (>2 weeks) therapy.
- VI-105. The correct answer is C.** (*Chap. 217*) Toxoplasmosis is a relatively common infection; serologic data indicate that up to two-thirds of the U.S. adult population may have had some form of the infection. The most serious manifestations appear to arise when the disease is acquired during pregnancy. Infection during the first trimester can result in spontaneous abortion, stillbirth, prematurity, or severe disease in any of several organ systems; infection during the third trimester most commonly leads to neonatal infection, which, however, tends to be asymptomatic. Infections acquired before pregnancy generally are of little consequence to the offspring. Immunocompromised persons usually have recrudescence. Diagnosis in these patients is often difficult to make, in part because the serologic responses are blunted by the underlying disease process. Serologic screening of asymptomatic immunocompromised patients may be helpful for recognizing toxoplasmosis at a later date.
- VI-106. The answer is C.** (*Chap. 222*) *Schistosoma mansoni* infection of the liver causes cirrhosis from vascular obstruction caused by periportal fibrosis but relatively little hepatocellular injury. Hepatosplenomegaly, hypersplenism, and esophageal varices develop quite commonly, and schistosomiasis is usually associated with eosinophilia. Spider nevi, gynecomastia, jaundice, and ascites are less commonly observed than they are in alcoholic and postnecrotic fibrosis.
- VI-107. The answer is C.** (*Chaps. 57, 172*) The rash of secondary syphilis is a maculopapular squamous eruption characterized by scattered reddish-brown lesions with a thin scale. The eruption often involves the palms and the soles, which is an important clue in the differential diagnosis. This rash can resemble atypical pityriasis rosea or erythema multiforme. The nontreponemal serologic tests such as the Venereal Disease Research Laboratory (VDRL) or RPR tests are positive. Patients usually give a history of a chancre at the site of the primary infection—in a heterosexual male usually the penis, but possibly the anus or pharynx. Treatment for both HIV-positive and HIV-negative adults is 2.4 million units

of benzathine penicillin by intramuscular injection. If this treatment is successful, the nontreponemal serologic tests should become negative.

- VI-108. The answer is E.** (*Chap. 56*) Acne vulgaris is a self-limited disease mainly of young adults that causes inflamed cysts (comedones), which sometimes result in scarring. Closed comedones, or whiteheads, seen as white lesions of 1 to 2 mm, are often accompanied by inflammatory papules, pustules, or nodules as a consequence of the extrusion of oily and keratinous cyst debris. On the other hand, blackheads, or open comedones, which are filled with easily expressible dark material, do not usually cause serious problems. Vigorous facial scrubbing is contraindicated since this trauma could lead to rupture of comedones. Other predisposing factors include the use of systemic glucocorticoids, phenytoin, isoniazid, or phenobarbital. Treatment strategies include oral tetracycline or erythromycin therapy to decrease cyst colonization. Severe acne may be treated with a 20-week course of oral retinoic acid therapy, which may prevent formation of comedones by altering the pattern of epidermal desquamation. Pregnant patients should avoid retinoic acid given the teratogenic nature of this compound; this drug also causes extremely dry skin and hypertriglyceridemia.
- VI-109. The answer is E.** (*Chap. 17. Mackowiak, Arch Intern Med 158:1870, 1998.*) A host of stimuli, including infection with virtually any microorganism, cause macrophages, lymphocytes, fibroblasts, and other cells to elaborate the key mediators of fever production, such as tumor necrosis factor (TNF) α , TNF- β (lymphotoxin), IFN- α , and the interleukins, which are 17-kDa glycoproteins that promote the synthesis of E series prostaglandins in the hypothalamus and thus reset the central thermostat at a higher level. Aspirin and nonsteroidal anti-inflammatory agents act by inhibiting cyclooxygenase activity so that prostaglandin E₂ (PGE₂) cannot be synthesized; they do not act by reducing TNF and IL-1 production. Glucocorticoids suppress fever by both interfering with arachidonic acid metabolism and downregulating the production of endogenous pyrogens. TNF and IL-1 also possess diverse effects, including the induction of cachexia by TNF.
- VI-110. The answer is A.** (*Chap. 138. Shapiro, N Engl J Med 325:1453–1460, 1991.*) The incidence of pneumococcal bacteremia drops after 2 years of age but rises again in those over age 55. All splenectomized patients, even those without underlying disease, should receive pneumococcal vaccine. The “crisis” in pneumococcal pneumonia ordinarily corresponds to the appearance of type-specific antibodies, not maximum leukocytosis. Alcoholic persons who develop pneumococcal pneumonia have a poor prognosis for several reasons: their tendency to aspirate pharyngeal flora, poor functioning of bronchial clearance mechanisms, and impaired leukocyte response (hypogammaglobulinemia generally is not a contributing factor). Pneumococcal pneumonia frequently precedes pneumococcal meningitis. Pneumococci cause pharyngitis extremely rarely.
- VI-111. The answer is D.** (*Chap. 140*) Streptococcal M protein is the factor most strongly associated with virulence; strains rich in M protein resist phagocytosis. Streptococcal pyoderma may lead to acute glomerulonephritis but not to acute rheumatic fever. The reason for this phenomenon is not understood. Group A streptococci elaborate a host of toxins important in infections: membrane-damaging streptolysins, DNAses, proteases, and pyrogenic exotoxins A, B, and C. Penicillin therapy for streptococcal pharyngitis decreases the incidence of suppurative and nonsuppurative complications but does not alter the duration of the sore throat. Nonenterococcal group D streptococci, such as *S. bovis*, are quite pathogenic and tend to cause endocarditis in patients with colonic neoplasms.
- VI-112. The answer is D.** (*Chap. 174*) Leptospirosis can be transferred from infected animals directly to humans who have contact with contaminated tissue or urine. Leptospirosis is often confused with influenza because of its initial manifestations: fever, headache, and myalgias. It causes hepatitis that is often associated with very elevated serum bilirubin levels, probably as a result of both intravascular hemolysis and impaired bilirubin excre-

tion. Leptospiral meningitis resembles a viral, or aseptic, meningitis; cerebrospinal fluid has a normal glucose concentration, and although a few neutrophils may be present, lymphocytes are the predominant cell type observed. The diagnosis of acute leptospirosis is made best by blood cultures; dark-field microscopy too often gives false-positive or false-negative results.

- VI-113. The answer is B.** (*Chap. 147*) Gonococemia tends to be a problem of menstruating women, although men also are affected. The characteristic skin lesions are small pustules that usually occur first on the fingers and feet. The arthritis associated with gonococemia is rarely symmetric, a clinical finding that is often helpful in making the diagnosis. Gonococci that produce β -lactamase are resistant to penicillin and ampicillin but are sensitive to the newer cephalosporins, such as ceftriaxone. Treatment with spectinomycin is also effective; this agent is usually recommended as the first choice for treatment failures attributed to penicillinase production by the organism. Gonococci with pili are more virulent than are gonococci without pili (pili may help the organism stick to epithelial cells to initiate infection), but the latter type may facilitate spread.
- VI-114. The answer is D.** (*Chap. 184*) The most common features of infectious mononucleosis are fever, sore throat, and lymphadenopathy. Sore throat, the most commonly described symptom, is observed in $\sim 80\%$ of young adults with this infection. Atypical lymphocytes, identified as T cells with suppressor-cytotoxic action responding to EBV-infected B lymphocytes, appear in the peripheral blood during the first week of illness. Heterophil antibodies, which are sheep red-cell agglutinins associated with the immunoglobulin M serum fraction, usually persist in the serum for a few months. By contrast, antibodies to EBV, especially to EBV nuclear antigens, can often be detected for years in the serum of persons who have had infectious mononucleosis. The incubation period in young adults is thought to be 30 to 50 days; in children, the incubation period is much shorter.
- VI-115. The answer is E.** (*Chap. 214*) Only in *P. vivax* and *P. ovale* infections may relapses occur because a portion of the intrahepatic forms remain dormant. *P. vivax* depends on the Duffy antigen to enter red cells; patients who lack this antigen are resistant. *P. falciparum* produces a form of disease that can lead to coma and death. Seizures and hypoglycemia, which are grave prognostic signs, may also be present. Renal failure in falciparum malaria seems to occur on the basis of tubular sequestration of parasitized erythrocytes and tends to abate. Renal failure with *P. malariae* infection may be due to deposition of soluble immune complexes in glomeruli. Repeated malarial infections can result in massive splenomegaly.
- VI-116. The answer is C.** (*Chap. 145*) *Clostridium* spp. are present in high numbers in normal intestinal flora and soil, and it is not surprising that they are common isolates from wound cultures. The presence of necrotic tissue and a low oxidation reduction potential are necessary to establish severe disease. Treatment is based on the clinical setting, and a culture positive for clostridia alone does not warrant therapy. *C. perfringens* produces at least 12 toxins, one of the most important of which is the alpha toxin. It has been associated with hemolysis and capillary and platelet damage. *C. perfringens* is a common cause of food poisoning associated with contaminated meats and poultry. The serous discharge from the overlying skin in a patient with gas gangrene has many gram-positive rods but few inflammatory cells, and this emphasizes the importance of an early Gram stain when the diagnosis is suspected. More than 70% of cases of *C. septicum* septicemia reported in the literature are associated with malignant neoplasms, especially of the gastrointestinal tract.
- VI-117. The answer is B.** (*Chap. 167*) Anaerobic pulmonary infections most often develop in the setting of aspiration. The sudden development of a bacterial pneumonia in a healthy teenager would most likely be caused by *Streptococcus pneumoniae*. Both anaerobic and aerobic organisms are implicated in Ludwig's angina, an infection that originates in the third molar and can spread rapidly through soft tissues of the mandible and pharynx.

Pharyngeal anaerobic bacteria, including *Bacteroides melaninogenicus*, *Fusobacterium* spp. and anaerobic cocci, cause bacterial aspiration pneumonia in a patient who has a diminished gag reflex, such as occurs with a seizure disorder. It is important to differentiate bacterial aspiration, which requires antibiotic therapy, from aspiration of stomach contents, which usually occurs after general anesthesia and resolves with symptomatic therapy. Anaerobic bacteria are a very unusual cause of endocarditis, which, as is the case with aerobic gram-negative organisms, may in part be explained by a failure to adhere to damaged valves. Severe external otitis is usually caused by *Pseudomonas*.

- VI-118. The answer is C.** (*Chap. 183*) Fewer than 5% of patients will have a second recurrence of herpes zoster unless they are immunosuppressed. Acute cerebellar ataxia is the most common form of neurologic involvement in children. This benign condition usually develops 3 weeks after the rash and resolves spontaneously. Chickenpox is one of the most contagious diseases; it infects up to 90% of seronegative persons, presumably via the respiratory route. Varicella pneumonia can cause fever and severe hypoxia and thus can complicate the course of chickenpox infection in up to 20% of adults. Varicella-zoster immune globulin is recommended only for immunodeficient patients under age 15 who have been exposed to varicella.
- VI-119. The answer is C.** (*Chap. 185*) Perinatal transmission of CMV occurs by passage through an infected birth canal or through the breast milk of a seropositive mother. Although such transmission is very common, symptomatic infection is distinctly unusual except in premature infants in whom interstitial pneumonitis may develop. Congenital infection with CMV occurs in ~1% of births in the United States, but detectable disease develops in <0.05% of births, almost exclusively in association with primary maternal infections. CMV produces a syndrome very similar to mononucleosis associated with EBV. Cervical lymphadenopathy and exudative pharyngitis are usually not present, however, and heterophil antibodies are absent. CMV pneumonia can prove fatal in >80% of bone marrow transplant patients. Salivary excretion of the virus or positive sputum cultures do not implicate CMV as the cause of pulmonary infiltrates. The definitive diagnosis rests on the demonstration of the characteristic pathologic finding— intranuclear inclusions in enlarged, epithelial cells— on lung biopsy. The diagnosis of CMV infection rests on characteristic pathologic findings, a fourfold rise in serology titer, or culture of CMV, usually from urine, saliva, or buffy coat. Because viral excretion can continue for weeks to months, isolation of CMV does not always indicate acute infection.
- VI-120. The answer is D.** (*Chap. 192*) Both Norwalk virus and rotavirus infect the small intestinal epithelium and cause malabsorption and osmotic diarrhea. Worldwide, rotavirus is the most important cause of dehydrating diarrhea in infants. Rotavirus is shed in large quantities in the stool, allowing for easy diagnosis by culture or immunoassays to detect viral antigens. Norwalk virus presumably is spread by the fecal-oral route and has also been implicated in food-borne and waterborne epidemics. The clinical manifestations of infection by both viruses are characterized by vomiting, diarrhea, and occasionally low-grade fever. Rotavirus is a major cause of diarrhea in children under 3, while Norwalk virus causes disease more often in older children and adults.
- VI-121. The answer is E.** (*Chap. 143*) Neonatal tetanus is associated with a mortality rate >60%. It is caused by infections of the umbilical stump. In third-world countries the infection is often associated with practices of applying dirt or feces to the umbilical stump to speed sloughing. Human immune globulin cannot affect tetanus toxin that is already bound in the central nervous system, but it can be helpful if given early to bind any free toxin. Such small amounts of tetanospasmin are present that no immunity develops and active immunization must be initiated. Trismus, or lockjaw, is the most common manifestation of tetanus; it is caused by neuromuscular blockade and central disinhibition of motor neurons. Immune globulin provides protective antibody levels for up to 4 weeks and should be given along with toxoid for serious wounds if fewer than two previous doses of toxoid have been given.

VII. DISORDERS OF THE CARDIOVASCULAR SYSTEM

QUESTIONS

DIRECTIONS: Each question below contains five suggested responses. Choose the **one best** response to each question.

VII-1. A 48-year-old man is admitted to the coronary care unit with an acute inferior myocardial infarction. Two hours after admission, his blood pressure is 86/52 mmHg; his heart rate is 40 beats per minute with sinus rhythm. Which of the following would be the most appropriate initial therapy?

- (A) Immediate insertion of a temporary transvenous pacemaker
- (B) Intravenous administration of atropine sulfate, 0.6 mg
- (C) Administration of normal saline, 300 mL over 15 min
- (D) Intravenous administration of dobutamine, 0.35 mg/min
- (E) Intravenous administration of isoproterenol, 5.0 μ g/min

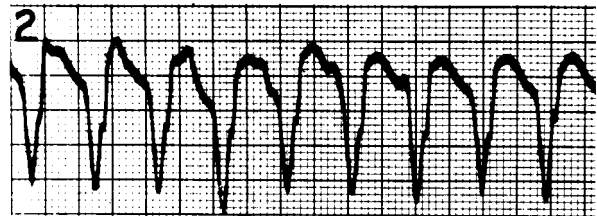
VII-2. A 68-year-old man with a history of hypertension, diabetes, and urinary retention awoke feeling nauseated and light-headed. He did not respond to questions from his wife. When the emergency medical technicians arrived, his blood pressure was 60 by palpation. IV fluids and oxygen were administered. Vital signs obtained in the ER were blood pressure 60, heart rate 120 and regular, temperature 38.9°C (102°F), and respiratory rate 30. A brief physical examination revealed coarse rales approximately halfway up in the chest bilaterally and inaudible heart sounds. An indwelling urinary catheter was placed with drainage of 10 to 20 mL of dark urine. Chest x-ray revealed bilateral interstitial infiltrates; ECG was unremarkable except for sinus tachycardia. Antibiotics were administered, and the patient was transferred to the ICU, where a right heart catheterization was performed. Pulmonary capillary wedge pressure was 28 mmHg. Cardiac output was 1.9 L/min. Right atrial mean pressure was 10 mmHg. The most likely cause of this man's hypotension was

- (A) left ventricular dysfunction
- (B) right ventricular infarction
- (C) gram-negative sepsis

VII-2. (Continued)

- (D) gastrointestinal bleeding
- (E) pulmonary emboli

VII-3. A middle-aged man who suddenly collapsed on the golf course is brought to the emergency department. The emergency medical technicians diagnosed cardiorespiratory arrest, performed CPR, applied a 200-J shock to the patient's chest, and inserted an endotracheal tube and an intravenous line. At the time of arrival in the emergency room, the patient has no spontaneous pulse or respiration. After viewing the rhythm strip shown below, you order additional defibrillatory shocks: first 200 J, then 300 J, and finally 360 J. CPR is continued. Which of the following is the most appropriate drug to administer at this time?



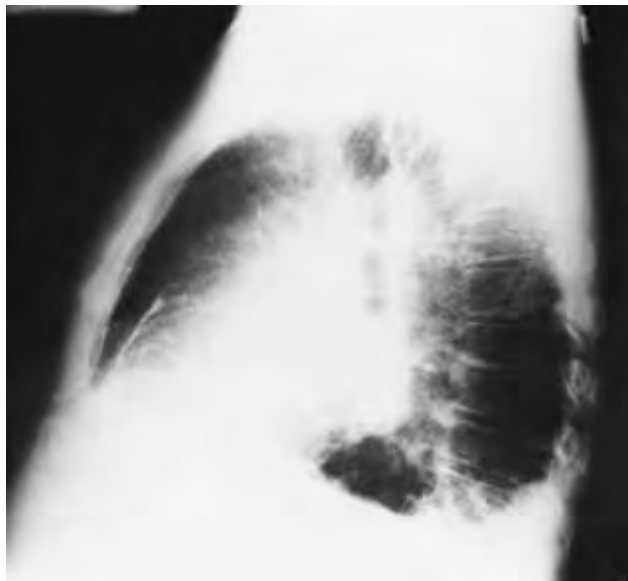
From Schlant, et al: *Hurst's The Heart*, 8/e. New York, McGraw-Hill, 1994, with permission.

- (A) Procainamide
- (B) Bretylium tosylate
- (C) Epinephrine
- (D) Lidocaine
- (E) Sodium bicarbonate

VII-4. Which of the following statements concerning the use of captopril is true?

- (A) Decreases plasma renin activity
- (B) Increases the degradation of circulating bradykinin
- (C) Increases the formation of angiotensin II
- (D) Cannot be used safely in combination with a beta-blocking agent
- (E) Contraindicated in patients with bilateral renal artery stenosis

VII-5. Which of the following physical findings is associated with the chest x-ray shown below?



- (A) Wide splitting of the second heart sound
- (B) Opening snap and diastolic rumble
- (C) Pericardial knock
- (D) Late-peaking systolic ejection murmur
- (E) Central cyanosis

VII-6. A 55-year-old man with known coronary heart disease develops recurrent anginal symptoms 2 months after undergoing an apparently successful percutaneous transluminal coronary angioplasty (PTCA) procedure. The original PTCA procedure was performed because of angina unresponsive to medical therapy in the setting of two proximal 90% occlusions (one in the right coronary artery and the other in the left circumflex). Cardiac catheterization reveals that the left circumflex lesion has reoccluded. Which of the following statements concerning the patient's current condition is correct?

- (A) The patient probably will require coronary artery bypass surgery
- (B) If the patient had been treated with aspirin daily from the time of his initial PTCA, this problem would have been less likely
- (C) A cholesterol-lowering agent would have been useful in preventing this problem
- (D) The administration of warfarin therapy for 6 months after PTCA is indicated to prevent this problem
- (E) Coronary artery smooth-muscle hyperplasia probably played a role in the current problem

VII-7. A 67-year-old man who has experienced recurrent episodes of dizziness over the last several months is admitted to the hospital because of a fainting episode. No

VII-7. (Continued)

evidence of acute myocardial infarction is documented. On the evening of admission, the patient tells his nurse that approximately 10 min earlier he experienced several minutes of dizziness. His current rhythm appears to be normal sinus; however, a monitoring strip obtained at the time of this episode reveals absent QRS complexes every third beat. The PR interval, while slightly prolonged, is constant from beat to beat. P waves are present at regular intervals. Which of the following is the most appropriate therapeutic action?

- (A) Insertion of permanent cardiac pacemaker
- (B) Insertion of temporary cardiac pacemaker followed by insertion of permanent cardiac pacemaker
- (C) Administration of atropine, 2 mg IV
- (D) Administration of isoproterenol, 2 mg/min IV
- (E) No specific therapy is required for this benign arrhythmia

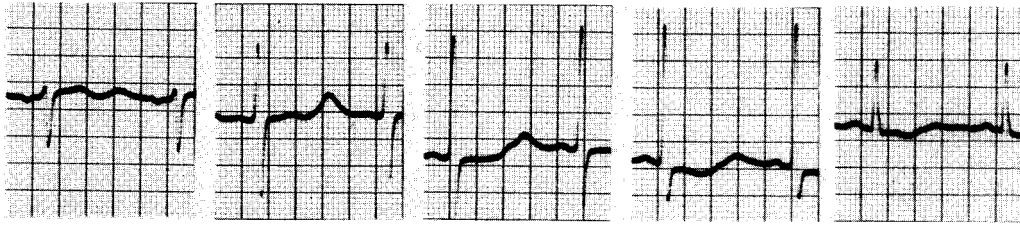
VII-8. A 53-year-old man presents to the emergency room after the acute onset of chest pain. The episode occurred 8 h prior to his arrival and lasted for a total of 20 to 30 min. The chest pain is now resolved. The patient has a long history of diabetes mellitus and hypocholesterolemia and has smoked approximately 1 to 1 1/2 packs per day of cigarettes for the past 30 years. On physical exam he has a blood pressure of 84/52, and his pulse is 54. He has jugular venous distention to the angle of the mandible and clear lung fields. His rhythm strip reveals a Wenckebach pattern. Given his hypotension, a Swan-Ganz catheter is placed. Right atrial pressure is estimated at 16 mmHg (normal 0–5), pulmonary artery pressure at 20/10 mmHg (normal 12–28/3–13), and the pulmonary capillary wedge pressure is 8 mmHg (normal range 3–10). Which of the following is most consistent with this clinical picture?

- (A) An anterior wall myocardial infarction
- (B) A right ventricular infarction
- (C) A ruptured mitral valve leaflet
- (D) A constrictive pericarditis following a myocardial infarction
- (E) A lateral wall myocardial infarction

VII-9. Examination of the carotid pulse reveals two impulses or peaks during ventricular systole. Which of the following physical findings probably would be associated with this finding?

- (A) Diastolic murmur beginning after an opening snap
- (B) Decrease in systolic arterial pressure during inspiration
- (C) Systolic murmur increasing during the Valsalva maneuver
- (D) Right-sided third heart sound
- (E) Left-sided third heart sound

VII-10. The electrocardiogram shown below is consistent with which of the following clinical situations?



From Schlant, et al: *Hurst's The Heart*, 8/e. New York, McGraw-Hill, 1994, with permission.

- (A) A 55-year-old man complaining of crushing substernal chest pain
- (B) A 25-year-old woman with acute renal failure resulting from lupus nephritis
- (C) A 27-year-old man with prolonged neutropenia after induction therapy for acute myeloid leukemia who is receiving amphotericin B
- (D) A 57-year-old woman with metastatic breast cancer receiving etidronate
- (E) A 72-year-old woman receiving digitalis therapy for chronic congestive heart failure

VII-11. Digitalis glycosides enhance myocardial contractility primarily by which of the following mechanisms?

- (A) Opening of calcium channels
- (B) Release of calcium from the sarcoplasmic reticulum
- (C) Stimulation of myosin ATPase
- (D) Stimulation of membrane phospholipase C
- (E) Inhibition of membrane Na^+ , K^+ -ATPase

VII-12. A 65-year-old man with a long history of untreated hypertension complains of recurrent shortness of breath on minimal exertion. Examination of the cardiovascular system is normal except for a prominent precordial impulse. Chest x-ray is normal except for a prominent left ventricular shadow. An exercise tolerance test with thallium scanning reveals no evidence of myocardial ischemia. Two-dimensional echocardiography reveals left ventricular hypertrophy. Radionuclide ventriculography reveals normal right and left ventricular ejection fractions. What is the most likely explanation for the patient's symptoms?

- (A) Chronic obstructive pulmonary disease
- (B) Reactive airways disease
- (C) Systolic congestive heart failure
- (D) Diastolic congestive heart failure
- (E) Myocardial ischemia

VII-13. Clues to the presence of atrioventricular nodal block (as opposed to trifascicular block) include which of the following?

- (A) Clinical evidence of inferior myocardial infarction
- (B) No change in the escape rhythm with exercise
- (C) An escape-focus rate slower than 40 beats per minute

VII-13. (Continued)

- (D) A widened QRS complex at the escape focus
- (E) Unresponsiveness of the escape focus to atropine

VII-14. Which of the following agents has been shown to reduce mortality in patients with congestive heart failure?

- (A) Digitalis
- (B) Furosemide
- (C) Enalapril
- (D) Procainamide
- (E) Aspirin

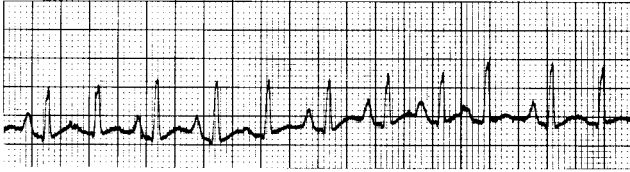VII-15. A 68-year-old Haitian man presents with a chronic nonproductive cough, dyspnea on exertion, and chronic nonexertional chest pain. The patient notes a loss of 10 pounds over the past 6 months, decreased appetite, and swelling of the ankles. Physical findings reveal an ill-appearing man with decreased skeletal mass. Blood pressure is 100/70 without a significant inspiratory decrease in systolic pressure. Heart rate is 110; respiratory rate is 25; temperature is 37.2°C (99.0°F) orally. Significant physical findings include the absence of rales on chest examination and the presence of jugular venous distention with a decline during inspiration. The apical cardiac pulse is reduced. The heart sounds are distant; an early third heart sound occurs very shortly after aortic valve closure; there are no murmurs. Both the liver and the spleen are enlarged, and there is a fluid wave on abdominal examination. Electrocardiography displays low QRS voltage but is otherwise unremarkable. Chest x-ray reveals clear lungs and an enlarged cardiac silhouette. Which of the following findings is most likely to appear on echocardiographic examination?

- (A) Enlarged right ventricular size
- (B) Pericardial effusion

VII-15. (Continued)

- (C) Thickened myocardium
- (D) Thickened pericardium
- (E) Right ventricular diastolic collapse

VII-16. A 60-year-old man is admitted to a hospital because of respiratory failure and tachycardia. Rectal temperature is 38.3°C (101°F), respiratory rate is 32 breaths per minute, and blood pressure is 100/60 mmHg. His admission electrocardiogram is shown below. Which of the following measures would constitute the most appropriate management for this man?



- (A) Electrical cardioversion after the blood pressure is raised
- (B) Supplemental oxygenation or mechanical ventilation
- (C) Administration of digitalis
- (D) Administration of quinidine
- (E) Administration of verapamil

VII-17. Each of the following patients was noted to have an abnormally high serum cholesterol and was placed on a reduced calorie, cholesterol, and fat diet for the past 3 months. None has any history of ischemic heart disease. In which of the following patients would it be most appropriate to recommend lipid-lowering drug therapy at this time?

- (A) A 52-year-old smoker and diabetic with an LDL cholesterol value of 3.2 mmol/L (120 mg/dL)
- (B) A 60-year-old hypertensive woman with an LDL cholesterol value of 3.5 mmol/L (140 mg/dL)
- (C) A 50-year-old man with cholesterol of 6 mmol/L (230 mg/dL)

VII-17. (Continued)

- (D) A 45-year-old man with LDL cholesterol of 5 mmol/L (200 mg/dL)
- (E) A 58-year-old male smoker with cholesterol of 5.5 mmol/L (220 mg/dL) and LDL cholesterol of 4 mmol/L (150 mg/dL)

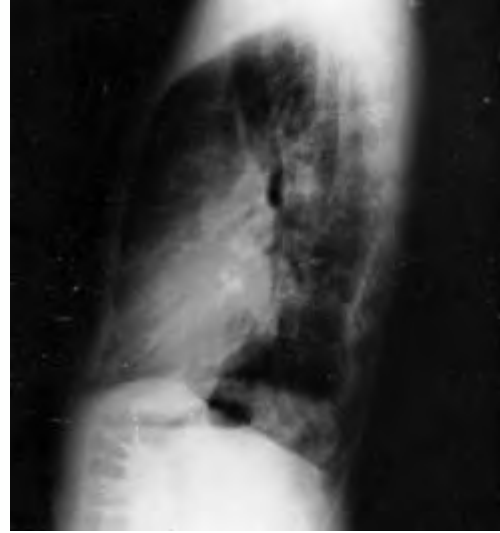
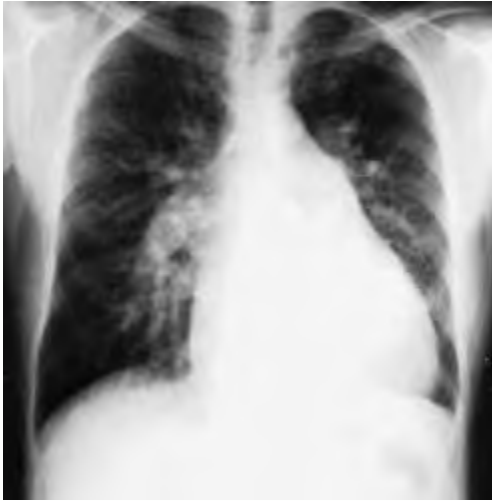VII-18. Which of the following statements regarding secundum atrial septal defect is true?

- (A) Surgical correction is advisable when the pulmonary-to-systemic flow ratio has reached 2.0
- (B) Affected persons are usually symptomatic in childhood
- (C) Electrocardiography shows a leftward axis
- (D) Echocardiography shows a normal ventricular septal motion
- (E) Atrial arrhythmias are uncommon

VII-19. A 75-year-old man presents with recurrent episodes of shortness of breath on minimal exertion. He has no prior significant past medical history. Physical examination reveals blood pressure of 110/70 without pulsus paradoxus, heart rate of 110, respiratory rate of 25, and temperature of 37°C (98.6°F) orally. Jugular veins are distended and the heart sounds are distant, but there are third and fourth extra heart sounds. The liver is enlarged, and pedal edema is present. The electrocardiogram shows nonspecific ST-T wave changes and occasional premature ventricular contractions. The chest x-ray reveals clear lung fields and a mildly dilated cardiac silhouette. Echocardiography reveals normal systolic function and thickened ventricular walls with a “speckled” appearance. Which of the following conditions is most consistent with the patient’s clinical presentation?

- (A) Alcoholic cardiomyopathy
- (B) Hemochromatosis
- (C) Amyloidosis
- (D) Viral myocarditis
- (E) Tuberculosis

VII-20. The chest x-rays below probably would have been taken of which of the following persons?



- (A) A 38-year-old woman who has hemoptysis, dyspnea on exertion, and fatigability
- (B) A 36-year-old woman who has a heart murmur but is asymptomatic
- (C) A 32-year-old woman who has a continuous murmur, widened systemic pulse pressure, and dyspnea on exertion
- (D) A 40-year-old woman who has a loud first heart sound, a diastolic rumble, a large *v* wave in her jugular pulse, and ascites
- (E) None of the above

VII-21. A 20-year-old woman has mild pulmonic stenosis (transvalvular gradient is 20 mmHg). Which of the following statements regarding this situation is true?

- (A) Heart size on chest x-ray is likely to be enlarged
- (B) Electrocardiogram is likely to be abnormal
- (C) There is loss of the jugular *a* wave
- (D) Compared to other valvular defects, the risk of endocarditis is relatively low
- (E) Frequent monitoring for progression of the stenosis is indicated

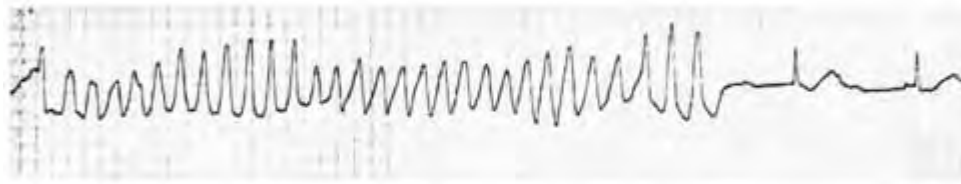
VII-22. Which of the following findings would be expected in a person with coarctation of the aorta?

- (A) Both a systolic murmur and a diastolic murmur would be heard best along the left sternal border
- (B) A higher blood pressure in the left arm than in the right
- (C) Inability to augment cardiac output with exercise
- (D) Often associated with a bicuspid aortic valve
- (E) Hypertension typically resolves after complete surgical repair

VII-23. A 15-year-old boy residing with his parents on a military base presents with a fever of 38.6°C (101.5°F) and complains of lower back, knee, and wrist pain. The arthritis is not localized to any one joint. He gives a history of a severe sore throat several weeks earlier. Physical examination of the skin reveals pea-sized swellings over the elbows and wrists. He also has two serpiginous, erythematous pink areas on the anterior trunk, each about 5 cm in diameter. Laboratory investigation includes negative blood cultures, negative throat culture, normal CBC, and an erythrocyte sedimentation rate (ESR) of 100. An anti-streptolysin-O (ASO) titer is elevated. At this point, appropriate therapy would consist of

- (A) supportive care alone
- (B) parenteral penicillin
- (C) parenteral penicillin and glucocorticoids
- (D) parenteral penicillin and aspirin
- (E) parenteral penicillin, aspirin, and diazepam

VII-24. A 62-year-old woman was started on a regimen of quinidine sulfate because of asymptomatic ventricular couplets. One week later, she was admitted to the hospital after a syncopal episode. Serum electrolyte concentrations were normal. The arrhythmia shown below appeared transiently on her cardiac monitor. The recommended course at this time is to



- (A) increase the quinidine dose
- (B) discontinue the administration of quinidine and observe
- (C) begin the intravenous administration of procainamide 2 mg/min
- (D) administer sodium bicarbonate, 70 meq, intravenously
- (E) administer potassium chloride, 10 meq, intravenously over 1 h

VII-25. Each patient below is alert and oriented and has a blood pressure of 110/60. In which patient would adenosine constitute appropriate initial therapy?

- (A) A 65-year-old man with no ischemic heart disease and wide complex tachycardia
- (B) A 65-year-old woman with known ischemic disease and narrow complex tachycardia
- (C) A 25-year-old woman with known preexcitation syndrome and narrow complex tachycardia
- (D) A 28-year-old man with known preexcitation syndrome and wide complex tachycardia
- (E) A 44-year-old man with atrial fibrillation without a prior history of heart disease

VII-26. A 72-year-old man with a long history of tobacco use presents to the emergency room with shortness of breath. He is mildly cyanotic and hypotensive. On exam he has poor air movement bilaterally and has evidence of an elevated jugular venous pressure. A Swan-Ganz is placed revealing right atrial pressures of 15 mmHg (normal range 0–5), a pulmonary artery pressure of 70/28 (normal range 12–28/3–13), and a pulmonary capillary wedge pressure of 10 (normal range 3–11). Which of the following is most consistent with this clinical picture?

- (A) Inferior myocardial infarction
- (B) Mitral stenosis
- (C) Cor pulmonale
- (D) Mitral regurgitation
- (E) Constrictive pericarditis

VII-27. A 23-year-old man presents to the emergency room with palpitations; his heart rate is 180 and he has a normal systolic blood pressure. An attempt to slow his heart rate is made using verapamil. Unfortunately, the patient's condition rapidly deteriorates. He is now pulseless, and a rhythm strip reveals ventricular fibrillation. Which of the following is most consistent with the patient's initial cardiac rhythm at presentation?

VII-27. (Continued)

- (A) Atrial flutter
- (B) Sinus tachycardia
- (C) Atrial fibrillation with aberrant conduction
- (D) Atrial fibrillation
- (E) Proximal supraventricular tachycardia (PSVT)

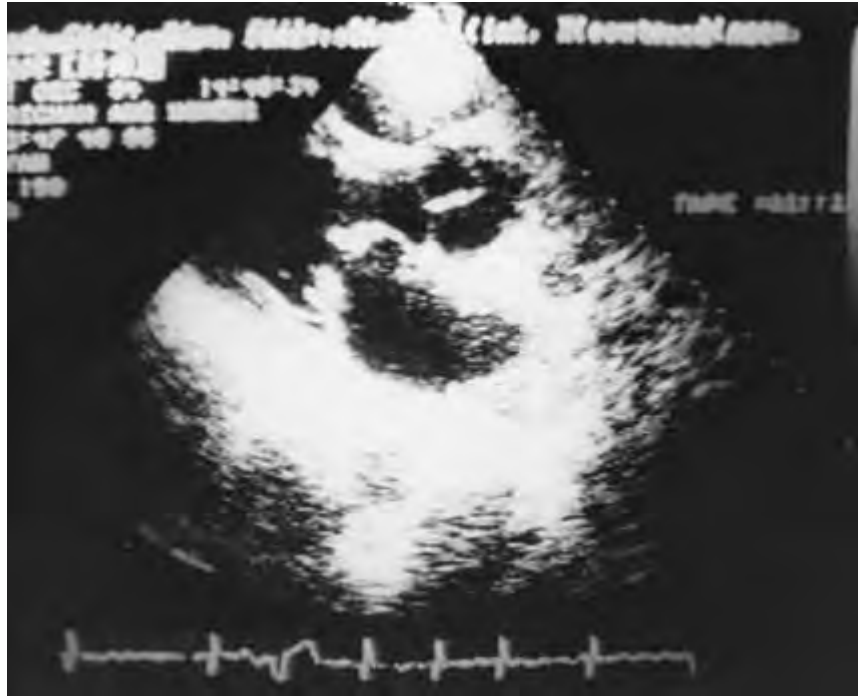VII-28. Which of the following statements best describes long-acting nitrate preparations?

- (A) Tolerance often develops
- (B) Their effect can be blocked by high doses of beta₂ selective inhibitors
- (C) Transdermal patches are more likely to be associated with headaches than are sublingual nitrates
- (D) Oral preparations are more effective than sublingual ones
- (E) Oral administration of isosorbide should not exceed 15 mg every 3 to 4 h

VII-29. A 70-year-old retired banker with no past medical history presents to the emergency department 4 h after the onset of severe substernal crushing chest pain with radiation to the left arm and neck. Electrocardiography reveals significant ST-segment elevation in leads I, L, V₅, and V₆. The patient has no clear-cut medical contraindications to anticoagulation. Which of the following would be the optimal management strategy at this time?

- (A) Intravenous tissue plasminogen activator alone
- (B) Intravenous tissue plasminogen activator and aspirin
- (C) Intravenous tissue plasminogen activator and heparin
- (D) Intravenous tissue plasminogen activator, heparin, and aspirin
- (E) Thrombolytic therapy is contraindicated because of the patient's age

VII-30. This two-dimensional echocardiogram most likely was recorded in which of the following patients?



- (A) A 54-year-old man with syncopal episodes when bending forward
- (B) A previously healthy 68-year-old man with sudden onset of pulmonary edema and a new holosystolic murmur
- (C) A 17-year-old girl with atypical chest pain and a midsystolic click
- (D) A 42-year-old woman with palpitations, exertional dyspnea, and episodes of hemoptysis
- (E) An asymptomatic 32-year-old cardiologist

VII-31. A 14-year-old boy is brought into the emergency room pulseless and undergoing cardiopulmonary resuscitation. He collapsed while playing basketball. There is no history of trauma, and no prior history of cardiovascular disease. Which of the following conditions would most likely be identified at the time of autopsy?

- (A) Normal findings
- (B) Anomalous left coronary artery
- (C) Ruptured aorta
- (D) Hypertrophic cardiomyopathy
- (E) Coronary artery disease

VII-32. A previously healthy 58-year-old man is admitted to the hospital because of an acute inferior myocardial infarction. Within several hours, he becomes oliguric and hypotensive (blood pressure is 90/60 mmHg). Insertion of a pulmonary artery (Swan-Ganz) catheter reveals the following pressures: pulmonary capillary wedge, 4 mmHg; pulmonary artery, 22/4 mmHg; and mean right atrial, 11 mmHg. This man would best be treated with

- (A) fluids
- (B) digoxin

VII-32. (Continued)

- (C) norepinephrine
- (D) dopamine
- (E) intraaortic balloon counterpulsation

VII-33. A 63-year-old black woman with a long history of hypertension and diabetes is brought to the emergency department by relatives because she has become incoherent over the past 24 h. Physical examination reveals a disoriented woman whose blood pressure is 230/160, respiratory rate is 25, and pulse is 110. The patient is afebrile. The chest reveals bibasilar rales. Cardiac examination is remarkable only for the presence of an S₄. There is no organomegaly or focal neurologic findings. The patient is oriented to person only.

The family revealed that the patient has not been taking her antihypertensive medicines in the past several weeks. The patient is placed on a cardiac monitor, and both intravenous and intraarterial lines are placed. An emergent CT scan reveals no evidence of hemorrhage or mass lesion. The most appropriate next step in management would be to

VII-33. (Continued)

- (A) observe the patient in a quiet room for 1 h before administering therapy
- (B) wait for laboratory values to return before deciding on specific therapy
- (C) administer sodium nitroprusside
- (D) administer diazoxide
- (E) administer intravenous nicardipine

VII-34. Which of the following statements regarding physiologic maneuvers used to distinguish one cardiac condition from another is true?

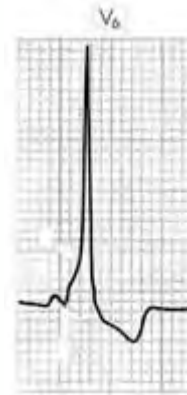- (A) The Valsalva maneuver results in increased length and intensity for most systolic murmurs, except those caused by mitral valve prolapse and hypertrophic cardiomyopathy
- (B) In the case of mitral valve prolapse, squatting results in increased intensity of the systolic murmur
- (C) Handgrip exercise decreases the intensity of the murmurs of mitral stenosis and mitral regurgitation
- (D) Murmurs of tricuspid regurgitation and tricuspid stenosis increase during inspiration
- (E) The murmur of aortic stenosis decreases after a ventricular premature beat

VII-35. Which of the following patients should undergo operative excision of an abdominal aortic aneurysm and replacement with a vascular graft?

- (A) A 58-year-old man with an 8-cm abdominal aneurysm who sustained a myocardial infarction 3 months ago
- (B) A 65-year-old man with a 7-cm aneurysm who sustained a myocardial infarction 1 year ago
- (C) A 65-year-old woman with a 4-cm aneurysm and no prior history of heart or lung disease
- (D) A 58-year-old man with a 7-cm aneurysm and FEV₁ of 0.8 L
- (E) A 67-year-old man with an 8-cm aneurysm and creatinine 3.2 mg/dL

VII-36. A 68-year-old man who has had a recent syncopal episode is hospitalized with congestive heart failure. His blood pressure is 160/80 mmHg, his pulse rate is 80 beats per minute, and there is a grade III/VI harsh systolic murmur. An echocardiogram shows a disproportionately thickened ventricular septum and systolic anterior motion of the mitral valve. Which of the following findings would most likely be present in this man?

- (A) Radiation of the murmur to the carotid arteries
- (B) Decrease of the murmur with handgrip
- (C) Delayed carotid upstroke
- (D) Reduced left ventricular ejection fraction
- (E) Signs of mitral stenosis

VII-37. Which factor accounts for the prolonged QRS complex depicted in this figure?

- (A) Left ventricular hypertrophy
- (B) Accessory conducting fibers parallel to the AV junction
- (C) Right ventricular infarction
- (D) Left bundle branch block
- (E) Right bundle branch block

VII-38. A 73-year-old patient develops acute renal failure secondary to bladder obstruction. His serum creatine is 327 $\mu\text{mol/L}$ (3.7 mg/dL) with a potassium of 6.5 meq/L. The patient had an electrocardiogram, which revealed peaked T waves as the only abnormality. If the hyperkalemia were not corrected, what would be the expected next electrocardiographic abnormality?

- (A) T-wave inversion
- (B) PR prolongation and P-wave flattening
- (C) Prolongation of the QT interval
- (D) Widening of the QRS interval
- (E) Torsade de pointes

VII-39. For the last 6 h, a 33-year-old man has had sharp, pleuritic substernal chest pain that is relieved when he sits upright. His electrocardiogram shows diffuse ST-segment elevation. Which of the following observations supports a diagnosis of acute pericarditis?

- (A) ST-segment depression
- (B) PR-segment depression
- (C) Diffuse T-wave inversion with ST-segment elevation
- (D) A normal serum creatine phosphokinase concentration
- (E) The presence of an S₃ gallop

VII-40. Which of the following electrocardiographic findings represents a manifestation of digitalis toxicity?

- (A) ST-segment depression
- (B) T-wave inversion

VII-40. (Continued)

- (C) Atrial flutter
- (D) Atrial tachycardia with variable block
- (E) A shortening of the PR interval

VII-41. What is the most common cause of pulseless electrical activity (PEA)?

- (A) Acidosis
- (B) Hypovolemia
- (C) Tension pneumothorax
- (D) Pericardial tamponade
- (E) Severe pulmonary embolism

VII-42. Which of the following congenital cardiac disorders will lead to a left-to-right shunt, generally with cyanosis?

- (A) Anomalous origin of the left coronary artery from the pulmonary trunk
- (B) Patent ductus arteriosus without pulmonary hypertension
- (C) Total anomalous pulmonary venous connection
- (D) Ventricular septal defect
- (E) Sinus venosus atrial septal defect

VII-43. Absolute contraindications to the use of thrombolytic agents in the setting of an acute anterior myocardial infarction include which of the following?

- (A) Left carotid artery occlusion with hemiparesis 1 month ago
- (B) Diabetic retinopathy
- (C) Cardiopulmonary resuscitation (CPR) for ~ 1 to 2 min
- (D) Patient age >70
- (E) Patient on warfarin for atrial fibrillation, with an INR of 1.8

VII-44. Which of the following situations in the peri-infarction period would suggest the presence of ventricular septal perforation?

- (A) Systolic murmur, large *v* waves in pulmonary capillary wedge tracing; Po_2 in right atrium equals that in right ventricle

VII-44. (Continued)

- (B) Systolic murmur, large *v* waves in pulmonary capillary wedge tracing; Po_2 in the right atrium is greater than that in the right ventricle
- (C) Systolic murmur, large *v* waves in pulmonary capillary wedge tracing; Po_2 in the right atrium is less than that in the right ventricle
- (D) Diastolic murmur, large *v* waves in the pulmonary capillary wedge tracing; Po_2 in the right atrium is less than that in the right ventricle
- (E) Diastolic murmur, large *v* waves in the pulmonary capillary wedge tracing; Po_2 in the right atrium is greater than that in the right ventricle

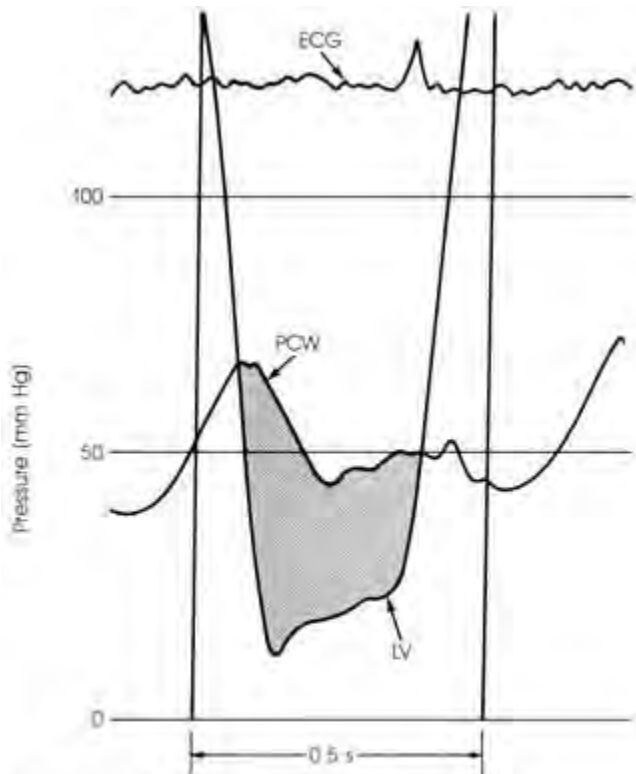
VII-45. A 65-year old man with long-standing hypertension presents to the emergency room complaining of palpitations. The patient is found to be in atrial fibrillation, and verapamil is administered to slow his ventricular rate. The patient spontaneously converts to normal sinus rhythm. A workup for cardiac ischemia and hyperthyroidism is negative. Over the next 48 h the patient has multiple episodes of paroxysmal atrial fibrillation. Which of the following antiarrhythmic agents would be most successful in treating his paroxysmal atrial fibrillation (PAFib)?

- (A) Verapamil
- (B) Sotalol
- (C) Digitalis
- (D) Propafenone
- (E) Amiodarone

VII-46. The patient described in Question VII-45 becomes refractory to the above agents and develops chronic atrial fibrillation. In addition to pharmacologic control of his ventricular rate, which of the following interventions would you suggest?

- (A) Low-dose aspirin (75 mg/d)
- (B) High-dose aspirin (325 mg/d)
- (C) Warfarin to an INR goal of 1.8 to 3.0
- (D) Warfarin to an INR goal of 3.0 to 4.0
- (E) No anticoagulation is necessary in the absence of valvular heart disease.

VII-47. This figure most likely represents the pulmonary capillary wedge and left ventricular pressure tracing from which of the following patients?



From Grossman W. (ed.): *Cardiac Catheterization and Angiography*. 3d ed. Philadelphia, Lea & Febiger, 1986, with permission.

- (A) A 40-year-old woman with a history of rheumatic fever, orthopnea, and hemoptysis
- (B) A 24-year-old intravenous drug abuser with fever, a holosystolic murmur, and large mitral valve vegetation
- (C) A 26-year-old man with long arms, abnormal lenses, and a diastolic murmur
- (D) A 72-year-old man with left ventricular hypertrophy, syncope, and a systolic murmur
- (E) A 35-year-old woman with elevated neck veins and a large mediastinal mass caused by non-Hodgkin's lymphoma

VII-48. A 22-year-old Michigan woman presents to her local emergency room complaining of dizziness over the past several days, including two syncope episodes followed in each case by unresponsiveness for several minutes. She has always been in excellent health, having played varsity soccer in college. Her last illness occurred 4 months ago, when she developed fever, chills, and generalized weakness; those symptoms cut short a 2-week camping trip to the Cape Cod National Seashore. She uses oral contraceptives but no other prescription medications. She admits to inhaling cocaine over the last 4 months. Physical examination reveals blood pressure of 100/62

VII-48. (Continued)

and pulse of 30 but is otherwise unremarkable. Chest x-ray and serum chemistries are unremarkable. ECG demonstrates complete heart block with nonspecific ST- and T-wave changes. There is no evidence of prior myocardial infarction. The most likely cause of her complete heart block is

- (A) myocardial infarction from cocaine use
- (B) myocardial infarction caused by a coronary artery embolus
- (C) infection resulting from *Ixodes dammini*
- (D) infection caused by *Borrelia burgdorferi*
- (E) infection caused by HIV

VII-49. A 70-year-old man is admitted to the hospital with chest pain of 8 h duration. ECG demonstrates anterior ST elevation, for which he is given tissue plasminogen activator, heparin, and intravenous nitroglycerin. His symptoms resolve, and serum chemistries reveal a peak CPK of 1400 and a CK-MB fraction of 80. He is eventually started on oral medications and transferred out of the cardiac intensive care unit. His subsequent hospital course is uneventful until day 4, when he develops severe shortness of breath. Blood pressure is 110/70, and pulse is 120. Examination reveals a new systolic murmur. The most appropriate therapeutic intervention would be

- (A) emergent cardiac surgery consultation and transfer to the operating room
- (B) IV heparin
- (C) IV heparin and streptokinase
- (D) IV heparin and furosemide
- (E) IV sodium nitroprusside

VII-50. Which of the following would be the most appropriate drug of choice in the management of torsades de pointes?

- (A) Atropine
- (B) Procainamide
- (C) Isoproterenol
- (D) Epinephrine
- (E) Magnesium sulfate

VII-51. A 68-year-old man with known aortic sclerosis was admitted with chest pain and ruled out for myocardial infarction but had recurrent symptoms during weaning from IV heparin and nitroglycerin over the ensuing 5 days. Cardiac catheterization revealed three-vessel disease with a normal ejection fraction, and he underwent coronary bypass grafting. On postoperative day 3, he complained of pain in the right arm and was found to have an absent right brachial pulse and a cold distal right arm. Laboratory work revealed a hematocrit of 38%, platelets 32,000, prothrombin time 15, INR 1.4, and partial thromboplastin time 65. What is the most likely explanation for this patient's absent brachial pulse?

VII-51. (Continued)

- (A) Left ventricular thrombus caused by a myocardial infarction with a subsequent brachial artery embolus
- (B) Embolization from aortic sclerosis
- (C) Embolization from paradoxical emboli through a patent foramen ovale from a deep venous thrombosis (DVT) arising postoperatively
- (D) Thrombosis in situ caused by postoperative hypercoagulability
- (E) Heparin-induced thrombocytopenia

VII-52. A 60-year-old man without a significant medical history presents for his annual physical. An electrocardiogram demonstrates two ventricular premature complexes (VPCs) within the 12-lead tracing. Which of the following statements is true?

- (A) VPCs are seen only in patients with a history of coronary disease
- (B) This patient's VPCs predict a higher incidence of cardiac mortality
- (C) VPCs such as those documented in this patient rarely cause symptoms
- (D) Both the frequency and the nature of VPCs can be correlated with increased mortality in patients with known coronary artery disease
- (E) There is no association between the frequency of VPCs and age

VII-53. A female infant is born to a consanguineous marriage of second cousins without complications. In utero, the fetal heart rate was between 80 and 90 beats per minute. The bradycardic heart rate persisted after birth. Approximately 2 weeks after birth the child underwent audiography, which demonstrated bilateral sensory neural deafness. These tests were repeated 2 weeks later with similar results. Unfortunately the mother suffered a cardiac arrest 7 months later and died. She had normal hearing. Which of the following statements concerning this patient's disorder is true?

- (A) The child has Romano-Ward syndrome
- (B) Romano-Ward and Jervell and Lang-Nielsen syndromes are genetically distinct
- (C) The patient's electrocardiogram revealed a shortened QT interval
- (D) The mutation lies within a cardiac ion channel
- (E) Use of beta blockers is contraindicated

VII-54. Which of the following statements regarding the activation of cardiac myocytes is true?

- (A) The force of contraction of cardiac muscle is not related to muscle length
- (B) The intracellular concentration of sodium is low
- (C) The rise in intracellular sodium is the triggering event in myocyte contraction

VII-54. (Continued)

- (D) Calcium binds to troponin C and releases cells from the inhibitory influence of this repressor
- (E) Creatine phosphate provides the source of the energy that drives myocyte contraction

VII-55. A 72-year-old woman with a prior history of hypertension is receiving low-dose atenolol, an unknown diuretic, and long-acting diltiazem. She has no other significant cardiac history. The patient is brought to the emergency room after having passed out while getting up to go to the bathroom at 6 A.M. this morning. She is seen by the surgical service, which finds her to have an orbital fracture from when she struck the sink. Internal medicine consultation is requested when an ECG reveals sinus bradycardia at 40 with occasional sinus arrest with pauses of 2 to 3 s but no other abnormalities. She remains somewhat light-headed. Blood pressure is 90/50. Physical examination is otherwise benign. She has been without oral intake since the previous evening. The next steps in treating this patient's arrhythmia would consist of

- (A) placement of a temporary wire; implant permanent pacer this afternoon
- (B) placement of a temporary wire; discontinue diltiazem and atenolol and follow
- (C) placement of external pacing pads; implant permanent pacer this afternoon
- (D) discontinue diltiazem and admit
- (E) proceed directly to permanent pacer implantation

VII-56. Tetralogy of Fallot consists of which of the following abnormalities?

- (A) Atrial septal defect (ASD), ventricular septal defect, an aorta that overrides the outflow, and right ventricular hypertrophy
- (B) ASD, ventricular septal defect, an aorta that overrides the outflow, and a left ventricular hypertrophy
- (C) ASD, ventricular septal defect, an aorta that overrides the outflow, and coronary artery anomalies
- (D) Ventricular septal defect, an aorta that overrides the left and right ventricles, obstruction of the right ventricular outflow tract, and right ventricular hypertrophy
- (E) ASD, tricuspid regurgitation, and atrialized right ventricle and right ventricular failure

VII-57. A 64-year-old man with known allergies to penicillin and lobster undergoes a left hip replacement. Recovery is uneventful until the day before discharge, when he begins experiencing palpitations. ECG reveals his baseline right bundle branch block and new atrial flutter at a rate of 110 to 120. He is otherwise asymptomatic. Heparin is started. He remains in atrial fibrillation over the next 2 days while a workup demonstrates normal po-

VII-57. (Continued)

tassium, magnesium, thyroid-stimulating hormone, and chest x-ray. The decision is made to proceed with chemical cardioversion. He is given intravenous procainamide. Halfway through the infusion, the telemetry suddenly reveals a rate of 240 with narrow QRS complexes. He is found to be pulseless, CPR is begun, and he is defibrillated with 100 J, which restores sinus rhythm that degenerates into atrial fibrillation. This reaction could have been prevented if

- (A) the patient's allergy to procainamide had been known
- (B) the infusion of procainamide had been administered more slowly
- (C) pretreatment before procainamide had been undertaken with digoxin, propranolol, or verapamil
- (D) quinidine had been used instead of procainamide
- (E) his QTc had been followed more carefully at periodic points during the procainamide infusion

VII-58. Which of the following statements concerning Eisenmenger's syndrome is true?

- (A) Eisenmenger's syndrome is a complication of a ventricular septal defect but not of an atrial septal defect.
- (B) Eisenmenger's syndrome arises due to right to left intracardiac shunting.
- (C) The initial morphologic changes are irreversible.
- (D) As the disease progresses, pulmonary vascular resistance increases and the intracardiac shunt reverses.
- (E) The initial murmur associated with the congenital defect will typically worsen as the Eisenmenger's syndrome develops.

VII-59. Which of the following statements regarding cardiac imaging is correct?

- (A) Sestamibi imaging can be readily used to identify hibernating myocardium
- (B) Thallium cannot be readily used to identify hibernating myocardium
- (C) Dipyridamole stress testing is safe in patients with chronic obstructive pulmonary disease (COPD)
- (D) The effects of dipyridamole can be reversed with intravenous theophylline
- (E) Sestamibi should not be injected during an episode of chest pain

VII-60. Which of the following statements concerning ventricular free-wall rupture after a myocardial infarction is true?

- (A) Typically occurs late in the post-MI course (>2 weeks)
- (B) Often occurs in the center of the infarcted area
- (C) It is more common after the first MI as opposed to subsequent MIs
- (D) It is more common in patients with left ventricular hypertrophy
- (E) Due to the thinness of the right ventricular wall, patients with inferior myocardial infarctions are at greatest risk

VII-61. Cystic medial necrosis is prevalent in which of the following disorders?

- (A) Takayasu's arteritis
- (B) Ehlers-Danlos syndrome type IV
- (C) Congenital aortic aneurysms
- (D) Syphilitic aortitis
- (E) Giant cell arteritis

VII-62. A 30-year-old man is transported to the emergency room after a motor vehicle accident. He is complaining of moderate chest pain. He becomes hypotensive and his blood pressure pattern reveals a pulsus paradoxus. His heart sounds appear distant. An examination of his neck veins fails to reveal a Kussmaul's sign. His electrocardiogram is unremarkable, and a chest x-ray reveals an enlarged cardiac silhouette. A right heart catheter is placed. Which of the following values is consistent with this patient's diagnosis?

	Right Atrial Pressure, mmHg	Pulmonary Arterial Pressure, mmHg	Pulmonary Capillary Wedge Pressure, mmHg
(A)	16	75/30	11
(B)	16	34/16	16
(C)	16	100/30	28
(D)	16	45/22	20
(E)	16	22/12	10
Normal values	0–5	12–28/3–13	3–11

- VII-63.** A 16-year-old boy is referred by his high school coach for a physical examination before joining the football team. His older brother died suddenly during football practice; no autopsy was obtained. The patient has a loud systolic murmur. Which of the following would be consistent with hypertrophic cardiomyopathy?
- (A) A crescendo-decrescendo systolic murmur
 - (B) Radiation into the neck
 - (C) Delayed carotid upstrokes
 - (D) A decrease in the murmur on Valsalva or standing
 - (E) An increase with passive leg raising
- VII-64.** Which of the following disorders can lead to both cardiogenic and noncardiogenic pulmonary edema?
- (A) Exposure to high altitude
 - (B) Heroin overdose
 - (C) Central nervous system disorders
 - (D) Sarcoidosis
 - (E) Gram-negative septicemia
- VII-65.** In patients with established coronary artery disease and elevated LDL levels, which of the following statements regarding HMG-CoA reductase inhibitors is true?
- (A) The affect on both endothelial damage and thrombotic complications can be seen with only 6 months of therapy
 - (B) Although there is a significant change in mortality from cardiovascular events, there is no significant decrease in total mortality
 - (C) Treatment is associated with a decrease in the number of invasive cardiac procedures, both angioplasty and coronary bypass
 - (D) The average decrease in LDL cholesterol of these agents is >50%
 - (E) Patients with homozygous familial hypercholesterolemia, typically with markedly elevated LDL levels, are particularly responsive to the LDL-lowering effect of all HMG-CoA reductase inhibitors
- VII-66.** You are asked to give medical clearance for a 75-year-old man prior to an elective carotid endarterectomy. His past medical history is significant for hypercholesterolemia and hypertension. He also has diet-control diabetes mellitus. His current medications include simvastatin and hydrochlorothiazide. He denies any current or prior cardiac symptoms and has never had a myocardial infarction. His physical examination is unrevealing with the exception of a right carotid bruit. His electrocardiogram is unremarkable with the exception of VPCs at a rate of 2 to 3 per minute. Laboratory analysis is unremarkable including normal renal function and liver function tests. His oxygen saturations are also normal. What would be the
- VII-66.** (Continued)
- expected serious complication rate (perioperative MI, pulmonary edema, or ventricular tachycardia) in this patient?
- (A) <0.1%
 - (B) 0.1–1.0%
 - (C) 1.0–3.0%
 - (D) 3.0–10%
 - (E) ≥10%
- VII-67.** Which of the following statements regarding the vascular biology of the atherosclerotic process is true?
- (A) The atheroma is the initial lesion of atherosclerosis
 - (B) Unlike LDL, lipoprotein (a) [Lp(a)] is not particularly atherogenic
 - (C) Atherosclerosis is a diffuse process
 - (D) Adhesion molecules such as VCAM-1 are expressed by endothelial cells and act as receptors for circulating lymphocytes and monocytes
 - (E) Early atherosclerotic lesions encroach on the vessel lumen but do not create significant limitations of flow, explaining the greater clinical significance of severe occlusive coronary disease seen on cardiac catheterization
- VII-68.** A 54-year-old woman presents to the office asking for a second opinion regarding her shortness of breath. She has a history of cigarette smoking for many years but stopped 2 years ago, when she was found to have breast cancer. She underwent a modified radical mastectomy but received no additional therapy. She also has a history of hypertension previously controlled with hydrochlorothiazide (HCTZ). Approximately 6 months ago, she saw her internist because of mild shortness of breath unresponsive to an increase in the HCTZ dose or a subsequent change to furosemide. She developed ankle swelling, worsened shortness of breath, and orthopnea. Blood pressure is 130/100 without pulsus paradoxus, and pulse is 110. She appears to be in moderate respiratory distress. Chest examination reveals faint bibasilar crackles. Heart sounds are decreased but unremarkable. The abdomen is benign. There is 2+ pitting edema. Chest x-ray reveals moderate cardiomegaly and bilateral pleural effusions. ECG demonstrates low voltage but no evidence of right ventricular strain. Which of the following statements is true?
- (A) The increasing doses of diuretics have helped her remain at home and free of worsening dyspnea
 - (B) The patient probably has direct myocardial invasion by a tumor
 - (C) An echocardiogram would offer absolute proof of the diagnosis
 - (D) The lack of pulsus paradoxus could suggest the presence of an atrial septal defect
 - (E) Heparin and IV nitroglycerin should be instituted until Doppler ultrasound of the lower extremities is

VII-68. (Continued)

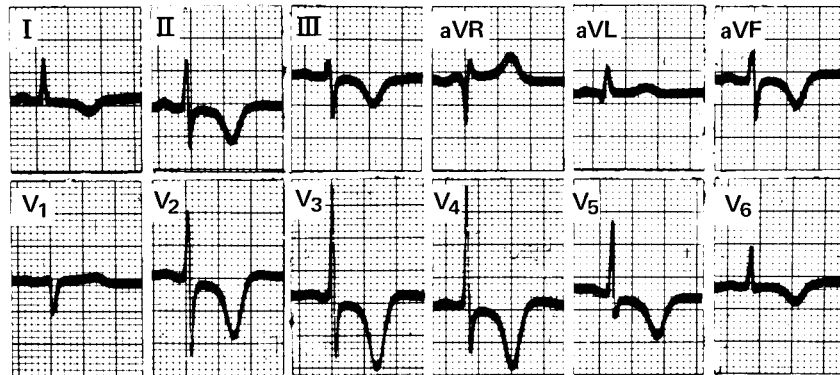
obtained and she is ruled out for myocardial infarction

VII-69. Which of the following has been demonstrated to reduce perioperative mortality in patients undergoing non-cardiac surgery?

VII-69. (Continued)

- (A) Nitrates
- (B) Beta blocker
- (C) Calcium channel blocker
- (D) α_2 Agonist
- (E) Diuretic therapy

VII-70. A 62-year-old man loses consciousness in the street, and resuscitative efforts are undertaken. In the emergency room an electrocardiogram is obtained, part of which is shown below. Which of the following disorders could account for this man's presentation?



From Marriott HJL: *Practical Electrocardiography*, 7th ed. Baltimore, Williams & Wilkins, 1983, p 400, with permission.

- (A) Hypokalemia
- (B) Hyperkalemia
- (C) Intracerebral hemorrhage
- (D) Digitalis toxicity
- (E) Hypocalcemic tetany

VII-71. Acute hyperkalemia is associated with which of the following electrocardiographic changes?

- (A) QRS widening
- (B) Prolongation of the ST segment
- (C) A decrease in the PR interval
- (D) Prominent U waves
- (E) T wave flattening

VII-72. Which of the following statements regarding exercise tolerance tests is true?

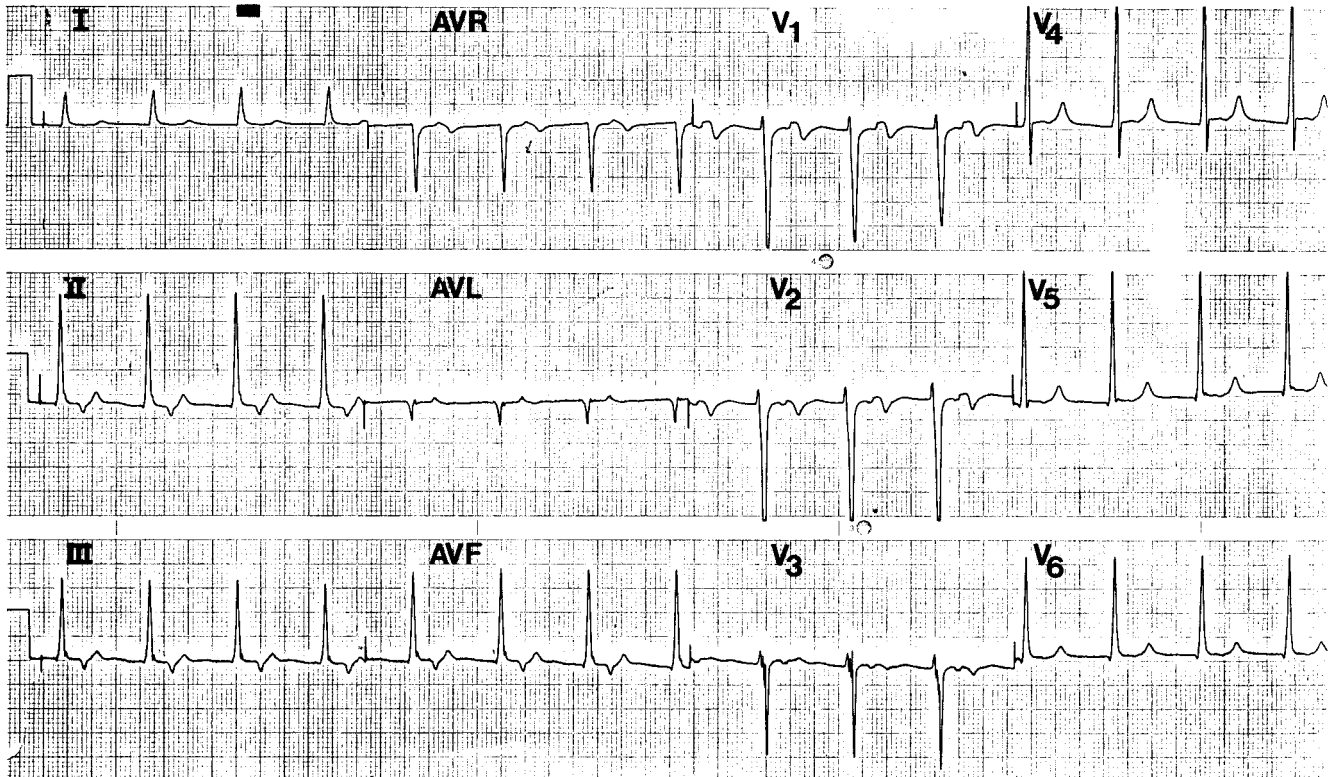
- (A) Requiring ≥ 2.0 mm of ST depression to define a test as positive enhances the sensitivity of the test compared with a situation in which only 0.5 mm of ST depression is required to count as positive
- (B) Given a specificity of 90% and a sensitivity of 80%, a positive test in a patient whose prior proba-

VII-72. (Continued)

bility of having coronary artery disease (based on clinical factors) is 10% suggests a $>80\%$ likelihood that the patient actually has coronary artery disease

- (C) Thallium 201 exercise scanning increases both the sensitivity and the specificity for detecting ischemic heart disease
- (D) A thallium 201 scan done at peak exercise that reveals a nonperfused area of myocardium indicates that the patient has suffered a prior myocardial infarction
- (E) A marked increase in blood pressure during the test suggests poor conditioning and probably will cause the test to be nondiagnostic

VII-73. The rhythm shown on the electrocardiogram below can be associated with



- | | |
|------------------------------------|------------------------------|
| (A) digitalis toxicity | (D) intracerebral hemorrhage |
| (B) hypokalemia | (E) hypercalcemia |
| (C) anterior myocardial infarction | |

VII-74. Mild heart failure resulting from left ventricular dysfunction is accurately described by which of the following statements?

- (A) Cardiac output would be depressed at rest
- (B) Plasma norepinephrine levels would be lower than those in normal controls during exercise
- (C) Myocardial norepinephrine content would be high
- (D) Left ventricular end-diastolic pressure rises less during exercise than it does in normal controls
- (E) Cardiac output would fail to rise appropriately when oxygen consumption was increased during exercise

VII-75. Drugs that would antagonize the interaction of catecholamines with adrenergic receptors include

- (A) methyl dopa
- (B) clonidine
- (C) phenylephrine
- (D) yohimbine
- (E) isoproterenol

VII-76. A 37-year-old man with Wolff-Parkinson-White syndrome develops a broad-complex irregular tachycardia

VII-76. (Continued)

at a rate of 200 beats per minute. He appears comfortable and has little hemodynamic impairment. Useful treatment at this point might include

- (A) digoxin
- (B) amiodarone
- (C) propranolol
- (D) verapamil
- (E) direct-current cardioversion

VII-77. Sudden cardiac death is accurately described by which of the following statements?

- (A) Ventricular tachycardia or ventricular fibrillation during the convalescent phase (3 days to 8 weeks) after a myocardial infarction is not a risk factor for subsequent sudden cardiac death
- (B) The presence of VPCs in a patient convalescing from a myocardial infarction increases the risk of sudden cardiac death
- (C) If only one person is present to provide basic life support, chest compressions should be performed at a rate of 80 per minute, and breaths twice in succession every 15 s

VII-77. (Continued)

- (D) Assuming there is no spontaneous pulse, a 400-J shock should be delivered immediately upon recognition of ventricular tachycardia or ventricular fibrillation
- (E) Intravenous sodium bicarbonate should be given approximately every 5 min during cardiac arrest

VII-78. A 17-year-old girl has an atrial septal defect of the sinus venosus type, with a 3:1 pulmonary-to-systemic blood flow ratio. True statements concerning her condition include which of the following?

- (A) The patient is likely to complain of chest pain, dyspnea on exertion, and recurrent palpitations
- (B) She probably has partial anomalous connection of the pulmonary veins
- (C) The magnitude of the shunt is a function of the amount of total blood flow
- (D) A systolic murmur probably would be due to flow across the defect
- (E) A diastolic rumble would strongly suggest the coexistence of mitral stenosis (Lutembacher's syndrome)

VII-79. The initial positive deflection in the jugular venous pulse (*a* wave) can be accentuated in which of the following conditions?

- (A) Reentrant paroxysmal supraventricular tachycardia (PSVT)
- (B) Tricuspid regurgitation
- (C) Atrial fibrillation
- (D) Multiple pulmonary emboli
- (E) First-degree AV block

VII-80. For which of the following patients would cardiac surgery be appropriately recommended?

- (A) An asymptomatic 20-year-old man with a loud midsystolic murmur due to a congenital bicuspid aortic valve
- (B) An asymptomatic 19-year-old man who has a loud murmur and a ventricular septal defect with a 1.5:1 pulmonary-to-systemic flow ratio
- (C) A 33-year-old man who has chest pain, fatigue, cyanosis, a large ventricular septal defect, a 2:1 right-to-left shunt, and a normal pulmonary outflow tract and pulmonic valve
- (D) A 52-year-old man who has chronic mitral regurgitation and has recently developed pulmonary edema associated with the onset of rapid atrial fibrillation
- (E) A 54-year-old man who has aortic stenosis and has chest pain on moderate to strenuous exertion

VII-81. True statements regarding balloon valvuloplasty include**VII-81.** (Continued)

- (A) balloon dilatation of a stenotic pulmonary valve is not feasible because of the danger of rupture of the thin-walled pulmonary artery
- (B) mitral valvuloplasty increases the effective diastolic valve area to normal size
- (C) balloon aortic valvuloplasty is contraindicated in calcific aortic stenosis because the fracture of calcium deposits on the leaflets leads to cerebral emboli
- (D) restenosis after aortic valvuloplasty is a significant problem
- (E) the prior use of aortic valvuloplasty increases the perioperative mortality after a definitive surgical repair

VII-82. True statements regarding hemodynamic changes occurring during exercise include which of the following?

- (A) Venous return is impeded by the pumping action of skeletal muscles
- (B) The increased adrenergic nerve impulses to the heart as well as an increased concentration of circulating catecholamines help augment the contractile state of the myocardium
- (C) Venoconstriction in exercising muscles as well as increased cardiac output leads to marked increases in systemic blood pressure
- (D) End-diastolic volume decreases in a failing heart during exercise
- (E) Although the heart rate increases during exercise, there is a concomitant reduction in the stroke volume

VII-83. A 34-year-old woman is bothered by palpitations and chest pain. On auscultation, the first heart sound is normal, but there is a midsystolic click and a late systolic murmur. Her electrocardiogram shows T-wave inversions in leads II, III, and aVF. True statements concerning her condition include which of the following?

- (A) An exercise stress test would most likely be positive
- (B) An echocardiogram may show abrupt posterior displacement of both mitral leaflets
- (C) The woman's chest pain could be due to partial obstruction of her coronary ostia
- (D) The click and murmur would be expected to occur later in systole when the woman stands
- (E) Spontaneous bacterial endocarditis is rare, and prophylactic antibiotics are not recommended

VII-84. A permanent atrioventricular sequential pacemaker (DDD) would be preferred to a standard ventricular pacemaker (VVI) in which of the following patients?

- (A) A 64-year-old woman with atrial fibrillation and a ventricular rate of 40 beats per minute

VII-84. (Continued)

- (B) A 56-year-old man with a prolonged PR interval
- (C) An active 46-year-old man with a sinus rhythm at a rate of 48
- (D) An 80-year-old woman with symptomatic bradyarrhythmias and normal left ventricular function
- (E) A 50-year-old man with hypertrophic cardiomyopathy and infranodal second-degree atrioventricular block

VII-85. In which of the following patients would you recommend a preoperative noninvasive functional assessment?

- (A) An emergent repair of a ruptured appendix
- (B) A 65-year-old man prior to undergoing a carotid endarterectomy, who underwent a coronary artery bypass graft (CABG) 2 years earlier and has had no prior symptoms
- (C) A 62-year-old man with hypertension, hypercholesteremia, and diabetes mellitus who is having recurrent chest pain with only minimal exertion prior to his radical prostatectomy
- (D) A 65-year-old man with a prior history of angina but no history of myocardial infarction planning to undergo an elective hip replacement
- (E) A 52-year-old woman with no cardiac symptoms and a normal physical exam prior to her breast biopsy for a newly identified mass

VII-86. Correct statements regarding cardiac transplantation include

- (A) the 5-year survival is 25 to 50%
- (B) a single P wave is seen on the electrocardiogram
- (C) risk factors for accelerated coronary vascular disease include the number of rejection episodes and hyperlipidemia
- (D) chronic rejection accounts for the majority of late (>1 year after transplant) deaths
- (E) immunosuppressive drugs can be discontinued after 5 years, since the risk of rejection after that point is extremely low

VII-87. A 50-year-old woman with a history of hypertension (but taking no medication currently) presents to the emergency ward with a complaint of sudden palpitations and faintness. Her pulse is 120, and the 12-lead ECG discloses a wide-complex tachycardia. Which of the following characteristics would suggest a ventricular origin for her tachycardia rather than supraventricular tachycardia with aberrant conduction?

- (A) A QRS complex of 0.12 s
- (B) A QRS complex of 0.22 s
- (C) Very irregular rhythm
- (D) Atrioventricular dissociation
- (E) A right bundle branch block pattern with a classic triphasic QRS complex in lead V₁

VII-88. A 23-year-old man has had recent onset of exertional dyspnea. A grade III/VI systolic murmur is heard at the left sternal border. Electrocardiography shows apical and lateral Q waves and left ventricular hypertrophy. Echocardiography reveals asymmetric septal hypertrophy without evidence of obstruction. Correct statements regarding this clinical situation include which of the following?

- (A) The man's dyspnea is best explained by lateral wall infarction
- (B) No familial predisposition is seen
- (C) The risk of sudden death is low
- (D) Calcium channel blockers may relieve the symptoms
- (E) The man's heart is normal histologically aside from changes of infarction

VII-89. Aortic regurgitation is accurately characterized by which of the following statements?

- (A) Most cases of aortic regurgitation (with or without associated lesions) are due to congenital (including Marfan's syndrome), syphilitic, or spondylitic causes
- (B) *Quincke's pulse* refers to the pistol-shot sound audible over the femoral arteries
- (C) The Graham Steell murmur of pulmonary regurgitation is frequently associated
- (D) The echocardiogram frequently reveals fluttering of the anterior leaflet of the mitral valve
- (E) Surgical correction should be performed immediately even if the patient is asymptomatic and retains normal left ventricular function

VII-90. Which of the following findings probably would be present in a patient who sustained recurrent pulmonary emboli?

- (A) Decreased lung volumes on spirometric testing
- (B) Left bundle branch block pattern on electrocardiographic examination
- (C) Tricuspid regurgitant flow on Doppler echocardiography
- (D) No right ventricular uptake on thallium 201 scintigraphy
- (E) On physical exam, there is wide splitting of the second heart sound (S₂) and a decrease in the second component

VII-91. True statements regarding the effect of alcohol on the heart include which of the following?

- (A) Chronic ingestion of alcohol will lead to a restrictive cardiomyopathy
- (B) Once heart failure develops, discontinuing the consumption of alcohol will not appreciably affect the natural history of the disease

VII-91. (Continued)

- (C) If thiamine deficiency is present in an alcoholic, high output failure is noted
- (D) If a patient with heart failure caused by ethanol continues to drink, he or she is unlikely to be alive in 3 years
- (E) The most common arrhythmia associated with a drinking binge is ventricular tachycardia

VII-92. True statements regarding cardiac neoplasms include

- (A) lymphoma is the most common malignant neoplasm that primarily involves the heart
- (B) the most common site for a myxoma is the right atrium
- (C) myxomas may arise as part of a familial syndrome that also includes pigmented skin lesions and endocrine abnormalities
- (D) a midsystolic “plop” typically indicates the presence of a cardiac myxoma
- (E) patients with myxoma typically present with chest pain and dyspnea on exertion

VII-93. A 65-year-old man with a history of multiple prior myocardial infarctions and episodes of congestive heart failure presents to the emergency room with sustained ventricular tachycardia (VT). His blood pressure is stable and he is mentating well. Administration of which of the following antiarrhythmic agents would be most appropriate?

- (A) Epinephrine
- (B) Lidocaine
- (C) Bretylium
- (D) Propafenone
- (E) Quinidine

VII-94. The rhythm of the patient in VII-93 converts to normal sinus after the administration of the above agent. Unfortunately, in spite of continued administration the patient develops several other episodes of sustained VT. The most recent episode is poorly tolerated with the development of significant hypotension requiring electrical cardioversion. An electrophysiologic study fails to reveal an inducible VT/VF rhythm. Which of the following treatment recommendations would be associated with the highest overall survival?

- (A) Sotalol
- (B) Amiodarone
- (C) Propafenone
- (D) Mexiletine
- (E) Placement of an implanted cardioverter/defibrillator (ICD)

VII-95. Which of the following statements regarding exercise and cardiovascular morbidity is true?**VII-95.** (Continued)

- (A) Regular exercise does not provide adequate protection against an MI during heavy physical exertion
- (B) Heavy physical exertion can trigger the onset of an acute MI
- (C) The incidence of MI is less frequent during the early morning hours after arising from sleep
- (D) The mechanism of cardiac ischemia involves decreased oxygen delivery due to vasoconstriction of the coronary arteries and not due to atherosclerotic plaque
- (E) The onset of symptoms is usually 30 min to 1 h after completion of physical exertion

VII-96. Which of the following statements regarding cholesterol reduction is true?

- (A) Pharmacologic cholesterol reduction does not significantly decrease the risk of cardiovascular mortality in patients with known cardiovascular disease
- (B) Pharmacologic reduction in cholesterol can decrease cardiovascular mortality in patients with and without coronary artery disease
- (C) In patients without diabetes mellitus but with cardiovascular disease, the pharmacologic interventions should be initiated when the LDL cholesterol level is >160
- (D) Cholesterol reduction does not alter the restenosis rate in patients after cutaneous cardiac catheterization
- (E) Cardiovascular morbidity has only been shown for the HMG-CoA reductase inhibitors

VII-97. Which of the following statements concerning acute rheumatic fever is true?

- (A) Migratory polyarthritis occurs in <10% of patients
- (B) Sydenham’s chorea typically occurs early in the course of the disease
- (C) Erythema marginatum is a common finding, occurring in >50% of cases
- (D) Secondary prophylaxis should be initiated in order to decrease recurrent episodes of rheumatic fever
- (E) Group A streptococci can usually be recovered in the upper respiratory tract of patients with rheumatic fever

Questions VII-98 to VII-100.**VII-98.** You are asked to evaluate a 65-year-old man in the emergency room complaining of the acute onset of chest pain. During your evaluation the patient becomes unresponsive and is pulseless. A cardiac monitor reveals ventricular fibrillation. What would be the most appropriate sequence of events?

VII-98. (Continued)

- (A) Immediately begin CPR, followed by intubation, followed by defibrillation starting at 100 J, followed by 200 J and then 360 J
- (B) Immediately begin CPR, followed by intubation then defibrillation starting at 200 J, then 300 J, then 360 J
- (C) Immediately begin CPR, followed by defibrillation at 100 J, then 200 J, then 360 J
- (D) Immediately begin CPR, followed by defibrillation at 200 J, then 300 J, then 360 J
- (E) Begin CPR, defibrillate at 200 J, then intubate

VII-99. Despite the efforts outlined in the answer to Question VII-98, the patient has persistent ventricular fibrillation. The use of which drug would be most appropriate?

- (A) Amiodarone
- (B) Lidocaine
- (C) Bretylium
- (D) Procainamide
- (E) Epinephrine

VII-100. The patient in Question VII-98 eventually develops a sinus rhythm with a stable blood pressure. He is transferred to the intensive care unit. It is discovered that the etiology of his ventricular fibrillation is most likely associated with a large anterior wall and myocardial infarction. During his postinfarction recovery phase, the patient undergoes a percutaneous coronary angioplasty with a stent placement; he quickly stabilizes. The patient has no further chest pain and no further arrhythmias during his hospitalization. Which of the following would be the most appropriate management decision with respect to his arrhythmia?

- (A) No antiarrhythmia therapy is required
- (B) An implantable cardioverter-defibrillator (ICD)
- (C) Beta blocker
- (D) Amiodarone
- (E) Flecainide

VII. DISORDERS OF THE CARDIOVASCULAR SYSTEM

ANSWERS

- VII-1. The answer is B.** (*Chap. 243*) The combination of hypotension and bradycardia suggests a vagal response in the setting of an acute myocardial infarction. Administration of the anticholinergic agent atropine is the treatment of choice. If the bradyarrhythmia and hypotension persist after 2.0 mg of atropine has been administered in divided doses, the insertion of a temporary pacemaker is indicated. Isoproterenol should be avoided in patients with acute myocardial infarction, since it may greatly increase myocardial oxygen consumption and thus intensify ischemia. Volume replacement or inotropic support may be required if hypotension persists after correction of the bradyarrhythmia, but they are not indicated as initial therapies.
- VII-2. The answer is A.** (*Chaps. 38, 243*) A patient presenting with hypotension and oliguria is critically ill and requires urgent definition of the etiology of this condition. The clinical presentation with shock, fever, and pulmonary infiltrates is consistent with either noncardiogenic or cardiogenic pulmonary edema. The elevated pulmonary capillary wedge pressure strongly suggests failure of left ventricular output as a result of primary myocardial dysfunction or obstruction caused by pericardial tamponade. Pulmonary emboli, septic shock, and hypovolemia from gastrointestinal blood loss would all cause the pulmonary capillary wedge pressure to be decreased. Although pericardial tamponade could produce elevated pulmonary capillary wedge pressure, the obstruction to right ventricular inflow should be associated with equally abnormal right atrial mean, right ventricular end-diastolic, and pulmonary artery end-diastolic pressures. Therefore, this patient is suffering from cardiogenic shock caused by left ventricular myocardial dysfunction on the basis of myocardial infarction, severe cardiomyopathy, or myocarditis. Given the relatively normal electrocardiogram and the fever, the last condition is a distinct possibility.
- VII-3. The answer is D.** [*Chap. 39. Standards and guidelines for cardiopulmonary resuscitation (CPR) in emergency cardiac care (ECC). JAMA 255:2905, 1986.*] The successful resuscitation of a patient with cardiac arrest depends on the rapidity of the initiation of resuscitative efforts, the clinical status of the patient before the arrest, and the mechanism of the event. In this case the patient has a reasonable chance of recovery because of his good initial performance status (the event occurred while he was golfing), rapid institution of CPR by trained personnel, and sustained ventricular tachycardia (VT) as the mechanism for the event. The most appropriate management of cardiac arrest induced by VT is an initial 200-J defibrillation. Additional shocks at higher energies, up to a maximum of 360 J, should be attempted in the event of an initial failure to abolish the VT. Whether the initial defibrillation attempt is successful or not, lidocaine should be given intravenously as a 1 mg/kg bolus, to be followed in 2 min by the same dose if the arrhythmia is persistent. Second-line drugs that can be used in the event of lidocaine failure include intravenous procainamide and bretylium. If persistent ventricular fibrillation (VF) is the cause of the event, epinephrine may be administered every 5 min. Intravenous sodium bicarbonate and calcium are no longer considered safe or necessary for routine administration. Intravenous calcium gluconate would be indicated in the setting of hyperkalemia as the triggering event for resistant VF, in the presence of known hypocalcemia, and in those who have received high doses of calcium channel antagonists.

- VII-4. The answer is E.** (*Chap. 246. Williams, N Engl J Med 319:1517, 1989.*) Captopril is an inhibitor of angiotensin converting enzyme and thus impairs the production of angiotensin II, a potent vasoconstrictor. Through removal of feedback inhibition, renin secretion is increased. Additional antihypertensive effects of captopril result from reduction of bradykinin degradation and stimulation of vasodilating prostaglandin production. Converting-enzyme inhibitors can be added to a regimen of beta blockade to achieve an additional antihypertensive effect. Captopril is contraindicated in patients with bilateral renal artery stenosis, since a reduction in systemic arterial pressure may lead to progressive renal hypoperfusion.
- VII-5. The answer is C.** (*Chap. 239*) The lateral-view chest film demonstrates calcification of the anterior pericardium, consistent with constrictive pericarditis. This pattern is seen in approximately one-half of patients with long-standing constriction, and pericardial thickening often can be confirmed by echocardiography. In patients with this disease, a pericardial knock is often heard 0.06 to 0.12 s after aortic valve closure, corresponding to the sudden cessation of ventricular filling. Murmurs are typically absent.
- VII-6. The answer is E.** (*Chap. 245*) PTCA to reduce one or more coronary stenoses in the treatment of chronic angina unresponsive to medical therapy, unstable angina, or acute myocardial infarction has been employed with increasing frequency. The risks and benefits of PTCA compare favorably with those of conventional surgery. Given the decreased cost and recovery and hospitalization time, PTCA is preferred whenever possible. While the current PTCA success rate exceeds 90%, a return of cardiac ischemia within 6 months strongly suggests restenosis of the dilated segment. Such restenosis appears to result from excessive local smooth-muscle cell hyperplasia triggered by platelet adhesion on the balloon-damaged surface. While the use of nitrates, calcium channel antagonists, heparin, and aspirin just before and up to 6 months after the procedure helps prevent an acute closure resulting from spasm and thrombus formation, no anatomic or pharmacologic strategy has substantially reduced the restenosis rate. When recurrent ischemia develops more than 6 months after a PTCA, progression of disease at another site is more likely than restenosis. However, repeat PTCA is quite successful in treating patients with restenosis; bypass surgery is required in $\leq 10\%$ of such patients.
- VII-7. The answer is A.** (*Chap. 229*) The electrocardiogram discloses sudden failure of atrial ventricular conduction without a preceding change in the PR interval, termed *Mobitz type II second-degree AV block*, which usually reflects significant disease of the conduction system. It may occur after a significant anterior myocardial infarction or in Lev's disease, which involves calcification and sclerosis of the fibrous cardiac skeleton (frequently involving the aortic and mitral valves), or Lenègre's disease, which involves only the conducting system. Mobitz type II block is inherently unstable and tends to progress to complete heart block with a slow, lower escape pacemaker. Therefore, pacemaker implantation is necessary in this condition, particularly if the patient is symptomatic, as in this case.
- VII-8. The answer is B.** (*Chaps. 228–243. Kinch, Ryan, N Engl J Med 330:1211–1217, 1994.*) Typically right ventricular infarction occurs when there is an inclusion of the right coronary artery proximal to the acute marginal branch. Isolated right ventricular infarction accounts for $<3\%$ of all cases of myocardial infarction but has an increased morbidity. It is associated with atherosclerotic disease. The clinical triad of hypotension, clear lung fields, and elevated jugular venous pressure is clinically consistent with a right ventricular infarction. In addition, Kussmaul's venous sign has also been shown to be a highly sensitive and specific feature for right ventricular infarction. Kussmaul's sign is the distention of the jugular vein on inspiration and is a classic feature of constrictive pericarditis. This sign is absent in pericardial tamponade. Other physical findings may include a right ventricular gallop, tricuspid regurgitation, and atrioventricular dissociation. Hemodynamically, patients are often hypotensive and relatively bradycardic. The right atrial pressure is typically >10 mmHg, and the pulmonary capillary wedge pressure is often normal with normal

pulmonary artery pressures as well. Electrocardiographically, a right myocardial infarction is best diagnosed by elevation of the ST-segment elevation in lead V_{4R} . Patients often present with a high degree of heart block or conduction delays and this indicates a poor prognosis in patients with inferior myocardial infarction. In addition to the standard treatment for myocardial infarction, treatment of right ventricular infarction would include volume loading, the avoidance of nitrates or diuretics, and maintenance of atrial ventricular synchrony.

- VII-9. The answer is C.** (*Chaps. 225, 236, 238*) Assessment of the central aortic pulse wave is best carried out by examination of the carotid pulsations. Normally, the carotid pulse is characterized by a fairly rapid rise to a somewhat rounded peak. If two such peaks are found, diagnostic considerations include aortic regurgitation and hypertrophic cardiomyopathy. In the latter condition, obstruction to outflow usually occurs in midsystole. Moreover, obstruction is more manifest during reduced left ventricular size, such as after a Valsalva maneuver with subsequent decreased venous return. A brief decline in pressure follows the sudden decrease in the rate of left ventricular ejection during midsystole because of the development of obstruction. The second peak is caused by a smaller positive pulse wave produced by the remainder of ventricular ejection and by reflected waves from peripheral sources. The so-called bisferiens pulse should be distinguished from pulsus alternans, in which there is a regular alteration of the pressure pulse amplitude from beat to beat, usually associated with severe impairment of left ventricular function and therefore occurring in the setting of a third heart sound. Pulsus paradoxus, which is found in pericardial tamponade, severe airway disease, and superior vena cava obstruction, reflects an exaggerated decrease in systolic arterial pressure during inspiration.
- VII-10. The answer is C.** (*Chap. 226*) This ECG reveals an abnormal increase in the amplitude of the U wave, a small deflection following the T wave that usually has the same polarity as the T wave. Recognition of a pronounced U wave is important, for it may represent increased susceptibility to a torsades de pointes type of ventricular tachycardia. Prominent U waves are most commonly seen after the use of antiarrhythmic drugs such as quinidine, procainamide, and disopyramide or are due to hypokalemia. The latter condition would be typical of a patient receiving amphotericin B, which typically produces severe renal potassium wasting as a result of renal tubular damage. A patient with acute renal failure and hyperkalemia would display peaked T waves or an increased QRS duration on the ECG. Hypercalcemia, such as occurs in patients with metastatic breast cancer, and digitalis intoxication tend to produce short QT intervals. Inverted U waves are sometimes a subtle sign of myocardial ischemia.
- VII-11. The answer is E.** (*Chap. 232*) Digitalis glycosides augment contractility of the heart and slow atrioventricular conduction and heart rate. The primary mechanism of action is inhibition of Na^+ , K^+ -ATPase, which is located in the sarcolemmal membrane. This action leads to intracellular accumulation of sodium and subsequently calcium by way of a sodium-calcium exchange mechanism.
- VII-12. The answer is D.** (*Chap. 232. Grossman, N Engl J Med 325:1557–1564, 1991.*) Despite the fact that this patient's ejection fraction is normal, the presence of left ventricular hypertrophy, suggested by physical examination and confirmed by noninvasive testing, implicates the heart as the source of the problem. The patient has no evidence of either ischemic heart disease or lung disease, yet his ejection fraction is normal. However, it is increasingly recognized that increased resistance to filling of one or more cardiac ventricles, so-called diastolic heart failure, can produce increased pulmonary capillary wedge pressures with resultant respiratory complaints. In conditions such as advanced myocardial hypertrophy, impaired diastolic relaxation occurs. While hypertrophic heart disease is probably the best recognized cause of diastolic dysfunction, resistance to filling also can be seen in a diverse spectrum of conditions, including aortic valve stenosis, constrictive pericarditis, dilated cardiomyopathy, and even the "stunned" myocardium seen in ischemic

heart disease. Treatment with beta blockers and calcium channel blockers may provide some degree of relief of symptoms related to diastolic dysfunction.

- VII-13. The answer is A.** (*Chap. 229*) The escape focus in atrioventricular nodal block is relatively high in the conduction system in an area of vagal innervation. Thus, a beneficial response to vagolytic drugs such as atropine and to exercise is usually apparent. The rate at the escape focus is relatively rapid, and the QRS complex is narrow. Unless complete heart block persists, some Wenckebach periodicity can be observed. Inferior myocardial infarction, mitral valve surgery, and digitalis toxicity can lead to atrioventricular nodal block.
- VII-14. The answer is C.** (*Chap. 232. SOLVD Investigators, N Engl J Med 325:293–302, 1991.*) The agents most typically used in the treatment of congestive heart failure—diuretics and cardiac glycosides—have never been formally shown to prolong survival. However, there have been at least four trials that have demonstrated benefit in the use of afterload reduction in the treatment of heart failure. Vasodilators, including angiotensin-converting enzyme (ACE) inhibitors and hydralazine, reduce left ventricular afterload; in the case of ACE inhibitors such as enalapril, anti-ischemic properties also may play a role by inhibiting the formation of angiotensin II in the coronary artery wall. There is no role for procainamide or other antiarrhythmics in treating patients with congestive heart failure unless the presence of ventricular tachycardia has been documented. Aspirin is indicated only for those with known coronary artery disease and a history of myocardial infarction or angina.
- VII-15. The answer is D.** (*Chap. 239. Fowler, JAMA 266:99–103, 1991.*) Obstruction to cardiac filling and concomitant elevated right-sided pressures that produce elevated neck veins, congestive organomegaly, and pedal edema may be found in several conditions. It often is difficult to distinguish between pericardial tamponade, constrictive pericarditis, restrictive cardiomyopathy, and right ventricular myocardial infarction. In cardiac tamponade, accumulation of fluid in the pericardium is sufficient to cause significant obstruction to the inflow of blood to the ventricles. There is an elevation of intracardiac pressures, a limitation to diastolic filling, and florid cardiac failure. An important physical finding in tamponade is a paradoxical pulse, which is an exaggeration of the normal inspiratory augmentation of right ventricular volume, and a reciprocal reduction in left ventricular volume manifested by a significant inspiratory decrease in systolic arterial pressure. Paradoxical pulse is rare in constrictive pericarditis, restrictive cardiomyopathy, and right ventricular infarction. Right ventricular infarction usually is distinguishable by the absence of low electrocardiographic voltage and frequently can be distinguished by the presence of an injury current on the acute electrocardiogram. The distinction between constrictive pericarditis and restrictive cardiomyopathy is more difficult. In constrictive pericarditis, which results from the healing of a former acute pericarditis or a chronic pericardial effusion with obliteration of the pericardial cavity, filling is reduced abruptly when the elastic limit of the pericardium is reached, unlike tamponade, in which filling is impeded throughout diastole. Patients with constrictive pericarditis often appear to have a chronic illness. Venous pressures decline during inspiration (Kussmaul's), and congestive organomegaly is common, as is ascites. The apical pulse is reduced, and heart sounds are typically distant. An early heart sound, or pericardial knock, may occur 0.06 to 0.12 s after aortic valve closure, earlier than the third heart sound associated with ventricular failure. The electrocardiogram frequently displays low QRS voltage. Restrictive cardiomyopathy (e.g., resulting from amyloidosis, hemochromatosis, sarcoidosis, or scleroderma) can be distinguished from chronic constrictive pericarditis by the presence of a well-defined apical beat, frequent attacks of acute left ventricular failure, left ventricular hypertrophy, true S3, bundle branch block, and occasional Q waves on the electrocardiogram in the latter condition. In acute pericardial tamponade, diastolic right ventricular collapse is characteristic. In restrictive cardiomyopathy, myocardial thickness is frequently increased and abnormalities of the pericardium are absent. Right ventricular size is typically enlarged in right ventricular myocardial infarction. Echocardiographic findings consistent with constrictive

pericarditis include the presence of a thickened pericardium (which is often calcified) in the absence of other findings. The patient in question may have tuberculous pericarditis that has progressed from the original acute stage to a chronic condition with obliteration of the pericardial space and loss of pericardial elasticity.

- VII-16. The answer is B.** (*Chap. 230*) The rhythm demonstrated in the electrocardiogram presented is multifocal atrial tachycardia, which is characterized by variable P-wave morphology and PR and RR intervals. Control of multifocal atrial tachycardia, which usually is associated with severe pulmonary disease, comes with improved ventilation and oxygenation. Carotid sinus massage, electrical cardioversion, and the administration of digitalis, verapamil, or quinidine are of little benefit, although verapamil may temporarily slow the ventricular rate.
- VII-17. The answer is D.** (*Chap. 242*) Given the clearly defined benefits of lipid lowering in patients at risk for ischemic heart disease, screening measurement of blood cholesterol levels (nonfasting) is recommended for all adult patients, especially young patients with a family history of premature heart disease. If hyperlipidemia is detected, secondary causes such as hypothyroidism, nephrotic syndrome, and uremia should be considered, along with stopping drugs that can aggravate the condition, including oral contraceptives, estrogens, thiazides, and beta blockers. Once these effects are considered, the primary step is attention to diet. Attempts should be made to bring the patient to normal weight and encourage the patient to undergo dietary therapy with reduced intake of calories, cholesterol, and saturated fat. However, patients who remain at high risk after 3 months of an intensive regimen of dietary therapy should be strongly considered for lipid-lowering drug therapy. Such therapy is recommended for any adult patient whose LDL cholesterol remains >4.9 mmol/L (190 mg/dL) or >4.1 mmol/L (160 mg/dL) in the presence of two or more risk factors. A more aggressive approach is recommended for patients with a prior history of ischemic heart disease. Other risk factors for early atherosclerosis include diabetes mellitus, hypertension, familial hyperlipidemias, hypothyroidism, systemic lupus, and homocysteinemia. Drugs that act to lower LDL cholesterol include bile acid-binding resins such as cholestyramine, nicotinic acid, and hydroxymethylglutaryl coenzyme A (HMG-CoA) reductase inhibitors.
- VII-18. The answer is A.** (*Chap. 234. Brickner et al, N Engl J Med 342:256–263, 2000.*) Atrial septal defect (ASD) is usually asymptomatic in childhood. Clinical presentation occurs in the third or fourth decade of life and results from atrial arrhythmias and pulmonary hypertension. A common cause of symptoms and of right heart failure is coexistent left ventricular dysfunction; even mild left atrial pressure is not tolerated well when transmitted into the systemic venous circulation. Secundum atrial septal defect is associated with a rightward axis on electrocardiography; the axis is leftward in primum defects. Echocardiography also reveals evidence of right ventricular volume overload, including abnormal motion of the ventricular septum (i.e., right-to-left movement) during diastole. Though small shunts are well tolerated, operative repair usually is indicated when the pulmonary flow is at least 1.5 times the systemic flow.
- VII-19. The answer is C.** (*Chaps. 238, 239*) The restrictive cardiomyopathies are characterized pathophysiologically by an impairment to ventricular filling. The cardiac silhouette is usually mildly, if at all, enlarged. Electrocardiography typically displays low-voltage QRS complexes, atrioventricular conduction defects, and a host of nonspecific arrhythmias. Echocardiography frequently reveals normal systolic and increased left ventricular wall thickness. In amyloidosis, the left ventricular wall appears to be “speckled.” While primary cardiac amyloidosis typically produces diastolic dysfunction or restrictive cardiomyopathy as in this question, systolic dysfunction, arrhythmias, and orthostatic hypotension may be alternative presentations. Hemochromatosis also may cause a restrictive picture, but the speckled appearance noted in the echocardiogram would be absent. Alcoholism and viral infections typically cause dilated cardiomyopathies. Chronic tuberculous pericarditis can

manifest clinical symptoms similar to those seen in restrictive cardiomyopathy. Patients with constrictive pericarditis have clinical presentations similar to those of patients with restrictive cardiomyopathy but tend to have normal ventricular wall thickness on echocardiography, pericardial calcification, and the absence of third or fourth heart sounds on chest auscultation.

- VII-20. The answer is B.** (*Chaps. 234, 237*) The chest x-rays presented in the question show enlargement of the right ventricle and main pulmonary artery and pulmonary vascular plethora, or “shunt” vasculature—classic findings for an ASD, which could well be asymptomatic in a 36-year-old woman. The chest x-ray of a patient with mitral stenosis and hemoptysis and dyspnea would show left atrial enlargement and, in the presence of primary or secondary tricuspid regurgitation, ascites and a large jugular venous *v* wave. Continuous murmur, widened systemic pulse pressure, and dyspnea on exertion in combination suggest patent ductus arteriosus, which would produce x-ray evidence of left ventricular and perhaps left atrial enlargement and shunt vasculature without right ventricular enlargement.
- VII-21. The answer is D.** (*Chap. 234*) Adults with mild pulmonic stenosis are generally asymptomatic. Unlike congenital aortic stenosis, this condition usually does not progress; thus, follow-up need not be frequent. The risk of endocarditis is somewhat lower for pulmonic valves than for the other heart valves, whether normal or stenotic. Clinical signs of mild pulmonic stenosis include a prominent *a* wave on jugular venous pulse, a normal electrocardiogram, and normal cardiac size on chest x-ray.
- VII-22. The answer is D.** (*Chap. 234. Brickner et al, N Engl J Med 342:256–263, 2000.*) Coarctation of the aorta usually occurs just distal to the origin of the left subclavian artery; if it arises above the left subclavian, blood pressure elevation may be evident only in the right arm. The associated murmur is continuous only if obstruction is severe; otherwise, a systolic ejection murmur is heard anteriorly and over the back. Coarctation of the aorta commonly is accompanied by a bicuspid aortic valve, which can produce the diastolic murmur of aortic regurgitation. X-ray findings include the “3” sign, caused by aortic dilation just proximal and distal to the area of stenosis, and rib notching, caused by increased collateral circulation through dilated intercostal arteries. Hypertension is the major clinical problem and may persist even after complete surgical correction. Unless hypertension is very severe or left ventricular failure has ensued, cardiac output responds normally to exercise.
- VII-23. The answer is D.** (*Chap. 236*) Acute rheumatic fever is a nonsuppurative complication of infection with group A streptococci. While the incidence of rheumatic fever has been declining, there have been recent domestic outbreaks on military bases. In such outbreaks the attack rate of rheumatic fever after streptococcal pharyngitis may be as high as 3%. The diagnosis of rheumatic fever requires two of the following major manifestations of the illness: carditis, migratory polyarthritis, chorea, erythema marginatum, and subcutaneous nodules. The patient in question has three such features. In addition to fever, he has evidence of a recent history of streptococcal infection by virtue of an elevated ASO titer. Even if streptococci cannot be isolated, it is preferable to administer a therapeutic course of parenteral penicillin (a single injection of 1.2 million units of benzathine penicillin IM for 10 days). Prophylactic therapy with penicillin should be administered indefinitely to prevent recurrent attacks. Glucocorticoid therapy is probably unnecessary, especially in patients without carditis. Arthritis can be managed entirely with salicylates. Prophylactic therapy for the associated movement disorder is unnecessary.
- VII-24. The answer is B.** (*Chap. 230*) The rhythm strip shows polymorphic ventricular tachycardia characteristic of torsades de pointes (“twisting of the points”). This life-threatening rhythm is associated with prolongation of the QT interval, resulting in this case from the administration of quinidine. The appropriate therapy is to discontinue the offending agent and withhold other agents that prolong the QT interval, such as procainamide. Hypoka-

lemia can prolong the QT interval and result in this rhythm; however, this patient had normal serum electrolyte concentrations.

- VII-25. The answer is B.** (*Chap. 230. Oates, N Engl J Med 325:1621–1629, 1991.*) Adenosine is currently approved for the termination of paroxysmal supraventricular tachycardias at doses of 6 mg and, if 6 mg fails, 12 mg. The primary mechanism of adenosine is to decrease conduction velocity through the AV node. As such, it is an ideal drug for acute termination of regular reentrant supraventricular tachycardia involving the AV node. Side effects may include chest discomfort and transient hypotension. The half-life is extremely short, and the side effects tend to be brief. Patients with wide complex tachycardia suggestive of ventricular tachycardia or known preexcitation syndrome should be treated with agents that decrease automaticity, such as quinidine and procainamide. However, in patients with apparent ventricular tachycardia who have neither a history of ischemic heart disease nor preexcitation syndrome, adenosine may be a useful diagnostic agent to determine whether a patient has a reentrant tachycardia, in which case the drug may terminate it; an atrial tachycardia, in which case the atrial activity may be unmasked; or a true, preexcited tachycardia, in which case adenosine will have no effect. While adenosine is not the recommended primary therapy for patients with wide complex tachyarrhythmia, patients with junctional tachycardia who have evidence of poor ventricular function or concomitant β -adrenergic blockade may be reasonable candidates for its use.
- VII-26. The answer is C.** (*Chaps. 228, 237. Sharkey, Am J Med 83:111–122, 1987.*) Right heart failure most commonly occurs as a result of pulmonary artery hypertension. Pulmonary artery hypertension in turn arises from increased pulmonary vascular resistance with chronic lung disease. The capillary wedge pressure, which measures left atrial end-diastolic pressure, is typically not elevated in this disorder. Secondary to the increased pulmonary artery hypertension, right atrial pressures are also elevated.
- VII-27. The answer is C.** (*Chap. 230. Ganz, Friedman, N Engl J Med 332:162–173, 1995.*) If vagal maneuvers are unsuccessful in terminating a regular supraventricular tachycardia, therapy should be directed toward blocking the atrioventricular (AV) node. Adenosine has the most rapid onset and is therefore the drug of choice. About 90% of supraventricular tachycardia is due to atrial ventricular nodal reentry or atrial ventricular reentry and is often terminated by adenosine. Multifocal atrial tachycardia, atrial flutter, or fibrillation almost always persists. The calcium channel blocker verapamil or diltiazem can also be used in terminating supraventricular tachycardia. Neither adenosine nor calcium channel blockers should be given to patients who have atrial fibrillation with an anterograde conducting accessory pathway. By blocking the atrioventricular nodal conduction, conduction down the accessory pathway is increased, which leads to an increase in the ventricular rate and a hemodynamic collapse. The ideal emergent treatment for such patients is intravenous procainamide. Hemodynamic collapse may also result when calcium channel blockers are administered to patients whose ventricular tachycardia is mistakenly believed to be supraventricular tachycardia with aberrant intraventricular conduction.
- VII-28. The answer is A.** (*Chap. 244*) Nitrates are generalized smooth-muscle dilators whose direct effect on the vasculature cannot be blocked by any currently available agents. Long-acting preparations of nitroglycerin may be completely degraded by the liver in some patients and thus are generally less effective than sublingual forms. Because individual variability in metabolism is considerable, doses should be titrated against side effects and should not conform to a rigidly standardized regimen. Tolerance is common and must be considered if a patient fails to respond to a previously efficacious dose. Long-acting preparations such as transdermal patches are less likely to produce the nitrate-associated side effects of headaches and dizziness than are the more rapidly acting sublingual forms.
- VII-29. The answer is D.** (*Chap. 243. Anderson, N Engl J Med 329:703–709, 1993.*) It is now recognized that most cases of acute myocardial infarction occur because of thrombus

formation at the site of an atherosclerotic plaque, with resultant sudden coronary artery obstruction. The ability to lyse such clots by means of intravenous administration of plasminogen-activating agents has resulted in the reduction of mortality from early postmyocardial infarction. A problem with the use of thrombolytic therapy has been reocclusion of the reperfused arteries. Administration of adjunctive agents may reduce this risk. Aspirin has such an activity based on interference with platelet aggregation. Heparin forms a complex with antithrombin 3, blocking the action of several protease procoagulants, including thrombin. When given in association with tissue plasminogen activator, heparin reduces mortality to a greater degree than occurs when tissue plasminogen activator is given alone. Thrombolytic therapy including adjunctive heparin and aspirin is beneficial in patients at least up to 75 years of age. Absolute contraindications to the use of such thrombolytic therapy include major surgery or trauma within the past 6 weeks, gastrointestinal or genitourinary bleeding within 6 months, a known history of bleeding diathesis, and the presence of aortic dissection or pericarditis. Additional risks include the presence of a known intracranial tumor, neurosurgery, stroke, and head trauma within the past 6 months. This patient meets the required electrocardiographic criteria for an acute Q-wave infarction in evolution and is seen early enough in the event to be expected to receive a significant benefit from thrombolytic therapy. Even patients who are seen between 6 and 12 h after the onset of symptoms may experience some improvement from the initiation of thrombolytic therapy.

- VII-30. The answer is D.** (*Chaps. 235, 236*) The echocardiogram shows that the left atrium is enlarged, and there is calcification and thickening of the mitral valve and chordal apparatus. The mitral leaflets show diastolic doming resulting from fusion of the valve commissures. These are the typical findings of rheumatic mitral stenosis, as exemplified by this 42-year-old woman. The aortic leaflets are also mildly thickened, consistent with rheumatic disease. The symptoms of the patient described in option (A) are suggestive of a left atrial myxoma. The patient in option (B) has acute mitral regurgitation. The patient in option (C) has mitral valve prolapse.
- VII-31. The answer is D.** (*Chaps. 39, 238. Maron et al, Circulation 62:218–229, 1980.*) The cause of sudden death in competitive athletes is often associated with cardiovascular abnormalities. The most common cause of death is hypertrophic cardiomyopathy, which is present in approximately 50% of young athletes who die from sudden death. Other cardiovascular abnormalities that have been identified have been an anomalous origin of the left coronary artery from the sinus of Valsalva, idiopathic concentric left ventricular hypertrophy, coronary artery disease, and ruptured aorta. These latter findings are relatively uncommon.
- VII-32. The answer is A.** (*Chap. 243*) The man described in the question probably has a right ventricular infarction complicating his inferior myocardial infarction because right atrial pressure is elevated out of proportion to left atrial (pulmonary capillary wedge) pressure. Cardiac output is depressed on the basis of an insufficient left heart filling pressure. The best treatment consists of the administration of fluids.
- VII-33. The answer is C.** (*Chap. 246. Calhoun, N Engl J Med 323:1177–1183, 1991.*) A hypertensive emergency is defined by the presence of end-organ damage in the setting of a severe elevation in blood pressure, usually with a diastolic pressure >130 mmHg. Syndromes qualifying as a hypertensive emergency include hypertensive encephalopathy as in this patient, cerebral infarction, intracerebral hemorrhage, myocardial ischemia or infarction, pulmonary edema, aortic dissection, eclampsia, acute renal insufficiency, severe ophthalmoscopic changes, and severe microangiopathic hemolytic anemia. Those with a severe elevation of blood pressure but without evidence of end-organ injury can be managed in a more gradual fashion with attempts to lower the blood pressure over a period of 24 to 48 h. However, for those with true hypertensive emergencies, immediate therapy, even before the results of all laboratory tests are available, should be undertaken. Hyper-

tensive emergencies require immediate but not precipitous lowering of the mean arterial pressure by approximately 25% with an attempt to reduce the diastolic blood pressure to 100 to 110 mmHg over a period of minutes to hours. Sodium nitroprusside is the drug of choice because it allows for titratable blood pressure reduction. However, the administration of this agent by continuous intravenous infusion requires continuous monitoring of the arterial blood pressure, which has been provided for in this patient. Diazoxide can be used in situations where arterial monitoring is not immediately available. However, the use of diazoxide may be complicated by hypotension and tachycardia (thereby exacerbating myocardial ischemia). Intravenous labetalol, a titratable beta blocker, and intravenous nicardipine, a calcium channel antagonist, may prove to be acceptable alternatives. The symptoms of hypertensive encephalopathy may include headache, nausea, vomiting, visual disturbances, confusion, and generalized weakness. Focal neurologic signs such as asymptomatic reflexes also may be seen.

- VII-34. The answer is D.** (*Chaps. 225, 226. Brickner et al, N Engl J Med 342:256–263, 2000.*) Inspiration, which augments systemic venous return because of negative intrathoracic pressure, causes accentuation of right-sided murmurs. Prolonged expiratory pressure against a closed glottis (Valsalva maneuver) reduces the intensity of most murmurs by diminishing both right and left ventricular filling. With reduced filling and thus reduced chamber size, the murmurs of hypertrophic cardiomyopathy and mitral valve prolapse increase. The cycle after a premature ventricular beat will have a larger stroke volume, and so the gradient across an obstructed semilunar valve (aortic or pulmonary) will increase, leading to a louder murmur. Squatting, which increases both venous return and chamber size as well as systemic arterial resistance, increases most murmurs, except those caused by hypertrophic cardiomyopathy and mitral valve prolapse. Sustained handgrip, which increases heart rate and systemic arterial pressure, often accentuates the murmurs of mitral stenosis and mitral regurgitation by impeding outflow and decreasing diastolic filling.
- VII-35. The answer is B.** (*Chap. 247. Ernst, N Engl J Med 328:1167–1172, 1993.*) The vast majority of aortic aneurysms are due to atherosclerosis; 75% of such aneurysms are located in the distal aorta below the renal arteries. Although these aneurysms are typically asymptomatic, rupture may occur with devastating consequences. The prognosis is related to the size of the aneurysm as well as the presence of coexistent vascular diseases. Patients with aneurysms >6 cm who are not treated surgically have 50% mortality in 1 year, while those with lesions between 4 and 6 cm have 25% mortality during the first year. Surgical excision and replacement with a prosthetic graft are indicated for patients with aneurysms >6 cm in diameter as well as in symptomatic patients or those with rapidly enlarging aneurysms regardless of the absolute diameter. Depending on the degree of operative risk, surgery also may be recommended in those with aneurysms with diameters between 5 and 6 cm. Contraindications to elective reconstruction include myocardial infarction within the past 6 months, intractable congestive heart failure, ongoing severe angina pectoris, severe obstructive lung disease, severe chronic renal failure, history of stroke with residual neurologic deficits, and life expectancy <2 years. An extensive preoperative evaluation including assessment of coronary disease, renal failure, and pulmonary function studies should be carried out, and if abnormalities are found, they should be ameliorated when possible. For patients in whom the diameter of the aneurysm is <6 cm or in whom there is significant operative risk, serial ultrasound may be helpful in defining a group that more urgently requires surgical intervention based on expansion of ≥ 0.5 cm over time.
- VII-36. The answer is B.** (*Chaps. 225, 238*) Echocardiographic evidence of a disproportionately thickened ventricular septum and systolic anterior motion of the mitral valve strongly suggests idiopathic hypertrophic subaortic stenosis (IHSS). The typical harsh systolic murmur usually does not radiate to the carotid arteries and decreases when ventricular volume enlarges with isometric exercise (e.g., handgrip). The carotid upstroke is brisk and often bifid. Congestive failure often occurs because of reduced ventricular compliance despite

normal ventricular systolic function. Malposition of the mitral apparatus, a result of the distorted septum, often leads to some degree of mitral regurgitation.

- VII-37. The answer is B.** (*Chaps. 226, 230*) A delta wave or slowed QRS upstroke is depicted. This finding occurs in the Wolff-Parkinson-White syndrome, in which accessory Kent bundles result in an apparently short PR interval caused by the bypassed AV node and early onset of the QRS complex. Left bundle branch block could result in marked initial delay, whereas right bundle branch block results in late delay. Left ventricular hypertrophy causes minor uniform QRS prolongation. Right ventricular infarction has little effect on QRS duration in the absence of right bundle branch block.
- VII-38. The answer is B.** (*Chap. 226*) Alterations in the serum potassium level can dramatically alter the electrocardiogram. Hyperkalemia can produce a progressive evolution of changes in the electrocardiogram, which can ultimately lead to ventricular fibrillation and death. The presence of electrocardiographic changes is probably a better measurement of clinically significant potassium toxicity than is the serum potassium level. As the serum potassium begins to rise, the T waves across the entire 12-lead ECG begin to peak. This affect can easily be confused with the peaked T waves of an acute myocardial infarction. The difference is that the changes in an infarction are confined to those leads overlying the area of the infarct. In hyperkalemia the changes are widespread. With continued increase in the serum potassium level, the PR interval becomes progressively prolonged and the P waves gradually flatten. Ultimately the QRS complex will widen until it merges with the T wave forming a *sine-wave* pattern, and ventricular fibrillation may eventually develop. Any change in the ECG that is due to hyperkalemia mandates immediate clinical intervention.
- VII-39. The answer is B.** (*Chap. 239*) Acute pericarditis is associated with ST-segment elevation and frequently PR-segment depression. Usually reciprocal ST-segment depression is not present. T waves begin to invert only after the ST segment becomes isoelectric. Elevations in serum creatine phosphokinase levels to twice normal may be associated with uncomplicated pericarditis.
- VII-40. The answer is D.** (*Chaps. 226, 232*) Digitalis glycosides are effective in increasing myocardial contractility and in the treatment of certain atrial tachyarrhythmias. However, digoxin actually increases myocardial automaticity (increase in premature beats) and facilitates reentry (atrial tachycardias). Digoxin also slows conduction through AV nodal tissue and has central effects that can mimic vagal influence on the heart and thus may produce sinus arrest. Paroxysmal atrial tachycardia with variable block represents the classic rhythm of digitalis intoxication. Digoxin is profibrillatory, but its administration should not lead to atrial flutter. Therapeutic levels of digitalis generate characteristic ST-segment and T-wave changes in most individuals taking the drug. These changes are known as the digitalis effect and consist of ST-segment depression with flattening or inversion of the T wave. The digitalis effect is most prominent in leads with tall R waves. The digitalis effect is normal and predictable and does not require discontinuation of the drug.
- VII-41. The answer is B.** (*Chap. 39*) The most common cause of pulseless electrical activity is hypovolemia. Other causes include myocardial infarction, severe acidosis, tension pneumothorax, pericardial tamponade, severe hypoxemia, hypothermia, hyperkalemia, massive pulmonary embolism, as well as a drug overdose. In addition to correcting the cause of the pulseless electrical activity, CPR should be initiated on all patients. Patients are then intubated, a large-bore intravenous access is established, and patients should be fluid-resuscitated while the underlying cause is corrected. In addition epinephrine, 1-mg IV push, should be used and repeated every 3 to 5 min unless bradycardia is present, in which case atropine may be used in addition to the epinephrine.

- VII-42. The answer is C.** (*Chap. 234. Brickner et al, N Engl J Med 342:252–263, 334–342, 2000.*) Left-to-right shunts occur in all types of atrial and ventricular septal defects but generally do not result in cyanosis, whereas large right-to-left shunts frequently do. The magnitude of the shunt depends on the size of the defect, the diastolic properties of both ventricles, and the relative impedance of the pulmonary and systemic circulations. Defects of the sinus venosus type occur high in the atrial septum near the entry of the superior vena cava or lower near the orifice of the inferior vena cava and may be associated with anomalous connection of the right inferior pulmonary vein to the right atrium. In the case of anomalous origin of the left coronary artery from the pulmonary artery, as pulmonary vascular resistance declines immediately after birth, perfusion of the left coronary artery from the pulmonary trunk ceases and the direction of flow in the anomalous vessel reverses. Twenty percent of patients with this defect can survive to adulthood because of myocardial blood supply flowing totally through the right coronary artery. In the absence of pulmonary hypertension, blood will flow from the aorta to the pulmonary artery throughout the cardiac cycle, resulting in a “continuous” murmur at the left sternal border. In total anomalous pulmonary venous connection, all the venous blood returns to the right atrium; therefore, an interatrial communication is required and right-to-left shunts with cyanosis are common.
- VII-43. The answer is A.** (*Chap. 243. Anderson, Willerson, N Engl J Med 329:703–709, 1993.*) While prompt initiation of thrombolytic therapy during an acute myocardial infarction is associated with improvement in mortality and limitation of the size of the infarct, all thrombolytic agents, including tissue plasminogen activator, are associated with an increased risk of major bleeding. These agents should not be given if there is a history of a cerebrovascular accident, a surgical procedure within the past 2 weeks, active peptic ulcer disease, or marked hypertension during acute presentation (systolic pressure >180 or diastolic pressure >100 mmHg). Other situations in which the risk of bleeding may be higher, such as advanced age, diabetic retinopathy, CPR for <10 min, are not absolute contraindications, and the potential benefit from the administration of thrombolytic therapy should be considered carefully in each case.
- VII-44. The answer is C.** (*Chap. 243*) Apical systolic murmurs associated with a myocardial infarction may represent either mitral regurgitation (on the basis of papillary muscle rupture or newly dilated heart size) or ventricular septal defect. In both conditions, large *v* waves may be recorded in the pulmonary capillary wedge position. In the case of a ventricular septal defect but not mitral regurgitation, there will be an increase in the partial pressure of oxygen as a catheter is advanced from the right atrium to the right ventricle.
- VII-45. The answer is E.** (*Chap. 230. Roy et al, N Engl J Med 342:913–920, 2000.*) In patients with atrial fibrillation, the restoration and maintenance of sinus rhythm should be the goal of therapy. If sinus rhythm can be restored either electrically or pharmacologically, many agents have been used in order to prevent the recurrence of atrial fibrillation. A recent randomized trial comparing amiodarone to either sotalol or propafenone has suggested that amiodarone is more effective than either of the other two agents in the prevention of a recurrent atrial fibrillation. Only 35% of patients assigned to amiodarone had a recurrence of their atrial fibrillation as opposed to 63% assigned to either the sotalol or propafenone arms. In patients in whom atrial fibrillation cannot be converted to sinus rhythm, control of the ventricular rate should be the goal of therapy. This can usually be accomplished by digitalis, beta blockers, or calcium channel blockers, either alone or in combination.
- VII-46. The answer is C.** (*Chap. 230. The Boston Area Anticoagulation Trial for Atrial Fibrillation Investigators, N Engl J Med 323:1505–1558, 1990; Pritchett, N Engl J Med 326:1264–1271, 1992.*) Patients with chronic atrial fibrillation are always at risk for systemic embolization. This is particularly true of patients who have underlying organic heart disease. These patients typically have mitral valve disease, poor left ventricular function, or hypertension as well as a prior history of transient ischemic attacks or history of systemic embolization. In these patients warfarin is the preferred anticoagulant. Although antico-

agulation is associated with hemorrhagic complications, the risk is largely associated with INRs above the recommended range of 1.8–3.0. For patients with mechanical prosthetic valves, the recommended range of anticoagulation is higher.

- VII-47. The answer is A.** (*Chaps. 228, 236*) A gradient between the left atrium (as measured by the pulmonary capillary wedge tracing) and the left ventricle in diastole indicates mitral stenosis as exemplified by the woman with a history of rheumatic fever and hemoptysis. The intravenous drug abuser with mitral regurgitation caused by mitral valve vegetation would exhibit large *v* waves on the pulmonary capillary wedge tracing. The aortic regurgitation associated with Marfan's syndrome would cause an equilibration between left ventricular and peripheral pressures. A feature of severe aortic regurgitation that occurs when left ventricular pressure exceeds pulmonary capillary wedge (i.e., left atrial) pressure during early diastole may result in premature mitral valve closure. In aortic stenosis, as exemplified by the elderly man with left ventricular hypertrophy, the left ventricular pressure is higher than the aortic pressure during systole. In pericardial tamponade, as might be seen in the patient with lymphoma, there is equalization of right and left diastolic pressures.
- VII-48. The answer is D.** (*Chaps. 176, 229. McAlister et al, Ann Intern Med 110:339–345, 1989.*) This patient's clinical scenario is consistent with secondary manifestations of Lyme disease, which is caused by the spirochete *Borrelia burgdorferi*. Her exposure presumably occurred on Cape Cod, a high-risk area of New England. Lyme disease occurs in three stages: the initial infection shortly after the tick bite, manifested by a skin rash (erythema chronica migrans) and often flulike symptoms; a secondary stage with cardiac and/or neurologic signs and symptoms; and a tertiary stage with arthritis.
- Lyme carditis most often is manifested by AV nodal conduction disturbances, including first-, second-, or third-degree heart block. Antibiotic therapy, typically high-dose penicillin, usually leads to resolution of the heart block without the need for permanent pacing, although a temporary pacemaker may be necessary. Spirochetes can be detected within cardiac tissue, suggesting that the carditis is due to the presence of the organism. Other cardiac manifestations include nonspecific ECG changes, myocardial inflammation, and left ventricular dysfunction.
- Cocaine can result in myocardial ischemia and infarction, but this would more likely be an acute complication, making the timing incorrect in this case. *Ixodes dammini* is the deer tick whose bite transmits the infection to humans. This patient's presentation is inconsistent with an acute coronary embolus. Complete heart block is not commonly seen with HIV carditis.
- VII-49. The answer is E.** (*Chap. 243*) This patient is most likely having a ventricular septal rupture and a subsequent defect, a not uncommon complication of myocardial infarction (MI) that explains the need to auscultate the heart on a daily basis during the early period after a myocardial infarction. Myocardial rupture after an MI can occur either in the free wall, with bleeding into the pericardium, tamponade, and a high incidence of fatality, or in the ventricular septum, with a greater potential for successful therapy despite the fact that this is a critical complication. Therapy is geared toward decreasing afterload and systemic vascular resistance. Interventions to be considered include IV nitroglycerin, IV sodium nitroprusside, and/or *intraaortic* balloon counterpulsation. Often cardiac surgery with septal repair is the only viable long-term intervention; however, this is best undertaken when the patient has stabilized and ideally once the infarction has healed. In many cases, the patient does not stabilize, at which point acute surgical intervention is indicated.
- VII-50. The answer is E.** (*Chaps. 39, 230. Ben-David, Zipes, Lancet 341:1578–1582, 1993.*) Magnesium sulfate is the first drug of choice in the management of torsades de pointes; magnesium isoproterenol may also be used. The use of temporary pacing may suppress the ventricular tachycardia, which often does not recur after cessation of pacing. In addi-

tion, class IB drugs may also be tried in the treatment of torsades de pointes, since they decrease the action potential.

- VII-51. The answer is E.** (*Chap. 118. King et al, Ann Intern Med:8:325–332, 1980.*) Heparin-induced thrombocytopenia (HIT) syndrome occurs in 1 to 5% of patients treated with heparin and probably is due to platelet aggregation caused by heparin-induced antibodies. Therapy usually consists of discontinuation of the heparin and the use of other anticoagulants, in particular warfarin, with several days of overlap if possible. If the platelet count falls beneath $\sim 50,000/\mu\text{L}$, heparin should be discontinued. If proximal DVT is present, consideration may have to be given to the placement of an inferior vena caval filter. Arterial thrombosis also may be a manifestation of the HIT syndrome and represents a separate indication for the discontinuation of heparin. The thrombosis is thought to be due to antibody-mediated platelet activation, which can lead to platelet aggregation.
- VII-52. The answer is D.** (*Chap. 230*) VPCs are a common finding seen in $\sim 60\%$ of men who undergo Holter monitoring; in the absence of known coronary artery disease (CAD), they are not of particular significance. They can cause symptoms such as palpitations, perhaps as a result of the cannon *a* waves that can result from contraction of the ventricle while the mitral valve is still open. Symptoms also may stem from the fact that stroke volume often is decreased by decreased overall ventricular filling. Rarely, frequent VPCs can result in syncopal symptoms on this basis. In patients with known CAD, the incidence (80%), frequency, and significance of VPCs rise. Both the frequency ($>10/\text{h}$), and the complexity (couplets or greater) have been associated with increased mortality in this patient population. Epidemiologic evidence suggests an increase in the frequency of VPCs with advancing age.
- VII-53. The answer is D.** (*Chap. 230. Splawski et al, N Engl J Med 336:1562–1567, 1997.*) The Jervell and Lang-Nielsen syndrome is an autosomal recessive disorder associated with a prolonged QT interval and congenital sensory deafness. The Romano-Ward syndrome is an autosomal dominant form of the long QT syndrome and is not associated with deafness. Recently both disorders have been mapped and are associated with a mutation within a cardiac ion channel. The Jervell and Lang-Nielsen syndrome is inherited as an autosomal recessive trait with respect to the deafness phenotype. However, the QT prolongation is inherited as a dominant trait. It is important to note that parents of patients with the Jervell and Lang-Nielsen syndrome are obligate heterozygotes for long QT-associated abnormalities, as was the case in this family. The Romano-Ward syndrome has been mapped to several different loci, all involved with conduction abnormalities. The Jervell and Lang-Nielsen syndrome maps to the short arm of chromosome 11, and this is one of the loci associated with the Romano-Ward syndrome. There are several other genes that map for the autosomal dominant long QT syndrome (Romano-Ward), specifically the long arm of chromosome 7, the short arm of chromosome 3, and a fourth gene that was mapped to chromosome 4. All of these genes encode cardiac ion channels. The treatment of choice is beta blockade. These patients tend to develop torsades de pointes, and beta blockade suppresses the β -adrenergic-induced instability of a QT interval.
- VII-54. The answer is D.** (*Chap. 231*) A resting cardiac cell has low intracellular sodium, but higher potassium, as opposed to the extracellular compartment, which has high sodium but lower potassium. These differences, which are maintained by the ATP-dependent $\text{Na}^+ - \text{K}^+$ pump, result in the resting potential seen in myocytes. A slow inward current of Ca^{2+} occurs during the plateau phase of the action potential, ultimately leading to a larger release of calcium from the sarcoplasmic reticulum, and myocyte contraction after calcium complexes with troponin C and removes this repression of contraction. Repolarization consists of the regaining of calcium by the sarcoplasmic reticulum by pumping against a concentration gradient. In all striated muscle, including cardiac muscle, the force of contraction depends on initial muscle length. This forms the basis of the Frank-Starling relationship.

- VII-55. The answer is B.** (*Chaps. 229, 246*) This elderly patient has developed significant symptomatic sinus bradycardia and sinus arrest while on a beta blocker. She is receiving the beta blocker as therapy for hypertension, not as an antianginal medication. Some patients, particularly elderly ones, can be quite sensitive to AV nodal blocking agents such as beta blockers and calcium channel blockers such as diltiazem, particularly when used in combination. Therefore, one would want to establish the continued need for a permanent pacemaker in this patient when she was not on an AV nodal agent. Her ongoing symptoms, borderline vital signs, and acute fracture all argue for stabilizing her rhythm status through a temporary pacer insertion.
- VII-56. The answer is D.** (*Chap. 234. Brickner et al, N Engl J Med 342:334–342, 2000.*) Tetralogy of Fallot is the most common cyanotic congenital heart deficiency of infancy. Tetralogy of Fallot is characterized by a large ventricular septal defect, an aorta that overrides the right and left ventricles, obstruction of the right ventricular outflow tract, and right ventricular hypertrophy. The obstruction of the outflow tract may be subvalvular, valvular, supravalvular, or within the pulmonary arterial branches. Several other abnormalities may occur in association with tetralogy of Fallot. These include ASD in <10% of patients and coronary artery anomalies. Most patients with tetralogy of Fallot have substantial right-to-left shunting and therefore develop cyanosis. The echocardiogram is used to establish the diagnosis and assess the presence of associated abnormalities. Surgical repair is recommended to relieve symptoms and to improve survival. Historically, infants underwent one of three palliative procedures to increase pulmonary blood flow, but currently complete surgical correction is recommended.
- VII-57. The answer is C.** (*Chap. 230*) This patient did not suffer an allergic reaction to procainamide. Torsades de pointes on the basis of a prolonged QT interval would have caused an unstable complex. The most likely explanation for his rhythm was one-to-one conduction of atrial flutter through the AV node. This could have been prevented through an adequate AV nodal blockade before the administration of procainamide. Quinidine, which could have resulted in the same response, also requires adequate AV nodal blockade before its administration. Both quinidine and procainamide actually speed conduction through the AV node and must be used cautiously, ideally after the adequate administration of a nodal agent.
- VII-58. The answer is D.** (*Chap. 234. Brickner et al, N Engl J Med 342:334–342, 2000.*) A patient with Eisenmenger's syndrome has a large left-to-right intracardiac shunt that causes severe pulmonary vascular disease. The exposure of the pulmonary vasculature to increased blood flow will result in pulmonary vascular obstructive disease. The initial morphologic alterations, which typically consists of medial hypertrophy and intimal proliferation and fibrosis, are usually reversible. However, as the disease progresses, the more advanced morphologic changes, which are plexiform lesions and necrotizing arteritis, are irreversible. As a result, the obliteration of much of the pulmonary vascular bed leads to increased pulmonary vascular resistance. As the pulmonary vascular resistance exceeds systemic resistance, the intracardiac shunt is reversed. In a patient who has a murmur in early childhood, as the Eisenmenger's syndrome develops, the murmur disappears. This change in the murmur is associated with pulmonary disease progression and may often lead to the mistaken assumption that the intracardiac communication has closed.
- VII-59. The answer is D.** (*Chaps. 227, 244*) Technetium 99m sestamibi differs from thallium 201 in that sestamibi does not redistribute as well as thallium does in hibernating myocardium. Positron emission tomography is the "gold standard" for detecting myocardial viability but is not routinely available. Thallium, which is dependent on the Na^+ , K^+ -ATPase pump for uptake, can be used to assess the viability of myocardial tissue. Dipyridamole is an inhibitor of adenosine metabolism and can result in bronchospasm. Therefore, caution must be used in patients with severe ($\text{FEV}_1 < 40\%$ of predicted) obstructive pulmonary disease. Injection of sestamibi can be done safely during chest pain. Normal

perfusion during pain, as well as hypoperfusion that fails to reverse with the resolution of symptoms, suggests that the symptoms do not stem from inadequate myocardial perfusion.

- VII-60. The answer is C.** (*Chap. 243. Oliva et al, J Am Coll Cardiol 22:720–726, 1993; Reddy, Roberts, Am J Cardiol 63:906–911, 1989.*) Ventricular free-wall rupture occurs in up to 10% of patients who die in hospitals after a myocardial infarction. It represents the second most common cause of death, the first being heart failure. The incidence has increased since the advent of coronary care units, probably due to improved survival rates of patients with myocardial infarction. Predisposing factors include advanced age as well as the first myocardial infarction, probably due to lack of coronary collaterals. Ventricular free-wall rupture is most commonly seen 1 to 4 days after a MI but can rarely occur up to 3 weeks post-MI. Lateral or anterior walls are most often involved, and it is typically seen with large MIs involving >20% of the ventricle. Ventricular free-wall rupture is rare in patients with hypertrophied ventricles or with extensive collaterals. The free-wall rupture typically occurs in the junction of the infarct with normal tissue and less often in the center of the infarct. The latter area is typically involved in late free-wall rupture events. Patients can present with either a sudden acute rupture causing cardiovascular collapse, tamponade, or pulseless electrical activity (PEA). Incomplete ruptures can be contained by an organizing thrombus and eventually form a pseudoaneurysm. Subacute free-wall ruptures have also been reported. Patients are typically diagnosed by echocardiogram, and treatment involves operative repair, if possible.
- VII-61. The answer is D.** (*Chap. 231*) Cystic medial necrosis is a descriptive term for pathologic changes seen in the aorta. This entity consists of degeneration of collagen and elastin fibers in the tunica media of the aorta as well as cell loss in the medial layer. A mucoid material replaces the space occupied by the degenerated cells. This abnormality typically is seen in the proximal aorta and the sinuses of Valsalva, leading to weakness and aneurysm formation. Cystic medial necrosis is a risk factor for aortic dissection. This condition is particularly prevalent in patients with Marfan syndrome and Ehlers-Danlos syndrome type IV. Cystic medial necrosis also occurs in pregnant women, in patients with hypertension, and in patients with a history of valvular heart disease.
- VII-62. The answer is B.** (*Chap. 239. Reddy et al, Circulation 58:265–272, 1978.*) This patient presents with pericardial tamponade. Patients often have distant heart sounds and on examination typically have a pulsus paradoxus. Jugular veins are distended and typically show a prominent x descent and an absent y descent, as opposed to constrictive pericarditis. In addition, Kussmaul's sign is absent in tamponade but present in constrictive pericarditis. The electrocardiogram is either normal or shows low voltage. Rarely, electrical alternans may be present. Echocardiographic findings typically reveal right atrial collapse and right ventricular diastolic collapse. Cardiac catheterization will reveal equalization of diastolic pressures across the cardiac chambers. Therefore the pulmonary capillary wedge pressure will be equal to the diastolic pulmonary arterial pressure, and this will be equal to the right atrial pressure. These catheterization findings are also present in a patient with constrictive pericarditis.
- VII-63. The answer is A.** (*Chaps. 225, 238*) The murmur of hypertrophic cardiomyopathy is caused by the turbulence created by flow past the intracavitary obstruction in the left ventricle. Therefore, all maneuvers that increase left ventricular blood volume will “move” the muscular obstruction protruding into the outflow track away from the opposite wall, decreasing the obstruction and the murmur. Ventricular volume-expanding maneuvers include squatting and passive leg raising. Conversely, maneuvers that decrease left ventricular size increase the outflow obstruction and the intensity of the murmur. Such maneuvers include the Valsalva maneuver (decreased venous return to the right ventricle), standing, and the inhalation of amyl nitrate, which is no longer routinely used.
- VII-64. The answer is D.** (*Chaps. 232, 318*) Pulmonary edema can be categorized as either cardiogenic or noncardiogenic. In cardiogenic pulmonary edema, an increase in pulmonary

venous pressure is antecedent to the interstitial edema that progresses to frank alveolar edema. Pulmonary edema is influenced by the counterbalancing Starling forces. Pulmonary edema occurring without a preceding increase in pulmonary venous pressure but still resulting from an imbalance of Starling forces is known as noncardiogenic pulmonary edema. Examples of this condition include shock (e.g., hemorrhagic pancreatitis, gram-negative septicemia, postcardiopulmonary bypass), aspiration, and widespread pulmonary infections. At least three forms of pulmonary edema that are not due to increases in vessel permeability, decreased lymphatic flow, or other alterations in Starling forces have been identified: narcotic overdose, high-altitude exposure in unconditioned individuals, and neurogenic pulmonary edema. Sarcoidosis can cause cardiogenic pulmonary edema from cardiomyopathy or dyspnea from diffuse lung disease.

- VII-65. The answer is C.** (*Chaps. 242, 344. National Cholesterol Education Program, Adult Treatment Panel II, National Institute of Health, Pub 93-3095, 9/1993. Scandinavian Simvastatin Survival Study Group. Lancet 344:1383–1389, 1994.*) Several large-scale, randomized, placebo-controlled studies have demonstrated the benefits of HMG-CoA reductase inhibitors in both patients with known coronary artery disease and patients at significant risk for cardiac events without a prior known myocardial infarction. These studies have documented a statistically significant decrease in cardiac events and the need for invasive cardiac procedures in both patients with coronary disease and those at significant risk for cardiac disease. Importantly, the 4S trial demonstrated decreased total mortality in patients treated with this type of agent, helping to diminish prior concerns about the lack of an overall benefit in regard to total mortality in patients treated with lipid-lowering agents. HMG-CoA reductase inhibitors are the most potent medications for lowering LDL. Their mechanism of action is due to inhibition of the key steps in cholesterol biosynthesis, leading to an upregulation of LDL receptors and increased clearance of LDL from the circulation. Patients with known homozygous familial hypercholesterolemia have various genotypes that lead to a complete absence or functional absence of the LDL receptor; therefore, they may have a minimal response to these agents because of their inability to upregulate LDL receptors. The improvement of vasomotor responses to endothelial damage occurs within 6 months or less; however, the reduction in the thrombotic complications of atherosclerosis requires more prolonged treatment to effectively remove lipid from deeper areas within the atheroma.
- VII-66. The answer is B.** (*Chap. 224. Goldman et al, N Engl J Med 297:845–850, 1977; Mangano, Goldman, N Engl J Med 333:1750–1756, 1995.*) Cardiovascular disease is the leading cause of death in the United States. Many patients have undiagnosed cardiovascular disease and therefore are at unsuspected risk for perioperative cardiac morbidity, defined as perioperative MI, pulmonary edema, or ventricular tachycardia. Multivariable analysis first proposed by Goldman and colleagues identified several risk factors including age >70 years, a recent MI within 6 months, evidence of aortic stenosis or pulmonary edema on exam, abnormalities within the electrocardiogram or laboratory analysis, as well as the type of surgical procedure being performed, with an emergency surgery being more highly associated with complication risk. In this patient the only risk is his age >70 years. The presence of 2 to 3 PVCs per minute is within normal range. His hypertension, hypercholesterolemia, and diabetes mellitus, although significant, were not identified as independent risk factors. Therefore this man's risk of serious complication is ~0.6%.
- VII-67. The answer is D.** (*Chap. 241. Libby, Circulation 91:2844, 1995.*) The fatty streak is the initial lesion of atherosclerosis, resulting from lipid deposition in the arterial wall and subsequent recruitment of monocytes and lymphocytes via endothelial attachment to adhesion molecules such as VCAM-1 and ICAM-1 and other receptors, such as members of the selectin family. Inflammation and mitogenesis play significant roles in atherosclerosis through leukocytes and elaboration of mediators such as cytokines (e.g., TNF- α , interleukins, and growth factors such as PDGF). Early atherosclerosis occurs in an abluminal direction, with lesions not being apparent on a routine coronary angiography, since only the lumen is defined. Nevertheless, these non-flow-limiting-lesions are often responsible

for myocardial infarction resulting from plaque rupture. Risk factor modification may decrease the likelihood of plaque formation and rupture. For example, lipid-lowering agents have caused only minimal changes in the frequency of coronary stenoses measured by angiography, yet a major clinical benefit has been noted. Other lipoproteins such as triglyceride-rich particles or Lp(a) are also atherogenic. Even within a given arterial bed, atherosclerosis tends to occur focally; typically in certain predisposed regions.

- VII-68. The answer is D.** (*Chaps. 225, 239*) This patient has a history and physical examination consistent with pericardial effusion and possibly hemodynamically significant tamponade. Her history of breast cancer raises the possibility of malignant pericardial effusion. Empirical treatment with escalating doses of diuretics may in fact have worsened her status by decreasing her ventricular volume and pressure, thus decreasing the difference between the intrapericardial pressure and the intraventricular pressure and worsening the effects of the tamponade. On examination, the narrow pulse pressure is one element that suggests the possibility of tamponade. No pulsus paradoxus is seen in approximately 10% of patients with tamponade and can reflect either an atrial septal defect or, perhaps more likely in this clinical scenario, preexisting increased diastolic pressure. Typically, the neck veins would be elevated. Bronchial breath sounds at the inferior border of the left scapula constitute Ewart's sign and are suggestive of pericardial effusion. ECG changes associated with pericardial effusion include low voltage and electrical alternans as the heart swings within the pericardial fluid. An echocardiogram would be very helpful in this clinical situation to establish the pericardial fluid volume and diagnose tamponade. The definitive diagnosis of tamponade is made by measuring intrapericardial pressure with simultaneous hemodynamic monitoring. The intrapericardial pressure should fall after pericardiocentesis. Cytology from the fluid in this case returned positive for recurrent breast carcinoma; metastatic deposits are frequently found on the pericardial surface but less commonly in the myocardium.
- VII-69. The answer is B.** (*Chap. 224. Mangano, Goldman, N Engl J Med 335:1713–1720, 1996.*) In patients who have or are at risk for coronary artery disease and who must undergo noncardiac surgery, treatment with atenolol during hospitalization can significantly reduce mortality as well as the incidence of cardiovascular complications. This benefit may last as long as 2 years after surgery.
- VII-70. The answer is C.** (*Chap. 226*) The electrocardiographic T wave represents myocardial repolarization, and its configuration can be altered nonspecifically by metabolic abnormalities, drugs, neural activity, and ischemia through a dispersion effect on the activation or repolarization of action potentials. Although myocardial ischemia and subendocardial infarction can produce deep, symmetric T wave inversions which would result in tachyarrhythmias and syncope, noncardiac phenomena such as intracerebral hemorrhage can similarly affect ventricular repolarization. Hyperkalemia is manifested by tall, peaked T waves, not inverted ones. Hypocalcemia is manifested by prolonged QT intervals.
- VII-71. The answer is A.** (*Chap. 226*) Hyperkalemia leads to partial depolarization of cardiac cells. As a result, there is slowing of the upstroke of the action potential as well as reduced duration of repolarization. The T wave becomes peaked, the RS complex widens and may merge with the T wave (giving a sine-wave appearance), and the P wave becomes shallow or disappears. Prominent U waves are associated with hypokalemia; ST-segment prolongation is associated with hypocalcemia.
- VII-72. The answer is C.** (*Chap. 227*) Making a test's cutoff point for positivity more stringent (i.e., >2.0 mm of ST depression rather than 0.5 mm) will enhance specificity (there will be fewer false positives) at the expense of sensitivity (there will be more false negatives). Bayesian analysis dictates that low prior probability (e.g., 10%—odds 1:9) can be enhanced only to a 50% posttest (or posterior) probability for a test with the given operating characteristics [$1:9 \times \text{sensitivity} / (1 - \text{specificity})$], where sensitivity is defined as the

probability of a positive test result in a patient with the disease and specificity is defined as the probability of a negative test result in a patient without the disease. Thallium scans can increase the sensitivity for detecting coronary artery disease by about 20% and can increase specificity by 10%. Such scans are most useful in patients with an uninterpretable or nondiagnostic electrocardiogram resulting from failure to achieve 85% of the predicted maximal heart rate, left ventricular hypertrophy, left bundle branch block, or drug effects. A prior myocardial infarction can be inferred if a defect on thallium scintigraphy noted during exercise also fails to be perfused at rest. Blood pressure and heart rate should rise during a normal exercise tolerance test. Failure of the blood pressure to rise or an actual decrease may suggest global left ventricular dysfunction.

- VII-73. The answer is A.** (*Chap. 226*) The electrocardiogram presented in the question demonstrates nonparoxysmal junctional tachycardia. The junctional rhythm is at a rate of 82 beats per minute, which is faster than the usual escape nodal rhythm. Retrograde P waves can be seen. This rhythm can occur after mitral valve surgery and in association with digitalis toxicity, acute myocarditis, and inferior myocardial infarction. These processes can all irritate the atrioventricular node and accelerate its action.
- VII-74. The answer is E.** (*Chap. 232. Cohn, N Engl J Med 311:819, 1984.*) Stroke volume and cardiac output at rest are not sensitive indexes of myocardial dysfunction. Stroke volume is often normal, though at the expense of higher end-diastolic volume (Frank-Starling mechanism). Even when stroke volume begins to diminish, cardiac output can be maintained by increases in heart rate. However, when the heart is stressed by exercise, cardiac output does not rise proportionately to oxygen consumption and left ventricular end-diastolic pressure rises more than it does in normal controls. Although plasma norepinephrine levels are elevated in persons with left ventricular dysfunction, myocardial levels are typically low.
- VII-75. The answer is D.** (*Chaps. 70, 72*) The antihypertensive agent prazosin blocks α_1 receptors that mediate vasoconstriction. Clonidine and methyl dopa are antihypertensive agents that work by stimulating α_2 receptors in the brainstem, thereby reducing sympathetic outflow. Phenylephrine, an α_1 agonist with pressor effects, is frequently employed in over-the-counter nasal decongestants. By antagonizing presynaptic α_2 receptors, yohimbine increases parasympathetic activity that may augment penile blood flow and may be useful in the treatment of erectile impotence. Isoproterenol stimulates β_1 and β_2 receptors and can increase chronotropy in the setting of heart block.
- VII-76. The answer is E.** (*Chap. 230*) Persons who have Wolff-Parkinson-White syndrome are predisposed to develop two major types of atrial tachyarrhythmias. The first, which resembles paroxysmal supraventricular tachycardia (SVT) with reentry, involves the atrioventricular node in anterograde conduction and the bypass tract in retrograde conduction. This tachycardia typically has a narrow QRS complex and can be treated similarly to other forms of SVT. The other, more dangerous tachyarrhythmia (present in the man described in the question) is atrial fibrillation, which usually is conducted anterograde down the bypass tract and has a wide QRS configuration. The ventricular rate in such a situation is quite rapid, and cardiovascular collapse or ventricular fibrillation may result. The usual treatment is direct-current cardioversion, though quinidine may slow conduction through the bypass tract. Verapamil and propranolol have little effect on the bypass tract and may further depress ventricular function, which already is compromised by the rapid rate. Digoxin may accelerate conduction down the bypass tract and lead to ventricular fibrillation.
- VII-77. The answer is C.** (*Chap. 39. Eldar et al, Ann Intern Med 117:31–36, 1992.*) Frequent premature ventricular complexes (defined as >30 per minute), salvos or nonsustained ventricular tachycardia, and a low ejection fraction ($<20\%$) are associated with an increased risk of sudden cardiac death. Advanced forms (triplets or longer) are more predictive of risk than is even a high density of unifocal premature beats. It is unclear whether

suppressing ectopic activity can reduce risk. Conventional techniques of cardiopulmonary resuscitation require lung inflation every 15 s and chest compressions 80 times per minute if only one provider is present. In the case of ventricular fibrillation or ventricular tachycardia in a pulseless patient, the first shock should be delivered at 200 J, followed by additional higher-energy shocks (up to 360 J in the absence of a response). Intravenous sodium bicarbonate, formerly recommended, is no longer considered routinely necessary and may be dangerous (unless pH monitoring indicates profound acidosis).

- VII-78. The answer is B.** (*Chap. 234. Carabello, Crawford, N Engl J Med 337:32–41, 1997.*) Atrial septal defects (ASDs) of the sinus venous type are located high in the atrial septum and commonly are associated with anomalous pulmonary venous return. The magnitude of the shunt depends on defect size, relative ventricular compliance, and the relative resistances in the pulmonary and systemic circuits but not on total blood flow. The systolic ejection murmur associated with ASD arises from increased flow across the pulmonic valve; a diastolic rumble resulting from increased flow across the tricuspid valve is common and should not necessarily be attributed to mitral stenosis, which is associated with ASD in a disorder known as Lutembacher's syndrome. Most persons with a large ASD are asymptomatic until late in adult life.
- VII-79. The answer is D.** (*Chap. 225*) Large *a* waves indicate contraction of the right atrium against increased resistance, as might occur with obstruction at the tricuspid valve (tricuspid stenosis) or more commonly with increased resistance to right ventricular filling. Right ventricular filling could be impaired in pulmonary stenosis or in any condition that causes pulmonary hypertension, such as multiple pulmonary emboli. The *a* wave also will be pronounced if the right atrium contracts while the tricuspid valve is closed by right ventricular systole, as would be the case in atrioventricular dissociation, complete heart block, or junctional rhythm. The *a* wave is absent in patients with atrial fibrillation, since no organized atrial contraction occurs. There is delay in the normal *a* wave pattern in a patient with first-degree AV block.
- VII-80. The answer is E.** (*Chaps. 234, 236. Carabello, Crawford, N Engl J Med 337:32–41, 1997; Brickner et al, N Engl J Med 342:256–263, 2000.*) The risks of cardiac surgery always must be weighed against the potential benefits. The risk is extremely low in the correction of ASDs, and surgery may prevent the development of atrial arrhythmia and pulmonary hypertension, complications that can arise later in life. Small ventricular septal defects, in contrast, almost never cause hemodynamic problems later in life. The presence of Eisenmenger's reaction—cyanosis and a right-to-left shunt from pulmonary hypertension—is a contraindication to surgery regardless of the underlying lesion. Persons with symptomatic aortic stenosis warrant consideration for surgery because hemodynamic deterioration can ensue quickly. Chronic mitral regurgitation, however, is far more indolent, and mild symptoms or acute decompensation from a correctable cause does not necessarily require surgical intervention.
- VII-81. The answer is D.** (*Chap. 236. Carabello, Crawford, N Engl J Med 337:32–41, 1997; Safian et al, N Engl J Med 319:125–130, 1988.*) Safe and effective (it reduces gradients from 75 to 15 mmHg), balloon valvuloplasty is the preferred treatment for pulmonary stenosis. Rheumatic mitral stenosis secondary to commissural fusion with associated leaflet thickening is the mitral lesion most amenable to treatment with balloon dilatation. Such dilatation can increase valve size to 2.0 cm² or more but usually not to the normal 3.5 to 5.0 cm². The indications for balloon aortic valvuloplasty in patients who are poor operative risks include congenital, rheumatic, and acquired calcific aortic stenosis. In the last group, valvuloplasty fractures leaflet calcium and provides new hinge points along which leaflets may open. Surprisingly, stroke is an uncommon complication of this procedure, and most patients experience a reduction in symptoms. The best results are obtained in patients with preserved left ventricular function before the procedure. Restenosis is common but can be treated with repeat aortic valvuloplasty.

- VII-82. The answer is B.** (*Chap. 231*) The cardiac output must increase during exercise, since oxygen demand is greater. This increase is accomplished by a physiologic augmentation in stroke volume and heart rate. The pumping action of hyperventilation increases ventricular filling, and therefore stroke volume rises. Catecholamine synthesis and secretion increase, leading to a faster heart rate and greater stroke volume through augmented myocardial contractility. Since blood pressure is determined by cardiac output and resistance, once cardiac output increases, blood pressure also tends to rise. However, vasodilation in muscle beds counteracts this tendency somewhat. In a normal heart, catecholamine-mediated changes in the force-volume curve lead to decreased or similar end-diastolic volumes (filling pressure) during exercise; heart failure is characterized by marked and sometimes dangerous rises in end-diastolic volume, possibly even to the point of pulmonary edema.
- VII-83. The answer is B.** (*Chap. 236. Marks, N Engl J Med 320:1031, 1989.*) The systolic click-murmur syndrome is associated with mitral valve prolapse, which can place excessive stress on the papillary muscles and lead to ischemia and chest pain. Although often associated with inferior T-wave changes, the systolic click-murmur syndrome only occasionally results in an ischemic response to exercise. On standing or during the Valsalva maneuver, as ventricular volume gets smaller, the click and murmur move earlier in systole. Echocardiography reveals midsystolic prolapse of the posterior mitral leaflet or, on occasion, both mitral leaflets into the left atrium. Persons with mitral regurgitation from prolapse are at risk of developing subacute bacterial endocarditis and should be treated accordingly.
- VII-84. The answer is E.** (*Chap. 229. Kusumotu, Goldschlager, N Engl J Med 334:89–97, 1996.*) The choice of a permanent pacemaker type depends on the underlying conduction disease and the patient's clinical profile. DDD pacing preserves the normal relationship between atrial and ventricular contraction, and physiologic atrial sensing with ventricular pacing improves exercise tolerance in young, active persons. As this form of pacing preserves the normal atrial contribution to cardiac output, it is desirable in patients with decreased left ventricular function or hypertrophied ("stiff") left ventricular chambers. DDD pacing is contraindicated in atrial fibrillation or flutter, since the ventricular rate response is unpredictable.
- VII-85. The answer is D.** (*Chap. 228. Mangano, Goldman, N Engl J Med 333:1750–1756, 1995; Eagle et al, Ann Intern Med 110:859–866, 1989.*) Preoperative noninvasive assessment can be useful in patients with suspected coronary disease. Patients who require emergent surgical procedures are not able to undergo the elective preoperative assessment. In addition, patients who have recently had coronary revascularization either through surgery or percutaneously within 5 years and have had no further symptoms should not undergo routine preoperative noninvasive assessment. The patient described in (C) is having active coronary symptoms and should proceed to coronary angiography prior to his elective surgical procedure. The patient in (E) is undergoing a low-risk surgical procedure and has no coronary risk factors and no current symptoms and therefore routine preoperative noninvasive testing is not required. The patient in (D), however, does have suspected coronary disease with intermittent angina and is undergoing elective hip procedure. He would be best served by undergoing an outpatient noninvasive functional assessment, and recommendation is dependent upon the analysis of this test prior to his elective surgery in order to minimize his perioperative cardiac morbidity.
- VII-86. The answer is C.** (*Chap. 233. Hunt, JAMA 280:1692–1698, 1998.*) A 5-year survival rate of 70% suggests that cardiac transplantation is the therapy of choice for patients with end-stage heart disease. Because the posterior walls of the host's atria are left in place at the time of transplantation, the recipient's sinus node remains innervated and under the influence of the autonomic nervous system, but the donor sinus node controls the rate of the transplanted heart (and has a regular PR interval, in contrast to the dissociated P waves

generated by the residual host atria). Accelerated coronary vascular disease (chronic rejection) is the major factor limiting long-term survival. The vascular disease, which may be ameliorated somewhat by early posttransplant use of diltiazem, is a consequence of fibrointimal hyperplasia brought on by injury during rejection episodes and high serum lipids. The high serum lipids are a side effect of the immunosuppressive medicines that must be administered. Immunosuppression must continue for a lifetime. Neoplasms, particularly Epstein-Barr virus-associated lymphomas, represent another class of late complications.

- VII-87. The answer is D.** (*Chap. 230. Wellens et al, Am J Med 64:27–33, 1978.*) Ventricular tachycardia (VT) generally accompanies some form of structural heart disease, most commonly chronic ischemic heart disease associated with a prior myocardial infarction. The ECG diagnosis of VT is suggested by a wide-complex tachycardia at a rate exceeding 100 beats per minute. It is important, however, to differentiate supraventricular tachycardia with aberration of intraventricular conduction from VT, since the clinical implications and management of these two entities are so different. A very irregular rhythm suggests atrial fibrillation (AF) with conduction via a bypass tract (WPW syndrome). If a tracing previously obtained during sinus rhythm demonstrates a bundle branch block pattern with the same morphologic features as those which occur during the tachycardia, a supraventricular origin is favored. Characteristics of the 12-lead ECG during the arrhythmia that suggest a ventricular origin are (1) a QRS complex >0.14 s in the absence of antiarrhythmic therapy (although a QRS complex >0.20 s suggests a preexcitation syndrome), (2) AV dissociation or variable retrograde conduction, (3) a superior QRS axis in the presence of a right bundle block pattern, (4) concordance of the QRS pattern in all precordial leads, and (5) other QRS patterns that are inconsistent with typical bundle branch block patterns. Intracardiac electrical recordings would be required to confirm this important distinction.
- VII-88. The answer is D.** (*Chap. 238. Spirito et al, N Engl J Med 336:775–785, 1997.*) The symptoms of dyspnea in persons with asymmetric septal hypertrophy are related as much to decreased left ventricular (diastolic) compliance as to the degree of obstruction. The use of calcium channel blockers often relieves dyspnea by decreasing left ventricular stiffness. Sudden death in affected persons does not correlate with the degree of obstruction and is thought to be due to arrhythmias. On electrocardiography, Q waves commonly are seen and do not imply a coexistent infarction. Histologic abnormalities consist of disorganized arrangements of myocytes in the ventricular septum. As many as 50% of these cases have familial predisposition, often resulting from one of several mutations in the beta cardiac myosin heavy chain gene on chromosome 14.
- VII-89. The answer is D.** (*Chap. 236. Carabello, Crawford, N Engl J Med 337:32–41, 1997.*) In approximately two-thirds of patients with aortic regurgitation (AR), the disease is rheumatic in origin, although this etiology is less common in those with isolated AR. Manifestations of the rapidly falling arterial pressure during late systole and diastole include Corrigan's "water-hammer" pulse, capillary pulsations visible at the root of nails (Quincke's pulse), a pistol-shot (Traube's) sound over the femoral arteries, and a to-and-fro murmur (Duroziez's sign) audible over a lightly compressed femoral artery. In addition to a midsystolic ejection murmur, a second associated murmur may be the Austin Flint murmur, a low-pitched, rumbling diastolic bruit. Such a murmur is produced by the anterior displacement of the anterior leaflet of the mitral valve by the aortic regurgitant stream (characteristically seen on echocardiography). Close follow-up by means of echocardiography is necessary to ensure that an operation is performed before irreversible left ventricular dysfunction occurs.
- VII-90. The answer is C.** (*Chap. 237*) Pulmonary hypertension resulting from chronic pulmonary vascular disease such as that produced by multiple pulmonary emboli produces characteristic findings on physical examination, including a loud pulmonary second heart sound, a prominent *a* wave in the jugular venous pulse, and the systolic murmur of tricuspid

regurgitation (the abnormal jet of blood flow is easily detectable on Doppler echocardiography). Pulmonary function testing may reveal an enlarged dead space, but there usually are no abnormalities on spirometry. The usual findings on ECG include P pulmonale (tall, peaked P waves) and right axis deviation. The hypertrophied right ventricle can be imaged on thallium 201 scintigraphy, whereas this chamber normally remains invisible because of the marked uptake of the left ventricle.

- VII-91. The answer is D.** (*Chaps. 238, 387*) Chronic alcoholics may develop a clinical picture virtually identical to that of idiopathic dilated cardiomyopathy. Ceasing the consumption of alcohol may result in halting the progression of heart disease. With continued alcohol abuse, however, 75% of afflicted persons will die within 3 years. While beriberi heart disease leads to high output failure, alcoholic cardiomyopathy is associated with a low cardiac output. Atrial arrhythmias, particularly fibrillation, are the most common electrical disorder seen in what is termed “holiday heart syndrome.”
- VII-92. The answer is C.** (*Chap. 240*) The most common type of primary cardiac tumor is the benign myxoma, which most frequently arises in the left atrium. Auscultation may reveal a “tumor plop” in diastole as the tumor hits the ventricular wall. Although most myxomas are sporadic, some are familial with autosomal dominant inheritance. Features of the familial syndromes associated with cardiac myxomas include pigmented nevi, nodular disease of the adrenal cortex, mammary fibroadenomas, and testicular and pituitary tumors. Systemic symptoms that are typically confused with those of endocarditis, noncardiac malignancy, or collagen vascular disease may be associated with myxomas. Sarcoma is the most common primary malignant cardiac tumor.
- VII-93. The answer is B.** (*Chap. 230*) Epinephrine should be administered only to a patient who is unstable or unconscious. Epinephrine may exacerbate underlying arrhythmias. The first intravenous agent that should be used in the management of sustained VT in a patient in the emergency room with a history of coronary disease, especially given his episodes of congestive heart failure, is lidocaine. Lidocaine can be safely administered at a dose of 1–1.5 mg/kg to a maximum dose of 3 mg/kg. Should lidocaine be ineffective, the use of procainamide at a dose of 20–30 mg/min to a maximum dose of 17 mg/kg may be effective. Procainamide, if it does not terminate the tachycardia, will almost always slow the rate, which may allow for better perfusion. Bretylium and/or intravenous amiodarone have also proved to be effective. If pharmacologic intervention is unsuccessful patients are typically given sedation and undergo a synchronized counter-shock beginning at 100 J and progressing to 200 J, 300 J, or 360 J, depending on efficacy.
- VII-94. The answer is E.** (*Chap. 230. Moss et al, N Engl J Med 335:1933–1940, 1996; Avid Investigators, N Engl J Med 337:1576–1583, 1997.*) Amiodarone seems to be the most reliable antiarrhythmic agent in reducing the frequency of recurrent ventricular tachycardia followed by sotalol. Many of the antiarrhythmic agents are associated with an increased mortality, specifically propafenone. In randomized control studies comparing ICDs to either amiodarone or sotalol therapy, significant reduction in mortality is associated with the ICD arm. This is particularly true in patients with known coronary disease.
- VII-95. The answer is B.** (*Chaps. 243, 244. Mittleman, N Engl J Med 329:1677–1683, 1993; Willich, N Engl J Med 329:1684–1690, 1993.*) Heavy physical exertion can trigger the onset of an acute myocardial infarction and is most common in patients with a sedentary lifestyle. Although regular exercise cannot prevent the development of a myocardial infarction, it does add protection against it. The incidence of MI is highest in the early morning hours, following awakening from sleep, and declines over the remainder of the day. This is likely due to the rise of β -adrenergic levels. The mechanism of cardiac ischemia is thought to be secondary to acute atherosclerotic plaque rupture, probably due to the development of increased cardiac blood flow and a surge of catecholamines. The onset of

symptoms is typically during the peak of physical exertion and decreases after discontinuation of the activity.

- VII-96. The answer is B.** (*Chap. 242. Havel, Rapaport, N Engl J Med 332:1491–1498, 1995; Levine et al, N Engl J Med 332:512–521, 1995.*) Pharmacologic reduction of cholesterol, specifically LDL cholesterol, can significantly improve cardiovascular mortality in patients both with or without cardiovascular disease. Many studies have demonstrated that cholesterol reduction with agents such as bile acid sequestrates, HMG-CoA reductase inhibitors, niacin, or fibrates can reduce plasma LDL cholesterol and improve cardiovascular mortality and morbidity. In patients with known coronary artery disease, initiation of pharmacologic therapy should begin when the LDL cholesterol is ≥ 130 mg/dL, with a goal of therapy of < 100 mg/dL. The initiation of therapy in patients without coronary disease depends upon the number of risk factors, which include tobacco use, obesity, physical inactivity, hypertension, insulin resistance, age, male gender, and a family history of coronary disease. In patients with diabetes mellitus either with or without coronary disease, drug therapy should be initiated when the LDL cholesterol is > 100 in order to maintain the LDL cholesterol < 100 mm/dL.
- VII-97. The answer is D.** (*Chap. 235*) Rheumatic fever is associated with five major criteria that include carditis or pancarditis, which involves the pericardium, myocardium, and endocardium. Patients typically present with sinus tachycardia, murmur of mitral regurgitation, evidence of heart failure, and presence of a pericardial friction rub or cardiomegaly on examination. Healing of the rheumatic valvulitis causes the classic fibrous thickening of the mitral valves. This leads to valvular stenosis and/or regurgitation. A migratory polyarthritis is present in as many as 75% of cases and most often affects the ankles, wrists, knees, and elbows over a period of days. Sydenham's chorea is a rare complication occurring in $< 10\%$ of patients and is typically a late finding and may occur as long as several months after the presentation of acute rheumatic fever. Erythema marginatum is a rare manifestation occurring in $< 10\%$ of cases. It presents as an evanescent macular eruption with rounded borders, usually concentrated on the trunk. Group A *Streptococci* can be recovered only in ~ 25 – 40% of patients at the time of diagnosis. After initiation of standard conventional antibiotic treatment, secondary prophylaxis should be initiated to prevent subsequent colonization. In high-risk patients, benzathine penicillin-G given every 3 weeks is effective in reducing the risk of recurrent rheumatic fever.
- VII-98. The answer is D.** (*Chap. 39*) The guideline established for ventricular fibrillation or pulseless ventricular tachycardia is to begin with CPR until the defibrillator can be attached. Intubation should not be attempted until the patient is defibrillated, beginning with 200 J and increasing to 300 J, followed by 360 J if no response. A rhythm is evaluated after the first three shocks are completed. The three shocks should be given in immediate succession. If persistent or recurrent ventricular fibrillation or pulseless ventricular tachycardia continues, CPR is reinitiated. The patient should then be intubated, intravenous access obtained, and appropriate medications initiated. The role of intubation prior to defibrillation has not been shown to be beneficial.
- VII-99. The answer is E.** (*Chaps. 39, 230*) Epinephrine should be the first drug administered during ventricular fibrillation or pulseless ventricular tachycardia. In addition, epinephrine is the first drug of choice in asystole as well as pulseless electrical activity (PEA). Epinephrine stimulates both the α and β receptors and is administered in cardiac arrest primarily due to its α -adrenergic stimulating properties. Atropine is a drug of choice in the management of symptomatic second-degree atrial ventricular block type 1 associated with a bradycardiac arrest. The standard algorithm set forth by the American Medical Association after the patient has completed three successive attempts at defibrillation at 200 J, 300 J, and 360 J would be to administer epinephrine at a dose of 1 mg by IV push every 3 to 5 min. Defibrillation should be reattempted after each administration of drug at a level of 360 J within 30 to 60 s after the drug has been administered.

VII-100. The answer is C. (*Chaps. 39, 230, 243. Gottlieb et al, N Engl J Med 339:489–497, 1998.*) Among those patients in whom an acute transmural myocardial infarction is the cause of out-of-hospital cardiac arrest, the management is the same as for any patient who suffers cardiac arrest during the acute phase of a documented myocardial infarction. For these patients extensive diagnostic studies are conducted. Once the etiology of the ischemia is determined, future management should be guided to correct the abnormality, as it was in this case. In general after revascularization by angioplasty or bypass surgery, beta blockers are commonly used to reduce further ischemic burden. The patients who develop ventricular tachycardia or ventricular fibrillation late in their hospital course, i.e., after the first 48 h, have an increased mortality rate. This increase in mortality rate is both in hospital as well as long term, and these patients should be considered for electrophysiologic studies.

This page intentionally left blank.

VIII. DISORDERS OF THE RESPIRATORY SYSTEM

QUESTIONS

DIRECTIONS: Each question below contains five suggested responses. Choose the **one best** response to each question.

VIII-1. A young man is brought to the emergency department after having been submerged for a prolonged period in a nearby pond. Cardiopulmonary resuscitation was performed at the scene. The patient is being ventilated by mask and bag upon arrival in the emergency department. A brief examination reveals that the patient has no obvious sites of trauma and is conscious but not communicative. His blood pressure is 90/60, pulse is 120, temperature is 36°C (96.8°F), and respiratory rate is 30. Cardiac rhythm reveals sinus tachycardia. Pulse oximetry reveals oxygen saturation of 83%. Which of the following is the best method to reverse the patient's apparent hypoxemia?

- (A) Administration of sodium bicarbonate
- (B) Administration of acetazolamide
- (C) Administration of supplemental oxygen
- (D) Application of continuous positive airway pressure (CPAP) and administration of supplemental oxygen
- (E) Administration of supplemental oxygen and endotracheal suction to remove aspirated fluid

VIII-2. A patient who is being evaluated for shortness of breath is found to have an arterial P_{O_2} of 7.9 kPa (59 mmHg) while breathing room air at sea level and an arterial P_{O_2} of 8.1 kPa (61 mmHg) while breathing 40% inspired O_2 . The arterial P_{CO_2} is normal. Which of the following conditions would most likely account for these findings?

- (A) Idiopathic pulmonary fibrosis
- (B) Chronic obstructive pulmonary disease
- (C) Severe asthma exacerbation
- (D) α_1 -Antitrypsin deficiency
- (E) Osler-Rendu-Weber syndrome

VIII-3. A 63-year-old man has pneumococcal pneumonia with extensive air-space consolidation in the left upper and left lower lobes. He complains of extreme shortness of breath when positioned with his left side down. An arterial blood sample drawn in this position shows a P_{O_2}

VIII-3. (Continued)

of 6.2 kPa (46 mmHg); 10 min earlier, an arterial blood sample drawn while his right side was dependent had revealed a P_{O_2} of 8.2 kPa (66 mmHg). The most likely explanation for the drop in P_{O_2} when the man was lying on his left side is

- (A) increased blood flow to the dependent lung
- (B) reduced ventilation to the dependent lung
- (C) increased airway resistance in the dependent lung
- (D) accumulation of interstitial edema in the dependent lung
- (E) increased stiffness of the chest wall on the dependent side

VIII-4. A 65-year-old man presents with progressive shortness of breath. Other than a history of heavy tobacco use, the patient has a benign past medical history. Breath sounds are absent two-thirds of the way up on the left side of the chest. Percussion of the left chest reveals less resonance than normal. While you place your hand on the left side of the chest and have the patient say "ninety-nine," no tingling is appreciated in the hand. The trachea appears to be deviated toward the left. Which of the following diagnoses is most likely?

- (A) Bacterial pneumonia
- (B) Viral pneumonia
- (C) Bronchial obstruction
- (D) Pleural effusion
- (E) Pneumothorax

VIII-5. The best way to make a diagnosis of cystic fibrosis in a patient suspected of having this disorder is

- (A) sweat chloride test
- (B) sputum culture
- (C) pulmonary function testing
- (D) stool for fetal fat content
- (E) DNA analysis

VIII-6. A 21-year-old college student with no prior medical problems begins working as a laboratory technician.

VIII-6. (Continued)

He subsequently presents because of several recent episodes of shortness of breath, cough, fever, chills, and malaise. Each episode has lasted several days. The patient is seen during the recovery phase of an episode of this type; findings at physical examination are normal. Chest x-ray reveals several ill-defined, diffuse, patchy infiltrates. The laboratory evaluation is positive only for an increased erythrocyte sedimentation rate. Pulmonary function studies display reduced lung volumes.

On further questioning, it is learned that these episodes begin on days when the patient is required to tend to experiments involving laboratory rats at the animal facility. What is the best treatment for this condition?

- (A) Inhaled cromolyn sodium
- (B) Prednisone
- (C) Inhaled beclomethasone
- (D) Discontinuation of visits to the animal facility
- (E) No treatment

VIII-7. The primary pathophysiologic problem in idiopathic pulmonary fibrosis is believed to be

- (A) microorganism-mediated activation of pulmonary neutrophils
- (B) immune complex-mediated activation of alveolar macrophages
- (C) direct immune complex-mediated pulmonary interstitial damage
- (D) primary fibroblast proliferation
- (E) viral-mediated pulmonary epithelial damage

VIII-8. A 59-year-old man with a long-standing smoking history presents with persistent dyspnea. His FEV₁ is 1.0 L/min, arterial blood gas reveals P_{O₂} of 60 mmHg, P_{CO₂} of 40 mmHg, pH 7.45, and O₂ saturation of 90%. He has hyperlucent lungs on chest x-ray and decreased breath sounds on physical examination. The patient's current medical regimen consists of theophylline (300 mg twice daily) and inhaled isoproterenol. The most important addition to the patient's therapy would be

- (A) trimethoprim-sulfamethoxazole
- (B) substitution of albuterol for isoproterenol
- (C) oxygen therapy
- (D) prednisone
- (E) addition of inhaled beclomethasone

VIII-9. Although asthma is a heterogeneous disease, a given individual with asthma would be most likely to

- (A) relate a personal or family history of allergic diseases
- (B) conform to a characteristic personality type
- (C) display a skin-test reaction to extracts of airborne allergens

VIII-9. (Continued)

- (D) demonstrate nonspecific airway hyperirritability
- (E) have supranormal serum immunoglobulin E

VIII-10. A diagnosis of allergic bronchopulmonary aspergillosis in a person who has asthma and recurrent pulmonary infiltrates would be supported by which of the following findings?

- (A) Delayed, tuberculin-type skin-test reaction to *Aspergillus fumigatus*
- (B) The presence of eosinophilia
- (C) Immediate skin test reaction to *A. fumigatus*
- (D) Positive antinuclear antibody (ANA) serologic test
- (E) The presence of alveolar neutrophilia on bronchoalveolar lavage (BAL)

VIII-11. A 22-year-old woman with a history of intermittent wheezing in response to exercise presents to the emergency room with shortness of breath. Her attack occurred during an aerobics class. At this point she is having obvious difficulty breathing and has diffuse wheezes on pulmonary examination. O₂ saturation is 95% by pulse oximetry. The most effective treatment at this point would be

- (A) intravenous aminophylline
- (B) inhaled cromolyn sodium
- (C) inhaled albuterol
- (D) intravenous hydrocortisone
- (E) inhaled beclomethasone

VIII-12. Both dyskinetic ciliary syndromes and cystic fibrosis lead to recurrent pneumonia, bronchitis, and eventually bronchiectasis. Which of the following manifestations is typical of Kartagener's syndrome?

- (A) Intestinal obstruction
- (B) Dextrocardia
- (C) Steatorrhea
- (D) Interstitial pulmonary fibrosis
- (E) Infertility

VIII-13. A patient with advanced adult respiratory distress syndrome (ARDS) has suffered a pneumothorax after being exposed to 10 cmH₂O positive end-expiratory pressure (PEEP). Which of the following modes of mechanical ventilation would be best?

- (A) Assist/control mode of ventilation
- (B) Synchronized intermittent mandatory ventilation
- (C) Pressure-control ventilation
- (D) Pressure-support ventilation
- (E) Continuous positive airway pressure

VIII-14. A 48-year-old Haitian man presents with shortness of breath. Chest x-ray reveals a right pleural effusion

VIII-14. (Continued)

extending about halfway up the chest. The patient has no other known medical problems and is on no medicines. The rest of the general physical examination is unremarkable. Diagnostic thoracentesis reveals the following: lactate dehydrogenase (LDH) 1.7 $\mu\text{kat/L}$ (100 U/L), glucose 6.4 mmol/L (150 mg/dL), and amylase 1.6 $\mu\text{kat/L}$ (90 U/L). Cell count reveals 1000 red cells per microliter and 1000 white cells per microliter (differential: 50% neutrophils, 25% lymphocytes, and 25% monocytes). A ventilation-perfusion lung scan is indeterminate on the right side because of the large effusion, but there are no ventilation-perfusion mismatches elsewhere. The next most appropriate step would be

- (A) pulmonary arteriogram
- (B) abdominal computed tomography (CT)
- (C) chest CT
- (D) needle biopsy of pleura
- (E) administration of isoniazid with ethambutol

VIII-15. A 45-year-old woman presents with fever and cough. She has had no past medical problems and was well until about 3 days ago. Physical examination is remarkable for a temperature of 39°C (102.2°F) and the presence of diffuse rales on chest examination. Except for an elevated white count with a left-shifted differential, her blood tests are normal. Chest radiography reveals patchy bilateral infiltrates. She is unable to produce sputum. She has resting hypoxemia and requires hospital admission. Which is the most reasonable choice of antibiotics at this time?

- (A) Penicillin G
- (B) Cefotaxime
- (C) Erythromycin
- (D) Ampicillin plus sulbactam
- (E) Ampicillin plus sulbactam plus erythromycin

VIII-16. A 60-year-old man with emphysema and bronchitis is brought to an emergency room by an ambulance crew that has been giving him oxygen by mask. Three days ago, he noted that his sputum had changed color and increased in amount. His wife called the ambulance when he became suddenly short of breath and confused. On arrival at the hospital, he is somnolent. Midinspiratory crackles and diffuse expiratory wheezes are audible on examination of the chest, and he has marked peripheral

VIII-16. (Continued)

edema and ascites. Hemoglobin is 180 g/L (18 g/dL). Arterial blood gases are pH 7.08, P_{O_2} is 19.8 kPa (148 mmHg), and P_{CO_2} is 14.2 kPa (106 mmHg). The most appropriate immediate therapy for this man would be

- (A) intravenous infusion of sodium bicarbonate
- (B) endotracheal intubation and assisted ventilation
- (C) administration of isoetharine by air-compressor nebulizer
- (D) discontinuation of supplemental oxygen
- (E) subcutaneous injection of epinephrine

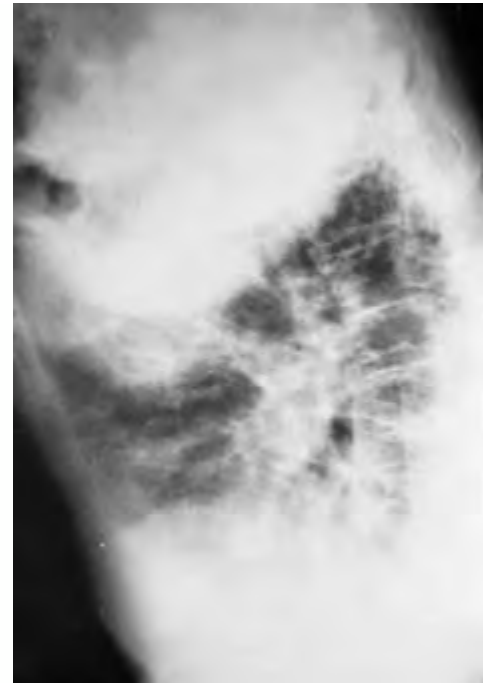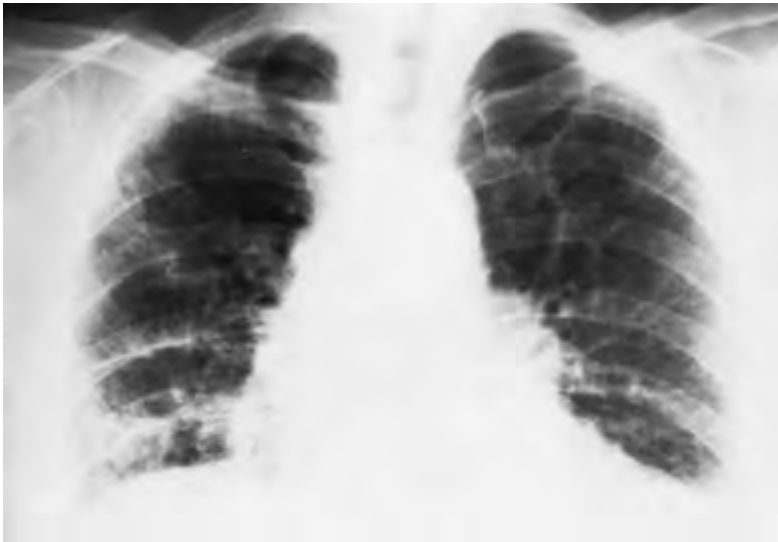
VIII-17. A 23-year-old woman complains of dyspnea and substernal chest pain on exertion. Evaluation for this complaint 6 months ago included arterial blood-gas testing, which revealed pH 7.48, P_{O_2} 79 mmHg, and P_{CO_2} 31 mmHg. Electrocardiography then showed a right axis deviation. Chest x-ray now shows enlarged pulmonary arteries but no parenchymal infiltrates, and a lung perfusion scan reveals subsegmental defects that are thought to have a “low probability for pulmonary thromboembolism.” Echocardiography demonstrates right heart strain but no evidence of primary cardiac disease. The most appropriate diagnostic test now would be

- (A) open lung biopsy
- (B) Holter monitoring
- (C) right-heart catheterization
- (D) transbronchial biopsy
- (E) serum α_1 -antitrypsin level

VIII-18. A 34-year-old man complains of shortness of breath after minimal exertion. He has no systemic symptoms. He developed a nonproductive cough 10 months ago. A chest x-ray, which was reportedly normal, was done at that time. Examination now reveals a respiratory rate of 28 breaths per minute, and diffuse end-inspiratory crackles are heard over his lower lung fields. His chest x-rays are shown below. An arterial P_{O_2} measured while the patient is breathing room air is 55 mmHg, and arterial P_{CO_2} is 26 mmHg. Routine blood counts are normal. The next step in his evaluation should be

- (A) angiotensin-converting enzyme level
- (B) transbronchial biopsy
- (C) bronchoalveolar lavage
- (D) salivary gland biopsy
- (E) serology for rheumatoid factor

VIII-18. (Continued)



VIII-19. A 53-year-old man is noted to be tachypneic and confused 48 h after suffering multiple orthopedic and internal injuries in an automobile accident. Chest x-ray is interpreted as normal, but arterial blood-gas values are as follows: pH 7.49, P_{O_2} 52 mmHg, and P_{CO_2} 30 mmHg. The course of action most likely to confirm the diagnosis of this man's condition would be to

- (A) order a ventilation-perfusion scan
- (B) order pulmonary angiography
- (C) order impedance plethysmography
- (D) order blood testing for fibrin split products
- (E) repeat the physical examination

VIII-20. Which of the following statements concerning obstructive sleep apnea syndrome is true?

- (A) Men and women are equally affected.
- (B) Cor pulmonale and not systemic hypertension is usually seen.
- (C) Sedatives are often useful in the improvement of quality of sleep.
- (D) Estrogens are frequently useful in improving respiratory drive.
- (E) Personality changes may be the presenting complaint.

VIII-21. A 54-year-old man has a nonproductive cough and exertional breathlessness. He also notes low-grade fever, malaise, and a weight loss of 7 kg (15 lb) over 6 weeks. His white blood cell count is 13,500/ μ L. He has a history of mild asthma. A chest x-ray discloses peripheral lung infiltrates. The most likely diagnosis is

- (A) idiopathic pulmonary fibrosis
- (B) alveolar proteinosis
- (C) polymyositis
- (D) chronic eosinophilic pneumonia
- (E) lymphangiomyomatosis

VIII-22. Owing to profound hypoxemia, tracheal intubation is performed on a drowning victim, and mechanical ventilation is begun. Inspired oxygen concentration is 80%. Initially, the man is agitated and fights the respiratory. Arterial blood gases are obtained and show pH 7.21, P_{O_2} 70 mmHg, and P_{CO_2} 56 mmHg. The most appropriate management step at this time would be to

- (A) add positive end-expiratory pressure (5 cmH₂O)
- (B) sedate the man and control his ventilation
- (C) infuse sodium bicarbonate intravenously
- (D) raise the inspired oxygen concentration
- (E) initiate extracorporeal membrane oxygenation

VIII-23. One week after a right total hip replacement a 65-year-old woman develops the sudden onset of shortness of breath. A workup reveals normotension, a prominent second heart sound, hypoxemia, sinus tachycardia with new right axis deviation on the electrocardiogram, and a normal chest x-ray. Oxygen is administered. Impedance plethysmography is consistent with a large proximal clot in the left leg. Which of the following would be the most reasonable next step?

- (A) Performance of a pulmonary angiogram
- (B) Performance of perfusion scintigraphy

VIII-23. (Continued)

- (C) Administration of tissue plasminogen activator
- (D) Administration of heparin
- (E) Administration of warfarin

VIII-24. Which of the following is associated with cystic fibrosis?

- (A) Impaired fertility due to immobile sperm
- (B) Systemic hypertension
- (C) Steatorrhea
- (D) Dextrocardia
- (E) Alveolar destruction

Questions VIII-25 to VIII-26.

A 35-year-old man seeks medical attention for breathlessness on exertion. He has never smoked cigarettes and has not been coughing. One sibling died of respiratory failure at 40 years of age. His three children are healthy. Physical examination reveals him to be tachypneic as he exhales through pursed lips. His chest is tympanitic on percussion, and breath sounds are poorly heard on auscultation. Chest x-ray shows flattened diaphragms with peripheral attenuation of bronchovascular markings that is most noticeable at the lung bases.

VIII-25. Expected results of the pulmonary function testing of the man described above would include

- (A) increased lung elastic recoil
- (B) increased total lung capacity
- (C) reduced functional residual capacity
- (D) increased vital capacity
- (E) increased diffusing capacity

VIII-26. Which of the following would be the most reasonable next step in the assessment of the patient described above?

- (A) Acid starch gel
- (B) Measurement of sweat chloride concentration
- (C) High-resolution CT scan
- (D) Exercise stress test
- (E) Echocardiogram

VIII-27. Which of the following statements concerning the pathogenesis of α_1 -antitrypsin deficiency is true?

- (A) Emphysema results from an inability to inhibit alveolar destruction by neutrophils.
- (B) Clinical deficiency of α_1 -antitrypsin usually results from one of several nonsense mutations that cause a truncated protein product.
- (C) The disease is inherited in a dominant fashion.
- (D) Mutations of the α_1 -antitrypsin gene of the Z type produce less severe emphysema than do mutations of the S type.

VIII-27. (Continued)

- (E) Treatment with purified α_1 -antitrypsin is unable to raise the serum level significantly to cause adequate protection of the lung.

VIII-28. To decrease the likelihood of drug toxicity, the theophylline dose should be reduced in a patient with asthma in which of the following circumstances?

- (A) Active tobacco user
- (B) Azithromycin use for *Mycoplasma pneumoniae*
- (C) Augmented use for recurrent otitis media
- (D) Marijuana abuse
- (E) Phenobarbital use for a seizure disorder

VIII-29. Which of the following is a known consequence of asbestos exposure?

- (A) The same increased risk of mesothelioma as cigarette use
- (B) Pleural effusions, often initially benign
- (C) An increased incidence of both adenocarcinoma of the lung and small cell carcinoma of the lung
- (D) Pleural mesothelioma but not peritoneal mesothelioma
- (E) An obstructive pattern, typically revealed by pulmonary function testing

VIII-30. In which of the following clinical circumstances would it be appropriate to use a rigid bronchoscope instead of a flexible fiberoptic bronchoscope?

- (A) A 22-year-old man with known HIV infection who complains of shortness of breath and has diffuse interstitial infiltrates on chest x-ray
- (B) A 65-year-old man with a long history of smoking who has shortness of breath and right upper lobe collapse
- (C) A 33-year-old woman with a history of acute myeloid leukemia complaining of severe dyspnea who is currently 4 months after an allogeneic bone marrow transplant and has a reticulonodular pulmonary infiltrate
- (D) A 50-year-old woman with a heavy smoking history who currently complains of intermittent hemoptysis
- (E) A 28-year-old man with a history of acute myeloid leukemia who is currently 30 days after an allogeneic bone marrow transplant with a significant pulmonary hemorrhage and bilateral alveolar infiltrates on chest x-ray

VIII-31. Which of the following is the most common initial symptom of byssinosis?

- (A) Wheezing
- (B) Dyspnea on exertion
- (C) Cough

VIII-31. (Continued)

- (D) Hemoptysis
- (E) Chest tightness

VIII-32. A 27-year-old woman with a history of common variable immunodeficiency has had many upper and lower respiratory tract infections. She now presents with a third episode of recurrent cough and copious purulent sputum production, which is sometimes blood-tinged. She is afebrile, and her pulmonary exam is normal. Chest radiography reveals the presence of several parallel linear opacities and a few ringlike shadows. The diagnosis that most likely accounts for this patient's symptoms is

- (A) bronchiectasis
- (B) non-small cell lung cancer
- (C) *Mycoplasma* infection
- (D) viral pneumonia
- (E) pulmonary thromboembolism

VIII-33. In which of the following situations would single-lung transplantation be contraindicated?

- (A) A 48-year-old man with chronic obstructive pulmonary disease and an FEV₁ of 20% of the predicted value
- (B) A 50-year-old man with idiopathic pulmonary fibrosis, resting hypoxia, and a total lung capacity of 50% of the predicted value
- (C) A 23-year-old woman with primary pulmonary hypertension with a mean pulmonary artery pressure of 70 mmHg
- (D) A 23-year-old woman with cystic fibrosis and an FEV₁ of 20% of the predicted value
- (E) A 25-year-old man with an α_1 -antitrypsin deficiency and resting hypoxia

VIII-34. A 50-year-old male chronic alcoholic presents with a 2-week history of fever, night sweats, cough, productive sputum, and pleuritic chest pain. The patient has had a recent negative HIV test and has no other medical problems. Chest x-ray reveals a 3-cm cavitary lesion in the posterior segment of the left lower lobe. This cavity contains an air-fluid level. Which of the following is the most likely etiologic agent?

- (A) *S. pneumoniae*
- (B) *H. influenzae*
- (C) *Mycobacterium tuberculosis*
- (D) *M. pneumoniae*
- (E) *Actinomyces*

VIII-35. A 55-year-old man presents with several months of dyspnea and a nonproductive cough. Physical examination reveals dry crackles at both lung bases. Chest radiography and high-resolution CT reveal a bibasilar reticular nodular pattern in the lung fields. Spirometry reveals reductions in total lung capacity, vital capacity, and resid-

VIII-35. (Continued)

ual volume. The carbon monoxide diffusion capacity is reduced to 35% of normal. Resting arterial hypoxemia is demonstrated on arterial blood-gas testing. Transbronchial biopsy results reveal an increase in inflammatory cells on the alveolar surface, predominantly macrophages, as well as diffuse intraalveolar fibrosis. The mainstay of therapy at this point would be

- (A) oral prednisone
- (B) oral cyclophosphamide
- (C) 4-week course of oral azithromycin
- (D) lung transplantation
- (E) bronchodilator therapy

VIII-36. A 19-year-old normal nonsmoking woman has a moderately severe pulmonary embolism while on oral contraceptive pills. Which of the following is the most likely predisposing factor?

- (A) Abnormal factor V
- (B) Abnormal protein C
- (C) Diminished protein C level
- (D) Diminished protein S level
- (E) Diminished antithrombin III level

VIII-37. A 65-year-old man presents for an evaluation because he is "feeling poorly." Symptoms include morning headache and poor sleep quality. He is quite tired during the day and frequently falls asleep while he reads or watches television. Physical examination reveals a ruddy complexion but is otherwise unremarkable. Laboratory examination is normal except for elevations in hematocrit and plasma HCO₃⁻ concentration. Polysomnography demonstrates a decreased ventilatory response to hypercapnia and many episodes of central apnea (no diaphragmatic activity is noted). The maximum respiratory pressure that he generates against an occluded airway is normal. Spirometry and blood gases are normal. Of the following, which is the most likely cause of the patient's problem?

- (A) Obstructive sleep apnea
- (B) Ankylosing spondylitis
- (C) Amyotrophic lateral sclerosis
- (D) Myasthenia gravis
- (E) Carotid body dysfunction

VIII-38. Which of the following is a typical manifestation of chronic hyperventilation?

- (A) Hypoxemia
- (B) Hyperphosphatemia
- (C) Tetany
- (D) Increased frequency of thromboembolic disease
- (E) Clubbing

VIII-39. Which of the following circumstances leading to the acute respiratory distress syndrome and the necessity for mechanical ventilation would have the best prognosis?

VIII-39. (Continued)

- (A) A 33-year-old man with a heroin overdose
- (B) A 68-year-old man with an acute myocardial infarction and 2 h of hypotension
- (C) A 25-year-old man poststatus a gunshot wound, major volume loss, hypotension, and acute renal failure
- (D) A 21-year-old woman with acute myeloid leukemia with gram-negative sepsis during induction therapy
- (E) A 45-year-old fireman with severe smoke inhalation injury and arterial Pa_{O_2} of 60 mmHg despite 100% FI_{O_2}

VIII-40. Which of the following strategies best deals with the complications of mechanical ventilation?

- (A) Less frequent but larger inspiratory tidal volumes
- (B) The use of prophylactic antibiotics
- (C) A larger size endotracheal tube in order to increase the inspiratory pressure
- (D) H_2 -receptor antagonist
- (E) High inspired oxygen tension in order to maintain arterial saturation at or near 100%

VIII-41. A 65-year-old man with chronic bronchitis presented to the emergency room 2 weeks ago with acute respiratory failure. He was intubated and treated with diuretics and antibiotics. However, after apparent improvement during a 1-week stay in the intensive care unit on mechanical ventilation, he has failed three attempts at being weaned from the ventilator. Which of the following factors could account for the difficulty in removing this patient from the ventilator?

- (A) Metabolic acidosis
- (B) Oxygen toxicity
- (C) A P_{CO_2} too high before extubation
- (D) Overdiuresis resulting in hypokalemia
- (E) Adrenal insufficiency

VIII-42. Hypoxemia occurring after pulmonary thromboembolism is a result of which of the following?

- (A) Tachycardia
- (B) Increased right heart filling pressures
- (C) Increased dead-space ventilation in the area of vascular occlusion
- (D) Perfusion of areas poorly ventilated because of airway constriction
- (E) Inadequate time for oxygen diffusion secondary to a reduction in the capillary bed

VIII-43. Which of the following conditions would be likely to result in an increased residual volume on plethysmographic pulmonary function testing?

- (A) Chronic obstructive pulmonary disease
- (B) Sarcoidosis

VIII-43. (Continued)

- (C) Interstitial lung disease
- (D) Obesity
- (E) Kyphoscoliosis

VIII-44. A 51-year-old man develops pancreatitis associated with the passage of a gallstone. His treatment includes meperidine and intravenous normal saline. Two days later he becomes anxious, tachypneic, and short of breath. An emergency chest x-ray demonstrates diffuse, bilateral interstitial and alveolar infiltrates. A year ago he suffered a myocardial infarction, but since then he has had no evidence of congestive heart failure. In this case, adult respiratory distress syndrome can be distinguished from cardiogenic pulmonary edema by which of the following?

- (A) Measurement of lung water
- (B) Measurement of arterial P_{CO_2}
- (C) Measurement of pulmonary artery wedge pressure
- (D) Measure of lung compliance
- (E) Calculation of the alveolar-arterial P_{O_2} difference

VIII-45. A 44-year-old woman arrives in your clinic complaining of a nonproductive dry cough that has been persistent for the past several months. The patient is also complaining of a 5 to 10% weight loss over the same period. She has low-grade fevers but denies night sweats; she denies any history of hemoptysis. The patient is a long-term smoker. She began smoking at age 13 and currently smokes about 1 to 1½ packs per day. Her physical examination is unremarkable. A chest x-ray shows micronodular interstitial lung infiltrates bilaterally and hyperinflated lungs. No defined mass or cystic cavities are noted. Pulmonary function testing reveals a normal pattern; however, there is a mild reduction in CO diffusing capacity, which is 90% predicted value. The chest radiograph findings are confirmed on high-resolution CT in which 1- to 2-mm cystic and nodular changes are noted, primarily in the upper lung fields. BAL is performed and reveals an increased number of CD1a reactive cells within the lavage. The most appropriate treatment recommendation for this patient would be

- (A) Smoking cessation
- (B) Initiation of a β -agonist metered dose inhaler
- (C) Inhaled glucocorticoids
- (D) Systemic glucocorticoids
- (E) Cyclophosphamide chemotherapy

Questions VIII-46 to VIII-47.

A 35-year-old man calls your office stating he has developed a minimally productive cough that has kept him up most of the evening. He has no other past medical history and is currently taking no medications. He complains of a fever to 38.3°C (101°F), with an occasional chill but no rigor. The patient denies chest pain but does admit to mild

Questions VIII-46–VIII-47. (Continued)

rhinorrhea. He also complains of an abdominal pain, nausea, and vomiting.

VIII-46. You decide to do which of the following?

- (A) No intervention except recommend fluid intake
- (B) Prescribe dexbrompheniramine plus pseudoephedrine
- (C) Recommend a nonsedating antihistamine
- (D) Start systemic glucocorticoids
- (E) Prescribe ampicillin with clavulanic acid

VIII-47. The same patient arrives in your office 72 h later with progressive symptoms. He is still complaining of continued low-grade fevers to 38.3°C (101°F). His cough is now productive of yellow greenish thick phlegm and is protracted, often resulting in vomiting. He denies any headache, sinus tenderness, or maxillary tooth pain. You prescribe which of the following?

- (A) Dexbrompheniramine plus pseudoephedrine
- (B) Nonsedating antihistamine
- (C) Erythromycin
- (D) Ampicillin with clavulanic acid
- (E) Glucocorticoids

VIII-48. A 25-year-old man with cystic fibrosis undergoes a double-lung transplantation. He is now 60 days post-transplant. He presents to your office complaining of malaise, low-grade fevers, dyspnea, and a nonproductive cough. His room air oxygen saturation is approximately 88%, his chest x-ray is unchanged from baseline, and spirometry shows a 15% decline from those results obtained 3 weeks earlier. A bronchoscopic lung biopsy reveals perivascular lymphocytic infiltrate. Which of the following would be the most reasonable next step?

- (A) Start erythromycin
- (B) Start intravenous piperacillin and gentamicin
- (C) Administer high-dose methylprednisolone
- (D) Administer inhaled glucocorticoids
- (E) Start ganciclovir for presumed cytomegalovirus infection

VIII-49. A 72-year-old woman presents with an acute onset of pleuritic chest pain, dyspnea, and tachycardia 2 days after fracturing her left foot misstepping on an uneven sidewalk. During those 2 days the patient has spent most of her time bedridden. The patient is brought by ambulance to the emergency room. A ventilation-perfusion scan (\dot{V}/\dot{Q}) is performed confirming the clinical suspicion of a pulmonary embolism. Which of the following treatment recommendations is likely to result in a decrease in a recurrent thromboembolic event?

- (A) Initiation of heparin only until the patient is fully ambulatory; once ambulatory, no further treatment is indicated

VIII-49. (Continued)

- (B) The initiation of warfarin and heparin simultaneously
- (C) The initiation of warfarin once a therapeutic partial-thromboplastin time has been achieved, and then the warfarin continued for an additional 6 weeks
- (D) The initiation of warfarin once a therapeutic partial-thromboplastin time has been achieved, and then the warfarin continued for an additional 6 months
- (E) An insertion of an inferior vena cava (IVC) filter

VIII-50. Which of the following electrocardiographic abnormalities is commonly associated with a pulmonary embolism?

- (A) Left bundle branch block
- (B) First-degree AV block
- (C) T-wave inversion in the anterior leads V_1 – V_4
- (D) T-wave inversion in the lateral leads I, aV_L , V_5 – V_6
- (E) Q waves in the anterior leads V_1 – V_4

VIII-51. A 35-year-old premenopausal woman presents with the diagnosis of pulmonary hypertension. She complains of dyspnea, nonproductive cough, and recurrent episodes of chest pain. Part of her pulmonary workup includes a bronchoscopy with a bronchoscopic biopsy. Histologic review of the biopsy specimen reveals pulmonary lymphangioleiomyomatosis (LAM). Which of the following statements concerning pulmonary LAM is correct?

- (A) Pulmonary LAM is more common in blacks than whites.
- (B) Hemoptysis is common but seldom life-threatening.
- (C) Pulmonary function tests often show a clear restrictive pattern.
- (D) A chylous pleural effusion is a common complication.
- (E) Carbon dioxide diffusing capacity is often reduced.

Questions VIII-52 to VIII-53.

An 18-year-old male patient arrives in your office complaining of a 2-day history of an upper respiratory viral syndrome. He complains of a nonproductive cough and dyspnea on exertion, and audible wheezing is observed on physical examination. His room air O_2 saturation is 99%. You administer a β agonist through a nebulizer. A transient decrease in the arterial O_2 tension is noted.

VIII-52. Which of the following is a likely mechanism for this observation?

- (A) Hyperkalemia
- (B) Relaxation of the compensatory vasoconstriction
- (C) Hypoglycemia
- (D) Tolerance of the β agonist
- (E) Bronchial hyperresponsiveness

VIII-53. The patient in Question VIII-52 improves after two treatments of β -agonist therapy. He is then discharged with a β -agonist metered-dose inhaler; in addition you prescribe an inhaled glucocorticoid. Which of the following is a typical complication of inhaled glucocorticoid therapy?

- (A) Adrenal suppression
- (B) Hypertriglyceridemia
- (C) Leukocytosis

VIII-53. (Continued)

- (D) Cataracts
- (E) Esophageal candidiasis

VIII-54. Which of the following statements concerning central sleep apnea (CSA) is true?

- (A) CSA is more common than obstructive sleep apnea (OSA) in patients with heart failure.
- (B) Daytime hypercapnia is not seen in patients with CSA.
- (C) Obesity is a common finding.
- (D) CPAP is not effective in treating patients with CSA as opposed to the treatment of patients with OSA.
- (E) Unlike in OSA, snoring is an uncommon complaint.

VIII. DISORDERS OF THE RESPIRATORY SYSTEM

ANSWERS

- VIII-1. The answer is D.** (*Chap. 392. Modell, N Engl J Med 328:253–256, 1993.*) Ninety percent of drowning patients aspirate fluid; however, the vast majority aspirate <22 mL/kg. Although aspiration of fresh water can produce acute hypervolemia with dilutional hyponatremia and possibly even hemolysis, these are rare occurrences. Aspiration of seawater can cause hypovolemia with ensuing hypernatremia. In the absence of documentation of such an electrolyte problem, no specific therapy is required. Aspiration of water of any type leads to considerable venous admixture (i.e., ventilation-perfusion abnormalities), which can produce hypoxemia. The most important therapeutic maneuvers, after resuscitation on the scene, are to provide supplemental oxygen, intravenous access, and transportation to a hospital where the patient can be evaluated for adequacy of ventilation, cardiac function, and blood volume. The best way to reverse drowning-associated hypoxemia consists of the application of CPAP. CPAP may be combined with mechanical inflation of the lung as needed; mechanical inflation may be particularly effective in those who have aspirated fresh water, which leads to a change in the surface-tension characteristics of pulmonary surfactant. Correction of severe metabolic acidosis with bicarbonate is controversial. Finally, the universal need for glucocorticoid therapy and antibiotics is no longer accepted.
- VIII-2. The answer is E.** (*Chap. 250*) The general mechanisms responsible for hypoxemia include alveolar hypoventilation, impaired diffusion, ventilation-perfusion inequality, and shunting (blood bypassing ventilated areas of the lung). In each of these cases, except for shunting, the arterial P_{O_2} increases significantly when the inspired P_{O_2} is raised. Examples of shunts (which could account for the lack of response to oxygen therapy described in the question) include congenital heart disease that produces direct right-to-left intracardiac flow (usually associated with pulmonary hypertension), intrapulmonary vascular shunting (i.e., congenital telangiectatic disorders such as Osler-Rendu-Weber syndrome), and, most commonly, perfused alveoli that are not ventilated because of atelectasis or fluid buildup (pneumonia or pulmonary edema). Since impaired diffusion usually is not severe enough to lead to disordered gas exchange except during exercise, most cases of normocapnic hypoxemia are due to ventilation-perfusion mismatch. Many processes that affect the lungs (alveolar disease, interstitial lung disease, pulmonary vascular disease, airway disease) do so unevenly, leading to some areas with adequate perfusion and poor ventilation and some with good ventilation and poor perfusion.
- VIII-3. The answer is A.** (*Chap. 250*) In a person standing erect, blood flow per unit volume increases from the apex of the lung to the base. Ventilation also increases from the apex to the base, but the gradient is less than that for blood flow, making the ventilation-perfusion ratio lower at the bottom of the lung than it is at the top. Both ventilation and perfusion are affected by posture; as a general rule, the dependent regions are better perfused than ventilated and have the lowest ratio of ventilation to perfusion. Thus, a person with unilateral air-space disease may have an increase in venous admixture when the diseased lung is dependent. In that situation, blood flow increases to the diseased lung, perfusing atelectatic and poorly ventilated alveoli, and hypoxemia ensues.
- VIII-4. The answer is C.** (*Chap. 249*) In evaluating a patient with shortness of breath, examination of the thorax is crucial. Tracheal deviation to the left indicates either a pleural

effusion on the right or loss of volume on the left. Volume loss typically is due to an obstructed bronchus that produces atelectasis in the affected segment or lobe. Loss of aerated lung will be reflected in dullness to percussion, absent breath sounds on auscultation, and a decrease in tactile fremitus. A consolidative process such as bacterial pneumonia may well produce increased fremitus as well as bronchial breath sounds and whispered pectoriloquy, since sounds are well transmitted through a consolidated area. In a pneumothorax, a percussion of the chest would reveal hyperresonance, although breath sounds and fremitus would be absent. A possible cause of obstruction and atelectasis of a large amount of left lung tissue could be obstruction of a major bronchus by carcinoma of the lung, especially in an older patient who is a heavy smoker.

- VIII-5. The answer is A.** (*Chap. 257. Stutts, Science 269:847, 1995.*) Cystic fibrosis, an autosomal recessive disease, results from a mutation in a gene on chromosome 7. Because of the multiple potential mutations that have been described in this gene, it is currently not feasible to use DNA-based diagnosis to identify patients with this disorder or heterozygous carriers. The gene codes for a protein called the cystic fibrosis transmembrane regulator (CFTR), which is a single-chain 1480 amino acid–containing protein that functions as a cyclic AMP–regulated chloride channel. All affected tissues, including airway and intestinal epithelium, sweat ducts, and exocrine pancreatic ducts, express an abnormal CFTR protein. The most common mutation in this protein is an absence of phenylalanine in amino acid position 508, resulting from a 3-basepair DNA deletion. A consequence of this and the other mutations in the CFTR protein is failure of normal calcium chloride transport. Therefore, secretions are dehydrated and poorly cleared. The diagnosis of cystic fibrosis now depends on a combination of clinical criteria and a demonstration that sweat chloride values are abnormally low. About half of the 1 to 2% of patients with cystic fibrosis who have normal sweat chloride values have a specific single G to T mutation in the CFTR gene.
- VIII-6. The answer is D.** (*Chap. 253. Beckett, N Engl J Med 342: 406–413, 2000.*) Given the temporal relationship of the symptoms to the work with rats, serologic evidence for inflammation, the nonspecific radiographic findings, and the restrictive pulmonary physiology suggested by spirographic examination, the most likely diagnosis is acute hypersensitivity pneumonitis, with male rat urine probably being the offending antigen. Without treatment, the patient could develop the subacute or chronic form of the disease with potentially serious physiologic impairment. While steroids can be helpful in severe or chronic cases, the best therapy is to remove the offending antigen or remove the patient from an environment where exposure is inevitable. This approach is difficult when the patient's life-style or livelihood requires a radical change; in the case presented, however, simply restricting the student's laboratory efforts to those not involving direct animal care seems relatively nondisruptive.
- VIII-7. The answer is B.** (*Chap. 259*) Bronchoalveolar lavage in patients with idiopathic pulmonary fibrosis, a chronic inflammatory disorder of the lower respiratory tract characterized by dyspnea and reticulonodular infiltrates on chest radiography, discloses an abundance of alveolar macrophages. Probably related to locally generated immune complexes, alveolar macrophages become activated and then produce several mediators that recruit and induce fibroblast proliferation, which causes secondary damage. Macrophage-derived mediators believed to be important in this process include fibronectin, a 200-kDa dimeric glycoprotein that interacts with connective tissue matrix as well as specific receptors on fibroblasts, and platelet-derived growth factor, whose β chain is encoded by the *c-sis* proto-oncogene. Platelet-derived growth factor is believed to play an important role in recruiting fibroblasts to the site of inflammation. Macrophages also produce chemotaxins such as leukotriene B₄ and interleukin 8, which attract neutrophils and eosinophils into the region.
- VIII-8. The answer is C.** (*Chap. 258. Oswald-Mammosser, Chest 107:1193, 1995.*) The patient has evidence of obstructive lung disease on the basis of hyperinflation, decreased

breath sounds, decreased FEV₁, and a heavy smoking history. He has chronic hypoxemia and a moderate degree of CO₂ retention. He may have an intermediate syndrome between emphysema and chronic bronchitis. Smoking cessation, yearly vaccination against influenza, and a one-time vaccination against *Streptococcus pneumoniae* infection are indicated. There are no definitive data to support the use of chronic antibacterial prophylaxis or systemic glucocorticoids, though occasional patients will benefit from steroid therapy given either systemically or by inhalation. The major issue is hypoxemia, which should be treated with continuous (at least nocturnal) oxygen therapy. Several trials have documented the benefit of oxygen therapy for lowering mortality, improving neuropsychological status, and decreasing the incidence of heart failure. Albuterol, a selective β_2 agonist, induces bronchodilation with few cardiac side effects; however, the benefit of oxygen therapy is likely to be much greater than that of changing the inhaled sympathomimetic.

- VIII-9. The answer is D.** (*Chap. 252. Larsen, N Engl J Med 326: 1540–1542, 1992; Goldstein et al, Ann Intern Med 121:698–708, 1994.*) The importance of immune mechanisms in the pathogenesis of asthma is suggested by the common association between the disease and the presence of allergic diseases, skin-test sensitivity, and increased serum IgE levels. In addition, many susceptible persons develop bronchospasm after inhalation challenge with airborne allergens. A large proportion of asthmatic subjects, however, have none of these markers of immunologic activity and are classified as having idiosyncratic asthma. When tested for bronchial hyperirritability with various nonantigenic bronchoprovocational agents (e.g., histamine and cold air), asthmatic subjects are found to be more sensitive than normal, and the bronchoconstriction is generally reversible after exposure to a β -adrenergic agonist; the reason for this airway hyperirritability, which is a common feature of all asthmatic persons, is unknown. Although psychologic factors certainly influence the expression of asthma, no single personality type is considered “asthmatic.”
- VIII-10. The answer is C.** (*Chap. 253. Rosenberg et al, Ann Intern Med 86:405–414, 1977.*) Allergic bronchopulmonary aspergillosis is a hypersensitivity pneumonitis that involves an allergic reaction to antigens from *Aspergillus* spp., most commonly *A. fumigatus*. The diagnosis should be suspected in asthmatic persons who have recurrent pulmonary infiltrates associated with peripheral blood or sputum eosinophilia. However, the presence of peripheral blood eosinophilia is not diagnostic for this disorder; it may be present in a patient with asthma not associated with allergic bronchopulmonary aspergillosis. All forms of the disease may be associated with elevations in erythrocyte sedimentation rate, C-reactive protein, rheumatoid factor, and serum immunoglobulins. ANAs are rarely present and appear to have no pathogenic role. Suggestive laboratory findings include serum IgE levels elevated to many times normal and the presence of aspergilli in the sputum. Antigenic skin testing is positive in immediate (type I, wheal-and-flare) reaction, and reaction is evident after 4 to 6 h (type III, erythema and induration). Delayed, tuberculin-type (type IV, cell-mediated) reactions, however, do not occur. Serum precipitins to aspergilli are found in the majority of affected persons. The inflammatory response leads to dilatation of central airways and is often evident radiographically as mucoid impaction. On BAL a marked lymphocytic alveolitis is almost universal although not pathognomonic. Lymphocytes typically have a decreased helper-to-suppressor ratio. Although alveolar neutrophilia is often a prominent feature initially, it tends to fade in the absence of recurrent exposure.
- VIII-11. The answer is C.** (*Chap. 252. McFadden, Am J Med 99:651, 1995.*) Asthmatic patients who present with an acute attack and lack signs of impending ventilatory collapse should be treated with an inhaled aerosolized β_2 agonist such as albuterol or isoproterenol. Such medicines can be given up to every 20 min by inhaled nebulizer for three doses, with the frequency reduced thereafter. Such drugs are five times more effective than intravenous aminophylline. Intravenous or inhaled steroids will have a delayed onset of action, if they are destined to be beneficial at all. Patients should be reassured that mortality from asthma is unlikely; however, it is nonetheless advisable to respect an acute asthmatic attack, especially one accompanied by CO₂ retention.

- VIII-12. The answer is B.** (*Chaps. 256, 257. Stern, N Engl J Med 336:487–491, 1997.*) Cilia, which are responsible for the motility and mucous clearance functions of many cell types, are composed of a double tubular structure. Abnormalities in one of the anatomic components of cilia can lead to a lack of coordinated ciliary action. Kartagener's syndrome, the best known of the dyskinetic ciliary syndromes, is caused by an absence of the inner or outer dynein arms normally present in functional cilia. Impaired ciliary motion is most prominently reflected in the lack of sperm motility and the impaired epithelial function of the fallopian tubes and respiratory tract. Kartagener's syndrome typically has situs inversus accompanied by both bronchiectasis and sinusitis. Infertility results from impaired motility of sperm and epithelial function of fallopian tubes, while chronic sinopulmonary infections result from impaired function of the respiratory tract. Recurrent bronchitis and pneumonia caused by impaired removal of airway secretions can lead to diffuse bronchiectasis, with abnormality dilated airways and copious sputum production, but not to interstitial pulmonary fibrosis. Cystic fibrosis is also associated with infertility due to obstruction of the vas deferens. Patients often present with intussusception or intestinal obstruction secondary to meconium ileus. The presence of steatorrhea is secondary to pancreatic insufficiency.
- VIII-13. The answer is C.** (*Chap. 266*) A patient with the stiff lungs characteristic of ARDS often requires the institution of 0 to 5 cmH₂O of PEEP to maintain adequate oxygenation. However, such high pressures may disrupt lung tissue, causing subcutaneous emphysema or pneumothorax. Patients with such complications probably are best served by the use of pressure-control ventilation, in which a given pressure is imposed at the airway opening during the inspiratory phase and delivers whatever tidal volumes and inspiratory flow rates are possible on the basis of set pressure. In addition to its use in situations where barotrauma has occurred, pressure-control ventilation may be helpful in postoperative thoracic surgical patients who have newly created suture lines. Because of the asynchronous nature of pressure-control ventilation relative to the patient's own ventilatory efforts, such ventilation usually requires heavy sedation. However, newer modifications of pressure-control ventilation allow the patient to initiate breaths to be given at a set pressure, allowing its use without such sedation.
- VIII-14. The answer is D.** (*Chap. 262. Berkman, Postgrad Med J 69:12, 1993.*) The initial step in the evaluation of a pleural effusion is the determination of the presence of either a transudative effusion, usually caused by congestive heart failure, cirrhosis, or nephrotic syndrome, or an exudative pleural effusion, which may be due to a host of causes. The working definition of an exudative effusion is one that meets any of the following criteria: (1) pleural fluid to serum protein concentration ratio >0.5, (2) pleural fluid to serum LDH concentration ratio >0.6, (3) pleural fluid LDH concentration greater than two-thirds of the upper limit of normal serum LDH. This patient's effusion is an exudate. Additional studies to be done include measurement of pleural glucose and cultures for bacterial mycobacteria and fungi. If the glucose is <60 mg/dL, malignancy, empyema, or rheumatoid pleuritis should be considered. Esophageal rupture, pancreatitis, and malignancy can cause an elevated pleural fluid amylase. If no diagnosis is apparent after the above studies, occult pulmonary embolism should be considered. If there is still no diagnosis based on these studies, it is then appropriate to perform a needle biopsy of the pleura with particular attention to histologic analysis for tuberculosis or cancer.
- VIII-15. The answer is E.** (*Chap. 255. Fang, Medicine 69:307–316, 1992.*) Patients who require hospitalization for pneumonia acquired in the community optimally receive prompt microbiologic diagnosis. Recent studies have shown that about one-third of patients with such community-acquired pneumonias are alcohol abusers or have chronic obstructive pulmonary disease. The potential microbiologic etiology for this spectrum of disease is *S. pneumoniae*, *Haemophilus influenzae*, *Legionella* spp., *Chlamydia*, anaerobes, *Staphylococcus aureus*, and *Mycoplasma*. If the likelihood of pneumococcal pneumonia is high on the basis of the sputum Gram stain, penicillin and ampicillin still remain the drugs of choice, given a relatively low rate of penicillin-resistant organisms. However, if the like-

likelihood of aerobic bacterial infection is high, second-generation cephalosporins such as cefotaxime are appropriate. If anaerobic infection is considered likely, metronidazole or ampicillin plus sulbactam should be used. In the current case, given the lack of clear-cut microbiologic evidence for a specific infection, the absence of sputum, and the equivocal findings on the chest x-ray, *Chlamydia* or *Legionella* should be strongly considered. The best empiric regimen in this situation would be ampicillin plus sulbactam in addition to erythromycin. A microbiologic diagnosis should be made in the next few days to allow narrowing of the antibiotic regimen.

- VIII-16. The answer is B.** (*Chap. 258. Barnes, N Engl J Med 343:269–280, 2000.*) Certain persons with severe obstructive lung disease appear to respond to uncontrolled oxygen therapy by dangerously reducing their minute ventilation. Because they are relatively insensitive to changes in arterial P_{CO_2} , hypoxemia is the major ventilatory stimulus in these persons. When hypoxemia is suddenly treated with supplemental oxygen therapy given in an uncontrolled fashion, ventilation drops and worsening ventilation-perfusion relationships occur, arterial P_{CO_2} rises, acidosis results, and coma may develop. However, abrupt removal of supplemental oxygen may precipitate life-threatening hypoxemia. Because acidosis must nevertheless be reversed rapidly by increasing ventilation, endotracheal intubation should be performed, followed by mechanical ventilation of a sufficient amount to return arterial pH to the physiologic range. Inhaled bronchodilators cannot be given to comatose, unintubated persons. Epinephrine is relatively ineffective in persons with acute or chronic respiratory failure and is dangerous in elderly, acidemic patients.
- VIII-17. The answer is C.** [*Chap. 260. Rich, Primary Pulmonary Hypertension, in Braunwald E (ed), Heart Disease, 1996.*] Primary pulmonary hypertension is an uncommon disease that usually affects young women. Early in the illness affected persons often are diagnosed as psychoneurotic because of the vague nature of presenting complaints, for example, dyspnea, chest pain, and evidence of hyperventilation without hypoxemia on arterial blood-gas testing. However, progression of the disease leads to syncope in approximately one-half of cases and signs of right heart failure on physical examination. Chest x-ray typically shows enlarged central pulmonary arteries with or without attenuation of peripheral markings. The diagnosis of primary pulmonary hypertension is made by documentation of elevated pressures by right heart catheterization and exclusion of other pathologic processes. Lung disease of sufficient severity to cause pulmonary hypertension would be evident by history and on examination. Major differential diagnoses include thromboemboli and heart disease; outside the United States, schistosomiasis and filariasis are common causes of pulmonary hypertension, and a careful travel history should be taken.
- VIII-18. The answer is B.** (*Chap. 259*) The chest x-rays presented show diffuse, severe interstitial infiltrates without hilar adenopathy. Although sarcoidosis may produce this radiographic picture, it is also compatible with idiopathic interstitial pneumonitis, hypersensitivity pneumonitis, collagen vascular disease, inhalation of inorganic dusts, and many other processes. The degree of respiratory system dysfunction demonstrated by this patient necessitates rapid evaluation and a definitive histologic diagnosis so that appropriate therapy can be initiated. Angiotensin-converting enzyme levels, although elevated in many patients with sarcoidosis, are not sufficiently sensitive or specific to replace tissue biopsy in the workup of persons with interstitial infiltrates. Although biopsy of extrapulmonary tissue may demonstrate noncaseating granulomas in patients with sarcoidosis, such biopsies may be negative in patients with active disease. A pathologic diagnosis is absolutely required in patients presenting with interstitial lung disease of uncertain etiology. Fiberoptic bronchoscopy should be performed to rule out infection or malignancy; an accompanying transbronchial biopsy may yield a diagnosis about 25% of the time. BAL to assess the degree of inflammation may be helpful in monitoring disease activity, but its precise role in interstitial lung disease has not been defined. Despite its relatively low yield, the relatively low risk makes an attempt at transbronchial biopsy reasonable before definitely obtaining tissue at open-lung biopsy.

- VIII-19. The answer is E.** (*Chap. 261*) The clinical triad of dyspnea, confusion, and petechiae in a person who has had recent long-bone fractures establishes the diagnosis of fat embolism syndrome. This disorder, which usually occurs within 48 h of injury, may lead to respiratory failure and death. Petechiae most often are found across the neck, in the axillae, and in the conjunctivae; however, their appearance is often evanescent. No laboratory test is specific for fat embolism.
- VIII-20. The answer is E.** (*Chap. 264. Fujita, Ear Nose Throat J 72:67, 1993.*) Obstructive sleep apnea syndrome is a complex entity that involves intermittent upper-airway obstruction during sleep. Most of the manifestations, such as hypertension, cor pulmonale, chronic fatigue, personality changes, and disordered sleep behavior, resolve when obstruction is bypassed by a tracheostomy or endotracheal tube. Although the syndrome is more common in men, the prevalence increases in women after menopause. Alcohol and sedatives can exacerbate ventilatory obstruction by decreasing upper-airway muscle tone. Treatment of severe obstructive sleep apnea includes tricyclics to improve upper-airway muscle tone, uvulopalatopharyngoplasty to create a more spacious airway, continuous nasal positive airway pressure to prevent muscular collapse, and tracheostomy to bypass the obstruction completely. Estrogens, which once were thought to be beneficial in improving respiratory drive, are not now considered a mainstay of treatment.
- VIII-21. The answer is D.** (*Chap. 253. Hayakawa, Chest 105:1462, 1992.*) Chronic eosinophilic pneumonia is an interstitial lung disorder of unknown cause that produces a systemic illness characterized by fever, weight loss, and malaise. Although lung biopsy shows an eosinophilic infiltrate involving both the interstitium and the alveolar space, there may not be an associated eosinophilia in the peripheral blood. The diagnosis should be suggested by the “photonegative pulmonary edema” pattern, with central sparing and nonsegmental, patchy infiltrates in the lung periphery. This disorder often responds dramatically to glucocorticoid therapy. Idiopathic pulmonary fibrosis and polymyositis produce diffuse reticular, nodular, or reticulonodular infiltrates on chest x-ray. Alveolar proteinosis is a rare disorder that most often produces a diffuse air-space filling pattern radiating from hilar regions on chest x-ray, often with air bronchograms. Alveolar proteinosis does not cause fever unless it is complicated by an infection such as nocardiosis. Lymphangiomyomatosis is also rare. It occurs exclusively in women of childbearing age. The chest x-ray shows reticulonodular infiltration, but the lungs often appear hyperinflated. Lymphangiomyomatosis is complicated by pleural effusion and pneumothorax but not by fever.
- VIII-22. The answer is B.** (*Chap. 266. Hinson, Annu Rev Med 43:341, 1992.*) Some persons who become agitated or anxious on a mechanical ventilator receive inadequate ventilation because they are breathing out of phase with the machine. The man described in the question has adequate oxygenation; a P_{O_2} of 70 mmHg means that his hemoglobin is >90% saturated. However, he is hypoventilating and has developed an acute respiratory acidosis. PEEP improves oxygenation by raising the lung volume and reducing shunting, but it does not have a large effect on carbon dioxide clearance. Therefore, the appropriate first step in management would be to administer a sedative and control the man’s ventilation to reduce arterial P_{CO_2} and raise pH.
- VIII-23. The answer is D.** (*Chap. 261*) Patients at high risk for thromboembolic disease include those who have had recent anesthesia, recent childbirth, heart failure, leg fracture, prolonged bed rest, obesity, estrogen use, or cancer. The clinical scenario presented is highly consistent with a pulmonary embolism arising from venous thrombosis of a proximal lower extremity in a postoperative patient. While the electrocardiogram is usually normal except for sinus tachycardia, the finding of new right-sided heart strain is compatible with a significant pulmonary embolus. The positive impedance plethysmogram for an above-the-knee venous thrombosis obviates the need for additional diagnostic testing. The patient must receive antithrombotic therapy (heparin) in an attempt to inhibit clot growth, promote resolution, and prevent recurrence. Warfarin requires several days to achieve anticoagu-

lation and is therefore not appropriate in the acute setting. While thrombolytic therapy can clearly hasten the resolution of thrombi and may be appropriate for large, deep venous thromboses and pulmonary embolisms large enough to cause hypotension, its role in altering the natural history of this disorder has not been defined. Furthermore, recent surgery is a contraindication to the use of thrombolytic agents, which, even in the case of more specific newer agents such as tissue plasminogen activator, carry significant hemorrhagic risk. Lower-molecular-weight heparins (e.g., enoxaparin) have several potential advantages, including a longer half-life and a more predictable dose response, compared with unfractionated heparin; however, this newer agent has not received FDA approval for the treatment of pulmonary embolism or deep venous thrombosis.

- VIII-24. The answer is C.** (*Chap. 257. Stern, N Engl J Med 336:487–491, 1997.*) Although the majority of patients with cystic fibrosis are diagnosed in childhood, a significant number of patients are not identified until their late teens, twenties, or even thirties. Accurate diagnosis requires that the sweat chloride test be given to all patients with clinical features of cystic fibrosis. Airway obstruction resulting from bronchiectasis is associated with sinusitis and infertility in males with both cystic fibrosis and the immotile cilia syndrome, but only males with immotile cilia have Kartagener's syndrome (bronchiectasis, sinusitis, and dextrocardia). Patients with cystic fibrosis may have any of several gastrointestinal manifestations including obstruction, intussusception, fecal impaction, volvulus, portal hypertension, and steatorrhea. Steatorrhea is a manifestation of pancreatic insufficiency. Nearly all patients with cystic fibrosis display clubbing.
- VIII-25. The answer is B.** (*Chap. 258*) The man described in the question presents with physical signs (pursed lip breathing, chest hyperexpansion) and radiographic evidence (flattened diaphragms, attenuated markings) suggestive of obstructive lung disease with loss of lung tissue. Reduced expiratory air-flow rates are produced by narrowing of airways (e.g., in asthma), loss of airways (e.g., in bronchiolitis obliterans), or loss of elastic tissue (e.g., in emphysema). Pathophysiologically, these conditions cause increased resistance as airways are narrowed or collapse as well as decreased driving pressure that represents loss of elastic recoil. Air trapping and reduced lung recoil lead to an increase in both total lung capacity (TLC) and functional residual capacity (FRC), which is the volume at which the tendency of the lung to recoil inward is just balanced by the tendency of the chest to recoil outward. Although TLC is increased, vital capacity, the maximum amount of gas that can be exhaled from the lungs with a single breath, is reduced owing to the great increase in residual volume produced by gas trapping. Not only is vital capacity reduced, it takes longer to empty the lungs; thus, forced expiratory volume in 1 s (FEV₁) is reduced as a percentage of vital capacity. When alveolar capillaries are destroyed by emphysema, the diffusing capacity, which reflects in part the surface area of alveolar membrane available for gas exchange, is reduced.
- VIII-26. The answer is A.** (*Chap. 258*) To establish baseline information in persons who have emphysema, spirometry should be performed, and for persons with significant complaints or physical findings, arterial blood gases also should be checked. Although cigarette smoking accounts for the vast majority of cases of emphysema, a small percentage of persons who develop this illness have had no exposure to tobacco products. A subset of this nonsmoking, emphysematous population is deficient in α_1 -antitrypsin, which is a protease inhibitor that normally is found in the serum. It is currently believed that release of proteolytic enzymes from inflammatory cells accounts for the lung destruction that typifies emphysema, and α_1 -antitrypsin deficiency, a familial disorder, the genotype of which is acid starch gel and immunoelectrophoresis, permits this destruction to occur unimpeded. Exercise testing is not necessary as an initial screening test for emphysema but should be considered before oxygen therapy is prescribed. A male who has emphysematous respiratory failure, gives no history of respiratory infections, and has children would not have cystic fibrosis (affected men are sterile); therefore, a sweat chloride test would not be a useful procedure. High-resolution CT scan would unlikely add any significant alteration

to the differential diagnosis, and both an exercise stress test as well as an echocardiogram are not necessary in the evaluation of this patient.

- VIII-27. The answer is A.** (*Chap. 258*) Reduced serum levels of the antiprotease α_1 -antitrypsin, which is synthesized primarily in the liver, are associated with an inability to control the alveolar-damaging effects of neutrophil elastase and clinical emphysema. α_1 -Antitrypsin is encoded by a 7-exon gene spanning 12.2 kilobases on chromosome 14. Common disease-producing mutations of the normal M gene are the Z type, in which a single amino-acid substitution results in a hyperaggregative, improperly processed protein, and the S type, which results in a product with a shortened half-life and also is due to a single amino-acid change. Heterozygotes (either M2 or M5) appear to have sufficient, albeit reduced, levels of α_1 -antitrypsin to prevent severe lung damage. Since the S type produces less clinical antiprotease “deficiency,” the pulmonary disease produced in SS homozygotes is much less severe than that seen in patients whose genotype is ZZ. Intravenous administration of normal human purified α_1 -antitrypsin can increase serum levels to a point at which sufficient antiprotease activity is provided to protect alveoli from elastase-induced damage.
- VIII-28. The answer is B.** (*Chap. 252*) Although inhaled sympathomimetics are now considered the first-choice treatment for acute asthmatic attacks, methylxanthines such as theophylline are effective bronchodilators and continue to be used extensively in this disorder. The therapeutic plasma concentration is 10 to 20 $\mu\text{g/mL}$, but the dose required to achieve these levels varies widely, depending on the clinical situation. The theophylline dose should be reduced in any condition in which the clearance of this drug is significantly impaired, such as in the very young, the elderly, and those with liver or cardiac dysfunction. Many drugs interfere with the metabolism of theophylline. Some commonly used agents, including allopurinol, propranolol, cimetidine, and erythromycin, interfere with theophylline clearance and thus lead to increased levels of this methylxanthine. Drugs that activate hepatic microsomal enzymes, such as cigarettes, marijuana, phenobarbital, and phenytoin, may lower theophylline levels.
- VIII-29. The answer is B.** (*Chap. 254*) Inhalation of asbestos fibers for 10 years or more may lead to interstitial fibrosis that typically begins in the lower lobes and later spreads to the middle and upper lung fields. This fibrosis is associated with a restrictive pattern on pulmonary function testing. The chest x-ray shows linear densities, thickening or calcification of the pleura (pleural plaques), and, in severe cases, honeycombing. Exposure to asbestos also may cause exudative pleural effusions. These effusions are often blood-stained and may be painful. The diagnosis may be elusive if a careful occupational exposure is not obtained. These effusions are benign, but affected persons may later sustain malignant mesotheliomas of the pleura or peritoneum. Unlike pulmonary fibrosis, pleural effusions and mesotheliomas may develop after brief exposures to asbestos, often exposures of 1 to 2 years. Mesotheliomas are not associated with cigarette smoking, but the combination of exposure to asbestos and cigarette smoking has a multiplicative effect on the risk of development of lung cancer. Exposure to asbestos increases the risk for both adenocarcinoma and squamous cell (but not small cell) carcinoma of the lung; this suggests that lung cancer screening may be useful in selected individuals.
- VIII-30. The answer is E.** (*Chap. 251*) The flexible fiberoptic bronchoscope is ideal for many clinical situations, including those designed to determine many endobronchial pathologic states, including tumors, granulomas, bronchitis, foreign bodies, and sites of bleeding. Washing or infiltration of a higher volume of sterile saline (bronchoalveolar lavage) can be used to detect abnormal cells or recover pathogens such as *Pneumocystis carinii* in patients with HIV infection. Brushing or biopsy at the surface of an endobronchial lesion can enhance the recovery of cellular material or tissue that can be very helpful in detecting neoplasms or infection. Pulmonary hemorrhage can complicate a transbronchial biopsy if the patient is at risk for a bleeding diathesis. Pneumothorax can occur if the forceps are

too close to the pleural surface. Because a rigid bronchoscope has a larger suction channel and allows ventilation, this instrument is still useful for the retrieval of foreign bodies and the suctioning of massive hemorrhages.

- VIII-31. The answer is E.** (*Chap. 254. Beckett, N Engl J Med 342:406–413, 2000.*) Pulmonary disease secondary to cotton dust exposure is one of the most common occupational lung diseases. During the production of yarn for cotton, linen, and rope making, exposure to cotton, flax, or hemp produces a host of respiratory symptoms. Exposure to cotton dust (byssinosis) is characterized as chest tightness toward the end of the first day of the workweek. Such symptoms are associated with a significant drop in the forced expiratory volume during the workday. Although most workers have no recurrence after the workweek, up to 25% may have a progressive symptom complex consisting of recurrent chest tightness, eventually leading to an obstructive pattern on pulmonary function testing. The chest tightness appears to be due to bronchospasm, which may be reversible with bronchodilators. The best treatment is a reduction of dust exposure.
- VIII-32. The answer is A.** (*Chap. 256*) Bronchiectasis represents an abnormal permanent dilation of the bronchi, typically on the basis of chronic destruction and inflammation caused by repetitive infection or other chronic insults. Many infectious agents, including adenovirus, influenza virus, *S. aureus*, tuberculosis, and anaerobic infection, can each predispose a patient to the bronchiectatic state. Problems of primary immune defenses such as immunoglobulin deficiency, primary ciliary disorders, and cystic fibrosis also can produce dilated bronchi. This anatomic problem leads to recurring cough and purulent sputum production, frequently associated with hemoptysis resulting from friable, inflamed airway mucosa. Repetitive bronchiectatic episodes tend to produce increased problems. Physical examination is nonspecific; however, the chest radiograph is frequently abnormal, and the findings may include cystic spaces caused by saccular bronchiectasis or the so-called tram track (parallel linear shadows) or rings (produced if the inflamed thickened airways are seen in cross section). Treatment requires elimination of the underlying problem (e.g., by immunoglobulin infusions), improved clearance of tracheobronchial secretions, control of infection, and the use of bronchodilators to reverse airflow obstruction.
- VIII-33. The answer is D.** (*Chap. 267. Arcasoy, Kotloff, N Engl J Med 340: 1081–1091, 1999.*) Emphysema, either smoking-induced or resulting from α_1 -antitrypsin deficiency, is the indication for almost 50% of all single-lung transplants. It is important to determine the optimal lung transplant window in which the patient has severe limitations secondary to his or her disease but has not passed the point at which lung transplant surgery would be dangerously complicated. Life expectancy of <2 years and severe obstructive lung disease (FEV_1 of <30% of the predicted value) are required. Patients with pulmonary fibrosis must have profound impairment of total lung capacity and resting hypoxia; those with pulmonary hypertension need to be severely functionally limited and have pulmonary artery pressures >50 mmHg. Patients with cystic fibrosis must also have severe limitations in expiratory capacity as well as abnormalities in arterial blood gases. They are not candidates for single-lung transplantation because of the risk of disseminated infection. Instead, they require a bilateral lung transplant or a related donor bilobe transplant to reduce the likelihood of disseminated infection. In each of the other situations, single-lung transplantation can be performed with acceptable risk and tangible benefit for the patient.
- VIII-34. The answer is E.** (*Chap. 255. Bartlett, Mundy, N Engl J Med 333:1618–1624, 1995.*) Microbial pathogens may enter the lung by several routes, including aspiration of organisms that colonize the oropharynx, inhalation of infectious aerosols, direct inoculation (e.g., from tracheal intubation or stab wounds), and hematogenous dissemination from an extrapulmonary site. In a chronic alcoholic, presumably with a higher likelihood of aspiration of oral contents, one must seriously consider the presentation of an aspiration pneumonia caused by anaerobic oral flora. Moreover, certain oral anaerobes, such as *S. aureus*, *S. pneumoniae* serotype III, aerobic gram-negative bacilli, oral anaerobes, *M. tuberculosis*,

and fungi, produce tissue necrosis and pulmonary cavities. *H. influenzae*, *M. pneumoniae*, and other type serotypes of *S. pneumoniae* are less likely to cause cavities. Cavities associated with *M. tuberculosis* do have air-fluid levels but are typically in the upper lobe as a result of the fact that they require high oxygen tension for optimal growth. By contrast, a cavity containing an air-fluid level in a dependent, fully ventilated, fully draining bronchopulmonary segment suggests that the culprit is an oral anaerobe. One particular oral anaerobe, *Actinomyces* spp., can produce a chronic fibrotic necrotizing process that can cross tissue planes to involve the pleural space, ribs, vertebrae, and subcutaneous tissue with the eventual discharge of sulfur granules.

- VIII-35. The answer is A.** (*Chap. 259. Hunninghack, Am J Respir Crit Care Med 151:915, 1995.*) This patient presents with the classic history, physical findings, and pathologic findings consistent with idiopathic pulmonary fibrosis. This is an unremitting interstitial lung disease which produces scarring and ablation of alveoli with a concomitant restrictive lung pattern. If progressive and/or unresponsive to therapy, the disease will lead to progressive loss of pulmonary function and ultimately to right-sided heart failure. The primary cause is unknown, although the pathophysiology clearly involves the activation of alveolar macrophages, with secondary cytokine release causing alveolar damage with associated fibrosis. Once the diagnosis is made, even at an advanced stage, a trial of glucocorticoids is indicated. High-dose steroid therapy for 8 weeks usually is initiated with gradual tapering if objective improvement is noted. Cyclophosphamide may be useful in patients who are unresponsive to glucocorticoids. The dose of cyclophosphamide should be titrated to ensure that the total neutrophil count does not drop below $1000/\mu\text{L}$. Drugs such as penicillamine, cyclosporine, and colchicine, each of which could potentially play a role in inhibiting macrophage-produced growth factors, remain investigative. Although measures to prevent progressive restrictive physiology include diuretics and oxygen for congestive heart failure, rapid treatment of infection, and the routine use of prophylactic pneumococcal influenza vaccine, in the situation of a patient who is in otherwise good medical condition but has profoundly deranged pulmonary physiology secondary to fibrosis, lung transplantation should be considered.
- VIII-36. The answer is A.** (*Chap. 261. Ridker, N Engl J Med 332:912, 1995.*) Many patients who develop pulmonary thromboembolism have an underlying inherited predisposition that remains clinically silent until they are subjected to an additional stress, such as the use of oral contraceptive pills, surgery, or pregnancy. The most frequently inherited predisposition to thrombosis is so-called activated protein C resistance. The inability of a normal protein C to carry out its anticoagulant function is due to a missense mutation in the gene coding for factor V in the coagulation cascade. This mutation, which results in the substitution of a glutamine for an arginine residue in position 506 of the factor V molecule, is designated the factor V Leiden gene. Based on the Physicians Health Study, about 3% of healthy male physicians carry this particular missense mutation. Carriers are clearly at an increased risk for deep venous thrombosis and also for recurrence after the discontinuation of warfarin. The allelic frequency of factor V Leiden is more common than are all other identified inherited hypercoagulable states combined, including deficiencies of protein C, protein S, and antithrombin III and disorders of plasminogen.
- VIII-37. The answer is E.** (*Chap. 263*) The hypoventilation syndromes are defined as disorders that yield to hypercapnia (usually a Pa_{CO_2} in the range of 50 to 80 mmHg). The clinical manifestations of such a syndrome include respiratory acidosis with a compensatory rise in the plasma bicarbonate concentration and a decrease in chloride concentration. The hypercapnia leads to an obligatory decrease in the arterial oxygen tension with subsequent cyanosis and secondary polycythemia. Moreover, chronic hypercapnia can induce pulmonary vasoconstriction, which can eventually lead to right ventricular failure. Problems of hypoventilation normally are exacerbated at night, leading to worsened hypercapnia during sleep with subsequent morning headache and daytime somnolence with eventual intellectual impairment. A polysomnogram can distinguish whether the defect is in the

metabolic control system (chemoreceptors or brainstem initiating neurons) versus the neuromuscular system (brainstem neurons, spinal cord, respiratory nerves) or in the ventilatory apparatus (e.g., chest wall, lungs, airways) itself. Those with a central problem such as higher CNS malfunction or chemoreceptor insufficiency have normal spirometry, blood gases, and tests of voluntary hyperventilation. However, they would have a markedly blunted response to hypoxia or hypercapnia. Respiratory neuromuscular dysfunction that produces a decrease in the ability to exhale would lead to an abnormal spirometric evaluation and also would make it impossible for the patient to generate normal inspiratory and expiratory muscle pressures against a closed airway. Those with problems with the ventilatory apparatus, such as those which typically occur in obstructive sleep apnea, would be able to generate adequate expiratory and inspiratory muscle pressures and generally would have markedly abnormal blood gases (e.g., a widened arterial alveolar oxygen tension gradient).

- VIII-38. The answer is C.** (*Chap. 263*) In all cases of chronic hyperventilation the mechanism involves an increase in respiratory drive that may well be physiologic (e.g., chronic hypoxemia) but can be detrimental because of the ensuing alkalemia. This disturbance in blood pH can produce neurologic symptoms such as dizziness, syncope, and seizure activity caused by cerebral vasoconstriction. The neuromuscular side effects of chronic alkalemia can include paresthesia, muscle weakness (from hypophosphatemia), and hypocalcemia-induced carpopedal spasm tetany. The primary respiratory alkalosis can lead to central sleep apnea. The disorders that most frequently lead to unexplained hyperventilation are pulmonary vascular diseases such as chronic thromboembolism and anxiety. In patients who have symptoms clearly secondary to hyperventilation, inhalation of a low concentration of carbon dioxide can be helpful. Both hypoxemia and chronic thromboembolic disease can lead to a chronic hyperventilation syndrome but are not a manifestation of the disorder.
- VIII-39. The answer is A.** (*Chap. 265. Milberg, JAMA 273:306, 1995; Ware, Matthay, N Engl J Med 342:1334–1349, 2000.*) The acute respiratory distress syndrome is a condition characterized by hypoxemic respiratory failure resulting from noncardiogenic pulmonary edema. Whatever the initial insult, the final common pathway of diffuse lung injury represents a cascade of cellular events that are associated with cytokine production by inflammatory cell activation and the production of inflammatory mediators which damage alveolar and pulmonary endothelial cells, leading to increased vascular permeability and loss of surfactant production by type II pneumocytes. When the injury is severe, mechanical ventilation is required. Despite the critical involvement of the inflammatory response in the generation of acute respiratory distress syndrome, glucocorticoids have shown no benefit in the treatment of this condition, except in childhood meningococemia and *P. carinii* pneumonia. Although mortality rates for acute respiratory distress syndrome range from 50 to 70% it is likely that improvements in therapy are reducing this dire outcome. Age >65 years, multiorgan system failure, sepsis, and severe gas exchange disturbances are all negative prognostic factors. However, those with uncomplicated overdoses tend to have a relatively improved outcome. Those who survive are likely to return to the preexisting level of function.
- VIII-40. The answer is D.** (*Chap. 266. Tobin, N Engl J Med 330:1056–1061, 1994.*) Endotracheal intubation with positive-pressure mechanical ventilation may save lives in multiple settings associated with respiratory failure. This highly invasive technique has both direct and indirect effects on many organ systems. Lung complications include barotrauma (especially in the setting of the use of high levels of PEEP), nosocomial pneumonia, oxygen toxicity, tracheal stenosis, and deconditioning of respiratory muscles. If a clinically significant pneumothorax occurs (e.g., associated with hypoxemia, decreased lung compliance, and hypotension), placement of a thoracostomy tube is required. While nosocomial pneumonia is common in patients intubated for >72 h because of aspiration of oral pharyngeal contents caused by leaks around the endotracheal tube cuff, the use of prophylactic

antibiotics is not indicated. Moreover, it can be difficult to distinguish between colonization and true infection, since virtually all ventilated patients can be shown to have potentially pathogenic bacteria in the lower respiratory tract. Oxygen toxicity, which may result from the effect of oxygen free radicals on lung tissues, needs to be managed with the conservative use of inspired oxygen tensions. Right-sided heart hemodynamic monitoring often is required to provide optimal levels of intravascular volume replacement in these patients. It is important to maintain adequate venous return, but increased lung water also must be avoided. Mild to moderate cholestasis and stress ulceration are two important gastrointestinal effects of mechanical ventilation. If the total bilirubin values are >4.0 mg/dL, it is likely that a cause of liver damage other than intubation is operative. Prophylactic therapy with sucralfate or an H_2 -receptor antagonist is helpful in preventing stress-related ulcers in intubated patients. In general, the size of the endotracheal tube needs to be balanced with the physiologic requirements for a low-resistance airway. The data suggest that women are more likely to develop airway injury with intubation and this is probably due to a smaller sized trachea. In general, women should use a 7.5-mm tube and men an 8.0-mm tube in order to minimize tracheal injury. In addition, the development of a high-volume, low-pressure endotracheal cuff has decreased the risk of tracheal stenosis markedly.

- VIII-41. The answer is D.** (*Chap. 266. Tobin, N Engl J Med 330:1056–1061, 1994.*) There are many reasons why patients fail removal from assisted ventilation. Sedatives, which are commonly prescribed earlier in the hospital stay for agitation or sleep, may not have been discontinued or metabolized and could contribute to impairment of respiratory drive. Persistent secretions that could be removed by suctioning also might contribute to the problem. A very important issue is maintenance of a continued drive to breathe. The central respiratory centers are sensitive to blood pH and will promote ventilation when sufficient acidosis (greater than that normally noted in a bronchitic patient with chronic CO_2 retention) ensues. Thus, creation of metabolic alkalosis with diuretic therapy or running the assisted minute ventilation too high (i.e., lower P_{CO_2} and higher pH than normal for the patient) could account for failed extubation. Neuromuscular weakness caused by diuretic-induced hypokalemia, malnutrition, and occult hypothyroidism are potential factors leading to difficulty in independent ventilation and trouble in weaning. Increased oxygen tension can have toxic effects on the lung parenchyma, which could lead to impaired arterial saturation. However, a satisfactory oxygenation does not reliably predict successful weaning.
- VIII-42. The answer is D.** (*Chap. 261. Goldhaber, N Engl J Med 339:93–104, 1998.*) Hypoxemia occurs commonly after massive pulmonary thromboembolism, although normal arterial oxygen tension does not exclude the diagnosis. The most important mechanism producing hypoxemia in this setting is an increase in venous admixture caused by continued perfusion of poorly ventilated areas. Ventilation may be decreased by atelectasis or by airway constriction in response to the release of bronchoactive mediators. A fall in cardiac output that produces a low mixed venous P_{O_2} can increase the effect of venous admixture. Increased dead-space ventilation would not be a cause of hypoxemia.
- VIII-43. The answer is A.** (*Chap. 250. Barnes, N Engl J Med 343:269–280, 2000.*) The volume remaining in the lungs at the conclusion of a complete forced expiration is termed the *residual volume* and can be determined either by the body plethysmography or by helium dilution methods. At the residual volume there is a balance between the intrinsic outward recoil of the chest wall and the force maintained by the respiratory muscles to decrease lung volumes further. Therefore, increases in the residual volume can result from the functionally weak musculature of the chest wall that might be observed in neuromuscular disorders that affect the ability to expire forcefully (Guillain-Barré syndrome, muscular dystrophies, cervical spine injury). Furthermore, diseased airways will collapse at low lung volumes, preventing further emptying and also producing an abnormally high residual volume. Thus, any condition in which airway obstruction plays a major role (chronic bronchitis, emphysema, asthma, cystic fibrosis) may be associated with increased

residual volume. By contrast, pulmonary parenchymal disease (e.g., sarcoidosis) produces normal expiration and reduced lung volumes. If inspiratory dysfunction is the primary chest wall problem (as in kyphoscoliosis and obesity), residual volume will be relatively unaffected or slightly decreased.

VIII-44. The answer is C. (*Chap. 265. Kolleff, N Engl J Med 332:27, 1995.*) ARDS is a clinical triad of hypoxemia, diffuse lung infiltrates, and reduced lung compliance not attributable to congestive cardiac failure. This syndrome's many causes suggest its complex pathogenesis. However, the pathologic outcome is the same: an increase in lung water caused by an increase in alveolar capillary permeability. This noncardiogenic pulmonary edema is identical to congestive cardiac pulmonary edema in its effect on the mechanical properties of the lung and on gas exchange. Just as in cardiac pulmonary edema, the increase in lung water associated with ARDS produces interstitial edema and alveolar collapse, and so the affected lung becomes stiff and the alveolar-arterial oxygen tension difference widens. Unlike cardiac edema, however, the increase in lung water in ARDS occurs as a result of an increase in alveolar capillary permeability and is not due to an increase in hydrostatic forces. Edema fluid in ARDS therefore often contains macromolecules (such as serum proteins), and measurement of pulmonary artery wedge pressure is normal or low. In clinical practice, determination of pulmonary artery wedge pressure is the most helpful discriminant between ARDS and cardiac failure.

VIII-45. The answer is A. (*Chap. 259. Vassallo et al, N Engl J Med 342:1969–1978, 2000.*) The patient described has Langerhans' cell histiocytosis. This disorder has also been called other names including systemic histiocytosis X, Letterer-Siwe disease, and Hand-Schüller-Christian disease. Langerhans' cell histiocytosis is a disease of middle-aged patients with a slight increase in frequency of women over men. There is a strong association with smoking in >90% of patients diagnosed with it. It is thought that cigarette smoke induces secretion of bombesin-like peptides from neuroendocrine cells within the lung. Other components of tobacco smoke have also been implicated in the pathogenesis of Langerhans' cell histiocytosis. The extrapulmonary lesions of patients with this disease are numerable and demonstrate an abundant expression of transforming growth factor β and granulocyte-macrophage colony stimulating factor. The most common presenting symptoms include a nonproductive cough with dyspnea; constitutional symptoms include weight loss, fever, night sweats, and anorexia, and their presence may lead to a search for an occult cancer. Other symptoms are due to the involvement of other organs in approximately 5 to 15% of all patients. The degree and extent of abnormalities on pulmonary function testing depend upon the extent of the disease. Most patients have normal pulmonary function tests; however, patients with advanced disease may show an obstructive or restrictive pattern. The most consistent abnormality is a reduction in the CO diffusing capacity. Chest radiographs are often abnormal. The most common early abnormalities include a micronodular or reticulonodular interstitial pattern. The infiltrates are typically bilateral and symmetric. In advanced stages, nodule lesions tend to be less frequent and cystic changes become more prominent, with cavitory lesions approaching 2 cm in size. Lung volumes are typically normal or increased. High-resolution CT often confirms the nodular and cystic changes, which are most prominent in the middle and upper lobes. Diagnostic confirmation can be obtained by BAL, transbronchial bronchoscopic lung biopsy, or surgical lung biopsy. The presence of increased number of Langerhans' cells in the BAL fluid is associated with strong staining with antibodies against CD1a. This is strongly suggestive of pulmonary Langerhans' cell histiocytosis, but its variable history makes the management of this disorder somewhat complicated. The essential part of treatment, however, is smoking cessation, which leads to stabilization of symptoms in the majority of patients; a substantial proportion may show mild improvement. It is unknown whether smoking cessation has any influence on long-term prognosis. Glucocorticoids have been the mainstay of medical therapy for pulmonary Langerhans' cell histiocytosis, but there are limited data supporting their efficacy. It is also unclear how glucocorticoids should be instituted and whether

inhaled or systemic therapy is more efficacious. It is reasonable to use glucocorticoids for patients who have progressive disease or systemic symptoms, although this treatment should be generally attempted only after smoking cessation has been achieved. Chemotherapeutic agents such as vinblastine, methotrexate, or cyclophosphamide have been used in patients with progressive disease that is unresponsive to glucocorticoids or in patients with multiorgan involvement.

VIII-46. The answer is B. (*Chap. 33. Irwin, Madison, N Engl J Med 343:1715–1721, 2000.*)

The differential diagnosis of acute cough in an adult patient includes viral rhinitis or rhinosinusitis, bacterial sinusitis, allergic rhinitis, exacerbation of chronic obstructive pulmonary disease, asthma, and bacterial infection. The patient denies any rigors but has a minimally productive cough with mild rhinorrhea, suggestive of a viral rhinitis. Occasionally it can be difficult to differentiate between viral rhinosinusitis and bacterial sinusitis, but the absence of sinus discomfort, maxillary toothache, and purulent nasal secretions makes the latter diagnosis less likely. The treatment would be supportive with a common over-the-counter antihistamine with a decongestant; intranasal ipratropium has also shown relief of rhinorrhea and sneezing secondary to the common cold. The use of a sedating antihistamine and nonsedating antihistamine without symptoms of allergic rhinitis is not indicated, and nonsedating antihistamines seem to be less effective. In addition there is no convincing evidence that intranasal or systemic glucocorticoids are beneficial or that zinc lozenges are consistently beneficial.

VIII-47. The answer is C. (*Chap. 33. Irwin, Madison, N Engl J Med 343:1715–1721, 2000.*)

The patient now has progressive symptoms, and the presence of a productive cough with vomiting is suggestive of a *Bordetella pertussis* infection. The treatment of choice for patients with *B. pertussis* infection is erythromycin, 500 mg 4 times daily for 14 days, or, if allergic, trimethoprim/sulfamethoxazole, 160/800 mg twice daily for 14 days. Given their in vitro activity, other macrolides are also likely to be effective. Systemic glucocorticoids have been beneficial in severely affected children, but their efficacy has not been established in adults. There is often a history of contact with a patient who has a known case of pertussis. Patients often present with the infrequently heard but characteristic whoop, and coughing with vomiting is pathognomonic. Laboratory diagnosis of pertussis is difficult to establish because there is usually a delay between the onset of cough and the suspicion of the disease. In addition, there are no reliable serologic tests for *B. pertussis* infection. Cultures on nasopharyngeal secretions are usually negative after 2 weeks. Serologic confirmation of the recent *B. pertussis* infection requires evidence of an elevated level of antibodies against one of the various virulence factors of the organism; this can be provided by an enzyme-linked immunosorbent assay (ELISA).

VIII-48. The answer is C. (*Chap. 267. Arcasoy, Kotloff, N Engl J Med 340:1081–1091, 1999.*)

The patient is suffering from an acute rejection, which is highest in patients that have HLA mismatching, particularly at the HLA-DR and HLA-B loci. The incidence is greatest within the first 100 days after transplantation and declines steadily thereafter. When present, clinical manifestations are nonspecific and typically include malaise, low-grade fever, dyspnea, cough, impaired oxygenation, and leukocytosis. Chest radiograph may demonstrate alveolar, nodular, or interstitial opacities. However, episodes of rejection after the first month are more likely to be nonspecific. A fallen spirometric value >10% is a common finding. Bronchoscopic lung biopsy offers a safe and accurate diagnostic procedure. The histologic hallmark of perivascular lymphocytic infiltrate is the typical finding. Treatment of acute rejection consists of high-dose intravenous methylprednisolone at a dose of 10 to 15 mg/kg per day. Clinical efficacy is substantially lower in patients in whom the diagnosis of acute rejection occurs after the first 6 months as many of these patients are suffering from chronic rejection. Chronic rejection is typically treated with cyclosporine or tacrolimus. An acute bacterial infection or viral infection is unlikely given the lack of radiographic findings.

- VIII-49. The answer is D.** (*Chap. 261. Goldhaber, N Engl J Med 339:93–104, 1998.*) The patient has the clinical manifestations of a pulmonary embolism. Her risk factor is immobility after suffering a fracture of her foot. Short-term anticoagulation with heparin is indicated. However, long-term anticoagulation is required in order to reduce rate of recurrence. Heparin without oral anticoagulation is used in women who are pregnant because of the teratogenic effects of warfarin. The insertion of an IVC filter can usually prevent major pulmonary embolism. However, the filters offer no advantage in patients with proximal deep venous thrombosis and do not halt the thrombotic process. Furthermore, IVC filters do not reduce the 2-year mortality rate as compared with anticoagulation alone. The optimal duration of anticoagulation after pulmonary embolism is uncertain; a treatment period of 6 months seems to prevent far more recurrence than a period of 6 weeks among patients with a first episode of pulmonary embolism. An indefinite (life-long) period of anticoagulation should be considered in patients with recurrent pulmonary embolism if the risk of major bleeding is low.
- VIII-50. The answer is C.** (*Chap. 261. Goldhaber, N Engl J Med 339:93–104, 1998.*) Electrocardiography should be incorporated into the diagnostic workup in a patient with a suspected pulmonary embolism. The most frequent electrocardiographic abnormality is T-wave inversion of the anterior leads, especially leads $V_1 - V_4$. These are probably reciprocal changes reflecting inferior-posterior ischemia. New-onset right bundle branch block or atrial fibrillation is uncommon. Left bundle branch block lateral changes and Q waves are not typically associated with pulmonary embolism.
- VIII-51. The answer is D.** (*Chap. 259*) Pulmonary LAM is a rare condition that affects premenopausal women. Women are often misdiagnosed as having chronic obstructive pulmonary disease or asthma. Histologically, LAM is characterized by proliferation of atypical pulmonary interstitial smooth-muscle cells. The disease tends to accelerate during pregnancy and abates after oophorectomy. Common complaints at presentation are of dyspnea, cough, and chest pain; hemoptysis is also common and may be life-threatening. Spontaneous pneumothorax is a common complication, as is the development of a chylous pleural effusion or recurrent pneumothorax. Median survival is 8 to 10 years from diagnosis. Oophorectomy, progesterone, and tamoxifen have been used with some efficacy. However, lung transplantation remains the only hope for cure.
- VIII-52. The answer is B.** (*Chap. 252. Nelson, N Engl J Med 333:499–506, 1995.*) The patient clinically has asthma, likely triggered by an upper respiratory viral infection. There is audible wheezing noted, and the patient is appropriately started on a β agonist. A transient decrease in arterial O_2 tension of >5 mmHg is often seen. The most likely mechanism is probably the relaxation of the compensatory vasoconstriction in areas of decreased ventilation. This is combined with an increase in the pulmonary blood flow due to increased cardiac output. This is not usually a seriously problem if the patient's O_2 saturation is monitored or if supplemental O_2 is administered. In addition, acute metabolic responses to β -adrenergic agonist include hyperglycemia, hypokalemia, and hypomagnesemia. Tolerance to β agonist is due to its long-term administration and is manifested by a decrease in its effectiveness. Bronchial hyperresponsiveness is seen in patients after the cessation of treatment with long-acting β -agonist therapy.
- VIII-53. The answer is D.** (*Chap. 252. Barnes, N Engl J Med 332:868–875, 1995.*) Glucocorticoids are the most effective therapy available for patients with asthma. They may be administered either orally or much more safely by inhalation. Inhaled glucocorticoids have far fewer systemic side effects than oral glucocorticoids. Local side effects include dysphonia and oropharyngeal candidiasis (thrush); esophageal candidiasis has not been described. Other local complications include increased frequency of infections in the lower respiratory tract (e.g., tuberculosis), cough, and throat irritation. Systemic side effects are also rare. There is a notable suppression of the hypothalamic-pituitary-adrenal axis; however, the degree of suppression as determined by cortisol excreted in the urine during a

24-h analysis seems to be minimal. Prolonged adrenal suppression has also not been seen, even with the use of high doses of inhaled glucocorticoids. Glucocorticoids also reduce bone mass directly by inhibiting bone formation. There have been concerns that inhaled glucocorticoids may cause stunting of growth in prepubescent patients. Glucocorticoids may also cause skin bruising, which has typically been noted in older patients. Cataracts have been reported in patients who have received both oral as well as high-dose inhaled glucocorticoids. The prevalence of posterior subcapsular cataracts correlated well with both the daily dose and the duration of oral glucocorticoid therapy but not with the dose and duration of inhaled glucocorticoid therapy. Inhaled glucocorticoids may reduce the number of circulating eosinophils and may slightly increase the number of circulating neutrophils. Inhaled glucocorticoids may also cause central nervous system side effects including emotional lability, euphoria, depression, or aggressiveness.

VIII-54. The answer is A. (*Chap. 264. Javaheri, N Engl J Med 341:949–954, 1999.*) CSA is a transient abolition of the central drive of ventilation. This can result in cessation of the respiratory drive during sleep. Many healthy individuals demonstrate a small number of central apneas during sleep, particularly during rapid eye movement (REM) sleep. These apneas are not associated with any physiologic or clinical disturbances. In patients with clinically important CSA, daytime hypercapnia and hypoxemia are usually evident. The clinical picture is characterized by recurrent respiratory failure, polycythemia, pulmonary hypertension, and heart failure. CSA is more commonly associated with heart failure than is OSA. As many as 40% of patients with heart failure have CSA. Many patients with CSA are suspected clinically of having OSA because of a history of snoring, sleep disturbance, and daytime sleepiness. A definitive diagnosis of CSA requires polysomnographic study. The key observation is that recurrent apneas are not accompanied by an increased respiratory effort, as is typical in OSA. Management of patients with CSA involves the use of nocturnal supplemental oxygen. Other patients have responded to serum acidification with acetazolamide. Recent reports, however, have indicated a good response to nasal CPAP, which is also seen for patients with OSA. The mechanism by which CPAP abolishes CSA probably involves a small increase in the P_{aCO_2} as a result of the added expiratory mechanical load.

This page intentionally left blank.

IX. DISORDERS OF THE KIDNEY AND URINARY TRACT

QUESTIONS

DIRECTIONS: Each question below contains five suggested responses. Choose the **one best** response to each question.

IX-1. A patient with lymphoma who is known to excrete 1.5 g urinary protein per day has a negative dipstick evaluation for urinary protein. The reason for the seeming inconsistency is

- (A) the size of the excreted protein is too small to be picked up by the test strip
- (B) the urine is not concentrated enough
- (C) only heavy chain sequences are recognized by the test strip
- (D) Tamm-Horsfall protein blocks the reaction between the secreted protein and the test strip
- (E) dipsticks preferentially detect albumin compared with immunoglobulin because albumin is negatively charged

IX-2. A 75-year-old female nursing home resident is brought to the emergency department because of increasing obtundation. She is found to communicate poorly. Brief physical examination reveals diminished skin turgor. Blood pressure is 100/60, pulse 120, respiratory rate 20, and temperature 37°C (98.6°F). Blood tests reveal the following serum electrolytes: sodium 160 mmol/L, potassium 5.0 mmol/L, bicarbonate 30 mmol/L, chloride 110 mmol/L. The most appropriate management at this time would include administration of 5% dextrose in

- (A) normal saline, 100 mL/h
- (B) normal saline solution, 250 mL/h
- (C) half normal saline, 100 mL/h
- (D) half normal saline, 200 mL/h
- (E) water, 150 mL/h

IX-3. Laboratory evaluation of a 19-year-old man being worked up for polyuria and polydipsia yields the following results:

Serum electrolytes (mmol/L): Na⁺ 144; K⁺ 4.0;
Cl⁻ 107; HCO₃⁻ 25
BUN: 6.4 mmol/L (18 mg/dL)
Blood glucose: 5.7 mmol/L (102 mg/dL)
Urine electrolytes (mmol/L): Na⁺ 28; K⁺ 32
Urine osmolality: 195 mosmol/kg water

IX-3. (Continued)

After 12 h of fluid deprivation, body weight has fallen by 5%. Laboratory testing now reveals the following:

Serum electrolytes (mmol/L): Na⁺ 150; K⁺ 4.1;
Cl⁻ 109; HCO₃⁻ 25
BUN: 7.1 mmol/L (20 mg/dL)
Blood glucose: 5.4 mmol/L (98 mg/dL)
Urine electrolytes (mmol/L): Na⁺ 24; K⁺ 35
Urine osmolality: 200 mosmol/kg water

One hour after the subcutaneous administration of 5 units of arginine vasopressin, urine values are as follows:

Urine electrolytes (mmol/L): Na⁺ 30; K⁺ 30
Urine osmolality: 199 mosmol/kg water

The likely diagnosis in this case is

- (A) nephrogenic diabetes insipidus
- (B) osmotic diuresis
- (C) salt-losing nephropathy
- (D) psychogenic polydipsia
- (E) none of the above

IX-4. A 70-year-old man with diabetes mellitus and hypertension has the following serum chemistries:

Electrolytes (mmol/L): Na⁺ 138; K⁺ 5.0; Cl⁻ 106;
HCO₃⁻ 20
Glucose: 11 mmol/L (200 mg/dL)
Creatinine: 176 μmol/L (2.0 mg/dL)

Which of the following may contribute to worsening hyperkalemia?

- (A) Propranolol
- (B) Verapamil
- (C) Theophyllin
- (D) Carbenicillin
- (E) Hydrochlorothiazide

IX-5. A 40-year-old male alcoholic presents with a 6-day history of binge drinking. Serum chemistry tests reveal the following:

IX-5. (Continued)

Electrolytes (mmol/L): Na⁺ 145; K⁺ 5.0; Cl⁻ 105;
 HCO₃⁻ 15
 BUN: 7.1 mmol/L (20 mg/dL)
 Creatinine: 133 μg/L (1.5 mg/dL)
 Glucose: 9.6 mmol/L (172 mg/dL)

The nitroprusside (Acetest) agent gives a minimally positive result. Optimal therapy to ameliorate the patient's acid-base disorder would include 5% dextrose in

- (A) water
- (B) normal saline
- (C) normal saline, insulin, and sodium bicarbonate
- (D) half normal saline and insulin
- (E) half normal saline, insulin, and sodium bicarbonate

IX-6. A 45-year-old woman who has had slowly progressive renal failure begins to complain of increasing numbness and prickling sensations in her legs. Examination reveals loss of pinprick and vibration sensation below the knees, absent ankle jerks, and impaired pinprick sensation in the hands. Serum creatinine concentration, checked during her most recent clinic visit, is 790 μmol/L (8.9 mg/dL). The woman's physician should now recommend

- (A) a therapeutic trial of phenytoin
- (B) a therapeutic trial of pyridoxine (vitamin B₆)
- (C) a therapeutic trial of cyanocobalamin (vitamin B₁₂)
- (D) initiation of renal replacement therapy
- (E) neurologic referral for nerve conduction studies

IX-7. In patients with chronic renal failure, which of the following is the most important contributor to renal osteodystrophy?

- (A) Impaired renal production of 1,25-dihydroxyvitamin D₃ [1,25 (OH)₂ D₃]
- (B) Hypocalcemia
- (C) Hypophosphatemia
- (D) Loss of vitamin D and calcium via dialysis
- (E) The use of calcitriol

IX-8. A 50-year-old man is hospitalized for treatment of enterococcal endocarditis. He has been receiving ampicillin and gentamicin for the past 2 weeks but is persistently febrile. Laboratory results are as follows:

Serum electrolytes (mmol/L): Na⁺ 145; K⁺ 5.0;
 Cl⁻ 110; HCO₃⁻ 20

IX-8. (Continued)

BUN: 14.2 mmol/L (40 mg/dL)
 Serum creatinine: 300 μmol/L (3.5 mg/dL)
 Urine sodium: 20 mmol/L
 Urine creatinine: 3000 mmol/L (35 mg/dL)

Which of the following is the most likely cause of this patient's acute renal failure?

- (A) Tubular necrosis
- (B) Insensible skin losses
- (C) Renal artery embolism
- (D) Cardiac failure
- (E) Nausea and vomiting

IX-9. A 23-year-old man has recurrent episodes of hematuria over the past year. Each of the episodes seems to be associated with an upper respiratory infection. Physical examination currently is normal. Urinalysis reveals a relatively bland sediment; dipstick is positive for both protein and blood. Renal biopsy most likely will reveal

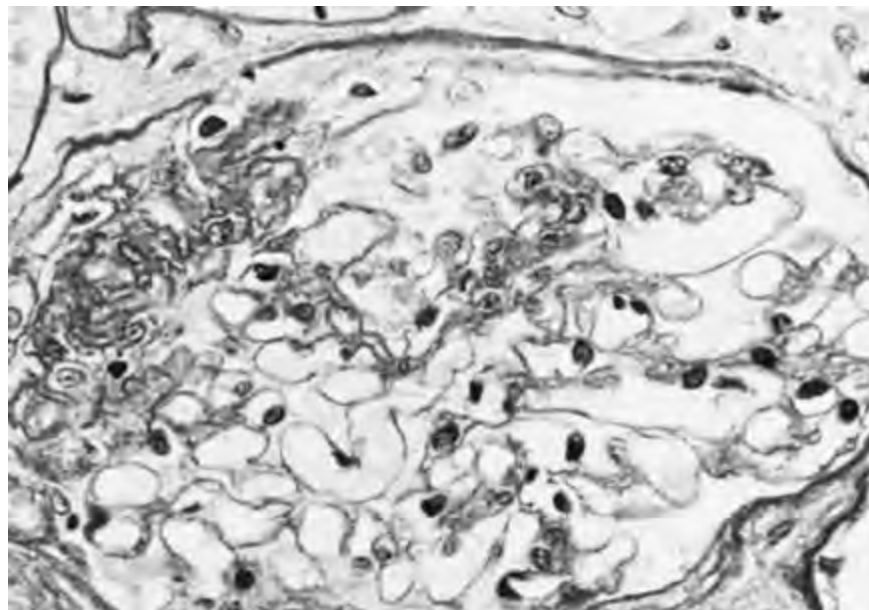
- (A) extensive extracapillary proliferation on light microscopy
- (B) diffuse mesangial proliferation on light microscopy
- (C) autosomal dominant polycystic kidney disease
- (D) diffuse mesangial deposition of IgA on immunofluorescence
- (E) deposition of C3 in capillary walls on immunofluorescence

IX-10. The condition of a 50-year-old obese woman with a 5-year history of mild hypertension controlled by a thiazide diuretic is being evaluated because proteinuria was noted during her routine yearly medical visit. Physical examination disclosed a height of 167.6 cm (66 in.), weight 91 kg (202 lb), blood pressure 130/80 mmHg, and trace pedal edema. Laboratory values are as follows:

Serum creatinine: 106 μmol/L (1.2 mg/dL)
 BUN: 6.4 mmol/L (18 mg/dL)
 Creatinine clearance: 87 mL/min
 Urinalysis: pH 5.0; specific gravity 1.018; protein 3+;
 no glucose; occasional coarse granular cast
 Urine protein excretion: 5.9 g/d

IX-10. (Continued)


The results of a renal biopsy are shown below. Sixty percent of the glomeruli appeared as shown (by light microscopy); the remainder were unremarkable.



- The most likely diagnosis is
- (A) hypertensive nephrosclerosis
 - (B) focal and segmental sclerosis

- (C) minimal-change (nil) disease
- (D) membranous glomerulopathy
- (E) crescentic glomerulonephritis

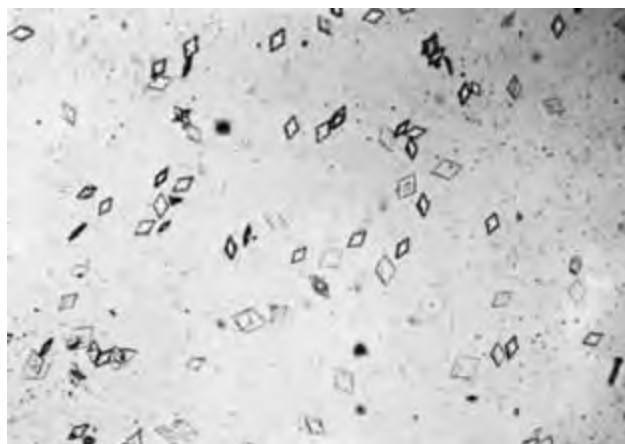
IX-11. In a person who has carcinoma of the lung and the depicted urinalysis, renal biopsy most likely will show



- (A) minimal-change disease
- (B) diffuse proliferative glomerulonephritis
- (C) membranoproliferative glomerulonephritis
- (D) membranous glomerulopathy
- (E) focal glomerulosclerosis

IX-12. Which of the following case histories would most likely be associated with the urinary sediment depicted?

IX-12. (Continued)



- (A) A 23-year-old man with newly diagnosed lymphoblastic lymphoma who is found to have a rising creatinine level 2 days after the administration of combination chemotherapy
- (B) A 23-year-old woman 1 year after surgery performed because of morbid obesity
- (C) A 45-year-old woman with a history of multiple urinary tract infections with urea-splitting organisms

IX-12. (Continued)

- (D) A 40-year-old man with edema, hypoalbuminemia, and proteinuria
- (E) An 18-year-old man with flank pain, hematuria, and a positive family history for renal stones in youth

IX-13. A 72-year-old woman with rheumatic heart disease is being treated with ampicillin and gentamicin for enterococcal endocarditis. One week into the course she develops a morbilliform skin rash and fever. Laboratory evaluation is remarkable for a doubling of serum creatinine and blood urea nitrogen from their baseline values. Urinalysis dipstick is positive for blood, protein, and white cells. Ultrasonography reveals bilaterally enlarged kidneys. Based on the available data, the most likely cause of the patient's azotemia is

- (A) tubular necrosis caused by aminoglycoside
- (B) membranous nephropathy resulting from endocarditis
- (C) enterococcal pyelonephritis
- (D) cystitis
- (E) hypersensitivity reaction to ampicillin

IX-14. A 40-year-old woman who has never had significant respiratory disease is hospitalized for evaluation of hemoptysis. Urinalysis reveals 2+ proteinuria and microscopic hematuria. BUN concentration is 7.1 mmol/L (20 mg/dL), and serum creatinine concentration is 177 μ mol/L (2.0 mg/dL). Serologic findings include normal complement levels and a negative assay for fluorescent antinuclear antibodies. Renal biopsy reveals granulomatous necrotizing vasculitis with scattered immunoglobulin and complement deposits. The most likely diagnosis in this case is

- (A) mesangial lupus glomerulonephritis
- (B) Henoch-Schönlein purpura
- (C) microscopic polyarteritis
- (D) Wegener's granulomatosis
- (E) Goodpasture's syndrome

IX-15. Which of the following patients is most likely to develop destruction of renal papillae with concomitant tubulointerstitial damage?

- (A) A middle-aged man who has consumed "moonshine" alcohol distilled in an automobile radiator
- (B) An older man with early-stage prostate adenocarcinoma
- (C) A young adult woman with β -thalassemia
- (D) An older woman who uses analgesics for chronic headaches
- (E) A middle-aged woman with her first episode of a urinary tract infection which is associated with py-

IX-15. (Continued)

uria, flank pain, and fever but responds well to a short course of oral antibiotics

IX-16. A 45-year-old woman with long-standing systemic lupus erythematosus (SLE) who has had intermittent bouts of acute renal failure over the past 6 years presents with anorexia. Physical examination is noncontributory. Laboratory evaluation includes hematocrit 29%, white count 5000 with a normal differential, and platelet count 27,500/ μ L. Renal biopsy shows sclerosis of 14/15 glomeruli, tubular atrophy, and interstitial fibrosis. The following values are also found:

Serum electrolytes (mmol/L): Na⁺ 136; K⁺ 6; Cl⁻ 90;
HCO₃⁻ 20
BUN: 35.5 mmol/L (100 mg/dL)
Serum creatinine: 665 μ mol/L (7.5 mg/dL)

Anti-double-strand DNA and C3 levels have been stable. Renal biopsy shows obliterative sclerosing glomerular lesions. The most appropriate management strategy would be

- (A) high-dose intravenous methylprednisolone
- (B) high-dose intravenous methylprednisolone and azathioprine
- (C) high-dose intravenous methylprednisolone and intravenous cyclophosphamide (500 mg/m²)
- (D) intravenous cyclophosphamide (500 mg/m²) plus low-dose prednisone
- (E) dialysis

IX-17. A 30-year-old woman with diabetic nephropathy received a cadaveric renal allograft. On the third postoperative day her serum creatinine concentration was 160 μ mol/L (1.8 mg/dL). She is being treated with cyclosporine and prednisone. On the sixth postoperative day she experiences a decrease in urine output from 1500 mL/d to 1000 mL/d; the serum creatinine concentration increases to 194 μ mol/L (2.2 mg/dL). Her blood pressure remains stable at 170/90 mmHg, and her temperature is 37.2°C (99°F). The best initial step in management would be to

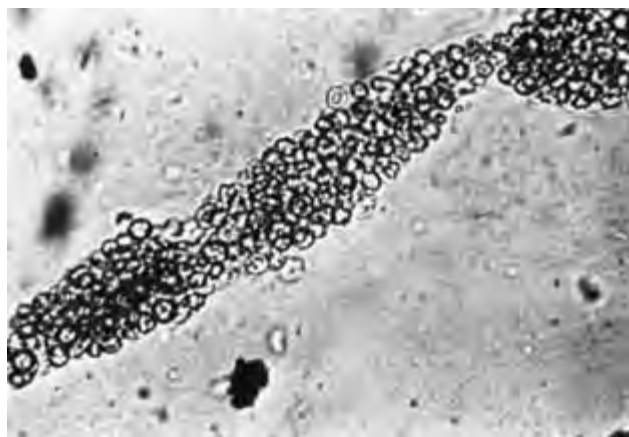- (A) decrease the dose of cyclosporine
- (B) obtain ultrasonography of the renal allograft
- (C) obtain a biopsy of the renal allograft
- (D) administer pulsed steroid therapy
- (E) administer an intravenous bolus of furosemide

IX-18. A 55-year-old man undergoes intravenous pyelography (IVP) as part of a workup for hypertension. A 3-cm solitary radiolucent mass is noted in the left kidney; the study otherwise is normal. The man complains of no symptoms referable to the urinary tract, and examination of urinary sediment is within normal limits. Which of the following studies should be performed next?

IX-18. (Continued)

- (A) Repeat IVP in 6 months
- (B) Early-morning urine collections for cytology (three samples)
- (C) Selective renal arteriography
- (D) Renal ultrasonography
- (E) CT scanning (with contrast enhancement) of the left kidney

IX-19. A previously healthy 45-year-old man who developed weight gain, fatigue, and vomiting within the past week presents to his physician. He had been seen 3 months earlier for a routine checkup, at which time a physical examination, complete blood count, and serum chemistries were all normal. Relevant physical findings now include blood pressure of 155/110 mmHg and periorbital edema. Serum studies reveal a BUN of 30 mmol/L (85 mg/dL) and a creatinine of 796 $\mu\text{mol/L}$ (9 mg/dL). Urinalysis reveals 2+ proteinuria and a microscopic examination of the sediment is depicted below. Which of the following statements is correct?



- (A) Renal biopsy is indicated
- (B) The clinical scenario is typical of a patient who presents with IgA nephropathy
- (C) Extracapillary proliferation is probable
- (D) Complete spontaneous resolution of the renal disease is likely
- (E) A trial of high-dose glucocorticoids is contraindicated

IX-20. Which of the following is a risk factor for carcinoma of the bladder?

IX-20. (Continued)

- (A) Exposure to alcohol intake
- (B) Use of cyclophosphamide
- (C) History of renal carcinoma
- (D) Positive family history
- (E) Infestation with *Schistosoma mansoni*

IX-21. A 10-year-old girl complaining of profound weakness, occasional difficulty walking, and polyuria is brought to the pediatrician. Her mother is sure the girl has not been vomiting frequently. The girl takes no medicines. She is normotensive, and no focal neurologic abnormalities are found. Serum chemistries include sodium 142 mmol/L, potassium 2.5 mmol/L, bicarbonate 32 mmol/L, and chloride 100 mmol/L. A 24-h urine collection on a normal diet reveals sodium 200 mmol/d, potassium 50 mmol/d, and chloride 30 mmol/d. Renal ultrasound demonstrates symmetrically enlarged kidneys without hydronephrosis. A stool phenolphthalein test and a urine screen for diuretics are negative. Plasma renin levels are found to be elevated. Which of the following conditions is most consistent with the above data?

- (A) Conn's syndrome
- (B) Chronic ingestion of licorice
- (C) Bartter's syndrome
- (D) Wilms' tumor
- (E) Proximal renal tubular acidosis

IX-22. Normal serum complement levels would be seen in patients with hematuria, proteinuria, and hypertension resulting from which of the following?

- (A) Mixed essential cryoglobulinemia
- (B) Hepatitis C-associated membranoproliferative glomerulonephritis
- (C) Diffuse proliferative lupus nephritis
- (D) Henoch-Schönlein purpura
- (E) Poststreptococcal glomerulonephritis

IX-23. In acute renal failure, dietary protein should be restricted in which of the following?

- (A) All patients
- (B) All patients with BUN >100
- (C) All patients with creatinine >10
- (D) Only in patients who are well nourished on hospital admission
- (E) If azotemia is advanced and dialysis is not an option

IX-24. A 43-year-old homeless man is brought into the emergency room. His past medical history is significant for a long history of alcohol abuse. He is found obtunded with evidence of clumsiness on neurologic examination. The emergency medical services who brought the man to the emergency room believed that he had been drinking ethylene glycol. Which set of laboratory values is most likely associated with the above clinical scenario?

	Na ⁺	K ⁺	Cl ⁻	HCO ₃ ⁻	Serum Creatinine, μmol/L (mg/dL)	pH	
						(Serum, mmol/L)	
(A)	140	2.5	114	14	265 (3.0)	7.30	6.2
(B)	139	6.3	108	19	265 (3.0)	7.35	5.0
(C)	139	5.1	104	21	265 (3.0)	7.37	5.0
(D)	143	4.8	100	10	265 (3.0)	7.25	5.0
(E)	135	4.5	107	21	265 (3.0)	7.37	5.0

IX-25. A 53-year-old woman with longstanding depression and a history of rheumatoid arthritis is brought in by her daughter, who states that she found an empty bottle of acetylsalicylic acid by her mother's bedside. The patient is found confused and lethargic and unable to provide a definitive history. What is the most likely set of laboratory values?

	Na ⁺	K ⁺	Cl ⁻	HCO ₃ ⁻	Serum Creatinine μmol/L (mg/dL)	Room Air ABG		
						P _{O₂}	P _{CO₂}	pH
(A)	140	3.9	85	26	141 (1.6)	100	40	7.40
(B)	140	3.9	85	16	141 (1.6)	100	20	7.40
(C)	140	5.8	100	20	141 (1.6)	100	34	7.38
(D)	150	2.9	100	36	141 (1.6)	80	46	7.50
(E)	116	3.7	85	22	141 (1.6)	80	46	7.50

IX-26. A 37-year-old man is admitted with confusion. Physical examination shows a blood pressure of 140/70 with no orthostasis, normal jugular venous pressure, and no edema. Serum chemistries are notable for sodium 120 mmol/L, K⁺ 4.2 mmol/L, bicarbonate 24 mmol/L, and uric acid 0.177 mmol/L (2 mg/dL). The most likely diagnosis is

- (A) hepatic cirrhosis
- (B) cerebral toxoplasmosis with SIADH
- (C) Addison's disease
- (D) significant gastrointestinal fluid loss
- (E) congestive heart failure

IX-27. A 56-year-old diabetic woman with end-stage renal disease (ESRD) has been treated with peritoneal dialysis (prescription of four 2-L exchanges per day) for 6 years. She is 5 ft. 6 in. tall and weighs 70 kg (154 lb). The patient complains of anorexia, abdominal discomfort, fatigue, and insomnia. Medications include erythropoietin, calcium carbonate, metoprolol, and a water-soluble vitamin supplement. Laboratory studies are notable for hematocrit 38%, BUN 56 mg/dL, bicarbonate 14 meq/L, calcium 10.4 mg/dL, and phosphate 2.3 mg/dL.

IX-27. (Continued)

The most likely diagnosis is

- (A) mycobacterial peritonitis
- (B) dialysis disequilibrium
- (C) uremia
- (D) peritoneal carcinomatosis
- (E) diabetic ketoacidosis

IX-28. Which of the following maneuvers may lead to the development of hyperammonemia?

- (A) Protein restriction
- (B) A branched-chain amino acid-enriched protein mixture
- (C) The use of neomycin
- (D) The use of lactulose
- (E) The use of loop diuretics

IX-29. Nephrocalcinosis can be associated with

- (A) the routine use of calcium-based phosphate binders
- (B) the routine use of aluminum-based phosphate binders
- (C) calcitonin-related peptide

IX-29. (Continued)

- (D) secondary hyperparathyroidism
- (E) Crohn's disease

IX-30. A 35-year-old man is in your clinic with the chief complaint of progressive lower extremity edema. On laboratory analysis he is found to have a 24-h urine collection that is significant for 5.3 g of protein. Which of the following statements is true?

- (A) Lower serum lipid levels
- (B) An elevated serum calcium value is likely to be obtained
- (C) The patient has an increased risk of a hemorrhage
- (D) The most likely etiology is IgA glomerulonephritis
- (E) The patient has an elevated thyroxin level

IX-31. A 60-year-old man with alcoholism presents to the emergency department with severe confusion, vomiting, and tachycardia. Blood pressure is 90/60, heart rate is 110, and respiratory rate is 32. Laboratory studies are remarkable for the following (mmol/L): Na⁺ 128, K⁺ 3.9, Cl⁻ 90, bicarbonate 6. BUN was 12 mg/dL, and creatinine was 2.9 mg/dL. Acetest is negative. Urinalysis shows 4+ calcium oxalate crystals. The most likely diagnosis is

- (A) alcoholic rhabdomyolysis with acute tubular necrosis
- (B) alcoholic ketoacidosis
- (C) renal tubular acidosis type 1
- (D) ingestion of ethylene glycol
- (E) alcoholic hepatitis with pancreatitis and multiple organ dysfunction

IX-32. A 72-year-old man develops acute renal failure after cardiac catheterization. Physical examination is notable for diminished peripheral pulses, livedo reticularis, epigastric tenderness, and confusion. Laboratory studies include (mg/dL) BUN 131, creatinine 5.2, and phosphate 9.5. Urinalysis shows 10 to 15 WBC, 5 to 10 RBC, and one hyaline cast per high-power field (HPF). The most likely diagnosis is

- (A) acute interstitial nephritis caused by drugs
- (B) rhabdomyolysis with acute tubular necrosis
- (C) acute tubular necrosis secondary to radiocontrast exposure
- (D) cholesterol embolization
- (E) renal arterial dissection with prerenal azotemia

IX-33. The hyperlipidemia of nephrotic syndrome is characterized by

- (A) elevation of all plasma lipids but no increase in atherogenesis
- (B) elevation of total cholesterol but no increase in atherogenesis

IX-33. (Continued)

- (C) selective elevation of low-density lipoprotein (LDL) cholesterol with increased atherogenesis
- (D) no response to HMG-CoA reductase inhibitors
- (E) myositis in 20% of patients treated with lipid-lowering agents

IX-34. ACE inhibitors would be expected to slow the progression of renal insufficiency in which of the following conditions?

- (A) Analgesic nephropathy
- (B) Contrast dye-associated nephropathy
- (C) Chronic glomerulonephritis with >1 g/d proteinuria
- (D) Autosomal dominant polycystic kidney disease (ADPKD)
- (E) Amphotericin-induced nephropathy

IX-35. Which of the following statements about polycystic kidney disease is true?

- (A) Polycystic kidney disease is an autosomal recessive disorder linked to a causative gene on the short arm of chromosome 16.
- (B) Erythropoietin levels are often low due to progressive renal failure.
- (C) Chronic diverticular disorder is a rare finding.
- (D) Nephrotic-range proteinuria is an uncommon finding.
- (E) The development of an intracranial saccular aneurysm (berry aneurysm) is associated with renal failure and does not have a specific association with polycystic kidney disease.

IX-36. Which of the following medications commonly does not cause hypokalemia?

- (A) β -Adrenergic agonists
- (B) Theophylline
- (C) Calcium channel blockers
- (D) Diuretic therapy
- (E) Amphotericin B

IX-37. In patients with urinary incontinence, which condition puts them at highest risk for the development of hydronephrosis?

- (A) Alzheimer's disease
- (B) Guillain-Barré syndrome
- (C) Normal-pressure hydrocephalus
- (D) Low-grade astrocytoma
- (E) Hypothyroidism

IX-38. Which of the following genetic abnormalities is associated with the development of hyperkalemia?

- (A) 11 β -hydroxylase deficiency

IX-38. (Continued)

- (B) Liddle's syndrome
- (C) Bartter's syndrome
- (D) Gitelman's syndrome
- (E) Autosomal dominant polycystic kidney disease

IX-39. Which of the following statements is true concerning acute poststreptococcal glomerulonephritis (PSGN)?

- (A) The latent period appears to be longer when PSGN is associated with cutaneous rather than pharyngeal infections.
- (B) Serologic evidence of a streptococcal infection can usually be found regardless of antimicrobial therapy.
- (C) Antimicrobial therapy for streptococcal infection is without value once the presence of renal disease is established.
- (D) Long-term antistreptococcal prophylaxis is indicated after a prior documented case of PSGN.
- (E) Progressive deterioration in renal function is more common in children than in adults with PSGN.

IX-40. A 19-year-old man arrives in your office complaining of generalized weakness, nausea, vomiting, and malaise. He states the color of his urine over the past several days has turned a "red," or "smoky" color. He states that he was well until approximately 10 days prior to his visit, when he had severe pharyngitis with a high-grade fever, although his pharyngitis and fever have now resolved. Physical examination reveals a blood pressure of 180/96, pulse of 98, and a temperature of 37.1°C (98.7°F). Laboratory values reveal a serum creatinine of 177 μmol/L (2 mg/dL). Which of the following statements is true?

- (A) The presence of dysmorphic red blood cells with red blood cell casts and leukocyte casts on microscopic examination is a universal finding.
- (B) A 24-h urine collection reveals 4 g of protein.
- (C) Mixed cryoglobulinemia is an unusual finding.
- (D) The levels of serum C3 and CH50 are usually within normal limits.
- (E) Electron microscopy typically reveals large electron-dense immune deposits in the subendothelial, subepithelial, and mesangial areas.

IX-41. Diseases involving the renal glomeruli are frequently encountered. Both humoral and cellular mechanisms play a part in the pathogenesis of glomerular injury. Which of the following glomerular diseases is associated with glomerulosclerosis as opposed to cellular proliferation?

- (A) IgA nephropathy
- (B) Diabetic nephropathy
- (C) Poststreptococcal glomerulonephritis
- (D) Henoch-Schönlein purpura
- (E) Glomerulonephritis related to hepatitis C infection

IX-42. An 87-year-old man presents to the emergency room obtunded. On physical examination he has a pulse of 120, blood pressure of 142/80, and weight of 72 kg (158 lb). He has diminished skin turgor and dry mucous membranes. He also has a fever of 38.9°C (102.0°F). Laboratory analysis reveals the following results:

Serum electrolytes (mmol/L): Na⁺ 164; K⁺ 4.6;
Cl⁻ 108; HCO₃⁻ 26
BUN: 17.1 mmol/L (48 mg/dL)
Serum creatinine: 168 μmol/L (1.9 mg/dL)

The most appropriate treatment plan would be which of the following?

- (A) D₅W at 300 mL/h
- (B) D₅ half-normal saline at 300 mL/h
- (C) D₅W at 150 mL/h
- (D) D₅W at 75 mL/h
- (E) Ringer's lactate at 160 mL/h

IX-43. A 48-year-old woman is hospitalized for elective knee surgery. Routine preoperative laboratory evaluation reveals the following:

Serum electrolytes (mmol/L): Na⁺ 138; K⁺ 3.5;
Cl⁻ 110; HCO₃⁻ 20
Blood glucose: 5.2 mmol/L (95 mg/dL)
Serum creatinine: 160 μmol/L (1.8 mg/dL)
BUN: 7.1 mmol/L (20 mg/dL)
Urinalysis: pH 5.2; specific gravity 1.005; protein 1+;
glucose 2+; 3 to 5 white blood cells per high-power field

The patient states that she voids several times during the night but is unaware of any problem with her kidneys. Which of the following disorders would be most likely associated with the findings in this case?

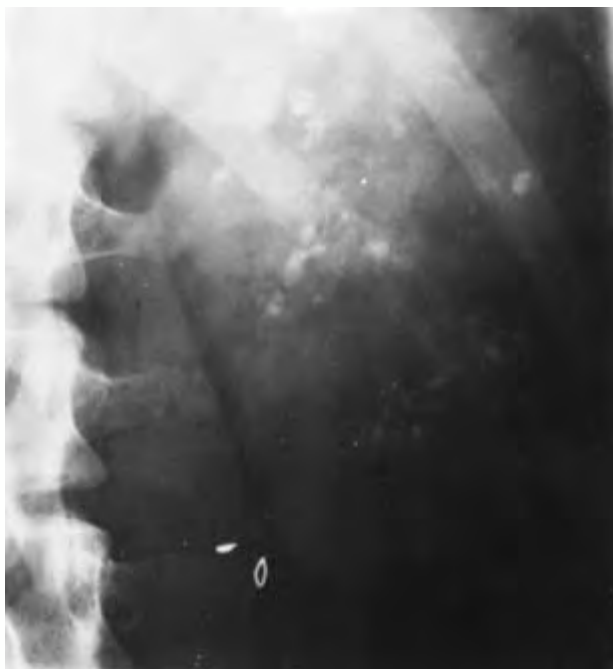- (A) Multiple myeloma
- (B) Diabetic nephropathy
- (C) IgA nephropathy
- (D) Penicillamine-induced nephropathy
- (E) Lupus nephritis

IX-44. A 45-year-old woman presents with the third episode of nephrolithiasis. Laboratory studies disclose the following:

Serum electrolytes (mmol/L): Na⁺ 134; K⁺ 2.5;
Cl⁻ 106; HCO₃⁻ 18
Serum chemistries: creatinine 97 μmol/L (1.1 mg/dL);
calcium 2.4 mmol/L (9.5 mg/dL); albumin 40 g/L
(4.0 g/dL)
Arterial blood gas values: P_{CO2} 4 kPa (30 mmHg);
P_{O2} 14 kPa (108 mmHg); pH 7.30
Urine pH: 7.2

A plain film of the abdomen is shown below. Which of the following statements about this clinical picture is correct?

IX-44. (Continued)



- (A) The findings are consistent with the presence of multiple myeloma.
- (B) The findings are consistent with the presence of medullary sponge kidney.
- (C) There is evidence of type I distal renal tubular acidosis (RTA).
- (D) Family members are typically not affected.
- (E) Intravenous pyelography is typically unremarkable.

IX-45. Which of the following statements is correct regarding renal transplantation?

- (A) A potential living donor who does not share the same blood type as the recipient cannot be considered even if the tissue types are HLA-identical.
- (B) The degree of HLA mismatch with cadaveric donor kidneys is a determinant of long-term graft survival.
- (C) Progressive renal failure in a transplant recipient, termed *chronic rejection*, is not associated with renal vascular damage.
- (D) Allopurinol must be coadministered with azathioprine to prevent urate nephropathy associated with drug-induced cell turnover.
- (E) Cyclosporine inhibits interleukin (IL) 2 production by cytotoxic (CD8+) T cells.

IX-46. A 45-year-old man with a diagnosis of ESRD secondary to diabetes mellitus is being treated with peritoneal dialysis. This is being carried out as a continuous ambulatory peritoneal dialysis (CAPD). He undergoes four 2-L exchanges per day and has been doing so for approximately 4 years. Complications of peritoneal dialysis include which of the following?

IX-46. (Continued)

- (A) Hypotension after drainage of dialysate
- (B) Hypoalbuminemia
- (C) Hypercholesterolemia
- (D) Hypoglycemia
- (E) Pleural effusion

IX-47. A 45-year-old woman with a long history of asthma now presents with progressive lower extremity skin rash as well as renal insufficiency. On physical examination she is short of breath, with audible wheezing. Her skin examination reveals numerous raised papules, which are erythematous in color, on both lower extremities. The lesions are nonblanching and raised, with areas of necrosis. Which of the following statements is correct?

- (A) The peripheral white blood count is within normal limits.
- (B) Antineutrophilic cytoplasmic autoantibodies (ANCA) are found in a cytoplasmic distribution consistent with antiproteinase-3 (PR3-ANCA).
- (C) A history of a progressive lower extremity neuropathy is a rare finding.
- (D) A normal chest x-ray is a typical finding.
- (E) Patient has a history of coronary disease.

IX-48. You are called to see a 62-year-old man who has recently undergone a transurethral resection of his prostate. Postoperatively he is found to be confused and stuporous. The patient interoperatively received 4 L of 5% dextrose as intravenous fluids. Clinically he is euvolemic with a blood pressure of 142/82 mmHg. He weighs 68 kg. Serum electrolytes (mmol/L) are obtained, which reveal Na⁺ 114 and K⁺ 3.8, and serum osmolality is 230. The correct management decision would be which one of the following?

- (A) Free water restriction
- (B) Normal saline at a rate of 180 mL/h for 3 h then reevaluate with repeat serum chemistries
- (C) 3% saline at 90 mL/h for 3 h and reevaluate with repeat serum chemistries
- (D) 3% saline at 180 mL/h for 3 h and reevaluate with repeat serum chemistries
- (E) Normal saline at 90 mL/h for 3 h and reevaluate with repeat serum chemistries

IX-49. A 45-year-old patient with membranous glomerulonephritis and renal insufficiency has nephrotic-range proteinuria. On physical examination the patient has 3+ lower extremity edema, and the patient's serum albumin is 21 g/L (2.1 g/dL) and serum creatinine is 106 μmol/L (1.2 mg/dL). An attempt to improve the lower extremity edema is made with the oral loop diuretic furosemide. Unfortunately, a poor response is obtained. Which of the following mechanisms likely contributes to the suboptimal response to diuretics?

IX-49. (Continued)

- (A) Decreased renal tubular secretion of furosemide
- (B) Diminished bioavailability of furosemide
- (C) Binding of furosemide to albumin in the tubular fluid
- (D) Decreased proximal reabsorption of sodium
- (E) Decreased distal reabsorption of sodium

IX-50. A 46-year-old man with long-standing diabetes mellitus and ESRD is undergoing hemodialysis. He has completed his run of dialysis and you find him somewhat confused, with a blood pressure of 86/42. Which of the following factors most likely contributed to the post-dialysis hypotension?

- (A) Reduced temperature dialysate
- (B) Concomitant use of antihypertensive therapy
- (C) Impaired autonomic response
- (D) Poor dietary intake during dialysis
- (E) Hyperphosphatemia

IX-51. A 46-year-old man has long-standing hypertension, and his current medications include hydrochlorothiazide. He presents with right flank pain radiating to his groin. Urinalysis reveals 3+ hematuria without proteinuria. He has had a similar episode previously. Routine laboratory analysis reveals a normal serum creatinine of 88 $\mu\text{mol/L}$ (1.0 mg/dL), serum calcium of 2.6 mmol/L (10.3 mg/dL), serum uric acid of 268 $\mu\text{mol/L}$ (4.5 mg/dL), and a total urine calcium of 200 mg per 24 h. The patient passes a stone, and upon microscopic analysis of the stone it is found to contain calcium. The most likely cause of the patient's recurrent nephrolithiasis is which one of the following?

- (A) Idiopathic absorptive hypercalciuria
- (B) A common complication of thiazide diuretic
- (C) Diathesis
- (D) Primary hyperparathyroidism
- (E) Hypocitraturia

IX. DISORDERS OF THE KIDNEY AND URINARY TRACT

ANSWERS

- IX-1. The answer is E.** (*Chap. 47*) Up to 150 mg/d of protein may be excreted by a normal person. The bulk of normal daily excretion is made up of the Tamm-Horsfall mucoprotein. Urine dipsticks may register a trace result in response to as little as 50 mg protein per liter and are definitively positive once the urine protein exceeds 300 mg/L. A false negative may occur if the proteinuria is due to immunoglobulins, which are positively charged. If proteinuria is suspected or documented, a 24-h urine collection should be undertaken to measure the absolute protein excretion. Urine immunoelectrophoresis also may identify the particular immunoglobulin that is produced in excess.
- IX-2. The answer is E.** (*Chap. 49*) Because of the powerful effect of ADH secretion in the setting of hypertonicity, severe persistent hyponatremia is possible only in patients who cannot respond to thirst by ingesting water. A nursing home patient with a fever may lose significant amounts of body fluid, which can result in dangerous levels of hyponatremia. Manifestations of hyponatremia include central nervous system dysfunction such as neuromuscular irritability, seizures, obtundation, or coma. Calculation of water replacement needs is based on total-body water, since water loss occurs from both intracellular and extracellular sites. In this case, a 60-kg woman has a plasma sodium of 160 mmol/L, which one would like to lower to 140 mmol/L. Total-body water is roughly 60% of weight (36 L). To reduce the plasma sodium, this volume must be increased to 160/140 times 36 L, or about 41 L. Thus, a positive water balance of 5 L (41 – 36) is needed. This deficit is best corrected fairly slowly, with the aim being to replace about half the water deficit in the first day. If correction is done in this conservative fashion with close monitoring of electrolytes, progressive central nervous system dysfunction is not likely. If the patient had signs of circulatory collapse indicating an associated sodium deficiency, treatment would begin with normal saline to provide intracellular volume. In certain situations, such as hyperosmolar diabetic coma, the plasma osmolarity is elevated because of hyperglycemia as well as hyponatremia. Therefore, initial treatment should consist of normal saline to ensure circulatory integrity and insulin to lower plasma glucose and partially reduce intracellular osmolarity. Finally, half normal saline could be used to slowly replace the remaining water and salt deficits.
- IX-3. The answer is A.** (*Chaps. 47, 329*) Failure to concentrate urine despite substantial hypertonic dehydration suggests a diagnosis of diabetes insipidus. A nephrogenic origin will be postulated if there is no increase in urine concentration after exogenous vasopressin. The only useful mode of therapy is a low-salt diet and use of a thiazide or amiloride, a potassium-sparing distal diuretic agent. The resultant volume contraction presumably enhances proximal reabsorption and thereby reduces urine flow.
- IX-4. The answer is A.** (*Chap. 47. Gennari, N Engl J Med 339:451–458, 1998.*) This man's electrolyte pattern is consistent with a hyporeninemic hypoaldosteronism state, or type IV renal tubular acidosis. The defect is believed to be due to an insufficiency of both angiotensin- and adrenal mineralocorticoid-secreting capacity. Inhibition of the renin-angiotensin system by β -adrenergic blockade such as propranolol can cause hyperkalemia; in addition, nonsteroidal anti-inflammatory agents or angiotensin-converting enzyme (ACE) inhibitors may also lead to hyperkalemia. The use of carbenicillin, theophyllin, and hy-

drochlorothiazide promote the loss of potassium through the distal renal tubule. Calcium channel blockers such as verapamil have no significant effect on serum potassium concentrations at the usual doses.

- IX-5. The answer is B.** (*Chap. 50. Wrenn, Am J Med 91:119, 1991.*) A reasonable way to approach the diagnosis of metabolic acidosis is to separate patients into those with an increased anion gap and those with a normal anion gap (hyperchloremic acidosis). A calculation of these unmeasured anions consists of the sum of plasma bicarbonate and chloride minus the plasma sodium concentration (the normal value is 8 to 16 mmol/L). Reasons for increased acid production include diabetic ketoacidosis, alcoholic ketoacidosis (as in this patient), starvation, lactic acidosis caused by circulatory failure, certain drugs and toxins, and poisoning resulting from salicylates, ethylene glycol, or methanol. Finally, renal failure increases the anion gap because sulfate, phosphate, and organic acid ions are not excreted normally. Normal anion gap acidosis is due to renal tubular dysfunction or colonic losses. Since the ratio of β -hydroxybutyrate to acetoacetate is high in alcoholic ketoacidosis, ketonemia can be missed by the routinely employed nitroprusside (Acetest) reagent, which detects acetoacetate but not β -hydroxybutyrate. Patients suffering from alcoholic ketoacidosis do well on infusions of glucose and saline. Neither insulin nor alkali is required in these situations unless the acidosis is extreme (bicarbonate <6 to 8 mmol/L).
- IX-6. The answer is D.** (*Chap. 270*) Development of advancing peripheral neuropathy is an indication for dialysis. Delaying dialysis could allow the development of irreversible motor deficits, such as foot drop. Prompt institution of dialysis, by contrast, usually prevents the progression of uremic peripheral neuropathy and may ameliorate early sensory defects. No pharmacologic agent would be of significant benefit in the clinical situation described.
- IX-7. The answer is A.** (*Chap. 270. Ifudu, N Engl J Med 339:1054–1062, 1998.*) Renal osteodystrophy is a common complication of chronic renal disease, and the most common complication secondary to impaired renal production of $1,25(\text{OH})_2\text{D}_3$. This leads to a decreased calcium absorption within the gut as well as impaired renal phosphate excretion. The resulting hyperphosphatemia causes a secondary hyperparathyroidism. Hyperparathyroidism is subsequently worsened by hypocalcemia, which is present because of the hyperphosphatemia and the decreased enzymatic conversion of 25-hydroxyvitamin D to $1,25(\text{OH})_2\text{D}_3$. Finally $1,25(\text{OH})_2\text{D}_3$ deficiency worsens hyperparathyroidism as the former is a direct inhibitor of parathyroid hormone secretion into the bone. The resultant decreased serum calcium concentration leads to secondary hyperparathyroidism. In addition, other causes of renal osteodystrophy include chronic metabolic acidosis, due to dissolution of bone buffers and decalcification, and the long-term administration of aluminum-containing antacids. There is no significant loss of vitamin D or calcium associated with currently employed dialysis techniques, and the treatment of renal osteodystrophy often employs calcitriol.
- IX-8. The answer is A.** (*Chap. 50*) To offer optimal management to patients with acute renal failure, it is helpful to distinguish prerenal azotemia (generally managed with volume replacement or amelioration of cardiac dysfunction) from intrinsic renal dysfunction. Sodium reabsorption, which is quite avid in prerenal azotemia, is impaired in intrinsic renal disease. However, creatinine is reabsorbed less efficiently than sodium in both conditions. Therefore, the fractional excretion of sodium is very helpful in distinguishing between these two etiologies of renal failure. The fractional excretion of sodium is calculated by multiplying the urine sodium by the plasma creatinine, dividing this by the plasma sodium times the urine creatinine, and multiplying by 100. In this case the result is approximately 1.4, which suggests that impaired reabsorption of sodium is ongoing and that intrinsic renal failure is occurring. Only about 15% of patients receiving nephrotoxins such as aminoglycosides or radiocontrast agents have renal failure associated with a fractional excretion of sodium of $<1\%$ and so an elevated value in this case points in the direction

of nephrotoxic injury. The other causes of acute renal failure listed here are all associated with prerenal azotemia and therefore with a more avid reabsorption of sodium than that described.

- IX-9. The answer is D.** (*Chap. 274*) One of the more common forms of asymptomatic urinary abnormalities is Berger's disease, which may be a cause of recurrent hematuria of glomerular origin. Such episodes of macroscopic hematuria and may be associated with minor flulike illnesses or vigorous exercise. Skin rash, arthritis, and abdominal pain usually are absent, which tends to distinguish this entity from Henoch-Schönlein purpura. Occasionally patients develop a nephrotic or nephritic syndrome. Serum IgA levels are increased in about 50% of all cases, though serum complement is normal. Renal biopsy in these situations may reveal a spectrum of changes, though diffuse mesangial proliferation or focal and segmental proliferative glomerulonephritis is most common. The essential feature of Berger's disease is the finding of diffuse mesangial deposition of IgA on immunofluorescence microscopy. IgG, C3, and properdin, but not C1q or C4, also may be found on this study. Although the disease progresses slowly, about 50% of patients develop end-stage renal failure within 25 years of the original presentation. Men with hypertension and proteinemia (>1 g/d) are most likely to progress. Except for a recent report suggesting that omega-3 fatty acids may play a role, specific therapy has not been useful. However, glucocorticoids or antibiotics may reduce the frequency of episodic gross hematuria. IgA deposition in the kidney and recurrent renal failure may occur in about 35% of those who receive a renal allograft. Fortunately, such recurrent pathologic findings usually are not associated with loss of renal function.
- IX-10. The answer is B.** (*Chap. 274*) The characteristic pattern of focal (not all glomeruli) and segmental (not the entire glomerulus) glomerular scarring is shown. The history and laboratory features are also consistent with this lesion: some associated hypertension, diminution in creatinine clearance, and a relatively inactive urine sediment. The "nephropathy of obesity" may be associated with this lesion secondary to hyperfiltration; this condition may be more likely in obese patients with hypoxemia, obstructive sleep apnea, and right-sided heart failure. Hypertensive nephrosclerosis exhibits more prominent vascular changes and patchy, ischemic, totally sclerosed glomeruli. In addition, nephrosclerosis seldom is associated with nephrotic-range proteinuria. Minimal-change disease usually is associated with symptomatic edema and normal-appearing glomeruli as demonstrated by light microscopy. This patient's presentation is consistent with that of membranous nephropathy, but the biopsy is not. With membranous glomerular nephritis all glomeruli are uniformly involved with subepithelial dense deposits. There are no features of crescentic glomerulonephritis present.
- IX-11. The answer is D.** (*Chap. 274*) Persons who have solid tumors and develop nephrotic syndrome usually have membranous glomerulopathy. Diagnosis of the nephrotic syndrome may precede recognition of the primary tumor. In several cases, tumor antigens have been discovered in the glomerular deposits; the nephrotic syndrome may remit after effective tumor therapy. Patients with Hodgkin's disease may develop nephrotic syndrome on the basis of minimal-change disease (diffuse epithelial foot process effacement on ultrastructural examination).
- IX-12. The answer is A.** (*Chaps. 277, 279*) Cystine crystals appear as flat hexagonal plates and are found in association with cystine stones, which are caused by a hereditary deficiency in tubular cystine transport. Struvite stones result from chronic urinary tract infection with *Proteus* spp. These bacteria degrade urea to carbon dioxide and ammonia, which alkalinizes the urine, thereby favoring the formation of the insoluble triple salt $MgNH_4PO_4$. Struvite crystals can appear in the urine as rectangular prisms. Patients with proteinuria resulting from albuminuria exhibit a sediment characteristic of the nephrotic syndrome with oval fat bodies. Patients with intestinal malabsorption with concomitant steatorrhea, as in the case of a jejunioileal bypass done for obesity, may hyperabsorb oxalate

and form calcium oxalate renal stones. Calcium oxalate crystals appear bipyramidal or as biconcave ovals. The sediment depicted here displays flat, square plates, which represent one of the several forms uric acid crystals manifest. Hyperuricemia may accompany rapid cell turnover (as occurs in the rapid lysis of lymphomas with large tumor burdens after chemotherapy). In such settings aggressive hydration, the use of allopurinol, and urinary alkalization may provide effective prophylaxis against uric acid nephropathy.

- IX-13. The answer is E.** (*Chap. 277*) A number of drugs may elicit an acute interstitial nephritis. The classic offender is methicillin, although ampicillin, penicillin, cephalothin, thiazides, furosemide, and nonsteroidal anti-inflammatory drugs also have been associated with this problem. Hematuria, fever, and skin rash may occur within 1 to 2 weeks of exposure to the drug. Urinalysis reveals protein, pyuria, and eosinophiluria. Ultrasonography discloses enlarged kidneys. A biopsy (usually not necessary, since withdrawal of the offending drug leads to complete resolution) will reveal normal glomeruli but infiltration of the interstitium with polymorphonuclear leukocytes, lymphocytes, plasma cells, and eosinophils.
- IX-14. The answer is D.** (*Chap. 275*) A variety of diseases involve both pulmonary and renal (and often dermal) microvasculature and may present with either prominent pulmonary or renal manifestations. When a firm diagnosis cannot be made serologically or by biopsy of skin or lesions of the upper respiratory tract, renal biopsy may be necessary. In the case described in this question, the serologic findings, though not specific, are typical of Wegener's granulomatosis, a diagnosis established by the renal biopsy report. Granulomas are an uncommon microscopic finding in polyarteritis as well as in lupus nephritis and Henoch-Schönlein purpura, though a spectrum of pathologic abnormalities may be seen in the latter two conditions. Antineutrophil antibodies in the serum are highly suggestive of Wegener's granulomatosis and other systemic vasculitides. The renal biopsy in Goodpasture's syndrome usually reveals linear immunoglobulin deposits.
- IX-15. The answer is D.** (*Chap. 277. Bennett, DeBroe, N Engl J Med 320:1269–1271, 1989. DeBroe, Elseviers, N Engl J Med 338:446–452, 1998.*) Patients with damage to renal papillae may be unable to excrete maximally concentrated urine owing to chronic tubular damage. Moreover, the necrosed papillae can lead to the gradual development of renal failure. Renal papillary necrosis has been classically associated with long-term analgesic abuse. This is most commonly manifested by chronic use of acetaminophen or phenacetin. In addition to analgesic abuse, renal papillary necrosis can also be caused by sickle cell anemia, diabetic nephropathy, or acute obstructive uropathy. It is not associated with the presence of early-stage prostate cancer in the absence of prostatic hypertrophy. In addition, patients can present with renal papillary necrosis after multiple episodes of pyelonephritis, but this is uncommon after a single uncomplicated episode. Aspirin can potentiate the deleterious effects of chronic analgesic abuse by inhibiting the production of renal vasodilatory prostaglandins. Ingestion of lead, such as that caused by lead leaching out from an unusual distilling apparatus, can lead to a nephropathy manifested by tubular atrophy and fibrosis of small renal arteries.
- IX-16. The answer is E.** (*Chap. 275*) The pathophysiology of nephrotoxic involvement by SLE is thought to be immune complex deposition. Renal disease in SLE can range from mild abnormalities of the urinalysis to a fulminant inflammatory process that leads to progressive renal failure. Renal biopsy findings in patients with SLE who have worsening renal function can range from minimal glomerular lesions to diffuse proliferative lupus glomerulonephritis and membranous lupus glomerulonephritis. Patients with membranous lupus glomerulonephritis may be managed conservatively with therapy directed toward extrarenal manifestations. By contrast, those with more extensive or proliferative glomerular lesions require a more aggressive approach using glucocorticoids (with or without another immunosuppressive agent, such as azathioprine or cyclophosphamide). However, little is gained by using immunosuppressant therapy in patients with advanced renal failure

characterized by obliterative sclerosing lesions of the glomeruli. If such patients have other indications for dialysis, such as systemic symptoms and hyperkalemia, they are best managed with dialysis followed by renal transplantation. Measurement of serologic evidence of disease (e.g., double-stranded DNA autoantibodies or a decrease in serum complement components) may be helpful. Patients with end-stage lupus nephritis can be managed successfully with hemodialysis. Moreover, patients with SLE who have undergone renal allografting rarely experience recurrence of disease in the new kidney.

- IX-17. The answer is B.** (*Chap. 272*) In the first week after renal transplantation the differential diagnosis of graft dysfunction includes early rejection, hypovolemia, cyclosporine intoxication, acute tubular necrosis, urinary obstruction, and renal artery thrombosis. Cyclosporine can mask many of the classic signs of rejection, such as fever and graft tenderness; renal biopsy often is needed to make the diagnosis. However, renal ultrasonography should precede any manipulation to rule out mechanical outflow obstruction, as it should in any patient with acute deterioration of renal function.
- IX-18. The answer is D.** (*Chap. 94*) The most important differential diagnosis in the case presented is between a renal cell carcinoma and a benign cystic lesion. Urinalysis may be normal in the presence of renal cell carcinoma, and urinary cytology is unfortunately of little value in the diagnosis of this lesion. Ultrasonography will reveal whether the lesion is cystic. If the lesion fulfills the criteria for a simple cyst (lack of internal echoes, smooth borders, through transmission) and the patient does not have hematuria, the cyst can be considered benign with a diagnostic accuracy of 97%. If greater assurance is required or if there are changes on follow-up radiologic studies, needle aspiration should be carried out. If the ultrasound appearance is not consistent with a simple cyst, contrast-enhanced CT scanning, the optimal test for the diagnosis and staging of renal cell carcinoma, should be performed.
- IX-19. The answer is D.** (*Chap. 274. Hricik, Chung-Park, N Engl J Med 339:888–899, 1998.*) The syndrome described is typical of rapidly progressive glomerulonephritis (GN) with rapid onset of acute renal failure in the setting of glomerular disease (manifested by red blood cell casts and proteinuria). The patient's vomiting is consistent with the development of azotemia over a short time period. Renal biopsy is highly recommended early in the course of such a disease to define the nature and severity of the glomerular lesion for both prognostic and therapeutic purposes. The hallmark pathologic lesion associated with this clinical scenario is crescentic glomerulonephritis, the manifestation of extracapillary endothelial proliferation. Such a finding on renal biopsy carries an ominous prognosis, especially if crescents are present in 70% of glomeruli or if glomerular filtration rate (GFR) is <5 mL/min. Spontaneous resolution rarely occurs except in cases associated with an infectious cause, such as endocarditis and streptococcal disease. Though controlled trials are lacking, it appears that high-dose methylprednisolone given parenterally ("pulse steroids") can stave off the need for hemodialysis in some patients. Plasmapheresis may benefit some patients, especially those who have antiglomerular basement antibodies.
- IX-20. The answer is B.** (*Chaps. 94, 222, 280*) Carcinoma of the bladder typically affects older men. Transitional cell carcinoma is the most common histologic subtype and is associated with a more favorable prognosis than is adenocarcinoma or squamous carcinoma. Squamous carcinomas occur more frequently in Egypt and are associated with *S. haematobium* and not *S. mansoni*, which typically causes an infection of the intestines or biliary tract. Risk factors for carcinoma of the bladder include exposure to the aromatic amines, which result from cigarette smoke or products of the dye, rubber, and chemical industries, but it is not associated with positive family history or a prior diagnosis of renal carcinoma. Chronic bladder irritation, such as that produced by the metabolites of cyclophosphamide or ifosfamide as well as by recurrent bladder stones or infections, also leads to a higher incidence of carcinoma of the bladder.

- IX-21. The answer is C.** (*Chaps. 49, 276. Narins, Am J Med 72:496, 1982.*) The evaluation of patients with hypokalemia should first include a consideration of redistribution of body potassium into cells as occurs in alkalosis, β_2 -agonist excess with refeeding syndrome and/or insulin therapy, vitamin B₁₂ therapy, patients with pernicious anemia, and periodic paralysis. In periodic paralysis serum bicarbonate is normal. If the patient is hypertensive and plasma renin is elevated, renovascular hypertension or a renin-secreting tumor (including Wilms') must be considered and appropriate imaging studies must be carried out. If plasma renin levels are low, mineralocorticoid effect may be high, due either to endogenous hormone (glucocorticoid overproduction or aldosterone overproduction as in Conn's syndrome) or to exogenous agents (licorice or steroids). In a normotensive patient a high serum bicarbonate excludes renal tubular acidosis. High urine chloride excretion makes gastrointestinal losses less likely and implies primary renal potassium loss as might be seen in diuretic abuse (ruled out by the urine screen) or Bartter's syndrome. In Bartter's syndrome, hyperplasia of the granular cells of the juxtaglomerular apparatus leads to high renin levels and secondary aldosterone elevations. Such hyperplasia appears to be secondary to chronic volume depletion caused by a hereditary (autosomal recessive) defect that interferes with salt reabsorption in the thick ascending loop of Henle. Chronic potassium depletion, which frequently initially presents in childhood, leads to polyuria and weakness.
- IX-22. The answer is D.** (*Chap. 275. Hricik, Chung-Park, N Engl J Med 339:888–899, 1998.*) Cryoglobulinemia with renal involvement is associated with hypocomplementemia in the majority of cases. In addition it has been well recognized that hepatitis C is often associated with cryoglobulinemia. Diffuse proliferative lupus nephritis (WHO class IV) is the most aggressive form of the disease and is also associated with hypocomplementemia. Early in the course of postinfectious glomerulonephritis, immune complex deposition is in full force and serum complements are low. Henoch-Schönlein purpura, the systemic manifestation of IgA nephropathy, is not associated with hypocomplementemia. Other causes of hypocomplementemic glomerulonephritis are glomerulonephritis associated with bacterial endocarditis or other chronic infections as well as membranoproliferative glomerulonephritis.
- IX-23. The answer is E.** (*Chap. 269*) Years before dialysis was routinely available, it was well established that protein restriction (prescribed or self-imposed) could alleviate some of the symptoms of uremia; unfortunately, prolonged protein restriction led to the development of malnutrition and its associated complications. In the setting of chronic renal failure, a number of clinical studies have suggested that modest protein restriction may slow the rate of progression of renal failure, particularly in patients with glomerular disease and daily protein excretion rates >1 g/d. There are insufficient data in the setting of acute renal failure to adequately assess the importance of protein intake. However, in view of the hypercatabolism that accompanies many cases of acute renal failure, most practitioners provide adequate protein to patients (e.g., ≥ 1.0 to 1.2 g protein per kg per day) and provide dialysis if uremia ensues. There are no set laboratory "cutoffs" (BUN >100) that indicate the need for dialysis.
- IX-24. The answer is D.** (*Chap. 50. Adroque, Madias, N Engl J Med 338:26–34, 1998.*) Ingestion of ethylene glycol can produce severe, high-anion-gap metabolic acidosis, caused by the accumulation of toxic metabolites. Furthermore, the degree of acidosis is disproportionate to the degree of renal insufficiency. Ethylene glycol intoxication often requires a large amount of alkali to correct the severe acidemia. Additional measures include gastric lavage, oral charcoal, and intravenous or oral ethanol. Ethanol has a higher affinity for alcohol dehydrogenase and will therefore inhibit the generation of toxic metabolites from the ethylene glycol. In severe cases hemodialysis is required. In addition, forced diuresis can prevent acute renal failure in some patients with ethylene glycol intoxication.
- IX-25. The answer is B.** (*Chap. 50. Adroque, Madias, N Engl J Med 338:26–34, 1998.*) This represents a respiratory alkalosis with a combined metabolic acidosis. This is typical of salicylate toxicity. Salicylate intoxication can result in respiratory alkalosis, mixed res-

piratory alkalosis and metabolic acidosis, or, less commonly, a simple metabolic acidosis. Respiratory alkalosis is caused by direct stimulation of the respiratory center by salicylate. The accumulation of lactic acid and ketoacids leads to the concomitant metabolic acidosis. The severity of the neurologic manifestations largely depends on the concentration of salicylate in the central nervous system. Therapy is directed at limiting further drug absorption by administering activated charcoal and promoting the exit of salicylate from the central nervous system. This can be accomplished by alkalinizing the serum, typically by the addition of intravenous fluids with sodium bicarbonate with the goal of raising the serum pH to between 7.45 and 7.50. Increasing the GFR will also enhance salicylate excretion. Hemodialysis is reserved for severe cases, especially those involving fulminant renal failure.

- IX-26. The answer is B.** (*Chap. 49. Beck, N Engl J Med 301:528–530, 1979.*) Hyponatremia can be broadly categorized as hypovolemic, euvolemic, or hypervolemic. Hepatic cirrhosis in this case is unlikely because of the absence of edema. Gastrointestinal fluid loss is unlikely because of normal blood pressure without orthostasis. Furthermore, depending on whether the fluid loss is upper (vomiting with resultant alkalosis) or lower (diarrhea with resultant acidosis), it often is accompanied by a disturbance in acid-base balance. Addison's disease is possible, although it often is associated with orthostasis, some degree of hypotension, and hyperkalemia (due to aldosterone deficiency). The uric acid can be very helpful in the differential diagnosis of hyponatremia. It is typically elevated in patients with congestive heart failure and renal failure, two other important causes of hyponatremia, and tends to be quite low in patients with SIADH.
- IX-27. The answer is C.** (*Chap. 271*) Mycobacterial peritonitis and fungal peritonitis are relatively rare but important problems, particularly in patients who receive repeated courses of antibacterial therapy for suspected or documented bacterial peritonitis. Dialysis disequilibrium is a syndrome characterized by headache, confusion, and occasionally seizures; it is seen in association with the excessively rapid correction of uremia with dialysis (usually hemodialysis). It is thought to be related to cerebral edema caused by the rapid removal of extracellular solute (urea) with resultant osmotic transfer of water into the cells. Peritoneal carcinomatosis (from ovarian or widespread gastrointestinal carcinoma) is possible in this case, although there is no history of cancer.
- IX-28. The answer is E.** (*Chap. 50*) Hypokalemia impairs the renal excretion of ammonium, which thereby results in hyperammonemia in cases of hepatic failure. The use of loop diuretics promotes kaliuresis and therefore may lead to hyperammonemia. The alternative choices typically improve hyperammonemia in selected cases.
- IX-29. The answer is E.** (*Chap. 277*) Nephrocalcinosis is an uncommon cause of interstitial renal disease associated with a variety of metabolic disorders. The routine (with or after a meal) use of calcium-based phosphate binders rarely results in hypercalcemia, although injudicious use may lead to complications. Crohn's disease and other abnormalities of ileal fat absorption may cause nephrocalcinosis because of excessive absorption of dietary oxalate and calcium oxalate nephrolithiasis.
- IX-30. The answer is E.** (*Chap. 274. Orth, Ritz, N Engl J Med 338:1202–1211, 1998.*) The patient has nephritic-range proteinuria as documented by a 24-h urine collection of $>3.5\text{g}/1.73\text{m}^2$. Such patients typically have hypoalbuminemia, peripheral edema, and hyperlipidemia as well as lipiduria. It is thought that the hypoalbuminemia is further compounded by increased renal catabolism. The physiology of the edema formation in nephrotic syndrome is less well understood; it is thought that the presence of hypoalbuminemia results in decreased intravascular oncotic pressure leading to leakage of extracellular fluid from blood into the interstitial fluid. As a result, the intravascular volume falls, thereby stimulating activation of the renin-angiotensin-aldosterone axis and consequently increasing the release of vasopressin (antidiuretic hormone). In addition, there is suppression of the re-

lease of atrial natriuretic peptide, and this suppression contributes to the primary renal salt and water retention that contributes to the formation of edema. Patients with nephrotic-range proteinuria often have elevated serum lipid levels as a consequence of increased hepatic lipoprotein synthesis. Both LDL-cholesterol and total cholesterol are increased in the majority of patients, and, though not proven conclusively, this state of hyperlipidemia may accelerate atherosclerosis as well as the progression of further renal disease.

Patients often present with a hypercoagulable state due to increased urinary loss of antithrombin III as well as altered levels or activity of proteins C and S. There is also impaired fibrinolysis. As a consequence of these alterations, patients can develop spontaneous peripheral arterial or venous thrombosis, renal vein thrombosis, and pulmonary embolism.

Although IgA GN is the most common glomerulopathy, it only occasionally causes nephrotic syndrome. The most common cause of nephrotic syndrome in adults is membranous GN which represents approximately 40% of all cases. The most common cause of nephritic syndrome in children is minimal-change glomerulopathy. Membranous GN can be linked to neoplasms—either carcinoma, sarcoma, lymphoma, or more rarely leukemia. This possibility should be specifically considered in older patients who present with new-onset nephrotic syndrome. Other metabolic abnormalities include hypocalcemia and secondary hyperparathyroidism as a consequence of vitamin D deficiency due to enhanced urinary excretion of cholecalciferol-binding protein. In addition, loss of thyroxin-binding globulin often results in depressed thyroxin levels. There is also an increased susceptibility to infection, which may affect low levels of IgG urinary loss as well as increased catabolism.

- IX-31. The answer is D.** (*Chap. 50*) The key element is the anion gap, calculated as $(\text{Na} + \text{K}) - \text{Cl}$ (normal 8 to 12). The anion gap is 32 in this case. Causes of high-anion-gap acidosis include diabetic or alcoholic ketoacidosis, renal failure, and the excessive ingestion of salicylates, methanol, ethanol, or ethylene glycol. The clues here are the negative Acetest (making alcoholic and/or diabetic ketoacidosis less likely) and the presence of calcium oxylate crystals (oxylate is a by-product of ethylene glycol). Hemodialysis should be provided in these cases of toxic ingestion, since the products are water-soluble and can quickly cause damage to the CNS if not promptly removed.
- IX-32. The answer is D.** (*Chap. 269*) Cholesterol embolization (also known as atheroembolic renal disease) is characterized by pyuria, progressive renal failure (usually nonoliguric), and associated organ dysfunction (including bowel, pancreas, and CNS). Hypocomplementemia and eosinophiluria also may be seen. The urinalysis is not compatible with acute tubular necrosis because of the absence of granular casts.
- IX-33. The answer is C.** (*Chap. 274. Joven et al., N Engl J Med, 323:579–584, 1990.*) Dyslipidemia is present in the vast majority of patients with nephrotic syndrome and typically is characterized by a relatively selective increase in LDL cholesterol. There is evidence of accelerated atherosclerosis in these patients. Although there appears to be an increased risk of myositis in patients with renal failure treated with lipid-lowering agents, the risk is relatively low (far below 20%). Combination therapy (e.g., an HMG-CoA reductase inhibitor and a fibric acid derivative) should be used with caution.
- IX-34. The answer is C.** (*Chaps. 270, 273. Maschio et al., N Engl J Med 334:939–945, 1996.*) Evidence continues to accumulate that ACE inhibition can slow the progression of chronic renal insufficiency in a variety of disease states. In general, patients with protein excretion rates 1 g/d tend to derive the greatest benefit. For reasons that are not entirely clear, patients with ADPKD tend not to benefit from this therapy (and do not appear to benefit from a low-protein diet).
- IX-35. The answer is D.** (*Chap. 276. Gabow, N Engl J Med 329:332–342, 1993.*) Autosomal dominant polycystic kidney disease is one of the most common hereditary disorders. Spon-

taneous mutations occur but account for only 10% or fewer of all cases. The majority of cases are linked to a causative gene located on the short arm of chromosome 16, referred to as ADPKD1. A second causative gene (ADPKD2) has not been identified but seems to be at a locus distinct from ADPKD1, which appears to be the cause of the gene in $\geq 90\%$ of families in the white population.

A rare syndrome known as *autosomal recessive polycystic kidney disease* affects between 1 in 10,000 and 1 in 40,000 individuals in the United States, and the causative gene has been localized to chromosome 6. Patients are typically diagnosed during the first year of life, presenting with bilateral abdominal masses. Death in the neonatal period is common due to pulmonary hypoplasia.

The most common complication of polycystic kidney disease is pain secondary to large cystic kidneys; in addition, most patients are hypertensive. In addition to the chronic pain, acute pain may represent cystic hemorrhage, infection, or, less commonly, a renal stone. Proteinuria occurs in about 1/3 of patients but is typically mild, with < 1 g per 24-h collection. The rare patient with nephrotic-range proteinuria often has superimposed glomerular disease.

Certain endocrine functions of the kidney also appear to be altered. Renal secretion seems to be elevated and likely causes a predilection for hypertension. Although polycythemia is rare, the hematocrit seems to be better maintained in patients with renal failure due to ADPKD than in patients with other forms of renal disease.

Extrarenal complications are common and often include hepatic and pancreatic cysts; and cardiac valvular abnormalities are also noted. The principal noncystic gastrointestinal manifestation is the development of colonic diverticular disease, which has been reported in as many as 82% of patients with ADPKD. The most devastating extrarenal manifestation, however, is the development of intracranial saccular aneurysms, often called berry aneurysms. These are generally accepted to be a manifestation of polycystic kidney disease, but occur with an unknown frequency.

- IX-36. The answer is C.** (*Chap. 49. Gennari, N Engl J Med 339:451–458, 1998.*) A wide range of drugs have been implicated in causing hypokalemia as a significant side effect. These drugs include the β_2 sympathomimetic agonists of many drugs including decongestants, bronchial dilators, and inhibitors of uterine contraction. The hypokalemia caused by these drugs is sustained for up to 4 h. Intestinal ingestion of excess amounts of pseudoephedrine can cause severe hypokalemia.

Theophylline and caffeine are not sympathomimetic drugs; however, these agents stimulate the release of sympathetic amines, which may also increase the Na^+ , K^+ -ATPase activity and thereby lead to hypokalemia. Severe hypokalemia is an almost invariable feature of acute theophylline toxicity.

Although calcium channel blockers increase cellular uptake of potassium in experimental studies, these drugs typically have no effect on serum potassium concentration at the usual doses. However, ingestion of large amounts of verapamil can cause hypokalemia.

The most common cause of drug-induced hypokalemia is diuretic therapy. Both thiazide and loop diuretics block chloride-associated sodium reabsorption. As a result of the increased delivery of sodium to the collecting tubules, there is a favorable electrochemical gradient leading to increased potassium secretion.

Amphotericin B causes renal potassium wasting through the inhibition of the secretion of hydrogen ions by the collecting duct. In addition, severe magnesium depletion is another manifestation of amphotericin B usage.

- IX-37. The answer is B.** (*Chap. 48. Resnick, N Engl J Med 320:1, 1989.*) The force for bladder emptying is provided by the detrusor muscle, which is innervated by parasympathetic outflow from the sacral plexus. The involuntary control that prevents automatic bladder emptying emanates from sympathetic innervation of the bladder outlet. A sacral spinal reflex arc mediates automatic detrusor contraction when the intravesical pressure exceeds 20 cmH_2O (a volume of 400 mL) unless it is inhibited by cortical centers via the reticulospinal tracts. Diseases leading to damage of inhibitory neural pathways in the brain

or spinal cord, such as multiple strokes, Alzheimer's disease, brain tumors, and normal-pressure hydrocephalus, create detrusor instability. In this situation the bladder will empty automatically before it is filled owing to unchecked operation of the spinal reflex arc. By contrast, conditions leading to chronic overflow incontinence caused by obstruction at the bladder neck or a hypotonic bladder caused by autonomic neuropathy can result in hydronephrosis and impaired renal function. The most common example of outflow obstruction is benign prostatic hypertrophy. Examples of conditions in which autonomic peripheral neuropathy can lead to overflow incontinence include diabetes mellitus, hypothyroidism, uremia, collagen vascular diseases, Guillain-Barré syndrome, and exposure to certain toxins (including alcohol). Cholinergic agents such as bethanechol sometimes can aid bladder emptying in those with overflow incontinence.

- IX-38. The answer is E.** (*Chaps. 49, 276. Gennari, N Engl J Med 339:451–458, 1998.*) Mutation of the β -hydroxylase gene is a common cause of congenital adrenal hyperplasia. This is a hereditary disease often leading to mineralo- or glucocorticoid excess and subsequent hypokalemia with the development of metabolic alkalosis. In addition, Liddle's syndrome can lead to an apparent mineralocorticoid excess syndrome. Both Bartter's and Gitelman's syndromes are genetic mutations that inactivate or impede the activity of the chloride-associated Na^+ transporter within the loop of Henle (Bartter's) or the early distal tubule (Gitelman's). This causes a metabolic alkalosis with hypokalemia. The presence of hypertension is not a typical finding with the above two genetic disorders. ADPKD often leads to chronic renal insufficiency with the development of hyperkalemia.
- IX-39. The answer is A.** (*Chap. 274. Hricik et al., N Engl J Med 339:888–899, 1998.*) Studies during epidemics of streptococcal disease have shown that the latent period between symptomatic pharyngitis and the appearance of PSGN is 6 to 10 days. The latent period after cutaneous infection is more difficult to establish but appears to be longer. Persons who receive early antimicrobial therapy for streptococcal infection may develop glomerulonephritis but not mount the immune response to the streptococcal enzymes (e.g., streptolysin O) on which laboratory testing for antecedent streptococcal infection is based. Antimicrobial therapy is recommended for persons who have acute glomerulonephritis and continuing streptococcal infection. Long-term prophylaxis, however, is unwarranted because affected persons are not markedly predisposed to recurrent episodes of PSGN. For unknown reasons, PSGN leads to permanent, progressive renal insufficiency more often in adults than in children.
- IX-40. The answer is E.** (*Chap. 274. Hricik, Chung-Park, N Engl J Med 339:888–899, 1998.*) This patient presents with characteristic symptoms and findings of PSGN. PSGN is an acute reversible disease and is characterized by spontaneous recovery in the vast majority of patients. The typical urinalysis has a urinary sediment that is nephritic in nature, displaying dysmorphic red blood cells, red cell casts, leukocytes, occasional leukocyte casts, and proteinuria. However, fewer than 5% of patients will actually develop nephrotic-range proteinuria. The serum creatinine is typically elevated in the range of 88 to 177 $\mu\text{mol/L}$ (1 to 2 mg/dL), and complement levels such as C3 and CH50 are typically depressed in >90% of cases. The vast majority of patients will have transient hypergammaglobulinemia as well as mixed cryoglobulinemia. Most patients will present with gross hematuria, headache, and generalized symptoms of anorexia, nausea, vomiting, and malaise. Physical examination may reveal hypervolemia, edema, and hypertension. The edema probably results from increased sodium retention due to the decrease in the GFR. Swelling of the renal capsule can cause occasional flank or back pain. Diagnosis is made in >90% of patients with circulating antibodies against streptococcal enzymes such as antistreptolysin O (ASO), anti-DNAse B, and anti-streptokinase (ASKase). Electron microscopy often reveals the presence of electron-dense immune deposits in the subendothelial, subepithelial, and mesangial areas. More extensive immunoglobulin deposition throughout the glomerular capillary wall is associated with a worse prognosis.

IX-41. The answer is B. (*Chaps. 273, 274. Hricik, Chung-Park, N Engl J Med 339:888–899, 1998.*) The glomerular diseases can be classified according to the presence or absence of proliferative changes. In the primary renal disorders, proliferative changes are common in IgA nephropathy, IgM nephropathy, and mesangioproliferative glomerulonephritis as well as in membranoproliferative glomerulonephritis. Proliferative changes are not seen in focal segmented glomerulosclerosis, membranous glomerulopathy, minimal-change disease, or thin basement membrane disease. Glomerular diseases can also be caused by systemic disease such as lupus nephritis or PSGN, the glomerulonephritis associated with either hepatitis B or C infection. All of these are associated with proliferative changes within the glomerular capsule. In addition, the glomerular diseases associated with Wegener's granulomatosis, polyarteritis nodosa, or Henoch-Schönlein purpura are also associated with proliferative changes.

Diabetes mellitus is a major cause of renal morbidity and mortality. Diabetic glomerulosclerosis is associated with morphologic changes that include capillary basement membrane thickening, diffuse diabetic glomerulosclerosis, and nodular glomerulosclerosis. The typical lesions in nodular glomerulosclerosis, or Kimmelstiel-Wilson syndrome, take the form of ovoid spherical hyaline deposits within the periphery of the glomeruli. Cellular proliferative changes are not typical of diabetic glomerular nephropathy.

IX-42. The answer is C. (*Chap. 49. Adroque, Madias, N Engl J Med 342:1493–1499, 2000.*) This 87-year-old man presents with a hypernatremia caused by pure water depletion, likely due to insensible losses. The most appropriate infusion would be replenishment of free water with 5% dextrose. The estimated total-body water volume is 50% of his weight, which is 36 L (0.5×72). The retention of 1 L of 5% dextrose will reduce the serum sodium concentration by approximately 4.4 mmol/L [$(0 - 164) \div (36 + 1) = -4.4$ mmol/L]. The goal of treatment is to reduce the serum sodium concentration slowly. This can be achieved by lowering the serum sodium by 10 mmol/L over a 24-h period. Therefore, 2.3 L of 5% dextrose ($10 \div 4.4$) is required. In addition, 1.5 L is added to compensate for average obligatory water losses over the 24-h period; therefore, approximately 3.8 L will be administered over a 24-h period, which corresponds to a rate of 160 mL/h. In addition, the serum glucose concentration will need to be closely monitored and insulin therapy initiated at the first indication of hyperglycemia. Hyperglycemia could significantly aggravate the patient's free water balance. Also, close monitoring of the patient's clinical status and laboratory values will be required during the first 6 to 24 h.

IX-43. The answer is A. (*Chap 277*) Glycosuria (with a normal blood glucose concentration), proteinuria, and hyperchloremic acidosis constitute evidence of proximal renal tubular dysfunction [type II renal tubular acidosis (RTA)]. Frequent nocturia, presumably resulting from an impaired ability to concentrate urine, also suggests renal insufficiency caused by tubulointerstitial disease. Multiple myeloma may present in this manner, and similar renal abnormalities may be associated with analgesic abuse and Sjögren's syndrome. The findings in this case are not characteristic of primary glomerular diseases, such as diabetic nephropathy, or membranous glomerulonephritis.

IX-44. The answer is B. (*Chaps. 276, 277, 279*) This patient has recurrent renal calculi and nephrocalcinosis and has a normal serum calcium level. The serum electrolyte pattern is typical of distal (type I) RTA and not proximal (type II) RTA. There is evidence of renal potassium wasting and hyperchloremic metabolic acidosis with the presence of alkaline urine. Nephrocalcinosis and distal RTA are consistent with hypervitaminosis D, medullary sponge kidney, hyperparathyroidism, sarcoidosis, or multiple myeloma. However, in all these conditions except medullary sponge kidney, there is an increased serum calcium concentration responsible for nephrocalcinosis. Intravenous pyelography is abnormal in patients with medullary sponge kidney. Intravenous pyelography shows a typical "paintbrush" pattern in the renal papillae, with tiny papillary cysts that contain calcium deposits. Although medullary sponge kidney is usually sporadic, some cases have an apparent autosomal dominant inheritance pattern.

- IX-45. The answer is B.** (*Chap. 272*) Living volunteer donors should be healthy, have normal renal arteries, and have the same blood group as the recipient. The one exception to the last rule occurs in the case of a type O donor, who can donate to a recipient with any blood group, since no endothelial antigens in the ABO system are present to engender rejection. The donor and recipient should be as closely HLA-matched as possible, and the mixed lymphocyte response (MLR) should be absent. DNA typing techniques have obviated the need for MLR testing in related donors. In the case of cadaveric donor kidneys, there is a direct relationship between the degree of HLA incompatibility and graft loss. For example, there is a projected 10-year graft survival rate of 27% if there are five HLA mismatches but a 52% rate if there is only one mismatch. Chronic rejection frequently is due to nephrosclerosis, which often is initially characterized by proliferation of the intima (with eventual fibrosis) in the renal vasculature. Prophylaxis against rejection includes the use of cyclosporine, which inhibits production of the immunostimulatory molecule IL-2 by helper-inducer T lymphocytes (CD4+) and the mercaptopurine analogue azathioprine. Azathioprine is metabolized by the purine degradative pathway to uric acid via the action of xanthine oxidase. Thus, coadministration of the xanthine oxidase inhibitor allopurinol could interfere with drug catabolism and lead to a dangerously toxic effect of a given dose of azathioprine.
- IX-46. The answer is B.** (*Chap. 271. Pastan, Bailey, N Engl J Med 338:1428–1437, 1998.*) Peritonitis is the most common serious complication of peritoneal dialysis. Patients typically present with abdominal pain, fever, and a cloudy peritoneal dialysate. Persistent or recurrent peritonitis may require the removal of the catheter. Further complications include losses of amino acids as well as albumin, which may be as much as 5 to 15 g/d. In addition, patients can absorb glucose through the peritoneal dialysate, resulting in hyperglycemia not hypoglycemia. The resulting hyperglycemia can cause a hypertriglyceridemia, especially in patients with diabetes mellitus. Leakage of the dialysate fluid into the pleural space can also occur and can be diagnosed by analysis of the pleural fluid, which typically has an elevated glucose concentration. Rapid fluid shifts are uncommon with peritoneal dialysis, and this approach may be favored for patients with congestive heart failure or unstable angina.
- IX-47. The answer is E.** (*Chaps. 275, 317. Jennette, Falk, N Engl J Med 337:1512–1523, 1997.*) The patient in question has Churg-Strauss syndrome. Churg-Strauss syndrome has three phases: allergic rhinitis with asthma and eosinophilia; eosinophilic infiltrative disease such as eosinophilic pneumonia; and systemic small-vessel vasculitis. The vasculitic phase usually develops within 3 years of onset of asthma. Approximately 70% of patients with Churg-Strauss syndrome have ANCA. The antibodies are usually perinuclear and not cytoplasmic, consistent with antimyeloperoxidase (MPO-ANCA) antibodies. The cytoplasmic ANCA antiproteinase-3 is typically found in Wegner's granulomatosis. Many patients with Churg-Strauss syndrome develop an eosinophilic pneumonia or evidence of eosinophilic infiltrative disease. In addition, patients can develop gastroenteritis, coronary arteritis, and myocarditis, which are the principal causes of morbidity and mortality, resulting in over 50% of deaths. In addition, patients often complain of frequent neuropathy.
- IX-48. The answer is C.** (*Chap. 49. Adroge, Madias, N Engl J Med 342:1581–1589, 2000.*) There is no definitive consensus on the optimal treatment of patients with symptomatic hyponatremia. The correction of the hyponatremia should be sufficient to reverse the clinical manifestations associated with it. In this situation, the patient is obtunded and confused with significant neurologic compromise. Even seizures can be induced by hyponatremia and can be stopped by rapid increases of the serum sodium. However, one must be cautious to avoid the catastrophic development of osmotic demyelination. In this situation the patient's total-body water is 34 L (0.5×68). The planned treatment should increase the serum sodium by 1 mmol/L per hour, and this is best accomplished with hypertonic saline. A liter of 3% saline will increase the serum sodium by 11.4 mmol/L [$(513 - 114) \div$

$(34 + 1) = 11.4$]. A rise of 3 mmol/L over 3 h corresponds to approximately 0.27 L ($3 \div 11.4$), or approximately 90 mL/h.

- IX-49. The answer is C.** (*Chap. 270. Brater, N Engl J Med 339:387–395, 1998.*) Several mechanisms result in decreased diuretic response in patients with nephrotic syndrome. These include diminished nephron response to the diuretics as well as binding of the diuretic to urinary protein. However, in most patients with nephrotic syndrome as well as those with cirrhosis, renal tubular secretion of furosemide is normal, unless the patient has significant renal insufficiency. In addition, patients with nephrotic syndrome have an increase of both proximal and distal reabsorption of sodium. These factors can be overcome by higher doses and more frequent administration of loop diuretics. In addition, the addition of a thiazide diuretic may also enhance efficacy. If these strategies fail and the patient has severe hypoalbuminemia [<20 g/L (2g/dL)], a trial of a loop diuretic with albumin can be tried.
- IX-50. The answer is C.** (*Chap. 271. Pastan, Bailey, N Engl J Med 338:1428–1437, 1998.*) Hypotension is the most common acute complication after hemodialysis. Numerous factors appear to increase the risk of hypotension, including excessive ultrafiltration with inadequate compensatory vascular filling. In addition, patients often have impaired vasoactive or autonomic responses, especially those patients with long-standing diabetes mellitus. In addition, patients may also have impaired cardiac reserve, and most patients are on significant hypertensive therapy, which in the setting of increased ultrafiltration may lead to a more rapid precipitation of hypotension.
- Although less common, food ingestion during or shortly after hemodialysis can also lead to hypotension secondary to vascular redistribution. The temperature of the dialysate seems also to be important in the regulation of blood pressure. Temperatures of 37°C may cause heat retention and vasodilation. Low temperature dialysates often cause an increase in vascular resistance. Hyperkalemia, hypokalemia, or hypocalcemia, but not hyperphosphatemia, are associated with hypotension.
- IX-51. The answer is A.** (*Chap. 279. Preminger, Semin Nephrol 12:200–216, 1992.*) The differential diagnosis of calcium renal calculi is broad and includes idiopathic hypercalciuria. Calcareous calculi represent approximately 75% of all renal stones; the remaining 25% of the renal calculi are noncalcareous and are composed of either uric acid struvite or cystine. Calcareous calculi are composed of either calcium oxalate or calcium phosphate. The causes of calcareous stone formation include hypercalciuria, hyperoxaluria, hyperuricosuria, hypomagnesuria, and hypocitruria. The association of hypercalciuria with recurrent calcium nephrolithiasis has long been recognized. Of the variety of causes of hypercalciuria, the most common is absorptive hypercalciuria. This results in an increase in intestinal calcium absorption and therefore an increased filtered load. The exact cause of the hyperabsorption is unknown, and it is thought that this process develops through a vitamin D-independent pathway. Most patients with this process have a normal serum calcium level, a normal serum parathyroid level, and a normal fasting 24-h urinary calcium level. Primary hyperparathyroidism can be diagnosed from an elevated serum calcium level with an elevated serum parathyroid level. In addition, patients typically have elevated fasting 24-h urinary calcium levels. Normal serum calcium and a normal 24-h urinary calcium make the diagnosis of primary hyperparathyroidism unlikely. Hyperoxaluria is typically secondary to inflammatory bowel disease or dietary overindulgence in oxalate-rich foods, but it may also be caused by an excessive amount of vitamin C ingestion. This is thought to cause stone formation because of reduced urinary output due to fluid losses from the intestinal tract. The resultant hypocitruria caused by hypokalemia as well as metabolic acidosis in addition to low urinary magnesium concentrations may also cause stone formation. Hypocitruria is a common finding but remains uncommon as a sole etiologic cause of recurrent nephrolithiasis. The use of thiazide diuretics decreases the urinary calcium excretion and therefore decreases the frequency of calcium stone formation.

This page intentionally left blank.

X. DISORDERS OF THE GASTROINTESTINAL SYSTEM

QUESTIONS

DIRECTIONS: Each question below contains five suggested responses. Choose the **one best** response to each question.

X-1. A 56-year-old woman has had profuse watery diarrhea for 3 months. Laboratory studies of fecal water show the following:

Sodium: 39 mmol/L
Potassium: 96 mmol/L
Chloride: 15 mmol/L
Bicarbonate: 40 mmol/L
Osmolality: 270 mosmol/kg H₂O (serum osmolality: 280 mosmol/kg H₂O)

The most likely diagnosis is

- (A) villous adenoma
- (B) lactose intolerance
- (C) laxative abuse
- (D) pancreatic insufficiency
- (E) nontropical sprue

X-2. A 56-year-old man presents to his internist with jaundice. The patient is receiving no medication, and his only symptomatic complaint is mild fatigue over the past 2 months. Physical examination is remarkable only for the presence of scleral icterus. The patient has no significant past medical history. Analysis of serum chemistry reveals the following:

SGOT: 0.58 μ kat/L (35 U/L)
SGPT: 0.58 μ kat/L (35 U/L)
Total bilirubin: 91.7 μ mol/L (7 mg/dL)
Direct bilirubin: 85.5 μ mol/L (5 mg/dL)
Alkaline phosphatase: 12 μ kat/L (720 U/L)

Which of the following is the next most appropriate diagnostic step?

- (A) CT of the abdomen
- (B) Liver biopsy
- (C) Review of peripheral blood smear
- (D) Endoscopic retrograde cholangiopancreatography (ERCP)
- (E) No further evaluation necessary; the patient has Dubin-Johnson syndrome

X-3. A 24-year-old patient known to be infected with HIV-1 presents with a 2-week history of intermittent bloody diarrhea, urgency, abdominal pain, and malaise. Stool culture for enteropathogenic organisms is negative, and analysis for ova and parasites is similarly unrevealing. The patient is taking no medication. The diarrheal symptoms do not respond to a course of trimethoprim-sulfamethoxazole. Colonoscopic examination reveals multiple areas of ulceration and mucosal erosion. Biopsy reveals the presence of cells containing a large, densely staining nucleus and abundant intracytoplasmic inclusions. The most appropriate therapy for this patient is

- (A) pentamidine
- (B) pyrimethamine
- (C) ganciclovir
- (D) acyclovir
- (E) isoniazid

X-4. A 48-year-old woman develops fevers, chills, and icteric sclera. In addition to a fever of 39.2°C (102.5°F), the physical examination is remarkable for an ill-appearing jaundiced female with right upper quadrant pain. Ultrasonography reveals a dilated common bile duct with stones in the gallbladder and in the duct itself. The patient is placed on broad-spectrum antibiotics to cover organisms known to infect the biliary tract. The procedure most appropriate now is

- (A) laparotomy to cannulate the common bile duct, remove the stone, and perform a cholecystectomy
- (B) laparoscopic cholecystectomy
- (C) placement of an external stent for biliary drainage
- (D) endoscopic retrograde cholangiopancreatography
- (E) antibiotics for several days

X-5. A 45-year-old man says that for the past year he occasionally has regurgitated food particles eaten several days earlier. His wife complains that his breath has been foul-smelling. He has had occasional dysphagia for solid foods. The most likely diagnosis is

X-5. (Continued)

- (A) gastric outlet obstruction
- (B) scleroderma
- (C) achalasia
- (D) Zenker's diverticulum
- (E) diabetic gastroparesis

X-6. A 57-year-old man seeks attention in the emergency department for weakness and melena, which he has had for 3 days. He says he has not had significant abdominal pain and had no prior gastrointestinal bleeding. On examination he is disheveled and unshaven, appears older than his stated age, and has a 20 mmHg orthostatic drop in blood pressure. Findings include bilateral temporal wasting, anicteric and pale conjunctivae, spider angiomas on his upper torso, muscle wasting, hepatosplenomegaly, and hyperactive bowel sounds without abdominal tenderness to palpation. Stool is melanic. Nasogastric aspiration reveals "coffee-grounds" material, which quickly clears with lavage. Hematocrit is 30 percent, and mean corpuscular volume is 105 fL. Saline gastric lavage is initiated. The appropriate next step in the management of this man's illness would be to

- (A) perform gastroscopy
- (B) pass a Sengstaken-Blakemore tube and begin an intravenous infusion of vasopressin (Pitressin)
- (C) order an upper gastrointestinal series
- (D) order immediate visceral angiography
- (E) insert a large-bore intravenous line and type and cross-match the man's blood

X-7. A 42-year-old woman presents with a complaint of watery diarrhea and abdominal pain that has occurred intermittently over the past 4 years. After the passage of three or four loose stools in the morning, she feels well for the rest of the day and never has nocturnal diarrhea. Physical examination reveals an anxious woman with a tender left lower abdominal quadrant and no fecal material in the rectum; the results are otherwise normal. Sigmoidoscopic examination discloses excess mucus, but the mucosa appears normal. Barium enema is normal except for sigmoid spasticity, and examination of a stool specimen reveals well-formed feces that are negative for blood, pathogenic bacteria, and parasites. Results of thyroid studies are normal. A trial of milk restriction results in no change in symptoms. At this point the physician should

- (A) consider a trial of diphenoxylate or loperamide to control symptomatic diarrhea
- (B) tell the patient that her symptoms are largely emotional in origin
- (C) consider a trial of psyllium to increase stool bulk
- (D) obtain stool electrolytes and osmolality
- (E) perform a jejunal aspirate and analyze the fluid for parasites

X-8. Which of the following statements about achalasia is correct?

- (A) The underlying abnormality appears to be defective innervation of the esophageal body and lower gastric sphincter
- (B) Dysphagia, chest pain, and regurgitation are the predominant symptoms
- (C) Chest x-rays often reveal a large gastric air bubble
- (D) Manometry reveals a normal or elevated pressure of the lower gastric sphincter
- (E) Omeprazole is effective in controlling the symptoms in many patients

X-9. A 45-year-old man presents with sharp epigastric pain relieved by antacids and food. Barium study of the upper gastrointestinal tract reveals a crater in the proximal portion of the duodenal bulb. Which of the following statements concerning therapeutic alternatives is correct?

- (A) Atropine or related anticholinergic agents are effective in improving the symptoms
- (B) Sucralfate is effective in eradicating *Helicobacter pylori* colonization
- (C) Cimetidine or other H₂-receptor antagonists are more effective than sucralfate in promoting healing
- (D) Sucralfate can significantly reduce the bioavailability of fluoroquinolone antibiotics
- (E) Omeprazole, a specific inhibitor of parietal cell H⁺, K⁺-ATPase, is contraindicated in routine situations because of its carcinogenic potential

X-10. A 75-year-old woman with a history of aspirin-induced gastritis 5 years ago now has severe knee and hip pain that is thought to be due to osteoarthritis. She requires treatment with nonsteroidal anti-inflammatory agents. Which of the following agents would be most helpful for prophylaxis against recurrent gastrointestinal bleeding?

- (A) Omeprazole
- (B) Misoprostol
- (C) Nizatidine
- (D) Sucralfate
- (E) Atropine

X-11. Four months ago, a 36-year-old man with a peptic ulcer underwent a Billroth II anastomosis, antrectomy, vagotomy, and gastrojejunostomy. He now returns for evaluation of a stomal (anastomotic) ulcer. Fasting serum gastrin level is 350 ng/L; 5 min after the intravenous infusion of secretin the serum gastrin level is 200 ng/L. The man should be advised that the most appropriate treatment for his condition is

- (A) total vagotomy
- (B) total gastrectomy
- (C) resection of the distal antrum attached to the duodenal stump

X-11. (Continued)

- (D) laparotomy to search for a gastrin-producing tumor
- (E) medical therapy with liquid antacids

X-12. Which of the following statements regarding eosinophilic enteritis is correct?

- (A) Peripheral blood eosinophilia is rare.
- (B) It affects only the small intestine.
- (C) The majority of patients have a history of food allergies or asthma.
- (D) Treatment with glucocorticoids is not indicated.
- (E) It may be difficult to distinguish from regional enteritis.

X-13. Which of the following diagnostic studies for malabsorption is usually normal in persons who have bacterial overgrowth syndrome?

- (A) Fecal fat quantitation (24 h)
- (B) Stage II Schilling test (intrinsic factor given with vitamin B₁₂)
- (C) D-Xylose absorption test
- (D) Lactulose breath test
- (E) Quantitative cultures of jejunal aspirates

X-14. A 30-year-old man complains of abdominal cramps, bloating, and diarrhea. He believes that these symptoms are exacerbated after the ingestion of dairy products. He is otherwise well and has no abnormalities on physical or laboratory examination. Which is the most specific and sensitive measurement to diagnose this patient's condition?

- (A) Breath hydrogen after ingestion of 50 g lactose
- (B) Blood glucose after ingestion of 100 g lactose
- (C) Breath labeled carbon dioxide after ingestion of oral glycine-1-[¹⁴C] glycocholate
- (D) Urine xylose after ingestion of 25 g D-xylose
- (E) Vitamin A serum level

X-15. A 72-year-old woman with known mitral stenosis and atrial fibrillation presents with severe abdominal pain. The pain began fairly suddenly 24 h ago and was located in the periumbilical region; however, today the pain is present throughout the abdomen. Other than the aforementioned cardiac disease, the past medical history is unremarkable. Her only medication is digoxin 0.25 mg/d. Physical examination reveals an anxious patient with a temperature of 38.3°C (101°F) orally, blood pressure of 100/60, pulse of 120, and respiratory rate of 26. Her skin is cold and clammy. The oral mucosa is dry. Cardiac auscultation is remarkable for a grade 2/4 diastolic rumble. Bowel sounds are normal. There is mild abdominal distention and tenderness without rebound. Stool is guaiac-positive but not grossly bloody or melenic. Initial laboratory evaluation reveals a WBC of 16,000/ μ L with a dif-**X-15.** (Continued)

ferential of 75% neutrophils, 10% bands, 10% lymphocytes, and 5% monocytes; hematocrit of 42%; and platelet count of 522,000/mL. Plain film of the abdomen reveals air-fluid levels. The most appropriate diagnostic maneuver at this time is

- (A) exploratory laparotomy
- (B) laparoscopy
- (C) angiography
- (D) CT of the abdomen
- (E) upper GI series with small bowel follow-through

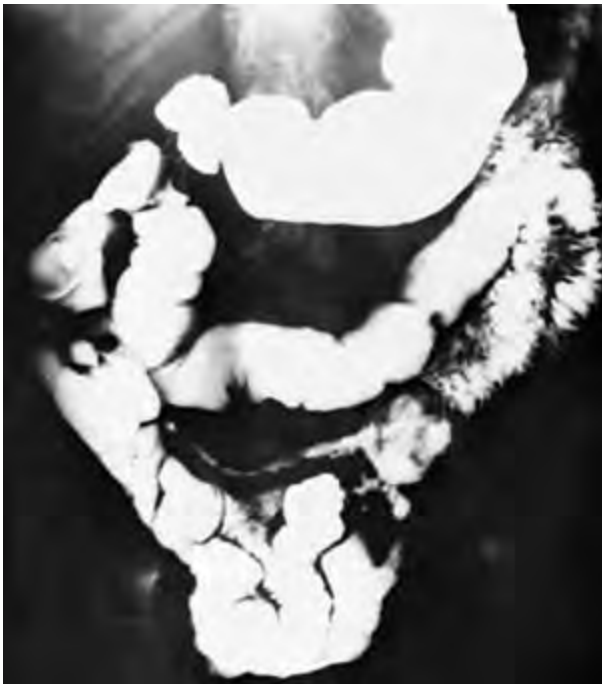X-16. A 70-year-old Irish consular official seeks local medical attention for diarrhea and weight loss, which have been present for 2 years. He says he has always been in good health "even though I'm the runt of the litter" (he is the smallest of eight siblings). Laboratory studies include normal complete blood cell count and serum electrolyte concentrations. Serum D-xylose concentration is 0.76 mmol/L (15 mg/dL) 2 h after an oral challenge, and 24-h fecal fat determination is 12 g on a 100-g fat diet. A representative biopsy specimen of his jejunum is shown below. Which of the following statements about the man's illness is correct?

- (A) This condition is believed to be due to a gram-negative bacillus.
- (B) Abdominal pain, arthralgia, low-grade fever, and lymphadenopathy are frequently present.
- (C) Glucocorticoid therapy is the treatment of choice.
- (D) Adherence to a strict gluten-free diet usually results in normalization of malabsorption tests and reversal of jejunal pathology.
- (E) A rebiopsy after gluten challenge is indicated at this time.

X-17. A 28-year-old man has had diarrhea and crampy abdominal pain of the right lower quadrant for the past 4 weeks. During the past 10 days he also has had episodic low-grade fever, abdominal distention, and anorexia without vomiting but leading to a weight loss of 3.2 kg (7 lb). On examination, he is mildly uncomfortable. Vital signs

X-17. (Continued)

are temperature 37.8°C (100.1°F), pulse 100 beats per minute, and blood pressure 110/60 mmHg. His sclerae are anicteric, and there is no palpable lymphadenopathy. A tender, indistinct fullness is palpable in the right lower quadrant of the abdomen, but otherwise the abdomen is soft and without rebound tenderness or palpable hepatosplenomegaly. Rectal examination reveals no masses or focal tenderness, but the stool is guaiac-positive. Laboratory values include a hematocrit of 30% and a white blood cell count of 11,300/ μL with a shift to the left. Flat-plate and upright x-rays of the abdomen show some air-filled loops of small bowel but no air-fluid levels. Sigmoidoscopy is unremarkable. On barium enema examination, barium fails to reflux into the terminal ileum, but the colon is otherwise normal. A representative film from a small-bowel barium examination is shown below. Which of the following disorders is most consistent with the clinical picture described?



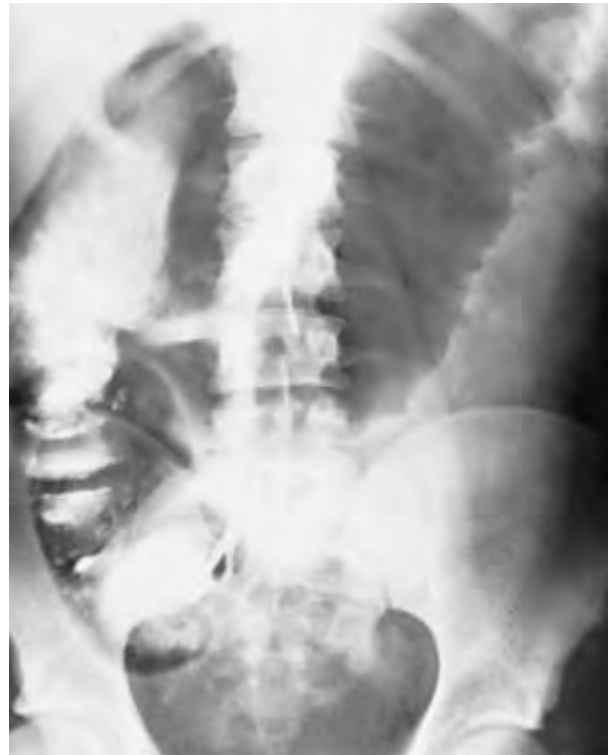- (A) Perforated appendix with appendiceal abscess
- (B) Whipple's disease
- (C) Regional enteritis
- (D) Adenocarcinoma of the small intestine
- (E) Lymphoma of the small intestine

X-18. A 20-year-old man was found to have ulcerative proctitis 2 years ago. Mild rectal bleeding was well controlled on daily steroid enemas, which were discontinued a year ago. For the past 3 months he has had increasingly frequent bloody diarrhea (now 6 to 10 times a day), lower abdominal cramps, low-grade fever, anorexia, and a 5-kg (11-lb) weight loss. Physical examination of this thin, pale young man, who appears acutely ill, reveals these vital

X-18. (Continued)

signs: temperature 37.8°C (100°F), pulse 110 beats per minute, and blood pressure 120/70 mmHg. The lower abdomen is mildly and diffusely tender, but there is no rebound tenderness and bowel sounds are active. Stool is grossly bloody. Sigmoidoscopy, limited to 10 cm because of discomfort, shows marked mucosal erythema and friability; diffuse ulceration is present, and an exudate contains pus and blood.

Three hours after a barium enema, which shows ulcerations throughout the colon, the man's abdominal pain worsens markedly. Vital signs now are temperature 39.6°C (103.2°F), pulse 130 beats per minute, and blood pressure 90/60 mmHg. On examination the abdomen is distended and diffusely tender with rebound; bowel sounds are infrequent. An abdominal flat-plate x-ray is pictured below.



The most likely diagnosis for the disorder described above is

- (A) acute colonic perforation
- (B) inferior mesenteric artery occlusion
- (C) nonthrombotic mesenteric ischemia
- (D) volvulus
- (E) toxic megacolon

X-19. For the past 6 months a 50-year-old man has had diarrhea and migratory arthralgias and has lost 9.1 kg (20 lb). An upper gastrointestinal barium study shows a malabsorption pattern in the small bowel. Stool fat content is 35 g per 24 h. After oral administration of 25 g of D-xylose, a 5-h urine collection contains 0.8 g of

X-19. (Continued)

D-xylose. A peroral small-bowel biopsy reveals subtotal villus atrophy, dilated lymphatics, and infiltration of the lamina propria with macrophages that stain positively with periodic acid–Schiff (PAS) stain. The man's physician should now

- (A) start him on a gluten-free diet
- (B) prescribe prednisone, 60 mg/d and tapered over 2 months
- (C) prescribe prednisone, 60 mg/d indefinitely
- (D) prescribe trimethoprim-sulfamethoxazole for at least 1 year
- (E) recommend an exploratory laparotomy with splenectomy and biopsy of retroperitoneal nodes

X-20. As a consequence of severe liver damage, hepatic amino acid handling is deranged. In this situation, plasma levels of which of the following are likely to be lower than normal?

- (A) Ammonia (NH_3)
- (B) Ammonium (NH_4^+)
- (C) Alanine
- (D) Urea
- (E) Glycine

X-21. A 50-year-old man without significant past medical history or recent exposure to alcohol presents with mid-epigastric abdominal pain, nausea, and vomiting. The physical examination is remarkable for the absence of jaundice and any other specific physical findings. Which of the following is the best strategy for screening for acute pancreatitis?

- (A) Measurement of serum amylase
- (B) Measurement of serum lipase
- (C) Measurement of both serum amylase and serum lipase
- (D) Isoamylase level analysis
- (E) Magnetic resonance imaging

X-22. Which of the following statements regarding primary biliary cirrhosis (PBC) is correct?

- (A) A positive anti-pus antibody test is present in more than 90 percent of these patients.
- (B) Glucocorticoid treatment is helpful.
- (C) The majority of these patients are men.
- (D) Administration of D-penicillamine appears to be an effective treatment.
- (E) Rheumatoid arthritis, CREST syndrome, and scleroderma occur with increased frequency in patients with PBC.

X-23. A 19-year-old female exchange student from London has had bouts of jaundice, fever, malaise, arthralgias, and marked elevation of hepatic transaminases over the past 6 months. The patient was not exposed to hepatotoxic

X-23. (Continued)

drugs. Hypergammaglobulinemia has been noted. Serologic evaluation for infection with hepatitis A, B, and C has been negative, as have tests for systemic lupus. Liver biopsy now reveals bridging necrosis. Which of the following tests will be most helpful in confirming the diagnosis?

- (A) Rheumatoid factor
- (B) Hemoglobin electrophoresis
- (C) Antibodies to liver and kidney microsomal antigens
- (D) Antibodies to hepatitis D virus
- (E) Antibodies to hepatitis E virus

X-24. Which of the following is an important physiologic function of bile acids?

- (A) Conjugation with toxic substances, thus allowing their excretion
- (B) Allowing the excretion of hemoglobin breakdown products
- (C) Aiding the absorption of vitamin B_{12}
- (D) Facilitating absorption of dietary fats
- (E) Maintaining appropriate intestinal pH

X-25. A 37-year-old man with chronic alcoholism is admitted to the hospital with acute pancreatitis. On the third hospital day sudden, complete blindness develops in the left eye. The most likely explanation is

- (A) alcohol withdrawal symptoms
- (B) transient ischemic attack (transient monocular blindness)
- (C) occlusion of the retinal vein
- (D) acute glaucoma
- (E) Purtscher's retinopathy

X-26. In which one of the following situations would therapy with oral chenodeoxycholic acid be most effective in dissolving gallstone(s)?

- (A) A 27-year-old Asian woman with thalassemia
- (B) A 49-year-old woman with two 2-cm stones
- (C) A 60-year-old man with gallstones visible on chest x-ray
- (D) A 45-year-old woman with a history of gallstone pancreatitis and a residual 1-cm radiolucent gallstone
- (E) A 55-year-old man with a history of biliary colic, several small gallstones seen on ultrasonography, and a poorly opacified gallbladder after oral cholecystography

X-27. Which of the following could falsely depress the serum amylase level in a patient suspected of having acute pancreatitis?

- (A) Hypertriglyceridemia
- (B) Hypercholesterolemia

X-27. (Continued)

- (C) Hypocalcemia
- (D) Associated pleural effusion
- (E) Associated intestinal infarction

X-28. Mechanical obstruction of the colon is most commonly caused by

- (A) adhesions
- (B) carcinoma
- (C) volvulus
- (D) hernia
- (E) sigmoid diverticulitis

X-29. In which of the following causes of fatty liver is microvesicular fat seen in biopsy specimens of liver?

- (A) Jejunioileal bypass for morbid obesity
- (B) Acute fatty liver of pregnancy
- (C) Total parenteral nutrition
- (D) Prolonged intravenous hyperalimentation
- (E) Carbon tetrachloride poisoning

X-30. A 35-year-old woman complains of right upper quadrant pain, which occurs after she eats a large meal. Occasionally the episodes are accompanied by nausea and vomiting. A plain x-ray of the abdomen discloses gallstones. Ultrasonography reveals gallstones and a normal-sized common bile duct. The patient's blood chemistry and CBC are normal. The most therapeutic maneuver at this time would be

- (A) observation
- (B) laparoscopic cholecystectomy
- (C) ursodeoxycholic acid
- (D) shock wave lithotripsy
- (E) ursodeoxycholic acid and shock wave lithotripsy

X-31. A 22-year-old woman with a history of ulcerative colitis presents with jaundice, pruritus, and intermittent right upper quadrant abdominal pain. The most likely finding on ERCP is

- (A) malignant stricture of the common bile duct
- (B) stones in the common bile duct
- (C) normal findings
- (D) diffuse strictures
- (E) blocked ampula of Vater

X-32. One month ago, a 21-year-old woman was begun on daily isoniazid therapy because of a positive tuberculin skin test. She now feels well, and her physical examination is unremarkable. Routine laboratory data include the following: serum alanine aminotransferase (ALT) 2.5 $\mu\text{kat/L}$ (150 Karmen units/mL), total bilirubin 17 $\mu\text{mol/L}$ (1.0 mg/dL), and alkaline phosphatase 25 units. The most appropriate action by the woman's physician would be to order

X-32. (Continued)

- (A) another antituberculous drug
- (B) glucocorticoids
- (C) a liver biopsy
- (D) an ultrasound of the gallbladder
- (E) continuation of isoniazid therapy

X-33. A 45-year-old man with Laennec's cirrhosis and a history of hepatic encephalopathy comes to the local emergency room because of alcoholic intoxication. Physical examination is remarkable for palmar erythema, spider angiomas, and bilateral gynecomastia. Liver span is 8 cm, and the edge cannot be felt; a spleen tip, however, is palpable. Stool is guaiac-negative. He has no asterixis. Laboratory studies include the following:

Hematocrit: 38%

Mean corpuscular volume: 104 fL

White blood cell count: 4000/ μL

Platelet count: 97,000/ μL

Prothrombin time: 17.5 s

Total serum bilirubin: 14 $\mu\text{mol/L}$ (0.8 mg/dL)

Serum aspartate aminotransferase (AST): 0.5 $\mu\text{kat/L}$
(30 U/L)

Serum alkaline phosphatase: 1.0 $\mu\text{kat/L}$ (60 U/L)

The man is given intravenous hydration and vitamin and mineral supplements, including folic acid (1 mg), thiamine (100 mg), magnesium (2 g), and vitamin K (10 mg). After spending the night in the hospital's detoxification unit, he awakens sober and alert. Repeat prothrombin time is 12 s. The most likely explanation for the elevation in the man's initial prothrombin time is

- (A) alcoholic hepatitis
- (B) folate deficiency
- (C) intestinal malabsorption
- (D) disseminated intravascular coagulation
- (E) laboratory error

X-34. A 67-year-old woman who has previously been healthy undergoes emergency surgery for a ruptured abdominal aortic aneurysm. Intraoperatively she requires 8 units of packed red blood cells to maintain her blood pressure and hematocrit. After surgery she is hemodynamically stable. On the third postoperative day she appears jaundiced, but abdominal examination is unremarkable and she is afebrile. Total serum bilirubin concentration at this time is 141 $\mu\text{mol/L}$ (8.3 mg/dL) [direct, 107 $\mu\text{mol/L}$ (6.3 mg/dL)]. Serum alkaline phosphatase level is 6 $\mu\text{kat/L}$ (360 U/L), and serum AST level is 0.85 $\mu\text{kat/L}$ (51 Karmen units/mL). The most likely explanation for the woman's jaundice is

- (A) a stone in the common bile duct
- (B) halothane hepatitis
- (C) posttransfusion hepatitis

X-34. (Continued)

- (D) acute hepatic infarct
- (E) benign intrahepatic cholestasis

X-35. A 35-year-old former hemodialysis nurse is seen because of a 6-month history of fatigue and amenorrhea. On examination she has scleral icterus, a mildly tender liver, and a tibial rash consistent with erythema nodosum. ALT and AST levels are both in the range of 1.5 μ kat/L (100 U/L) and bilirubin is 51.3 μ mol/L (3 mg/dL), while alkaline phosphatase and serum albumin levels are normal. Hepatitis serologic testing detects HBsAg and IgG anti-HBcAg. Liver biopsy discloses a mononuclear cell portal infiltrate and hepatocyte destruction at the periphery of lobules. Which of the following therapeutic strategies is best?

- (A) Administration of low-dose cyclophosphamide, 50 mg/d for 2 months
- (B) Administration of prednisone, 20 to 40 mg/d for 2 months and then a taper based on the response
- (C) Administration of prednisone, 10 mg every other day for 3 months
- (D) Administration of acyclovir, 400 mg every 6 h for 2 weeks
- (E) Administration of interferon α , 10 million units three times per week for 4 months

X-36. A 64-year-old man with insulin-dependent adult-onset diabetes mellitus seeks emergency medical treatment after 2 days of increasingly severe abdominal pain in the right upper quadrant that has spread over the entire abdomen and is associated with nausea, vomiting, fever, and chills. On examination, he is alert and oriented but appears to be quite acutely distressed. Vital signs are temperature 39.4°C (103°F), pulse 140 beats per minute, and blood pressure 100/60 mmHg. His sclerae are mildly icteric. His abdomen is diffusely tender with marked guarding in the right upper quadrant; there is no palpable hepatosplenomegaly, and there are no audible bowel sounds. Rectal examination reveals no focal tenderness; stool is guaiac-negative. Laboratory values are as follows:

Hematocrit: 34%

White blood cell count: 22,500/ μ L with a marked left shift

Plasma glucose: 17.8 mmol/L (325 mg/dL)

Blood urea nitrogen: 10.5 μ mol/L (30 mg/dL)

Serum AST: 2.1 μ kat/L (125 Karmen units/mL)

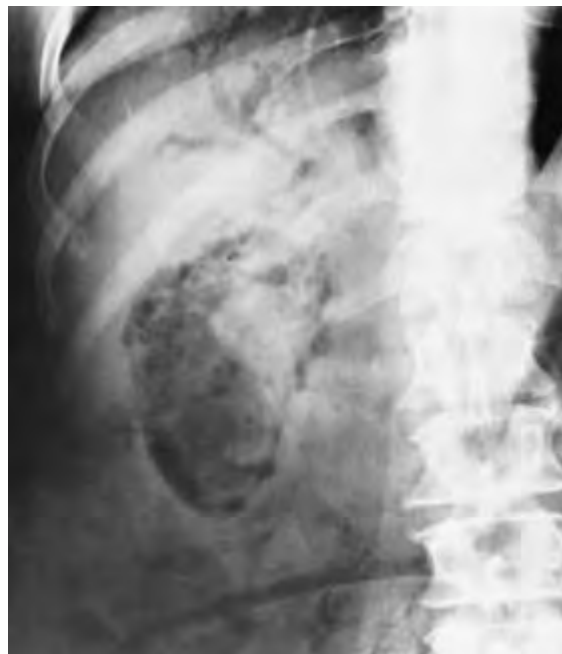Serum alkaline phosphatase: 210 units

Serum amylase: 3.3 μ kat/L (200 U/dL)

His abdominal flat-plate x-ray is shown below. During the first 4 h of hospitalization the man's condition is stabilized somewhat by the administration of intravenous fluids and insulin. A nasogastric tube is inserted, blood cultures are drawn, and he is begun on broad-spectrum antibiotics.

X-36. (Continued)

The most appropriate management at this point would be to order



- (A) conservative medical measures only for the next 48 to 72 h
- (B) an abdominal ultrasound examination
- (C) an upper gastrointestinal examination with Gastrografin dye
- (D) endoscopic retrograde cholangiopancreatography
- (E) preparations for an emergency laparotomy

X-37. Chronic active hepatitis is most reliably distinguished from chronic persistent hepatitis by the presence of

- (A) extrahepatic manifestations
- (B) hepatitis B surface antigen in the serum
- (C) antibody to hepatitis B core antigen in the serum
- (D) a significant titer of anti-smooth-muscle antibody
- (E) characteristic liver histology

X-38. A 52-year-old woman is hospitalized for medical management of severe alcoholic hepatitis. On the ninth hospital day she develops a temperature of 38.3°C (101°F) and generalized abdominal discomfort. Abdominal examination reveals a fluid wave and significant and diffuse abdominal tenderness without guarding; hepatosplenomegaly is present but is unchanged from the admission examination. Rectal and pelvic examinations reveal no area of localized tenderness; stool guaiac testing is positive. Hematocrit is 27% white blood cell count is 12,000/ μ L, and liver function tests are unchanged from admission: total serum bilirubin 214 μ mol/L (12.5 mg/

X-38. (Continued)

dL, serum AST 2.5 $\mu\text{kat/L}$ (150 Karmen units/mL), and serum alkaline phosphatase 3.0 $\mu\text{kat/L}$ (180 U/L).

The procedure most likely to yield diagnostic information in this case would be

- (A) serum amylase determination
- (B) blood culture
- (C) supine and upright x-rays of the abdomen
- (D) abdominal sonography
- (E) paracentesis

X-39. Which of the following conditions are known to predispose to the formation of cholesterol gallstones?

- (A) Hypertriglyceridemia
- (B) Hypercholesterolemia
- (C) Autoimmune hemolytic anemia
- (D) Sickle cell anemia
- (E) Surgical resection of the ileum

X-40. A 58-year-old man with biopsy-proven hepatic cirrhosis is hospitalized because of massive ascites and pedal edema. There is no evidence of respiratory compromise or hepatic encephalopathy. Initial laboratory values are as follows:

Serum electrolytes (mmol/L): Na^+ 130; K^+ 3.6; Cl^- 85; HCO_3^- 30

Serum creatinine: 88 $\mu\text{mol/L}$ (1.0 mg/dL)

Blood urea nitrogen: 6.4 $\mu\text{mol/L}$ (18 mg/dL)

Bed rest, sodium and water restriction, and the administration of spironolactone (50 mg/d) produce no significant weight change after 5 days. Which of the following therapeutic measures would be most appropriate at this time?

- (A) Intravenous furosemide, 80 mg now
- (B) Oral spironolactone, 100 mg/d
- (C) Oral acetazolamide, 250 mg/d
- (D) Placement of a peritoneovenous shunt
- (E) Therapeutic paracentesis

X-41. A 20-year-old woman with a family history of inflammatory bowel disease (IBD) presents with a history of intermittent right lower quadrant pain and diarrhea. She has lost 4.5 kg (10 lb) over the past year. Physical examination is remarkable for a thin woman who has a palpable mass in the right lower quadrant. Colonoscopy shows no evidence of rectal involvement but does show aphthous ulcerations in the proximal colon. Of the following serologic markers, which has a >50% likelihood to be elevated in this situation?

- (A) Anti-goblet cell autoantibody
- (B) Elevated titre against *Entamoeba histolytica*
- (C) Carcinoembryonic antigen

X-41. (Continued)

- (D) Antineutrophil cytoplasmic antibody
- (E) Anti-*Saccharomyces cerevisiae* antibody

X-42. 23-year-old woman with long-standing Crohn's disease has abdominal pain and an active enterocutaneous fistula. She is on mesalamine, prednisone, and azathioprine, yet her disease continues to be refractory. Infliximab is prescribed because it

- (A) inhibits T cells by inhibition of interleukin (IL) 2 production
- (B) disrupts the de novo pathway of purine metabolism in lymphocytes
- (C) is a stable form of IL-10
- (D) is a monoclonal antibody against tumor necrosis factor (TNF)
- (E) is a monoclonal antibody against neutrophils

X-43. A 52-year-old man with a history of chronic alcoholism presents with abdominal pain, nausea, and vomiting. Laboratory evaluation reveals a white blood cell count of 20,000/ μL , hematocrit of 25%, and platelet count of 130,000/ μL . Chemistry reveals an elevated lactate dehydrogenase (LDH) (three times normal) and serum calcium of 1.9 mmol/L (7.6 mg/dL). CT scanning of the abdomen reveals fluid around the pancreas. The patient is given intravenous fluids, analgesics, and nasogastric suction. Which of the following is the most appropriate additional therapy?

- (A) Imipenem
- (B) Methylprednisone
- (C) Aprotinin
- (D) Rinitidine
- (E) Toredol

X-44. A 52-year-old woman has hepatomegaly. Percutaneous liver biopsy reveals "adenocarcinoma," but the woman refuses further evaluation or treatment. A year later she presents with weight loss [13.6 kg (30 lb)] and a skin rash that has waxed and waned. Examination shows angular stomatitis and a firm, enlarged liver. An erythematous, bullous, necrotic skin rash (Plate G) is present on the face, perineum, and legs. Sonography reveals an enlarged pancreas. Hematologic testing shows that the woman is anemic. The diagnostic test of choice would be

- (A) serum amylase determination
- (B) plasma glucagon determination
- (C) plasma vasoactive intestinal polypeptide (VIP) determination
- (D) plasma gastrin determination
- (E) pancreatic arteriography

X-45. A 35-year-old woman with a history of acute lymphoblastic leukemia is seen 7 weeks after receiving an

X-45. (Continued)

allogeneic bone marrow transplant. Routine prophylaxis for graft-versus-host disease with glucocorticoids and methotrexate is being administered. She complains of midsternal pain upon swallowing. Biopsy of one of the lesions noted on endoscopy (Plate H) would reveal

- (A) lymphoblasts on a Wright's-stained smear
- (B) multinucleated giant cells on Wright's staining
- (C) hyphal forms on silver staining
- (D) small cysts on silver staining
- (E) overgrowth of bacteria on Gram's stain

X-46. Chronic reflux esophagitis is LEAST likely to result in the development of

- (A) gastrointestinal bleeding
- (B) an esophageal peptic stricture
- (C) a lower esophageal ring
- (D) Barrett's esophagus (esophagus lined by columnar epithelium)
- (E) adenocarcinoma

X-47. A patient with scleral icterus and a positive reaction for bilirubin by urine dipstick testing could have which of the following disorders?

- (A) Autoimmune hemolytic anemia
- (B) Dubin-Johnson syndrome
- (C) Crigler-Najjar type II disorder
- (D) Thalassemia intermedia
- (E) Gilbert's syndrome

X-48. Which one of these extraintestinal complications of inflammatory bowel disease is LEAST likely to be associated with ulcerative colitis?

- (A) Pericholangitis
- (B) Pyoderma gangrenosum
- (C) Arthritis
- (D) Uveitis
- (E) Oxalate kidney stones

X-49. Which of the following statements describing Meckel's diverticulum is correct?

- (A) It is the most common congenital anomaly of the digestive tract.
- (B) Mechanical obstruction resulting from stricture may occur.
- (C) In young adults inflammatory complications may produce a clinical syndrome indistinguishable from gastroenteritis.
- (D) It is usually present in the jejunum.
- (E) Barium studies are valuable in the diagnosis of diverticula associated with gastrointestinal bleeding.

X-50. Which one of the following statements about hepatitis B *e* antigen (HBeAg) is LEAST accurate?**X-50.** (Continued)

- (A) HBeAg can be detected transiently in the sera of patients ill with acute hepatitis B infection.
- (B) The presence of HBeAg in the serum is correlated with infectiousness.
- (C) The absence of HBeAg in the serum rules out chronic infection caused by the hepatitis B virus.
- (D) HBeAg is immunologically distinct from HBsAg but is genetically related to HBcAg.
- (E) The disappearance of HBeAg from the serum may be a harbinger of resolution of acute hepatitis B infection.

X-51. Which of the following statements regarding delta hepatitis virus (HDV) is correct?

- (A) HDV is a defective DNA virus.
- (B) HDV can infect only persons infected with hepatitis B virus (HBV).
- (C) The HDV genome is partially homologous with HBV DNA.
- (D) HDV infection has been found only in limited areas of the world.
- (E) Simultaneous infection with HDV and HBV results in an increased risk of the development of chronic hepatitis.

X-52. An 18-year-old man presents with 4 to 6 h of crampy abdominal pain, currently located in the right lower quadrant. Vital signs reveal a temperature of 38°C (100.4°F) and a heart rate of 100 beats per minute. Physical examination is otherwise unremarkable except for right lower quadrant tenderness on deep palpation. The WBC count is 15,000/ μ L, with a left shifted differential. The most appropriate maneuver would be

- (A) laparotomy
- (B) plane abdominal radiographs
- (C) ultrasonography
- (D) CT scanning
- (E) magnetic resonance image

X-53. Which of the following statements regarding the prophylaxis of viral hepatitis is true?

- (A) Although immune globulin (Ig) is effective in preventing clinically apparent type A hepatitis, not all Ig preparations have adequate anti-HAV titers to be protective.
- (B) If given soon enough after exposure to hepatitis B, hepatitis immune globulin (HBIg) is effective in preventing infection.
- (C) HBIg and hepatitis B vaccine can be effectively administered simultaneously.
- (D) Hepatitis B vaccine is ineffective in preventing delta hepatitis infection in persons who are not HBsAg carriers.

X-53. (Continued)

- (E) Ig prophylaxis after needle-stick, sexual, or perinatal exposure to hepatitis C is effective in preventing infection.

X-54. A 65-year-old woman presents with fatigue. She has lost about 7 kg (15 lb) over the past 6 months. Review of systems is otherwise negative. Past medical history is remarkable only for consumption of three cocktails daily for most of her adult life. The physical examination shows no specific findings. Laboratory tests reveal a WBC of 8500/ μ L, hematocrit at 35%, and platelet count of 250,000/ μ L. The bilirubin and hepatic enzymes are normal. The prothrombin time is normal. The serum alkaline phosphatase is 600 units/ μ L. Assuming that elevated alkaline phosphatase is proved to be of hepatic origin, which of the following is most likely in this patient?

- (A) Viral hepatitis
 (B) Alcoholic cirrhosis
 (C) Carcinoma of the head of the pancreas
 (D) Common bile duct stone
 (E) Non-Hodgkin's lymphoma

X-55. A 55-year-old man with long-standing reflux esophagitis has developed improvement in his heartburn. However, he also complains of progressive dysphagia after swallowing both liquids and solids. He often has chest pain with swallowing. Sometimes he can get food to pass by "bearing down." Physical examination is unremarkable, but a chest x-ray shows absence of the gastric air bubble and an air-fluid level in the mediastinum. An infusion of cholecystikinin during esophageal manometry would show

- (A) no change in lower esophageal sphincter pressure
 (B) increase in lower esophageal sphincter pressure
 (C) fall in lower esophageal sphincter pressure
 (D) rise in upper esophageal sphincter pressure
 (E) fall in upper esophageal sphincter pressure

X-56. A 40-year-old man has a history of ulcerative colitis. Features of his illness that would contribute to an increased risk of developing colon cancer include which of the following?

- (A) Disease duration of less than 10 years
 (B) History of toxic megacolon
 (C) Presence of pancolitis (total colonic involvement)
 (D) Presence of pseudopolyps on colonoscopy
 (E) High steroid requirements

X-57. Subacute ischemic colitis can best be described by which of the following statements?

- (A) Cobblestoning is noted on contrast studies.
 (B) Patients present with an acute abdomen.

X-57. (Continued)

- (C) Involvement of the rectum is common.
 (D) Symptoms and signs of nonocclusive ischemic colitis rarely resolve.
 (E) Angiography is the definitive diagnostic procedure.

X-58. Which statement regarding acute bleeding from colonic diverticula is correct?

- (A) Diverticulitis usually is present.
 (B) The source of hemorrhage is more likely to be on the left side than on the right side of the colon.
 (C) Bleeding usually becomes life-threatening.
 (D) Angiographic detection of bleeding may be helpful.
 (E) It is an uncommon cause of acute lower GI bleeding in the elderly.

X-59. A 55-year-old male smoker presents with burning epigastric pain several hours after a meal, which is relieved by antacids. Upper gastrointestinal endoscopy discloses an ulcer with a well-demarcated border at the duodenal bulb. Histologic examination of a biopsy specimen of the ulcer crater reveals eosinophilic necrosis with surrounding fibrosis without evidence of malignancy. Furthermore, analysis of a histologic section involving the gastric mucosa reveals invasion with a gram-negative rod. Which of the following is the most appropriate therapy?

- (A) Mylanta
 (B) Ranitidine
 (C) Omeprazole
 (D) Bismuth subsalicylate plus metronidazole
 (E) Omeprazole plus clarithromycin plus metronidazole

X-60. A 38-year-old male insurance agent with a benign past medical history presents to his primary care physician complaining of indigestion. He notes that "heartburn" has occurred weekly for about 1 year, especially after eating a heavy meal. He has no risk factors for coronary artery disease and does not complain of weight loss, vomiting, dysphagia, or bleeding. Physical and routine laboratory examinations are unrevealing. Which of the following is the most appropriate next step?

- (A) Upper gastrointestinal barium radiography
 (B) Upper gastrointestinal endoscopy
 (C) Ambulatory esophageal pH testing
 (D) Serology for *H. pylori*
 (E) Prescribe omeprazole

X-61. An 18-year-old man is evaluated because of weight loss and diarrhea. On examination he is found to have pedal edema and decreased breath sounds at the right lung base. A thoracentesis reveals milky fluid. Subsequent lab-

X-61. (Continued)

oratory workup reveals lymphocytopenia, hypoproteinemia, and hypogammaglobulinemia. Which of the following features would also be expected with this condition?

- (A) Neoplastic lymphocytes in the blood
- (B) Dilated and telangiectatic lymphatic vessels in the lamina propria on small-bowel biopsy
- (C) Hypergammaglobulinemia
- (D) Response to a high-fat diet
- (E) 1 g D-xylose in 5-h urine collection after 25 g oral D-xylose

X-62. A 28-year-old woman complains of chronic diarrhea. After a lengthy history and a negative physical examination, you suspect surreptitious laxative abuse. Which of the following tests would be most consistent with this hypothesis?

- (A) Abnormal osmotic gap
- (B) Fecal leukocytes noted
- (C) Excess stool fat
- (D) Charcot-Leyden crystals noted
- (E) Inflammatory cells on small bowel biopsy

X-63. A 65-year-old seemingly well-adjusted individual with benign past medical history complains of constipation (excessive straining and fewer than three lumpy bowel movements per week). The problem has lasted for several years and is nonprogressive. The physical examination and CBC are unremarkable. You should

- (A) prescribe hydration and dietary fiber
- (B) order colonoscopy
- (C) perform colonic transit test
- (D) order thyroid function tests
- (E) test stool for laxatives

X-64. A 45-year-old man presents with a history of crushing nonradiational chest pain. Electrocardiography and exercise stress testing reveal no evidence of cardiac edema. A more detailed history is taken, and the patient states that he has had a sensation of sticking after swallowing. He notes this sensation equally whether he is eating solids or liquids. The diagnosis that would most likely account for these symptoms is

- (A) achalasia
- (B) diffuse esophageal spasm
- (C) lower esophageal (Schatzki) ring
- (D) esophageal carcinoma
- (E) Zenker's diverticulum

X-65. A 35-year-old woman presents to the emergency room because of acute pain in the left upper quadrant after eating a meal. The pain radiates to the left side of the chest and has been relieved by the expulsion of flatus. The elec-

X-65. (Continued)

trocardiogram is normal, as are routine blood tests, including liver function studies. The most likely diagnosis in this case is

- (A) magenblase syndrome
- (B) splenic flexure syndrome
- (C) ingestion of beans
- (D) peptic ulcer disease
- (E) *Giardia* infection

X-66. Which of the following represents an incorrect mechanism of action for the laxative noted?

- (A) Psyllium increases stool bulk.
- (B) Docusate salts lower the surface tension of stool.
- (C) Sorbitol stimulates colonic motor activity.
- (D) Cisapride enhances intestinal transit.
- (E) Castor oil stimulates intestinal secretion.

X-67. Which of the following conditions does not cause secretory diarrhea?

- (A) Medullary carcinoma of the thyroid
- (B) Resection of the distal ileum
- (C) Zollinger-Ellison syndrome
- (D) Somatostatinoma
- (E) Carcinoid tumor

X-68. A 54-year-old man with known alcoholic cirrhosis develops worsening ascites over the course of several weeks. A diagnostic paracentesis reveals turbid fluid; protein, 50 g/L; albumin, 4.0 g/L (serum albumin, 3.5 g/L); RBC, 1000/ μ L; WBC, 5000/ μ L (mostly lymphocytes); cytology negative for neoplasm. Which of the following is the most likely cause for the patient's clinical deterioration?

- (A) New hepatic or intraabdominal neoplasm
- (B) Congestive heart failure
- (C) Worsening cirrhosis
- (D) Spontaneous bacterial peritonitis
- (E) Tuberculosis

X-69. A 66-year-old man presents with fatigue and tea-colored urine. Physical examination reveals icteric sclerae but is otherwise unremarkable. Which of the following conditions is LEAST likely to account for these findings?

- (A) Pancreatic cancer
- (B) Gallbladder cancer
- (C) Primary biliary cirrhosis
- (D) Autoimmune hemolytic anemia
- (E) Viral hepatitis

X-70. Which of the following features is more commonly associated with ulcerative colitis than with Crohn's disease?

X-70. (Continued)

- (A) Fistulas
- (B) Rectal bleeding
- (C) Segmental involvement
- (D) An abdominal mass
- (E) Mesenteric lymph node involvement

X-71. A 25-year-old Sephardic Jew from Israel presents with pleuritic chest pain, left knee pain, diffuse abdominal pain, and fever. Physical examination reveals an acutely ill individual with a temperature of 40°C (104°F). The abdomen is distended and rigid. He has had a history of similar painful attacks that last for about a day every month since he was an early teenager. Laboratory exam is remarkable for an elevated erythrocyte sedimentation rate and a white cell count of 25,000/ μL with a left-shifted differential. The best therapy to prevent further attacks is

- (A) appendectomy
- (B) sulfasalazine
- (C) prednisone
- (D) colchicine
- (E) azathioprine

X-72. Gastrointestinal complaints are common in clinical practice. Which of the following complaints is suggestive of a functional disorder?

- (A) Diarrhea at night
- (B) Acute abdominal pain
- (C) Undigested meat in the stool
- (D) Change in stool diameter
- (E) Alternating periods of diarrhea and constipation

X-73. A 55-year-old man who has complained of heartburn over the past 10 years undergoes endoscopy. The endoscopist notes a change in the appearance of the epithelium in the distal esophagus. Biopsy reveals erosion of the squamous mucosa and replacement with metaplastic columnar epithelium. Which of the following steps should be taken?

- (A) Repeat endoscopy and biopsy in 12 months
- (B) Resection of the distal esophagus
- (C) Esophageal dilation
- (D) Treatment with a beta blocker
- (E) Elevation of the head of the patient's bed

X-74. A 37-year-old woman presents for evaluation because of recurrent abdominal pain. The pain is cramping in nature and is relieved by defecation. Physical examination is unremarkable. The patient is taking enalapril for hypertension. Laboratory studies reveal normal CBC and liver function tests, except that the total serum bilirubin level is 2.5 mg/dL (42 $\mu\text{mol/L}$); the direct fraction is 0.2 mg/dL (3.7 $\mu\text{mol/L}$). The most important next step is

X-74. (Continued)

- (A) examination of the peripheral blood smear
- (B) computed tomography of the abdomen
- (C) endoscopic retrograde pancreaticoduodenography
- (D) urine dipstick test
- (E) reassurance

X-75. Which of the following cell types is most directly responsible for the excess deposition of collagen in the liver typically seen in alcoholic cirrhosis?

- (A) Kupffer cell
- (B) Hepatocyte
- (C) Stellate cell
- (D) Cannicular cell
- (E) Endothelial cell

X-76. Which of the following statements concerning gastrinoma is correct?

- (A) Most are benign.
- (B) Most are unifocal.
- (C) They are associated with multiple endocrine neoplasia (MEN) syndrome type II.
- (D) They usually secrete multiple hormones.
- (E) The secretin injection test reveals a reduction in gastrin levels.

X-77. Which of the following statements concerning the relationship of duodenal ulcer and *H. pylori* infection is correct?

- (A) Virtually all patients with a duodenal ulcer harbor *H. pylori*.
- (B) Most patients infected with *H. pylori* will develop an ulcer.
- (C) *H. pylori* invades the gastric mucosa.
- (D) The demonstration of *H. pylori* as a causative feature in a given patient with a duodenal ulcer requires biopsy.
- (E) The relapse rate for duodenal ulcer is equivalent whether *H. pylori* eradication therapy or H_2 -receptor antagonists are used.

X-78. A patient with end-stage hepatic failure due to chronic HBV infection undergoes liver transplantation. Which of the following statements regarding the risk of recurrent disease in the posttransplant setting is correct?

- (A) The likelihood of chronic infection is small.
- (B) Fulminant hepatitis due to hepatitis B never occurs.
- (C) Prophylaxis with HBIG can reduce the risk of post-transplant recurrence.
- (D) Prophylaxis with the nucleoside analogue lamivudine has no role.

X-78. (Continued)

- (E) Preoperative use of hepatitis B vaccine has been effective in reducing the risk of posttransplant recurrence.

X-79. A 25-year-old male intravenous drug abuser presents with 1 week of a flulike syndrome and 2 days of tenderness in the right upper quadrant. Examination at the time of presentation was remarkable for a fever of 38.3°C (101°F), normal vital signs, scleral icterus, and right upper quadrant pain. Laboratory examination was most notable for aminotransferases in the 3000 IU/ μ L range and a serum bilirubin of 178 μ mol/L (10 mg/dL), 50% of which was direct. During the first 3 hospital days the patient has intermittent nausea and vomiting and poor oral intake. Serologic studies reveal the presence of HBsAg and anti-HBc IgM. On the fourth hospital day the patient becomes confused. Neurologic examination is nonfocal, though the patient exhibits asterixis. He is noted to have bleeding from intravenous sites and a diminution in the size of his previously enlarged liver. His prothrombin time is 20 s and his bilirubin is now up to 510 μ mol/L.

In addition to supportive care, the most appropriate therapy for this patient is

- (A) interferon α
- (B) plasmapheresis
- (C) intravenous gammaglobulin
- (D) liver transplantation
- (E) total parenteral nutrition

X-80. A 56-year-old patient with cirrhosis of the liver presents with massive hematemesis. Two large-bore intravenous lines are placed; somatostatin, fluids, and blood products are administered; and the patient is intubated. Emergency endoscopy reveals bleeding esophageal varices. The patient becomes stable hemodynamically but is still bleeding. The most appropriate next step is

- (A) intravenous propranolol
- (B) intravenous vasopressin
- (C) balloon tamponade
- (D) endoscopic injection sclerotherapy
- (E) endoscopic variceal band ligation

X-81. A 35-year-old woman with known hepatitis C virus infection has persistently elevated hepatic transaminases and chronic fatigue as well as intermittent fever. Liver biopsy reveals a dense mononuclear infiltrate along the portal tracts with destruction of the hepatocytes at the periphery of lobules. Some hepatocellular dropout is noted to span lobules. The patient's serum contains antibodies against liver, kidney, and muscle antigens. Which of the following statements concerning the patient's treatment is correct?

X-81. (Continued)

- (A) She should receive glucocorticoids.
- (B) A successful response to interferon will be accompanied by a transient elevation in aminotransferase activity.
- (C) A good response to therapy is associated with a relatively low burden of hepatitis C virus.
- (D) Therapy may be deferred because progression to cirrhosis is unlikely.
- (E) The presence of antiliver antibodies suggests that an autoimmune process has supervened.

X-82. A 55-year-old male alcoholic has recurrent attacks of severe mid-epigastric pain after eating. Serum amylase determinations after such attacks have been in the normal range. The examination reveals mild cachexia but is otherwise unremarkable. On further questioning, the patient states that he has been sober for the past 10 years but prior to that time had multiple episodes of alcohol-induced pancreatitis. He is currently taking pancreatic replacement enzymes by mouth. An ERCP reveals a stricture of the pancreatic duct but is otherwise unremarkable. Computed tomography of the abdomen reveals calcifications in the pancreas but does not show any evidence of malignancy. The patient is taking 30 mg of continuous-release morphine sulfate twice a day. The best strategy at this point would be to

- (A) double the dose of morphine
- (B) double the dose of pancreatic replacement enzymes
- (C) resect the head of the pancreas
- (D) institute a low-fat diet
- (E) begin a continuous search for other causes of abdominal pain

X-83. The secretin-cholecystokinin test is useful in the evaluation of patients with suspected chronic pancreatitis. Which statement regarding this test is correct?

- (A) Those with chronic pancreatitis usually have a high bicarbonate output after stimulation.
- (B) Secretion of pancreatic enzymes may be measured.
- (C) In patients with early chronic pancreatitis, enzyme output is relatively more deranged than failure to achieve an adequate bicarbonate concentration.
- (D) Endocrine hormone output after stimulation is an end-point of the test.
- (E) The test can distinguish between chronic pancreatitis and pancreatic carcinoma.

X-84. A 53-year-old woman with hypertension and hypercholesterolemia presents with right upper quadrant pain and fever. Examination reveals a moderately ill-appearing woman who has a temperature of 39°C (103°F), blood pressure of 110/70, pulse of 110, and respiratory rate of

X-84. (Continued)

25. The rest of the physical examination is remarkable for scleral icterus and right upper quadrant rebound tenderness. Laboratory examination reveals a white blood cell count of 18,000 with 70% neutrophils, 10% band forms, 10% monocytes, and 10% lymphs; a hematocrit of 36.2%; and a platelet count of 522,000/ μ L. Serum chemistries are remarkable for a total bilirubin of 6 mg/dL and a direct bilirubin of 4 mg/dL; serum aminotransferases are mildly elevated, and alkaline phosphatase is two times normal. Computed tomography of the abdomen reveals dilation of the common bile duct and no other abnormalities. The next most appropriate diagnostic study is

- (A) magnetic resonance imaging
- (B) ultrasonography
- (C) liver biopsy

X-84. (Continued)

- (D) cholangiography
- (E) exploratory laparotomy

X-85. A 35-year-old woman who underwent successful therapy for acute leukemia 10 years ago is seropositive for hepatitis C. Polymerase chain reaction testing confirms the presence of virus in a blood sample. She has mildly elevated serum transaminases. A liver biopsy discloses moderately severe chronic hepatitis without fibrosis. The most appropriate therapy is

- (A) propranolol
- (B) acyclovir
- (C) ribavirin
- (D) interferon plus ribavirin
- (E) no therapy is indicated

X. DISORDERS OF THE GASTROINTESTINAL SYSTEM

ANSWERS

- X-1. The answer is A.** (*Chap. 42. Donowitz, N Engl J Med 322:725, 1995.*) In the case described, the osmolality of fecal water is approximately equal to serum osmolality. Furthermore, there is no osmotic “gap” in the fecal water; the osmolality of the fecal water can be accounted for by the stool electrolyte composition: $\{2 \times [(Na^+) + (K^+)]\} = [2 \times (39 + 96)] = 270$. A villous adenoma of the colon typically produces a secretory diarrhea. Lactose intolerance, nontropical sprue, and excessive use of milk of magnesia produce osmotic diarrheas with osmotic “gaps” caused by lactose, carbohydrates, and magnesium, respectively. Pancreatic insufficiency causes steatorrhea, not watery diarrhea.
- X-2. The answer is A.** (*Chaps. 45, 293, 294. Frank, JAMA 262:3031, 1989.*) Initial considerations in evaluating a patient with jaundice require a determination of whether the patient has primarily unconjugated hyperbilirubinemia or conjugated hyperbilirubinemia, in which case >50% of the serum bilirubin is direct-reacting. Since this patient has clear-cut conjugated hyperbilirubinemia, he may have the (solubilized) bilirubin detectable in the urine. The major differential diagnosis in this case is between impaired hepatocyte bilirubin excretion and extrahepatic biliary obstruction. In the former case, interference with the biliary excretion of bilirubin that has been previously conjugated by hepatocytes leads to the entry of this pigment into the systemic circulation. Such intrahepatic obstruction may occur in drug reactions, alcoholic hepatitis, the third trimester of pregnancy, the postoperative state, and viral or autoimmune hepatitis. In the case of the Dubin-Johnson and Rotor syndromes, the conjugated hyperbilirubinemia is due to a congenital defect in bilirubin excretion and generally is not associated with abnormalities of alkaline phosphatase or hepatic aminotransferases. Patients who have conjugated hyperbilirubinemia and abnormal liver enzymes generally fall into two groups: those whose aminotransferase elevation is dominant and who are suspected of having a hepatocellular disorder and those who have primary elevation of alkaline phosphatase and are likely to have either intra- or extrahepatic biliary obstruction. In the latter group of patients, it is imperative to rule out extrahepatic obstruction by means of ultrasonography of the right upper quadrant or abdominal CT. If the biliary ducts are not dilated on radiologic evaluation, the next most appropriate procedure would be percutaneous transhepatic cholangiogram or endoscopic retrograde cholangiopancreatography.
- X-3. The answer is C.** (*Chaps 42, 185, 308. Goodgame, Ann Intern Med 119:924, 1993.*) Diarrhea in patients with AIDS may be due to many microbiologic agents. Patients infected with HIV-1 are at risk of infection with nonopportunistic pathogens such as *Salmonella*, *Shigella*, *Campylobacter*, *Entamoeba*, *Chlamydia*, *Neisseria gonorrhoeae*, *Treponema pallidum*, and *Giardia lamblia* and are also at risk for infections that occur in the presence of immunodeficiency. Infectious agents in the latter category include protozoa such as *Cryptosporidium*, *Isospora belli*, and *Blastocystis*; bacteria such as *Mycobacterium avium-intracellulare*; and viral pathogens such as cytomegalovirus (CMV), herpes simplex virus, adenovirus, and HIV itself. CMV infection of the gastrointestinal tract may present with upper GI symptoms, nausea, vomiting, abdominal pain, or symptoms of ulcerative colitis such as bloody diarrhea. A diagnosis of CMV infection, which almost certainly represents reinfection or reactivation since affected persons are virtually always previously exposed to CMV, can be made by finding typical cytomegalic cells on histopathologic analysis.

Such cells, which provide evidence of the CMV-mediated cytopathic effect, are characterized by being large (25 to 35 μm) with a basophilic internuclear inclusion (sometimes surrounded by a clear halo—the “owl’s eye” effect) and frequently are associated with clusters of intracytoplasmic inclusions. Serious CMV-mediated gastroenteritis should be treated with ganciclovir, which may result in weight gain and improved quality of life. Foscarnet, an inhibitor of viral DNA polymerase, may be useful in cases of ganciclovir failure or intolerance. Antibacterial antibiotics, antifungal agents, antituberculous drugs, and acyclovir play no role in treating histologically proven CMV colitis.

- X-4. The answer is D.** (*Chap. 283. Brugge, Van Dam, N Engl J Med 341:1808–1816, 1999.*) Through improvements in the quality of the instruments, ERCP has become the standard for diagnosing and treating many pancreatic and biliary diseases. Accessory tools allow for cannulation and drainage of the biliary system and the implantation of stents, as well as performance of sphincterotomies and the use of baskets and balloons for the removal of stones. It is because of these capabilities that ERCP is now the preferred approach for treating patients with acute cholangitis. Biliary sphincterotomy performed by ERCP would allow extractions of stones; biliary decompression could be obtained via placement of a stent or drain across the sphincter. The complication rate using ERCP to drain the biliary tree is lower than that obtained with surgery or transhepatic drainage. The procedure should be done early in the course of the illness to reduce the patient’s eventual morbidity or mortality. ERCP also plays a major part in the diagnosis and treatment of other biliary problems including biliary strictures and malignant biliary obstruction. A tissue diagnosis can sometimes be made endoscopically (e.g., in the case of pancreatic islet cell adenomas such as Zollinger-Ellison syndrome or in insulinomas).
- X-5. The answer is D.** (*Chaps. 31, 284*) A Zenker’s diverticulum typically causes halitosis and regurgitation of saliva and food particles consumed several days earlier. When a Zenker’s diverticulum fills with food, it may produce dysphagia by compressing the esophagus. Gastric outlet obstruction can cause bloating and regurgitation of newly ingested food. Gastrointestinal disorders associated with scleroderma include esophageal reflux, the development of wide-mouthed colonic diverticula, and stasis with bacterial overgrowth. Achalasia typically presents with dysphagia for both solids and liquids. Gastric retention caused by the autonomic neuropathy of diabetes mellitus usually results in postprandial epigastric discomfort and bloating.
- X-6. The answer is E.** (*Chaps. 44, 299*) The presence of coffee-grounds material in a nasogastric aspirate from a person with melena indicates recent bleeding of the upper gastrointestinal tract. In a patient with obvious signs of cirrhosis, esophageal varices must be considered in the differential diagnosis of upper gastrointestinal bleeding; other possible diagnoses include peptic ulcer, gastroduodenitis, esophagitis, and a Mallory-Weiss tear. Before diagnostic procedures such as endoscopy and an upper gastrointestinal series are undertaken, the placement of a large-bore intravenous line and commencement of volume replacement therapy are mandatory to prevent hypotension. Moreover, blood should be typed and cross-matched in case of further bleeding. Diagnostic angiography is indicated only when brisk bleeding prevents diagnosis by endoscopy or barium study. Specific therapy for variceal bleeding—i.e., passage of a Sengstaken-Blakemore tube and intravenous infusion of vasopressin, banding, or endoscopic sclerotherapy—should be considered if diagnostic studies reveal bleeding varices.
- X-7. The answer is A.** (*Chap. 288. Lynn, Med Clin North Am 79:373, 1995.*) This presentation is classic for one of the three clinical variants of the irritable bowel syndrome, each of which is associated with abnormal colonic motility and increased visceral perception. Other groups have chronic abdominal pain and constipation or alternating constipation and diarrhea. The chronic nature of the condition and the presence of formed stool argue against a workup for secretory or osmotic diarrhea. Giardiasis, while typically occult and requiring jejunal sampling for diagnosis, usually presents with belching and pain, not

diarrhea of 4 years' duration. The absence of discernible significant organic pathology should not prompt a discussion with the patient that centers on a psychogenic cause of her problem; such an approach frequently leads to alienation of the patient. Instead, an effort to effect safe symptomatic improvement of the diarrhea with antispasmodics is worthwhile. Psyllium to increase stool bulk is a good choice for patients with irritable bowel syndrome who complain of constipation.

- X-8. The answer is B.** (*Chap. 284*) Achalasia is a motor disorder of esophageal smooth muscle in which the lower esophageal sphincter (LES) does not relax properly in response to swallowing and normal esophageal peristalsis is replaced by abnormal contractions. Manometry reveals a normal or elevated LES pressure and reduced or absent swallow-induced relaxation. A decreased number of ganglion cells are noted in the esophageal body and LES of patients with achalasia, suggesting that defective innervation of these areas is the underlying abnormality. Dysphagia, chest pain, and regurgitation are the predominant symptoms. The chest x-ray often reveals absence of the gastric air bubble, and the barium swallow reveals a dilated esophagus. Calcium channel antagonists such as nifedipine relax smooth muscle and have been effective in treating some patients. However, the mainstay of therapy remains pneumatic dilation.
- X-9. The answer is D.** (*Chap. 285. Fendrick, Ann Intern Med 123:260, 1995.*) A physician has many alternatives in deciding on a therapeutic course in a patient with a radiographically or endoscopically proven duodenal ulcer. Therapy is based on neutralization of gastric acids by antacids, inhibition of gastric acid secretion by antisecretory agents such as H₂-receptor antagonists, prostaglandins (PGE₁, PGE₂), and proton pump inhibitors (e.g., omeprazole). Drugs such as sucralfate act locally by impeding diffusion of hydrogen ions to the base of the ulcer and by binding other injurious molecules. Colloidal bismuth stimulates gastric mucosal secretion of prostaglandins and glycoprotein mucus and may eradicate *H. pylori* colonization. All patients should receive therapy to eradicate *H. pylori*. Treatment for 4 to 6 weeks with any individual member of any of the above classes probably will be sufficient to induce healing in most patients. For the average patient, maintenance therapy is not required. While there is no evidence that dietary changes are important, elimination of cigarette smoking should be undertaken. There is no evidence, for example, that cimetidine or any other related H₂-receptor antagonist is superior to sucralfate in promoting ulcer healing. Side effects among the various drug classes differ. Sucralfate is associated with a very low rate of side effects; however, it can reduce the bioavailability of the fluoroquinolone antibiotics, and so these drugs should not be used concomitantly.
- X-10. The answer is B.** (*Chap. 285. Silverstein, Ann Intern Med 123:241, 1995.*) Gastric mucosal injury, potentially resulting in ulcers and erosive gastritis, may be produced by aspirin and nonsteroidal anti-inflammatory drugs (NSAIDs) including indomethacin, ibuprofen, and naproxen. These agents may be directly toxic to the gastric mucosa by depleting protective endogenous mucosal prostaglandins. Moreover, they more directly interrupt the mucosal barrier, allowing back-diffusion of hydrogen ions as well as reducing gastric mucus secretion and increasing gastric acid secretion. The prostaglandin E₁ analogue misoprostol is effective in preventing ulcers and gastritis caused by NSAIDs. Its mechanism of action is believed to be stimulation of gastric mucus and duodenal bicarbonate secretion as well as the maintenance of the gastric mucosal barrier via epithelial cell restitution. The recently approved selective cyclooxygenase-II inhibitors such as celecoxib are much less damaging to platelets and to the gastric mucosae.
- X-11. The answer is C.** (*Chap. 285*) The causes of stomal (anastomotic) ulceration after peptic ulcer surgery include incomplete vagotomy, retained gastric antrum, the Zollinger-Ellison syndrome (gastrinoma), poor gastric emptying, ingestion of ulcerogenic drugs, and especially persistent *H. pylori* infection. In the case presented, if the previous antrectomy had been complete, the serum gastrin level should not be elevated. An elevated serum

gastrin level that declines after intravenous administration of secretin is characteristic of a retained gastric antrum attached to the duodenal stump. Neither frequent antacid therapy nor a total vagotomy is effective in healing a stomal ulcer; thus, resection of the retained antrum is indicated. In the Zollinger-Ellison syndrome, the serum gastrin level paradoxically increases after the intravenous infusion of secretin.

- X-12. The answer is E.** (*Chap. 286*) Eosinophilic enteritis is a disorder of the stomach, small intestine, colon, or all three in which some part of the gut wall is infiltrated by eosinophils. The diagnosis also requires the presence of peripheral blood eosinophilia. Although early reports emphasized the presence of food allergies, less than half these patients have a history of food allergies or asthma. The presence of anemia, Hemoccult-positive stools, abnormalities of the ileum and cecum on barium radiographic studies, and a favorable response to the administration of steroids may make eosinophilic enteritis difficult to distinguish from Crohn's disease. Although no controlled trials of glucocorticoid therapy have been performed, the symptoms usually respond to short-term glucocorticoid therapy.
- X-13. The answer is C.** (*Chap. 286*) Malabsorption caused by bacterial overgrowth results from bacterial utilization of ingested vitamins and the deconjugation of bile salts by bacteria in the proximal jejunum. Deconjugated bile salts do not form micelles in the jejunum, and long-chain fatty acids cannot be absorbed. The bacteria also separate ingested vitamin B₁₂ from intrinsic factor, thus interfering with its absorption from the ileum. The absorption of simple carbohydrates generally is not impaired, though complex carbohydrates may be metabolized by bacteria. Thus, persons with bacterial overgrowth have steatorrhea, an abnormal Schilling test (even with the administration of intrinsic factor), increased metabolism of nonabsorbable carbohydrates (e.g., lactulose), and increased bacterial concentrations in jejunal aspirates. Absorption of D-xylose, a simple carbohydrate, is often normal.
- X-14. The answer is A.** (*Chap. 286*) The incidence of isolated lactase deficiency is about 10% in the adult white population but higher in black Americans and Asians. Patients with acquired lactase deficiency have failure of normal hydrolysis of disaccharides in the brush border of intestinal epithelial cells. Common symptoms include abdominal cramps, bloating, and diarrhea after the ingestion of milk or dairy products. Since the lactose is not hydrolyzed and absorbed, an osmotic effect shifts fluid into the lumen. The symptoms are not due to an allergic reaction. Blood glucose fails to rise normally after the ingestion of an oral dose of lactose. However, this test is plagued by frequent false-positive and false-negative results. Measurement of hydrogen released after the ingestion of 50 g lactose is more sensitive and specific. Hydrogen release resulting from the action of colonic bacteria on unabsorbed lactose causes a rapid rise in breath hydrogen, indicative of a failure to absorb the disaccharide. Interestingly, patients with lactase deficiency may tolerate yogurt because of the presence of bacterial-derived lactases.
- X-15. The answer is C.** (*Chap. 289*) Occlusive acute ischemia of the small intestine may result from an arterial thrombus or embolus in the celiac or superior mesenteric arteries and occurs most commonly in patients with atrial fibrillation, artificial heart valves, or valvular heart disease. Arterial thrombosis is associated with extensive atherosclerosis, low cardiac output, or both. Acute mesenteric ischemia, such as might be caused by an embolus originating in the dilated left atrium of a patient with rheumatic valvular disease, produces colicky periumbilical pain that changes to diffuse and constant discomfort. Vomiting and diarrhea also may occur. Abdominal examination reveals mild tenderness and distention but often is not dramatic even in the face of intestinal necrosis. Mild gastrointestinal bleeding, rather than massive hemorrhage, is the rule. Abdominal films disclose air-fluid levels and distention. Barium study, if undertaken, will reveal nonspecific dilation, poor motility, and thick mucosal folds ("thumb printing") of the small intestine. Gangrene may occur with more dramatic manifestations of peritonitis, sepsis, and shock 24 to 72 h after the initial insult. When acute mesenteric ischemia is suspected, patients should undergo

immediate celiac and mesenteric angiography to localize the embolus, and then embolectomy should be performed. However, in many cases the ischemic duration has been prolonged, and at the time of surgery, resection of a segment of small bowel may be necessary. Moreover, many patients who require surgery to correct the complications of acute mesenteric ischemia are poor operative risks because of age, dehydration, sepsis, and comorbid disease.

- X-16. The answer is D.** (*Chap. 286. Trier, N Engl J Med 325:1709–1719, 1991.*) The histologic specimen pictured in the question shows villous atrophy, crypt hyperplasia, and inflammation typical of intestinal changes in nontropical sprue (celiac disease), an illness with a high incidence in Ireland. The disease, which is caused by gluten (water-insoluble wheat protein)-mediated intestinal damage, is associated with an increased incidence of histocompatibility antigens HLA-DR3 and HLA-DQw2. Although two-thirds of symptomatic cases present in childhood, the onset of the clinical symptoms of malabsorption may occur at any age. Persons with subclinical sprue during adolescence may have mild growth retardation and may be smaller than their siblings. Because the villous absorptive surface is markedly reduced in affected persons, an acquired lactase deficiency is often present and causes symptoms of milk intolerance. A strict gluten-free diet or the use of glucocorticoids in patients with refractory disease usually relieves the symptoms and signs of malabsorption and promotes the restoration of normal jejunal histology. Failure to respond to a gluten-free diet suggests alternative diagnoses such as intestinal lymphoma, and gluten challenge followed by biopsy is indicated. A malabsorptive syndrome associated with abdominal pain, arthralgias, low-grade fever, and lymphadenopathy is not typical of celiac disease and should suggest another diagnosis, such as Whipple's disease or intestinal lymphoma.
- X-17. The answer is C.** (*Chap. 287*) Radiographic demonstration of luminal narrowing, mucosal ulceration, and cobblestoning in the ileum is compatible with a diagnosis of regional enteritis. In Whipple's disease, x-rays characteristically show marked thickening of mucosal folds in the duodenum and jejunum. On barium enema, an appendiceal abscess usually presents as a mass indenting the cecal tip. Adenocarcinoma of the small bowel usually occurs as an ulcerated mass lesion in the duodenum. Infiltrating lymphomas of the distal bowel may be difficult to distinguish from regional enteritis radiographically, but stenotic bowel segments would not suggest lymphoma.
- X-18. The answer is E.** (*Chap. 287*) The clinical history and x-ray presented in the question are consistent with toxic megacolon in association with severe ulcerative colitis. Toxic megacolon is most likely to occur when hypomotility agents such as diphenoxylate and loperamide are given to persons with severe colitis or when such persons undergo a barium enema radiographic procedure. In the case presented, a barium enema was not only dangerous but in fact unnecessary, because the presence of diarrhea and signs of systemic illness indicated that the disease no longer was limited to the rectum. Colonic perforation also may be associated with severe ulcerative colitis; the presence of subdiaphragmatic air on abdominal x-rays would be suggestive.
- X-19. The answer is D.** (*Chap. 286. Relman, N Engl J Med 327:293–301, 1992.*) The man described in the question has Whipple's disease, a bowel disorder associated with dilated gut lymphatics and characterized by weight loss, abdominal pain, diarrhea, malabsorption, central nervous system manifestations, and arthralgias. Electron microscopy has revealed the presence of bacilliform bodies in the lamina propria; these rod-shaped structures, which are located within or adjacent to macrophages that contain PAS-positive granules, have been identified as the gram-negative actinomycete *Tropheryma whippelii*. The treatment of choice is at least 1 year of therapy with antibiotics; trimethoprim-sulfamethoxazole is the first-line therapy. Clinical recovery is accompanied by the disappearance of the bacilliform bodies.

- X-20. The answer is D.** (*Chap. 292*) Amino acids (except for the branched-chain amino acids leucine, isoleucine, and valine) are taken up by the liver via the portal circulation and are metabolized to urea. Severe liver damage disrupts normal amino acid metabolism and is reflected in elevated serum levels of non-branched-chain amino acids. Since urea cannot be produced, ammonia cannot be handled. Elevated levels of serum ammonia certainly play a large role in the development of hepatic encephalopathy in patients with liver failure and portal hypertension. Therefore, levels of ammonia and, in the case of alkylolosis, ammonium ion rise at the expense of urea. Other mechanisms leading to increased blood ammonia levels include excessive amounts of intestinal nitrogen (e.g., resulting from bleeding); decreased intestinal motility allowing greater bacterial deamination of amino acids; depressed renal function leading to an increase in blood urea nitrogen and a greater opportunity for bacterial urease to convert this to ammonia; alkalosis, which will preferentially lead the $\text{NH}_4^+/\text{NH}_3$ equilibrium in favor of ammonia; and portal hypertension, which will allow ammonia from the gut to bypass hepatic detoxification.
- X-21. The answer is C.** (*Chap. 303*) Though widely used as a screening test to rule out acute pancreatitis in a patient with acute abdominal or back pain, only about 85% of patients with acute pancreatitis have an elevated serum amylase level. Confounding issues include delay between symptoms and obtaining blood samples, the presence of chronic pancreatitis, and hypertriglyceridemia, which can falsely lower levels of both amylase and lipase. Because the serum amylase level may be elevated in other conditions such as renal insufficiency, salivary gland lesions, tumors, burns, and diabetic ketoacidosis as well as in other abdominal diseases such as intestinal obstruction or peritonitis, amylase isoenzyme levels have been used to distinguish among these possibilities. Therefore, the pancreatic isoenzyme level can be used to diagnose acute pancreatitis more specifically in the setting of a confounding condition. The serum lipase assay is less subject to confounding variables. However, the sensitivity of the serum lipase level for acute pancreatitis may be as low as 70%. Therefore, the recommended screening test for acute pancreatitis is both serum amylase and serum lipase activities.
- X-22. The answer is E.** (*Chap. 297. Poupon, N Engl J Med 330:1342, 1994.*) PBC is a disease of unknown etiology, but its frequent association with autoimmune disorders such as rheumatoid arthritis, CREST syndrome, scleroderma, and sicca syndrome has suggested that an abnormal immune response plays an etiologic role. The disease typically affects middle-aged women and runs a slowly progressive course, with death resulting from hepatic insufficiency occurring within 10 years of diagnosis. A positive antimitochondrial antibody test is relatively sensitive and specific for PBC, occurring in >90% of patients. Other serum abnormalities include increased alkaline phosphatase and 5'-nucleotidase activities and the presence of cryoproteins. Treatment is entirely supportive, although ursodiol may be helpful and liver transplantation must be considered in severe cases. Neither glucocorticoids nor D-penicillamine has proved to be effective. Colchicine, methotrexate, ursodiol, and cyclosporine may each play a role in slowing the progression of disease. Ursodiol treatment leads to symptomatic improvement but may not prevent progression to cirrhosis. Impaired bile excretion may lead to sequelae associated with malabsorption of the fat-soluble vitamins A, D, E, and K.
- X-23. The answer is C.** (*Chap. 297. Krawitt, N Engl J Med 334:897, 1996.*) Autoimmune hepatitis is a serious disorder characterized by progressive hepatic inflammation with a 6-month mortality of 40%. Typical cases have features of autoimmunity such as arthritis, vasculitis, and sicca syndrome. Serologic correlates include hypergammaglobulinemia (generally >2.5 g/dL), rheumatoid factor, and circulating autoantibodies (i.e., antinuclear, smooth muscle, and thyroid). There are several variants: (1) type 1, the classic syndrome seen in young women with lupoid features and circulating ANA; (2) type 2a, also seen in young women (mainly from western Europe) but associated with high titers of antibodies to liver and kidney microsomal antigens (LKM-1) and responsive to glucocorticoids; (3) type 2b, which occurs in older (Mediterranean) men and is associated with low LKM-

1 levels and interferon responsiveness; and (4) type 3, seen in patients who lack ANA and anti-LKM but have circulating antibodies to soluble live antigens. Rheumatoid factor elevation is nonspecific and is not helpful in establishing the diagnosis. Hepatitis D infection would require prior infection with hepatitis B. Hepatitis E is rare in western Europe and never progresses to chronicity.

- X-24. The answer is D.** (*Chap. 302*) Synthesized from hepatic cholesterol, the primary bile acids cholic acid and chenodeoxycholic acid are conjugated with glycine or taurine and excreted into the bile. Other secondary bile acids may be formed in the intestine by the action of colonic bacteria. One of the most important characteristics of bile acids is their detergent properties, which allow them to form molecular aggregates with cholesterol that are termed *micelles*. Cholesterol is poorly soluble in water; its solubility in bile is dependent on both the lipid concentration and the relevant amount of bile acids and lecithin. Bile acids also are required for the normal intestinal absorption of dietary fats by a similar micellar transport mechanism. Finally, bile acids are important in facilitating water and electrolyte transport in the intestine. To maintain the reusable pool of bile acids, the molecules are actively reabsorbed in the distal ileum, taken up in the portal bloodstream, and returned to hepatocytes for reconjugation and resecretion. Compared with a normal-size bile acid pool of 2 to 4 g, the daily fecal loss of bile acids is only in the range of 0.5 g.
- X-25. The answer is E.** (*Chap. 304*) Purtscher's retinopathy is a relatively rare but devastating complication of acute pancreatitis. It is characterized by sudden loss of vision and the presence of cotton-wool spots and hemorrhages in the area of the optic disc and macula. The cause is thought to be occlusion of the posterior retinal artery by aggregated granulocytes.
- X-26. The answer is D.** (*Chap. 302. Johnston, N Engl J Med 328:412, 1993.*) Selected patients with gallstones may respond well to treatment with oral chenodeoxycholic acid, its related molecule ursodeoxycholic acid, or both. Patients who are candidates for such therapy must have either cholesterol (rather than pigment, as in thalassemia) or mixed radiolucent gallstones. Second, gallstones >1.5 cm in diameter and those in gallbladders that fail to opacify after oral cholecystography will be very unlikely to respond to dissolution therapy. Chenodeoxycholic acid is thought to work by decreasing HMG-CoA reductase activity and thus hepatically secreted cholesterol. Deoxycholic acid works by a similar mechanism as well as by retarding cholesterol crystal nucleation. Up to 2 years of therapy with these agents often is required to dissolve a gallstone; after withdrawal, there is a recurrence rate of up to 30 to 50%. The same group of patients who are candidates for medical therapy to dissolve gallstones are also generally the patients who are candidates for gallstone lithotripsy, a method of fragmenting stones by extracorporeal shock waves.
- X-27. The answer is A.** (*Chaps. 303, 304*) Serum amylase is an effective screening test for acute pancreatitis. Levels >300 U/dL make the diagnosis extremely likely, especially if intestinal perforation and infarction are excluded (both of these conditions can raise serum amylase). In all but 15% of patients with acute pancreatitis, the serum amylase level is elevated within 24 h and begins to decline by 3 to 5 days in the absence of extensive pancreatic necrosis, partial infarction, or pseudocyst formation. Reasons for normal values could be a delay in obtaining the blood test, the presence of chronic rather than acute pancreatitis, and the presence of hypertriglyceridemia. Both serum amylase and lipase (perhaps the single best enzyme to diagnose acute pancreatitis) will be falsely low in patients with hypertriglyceridemia. Serum trypsinogen may have theoretical advantages over amylase and lipase insofar as the pancreas is the only source of this enzyme.
- X-28. The answer is B.** (*Chap. 290*) Carcinoma of the colon is the most common cause of mechanical obstruction of the colon and is followed in frequency by sigmoid diverticulitis and volvulus. These three causes account for 90% of cases of colonic obstruction. Adhe-

sions and hernias cause about 75% of cases of small-intestine obstruction but are uncommon causes of colonic obstruction.

- X-29. The answer is B.** (*Chap. 300*) Fatty liver refers to the infiltration of hepatocytes by triglyceride. Typically, the fat accumulates in large cytoplasmic droplets. However, in acute fatty liver of pregnancy and in Reye's syndrome (fatty liver with encephalopathy, thought to be caused by viruses or drugs), the fat is contained in small vacuoles and is termed *microvesicular fat*. The reason for the specific morphologic appearance of fat in these two disorders is unknown, but it provides a useful histologic differential point.
- X-30. The answer is B.** (*Chap. 302*) Though the presence of asymptomatic gallstones in a patient without a comorbid disease such as diabetes requires prophylactic cholecystectomy, those with symptomatic biliary stone disease are more likely to have complications and probably should also have definitive therapy. Complications from gallbladder surgery are low, especially with laparoscopic cholecystectomy; surgical treatment is probably the best approach. This patient's symptoms are beginning to interfere with the patient's general routine, and an operation is indicated. Selected patients may be candidates for gallstone dissolution therapy with ursodeoxycholic acid, with or without shock wave lithotripsy. Patients most appropriate for the approach of gallstone dissolution include those with a radioluculent, solitary stone <2 cm in diameter in a well-contracted gallbladder. In this patient's case, the stone is radiopaque. Moreover, gallstones will reoccur in about 30% of patients treated with a combination of medical litholytic and shock wave lithotripsy approaches.
- X-31. The answer is D.** (*Chap. 302*) This patient is presenting with cholestasis. Pain would be suggestive of intermittent biliary obstruction and would not be as typical of intrahepatic cholestasis, given the normal hepatic transaminases, which would rule out hepatitis. Patients with ulcerative colitis are at particular risk for certain extraintestinal manifestations such as sclerosing cholangitis. Other complications of intermittent biliary obstruction include complete biliary obstruction, secondary biliary cirrhosis, hepatic failure, or portal hypertension. ERCP is the most appropriate diagnostic maneuver and will demonstrate multifocal, diffusely distributed strictures along with normal intervening segments of bile duct. Cholangiocarcinoma is a late complication of sclerosing cholangitis in about 8% of the total population with this entity.
- X-32. The answer is E.** (*Chap. 296*) About 10% of persons treated with isoniazid develop mild elevations of serum aminotransferase levels during the first few weeks of therapy. These levels usually return to normal despite continued use of isoniazid. About 1% of persons with elevated aminotransferase levels develop symptoms of hepatitis and are at high risk for developing fatal hepatic failure. The older the patient, the higher the risk of isoniazid hepatitis; thus, because the patient described in this question is young and asymptomatic, isoniazid can safely be continued as long as she is watched for symptoms of hepatitis. A liver biopsy would not be indicated at this time.
- X-33. The answer is C.** (*Chaps. 298, 299*) Alcohol produces impairment in the absorption of many nutrients, including vitamin K. (The use of neomycin in the treatment of hepatic encephalopathy also can lead to a decrease in vitamin K.) When hypoprothrombinemia in a person with liver disease is easily corrected by parenteral vitamin K administration, decreased intestinal absorption of vitamin K should be suspected. Coagulopathy resulting from impaired hepatic function, as is seen in alcoholic hepatitis, is unlikely to be corrected by exogenous vitamin K. Although the patient discussed in the question is probably deficient in folate, as evidenced by the high mean corpuscular volume, folic acid administration has no effect on prothrombin time. Exogenous vitamin K would not correct the hypoprothrombinemia associated with disseminated intravascular coagulation.

- X-34. The answer is E.** (*Chap. 294*) Benign postoperative intrahepatic cholestasis can develop as a consequence of major surgery for a catastrophic event in which hypotension, extensive blood loss into tissues, and massive blood replacement are notable. Factors contributing to jaundice include the pigment load from transfusions, decreased liver function resulting from hypotension, and decreased renal bilirubin excretion caused by tubular necrosis. Jaundice becomes evident on the second or third postoperative day, with bilirubin levels (mainly levels of conjugated bilirubin) peaking by the tenth day. Serum alkaline phosphatase concentration may be elevated up to tenfold, but AST levels are only mildly elevated. Hepatitis, choledocholithiasis, and hepatic infarct are unlikely diagnoses in the absence of abdominal tenderness, fever, or a significant rise in AST levels. The incubation period of posttransfusion hepatitis is 7 weeks, making this diagnosis unlikely.
- X-35. The answer is E.** (*Chap. 297. Niederau, N Engl J Med 334:1422, 1996.*) Glucocorticoid therapy has been shown to prolong survival in patients with chronic active hepatitis of nonviral etiology. This patient, who has evidence of chronic hepatitis B infection as the cause of her chronic active hepatitis (this diagnosis has been made because of piecemeal necrosis on liver biopsy), would not benefit from the administration of steroids. Although many agents have been tried in chronic active viral hepatitis, none have been shown to be effective in the majority of patients. A 4-month course of interferon α is associated with a 40% seroconversion rate from HBeAg positivity to detectable levels of anti-HBe. Interferon therapy is also beneficial in patients with chronic hepatitis C infection.
- X-36. The answer is E.** (*Chap. 302*) The radiograph reproduced in the question shows emphysematous cholecystitis, a form of acute cholecystitis in which the gallbladder, its wall, and sometimes even the bile ducts contain gas secondary to infection by gas-producing bacteria. This condition occurs most frequently in elderly men and diabetic persons. The morbidity and mortality associated with emphysematous cholecystitis exceed those of acute cholecystitis. Once preoperative preparations are complete, laparotomy and cholecystectomy should be performed promptly.
- X-37. The answer is E.** (*Chap. 297*) Although chronic active hepatitis may be associated with extraintestinal manifestations (e.g., arthritis) and the presence in the serum of autoantibodies (e.g., anti-smooth-muscle antibody), these factors are not invariably present. The distinction between chronic active and chronic persistent hepatitis can be established only by liver biopsy. In chronic active hepatitis there is piecemeal necrosis (erosion of the limiting plate of hepatocytes surrounding the portal triads), hepatocellular regeneration, and extension of inflammation into the liver lobule; these features are not seen in chronic persistent hepatitis. Both diseases may be associated with serologic evidence of hepatitis B infection.
- X-38. The answer is E.** (*Chap. 299. Rolachon, Hepatology 22:1171, 1995.*) Persons who have cirrhosis, particularly alcoholic cirrhosis and ascites, may develop acute bacterial peritonitis without a clearly definable precipitating event. The clinical presentation of spontaneous bacterial peritonitis may be subtle, such as fever of unknown origin and mild abdominal pain, and may be attributed to other causes. Diagnosis is based on a careful examination of ascitic fluid obtained by paracentesis and should include cell count, Gram's stain, and culture. The most common organisms causing this syndrome are enteric gram-negative bacilli, with pneumococci and other gram-positive rods being less likely. Empiric therapy with cefotaxime or ampicillin and an aminoglycoside is appropriate. Recurrence is common; quinolone prophylaxis is helpful.
- X-39. The answer is E.** (*Chap. 302*) Obesity, clofibrate therapy, age, and oral contraceptive therapy predispose to gallstone formation by increasing biliary cholesterol excretion. Extensive ileal resection leads to malabsorption of bile salts, depletion of the bile acid pool, and an inability to micellize cholesterol, resulting in an increased risk of gallstone for-

mation. No correlation exists between serum cholesterol concentration and biliary cholesterol secretion; consequently, hypercholesterolemia per se does not predispose to cholelithiasis. Other important predisposing factors to the formation of cholesterol gallstones include gallbladder hypomotility resulting from prolonged parenteral nutrition, fasting, or pregnancy. Pigment gallstones may occur when the bilirubin level is high, such as in hemoglobinopathies or hemolytic anemia.

- X-40. The answer is E.** (*Chap. 299. Ochs, N Engl J Med 332:1192, 1995.*) If fluid and sodium restriction are unsuccessful in the mobilization of ascitic fluid, cautious diuresis is indicated; spironolactone, rather than furosemide or acetazolamide, would be the drug of choice. Aggressive diuretic therapy can lead to volume depletion, azotemia, electrolyte disturbances, and hepatic encephalopathy. Therapeutic paracentesis (4 to 6 L) is now felt to be effective, especially if albumin is infused to avoid exacerbation of intravascular depletion. The peritoneovenous (LeVeen) shunt (such a shunt may now be placed by the transjugular route) should be reserved for cases of intractable ascites; its use is accompanied by significant complications, including infection and disseminated intravascular coagulation.
- X-41. The answer is E.** (*Chap. 287*) This patient presents with symptoms and findings compatible with classic Crohn's disease. She has rectal sparing on colonoscopy, but her disease is confined mainly to the terminal ileum area with an inflammatory mass and aphthous ulcerations on endoscopy. Polygenic disorders, both ulcerative colitis and Crohn's disease run in families. While infections with organisms such as *Campylobacter*, *Salmonella*, and *Escherichia coli* can mimic IBD in the nonimmunocompromised and mycobacterial and CMV infection in the immunosuppressed, this patient has classic IBD. Several serologic markers may be helpful in distinguishing between the two subtypes of inflammatory bowel disease. Anti-goblet cell autoantibodies, or antibodies against pancreatic acinar cells are present in up to 40% of patients with IBD and are particularly common in those with ulcerative colitis. Perinuclear antineutrophil cytoplasmic antibodies are found in about 60 to 70% of ulcerative colitis patients and in 5 to 10% of patients with Crohn's disease. Anti-*Saccharomyces cerevisiae* antibodies, which recognize mannose sequences in the cell wall of this yeast, are present in 60 to 70% of Crohn's disease patients and in 10 to 15% of ulcerative colitis patients' antibodies and are particularly associated with Crohn's disease of the small bowel.
- X-42. The answer is D.** (*Chap. 287. Present, N Engl J Med 340:1398–1405, 1999.*) The initial therapy for patients with mild to moderate Crohn's disease is treatment with sulfasalazine or a drug that represents an active ingredient of the parent compound (5-aminosalicylic acid or mesalamine). Many patients will require additional therapy such as glucocorticoids (e.g., prednisone at a dose of 40 to 60 mg/d). Steroids should be stopped once a remission has been induced. Metronidazole, the antianaerobic antibacterial, has a role in active inflammatory, fistulous, and perianal Crohn's disease. Azathioprine and 6-mercaptopurine analogues have a role in helping to get patients off steroids. Cyclosporine or tacrolimus, which inhibits T cell function by preventing IL-2 production, may help patients refractory to intravenous glucocorticoids. Infliximab is a chimeric mouse-human monoclonal antibody against TNF, which is the key cytokine mediating intestinal inflammation. This new agent is extremely effective in Crohn's disease, particularly in those with refractory perianal or enterocutaneous fistulas. The drug is well tolerated; antibodies to the murine portion of this molecule occur in about 13%.
- X-43. The answer is A.** (*Chap. 304. Baron, Morgan, N Engl J Med 340:1412–1417, 1999.*) This patient is suffering from severe acute pancreatitis. Factors that adversely affect survival include older age, leukocytosis, hyperglycemia, and elevated serum LDH or serum AST. Depressed hematocrit, ascitic fluid, hypocalcemia, hypoxemia, renal failure, or hypoalbuminemia also signify an adverse prognosis. If the CT scan shows either necrosis or peripancreatic fluid, the patient also has a poor prognosis. Standard therapy for pancreatitis

includes analgesics, intravenous fluids, bowel rest, and nasogastric suction. Pancreatic secretion is essentially abolished in acute pancreatitis so anticholinergic drugs have little benefit. Prophylactic antibiotics have little role in mild to moderate pancreatitis. However, recent controlled trials show that broad-spectrum antibiotics such as imipenem will reduce deaths. Prospective trials have failed to find a benefit for the use of glucagon, histamine blockers, protease inhibitors such as aprotinin, steroids, calcitonin, and NSAIDs. There are suggestions that octreotide may reduce the mortality rate and the antiprotease gabexate may reduce pancreatic damage.

- X-44. The answer is B.** (*Chap. 93*) The combination of weight loss, anemia, and a bullous skin eruption in a patient with hepatic metastases and evidence of a pancreatic lesion is highly suggestive of a glucagonoma. This tumor of pancreatic alpha cells is usually malignant, metastasizes early, often occurs in middle-aged women, and is accompanied by hyperglycemia, painful stomatitis and cheilosis, hypoaminoacidemia, and a characteristic skin rash—necrolytic migratory erythema. With appropriate histologic techniques, the diagnosis of a pancreatic alpha-cell tumor can be established by liver biopsy, but marked plasma hyperglucagonemia is pathognomonic. Arteriography may demonstrate a pancreatic tumor but is not diagnostic. Treatment consists of early surgical chemotherapy of metastatic disease is usually ineffective.
- X-45. The answer is C.** (*Chaps. 283, 284*) Though candidal infection is a common cause of esophagitis, typically manifested by dysphagia, it may be seen with immunodeficiency states such as AIDS, with the use of immunosuppressive agents including glucocorticoids, and with the use of broad-spectrum antibiotics. Esophagitis also may be seen in diabetics, patients with systemic lupus erythematosus, and those who experienced a corrosive esophageal injury. Oral thrush is a helpful but not invariant coexisting finding. Candidal esophagitis may be complicated by bleeding, perforation, stricture, or systemic invasion. Upper gastrointestinal radiography may reveal multiple nodular filling defects. Endoscopic evaluation typically reveals a whitish exudate in the setting of underlying erythematous mucosa. The definitive diagnosis would require the demonstration of yeast or hyphal forms on Gram's, PAS, or silver stain. Uncomplicated cases of candidal esophagitis respond well to fluconazole, which is preferred to ketoconazole because of reduced bioavailability of ketoconazole at increased gastric pH.
- X-46. The answer is C.** (*Chap. 284*) Chronic acid-induced (reflux) esophagitis may cause bleeding from diffuse erosions or discrete ulcerations. Peptic damage to the submucosa can result in fibrosis and subsequent stricture. Barrett's esophagus is formed as destroyed squamous epithelium is replaced by columnar epithelium, usually similar to that of the adjacent gastric mucosa. Adenocarcinoma may develop in 2 to 5% of persons with a Barrett's esophagus. A lower esophageal ring is a structural lesion that is not related to reflux esophagitis.
- X-47. The answer is B.** (*Chaps. 45, 294*) A simple and important method to determine whether the cause of jaundice is conjugated or unconjugated hyperbilirubinemia is measurement of the urinary excretion of bilirubin. Under normal circumstances the urine contains no bilirubin since the unconjugated, water-soluble bilirubin, which accounts for 96% of the bilirubin in serum, is tightly bound to albumin and is not filtered by the glomeruli. Even in cases of unconjugated hyperbilirubinemia resulting from overproduction (as in hemolysis and the ineffective erythropoiesis characteristic of certain hemoglobinopathies) or decreased conjugation, there is no urinary excretion of bilirubin. Congenital deficiencies of the glucuronyl transferase enzyme responsible for converting bilirubin into its soluble form include Gilbert's syndrome and Crigler-Najjar disorder types I and II (in type I disease, the transferase enzyme is totally absent). In cases of conjugated hyperbilirubinemia, in which >50% of the serum bilirubin is composed of the conjugated type, enough bilirubin remains unbound that filtration of this substance occurs and the urine dipstick becomes positive. In addition to extrahepatic obstruction, causes of conjugated hyperbil-

irubinemia include defects in hepatic excretion of a congenital (e.g., Dubin-Johnson or Rotor syndrome) or an acquired (hepatocellular disease or estrogen use) nature.

- X-48. The answer is E.** (*Chap. 287*) Most extraintestinal disorders of inflammatory bowel disease are associated with both Crohn's disease and ulcerative colitis, including pericholangitis, uveitis, and a variety of skin and joint manifestations. Complications that are unique to Crohn's disease because of inflammation of the terminal ileum include hypocalcemia, which is caused by malabsorption of vitamin D, and the formation of urinary oxalate stones, which results from increased colonic absorption of dietary oxalate. Owing to bile-salt malabsorption caused by ileal disease, cholesterol gallstones tend to form in persons with regional enteritis.
- X-49. The answer is A.** (*Chap. 289*) Meckel's diverticulum is the most commonly occurring congenital anomaly of the gastrointestinal tract and is found in 2% of adult autopsies. The diverticulum may contain ectopic gastric mucosa, and local acid secretion may produce ileal ulceration and lower gastrointestinal bleeding. In young adults Meckel's diverticulitis can mimic acute appendicitis. Technetium, taken up by diverticular gastric mucosa, can detect the lesion, which is easily missed on conventional barium x-rays. Gastrointestinal obstruction may occur if the diverticulum intussuscepts or twists on a fibrous remnant of the omphalomesenteric duct. Surgical excision is the treatment for any significant complication of a Meckel's diverticulum.
- X-50. The answer is C.** (*Chap. 295*) HBeAg is a protein that is associated with the HBV core particle. HBeAg is a soluble protein found only in HBsAg-positive serum and is immunologically distinct from HBsAg as well as from intact HBcAg, an antigen expressed on the hepatitis B virus nucleocapsid core. Interestingly, both HBcAg and HBeAg are encoded on the so-called C-gene of the hepatitis B genome. Owing to the close association of HBeAg and HBsAg, the presence of HBeAg in the serum is linked with infectiousness, and the antigen is present during the viremic period of acute hepatitis B. HBeAg correlates well with viral replication, and detection of HBeAg persistence predicts for the subsequent development of chronic hepatitis B infection; however, the absence of HBeAg in serum does not preclude the development of chronic hepatitis B infection. In acute hepatitis B, the disappearance of HBeAg from serum often presages resolution of the acute infection; however, HBeAg-negative persons should be considered infectious until antibody to HBsAg is no longer detected in the serum.
- X-51. The answer is B.** (*Chap. 295. Hoofnagle, JAMA 261:1321, 1989.*) HDV is a defective RNA virus that coinfects with and requires the helper function of HBV for its replication and expression. Therefore, the duration of HDV infection is determined by and limited to the duration of HBV infection. Although the delta core is encapsulated by an outer coat of HBsAg, the delta antigen has no antigenic similarity to that of any of the HBV antigens, and the RNA genome is not homologous with HBV DNA. HDV infection has a worldwide distribution and exists in two epidemiologic patterns: endemic and epidemic. In endemic areas (Mediterranean countries) HDV infection is found among those with HBV infection and is transmitted predominantly by nonpercutaneous routes, such as close personal contact. In nonendemic areas such as the United States and northern Europe, HDV infection is limited to persons with frequent exposure to blood products, such as intravenous drug addicts and hemophiliacs. In general, patients with simultaneous HBV and HDV infections do not have an increased risk of developing chronic hepatitis compared with patients with acute HBV infection alone. HDV superinfection of patients with chronic HBV infection carries an increased risk of fulminant hepatitis and death.
- X-52. The answer is A.** (*Chap. 291. Rao et al, N Engl J Med 338:141–146, 1998.*) This patient falls into the typical age spectrum for the diagnosis of acute appendicitis (between the second and third decade of life). He also displays the typical clinical scenario of 4 to 6 h of nonspecific mild crampy abdominal pain followed by movement of the pain to the

right lower quadrant. Patients generally have anorexia, nausea, and vomiting. Right lower quadrant tenderness is required for the diagnosis of appendicitis, which is generally made clinically. With the typical picture displayed by this patient, including leukocytosis, the diagnosis is very likely. Therefore, additional observation or a plain abdominal radiograph (which would display a fecalith in about 5%) is not indicated. Although a CT scan may reveal extrinsic compression on the intestinal wall or a calcified fecalith, the value of such a study is not established. Ultrasonography could demonstrate an enlarged and thick-walled appendix. However, the best approach for someone whose clinical course is highly suspect for acute appendicitis is surgical removal of the diseased organ.

- X-53. The answer is C.** (*Chap. 295*) The prevention of viral hepatitis is of particular importance because of the limited therapeutic options. The prophylactic approach varies with the type of hepatitis. All preparations of Ig contain sufficient titers of anti-HAV to prevent clinically apparent type A hepatitis. If they are given early enough, infection will be prevented in approximately 80% of patients. For intimate contacts, 0.02 mL/kg of Ig is recommended as soon as possible after exposure. An inactivated HAV vaccine is the preferred approach to preexposure (before travel to an endemic area) prophylaxis. The prevention of hepatitis B is based on passive immunoprophylaxis with both HBIg and hepatitis B vaccine. HBIg appears to be effective in reducing clinically apparent illness but does not appear to prevent infection. Hepatitis B vaccine has been shown to be highly effective in preventing HBV infection. Because only persons with HBV infection are susceptible to delta hepatitis, hepatitis B vaccine is effective in preventing delta infection in persons who are not carriers of HBsAg. There is no effective prophylaxis of HDV infection in patients who are already HBsAg carriers. Postexposure prophylaxis of hepatitis C with IG is not effective.
- X-54. The answer is E.** (*Chap. 293*) The pattern of this patient's liver tests, i.e., an isolated elevation of the serum alkaline phosphatase, is most compatible with an infiltrative disease such as tuberculosis or lymphoma, each of which causes irritation of the bile ductules. Although partial bile duct obstruction could also account for the elevated alkaline phosphatase, obstruction due to a stone or to a proximal pancreatic tumor would almost certainly produce some degree of hyperbilirubinemia. In most cases of alcoholic hepatitis or cirrhosis, the AST will be elevated out of proportion to ALT and there would be mild hyperbilirubinemia. The prothrombin time will also often be elevated in this situation. In acute viral hepatitis or hepatitis mediated by toxins or heart failure, the hepatic enzymes are usually quite elevated, with a predominance of ALT relative to AST.
- X-55. The answer is B.** (*Chap. 284. Spechler, Gastroenterology 117:229–233, 1999.*) Dysphagia is a symptom that almost always has a significant physiologic cause. In this case the patient has dysphagia to both solids and liquids. The fact that "bearing down" (the Valsalva maneuver) aids passage of food to the stomach implies that the patient has increased basal lower esophageal sphincter tone. In achalasia, as exhibited by this patient, the esophageal smooth muscle in the lower esophageal sphincter does not relax normally with swallowing. Failure of sphincter relaxation is due to a loss of neurons of the distal esophagus. Basal lower esophageal sphincter pressure would be normal or elevated on manometry (measurement of esophageal tone). Cholecystokinin (CCK) normally causes a fall in the sphincter pressure; however, there is a paradoxical increase in lower esophageal sphincter tone in achalasia due to the lack of being able to transmit normal inhibition mediated by CCK. It is important to exclude secondary causes of distal esophageal problems such as gastric or esophageal carcinoma by means of endoscopy. Radiologic findings in patients with achalasia include an absence of the gastric air bubble on chest radiography. An air-fluid level in the mediastinum due to retained food might also be noted.
- X-56. The answer is C.** (*Chap. 287*) Risk factors for the development of colon carcinoma in persons who have ulcerative colitis include the presence of the disease for more than

10 years, extensive mucosal involvement (pancolitis), and a family history of carcinoma of the colon. The risk of cancer in persons with pancolitis is estimated to be 12% at 15 years, 23% at 20 years, and 42% at 24 years. Neither a history of toxic megacolon nor the prolonged use of high-dose steroids increases the risk of cancer. Pseudopolyps, although frequently associated with severe disease, are not precancerous lesions.

- X-57. The answer is A.** (*Chap. 289*) Ischemic colitis most often occurs in elderly persons who have vascular disease. Areas of the colon with extensive collateral circulation, such as the rectum, usually are spared. Angiography of arteries and veins rarely is indicated for diagnosis or therapy because vessel occlusions are almost never detected. Barium studies reveal edema, cobblestoning, thumbprinting, and ulceration. Even though acute ischemic colitis may present with rectal bleeding and lower abdominal pain, most cases do not present with the severity of signs and symptoms suggestive of an acute abdomen. This disease usually does not recur, and symptoms tend to resolve in 2 to 4 weeks. Ischemic colitis sometimes is diagnosed retrospectively as the cause of a colonic stricture.
- X-58. The answer is D.** (*Chap. 289*) Acute hemorrhage from colonic diverticula is the most common cause of lower gastrointestinal bleeding among elderly persons. Although diverticula are more common on the left side of the colon, bleeding tends to originate from the ascending (right) colon. Bleeding usually stops with bed rest and transfusion; however, when conservative measures fail to curb hemorrhage, intraarterial infusion of vasoconstrictive medications introduced during angiography can be effective. Although acute diverticulitis may be associated with occult bleeding, gross hemorrhage rarely occurs.
- X-59. The answer is E.** (*Chap. 285. Peura, Am J Med 105:424–430, 1998.*) This patient has the classic clinical symptoms and endoscopic findings of a duodenal ulcer. The incidence of duodenal ulcers is about 10% of the population of industrialized countries. The pathophysiology of duodenal ulcers includes excess gastric acid secretion; however, *H. pylori* infection, as documented in this patient, may be playing a critical role. The mechanism by which gastric infection with *H. pylori* causes duodenal ulcers is not clear. However, *H. pylori* gastric infection might induce increased acid secretion through both direct actions of the bacterium as well as indirect stimulation of pro-inflammatory cytokines such as IL-8, TNF, and IL-11. Whatever the mechanism, it is now a consensus recommendation that *H. pylori* infection should be eradicated in patients with documented peptic ulcer disease. No single- or double-agent regimen has been reliably effective in eradicating the organism. In general, a combination of two antibiotics plus either a proton pump inhibitor (omeprazole or lansoprazole) is required to achieve a high likelihood of eradication. Therefore, recommended regimens include bismuth plus metronidazole and tetracycline; or ranitidine plus a tetracycline and clarithromycin or metronidazole; or omeprazole plus clarithromycin and metronidazole or amoxicillin. Such triple therapy is effective in eradicating the organism in approximately 90% of the cases; drawbacks include poor patient compliance and side effects. A worrisome feature about overtreatment of *H. pylori* infection is the possible emergence of resistant strains.
- X-60. The answer is D.** (*Chap. 41*) Indigestion and heartburn are amongst the most common symptoms and are often due mild gastroesophageal reflux disease (GERD). Ulcer disease and malignancy account for a small minority of patients with dyspepsia. To distinguish between GERD/functional dyspepsia and more serious illnesses, one should be watchful for “alarm” factors such as odynophagia (suggests esophageal infection), dysphagia (blockage), unexplained weight loss, recurrent vomiting, bleeding, a mass, or lymphadenopathy. Even in the absence of alarm factors, a 50-year-old patient with chronic dyspepsia should undergo endoscopy. However, those under age 45 who are likely to have a benign cause for this symptom need only have a blood sample for *H. pylori* serology to help direct therapy. If the serology is negative, an H₂ antagonist should be tried first, with a proton-pump inhibitor such as omeprazole being reserved for unresponsive cases. Although the

value of *H. pylori* eradication in nonulcer dyspepsia is unproven, if such an approach does work in a seropositive patient, no further therapy would be required.

- X-61. The answer is B.** (*Chap. 286*) Patients with intestinal lymphangiectasia—characterized by protein-losing enteropathy, hypoproteinemia, hypogammaglobulinemia, edema, chylous effusions, fat malabsorption, and lymphocytopenia—typically present in childhood or young adulthood. The generalized congenital disorder of lymphatic development includes the dilated lymph vessels typically seen on small-bowel biopsy. The abnormal lymphatics are presumed to rupture into the bowel lumen, leading directly to hypoproteinemia and steatorrhea. Absorption of carbohydrates such as D-xylose and lactose that are not dependent on lymphatics typically is preserved. The decreased lymph flow associated with a low-fat diet supplemented by medium-chain triglycerides (transported by the portal vein rather than the lymph) results in significant clinical improvement. Despite hypogammaglobulinemia, infections with encapsulated organisms are not increased.
- X-62. The answer is A.** (*Chap. 42. Fine, Schiller, Gastroenterology 116:1464–1486, 1999.*) Chronic diarrhea (lasting >4 weeks) may be due to a host of causes including medications [especially habitual use of laxatives, which may be stimulant (senna, castor oil) or osmotic (e.g., Mg-containing) in nature], enterocolic fistulae, hormones (from certain endocrine tumors such as carcinoid, VIPoma, medullary carcinoma of the thyroid), carbohydrate malabsorption (e.g., lactase deficiency, which leads to a low stool pH), fat malabsorption, pancreatic exocrine insufficiency, mucosal malabsorption (e.g., celiac sprue, seen on small-bowel biopsy), or IBD. Diarrhea can occur due to invasion of the small bowel with lymphoma cells or eosinophils, in which the Charcot-Leyden crystals from extruded eosinophils may be seen. If inflammation or infection is the cause, fecal leukocytes will usually be found. Laxative use is consistent with an osmotic gap: $2([\text{Na}] + [\text{K}]) < 290$ mosmol/kg. However, certain anionic laxatives containing sulfates or phosphates produce diarrhea without an osmotic gap, since sodium secretion occurs in response. In these cases, direct measurement of the laxative in the stool would be required to confirm the suspicion of laxative abuse.
- X-63. The answer is A.** (*Chap. 42*) In >90% of cases where patients complain of constipation, there is no underlying cause such as cancer, depression, or hypothyroidism. Therefore, unless the routine history and physical examination yield clues to a more serious disorder, expensive and complicated diagnostic studies are not indicated. The average patient with bona fide constipation will respond to a simple regimen of exercise, liberal water intake, and dietary fiber supplements. In any older patient, in particular, who has a worrisome feature, colonoscopy would be advisable. Only if routine measures fail would it be necessary to perform tests of colonic eliminatory function such as colonic transit time assays or anorectal and pelvic floor tests, anorectal manometry, the balloon expulsion test (a reasonable screening test), or defecography.
- X-64. The answer is B.** (*Chaps. 40, 284*) “Sticking” during the passage of food through the mouth, pharynx, or esophagus is almost always associated with a significant pathologic problem. The history can provide the correct diagnosis in over three-fourths of patients with dysphagia. Motor dysphagias, such as those caused by achalasia and diffuse esophageal spasm, are equally affected by solids and liquids from the onset. Patients with an esophageal carcinoma typically initially have problems swallowing solid food, but with progression of the cancer, difficulty with liquids also is encountered. Since this patient has dysphagia with both solids and liquids and has severe chest pain, diffuse esophageal spasm is the likely diagnosis. Diagnostic studies would include both barium swallow esophagoscopy and upper endoscopy to exclude an associated structural abnormality.
- X-65. The answer is B.** (*Chap. 41*) A host of gastrointestinal complaints are commonly described by patients as indigestion. Among them are abdominal pain, nonulcer dyspepsia (symptoms suggesting a diagnosis of peptic ulcer despite the absence of a documented

ulcer), heartburn, food intolerance, aerophagia, and gaseousness-bloating-flatulence. Many patients have chronic, repetitive eructation (belching) that can result from air swallowing rather than excessive gas production in the stomach or intestine. Accumulation of swallowed air in the stomach may lead to postprandial fullness and the finding of a large amount of air in the gastric fundus on x-ray, the so-called magenblase (i.e., gastric bubble) syndrome. In this situation, the patient experiences discomfort when lying supine after a large meal, allowing air to be “trapped” below the gastroesophageal junction without the ability to be eructated. If the swallowed air can successfully pass the stomach, diffuse abdominal distention may occur or the air may be trapped in the splenic flexure of the colon. Such trapping can lead to the so-called splenic flexure syndrome, which is characterized by left upper quadrant fullness with radiation to the left side of the chest. Relief occurs after defecation or expulsion of flatus. The splenic flexure syndrome is associated with increased tympany in the left lateral abdomen with a large amount of splenic flexure air on plain abdominal radiography. Bloating and excess flatulence caused by excessive air production in the intestine often occur after the ingestion of certain foods. For example, beans contain oligosaccharides (stachyose and raffinose) that cannot be split by intestinal mucosal enzymes but are metabolized by colonic bacteria. The ingestion of fructose or sorbitol and infection with the protozoal organism *Giardia lamblia* also may lead to excessive production of intestinal gas and a sensation of bloating. Gallstone-associated pain would be most likely to be localized to the epigastrium or the right upper quadrant.

- X-66. The answer is C.** (*Chap. 42*) Constipation, which is defined as fewer than three defecatory episodes per week, is a common complaint in clinical practice. It is important to consider serious causes such as obstruction resulting from colonic neoplasms or strictures and pathologic states of disturbed colonic motility such as multiple sclerosis, central nervous system lesions, and Chagas’ disease. Other causes of constipation include drugs such as anticholinergics, narcotics, iron supplements, and calcium channel blockers; endocrinopathies such as hypothyroidism and diabetes; and collagen vascular diseases such as progressive systemic sclerosis. In most patients, however, constipation has no clear-cut cause and is due to either irritable bowel syndrome or other functional-psychological causes. Treatment of constipation must be individualized. Fiber supplementation with agents such as psyllium may increase stool bulk and is appropriate for many patients. Emollients such as mineral oil and docusate salts soften and lower the surface tension of the stool by allowing the mixing of aqueous and fatty substances. Hypertonic agents such as lactulose and sorbitol cause an osmotic impetus to diarrhea. Stimulants include castor oil, senna, and phenolphthalein bisacodyl, which enhance intestinal secretion and motility. Cisapride is prokinetic and promotes intestinal transit through the proximal colon; its role in the treatment of constipation remains unclear.
- X-67. The answer is D.** (*Chap. 42*) Diarrhea, which is defined as an increase in daily stool volume above 200 g, can be classified into acute and chronic forms. By far the most common causes of acute diarrhea are infectious agents. Diarrhea that persists for weeks or months and is considered chronic may be due to inflammation or an orally ingested nonabsorbed solute such as a maldigested or malabsorbed nutrient that exerts osmotic force and thus draws fluid into the intestinal lumen, altered intestinal motility (usually associated with neurologic diseases), or intestinal secretion by which abnormal fluid transport occurs (not usually related to the ingestion of food). Secretory diarrhea usually persists despite fasting. The best example of secretory diarrheas are those caused by abnormal hormonal secretion, such as metastatic carcinoid, in which a variety of vasoactive substances, including serotonin, histamine, and prostaglandin, are secreted by the tumor. Zollinger-Ellison syndrome, which is due to a gastrin-producing tumor, causes diarrhea in one-third of affected patients as a result of both high volumes of secreted hydrochloric acid and the maldigestion of fat caused by inactivation of pancreatic lipase. Other examples of secretory diarrheas include those caused by neoplasms such as pancreatic adenomas, villous adenomas, and medullary carcinoma of the thyroid. Systemic mastocytosis, which is seen with skin lesions typical of urticaria pigmentosa, is associated with diarrhea caused

by histamine release from mast cells which have infiltrated the small intestine. The absence of a terminal ileum as a result of surgery or severe disease also causes secretory diarrhea through stimulation of colonic secretion by bile salts that have escaped absorption in a dysfunctional or absent terminal ileum. Somatostatinoma, a rare pancreatic tumor, causes steatorrhea, not intestinal secretion.

- X-68. The answer is E.** (*Chap. 46*) Although the underlying cause of the ascites is clear (portal hypertension due to alcoholic liver disease), the reason for the acute accumulation is speculative until a paracentesis is performed. Entities such as hepatocellular carcinoma, portal vein thrombosis, new congestive heart failure (CHF), spontaneous bacterial peritonitis (SBP), and tuberculosis must be considered in addition to the possibility of progression of the basic disease process. In this case the negative cytologic examination makes cancer unlikely. Both cirrhosis and CHF would generally be transudates (ascites protein <25 g/dL. Moreover, a serum-ascites albumin gradient of >1.1 suggests portal hypertension; a small gradient suggests an exudate. In SBP, the white blood cell ascitic fluid differential would include mainly neutrophils, in contrast with the lymphocytes in this case, which makes tuberculosis a possibility. The diagnosis could require a peritoneal biopsy unless the acid-fast stain or culture from the diagnostic paracentesis was positive.
- X-69. The answer is D.** (*Chaps. 45, 288*) Bilirubin, a breakdown product of heme derived from senescent red blood cells, is transported to the liver in an insoluble albumin-bound (unconjugated) state, which is not renally excreted. The conjugation, or solubilization, of bilirubin occurs in the endoplasmic reticulum of the hepatocyte when the molecule is covalently attached to glucuronic acid. The conjugated bilirubin is then transported into the bile, then into the colon where most is excreted into the feces. Processes that prevent excretion of conjugated bilirubin due to intrahepatic diseases [viral hepatitis, drug use (estrogens, chlorpromazine, 6-mercaptopurine)] or extrahepatic obstruction (blockage due to cancer of the biliary system or pancreas; bile duct diseases such as sclerosing cholangitis, primary biliary cirrhosis, or choledocholithiasis) lead to an increase of this species in the blood. Elevated levels of this soluble form of bilirubin can be detected visually as tea- or cola-colored urine. Ultrasonography, CT, or ERCP would be necessary to distinguish between extra- and intrahepatic causes of conjugated-hyperbilirubinemia. An increased load of unconjugated bilirubin produced in states of excessive red cell destruction would generally not be detected in a urine test for bilirubin.
- X-70. The answer is B.** (*Chap. 287*) There are many similar manifestations of Crohn's disease (CD) and ulcerative colitis (UC). However, UC almost always displays continuous rather than the more segmental involvement characteristic of CD. UC rarely involves the entire bowel wall, whereas such transmural disease in CD can lead to abdominal masses, mesenteric node inflammation, and fistula formation. Since CD is much less likely to involve the rectum, hematochezia is less common than it is in UC. Extraintestinal manifestations, colonic malignancy, and toxic megacolon can occur with either entity; a distinction between the two diseases can be made in about 80% of cases.
- X-71. The answer is D.** (*Chap. 289. Pras, N Engl J Med 326:1509, 1992.*) Familial Mediterranean fever (FMF) is an inherited disorder linked to chromosome 16 and predominately occurring in Arabs, Armenians, and Sephardic Jews. The disease is characterized by recurrent episodes of fever, peritonitis, and/or pleuritis. Arthritis, skin lesions, and amyloidosis also are seen. An initial attack, especially if it is manifested by fever alone, can present a diagnostic dilemma; recurrent attacks in a person in the appropriate ethnic group make the diagnosis more straightforward. The greatest hazard is prolonged hospitalization with unnecessary tests. Chronic administration of colchicine reduces the number of attacks.
- X-72. The answer is E.** (*Chap. 282*) As in most of internal medicine, a thorough clinical history is likely to yield important, if not essential, clues regarding the primary pathologic abnormality. Complaints of abdominal pain, distention, and stool frequency and type are

very common. Abdominal pain is likely to be more serious if it is acute rather than chronic. The character of the pain, its location, and the exacerbating factors (especially those related to eating) must be elicited carefully. If a patient complains of diarrhea only during the day, it is much more likely to be functional than it would be if the diarrhea occurred at night or during both the day and the night. Blood loss is almost always suggestive of an organic cause, as is fever or weight loss. Crampy abdominal pain is relieved by defecation; it may well be due to a functional bowel syndrome. Either pellet-like stools or alternation of diarrhea and constipation is similarly compatible with functional bowel syndrome. However, a definite change in stool diameter suggests a colonic neoplasm. Stool characteristics also may be helpful historic features. For example, a pungent stool odor with the presence of undigested meat in the bowel movement may be suggestive of pancreatic insufficiency. White-colored stool signifies cholestasis or steatorrhea. Mucus mixed in with the stool is also suggestive of functional bowel syndromes, whereas pus is more likely to be found in association with an infection or inflammation.

- X-73. The answer is A.** (*Chap. 284*) Although not every patient with heartburn requires upper endoscopy, indications include dysphagia, a structural mass or ulcer on contrast radiograph, and prolonged or persistent symptoms. This patient underwent appropriate esophagoscopy and was found to have Barrett's esophagus, a replacement of the distal squamous mucosa with columnar epithelium which is similar to the stomach lining both morphologically and functionally, being more resistant to digestion in a low-pH environment. This metaplastic epithelium is more likely to undergo malignant transformation and should be surveyed by repeat studies with biopsy every 12 to 24 months, particularly if dysplasia is present. Dilation would be appropriate if a benign stricture were noted.
- X-74. The answer is E.** (*Chap. 45*) The patient's complaints are most likely not related to the abnormality in bilirubin metabolism suggested by the elevated concentration of total bilirubin. The patient has an elevation in the unconjugated, relatively water-insoluble albumin-bound form of bilirubin. The urine dipstick test would almost certainly be negative because bilirubin is excreted into the urine only in the conjugated form. For the unconjugated bilirubin level to rise, there must be either an overproduction of bilirubin, as in the case of hemolysis, or ineffective marrow production, impaired hepatic uptake of bilirubin, or impaired conjugation with glucuronide to allow for excretion. Given that the patient's CBC is normal, there is no evidence that she has hemolysis to account for overproduction. Moreover, the LDH and SGOT are normal, further supporting the lack of ongoing red cell destruction. Rare cases of drug-induced jaundice may be due to impaired hepatic uptake of bilirubin, but the remaining patients have impaired glucuronide conjugation resulting from a hereditary deficiency of the glucuronyl enzyme. Neonatal jaundice, which occurs between the second and fifth days of life, is in fact due to a relatively low level of glucuronyl transferase activity. There are three inherited deficiencies of this enzyme that can result in elevations of unconjugated serum bilirubin. This patient most likely has Gilbert's syndrome, which is associated with a mild decrease in enzyme activity and produces asymptomatic elevations in unconjugated hyperbilirubin. In Crigler-Najjar syndromes types II and I the enzyme is moderately diminished or totally absent. In the type I disorder childhood mortality from profound kernicterus-induced central nervous system dysfunction occurs. While impairments in glucuronyl transferase activity also may be acquired, in most liver diseases bilirubin excretion is impaired to a greater degree than is bilirubin conjugation, leading primarily to conjugated hyperbilirubinemia. Therefore, in this patient's case no further testing is necessary.
- X-75. The answer is C.** (*Chap. 296. Tilg, Diehl, N Engl J Med 343:1467–1476, 2000.*) The mechanism by which patients who consume alcohol progress from fatty liver to cirrhosis is believed to involve a complex cascade of cytokine-mediated liver injury. In the early stages the release of cytokines is promoted by the toxin itself, in this example alcohol, but in later stages by bacterial endotoxins. Proinflammatory cytokines such as TNF- α and IL-6, generally from the hepatic macrophage (Kupffer cell), promote cholestasis and the

hepatocyte-mediated synthesis of acute-phase proteins. In response to injury the Kupffer cell may also elaborate transforming growth factor β , which stimulates the hepatic stellate cell to promote collagen deposition and fibrosis. New therapies for toxic hepatitis that could interrupt this cytokine cascade, such as TNF receptor antagonists, are in development.

- X-76. The answer is D.** (*Chap. 285. Jensen, JAMA 271:1429, 1994.*) Zollinger-Ellison syndrome consists of ulcerative disease of the upper GI tract, marked increases in gastric acid secretion, and non- β islet cell tumors of the pancreas (gastrinomas). Gastrinomas generally occur as multiple tumors in the pancreatic head and are usually malignant, with one-third of these patients presenting with metastatic disease. Metastasis is most commonly found in the regional lymph nodes and liver. In 20 to 60% of those with Zollinger-Ellison syndrome the gastrinoma is a component of the multiple endocrine neoplasia syndrome type I. This is an autosomal dominant disorder that is linked to chromosomes 11 (q11 through q13). Patients with MEN type I have neoplasms of the parathyroid glands, pancreatic islets, and pituitary. In addition to gastrin, most gastrinomas secrete other hormones, including ACTH, glucagon, and vasoactive intestinal peptide. Clinical features of Zollinger-Ellison syndrome include persistent ulcers and elevated basal-acid output, often leading to diarrhea. The diagnosis of gastrinoma requires a demonstration of increased serum gastrin levels, which, if not above 1000 ng/L, may require a provocative test to demonstrate hypersecretion. In normal patients, secretin infusions would produce either no change or small reductions in the serum gastrin levels; however, Zollinger-Ellison patients routinely display a marked and prompt increase in serum gastrin after secretin injection.
- X-77. The answer is A.** (*Chap. 285. Walsh, N Engl J Med 338:984, 1995.*) Although only 15 to 20% of persons infected with the spiral-shaped gram-negative bacillus *H. pylori* will develop an ulcer, 95 to 100% of those with a documented duodenal ulcer can be shown to have *H. pylori* infection. Typically, the organism is found in the deep portion of the mucus gel; although bacteria may adhere to the luminal surfaces of the gastric epithelial cells, they do not invade the mucosa. It appears that the bacteria activate inflammatory cells that produce mucosal damage and release enzymes, such as proteases and phospholipases, which degrade the mucus gel layer. The prevalence of gastric colonization with *H. pylori* increases with age and with lower socioeconomic status. There are multiple ways to diagnose *H. pylori* infection, including histologic examination, culture, measurement of urease activity, and serologic studies. The most effective way to decrease the relapse rate for duodenal ulcer is to institute therapy that successfully eradicates *H. pylori*. The relapse rate is much higher if H_2 -receptor antagonists are used alone. The most effective regimen for eradicating *H. pylori* is so-called triple therapy with bismuth, metronidazole, and either amoxicillin or tetracycline.
- X-78. The answer is C.** (*Chap. 301. Poterucha, Wiesner, Ann Intern Med 126:805–807, 1997.*) Liver transplantation is becoming increasingly routine as a therapeutic strategy in patients with severe, irreversible liver disease. Ideally, the procedure is done when the patient is still in stable condition. Indications in adults include end-stage cirrhosis of all causes, even in those with alcoholic cirrhosis, chronic viral hepatitis, and hepatocellular carcinoma. HBV almost always recurs after transplantation and causes fulminant hepatitis in about 10%. Preoperative vaccination with hepatitis B vaccine, short-term HBIg, or interferon has not been effective. Prophylactic use of HBIg during and for at least 6 months after transplantation increases the success in patients with chronic hepatitis B to levels noted in those with other causes of hepatic failure. Prolonged therapy with HBIg is expensive; early reports suggesting the effectiveness of the nucleoside analogue lamivudine have been encouraging.
- X-79. The answer is D.** (*Chaps. 295, 301. Samuel, N Engl J Med 329:1842, 1993.*) Although most patients with acute viral hepatitis recover completely and a smaller proportion develop chronic hepatitis, death may occur in up to 2 to 3% because of fulminant hepatitis.

This catastrophic event is seen primarily in patients affected with hepatitis B and/or D as well as hepatitis E. In addition to confusion, disorientation, and edema indicative of hepatic failure with encephalopathy, the liver usually shrinks and the prothrombin time is prolonged by a profound shutdown of hepatic protein synthesis. Since the mortality is high (>80% in those who develop hepatic coma) yet all the extrahepatic manifestations are essentially reversible, liver transplantation may be lifesaving in the few patients for whom a suitable donor can be found in a timely fashion. If cerebral edema has already ensued, liver transplantation is probably inappropriate. Long-term prophylaxis with hepatitis B immunoglobulin (HBIg) is associated with a significant lowering of the risk of reinfection. Since long-term HBIg prophylaxis is cumbersome and expensive, alternatives are being explored, particularly the use of nucleoside analogues such as famcyclovir and lamivudine.

- X-80. The answer is E.** (*Chap. 299. Menon, Kamath, Mayo Clin Proc 75:501–509, 2000.*) One of the most important complications of hepatic cirrhosis is variceal bleeding, which, along with ascites and encephalopathy, results from portal hypertension. The primary prophylaxis of known or previously bleeding varices includes cessation of alcohol if relevant, beta blockers, nitrates, and possibly endoscopic variceal band ligation (EVL). Once bleeding develops, the first considerations are hemodynamic stabilization and airway protection. Emergency endoscopy is required to define the nature and site of bleeding. Medical therapy with vasopressin, with or without nitroglycerine, or with somatostatin or octreotide can be used to slow the bleeding while awaiting endoscopy. Although endoscopic injection sclerotherapy controls the active hemorrhage in 90%, recent studies have suggested that EVL may be superior due to equal control rates with less rebleeding, fewer procedure-related complications, and reduced number of sessions. Balloon tamponade can be used if clinical stability cannot be achieved and/or endoscopy is not immediately available.
- X-81. The answer is C.** (*Chap. 297. Tong, N Engl J Med 332:1463, 1995.*) Chronic hepatitis follows acute hepatitis C in 50 to 70% of cases. Many such cases are asymptomatic; however, this patient has symptoms including fatigue and pathologic findings of active disease that include bridging necrosis, both clearly risk factors for the eventual development of cirrhosis. Chronic hepatitis C tends to be very slowly and insidiously progressive in most patients. The course is worse in those who have a high level of hepatitis C as assessed by sensitive PCR-based detection methods. Curiously, patients with chronic hepatitis C often have autoantibodies to liver and muscle antigens, as is typical of patients with autoimmune hepatitis. Glucocorticoids are ineffective in treating chronic hepatitis C. As is the case for chronic hepatitis B infection, interferon α , possibly with ribavirin is the treatment of choice. With prolonged treatment, a biochemical response is likely. In chronic hepatitis B patients treated with interferon there is often a transient elevation in aminotransferase activity; however, with chronic hepatitis C, transaminase levels drop precipitously. Responses occur within the first 3 months of therapy. Asymptomatic hepatitis C carriers with normal enzyme levels need not be treated.
- X-82. The answer is C.** (*Chap. 304. Steer, N Engl J Med 332:1482, 1995.*) This patient has chronic pancreatitis requiring narcotic analgesia, based on historical features and CT revealing calcifications in the pancreas. Pain management for patients with chronic pancreatitis is fraught with the problems of chronic narcotic use. The attacks of abdominal pain in patients with chronic pancreatitis should be treated similarly to those of patients with acute pancreatitis. Alcohol should be avoided completely, as should large meals rich in fat. If a stricture of the pancreatic duct is demonstrated in ERCP, local resection may ameliorate the pain. Although such a finding is unusual, dealing in an anatomic fashion with patients who have such ductal obstruction can lead to long-term pain relief in about 50%. In some patients resection of most of the pancreas is required. Such radical surgery is contraindicated in those who are depressed or continue to drink alcohol. Furthermore, the cost of the pain relief achieved by surgery is pancreatic endocrine and exocrine insufficiency. Nonsurgical anatomic approaches such as sphincterotomy, dilatation of strictures, removal of calculi, and extension of the ventral or dorsal pancreatic duct are associated

with significant complications and have not yet been shown to be definitively effective. Nonanatomic approaches include pancreatic enzyme treatment, diet restriction (moderate fat, high protein and carbohydrate, restriction of long-chain triglycerides), and non-narcotic analgesics. Although the cost of chronic pancreatitis to society is great, most patients do well with vigorous enzyme replacement therapy and abstention from alcohol.

X-83. The answer is B. (*Chap. 303*) The secretin test may be used to detect diffuse pancreatic disease. The secretin response of the pancreas is directly related to the functional mass of pancreatic tissue; therefore, failure to secrete adequate amounts of bicarbonate-containing fluid and/or pancreatic enzymes indicates some degree of pancreatic insufficiency. In patients with early chronic pancreatitis the bicarbonate output is usually low, without a concomitant severe drop in enzyme levels. The test involves the administration of secretin and cholecystokinin, followed by the collection and measurement of duodenal contents. The contents are assayed for the volume of output and bicarbonate content as well as for pancreatic amylase, lipase, trypsin, and chymotrypsin. The pancreas has a great reserve of enzyme secretion ability; intraluminal lipolytic and other digestive functions require only small amounts of enzymes. Consequently, patients with chronic pancreatitis often have low outputs of bicarbonate after secretin while still having normal fecal fat excretion. Steatorrhea occurs only in the setting of markedly low intraluminal levels of pancreatic lipase. Since the normal secretin-CCK test permits only the identification of chronic pancreatic damage, it cannot distinguish between chronic pancreatitis and pancreatic carcinoma, which usually does not produce a major loss of exocrine pancreatic function.

X-84. The answer is D. (*Chap. 302*) Complications of gallstones include acute cholecystitis, biliary colic, gallstone ileus, fistula formation, porcelain gallbladder caused by calcium and salt deposition in the wall, and stones in the common bile duct, which occur in 10 to 15% of these patients. Occult duct stones remain behind after approximately 1 to 5% of cholecystectomies. Occasionally, primary stones can arise in the ducts in the setting of pigment stones or congenital abnormalities.

Patients with acute cholangitis have biliary colic, jaundice, and spiking fevers with chills (so-called Charcot's triad). Many patients with this condition respond rapidly to supportive measures, including antibiotics; however, in the case of suppurative acute cholangitis a completely obstructive ductal system can lead to profound illness, including circulatory collapse. Since most patients who have biliary obstruction caused by duct stones have associated chronic cholecystitis, the gallbladder is relatively indistensible. Therefore, the presence of a palpable gallbladder (Courvoisier's sign) suggests carcinoma of the pancreas. The most appropriate diagnostic study for choledocholithiasis is cholangiography, usually by preoperative ERCP with endoscopic papillotomy and stone extraction, which is now considered the preferred approach compared with laparotomy. Laparoscopic cholecystectomy can be combined with ERCP to treat the entire problem and reduce the incidence of complicated biliary tract disease with the need for choledocholithotomy and T-tube drainage.

X-85. The answer is D. (*Chap. 297. Gross, Mayo Clin Proc 73:355–360, 1998.*) Approximately 1.5% of the U.S. population is chronically infected with hepatitis C. Because such chronic infection can lead to cirrhosis and/or hepatocellular carcinoma, prophylactic therapies must be considered in the appropriate patient. Before 1992, transfusional therapy was an important risk factor; intravenous drug use now accounts for the majority of new infections. The risk for cirrhosis is about 20% at 20 years of infection. In this patient, histologic evidence of inflammation without fibrosis suggests a 50% chance of progression over the next 10 years. Therefore, treatment is indicated. The most effective treatment is probably interferon (recombinant interferon α -2b, 3 million units subcutaneously, thrice weekly) plus oral ribavirin. The combination has been shown to be particularly useful for those who failed interferon monotherapy. Bothersome complications with interferon are common; ribavirin (a nucleoside analogue that suppresses disease activity) is associated with hemolytic anemia, which is usually mild.

This page intentionally left blank.

XI. DISORDERS OF THE IMMUNE SYSTEM, CONNECTIVE TISSUE, AND JOINTS

QUESTIONS

DIRECTIONS: Each question below contains five suggested responses. Choose the **one best** response to each question.

- XI-1.** Of the following, which is expressed earliest in B cell development?
- (A) Surface IgD
 - (B) Surface IgG
 - (C) Surface IgM
 - (D) Cytoplasmic μ chains
 - (E) Fc receptors
- XI-2.** A 29-year-old man with episodic abdominal pain and stress-induced edema of the lips, tongue, and occasionally larynx is likely to have low functional or absolute levels of which of the following proteins?
- (A) C5A (complement cascade)
 - (B) IgE
 - (C) T cell receptor, α chain
 - (D) Cyclooxygenase
 - (E) C1 esterase inhibitor
- XI-3.** A 35-year-old woman comes to the local health clinic because for the past 6 months she has had recurrent urticarial lesions, which occasionally leave a residual discoloration. She also has had arthralgias. Sedimentation rate obtained now is 85 mm/h. The procedure most likely to yield the correct diagnosis in the case would be
- (A) a battery of wheal-and-flare allergy skin tests
 - (B) measurement of total serum IgE concentration
 - (C) measurement of C1 esterase inhibitor activity
 - (D) skin biopsy
 - (E) patch testing
- XI-4.** A 23-year-old man seeks medical attention for perennial nasal congestion and postnasal discharge. He states he does not have asthma, eczema, conjunctivitis, or a family history of allergic disease. His nasal secretions are rich in eosinophils. The test most likely to yield a specific diagnosis in this setting is
- (A) serum IgE level (competitive radioimmunosorbent technique)
 - (B) serum IgE level (radiodiffusion technique)
- XI-4.** (Continued)
- (C) elimination diet test
 - (D) skin testing
 - (E) sinus x-rays
- XI-5.** A patient undergoing evaluation for possible infection with *Mycobacterium tuberculosis* develops a skin wheal 48 h after intradermal placement of TB purified-protein derivative (PPD). Which of the following cellular events accounts for these findings?
- (A) Interleukin (IL)-7-induced B cell activation and secretion of antibodies
 - (B) IL-3-mediated B cell activation and induction of help for T cell activation
 - (C) Monocyte-derived IL-6 activation of T cells
 - (D) Complement-mediated endothelial cell damage
 - (E) CD44-mediated monocyte adhesion to endothelial cells
- XI-6.** A fifty-year-old patient with a 3-year history of asthma and a long history of seasonal coryza recently was noted to have developed an erythematous rash on his lower extremities. Biopsy of the rash revealed small-vessel vasculitis with necrotizing granulomatous inflammation. Chest x-ray disclosed nonspecific bilateral interstitial infiltrates. An antineutrophil cytoplasmic autoantibody was noted in the patient's serum. Which of the following laboratory findings is most likely in this situation?
- (A) Blood culture positive for *M. tuberculosis*
 - (B) Elevated serum rheumatoid factor
 - (C) Elevated eosinophil count
 - (D) Positive cold agglutinin titre
 - (E) Elevated serum cryoglobulins
- XI-7.** A 47-year-old man has had fever, weight loss, arthralgias, pleuritic chest pain, and midabdominal pain for the past 2 months. One week ago he noticed difficulty dorsiflexing his right great toe. Blood pressure is 150/95 mmHg (he has always been normotensive), and laboratory studies reveal anemia of chronic disease, high

XI-7. (Continued)

erythrocyte sedimentation rate, and polymorphonuclear leukocytosis. The chest x-ray is clear. The most likely diagnosis is

- (A) giant cell arteritis
- (B) allergic granulomatosis
- (C) Wegener's granulomatosis
- (D) polyarteritis nodosa
- (E) hypersensitivity vasculitis

XI-8. Which of the following statements regarding the renal involvement associated with systemic lupus erythematosus (SLE) is true?

- (A) Clinically apparent renal disease occurs in 90% of affected persons
- (B) Interstitial nephritis is a rare finding on renal biopsy
- (C) Renal biopsy is not initially necessary in patients with deteriorating renal function and active urine sediment
- (D) Renal disease is uncommon in patients with high-titer anti-double-stranded DNA antibodies
- (E) Urinalysis in affected persons usually reveals proteinuria but little sediment and no red blood cells

XI-9. A 25-year-old woman presents with a history of recurrent expectoration of foul-smelling sputum and intermittent fevers. Chest x-ray discloses characteristic "tram-tracking" bronchial thickening. Physical examination reveals coarse rhonchi in the right chest and splenomegaly. Blood test results are normal except for low levels of serum IgG and IgA. Her past medical history is remarkable for frequent upper respiratory infections and for a history of diarrhea 3 years ago due to *Giardia lamblia* infection. The most appropriate therapy would be

- (A) glucocorticoids
- (B) glucocorticoids and an alkylating agent
- (C) monthly intravenous immunoglobulin
- (D) splenectomy
- (E) bone marrow transplantation

XI-10. A 20-year-old woman presents with a 2-week history of facial rash, fever of 39°C (102.2°F), and progressive malaise. In addition to her dermatologic findings (Plate I), physical examination also reveals swollen and tender knees and wrists bilaterally. Additional skin lesions that may be found in patients with this disorder include

- (A) silvery scales on elbows and knees
- (B) ulcerative lesions of the lower extremities
- (C) hemorrhagic bullae
- (D) hyperkeratosis
- (E) vesicles in a dermatomal distribution

XI-11. Patients with SLE often develop renal failure. Which of the following represents a known mechanism**XI-11.** (Continued)

for the development of kidney damage in patients with SLE?

- (A) Prerenal azotemia
- (B) Hypercalcemia causing renal tubular damage
- (C) Trapping of antibody-double-stranded DNA complexes in glomeruli
- (D) Renal artery occlusion
- (E) Precipitation of antibody-double-stranded DNA complexes in renal tubules producing interstitial nephropathy

XI-12. Which of the following statements concerning the HLA-D region on the sixth human chromosome is correct?

- (A) It is located outside the major histocompatibility gene complex (MHC)
- (B) It encodes proteins involved in the mixed lymphocyte response
- (C) It encodes ubiquitously expressed proteins
- (D) Siblings matched for HLA-A, -B, and -C antigens will usually be matched at the D region
- (E) It is located close to genes encoding for cytokines such as granulocyte-macrophage colony stimulating factor, IL-3, and platelet-derived growth factor

XI-13. Which of the following statements best describes the role of polymerase chain reaction (PCR) in the diagnosis of HIV infection?

- (A) It should be used if the western blot is indeterminate
- (B) It is a useful screening test
- (C) It should be used if two consecutive serologic tests (ELISA) are positive
- (D) It should be used if the initial serologic test is positive, but the second is negative
- (E) It has no real role

XI-14. A 65-year-old man presents with several lesions on both thighs as well as a similar lesion in his mouth. He noted pruritus in these areas several weeks ago. The patient is generally well and on no medications. Each of the lesions (see Plate J) is approximately 1 to 4 cm in size. Thumb pressure fails to cause extension of the lesion. The most likely diagnosis is

- (A) pemphigus vulgaris
- (B) bullous pemphigoid
- (C) herpes zoster
- (D) impetigo
- (E) dermatitis herpetiformis hepatotoxicity

XI-15. The patient in Plate K has scaly plaques that tend to develop on injured skin as well. Which of the following represents the path of the physiologic mechanism that accounts for these lesions?

XI-15. (Continued)

- (A) Immune complex deposition
- (B) Mast cell activation
- (C) T cell activation
- (D) Deposition of monoclonal immunoglobulin
- (E) Fungal infection

XI-16. For 25 years, a 55-year-old man has had recurrent episodes of nonpruritic red patches on both elbows, typically covered with thick, white scales (see Plate K). He has one brother with a similar condition. Both siblings state that their lesions are exacerbated by stress. Physical examination reveals similar lesions on the lower legs. A biopsy of such a lesion would reveal

- (A) an increased number of mitotic figures in skin cells
- (B) neutrophils at the tips of follicular openings
- (C) degeneration of the basal cell layer
- (D) infiltration of neutrophils in small dermal vessels
- (E) patchy infiltration of upper dermis with atypical lymphocytes that have convoluted nuclei

XI-17. Which of the following statements regarding central nervous system disease in patients with HIV infection is correct?

- (A) The most common cause of central nervous system (CNS) disease is the AIDS dementia complex
- (B) The most common cause of seizures is cryptococcal meningoencephalitis
- (C) Antiretroviral agents have no role
- (D) The most common finding on MRI is multiple white matter lesions
- (E) Actual histologic evidence of direct HIV involvement is rare

XI-18. Which of the following statements concerning the lesion in Plate O in patients with HIV infection is correct?

- (A) The incidence of this lesion is increasing
- (B) Lymph node involvement implies metastatic spread and portends more aggressive disease and a poor prognosis
- (C) The lesion is caused by a retrovirus
- (D) The most important determinant of response to interferon is the CD8⁺ count, not tumor burden
- (E) In general, the tumor tends to respect tissue planes and is rarely invasive

XI-19. A 50-year-old woman with severe adult-onset diabetes mellitus who requires insulin for glucose control gradually develops shortness of breath over the period of a few months. Chest x-ray reveals bilateral interstitial infiltrates. An open-lung biopsy discloses infiltration with eosinophils compatible with Loeffler's pneumonia. Given the patient's diabetes, an alternative to steroids would be advisable. Which of the following would be most appropriate in this clinical situation?

XI-19. (Continued)

- (A) IL-2
- (B) Trimethoprim-sulfamethoxazole
- (C) Acyclovir
- (D) Mebendazole
- (E) Zafirlukast

XI-20. A 30-year-old Turkish sailor reports several occurrences of painful oral ulcers in the tongue and the inner aspect of the cheek over the past year. He currently presents with several painful skin lesions, including an ulcer on the left side of his scrotum and painful red nodules on both shins. He also reports occasional bilateral knee and wrist pain. Which of the following tests would be compatible with the patient's diagnosis?

- (A) Elevated level of serum IgE levels
- (B) Biopsy of the skin lesion showing infiltration with neutrophils
- (C) Positive syphilis fluorescent antibody test from material obtained from the scrotal lesion
- (D) The formation of a red nodule 2 days after a sterile needle is pricked into the patient's forearm
- (E) Positive herpes simplex virus culture from the genital lesion

XI-21. Dendritic cells are critical components of the immune system because they

- (A) produce antibodies that bind to specific microorganisms
- (B) are capable of directly recognizing specific antigens on the surface of pathogens
- (C) present antigens to lymphocytes in the context of the MHC and co-stimulatory molecules present on their cell surface
- (D) engulf microorganisms and kill them by secreting toxic substances such as superoxides, hydroxyl radicals, and lysozyme
- (E) provide critical help to activate B cells so that specific antimicrobial antibodies can be secreted

XI-22. Which of the following is the LEAST common immunologic manifestation of HIV infection?

- (A) Cutaneous reactions to drugs
- (B) Anaphylactic reactions to drugs
- (C) Anticardiolipin antibodies
- (D) Oligoarticular arthritis
- (E) Fibromyalgia

XI-23. A woman who has rheumatoid arthritis suddenly develops pain and swelling in the right calf. The most likely diagnosis is

- (A) ruptured plantaris tendon
- (B) pes anserinus bursitis
- (C) ruptured popliteal cyst

XI-23. (Continued)

- (D) thrombophlebitis
- (E) Achilles tendonitis

XI-24. A 70-year-old woman presents with blurring of vision in the left eye since waking earlier in the morning. She reports 2 months of fevers, sweats, anorexia, and a 4.5-kg (10-lb) weight loss. She also reports increasingly severe left temporal headaches over the same time period. Her physical examination reveals scalp tenderness over the left temporal region. Her laboratories reveal a normochromic, normocytic anemia, mildly elevated alkaline phosphatase, and an erythrocyte sedimentation rate of 92. Appropriate action includes

- (A) obtaining an emergent MRI/MRA of her head
- (B) referring the patient for a biopsy of her temporal artery, but abstaining from initiating therapy until the biopsy results are available
- (C) initiating high-dose glucocorticoid therapy and referring the patient for a temporal artery biopsy
- (D) obtaining a head CT to rule out metastatic disease and scheduling a colonoscopy
- (E) performing a lumbar puncture to rule out meningitis

XI-25. A 65-year-old obese man complains of progressive pain in both knees, exacerbated by walking. Past medical history is unremarkable. Physical examination discloses normal pulses and circulation and no joint effusions. Bony crepitus is evident upon movement of either knee joint. Routine laboratory studies, including an ESR, are normal. Radiographs of the knees reveal joint space narrowing. What is the most important pathophysiologic feature in this situation?

- (A) Deposition of calcium pyrophosphate crystals
- (B) Deposition of urate crystals
- (C) Lymphocytic infiltration of synovium
- (D) Neutrophilic infiltration of synovium
- (E) Loss of articular cartilage

XI-26. Which of the following is appropriate initial therapy in the clinical scenario described in question XI-25?

- (A) Heat and an exercise program
- (B) 2 weeks of joint rest
- (C) Glucocorticoid injection of the affected joint(s)
- (D) A short course of systemic glucocorticoid
- (E) A trial of celecoxib

XI-27. Which of the following systemic manifestations is LEAST characteristic of early adult rheumatoid arthritis?

- (A) High fever
- (B) Weight loss
- (C) Muscle wasting
- (D) Vague musculoskeletal symptoms
- (E) Fatigue

XI-28. Which of the following conditions is LEAST likely to occur in late extraarticular seropositive rheumatoid arthritis?

- (A) Neutropenia
- (B) Dry eyes
- (C) Leg ulcers
- (D) Sensorimotor polyneuropathy
- (E) Hepatitis

XI-29. Within minutes after injection of radiocontrast at the time of abdominal CT, a patient develops urticaria, flushing, and congestion of tongue and larynx. Respiratory stridor develops and intubation is emergently required. The mechanism of this event is

- (A) direct activation of mediator release from mast cells or basophils or both
- (B) IgE-mediated reaction against protein-hapten conjugates
- (C) IgE-mediated reaction against native proteins
- (D) deficiency of C1 esterase inhibitor
- (E) inherited inability to normally catabolize the radiocontrast agent

XI-30. A 35-year-old woman relates a 1-year history of recurrent crops of small, reddish-brown pruritic skin bumps. She also notes facial flushing, lightheadedness, and lower abdominal pain. Pressure on one of these skin lesions results in increased itching and redness. Some attacks are brought on by the use of alcohol or nonsteroidal anti-inflammatory agents. An upper GI series reveals an ulcer crater in the duodenal bulb. Skin biopsy would reveal

- (A) aggregates of neutrophils in small venules
- (B) mast cell infiltration
- (C) hyperkeratosis and infiltration of lymphocytes into the dermis
- (D) malignant-appearing neovascularization
- (E) normal findings

XI-31. In which of the following clinical situations would a diagnosis of ankylosing spondylitis most likely be correct?

- (A) For the past 10 years, a 28-year-old man has had low back pain and stiffness, worse at night and relieved with activity
- (B) For the past 5 years, a 32-year-old man has had low back pain made worse with activity but improved with bed rest
- (C) For the past 10 years, a 34-year-old man has had intermittent bouts of mild low back pain; now, however, he suddenly is unable to dorsiflex his right great toe
- (D) For the past 10 years, a 65-year-old man has had low back pain radiating down both posterior thighs to the knees

XI-31. (Continued)

- (E) For the past 15 years, a 72-year-old man has had progressive low back pain made worse with walking but improved with rest and leaning forward

XI-32. A 30-year-old woman presents complaining of frequent upper respiratory infections characterized by heavy sputum production. She has a history of eczema, wheezing, and intermittent diarrhea. She has never been hospitalized for any of her infections but is concerned about their recurrent nature. At this time she feels well and her physical examination is unremarkable. Routine laboratory studies are unremarkable; however, quantitative immunoglobulin levels show that she has normal levels of serum IgM and IgG but depressed levels of serum IgA. The most important thing to tell this patient is

- (A) she will require life-long infusions of intravenous immunoglobulin
- (B) she will require immunoglobulin infusions at times when she develops a probable bacterial infection
- (C) she is likely to develop systemic lupus erythematosus
- (D) blood transfusions could have grave consequences
- (E) prophylactic therapy with trimethoprim-sulfamethoxazole should be initiated at this time

XI-33. A 26-year-old woman with SLE is noted to have a prolonged partial thromboplastin time. This abnormality is associated with

- (A) leukopenia
- (B) drug-induced lupus
- (C) central nervous system vasculitis
- (D) central nervous system hemorrhage
- (E) deep venous thrombosis

XI-34. A patient with diffuse cutaneous scleroderma (systemic sclerosis) who had been stable for several years is recently noted to have hypertension. This patient is at significant risk of dying from

- (A) thrombotic stroke
- (B) central nervous system hemorrhage
- (C) renal failure
- (D) pulmonary hypertension
- (E) pulmonary fibrosis

XI-35. For the past 2 years, a 27-year-old man has had recurrent episodes of asymmetric inflammatory oligoarticular arthritis involving his knees, ankles, and elbows lasting from 2 to 4 weeks. He also states he has had recurrent, painful “canker sores” in his mouth for the past 10 years. Now, he presents with fever, arthritis, mild abdominal pain, severe headache, and superficial thrombophlebitis in the left leg. The most likely diagnosis in this man is

XI-35. (Continued)

- (A) regional enteritis
- (B) systemic lupus erythematosus
- (C) Behçet’s syndrome
- (D) Whipple’s disease
- (E) ulcerative colitis

XI-36. A 37-year-old woman with Raynaud’s phenomenon complains of progressive weakness with inability to arise out of a sitting position without assistance. On examination, the patient has swollen “sausage-like” fingers, alopecia, erythematous patches on the knuckles, facial telangiectasias, and proximal muscle weakness. Laboratory evaluation includes a normal CBC and serum chemistries, except for creatine phosphokinase, 4.5 μ kat/L (270 U/L), and aldolase, 500 nkat/L (30 U/L). The following serologic profile is found: rheumatoid factor is positive at 1:1600; ANA is also positive at 1:1600 with a speckled pattern and very high titers of antibodies against the ribonuclease-sensitive ribonucleoprotein component of extractable nuclear antigen. This patient probably has

- (A) early rheumatoid arthritis
- (B) systemic sclerosis
- (C) systemic lupus erythematosus
- (D) dermatomyositis
- (E) mixed connective-tissue disease (MCTD)

XI-37. An 18-year-old man presents with abdominal pain, nausea, and vomiting. He also notes the onset of a rash and painful joints. Physical examination is remarkable for the presence of palpable purpura distributed over the buttocks and lower extremities as well as guaiac-positive stool. Laboratory evaluation is remarkable for urinalysis that discloses mild proteinuria and red blood cell casts. Other serum studies are normal. Skin biopsy would likely reveal

- (A) necrotizing angitis
- (B) eosinophilic angitis
- (C) leukocytoclastic vasculitis
- (D) extravasated red blood cells without vasculitis
- (E) mast cell infiltration

XI-38. A 70-year-old man with a history of hypertension, peptic ulcer disease, chronic renal insufficiency, and diabetes presents with an acutely swollen and painful left knee. His vital signs and general physical examination are unremarkable, but his left knee has an obvious effusion and is warm, swollen, and red. Arthrocentesis reveals WBC of 50,000/ μ L, negative Gram stain, and strongly birefringent needle-shaped intracellular crystals. Which of the following statements concerning this situation is correct?

- (A) The serum uric acid level will be elevated
- (B) Intraarticular glucocorticoid may be given now
- (C) Antibiotics are required

XI-38. (Continued)

- (D) A 24-h urine collection will reveal a high level of uric acid
- (E) Allopurinol should be given now

XI-39. A 50-year-old woman has had Raynaud's phenomenon of the hands for 15 years. The condition has become worse during the last year, and she has developed arthralgias and arthritis involving the hands and wrists as well as mild sclerodactyly and difficulty swallowing solid foods. Laboratory studies reveal a positive serum antinuclear antibody assay at a dilution of 1:160. Anticentromere antibodies are present in high titers; antiribonucleoprotein antibodies are not detectable. The most likely diagnosis of this woman's disorder is

- (A) systemic sclerosis
- (B) mixed connective-tissue disease
- (C) overlap syndrome
- (D) dermatomyositis
- (E) systemic lupus erythematosus

XI-40. A 35-year-old man has had recurrent diarrhea for at least 5 years. About 7 years ago many reddish-brown macules appeared on his torso and extremities (see Plate L). Rubbing these lesions gently results in the formation of a wheal. He also has been bothered by severe generalized itching, which is made worse when he takes aspirin for his frequent headaches. He has lost 11.4 kg (25 lb) in the past few months. Biopsy of the lesion would reveal infiltration with

- (A) lymphoma cells
- (B) leukemic cells
- (C) neutrophils
- (D) mast cells
- (E) eosinophils

XI-41. True statements about human T cells include which of the following?

- (A) They are the principal cells in the cortical "germinal centers" and medullary cords of lymph nodes
- (B) They carry membrane-bound IgD on their surface
- (C) They constitute 70 to 80% of circulating blood lymphocytes
- (D) They arise from stem cells in the thymus
- (E) They are the main effectors of antibody-dependent, cell-mediated cytotoxicity

XI-42. A 27-year-old woman with SLE is in remission; current treatment is azathioprine, 75 mg/d, and prednisone, 5 mg/d. Last year she had a life-threatening exacerbation of her disease. She now strongly desires to become pregnant. Which of the following is the LEAST appropriate action?

XI-42. (Continued)

- (A) Advise her that the risk of spontaneous abortion is high
- (B) Warn her that exacerbations can occur in the first trimester and in the postpartum period
- (C) Tell her it is unlikely a newborn will have lupus
- (D) Advise that fetal loss rates are higher if anticardiolipin antibodies are detected in her serum
- (E) Stop the prednisone just before she attempts to become pregnant

XI-43. Human immunoglobulin A (IgA) can be described by which of the following statements?

- (A) It is the predominant immunoglobulin in plasma
- (B) It exists in four subclasses, of which IgA2 is predominant
- (C) It can prevent attachment of microorganisms to epithelial cell membranes
- (D) It is prominent early in the immune response and is the major class of antibody in cold agglutinins
- (E) It has the shortest half-life of the five classes of immunoglobulin

XI-44. Which of the following is LEAST likely to be seen in Sjögren's syndrome?

- (A) Dental caries
- (B) Corneal ulceration
- (C) Renal tubular acidosis
- (D) Lymphoma
- (E) Cardiac fibrosis

XI-45. A 34-year-old man with AIDS complains of general malaise, low-grade fevers, and diffuse myalgias of 1 month's duration. His medications include only zidovudine and zalcitabine, which he has been taking for 8 months. Physical examination is remarkable for oral thrush, diffuse lymphadenopathy, and generalized muscle tenderness and weakness. The remainder of his examination is normal. Complete blood count reveals a hematocrit of 27%, WBC of 2900/ μ L with 60% neutrophils, 30% lymphocytes, and 10% monocytes. Creatine phosphokinase is 6000 U/L. Which of the following is most likely to yield the diagnosis?

- (A) Blood cultures
- (B) Lymph node biopsy
- (C) Electromyography
- (D) Discontinuing the zidovudine
- (E) Muscle biopsy

XI-46. Which of the following statements about the human major histocompatibility complex (MHC) is correct?

- (A) Class I histocompatibility genes are located on chromosome 7 and class II genes are located on chromosome 6

XI-46. (Continued)

- (B) Class I gene products form a heterodimer with β_2 -microglobulin
- (C) The principal function of histocompatibility molecules is to activate neutrophils and monocytes
- (D) The class II molecule-peptide complex is preferentially recognized by natural killer cells
- (E) The HLA-B27 gene product participates in the pathophysiology of ankylosing spondylitis

XI-47. A 70-year-old man with renal insufficiency and recurrent attacks of proven gouty arthritis has elevated serum and urine uric acid levels. He is now asymptomatic. The most appropriate approach is

- (A) no chronic therapy
- (B) chronic allopurinol
- (C) chronic colchicine
- (D) chronic probenecid
- (E) chronic celecoxib

XI-48. A 55-year-old woman complains of stiff, aching hands, especially in the morning. Radiographs of the hands reveal expansion at the base of the terminal phalanges, tapering of the proximal phalanges, and cuplike erosions and bony proliferation of the distal terminal phalanges. This patient most likely has

- (A) systemic lupus erythematosus
- (B) rheumatoid arthritis
- (C) psoriatic arthritis
- (D) gouty arthritis
- (E) osteoarthritis

XI-49. An otherwise-healthy 75-year-old man who underwent a left total hip replacement 6 months ago develops slowly progressive left hip pain. He feels relatively well. Physical examination is unremarkable except for pain on internal rotation of the left hip. Routine laboratory studies are unremarkable except for an elevated ESR. Radiographs reveal loosening of the hip prosthesis. The next most appropriate action is

- (A) begin a 6-week course of IV vancomycin
- (B) administer a 6-month course of oral rifampin and ciprofloxacin
- (C) administer a 6-month course of ciprofloxacin
- (D) joint aspiration
- (E) begin a 6-week course of IV vancomycin; replace the joint after 3 weeks of therapy

XI-50. A 23-year-old sexually active woman, currently menstruating, develops fever and chills. She complains of intermittent pain and stiffness of the ankles, wrists, and hands. Physical examination reveals hemorrhagic pustules on the dorsal surface of both hands. Aspiration of the left ankle joint yields 1 mL of fluid with a WBC count of

XI-50. (Continued)

12,000/ μ L with a negative Gram stain. The most useful diagnostic study is likely to be

- (A) serum fluorescent antitreponemal antibody
- (B) cultures of skin and cervix
- (C) culture of the joint fluid
- (D) serum antibody against *Borrelia burgdorferi*
- (E) acid-fast stain of joint fluid

XI-51. A 55-year-old housewife who is a heavy cigarette smoker and diabetic presents with the gradual onset of pain and stiffness in the left shoulder after falling on her left arm when she slipped on an icy surface. The shoulder is tender to palpation, and range of motion is severely limited. Other joints are unremarkable. Radiographs show osteopenia in the proximal left humerus. Which one of the following is likely to be associated with this syndrome?

- (A) Response to systemic methotrexate
- (B) Relief with joint immobility
- (C) Elevated serum rheumatoid factor
- (D) Ability to inject a limited amount of contrast on arthroscopy
- (E) Elevated serum monoclonal immunoglobulin

XI-52. Which of the following statements about fibromyalgia is true?

- (A) The condition is found predominantly in men
- (B) Disturbed sleep has been implicated as a factor in the pathogenesis
- (C) All patients have psychological abnormalities
- (D) Joint examination yields nonspecific swelling
- (E) Low-dose glucocorticoids are often beneficial

XI-53. A physician working on a Hopi Indian reservation in New Mexico develops a flulike illness with the additional features of cough; conjunctivitis; painful, red lesions on his legs; and a painful, swollen right knee. In this situation

- (A) culturing the joint fluid will probably yield the diagnosis
- (B) penile swab may be helpful in establishing the diagnosis
- (C) synovial fluid analysis will reveal needle-shaped crystals
- (D) the arthritis could be a sterile manifestation of acute hypersensitivity
- (E) synovial biopsy will be unable to establish the diagnosis

XI-54. Which statement regarding T cell immunophenotype is correct?

- (A) The T cell antigen receptor is the earliest surface marker of T cell lineage

XI-54. (Continued)

- (B) The expressions of CD4 (T4) and CD8 (T8) surface antigens are mutually exclusive
- (C) The T cell antigen receptor accounts for the ability of T cells to form rosettes with sheep red blood cells
- (D) The T cell antigen receptor complex consists of a signal-transducing moiety and an antigen-recognition moiety
- (E) Mature T cells display nuclear proteins that are members of the immunoglobulin gene super-family

XI-55. Which statement about isolated immunoglobulin A deficiency is correct?

- (A) Immunoglobulin replacement therapy is indicated
- (B) The risk of adverse reactions to transfusions is increased.
- (C) The incidence of autoimmune disease is decreased
- (D) Secretory IgA levels usually are normal
- (E) The reduced number of IgA-bearing B cells accounts for the reduced serum IgA levels

XI-56. Which statement regarding immune-complex disease is correct?

- (A) Even under normal conditions only a small subsets of immune complexes are removed by the reticulo-endothelial system
- (B) Signs and symptoms stem from the deposition of massive amounts of immune complexes in the reticuloendothelial system
- (C) Persistence of immune complexes in the circulation seems to be a requirement for the development of renal manifestations
- (D) Renal lesions depend on antigen-antibody combinations in which antibody is in slight excess
- (E) The rash of hypersensitivity vasculitis may be an example of immune-complex disease

XI-57. Which statement regarding HLA class I molecules is correct?

- (A) They consist of four polypeptide chains
- (B) Two β_2 -microglobulin subunits are included
- (C) They share less than 25% homology with one another
- (D) They are distributed unevenly from one racial group to another
- (E) They are expressed on all mature hematopoietic cells

XI-58. A 63-year-old woman with a history of rheumatoid arthritis since age 42 is seen for the first time by a new physician. The patient has been doing poorly of late. Though her joint disease has not been a problem, she has lost weight and has been plagued by chronic foul smelling diarrhea, easy bruising, profound fatigue, and peripheral**XI-58.** (Continued)

edema. On examination she has waxy skin plaques clustered in the axillary folds, a large tongue, a quiet precordium, hepatosplenomegaly, guaiac-positive stool, and peripheral neuropathy. Laboratory evaluation includes the findings of proteinuria (5 g/d), normal serum chemistry except slightly low albumin and slightly elevated alkaline phosphatase, and low-voltage QRS complexes on electrocardiography. In order to expeditiously diagnose the problem, one could

- (A) perform a bone marrow aspirate and biopsy
- (B) obtain three serial sputum samples for acid-fast bacillus (AFB) culture
- (C) perform an abdominal CT examination
- (D) obtain an abdominal subcutaneous fat pad aspirate
- (E) perform a serum protein electrophoresis

XI-59. Which of the following statements best characterizes SLE?

- (A) Twenty percent of patients receiving procainamide develop a positive ANA test
- (B) Nephritis is a frequent consequence of hydralazine-induced lupus
- (C) Most patients on hydralazine develop a positive ANA test; however, only 10% suffer from lupus-like symptoms
- (D) If patients with drug-induced lupus fail to respond within several weeks of discontinuing the offending agent, a trial of COX-2 inhibitors is indicated
- (E) If a patient with drug-induced lupus has persistent symptoms for longer than 6 months, an anti-ds antibody and CH50 levels should be drawn

XI-60. A 50-year-old man with hearing loss, hoarseness, and vertigo has noted recurrent pain and swelling in both ears that is associated with a systemic illness consisting of fever, fatigue, and weight loss. He sometimes experiences redness on the bridge of the nose. Unrelated to these episodes the patient also has intermittent stiffness and tenderness in a knee or hand. This patient most likely has

- (A) serum antibodies to type II collagen
- (B) high levels of rheumatoid factor
- (C) serum anti-double-stranded DNA antibody
- (D) serum anti-RNA antibody
- (E) granulomatous infiltration of nasal structures

XI-61. Which of the following statements about sarcoidosis is correct?

- (A) Accumulation of suppressor-cytotoxic T lymphocytes occurs in sites of disease activity
- (B) Geography and race do not affect the incidence
- (C) Chest radiography and pulmonary function testing are sensitive means of evaluating the intensity of pulmonary inflammation

XI-61. (Continued)

- (D) Transbronchial biopsy may reveal granulomata in a high percentage of patients and is a useful means of diagnosis
- (E) Asymptomatic hilar adenopathy accounts for 80% of cases of sarcoidosis in the United States

XI-62. Which statement concerning rheumatoid factors is correct?

- (A) They are antibodies to the Fc fragment of immunoglobulin M
- (B) They are associated exclusively with rheumatoid arthritis and lupus
- (C) Their presence in the serum of persons with rheumatoid arthritis correlates with a worse prognosis than that for persons with seronegative disease
- (D) Their presence correlates with articular manifestations of rheumatoid arthritis
- (E) They frequently do not appear in the serum of persons with rheumatoid arthritis until late in the course of the illness

XI-63. The diagnosis of many rheumatic diseases, including rheumatoid arthritis, is based entirely on clinical grounds. Which clinical characteristic is most closely associated with rheumatoid arthritis?

- (A) Prolonged morning stiffness
- (B) Migratory polyarthritis
- (C) Arthritis involving the distal interphalangeal joints
- (D) Arthritis of the hips
- (E) Pyoderma gangrenosum

XI-64. A 27-year-old man presents because of a painful, swollen knee and ankle of 2 weeks' duration. He has never had joint disease prior to this time. The patient also complains of low back pain and a recent history of clear penile discharge. On examination he has vesicles (some of which have crusted over) on the palms, soles, and glans penis; injected conjunctivae; a swollen right index finger; and arthritis of the right knee and left ankle. Correct statements regarding this patient include

- (A) early use of cyclophosphamide is indicated
- (B) his joint disease will probably improve after a course of tetracycline
- (C) he is probably HLA-B27-positive
- (D) x-ray of the pelvis would probably demonstrate blurring of the sacroiliac joint
- (E) his symptoms are mediated by immune-complex deposition

XI-65. A 40-year-old woman presents with purulent nasal discharge, cough, hemoptysis, and dyspnea. Chest x-ray reveals bilateral nodules; creatinine and ESR are elevated; urinalysis reveals hematuria and proteinuria. Accurate statements regarding this woman's condition include

XI-65. (Continued)

- (A) she probably has circulating anti-basement membrane antibodies
- (B) she probably has circulating antineutrophil antibodies
- (C) diffuse adenocarcinoma would probably be found if a lung biopsy was carried out
- (D) plasmapheresis should be undertaken
- (E) even with appropriate therapy, her prognosis is poor

XI-66. Acute sarcoidosis is characterized by which of the following syndromes?

- (A) Cough, hemoptysis, and interstitial pulmonary involvement
- (B) Myopathy, keratotic skin lesions on the palms and soles, and arthralgias
- (C) Fever, pulmonary stenotic murmur, and nailbed lesions
- (D) Erythema nodosum, arthralgias, and pulmonary nodules
- (E) Fever, parotid enlargement, uveitis, and facial nerve palsy

XI-67. A 52-year-old woman presents with nasal discharge and stuffiness, difficulty in breathing through the nose, and sinus pain. ENT examination reveals ulcers on the nasal septum and perforation of the soft palate. There is no history of prior illness or drug abuse. Biopsy of involved material under anesthesia reveals noncaseating granulomatous inflammation with necrotic debris. No malignant cells, vasculitis, or microorganisms are noted. Correct statements concerning this patient's condition include which of the following?

- (A) The history and findings are consistent with Wegener's granulomatosis
- (B) If she is not appropriately treated, the disease will probably be fatal
- (C) The treatment of choice is cytotoxic therapy
- (D) The disease, if unchecked, can progress to involve the mediastinum and lungs
- (E) Optimal treatment should involve surgical debridement

XI-68. Which of the following findings on joint aspiration is most likely to be associated with calcium pyrophosphate deposition disease (pseudogout)?

- (A) Fluid, clear and viscous; white blood cell count, 400/ μ L; crystals, rhomboidal and weakly positively birefringent
- (B) Fluid, cloudy and watery; white blood cell count, 8000/ μ L; no crystals
- (C) Fluid, dark brown and viscous; white blood cell count, 1200/ μ L; crystals, needle-like and strongly negatively birefringent

XI-68. (Continued)

- (D) Fluid, cloudy and watery; white blood cell count, 12,000/ μL ; crystals, needle-like and strongly negatively birefringent
- (E) Fluid, cloudy and watery; white blood cell count, 4800/ μL ; crystals, rhomboidal and weakly positively birefringent

XI-69. A 65-year-old woman with long-standing diabetes presents with severe pain in the left ankle and foot. She gives a history of twisting the ankle about 2 months earlier. Physical examination reveals decreased sensation to pinprick in both legs from the knees downward and swelling of the left foot and ankle with an outward bulge in the sole. There is no evidence of vascular compromise. Radiographs show osteophytes as well as tapering of the distal metatarsal bones. Aspiration of the ankle joint reveals a small amount of sterile xanthochromic fluid without crystals. The most appropriate treatment for this problem is

- (A) a 6-week course of vancomycin
- (B) foot brace
- (C) joint drainage
- (D) nonsteroidal anti-inflammatory agent
- (E) exercise program

XI-70. A 65-year-old man with advanced intrathoracic lung cancer complains of painful burning in his fingertips. Physical examination reveals widened fingertips, convexity of the nail contour, and flattening of the proximal nail-cuticle angle. The nail bed is spongy. This process is most likely due to

- (A) vascular oversupply due to angiogenic factors
- (B) bony resorption due to parathyroid hormone-like substance
- (C) infection with coagulase-negative staphylococci
- (D) abnormal platelet-endothelial interaction
- (E) neuropathy

XI-71. A 55-year-old woman with active rheumatoid arthritis continues to have signs and symptoms of polyarthritis despite the use of celecoxib. She failed a trial of prednisone 4 months ago due to intolerance and lack of efficacy. The next most appropriate therapy is

- (A) gold salts
- (B) etanercept
- (C) cyclosporine
- (D) solumedrol pulse
- (E) shark cartilage

XI. DISORDERS OF THE IMMUNE SYSTEM, CONNECTIVE TISSUE, AND JOINTS

ANSWERS

- XI-1. The answer is D.** (*Chap. 305*) Lymphoid cells, including both T and B lymphocytes, arise from hematopoietic stem cells. Those cells destined to enter the B cell lineage arise continuously in the bone marrow. The earliest cells destined to become B cells express surface CD10 (CALLA) protein, an endopeptidase thought to inactivate certain peptide hormones. These pre-B cells are large lymphoid cells containing cytoplasmic μ chains, the heavy chain of IgM, which can be detected by immunofluorescence. Cytoplasmic light chains are not present, and pre-B cells lack membrane-bound IgM or immunoglobulin of any other class. In the process of B cell maturation, smaller lymphoid cells will appear that bear a narrow rim of cytoplasmic IgM; later, cells with membrane-bound IgM develop.
- XI-2. The answer is E.** (*Chap. 305. Frank, N Engl J Med 316:1525–1530, 1987.*) Complement activity, resulting from the sequential interaction of a large number of plasma and cell-membrane proteins, plays an important role in the inflammatory response. The classic pathway of complement activation is initiated by an antibody-antigen interaction. The first complement component (C1, a complex composed of three proteins) binds to immune complexes with activation mediated by C1q. Active C1 then initiates the cleavage and concomitant activation of components C4 and C2. The activated C1 is destroyed by a plasma protease inhibitor termed *C1 esterase inhibitor*. This molecule also regulates clotting factors XI and kallikrein. Patients with deficiency of C1 esterase inhibitor may develop angioedema, sometimes leading to death via asphyxia. Attacks may be precipitated by stress or trauma. In addition to low antigenic or functional levels of C1 esterase inhibitor, patients with this autosomal dominant condition may have normal levels of C1 and C3, but low levels of C4 and C2. Danazol therapy produces a striking increase in the level of this important inhibitor and alleviates symptoms in many patients. An acquired form of angioedema due to C1 esterase inhibitor deficiency has been described in patients with autoimmune or malignant disease.
- XI-3. The answer is D.** (*Chap. 310*) Urticaria and angioedema are common disorders, affecting approximately 20% of the population. In acute urticarial angioedema, attacks of swelling are of less than 6 weeks' duration; chronic urticarial angioedema is by definition more long-standing. Urticaria usually is pruritic and affects the trunk and proximal extremities. Angioedema is generally less pruritic and affects the hands, feet, genitalia, and face. The woman described in the question has chronic urticaria, which probably is due to a cutaneous necrotizing vasculitis. The clues to the diagnosis are the arthralgias, presence of residual skin discoloration, and elevated sedimentation rate—which would be uncharacteristic of other urticarial diseases. Diagnosis can be confirmed by skin biopsy. Chronic urticaria is rarely of an allergic cause; hence, allergy skin tests and measurement of total IgE levels are not helpful. Measurement of C1 esterase inhibitor activity is useful in diagnosing hereditary angioedema, a disease not associated with urticaria. Patch tests are used to diagnose contact dermatitis.
- XI-4. The answer is D.** (*Chap. 310. Naclerio, N Engl J Med 325:860–869, 1991.*) Allergic rhinitis can be either seasonal as a result of pollen exposure or perennial as a result of exposure to dust or mold spores (or both). In these IgE-mediated reactions to inhaled foreign substances, nasal eosinophilia is common. Vasomotor rhinitis is a chronic, non-

allergic condition in which vasomotor control in the nasal membranes is altered. Irritating stimuli, such as odors, fumes, and changes in humidity and barometric pressure, can cause nasal obstruction and discharge in affected persons, and nasal eosinophilia is not noted. Because the man described in the question has either perennial allergic rhinitis due to dust or mold-spore allergy or eosinophilic nonallergic rhinitis, skin testing for responses to suspected allergens should be diagnostic. Though total serum IgE may be elevated, demonstration of specificity is critical. Specificity can be demonstrated by binding to a solid-phase antigen and detected by uptake of radiolabeled anti-IgE (radioallergosorbent technique; RAST). RAST is more difficult than skin testing due to the requirement for defined antigens and standardization. Pollen skin tests are unlikely to be helpful because of the perennial nature of the condition described. An elimination diet can be used diagnostically or therapeutically in persons with suspected food allergy; however, food allergy rarely causes rhinitis. Sinus x-rays, whether positive or negative, would not reveal the underlying cause of the rhinitis.

- XI-5. The answer is C.** (*Chap. 305*) Reactions are initiated by mononuclear leukocytes and require 48 to 72 h to evidence a response after antigen exposure. Such delayed-type hypersensitivity reactions are best exemplified by local reactions to skin challenge in persons previously exposed to the test antigen. The cellular events resulting in such hypersensitivity responses are centered around T cells [particularly lymphokine-secreting helper T cells (T_H1)] and macrophages. Antigen processed by monocytes-macrophages is presented to specific T cells. Macrophages secrete IL-1 and IL-6 to clonally amplify the specific T cell and also secrete lymphokines such as IL-2 and interferon γ to recruit additional T cells and macrophages to participate in the inflammatory response. Macrophages recruited in this fashion may undergo epithelioid cell transformation to form giant cells, perhaps in response to IL-4 and interferon γ . In addition to mycobacterial infections, diseases in which delayed-type hypersensitivity is important include histoplasmosis, chlamydial infections, schistosomiasis, and berylliosis.
- XI-6. The answer is C.** (*Chap. 317. Jennette, Falk, N Engl J Med 337:1512–1523, 1997.*) Based on biopsy results, this patient has one of the small-vessel vasculitides that include Henoch-Schönlein purpura, cryoglobulinemic vasculitis, microscopic polyangiitis, Wegener's granulomatosis, and Churg-Strauss syndrome. Three of these entities, microscopic polyangiitis, Wegener's granulomatosis, and Churg-Strauss syndrome, are distinguished by the common finding of antineutrophil cytoplasmic antibodies in serologic samples. Necrotizing granulomas are seen both in Wegener's granulomatosis and Churg-Strauss syndrome. Distinguishing these two entities from each other might be difficult; however, asthma is rarely seen in Wegener's granulomatosis but is a hallmark of Churg-Strauss syndrome, as is eosinophilia. The vasculitic phase of Churg-Strauss syndrome develops within 3 years of the onset of asthma. Renal disease is less frequent and severe than in Wegener's granulomatosis. While coronary arteritis and myocarditis are the most common causes of morbidity and mortality in Churg-Strauss syndrome, high-dose steroid treatment early in the course of the disease is likely to reduce the incidence of such problems.
- XI-7. The answer is D.** (*Chap. 317*) Polyarteritis nodosa is a vasculitis of medium-sized vessels. Early systemic features include fever, weakness, anorexia, weight loss, myalgias, and arthralgias (although severe and persistent arthritis is uncommon). Pericarditis and pleuritis also can occur. Mononeuritis multiplex develops because of involvement of the vasa vasorum; it is reflected in the man described by the sudden loss of the ability to dorsiflex his right great toe. Abdominal pain occurs in 60 to 70% of affected persons and is related to disease involvement of mesenteric arteries. Hypertension develops from arterial occlusion and occurs before renal involvement. Laboratory findings of elevated erythrocyte sedimentation rate, anemia of chronic disease, and polymorphonuclear leukocytosis all occur with polyarteritis nodosa. Pulmonary involvement is unusual and serves to distinguish this entity clinically from allergic granulomatosis and Wegener's granulomatosis. *Hypersensitivity vasculitis* is a term applied to small-vessel vasculitides associated with a

range of findings from purely cutaneous disease to minimal skin disease but life-threatening involvement of major organs. Giant cell arteritis involves the aorta and other great vessels, producing constitutional symptoms and large-vessel occlusion in young women (Takayasu's disease) and in the elderly (temporal arteritis, polymyalgia rheumatica).

- XI-8. The answer is C.** (*Chap. 311*) Renal disease is clinically evident in about half of persons with SLE. However, nearly all persons with SLE have some evidence of renal disease on renal biopsy. Renal disease associated with SLE includes both glomerulonephritis and interstitial nephritis. Glomerular disease has been classified into membranous nephritis and mesangial, focal, and diffuse glomerulonephritis. Immune-complex interstitial nephritis occurs most commonly in persons who have diffuse glomerulonephritis. Urinalysis performed in persons with active renal disease usually reveals microscopic hematuria, red cell casts, and proteinuria; the exception is membranous lupus nephritis, in which proteinuria is the dominant finding. Drug-induced lupus rarely leads to renal disease. Anti-dsDNA antibodies at high titer are associated with severe nephritis. Renal biopsy is not necessary in SLE patients whose renal function is rapidly deteriorating when they have an active sediment. If such patients fail to respond to the prompt initiation of glucocorticoid therapy demanded in such a situation, then biopsy should be undertaken. Patients with mild clinical disease should have a biopsy to determine if they have active, severe, inflammatory lesions, which might respond to therapy.
- XI-9. The answer is C.** (*Chap. 308. Sneller, Ann Intern Med 118:720–730, 1993.*) Common variable immunodeficiency represents a heterogeneous group of adults who have in common deficiencies of all major immunoglobulin classes. The defect is believed to be due to an abnormality in B cell maturation, though most of these patients tend to have normal levels of clonally diverse B lymphocytes. The B cells can recognize antigen and proliferate but fail to differentiate to the immunoglobulin-secreting stage. Associated with this abnormality is nodular lymphoid hyperplasia in various organs (including the gut) and splenomegaly. This panhypogammaglobulinemic disorder should be suspected in adults with chronic pulmonary infections, unexplained bronchiectasis (like the case presented in this example), chronic giardiasis, malabsorption, and atrophic gastritis. Patients develop intestinal neoplasms at increased frequency. They also develop autoimmune conditions, such as Coombs-positive hemolytic anemia and idiopathic thrombocytopenic purpura. There is some suggestion that, in addition to failure of B cells to secrete immunoglobulin, T cells have an impaired ability to release lymphokines. The mainstay of therapy for common variable immunodeficiency is to increase the antibody content by administration of intravenous immunoglobulin concentrates. The goal is to increase the IgG level to 5 g/L, which can generally be accomplished by monthly administration of 200 to 400 mg/kg of intravenous immunoglobulin. True anaphylactic reactions to immunoglobulin treatment are rare.
- XI-10. The answer is C.** (*Chaps. 58, 311*) SLE is a systemic multiorgan disease that involves connective tissue and blood vessels. Fever and skin lesions are the most common manifestations, while arthritis and renal pulmonary disease are also typical. The characteristic rash, as exemplified by the patient in this question, is an erythematous, confluent, macular eruption in a butterfly pattern on the face with fine scaling. Other possible skin lesions include erythematous urticarial lesions on the face and arms, hemorrhagic bullae during acute flares, and discoid plaques, which would typify chronic discoid lupus erythematosus. Lupus vasculitis may also present with palpable purpura. Skin biopsy reveals an atrophic epidermis with liquefaction necrosis at the dermal-epidermal junction, edema of the dermis, and a lymphocytic infiltrate. Fibrinoid degeneration of the connective tissue and blood vessel walls may also be noted. Immunofluorescent studies demonstrate staining for immunoglobulins in a granular or globular pattern along the dermal-epidermal junction.
- XI-11. The answer is C.** (*Chap. 311. Hahn, N Engl J Med 338:1359–1368, 1998.*) One of the most important pathogenic mechanisms in patients with SLE is the inappropriate pro-

duction of significant amounts of serum antibodies to double-stranded DNA. While not generally present in large enough amounts to actually precipitate in renal tubules, as is the case with the M-component in patients with multiple myeloma, such antibody-DNA complexes are important both for diagnosis and for the pathobiology of SLE. The precise mechanism by which DNA-protein and RNA-protein complexes, which should be tolerated by the immune system, become immunogenic is not clear; however, presentation of these antigens in unusual fashions could allow the immune system to become activated. These anti-DNA antibodies may cause glomerular infarcts by being trapped in the glomerular capillaries or by direct attachment to glomerular structures. The decrease in the ability of patients to clear these antibody-containing complexes may predispose to lupus nephritis. Some antibodies to DNA may bind directly to membranes of renal tubular cells, penetrating the cells and then binding to critical cytoplasmic or nuclear structures. Such binding could produce programmed cell death (*apoptosis*).

- XI-12. The answer is D.** (*Chap. 306*) The MHC, located on the short arm of chromosome 6, contains genes involved in the recognition of self, antigen presentation to T and B cells, and the rejection of tissue allografts. Ubiquitously expressed class I molecules are the products of the HLA-A, -B, and -C genes. Also in the MHC, the HLA-D region, separated from the ABC genes by an area responsible for certain complement components (C2, C4B, Bf, C4A) and tumor necrosis factor, codes for class II molecules, which are only expressed on T cells, B cells, and monocytes (and their derivatives, such as Langerhans' skin cells). Class I molecules are responsible for the mixed lymphocyte reaction (MLR), which is important in determining compatibility of donor and host tissues in a potential transplant situation. Because the ABC and D regions are closely linked, recombination between these two areas is uncommon (approximately 2%). Thus, an ABC-matched sibling is usually, but not always, matched at the D locus as well. In addition to a recombination event, another reason for a positive MLR in an HLA-ABC matched sibling pair is histoincompatibility at minor loci, which are located throughout the genome.
- XI-13. The answer is A.** (*Chap. 309*) The standard serologic test for HIV infection, the enzyme-linked immunosorbent assay (ELISA), has a sensitivity of >99.5%. However, this test is not particularly specific in that low-risk patients are subject to a false-positive rate of >10%. If the ELISA test is indeterminate or positive, the test should be repeated. If the repeat is positive or indeterminate, one should proceed to the next step, which is a western blot test. If the repeat ELISA is negative, then the person can be assumed not to have HIV infection. A western blot test involves the reaction of the serum with a strip impregnated with HIV-1 antigens. Binding of antibodies in the patient's serum to the antigens on the strip is detected with an enzyme-conjugated anti-human antibody. A positive western blot test requires the detection of antibodies to several HIV-1 gene products. If the western blot is indeterminate, perhaps due to infection in evolution or due to cross-reacting antibodies in the patient's serum, one should proceed to a PCR test and repeat the western blot in 1 month. If the PCR is negative and there is no progression on the western blot, the diagnosis of HIV infection is ruled out. The PCR test is extraordinarily sensitive, but the false-positive rate would be too high for use as a cost-efficient screening test. A DNA PCR test for HIV involves the isolation of DNA from blood mononuclear cells and incubation with primers from both the gag and LTR regions, followed by amplification and hybridization to detect HIV proviral DNA. An RNA PCR test can be used to monitor the level of HIV genome present in plasma (i.e., before cell entry and reverse transcription of the RNA genome).
- XI-14. The answer is B.** (*Chap. 58*) Bullous pemphigoid is a blistering skin disease of the elderly. Extensive blisters may appear after a prodrome of urticarial or eczematous eruption over the lower abdomen, groin, and flexor surfaces of the extremities. Oral mucosal involvement is seen in about 10 to 40% of patients. Unlike pemphigus vulgaris, there is no ethnic or racial association. Nikolsky's sign (extension of the blister on pressure by the examining finger) is negative. Light microscopic examination of a lesional biopsy would

reveal subepidermal bullae; immunofluorescent studies would demonstrate IgG deposits along the basement membrane zone. Bullous pemphigoid is believed to be an autoimmune disease; 70% of patients' serum contains circulating IgG autoantibodies capable of binding the epidermal basement membrane of normal human skin. These autoantibodies and their subsequent deposition in the skin are believed to activate complement, leading to the blister-producing inflammatory cell infiltrate. The mainstay of treatment is systemic glucocorticoids. However, minimal disease may be managed with topical steroids alone. Azathioprine is useful if alternative systemic therapy is required.

- XI-15. The answer is C.** (*Chap. 301. Robert, Kupper, N Engl J Med 341:1817–1828, 1999.*) Psoriasis is a common skin disease characterized by scaly erythematous plaques. The lesions display inflammatory infiltrates and epidermal hyperproliferation. The primary pathophysiologic mechanism in this disease is activation of cutaneous T cells. Although CD4+ T cells may initiate the process, CD8+ cells and the cytokines they produce are responsible for the lesions of psoriasis. The Koebner phenomenon, the development of new lesions on injured skin, probably results from IL-1_a being released from damaged skin cells that then recruits other cells capable of mediating further inflammation. Evidence for the critical role of T cells in psoriasis is the clinical response seen after the administration of anti-T cell agents such as cyclosporine, antibodies to the receptor-binding domain of IL-2, and psoralen plus ultraviolet A radiation (PUVA) therapy, which reduces the T cell number. Other skin diseases mediated by T cell activation include allergic contact dermatitis, atopic dermatitis, cutaneous graft vs. host disease, and cutaneous T cell lymphoma (mycosis fungoides).
- XI-16. The answer is A.** (*Chaps. 57, 58*) Psoriasis is a very common skin disorder that typically involves the elbows, knees, gluteal cleft, and scalp. Traumatized areas may also be involved (Koebner phenomenon). The lesions are characterized by erythematous, sharply demarcated papules and rounded plaques covered by a silvery scale. Histologically, the epidermis shows intraepidermal collections of neutrophils (microabscesses of Munro), but capillaries are usually not filled with neutrophils, a finding more characteristic of leukocytoclastic vasculitis. Infiltration of the dermis with lymphocytes that have convoluted nuclei would suggest cutaneous T cell lymphoma (mycosis fungoides). The dermatopathology of psoriasis is characterized by inflammation and alteration of the cell cycle manifested by a marked thickening of the epidermis, increased keratinocyte mitotic figures and inflammatory cells in the dermis (usually lymphocytes and monocytes), and neutrophils in the upper dermis. Though treatment depends on the type, location, and extent of disease, localized application of glucocorticoids in conjunction with keratolytic agents such as salicylic acid may be used. If psoriasis is widespread, B spectrum ultraviolet light alone or in combination with coal tar (Goeckerman regimen) may be required. Psoralen plus ultraviolet A radiation (PUVA) can also be used.
- XI-17. The answer is A.** (*Chap. 309*) Most patients with HIV infection evidence clinical disease of the CNS at some point in their course. Cerebrospinal fluid (CSF) findings are abnormal in approximately 90% of patients, even during asymptomatic states of infection. Such abnormalities include pleocytosis, isolation of virus and antiviral antibodies, and elevated CSF protein. The most common CNS disease in HIV-infected persons is the AIDS dementia complex, which refers to a syndrome of signs and symptoms that generally occurs late in the course of disease. In addition to dementia, patients may have various additional problems such as unsteady gait and poor balance or behavior problems such as apathy and lack of initiative. The precise cause of the AIDS dementia complex is unclear, but it is probably due to direct effects of HIV infection in the CNS. Between 80 and 90% of patients with HIV infection can be shown to have some degree of histologic evidence of CNS involvement. The radiologic correlate of AIDS dementia complex is general atrophy, ventricular dilation, and bright spots on T2-weighted MRI images. The ring-enhancing lesions in toxoplasmosis are seen in about 15% of all HIV-infected patients with CNS disease and are the second most common cause of seizures after the AIDS dementia complex. The

third most common cause of seizures is cryptococcal meningitis. Progressive multifocal leukoencephalopathy is relatively unusual and produces multiple white-matter lesions on T2-weighted MR images. Neurosyphilis, CNS lymphoma, and tuberculous meningitis are other less common CNS diseases in patients with HIV infection. Antiretroviral treatment has been associated with some improvement in patients with the AIDS dementia complex and therefore merits a therapeutic trial in patients so afflicted.

- XI-18. The answer is E.** (*Chap. 309. Antmen, Clang, N Engl J Med, 372:1027–1038, 2000.*) Kaposi's sarcoma (KS) is a neoplasm consisting of multiple vascular nodules in the skin, mucous membranes, and viscera. The course ranges from indolent with only minor skin or lymph node involvement to fulminant with extensive visceral involvement. Generally, the tumor respects tissue planes and is rarely invasive. Unlike many other tumors, lymph node involvement may occur early and is of no special clinical significance. The chest x-ray in pulmonary KS characteristically shows bilateral lower-lobe infiltrates that obscure the margins of the mediastinum and diaphragm. Pleural effusions are seen in 70% of cases. Treatment may consist of local therapy with radiation, intralesional chemotherapy, cryotherapy, systemic chemotherapy, or interferon. The response to interferon is most dependent upon the CD4+ count with response rates of 80% in patients with CD4+ cells >600/ μ L and <10% in patients with CD4+ cells <150/ μ L. Interestingly, the incidence of KS is declining. A growing body of epidemiologic and virologic data points to the likelihood that a sexually transmitted cofactor plays an important role in the development of KS. Human herpesvirus-8 can be cultured from skin lesions in 95% of patients. As safer sexual practices are employed, the risk of transmission of this factor and thus the risk of KS has decreased.
- XI-19. The answer is E.** (*Chap. 310. Rothenberg, N Engl J Med 338:1592–1600, 1998.*) Eosinophil-mediated diseases that are associated with high numbers of peripheral blood eosinophils include helminthic infections, idiopathic hypereosinophilic syndrome or vasculitis, or drug reactions. Eosinophil accumulation can be limited to specific organs such as eosinophilic cellulitis, eosinophilic pneumonias (Loeffler's syndrome), and eosinophilic fasciitis (Shulman's syndrome). Eosinophils can produce toxic inflammatory mediators, which can lead to organ damage. Such mediators are stored in granules synthesized after the cell is activated. The crystalloid core of these granules contains peroxidase, a neurotoxin, and a cationic protein. Some of these proteins can trigger further degranulation of mast cells and basophils, which intensifies the inflammatory cascade. Eosinophils generate large amounts of the leukotrienes that are metabolized to leukotriene D₄ and which increase vascular permeability and stimulate smooth-muscle contraction. Glucocorticoids are the most effective agents for reducing eosinophil number in the blood and for decreasing the secretion of eosinophil-generated inflammatory mediators. Other useful agents include interferon α , which can inhibit the degranulation of eosinophils, and myelosuppressive drugs such as hydroxyurea. Cyclosporine is effective by blocking the elaboration of eosinophil-generated cytokines. The newly approved 5-lipoxygenase inhibitors (e.g., zileuton) prevent the generation of leukotrienes C₄, D₄, and E₄. Zafirlukast blocks the leukotriene D₄ receptor, which thereby prevents the vascular permeability induced by eosinophil-derived leukotrienes. Ziluton and zafirlukast have been shown to be effective in patients with asthma. Third-generation antihistamines such as cetirizine, as well as cromolyn and phosphodiesterase inhibitors, have also proven effective in patients with eosinophil-related diseases.
- XI-20. The answer is D.** (*Chap. 316. Sakanet et al, N Engl J Med 341:1284–1291, 1999.*) Behçet's disease is manifested by recurrent oral and genital ulcers, ulceration of the uvea, and skin lesions. Skin lesions are most commonly erythema nodosum (painful red nodules generally on the legs), but pseudofolliculitis, papulopustular lesions, or acneiform lesions can also occur. Ulcers may occur on the scrotum and penis in men or on the vulva in women. Ocular lesions can manifest as uveitis or involve the retina, which can lead to blindness. Arthritis occurs in about half the patients. Gastrointestinal involvement is much

less common but can occasionally lead to perforation and be confused with inflammatory bowel disease. Small-vessel vasculitis, of unknown etiology, accounts for most of the aforementioned pathologic lesions. This disease, which is more prevalent in Turkey, Japan, Korea, China, Iran, and Saudi Arabia, can usually be diagnosed clinically on the basis of recurrent oral ulceration and at least two of the following: genital ulceration, eye lesions, skin lesions, or a positive pathergy test. The pathergy test involves pricking a sterile needle into the patient's arm. A positive test occurs when an aseptic erythematous nodule or pustule develops 2 days after the induced trauma. The disease can be confused with inflammatory bowel disease, herpes simplex virus infection, and Sweet's syndrome (neutrophilic infiltration of the dermis). Behçet's disease generally responds to immunosuppressive agents such as glucocorticoids.

- XI-21. The answer is C.** (*Chap. 305. Delves, Roitt, N Engl J Med 343:37–49, 2000.*) Dendritic cells are a key cellular component of innate immunity. These cells endocytose extracellular antigens and present them in a fashion capable of recognition by immune effector cells. Certain cytokines such as interferon α may activate dendritic cells. Activation allows upregulation of costimulatory molecules such as CD84 and CD86 on the dendritic cell surface, which can then in turn activate lymphocytes, particularly T cells. The activated dendritic cells travel to the local draining lymph node where they present the antigen to T cells in the context of short peptides, resulting from proteolytic cleavage, in association with the MHC. Dendritic cells are particularly important in presenting antigens that have not yet been seen by the immune system. Work is now underway to devise dendritic cell-based vaccine strategies in which potential antigens on the surface of neoplastic cells can be presented by dendritic cells to the immune system.
- XI-22. The answer is B.** (*Chap. 309. Kaye, Ann Intern Med 11:158, 1989.*) In contrast to the profound immunodeficiency that characterizes most manifestations of AIDS, a host of immunologic and rheumatologic disorders are common in patients with HIV infection. Certainly the most common such reaction is cutaneously manifested sensitivity to the antibiotics required for treatment of the secondary infections so common in these patients. Some 65% of patients who receive trimethoprim-sulfamethoxazole develop an erythematous morbilliform pruritic eruption. Fortunately, anaphylaxis is very rare, and desensitization is possible. Patients infected with HIV may develop diseases that resemble classic autoimmune diseases in non-HIV-infected persons. A variant of Sjögren's syndrome characterized by dry eyes, dry mouth, and lymphocytic infiltrates of the salivary gland and lung may be seen. HIV-associated arthropathy is characterized by a nonerosive oligoarticular arthritis that generally involves the large joints. Widespread musculoskeletal pain of at least 3 months' duration with tender points, typical of fibromyalgia, may occur in up to 10% of HIV-infected IV drug abusers. Reactive arthritides, such as Reiter's syndrome or psoriatic arthritis, have also been described.
- XI-23. The answer is C.** (*Chap. 312*) Persons who have rheumatoid arthritis can develop popliteal cysts as a complication of synovitis of the knee. Popliteal cysts can expand upward into the thigh or downward into the calf. Rupture of a popliteal cyst produces sudden pain and swelling; because these symptoms resemble those of thrombophlebitis—though perhaps more dramatic in onset—an arthrogram may be needed to confirm the diagnosis. Although rupture of the plantaris tendon can occur in persons exposed to mechanical trauma, it would not be the most likely diagnosis for the woman described in the question. The anserine bursa is located on the medial aspect of the knee joint and not in the calf. Achilles tendonitis should not cause pain and swelling of the calf.
- XI-24. The answer is C.** (*Chap. 317*) This patient has symptoms and laboratory values characteristic of temporal arteritis. The disease classically presents with fever, anemia, elevated erythrocyte sedimentation rate (ESR), and headaches in an elderly patient. Other manifestations include fatigue, malaise, sweats, anorexia, weight loss, and arthralgias. Scalp tenderness and jaw claudication may occur as well. Laboratory findings include an elevated

ESR and normochromic or slightly hypochromic anemia. Liver function abnormalities are common, particularly increased alkaline phosphatase levels. A catastrophic potential complication, particularly in untreated patients, is ocular involvement due to ischemic optic neuritis, which may lead to sudden and irreversible blindness. The diagnosis is often made clinically and confirmed by temporal artery biopsy. A temporal artery biopsy should be obtained as quickly as possible and, in the setting of ocular symptoms, therapy should not be delayed pending a biopsy. Therapy consists of high-dose glucocorticoids to which the disease is quite responsive. MRI/MRA cannot establish the diagnosis and hence are not warranted. This patient's presentation is classic for temporal arteritis and would be unusual for either metastatic colon cancer or meningitis.

- XI-25. The answer is E.** (*Chap. 321*) This patient displays the typical epidemiologic (obesity), clinical (pain on exercise, lack of abnormal laboratory values), and radiographic features of OA. The cardinal feature pathologically is loss of articular cartilage, although the disease affects the entire joint, including bone, synovium, meniscus, ligaments, and neuromuscular structures. The cartilaginous remodeling characteristics of OA leads to bony changes including "sclerosis" and osteophytes, which in turn can restrict joint movement and lead to periarticular muscle wasting. The molecular pathology of the cartilage damage seen in OA may include overactivity of degradative lysosomal enzymes, matrix metalloproteinases, and cytokine cascades. Nitric oxide has also recently been implicated in articular cartilage damage, and its inhibition could eventually represent a therapeutic strategy. Although both synovial inflammation and crystal deposition can be seen in chronic OA, these processes are probably secondary events.
- XI-26. The answer is A.** (*Chap. 321. Felson et al, Ann Intern Med 133:726–737, 2000.*) Nonpharmacologic approaches in the management of patients with symptomatic osteoarthritis (OA) are worth trying initially. Weight loss, application of heat (hot shower or bath), and an exercise program designed to improve joint range of motion and periarticular muscle strength could each be quite helpful. If analgesics are required, acetaminophen has been shown to be as effective as ibuprofen. Systemic glucocorticoids have no role in OA, although joint glucocorticoid injection can provide short-term benefit (repetitive use should be avoided). The cyclooxygenase-2 specific nonsteroidal anti-inflammatory agents celecoxib and rofecoxib are associated with a lower incidence of GI bleeding and do not inhibit platelet aggregation. Their use should probably be restricted to those with risk factors for bleeding, particularly GI hemorrhage. Intraarticular injection of hyaluronic acid and topical capsaicin cream may each be helpful in selected patients. Glucosamine and chondroitin sulfate are being evaluated as possible additionally useful therapies.
- XI-27. The answer is A.** (*Chap. 312*) Systemic manifestations in early rheumatoid arthritis may be severe, but are frequently nonspecific. Such nonspecific constitutional symptoms require a period of observation before synovitis supervenes and the diagnosis becomes clear. Weight loss and muscle wasting may be as severe as in persons who have a malignancy or primary muscle disease. In about 10% of patients, the disease begins in a more fulminant fashion with the rapid onset of polyarthritis associated with fever, lymphadenopathy, and splenomegaly.
- XI-28. The answer is E.** (*Chap. 312*) Many of the systemic manifestations of late rheumatoid arthritis are related to the presence of rheumatoid factors in high titer in the serum. Joint disease, paradoxically, may not be active during this stage of the illness. Nail-fold thrombi, leg ulcers, and sensorimotor polyneuropathy are all manifestations of rheumatoid vasculitis and presumably are related to the effect of immune complexes containing rheumatoid factors. High levels of immune complexes are detected by immune-complex assays done at this stage of disease. Felty's syndrome, characterized by neutropenia and splenomegaly, occurs late in the course of rheumatoid arthritis and is related to the presence of high titers of rheumatoid factors. Many affected persons also have rheumatoid vasculitis. Between 15 and 20% of patients with rheumatoid arthritis develop Sjögren's syndrome with asso-

ciated dry eyes. Hepatitis is not a common feature of late extraarticular seropositive rheumatoid arthritis.

- XI-29. The answer is A.** (*Chap. 310. Bochner, N Engl J Med 324:1785–1790, 1991.*) Anaphylaxis is the word used to describe the rapid and generalized immunologically mediated events characterized clinically by cutaneous wheals and upper or lower airway obstruction (or both) after exposure to a specific antigen. The angioedema and urticaria that occur during anaphylaxis are believed to be due to the release of mast cell (and possibly basophil) mediators (histamine and serum proteases from preformed granules, arachidonic acid metabolites such as leukotrienes, and cytokines including, but not limited to, tumor necrosis factor α , interferon γ , and interleukin 1). The mechanism of this release depends on the inciting agent. For example, anaphylaxis in response to bee stings, foods, and heterologous serum (e.g., tetanus antitoxin) is believed to be on the basis of IgE-mediated reaction against the relevant protein. On the other hand, anaphylaxis to penicillin and other antibiotics is due to IgE recognition of protein-hapten conjugants. Dialysis-induced anaphylaxis is due to complement activation. Finally, radiocontrast media directly activate mast cells or basophils or both to release the mediators of anaphylaxis.
- XI-30. The answer is B.** (*Chap. 310*) Most patients with systemic mastocytosis have an indolent syndrome characterized by mast cell infiltration of the skin, gastrointestinal mucosa, liver, and spleen. Cutaneous manifestations include the small, reddish-brown macules or papules, termed *urticaria pigmentosa*, which would be characterized histopathologically as having excess numbers of mast cells. These lesions are associated with Darier's sign, in which urticaria and erythema develop in response to trauma. Histamine-mediated hypersecretion of gastric acid accounts for an increased incidence of gastritis and peptic ulcers in patients with systemic mastocytosis. Bone pain, organomegaly, or lymphadenopathy may also be seen. In addition to documentation of mast cells in various organs, biochemical confirmation can be made by urine collection for histamine metabolites or by measuring increased blood levels of histamine or mast cell–derived neutral protease tryptase. The spectrum of mast cell disease ranges from indolent to more aggressive varieties characterized by mast cell infiltration of liver and spleen and in some cases the invariably fatal development of mast cell leukemia.
- XI-31. The answer is A.** (*Chap. 315*) The diagnosis of ankylosing spondylitis is made on clinical grounds. Historic features suggesting inflammatory back disease include pain and prolonged stiffness that are worse at night and during rest periods and characteristically relieved with activity. In contrast, mechanical low back pain usually is eased with bed rest and made worse with activity, such as sitting, standing, walking, and lifting. Signs of nerve-root compression are not part of the clinical spectrum of ankylosing spondylitis. Ankylosing spondylitis usually presents before the age of 40 years; on the other hand, degenerative joint disease and degenerative disk disease are common causes of back pain in the elderly. Back pain made worse with walking and improved with rest and lumbar flexion is characteristic of the pseudoclaudication syndrome associated with lumbar spinal stenosis.
- XI-32. The answer is D.** (*Chap. 308. Burrows, Cooper, Adv Immunol 65:245–276, 1997.*) IgA deficiency is the most common of the primary immunodeficiencies. IgA deficiency is more common in Caucasians than in individuals of Asian or African origin. Patients with isolated IgA deficiency have a mild to moderate clinical syndrome consisting of recurrent respiratory infections, although some may progress to bronchiectasis, chronic diarrheal diseases, and eczema. These individuals are more likely to experience infections, drug allergies, and other immune disorders such as lupus, vitiligo, thyroiditis, and rheumatoid arthritis than are age-matched controls. Because of the development of significant levels of antibodies to IgA, affected individuals are susceptible to severe anaphylactic reactions when transfused with blood products, which may be contaminated with IgA. Chronic immunoglobulin therapy will not increase the low levels of IgA; moreover, such infusions

carry the risk of anaphylaxis. Only the rare patient with IgA deficiency who is also deficient in IgG2 and IgG4 antibodies would benefit from immunoglobulin infusions.

- XI-33. The answer is E.** (*Chap. 311*) Patients with SLE may have a host of autoantibodies. Virtually all have antinuclear antibodies directed at multiple nuclear and cytoplasmic antigens. Approximately 50% have an anticardiolipin antibody, which is associated with a prolonged partial thromboplastin time and false-positive serologic tests for syphilis. This so-called lupus anticoagulant may be manifested by thrombocytopenia, venous or arterial clotting, recurrent fetal loss, and valvular heart disease. Though thrombotic problems are most common, if the antibody is associated with hypoprothrombinemia, severe thrombocytopenia, or antibodies to clotting factors (usually VIII or IX), bleeding may result. Confirmation that the partial thromboplastin time is prolonged on the basis of a lupus anticoagulant may be proved by failure of normal plasma to correct the defect.
- XI-34. The answer is C.** (*Chap. 313*) Patients with the more malignant variant of systemic sclerosis (scleroderma) have diffuse cutaneous disease characterized by skin thickening in the extremities, face, and trunk. It is this subset of patients, in contrast to those with limited cutaneous disease who often have the CREST syndrome, who are at risk for developing kidney and other visceral disease. Hypertension heralds the onset of a renal crisis manifested by malignant hypertension, encephalopathy, retinopathy, seizures, and left ventricular failure. The renin-angiotensin system is markedly activated; therefore, angiotensin-converting enzyme inhibitors are particularly effective. Even patients who require dialysis may reverse course and have a slow return of renal function after the passage of several months. Patients with systemic sclerosis may also develop esophageal dysfunction, hypomotility of the small intestine (which can produce pain and malabsorption), pulmonary fibrosis sometimes progressing to pulmonary hypertension, and heart failure due to myocardial fibrosis.
- XI-35. The answer is C.** (*Chap. 316*) Behçet's syndrome, a recurrent disease of unknown cause, is characterized by painful oral and genital ulcers, eye inflammation, arthritis, central nervous system symptoms, thrombophlebitis, fever, and abdominal symptoms. The combination of fever, aphthous ulcers, arthritis, and abdominal pain may mimic inflammatory bowel disease, although central nervous system involvement (e.g., severe headache) and thrombophlebitis would make this diagnosis less likely. Whipple's disease is associated with arthritis, abdominal pain, and central nervous system disease, but not with aphthous ulcers and thrombophlebitis; also, Whipple's disease usually affects middle-aged men. Fever, arthritis, abdominal pain, and headache would be compatible with a diagnosis of systemic lupus erythematosus. However, the mucosal lesions of lupus are painless and occur on the hard and soft palate, and thrombophlebitis is not a characteristic feature. The diagnosis of Behçet's disease now requires the presence of recurrent oral ulcers plus two of the following: recurrent genital ulcerations, eye lesions, skin lesions, or a positive pathergy test (inflammatory reactivity to scratches or intradermal saline).
- XI-36. The answer is E.** (*Chap. 313*) MCTD is a syndrome characterized by high titers of circulating antibodies to the ribonucleoprotein component of extractable nuclear antigen in association with clinical features similar to those of SLE, systemic sclerosis, polymyositis, and rheumatoid arthritis. The average patient with MCTD is a middle-aged woman with Raynaud's phenomenon who also has polyarthritis, sclerodactyly (including swollen hands), esophageal dysfunction, pulmonary fibrosis, and inflammatory myopathy. Cutaneous manifestations include telangiectasias on the face and hands, alopecia, a lupuslike heliotropic rash, and erythematous patches over the knuckles. Myopathy may involve severe weakness of proximal muscles associated with high levels of creatine phosphokinase and aldolase. Both pulmonary involvement and esophageal dysmotility are common but are frequently asymptomatic until quite advanced. Almost all patients have high titers of rheumatoid factor and antinuclear antibodies. Such antibodies are directed toward the ribonuclease-sensitive ribonucleoprotein component of extractable nuclear antigen.

- XI-37. The answer is C.** (*Chap. 317*) Hypersensitivity vasculitis refers to a group of disorders presumed to be associated with a reaction to an antigen such as an infectious agent or drug. The common denominator of this group is the involvement of small vessels, especially postcapillary venules. Vasculitis is leukocytoclastic, meaning that nuclear debris remaining from neutrophilic infiltration is present. In the subacute or chronic stages, mononuclear cells predominate. Henoch-Schönlein purpura is caused by immune complexes containing IgA antibody, which may be due to a reaction to drugs, certain foods, insect bites, or immunization. Such complexes are deposited in the skin, gastrointestinal mucosal vessels, and glomeruli. The disease is characterized by arthralgias, glomerulonephritis, and gastrointestinal signs and symptoms (particularly nausea, vomiting, diarrhea, constipation, or passage of blood and mucus per rectum). However, the most characteristic finding is palpable purpura on the buttocks and lower extremities. Though the disease is usually self-limited, it can progress to a chronic form. Patients occasionally require glucocorticoid therapy.
- XI-38. The answer is B.** (*Chap. 322. Emerson, N Engl J Med 334:445–451, 1996.*) Monosodium urate gout (diagnosed based on the presence of urate, birefringent needle-shaped intracellular crystals on an obligatory joint fluid examination) usually affects one joint initially, especially the great toe. Although abnormalities of uric acid metabolism (high serum or urinary levels) are often seen at some point, many present with normal or low serum uric acid. Treatment typically consists of a nonsteroidal anti-inflammatory agent or colchicine, but these agents are relatively contraindicated in this patient due to comorbid conditions. Steroid injection is a simple and highly effective alternative. Urate-lowering drugs should not be initiated during acute attacks.
- XI-39. The answer is A.** (*Chap. 313*) Systemic sclerosis can be classified into two variants depending on whether scleroderma is present only in the fingers (sclerodactyly) or whether it is also present proximal to the metacarpophalangeal joints. The former disorder is associated with a constellation of findings labeled the CREST syndrome: calcinosis, Raynaud's phenomenon, esophageal dysmotility, sclerodactyly, and telangiectasia. Although once thought not to be associated with significant internal organ involvement, the CREST variant of systemic sclerosis has occurred in association with the development of pulmonary arterial hypertension or biliary cirrhosis. The fluorescent antinuclear antibody (ANA) test is positive in 40 to 80% of persons with systemic sclerosis. Antibodies are produced to deoxyribonucleoprotein, nucleolar, centromere, and topoisomerase 1 antigens. MCTD is the overlap of three rheumatic disease syndromes: SLE, polymyositis, and the CREST variant of systemic sclerosis. It is associated with high titers of ANAs directed against the extractable nuclear antigen ribonucleoprotein. Arthritis and a positive ANA test are not sufficient to make a diagnosis of SLE. Overlap syndromes are diseases that fulfill diagnostic criteria for two rheumatic diseases. In the case described, symptoms and signs were insufficient to fulfill the diagnostic criteria for more than one rheumatic syndrome.
- XI-40. The answer is D.** (*Chaps. 57, 310*) Urticaria pigmentosa is a disorder of mast cells. The development of a wheal on gentle stroking of a pigmented macule (Darier's sign) is a useful diagnostic maneuver. Prognosis is said to worsen with age of onset: half the patients who develop multiple lesions by 4 years of age are disease-free by adolescence. Onset in adulthood is more ominous, with active lesions persisting indefinitely; systemic mastocytosis, which may have a fatal outcome, occurs frequently in affected adults. Symptomatic improvement has been reported with oral cromolyn. Affected persons should be warned to avoid substances and environmental factors known to cause mast-cell degranulation (e.g., cold, heat, trauma, or the ingestion of alcohol, aspirin, or morphine-opium alkaloid drugs). Although the disorder is usually an isolated event, familial disease occurs, indicating autosomal dominant inheritance in some cases.
- XI-41. The answer is C.** (*Chap. 305*) T lymphocytes are the principal mediators of cellular immunity and also serve important helper and suppressor functions in the regulation of

antibody synthesis by B lymphocytes. In humans, they have the property of forming rosettes with sheep erythrocytes (E-rosettes), and they lack readily detectable immunoglobulin of any class on their membranes. Although the maturation of T cells is thymus-dependent, the cells arise from precursors in bone marrow. T cells constitute about 70 to 80% of blood lymphocytes; they comprise greater than three-quarters of thymus lymphocytes but less than one-quarter of bone marrow lymphocytes. In lymph nodes, they are found in paracortical areas. Specific monoclonal antibodies have been developed to characterize various subsets of T cells—cells that carry a CD4+ surface antigen are helper cells, and those with a CD8+ antigen function as cytotoxic-suppressor cells. Antibody-dependent cell-mediated cytotoxicity is a property of a class of non-B, non-T lymphocytes called *large granular lymphocytes* (LGL cells). Antibody-dependent cell-mediated cytotoxicity can also be mediated by monocyte-macrophages and neutrophils.

- XI-42. The answer is E.** (*Chap. 311*) Although most clinicians believe that women with SLE should not become pregnant if they have active disease or advanced renal or cardiac disease, the presence of SLE itself is not an absolute contraindication to pregnancy. The outcome of pregnancy is best for those women in remission at the time of conception. Even in women with quiescent disease, exacerbations may occur (usually in the first trimester and in the immediate postpartum period), and 25 to 40% of pregnancies end in spontaneous abortion. Fetal loss rates are higher in patients with lupus anticoagulant or anticardiolipin antibodies. Flare-ups should be anticipated and vigorously treated with steroids. Steroids given throughout pregnancy also usually have no adverse effects on the child. In the case presented, the fact that the woman had a life-threatening bout of disease a year ago would argue against stopping her drugs at this time. Neonatal lupus, which is manifested by thrombocytopenia, rash, and heart block, is rare but can occur in mothers with anti-Ro antibodies.
- XI-43. The answer is C.** (*Chap. 305*) Immunoglobulin A is the predominant immunoglobulin in body secretions (IgG is predominant in serum). Each secretory IgA molecule is a dimer consisting of a secretory component and a J chain. The secretory component, a protein of molecular weight 70,000, is synthesized by epithelial cells and facilitates IgA transport across mucosal tissues. The J chain is a small glycopeptide that aids the polymerization of immunoglobulins. IgA exists as two subclasses: IgA1 (75% of the total) and IgA2 (25% but more prevalent in secretions). IgA provides defense against local infections in the respiratory, gastrointestinal, and genitourinary tracts, and prevents access of foreign substances to the general systemic immune system. It also can prevent virus binding to epithelial cells. IgM, not IgA, is the principal immunoglobulin in the primary immune response and is the usual antibody in cold agglutinins. The half-life of IgA is about 6 days; IgE has the shortest half-life, approximately 2 to 2.5 days.
- XI-44. The answer is E.** (*Chap. 314*) Sjögren's syndrome, an autoimmune destruction of the exocrine glands, can be primary or it can occur in association with rheumatoid arthritis, SLE, or systemic sclerosis. A mononuclear cell infiltrate, which can be seen in virtually any organ, is pathognomonic if found in the salivary gland in association with keratoconjunctivitis sicca (conjunctival and corneal dryness) and xerostomia (lack of salivation). Since minor salivary glands will be obtained in a lip biopsy, such a procedure can be diagnostic. Severe dryness of the mouth can lead to an increased incidence of dental caries. Corneal dryness may be severe enough to result in ulceration. The most common form of renal involvement (seen in 40% of patients with primary Sjögren's) is an interstitial nephritis resulting in renal tubular acidosis. Hypersensitivity vasculitis, manifested by palpable purpura of the lower extremities, is not uncommon. Sensory neuropathies, interstitial pneumonitis, and autoimmune thyroid disease may also accompany primary Sjögren's syndrome. Finally, pseudolymphoma, characterized by lymphadenopathy and enlargement of the parotid gland, and frank non-Hodgkin's lymphoma may occur. Cardiac disease is very rare in Sjögren's syndrome.

- XI-45. The answer is E.** (*Chap. 309*) The differential diagnosis of myopathy in an AIDS patient is vast and includes infection, zidovudine-induced myositis, vasculitis, and polymyositis. Electromyography would likely show similar findings in all of these conditions. Blood cultures may be useful if the etiology is infectious, but generally are of little benefit in further narrowing the differential diagnosis. Similarly, lymph node biopsy may detect specific infections or malignant processes, but will not necessarily determine the etiology of the myopathy. Discontinuing the zidovudine, a drug which can cause myositis, will aid in determining the diagnosis only in zidovudine-induced myopathy. Muscle biopsy is the procedure best suited to establish a definitive diagnosis.
- XI-46. The answer is B.** (*Chap. 306. Klein, Sato, N Engl J Med 343:702–709, 2000.*) The human MHC, also known as the human leukocyte antigen (HLA) complex, is a 4-Mb region on chromosome 6 that is packed with genes including those encoding HLA class I and class II molecules, which are involved in the immunologic specificity. Class I genes produce polymorphic proteins that bind to a β_2 -microglobulin peptide-binding groove. The class II peptide complex is recognized by CD4+ T cells. Class I genes are expressed in all nucleated cells, although to a higher degree in leukocytes. Class II genes are expressed on myeloid cells and can be induced by stimuli such as inflammatory cytokines, e.g., interferon γ . Certain HLA types are associated with susceptibility to specific infectious diseases such as tuberculosis and leprosy or with resistance to malaria. There are now many examples of specific HLA alleles being associated with susceptibility to certain immunologically mediated diseases such as Behçet's syndrome and ankylosing spondylitis. Though HLA-B27 is very highly associated with ankylosing spondylitis, there is little evidence for any molecular role for the gene product in the disease.
- XI-47. The answer is B.** (*Chap. 322. Perez-Ruiz et al; Nephron 86:287–291, 2000.*) Indications for chronic hypouricemic therapy include recurrent attacks of gouty arthritis, hyperuricemia refractory to diet and weight reduction, elevated urinary uric acid, and uric acid stones. The uricosuric agent probenecid is indicated only if the baseline urinary uric acid excretion is normal. Allopurinol is safe and effective in the setting of chronic renal failure. It should be used with care in patients taking thiazide diuretics due to the increased incidence of rash. Colchicine prophylaxis can be initiated in a patient with frequent episodes of gout who is receiving allopurinol (which can exacerbate an attack). The non-steroidal anti-inflammatory agents, whether cyclooxygenase-2-specific or not, do not have a role as prophylactic agents.
- XI-48. The answer is C.** (*Chap. 324. Gladman, Rheum Dis Clin North Am 24:829–844, 1998.*) There are three main varieties of psoriatic arthritis (an inflammatory arthritis affecting 5 to 42% of patients with psoriasis): asymmetric inflammatory arthritis, symmetric arthritis [more common in women, usually in the hands, similar to rheumatoid arthritis (RA), but without nodules], and psoriatic spondylitis. The pathology is similar to that seen in RA (early neutrophil and later monocytic synovial infiltration). There are no characteristic laboratory abnormalities in patients with psoriatic arthritis, but radiographs, if they reveal features unique to this disease relative to RA, may be diagnostically helpful. Such special features include the pencil-in-cup appearance of the distal terminal phalanx due to cuplike erosions and bony proliferation with tapering of the proximal phalanx; proliferation of the bone near osseous erosions, terminal pharyngeal osteolysis, bone proliferation and periostitis, and telescoping of one bone into another (opera-glass deformity). Inflammation of the tendons and ligaments (*ethesopathy*) is also characteristic. Nonsteroidal anti-inflammatory agents are the therapeutic mainstays; sulfasalazine or methotrexate is often required in difficult cases.
- XI-49. The answer is D.** (*Chap. 323. Zimmerli et al, JAMA 279: 1537–1541, 1998.*) If an infection in a prosthetic joint is documented after joint aspiration, cure usually requires a combination of organism-specific antibiotic plus joint replacement. There is, however, an

emerging literature documenting that a nonsurgical cure of staphylococcal infections may be possible with a prolonged course of rifampin plus ciprofloxacin, each given orally. Prevention of prosthetic joint infections via perioperative antibiotic prophylaxis, laminar intraoperative airflow, and aggressive treatment of extraarticular infections in the postoperative period is the best approach. Infectious complications of joint replacement surgery occur in 1 to 4% of patients and include acute infections with *Staphylococcus aureus*, streptococci, or enteric gram-negative rod bacteria as well as more indolent infections presenting much later (and in a more subtle fashion) caused by coagulase-negative streptococci or diptheroids.

- XI-50. The answer is B.** (*Chap. 323. Cucurull, Espinoza, Rheum Dis Clin North Am 24:305–322, 1998.*) Gonococcal arthritis is the most common infectious arthritis in young patients and particularly affects pregnant or menstruating women who have asymptomatic carriage of the organism in the urethra, cervix, or pharynx. A monarticular “septic arthritis” picture is rare. A migratory polyarthritis and/or tenosynovitis of distal joints associated with fever, chills, and a characteristic pustular rash on the trunk and extremities represents the classic clinical syndrome. Blood cultures are almost always negative, and joint aspiration is often difficult and generally yields a bland culture and gram-negative formula. It is most useful to culture the skin lesions or mucosal sites [in specialized medium (Thayer-Martin agar, rapidly transported to the laboratory in a 5% CO₂ atmosphere)]. Due to the frequency of penicillin-resistant gonococci, treatment with ceftriaxone should be initiated, pending culture results.
- XI-51. The answer is D.** (*Chap. 326*) This patient has typical adhesive capsulitis of the left shoulder, also known as “frozen shoulder.” This condition develops in older women, many of whom have comorbid conditions such as chronic lung disease, diabetes, or coronary artery disease. An injury may initiate a sequence of events, beginning with lack of movement and ending with immobility and osteopenia on radiography. The diagnosis may be confirmed at arthroscopy if only a limited amount (<15 mL) of contrast fluid can be injected into the joint. Improvement may be spontaneous, but physical therapy to mobilize the joint is often helpful. Therapy in difficult cases may include forceful injection of contrast to lyse adhesions or manipulation under anesthesia.
- XI-52. The answer is B.** (*Chap. 325*) Fibromyalgia is characterized by widespread musculoskeletal pain, stiffness, paresthesia, nonrestorative sleep, and easy fatigability associated with multiple tender points, which are widely and symmetrically distributed. Fibromyalgia is more prevalent in women. Several causative mechanisms for fibromyalgia have been postulated. Disturbed sleep has been implicated as a factor in the pathogenesis. Many patients fit a psychiatric diagnosis, the most common being depression, anxiety, somatization, and hypochondriases. There is disagreement about whether some of these abnormalities may represent reactions to chronic pain or if fibromyalgia is a reflection of psychiatric disturbance. However, fibromyalgia also occurs in patients without psychiatric diagnoses. Patients may complain of joint pain and perceive their joints are swollen; however, joint examination is normal. Glucocorticoids have little benefit and should not be used. Other therapies include local measures, biofeedback, anxiolytics, and antidepressants.
- XI-53. The answer is D.** (*Chaps. 323, 202*) The patient has desert fever, a syndrome caused by coccidioidomycosis infection, which is endemic in the southwest United States. This syndrome is largely an acute hypersensitivity reaction to the primary pulmonary infection, which is symptomatic in only 40% of affected persons. Manifestations of hypersensitivity may include erythema nodosum, erythema multiforme, arthralgia, arthritis, conjunctivitis, and episcleritis. However, disseminated coccidioidomycosis may occur during the primary infection and could result in osteomyelitis (which may seed an adjacent synovium directly), fungal arthritis, skin lesions, or CNS disease. Even in the case of hematogenously derived joint infection, synovial fluid cultures will rarely be positive; synovial biopsy for culture

and histology may be required. Serologic tests, while possibly acutely negative in a patient with primary pulmonary infection only, can be quite helpful, particularly when there is disseminated involvement.

- XI-54. The answer is D.** (*Chap. 305*) T cell precursors leave the yolk sac, fetal liver, or bone marrow and migrate to the thymus, where they undergo further maturation. Even before T cell receptor gene rearrangements occur, pre-T cells express the CD7 antigen, the earliest marker of T cell lineage. After the CD2 adhesion molecule, which functions as the receptor for sheep red blood cells, is expressed on the cell surface, assembly of the T cell receptor complex begins. This complex consists of the five proteins that make up the CD3 signal transduction moiety plus the two antigen-recognizing heterodimer molecules that form the actual T cell antigen receptor. The proteins that can function as part of the T cell antigen receptor all have a variable (produced by V-J recombination) and constant region and bear homology to the immunoglobulin heavy and light chains. Along with the histocompatibility proteins and the CD2, CD4, and CD8 molecules, the T cell antigen receptor chains are members of the immunoglobulin gene superfamily, which provides the immunologic diversity required to distinguish self from nonself and recognize an inordinate number of foreign antigens. After CD3 T cell receptor expression, but before suppressor or helper phenotype is determined, there is a thymic stage wherein both CD4 and CD8 antigens are expressed. Some lymphoblastic lymphomas arise at this stage of T cell development.
- XI-55. The answer is B.** (*Chap. 308. Buckley, N Engl J Med 325:110, 1991.*) Isolated IgA deficiency is the most common immunodeficiency disorder, with an incidence between 1:600 and 1:800. Affected persons have a normal or reduced number of B cells with surface IgA, but seem to have overabundant immature cells that coexpress IgA and IgM, suggesting a block in B cell terminal differentiation. This presumption is substantiated by in vitro studies showing that lymphocytes from IgA-deficient persons can synthesize but are unable to secrete IgA. Both serum IgA and secretory IgA usually are reduced. Although IgA deficiency need not be associated with clinical disease, it frequently is. Recurrent sinopulmonary infection is most common. Allergy occurs with an incidence of 1:200 to 1:400, compared with 1:600 to 1:800 in the general population. Approximately 30 to 40% of IgA-deficient persons have antibodies directed against IgA, thus predisposing them to anaphylactoid reactions following the infusion of blood products unless the blood is obtained from IgA-deficient donors. Persons with isolated IgA deficiency are also at greater risk for developing autoimmune diseases, including lupus and rheumatoid arthritis. Immunoglobulin treatment will not restore IgA levels to normal and is of little value in this condition.
- XI-56. The answer is C.** (*Chap. 305*) Most antigen-antibody complexes are cleared by cells of the reticuloendothelial system. It appears that in some conditions the reticuloendothelial system can be overwhelmed by immune complexes, thereby impeding the removal and leading to the deposition of immune complexes. Deposition of these complexes in tissues other than those of the reticuloendothelial system is responsible for the signs and symptoms of immune-complex disease. In animal models, the persistence of complexes is necessary for the development of renal disease; also, slight antigen excess has been found to predispose to the formation of antigen-antibody complexes, which persist in the circulation and lead to inflammatory illness. Immune complex-mediated vascular damage can lead to cutaneous necrotizing vasculitis. Electron microscopy reveals subendothelial immune complexes that presumably incite an array of inflammatory cells to migrate toward the vessel.
- XI-57. The answer is D.** (*Chap. 306*) Class I HLA antigens are encoded at the A, B, and C loci of the human major histocompatibility complex on chromosome 6. Each such antigen consists of an 11.5-kDa β_2 -microglobulin subunit (also encoded in the HLA region) and a 44-kDa chain with three separate domains that contain the antigenic specificity. Only certain areas of the heavy chain are diverse, so individual molecules share >80% sequence homology. Class I molecules are expressed on all cells except mature red blood cells.

These antigens are defined serologically and are useful in predicting results for organ transplants. Because class I antigens are not distributed evenly from one racial group to another, it can be more difficult for a person of African descent, for example, to procure a bone marrow donor from a registry where most of the potential donors descend from Northern Europe.

- XI-58. The answer is D.** (*Chap. 319*) This patient has many of the hallmarks of systemic amyloidosis. An abdominal fat pad aspirate or a rectal biopsy is the best way to make the diagnosis, although biopsy of any affected organ may be carried out. A positive Congo red histologic stain helps to establish the diagnosis. The classification of amyloid protein fibrils that are deposited in the tissues is based on their biochemical type. AL amyloid residues bear homology to immunoglobulin light chains and are seen in de novo or myeloma-associated disease. The AA type of amyloid, made up of a protein of 76 amino acids, is seen secondary to a host of chronic inflammatory conditions, including long-standing rheumatoid arthritis, tuberculosis, bronchiectasis, familial Mediterranean fever, and leprosy. Other types of amyloid proteins are seen in familial amyloid polyneuropathy, medullary carcinoma of the thyroid, and Alzheimer's disease (the beta, or A4, protein). Amyloidosis should be suspected in any patient with an underlying chronic inflammatory disease who develops hepatomegaly, splenomegaly, malabsorption, cardiac disease, or proteinuria. Cardiac disease usually consists of congestive heart failure with low QRS-complex voltage, arrhythmias, and exquisite sensitivity to digitalis. Waxy papules or plaques in the axillary folds may signal the deposition of amyloid in the skin; purpura after minor trauma is not uncommon. Gastrointestinal problems caused by amyloid include macroglossia, malabsorption, and bleeding. In addition to amyloid-induced synovitis, peripheral neuropathy and carpal tunnel syndrome may be seen.
- XI-59. The answer is E.** (*Chap. 311*) The most common cause of drug-induced SLE is procainamide, which produces a positive ANA in 75% of those who take it and a 20% incidence of clinical lupus. In contrast, hydralazine induces an ANA in 25% and a clinical lupus syndrome in 10%. Slow acetylators seem to have more problems with drug-induced autoimmune phenomena. Though up to 50% of those with drug-induced lupus have arthralgias, pleuropericarditis, or both, renal disease is rare. In an effort to distinguish drug-induced lupus (which should last <6 months) from de novo lupus (a disease uniquely positive for anti-dsDNA and anti-Sm), a complete ANA panel should be sent. Most patients will respond initially to withdrawal of the offending drug; if not, then a brief trial of steroids is indicated.
- XI-60. The answer is A.** (*Chap. 325*) Relapsing polychondritis is an uncommon disorder affecting middle-aged individuals characterized by progressive episodes of inflammation of various cartilaginous structures, especially the ears, nose, and laryngotracheal tree. About 30% have an associated rheumatologic disorder, but others have other conditions such as inflammatory bowel disease, primary biliary cirrhosis, or myelodysplasia. Additional clinical features may include scleritis, neurosensory hearing loss, polyarthritis, vasculitis, cardiac abnormalities, skin lesions, and glomerulonephritis. Although the underlying pathophysiologic basis for this disease is unclear, there is an association with the HLA-DR4 allele and with antibodies to type II collagen. There is evidence for an autoimmune lymphocytic reaction against cartilage matrix protein. The diagnosis is generally made on clinical grounds, although a cartilage biopsy would be confirmatory. Patients with Wegener's granulomatosis could also have nasal and bronchial tree involvement but have granulomatous inflammation (unlike relapsing polychondritis patients) and do not have auricular involvement. Antineutrophil and immune complexes have also been noted in this disease, but they are not pathognomonic.
- XI-61. The answer is D.** (*Chap. 318*) Sarcoidosis is a systemic granulomatous inflammatory disorder that frequently involves the lungs, where it causes a typical interstitial lung disease that may be asymptomatic, may cause transient respiratory difficulties with or without hilar

adenopathy, or may progress to end-stage pulmonary fibrosis. Extrapulmonary sarcoidosis may involve the eyes, skin, liver, bones, gastrointestinal tract, kidneys, nervous system, and heart. In the United States, 10 to 20% of cases consist of asymptomatic hilar adenopathy detected on chest radiographs taken for other reasons; these cases may constitute a higher fraction of the total in other countries where routine preemployment chest radiography is more widely practiced. The disease occurs more frequently among blacks than whites by a substantial margin. At sites of disease activity, such as the lung, there is an accumulation of activated helper-inducer (CD4+) lymphocytes, with release of immunologic mediators such as IL-2 and interferon γ , and resultant granuloma formation. In contrast to other interstitial lung diseases, the diagnosis may frequently be made by the demonstration of the characteristic granulomatous inflammation in tissue obtained by transbronchial biopsy. Prognosis depends on the risk of progression to advanced pulmonary fibrosis, and those persons with intense pulmonary inflammation may benefit from treatment with glucocorticoids. Chest radiography and pulmonary function testing cannot distinguish accurately between active inflammation and established fibrosis; hence, most clinicians familiar with the disease utilize procedures such as bronchoalveolar lavage or gallium-67 scanning, or both, to assess the intensity of the alveolitis present. These procedures may be performed serially during the course of the patient's illness to follow the progress of the disease and response to therapy.

- XI-62. The answer is C.** (*Chap. 312*) Rheumatoid factors are antibodies to the Fc fragment of immunoglobulin G. They may be of the IgG, IgA, or IgM class; the widely used latex and sheep-cell agglutination tests detect rheumatoid factors primarily of the IgM class. Chronic antigenic stimulation is one of the processes important in the production of rheumatoid factors. Rheumatoid factors are associated not only with rheumatoid arthritis and other autoimmune diseases but also with lymphoreticular malignancies and chronic infections, such as subacute bacterial endocarditis. Rheumatoid factors are usually present within the first year of onset of rheumatoid arthritis; their presence correlates with the extraarticular manifestations of the disease. Patients with rheumatoid arthritis who have positive serologic tests for IgM rheumatoid factor have a worse prognosis than those who are seronegative.
- XI-63. The answer is A.** (*Chap. 312*) Joint stiffness in the morning or after periods of inactivity lasting more than 1 h is characteristic of inflammatory rheumatic disease. Arthritis characteristic of rheumatoid arthritis is persistent, remaining in the same joints for months. Migratory arthritis, in which short-lived arthritis symptoms in one joint subside as symptoms begin in another joint, is not characteristic of rheumatoid arthritis. Persons who have rheumatoid arthritis can have involvement of the cervical spine, the wrist joints, and all the small joints of the hand except the distal interphalangeal joints. Wrist-joint arthritis can lead to median-nerve entrapment (carpal tunnel syndrome).
- XI-64. The answer is C.** (*Chap. 315*) This patient has an acute inflammatory asymmetric polyarthritis associated with ocular (conjunctivitis, occasionally anterior uveitis) and cutaneous (keratoderma blennorrhagicum on palms and soles; circinate balanitis on the glans penis) disease. Moreover, he has had a recent episode of urethritis, possibly caused by *Chlamydia*. He therefore has so-called reactive arthritis, also known as Reiter's syndrome. This entity can follow certain infectious illnesses, most notably dysentery or venereal disease usually in patients who are HLA-B27-positive. The constitutional symptoms associated with the acute illness can be severe. The ESR is frequently elevated. Sacroiliitis and spondyloarthropathy may be seen as late sequelae. Patients will respond to nonsteroidal agents, but there is little evidence to support the benefit of antibiotics, other than in eradicating chlamydia, if present.
- XI-65. The answer is B.** (*Chap. 317. Hoffman, Ann Intern Med 116:488–498, 1992.*) This patient presents with findings characteristic of Wegener's granulomatosis. Sinus disease (manifested by bloody or purulent nasal discharge), pulmonary disease, and glomerulo-

nephritis are seen in greater than 80 percent of affected patients. Sinus involvement would be unlikely in Goodpasture's syndrome, which is associated with anti-basement membrane antibodies. Other findings characteristic of Wegener's include ocular involvement, skin lesions, and nervous system manifestations (including cranial neuritis or mononeuritis multiplex), as well as elevated ESR, anemia, leukocytosis, and hypergammaglobulinemia. The diagnosis can be made by finding necrotizing granulomatous vasculitis in an involved site. Although the immunopathogenesis of this entity is unclear, antibodies to a neutrophil protein (found in the azurophilic granules) can be frequently found. The disease can be successfully treated in over 90 percent of patients with the use of glucocorticoids and cyclophosphamide. The glucocorticoids are gradually tapered and the cyclophosphamide, the mainstay of treatment, should be continued for about 1 year after complete remission.

- XI-66. The answer is E.** (*Chap. 318*) While 10 to 20% of patients with sarcoidosis present with asymptomatic disease found incidentally on chest x-ray and 40 to 70% have the characteristic insidious development of disease, the remainder present over the span of a few weeks. Constitutional and respiratory symptoms dominate the acute presentation. Two distinct patterns of acute sarcoidosis are recognized. Lofgren's syndrome, seen in Scandinavian, Irish, and Puerto Rican females, is characterized by erythema nodosum, arthralgias, and bilateral hilar lymphadenopathy. The constellation of findings in the Heerfordt-Waldenstrom syndrome consists of fever, parotid enlargement, anterior uveitis, and facial nerve palsy. Interstitial pulmonary involvement would be rare in acute sarcoidosis. Myopathy and skin lesions are most consistent with dermatomyositis. Although 5% of patients with sarcoidosis have cardiac abnormalities, valvular heart disease—other than occasional instances of papillary muscle dysfunction—is rare.
- XI-67. The answer is B.** (*Chap. 317*) Patients with midline granuloma, characterized by local inflammation and destructive mutilation of head and neck tissues, may present with nasal and sinus symptoms. Ulcerations of the nasal septum and soft and hard palates are harbingers of very destructive processes in any area in the neck or above. Granulomatous infiltration and necrosis will be noted on pathologic examination of the involved areas. Radiation therapy is the treatment of choice and is successful in averting the almost certainly fatal course in untreated patients. Midline granuloma can be difficult to distinguish from cocaine-induced septal perforation, malignant lymphoma, and a host of chronic infections including histoplasmosis, blastomycosis, coccidioidomycosis, leprosy, tuberculosis, syphilis, and leishmaniasis. While Wegener's granulomatosis is associated with similar upper airway findings, the absence of vasculitis on biopsy, the absence of pulmonary and renal disease, and the presence of palatal perforation make the diagnosis of midline granuloma much more likely. Midline granuloma never involves structures below the neck.
- XI-68. The answer is E.** (*Chaps. 320, 323. Baker, N Engl J Med 329:1013–1020, 1993.*) The analysis of synovial fluid begins at the bedside. When fluid is withdrawn from a joint into a syringe, its clarity and color should be assessed. Cloudiness or turbidity is caused by the scattering of light as it is reflected off particles in the fluid; these particles are usually white blood cells, although crystals may also be present. The viscosity of synovial fluid is due to its hyaluronate content. In inflammatory joint disease, synovial fluid contains enzymes that break down hyaluronate and reduce fluid viscosity. In contrast, synovial fluid taken from a joint in a person with degenerative joint disease, a noninflammatory condition, would be expected to be clear and have good viscosity. The color of the fluid can indicate recent or old hemorrhage into the joint space. Pigmented villonodular synovitis is associated with noninflammatory fluid that is dark brown in color (“crankcase oil”) as a result of repeated hemorrhage into the joint. Gout and calcium pyrophosphate deposition disease produce inflammatory synovial effusions, which are cloudy and watery. In addition, these disorders may be diagnosed by identification of crystals in the fluid—sodium urate crystals of gout are needle-like and strongly negatively birefringent, whereas calcium pyrophosphate crystals are rhomboidal and weakly positively birefringent.

- XI-69. The answer is B.** (*Chap. 325*) Neuropathic joint disease, or “Charcot’s foot,” may develop in about 0.5% of patients with diabetes (formerly most commonly seen in advanced syphilis). The pathophysiology of this destructive process may represent a combination of autonomic dysfunction leading to increased blood flow with bone resorption plus loss of proprioception resulting in damage from repetitive traumas. The disease can be difficult to distinguish clinically and radiologically from severe osteoarthritis, with bony loss and osteophytes being noted in radiographs in each condition. The ankle joints are most commonly affected; patients often give a history of some initiating trauma. The joint is often swollen, and in the case of ankle involvement, collapse of the tarsal bones may lead to a concave sole, or “rocker foot.” The diagnosis is made clinically and after osteomyelitis, osteoarthritis, and calcium pyrophosphate deposition disease are excluded. Treatment includes no weight-bearing; stabilization of the foot, usually with a brace (followed carefully due to the neuropathy); and sometimes surgical joint fusion.
- XI-70. The answer is D.** (*Chap. 325*) This patient has classic nail clubbing, or hypertrophic osteoarthropathy, which can occur as a primary disease process but is mainly secondary to other conditions such as severe pulmonary infections, congenital heart disease, and, most notably, lung cancer, where it occurs in 5 to 10% of patients. The bone changes include periostitis followed by new bone formation and cortical thickening with proliferation of nearby connective tissue, which gives the nails their clubbed appearance and accounts for sponginess of the nail bed. Pain, sometimes associated with synovial effusions in the ankles, wrist, and knees, can occur. Although once thought to be due to elaboration of a protein or prostaglandin, recent studies suggest a role for platelet clumps, which, upon interaction with the endothelium in the distal extremities, result in the local release of substances capable of eliciting proliferation of connective tissue and periosteum such as platelet-derived growth factor and transforming growth factor β . Optimal treatment includes reversal of the underlying disease process if possible; nerve block may be needed if symptoms are severe.
- XI-71. The answer is B.** (*Chap. 312. Klippel, N Engl J Med 343:1640–1641, 2000.*) The synovium in patients with RA is characterized by lymphocytic infiltration (CD4+ and CD8+ T cells) and fibroblast proliferation and notable for the presence of a host of proinflammatory cytokines secreted by activated immune and supporting cells. Moreover, neutrophils migrate into the synovial fluid. One or more of these events, perhaps mainly IL-1 and tumor necrosis factor (TNF) secretion, stimulate collagen breakdown, which leads to the bone and cartilage destruction associated with chronic RA. Moreover, systemic secretion of TNF- α may account for the constitutional symptoms of malaise and fatigue typical in RA patients. Therefore, agents that neutralize TNF- α such as the type II TNF- α receptor fused to an immunoglobulin (etenercept) and a humanized monoclonal anti-TNF- α antibody (infliximab) have been considered for use in RA. Recent studies have demonstrated that these agents control signs and symptoms in RA patients that have failed disease-modifying antirheumatic drugs such as methotrexate, gold, D-penicillamine, the antimalarials, and sulfasalazine. Serious infections may be more likely in patients receiving an anti-TNF- α drug, and their long-term impact on the natural history of RA has not yet been determined, although recent studies do suggest that their use may limit joint damage compared with methotrexate. Immunosuppressive drugs such as cyclosporine may occasionally be effective, but they are often associated with unacceptable side effects.

This page intentionally left blank.

XII. ENDOCRINE AND METABOLIC DISORDERS

QUESTIONS

DIRECTIONS: Each question below contains five suggested responses. Choose the **one best** response to each question.

- XII-1.** The use of repeated phlebotomy in the treatment of persons with symptomatic hemochromatosis may be expected to result in
- (A) increased skin pigmentation
 - (B) improved cardiac function
 - (C) return of secondary sex characteristics
 - (D) decreased joint pain
 - (E) an unchanged 5-year survival rate
- XII-2.** A 19-year-old man has had a 5-year history of hyperglycemic episodes and glycosuria. However, he has never been hospitalized for diabetic ketoacidosis. Which of the following statements regarding the mode of inheritance of his disease is correct?
- (A) This disease is inherited in an autosomal recessive fashion.
 - (B) If the patient has children, they will have approximately a 50% chance of developing diabetes.
 - (C) The diabetic susceptibility gene in this patient resides on human chromosome 6.
 - (D) The patient is likely to carry one of a limited number of HLA-D locus alleles.
 - (E) The patient has an unusual susceptibility to a viral infection.
- XII-3.** Which of the following studies is most sensitive for detecting diabetic nephropathy?
- (A) Serum creatinine level
 - (B) Creatinine clearance
 - (C) Urine albumin
 - (D) Glucose tolerance test
 - (E) Ultrasonography
- XII-4.** Which of the following statements concerning intensive insulin therapy for diabetes (the use of an external insulin pump or three or more daily insulin injections guided by frequent blood glucose monitoring) is correct?
- (A) All patients with diabetes mellitus should receive such therapy.
- XII-4.** (Continued)
- (B) It has been definitively shown that compared with standard therapy, such intensive therapy reduces the likelihood of retinopathy in patients with insulin-dependent diabetes mellitus.
 - (C) Such therapy will consistently return blood glucose to normal levels, but a reduction of long-term complications has not been demonstrated.
 - (D) With careful monitoring, an increase in the number of hypoglycemic episodes is avoided.
 - (E) Intensive insulin therapy failed to reduce the level of glycosylated hemoglobin.
- XII-5.** Evidence of continuing ovarian estrogen production in a 29-year-old woman who is being evaluated for secondary amenorrhea is provided by
- (A) normal plasma estrone and luteinizing hormone (LH) levels
 - (B) a normal plasma prolactin level
 - (C) an increase in plasma estradiol level after the administration of human chorionic gonadotropin (hCG)
 - (D) the appearance of menses after a short course of progesterone therapy
 - (E) a lack of hot flashes
- XII-6.** Which of the following inhibits growth hormone secretion from the anterior pituitary gland?
- (A) Somatostatin
 - (B) Growth hormone–releasing hormone (GHRH)
 - (C) Hypoglycemia
 - (D) Arginine
 - (E) Serotonin
- XII-7.** A 7-year-old girl is referred for evaluation of vaginal bleeding for 2 months. The mother says that she has not been exposed to exogenous estrogens. Physical examination reveals height at the 98th percentile, Tanner stage III breast development, and no axillary or pubic hair. No abdominal or pelvic masses are palpated. Neurologic

XII-7. (Continued)

examination is normal. Radiographic and laboratory evaluations reveal the following:

Brain MRI: normal pituitary and hypothalamus

Bone age: 10 years

Urinary 17-ketosteroids: 1.7 μmol (0.5 mg)/g creatinine per 24 h

Urinary gonadotropins: undetectable

The appropriate next step in the management of this girl would be

- (A) exploratory laparotomy
- (B) treatment with medroxyprogesterone acetate
- (C) measurement of plasma androstenedione level
- (D) abdominal CT scanning and/or pelvic sonography
- (E) karyotype analysis

XII-8. A 40-year-old man presents with an insidious onset of fatigue, headaches, muscle weakness, and paresthesia. Physical examination reveals hypertension, an enlarged tongue, wide spacing of the teeth, and a doughy appearance to the skin. Which of the following laboratory results would be consistent with the expected diagnosis?

- (A) Elevated serum thyroxine level
- (B) Fasting serum glucose = 3.3 mmol/L (60 mg/dL)
- (C) Elevated insulin-like growth factor (IGF-I)
- (D) Growth hormone concentration = 0.2 $\mu\text{g/L}$ (0.2 ng/mL) 1 h after oral administration of 100 g glucose
- (E) Decreased IGF binding protein 3

XII-9. Which of the following statements concerning the diagnosis of pheochromocytoma is correct?

- (A) Measurement of plasma catecholamines is the preferred initial screening test.
- (B) Random urine samples are equivalent in diagnostic accuracy to the measurement of catecholamines or catecholamine metabolites in a 24-h urine collection.
- (C) After collection, the urine should be treated with dilute sodium hydroxide and refrigerated.
- (D) The ideal time to collect urine is during a period of clinical stability.
- (E) Strenuous exertion may falsely elevate the level of free urinary catecholamines.

XII-10. An 18-year-old woman arrives in your clinic with primary amenorrhea, sexual infantilism, and clitoromegaly. She had ambiguous external genitalia at birth. A laparotomy was performed at 17 months of age and revealed normal internal female genitalia. An ovarian biopsy revealed apparently normal primordial follicles. Laboratory studies revealed a normal female karyotype and high se-

XII-10. (Continued)

rum testosterone and androstenedione concentrations. Undetectable serum estradiol and estrone concentrations were also noted. There was a high serum follicle-stimulating hormone and LH concentration. Pelvic imaging disclosed multiple ovarian cysts. What is the most likely diagnosis?

- (A) Congenital adrenal hyperplasia
- (B) Aromatase deficiency
- (C) McCune-Albright syndrome
- (D) Kallmann's syndrome
- (E) Galactosemia

XII-11. A female patient arrives in your clinic with a serum calcium of 2.7 mmol/L (10.8 mg/dL). The patient is asymptomatic, and this abnormality is found on routine laboratory analysis. A workup includes a normal CBC, normal liver function tests, and a normal serum protein electrophoresis. A serum parathyroid hormone level is 136 ng/L (136 pg/mL), a 24-h urinary calcium is 268 mg, and a serum alkaline phosphatase level is 106 U/L. The patient has no history of orthopedic fractures or nephrolithiasis. A bone densitometry study is performed that reveals a lumbar spine z-score of -0.86 , a femoral neck z-score of -1.34 , and a radius z-score of -1.42 . A parathyroidectomy is likely to result in which of the following?

- (A) Normalization of the serum calcium level, improvement of the bone densitometry studies, and a decreased incidence of nephrolithiasis
- (B) Normalization of the serum calcium level, improvement of the bone densitometry studies, and a decreased incidence of renal failure
- (C) Normalization of the serum calcium level, improvement of the bone densitometry studies, and a decreased incidence of pelvic and hip fractures
- (D) Normalization of the serum calcium level, improvement of the bone densitometry studies, and a decrease in the incidence of radial fractures
- (E) Normalization of the serum calcium level and improvement of the bone densitometry studies only

XII-12. A 42-year-old alcoholic man has eaten poorly for the last 10 days but has continued to drink. His family brings him to the emergency room. On neurologic examination he is confused but otherwise normal. Blood glucose concentration is 2.8 mmol/L (50 mg/dL). Intravenous infusion of a bolus of 50% glucose solution is given. His confusion worsens, and he develops horizontal nystagmus, ataxia, and a heart rate of 130 beats per minute. At this point, the man's physician should

- (A) order an immediate CT scan of the head
- (B) perform a lumbar puncture

XII-12. (Continued)

- (C) administer another bolus of 50% glucose solution
- (D) administer intravenous folic acid, 5 mg
- (E) administer intramuscular thiamine, 50 mg

XII-13. A 24-year-old woman with a several-year history of chronic, debilitating, cramping abdominal pain has been evaluated several times for this problem. In each case the possibility of psychogenic causes has been raised because of the absence of abdominal tenderness, fever, and leukocytosis during the episodes. The patient has had intermittent vomiting, constipation, arm and chest pain, and difficulty in urination. She also complains of increasing leg weakness. The attacks of abdominal pain are often associated with anxiety, insomnia, and disorientation. A prior workup has also included abdominal angiography, abdominal CT, and endoscopy. The results of all the diagnostic studies were normal. The patient's current physical examination and routine laboratory examination, including complete blood count and serum chemistries, are unremarkable. The urinary pyrrole porphobilinogen excretion is elevated. Which of the following is the most appropriate advice for this patient?

- (A) The patient's offspring may be at risk only if the father is also a carrier of this disease.
- (B) Intravenous administration of heme may ameliorate the attacks.
- (C) Narcotic analgesics should not be used during acute attacks.
- (D) The patient should avoid aspirin.
- (E) The patient should avoid prolonged exposure to the sun.

XII-14. A 54-year-old obese male presented with fasting blood serum glucose of 12.2 mmol/L (220 mg/dL); this was repeated several times with similar results. He underwent a diet and exercise program, but after 6 months was able to decrease his weight only from 127 to 118 kg (280 to 260 lb). There was no significant change in his fasting serum glucose level. A test for thyroid function was normal. A fasting cholesterol level was 7.5 mmol/L (290 mg/dL), with a low-density lipoprotein (LDL) cholesterol of 4.9 mmol/L (190 mg/dL). His renal and hepatic function are within normal limits. Which of the following oral anti-diabetic agents would you recommend?

- (A) Metformin
- (B) Glipizide
- (C) Repaglinide
- (D) Acarbose
- (E) None, only insulin therapy should be initiated

XII-15. A full cholesterol panel is performed on the patient described in Question XII-14. In addition to the stated cholesterol and LDL cholesterol levels, the serum triglyc-

XII-15. (Continued)

eride level is 3.4 mmol/L (300 mg/dL) and the high-density lipoprotein (HDL) cholesterol level is 0.9 mmol/L (35 mg/dL). Which of the following would be the most appropriate therapeutic recommendation?

- (A) Diet and exercise
- (B) Initiation of an HMG-CoA reductase inhibitor
- (C) Nicotinic acid
- (D) Fibrate therapy
- (E) No pharmacologic therapy is indicated at this time; the patient should be reevaluated after tighter glycemic control is achieved

XII-16. A 20-year-old woman has a history of multiple fractures since childhood, kyphoscoliosis, bluish-gray teeth, and conductive hearing loss. Examination of the face reveals blue sclerae. Several relatives on her mother's side have been similarly affected. She has no history of physical abuse or abnormal serum chemistries. The most likely mechanism of the patient's abnormalities is

- (A) excessive deposition of normal collagen fibrils in bone
- (B) inability to convert procollagen to collagen
- (C) mutation in the gene for type I procollagen
- (D) mutation in the gene for type II procollagen
- (E) mutation in the gene for type III procollagen

XII-17. A clinical presentation that includes long thin extremities, dislocation of the ocular lens, and aortic aneurysms is most likely due to a derangement in which of the following molecules?

- (A) Procollagen type I
- (B) Procollagen type II
- (C) Proteoglycan
- (D) Elastin
- (E) Fibrillin

XII-18. A 25-year-old man with a renal allograft and a history of an intracerebral abscess is evaluated for profound polyuria. He is admitted to the hospital for a water deprivation test. No fluids are given after 12 midnight. By 11 A.M. he has lost 1 kg, and urine osmolality has been 120 mosmol/kg for the last 3 h. Plasma osmolality is 320 mosmol/kg (serum sodium is 155 mmol/L). At 11 A.M. 1 μ g desmopressin is given by subcutaneous injection; 45 min later the urine osmolality is measured at 121 mosmol/kg. The patient is then allowed to drink. Treatment of this patient should include

- (A) vasopressin tannate in oil
- (B) hydrochlorothiazide
- (C) desmopressin
- (D) chlorpropamide
- (E) demeclocycline

- XII-19.** A person with hypercalcemia caused by sarcoidosis would have which of the following findings?
- (A) A normal chest x-ray
 - (B) Increased absorption of calcium from the gastrointestinal tract
 - (C) Normal urine calcium excretion
 - (D) Increased serum parathyroid hormone level
 - (E) Hypogammaglobulinemia
- XII-20.** The most likely etiology for the eating disorder anorexia nervosa is
- (A) decreased levels of luteinizing hormone–releasing hormone (LHRH)
 - (B) decreased levels of growth hormone
 - (C) decreased levels of insulin-like growth factor I (somatomedin C)
 - (D) low levels of serum thyroxine
 - (E) psychiatric disorder
- XII-21.** A 45-year-old obese man without known medical problems complains of feeling very sleepy during the day and often falling asleep while listening to friends. The most likely cause of this patient's problem is
- (A) narcolepsy
 - (B) upper airway obstruction at night
 - (C) glucocorticoid excess
 - (D) growth hormone excess
 - (E) estrogen excess
- XII-22.** A 67-year-old man with chronic arthritis is found to have passed a uric acid stone after an episode of renal colic. On workup he is found to have multiple radiolucent stones in the left renal pelvis, uric acid excretion of 5.4 mmol/d (900 mg/d), a serum uric acid concentration of 580 $\mu\text{mol/L}$ (9.8 mg/dL), a serum creatinine concentration of 160 $\mu\text{mol/L}$ (1.8 mg/dL), and monosodium urate crystals in an effusion in the left knee. The drug of choice for long-term therapy in this patient is
- (A) probenecid alone
 - (B) probenecid and sodium bicarbonate
 - (C) allopurinol
 - (D) colchicine
 - (E) sulfinpyrazone
- XII-23.** An obese woman has hypertriglyceridemia without hypercholesterolemia. The most appropriate first step in the treatment of this woman would be
- (A) weight reduction
 - (B) nicotinic acid
 - (C) gemfibrozil
 - (D) clofibrate therapy
 - (E) bile acid–binding resin therapy
- XII-24.** An X-linked recessive disease characterized by nephrolithiasis, arthritis, self-mutilative behavior, and mental retardation is associated with
- (A) failure to excrete uric acid because of inherited defective renal tubular function
 - (B) failure to excrete uric acid because of xanthine oxidase mutation
 - (C) uric acid overproduction caused by inherited acceleration of purine degradation
 - (D) increased urate production caused by an inability to convert purine bases to ribonucleotides
 - (E) increased urate production caused by increased levels of phosphoribosylpyrophosphate
- XII-25.** In designing a hormone replacement program for patients with coexistent thyroid and adrenal failure,
- (A) the dose of glucocorticoid must be increased slowly once thyroid replacement has been initiated
 - (B) the dose of thyroid hormone must be increased slowly once glucocorticoid replacement has been initiated
 - (C) mineralocorticoid replacement must also be included if combined therapy is required
 - (D) thyroid replacement must not be initiated until treatment with glucocorticoid has been instituted
 - (E) growth hormone replacement must also be included if combined therapy is required
- XII-26.** A 20-year-old man presents with weakness. Physical examination reveals mild jaundice and a liver two fingers beneath the right costal margin. Laboratory evaluation is remarkable for the presence of elevated hepatic transaminases (four times normal). Other laboratory results are negative, including serology for hepatitis A, B, and C; ANA; rheumatoid factor; iron; and iron binding. Serum ceruloplasmin is 50 mg/L (5 mg/dL). The patient denies intake of alcohol and exposure to known hepatotoxins. The most appropriate treatment is
- (A) liver transplantation
 - (B) interferon- α
 - (C) penicillamine
 - (D) glucocorticoids
 - (E) desferrioxamine
- XII-27.** A 63-year-old woman with a history of stage II breast cancer 8 years prior is seen in your clinic. Her breast cancer was treated with lumpectomy, adjuvant chemotherapy, and localized radiotherapy. She completed 5 years of tamoxifen. She has no symptoms of recurrent disease. A routine bone densitometry study reveals moderate osteoporosis. She does have a family history of osteoporosis, and her mother suffered a hip fracture in her early 70's. Which of the following therapeutic options would be most appropriate?

XII-27. (Continued)

- (A) A calcium supplement and multivitamin
- (B) Raloxifene
- (C) Calcitonin
- (D) Hormone replacement therapy with estrogen and progesterone
- (E) Hormone replacement therapy with estrogen alone

XII-28. Cholestyramine and colestipol are binding resins that are used to treat patients with hypercholesterolemia. Their serum-cholesterol-lowering effects are thought to be mediated by

- (A) causing mild diarrhea and a mild degree of fat malabsorption
- (B) binding of intestinal cholesterol, thus decreasing its net absorption from dietary sources
- (C) decreasing the intestinal synthesis of very-low-density lipoproteins
- (D) interrupting the enterohepatic circulation of cholesterol by sequestering bile acids in the intestine
- (E) none of the above

XII-29. A 30-year-old woman is seen in your clinic during her first pregnancy. She is 26 weeks pregnant and has had an uncomplicated pregnancy so far. She has no family history for diabetes mellitus. She has no other significant past medical history. On physical exam she has normal vital signs, including a normal blood pressure. She is not obese. A 50-g oral glucose challenge is given to the patient. One hour later a serum glucose level of 8.3 mmol/L (150 mg/dL) is obtained. Which of the following statements is correct?

- (A) The patient has gestational diabetes mellitus
- (B) The test is valid only if performed during the morning after an overnight fast
- (C) The test should be repeated and a serum glucose level obtained 2 h after the oral glucose challenge
- (D) The test should be repeated with a 100-g glucose challenge and serum glucose levels measured 1, 2, and 3 h after the test
- (E) The test should be repeated using a 75-g oral glucose challenge and measuring the serum glucose 2 h after the test

XII-30. The patient described in Question XII-29 has been diagnosed with gestational diabetes mellitus. Diet and frequent glucose monitoring have failed to decrease her serum fasting glucose to ≤ 5.8 mmol/L (105 mg/dL). You recommend which of the following treatment options?

- (A) Acarbose
- (B) Insulin
- (C) Sulfonylurea
- (D) Metformin
- (E) Rosiglitazone

XII-31. Obese persons are at an increased risk for which of the following disorders?

- (A) Hypothyroidism
- (B) Cholelithiasis
- (C) Type 1 diabetes mellitus
- (D) Elevated levels of HDL cholesterol
- (E) Central sleep apnea

XII-32. Which of the following statements concerning Kallmann's syndrome is true?

- (A) It is characterized by hypergonadotropic hypogonadism.
- (B) It is more common in women than men.
- (C) It is an X-linked recessive disorder.
- (D) It is characterized by a mutation that increases the activity of the α -subunit of the stimulatory G protein ($G_{s\alpha}$).
- (E) Anosmia is a rare finding.

XII-33. A 25-year-old man complains of diffuse bone pain. Physical examination is remarkable for the presence of an enlarged spleen (9 cm below the left costal margin). CBC discloses pancytopenia. A bone marrow examination reveals normal hematopoiesis; however, large multinucleated, macrophage-like cells engorged with cytoplasmic fibrils are present. The relevant family history includes Eastern European Jewish origins. An appropriate therapeutic intervention in this patient is administration of

- (A) penicillamine
- (B) desferrioxamine
- (C) aglucerase
- (D) leuprolide
- (E) none of the above

XII-34. Which of the following regimens is best for the preoperative management of a patient with a known pheochromocytoma?

- (A) Propranolol alone
- (B) Propranolol followed by phenoxybenzamine
- (C) Phenoxybenzamine followed by propranolol
- (D) Prazosin alone
- (E) Propranolol followed by prazosin

XII-35. Which of the following statements concerning leptin is true?

- (A) Leptin acts by stimulating specific leptin receptor isoforms in muscle tissue.
- (B) Leptin is a 16-kDa protein secreted by the pancreas.
- (C) Inactivating mutations within the leptin receptor cause marked anorexia.
- (D) Serum leptin levels in patients with anorexia nervosa, bulimia, and other nonspecific eating dis-

XII-35. (Continued)

orders are similar to those of healthy persons with comparable body mass index.

- (E) Leptin levels decrease exponentially with increasing body fat mass.

XII-36. Which of the following may be a direct consequence of severe magnesium deficiency?

- (A) Hypophosphatemia
 (B) Hypercalcemia
 (C) Hypokalemia
 (D) Hyponatremia
 (E) Shortening of the QT/QT_c interval

XII-37. A 55-year-old woman presents to her physician with mild fatigue. Her past medical history is unremarkable. She is taking no medication. No abnormalities are detected on physical examination. The only abnormality detected on routine blood testing is an elevated calcium [2.96 mmol/L (11.9 mg/dL)] and a serum inorganic phosphorus of 0.65 mmol/L (2 mg/dL). An immunoreactive parathyroid hormone level is undetectable. The most likely etiology for this patient's high serum calcium is

- (A) primary hyperparathyroidism
 (B) malignancy
 (C) hypervitaminosis
 (D) hyperthyroidism
 (E) familial hypocalciuric hypercalcemia

XII-38. A 64-year-old man seeks medical attention because of an annoying cough. Physical examination is remarkable only for supraclavicular lymphadenopathy. Chest x-ray shows a parahilar mass and paratracheal lymph node enlargement. Serum and urine chemistries are as follows:

Sodium: 120 mmol/L
 Potassium: 4 mmol/L
 Bicarbonate: 23 mmol/L
 Serum osmolality: 250 mosmol/kg H₂O
 Urine osmolality: 600 mosmol/kg H₂O
 Urine sodium: 80 mmol/L

The most likely pathophysiologic basis for this man's hyponatremia is

- (A) production of a vasopressin-like molecule by tumor tissue
 (B) production of authentic vasopressin by tumor tissue
 (C) potentiation of vasopressin action on the renal tubule by a tumor product
 (D) stimulation of neurohypophyseal vasopressin secretion by a tumor product
 (E) central nervous system metastases resulting in loss of vasopressin regulation

XII-39. Patients who are heterozygous for defective copies of the genes coding for either lipoprotein lipase or apoprotein CII will exhibit which of the following abnormalities?

- (A) Excessive chylomicronemia
 (B) Excessive amounts of LDL in serum
 (C) Excessive amounts of very low density lipoprotein in serum
 (D) Excessive amounts of chylomicron remnant
 (E) Excessive amounts of intermediate-density lipoproteins

XII-40. A 32-year-old man sustains a myocardial infarction. He relates a history of early myocardial infarctions in several aunts and uncles. Moreover, it is noted that he has nodular swellings in the Achilles tendon and other tendons in the dorsum of the hand. A serum cholesterol is 10 mmol/L (400 mg/dL). A defect in which of the following proteins is the most likely etiology of this patient's clinical problem?

- (A) Apoprotein E
 (B) Apoprotein CII
 (C) Lipoprotein lipase
 (D) Lipoprotein B
 (E) LDL receptor

XII-41. In persons with congenital adrenal hyperplasia resulting from inherited defects of adrenal steroid C-21 hydroxylase, excessive androgen production is the result of

- (A) autonomous adrenal production of steroids
 (B) autonomous pituitary production of ACTH
 (C) extraglandular formation from large amounts of nonadrogenic adrenal steroids
 (D) failure of production of an adrenal product necessary for negative feedback on pituitary ACTH secretion
 (E) positive feedback on pituitary ACTH secretion by abnormal adrenal products

XII-42. A 38-year-old woman with obesity, dermal striae, and hypertension is referred for endocrinologic evaluation of possible cortisol excess. The woman receives a midnight dose of 1 mg of dexamethasone; a plasma cortisol level drawn at 8 A.M. the next day is 386 nmol/L (14 µg/dL). At this point in the evaluation the most appropriate diagnostic maneuver would be

- (A) CT scanning of the pituitary gland
 (B) abdominal CT scanning
 (C) measurement of 24-h 17-hydroxycorticosteroid excretion in urine
 (D) measurement of a 24-h urine free cortisol
 (E) a 2-day high-dose dexamethasone suppression test (2.0 mg every 6 h for 48 h)

XII-43. In a 36-year-old woman who has had insulin-dependent diabetes mellitus since age 14, hyperkalemia is being evaluated. On physical examination her blood pressure is 146/96 mmHg. Laboratory evaluation discloses the following:

Fasting plasma glucose: 6 mmol/L (110 mg/dL)
Serum creatinine: 194 μ mol/L (2.2 mg/dL)
Serum sodium: 135 mmol/L
Serum potassium: 6.2 mmol/L
Serum chloride: 116 mmol/L
Serum bicarbonate: 14 mmol/L

After a short ACTH infusion test, the plasma cortisol concentration increases from 386 to 717 nmol/L (14 to 26 μ g/dL). After the administration of 80 mg of furosemide and 3 h of upright posture, the plasma renin activity and aldosterone concentration are unchanged from baseline values. The most appropriate therapeutic regimen to correct the electrolyte imbalance would be

- (A) administration of fludrocortisone
- (B) administration of furosemide
- (C) administration of hydrocortisone and furosemide
- (D) hemodialysis
- (E) administration of potassium-binding anion-exchange resins

XII-44. A 22-year-old woman who has had diabetes mellitus for 6 years now wishes to become pregnant. She takes 32 units of NPH insulin each morning, and her urine glucose values (done twice daily) are “usually trace or 1+.” Her hemoglobin A_{1c} level is 9.8% (normal, 5 to 8%). She takes oral contraceptive pills. Her physician should advise her that

- (A) home glucose monitoring and a daily regimen of multiple subcutaneous injections of regular insulin are necessary now
- (B) oral contraceptive agents can falsely elevate HbA_{1c} levels
- (C) attempts to achieve better diabetic control can wait until she has become pregnant
- (D) the current insulin regimen probably will be adequate until the last trimester of pregnancy
- (E) hospitalization probably will be necessary for most of her pregnancy to ensure normal delivery and perinatal survival

XII-45. A 24-year-old man with diabetes since age 9 sees his physician for a routine checkup. He has no complaints and is taking 40 units NPH and 5 units regular insulin each morning as prescribed. Ophthalmoscopic examination reveals the findings in Plate N. On the basis of these findings, his physician should recommend

- (A) vitrectomy
- (B) photocoagulation

XII-45. (Continued)

- (C) hypophysectomy
- (D) follow-up examination in 3 months
- (E) more vigorous control of the blood sugar level

XII-46. In a 40-year-old man with long-standing hypogonadism resulting from total surgical castration for bilateral seminomas at age 17, the effectiveness of testosterone cypionate therapy can best be monitored by the assessment of

- (A) plasma testosterone level
- (B) plasma LH level
- (C) plasma testosterone cypionate level
- (D) change in muscle mass
- (E) frequency of nocturnal erections

XII-47. During a routine checkup, a 67-year-old man is found to have a level of serum alkaline phosphatase three times the upper limit of normal. Serum calcium and phosphorus concentrations and liver function test results are normal. He is asymptomatic. The most likely diagnosis is

- (A) metastatic bone disease
- (B) primary hyperparathyroidism
- (C) occult plasmacytoma
- (D) Paget’s disease of bone
- (E) osteomalacia

XII-48. The most important regulator of serum 1,25(OH)₂ vitamin D concentration is

- (A) serum calcium
- (B) serum magnesium
- (C) serum 25(OH) vitamin D
- (D) parathyroid hormone
- (E) prolactin

XII-49. A 63-year-old woman presents to your clinic complaining of a 4- to 5-month history of anorexia, fatigue, and visual disturbances. She has a long history of hyperlipidemia but no other significant past medical history. On physical examination she is thin but in no acute distress. Her vital signs are unremarkable, including a normal blood pressure. She has normal facial features, and no other obvious abnormalities are noted. On formal neurologic testing, however, she has evidence of bilateral superior arcuate visual field defects. Radiologic examination of the chest reveals multiple bilateral hilar lymph nodes with diffuse reticulonodular infiltrates. Pulmonary function tests reveal a mild decrease in both the total lung capacity (TLC) and in a single-breath carbon monoxide diffusion capacity (DL_{CO}). Laboratory analysis reveals a hematocrit of 34.8%. She has a normal white blood count and platelet count. Her erythrocyte sedimentation rate is 75 mm/h. A serum sodium level of 128 mmol/L

XII-49. (Continued)

(128 meq/L) and a potassium level of 4.2 mmol/L (4.2 meq/L) are noted. A serum osmolality of 265 (mosmol/kg of water), total cholesterol of 7.7 mmol/L (298 mg/dL), LDL cholesterol level of 4.7 mmol/L (181 mg/dL), and a HDL cholesterol level of 1.2 mmol/L (46 mg/dL) are noted. Her serum triglyceride level is 2.0 mmol/L (176 mg/dL), and random serum glucose is measured at 8.16 mmol/L (147 mg/dL). Endocrine studies reveal a TSH of 0.07 mU/L, a total thyroxine of 87 nmol/L (6.8 μ g/dL), a total triiodothyronine of 1.1 nmol/L (70 ng/dL), a prolactin levels of 3.3 μ g/L (3.3 ng/mL), α -subunit level of <0.2, follicle-stimulating hormone (FSH) level of 3.3 IU/L, a fasting serum cortisol level of 690 nmol/L (2.5 μ g/dL), and a 60-min postadministration of cosyntropin cortisol level of 360 nmol/L (13 μ g/dL). Tests for ANA and rheumatoid factor are unremarkable. A T1-weighted MRI scan is obtained after the administration of gadolinium and reveals a masslike lesion in the pituitary gland that extends into the hypophyseal stalk. Which of the following diagnoses is most consistent with this clinical presentation?

- (A) Nelson's syndrome
- (B) A growth hormone–secreting tumor
- (C) A nonfunctioning pituitary adenoma
- (D) Granulomatous hypophysitis
- (E) Lymphocytic hypophysitis

XII-50. A 20-year-old competitive swimmer is examined because of primary amenorrhea. Her height is 170 cm (67 in.), and she weighs 50 kg (110 lb). Her breasts are well developed. Findings on pelvic examination are normal, and the pubic hair appears to be normal. Cervical mucus is abundant and demonstrates ferning on drying. Urine spot and blood tests for pregnancy are negative. She is given 10 mg of medroxyprogesterone acetate twice a day for 5 days, and 3 days later she experiences menstrual bleeding for the first time. The most likely cause of the amenorrhea is

- (A) functional hypothalamic amenorrhea
- (B) 45,X gonadal dysgenesis
- (C) polycystic ovarian disease
- (D) chromophobe adenoma of the pituitary
- (E) prolactinoma of the pituitary

XII-51. A 21-year-old woman is examined because of secondary amenorrhea. Cyclic menses had commenced at age 14 years. When she was 19 years old she became pregnant and was hospitalized during the sixth month of that pregnancy because of bleeding and hypotension that proved to be the result of a spontaneous abortion with retained placental fragments; she received 10 units of blood, and a dilation and curettage was performed. No menses have occurred during the 2 years since the hospitalization. She now wishes to become pregnant.

XII-51. (Continued)

Findings on physical examination, including a recto-pelvic examination, are normal. Results on complete blood counts, SMA-12, and chest x-ray are within normal limits. Serum thyroid-stimulating hormone concentration is 1.5 mU/L and an 8 A.M. plasma cortisol measurement is 470 nmol/L (17 μ g/dL). No menstrual bleeding occurs after the administration of 10 mg medroxyprogesterone acetate per day for 10 days or cyclic estrogen and progestogen (1.25 mg conjugated estrogens by mouth each day for 3 weeks with 10 mg medroxyprogesterone acetate per day for the last 7 days). At this point the most appropriate diagnostic study would be

- (A) CT scan of the pituitary with contrast
- (B) CT scan of the abdomen followed by wedge resection of the ovaries
- (C) hysterosalpingography
- (D) metyrapone test
- (E) chromosomal analysis

XII-52. A 36-year-old woman has noticed the absence of menses for the last 4 months. A pregnancy test is negative. Serum levels of LH and FSH are elevated, and the serum estradiol level is low. These findings suggest

- (A) bilateral tubal obstruction
- (B) panhypopituitarism
- (C) polycystic ovarian disease
- (D) premature menopause
- (E) exogenous estrogen administration

XII-53. A newborn infant with ambiguous genitalia develops vomiting and profound volume depletion. A diagnosis of congenital adrenal hyperplasia resulting from C-21 hydroxylase deficiency would be supported by which of the following findings?

- (A) Elevated urinary 17-ketosteroid concentration
- (B) Elevated plasma 11-deoxycortisol concentration
- (C) High levels of urinary dehydroepiandrosterone (DHEA) with low levels of urinary pregnanetriol and cortisol metabolites
- (D) Elevated plasma levels of aldosterone
- (E) Elevated levels of plasma 17-hydroxyprogesterone

XII-54. In women with gonadal dysgenesis, development of malignancy in the streak gonads is most likely to occur when the karyotype is

- (A) 46XX_i (isochromosome X)
- (B) 46,XX
- (C) 45,X
- (D) 45,X/46,XY mosaicism
- (E) 45X,46XX mosaicism

XII-55. The most common presentation of primary hyperparathyroidism is

XII-55. (Continued)

- (A) bone fracture
- (B) increased serum creatinine
- (C) osteitis fibrosa cystica
- (D) calcium kidney stones
- (E) asymptomatic hypercalcemia

XII-56. A 34-year-old woman has had three hospital admissions during the last year because of nephrolithiasis. The rate of 24-h urinary calcium excretion has been above the normal range on all three occasions, and serum calcium concentrations were between 2.5 and 2.8 mmol/L (10.2 and 11.5 mg/dL). The serum phosphorus concentration was 0.77 mmol/L (2.4 mg/dL), and the parathyroid hormone level was 229 nL eq/mL (normal, less than 150 nL eq/mL). The most appropriate management at this time would be

- (A) to begin administration of prednisone, 40 mg daily, and taper the dose over a period of 4 weeks
- (B) to administer thiazide diuretics to decrease calcium excretion
- (C) symptomatic treatment of renal lithiasis only
- (D) calcium supplementation to prevent progressive bone loss
- (E) surgical exploration of the neck

XII-57. Which of the following conditions is MOST likely to cause hyperthyroidism associated with high thyroidal radioactive iodine uptake (RAIU)?

- (A) Subacute thyroiditis
- (B) Struma ovarii
- (C) Choriocarcinoma
- (D) Ingestion of exogenous levothyroxine
- (E) Recent intravenous pyelography

XII-58. Which of the following conditions is characteristic of the presentation of osteomalacia in adults?

- (A) Bowing of the tibia
- (B) Pseudofractures
- (C) Increased thickness of the epiphyseal growth plate
- (D) Hypocalcemia
- (E) Hyperphosphatemia

XII-59. A 61-year-old woman noticed severe sharp pain in her back after lifting a suitcase. A compression fracture of the T11 vertebral body is identified on x-ray examination. Routine laboratory evaluation discloses a serum calcium concentration of 2 mmol/L (8.0 mg/dL), a serum phosphorus concentration of 0.77 mmol/L (2.4 mg/dL), and increased serum alkaline phosphatase activity. The serum parathyroid hormone level was subsequently found to be elevated as well. The most likely diagnosis is

- (A) Paget's disease of bone
- (B) ectopic parathyroid hormone secretion

XII-59. (Continued)

- (C) primary hyperparathyroidism
- (D) postmenopausal osteoporosis
- (E) vitamin D deficiency

XII-60. A 60-year-old woman has lower-back pain. Radiographic examination reveals diffuse demineralization and a compression fracture of the fourth lumbar vertebra. The serum calcium concentration is 2.8 mmol/L (11.5 mg/dL). The blood count is normal. This clinical picture is most compatible with the presence of which of the following conditions?

- (A) Postmenopausal osteoporosis
- (B) Paget's disease
- (C) Primary hyperparathyroidism
- (D) Multiple myeloma
- (E) Osteomalacia

XII-61. Which of the following conditions is MOST likely to be associated with a normal serum 25(OH) vitamin D level?

- (A) Dietary deficiency of vitamin D
- (B) Chronic severe cholestatic liver disease
- (C) Chronic renal failure
- (D) Anticonvulsant therapy with phenobarbital or phenytoin
- (E) High-dose glucocorticoid therapy

XII-62. A 42-year-old white male presents to your clinic for routine follow-up examination. He was diagnosed with type 2 diabetes mellitus approximately 10 years ago and has been well controlled on glipizide. There is no history of coronary disease. He is also a nonsmoker. His physical exam is notable for a blood pressure of 140/90; there are no other abnormalities noted. A 24-h urine collection for albumin reveals 200 mg. Additional routine laboratory analyses are within normal limits. Which of the following would be most appropriate therapeutic option?

- (A) Change his diabetic therapy to insulin
- (B) Begin a diet and exercise program
- (C) Initiate a low-sodium diet
- (D) Begin beta-blocker antihypertensive therapy
- (E) Begin use of an ACE inhibitor

XII-63. A 25-year-old previously healthy woman develops Sheehan's syndrome (infarction of the pituitary) after an intrapartum hemorrhage. Which of the following tests will be abnormal the day after her pituitary ceases to function?

- (A) Total T₃
- (B) ACTH stimulation test
- (C) Total T₄
- (D) GF-I
- (E) Insulin tolerance test

XII-64. Four weeks postpartum, a 32-year-old woman develops palpitations, heat intolerance, and nervousness. She is diagnosed with hyperthyroidism. Her thyroid is not enlarged or tender. The 24-h uptake of radioactive iodine is 1%. The most appropriate treatment for this woman is

- (A) radioactive iodine ablation of her thyroid gland
- (B) methimazole
- (C) prednisone 60 mg a day followed by a rapid taper
- (D) a beta blocker
- (E) iodine drops (SSKI)

XII-65. A 23-year-old woman is diagnosed with Graves' disease shortly after discovering she is pregnant. Appropriate therapy includes

- (A) radioactive iodine to ablate her thyroid gland
- (B) propylthiouracil therapy with the goal of maintaining her thyroid function tests in the high-normal or slightly high range
- (C) methimazole therapy
- (D) a beta blocker
- (E) propylthiouracil therapy with care taken to maintain her thyroid function tests in the mid-normal range

XII-66. A 33-year-old healthy woman who is taking no medications develops amenorrhea and galactorrhea. Her prolactin level is 45 $\mu\text{g/L}$ (45 ng/mL). IGF-I and 24-h free cortisol measurements are normal. MRI reveals a 2.5-cm by 2.0-cm sellar mass which nearly abuts the optic chiasm. Formal visual fields are normal. Probable diagnosis and appropriate treatment are

- (A) prolactinoma requiring immediate surgery
- (B) prolactinoma requiring treatment with a dopamine agonist
- (C) nonfunctioning pituitary adenoma requiring surgery
- (D) prolactinoma requiring serial MRIs plus oral contraceptives
- (E) nonfunctioning pituitary adenoma requiring serial MRIs plus oral contraceptives

XII-67. An 81-year-old man is found by his family to be disoriented and confused. In the emergency room, he is found to be hypoglycemic. He is afebrile, but his physical exam is otherwise normal. A bolus of intravenous dextrose is administered, and the patient quickly recovers. His glucose is 6.8 mmol/L (122 mg/dL), and his neurologic exam has returned to baseline. Further history reveals that the patient has type 2 diabetes mellitus, for which he takes a sulfonylurea. He also has a history of congestive heart failure, for which he was hospitalized three times last year. Which of the following statements reflects appropriate management?

- (A) He should be hospitalized.

XII-67. (Continued)

- (B) The sulfonylurea should be discontinued and replaced with metformin, a medication that does not cause hypoglycemia.
- (C) The patient may be discharged from the emergency room without further intervention.
- (D) The patient may be discharged from the emergency room on a reduced dose of sulfonylurea.
- (E) He should undergo a workup for a possible insulinoma.

XII-68. Causes of hypertriglyceridemia include all the following EXCEPT

- (A) alcohol
- (B) diabetes mellitus
- (C) obesity
- (D) cigarette smoking
- (E) pregnancy

XII-69. A 65-year-old woman with a history of stage I breast carcinoma (status: post lumpectomy and radiotherapy) has a quantitative digital radiography (QDR) bone density test. She is found to have a bone density more than two standard deviations below the average peak bone mass (*t*-score) and below the average age-matched bone density (*z*-score). Which of the following would be the most appropriate therapeutic option?

- (A) Alendronate
- (B) Estrogen
- (C) Weight-bearing exercise
- (D) Calcium and vitamin D supplement
- (E) Nasal calcitonin

XII-70. A 41-year-old previously healthy woman presents to an emergency room complaining of nausea and vomiting. Her calcium is found to be 2.9 mmol/L (11.7 mg/dL) with an albumin of 40 g/L (4.0 g/dL). Hyperparathyroidism is diagnosed, and an exploration of her four parathyroid glands reveals one large parathyroid tumor, which is removed. One day after the operation the patient complains of paresthesia in her hands and around her mouth. Her calcium is 1.8 mmol/L (7.3 mg/dL). Her phosphorus is 0.6 mmol/L (1.8 mg/dL). Four months later she still requires aggressive calcium and vitamin D supplementation. The most likely etiology of her hypocalcemia is

- (A) hypoparathyroidism secondary to inadvertent surgical removal of all four parathyroid glands
- (B) hypoparathyroidism secondary to atrophy of the three remaining parathyroid glands
- (C) hungry bone syndrome
- (D) parathyroid cancer
- (E) magnesium deficiency

XII-71. Six hours after a transsphenoidal resection of his growth hormone-secreting tumor, a 33-year-old man

XII-71. (Continued)

complains of increased thirst. His urine output has been 350 mL/h for the last 2 h. Urine specific gravity is 1.001, and urine osmolality is 210 mmol/kg. A serum sodium is 147 mmol/L (147 meq/L). Appropriate management at this time includes

- (A) administering 2 μg desmopressin subcutaneously once and encouraging the patient to drink water when thirsty
- (B) performing a water deprivation test
- (C) placing the patient on 500 mL/d fluid restriction
- (D) administering 2 μg desmopressin subcutaneously bid and encouraging the patient to drink water when thirsty
- (E) obtaining an MRI of the brain

XII-72. A 73-year-old man in the intensive care unit is suspected of having panhypopituitarism. He is hypotensive and is not responding to antibiotics or pressors. He reports lack of libido, fatigue, cold intolerance, and recent weight gain. His cortisol is 135 nmol/L (4.8 $\mu\text{g}/\text{dL}$), TSH 0.3 $\mu\text{U}/\text{mL}$, T_4 289 nmol/L (4.5 $\mu\text{g}/\text{dL}$), total T_3 0.63 nmol/L (40 ng/mL), $T_3\text{RU}$ 26%, LH 0.2 IU/L, FSH 0.5 IU/L, GH 2 $\mu\text{g}/\text{L}$. Testosterone is below normal. What conclusions can you make about this patient's pituitary function?

- (A) He has panhypopituitarism. He should be started immediately on 100 mg hydrocortisone intravenously q6h, levothyroxine, and testosterone.
- (B) He has normal pituitary function, and other reasons for his symptoms should be investigated.
- (C) The status of his pituitary-adrenal axis is unclear. He should be given dexamethasone, and a cosyntropin stimulation test should be performed. Thyroid hormone and testosterone replacement are unnecessary.
- (D) The status of his pituitary-adrenal axis is unclear. He should be given dexamethasone, and a cosyntropin stimulation test should be performed. Thyroid hormone and testosterone replacement should be started.
- (E) He has panhypopituitarism. He should be started immediately on 100 mg hydrocortisone intravenously q6h and levothyroxine. The testosterone replacement can wait until he is out of the intensive care unit.

XII-73. A 73-year-old woman is admitted to the hospital with chest pain. An astute intern sends her for thyroid function tests after learning that the patient has gained 23 kg (50 lb) over the last year and suffers from cold intolerance. Cardiac catheterization reveals three-vessel disease, and coronary artery bypass is recommended. While preparing the patient for surgery the next day, the intern checks the thyroid function tests. The TSH is 81 mU/mL. What course of action is most appropriate?

XII-73. (Continued)

- (A) Postpone the surgery, start levothyroxine replacement at 0.025 mg/d, and increase the dose slowly. When the patient is euthyroid, recommend surgery.
- (B) Give T_3 to make the patient euthyroid quickly so that surgery need be postponed no more than a week.
- (C) Proceed to surgery as scheduled. Start levothyroxine postoperatively.
- (D) Check a cosyntropin stimulation test, because she may have hypopituitarism and surgery may be dangerous without glucocorticoid replacement.
- (E) Start propylthiouracil therapy before surgery.

XII-74. A 32-year-old woman is diagnosed as having Cushing's disease. A transsphenoidal procedure is performed. Two days after the surgery a 24-h urine free cortisol is 5.5 nmol/d (2 $\mu\text{g}/\text{d}$). Six weeks later, a repeat 24-h urine free cortisol is 8.3 nmol/d (3 $\mu\text{g}/\text{d}$). Her thyroid function tests are normal. What is the most likely explanation for these results, and what therapy should be initiated?

- (A) The patient's Cushing's disease is cured, and she needs no further therapy.
- (B) The patient's Cushing's disease is cured, and she should be treated with glucocorticoids.
- (C) The patient still has Cushing's disease.
- (D) The patient never had Cushing's disease.
- (E) The surgeon has inadvertently induced permanent adrenal insufficiency by removing normal pituitary tissue. She requires treatment with glucocorticoids.

XII-75. A 45-year-old woman presents with weakness, central obesity, wide purple striae, and facial plethora. She is not taking exogenous glucocorticoids. She does not drink alcohol. She is not depressed, though she complains of insomnia. A 1-mg dexamethasone suppression test is performed. The patient's 8 A.M. cortisol after receiving the dexamethasone at midnight the night before is 303.5 nmol/L (11 $\mu\text{g}/\text{dL}$). A 24-h urine free cortisol is 580 nmol/d (210 $\mu\text{g}/\text{d}$). A high-dose dexamethasone suppression test (2 mg q6h \times 2 days) is performed. The 24-h urine free cortisol on the second day is 50 nmol/d (18 $\mu\text{g}/\text{d}$). Where is the tumor that is causing the Cushing's syndrome?

- (A) Pituitary
- (B) Adrenal gland
- (C) Ectopic
- (D) It is unclear from the information given. The tumor could be in the pituitary or could be ectopic.
- (E) It is unclear from the information given. The tumor could be in the adrenal gland or could be ectopic.

XII-76. A 64-year-old man is admitted with angina and found to be hyperthyroid. He is scheduled for a cardiac

XII-76. (Continued)

catheterization. What effect is the procedure likely to have on his thyroid function?

- (A) None
- (B) Exacerbate the hyperthyroidism
- (C) Improve the hyperthyroidism
- (D) If the hyperthyroidism is secondary to Graves' disease, it may improve; if it is secondary to toxic multinodular goiter, the hyperthyroidism may worsen
- (E) If the patient has Graves' disease, the hyperthyroidism may worsen; if he has toxic multinodular goiter, it may improve

XII-77. A 25-year-old female nurse presents with palpitations and heat intolerance. Her thyroid is not painful. TSH is <0.01 mU/L, free T_4 is 243 nmol/L (19 μ g/dL), T_3 resin uptake is 38%, and total T_3 is 3.6 nmol/L (230 ng/dL). The 24-h radioactive iodine uptake is 0%. Thyroglobulin is low. What is the most likely diagnosis?

- (A) Graves' disease
- (B) Silent thyroiditis
- (C) Subacute thyroiditis
- (D) Toxic multinodular goiter
- (E) Thyrotoxicosis factitia

XII-78. Which of the following has been associated with an effective approach towards the prevention of diabetic retinopathy?

- (A) A reduction in the serum triglyceride level
- (B) Improved control of blood glucose concentrations
- (C) Use of an ACE inhibitor
- (D) Use of aspirin therapy
- (E) Smoking cessation

XII-79. Which of the following statements concerning multiple endocrine neoplasia type I (MEN I) is true?

- (A) Its mode of inheritance is autosomal dominant
- (B) Cushing's disease caused by an ACTH-producing pituitary tumor is the most common syndrome associated with a pituitary syndrome in MEN I
- (C) It is caused by a mutation in the c-RET proto-oncogene
- (D) The hyperparathyroidism usually is caused by four-gland hyperplasia, not by an adenoma
- (E) Pituitary tumors occur in less than half of MEN I patients

XII-80. A 19-year-old man with type 1 diabetes mellitus presents to the emergency room with nausea and vomiting. His arterial pH is 7.16 with potassium of 5.4 mmol/L, bicarbonate of 7 mmol/L, sodium of 132 mmol/L, phosphate of 0.9687 mmol/L (3.0 mg/dL), and glucose of 26 mmol/L (475 mg/dL). In addition to intravenous saline,

XII-80. (Continued)

which electrolyte additive should also be considered in this case?

- (A) Bicarbonate
- (B) Potassium
- (C) Dextrose
- (D) Phosphate
- (E) None of the above

XII-81. Which of the following statements concerning patients with polyglandular autoimmune syndrome type II (Schmidt's syndrome) is true?

- (A) The onset of this disease is typically found during childhood.
- (B) It has an autosomal recessive mode of inheritance.
- (C) In addition to Addison's disease, the second most common endocrine abnormality is hypothyroidism.
- (D) Mucocutaneous candidiasis is a typical hallmark of this syndrome.
- (E) Hypoparathyroidism is a common feature.

XII-82. A 52-year-old white male with a 10-year history of type 2 diabetes mellitus presents to your clinic for routine follow-up. His current oral hypoglycemic regimen includes metformin. His daily fasting serum blood glucose is averaging 6.7 mmol/L (120 mg/dL). An ophthalmologic exam reveals mild to moderate proliferative changes without macular edema. An appropriate recommendation would include which of the following?

- (A) Change in medication from metformin to a sulfonylurea
- (B) Change of medication from metformin to insulin
- (C) Initiate aspirin therapy
- (D) No intervention is required
- (E) Start photocoagulation

XII-83. Which of the following is a characteristic of generalized lipodystrophy (also called *lipotrophic diabetes*)?

- (A) Heart failure due to hypertrophic cardiomyopathy is a common feature.
- (B) The congenital form is sex-linked recessive.
- (C) Obesity is a central feature.
- (D) Metabolic abnormalities such as insulin resistance, hyperglycemia, and hypertriglyceridemia are characteristic.
- (E) Linear growth is retarded during childhood.

XII-84. A 24-year-old woman with type 1 diabetes mellitus presents with 6 h of vomiting. She is diagnosed with diabetic ketoacidosis (DKA). On presentation to the hospital, her arterial pH is 7.20, her glucose is 24 mmol/L (430 mg/dL), her potassium is 5.7 mmol/L, and her serum inorganic phosphorus is 1.2 mmol/L (3.6 mg/dL). However, after the initiation of treatment for DKA, the serum

XII-84. (Continued)

inorganic phosphorus quickly falls to 0.43 mmol/L. Which of the following statements is true?

- (A) She probably has severe phosphorus deficiency.
- (B) Phosphorus therapy should be administered.
- (C) Most patients with DKA are severely depleted of phosphorus.
- (D) The fact that her serum inorganic phosphorus concentration was high on presentation is reassuring.
- (E) Patients with DKA and severe phosphorus deficiency usually have been vomiting for several days before presentation.

XII-85. A 46-year-old woman arrives in your clinic for routine examination. She has no specific complaints, and a full review of systems is unrevealing. On physical examination she has normal vital signs and a 1.5-cm thyroid nodule is palpated in the right lobe of her thyroid; there are no other abnormal findings. A laboratory test reveals a serum TSH level of 2.3 mU/L. Which of the following would be the most appropriate recommendation?

- (A) Fine-needle aspiration biopsy
- (B) Unilateral thyroid lobectomy
- (C) Thyroxine suppressive therapy
- (D) Radioiodine therapy
- (E) No intervention needed; a wait and watch approach is recommended

XII-86. Which of the following statements regarding erectile dysfunction is correct?

- (A) Patients with testosterone deficiency are able to achieve erections with visual stimuli.
- (B) Patients with psychogenic erectile dysfunction have excess parasympathetic stimulation which decreases penile smooth muscle tone.
- (C) Both beta blockers and α -adrenergic blockers are commonly implicated in erectile dysfunction.
- (D) Individuals with diabetes mellitus have normal levels of nitric oxide synthase in both endothelial and neural tissues.
- (E) Increased prolactin levels cause erectile dysfunction by a direct reduction of testicular androgen synthesis.

XII-87. Which of the following statements concerning the use of sildenafil for the treatment of erectile dysfunction is correct?

- (A) Sildenafil inhibits phosphodiesterase isoenzyme type V levels, thereby increasing the concentration of cyclic AMP.
- (B) Sildenafil may cause a transient alteration in color vision.
- (C) Sildenafil may also increase the patient's libido.

XII-87. (Continued)

- (D) Sildenafil is hepatically cleared and therefore no dose reduction is required for patients with impaired renal function.
- (E) Sildenafil is ineffective in the treatment of patients with diabetes mellitus who also have erectile dysfunction.

XII-88. A 75-year-old man with type 2 diabetes mellitus presents with severe ear pain, drainage, fever, and leukocytosis. In addition, he has facial nerve paralysis and there is soft tissue swelling around the ear. Which of the following statements about his condition are true?

- (A) It usually is caused by *Pseudomonas aeruginosa*.
- (B) Although this is a severe infection, when appropriate treatment is initiated the mortality rate remains low.
- (C) A 4-week course of ticarcillin or carbenicillin plus tobramycin is the treatment of choice.
- (D) Surgical debridement is seldom required.
- (E) CT of the head and orbits is typically unremarkable.

XII-89. A 43-year-old man with long-standing type 1 diabetes mellitus presents to the emergency room with extreme discomfort involving the scrotum. He has not been sexually active over the past 3 months. There has been no history of sexually transmitted diseases or trauma. On physical examination his temperature is 38.3°C (100.9°F) with a blood pressure of 90/50 mmHg. His pulse is 120. Examination of the genitalia reveals bilateral distended testes; there is no evidence of an inguinal hernia. The scrotum is swollen bilaterally with diffuse erythema. The scrotal sac is extremely tender. There is a single bullous lesion, which is accompanied by localized anesthesia. Which of the following would be the most appropriate therapeutic recommendation?

- (A) Initiation of oral amoxicillin/clavulanate and metronidazole
- (B) Immediate hospitalization and administration of high-dose intravenous penicillin
- (C) Immediate hospitalization and initiation of intravenous clindamycin
- (D) Immediate hospitalization and intravenous administration of both high-dose penicillin and clindamycin
- (E) Immediate hospitalization with administration of high-dose intravenous penicillin and clindamycin and surgical consultation for emergent debridement

XII-90. Which of the following statements concerning the parathyroid hormone-related protein is true?

- (A) Parathyroid hormone-related protein is found in many tissues in both the fetus and adult.

XII-90. (Continued)

- (B) Unlike parathyroid hormone, parathyroid hormone–related protein has no phosphaturic action.
- (C) Parathyroid hormone–related protein can induce osteolysis but has little or no effect on cartilage formation.
- (D) Only the carboxy terminal portion of parathyroid hormone–related protein is related to the parathyroid hormone.
- (E) Parathyroid hormone–related protein is not expressed in the central nervous system.

XII-91. Which of the following medications is known to cause hyperprolactinemia?

- (A) Metoclopramide
- (B) Levothyroxine
- (C) Glucocorticoids
- (D) Propanolol
- (E) Cigarette use

XII-92. Which of the following medications is known to cause hypoglycemia?

- (A) Acetaminophen
- (B) Pentamidine
- (C) Epinephrine
- (D) Verapamil
- (E) Thiazides

XII-93. Anovulatory cycles are characterized by which of the following?

- (A) Elevated levels of plasma progesterone
- (B) Dysmenorrhea
- (C) A shortened luteal phase
- (D) Lack of a normal LH and FSH surge
- (E) The absence of any uterine bleeding

XII-94. A 15-year-old boy has had hypothyroidism since early childhood. For several years he has noticed frequent episodes of numbness and tingling of his hands, occasionally accompanied by muscle spasms. Physical examination reveals a positive Chvostek sign, short stature, and short left fourth metacarpals (absent knuckles). The boy's mother is also short and has absent knuckles. Serum calcium concentration is 1.9 mmol/L (7.5 mg/dL). Further investigation of the boy's disorder would be expected to reveal which of the following?

- (A) Antibodies to parathyroid and thyroid tissue
- (B) Low levels of parathyroid hormone concentration
- (C) A diminished increase in urinary cyclic AMP in response to the administration of parathyroid hormone
- (D) Hypophosphatemia
- (E) Moniliasis

XII-95. Which of the following statements regarding obesity is correct?**XII-95.** (Continued)

- (A) A peripheral distribution of body fat is associated with a higher morbidity than is a central distribution of body fat.
- (B) A body mass index (BMI) >28 is associated with a high risk of morbidity such as stroke, ischemic heart disease, or diabetes mellitus that is three to four times the risk in the general population.
- (C) Obesity in children increases morbidity only if it persists into adulthood.
- (D) The increased morbidity associated with a high body mass index is greater for blacks than whites.
- (E) Obesity in humans is likely due to one of several single-gene defects.

XII-96. A 72-year-old man presents to your clinic complaining of right-sided headaches and left leg pain. The pain is described as constant and is worse at night. The leg pain does not seem to increase with exertion. On physical examination the vital signs are stable and the patient is afebrile. The patient has noted an anterior skull deformity as well as a deformity of the anterior portion of the left tibia. The overlapping area of both the skull and the tibia are warm and erythematous. There is also right sensorineural deafness. Radiographically there is localized enlargement of bone over the right anterior portion of the skull and the left tibia. The radiographic features involving the left tibia involve cortical thickening and sclerotic changes. Radionucleotide bone imaging reveals intense uptake within the right side of the skull and the left tibia. There is also intense uptake of the right hip and right humerus. Laboratory analysis reveals a normal serum calcium level, but there is a markedly elevated alkaline phosphatase and an increased level of urinary hydroxyproline. Which of the following would be the appropriate management recommendation?

- (A) Pain control with nonsteroidal analgesics
- (B) Pain control with narcotic analgesics
- (C) Alendronate
- (D) Calcitonin
- (E) Calcium and vitamin D

XII-97. Characteristic manifestations of Nelson's syndrome (a pituitary tumor arising after bilateral adrenalectomy) include which of the following?

- (A) Hyperpigmentation
- (B) The tumor is small and seldom affects the optic chiasm
- (C) Increased urinary 17-ketosteroid excretion
- (D) Failure of high doses of dexamethasone to suppress plasma cortisol levels
- (E) Decreased plasma ACTH levels

XII-98. A 30-year-old man, the father of three children, has had progressive breast enlargement during the last 6 months. He does not use any drugs. Laboratory evaluation

XII-98. (Continued)

reveals that both LH and testosterone are low. Further evaluation of this patient should include which of the following?

- (A) Blood sampling for SGOT and serum alkaline phosphatase and bilirubin levels
- (B) Measurement of estradiol and human chorionic gonadotropin levels
- (C) A 24-h urine collection for the measurement of 17-ketosteroids
- (D) Karyotype analysis to exclude Klinefelter syndrome
- (E) Breast biopsy

XII-99. True statements concerning type 1 diabetes mellitus include which of the following?

- (A) Direct vertical transmission has been shown by pedigree analysis to occur with a high prevalence.
- (B) The concordance rate for monozygotic twins less than 40 years of age is >80%.
- (C) The risk of type 1 diabetes is not influenced by the person's HLA type.
- (D) Circulating anti-insulin antibodies are usually present in patients with juvenile-onset type 1 diabetes studied soon before or soon after the onset of symptoms.
- (E) Mumps virus and coxsackievirus have been identified as possible causative agents in juvenile-onset type 1 diabetes.

XII-100. The diagnosis of diabetes mellitus is certain in which of the following situations?

- (A) Abnormal oral glucose tolerance in a 24-year-old woman who has been dieting
- (B) Successive fasting plasma glucose concentrations of 8, 9, and 8.5 mmol/L (147, 165, and 152 mg/dL) in an asymptomatic, otherwise healthy businesswoman
- (C) A serum glucose level >7.8 mmol/L (140 mg/dL) in a woman in her twenty-fifth week of gestation after a 50-g oral glucose load
- (D) Persistent asymptomatic glycosuria in a 30-year-old woman
- (E) Persistently elevated nonfasting serum glucose levels

XII-101. Characteristics of hyperosmolar coma include

- (A) the presence of ketoacids
- (B) marked elevation of serum free fatty acids
- (C) association with thrombosis and bleeding from disseminated intravascular coagulation
- (D) markedly elevated serum sodium level
- (E) best initial therapeutic response with large volumes of free water and large doses of insulin

XII-102. A 45-year-old woman has had diabetes for the past 8 years and has been treated with either oral hypoglycemic agents or insulin. She has been doing well on human NPH insulin for the past several months. However, in the last week she has developed symptoms of hyperglycemia. Doubling her insulin dose does not help, and she is admitted to the hospital. Physical examination of this nonobese woman shows no sign of infection, ketoacidosis, or Cushing's syndrome. After admission, the insulin dose is increased progressively to 240 units daily, but blood glucose concentration never falls below 19 mmol/L (350 mg/dL). True statements regarding this woman's condition include which of the following?

- (A) IgG anti-insulin antibodies are likely to be present in high titer.
- (B) Cell-surface insulin receptors are likely to be decreased in number.
- (C) Anti-insulin-receptor antibodies, increased erythrocyte sedimentation rate, and other signs of autoimmune disease are likely to be present.
- (D) Insulin desensitization procedures should be instituted.
- (E) The use of glucocorticoids is contraindicated.

XII-103. Which of the following would be associated with a poor prognosis for the development of (or progression of) symptomatic renal failure in a 29-year-old woman who has had type 1 diabetes mellitus since the age of 14 years?

- (A) Urine albumin excretion of 0.12 to 0.17 g/d on three separate occasions
- (B) High dietary intake of protein
- (C) Hyperlipidemia
- (D) Nocturia, three times per night
- (E) Insulin requirement >120 units per day

XII-104. A 40-year-old physician's assistant has had episodic confusion, diaphoresis, and palpitations for the past 4 weeks. She has had several nightmares and three syncope episodes. Fasting hypoglycemia with inappropriately elevated plasma insulin concentration is documented in the hospital. Plasma C-peptide concentration also is increased. Her physician should

- (A) measure plasma insulin antibody levels
- (B) measure plasma insulin levels
- (C) measure plasma or urine sulfonylurea levels
- (D) perform an abdominal CT scan
- (E) consult a surgeon for pancreatic surgery

XII-105. Causes of fasting hypoglycemia that are due primarily to overutilization of glucose include

- (A) acromegaly
- (B) hepatoma
- (C) alcohol ingestion
- (D) congestive heart failure from cor pulmonale
- (E) hypopituitarism

XII-106. Testosterone replacement in a patient with Klinefelter syndrome (47,XXY) would be indicated in order to

- (A) maintain spermatogenesis
- (B) prevent antisocial behavior
- (C) treat infertility
- (D) cause the disappearance of gynecomastia
- (E) promote virilization

XII-107. Increased gonadal production of estrogen is characteristic of

- (A) testicular feminization
- (B) polycystic ovarian disease
- (C) congenital adrenal hyperplasia
- (D) third trimester of pregnancy
- (E) arrhenoblastoma

XII-108. Known causes of ambiguous genitalia include

- (A) the sex-chromosome pattern XYY
- (B) the mosaic sex-chromosome pattern 45,X/46,XY
- (C) Turner's syndrome
- (D) hypogonadotrophic hypogonadism
- (E) XX male syndrome

XII-109. Correct statements concerning hypervitaminosis D include which of the following?

- (A) It may result from prolonged sun exposure.
- (B) It usually results from a single excessive dose of vitamin D₂ or D₃.
- (C) The consequences include hypercalcemia, hypercalciuria, and renal impairment.
- (D) Anephric patients cannot develop vitamin D toxicity.
- (E) Serum 1,25(OH) vitamin D levels are elevated.

XII-110. A 25-year-old woman presents to her internist complaining of fatigue. Although she does not seem to be depressed, she admits to a diminished appetite and loss of interest in sex. She is also intolerant of the cold and notes that her hair is falling out. She has trouble caring for her 1½-year-old child and recounts a very difficult parturition with a great deal of blood loss. She is on no medicines, has been amenorrheic since the birth of the child, and did not nurse the infant. Which of the following results would be consistent with this patient's diagnosis?

- (A) A growth hormone level of 11 $\mu\text{g/L}$ after stimulation with hypoglycemia
- (B) An **A.M.** serum cortisol level of 20 $\mu\text{g/L}$
- (C) Normal urinary free cortisol levels
- (D) A decreased serum TSH and thyroxine level
- (E) A normal ACTH stimulation test

XII-111. Manifestations of hypothyroidism include

- (A) prolongation of the QT/QT_C interval
- (B) depressed serum cholesterol
- (C) microcytic anemia
- (D) increased serum creatine phosphokinase
- (E) decreased serum lactate dehydrogenase level

XII-112. A 25-year-old man presents with a several-month history of fatigue, weakness, anorexia, and nausea. Physical examination reveals a slightly emaciated, thin, tanned man whose baseline blood pressure is 90/60. He complains of extreme light-headedness during the assessment of orthostatic vital signs. Laboratory evaluation reveals hyponatremia and hyperkalemia. The plasma cortisol level fails to rise significantly 60 min after intramuscular administration of 250 μg cosyntropin. Which of the following conditions could have caused this clinical picture?

- (A) Withdrawal from prolonged (>1 year) administration of steroids for asthma
- (B) Disseminated tuberculosis
- (C) Craniopharyngioma
- (D) The current use of inhaled glucocorticoids for chronic asthma
- (E) The use of phenobarbital for a seizure disorder

XII-113. In which of the following porphyria syndromes may the diagnosis be made on the basis of a positive Watson-Schwartz reaction in the urine (detection of porphobilinogen)?

- (A) Intermittent acute porphyria
- (B) Congenital erythropoietic porphyria
- (C) Protoporphyrin
- (D) Porphyria cutanea tarda
- (E) X-linked sideroblastic anemia

XII-114. Correct statements concerning inherited defects of metabolism include which of the following?

- (A) Niemann-Pick disease is caused by a deficiency of glucosylceramidase and is associated with a characteristic bone marrow storage cell.
- (B) Despite the use of heterozygote detection programs in North America, the incidence of disease resulting from hexosaminidase A deficiency has not been reduced.
- (C) Errors in glycogen elongation or branching are incompatible with a normal life expectancy.
- (D) Early diagnosis of phenylketonuria is possible but is of little therapeutic benefit.
- (E) Cystinuria, the most common inborn error of amino acid transport, is associated with increased urinary excretion of all dibasic amino acids.

XII. ENDOCRINE AND METABOLIC DISORDERS

ANSWERS

- XII-1. The answer is B.** (*Chap. 345*) In persons with symptomatic hemochromatosis, repeated phlebotomy, by removing excessive iron stores, results in marked clinical improvement. Specifically, the liver and spleen decrease in size, liver function improves, cardiac failure is reversed, and skin pigmentation (“bronzing”) diminishes. Carbohydrate intolerance may abate in up to half of all affected persons. For unknown reasons, there is no improvement in the arthropathy or hypogonadism (resulting from pituitary deposition of iron) associated with hemochromatosis. The 5-year survival rate increases from 33 to 90% with treatment; prolonged survival may actually increase the risk of hepatocellular carcinoma, which affects one-third of persons treated for hemochromatosis. However, if phlebotomy is begun in the precirrhotic stage, which is possible with effective genetic screening, liver cancer will not develop.
- XII-2. The answer is B.** (*Chap. 333*) Although non-insulin-dependent diabetes mellitus disease (nonketogenic) is familial, the exact mode of inheritance is not known except for the specific variant known as maturity-onset diabetes of the young (MODY), which is manifested by mild hyperglycemia without ketosis. On the basis of family studies, this disease is inherited in an autosomal dominant fashion with almost complete penetrance. Therefore, 50% of the children of a diabetic parent with MODY will develop the disease. There is linkage between MODY and mutations in the glucokinase gene on the short arm of chromosome 7. This abnormality is not present in ordinary non-ketotic diabetics. Unlike the case in insulin-dependent diabetes, no HLA relationships have been identified. Moreover, an autoimmune etiology for the disease is not felt to be important; this is also a distinctive feature compared with typical juvenile-onset insulin-dependent diabetes.
- XII-3. The answer is C.** (*Chap. 333. Nathan, N Engl J Med 328:1676–1685, 1993.*) Nephropathy is a leading cause of death in diabetic patients. Diabetic nephropathy may be functionally silent for 10 to 15 years. Clinically detectable diabetic nephropathy begins with the development of microalbuminuria (30 to 300 mg of albumin per 24 h). The glomerular filtration rate actually may be elevated at this stage. Only after the passage of additional time will the proteinuria be overt enough (0.5 g/L) to be detectable on standard urine dipsticks. Microalbuminuria precedes nephropathy in patients with both non-insulin-dependent and insulin-dependent diabetes. An increase in kidney size also may accompany the initial hyperfiltration stage. Once the proteinuria becomes significant enough to be detected by dipstick, a steady decline in renal function occurs, with the glomerular filtration rate falling an average of 1 mL per minute per month. Therefore, azotemia begins about 12 years after the diagnosis of diabetes. Hypertension clearly is an exacerbating factor for diabetic nephropathy.
- XII-4. The answer is B.** (*Chap. 333. The Diabetes Control and Complications Trial Research Group, N Engl J Med 329:977–986, 1993.*) After many years of uncertainty, the NIH-sponsored multicenter Diabetes Control and Complications Trial established the fact that intensive therapy was more effective than standard therapy in reducing the development of retinopathy, the progression of retinopathy in patients who already had mild disease, and the occurrence of microalbuminuria and clinical neuropathy. There was, however, an increased likelihood of severe hypoglycemia despite the intensive monitoring practiced in the treated group. Enrollment required the presence of insulin-dependent diabetes mellitus

for 1 to 5 years; therefore, these results cannot be definitely generalized to all patients with diabetes, although it is possible that patients with non-insulin-dependent diabetes mellitus also may benefit from strict glucose control. Patients in the intensively treated arm of this trial exhibited better control of blood glucose levels and lower levels of glycosylated hemoglobin. However, return of blood glucose to normal was not achieved. Moreover, patients who undertake such intensive therapy must be highly motivated and capable of withstanding its physical and emotional rigors.

XII-5. The answer is D. (*Chaps. 52, 336*) Progesterone therapy results in secretory differentiation of an estrogen-primed proliferative endometrium, and the endometrium is sloughed after progesterone withdrawal only if it has been stimulated first by estrogen. Thus, in a woman being evaluated for secondary amenorrhea, the appearance of menses after a short course of progesterone is indicative of an estrogen-primed endometrium and provides good evidence of ovarian estrogen secretion. Estrone levels do not reflect direct ovarian estrogen secretion because estrone is derived principally from the peripheral conversion of androstenedione, which is secreted from the adrenal glands as well as from the ovaries. A woman with amenorrhea caused by hypogonadotropic hypogonadism, also called hypothalamic amenorrhea, has deficient ovarian estrogen secretion but may demonstrate an increase in plasma estradiol after hCG administration. Prolactin secretion is increased by estrogen stimulation, accounting for a slightly higher mean prolactin level in women compared with that in men. However, a normal prolactin level is not evidence of persistent estrogen secretion. Although hot flashes are common in menopause, a low-estrogen state, they are not seen in hypothalamic amenorrhea, a common cause of secondary amenorrhea and a low-estrogen state.

XII-6. The answer is A. (*Chap. 328*) Growth hormone, also known as *somatotropin*, is secreted by somatotroph cells, which account for 50% of the anterior pituitary glands. The release of growth hormone from the anterior pituitary is pulsatile in nature, increasing after meals, with exercise, and during slow-wave sleep. Growth hormone, which is necessary for normal growth, exerts its effects through mediators such as somatomedins and insulin-like growth factors. In addition to its involvement in growth, somatotropin is involved in stimulating the incorporation of amino acids into protein and inhibiting glucose uptake by tissues. By the latter effect, growth hormone helps restore low blood sugars to normal and is therefore a counterregulatory hormone to insulin. Both hypoglycemia and insulin stimulate growth hormone release, as does the presence of free amino acids such as arginine. Hypothalamic secretagogues also control growth hormone release. These molecules include the stimulatory hormone GHRH and the inhibitory hormone somatostatin (somatotropin release–inhibitory factor). The former is probably more important, since sectioning of the pathways between the hypothalamus and the anterior pituitary results in inhibition of growth hormone release. Other neurotransmitters influence growth hormone release, including hypothalamus-derived dopamine, which stimulates GHRH. α -Adrenergic agonists stimulate growth hormone release, and α -adrenergic blockers inhibit growth hormone increases. Serotonin agonists stimulate growth hormone release; this perhaps accounts for the nocturnal surge in growth hormone secretion.

XII-7. The answer is D. (*Chaps. 52, 336*) In a 7-year-old girl, isosexual precocity that is associated with undetectable levels of gonadotropins and urinary 17-ketosteroid levels appropriate for her chronologic age is most likely due to an estrogen-secreting tumor. Tumor localization procedures, such as abdominal CT and pelvic sonography, should be performed before laparotomy. Plasma androstenedione measurement is unlikely to be helpful if urinary 17-ketosteroid excretion is low or normal. In idiopathic precocious puberty, a diagnosis of exclusion, urinary gonadotropins are normal for chronologic age or are elevated; in addition, if plasma gonadotropins are measured frequently during a 24-h period, the characteristic pubertal nocturnal surge should be seen in patients with idiopathic precocious puberty.

XII-8. The answer is C. (*Chap. 328*) Growth hormone excess in adults results in a clinical syndrome known as *acromegaly*, an insidious disease characterized by bony and soft tissue overgrowth, enlargement of the jaw and tongue, wide spacing of the teeth, and coarsened facial features. Hypertension may occur as a result of expansion of plasma volume and total body sodium. Laryngeal hypertrophy leads to a hollow-sounding voice. A moist, oily, doughy handshake is also characteristic. Because of the slow onset, relatives and friends who see the patient daily may not notice these changes. The diagnosis is more likely to be made by those who have not seen the patient before or for many years.

Laboratory abnormalities include abnormal glucose tolerance and mild hyperprolactinemia. The reason for growth hormone excess in virtually all patients with acromegaly is a pituitary adenoma. Useful screening tests for the diagnosis of acromegaly include measurements of glucose-suppressed growth hormone concentrations (60 min after the oral administration of 100 g glucose, growth hormone normally should be suppressed to a value $<1 \mu\text{g/L}$) and IGF binding protein 3. IGF-I concentrations are elevated secondary to the high levels of growth hormone. Once a laboratory test has confirmed the clinical suspicion of acromegaly, MRI or CT should be undertaken to define the presumptive pituitary adenoma. Thyroid function, gonadotropins, and sex steroids may be decreased because of tumor mass effect.

XII-9. The answer is E. (*Chap. 332*) Since provocative testing plays a very small role in the diagnosis of pheochromocytoma, the most frequently employed assays include measurement of catecholamines or catecholamine metabolites in a single 24-h urine sample. The three assays used include measurement of vanillylmandelic acid, metanephrines, and unconjugated (“free”) catecholamines. Accuracy of diagnosis depends on the collection of a full 24-h urine sample that is treated with acid and refrigerated during and after the collection. The diagnostic yield would be increased if the 24-h urine collection included a time period during which the patient experienced a hypertensive paroxysm. False-positive increases in urinary free catecholamine excretion may occur if the patient is taking methyl dopa, levodopa, or sympathomimetic amines. Endogenous plasma and urinary catecholamines also may be increased during hypoglycemia, strenuous exercise, and significant central nervous system disease. Urinary metanephrines and vanillylmandelic acid are also falsely positive in situations in which endogenous catecholamines may be increased or if the patient is receiving a monoamine oxidase inhibitor. Since plasma catecholamines are highly subject to endogenous variation in catecholamine secretion, they have not been particularly useful as an initial screening test for the diagnosis of pheochromocytoma.

XII-10. The answer is B. (*Chaps. 336, 338. Adashi, Hennebold, N Engl J Med 340:709–718, 1999.*) Aromatase deficiency can result in non-adrenal female pseudohermaphroditism, which is characterized by virilized external genitalia at birth and by primary amenorrhea, sexual infantilism, eunuchoid proportions, tall stature, high androgen serum levels, low or undetectable estradiol and estrone concentrations, hypergonadotropism, and multicystic ovaries in adolescence. The high androgen serum levels probably result from the disruption in the conversion of androgens to estrogens, which results in hypergonadotropism. The latter causes the multicystic ovaries—a common finding in this disorder. This disorder suggests that the congenital absence of aromatase is compatible with normal ovarian development and that aromatase deficiency must be considered in the differential diagnosis of primary amenorrhea. Congenital adrenal hyperplasia is the most frequent cause of adrenal insufficiency in newborns. 21-Hydroxylase deficiency and 11- β -hydroxylase deficiency are most common and affect only adrenal function. 3- β -Hydroxysteroid dehydrogenase deficiency affects both adrenal and gonadal function. This is transmitted as an autosomal recessive trait, and 3- β -hydroxysteroid dehydrogenase deficiency is characterized by symptoms of both cortisol and aldosterone deficiency, which may be fatal if not diagnosed early. Affected females have either normal sexual development or mild virilization, usually detected at puberty. Some patients will present with chronic anovulation, but primary amenorrhea is a less common presenting symptom. The McCune-Albright

syndrome is characterized by patchy cutaneous hyperpigmentation, polyostotic fibrous dysplasia, and several endocrine disorders including toxic multinodular goiter. Patients often have amenorrhea and galactorrhea, Cushing's syndrome, as well as the development of precocious puberty. The precocious puberty is gonadotropin-independent, and the defect lies within a constitutively active G protein. Kallmann's syndrome is an X-linked disorder characterized by hypogonadotropic hypogonadism, which is associated with anosmia. This disorder more commonly affects men than women. Galactosemia results in hepatomegaly, jaundice, and failure to thrive soon after birth, and is caused by a deficiency of galactose-1-phosphate uridylyltransferase. This enzyme catalyzes the conversion of galactose-1-phosphate to uridylyl-dephosphogalactose. Women with galactosemia may have either primary or secondary amenorrhea, despite a lifelong galactose-free diet. Ovarian biopsies in women with galactosemia reveal few primordial follicles, but numerous atretic follicles. It is unclear whether the ovarian failure is caused by the accumulation of galactose-1-phosphate or a deficiency of downstream metabolites.

- XII-11. The answer is E.** (*Chaps. 341, 342. Silverberg et al, N Engl J Med 341:1249–1254, 1999.*) Primary hyperparathyroidism is commonly diagnosed in asymptomatic patients. Patients who present with symptoms of bone disease typically have the triad of painful arthralgias, abdominal discomfort, and nephrolithiasis. These patients should undergo a definitive parathyroidectomy. The appropriate treatment for patients with asymptomatic hyperparathyroidism is unclear; many have a benign clinical course without significant progression. Most asymptomatic patients who undergo parathyroidectomy have normalization of the biochemical values as well as increased bone marrow density studies. Most asymptomatic patients who do not undergo parathyroidectomy do not have progression of their disease. For patients choosing a wait and watch approach who subsequently develop symptomatic hyperparathyroidism, a parathyroidectomy should then be performed.
- XII-12. The answer is E.** (*Chaps. 75, 387*) The causes of thiamine deficiency in alcoholic persons include poor dietary intake, impaired absorption and storage, and accelerated destruction of thiamine diphosphate. Both the cardiovascular and the neurologic signs of thiamine deficiency (beriberi) can become abruptly evident after the administration of glucose to thiamine-depleted asymptomatic persons. Nystagmus, ataxia, and confusion, often accompanied by ophthalmoplegia, are strongly suggestive of Wernicke's encephalopathy; cardiovascular involvement may be signaled by tachycardia as an early manifestation of peripheral vasodilation. Thiamine should be administered promptly—preferably before glucose is given—to any person in whom subclinical thiamine deficiency is suspected.
- XII-13. The answer is B.** (*Chap. 346*) Acute attacks of abdominal pain that are often precipitated by diet or drugs such as barbiturates, sulfonamides, anticonvulsants, and alcohol and that have no clear-cut etiology despite an aggressive diagnostic workup may be due to acute intermittent porphyria. The porphyrias are inherited or acquired disorders of heme biosynthesis. Acute intermittent porphyria, which is caused by an autosomal dominant mutation, is characterized by a half-normal level of HMB synthase (the enzyme that catalyzes the condensation of four pyrrole porphobilinogen molecules to form the linear tetrapyrrole hydroxymethylbilane, which ultimately undergoes cyclization). Heterozygotes are prone to a host of sympathomimetic symptoms and psychological problems in addition to recurrent abdominal pain. Peripheral neuropathy, which is due to axonal degeneration of motor neurons, also may occur. The diagnostic test of choice is demonstration of increased urinary pyrrole porphobilinogen excretion as well as increased levels of urinary δ -aminolevulinic acid. Usually there is no skin disease, even after sun exposure. During acute attacks, narcotics may be given without fear of exacerbation of the attack; phenothiazines also may be administered safely. Heme therapy, presumably by including feedback inhibition of early heme biosynthesis, can abrogate attacks. However, recovery from the severe motor neuropathy may take years.

- XII-14. The answer is A.** (*Chap. 333. DeFronzo, Ann Intern Med 131:281–303, 1999.*) The recently completed United Kingdom Prospective Diabetes Study (UKPDS) has shown that type 2 diabetes mellitus is a progressive disorder that can be treated initially with oral agent monotherapy. Eventually, however, the addition of other oral agents or, in many patients, insulin therapy will be needed in order to achieve the targeted glycemic level. In the UKPDS, the improved glycemic control was seen irrespective of the agent used (sulfonylureas, metformin, or insulin). Approximately 25% of patients treated with sulfonylureas will achieve a target fasting plasma glucose level. Therefore, 75% of patients will require the addition of a second agent. The high secondary failure rate was also observed with metformin monotherapy. There seems to be no demonstrable superiority of one sulfonylurea over another. In most studies, sulfonylureas have neutral or only slightly beneficial effects on plasma lipid levels. In addition, sulfonylurea therapy is usually associated with a modest weight gain. This has been implicated as a cause of secondary drug failure. Metformin shows similar efficacy when compared to sulfonylurea monotherapy. In addition, however, the use of metformin is associated with significant decreases in plasma triglyceride and LDL cholesterol levels, and patients treated with metformin show modest weight loss during the first 6 months of treatment; therefore metformin should be recommended in obese patients with elevated serum cholesterol levels. The clinical efficacy of acarbose is less than that of sulfonylureas or metformin. In limited studies repaglinide, a non-sulfonylurea insulin secretagogue, showed similar efficacy when compared to sulfonylurea monotherapy. Repaglinide has no significant effect on plasma lipid levels. In drug-naive patients treated with repaglinide, body weight increased by ~3%.
- XII-15. The answer is B.** (*Chaps. 242, 344. Knopp, N Engl J Med 341:498–511, 1999.*) The most appropriate treatment recommendation for this patient would be initiation of a statin. The statin class of drugs inhibits hydroxymethylglutaryl-coenzyme A (HMG-CoA). Treatment recommendations for patients without coronary disease and fewer than two risk factors is to initiate dietary therapy with an LDL cholesterol level of ≥ 4.1 mmol/L (≥ 160 mg/dL) and to initiate pharmacologic therapy with an LDL cholesterol level of ≥ 4.9 mmol/L (≥ 190 mg/dL). In cases of diabetes mellitus, it is recommended that patients without coronary disease begin drug therapy with an LDL cholesterol level of ≥ 3.4 mmol/L (≥ 130 mg/dL), with a desired goal of ≤ 2.6 mmol/L (≤ 100 mg/dL).
- XII-16. The answer is C.** (*Chap. 351*) Osteogenesis imperfecta, which is usually transmitted in an autosomal dominant fashion, results in brittle bones because of a generalized decrease in bone mass. Although the clinical course is variable, some patients have multiple fractures in childhood, undergo some remission during puberty, and begin to suffer fractures again later in life. Associated abnormalities include blue sclerae, brown or translucent bluish-gray discoloration of the teeth, and progressive hearing loss. The family history is usually positive. The most common molecular defect is a mutation in one of the two genes coding for type I procollagen. Some mutations result in a decreased synthesis of pro- α I collagen genes, whereas other mutations result in the synthesis of structurally abnormal procollagen alpha chains. Most patients with Ehlers-Danlos syndrome have a defect in the synthesis of type III procollagen, and those with chondrodysplasia have a defect in the gene for type II procollagen.
- Type I collagen is the most abundant of the 18 different collagens identified thus far. It is composed of two identical chains: alpha I and alpha II. After procollagen chains are translated from messenger RNA in ribosomes, they pass into the rough endoplasmic reticulum, where hydrophobic signal peptides at the N terminus are cleaved (resulting in up to a 50% reduction of protein mass). Additional posttranslational modification includes conversion of proline residues to hydroxyproline and hydroxylation of lysine residues. After the requisite number of posttranslational conversions, the protein can fold into its native triple-helical conformation.
- XII-17. The answer is E.** (*Chap. 351*) Marfan syndrome, which is inherited in an autosomal recessive fashion, is characterized by long thin extremities, reduced vision from dislocation

of the lens (ectopia lentis), and proximal aortic aneurysms. This disease must be distinguished from homocysteinuria, which also may cause ectopia lentis, congenital arachnoidactyly, and familial aortic aneurysms. Patients with Marfan syndrome are usually tall and have severe chest deformities, including pectus excavatum and pectus carinatum. Mitral valve prolapse and dilation of the aortic root are not uncommon and may be detected by echocardiography early in life. Most patients with Marfan syndrome have mutations in the gene for fibrillin, a glycoprotein of 350 kDa. Fibrillin is a major component of elastin-associated microfibrils, which are abundant in large blood vessels and the lens suspensory ligaments.

- XII-18. The answer is B.** (*Chap. 353*) The evaluation of polyuric syndromes should include simultaneous measurements of urine and plasma osmolality. Ideally, the plasma osmolality should be elevated so that the determination of an inappropriately dilute urine is possible. Such an effort may require an overnight water deprivation test. This test must be carried out carefully to ensure that a dangerous level of dehydration does not occur. Once 1 kg of body weight is lost and the plasma osmolality is elevated, the finding of a urine osmolality stable for 3 h at a low level confirms the diagnosis of diabetes insipidus. At that point vasopressin is administered, and the urine osmolality is checked between 30 and 60 min thereafter. In cases of central diabetes insipidus, the rise in urine osmolality exceeds 9%, whereas in nephrogenic diabetes insipidus, which frequently is due to renal dysfunction, as in the case presented, there is little, if any, increment. The treatment for nephrogenic diabetes insipidus can include the administration of diuretics to cause a fall in glomerular filtration rate and a concomitant increase in proximal tubular fluid resorption, decreased distal fluid delivery, and diminished production of dilute urine. This therapeutic strategy should be accompanied by sodium restriction.
- XII-19. The answer is B.** (*Chaps. 318, 340*) The hypercalcemia of sarcoidosis is usually associated with disseminated disease. Therefore, almost all persons with sarcoidosis who have hypercalcemia also have an abnormal chest x-ray (diffuse fibronodular infiltration, marked enlargement of hilar nodes, or both). This is an important point in the differential diagnosis of hypercalcemia—sarcoidosis is unlikely as a cause of hypercalcemia if the chest x-ray is normal. Hypergammaglobulinemia is another helpful clue to the presence of sarcoidosis. The hypercalcemia of sarcoidosis is thought to be the consequence of increased synthesis of $1,25(\text{OH})_2$ vitamin D_3 and the subsequent increased intestinal absorption of calcium. The elevated serum calcium concentration in sarcoidosis causes a decreased level of serum parathyroid hormone, resulting in marked hypercalciuria.
- XII-20. The answer is E.** (*Chap. 78*) A host of endocrinologic abnormalities may occur as a consequence of the loss of muscle mass and fat in patients with severe anorexia nervosa. The disease usually begins shortly after puberty and is characterized by profound weight loss caused by a lack of caloric intake and a high level of physical activity. Other features include cold intolerance caused by a secondary defect in regulatory thermogenesis, hypothalamic amenorrhea, hypokalemia, low serum immunoglobulins, normal or elevated growth hormone levels, decreased levels of somatomedin C, and low serum triiodothyronine concentrations. Again, all these abnormalities seem to result from, rather than cause, the eating disorder. Most authorities favor a psychiatric etiology. Unfortunately, the benefits of psychiatric intervention and behavior modification have been somewhat marginal. Hospitalization may be required to save the patient's life if the anorexia nervosa is quite severe.
- XII-21. The answer is B.** (*Chaps. 77, 264*) Grossly obese patients are more likely than are the nonobese to have high blood pressure, peripheral vascular disease, cerebrovascular disease, diabetes, and hyperlipidemia. The so-called Pickwickian syndrome, which is characterized by hypersomnolence during the day, is thought to be due to nocturnal upper airway obstruction that leads to hypoxemia and hypercapnia and causes arousal with each episode. This chronic arousal pattern at night causes sleep deprivation and daytime somnolence.

The obese habitus, in addition to sleep-induced relaxation of the throat muscles, is believed to cause the aforementioned upper airway obstruction. These patients tend to develop blunted respiratory responses to hypercapnia and hypoxemia as well as ventilation-perfusion mismatches. Progestational agents stimulate the ventilatory response in such patients. Hyperinsulinemia, insulin resistance, diabetes, and hyperlipidemia may all be more common in obese persons but are not believed to play a role in the obesity-hypoventilation syndrome or in daytime somnolence.

- XII-22. The answer is C.** (*Chaps. 279, 322, 347*) Colchicine is useful in the treatment of acute gouty arthritis but not in that of chronic tophaceous gout. However, it can be a useful ancillary drug in the treatment of chronic gout at the start of allopurinol therapy to prevent the precipitation of acute gouty arthritis. Chronic gout can be treated either with uricosuric agents (probenecid and sulfinpyrazone) or with an inhibitor of uric acid synthesis (allopurinol). The ideal candidate for uricosuric agents is a patient under age 60 years who has normal renal function, a uric acid excretion of <700 mg/day, and no history of renal stones. Specific indications for choosing allopurinol over a uricosuric agent include the presence of uric acid nephrolithiasis, high uric acid excretion, and impairment of renal function; hence, allopurinol is the appropriate initial drug in this patient. Combinations of allopurinol and uricosuric agents may be employed when uric acid levels cannot be controlled with either drug alone.
- XII-23. The answer is A.** (*Chaps. 77, 344*) Whether hypertriglyceridemia in an overweight person is due to familial hypertriglyceridemia, multiple lipoprotein-type hyperlipidemia, or sporadic hypertriglyceridemia, the primary mode of therapy should be weight reduction. Dietary saturated fats should be restricted as part of the weight reduction regimen. Hypothyroidism and diabetes mellitus, if present, should be treated, and the use of alcohol and oral contraceptives should be avoided. If these measures are inadequate, drug therapy with nicotinic acid or gemfibrozil should be tried. Bile acid-binding resins such as cholestyramine and colestipol are used in the treatment of hypercholesterolemia but are not useful for treating hypertriglyceridemia.
- XII-24. The answer is D.** (*Chap. 347*) Uric acid is the end product of purine metabolism. The serum urate level depends on dietary ingestion of purines as well as endogenous sources of purine production. Such sources include de novo purine biosynthesis and “salvage” of purine bases by hypoxanthine phosphoribosyltransferase (HPRT). HPRT catalyzes the addition of phosphated sugars to purine bases to form the ribonucleotides inosine monophosphate and guanosine monophosphate. Increased salvage activity prevents de novo synthesis by reducing phosphoribosylpyrophosphate (PRPP) levels and thus increasing the concentrations of the inhibitory ribonucleotides. A salvage pathway deficiency resulting from an increase in PRPP synthetase or a decrease in HPRT function will cause the overproduction of purines from the 11-step de novo pathway. Therefore, persons deficient in HPRT develop hyperuricemia and nephrolithiasis as well as gouty arthritis. Complete deficiency of HPRT, which is known as the *Lesch-Nyhan syndrome*, is also typified by self-mutilation and choreoathetosis.
- XII-25. The answer is D.** (*Chaps. 330, 331*) When coexistent adrenal insufficiency is suspected, it is important that thyroid replacement not be initiated until treatment with a glucocorticoid has begun. Adrenocortical insufficiency can be precipitated by an increase in the clearance rate of glucocorticoids engendered by correction of the hypothyroid state.
- XII-26. The answer is C.** (*Chap. 348*) The hallmark of Wilson’s disease is the accumulation of excess copper deposits. The precise reason for this increased deposition of copper is not known, but serum ceruloplasmin levels are low because of secondary inhibition of formation of this protein as a result of the excess of copper. Whatever the reason, the ability of hepatocytes to store copper is exceeded, and this mineral ultimately is released in the blood with subsequent uptake in extrahepatic sites, including the brain and Desce-

met's membrane of the cornea (which produces the characteristic Kayser-Fleischer rings). Liver disease may take the form of acute hepatitis, fulminant hepatitis, cirrhosis, or chronic active hepatitis, as in this patient. Neurologic manifestations such as tremors, spasticity, chorea, drooling, and unusual psychiatric behavior may be primary. The diagnosis can be made because of a depressed serum concentration of ceruloplasmin in the presence of Kayser-Fleischer rings or a low serum ceruloplasmin in the presence of an elevated hepatic concentration of copper determined on a liver biopsy specimen. The mainstay of therapy for Wilson's disease is orally administered penicillamine, which removes and detoxifies the excess copper deposits. Problems associated with penicillamine treatment include sensitivity and the need for lifelong therapy. The one contraindication to the use of penicillamine therapy is fulminant hepatitis (usually accompanied by Coombs-negative hemolytic anemia). This syndrome is almost always fatal if a liver transplant cannot be performed.

XII-27. The answer is B. (*Chap. 342. Mincey et al, Mayo Clin Proc 75:821–829, 2000; Ettinger et al, Multiple Outcomes of Raloxifene Evaluation (MORE) Investigators, JAMA 282:637–645, 1999.*) Currently in the United States alendronate and raloxifene are approved for the prevention of osteoporosis. Alendronate, raloxifene, and calcitonin are approved for treatment of osteoporosis. Alendronate has the greatest positive effect on bone mineral density and reduces the incidence of vertebral and nonvertebral fractures. In addition, raloxifene and calcitonin also appear to reduce the incidence of vertebral fractures. Given the patient's prior diagnosis of breast cancer, estrogen therapy for the prevention and treatment of osteoporosis is usually contraindicated. The anti-estrogen effect of raloxifene may also prove beneficial in patients with a history of breast cancer, and the agents listed above would be the most appropriate option. In the clinical setting, use of either alendronate or raloxifene would be appropriate.

XII-28. The answer is D. (*Chap. 344*) Cholestyramine and colestipol are bile acid-binding resins that decrease the reabsorption of bile acids from the intestine, thus secondarily decreasing the enterohepatic circulation of cholesterol. The liver responds to the acid depletion by increasing the synthesis of bile acids. The additional cholesterol required for bile acid synthesis is obtained by the liver by increasing the number of receptors for LDL, which in turn lowers the plasma level of LDL. The most common side effects of these resins are constipation and bloating, although mild steatorrhea may occur when they are used in high doses.

XII-29. The answer is D. (*Chap. 333. Kjos, Buchanan, N Engl J Med 341:1749–1756, 1999.*) At 24 to 28 weeks, women with low-risk clinical characteristics may not need further testing. The risk in these women is low. Although the effect of *not* performing glucose screening has never been evaluated, women with any clinical characteristic placing them at risk should undergo glucose testing. In most populations a two-step testing procedure will limit the number of full glucose tolerant tests performed. The screening test is typically given as a 50-g 1-h glucose challenge test. The 50-g oral glucose challenge test is meant as a screening test. A serum glucose cut-off point of ≥ 7.7 mmol/L (140 mg/dL) has a sensitivity of $\sim 80\%$. A more stringent cut-off at 7.2 mmol/L (130 mg/dL) is associated with a sensitivity of 90%. In patients who test positive, a full glucose tolerance test should be performed. The diagnosis of gestational diabetes is based on the results of the oral glucose tolerance test. Although there is no specific agreement about the conduct or interpretation of the oral glucose tolerance test in pregnant women, the approach that was recommended in 1979 by the National Diabetes Data Group is based on a 3-h, 100-g test. This is typically performed after an overnight fast and values at 1 h ≥ 10.0 mmol/L (180 mg/dL), at 2 h of > 8.6 mmol/L (155 mg/dL), or at 3 h of ≥ 7.7 mmol/L (140 mg/dL) are thought to be associated with gestational diabetes mellitus. The World Health Organization have proposed different criteria for interpreting the results of a 75-g 2-h glucose tolerant test in pregnant women, but at present there are no data on perinatal or maternal outcomes to support the use of these criteria.

- XII-30. The answer is B.** (*Chap 333. Kjos, Buchanan, N Engl J Med 341:1749–1756, 1999.*) The goal in treating patients with gestational diabetes mellitus is to achieve a fasting serum glucose level of ≤ 105 mg/dL (5.8 mmol/L). This is often accomplished with dietary therapy and frequent glucose monitoring. Fetal measurements have been used to identify pregnancies at risk for perinatal morbidity. Evidence of fetal hyperinsulinism or macrosomia should be treated with more aggressive therapy. Women in whom signs of fetal morbidity or in whom blood glucose concentrations exceed target levels are treated with more intensive therapy. Insulin therapy decreases the frequency of fetal macrosomia and perinatal morbidity. Optimal insulin regimens have not been determined, and tailoring of the regimens to achieve a blood glucose target level in individual patients is recommended. Oral hypoglycemic agents have not been used routinely for the treatment of this group of patients.
- XII-31. The answer is B.** (*Chap. 77*) Although only a minority of obese persons have diabetes mellitus, >80% of type 2 diabetics are obese. Obesity appears to be a major contributory factor to the development of diabetes, largely through its effects on insulin sensitivity. A clear relationship also exists between hypertension and obesity in adults, though the mechanism is unclear. Hypertriglyceridemia is associated commonly with obesity and correlates with the degree of obesity; increased hepatic production of very-low-density lipoproteins (VLDL) from free fatty acids is felt to be the major cause of increased triglyceride levels in obese persons, although peripheral defects in VLDL clearance may be present in some. Weight loss can reduce or reverse all these complications. The prevalence of cholelithiasis is increased with increasing adiposity, but the same cannot be said of hypothyroidism—only a small percentage of hypothyroid persons are obese, and an even smaller fraction of obese persons are hypothyroid.
- XII-32. The answer is C.** (*Chaps. 328, 338. Adashi, Hennebold, N Engl J Med 340:709–718, 1999.*) Kallmann's syndrome is characterized by embryonic failure of migration of both the olfactory neurons and the GnRH-producing neurons. Without these synaptic connections, the neurons do not aggregate in the hypothalamus and the olfactory bulbs and tracts are not formed. The characteristic feature of Kallmann's syndrome is hypogonadotropic hypogonadism, which is associated with anosmia. This syndrome occurs in both sexes but is five times as common in men as in women. In most affected families, this syndrome is inherited as an X-linked recessive trait. Mutations within the stimulatory G protein are characteristic of the McCune-Albright syndrome.
- XII-33. The answer is C.** (*Chap. 349. Beutler, N Engl J Med 325:1354, 1991.*) Gaucher disease, an autosomal recessive syndrome, is caused by a deficiency of the enzyme glucocerebrosidase. The absence of this enzyme results in the accumulation of extremely insoluble glucocerebroside as a result of failure of lysosome-mediated glycolipid degradation. The gene encoding this enzyme is on the long arm of chromosome 1. In North America, this disease is most commonly due to a point mutation of cDNA nucleotide 1226, typically found in Jewish persons of Eastern European origin. Though some types of Gaucher disease can present with dramatic neurologic manifestations or cause death early in life, the most common type is the adult-onset, or type I, variety. The disease is manifested by hepatomegaly and splenomegaly, which may contribute to thrombocytopenia. Hepatic involvement can result in fibrosis and abnormal liver function. Bone involvement—particularly flaring of the distal femur, aseptic necrosis of the femoral heads, and bone infarcts—is a common complication. Laboratory abnormalities include pancytopenia, abnormal results of liver function tests, and elevation of serum acid phosphatase. While the diagnosis should be made on the basis of the clinical presentation, bone marrow examinations are frequently performed to evaluate the associated hematologic abnormalities. Such an examination will invariably reveal the presence of so-called Gaucher cells, which are storage macrophages that contain excessive amounts of glucocerebroside, identified as engorgement with a fine, scroll-like pattern. The diagnosis can be confirmed by

determination of leukocyte β -glucosidase activity. While splenectomy is effective in correcting the thrombocytopenia and anemia, the bone disease is of course not affected by this procedure. A major recent change in therapy for Gaucher disease has been the availability of aglucerase, the commercially produced modified glucocerebrosidase (mannose-terminated). Therapy with this agent appears to be effective and safe; however, the cost can range to several hundred thousand dollars per year. Other potential therapeutic strategies include allogeneic transplantation or autologous transplantation of stem cells into which a normal glucocerebrosidase gene has been inserted. This gene transfer approach has not been clinically applied.

XII-34. The answer is C. (*Chap. 332. Bravo, N Engl J Med 311:1298, 1984.*) Pheochromocytomas produce and secrete catecholamines, which may lead to paroxysmally high blood pressure. Approximately 80% of these tumors are solitary adrenal lesions, but 10% are bilateral and 10% are extraadrenal. Pheochromocytoma is also associated with familial multiple endocrine neoplasia types IIa and IIb (hyperparathyroidism and medullary carcinoma are the other endocrinologic manifestations). Once the diagnosis is confirmed, usually by documenting excess urinary catecholamine metabolites over a 24-h period plus localization by CT scanning, it is important to prepare the patient for surgery by preventing the effects of catecholamine release through treatment with phenoxybenzamine, a long-acting α -adrenergic blocker. Liberal salt intake also should be instituted to help restore the contracted plasma volume to normal before surgery. Beta blockers should not be given before alpha blockade has been established because of the potential for hypertension as a result of the antagonism of beta-mediated vasodilation in skeletal muscle beds. However, propranolol is useful in treating the reflex tachycardia induced by phenoxybenzamine. While prazosin is an effective agent for the treatment of hypertensive crises associated with pheochromocytoma, its use as a primary agent in the management of this disorder has not been established.

XII-35. The answer is D. (*Chaps. 77, 78. Montzoros, Ann Intern Med 130:671–680, 1999.*) Leptin is a 16-kDa adipocyte-derived hormone that circulates in the serum in the free and bound form. Serum levels of leptin reflect the amount of energy stored in adipose tissue. Both short-term energy changes as well as serum levels of several cytokines influence circulating leptin levels. Leptin functions by binding to specific receptor isoforms in the hypothalamus, which then alters the expression of several neuropeptides. These neuropeptides regulate energy intake and expenditure. Leptin seems to play a fundamental role in the pathogenesis of obesity as well as mediating the neuroendocrine response to food deprivation. Serum leptin levels in patients with anorexia nervosa, bulimia, and nonspecific eating disorders are similar to those of healthy persons with comparable body mass index. However, there seems to be an increase in the transport of leptin to the cerebrospinal fluid. Disruption of the leptin receptor in mice causes profound obesity. The first person with extreme, early-onset obesity due to an inactivating mutation of the leptin gene has been identified. However, several population studies have failed to demonstrate this as a common abnormality. Therefore, leptin-deficient persons probably represent a minority of obese humans. Most patients with obesity have increased leptin levels. This indicates that obesity is a leptin-resistant state in most obese persons.

XII-36. The answer is C. (*Chaps. 340, 341*) Magnesium deficiency may occur as a result of generalized nutritional insufficiency or lack of supplementation in programs of total parenteral nutrition. Other causes include gastrointestinal malabsorption of any cause, chronic diarrhea, chronic alcoholism, increased renal excretion (from cisplatin, amphotericin B, aminoglycosides, or loop diuretics), and various endocrine disorders (e.g., hyperparathyroidism, hypoparathyroidism, diabetic ketoacidosis, Conn's syndrome, and syndrome of inappropriate secretion of vasopressin). The clinical sequelae of severe magnesium deficiency [<0.5 mmol/L (1.0 meq/L)] include anorexia, vomiting, lethargy, paresthesia, muscle cramps, irritability, decreased attention span, and confusion. Hypocalcemia, as a result

of diminished responsiveness and the release of parathyroid hormone, may be severe enough to produce tetany. About half of patients with hypomagnesemia may become hypokalemic (the mechanism is unclear, but secondary hyperaldosteronism may play a role). Low levels of serum calcium, potassium, and magnesium all serve to promote dangerous cardiac arrhythmias, especially in a patient receiving digitalis. Hyponatremia is not a known consequence of hypomagnesemia, although the syndrome of inappropriate secretion of vasopressin may cause a low serum magnesium. Because of QT prolongation, dangerous arrhythmias are more likely to occur.

- XII-37. The answer is B.** (*Chap. 341. Burtis, N Engl J Med 322:1106–1112, 1990.*) Patients who present with hypercalcemia and hypophosphatemia should be thought of as having an excess of parathyroid hormone activity. Patients with nonparathyroid hormone–like mediated hypercalcemia, such as those with excessive levels of vitamin D caused by intoxication or sarcoidosis or by increased bone turnover as in hyperthyroidism, would not be expected to have a low serum phosphate. Second, patients with familial hypocalciuric hypercalcemia, an autosomal dominant trait, often have normal or slightly low levels of immunoreactive parathyroid hormone. Thus, those with hypercalcemia and hypophosphatemia without elevated levels of parathyroid hormone are likely to have the hypercalcemia of malignancy. The clinical setting usually but not invariably makes this diagnosis obvious. It is now clearly recognized that many solid tumors, including carcinomas of the lung and kidney, may produce a parathyroid hormone–related protein that will not be identified by the currently available assays that detect true parathyroid hormone elaborated from the parathyroid gland. This parathyroid-related protein synthesized by tumors bears striking amino acid homology to that of native parathyroid hormone with regard to amino acids 1 through 13 but is thereafter unique. In fact, it is now recognized that the majority of patients with cancer and hypercalcemia have humoral hypercalcemia, as determined by elevated urinary cyclic AMP excretion.
- XII-38. The answer is B.** (*Chap. 329*) Patients with lung cancer, particularly small cell carcinoma, frequently present with the syndrome of inappropriate vasopressin (AVP, antidiuretic hormone) secretion. Indeed, more than half of patients with such tumors show evidence of inappropriate secretion of AVP, even when serum sodium concentration remains normal. AVP is produced by the tumor tissue itself and is chemically identical to arginine vasopressin secreted by the neurohypophysis. Central nervous system lesions of infectious, inflammatory, and vascular etiologies also can result in inappropriate AVP secretion, but intracerebral metastases from lung carcinomas usually are not responsible for inappropriate AVP secretion.
- XII-39. The answer is A.** (*Chap. 344*) Dietary triglycerides in cholesterol are packaged by gastrointestinal epithelial cells into large lipoprotein particles called *chylomicrons*. After secretion into the intestinal lymph and passage into the general circulation, chylomicrons bind to the enzyme lipoprotein lipase, which is located on endothelial surfaces. This enzyme is activated by a protein contained in the chylomicron, apoprotein CII, liberating free fatty acids and monoglycerides, which then pass through the endothelial cells and enter adipocytes or muscle cells. Therefore, complete inactivation of either lipoprotein lipase or apoprotein CII as a result of the inheritance of two defective copies of the relevant gene results in an accumulation of chylomicrons (type I lipoprotein elevation) that is due to failure of conversion to the chylomicron remnant particle. Patients with familial lipoprotein lipase deficiency usually present in infancy with recurrent attacks of abdominal pain caused by pancreatitis. They also have eruptive xanthomas resulting from triglyceride deposition. Treatment should consist of a low-fat diet that may be supplemented by medium-chain triglycerides, which are not incorporated into chylomicrons. The absence of functional apoprotein CII, with consequent failure to activate lipoprotein lipase, presents with a similar phenotype, although the affected patients are typically detected at a somewhat later age than are patients with familial lipoprotein lipase deficiency.

- XII-40. The answer is E.** (*Chap. 344. Brown, Science 232:34, 1986.*) The most common hyperlipidemic syndrome known to be caused by a single gene defect is familial hypercholesterolemia, an autosomal dominant disorder caused by a mutant LDL receptor. Heterozygotes have a two- to threefold elevation in serum cholesterol because of a reduction in the ability of the liver and other tissues to take up cholesterol-rich LDL lipoprotein particles from the plasma. The clinical features of this syndrome usually are manifest by premature and accelerated coronary atherosclerosis as well as by tendon xanthomas, particularly in the Achilles tendon and tendons near the knee, the elbow, and the dorsum of the hand. These nodules are caused by deposits of lipid-swollen macrophages. The extremely high LDL levels lead to an enhanced infiltration of cholesterol into the artery wall after episodes of endothelial damage, thus leading to enhanced atherosclerosis. The presence of very elevated plasma cholesterol levels, the occurrence of tendon xanthomas, and a family history of atherosclerosis or hyperlipidemia are highly suggestive of familial hypercholesterolemia.
- XII-41. The answer is D.** (*Chap. 331*) In the various forms of congenital adrenal hyperplasia, including steroid C-21 hydroxylase deficiency, both pituitary and adrenal regulatory mechanisms function appropriately. The enzymatic defect in cortisol production results in an absence of the product (cortisol) necessary for feedback inhibition of ACTH secretion by the pituitary gland. ACTH in turn causes the production of increased amounts of cortisol precursors such as 17-hydroxyprogesterone, which is converted to androgens by the adrenal gland. Therapy with appropriate doses of glucocorticoid causes suppression of pituitary ACTH and adrenal androgen secretion, indicating that inhibiting and stimulating control mechanisms of the hypothalamic-pituitary-adrenal axis can function normally.
- XII-42. The answer is D.** (*Chaps. 328, 331*) In a single-dose overnight dexamethasone suppression test, which is a screening procedure in the workup of possible cortisol excess, suppression of plasma cortisol concentration to <140 nmol/L (5 μ g/dL) implies normal hypothalamic-pituitary-adrenal feedback and excludes a diagnosis of Cushing's syndrome. However, failure to suppress plasma cortisol after this procedure is not necessarily diagnostic and must be investigated further. Several factors can affect the validity of screening dexamethasone testing. For example, in 10 to 15% of cases obesity interferes with normal suppression of cortisol after an overnight dexamethasone test. However, obese persons uniformly show normal excretion of free cortisol in urine [<275 nmol/d (<100 μ g/d)]. A 24-h urine free cortisol or 2-day low-dose dexamethasone test is necessary to exclude or establish the diagnosis of Cushing's syndrome in all persons with an abnormal or equivocal 1-mg overnight dexamethasone suppression test. The high-dose test, which is reserved for patients with established Cushing's syndrome, serves to delineate the specific cause. Imaging procedures should be performed only after a diagnosis of cortisol excess has been established.
- XII-43. The answer is B.** (*Chap. 331*) Hyporeninemic hypoaldosteronism occurs most commonly in adults with diabetes mellitus in association with mild renal failure, metabolic acidosis, and hyperkalemia. The defect in aldosterone synthesis is almost certainly caused by hyporeninism, since in these patients aldosterone secretion increases promptly after the administration of ACTH but not after salt restriction or postural changes. Most patients respond to the administration of potent mineralocorticoids (fludrocortisone), diuretics such as furosemide, or both, but in general mineralocorticoids should not be the sole therapeutic agents in patients with hypertension. Furosemide will treat both the hyperkalemia and the acidosis; this diuretic will be more effective if sodium intake is reduced. Hemodialysis may be useful in emergency situations to correct hyperkalemia. Potassium restriction and enhancement of potassium excretion with anion-exchange resins are both likely to predispose to total-body potassium deficits.
- XII-44. The answer is A.** (*Chap. 333. Coustan, N Engl J Med 319:1663, 1988.*) The prognosis for pregnancies complicated by diabetes mellitus has improved markedly, and perinatal

mortality has decreased to the point where infant survival is similar to that in the population at large. This improved outcome is a result of aggressive treatment of maternal hyperglycemia and advances in the techniques of fetal surveillance and neonatal care. When mean maternal blood glucose levels exceed 8.3 mmol/L (150 mg/dL) in the third trimester, perinatal mortality is almost six times that associated with mean maternal glucose levels below 5.6 mmol/L (100 mg/dL). Congenital malformations, the leading cause of perinatal mortality in infants of diabetic pregnancies, remain a problem; such abnormalities are thought to be related to poor glucose control early in the first trimester (during early embryogenesis), a time when many women do not yet know they are pregnant. Optimal care of a diabetic woman who wishes to become pregnant requires that a major attempt be made to achieve as normal a mean blood glucose concentration as possible before conception and throughout the duration of the pregnancy. Hospitalization may be required for education or treatment of complications but should not be necessary for extended periods of time. Multiple subcutaneous injections of insulin or continuous subcutaneous injection of insulin should be considered to provide “tight” control in all diabetic women who wish to become pregnant.

- XII-45. The answer is B.** (*Chap. 333*) Dot hemorrhages and several larger lesions near the disk (caused by superficial retinal bleeding) are characteristic changes of background diabetic retinopathy. However, the presence of innumerable fine frondlike vessels extending around and partly covering the disk is indicative of the neovascularization of proliferative retinopathy, which requires urgent treatment. The therapy of choice is photocoagulation by xenon arc or ruby or argon laser, which significantly improves the visual prognosis in patients with proliferative retinopathy. Hypophysectomy is no longer used to treat proliferative retinopathy because of the morbidity and lack of effectiveness of the procedure. Vitrectomy should be reserved for more advanced cases, such as non-resolving vitreal hemorrhage and retinal detachment.
- XII-46. The answer is A.** (*Chap. 335*) Testosterone esters are hydrolyzed by esterases in the blood as they are absorbed from the oily depots in which they are administered, and as a consequence, the esters themselves rarely can be detected in blood. Therefore, the effectiveness of therapy with agents such as testosterone cypionate can be monitored by measuring the plasma levels of testosterone itself. In men with recent onset of hypogonadism, plasma LH levels should be suppressed into the normal range by testosterone, but when LH levels have been high for many years, LH secretion becomes semi-autonomous and may not return to the normal range for many months or years after the restoration of blood testosterone levels to normal. The frequency of nocturnal erections may or may not reflect plasma testosterone levels on a day-to-day or week-to-week basis, and muscle mass depends on factors in addition to plasma testosterone levels, including exercise level.
- XII-47. The answer is D.** (*Chap. 343*) Paget’s disease of bone is relatively common, and the incidence increases with age. An estimated prevalence of 3% in persons over age 40 years is a generally accepted figure. Most frequently, the disease is asymptomatic and is diagnosed only when the typical sclerotic bones are incidentally detected on x-ray examinations done for other reasons or when increased alkaline phosphatase activity is recognized on routine laboratory measurements. The etiology is unknown, but increased bone resorption followed by intensive bone repair is thought to be the mechanism that causes increased bone density and increased serum alkaline phosphatase activity as a marker of osteoblast activity. Since increased mineralization of bone takes place (although in an abnormal pattern), hypercalcemia is not present unless a severely affected patient becomes immobilized. Hypercalcemia in fact would be an expected finding in a patient with primary hyperparathyroidism, bone metastases, or plasmacytoma, with plasmacytoma typically producing no increase in alkaline phosphatase activity. Osteomalacia resulting from vitamin D deficiency is associated with bone pain and hypophosphatemia; normal or decreased serum calcium concentration produces secondary hyperparathyroidism, further aggravating the defective bone mineralization.

- XII-48. The answer is D.** (*Chap. 341*) A major function of parathyroid hormone is to act as a trophic hormone to regulate the rate of formation of 1,25(OH)₂ vitamin D. The mechanism by which parathyroid hormone exerts this effect may be secondary to its effects on phosphorus metabolism. Other hormones, including prolactin and estrogen, also may play a role in stimulating the production of 1,25(OH)₂ vitamin D.
- XII-49. The answer is D.** (*Chap. 328. Madsen, Karluk, N Engl J Med 343:1399–1406, 2000.*) The patient in this case has an enlarging pituitary mass causing the visual field defects and panhypopituitarism. The patient's hyperlipidemia is likely explained by the presence of central hypothyroidism, documented by the low levels of serum thyroxine with a low TSH. The patient also has low glucocorticoid activity with inadequate adrenal reserve, likely due to long-term ACTH deficiency, and a low level of FSH. The latter value is below that expected in a normal postmenopausal woman and is consistent with the finding of hypopituitarism. The patient does not have overt diabetes insipidus. Her low serum sodium level and low osmolality, however, are compatible with dysfunction of the posterior pituitary or hypothalamus. Abnormalities of the pituitary gland and the hypothalamus were elucidated by coronal T1-weighted images on MRI study. Tumors that should be considered in patients with hypopituitarism include clinically nonfunctioning adenomas. However, these tumors are often associated with elevated serum levels of the α subunit. In this patient the α -subunit level is normal. The presence of normal facial features and normal serum glucose makes a growth hormone–secreting pituitary adenoma less likely. The thickening of the pituitary stalk is uncommon in a pituitary adenoma and is most consistent with an infiltrative process. The tumor-like lesions of the pituitary gland and stalk include abscesses, but the long history of this patient's illness argues against an infectious process. In addition to nonsuppurative inflammatory lesions, the differential diagnosis includes lymphocytic hypophysitis and granulomatous hypophysitis. Lymphocytic hypophysitis is associated with late pregnancy or postpartum period. This disorder may have an autoimmune origin and is associated with other autoimmune disorders, especially autoimmune thyroiditis. Tests for antinuclear antibodies (ANA) and rheumatoid factor are often positive. The erythrocyte sedimentation rate may be elevated. Granulomatous hypophysitis may be an isolated lesion or a component of systemic sarcoidosis. This patient had radiographic abnormalities within her chest consistent with the diagnosis of sarcoidosis, but unfortunately there are no specific laboratory tests for sarcoidosis.
- XII-50. The answer is C.** (*Chaps. 52, 336*) The fact that withdrawal bleeding occurred after the administration of progestogen indicates that estrogen was being produced. Women with chronic anovulation who react in this way are said to be in the state of "estrus" because of acyclic production of estrogen. This diagnostic response clearly excludes causes of amenorrhea associated with suppression of ovarian function, including pituitary disease, either functional or organic, and conditions associated with streak gonads. The most likely cause of amenorrhea in such a situation is polycystic ovarian disease (PCOD), in which the ovaries produce androgens that can be converted to estrogens (largely estrone) in extraglandular tissues. In most women with PCOD, menarche occurs at the expected time and amenorrhea supervenes after a variable time. However, in some women this disorder has an early onset and may cause primary amenorrhea. Other causes of anovulation in the presence of estrogen include estrogen-secreting tumors of the ovary and adrenal tumors.
- XII-51. The answer is C.** (*Chaps. 52, 336*) Asherman's syndrome, or destruction of the endometrium, occurs after vigorous curettage, usually in association with postpartum hemorrhage or therapeutic abortion. The diagnosis is confirmed by hysterosalpingography or by direct visualization of the scarred endometrium using a hysteroscope. Treatment consists of dilation and curettage, followed by the insertion of an intrauterine device for 8 weeks.
- XII-52. The answer is D.** (*Chaps. 52, 336*) Low circulating levels of estrogens coupled with elevated gonadotropin levels exclude the presence of pituitary disease and indicate primary

ovarian failure, which is premature at this patient's age. Bilateral tubal obstruction would cause infertility but not amenorrhea. PCOD is associated with typical physical findings of weight gain and hirsutism, an earlier age of onset, and elevated circulating levels of estrogens.

- XII-53. The answer is A.** (*Chaps. 331, 338*) The clinical situation described in the question is characteristic of congenital adrenal hyperplasia caused by a deficiency of either C-21 hydroxylase or 3β -ol-dehydrogenase. Urinary 17-ketosteroids are elevated in both disorders, whereas urinary pregnanediol and pregnanetriol and plasma 17-hydroxyprogesterone and androstenedione levels are elevated in association with C-21 hydroxylase deficiency. Plasma 11-deoxycortisol is elevated in patients with C-11 hydroxylase deficiency, a disorder producing hypertension because of overproduction of mineralocorticoids and consequently not associated with vomiting and volume depletion. Congenital adrenal hyperplasia caused by C-21 hydroxylase deficiency, the most common cause of ambiguous genitalia in newborns, results in virilization of females at birth and premature androgenation of males. 3β -Hydroxysteroid dehydrogenase (3β -HSD) is diagnosed by very high levels of urinary metabolites of pregnanetriol and cortisol. Elevation of 17-hydroxyprogesterone does not imply a coexisting C-21 deficiency.
- XII-54. The answer is D.** (*Chap. 338*) Tumors of the streak gonads are unusual in the common forms of gonadal dysgenesis, including those associated with normal karyotypes (46,XX), X-chromosome deletion (45,X), structurally abnormal X chromosomes (46,XX_i), and X chromosome mosaicism (45,X/46,XX). However, malignant tumors of the streaks (so-called gonadoblastomas) are common when gonadal dysgenesis is associated with cell lines containing Y chromosomes or fragments of Y chromosomes. Consequently, the gonadal streaks should be resected whenever a Y chromosome is present in a woman with gonadal dysgenesis.
- XII-55. The answer is E.** (*Chap. 341*) Persons who have hyperparathyroidism can present with manifestations of hypercalcemia, such as kidney stones or osteitis fibrosa cystica, a form of bone involvement characteristic of the disease. However, with the widespread application of biochemical screening as a routine tool in patient evaluation, more and more patients are diagnosed early in the course of the disease, when it is manifested only by asymptomatic hypercalcemia. At present, this is the most common source of diagnoses of hyperparathyroidism. A solitary parathyroid adenoma is the most common cause of this entity.
- XII-56. The answer is E.** (*Chaps. 279, 341*) Patients with primary hyperparathyroidism are usually asymptomatic, and mild degrees of hypercalcemia in such patients usually can be managed with adequate hydration. Whether observation alone is appropriate in these patients is controversial, especially when the diagnosis is made at a young age, since surveillance of renal function and bone status is lifelong and cumbersome. However, definitive treatment is clearly indicated when complications arise. In this patient, hypercalcemia and nephrolithiasis constitute a clear-cut indication for surgical treatment of the hyperparathyroidism. An additional reason would be to prevent bone loss in this young woman that would place her at increased risk for the development of skeletal complications at a later time. Glucocorticoids are usually ineffective in the management of primary hyperparathyroidism and would affect bone metabolism negatively, besides producing other serious side effects when administered on a long-term basis. Thiazide diuretics and calcium supplementation are contraindicated in this patient because of the risk of inducing hypercalcemia.
- XII-57. The answer is C.** (*Chap. 330*) RAIU is often a useful test in distinguishing among the various causes of hyperthyroidism. Elevation of RAIU above the normal range usually indicates thyroid hyperfunction (some persons with hyperthyroidism have a normal or low RAIU). Painless thyroiditis is a variant of chronic lymphocytic thyroiditis associated with

transient thyrotoxicosis from the release of preformed hormone. Radiographic contrast studies such as intravenous pyelography and oral cholecystography use organic media that release iodide and thus serve as sources for the dilution of administered radioactive iodine; as a result, RAIU may be falsely low for as long as 6 months. *Thyrotoxicosis factitia* is the term used to designate thyrotoxicosis resulting from the ingestion of thyroid hormones. Ingestion of liothyromine (T_3) results in a low serum thyroxine (T_4) concentration, while the ingestion of levothyroxine leads to elevations of both T_4 and T_3 . In either case, feedback of exogenous thyroid hormone decreases TSH secretion and lowers RAIU. Struma ovarii, which is an ovarian tumor with thyroidlike tissue that releases thyroid hormone, is a rare cause of thyrotoxicosis. Measurement of RAIU over the thyroid gland would not, of course, detect the abdominal source of increased RAIU in women affected with struma ovarii. Choriocarcinoma releases factors with TSH-like activity that enhance the uptake of radioactive iodine.

- XII-58. The answer is B.** (*Chap. 343*) Osteomalacia and rickets are both characterized by defective mineralization of bone; osteomalacia affects the adult skeleton, and rickets impairs the developing skeleton. Muscle weakness, hypocalcemia, hypophosphatemia, skeletal pain, and pseudofractures are cardinal features of both forms of osteomalacia. Although common in children who have rickets, bowing of the tibia and increased thickness of the epiphyseal growth plates are not prominent in affected adults.
- XII-59. The answer is E.** (*Chaps. 75, 340, 341, 343*) The combination of hypocalcemia, hypophosphatemia, elevated serum parathyroid hormone levels, and bone fractures is consistent with a diagnosis of osteomalacia in this patient. In the absence of other gastrointestinal or renal abnormalities leading to malabsorption or increased renal loss of calcium or phosphorus, vitamin D deficiency is likely to be present. Inadequate intake of vitamin D and calcium together and limited exposure to the sun are common in this age group. Postmenopausal osteoporosis is associated with vertebral and hip fractures as well, but laboratory abnormalities are not present. Primary hyperparathyroidism is associated with increased serum calcium concentration, as is ectopic parathyroid hormone secretion (although the existence of the latter has been questioned). Paget's disease of bone does not produce hypocalcemia, and it causes typical sclerotic changes on x-ray examination.
- XII-60. The answer is C.** (*Chaps. 340, 341*) The presenting findings in both primary hyperparathyroidism and multiple myeloma can include hypercalcemia and vertebral compression fractures. The absence of several key features—*anemia, elevated erythrocyte sedimentation rate, abnormal serum protein electrophoresis, and Bence Jones proteinuria*—is helpful in eliminating the possibility of multiple myeloma. If doubt remains about the diagnosis of myeloma, a marrow aspiration should be performed. The presence of hypercalcemia makes unlikely the diagnoses of osteomalacia, which is associated with hypocalcemia, and osteoporosis and Paget's disease, which are associated with normal blood calcium values.
- XII-61. The answer is C.** (*Chaps. 340, 341*) Measurement of the serum concentration of 25(OH) vitamin D, the major circulating form of vitamin D, can be used to assess the adequacy of dietary intake and absorption of the vitamin. (Vitamin D also is made in the skin in the presence of sunlight). Once ingested or synthesized, vitamin D is metabolized to 25(OH) vitamin D in the liver. This reaction is not tightly regulated, and an increase in dietary intake or endogenous production of vitamin D is reflected by linear elevations of serum 25(OH) vitamin D levels. Levels are reduced in patients with severe chronic parenchymal and cholestatic liver disease but usually are normal in patients with renal failure. Anticonvulsant drugs and glucocorticoids induce hepatic microsomal enzymes, which metabolize vitamin D and 25(OH) vitamin D into inactive products; this phenomenon, along with other complex effects on calcium metabolism, helps explain why these drugs cause osteopenia.

- XII-62. The answer is E.** (*Chap. 333. Rits, Orth, N Engl J Med 341:1127–1133, 1999.*) Patients with type 2 diabetes mellitus are at an increased risk for the development of renal failure. The risk of nephropathy is strongly determined by genetics, and familial clustering is typically seen in diabetic patients. Factors that increase the risk of progression to end-stage renal failure include hypertension, albuminuria, poor glycemic control, smoking, high dietary intake of protein, and hyperlipidemia. Once nephropathy is developed, patients can decrease the risk of progression by achieving better glycemic control and maintaining better control of their blood pressure. In addition, cessation of smoking as well as the restriction of dietary protein are also thought to be helpful. Patients with diabetes who have microalbuminuria have not yet begun to lose glomerular filtration, but are at a high risk for the development of renal complications. Microalbuminuria is defined as a urinary albumin excretion rate of 30 to 300 mg per 24 h on two of three measurements. The test results cannot be interpreted correctly in the presence of a urinary tract infection, fever, uncontrolled hyperglycemia, or hypertension or in the presence of congestive heart failure. Patients with diabetes who have microalbuminuria also have an extremely high risk for the development of cardiovascular complications. A 1995 consensus statement recommended antihypertensive treatment, preferably with ACE inhibitors, be started once microalbuminuria has been documented.
- XII-63. The answer is E.** (*Chap. 328*) Because the half-life of T_4 is ~ 1 week, the total T_4 will still be normal the day after the pituitary ceases to function. T_3 is derived primarily from T_4 , and so it will still also be normal. IGF-I is a useful test for detecting growth hormone excess as occurs in acromegaly, but it is not a sensitive test of growth hormone deficiency. In addition, IGF-I would not fall rapidly to a new steady level. Likewise, an ACTH stimulation test would be normal even though the patient had adrenal insufficiency. The adrenal glands would not yet have atrophied and could still respond to exogenous ACTH. A test more likely to detect adrenal insufficiency in this case would be an insulin tolerance test, in which a small dose of regular insulin is administered in a monitored setting to induce hypoglycemia therapy stimulation and the release of counterregulatory hormones, including cortisol. Increased cortisol secretion in this case relies on the pituitary's ability to release ACTH, not just on the adrenal's ability to respond to ACTH. The insulin tolerance test should never be performed in elderly patients and patients with heart disease.
- XII-64. The answer is D.** (*Chap. 330*) This patient has postpartum thyroiditis, which occurs in 5 to 9% of all postpartum women. Appropriate treatment is symptomatic because the hyperthyroidism is caused by the release of preformed thyroid hormone from a damaged thyroid gland. Therefore, therapies aimed at decreasing the formation of thyroid hormone, such as methimazole, or at inhibiting its release, such as SSKI, will be ineffective. Radioactive iodine also will be ineffective, since it will not be taken up by the damaged thyroid gland (reflected in the 1% 24-h iodine uptake). In addition, the hyperthyroidism will resolve spontaneously. Steroids are effective in subacute thyroiditis, which is characterized by a tender thyroid and often is preceded by a viral illness, but are not used in postpartum thyroiditis. Therapies, such as beta blockers, aimed at treating symptoms are the most effective treatment.
- Postpartum thyroiditis is a form of lymphocytic thyroiditis, a painless inflammation of the thyroid that is thought to be autoimmune in etiology. About one-third of patients enter a hypothyroid phase after experiencing hyperthyroidism. Eighty percent of these women recover normal thyroid function, but 20% remain hypothyroid and require indefinite replacement therapy. Therefore, serial thyroid function testing is indicated.
- XII-65. The answer is B.** (*Chaps. 7, 330. Daniels, Endocrine Pract 1:287, 1995.*) Radioactive iodine should never be given to a pregnant woman. In addition, both methimazole and beta blockers should be avoided in pregnant women. Methimazole may lead to an increased incidence of aplasia cutis, a fetal scalp defect. Beta blockers may lead to neonatal hypoglycemia. Antithyroid drugs, including propylthiouracil, cross the placenta and affect fetal thyroid function. Studies have shown that when a treated pregnant woman's thyroid func-

tion is in the mid-normal range, the fetus is hypothyroid. When the mother's thyroid tests are maintained in the high-normal or slightly hyperthyroid range, the fetus is likely to have normal thyroid function. Severe maternal hyperthyroidism is potentially dangerous for the fetus, but mild maternal hyperthyroidism poses a much smaller risk.

- XII-66. The answer is C.** (*Chap. 328*) Although the most common pituitary tumor is a prolactinoma, this tumor is more likely a nonfunctioning pituitary adenoma. Though the prolactin level is elevated, one would expect it to be much higher with a prolactinoma this large. The mildly elevated prolactin most likely results from compression of the infundibular stalk. This tumor should be removed, as it is macroscopic and near the optic chiasm. Further growth could result in impairment of the patient's vision. The surgery usually is performed using a transsphenoidal approach, a technique that avoids the morbidity of a craniotomy and carries minimal risk in the hands of an experienced surgeon.
- XII-67. The answer is A.** (*Chap. 334. DeFronzo, N Engl J Med 333:541, 1995. Groop, Diabetes Care 15:737, 1992.*) Sulfonylureas have long half-lives. One such agent, chlorpropamide, has a half-life of 24 h. Though the patient's glucose is normal after an intravenous dextrose infusion, he may become hypoglycemic again hours later. He therefore should be hospitalized with careful monitoring of glucose and mental status until the effects of the sulfonylurea have resolved. Though metformin does not cause prolonged hypoglycemia, it is contraindicated in patients with organ failure, as the combination may predispose to lactic acidosis. Sulfonylurea administration is by far the most likely cause of this man's first episode of hypoglycemia, and a workup for insulinoma is unlikely to be revealing.
- XII-68. The answer is D.** (*Chap. 344*) Cigarette smoking has been shown to be associated with low HDL but not with hypertriglyceridemia. Alcohol, diabetes mellitus, obesity, and pregnancy are all causes of hypertriglyceridemia. In addition, many medications may cause hypertriglyceridemia, including estrogen, isotretinoin, beta blockers, glucocorticoids, and thiazides.
- XII-69. The answer is A.** (*Chap. 340. Liberman, N Engl J Med 333:1437, 1995; Mincey et al, Mayo Clin Proc 75:821–829; 2000.*) Alendronate and raloxifene are currently approved in the United States for the prevention of osteoporosis. Alendronate, raloxifene, and calcitonin are approved for treatment. While estrogen therapy is considered standard for the prevention and treatment of osteoporosis, use of estrogen in women with a history of breast cancer is usually contraindicated. Alendronate has been shown to increase bone density and decrease fracture rates. Alendronate is available as a once-a-week formulation, which allows for more convenient dosing and greater compliance. Its most common complication is esophagitis, and so it is recommended that it be taken with a full glass of water and that the patient remain upright for at least half an hour after taking the pill. Pamidronate, another bisphosphonate, can be given only intravenously and is not used for osteoporosis. Estrogen replacement therapy, weight-bearing exercise, and nasal calcitonin have all demonstrated efficacy in the treatment of osteoporosis. Nasal calcitonin may not be as effective as estrogen or alendronate and usually is not chosen as a first-line treatment.
- XII-70. The answer is C.** (*Chap. 341*) Hypoparathyroidism would cause a high, not low, phosphate. Transient hypoparathyroidism caused by atrophy of the remaining parathyroid glands may occur after parathyroid adenoma removal. However, this condition would be expected to resolve over 24 to 48 h. Magnesium deficiency may cause hypocalcemia, but this process is mediated through impairment of parathyroid hormone (PTH) secretion and end-organ resistance to PTH. Therefore, magnesium deficiency also would be expected to result in a high serum phosphate. Parathyroid cancer would be expected to cause hypercalcemia if it was not completely removed at surgery. However, complete excision could result in hypoparathyroidism because of atrophy of the other parathyroid glands. Again, one would expect this to resolve rapidly. Hungry bone syndrome occurs when calcium-

starved bones that have been under the influence of high PTH take up calcium avidly after the removal of a parathyroid adenoma. Aggressive calcium supplementation may be necessary for months after surgery. Risk factors for the development of this syndrome include a high preoperative alkaline phosphatase level and a large tumor.

XII-71. The answer is A. (*Chap. 328*) This patient has postoperative diabetes insipidus, a common complication of surgery in the area of the hypothalamus. A water deprivation test is not necessary for the diagnosis because the patient already manifests the elements necessary to make the diagnosis: a serum sodium greater than normal, accompanied by inappropriately dilute urine. Fluid restriction could be dangerous in this patient, who could develop life-threatening hypernatremia. Instead, the patient should be encouraged to drink when thirsty and should be given one dose of desmopressin. If the patient's thirst mechanism is intact, he will be thirsty until his serum sodium level corrects. He should not be placed on a standing dose of desmopressin bid, as the effects of the first dose may not have resolved 12 h later. In addition, postoperative diabetes insipidus can be followed by SIADH, leading to iatrogenic hyponatremia caused by this regimen. Instead, the patient should be given one dose of desmopressin, be encouraged to drink when thirsty, and have his serum sodium monitored twice a day. The urine osmolality or specific gravity and urine output also should be monitored. A brain MRI is not necessary unless there is no other evidence of a central nervous system complication, since this is a common, expected, and usually transient complication of this type of neurosurgery. Classically, these patients experience a short period of diabetes insipidus, followed by an episode of SIADH, followed by diabetes insipidus. In practice, many patients do not experience all three stages.

XII-72. The answer is C. (*Chap. 328*) This patient may have hypopituitarism, but it is unclear from his laboratory results. A random cortisol of 135 nmol/L (4.8 $\mu\text{g/dL}$) in the middle of the stress of hypotension and an illness severe enough to warrant an intensive care unit are quite suggestive of adrenal insufficiency (though one cannot differentiate between primary and secondary causes with a cortisol alone). However, the patient's cortisol level is not diagnostic, and dexamethasone should be given to this critically ill patient to provide him with adequate glucocorticoid coverage while a cosyntropin stimulation test is performed. Dexamethasone will not interfere with the performance of the cosyntropin stimulation test. This will ensure that an accurate diagnosis is made before the patient is committed to lifelong glucocorticoid therapy. Hydrocortisone, prednisone, and methylprednisolone all cross-react with the cortisol assays and produce falsely elevated values. The thyroid function tests could reflect secondary hypothyroidism, but it is more likely that they represent the sick euthyroid state, since the TSH is only mildly low and the total T_3 is proportionally lower than the free T_4 index. Thyroid hormone replacement in patients with the sick euthyroid syndrome has not been shown to improve the outcome. The low testosterone, accompanied by the low LH and FSH, provides evidence of secondary hypogonadism. Of note, severe illness can produce temporary hypogonadism. In these cases, testosterone recovers when the patient recovers. This patient could have hypogonadism, but one must wait until he recovers from his illness to determine this definitively. Further, though testosterone is important for his long-term health, it will not contribute to recovery from his acute illness.

XII-73. The answer is C. (*Chap. 330. Laderson, Am J Med 77:261, 1984.*) A TSH of 81 mU/L is evidence of primary hypothyroidism. Studies have shown that hypothyroidism does not significantly increase cardiac surgery mortality, and giving thyroid hormone before surgery could exacerbate cardiac ischemia angina. Therefore, cardiac surgery should not be delayed while one waits for thyroid hormone levels to be restored. In patients with primary hypothyroidism and heart disease, thyroid hormone should be replaced gradually, starting with a low dose of 0.025 mg a day and increasing the dose slowly. Rapid replacement with the shorter-acting T_3 (Cytomel) may exacerbate the patient's angina, as might the fluctuations in thyroid hormone levels. There is no evidence that this patient has hy-

popituitarism, since the high TSH provides evidence of primary, not secondary, hypothyroidism. Propylthiouracil is a medication that may be given to a person with hyperthyroidism, not one with hypothyroidism.

- XII-74. The answer is B.** (*Chaps. 328, 331*) After an ACTH-producing tumor is removed from the pituitary, the patient will have adrenal insufficiency and require glucocorticoids for a year. Normal ACTH-producing pituitary cells have atrophied but do eventually recover to function normally. The patient should have been started on glucocorticoids the time of surgery with a slow taper over a period of months. The choice of dexamethasone as the glucocorticoid would allow accurate assessment of the hypothalamic-pituitary-adrenal axis in the immediate postoperative setting. Prednisone could be initiated in place of dexamethasone after testing is completed. It would be very unusual to remove enough normal ACTH-producing pituitary cells to cause adrenal insufficiency while leaving enough TSH-producing cells to maintain normal thyroid function.
- XII-75. The answer is D.** (*Chaps. 328, 331. Oldfield, N Engl J Med 325:897, 1991.*) Pituitary tumors suppress with high-dose dexamethasone and are more common than adrenal and ectopic tumors. Suppression is defined as a >90% decrease in the 24-h urine free cortisol on the second day. However, some ectopic ACTH-producing tumors, particularly carcinoids, also are suppressed with high-dose dexamethasone. The next step in localizing the tumor is the performance of a petrosal sinus catheterization. Concomitant administration of CRH during this procedure will increase its accuracy. If peripheral ACTH levels are more than double central levels, the tumor is most likely ectopic. If, however, the central ACTH levels are more than double the peripheral levels, the tumor is more likely to be pituitary in origin. If testing suggests a pituitary origin, an MRI with and without gadolinium is warranted. If testing suggests an ectopic source, locating the tumor can be difficult. One might start with a fine-cut CT scan of the lungs. Octreotide scans sometimes may be helpful in locating ectopic tumors. If the 24-h urine free cortisol had not suppressed, one would expect the tumor to be either adrenal or ectopic in origin.
- XII-76. The answer is D.** (*Chap. 330*) The contrast used in catheterization procedures contains iodine. Iodine tends to worsen hyperthyroidism caused by autonomous nodules, whereas it inhibits the release of thyroid hormone in patients with autoimmune thyroid disease such as Graves' disease and Hashimoto's thyroiditis. Iodine-containing medications sometimes are used in the treatment of Graves' disease. If a patient is known to have an autonomous nodule, he or she should receive an antithyroid drug such as methimazole or propylthiouracil before undergoing catheterization. Further, the antithyroid medication should be continued for at least 2 weeks after the procedure.
- XII-77. The answer is E.** (*Chap. 330*) This entity of self-induced thyrotoxicosis is most commonly seen in medical and paramedical personnel and in those with easy access to thyroid hormone. Weight loss induction is one motivation for taking the unprescribed thyroid hormone in supraphysiologic doses. The patient's thyroid is suppressed because of negative feedback. Therefore, the 24-h radioactive iodine uptake is low, as in thyroiditis. This entity can be distinguished from thyroiditis by the presence of a low thyroglobulin. Graves' disease and toxic multinodular goiters cause an elevated 24-h radioactive iodine uptake.
- XII-78. The answer is B.** (*Chaps. 28, 333. Ferris et al, N Engl J Med 341:667–678, 1999.*) Preventing diabetic retinopathy is the most effective approach toward the preservation of vision. The Diabetes Control and Complications Trial (DCCT) studied 1441 patients with type 1 diabetes. Approximately 50% of these patients had mild to moderate nonproliferative retinopathy at baseline. The patients were randomly assigned to receive either intensive or conventional therapy and were followed for a mean of 6.5 years. Improved glycemic control produced a remarkable reduction not only in the rate of the development of retinopathy but also in the progression of already established mild to moderate retinopathy. It should be noted that better control of hyperglycemia lowers but does not eliminate the

risk of retinopathy and other complications of diabetes mellitus. Several studies suggest that the treatment of hypertension may also slow the progression of diabetic retinopathy. This may not be a specific class effect as patients treated with both captopril, an ACE inhibitor, and atenolol showed equal benefits towards the reduction of progressive retinopathy. In addition, reduction in the serum lipid concentration may also slow the progression of diabetic retinopathy. The use of aspirin has little or no effect on diabetic retinopathy. Although smoking cessation clearly decreases the risk of cardiovascular morbidity in patients with diabetes mellitus, it is unclear whether this prevents the progression of diabetic retinopathy.

- XII-79. The answer is D.** (*Chap. 339. Chandrasekharappa, Science 276:404, 1997.*) MEN I is characterized by hyperparathyroidism, pancreatic islet cell tumors, and pituitary tumors. The hyperparathyroidism can be particularly difficult to manage, as it usually is caused by four-gland hyperplasia and recurs after surgery. Hyperparathyroidism is the most common manifestation of the syndrome. Most individuals are affected by age 40. Islet cell tumors are the second most common manifestation of MEN I. Pituitary tumors occur in more than half of MEN I patients. The most common type of pituitary tumor found in this population is a prolactinoma. The gene implicated in the pathogenesis of MEN I has been cloned. It is located on chromosome 11 and has been named MENIN. MEN I is inherited in an autosomal dominant fashion. A c-RET proto-oncogene mutation has been identified in 93 to 95% of patients with MEN II, not in those with MEN I.
- XII-80. The answer is B.** (*Chap. 333*) The mainstay of therapy for diabetic ketoacidosis (DKA) is insulin and intravenous fluids. DKA cannot be reversed without insulin. The usual fluid deficit is 3 to 5 L, and both salt solutions and free water are needed. Because glucose levels drop more quickly than ketones disappear from the plasma, it is usually necessary to give intravenous dextrose when the blood glucose level drops below about 14 to 16.7 mmol/L (250 to 300 mg/dL). This allows continued administration of insulin to clear the ketones from the blood. Although the serum potassium concentration is high, there is a total body potassium deficit of several hundred millimoles. The potassium concentration will drop quickly as the pH rises, causing potassium to enter cells. Bicarbonate therapy is not recommended unless the arterial pH falls below 7.10 or 7.00 because the rapid alkalization may impair oxygen delivery to tissues and impair left ventricular function. In addition, insulin therapy is effective in reversing the acidemia without the assistance of bicarbonate therapy.
- XII-81. The answer is C.** (*Chap. 339. Neufeld et al, Medicine 60:355–362, 1981.*) Polyglandular autoimmune syndrome type II (Schmidt's syndrome) is characterized by lymphocytic infiltration of the adrenal and thyroid glands along with type 1 diabetes mellitus in about half of affected families. Hypogonadism is also common. A few patients develop transient hypoparathyroidism caused by antibodies that compete with parathyroid hormone for binding to the parathyroid receptor. Mucocutaneous candidiasis does not occur as part of this syndrome. Instead, it occurs in most patients with polyglandular autoimmune syndrome type I. Patients who are found to have hypothyroidism should first be checked for adrenal insufficiency prior to the initiation of thyroid replacement medication.
- XII-82. The answer is E.** (*Chaps. 28, 333. Ferris et al, N Engl J Med 341:667–678, 1999.*) Blindness resulting from proliferative diabetic retinopathy continues to be a growing health epidemic. The use of retinal photocoagulation can effectively treat neovascular changes to the retina and can even reverse the development of macular edema. The diabetic retinopathy study enrolled 1742 patients with severe nonproliferative or proliferative diabetic retinopathy. Patients were randomly assigned to treat only one eye with photocoagulation; the other eye received no treatment. After a 5-year follow-up, a 50% reduction in severe visual loss in the eyes that had received photocoagulation as compared to the eyes that received no photocoagulation suggested that photocoagulation can reduce the development of severe diabetic retinopathy. The timing of this therapy is somewhat debatable. The

Early Treatment Diabetic Retinopathy Study (ETDRS) enrolled 3711 patients with either nonproliferative or early proliferative diabetic retinopathy. Again, only one eye was treated, and there was a significant reduction in the progression of diabetic retinopathy in the treated eye. It was determined that aspirin or other antiplatelet therapy was ineffective in reducing the progressive retinal changes. This patient already has excellent glycemic control with the use of metformin; it is unclear whether or not more aggressive treatment with insulin would be more effective as the DCCT trial analyzed only patients with type 1 diabetes mellitus.

- XII-83. The answer is D.** (*Chap. 354*) Generalized lipodystrophy is characterized by loss of body fat and metabolic abnormalities, including insulin resistance, hyperglycemia, hypertriglyceridemia, and a high metabolic rate despite normal thyroid function. The congenital form is autosomal recessive, while the acquired form often develops after an illness such as measles, chickenpox, whooping cough, or infectious mononucleosis. Other abnormalities associated with this disorder include paradoxical fatty engorgement of the liver and enlarged kidneys and genitalia. Mental retardation is seen in about half the congenital cases. Linear growth is accelerated in the first few years of life, but epiphyses close early so that the final height is usually normal. A few patients will develop hypertrophic cardiomyopathy, but it rarely leads to heart failure. Fatty liver has been noted during infancy and can lead to cirrhosis and its complications.
- XII-84. The answer is D.** (*Chaps. 75, 334, 340*) Less than 5% of cases of DKA are accompanied by severe phosphorus deficiency, though serum inorganic phosphorus often falls after therapy for DKA is initiated as phosphorus is shifted into cells. Patients who present in DKA with hypokalemia and hypophosphatemia are more likely to be severely potassium- and phosphorus-depleted and probably will require treatment with phosphorus. Such a patient usually has been sick for many days, has maintained a good fluid intake, and has not had significant vomiting. The insulin deficiency and metabolic acidosis mobilize intracellular phosphate stores, and the patient excretes the phosphorus briskly for days before presentation.
- XII-85. The answer is A.** (*Chap. 330. Hermus, Huysmans, N Engl J Med 338:1438–1447, 1998.*) A clinically solitary thyroid nodule is a discrete swelling within an otherwise palpably normal thyroid gland. With time, many solitary thyroid nodules may enlarge, shrink, or eventually disappear spontaneously. However, most do not change appreciably. The majority of these nodules are benign colloid nodules. Other causes of benign solitary nodules are thyroid adenomas, cysts, and thyroiditis. Approximately 5% of all solitary thyroid nodules are thyroid carcinomas. Fine-needle aspiration biopsy is indicated in all patients with solitary thyroid nodules and is especially helpful in patients with no other obvious signs of carcinoma. When this technique is used, approximately 70% of nodules are found to be cytologically benign. The false-negative rate is <5%. Approximately 4% of these lesions are found to be malignant. In the remaining patients, an indeterminate finding is made. This is typically due to the insufficient number of follicular cells recovered in order to make a definitive diagnosis. In these patients thyroid scintigraphy with iodine 123 (or iodine 131) should demonstrate a hyperfunctioning nodule. Autonomously functioning nodules are rarely malignant. A negative iodine 123 thyroid scintigraph should be followed up with surgery.
- XII-86. The answer is A.** (*Chap. 51. Lue, N Engl J Med 342:1802–1813, 2000.*) Androgens increase libido, but their exact role in erectile dysfunction remains unclear. Individuals with castrate levels of testosterone can still achieve erections from visual or sexual stimuli. Increased prolactin levels decrease libido by suppressing gonadotropin-releasing hormone (GnRH), which indirectly leads to a decreased serum testosterone level. Patients with diabetes mellitus have reduced amounts of nitric oxide synthase in both endothelial and neural tissues. Psychogenic erectile dysfunction is caused by a psychogenic stimulus to the sacral cord which inhibits reflexogenic responses. In addition, excess sympathetic stim-

ulation may cause increased penile smooth muscle tone. Among the antihypertensive agents, the thiazide diuretics and beta blockers have been implicated most frequently. Calcium channel blockers and angiotensin-converting enzymes are less frequently sited. Alpha blockers are less likely to be associated with erectile dysfunction.

- XII-87. The answer is B.** (*Chap. 51. Lue, N Engl J Med 342:1802–1813, 2000; Goldstein et al, Sildenafil Study Group, N Engl J Med 338:1397–1404, 1998.*) Sildenafil has been proven effective in the treatment of erectile dysfunction. Sildenafil is a selective inhibitor of cyclic GMP-specific phosphodiesterase type V. This is the predominant isoenzyme which metabolizes cyclic GMP in the corpus cavernosum. The mechanism by which cyclic GMP stimulates relaxation in the smooth muscles remains to be elucidated. Sildenafil has no effect on libido or sexual performance. Sildenafil is effective in the management of erectile dysfunction from a broad range of causes. These include psychogenic, diabetic, vasculogenic, postradical prostatectomy, and spinal cord injury. The onset of action is ~60 to 90 min; reduced initial doses should be considered for patients who are elderly or who have renal insufficiency. In addition, patients taking nitrates for coronary disease should avoid sildenafil. Side effects associated with sildenafil include headaches, facial flushing, dyspepsia, and nasal congestion. In addition, ~7% of men may experience a transient altered color vision (blue halo effect).
- XII-88. The answer is A.** (*Chaps. 155, 333. Joshi et al; N Engl J Med 341:1906–1912, 1999.*) This patient has malignant external otitis, which usually is caused by *Pseudomonas aeruginosa*. It tends to occur in older patients with diabetes mellitus who present with severe ear pain, drainage, fever, leukocytosis, and soft tissue swelling around the ear. The facial nerve is paralyzed in about 50% of cases, and this subset carries a poor prognosis with a 50% mortality rate. A mound of granulation tissue is usually present at the junction of the osseous and cartilaginous portions of the ear. The treatment of choice is a 6-week course of ticarcillin or carbenicillin plus tobramycin. In addition, surgical debridement is often necessary. CT of the mastoid or temporal bone typically reveals bony erosions and new bone formation, while the floor of the skull may have soft tissue densities associated with areas of cellulitis.
- XII-89. The answer is E.** (*Chaps. 128, 333. Joshi et al, N Engl J Med 341:1906–1912, 1999.*) Necrotizing fasciitis is caused by mixed aerobic-anaerobic bacteria. Infection typically begins in a breach in the integrity of a mucus membrane barrier, such as the mucosa of the gastrointestinal or genitourinary tract. The portal can be a malignancy, hemorrhoid, or fissure. Other predisposing factors include peripheral vascular disease, diabetes mellitus, or immunosuppression from chemotherapy. Leakage into the perineal area results in a syndrome called *Fournier's gangrene*. This is characterized by massive tissue swelling of the scrotum and penis with extension into the perineum or the abdominal wall and anterior portion of the lower extremities. A cutaneous wound or eschar is often noted. Crepitus is a useful finding but is noted in only half of the cases. Soft tissue gas may be detected more frequently by plain radiography than by clinical examination. Emergency evaluation and treatment of necrotizing fasciitis are imperative. Both clindamycin and penicillin are used secondary to the possibility of clindamycin resistance and the potentially life-threatening nature of this infection. Prompt aggressive surgical debridement is crucial in decreasing mortality.
- XII-90. The answer is A.** (*Chap. 341. Strewler, N Engl J Med 342:177–185, 2000.*) The secretion of parathyroid hormone-related protein is the predominant cause of hypercalcemia in patients with cancer. Among patients with solid tumors and hypercalcemia, ~80% have increased levels of parathyroid hormone-related protein. Parathyroid hormone-related protein increases both bone and renal tubular resorption of calcium. Both parathyroid hormone-related protein and parathyroid hormone have phosphaturic action. In addition to the humeral effects, parathyroid hormone-related protein can also induce local osteolysis around bone metastases. Parathyroid hormone-related protein is found in many

tissues in both fetuses and adults, including epithelia, mesenchymal tissues, endocrine glands, and the central nervous system. Gene-knockout models in mice have suggested that parathyroid hormone–related protein is critical for embryonic development. A homozygous null mutation of the parathyroid hormone–related protein in mice reveals severe defects in the development of cartilage. The domain of the protein that is homologous between the parathyroid hormone and the parathyroid hormone–related protein is amino acids 1–13 of the amino portion of the protein.

- XII-91. The answer is A.** (*Chap. 328*) Medications are important causes of hyperprolactinemia. Drugs implicated in hyperprolactinemia include dopamine-blocking drugs (e.g., phenothiazines, butyrophenones, metoclopramide, resperidone) and dopamine-depleting drugs (e.g., methyl dopa and reserpine). In addition, chronic cocaine use can cause hyperprolactinemia. Severe primary hypothyroidism can cause hyperprolactinemia either through the increase in the thyroid-releasing hormone (TRH) level or through a decrease in dopaminergic tone. Therefore, levothyroxine would not be expected to cause hyperprolactinemia. Glucocorticoids and cigarette use do not cause elevations of the serum prolactin level.
- XII-92. The answer is B.** (*Chap. 334*) Drugs are important causes of hypoglycemia. Insulin, sulfonylureas, disopyramide, and pentamidine all cause hypoglycemia through hyperinsulinemia. Sulfonamides and salicylates may interact with the sulfonylurea receptor. Thiazides can cause an exacerbation of glucose intolerance and worsen hyperglycemia. Beta agonists such as epinephrine and calcium channel blockers have no effect on serum glucose levels. Acetaminophen when taken in normal dosages does not affect the serum glucose concentration; however, an overdose causing hepatic damage could lead to severe hypoglycemia.
- XII-93. The answer is D.** (*Chaps. 52, 336*) The luteal phase of the menstrual cycle follows ovulation and is characterized by an increase in progesterone secretion by the corpus luteum. With anovulatory cycles, the corpus luteum does not form and progesterone levels remain low. Furthermore, with anovulatory cycles, the characteristic surge of LH and FSH at midcycle is absent and menses are usually painless. Irregular estrogen breakthrough bleeding that occurs with anovulatory cycles is the consequence of persistent ovarian estradiol secretion and an absence of luteal-phase progesterone secretion.
- XII-94. The answer is C.** (*Chap. 341*) Familial hypocalcemia, short stature, and abnormalities of the metacarpal and metatarsal bones are characteristic features of congenital pseudohypoparathyroidism (Albright's hereditary osteodystrophy). The underlying defect is renal resistance to the action of parathyroid hormone, caused in many patients by a mutation in a guanyl-nucleotide-binding protein. Although plasma levels of parathyroid hormone are elevated, urinary cyclic AMP is low, and there is a diminished response of urinary cyclic AMP to the exogenous administration of the hormone. The basal ganglia are frequently calcified. No antibodies to parathyroid tissue can be demonstrated, and unlike the situation in idiopathic hypoparathyroidism, the frequency of monilial infection is not increased. Hypothyroidism is common in persons with pseudohypoparathyroidism; it is usually a result of resistance to TSH resulting from the same defect in membrane adenylate cyclase activity that causes resistance to parathyroid hormone. As with true hypoparathyroidism, patients have low calcium and high phosphate levels.
- XII-95. The answer is B.** (*Chap. 77. Rosenbaum et al, N Engl J Med 337:396–407, 1997; Calle et al, N Engl J Med 341:1097–1105, 1999.*) Obesity is the most common and costly nutritional problem in the United States and affects approximately one-third of all adults. A BMI > 28 is associated with the risk of morbidity such as stroke, ischemic heart disease, or diabetes mellitus that is three to four times the risk in the general population. A central distribution of body fat is associated with a higher risk of morbidity and mortality than a more peripheral distribution of body fat. Obesity in childhood appears to increase the risk of subsequent morbidity, whether or not obesity persists into adulthood. The risk

associated with a high BMI is greater for whites than for blacks. With the exception of a few single-gene disorders that result in obesity (e.g., Prader-Willi syndrome), obesity is probably due to subtle alterations between multiple genetic and environmental factors that favor the net deposition of calories as fat.

- XII-96. The answer is C.** (*Chap. 343. Delmas, Meunier, N Engl J Med 336:558–566, 1997.*) Paget's disease of the bone is characterized by a localized increase in bone remodeling. This leads to marked bone hypertrophy as well as abnormal bone structure. Patients often present with pain and bone deformities. If the skull is affected, it may be grossly enlarged with irreversible hearing loss. Fractures are often noted and may be secondary to only minimal trauma. Complications resulting from nerve entrapment may be serious, especially if the spine is affected. The most characteristic feature of Paget's disease noted radiographically is the localized enlargement of bone. Other radiographic features include cortical thickening and sclerotic changes. Radionucleotide bone scanning is the most reliable means of identifying Paget's lesions. Serum alkaline phosphatase concentrations may be markedly elevated, and urinary hydroxyproline excretion is usually increased. Patients with Paget's disease who have bone pain or articular pain may benefit from therapy with acetaminophen and nonsteroidal anti-inflammatory drugs. In addition patients should receive antiresorptive therapy. An oral bisphosphonate, such as alendronate, should be the first choice of therapy. Intravenous pamidronate is an alternative if the patient's long-term compliance with oral treatment is doubtful.
- XII-97. The answer is A.** (*Chap. 328*) The development of a pituitary adenoma in a patient who has undergone bilateral adrenalectomy for the treatment of Cushing's disease is termed *Nelson's syndrome*. This disorder is characterized by hyperpigmentation, erosion of the sella turcica, and high plasma ACTH levels. Because of adrenalectomy, urinary 17-ketosteroid excretion usually is low; plasma cortisol levels are determined by the regimen of replacement therapy. These tumors can cause significant mass effects such as bitemporal hemianopia from optic chiasm compression or oculomotor nerve palsy from cavernous sinus invasion.
- XII-98. The answer is B.** (*Chap. 337*) Pathologic gynecomastia develops when the effective testosterone-to-estrogen ratio is decreased owing to diminished testosterone production (as in primary testicular failure) or increased estrogen production. The latter may arise from direct estradiol secretion by a testis stimulated by LH or hCG or from an increase in peripheral aromatization of precursor steroids, most notably androstenedione. Elevated androstenedione levels may result from increased secretion by an adrenal tumor (leading to an elevated level of urinary 17-ketosteroids) or decreased hepatic clearance in patients with chronic liver disease. A variety of drugs, including diethylstilbestrol, heroin, digitalis, spironolactone, cimetidine, isoniazid, and tricyclic antidepressants, also can cause gynecomastia. In the case presented in the question, the history of paternity and the otherwise normal physical examination indicate that a karyotype is unnecessary, and the bilateral breast enlargement essentially excludes the presence of carcinoma and thus the need for biopsy. The presence of a low LH and testosterone suggests either estrogen or hCG production. Given the presence of a normal testicular exam, a primary testicular tumor is not suspected. Carcinoma of the lung or germ cell tumors can each produce hCG, causing gynecomastia.
- XII-99. The answer is E.** (*Chap. 333. Atkinson, Maclaren, N Engl J Med 331:1428–1436, 1994.*) There is considerable disagreement regarding the genetics of diabetes mellitus, but certain aspects appear to be clear-cut. Genetic factors are probably permissive for the development of type 1 (immune-mediated) and are related more directly to the development of type 2 (non-immune-mediated) diabetes. The genetic locus for diabetes appears to be located near the HLA genes on the sixth chromosome. The presence of HLA antigen B8 or B15 increases the risk for developing type 1 diabetes nearly threefold, antigens DR3 and DR4 fourfold to fivefold, and antigen combinations (e.g., B8/B15) up to tenfold.

However, homozygosity for a high-risk allele (e.g., DR3/DR3) does not increase the risk further. Evidence implicates positions 45 and 57 of the DQ β chain as having importance in determining genetic susceptibility to type 1 diabetes. The concordance rate for monozygotic twins under 40 years of age is <50%. Pedigree analysis has shown a very low prevalence of vertical transmission for type 1 diabetes. The onset of juvenile diabetes has a seasonal variation and may follow mumps, hepatitis, or coxsackievirus infections, among others. These infections in genetically predisposed persons are theorized to produce an immune response with the development of cytotoxic islet cell antibodies, which complete the destruction of the beta cells. This theory would explain why circulating anti-islet cell antibodies are usually detectable soon after the onset of type 1 diabetes. In some cases anti-islet cell antibodies have been demonstrated in twins of diabetics destined to develop the disease even before glucose tolerance became abnormal.

XII-100. The answer is B. (*Chaps. 7, 333*) The occurrence of hyperglycemic ketoacidosis or hyperglycemic hyperosmolar coma is diagnostic of diabetes mellitus. Similarly, persistent fasting hyperglycemia [glucose concentration >7.8 mmol/L (140 mg/dL)], even if it is asymptomatic, has been recommended by the National Diabetes Data Group as a criterion for the diagnosis of diabetes. However, abnormal glucose tolerance—whether after eating or after a standard “glucose tolerance test”—can be caused by many factors (e.g., anxiety, infection or other illness, lack of exercise, or inadequate diet). Similarly, glycosuria may have renal as well as endocrinologic causes. Therefore, these two conditions cannot be considered diagnostic of diabetes. Gestational diabetes is diagnosed in women between the twenty-fourth and twenty-eighth weeks of gestation, first using a 50-g oral glucose load if the 1-h glucose level >7.8 mmol/L (140 mg/dL); a 100-g oral glucose test is performed after an overnight fast. Gestational diabetes is initially treated with dietary measures; if the postprandial glucose level remains elevated, insulin therapy is often started. About 30% of women with gestational diabetes will eventually develop true diabetes mellitus.

XII-101. The answer is C. (*Chap. 333*) Diabetic, hyperosmolar, nonketotic coma is a medical emergency that usually occurs as a complication of maturity-onset diabetes. Typically, affected persons are elderly (often living alone or in a nursing home), have a history of recent stroke or infection, and are unable to drink sufficient water to balance urinary fluid losses. These factors combine to cause sustained hyperglycemic diuresis with profound volume depletion and decreased urine output. Presenting features often include signs of circulatory compromise as well as central nervous system manifestations ranging from confusion or seizures to coma. Ketoacidosis is absent, perhaps because the concentration of portal-vein insulin is high enough to prevent full activation of hepatic ketogenesis. Serum levels of free fatty acids are generally lower than in diabetic ketoacidosis, and although hypertonicity is marked, measured serum sodium concentration is kept from being significantly elevated by the profound hyperglycemia. Infections are common, and disseminated intravascular coagulation can occur as a result of elevated plasma viscosity (both bleeding and in situ thrombosis have been reported). Although the administration of free water eventually becomes necessary, the treatment of salt deficits has the highest initial therapeutic priority. Several liters of isotonic saline should be given over the first 2 h, followed by half-normal saline and then a 5% glucose solution when blood glucose levels approach normal. Hypotonic fluids should not be used initially because most of the water enters the intracellular compartment, possibly leading to cerebral edema, rather than remaining in the plasma and interstitial spaces, where it is needed to support the circulation. Insulin also is required, but usually in lower doses than in patients with diabetic ketoacidosis.

XII-102. The answer is A. (*Chap. 333. Flier, Diabetes 41:1207, 1992.*) Chronic insulin resistance is defined as a need for more than 200 units of insulin per day for several days in the absence of infection or ketoacidosis. This definition was based on the assumption that the normal human pancreas produces this much insulin daily; in fact, normal daily insulin

production is probably 30 to 40 units, so that relative resistance is present when more than this amount is required to control blood sugar levels. The most common causes of insulin resistance are obesity and anti-insulin antibodies of the IgG type. Antibodies develop within 60 days of the initiation of insulin therapy in nearly all diabetic persons. It is assumed that the binding of insulin by these antibodies is the major cause of severe insulin resistance, but the correlation between antibody titer and resistance is not always close. Uncontrolled hyperglycemia is the major consequence of insulin resistance, although ketoacidosis also may result. A history of discontinuous insulin use is common, and concomitant insulin allergy occurs in a minority of affected persons. Most patients require high doses of steroids, which frequently begin to take effect in a few days.

Acanthosis nigricans is a cutaneous disorder that is associated with two types of insulin resistance: type A, in which young women show accelerated growth, evidence of virilization, and decreased numbers of insulin receptors, and type B, in which older women have anti-insulin-receptor antibodies and other symptoms and signs of autoimmune disease (arthralgias, positive assay for antinuclear antibody, and others). The absence of acanthosis nigricans in the woman described in the question makes it unlikely that decreased numbers of insulin receptors or the presence of anti-insulin-receptor antibodies is playing a role in her insulin resistance.

- XII-103. The answer is A.** (*Chap. 333. Ritz, Orth, N Engl J Med 341:1127–1133, 1999.*) Approximately 40% of patients with type 1 diabetes mellitus sustain diabetic nephropathy. The progression of renal disease is markedly accelerated by hypertension, and even mild degrees of hypertension in diabetic patients should be treated aggressively. A hallmark of diabetic nephropathy is the presence of so-called macroproteinuria (excretion of >0.55 g/d), and once this phase is reached, there is a steady decline in renal function. So-called microalbuminuria, the excretion of 0.03 to 0.3 g/d of albumin, is also statistically predictive of the progression of renal disease. In contrast, nocturia is usually a manifestation of undertreatment of diabetes and is an indication not of renal failure but of an osmotic diuresis. There is no clear-cut relation between insulin requirement and the development of any of the long-term complications of diabetes, including nephropathy; the development of these complications correlates better with the duration than with the severity of diabetes mellitus. The evidence that high dietary protein intake together with the presence of hyperlipidemia increases the risk of both nephropathy and the progression to end-stage renal disease is tenuous.
- XII-104. The answer is C.** (*Chap. 334. Grunberger, Ann Intern Med 108:252, 1988.*) Because factitious hypoglycemia resulting from insulin injection or sulfonylurea ingestion is common, the finding of hyperinsulinemia associated with a low blood sugar concentration can no longer be considered diagnostic of an islet cell tumor (insulinoma). Suspicion of factitious disease should be especially high in medical personnel and in the relatives of diabetics. The alpha and beta subunits of insulin are cleaved from proinsulin in the beta cell and are released in equimolar amounts with the connecting (C) peptide; elevation of plasma C-peptide levels signifies endogenous hyperinsulinemia, because exogenous insulin administration suppresses beta-cell function. Therefore, the triad of fasting hypoglycemia, hyperinsulinemia, and elevated plasma C-peptide levels is consistent with either endogenous hyperinsulinemia or the ingestion of a sulfonylurea; documentation of the latter in urine or plasma would be diagnostic. Proinsulin usually is released into the circulation in small quantities. However, in patients with insulinoma, proinsulin concentration frequently exceeds 20% of total insulin; ingestion of a sulfonylurea, by contrast, does not cause a disproportionate elevation of plasma proinsulin levels. Insulin antibody measurements in this case would not be expected to be helpful; antibodies may not develop for several months after the start of insulin injections, and the high C-peptide levels essentially rule out an exogenous source of insulin. However, in some circumstances antibodies to specific species of insulin can be identified and hence establish that exogenous insulin has been taken. Attempts to localize an islet cell tumor by radiologic means should be done only after factitious types of hypoglycemia have been excluded.

- XII-105. The answer is B.** (*Chap. 334*) Hypoglycemia caused by overutilization of glucose can be associated with either high or low insulin levels. Hypoglycemia associated with hyperinsulinism can occur in persons who have a pancreatic insulinoma or who take exogenous insulin or ingest sulfonylurea drugs. Low plasma insulin levels can be associated with overutilization of glucose; examples include large, solid extrapancreatic tumors (e.g., hepatoma and sarcoma), in which high levels of insulin-like growth factors may play a role, and systemic carnitine deficiency, in which peripheral tissues are unable to use free fatty acids for energy production and the liver cannot synthesize ketone bodies. Underproduction of glucose may occur with acquired liver disease, such as hepatic congestion resulting from right-sided heart failure or viral hepatitis, or with hormone deficiencies, such as adrenal insufficiency and hypopituitarism. Neither cortisol nor growth hormone is critical to the prevention of acute hypoglycemia, at least in adults. Cortisol deficiency is associated with low levels of gluconeogenic precursors and therefore an impaired ability to tolerate a fasting state. Likewise, growth hormone deficiency can cause hypoglycemia in young children. Alcohol ingestion causes low rates of glucose production and can therefore precipitate hypoglycemia similarly in adults with hypopituitarism.
- XII-106. The answer is E.** (*Chap. 335*) Klinefelter syndrome frequently is not diagnosed in patients until the time of expected puberty or during adult life when incomplete virilization or another manifestation of androgen deficiency first becomes apparent. Testosterone replacement is likely to promote virilization and restore potency in these patients. However, if gynecomastia is already present, testosterone replacement therapy does not produce regression of the breast tissue and may even aggravate the gynecomastia. Surgical resection of the breast is usually necessary in this situation. Since the basic testicular lesion consists of progressive hyalinization of the seminiferous tubules, spermatogenic function is irreversibly impaired, and no form of hormonal therapy is effective in maintaining spermatogenesis. Even in normal persons, testosterone treatment produces hypospermia because of the inhibition of gonadotropin production. Although antisocial behavior may be a part of Klinefelter syndrome, it is unlikely to be a manifestation of androgen deficiency and is not correctable by testosterone replacement.
- XII-107. The answer is A.** (*Chaps. 336, 338*) In persons with testicular feminization, estradiol secretion by the testes is markedly increased (but not to the level produced by normal ovaries); the mechanism is lack of suppression of LH by testosterone and consequently increased stimulation of gonadal testosterone and estradiol secretion. Ovaries containing follicle cysts may be a source of increased estrogen production, particularly during the postmenopausal years, when gonadotropin levels are very high. The increase in estrogen production that is characteristic of PCOD is the consequence of peripheral conversion of androstenedione to estrogen, not of direct gonadal production. During the third trimester of pregnancy estrogen production is increased because of the formation of estrogen by the placenta rather than by the ovary. Arrhenoblastoma is a virilizing ovarian tumor and does not secrete estrogen. Congenital adrenal hyperplasia causes virilization due to increased adrenal output of androgens.
- XII-108. The answer is B.** (*Chap. 338*) Ambiguous genitalia result when androgen production (or action) is defective in a male fetus or when androgen production is enhanced in a female fetus. Such aberrations can arise from a variety of causes. The most common cause is congenital adrenal hyperplasia, followed by mixed gonadal dysgenesis, which is a non-familial aberration of the sex chromosomes that interferes with normal sexual development, including 45,X/46,XY mosaicism. Examples of single-gene mutations leading to abnormal sexual differentiation include the Reifenstein syndrome, in which genetic males have incompletely developed male genitalia because of androgen resistance, and 5 α -reductase deficiency, in which testosterone cannot be converted to dihydrotestosterone. The historical use of progestational agents to treat pregnant women presenting with threatened abortion was associated with variable degrees of hypospadias in male offspring. Hypogonadotropic hypogonadism is associated with microphallus in male infants but not with hypospadias

or abnormal sexual differentiation. Men whose chromosome pattern is 47,XYY are anatomically normal. Women whose chromosome pattern is 45XO are anatomically normal. The male XX syndrome have findings resembling those with Klinefelter's syndrome—they have small firm testes, gynecomastia, and a penis that is normal to small in size. The majority of XX males have a fragment of the Y chromosome translocated to one of the X chromosomes. The management of XX male syndrome is similar to that of Klinefelter syndrome.

- XII-109. The answer is C.** (*Chaps. 340, 341*) Vitamin D toxicity generally occurs after chronic ingestion of large doses of vitamin D₂ or D₃ (usually in excess of 50,000 to 100,000 IU daily for months). Ingestion of a single large dose of vitamin D₂ or D₃ does not cause acute toxicity because excessive quantities are stored in body fat and released slowly into the bloodstream. Some vitamin D metabolites, such as 1,25(OH)₂ vitamin D, could conceivably cause toxicity after a single overdose. Hypervitaminosis D has not been reported after prolonged sun exposure, partly because the vitamin is released slowly from the skin after its conversion from previtamin D. Hypervitaminosis D cause hypercalcemia, hypercalciuria, and soft tissue calcification, particularly in the kidneys. It is believed that high circulating levels of 25(OH) vitamin D directly stimulate intestinal calcium absorption and bone resorption, since toxicity can occur in anephric persons.
- XII-110. The answer is D.** (*Chap. 328*) The enlarged pituitary gland of pregnancy is particularly vulnerable to ischemic necrosis (Sheehan's syndrome) if hypotension occurs in the postpartum period. Symptoms and signs of panhypopituitarism even several years after a difficult childbirth are consistent with this condition. Continued amenorrhea, decreased libido, cold intolerance typical of hypothyroidism, and loss of hair should therefore prompt an evaluation for anterior pituitary hypofunction. Lowering the blood sugar by giving a small amount of IV insulin normally triggers the release of counterregulatory hormones, including growth hormone and cortisol. The urinary free cortisol itself is not helpful, since a normal or low value is compatible with a stressless period, not just with panhypopituitarism. Since the patient probably has central hypothyroidism, the TSH will be inappropriately low in the face of low peripheral hormone. The response to ACTH stimulation should be blunted because the adrenal glands are not "primed" to respond to the pituitary release. Treatment of panhypopituitarism consists of hydrocortisone and thyroid hormone. Growth hormone injections are rarely required.
- XII-111. The answer is D.** (*Chap. 330*) Hypothyroidism should be suspected in the setting of certain laboratory findings that are not clearly associated with an obvious explanation. In addition to an increased ratio of preejection period to left ventricular ejection time on cardiac systolic time intervals, decreased QRS amplitude on electrocardiographic examination is common. Elevated creatine phosphokinase and lactic dehydrogenase serum values may mimic a myocardial infarction. Hypothyroidism also is typically associated with macrocytic red blood cell indices caused by coexistent pernicious anemia or unknown factors. Serum cholesterol is elevated in many patients with primary hypothyroidism.
- XII-112. The answer is B.** (*Chap. 331*) Weakness, hypotension, weight loss, nausea, and vomiting are all present in over 80% of patients with adrenal insufficiency, as documented by the failure of exogenously administered ACTH to effect a rise in the serum cortisol level. Hyperpigmentation, resulting from the melanocyte-stimulating hormone released in excess along with ACTH in cases of primary adrenal failure, is not seen in cases of secondary failure that occur because of suppressed ACTH. The best example of the latter condition is long-term steroid administration, which depresses ACTH release. Any cause of panhypopituitarism, such as a brain tumor's invasion of the sellar region, also can lead to adrenal failure on a secondary basis. Measurement of serum ACTH will distinguish between primary and secondary adrenal insufficiency. Destruction of the adrenal glands may occur as a consequence of infection with mycobacteria, cytomegalovirus, histoplasmosis, coccidioidomycosis, or cryptococcosis. Noninfectious causes of adrenal gland failure in-

clude bilateral tumor metastasis, bilateral hemorrhage, amyloidosis, sarcoidosis, autoimmune disease, and the administration of certain medications (e.g., rifampin, ketoconazole, and phenytoin).

XII-113. The answer is A. (*Chap. 346*) The porphyrias represent disorders of heme biosynthesis. The biochemical abnormalities and clinical manifestations depend on the step that is blocked and the accumulation of precursor metabolites. Congenital erythropoietic porphyria is a rare autosomal recessive disorder that results from a defect in the enzyme uroporphyrinogen II cosynthase, which is expressed solely in maturing erythroid cells. Porphobilinogen is preferentially converted to uroporphyrinogen I and then to coproporphyrinogen I. These metabolites account for the red urine observed in children with this disorder, but excretion of porphobilinogen is normal. Intermittent acute porphyria, characterized by attacks of recurrent neurologic and psychiatric dysfunction, is an autosomal dominant deficiency of porphobilinogen deaminase, the enzyme that converts porphobilinogen to uroporphyrinogen I. Thus, urinary levels of porphobilinogen are high during attacks. Hereditary coproporphyria is a similar disease caused by partial deficiency of coproporphyrinogen oxidase. A deficiency of protoporphyrinogen oxidase, the next to last enzyme involved in heme synthesis, leads to variegate porphyria manifested by attacks of neuropsychiatric dysfunction and photosensitivity and overexcretion of the proximal metabolite, porphobilinogen. Porphyria cutanea tarda, which is an inherited or acquired deficiency of hepatic uroporphyrinogen decarboxylase, is not associated with excess porphobilinogen production, probably because aminolevulinic acid synthase activity is not enhanced. Mild skin photosensitivity is the major manifestation of protoporphyria, and is due to a deficiency of ferrochelatase, the final enzyme in heme biosynthesis. Protoporphyrins may accumulate in erythrocytes, but urinary porphobilinogen is normal. X-linked sideroblastic anemia results from the deficient activity of the erythroid form of ALA synthesis. This is associated with ineffective erythropoiesis, weakness, and pallor. The diagnosis is made by examination of the bone marrow.

XII-114. The answer is E. (*Chaps. 349, 350, 352, 353*) In Niemann-Pick disease, accumulation of sphingomyelins occurs usually because of a sphingomyelinase deficiency. Organomegaly and neurologic involvement are clinical features, but there is highly variable expression that depends on the subtype. The most common lysosomal storage disease, adult Gaucher disease, is characterized by splenomegaly, pancytopenia, hepatic dysfunction, and bone pain. Accumulation of glucosylceramides presumably accounts for the clinical manifestations and for the distinctive Gaucher cell observed on bone marrow examinations. Tay-Sachs disease, which is caused by a deficiency of hexosaminidase A with concomitant accumulation of sphingolipids, presents as rapidly progressive neurologic deterioration during infancy and with a characteristic macular cherry-red spot. Heterozygote detection programs (enzyme assays in Ashkenazi Jews) have reduced the incidence of this disease in North America.

Diseases of glycogen metabolism can result in disorders whose pathophysiology is based either on hepatic hypoglycemia, as in von Gierke's disease (glucose-6-phosphatase deficiency), or on muscle-energy deficiency, as in McArdle disease (muscle phosphorylase deficiency). Muscle-energy diseases generally result in painful cramping or myoglobine-mia after exercise, and so strenuous exercise should be avoided. These diseases are otherwise compatible with a normal life.

A defect in the phenylalanine hydroxylase enzyme complex leads to accumulation of phenylalanine in blood and urine with associated brain damage. The plasma phenylalanine concentration usually does not rise until the institution of protein feedings but is abnormal by the fourth day of life. A diet low in phenylalanine, if instituted during the first month of life, can avert mental retardation. Screening all newborns for blood phenylalanine concentration has been beneficial in this regard.

Excessive urinary excretion of the dibasic amino acids cysteine, lysine, arginine, and ornithine as a result of impaired tubular reabsorption is the pathophysiologic hallmark of cystinuria, the most common inborn error of amino acid transport. Because of the insolubility of cysteine, the primary clinical manifestation of this disorder is cysteine nephrolithiasis.

XIII. NEUROLOGIC DISORDERS

QUESTIONS

DIRECTIONS: Each question below contains five suggested responses. Choose the **one best** response to each question.

XIII-1. For the past 5 weeks a 35-year-old woman has had episodes of intense vertigo lasting several hours. Each episode is associated with tinnitus and a sense of fullness in the right ear; during the attacks, she prefers to lie on her left side. Examination during an attack shows that she has fine rotary nystagmus, which is maximal on gaze to the left. There are no ocular palsies, cranial-nerve signs, or long-tract signs. An audiogram shows high-tone hearing loss in the right ear, with recruitment but no tone decay. The most likely diagnosis in this case is

- (A) labyrinthitis
- (B) Ménière's disease
- (C) vertebral-basilar insufficiency
- (D) acoustic neuroma
- (E) multiple sclerosis

XIII-2. A 25-year-old woman presents to the emergency department with a severe, throbbing headache of the right supraorbital area for the past hour. She also complains of nausea and photophobia. She has had similar attacks in the past, often brought on by menstruation. About 45 min ago she took 400 mg of ibuprofen. Which of the following would be the best therapeutic choice at this time?

- (A) Meperidine, 50 mg intramuscularly
- (B) Codeine, 60 mg orally
- (C) Naproxen, 750 mg orally
- (D) Sumatriptan, 6 mg subcutaneously
- (E) Verapamil, 300 mg orally

XIII-3. A 29-year-old woman who uses oral contraceptives comes to the emergency room because when she looked in the mirror this morning, her face was twisted. It felt numb and swollen. While eating breakfast, she found that her food tasted different and she drooled out of the right side of her mouth when swallowing. Neurologic examination discloses only a dense right facial paresis equally involving the frontalis, orbicularis oculi, and orbicularis oris. Finger rubbing is appreciated as louder in the right ear than in the left. The physician should

XIII-3. (Continued)

- (A) instruct the patient in using a patch over the right eye during sleep
- (B) recommend that she discontinue the use of oral contraceptives
- (C) order brainstem auditory evoked potentials to assess her hearing asymmetry
- (D) inform her that her chances of substantial improvement within several weeks are only about 40%
- (E) order an echocardiogram to rule out mitral valve prolapse as a source of emboli

XIII-4. A 78-year-old woman with metastatic breast cancer arrives in your clinic for evaluation. She is currently receiving palliative chemotherapy. The patient lives with her husband and her 40-year-old son. Over the past several months she has fractured two vertebral bodies and has been hospitalized for a deep venous thrombosis. Both she and her family have sought aggressive treatment. Her husband is ill from advanced coronary artery disease, and the patient is his primary caregiver. Unfortunately, as her disease has progressed she has become too sick to care for her husband. Her pain remains poorly controlled, and she is receiving naproxen and morphine, in both the long-acting as well as immediate-release form. She has lost ~11.5 kg (25 lb) over the past 3 months, and her appetite is described as poor. On further questioning the patient volunteers that she feels her future is over and that only pain and suffering lie ahead. The patient is gravely worried about the care her husband will receive in the future with her loss. She feels she is no longer able to serve as his caregiver and feels saddened by this. She is focused on the suffering she is putting both her husband and friends and family through with her physical and emotional decline. She states that she is sad and nervous about the future and has been unable to focus on anything else. Which of the following diagnoses best describes the mental status of this patient?

- (A) Grief
- (B) Adjustment disorder
- (C) Depression

XIII-4. (Continued)

- (D) Posttraumatic stress disorder (PTSD)
- (E) Dysthymic disorder

XIII-5. A 45-year-old man presents with a daily headache. He describes two attacks per day over the past 3 weeks. Each attack lasts about an hour and awakens the patient from sleep. The patient has noted associated tearing and reddening of his right eye as well as nasal stuffiness. The pain is deep, excruciating, and limited to the right side of the head. The neurologic examination is nonfocal. The most likely diagnosis of this patient's headache is

- (A) migraine headache
- (B) cluster headache
- (C) tension headache
- (D) brain tumor
- (E) giant cell arteritis

XIII-6. A 25-year-old woman who was the driver of a car struck in the rear by another car while she was stopped at a red light presents to the emergency department with neck pain as well as discomfort in the axilla, upper arm, elbow, dorsal forearm, and index and middle fingers. Coughing exacerbates the pain. Neurologic examination reveals weakness in the right second and third fingers, forearm, and wrist. The right triceps reflex is diminished. The most likely diagnosis in this case is

- (A) syringomyelia
- (B) cervical sprain
- (C) thoracic outlet syndrome
- (D) cervical disk herniation
- (E) brachial plexopathy

XIII-7. A patient with previous spells of diplopia, ataxia, dysarthria, and dizziness becomes acutely comatose. The most likely cause is

- (A) basilar artery thrombosis
- (B) subarachnoid hemorrhage
- (C) carotid occlusion
- (D) cerebellar hemorrhage
- (E) pontine hemorrhage

XIII-8. A 75-year-old woman complains of dizziness and lightheadedness while walking. The patient has had long-standing diabetes and is taking an oral hypoglycemic agent. She has no other medical problems and lives alone. Physical examination reveals visual acuity of 20/80 in both eyes and sensory neuropathy in a stocking-glove distribution. On close questioning, she denies any symptoms of "herself spinning or the world spinning." She has no apparent anxiety or depression. Orthostatic vital signs are normal. A head-tilt maneuver reveals no nystagmus. The most likely diagnosis in this case is

XIII-8. (Continued)

- (A) dysequilibrium of aging
- (B) benign positional vertigo
- (C) Ménière's disease
- (D) brainstem stroke
- (E) neoplasm of the central nervous system

XIII-9. A 35-year-old woman complaining of trouble with her "peripheral vision" is subjected to visual field examination. While one eye is tested at a time, she is asked to focus on a central target while the examiner's fingers are moved in from various directions. She is unable to distinguish objects brought laterally toward the midline, encompassing about half the visual field in each eye. Which of the following lesions would most likely account for these findings?

- (A) Open-angle glaucoma
- (B) Closed-angle glaucoma
- (C) Multiple sclerosis
- (D) Pituitary tumor
- (E) Embolic occlusion of the posterior cerebral artery

XIII-10. Evoked-potential testing is most useful in diagnosing

- (A) brainstem involvement in stroke
- (B) a clinically occult lesion in multiple sclerosis
- (C) large hemispherical strokes
- (D) spinal cord compression
- (E) shearing of white matter tracts after head injury

XIII-11. A 25-year-old weight lifter comes to the emergency department frightened by recent headaches. He recently read a newspaper article about cerebral aneurysms. He reports 5 to 10 sudden, severe headaches, all occurring during coitus, with each lasting about 1 h. The physician should

- (A) recommend that the patient seek psychiatric help for his sexual dysfunction
- (B) perform a CT scan with contrast and schedule four-vessel cerebral angiography to search for an aneurysm or arteriovenous malformation
- (C) inform the patient that coital headache is a benign clinical syndrome that may be helped by the administration of propranolol, 20 mg three times a day
- (D) tell the patient to report back to the emergency department for a cerebrospinal fluid (CSF) examination and CT scan without contrast to search for subarachnoid blood
- (E) determine whether other members of his family have a history of migraine

XIII-12. A 60-year-old male diabetic patient complains of the acute onset of diplopia. He denies headache, fever,

XIII-12. (Continued)

stiff neck, or other symptoms. The only abnormality on neurologic examination pertains to eye movements. The patient's right eyelid is ptotic. The pupil is deviated downward and outward. The patient cannot move the eye upward, downward, or inward. There is, however, no anisocoria, and normal pupillary responses are present bilaterally. The appropriate course of action at this time is

- (A) administration of high-dose steroids
- (B) administration of a topical ophthalmic β -adrenergic blocker
- (C) cerebral angiography
- (D) visual field testing
- (E) reexamination in 1 month

XIII-13. Presbycusis, the hearing loss associated with aging, may affect 33% of people age 75 or older. The most common cause of this problem is

- (A) fixation of middle ear bones
- (B) tympanic membrane failure
- (C) loss of neuroepithelial cells
- (D) vascular lesions in central auditory pathways
- (E) exposure to ototoxins such as furosemide

XIII-14. Bradykinesia, a decreased ability to initiate volitional movements, as well as constant impedance to the examiner's efforts to extend the arm would most likely be due to lesions in which of the following structures?

- (A) Anterior horn cell of the spinal cord
- (B) Descending corticospinal fibers
- (C) Basal ganglia
- (D) Internal capsule
- (E) Cerebral cortex

XIII-15. A 70-year-old man complains of pain and stiffness in both shoulders and hips. Examination reveals atrophic shoulder girdle and gluteal musculature. Reflexes and cerebellar function are intact. There is no sensory loss. The serum creatine kinase level is normal. Temporal artery biopsy is negative. The most appropriate therapeutic strategy at this time is

- (A) prednisone, 60 mg daily
- (B) prednisone, 10 mg daily
- (C) potassium repletion
- (D) naproxen, 750 mg twice daily
- (E) reassurance; no treatment is required

XIII-16. A 65-year-old man with advanced pancreatic cancer complains of increasing abdominal pain. He is taking codeine 60 mg every 4 h. Examination reveals an alert man with a benign abdomen and normal neurologic function. The best step at this point would be to

XIII-16. (Continued)

- (A) add phenytoin
- (B) add indomethacin
- (C) increase the dose of codeine
- (D) add sustained-release morphine sulfate and use the codeine as circumstances require (prn)
- (E) refer the patient for a celiac block

XIII-17. A 55-year-old woman presents because of intermittent, brief, extreme stabbing pains in her lips and right cheek. The pain can be brought on by touching her face. The results of an examination of the structures of the face and cranial nerves are entirely normal. Appropriate initial treatment for this condition would consist of

- (A) ergotamine
- (B) amitriptyline
- (C) propranolol
- (D) carbamazepine
- (E) referral to an otolaryngologist for nerve block

XIII-18. During the evaluation of a patient with a gait disorder, it is noted that the patient is unable to identify accurately the direction of examiner-initiated movement of the great toe. Pain and temperature sense in the same distribution are intact. This abnormality reflects a lesion in which of the following structures?

- (A) Posterior column on the same side as the affected toe
- (B) Spinothalamic tract on the same side as the affected toe
- (C) Thalamic nucleus on the same side as the affected toe
- (D) Lower sensory neuron on the same side as the affected toe
- (E) Frontal cortex on the opposite side from the affected toe

XIII-19. A patient being evaluated for aphasia is unable to repeat sentences correctly or name objects properly. However, the patient's speech is effortless and melodic. There are frequent errors in word choice and obvious difficulties in comprehension. The remainder of the patient's neurologic examination is normal. Damage in which area of the brain would account for this type of aphasia?

- (A) Posterior temporal and parietal lobes, dominant hemisphere
- (B) Frontal and parietal lobes, dominant hemisphere
- (C) Prefrontal and frontal regions, dominant hemisphere
- (D) Posterior parietal and temporal lobes, nondominant hemisphere
- (E) Parietal and occipital lobes, nondominant hemisphere

XIII-20. A patient is evaluated for anisocoria. The right pupil is small and round compared with the left pupil in room light; this difference is magnified when the room is darkened. The right pupil responds briskly to light, constricts when pilocarpine is placed in the eye, and dilates when atropine is placed in the eye. Minimal dilation is produced by 4% cocaine. This patient has a lesion in the

- (A) right optic nerve
- (B) right iris
- (C) right third nerve
- (D) right sympathetic chain
- (E) left occipital lobe

XIII-21. Which of the following would help exclude the diagnosis of seizure in a patient with sudden loss of consciousness?

- (A) A brief period of tonic-clonic movements at the time of falling
- (B) An aura of a strange odor before falling
- (C) Sudden return to normal mental function upon awakening, though with a feeling of physical weakness
- (D) Urinary incontinence
- (E) Laceration of the tongue

XIII-22. A 55-year-old man who lost his job approximately 5 months ago complains of profound difficulty sleeping at night. He recently found a new job but has continued to experience difficulty sleeping. He notes that he falls asleep more easily while watching television early in the evening and feels sleepy outside the house. He is preoccupied with his inability to sleep at night. General physical examination and routine laboratory screening are unremarkable. He denies the use of alcohol, coffee, and other drugs. What is the most appropriate approach?

- (A) Administration of a benzodiazepine
- (B) Administration of stimulants
- (C) Administration of estrogen
- (D) Administration of tricyclic antidepressants
- (E) No therapy

XIII-23. A 65-year-old man presents with severe right-sided eye and facial pain, nausea, vomiting, colored halos around lights, and loss of visual acuity. His right eye is quite red, and that pupil is dilated and fixed. Which of the following diagnostic tests would confirm the diagnosis?

- (A) CT of the head
- (B) MRI of the head
- (C) Cerebral angiography
- (D) Tonometry
- (E) Slit-lamp examination

XIII-24. A 35-year-old woman presents with an apparent seizure. She was feeling well when she noted that her right

XIII-24. (*Continued*)

thumb began suddenly to retract repetitively, followed by right hand movements. Within 1 min her right arm and the right side of her face also began to contract. About 2 min later the patient developed diffuse convulsive motor activity and loss of consciousness lasting about 5 min. After her recovery of consciousness the patient was amnesic for the event and also had about 6 h of weakness in her right arm. Which of the following is the most likely cause of this type of seizure?

- (A) Herpes encephalitis
- (B) Temporal lobe epilepsy
- (C) Juvenile myoclonic epilepsy
- (D) Abscess or tumor in the left motor strip
- (E) Cerebral embolism

XIII-25. A 19-year-old man has had an 8-year history of recurrent episodes of loss of conscious activity that last for seconds to several minutes. Sometimes he has as many as 100 of these lapses. The patient regains awareness of his environment very quickly. There is no major motor manifestation during the episodes or a period of confusion afterward. The patient's neurologic examination is totally normal. Which of the following drugs would be the most effective for this patient's problem?

- (A) Phenytoin
- (B) Carbamazepine
- (C) Phenobarbital
- (D) Ethosuximide
- (E) Primidone

XIII-26. A patient who complains of imbalance is found to walk with a wide-based gait and to sway forward and backward upon standing. Balance cannot be maintained when the patient is standing with the feet together and with the eyes open or closed. No limb ataxia or nystagmus can be elicited. These findings are most consistent with a lesion or lesions in the

- (A) vestibular apparatus
- (B) midline cerebellar zone
- (C) intermediate cerebellar zone
- (D) lateral cerebellar zone
- (E) left frontal cortex

XIII-27. Which of the following brain tumors tends to occur in immunosuppressed persons, arise in periventricular regions, and respond both clinically and radiographically to glucocorticoid therapy?

- (A) Glioblastoma
- (B) Ependymoma
- (C) Meningioma
- (D) Medulloblastoma
- (E) B cell lymphoma

XIII-28. A 59-year-old chronic alcoholic has loss of consciousness and shaking of his entire body for approximately 5 min. He is somewhat confused after this episode and is brought to the emergency department, where another episode occurs. The patient develops incontinence during the event and again is confused afterward. CT of the brain and a lumbar puncture are negative. No major metabolic abnormalities were detected on blood testing. Appropriate therapy for this condition consists of

- (A) phenytoin, 1000 mg given in a slow IV push
- (B) diazepam, 10 mg IV bolus
- (C) phenobarbital, 400 mg given over 30 min
- (D) carbamazepine, 600 mg orally daily
- (E) no specific anticonvulsant therapy

XIII-29. A patient who is being treated for temporal lobe epilepsy (complex partial seizures) and is having recurrent seizures on his chronic regimen of carbamazepine is given phenobarbital as a second drug. However, the seizures increase in frequency. What is the probable reason for the apparently deleterious effect of adding phenobarbital?

- (A) Intracerebral bleeding from worsening bone marrow suppression
- (B) Decreased carbamazepine level
- (C) Decreased stability of CNS neuronal membranes
- (D) Hypokalemia
- (E) Increased intracranial pressure

XIII-30. Which of the following statements regarding glaucoma is true?

- (A) If recognized early, the optic neuropathy of glaucoma is reversible.
- (B) Primary closed-angle glaucoma is the most common type in the United States.
- (C) Topical β -adrenergic antagonists have few if any side effects due to low systemic absorption.
- (D) The Schiøtz indentation tonometer is the most frequently used device to measure interocular pressure in both hospitals and clinics.
- (E) The initial symptom of optic neuropathy due to glaucoma is loss of central vision.

XIII-31. A 65-year-old man with a long-standing history of hypertension complains of recurrent 30-min episodes of right arm weakness occasionally associated with difficulty speaking. The results of his neurologic examination at this time are normal. Cerebral angiography reveals 80% stenosis of the left internal carotid artery. The most appropriate therapy at this point would be

- (A) intravenous heparin with a plan to convert to oral warfarin
- (B) oral warfarin
- (C) aspirin

XIII-31. (Continued)

- (D) ticlopidine
- (E) carotid endarterectomy

XIII-32. A 54-year-old man with long-standing hypertension presents to the emergency department with severe occipital headache and dizziness. He has noted several hours of nausea and vomiting. Neurologic examination reveals an inability to stand. His eyes are deviated to the right side, and he has mild left-sided facial weakness. Assuming that blood is seen on CT scanning, which is the most appropriate therapeutic strategy at this time?

- (A) Intravenous high-dose dexamethasone
- (B) Intravenous mannitol
- (C) Intravenous nitroprusside
- (D) Surgical removal of a clot
- (E) Cerebral angiography

XIII-33. For the past 6 weeks, a 64-year-old woman has had a headache and difficulty reading. Her husband has noted a mild but progressive intellectual decline in her during this period. On examination, she has grasping reactions and myoclonic jerks when loud noises occur. CT and CSF examination are normal. The most likely diagnosis is

- (A) multiple sclerosis
- (B) Alzheimer's disease
- (C) bilateral subdural hematoma
- (D) Creutzfeldt-Jakob disease
- (E) subacute sclerosing panencephalitis

XIII-34. The most common presenting finding or symptom of multiple sclerosis is

- (A) internuclear ophthalmoplegia
- (B) transverse myelitis
- (C) cerebellar ataxia
- (D) optic neuritis
- (E) urinary retention

XIII-35. A 45-year-old woman presents with a generalized tonic-clonic seizure, the first in her life. MRI evaluation reveals a midline mass along the falx cerebri. The mass enhances with gadolinium, which documents the existence of tumor vessels supplied by the external carotid artery. The optimal therapy would be

- (A) surgery
- (B) radiation
- (C) radiation plus surgery
- (D) radiation plus surgery plus chemotherapy
- (E) radiation plus chemotherapy

XIII-36. The most common cause of death in patients with intracerebral metastatic lesions resulting from carcinoma is

XIII-36. (Continued)

- (A) intractable seizures
- (B) infection
- (C) radiation toxicity
- (D) progressive intracerebral metastases
- (E) systemic tumor

XIII-37. A comatose patient is being evaluated by caloric stimulation of the vestibular apparatus. Cold-water irrigation of the right external auditory canal leads to deviation of both eyes to the right for 2 min, followed by a slow drift back to the midline. This finding is most consistent with a lesion in the

- (A) right labyrinth
- (B) midbrain
- (C) medulla
- (D) pons
- (E) cerebral hemispheres

XIII-38. A 68-year-old woman presents with an 18-month history of progressive loss of recent memory and inattentiveness. At this time she is having difficulty speaking, her judgment appears to be impaired, and she occasionally evidences paranoid behavior. In addition to neurofibrillary tangles, the neuropathologic findings in this condition include plaques made of

- (A) low-density lipoprotein
- (B) unesterified cholesterol
- (C) β -amyloid protein
- (D) immunoglobulin proteins
- (E) protease inhibitor

XIII-39. A 68-year-old man develops a rest tremor of the right hand and arm. The patient moves slowly and has a diminished range of facial expressions. He has no postural abnormalities. Which of the following drugs would be most appropriate at this time?

- (A) Deprenyl
- (B) Levodopa
- (C) Carbidopa-levodopa (Sinemet)
- (D) Bromocriptine
- (E) Benztropine

XIII-40. A 69-year-old man is brought to the doctor by his wife because she complains that he has been “talking strangely.” The patient enunciates words slowly and with difficulty. The melody of speech is abnormal. The speech is agrammatic in the sense that many prepositions and articles are omitted. When a word can be discerned, it usually is appropriate for the conversation, and the patient appears to comprehend what is said to him. The lesion accounting for this problem is most likely to be in the

- (A) left frontal lobe
- (B) right frontal lobe

XIII-40. (Continued)

- (C) left parietal lobe
- (D) right parietal lobe
- (E) bilateral temporal lobes

XIII-41. A 50-year-old woman presents to her primary care physician complaining of intermittent unprovoked attacks of severe shortness of breath, palpitations, shaking, diffuse numbness, and an intense fear of dying or going crazy. These attacks are not precipitated by any obvious anxiety-provoking situation. Moreover, the patient is particularly loath to leave her house without a companion. General physical examination and routine laboratory studies, which include normal electrolytes, thyroid function tests, electrocardiography, and continuous cardiac rhythm monitoring, have convinced the physician that there is no clear-cut organic cause of this problem. The patient is not on chronic medicine and does not abuse alcohol. The most appropriate therapy for this patient is

- (A) diazepam
- (B) flurazepam
- (C) imipramine
- (D) lithium
- (E) fluphenazine

XIII-42. A previously active 25-year-old woman presents with profound fatigue. She had an upper respiratory infection about 6 months ago from which she has never recovered. She now complains of intermittent headaches, sore throat, muscle and joint aches, and occasional feverishness. Her fatigue is so severe that she is unable to work. She now complains of excessive irritability, confusion, and inability to concentrate. Her physician has documented the presence of fever to 38.6°C (101.5°F) orally and the presence of palpable anterior cervical adenopathy both now and approximately 2 months ago. The patient has undergone an extensive workup, including complete blood count, serum chemistry analysis, HIV serology, Epstein-Barr Virus serology, cytomegalovirus serology, and CT scan of the head, all of which were negative or not consistent with an acute infection. The patient has had no psychiatric or medical problems. Appropriate therapy at this time would consist of

- (A) acyclovir
- (B) glucocorticoids
- (C) vitamin B₁₂ injections
- (D) intravenous immunoglobulin
- (E) ibuprofen

XIII-43. A 59-year-old man who has alcoholic cirrhosis but has been abstinent for 10 years has progressive dysarthria, tongue dystonia, shuffling gait, and fast tremor that worsens as his hand moves toward a target. These symptoms are most likely caused by

XIII-43. (Continued)

- (A) Wilson's disease
- (B) acquired hepatocerebral degeneration
- (C) Wernicke's disease
- (D) Marchiafava-Bignami disease
- (E) paraneoplastic syndrome

XIII-44. The most likely diagnosis for a patient with impotence and urinary incontinence who, over years, sustains tremor at rest, bradykinesia, rigidity, severe orthostatic hypotension, and anhidrosis is

- (A) the autonomic form of the Landry-Guillain-Barré syndrome
- (B) Shy-Drager syndrome
- (C) guanethidine intoxication
- (D) micturition syncope
- (E) Parkinson's disease

XIII-45. A 65-year-old man with long-standing schizophrenia is admitted to the general medical service because of atypical pneumonia. The patient has been on chlorpromazine for at least 10 years. In addition to findings related to his pneumonia and thought disorder, he repetitively smacks his lips and thrusts his tongue as well as exhibiting a bizarre stooped posture. Which of the following would be the best approach to reverse these troublesome neurologic symptoms?

- (A) Administration of benztropine
- (B) Administration of oxazepam
- (C) Administration of propranolol
- (D) Administration of levodopa-carbidopa (Sinemet)
- (E) Reduction of the dose of chlorpromazine

XIII-46. A 42-year-old man who has had difficulty concentrating on his job lately comes to medical attention because of irregular, jerky movements of his extremities and fingers. A sister and an uncle died in mental institutions, and his mother became demented in middle age. The most likely diagnosis is

- (A) alcoholic cerebral degeneration
- (B) Huntington's chorea
- (C) Wilson's disease
- (D) Hallervorden-Spatz disease
- (E) Gilles de la Tourette's disease

XIII-47. A 72-year-old woman presents with brief, intermittent excruciating episodes of lancinating pain in the lips, gums, and cheek. These intense spasms of pain may be initiated by touching the lips or moving the tongue. The results of a physical examination are normal. MRI of the head is also normal. The most likely cause of this patient's pain is

- (A) acoustic neuroma
- (B) meningioma

XIII-47. (Continued)

- (C) temporal lobe epilepsy
- (D) trigeminal neuralgia
- (E) facial nerve palsy

XIII-48. A 30-year-old patient presenting with a gradual decline in mental function is found to have a large lesion on CT examination of the brain. Biopsy reveals glioblastoma multiforme. Physical examination of the skin reveals large, cream-brown cutaneous macules and numerous subcutaneous nodules. Gene mutations in which of the following account for this clinical syndrome?

- (A) Rb protein
- (B) Neurofibromin
- (C) Hexosaminidase A
- (D) KALIG-1
- (E) Amyloid precursor protein

XIII-49. A 43-year-old man arrives in the emergency room with ataxia. The patient has no significant past medical history. Although his travel history is extensive, he has spent most of the past 15 years in Europe, with approximately three-fourths of his time in the United Kingdom. The patient's wife accompanies him to the emergency room and claims that over the past 1 to 2 years he has had episodes of poor judgment and notable memory loss. He now has a tremor, which has developed over the past several months. The patient's wife also notes that in addition to his mental decline he has become more irritable over the past several weeks; he has been noted to have occasional violent outbursts and now has difficulty walking. On physical exam the patient is easily agitated. He is hyperreflexive and spastic. His Babinski sign is positive. Which of the following is most consistent with this clinical picture?

- (A) Alzheimer's disease
- (B) Huntington's chorea
- (C) Creutzfeldt-Jakob disease
- (D) Amyotrophic lateral sclerosis
- (E) Parkinson's disease

XIII-50. Which of the following is consistent with the diagnosis in the patient described in Question XIII-49?

- (A) He is homozygous for the apo E4 allele.
- (B) The molecular defect involves the expansion of a trinucleotide repeat.
- (C) There is an abnormal accumulation of metabolites of prion protein.
- (D) There is destruction of the lower motoneuron.
- (E) There are large intracytoplasmic inclusions throughout the neuroaxis, called *Lewy bodies*.

XIII-51. A 45-year-old man complains of severe right arm pain. He gives a history of having slipped on the ice and

XIII-51. (Continued)

severely contusing his right shoulder approximately 1 month ago. At this time he has sharp, knifelike pain in the right arm and forearm. Physical examination reveals a right arm that is more moist and hairy than the left arm. There is no specific weakness or sensory change. However, the right arm is clearly more edematous than the left, and the skin appears somewhat atrophic in the affected limb. The patient's pain is most likely due to

- (A) subclavian vein thrombosis
- (B) brachial plexus injury
- (C) reflex sympathetic dystrophy
- (D) acromioclavicular separation
- (E) cervical radiculopathy

XIII-52. An 18-year-old man is brought to the emergency department because of a bicycle accident. He was riding with a group of friends who noted that the patient's bike hit a rock, the bike tumbled, and the patient's head hit the pavement. Unconsciousness lasted about 30 s. It is now approximately 1 h after the accident. At this time the patient is alert, though he has thrown up once and complains of difficulty in concentration and blurred vision. Furthermore, he is complaining of a severe frontal headache. The physical examination is notable for the absence of blood at the tympanic membranes and the mastoid processes and a completely nonfocal neurologic examination. Skull x-rays and MRI are normal. The most appropriate course of action at this point is to

- (A) obtain a neurosurgical consultation
- (B) admit the patient to the hospital for observation
- (C) administer phenytoin and admit the patient to the hospital for observation
- (D) perform an electroencephalogram
- (E) discharge the patient home in the care of his friends

XIII-53. A 70-year-old man is brought in by his wife because of increased drowsiness and generally confused thinking over the past 2 months. Before a seemingly minor motor vehicle accident about 2 months ago, the patient had been running a small business without difficulty. There are no focal or lateralizing signs on neurologic examination. Noncontrast CT scan of the brain is normal except that there are no cortical sulci and the ventricles are small. The most likely diagnosis is

- (A) Alzheimer's disease
- (B) metabolic encephalopathy
- (C) subdural hematoma
- (D) cerebrovascular accident
- (E) depression

XIII-54. The bone most commonly fractured in association with an epidural hematoma is

XIII-54. (Continued)

- (A) frontal
- (B) parietal
- (C) temporal
- (D) occipital
- (E) sphenoidal

XIII-55. A patient presents with a rapidly progressive dementia associated with prominent myoclonic jerks that are provoked by her being startled as well as signs and symptoms of cerebellar dysfunction and emotional lability. Routine CSF analysis is unremarkable. MRI shows minimal cortical loss. Electroencephalography discloses periodic sharp wave complexes on a generalized slow background. This disease is caused by

- (A) a slow-virus infection
- (B) deposition of fibrillary amyloid
- (C) deposition of aluminum
- (D) a proteinaceous infectious particle
- (E) spirochetes

XIII-56. A 60-year-old mildly obese woman complains of a very bothersome burning pain on the anterolateral aspect of her right thigh from the groin almost as far distally as the knee. Examination shows reduction of sensation to touch and pinprick in the affected area. There is no loss of muscle strength, and reflexes are normal. The most likely diagnosis is

- (A) ruptured intervertebral disk
- (B) femoral hernia
- (C) nutritional neuropathy
- (D) compression of the lateral femoral cutaneous nerve
- (E) disruption of the lumbosacral plexus

XIII-57. The major pathologic feature of idiopathic inflammatory polyneuropathy (Guillain-Barré syndrome) is

- (A) loss of anterior horn cells
- (B) destruction of axons
- (C) inflammation of sensory ganglia
- (D) wallerian degeneration
- (E) segmental demyelination

XIII-58. Cataracts, frontal baldness, testicular atrophy, and muscle weakness and wasting occur in association with

- (A) myotonic dystrophy
- (B) limb-girdle dystrophy
- (C) pseudohypertrophic dystrophy
- (D) facioscapulohumeral dystrophy
- (E) myotonia congenita

XIII-59. The form of muscular dystrophy most likely to be encountered in persons older than 50 years of age is

XIII-59. (Continued)

- (A) facioscapulohumeral dystrophy
- (B) oculopharyngeal dystrophy
- (C) myotonic dystrophy
- (D) Duchenne's dystrophy
- (E) limb-girdle dystrophy

XIII-60. Delayed relaxation of a muscle after voluntary contraction is characteristic of certain dystrophic diseases and periodic paralysis. This phenomenon is called

- (A) myokymia
- (B) myoedema
- (C) myotonia
- (D) contracture
- (E) fibrillation

XIII-61. A 65-year-old woman with diabetes mellitus has a 3-month history of sacral pain. In the past month a burning pain progressively developed over the lateral aspect of her left foot and was followed by loss of sensation and weakness of plantar flexion and dorsiflexion. Electromyography showed fibrillations in the left gastrocnemius, extensor hallucis, and quadriceps muscles. Nerve conduction was normal in the legs. A myelogram showed normal results. Now she complains that her knee "gives out" while she is walking; she has an absence of left knee and ankle jerks. Her physician should

- (A) inform the patient that normal results on her myelogram make a diabetic neuropathy the most likely diagnosis
- (B) arrange for a pelvic examination and schedule a CT scan of the pelvis to search for a malignancy compressing or infiltrating the lumbar-sacral plexus
- (C) arrange for a repeat myelogram because of new quadriceps weakness
- (D) arrange for CT scan of the head to search for an expanding mass over the right sensorimotor strip that would affect the foot and leg
- (E) reexamine her at 2-month intervals to determine the progression of her condition

XIII-62. The weakness associated with myasthenia gravis is due to which of the following disorders in the neuromuscular junction?

- (A) Reduced acetylcholine in presynaptic vesicles
- (B) Presynaptic block in the release of acetylcholine
- (C) Presence of antibodies against presynaptic membranes
- (D) Degradation and blockage of postsynaptic receptors
- (E) Damage of postsynaptic membranes by T lymphocytes

XIII-63. A 49-year-old man with long-standing hypertension presents with right-sided weakness involving the face, arm, and leg which has evolved over the past 6 h. Neurologic examination is remarkable only for a right-sided hemiparesis without associated aphasia, papilloedema, or sensory loss. CT scan done after several days most likely would reveal

- (A) a small infarction in the left internal capsule
- (B) a large infarction in the left cerebral cortex
- (C) a left internal capsule hemorrhage
- (D) a left cerebral cortical hemorrhage
- (E) normal findings

XIII-64. A 54-year-old woman with metastatic breast cancer and extensive bony involvement presents with headache and diplopia. Neurologic examination reveals no evidence of increased intracranial pressure, and the only new abnormalities are slight disorientation and the inability to abduct the right eye. Head CT without contrast is negative. Lumbar puncture reveals a mononuclear pleocytosis and elevated protein, but the results, including those of cytologic examination, are otherwise unremarkable. Among the following studies, which is the most likely to establish a diagnosis?

- (A) Contrast CT of the head
- (B) MRI of the head
- (C) CT of the right orbit performed with bone windows
- (D) Retinal angiography
- (E) Repeat lumbar puncture

XIII-65. A 27-year-old man seeks advice because he has noticed fasciculations in his calf muscles. He has no other complaints. Examination shows that muscle bulk and strength, tendon and plantar reflexes, and sensory function are all normal. He should undergo

- (A) muscle biopsy
- (B) sural nerve biopsy
- (C) myelography
- (D) electromyography
- (E) none of the above

XIII-66. Which of the following statements concerning porphyric neuropathy is true?

- (A) It is rarely associated with confusion or seizures.
- (B) It predominantly involves the sensory system.
- (C) It is symmetric, and weakness is often more proximal than distal.
- (D) It causes elevated protein concentration in CSF.
- (E) It is associated with inflammation of nerves.

XIII-67. A patient has a total right hemianesthesia at the time of a cerebral infarction. One year later he complains

XIII-67. (Continued)

of constant severe burning pain with occasional sharp jabs of pain in the left side of his face and left arm. The chronic pain syndrome is most likely

- (A) part of a biologic depressive syndrome secondary to a right parietal lobe stroke
- (B) caused by a lesion in the spinal cord affecting the right spinothalamic tract
- (C) a sequela of thalamic infarction
- (D) secondary to a shoulder-hand syndrome involving the side affected by the stroke
- (E) tic douloureux

XIII-68. A 55-year-old man is evaluated for weakness. Over the past few months he has noted slowly progressive weakness and cramping of his left leg. Lately he has also had some trouble swallowing food. He is awake and alert. Findings on the neurologic examination are normal except for marked atrophy with fasciculations in the muscles of both legs, hyperactive reflexes in the upper and lower extremities, a diminished gag reflex, and a positive extensor plantar response. Which of the following represents the most likely diagnosis?

- (A) Cervical spondylosis
- (B) Guillain-Barré syndrome
- (C) Lambert-Eaton syndrome
- (D) Vitamin B₁₂ deficiency
- (E) Amyotrophic lateral sclerosis

XIII-69. Duchenne's muscular dystrophy is characterized by

- (A) autosomal dominant inheritance
- (B) onset in the second decade of life
- (C) normal cardiac muscle
- (D) universal elevation of serum creatine kinase
- (E) the requirement in prenatal diagnosis for family studies for analysis of restriction fragment length polymorphisms (RFLPs)

XIII-70. A 68-year-old previously healthy woman develops a lilac-colored rash in a butterfly distribution about the eyes, on the bridge of the nose, and on the cheeks. She has a similar rash on her knuckles. She has had an associated muscle weakness manifested by difficulty arising from a chair and climbing stairs. She takes no medicines. Other than the rash and proximal muscle weakness, the woman's examination is unremarkable. The most appropriate subsequent procedure would be

- (A) barium enema, upper GI series, intravenous pyelography, mammography, and chest x-ray
- (B) hemogram, serum chemistries, Pap smear, urinalysis, mammography, and chest x-ray
- (C) biopsy of an affected muscle

XIII-70. (Continued)

- (D) electromyography (EMG)
- (E) glucocorticoid treatment

XIII-71. Which of the following statements correctly characterizes Wernicke's encephalopathy?

- (A) The most prominently affected area is the frontal cortex, bilaterally.
- (B) Most patients present with the triad of encephalopathy, ophthalmoplegia, and ataxia.
- (C) In the absence of a response to glucose, thiamine should be administered.
- (D) After the patient responds to emergent treatment, profound amnesic psychosis may supervene.
- (E) Intake of alcohol is required to produce the full-blown syndrome.

XIII-72. A 13-year-old girl presents to your clinic with progressive memory loss and a decline in school performance. She is a recent immigrant from South America. She has had several generalized seizures. She now complains of ataxia. On physical exam she is a pleasant adolescent. Her neurologic exam is significant for hyperreflexia of the lower extremities and a positive Babinski sign. She has evidence of central ataxia. Her past medical history is significant for an episode of measles at age 3. She had no childhood vaccination program. An electroencephalogram (EEG) was performed and shows a characteristic periodic pattern with bursts every 3 to 8 s of high voltage. Which of the following diagnoses is consistent with the above clinical picture?

- (A) Progressive multifocal leukoencephalopathy (PML)
- (B) Subacute sclerosing panencephalitis (SSPE)
- (C) Tropical spastic paraparesis
- (D) Gerstmann-Straussler-Scheinker syndrome
- (E) Postherpetic encephalopathy

XIII-73. A 39-year-old man presents with acute low back pain radiating into the posterior aspect of the right thigh and continuing down to the lateral aspect of the foot. On examination, the right patellar reflex is normal but the right Achilles tendon reflex is depressed compared with the left. Muscle power in the right lower extremity is full when the patient is examined in the supine position. The patient can stand on his heels and on the toes of the left foot, but the right toes are weak. MRI of the lumbosacral spine reveals a right-sided disk protrusion. The most likely site of disk protrusion is the

- (A) L2–L3 interspace
- (B) L3–L4 interspace
- (C) L4–L5 interspace
- (D) L5–S1 interspace
- (E) S1–S2 interspace

XIII-74. A 28-year-old woman who is 28 weeks pregnant presents with a 2-week history of burning pain in the lateral aspect of the left thigh. She has not noted back pain, weakness, or a change in bladder function. Examination reveals normal muscle strength in the legs. Deep tendon reflexes are normal. On sensory examination she notes decreased light touch in an oval-shaped area on the lateral aspect of the left thigh starting just above the knee. This most likely represents a lesion of the

- (A) L3 nerve root
- (B) femoral nerve
- (C) lateral femoral cutaneous nerve
- (D) saphenous nerve
- (E) obturator nerve

XIII-75. A 50-year-old man presents with a 2-month history of difficulty walking. He states that he trips over his toes and must lift his legs high with each step to avoid falling. He has no low back pain or sensory complaints in the legs. He is not taking medications. There is no family history of a similar problem. Thigh flexion, extension, adduction, and abduction are normal. There is mild weakness of foot dorsiflexion, inversion, and eversion. Plantar flexion of the foot is strong. Deep tendon reflexes are brisk throughout. This most likely represents

- (A) bilateral L5 radiculopathy
- (B) a bilateral lesion of the common peroneal nerve
- (C) nutritional polyneuropathy
- (D) hereditary sensorimotor polyneuropathy
- (E) amyotrophic lateral sclerosis (motor neuron disease)

XIII-76. A 4-year-old boy presents with a 3-week history of headache, ataxia, and vomiting. A head CT shows a posterior fossa mass arising from the midline cerebellum and involving the fourth ventricle. The most likely pathology of this tumor is

- (A) oligodendroglioma
- (B) craniopharyngioma
- (C) glioblastoma multiforme
- (D) medulloblastoma
- (E) hemangioblastoma

XIII-77. Which of the following statements concerning Friedreich's ataxia is true?

- (A) Friedreich's ataxia is an autosomal dominant disorder.
- (B) Friedreich's ataxia is caused by an increase in the number of CAG trinucleotide repeats.
- (C) The diagnosis is characterized by onset in the sixth decade of life.
- (D) The clinical characteristics of Friedreich's ataxia often include both blindness and deafness.

XIII-77. (Continued)

- (E) Skeletal deformities are a rare finding in patients with Friedreich's ataxia.

XIII-78. Which of the following statements regarding Gerstmann's syndrome is true?

- (A) Affected patients have difficulty distinguishing right from left.
- (B) It results from a lesion of the nondominant parietal lobe.
- (C) Prosopagnosia is a prominent feature.
- (D) Apraxia is a prominent feature.
- (E) Pure word deafness is a prominent feature.

XIII-79. Which of the following is likely to be found in a patient with Wernicke's aphasia?

- (A) Fluent speech output
- (B) Normal repetition
- (C) Acalculia
- (D) Dysarthric speech pattern
- (E) Right facial weakness

XIII-80. Patients with tuberous sclerosis are at an increased risk of developing which of the following tumors?

- (A) Meningioma
- (B) Giant cell astrocytoma
- (C) Pheochromocytoma
- (D) Schwannoma
- (E) Renal cell carcinoma

XIII-81. A 25-year-old woman presents with a sudden onset of diplopia. On examination she is unable to adduct the left eye past the midline. Nystagmus is noted in the right eye on abduction. Otherwise, extraocular movements are normal. The most likely location of the lesion is the

- (A) right frontal lobe
- (B) left labyrinth
- (C) midbrain, affecting the rostral interstitial nucleus of the medial longitudinal fasciculus
- (D) left occipital cortex
- (E) left upper pons, affecting the medial longitudinal fasciculus

XIII-82. A 64-year-old right-handed woman is able to produce and comprehend spoken language, repeat, write, and name objects in the left visual field. However, she is completely unable to read, including sentences she herself has recently written. Which syndrome most accurately defines this patient's presentation

- (A) Gerstmann's syndrome
- (B) Wernicke's aphasia

XIII-82. (Continued)

- (C) Broca's aphasia
- (D) Alexia without agraphia
- (E) Nonfluent transcortical aphasia

XIII-83. A 22-year-old moderately obese woman complains of an excruciating headache over the past week. She denies other symptoms; her only medication is an oral contraceptive. On examination, the only findings are mild bilateral papilledema and a left sixth nerve palsy. MRI is normal; the ventricles are described as "slit-like." CSF manometry yields a pressure of 490 mmH₂O. CSF chemistry and cytology are unremarkable. True statements regarding this condition include which of the following?

- (A) It can be associated with cavernous sinus thrombosis.
- (B) A carbonic anhydrase inhibitor may alleviate the symptoms.
- (C) Despite the presence of papilledema, visual acuity is seldom affected.
- (D) Visual evoked potentials would be expected to be abnormal.
- (E) It can be associated with a subdural hematoma.

XIII-84. Which of the following statements concerning Friedreich's ataxia is true

- (A) Skin lesions represent a common manifestation of this disorder.
- (B) The onset of symptoms occurs after age 25 years.
- (C) The molecular defect involves the expansion of a trinucleotide repeat sequence.
- (D) Friedreich's ataxia is associated with an increased risk of cancer.
- (E) It is transmitted in an autosomal dominant manner.

XIII-85. Which of the following statements concerning spina bifida is true?

- (A) Additional congenital abnormalities are a rare finding.
- (B) Chromosomal abnormalities can be identified in approximately one-half of patients.
- (C) A myelomeningocele is the most common type of spina bifida.
- (D) Spina bifida occulta occurs most often at L1 or L2.
- (E) Spina bifida is more common in blacks.

XIII-86. A 64-year-old attorney with a 10-year history of adult-onset diabetes mellitus presents with the complaint of chronic burning dysesthesia in the feet. This symptom has been present for a year. He has been told that his pain is part of a diabetic neuropathy. He tried narcotics and antiepileptic medications in the past, but they made him too drowsy to work. The physician suggests a tricyclic antidepressant. The best choice is

XIII-86. (Continued)

- (A) doxepin
- (B) amitriptyline
- (C) imipramine
- (D) nortriptyline
- (E) desipramine

XIII-87. A 35-year-old man with a history of intravenous drug abuse presents with the subacute onset of left shoulder pain. He has been evaluated by an orthopedic surgeon and a neurologist, who have found his examination normal. Plain films of the shoulder and MRI of the cervical spine, as well as electromyography, have been normal. He is undergoing physical therapy. In the office, the physician notes that he is hiccuping. Which of the following tests would be most useful?

- (A) Abdominal CT
- (B) Barium swallow
- (C) MRI of the brain
- (D) Cervical myelography
- (E) Gastric endoscopy

XIII-88. A 72-year-old man with a history of hypertension and coronary artery disease is comatose in the cardiac intensive care unit after a ventricular tachycardiac arrest. Irrigation of the patient's left ear with 60 mL of cool water results in a bilateral conjugate tonic deviation of the eyes toward the left with no fast corrective movements to the midline. This finding indicates that

- (A) there is a lesion between the midbrain and the pons
- (B) there is danger of imminent transtentorial herniation
- (C) there is an intact brainstem eye movement circuit with bilateral hemispheric dysfunction
- (D) there has been an interruption in the reticular activating system
- (E) the patient is in status epilepticus

XIII-89. A 30-year-old woman presents with a complaint of visual difficulty. She bumps into objects that are beside her and has noticed that she must turn her head to either side to see things on the right and left. She also has noticed a change in her usually regular menstrual cycle. Which test is most likely to be abnormal?

- (A) Visual evoked potentials
- (B) Serum prolactin level
- (C) Blood glucose
- (D) CSF protein
- (E) Neuropsychological testing

XIII-90. A 65-year-old man with a history of hypertension and chronic obstructive pulmonary disease secondary to tobacco smoking presents to a physician after his wife

XIII-90. (Continued)

notes that his left eyelid is drooping. On examination, the left pupil is 2 mm in diameter and the right is 4 mm. In dim light, the left pupil measures 2.5 mm while the right measures 5 mm. A left ptosis is seen. The skin of the face is dry bilaterally. The remainder of the neurologic examination is normal. The first step in the workup should be

- (A) cerebral MRI
- (B) ultrasound study of the carotid arteries
- (C) chest x-ray
- (D) ophthalmology consultation
- (E) blood glucose determination

Questions XIII-91 to XIII-92.

A 28-year-old woman presents to your clinic complaining of blurred vision and left leg numbness. She states that she has some mild left eye discomfort. On physical exam she has decreased visual acuity of the left eye. However, the remainder of her cranial nerves are within normal limits. She has a normal motor exam, yet she has loss of sensation in the L4–S1 distribution of the right leg. The patellar reflex of the right leg is absent, and a Babinski sign was negative. A T2-weighted MRI of her head reveals multiple bright signal abnormalities in the white matter.

XIII-91. Which of the following results would you expect from examination of the CSF in this patient?

- (A) A normal examination
- (B) A CSF cell count of 100/mL
- (C) The presence of polymorphonuclear cells
- (D) CSF protein level of 1.0 g/L (100 mg/dL)
- (E) The presence of oligoclonal bands by agarose gel electrophoresis

XIII-92. Adverse prognostic features in the patient described include which of the following?

- (A) The presence of optic neuritis
- (B) Female sex
- (C) Age
- (D) Multiple cranial abnormalities
- (E) Findings in the CSF

XIII-93. A 68-year-old right-handed woman is known to have an anaplastic astrocytoma. She is able to produce grammatically correct language with no paraphasias, but her speech is uttered in a monotone that fails to convey her intended emotional meaning. There are no associated neurologic signs. The most likely location of her tumor is the

- (A) right parietal lobe
- (B) right frontal lobe
- (C) right basal ganglia

XIII-93. (Continued)

- (D) left frontal lobe
- (E) left temporal lobe

XIII-94. A 72-year-old right-handed man with a history of atrial fibrillation and chronic alcoholism is evaluated for dementia. His son gives a history of a stepwise decline in the man's function over the past 5 years with the accumulation of mild focal neurologic deficits. On examination he is found to have a pseudobulbar affect, mildly increased muscle tone, and brisk deep tendon reflexes in the right upper extremity and an extensor plantar response on the left. This history and examination are most consistent with which of the following?

- (A) Binswanger's disease
- (B) Alzheimer's disease
- (C) Creutzfeld-Jakob disease
- (D) Vitamin B₁₂ deficiency
- (E) Multi-infarct dementia

XIII-95. Which of the following statements is true of Stokes-Adams attacks?

- (A) Patients almost always have a family history of the disorder.
- (B) They are caused by high-degree atrioventricular block.
- (C) They are caused by recurrent paroxysmal tachyarrhythmias.
- (D) They are usually preceded by an aura.
- (E) Focal neurologic signs are common after these episodes.

Questions XIII-96 to XIII-97.

A 63-year-old woman arrives in the emergency room complaining of several days of progressive lower extremity weakness. She describes a "rubbery leg" feeling that presented approximately 2 days prior to her arrival. She is now having difficulty ambulating. Her past medical history is significant only for a gastrointestinal infection, which was self-limiting and occurred approximately 1 to 2 weeks prior to her presentation. On physical exam her vital signs are stable and she is afebrile. Her neurologic exam is significant for intact cranial nerves; her lower extremity motor strength is 4–/5 bilaterally, and it is 4+/5 in the upper extremities bilaterally. She has a slight reduction in sensation to light touch and pinprick in the lower extremities only. She has a sensory level at the mid thigh. She has no patellar or ankle deep tendon reflexes bilaterally.

XIII-96. Which of the following organisms most likely caused this patient's gastrointestinal infection?

- (A) Cytomegalovirus
- (B) *Shigella*

XIII-96. (Continued)

- (C) *Campylobacter jejuni*
- (D) Rotavirus
- (E) *Escherichia coli*

XIII-97. Which of the following treatment recommendations should be initiated in the patient described?

- (A) Low-dose glucocorticoids
- (B) High-dose glucocorticoids
- (C) High-dose intravenous immunoglobulin (IVIg)
- (D) Cyclophosphamide
- (E) Azathioprine

XIII-98. A 65-year-old man suffers an out-of-hospital cardiac arrest. Bystander cardiopulmonary resuscitation is performed for ~20 min before emergency medical services arrive. The patient is defibrillated three times using standard ACLS guidelines, and sinus rhythm is restored. The patient is brought to the local emergency room and admitted to intensive care. You are asked to perform a neurologic examination 24-h later for consultation purposes. On physical and neurologic exam the patient has absent motor responses, an extensor response to painful stimuli, and spontaneous eye movements that are neither orienting nor roving conjugate. What is the likelihood that this patient will recover with only a moderate neurologic disability?

- (A) None
- (B) 1%
- (C) 5%
- (D) 10%
- (E) 50%

XIII-99. Which of the following structures have been implicated in the generation of sleep?

- (A) Brainstem reticular formation
- (B) Midbrain
- (C) Subthalamus
- (D) Emboliform nucleus
- (E) Basal forebrain

XIII-100. A 12-year-old girl complains of muscle aches and difficulty climbing stairs and combing her hair. She has a rash over the malar area of her face and the extensor surfaces of her hands and fingers. Which of the following statements concerning this syndrome is true?

- (A) The patient probably will have a normal erythrocyte sedimentation rate.
- (B) There is an increased risk of an underlying malignancy.
- (C) This is a relatively benign disorder and is usually self-remitting.

XIII-100. (Continued)

- (D) Biopsy of an affected muscle most likely would show perifascicular atrophy.
- (E) Biopsy of an affected muscle most likely would show fiber type grouping.

Questions XIII-101 to XIII-102.

A 36-year-old woman arrives in the emergency room complaining of severe headache that has lasted for several days. She has a past medical history of migraine headaches but states that her present headache is different in quality as well as duration. She has had several self-limiting transient headaches over the past week, but 3 days prior to her arrival today she experienced a sudden sharp severe headache. The headache was more intense on the right side and radiated over the entire cranium. Although the headache is now less severe, it still persists. On physical exam the patient is afebrile with a normal blood pressure. She has no sinus tenderness. She denies any photophobia. Her cranial nerve exam is unremarkable. A fundoscopic exam reveals mild papilledema. She has mild to moderate nuchal rigidity. The remainder of her neurologic and mental status exam is unremarkable.

XIII-101. Which of the following diagnoses is most consistent with this patient's presentation?

- (A) Migraine headache
- (B) Temporal arteritis
- (C) Meningitis
- (D) Primary CNS tumor
- (E) Subarachnoid hemorrhage

XIII-102. The patient described has a noncontrast head CT, which is unremarkable. Which of the following studies would be most appropriate?

- (A) A noncontrast head MRI
- (B) A head MRI with intravenous gadolinium
- (C) Lumbar puncture with examination of the CSF
- (D) EEG
- (E) A fine-resolution head CT with intravenous contrast

XIII-103. A patient complains of hearing loss in the right ear. A 256-Hz tuning fork is placed in the middle of the forehead; the patient reports that he hears the tone in his right ear. He also notes better perception of a tone when the tuning fork is placed in contact with the right mastoid process than when it is placed outside his right ear. Lesions in which of the following structures could account for these findings?

- (A) Eighth nerve
- (B) Central auditory pathways
- (C) Cochlea

XIII-103. (Continued)

- (D) Cerebellar angle
- (E) Middle ear

XIII-104. Useful tests for myasthenia gravis would include which of the following?

- (A) Repetitive motor-nerve stimulation
- (B) Conventional electromyography
- (C) Muscle biopsy
- (D) Nerve conduction studies
- (E) Curare challenge testing

XIII-105. A 54-year-old man presents to the emergency room complaining of 2 days of low back pain. He has had several episodes of low back pain in the past, all of which were self-limiting. The current episode of low back pain is described as more constant as well as more severe when compared to prior episodes. The low back pain is nonradiating in nature. The patient states that he has had no episodes of trauma and denies any bowel or bladder dysfunction. On physical exam he is a well-appearing man in no acute distress. He has a mild lumbar tenderness to deep palpation and bilateral paraspinal tenderness. A lower motor examination is unremarkable. There is mild loss of sensation to both pinprick and light touch in the buttocks and perineal area. Which of the following would be the most appropriate treatment recommendation?

- (A) NSAIDs and strict bed rest
- (B) Narcotic analgesics and strict bed rest
- (C) Neurosurgical evaluation
- (D) A muscle relaxant with a narcotic analgesic
- (E) Initiation of physical therapy with narcotic analgesics

XIII-106. A lesion in the corticospinal tract rather than in an anterior horn neuron projecting to muscle cells is suggested by

- (A) spasticity
- (B) marked atrophy
- (C) fasciculations
- (D) involvement of individual muscles
- (E) decreased patellar reflexes

XIII-107. The tremor associated with Parkinson's disease is characterized by

- (A) worsening with voluntary movement
- (B) occurrence with flexed posture
- (C) occurrence at a rate of 10 to 20 Hz
- (D) association with flaccidity
- (E) abolition by moderate intake of alcohol

XIII-108. Which of the following antiepileptic drugs is the most appropriate choice for a patient with absence seizures?

XIII-108. (Continued)

- (A) Ethosuximide
- (B) Phenytoin
- (C) Carbamazepine
- (D) Phenobarbital
- (E) Lorazepam

XIII-109. Chronically progressive spinal cord disease with sensory and motor signs evolving over years may be due to

- (A) Kennedy's disease
- (B) multiple sclerosis
- (C) Tay-Sach's disease
- (D) lumbar disk disease
- (E) amyotrophic lateral sclerosis

XIII-110. A person with long-standing alcoholism arrives in the emergency room complaining of diplopia. In physical exam you note the presence of bilateral lateral-rectus (sixth-nerve) palsies as the only cranial nerve abnormality. The most likely etiology of this finding would be which of the following?

- (A) Brainstem hemorrhage
- (B) Subdural hematoma
- (C) Orbital fractures
- (D) Neurosyphilis
- (E) Wernicke's encephalopathy

XIII-111. A 60-year-old man comes to the emergency room with the sudden onset of a neurologic deficit. After examining the patient, the physician orders cerebral angiography. The results show occlusion of the left vertebral artery from its origin to the site where it joins the basilar artery. The right vertebral artery, the basilar artery, and both carotid arteries are patent. Examination in the emergency room would disclose which of the following?

- (A) Left hemiparesis sparing the face
- (B) Deviation of the uvula to the left on phonation
- (C) Paralysis of the left arm and leg
- (D) Left internuclear ophthalmoplegia
- (E) Diminished pain and temperature sensation in the right arm and leg

XIII-112. Which of the following may occur ipsilateral to a disease process within the cavernous sinus?

- (A) Ptosis
- (B) A loss of sensation of the palate and pharynx
- (C) Numbness of the chin
- (D) Marked decrease in visual acuity
- (E) The presence of palatal weakness and dysphagia

XIII-113. Which of the following characteristics would provide a patient the greatest chance of remaining seizure-free when anticonvulsants are stopped?

XIII-113. (Continued)

- (A) Complete medical control of seizures for approximately 6 months
- (B) Complex partial seizures with secondary generalization
- (C) Patient under the age of 30
- (D) The requirement of a single drug for seizure control
- (E) Patient had craniotomy 1 year earlier for a single CNS metastasis from a lung adenocarcinoma

XIII-114. Which of the following statements concerning the use of lithium is correct?

- (A) Lithium is effective for treating acute manic/hypomanic episodes but plays no role in prophylaxis against future attacks.
- (B) Hyperthyroidism is an important long-term complication.
- (C) Nephrogenic diabetes insipidus is common.
- (D) Lithium causes hypocalcemia in ~10% of patients.
- (E) During acute mania, lithium can be administered with behavior control as the sole end-point.

XIII-115. Which of the following is a common side effect of the long-term use of valproic acid?

- (A) Gingival hypertrophy
- (B) Hirsutism
- (C) Polycystic ovaries and hyperandrogenism

XIII-115. (Continued)

- (D) Aplastic anemia
- (E) Dupuytren's contracture

XIII-116. In addition to progressive memory loss, which of the following clinical findings is helpful in suggesting the diagnosis of Alzheimer's disease?

- (A) Onset of symptoms before age 40
- (B) Episodes of altered consciousness
- (C) Neurofibrillary tangles
- (D) Diminished independence in activities of daily living
- (E) Absence of a family history of a similar disorder

XIII-117. A 55-year-old woman presents to the emergency room complaining of the sudden onset of severe vertigo. Her symptoms have lasted ~4 to 5 h. Although her vertigo is somewhat improved, she remains unsteady on her feet. On further questioning the patient admits to the presence of "ringing" in her left ear with a loss of hearing acuity. Which of the following disorders is most consistent with this clinical picture?

- (A) Benign positional vertigo
- (B) A transient ischemic attack
- (C) Multiple sclerosis
- (D) Ménière's disease
- (E) Labyrinthitis

XIII. NEUROLOGIC DISORDERS

ANSWERS

- XIII-1. The answer is B.** (*Chap. 21*) The symptoms and signs described in the question are most consistent with Ménière's disease. In this disorder, paroxysmal vertigo resulting from labyrinthine lesions is associated with nausea, vomiting, rotary nystagmus, tinnitus, high-tone hearing loss with recruitment, and, most characteristically, fullness in the ear. Labyrinthitis would be an unlikely diagnosis in this case because of the hearing loss and multiple episodes. Vertebral-basilar insufficiency and multiple sclerosis typically are associated with brainstem signs. Acoustic neuroma only rarely causes vertigo as its initial symptom, and the vertigo it does cause is mild and intermittent.
- XIII-2. The answer is D.** (*Chap. 15. Welch, N Engl J Med 329:1476–1483, 1993.*) While the pathophysiology of migraine remains unclear, electrical stimulation of midline dorsal raphe in the brainstem leads to characteristic pain. Pharmacologically, serotonin-mediated neurotransmission appears to be critical in the generation of migrainous pain. Sumatriptan and dihydroergotamine both work by blocking 5-hydroxytryptamine receptors (type I, especially the D subtype). While nonsteroidal anti-inflammatory drugs (NSAIDs) such as ibuprofen and naproxen are helpful in patients with mild to moderate migraine, presumably by reducing inflammatory stimuli from cyclooxygenase inhibition leading to reduced prostaglandin generation, the patient in the question has too severe an attack to benefit from the additional use of this class of agents. Also, the use of narcotic analgesics as a primary therapy is no longer recommended; sumatriptan will relieve a migraine headache in ~75% of patients within 1 h of treatment. Unfortunately, because of its short half-life (with either oral or subcutaneous administration), headache recurs in up to one-third of patients. Sumatriptan-associated side effects are usually mild to moderate and highly reversible; they include reactions at the injection site, flushing sensations, and neck pain or stiffness. Although up to 5% of patients treated with sumatriptan experience chest tightness or pressure, myocardial ischemia is exceedingly rare. Nonetheless, this drug should not be given to those with a history of myocardial infarction, ischemic heart disease, or Prinzmetal's angina. Both β -adrenergic antagonists and calcium channel blocking drugs are effective prophylactic agents in patients with frequent migraines.
- XIII-3. The answer is A.** (*Chap. 367*) The abrupt appearance of an isolated peripheral facial palsy, which may include ipsilateral hyperacusis resulting from involvement of fibers to the stapedius and loss of taste on the anterior two-thirds of the tongue resulting from involvement of the fibers of the chorda tympani, is most often idiopathic, as in Bell's palsy. If the patient is unable to close the eye, artificial tears may be helpful during the day to prevent drying, and the eye should be patched at night to prevent corneal abrasion. Excellent recovery occurs in 80% of these cases. Oral contraceptives and mitral valve prolapse are not associated with the causes of this clinical picture. Evoked potentials are not helpful diagnostically.
- XIII-4. The answer is C.** (*Chap. 385. Block, Ann Intern Med 132:209–218, 2000.*) Several factors indicate the patient is depressed. Physicians caring for terminally ill patients should always consider the diagnosis of depression. The diagnosis of depression should be considered in any geriatric patient who complains about increasing levels of somatic concern. The fact that the patient is unable to imagine anything positive in her future and the fact

that she feels inability to contribute and believes her presence is only a burden to others suggests underlying depression. An important point is that although many patients and clinicians believe that depression is a normal feature of a terminal illness, most terminally ill patients do not become depressed. The differential diagnosis includes anxiety. Anxiety may coexist with depression and in some patients may be manifested as an anxious depression. In addition, organic mental disorders such as delirium may be caused by metastatic disease or paraneoplastic syndrome.

- XIII-5. The answer is B.** (*Chap. 15*) Cluster headaches, which can cause excruciating hemi-cranial pain, are notable for their occurrence during characteristic episodes. Usually attacks occur during a 4- to 8-week period in which the patient experiences one to three severe brief headaches daily. There may then be a prolonged pain-free interval before the next episode. Men between ages 20 and 50 are most commonly affected. The unilateral pain is usually associated with lacrimation, eye reddening, nasal stuffiness, ptosis, and nausea. During episodes alcohol may provoke the attacks. Even though the pain caused by brain tumors may awaken a patient from sleep, the typical history and normal neurologic examination do not mandate evaluation for a neoplasm of the central nervous system. Acute therapy for a cluster headache attack consists of oxygen inhalation, although intranasal lidocaine and subcutaneous sumatriptan may also be effective. Prophylactic therapy with prednisone, lithium, methysergide, ergotamine, or verapamil can be administered during an episode to prevent further cluster headache attacks.
- XIII-6. The answer is D.** (*Chap. 16*) Herniation of a lower cervical disk may be due to trauma, especially in the setting of neck hyperextension. If the disk herniates laterally, it will generally compress the nerve route exiting the lower of the two vertebrae that account for the intervertebral space. For example, if the disk between the fifth and sixth cervical vertebrae herniates, the full syndrome will be characteristic of a C6 radiculopathy: pain in the trapezius, shoulder, radial forearm, and thumb; absent biceps reflex; and preserved triceps reflex. A C7 radiculopathy caused by a disk protruding between the sixth and seventh cervical vertebrae will produce the following: pain in the shoulder blade, pectoral and medial axillary region, upper arm, elbow, dorsal forearm, and index and middle fingers; paresthesia and sensory loss in the second and third fingers or the tips of all the fingers; weakness in forearm and wrist extension as well as hand grip; and a preserved biceps reflex but a diminished triceps reflex. Coughing and sneezing often exacerbate the pain caused by a herniated cervical disk. Unlike the lateral disk syndromes mentioned above, a disk that herniates centrally may be painless but cause symptoms in the lower extremities.
- XIII-7. The answer is A.** (*Chaps. 24, 361*) Patients with basilar artery stenosis frequently have spells of ischemic brainstem dysfunction before a catastrophic stroke caused by arterial thrombosis. Timely anticoagulation and allowing a higher blood pressure can arrest the progression of this potentially fatal stroke. Acute coma can occur in association with each of the cerebrovascular accidents mentioned in the question except carotid occlusion. Subarachnoid hemorrhage causes an acute increase in intracranial pressure that reduces blood flow to the brain. Unilateral cortical infarction does not cause coma, but damage to brainstem structures via infarction or compression will cause coma.
- XIII-8. The answer is A.** (*Chaps. 21, 22. Froehling, JAMA 271:385–388, 1994.*) The evaluation of a “dizzy” patient relies on a combination of careful history taking and neurologic examination. It is important to get a sense of whether the patient has true vertigo, which is usually manifest as the sensation that either the world or the patient is spinning. Some elderly patients complain of dizziness while ambulating or standing without true vertigo, although they may have mild lightheadedness. Typically these patients have peripheral neuropathy, myelopathy, parkinsonian rigidity, cerebellar ataxia, or poor vision. Such patients actually have multiple sensory-defect dizziness, also known as *benign dysequilibrium of aging*. Unlike patients with benign paroxysmal positional vertigo, they should not display excess nystagmus on head-tilt testing. Central lesions are unlikely given a neuro-

logic examination that was normal except for the peripheral neuropathy and other sensory deficits.

- XIII-9. The answer is D.** (*Chaps. 28, 328*) Knowledge of visual pathway anatomy is necessary for an understanding of visual field defects. Monocular visual field loss often results from retinal fiber loss, corresponding to lesions visible on ophthalmoscopic examination. Retinal fibers traveling in the optic nerve change direction at the optic chiasm so that the right brain appreciates left visual space and the left brain appreciates right visual space. Therefore, a discrete vertical midline characterizes all visual pathway disorders resulting from lesions at or posterior to the chiasm. Because chiasmal lesions interrupt the central fibers that mediate temporal vision (with peripheral fibers mediating more midline vision), a pituitary tumor or craniopharyngioma (which typically impinges centrally) results in loss of visual fields in the bitemporal regions. If a lesion exists well posterior to the optic chiasm, such as loss of visual cortex in the one occipital lobe as a result of an embolism in the posterior cerebral artery, a complete loss of visual perception in one field will result. For example, destruction of the right visual cortex will lead to complete left homonymous hemianopia with loss of temporal vision in the left eye and medial vision in the right eye.
- XIII-10. The answer is B.** (*Chap. 357*) The testing of evoked potentials is of the greatest utility in detecting subclinical spinal cord and optic nerve lesions. Up to two-thirds of persons with multiple sclerosis have neurologic deficits that are evident on visual or peroneal somatic evoked potentials but *not* on physical examination. A “second lesion” of this type frequently establishes the diagnosis of multiple sclerosis. Evoked potentials may be abnormal in the other conditions listed in the question.
- XIII-11. The answer is C.** (*Chap. 15*) Errors made in the investigation of patients with a sudden onset of severe headache can result in catastrophic subarachnoid hemorrhage from a ruptured aneurysm. Patients frequently have “warning” bleeding that causes severe headache and brings them for medical attention. Sudden headache during physical exertion is a presentation of a ruptured intracranial aneurysm. A careful CSF examination is the most sensitive test, but noncontrast CT may show the subarachnoid blood and make the lumbar puncture unnecessary. A patient with a reasonable suspicion for aneurysmal bleeding should not be sent home to wait for other symptoms because the next symptom is often a catastrophic subarachnoid hemorrhage. In the patient described, however, the repeated onset of headache with coitus is characteristic of a benign coital headache syndrome. If the patient had only a single sudden coital headache, an investigation for a cerebral aneurysm would be appropriate. A family history of migraine usually is not helpful for the diagnosis of coital headache.
- XIII-12. The answer is E.** (*Chaps. 28, 367*) Isolated lesions of the third nerve with pupillary sparing are common and are usually due to microinfarction in association with diabetes or hypertension. Thus, older patients with such a third nerve palsy can be followed expectantly in the absence of signs of subarachnoid hemorrhage or other, more diffuse processes. More detailed reinvestigation is mandated if recovery is not complete, as it usually is, within a 3-month period. The third nerve is a midline structure that contains both sympathetic motor and visceral nuclei. It innervates the ipsilateral medial rectus, inferior rectus, and inferior oblique muscles as well as the contralateral superior rectus muscle. A central nucleus innervates both levator palpebrae superioris muscles. Moreover, axons from visceral nuclei project ipsilateral parasympathetic outflow to the pupillary sphincter and ciliary ganglion, which control pupillary reflexes as well as accommodation. Therefore, a midbrain infarction (involving the nucleus of the oculomotor nerve), if complete, will produce a unilateral third nerve palsy characterized by ipsilateral ptosis and inability to turn the eye upward, downward, and inward. Bilateral ptosis and paralysis of the contralateral superior rectus muscle will result. Pupillary involvement will also be complete. More distal lesions can produce single or multiple extraocular muscle abnormalities with or without pupillary derangement. It is also important to recognize that the third nerve

may be impinged along its extracranial extent. Particularly noteworthy is compression against the tentorial edge, which may occur during profound intracranial hypertension with temporal lobe herniation. In herniation the pupillary fibers are affected first, causing pupillary dilation and unresponsiveness to light. Cavemous sinus thrombosis may also affect the third nerve; this process typically affects the fourth and sixth nerves.

- XIII-13. The answer is C.** (*Chap. 29*) The primary evaluation of a patient with hearing impairment consists of determining of whether the loss is sensorineural (lesions in the inner ear, eighth nerve, or central auditory pathways) or conductive (lesions in the external auditory canal or middle ear). The demonstration that bone conduction is better than air conduction suggests a conductive hearing loss. About a third of persons over age 70 require a hearing aid because of presbycusis, which is manifested by a loss of discrimination for particular sounds and difficulty understanding speech in noisy environments. This is usually due to sensorineural deafness, with lesions in the neuroepithelial cells (hair cells), the neurons, or the stria vascularis of the peripheral auditory system. Though of lesser magnitude, degeneration of central auditory pathways may also be a problem in those with presbycusis. Hearing aids are the mainstay of treatment for persons with this condition; however, cochlear implants, by providing a neural prosthesis, may aid patients with profound sensorineural deafness.
- XIII-14. The answer is C.** (*Chaps. 21, 363*) Lesions in the basal ganglia, instead of resulting in the clasp-knife spasticity and hyperreflexia of upper motor neuron lesions or the hypotonia of lower motor neuron lesions, may result in a host of movement disorders, including akinesia or bradykinesia, lead-pipe rigidity, chorea, irregular and variable continuous movements, dystonia (increased muscle tone that causes fixed abnormal postures), myoclonus (brief involuntary random muscular contractions), asterixis (quick arrhythmic movements), hemiballismus (violent flinging motion of an arm), tremor, and tics (stereotyped, purposeless, and irregularly repetitive movements). These so-called extrapyramidal syndromes do not involve the characteristic weakness of muscles or muscle groups typical of lesions of the corticospinal tracts. It is possible that these extrapyramidal syndromes can coexist with lesions in the corticospinal tract or cerebellum, and this makes precise delineation of the abnormality difficult. Other degenerative conditions, such as Shy-Drager syndrome, have many elements of Parkinson's disease (bradykinesia, bland facial expression, rest tremor, and muscular rigidity), but postural hypotension, abnormal eye movements, and Babinski's signs may also occur. In addition to dopamine, important neurotransmitters in the basal ganglia include γ -aminobutyric acid, enkephalin, and substance P.
- XIII-15. The answer is D.** (*Chap. 22*) Polymyalgia rheumatica typically occurs in elderly patients and is characterized by complaints of weakness, stiffness, and pain in the proximal musculature. There may be an associated inflammatory arthritis, an elevated erythrocyte sedimentation rate, or an accompanying temporal arteritis. Inflammatory myositis is ruled out by the presence of normal creatine kinase levels; a muscle biopsy will show atrophy without evidence of inflammation. Unless temporal arteritis is also present, NSAIDs constitute the treatment of choice; low-dose prednisone may be administered if the initial agents fail.
- XIII-16. The answer is D.** (*Chap. 12*) The patient is already on maximal doses of a relatively weak narcotic analgesic that also has quite a few side effects. Increasing the dose of codeine or adding an NSAID such as indomethacin is likely to be of little benefit. Neuropathic pain, unlike the somatic pain afflicting the patient, might be managed with the help of an anticonvulsant such as phenytoin. Since the patient has not failed an adequate trial of narcotics, referral for a nerve-altering intervention is premature. One should institute a sustained-release preparation of morphine, with another narcotic to be taken between doses of morphine until a sufficient level of analgesia is achieved.

- XIII-17. The answer is D.** (*Chaps. 15, 367*) A disease of middle-aged and elderly patients, particularly women, paroxysmal facial pain (tic douloureux, trigeminal neuralgia) is usually of idiopathic origin. It may occur in association with multiple sclerosis, herpes zoster, or a tumor. Brief, intense, lancinating pains brought on by manipulation of trigger zones in the lips or face, without motor or sensory paralysis, characterize this disorder. The treatment of first choice is the anticonvulsant carbamazepine, which is effective in most patients. In cases of nonresponse or intolerance to carbamazepine, radiofrequency ablation of the gasserian ganglion of the trigeminal nerve may be beneficial.
- XIII-18. The answer is A.** (*Chaps. 23, 364*) Peripheral nerve trunks contain fibers of various sizes. Small fibers mediate sensations of pain and temperature, and larger fibers are involved in touch, vibration, and joint position sense. Therefore, a lesion in a peripheral nerve would be expected to affect all such functions. The different fibers segregate near the dorsal roots. The smaller fibers cross and ascend in the contralateral side through the spinal cord to the brainstem and to the ventral posterior lateral nucleus of the thalamus, ultimately projecting to the parietal cortex. The larger fibers that mediate tactile and position sense project upward in the posterior columns of the spinal cord and synapse initially in the cuneate nuclei of the lower medulla; a secondary neuron crosses to ascend in the medial lemniscus and synapses in the ventral posterolateral nucleus of the thalamus with ultimate projections to the parietal cortex. Therefore, loss of joint position without loss of pain sensation would reflect a lesion in the ipsilateral posterior column, contralateral brainstem, thalamus, or parietal cortex.
- XIII-19. The answer is A.** (*Chap. 25. Domasio, N Engl J Med 326:531–539, 1992.*) Patients with Wernicke's aphasia usually have damage in an area of the posterior temporal and parietal regions, which are supplied by the lower division of the middle cerebral artery. Not only are spoken and written communication affected, auditory and visual understanding may also be deranged. At first glance, speech in a person with lesions in this area appears to be effortless and well woven together. However, because of problems in finding words, the content is often unintelligible, as there are frequent errors in word choice and substitution of incorrect phonemes (e.g., "trable" for "table"). Patients with lesions in this location rarely have associated motor defects, but problems in sensory processing are possible, depending on the degree of parietal lobe disease. As in true Broca's aphasia, these patients have difficulty repeating sentences and naming things properly. Patients with Wernicke's aphasia may experience paranoid ideation and become agitated and hostile.
- XIII-20. The answer is D.** (*Chaps. 28, 367*) The features described in the question are consistent with sympathetic denervation of the right eye, the so-called Horner pupil. This lesion, which is frequently produced by pulmonary neoplasms of the superior sulcus, is usually associated with ipsilateral ptosis and anhidrosis. Pupillary light responses should be normal, as should the response to mydriatics [substances causing pupillary dilation (e.g., anticholinergics)] and miotics [drugs causing pupillary constriction (e.g., cholinergics, β -adrenergic blockers)]. However, since the sympathetic nerve endings are depleted, cocaine cannot cause local release of sympathomimetic substances and is a poor mydriatic. An oculomotor palsy would also produce ipsilateral ptosis, but a dilated pupil that is poorly reactive to light on that side would be the cause of anisocoria.
- XIII-21. The answer is C.** (*Chap. 360*) Patients with loss of consciousness resulting from a seizure usually have mental confusion, headache, and drowsiness postictally, whereas patients with a brief syncopal spell recover fully as soon as blood pressure returns to normal. Auras, urinary incontinence, and a laceration of the tongue are clues that the cause of the loss of consciousness was a seizure. Moreover, syncope rarely occurs during recumbency.
- XIII-22. The answer is A.** (*Chap. 27*) Chronic or long-term insomnia, by definition, lasts for months or years and is usually reflective of a psychiatric or chronic medical condition, drug use (including caffeine or alcohol), or a primary sleep disorder. Psychophysiologic

insomnia is characterized by preoccupation with the inability to sleep at night. The problem often is triggered by a stressful event but may persist for long periods because of the acquisition of poor sleep habits. Patients are often aroused by their own failed efforts to sleep. They more readily sleep at unusual times or places. This patient does not have narcolepsy, since excessive daytime sleep and cataplexy are not included in his syndrome. Narcolepsy may be treated with stimulants such as methylphenidate. Moreover, he has no findings suggestive of sleep apnea syndromes, which might benefit from the use of conjugated estrogens. Instead, rigorous attention to sleep hygiene, such as making sure the bedroom is used only for sleep and removing distracting stimuli at bedtime, is most appropriate. Benzodiazepine hypnotics may be helpful during the initiation of treatment by serving to allow behavioral therapy, which is probably the most specific way to treat this problem.

- XIII-23. The answer is D.** (*Chap. 28*) The patient in question is suffering from acute angle-closure glaucoma, resulting from obstruction of the outflow of aqueous humor at the iris. The buildup of intraocular pressure can be confirmed by measurement and requires urgent treatment with hyperosmotic agents. Permanent treatment requires laser or surgical iridotomy. Angle-closure glaucoma is less common than primary open-angle glaucoma, which is asymptomatic and is usually detectable only through measurements of intraocular pressure at a routine eye examination.
- XIII-24. The answer is D.** (*Chap. 360*) It is important to classify seizures on the basis of whether they begin in a focal area of the brain, remain localized or secondarily generalize, or are generalized from the earliest manifestation. This patient exhibited the classic “Jacksonian march,” with repetitive shaking of contiguous ipsilateral body parts, caused by a demonstrable progression of epileptiform discharges in the contralateral motor cortex usually resulting from a focus from a tumor or abscess. This patient therefore had a simple partial seizure with secondary generalization. In this case the focus was obvious; in some cases the focal features can be discerned only on the basis of a postictal deficit (e.g., Todd’s paralysis of an extremity). Juvenile myoclonic epilepsy begins in adolescence and is characterized by postawakening myoclonic seizures marked by sudden, brief muscle contractions involving one body part or the entire body. Complex partial seizures, also referred to as temporal lobe epilepsy (typical of herpes simplex encephalitis), involve episodic changes in behavior with loss of attachment to the environment and typically are associated with a minor automatism such as lip smacking or picking at clothes.
- XIII-25. The answer is D.** (*Chap. 360*) Different types of seizures respond better to certain classes of anticonvulsant drugs. For example, generalized tonic-clonic seizures may be treated successfully with phenytoin, carbamazepine, phenobarbital, or valproic acid. Carbamazepine and phenytoin are also effective for the treatment of partial seizures, though persons with complex partial seizures may require more than one type of drug at a time. Partial absence seizures, such as those described in the question, are best treated with ethosuximide or valproic acid, although clonazepam (a benzodiazepine) may also be effective. The side effects of ethosuximide include ataxia, lethargy, GI irritation, skin rash, and bone marrow suppression.
- XIII-26. The answer is B.** (*Chaps. 22, 364*) Alcoholic cerebellar degeneration is an example of a disease primarily of the midline area of the cerebellum (vermis). A characteristic cerebellar gait disorder is manifested by a wide-based walk and stance and the inability to stand with the feet together even with the eyes open. Patients complain of imbalance and frequently try to hold on to objects as they walk. However, unlike more diffuse cerebellar disease, there is no associated limb ataxia or nystagmus.
- XIII-27. The answer is E.** (*Chap. 370. Fine, Ann Intern Med 119:1093–1104, 1993.*) Lymphoma of the brain (usually diffuse large cell) is increasingly common as a sporadic tumor and occurs frequently in immunosuppressed patients, especially those with AIDS. Its clin-

ical sensitivity to glucocorticoids can mistakenly suggest a diagnosis of multiple sclerosis, and its complete disappearance or dramatic improvement on CT after steroid therapy is baffling. Radiosensitivity is a well-known feature of most primary CNS lymphomas, which almost always are of B cell origin.

- XIII-28. The answer is E.** (*Chaps. 360, 387*) When a patient presents with a generalized tonic-clonic seizure, it is important to consider alcohol as a potential etiology. Persons who heavily abuse alcohol may have seizures from a cerebral contusion or subdural hematoma caused by trauma, metabolic abnormalities, CNS infection, or alcohol withdrawal. Seizures taking place during alcohol withdrawal or binge drinking are usually brief tonic-clonic seizures that occur in a flurry of several over a short period of time. Once other causes for seizures in alcoholics are ruled out, it is not necessary to administer chronic antiepileptic treatment. First, such seizures tend to be self-limited and abate once withdrawal is complete or binge drinking has stopped. Second, the use of anticonvulsant medicines in this typically noncompliant group of patients with a host of other medical problems is fraught with the dangers of severe side effects.
- XIII-29. The answer is B.** (*Chap. 360*) Antiepileptic drugs commonly have a host of side effects. For example, phenytoin has a narrow therapeutic index and is associated with neurologic symptoms such as ataxia and nonneurologic symptoms such as gum hyperplasia, lymphadenopathy, hirsutism, and osteomalacia. Carbamazepine is notable for causing bone marrow suppression and gastrointestinal irritation as well as ataxia, dizziness, and vertigo. Phenobarbital enhances the metabolism of many other drugs via liver enzyme induction. In fact, carbamazepine levels, which are potentially increased by erythromycin, are decreased by phenobarbital. Especially if the phenobarbital is not destined to have a major therapeutic effect in this patient with complex partial seizures, the induction of a reduced carbamazepine level may actually lead to worse control. It may be necessary to increase the carbamazepine dose to achieve a therapeutic level in order to give the combination therapy an adequate trial. The bone marrow suppression of carbamazepine may produce a dose-dependent mild to moderate depression in the white blood count cell but is not notable for causing severe thrombocytopenia.
- XIII-30. The answer is D.** (*Chap. 28. Alward, N Engl J Med 339:1298–1307, 1998.*) Glaucoma is the leading cause of irreversible blindness in the world. When sufficient axonal loss occurs, peripheral vision declines. Loss of central vision occurs much later in the disease process. Retinopathy due to glaucoma is irreversible. Treatment is focused on lowering intraocular pressure. Reduction in intraocular pressure has been demonstrated to protect against further damage to the optic nerve. Primary open-angle is by far the most common type of glaucoma in the United States. Closed-angle glaucoma is more common among Asians. The Schiøtz tonometer, due to the fact that it is inexpensive, is the most frequently used device to measure intraocular pressure in the United States. It is used in both hospitals and outpatient clinics. β -Adrenergic antagonists are one of the more commonly used drugs and are initially begun as a topical agent. Unfortunately, excess drug drains through the nasolacrimal duct into the nose and is absorbed into the systemic circulation. Therefore systemic side effects can occur and may be severe. It is not unusual for patients to be treated with a bronchodilator drug for new-onset bronchospasms without the physician considering the use of topical β -adrenergic antagonist, used for glaucoma treatment, which may have contributed to the condition.
- XIII-31. The answer is E.** (*Chap. 361. Gilman, N Engl J Med 326:1671–1676, 1992.*) Transient ischemic attacks (TIAs) are caused by low flow in large vessels such as the internal carotid artery, embolism from an arterial or cardiac source, or lacunar (small penetrating vessel) atherosclerosis. As exemplified in this case, a low-flow TIA usually is brief and recurrent and is frequently due to a tightly stenotic atherosclerotic lesion at the internal carotid artery. Hypoperfused distal branches of the middle cerebral artery cause hip, shoulder, or arm weakness and possible aphasic symptoms, depending on the amount of territory

involved. Transient recurrent monocular blindness (amaurosis fugax) may also be a manifestation of an internal carotid artery occlusion. Embolic TIAs tend to be of longer duration than the low-flow TIAs described above. Lacunar TIAs occur because of blockage of one of the intracerebral penetrating vessels arising from the middle cerebral, basilar, or vertebral arteries. On the basis of the cerebral angiography performed in this case, it is apparent that the patient in fact had a low-flow TIA caused by a tightly stenotic lesion of the internal carotid artery. Heparin may be useful for impending stroke resulting from this pathophysiology, warfarin may be appropriate after embolic phenomena, and antiplatelet agents may have prophylactic value for secondary strokes. However, the procedure of choice in this case is carotid endarterectomy. If the lesion had not been tightly stenotic (<70% stenosis), the value of such surgery would have been less clear.

- XIII-32. The answer is D.** (*Chap. 361*) There are four major hypertensive hemorrhage syndromes. The most common site for bleeding is the internal capsule adjacent to the basal ganglia, which generally produces contralateral hemiplegia with eye deviation away from the side of the weakness. As the blood expands within the brain, stupor and coma may occur rapidly. Thalamic hemorrhage results in hemiplegia from pressure on the adjacent internal capsule as well as in a prominent sensory deficit. The eyes typically deviate downward and inward, and the pupils are unequal. Pontine hemorrhages produce a rapid onset of deep coma, quadriplegia, and pinpoint pupils that do not react to light. Cerebellar hemorrhages develop over several hours and are manifested by nausea, vomiting, vertigo, dizziness, and occipital headache. The eyes tend to deviate away from the hemorrhage; there may be an ipsilateral sixth nerve palsy, blepharospasm, or ocular bobbing. Cerebellar findings tend to be limited. It is important to recognize this lesion, since it is treatable until the point of coma from brainstem compression. While osmotic therapy to reduce intracranial pressure may be helpful, the most important therapy for such infratentorial clots is surgical removal. Neurosurgical therapy for acute supratentorial clots such as those which may be caused by a thalamic or capsular hemorrhage is more controversial because of the difficulty in reaching these central areas safely.
- XIII-33. The answer is D.** (*Chap. 362*) Very few diseases cause rapid dementia that is noticeable in a period of weeks. Among them are depression, metabolic encephalopathy, encephalitis, poisoning, Binswanger's disease (white-matter infarction), and Creutzfeldt-Jakob disease. (Alzheimer's disease has a more insidious onset.) Creutzfeldt-Jakob disease is a slow-virus infection that causes a spongiform change in the cerebral cortex; it is characterized by rapid dementia, startle myoclonus, and frequently signs of occipital and cerebellar disease. CT and CSF examination are nearly always normal in affected persons; after a period of time electroencephalography shows rapid, synchronous sharp waves, a diagnostic finding.
- XIII-34. The answer is D.** (*Chap. 371*) Optic neuritis is the initial symptom in approximately 40% of persons who are eventually diagnosed with multiple sclerosis. This rapidly developing ophthalmologic disorder is associated with partial or total loss of vision, pain on motion of the involved eye, scotoma affecting macular vision, and a variety of other visual-field defects. Ophthalmoscopically visible optic papillitis occurs in about half the cases.
- XIII-35. The answer is A.** (*Chap. 370. Black, N Engl J Med 324:1555–1564, 1991.*) Meningiomas are the most common type of benign brain tumor and account for 15% of primary CNS neoplasms. They may grow to an extremely large size before detection. Meningiomas most commonly present in women in the fifth or sixth decade. They may arise around the midline between the cerebral hemispheres, in the olfactory groove, and along the sphenoidal ridge, the foramen magnum, and the tentorium of the cerebellum. The neoplastic cells arise from pia or arachnoid tissue, though up to seven histologic subtypes have been identified. Cytogenetic analysis typically reveals abnormalities of chromosome 22. If possible, depending on the site, meningiomas should be totally removed surgically. Parasagittal tumors are usually resectable and have low recurrence rates. Chemotherapy plays no role, and radiation is reserved for postsurgical treatment for the rare malignant menin-

giomas and for symptomatic patients whose tumors cannot be excised completely. Meningiomas represent a stark contrast to primary high-grade malignant astrocytoma (glioblastoma), in which median survival, even with trimodality therapy, is little more than a year.

- XIII-36. The answer is E.** (*Chap. 370*) The most common tumors of the CNS by far are those derived from metastatic systemic cancer. The most common sources of intracerebral metastases are cancer of the lung in men and breast cancer in women. Melanoma, though a less common tumor, has a definite predilection for spread to the CNS. As patients fare better from the standpoint of their primary neoplasms compared with historic controls, as is the case for ovarian cancer or sarcoma, the incidence of intracerebral metastases rises. Headache, focal neurologic deficits, and seizures are common ways in which those with intracerebral metastases may present. Treatment usually consists of a combination of glucocorticoids and radiation therapy. However, patients with solitary lesions, particularly if they are asymptomatic in the presence of minimal systemic disease (particularly if there has been a disease-free interval >1 year), should be considered for surgical resection. Though most patients with metastatic cancer to the brain improve clinically and by radiographic evaluation after treatment, their 1-year survival is <20%. The presence of intracerebral metastases is actually a marker for advanced systemic disease, since the vast majority of these patients die not from complications of therapy or from the intracerebral tumor itself but from advanced recurrent systemic malignancy.
- XIII-37. The answer is E.** (*Chap. 366*) Bilateral conjugate eye movement to the side of the caloric stimulation indicates integrity of the brainstem pathways from the medulla to the midbrain (where the third nerve originates), as do full conjugate oculocephalic motions (doll's-eye maneuvers). The absence of the rapid corrective phase manifested by nystagmus-like leftward gazing indicates a bilateral hemispheric lesion. Failure of an eye to adduct properly in the initial phase of the caloric response indicates a lesion in the ipsilateral third nerve (midbrain) or in the medial longitudinal fasciculus producing internuclear ophthalmoplegia. In the former case, the pupil would be dilated and the eye would be abducted at rest.
- XIII-38. The answer is C.** (*Chap. 362. Yankner, N Engl J Med 325:1849–1857, 1991.*) Alzheimer's disease is the most common cause of dementia in the elderly. It is highly prevalent, affecting up to 45% of those over age 85. In a relatively small percentage of cases, the disease occurs in a familial pattern; this is thought to be due to autosomal dominant inheritance with linkage to chromosome 21 or 19. The clinical beginnings of the disease tend to be subtle. The initial symptoms are usually limited to loss of recent memory. Psychiatric symptoms may then supervene and can include depression, anxiety, delusions, and paranoid behavior. An extrapyramidal component exists so that patients walk in a shuffling manner with short steps. Radiographic evaluation usually reveals neuronal atrophy. Neuropathologically, the disease is characterized by neurofibrillary tangles, which may contain an abnormally phosphorylated form of a microtubular protein known as *tau*, as well as spherical deposits known as *senile plaques*. A protein known as β -amyloid can be found in these plaques. Certain families with inherited Alzheimer's disease have been found to harbor a point mutation in the amyloid precursor protein. From a neurotransmitter standpoint, acetylcholine, a neurotransmitter that is important in memory formation, is synthesized at abnormally low levels. The current model for the pathogenesis of Alzheimer's disease is that altered cleavage of the amyloid precursor protein generates the so-called β -amyloid protein, which then binds to a protease inhibitor–enzyme complex, in turn preventing the normal inactivation of extracellular proteases. It is these abnormally activated extracellular proteases that may mediate the neuronal degeneration characteristic of Alzheimer's disease. Therapeutic strategies that could inhibit the generation of β -amyloid are of potential therapeutic interest.
- XIII-39. The answer is A.** (*Chap. 363. Standaert, Med Clin North Am 77:169–183, 1993.*) Parkinson's disease is a chronic degenerative disease of middle-aged and elderly persons

that is characterized pathologically by a decrease in dopaminergic transmission in the caudate nucleus and putamen. Early manifestations of the disease include a unilateral rest tremor with a frequency of 4 to 5 per second. The tremor may progress to involve structures on both sides of the body, with eventual postural imbalance, profound restriction of movement, and eventual degeneration to a chair-bound existence. Total paralysis is highly uncharacteristic, and tendon reflexes as well as sensory examination are normal. The early stage of the disease can be treated with deprenyl, a monoamine oxidase inhibitor that slows disease progression. Treatment of more progressive Parkinson's disease requires dopamine replacement in the form of levodopa. Levodopa is given in combination with a dopa-decarboxylase inhibitor (carbidopa), which prevents bloodstream destruction of levodopa but is unable to pass through the blood-brain barrier. Carbidopa in combination with levodopa in a ratio of 1:4 or 1:10 (Sinemet) is available. Though costly, dopamine-receptor agonists such as bromocriptine may be used to lower the required dose of Sinemet. Anticholinergic drugs such as benztropine and trihexyphenidyl may constitute useful adjunctive therapy but must be used carefully because of the side effects of confusion, glaucoma, urinary retention, and progression of dementia. Amantadine, which causes the release of dopamine from presynaptic terminals, may also be useful early in the disease. Unfortunately, as the disease progresses, the therapeutic index of the levodopa-carbidopa combination decreases. If levodopa-induced hallucinations occur, clozapine may be helpful, although neutropenia may occur.

- XIII-40. The answer is A.** (*Chap. 25*) Most lesions that lead to aphasia, a disturbance in the production or comprehension of speech and language, occur in the dominant cerebral hemisphere. Ninety percent of people are right-handed; the left hemisphere is dominant in 95% of right-handed people, and 50% of those who are left-handed. Broca's, or major motor, aphasia denotes a syndrome in which the praxis of speech is severely disturbed. This problem usually results from a large lesion in the posterior frontal lobe along the insula and sylvian fissure, not simply in Broca's area in the inferior frontal lobe. Patients have great difficulty in articulation, grammar, and writing, though comprehension and fluency are relatively well preserved. Emboli of the superior division of the left middle cerebral artery are the most common cause of this syndrome.
- XIII-41. The answer is C.** (*Chap. 385. Shader, N Engl J Med 328:1398–1405, 1993.*) Anxiety symptoms are extraordinarily common in medical patients. Such symptoms may occur as a consequence of a primary psychiatric problem or may be due to drug therapy or medical illness. There are several different subcategories of anxiety disorders, including PTSD, phobic disorders (e.g., agoraphobia, social phobias, and simple phobias), obsessive-compulsive disorder, generalized anxiety disorder, and panic disorder. The most important feature of panic disorders is the sudden onset of overwhelming feelings of terror and fear associated with multiple symptoms, including dyspnea, palpitations, and faintness. Attacks usually occur away from home and tend to be recurrent. Panic disorder may well have a genetic basis insofar as it occurs to a greater degree in first-degree relatives. In addition to the elicitation of often complex medical workups for these dramatic symptoms, the morbidity of panic disorder often stems from its association with agoraphobia and the house-bound situation to which patients restrict themselves. Major depression, substance abuse, and suicide may complicate panic disorders. As in the case of a patient presenting with a generalized anxiety disorder, it is important to rule out a host of medical conditions. The list of such medical disorders is long and includes angina, carcinoid syndrome, hyperthyroidism, menopausal symptoms, mitral valve prolapse, pheochromocytoma, porphyria, pneumothorax, pulmonary embolus, and temporal lobe epilepsy. Complications also include the use or abuse of drugs such as alcohol, amphetamines, aminophylline, anticholinergics, antihistamines, caffeine, cocaine, glucocorticoids, monosodium glutamate, salicylates, and thyroid replacement drugs. The currently accepted theories concerning the etiology of panic disorder center on a genetic susceptibility to an environmental event that triggers adrenergic overload. While tricyclic antidepressants, monoamine oxidase inhibitors, and benzodiazepines are effective in the treatment of panic disorder,

the drug of first choice is usually a low dose of a tricyclic such as imipramine. The newer serotonin reuptake–inhibitor antidepressants, such as fluoxetine and sertraline, may also be effective. It is important to maintain patients with panic disorder on long-term medication because the relapse rate is very high if these medicines are discontinued. The only benzodiazepine approved for use in panic disorder is alprazolam; however, clonazepam is also useful, especially in view of its longer half-life. In fact, the benzodiazepines may be used to prevent the episodes while the tricyclic dose is being increased over the 1 to 2 weeks required to achieve full therapeutic efficacy.

- XIII-42. The answer is E.** (*Chap. 384*) Although a viral cause has been postulated, no clear-cut etiology has been demonstrated for chronic fatigue syndrome. Furthermore, while several subtle immunologic abnormalities have been documented in certain patients with this syndrome, there is no definitive diagnostic test. The diagnosis of chronic fatigue syndrome relies on the Centers for Disease Control and Prevention's working definition. A definitive diagnosis is based on the presence of both of the major criteria: persistent or relapsing fatigue that does not resolve with bed rest and is severe enough to reduce average daily activity by 50% percent and exclusion of other chronic conditions, including pre-existing psychiatric diseases. The physical examination must include two of the following three physical findings by a doctor on at least two occasions 1 month apart: low-grade fever, pharyngitis, and palpable lymphadenopathy. Finally, at least six of the common symptoms must be present; these symptoms include mild fever or chills, sore throat, painful lymph nodes in the cervical chains, muscle weakness, muscle discomfort, fatigue after minimal exercise, new headaches, arthralgias, neuropsychological symptoms, and sleep disturbance. Patients who do not have the required physical findings need to fulfill eight of the symptom criteria. Since there is no specific therapy for this disease, treatment requires an understanding of the patient and the avoidance of unproven therapies such as acyclovir, vitamin B₁₂, intravenous gamma globulin, and steroids. Treatment should be symptom-directed. Thus, NSAIDs, decongestants, and antidepressants may be helpful, depending on the symptoms. Finally, life-style modification, including a graded exercise program, minimal caffeine intake, and avoidance of complete rest, is advisable.
- XIII-43. The answer is B.** (*Chaps. 364, 387*) Acquired hepatocerebral degeneration is a neurologic syndrome that consists mainly of extrapyramidal signs. A well-known consequence of chronic liver disease, this disorder simulates Wilson's disease in many ways, including the presence of neuropathologic lesions in the cortex, basal ganglia, and other deep nuclei. Many cases become evident after a bout of hepatic encephalopathy, but others occur insidiously in persons who never have had encephalopathy.
- XIII-44. The answer is B.** (*Chap. 363*) The combination of autonomic insufficiency and parkinsonian symptoms is known as the Shy-Drager syndrome. The autonomic form of the Landry-Guillain-Barré syndrome causes acute autonomic paralysis but does not cause the parkinsonian symptoms of tremor at rest, bradykinesia, and rigidity. A number of antihypertensive agents cause orthostatic hypotension, but none cause parkinsonism. Micturition syncope is a condition in which syncope occurs because of vagal surge at the time of release of intravesicular pressure.
- XIII-45. The answer is E.** (*Chap. 385. Michels, N Engl J Med 329:552–560, 628–638, 1993.*) The outlook for patients with schizophrenic disorders has improved with the use of antipsychotic medications such as the phenothiazines, which include chlorpromazine, fluphenazine, and thioridazine. In particular, these medicines are useful for the treatment of the “positive” symptoms of schizophrenia, such as hallucinations and psychotic agitation. However, they are less useful against the “negative” symptoms typified by social withdrawal. In general, antipsychotic medications block dopamine neurotransmission in nigrostriatal structures. This dopamine blockade can induce extrapyramidal side effects that mimic Parkinson's disease. Although many antipsychotics have intrinsic anticholinergic action, which can result in dry mouth, hypotension, and urinary retention, the addition of

benztropine, another anticholinergic medicine used in the treatment of Parkinson's disease, may be effective in treating these extrapyramidal side effects. A particularly notable side effect of antipsychotic medicines is akathisia, which is characterized by obligatory movement of the extremities and motor restlessness. Akathisia may respond to the institution of beta-blocking drugs or antiparkinsonian agents but most likely would benefit from a decrease in the dose of the neuroleptic agent. The most common serious side effect of neuroleptic medicines is tardive dyskinesia, manifest by involuntary repetitive movements of musculature such as tongue thrusting and lip smacking. Involuntary limb movements and postural dystonia may also be part of this syndrome. While newer antipsychotic medications such as clozapine may have a role to play in the treatment or amelioration of tardive dyskinesia, currently the best approach is to lower the dose of the neuroleptic agent. Of course, such reductions may not be possible without exacerbation of the underlying thought disorder.

- XIII-46. The answer is B.** (*Chap. 362*) Huntington's chorea, which is inherited as an autosomal dominant trait, is characterized by dementia and choreiform movements. The motor disorder may include grimacing, respiratory spasms, speech irregularity, and a dancing, jangling quality in the gait. Laboratory workup is normal except that atrophy of the caudate nucleus may be seen on a carefully evaluated CT or MRI scan. Through the use of DNA linkage analysis, patients can be tested before disease development if this is appropriate from a psychosocial standpoint. The disease-specific gene is located on the short arm of chromosome 4.
- XIII-47. The answer is D.** (*Chap. 367*) Brief paroxysms of severe, sharp pains in the face without demonstrable lesions in the jaw, teeth, or sinuses are called tic douloureux, or trigeminal neuralgia. The pain may be brought on by stimuli applied to the face, lips, or tongue or by certain movements of those structures. Aneurysms, neurofibromas, or meningiomas impinging on the fifth cranial nerve at any point during its course typically present with trigeminal neuropathy, which will cause sensory loss on the face, weakness of the jaw muscles, or both; neither symptom is demonstrable in this patient. The treatment for this idiopathic condition is carbamazepine or phenytoin if carbamazepine is not tolerated. When drug treatment is not successful, surgical therapy, including the commonly applied percutaneous retrogasserian rhizotomy, may be effective. A possible complication of this procedure is partial facial numbness with a risk of corneal anesthesia, which increases the potential for ulceration.
- XIII-48. The answer is B.** (*Chaps. 81, 359, 370*) Neurofibromatosis type 1 is an autosomal dominant condition carried on the long arm of chromosome 17. It is characterized by tumors involving the sheaths of peripheral nerves and is associated with café au lait spots (tanned cutaneous flat lesions). The neurofibromas are rarely symptomatic, although they may occasionally entrap nerve roots. In addition to sarcomatous degeneration, CNS tumors, including optic glioma, glioblastoma, and meningioma, may occur in patients with neurofibromatosis. Mutations in the gene encoding the protein neurofibromin account for this disease. The structure of this protein suggests that it may have GTPase-activating properties and thus may be a tumor-suppressor gene. Neurofibromatosis type II, in which bilateral acoustic neuromas are found in addition to multiple neurofibromas, is believed to be caused by mutations in the gene that encodes the protein merlin, a 587-amino-acid cytoskeletal protein. Other neurologic disorders known to be caused by gene mutations include ocular retinoblastoma, which is caused by mutations in the Rb protein on chromosome 13; hexosaminidase A mutations, which account for Tay-Sachs disease; and KALIG-1 mutations, which give rise to Kallman's syndrome.
- XIII-49. The answer is C.** (*Chap. 375. Johnson, Gibbs Jr, N Engl J Med 339:1994–2004, 1998.*) Creutzfeldt-Jakob disease has obtained notoriety given the recent outbreaks of bovine spongiform encephalopathy. A number of transmissible spongiform encephalopathies have been described. Patients are clinically diagnosed in middle age. Most patients' express

vague feelings of fatigue, disrupted sleep, and anorexia. Approximately one-third of patients have more severe neurologic symptoms such as memory loss, confusion, and atypical behavior patterns. Ataxia, aphasia, visual loss, and hemiparesis are other common neurologic findings. The diagnosis of Creutzfeldt-Jakob disease is suggested by the clinical course of progressive diminishing cognitive function from a week-to-week basis. Patients often develop myoclonic jerking and myoclonus. The clinical progression of ataxia as well as choreoathetosis is noted. During the late stages of the disease the patient may become mute and akinetic. The mean survival time is only 5 months.

- XIII-50. The answer is C.** (*Chap. 375. Johnson, Gibbs Jr, N Engl J Med 339:1994–2004, 1998.*) Histologic examination of brain and immunostaining for prion protein is the “gold standard” for diagnosis of Creutzfeldt-Jakob disease. The critical features are spongiform changes accompanied by neuronal loss and gliosis. In virtually all cases, immunocytochemical staining for prion protein shows diffuse synaptic and perivacuolar staining.
- XIII-51. The answer is C.** (*Chap. 367*) Pain, loss of function (without clear-cut sensory or motor deficits), and a localized autonomic impairment are called reflex sympathetic dystrophy (also known as shoulder-hand syndrome, or causalgia). Precipitating events in this unusual syndrome include myocardial infarction, shoulder trauma, and limb paralysis. In addition to the neuropathic-type pain, autonomic dysfunction, possibly resulting from neuroadrenergic and cholinergic hypersensitivity, produces localized sweating, changes in blood flow, and abnormal hair and nail growth as well as edema or atrophy of the affected limb. Treatment is difficult; however, anticonvulsants such as phenytoin and carbamazepine may be effective, as they are in other conditions in which neuropathic pain is a major problem.
- XIII-52. The answer is E.** (*Chap. 369. White, N Engl J Med 327:1507–1511, 1992.*) Concussion, the transient loss of consciousness consequent to blunt impact to the skull, is believed to occur because of electrophysiologic dysfunction of the upper midbrain as a result of sudden movement of the brain within the skull. About 3% of those with concussions also have an associated intracranial hemorrhage, but the absence of a skull fracture decreases the risk. Amnesia for events just prior to the trauma is common, as are a single episode of emesis, severe bilateral frontal headache, faintness, blurred vision, and problems with concentration. However, minor injuries are characterized by an absence of neurologic signs, normal skull x-ray, and normal CT or MRI scans. In the absence of persistent confusion, behavioral changes, decreased alertness, or focal neurologic signs, patients may be discharged to be observed by responsible individuals. Several more worrisome clinical syndromes may accompany more severe head injury. Such symptoms are characterized by (1) delirium and wishing not to be moved, (2) severe memory loss, (3) focal deficit, (4) global confusion, (5) repetitive vomiting and nystagmus, (6) drowsiness, and (7) diabetes insipidus. Positive findings on CT scan or EEG would be common with these types of postconcussive syndromes, neurosurgical evaluation would be required, and prophylactic phenytoin, glucocorticoids, and haloperidol could be considered.
- XIII-53. The answer is C.** (*Chap. 369*) The cause of chronic subdural hematoma may be a trivial or inapparent injury, such as might be incurred after a sudden deceleration experienced in a motor vehicle accident. The symptoms are relatively nonspecific and usually are characterized by an intermittent headache accompanied by some degree of personality change, drowsiness, or confusion. This condition is easily confused with drug intoxication, stroke, dementia, and depression. For the patient in the question, however, the lack of focal findings argues against stroke, and the rapidity of onset would be unusual for dementia. CT scan does not define the hematomas, because they have become isodense with the passage of time (2 to 6 weeks since the injury); however, the absence of sulci and the small size of the ventricles, coupled with the clinical scenario, are highly suggestive of bilateral subdural hematomas. Surgical evacuation of the hematomas is the treatment of choice.

- XIII-54. The answer is C.** (*Chap. 369. White, N Engl J Med 327:1507–1511, 1992.*) Epidural bleeding may cause rapidly deteriorating mental status after an initial lucid interval following head trauma. Such hematomas occur in 1 to 3% of all head injuries. The typical profile of a patient with an acute epidural hematoma is that of an alcoholic who sustains severe trauma and fractures the squamous portion of the temporal bone, tearing the origin of dural vessels arising from the middle meningeal artery. Therefore, the most common location of an epidural hematoma is overlying the lateral temporal convexity. These hematomas expand rapidly because of the force of arterial bleeding, strip the dura from the attached inner table of the skull, and produce a characteristic bulge-type clot on CT. This dramatically evolving picture requires neurosurgical intervention, usually in the form of clot evacuation.
- XIII-55. The answer is D.** (*Chap. 373*) Rapidly progressive dementia with myoclonus is the hallmark of Creutzfeldt-Jakob disease. While most cases are sporadic, a small percentage are familial with an autosomal dominant pattern of inheritance. In addition to dementia, myoclonus, and cerebellar signs, the electroencephalogram shows a characteristic pattern, as described in the question. CT scanning or MRI is usually not specifically helpful except that the degree of dementia is out of proportion to the degree of radiographic brain loss. Definitive diagnostic accuracy requires a brain biopsy, which would show vascular degeneration, neuronal loss, and glial hypertrophy without significant inflammation. While Creutzfeldt-Jakob disease was formerly thought to be a disease of viral etiology, it is now accepted that the cause is the deposition of a proteinaceous infectious particle (prion) devoid of nucleic acid that is encoded by a gene on the short arm of human chromosome 20. The function of this protein is at present unknown, but certain mutations in this gene have been found in families with hereditary Creutzfeldt-Jakob disease.
- XIII-56. The answer is D.** (*Chap. 377*) Entrapment of the lateral femoral cutaneous nerve, which can occur at the site where it enters the thigh beneath the inguinal ligament near the anterior superior iliac spine, causes a sensory neuropathy known as *meralgia paresthetica*. The symptoms of this disorder, which typically occur in obese persons, include pain and decreased tactile sensation over the lateral aspect of the thigh. Treatment consists of infiltration with a local anesthetic or, if this procedure proves ineffective, surgical sectioning of the nerve.
- XIII-57. The answer is E.** (*Chap. 377*) The inflammatory response in Guillain-Barré syndrome strips myelin between the nodes of Ranvier in peripheral nerves. This phenomenon explains both the slowing of nerve conduction and the potential for recovery. Axons are destroyed only in extensively involved areas as a secondary phenomenon. To date, no convincing evidence has emerged to support the contention that the CNS is involved in Guillain-Barré syndrome.
- XIII-58. The answer is A.** (*Chap. 383*) Myotonia, muscle wasting, cataracts, testicular atrophy, and frontal baldness characterize the hereditary disorder myotonic dystrophy. The onset usually occurs in early adulthood. In affected persons, mental retardation is common, atrial arrhythmia is a frequent complication, and diabetes mellitus is more prevalent than it is in the general population. Myotonic dystrophy is the type of muscular dystrophy most commonly observed in hospitalized patients.
- XIII-59. The answer is B.** (*Chap. 383*) Oculopharyngeal dystrophy is a dominantly inherited disease that occurs in families of French-Canadian or middle European ancestry. Because it causes late-onset progressive ptosis and difficulty swallowing, it may be difficult to distinguish from myasthenia gravis, which is not a dystrophic muscle disease. Proximal weakness and ophthalmoplegia suggest the presence of a progressive external ophthalmoplegia.

- XIII-60. The answer is C.** (*Chap. 383*) Myotonia is a phenomenon in which brief, persistent contractions of a muscle occur after voluntary contraction or sometimes percussion. Myokymia refers to continuous small-muscle movement that is frequently difficult to distinguish from fasciculations. Fibrillation is the electromyographically detected spontaneous firing of muscle fibers and is not visible except in the tongue. Myoedema is a poorly defined sign, similar to myotonia, in which a ridge of percussed muscle remains contracted for 5 to 8 s. It was once thought to be related to hypoalbuminemia, but this relationship probably does not exist.
- XIII-61. The answer is B.** (*Chap. 16*) Malignancy in the pelvis not infrequently causes compression or infiltration of nerves exiting the spinal cord en route to the leg. This results in a stepwise progression of sensory and motor deficits in areas supplied by the involved nerve roots or trunks. Continuous pain in the distribution of a specific nerve or root is also common. In this patient the neurologic deficits began in an S1 distribution but then progressed to the L5 and finally the L4 roots, suggesting an expanding paravertebral mass. Isolated spontaneous activity of muscle fibers, called *fibrillations*, is characteristic of denervation. Nerve conduction will be normal in the leg if the lesion is proximal to the measuring electrodes, that is, in the pelvis. An expanding cortical mass may also cause progressive numbness in the foot and leg and may be missed on a CT scan that does not take cuts all the way up to the vertex. Back pain and neuropathic pain would not occur with a cortical lesion, and the reflexes under such circumstances should be hyperactive.
- XIII-62. The answer is D.** (*Chap. 380*) More than three-quarters of patients with myasthenia have circulating antibodies against components of the postsynaptic membrane, including acetylcholine receptors. Antibody action leads to an unfolding, or “simplification,” of the membrane and consequently a reduced number of acetylcholine receptors. As a result, existing acetylcholine in the synapse is less effective in producing muscle contraction.
- XIII-63. The answer is A.** (*Chap. 361. Fisher, Neurology 32:871–876, 1982.*) A pure motor hemiparesis on one side (with ipsilateral face and body involvement) and no other cortical deficits (aphasia or cortical sensory loss) suggests an internal capsular lesion. The major differential diagnosis in this setting is between a hypertensive hemorrhage and an internal capsular lacunar infarct. Both entities may present with a fluctuating course over hours; however, hemorrhages tend to produce some manifestation of increased intracranial pressure. Lacunar infarctions result from atherothrombotic and hyalinization changes in the penetrating branches of the circle of Willis, the middle cerebral artery stem, and the vertebrobasilar system. Apart from the internal capsule, common locations for lacunar infarctions include the thalamus, where they produce a pure sensory deficit, and the base of the pons, where they produce hemiparesis and dysarthria with a clumsy hand. CT scanning can document most supratentorial lacunar infarctions, whose size usually ranges from 0.5 to 2 cm.
- XIII-64. The answer is E.** (*Chap. 370*) The typical symptoms of neoplastic meningitis include headache, confusion, radiculopathy, and cranial nerve abnormalities in patients with a variety of tumors, including non-Hodgkin’s lymphoma, leukemia, melanoma, breast cancer, lung cancer, and stomach cancer. Given these symptoms, especially with a negative CT, MRI, or both, the diagnosis of leptomeningeal metastases from breast cancer is quite likely. A single lumbar puncture is a relatively insensitive test; repeat examinations of CSF are often required to establish the diagnosis of cancer that has spread to the meninges. Especially in cases where the cancer cells are “caked” onto the inferior portion of the brain, eradication by chemotherapy alone (usually methotrexate, thiopeta, or cytosine arabinoside) is difficult, and radiation therapy should be administered as well.
- XIII-65. The answer is E.** (*Chaps. 21, 383*) Fasciculations may occur in a variety of metabolic and toxic disorders, including amyotrophic lateral sclerosis, progressive bulbar palsy, rup-

tured intervertebral disk, and peripheral neuropathy. However, they should not be viewed with alarm in the absence of weakness, muscle atrophy, or loss of tendon reflexes. The best treatment a physician can offer a person who is asymptomatic except for fascicular twitches is reassurance and, if appropriate, advice to reduce coffee intake.

- XIII-66. The answer is C.** (*Chap. 377*) Although porphyric neuropathy may occur without involvement of the CNS, with acute paralysis there is frequently a history of confusion or coma. Predominantly a motor neuropathy, porphyric neuropathy can cause significant sensory loss in some persons. In this respect it may simulate inflammatory polyneuropathy, though inflammation does not occur. Curiously, protein concentration in CSF is usually normal in affected persons.
- XIII-67. The answer is C.** (*Chap. 12*) One of the most distressing sequelae of thalamic damage is a chronic pain syndrome (Déjerine-Roussy syndrome) that occurs months to a few years after the initial lesion. The findings of total hemianesthesia and loss of all sensory modalities in the face, arm, and leg are characteristic of thalamic infarction. Lesions of the spinothalamic tract may also cause neuropathic pain syndromes, but hemianesthesia of the face does not occur with spinal cord lesions. Parietal lobe lesions usually affect the cortical senses (i.e., two-point discrimination, graphesthesia, or stereognosis) rather than causing a total hemianesthesia. Depression is not commonly associated with burning pain. Tic douloureux is not associated with sensory loss.
- XIII-68. The answer is E.** (*Chap. 365. Prados, Neurology 43:751–755, 1993.*) Amyotrophic lateral sclerosis (ALS) is an untreatable disease that results in the progressive loss of upper and lower motor neuron function. Other components of the nervous system remain intact, including the neurons required for ocular motility. Limb weakness and cramping is the first symptom, followed by muscular atrophy, fasciculations, and loss of function of the cranial nerve musculature. Early in the disease, upper-tract signs may predominate, resulting in spasticity. Pneumonia resulting from failure of clearance of secretions is usually the terminal event. Treatable causes of motor neuron diseases such as cervical spondylosis (no bulbar involvement) and lead poisoning should be excluded whenever the diagnosis of ALS is considered. Guillain-Barré syndrome produces an ascending, rapidly developing paralysis. Vitamin B₁₂ deficiency should lead to abnormalities in posterior column function. Lambert-Eaton syndrome is a paraneoplastic neuromuscular disorder that does not feature upper-tract signs.
- XIII-69. The answer is D.** (*Chap. 383. Koenig, Cell 50:509–517, 1987.*) Duchenne's muscular dystrophy is an X-linked recessive disorder in which affected boys develop progressive weakness of limb girdle muscles beginning at age 5 or earlier. By age 12 walking is impossible, and these patients usually succumb to respiratory failure by age 25. Most muscular tissues, including cardiac tissues, are involved. An abnormally high creatine kinase level is found in all these patients before disease onset and in many female carriers. The responsible gene has been identified. This 2000-kb gene codes for a product termed *dystrophin*, a 400-kDa protein localized to the muscle plasma membrane. Since about 60% of these patients have an exon deletion or duplication in the dystrophin gene, it is possible to test directly for these genetic abnormalities in utero, obviating the need for more cumbersome family studies to determine RFLPs for linkage.
- XIII-70. The answer is D.** (*Chap. 382. Dalakas, N Engl J Med 325:1487–1498, 1991.*) This patient displays the characteristic heliotropic rash, with knuckle involvement and proximal muscle weakness, typical of dermatomyositis. Although a biopsy could be done, the disease is patchy and the absence of lymphocytic infiltration would not rule out the diagnosis. EMG is diagnostic in about 40% of affected persons. Since the diagnosis is straightforward and dermatomyositis is frequently associated with malignancy in those over age 60, it is reasonable to screen for cancer. In addition to the common epithelial malignancies, myeloproliferative disorders can be heralded by dermatomyositis. However, an

unfocused radiologic diagnostic attack definitely should be suspended in favor of the simple and cost-effective tests outlined in choice B. Although steroids probably will be symptomatically beneficial even in those with malignancies, their use probably should be delayed until the screening is completed. If an early neoplasm can be found and treated, the dermatomyositis may respond without the need to resort to the dangers of high-dose glucocorticoid therapy.

- XIII-71. The answer is D.** (*Chap. 387. Charness, N Engl J Med 321:442–454, 1989.*) Wernicke's encephalopathy is a consequence of thiamine (vitamin B₁) deficiency. Although it is most commonly observed in chronic alcoholics in this country, well-documented cases have occurred in prisoners of war in whom alcohol played no role. Certain areas in the thalamus, hypothalamus, midbrain, floor of the fourth ventricle, and cerebellar vermis are prone to destruction as a consequence of thiamine deficiency. While most patients present with some form of abnormal mental functioning, the classic triad of ophthalmoplegia, confusion, and ataxia is rarely encountered. As can be seen in autopsy series, many patients frequently go undiagnosed. When the diagnosis is suspected, thiamine should be administered before glucose, since glucose can precipitate worsening of the disease. Thiamine will relieve the ocular palsies within hours, although improvement in ataxia and in apathy and confusion takes longer. Many of those who recover from the acute encephalopathy will be left with a profound defect in memory and learning known as *Korsakoff's psychosis*.
- XIII-72. The answer is B.** (*Chap. 373*) SSPE is a rare disease in the United States. The incidence has declined significantly since the introduction of the measles vaccine. Most patients give a history of primary measles at an early age followed by a latent interval of approximately 6 to 8 years. Patients will typically present with progressive neurologic dysfunction, including personality changes as well as a decline in school performance. Many patients eventually develop generalized seizures and myoclonus and will eventually develop ataxia and visual disturbances. The EEG shows a characteristic periodic pattern with high-voltage bursts every 3 to 8 s. CT scan and MRI show evidence of multifocal white matter lesions, cortical atrophy, and ex vacuo ventricular enlargement. No definitive therapy is currently available, although the use of isoprinosone has been reported to prolong survival. PML is a progressive demyelinating disorder in patients with an underlying immunocompromised state. PML is a result of exposure to the JC virus. Tropical spastic paraparesis has been reported in patients with HTLV-I infection. HTLV-I is endemic to the Caribbean basin as well as Japan. Gerstmann-Straussler-Scheinker syndrome is a hereditary syndrome of spinocerebellar degeneration. The causative agent may be related to a prion protein.
- XIII-73. The answer is E.** (*Chaps. 16, 368*) A disk at the L2–L3 interspace would compress the L2 root. There may be weakness of hip flexion and sensory loss along the upper border of the thigh below the inguinal ligament. No tendon reflex is mediated by this root. A lesion of the L3 root would cause weakness of hip flexion and knee extension and sensory loss over the midportion of the anterior thigh. No tendon reflex is mediated by this root. A lesion of the L4 root would result in a depressed or absent patellar reflex, weakness of knee extension and foot dorsiflexion, and sensory loss over the anterior knee and the medial portion of the foreleg. A lesion of the L5 root would result in weakness of knee flexion, dorsiflexion of the ankle and great toe, and weakness of inversion and eversion of the foot. Sensory loss would be noted over the lateral aspect of the foreleg and the dorsal surface of the foot. A lateral disk protrusion at the S1–S2 interspace would compress the S1 nerve root. The S1 root mediates the Achilles tendon reflex, innervates part of the gastrocnemius, and provides sensation to the lateral aspect and sole of the foot.
- XIII-74. The answer is C.** (*Chap. 16*) A lesion of the L3 root would produce symptoms that include the anterior portion of the thigh. There may also be weakness of hip flexion and knee extension. The same is true for the femoral nerve. The saphenous nerve is the cutaneous sensory continuation of the femoral nerve and supplies the medial aspect of the

foreleg. The obturator nerve primarily supplies motor innervation to the thigh adductors but has a small sensory component at the medial thigh. The area described in the question corresponds to the lateral femoral cutaneous nerve. A lesion of this nerve is referred to as *meralgia paresthetica*. This nerve, which is made up of fibers from the L2 and L3 roots, travels over the bony rim of the pelvis and under the inguinal ligament to enter the thigh. It is a thin nerve that is easily compressed in patients with weight gain, those who wear a heavy work belt, and pregnant subjects. An intrapelvic mass may also cause compression of this nerve.

- XIII-75. The answer is E.** (*Chaps. 16, 365*) Choices A through D would involve depressed or absent reflexes and include sensory symptoms and signs on examination. A lesion of the common peroneal nerve would not cause weakness of foot inversion. The combination of subacute, painless distal muscle weakness with brisk tendon reflexes is most consistent with amyotrophic lateral sclerosis, a disease of unknown etiology in which there is loss of both upper and lower motor neurons.
- XIII-76. The answer is D.** (*Chap. 370*) An oligodendroglioma is a tumor that arises from oligodendrocytes in the white matter of the cerebral hemispheres. It is most common in early to middle adulthood. Although craniopharyngioma is more common in children than in adults, it commonly arises in a suprasellar location. Glioblastoma multiforme, the most aggressive glial tumor, is most commonly located within the cerebral hemispheres of older adults. Cerebellar hemangioblastoma, a tumor associated with von Hippel-Lindau syndrome, is usually cystic and rarely occurs in childhood. Medulloblastomas are commonly seen in childhood, are more common in males than in females, and arise from the cerebellar vermis. In contrast, when seen in adults, medulloblastomas frequently occupy the cerebellar hemispheres.
- XIII-77. The answer is D.** (*Chap. 364. Martin, N Engl J Med 340:1970–1980, 1999.*) Friedreich's ataxia is an autosomal recessive disorder. It is caused by an increase in the number of trinucleotide GGA repeats. The Friedreich's ataxia gene is found on chromosome 9 and encodes the protein frataxin. This disorder is characterized by onset within the first two decades of life. Patients typically present with limb ataxia, cerebellar dysarthria, hyporeflexia, and sensory loss. The majority of patients have skeletal deformities as well as hypertrophic cardiomyopathy. Patients also have an increased incidence of blindness, deafness, and diabetes mellitus. The latter suggests that this disorder may be systemic and not limited to the CNS.
- XIII-78. The answer is A.** (*Chap. 25*) Gerstmann's syndrome results from a lesion of the dominant parietal lobe and consists of dysgraphia, acalculia, finger agnosia, and loss of or difficulty with left-right discrimination. Prosopagnosia, or the inability to recognize faces, results from bilateral damage to the visual association areas of the occipital lobe.
- XIII-79. The answer is A.** (*Chap. 25*) Wernicke's aphasia is caused by a lesion in the posterior superior temporal gyrus of the dominant hemisphere. It is characterized by impaired language comprehension, inability to repeat, and fluent speech output with paraphasic errors. The only associated neurologic sign may be a right superior quadrantanopia secondary to the proximity of the inferior optic radiation to Wernicke's area in the left temporal lobe.
- XIII-80. The answer is B.** (*Chap. 370*) Tuberos sclerosis is characterized by cutaneous lesions, seizures, and mental retardation. Gene carriers are at an increased risk of developing ependymomas as well as childhood astrocytomas, most of which are subependymal giant cell astrocytomas. Patients with Von Hippel-Lindau syndrome are at an increased risk for the development of renal cell carcinoma and pheochromocytomas. Patients with neurofibromatosis are at an increased risk of meningiomas as well as schwannomas and astrocytomas.

- XIII-81. The answer is E.** (*Chap. 367*) A lesion of the right frontal lobe involving the cortical gaze center would result in a gaze preference to the right. A left labyrinthine lesion would cause bilateral nystagmus and vertigo. The rostral interstitial nucleus of the medial longitudinal fasciculus (MLF) controls vertical gaze, which is not affected in this case. A lesion of the left occipital cortex would result in a right homonymous hemianopia. The MLF connects the horizontal gaze center in the pons with the oculomotor nuclei. Lesions of the MLF, which are common in multiple sclerosis, result in an internuclear ophthalmoplegia, or failure of adduction of the eye on the side of the lesion, accompanied by contralateral nystagmus.
- XIII-82. The answer is D.** (*Chap. 25*) The syndrome described in the question is alexia without agraphia. This clinical syndrome is caused by isolation of the intact language network in the left hemisphere from visual input secondary to damage to the left occipital lobe and a posterior portion of the splenium of the corpus callosum. Damage to the left occipital lobe results in a right homonymous hemianopia and occasionally color anomia. The patient is unable to read because visual input to the intact right occipital lobe cannot reach the language network in the left hemisphere as a result of the interruption of crossing fibers in the splenium. There is most frequently a cerebrovascular etiology.
- XIII-83. The answer is B.** (*Chaps. 15, 28, 362*) Headache associated with papilledema and a sixth nerve palsy points to increased intracranial pressure. A normal cranial MRI, with the exception of “slit-like” ventricles, and increased CSF pressure along with normal CSF parameters are consistent with a diagnosis of pseudotumor cerebri, or benign intracranial hypertension. Those affected are usually young obese females. Although cases are idiopathic, an underlying venous thrombosis may be present; this may be associated with an inherited coagulopathy with or without the use of oral contraceptives. Other precipitants include vitamin A and vitamin D intoxication, the use of tetracycline antibiotics and lithium, and the use or tapering of glucocorticoids. After treatment of the underlying disorder, if any, treatment may include serial lumbar punctures, a carbonic anhydrase inhibitor, optic nerve sheath fenestration, or a lumboperitoneal shunt. Treatment is undertaken to relieve the symptoms and preserve vision, which may be compromised by chronic papilledema. For this reason, these patients should have full visual field testing at presentation and ophthalmologic follow-up.
- XIII-84. The answer is C.** (*Chap. 364*) Friedreich’s ataxia (FA) is the most common of the inherited spinocerebellar ataxias, displaying autosomal recessive inheritance. The molecular defect was recently shown to involve a GAA trinucleotide repeat expansion on chromosome 9. Affected persons usually present with progressive ataxia before age 25. Other symptoms include progressive dysarthria, pyramidal-type weakness with bilateral extensor plantar responses, posterior column sensory loss, and an axonal sensory polyneuropathy with absent deep tendon reflexes in the lower extremities. Scoliosis and pes cavus (skeletal deformities) may also be seen in these patients. Nearly all FA patients have abnormal ECGs, and many experience supraventricular tachyarrhythmias secondary to cardiac involvement. Diabetes mellitus and glucose intolerance are more common in FA patients than in the general population. Patients with ataxia telangiectasia have a DNA repair defect, and this syndrome is associated with an increased incidence of cancer.
- XIII-85. The answer is C.** (*Chaps. 65, 368. Botto et al, N Engl J Med 341:1509–1519, 1999.*) Spina bifida occurs in approximately 1 in 1000 pregnancies in the United States and affects ~300,000 children worldwide. Approximately 20% of affected infants have additional congenital abnormalities. Chromosomal abnormalities, single-gene mutations, and teratogenic causes can be identified in <10% of affected children. Myelomeningocele is the most common type of spina bifida and is characterized by herniation of the spinal cord, nerves, or both through a bony defect of the spine. Spina bifida occulta is the mildest form of spina bifida. It occurs most often in S1, S2, or both and is characterized by a bony

defect of the spine that is usually covered by normal skin. A meningocele, a third type of spina bifida, is a sacular herniation of meninges and CSF through a bony defect in the spine. Spina bifida occurs more commonly in whites. Recent data suggest that infants of women who consume at least 400 mg of folic acid daily during pregnancy have a decreased incidence of neural-tube defects.

- XIII-86. The answer is E.** (*Chap. 12*) All the tricyclic antidepressants listed in the question are moderately effective in relieving neuropathic pain. Desipramine is the least sedating among these choices.
- XIII-87. The answer is A.** (*Chaps. 12, 388*) Abdominal CT might demonstrate an abscess just beneath the diaphragm on the left. This process irritates the diaphragm, causing hiccups and referred pain to the left shoulder. The convergence of the visceral and cutaneous sensory inputs onto a single spinal pain transmission neuron is the anatomic basis of the referred pain. Spinal pain transmission neurons at the C3, C4, and C5 levels receive cutaneous input from the shoulder and visceral input from the diaphragm. Because pain sensation usually comes from the skin, activity evoked in spinal pain neurons from visceral structures is mislocalized by the patient to the dermatome innervated by the same spinal segment (so-called referred pain). The other tests listed in the question would not reveal the visceral irritant that produces his symptoms.
- XIII-88. The answer is C.** (*Chap. 24*) In the evaluation of a comatose patient, eye movements provide invaluable information about the function of the CNS and can help localize the cause of coma to hemispheric versus brainstem. The evaluation described in the question is the oculovestibular reflex, which gives the examiner information about the eye movement circuit from the external auditory canal to the pons and midbrain. In an awake patient with normally functioning hemispheres and brainstem, irrigation of one external auditory canal with cool water results in a tonic conjugate gaze of both eyes toward the side of the irrigation, followed by a fast corrective saccade in the reverse direction. If the patient has suffered bihemispheric damage (e.g., anoxic, metabolic), as in this case, the tonic deviation occurs without the quick corrective saccade.
- XIII-89. The answer is B.** (*Chaps. 28, 328*) This scenario is most consistent with a pituitary tumor compressing the optic chiasm and causing a bitemporal hemianopia. This midline tumor would initially compress the center of the chiasm, damaging the retinal fibers arising from the nasal portion of the retina, which cross in the chiasm. These nasal retinal fibers carry information from the temporal visual fields.
- XIII-90. The answer is C.** (*Chaps. 28, 88*) The classic triad of Horner's syndrome consists of ipsilateral miosis, ptosis, and anhidrosis. However, the anhidrosis is often absent or difficult to appreciate. The majority of cases are idiopathic, but Horner's syndrome may be caused by a neoplasm impinging on the sympathetic chain or sympathetic cervical ganglia. Damage to the sympathetic contribution to the third cranial nerve results in paresis of the iris dilator muscle. Given this patient's history of smoking and lack of any other abnormalities on examination that would raise a suspicion of intracerebral pathology, a chest x-ray to look for an apical tumor (Pancoast's tumor) compressing the sympathetic chain or superior cervical ganglion would be the next best step in the workup.
- XIII-91. The answer is E.** (*Chap. 371. Rudick et al, N Engl J Med 337:1604–1611, 1997.*) This clinical scenario is consistent with the diagnosis of multiple sclerosis. The disease affects middle-aged women more commonly than men and may have an insidious onset of symptoms. This patient has optic neuritis with visual loss; it typically begins as blurring of the central visual field, which may remain as a mild abnormality or progress to severe visual loss. Complete loss of vision is a rare finding. The patient also presents with a mild sensory loss. It is important to note that visual blurring in multiple sclerosis may result from either optic neuritis or diplopia. The two causes can be distinguished on physical

exam. Diplopia in multiple sclerosis is often due to an internuclear ophthalmoplegia (INO) or to a sixth-nerve palsy. This patient has the typical finding of T2-weighted bright signal abnormalities in the white matter, which is characteristic in patients with multiple sclerosis. CSF abnormalities consist of a mononuclear cell pleocytosis. CSF cell counts are typically $<20/\text{mL}$, and the finding of polymorphonuclear leukocytes in the CSF makes the diagnosis of multiple sclerosis unlikely. Occasionally multiple sclerosis patients exhibit mild elevations in the total CSF protein content; however, in $\sim 80\%$ of patients the CSF total protein level is normal. Oligoclonal banding of CSF IgG agarose gel electrophoresis is a hallmark finding in patients with multiple sclerosis. Two or more oligoclonal bands are found in 75 to 90% of patients with multiple sclerosis. It is extremely important that paired serum samples be studied to exclude a systemic origin of the oligoclonal bands.

- XIII-92. The answer is D.** (*Chap. 371. Rudick et al, N Engl J Med 337:1604–1611, 1997.*) Adverse prognostic features that predict a more severe clinical course include progression of disease from the onset of symptoms, motor and cerebellar signs at presentation, a short interval between the first two relapses, poor recovery from a clinical relapse, and the presence of multiple cranial lesions on T2-weighted MRI at presentation. Patients with multiple cranial MRI lesions are much more likely to have major disability later on in their clinical course.
- XIII-93. The answer is B.** (*Chaps. 25, 370*) A tumor located in the left posterior frontal lobe (Broca's area) might be expected to result in nonfluent aphasia and a right hemiparesis involving the face and arm to a greater degree than the leg. Damage to the posterior superior left temporal gyrus (Wernicke's area) would result in fluent aphasia and possibly a right superior quadrantanopia. A tumor located in the right parietal lobe may cause a syndrome of left hemineglect and denial of the deficit (anosagnosia). A lesion of the right basal ganglia would result in a contralateral movement disorder. The syndrome described in the question is motor aprosodia, or the inability to convey emotional meaning through melodic stress and intonation, while the ability to produce grammatically correct language remains intact. This situation results from involvement of the right frontal lobe.
- XIII-94. The answer is E.** (*Chaps. 26, 362*) All the choices given in the question are causes of or may be associated with dementia. Binswanger's disease, the cause of which is unknown, often occurs in patients with long-standing hypertension and/or atherosclerosis; it is associated with diffuse subcortical white matter damage and has a subacute insidious course. Alzheimer's disease, the most common cause of dementia, is also slowly progressive and can be confirmed at autopsy by the presence of amyloid plaques and neurofibrillary tangles. Creutzfeldt-Jakob disease, a prion disease, is associated with a rapidly progressive dementia, myoclonus, rigidity, a characteristic EEG pattern, and death within 1 to 2 years of onset. Vitamin B₁₂ deficiency, which often is seen in the setting of chronic alcoholism, most commonly produces a myelopathy that results in loss of vibration and joint position sense and brisk deep tendon reflexes (dorsal column and lateral corticospinal tract dysfunction). This combination of pathologic abnormalities in the setting of vitamin B₁₂ deficiency is also called *subacute combined degeneration*. Vitamin B₁₂ deficiency may also lead to a subcortical type of dementia. Multi-infarct dementia, as in this case, presents with a history of sudden stepwise declines in function associated with the accumulation of bilateral focal neurologic deficits. Brain imaging demonstrates multiple areas of stroke.
- XIII-95. The answer is B.** (*Chaps. 21, 229*) Stokes-Adams attacks are a form of cardiac syncope resulting from a high degree of atrioventricular block, which may be persistent or intermittent. Usually there are no premonitory symptoms with these attacks, which occur when cardiac asystole lasts longer than ~ 8 s. Prompt and complete recovery after the attacks is the rule, with focal neurologic signs being rare. These episodes may occur several times per day, and an ECG taken between attacks may be normal as a result of the transitory nature of the atrioventricular block. This disorder is not familial. Recurrent paroxysmal

tachyarrhythmias are another cause of cardiac syncope, which results from a sudden drop in cardiac output.

- XIII-96. The answer is C.** (*Chap. 378. Ropper, N Engl J Med 326:1130–1136, 1992; Rees et al, N Engl J Med 333:1374–1379, 1995.*) The Guillain-Barré syndrome is the most common cause of acute neuromuscular paralysis. The organism that has most frequently been associated with Guillain-Barré syndrome is *C. jejuni*, a gram-negative rod that is now the most common cause of bacterial gastroenteritis in developed countries. The Guillain-Barré syndrome typically begins with fine paresthesias in the toes or fingertips. This is followed within days by leg weakness that makes walking and climbing stairs difficult. Weakness usually ascends from the thighs to the arms in a matter of days. Pain is a common finding and is described as consistent with bilateral sciatica. On examination patients typically have symmetric limb weakness, bilateral weakness of facial muscles, absent or greatly diminished tendon reflexes, and minimal loss of sensation despite the presence of paresthesia.
- XIII-97. The answer is C.** (*Chap. 378. Ropper, N Engl J Med 326:1130–1136, 1992; van der Meche, Schmitz, N Engl J Med 326:1123–1129, 1992.*) All patients with Guillain-Barré syndrome should be observed in the hospital for several days. Formerly, the standard of care of treatment was the use of glucocorticoids, but in a randomized controlled trial using conventional doses of prednisolone for 2 weeks and in another study using high-dose intravenous methylprednisolone no benefit was found, and glucocorticoids can no longer be considered useful therapy for Guillain-Barré syndrome. The time to neurologic recovery and the duration of mechanical ventilation were found to be decreased by 50% by plasma exchange in several studies, and plasma exchange is now the standard treatment option. The type of replacement fluid, usually saline or albumin, does not seem to influence the outcome. A recent study demonstrated the efficacy of daily infusions of IVIg. IVIg is at least as effective as plasma exchange and is preferred in patients who are clinically unstable because of its ease and rapidity of administration. No significant benefit is derived from the use of cyclophosphamide or azathioprine.
- XIII-98. The answer is B.** (*Chaps. 24, 376. Levy et al, JAMA 253:1420–1426, 1985.*) Most patients sustaining cardiac arrest either undergo irreversible asystole or reawaken quickly and make a good physical as well as neurologic recovery. However, a few patients will experience severe brain injury and remain in a postcardiac arrest coma. Poor outcome can be predicted 24-h after the onset of coma by motor responses that are either absent, extensor, or flexor. Spontaneous eye movements that are neither orienting nor roving conjugate also predict a poor neurologic recovery. Patients with these neurologic findings on examination have a <1% chance of a meaningful neurologic recovery. This contrasts with patients who at 24-h post-onset of coma show improvement in their eye-opening responses and are able to obey commands or have motor responses that are withdrawal or localizing.
- XIII-99. The answer is C.** (*Chap. 27*) Structures A through C and E have all been implicated in the generation of wakefulness or EEG arousal. The generation of sleep, by contrast, has been localized to the thalamus, the medullary reticular formation, or the basal forebrain. The emboliform nucleus is one of the “roof nuclei” of the cerebellum and has not been implicated in the generation of circadian rhythms.
- XIII-100. The answer is D.** (*Chap. 382*) The syndrome described in the question is pediatric dermatomyositis, an inflammatory myopathy. It is characterized by myalgias, proximal weakness, a “heliotrope” rash over the malar aspect of the face and extensor surfaces, elevated ESR, and response to glucocorticoids. The pathologic hallmark on muscle biopsy is perifascicular atrophy, which is thought to be due to preferential inflammation of the perifascicular capillaries. Fiber type grouping, on the other hand, is the pathologic signature of neurogenic muscle disease. In adults, dermatomyositis is associated with an underlying

malignancy at a rate of approximately 20 to 30%. This is not true of childhood dermatomyositis.

- XIII-101. The answer is E.** (*Chaps. 15, 361. Edlow, Caplin, N Engl J Med 342:29–36, 2000.*) The patient's presentation is consistent with a subarachnoid hemorrhage, which typically presents as a sudden onset of severe headache, frequently described as being the worst headache of the patients' life. Occasionally a transient loss of consciousness accompanies the headache. Physical exam may show retinal hemorrhages, nuchal rigidity, diminished levels of consciousness, or focal neurologic signs. Patients with these classic findings present little diagnostic difficulty. However, many patients present with some but not all of the above findings. Approximately 20 to 50% of patients with documented subarachnoid hemorrhage report a distinct, unusually severe headache in the days or weeks before the index episode of bleeding, referred to as the *warning headache*. The so-called thunderclap headache develops in seconds and achieves maximal intensity in minutes. These headaches may last hours to days. The differential diagnosis of a thunderclap headache is broad and includes subarachnoid hemorrhage, an acute expansion dissection, thrombosis of an unruptured aneurysm, or cerebral venous sinus thrombosis. All patients with thunderclap headaches should be evaluated for a possible subarachnoid hemorrhage.
- XIII-102. The answer is C.** (*Chap. 361. Edlow, Caplin, N Engl J Med 342:29–36, 2000.*) Lumbar puncture should be performed in patients whose clinical presentation suggests a subarachnoid hemorrhage and whose CT scan is negative, equivocal, or technically inadequate. The CSF pressure should always be measured. High intracranial pressure is an important clue in the occasional patient with cerebral venous sinus thrombosis or pseudotumor cerebri. After an aneurysmal hemorrhage, erythrocytes rapidly disseminate throughout the subarachnoid space. Released hemoglobin is metabolized to the pigmented oxyhemoglobin, which is reddish-pink in color. This process results in xanthochromia. The presence of xanthochromia is the primary criterion for a diagnosis of a subarachnoid hemorrhage in patients with a negative CT scan.
- XIII-103. The answer is E.** (*Chap. 29*) Localization of the tone in the affected ear when the tuning fork is placed in the midline position (Weber's test) suggests unilateral conductive loss (external or middle ear), while perception in the unaffected ear suggests sensorineural hearing loss. A tone heard louder by bone conduction than by air conduction (Rinne's test) also suggests conductive rather than sensorineural hearing loss. Assuming that the patient's bone conduction is normal (since he perceived the tone when the fork was at the mastoid process) and that only his air conduction is diminished, one can presume that the lesion is in the external auditory canal or the middle ear. A common cause of conductive hearing loss in the elderly is otosclerosis (stapes footplate fusion), which is potentially treatable by surgical reconstructive procedures involving the middle ear.
- XIII-104. The answer is A.** (*Chaps. 356, 380*) Conventional electromyography (EMG) and nerve conduction studies as well as muscle biopsy procedures are not useful in an evaluation of myasthenia gravis, because myasthenia is not a disease of muscle or nerve. (Electron microscopy of muscle can show unfolding of the postsynaptic muscle membrane, but this procedure is not commonly done.) Curare testing to precipitate myasthenic weakness is dangerous, un dependable, and mainly of historic interest. Single-fiber EMG measures the timing of firing of two fibers in the same motor unit. The timing between pairs is inconsistent in myasthenia, giving rise to "jitter" in the oscilloscope tracing; this finding is virtually diagnostic of myasthenia. Repetitive stimulation of motor nerves to observe a decremental response also is a useful procedure in testing for myasthenia gravis.
- XIII-105. The answer is C.** (*Chap. 16. Deyo, Weinstein, N Engl J Med 344:363–370, 2001.*) The patient has a history of multiple episodes of lower back pain, which were self-remitting. The patient's current episode is constant and more severe than prior episodes. His neurologic examination, however, is worrisome because of a cauda equina syndrome, as

manifested by “saddle” sensory deprivation. Patients with sensory or motor neurologic involvement consistent with cauda equina syndrome should be evaluated for prompt neurosurgical evaluation in order to relieve the stress on the distal nerve root.

- XIII-106. The answer is A.** (*Chaps. 21, 365*) The distinction between upper motor neuron and lower motor neuron lesions is critical in clinical medicine. Lesions proximal to the anterior horn cells (in general, the cerebral motor cortex or the corticospinal tract) produce the characteristic upper motor neuron syndrome of spasticity, increased reflexes, and an extensor plantar response (Babinski’s sign). By contrast, atrophy of the muscles in a paretic limb suggests lower motor neuron disease. Such disorders, which may affect individual muscles, are accompanied by fascicular twitches, which are manifestations of the hyperactivity of the diseased motor unit(s).
- XIII-107. The answer is B.** (*Chaps. 21, 367. Lang, Lozano, N Engl J Med 339:1044–1053, 1998.*) Rest tremor, which frequently is associated with Parkinson’s disease, occurs at a rate of four to five beats per second. The rest tremor of Parkinson’s disease is associated with flexed posture, slowness of movement, rigidity, postural instability, and suppression by willful activity. Many tremors that worsen during movement are exaggerations of the normal physiologic tremor. The essential-familial tremor is a faster action tremor (~8 Hz) that is responsive to moderate doses of alcohol or β -adrenergic blockade.
- XIII-108. The answer is A.** (*Chap. 360. Devinsky, N Engl J Med 340:1565–1570, 1999.*) Absence seizures (petit mal) are characterized by sudden, brief lapses of consciousness. The seizures typically last for only seconds, consciousness rapidly returns, and patients typically have preservation of postural control. There is no postictal confusion. Nevertheless, absence seizures are a form of a generalized seizure disorder, and the first-line antiepileptic pharmacologic therapy should include ethosuximide or valproic acid. Second-line therapy includes lamotrigine.
- XIII-109. The answer is B.** (*Chaps. 365, 368*) Several disorders produce chronic progressive spinal cord disease with sensory and motor involvement. Syndromes of spinocerebellar degeneration may involve the motor and sensory spinal cord systems in addition to causing ataxia. Multiple sclerosis usually causes a relapsing illness but can cause a progressive, usually cervical myelopathy in elderly women. Cervical spondylosis, or bony compression of the cervical cord by osteophytic bars, is another common cause of myelopathy in the elderly. Lumbar disk compression of the cauda equina, which is made up of peripheral nerves, does not cause spinal cord signs. Amyotrophic lateral sclerosis is a disease of spinal cord motor neurons and corticospinal tracts but has no sensory signs. Kennedy’s disease is an x-linked spinobulbar muscular atrophy in which there is progressive weakness and wasting of the limb and bulbar muscles. Adult Tay-Sach’s disease is a very slowly progressive disarthria with radiographically evident cerebellar atrophy.
- XIII-110. The answer is E.** (*Chaps. 367, 389*) Bilateral lateral-rectus palsies that develop acutely in alcoholic persons should suggest Wernicke’s encephalopathy, which requires prompt treatment with thiamine. Bilateral sixth-nerve malfunction may be a falsely localizing sign resulting from increased intracranial pressure, as in subdural hematoma, but does not occur as an isolated disturbance caused by intrinsic brainstem diseases (e.g., hemorrhage). Orbital fractures usually entrap the fourth nerve, less commonly the sixth; only rarely is the palsy bilateral. Although neurosyphilis can cause cranial nerve palsies from adhesive meningitis, palsy of oculomotor-related nerves is a rarity.
- XIII-111. The answer is E.** (*Chap. 361*) Unilateral occlusion of a vertebral artery typically results in Wallenberg’s lateral medullary syndrome. With an infarct on the left, this is likely to include damage to the left ninth and tenth cranial nerves, the left inferior cerebellar peduncle, and the spinothalamic fibers subserving pain and temperature on the right side. Vertigo and nystagmus are common since the lower vestibular complex may be affected.

Horner's syndrome is also common with a smaller pupil and ptosis *ipsilateral* to the lesion. Only rarely is the medullary pyramid involved (Babinski-Nageotte syndrome), which results in a *contralateral* hemiparesis that spares the face; hypoglossal weakness may then be present ipsilateral to the lesion. Lesions of the median longitudinal fasciculus that produce internuclear ophthalmoplegia occur in the pons and midbrain in the territory of branches of the basilar artery. The uvula would deviate to the right. The motor strip is typically uninvolved in this disorder.

- XIII-112. The answer is A.** (*Chap. 367*) Cranial nerves III, IV, and VI all pass through the cavernous sinus, so that complete ophthalmoplegia, including ptosis, may result from a disease process there. Since the supraorbital and maxillary divisions of the fifth nerve, but not the mandibular branch, pass through the cavernous sinus, the brow and cheek may be numb, but not the chin. The optic nerve will be involved only if the process extends superiorly. Sensation and motor involvement of the palate and oropharyngeal muscles involve cranial nerves IX and X, and these cranial nerves do not transgress the cavernous sinus.
- XIII-113. The answer is D.** (*Chap. 360. Callahan, N Engl J Med 318:942–946, 1988.*) Although many patients with epilepsy require anticonvulsants throughout life, about half remain seizure-free long enough to warrant a trial without medications, many of which have imposing side effects. Favorable prognostic factors for remaining seizure-free include few seizures before control is attained, control on single first-choice drug therapy, a history of simple partial seizures or primary generalized seizures, the absence of a structural lesion, and a normal EEG before drug withdrawal. Even if a patient has had a long seizure-free interval (around 2 years) and has a good chance of remaining seizure-free without anticonvulsants, the drug should be tapered over 3 to 6 months. Moreover, the patient and the physician should be aware of the consequences of a relapse and should be willing to accept the risk. About 60% of adults and 70% of children will remain seizure-free after discontinuation of their medication.
- XIII-114. The answer is C.** (*Chaps. 341, 365, 385*) Lithium has revolutionized the treatment of bipolar affective disorders. It is effective both during acute mania and in the prevention of recurrent attacks. Although side effects—particularly gastrointestinal upset, mild tremor, and thirst—are common, the drug is safe if used carefully. The lithium dose should be titrated to serum levels: control of mania should be achieved at a level between 0.8 and 1.4 mmol/L, and maintenance levels should be between 0.6 and 1.0 mmol/L. Lithium intoxication is manifested by depression of mental status; treatment is mainly supportive. Other important long-term side effects include hypothyroidism (by inhibiting the secretion of thyroid hormone) and renal complications. Effects on the renal tubules produce nephrogenic diabetes insipidus with polyuria, polydipsia, and impaired urinary concentrating ability in about 25% of patients on the drug. Lithium can induce hypercalcemia in ~10% of patients. The hypercalcemia is dependent on the concurrent use of lithium and typically resolves with its discontinuation.
- XIII-115. The answer is C.** (*Chap. 360. Devinsky, N Engl J Med 340:1565–1570, 1999.*) The long-term use of valproic acid may cause polycystic ovaries and hyperandrogenism. In addition, long-term side effects include ataxia, sedation, hepatotoxicity, and thrombocytopenia. The side effects of long-term use of phenytoin include gingival hyperplasia, hirsutism, ataxia, and cerebellar dysfunction. The long-term use of carbamazepine gives rise to ataxia, diplopia, aplastic anemia, and hepatotoxicity. The long-term use of phenobarbital has been implicated in connective-tissue disorders such as frozen shoulder syndrome and Dupuytren's contracture. In addition, phenobarbital may cause increased sedation and confusion as well as depression.
- XIII-116. The answer is D.** (*Chap. 362. Mayeux, Sano, N Engl J Med 341:1670–1679, 1999.*) The definitive diagnosis of Alzheimer's disease remains illusive. Dementia is established

by examination as well as by documentation of subjective testing. All patients with Alzheimer's disease have impairment in their memory and have at least one other cognitive function that is impaired, e.g., language or perception. Patients typically have worsening of their memory loss. Patients should not have an alteration of consciousness. The onset of Alzheimer's disease occurs between the ages of 40 and 90, and the absence of other brain disorders or systemic disease that may cause dementia should be established. In addition, the diagnosis of Alzheimer's disease is supported by the loss of motor skills, diminished independence and activities of daily living, altered patterns of behavior, a positive family history, and cerebral atrophy on CT. The presence of neurofibrillary tangles and senile plaques is made at postmortem examination; it confirms the diagnosis of clinical Alzheimer's disease but is not part of the clinical diagnostic criteria.

- XIII-117. The answer is D.** (*Chap. 21. Furman, Cass, N Engl J Med 341:1590–1596, 1999.*) Benign paroxysmal positional vertigo is typically provoked by sudden changes in position. Benign positional vertigo may typically last for only seconds. In Ménière's disease, however, the vertigo occurs spontaneously and may last for as long as several hours. In addition, the vertigo is accompanied by unilateral hearing loss and tinnitus. The vertigo, which is associated with vertebrobasilar insufficiency, is usually associated with brainstem symptoms such as diplopia, dysarthria, and facial numbness. Vertigo may also be a symptom of a panic attack. Vestibular neuronitis (labyrinthitis) is typically an isolated episode, although it may last as long as several days. The diagnosis of benign paroxysmal positional vertigo can be established through the Dix-Hallpike test (also called the Bárány test). The diagnostic criteria include the occurrence of characteristic torsional and vertical nystagmus with the upper pole of the eye being toward the dependent ear.

XIV. ENVIRONMENTAL AND OCCUPATIONAL HAZARDS

QUESTIONS

DIRECTIONS: Each question below contains five suggested responses. Choose the **one best** response to each question.

XIV-1. Which of the following statements about acetaminophen overdose is correct?

- (A) Alcohol diminishes the chance of liver injury due to enhancement of detoxifying enzymes.
- (B) There is no correlation between blood levels of the drug and the likelihood of liver injury.
- (C) Hepatic injury is manifest clinically within 48 h of ingestion.
- (D) The glutathione system produces the toxic metabolite.
- (E) The use of reducing agents soon after ingestion can reduce the likelihood of injury.

XIV-2. A 35-year-old cleaning woman presents with pain in the right knee. The joint is fully mobile and there is no ligamentous instability, but there is tenderness on palpation of the right patella. The most appropriate next step is rest and

- (A) steroid injection into the prepatellar bursa
- (B) steroid injection into the knee
- (C) dicloxacillin
- (D) arthroscopy
- (E) aspiration of the prepatellar bursa for culture

XIV-3. A maintenance worker is inadvertently exposed to the fuel core in a nuclear power plant accident. This 40-year-old man has received an estimated 9 Gy of total-body irradiation. He is brought to the emergency room. The most appropriate statement concerning the current situation is

- (A) The patient will likely die within 48 h of acute neurologic and cardiovascular failure.
- (B) The patient will experience a transient drop in his white blood cell and platelet count.
- (C) Problems are not likely to develop at this level of exposure.
- (D) The patient will require intensive supportive care, including bone marrow transplantation.
- (E) Intensive fluids and gastrointestinal support will suffice.

XIV-4. A 35-year-old man has been working as a painter in the inner city for several years. He had previously been healthy but presents now with a several-month history of headache, difficulty concentrating, and joint pain. Physical examination reveals a peripheral neuropathy but is otherwise unremarkable. Laboratory examination reveals a normocytic anemia. Which of the following laboratory studies is most likely to confirm the suspected diagnosis?

- (A) Blood lead level
- (B) Serum lead level
- (C) Blood arsenic level
- (D) Serum arsenic level
- (E) Serum cadmium level

XIV-5. A 40-year-old worker in the computer microchip manufacturing industry develops diarrhea with rectal bleeding and dermatitis. Arsenic poisoning is suspected. Which of the following is the most likely associated laboratory abnormality?

- (A) Neutropenia
- (B) Macrocytic anemia
- (C) Normocytic anemia
- (D) Microcytic anemia
- (E) Prolongation of the QT interval

XIV-6. An older woman, known to have a history of psychiatric problems is found dead in the bathtub by local police, the victim of a presumed suicide. She is taken to the local morgue after the crime investigation is complete. A few hours later, the funeral director is shocked to hear the sounds of movement and voice emanating from the "cadaver." He calls the emergency medical technicians, who upon arrival should

- (A) assess the funeral director for a psychotic break
- (B) administer epinephrine
- (C) administer solumedrol
- (D) commence rewarming
- (E) commence cardiac monitoring to determine if resuscitation is appropriate

XIV-7. A 45-year-old electrical company worker inadvertently steps on a live transmission wire during repair work after a severe ice storm. He suffers cardiac arrest but is rapidly resuscitated successfully and is brought to the hospital. There is no suggestion of skeletal fractures on physical or radiographic examination, although his left leg does appear to be injured. A few hours after admission, his blood pressure becomes unstable, the output of his (reddish-appearing) urine falls, and acidosis is diagnosed. The most appropriate therapy at this time is

- (A) fasciotomy
- (B) intubation
- (C) placement of cardiac pacemaker
- (D) administration of intravenous sodium bicarbonate
- (E) hemolysis

XIV-8. A 20-year-old man presents with depressed mental status after a suicide attempt in which antifreeze was ingested. The patient arrives several hours after the ingestion. He appears intoxicated. Of the following, which is the most appropriate therapy at this time?

- (A) Ethanol infusion
- (B) Disulfiram therapy
- (C) Fomepizole therapy
- (D) Dilantin infusion
- (E) Heparin infusion

XIV-9. Which of the following is most appropriately administered to an individual who has ingested an overdose of aspirin?

- (A) Acetazolamide
- (B) Sodium bicarbonate
- (C) *N*-acetylcysteine
- (D) Flumazil
- (E) Allopurinol

XIV-10. A 20-year-old man is bitten on the right leg by a diamondback rattlesnake. He is brought to the hospital within 1 h, monitored, and given IV fluids. Local wound care is initiated immediately. His leg begins to swell and he becomes tachypneic; his other vital signs are stable. Laboratory studies reveal a low serum fibrinogen. Which of the following represents the critical therapeutic maneuver at this time?

- (A) Reassurance, since rattlesnake bites cause self-limited problems
- (B) Insertion of an endotracheal tube for airway protection
- (C) Administration of physostigmine
- (D) Administration of heparin
- (E) Administration of antivenin

XIV. ENVIRONMENTAL AND OCCUPATIONAL HAZARDS

ANSWERS

- XIV-1. The answer is E.** (*Chaps. 296, 396*) The routine use of the sulfhydryl compounds cysteamine and *N*-acetylcysteine in patients who have ingested large amounts of the analgesic acetaminophen and who have high blood levels early after ingestion has reduced the incidence of substantial toxic liver damage. These reducing agents provide a reservoir of sulfhydryl groups to replenish glutathione stores, thereby allowing more successful detoxification of acetaminophen, or to bind to the toxic metabolites produced by cytochrome P450 enzymes. Since alcohol induces the P450 system, it can actually potentiate acetaminophen hepatotoxicity. It is important to administer the reducing agents early on after ingestion based on drug levels and not on abnormal hepatic enzymes in the blood, which may not occur until several days have passed.
- XIV-2. The answer is A.** (*Chaps. 326, 391*) This patient has typical “housemaid’s knee,” an inflammatory condition of the prepatellar bursa due to repetitive kneeling on hard surfaces. Since this is unlikely to be an infection, neither diagnostic tap nor antibiotics are needed. Moreover, the knee joint itself is without pathology. Appropriate therapy consists of rest, a nonsteroidal anti-inflammatory agent, and/or glucocorticoid injection.
- XIV-3. The answer is D.** (*Chap. 394*) The effects of total-body irradiation on the human are dose-dependent. Doses >100 Gy result in death within 48 h due to neurologic and cardiovascular collapse. Doses >5 Gy produce denudation of the gastrointestinal mucosa and result in death due to dehydration and sepsis unless aggressive supportive care is provided. The marrow component is even more sensitive than the gastrointestinal tract, with doses >2 Gy causing significant cytopenias. The marrow may recover in time (i.e., without a transplant) at doses <8 Gy; yet doses >10 Gy are often fatal due to gastrointestinal problems even with supportive care. Therefore marrow transplantation may be most reasonable for individuals exposed to total-body doses of 8–10 Gy.
- XIV-4. The answer is A.** (*Chap. 395*) Although federal regulations have decreased the workplace exposure to lead, those in the painting (and particularly paint removal) business, battery manufacture, demolition, and ceramics trades still may accumulate a toxic body burden of lead. Lead may be absorbed through ingestion, inhalation, and, in the case of organic iron, via the skin as well. Lead crosses the blood-brain barrier and may accumulate in almost any tissue; 95% of blood lead is sequestered in red cells, rather than in serum (hence serum values are not useful). Symptoms of lead toxicity may appear in adults when the blood level >3.9 $\mu\text{mol/L}$ (80 $\mu\text{g/dL}$). The clinical syndrome of lead intoxication includes headache, abdominal pain, irritability, peripheral neuropathy, normocytic anemia, and renal failure. Treatment of lead toxicity includes eliminating further exposure and use of a chelating agent such as calcium EDTA, dimercaprol, penicillamine, or succimer; treatment should begin at the onset of symptoms or at a blood lead level of 3.9 $\mu\text{mol/L}$ in adults.
- XIV-5. The answer is E.** (*Chap. 395*) Occupational exposure to arsenic may occur in the smelting industry (due the presence of arsenic as a byproduct of purifying ores) and the microelectronics industry due to the use of gallium arsenate. Inorganic arsenic (currently used successfully and safely for the treatment of patients with acute promyelocytic leu-

kemia) is more toxic than organic arsenic. Arsenic is rapidly cleared from the GI tract, kidneys, and lungs, where it originally resides, but leaves a long-term residue in the integument. Acute arsenic toxicity manifests as increased vascular permeability and intestinal inflammation. Cardiomyopathy may be seen with chronic exposure, with conduction system disease, including QRS widening, ST prolongation, and multifocal atrial tachycardia. Treatment of chronic poisoning should include chelation with dimercaprol.

- XIV-6. The answer is D.** (*Chap. 20*) Hypothermia, or an unintentional drop of the body's core temperature below 35°C (95°F), may occur as a direct result of exposing an abnormal individual to the cold (or even prolonged immersion in water), or as a consequence of a severe systemic disorder such as hypothyroidism, hypoglycemia, uremia, acute spinal cord or brain injury, or profound burns (excessive heat loss in the damaged skin). Older individuals or those who drink alcohol or take drugs such as phenothiazines, benzodiazepines, or barbiturates, which produce centrally mediated vasoconstriction, are more susceptible to cold weather. Once the diagnosis is made by the finding of a depressed core temperature, preferably at two sites, then oxygen therapy and cardiac monitoring should be initiated; rewarming should commence with resuscitative efforts as needed. In general, a patient should not be declared dead until warmed except in the presence of a known DNR order, a frozen chest wall that cannot be compressed, or obviously lethal injuries. For patients with advanced hypothermia, active external rewarming is required (rather than simple warming of the head and extremities, which, by removing peripheral vasoconstriction, could actually lower the core temperature). Strategies for active external rewarming include heating blankets; heated intravenous or lavage fluids as well as hemodialysis, continuous arteriovenous rewarming, and even cardiopulmonary bypass constitute active internal rewarming.
- XIV-7. The answer is A.** (*Chap. 393*) High-voltage shocks (>1000 V) produce more morbidity due to extensive tissue damage than to electrocution injury. The electrochemical changes consequent to high-voltage contact produce contact damage, including myonecrosis and nerve damage. Compartment syndromes (which may be uncharacteristically painless due to associated nerve damage) and rhabdomyolysis leading to acute tubular necrosis must be treated urgently. Fasciotomy to treat such "silent" compartment syndromes and debridement of devitalized tissue are often required.
- XIV-8. The answer is C.** (*Chap. 396. Brent et al, Methylpyrazole for Toxic Alcohols Study Group, N Engl J Med 340:832–838, 1999.*) This patient has ingested a potentially lethal quantity of ethylene glycol, commonly included in windshield-washer solutions and antifreeze. The syndrome of ingestion is clinically similar to alcohol ingestion. Ethylene glycol is oxidized by alcohol dehydrogenase to glycoaldehyde and is eventually metabolized to oxalic acid. An intermediate metabolite, glycolic acid, may be a CNS depressant and produces an anion gap metabolic acidosis and tubular damage, potentially leading to renal failure. The presence of unmeasured osmoles or an elevated anion gap (even before the serum ethylene glycol or glycolate levels are known) should prompt initiation of therapy, including gastric aspiration with the use of activated charcoal, administration of sodium bicarbonate, fluids, pyridoxine, and thiamine. If any indication of severe intoxication is present (e.g., the aforementioned metabolic abnormalities, renal impairment, ethanol-type intoxicated behavior), one of the drugs capable of inhibiting alcohol dehydrogenase should be administered. Traditional ethanol infusions were used for this purpose; however, the preferred agent is probably fomepizole. Despite the expense of this newer agent, it does not cause the CNS depression or metabolic derangements seen with ethanol. The ethanol or fomepizole should be administered until the ethylene glycol falls to <1.5 mmol/L (10 mg/dL). Hemodialysis is required in cases that fail to respond to antidotal therapy.
- XIV-9. The answer is B.** (*Chap. 396*) Salicylate toxicity can result in respiratory alkalosis due to stimulation of central respiratory centers, increase the rate of oxygen consumption/heat production, yet inhibit the Krebs cycle and lipid metabolism. Ketoacidosis occurs in later stages of salicylate poisoning. Salicylate is a weak acid; although most is albumin-bound,

the free salicylates in the blood exist in the ionized state. Under normal circumstances, salicylates are mainly metabolized by the liver, and an overdose saturates these metabolic pathways, making renal excretion the most important for detoxification in this situation. Therefore, urinary alkalinization via administration of sodium bicarbonate enhances elimination by ensuring that the drug exists only in the ionized form, thereby preventing reabsorption.

XIV-10. The answer is E. (*Chap. 397*) Bites from poisonous snakes are medical emergencies. Venoms contain complex mixtures of enzymes, low-molecular-weight polypeptides, glycoproteins, and metal ions, which promote vascular leakage, bleeding, tissue necrosis, and myocardial and neurologic toxicity. The victim should be brought to medical care as soon as possible, gentle suction applied to the wound, and the extremity splinted. General systemic supportive measures are advisable, with close monitoring of both the wound and of vital signs as well as of laboratory parameters with particular reference to hematologic and coagulation issues. The relevant antivenin should be administered as soon as one concludes that progressive local or systemic toxicity, such as coagulopathy, is occurring. While there is a risk of anaphylaxis due to the antivenins which are equine in origin, such problems can be limited with the use of fluid volume expansion and preadministration of diphenhydramine and cimetidine.

This page intentionally left blank.

APPENDIX

LABORATORY VALUES OF CLINICAL IMPORTANCE

INTRODUCTORY COMMENTS

All laboratory appendices should be interpreted with caution since normal values differ widely among clinical laboratories. The values given in this Appendix are meant primarily for use with this text. In preparing the Appendix, the editors have taken into account the fact that the system of international units (SI, système international d'unités) is now used in most countries and in most medical and scientific journals.¹ However, clinical laboratories in many countries continue to report values in traditional units. Therefore, both systems are used in the Appendix. Values in SI units appear first and traditional units appear in parentheses after the SI units. The dual system is also used in the text except for (1) those instances in which the numbers remain the same but only the terminology is changed (mmol/L for meq/L or IU/L for mIU/mL), when only the SI units are given; and (2) most pressure measurements (e.g., blood and cerebrospinal fluid pressures), when the traditional units (mmHg, mmH₂O) are used. In all other instances in the text the SI unit is followed by the traditional unit in parentheses. The SI base units, SI derived units, other units of measure referred to in Appendix A, and SI prefixes are listed in Tables A-1 to A-3. Conversions from one system to another can be made as follows:

$$\text{mmol/L} = \frac{\text{mg/dL} \times 10}{\text{atomic weight}}$$

$$\text{mg/dL} = \frac{\text{mmol/L} \times \text{atomic weight}}{10}$$

Table 1

Radiation-Derived Units

Quantity	Old Unit	SI Unit	Name for SI Unit (and Abbreviation)	Conversion
Activity	curie (Ci)	Disintegrations per second (dps)	becquerel (Bq)	1 Ci = 3.7 × 10 ¹⁰ Bq
				1 mCi = 37 mBq
				1 μCi = 0.037 MBq or 37 GBq
				1 Bq = 2.703 × 10 ⁻¹¹ Ci
Absorbed dose	rad	joule per kilogram (J/kg)	gray (Gy)	1 Gy = 100 rad 1 rad = 0.01 Gy 1 mrad = 10 ⁻³ cGy

¹Young DS: Implementation of SI units for clinical laboratory data. *Ann Intern Med* 106:114, 1987

Quantity	Old Unit	SI Unit	Name for SI Unit (and Abbreviation)	Conversion
Exposure	roentgen (R)	coulomb per kilogram (C/kg)	—	1 C/kg = 3876 R
				1 R = 2.58 × 10 ⁻⁴ C/kg
Dose equivalent	rem	joule per kilogram (J/kg)	sievert (Sv)	1 mR = 258 pC/kg
				1 Sv = 100 rem
				1 rem = 0.01 Sv 1 mrem = 10 μSv

Table 2

Body Fluids and Other Mass Data

	Reference Range	
	SI Units	Conventional Units
Ascitic fluid: See Chap. 46		
Body fluid, total volume (lean) of body weight	50% (in obese) to 70%	
Intracellular	0.3–0.4 of body weight	
Extracellular	0.2–0.3 of body weight	
Blood		
Total volume		
Males	69 mL per kg body weight	
Females	65 mL per kg body weight	
Plasma volume		
Males	39 mL per kg body weight	
Females	40 mL per kg body weight	
Red blood cell volume		
Males	30 mL per kg body weight	1.15–1.21 L/m ² of body surface area
Females	25 mL per kg body weight	0.95–1.00 L/m ² of body surface area

Table 3

Cerebrospinal Fluid^a

Constituent	Reference Range	
	SI Units	Conventional Units
Osmolarity	292–297 mmol/kg water	292–297 mOsm/L
Electrolytes		
Sodium	137–145 mmol/L	137–145 meq/L
Potassium	2.7–3.9 mmol/L	2.7–3.9 meq/L
Calcium	1.0–1.5 mmol/L	2.1–3.0 meq/L
Magnesium	1.0–1.2 mmol/L	2.0–2.5 meq/L
Chloride	116–122 mmol/L	116–122 meq/L
CO ₂ content	20–24 mmol/L	20–24 meq/L
P _{CO₂}	6–7 kPa	45–49 mmHg
pH	7.31–7.34	
Glucose	2.2–3.9 mmol/L	40–70 mg/dL
Lactate	1–2 mmol/L	10–20 mg/dL

Table 3 (Continued)

Constituent	Reference Range		Constituent	Reference Range	
	SI Units	Conventional Units		SI Units	Conventional Units
Total protein	0.2–0.5 g/L	20–50 mg/dL	Differential:		
Albumin	0.066–0.442 g/L	6.6–44.2 mg/dL	Lymphocytes	60–70%	
IgG	0.009–0.057 g/L	0.9–5.7 mg/dL	Monocytes	30–50%	
IgG index ^b	0.29–0.59		Neutrophils	None	
Oligoclonal bands (OGB)	<2 bands not present in matched serum sample				
Ammonia	15–47 μmol/L	25–80 μg/dL			
Creatinine	44–168 μmol/L	0.5–1.9 mg/dL			
Myelin basic protein	<4 μg/L				
CSF pressure		50–180 mmH ₂ O			
CSF volume (adult)	~150 mL				
Leukocytes					
Total	<5 per μL				

^aSince cerebrospinal fluid concentrations are equilibrium values, measurements of the same parameters in blood plasma obtained at the same time are recommended. However, there is a time lag in attainment of equilibrium, and cerebrospinal levels of plasma constituents that can fluctuate rapidly (such as plasma glucose) may not achieve stable values until after a significant lag phase.

$${}^b\text{IgG index} = \frac{\text{CSF IgG}(\text{mg/dL}) \times \text{serum albumin}(\text{g/dL})}{\text{Serum IgG}(\text{g/dL}) \times \text{CSF albumin}(\text{mg/dL})}$$

Table 4

Chemical Constituents of Blood

Constituent	Specimen	Reference Range	
		SI Units	Conventional Units
Acetoacetate	P	<100 μmol/L	<1 mg/dL
Albumin	S	35–55 g/L	3.5–5.5 g/dL
Aldolase		0–100 nkat/L	0–6 U/L
Alpha ₁ antitrypsin	S	0.8–2.1 g/L	85–213 mg/dL
Alpha fetoprotein (adult)	S	<30 μg/L	<30 ng/mL
Aminotransferases	S		
Aspartate (AST, SGOT)		0–0.58 μkat/L	0–35 U/L
Alanine (ALT, SGPT)		0–0.58 μkat/L	0–35 U/L
Ammonia, as NH ₃	P	6–47 μmol/L	10–80 μg/dL
Amylase	S	0.8–3.2 μkat/L	60–180 U/L
Angiotensin-converting enzyme (ACE)		<670 nkat/L	<40 U/L
Anticonvulsant drug levels: see Table 360-8			
Arterial blood gases			
[HCO ₃ ⁻]		21–28 mmol/L	21–30 meq/L
P _{CO₂}		4.7–5.9 kPa	35–45 mmHg
pH		7.38–7.44	
P _{O₂}		11–13 kPa	80–100 mmHg
β-Hydroxybutyrate	P	<300 μmol/L	<3 mg/dL
Bilirubin, total	S (Malloy-Evelyn)	5.1–17 μmol/L	0.3–1.0 mg/dL
Direct	S	1.7–5.1 μmol/L	0.1–0.3 mg/dL
Indirect	S	3.4–12 μmol/L	0.2–0.7 mg/dL
Calcium, ionized		1.1–1.4 mmol/L	4.5–5.6 mg/dL
Calcium	P	2.2–2.6 mmol/L	9–10.5 mg/dL
Carbon dioxide content	P (sea level)	21–30 mmol/L	21–30 meq/L
Carbon dioxide tension (P _{CO₂})	Arterial blood (sea level)	4.7–5.9 kPa	35–45 mmHg
Carbon monoxide content	Blood	Symptoms with 20% saturation of hemoglobin	
Chloride	S (as Cl ⁻)	98–106 mmol/L	98–106 meq/L
Cholesterol: see Table A-9			
Complement	S		
C3		0.55–1.20 g/L	55–120 mg/dL
C4		0.20–0.50 g/L	20–50 mg/dL
Coproporphyrins (types I and III)	U	150–460 μmol/d	100–300 μg/d
Creatine kinase	S (total)		
Females		0.17–1.17 μkat/L	10–70 U/L
Males		0.42–1.50 μkat/L	25–90 U/L
Creatine kinase-MB		0–7 μg/L	
Creatinine	S	<133 μmol/L	<1.5 mg/dL
Erythropoietin	S	5–36 U/L	
Fatty acids, free (nonesterified)	P	180 mg/L	<18 mg/dL
Ferritin	S		
Women		10–200 μg/L	10–200 ng/mL
Men		15–400 μg/L	15–400 ng/mL
Fibrinogen: See “Hematologic Evaluations: Platelets and Coagulation Parameters”			
Fibrinogen split products: See “Hematologic Evaluations: Platelets and Coagulation Parameters”			
Glucose (fasting)	P		
Normal		4.2–6.4 mmol/L	75–115 mg/dL
Diabetes mellitus		>7.8 mmol/L	>140 mg/dL

(Continued)

Table 4 (Continued)

Constituent	Specimen	Reference Range	
		SI Units	Conventional Units
Glucose, 2 h postprandial	P		
Normal		<7.8 mmol/L	<140 mg/dL
Impaired glucose tolerance		7.8–11.1 mmol/L	140–200 mg/dL
Diabetes mellitus		>11.1 mmol/L	>200 mg/dL
Hemoglobin	B (sea level)		
Male		140–180 g/L	14–18 g/dL
Female		120–160 g/L	12–16 g/dL
Hemoglobin A _{1c} Up to 6% of total hemoglobin			
Iron	S	9–27 μ mol/L	50–150 μ g/dL
Iron-binding capacity	S	45–66 μ mol/L	250–370 μ g/dL
Saturation		0.2–0.45	20–45%
Lactate dehydrogenase	S	1.7–3.2 μ kat/L	100–190 U/L
Lactate dehydrogenase isoenzymes	S (agarose)		
Fraction 1 (of total)		0.14–0.25	14–26%
Fraction 2		0.29–0.39	29–39%
Fraction 3		0.20–0.25	20–26%
Fraction 4		0.08–0.16	8–16%
Fraction 5		0.06–0.16	6–16%
Lactate	P, venous	0.6–1.7 mmol/L	5–15 mg/dL
Lipase	S	0–2.66 μ kat/L	0–160 U/L
Lipids: see Table A-9			
Lipids, triglyceride: S see “Triglycerides”			
Lipoprotein: see Table A-9			
Lipoprotein (a)	S	0–300 mg/L	0–3 mg/dL
Magnesium	S	0.8–1.2 mmol/L	1.8–3 mg/dL
Myoglobin	S		
Male		19–92 μ g/L	
Female		12–76 μ g/L	
Osmolality	P	285–295 mmol/kg serum water	285–295 mosmol/kg serum water
Oxygen content	B, arterial (sea level) B, venous arm (sea level)		17–21 vol% 10–16 vol%
Oxygen percent saturation (sea level)	B, arterial B, venous, arm	0.97 mol/mol 0.60–0.85 mol/mol	97% 60–85%
Oxygen tension (P _{O₂})	Blood	11–13 kPa	80–100 mmHg
pH	B	7.38–7.44	
Phosphatase, acid	S	0.90 nkat/L	0–5.5 U/L
Phosphatase, alkaline	S	0.5–2.0 nkat/L	30–120 U/L
Phosphorus, inorganic	S	1.0–1.4 mmol/L	3–4.5 mg/dL
Porphobilinogen	U	None	None
Potassium	S	3.5–5.0 mmol/L	3.5–5.0 meq/L
Prostate-specific antigen (PSA)	S		
Female		<0.5 μ g/L	<0.5 ng/mL
Male: <40 years		0.0–2.0 μ g/L	0.0–2.0 ng/mL
≥40 years		0.0–4.0 μ g/L	0.0–4.0 ng/mL
PSA, free, in males 45–75 years, with PSA values between 4 and 20 μ g/mL	S	>0.25 associated with benign prostatic hyperplasia	>25% associated with benign prostatic hyperplasia
Protein, total	S	55–80 g/L	5.5–8.0 g/dL
Protein fractions	S		
Albumin		35–55 g/L	3.5–5.5 g/dL (50–60%)
Globulin		20–35 g/L	2.0–3.5 g/dL (40–50%)
Alpha ₁		2–4 g/L	0.2–0.4 g/dL (4.2–7.2%)
Alpha ₂		5–9 g/L	0.5–0.9 g/dL (6.8–12%)
Beta		6–11 g/L	0.6–1.1 g/dL (9.3–15%)
Gamma		7–17 g/L	0.7–1.7 g/dL (13–23%)
Pyruvate	P, venous	60–170 μ mol/L	0.5–1.5 mg/dL
Sodium	S	136–145 mmol/L	136–145 meq/L
Transferrin	S	2.3–3.9 g/L	230–390 mg/dL
Triglycerides	S	<1.8 mmol/L	<160 mg/dL
Troponin I	S	0–0.4 μ g/L	0–0.4 ng/mL
Troponin T	S	0–0.1 μ g/L	0–0.1 ng/mL
Urea nitrogen	S	3.6–7.1 mmol/L	10–20 mg/dL
Uric acid:	S		
Men		150–480 μ mol/L	2.5–8.0 mg/dL
Women		90–360 μ mol/L	1.5–6.0 mg/dL
Urobilinogen	U	1.7–5.9 μ mol/d	1–3.5 mg/d

NOTE: B, blood; P, plasma; S, serum; U, urine.

Table 5

Drug	Therapeutic Range		Toxic Level	
	Conventional Units	SI Units	Conventional Units	SI Units
Acetaminophen	10–30 µg/mL	66–199 µmol/L	>200 µg/mL	>1324 µmol/L
Amikacin				
Peak	25–35 µg/mL	43–60 µmol/L	>35 µg/mL	>60 µmol/L
Trough	4–8 µg/mL	6.8–13.7 µmol/L	>10 µg/mL	>17 µmol/L
Amitriptyline	120–250 ng/mL	433–903 nmol/L	>500 ng/mL	>1805 nmol/L
Amphetamine	20–30 ng/mL	148–222 nmol/L	>200 ng/mL	>1480 nmol/L
Barbiturates, most short-acting			>20 mg/L	>88 µmol/L
Bromide			>1250 µg/mL	>15.6 mmol/L
Carbamazepine	6–12 µg/mL	26–51 µmol/L	>15 µg/mL	>63 µmol/L
Chlordiazepoxide	700–1000 ng/mL	2.34–3.34 µmol/L	>5000 ng/mL	>16.7 µmol/L
Clonazepam	15–60 ng/mL	48–190 nmol/L	>80 ng/mL	>254 nmol/L
Clozapine	200–350 ng/mL	0.6–1 µmol/L		
Cocaine	100–500 ng/mL	330–1650 nmol/L	>1000 ng/mL	>3300 nmol/L
Desipramine	75–300 ng/mL	281–1125 nmol/L	>400 ng/mL	>1500 nmol/L
Diazepam	100–1000 ng/mL	0.35–351 µmol/L	>5000 ng/mL	>17.55 µmol/L
Digoxin	0.8–2.0 ng/mL	1.0–2.6 nmol/L	>2.5 ng/mL	>3.2 umol/L
Doxepin	30–150 ng/mL	107–537 nmol/L	>500 ng/mL	>1790 nmol/L
Ethanol			>300 mg/dL	>65 mmol/L
Behavioral changes	>20 mg/dL	>4.3 mmol/L		
Legal intoxication	>80 mg/dL	>17 mmol/L		
Ethosuximide	40–100 µg/mL	283–708 µmol/L	>150 µg/mL	>1062 µmol/L
Flecainide	0.2–1.0 µg/mL	0.5–2.4 µmol/L	>1.0 µg/mL	>2.4 µmol/L
Gentamicin				
Peak	8–10 µg/mL	16.7–20.9 µmol/L	>10 µg/mL	>21 µmol/L
Trough	<2–4 µg/mL	<4.2–8.4 µmol/L	>4 µg/mL	>8.4 µmol/L
Imipramine	125–250 ng/mL	446–893 nmol/L	>500 ng/mL	>1784 nmol/L
Lidocaine	1.5–6.0 µg/mL	6.4–26 µmol/L		
CNS or cardiovascular depression			6–8 µg/mL	26–34.2 µmol/L
Seizures, obtundation, decreased cardiac output			>8 µg/mL	>34.2 µmol/L
Lithium	0.6–1.2 meq/L	0.6–1.2 nmol/L	>2 meq/L	>2 mmol/L
Methadone	100–400 ng/mL	0.32–1.29 µmol/L	>2000 ng/mL	>6.46 µmol/L
Methotrexate	Variable	Variable		
Low-dose (1–2 weeks)			>9.1 ng/mL	>20 nmol/L
High-dose (48 h)			>227 ng/mL	>0.5 µmol/L
Morphine	10–80 ng/mL	35–280 µmol/L	>200 ng/mL	>700 nmol/L
Nitroprusside (as thiocyanate)	6–29 µg/mL	103–499 µmol/L		
Nortriptyline	50–170 ng/mL	190–646 nmol/L	>500 ng/mL	>1.9 µmol/L
Phenobarbital	10–40 µg/mL	43–170 µmol/L		
Slowness, ataxia, nystagmus			35–80 µg/mL	151–345 µmol/L
Coma with reflexes			65–117 µg/mL	280–504 µmol/L
Coma without reflexes			>100 µg/mL	>430 µmol/L
Phenytoin	10–20 µg/mL	40–79 µmol/L	>20 µg/mL	>79 µmol/L
Procainamide	4–10 µg/mL	17–42 µmol/L	>10–12 µg/mL	>42–51 µmol/L
Quinidine	2–5 µg/mL	6–15 µmol/L	>6 µg/mL	>18 µmol/L
Salicylates	150–300 µg/mL	1086–2172 µmol/L	>300 µg/mL	>2172 µmol/L
Theophylline	8–20 µg/mL	44–111 µmol/L	>20 µg/mL	>110 µmol/L
Thiocyanate				
After nitroprusside infusion	6–29 µg/mL	103–499 µmol/L		
Nonsmoker	1–4 µg/mL	17–69 µmol/L	>120 µg/mL	>2064 µmol/L
Smoker	3–12 µg/mL	52–206 µmol/L		
Tobramycin				
Peak	8–10 µg/mL	17–21 µmol/L	>10 µg/mL	>21 µmol/L
Trough	<4 µg/mL	<9 µmol/L	>4 µg/mL	>9 µmol/L
Valproic acid	50–150 µg/mL	347–1040 µmol/L	>150 µg/mL	>1040 µmol/L
Vancomycin				
Peak	18–26 µg/mL	12–18 µmol/L		
Trough	5–10 µg/mL	3–7 µmol/L	>80–100 µg/mL	>55–69 µmol/L

Table 6

Circulatory Function Tests

Test	Results: Reference Range		Test	Results: Reference Range	
	SI Units (Range)	Conventional Units (Range)		SI Units (Range)	Conventional Units (Range)
Arteriovenous oxygen difference	30–50 mL/L	30–50 mL/L	Oxygen consumption index	110–150 mL	110–150 mL
Cardiac output (Fick)	2.5–3.6 L/m ² of body surface area per min	2.5–3.6 L/m ² of body surface area per min	Maximum oxygen uptake	35 mL/min (20–60 mL/min)	35 mL/min (20–60 mL/min)
Contractility indexes			Pulmonary vascular resistance	2–12 (kPa·s)/L	20–120 (dyn·s)/cm ⁵
Max. left ventricular <i>dp/dt</i>	220 kPa/s (176–250 kPa/s)	1650 mmHg/s (1320–1880 mmHg/s)	Systemic vascular resistance	77–150 (kPa·s)/L	770–1500 (dyn·s)/cm ⁵
(<i>dp/dt</i>)/DP when DP = 5.3 kPa (40 mmHg)(DP, diastolic pressure)	(37.6 ± 12.2)/s	(37.6 ± 12.2)/s			
Mean normalized systolic ejection rate (angiography)	3.32 ± 0.84 end-diastolic volumes per second	3.32 ± 0.84 end-diastolic volumes per second			
Mean velocity of circumferential fiber shortening (angiography)	1.66 ± 0.42 circumferences per second	1.66 ± 0.42 circumferences per second			
Ejection fraction: stroke volume/end-diastolic volume (SV/EDV)	0.67 (0.55–0.78)	0.67 (0.55–0.78)			
End-diastolic volume	75 mL/m ² (60–88 mL/m ²)	75 mL/m ² (60–88 mL/m ²)			
End-systolic volume	25 mL/m ² (20–33 mL/m ²)	25 mL/m ² (20–33 mL/m ²)			
Left ventricular work					
Stroke work index	30–110 (g·m)/m ²	30–110 (g·m)/m ²			
Left ventricular minute work index	1.8–6.6 [(kg·m)/m ²]/min	1.8–6.6 [(kg·m)/m ²]/min			

Table 7

Normal Values of Doppler Echocardiographic Measurements in Adults

	Range	Mean
RVD (cm)	0.9 to 2.6	1.7
LVID (cm)	3.5 to 5.7	4.7
Posterior LV wall thickness (cm)	0.6 to 1.1	0.9
IVS wall thickness (cm)	0.6 to 1.1	0.9
Left atrial dimension (cm)	1.9 to 4.0	2.9
Aortic root dimension (cm)	2.0 to 3.7	2.7
Aortic cusps separation (cm)	1.5 to 2.6	1.9
Percentage of fractional shortening	34 to 44%	36%
Mitral flow (m/s)	0.6 to 1.3	0.9
Tricuspid flow (m/s)	0.3 to 0.7	0.5
Pulmonary artery (m/s)	0.6 to 0.9	0.75
Aorta (m/s)	1.0 to 1.7	1.35

NOTE: RVD, right ventricular dimension; LVID, left ventricular internal dimension; LV, left ventricle; IVS, interventricular septum.

SOURCE: From H Feigenbaum, *Echocardiography*, 5th ed, Philadelphia, Lea & Febiger, 1994

Table 8

Gastrointestinal Tests. See also "Stool Analysis"

Test	Results	
	SI Units	Conventional Units
Absorption tests		
D-Xylose: after overnight fast, 25 g xylose given in oral aqueous solution		
Urine, collected for following 5 h	33–53 mmol (or >20% of ingested dose)	5–8 g (or >20% of ingested dose)
Serum, 1 h after dose	1.7–2.7 mmol/L	25–40 mg/dL
Vitamin A: a fasting blood specimen is obtained and 200,000 units of vitamin A in oil is given orally	Serum level should rise to twice fasting level in 3–5 h	Serum level should rise to fasting level in 3–5 h
Bentiromide test (pancreatic function): 500 mg bentiromide (chymex) orally; <i>p</i> -aminobenzoic acid (PABA) measured		
Plasma		>3.6 (±1.1) μg/mL at 90 min
Urine	>50% recovered in 6 h	>50% recovered in 6 h
Gastric juice		
Volume		
24 h	2–3 L	2–3 L
Nocturnal	600–700 mL	600–700 mL
Basal, fasting	30–70 mL/h	30–70 mL/h
Reaction		
pH	1.6–1.8	1.6–1.8
Titrateable acidity of fasting juice	4–9 μmol/s	15–35 meq/h
Acid output		
Basal		
Females (mean ± 1 SD)	0.6 ± 0.5 μmol/s	2.0 ± 1.8 meq/h
Males (mean ± 1 SD)	0.8 ± 0.6 μmol/s	3.0 ± 2.0 meq/h
Maximal (after SC histamine acid phosphate, 0.004 mg/kg body weight, and preceded by 50 mg promethazine, or after betazole, 1.7 mg/kg body weight, or pentagastrin, 6 μg/kg body weight)		
Females (mean ± 1 SD)	4.4 ± 1.4 μmol/s	16 ± 5 meq/h
Males (mean ± 1 SD)	6.4 ± 1.4 μmol/s	23 ± 5 meq/h
Basal acid output/maximal acid output ratio	≤0.6	≤0.6
Gastrin, serum	40–200 μg/L	40–200 pg/mL
Secretin test (pancreatic exocrine function): 1 unit/kg body weight, IV		
Volume (pancreatic juice) in 80 min	>2.0 mL/kg	>2.0 mL/kg
Bicarbonate concentration	>80 mmol/L	>80 meq/L
Bicarbonate output in 30 min	>10 mmol	>10 meq

Table 9

Metabolic and Endocrine Tests

Substance	Specimen	Reference Range		Substance	Specimen	Reference Range	
		SI Units	Conventional Units			SI Units	Conventional Units
Adrenocorticotropin (ACTH), 8 A.M.	P	1.3–16.7 pmol/L	6.0–76.0 pg/mL	Growth hormone, after 100 g oral glucose		<2 µg/L	<2 ng/mL
Aldosterone, 8 A.M., (patient supine, 100 mmol/L Na and 60–100 mmol/L K intake)	P	<220 pmol/L	<8 ng/dL	Hemoglobin A _{1c}	WB	0.038–0.064	3.8–6.4%
Aldosterone	U	14–53 nmol/d	5–19 µg/d	17-Hydroxycorticosteroids	U	5.5–28 µmol/d	2–10 mg/d
Androstenedione	P			5-Hydroxyindoleacetic acid (5-HIAA)	U	≤31.4 µmol/d	≤6 mg/d
Women		3.5–7.0 nmol/L	1–2 ng/mL	17-Hydroxyprogesterone	P		
Men		3.0–5.0 nmol/L	0.8–1.3 ng/mL	Women			
Angiotensin II, 8 A.M.	P	10–30 nmol/L	10–30 pg/mL	Follicular phase		0.6–3 nmol/L	0.2–1.0 µg/L
Arginine vasopressin (AVP), random fluid intake	P	1.4–5.6 pmol/L	1.5–6.0 ng/L	Luteal phase		1.5–10.6 nmol/L	0.5–3.5 µg/L
Calciferols (vitamin D)	P			Men		0.2–9.0 nmol/L	0.06–3.0 µg/L
1,25-dihydroxyvitamin D [1,25(OH) ₂ D]		40–160 pmol/L	16–65 pg/mL	Insulin, fasting	S, P	43–186 pmol/L	6–26 µU/mL
25-hydroxyvitamin D [25(OH)D]		20–200 nmol/L	8–80 ng/mL	Insulin-like growth factor (somatomedin C, IGF-1/SM C)	S		
Calcitonin	P			16–24 years		182–780 µg/L	182–780 ng/mL
Women		≤8 ng/L	≤8 pg/mL	25–39 years		114–492 µg/L	114–492 ng/mL
Men		≤4 ng/L	≤4 pg/mL	40–54 years		90–360 µg/L	90–360 ng/mL
Catecholamines				>54 years		71–290 µg/L	71–290 ng/mL
Epinephrine	U	<275 nmol/d	<50 µg/d	17-Ketosteroids	U		
Free	U	<590 nmol/d	<100 µg/d	Women		20–59 µmol/d	6–17 mg/d
Metanephrine	U	<7 µmol/d	<1.3 mg/d	Men		20–69 µmol/d	6–20 mg/d
Norepinephrine	U	89–473 nmol/d	15–80 µg/d	Oxytocin			
Vanillylmandelic acid (VMA)	U	<40 µmol/d	<8 mg/d	Random		1–4 pmol/L	1.25–5 ng/L
Chorionic gonadotropin, β subunit (β-hCG), men and nonpregnant women	P	<3 IU/L	<3 mIU/mL	Ovulatory peak in women		4–8 pmol/L	5–10 ng/L
Cortisol				Parathyroid hormone	S	10–60 ng/L	10–60 pg/mL
Free	U	25–140 nmol/d	10–50 µg/d	Parathyroid hormone–related protein	P	<1.3 pmol/L	<1.3 pmol/L
8 A.M.	P	140–690 nmol/L	5–25 µg/dL	Progesterone	P		
4 P.M.	P	80–330 nmol/L	3–12 µg/dL	Women, luteal, peak		6–60 nmol/L	2–20 ng/mL
Dehydroepiandrosterone (DHEA)	P	7–31 nmol/L	2–9 ng/dL	Men, prepubertal girls, preovulatory women, postmenopausal women		<6 nmol/L	<2 ng/mL
11-Deoxycortisol (compound S)	P	<30 nmol/L	<1 µg/dL	Prolactin	S	2–15 µg/L	2–15 ng/mL
DHEA sulfate	P	1.3–6.8 µmol/L	500–2500 µg/dL	Radioactive iodine uptake, 24 h (range varies in different areas due to variations in iodine intake)			5–30%
Estradiol	P			Renin (adult, normal-Na diet)	P		
Women (higher at ovulation)		70–220 pmol/L	20–60 pg/mL	Supine		0.08–0.83 ng/(L·s)	0.3–3.0 ng/(mL/h)
Men		<180 pmol/L	<50 pg/mL	Upright		0.28–2.5 ng/(L·s)	1.0–9.0 ng/(mL/h)
Gastrin	S	40–200 ng/L	40–200 pg/mL	Resin triiodothyronine (T ₃)		0.25–0.35	25–35%
Glucagon	P	50–100 ng/L	50–100 pg/mL	Reverse T ₃ (rT ₃)	P	0.15–0.61 nmol/L	10–40 ng/dL
Gonadotropins				Semen analysis: see Chap. 335			
Follicle-stimulating hormone (FSH)	P			T ₃	P	1.1–2.9 nmol/L	70–190 ng/dL
Women				Testosterone	P		
Mature, premenopausal, except at ovulation		1.4–9.6 IU/L	1.4–9.6 mIU/mL	Women		<3.5 nmol/L	<1 ng/mL
Ovulatory surge		2.3–21 IU/L	2.3–21 mIU/mL	Men		10–35 nmol/L	3–10 ng/mL
Postmenopausal		34–96 IU/L	34–96 mIU/mL	Prepubertal boys and girls		0.17–0.7 nmol/L	0.05–0.2 ng/mL
Men		0.9–15 IU/L	0.9–15 mIU/mL	Thyroglobulin	S	0–60 µg/L	0–60 ng/mL
Luteinizing hormone (LH)	P			Thyroid stimulating hormone (TSH)		0.4–5.0 mU/L	0.4–5.0 µU/mL
Children, prepubertal		1.0–5.9 IU/L	1.0–5.9 mIU/mL	Thyroxine (T ₄)	SR	64–154 nmol/L	5–12 µg/dL
Women							
Mature, premenopausal, except at ovulation		0.8–26 IU/L	0.8–26 mIU/mL				
Ovulatory surge		25–57 IU/L	25–57 mIU/mL				
Postmenopausal		40–104 IU/L	40–104 mIU/mL				
Men		1.3–13 IU/L	1.3–13 mIU/mL				

NOTE: P, plasma; S, serum; SR, serum radioimmunoassay; U, urine; WB, whole blood.

Table 10

Classification of Total Cholesterol, LDL-Cholesterol, and HDL-Cholesterol Values

	Total Plasma Cholesterol		LDL-Cholesterol		HDL-Cholesterol	
	SI, mmol/L	C, mg/dL	SI, mmol/L	C, mg/dL	SI, mmol/L	C, mg/dL
Desirable	<5.2	<200	<3.36	<130	>1.55	>60
Borderline	5.20–6.18	200–239	3.36–4.11	130–159	0.9–1.55	35–60
Undesirable	≥6.21	≥240	≥4.14	≥160	<0.9	<35

NOTE: LDL, low-density lipoprotein; HDL, high-density lipoprotein; SI, SI units; C, conventional units

SOURCE: Modified from the report of the Expert Panel on Detection, Evaluation, and Treatment of High Blood Cholesterol in Adults: Second Report

of the National Cholesterol Education Program (NCEP) expert panel on detection, evaluation, and treatment of high blood cholesterol (Adult Treatment Panel II). Circulation 89:1329, 1994.

Table 11

Vitamins and Trace Minerals

	Specimen	Reference Range	
		SI Units	Conventional Units
Carotenoids	S	0.9–5.6 $\mu\text{mol/L}$	50–300 $\mu\text{g/dL}$
Ceruloplasmin	S	270–370 mg/L	27–37 ng/dL
Copper	S	11–22 $\mu\text{mol/L}$	70–140 $\mu\text{g/dL}$
Folic acid	RC	340–1020 nmol/L	150–450 ng/mL
		cells	cells
Folic acid	S	7–36 nmol/L cells	3–16 ng/mL cells
Lead	S	<1 $\mu\text{mol/L}$	<20 $\mu\text{g/dL}$
Vitamin A	S	0.7–3.5 $\mu\text{mol/L}$	20–100 $\mu\text{g/dL}$
Vitamin B ₁ (thiamine)	S	0–75 nmol/L	0–2 $\mu\text{g/dL}$
Vitamin B ₂ (riboflavin)	S	106–638 nmol/L	4–24 $\mu\text{g/dL}$
Vitamin B ₆	P	20–121 nmol/L	5–30 ng/ml
Vitamin B ₁₂	S	148–443 pmol/L	200–600 pg/mL
Vitamin C (ascorbic acid)	S	23–57 $\mu\text{mol/L}$	0.4–1.0 mg/dL
Vitamin D ₃ , 1,25-dihydroxy	S	60–108 pmol/L	25–45 pg/mL
Vitamin D ₃ , 25-hydroxy	P		
Summer		37.4–200 nmol/L	15–80 ng/mL
Winter		34.9–105 nmol/L	14–42 ng/mL
Vitamin E	S	12–42 $\mu\text{mol/L}$	5–18 $\mu\text{g/mL}$
Zinc	S	11.5–18.5 $\mu\text{mol/L}$	75–120 $\mu\text{g/dL}$

NOTE: P, plasma; RC, red cells; S, serum.

Table 12

Pulmonary Function Tests

See Table A-19: Summary of Values Useful in Pulmonary Physiology

Table 13

Renal Function Tests

	Reference Range	
	SI Units	Conventional Units
Clearances (corrected to 1.72 m ² body surface area):		
Measures of glomerular filtration rate:		
Inulin clearance (Cl)		
Males (mean \pm 1 SD)	2.1 \pm 0.4 mL/s	124 \pm 25.8 mL/min
Females (mean \pm 1 SD)	2.0 \pm 0.2 mL/s	119 \pm 12.8 mL/min
Endogenous creatinine clearance	1.5–2.2 mL/s	91–130 mL/min
Urea	1.0–1.7 mL/s	60–100 mL/min
Measures of effective renal plasma flow and tubular function:		
<i>p</i> -Aminohippuric acid clearance (Cl _{PAH}):		
Males (mean \pm 1 SD)	10.9 \pm 2.7 mL/s	654 \pm 163 mL/min
Females (mean \pm 1 SD)	9.9 \pm 1.7 mL/s	594 \pm 102 mL/min
Concentration and dilution test:		
Specific gravity of urine:		
After 12-h fluid restriction	≥1.025	≥1.025
After 12-h deliberate water intake	≤1.003	≤1.003
Protein excretion, urine		
Males	<0.15 g/d	<150 mg/d
Females	0–0.06 g/d	0–60 mg/d
Females	0–0.09 g/d	0–90 mg/d
Specific gravity, maximal range	1.002–1.028	1.002–1.028
Tubular reabsorption, phosphorus	0.79–0.94 of filtered load	79–94% of filtered load

Table 14

Hematologic Evaluations. See also "Chemical Constituents of Blood"

	Reference Range			Reference Range	
	SI Units	Conventional Units		SI Units	Conventional Units
Bone marrow: see Table A-6			Platelets and coagulation parameters:		
Carboxyhemoglobin			Alpha ₂ antiplasmin		70–130%
Nonsmoker	0–0.023	0–2.3%	Antithrombin III		80–120%
Smoker	0.021–0.042	2.1–4.2%	Bleeding time (Simplat)	<7 min	<7 min
Erythrocyte			Euglobulin lysis time	>2 h	>2 h
Count	4.15–4.90 × 10 ¹² /L	4.15–4.90 × 10 ⁶ /mm ³	Factor II		60–100%
Distribution width	0.13–0.15	13–15%	Factor V		60–100%
Glucose-6-phosphate dehydrogenase	0.78 ± 0.13 MU/mol Hb	12.1 ± 2 IU/g Hb	Factor VII		60–100%
Life span			Factor IX		60–100%
Normal survival	120 days	120 days	Factor X		60–100%
Chromium-labeled, half-life (t _{1/2})	28 days	28 days	Factor XI		60–100%
Mean corpuscular hemoglobin (MCH)	28–33 pg/cell	28–33 pg/cell	Factor XII		60–100%
Mean corpuscular hemoglobin concentration (MCHC)	320–360 g/L	32–36 g/dL	Factor XIII		60–100%
Mean corpuscular volume (MCV)	86–98 fl	86–98 μm ³	Fibrinogen	2–4 g/L	200–400 mg/dL
Ham's test (acid serum)	Negative	Negative	Plasminogen		2.4–4.4 CTA U/mL
Haptoglobin (serum)	0.5–2.2 g/L	50–220 mg/dL	Protein C (antigenic assay)		58–148%
Hematocrit			Protein S (antigenic assay)		58–148%
Males	0.42–0.52	42–52%	Partial thromboplastin time (activated PTT) comparable to control		
Females	0.37–0.48	37–48%	Prothrombin time (quick one-stage) control ± 1 s		
Hemoglobin			Platelets	130–400 × 10 ⁹ /L	130,000–400,000/mm ³
Plasma	0.01–0.05 g/L	1–5 mg/dL	Thrombin time control ± 3 s		
Whole blood			von Willebrand's antigen		60–150%
Males	8.1–11.2 mmol/L	13–18 g/dL	Protoporphyrin, free erythrocyte (FEP)	0.28–0.64 μmol/L of red blood cells	16–36 μg/dL of red blood cells
Females	7.4–9.9 mmol/L	12–16 g/dL	Red cells: see "Erythrocytes"		
Hemoglobin A ₂ (HbA ₂)	0.015–0.035	1.5–3.5%	Schilling test, orally administered vitamin B ₁₂ excreted in urine		7–40%
Hemoglobin, fetal (HbF)	<0.02	<2%	Sedimentation rate		
Leukocytes			Westergren, <50 years of age		
Alkaline phosphatase (LAP)	0.2–1.6 μkat/L	13–100 μ/L	Males		0–15 mm/h
Count	4.3–10.8 × 10 ⁹ /L	4.3–10.8 × 10 ³ /mm ³	Females		0–20 mm/h
Differential			Westergren, >50 years of age		
Neutrophils	0.45–0.74	45–74%	Males		0–20 mm/h
Bands	0–0.04	0–4%	Females		0–30 mm/h
Lymphocytes	0.16–0.45	16–45%	Sucrose hemolysis	Negative	Negative
Monocytes	0.04–0.10	4–10%	Viscosity		
Eosinophils	0–0.07	0–7%	Plasma	1.7–2.1	1.7–2.1
Basophils	0–0.02	0–2%	Serum	1.4–1.8	1.4–1.8
T cells: see Chap. 309			White blood cells: see "Leukocytes"		
Methemoglobin: <2 mg/L (<2 μg/mL)					
Osmotic fragility					
Slight hemolysis		0.45–0.39%			
Complete hemolysis	0.33–0.30%				

Table 15

Differential Nucleated Cell Counts of Bone Marrow

	Normal, Mean % ^a	Range, % ^b		Normal, Mean % ^a	Range, % ^b
Myeloid	56.7		Erythroid	25.6	
Neutrophilic series	53.6		Pronormoblasts	0.6	0.2–1.3
Myeloblast	0.9	0.2–1.5	Basophilic normoblasts	1.4	0.5–2.4
Promyelocyte	3.3	2.1–4.1	Polychromatophilic normoblasts	21.6	17.9–29.2
Myelocyte	12.7	8.2–15.7	Orthochromatic normoblasts	2.0	0.4–4.6
Metamyelocyte	15.9	9.6–24.6	Megakaryocytes	<0.1	
Band	12.4	9.5–15.3	Lymphoreticular	17.8	
Segmented			Lymphocytes	16.2	11.1–23.2
Eosinophilic series	3.1	1.2–5.3	Plasma cells	2.3	0.4–3.9
Basophilic series	<0.1	0–0.2	Reticulum cells	0.3	0–0.9

^aFrom MM Wintrobe et al, *Clinical Hematology*, 8th ed. Philadelphia, Lea & Febiger, 1981.^bRange observed in 12 healthy men.

Table 16

	Specimen	Reference Range	
		SI Units	Conventional Units
α_2 Antitrypsin (adult)	S	0.76–1.89 g/L	76–189 mg/dL
Antiglomerular basement membrane antibodies	S		
Qualitative		Negative	Negative
Quantitative		<5 kU/L	<5 U/mL
Antineutrophil cytoplasmic autoantibodies, cytoplasmic (C-ANCA)	S		
Qualitative		Negative	Negative
Quantitative (antibodies to proteinase 3)		<2.8 kU/L	<2.8 U/mL
Antineutrophil cytoplasmic autoantibodies, perinuclear (P-ANCA)	S		
Qualitative		Negative	Negative
Quantitative (antibodies to myeloperoxidase)		<1.4 kU/L	<1.4 U/mL
Autoantibodies			
Antiadrenal antibody	S	NA	Negative at 1:10 dilution
Anti-double-stranded (native) DNA	S	NA	Negative at 1:10 dilution
Antigranulocyte antibody	S	NA	Negative
Anti-Jo-1 antibody	S	NA	Negative
Anti-La antibody	S	NA	Negative
Antimitochondrial antibody	S	NA	Negative
Antinuclear antibody	S	NA	Negative at 1:40 dilution
Antiparietal cell antibody	S	NA	Negative at 1:20 dilution
Anti-Ro antibody	S	NA	Negative
Anti-RNP antibody	S	NA	Negative
Anti-Scl-70 antibody	S	NA	Negative
Anti-Smith antibody	S	NA	Negative
Anti-smooth-muscle antibody	S	NA	Negative at 1:20 dilution
Antithyroglobulin antibody	S	NA	Negative
Antithyroid antibody	S	<0.3 kIU/L	<0.3 IU/mL
Bence Jones protein	S	NA	None detected
Qualitative	U	NA	None detected in a 50-fold concentration
Quantitative	U		
Kappa		<0.03 g/L	<2.5 mg/dL
Lambda		<0.05 g/L	<5.0 mg/dL
C1 esterase-inhibitor protein	S		
Antigenic		0.12–0.25 g/L	12.4–24.5 mg/dL
Functional		Present	Present
Complement			
C3 (adult)	S	0.86–1.84 g/L	86–184 mg/dL
C4 (adult)	S	0.20–0.58 g/L	20–58 mg/dL
Total complement (adult)	S	63–145 kU/L	63–145 U/mL
Factor B	S	0.17–0.42 g/L	17–42 mg/dL
Cryoproteins	S	NA	None detected
CSF	CSF		
Agarose electrophoresis		NA	No banding seen in an 80-fold concentration
Quantitation of albumin (adult)		0.11–0.51 g/L	11.0–50.9 mg/dL
Quantitation of IgG (adult)		0.0–0.08 g/L	0.0–8.0 mg/dL
Immunoglobulins	S		
IgA		0.9–3.2 g/L	90–325 mg/dL
IgD		0–0.08 g/L	0–8 mg/dL
IgE		<0.00025 g/L	<0.025 mg/dL
IgG		8.0–15.0 g/L	800–1500 mg/dL
IgM		0.45–1.5 g/L	45–150 mg/dL
Rheumatoid factor	S, JF	<30 kIU/L	<30 IU/mL
Serum protein electrophoresis	S	NA	Normal pattern
T cells: see Chap. 309			
Viscosity	S	1.4–1.8 relative viscosity units, as compared with water	1.4–1.8 relative viscosity units, as compared with water

NOTE: CSF, cerebrospinal fluid; JF, joint fluid; S, serum; U, urine; NA, not applicable.

SOURCE: Adapted from A Kratz, KB Lewandrowski: *N Engl J Med* 339:1063, 1998.

Table 17

	Reference Range	
	SI Units	Conventional Units
Bulk		
Wet weight	<197.5 (115 ± 41) g/d	<197.5 (115 ± 41) g/d
Dry weight	<66.4 (34 ± 15) g/d	<66.4 (34 ± 15) g/d
α_1 Antitrypsin	0.98 (±0.17) mg/g dry weight	0.98 (±0.17) mg/g dry weight
Coproporphyrin	600–1500 nmol/d	400–1000 μ g/d
Fat (on diet containing at least 50 g fat), measured on a \geq 3-day collection		
Fat		
Percent of dry weight	<0.30	<30.4%
Coefficient of fat absorption	>0.95	>95%
Fatty acid		
Free	0.01–0.10	1–10% of dry matter
Combined as soap	0.005–0.12	0.5–12% of dry matter
Nitrogen	<1.7 (1.4 ± 0.2) g/d	<1.7 (1.4 ± 0.2) g/d
Protein content	Minimal	Minimal
Urobilinogen	68–470 μ mol/d	40–280 mg/d
Water	~0.65	~65%

Table 18

	Reference Range	
	SI Units	Conventional Units
Acidity, titratable	20–40 mmol/d	20–40 meq/d
Ammonia	30–50 mmol/d	30–50 meq/d
Amylase		4–400 U/L
Amylase/creatinine clearance ratio [(Cl _{am} /Cl _{cr}) × 100]	1–5	1–5
Calcium (10 meq/d or 200-mg/d dietary calcium)	<7.5 mmol/d	<300 mg/d
Creatine, as creatinine		
Women	<760 μ mol/d	<100 mg/d
Men	<380 μ mol/d	<50 mg/d
Creatinine	8.8–14 mmol/d	1.0–1.6 g/d
Glucose, true (oxidase method)	0.3–1.7 mmol/d	50–300 mg/d
5-Hydroxyindoleacetic acid (5-HIAA)	10–47 μ mol/d	2–9 mg/d
Protein	<0.15 g/d	<150 mg/d
Potassium (varies with intake)	25–100 mmol/d	25–100 meq/d
Sodium (varies with intake)	100–260 mmol/d	100–260 meq/d

Table 19

Summary of Values Useful in Pulmonary Physiology

	Symbol	Typical Values	
		Man Aged 40, 75 kg, 175 cm Tall	Woman Aged 40, 60 kg, 160 cm Tall
PULMONARY MECHANICS			
Spirometry—volume-time curves			
Forced vital capacity	FVC	4.8 L	3.3 L
Forced expiratory volume in 1 s	FEV ₁	3.8 L	2.8 L
FEV ₁ /FVC	FEV ₁ %	76%	77%
Maximal midexpiratory flow	MMF (FEF 25–27)	4.8 L/s	3.6 L/s
Maximal expiratory flow rate	MEFR (FEF 200–1200)	9.4 L/s	6.1 L/s
Spirometry—flow-volume curves			
Maximal expiratory flow at 50% of expired vital capacity	V _{max} 50 (FEF 50%)	6.1 L/s	4.6 L/s
Maximal expiratory flow at 75% of expired vital capacity	V _{max} 75 (FEF 75%)	3.1 L/s	2.5 L/s
Resistance to airflow:			
Pulmonary resistance	RL (R _L)	<3.0 (cmH ₂ O/s)/L	
Airway resistance	Raw	<2.5 (cmH ₂ O/s)/L	
Specific conductance	SGaw	>0.13 cmH ₂ O/s	
Pulmonary compliance			
Static recoil pressure at total lung capacity	P _{st} TLC	25 ± 5 cmH ₂ O	
Compliance of lungs (static)	CL	0.2 L cmH ₂ O	
Compliance of lungs and thorax	C(L + T)	0.1 L cmH ₂ O	
Dynamic compliance of 20 breaths per minute	C _{dyn} 20	0.25 ± 0.05 L/cmH ₂ O	
Maximal static respiratory pressures:			
Maximal inspiratory pressure	MIP	>90 cmH ₂ O	>50 cmH ₂ O
Maximal expiratory pressure	MEP	>150 cmH ₂ O	>120 cmH ₂ O
LUNG VOLUMES			
Total lung capacity	TLC	6.4 L	4.9 L
Functional residual capacity	FRC	2.2 L	2.6 L
Residual volume	RV	1.5 L	1.2 L
Inspiratory capacity	IC	4.8 L	3.7 L
Expiratory reserve volume	ERV	3.2 L	2.3 L
Vital capacity	VC	1.7 L	1.4 L
GAS EXCHANGE (SEA LEVEL)			
Arterial O ₂ tension	Pa _{O₂}	12.7 ± 0.7 kPa (95 ± 5 mmHg)	
Arterial CO ₂ tension	Pa _{CO₂}	5.3 ± 0.3 kPa (40 ± 2 mmHg)	
Arterial O ₂ saturation	Sa _{O₂}	0.97 ± 0.02 (97 ± 2%)	
Arterial blood pH	pH	7.40 ± 0.02	
Arterial bicarbonate	HCO ₃ ⁻	24 + 2 meq/L	
Base excess	BE	0 ± 2 meq/L	
Diffusing capacity for carbon monoxide (single breath)	DL _{CO}	0.42 mLCO/s/mmHg (25 mL CO/min/mmHg)	
Dead space volume	V _D	2 ml/kg body wt	
Physiologic dead space; dead space-tidal volume ratio	V _D /V _T		
Rest		≤35% V _T	
Exercise		≤20% V _T	
Alveolar-arterial difference for O ₂	P(A - a) _{O₂}	≤2.7 kPa ≤20 kPa (≤20 mmHg)	

BIBLIOGRAPHY

- Adashi EY, Hennebold JD: Single-gene mutations resulting in reproductive dysfunction in women. *N Engl J Med* 340:709–718, 1999.
- Adrogue HJ, Madias NE: Hyponatremia. *N Engl J Med* 342:1493–1499, 2000.
- Adrogue HJ, Madias NE: Hyponatremia. *N Engl J Med* 342:1581–1589, 2000.
- Adrogue HJ, Madias NE: Management of life-threatening acid-base disorders. First of two parts. *N Engl J Med* 338:26–34, 1998.
- Alward WL: Medical management of glaucoma. *N Engl J Med* 339:1298–1307, 1998.
- American Society of Clinical Oncology recommendations for the use of hematopoietic colony-stimulating factors: Evidence-based, clinical practice guidelines. *J Clin Oncol* 12:2471–2508, 1994.
- American Thoracic Society and Centers for Disease Control: Treatment of tuberculosis and tuberculosis infection in adults and children. *Am J Respir Crit Care Med* 149:1359, 1994.
- Ammann RW, Eckert: Cestodes. Echinococcus. *Gastroenterol Clin North Am* 37:655–689, 1996.
- Ananthasubramaniam K, Shurafa M, Prasad A: Heparin-induced thrombocytopenia and thrombosis. *Prog Cardiovasc Dis* 42:247–260, 2000.
- Anderson HV, Willerson JT: Thrombolysis in acute myocardial infarction. *N Engl J Med* 329:703–709, 1993.
- Andrews NC: Disorders of iron metabolism. *N Engl J Med* 341:1986–1995, 1999.
- Artman K, Chang Y: Medical progress: Kaposi's sarcoma. *N Engl J Med* 342:1027–1038, 2000.
- Arcasoy SM, Kotloff RM: Lung transplantation. *N Engl J Med* 340:1081–1091, 1999.
- Atkinson MA, Maclaren NK: *N Engl J Med* 331:1428–1436, 1994.
- Avid Investigators: A comparison of antiarrhythmic-drug therapy with implantable defibrillators in patients resuscitated from near-fatal ventricular arrhythmias. *N Engl J Med* 337:1576–1583, 1997.
- Baker DG, Schumacher HR: Acute monoarthritis. *N Engl J Med* 329:1013–1020, 1993.
- Balfour HH, Jr: Antiviral drugs. *N Engl J Med* 340:1255–1268, 1999.
- Barlogie B, Epstein J, Selvanayagam P, et al: Plasma cell myeloma: New biological insights and advances in therapy. *Blood* 73:865–879, 1989.
- Barnes PJ: Chronic obstructive pulmonary disease. *N Engl J Med* 343:269–280, 2000.
- Barnes PJ: Inhaled glucocorticoids for asthma. *N Engl J Med* 332:868–875, 1995.
- Baron TH, Morgan DE: Acute necrotizing pancreatic. *N Engl J Med* 340:1412–1417, 1999.
- Bartlett JG, Mundy LM: Community-acquired pneumonia. *N Engl J Med* 333:1618–1624, 1995.
- Bataille R, Harousseau JL: Multiple myeloma. *N Engl J Med* 336:1657–1664, 1997.
- Beck LH: Hypouricemia in the syndrome of inappropriate secretion of antidiuretic hormone. *N Engl J Med* 301:528–530, 1979.
- Beckett WS: Occupational respiratory diseases. *N Engl J Med* 342:406–413, 2000.
- Ben-David J, Zipes DP: Torsades de pointes and proarrhythmia. *Lancet* 341:1578–1582, 1993.
- Bennett WM, DeBroe ME: Analgesic nephropathy. A preventable renal disease. *N Engl J Med* 320:1269–1271, 1989.
- Berkman N, Kramer MR: Diagnostic tests in pleural effusion: An update. *Postgrad Med J* 69: 12–18, 1993.
- Beutler E: Glucose 6-phosphate dehydrogenase deficiency. *N Engl J Med* 324:169–174, 1991.
- Beutler E: Gaucher's disease. *N Engl J Med* 325:1354–1360, 1991.
- Bick RL, Strauss JF, Frankel EP: Thrombosis and hemorrhage in oncology patients. *Hematol Oncol Clin North Am* 10:875–907, 1996.
- Bisno AL, Stevens DL: Streptococcal infections of skin and soft tissues. *N Engl J Med* 334:240–245, 1996.
- Black P McL: Brain tumors. *N Engl J Med* 324:1555–1564, 1991.
- Block SD: Assessing and managing depression in the terminally ill patient. *Ann Intern Med* 132:209–218, 2000.
- Bochner BS, Lichtenstein LM: Anaphylaxis. *N Engl J Med* 324:1785–1790, 1991.
- Bosl GJ, Motzer RJ: Testicular germ-cell cancer. *N Engl J Med* 337:242–253, 1997.
- Boston Area Anticoagulation Trial for Atrial Fibrillation Investigators: The effect of low dose warfarin on the risk of stroke in patients with non-rheumatic atrial fibrillation. *N Engl J Med* 323:1505–1558, 1990.
- Botto LD, Moore CA, Khoury MJ, Erickson JD: Neural-tube defects. *N Engl J Med* 341:1509–1519, 1999.

- Brater DC: Diuretic therapy. *N Engl J Med* 339:387–395, 1998.
- Bravo EL, Gifford RW: Pheochromocytoma: Diagnosis, localization and management. *N Engl J Med* 311:1298–1303, 1984.
- Brent J, Mc Martin K, Philips S, Burkhart KK, Donovan JW, Wells M, Kulig K: Fomepizole for the treatment of ethylene glycol poisoning. Methylpyrazole for Toxic Alcohols Study Group. *N Engl J Med* 340:832–838, 1999.
- Brickner ME, Hillis LD, Lange RA: Congenital heart disease in adults: First of two parts. *N Engl J Med* 342:256–263, 2000.
- Brickner ME, Hillis LD, Lange RA: Congenital heart disease in adults: Second of two parts. *N Engl J Med* 342:334–342, 2000.
- Brown MS, Goldstein JL: A receptor-mediated pathway for cholesterol homeostasis. *Science* 232:34–47, 1986.
- Bruce AJ, Brodland DG: Overview of skin cancer detection and prevention for the primary care physician. *Mayo Clin Proc* 75:491–500, 2000.
- Brugge WR, Van Dam J: Pancreatic and biliary endoscopy. *N Engl J Med* 341:1808–1816, 1999.
- Buckley RH, Schiff RI: The use of intravenous immune globulin in immunodeficiency diseases. *N Engl J Med* 325:110–117, 1991.
- Burgio KL, Locher JL, Goode PS, Hardin JM, McDowell BJ, Dombrowski M, Candib D: Behavioral versus drug treatment for urge urinary incontinence in older women: A randomized trial. *JAMA* 280:1995–2000, 1998.
- Burrows PD, Cooper MD: IgA deficiency. *Adv Immunol* 65: 245–276, 1997.
- Burtis WJ, Brady TG, Orloff JJ, et al: Immunochemical characterization of circulating parathyroid hormone-related protein in patients with humoral hypercalcemia of cancer. *N Engl J Med* 322:1106–1112, 1990.
- Calhoun DA, Oparil S: Treatment of hypertensive crisis. *N Engl J Med* 323: 1177–1183, 1991.
- Callahan N, Garrett A, Goggin T: Withdrawal of anticonvulsant drugs in patients free of seizures for two years: A prospective study. *N Engl J Med* 318:942–946, 1088.
- Calle EE, Thun MJ, Petrelli JM, Rodriguez C, Heath CW: Body-mass index and mortality in a prospective cohort of U.S. adults. *N Engl J Med* 341:1097–1105, 1999.
- Carabelle BA, Crawford FA: Valvular heart disease. *N Engl J Med* 337:32–41, 1997.
- Cardo DM, Culver DH, Ciesielski CA, Srivastava PU, Marcus R, Abiteboul D, Heptonstall J, Ippolito G, Lot F, McKibben PS, Bell DM: A case-control study of HIV seroconversion in health care workers after percutaneous exposure. *N Engl J Med* 337:1485–1490, 1997.
- Caroff SN, Mann SC: Neuroleptic malignant syndrome. *Med Clin North Am* 77:185–202, 1993.
- Carpenter CC, Fischl MA, Hammer SM: Antiretroviral therapy for HIV infection in 1996 recommendations of an international panel. *JAMA* 276:146–154, 1996.
- Carter H, Landis PK, Metter EJ, Fleisher LA, Pearson JD: Prostate-specific antigen testing of older men. *J Natl Cancer Inst* 91: 1733–1737, 1999.
- Castro O: Management of sickle cell disease: Recent advances and controversies. *Br J Haematol* 107:2–11, 1999.
- Catalina G, Navarro V. Hepatitis C: A challenge for the generalist. *Hosp Pract* 35:97–108, 2000.
- Chandrasekharappa SC, Guru SC, Manicham P, et al: Positional cloning of the gene for multiple endocrine neoplasia type 1. *Science* 276:404–406, 1997.
- Charness ME, Simon RP, Greenberg DA, et al: Ethanol and the nervous system. *N Engl J Med* 321:442–454, 1989.
- Cherubin CE, Eng RH: Quinolones for the treatment of infections due to Salmonella. *Rev Infect Dis* 13:343–344, 1991.
- Cohen JN, Levine TB, Olvari MT, et al: Plasma norepinephrine as a guide to prognosis in patients with chronic congestive heart failure. *N Engl J Med* 311: 819–823, 1984.
- Connolly HM, et al: Valvular heart disease associated with fenfluramine-phentermine. *N Engl J Med* 337:581–588, 1997.
- Coustan DR: Pregnancy in diabetic women. *N Engl J Med* 319:1663–1665, 1988.
- Craven DE, Steger KA: Epidemiology of nosocomial pneumonia. New perspectives of an old disease. *Chest* 108: 1s–16s, 1995.
- Cucurull E, Espinoza LR: Gonococcal arthritis. *Rheum Dis Clin North Am* 24:305–322, 1998.
- Dalakas MC: Polymyositis dermatomyositis and inclusion body myositis. *N Engl J Med* 325:1487–1498, 1991.
- Daniels GH, et al: Thyroid disease and pregnancy: A clinical overview. *Endocrine Pract* 1:287, 1995.
- DeBroe ME, Elseviers MM: Analgesic nephropathy. *N Engl J Med* 338:446–452, 1998.
- DeFronzo RA: Pharmacologic therapy for type 2 diabetes mellitus. *Ann Intern Med* 131:281–303, 1999.
- DeFronzo RA, Goodman AM, and the multicenter Metformin Study Group: Efficacy of metformin in patients with non-insulin-dependent diabetes mellitus. *N Engl J Med* 333:541–549, 1995.
- Degos L, Dombret H, Chomienne C, et al: All-trans retinoic acid as a differentiating agent in the treatment of acute promyelocytic leukemia. *Blood* 85:2643–2653, 1995.
- Delmas PD, Meunier PJ: The management of Paget's disease of bone. *N Engl J Med* 336:558–566, 1997.
- Delves PJ, Roitt IM: Immune system. The first of two parts. *N Engl J Med* 343:37–49, 2000.
- Deresiewicz RL, Thaler SJ, Hsul L, Zamania AA: Clinical and neuroradiographic manifestations of eastern equine encephalitis. *N Engl J Med* 336:1867–1874, 1997.

- Desch CE, Benson AB III, Smith TJ, Flynn PJ, Kraose C, Loprinzi CL, Minsky BD, Petrelli NJ, Pfister DG, Somerfield MR: Recommended colorectal cancer surveillance guidelines by the American Society of Clinical Oncology. *J Clin Oncol* 17:1312, 1999.
- Devinsky O: Patients with refractory seizures. *N Engl J Med* 340:1565–1570, 1999.
- Deyo RA, Weinstein JN: Lower back pain. *N Engl J Med* 344:363–370, 2001.
- The Diabetes Control and Complications Trial Research Group: The effect of intensive treatment of diabetes on the development and progression of long-term complications in insulin-dependent diabetes mellitus. *N Engl J Med* 329:977–986, 1993.
- Dixon TC, Meselson M, Guillemin J, Hanna PC: Anthrax. *N Engl J Med* 341:815–826, 1999.
- Domasio AR: Aphasia. *N Engl J Med* 326:531–539, 1992.
- Donowitz M, Koffe FT, Saidi R: Evaluation of patients with chronic diarrhea. *N Engl J Med* 322:725–729, 1995.
- Dumler JS, Bakken GS: Human ehrlichiosis: Newly recognized infections transmitted by ticks. *Annu Rev Med* 49:201–213, 1998.
- Dupont HL, Chappell CL, Sterling CR, et al: The infectivity of *Cryptosporidium parvum* in healthy volunteers. *N Engl J Med* 332:855–859, 1995.
- Eagle KA, Coley CM, Newell JB, Brewster DC, Darling RC, Strauss HW, Guiney TE, Boucher CA: Combining clinical and thallium data optimizes preoperative assessment of cardiac risk before major vascular surgery. *Ann Intern Med* 110:859–866, 1989.
- Early Breast Cancer Trialists Collaborative Group: Polychemotherapy for early breast cancer: An overview of the randomized trials. *Lancet* 352:930–942, 1998.
- Edlow JA: Lyme disease and related tick-borne illnesses. *Ann Emerg Med* 33:680–693, 1999.
- Edlow JA, Caplin LR: Avoiding pitfalls of the diagnosis of subarachnoid hemorrhage. *N Engl J Med* 342:29–36, 2000.
- Eldar M, Sievner Z, Goldbourt U, Reicher-Reiss H, Kaplinsky E, Behar S: Primary ventricular tachycardia in acute myocardial infarction: Clinical characteristics and mortality. *Ann Intern Med* 117:31–36, 1992.
- Ellerbroek N, Holmes F, Singletary E, et al: Treatment of patients with isolated axillary nodal metastases from an occult primary carcinoma consistent with breast origin. *Cancer* 66:1461–1467, 1990.
- Emmerson BT: The management of gout. *N Engl J Med* 334:445–451, 1996.
- Ernst CB: Abdominal aortic aneurysm. *N Engl J Med* 328:1167–1172, 1993.
- Ettinger B, Black DM, Mitlak BH, Knickerbocker RK, Nickelsen T, Genant HK, Christiansen C, Delmas PD, Zanchetta JR, Stakkestad J, Gluer CC, Krueger K, Cohen FJ, Eckert S, Ensrud KE, Avioli LV, Lips P, Cummings SR: Reduction of vertebral fracture risk in postmenopausal women with osteoporosis treated with raloxifene: Results from a 3-year randomized clinical trial. Multiple Outcomes of Raloxifene Evaluation (MORE) Investigators. *JAMA* 282:637–645, 1999.
- Fang G-D, Fine M, Orloff J, et al: New and emerging etiologies for community acquired pneumonia with implications for therapy. *Medicine* 69:307–316, 1992.
- Fauci AS: The human immunodeficiency virus: Infectivity and mechanisms of pathogenesis. *Science* 239:617–622, 1998.
- Felson DT, Lawrence RC, Hochberg MC, et al: Osteoarthritis: New insights. Part 2: Treatment approaches. *Ann Intern Med* 133:726–737, 2000.
- Fendrick AM, Chernew ME, Hirth RA, et al: Alternative management strategies for patients with suspected peptic ulcer disease. *Ann Intern Med* 123:260–269, 1995.
- Ferris FL, Davis MD, Aiello LM: Treatment of diabetic retinopathy. *N Engl J Med* 341:667–678, 1999.
- Fine H, Mayer RJ: Primary central nervous system lymphoma. *Ann Intern Med* 119:1093–1104, 1993.
- Fine KD, Schiller LR: AGA technical review on the evaluation and management of chronic diarrhea. *Gastroenterology* 116:1464–1486, 1999.
- Fishbein DB, Robinson LE: Rabies. *N Engl J Med* 329:1632–1638, 1993.
- Fisher B, Dignam J, Wolmark N, Mamounase E, Costantino J, Poller W, Fisher ER, Wickerham DL, Deutsch M, Margolese R, Dimitrov N, Kavanah M: Lumpectomy and radiation therapy for the treatment of intraductal breast cancer. Findings from the National Surgical Adjuvant Breast and Bowel Project B-17. *J Clin Oncol* 16:441–452, 1998.
- Fisher CM: Lacunar strokes and infarcts: A review. *Neurology* 32:871–876, 1982.
- Fishman JA, Rubin RH: Infection in organ-transplant recipients. *N Engl J Med* 338:1741–1751, 1998.
- Flier JS: Syndromes of insulin resistance: From patient to gene and back again. *Diabetes* 41:1207–1219, 1992.
- Flexner C: HIV-protease inhibitors. *N Engl J Med* 338:1281–1292, 1998.
- Fowler NO: Tuberculous pericarditis. *JAMA* 266:99–103, 1991.
- Frank BB: Clinical evaluation of jaundice: A guideline of the patient care committee of the American Gastroenterological Association. *JAMA* 262:3031–3034, 1989.
- Frank MM: Complement in the pathophysiology of human disease. *N Engl J Med* 316:1525–1530, 1987.
- Friedberg JW, Neuberg D, Stone RM, Alyea E, Jallow H, LaCasce A, Mauch PM, Gribben JG, Ritz J, Nadler LM, Soiffer RJ, Freedman AS: Outcome in patients with myelodysplastic syndrome after autologous bone marrow transplantation for non-Hodgkin's lymphoma. *J Clin Oncol* 17:3128–3135, 1999.
- Froehling DA, Silverstein MD, Mohr DN, et al: Does this dizzy patient have a serious form of vertigo? *JAMA* 271:385–388, 1994.

- Fujita S: Obstructive sleep apnea syndrome: Pathophysiology, upper-airway evaluation, and surgical treatment. *Ear Nose Throat J* 72:67–72, 75–76, 1993.
- Furman JM, Cass SP: Benign paroxysmal positional vertigo. *N Engl J Med* 341:1590–1596, 1999.
- Gabow PA: Autosomal dominant polycystic kidney disease. *N Engl J Med* 329:332–342, 1993.
- Ganz LI, Friedman PL: Supraventricular tachycardia. *N Engl J Med* 332:162–173, 1995.
- Gennari FJ: Hypokalemia. *N Engl J Med* 339:451–458, 1998.
- George JN: How I treat patients with thrombotic thrombocytopenic purpura-hemolytic uremic syndrome. *Blood* 96:1223–1229, 2000.
- Gilman S: Advances in neurology. Part II. *N Engl J Med* 326:1671–1676, 1992.
- Gladman DD: Psoriatic arthritis. *Rheum Dis Clin North Am* 24:829–844, 1998.
- Goldhaber SZ: Pulmonary embolism. *N Engl J Med* 339:93–104, 1998.
- Goldman L, Caldera DL, Nussbaum SR, Southwick FS, Krogstad D, Murray B, Burke DS, O'Malley TA, Gorroll AH, Caplan CH, Nolan J, Carabello B, Slater EE: Multifactorial index of cardiac risk in non-cardiac surgical procedures. *N Engl J Med* 297:845–850, 1977.
- Goldstein I, Lue TF, Padma-Nathan H, Rosen RC, Steers WD, Wicker PA: Oral sildenafil in the treatment of erectile dysfunction. Sildenafil Study Group. *N Engl J Med* 338:1397–1404, 1998.
- Goldstein RA, Paul WE, Matcalfe DD, et al: Asthma. *Ann Intern Med* 121:698–708, 1994.
- Goodgame RW: Gastrointestinal cytomegalovirus disease. *Ann Intern Med* 119:924–935, 1993.
- Gottlieb SS, McCarter RJ, Vogel RA: Effect of beta-blockade on mortality among high-risk and low-risk patients after myocardial infarction. *N Engl J Med* 339:489–497, 1998.
- Greaves M: Antiphospholipid antibodies and thrombosis. *Lancet* 353:1348–1353, 1999.
- Grisold W, Drlicek M: Paraneoplastic neuropathy. *Curr Opin Neurol* 12:617–625, 1999.
- Gross JB Jr: Clinician's guide to hepatitis C. *Mayo Clin Proc* 73:355–360, 1998.
- Grossman W: Diastolic dysfunction in congestive heart failure. *N Engl J Med* 325:1557–1564, 1991.
- Grunberger G, Weiner JL, Silverman R, et al: Factitious hypoglycemia due to surreptitious administration of insulin: Diagnosis, treatment, and long-term follow-up. *Ann Intern Med* 108:252–257, 1988.
- Hahn BH: Antibodies to DNA. *N Engl J Med* 338:1359–1368, 1998.
- Haluska FG, Multani PS: Melanoma. *Cancer Chemother Biol Response Modif* 18:470–488, 1999.
- Harrison LC, Campbell IL, Allison J, et al: MHC molecules and beta-cell destruction. Immune and non-immune disorders. *Diabetes* 38:815–818, 1989.
- Hauke RJ, Armitage JO: A new approach to non-Hodgkin's lymphoma. *Intern Med* 39:197–208, 2000.
- Havel RJ, Rapaport E: Management of primary hyperlipidemia. *N Engl J Med* 332:1491–1498, 1995.
- Hayakawa H, Sato A, Toyoshima M, et al: A clinical study of idiopathic eosinophilic pneumonia. *Chest* 105:1462–1466, 1992.
- Hermus AR, Huysmans DA: Treatment of benign nodular thyroid disease. *N Engl J Med* 338:1438–1447, 1998.
- Heyland DK, et al: Total parenteral nutrition in the critically ill patient: A meta-analysis. *JAMA* 280:2013–2019, 1998.
- Heyman MR, Schiffer CA: Platelet transfusion therapy for the cancer patient. *Semin Oncol* 17:198–209, 1990.
- Heymansfield SB et al: Recombinant leptin for weight loss in obese and lean adults: A randomized, controlled, dose-escalation trial. *JAMA* 282: 1568–1575, 1999.
- Hinson JR, Marini JF: Principles of mechanical ventilation in respiratory failure. *Annu Rev Med* 43:341–361, 1992.
- Hoffbrand AV, Wonke B: Iron chelation therapy. *J Intern Med* 740(Suppl):37–41, 1997.
- Hoffman GS, Kerr GS, Leavitt RY, Hallahan CW, Lebovics RS, Travis WD, Rottem M, Fauci AS. Wegener granulomatosis: An analysis of 158 patients. *Ann Intern Med* 116:488–498, 1992.
- Hollingsberg P, Hafler DA: Seminars in medicine of the Beth Israel Hospital, Boston. Pathogenesis of diseases induced by human lymphotropic virus type 1 infection. *N Engl J Med* 328:1173–1182, 1993.
- Hoofnagle JH: Type D (delta): Hepatitis. *JAMA* 261:1321–1325, 1989.
- Hook EW, Marra CM: Acquired syphilis in adults. *N Engl J Med* 326:1060–1069, 1992.
- Hooper DC, Wolfson JS: Fluoroquinolone antimicrobial agents. *N Engl J Med* 324:384–394, 1991.
- Hricik DE, Chung-Park M: Glomerulonephritis. *N Engl J Med* 339:888–899, 1998.
- Hughes JR, Goldstein MG, Hurt RD, Shiffman S: Recent advances in the pharmacotherapy of smoking. *JAMA* 281:72–76, 1999.
- Hunninghake GW, Kalica AR: Approaches to the treatment of pulmonary fibrosis. *Am J Respir Crit Care Med* 151: 915–918, 1995.
- Hunt SA: Current status of cardiac transplantation. *JAMA* 280:1692–1698, 1998.
- Ifudu O: Care of patients undergoing hemodialysis. *N Engl J Med* 339:1054–1062, 1998.
- International Perinatal HIV Group. The mode of delivery and the risk of vertical transmission of human immunodeficiency virus type I-meta-analysis of 15 prospective cohort studies. *N Engl J Med* 325: 1371, 1999.
- Irwin RS, Madison JM: The diagnosis and treatment of cough. *N Engl J Med* 343:1715–1721, 2000.
- Javaheri S: Mechanism of central sleep apnea in patients with heart failure. *N Engl J Med* 341:949–954, 1999.

- Jennette JC, Falk RJ: Small-vessel vasculitis. *N Engl J Med* 337:1512–1523, 1997.
- Jensen RT, Fraken DL: Zollinger-Ellison syndrome. Advances in treatment of gastric hypersecretion and the gastrinoma. *JAMA* 271:1429–1435, 1994.
- Johnston GD, Kaplan MM: Pathogenesis and treatment of gallstones. *N Engl J Med* 328:412–421, 1993.
- Johnson RT, Gibbs CJ Jr: Creutzfeldt-Jakob disease and related transmissible spongiform encephalopathies. *N Engl J Med* 339:1994–2004, 1998.
- Joshi N, Caputo GM, Weitekamp MR, Karchmer AW: Infections in patients with diabetes mellitus. *N Engl J Med* 341:1906–1912, 1999.
- Joven J, Villabona C, Vilella E, Masana L, Alberti R, Valles M: Abnormalities of lipoprotein metabolism in patients with the nephrotic syndrome. *N Engl J Med* 323:579–584, 1990.
- Kaye BR: Rheumatologic manifestations of infection with human immunodeficiency virus (HIV). *Ann Intern Med* 11:158–167, 1989.
- Kinch JW, Ryan TJ: Right ventricular infarction. *N Engl J Med* 330:1211–1217, 1994.
- King DJ, et al: Heparin-induced thrombocytopenia. *Ann Intern Med* 8:325–332, 1980.
- Kirchoff LV: American trypanosomiasis (Chagas' disease): A tropical disease now in the United States. *N Engl J Med* 329:639–644, 1993.
- Kjos SL, Buchanan TA: Gestational diabetes mellitus. *N Engl J Med* 341:1749–1756, 1999.
- Klein J, Sato A: The HLA system. First of two parts. *N Engl J Med* 343:702–709, 2000.
- Klippel JH: Biologic therapy for rheumatoid arthritis. *N Engl J Med* 343:1640–1641, 2000.
- Knopp RH: Drug treatment of lipid disorders. *N Engl J Med* 341:498–511, 1999.
- Koenig M, Hoffman EP, Bertelson CJ, et al: Complete cloning of the Duchenne muscular dystrophy (DMD) cDNA and preliminary genomic organization of the DMD gene in normal and affected individuals. *Cell* 50:509–517, 1987.
- Kollef MH, Schuster DP: The acute respiratory distress syndrome. *N Engl J Med* 332:27–31, 1995.
- Krawitt EL: Autoimmune hepatitis. *N Engl J Med* 334:897–903, 1996.
- Kuntz RE, Tosteson AN, Berman AD, et al: Predictors of event-free survival after balloon aortic valvuloplasty. *N Engl J Med* 325:17–23, 1991.
- Kusumoto FM, Goldschlager N: Cardiac pacing. *N Engl J Med* 334:89–97, 1996.
- Kyle RA: The role of bisphosphonates in multiple myeloma. *Ann Intern Med* 132:734–736, 2000.
- Laderson PW, Levin AA, Ridgway EC, et al: Complication of surgery in hyperthyroid patients. *Am J Med* 77:261–266, 1984.
- Lang AE, Lozano AM: Parkinson's disease. First of two parts. *N Engl J Med* 339:1044–1053, 1998.
- Larsen GL: Asthma in children. *N Engl J Med* 326:1540–1545, 1992.
- Lee WM: Drug-induced hepatotoxicity. *N Engl J Med* 333:1118–1127, 1995.
- Lenzi R, Hess KR, Abbruzzese MC, Raber MN, Ordenez NG, Abbruzzese JL: Poorly differentiated carcinoma and poorly differentiated adenocarcinoma of unknown origin: Favorable subsets of patients with unknown primary carcinoma. *J Clin Oncol* 15:2056–2066, 1997.
- Levi M, Ten Cate H: Disseminated intravascular coagulation. *N Engl J Med* 341:586–592, 1999.
- Levine GN, Keane JF, Vita JA: Cholesterol reduction in cardiovascular disease. *N Engl J Med* 332:512–521, 1995.
- Levy DE, Caronna JJ, Singer BH, Lapinski RH, Frydman H, Plum F: Predicting outcome from hypoxic-ischemic coma. *JAMA* 253:1420–1426, 1985.
- Levy MH: Pharmacologic treatment of cancer pain. *N Engl J Med* 335:1124–1132, 1996.
- Libby P: Molecular bases of the acute coronary syndromes. *Circulation* 91:2844–2850, 1995.
- Lieberman UA, Weiss SR, Minne HW, et al: Effect of oral alendronate on bone mineral density and the incidence of fractures in postmenopausal osteoporosis. *N Engl J Med* 333:1437–1443, 1995.
- Lowy FD: *Staphylococcus aureus* infections. *N Engl J Med* 339:520–532, 1998.
- Lue TF: Erectile dysfunction. *N Engl J Med* 342:1802–1813, 2000.
- Lynn RB, Friedman LS: Irritable bowel syndrome. Managing the patient with abdominal pain and altered bowel habits. *Med Clin North Am* 79:373–390, 1995.
- Mackowiak PA: Concepts of fever. *Arch Intern Med* 158:1870–1881, 1998.
- Madsen JR, Karluk D: A 71-year-old woman with an enlarging pituitary mass. Case Records of the Massachusetts General Hospital. *N Engl J Med* 343:1399–1406, 2000.
- Mangano DT, Goldman L: Preoperative assessment of patients with known or suspected coronary disease. *N Engl J Med* 333:1750–1756, 1995.
- Mangano DT, Goldman L: Effect of Atenolol on mortality and cardiovascular morbidity after non-cardiac surgery. *N Engl J Med* 335:1713–1720, 1996.
- Mannheimer SB, Soave R: Protozoal infections in patients with AIDS. Cryptosporidiosis, isosporiasis, cyclosporiasis, and microsporidiosis. *Infect Dis Clin North Am* 8:483–498, 1994.
- Mannucci PM: Hemostatic drugs. *N Engl J Med* 339:245–253, 1998.
- Mannucci PM, Tuddenham EG: The hemophilias: Progress and problems. *Semin Hematol* 36:104–117, 1999.
- Marks AR, Choong CY, Sanfilippo AJ, et al: Identification of high-risk and low-risk subgroups of patients with a mitral valve prolapse. *N Engl J Med* 320:1031–1036, 1989.

- Maron BJ, Roberts WC, McAllister HA, Rosing DR, Epstein SE: Sudden death in young athletes. *Circulation* 62: 218–229, 1980.
- Martin JB: Molecular basis of the neurodegenerative disorders. *N Engl J Med* 340:1970–1980, 1999.
- Maschio G, Alberti D, Janin G, et al: Effect of the angiotensin-converting-enzyme inhibitor benazepril on the progression of chronic renal insufficiency. The Angiotensin-Converting-Enzyme Inhibition in Progressive Renal Insufficiency Study Group. *N Engl J Med* 334: 939–945, 1996.
- Maser: Consensus statement on the use of corticosteroids as adjunctive therapy for pneumocystis pneumonia in the acquired immunodeficiency syndrome. The National Institutes of Health–University of California Expert Panel for Corticosteroids as Adjunctive Therapy for Pneumocystis Pneumonia. *N Engl J Med* 323:1500–1504, 1990.
- Mayeux R, Sano M: Treatment of Alzheimer's disease. *N Engl J Med* 341:1670–1679, 1999.
- McAlister HF, Klementowicz PT, Andrews C, et al: Lyme carditis: An important cause of reversible heart block. *Ann Intern Med* 110:339–345, 1989.
- McFadden ER, Jr, Gilbert IA: Asthma. *N Engl J Med* 327: 1928–1937, 1993.
- Means RT Jr: Advances in the anemia of chronic disease. *Int J Hematol* 70:7–12, 1999.
- Menon KV, Kamath PS: Managing the complications of cirrhosis. *Mayo Clin Proc* 75:501–509, 2000.
- Michels R, Marzuk PM: Progress in psychiatry. *N Engl J Med* 329:552–560, 628–638, 1993.
- Milberg JA, Davis DR, Steinberg KP, Hudson LD: Improved survival of patients with acute respiratory distress syndrome (ARDS): 1983–1993. *JAMA* 273:306–309, 1995.
- Mincey BA, Moraghan TJ, Perez EA: Prevention and treatment of osteoporosis in women with breast cancer. *Mayo Clin Proc* 75:821–829, 2000.
- Mittleman MA, Maclure M, Tofler GH, Sherwood JB, Goldberg RJ, Muller FE: Triggering of acute myocardial infarction by heavy physical exertion. *N Engl J Med* 329:1677–1683, 1993.
- Modell JH: Drowning. *N Engl J Med* 328:253–256, 1993.
- Montzoros CS: The role of leptin in human obesity and disease: A review of current evidence. *Ann Intern Med* 130:671–680, 1999.
- Morris MJ, Scher HI: Novel strategies and therapeutics for the treatment of prostate carcinoma. *Cancer* 89:1329–1348, 2000.
- Moss AJ, Hall WJ, Cannom DS, Daubert JP, Higgins SL, Klein H, Levine JH, Saksena S, Waldo AL, Wilber D, Brown MW, Heo M: Improved survival with an implanted defibrillator in patients with coronary disease at high risk for ventricular arrhythmia. *N Engl J Med* 335:1933–1940, 1996.
- Naclerio RM: Allergic rhinitis. *N Engl J Med* 325:860–869, 1991.
- Narins RG, Jones ER, Stom MC, et al: Diagnostic strategies in disorders of fluid, electrolyte, and acid-base homeostasis. *Am J Med* 72:496–520, 1982.
- Nathan DM: Long-term complications of diabetes mellitus. *N Engl J Med* 328:1676–1685, 1993.
- National Institutes of Health–University of California Expert Panel for Corticosteroids as Adjunctive Therapy for Pneumocystis Pneumonia: Consensus statement on the use of corticosteroids as adjunctive therapy for Pneumocystis pneumonia in AIDS. *N Engl J Med* 323:1500–1504, 1990.
- Nelson HS: Beta-adrenergic bronchodilators. *N Engl J Med* 333:499–506, 1995.
- Neufeld M, Maclaren NK, Blizzard RM: Two types of autoimmune Addison's disease associated with different polyglandular autoimmune (PGA) syndromes. *Medicine* 60:355–362, 1981.
- Niederer C, Heintges T, Lange S, et al: Long-term follow-up of HbeAg-positive patients treated with interferon alfa for chronic hepatitis B. *N Engl J Med* 334:1422, 1996.
- Oates JA, Wood AJJ: Adenosine and supraventricular tachycardia. *N Engl J Med* 325:1621–1629, 1991.
- Ochs A, Rössle M, Haag K, et al: The transjugular intrahepatic portosystemic stent-shunt procedure for refractory ascites. *N Engl J Med* 332:1192, 1995.
- Oldfield EH, et al: Petronal sinus sampling with and without corticotropin-releasing hormone for the differential diagnosis of Cushing's syndrome. *N Engl J Med* 325: 897, 1991.
- Oliva PB, Hammill SC, Edwards WD: Cardiac rupture, a clinically predictable complication of acute myocardial infarction: Report of 70 cases with clinical pathologic correlations. *J Am Coll Cardiol* 22:720–726, 1993.
- Orth SR, Ritz E: The nephrotic syndrome. *N Engl J Med* 338:1202–1211, 1998.
- Osborne CK: Tamoxifen and the treatment of breast cancer. *N Engl J Med* 339:1609–1618, 1998.
- Oswald-Mammosser M, Weitzenblum E, Quoix E, et al: Prognostic factors in COPD patients receiving long-term oxygen therapy. Importance of pulmonary artery pressure. *Chest* 107:1193–1198, 1995.
- Ozols RF: Management of advanced ovarian cancer consensus summary. *Semin Oncol* 27:47–49, 2000.
- Passaro DJ, Parsonnet J: Advances in the prevention and management of traveler's diarrhea. *Curr Clin Top Infect Dis* 58:217–236, 1998.
- Pastan S, Bailey J: Dialysis therapy. *N Engl J Med* 338: 1428–1437, 1998.
- Perez-Ruiz F, Calabozo M, Herrero-Beites AM, et al: Improvement of renal function in patients with chronic gout after proper control of hyperuricemia and gouty bouts. *Nephron* 86:287–291, 2000.
- Petri WA Jr, Singh U: Diagnosis and management of amebiasis. *Clin Infect Dis* 29:1117–1125, 1999.
- Pettitt AR, Zuzel M, Cawley JC: Hairy cell leukaemia: Biology and management. *Br J Haematol* 106:2–8, 1999.

- Peura D: *Helicobacter pylori*: Rational management options. *Am J Med* 105:424–430, 1998.
- Piscitelli SC, Gallicano KD: Interactions among drugs for HIV and opportunistic infections. *N Engl J Med* 344: 984–996, 2001.
- Pizzo PA: Fever in immunocompromised patients. *N Engl J Med* 341:893–900, 1999.
- Poterucha JJ, Wiesner RH: Liver transplantation and hepatitis B. *Ann Intern Med* 126:805–807, 1997.
- Poupon RE, Poupon R, Balkau B: Ursodiol for the long-term treatment of primary biliary cirrhosis. The UDCA-PBC Study Group. *N Engl J Med* 330:1342, 1994.
- Prados J, Finison L, Andres PL, et al: The natural history of amyotrophic lateral sclerosis and the use of natural history controls in the therapeutic trials. *Neurology* 43: 751–755, 1993.
- Pras E, Aksentijevich I, Gruberg L, Balow JE, Jr, Prosen L, Dean M, Steinberg AD, Pras M, Kastner DL: Mapping of a gene causing familial Mediterranean fever to the short arm of chromosome 16. *N Engl J Med* 326:1509–1513, 1992.
- Preminger GM: Renal calculi: Pathogenesis, diagnosis, and medical therapy. *Semin Nephrol* 12:200–216, 1992.
- Present DH et al: Infliximab for the treatment of fistulas in patients with Crohn's disease. *N Engl J Med* 340: 1398–1405, 1999.
- Pritchett EL: Management of atrial fibrillation. *N Engl J Med* 326:1264–1271, 1992.
- Pui CH, Evans WE: Acute lymphoblastic leukemia. *N Engl J Med* 339: 605–615, 1998.
- Rao PM et al: Effect of computed tomography of the appendix on treatment of patients and use of hospital resources. *N Engl J Med* 338:141–146, 1998.
- Reddy PS, Curtiss EI, O'Toole JD, Shaver JA: Cardiac tamponade: Hemodynamic observations in man. *Circulation* 58:265–272, 1978.
- Reddy SG, Roberts WC: Frequency of the rupture of the left ventricular free-wall or ventricular septum among necropsy cases of fatal acute myocardial infarction since introduction of coronary care units. *Am J Cardiol* 63: 906–911, 1989.
- Rees JH, Soudain SE, Gregson NA, Hughes RA: Campylobacter jejuni infection in the Guillian-Barré syndrome. *N Engl J Med* 333:1374–1379, 1995.
- Relman DA, Schmidt TM, MacDermott RP, Falkow S: Identification of the uncultured bacillus of Whipple's disease. *N Engl J Med* 327:293–301, 1992.
- Resnick NM, Valla SV, Laurine E: The pathophysiology of urinary incontinence among institutionalized elderly persons. *N Engl J Med* 320:1–7, 1989.
- Revler JB, Broudy VC, Cooney TG: Adult scurvy. *JAMA* 253:805–807, 1985.
- Rex JH, Walsh TJ, Sobel JD, Filler SG, Pappas PG, Dismukes WE, Edwards JE: Practice guidelines for the treatment of candidiasis. Infectious Diseases Society of America. *Clin Infect Dis* 30:662–678, 2000.
- Rich S: Primary pulmonary hypertension. *Prog Cardiovasc Dis* 31: 205–238, 1988.
- Ridker PM, Hennekens CH, Lindpaintner K, et al: Mutation in the gene coding for coagulation factor V and the risk of myocardial infarction, stroke, and venous thrombosis in apparently healthy men. *N Engl J Med* 332: 912–916, 1995.
- Ritz E, Orth SR: Nephropathy in patients with type 2 diabetes mellitus. *N Engl J Med* 341:1127–1133, 1999.
- Robert C, Kupper TS: Inflammatory skin diseases, T-cells, and immune surveillance. *N Engl J Med* 341:1817–1828, 1999.
- Rolachon A, Cordier L, Bacq Y, et al: Ciprofloxacin and long-term prevention of spontaneous bacterial peritonitis: Results of a prospective controlled trial. *Hepatology* 22:1171–1174, 1995.
- Ropper AH: The Guillian-Barré syndrome. *N Engl J Med* 326:1130–1136, 1992.
- Rosen FS, Cooper MD, Wedgewood RJP: The primary immunodeficiencies. *N Engl J Med* 311:235–242, 300–310, 1984.
- Rosenbaum M, Leibel RL, Hirsch J: Obesity. *N Engl J Med* 337:396–407, 1997.
- Rosenberg M, Patterson R, Mintzer R, et al: Clinical and immunologic criteria for the diagnosis of allergic bronchopulmonary aspergillosis. *Ann Intern Med* 86: 405–414, 1977.
- Rothenberg ME: Eosinophilia. *N Engl J Med* 338:1592–1600, 1998.
- Roujeau JC, Stern RS: Severe adverse cutaneous reactions to drugs. *N Engl J Med* 331:1272, 1994.
- Roy D, Talajic M, Dorian P, Connolly S, Eisenberg MJ, Green M, Kus T, Lambert J, Dubuc M, Gagne P, Nattel S, Thibeault B: Amiodarone to prevent recurrence of atrial fibrillation. *N Engl J Med* 342:913–920, 2000.
- Rudick RA, Cohen JA, Weinstock-Guttman B, Kinkel RP, Ransohoff RM: Management of multiple sclerosis. *N Engl J Med* 337:1604–1611, 1997.
- Safian RD, Berman AD, Diver DJ, McKay LL, Come PC, Riley MF, Warren SE, Cunningham MJ, Wyman RM, Weinstein JS, et al: Balloon aortic valvuloplasty in 170 consecutive patients. *N Engl J Med* 319:125–130, 1988.
- Sakanet T, Takeno M, Suzuki N, et al: Behçet's disease. *N Engl J Med* 341:1284–1291, 1999.
- Samuel D, Muller R, Alexander G, et al: Liver transplantation in European patients with hepatic B surface antigens. *N Engl J Med* 329:1842–1847, 1993.
- Scandinavian Simvastatin Survival Study (4S): Randomized trial of cholesterol lowering in 4444 patients with coronary heart disease. *Lancet* 344:1383–1389, 1994.
- Schneider E, Hajjeh RA, Spiegel RA, Jibson RW, Harp EL, Marshall GA, Gunn RA, McNeil MM, Pinner RW, Baron RC, Burger RC, Hutwagner LC, Crump C, Kaufman L, Reef SE, Feldman GM, Pappapanis D, Werner SB: A coccidioidomycosis outbreak following

- the Northridge, California earthquake. *JAMA* 277: 904–908, 1997.
- Shader RI, Greenblatt DJ: Use of benzodiazepines in anxiety disorder. *N Engl J Med* 328:1398–1405, 1993.
- Shafran SD, Singer J, Zarowny DP, Phillips P, Salit I, Walmsley SL, Fong IW, Gill MJ, Rachlis AR, Lalonde RG, Fanning MM, Tsoukas CM: A comparison of two regimens for the treatment of *Mycobacterium avium* complex bacteremia in AIDS: Rifabutin, ethambutol, and clarithromycin versus rifampin, ethambutol, clofazimine, and ciprofloxacin. *N Engl J Med* 335:377–383, 1996.
- Shapiro ED, Berg AT, Austrian R, et al: The protective efficacy of polyvalent pneumococcal vaccine. *N Engl J Med* 325:1453–1460, 1991.
- Sharkey SW: Beyond the wedge: Clinical physiology and the Swan-Ganz catheter. *Am J Med* 83:111–122, 1987.
- Sillevis Smitt P, Kinoshita A, De Leeuw B, Moll W, Coesmans M, Jaarsma D, Henzen-Logmans S, Vecht C, DeZeeuw C, Sekiyama N, Nakanishi S, Shigemoto R: Paraneoplastic cerebellar ataxia due to autoantibodies against a glutamate receptor. *N Engl J Med* 342:21–27, 2000.
- Silverberg SJ, Shane E, Jacobs TP, Siris E, Bilezikian JP: A 10-year prospective study of primary hyperparathyroidism with or without parathyroid surgery. *N Engl J Med* 341:1249–1254, 1999.
- Silverstien FE, Graham DY, Seniors JR, et al: Misoprostol reduces serious gastrointestinal complications in patients with rheumatoid arthritis receiving nonsteroidal anti-inflammatory drugs. A randomized, double-blind, placebo-controlled trial. *Ann Intern Med* 123:241–249, 1995.
- Sneller MC, Strober W, Isenstein E, et al: New insights into common variable immunodeficiency. *Ann Intern Med* 118:720–730, 1993.
- Snilkstein MJ, Knapp GL, Kulig KW, Rumack BH: Efficacy of oral N-acetylcysteine in the treatment of acetaminophen overdose: Analysis of the national multicenter study. *N Engl J Med* 319:1557–1562, 1988.
- SOLVD Investigators: Effect on survival in patients with induced left ventricular ejection fractions and congestive heart failure. *N Engl J Med* 325:293–302, 1991.
- Spach DH, Liles WC, Campbell GL, et al: Tick-borne diseases in the United States. *N Engl J Med* 329:936–947, 1993.
- Spechler SJ: AGA technical review on treatment of patients with dysphagia caused by benign disorders of the distal esophagus. *Gastroenterology* 117: 229–233, 1999.
- Spirito P, Seidman CE, McKenna WJ, Maron BJ: The management of hypertrophic cardiomyopathy. *N Engl J Med* 336:775–785, 1997.
- Splawski I, Timothy KW, Vincent GM, Atkinson DL, Keating MT: Molecular basis of the long-QT syndrome associated with deafness. *N Engl J Med* 336:1562–1567, 1997.
- Stamm WE: Catheter-associated urinary tract infections: Epidemiology, pathogenesis, and prevention. *Ann Intern Med* 3B(Suppl):65s–71s, 1991.
- Standaert DG, Stern MB: Update on the management of Parkinson's disease. *Med Clin North Am* 77:169–183, 1993.
- Standards and guidelines for cardiopulmonary resuscitation (CPR) in emergency cardiac care (ECC). *JAMA* 255: 2905–2989, 1986.
- Steer ML, Waxman I, Freedman S: Chronic pancreatitis. *N Engl J Med* 332:1482–1490, 1995.
- Stern RC: The diagnosis of cystic fibrosis. *N Engl J Med* 336:487–491, 1997.
- Stone RM, Bridges KR, Libby P: Hematological-oncological disorders and cardiovascular disease in *Heart Disease*, 6th ed, E Braunwald, DP Zipes, P Libby (eds.). Saunders, Philadelphia, 2001.
- Strewler GJ: The physiology of parathyroid hormone-related protein. *N Engl J Med* 342:177–185, 2000.
- Stutts, Canessa CM, Olsen JC, et al: CFTR as a camp-dependent regulator of sodium channels. *Science* 269: 847–850, 1995.
- Takahashi Y, Murai C, Shibata S, Munakata Y, Ishii T, Ishii K, Saitoh T, Sawai T, Sugamora K, Sasaki T: Human parvovirus B19 as a causative agent for rheumatoid arthritis. *Proc Natl Acad Sci USA* 95:8227–8232, 1998.
- Tefferi A: Myelofibrosis with myeloid metaplasia. *N Engl J Med* 342:1255–1265, 2000.
- Tilg H, Diehl AM: Mechanisms of disease: Cytokines in alcoholic and nonalcoholic steatohepatitis. *N Engl J Med* 343:1467–1476, 2000.
- Tobin MJ: Mechanical ventilation. *N Engl J Med* 330:1056–1061, 1994.
- Toh BH, van Driel IR, Gleeson PA: Pernicious anemia. *N Engl J Med* 337:1441–1448, 1997.
- Tong MJ, el-Farra NS, Reikes AR, et al: Clinical outcomes after infusion-associated hepatitis C. *N Engl J Med* 332:1463–1466, 1995.
- Trier JS: Celiac sprue. *N Engl J Med* 325:1709–1719, 1991.
- van der Meche FG, Schmitz PI: A randomized trial comparing intravenous immune globulin and plasma exchange in Guillian-Barré syndrome. *N Engl J Med* 326: 1123–1129, 1992.
- Varley JM, Evans DG, Birch JM: Li-Fraumeni syndrome—a molecular and clinical review. *Br J Cancer* 76:1–14, 1997.
- Vassallo R, Ryu JH, Colby TV, et al: Pulmonary Langerhans' cell histiocytosis. *N Engl J Med* 342:1969–1978, 2000.
- Vokes EE, Weichselbaum RR, Lippman SM, et al: Head and neck cancer. *N Engl J Med* 328:184–194, 1993.
- Walsh JH, Peterson WL: The treatment of *Helicobacter pylori* infection in the management of peptic ulcer disease. *N Engl J Med* 338:984–991, 1995.

- Ware LB, Matthay MA: The acute respiratory distress syndrome. *N Engl J Med* 342:1334–1349, 2000.
- Warshaw AL, Fernandez-del Castillo C: Pancreatic carcinoma. *N Engl J Med* 326:455–465, 1992.
- Watanabe T, Muto T: Recent advances in the treatment of rectal carcinoma. *Crit Rev Oncol Hematol* 32:5–17, 1999.
- Weatherall DJ, Provan AB: Red cells I: Inherited anaemias. *Lancet* 355:1169–1175, 2000.
- Weinberg RA: The retinoblastoma protein and cell cycle control. *Cell* 81:323–330, 1995.
- Weisenburger DD, Armitage JO: Mantle cell lymphoma—an entity comes of age. *Blood* 87:4483–4494, 1996.
- Welch KMA: Drug therapy of migraine. *N Engl J Med* 329:1476–1483, 1993.
- Wellens HJ, Bar FW, Lie KI: The value of the electrocardiogram in the differential diagnosis of a tachycardia with a widened QRS complex. *Am J Med* 64:27–33, 1978.
- Wheats J, Hafner R, Korzun AH, et al: Itraconazole treatment of disseminated histoplasmosis in patients with the acquired immunodeficiency syndrome. AIDS Clinical Trial Group. *Am J Med* 98:336–342, 1995.
- Wheeler AP, Bernard GR: Treating patients with severe sepsis. *N Engl J Med* 240:207–214, 1999.
- White RJ, Likavech MJ: The diagnosis in initial management of head injury. *N Engl J Med* 327: 1507–1511, 1992.
- Wierda WG, Kipps TJ: Chronic lymphocytic leukemia. *Curr Opin Hematol* 6:253–261, 1999.
- Williams GH: Converting enzyme inhibitors in the treatment of hypotension. *N Engl J Med* 319:1517–1525, 1989.
- Willich SN, Lewis M, Lowel H, Arntz HR, Schubert F, Schroder R: Physical exertion as a trigger of acute myocardial infarction. *N Engl J Med* 329:1684–1690, 1993.
- Wilt TJ, Ishani A, Stark G, MacDonald R, Lau J, Mulrow C: Saw palmetto extracts for treatment of benign prostatic hyperplasia: A systematic review. *JAMA* 280:1604–1609, 1998.
- Working Group on Severe Streptococcal Infections: Defining the group A streptococcal toxic shock syndrome. Rationale and consensus definition. *JAMA* 269:390–391, 1993.
- Wrenn KD, Solvis SM, Minion GE, et al: The syndrome of alcoholic ketoacidosis. *Am J Med* 91:119–128, 1991.
- Yankner BA, Mesulam M-M: Beta-amyloid and the pathogenesis of Alzheimer's disease. *N Engl J Med* 325:1849–1857, 1991.
- Young NS, Maciejewski J: The pathophysiology of acquired aplastic anemia. *N Engl J Med* 336:1365–1372, 1997.
- Zangwill KM, Hamilton DH, Perkins BA, et al: Cat scratch disease in Connecticut: Epidemiology, risk factors, and evaluation of a new diagnostic test. *N Engl J Med* 329:8, 1993.
- Zimmerli W, Widmer AF, Blatter M, et al: Role of rifampin for treatment of orthopedic implant-related staphylococcal infections: A randomized controlled trial. Foreign-Body Infection (FBI) Study Group. *JAMA* 279:1537–1541, 1998.