

BONE MARROW PATHOLOGY

This book is dedicated to Professor David A.G. Galton

BONE MARROW PATHOLOGY

BARBARA J. BAIN

MBBS, FRACP, FRCPath
Reader in Diagnostic Haematology
St Mary's Hospital Campus of
Imperial College School of Medicine, London
and Honorary Consultant Haematologist
St Mary's Hospital, London

DAVID M. CLARK

MD, MRCP, FRCPath
Consultant Histopathologist
United Lincolnshire Hospitals NHS Trust
Honorary Consultant Histopathologist
University Hospital, Nottingham
and Special Lecturer in Pathology
University of Nottingham

IRVIN A. LAMPERT

MB, ChB, DCP, FRCPath
Consultant Histopathologist
Ealing Hospital, London
Honorary Senior Lecturer,
Hammersmith Hospital Campus of
Imperial College School of Medicine
and Honorary Consultant Histopathologist
Hammersmith Hospital, London

BRIDGET S. WILKINS

DM, PhD, FRCPath
Consultant Histopathologist
Newcastle upon Tyne Hospitals NHS Trust
and Honorary Senior Lecturer
University of Newcastle

THIRD EDITION



**Blackwell
Science**

© 1992, 1996, 2001
Blackwell Science Ltd
Editorial Offices:
9600 Garsington Road, Oxford OX4 2DQ, UKQ
23 Ainslie Place, Edinburgh EH3 6AJ
350 Main Street, Malden
MA 02148-5020, USA
54 University Street, Carlton
Victoria 3053, Australia

Other Editorial Offices:
Blackwell Science KK
MG Kodemmacho Building
7-10 Kodemmacho Nihombashi
Chuo-ku, Tokyo 104, Japan

Iowa State University Press
A Blackwell Science Company
2121 S. State Avenue
Ames, Iowa 50014-8300, USA

The right of the Authors to be
identified as the Authors of this Work
has been asserted in accordance
with the Copyright, Designs and
Patents Act 1988.

All rights reserved. No part of
this publication may be reproduced,
stored in a retrieval system, or
transmitted, in any form or by any
means, electronic, mechanical,
photocopying, recording or otherwise,
except as permitted by the UK
Copyright, Designs and Patents Act
1988, without the prior permission
of the copyright owner.

First published 1992
Second edition 1996
Third edition 2001
3 2006

Set by Graphicraft Limited, Hong Kong
Printed and bound in Singapore
by Fabulous Printers Pte Ltd

The Blackwell Science logo is a
trade mark of Blackwell Science Ltd,
registered at the United Kingdom
Trade Marks Registry

DISTRIBUTORS

Marston Book Services Ltd
PO Box 269
Abingdon, Oxon OX14 4YN
(Orders: Tel: 01235 465500
Fax: 01235 465555)

USA

Blackwell Science, Inc.
Commerce Place
350 Main Street
Malden, MA 02148-5018
(Orders: Tel: 800 759 6102
781 388 8250
Fax: 781 388 8255)

Australia

Blackwell Science Pty Ltd
54 University Street
Carlton, Victoria 3053
(Orders: Tel: 3 9347 0300
Fax: 3 9347 5001)

A catalogue record for this title
is available from the British Library
ISBN 978-0-632-05578-4

Library of Congress
Cataloging-in-Publication Data

Bone marrow pathology/Barbara
J. Bain . . . [et al.].-3rd ed.

p. cm.

Rev. ed. of: Bone marrow pathology/
Barbara J. Bain, David M. Clark,
Irvin A. Lampert. 2nd ed. 1996.
Includes bibliographical references
and index.

ISBN 978-0-632-05578-4

1 Bone marrow-histopathology.

I Bain, Barbara J. II Bain, Barbara J.

Bone marrow pathology.

[DNLM: 1. Bone Marrow Diseases—

pathology. 2. Bone Marrow—

pathology. WH 380 B71 16 2001]

RC645.7.B35 2001

616.4'107—dc21

00-051929

For further information on
Blackwell Science, visit our website:
www.Blackwellpublishing.com

CONTENTS

	Preface to the third edition, vi
	Acknowledgements, vii
	Abbreviations, viii
1	The normal bone marrow, 1
2	Special techniques applicable to bone marrow diagnosis, 51
3	Infection and reactive changes, 90
4	Acute myeloid leukaemia, the myelodysplastic syndromes and histiocytic neoplasms, 141
5	Chronic myeloproliferative and myeloproliferative/ myelodysplastic disorders, 191
6	Lymphoproliferative disorders, 231
7	Multiple myeloma and related disorders, 332
8	Disorders of erythropoiesis, granulopoiesis and thrombopoiesis, 360
9	Miscellaneous disorders, 391
10	Metastatic tumours, 430
11	Diseases of bone, 462
	Appendix, 474
	Index, 483

PREFACE TO THE THIRD EDITION

In this book we have set out to provide a practical guide to bone marrow diagnosis, based on an integrated assessment of peripheral blood and bone marrow aspirate films, trephine biopsy sections and various supplementary investigations. We believe that a trephine biopsy specimen should not be examined and interpreted in isolation. We have therefore discussed the clinical context of bone marrow diagnosis and have given equal weight to cytological and histological features. Since bone marrow diagnosis is no longer based on morphological features alone we have also, in this edition, discussed in considerable detail the role of immunophenotypic, cytogenetic and molecular genetic analysis.

We have dealt very fully with haematological disorders for which bone marrow examination is commonly performed. However, we have also sought to be as comprehensive as possible, includ-

ing whatever information is available on uncommon and rare disorders so that the book will serve as a useful reference source. When possible, we have illustrated rare as well as common conditions and have cited the relevant scientific literature extensively.

In this edition we have introduced a new section entitled 'Problems and pitfalls' which we believe will be of value. We have also expanded the description of technical methods. We hope that haematologists and histopathologists will continue to find *Bone Marrow Pathology* a useful aid in their day-to-day practice and that trainees in these disciplines will find it indispensable.

BJB, DMC, IAL, BSW
December 2000

ACKNOWLEDGEMENTS

We should like to thank our many friends and colleagues in North America, Europe, Africa, Asia and Australia who have provided illustrations or have permitted us to photograph microscopic slides from their personal collections. They are individually acknowledged in the legends of specific figures. In addition we should like to thank our technical and medical colleagues in St Mary's Hospital, Hammer-smith Hospital, Nottingham University Hospitals

and Southampton University Hospitals for the direct and indirect help they have given us.

This book is dedicated to Professor Emeritus David Galton who taught us and countless other haematologists and histopathologists for a great many years. Those who have worked with him have admired him both for his diagnostic skills and for his mindfulness of the individual patient. It is with much pleasure that we make this dedication to him.

ABBREVIATIONS

aCML	atypical CML	EMA	epithelial membrane antigen
AIDS	acquired immune deficiency syndrome	ESR	erythrocyte sedimentation rate
AILD	angio-immunoblastic lymphadenopathy (with dysproteinaemia)	ET	essential thrombocythaemia
ALCL	anaplastic large cell lymphoma	FAB	French–American–British (co-operative group)
ALIP	abnormal localization of immature precursors	FICTION	fluorescent immunophenotyping and interphase cytogenetics
ALL	acute lymphoblastic leukaemia	FISH	fluorescence <i>in situ</i> hybridization
AML	acute myeloid leukaemia	G-CSF	granulocyte colony-stimulating factor
ATLL	adult T-cell leukaemia/lymphoma	GM-CSF	granulocyte–macrophage colony-stimulating factor
ATRA	all- <i>trans</i> retinoic acid	GMS	Grocott’s methenamine silver (stain)
<i>BCL2</i>	B-cell leukaemia/lymphoma 2	GPI	glycosyl phosphatidylinositol
<i>BCR</i>	breakpoint cluster region	GVHD	graft-versus-host disease
BFU-E	erythroid burst-forming unit	H&E	haematoxylin and eosin (stain)
BM	bone marrow	Hempas	hereditary erythroid multinuclearity with positive acidified serum test
B-PLL	B-lineage prolymphocytic leukaemia	HHV	human herpesvirus
CD	cluster of differentiation	HIV	human immunodeficiency virus
CDA	congenital dyserythropoietic anaemia	HLA	human leucocyte antigen
CFU	colony-forming unit	HTLV-I	human T-cell lymphotropic virus I
CFU-GM	granulocyte–monocyte CFU	Ig	immunoglobulin
CFU-Meg	megakaryocyte CFU	<i>IGH</i>	immunoglobulin heavy chain (gene)
CGL	chronic granulocytic leukaemia	IL	interleukin
CHAD	cold haemagglutinin disease	ISH	<i>in situ</i> hybridization
CLL	chronic lymphocytic leukaemia	JMML	juvenile myelomonocytic leukaemia
CML	chronic myeloid leukaemia	LDH	lactate dehydrogenase
CMMML	chronic myelomonocytic leukaemia	LE	lupus erythematosus
CMV	cytomegalovirus	LGL	large granular lymphocyte
CT	computerized tomography	LGLL	large granular lymphocyte leukaemia
CyIg	cytoplasmic immunoglobulin	LTC-IC	long-term culture-initiating cell
DIC	disseminated intravascular coagulation	MALT	mucosa-associated lymphoid tissue
DNA	deoxyribonucleic acid	MBR	major breakpoint region
EBER	Epstein–Barr early RNA	McAb	monoclonal antibody
EBNA	Epstein–Barr nuclear antigen	MCR	minor cluster region
EBV	Epstein–Barr virus	MDS	myelodysplastic syndromes
EDTA	ethylene diamine tetra-acetic acid	M:E	myeloid : erythroid ratio
EGIL	European Group for the Immunological Classification of Leukaemia	MGG	May–Grünwald–Giemsa (stain)

MGUS	monoclonal gammopathy of undetermined significance	RAEB	refractory anaemia with excess of blasts
MIC	morphologic, immunologic, cytogenetic (classification)	RAEB-T	refractory anaemia with excess of blasts in transformation
MIC-M	morphological, immunological, cytogenetic, molecular genetic (classification)	RARS	refractory anaemia with ring sideroblasts
MPD	myeloproliferative disorder	REAL	Revised European–American Lymphoma (classification)
MPO	myeloperoxidase	RNA	ribonucleic acid
mRNA	messenger RNA	RT-PCR	reverse transcriptase polymerase chain reaction
NEC	non-erythroid cells	SBB	Sudan black B (stain)
NHL	non-Hodgkin’s lymphoma	SD	standard deviation
NK	natural killer	SKY	spectral karyotyping
PAS	periodic acid–Schiff (stain)	SLVL	splenic lymphoma with villous lymphocytes
PB	peripheral blood	SmIg	surface membrane immunoglobulin
PCR	polymerase chain reaction	TAR	thrombocytopenia-absent radii (syndrome)
Ph	Philadelphia chromosome	TCR	T-cell receptor
PLL	prolymphocytic leukaemia	TdT	terminal deoxynucleotidyl transferase
PNET	primitive neuro-ectodermal tumour	T-PLL	T-lineage prolymphocytic leukaemia
PNH	paroxysmal nocturnal haemoglobinuria	TRAP	tartrate-resistant acid phosphatase
POEMS	polyneuropathy, organomegaly, endocrinopathy, M-protein, skin changes (syndrome)	WBC	white blood cell (count)
PRV	polycythaemia rubra vera	WHO	World Health Organization
RA	refractory anaemia	ZN	Ziehl–Neelsen

ONE

THE NORMAL BONE MARROW

The distribution of haemopoietic marrow

During extra-uterine life haemopoiesis is normally confined to the bone marrow. Bones are composed of cortex and medulla. The cortex is a strong layer of compact bone; the medulla is a honeycomb of cancellous bone, the interstices of which form the medullary cavity and contain the bone marrow. Bone marrow is either red marrow containing haemopoietic cells or yellow marrow which is largely adipose tissue. The distribution of haemopoietic marrow is dependent on age. In the neonate virtually the entire bone marrow cavity is fully occupied by proliferating haemopoietic cells; haemopoiesis occurs even in the phalanges. As the child ages, haemopoietic marrow contracts centripetally, being replaced by fatty marrow. By early adult life haemopoietic marrow is largely confined to the skull, vertebrae, ribs, clavicles, sternum, pelvis and the proximal half of the humeri and femora; however, there is considerable variation between individuals as to the distribution of haemopoietic marrow [1]. In response to demand, the volume of the marrow cavity occupied by haemopoietic tissue expands.

The organization of the bone marrow

Bone

The cortex and the medulla differ functionally as well as histologically. Bone may be classified in two ways. Classification may be made on the basis of the macroscopic appearance into: (i) compact or dense bone with only small interstices that are not visible macroscopically; and (ii) cancellous (or trabecular) bone with large, readily visible interstices. Bone

may also be classified histologically on the basis of whether there are well-organized osteons in which a central Haversian canal is surrounded by concentric lamellae composed of parallel bundles of fibrils (lamellar bone) (Fig. 1.1) or, alternatively, whether the fibrils of the bone are in disorderly bundles (woven bone) (Fig. 1.2).

The cortex is a solid layer of compact bone which gives the bone its strength. It is composed largely of lamellar bone but also contains some woven bone. The lamellar bone of the cortex consists of either well-organized Haversian systems or angular fragments of lamellar bone which occupy the spaces between the Haversian systems; in long bones there are also inner and outer circumferential lamellae. Extending inwards from the cortex is an anastomosing network of trabeculae which partition the medullary space (Fig. 1.3). The medullary bone is trabecular or cancellous bone; it contains lamellae but the structure is less highly organized than that of the cortex. Most of the cortical bone is covered on the external surface by periosteum which has an outer fibrous layer and an inner osteogenic layer. At articular surfaces, and more extensively in younger patients, bone fuses with cartilage rather than being covered by periosteum. The bony trabeculae and the inner surface of the cortex are lined by endosteal cells including osteogenic cells (osteoblasts) and osteoclasts. Osteocytes are found within lacunae in bony trabeculae and in cortical bone. Although osteoblasts and osteoclasts share the surface of the bone trabeculae, they originate from different stem cells. Osteoblasts, and therefore osteocytes, are of mesenchymal origin, being derived from the same stem cell as chondrocytes and probably also stromal fibroblasts. Osteoclasts, however, are derived from a haemopoietic stem cell, being formed by fusion of cells of the monocyte lineage.

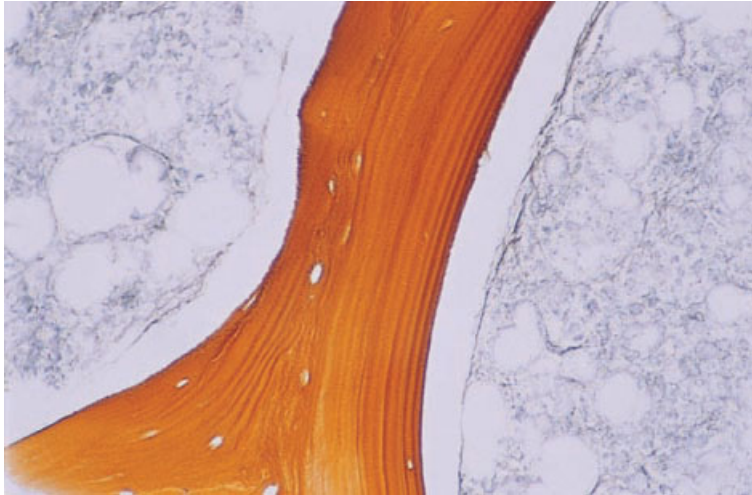


Fig. 1.1 BM trephine biopsy section showing normal bone structure; the trabeculae are composed of lamellar bone. Paraffin-embedded, reticulin stain $\times 188$.

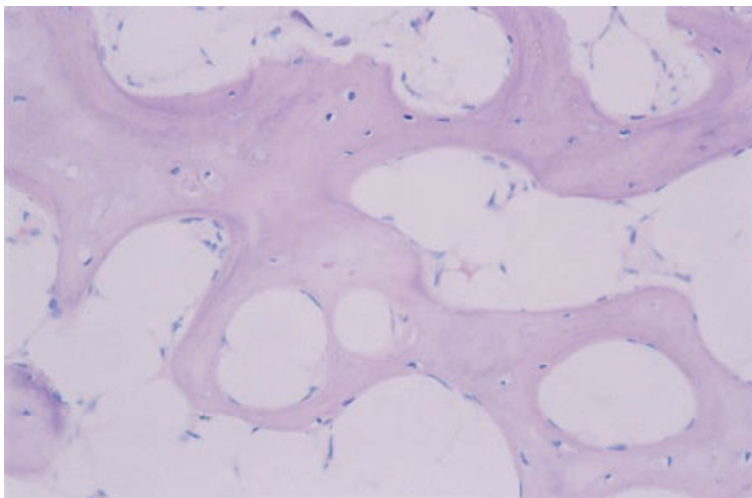


Fig. 1.2 BM trephine biopsy section showing woven bone (pale pink; without lamellae) in a hypocellular but otherwise unremarkable bone marrow. Paraffin-embedded, H&E $\times 188$.

The cells that give rise to bone-forming cells are designated osteoprogenitor cells; they are flattened, spindle-shaped cells which are capable of developing into either osteoblasts or chondrocytes, depending on micro-environmental factors. Osteoblasts synthesize glycosaminoglycans of the bone matrix and also the collagenous fibres which are embedded in the matrix, thus forming osteoid or non-calcified bone; subsequently mineralization occurs. Bone undergoes constant remodelling. In adult life, remodelling of the bone takes place particularly in

the subcortical regions. Osteoblasts add a new layer of bone to trabeculae (apposition), while osteoclasts resorb other areas of the bone; up to 25% of the trabecular surface may be covered by osteoid. The osteoclasts which are resorbing bone lie in shallow hollows, known as Howship's lacunae, created by the process of resorption, while osteoblasts are seen in rows on the surface of trabecular bone or on the surface of a layer of osteoid. As new bone is laid down, osteoblasts become immured in bone and are converted into osteocytes. The bone that replaces

Fig. 1.3 BM trephine biopsy section showing normal bone structure; there are anastomosing bony trabeculae. Paraffin-embedded, H&E $\times 48$.

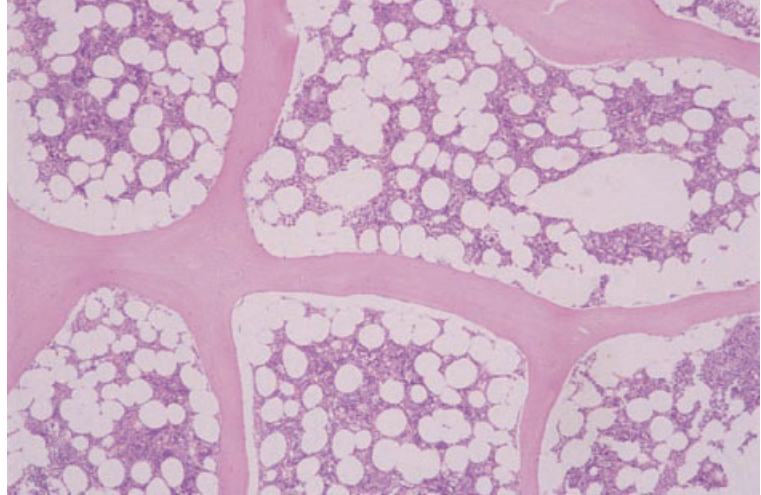
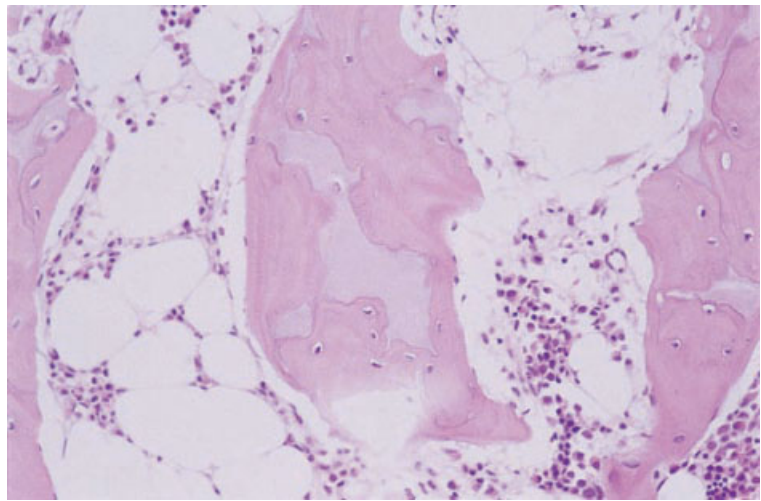


Fig. 1.4 BM trephine biopsy section from a child showing endochondrial ossification in an island of cartilage. Paraffin-embedded, H&E $\times 188$.



osteoid is woven bone which, in turn, is remodelled to form lamellar bone. The difference between the two can be easily appreciated by microscopy using polarized light. The organized fibrillar structure of lamellar bone, with bundles of parallel fibrils running in different directions in successive lamellae, gives rise to alternating light and dark layers when viewed under polarized light.

Trephine biopsies from children may contain cartilage as well as bone and endochondrial bone formation may be observed (Figs 1.4 and 1.5).

Transition from resting cartilage to proliferating and hypertrophic cartilage can be observed, followed by a zone of calcifying cartilage, invading vessels and bone. Mature cartilage can also be seen in trephine biopsy specimens from adults (Fig. 1.6).

Other connective tissue elements

The haemopoietic cells of the bone marrow are embedded in a connective tissue stroma which occupies the intertrabecular spaces of the medulla.

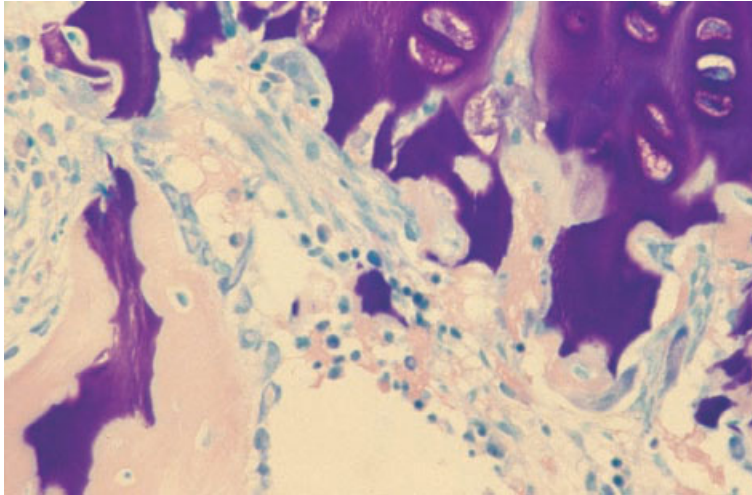


Fig. 1.5 BM trephine biopsy section from a child showing endochondrial ossification; a bony spicule with a core of cartilage is lined by osteoblasts. Paraffin-embedded, Giemsa $\times 376$.

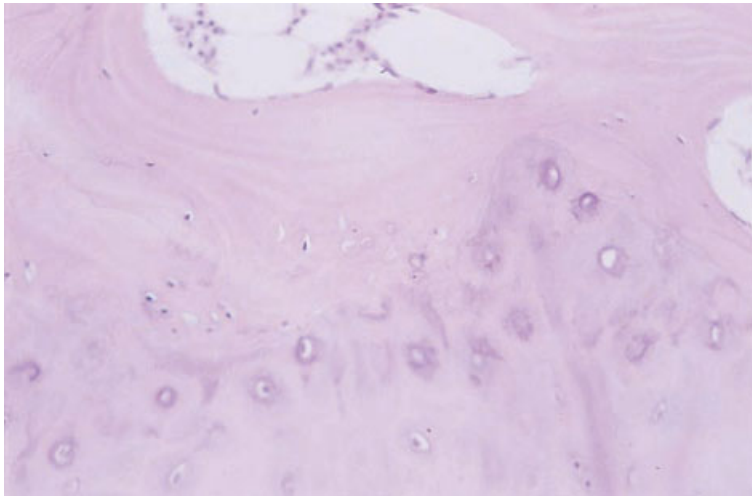


Fig. 1.6 BM trephine biopsy specimen from an adult showing cartilage adjacent to the cortex. By contrast with childhood appearances, a well-defined layer of cortical bone separates this cartilage from the bone marrow. Cartilage cells are dispersed singly or in small groups and are not aligned into columns, as they are in childhood. Paraffin-embedded, H&E $\times 188$.

The stroma is composed of fat cells and a meshwork of blood vessels, branching fibroblasts, macrophages, some myelinated and non-myelinated nerve fibres and a small amount of reticulin. Stromal cells include cells that have been designated reticulum or reticular cells. This term probably includes two cell types of different origin. Phagocytic reticulum cells are macrophages and originate from a haemopoietic progenitor. Non-phagocytic reticulum or reticular cells are closely related to fibroblasts, adventitial cells of sinusoids (see below) and probably also osteoblasts and chondrocytes. They differ from phagocytic reticulum cells in that the majority are

positive for alkaline phosphatase. There is close interaction between haemopoietic cells and their micro-environment, with each modifying the other.

The blood supply of the marrow is derived in part from the central nutrient artery which enters long bones at mid-shaft and bifurcates into two longitudinal central arteries [2]. Similar arteries penetrate flat and cuboidal bones. There is a supplementary blood supply from cortical capillaries which penetrate the bone from the periosteum. The branches of the central artery give rise to arterioles and capillaries which radiate towards the endosteum and mainly enter the bone, subsequently turning back

to re-enter the marrow and open into a network of thin-walled sinusoids [2]. Only a minority of capillaries enter the sinusoids directly without first supplying bone. The sinusoids drain into the central venous sinusoid which accompanies the nutrient artery. Sinusoids are large, thin-walled vessels through which newly formed haemopoietic cells enter the circulation. They are often collapsed in histological sections and are therefore not readily seen. In the presence of marrow sclerosis, these vessels are often held open and are then very obvious. The walls of sinusoids consist of endothelial cells, forming a complete cover with overlapping junctions, and an incomplete basement membrane. The outer surface is clothed by adventitial cells—large, broad cells which branch into the perivascular space and therefore provide scaffolding for the haemopoietic cells, macrophages and mast cells. Adventitial cells are thought to be derived from fibroblasts; they are associated with a network of delicate extracellular fibres which can be stained with a reticulin stain. Reticulin fibres are concentrated close to the periosteum as well as around blood vessels. It is likely that both adventitial cells and fibroblasts can synthesize reticulin [3], which is a form of collagen.

The marrow fat content varies inversely with the quantity of haemopoietic tissue. Fat content also increases as bone is lost with increasing age. Marrow fat is physiologically different from subcutaneous fat. The fat of yellow marrow is the last fat in the body to be lost in starvation. When haemopoietic tissue is lost very rapidly, it is replaced initially by interstitial mucin. Subsequently this mucin is replaced by fat cells.

Haemopoietic and other cells

Haemopoietic cells lie in cords or wedges between the sinusoids. In man normal haemopoiesis, with the exception of some thrombopoiesis at extramedullary sites, is confined to the interstitium. In pathological conditions haemopoiesis can occur within sinusoids. Mature haemopoietic cells enter the circulation by passing transcellularly, through sinusoidal endothelial cells [2]. The detailed disposition of haemopoietic cells will be discussed below.

Bone marrow also contains lymphoid cells, small numbers of plasma cells and mast cells (see below).

Examination of the bone marrow

Bone marrow was first obtained from living patients for diagnostic purposes during the first decade of the last century but it was not until the introduction of sternal aspiration in the late 1920s that this became an important diagnostic procedure. Specimens of bone marrow for cytological and histological examination may be obtained by aspiration biopsy, by core biopsy using a trephine needle or an electric drill, by open biopsy and at autopsy. The two most important techniques, which are complementary, are aspiration biopsy and trephine biopsy.

Bone marrow aspiration causes only mild discomfort to the patient. A trephine biopsy causes moderate discomfort and, in an apprehensive patient, sedation can be useful. In children, aspiration and trephine biopsies are often performed under general anaesthesia.

Bone marrow aspiration

Aspiration biopsy is most commonly carried out on the sternum or the ilium. Aspiration from the medial surface of the tibia can yield useful diagnostic specimens up to the age of 18 months but is mainly used in neonates in whom other sites are less suitable. Aspiration from ribs and from the spinous processes of vertebrae is also possible but is now little practised. Sternal aspiration should be carried out from the first part of the body of the sternum, at the level of the second intercostal space. Aspiration from any lower in the sternum increases the risks of the procedure. Aspiration from the ilium can be from either the anterior or the posterior iliac crest. Aspiration from the anterior iliac crest is best carried out by a lateral approach, a few centimetres below and posterior to the anterior superior iliac spine. Approach through the crest of the ilium with the needle in the direction of the main axis of the bone is also possible but is more difficult because of the hardness of the bone. Aspirates from the posterior iliac crest are usually taken from the posterior superior iliac spine. When aspiration is carried out at the same time as a trephine biopsy, it is easiest to perform the two procedures from adjacent sites. This necessitates the use of the ilium. If a trephine biopsy is not being carried out, there is a choice between the sternum and the iliac crest. Either is

suitable in adults and older children, although great care must be exercised in carrying out sternal aspirations. In a study of 100 patients in whom both techniques were applied, sternal aspiration was found to be technically easier and to produce a suitable diagnostic specimen more frequently, although on average the procedure was more painful, both with regard to bone penetration and to the actual aspiration [4]. Sternal aspiration is also more dangerous. Although deaths are very rare, at least 20 have been reported and we are aware of three further fatalities, not reported in the scientific literature; deaths have been mainly consequent on laceration of vessels or laceration of the heart with pericardial tamponade. Sternal aspiration is unsuitable for use in young children. Posterior iliac crest aspiration is suitable for children, infants and many neonates. Tibial aspiration is suitable for very small babies but has no advantages over iliac crest aspiration in older infants.

Bone marrow specimens yielded by aspiration are suitable for the following: (i) preparation of wedge-spread films and films of crushed marrow fragments; (ii) study of cell markers (by flow cytometry or on films or cytopsin preparations); (iii) cytogenetic study; (iv) ultrastructural examination; (v) culture for micro-organisms; and (vi) culture to study haemopoietic precursors and preparation of histological sections of fragments. Cytogenetic analysis is most often indicated in suspected haematological neoplasms but it also permits rapid diagnosis of suspected congenital karyotypic abnormalities such as trisomy 18; diagnosis is possible within a day, in comparison with the 3 days needed if peripheral blood lymphocytes are used.

Bone marrow aspiration may fail completely, this being referred to as a 'dry tap'. Although this can happen when bone marrow histology is normal, a dry tap usually indicates significant disease, most often metastatic cancer, chronic myeloid leukaemia, idiopathic myelofibrosis or hairy cell leukaemia [5], with associated fibrosis.

Trephine biopsy of bone marrow

Trephine or needle biopsy is most easily carried out on the iliac crest, either posteriorly or anteriorly, as described above. The posterior approach appears now to be more generally preferred. If a trephine

biopsy and a bone marrow aspiration are both to be carried out, they can be performed through the same skin incision but with two areas of periosteum being infiltrated with local anaesthetic and with the needle being angled in different directions. Core biopsy specimens, obtained with a trephine needle, are suitable for histological sections, touch preparations (imprints) and electron microscopy. A touch preparation is particularly important when it is not possible to obtain an aspirate since it allows cytological details to be studied. In addition, touch preparations may show more neoplastic cells than are detected in an aspirate and may detect bone marrow infiltration when it is not detected on an aspirate, for example in hairy cell leukaemia, multiple myeloma or lymphoma [6]. Touch preparations may be made either by touching the core of bone on a slide or rolling the core gently between two slides. Biopsy specimens can be used for cytogenetic study but aspirates are much more suitable. Frozen sections of trephine biopsy specimens are possible and allow the application of a wide range of immunological markers. However, they are not usually very satisfactory because of technical problems, including difficulty in cutting sections, poor adhesion of sections to glass slides during staining procedures and poor preservation of morphological detail. Histological sections may be prepared from fixed biopsy specimens which have either been decalcified and paraffin-embedded or have been embedded in plastic without prior decalcification.

Processing of trephine biopsies

The two principal methods of preparation of fixed trephine biopsy specimens have advantages and disadvantages. Problems are created because of the difficulty of cutting tissue composed of hard bone and soft, easily torn bone marrow. Alternative approaches are to decalcify the specimen or to embed it in a substance that makes the bone marrow almost as hard as the bone. Decalcification can be achieved with weak organic acids, e.g. formic acid and acetic acid, or by chelation, e.g. with ethylene diamine tetra-acetic acid (EDTA). Decalcification and paraffin-embedding lead to considerable shrinkage and loss of cellular detail. Nuclear staining may become blurred. Some cytochemical activity is lost; for example chloro-acetate esterase activity is

lost when acid decalcification is used. Because sections are thicker, cellular detail is harder to appreciate. However, immunological techniques are much more readily applicable to paraffin-embedded than to plastic-embedded specimens and, with careful techniques, very good histochemical results can be obtained. Plastic-embedding techniques are more expensive and, for laboratories which are processing only small numbers of trephine biopsy specimens, are technically more difficult. However, there is no shrinkage, preservation of cellular detail is excellent and the thinness of the sections means that fine cytological detail can be readily appreciated. Some enzyme activities, for example chloro-acetate esterase, are retained. Although immunological techniques can be applied, excessive background staining is often a problem. Plastics with differing qualities are available for embedding. Methyl methacrylate requires lengthy processing and is therefore not very suitable for routine diagnostic laboratories. Glycol methacrylate is more satisfactory; however, when cellularity is low, sections tend to tear and, in this circumstance, a small amount of decalcification may be useful. Methods which we have found satisfactory are given in the Appendix.

Relative advantages of aspiration and core biopsy

Bone marrow aspiration and trephine biopsy each have advantages and limitations. The two procedures should therefore be regarded as complementary. Bone marrow aspirates are unequalled for demonstration of fine cytological detail. They permit a wider range of cytochemical stains and immunological markers than is possible with histological sections. Aspiration is particularly useful, and may well be performed alone, when investigating patients with suspected iron deficiency anaemia, anaemia of chronic disease, megaloblastic anaemia and acute leukaemia. Trephine biopsy is essential for diagnosis when a 'dry tap' or 'blood tap' occurs as a consequence of the marrow being fibrotic or very densely cellular. Only a biopsy allows a complete assessment of marrow architecture and of the pattern of distribution of any abnormal infiltrate. This technique is particularly useful in investigating suspected aplastic or hypoplastic anaemia, lymphoma, metastatic carcinoma, myeloproliferative disorders

and diseases of the bones. We have also found trephine biopsy generally much more useful than bone marrow aspiration when investigating patients with the advanced stages of HIV infection in whom hypocellular, non-diagnostic aspirates are common. It should not be forgotten, however, that trephine biopsy undoubtedly causes more pain to the patient than does aspiration.

Complications of bone marrow aspiration and trephine biopsy are very rare. Cardiac and great vessel laceration has been mentioned above. Otherwise, haemorrhage is uncommon but, when procedures are carried out on patients with a haemostatic defect, prolonged firm pressure is necessary afterwards to ensure that bleeding has stopped. Haemorrhage is also occasionally a problem when a biopsy is carried out on bone with an abnormal vasculature, for example in Paget's disease. Severe retroperitoneal haemorrhage has also been observed in patients with osteoporosis and in several patients with normal bones but with haematological disorders. Damage to the lateral cutaneous nerve of the thigh occurs rarely and is suggestive of poor technique. Pneumothoraces have occurred following sternal aspiration and sternomanubrial separation has been observed in one patient. In patients with osteosclerosis, needles may break. Infection is a rare complication.

Other techniques

It is occasionally necessary to obtain a bone marrow specimen by open biopsy under a general anaesthetic. This is usually only required when a specific lesion has been demonstrated, by radiology or bone scanning, at a relatively inaccessible site.

At autopsy, specimens of bone marrow for histological examination are most readily obtained from the sternum and the vertebral bodies, although any bone containing red marrow can be used. Unless the autopsy is performed soon after death, the cytological detail is often poor.

Cellularity

Bone marrow cellularity can be assessed most accurately in histological sections (Fig. 1.7), although assessment can also be made on aspirated bone marrow fragments in wedge-spread films (Fig. 1.8).

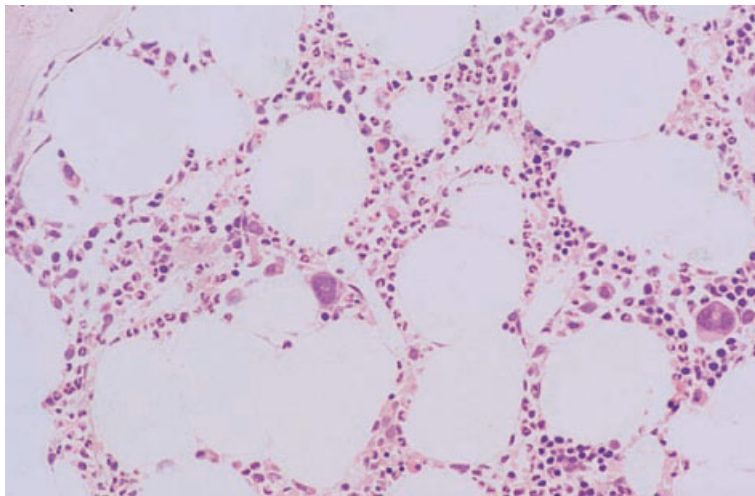


Fig. 1.7 Section of normal BM: normal distribution of all three haemopoietic lineages; note the megakaryocyte adjacent to a sinusoid. Plastic-embedded, H&E $\times 188$.

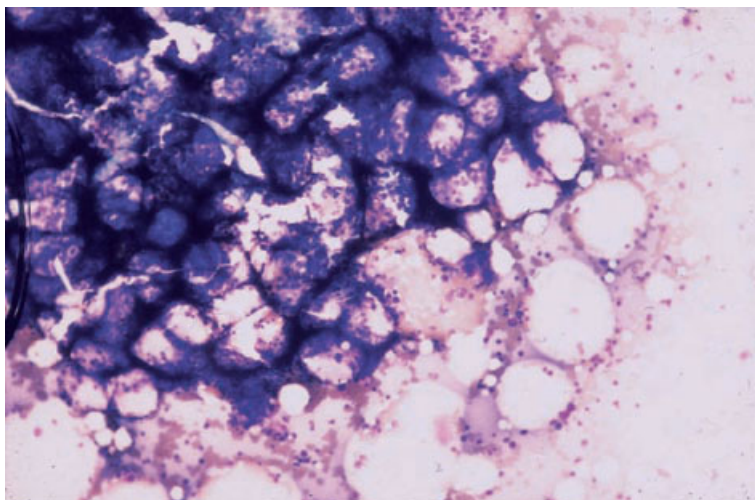


Fig. 1.8 Aspirate of normal BM: fragment showing normal cellularity. MGG $\times 377$.

Specimens which are suitable for histological assessment of cellularity are: (i) aspirated fragments; (ii) needle or open biopsy specimens; and (iii) autopsy specimens. The cellularity of the bone marrow in health depends on the age of the subject and the site from which the marrow specimen was obtained. It is also influenced by technical factors, since decalcification and paraffin-embedding lead to some shrinkage of tissue in comparison with plastic-embedded specimens; estimates of cellularity based on the former are approximately 5% lower than estimates based on the latter [7].

The cellularity of histological sections can be assessed most accurately by computerized image analysis or, alternatively, by point-counting using an eyepiece with a graticule; the process is known as histomorphometry. Results of the two procedures show a fairly close correlation [7,8]. Cellularity can also be assessed subjectively. Such estimates are less reproducible and may lead to some under-estimation of cellularity but show a reasonable correlation with histomorphometric methods; in one study the mean cellularity was 78% by histomorphometry (point-counting) and 65% by visual estimation, with the

correlation between the two methods being 0.78 [7]. Bone marrow cellularity is expressed as the percentage of a section that is occupied by haemopoietic tissue. However, the denominator may vary. The cellularity of sections of fragments is expressed in terms of haemopoietic tissue as a percentage of the total of haemopoietic and adipose tissue. In the case of a trephine biopsy, however, the cellularity may be expressed either as a percentage of the entire biopsy (including bone) [9] or as a percentage of the marrow cavity [7,10]. There are advantages in the latter approach, in which the area occupied by bone is excluded from the calculation, since the percentages obtained are then directly comparable with measurements made on histological sections of aspirated fragments or estimates made from fragments in bone marrow films.

The bone marrow of neonates is extremely cellular, negligible fat cells being present. Cellularity decreases fairly steadily with age, with an accelerated rate of decline above the age of 70 years (Figs 1.9 and 1.10) [9–13]. The decreasing percentage of the marrow cavity occupied by haemopoietic tissue is a consequence both of a true decline in the amount of haemopoietic tissue and of a loss of bone substance with age requiring adipose tissue to expand to fill the larger marrow cavity. In subjects with osteoporosis this effect can be so great that even young persons who are haematologically normal may have as little as 20% of their marrow cavity occupied by haemopoietic cells [11]. In haematologically normal subjects without bone disease, typical reported rates of decline in average marrow cellularity (expressed as a percentage of haemopoietic cells plus adipose cells) are: (i) from 64% in the second decade to 29% in the eighth decade in the iliac crest [10]; (ii) from 85% at age 20 to 40% at age 60, also in the iliac crest [11]; and (iii) from 66% at age 20 to 30% at age 80 in the sternum [13].

Bone marrow cellularity is determined also by the bone on which the assessment is made. Study of the two tissues by the same techniques has shown that the cellularity of lumbar vertebrae is, on average, about 10% more than the cellularity of the iliac crest [9]. Vertebrae are also more cellular than the sternum. Because of the considerable dependence of the assessment of cellularity on methods of processing and counting, it is much more difficult to

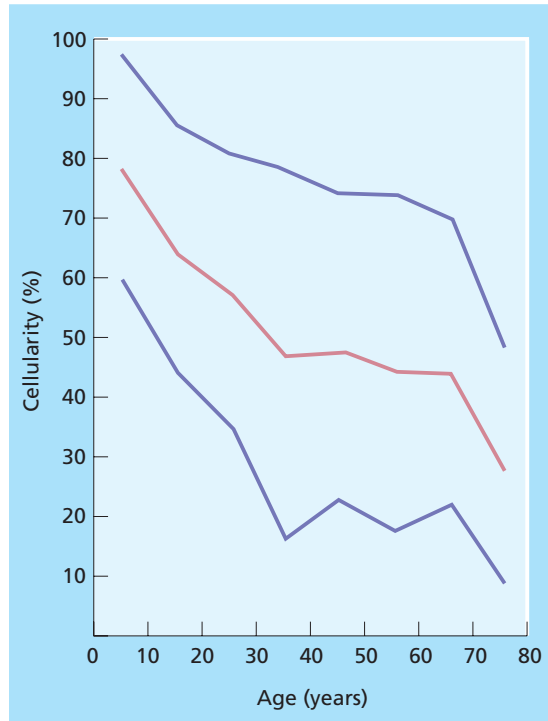


Fig. 1.9 Mean and 95% range of cellularity at various ages of anterior iliac crest bone marrow which has been decalcified and paraffin-embedded. Cellularity is expressed as a percentage of the bone marrow cavity. Calculated from Hartssock *et al.* [10].

make generalizations when different tissues have not been assessed by the same techniques. Bennike *et al.* [4], in comparing the two sites in 100 subjects, considered the sternum to be on average somewhat more cellular than the iliac crest. However, comparison of the results of histomorphometric studies by different groups found that, comparing a single study of the sternum with four studies of the iliac crest, the sternum was generally *less* cellular [9–13]. It should be noted that the lowest estimates of iliac crest cellularity are from a study using decalcified, paraffin-embedded bone marrow specimens [10], while the highest estimates are from a study using non-decalcified plastic-embedded specimens [9]. Some studies have been conducted on biopsy specimens [13] and others on specimens obtained at autopsy [9,10,12]. Because of such technical considerations it is difficult to make any generalizations

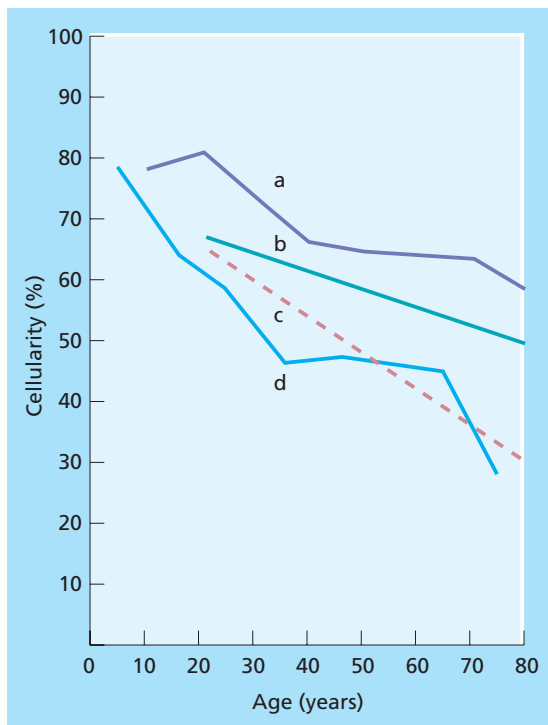


Fig. 1.10 Mean value of bone marrow cellularity at various ages expressed as percentage of bone marrow cavity: (a) iliac crest, autopsy, not decalcified (recalculated from Frisch *et al.* [9]); (b) iliac crest, autopsy, not decalcified [12]; (c) sternum, biopsy, not decalcified [13]; (d) ilium, autopsy, decalcified [10].

about normal bone marrow cellularity. However, it is possible to say that, except in extreme old age, cellularity of less than 20% indicates hypoplasia and, except in those less than 20 years of age, cellularity of more than 80% is likely to indicate hyperplasia.

In making a subjective assessment of the cellularity of films prepared from aspirates, the cellularity of fragments is of more importance than the cellularity of trails, although occasionally the presence of quite cellular trails despite hypocellular fragments suggests that the marrow cellularity is adequate. An average fragment cellularity between 25 and 75% is usually taken to indicate normality, except at the extremes of age.

Because of the variability of cellularity from one intertrabecular space to the next, it is not possible to assess marrow cellularity if few fragments are aspirated or if a biopsy core is of inadequate size. In particular, a small biopsy sample containing only a small amount of subcortical marrow does not allow assessment of cellularity since this area is often of low cellularity, particularly in the elderly. A biopsy specimen containing at least five or six intertrabecular spaces is desirable, not only for an adequate assessment of cellularity but to give a reasonable probability of detecting focal bone marrow lesions. This requires a core of 20–30 mm in length. Smaller specimens may fail to show a focal lesion that is present in the bone marrow (Fig. 1.11).

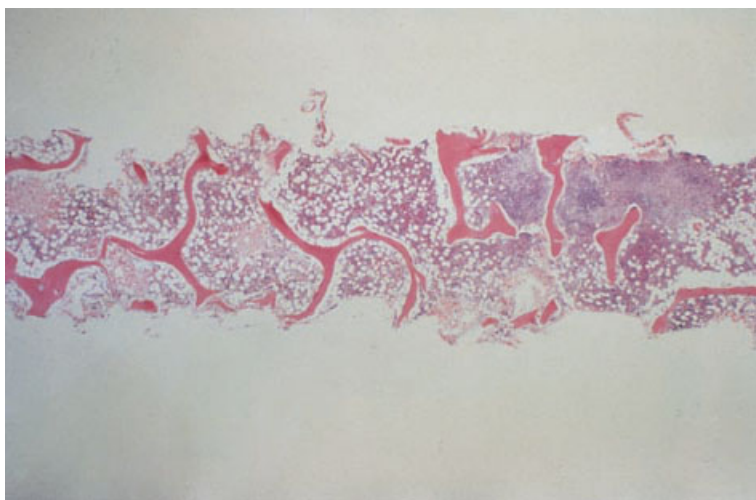


Fig. 1.11 A section of a trephine biopsy specimen of adequate size from a patient with Hodgkin's disease showing only a small area of infiltration at one end of the specimen, illustrating how a small biopsy may miss focal lesions. Paraffin-embedded, H&E $\times 24$. (By courtesy of Dr K MacLennan, Leeds.)

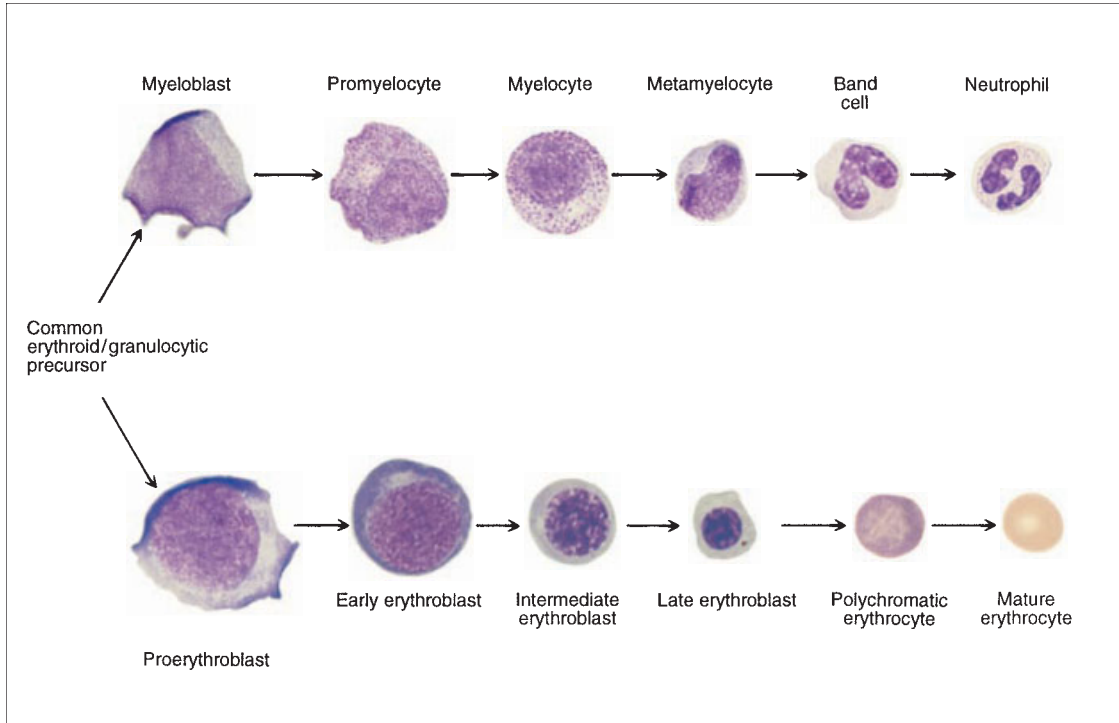


Fig. 1.12 A semi-diagrammatic representation of granulopoiesis and erythropoiesis. Cell division occurs up to the myelocyte and intermediate erythroblast stages.

Haemopoietic cells

A multipotent stem cell gives rise to all types of myeloid cell: (i) erythrocytes and their precursors; (ii) granulocytes and their precursors; (iii) macrophages, monocytes and their precursors; (iv) mast cells; and (v) megakaryocytes and their precursors (Fig. 1.12). It should be mentioned that the term 'myeloid' can be used with two rather different meanings. It is used to indicate all cells derived from the common myeloid stem cell and also to indicate only the granulocytic and monocytic lineages, as in the expression 'myeloid:erythroid ratio' (M:E). It is usually evident from the context which sense is intended but it is important to avoid ambiguity in using this term. The common myeloid stem cell and stem cells committed to the specific myeloid lineages cannot be identified morphologically but it is likely that they are cells of similar size and appearance to a lymphocyte. The various myeloid lineages differ

both morphologically and in their disposition in the bone marrow. The normal bone marrow contains, in addition to myeloid cells, smaller numbers of lymphoid cells (including plasma cells) and the stromal cells which have been discussed above.

Erythropoiesis

Cytology

Precursors of erythrocytes are designated erythroblasts. The term normoblast can also be used but has a narrower meaning; 'erythroblast' includes all recognizable erythroid precursors, whereas 'normoblast' is applicable only when erythropoiesis is normoblastic. There are at least five generations of erythroblast between the morphologically unrecognizable erythroid stem cell and the erythrocyte. Erythroblasts develop in close proximity to a macrophage, the cytoplasmic processes of which extend

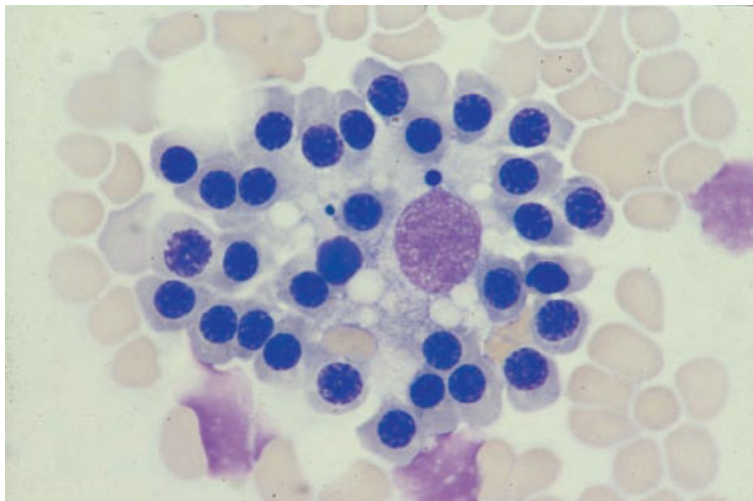


Fig. 1.13 BM aspirate: an erythroid island. MGG ×940.

between and around individual erythroblasts. Several generations of erythroblast are associated with one macrophage, the whole cluster of cells being known as an erythroblastic island [14]. Intact erythroblastic islands are sometimes seen in bone marrow films (Fig. 1.13). Erythroblasts are conventionally divided, on morphological grounds, into four categories—proerythroblasts and early, intermediate and late erythroblasts. An alternative terminology is: proerythroblast, basophilic erythroblast, early polychromatophilic erythroblast and late polychromatophilic erythroblast. The term orthochromatic erythroblast is better avoided since the most mature erythroblasts are only orthochromatic (that is acidophilic, with the same staining characteristics as mature red cells) when erythropoiesis is abnormal.

Proerythroblasts (Fig. 1.14) are large round cells with a diameter of 12–20 μm and a large round nucleus. The cytoplasm is deeply basophilic with a pale perinuclear zone, attributable to the Golgi apparatus, sometimes being apparent. The nucleus has a finely granular or stippled appearance and contains several nucleoli.

Early erythroblasts (Fig. 1.15) are smaller than proerythroblasts and more numerous. The nucleocytoplasmic ratio is somewhat lower. They have strongly basophilic cytoplasm and a granular or stippled chromatin pattern without visible nucleoli. A perinuclear halo, which is less strongly basophilic than the rest of the cytoplasm, may be apparent.

Intermediate erythroblasts (Figs 1.14 and 1.15)

are smaller again, with a lower nucleocytoplasmic ratio than that of the early erythroblast, less basophilic cytoplasm and moderate clumping of the chromatin. They are more numerous than early erythroblasts.

Late erythroblasts (Figs 1.14 and 1.15) are smaller and more numerous than intermediate erythroblasts. They are only slightly larger than mature red cells. Their nucleocytoplasmic ratio is lower than that of the intermediate erythroblast and the chromatin is more clumped. The cytoplasm is only weakly basophilic and in addition has a pink tinge due to the increased amount of haemoglobin. Because of the resultant pinky-blue colour the cell is described as polychromatophilic.

Late erythroblasts extrude their nuclei to form polychromatophilic erythrocytes, which are slightly larger than mature erythrocytes. These cells can be identified by a specific stain as reticulocytes; when haemopoiesis is normal they spend about 2 days of their 3-day life span in the bone marrow.

Small numbers of normal erythroblasts show atypical morphological features such as irregular nuclei, binuclearity and cytoplasmic bridging between adjacent erythroblasts [15].

Histology

Erythroblastic islands (Figs 1.16 and 1.17) are recognizable as distinctive clusters of cells in which one or more concentric circles of erythroblasts closely

Fig. 1.14 Aspirate of normal BM: a proerythroblast, intermediate erythroblast, four late erythroblasts, a myelocyte, large and small lymphocytes and a neutrophil. MGG $\times 940$.

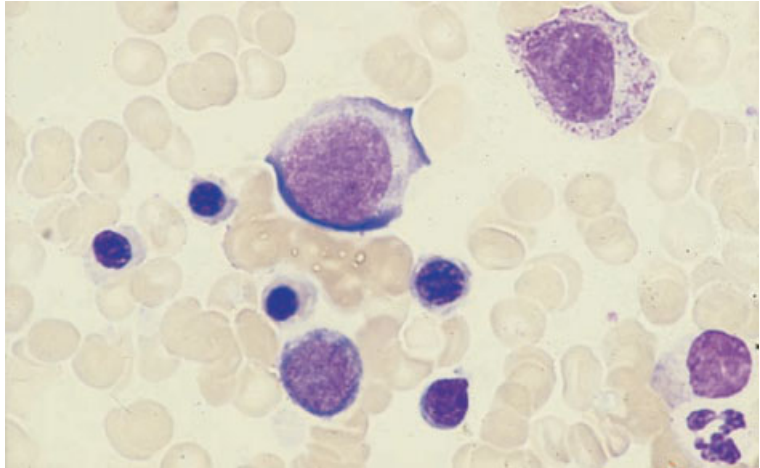


Fig. 1.15 Aspirate of normal BM: early, intermediate and late erythroblasts and a lymphocyte. MGG $\times 940$.

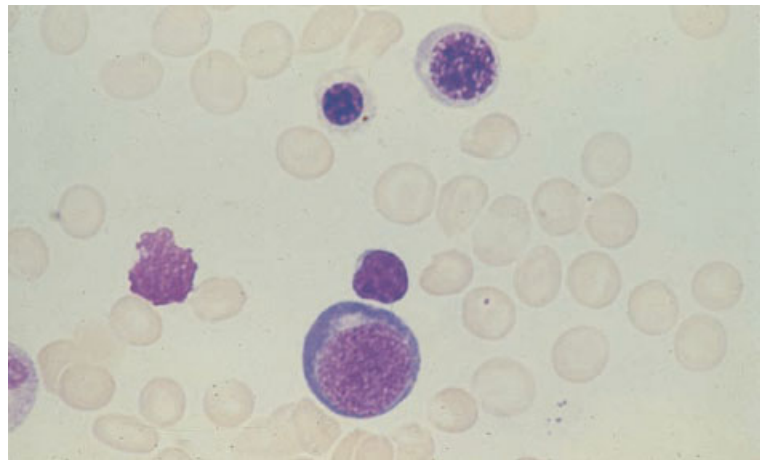
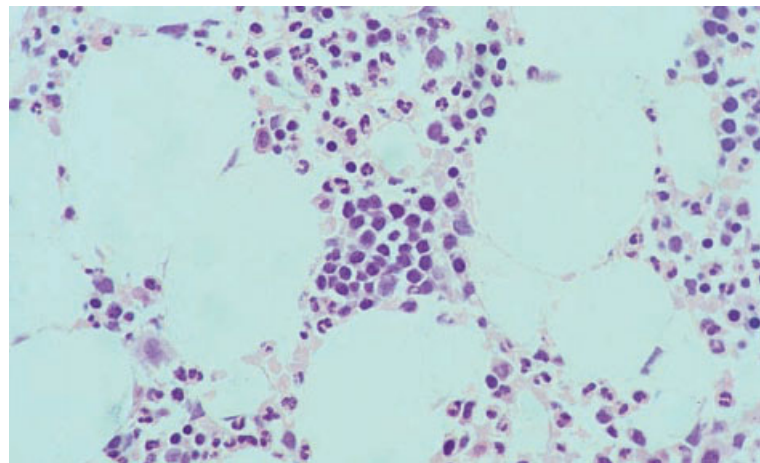


Fig. 1.16 Section of normal BM: an erythroid island (centre). Plastic-embedded, H&E $\times 377$.



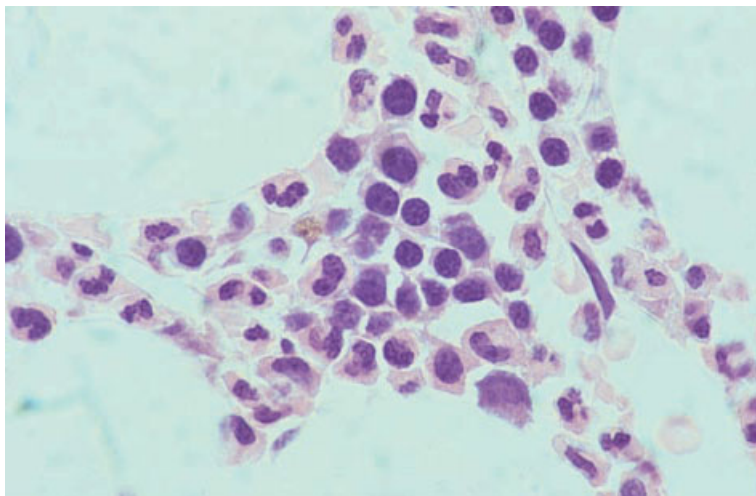


Fig. 1.17 Section of normal BM: an erythroid island containing intermediate and late erythroblasts and a haemosiderin-laden macrophage; a Golgi zone is seen in some of the intermediate erythroblasts. Plastic-embedded, H&E $\times 970$.

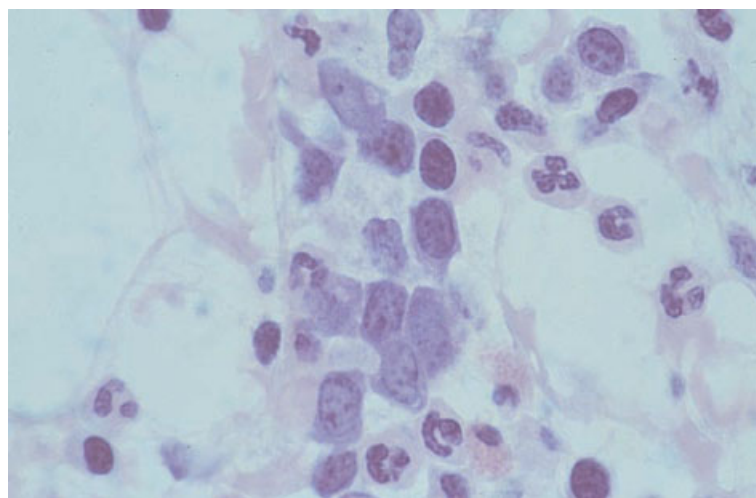


Fig. 1.18 Section of normal BM: an erythroid island containing early and intermediate erythroblasts. Plastic-embedded, Giemsa $\times 940$.

surround a macrophage. The erythroblasts which are closer to the macrophage are less mature than the peripheral ones. The central macrophage sends out extensive slender processes which envelop each erythroblast. The macrophage phagocytoses defective erythroblasts and extruded erythroblast nuclei; nuclear and cellular debris may therefore be recognized in the cytoplasm and a Perls' stain (see page 54) may demonstrate the presence of haemosiderin. Erythropoiesis occurs relatively close to marrow sinusoids although it is probable that, as

in the rat [16], only a minority of erythroblastic islands actually abut on sinusoids.

Early erythroblasts (Fig. 1.18) are large cells; they have relatively little cytoplasm and large nuclei with dispersed chromatin and multiple, small, irregular or linear nucleoli often abutting on the nuclear membrane. The nuclei are rounder than those of myeloblasts but, in contrast to the nuclei of early erythroid cells in bone marrow aspirates of healthy subjects, in histological sections some appear ovoid or slightly irregular. More mature erythroid cells

Fig. 1.19 Section of normal BM: erythroid island containing three early, one intermediate and numerous late erythroblasts; note the cytoplasmic basophilia of early erythroblasts. Plastic-embedded, Giemsa $\times 940$.

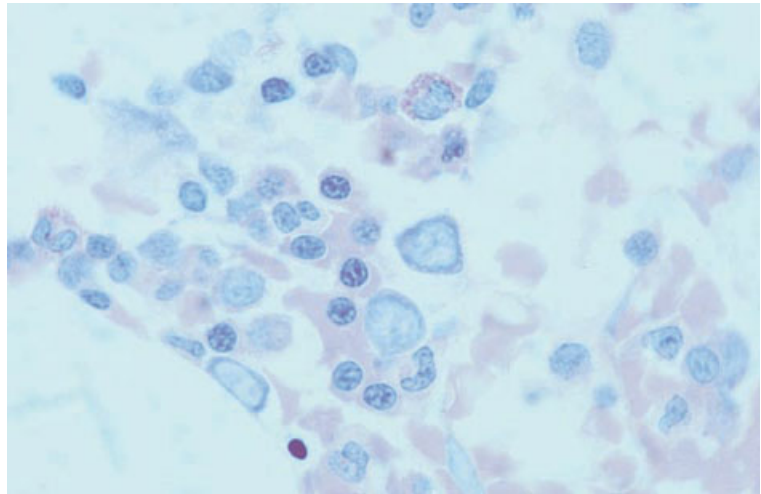
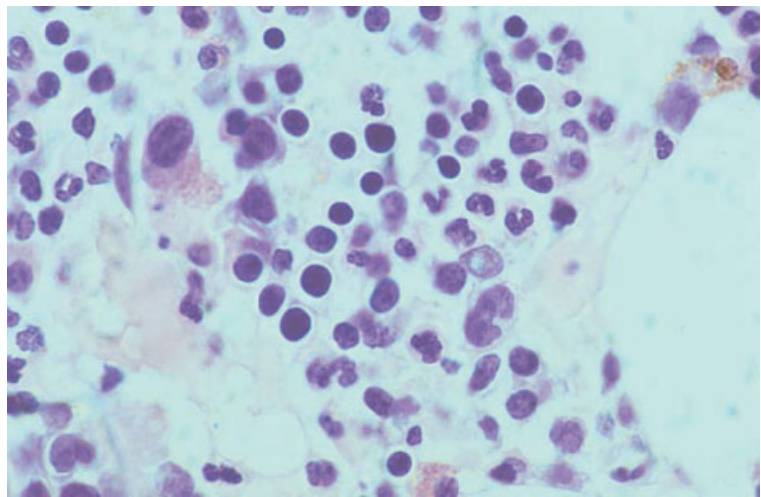


Fig. 1.20 Section of normal BM: erythroid island showing intermediate and late erythroblasts with haloes surrounding the nuclei. Paraffin-embedded, H&E $\times 940$.



have condensed nuclear chromatin and cytoplasm which is less basophilic. The chromatin in the erythroblast nuclei is evenly distributed and, as chromatin condensation occurs, an even, regular pattern is retained.

There are four features which are useful in distinguishing erythroid precursors in the marrow from other cells: (i) in normal bone marrow they occur in distinctive erythroblastic islands containing several generations of cells of varying size and maturity; (ii) erythroblasts adhere tightly to one another; (iii)

their nuclei are round; and (iv) in late erythroblasts the chromatin is condensed in a regular manner whereas nuclei of small lymphocytes show coarse clumping. With a Giemsa stain (Fig. 1.19), the intense cytoplasmic basophilia with a small, negatively staining Golgi zone adjacent to the nucleus is also distinctive. In paraffin-embedded specimens (Fig. 1.20), artefactual shrinking of cytoplasm of later erythroblasts can be useful in distinguishing them from lymphocytes. Shrinkage artefact is absent in plastic-embedded sections, in which the

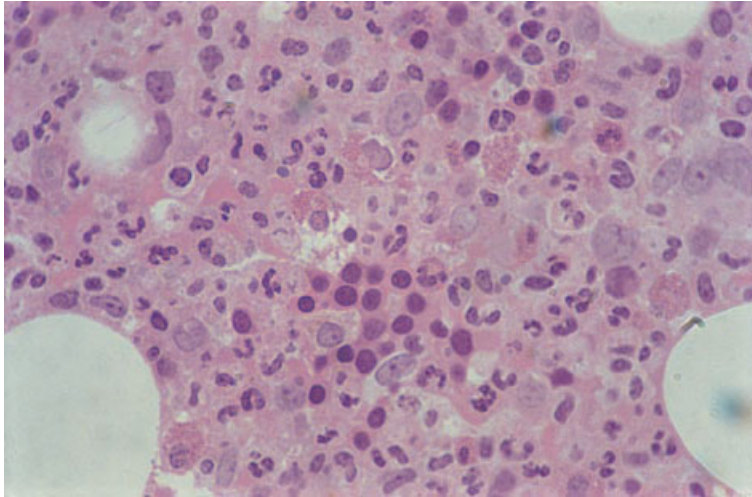


Fig. 1.21 Syncytial appearance of erythroblasts in an erythroid island in sections from a resin-embedded trephine biopsy specimen. Plastic-embedded, H&E $\times 592$.

identification of erythroid cells is aided by their syncytial appearance (Fig. 1.21).

When the bone marrow is regenerating rapidly, erythroid islands may be composed of cells, all of which are at the same stage of maturation. This results in some islands consisting only of immature elements. A similar pattern is sometimes seen when erythropoiesis is abnormal, for example in myelodysplasia, in which the intramedullary death of erythroblasts is a major mechanism.

The identification of abnormal erythroblasts can be more difficult than the identification of their normal equivalents, for example, if well-organized erythroblastic islands are not present or if they contain only immature cells. When there is any difficulty in recognizing erythroid precursors, their identity can be confirmed by cytochemical or immunocytochemical staining (see page 67).

Granulopoiesis

Cytology

There are at least four generations of cells between the morphologically unrecognizable committed granulocyte–monocyte precursor and the mature granulocyte but cell division does not necessarily occur at the same point as maturation from one

stage to another. The first recognizable granulopoietic cell is the myeloblast (Figs 1.22 and 1.23). It is similar in size to the proerythroblast, about 12–20 μm . It is more irregular in shape than a proerythroblast and its cytoplasm is moderately rather than strongly basophilic. The chromatin pattern is diffuse and there are several nucleoli. Myeloblasts are generally defined as being cells that lack granules but, in the context of the abnormal myelopoiesis of acute myeloid leukaemia and the myelodysplastic syndromes, primitive cells with granules may also be accepted as myeloblasts. Myeloblasts are capable of cell division and mature to promyelocytes.

Promyelocytes (Fig. 1.23) have a nucleolated, slightly indented nucleus, a Golgi zone and primary or azurophilic granules which are reddish-purple with a Romanowsky stain. Promyelocytes are larger than myeloblasts, usually 15–25 μm , and their cytoplasm is often more strongly basophilic. By light microscopy, promyelocytes of the three granulocytic lineages cannot be distinguished but, by ultrastructural examination, the distinction can be made. Promyelocytes are capable of cell division and mature to myelocytes.

Myelocytes (Fig. 1.23) are smaller than promyelocytes and are quite variable in size—from 10 to 20 μm . Their nuclei show partial chromatin condensation and lack nucleoli. Their cytoplasm is less

Fig. 1.22 Aspirate of normal BM: a myeloblast, three neutrophils and two monocytes; the myeloblast has a high nucleocytoplasmic ratio, a diffuse chromatin pattern and a nucleolus. MGG $\times 940$.

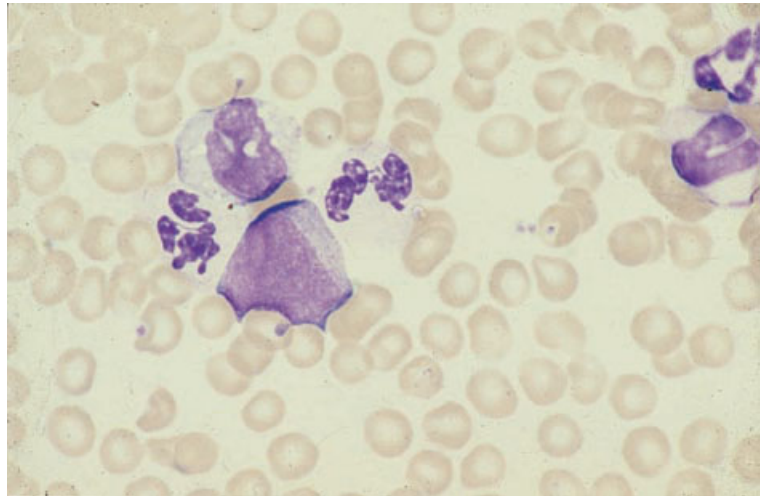
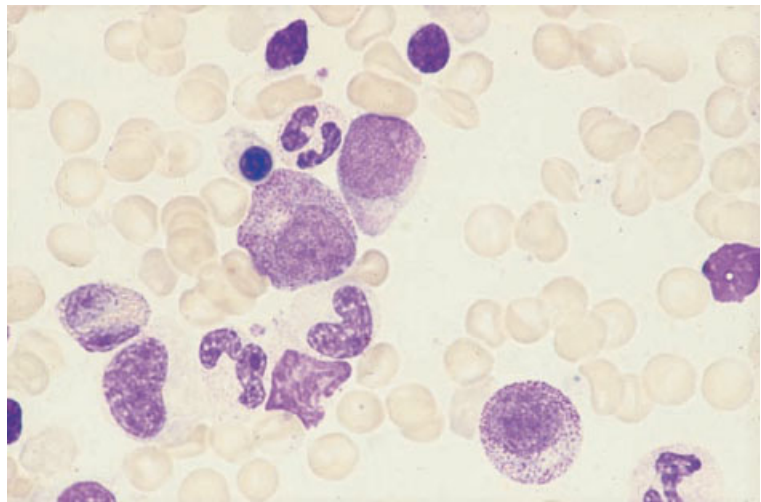


Fig. 1.23 Aspirate of normal BM: a myeloblast and a promyelocyte (centre), a myelocyte (lower right), a metamyelocyte, band forms, a neutrophil and a late erythroblast; the promyelocyte is larger than the myeloblast and is showing some chromatin condensation but with persisting nucleoli, well-developed cytoplasmic granulation and a Golgi zone. MGG $\times 940$.



basophilic than that of promyelocytes and specific neutrophilic, eosinophilic and basophilic granules can now be discerned, staining lilac, orange-red and purple, respectively. Eosinophil myelocytes may also contain some granules that take up basic dyes and stain purple; these differ ultrastructurally from the granules of the basophil lineage and are best designated pro-eosinophilic granules. There are probably normally at least two generations of myelocytes so that at least some cells of this category are

capable of cell division. Late myelocytes mature to metamyelocytes which are 10–12 μm in diameter and have a markedly indented or U-shaped nucleus (Fig. 1.23). The metamyelocyte is not capable of cell division but matures to a band form which has a ribbon-shaped nucleus. The band cell, in turn, matures to a polymorphonuclear granulocyte with a segmented nucleus and specific neutrophilic, eosinophilic or basophilic granules. The bone marrow is a major reservoir for mature neutrophils.

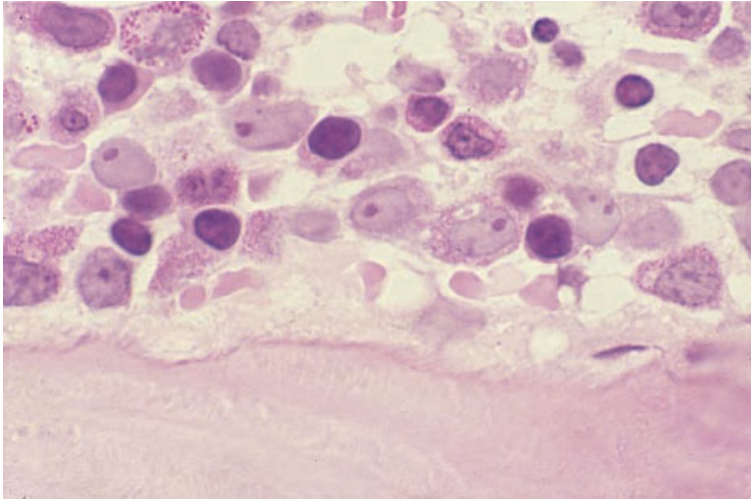


Fig. 1.24 Section of normal BM: myeloblasts and promyelocytes adjacent to a bony trabecula. Plastic-embedded, H&E $\times 970$.

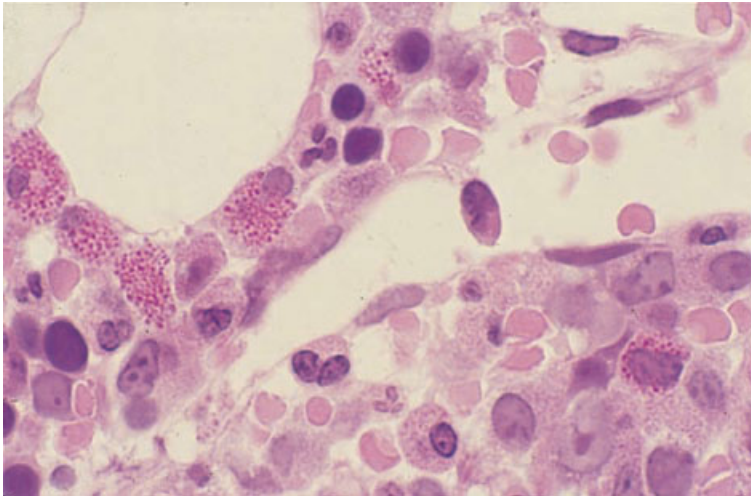


Fig. 1.25 Section of normal BM: promyelocytes, myelocytes and maturing neutrophils and eosinophils adjacent to a sinusoid. Plastic-embedded, H&E $\times 970$.

Histology

Myeloblasts (Fig. 1.24) are the earliest granulocyte precursors identifiable histologically; they are present in small numbers and are most frequently found adjacent to the bone marrow trabecular surfaces or to arterioles. They are fairly large cells with round to oval nuclei and one to five relatively small nucleoli. There is no chromatin clumping. They have relatively little cytoplasm. They are readily distinguished from lymphoid cells by the absence of chromatin clumping and the presence of nucleoli. Myeloblasts are far outnumbered in normal mar-

rows by the promyelocytes (Figs 1.24 and 1.25) and myelocytes (Fig. 1.25) which are recognized, at least in plastic-embedded sections, by their granularity. Primary and neutrophilic granules may be seen as faintly eosinophilic granules in good quality haematoxylin and eosin (H&E) stains on sections cut from plastic-embedded specimens, but they are best seen with a Giemsa stain. Granules of cells of eosinophil lineage are large, refractile and more strongly eosinophilic. They are therefore easily recognized on both H&E and Giemsa stains of either paraffin- or plastic-embedded biopsies. Basophil granules are water-soluble and, since trephine biopsy

specimens are fixed in aqueous fixatives, basophils are not recognizable in histological sections. As maturation occurs, granulocytic precursors are found progressively more deeply in the haemopoietic cords but away from the sinusoids. When they reach the metamyelocyte stage, they appear to move towards the sinusoids and, at the polymorphonuclear granulocyte stage, cross the wall to enter the circulation.

In undecalcified plastic-embedded sections, and in sections from specimens decalcified using EDTA, the chloro-acetate esterase stain is a reliable marker of neutrophil haemopoiesis from the promyelocyte stage onwards. Overnight incubation of acid-decalcified sections in a buffer at pH 6.8 partially restores chloro-acetate esterase activity. Alternatively, the identity of the granulocytic lineage may be confirmed by immunocytochemistry (see page 66).

Monocytopenia

Cytology

Monocytes are derived from a morphologically unrecognizable common granulocytic-monocytic precursor. The earliest morphologically recognizable precursor is a monoblast, a cell which is larger than a myeloblast with abundant cytoplasm showing a variable degree of basophilia and with a large

nucleus which may be either round or lobulated. Monoblasts are capable of division and mature into promonocytes which are similar in size to promyelocytes; they have cytoplasmic granules and usually some degree of nuclear lobulation. Promonocytes mature into monocytes which migrate rapidly into the peripheral blood. Monocytes are 12–20 μm in diameter. They have a lobulated nucleus and abundant cytoplasm which is weakly basophilic. The cytoplasm may contain small numbers of fine azurophilic granules and often has a ground-glass appearance, in contrast to the clear cytoplasm of a lymphocyte.

Monocytes mature into macrophages (Fig. 1.26) in the bone marrow as well as in other tissues. These are large cells, 20–30 μm in diameter, of irregular shape, with a low nucleocytoplasmic ratio and voluminous weakly basophilic cytoplasm. When relatively immature, they may have an oval nucleus with a fairly diffuse chromatin pattern. When mature, the nucleus is smaller and more condensed and the cytoplasm may contain lipid droplets, recognizable degenerating cells and amorphous debris; an iron stain commonly shows the presence of haemosiderin. Bone marrow macrophages may develop into various storage cells which will be discussed in later chapters.

Both monocytes and their precursors are quite infrequent among marrow cells since, in contrast to mature neutrophils, they are released rapidly into

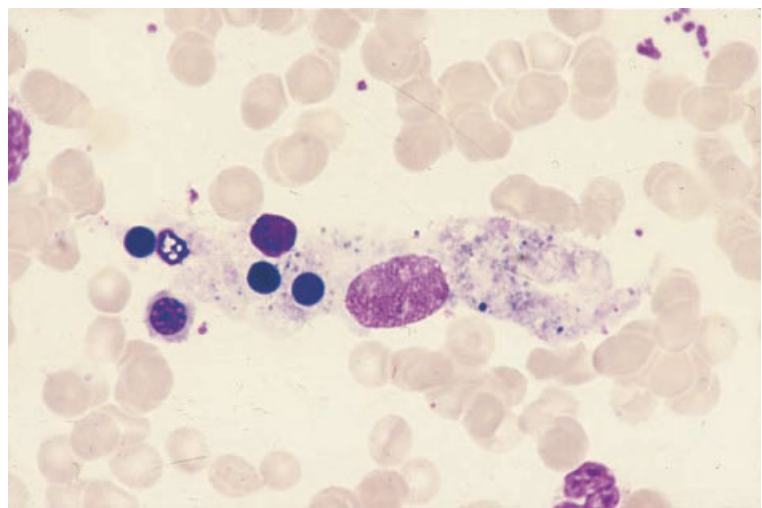


Fig. 1.26 Aspirate of normal BM: a macrophage containing granular and refractile debris and several normoblast nuclei. MGG $\times 940$.

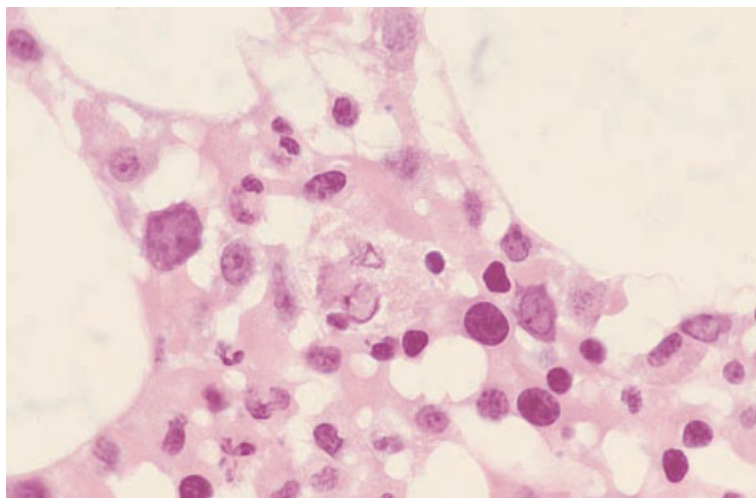


Fig. 1.27 Section of normal BM: a macrophage containing cellular debris. Plastic-embedded, H&E $\times 940$.

the peripheral blood rather than being stored in the bone marrow. Macrophages (histiocytes), however, are readily apparent.

Histology

Monocytes are recognized in histological sections of the marrow as cells which are larger than neutrophils with lobulated nuclei; monocyte precursors are not usually recognizable. In haematologically normal subjects, only small numbers of randomly distributed monocytes are present.

Macrophages (Fig. 1.27) are identified as irregularly scattered, relatively large cells with a small nucleus and abundant cytoplasm. In thin sections, only the cytoplasm may be visible, the nucleus being out of the plane of the section. Phagocytosed debris may be prominent in the cytoplasm. Some are associated with erythroblasts (forming erythroblastic islands), plasma cells or lymphoid nodules. Immunohistochemistry of trephine biopsy sections highlights a prominent network of dendritic macrophages dispersed through the stroma (Fig. 1.28).

Megakaryopoiesis and thrombopoiesis

Cytology

In normal marrow, the earliest morphologically recognizable cell in the megakaryocyte lineage is

the megakaryocyte itself although, when haemopoiesis is abnormal, a megakaryocyte precursor of similar size and morphology to a myeloblast can sometimes be recognized. Megakaryocytes undergo endoreduplication as they mature, resulting in a large cell (30–160 μm) with a marked degree of heterogeneity in both nuclear DNA content (ploidy) and nuclear size. Megakaryocytes can be classified by their ploidy level. In normal marrow they range from 4 N (tetraploid) to 32 N with the dominant ploidy category being 16 N. Megakaryocytes can also be classified on the basis of their nuclear and, more particularly, their cytoplasmic characteristics into three stages of maturation [17]. Group I megakaryocytes (Fig. 1.29) have strongly basophilic cytoplasm and a very high nucleocytoplasmic ratio. Group II megakaryocytes have a lower nucleocytoplasmic ratio and cytoplasm which is less basophilic; the cytoplasm contains some azurophilic granules. Group III megakaryocytes (Fig. 1.30) have plentiful weakly basophilic cytoplasm containing abundant azurophilic granules; the cytoplasm at the cell margins is agranular. Group III megakaryocytes are mature cells, capable of producing platelets and no longer synthesizing DNA. There is some correlation between the three stages of maturation and ploidy level. All stages of maturation include megakaryocytes which are 8 N, 16 N and 32 N but 4 N megakaryocytes are confined to group I and 32 N megakaryocytes are more numerous in group III.

Fig. 1.28 Section of trephine biopsy specimen showing a network of dendritic macrophages. Paraffin-embedded, immunoperoxidase with CD68 monoclonal antibody $\times 470$.

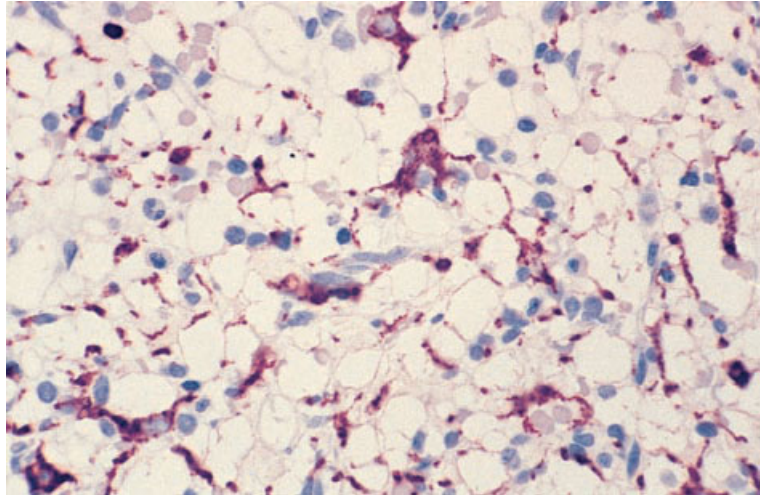
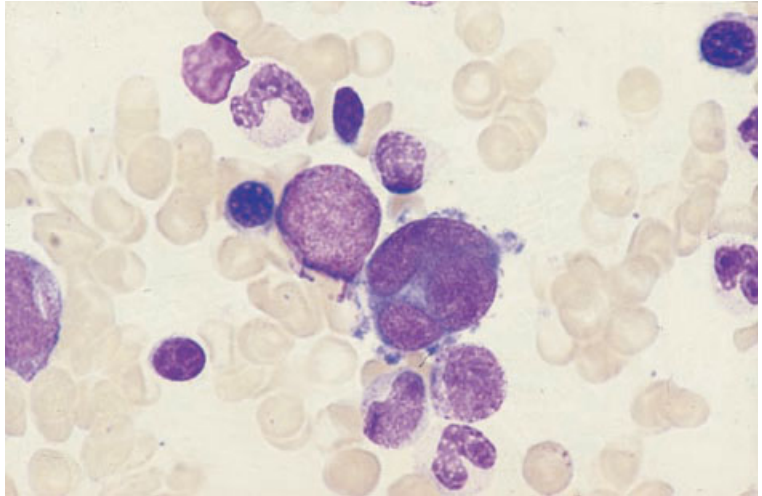


Fig. 1.29 Aspirate of normal BM: an immature megakaryocyte with a polyploid nucleus showing little chromatin condensation: the cytoplasm is scanty and basophilic. MGG $\times 940$.



The nuclei of the great majority of normal polyploid megakaryocytes form irregular lobes joined by strands of chromatin. A minority have either a non-lobulated nucleus or more than one nucleus. The final stage in megakaryocyte maturation is an apparently bare nucleus (actually with a thin cytoplasmic rim), the great bulk of the cytoplasm having been shed as platelets (Fig. 1.31).

An increased demand for platelets, for example due to peripheral destruction, leads to an increase in ploidy level and cell size, apparent in a bone marrow film as an increased volume of cytoplasm and a

large, usually well-lobulated nucleus. It should be noted that whether or not megakaryocytes appear to be budding platelets shows little correlation with the number of platelets being produced. In patients with thrombocytosis, particularly with essential thrombocythaemia, there are often many 'budding' megakaryocytes but in auto-immune thrombocytopenia, in which platelet production is also greatly increased, 'budding' megakaryocytes are quite uncommon.

It is necessary to assess megakaryocyte numbers as well as morphology. In films of an aspirate

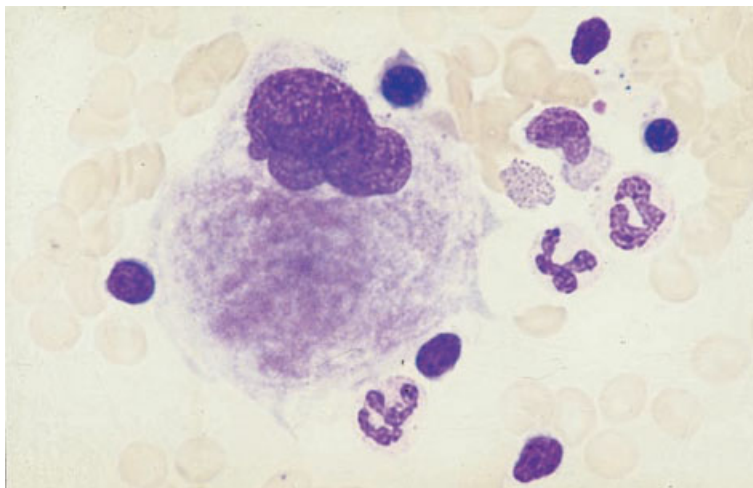


Fig. 1.30 Aspirate of normal BM: a mature megakaryocyte with a lobulated nucleus and voluminous granular cytoplasm. MGG $\times 940$.

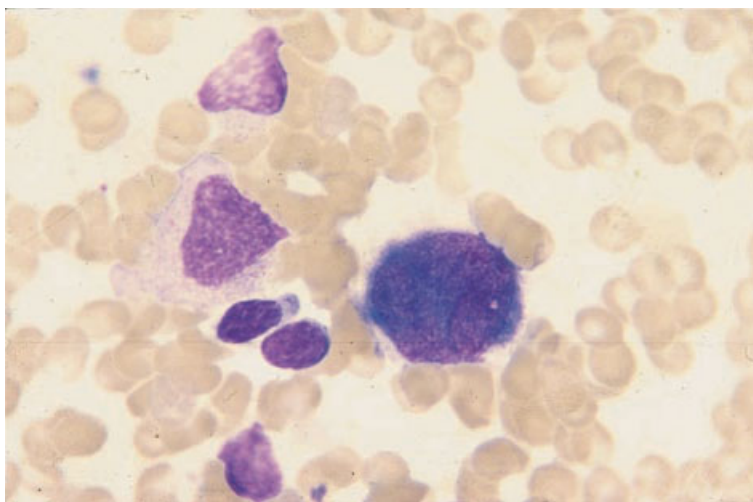


Fig. 1.31 Aspirate of normal BM: a late megakaryocyte which has shed most of its cytoplasm as platelets. MGG $\times 940$.

this can only be a subjective assessment—that megakaryocytes are decreased, normal or increased. A more accurate assessment can be made from histological sections of aspirated fragments or from sections of trephine biopsy samples. Somewhat fewer megakaryocytes are seen in sections of aspirated fragments than in trephine biopsies, possibly because these large cells are not as readily aspirated as smaller marrow cells.

Megakaryocytes may 'engulf' other haemopoietic cells (lymphocytes, erythrocytes, erythroblasts and

granulocytes and their precursors), a process known as emperipolesis or pseudophagocytosis (Fig. 1.32). This process differs from phagocytosis in that the engulfed cells have entered dilated cavities in the demarcation membrane system rather than being in phagocytic vacuoles; on examination of bone marrow films the cells within the megakaryocyte are observed to be intact and morphologically normal.

Identification of megakaryocytes is aided by cytochemistry and immunocytochemistry (see pages 59 and 67).

Fig. 1.32 Aspirate of non-infiltrated BM from a patient with Hodgkin's disease: a mature megakaryocyte exhibiting emperipolesis. MGG $\times 940$.

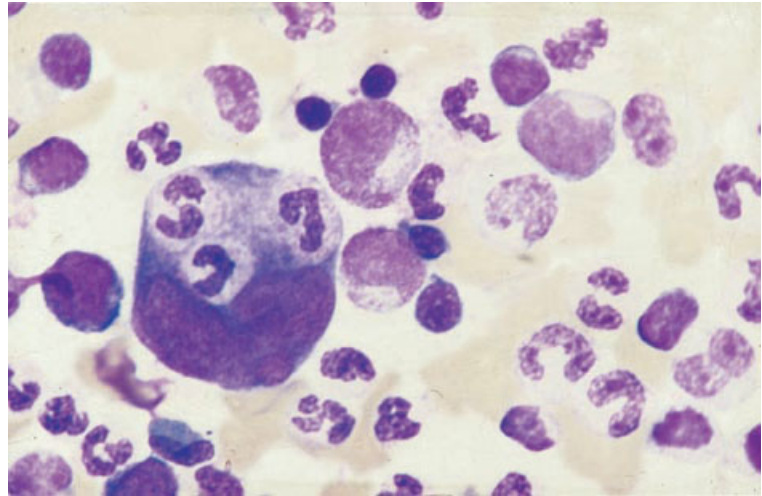
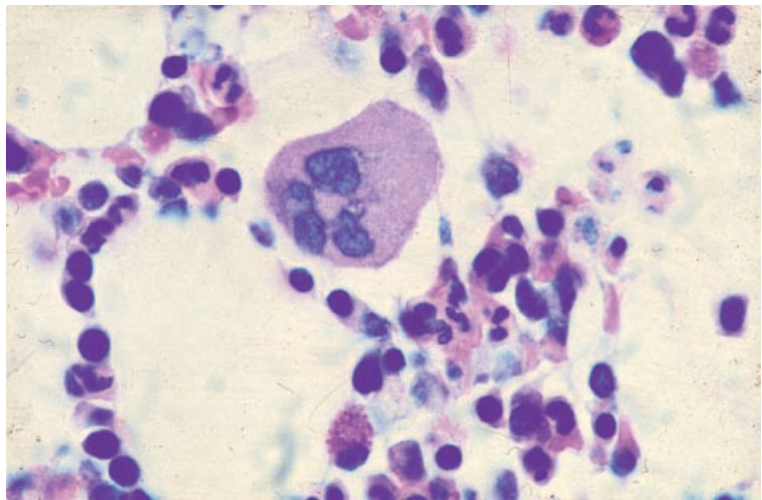


Fig. 1.33 Section of normal BM showing cells of all haemopoietic lineages including a normal megakaryocyte with finely granular cytoplasm. Paraffin-embedded, Giemsa $\times 940$.



Histology

Megakaryocytes are by far the largest of normal bone marrow cells, their size being related to their ploidy. They have plentiful cytoplasm and usually a lobulated nucleus. With a Giemsa stain, the demarcation of platelets within the cytoplasm is apparent.

Megakaryocytes are most frequently found associated with sinusoids, at some distance from bony trabeculae (Figs 1.7, 1.33 and 1.34). They are found in a paratrabeular position only when

haemopoiesis is abnormal. Serial sections show that, in normal marrow, all megakaryocytes abut on sinusoids [18]. Megakaryocytes lie directly outside the sinusoid and discharge platelets by protruding cytoplasmic processes through endothelial cells; such processes break up into platelets. 'Bare nuclei' which have shed almost all their cytoplasm in this manner can be recognized in histological sections (Fig. 1.35) as well as in bone marrow films. Intact megakaryocytes and bare nuclei can also enter the circulation and are seen within vessels in histological

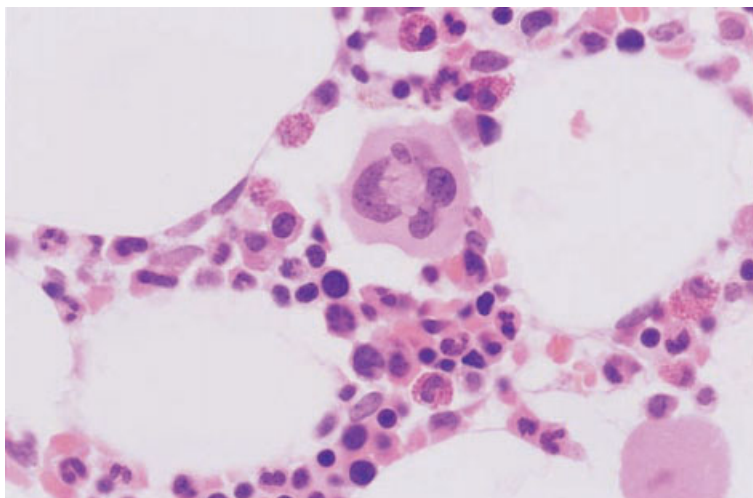


Fig. 1.34 Section of normal BM showing a normal megakaryocyte and other normal haemopoietic cells. Paraffin-embedded, H&E $\times 940$.

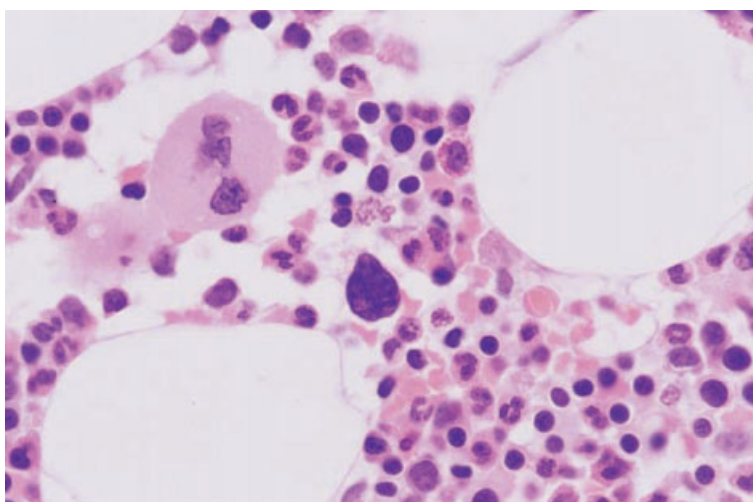


Fig. 1.35 Section of normal BM showing a normal mature megakaryocyte and a 'bare' megakaryocyte nucleus. Paraffin-embedded, H&E $\times 940$.

sections of lung, spleen, liver and other organs. Multiple mitotic figures are sometimes observed in megakaryocytes (Fig. 1.36). Emperipolesis is readily observed in histological sections (Fig. 1.37).

In assessing the morphology of megakaryocytes, it is important to remember that the megakaryocyte is a very large cell and only a cross-section of it is being examined. It is therefore not possible to determine the size or degree of nuclear lobulation of single megakaryocytes. However, by examining a large number of cells it is possible to form a judgement as

to the average size of the megakaryocytes, the average degree of lobulation, and whether hypolobulated or micromegakaryocytes are present.

When haemopoiesis is normal, megakaryocytes do not form clusters of more than two or three cells. Larger clusters of megakaryocytes are seen in regenerating marrow, following chemotherapy and bone marrow transplantation, and also in various pathological states; this feature is diagnostically useful.

Megakaryocytes can be quantified by counting

Fig. 1.36 Section of trephine biopsy specimen from a patient with polycythaemia rubra vera showing two megakaryocytes, one of which shows multiple mitotic figures; note shrinkage haloes around intermediate and late erythroblasts. H&E $\times 940$.

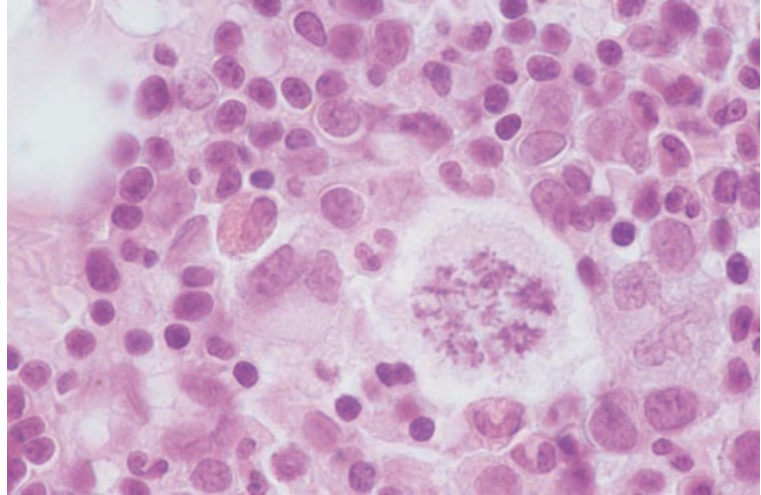
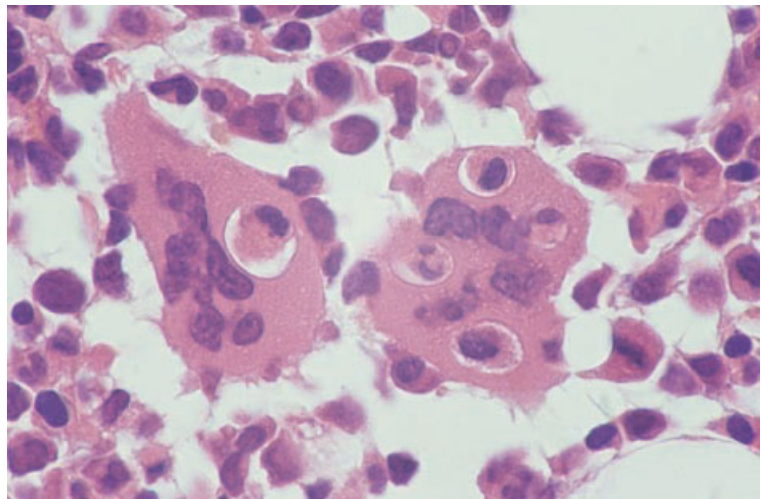


Fig. 1.37 Section of trephine biopsy specimen from a patient with AIDS: two megakaryocytes show prominent emperipolesis; in normal marrow emperipolesis is less striking. H&E $\times 940$.



their number per unit area, or a subjective impression can be formed as to whether they are present in decreased, normal or increased numbers. Depending on the processing and staining techniques employed, estimates of mean megakaryocyte number in normal marrow vary from 7 to 15 per mm^2 [19]. If an immunocytochemical technique is used, estimates are considerably higher, with the mean normal value being 25 per mm^2 ; this is probably because more small megakaryocytes and megakaryocyte precursors are recognized [19].

Mast cells

Cytology

Mast cells (Fig. 1.38) are derived from the multipotent myeloid stem cell. In bone marrow films they appear as oval or elongated cells varying in size from 5 to 25 μm . The nucleus is central, relatively small and either round or oval. The cytoplasm is packed with granules which stain deep purple with Romanowsky stains. Mast cells can be distinguished

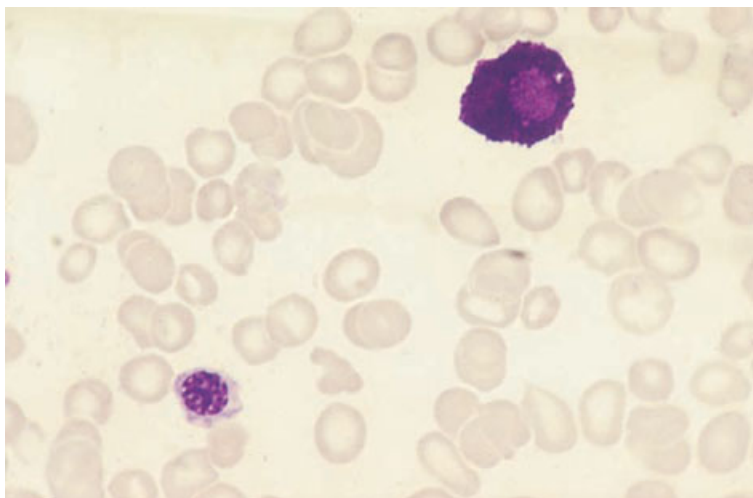


Fig. 1.38 Aspirate of normal BM: a mast cell and a normoblast; the mast cell has a round nucleus and cytoplasm packed with deeply basophilic granules. MGG $\times 940$.

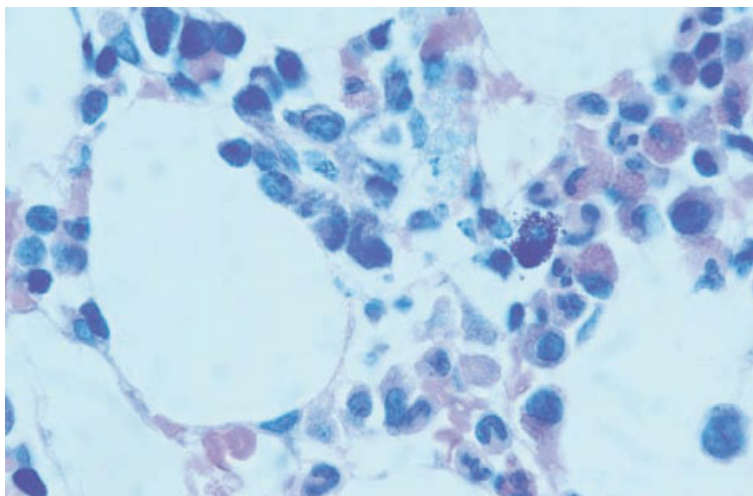


Fig. 1.39 Section of trephine biopsy specimen from a patient with renal failure: a mast cell and maturing granulocytes. Plastic-embedded, Giemsa $\times 940$.

from basophils by the different nuclear characteristics (non-lobulated nucleus with less chromatin clumping) and by the fact that the granules do not obscure the nucleus.

Histology

Mast cells are rare in normal marrow. They are difficult to recognize in H&E-stained histological sections because the granules do not stain distinctively. They are readily recognizable in a Giemsa stain (Fig. 1.39) in which the granules stain metachro-

matically; their vivid purple colour makes them conspicuous. Mast cell granules also give positive reactions for chloro-acetate esterase, are periodic acid-Schiff (PAS)-positive and stain metachromatically with toluidine blue. Mast cells are distributed irregularly in the medullary cavity but are most numerous near the endosteum, in the periosteum, in association with the adventitia of small blood vessels and at the periphery of lymphoid nodules or aggregates [20]. They appear as elliptical or elongated cells with an average diameter of 12 μm . Their cytoplasmic projections stretch out between haemopo-

Fig. 1.40 Section of a trephine biopsy specimen showing a reactive increase in interstitial and paratrabecular mast cells. Immunoperoxidase, mast cell tryptase (McAb AA1) $\times 188$.

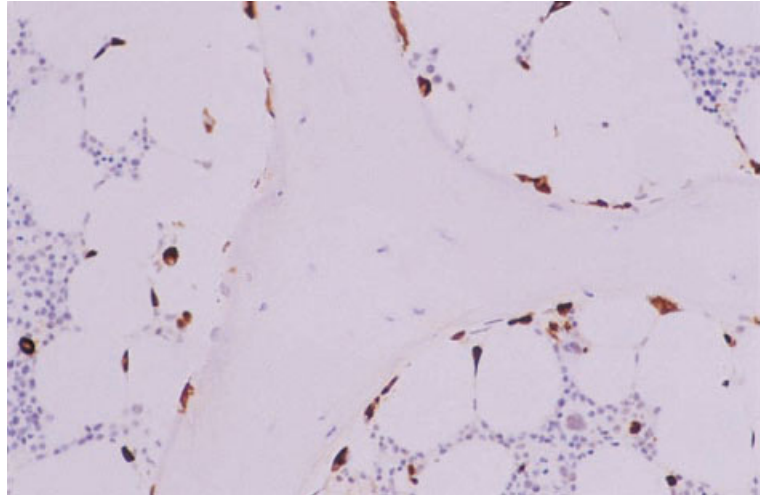
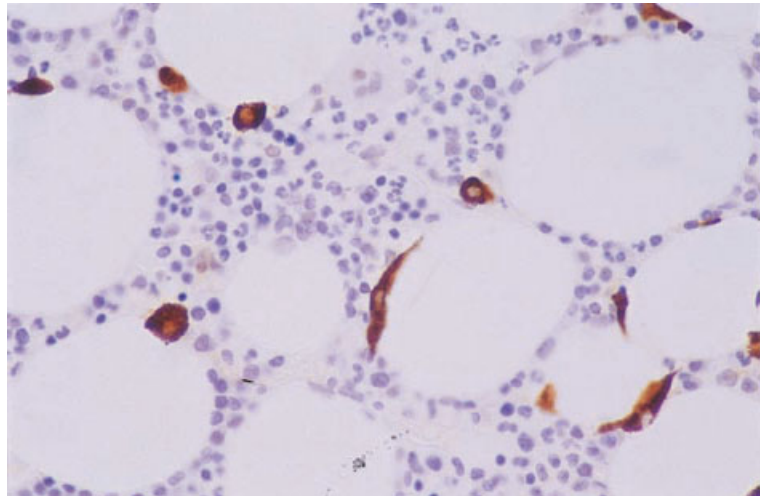


Fig. 1.41 Section of a trephine biopsy specimen showing a reactive increase in mast cells; note that some mast cells are round and some are spindle-shaped. Immunoperoxidase, mast cell tryptase (McAb AA1) $\times 376$.



etic cells. Their distribution and cytological features can be demonstrated by immunohistochemistry (Figs 1.40 and 1.41).

Osteoblasts and osteoclasts

Osteoblasts and osteoclasts differ in their origin but have complementary functions. Osteoblasts have a common origin with other mesenchymal cells and are responsible for bone deposition. Osteoclasts are formed by fusion of cells of monocyte lineage and are responsible for dissolution of bone.

Cytology

Osteoblasts (Fig. 1.42) are mononuclear cells with a diameter of 20–50 μm . They have an eccentric nucleus, moderately basophilic cytoplasm and a Golgi zone which is not in apposition to the nuclear membrane. The nucleus shows some chromatin condensation and may contain a small nucleolus. Osteoblasts can be distinguished from plasma cells, to which they bear a superficial resemblance, by the lesser degree of chromatin condensation and the separation of the Golgi zone from the nucleus.

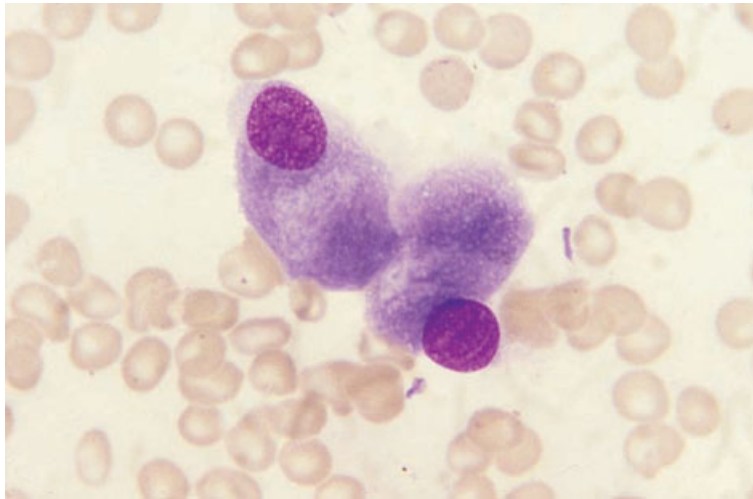


Fig. 1.42 Aspirate of normal BM: two osteoblasts; note the eccentric nucleus and basophilic cytoplasm; these cells can be distinguished from plasma cells by their larger size and the position of the Golgi zone which is not immediately adjacent to the nucleus. MGG $\times 940$.

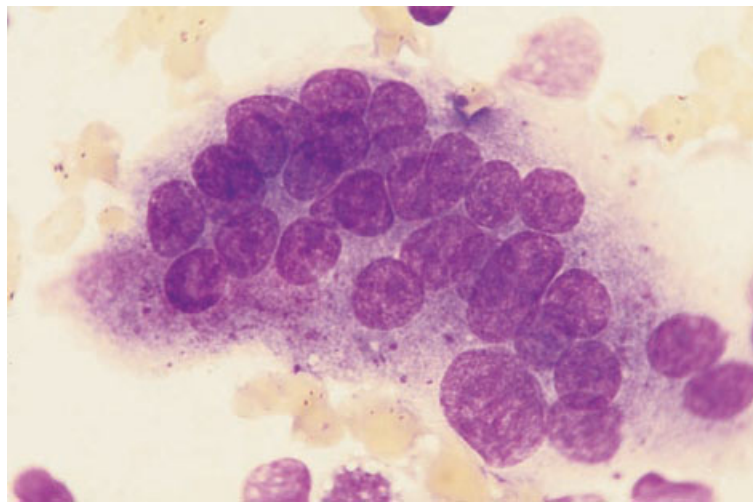


Fig. 1.43 Aspirate of normal BM: an osteoclast: note the highly granular cytoplasm and the multiple nuclei which are uniform in size and have indistinct medium sized single nucleoli. MGG $\times 940$.

Osteoblasts are uncommon in bone marrow aspirates of healthy adults but, when present, often appear in small clumps. They are much more numerous in the bone marrow of children.

Osteoclasts (Fig. 1.43) are multinucleated giant cells with a diameter of 30–100 μm or more. Their nuclei tend to be clearly separate, uniform in appearance and slightly oval with a single lilac-staining nucleolus. The voluminous cytoplasm contains numerous azurophilic granules which are coarser than those of megakaryocytes. Osteoclasts

are not commonly seen in marrow aspirates of healthy adults but are much more often seen in aspirates from children.

Histology

Osteocytes, osteoblasts and osteoclasts in histological sections are identified by their position and their morphological features. Osteocytes (Fig. 1.44) lie within bone lacunae. Osteoblasts (Fig. 1.45) appear in rows along a bone spicule or a layer of

Fig. 1.44 Section of normal BM: bone spicule containing osteocyte; note myeloblasts in adjacent marrow. Plastic-embedded, H&E $\times 940$.

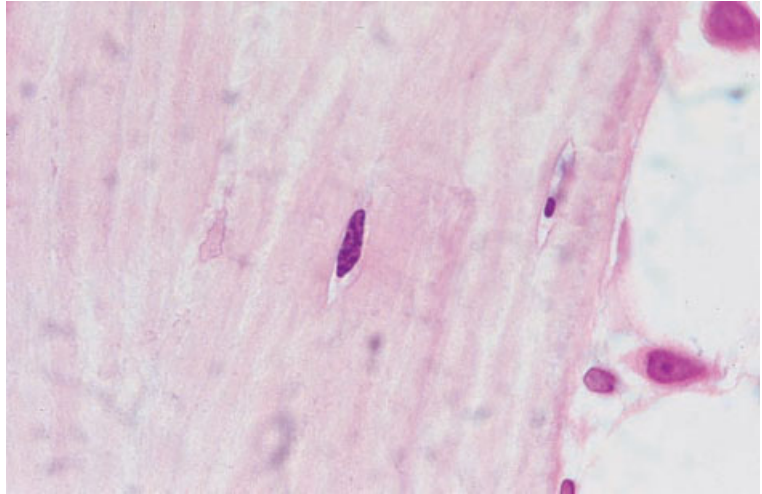
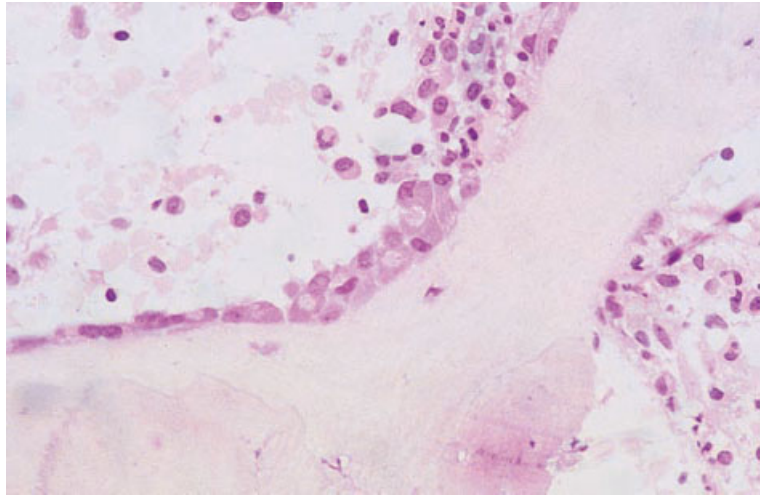


Fig. 1.45 Section of BM from a patient with Fanconi's anaemia: the trabecula is lined by osteoblasts; note the distinct Golgi zones which do not abut on the nuclear membrane. Plastic-embedded, H&E $\times 377$.



osteoid and their eccentric nuclei and prominent Golgi zones are apparent. Osteoclasts (Fig. 1.46) are likely to be found on the other side of a spicule from osteoblasts or some distance away. They are identified as multinucleated cells lying in hollows known as Howship's lacunae. They show tartrate-resistant acid phosphatase activity in EDTA- but not acid-decalcified specimens.

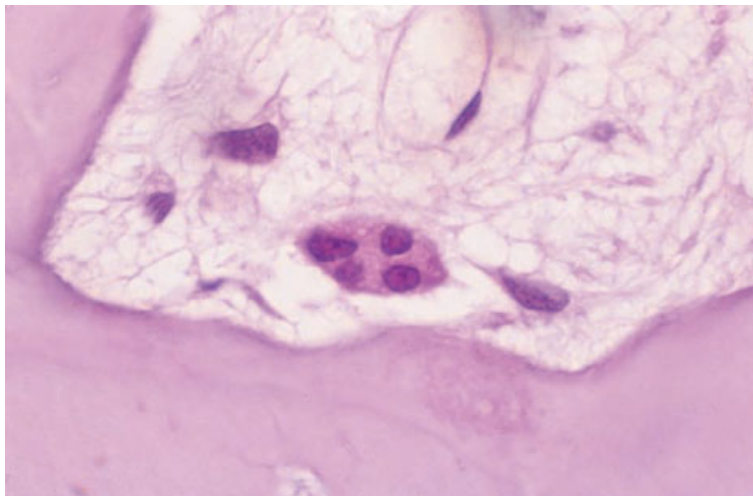
Fat cells

Fat cells are almost always recognizable in bone

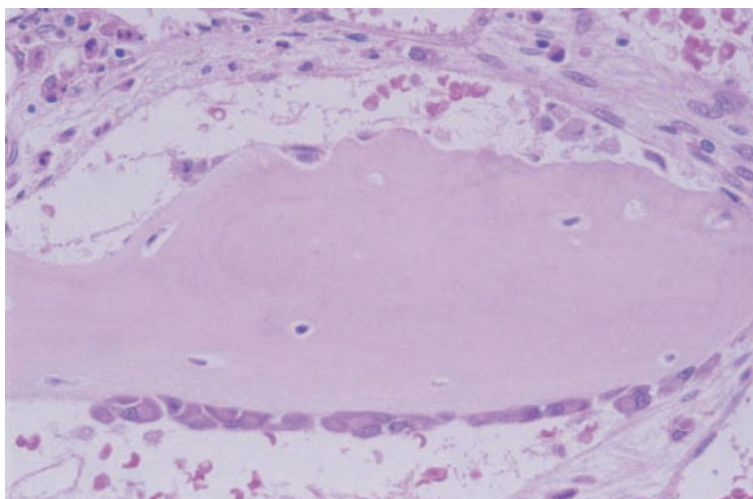
marrow specimens, exceptions being found in very young infants and when the bone marrow is markedly hypercellular.

Cytology

Stromal fat cells are present mainly in aspirated fragments. Since the fat dissolves during processing the cytoplasm appears completely empty. In isolated fat cells (Fig. 1.47), an oval nucleus, either peripheral or central, is present within apparently empty cytoplasm.



(a)



(b)

Fig. 1.46 (a) Section of BM from a patient with renal osteodystrophy: osteoclast with four nuclei. Paraffin-embedded, H&E $\times 970$. (b) Section of BM showing a bone spicule; one side is lined with osteoblasts while the other shows Howship's lacunae, two of which contain osteoclasts. H&E $\times 376$.

Histology

In sections of bone marrow, the fat cells appear in clusters, separated by haemopoietic tissue. They are often particularly prominent adjacent to trabeculae. Fat cells appear as empty spaces with an oval nucleus at one edge of the cell.

Lymphopoiesis

Lymphocytes

Both B and T lymphocytes share a common origin

with myeloid cells, all of these lineages being derived from a pluripotent stem cell. The bone marrow contains mature cells and precursor cells of both T- and B-lymphoid lineages. T cells are more numerous among mature cells whereas, among precursor cells, those of B lineage are more frequent.

Cytology

Bone marrow lymphocytes are small cells with a high nucleocytoplasmic ratio and scanty, weakly basophilic cytoplasm. The nuclei show some chromatin condensation but the chromatin often

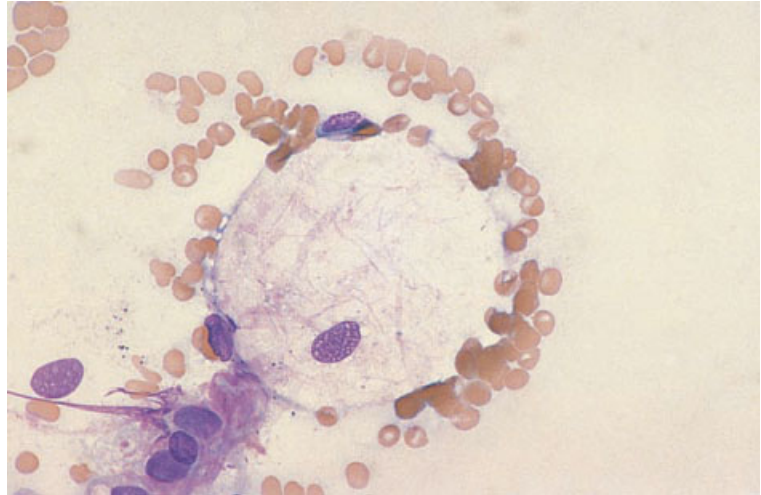


Fig. 1.47 BM aspirate showing a fat cell. MGG $\times 470$.

appears more diffuse than that of peripheral blood lymphocytes. Lymphocytes are not very numerous in the marrow in the first few days of life but otherwise during infancy they constitute a third to a half of bone marrow nucleated cells [21]. Numbers decline during childhood and in adults they do not generally comprise more than 15–25% of nucleated cells, unless the marrow aspirate has been considerably diluted with peripheral blood. If there is no haemodilution, they usually account for approximately 10% of nucleated cells. The majority of lymphocytes in normal bone marrow are CD8-positive T lymphocytes.

The bone marrow of children with various illnesses, and even the bone marrow of perfectly healthy children, may show significant numbers of immature cells with a cytological resemblance to leukaemic lymphoblasts, referred to as haematogones (see page 241); these are B-lymphocyte precursors.

Histology

Normal marrow contains scattered interstitial lymphocytes and sometimes small lymphoid nodules or follicles. Estimates of lymphocyte numbers based on histological sections are considerably lower than those based on aspirates. In one study approximately 10% of bone marrow cells were lymphocytes

with the ratio of T to B cells being 6:1 [22]. Lymphocytes appear to concentrate about arterial vessels near the centre of the haemopoietic cords. Lymphoid follicles of normal marrow have small blood vessels at their centre and may contain a few macrophages, peripheral mast cells or plasma cells. Lymphoid follicles are discussed further on page 114.

Plasma cells

Cytology

Plasma cells (Fig. 1.48) are infrequent in normal bone marrow in which they rarely constitute more than 1% of nucleated cells. In healthy children they are even less frequent [23]. They are distinctive cells with a diameter of 15–20 μm and an eccentric nucleus, moderately basophilic cytoplasm and a prominent paranuclear Golgi zone. The cytoplasm may contain occasional vacuoles and sometimes stains pink with a May–Grünwald–Giemsa (MGG) stain, consequent on the presence of carbohydrate. The nuclear chromatin shows prominent coarse clumps, although the clock-face chromatin pattern which is often discernible in histological sections is usually less apparent in films. Occasional normal plasma cells have two or more nuclei. Plasma cells may occur in small clumps and may be detected within aspirated marrow fragments and around capillaries.

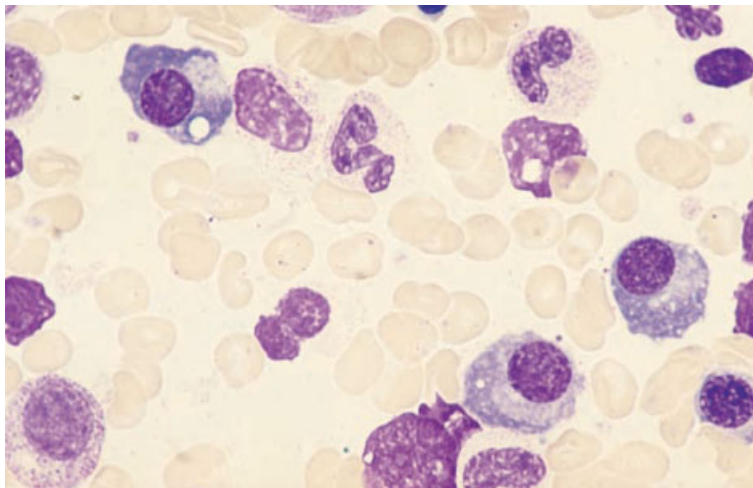


Fig. 1.48 Aspirate of BM from a patient with an inflammatory condition: three plasma cells; note the basophilic cytoplasm, eccentric nucleus and Golgi zone adjacent to the nucleus. MGG $\times 940$.

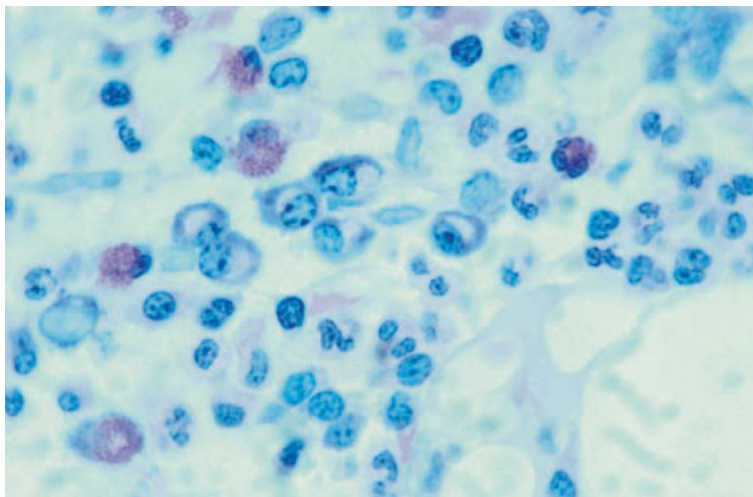


Fig. 1.49 Section of BM from patient with Hodgkin's disease (without marrow infiltration): pericapillary plasma cells, neutrophils, eosinophils and erythroblasts. Plastic-embedded, Giemsa $\times 940$.

Histology

Normal marrow contains scattered interstitial plasma cells but plasma cells may also be associated with macrophages and are preferentially located around capillaries (Fig. 1.49). Typical mature plasma cells in histological sections are readily identified by their eccentric nuclei and prominent Golgi zones. The chromatin is coarsely clumped and often distributed at the periphery of the nucleus with clear spaces between the chromatin clumps,

giving the appearance of a cartwheel or clock-face. In Giemsa-stained sections the cytoplasm, with the exception of the Golgi zone, is deeply basophilic.

The cellular composition of bone marrow

Cytology

The cellular composition of aspirated bone marrow is determined by the volume of the aspirate since

the larger the volume aspirated the more sinusoidal blood is sucked into the aspirate. Dilution of marrow with blood leads to a higher percentage of lymphocytes and mature granulocytes and a lower percentage of granulocyte and erythroid precursors. Dresch *et al.* [24] found, for example, that as the volume of aspirate from the sternum increased from 0.5 to 4.5 ml the total concentration of nucleated cells fell to about one sixth; the percentage of granulocyte precursors (myeloblasts to metamyelocytes) declined from approximately 55% to approximately 30%, while the percentage of mature neutrophils showed a more than twofold rise. Ideally, a cell count should be performed on films prepared from the first one or two drops of aspirated marrow. If large volumes are required for further tests, a second syringe can be applied to the needle after the syringe containing the first few drops has been removed. The differential count is then representative of the cellular composition of the bone marrow.

Determining the cellular composition of marrow requires that large numbers of cells be counted so that a reasonable degree of precision is achieved. This is particularly important when the cell of interest is one that is normally infrequent, such as the myeloblast or the plasma cell. A 500-cell count provides a reasonable compromise between what is desirable and what is practicable. The cell count should be performed in the trails behind fragments so that the cells counted represent cells that have come from fragments rather than contaminating peripheral blood cells. Alternatively, the cell count can be performed on squashed bone marrow fragments. Because some cells, for example plasma cells and lymphocytes, are distributed unevenly through the marrow, it is important to count the trails behind several fragments or the squashes of several fragments. Because cells of different lineages may not be released from the fragments into the trails to the same extent there may not be good correlation between differential counts on wedge-spread films and squashes. It is likely that counts on squashes are more valid. However, counts are usually performed on wedge-spread films and hence published reference ranges are based on such counts.

It is customary and useful to determine the M:E ratio of aspirated marrow since consideration of

this value, together with an assessment of the overall cellularity, allows an assessment of whether erythropoiesis and granulopoiesis are hypoplastic, normal or hyperplastic. It is simplest to include in the myeloid component all granulocytes and their precursors and any monocytes and their precursors. However, some haematologists exclude mature neutrophils and others include neutrophils but exclude eosinophils, basophils and monocytes. These inclusions and exclusions will make a slight difference to what is regarded as a normal M:E ratio but their effects are heavily outweighed by differences caused by different aspiration volumes. The larger the volume of the aspirate the higher the M:E ratio, particularly if mature neutrophils are included in the count.

The bone marrow at birth has major erythroid and myeloid components with few lymphocytes and very few plasma cells [21,23,25,26] (Fig. 1.50). The percentage of erythroid cells declines steeply in the first weeks [25,26]. The percentage of lymphocytes increases during the first month and remains at a high level until 18 months of age [21]. In children above the age of 2 years the proportions of different cell types do not differ greatly from those in normal adult bone marrow. However, children may have increased numbers of immature lymphoid cells (see page 241). Typical values determined for the cellular composition of normal marrow at various ages are shown in Tables 1.1 and 1.2. Bain [15] found a significantly higher proportion of granulocytes in the bone marrow of women than of men. This was not observed in a smaller cohort studied by den Ottonlander [32].

Histology

It is possible to perform differential counts and estimate an M:E ratio from plastic-embedded bone marrow biopsy sections [33,34] although this is rarely necessary in practice. Such counts have the potential to be more accurate than those obtained from aspirates since there is no dilution with sinusoidal blood. It is also possible that larger cells or cells adjacent to trabeculae might be less likely to be aspirated. However, an element of inaccuracy is introduced by the fact that larger cells appear at more levels of the biopsy so are more likely to be

Table 1.1 Mean values (observed range) for bone marrow cells in healthy infants and children.

	Birth [21] (n=57)	0–24 hours [26] (n=19)	8–10 days [25] (n=23)	3 months [26] (n=12)
M:E ratio	4.4	1.2	1.35	2.4
Myeloblasts	0.3*	1 (0.5–2)	1 (0–3)	1.5 (0–4)
Promyelocytes	0.8	1.5 (0.5–5)	2 (0.5–7)	2 (1.5–5)
Myelocytes	4	4 (1–9)	4 (1–11)	5 (0.5–16)
Metamyelocytes	19	14 (4.5–25)	18 (7–35)	11 (3–33)
Bands	29	22 (10–40)	20 (11–45)	15 (2–24)
Neutrophils	7			
Eosinophil series	2.7	3.5 (1–8)†	3 (0–6)†	2.5 (0–6)†
Basophil series	0.12	— (0–1.5)†	— (0–1)†	— (0–0.5)
Monocytes	0.9	— (0–2.5)†	1 (0–3)	0.5 (0–1)
Erythroid	14.5	39.5 (23.5–70)†	7.5 (0–20.5)†	16 (3.5–33.5)†
Lymphocytes	15	12 (4–22)	37 (20–62)	47 (31–81)
Plasma cells	0	0	0	0

* ‘Unknown blasts’.

† Approximate (sum of ranges for different categories).

counted in any given section. Lack of dilution by blood means that the estimated M:E ratio is likely to be lower than that determined from an aspirate. This is borne out by the results of a study of 13 healthy subjects which found a mean M:E ratio of 1.52 with a range of 1.36–1.61 [33].

Interpretation of bone marrow aspirates and trephine biopsies

Examination of a bone marrow aspirate in isolation permits cytomorphological features to be ascertained but does not permit full interpretation of the

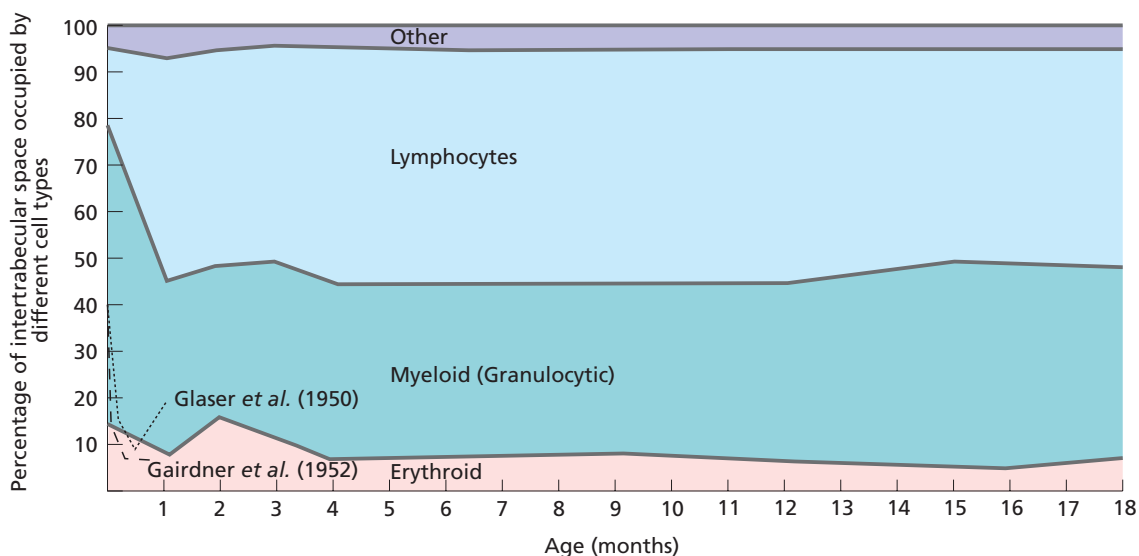


Fig. 1.50 The percentage of the intertrabecular space occupied by cells of different lineages during the first 18 months of life, derived from Rosse *et al.* [21]; the higher initial erythroid percentage and sharp fall in erythroblast number observed by Glaser *et al.* [25] and Gairdner *et al.* [26] are shown as dotted lines.

Table 1.1 (*cont'd*)

3 months [21] (n = 24)	1 year [21] (n = 12)	18 months [21] (n = 19)	2–6 years [27] (n = 12)	2–9 years [28] (n = 13)
4.9	4.8	5	5.8 (2–13)	5.3
0.6*	0.5*	0.4*	1	1.3 (0.7–1.8)
0.8	0.7	0.6	0.5	2.8 (0.8–4.8)
2	2	2.5	17	26.7 (18–35)†
12	11	12	20	22 (15.7–29)
15	14	14	11	4.5 (0.9–8)
3.5	6	6	10	8.3 (2.6–14)
2.5	2	3	6	1.2 (0–2.5)
0.1	0.1	0.1	—	0
0.7	1.5	2	0.4	0
12	8	8	13	12.5 (9.5–22.3)†
44	49	46	21	18.2 (8.5–28)
0	0.03	0.06	—	0.13 (0.05–0.41)

findings. The haematologist must also know the age and sex of the patient, the full blood count and relevant clinical details, and must have examined a peripheral blood film. Similarly, examination of trephine biopsy sections in isolation permits detection of histomorphological abnormalities but not a full assessment of a case. The pathologist should beware of the risks of either over-interpreting biopsy findings or failing to offer an adequate interpretation because of lack of consideration of clinical and haematological features and aspirate findings. It is desirable that trephine biopsies are either reported by a haematopathologist who is also able to interpret bone marrow aspirates or that the histopathologist and haematologist examine aspirate films and biopsy sections together. It should be appreciated that a trephine biopsy is just one part of a jigsaw puzzle and it may not always be possible to make a definitive diagnosis. Sometimes it is desirable to seek a second opinion. When this is so, it is essential that the haematopathologist is sent full clinical and haematological information. Films of the peripheral blood and the bone marrow aspirate should accompany trephine biopsy specimens being sent for a second opinion.

Examination of bone marrow aspirate films

A minimum of two or three films should always be examined. If there is a likelihood of infiltration

of the marrow and the first films do not show any abnormality, it is important to stain and examine a larger number.

Bone marrow films should first be examined under low power ($\times 10$ objective) in order to assess cellularity and megakaryocyte numbers and to scan the entire film for any abnormal infiltrate. The film should then be examined with a $\times 40$ or $\times 50$ objective which will allow appreciation of most morphological features. At this stage, all cell lineages should be specifically and systematically examined from the point of view of both numbers and morphology—the erythroid series, granulocytic lineages including eosinophils and basophils, megakaryocytes, lymphocytes and plasma cells. Consideration should be given to whether there is an increased number of mast cells, macrophages, osteoblasts or osteoclasts and whether any non-haemopoietic cells are present. Only when a thorough assessment of several films has been carried out at this magnification should the film be examined under high power ($\times 100$) with oil immersion in order to assess fine cytological detail. A differential count of cells in the trails behind several fragments is best carried out under high power but only after assessment of whether there is any increase of minority populations, for example blast cells or plasma cells, confined to one film or to the cell trail behind one fragment. Films stained for iron should similarly be examined under low power to assess storage iron,

Table 1.2 Mean values and 95% ranges for bone marrow cells in sternal or iliac crest aspirates of healthy adult Caucasians.

Site	20–29 years [28]	20–30 years [29]	
	(Males and females, n = 28) sternum	(Males, n = 52) sternum	(Females, n = 40)
Volume aspirated	≤0.5 ml	0.2 ml	3 ml
M:E ratio	3.34	—	—
Myeloblasts	1.21 (0.75–1.67)	1.32 (0.2–2.5)	1.2 (0.1–2.3)
Promyelocytes	2.49 (0.99–3.99)	1.35 (0–2.9)	1.65 (0.5–2.8)
Myelocytes	17.36 (11.54–23.18)	15 (7.5–22.5)	16.6 (11.4–21.8)
Metamyelocytes	16.92 (11.4–22.44)	15.7 (9.2–22)	15.8 (11.0–20.6)
Band cells	8.7 (3.58–13.82)	10.5 (3–17.9)	8.3 (4–12.4)
Neutrophils	13.42 (4.32–22.52)	20.9 (9.9–31.8)	21.7 (11.3–32)
Eosinophils	2.93 (0.28–5.69)*	2.8 (0.1–5.6)*	3 (0–7.2)*
Basophils	0.28 (0–0.69)*	0.14 (0–0.38)	0.16 (0–0.46)
Monocytes	1.04 (0.36–1.72)	2.3 (0.5–4)	1.61 (0.2–3)
Erythroblasts	19.26 (9.12–29.4)†	12.9 (4.1–21.7)	11.5 (5.1–17.9)
Lymphocytes	14.6 (6.66–22.54)	16.8 (7.2–26.3)	18.1 (10.5–25.7)
Plasma cells	0.46 (0–0.96)	0.39 (0–1.1)	0.42 (0–0.9)

* Including eosinophil and basophil myelocytes and metamyelocytes.

† Approximate (sum of ranges for different categories of erythroblast).

‡ Promyelocytes were categorized either with myeloblasts or with myelocytes.

§ Neutrophils plus precursors: erythroblasts.

|| Including basophil precursors and mast cells.

¶ Neutrophil plus eosinophil myelocytes mean and range 8.9 (2.14–15.3); band cells included in neutrophil category; macrophages mean and range 0.4 (0–1.3).

with a ×40 or ×50 objective to detect abnormally prominent siderotic granulation and with a ×100 objective to assess whether siderotic granulation is reduced, normal or increased.

Films of squashed bone marrow fragments should similarly be examined in a systematic manner.

Reporting a bone marrow aspirate

The report of a bone marrow aspirate should commence with the clinical details given to the haematologist and a record of the full blood count and peripheral blood film appearances at the time of bone marrow aspiration. There should then be a statement as to the site of aspiration, the texture of the bone and the ease of aspiration. The aspirate report should include an assessment of overall cellularity, an M:E ratio and a description of each lineage. Storage iron in fragments and siderotic granules in cells should be described. If a

trephine biopsy was performed this should be stated and, if a trephine biopsy would normally have been expected but was not performed successfully, this should also be stated. Any supplementary tests for which samples were taken, for example immunophenotyping or cytogenetic analysis, should be listed so that the clinician is aware that other results are to be expected. Finally, a brief summary of significant findings should be made and an interpretation offered, bearing in mind that this might be the only part of the report read by some clinicians. Reports should distinguish between factual statements and opinions. The description of the aspirate should be purely factual whereas it is useful for the final summary to include an explanation of the significance of the findings and, when relevant, suggestions for further tests. The report should be signed or computer-authorized by the haematologist or haematopathologist responsible for it.

Table 1.2 (*cont'd*)

17–45 years [30]	Age not stated [31]	21–56 years [15] ¶	Age not stated [32]
(42 males, 8 females, <i>n</i> = 50) sternum	(Males, <i>n</i> = 12) sternum	(30 males, 20 females) iliac crest	(53 males, 14 females) site not stated
—	0.1–0.2 ml	—	—
6.9	2.3 (1.1–3.5)§	2.4 (1.3–4.6)	2.2 (0.8–3.6)
1.3 (0–3)	0.9 (0.1–1.7)	1.4 (0–3)	0.4 (0–1.3)
— ‡	3.3 (1.9–4.7)	7.8 (3.2–12.4)	} 13.7 (8–19.4)
8.9 (3–15)	12.7 (8.5–16.9)	7.6 (3.7–10.0)¶	
8.8 (4–15)	15.9 (7.1–24.7)	4.1 (2.3–5.9)	} 35.5 (22.2–48.8)
23.9 (12.5–33.5)	12.4 (9.4–15.4)	—	
18.5 (9–31.5)	7.4 (3.8–11)	34.2 (23.4–45)¶	} 1.7 (0.2–3.3)
1.9 (0–5.5)	3.1 (1.1–5.2)*	2.2 (0.3–4.2)	
0.2 (0–1)	<0.1 (0–0.2)¶	0.1 (0–0.4)	0.2 (0–0.6)
2.4 (0–6)	0.3 (0–0.6)	1.3 (0–2.6)¶	2.5 (0.5–4.6)
9.5 (2.5–17.5)	25.6 (15–36.2)	25.9 (13.6–38.2)	23.6 (14.7–32.6)
16.2 (7.5–26.5)	16.2 (8.6–23.8)	13.1 (6–20)	16.1 (6.0–26.2)
0.3 (0–1.5)	1.3 (0–3.5)	0.6 (0–1.2)	1.9 (0–3.8)

Examination of trephine biopsy sections

The interpretation of trephine biopsy sections is often viewed as one of the more difficult areas of surgical pathology. This is probably because the organized structure of haemopoietic tissue is not as readily apparent as that of many other tissues. However, as the preceding part of this chapter illustrates, the bone marrow is actually highly organized, with the various elements maturing in different micro-anatomical sites. Failure to recognize this and failure to identify individual categories of cell may lead to a lack of systematic analysis, with diagnoses being made only by a process of pattern recognition. Conversely, the haematologist, although experienced in cytology, may be unfamiliar with the interpretation of tissue sections, in which architectural features are often of prime importance.

A systematic approach, which is essential for accurate diagnosis, requires a working knowledge of the normal micro-anatomy and the pathological changes that may occur, coupled with a methodical examination of the various component parts. Initially, the whole section should be examined at low power, preferably using a $\times 4$ objective. This allows a general impression of the biopsy to be gained,

including overall cellularity and megakaryocyte number and distribution. Abnormalities of the bone are often apparent at this magnification. It should also be noted if the biopsy specimen is too small, or is composed largely of cortical bone and subcortical marrow, or shows crush artefact or other artefactual distortion of the architecture. Focal lesions, such as granulomas or infiltrates of metastatic tumour or lymphoma, are often better appreciated on low power examination. Following this, the bone, haemopoietic elements and marrow stromal elements should be studied using medium power ($\times 10$ or $\times 20$ objective) and a high power dry objective ($\times 40$); examination under oil immersion ($\times 100$ objective) is not necessary as a routine but is often useful to study fine cytological detail. The bone should be examined for trabecular thickness, number of osteoblasts and osteoclasts, and presence and number of Howship's lacunae; undecalcified plastic sections should be assessed for the quantity of osteoid (see Chapter 11). With a little experience, visual estimations of the marrow cellularity, of the relative amounts of granulocytic and erythroid elements, and of any deviations from normal can easily be made. The next step is to examine the various haemopoietic elements for the following features.

Erythroid series. The presence and appearance of erythroblastic islands, the morphology and degree of maturation of erythroblasts and evidence of dyserythropoiesis.

Granulocytic series. The morphology and relative proportions of immature and mature granulocytic precursors and the position of the immature precursors (promyelocytes and myeloblasts).

Megakaryocytes. The number, morphological features, localization and presence or absence of clusters, with special attention being paid to cell size and nuclear morphology.

Lymphoid series. The number, localization and morphology of lymphocytes and plasma cells and the presence, position and morphology of lymphoid aggregates.

Macrophages. The number of macrophages and any evidence of haemophagocytosis, phagocytosis of micro-organisms (usually fungi or protozoa) or of lysosomal storage diseases such as Gaucher's disease.

It is often easy to neglect to examine the stromal elements, yet these are disturbed in a variety of conditions. The important changes that should be noted include: (i) gelatinous change; (ii) fibrosis; (iii) ectasia of sinusoids; (iv) oedema; and (v) less commonly, amyloidosis and vasculitis.

A stain for reticulin should be examined in every case. Depending on laboratory policy, an iron stain may also be examined in all cases. Choice of further special stains is dependent on clinical features and histological findings.

Obviously, in many cases, as when there is heavy infiltration by leukaemic cells or metastatic carcinoma, the above scheme is modified.

Reporting trephine biopsy sections

The trephine biopsy report [35] should include a statement as to the length of the biopsy specimen and its integrity. The report of the microscopic appearance should describe the cellularity and any abnormality in bone, stroma or haemopoietic tissue. The reticulin stain and, if performed, the iron stain should be described. In sections from a plastic-embedded specimen, iron stores should be graded; with a decalcified biopsy specimen an assessment should be made as to whether stainable iron is absent, present or increased but further grading

should not be attempted (see page 56). Any other histochemical or immunohistochemical stains should be described. In describing the results of immunohistochemistry, the cluster of differentiation (CD) number of the antibody used should be stated (see page 63).

Following a description of biopsy histology, a conclusion should be given in which all relevant findings are summarized and interpreted (as for the bone marrow aspirate, bearing in mind that many clinical staff will read only the summary). If the report is provisional, either because further stains are pending or because a second opinion is being sought, this should be stated clearly in the concluding summary. The report must be signed or computer-authorized by the responsible pathologist or haematologist.

Guidelines and audit

Guidelines on best practice in performing, processing and reporting bone marrow aspirates and trephine biopsies have been published [36,37]. Periodic audit is advised.

Artefacts

Various artefacts in bone marrow aspirates and trephine biopsies need to be recognized so that they are not misinterpreted as evidence of disease. Artefacts are of three main types: (i) introduced by the biopsy process or by processing in the laboratory; (ii) consequent on extraneous material or tissue being included in the biopsy; and (iii) consequent on previous tissue damage at the biopsy site. The latter group are not, strictly speaking, artefacts since what is observed are real changes in the tissues. Nevertheless, they are potentially misleading in the same way as artefacts and will therefore be considered here.

Cytology

Processing artefacts can be induced in bone marrow aspirates by inadequate drying of the film, poor fixation or prolonged storage of the film prior to fixation and staining. If slides are fixed before they have dried adequately, there is an appearance suggesting that nuclear contents are leaking into

Fig. 1.51 BM aspirate showing the effect of fixing and staining the film before adequate drying has occurred; erythroblast nuclear content appears to have leaked into the cytoplasm. MGG $\times 940$.

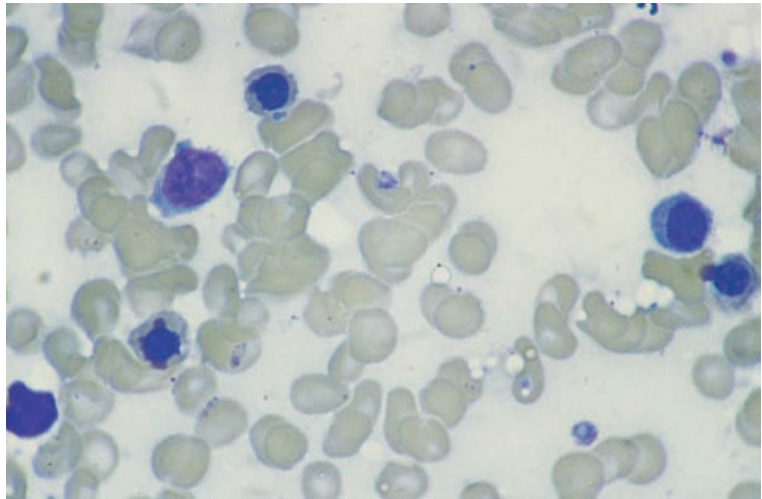
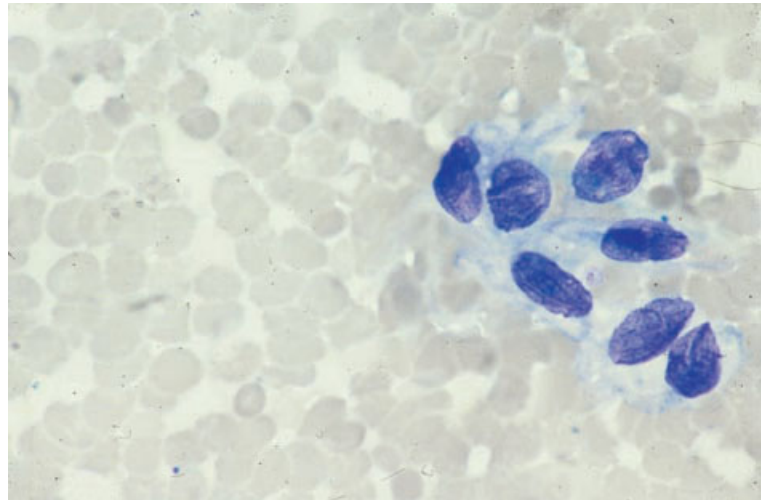


Fig. 1.52 Vena cava scraping showing endothelial cells; similar cells are occasionally observed in BM aspirates. MGG $\times 940$. (By courtesy of Dr Marjorie Walker, London.)



the cytoplasm and cellular outline is indistinct (Fig. 1.51). Water uptake into methanol used in fixation causes refractile 'inclusions' in red cells and poor definition of cellular details. Delayed fixation and staining of archival bone marrow slides usually leads to a strong blue or turquoise tint to the film; this can be avoided by fixing slides prior to storage although this limits the uses to which they can subsequently be put.

Extraneous non-haemopoietic cells which may appear in bone marrow aspirates include endothelial cells (Fig. 1.52) and epithelial cells (Fig. 1.53).

Endothelial cells may appear in masses and be pleomorphic. It is important that they are not confused with tumour cells. They have weakly basophilic cytoplasm and oval nuclei which appear grooved. Epithelial cells, both nucleated and anuclear, are more readily recognized by their voluminous, opaque, powder-blue cytoplasm. Extraneous material which may appear in bone marrow aspirate films includes crystals of glove powder. These are blue with an MGG stain (Fig. 1.54) and red with a PAS stain.

Abnormalities in bone marrow aspirates may

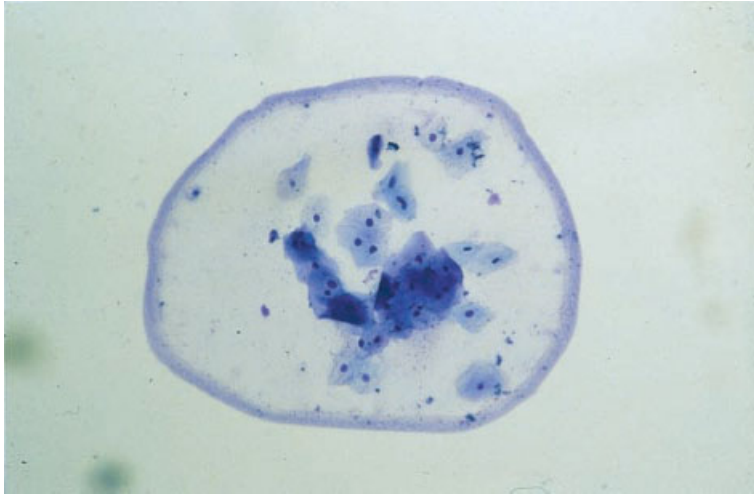


Fig. 1.53 BM aspirate, epithelial cells. MGG×94.

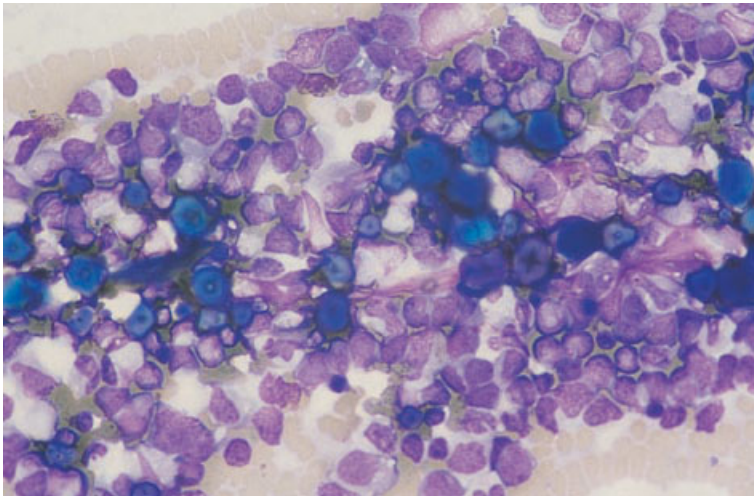


Fig. 1.54 Crystals of glove powder in a BM aspirate. MGG×376.

result from a previous biopsy performed at the same site a short time before. Increased numbers of macrophages, including foamy macrophages, can be found. The scars of previous biopsies are usually apparent and repeat biopsies should be carried out from the other side of the pelvis or a centimetre or so away from any recent biopsy on the same side. It should also be noted that, if the pelvis has previously been irradiated, biopsies will show bone marrow hypoplasia or aplasia which is not indicative of the appearance of the bone marrow at other sites. Biopsy of previously irradiated bone marrow should therefore generally be avoided.

Histology

A trephine biopsy specimen that is too short or a biopsy that is performed at the wrong angle may mean that the specimen includes only subcortical bone, which is often markedly hypocellular. This can create a mistaken impression of aplastic anaemia. Performing a biopsy and processing the specimen can induce crumbling of bone to amorphous material (Fig. 1.55), or bone marrow tissue may be absent from the intertrabecular spaces (Fig. 1.56). The latter artefact may be related to the use of blunt needles since it does not appear to be a

Fig. 1.55 BM trephine biopsy section, crushed bone. H&E $\times 188$.

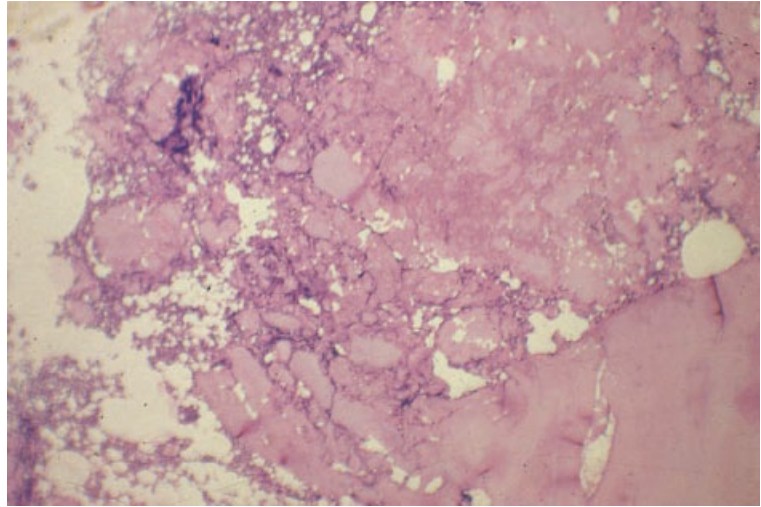
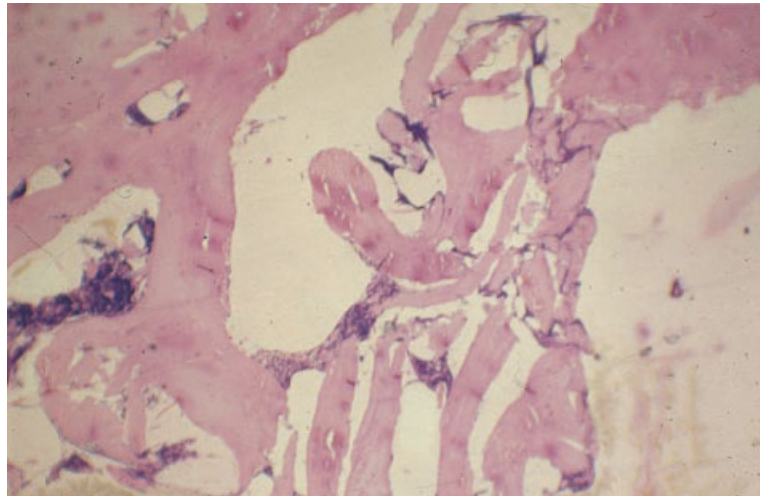


Fig. 1.56 BM trephine biopsy section showing apparently empty intertrabecular spaces consequent on squeezing of the biopsy specimen. H&E $\times 94$.



problem with disposable needles. Torsion artefact (Fig. 1.57) is common. The elongated nuclei which are produced by twisting should not be confused with the nuclei of fibroblasts. Usually, twisted bone marrow is not interpretable but sometimes it is possible to recognize neoplastic cells, e.g. myeloma cells or carcinoma cells, despite the artefact.

Artefacts can be introduced during fixation. If formol-saline is used as a fixative, it is necessary to allow at least 18 hours for fixation. If more rapid fixation is required then a protein precipitant formulation should be used. Poor fixation leads to glassy nuclei in which detailed structure cannot be

recognized (Fig. 1.58). Poor fixation is aggravated by the use of strong decalcifying agents. Often it is impossible to give any reliable interpretation of a poorly fixed marrow. Another fixation-related problem is deposition of formalin pigment (Fig. 1.59). Formalin pigment is blackish brown and should be distinguished from haemosiderin which is golden brown.

Artefacts induced during processing are most often a problem in paraffin-embedded tissue. Some degree of shrinkage artefact is usual. This is most apparent with erythroblasts for which the halo which surrounds the nucleus can be an aid to

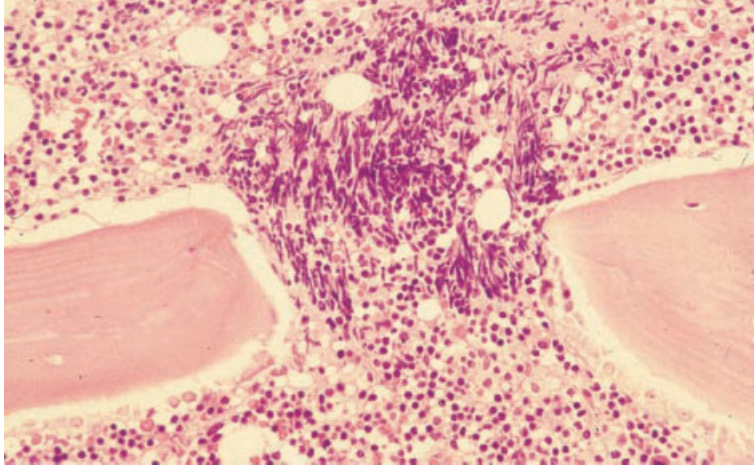


Fig. 1.57 BM trephine biopsy section from a patient with chronic lymphocytic leukaemia showing torsion artefact. H&E $\times 188$.

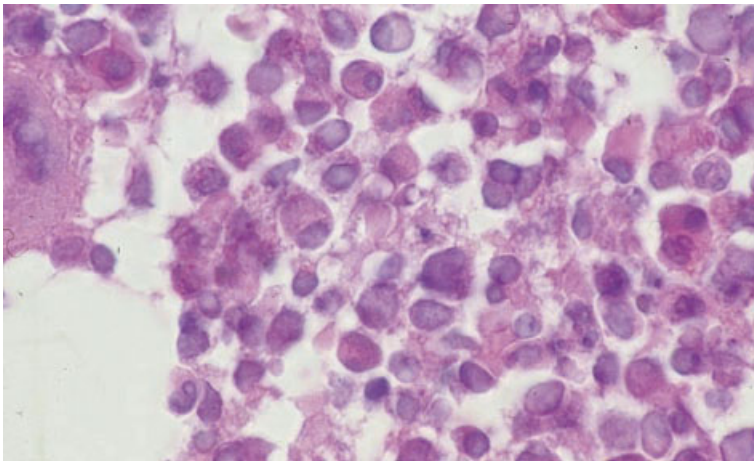


Fig. 1.58 BM trephine biopsy section showing nuclei which appear glassy and homogeneous as a consequence of fixation artefact. H&E $\times 940$.

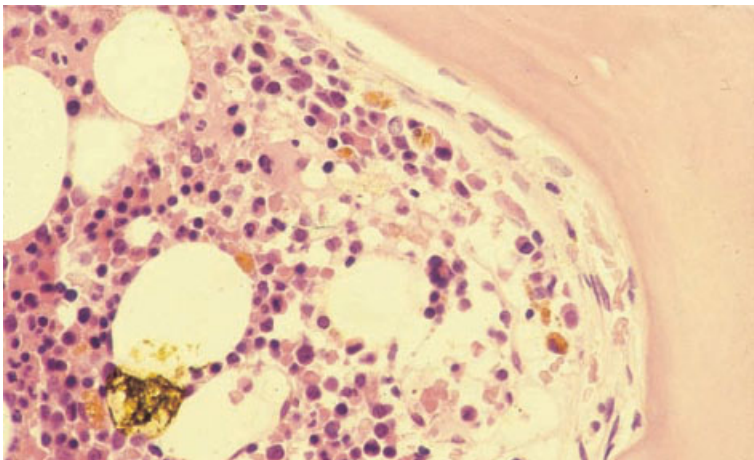


Fig. 1.59 BM trephine biopsy section showing formalin pigment. H&E $\times 376$.

Fig. 1.60 BM trephine biopsy section showing megakaryocytes surrounded by an empty space as a consequence of shrinkage artefact. H&E $\times 376$.

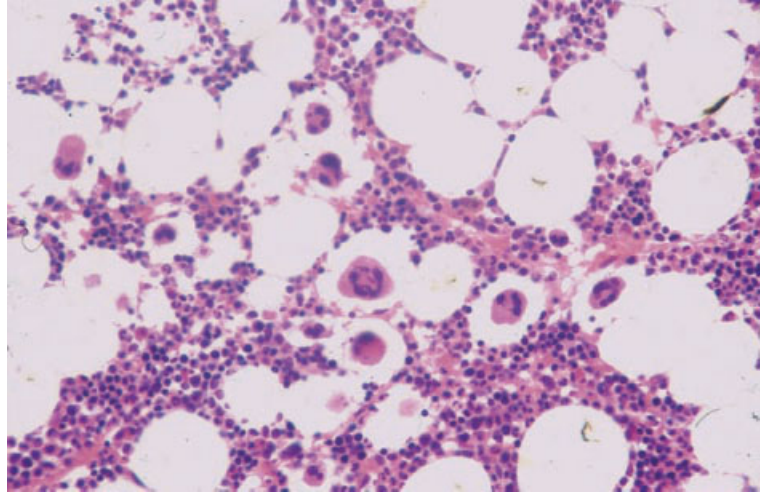
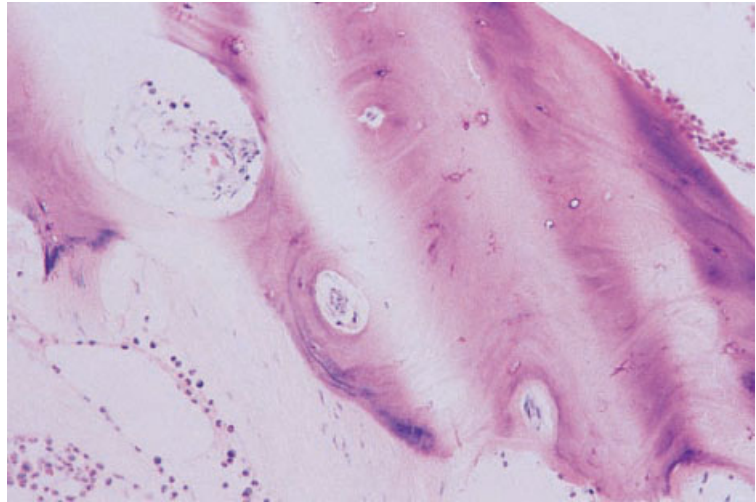


Fig. 1.61 BM trephine biopsy specimen showing an artefact caused by using a blunt knife. H&E $\times 376$.



identification. Shrinkage artefact also leads to megakaryocytes appearing within large empty spaces (Fig. 1.60). The use of a blunt knife can lead to tearing of sections or to the sections appearing banded (Fig. 1.61). Bony trabeculae may be lost during processing leaving a gap in the section (Fig. 1.62).

Artefactual inclusion of extraneous tissue in the biopsy is not uncommon. Trephine biopsy samples, particularly from children, may include cartilage (Fig. 1.63). Pieces of skin (Fig. 1.64), adipose tissue, striated muscle (Fig. 1.65), hair follicles (Fig. 1.66) and sweat glands (Figs 1.66 and 1.67) can be intro-

duced into the biopsy specimen during the biopsy process. Occasionally synovium (Fig. 1.68), or even a gouty tophus (Fig. 1.69), is included in the specimen. Other extraneous material can be transferred from the blade used in cutting sections and can be embedded with the bone marrow biopsy specimen (Fig. 1.70). Tissue from other biopsy specimens can contaminate the water bath in which sections are floated prior to mounting on glass slides. Such tissue may adhere to the trephine biopsy specimen or to the glass slide adjacent to the section, and may thus appear to represent part of the trephine biopsy

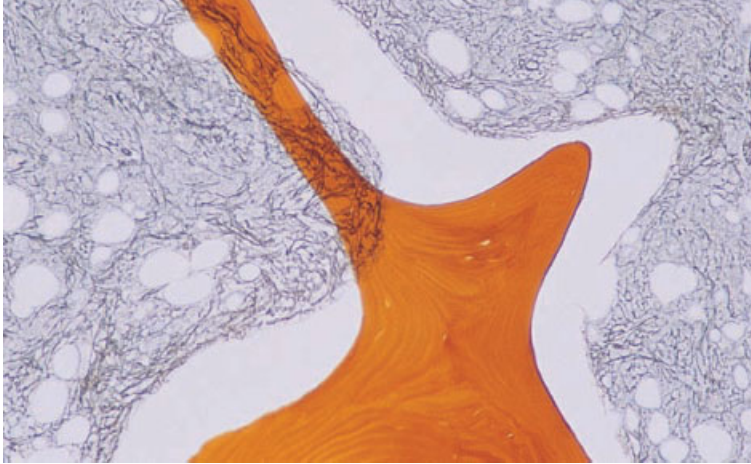


Fig. 1.62 BM trephine biopsy specimen showing displacement of bony trabeculae; if trabeculae are completely displaced confusion with dilated sinusoids can occur. Reticulin stain $\times 98$.

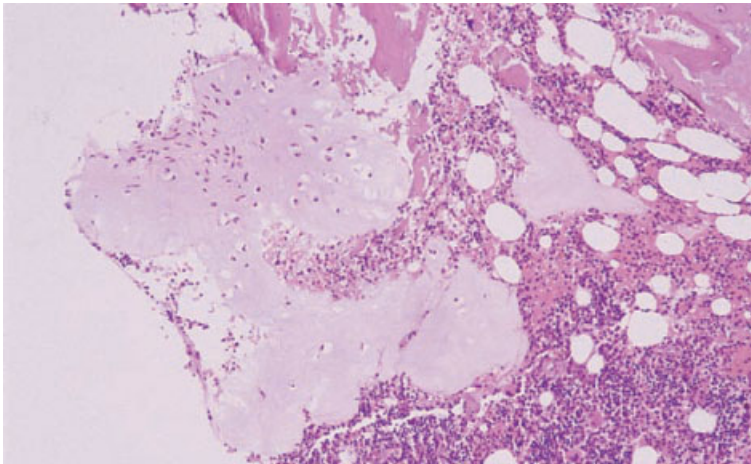


Fig. 1.63 An inclusion of paediatric cartilage in a trephine biopsy specimen. H&E $\times 188$.

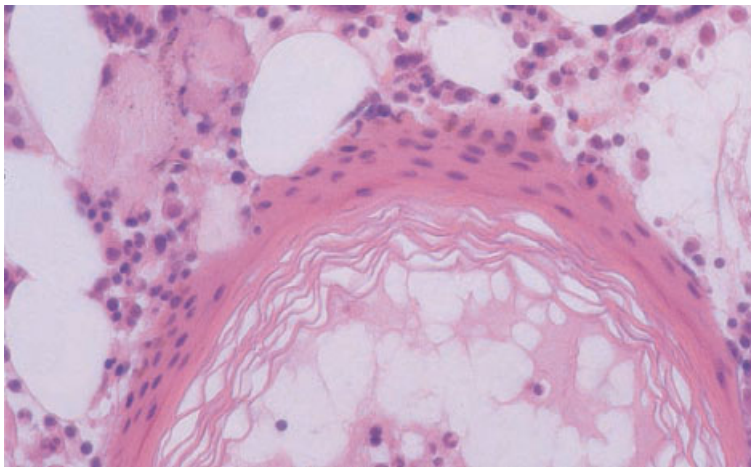
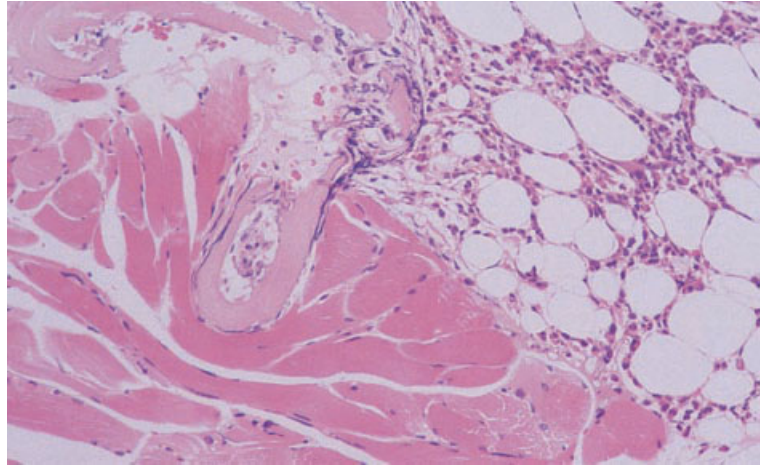
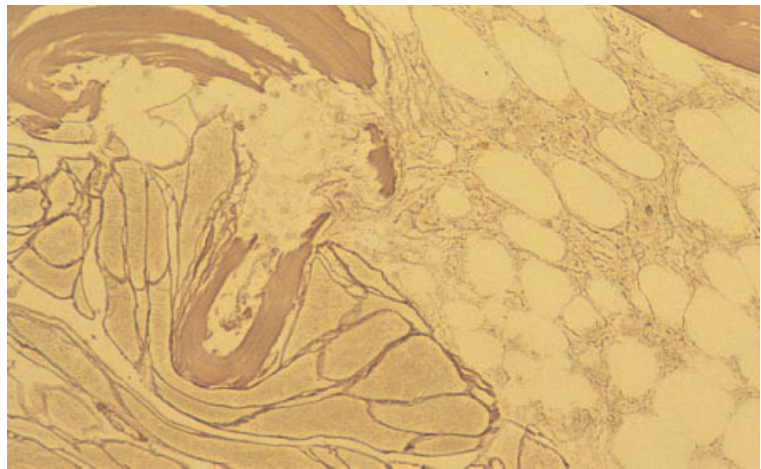


Fig. 1.64 BM trephine biopsy showing a piece of epidermis which has been driven into the biopsy specimen. H&E $\times 37$.



(a)



(b)

Fig. 1.65 Trephine biopsy showing striated muscle which has been driven into the biopsy specimen: (a) H&E $\times 384$; (b) reticulin stain $\times 384$.

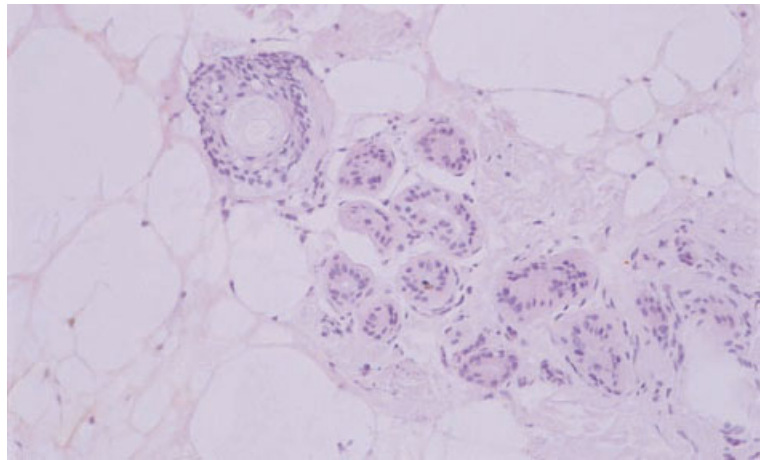


Fig. 1.66 A hair follicle and ducts of a sweat gland which have been driven into a trephine biopsy specimen. H&E $\times 94$.

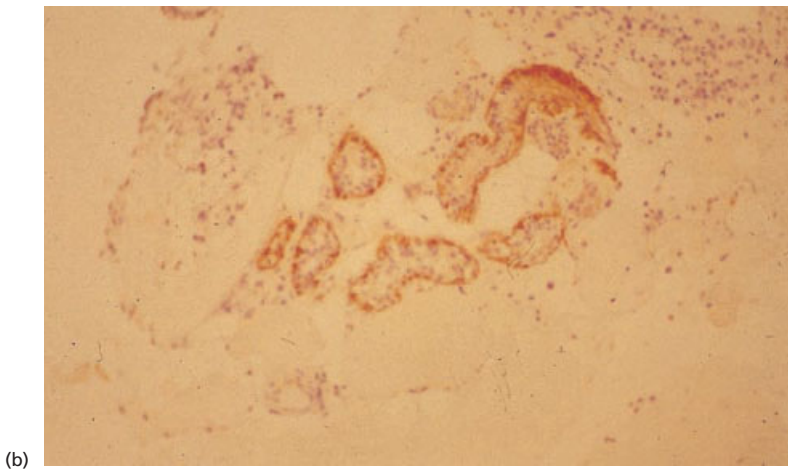
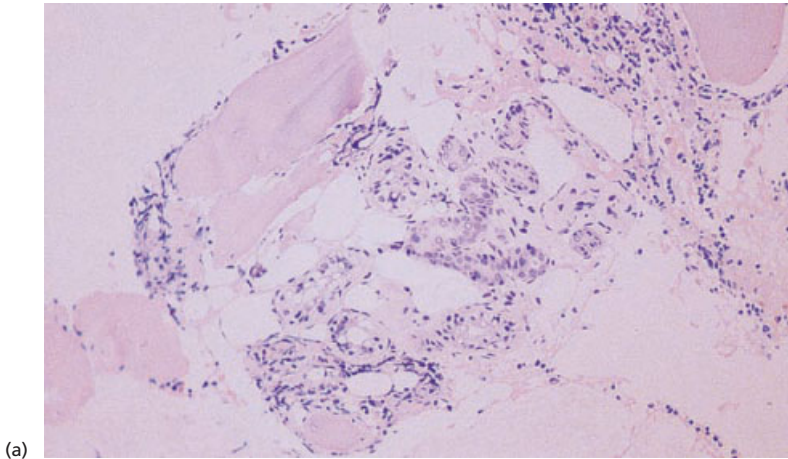


Fig. 1.67 BM trephine biopsy showing sweat glands which have been driven into the biopsy. (a) Giemsa $\times 96$. (b) Immunohistochemistry with an antibody to smooth muscle actin demonstrating the myoepithelial cells of the sweat gland. Immunoperoxidase $\times 94$.

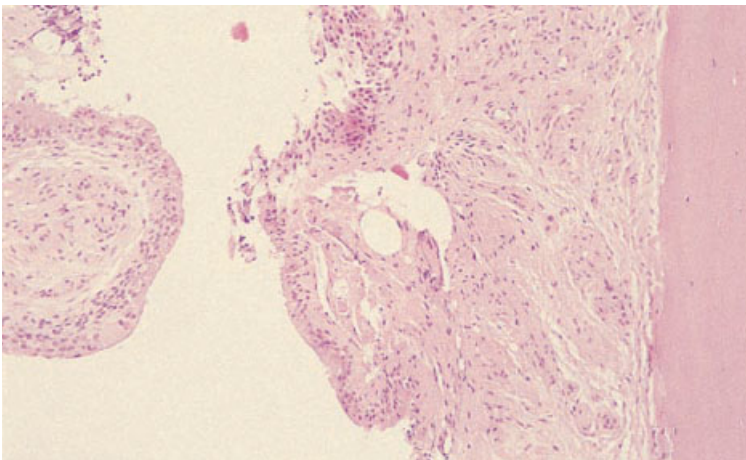


Fig. 1.68 Section of BM trephine biopsy specimen showing synovium on the periosteal surface of cortical bone. H&E $\times 94$.

Fig. 1.69 Section of trephine biopsy specimen showing a gouty tophus which has been driven into the bone marrow; the empty spaces represent areas where uric acid has been removed during processing. H&E $\times 94$.

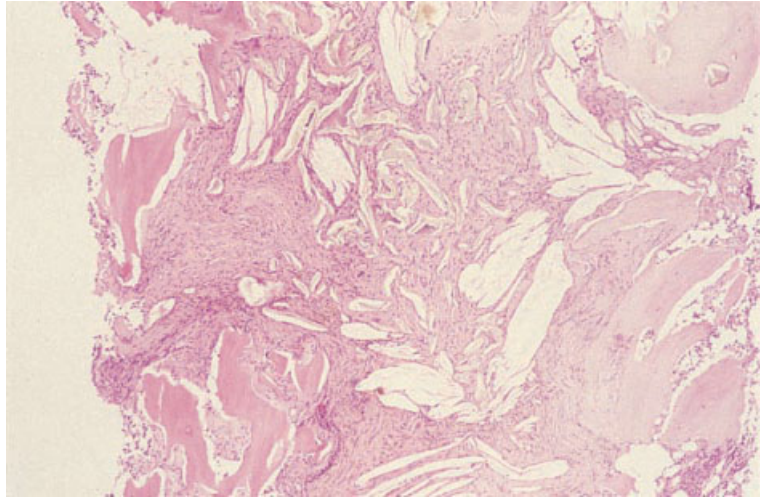
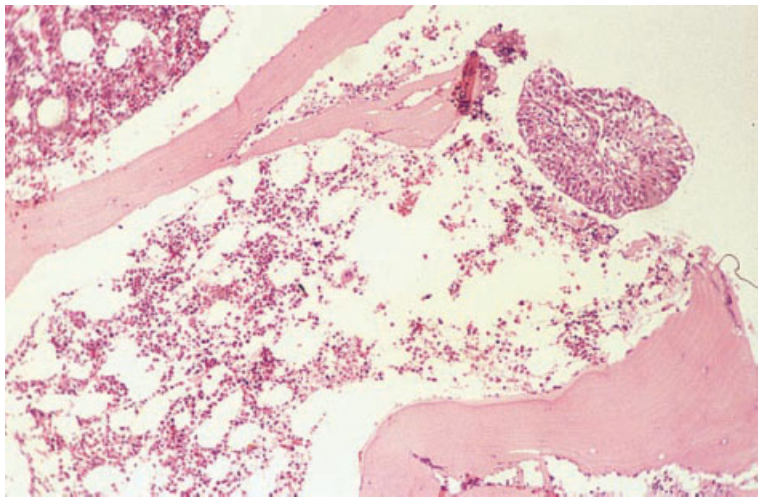


Fig. 1.70 BM trephine biopsy specimen showing dysplastic bladder epithelium which has been embedded with the biopsy as a result of contamination during processing. H&E $\times 96$.



specimen. Sometimes the abnormal tissue which is inadvertently included is dysplastic or neoplastic. Examination of reticulin stains can be helpful if there is doubt as to whether or not abnormal tissue is an intrinsic part of the biopsy specimen. If foreign tissue has been transferred with a knife, it will not be present if repeat sections are cut. However, sometimes extraneous tissue that was floating in a solvent solution is actually included in the block and will therefore also be present in repeat sections. Histopathology laboratories need good practices

for dealing with small friable biopsy specimens to avoid this problem and both haematologists and histopathologists must be aware of this potential problem. In a last resort the unexplained tissue can be dug out of the block and human leucocyte antigen (HLA) typed against the trephine biopsy specimen or any other candidate biopsy to establish its true origin.

Artefacts can be induced by a previous aspiration or trephine biopsy at the same site. A bone marrow aspiration performed immediately before a trephine

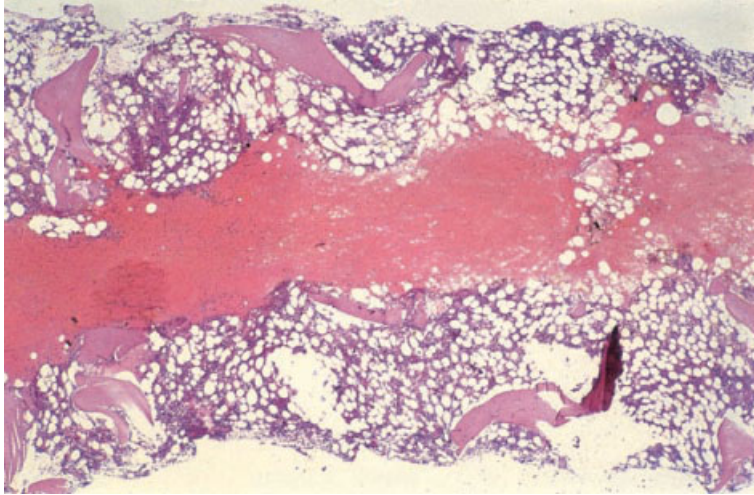


Fig. 1.71 BM trephine biopsy specimen showing needle track from a bone marrow aspiration performed immediately before the trephine biopsy. H&E $\times 38$.

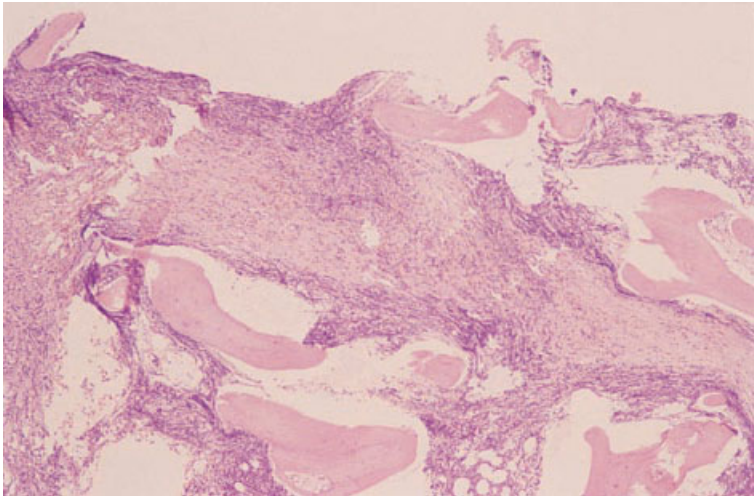
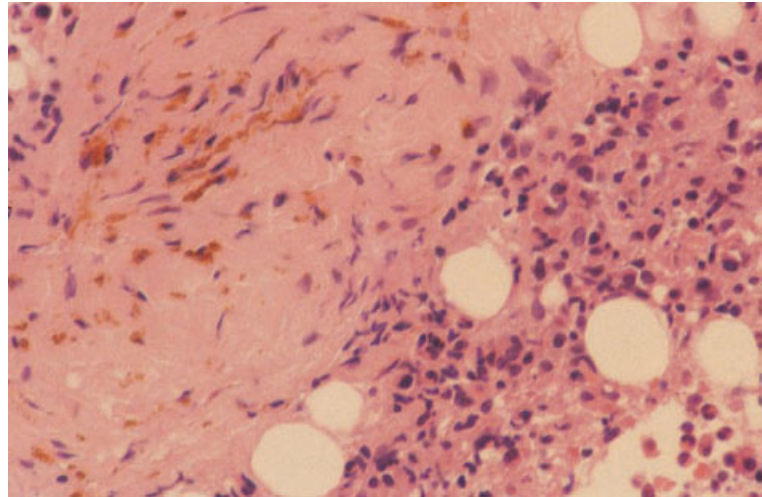


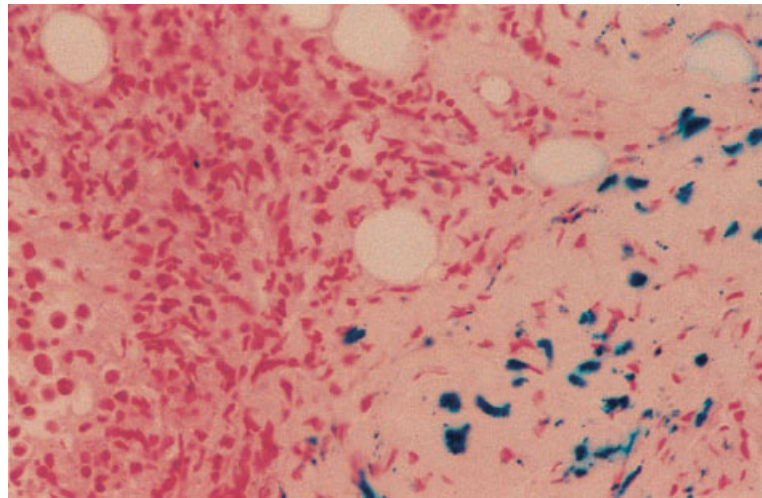
Fig. 1.72 BM trephine biopsy specimen showing a linear scar resulting from damage by a previous biopsy at the same site. H&E $\times 48$.

biopsy usually causes haemorrhage, disruption of the tissue and loss of haemopoietic cells. Occasionally, the actual track of the aspiration needle is apparent (Fig. 1.71). This artefact can be avoided if the aspiration and trephine biopsy needles are introduced several millimetres apart and angled somewhat differently. This can be done even if they are inserted through the same skin incision. A biopsy performed some time previously may lead to the pathological specimen showing fat necrosis, with focal collections of foamy macrophages, or granulation tissue. A biopsy performed inadver-

tently at the site of a healing fracture produces a similar histological picture. There is initially granulation tissue, increased reticulin deposition and new bone formation; this can be confused with myelofibrosis. Subsequently, granulation tissue is usually replaced by adipose tissue in which islands of haemopoietic cells develop. A trephine biopsy (Fig. 1.72) or other localized bone marrow damage (Fig. 1.73) can result in a biopsy specimen showing a scar which, in the case of a previous trephine biopsy, may be linear. Scars should not be confused with fibrosis resulting from other pathological processes.



(a)



(b)

Fig. 1.73 Section of BM trephine biopsy specimen from an intravenous drug abuser with Hodgkin's disease showing bone marrow scar; there is deposition of haemosiderin in the scar: (a) H&E $\times 376$; (b) Perls' stain $\times 376$.

References

- 1 Hashimoto M (1962) Pathology of bone marrow. *Acta Haematol (Basel)*, 27, 193–216.
- 2 de Bruyn PPH (1981) Structural substrates of bone marrow function. *Semin Hematol*, 18, 179–193.
- 3 Wickramasinghe SN. *Human Bone Marrow*. Blackwell Scientific Publications, Oxford, 1975.
- 4 Bennike T, Gormsen H and Moller B (1956) Comparative studies of bone marrow punctures of the sternum, the iliac crest, and the spinous process. *Acta Med Scand*, 155, 377–396.
- 5 Humphries J (1990) Dry tap bone marrow aspiration: clinical significance. *Am J Hematol*, 35, 247–250.
- 6 Aboul-Nasr R, Estey EH, Kantarjian HM, Freireich EJ, Andreeff M, Johnson BJ and Albitar M (1999) Comparison of touch imprints with aspirate smears for evaluating bone marrow specimens. *Am J Clin Pathol*, 111, 753–758.
- 7 Kerndrup G, Pallesen G, Melsen F and Mosekilde L (1980) Histomorphometric determination of bone marrow cellularity in iliac crest biopsies. *Scand J Haematol*, 24, 110–114.
- 8 Al-Adhath AN and Cavill I (1983) Assessment of cellularity in bone marrow fragments. *J Clin Pathol*, 36, 176–179.
- 9 Frisch B, Lewis SM, Burkhardt R and Bartl R. *Biopsy Pathology of Bone and Marrow*. Chapman & Hall, London, 1985.

- 10 Hartsock RJ, Smith EB and Petty CS (1965) Normal variations with ageing of the amount of hematopoietic tissue in bone marrow from the anterior iliac crest; a study made from 177 cases of sudden death examined by necropsy. *Am J Clin Pathol*, 43, 326–331.
- 11 Meunier P, Aaron J, Edouard C and Vignon G (1971) Osteoporosis and the replacement of cell populations of the marrow by adipose tissue. *Clin Orthop*, 80, 147–154.
- 12 Courpron P, Meunier P, Edouard C, Bernard J, Bringuier J-P and Vignon G (1973) Données histologiques quantitatives sur le vieillissement osseux humain. *Rev Rhum*, 40, 469–482.
- 13 Bryon PA, Gentilhomme O and Fiere D (1979) Étude histologique quantitative du volume et de l'hétérogénéité des adipocytes dans les insuffisance myéloïdes globales. *Pathol Biol (Paris)*, 27, 209–213.
- 14 Bessis M (1958) L'îlot érythroblastique, unité fonctionnelle de la moelle osseuse. *Rev Hematol*, 13, 8–11.
- 15 Bain BJ (1996) The bone marrow aspirate in healthy subjects. *Br J Haematol*, 94, 206–209.
- 16 Mohandas N and Prenant M (1978) Three-dimensional model of bone marrow. *Blood*, 51, 633–643.
- 17 Queisser U, Queisser W and Spiertz B (1971) Polyploidization of megakaryocytes in normal humans and patients with idiopathic thrombocytopenia and with pernicious anaemia. *Br J Haematol*, 20, 489–501.
- 18 Tavassoli M and Aoki M (1989) Localization of megakaryocytes in the bone marrow. *Blood Cells*, 15, 3–14.
- 19 Thiele J and Fischer R (1991) Megakaryocytopoiesis in human disorders: diagnostic features of bone marrow biopsies. An overview. *Virchows Arch A Pathol Anat Histopathol*, 418, 87–97.
- 20 Johnstone JM (1954) The appearance and significance of tissue mast cells in the human bone marrow. *J Clin Pathol*, 7, 275–280.
- 21 Rosse C, Kraemer MJ, Dillon TL, McFarland R and Smith NJ (1977) Bone marrow cell populations of normal infants: the predominance of lymphocytes. *J Lab Clin Med*, 89, 1225–1240.
- 22 Thaler J, Greil R, Dietze O and Huber H (1989) Immunohistology for quantification of normal bone marrow lymphocyte subsets. *Br J Haematol*, 73, 576–577.
- 23 Steiner ML and Pearson HA (1966) Bone plasmacytic values in children. *J Pediatr*, 68, 562–568.
- 24 Dresch C, Faille A, Poieriero O and Kadouche J (1974) The cellular composition of normal human bone marrow according to the volume of the sample. *J Clin Pathol*, 27, 106–108.
- 25 Glaser K, Limarzi L and Poncher HG (1950) Cellular composition of the bone marrow in normal infants and children. *Pediatrics*, 6, 789–824.
- 26 Gairdner D, Marks J and Roscoe JD (1952) Blood formation in infancy. Part I. The normal bone marrow. *Arch Dis Child*, 27, 128–133.
- 27 Diwany M (1940) Sternal marrow puncture in children. *Arch Dis Child*, 15, 159–170.
- 28 Jacobsen KM (1941) Untersuchungen über das Knochenmarkspunktat bei normalen Individuen verschiedener Altersklassen. *Acta Med Scand*, 106, 417–446.
- 29 Segerdahl E (1935) Über sternalpunktionen. *Acta Med Scand*, 64 (Suppl.), 1–105.
- 30 Vaughan SL and Brockmyr F (1947) Normal bone marrow as obtained by sternal puncture. *Blood*, 1 (special issue), 54–59.
- 31 Wintrobe MM, Lee RG, Boggs DR, Bithell TC, Athens JW and Foerster J. *Clinical Hematology*, 7th edn. Lea and Febiger, Philadelphia, 1974.
- 32 den Ottonlander GJ (1996) The bone marrow aspirate in healthy subjects. *Br J Haematol*, 95, 574–575.
- 33 Dancy JT, Deubelbeiss KA, Harker LA and Finch CA (1976) Neutrophil kinetics in man. *J Clin Invest*, 58, 705–715.
- 34 Wilkins BS and O'Brien CJ (1988) Techniques for obtaining differential cell counts from bone marrow trephine biopsy specimens. *J Clin Pathol*, 41, 558–561.
- 35 Bain BJ. Bone marrow. In: Domizio P and Lowe D (eds) *Reporting Histopathology Sections*. Chapman & Hall, London, 1997.
- 36 Bain BJ (2001) Bone marrow aspiration. *J Clin Pathol*, in press.
- 37 Bain BJ (2001) Bone marrow trephine biopsy. *J Clin Pathol*, in press.

TWO

SPECIAL TECHNIQUES APPLICABLE TO BONE MARROW DIAGNOSIS

Peripheral blood samples, bone marrow aspirates and trephine biopsy specimens are suitable for many diagnostic investigations, in addition to routine microscopy of Romanowsky-stained blood and bone marrow films and haematoxylin and eosin-stained histological sections. Some of these techniques, for example Perls' stain to demonstrate haemosiderin in a bone marrow aspirate, are so often useful that they are performed routinely, whereas other techniques are applied selectively. This chapter will deal predominantly with special techniques that are applicable to bone marrow aspirates and trephine biopsy sections but reference will be made to the peripheral blood where this is the more appropriate tissue for study.

Bone marrow aspirate films are stained routinely with a Romanowsky stain such as a May-Grünwald-Giemsa (MGG) or a Wright-Giemsa stain. Other diagnostic procedures that may be of use in individual cases include: (i) cytochemistry; (ii) immunophenotyping (by immunocytochemistry or flow cytometry); (iii) cytogenetic and molecular genetic analysis; (iv) ultrastructural examination; (v) culture for micro-organisms; and (vi) culture for assessment of haemopoietic progenitor cells.

In most countries, histological sections cut from bone marrow trephine biopsies are stained routinely with H&E. Most laboratories also use silver stains routinely to demonstrate reticulin and some employ, in addition, a Giemsa stain, a Perls' stain or both. We recommend the routine use of H&E, Giemsa and reticulin stains. Giemsa staining permits the easy identification of mast cells, facilitates recognition of plasma cells and helps in making a distinction between early erythroid cells and myeloblasts. If a Giemsa stain is not performed routinely, then it is important that it is used whenever necessary for these indications. Other tech-

niques that may be applied to trephine biopsy sections include: (i) a wider range of cytochemical stains; (ii) immunohistochemistry; (iii) cytogenetic and molecular genetic analysis; and (iv) ultrastructural examination.

Cytochemical and histochemical stains

Cytochemical stains on bone marrow aspirates

Perls' stain for iron

A Perls' or Prussian blue stain (Figs 2.1 and 2.2) demonstrates haemosiderin in bone marrow macrophages and within erythroblasts. Consequently, it allows assessment of both the amount of iron in reticulo-endothelial stores and the availability of iron to developing erythroblasts.

Assessment of storage iron requires that an adequate number of fragments are obtained. A bone marrow film or squash will contain both intracellular and extracellular iron, the latter being derived from crushed macrophages. It is usual to base assessment of iron stores mainly on intracellular iron since iron stains are prone to artefactual deposits and it can be difficult to distinguish between extracellular iron and artefact. Iron stores may be assessed as normal, decreased or increased, or may be graded as 1+ to 6+ as shown in Table 2.1, grades of 1+ to 3+ being considered normal. Alternatively, iron stores may be graded as 1+ to 4+ [3,4].

Examination of a Perls' stain of a bone marrow film allows adequate assessment of erythroblast iron as long as a thinly spread area of the film is examined with optimal illumination. A proportion of normal erythroblasts have a few (one to five) fine iron-containing granules randomly distributed in

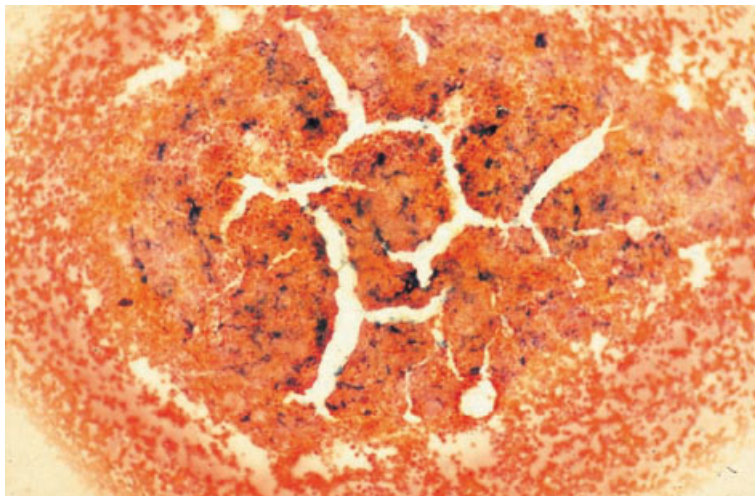


Fig. 2.1 Aspirate of normal BM: bluish-black iron in macrophages in a fragment. Perls' stain $\times 377$.

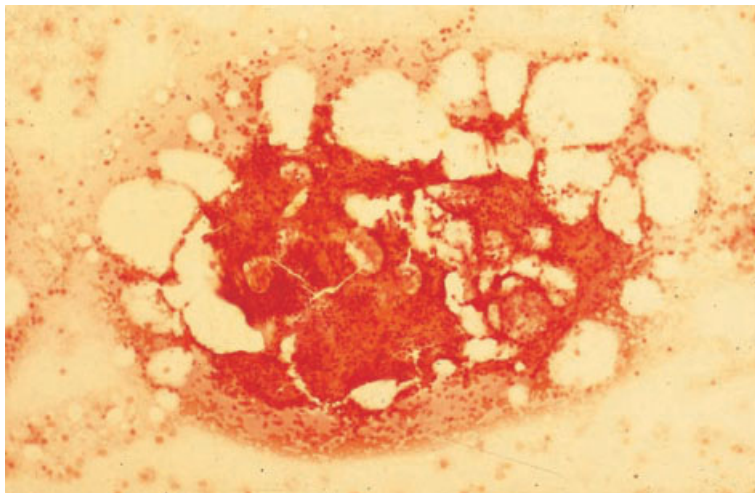


Fig. 2.2 Aspirate of normal BM: a fragment with no stainable iron. Perls' stain $\times 377$.

Table 2.1 Grading of bone marrow storage iron [1,2].

0	No stainable iron
1+	Small iron particles just visible in reticulum cells using an oil objective
2+	Small, sparse iron particles in reticulum cells, visible at lower power
3+	Numerous small particles in reticulum cells
4+	Larger particles with a tendency to aggregate into clumps
5+	Dense, large clumps
6+	Very large clumps and extracellular iron

the cytoplasm (Fig. 2.3). Such erythroblasts are designated sideroblasts. In haematologically normal subjects with adequate iron stores, 20–50% of bone marrow erythroblasts are sideroblasts [5–7]. Examination of an iron stain allows detection not only of an increased or decreased proportion of sideroblasts but also of abnormal sideroblasts. The latter include those in which siderotic granules are merely increased in size and number and those in which granules are also distributed abnormally within the cytoplasm, being sited in a ring around the nucleus rather than randomly (ring sideroblasts).

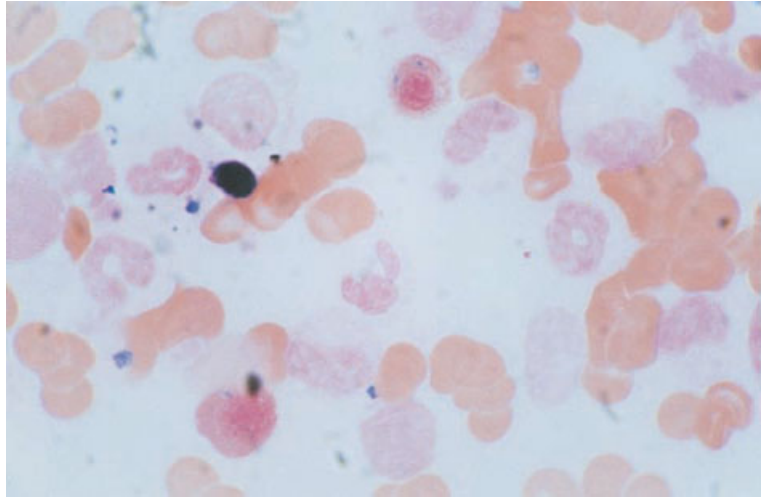


Fig. 2.3 BM aspirate from a healthy volunteer showing a normal sideroblast. Perls' stain $\times 960$.

In certain pathological conditions, plasma cells contain haemosiderin inclusions which are irregular in shape and relatively large. On an MGG stain they are greenish-black (Fig. 2.4a). Their nature is confirmed by a Perls' stain (Fig. 2.4b). Haemosiderin inclusions in plasma cells are observed mainly in iron overload (for example in haemochromatosis and transfusional siderosis) and in chronic alcoholism [8].

Problems and pitfalls

Since iron is distributed irregularly within bone marrow macrophages, it is necessary to assess a number of fragments before concluding that storage iron is absent or reduced. If necessary, a Perls' stain can be performed on more than one bone marrow film. Stain deposit on the slide must be distinguished from haemosiderin. Careful examination will show that it is not related to cells and is often in another plane of focus.

Other cytochemical stains

Cytochemical stains are employed mainly in the investigation of acute leukaemia and the myelodysplastic syndromes (MDS). In acute leukaemia there may be numerous blast cells in the peripheral blood and it is then useful to perform cytochemical stains on blood and bone marrow in parallel. Cytochemical investigation of suspected MDS should be

performed on bone marrow films since there are usually only small numbers of immature cells in the peripheral blood.

The techniques recommended for diagnosis and classification of acute leukaemia are either myeloperoxidase or Sudan black B staining, to identify cells showing granulocytic differentiation, plus a non-specific esterase or combined esterase stain, to identify cells showing monocytic differentiation. Enzyme cytochemistry for either α -naphthyl butyrate esterase or α -naphthyl acetate esterase is suitable as a 'non-specific' esterase staining method for the identification of monocytic differentiation. In a combined esterase stain either of these methods is combined with demonstration of naphthol AS-D chloroacetate esterase (chloro-acetate esterase), the latter to show granulocytic differentiation. The application of these stains will be discussed in Chapter 4.

Other cytochemical stains which are occasionally used include toluidine blue to demonstrate the metachromatic granules in basophils and mast cells and staining of cells of mast cell lineage for ϵ -aminocaproate. When immunophenotyping is available, periodic acid-Schiff (PAS) and acid phosphatase stains are redundant in the investigation of acute leukaemias, although differences can be observed between different types of acute lymphoblastic leukaemia (ALL) and acute myeloid leukaemia (AML) [9,10]. Either a Sudan black B or a myeloperoxidase stain should also be used in cases of suspected MDS to facilitate detection of Auer rods.

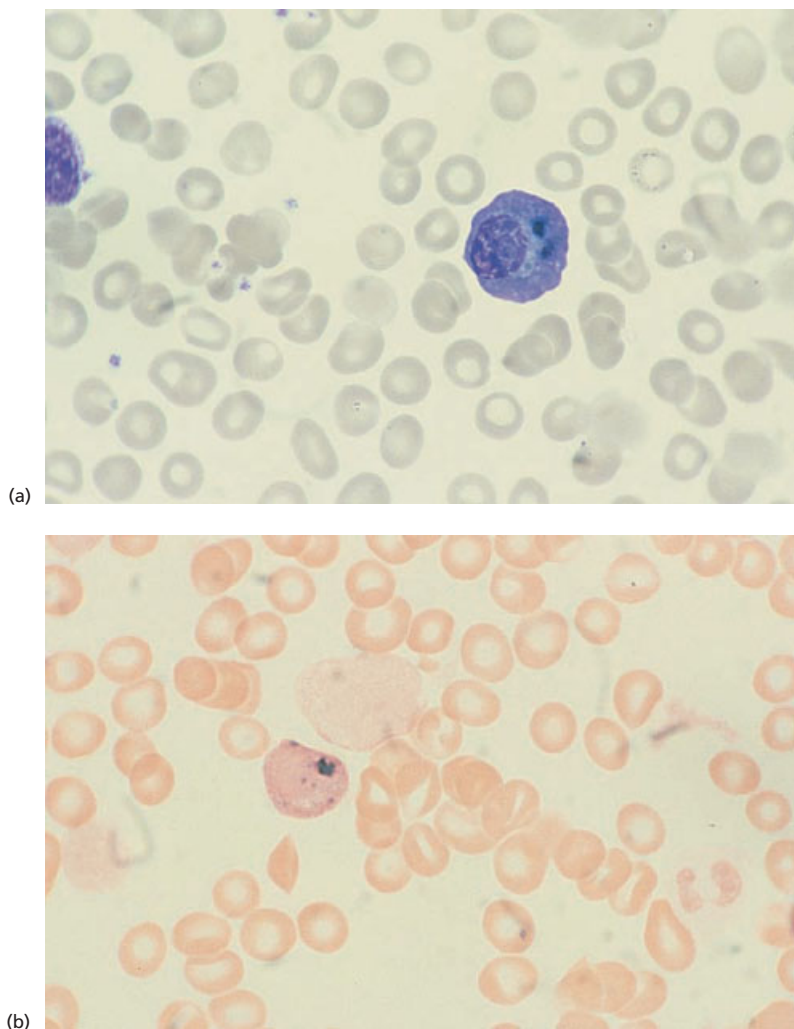


Fig. 2.4 BM aspirate from a patient with chronic alcoholism showing haemosiderin in plasma cells.

(a) MGG $\times 960$. (b) Perls' stain $\times 960$.

Cytochemistry now has little place in the investigation of lymphoproliferative disorders. However, the demonstration of tartrate-resistant acid phosphatase activity is still of value in the diagnosis of hairy cell leukaemia, particularly when a large panel of appropriate immunophenotyping reagents is not available.

Histochemical stains on trephine biopsy sections

Perls' stain for haemosiderin

Because of the irregular distribution of iron within bone marrow macrophages, a biopsy may show the

presence of iron when none has been detected in an aspirate. Haemosiderin can often be detected, particularly when it is increased, as golden brown refractile pigment in an unstained or H&E-stained section (Fig. 2.5). In a Giemsa-stained section it is greenish-blue (Fig. 2.6). An iron stain (Fig. 2.7) can be successfully carried out using either plastic-embedded or paraffin-embedded biopsy specimens. However, plastic-embedded specimens give more reliable results. Decalcification of a paraffin-embedded specimen, whether by acid decalcification or by chelation, leads to some leaching out of iron. Plastic-embedded samples are also superior for the detection of ring sideroblasts or other abnormal sideroblasts. These can sometimes also be detected

Fig. 2.5 Section of BM showing haemosiderin within macrophages in an HIV-positive patient with iron overload. Paraffin-embedded, H&E $\times 376$.

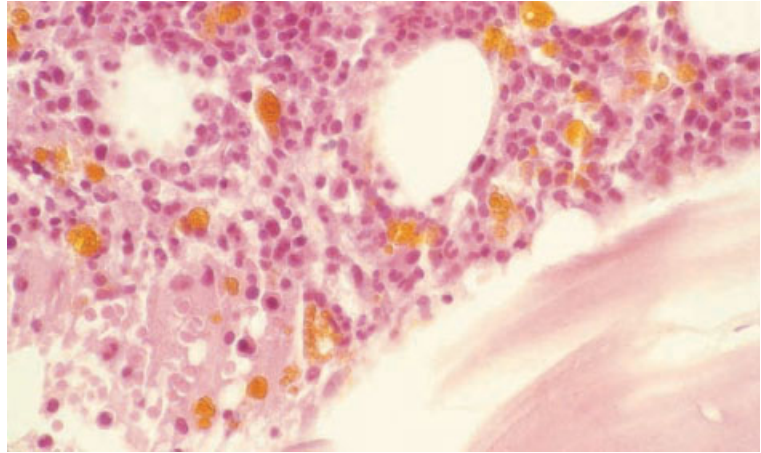


Fig. 2.6 Section of BM trephine biopsy specimen showing haemosiderin in stromal macrophages demonstrated by Giemsa staining. A distinctive yellow-green colour is obtained that is easily visible against background haemopoietic cell staining. Paraffin-embedded, Giemsa $\times 940$.

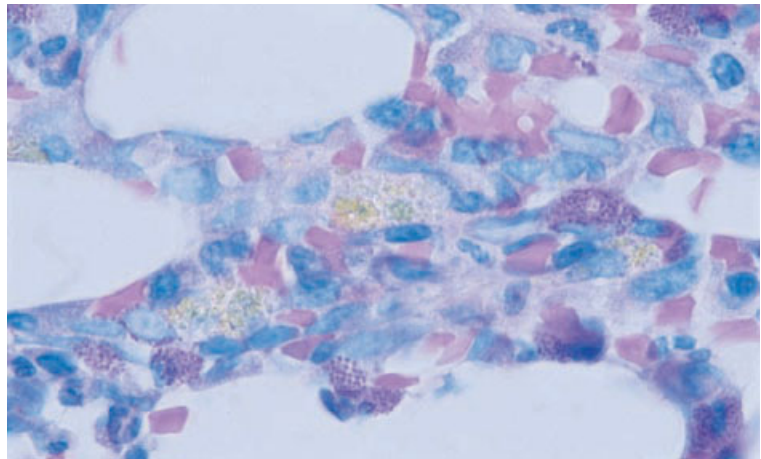
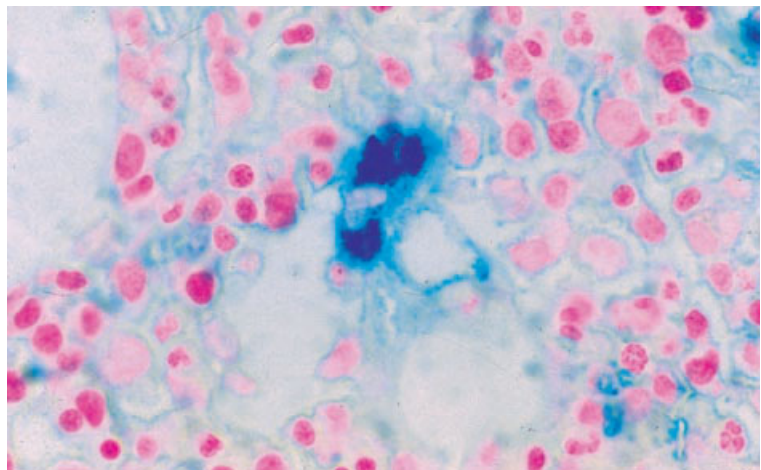


Fig. 2.7 Section of normal BM: macrophage containing iron. Plastic-embedded, Perls' stain $\times 940$.



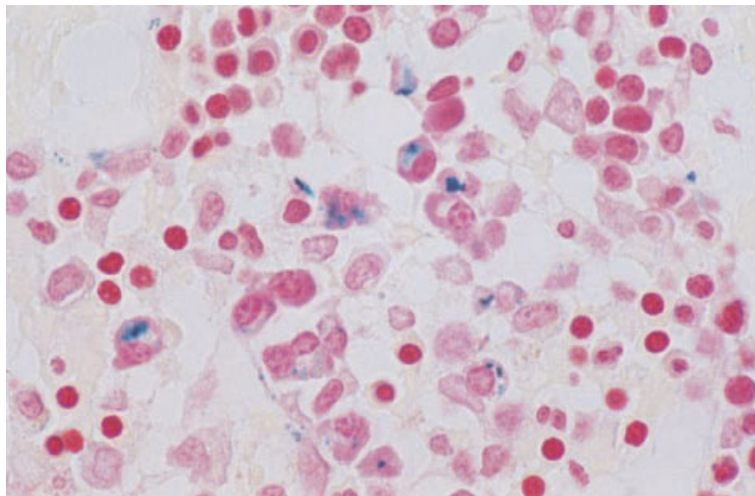


Fig. 2.8 Section of trephine biopsy specimen from a child with iron overload associated with congenital sideroblastic anaemia showing a number of plasma cells containing large haemosiderin deposits. Paraffin-embedded, Perls' stain $\times 960$.

in paraffin-embedded bone marrow fragments but not in decalcified trephine biopsy sections. However, no technique for processing and staining of a biopsy specimen allows assessment of whether siderotic granules are normal or decreased; this requires an iron stain of an aspirate. Haemosiderin deposits in plasma cells may, however, be sufficiently large that they can be detected on sections of paraffin-embedded trephine biopsy specimens (Fig. 2.8).

Practice differs between laboratories as to whether a Perls' stain for haemosiderin is performed routinely. If a bone marrow aspirate containing adequate fragments is available, then iron staining of trephine biopsy sections is redundant. However, it may well be more efficient for organizational reasons to perform an iron stain routinely rather than to perform it selectively only in those cases where it is likely to give information of specific diagnostic use.

Problems and pitfalls

The amount of iron that is leached out when a paraffin-embedded biopsy specimen is decalcified is variable and unpredictable. The amount of stainable iron is reduced and sometimes all stainable iron is removed. Loss of stainable iron is less with ethylene diamine tetra-acetic acid (EDTA) decalcification than with other methods. Because of the unpredictable leaching out of iron it is not

possible to quantify iron accurately on a decalcified biopsy specimen. It is only possible to say that iron is present or increased but not that it is decreased or absent.

There are conflicting reports of the comparability of iron stains performed on aspirates and biopsy specimens, not all of which are readily explicable by the factors already mentioned. Lundin *et al.* [3] found that in 8% of cases iron was detectable in a biopsy specimen and not in an aspirate and in another 8% the reverse was true; by assessing other factors they were not able to establish that one or other method was more valid. Fong *et al.* [4] found that in 8% of patients iron was present in an aspirate but was not detectable in a biopsy sample; however, this was not due to the process of decalcification since it was noted with regard to sections of marrow fragments as well as for trephine biopsy sections. Conflicting findings were reported by Krause *et al.* [11] who found that iron was always detectable in a biopsy when it was present in an aspirate, but two thirds of patients with absent iron in an aspirate had detectable iron on a biopsy specimen. It is clear that minor variations in technique may be critical. Our own observations are that when specimens are decalcified using manual processing techniques there may be a failure to detect iron in a trephine biopsy specimen when it is clearly present in an aspirate. Iron stains performed on aspirates and biopsies should clearly be regarded as complementary.

Reticulin and collagen stains

Histological sections, either from particle preparations or trephine biopsy specimens, can be stained for reticulin using a silver-impregnation technique and also for collagen using a trichrome stain. We have found a Martius Scarlet Blue stain superior to a van Gieson stain for the identification of collagen. Reticulin and collagen deposition can be quantified as shown in Table 2.2 [12] and illustrated in Figs 2.9–2.13. The majority of haematologically normal subjects have a reticulin grade of 0 or 1 but occasional subjects have a grade of 2. There is a

Table 2.2 Quantification of bone marrow reticulin and collagen [12].

0	No reticulin fibres demonstrable
1	Occasional fine individual fibres and foci of a fine fibre network
2	Fine fibre network throughout most of the section; no coarse fibres
3	Diffuse fibre network with scattered thick coarse fibres but no mature collagen
4	Diffuse often coarse fibre network with areas of collagenization

Fig. 2.9 Section of normal BM: reticulin grade 0, showing no stainable fibres. Plastic-embedded, Gomori's reticulin stain $\times 188$.

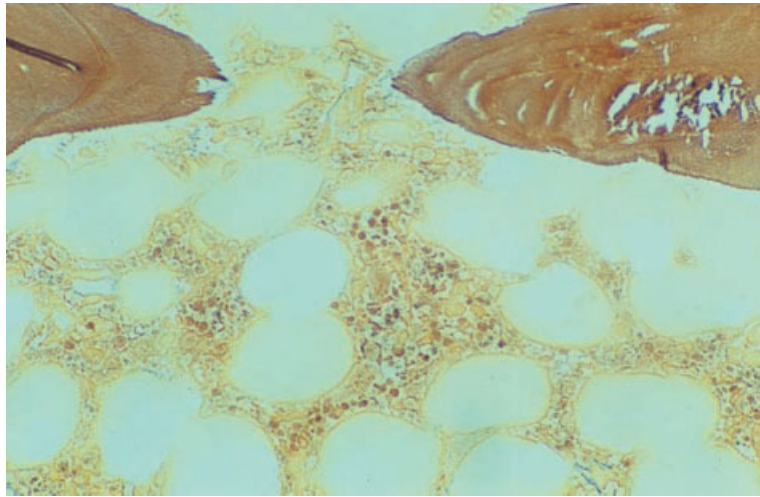
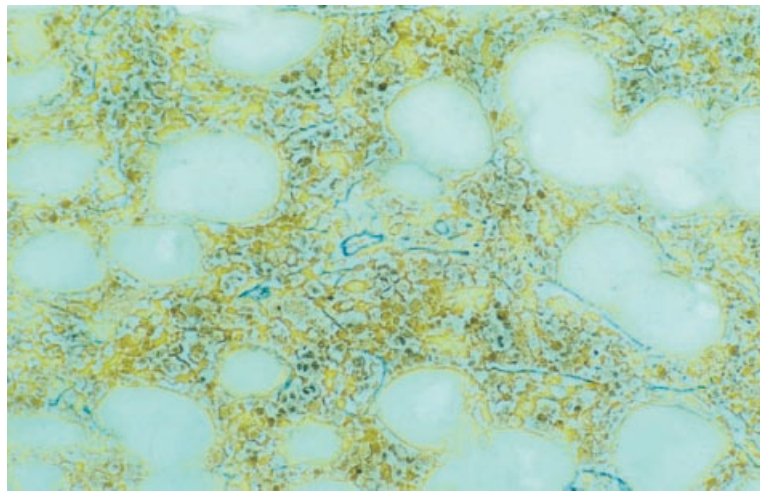


Fig. 2.10 Section of normal BM: reticulin grade 1, showing scattered fine fibres. Plastic-embedded, Gomori's reticulin stain $\times 188$.



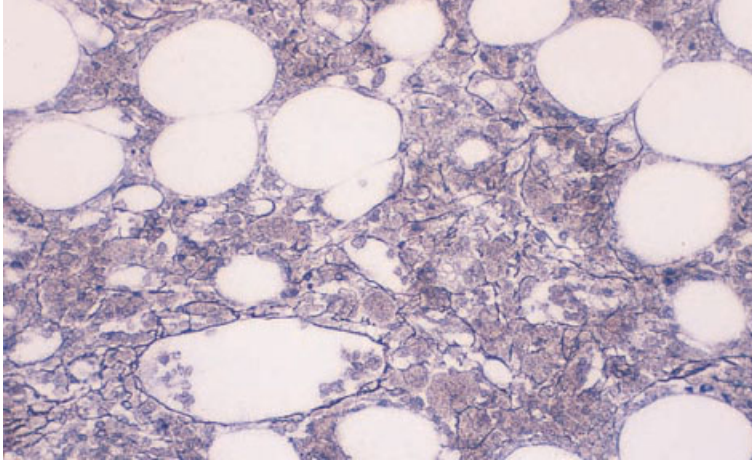


Fig. 2.11 Section of normal BM: reticulin grade 2, showing a fine fibre network but no coarse fibres. Paraffin-embedded, Gomori's reticulin stain $\times 195$.

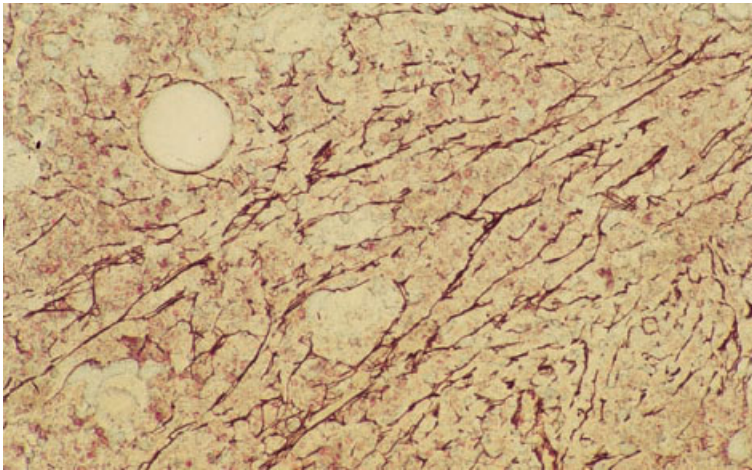


Fig. 2.12 Section of abnormal BM: reticulin grade 3, showing thick coarse fibres. Paraffin-embedded, Gordon and Sweet stain $\times 188$.

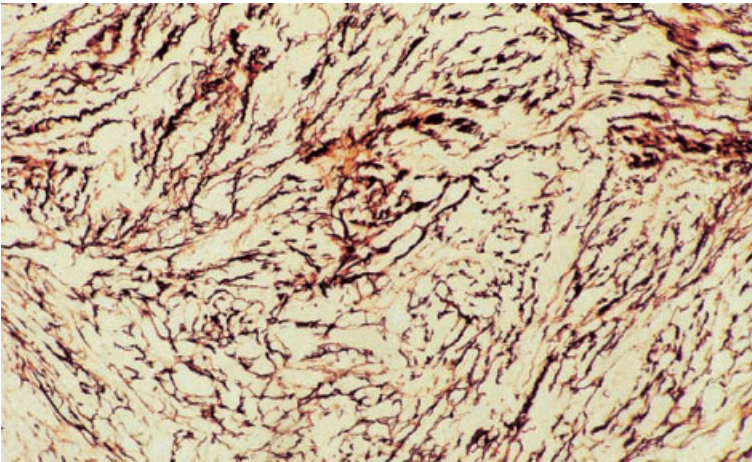


Fig. 2.13 Section of abnormal BM: reticulin grade 4, showing a coarse fibre network; collagen was present. Paraffin-embedded, Gordon and Sweet stain $\times 188$.

Table 2.3 Cytochemical and histochemical stains and their indications.

Cytochemical stain	Role
Chloro-acetate esterase (Leder)	Identification of granulocytic differentiation and mast cells
Periodic acid–Schiff (PAS)*	Staining of complex carbohydrates: identification of plasma cells and megakaryocytes (staining is variable); identification of some tumour cells; identification of fungi
Toluidine blue	Identification of mast cells
Alcian blue	Identification of cryptococci and some tumour cells; staining of stromal mucins
Grocott's methenamine silver stain (GMS)	Identification of fungi
Congo red stain	Identification of amyloid
Ziehl–Neelsen stain (ZN)	Identification of mycobacteria
Martius Scarlet Blue (MSB)	Staining of collagen and fibrin/fibrinoid

* Neutrophils are also PAS-positive.

tendency for more reticulin to be detected in iliac crest biopsies than in sections of particles aspirated from the sternum. Reticulin is concentrated around blood vessels and close to bone trabeculae and these areas should be disregarded in grading reticulin deposition.

The term myelofibrosis is used to indicate deposition of collagen in the marrow and sometimes also to indicate increased reticulin deposition. To avoid any ambiguity it is preferable to either grade reticulin/collagen deposition as shown in Table 2.2 or to use the term 'reticulin fibrosis' for grade 3 fibrosis and 'myelofibrosis' for grade 4. The term myelosclerosis has also been used in various senses; it is best regarded as a synonym for myelofibrosis.

A reticulin stain should be performed on every trephine biopsy specimen. It has two major roles. Firstly, increased reticulin deposition provides non-specific evidence of an abnormality of the bone marrow. Secondly, focal abnormality in the pattern of reticulin deposition can be very useful in detecting abnormalities that might be overlooked in an H&E-stained section. Abnormal infiltrates may show an associated increase in reticulin deposition or, less often, there may be a general increase in reticulin deposition but with an absence of reticulin in an area that is heavily infiltrated by non-haemopoietic cells. Focal abnormalities that may be highlighted by a localized increase in reticulin

deposition include granulomas and infiltrates of carcinoma or lymphoma cells.

Problems and pitfalls

To avoid confusion, pathologists should refer to reticulin and collagen deposition in a precise manner. Increased reticulin deposition provides evidence of a bone marrow abnormality but should not be over-interpreted since the causes are multiple. The causes of collagen deposition are fewer and this abnormality is therefore of more diagnostic significance. The significance of reticulin and collagen deposition is discussed in Chapter 3 (see page 130).

Other histochemical stains

Other potentially useful histochemical stains and their roles in diagnosis are shown in Table 2.3. A chloro-acetate esterase (Leder) stain is illustrated in Fig. 2.14.

Problems and pitfalls

The reactivity of histochemical stains is influenced by the choice of fixative, the method of embedding and the process of decalcification employed. Fixation in either Bouin's or Zenker's solution leads to reduced metachromatic staining of mast cells

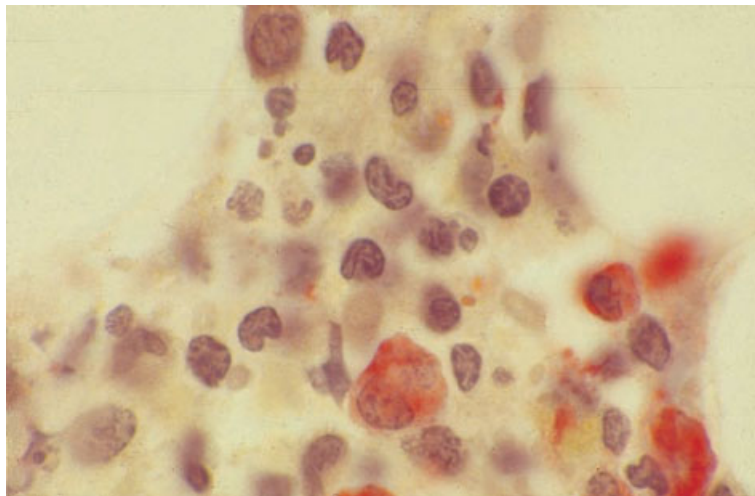


Fig. 2.14 Section of trephine biopsy specimen from a patient with large granular lymphocyte leukaemia stained for chloro-acetate esterase. Myeloid precursors are positive and lymphocytes are negative. Plastic-embedded, Leder's stain $\times 940$.

with a Giemsa stain and also reduces or abolishes chloro-acetate esterase activity. Other histochemical stains are satisfactory with fixation in formalin or Bouin's or Zenker's solution. However, it should be noted that prolonged storage of formalin at high ambient temperatures can lead to formic acid production; if the formalin is unbuffered, inadvertent decalcification may occur during the process of fixation with resultant adverse effects on staining. Histochemical stains are satisfactory with both paraffin- and plastic-embedding. Acid decalcification impairs chloro-acetate esterase activity whereas EDTA decalcification does not. Over-exposure to EDTA reduces or abolishes Giemsa staining.

We have found that many of the proprietary combined fixation-decalcification solutions, which are sometimes used to achieve rapid processing, impair histochemical stains. For example, haematoxylin staining may be impaired so that nuclear detail and cytoplasmic basophilia are not apparent. Giemsa staining may be severely impaired.

Immunophenotyping

Antigens may be expressed on the surface of cells, within the cytoplasm or within the nucleus. Depending on the techniques applied for immunophenotyping, there may be detection of only surface membrane antigens or cytoplasmic and nuclear antigens may also be detected. Detection of antigens may be by means of polyclonal antibodies, raised

in animals such as rabbits, but increasing use is being made of monoclonal antibodies produced by hybridoma technology. Many monoclonal antibodies, reactive with lymphoid or myeloid antigens, have been characterized at a series of international workshops and are described by cluster of differentiation (CD) numbers. A CD number refers to a group of antibodies that recognize the same antigen and also refers to the antigen expressed. It is important to note that monoclonal antibodies may recognize specific epitopes on antigens so that not all antibodies with the same CD number have exactly the same reactivity with normal and abnormal cells. A complete list of CD numbers is given in reference 13. Some important monoclonal antibodies have not yet been assigned a CD number, e.g. FMC7 and DBA44.

Immunophenotyping by immunofluorescence flow cytometry

If there are significant numbers of circulating abnormal cells, it is most convenient to perform flow cytometric immunophenotyping on a peripheral blood sample. Otherwise this procedure can be performed on a bone marrow aspirate or, alternatively, on a serous exudate, cerebrospinal fluid or a suspension of cells from a lymph node or other tissue. When peripheral blood is used, the procedure can be applied to either a mononuclear cell preparation or to whole blood in which the red cells have

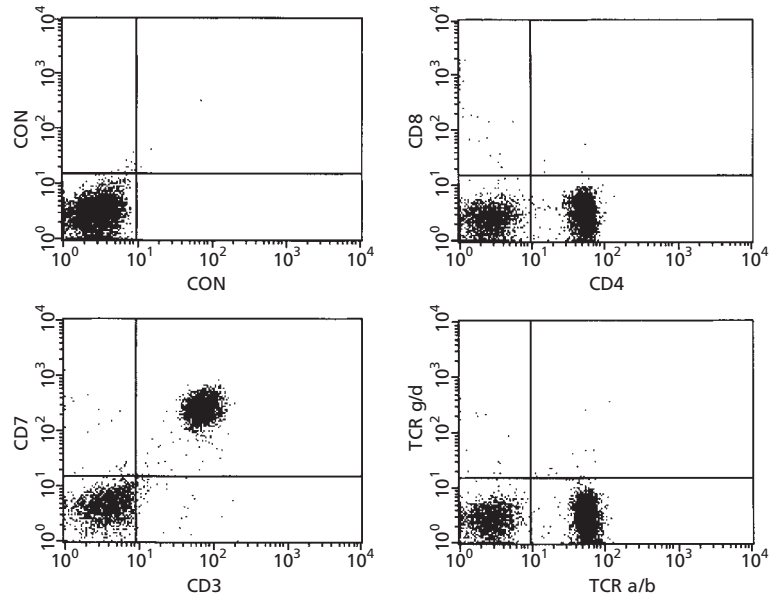


Fig. 2.15 Scatter plot showing flow cytometry immunophenotyping in a case of T-lineage prolymphocytic leukaemia. The leukaemic cells are positive for CD4, CD7 and TCR $\alpha\beta$; they are negative for CD8. (By courtesy of Mr R Morilla, London.)

been lysed [14]. The latter technique minimizes cell loss and potential artefacts that can be induced by exposure to Ficoll and density gradient separation. It also increases the speed and convenience of the procedure. Choice of appropriate proprietary lysis solutions is important to avoid reduction of expression of certain antigens [15].

The principle of flow cytometry is that cells bearing specific antigens are identified by means of a monoclonal antibody (or, occasionally, a polyclonal antiserum) labelled with a fluorochrome (Fig. 2.15). The flow cytometer permits classification of cells according to their light-scattering characteristics and the intensity of their fluorescence upon activation by laser light, detected after passing through an appropriate filter for the particular fluorochrome employed. Three or more fluorochromes can be used so that the simultaneous expression of two, three or more antigens can be studied. If permeabilization techniques are employed, cytoplasmic and nuclear antigens can be detected as well as those expressed on cell surfaces. Techniques are also available for the quantification of antigen expression.

Flow cytometry immunophenotyping is applicable to diagnosis and classification of haematological neoplasms. When expression of three or four antigens is assessed simultaneously it is also applicable to the detection of minimal residual disease.

Problems and pitfalls

Flow cytometry has the disadvantage that immunophenotype cannot be related directly to cytology. Results must always be interpreted in the light of the cytological features of the cells being studied.

When there are large numbers of circulating neoplastic cells, results of peripheral blood analysis are generally reliable. However, a low frequency of abnormal cells may not be detected. When flow cytometry is performed on cell suspensions from bone marrow or other tissues, results may be misleading in two circumstances. Firstly, an abnormal infiltrate may not be represented in the aspirate to any significant extent. This is often the case in follicular lymphoma with paratrabeccular infiltration but may also occur in any lymphoma in which reticulin deposition is increased in the infiltrated area, interfering with aspiration of abnormal cells. Secondly, if neoplastic cells are outnumbered by reactive cells, as in Hodgkin's disease and in T-cell-rich B-cell lymphoma, the immunophenotyping may relate only to reactive T lymphocytes, not to the minor population of neoplastic cells. In both of these circumstances immunohistochemistry is superior. In addition, correct techniques are of critical importance. For example, if gating techniques (see below) are used in order to determine the immunopheno-

type of a subpopulation of cells, it is essential to ensure that the gated cells are the neoplastic population.

Caution is required in interpreting flow cytometry findings during post-treatment follow-up of ALL. Normal immature lymphoid cells, known as haematogones, express CD10, CD34 and terminal deoxynucleotidyl transferase (TdT) and can thus be confused with residual leukaemic cells [16] unless the strength of expression of antigens is also considered. The detection of persisting cells with an aberrant combination of antigens is more reliable, as is polymerase chain reaction (PCR) analysis for rearranged immunoglobulin heavy chain (*IGH*) or T-cell receptor (*TCR*) genes (see below).

Immunocytochemistry

By convention, the term immunocytochemistry refers to the study of the antigen expression of cells by means of polyclonal or monoclonal antibodies applied to fixed cells on glass slides. The material investigated may be either a blood or bone marrow film or a cytocentrifuged preparation of washed mononuclear cells isolated from blood or bone marrow. The reaction of antibodies with cells carrying a specific antigen is detected by either: (i) direct labelling of the primary antibody with an enzyme such as peroxidase or alkaline phosphatase; or (ii) an indirect method using a second, labelled antibody that recognizes the first (e.g. a secondary antibody reactive with mouse immunoglobulins when the primary antibody is murine). A variety of indirect methods are available. Indirect labelling techniques offer the advantage of increased sensitivity but are more time-consuming to perform than direct labelling.

The use of washed, separated cells in cytocentrifuge preparations is necessary for immunocytochemistry to detect surface membrane immunoglobulins, including κ and λ light chains. Plasma immunoglobulins interfere with the staining if blood films or films of bone marrow aspirates are used. For detection of most other antigens, either cytocentrifuge preparations or wedge-spread films are satisfactory. If there are significant numbers of abnormal cells in the circulating blood, then a peripheral blood sample is very satisfactory for immunocytochemistry. Otherwise study of a bone marrow aspirate is necessary.

Immunocytochemistry can also be used to demonstrate the product of an oncogene or a cancer-suppressing gene. For example, PML protein, the product of the gene that is rearranged and dysregulated in acute promyelocytic leukaemia, can be demonstrated with a fluorochrome-labelled monoclonal antibody and an abnormal pattern of distribution can be shown in this type of leukaemia. Similarly, a labelled antibody can be used to demonstrate increased expression of p53 protein when the gene is dysregulated; p53 protein is below the level of detection when only the wild type gene is present.

Problems and pitfalls

Immunocytochemistry has the advantage that reactivity with an antibody can be related to cell morphology. However, it should be noted that cytocentrifugation introduces artefactual changes, such as nuclear lobulation. It is useful to examine an MGG-stained cytocentrifuge preparation in parallel with the immunocytochemical stains and wedge-spread films.

Cytochemistry is slow and labour intensive and thus is not suitable for large workloads or for producing rapid results. Interpretation is subjective and, because only a small number of cells can be assessed, results are imprecise. Some useful antibodies, for example FMC7, cannot be used successfully for immunocytochemistry although they are very reliable with flow cytometry.

Relative advantages of flow cytometry and immunocytochemistry

Flow cytometry has various advantages over immunocytochemistry and is therefore the preferred technique where it is available as:

- 1 it is rapid and less labour intensive;
- 2 it permits large numbers of cells to be analysed so that the percentage of cells bearing a specific antigen is estimated much more precisely and minor populations of cells may be identified;
- 3 multiple directly labelled antibodies can be used to study the co-expression of two, three or even four antigens;
- 4 it is possible to 'gate' for cells having particular characteristics in order to investigate antigen expression by a defined population ('gating' or selection of

a subpopulation may be based on light-scattering characteristics of cells or on expression of a specific antigen); and

5 the amount of antigen expressed on a specific population of cells can be quantified, whereas immunocytochemistry is *not* quantitative.

These advantages of flow cytometry mean that it can be used to identify minor normal populations, such as CD34-positive haemopoietic stem cells, and minor abnormal populations showing atypical combinations of antigen expression, as in the detection of minimal residual disease in patients treated for haematological neoplasms.

There are two important disadvantages of flow cytometry in comparison with immunocytochemistry:

1 without modification, the technique detects only surface membrane antigens and not antigens expressed within the cytoplasm or in the nucleus; and **2** cytological features of the cells studied cannot be appreciated.

The first disadvantage can be overcome readily by the use of techniques for permeabilizing cells so that antigens expressed in the nucleus or in the cytoplasm can be detected. The second defect cannot be overcome easily but use of light-scattering characteristics of cells does at least permit a determination of whether specific antigens are expressed on large or

small cells. Results of flow cytometry should not be interpreted in isolation; the cytological features of the cells being studied must be taken into account.

Immunocytochemistry has the advantage over flow cytometry that the precise cytological features of cells bearing a certain antigen can be recognized. As mentioned above, however, it is very labour intensive and more time-consuming than flow cytometry and results are not quantitative. Double or multiple antigen combinations on individual cells cannot be demonstrated routinely. Although techniques exist for sequential immunocytochemical staining of several antigens in the same preparation, these are largely restricted to use as research tools at present because of their practical difficulties.

Antibodies for flow cytometry and immunocytochemistry

Antibodies to be used in flow cytometry are selected depending upon the purpose of the investigation. There are relatively few circumstances in which a single antibody is used in isolation. Specific combinations are used for investigation of suspected acute leukaemia or possible lymphoproliferative disorders. Suggested panels are provided in Tables 2.4 and 2.5.

Table 2.4 Monoclonal and other antibodies useful in immunocytochemistry and flow cytometry immunophenotyping in suspected acute leukaemia.

<i>Primary panel</i>	
For detection of myeloid differentiation	CD117, CD13*, CD33, anti-MPO, CD65
For detection of B-lymphoid differentiation	CD19, CD22*, CD79a
For detection of T-lymphoid differentiation	CD2, CD3*, anti-TCR $\alpha\beta$, anti-TCR $\gamma\delta$
For detection of immature cells	Anti-TdT (anti-terminal deoxynucleotidyl transferase), CD34, HLA-DR
<i>Secondary panel</i>	
For further investigation of myeloid differentiation	Anti-glycophorin for erythroid differentiation, CD41 (or CD61) for megakaryocyte differentiation, CD14 for monocytic differentiation, CD11b for granulocytic or monocytic maturation
For further investigation of B-lineage differentiation	CD10, cytoplasmic immunoglobulin, surface membrane immunoglobulin
For further investigation of T-lineage differentiation	CD1a, CD4, CD5, CD8

* Testing is more sensitive if cytoplasmic rather than surface membrane antigen is tested for, either by 'permeabilizing' cells or by using immunocytochemistry rather than flow cytometry.

Table 2.5 Monoclonal and other antibodies useful in immunophenotyping suspected chronic lymphoproliferative disorders.

<i>Primary panel</i>	
To establish lineage	A pan-B marker such as CD79a, CD19 or CD24 and a pan-T marker such as CD2 or CD3
To establish clonality of B-lineage lymphoproliferative disorders and to establish the strength of expression of surface membrane immunoglobulin	Anti- κ and anti- λ
To distinguish B-lineage chronic lymphocytic leukaemia from other less common B- and T-lineage disorders	CD79b (or CD22), CD5, CD23 and FMC7 (CLL cells are usually CD5 and CD23 positive, CD22, CD79b and FMC7 weak or negative and show weak expression of Smlg; the reverse pattern is usual in most types of B-lineage NHL)
<i>Secondary panel</i>	
For further investigation of suspected B-lineage lymphoproliferative disorder	CD10 (more often positive in follicular lymphoma); CD11c, CD25, CD103 and HC2 (for suspected hairy cell leukaemia); anti-cyclin D1 (suspected mantle cell lymphoma); CD38, CD79a, CD138 and Cylg (for suspected plasma cell or lymphoplasmacytoid neoplasm)
For further investigation of suspected T-lineage lymphoproliferative disorder	CD4, CD8 (usually positive in large granular lymphocyte leukaemia), CD7 (usually positive in T-PLL), CD25 (usually positive in ATLL); CD11b, CD16, CD56, CD57 (for suspected large granular lymphocyte or NK cell leukaemia/lymphoma)
Anti-terminal deoxynucleotidyl transferase (anti-TdT)	Recommended if it is not certain if cells are precursor lymphocytes (ALL or lymphoblastic lymphoma) or mature lymphocytes
For planning of therapy	CD20 (or any other antigen that may be a target of monoclonal antibody therapy)

In addition, flow cytometry can be used for:

- 1 quantification of CD34-positive haemopoietic stem cells for stem cell harvesting and transplantation;
- 2 quantification of CD4-positive lymphocytes for assessment of immune status in HIV infection; and
- 3 quantification of DNA for cell cycle and ploidy studies; e.g. for detection of hyperdiploidy in ALL.

Problems and pitfalls

Because many immunophenotypic markers are not lineage-specific it is always necessary to use a panel of antibodies rather than relying on reactivity with a single antibody. Immunophenotypic markers showing good lineage specificity include CD79a and CD79b for the B lineage, CD3 for the T lineage and myeloperoxidase for myeloid cells. However, it should be noted that cross-reactivity of CD79a with some cases of T-lineage ALL has been reported [17].

Immunophenotypic markers with poor lineage specificity include TdT, HLA-DR, CD7 and CD10.

Immunohistochemistry

Immunohistochemistry refers to the demonstration of antigens in histological tissue sections. It has advantages and disadvantages in relation to flow cytometry and immunocytochemistry. For practical purposes, flow cytometry and immunohistochemistry should be regarded as complementary investigations.

In flow cytometry, a wider range of antibodies can be used and quantification of antigen expression can be achieved. There is also less likelihood of non-specific staining in flow cytometry than in immunohistochemistry. However, immunohistochemistry has the advantage that immunophenotypic information can be obtained and assessed in

association with preserved information regarding the spatial organization of labelled and unlabelled cells. Immunohistochemistry also permits assessment of the cytological features of cells expressing particular antigens, in a context which is often more familiar than that offered by immunocytochemistry (particularly cytocentrifuge preparations, in which significant morphological artefacts are induced by the centrifugation technique itself).

Because a large number of antigens can be stained individually in adjacent thin tissue sections, the lack of easy techniques for double-staining is not a major problem in immunohistochemistry performed for diagnostic and staging purposes. In a complex infiltrate it is relatively easy to demonstrate a variety of cell types differing in morphological and immunophenotypic characteristics. For example, in T-cell-rich B-cell lymphoma, the large, neoplastic cells can be shown to have a B-cell phenotype while the more numerous T cells are seen to be cytologically normal small lymphocytes.

Immunohistochemistry can permit the identification and characterization of an abnormal bone marrow infiltrate not represented in the patient's aspirate sample. This situation usually arises when there is significant reticulin fibrosis associated with an infiltrate, which hinders aspiration of cells from the involved area or areas of bone marrow. Such reticulin fibrosis occurs frequently in follicular lymphoma and almost invariably accompanies bone marrow infiltration by Hodgkin's disease.

When immunohistochemistry first gained widespread use in histopathology during the 1970s, it was commonly assumed that decalcification, particularly with methods involving exposure to acids, led to destruction of many antigens. This has proved to be untrue and the procedure can be performed very successfully with acid- or EDTA-decalcified trephine biopsies as well as with non-decalcified samples embedded in methacrylate resins. A few important technical modifications were required to overcome the different performance of bone marrow trephine biopsy specimens relative to other formalin-fixed tissues. For example, early antigen retrieval techniques, involving tissue digestion by proteolytic enzymes to reverse protein-protein binding induced by formalin fixation, were responsible for many initial poor results of immunohistochemistry in bone marrow trephine biopsy specimens as a conse-

quence of degradation of the antigenic target. Prior exposure to acid appears to render formalin-fixed tissue more susceptible to proteolysis and leads to degradation of some antigenic targets during incubation with the enzyme. In general, considerably shortened incubation times have therefore been found to be beneficial with these antigen retrieval methods. The major advance, however, has come through development of wet-heat methods for antigen retrieval, exposing tissue sections to acid or alkaline solutions in combination with microwave oven or pressure cooker heating. This has been as important for immunohistochemistry as a general tool in histopathology as it has been for bone marrow trephine biopsy specimens. It has encouraged a huge expansion in the development of new monoclonal antibodies for diagnosis in addition to making possible excellent results using many existing antibodies that were previously unsuccessful.

The second technical modification required for successful immunohistochemistry in bone marrow biopsy specimens was necessary to minimize non-specific staining due to endogenous enzyme activity. Most methods employ indirect labelling techniques with either peroxidase or alkaline phosphatase conjugated to the secondary antibody. The enzyme generates an insoluble, coloured product from a chromogenic substrate to permit visualization of the primary antigen-antibody interaction. Cells of the granulocyte series, particularly eosinophils, are rich in endogenous peroxidase activity and bone marrow stroma contains dendritic cells that are rich in alkaline phosphatases. When performing immunohistochemistry on bone marrow trephine biopsy specimens, additional steps are required to block such endogenous enzyme activities and minimize non-specific staining. To compound this problem, highly efficient amplification steps are included in many current immunohistochemistry methods, increasing sensitivity by exploiting the extremely high binding affinity of avidin or streptavidin for biotin. Endogenous biotin activity, particularly in mast cells, may also therefore require specific blockade to avoid false-positive staining.

In practice, the necessary technical modifications are easy to incorporate to achieve excellent results in bone marrow trephine biopsy samples with a range of primary antibodies. While this range is somewhat limited compared with that used in flow cytometry,

it is nonetheless extensive. Moreover, since much bone marrow trephine biopsy immunohistochemistry is performed in the investigation of lymphoproliferative disorders, it is valuable that the antibodies which can be used successfully are also entirely suitable for use with other formalin-fixed tissue samples such as biopsied lymph nodes.

Immunohistochemistry can be used to demonstrate surface membrane, cytoplasmic and nuclear anti-

gens. It can be used specifically to provide molecular genetic information, e.g. by demonstration of the protein product of oncogenes, such as *ALK*, *BCL1* and *BCL2*, or of cancer-suppressing genes, such as *p53*.

Tables 2.6 and 2.7 give details of useful antibodies for the immunohistochemical detection of antigen expression on haemopoietic and lymphoid cells in bone marrow trephine biopsies.

Table 2.6 Antigens expressed by myeloid cells and demonstrable by immunohistochemistry in fixed, decalcified bone marrow trephine biopsy specimens.

Antigen	Antibody	Specificity	Comments
CD34	QEnd 10	Primitive haemopoietic cells	Endothelial cells also positive
CD45	PD7/26, RP2/18, RP2/22	Lymphoid, granulocytic and monocytic cells	Proteolytic pre-treatment abolishes granulocytic and monocytic reactivity
Lysozyme (muramidase)	Polyclonal antisera	Granulocytic and monocytic cells	
Myeloperoxidase	Polyclonal antisera	Granulocytic and monocytic cells	
Alpha-1-antitrypsin	Polyclonal antisera	Granulocytic and monocytic cells	
CD66e	85A12	Granulocytic cells	Many metastases of epithelial origin also positive
CD68—broad specificity	KP1	Granulocytic and monocytic cells, including osteoclasts	Mast cells also positive
CD68—monocyte restricted	PG-M1	Monocytic cells, including osteoclasts	Mast cells also positive
CD163	10D6	Monocyte lineage cells including osteoclasts	
CD14	NCL-CD14-223	Monocytic cells	Developing monocytes strongly positive; macrophages weak or negative
Neutrophil elastase	NP57	Granulocytic cells	Promyelocytes and myelocytes strongly positive; metamyelocytes and mature neutrophils stain weakly or are negative
CD15	LeuM1, BY87	Monocytic and granulocytic cells, especially late granulocyte precursors	Membrane and cytoplasmic staining but membranes negative after proteolytic pre-treatment; expressed by neoplastic cells of Hodgkin's disease

Table 2.6 (*cont'd*)

Antigen	Antibody	Specificity	Comments
Calprotectin (previously called calgranulin)	Mac387	Late granulocyte precursors and monocytic cells	Macrophages weakly stained or negative
Eosinophil major basic protein	BMK13	Eosinophil granulocytes	
Mast cell tryptase	AA1	Mast cells	Avoidance of problems with diffusion of reaction product and non-specific background staining needs careful pre-treatment
CD117	57A5D8	Mast cells	The antibody is not sufficiently sensitive in fixed, decalcified trephine biopsy sections to detect haemopoietic progenitor cells
CD1a	MTB1, JPM30	Langerhans cells	Few, if any, such cells are normally present; used in diagnosis of Langerhans cell histiocytosis
Glycophorin A (α -sialoglycoprotein)	JC159, BRIC101	Erythroid cells	Very early proerythroblasts not stained
Glycophorin C (β -sialoglycoprotein)	Ret40f	Erythroid cells	Expression seen in earlier proerythroblasts than α - sialoglycoprotein; cross-reactivity with myeloblasts is seen in some cases of AML
Spectrin	Polyclonal antisera	Erythroid cells	No commercially available antibody at present [18]
Haemoglobin A	Polyclonal antisera	Haemoglobinized erythroid cells	Early erythroid precursors weak or negative
An epitope on the ABO blood group H glycoprotein	BNH9	Erythroid cells	Expressed from earliest recognizable stages of erythroid differentiation; also expressed by endothelial cells, megakaryocytes and cells of some large cell lymphomas
CD61	Y2/51	Megakaryocytes	Variable staining between cells; many early or dysplastic megakaryocytes unstained
CD42b	MM2/174	Megakaryocytes	Strong, uniform cytoplasmic staining, including early and dysplastic forms
Von Willebrand factor (previously known as Factor VIII-related antigen)	F8/86 and various polyclonal antisera	Megakaryocytes	Strong cytoplasmic staining; variable results with early and dysplastic forms

Table 2.7 Antigens expressed by lymphoid cells (B, T and NK lineages) and demonstrable by immunohistochemistry in fixed, decalcified bone marrow trephine biopsy specimens.

Antigen	Antibody	Specificity	Comments
CD45	PD7/26, RP218, RP2/22	Lymphoid, granulocytic and monocytic cells	Proteolytic pre-treatment minimizes granulocytic and monocytic staining
Terminal deoxynucleotidyl transferase (TdT)	NPT26	Primitive lymphoid cells and some primitive myeloid cells	In addition to ALL, up to 15% of AML are positive
CD10	56C6	Subsets of B cells	Expressed in common and pre-B ALL, Burkitt's lymphoma and follicle centre cell lymphoma; also expressed by a subset of marrow stromal cells
CD20	L26	Most B cells	Some early B-lineage lymphoid cells and cells showing plasmacytic differentiation are negative
CD79a	Mb1, HM47/A9, JCB117	Most B cells	Includes early B-lineage lymphoid cells and those with plasmacytic differentiation; may be negative in non-secretory myeloma; megakaryocytes are weakly positive
CDw75	LN1	B cells	Preferential staining of large, transformed B cells (e.g. centroblasts and immunoblasts)
CD45RA	4KB5	B cells and a subset of T-lineage lymphoid cells	Small, mature B cells stain preferentially
Immunoglobulin light chains— κ and λ	Polyclonal antisera are usually used	Plasma cells	Expression by other B cells usually too weak to be detected; excessive background staining may occur due to plasma immunoglobulins within the tissue
Immunoglobulin heavy chains— γ , α , μ , ϵ , δ	Polyclonal antisera are usually used	Plasma cells	Expression by other B cells usually too weak to be detected; excessive background staining may occur due to plasma immunoglobulins within the tissue
Rough endoplasmic reticulum-associated antigen (p63)	VS38c	Plasma cells	Osteoblasts and a subset of stromal cells also stain
CD138 (syndecan)	B-B4	Plasma cells	Some carcinomas and large cell NHL are positive
CD38	AT13/5	Plasma cells	Also expressed by thymocytes, early B cells, germinal centre B cells and some erythroid cells and neutrophils
Unclustered	DBA44	B cells	Relative specificity for hairy cell leukaemia; red cell membranes and some macrophages may also stain
Tartrate-resistant acid phosphatase	9C5 and 14G6	Hairy cell leukaemia	Mast cells, Langerhans cells, macrophages and osteoclasts also stain [19]
CD23	1B12	Subset of B cells	Small lymphocytic lymphoma/CLL positive; mantle cell, lymphoplasmacytoid and follicle centre cell lymphomas negative

Table 2.7 (*cont'd*)

Antigen	Antibody	Specificity	Comments
CD5	4C7	Subset of B cells, most T cells	Small lymphocytic lymphoma/CLL and mantle cell lymphoma positive; lymphoplasmacytoid and follicle centre cell lymphomas negative
BCL2	Bcl-2/100/D5, I24	T cells, mantle zone B lymphocytes and follicle centre cell lymphoma	Non-neoplastic germinal centre cells are negative; other B-cell lymphomas and some haemopoietic cells are positive; it is difficult to interpret positive staining in the bone marrow
Cyclin D1	DCS-6, P2D11F11	Mantle cell lymphoma (nuclear expression)	Apoptotic nuclei and some endothelial cell nuclei are positive; immunostaining is technically difficult
CD2	AB75	Most T cells	Also expressed by some monocytes
CD3	CD3-12 and polyclonal antisera	Most T cells	More specific than CD2; the monoclonal antibody is superior in performance to polyclonal antisera
T-cell receptor β chain	β F1	T cells expressing $\alpha\beta$ T-cell receptor	The majority of CD3-positive T cells and cells of many T-lineage neoplasms
CD45RO—broad specificity	UCHL-1	Antigen-experienced T cells (membrane expression)	Granulocytes, monocytes and macrophages are also positive (cytoplasmic expression); excessive decalcification may lead to non-specific nuclear staining
CD45RO—T-cell restricted	OPD4	Antigen-experienced T cells (membrane expression)	Less reactivity with non-lymphoid lineage cells than with UCHL1
CD43	MT1, DFT1	Most T cells and a subset of B cells; lymphocytic lymphoma/CLL and mantle cell lymphoma are usually positive; follicular lymphoma, lymphoplasmacytic lymphoma and marginal zone lymphomas are negative	Strong expression by granulocytic and monocytic cells
CD4	1F6	T-cell subset	There is often poor localization of reaction product to individual cells; macrophages are also positive
CD8	4B11	T-cell subset	
CD56	1B6	Natural killer cells and some cytotoxic T cells	Nerve fibres, neuro-ectodermal tumours, some leukaemic myeloblasts and cells of some cases of multiple myeloma are positive
CD57	Leu7, NC1	Natural killer cells and some cytotoxic T cells	Nerve fibres and neuro-ectodermal tumours are positive

Table 2.7 (cont'd)

Antigen	Antibody	Specificity	Comments
CD30	BerH2	Reed–Sternberg cells and mononuclear Hodgkin's cells, cells of anaplastic large cell lymphoma and some other pleomorphic large cell lymphomas	Plasma cells and some erythroid precursors positive if proteolytic pre-treatment is used; wet-heat antigen retrieval is preferred; some carcinomas, especially embryonal, are positive
CD15	LeuM1, BY87	Neoplastic cells in classical Hodgkin's disease (but may be negative in up to 15% of cases of Hodgkin's disease including lymphocyte-predominant)	Granulocytic and monocytic cells positive, particularly late granulocyte precursors
Epithelial membrane antigen	GP1.4	Cells of anaplastic large cell lymphoma	Some plasma cells are positive; neoplastic cells in some cases of Hodgkin's disease and many carcinomas are positive; some cases of anaplastic large cell lymphoma are negative
Anaplastic lymphoma-associated kinase	ALK-1	Cells of anaplastic large cell lymphoma	More likely to be positive in childhood than adult cases
Ki67 antigen	Ki67, MM1, MIB-1	Proliferating cells (nuclear expression)	Useful for assessing grade of lymphoma from infiltrates in bone marrow; proliferating haemopoietic cells are also positive

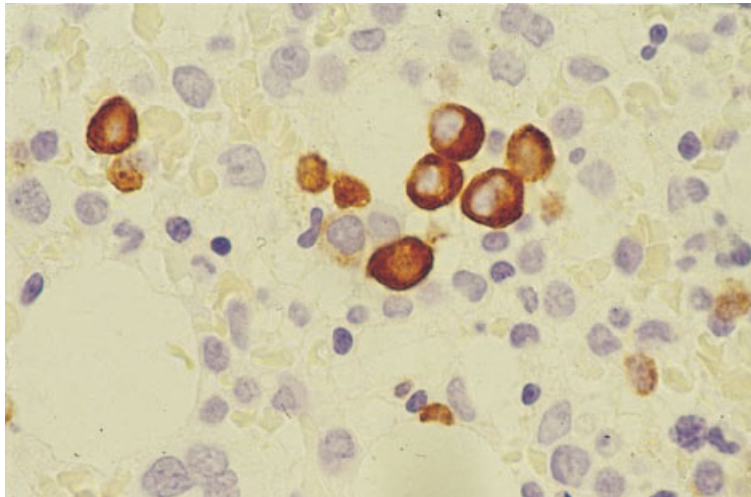


Fig. 2.16 Section of trephine biopsy specimen from a patient with a myelodysplastic syndrome showing elastase-positive granulocyte precursors. Paraffin-embedded, immunoperoxidase technique with anti-elastase McAb NP5 $\times 960$.

Immunohistochemical stains are illustrated in Figs 2.16–2.19. Monoclonal antibodies useful in the detection of micro-organisms are shown in Table 3.1 and those for use in the diagnosis of non-haemopoietic malignancy in Table 10.1.

Problems and pitfalls

Antigen cross-reactivity between cell types. Antigen cross-reactivity between different types of cell is a significant problem in immunohistochemistry

Fig. 2.17 Section of trephine biopsy specimen from a patient with M6 AML showing erythroblasts, one of which is binucleated. Paraffin-embedded, immunoperoxidase technique with antiglycophorin antibody McAb Ret40f $\times 940$.

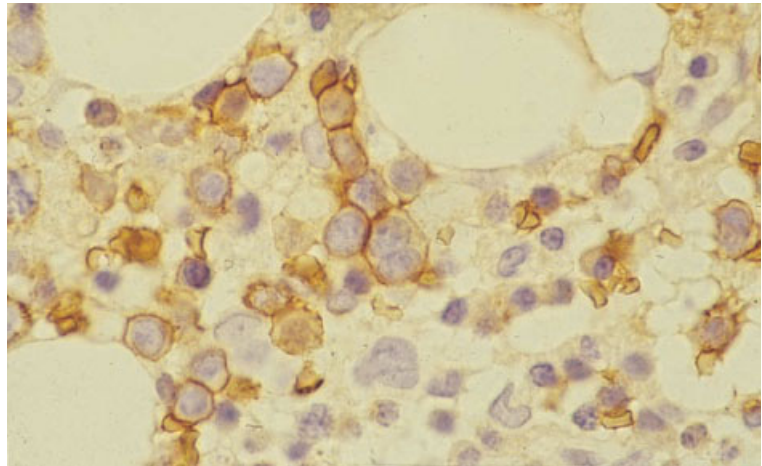


Fig. 2.18 Section of trephine biopsy specimen from a patient with a myelodysplastic syndrome showing a cluster of megakaryocytes. Paraffin-embedded, immunoperoxidase technique with CD61 McAb $\times 940$.

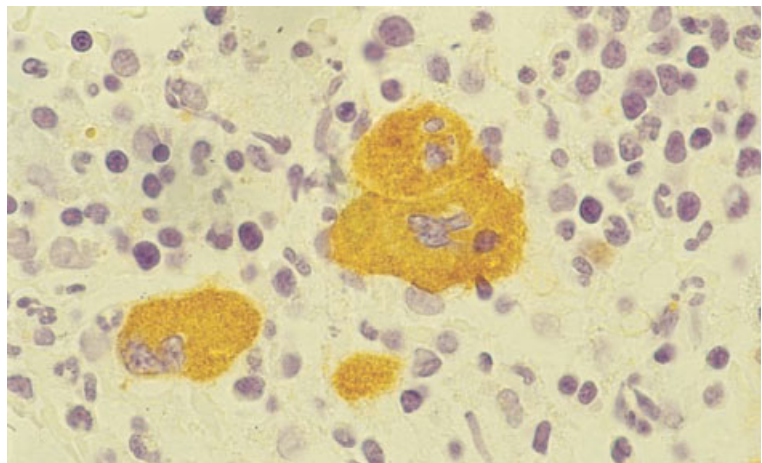
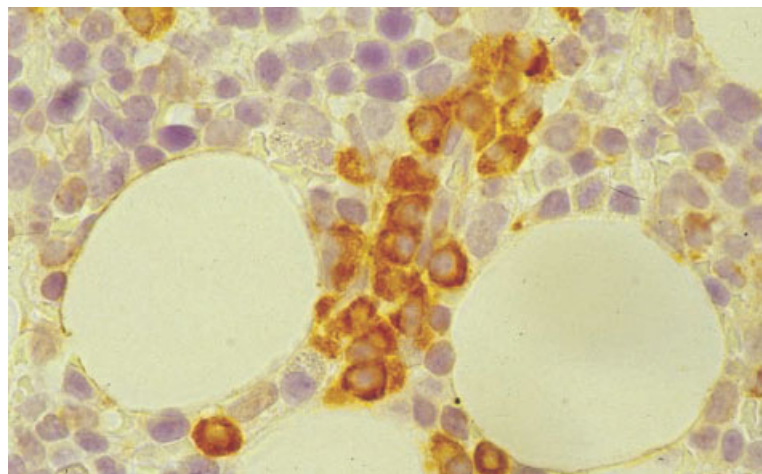


Fig. 2.19 Section of trephine biopsy specimen showing pericapillary plasma cells. Paraffin-embedded, immunoperoxidase technique with McAb VS38c $\times 940$.



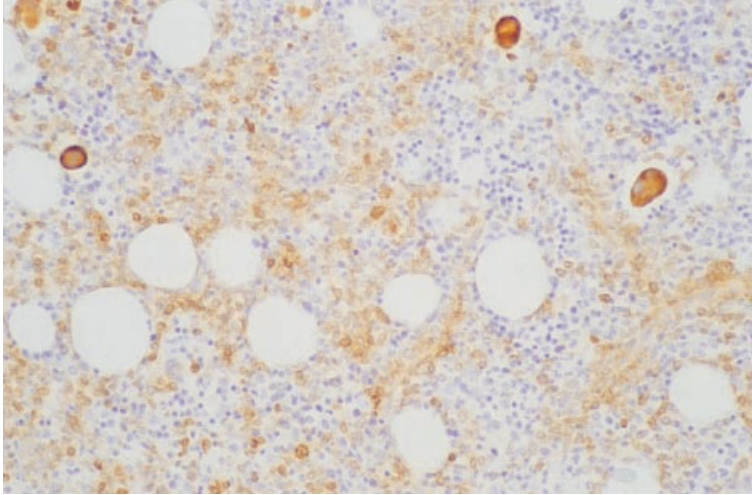


Fig. 2.20 BM trephine biopsy section from a patient with diffuse large B-cell lymphoma; there is heavy interstitial lymphoid infiltrate with lymphoma cells showing moderate activity for CD79a (clone Mb1), whereas three megakaryocytes show strong cross-reactivity. Immunoperoxidase, CD79a $\times 188$.

(Fig. 2.20). There is a tendency to regard antigen expression as being lineage-specific, whereas expression is more accurately considered as lineage-associated or lineage-restricted. Many antigens familiar in the context of expression by T cells, B cells or both in lymphoid tissues are also expressed by myeloid lineages. This is particularly the case with T-cell-associated antigens, which are widely expressed by cells of granulocytic and monocytic lineages. CD43 should be avoided as a T-cell marker in bone marrow because of extensive cross-reactivity of this type. Antibodies reactive with CD45RO should be selected with care; the clone OPD4 stains T cells preferentially, with little granulocytic and monocytic reactivity, while UCHL-1 often stains cells of the latter types strongly. Expression of CD45RO by granulocytes and monocytes can be distinguished from that shown by T cells since the former is cytoplasmic, whereas T cells show membrane staining. Bone marrow stromal macrophages express CD4 and, because of the poor localization of a rather weak signal that is often seen with the currently available antibody, accurate assessment of CD4-positive T cells may not be possible. Monoclonal antibodies reactive with CD3 are currently the best and most specific T-cell markers for use with bone marrow trephine biopsy sections.

For B cells, CD79a is probably the best antigenic target but some antibody clones cross-react with vascular smooth muscle and megakaryocytes; these reactivities rarely cause problems in interpretation.

In our experience, many bone marrow B cells appear negative or react only weakly for CD20; both CD79a and an alternative B-cell marker, 4KB5 (CD45RA), show consistently more small B cells than does CD20 both in normal bone marrow and in low grade lymphoproliferative disorders. For this reason, trephine biopsy immunostaining for assessment of CD20 expression for therapeutic purposes should not, at present, be regarded as reliable if a negative result is obtained. It should be noted that L26, the CD20 monoclonal antibody used to detect reactivity in trephine biopsy specimens, detects an intracellular epitope, whereas the monoclonal antibody used for therapy reacts with a surface membrane epitope. Antibodies directed against CD5 and BCL2 react with T cells as well as subsets of normal and neoplastic B cells; results should be interpreted with care in bone marrow lymphoid infiltrates, in which non-neoplastic T cells frequently predominate.

The specificity of CD45 antibodies for lymphoid cells can be improved if myeloid reactivity is reduced by proteolysis (performed as for antigen retrieval). Antibodies reactive with CD30 may cross-react with plasma cells and, depending on fixation, with erythroid cells. Expression in these cell types is cytoplasmic rather than Golgi- or membrane-associated as in Reed–Sternberg cells or cells of anaplastic large cell lymphoma. This cross-reactivity is unlikely to cause difficulty in the interpretation of possibly lymphoid infiltrates. However, it can be abolished by use of wet heat for antigen retrieval, rather than proteolysis.

Endothelial cell expression of CD34 can mimic reactivity in haemopoietic cells if tiny capillaries are viewed in cross-section. However, the granular nature of haemopoietic cell CD34 expression can be distinguished from the homogeneous pattern seen in endothelium.

Problems relating to fixation and decalcification. Use of proprietary combined fixative–decalcifier solutions can lead to extensive loss of immunoreactivity within tissues, as can excessive decalcification by EDTA. Even in optimally fixed and decalcified tissues, some antigens are difficult to demonstrate. Cyclin D1 and CD4 are problematical in this regard with currently available monoclonal antibodies. Non-specific nuclear staining may occur with a variety of antibodies in tissues that are poorly fixed, excessively decalcified or both. In our experience, the antibodies UCHL-1 (CD45RO), Ber-H2 (CD30) and NB84 are particularly prone to this problem.

Technical problems due to endogenous enzyme activity and non-specific antibody binding. Endogenous enzyme activity and non-specific antibody binding can both lead to technical problems. When immunostaining trephine biopsy sections with detection systems based on horseradish peroxidase, particular attention must be paid to blockade of endogenous peroxidase activity. Granulocytes express abundant peroxidase activity that is not destroyed by fixation or processing. Use of methanolic hydrogen peroxide is satisfactory but longer incubation (e.g. 30 minutes, compared with 15 minutes for most other tissues) is helpful. Because the solution oxidizes rapidly, replacement with freshly prepared methanol/H₂O₂ at intervals during incubation is helpful. Addition of sodium azide to the final chromogenic substrate provides additional peroxidase blockade in difficult cases.

When using an alkaline phosphatase–anti-alkaline phosphatase detection system, there is rarely any problem from endogenous alkaline phosphatase activity, since the enzyme is largely destroyed during processing. A weak background blush may be seen in some cases, due to residual activity in stromal cells. This can be inhibited by adding levamisole to the chromogenic substrate.

Occasionally, endogenous biotin expression can cause non-specific staining when avidin–biotin or

streptavidin–biotin detection systems are used. This is found particularly when using antibody AA1 to demonstrate mast cell tryptase. Such activity can be blocked by sequential incubation of sections with saturating solutions of avidin and biotin prior to immunostaining.

Non-specific binding of antibodies to protein residues in the tissue, which may be a particular problem with polyclonal antisera, can be blocked by pre-incubation of sections with bovine serum albumin or normal human serum. Background serum staining with anti-immunoglobulin light and heavy chain antibodies may be reduced by use of wet heat methods for antigen retrieval rather than proteolysis.

Problems of interpretation. Other problems in interpretation can occur. As mentioned above, immunostaining for antigens such as CD4 and cyclin D1 can be suboptimal and results need to be interpreted with care. Positive controls, with known reactivity, should always be performed to ensure that the technique has worked satisfactorily. It may be necessary to repeat the staining in some cases. It should be noted that cyclin D1 expression in mantle cell lymphoma is nuclear (and only a proportion of cells are positive). This nuclear staining should not be confused with non-specific weak cytoplasmic staining that is sometimes observed in other neoplastic lymphocytes.

Expression of CD5 by neoplastic B cells in chronic lymphocytic leukaemia (CLL) and mantle cell lymphoma is much weaker than the constitutive expression of this antigen by T cells. For this reason, it is important to ensure that the dilution of the antibody used is optimal for the detection of weakly expressed antigens on neoplastic cells. Similarly, it is important to use for comparison a positive control that represents one of these lymphomas, rather than normal tissue. The detection of neoplastic B cells in CD5-immunostained bone marrow trephine biopsy sections requires careful evaluation of sections since such cells are often present among a background population that contains numerous, strongly stained, non-neoplastic T cells.

Detection of BCL2 expression by cells in B-cell lymphoid infiltrates in bone marrow is seldom useful because of the abundance of non-neoplastic, BCL2-positive T cells, the rarity of follicle formation

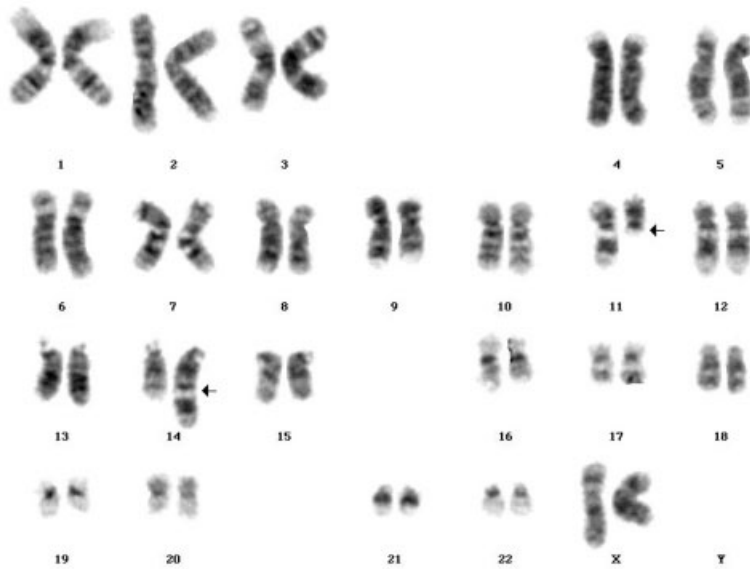


Fig. 2.21 A karyogram showing $t(11;14)(q13;q32)$ in mantle cell lymphoma. (By courtesy of Dr Fiona Ross, Salisbury.)

and the positive reactions that can be observed not only in follicular lymphoma but also in other B-cell lymphomas.

Cytogenetic analysis

Specific, non-random chromosomal abnormalities are a common finding in haematological neoplasms and often play a central role in pathogenesis. In addition, some haematological neoplasms are defined more precisely by the presence of specific chromosomal abnormalities than by haematological or histological features. For example, a specific subtype of AML, which can be designated M4Eo/inv(16)(p13q22)/*CBFB-MYH11* fusion AML, is better defined by the presence of inversion of chromosome 16 than by the cytological or histological features of acute myelomonocytic leukaemia with eosinophilia. The presence of certain chromosomal abnormalities also offers prognostic information. For example, in AML, the presence of $t(8;21)(q22;q22)$, $t(15;17)(q22;q21)$ or $inv(16)(p13q22)$ is indicative of a better prognosis. Cytogenetic analysis can also help in distinguishing a neoplastic from a reactive process, as when the demonstration of a clonal cytogenetic abnormality provides evidence that a case of 'idiopathic' hypereosinophilic syndrome is actually eosinophilic leukaemia.

Classical cytogenetic analysis can be performed only on cell suspensions such as those obtained from peripheral blood or bone marrow [20]. Cytogenetic analysis for investigation of suspected haematological neoplasms involves the examination of metaphase spreads which can be prepared from blood or from bone marrow aspirates either as direct preparations, in tumours with a high proliferative fraction, or after a preliminary period of culture either with or without mitogens. Cells are arrested in metaphase by exposure to a spindle poison such as colcemid. After cell lysis the chromosomes are visualized with stains such as Giemsa or quinacrine mustard (a fluorescent agent). Individual chromosomes are identified by their size, by the position of the centromere and by their banding pattern (the sequence of light and dark bands apparent after staining). The findings may be illustrated by a karyogram, an ordered array of chromosomes (Fig. 2.21). Alternatively, they may be expressed as a karyotype. For example, the karyotype $47,XY,+8$ [18], $46,XY$ [2] from the bone marrow of a male patient indicates the presence of a clone of cells with trisomy 8; of the 20 metaphases examined, two were normal.

Cytogenetic analysis has a major role in haematological diagnosis. Applications include:

1 confirmation of diagnosis, e.g. by demonstration of $t(15;17)(q22;q21)$ in M3 variant AML;

2 detection of chromosomal rearrangements that are indicative of good or bad prognosis and should be considered in the choice of treatment, e.g. demonstration of hyperdiploidy, indicative of good prognosis in ALL;

3 confirmation of a neoplastic process when this is otherwise difficult, e.g. in the hypereosinophilic syndrome or in lymphocytosis with large granular lymphocytes;

4 monitoring treatment, e.g. by estimation of the number of Philadelphia chromosome-positive metaphases when a patient with chronic granulocytic leukaemia is being treated with interferon;

5 post-transplant monitoring, e.g. by study of sex chromosomes in a sex-mismatched allogeneic stem cell or bone marrow transplant recipient;

6 diagnosis of therapy-related AML and MDS (see Chapter 4); and

7 confirmation of a constitutional abnormality that may underlie the development of a haematological malignancy, e.g. detection of trisomy 21 in a child with acute megakaryoblastic leukaemia in whom Down's syndrome is suspected, or demonstration of sensitivity to clastogenic agents, confirming a diagnosis of underlying Fanconi's anaemia in a patient presenting with AML.

Problems and pitfalls

Metaphase spreads in leukaemias are often of poor quality so that the characterization of an abnormality can be difficult. In addition, some specific chromosomal rearrangements, e.g. t(12;21)(p12;q22) in ALL, are difficult to detect by karyotypic analysis while others are impossible; for these rearrangements, molecular genetic techniques are required.

Cytogenetic analysis fails or yields too few metaphases for adequate analysis in a proportion of cases of acute leukaemia. Inappropriate techniques may mean that there is selection for residual normal cells, e.g. if direct examination rather than preliminary culture is used for the investigation of acute promyelocytic leukaemia.

When there is only partial replacement of the marrow by a neoplastic clone, e.g. in the MDS, a cytogenetically abnormal clone may be present but may not be identified if insufficient metaphases are examined.

In some slowly growing tumours it is not possible to obtain suitable metaphase preparations and metaphases may represent residual normal cells rather than neoplastic cells. This is often the case, for example, in CLL.

Molecular genetic analysis

Cytogenetic analysis has been part of the diagnostic assessment of haematological neoplasms for many years. More recently, techniques such as Southern blot analysis and PCR have allowed molecular genetic events associated with such chromosomal abnormalities to be studied. These techniques have also led to the detection of additional genetic abnormalities in haematological diseases. They are being used increasingly for diagnosis and follow-up of patients on a routine basis.

In addition, molecular genetic analysis can be used to establish clonality; this is particularly valuable in lymphoid neoplasms, where antigen receptor gene rearrangements provide unique clonal markers for neoplastic cell populations. Molecular genetic techniques are most readily applicable to peripheral blood or bone marrow aspirates but modified techniques suitable for application to trephine biopsies are being developed currently.

New concepts with regard to somatic hypermutation of antigen receptor (*IGH* and *TCR*) variable region genes in lymphoid cell maturation are emerging currently from molecular genetic analysis. Knowledge of such mechanisms in T-cell maturation is much less advanced than it is for the B-cell lineage. Basic understanding of the somatic mutation processes underlying affinity maturation of immunoglobulin molecules, which occur within germinal centres, allows distinction between lymphomas derived from pregerminal centre (non-mutated), germinal centre (hypermutated with evidence of ongoing acquisition of additional mutations) and postgerminal centre (hypermutated with no ongoing mutation) lymphoid cells. For example, subcategories of CLL have been described which differ by virtue of showing pregerminal centre (60%) and postgerminal centre (40%) patterns of *IGH* hypermutation.

Molecular analysis can also be used to identify viral DNA or RNA in blood or bone marrow (see Chapter 3).

Fluorescence and other *in situ* hybridization techniques

In situ hybridization (ISH) is a molecular genetic technique although it can also be regarded as an extension of conventional cytogenetics. It is based on the hybridization of a labelled probe to interphase nuclei or metaphase spreads. The technique can employ fluorescence microscopy (fluorescence *in situ* hybridization or FISH), enzymatic methods [21,22] or a radioactive label. Probes, consisting of synthetic DNA in various forms, visualized with the aid of fluorochromes, enzymes or radio-isotopes, can be used to detect numerical abnormalities of chromosomes or the presence of various chromosomal rearrangements. Target DNA may be identified by means of a probe conjugated to a fluorochrome. Alternatively, binding of the probe to target DNA can be identified by means of hybridization of the primary probe to complementary bases in a second complementary probe that also contains a reporter molecule [20]. Following stringency washes performed to remove excess probe, binding of the probe to its target DNA is detected by means of complexing of the reporter molecule in the second probe with a reporter-binding molecule conjugated either to a fluorochrome or to an enzyme such as peroxidase or alkaline phosphatase. By using different fluorochromes or two enzymes it is possible to identify simultaneously multiple (typically two or three) different specific DNA sequences in a single preparation of cells. Direct fluorescence methods are more rapid than indirect and give less non-specific background staining, whereas indirect fluorescence methods generally give a stronger signal. Enzymatic methods are currently less used but have the advantage that a fluorescence microscope is not needed.

Fluorescence and other ISH techniques are applicable to: (i) films of blood or bone marrow cells; (ii) imprints of trephine biopsy specimens; (iii) cytocentrifuge preparations; and (iv) films of cells that have been cultured with or without mitogens. These techniques have the particular advantage over classical cytogenetic analysis that they can be applied not only to metaphase spreads but also to interphase nuclei. Chromosome abnormalities can therefore be detected in neoplastic cells that do not readily enter mitosis, such as the neoplastic cells of CLL and multiple myeloma. In addition, ISH can be

applied to blood or bone marrow films previously stained with a Romanowsky stain or by immunocytochemistry, thus permitting correlation of cytological and immunophenotypic features with karyotypic information. Obviously, unlike cytogenetic analysis, ISH permits visualization of only restricted areas of individual chromosomes rather than giving a global view of the entire chromosome complement within a cell.

The probes most often employed in ISH techniques are: (i) repetitive sequence centromeric probes (available for all chromosomes and applicable to cells in interphase or metaphase); (ii) whole chromosome paints (available for all chromosomes but applicable only to cells in metaphase); and (iii) specific sequence probes, including those identifying oncogenes, cancer-suppressing genes and the breakpoints of recurring translocations (applicable to cells in interphase or metaphase).

Numerical abnormalities of chromosomes can be detected either with centromeric probes or with whole chromosome paints. When such probes are used, normal cells have two separate fluorescent signals. If there is an abnormality of chromosome number, the number of signals will vary. For example, in trisomy 12, FISH with a centromeric probe for chromosome 12 shows three signals per cell whereas, in monosomy 7, FISH with a centromeric probe for chromosome 7 shows only one signal per cell (Fig. 2.22). If using centromeric probes, rather than whole chromosome paints, care must be taken in making assumptions that gain or loss of a signal represents gain or loss of an entire chromosome target.

Several strategies can be used for detecting specific translocations or other rearrangements. Use of a single probe spanning a specific chromosomal breakpoint is useful when multiple chromosomal partners can disrupt a gene of interest, as is the case with *MLL* and *BCL6*. When both partner chromosomes are predictable a variety of techniques can be used. Whole chromosome paints can be used for the two chromosomes of interest. Alternatively, two probes can be selected which bind to specific oncogenes or bind to the two chromosomes of interest at a site close to the expected breakpoint. The two probes are labelled with different fluorochromes. In normal cells there will be two separate signals of different colours whereas, in cells in which a translocation

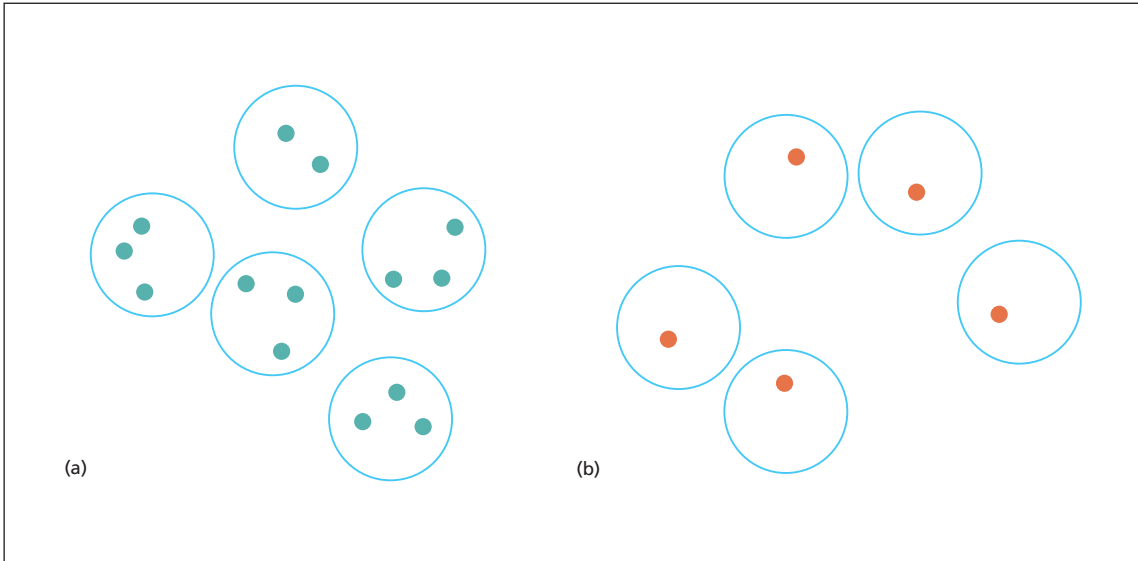


Fig. 2.22 Diagrammatic representation illustrating the principles of FISH, using a centromeric probe for the identification of trisomy or monosomy. (a) Centromeric probe for chromosome 12 in chronic lymphocytic leukaemia showing four trisomic cells and one disomic cell. (b) Centromeric probe for chromosome 7 in myelodysplastic syndrome showing all cells to have monosomy 7.

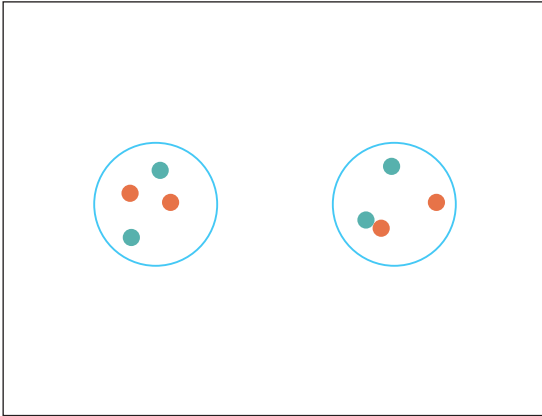


Fig. 2.23 Diagrammatic representation illustrating the principles of FISH, using two oncogene probes to detect a translocation. Probes for *BCR* (red) and *ABL* (green) have been used. In the normal cell (left) there are four separate signals. In the cell from a patient with $t(9;22)(q34;q11)$ associated with chronic granulocytic leukaemia (right) there are single normal *BCR* and *ABL* signals and a double red plus green signal where the two oncogenes have been juxtaposed. The red–green signal is yellow.

has occurred, the two colours come together on a single chromosome (Fig. 2.23). Alternatively, probes spanning the expected breakpoint on each chromosome can be used so that, if a translocation has occurred, the signals are split. Each abnormal chromosome then has two adjacent signals of different colours, while the two remaining normal chromosomes have a single colour signal (Fig. 2.24); this technique is sometimes referred to as D-FISH, signifying double fusion FISH. It is also possible to combine one probe spanning an expected breakpoint with another that is adjacent to the second breakpoint. A single probe spanning one of the breakpoints can also be used, a split signal being consistent with a translocation. In this case it is sometimes necessary to demonstrate that three signals represent a normal and a split signal rather than trisomy (Fig. 2.25). Triple colour FISH permits the use of a single probe identifying a sequence on one of the chromosomes implicated together with two separate probes identifying genes on either side of the breakpoint on the second chromosome. The latter two signals are dissociated when the relevant translocation occurs (Fig. 2.26).

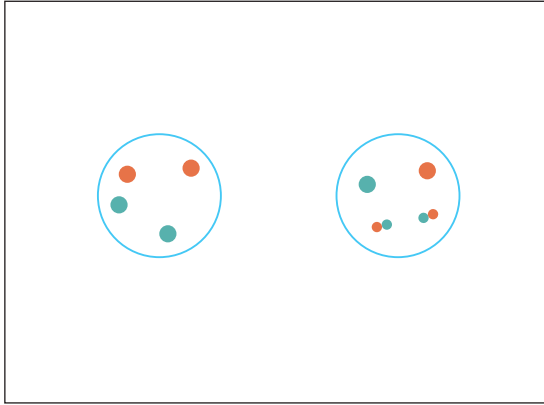


Fig. 2.24 Diagrammatic representation illustrating the principles of FISH, using two oncogene probes, both of which are split in a given translocation, to detect the translocation. Probes spanning *BCR* (red) and *ABL* (green) have been used. In the normal cell (left) there are four separate signals. In the cell from a patient with $t(9;22)(q34;q11)$ associated with chronic granulocytic leukaemia (right) there are single normal *BCR* and *ABL* signals and two double red plus green signals (fusion signals are yellow) representing *BCR-ABL* and *ABL-BCR*.

Probes spanning specific breakpoints are also useful for detecting isochromosome formation (Fig. 2.27) and chromosomal inversion. For example, inversion of chromosome 16 can be detected by using a probe that spans one of the breakpoints. When a pericentric inversion has occurred, the signal is split and appears on both the long and short arms of the chromosome in a metaphase spread (Fig. 2.28).

The FISH technique can also be used to identify deletion or amplification of chromosomal material. For example, specific probes can be used to show deletion of a cancer-suppressing gene such as *RBI* or *p53* or amplification of an oncogene such as *MYC*.

An ISH technique has the following advantages over classical cytogenetics:

- 1 living cells are not required;
- 2 some abnormalities can be recognized in interphase nuclei, making the technique particularly useful for neoplasms, such as CLL, with a low proliferative rate;
- 3 a suspected abnormality can be confirmed when morphology of the chromosomes is poor;
- 4 chromosomal rearrangements, such as inversion(16), which have only subtle alterations in the chromosome banding pattern and are therefore

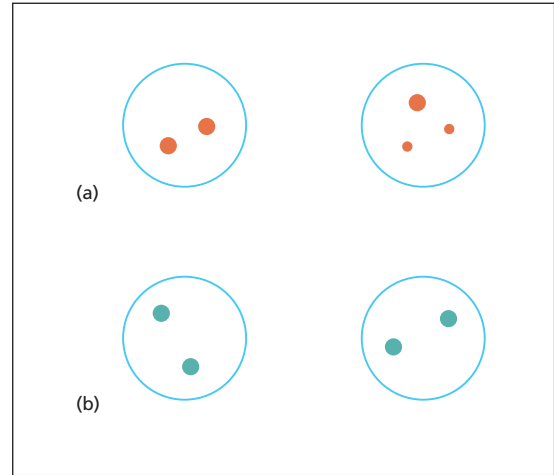


Fig. 2.25 Diagrammatic representation illustrating the principles of FISH, using a whole chromosome paint to detect a translocation. (a) In this case, a paint for chromosome 11 has been used. A normal cell (left) shows two signals, whereas a cell from a patient with $t(11;14)(q13;q32)$ associated with mantle cell lymphoma (right) shows three signals representing, respectively, one normal chromosome and two signals representing the two parts of chromosome 11 separated as a result of translocation. (b) To ensure that the three signals do not represent trisomy for chromosome 11, FISH can also be performed with a centromeric probe for chromosome 11; since the centromere is not split in the translocation this shows two signals in both the normal cell (left) and the cell with the translocation (right).

difficult to recognize on classical cytogenetic analysis if preparations are suboptimal, can be detected;

5 large numbers of cells can be scanned so that a low frequency abnormal population can be recognized; and

6 deletion of cancer-suppressing genes or amplification of oncogenes can be demonstrated.

Fluorescent immunophenotyping and interphase cytogenetics (FICTION) is a technique combining immunophenotyping with FISH. It can be used, for example, to demonstrate that trisomy 12 in CLL can occur in only a proportion of the clonal lymphocytes.

A recent development of FISH is spectral karyotyping (SKY) in which a complex panel of probes applied simultaneously permits the identification of all chromosomes in metaphase preparations.

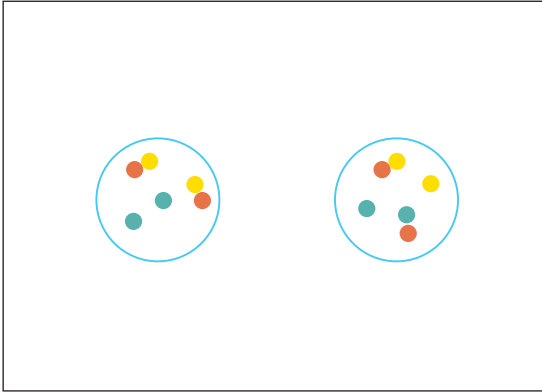


Fig. 2.26 Diagrammatic representation of triple colour FISH, a technique used to reduce the probability of false-positive results, utilizing an *ABL* probe (red), a *BCR* probe (green) and a probe for the *ASS* gene (yellow) which is just proximal to *ABL*. A normal cell (left) has two green *BCR* signals and two fused yellow-red signals representing *ABL* plus *ASS*; a cell from a patient with $t(9;22)(q34;q11)$ has one normal *BCR* signal (green) and one normal *ASS* plus *ABL* signal (yellow plus red); the translocation has separated *ASS* from *ABL* so that there is a separate *ASS* signal (yellow) and a *BCR-ABL* fusion signal (red plus green). The red-green fusion signal appears yellow.




Fig. 2.28 Diagrammatic representation of the use of FISH to demonstrate chromosomal inversion showing a normal cell (left) and a cell from a patient with M4Eo AML and $inv(16)(p13q22)$. A chromosome paint for the short arm of chromosome 16 has been used. In the normal cell there are two chromosomes, each with a single red signal. In the cell with an inversion there is one normal chromosome (with a single signal) and one abnormal chromosome (with a split signal). The inversion is pericentric and the inverted telomeric part of the short arm is now fused with the telomeric part of the long arm.

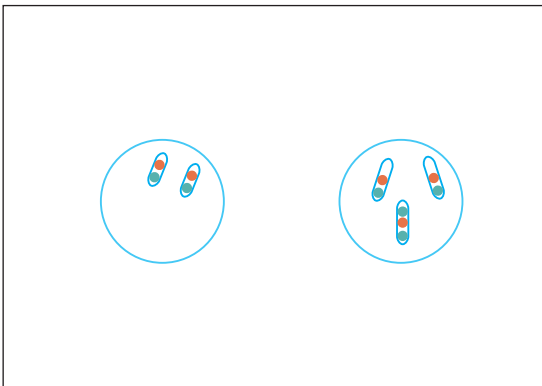

Fig. 2.27 Diagrammatic representation of demonstration of an isochromosome by FISH. A normal cell (left) is compared with a cell from a patient with T-lineage prolymphocytic leukaemia showing an isochromosome of the long arm of chromosome 8. A centromeric probe (red) has been combined with a probe for the *MYC* oncogene (green) which is located on 8q. The normal cell shows two chromosomes, each with a red signal and a green signal. The cell on the right shows, in addition, an isochromosome with two green (*MYC*) signals on either side of the centromeric (red) signal.

This technique is particularly useful for investigating complex chromosomal abnormalities. Because expensive equipment, reagents and software are required the technique is currently mainly used in research rather than in routine diagnosis.

Techniques for FISH are applicable to a more limited extent to trephine biopsy sections, in which at present they are best restricted to analysis of potential chromosomal gains. For mathematical reasons, analysis of chromosomal loss in tissue sections (in which many nuclei are only partly represented) is complex. Spatial resolution of FISH signals in histological sections is not adequate with current methods to permit routine application of dual colour techniques to demonstrate translocations, although split signals from a probe spanning an expected break-point can be resolved. Some of these limitations can be overcome by applying FISH to cytocentrifuge preparations from intact nuclei or whole cells extracted by proteolysis from thick sections. As for immunohistochemistry, pre-treatments are required to unmask target DNA sequences. Because these vary considerably with different fixation and decalcification

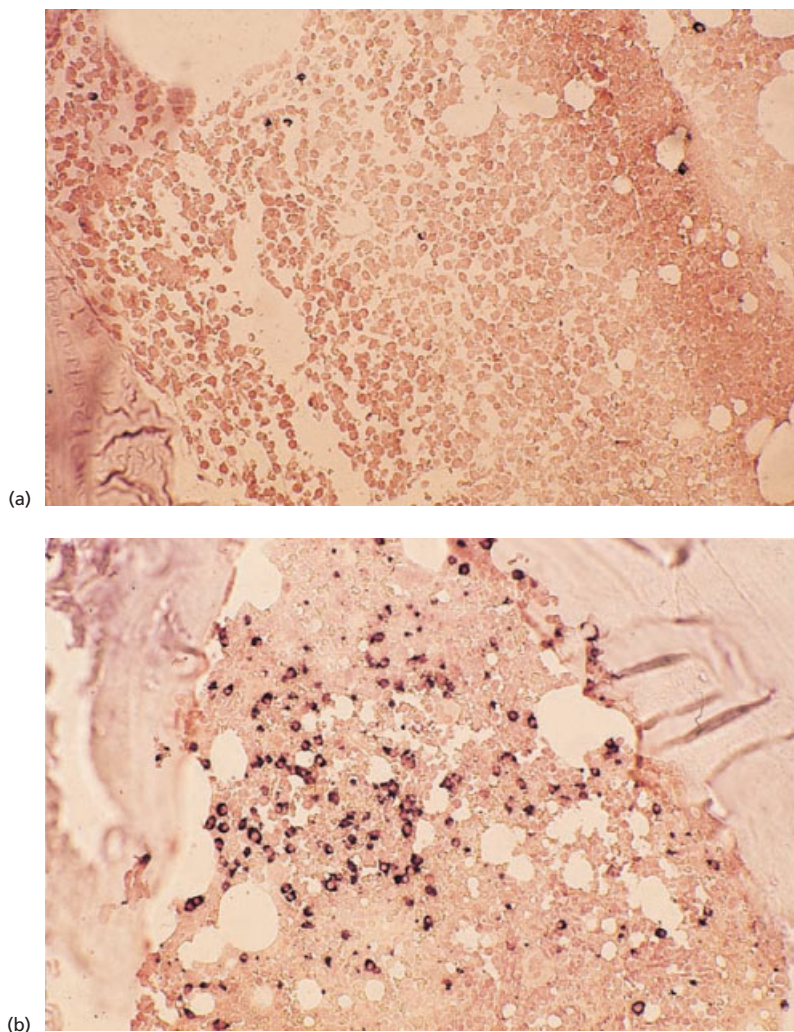


Fig. 2.29 *In situ* hybridization showing (a) κ and (b) λ light chain messenger RNA. There are only occasional κ -positive cells but λ -positive cells are numerous. Paraffin-embedded, immunoperoxidase-labelled probes $\times 160$.

protocols, FISH applied to bone marrow trephine biopsies is still predominantly a research tool.

It should be noted that ISH techniques to detect messenger RNA (mRNA) targets can also be applied to cytological and histological bone marrow preparations. Either enzymes or fluorochromes can be used to identify the target mRNA. Double labelling with two different fluorochromes is possible, e.g. for either κ or λ mRNA and for either TNF α or IL-1 β mRNA, in order to determine whether neoplastic light chain-restricted plasma cells are capable of synthesizing these cytokines. In diagnostic practice, ISH for the detection of mRNA is useful for demonstration of κ - or λ -expressing plasma cells (Fig. 2.29) and for the detection of viral mRNA, such

as Epstein–Barr early RNA (EBER) in Epstein–Barr virus (EBV) infection. Otherwise, its present role is in research.

Problems and pitfalls

FISH and other ISH techniques have various disadvantages:

1 in any single preparation, it is only possible to identify the specific abnormality for which relevant probes are being employed; for example, if cells are being investigated for the presence of t(8;21), other leukaemia-associated translocations such as t(15;17) or t(9;11) will not be detected;

2 secondary abnormalities are not recognized; for

example, if the proportion of Philadelphia-positive metaphases were being evaluated in a case of chronic granulocytic leukaemia, the presence of an isochromosome of 17q (which might be associated with impending acute transformation) would not be detected;

3 the use of whole chromosome paints does not permit the detection of rearrangements within a single chromosome, such as an inversion, or small deletions;

4 in screening for trisomies and monosomies there are some false-positive findings, caused by accidental co-localization of signals, so that a low frequency of the abnormality being sought cannot be detected reliably; and

5 if neoplastic cells are present in the bone marrow but cannot be aspirated because of associated fibrosis, there will be a failure to detect any relevant cytogenetic abnormality.

The first two of these disadvantages can be circumvented to some extent by the use of multicolour FISH or spectral karyotyping [21].

Southern blot analysis

In this technique DNA is extracted from a fresh, unfixed tissue sample and digested with a panel of restriction endonucleases. Sometimes, when the bone marrow is cellular, unfixed bone marrow films on glass slides may yield sufficient material for analysis. The restriction endonucleases used are enzymes that recognize specific nucleotide sequences between 4 and 10 base pairs in length and cut the DNA molecule wherever their target sequences occur. This results in DNA fragments of variable length that can be separated, according to their size, by gel electrophoresis. These are then transferred by capillary action onto a more solid nitrocellulose membrane to create a Southern blot. Fragments containing the DNA sequences of interest can then be identified by hybridization with a radiolabelled DNA probe followed by autoradiography. One of the major breakthroughs that Southern blot analysis allowed was the detection of clonality in B- and T-lymphoid neoplasms (see below). In addition, rearrangement of a gene arising from translocation or some other acquired chromosomal rearrangement can be detected. This technique is used, for example, for detecting rearrangement of the *MLL* or *BCL6* genes since rearrangement can result from a considerable

number of different translocations, not all of which can be detected by alternative techniques. The Southern blot technique is also applicable for the detection of translocations in which there is considerable heterogeneity of breakpoints precluding use of a simple PCR technique.

Southern blot analysis can be used to demonstrate clonal integration of HTLV-I proviral DNA and integration of defective HTLV-I in adult T-cell leukaemia/lymphoma [23].

Problems and pitfalls

The major drawbacks of Southern blot analysis as a diagnostic tool are the requirement for radioactive materials, long turnaround times and the need for relatively large quantities of DNA in the diagnostic sample, which limits the sensitivity of the method. The latter feature limits its applicability to trephine biopsy specimens [24].

The polymerase chain reaction

The polymerase chain reaction (PCR) [25,26] is a method of *in vitro* amplification of a defined DNA target that is flanked by regions of known sequence. The development of this technique has greatly expanded the diagnostic potential of molecular genetics as a result of its ability to generate almost limitless copies of selected target DNA sequences. The technique is 400–4000 times more sensitive than Southern blot analysis. It consists of a repeating cycle of three basic steps (denaturation, primer annealing and elongation), with each cycle potentially leading to a doubling of the amount of the target DNA sequence.

The first step (denaturation) involves heating the DNA sample to around 90°C which causes the double-stranded DNA molecule to separate into two complementary single strands. The next stage (primer annealing) requires short DNA primer sequences that are complementary to the ends of the target DNA segment that is to be amplified. The primer is added to the denatured single-stranded DNA and the sample is cooled. As cooling occurs, the primers anneal (link via the complementary nucleotide sequences) to the single-stranded target DNA. The third step (elongation) requires addition of free nucleotides to the ends of the primer DNA segments, producing complementary copies of each

of the two single-stranded target DNA sequences. This is achieved using a thermostable DNA polymerase. The strands of DNA thus generated are separated from their complementary strands by elevating the temperature again. The cycle is repeated by elevating and lowering the temperature of the container in which the reaction takes place. This process is performed in an automated thermal cycling instrument preset with specific temperatures and times that are optimized for each primer pair. The cycles of denaturing, annealing and elongation are repeated 10–40 times. Amplification is initially exponential since each cycle doubles the amount of DNA template present. In later cycles the rate of increase in the quantity of DNA is closer to linear than to exponential. Nevertheless, very large quantities of the target DNA sequence are generated. The size of the DNA segment can be estimated by electrophoresis, by comparison with known standards (Fig. 2.30). The DNA generated can be directly visualized by staining with ethidium bromide and viewing under UV light. This technique has many advantages over Southern blot analysis for diagnostic use, principally the short turnaround time, the lack of a requirement for radio-isotopes, the ability to amplify very small quantities of target DNA and its applicability to fixed tissue, including

archival samples and even stained or unstained blood or bone marrow films scraped off glass slides. Stained slides are, however, less satisfactory than paraffin-embedded tissue because DNA degradation is greater. Techniques are available for use with decalcified paraffin-embedded trephine biopsy specimens [27]; EDTA decalcification rather than formic acid decalcification is required to ensure that DNA is not degraded. The amplification achieved by PCR makes the technique very sensitive. The DNA fragments produced are suitable for sequencing. Because of these advantages PCR, or its modification reverse transcriptase-PCR (RT-PCR), has replaced Southern blot analysis for most diagnostic applications. To distinguish it from RT-PCR, PCR is sometimes referred to as genomic PCR or DNA-PCR.

In situ PCR is a modification of the PCR technique performed on tissue sections pre-treated with a proteinase to facilitate entry of primers [28].

PCR can be used for investigation of clonality (by amplification of *IGH* or *TCR* genes), for detection of rearrangement of genes resulting from acquired cytogenetic abnormalities and for detection of bacterial or viral sequences (for example, sequences of *Mycobacterium tuberculosis* in a bone marrow aspirate).

PCR can be used to demonstrate clonality of lymphoid cells by amplification of Epstein–Barr virus

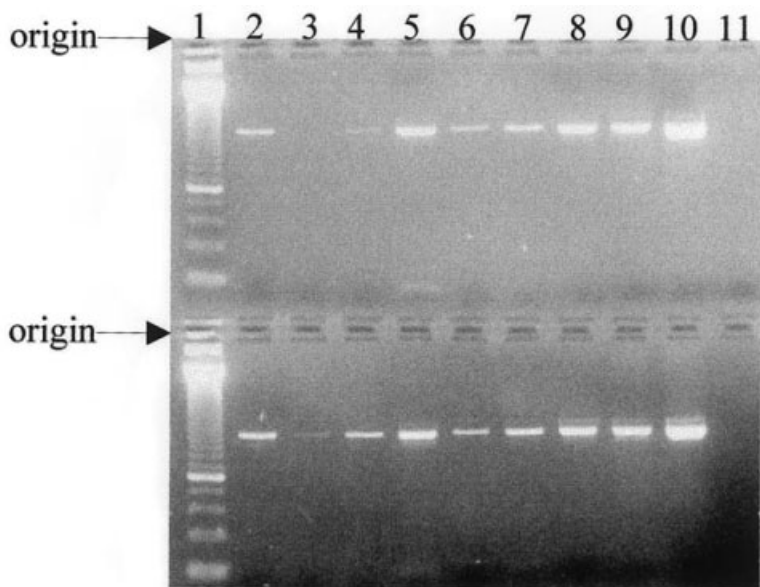


Fig. 2.30 Polyacrylamide gel stained with ethidium bromide and visualized with ultraviolet light showing PCR amplification of the 643 base pair BRCA1 exon 11A (top panel) and 482 base pair BRCA2 exon 11B (bottom panel). Lane 1 contains size standards and lanes 2–10 contain amplified samples of DNA extracted from EDTA-decalcified bone marrow trephine biopsy specimens. (By courtesy of Mrs Caroline Wickham, Exeter.)

DNA. Because of a variable number of terminal repeats in the circular episomal forms of the virus a polyclonal lymphoid population with a variety of forms of the virus can be distinguished from a monoclonal population with a single form. This can be useful for establishing clonality of EBV-induced natural killer cell lymphomas for which there are usually no alternative techniques for demonstrating clonality.

Problems and pitfalls

Great care is required to avoid contamination during PCR analysis as even the smallest quantity of DNA with a sequence complementary to the primers will be amplified. Meticulous technique is required.

Although PCR is applicable to archival material, poor preservation of DNA can lead to negative results [24]; amplification of a constitutional gene, for example *G6PD*, *BCR*, *ABL* or the β globin gene, can be used to control for DNA degradation. Preservation of DNA is determined by the fixative used and the method of processing. Formalin fixation has been found to give optimal results but other fixatives, e.g. B5, can be used [24]. As noted above, DNA from archival glass slides is often of inferior quality.

Negative results can result from sampling error when tissue infiltration is focal.

Variant breakpoints may be missed if appropriate primers are not used. For example, in testing for *BCL2* rearrangement in follicular lymphoma it is necessary to screen for breakpoints in the minor cluster region (MCR) as well as the major breakpoint region (MBR).

In some neoplasms, PCR is an insensitive diagnostic technique to amplify fusion genes because of the wide scatter of breakpoints. For example, in mantle cell lymphoma, genomic PCR detects only a little over 50% of cases, specifically those cases with a chromosome 11 breakpoint in the major translocation cluster [26].

Reverse transcriptase-polymerase chain reaction

PCR is applied to genomic DNA. Because of the presence of introns, a gene may be very large so that

satisfactory amplification is difficult. This problem can be circumvented by the use of mRNA as the starting material since the introns will have been excised and the segment to be amplified is shorter. The mRNA must first be transcribed into complementary DNA by means of reverse transcriptase. Amplification can then proceed, as in PCR of genomic DNA. RT-PCR is now very commonly employed for the detection of leukaemia and lymphoma-related fusion genes.

RT-PCR can also be used for the detection of viral mRNA (see Chapter 3).

Modifications of PCR and RT-PCR techniques

Modifications of PCR and RT-PCR techniques (Table 2.8) can increase sensitivity, specificity and usefulness and permit an approximate quantification of the number of copies of the fusion gene present. Among these modifications is multiplex PCR, in which a number of sets of primers are used to amplify simultaneously two or three different fusion genes. This makes it possible, for example, to screen simultaneously for the three fusion genes found in the three subtypes of AML associated with a better prognosis: *AML1-ETO*, *PML-RAR α* and *CBF β -MYH11*. The development of various techniques for quantification of the amount of target DNA or mRNA present means that PCR and RT-PCR are now becoming useful for the detection of minimal residual disease and for monitoring the response to therapy. One application of quantitative methods is in monitoring *BCR-ABL* during interferon therapy or following transplantation for chronic granulocytic leukaemia. In real-time PCR (RQ-PCR), the PCR technique results in displacement of a fluorogenic product-specific probe which is degraded during the reaction, generating a fluorescent signal.

Problems and pitfalls

RT-PCR requires intact RNA and is therefore not a suitable technique for use with most archival material. False-negative results can occur if there is degradation of RNA and amplification of a control mRNA sequence is therefore advised.

As for genomic PCR, the high sensitivity of the technique means that there is a risk of false-positive results if contamination is permitted to occur.

Table 2.8 Modifications of PCR and RT-PCR techniques.

Modification	Principle
Nested PCR	A second pair of primers, recognizing sequences internal to those recognized by the first pair, increases sensitivity and specificity
Multiplex PCR	A number of pairs of primers permit the recognition of two or three unrelated gene rearrangements in a single procedure
Quantitative PCR Real-time PCR (RQ-PCR) Competitive PCR Limiting dilution PCR Co-amplification of target and control genes	The PCR procedure becomes quantitative rather than merely qualitative, permitting quantification of minimal residual disease
Long-range PCR	A process in which fragments up to 10 kb are generated, using modified polymerases
5'-RACE (rapid amplification of cDNA ends)	A technique for the identification of unknown translocation partners when one partner is well characterized but the other is not
LA-PCR (long and accurate PCR)	A technique for the identification of precise translocation breakpoints using forward primers complementary to RACE-determined gene partners and reverse primers complementary to introns of the known translocation partner

Multicentre studies have sometimes shown a high rate of false-positive reactions so that inclusion of a negative control in each assay is considered to be critical [29]. RT-PCR techniques are poorly standardized and quality control is not optimal so that different laboratories produce divergent results in a significant proportion of cases [26].

Since RT-PCR uses a small tissue sample negative results can occur when infiltration, e.g. of a trephine biopsy specimen, is focal. Sometimes microscopy permits the detection of infiltration by lymphoma when results of RT-PCR are negative [24].

It must also be noted that sensitive techniques have detected gene rearrangements typical of leukaemia and lymphoma in people who do not have an identifiable neoplastic condition. This has been noted for *BCR-ABL*, *NPM-ALK*, *AF4-MLL* and *BCL2* rearrangement, characteristic, respectively, of chronic granulocytic leukaemia, large cell anaplastic lymphoma, acute lymphoblastic/biphenotypic leukaemia of infants and follicular lymphoma.

There are also problems in knowing when the detection of minimal residual disease is clinically significant. Detection of a residual clonal abnormality for a year or more after cessation of treatment is sometimes compatible with continued disease-free

survival. This has been noted for *AML-ETO*, *MYH11-CBF β* , *E2A-PBX* and *IGH* gene rearrangements [26,30].

Other molecular genetic techniques

Other molecular genetic techniques are rarely used in routine diagnosis but have research uses. They include:

- 1 northern blot analysis for investigation of RNA;
- 2 western blot analysis for investigation of proteins including the 'oncoproteins' that are the products of fusion genes;
- 3 comparative genomic hybridization (CGH) to detect segments of chromosomes that are under- or over-represented in leukaemic cells; and
- 4 DNA sequencing, which is necessary for cloning of new genes.

The application of molecular genetic techniques in the investigation of leukaemia and lymphoma

Molecular genetic techniques have two principal applications in the investigation of haematological neoplasms. Firstly, they can be used to demonstrate

that a monoclonal population is present and can give information on the nature of the lymphoid cell in which a mutation occurred (see below). Secondly, they can be used to demonstrate the presence of fusion genes or fusion RNA transcripts that are known to be associated with specific neoplasms. Demonstration of clonality is mainly done by investigation of *IGH* or *TCR* genes, although demonstration of rearrangement or mutation of any gene could be used as a marker of clonality.

Detecting clonal immunoglobulin and T-cell receptor rearrangements

Clonal populations of B or T lymphocytes can be detected by demonstrating clonal rearrangements of *IGH* or *TCR* genes using Southern blot analysis or PCR. The basic principle underlying the technique is similar since *TCR* and *IGH* genes are both made up of a number of variable (V), diversity (D) and joining (J) regions, present in germline DNA, which rearrange during lymphocyte development to produce a functioning gene. During rearrangement, single V, D and J regions are combined with a constant (C) region and simultaneously nucleotides (known as N) are added and removed between the V, D and J regions. This results in a unique DNA sequence in a cell and its progeny. Rearrangement of κ and λ genes is similar but these genes lack a D region.

Using Southern blot analysis, probes that detect either part of the *IGH* J region or the *TCR* β or γ chain genes are used to detect clonal rearrangements. In polyclonal populations of lymphocytes, there are a large number of different rearrangements and no single discrete band can be visualized. In a clonal population, since all the cells share the same rearrangement, there is a single discrete band on electrophoresis which is separate from the germline band.

The technique for detecting clonal rearrangements using PCR is somewhat different. Primers with sequences complementary to segments of the *IGH* V and J regions that are relatively constant are used to amplify part of the rearranged *IGH* gene. Differences in the numbers of nucleotides (N) inserted between the V and J regions during rearrangement result in multiple different sized segments of DNA being amplified in polyclonal populations, so that no discrete band is visualized.

In clonal populations, there is amplification of a single rearranged fragment which appears as a discrete band separate from the germline band on electrophoresis. The same principle is used to detect T-cell clones using probes complementary to sequences in the *TCR* γ and β chains.

Molecular genetic analysis has led to new concepts with regard to somatic hypermutation of antigen receptor (*IGH* and *TCR*) variable region genes in lymphoid cell maturation, with potential relevance to our understanding of the origins and behaviour of all lymphomas. Knowledge of such mechanisms in T-cell maturation is much less advanced than it is for the B-cell lineage.

Problems and pitfalls

Although PCR is more sensitive than Southern blotting at detecting small clonal populations, it will not detect all rearrangements. Approximately 80% of B-cell neoplasms will show clonal rearrangements on PCR using primers for *IGH* V regions, whereas the great majority will have a rearrangement detectable by Southern blot analysis. Hence caution is required in interpreting negative PCR results. The likelihood of detecting *IGH* gene rearrangement by PCR varies between different types of lymphoma, in one study ranging from around 40% with follicular lymphoma to around 80% with mantle cell and small lymphocytic lymphomas [26]. The negative results in follicular and certain other lymphomas are consequent on the high rate of somatic mutation which is responsible for a failure of consensus primers to bind to rearranged genes [24].

It should also be noted that rearrangement of *IGH* and *TCR* genes is not lineage-specific. Rearrangement of κ or λ light chain genes is much more specific for the B-lymphocyte lineage than *IGH* gene rearrangement. Inappropriate gene rearrangement is quite frequently seen in acute lymphoblastic leukaemia and occurs, although less often, in lymphomas of mature T and B cells. In addition, *IGH* or *TCR* gene rearrangements are sometimes found in acute myeloid leukaemia.

It is likewise important to recognize that, although the detection of a clonal rearrangement usually indicates a neoplastic process, clonal *IGH* and *TCR* gene rearrangements have been detected in some reactive conditions.

Detection of leukaemia/lymphoma-associated fusion genes

As discussed earlier, many haematological neoplasms are associated with a specific non-random chromosomal abnormality. The genes involved in many of these rearrangements have been identified, permitting the use of molecular genetic techniques for their detection. Some translocations can be detected by PCR, by employing specific primers with sequences complementary to segments of DNA that flank the chromosomal breakpoints. The intervening segment across the breakpoint will only be amplified if the translocation is present. However, this technique is only applicable if the breakpoint occurs in a relatively constant position and the fusion gene is not too long. Many more translocations can be detected by RT-PCR. Translocations that can be detected by PCR or RT-PCR include t(9;22)(q34;q11) in chronic granulocytic leukaemia and some acute lymphoblastic leukaemias, t(14;18)(q32;q21) in follicular lymphoma, t(2;5)(p23;q25) in anaplastic large cell lymphoma and various translocations or inversions associated with acute myeloid leukaemia including t(8;21)(q22;q22), t(15;17)(q22;q21) and inv(16)(p13q22).

Advantages of PCR and RT-PCR are that they give a more rapid result than conventional cytogenetic analysis and do not require viable cells for metaphase preparations. The highly sensitive nature of PCR analysis also means that this technique can be used to detect very small numbers of neoplastic cells; consequently, the method can be used for the detection of minimal residual disease and early relapse. However, it should be noted that, using these sensitive techniques, fusion genes characteristic of leukaemia or lymphoma are sometimes detected in normal tissues or tissues showing only reactive changes. For example, the rearrangement characteristic of follicular lymphoma has been detected in tonsils removed surgically for reactive conditions.

Problems and pitfalls

Disadvantages, other than the possibility of contaminating DNA being amplified, include the fact that not all rearrangements can be detected. This is because of the necessity for a chromosomal abnormality to have been fully characterized so that

specific primers for each breakpoint can be designed. It should also be noted that, in contrast to standard cytogenetic analysis, molecular genetic techniques permit the detection only of those abnormalities that are being specifically sought. Nevertheless, many chromosomal rearrangements can be detected by PCR and RT-PCR and some such rearrangements are sufficiently common that these techniques are very practical for the rapid and precise categorization of cases of acute leukaemia and for confirming the diagnosis of certain categories of lymphoma.

Ultrastructural examination

Ultrastructural examination, in which the structure of cells is studied by electron microscopy, can be applied to peripheral blood and bone marrow but is little used in routine diagnostic haematology. The advances in immunophenotyping have rendered electron microscopy redundant in identifying M0 and M7 AML. It remains of some use in identifying small Sézary cells (Fig. 2.31) and in making a precise diagnosis in congenital dyserythropoietic anaemia.

Ultrastructural examination can also be applied to trephine biopsy specimens but it is rarely necessary for diagnosis. It can be used for the detection of Birbeck granules for confirming the diagnosis of Langerhans cell histiocytosis but immunohistochemistry, including the application of a CD1a monoclonal antibody, is an alternative more readily available technique that can be used for this purpose.

Bone marrow culture for assessment of haemopoietic progenitor cell numbers

Short- and long-term culture techniques for haemopoietic cells have found extensive use in research but have only limited roles in the diagnostic assessment of bone marrow disorders.

Short-term culture

The major current use of short-term culture in clinical practice is for assessment of harvested bone marrow or peripheral blood stem cells prior to their use for engraftment.

Short-term haemopoietic cultures are performed using cells suspended at a known starting concentration in methyl cellulose or agar supplemented

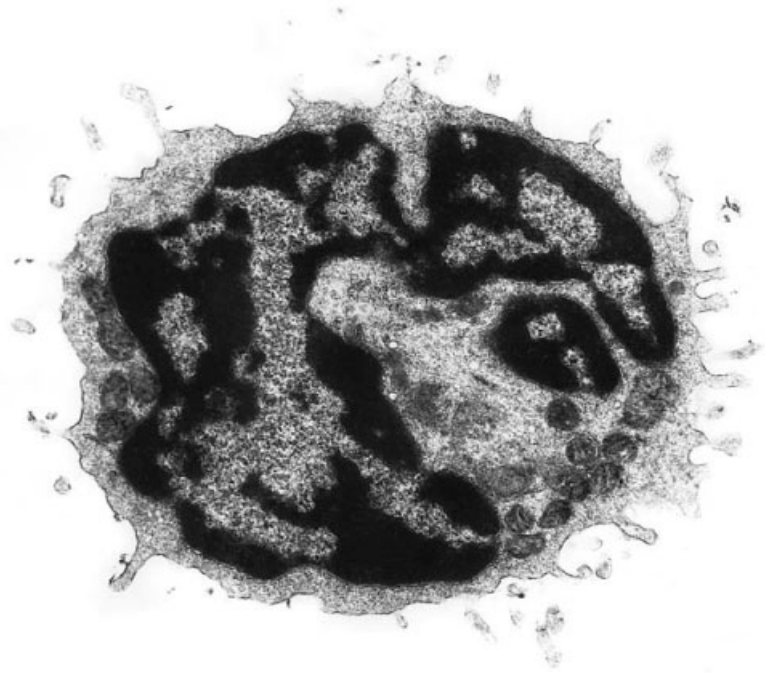


Fig. 2.31 Ultrastructural examination in Sézary syndrome showing a Sézary cell with a highly irregular nuclear outline. (By courtesy of Dr Estella Matutes, London.)

with culture medium, fetal bovine serum and growth-promoting substances such as granulocyte-macrophage colony-stimulating factor (GM-CSF), erythropoietin and thrombopoietin. They are then incubated at 37°C for 14 days, in a humidified atmosphere containing 5% CO₂. Depending upon the precise conditions of the assay, multipotential cells in the patient's (or donor's) sample will form colonies containing variable proportions of differentiating cells of various haemopoietic lineages. The starting cells are seeded at a sufficiently low concentration that individual colonies localized around each single multipotential parent cell can be visualized separately from any neighbouring colonies. The colonies can then be counted at low power magnification by standard light microscopy.

The most primitive multipotential cell type usually assayed in such a culture system is the mixed colony-forming unit (CFU-mix), which can generate erythroid bursts and colonies of granulocytic and monocytic cells. More commonly, however, GM-CSF, in the absence of other added growth factors, is used to supplement the culture medium and these conditions permit growth of mixed

granulocyte and monocyte colonies without any erythroid growth. This culture system constitutes the granulocyte-monocyte colony-forming unit (CFU-GM) assay and is the usual assay of haemopoietic cell growth potential in harvested marrow or mobilized peripheral blood stem cell collections prior to transplantation. Colony number correlates only loosely with CD34-positive cell counts in such collections. The CFU-GM provides an independent predictor of engraftment.

Occasionally, the erythropoietic potential of primitive haemopoietic cells requires assessment. This is done using the erythroid burst-forming unit (BFU-E) assay, in which erythropoietin is used to supplement the culture medium in the absence of granulocyte and monocyte growth-promoting factors. Primitive erythroid cells produce multiple, rather than single colonies, radiating as a so-called 'burst' around the progenitor cell (BFU-E), with each individual colony representing the offspring of a more mature erythroid precursor, the erythroid colony-forming unit (CFU-E). Erythroid colonies are readily seen by light microscopy because of the orange-red colour of their cytoplasmic haemoglobin.

Apart from the use of culture systems as assays for predicting haemopoietic function in transplantation, spontaneous colony formation (i.e. colony formation with no growth factor supplementation) is used by some laboratories to assist in diagnosing chronic myeloproliferative disorders. Spontaneous megakaryocyte colony-forming unit (CFU-Meg) activity, spontaneous BFU-E activity, or both, is demonstrable in peripheral blood or bone marrow cells from many patients with essential thrombocythaemia. Spontaneous BFU-E also form from peripheral blood and bone marrow cells of patients with polycythaemia rubra vera. Blood or marrow cells from normal individuals and patients with reactive thrombocytosis or secondary polycythaemia do not usually show spontaneous BFU-E activity. However, they may occasionally give rise to CFU-Meg. This potential for false-positive results and a relatively high false-negative rate in true cases of essential thrombocythaemia and polycythaemia rubra vera, together with the cumbersome nature of the assays, have limited the diagnostic application of short-term colony-forming assays.

Long-term culture

Long-term cultures, in which haemopoietic precursor cells are seeded onto layers of pre-grown marrow stroma, can potentially assess the activity of stem cells even more primitive than those which survive in short-term cultures. Assay of seeded cells is achieved, once they have adhered to the stroma, by replacing liquid medium with methylcellulose or agar-containing semi-solid medium and assessing colony formation as above. This system is known as the long-term culture-initiating cell (LTC-IC) assay. It is mainly employed in research, despite its possible value in predicting engraftment. Long-term cultures have also been used for *ex vivo* purging and expansion of haemopoietic cells for engraftment but these approaches have yet to find widespread clinical application.

Bone marrow culture for micro-organisms

Bone marrow culture for micro-organisms, for example mycobacteria, *Leishmania donovani* or *His-*

toplasma capsulatum, can be of use in diagnosis and will be discussed in the next chapter.

References

- Rath CE and Finch CA (1948) Sternal marrow hemosiderin; a method for determining available iron stores in man. *J Lab Clin Med*, 33, 81–86.
- Gale E, Torrance J and Bothwell T (1963) The quantitative estimation of total iron stores in human bone marrow. *J Clin Invest*, 42, 1076–1082.
- Lundin P, Persson E and Weinfeld A (1964) Comparison of hemosiderin estimation in bone marrow sections and bone marrow smears. *Acta Med Scand*, 175, 383–390.
- Fong TP, Okafor LA, Thomas W and Westerman MP (1977) Stainable iron in aspirated and needle-biopsy specimens. *Am J Hematol*, 2, 47–51.
- Douglas AS and Dacie JV (1953) The incidence and significance of iron-containing granules in human erythrocytes and their precursors. *J Clin Pathol*, 6, 307–313.
- Bainton DF and Finch CA (1964) The diagnosis of iron deficiency anemia. *Am J Med*, 37, 62–70.
- Hansen HA and Weinfeld A (1965) Hemosiderin estimations and sideroblast counts in the differential diagnosis of iron deficiency and other anemias. *Acta Med Scand*, 165, 333–356.
- Wulfhekel U and Düllman J (1999) Storage iron in bone marrow plasma cells. *Acta Haematol*, 101, 7–15.
- Hayhoe FGJ and Quaglino D. *Haematological Cytochemistry*, 2nd edn. Churchill Livingstone, Edinburgh, 1988.
- Bain BJ. *Leukaemia Diagnosis*, 2nd edn. Blackwell Science, Oxford, 1999.
- Krause JR, Brubaker D and Kaplan S (1979) Comparisons of stainable iron in aspirated and needle biopsy specimens of bone marrow. *Am J Clin Pathol*, 72, 68–70.
- Bauermeister DE (1971) Quantification of bone marrow reticulin—a normal range. *Am J Clin Pathol*, 56, 24–31.
- Bain BJ. *Interactive Haematology Imagebank*. Blackwell Science, Oxford, 1999.
- Gratama JW, Bolhuis RLH and Van't Veer MB (1999) Quality control of flow cytometric immunophenotyping of haematological malignancies. *Clin Lab Haematol*, 21, 155–160.
- Matutes E, Bain BJ, Reilly J, Barnett D and Linch D (2000) Revised guideline on immunophenotyping in acute leukaemias and chronic lymphoproliferative disorders, in press.
- Kallakury BVS, Hartmann D-P, Cossman J, Gootenberg JE and Bagg A (1999) Posttherapy surveillance of B-cell precursor acute lymphoblastic leukemia: value

- of polymerase chain reaction and limitations of flow cytometry. *Am J Clin Pathol*, 111, 759–766.
- 17 Pileri SA, Ascano S, Milani M, Visani G, Piccioli M, Orcioni CF *et al.* (1999) Acute leukaemia immunophenotyping in bone-marrow routine sections. *Br J Haematol*, 105, 394–401.
 - 18 Sadahira Y, Kanzaki A, Wada H and Yawata Y (1999) Immunohistochemical identification of erythroid precursors in paraffin embedded bone marrow biopsy sections: spectrin is a superior marker to glycophorin. *J Clin Pathol*, 52, 919–921.
 - 19 Janckila AJ, Walton SP and Yam LT (1998) Species specificity of monoclonal antibodies to human tartrate-resistant acid phosphatase. *Biotech Histochem*, 73, 316–324.
 - 20 Fonatsch C and Streubel B. Classical and molecular cytogenetics. In: Huhn D (ed) *New Diagnostic Methods in Oncology and Hematology*. Springer, Berlin, 1998.
 - 21 Kearney L (1999) The impact of the new FISH technologies on the cytogenetics of haematological malignancies. *Br J Haematol*, 104, 648–658.
 - 22 Fletcher JA (1999) DNA in situ hybridization as an adjunct to tumor diagnosis. *Am J Clin Pathol*, 112 (Suppl. 1), S11–S18.
 - 23 Tsukasaki K, Imaizumi Y, Tawara M, Fujimoto T, Fukushima T, Hata T *et al.* (1999) Diversity of leukaemic cell morphology in ATL correlates with prognostic factors, aberrant immunophenotype and defective HTLV-1 genotype. *Br J Haematol*, 105, 369–375.
 - 24 Pittaluga S, Tierens A, Dadoo YL, Delabie J and de Wolf-Peeters C (1999) How reliable is histologic examination of bone marrow trephine biopsy specimens for the staging of non-Hodgkin lymphoma? A study of hairy cell leukemia and mantle cell lymphoma involvement of the bone marrow trephine specimen by histologic, immunohistochemical, and polymerase chain reaction techniques. *Am J Clin Pathol*, 111, 179–184.
 - 25 Neubauer A, Thiede C and Nagel S. Molecular biology. In: Huhn D (ed) *New Diagnostic Methods in Oncology and Hematology*. Springer, Berlin, 1998.
 - 26 Bagg A and Kallakury BVS (1999) Molecular pathology of leukemia and lymphoma. *Am J Clin Pathol*, 112 (Suppl. 1), S76–S92.
 - 27 Wickham CI, Boyce M, Joyner MV, Sarsfield P, Wilkins BS, Jones DB and Ellard S (2000) Amplification of PCR products in excess of 600 base pairs using DNA extracted from decalcified, paraffin wax embedded bone marrow trephine biopsies. *J Clin Pathol Mol Pathol*, 53, 19–23.
 - 28 Evans PAS and Morgan GJ (1999) Molecular diagnostics in haemato-oncology. *CME Bull Haematol*, 2, 94–99.
 - 29 Yee K, Anglin P and Keating A (1999) Molecular approaches to the detection and monitoring of chronic myeloid leukemia: theory and practice. *Blood Rev*, 13, 105–126.
 - 30 Foroni L, Harrison CJ, Hoffbrand AV and Potter MN (1999) Investigation of minimal residual disease in childhood and adult acute lymphoblastic leukaemia by molecular analysis. *Br J Haematol*, 105, 7–24.

THREE

INFECTION AND REACTIVE CHANGES

Infection

The response of the bone marrow to infection is very variable, depending on the nature and chronicity of the infection, the age of the subject and the presence of any associated diseases. The response differs according to whether the infection is bacterial, rickettsial, viral or fungal. The peripheral blood and bone marrow responses to infection are non-specific and similar changes occur in many other conditions, including trauma and other tissue damage, administration of growth factors, carcinoma, Hodgkin's disease, non-Hodgkin's lymphoma and auto-immune disorders such as systemic lupus erythematosus. Only a minority of patients with an infection show peripheral blood or bone marrow changes suggestive of a particular micro-organism.

Bacterial and rickettsial infection

Peripheral blood

In adults, the usual haematological response to an acute bacterial infection is neutrophil leucocytosis with a left shift (an increase of band forms and possibly the appearance of neutrophil precursors in the peripheral blood) (Fig. 3.1). The neutrophils usually show toxic granulation and may show Döhle bodies and cytoplasmic vacuolation. When there is very severe bacterial infection and in neonates, alcoholics and patients with reduced bone marrow reserve, neutrophilia does not occur but there is a left shift with the above 'toxic' changes in neutrophils. Certain bacterial infections, specifically typhoid, paratyphoid and tularaemia, are characterized by neutropenia rather than neutrophilia. In

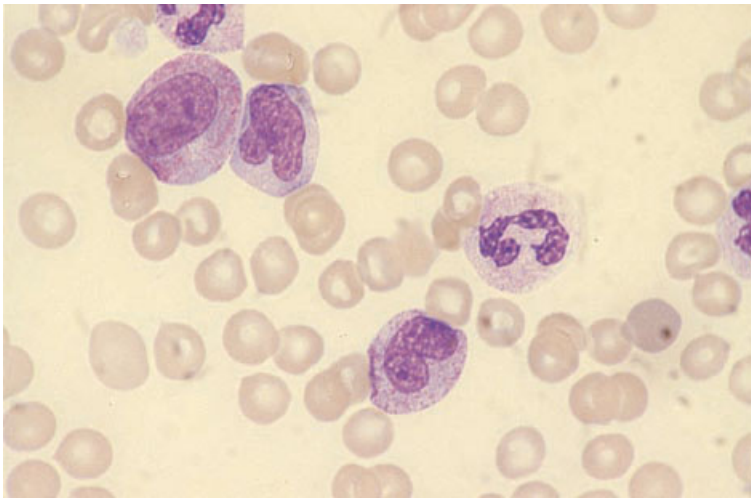


Fig. 3.1 PB, bacterial infection, left shift and toxic granulation. MGG $\times 940$.

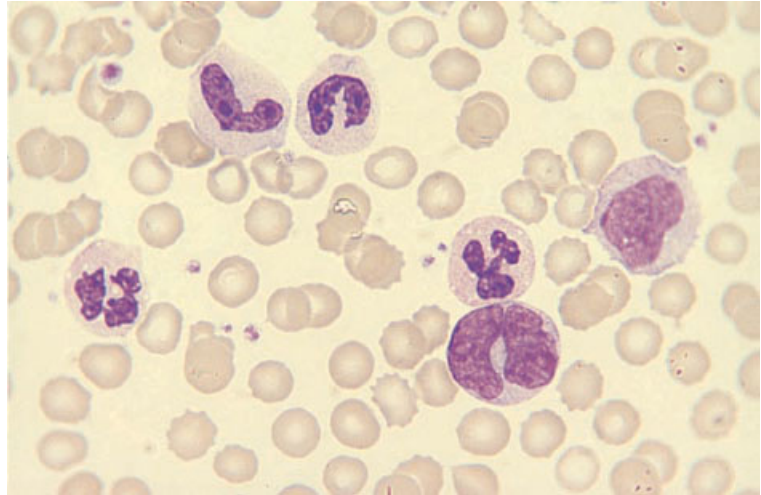


Fig. 3.2 PB, bacterial infection, monocytosis and neutrophilia. MGG $\times 940$.

severe infection, particularly if there is shock or hypoxia, nucleated red blood cells may appear in the blood, the presence of both granulocyte precursors and nucleated red cells being referred to as leuco-erythroblastosis. The lymphocyte count is reduced but a few atypical lymphocytes, including plasmacytoid lymphocytes, may be present; plasma cells are sometimes seen. The eosinophil count is reduced during acute infection but eosinophilia can occur during recovery. Children may respond to bacterial infection with lymphocytosis rather than neutrophilia, and certain bacterial infections, particularly whooping cough and sometimes brucellosis, are characterized by lymphocytosis. In bacterial infection, the platelet count is often reduced but sometimes increased.

Certain bacterial infections can be complicated by haemolytic anaemia. Infection by *E. coli* or *Shigella* species can be followed by a micro-angiopathic haemolytic anaemia as part of a haemolytic uraemic syndrome. Sepsis due to *Clostridium welchii* can be complicated by acute haemolysis with spherocytic red cells. Mycoplasma infection is commonly associated with the production of cold auto-antibodies so that red cell agglutinates are present in blood films made at room temperature and haemolytic anaemia sometimes occurs.

Rarely, neutrophils contain phagocytosed bacteria. The presence of bacteria, either extracellularly or within neutrophils, is usually seen only in over-

whelming infections, particularly when there is associated hyposplenism. In relapsing fever, however, the characteristic spiral organisms of *Borrelia* species appear episodically in the bloodstream and are seen lying free between red cells. In ehrlichial infections, organisms are often detectable within monocytes or granulocytes. They are detected in monocytes in human monocytic ehrlichiosis (caused by *Ehrlichia chaffeensis*) and in neutrophils in human granulocytic ehrlichiosis and human infection by *Ehrlichia ewingii* (the agent responsible for canine granulocytic ehrlichiosis) [1]. The detection of organisms within leucocytes is facilitated by examination of buffy coat films.

In more chronic infections, there may be anaemia, increased rouleaux formation, increased background staining and monocytosis (Fig. 3.2). Anaemia is initially normocytic and normochromic but, as the infection becomes increasingly chronic, the anaemia develops the characteristics of the anaemia of chronic disease with the cells produced being hypochromic and microcytic.

Pulmonary tuberculosis characteristically causes anaemia, increased rouleaux formation and, when severe, neutrophilia. Monocytosis occurs in a minority of patients. Monocytopenia is actually more common than monocytosis. In miliary tuberculosis, leucocytosis is uncommon and leucopenia is common. The lymphocyte count is reduced. A minority of patients have monocytosis. Pancytopenia

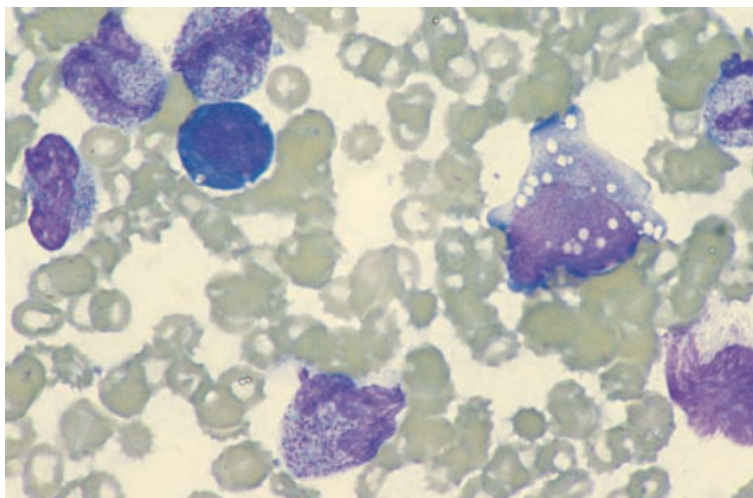


Fig. 3.3 BM aspirate film from a patient with severe infection showing heavy toxic granulation and vacuolation of neutrophil precursors. MGG $\times 940$.

may occur, sometimes as a consequence of haemophagocytosis and, less often, in association with bone marrow necrosis.

Rickettsial infections cause varied haematological effects which may include neutrophilia, neutropenia, lymphocytosis, the presence of atypical lymphocytes and thrombocytopenia which is sometimes severe.

Occasionally, severe infections are associated with a haematological picture which simulates leukaemia, designated a leukaemoid reaction (see below).

Bone marrow cytology

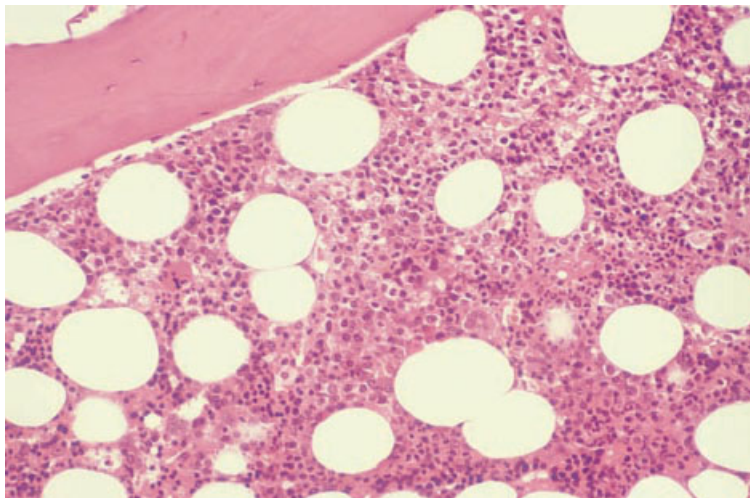
In severe bacterial infection, the bone marrow features reflect those of the peripheral blood. There is granulocytic hyperplasia with associated toxic changes (Fig. 3.3). In overwhelming infection, the marrow sometimes shows an increase of granulocyte precursors but with few maturing cells. Erythropoiesis is depressed and erythroblasts show reduced siderotic granulation. When there is thrombocytosis, megakaryocytes may be increased. Macrophages are increased and, in a minority of patients with severe infection, prominent haemophagocytosis occurs (see page 119). When infection is chronic, an increase of iron stores is apparent.

Microscopy or bone marrow culture occasionally

provides evidence of a specific infection. In Whipple's disease, the causative organisms may be seen within bone marrow macrophages [2]. In human monocytic ehrlichiosis, organisms can be detected in bone marrow monocytes, whereas in human granulocytic ehrlichiosis, caused by a related organism, they are present in granulocytes [3]. Bacteria visible within macrophages have also been reported in bacterial endocarditis. In typhoid fever, the bone marrow aspirate shows only non-specific features but bone marrow culture can be useful since it increases the detection rate by 50% in comparison with culture of the peripheral blood [4]. In brucellosis, the bone marrow is usually hypercellular with prominent haemophagocytosis and increased eosinophils and plasma cells [5]. Bone marrow cultures are occasionally positive when blood cultures are negative but, as the diagnosis can be made serologically, bone marrow aspiration is not indicated for this purpose.

In tuberculosis, the bone marrow aspirate shows non-specific features such as increased iron stores and an increase in macrophages, often with haemophagocytosis. Mycobacteria may be detected in a minority of cases using specific stains (Ziehl-Neelsen or auramine). Cultures should always be performed when this diagnosis is suspected. In lepromatous leprosy, bacilli may be apparent as negative images within bone marrow macrophages [6].

Fig. 3.4 BM trephine biopsy section, bacterial infection with leukaemoid reaction: there is increased cellularity and granulocytic hyperplasia with left shift; note emperipolesis of a mature neutrophil by a megakaryocyte. Paraffin-embedded, H&E $\times 195$.



Bone marrow histology

Severe bacterial infection leads to an increase in marrow cellularity due to granulocytic hyperplasia. There is often left shift of the granulocytic series, i.e. an increase in the numbers of immature precursors (myelocytes and promyelocytes) in relation to mature polymorphonuclear neutrophils (Fig. 3.4). However, the normal topographical arrangement of granulopoiesis is retained, with the more immature cells (mainly promyelocytes) found predominantly in the paratrabecular region [7]. Megakaryocytes are often increased in number [8]; they are morphologically normal, but there may be an increase in 'bare' megakaryocyte nuclei and increased emperipolesis. Erythropoiesis is often reduced although morphologically normal.

In more chronic bacterial infections, changes in other lineages become apparent. Bone marrow plasmacytosis is a common but non-specific response [9]. Very rarely, there may be up to 50% plasma cells in the marrow in reactive conditions including infections. The differential diagnosis of increased numbers of plasma cells in the marrow is discussed on page 166. In infections, plasma cells are distributed through the marrow in an interstitial manner, often with focal pericapillary accentuation. This may be accompanied by plasma cell satellitosis, in which a central macrophage is surrounded

by three or more plasma cells. The plasma cells have mature nuclear and cytoplasmic characteristics although there are often occasional binucleate forms and cells containing Russell bodies. Chronic infection is also associated with an increased frequency of reactive lymphoid aggregates (see page 144). Macrophages may be increased and commonly contain ingested granulocytes (Fig. 3.5). A wide variety of infectious agents, including bacteria, can cause a secondary haemophagocytic syndrome (see page 119). Stromal changes related to infection include prominent sinusoids, focal reticulin fibrosis and rarely, in very severe chronic infections, gelatinous change (see page 128). A decrease in marrow cellularity and loss of fat spaces usually accompany gelatinous transformation [10].

Mycobacterial infections can cause the same reactive changes as infection by other bacteria. However, haemophagocytosis and granuloma formation are particularly common. Whenever granulomas are present it is necessary to perform special stains such as a Ziehl-Neelsen stain or an auramine stain, in the latter instance mycobacteria being detected by fluorescence microscopy. In one study, immunohistochemistry with a polyclonal antibody to mycobacteria was found to be more sensitive than an acid-fast stain [11]. Occasional patients with mycobacterial infection have extensive necrosis which is indicative of poor prognosis. In those

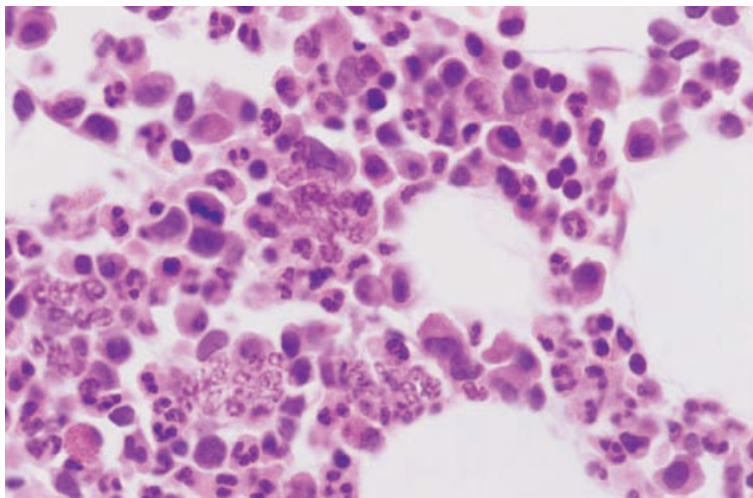


Fig. 3.5 Section of BM trephine specimen showing neutrophil shadows within macrophages in a patient with Hodgkin's disease; similar features are seen in bacterial infection. Paraffin-embedded, H&E $\times 940$.

with impaired immunity, there may be diffuse macrophage hyperplasia rather than granuloma formation. Macrophages may appear foamy. *Mycobacterium leprae* infection may cause granuloma formation and, in lepromatous leprosy, proliferation of foamy macrophages. Patients have also been reported in whom interstitial lepra bacilli were found in bone marrow sections, stained with a Fite stain, in the absence of any macrophage proliferation or granulomas [12].

In ehrlichiosis, the bone marrow is often hypercellular with both granulocytic and megakaryocytic hyperplasia. Granulomas are often present. Ehrlichial inclusions can be identified in macrophages [13] (Fig. 3.6). Ehrlichiae can be detected immunocytochemically [13].

Granuloma formation can also occur in rickettsial infections such as Q fever (infection by *Coxiella burnetii*) and Rocky Mountain spotted fever (infection by *Rickettsia rickettsii*).

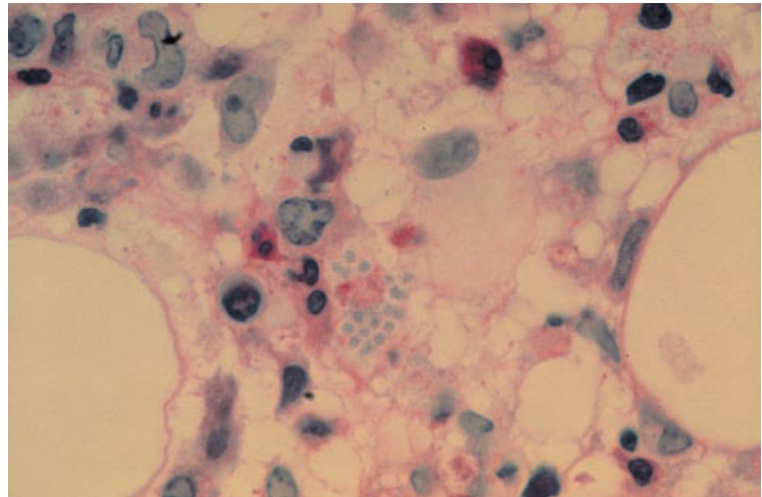
Problems and pitfalls

Mycobacteria are not always detectable with special stains in patients with haemophagocytosis or granulomas caused by miliary tuberculosis. Cultures are more sensitive than microscopy.

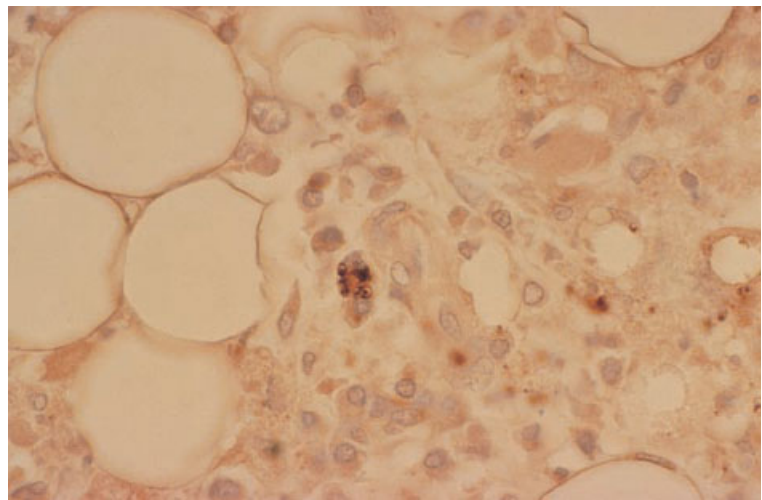
Acute myeloid leukaemia (AML) can be simulated by overwhelming infection with associated

cytopenia. Leukaemoid reactions can also simulate chronic myelomonocytic leukaemia (CMML). In a leukaemoid reaction, anaemia and thrombocytopenia are common. The white cell count is sometimes low with neutropenia and sometimes high; the blood film may show granulocyte precursors or be leuco-erythroblastic. Leukaemoid reactions are most often seen in association with very severe bacterial infection, particularly when there is co-existing megaloblastic anaemia. The bone marrow response to miliary tuberculosis can also simulate leukaemia. Toxic changes such as toxic granulation and neutrophil vacuolation are useful clues to the correct diagnosis. If necessary, a bone marrow examination makes the distinction. In severe infection there may be 'maturation arrest' with increased promyelocytes but there is no significant increase in blasts and the promyelocytes differ from those of acute hypergranular promyelocytic leukaemia in having prominent Golgi zones and no Auer rods.

The blood and bone marrow features of severe chronic infection may be difficult to distinguish from those of CMML since 'toxic' changes may be lacking. Consideration of the clinical features facilitates the distinction. It is imprudent to make a diagnosis of CMML in a patient with a significant infection unless there are dysplastic features of a type showing a strong association with the myelodysplastic syndromes (see Chapter 4).



(a)



(b)

Fig. 3.6 Intracellular ehrlichiae in a BM trephine biopsy section: (a) PAS stain with haematoxylin counterstain; (b) immunoperoxidase stain with anti-ehrlichial IgG antibody. (By courtesy of Dr CD Paddock, Dr RL Kerschmann and Dr BG Herndier, San Francisco, reprinted by permission of the *New England Journal of Medicine*, **329**, 1165, 1993.)

Viral infection

Peripheral blood

Viral infections usually provoke lymphocytosis. Often the cells that are produced are morphologically fairly normal but sometimes they have atypical features. Infectious mononucleosis consequent on infection by the Epstein–Barr virus (EBV) is characterized by the production of large numbers of atypical lymphocytes, often referred to as atypical mononuclear cells (Fig. 3.7). These are pleomorphic, usually large, and often have abun-

dant basophilic cytoplasm and nuclei with a diffuse chromatin pattern and nucleoli. The presence of large numbers of atypical mononuclear cells is not specific for EBV infection; this may also be a feature of primary infection by other viruses (cytomegalovirus (CMV), human immunodeficiency virus (HIV), hepatitis A and adenovirus) and of toxoplasmosis, as well as being seen in hypersensitivity reactions to drugs. Smaller numbers of similar atypical lymphocytes are seen in a wider variety of infective (and non-infective) conditions. Viral infections which may be associated with marked lymphocytosis without many atypical features

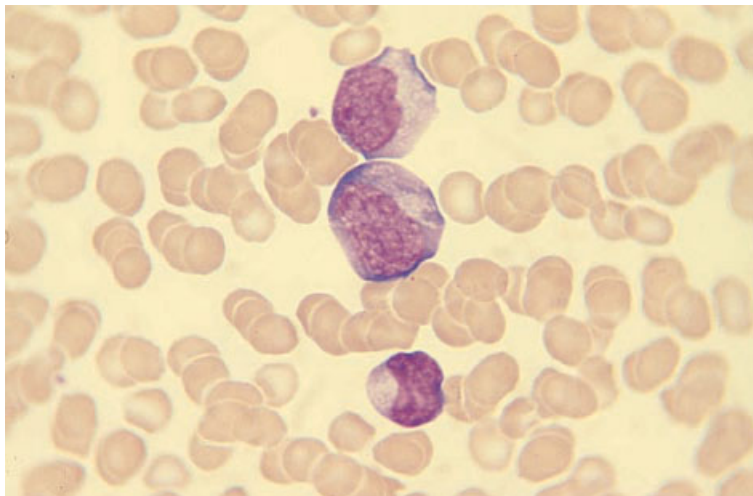


Fig. 3.7 PB, infectious mononucleosis, atypical lymphocytes. MGG $\times 940$.

include those due to Coxsackie virus, various adenoviruses and HIV; other haematological abnormalities produced by HIV are discussed below (see page 124). In immunosuppressed hosts, e.g. following bone marrow transplantation, CMV infection can cause neutropenia, thrombocytopenia and pancytopenia. CMV infection in such patients may be associated with very large virus-infected cells, which are probably endothelial in origin, in the feathered edge of the film [14]. Viral infections, particularly those due to herpesviruses, may be associated with a haemophagocytic syndrome (see page 119) with the peripheral blood showing resultant pancytopenia. In a few individuals, viral hepatitis, particularly non-A non-B non-C hepatitis, is followed in a period of a few weeks or months by pancytopenia caused by aplastic anaemia. In certain subjects who are unable to mount a normal immune response to EBV, infection by this virus may also be followed by chronic pancytopenia due to bone marrow aplasia. Parvovirus commonly causes transient pure red cell aplasia but, unless red cell survival is reduced, this may go unnoticed; less often, it is a cause of neutropenia or thrombocytopenia.

Viral infections may be complicated by cytopenias consequent on either damage to cells by immune complexes or auto-antibody production. Rubella and, less often, other viral infections may be followed by transient thrombocytopenia caused by damage to platelets by immune complexes. Infectious mononucleosis may be complicated by either auto-immune thrombocytopenia or auto-immune

haemolytic anaemia due to a cold antibody with anti-i specificity; in these cases, there are red cell agglutinates and occasional spherocytes. Rarely, viral infections, particularly measles, are followed by acute haemolysis due to an auto-antibody with anti-P specificity ('paroxysmal' cold haemoglobinuria); in these cases, the blood film usually shows only occasional spherocytes and subsequently polychromasia. Contrary to what might be anticipated from the name, there is only a single episode of haemolysis.

Chronic hepatitis C infection can be a cause of thrombocytopenia. Some patients develop mixed cryoglobulinaemia with associated haematological features (see page 355). A single case has also been reported of pure red cell aplasia associated with hepatitis C infection [15].

In patients with impaired immunity, EBV infection may be associated with a lymphoproliferative disorder which may evolve to lymphoma (see page 319).

If fresh tissue is available, molecular techniques can be used for the detection of viral infection. For example, in suspected EBV infection, reverse transcriptase polymerase chain reaction (RT-PCR) can be used to detect messenger RNA (mRNA) for EBNA-1 and -2, LMP-1, -2A and -2B, BZLF1 (ZEBRA 'protein') and BCRF1 (viral IL10).

Bone marrow cytology

In viral infection, the bone marrow shows an increase

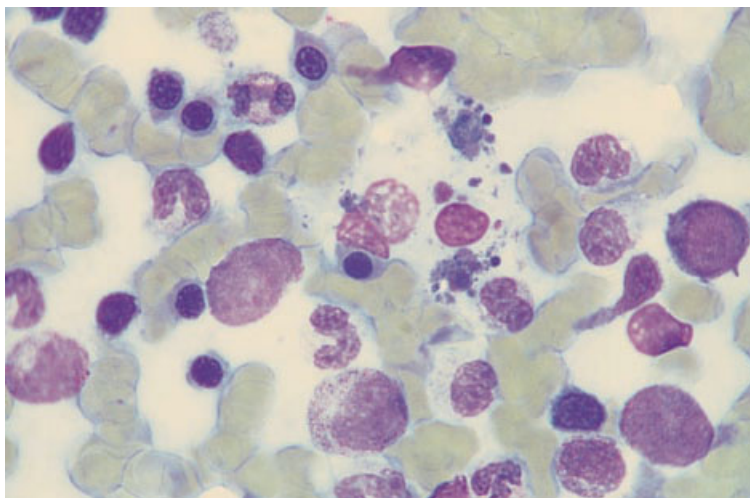


Fig. 3.8 BM aspirate. Platelets within a macrophage in a patient with severe thrombocytopenia during acute CMV infection. MGG $\times 960$.

of lymphocytes, either typical or atypical. In some infections, particularly by herpesviruses, haemophagocytosis is prominent (see page 119). In immunosuppressed hosts, CMV infection can also cause marked bone marrow hypocellularity with suppression of all lineages [16]. When haemolytic anaemia occurs, e.g. in infectious mononucleosis, erythroid hyperplasia will be apparent. In pure red cell aplasia consequent on parvovirus B19 infection there are prominent, very large proerythroblasts with a striking lack of more mature cells. In one patient with parvovirus-induced pancytopenia there were also large atypical cells of granulocyte lineage which were shown to contain viral antigens [17]. Parvovirus infection can be confirmed by immunofluorescence with monoclonal antibodies to either a capsid antigen [17] or a nuclear antigen, or by *in situ* DNA hybridization. When viral infections are complicated by thrombocytopenia due to increased platelet destruction, megakaryocytes are present in normal or increased numbers. Occasionally, platelets are visible within bone marrow macrophages (Fig. 3.8).

Bone marrow histology

Viral infections may lead to an increase of bone marrow lymphocytes, plasma cells and macrophages, with or without haemophagocytosis. Atypical lymphoid cells, morphologically identical to those in the peripheral blood, can be seen in the marrow in EBV and CMV infection; in CMV infection, eosinophilic intranuclear inclusions may be

seen, albeit rarely, in endothelial cells and in cells, probably macrophages, within granulomas or interspersed among haemopoietic cells [18]. Atypical lymphoid cells with intranuclear viral inclusions have also been detected in human herpesvirus 6 (HHV6) infection [19]. In the post-transplant setting, CMV [16] and HHV6 [20] infection can cause severe bone marrow hypoplasia. The presence of CMV (Fig. 3.9) and EBV can be confirmed by immunohistochemistry using monoclonal antibodies (Table 3.1). However, it should be noted that, even in patients with generalized CMV infection, it is unusual for virus-infected cells to be detectable in the bone marrow. Pure red cell aplasia is characteristically seen in infection by parvovirus B19 and is readily detected in trephine biopsy sections (see page 376). Very occasionally, it has been associated with erythroid hyperplasia, sometimes with marked dyserythropoiesis [25]. Parvovirus B19 capsid antigens may be detectable by immunohistochemistry although this technique is less sensitive than PCR [26]; curiously, in one study, the positive cells were among the few late erythroid cells while the giant proerythroblasts were negative [26]. Viral infections, particularly herpesvirus infections, can lead to formation of small non-caseating granulomas (see Table 3.3). Chronic hepatitis B and hepatitis C infection may be associated with the presence of reactive lymphoid nodules [27]. Hepatitis C infection can also be complicated by the development of low grade, B-cell lymphoma, often supervening in a patient with

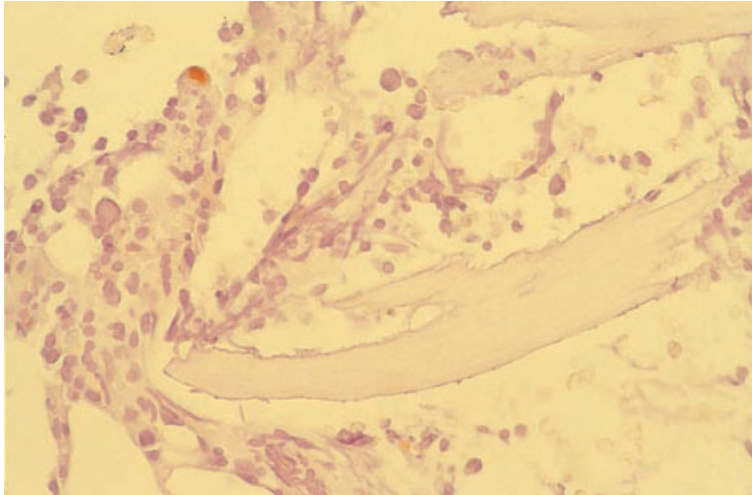


Fig. 3.9 BM trephine biopsy section from a renal transplant patient with CMV infection showing one positive cell (top left). Paraffin-embedded, immunoperoxidase with Dako-CMV McAb $\times 940$.

Table 3.1 Techniques applicable to trephine biopsy specimens for confirmation of certain viral infections.

Virus	Technique	Monoclonal antibody or other specific reagent
Parvovirus B19	Immunohistochemistry with detection of a nuclear antigen or a viral capsid antigen <i>In situ</i> hybridization for detection of viral DNA	R92F6 (Novocastra) directed at capsid proteins VP1 and VP2 Digoxigenin-labelled parvovirus B19 DNA probe [21]
Cytomegalovirus (CMV)	Immunohistochemistry with detection of nuclear and cytoplasmic antigen <i>In situ</i> hybridization for detection of viral DNA	AAC10 (Dako) directed at CMV lower matrix protein pp65; QB1/06 (Novocastra) directed at CMV late antigens CMV probe ISH kit (Novocastra) or CMV Bioprobe (ENZO Diagnostics) [22]
Epstein-Barr virus (EBV)	Immunohistochemistry for detection of latent membrane protein-1 (LMP-1)* or Epstein-Barr nuclear antigen-2 (EBNA-2) in latent infection EBV early lytic antigens Immunohistochemistry for detection of BZLF ('ZEBRA' protein) in lytic EBV infection <i>In situ</i> hybridization for detection of nuclear Epstein-Barr early RNA (EBER) Southern blot analysis to detect EBV clonality (dependent on the number of terminal repeats) [24]	CS1-4 directed at LMP-1 (Dakopatts or Novocastra); PE2 directed at EBNA-2 (Dako and Novocastra) G3-E31 (Novocastra) directed at 50–52 kD diffuse early antigen; W1-F2 (Novocastra) directed at 85 kD restricted early antigen Clone β Z.1 directed at β ZLF1 (Dako) EBER1 PNA probe/FITC kit (Dako) or EBER-probe ISH kit (Novocastra)
Herpes simplex	Immunohistochemistry for detection of various shared and type-specific antigens	Rabbit polyclonal antiserum (Dako)

* LMP McAb is a cocktail of clones (CS1-4) raised against a fusion protein containing 189 amino acids of the terminus of LMP. Cross-reaction with normal early myeloid and erythroid precursors, leukaemic myeloblasts and leukaemic lymphoblasts has been reported [23] but this has not been our experience when using formalin fixation and EDTA decalcification; we have observed no false-positive staining in normal bone marrow or in AML, and in ALL we have observed weak nuclear staining only, whereas the specific product would be cytoplasmic.

mixed type II cryoglobulinaemia; the lymphoid infiltrate is then monoclonal and more extensive.

As already noted, immunohistochemistry is useful in the diagnosis of viral infections. The special techniques applicable to trephine biopsies for confirmation of infection by specific viruses are summarized in Table 3.1.

Problems and pitfalls

Lymphocytosis with atypical lymphocytes can be confused with a lymphoproliferative disorder, particularly with mantle cell lymphoma and the mixed cell type of chronic lymphocytic leukaemia in which neoplastic cells are pleomorphic. When there is diagnostic difficulty, immunophenotyping is indicated to demonstrate or exclude a clonal proliferation of B lymphocytes.

Virus-induced haemophagocytic syndrome can be confused with malignant histiocytosis. The latter is a very rare condition and the diagnosis should be made with caution. It is characterized by proliferation of very immature cells of monocyte-macrophage lineage which, in contrast to the cells of virus-induced haemophagocytic syndrome, usually show little phagocytic activity. Marked haemophagocytosis therefore suggests that macrophage activation is reactive. Virus-induced haemophagocytosis can also be confused with other reactive haemophagocytic syndromes, including those associated with some T-cell and NK-cell lymphomas.

Fungal infection

Peripheral blood

Fungal infections have no specific haematological features. Some fungal diseases, for example actinomycosis and coccidioidomycosis, are associated with neutrophilia. *Aspergillus* and other fungi may evoke an allergic response and be associated with eosinophilia. When systemic fungal infections occur in immunocompromised hosts, fungi such as candida or histoplasma are occasionally seen in the peripheral blood. Candida may also be seen in blood films when there is infection originating from a colonized indwelling venous line.

Bone marrow cytology

Fungi are rarely seen in the bone marrow aspirate in immunologically normal subjects. Histoplasma is an exception, organisms sometimes being detected within bone marrow macrophages. Fungi are much more often detected in bone marrow aspirates from severely immunocompromised patients, such as those with HIV infection or following bone marrow transplantation, when *Candida albicans*, *Aspergillus fumigatus*, *Histoplasma capsulatum* (Fig. 3.10), *Cryptococcus neoformans* (Fig. 3.11) and *Penicillium marneffei* (Fig. 3.12) [28] may be seen. Organisms may be within macrophages or lying free. Although fungi may be seen in bone marrow aspirate films, a trephine biopsy is usually more sensitive in the

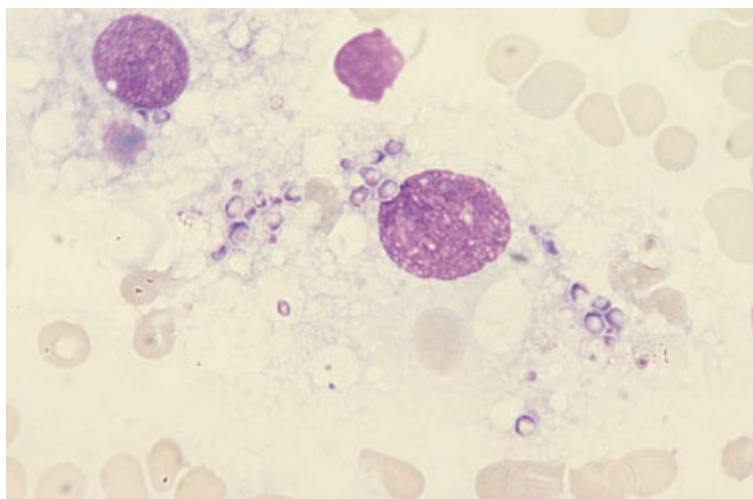


Fig. 3.10 BM aspirate. Histoplasmosis in a patient with AIDS, showing numerous organisms within a macrophage. MGG $\times 940$.

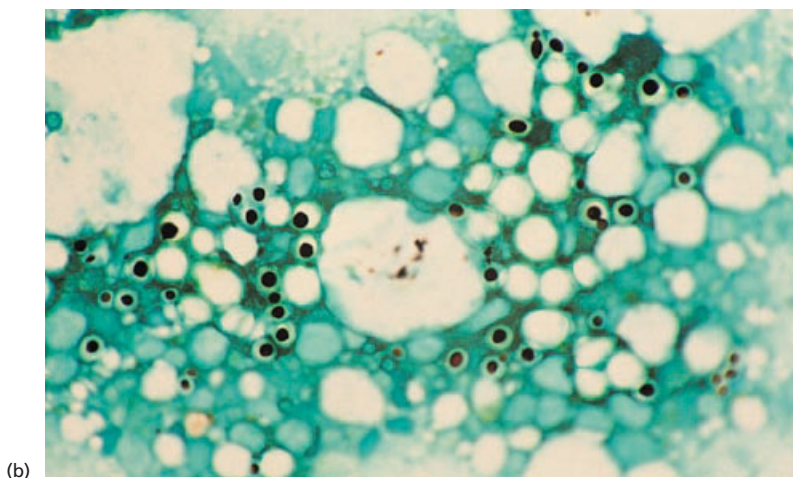
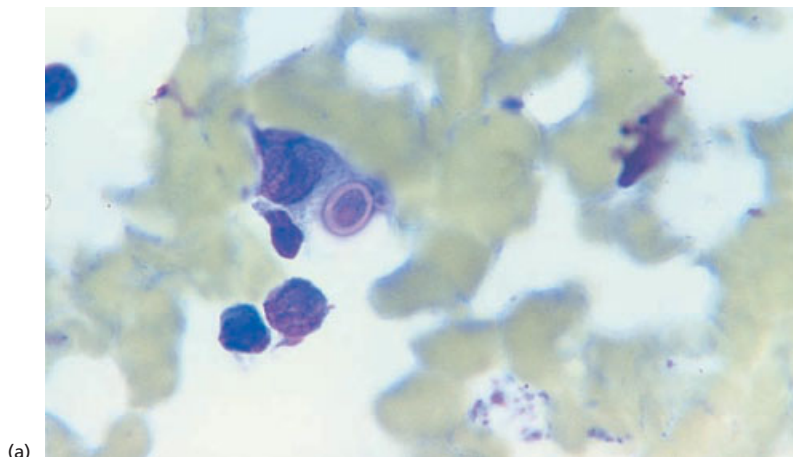


Fig. 3.11 (a) BM aspirate. Budding cryptococcus in an HIV-positive man. MGG $\times 960$. (b) BM aspirate. Budding cryptococcus in another HIV-positive man. GMS $\times 960$. (By courtesy of Dr Christine Costello, London.)

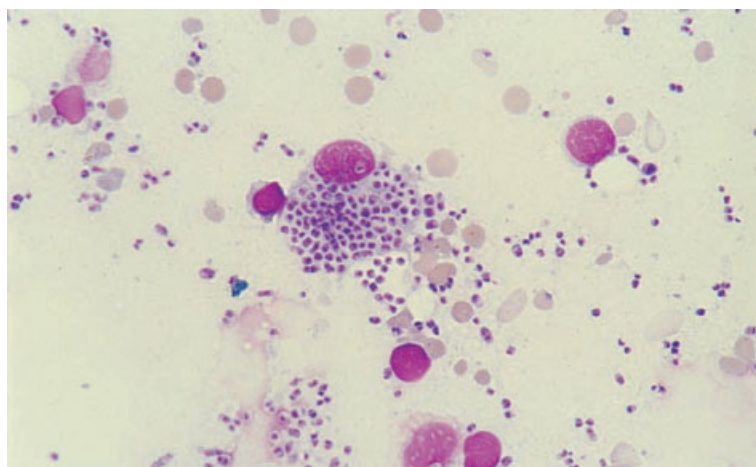


Fig. 3.12 BM aspirate. *Penicillium marneffei* in an HIV-positive man. MGG $\times 960$. (By courtesy of Dr KF Wong, Hong Kong.)

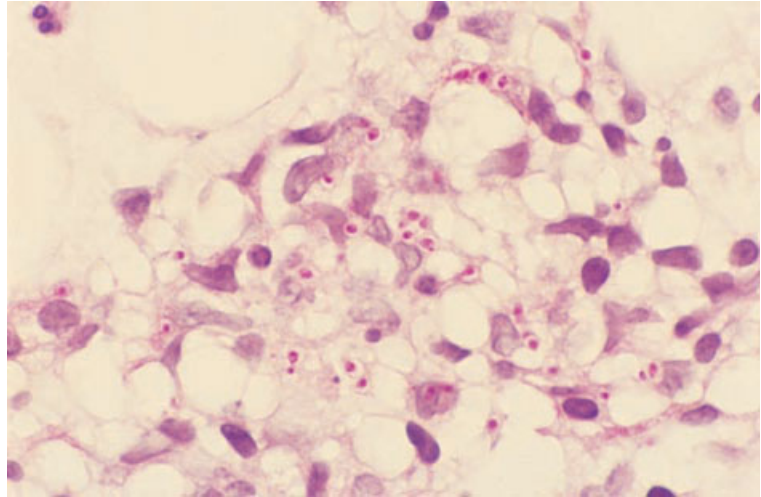


Fig. 3.13 BM trephine biopsy section from a patient with AIDS showing *Histoplasma capsulatum*. Paraffin-embedded, PAS-diastase $\times 960$.

detection of fungal infection. Fungi may also be cultured from the bone marrow, sometimes when peripheral blood culture is negative.

Bone marrow histology

In systemic fungal infections, particularly in immunocompromised patients such as those with acquired immune deficiency syndrome (AIDS) (see

page 123), organisms can sometimes be identified in the marrow (Figs 3.13–3.15). Usually fungi are within macrophages, including the altered macrophages comprising granulomas, or are associated with necrotic tissue. Rarely they are detectable only within megakaryocytes [29].

The histological features of the important fungi that can be seen in histological sections of bone marrow are summarized in Table 3.2. Cases of

Table 3.2 Differential diagnosis of fungal and protozoal pathogens.

Species	Tissue forms	Special stains
Fungi		
<i>Candida albicans</i>	Non-branching pseudohyphae and small (2–4 μm) budding yeast forms	PAS* and GMS
<i>Cryptococcus neoformans</i>	Yeast forms (5–10 μm), thick capsule, narrow-based unequal buds	PAS*, GMS and mucicarmine
<i>Histoplasma capsulatum</i>	Small (2–5 μm) yeast forms†	PAS* and GMS
<i>Penicillium marneffeii</i>	Small (2–6 μm) round or oval to sausage shape containing reddish-purple dot-like structures and sometimes septae	PAS* and GMS
Protozoa		
<i>Toxoplasma gondii</i>	Tachyzoites (ovoid 3 \times 6 μm , tiny nucleus, 'single-dot' appearance); occasionally cysts with numerous small bradyzoites	Giemsa, PAS‡, IHC
<i>Leishmania donovani</i>	Small (3 μm) intracellular amastigote, nucleus and paranuclear kinetoplast give 'double-dot' appearance	Giemsa

PAS, periodic acid–Schiff; GMS, Grocott's methenamine silver stain; IHC, immunohistochemistry.

* Pre-treatment with diastase to remove glycogen considerably reduces positive staining of neutrophils and megakaryocytes and facilitates the detection of micro-organisms.

† *Histoplasma capsulatum* var *duboisii*, which is the cause of African histoplasmosis, is a larger organism, 12–15 μm in diameter [30].

‡ Tachyzoites PAS-negative, cysts and bradyzoites usually PAS-positive [31].

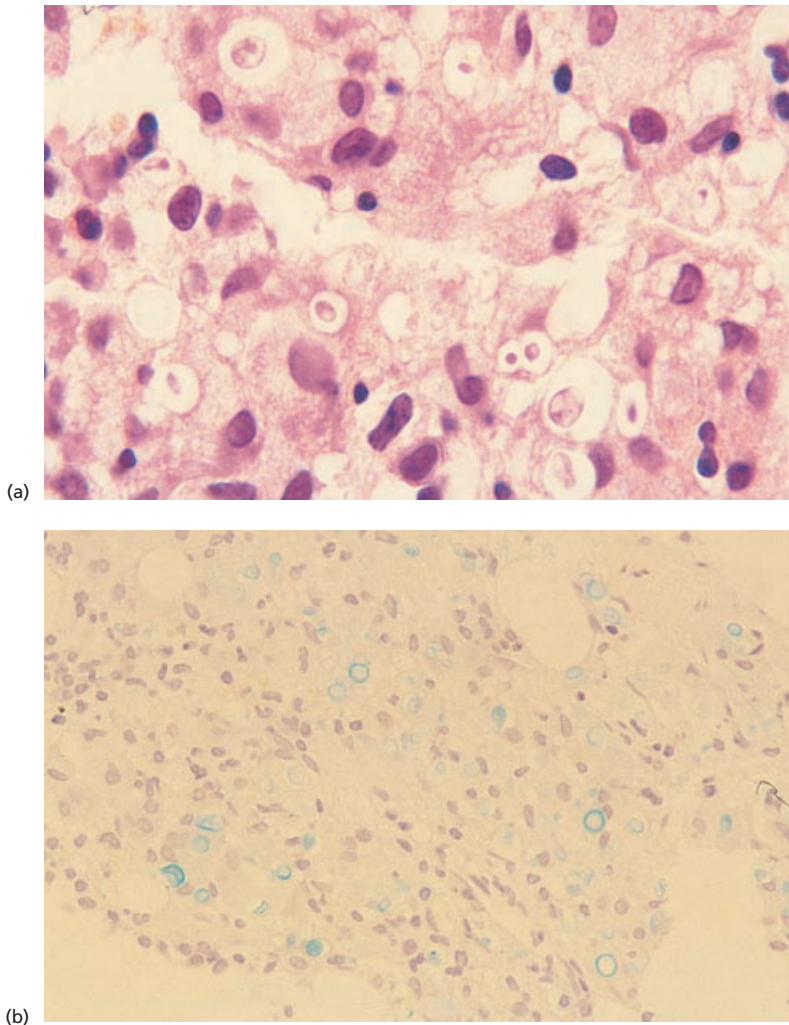


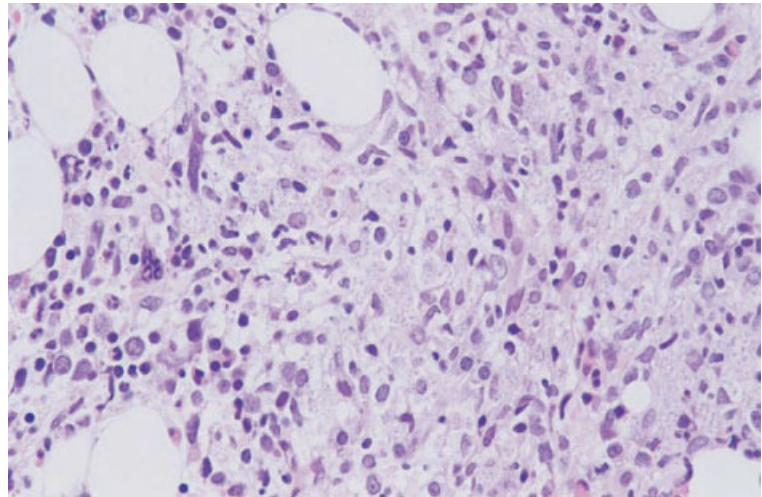
Fig. 3.14 BM trephine biopsy section, *Cryptococcus neoformans* in a patient with AIDS. Paraffin-embedded: (a) H&E $\times 960$; (b) alcian blue $\times 376$.

disseminated infection caused by unusual fungi—not previously known to be pathogenic—are also being recognized in patients with AIDS [32].

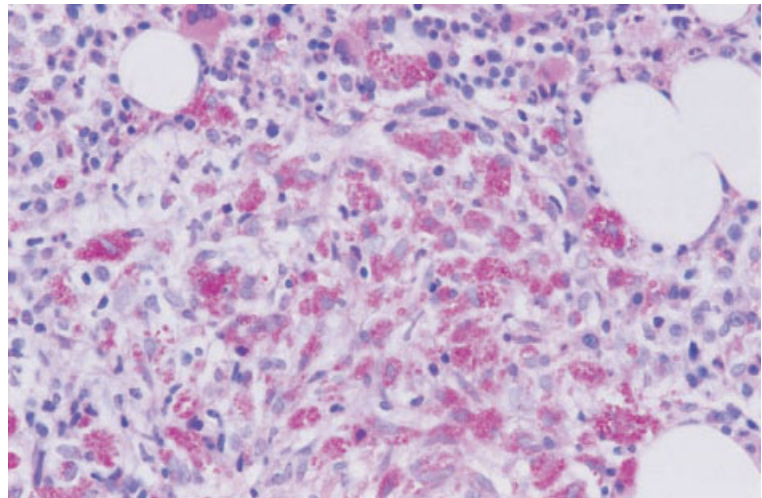
Problems and pitfalls

Diagnosis of fungal infection does not present any difficulty when organisms are detectable in the bone marrow. However, when there are granulomas without detectable micro-organisms, or if there are only reactive changes, diagnosis can be difficult. Bone marrow culture is more sensitive than bone marrow microscopy for the detection of fungi and

can be employed when bone marrow examination is done for investigation of a fever, particularly in immunosuppressed patients. For example, bone marrow cultures are positive in 90% of patients with disseminated histoplasmosis whereas the detection rate with microscopy of bone marrow aspirates is considerably lower and the proportion of patients with granulomas is lower still [33,34]. However, it should be noted that peripheral blood cultures for histoplasma have almost as high a success rate as bone marrow cultures [34]. Supplementary tests, such as testing urine or serum for cryptococcal or histoplasma antigens, can also be useful. The test for



(a)



(b)

Fig. 3.15 Section of BM trephine biopsy specimen in a patient with AIDS with *Penicillium marneffeii* infection. Paraffin-embedded: (a) H&E $\times 376$; (b) PAS $\times 376$.

histoplasma antigen in the urine is highly sensitive and in endemic areas this test can avoid the need for a bone marrow examination [35]. PCR for the detection of aspergillus DNA can also be useful.

Parasitic diseases

Peripheral blood

The presence of parasites within the bowel may lead to blood loss with consequent iron deficiency anaemia. Eosinophilia is also common in patients with helminth infections. In malaria and

babesiosis, parasites are seen within red cells. Malaria is associated with haemolytic anaemia and sometimes thrombocytopenia. Atypical lymphocytes are present both in malaria and in some patients with hyper-reactive malarial splenomegaly. Toxoplasmosis can be associated with lymphocytosis and the presence of considerable numbers of atypical lymphocytes. Leishmaniasis can cause leucopenia and phagocytosed parasites are occasionally detectable within peripheral blood monocytes or neutrophils. Other parasites detectable free in the peripheral blood are trypanosomes and microfilariae.

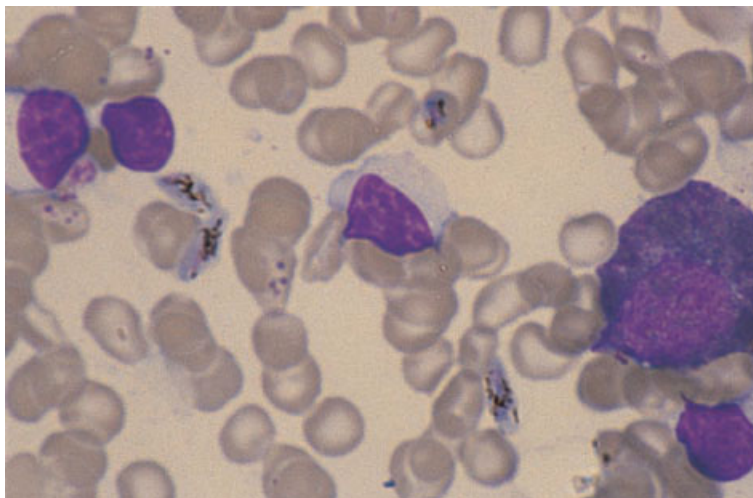


Fig. 3.16 BM aspirate from a patient with falciparum malaria showing gametocytes. MGG $\times 960$. (By courtesy of Dr D Swirsky, Leeds.)

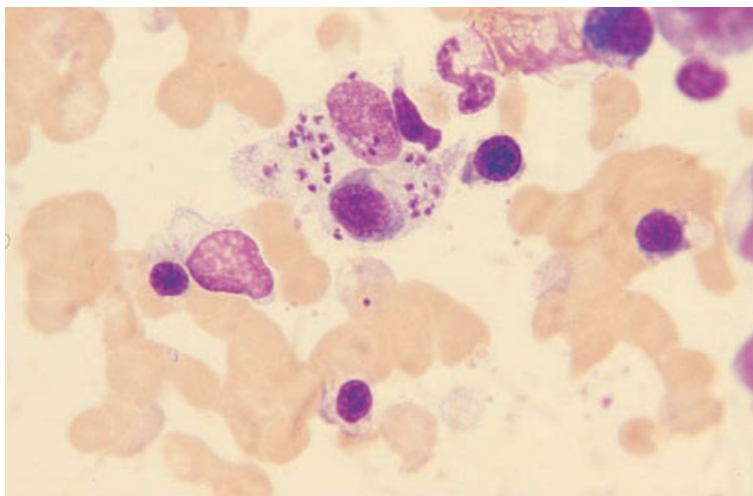


Fig. 3.17 BM aspirate, leishmaniasis, showing a macrophage containing numerous organisms which, in addition to a nucleus, have a small paranuclear kinetoplast giving them a characteristic 'double-dot' appearance. MGG $\times 940$.

Bone marrow cytology

Malaria parasites are sometimes detected, in red cells or neutrophils, in a bone marrow aspirate (Fig. 3.16), although bone marrow aspiration is not a recommended diagnostic method if malaria is suspected. The bone marrow in malaria also shows hypercellularity due to erythroid and granulocytic hyperplasia, dyserythropoiesis, giant metamyelocytes and increased eosinophils, lymphocytes, plasma cells and macrophages [36,37]. There may be haemophagocytosis and macrophages can also

contain malarial pigment. In hyper-reactive malarial splenomegaly there may be a marked increase in bone marrow lymphocytes [38]. A bone marrow aspirate is very useful in the diagnosis of leishmaniasis (Fig. 3.17) and is a recommended diagnostic method when this diagnosis is suspected. Trypanosomes are sometimes detected in the bone marrow, but less often than leishmania. Detection is more common in immunosuppressed patients [39]. Microfilaria are occasionally observed in a bone marrow aspirate in immunologically normal hosts (Fig. 3.18). Other parasites are rarely detected in the

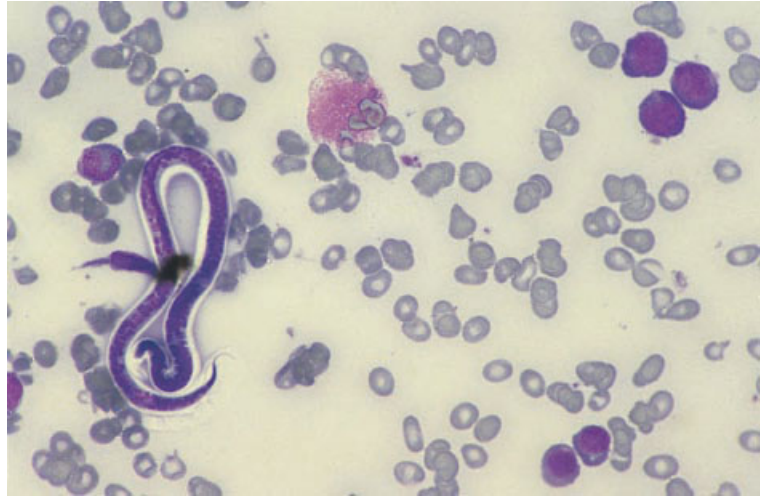

Fig. 3.18 BM aspirate from a patient with filariasis showing a microfilaria. MGG $\times 470$. (By courtesy of Mrs Seema M Zainal, Bahrein.)

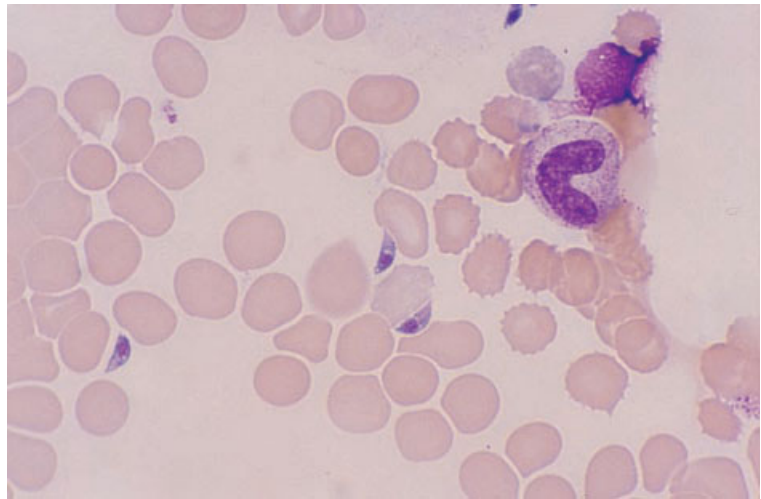


Fig. 3.19 BM aspirate showing *Toxoplasma gondii* in a patient who had had a renal transplant. MGG $\times 940$. (By courtesy of Dr R Cobcroft, Brisbane.)

bone marrow, except in severely immunosuppressed patients in whom pneumocystis [40] and toxoplasma (Fig. 3.19) have sometimes been found. Features useful in identifying various protozoan parasites are shown in Table 3.2.

An increase of bone marrow eosinophils and their precursors is often apparent when there is helminth infection.

Bone marrow histology

A bone marrow biopsy in malaria usually shows

increased cellularity and increased macrophage activity, often with haemophagocytosis. During acute attacks of malaria, sinusoids may be packed with parasitized red cells [37]. In patients who have suffered recurrent attacks of malaria, the bone marrow may be slate grey or black due to deposition of malaria pigment. It is important to distinguish malaria pigment (haemozoin) from formalin pigment.

In visceral leishmaniasis, there may be granuloma formation. In more severe cases there is a diffuse increase of macrophages. The organisms are

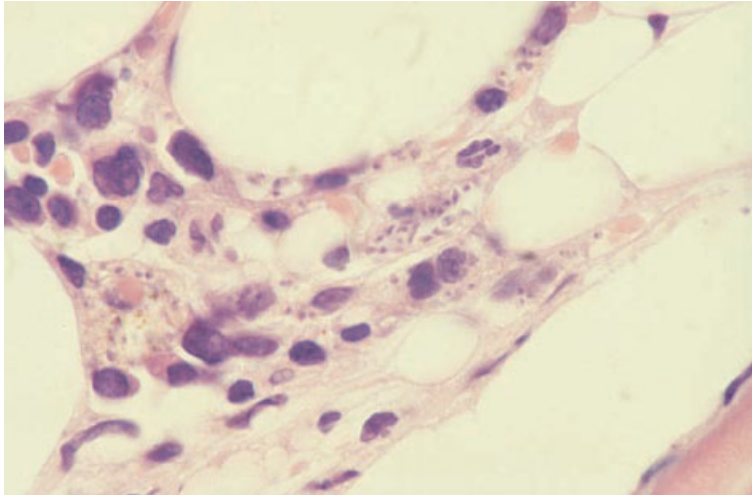


Fig. 3.20 BM trephine biopsy section from an HIV-positive man showing *Leishmania donovani* within macrophages. H&E $\times 960$.

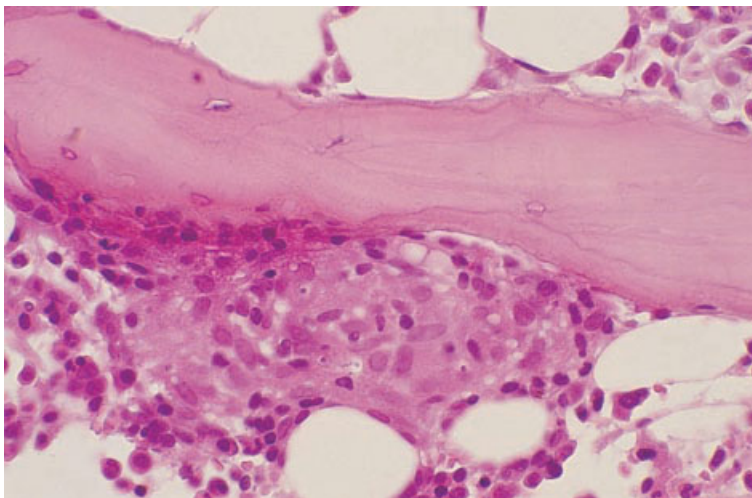


Fig. 3.21 BM trephine biopsy section, toxoplasmosis, showing a small granuloma in a paratrabecular position containing several small organisms with a single nucleus consistent with the tachyzoites of *Toxoplasma gondii*; fungal stains were negative and the patient had raised serum IgM antibodies to *Toxoplasma*. Plastic-embedded, H&E $\times 390$.

often seen within macrophages (Fig. 3.20); their small size ($3\ \mu\text{m}$) sometimes leads to their being confused with the fungus *Histoplasma capsulatum*. However, leishmania fail to stain with periodic acid–Schiff (PAS) or silver stains and a Giemsa stain will demonstrate a small paranuclear basophilic body, known as the kinetoplast, giving the organism a characteristic ‘double-dot’ appearance.

Granulomas are also seen in toxoplasmosis; rarely, in immunosuppressed individuals, organisms are seen in the marrow (Fig. 3.21). These usu-

ally take the form of tachyzoites, which are $3\text{--}6\ \mu\text{m}$ in diameter and have a tiny single nucleus. Occasionally, cysts containing numerous bradyzoites are present. These are of a similar size to tachyzoites and also have a single nucleus; the lack of a kinetoplast helps to distinguish them from leishmania. Toxoplasma can be identified with a polyclonal antibody.

Microsporidiosis rarely involves the bone marrow but involvement has been reported at autopsy in a patient with AIDS [41].

Extrapulmonary infection with *Pneumocystis carinii* is rare; it is invariably secondary to pulmonary disease, and appears to be more common in those patients who have received aerosolized pentamidine therapy. Approximately a third of patients with extrapulmonary infection have marrow involvement [42]. There are areas of 'frothy' exudate which is pink on an H&E stain; Grocott's methenamine silver stain demonstrates the cysts, which are 4–6 µm in diameter and often have a crumpled or cup-shaped appearance. Diagnosis is aided by immunohistochemistry using monoclonal antibody of the 3F6 clone (available commercially from Dako and Novocastra).

Bone marrow granulomas

A granuloma is a compact aggregate of macrophages. These may include a major component of epithelioid macrophages which have large amounts of pale pink cytoplasm and ovoid or elongated nuclei with a dispersed chromatin pattern. Often several epithelioid cells fuse to form a giant cell. Two major types of giant cell are recognized in granulomas: (i) Langhans' type, which has numerous nuclei arranged around the periphery of the cell; and (ii) foreign body type with nuclei scattered throughout the cell. Other cell types, including lymphocytes, plasma cells, neutrophils, eosinophils and fibroblasts, may be found within granulomas, but these are not a constant feature.

A wide range of aetiological agents are associated with marrow granulomas (Table 3.3). It should be noted that patients with immunodeficiency, such as AIDS, may fail to produce granulomas in response to infection with organisms that stimulate granuloma formation in normal individuals; this is probably consequent on the lack of important T-cell functions that facilitate formation of some types of granuloma.

Peripheral blood

There are no specific peripheral blood findings associated with the presence of bone marrow granulomas. The blood film may show features associated with the primary disease or, if bone marrow disease is extensive, there may be anaemia or pancytopenia with a leuco-erythroblastic blood film. Lymphopenia is also common [43].

Table 3.3 Bone marrow granulomas [43–46].

<i>Infection</i>
Tuberculosis
Atypical mycobacterial infection
Disseminated bacillus Calmette–Guérin (BCG) infection [47]
Brucellosis
Leprosy
Syphilis
Typhoid fever
Legionnaire's disease
Tularaemia [43]
Ehrlichiosis [44]
Q fever
Rocky Mountain spotted fever [43]
Leishmaniasis
Toxoplasmosis
Histoplasmosis
Cryptococcosis
Saccharomyces infection [43]
Blastomycosis
Coccidioidomycosis [48]
Paracoccidioidomycosis
Herpesvirus infection (EBV, CMV, herpes zoster)
Hantaan virus infection (Korean haemorrhagic fever) [49]
Cat scratch disease [49]
<i>Sarcoidosis</i>
<i>Malignant disease</i>
Hodgkin's disease*
Multiple myeloma [50]
Non-Hodgkin's lymphoma*
Chronic NK-cell lymphocytosis [51]
Mycosis fungoides [43]
Acute lymphoblastic leukaemia [43,46,49]
Myelodysplastic syndrome [46]
Metastatic carcinoma (breast or colon) [52,53]
<i>Drug hypersensitivity</i>
Phenytoin
Procainamide
Phenylbutazone [43]
Chlorpropamide
Sulfasalazine [54]
Ibuprofen [43]
Indometacin [43]
Allopurinol
Carbamazepine [55]
Associated with eosinophilic interstitial nephritis
<i>Reaction to foreign substances</i>
Anthraco-sis and silicosis [46,49,56]
Talc [57]
Berylliosis [58]

* With or without bone marrow infiltration.

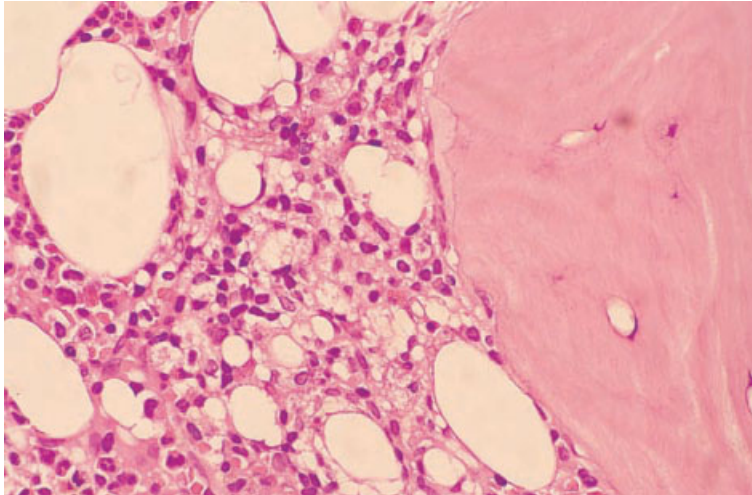


Fig. 3.22 BM trephine biopsy section, lipid granuloma. Paraffin-embedded, H&E $\times 390$.

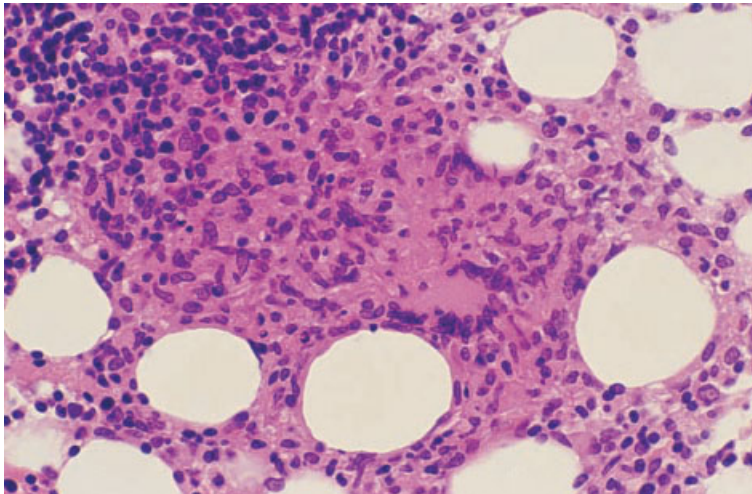


Fig. 3.23 BM trephine biopsy section, miliary tuberculosis, showing an epithelioid granuloma containing a Langhans' giant cell; there are numerous lymphocytes at the periphery of the granuloma. Paraffin-embedded, H&E $\times 390$.

Bone marrow cytology

There are no specific features in the bone marrow aspirate in patients with bone marrow granulomas. Occasionally, it is possible to recognize epithelioid cells.

Bone marrow histology

Lipid granulomas

Lipid granulomas (Fig. 3.22) were previously re-

ported to be the most common type of granuloma seen in the marrow, being present in up to 9% of biopsies [59]. In our experience, they are considerably less common than this. They are of no clinical importance and must be distinguished from epithelioid granulomas which they can sometimes resemble. Similar lesions may be seen in the liver, spleen and lymph nodes and some of these cases have been reported to be associated with the ingestion of mineral oil [60]. In the marrow they are usually located close to sinusoids or lymphoid nodules and measure from 0.2 to 0.8 mm in diameter. They contain fat

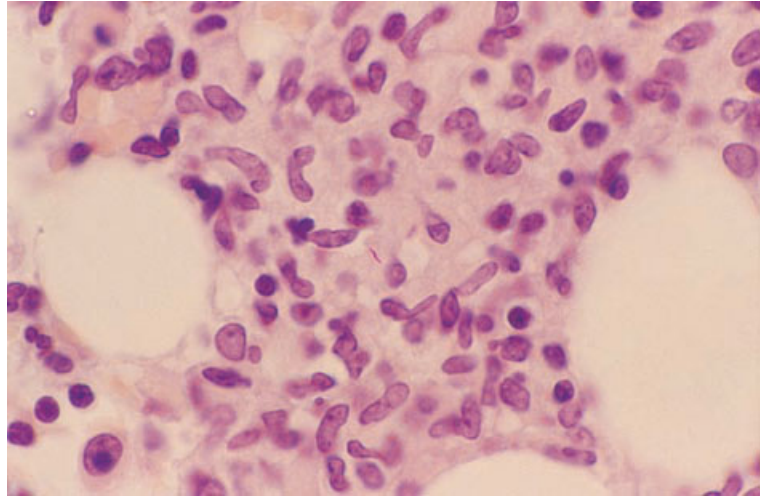


Fig. 3.24 BM trephine biopsy section, miliary tuberculosis, showing a granuloma containing an acid-fast bacillus. Paraffin-embedded, Ziehl–Neelsen stain $\times 970$.

vacuoles which vary in size but are usually smaller than the vacuoles in marrow fat cells; these are found both within macrophages and extracellularly. Lipid granulomas usually have plasma cells, eosinophils and lymphocytes within them, and approximately 5% contain giant cells. Occasionally, the fat vacuoles may be small and easily overlooked, giving the granulomas a sarcoid-like appearance.

Other granulomas

Unless a specific organism can be demonstrated within a granuloma, there are usually no histological features that allow a definitive diagnosis to be made [61]. Because of this, it is important for the pathologist to be aware of all relevant clinical details, in order to be able to suggest an appropriate differential diagnosis. All biopsies with granulomas should have special stains for acid-fast bacilli and fungi performed. Ideally, in those cases in which marrow granulomas with an infective aetiology are possible, for example in patients with a pyrexia of unknown origin, this should be anticipated and part of the marrow aspirate should be cultured for mycobacteria and fungi.

Granulomas are found on marrow biopsy in 15–40% of patients with miliary tuberculosis (Fig. 3.23). Tuberculous granulomas usually contain Langhans'-type giant cells and caseation is present in approx-

imately half the cases with marrow involvement [61]. Acid-fast bacilli cannot be demonstrated in most cases and, when seen, they are usually scanty (Fig. 3.24). Approximately 50% of patients with disseminated *Mycobacterium avium intracellulare* infection have marrow granulomas (Figs 3.25 and 3.26), ranging from small, ill-defined lymphohistiocytic aggregates to larger, more solid lymphohistiocytic lesions, and small, well-formed epithelioid granulomas [62]. Giant cells are only present in a minority of lesions and necrosis is not usually seen. When organisms are very numerous, the macrophages containing them may appear foamy (Fig. 3.26a) or may even resemble Gaucher's cells. Occasionally, organisms are recognizable on a Giemsa stain (Fig. 3.26b). Atypical mycobacteria may be demonstrated by special stains, sometimes in large numbers; they tend to be longer, more curved and more coarsely beaded than tubercle bacilli. They are PAS-positive, whereas *M. tuberculosis* is PAS-negative. Marrow granulomas containing foamy macrophages are occasionally seen in patients with leprosy; a Fite stain will demonstrate the acid-fast bacilli of *M. leprae* [6]. Foamy macrophages may also be a feature of granulomas due to typhoid. Small, poorly formed epithelioid granulomas are found in the bone marrow in most cases of brucellosis. Distinctive 'doughnut-type' granulomas may be seen in the marrow in Q fever [63], although they do not

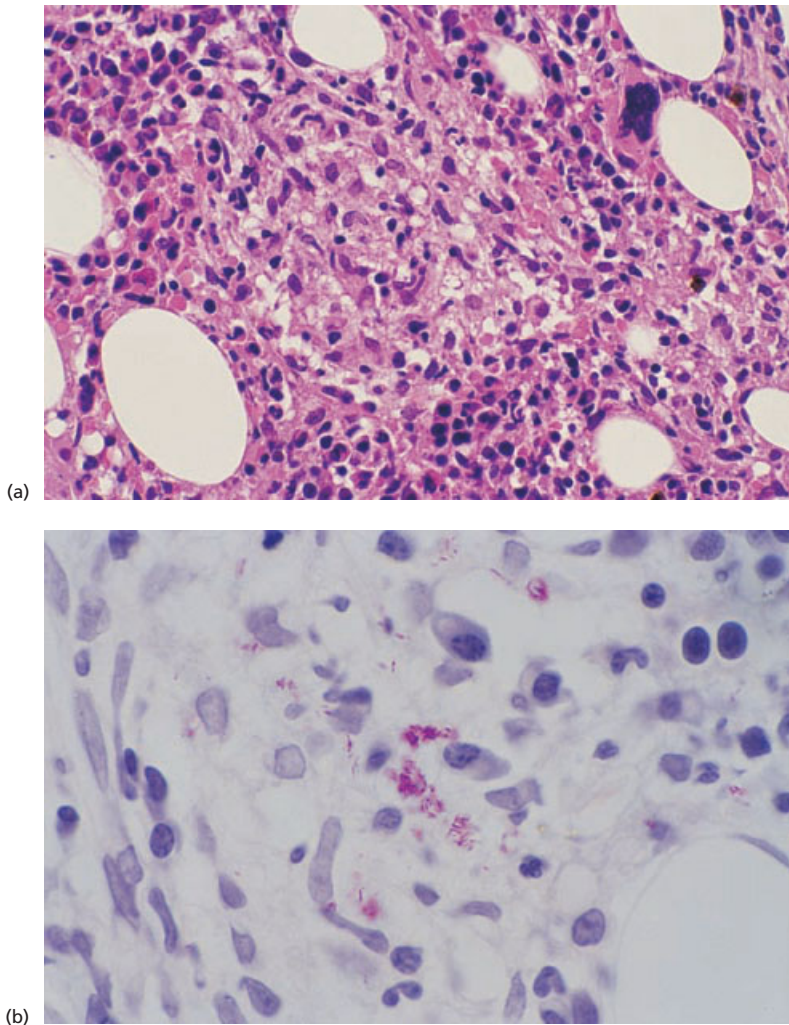
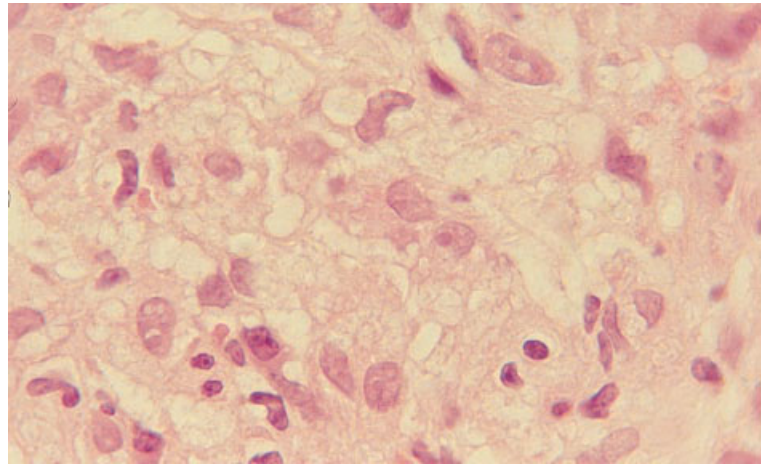


Fig. 3.25 BM trephine biopsy section from a patient with AIDS and disseminated *M. avium intracellulare* infection. (a) Poorly formed granuloma made up of epithelioid macrophages, many of which have vacuolated cytoplasm. Paraffin-embedded, H&E $\times 390$. (b) Large numbers of acid-fast bacilli; note the coarse beading of the organisms. Paraffin-embedded, Ziehl-Neelsen stain $\times 970$.

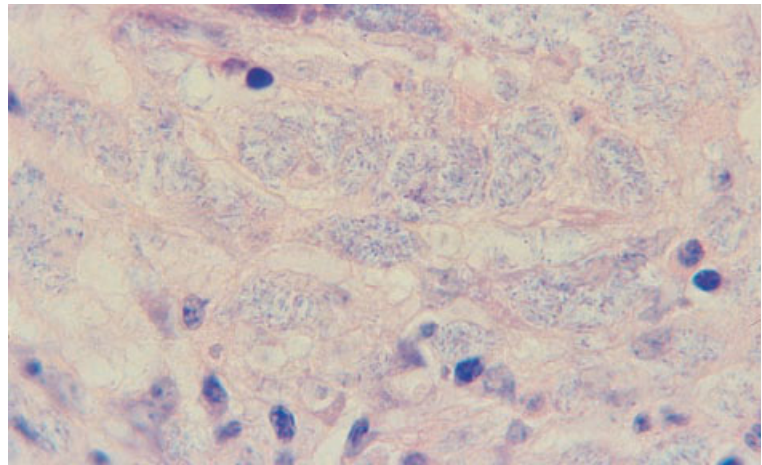
appear to be specific for this disease [18]. They have also been reported, for example, in CMV infection in immunodeficient subjects [64] and in Hodgkin's disease, infectious mononucleosis and typhoid fever. This type of granuloma often has a central empty space, surrounded by neutrophils, lymphocytes, histiocytes and concentrically arranged, laminated fibrinoid material; more haphazardly arranged lesions without a central space also occur, as do small areas of fibrinoid necrosis [63].

Disseminated infection by the fungus *H. capsulatum* usually involves the bone marrow; in normal hosts there are numerous granulomas, often with

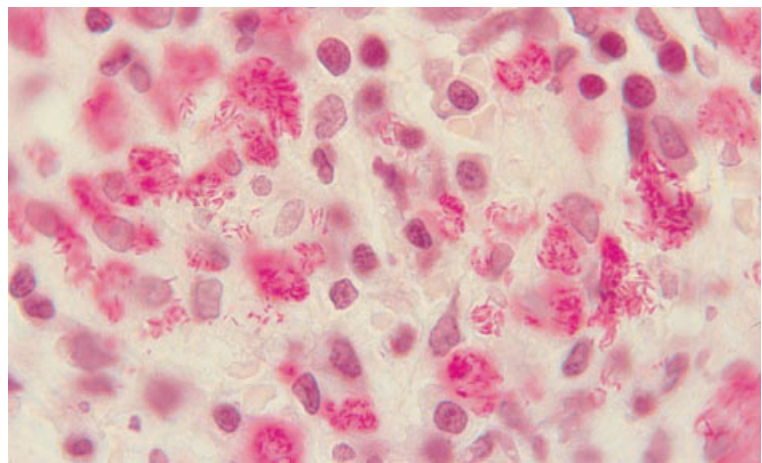
Langhans' giant cells and necrosis. Discrete granulomas are present in only a minority of immunodeficient hosts; more commonly such patients have ill-defined lymphohistiocytic aggregates or sheets of macrophages infiltrating between haemopoietic cells [65] (see Fig. 3.13). Tiny yeast forms, 2–5 μm in diameter, some of which show unequal budding, are present within macrophages. The organisms may be seen with an H&E stain, but are best visualized using Gomori's methenamine silver (GMS) stain or a PAS stain. *Cryptococcus neoformans* infection may cause granulomas. The organisms seen in tissue sections are yeasts (5–10 μm in diameter)



(a)



(b)



(c)

Fig. 3.26 BM trephine biopsy section from a patient with AIDS and *M. avium intracellulare* infection showing foamy macrophages packed with micro-organisms: (a) H&E; (b) Giemsa; (c) Ziehl-Neelsen stain. Paraffin-embedded, $\times 960$.

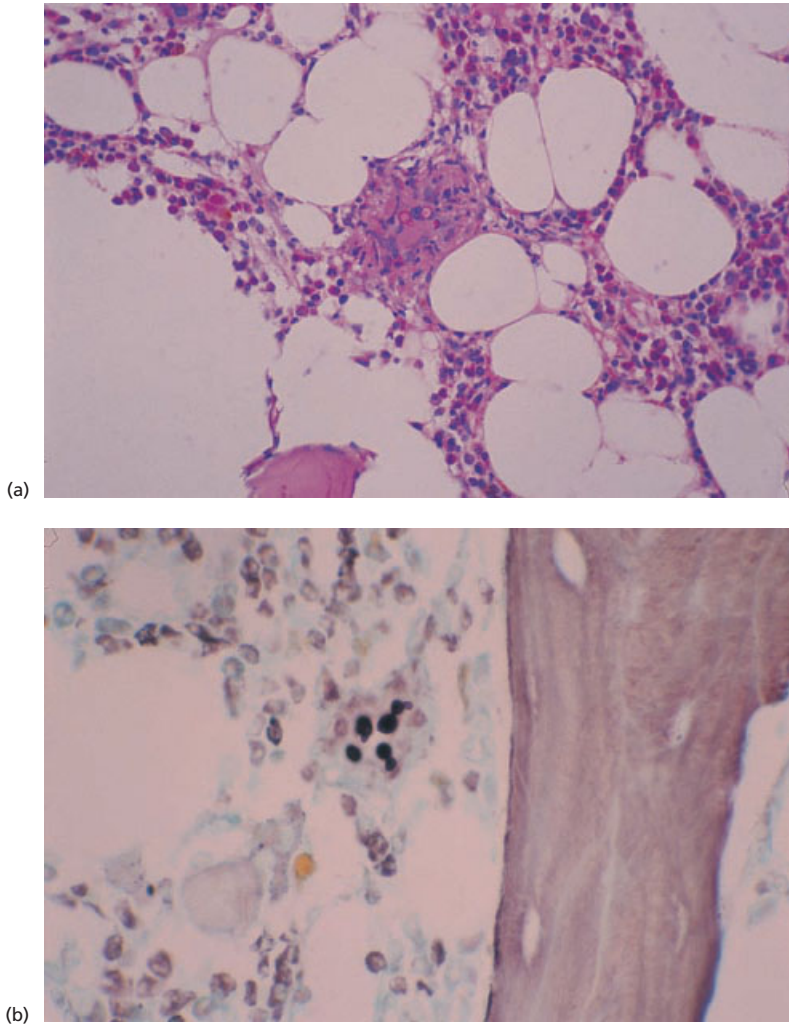


Fig. 3.27 BM trephine biopsy sections from a patient with *C. neoformans* infection. Paraffin-embedded. (a) A small epithelioid granuloma containing large yeast forms with narrow-based unequal budding. PAS $\times 195$. (b) Budding yeast forms. GMS $\times 390$.

with a wide capsular halo and narrow-based, unequal budding (Fig. 3.27); with a mucicarmine stain the capsule of the yeast is red. The capsule is also well stained with alcian blue (see Fig. 3.14b) and with PAS (Fig. 3.27a). Infection with the protozoans *Leishmania donovani* and *Toxoplasma gondii* may involve the marrow and provoke granuloma formation (see Figs 3.20 and 3.21).

In up to 60% of patients with infectious mononucleosis, small epithelioid granulomas are seen in histological sections of bone marrow biopsy; Langhans' giant cells and necrosis are not seen.

Marrow granulomas are seen less commonly in other viral infections.

Granulomas may be seen in Hodgkin's disease [66], non-Hodgkin's lymphoma (Fig. 3.28) and multiple myeloma [50] (Fig. 3.29) in association with neoplastic infiltration of the marrow. In both Hodgkin's disease and non-Hodgkin's lymphoma, granulomas also occur in the absence of marrow involvement; these are usually small, well-formed epithelioid granulomas, although larger, poorly formed lymphohistiocytic lesions have also been reported [67]. Since patients with lymphoma have

Fig. 3.28 BM trephine biopsy section showing a reactive granuloma in a patient with diffuse bone marrow involvement by low grade non-Hodgkin's lymphoma (follicular lymphoma). No evidence of an infective cause of the granuloma was found in this patient. Paraffin-embedded, H&E $\times 195$.

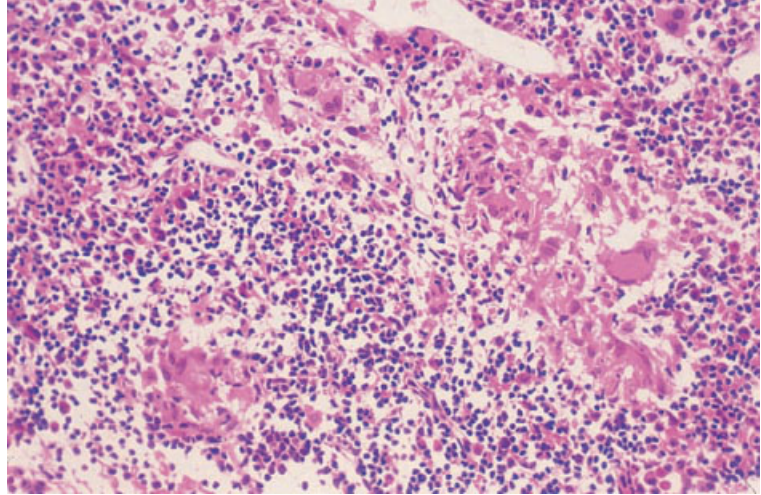
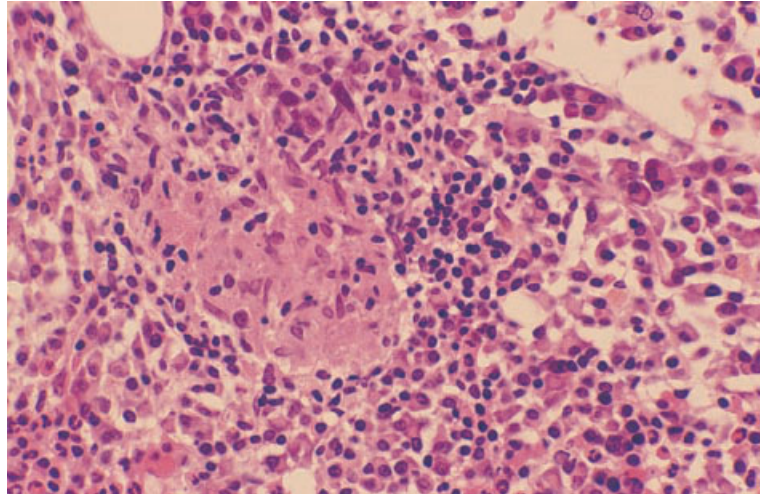


Fig. 3.29 BM trephine biopsy, multiple myeloma, showing large numbers of plasma cells and an epithelioid granuloma (centre). No evidence of an infective cause for the granuloma was found in this patient. Paraffin-embedded, H&E $\times 390$.



an increased susceptibility to many of the infections associated with marrow granulomas, these should always be excluded before attributing the granulomas to the underlying neoplastic disease. Bone marrow granulomas, in the absence of any apparent infection, have also been reported in single cases of hairy cell leukaemia treated with 2-chlorodeoxyadenosine [68], AML treated with interleukin-2 and lymphokine-activated killer cells [69] and, in a total of four cases, in chronic NK-cell lymphocytosis [70,71].

The bone marrow is commonly involved in sar-

coidosis; granulomas were seen in nine out of 21 patients in a biopsy series [61]. Often patients with marrow granulomas have evidence of multisystem involvement, such as hepatosplenomegaly, although chest radiography may be normal [72]. Typically there are numerous, well-formed epithelioid granulomas which, in approximately a third of cases, contain Langhans' giant cells; necrosis is seen very rarely. Sarcoid granulomas usually lack a surrounding zone of inflammatory cells. They are associated with prominent reticulin fibrosis and sometimes collagen formation. Giant cells in sarcoid granulo-

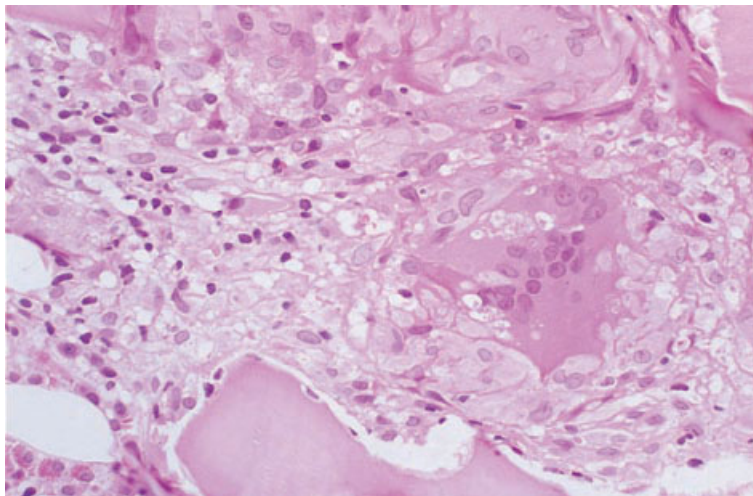


Fig. 3.30 BM trephine biopsy, sarcoidosis, showing a granuloma with a giant cell containing asteroid bodies. Plastic-embedded, H&E $\times 390$.

mas may contain asteroid and Schaumann bodies (Fig. 3.30).

The granulomas associated with drug hypersensitivity are poorly circumscribed lymphohistiocytic lesions, often containing eosinophils. Rarely, they are accompanied by a systemic vasculitis which may involve the vessels in the marrow.

Reactive lymphoid aggregates and polymorphous lymphoid hyperplasia

Reactive lymphoid aggregates, often referred to as 'benign lymphoid aggregates', are commonly present in the bone marrow, their incidence increasing with age. An increased frequency has been reported in association with infection, inflammation, haemolysis, myeloproliferative disorders and autoimmune diseases such as rheumatoid arthritis and thyrotoxicosis. Their frequency appears to be increased in Castleman's disease [73]. Bone marrow lymphoid aggregates, assessed histologically as benign, have been associated with the subsequent development of low grade lymphoma [74].

Peripheral blood

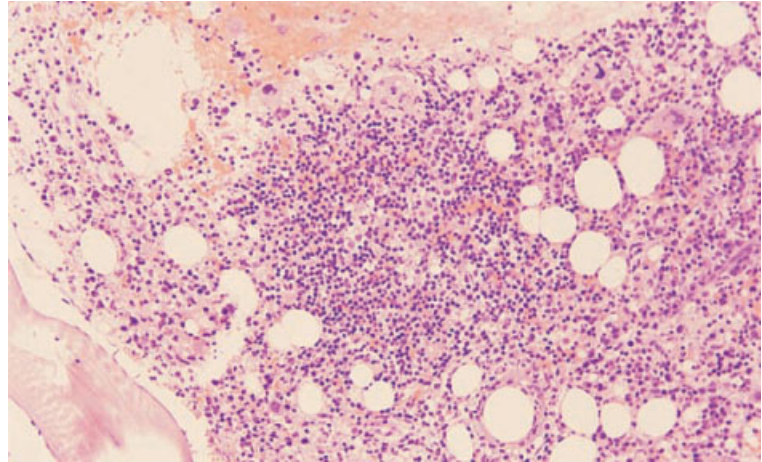
There are no specific peripheral blood features associated with the presence of reactive lymphoid aggregates in the bone marrow.

Bone marrow cytology

The bone marrow aspirate is usually normal but may show an increase in normal, mature lymphocytes.

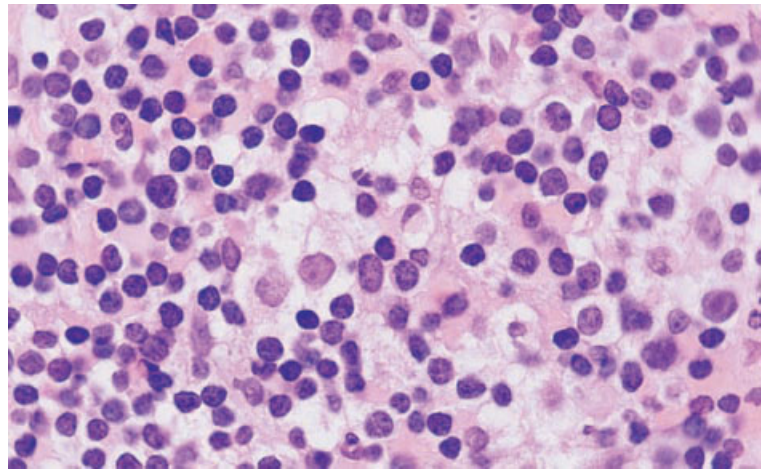
Bone marrow histology

Reactive lymphoid aggregates are usually few in number, not paratrabecular in position, well circumscribed and composed of small mature lymphocytes interspersed with some plasma cells, macrophages and sometimes occasional eosinophils, mast cells and immunoblasts [74–76] (Fig. 3.31). Their presence is usually indicative of a reactive process, particularly auto-immune disease. Although occasional paratrabecular infiltrates have been reported in apparently healthy people [77], this is very rare and a paratrabecular infiltrate is unlikely to be reactive. We would advocate careful follow-up of such cases. Reactive lymphoid aggregates may be associated with small blood vessels. The lymphocytes show more pleomorphism than those in neoplastic lymphoid aggregates. Occasionally germinal centres are seen [78] (Fig. 3.32). Reticulin fibres are increased within the nodule. Bone marrow biopsies showing reactive lymphoid aggregates have an increased incidence of lipid granulomas and plasmacytosis. When lymphoid nodules are relatively



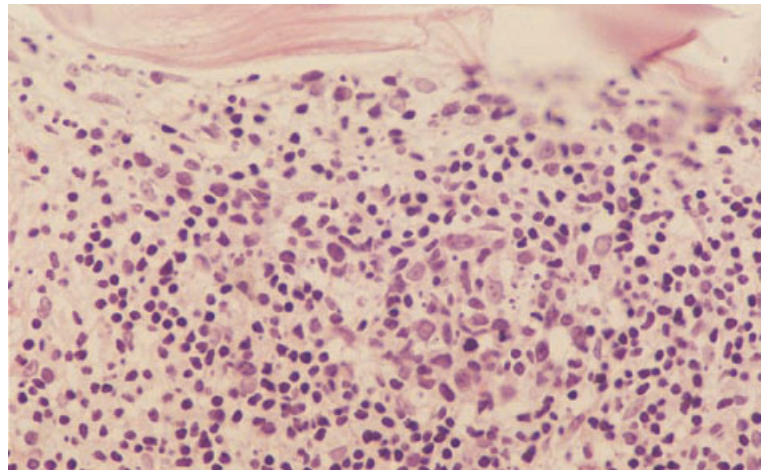
(a)

Fig. 3.31 Section of BM trephine biopsy showing: (a) a reactive lymphoid nodule and surrounding normal haemopoietic cells, H&E $\times 97$; (b) the centre of a lymphoid nodule containing several macrophages and occasional immunoblasts, in addition to normal small lymphocytes; paraffin-embedded, H&E $\times 970$.



(b)

Fig. 3.32 Section of BM trephine biopsy showing a secondary lymphoid follicle containing a germinal centre in a patient with rheumatoid arthritis. Paraffin-embedded, H&E $\times 192$. (By courtesy of Dr R Brunning, Minneapolis.)



large or numerous, immunohistochemical demonstration of a normal $\kappa:\lambda$ ratio (approximately 2:1) or of a mixture of T and B cells may be helpful in confirming their reactive nature [76,79,80]. However, it should be noted that, although lymphoid aggregates composed of homogeneous B cells are likely to be neoplastic and most reactive lymphoid aggregates contain a mixture of T and B cells [79,80], there may also be admixed reactive T cells in infiltrates of low grade B-cell lymphoma.

Unusual causes of reactive lymphoid infiltrates are thymoma, which has been associated with a nodular and interstitial infiltrate of polyclonal T cells [81], and persistent polyclonal B-cell lymphocytosis of middle-aged, mainly cigarette-smoking, females which has been associated with a nodular infiltrate, presumably of B cells [82].

More extensive lymphoid infiltrates, often with admixed eosinophils, macrophages, epithelioid cells, endothelial cells, plasma cells and immunoblasts, are common in AIDS (see Figs 3.43 and 3.44) and may also be seen in congenital immunodeficiency, angioimmunoblastic lymphadenopathy, following bone marrow transplantation and occasionally in association with auto-immune diseases such as rheumatoid arthritis. It is sometimes not possible to distinguish this condition, sometimes designated polymorphous reactive lymphoid hyperplasia, from T-cell lymphoma on the basis of histology alone. An extensive lymphoid infiltrate can also be seen in the lymphoproliferative disorder associated with phenytoin therapy [83].

Plasmacytosis and cytological abnormalities in plasma cells

A reactive increase of polyclonal plasma cells is common and is associated with a variety of conditions including HIV and other infections, chronic inflammatory diseases (particularly rheumatoid arthritis), haemopoietic and non-haemopoietic malignant disease, angio-immunoblastic lymphadenopathy, systemic Castleman's disease, cirrhosis, diabetes mellitus, iron deficiency, megaloblastic anaemia and haemolytic anaemia [9,84]. A reactive increase in plasma cells needs to be distinguished from bone marrow infiltration by neoplastic plasma cells, such as occurs in multiple myeloma and in many cases of immunocyte-derived amyloidosis, systemic

light chain disease and monoclonal gammopathy of undetermined significance (see Chapter 7).

Peripheral blood

Patients with reactive bone marrow plasmacytosis commonly show non-specific abnormalities in the peripheral blood consequent on the underlying disease. There is often anaemia which may have the features of the anaemia of chronic disease (either a normochromic, normocytic anaemia or, if the inflammatory process is severe, a hypochromic, microcytic anaemia). Rouleaux formation is commonly increased as a consequence of an increased concentration of polyclonal immunoglobulins and other reactive changes in plasma proteins. Occasional patients with reactive plasmacytosis have plasma cells in the peripheral blood, usually in small numbers.

Bone marrow cytology

In reactive plasmacytosis the bone marrow shows an increased number of plasma cells, not usually exceeding 10–20% of nucleated cells, but in rare cases up to 50%. The plasma cells are predominately mature (see Fig. 1.48) although occasional cells may have nucleoli, a diffuse chromatin pattern or some degree of nucleocytoplasmic asynchrony. Small numbers of bi- or trinucleated forms can be present. The plasma cells may contain cytoplasmic vacuoles or inclusions. Intranuclear inclusions have also been described but they are more characteristic of neoplastic plasma cells. Large homogeneous hyaline inclusions, often single, 2–3 μm in diameter and displacing the nucleus, are designated Russell bodies. They are occasionally identified in bone marrow aspirates (Fig. 3.33). Cells containing multiple vacuoles or inclusions are referred to as Mott cells, grape cells or morular cells. Cells may contain cytoplasmic crystals. Cells may have a pyknotic nucleus and voluminous pale-staining cytoplasm, as a result of greatly dilated endoplasmic reticulum; such cells are designated thesaurocytes indicating that they are storing the products they have synthesized. Cells that synthesize carbohydrate may have flaming pink cytoplasm ('flaming cells'). All these inclusions and unusual tinctorial qualities are consequent on increased immunoglobulin synthesis

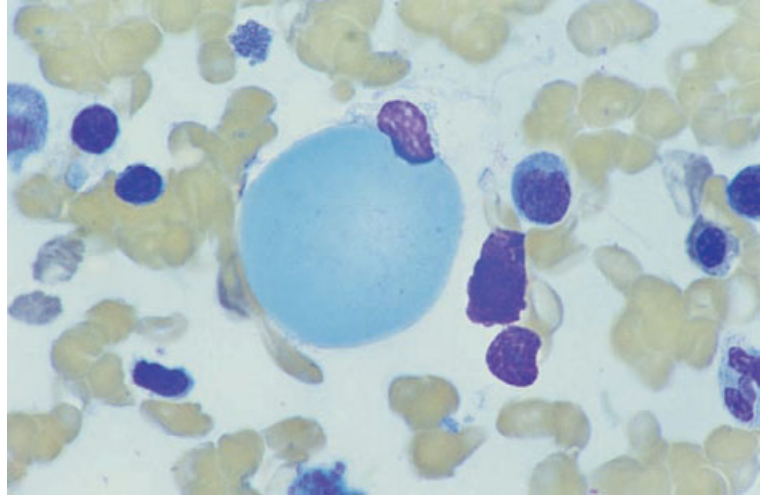


Fig. 3.33 BM aspirate film showing a Russell body in a plasma cell in a patient with reactive plasmacytosis. MGG $\times 940$.

within the rough endoplasmic reticulum. Nuclear inclusions, known as Dutcher bodies, are consequent on invagination from the cytoplasm. Cells of these various types are characteristic of conditions with immune stimulation but neoplastic plasma cells often show similar features. Plasmacytic satellitism (a central macrophage surrounded by plasma cells) and increased mast cells, eosinophils and megakaryocytes favour reactive rather than neoplastic plasmacytosis [9].

Occasionally, plasma cells contain haemosiderin inclusions which are irregular in shape, relatively large and stain greenish-black with a May-Grünwald-Giemsa (MGG) stain (see Fig. 2.4). Their presence is associated with iron overload (e.g. haemochromatosis and transfusion siderosis) and with chronic alcoholism [85].

Bone marrow histology

A trephine biopsy section in reactive plasmacytosis shows an interstitial infiltrate of plasma cells, particularly adjacent to capillaries (see Fig. 1.49). Plasma cells are sometimes clustered around macrophages. A minority of cases have small clusters of plasma cells but large homogeneous nodules, which are a feature of multiple myeloma, are not seen. The variety of inclusions described above may also be apparent in histological sections (Fig. 3.34) and some degree of cellular immaturity may be noted. Russell

bodies and Dutcher bodies stain pink with an H&E stain and show variable PAS staining. In reactive plasmacytosis immunocytochemistry shows that κ - and λ -expressing plasma cells are present in a ratio of approximately 2:1. About half the plasma cells express γ heavy chain, about a third α and the remainder μ [86].

Plasmacytosis may be associated with other reactive changes such as granulocytic hyperplasia, lymphoid aggregates and increased numbers of macrophages. The macrophages may have enhanced haemophagocytic activity and an increased iron content.

Mast cells

Small numbers of mast cells are present in normal bone marrow aspirates. However, it should be noted that the normal number of mast cells in the trephine biopsy of healthy subjects has not been defined. Mast cells are increased as a reactive change in association with a variety of pathological processes. Increased numbers have been noted in infection, inflammation, renal failure, lymphoproliferative disorders and reactive lymphocytosis, aplastic anaemia, paroxysmal nocturnal haemoglobinuria, myeloproliferative disorders and the myelodysplastic syndromes [87–89]. Mast cells accumulate in areas of connective tissue proliferation, for example in fracture callus and in zones of osteitis fibrosa in patients

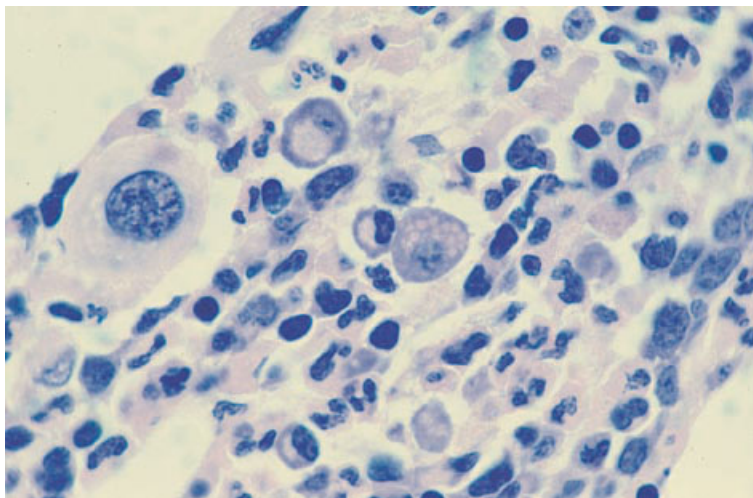


Fig. 3.34 BM trephine biopsy section, myelodysplastic syndrome, showing prominent plasma cells including one with multiple cytoplasmic vacuoles (Mott cell). Plastic-embedded, H&E $\times 940$.

with renal failure. Increased numbers of mast cells are present also in systemic mastocytosis but these neoplastic mast cells are usually morphologically abnormal (see page 221).

Peripheral blood

There are no specific peripheral blood features associated with a reactive increase of bone marrow mast cells.

Bone marrow cytology

The cytological features of bone marrow mast cells have been described on page 25. Lymphocytosis and plasmacytosis may co-exist with a reactive increase in mast cells.

Bone marrow histology

The characteristics of mast cells in histological sections have been described on page 26 and the features of systemic mastocytosis will be described on page 223. In histological sections, mast cells may be confused with fibroblasts or macrophages because of their elongated shape, oval nuclei and the poor staining of their granules with H&E. The lesions associated with drug hypersensitivity, previously designated 'eosinophilic fibrohistiocytic lesions' [90], are now known to represent proliferation of

eosinophils and mast cells, mainly in patients with systemic mastocytosis.

When mast cells are increased, there may be an associated increase in plasma cells and lymphocytes.

Histiocytosis

An increase in macrophages (histiocytes) is common in a variety of infective and inflammatory conditions and whenever there is bone marrow hyperplasia, ineffective haemopoiesis or increased breakdown of blood cells. All of the conditions capable of causing granuloma formation and haemophagocytic syndromes can also cause an increase of macrophages without granuloma formation or prominent haemophagocytosis. Macrophages present may range from relatively immature cells with limited phagocytic capacity to mature cells which may be foamy or contain cellular debris, haemosiderin or a few haemopoietic cells, erythrocytes, neutrophils or platelets.

Increased bone marrow macrophages may be seen after granulocyte-macrophage colony-stimulating factor (GM-CSF) therapy when they may constitute as many as 90% of bone marrow cells [91]. They have been prominent in patients with failure to engraft after bone marrow transplantation particularly, but not only, when GM-CSF has been given [92]. A marked increase in macrophages has been reported at presentation of acute lympho-

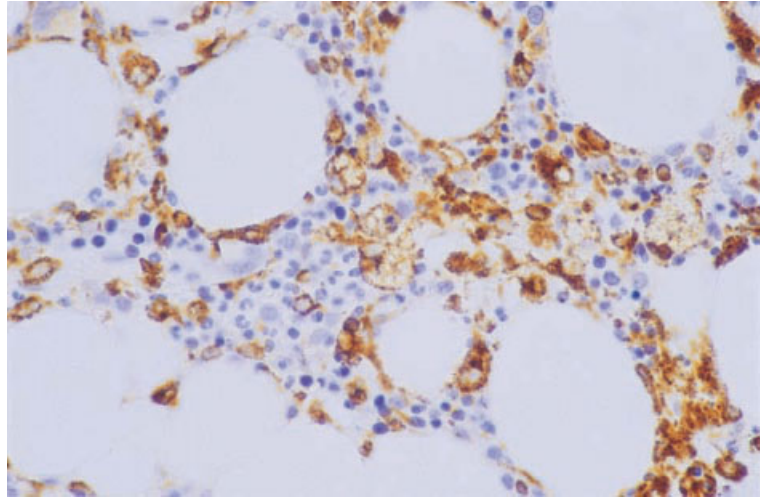


Fig. 3.35 BM trephine biopsy section showing a reactive increase in macrophages. Paraffin-embedded, immunoperoxidase, CD68 (McAb PG-M1) $\times 276$.

blastic leukaemia in a patient without any apparent infection [93].

Macrophages can be identified by immunohistochemical staining (Fig. 3.35).

Haemophagocytic syndromes

Haemophagocytic syndromes result from increased numbers of haemophagocytic macrophages with resultant cytopenias. Common clinical features are hepatomegaly, splenomegaly and fever. The proliferating macrophages are reactive in most cases but rarely they are part of a neoplastic clone (malignant histiocytosis) (see page 184) (Table 3.4). Reactive haemophagocytic syndromes are commonly caused by bacterial or viral infection, occurring either in previously healthy subjects or as a terminal complication in patients with a defective immune response. Haemophagocytic syndromes are relatively common when viral or mycobacterial infections occur in patients with AIDS or with haemopoietic or other malignancy. Haemophagocytosis may also be prominent in patients with lymphoma, particularly T-cell lymphoma, when there is no evidence of infection; it is likely that in these cases there is increased proliferation of macrophage precursors and enhanced phagocytic activity in response to lymphokines secreted by the lymphoma cells. Familial haemophagocytic lymphohistiocytosis is an autosomal recessive condition of early childhood

with helper T-cell and macrophage activation [128]; the condition is genetically heterogeneous. Since the cytological and histological features cannot be distinguished from those of infection-induced haemophagocytosis, the diagnosis must rest on clinical differences [127].

Malignant histiocytosis (see page 184) may be regarded as the tissue equivalent of acute monocytic leukaemia (AML of M5b type); with disease progression there is increasing bone marrow infiltration by malignant cells and increasing numbers of malignant cells appear in the peripheral blood. Phagocytosis is minor in comparison with that seen in reactive conditions.

It should be noted that the term 'erythrophagocytosis' refers to phagocytosis of mature erythrocytes, whereas haemophagocytosis refers to phagocytosis of nucleated cells. Erythrophagocytosis can occur in haemophagocytic syndromes but can also be consequent on the presence of antibody-coated or abnormal erythrocytes.

Peripheral blood

The haemophagocytic syndromes are characterized by pancytopenia. Phagocytic macrophages are rarely present in the peripheral blood although in malignant histiocytosis there may be small numbers of monoblasts. The blood film may also show the features of the primary condition, for example,

Table 3.4 Conditions associated with a haemophagocytic syndrome [45,94–127].

<i>Malignant histiocytosis</i>	Induced by rickettsiae Rocky Mountain spotted fever Q fever [108] <i>Rickettsia tsutsugamushi</i> infection [99]
<i>Reactive haemophagocytic syndromes</i>	
Induced by viral infection	Induced by protozoan and other parasites
Herpesviruses	Toxoplasmosis
EB virus (including fatal infectious mononucleosis in X-linked lymphoproliferative syndrome)	Leishmaniasis
Herpes simplex	Malaria [109]
Herpes zoster	Babesiosis [110]
Human herpesvirus 6 [94]	
Human herpesvirus 7 [95]	Induced by fungi
Cytomegalovirus	Histoplasmosis
Other viruses	Candidiasis [103]
Adenovirus	Trichosporonosis [111]
Measles (vaccine virus)	
Influenza A [96]	Associated with certain lymphomas, particularly T-cell lymphomas [112–114], including T-cell granular lymphocytic lymphoma [115] but occasionally natural killer (NK) lymphoma [116], B-cell lymphoma [117] and Hodgkin's disease [118]
Para-influenza	Kawasaki's disease
Vaccinia	Kikuchi's disease [119]
Rubella (congenital)	Anticonvulsant lymphadenopathy
Parvovirus B19 [97]	Sarcoidosis [114]
Respiratory syncytial virus [98]	Systemic lupus erythematosus [99] and other autoimmune disease [120]
Kyasanur forest disease	Graft-versus-host disease (GVHD) [121]
Dengue [99]	Following GM-CSF [122] or IL-3 [123] administration
Hepatitis A virus [100]	Cytophagic histiocytic panniculitis [124]
Induced by bacterial infection	Lysinuric protein intolerance [125]
<i>Salmonella typhi</i>	Griscelli syndrome [126]
Brucellosis	As a terminal complication in patients with various immunodeficiencies and malignant conditions (ALL, CLL, HD, NHL, hairy cell leukaemia, AML, carcinoma, Chediak–Higashi syndrome)—probably as a complication of infection
Staphylococcal, streptococcal, <i>E. coli</i> , <i>H. influenzae</i> , <i>Acinetobacter</i> species, <i>Bacteroides fragilis</i> , <i>Pseudomonas</i> species and <i>Klebsiella</i> species infections [99,100–104]	
Legionnaire's disease (<i>Legionella pneumophila</i>)	<i>Familial haemophagocytic lymphohistiocytosis</i> [127]
<i>Mycobacterium tuberculosis</i>	
Atypical mycobacterial infection	
Psittacosis [99]	
<i>Mycoplasma pneumoniae</i> infection [105]	
Human granulocytic and monocytic ehrlichiosis [106,107]	

atypical lymphocytes in patients with familial lymphohistiocytosis (Fig. 3.36) or EBV or other viral infection.

Bone marrow cytology

In the secondary haemophagocytic syndromes there are increased numbers of macrophages and haemophagocytosis is usually prominent, with many macrophages having ingested numerous cells of various haemopoietic lineages (Figs 3.37 and

3.38). The macrophages are mainly mature and lack atypical features. The bone marrow aspirate may also show other abnormalities due to the primary disease. For example, in viral infections there is usually an increase of lymphocytes, which may be immature or atypical, and in bacterial infection there is granulocytic hyperplasia with toxic changes in the neutrophil lineage. In familial haemophagocytic lymphohistiocytosis, the bone marrow findings (Fig. 3.39) are identical to those of infection-induced haemophagocytosis. Repeated bone marrow exam-

Fig. 3.36 PB film from a child with familial lymphohistiocytosis showing atypical lymphoid cells. MGG $\times 940$.

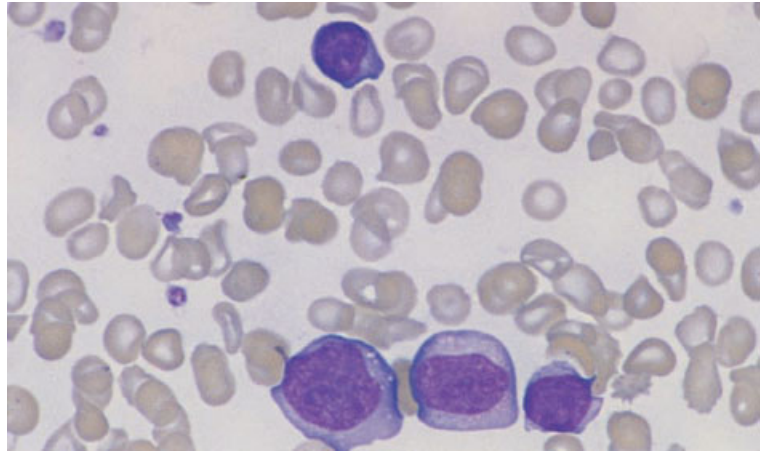


Fig. 3.37 BM aspirate, reactive haemophagocytosis in a patient with AIDS and miliary tuberculosis. MGG $\times 940$.

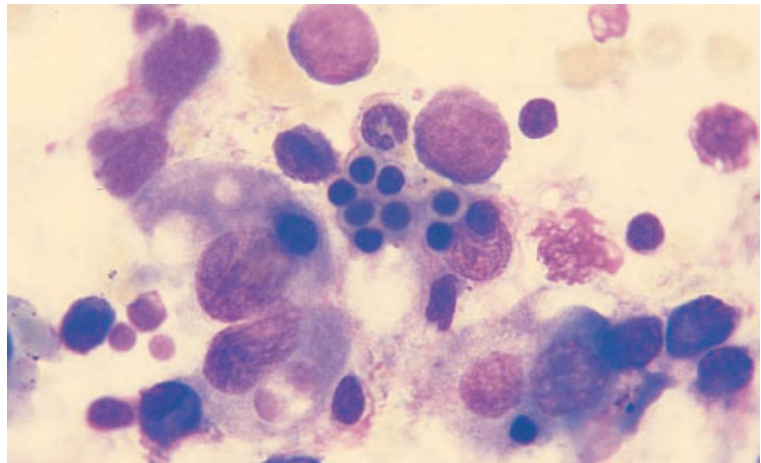
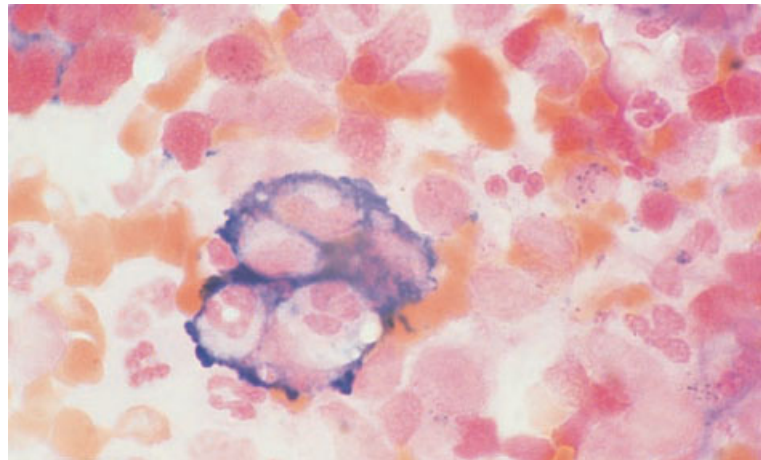


Fig. 3.38 BM aspirate, reactive haemophagocytosis, showing an iron-laden macrophage that has ingested neutrophils and neutrophil precursors. Perls' stain $\times 940$.



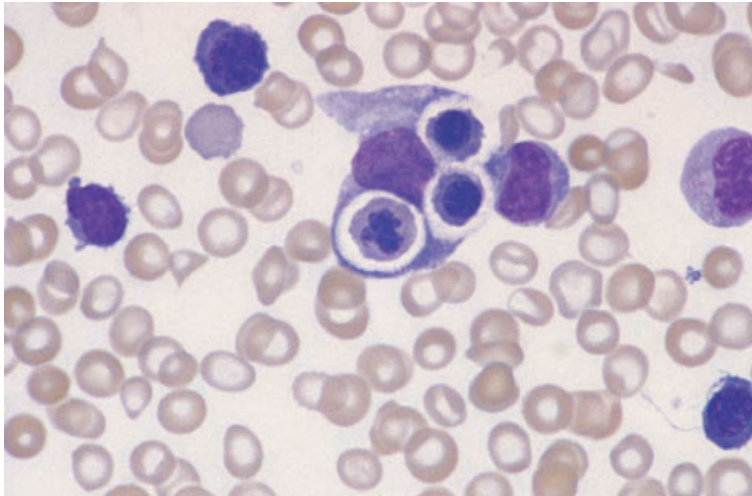


Fig. 3.39 BM aspirate, familial lymphohistiocytosis, showing haemophagocytosis and atypical lymphoid cells. MGG $\times 940$.

ination may be needed to establish the diagnosis, since abnormalities are detected at presentation in less than a third of patients [127]. When haemophagocytosis is secondary to a T-cell lymphoma the marrow may show closely intermingled lymphoma cells and macrophages but cases have also been reported in which the bone marrow shows only haemophagocytosis with the lymphomatous infiltrate being confined to other tissues [113].

In malignant histiocytosis, the bone marrow infiltrate may initially be very scanty. The abnormal population includes a much larger proportion of monoblasts and promonocytes while mature histiocytes are relatively less common. Phagocytic activity is not prominent.

Bone marrow histology

In early cases of reactive haemophagocytic syndrome (e.g. virus-induced) there is a hypercellular bone marrow with few macrophages [103]. Later there are more macrophages with hypoplasia of erythroid and myeloid lines; megakaryocyte numbers are either normal or increased. The degree of macrophage infiltration is variable (Fig. 3.40); in some cases it is inconspicuous, while in others there is diffuse replacement of the marrow by mature macrophages with a low nucleocytoplasmic ratio, dispersed chromatin, inconspicuous nucleoli and

abundant cytoplasm which is often vacuolated. Haemophagocytosis is often less apparent than in marrow films [103,129]; however, in some cases it is striking (Fig. 3.41). Features of the underlying disease may be present. Atypical lymphoid cells are seen in some cases of EBV infection. Lymphoma cells may be detected (see Fig. 6.61) but it should be noted that there may be no detectable lymphoma cells in the bone marrow in cases of lymphoma-associated haemophagocytic syndrome. Granulomas may be present in tuberculosis [130] and in a variety of other infections associated with a haemophagocytic syndrome (see Table 3.4).

If haemophagocytic lymphohistiocytosis is suspected, a trephine biopsy is recommended because clusters or sheets of macrophages may be detected in cases in which the bone marrow aspirate shows no significant abnormality [131].

In malignant histiocytosis, the marrow biopsy is often normal in the early stages of the disease. Later, infiltration may occur; infiltration is initially focal then diffuse.

Problems and pitfalls

The major problems in assessing haemophagocytic syndromes are: (i) distinguishing malignant histiocytosis from reactive conditions; and (ii), in reactive haemophagocytosis, determining whether the

Fig. 3.40 BM trephine biopsy section, AIDS, showing increased cellularity, dyserythropoiesis and numerous macrophages, some of which contain erythrocytes and apoptotic normoblasts (haemophagocytosis). Paraffin-embedded, H&E $\times 390$.

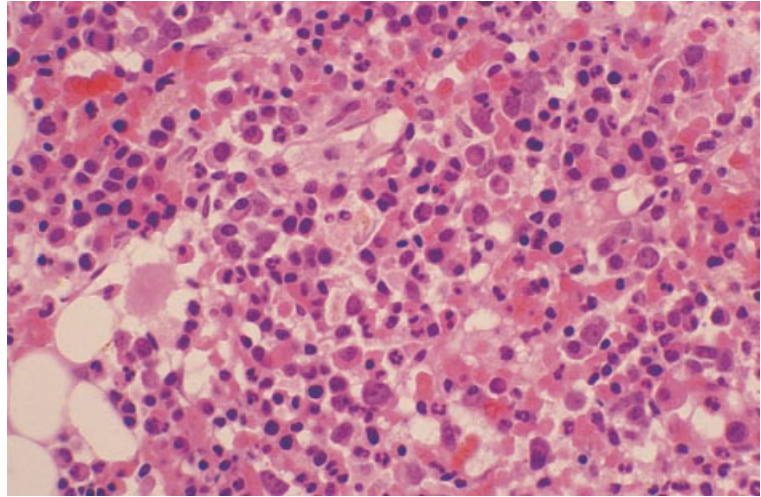
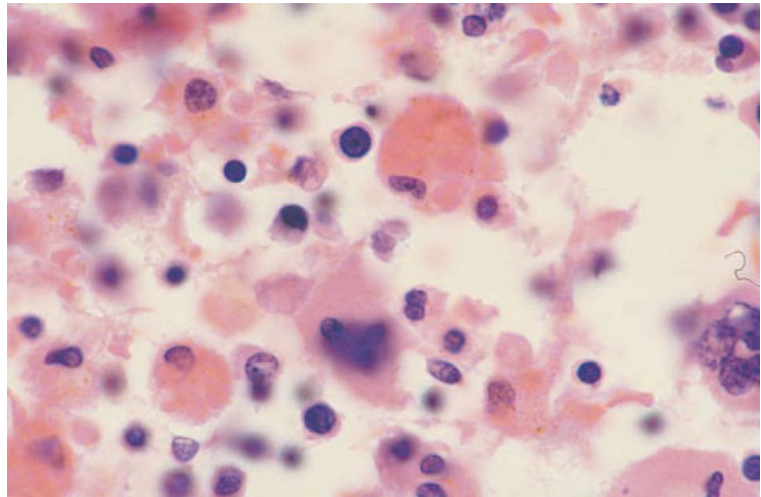


Fig. 3.41 BM section from an autopsy on a child with terminal haemophagocytic syndrome as a complication of Chediak–Higashi syndrome showing macrophages stuffed with red cells. Paraffin-embedded, H&E $\times 916$. (By courtesy of Dr Wendy Erber and Dr L Matz, Perth, Western Australia.)



underlying condition is an infection or, less often, a lymphoid neoplasm. Malignant histiocytosis is rare whereas reactive haemophagocytosis is relatively common. Demonstration of rearrangement of immunoglobulin heavy chain (*IGH*) or T-cell receptor (*TCR*) genes provides presumptive evidence of an underlying neoplasm but does not give definite evidence of the lineage involved. Molecular evidence of clonality is lacking when the associated neoplasm is of NK lineage. In malignant histiocytosis, cytogenetic analysis occasionally shows an

abnormality characteristic of neoplasms of monocyte lineage, thus confirming the diagnosis. In general, marked haemophagocytosis suggests a reactive rather than a neoplastic condition. Vigorous efforts should be made to identify an infective cause. *In situ* hybridization techniques (see Table 3.1) are useful for demonstrating underlying CMV or EBV infection [132], and stains and cultures for mycobacteria may be positive. Most childhood cases of haemophagocytic lymphohistiocytosis, both sporadic and familial, are infection-related. However, some

sporadic cases in children have atypical large granular lymphocytes; since T cells in such cases are sometimes shown to be clonal, it is possible that there is an underlying T-cell neoplasm [133].

HIV infection and the acquired immune deficiency syndrome

In HIV infection, the main indications for examination of the bone marrow are pyrexia of unknown origin and various cytopenias. It may also be required as a staging procedure in patients with lymphoma. A biopsy is very often useful, particularly in patients with a hypocellular aspirate. Part of any aspirate from a febrile patient should be submitted for microbiological culture. In addition to routine stains, biopsied tissues should be stained, when appropriate, for acid-fast bacilli and fungi.

Peripheral blood

The earliest haematological manifestations of HIV infection occur at the time of primary infection when atypical lymphocytes appear in the peripheral blood, often in association with a febrile illness which clinically can resemble infectious mononucleosis. Primary HIV infection also occasionally causes transient pancytopenia. Patients with established infection may have lymphocytosis, consequent on an increase in CD8-positive lymphocytes, or isolated thrombocytopenia resulting from peripheral destruction of platelets. Thrombocytopenia may also be a feature of a syndrome resembling thrombotic thrombocytopenic purpura and, in such cases, red cell fragments are present [134]. Late in the course of the disease, there is usually pancytopenia with very marked lymphopenia. Red cells may show anisocytosis and poikilocytosis. The reticulocyte count is reduced. Neutrophils may be dysplastic. Because of the frequency of opportunistic infections, the peripheral blood may also show non-specific reactive changes such as increased rouleaux formation, left shift and toxic changes in neutrophils, and the presence of immature monocytes and reactive lymphocytes. The haematological effects of the HIV infection itself, and the associated opportunistic infections, may be

compounded by the effects of therapy; patients taking zidovudine, particularly in the higher doses used in single-agent anti-retroviral therapy, usually have marked macrocytosis and there may be marked dysplastic changes in blood cells.

Bone marrow cytology

Early in the course of HIV infection the bone marrow is of normal cellularity or, during the course of intercurrent infection, shows granulocytic hyperplasia. When there is immune thrombocytopenia, megakaryocyte numbers are normal or increased. Common non-specific changes are infiltration by lymphocytes and plasma cells and an increase of macrophages or eosinophils. Erythropoiesis may show mild dysplastic features such as nuclear irregularity and fragmentation. In patients taking zidovudine, erythropoiesis is megaloblastic and dyserythropoiesis is more marked; dysplastic changes such as nuclear fragmentation are also noted in the granulocytic series. Giant metamyelocytes are quite common, their presence correlating with the occurrence of detached nuclear fragments in granulocytes [135]. Apoptosis is increased. With disease progression, the bone marrow becomes progressively more hypocellular and aspiration becomes difficult due to increased reticulin deposition. Gelatinous transformation is very common, being greatest in cachectic patients. Bone marrow necrosis is sometimes seen. In patients with advanced disease, the bone marrow aspirate may provide evidence of miliary tuberculosis, atypical mycobacterial infection or disseminated fungal or parasitic infection. Because of the deficient host response, mycobacterial infection may be associated with the presence of numerous bacteria within macrophages, which may be foamy or may morphologically resemble Gaucher's cells. Haemophagocytic syndromes (see page 119) secondary to tuberculosis or other infections are relatively common in patients with AIDS (see Fig. 3.37). Bone marrow involvement is common when lymphoma, particularly Burkitt's lymphoma or Hodgkin's disease, complicates AIDS. The former is often detected in a bone marrow aspirate but in Hodgkin's disease the aspirate is often negative, even when the bone marrow is infiltrated.

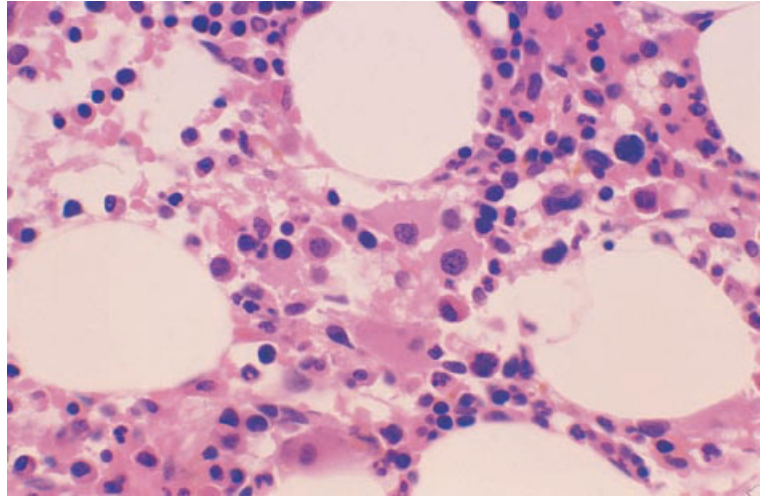


Fig. 3.42 BM trephine biopsy section, AIDS, showing clustering of megakaryocytes and a bare megakaryocyte nucleus. Paraffin-embedded, H&E $\times 390$.

Bone marrow histology

A wide variety of non-specific reactive changes are commonly seen in HIV infection [136–138]. The cellularity is increased in approximately 40% of cases, and decreased in 20–40%; hypocellularity is more common in patients on zidovudine therapy. Frequently the haemopoietic marrow has an oedematous appearance with the cells being separated by clear spaces. Focal gelatinous transformation (see page 128) is seen in up to 20% of cases. Dyserythropoiesis is common; the erythroblastic islands are often large and poorly organized, and megaloblastic change may be present, particularly in patients taking zidovudine. Granulocytic hyperplasia with left shift is seen in some patients, usually in response to infection. Megakaryocytes are usually present in normal or increased numbers, bare nuclei are a frequent finding and, occasionally, dysplastic forms are seen. Clustering of megakaryocytes may occur (Fig. 3.42). Haemopoietic cells may be present within vessels [139]. Plasma cells are increased in 50–60% of biopsy specimens and lymphoid aggregates are seen in approximately a third. The lymphoid aggregates are often large and poorly circumscribed. They consist largely of small lymphocytes, with variable numbers of plasma cells, macrophages and eosinophils (Figs 3.43 and 3.44);

sometimes there is proliferation of small vessels within the lesion. In some cases with a mixed infiltrate of lymphocytes and inflammatory cells the lesions may resemble a peripheral T-cell lymphoma [18]. Increased reticulin is seen in the majority of cases (Fig. 3.45). As a consequence there may be ‘streaming’ of haemopoietic cells and open sinusoids (in paraffin-embedded specimens), both features being apparent in H&E-stained sections. Rarely, the combination of marked marrow hypercellularity, severe reticulin fibrosis and increased numbers and clustering of megakaryocytes may closely resemble the appearance of a myeloproliferative disorder.

In all cases, a careful search should be made for evidence of opportunistic infections [140], in particular tuberculosis and atypical mycobacterial infection (see page 109), fungal infection (see Table 3.2), *P. carinii* infection and protozoal diseases (leishmaniasis and toxoplasmosis) (see page 105). Approximately 15% of biopsy specimens contain granulomas: the commonest cause is atypical mycobacterial infection; other causes include tuberculosis, histoplasmosis, cryptococcal infection and leishmaniasis (see page 105). In patients with AIDS, granuloma formation, in response to fungal and protozoal infections, is often poor. Associated changes in toxoplasmosis include interstitial oedema and focal

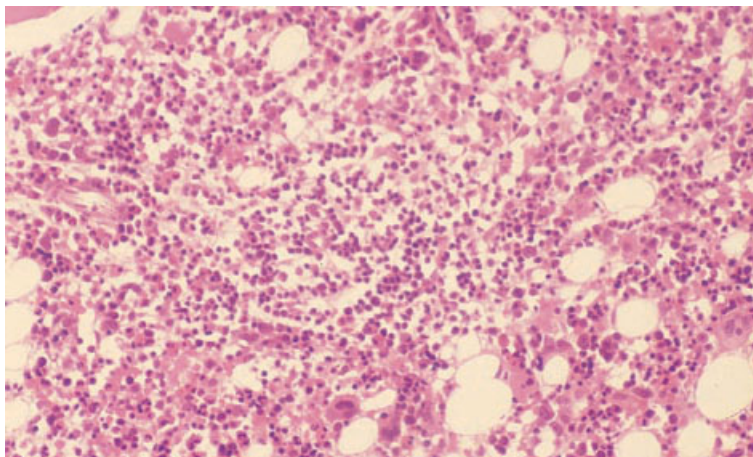


Fig. 3.43 BM trephine biopsy section, AIDS, showing increased cellularity and a polymorphous lymphoid aggregate (centre). Paraffin-embedded, H&E $\times 195$.

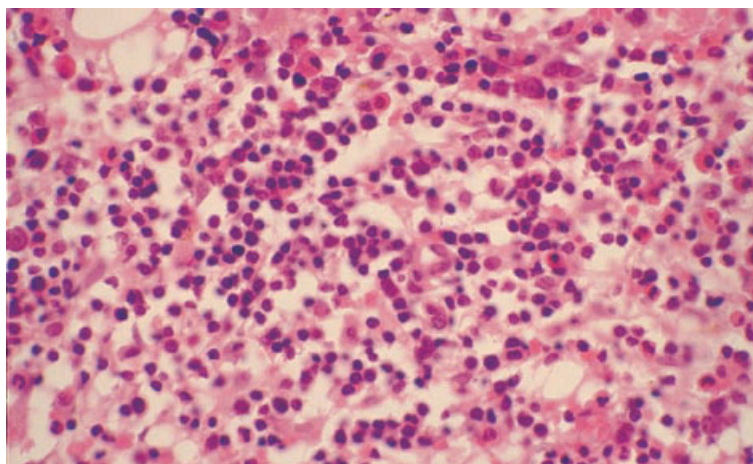


Fig. 3.44 BM trephine biopsy section, AIDS, showing a polymorphous lymphoid aggregate, composed of lymphocytes and small numbers of macrophages, eosinophils and plasma cells. Paraffin-embedded, H&E $\times 390$.

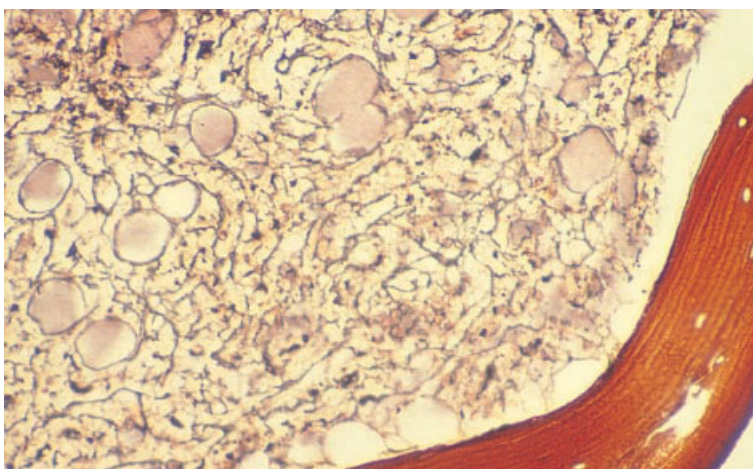


Fig. 3.45 BM trephine biopsy section, AIDS, showing reticulin fibrosis (grade 3). Paraffin-embedded, Gordon and Sweet stain $\times 195$.

necrosis with both free forms and pseudocysts being found within granulocytes, macrophages and megakaryocytes [31]. Organisms can be identified using a polyclonal antibody [31]. Atypical mycobacteria can be cultured from the marrow in up to 20% of cases of AIDS. Granulomas are present in approximately 50% of culture-positive cases and acid-fast bacilli can be seen with special stains in 60%. Atypical mycobacteria may be seen in biopsies in the absence of granulomas, usually within macrophages scattered throughout the marrow; occasionally cells which morphologically resemble Gaucher's cells (see page 109) are seen. Culture of the bone marrow and examination of sections for acid-fast bacilli has been found to be less sensitive than peripheral blood culture in the diagnosis of atypical mycobacterial infection in AIDS but, when bacilli can be found in a stained film, diagnosis is much more rapid than when it is dependent on culture [141]. Focal areas of epithelioid angiomatosis have been observed in the marrow of HIV-positive patients with bacillary angiomatosis or disseminated cat scratch disease, infective conditions consequent on infection by organisms of the *Rochalimaea* genus or the related *Afipia felis* [142,143]; a Warthin-Starry stain may demonstrate the causative organisms [143].

Bone marrow involvement by multicentric Castleman's disease has been reported in several HIV-positive patients who were also positive for HHV8 [144].

The incidence of non-Hodgkin's lymphoma is greatly increased in HIV infection [145]. Marrow involvement is common in non-Hodgkin's lymphoma associated with AIDS. These are almost always high grade lymphomas, either Burkitt's or Burkitt-like lymphoma, or diffuse large B-cell lymphoma (immunoblastic or anaplastic large cell subtypes). Bone marrow infiltration is much more common in Burkitt's lymphoma than in diffuse large B-cell lymphomas. Infiltration is usually diffuse (see Fig. 6.54).

Hodgkin's disease is now also recognized as an AIDS-related lymphoma. There is a propensity to involve the bone marrow early in the course of the illness so that a trephine biopsy may provide the first evidence of the disease [146].

Plasma cell tumours also occur as AIDS-related neoplasms. Although initial presentation is often at

extramedullary sites, the bone marrow may also be infiltrated [147].

Kaposi's sarcoma has a greatly increased incidence in AIDS and, when spread to the bone marrow occurs, may be detected by trephine biopsy.

Bone marrow necrosis

The term 'bone marrow necrosis' is conventionally used to describe necrosis of haemopoietic cells or necrosis of neoplastic cells that have replaced normal bone marrow cells. Bone marrow stromal cells may also be necrotic. There may or may not be associated death of bone cells and of bone. Bone marrow necrosis results from impairment of the blood supply, often in association with a hypercellular marrow. A high concentration of tumour necrosis factor in the blood may act as a mediator of necrosis [148]. Anti-phospholipid antibodies may also cause, or contribute to, bone marrow necrosis [149,150]. Causes are multiple (Table 3.5). Necrosis is followed either by haemopoietic regeneration, with or without small fibrotic scars, or occasionally by extensive fibrosis. Bone marrow necrosis commonly occurs at multiple sites. Clinical features include bone pain and fever. Fatal fat embolism can occur [159].

Peripheral blood

If bone marrow necrosis is extensive, pancytopenia occurs. The blood film shows leuco-erythroblastic, and sometimes micro-angiopathic [160], features. Recovery is associated with a rise in the reticulocyte count and recovery of the haemoglobin concentration and platelet and white cell counts.

Bone marrow cytology

A bone marrow aspirate is often macroscopically abnormal. It is sometimes opaque and whitish and sometimes reddish-purple. The stained film shows amorphous pink-staining material in which the faint outlines of necrotic cells can be seen (Fig. 3.46). Necrotic nuclei appear as darker-staining smudges. Some intact cells may also be present.

Bone marrow necrosis is more often noted in bone marrow trephine sections than in aspirates. This may be partly because a larger volume is sampled and partly because necrotic cells mixed with

Table 3.5 Causes of bone marrow necrosis [45,151–156].*Relatively common associations*

Sickle cell anaemia and haemoglobin S/C disease (particularly during pregnancy)
 Acute myeloid leukaemia (sometimes following administration of G-CSF [157])
 Acute lymphoblastic leukaemia
 Metastatic carcinoma
 Caisson disease

Less common associations

Chronic granulocytic leukaemia
 Essential thrombocythaemia [151]
 Lymphoma (mainly high grade non-Hodgkin's lymphoma but also Hodgkin's disease)*
 Chronic lymphocytic leukaemia
 Multiple myeloma
 Malignant histiocytosis
 Myelofibrosis
 Other haemoglobinopathies (S/D, S/β thalassaemia and sickle cell trait)
 Megaloblastic anaemia plus infection
 Acute haemolytic anaemia
 Embolism of the bone marrow, e.g. by vegetations from cardiac valves or tumour embolism [152]
 Disseminated intravascular coagulation
 Hyperparathyroidism
 Systemic lupus erythematosus [153]
 Primary anti-phospholipid syndrome [149]
 Infections
 Typhoid fever
 Gram-positive infections, e.g. streptococcal and staphylococcal infection
 Gram-negative infections, e.g. *E. coli*
 Diphtheria
 Miliary tuberculosis
 Cytomegalovirus infection [154]
 Q fever
 Mucormycosis
 Histoplasmosis
Fusobacterium necrophorum infection [155]
 Parvovirus infection [156]
 HIV infection (AIDS)

* Necrosis of low grade lymphoma has been observed following fludarabine therapy [158].

intact cells in an aspirate are often dismissed as an artefact.

Bone marrow histology

The appearances depend to some extent on the condition underlying the necrosis. In cases in which the necrosis is secondary to infiltration by leukaemia or lymphoma (Fig. 3.47), low power examination may reveal hypercellularity and loss of fat cells. In the early stages there is nuclear pyknosis and the cells have granular cytoplasm with indistinct margins. Later, there is nuclear karyorrhexis and

complete loss of cell outlines. Finally, all that remains is amorphous eosinophilic debris. Marrow necrosis is often accompanied by necrosis of the adjacent bone. In some patients, the necrosis is very extensive and biopsy of several different sites may be necessary before a diagnostic sample is obtained. Necrotic marrow is eventually repopulated with haemopoietic cells. The only signs of previous necrosis may be small areas of fibrous scarring around bony trabeculae that have lost osteocytes [161]. Occasionally there is extensive fibrosis (Fig. 3.48). Necrosis of haemopoietic and stromal cells may be followed by metaplastic new bone formation

Fig. 3.46 BM aspirate, bone marrow necrosis, showing amorphous debris containing karyorrhectic nuclei. MGG $\times 940$.

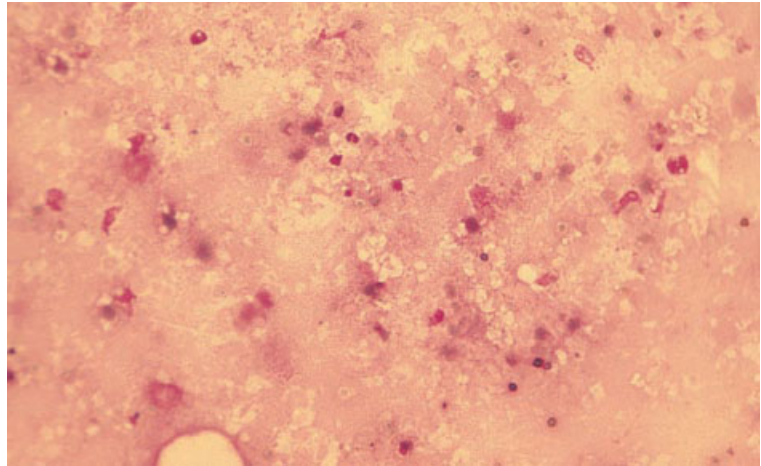


Fig. 3.47 BM trephine biopsy section, necrosis in a marrow infiltrated by high grade lymphoma. Note the necrosis of both the lymphoma cells infiltrating the marrow and of osteocytes within the bone trabecula. Paraffin-embedded, H&E $\times 195$.

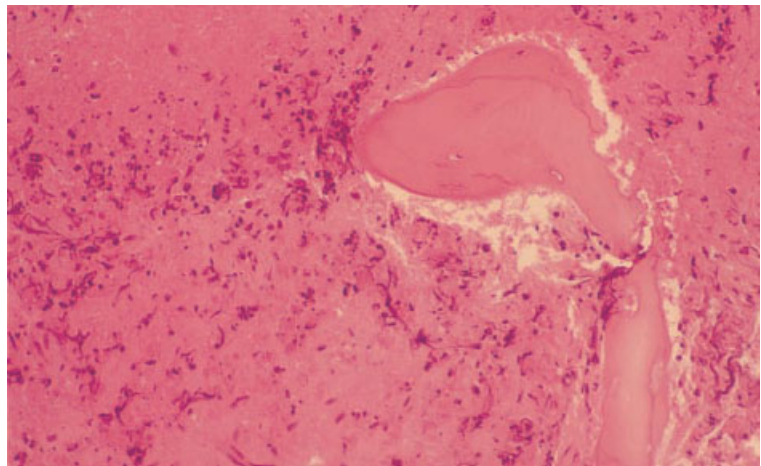
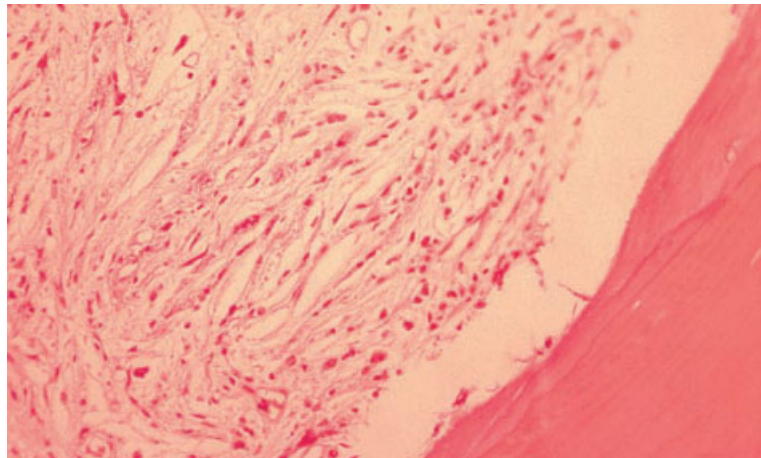


Fig. 3.48 BM trephine biopsy section, repair following marrow necrosis, showing collagen fibrosis. Paraffin-embedded, H&E $\times 188$.



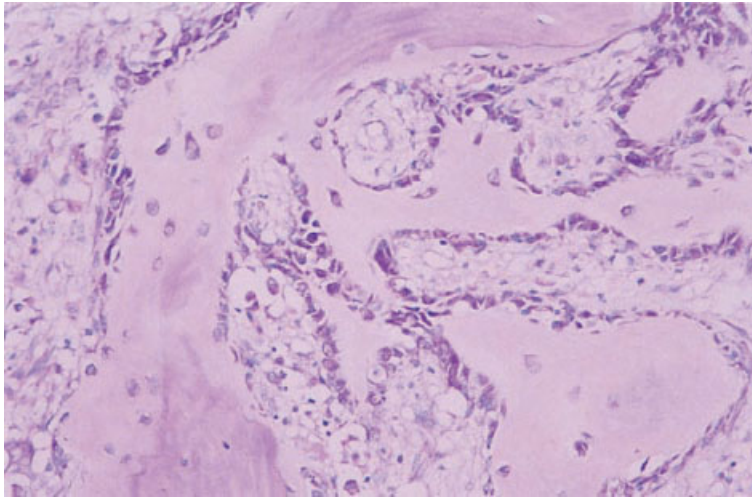


Fig. 3.49 BM trephine biopsy section showing new bone formation in an area of previous bone marrow necrosis. Paraffin-embedded, Giemsa $\times 188$.

(Fig. 3.49), initially woven bone which is subsequently remodelled into structurally normal bone.

Problems and pitfalls

Immunohistochemistry may be very misleading if used in an attempt to identify neoplastic cells within necrotic areas, as a consequence both of the tendency of antibodies to adhere in a non-specific way to necrotic tissue and of loss of some antigens by necrotic cells.

Gelatinous transformation

Gelatinous transformation, also known as serous degeneration or serous atrophy, is a condition in which there is loss of fat cells and haemopoietic cells from the bone marrow with replacement by an increased amount of ground substance. Common causes include anorexia nervosa and cachexia due to chronic debilitating illnesses such as carcinoma and tuberculosis or other chronic infection. The condition is also observed in AIDS, which is now the commonest cause of this abnormality. It has also been reported in association with renal failure, coeliac disease [162] and severe hypothyroidism [163]. It occurs at sites exposed to high-dose X-irradiation. Gelatinous transformation can also develop rapidly; it is seen in acute illnesses with

multiple organ failure [10] and in severe acute infections.

Peripheral blood

The peripheral blood shows variable cytopenia, often pancytopenia. In patients with anorexia nervosa, acanthocytes are seen but their presence has not been noted in other patients with gelatinous transformation.

Bone marrow cytology

The aspirate may not spread normally when a film is prepared. It contains amorphous material, sometimes fibrillar or finely granular, which is composed of acid mucopolysaccharide with a high content of hyaluronic acid. With Romanowsky stains it is pink or pinkish-purple (Fig. 3.50). This abnormal ground substance is positive with a PAS stain, the reaction being diastase resistant. Positive staining also occurs with alcian blue; this reaction is stronger at pH 2.5 than pH 1.0 [10]. A toluidine blue stain is weakly positive.

Bone marrow histology

The changes are usually focal; less commonly the whole of a biopsy section is affected. There is atrophy of fat cells, which are both reduced in number

Fig. 3.50 BM aspirate, gelatinous transformation, showing amorphous purplish-pink material. MGG $\times 377$.

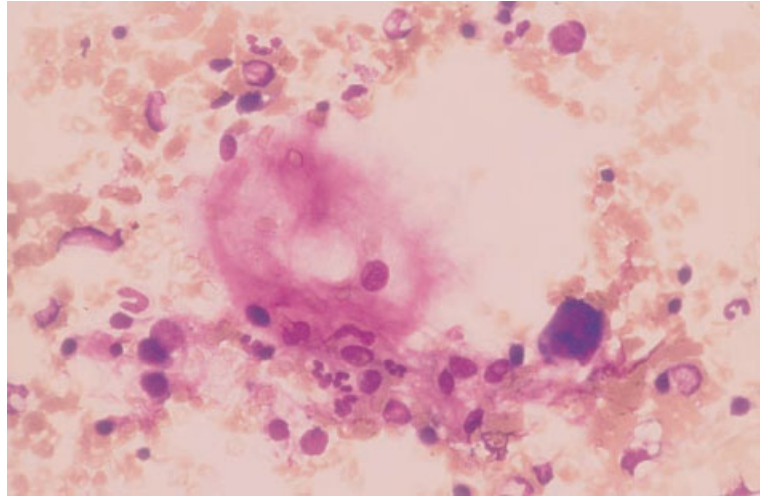
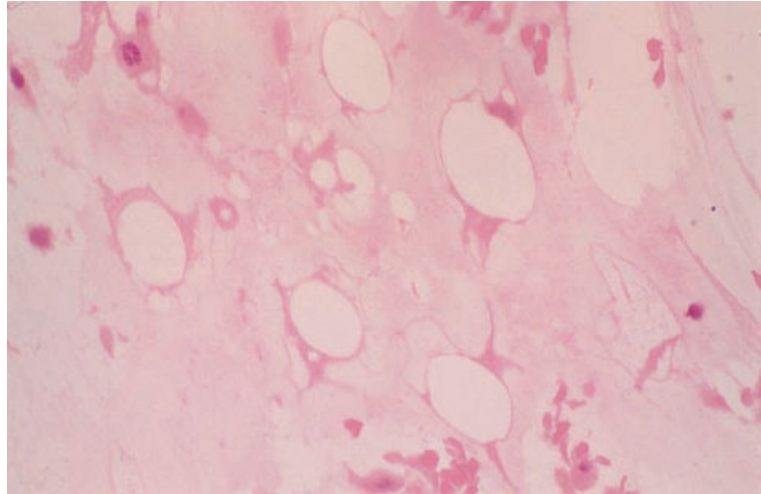


Fig. 3.51 BM trephine biopsy, gelatinous transformation, showing replacement of haemopoietic marrow and fat cells by amorphous pink material. H&E $\times 390$.



and are of variable size. In the affected areas there is a mild to marked hypoplasia of haemopoietic cells. Both fat and haemopoietic cells are replaced by amorphous material which, with H&E staining, has a light blue to pale pink colour and a finely granular appearance (Fig. 3.51). Its other staining characteristics are identical to those seen in marrow films (see above).

Bone marrow fibrosis

Bone marrow fibrosis indicates an increase of reti-

culin or of reticulin and collagen in the bone marrow. Such fibrosis may be focal or generalized. Reticulin and collagen deposition are graded 0–4 as shown in Table 2.2. Some patients with grade 4 fibrosis also have osteosclerosis. Increased reticulin formation and even collagen deposition can revert to normal if the causative condition is amenable to treatment.

An increase in bone marrow reticulin is common and is a useful non-specific indication that the marrow is abnormal. It is also of some use in differential diagnosis; for example, it may be increased in

Table 3.6 Causes of grade 4 bone marrow fibrosis [45,164].**Generalized myelofibrosis***Malignant disease*

Primary (idiopathic) myelofibrosis* (myelofibrosis with myeloid metaplasia)
 Myelofibrosis secondary to essential thrombocythaemia or polycythaemia rubra vera*
 Chronic granulocytic leukaemia*
 Transitional myeloproliferative syndrome
 Acute megakaryoblastic leukaemia*
 Other acute myeloid leukaemias
 Acute lymphoblastic leukaemia [165]
 Systemic mastocytosis*
 The myelodysplastic syndromes (particularly secondary MDS)
 Paroxysmal nocturnal haemoglobinuria
 Hodgkin's disease
 Non-Hodgkin's lymphoma
 Multiple myeloma
 Waldenström's macroglobulinaemia
 Secondary carcinoma*

Bone and connective tissue diseases

Marble bone disease—osteopetrosis
 Primary and secondary hyperparathyroidism
 Nutritional and renal rickets (vitamin D deficiency)
 Osteomalacia
 Primary hypertrophic osteoarthropathy [166]

Miscellaneous

Tuberculosis
 Other granulomatous diseases
 Grey platelet syndrome
 Systemic lupus erythematosus
 Systemic sclerosis
 Prior thorium dioxide administration

Focal or localized

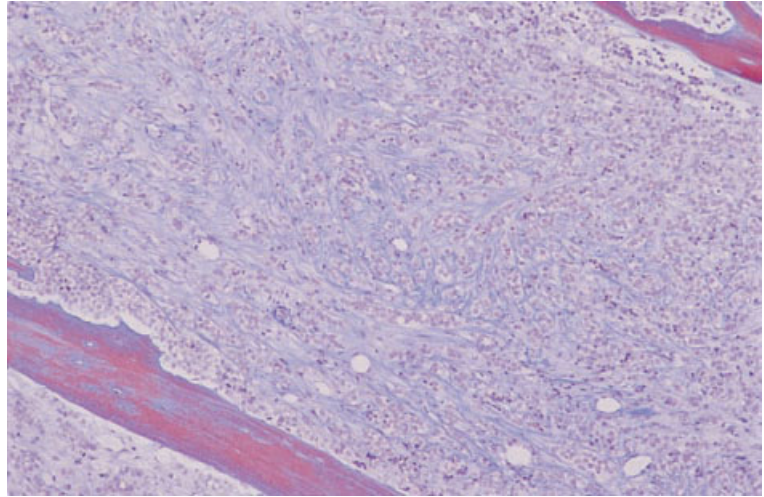
Osteomyelitis
 Paget's disease
 Following bone marrow necrosis
 Following irradiation of the bone marrow
 Adult T-cell leukaemia/lymphoma
 Healing fracture
 Site of previous trephine biopsy

* Osteosclerosis may also occur.

hypoplastic AML and hypoplastic myelodysplastic syndromes but is not increased in aplastic anaemia. Conditions characteristically associated with increased reticulin deposition, but with little if any collagen formation, include hairy cell leukaemia and HIV infection. Reticulin deposition may also be a feature of myeloproliferative disorders, such as

polycythaemia rubra vera and essential thrombocythaemia, and occurs in some patients with acute leukaemia (lymphoblastic as well as myeloid), myelodysplastic syndromes and multiple myeloma. The increase in reticulin in uncomplicated polycythaemia rubra vera and essential thrombocythaemia is not marked.

Fig. 3.52 BM trephine biopsy section showing marrow infiltrated by breast cancer with associated stromal fibrosis. Collagen is evident as blue strands when demonstrated by Martius Scarlet Blue trichrome stain. MSB $\times 94$.



A focal increase in reticulin may have a different significance from a general increase, often indicating the presence of a focal infiltrate.

Collagen deposition is uncommon and of greater diagnostic significance than an increase in reticulin. It is therefore useful to distinguish between these two degrees of abnormality, either by grading the fibrosis or by using the terms 'reticulin fibrosis' for a grade 3 abnormality and 'fibrosis' or 'myelofibrosis' for a grade 4 abnormality. Causes of bone marrow fibrosis are shown in Table 3.6.

Peripheral blood

Bone marrow fibrosis is commonly associated with a leuco-erythroblastic anaemia; red cells show anisocytosis and poikilocytosis with teardrop poikilocytes often being prominent. When fibrosis is extensive, there may also be thrombocytopenia and leucopenia. The blood may also show abnormalities related to the primary disease that has caused the fibrosis. When bone marrow fibrosis has developed acutely, as in acute megakaryoblastic leukaemia, there may be little anisocytosis and poikilocytosis and the blood film is not necessarily leuco-erythroblastic.

Bone marrow cytology

Bone marrow fibrosis often leads to failure to aspirate marrow or to aspiration of peripheral blood or a

diluted marrow specimen. Otherwise the aspirate may show carcinoma cells or the specific features of the primary disease that has led to the fibrosis. If there is associated osteosclerosis, the aspirate may contain increased numbers of osteoblasts and osteoclasts.

Bone marrow histology

The appearances of primary myelofibrosis (myelofibrosis with myeloid metaplasia) are described on page 204. In secondary fibrosis, findings range from a mild increase of fibroblasts and the presence of scattered collagen fibres to a dense fibrosis which obliterates normal haemopoietic tissue. An increase of reticulin can be suspected from an H&E stain by the distortion and angularity of fat cells and by the 'streaming' of haemopoietic cells held between parallel reticulin fibres. Fibrosis may also be suspected when sinusoids, which are normally collapsed in paraffin-embedded specimens, are held open. Increased reticulin deposition is confirmed by a silver impregnation technique such as the Gomori stain. Collagen fibres are detected as eosinophilic fibres which may be in bundles. The oval nuclei of fibroblasts are apparent in relation to the collagen fibres. It is important not to confuse either endothelial cells of collapsed capillaries or mast cells with fibroblasts. The presence of collagen is confirmed by a trichrome stain such as a Martius Scarlet Blue stain (Fig. 3.52). The distribution of reticulin

and collagen within the marrow depends on the causative condition. In renal osteodystrophy and primary hyperparathyroidism, fibrosis is usually paratrabecular. In Paget's disease, it is often preferentially paratrabecular. When associated with a myeloproliferative disorder or with the grey platelet syndrome, fibrosis may be spatially related to megakaryocytes.

Problems and pitfalls

When the bone marrow is very fibrotic, any bone marrow aspirate is likely to be very unrepresentative. No attempt should be made to assess cellularity. However, it is always worth looking for tumour cells or dysplastic haemopoietic cells, regardless of the quality of the aspirate. If no aspirate can be obtained, a trephine biopsy imprint can yield useful information as to the nature of any abnormal cells present.

Due weight must be given to the presence of focal reticulin deposition and the corresponding area in the H&E-stained sections should be carefully examined. A generalized increase in reticulin is an indication of an abnormal bone marrow and an explanation should be sought by reviewing of clinical, haematological and histological features.

When fibrosis is very pronounced, it may be difficult to distinguish residual haemopoietic cells, particularly megakaryocytes, from tumour cells. Immunohistochemistry is useful in this situation.

References

- 1 Goodman JL (1999) Ehrlichiosis—ticks, dogs and doxycycline. *N Engl J Med*, 341, 195–197.
- 2 Rausing A (1973) Bone marrow biopsy in the diagnosis of Whipple's disease. *Acta Med Scand*, 193, 5–8.
- 3 Barenfanger J, Patel PG, Dumler JS and Walker DH (1996) Clinical and pathology rounds: identifying human ehrlichiosis. *Lab Med*, 27, 372–374.
- 4 Farooqui BJ, Khurshid M, Ashfaq MK and Khan MA (1991) Comparative yield of *Salmonella typhi* from blood and bone marrow cultures in patients with fever of unknown origin. *J Clin Pathol*, 44, 258–259.
- 5 Al-Eissa YA, Assuhaimi SA, Al-Fawaz IM, Higgy KE, Al-Nasser MN and Al-Mobaireek KF (1993) Pancytopenia in children with brucellosis: clinical manifestations and bone marrow findings. *Acta Haematol*, 89, 132–136.
- 6 Lawrence C and Schreiber AJ (1979) Leprosy's footprints in bone marrow macrophages. *N Engl J Med*, 300, 834–835.
- 7 Schmid C, Frisch B, Beham A, Jager K and Kettner G (1990) Comparison of bone marrow histology in early chronic granulocytic leukaemia and in leukaemoid reaction. *Eur J Haematol*, 44, 154–158.
- 8 Thiele J, Holgado S, Choritz H and Georgii A (1983) Density distribution and size of megakaryocytes in inflammatory reaction of the bone marrow (myelitis) and chronic myeloproliferative disorders. *Scand J Haematol*, 31, 329–341.
- 9 Hyun BH, Kwa D, Gabaldon H and Ashton JK (1976) Reactive plasmacytic lesions of the bone marrow. *Am J Clin Pathol*, 65, 921–928.
- 10 Amos RJ, Deane M, Ferguson C, Jeffries G, Hinds CJ and Amess JAL (1990) Observations on the haemopoietic response to critical illness. *J Clin Pathol*, 43, 850–856.
- 11 Wiley EL, Perry A, Nightingale SD and Lawrence J (1994) Detection of *Mycobacterium avium-intracellulare* complex in bone marrow specimens of patients with acquired immunodeficiency syndrome. *Am J Clin Pathol*, 101, 446–451.
- 12 Suster S, Cabello-Inchausti B and Robinson MJ (1990) Nongranulomatous involvement of the bone marrow in lepromatous leprosy. *Am J Clin Pathol*, 92, 797–801.
- 13 Paddock CD, Suchard DP, Grumbach KL, Hadley WK, Kerschmann RL, Abbey NWBG *et al.* (1993) Brief report: fatal seronegative ehrlichiosis in a patient with HIV infection. *N Engl J Med*, 329, 1164–1167.
- 14 Pooley RJ Jr, Peterson L, Finn WG and Kroft SH (1999) Cytomegalovirus-infected cells in routinely prepared peripheral blood films of immunosuppressed patients. *Am J Clin Pathol*, 112, 108–112.
- 15 Davidovitz Y, Halpern Z, Vardi J, Ballin A and Meytes D (1998) Pure red cell aplasia responsive to interferon- α in a patient with hepatitis C infection. *Acta Haematol*, 100, 213–215.
- 16 Bilgrami S, Almeida GD, Quinn JJ, Tuck D, Bergstrom S, Dainiak NJL *et al.* (1994) Pancytopenia in allogeneic marrow transplant recipients: role of cytomegalovirus. *Br J Haematol*, 87, 357–362.
- 17 Kobayashi S, Maruta A, Yamamoto T, Katayama N, Higuchi R, Sakano YA *et al.* (1998) Human parvovirus B19 capsid antigen in granulocytes in parvovirus-B19-induced pancytopenia after bone marrow transplantation. *Acta Haematol*, 100, 195–199.
- 18 Brunning RD. Bone marrow. In: Rosai J (ed) *Ackerman's Surgical Pathology*, 7th edn, vol 2. Mosby, St Louis, 1989.

- 19 Prezioso PJ, Cangiarella J, Lee M, Nuovo GJ, Borkowsky W, Orlow SJ and Greco MA (1992) Fatal disseminated infection with human herpes virus-6. *J Pediatr*, 120, 921–923.
- 20 Johnston RE, Geretti A-M, Prentice HG, Clark AD, Wheeler AC, Potter M and Griffiths PD (1999) HHV-6-related secondary graft failure following allogeneic bone marrow transplantation. *Br J Haematol*, 105, 1041–1043.
- 21 Liu W, Ittman M, Liu J, Schoentag R, Tierno P, Greco MA *et al.* (1997) Human parvovirus in bone marrows from adults with acquired immunodeficiency syndrome: a comparative study using in situ hybridization and immunohistochemistry. *Hum Pathol*, 28, 760–766.
- 22 Rimsza LM, Vela EE, Frutiger YM, Rangel CS, Solano M, Richter LC, Grogan TM and Bellamy LC (1996) Rapid automated combined in situ hybridization and immunohistochemistry for sensitive detection of virus in paraffin-embedded tissue biopsies. *Am J Clin Pathol*, 106, 544–548.
- 23 Hamer RD, Scott M, Shahab I, Carey TT, Cousar JB and Macon WR (1996) Latent membrane protein antibody reacts with normal hematopoietic precursor cells and leukemic blasts in tissues lacking Epstein–Barr virus genome by polymerase chain reaction. *Am J Clin Pathol*, 106, 469–474.
- 24 Cleary ML, Nalesnik MA, Shearer WT and Sklar J (1988) Clonal analysis of transplant-associated lymphoproliferations based on the structure of genetic termini of the Epstein–Barr virus. *Blood*, 72, 349–352.
- 25 Rinn R, Chow WS and Pinkerton PH (1995) Transient acquired myelodysplasia associated with parvovirus B19 infection in a patient with congenital spherocytosis. *Am J Hematol*, 50, 71–72.
- 26 Dorvault C, Raikow R and Contis L (1998) Evaluation of a monoclonal antibody to human parvovirus in B5-fixed bone marrow biopsy specimens. *Am J Clin Pathol*, 110, 540–541.
- 27 Thiele J, Zirbes TK, Kvasnicka HM and Fischer R (1999) Focal lymphoid aggregates (nodules) in bone marrow biopsies: differentiation between benign hyperplasia and malignant lymphoma—a practical guide. *J Clin Pathol*, 52, 294–300.
- 28 Wong KF, Tsang DNC and Chan JKC (1994) Bone marrow diagnosis of penicilliosis. *N Engl J Med*, 330, 717–718.
- 29 Ferry JA, Pettit CJ, Rosenberg AE and Harris NL (1991) Fungi in megakaryocytes. An unusual manifestation of fungal infection of the bone marrow. *Am J Clin Pathol*, 96, 577–581.
- 30 Strauchen JA. *Diagnostic Histopathology of the Bone Marrow*. Oxford University Press, Oxford, 1996.
- 31 Brouland JP, Audouin J, Hofman P, Le Tourneau A, Basset D, Rio B *et al.* (1996) Bone marrow involvement by disseminated toxoplasmosis in acquired immunodeficiency syndrome: the value of bone marrow trephine biopsy and immunohistochemistry for the diagnosis. *Hum Pathol*, 27, 302–306.
- 32 Piehl MR, Kaplan RL and Haber MH (1988) Disseminated penicilliosis in a patient with acquired immunodeficiency syndrome. *Arch Pathol Lab Med*, 112, 1262–1264.
- 33 Wheat LJ, Connolly-Stringfield PA, Baker RL, Curfman MF, Eads ME, Israel KS *et al.* (1990) Disseminated histoplasmosis in the acquired immune deficiency syndrome: clinical findings, diagnosis and treatment, and review of the literature. *Medicine*, 69, 361–374.
- 34 McKinsey DS, Gupta MR, Riddler SA, Driks MR, Smith DL and Kurtin PJ (1989) Long-term amphotericin B therapy for disseminated histoplasmosis in patients with acquired immunodeficiency syndrome (AIDS). *Ann Intern Med*, 111, 655–659.
- 35 Wheat LJ, Connolly-Stringfield P, Kohler RB, Frame PT and Gupta MR (1989) Histoplasma capsulatum polysaccharide antigen detection in diagnosis and management of disseminated histoplasmosis in patients with acquired immunodeficiency syndrome. *Am J Med*, 87, 396–400.
- 36 Abdalla SH (1991) Hematopoiesis in human malaria. *Blood Cells*, 16, 401–416.
- 37 Phillips RE and Pavso G (1992) Anaemia of *Plasmodium falciparum* malaria. *Baillière's Clin Haematol*, 5, 315–330.
- 38 Bates I, Bedu-Addo G, Bevan DH and Rutherford TR (1991) Use of immunoglobulin gene rearrangements to show clonal lymphoproliferation in hyperreactive malarial splenomegaly. *Lancet*, 337, 505–507.
- 39 Kirchhoff LV (1993) American trypanosomiasis (Chagas' disease)—a tropical disease now in the United States. *N Engl J Med*, 329, 639–644.
- 40 Grimes MM, La Pook JD, Bar MH, Wasserman HS and Dwork A (1987) Disseminated *Pneumocystis carinii* infection in a patient with acquired immunodeficiency syndrome. *Hum Pathol*, 18, 307–308.
- 41 Yachnis AT, Berg J, Martinez-Salazar A, Bender BS, Diaz L, Rojiani AM *et al.* (1996) Disseminated microsporidiosis specially infecting the brain, heart, and kidneys. Report of a newly recognized pansporoblastic species in two symptomatic AIDS patients. *Am J Clin Pathol*, 106, 535–543.
- 42 Telsak EE, Cote RJ, Gold JMW, Campbell SW and Armstrong D (1990) Extrapulmonary *Pneumocystis carinii* infections. *Rev Infect Dis*, 12, 380–386.
- 43 Bodem CR, Hamory BH, Taylor HM and Kleopfer L (1983) Granulomatous bone marrow disease. A review of the literature and clinicopathological analysis of 58 cases. *Medicine (Baltimore)*, 62, 372–383.

- 44 Dumler JS, Dawson JE and Walker DH (1993) Human ehrlichiosis: hematopathology and immunohistologic detection of *Ehrlichia chaffeensis*. *Hum Pathol*, 24, 391–396.
- 45 Bain BJ and Wickramasinghe SNW. Pathology of the bone marrow: general considerations. In: Wickramasinghe SNW (ed) and Symmers W St C (series ed) *Systemic Pathology, Volume 2: Blood and Bone Marrow*, 3rd edn. Churchill Livingstone, Edinburgh, 1986.
- 46 Vilalta-Castel E, Váldez-Sánchez MD, Guerra-Vales JM, Teno-Esteban C, Garzón A, López JI *et al.* (1988) Significance of granulomas in bone marrow: a study of 40 cases. *Eur J Haematol*, 41, 12–14.
- 47 Epstein HD and Kruskall MS (1988) Spurious leukopenia due to *in vitro* granulocyte aggregation. *Am J Clin Pathol*, 89, 652–655.
- 48 Ampel NM, Ryan KJ, Carry PJ, Wieden MA and Schiffman RB (1986) Fungemia due to *Coccidioides immitis*. An analysis of 16 episodes in 15 patients and a review of the literature. *Medicine (Baltimore)*, 65, 312–321.
- 49 Hyun BH. *Colour Atlas of Clinical Hematology*. Igaku-Shoin Med US, New York, 1986.
- 50 Falini B, Tabilio A, Velardi A, Cernetti C, Aversa F and Martelli MF (1982) Multiple myeloma with a sarcoidosis-like reaction. *Scand J Haematol*, 29, 211–216.
- 51 Rabbani GR, Philyky RL and Tefferi A (1999) A long-term study of patients with chronic natural killer cell lymphocytosis. *Br J Haematol*, 106, 960–966.
- 52 Bhargava V and Farhi DC (1988) Bone marrow granulomas: clinicopathologic findings in 72 cases and review of the literature. *Hematol Pathol*, 2, 43–50.
- 53 Kettle P and Allen DC (1997) Bone marrow granulomas in infiltrating lobular breast cancer. *J Clin Pathol*, 50, 166–168.
- 54 Poland GA and Love KR (1986) Marked atypical lymphocytosis, hepatitis, and skin rash in sulfasalazine drug allergy. *Am J Med*, 81, 707–708.
- 55 Case Records of the Massachusetts General Hospital (1996) A seven-year-old boy with fever, lymphadenopathy, hepatosplenomegaly, and prominent eosinophilia. *N Engl J Med*, 335, 577–586.
- 56 Pelstring RJ, Kim K, Lower EE and Swerdlow SH (1988) Marrow granulomas in coal workers' pneumoconiosis. *Am J Clin Pathol*, 89, 553–556.
- 57 Lewis JH, Sundeen JT, Simon GL, Schulof RS, Wand GS, Gelfand RL *et al.* (1985) Disseminated talc granulomatosis: acquired immunodeficiency syndrome and fatal cytomegalovirus infection. *Arch Pathol Lab Med*, 109, 147–150.
- 58 Davis S and Trubowitz S. Pathologic reactions involving the bone marrow. In: Trubowitz S and Davis S (eds) *The Human Bone Marrow: Anatomy, Physiology and Pathophysiology*, vol. 2. CRC Press, Boca Raton, 1982.
- 59 Rywlin AM and Ortega R (1971) Lipid granulomas of the bone marrow. *Am J Clin Pathol*, 57, 457–462.
- 60 Hudson P and Robertson GM (1966) Demonstration of mineral oil in splenic lipid granulomas. *Lab Invest*, 15, 1134–1135.
- 61 Pease GL (1956) Granulomatous lesions in bone marrow. *Blood*, 11, 720–734.
- 62 Farhi DC, Mason UG and Horsburgh CR (1984) The bone marrow in disseminated *Mycobacterium avium intracellulare* infection. *Am J Clin Pathol*, 83, 463–468.
- 63 Okun DB, Sun NCJ and Tanaka KR (1979) Bone marrow granulomas in Q-fever. *Am J Clin Pathol*, 71, 117–121.
- 64 Young JF and Goulian M (1993) Bone marrow fibrin ring granulomas and cytomegalovirus infection. *Am J Clin Pathol*, 99, 65–68.
- 65 Kurtin PJ, McKinsey DS, Gupta MR and Driks M (1989) Histoplasmosis in patients with acquired immunodeficiency syndrome. Hematologic and bone marrow manifestation. *Am J Clin Pathol*, 93, 367–372.
- 66 Kadin ME, Donaldson SS and Dorfman RF (1970) Isolated granulomas in Hodgkin's disease. *N Engl J Med*, 283, 859–861.
- 67 Yu NC and Rywlin AM (1982) Granulomatous lesions of the bone marrow in non-Hodgkin's lymphoma. *Hum Pathol*, 13, 905–910.
- 68 Franco V, Florena AM, Quintini G and Musso M (1994) Bone marrow granulomas in hairy cell leukaemia following 2-chlorodeoxyadenosine therapy. *Histopathology*, 24, 271–273.
- 69 O'Brien DV, Boon AP and Boughton BJ (1992) Bone marrow granulomas in acute myeloid leukaemia following interleukin 2 and lymphokine-activated killer cells. *Histopathology*, 20, 271–272.
- 70 Amodie LA and Tefferi A (1996) Bone marrow granulomas and fevers of unknown origin associated with chronic natural killer cell lymphocytosis. *Br J Haematol*, 93 (Suppl. 2), 108.
- 71 Tefferi A and Li CY (1997) Bone marrow granulomas associated with chronic natural killer cell lymphocytosis. *Am J Hematol*, 54, 258–262.
- 72 Browne PM, Sharma OP and Salkin D (1978) Bone marrow sarcoidosis. *JAMA*, 240, 2654–2655.
- 73 Frizzera G, Banks PM, Massarelli G and Rosai J (1983) A systemic lymphoproliferative disorder with morphologic features of Castleman's disease. Pathological findings in 15 patients. *Am J Surg Pathol*, 7, 211–231.
- 74 Faulkner-Jones BE, Howie AJ, Boughton BJ and Franklin IM (1988) Lymphoid aggregates in bone marrow: study of eventual outcome. *J Clin Pathol*, 41, 768–775.

- 75 Rywlin AM, Ortega RS and Dominguez CJ (1974) Lymphoid nodules of bone marrow. *Blood*, 43, 389–400.
- 76 Sangster G, Crocker J, Nar P and Leylan MJ (1986) Benign and malignant (B cell) focal lymphoid aggregates in bone marrow trephines shown by means of an immunogold-silver technique. *J Clin Pathol*, 39, 453–457.
- 77 Harris NL and Ferry JA. Follicular lymphoma and related disorders. In: Knowles DW (ed) *Neoplastic Hematopathology*. Williams & Wilkins, Baltimore, 1992.
- 78 Farhi DC (1989) Germinal centres in the bone marrow. *Hematol Pathol*, 3, 133–136.
- 79 Horny HD, Wehrmann M, Griessner H, Tiemann M, Bultman B and Kaiserling E (1993) Investigation of bone marrow lymphocyte subsets in normal, reactive and neoplastic states using paraffin-embedded biopsy specimens. *Am J Clin Pathol*, 99, 142–149.
- 80 Bluth RF, Casey TT and McCurley TL (1993) Differentiation of reactive from neoplastic small-cell lymphoid aggregates in paraffin-embedded marrow particle preparations using L26 (CD20) and UCHL-1 (CD45 RO) monoclonal antibodies. *Am J Clin Pathol*, 99, 150–156.
- 81 Smith GP, Perkins SL, Segal GH and Kjeldsberg CR (1994) T-cell lymphocytosis associated with invasive thymomas. *Am J Clin Pathol*, 102, 447–453.
- 82 Agrawal S, Matutes E, Voke J, Dyer MJS, Khokhar T and Catovsky D (1994) Persistent polyclonal B-cell lymphocytosis. *Leuk Res*, 18, 791–795.
- 83 Gatter K and Brown D. *An Illustrated Guide to Bone Marrow Diagnosis*. Blackwell Science, Oxford, 1997.
- 84 Klein H and Block M (1953) Bone marrow plasmacytosis. *Blood*, 8, 1034–1041.
- 85 Wulfhekel U and Dullmann J (1999) Storage of iron in bone marrow plasma cells. Ultrastructural characterization, mobilization, and diagnostic significance. *Acta Haematol*, 101, 7–15.
- 86 Crocker J and Curran RC (1981) Quantitative study of the immunoglobulin-containing cells in trephine samples of bone marrow. *J Clin Pathol*, 34, 1080–1082.
- 87 Peart KM and Ellis HA (1972) Quantitative observations on iliac crest bone marrow mast cells in chronic renal failure. *J Clin Pathol*, 28, 947–955.
- 88 Yoo D, Lessin LS and Jensen WN (1978) Bone marrow mast cells in lymphoproliferative disorders. *Ann Intern Med*, 88, 753–757.
- 89 Prokimer M and Polliack A (1980) Increased bone marrow mast cells in preleukemic syndromes, acute leukaemia, and lymphoproliferative disorders. *Am J Clin Pathol*, 75, 34–38.
- 90 Rywlin AM, Hoffman EP and Ortega RS (1972) Eosinophilic fibrohistiocytic lesions of bone marrow: a new morphologic finding probably related to drug hypersensitivity. *Blood*, 40, 464–472.
- 91 Wilson PA, Ayscue LH, Jones GR and Bentley SA (1993) Bone marrow histiocytic proliferation in association with colony-stimulating factor therapy. *Am J Clin Pathol*, 99, 311–313.
- 92 Rosenthal NS and Fahri DC (1994) Failure to engraft after bone marrow transplantation, bone marrow morphologic findings. *Am J Clin Pathol*, 102, 821–824.
- 93 Hirayama Y, Yoshioka K and Shiozaki N (1995) Histiocytosis and two classes of M-proteinemia in pre-treated Ph positive ALL. *Am J Hematol*, 49, 358–359.
- 94 Huang LM, Lee CY, Lin KH, Chuu WM, Lee PI, Chen RL *et al.* (1990) Human herpesvirus-6 associated with fatal haemophagocytic syndrome. *Lancet*, 336, 60–61.
- 95 Kawa-Ha K, Tanaka K, Inoue M, Sakata N, Okada S, Kurata T *et al.* (1993) Isolation of human herpesvirus 7 from a child with symptoms mimicking chronic Epstein-Barr virus infection. *Br J Haematol*, 84, 545–548.
- 96 Potter MN, Foot ABM and Oakhill A (1991) Influenza A and virus-associated haemophagocytic syndrome: cluster of three cases in children with acute leukaemia. *J Clin Pathol*, 44, 297–299.
- 97 Komp DM, Buckley PJ, McNamara J and van Hoff J (1989) Soluble interleukin-2 receptors in hemophagocytic histiocytosis. *Pediatr Hematol Oncol*, 6, 253–264.
- 98 Lelong F (1993) Syndrome d'activation macrophagique. *Les Mercredis Cytologiques de Necker*, No 5.
- 99 Wong K-F and Chan JKC (1992) Reactive haemophagocytic syndrome—a clinico-pathologic study of 40 patients in an Oriental population. *Am J Med*, 93, 177–180.
- 100 Tsuda H and Fujisao S (1999) Th1/Th2 milieu in adult hemophagocytic syndrome. *Acta Haematol*, 101, 157–160.
- 101 Woda BA and Sullivan J (1993) Reactive histiocytic disorders. *Am J Clin Pathol*, 99, 460–463.
- 102 Manoharan A and Catovsky D. Histiocytic medullary reticulosis revisited. In: Schmalzl F, Huhn D and Schaefer HE (eds) *Haematology and Blood Transfusion. Volume 27: Disorders of the Monocyte Macrophage System*. Springer-Verlag, Berlin, 1981.
- 103 Risdall RJ, Brunning RD, Hernandez JI and Gordon DH (1984) Bacteria associated hemophagocytic syndrome. *Cancer*, 54, 2968–2972.
- 104 Bourquelot P, Bouscary D, Paul G, Picard F, Varet B, Dreyfus F and Tulliez M (1996) Hemophagocytic syndrome associated with *Bacteroides fragilis* infection in a patient with acute monoblastic leukemia. *Leuk Lymphoma*, 22, 177–179.

- 105 Gill K and Marrie TJ (1987) Hemophagocytosis secondary to *Mycoplasma pneumoniae* infection. *Am J Med*, 82, 668–670.
- 106 Abbott KC, Vukelja ST, Smith CE, McAllister CK, Konkol KA, O'Rourke TJ *et al.* (1991) Hemophagocytic syndrome: a cause of pancytopenia in human ehrlichiosis. *Am J Hematol*, 38, 230–234.
- 107 Walker DH and Dumler JS (1997) Human monocytic and granulocytic ehrlichioses. Discovery and diagnosis of emerging tick-borne infections and the critical role of the pathologist. *Arch Pathol Lab Med*, 121, 785–791.
- 108 Estrov Z, Bruck R, Shtalrid M, Berrebi A and Resnitzky P (1983) Histiocytic hemophagocytosis in Q-fever. *Arch Pathol Lab Med*, 108, 7.
- 109 Shome DK, Rakheja D and Sonkar S (1997) Haemophagocytosis in bone marrow aspirates. *Acta Haematol*, 98, 173–174.
- 110 Auerbach M, Haubenstock A and Soloman G (1980) Systemic babesiosis. Another cause of the hemophagocytic syndrome. *Am J Med*, 80, 301–303.
- 111 Higgins EM, Layton DM, Arya R, Salisbury J and du Vivier AWP (1994) Disseminated *Trichosporon beigelii* infection in an immunosuppressed child. *J Roy Soc Med*, 87, 292–293.
- 112 Jaffe ES, Costa J and Fauci AS (1981) Erythrophagocytic T lymphoma. *N Engl J Med*, 305, 103–104.
- 113 Chan E, Pi D, Chan GT, Todd D and Ho FC (1989) Peripheral T-cell lymphoma presenting as hemophagocytic syndrome. *Hematol Oncol*, 7, 275–285.
- 114 Sonneveld P, van Lom K, Kappers-Klunne M, Prins MER and Abels J (1990) Clinico-pathological diagnosis and treatment of malignant histiocytosis. *Br J Haematol*, 75, 511–516.
- 115 Noguchi M, Kawano Y, Sato N and Oshimi K (1997) T-cell lymphoma of CD3+CD4+CD56+ granular lymphocytes with hemophagocytic syndrome. *Leuk Lymphoma*, 26, 349–358.
- 116 Okuda T, Sakamoto S, Deguchi T, Misawa S, Kashimi K, Yoshihara T *et al.* (1991) Hemophagocytic syndrome associated with natural killer cell leukemia. *Am J Hematol*, 38, 321–323.
- 117 Takeshita M, Kikuchi M, Ohshima K, Nibu K, Suzumiya J, Hisano S *et al.* (1993) Bone marrow findings in malignant histiocytosis and/or malignant lymphoma with concurrent hemophagocytic syndrome. *Leuk Lymphoma*, 12, 79–89.
- 118 Chim CS and Hui PK (1997) Reactive hemophagocytic syndrome and Hodgkin's disease. *Am J Hematol*, 55, 49–50.
- 119 Mahadeva U, Allport T, Bain B and Chan WK (2000) Haemophagocytic syndrome with histiocytic necrotizing lymphadenitis (Kikuchi's disease). *J Clin Pathol*, 53, 636–638.
- 120 Kumakura S, Ishikura H, Umegae N, Yamagata S and Kobayashi S (1997) Autoimmune-associated hemophagocytic syndrome. *Am J Med*, 102, 113–115.
- 121 Janka GE (1989) Familial hemophagocytic lymphohistiocytosis: diagnostic problems and differential diagnosis. *Pediatr Hematol Oncol*, 6, 219–226.
- 122 Urabe AU (1994) Colony-stimulating factor and macrophage proliferation. *Am J Clin Pathol*, 101, 116.
- 123 Hurwitz N, Probst A, Zufferey G, Tichelli A, Pless M, Kappos L *et al.* (1996) Fatal vascular leak syndrome with extensive hemorrhage, peripheral neuropathy and reactive erythrophagocytosis: an unusual complication of recombinant IL-3 therapy. *Leuk Lymphoma*, 20, 337–340.
- 124 Cheah PL, Looi LM, Tan PE, Bosco J and Kuperan P (1992) Cytophagic histiocytic panniculitis: a diagnostic dilemma. *Hematol Oncol*, 10, 331–337.
- 125 Van den Bos C, de Konig TJ, Bierings MB, Poll-The BT, Zegers BJM, Rijkers GT and Révész T (1998) Hemopoietic and immunological abnormalities in two patients with lysinuric protein intolerance. *Br J Haematol*, 102, 314.
- 126 Çetin M, Hiçsönmez G and Gögüs S (1998) Myelodysplastic syndrome associated with Griscelli syndrome. *Leuk Res*, 22, 859–862.
- 127 Aricó M, Caselli D and Burgio GR (1989) Familial hemophagocytic lymphohistiocytosis: clinical features. *Pediatr Hematol Oncol*, 6, 247–251.
- 128 Ohadi M, Lalloz MR, Sham P, Zhao J, Dearlove AM, Shiach C *et al.* (1999) Localization of a gene for familial hemophagocytic lymphohistiocytosis at chromosome 9q21.3–22 by homozygosity mapping. *Am J Hum Genet*, 64, 165–171.
- 129 Risdall RJ, McKenna RW, Nesbitt ME, Krivit W, Balfour HH, Simmons RL and Brunning RD (1979) Virus-associated hemophagocytic syndrome: a benign histiocytic proliferation distinct from malignant histiocytosis. *Cancer*, 44, 993–1002.
- 130 Campo E, Condom E, Miro M-J, Cid M-C and Romagosa V (1986) Tuberculosis associated haemophagocytic syndrome. *Cancer*, 58, 2640–2645.
- 131 Hirst WJR, Layton DM, Singh S, Mieli-Vergani G, Chessells JM, Strobel S and Pritchard J (1994) Haemophagocytic lymphohistiocytosis, experience in two U.K. centres. *Br J Haematol*, 88, 731–739.
- 132 Han K, Kim Y, Kahng J, Lee J, Moon Y, Kang C and Shim S (1996) In situ hybridization studies of cytomegalovirus and Epstein-Barr virus in reactive histiocytic hyperplasia with hemophagocytosis. *Acta Haematol*, 96, 140–145.
- 133 Imashuku S, Hibi S, Morinaga S, Takagi K, Chen J, Mugishima H *et al.* (1997) Haemophagocytic lymphohistiocytosis in association with granular lymphocyte proliferative disorders in early child-

- hood: characteristic bone marrow morphology. *Br J Haematol*, 96, 708–714.
- 134 Nair JMG, Bellevue R, Bertoni M and Dosik H (1988) Thrombotic thrombocytopenia in patients with the acquired immunodeficiency syndrome (AIDS)-related complex: a report of two cases. *Ann Intern Med*, 109, 242–243.
- 135 Bain BJ (1997) The haematological features of HIV infection. *Br J Haematol*, 99, 1–8.
- 136 Osborne BM, Guarda LA and Butler JJ (1984) Bone marrow biopsies in the acquired immunodeficiency syndrome. *Hum Pathol*, 15, 1048–1053.
- 137 Scheider DR and Picker LJ (1985) Myelodysplasia in the acquired immunodeficiency syndrome. *Am J Clin Pathol*, 84, 144–152.
- 138 Castella A, Crosson TS, Mildvan D, Witt DH and Zalusky R (1985) The bone marrow in AIDS. *Am J Clin Pathol*, 84, 425–432.
- 139 Mehta K, Gascoyne P and Robboy S (1992) The gelatinous bone marrow (serous atrophy) in patients with acquired immunodeficiency syndrome. *Arch Pathol Lab Med*, 116, 504–508.
- 140 Bain BJ (1998) The haematologist and the infective complications of HIV infection. *Haematology*, 3, 153–164.
- 141 Hussong J, Peterson LR, Warren JR and Peterson L-AC (1998) Detecting disseminated *Mycobacterium avium* complex infections in HIV-positive patients. *Am J Clin Pathol*, 110, 806–809.
- 142 Relman DA, Loutit JS, Schmidt TM, Falkow S and Tompkins LS (1990) The agent of bacillary angiomatosis—an approach to the identification of uncultured pathogens. *N Engl J Med*, 323, 1573–1580.
- 143 Milam MW, Balerdi MJ, Toney JF, Foulis PR, Milam CP and Behnke RH (1990) Epithelioid angiomatosis secondary to disseminated cat scratch disease involving the bone marrow and skin in a patient with acquired immune deficiency syndrome: a case report. *Am J Med*, 88, 180–183.
- 144 Zietz C, Bogner JR, Goebel F-D and Lohrs U (1999) An unusual cluster of Castleman's disease during highly active antiretroviral therapy for AIDS. *N Engl J Med*, 340, 1923–1924.
- 145 Bain BJ (1998) Lymphomas and reactive lymphoid lesions in HIV infection. *Blood Rev*, 12, 154–162.
- 146 Karcher DS (1993) Clinically unsuspected Hodgkin disease presenting initially in the bone marrow of patients infected with the human immunodeficiency virus. *Cancer*, 71, 1235–1238.
- 147 Kumar S, Kumar D, Schnadig VJ, Selvanayagam P and Slaughter DP (1994) Plasma cell myeloma in patients who are HIV-positive. *Am J Clin Pathol*, 102, 633–639.
- 148 Knupp C, Pekela PH and Cornelius P (1988) Extensive bone marrow necrosis in patients with cancer and tumor necrosis factor activity in plasma. *Am J Hematol*, 29, 215–221.
- 149 Paydas S, Kocak R, Zorludemir S and Baslamisli F (1997) Bone marrow necrosis in antiphospholipid syndrome. *J Clin Pathol*, 50, 261–262.
- 150 Murphy PT, Sivakumaran M, Casey MC, Liddicoat A and Wood JK (1998) Lymphoma associated bone marrow necrosis with raised anticardiolipin antibody. *J Clin Pathol*, 51, 407–409.
- 151 Majumdar G, Phillips JK and Pearson TC (1994) Massive bone marrow necrosis and post-necrotic myelofibrosis in a patient with primary thrombocythaemia. *J Clin Pathol*, 47, 674–676.
- 152 Laso F-J, González-Díaz M, Paz J-I and De Castro S (1983) Bone marrow necrosis associated with tumor emboli and disseminated intravascular coagulation. *Arch Intern Med*, 143, 2220.
- 153 Upchurch KS (1988) Case records of the Massachusetts General Hospital. Case 38–1988. *N Engl J Med*, 319, 768–781.
- 154 Rustgi VK, Sacher RA, O'Brien P and Garagusi VF (1983) Fatal disseminated cytomegalovirus infection in an apparently normal adult. *Arch Intern Med*, 143, 372–373.
- 155 Epstein M, Pearson ADJ, Hudson SJ, Bray R, Jaylor M and Beesley J (1992) Necrobacillosis with pancytopenia. *Arch Dis Child*, 67, 958–959.
- 156 Petrella T, Bailly F, Mugneret F, Caillot D, Chavanat P, Guy H *et al.* (1992) Bone marrow necrosis and human parvovirus associated infection preceding a Ph1+ acute lymphoblastic leukemia. *Leuk Lymphoma*, 8, 415–419.
- 157 Katayama Y, Deguchi S, Shinagawa K, Teshima T, Notohara K, Taguchi KM *et al.* (1998) Bone marrow necrosis in a patient with acute myeloblastic leukemia during administration of G-CSF and rapid hematologic recovery after allotransplantation of peripheral blood stem cells. *Am J Hematol*, 57, 238–240.
- 158 Aboulafia DM and Demirel T (1995) Fatal bone marrow necrosis following fludarabine administration in a patient with indolent lymphoma. *Leuk Lymphoma*, 19, 181–184.
- 159 Case Records of the Massachusetts General Hospital (1998) Tachycardia, changed mental status, and pancytopenia in an elderly man with treated lymphoma. *N Engl J Med*, 339, 254–261.
- 160 Bermejo A, Gonzalez FA, Villegas A and Alarcon C (1995) Bone marrow necrosis. *Am J Hematol*, 50, 65–66.
- 161 Kiraly JF and Wheby MS (1976) Bone marrow necrosis. *Am J Med*, 60, 361–368.
- 162 Clarke BE, Brown DJ and Xipell JM (1983) Gelatinous transformation of the bone marrow. *Pathology*, 15, 85–88.

- 163 Savage RA and Sipple C (1987) Marrow myxedema: gelatinous transformation of marrow ground substance in patient with severe hypothyroidism. *Arch Pathol Lab Med*, 111, 375–377.
- 164 McCarthy DM (1985) Fibrosis of the bone marrow: content and causes. *Br J Haematol*, 59, 1–7.
- 165 Hann IM, Evans DIK, Marsden HB, Jones PM and Palmer MK (1978) Bone marrow fibrosis in acute lymphoblastic leukaemia of childhood. *J Clin Pathol*, 31, 313–315.
- 166 Fontenay-Roupie M, Dupuy E, Berrou E, Tobelem G and Bryckaert M (1995) Increased proliferation of bone-marrow derived fibroblasts in primitive hypertrophic osteoarthropathy with severe myelofibrosis. *Blood*, 85, 3229–3238.

FOUR

ACUTE MYELOID LEUKAEMIA, THE MYELODYSPLASTIC SYNDROMES AND HISTIOCYTIC NEOPLASMS

Acute myeloid leukaemia (AML) is a disease resulting from the neoplastic proliferation of a clone of myeloid cells, characterized by uncoupling of proliferation and maturation. The leukaemic clone may be derived from a pluripotent stem cell (capable of giving rise to both myeloid and lymphoid lineages), from a multipotent stem cell (capable of giving rise to more than one myeloid lineage) or from a committed precursor cell (for example, one capable of giving rise only to cells of granulocyte and monocyte lineages). Normal haemopoietic marrow is largely replaced by immature myeloid cells, mainly blast cells, which show a limited ability to differentiate into mature cells of the different myeloid lineages. Pancytopenia is common, as a result both of the replacement of normal bone marrow and of the defective capacity for maturation of the leukaemic clone.

The myelodysplastic syndromes (MDS) resemble AML in that normal polyclonal haemopoietic bone marrow is largely replaced by a neoplastic clone, usually derived from a multipotent stem cell. The neoplastic clone is characterized by defective maturation so that haemopoiesis is usually both morphologically dysplastic and functionally ineffective. In the great majority of patients with MDS, the bone marrow is hypercellular but there is increased intramedullary death of haemopoietic precursors leading to defective production of mature cells of one or more haemopoietic lineages; this process, which leads to various combinations of anaemia, neutropenia and thrombocytopenia, is designated ineffective haemopoiesis. In MDS, as in AML, there is imbalance between proliferation and maturation but the degree of abnormality is less than in AML so that the proportion of blast cells is lower. The neoplastic cells in MDS show a tendency to clonal evolution; emergence of a subclone with more

‘malignant’ characteristics may be manifested clinically as transformation to acute leukaemia. MDS may therefore be regarded as a preleukaemic condition.

Acute myeloid leukaemia

AML is a heterogeneous disease. In different patients the leukaemic clone shows differing patterns of differentiation and maturation. From 1976 onwards, an international co-operative group, the French–American–British (FAB) group, published a series of papers on the classification of AML. The FAB classification [1,2] became widely accepted and was subsequently incorporated into other systems of classification. It is based on the pattern of differentiation shown (for example: granulocytic, monocytic, erythroid, megakaryocytic) and the extent of maturation (for example: myeloblast, promyelocyte, granulocyte). Both differentiation and maturation are assessed and the predominant cell types in peripheral blood and bone marrow are determined. The FAB classification is summarized in Table 4.1. The FAB classification was incorporated into the morphologic, immunologic, cytogenetic (MIC) classification [3], the morphological, immunological, cytogenetic, molecular genetic (MIC-M) classification [4] and, most recently, the WHO classification [5]. The WHO classification is summarized in Table 4.2. The major aim of this classification is to recognize subtypes of AML that differ in their prognosis. The classification is hierarchical, so that therapy-related cases are first assigned to two specific categories. Cases falling into one of four cytogenetic subtypes are then categorized. Next, cases with multilineage dysplasia are assigned to a specific category. Finally, all remaining cases are categorized morphologically by a modification of the FAB classification. An important difference from the FAB classification is

Table 4.1 The FAB classification of acute myeloid leukaemia [1,2].

Criteria for diagnosis of AML	FAB category	Criteria for classification as specific FAB subtype of AML	Equivalent name
Blasts \geq 30% bone marrow cells* \geq 3% of blasts SBB- or MPO-positive†	M1	<ul style="list-style-type: none"> • Blasts \geq90% of bone marrow NEC (non-erythroid cells) • \geq3% of blasts MPO- or SBB-positive • Maturing monocytic component in bone marrow \leq10% • Maturing granulocytic component in bone marrow \leq10% 	Acute myeloblastic leukaemia without maturation
	M2	<ul style="list-style-type: none"> • Blasts 30–89% of BM NEC • BM maturing granulocytic component $>$10% NEC • BM monocytic component $<$20% of NEC and other criteria of M4 not met 	Acute myeloblastic leukaemia with maturation
	M3	<ul style="list-style-type: none"> • Characteristic morphology 	Acute promyelocytic leukaemia
	M3v	<ul style="list-style-type: none"> • Characteristic morphology 	Variant form of acute promyelocytic leukaemia
	M4	<ul style="list-style-type: none"> • Blasts \geq30% of BM NEC • Granulocytic component \geq20% of BM NEC • Monocytic component \geq20% of BM NEC and either PB monocytes $\geq 5 \times 10^9/l$ or BM like M2 but PB monocytes $\geq 5 \times 10^9/l$ and cytochemical proof of monocytic differentiation 	Acute myelomonocytic leukaemia
	M5a	<ul style="list-style-type: none"> • Blasts \geq30% of NEC • BM monocytic component \geq80% of NEC • Monoblasts \geq80% of BM monocytic component 	Acute monoblastic leukaemia
	M5b	<ul style="list-style-type: none"> • Monoblasts $<$80% of BM monocytic component • Blasts \geq30% of NEC BM monocytic component \geq80% of NEC 	Acute monocytic leukaemia
	M6	<ul style="list-style-type: none"> • Erythroid cells \geq50% of BM cells • BM blasts \geq30% of NEC 	Acute erythroleukaemia
	M7	<ul style="list-style-type: none"> • Blasts shown to be predominantly megakaryoblasts 	Acute megakaryoblastic leukaemia
	M0	<ul style="list-style-type: none"> • $<$3% of blasts MPO- or SBB-positive • Lymphoid markers negative • Immunological or ultrastructural evidence of myeloid differentiation 	Acute myeloid leukaemia with minimal evidence of myeloid differentiation

* Except in some M3 and some M6.

† Except in M0 and some M5a.

that cases with between 20 and 30% of bone marrow blasts are classified as AML rather than as refractory anaemia with excess of blasts in transformation, a FAB category of poor prognosis MDS. In addition, cases with an even lower blast percentage are accepted as AML if they have one of the specific

cytogenetic abnormalities listed—t(8;21), t(15;17), inv(16), t(16;16) or an 11q23 rearrangement. Since only an outline of the WHO classification has so far been published, we shall discuss AML mainly in terms of the FAB classification but will note where there are important differences from the WHO

Table 4.2 The WHO classification of the acute myeloid leukaemias [5].

<i>AML with recurrent cytogenetic translocations</i>
AML with t(8;21)(q22;q22), <i>AML1(CBFα)/ETO</i>
Acute promyelocytic leukaemia (AML with t(15;17)(q22;q11–12) and variants, <i>PML/RARα</i>)
AML with abnormal bone marrow eosinophils (inv(16)(p13q22) or t(16;16)(p13;q22), <i>CBFβ/MYH11</i>)
AML with 11q23 (<i>MLL</i>) abnormalities
<i>AML with multilineage myelodysplasia*</i>
With prior myelodysplastic syndrome
Without prior myelodysplastic syndrome
<i>AML and myelodysplastic syndromes, therapy-related</i>
Alkylating agent-related
Epipodophyllotoxin-related
Other types
<i>AML not otherwise categorized</i>
AML minimally differentiated
AML without maturation
AML with maturation
Acute myelomonocytic leukaemia
Acute monocytic leukaemia
Acute erythroid leukaemia
Acute megakaryocytic leukaemia
Acute basophilic leukaemia
Acute panmyelosis with myelofibrosis

* Defined as dysplastic features in two or more cell lines.

classification. We shall use a cut-off point of 20% blasts for categories of AML not defined by the FAB group but shall retain the FAB definitions for FAB categories.

AML occurs at all ages but becomes increasingly common with advancing age. The incidence rises from one to 10/100 000/year between the ages of 20 and 70 and is somewhat higher in men than in women.

The different categories of AML have many clinical features in common but some differences. Some degree of hepatomegaly and splenomegaly is common, particularly in those categories with a prominent monocytic component (M5 and, to a lesser extent, M4 AML). Lymphadenopathy and infiltration of the skin, gums and tonsils are also more common in AML with a prominent monocytic component. As a consequence of pancytopenia, patients commonly exhibit pallor and bruising and show

susceptibility to infection. A more marked bleeding tendency is usual in acute promyelocytic leukaemia (M3 AML), in which disseminated intravascular coagulation (DIC) is a frequent feature.

The different categories of AML have certain haematological features in common although the morphological features of the predominant leukaemic cells differ. Normocytic normochromic anaemia, neutropenia and thrombocytopenia are common. The total white cell count is usually elevated, as a result of the presence of circulating leukaemic cells, but some patients have a normal or low total count with few circulating immature cells. A normal or low count is most often observed in M3 and M7 AML. In adults, M7 AML commonly presents with the features of acute myelofibrosis, that is with pancytopenia, few circulating immature cells and a bone marrow which, as a consequence of bone marrow fibrosis, cannot be aspirated. (However, it should be noted that not all cases of acute myelofibrosis are examples of M7 AML.)

The blood film and bone marrow aspirate features are of prime importance in the diagnosis of AML. The bone marrow biopsy is of secondary importance except in those cases in which an adequate aspirate cannot be obtained. Assignment to a FAB category is more readily done on the basis of the blood and bone marrow aspirate findings and is not always straightforward from tissue sections. It may also be impossible, in tissue sections, to distinguish M1 and M0 AML from acute lymphoblastic leukaemia (ALL) unless immunohistochemistry is employed. Antibodies reactive with CD68, CD117, lysozyme, neutrophil elastase and myeloperoxidase (MPO) are useful in distinguishing AML from ALL in trephine biopsy sections [6–8]. The antigen (calprotectin) detected by the MAC387 antibody is also myeloid-associated, being expressed by cells of the monocyte lineage and by mature cells of the granulocyte lineage. To distinguish AML with erythroid or megakaryocytic differentiation from ALL, it is necessary to use antibodies reactive with antigens such as glycophorin and spectrin (erythroid) or CD42b, CD61 and von Willebrand's factor (megakaryocytic). Some cases of AML, particularly those belonging to the FAB M0 category, give negative reactions with some of the antibodies commonly used to detect myeloid differentiation (see Table 2.6). This and other problems in diagnosis will be discussed under 'Problems and pitfalls' (see page 166).

Acute myeloblastic leukaemia (M1 and M2 AML)

The term acute myeloblastic leukaemia indicates leukaemia in which lineage commitment (differentiation) is to one of the granulocyte lineages, usually the neutrophil lineage. Cases can be divided between the FAB categories M1 and M2, depending on whether leukaemic cells are predominantly myeloblasts or whether, alternatively, further maturation to promyelocytes and later cells is occurring (see Table 4.1). Cases of AML assigned to FAB M1 and M2 categories would, in the WHO classification, fall into various categories including 't(8;21)-associated AML', 'AML with and without maturation', 'AML with multilineage dysplasia' and 'acute basophilic leukaemia'.

Peripheral blood

Anaemia, thrombocytopenia and a high white cell count are usual. Neutropenia is common in M1 AML but cases of M2 AML may have a normal or high neutrophil count. The majority of cases have considerable numbers of circulating myeloblasts. These are large cells, usually about twice the diameter of an erythrocyte. They have a high nucleocytoplasmic ratio. The nucleus has a diffuse chromatin pattern and one or more nucleoli. The cytoplasm is weakly or moderately basophilic and may contain scanty azurophilic granules. In some cases, particu-

larly but not exclusively M2 AML, the blasts contain Auer rods; these are cytoplasmic crystals formed by fusion of primary granules with which they share staining characteristics. In M2 AML the peripheral blood may also contain morphologically abnormal promyelocytes and other maturing cells. Occasional patients with M2 AML have eosinophilia or basophilia. In AML associated with t(8;21)(q22;q22) the peripheral blood may show large blasts with basophilic cytoplasm and often a single long thin Auer rod, together with morphologically abnormal maturing cells. In AML associated with t(6;9)(p23;q34) there may be peripheral blood basophilia.

Bone marrow cytology

The bone marrow is markedly hypercellular. Numbers of megakaryocytes and developing erythroid cells are usually reduced. In M1 AML the bone marrow is almost totally replaced by myeloblasts, some of which may contain scanty granules or Auer rods (Fig. 4.1). In M2 AML myeloblasts are relatively less numerous and there are considerable numbers of maturing cells (Fig. 4.2). Many of these are morphologically abnormal and often difficult to categorize; abnormalities include: (i) hypogranularity; (ii) bizarre nuclear shapes; and (iii) the presence of Auer rods, not only in blasts but sometimes also in promyelocytes, myelocytes and neutrophils. In some cases of M2 AML the maturing granulocytic

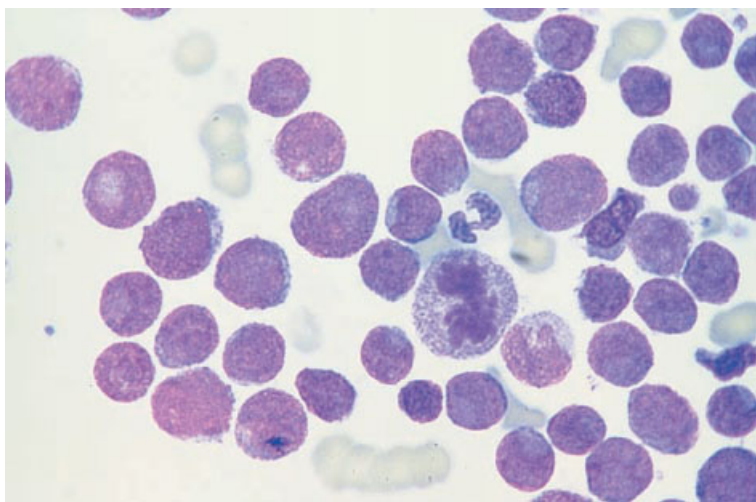


Fig. 4.1 BM aspirate, M1 AML. Note that some of the blast cells resemble lymphoblasts in that they are small and round with a high nucleocytoplasmic ratio and no granules. The presence of an agranular neutrophil and occasional blasts with granules suggests the correct diagnosis. MGG $\times 940$.

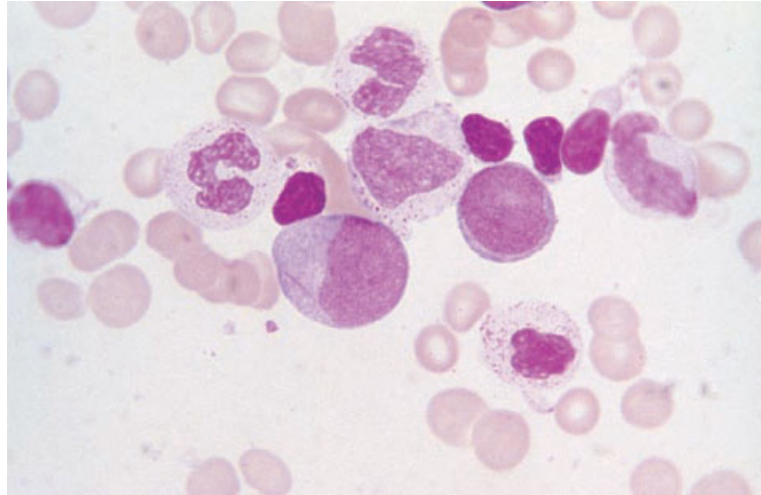


Fig. 4.2 BM aspirate, M2 AML, showing two myeloblasts, one of which contains a long slender Auer rod, and abnormal maturing cells. MGG $\times 940$.

component includes, or is composed of, basophils or eosinophils. In both M1 and M2 AML the erythrocytes and megakaryocytes may show dysplastic features.

In M2 AML associated with $t(8;21)$ the bone marrow, in addition to maturing cells of neutrophil lineage, commonly shows increased eosinophils; these are usually cytologically normal. Erythroid cells and megakaryocytes do not show dysplastic features. In M2 AML associated with $t(6;9)$, the bone marrow commonly shows not only blasts of basophil lineage but also increased numbers of mature basophils; there is often associated myelodysplasia and Auer rods are commonly present. In M2 AML associated with $12p-$, blasts are also of basophil lineage but there is very little maturation so that they may appear undifferentiated by light microscopy.

Cytochemistry

The myeloid nature of M2 AML is evident from the features of differentiation observable in May-Grünwald-Giemsa (MGG)-stained films but in M1 AML cytochemical staining [9] is often necessary to confirm the diagnosis. Either MPO or Sudan black B (SBB) staining must be positive in at least 3% of blasts to satisfy the FAB criteria of AML [1]; usually both stains are positive. These stains are also very useful in identifying Auer rods and reveal their presence in some cases in which they are not

identifiable in the MGG stain. A naphthol AS-D chloro-acetate esterase (chloro-acetate esterase) stain is also positive in myeloblasts in the majority of cases of M1 and M2 AML. Metachromatic staining with toluidine blue is useful in the diagnosis of cases with basophil differentiation but little maturation, for example cases of M2Baso AML associated with $12p-$.

Bone marrow histology

The marrow is markedly hypercellular (greater than 95% cells) in most cases. Often the cellularity seen in biopsy sections is greater than that estimated from aspirated fragments in films [10]. The morphology of the neoplastic cells in tissue sections is different from that seen in films of aspirates. In tissue sections, myeloblasts have large round to oval nuclei, delicate chromatin, one or more small well-defined nucleoli and scant basophilic cytoplasm (Fig. 4.3). In a half to two thirds of all cases there is a dense homogeneous infiltrate of blasts whereas, in the remainder, there is a mixture of blasts, more mature haemopoietic cells and inflammatory cells such as plasma cells, lymphocytes and mast cells [10,11]. Evidence of maturation is often apparent in M2 AML (Fig. 4.4). Leder's chloro-acetate esterase stain is usually positive in M2 AML (depending on the method of processing—see page 59) but is often negative in M1 AML. Dysplastic changes are

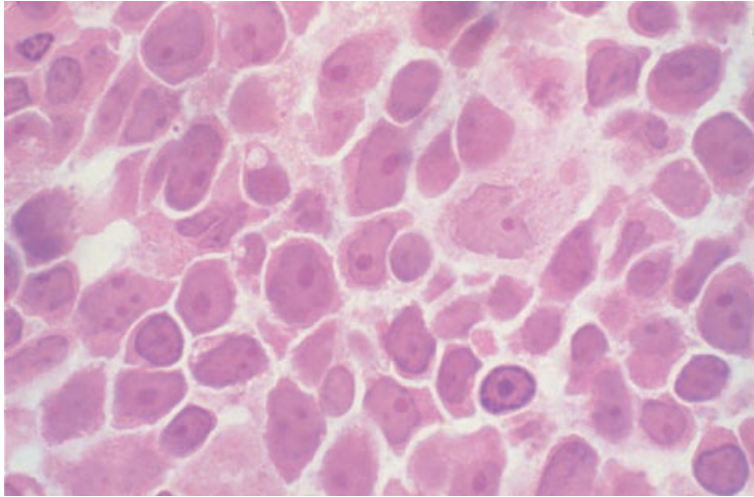


Fig. 4.3 Section of BM trephine biopsy specimen, M1 AML. There is a relatively uniform population of small blast cells with a high nucleocytoplasmic ratio and prominent nucleoli. Plastic-embedded, H&E $\times 970$.

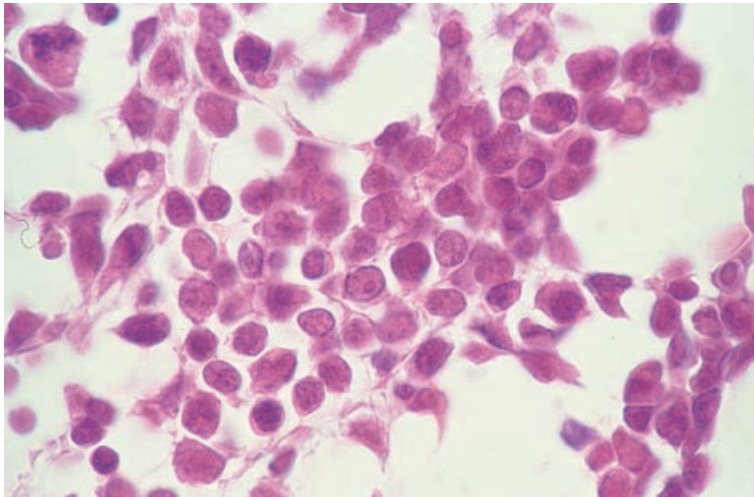


Fig. 4.4 Section of BM trephine biopsy specimen, M2 AML. There is a mixture of blast cells and maturing cells of the granulocytic series. Paraffin-embedded, H&E $\times 960$.

commonly detected in megakaryocytes and erythroid precursors (see page 172). In M2 AML associated with t(8;21) there is often a prominent infiltrate of eosinophils scattered among the blasts. Reticulin fibrosis is present in up to a third of cases [12] but collagen fibrosis is rare. Areas of bone marrow necrosis are sometimes present. Following chemotherapy, the marrow is hypoplastic and often shows necrosis, stromal oedema and gelatinous change. Residual leukaemic cells are often more apparent in tissue sections than in aspirate films. However, they can be difficult to distinguish from foci of immature regenerating granulocytic or erythroid precursors.

In M2 AML there are usually sufficient maturing granulocytic cells for a diagnosis of AML to be made from H&E-stained sections. However, a provisional diagnosis of M1 AML may require immunohistochemistry for confirmation if the diagnosis rests on a trephine biopsy specimen alone.

Cytogenetics and molecular genetics

Various subtypes of AML, characterized by specific chromosomal abnormalities, are included within the FAB M1 and M2 categories [8]. Of these, the commonest is M2 AML associated with t(8;21)(q22;q22)

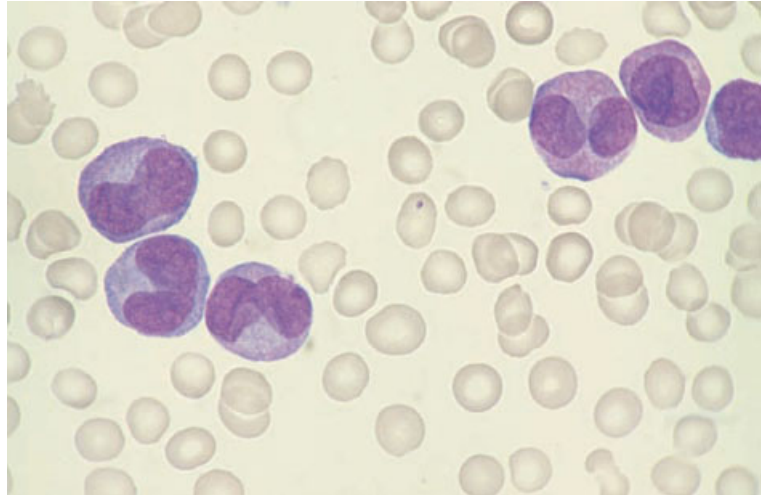


Fig. 4.5 PB film, M3 variant AML, showing hypogranular promyelocytes with characteristic deeply lobulated nuclei. Several cells have very fine granules. MGG $\times 940$.

and formation of an *AML1-ETO* fusion gene, which is recognized as a separate entity in the MIC, MIC-M and WHO classifications. A much less common subtype is that associated with $t(6;9)(p23;q34)$ and formation of a *DEK-CAN* fusion gene.

Acute (hypergranular) promyelocytic leukaemia

The majority of cases of acute promyelocytic leukaemia have hypergranular promyelocytes and are therefore designated acute hypergranular promyelocytic leukaemia, or M3 AML. A minority of cases have abnormal promyelocytes which are either microgranular or hypogranular when examined by light microscopy; such cases are variously referred to as the variant form of acute promyelocytic leukaemia, M3 variant AML, acute hypogranular promyelocytic leukaemia or acute microgranular promyelocytic leukaemia. Acute promyelocytic leukaemia is recognized as a specific entity in all leukaemia classifications. Rapid, correct diagnosis of M3 and M3 variant AML is of critical importance if early death from haemorrhage is to be avoided.

Peripheral blood

In M3 AML, the peripheral blood white cell count is not usually greatly elevated and the number of circulating leukaemic cells tends to be low. There is usually anaemia. The platelet count may be disproportionately low as a consequence of complicating

disseminated intravascular coagulation. The abnormal promyelocytes are large cells, usually two to three times the diameter of an erythrocyte. Their cytoplasm is packed with granules which stain bright pink or reddish-purple. Some cells contain bundles of Auer rods ('faggot cells') or giant granules. No Golgi zone is apparent. The nucleus is usually round or oval but cytoplasmic granulation is so marked that the nuclear outline is difficult to discern.

In M3 variant AML, the white cell count is usually elevated. Again, there is usually anaemia and marked thrombocytopenia. Abnormal promyelocytes are characteristically more frequent in the peripheral blood in M3 variant AML than in typical, hypergranular M3 AML. The promyelocytes may appear completely agranular or may have fine, dust-like reddish granules (Fig. 4.5). Some cells contain bundles of Auer rods or other crystalline inclusions. The nucleus is usually deeply lobed, often with two large lobes joined by a narrow bridge. The cytoplasm is usually weakly or moderately basophilic but some cases have promyelocytes with more marked basophilia and cytoplasmic protrusions or blebs. A careful search in cases of M3 variant AML often discloses a minor population of more typical, hypergranular promyelocytes, occasionally with multiple Auer rods.

Bone marrow cytology

Bone marrow aspiration is often difficult since the

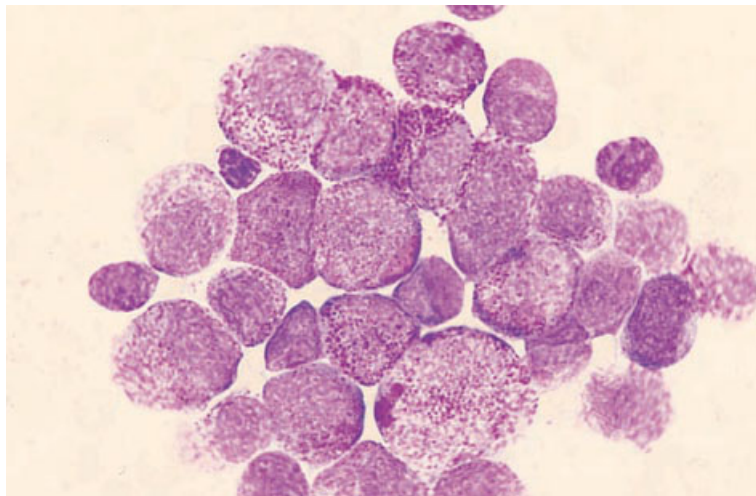


Fig. 4.6 BM aspirate, M3 AML, showing heavily granulated promyelocytes, one of which contains a giant granule. MGG $\times 940$.

hypercoagulable state leads to clotting of the specimen, even during aspiration. However, the bone marrow aspirate is important in diagnosis since, in M3 AML, there may be only infrequent leukaemic cells in the peripheral blood and, in M3 variant AML, the bone marrow often contains a higher proportion of typical hypergranular cells than does the peripheral blood.

The bone marrow aspirate is usually intensely hypercellular. The number of blasts is relatively low since the predominant cell is an abnormal promyelocyte (Fig. 4.6); in the majority of cases there are fewer than 30% of blasts in the marrow. In M3 AML the predominant cell is a hypergranular promyelocyte while, in M3 variant, the predominant cell is a hypogranular promyelocyte with a variable admixture of hypergranular forms. There is a marked reduction in the number of normal maturing granulocytes. Erythroid cells and megakaryocytes are also considerably reduced in number but are cytologically normal.

Cytochemistry

Cytochemical stains are unnecessary in typical hypergranular M3 AML but are important in confirming a diagnosis of M3 variant AML. Typically, there are positive reactions with MPO, SBB and chloroacetate esterase and negative reactions with non-specific esterase.

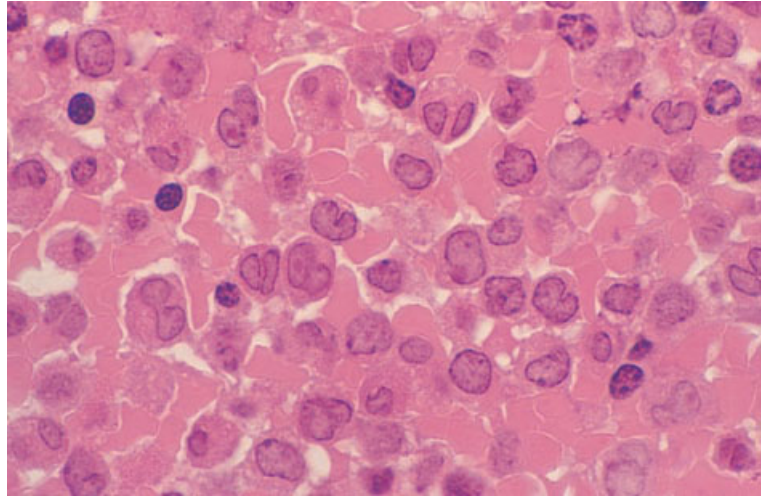
Bone marrow histology

There is usually marked hypercellularity with a homogeneous infiltrate of abnormal promyelocytes (Fig. 4.7). These cells have a characteristic appearance; they have prominent large granules that fill the cytoplasm and often obscure the nucleus. The nucleus may be oval or bilobed and has a single prominent nucleolus. Faggot cells may be detectable. In M3 variant AML the granules are much smaller and may be inconspicuous; the nuclei are often bilobed. Occasional cases of M3 AML show little increase in cellularity at presentation, an unusual feature in *de novo* AML.

Because of their hypergranularity, the leukaemic cells of M3 AML can be readily recognized in H&E-stained sections of trephine biopsy specimens. A proportion of cases of M3 variant AML can also be recognized from cytological features. Other cases of M3 variant AML, with very infrequent hypergranular cells, require histochemistry (Leder's stain) or immunohistochemistry (e.g. demonstration of neutrophil elastase) for confirmation if the diagnosis rests on the trephine biopsy specimen alone.

Collagen fibrosis may be observed at presentation in M3 AML. This is greatly increased by treatment with all-*trans* retinoic acid (ATRA) [13]. ATRA therapy leads to maturation of the leukaemic clone with the bone marrow remaining hypercellular in contrast to the hypocellular marrow that is seen

Fig. 4.7 Section of BM trephine biopsy specimen, M3 AML, showing abnormal promyelocytes with irregular, often bilobulated, nuclei containing prominent nucleoli and prominent cytoplasmic granules. Plastic-embedded, H&E $\times 970$.



when chemotherapy is administered. Extensive bone marrow necrosis has been reported in association with hyperleucocytosis caused by ATRA [14].

Cytogenetics and molecular genetics

M3 and M3 variant AML are uniformly associated with t(15;17)(q22;q21), a *PML-RAR α* fusion gene or both.

Acute myelomonocytic leukaemia

Acute myelomonocytic leukaemia (M4 AML) shows significant evidence of both granulocytic and monocytic differentiation. The granulocytic differentiation is usually neutrophilic but, in some variants, it is eosinophilic (M4Eo) or basophilic (M4Baso). Cases of AML assigned to FAB M4 category would, in the WHO classification, fall into various categories including 'AML with abnormal bone marrow eosinophils', 'AML associated with 11q23 rearrangements' and 'acute myelomonocytic leukaemia'.

Peripheral blood

There is usually anaemia and thrombocytopenia with an elevated white cell count and circulating leukaemic cells of both granulocytic and monocytic lineages. Myeloblasts and monoblasts show the usual cytological features of these lineages (see below).

Maturation of leukaemic cells is usual so that the leukaemic cell population commonly includes both monocytes and neutrophils. However, some cases of M4 AML have no evidence in the peripheral blood of the significant monocytic component which is present in the bone marrow. In AML associated with inv(16)(p13q22) or t(16;16)(p13;q22), there are usually only occasional eosinophils in the peripheral blood and these are not morphologically very abnormal. In AML associated with t(6;9)(p23;q34), there may be basophilia with some dysplastic basophils.

Bone marrow cytology

The bone marrow is hypercellular and shows a variable mixture of cells of granulocytic and monocytic lineages (Fig. 4.8). In the majority of cases, maturation of leukaemic cells is occurring and mature monocytes as well as maturing cells of granulocytic lineage can be readily recognized. However, there are a minority of cases in which, despite a peripheral blood monocytosis, the bone marrow cannot be distinguished morphologically from that of M2 AML. In such cases the significant monocytic component can be confirmed either by cytochemistry (see below) or by assays of serum or urinary lysozyme. The explanation of such cases is probably twofold. Firstly, leukaemic monocytes may be infrequent in the bone marrow because of early migration to the peripheral blood. Secondly, promonocytes can

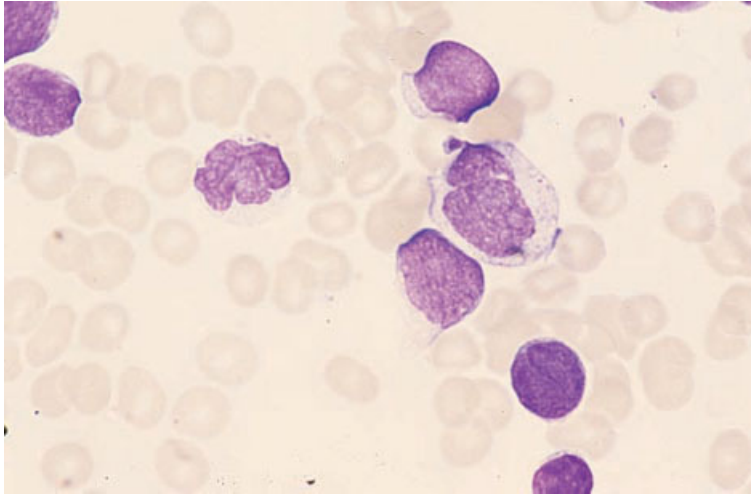


Fig. 4.8 BM aspirate, M4 AML, showing four myeloblasts, one monoblast and a monocyte. MGG $\times 940$.

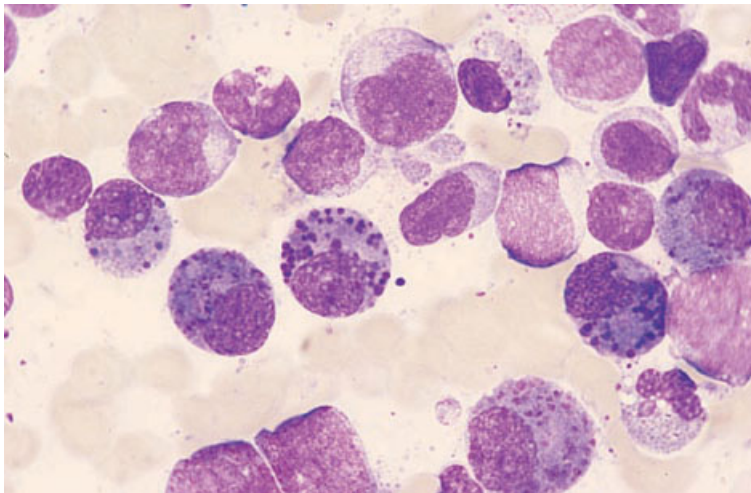


Fig. 4.9 BM aspirate, M4 AML with eosinophilia (M4Eo), showing characteristic eosinophil myelocytes, eosinophils, a monocyte and blast cells. MGG $\times 940$.

be difficult to distinguish morphologically from promyelocytes.

Megakaryocytes and erythroid precursors are usually reduced. Dysplastic features are sometimes present in these lineages.

In AML associated with $inv(16)(p13q22)$ or $t(16;16)(p13;q22)$, the bone marrow aspirate often shows a mixture of cells of monocyte and eosinophil lineages but cells of neutrophil lineage are relatively infrequent (Fig. 4.9). Some basophils may also be present. The cells of eosinophil lineage are a mixture of myelocytes and mature eosinophils. In the great majority of cases the eosinophil myelocytes

are morphologically abnormal with prominent pro-eosinophilic granules, which are basophilic in their staining characteristics, mixed with typical eosinophilic granules. The mature eosinophils may show cytological abnormalities such as nuclear hyper- or hypolobulation or the presence of occasional pro-eosinophilic granules. Some cells of granulocyte lineage, mainly immature cells, show Auer rods. There is usually maturation in the monocyte lineage so that mature monocytes are present. Megakaryocytes and erythroid cells do not show dysplastic features. It should, however, be noted that not all cases of AML associated with

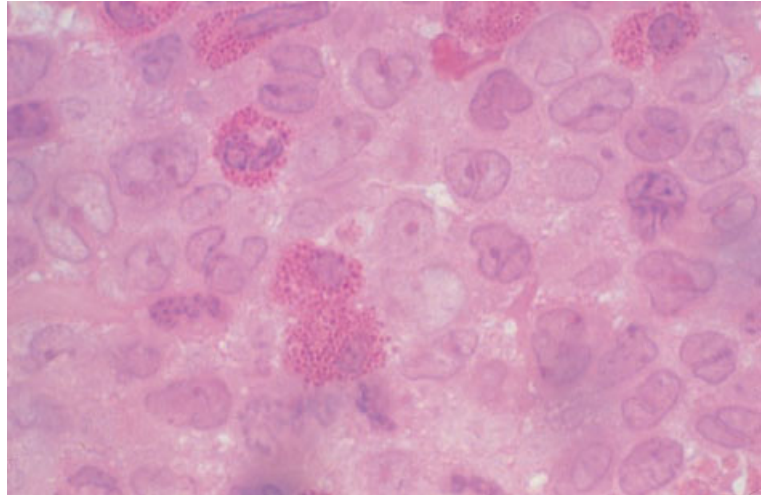


Fig. 4.10 Section of BM trephine biopsy specimen, M4Eo AML, showing monoblasts, myeloblasts, eosinophil myelocytes and eosinophils. Plastic-embedded, H&E $\times 970$.

these chromosomal rearrangements have the cytological features of M4Eo; some cases fall into either the M4 or M2 category of AML.

In AML associated with $t(6;9)(p23;q34)$, the bone marrow commonly shows, in addition to an increase in monocytes and their precursors, an increase of mature basophils and sometimes an increase of neutrophils or eosinophils. There are associated myelodysplastic features.

Cytochemistry

A double esterase stain, combining chloro-acetate esterase and non-specific esterase, is important in confirming a diagnosis of M4 AML. In AML associated with $inv(16)$, the eosinophils may show aberrant chloro-acetate esterase positivity. In addition, SBB and MPO stains may show Auer rods in occasional eosinophils and their precursors as well as in neutrophil precursors. A toluidine blue stain is useful for confirming basophil differentiation in M4Baso AML.

Bone marrow histology

The marrow is markedly hypercellular and there is an infiltrate composed of variable numbers of myeloblasts, monoblasts and maturing cells of both lineages. Maturing granulocytes may be neutrophils, eosinophils or both. Monoblasts have large

irregular nuclei with delicate chromatin and prominent nucleoli; cytoplasm is abundant and may be vacuolated. The distribution of monoblasts is not uniform: they are often seen in small clusters, particularly in the paratrabecular areas [10]. Dysplastic changes are often seen in other haemopoietic lineages and reticulin fibrosis may be present.

Trephine biopsy sections in AML associated with $inv(16)$ often show increased eosinophils and precursors (Fig. 4.10). However, M4Baso, associated with $t(6;9)$, cannot be distinguished from other cases of M4 AML since basophil granules are dissolved during processing. M4 and M4Eo AML can usually be readily recognized in H&E-stained sections so that histochemistry and immunohistochemistry are not needed in most cases.

Cytogenetics and molecular genetics

M4 AML is preferentially associated with translocations having an 11q23 breakpoint and rearrangement of the *MLL* gene. In addition, there are several other subtypes within the M4 AML category defined by associated cytogenetic and molecular genetic abnormalities. These are M4 and M4Eo AML associated with $inv(16)(p13q22)$ or $t(16;16)(p13;q22)$ and formation of a *CBF β -MYH11* fusion gene and M4Baso associated with $t(6;9)(p23;q34)$ and a *CAN-DEK* fusion gene. The former is a WHO category but the latter is not.

Acute monocytic/monoblastic leukaemia

AML showing predominantly or entirely monocytic differentiation is categorized as acute monocytic or acute monoblastic leukaemia—M5 AML—the former showing maturation of leukaemic cells to mature monocytes and the latter showing little maturation. The FAB group have assigned to these categories (designated M5) those cases of AML in which there is monocytic differentiation and in which less than 20% of bone marrow non-erythroid cells are granulocytes or their precursors. Cases are further divided into acute monoblastic leukaemia (M5a) and acute monocytic leukaemia (M5b) on the basis of whether or not the leukaemic clone is showing maturation (see Table 4.1). Cases of AML assigned to the FAB M5 category would, in the WHO classification, fall into various categories including 'AML associated with 11q23 rearrangements' and 'acute monocytic leukaemia'.

Peripheral blood

The peripheral blood usually shows anaemia, thrombocytopenia and leucocytosis with circulating leukaemic cells which are variously monoblasts, promonocytes or monocytes. Monoblasts are larger than myeloblasts, usually with a diameter about three times that of an erythrocyte. Their shape varies from round to oval or irregular. The cytoplasm is voluminous and varies from weakly to strongly

basophilic; it may contain very infrequent granules. The nucleus ranges from round to lobulated and is usually nucleolated; nucleoli vary from being large, single and prominent to being smaller and multiple. Promonocytes are large cells with an oval or lobulated nucleus and moderately basophilic cytoplasm containing fairly numerous azurophilic granules. Monocytes in M5 AML resemble normal monocytes in having lobulated nuclei and weakly basophilic, sometimes vacuolated, cytoplasm. They may show cytological abnormalities such as nuclei of bizarre shapes. In M5b AML, the peripheral blood contains monocytes and a variable number of promonocytes and monoblasts. In some cases of M5a AML the peripheral blood contains large numbers of monocytes and promonocytes, even though the predominant cell in the bone marrow is a monoblast. In other cases the peripheral blood leukaemic cells, like those in the marrow, are almost exclusively monoblasts.

Bone marrow cytology

The bone marrow is hypercellular and numbers of megakaryocytes and erythroid precursors are reduced. In M5a AML (Fig. 4.11) the great majority of cells are monoblasts. All cases in which at least 80% of bone marrow non-erythroid cells are monoblasts are classified as M5a, regardless of whether there are maturing cells in the peripheral blood. In M5b AML the marrow contains a mixture of monoblasts, promonocytes and monocytes (Fig. 4.12).

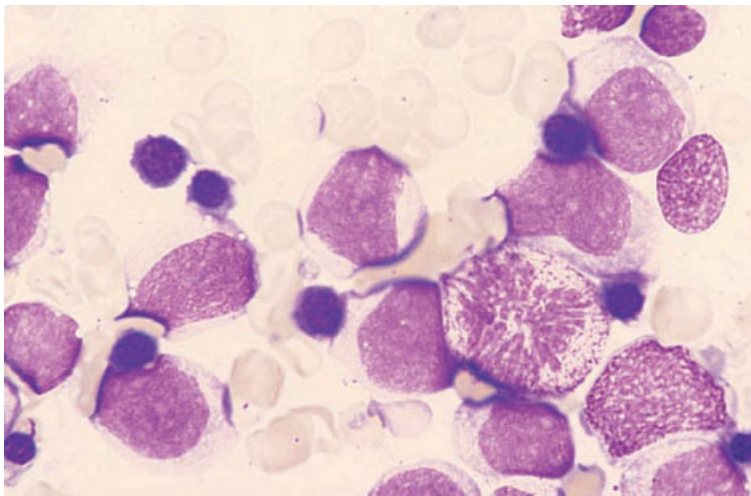


Fig. 4.11 BM aspirate, M5a AML, showing large blast cells with moderately abundant cytoplasm. MGG ×940.

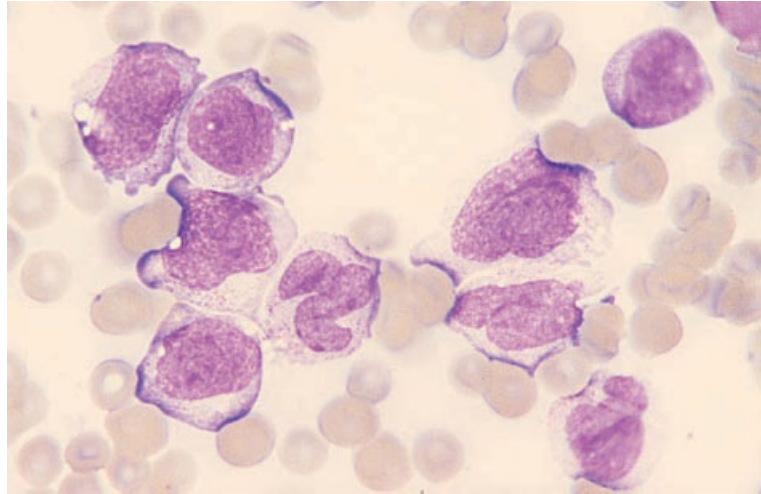


Fig. 4.12 BM aspirate, M5b AML, showing monoblasts, promonocytes and a monocyte. MGG ×940.

Cytochemistry

Cytochemical stains [9] are useful in confirming the nature of M5 AML, particularly in those cases of M5a with negligible maturation. Monoblasts are often negative for MPO and SBB, although positive results are obtained with promonocytes. The most useful stains are those for 'non-specific' esterases such as α -naphthyl acetate esterase or α -naphthyl butyrate esterase. An alternative is the demonstration of strong, fluoride-sensitive, positivity for naphthol-AS-acetate esterase, another 'non-specific' esterase. Monocyte differentiation can also be demonstrated by using a suspension of the bacterium *Micrococcus lysodeikticus* to show lysozyme activity. However, this test is now little used since the availability of monoclonal antibodies provides another means of confirming monocyte differentiation. Positive reactions with monoclonal antibodies, such as those of the CD11b and CD14 clusters, provide useful confirmation of the diagnosis of M5 AML in cases with negative reactions for non-specific esterases.

Bone marrow histology

The marrow is intensely hypercellular. In M5a AML (Fig. 4.13) there is a homogeneous infiltrate of monoblasts whereas in M5b AML (Fig. 4.14) there is a variable proportion of more mature cells of

monocyte lineage. The monoblasts are similar to those seen in M4 AML. The more mature monocytoid cells are smaller than monoblasts and have irregular nuclei that are often convoluted or lobulated, with delicate chromatin but without nucleoli.

Cytochemical stains to confirm the monocyte lineage are not generally applicable to tissue sections. Chloro-acetate esterase activity is usually absent. Immunohistochemistry is useful, particularly in M5a AML in which the diagnosis is less readily made from H&E-stained sections. Monoclonal antibodies that can be employed include antilysozyme, CD64, CD68, CD11b, CD14, CD15 and MAC387. Of CD68 monoclonal antibodies, the PG-M1 clone shows good specificity for M4 and M5 AML, while the KP1 clone is a sensitive marker of myeloid differentiation but does not discriminate between monocytic and granulocytic differentiation [15].

Cytogenetics and molecular genetics

Chromosomal rearrangements with an 11q23 breakpoint and with rearrangement of the *MLL* gene are strongly associated with M5 AML, particularly M5a AML. Other subtypes of M5 AML defined by the associated cytogenetic abnormality include M5a associated with t(8;16)(p11;p13), which is distinctive due to the frequent occurrence of haemophagocytosis by leukaemic cells (and, clinically, due to a relatively high incidence of coagulation abnormalities).

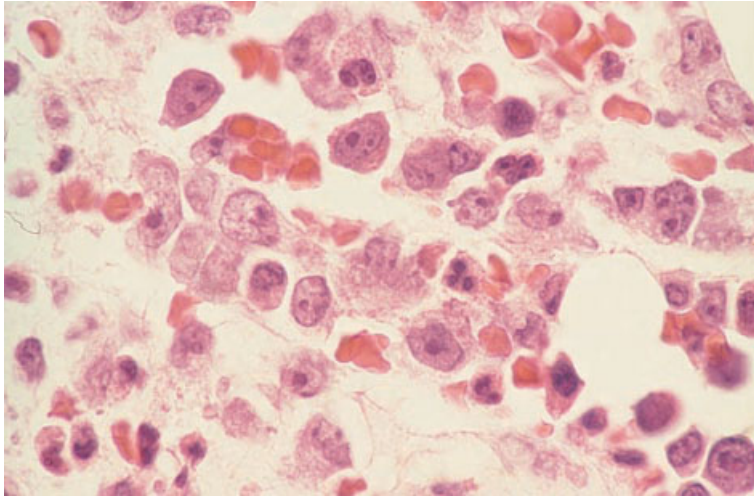


Fig. 4.13 BM trephine biopsy specimen, M5a AML, showing monoblasts which are large cells with plentiful cytoplasm and a prominent nucleolus. One blast (upper left) has phagocytosed red cells. H&E $\times 940$. (By courtesy of Dr FM Wood, Vancouver.)

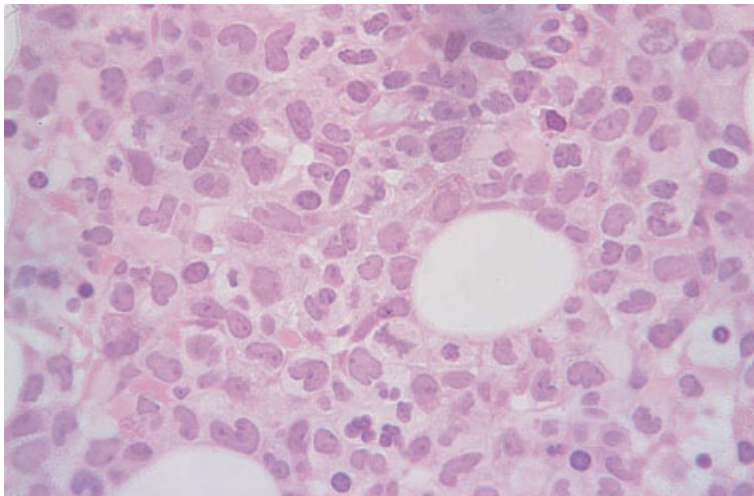


Fig. 4.14 BM trephine biopsy specimen, M5b AML, showing replacement of haemopoietic marrow and fat spaces by a mixture of monoblasts, promonocytes and monocytes. Plastic-embedded, H&E $\times 390$.

Acute erythroleukaemia

Acute erythroleukaemia (M6 AML) describes an AML in which erythroid cells represent a major part of the leukaemic population. The FAB group has recommended that cases be assigned to this category (M6) when at least 50% of bone marrow cells are erythroid and at least 30% of the remaining non-erythroid cells are blasts (see Table 4.1). Others have considered that a case can also reasonably be classified as erythroleukaemia if erythroid cells show prominent cytological abnormalities and constitute between 30 and 50% of bone marrow

nucleated cells [16]. There is a problem in assigning to a FAB category cases with almost exclusively erythroid cells including many very primitive erythroid cells [17]. In such cases, fewer than 30% of non-erythroid cells may be blasts and consequently the FAB criteria for M6 AML may not be fulfilled; nevertheless this seems to be the category where they fit most naturally. We suggest a designation of M6 variant AML with criteria for diagnosis being that more than 50% of bone marrow cells are erythroid and more than 30% are immature erythroid cells resembling proerythroblasts or basophilic erythroblasts.

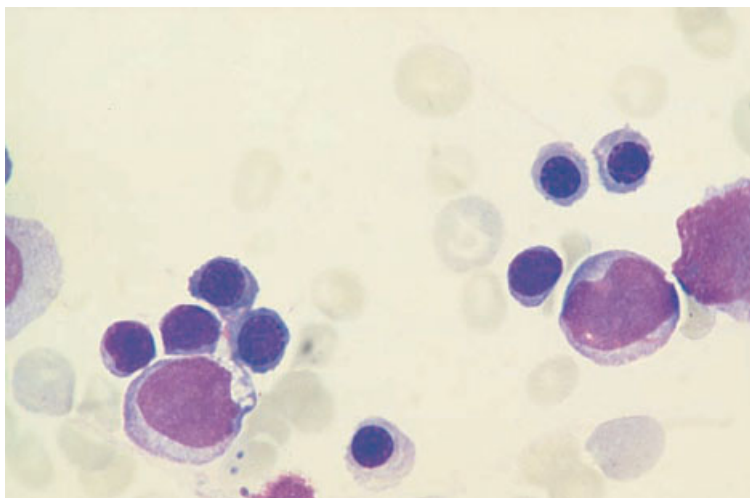


Fig. 4.15 BM aspirate, M6 AML, showing two myeloblasts and numerous erythroblasts. MGG $\times 940$.

It appears likely that a very high proportion of cases of M6 AML represent transformation of underlying MDS.

Cases of AML assigned to FAB M6 category would, in the WHO classification, fall into various categories. Most would probably be designated 'AML with multilineage dysplasia' and others 'acute erythroid leukaemia'.

Peripheral blood

The peripheral blood almost always shows anaemia, neutropenia and thrombocytopenia, usually with some circulating blasts. There may also be circulating erythroid precursors.

Bone marrow cytology

The bone marrow is hypercellular and shows both erythroid hyperplasia and, except in M6 variant, a significant population of blasts (Fig. 4.15). The morphology of erythroid cells varies between cases. In some patients, erythroid cells show striking cytological abnormalities which may include nuclear lobulation, karyorrhexis, multinuclearity, gigantism or megaloblastic or sideroblastic erythropoiesis. In other patients, cytological abnormalities are quite minor. The associated blasts are usually myeloblasts, which may contain Auer rods, or a mixed population including monoblasts or megakaryoblasts. Maturing

granulocytes often show dysplastic features such as hypogranularity and nuclear hypolobulation. Megakaryocytes are also commonly dysplastic with features such as nuclear hypolobulation or the presence of micromegakaryocytes.

Cytochemistry

Cytochemical stains may show various abnormalities. SBB, MPO and chloro-acetate esterase methods can be employed to confirm the nature of myeloblasts; the first two stains will also demonstrate Auer rods. An α -naphthyl acetate esterase stain can be used to identify monoblasts. Erythroblasts may be positive with a periodic acid-Schiff (PAS) stain; such positivity is not shown by normal erythroid precursors but it is not confined to neoplastic erythroblasts. Erythroblasts in M6 AML may also show focal staining for α -naphthyl acetate esterase and acid phosphatase. An iron stain may show the presence of ring sideroblasts.

Bone marrow histology

There is marked hypercellularity of the marrow with intense erythroid hyperplasia (Figs 4.16 and 4.17). The erythroid precursors are usually markedly abnormal and may have bizarre appearances. They often show nuclear lobulation or fragmentation, marked variation in size or megaloblastic

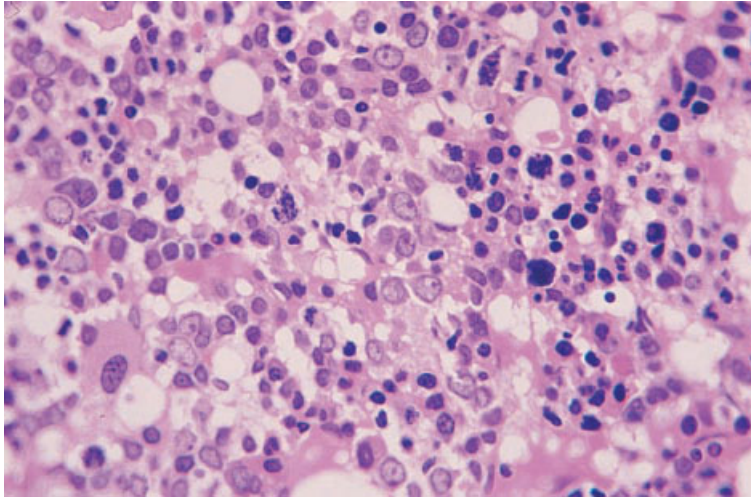


Fig. 4.16 Section of BM trephine biopsy specimen, M6 AML, showing a disorganized marrow containing large numbers of dysplastic erythroblasts and numerous myeloblasts. Paraffin-embedded, H&E $\times 390$.

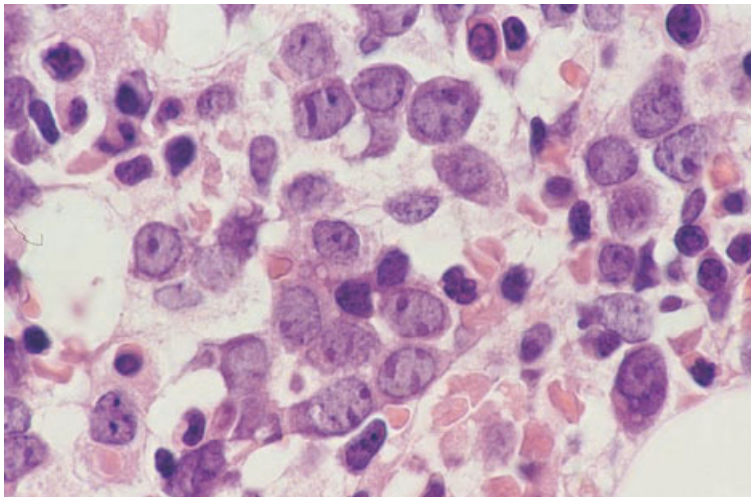


Fig. 4.17 Section of BM trephine biopsy specimen, M6 AML, showing ill-organized erythroblasts. Some have characteristic elongated nucleoli abutting on the nuclear membrane. Paraffin-embedded, H&E $\times 940$.

change. They are arranged in sheets without the formation of normal erythroblastic islands. Megakaryocytic dysplasia is often seen. Non-erythroid blasts (myeloblasts or monoblasts) may be relatively inconspicuous although, by definition, they must make up more than 30% of the non-erythroid cells in the marrow except in the condition that we designate M6 variant AML.

The diagnosis of M6 AML can usually be readily made from H&E-stained sections. In cases with predominantly primitive erythroid cells, immunohistochemistry may be needed. Useful reagents are

antibodies reactive with glycophorin, spectrin or haemoglobin A.

Cytogenetics and molecular genetics

M6 AML is often associated with abnormalities of chromosomes 5 and 7 and with complex chromosomal abnormalities.

Acute megakaryoblastic leukaemia

Acute megakaryoblastic leukaemia (M7 AML) has

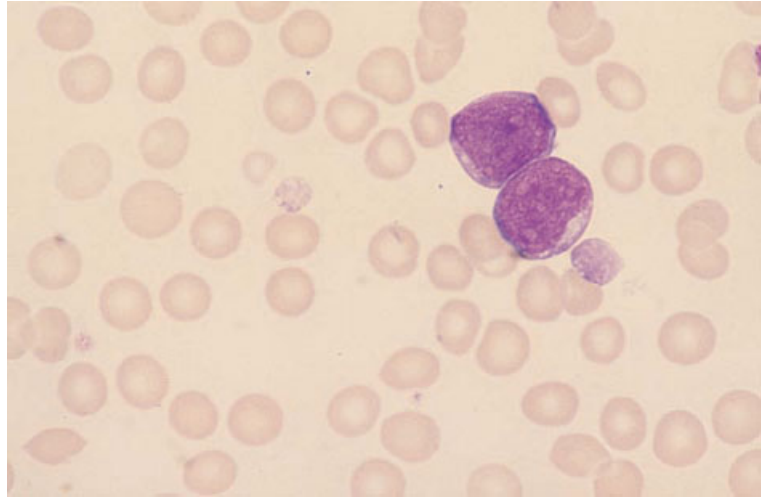


Fig. 4.18 BM aspirate of a patient with Down's syndrome and M7 AML, showing two megakaryoblasts and two giant platelets. MGG $\times 940$.

blasts constituting at least 30% of bone marrow cells, with megakaryoblasts being the predominant form. There may be admixture with cells of other lineages, for example, myeloblasts. The diagnosis is often difficult, particularly in adults, because of the paucity of leukaemic cells in the peripheral blood and the difficulty in obtaining a bone marrow aspirate. A trephine biopsy is then of critical importance in making the diagnosis. In children, circulating blasts are often present and the bone marrow can more often be aspirated easily.

Cases of AML assigned to FAB M7 category would, in the WHO classification, fall into various categories including 'acute megakaryocytic leukaemia' and 'acute panmyelosis with myelofibrosis'.

Peripheral blood

Commonly, the peripheral blood shows only pancytopenia with very infrequent or no circulating leukaemic blasts. Such patients usually lack organomegaly and have a fibrotic marrow; this condition has been described as 'acute myelofibrosis.' Other patients have features more typical of acute leukaemia, with hepatomegaly, splenomegaly and significant numbers of circulating blasts. Megakaryoblasts are similar in size to myeloblasts. They have a high nucleocytoplasmic ratio and agranular, moderately basophilic cytoplasm. In some cases there are distinctive features that suggest their

nature, such as formation of peripheral cytoplasmic blebs or an association with circulating micromegakaryocytes, but in other cases there are no features to suggest lineage.

Bone marrow cytology

Aspiration may be impossible or a poor aspirate containing scanty blasts may be obtained (Fig. 4.18). In addition to megakaryoblasts, the aspirate may contain some micromegakaryocytes or other markedly dysplastic megakaryocytes. There may be admixture with myeloblasts. Erythroid precursors sometimes show dysplastic features.

Cytochemistry

Cytochemistry is often not very useful. SBB, MPO and chloro-acetate esterase stains are negative except in any associated myeloblasts. PAS, acid phosphatase and α -naphthyl acetate esterase stains may be positive in cells showing cytoplasmic maturation but not in more immature cells of megakaryocyte lineage. The PAS stain sometimes shows a distinctive pattern with positivity being confined to cytoplasmic blebs. The differential staining pattern with α -naphthyl acetate esterase (positive) and α -naphthyl butyrate esterase (negative) can be useful in distinguishing megakaryoblasts from monoblasts, since the latter cells give positive

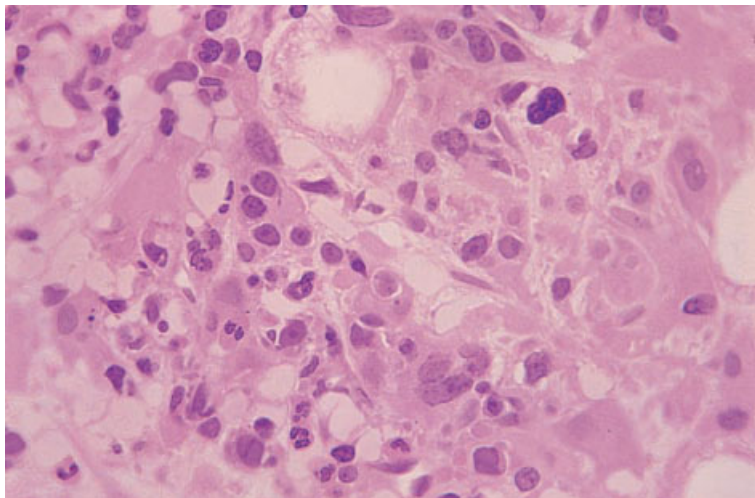


Fig. 4.19 Section of BM trephine biopsy specimen, M7 AML. There is collagen fibrosis and an infiltrate of dysplastic megakaryocytes and small blast cells. Plastic-embedded, H&E $\times 390$.

reactions for both of these non-specific esterases. Immunocytochemistry with monoclonal antibodies directed at platelet glycoproteins is now the most practicable way to confirm the diagnosis.

Bone marrow histology [18,19]

The marrow histology is very variable. In those cases that present clinically as acute myelofibrosis, the marrow is largely replaced by fibrous tissue containing blasts and dysplastic megakaryocytes (Fig. 4.19). In other cases the marrow is very hypercellular with an infiltrate of blasts; in some cases the blasts are relatively small and monomorphic while, in others, they are large and pleomorphic. Cases with a hypercellular marrow usually show increased reticulin and scattered collagen fibres. Dyserythropoiesis is common.

Immunohistochemical staining for von Willebrand antigen or for platelet GpIIIa (CD61) or GpIb (CD42b) is useful in the identification of megakaryoblasts. Immunohistochemistry is necessary for diagnosis in those cases with predominantly megakaryoblasts with few megakaryocytes.

Cytogenetics and molecular genetics

M7 AML in infants is strongly associated either with constitutional trisomy 21 or with acquired $t(1;22)(p13;q13)$.

Acute myeloid leukaemia with minimal evidence of myeloid differentiation

The availability of ultrastructural cytochemistry and of monoclonal antibodies detecting antigens specific for myeloid cells has revealed cases of acute leukaemia which are negative for markers of lymphoid lineages but have insufficient evidence of myeloid differentiation to meet the original FAB criteria for AML. Such cases have fewer than 3% SBB- or MPO-positive blasts; blasts are also negative for α -naphthyl acetate esterase and lysozyme activity. When such cases can be demonstrated to have peroxidase activity at ultrastructural level, or to be positive for myeloid antigens, such as CD13, CD14, CD33, CD117 or MPO, they should be classified as AML. The FAB group has suggested the designation AML M0 [20]. Cases of AML assigned to FAB M0 category would, in the WHO classification, fall into various categories including 'AML minimally differentiated'.

Peripheral blood

The peripheral blood usually shows anaemia, neutropenia, thrombocytopenia and the presence of circulating blasts (Fig. 4.20). The blasts are agranular and have cytological features similar to those of the blasts of AML M1, ALL L2 or, more rarely, ALL L1 (see page 236). They tend to be large with prominent nucleoli and abundant, often basophilic,

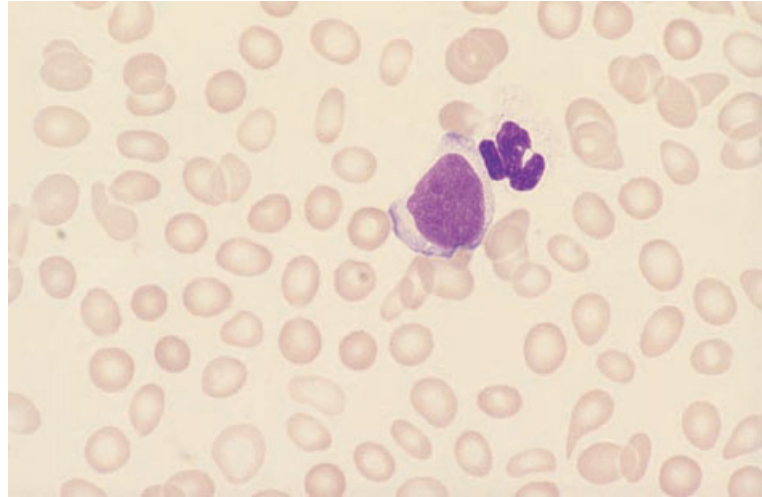


Fig. 4.20 PB film from a patient with M0 AML superimposed on MDS. Note the agranular neutrophil, anisocytosis and poikilocytosis. MGG $\times 940$.

cytoplasm but there are no constant features permitting the diagnosis from cytomorphology alone. The diagnosis may be suspected when apparently undifferentiated blasts are associated with dysplastic neutrophils or marked poikilocytosis.

Bone marrow cytology

The bone marrow features do not differ from those of M1 AML except that the blasts have scanty, if any, granules and have no Auer rods. Other lineages may show dysplastic features, suggesting that ALL is not the correct diagnosis.

Cytochemistry

Cytochemistry with all the stains that are usually used to identify cells of various myeloid lineages is either negative or is positive in fewer than 3% of blasts. Immunocytochemistry for the above antigens is therefore used to confirm the diagnosis.

Bone marrow histology

The trephine biopsy appearances do not differ from those of M1 AML. It is also often not possible to distinguish M0 AML from ALL, although the presence of dysplastic features suggests a diagnosis of AML. The diagnosis of AML cannot be confirmed by Leder's stain, which is uniformly negative in M0 AML.

Immunological markers, however, can permit the distinction. Lymphoblasts usually express CD45 and may express CD79a or CD3, whereas myeloblasts do not express CD79a or CD3 and are often CD45-negative or only weakly positive. Monoclonal or polyclonal antibodies reactive with myeloid antigens, including anti-MPO and CD15, may be positive in M0 AML.

Cytogenetics and molecular genetics

M0 AML is preferentially associated with abnormalities of chromosomes 5 and 7, trisomy 13 and translocations and deletions involving 12p [21], suggesting a relationship to M6 AML and to therapy-related and myelodysplasia-related AML.

Acute panmyelosis with myelofibrosis

The WHO expert group [5] has drawn attention to a rare entity in which there is trilineage differentiation associated with bone marrow reticulin fibrosis. This entity has some features in common with those cases of M7 AML that are associated with the clinicopathological features of 'acute myelofibrosis'.

Peripheral blood

The blood film shows no specific features. There may be circulating blast cells.

Bone marrow aspirate

The bone marrow aspirate is often inadequate for diagnosis because of the associated reticulin fibrosis. Increased blast cells and multilineage dysplasia may be apparent.

Bone marrow histology

Bone marrow histology is critical in making the diagnosis, with immunohistochemistry being important in showing trilineage differentiation. Immature cells are increased and dysplasia may be prominent. Reticulin is increased.

Acute eosinophilic leukaemia

The term 'eosinophilic leukaemia' covers a heterogeneous group of disorders in which eosinophils are increased in the peripheral blood. Acute eosinophilic leukaemia falls into the FAB categories of M2 or M4 AML and can be designated more specifically as M2Eo and M4Eo. There is no precise percentage of eosinophils and precursors which leads to a case being categorized as M2Eo or M4Eo AML but cases of M4 AML with cytologically atypical eosinophils are usually categorized as M4Eo, even if the eosinophil percentage is relatively low. This latter group would not, however, usually be referred to as 'eosinophilic leukaemia'. Eosinophilic leukaemia, which is not synonymous with 'AML

with abnormal bone marrow eosinophils', is not recognized specifically in the WHO classification. Cases without inv(16) would fall mainly into the WHO category 'AML with maturation'. For a case to be classified as acute eosinophilic leukaemia, blast cells must constitute at least 20% of bone marrow cells. Cases of chronic eosinophilic leukaemia have peripheral blood and bone marrow eosinophilia and fewer than 20% bone marrow blasts. They are classified with the myeloproliferative disorders.

Peripheral blood

The peripheral blood shows mature eosinophils and eosinophil precursors. Eosinophils may be cytologically atypical but this is not diagnostically useful since atypical eosinophils are also seen in reactive eosinophilia. Eosinophil precursors often show nucleocytoplasmic asynchrony and immature granules with basophilic staining characteristics (Fig. 4.21).

Bone marrow cytology

The bone marrow shows an increase, often very marked, in eosinophils and their precursors (Fig. 4.22). Occasionally, Charcot-Leyden crystals are present, these being formed by crystallization of eosinophil granule contents. Other myeloid lineages (e.g. neutrophils or monocytes) may also be part of the leukaemic clone.

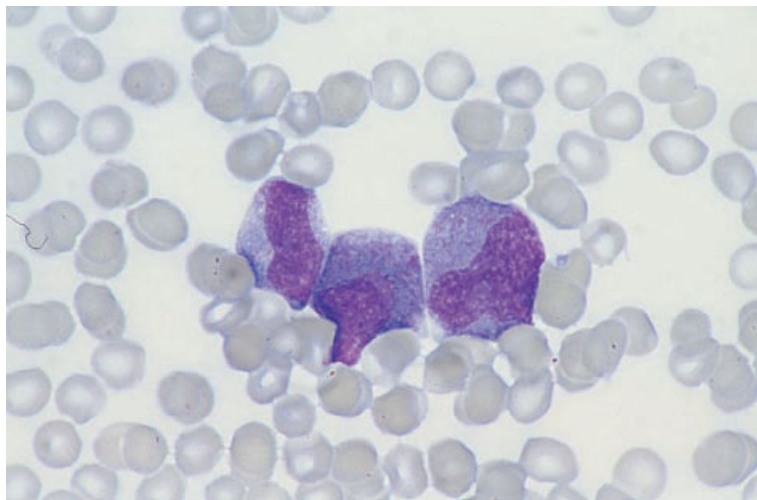


Fig. 4.21 PB film from a patient with acute eosinophilic leukaemia (M2Eo AML), showing eosinophil precursors with a mixture of primary and secondary granules. MGG $\times 960$. (By courtesy of Dr A Smith, Southampton.)

Fig. 4.22 BM aspirate from a patient with acute eosinophilic leukaemia (same case as in Fig. 4.21), showing eosinophils and their precursors and two Charcot–Leyden crystals. MGG $\times 384$. (By courtesy of Dr A Smith, Southampton.)

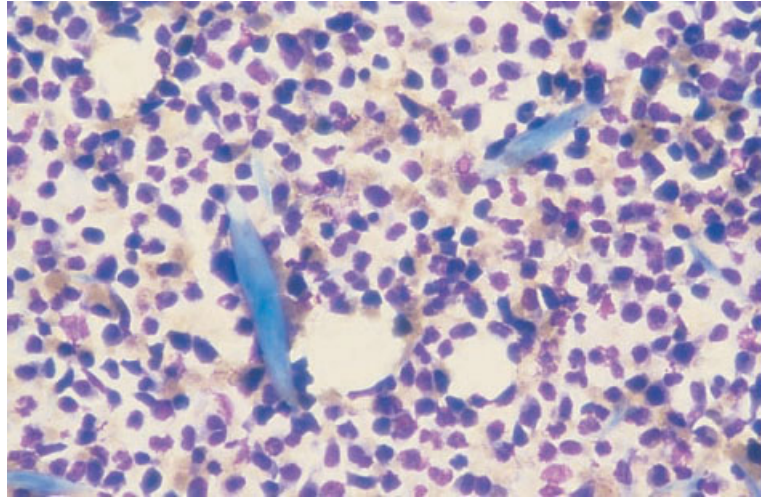
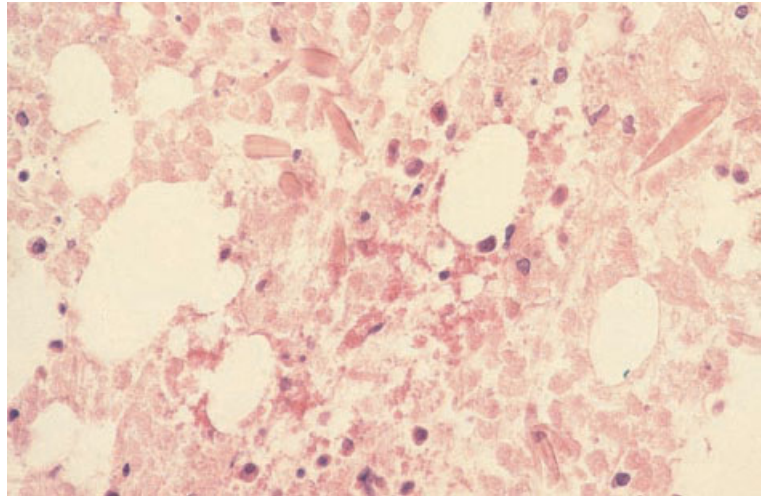


Fig. 4.23 Section of BM trephine biopsy specimen from a patient with acute eosinophilic leukaemia (same case as in Fig. 4.21), showing two Charcot–Leyden crystals in an area of necrotic bone marrow. H&E $\times 384$.



Cytochemistry

Eosinophils and precursors show strong peroxidase activity.

Bone marrow histology

Bone marrow trephine biopsy sections show an increase of eosinophils and their precursors (Figs 4.23 and 4.24).

Cytogenetics and molecular genetics

There is no specific cytogenetic association with

acute eosinophilic leukaemia. Rare cases have had $t(8;21)(q22;q22)$.

Acute basophilic leukaemia

Acute basophilic leukaemia is a rare form of AML which is not identified specifically in the FAB classification. Cases usually fall into the M2 or M4 categories and can be designated M2Baso and M4Baso. Some cases with little or no maturation fall into the M1 or M0 categories. Blasts in these cases can be identified as being of basophil lineage, either because they have basophil-type granules identifiable on light microscopy or by ultrastructural

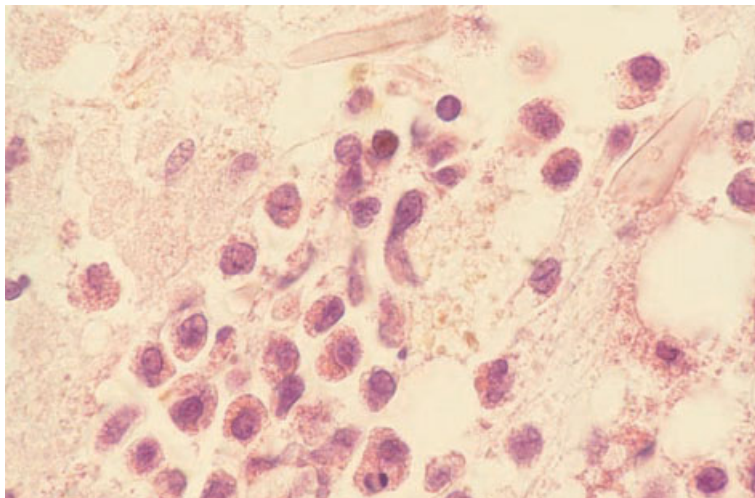


Fig. 4.24 Section of BM trephine biopsy specimen from a patient with acute eosinophilic leukaemia (same case as in Fig. 4.21), showing eosinophils and their precursors and two Charcot–Leyden crystals. H&E $\times 960$.

examination. The WHO classification has a specific category for acute basophilic leukaemia.

Peripheral blood

The blood film usually shows both blast cells and maturing basophils. The latter may be hypogranular.

Bone marrow cytology

The bone marrow aspirate shows more than 20% blast cells, usually with maturation to dysplastic basophils.

Bone marrow histology

Trephine biopsy sections show increased blast cells but are of no use currently in the detection of basophilic differentiation since basophil granules are dissolved during processing.

Acute mast cell leukaemia

Acute mast cell leukaemia is a rare condition which can occur *de novo* or as a transformation of systemic mastocytosis. It is not included in the FAB classification. The WHO classification assigns it to a separate category of ‘mast cell diseases’ but, since the mast cell is derived from the haemopoietic stem cell,

it seems to us more appropriate that it is classified as a form of AML.

Peripheral blood

The blood film shows immature mast cells which have round, oval or lobulated nuclei and a variable number of granules of mast cell type (Fig. 4.25).

Bone marrow cytology

The bone marrow aspirate shows immature cells of mast cell lineage. Immunocytochemistry for mast cell tryptase can be used to demonstrate mast cell differentiation if this is not certain from cytological features.

Cytochemistry

Mast cells stain metachromatically with toluidine blue. They are chloro-acetate esterase-positive.

Bone marrow histology

Trephine biopsy sections show effacement of the bone marrow by immature mast cells. These have more voluminous cytoplasm than most other blast cells so that, in an H&E-stained section, the round, oval or lobulated nuclei appear spaced apart

Fig. 4.25 PB film in acute mast cell leukaemia, showing circulating mast cell precursors. MGG ×940.

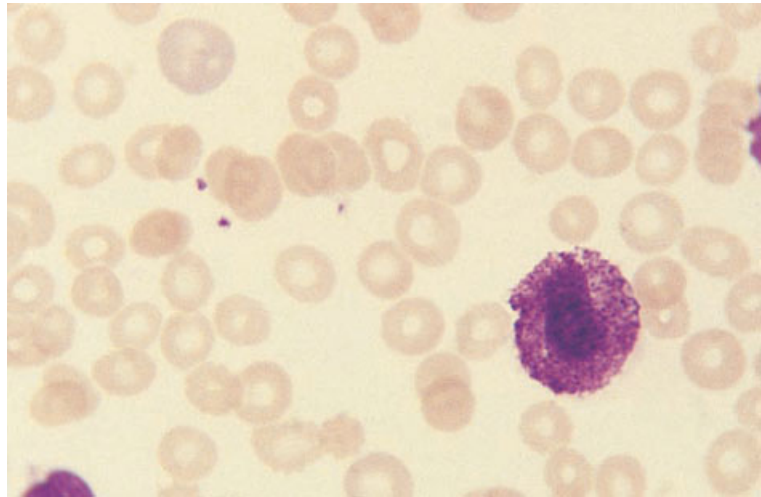
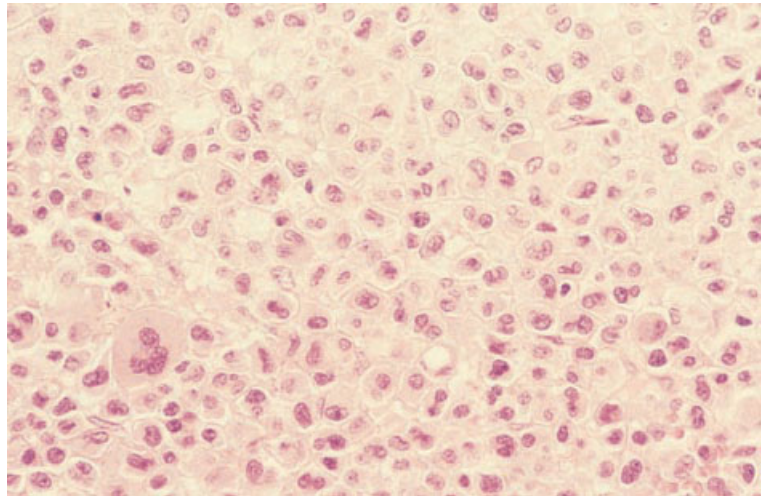


Fig. 4.26 BM trephine biopsy section in acute mast cell leukaemia, showing replacement of marrow by mast cells. H&E ×376.



(Fig. 4.26). With Giemsa staining, granules may be apparent. Immunohistochemistry for mast cell tryptase confirms the lineage.

Hypoplastic AML

A minority of cases of AML have a bone marrow which is hypocellular rather than hypercellular. Hypoplastic AML is defined variously, for example, as AML with bone marrow cellularity less than 50% [22] or less than 40% [23]. Blasts constitute at least 20% of nucleated cells. Cases of hypoplastic AML

may belong to various FAB categories but not M3. They may arise apparently *de novo* or be preceded by a hypoplastic variant of myelodysplasia. Clinical and haematological features differ from those of typical cases of AML with a hypercellular bone marrow. Hepatomegaly and splenomegaly are not commonly present. The median age is higher than that of AML in general [22]. The prognostic significance of hypoplastic AML is not yet clear. In one series, patients who were treated had a low remission rate and treated patients, overall, did not survive longer than those who received no specific treatment [22].

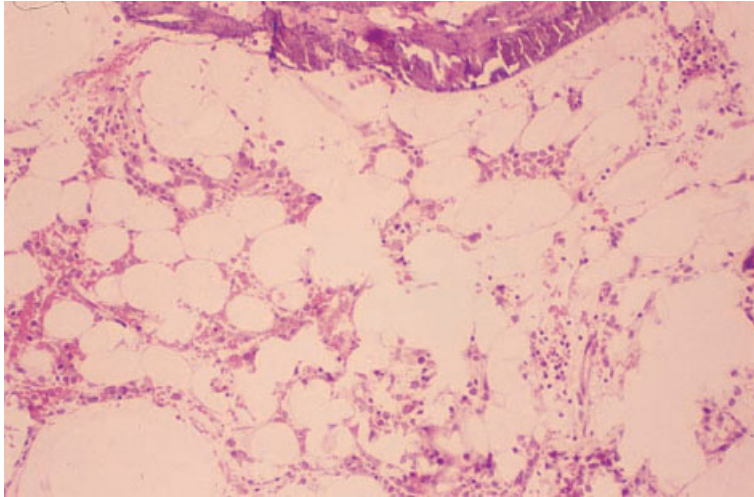


Fig. 4.27 Section of BM trephine biopsy specimen, hypoplastic AML. The marrow is hypocellular with preservation of fat cells. However, normal haemopoietic cells are not seen. Plastic-embedded, H&E $\times 97$.

However, in another series, treated patients had a high remission rate and improved survival [23].

Hypoplastic AML is not identified specifically in the WHO classification. Some cases fall into the categories designated 'AML with multilineage dysplasia' and 'AML, therapy-related'.

Peripheral blood

In contrast to cases of typical AML, pancytopenia is usual and peripheral blood blasts are often absent or infrequent. Blasts may contain Auer rods.

Bone marrow cytology

The bone marrow aspirate is often hypocellular and may therefore not be optimal for diagnosis. Blasts are increased and commonly show granulocytic rather than monocytic differentiation. There may be associated dysplastic features.

Cytochemistry

The blasts in hypoplastic AML have no specific cytochemical features.

Bone marrow histology

Because a poor aspirate is often obtained, trephine biopsy is usually important in diagnosis. The mar-

row shows irregular hypoplasia (Fig. 4.27) with small foci of blasts separated by fat cells (Fig. 4.28). Blasts make up more than 20% of bone marrow nucleated cells. There are often dysplastic changes in the other haemopoietic lineages. Reticulin may be increased.

Cytogenetics and molecular genetics

Cytogenetic abnormalities are non-specific but may include abnormalities of chromosomes 5 and 7.

Cytochemistry in AML

Cytochemistry permits the confirmation of a diagnosis of AML in all categories except M0 and M7. It is most important in M1 and M5a AML, which can be confused with ALL and high grade lymphoma respectively. Recommended cytochemical stains are either MPO or SBB (for identification of granulocytic differentiation) and a non-specific esterase stain such as α -naphthyl acetate esterase (for identification of monocytic differentiation).

Immunocytochemistry and flow cytometry in AML

Immunophenotyping [8] (Table 4.3) is of considerable importance in confirming the diagnosis of M0 and M7 AML, which may otherwise be confused

Fig. 4.28 Section of BM trephine biopsy specimen, hypoplastic AML (same case as in Fig. 4.27). High power examination reveals most of the cells present to be myeloblasts. Plastic-embedded, H&E $\times 970$.

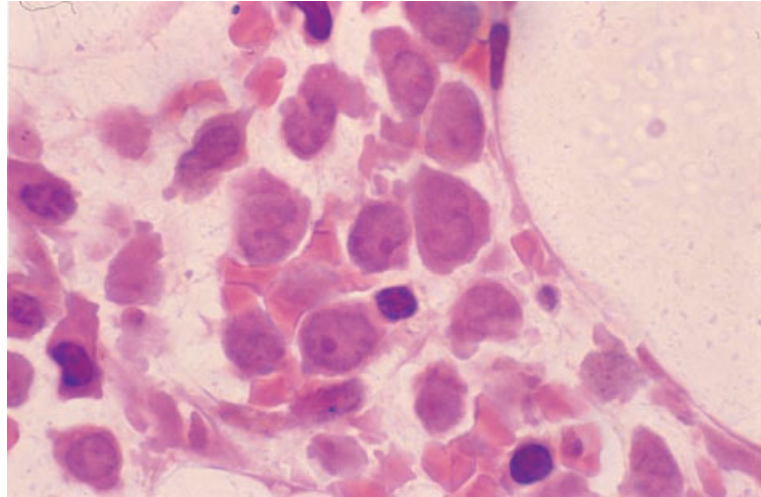


Table 4.3 Monoclonal and polyclonal antibodies useful for flow cytometry immunophenotyping in the diagnosis of AML.

Specificity	Antibodies
Panmyeloid	CD13, CD33, CD65, CD117, anti-myeloperoxidase
Markers of maturation	CD15, CD11b
Markers of monocytic differentiation	CD14, CD11b, CD64
Erythroid markers	Anti-glycophorin
Megakaryocytic markers	CD41, CD42a, CD42b, CD61
Markers of immaturity	CD34, anti-terminal nucleotidyl transferase

Table 4.4 Monoclonal and polyclonal antibodies useful in immunohistochemistry for the diagnosis of AML.

Specificity	Antibodies
Granulocytic and/or monocytic markers	Anti-myeloperoxidase, CD64, CD68, anti-neutrophil elastase
Megakaryocyte/platelet markers	CD42b, CD61, anti-von Willebrand's factor
Erythroid markers	Anti-glycophorin, anti-spectrin
Mast cell marker	Mast cell tryptase
Markers of immaturity	CD34, anti-terminal deoxynucleotidyl transferase

with ALL. It is also useful in the recognition of M6 variant AML since the primitive cells may be so immature that they are not readily recognizable from cytological features. Immunophenotyping is an alternative to cytochemistry for confirming the myeloid lineage of M1 and M5 AML. Other FAB categories are usually readily recognizable without recourse to immunophenotyping. Immunophenotyping is now generally performed by flow cytometry rather than by immunocytochemistry.

Immunohistochemistry in AML

Monoclonal and polyclonal antibodies that are useful in confirming a diagnosis of AML are shown in Table 4.4. Their use is most important in M0, M1, M5a and M7 categories. In M2, M3, M4 and M5b subtypes it is usually possible to make a diagnosis of AML from H&E-stained sections. It is our practice to perform immunohistochemical stains whenever there is diagnostic difficulty, for example, when bone

marrow aspiration has failed and there are only low numbers of circulating blast cells.

Cytogenetics and molecular genetics in AML

It is the somatic mutation that occurred in the stem cell giving rise to the leukaemic clone that determines the clinical and pathological features of AML. The molecular genetic abnormality is therefore one of the most fundamental characteristics of any case of AML and it is appropriate that it be incorporated into classification of this disease. The MIC classification sought to do this, when cytogenetic analysis was added to morphology and immunophenotyping in classifying acute leukaemia [3]. With the advent of molecular genetic analysis, it became possible to identify genes involved in the oncogenic event and a MIC-M classification, incorporating the results of molecular genetic analysis [4], became possible. The MIC-M categorization is open-ended, new categories being added when the oncogenic events have been defined (Table 4.5).

Some cases of AML following topoisomerase-II-interactive drugs have the same clinical features and cytogenetic and molecular genetic abnormalities as are seen in *de novo* AML. They can be described by the term '*de novo*-type' AML. The WHO classification incorporates the four numerically most important cytogenetic categories of *de novo* AML, associated with simple chromosomal rearrangements and a single major genetic event, but categorizes separately cases with the same cytogenetic abnormality that follow therapy with topoisomerase-II-interactive drugs. The MIC-M classification categorizes primarily by molecular event. It is applicable to cases of *de novo* and *de novo*-type AML in which there is one major oncogenic event. It is not applicable to many cases of AML in the elderly, myelodysplasia-related AML and therapy-related AML following alkylating agents and related drugs, all of which are consequent on an accumulation of multiple genetic events. This type of AML shows a different range of cytogenetic abnormalities. The most characteristic are monosomy 5, del(5)(q), monosomy 7, del(7)(q), trisomy 8, trisomy 9, del(11)(q), del(12)(p), monosomy 18, monosomy 19, del(20)(q), trisomy 21 and complex chromosomal rearrangements.

Problems and pitfalls in the diagnosis of AML

It is sometimes difficult to distinguish cases of M0 and M1 AML from ALL on the basis of examination of H&E-stained sections. Some histological features are useful. ALL is usually associated with effacement of the bone marrow whereas, in AML, there may be residual myeloid cells showing dysplastic features. ALL blasts tend to have more scanty cytoplasm and more chromatin condensation. If difficulty is experienced in making the distinction and if diagnosis depends on the trephine biopsy sections, immunohistochemistry should be used. However, it should be noted that immunohistochemistry for MPO and other myeloid antigens is less sensitive for the detection of myeloid differentiation than cytochemistry and immunophenotyping by flow cytometry. For this reason, there are some cases of M0 and M1 AML that cannot be distinguished from ALL histologically, even with the help of immunohistochemistry.

Other diagnostic problems relate mainly to M6 AML, M7 AML and hypoplastic AML. M6 AML and megaloblastic anaemia can be confused with each other in trephine biopsy sections or, less often, in a bone marrow aspirate. This is a very serious error which must be avoided. It arises mainly because the diagnosis of AML is not considered or because a case of M6 has megaloblastic erythropoiesis. Diagnostic error can be avoided by careful attention to cytological details (see page 371) supplemented, when necessary, by assays of vitamin B₁₂ and folic acid. A therapeutic trial of haematinic agents is sometimes useful.

M7 AML and acute panmyelosis with myelofibrosis, when accompanied by dense fibrosis, can be confused with chronic idiopathic myelofibrosis (see page 204). The clinical and haematological features of these three conditions differ. Marked splenomegaly is usual in idiopathic myelofibrosis but not in M7 AML or acute panmyelosis with fibrosis. A leuco-erythroblastic anaemia with marked poikilocytosis is likewise usual in idiopathic myelofibrosis but not in M7 AML or acute panmyelosis. Bone marrow aspiration usually fails or yields inadequate material for diagnosis in all these conditions. However, histology shows increased blast cells in M7 AML and acute panmyelosis and not in idiopathic myelofibrosis. AML with myelofibrosis can also be

Table 4.5 A morphological, immunophenotypic, cytogenetic, molecular genetic (MIC-M) classification of acute myeloid leukaemia (modified from [4,24,25]).

Cytogenetic abnormality	Molecular genetic abnormality	FAB category
t(1;11)(p32;q23)*	<i>MLL-AF1p</i> fusion	M5
t(1;11)(q21;q23)*	<i>MLL-AF1q</i> fusion	M4
t(1;11)(q23;p15)	<i>NUP98-PMX1</i>	M2
t(2;11)(q35;p15)	<i>NUP98-HOXD13</i>	Therapy-related
inv(3)(q21q26) or t(3;3)(q21;q26)	<i>EVI1</i> dysregulation	Various
t(3;5)(q25.1;q34)	<i>NPM-MLF1</i> fusion	Various
t(3;12)(q26;p13)	Fusion of various genes at 3q26 with <i>TEL</i> at 12p13	Various
t(3;21)(q26;q22)	Heterogeneous, mainly <i>AML1-EAP</i> , <i>AML1-EVI1</i> and <i>AML1-MDS1</i>	Variable
t(4;11)(q21;q23)*	<i>MLL-AF4</i> fusion	M5
t(4;12)(q11-12;p13)	<i>BTV-TEL (BTV-ETV6)</i>	M0
t(5;17)(q32;q21)	<i>NPM-RARα</i> fusion	M3-like
t(6;9)(p23;q34)	<i>DEK-CAN</i> fusion	M2Baso
t(6;11)(q27;q23)*	<i>MLL-AF6</i> fusion	M4 or M5
t(7;11)(p15;p15)	<i>NUP98-HOXA9</i> fusion	M2
inv(8)(p11q13)	<i>MOZ-TIF2</i> fusion	M7*
t(8;16)(p11;p13)	<i>MOZ-CBP</i> fusion	M4 or M5
t(8;21)(q22;q22)†	<i>AML1-ETO</i> fusion	M2
t(9;11)(p21-22;q23)*	<i>MLL-AF9</i> fusion	M5
t(9;22)(q34;q11)	<i>BCR-ABL</i> fusion	M0, M1 or M2
t(10;11)(p12;q23)*	<i>MLL-AF10</i> fusion	M5
t(10;11)(p11.2;q23)*	<i>MLL-ABI1</i> fusion	AML
t(10;11)(p13;q14)	<i>CALM-AF10</i> fusion	M4
ins(11;9)(q23;p22p23)*	<i>MLL-AF9</i> fusion	M5
inv(11)(p15q22)	<i>NUP98-DDX10</i> fusion	Various
t(11;16)(q23;p13)*	<i>MLL-CBFβ</i> fusion	Variable
t(11;17)(q23;q21)*	<i>MLL-AF17</i> fusion	M5
t(11;17)(q23;q21)	<i>PLZF-RARα</i> fusion	M3-like
t(11;19)(q23;p13.1)*	<i>MLL-ELL</i> fusion	M4 or M5
t(11;19)(q23;p13.3)*	<i>MLL-ENL</i> fusion	M4 or M5
t(11;20)(p15;q11)	<i>NUP98-TOP1</i> fusion	t-MDS or AML
t(11;22)(q23;q13)*	<i>MLL-p300</i> fusion	AML
+11, 11q+ or normal*	Partial tandem duplication of <i>MLL</i>	AML
t(12;13)(p13;q12)	<i>ETV6(TEL)-CDX2</i> fusion	AML
t(12;22)(p13;q11)	<i>MN1-TEL</i> fusion	Variable
t(15;17)(q22;q21)†	<i>PML-RARα</i> fusion	M3
inv(16)(p13q22)† or t(16;16)(p13;q22)†	<i>CBFβ-MYH11</i> fusion	M4Eo
t(16;21)(p11;q22)	<i>FUS-ERG</i> fusion	Variable
t(X;11)(q13;q23)*	<i>MLL-AFX</i> fusion	M4 or M5

* Grouped together in the WHO classification as 'AML with 11q23 (*MLL*) abnormalities.

† Specific WHO categories of AML.

confused with bone marrow infiltration by a non-haemopoietic tumour with secondary myelofibrosis. Dysplastic megakaryocytes and metastatic tumour cells can be distinguished by immunohistochemistry.

Hypoplastic AML must be distinguished from aplastic anaemia and from hypoplastic MDS. Increased reticulin deposition and dysplastic megakaryocytes suggest a diagnosis of AML or MDS

rather than aplastic anaemia. In addition, in hypoplastic AML and hypoplastic MDS there may be some circulating blasts and the bone marrow aspirate, although inadequate for diagnostic purposes, may also show blast cells. There is no increase in blast cells in aplastic anaemia. Accurate differential diagnosis of these three conditions requires good quality sections of trephine biopsy specimens, which need to be examined carefully with high power magnification so that the proportion of blast cells can be estimated. If there are more than 20% blast cells, the diagnosis is AML and, if blasts are increased but less than 20%, the diagnosis is MDS.

AML of M5a subtype can sometimes be confused with large cell non-Hodgkin's lymphoma. If monocytes are very immature, they may lack peroxidase and non-specific esterase activity. Flow cytometry immunophenotyping or immunohistochemistry is then very important in making the correct diagnosis.

The myelodysplastic syndromes

As discussed at the beginning of this chapter, the MDS are diseases consequent on a clonal haemopoietic disorder characterized by dysplastic, ineffective haemopoiesis. There is thus often a discrepancy between a hypercellular bone marrow and peripheral cytopenia. In any one patient, different haemopoietic lineages are not necessarily affected to the same degree and there may be defective production of cells of one lineage while in another lineage normal numbers of cells are produced. There may even be increased production of cells of one or more lineages—for example, neutrophils, monocytes or platelets—despite other features typical of MDS (see page 215).

The MDS are predominantly diseases of the elderly with an incidence of the order of 70 cases/100 000/year.

Clinical features of MDS result from the various cytopenias; there may be haemorrhage, susceptibility to infections and symptoms of anaemia. Some patients have hepatomegaly and splenomegaly. MDS show a tendency to evolve into more severe forms of MDS and into acute leukaemia. Most cases of MDS are apparently primary but a minority are secondary to exposure of the bone marrow to known mutagens, such as alkylating agents. There are

some differences in laboratory and clinical features between primary and secondary MDS.

Diagnosis of MDS requires consideration of clinical, peripheral blood, bone marrow and cytogenetic features. Peripheral blood and bone marrow aspirate findings are most important and, in a straightforward case, may be all that is required for diagnosis. Bone marrow trephine biopsy in general offers only supplementary information; however, sometimes it is necessary for confirmation of the diagnosis, for example, when an excess of blasts or an abnormal localization of blasts is detected in a patient who has other features suggestive but not diagnostic of MDS. Bone marrow trephine biopsy is particularly important in patients with secondary MDS, in whom a hypocellular bone marrow with increased fibrosis often leads to a non-diagnostic aspirate. In some patients, a firm diagnosis cannot be made on cytological and histological features alone, but diagnosis is possible when these are supplemented by cytogenetic analysis or other tests giving information about clonality. An iron stain should be performed in all patients with suspected myelodysplasia; this demonstrates any ring sideroblasts as well as permitting an assessment of iron stores. An MPO or SBB stain should be performed at least in all patients with any increase in blasts; this will facilitate the detection of Auer rods, which are of importance both in diagnosis and in classification.

The MDS are a heterogeneous group of disorders with very variable prognoses. They can be divided into various disease categories which have more uniform clinicopathological characteristics. Until now the most widely used categorization has been that proposed by the FAB group [1,2,26]. The FAB classification is based on the presence or absence of significant sideroblastic erythropoiesis, on the numbers of monocytes in the peripheral blood and on the number of blasts in the peripheral blood and bone marrow (Table 4.6). The FAB categories are:

- 1 refractory anaemia (RA) or refractory cytopenia;
- 2 refractory anaemia with ring sideroblasts (RARS);
- 3 refractory anaemia with excess of blasts (RAEB);
- 4 chronic myelomonocytic leukaemia (CMML); and
- 5 refractory anaemia with excess of blasts in transformation (RAEB-T).

More recently, a WHO classification of MDS has been proposed (Table 4.7) [5]. The most important difference from the FAB classification is that the

Table 4.6 The FAB classification of the myelodysplastic syndromes [1,2,8,26].

Category	Peripheral blood	Bone marrow
Refractory anaemia (RA) or refractory cytopenia*	Anaemia* Blasts $\leq 1\%$ Monocytes $\leq 1 \times 10^9/l$	Blasts $< 5\%$, ringed sideroblasts $\leq 15\%$ of erythroblasts
Refractory anaemia with ringed sideroblasts (RARS)	Anaemia Blasts $\leq 1\%$ Monocytes $\leq 1 \times 10^9/l$	Blasts $< 5\%$, ringed sideroblasts $> 15\%$ of erythroblasts
Refractory anaemia with excess of blasts (RAEB)	Anaemia Blasts $> 1\%$ Blasts $< 5\%$ Monocytes $\leq 1 \times 10^9/l$	Blasts $\geq 5\%$ Blasts $\leq 20\%$
Chronic myelomonocytic leukaemia (CMML)	Blasts $< 5\%$ Monocytes $> 1 \times 10^9/l$ Granulocytes often increased	Blasts up to 20% promonocytes often increased
Refractory anaemia with excess of blasts in transformation (RAEB-T)	Blasts $\geq 5\%$	Blasts $> 20\%$ $< 30\%$

* Or in the case of refractory cytopenia, either neutropenia or thrombocytopenia.

Table 4.7 The WHO classification of the myelodysplastic syndromes [5].

Refractory anaemia
 With ringed sideroblasts
 Without ringed sideroblasts
 Refractory cytopenia with multilineage dysplasia
 5q- syndrome
 Refractory anaemia with excess blasts
 Myelodysplastic syndrome, unclassifiable
 Myelodysplastic syndromes, therapy-related
 Alkylating agent-related
 Etoposide-related

RAEB-T category has been abolished. Cases with more than 20% of bone marrow blasts are classified as AML. In addition, CMML has been classified as a mixed myelodysplastic/myeloproliferative disease rather than as one of the MDS. The WHO group has also made a distinction between cases of RA and RARS with and without dysplasia of other lineages, since this is of prognostic significance.

Some morphological abnormalities are characteristic of MDS, without being specific for them, while others show sufficient specificity to be useful in confirming the diagnosis. Although the MDS are heterogeneous they also have many features in

common. We will therefore describe these syndromes as a group before discussing specific categories of disease. CMML will be discussed mainly in the next chapter (see page 215). The other FAB categories of MDS will be discussed in this chapter, retaining the FAB definitions since the WHO classification has been published only in outline.

Peripheral blood

Anaemia is seen in the great majority of patients. Red cells are usually normochromic and either normocytic or macrocytic. In patients with sideroblastic erythropoiesis there is commonly a dimorphic blood film with a mixture of a minority population of hypochromic microcytes and a majority population of normochromic cells which are either normocytic or, more commonly, macrocytic; Pappenheimer bodies, the nature of which can be confirmed with an iron stain, may be present. Microcytosis is seen in certain rare variants including acquired haemoglobin H disease. Some patients have occasional circulating erythroblasts which may include dysplastic forms such as megaloblasts and, in patients with sideroblastic erythropoiesis, ring sideroblasts.

Neutropenia is common, particularly in RAEB and RAEB-T. Neutrophils often show dysplastic features

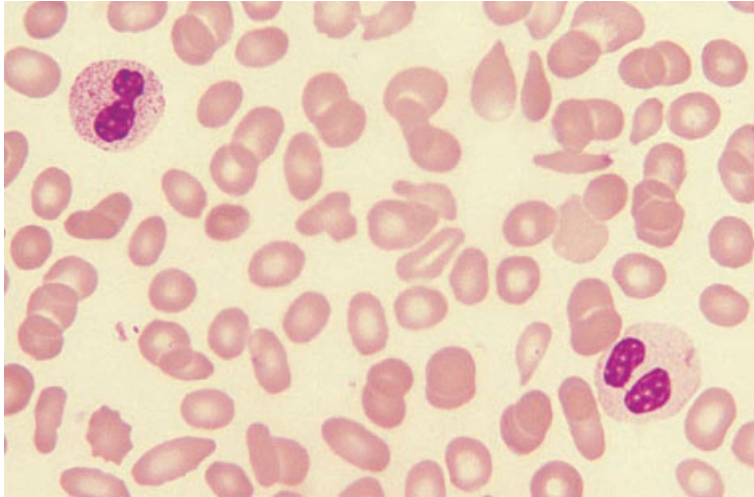


Fig. 4.29 PB film, MDS, showing anisocytosis, poikilocytosis and two pseudo-Pelger–Huët neutrophils, one of which is also hypogranular. MGG ×940.

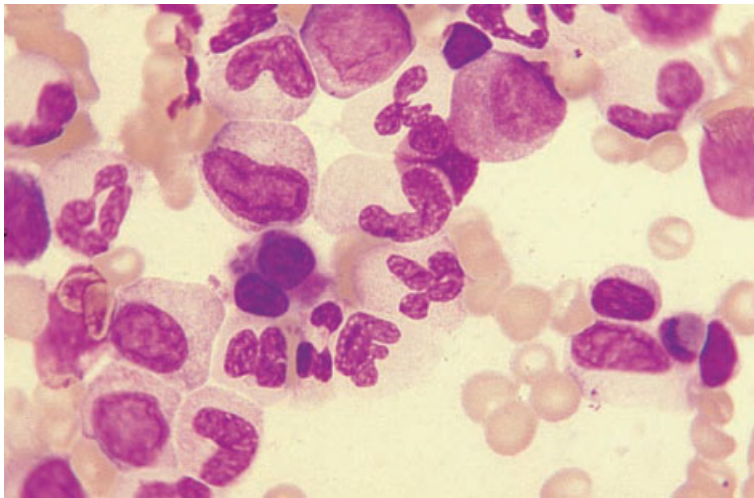


Fig. 4.30 BM aspirate, RA, showing a binucleate micromegakaryocyte which is budding platelets. MGG ×940.

including reduced granulation and the acquired or pseudo-Pelger–Huët anomaly. Hypogranular and agranular neutrophils (Fig. 4.29) are consequent on defective formation of secondary granules; agranular neutrophils are highly specific for the MDS [27]. The acquired Pelger–Huët anomaly refers to hypobulbation of nuclei associated with dense chromatin clumping (Fig. 4.29); nuclei of mature neutrophils may be completely non-lobed, dumb-bell or peanut-shaped, or bilobed with the shape resembling a pair of spectacles. This abnormality resembles the inherited Pelger–Huët anomaly, hence its name. The acquired anomaly is highly characteristic of the

MDS and almost pathognomonic [27]. Eosinophil and basophil counts are commonly reduced but, in a small minority of patients, are increased; dysplastic forms with abnormalities of either nuclear shape or cytoplasmic granulation can occur. Monocytosis is sometimes present and monocytes may show cytological abnormalities such as increased cytoplasmic basophilia or nuclei of unusual shape. Blast cells may be present in the peripheral blood in all categories of MDS but particularly in RAEB and RAEB-T. They usually have the cytological features of myeloblasts with scanty cytoplasm and few granules. Auer rods are sometimes present. Other

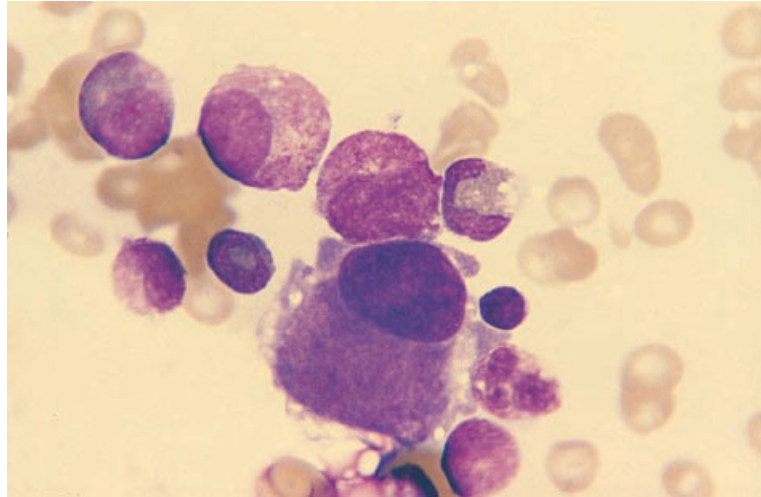


Fig. 4.31 BM aspirate, RA, 5q- syndrome, showing a megakaryocyte of normal size with a hypolobulated nucleus. MGG $\times 940$.

granulocyte precursors are quite uncommon in the peripheral blood.

The platelet count is usually either normal or reduced. In a minority of patients it is increased. Dysplastic features which may be noted in platelets include hypogranular and agranular forms ('grey' platelets) and giant platelets.

Patients with MDS have an increased incidence of auto-immune thrombocytopenia [28].

Bone marrow cytology

The bone marrow is hypercellular in the majority of patients but is sometimes normocellular and in about 10% of patients is hypocellular. Hypercellularity may be due to hyperplasia of erythroid or granulocytic series or both.

Erythropoiesis may be normoblastic, macronormoblastic or megaloblastic. In patients with sideroblastic erythropoiesis there are some erythroblasts with poorly haemoglobinized or vacuolated cytoplasm. Other dysplastic features may include: (i) binuclearity and multinuclearity; (ii) internuclear bridges; (iii) nuclear lobulation; (iv) irregularity or fragmentation of nuclei; (v) gigantism; (vi) increased pyknosis; and (vii) basophilic stippling. The bone marrow erythroid component (calculated from cellularity and the percentage of erythroblasts) has been found to be predictive of response to therapy with erythropoietin plus GM-CSF [29].

Granulopoiesis is usually hyperplastic. Defects of granulation may be apparent from the promyelocyte stage onwards and defects of nuclear lobulation may also be present.

Megakaryocyte numbers are usually normal or increased but sometimes decreased. One of the features most specific for the MDS is the presence of micromegakaryocytes [27], cells of about the size of a myeloblast with one or two small round nuclei (Fig. 4.30). Megakaryocytes may also be of normal size but have a large non-lobulated nucleus (Fig. 4.31); this abnormality is less specific for MDS but is characteristic of cases with 5q- as an acquired chromosomal abnormality [30]. Other megakaryocyte abnormalities include bizarre nuclear shapes and the presence of multiple separate nuclei. Poor granulation of megakaryocyte cytoplasm is also common in the MDS and has been found to be highly specific [31].

The bone marrow aspirate may show non-specific abnormalities such as increased numbers of macrophages, sea-blue histiocytes, lymphocytes, plasma cells or mast cells.

Cytochemistry

The cytochemical stain of most value is an iron stain. This should be performed in all cases of suspected MDS, in order to quantify iron stores and to detect and enumerate ring sideroblasts and other abnormal

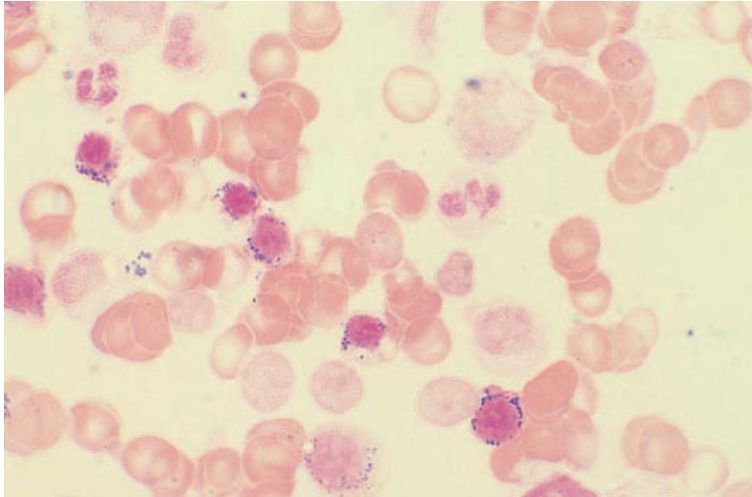


Fig. 4.32 BM aspirate, RARS, showing numerous ring sideroblasts, several of which can be seen to have defectively haemoglobinized cytoplasm. Perls' stain $\times 940$.

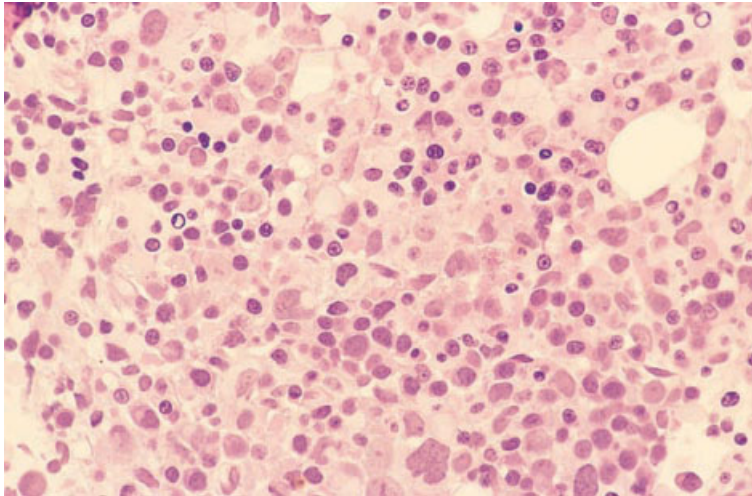


Fig. 4.33 BM trephine biopsy section, RA, showing marked hypercellularity with disorganization of haemopoiesis and marked dyserythropoiesis. Note the apoptotic erythroblasts with peripheral condensation of their nuclear chromatin. Plastic-embedded, H&E $\times 390$.

sideroblasts. Ring sideroblasts have iron-positive granules in a circle close to the nuclear membrane (Fig. 4.32). Other abnormal sideroblasts have scattered iron-positive granules which are both larger and more numerous than those of normal siderocytes. Ring sideroblasts are highly suggestive of MDS if the other known causes of sideroblastic erythropoiesis (see page 36) can be eliminated. Abnormal sideroblasts, other than ring sideroblasts, are common both in MDS and in other disorders of erythropoiesis so are not useful in the differential diagnosis of suspected MDS. Other cytochemical stains are of use in identifying abnormal cells of

megakaryocyte lineages, in characterizing blasts and in detecting Auer rods. MPO and SBB stains will identify myeloblasts and may also show cells of the neutrophil lineage to have defective primary granules. Non-specific esterase stains are useful for identifying monoblasts; non-specific esterase and PAS stains are valuable for identifying abnormal megakaryocytes.

Bone marrow histology

In the majority of cases the marrow is hypercellular (Fig. 4.33), but a significant minority have a hypo-

Fig. 4.34 BM trephine biopsy section, RAEB-T, showing increased numbers of blasts forming a small cluster (centre) (an abnormal localization of immature precursors or ALIP). Plastic-embedded, H&E $\times 970$.

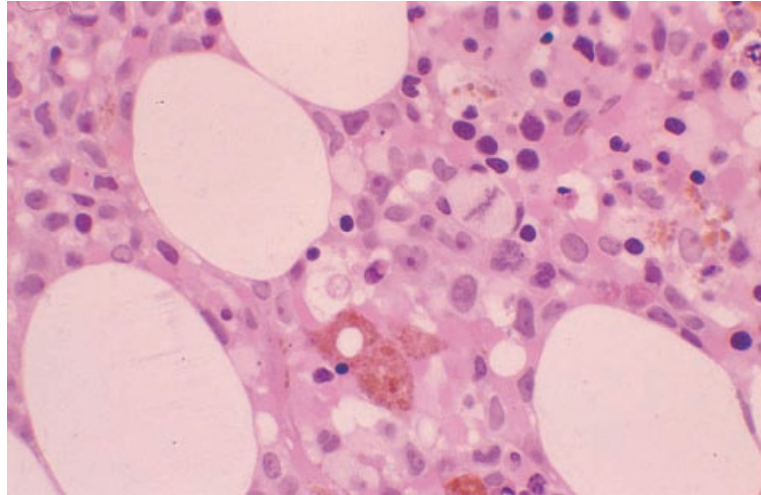
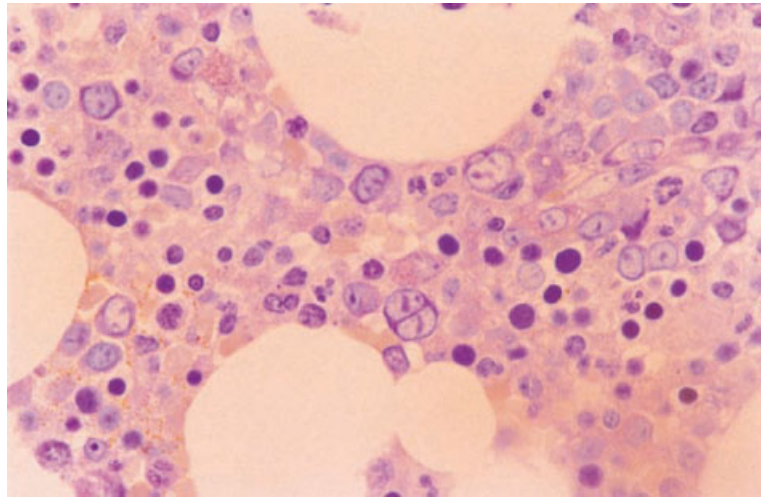


Fig. 4.35 BM trephine biopsy section in MDS, showing numerous immature erythroid cells including a binucleate form; the erythroblasts are not grouped into a compact erythroid island. Paraffin-embedded, Giemsa $\times 970$.



cellular marrow [32,33]. There may be considerable variation of the cellularity between adjacent intertrabecular spaces [34]. In addition to cytological evidence of dysplasia, there is derangement of normal architecture. In histological sections, dysplasia is most obvious in the erythroid precursors and megakaryocytes; however, the acquired Pelger-Huët anomaly can be detected in good quality sections of paraffin-embedded material and, in good plastic-embedded material, Auer rods may also be identified. Disturbance of normal architecture results in groups of granulocytic precursors being found in the central parts of intertrabecular spaces

(Fig. 4.34) and erythroid precursors and megakaryocytes in the paratrabeular regions. Erythroblastic islands may be poorly formed or very large and erythroid precursors may be multinucleated or show nuclear budding or fragmentation, megaloblastic change or cytoplasmic vacuolation (Fig. 4.35). Megakaryocytic dysplasia is present in the vast majority of cases and is usually more apparent in histological sections than in marrow films. They are usually increased in number and clustering is often seen (Fig. 4.36). Typically, they have hypolobulated nuclei which are often hyperchromatic; the small dysplastic megakaryocytes are usually referred to as

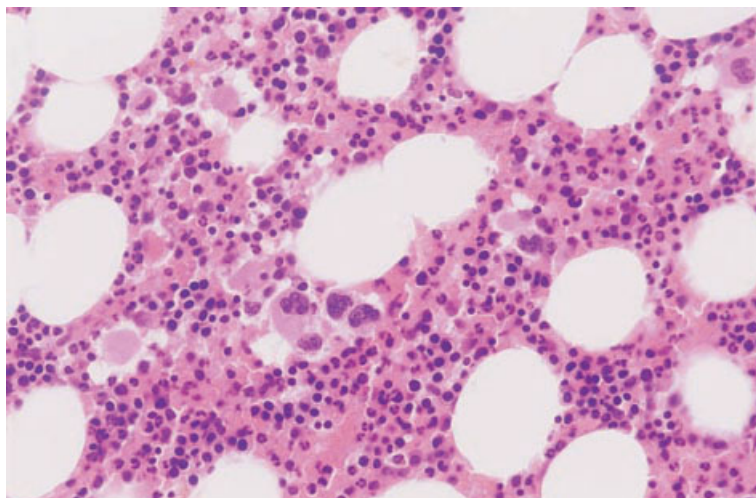


Fig. 4.36 BM trephine biopsy section, RA, showing an aggregate of dysplastic megakaryocytes. Paraffin-embedded, H&E $\times 192$.

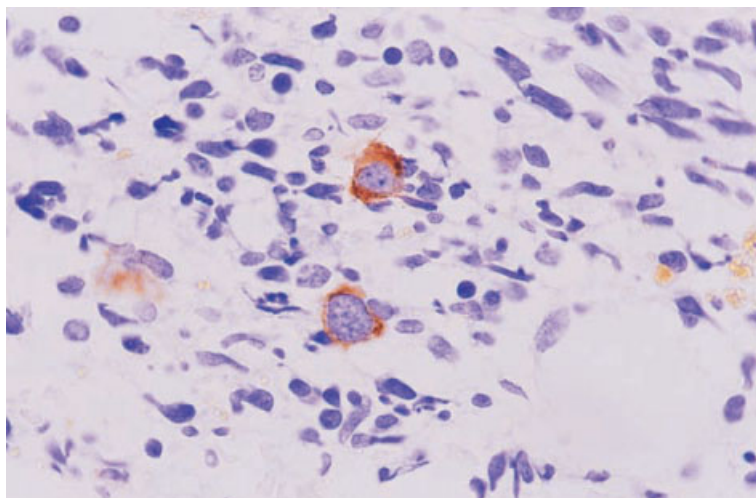


Fig. 4.37 BM trephine biopsy section, therapy-related MDS, showing dysplastic small megakaryocytes. Paraffin-embedded, immunoperoxidase with a CD61 monoclonal antibody $\times 970$.

micromegakaryocytes [33,35]. Emperipolesis is increased [36]. Immunohistochemical staining with anti-GpIIIa (CD61) and anti-GpIb (CD42b) may be used to accentuate the abnormal megakaryocytes (Fig. 4.37) [37]. Increased numbers of apoptotic erythroid and granulocytic precursors are commonly seen in MDS consequent on ineffective haemopoiesis (see Fig. 4.33) [38]. In a minority of cases, haemopoietic cells, particularly megakaryocytes, are present within sinusoids [36]. Reticulin fibrosis has been reported in a fifth [39] to almost a half [33] of cases of MDS, as defined by the FAB

group. It is more common in chronic myelomonocytic leukaemia (now designated a myelodysplastic/myeloproliferative disorder) than in other subtypes [33,39]. The presence of reticulin fibrosis correlates with megakaryocyte numbers and atypia [39]. Severe collagen fibrosis is rare in all subtypes [33,39]. It is seen most often in secondary MDS. Reticulin fibrosis correlates with unfavourable cytogenetic abnormalities and is indicative of a worse prognosis. Other non-specific reactions are commonly seen including oedema, ectasia of sinusoids, increased numbers of plasma cells and increased

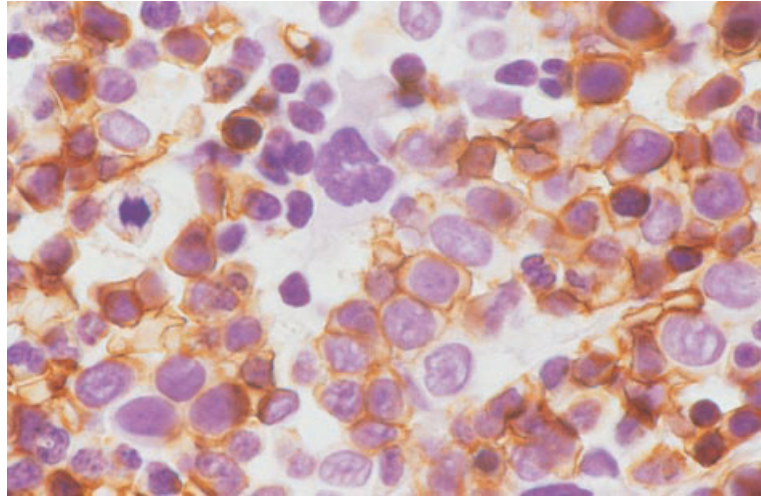


Fig. 4.38 Trephine biopsy section from a patient with RARS, showing a clump of early erythroid cells that can be distinguished from an ALIP by their weak but definite reaction with antiglycophorin. Paraffin-embedded, immunoperoxidase, antiglycophorin $\times 940$.

numbers of lymphoid follicles. Haemosiderin-laden macrophages are a frequent finding, particularly in patients who have received transfusions.

One feature that has been the subject of much debate is the significance of small groups of immature granulocytic precursors (promyelocytes and myeloblasts) in a central position within intertrabecular spaces (see Fig. 4.34). This has been termed abnormal localization of immature precursors (ALIP). Some studies have found this phenomenon to be an independent predictor of prognosis and to be associated with an increased incidence of leukaemic transformation [40]. Although ALIP is more frequent in the subtypes of myelodysplasia with increased numbers of blasts in the marrow, several recent studies have failed to confirm any independent influence on prognosis [33,34,41]. Others, however, have confirmed prognostic significance independent of the blast percentage in an aspirate [36] or in histological sections [42]. It should be noted that it can be difficult, particularly in paraffin-embedded sections, to distinguish between small groups of immature erythroid precursors and the clusters of immature cells of granulocytic lineage that are seen in ALIP. Aggregates of immature erythroid cells, which can mistakenly be taken as evidence of ALIP, can be distinguished by their positive reactions with antibodies to glycophorin or spectrin, whereas the immature cells in ALIP may react positively with CD68, antimyeloperoxidase and antineutrophil elastase antibodies. Other histological

features found to be of poor prognostic significance, in one study using multivariate analysis, were an elevated blast percentage, increased haemosiderin, megakaryocyte atypia and reduced erythropoiesis, while increased mast cells were of good prognostic significance [42].

Immunocytochemistry and flow cytometry in MDS

Immunophenotyping can be used to confirm the lineage of any blast cells present but, in general, immunophenotyping is of little value in MDS.

Immunohistochemistry

The value of immunohistochemistry in MDS can be summarized as follows:

- 1** abnormal topography can be detected, e.g. the presence of ALIP or the presence of erythroid cells or megakaryocytes in a paratrabecular position;
- 2** immature cells in ALIP can be distinguished from clusters of immature erythroid cells (Fig. 4.38);
- 3** abnormally large erythroid islands can be identified;
- 4** micromegakaryocytes can be identified and the presence of megakaryocyte clustering or dysplasia highlighted (see Fig. 4.37);
- 5** prognostic information can be gained by the use of CD34 antibodies (Fig. 4.39)—the presence of more than 1% of CD34-positive cells is indicative of a worse prognosis in MDS as a whole and within the

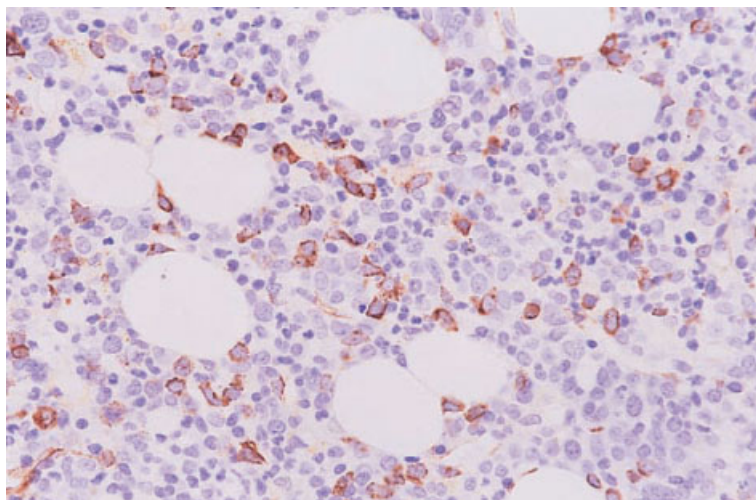


Fig. 4.39 Trephine biopsy section from a patient with RAEB showing numerous CD34-positive immature cells. Paraffin-embedded, immunoperoxidase anti-CD34 $\times 388$.

RAEB category [43]; clusters of CD34-positive cells are predictive of leukaemic transformation; and making a distinction between hypocellular MDS and aplastic anaemia can be facilitated (see below).

Cytogenetics and molecular genetics

The cytogenetic abnormalities associated with MDS are heterogeneous. The most characteristic abnormalities are monosomies, deletions and unbalanced translocations. Abnormalities often observed include monosomy 5, monosomy 7, trisomy 8, del(5)(q), del(7)(q), del(9)(q) and del(20)(q). In MDS secondary to alkylating agents, monosomies and deletions of chromosomes 5 and 7 are common, whereas MDS secondary to topoisomerase-II-interactive drugs is characterized by balanced translocations with 3q26, 11q23 and 21q22 breakpoints.

Clonal cytogenetic abnormalities can confirm the diagnosis of MDS. The type of abnormality found is also of prognostic significance.

MDS is typically associated with multiple oncogenic events, formation of fusion genes, mutations of oncogenes and both mutation and loss of cancer suppressing genes. Genes that may be mutated include *N-RAS*, *p53*, *IRF1*, *BCL2*, *p15^{INK4b}*, *EVII* and *MLL*.

Problems and pitfalls

Diagnostic errors can result from a failure to assess clinical features, peripheral blood and bone marrow

cytology, bone marrow histology and the results of cytogenetic analysis in all cases. Cytology and histology are complementary in the investigation of MDS since sometimes one will give information that could not be gained from the other. For example, ring sideroblasts and neutrophil dysplasia are best detected in an aspirate, whereas ALIP is detected only by means of trephine biopsy. Similarly, it is sometimes cytogenetic analysis that permits an unequivocal diagnosis when other features have been suggestive of MDS but not pathognomonic.

Some cases of MDS have pathological features that are strongly suggestive of the diagnosis. In other patients the diagnosis of MDS is a presumptive one, based on the presence of features that are characteristic but not diagnostic. In the latter group the exclusion of other diagnoses is particularly important. A careful clinical assessment is essential, in order to exclude relevant systemic illness and exposure to drugs, alcohol, heavy metals and growth factors. Some of the non-neoplastic causes of bone marrow dysplasia are discussed on page 392. Important pitfalls are relevant drug exposure that has not been disclosed to the pathologist and unexpected HIV positivity.

If dysplastic features are confined to the erythroid lineages, it is important to consider alternative causes of dyserythropoiesis such as the congenital dyserythropoietic anaemias and various thalassaemic conditions. Unstable haemoglobins are also sometimes associated with quite marked dyserythropoiesis.

Fig. 4.40 BM trephine biopsy section from an HIV-positive patient taking a high dose of zidovudine. The patient had megaloblastic erythropoiesis and a cluster of early megaloblasts was confused with ALIP; the linear nucleoli of the megaloblasts are a clue to their true nature. Paraffin-embedded, H&E $\times 940$.

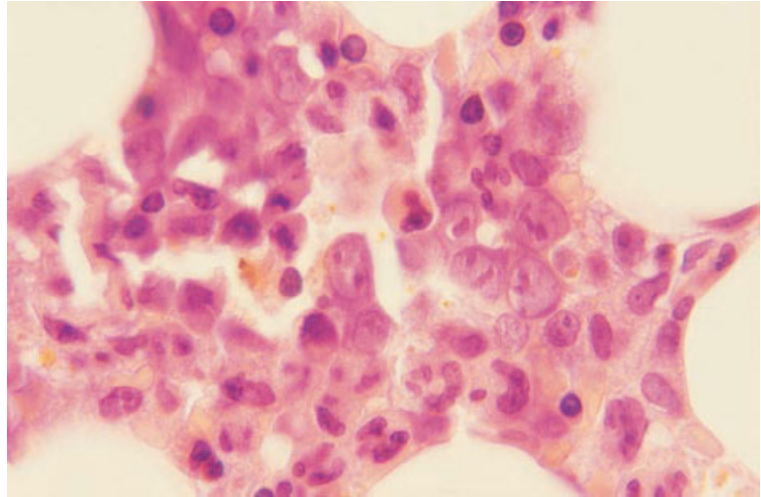
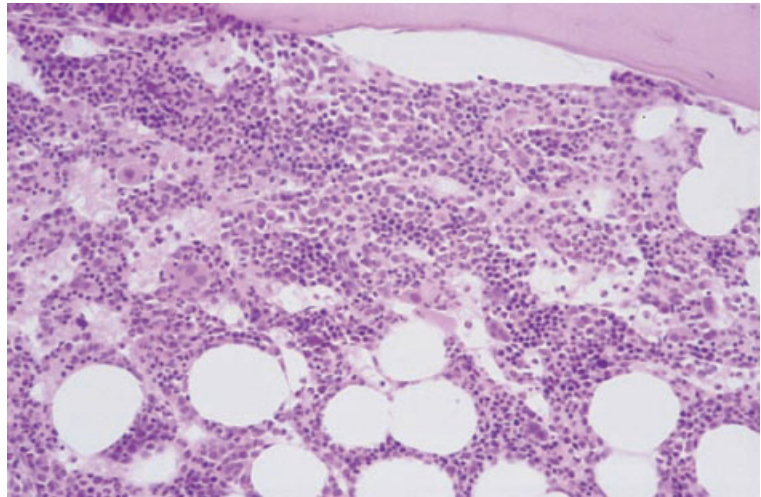


Fig. 4.41 BM trephine biopsy section from a patient with RARS showing large sheets of dysplastic erythroid cells separated by dilated sinusoids; the growth pattern appears so cohesive that the appearance could be confused with infiltration by carcinoma cells. Paraffin-embedded, H&E $\times 94$.



It can sometimes be difficult to distinguish megaloblastic erythropoiesis as a consequence of MDS from that attributable either to a deficiency of vitamin B₁₂ or folic acid or to the administration of drugs that interfere with DNA synthesis (Fig. 4.40). A useful feature is the lack of associated white cell changes—giant metamyelocytes and hypersegmented neutrophils—when megaloblastosis is a feature of MDS. However, it should be noted that white cell abnormalities may be lacking in megaloblastic erythropoiesis caused by drug exposure. Occasionally cohesive clumps or sheets of erythroid cells, all

at a similar stage of maturation, can be confused with infiltration by carcinoma cells (Fig. 4.41).

The differential diagnosis of RARS includes sideroblastic erythropoiesis secondary to drugs or heavy metals (see page 397), copper deficiency (see page 397), the mitochondrial cytopathies (see page 407) and thiamine-responsive anaemia with diabetes mellitus and sensorineural deafness. The latter condition may show granulocytic and megakaryocytic dysplasia in addition to ring sideroblasts [44].

The differential diagnosis of hypoplastic AML and hypoplastic MDS (Fig. 4.42) has been discussed on

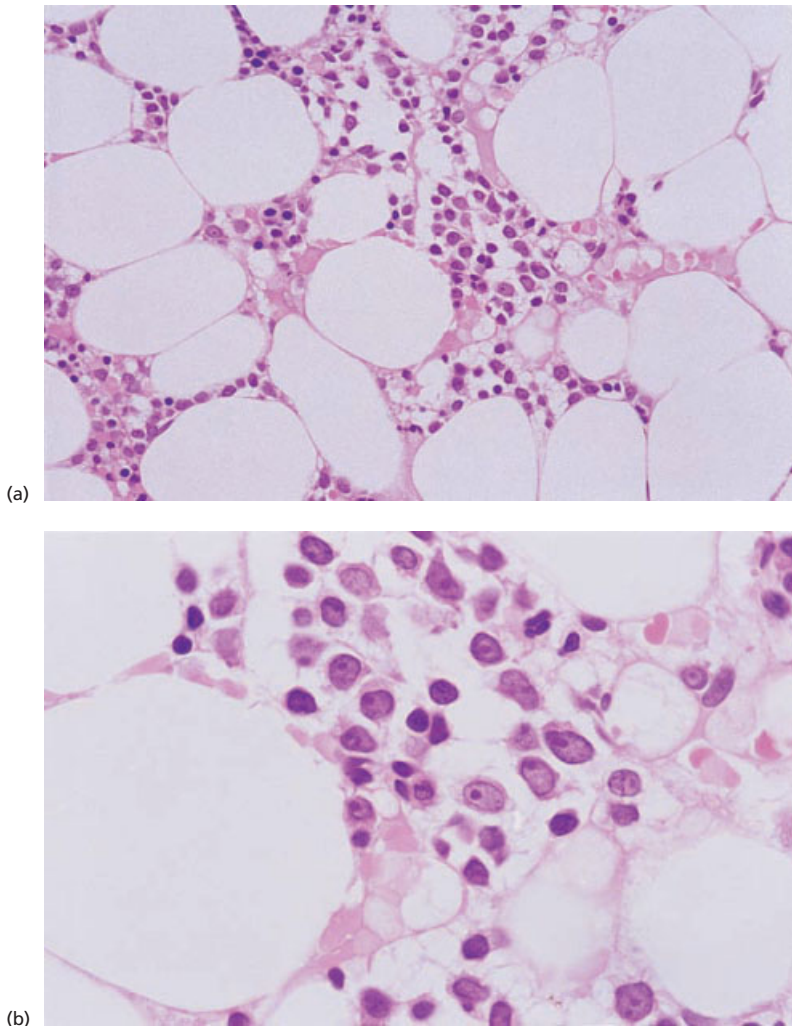


Fig. 4.42 BM trephine biopsy section from a patient with hypoplastic MDS (RAEB) showing: (a) a disorganized marrow of low cellularity; (b) at higher power it is apparent that blast cells are increased. Paraffin-embedded $\times 388$ and $\times 970$.

page 167. Immunohistochemistry has been found to be of some value in making a distinction between hypoplastic MDS and aplastic anaemia [45,46]. Cases of hypocellular MDS have been found to have higher numbers of CD34-positive cells and cells expressing proliferating cell nuclear antigen [45].

Lymphoid aggregates are sometimes present in MDS, giving rise to a differential diagnosis with non-Hodgkin's lymphoma, particularly T-cell lymphoma, with associated dysplastic features. It should also be remembered that some patients with lymphomatous infiltration of the bone marrow have

secondary dysplastic changes resembling those of MDS (Fig. 4.43).

In the rare patients with MDS who present with isolated thrombocytopenia it is sometimes difficult to make a distinction from auto-immune thrombocytopenic purpura. Dysplastic features may be very minor.

It should be noted that, even with a careful assessment of clinical features and use of all available diagnostic methods, it may still not be possible to make a firm diagnosis of MDS. In such patients follow-up with regular review of the diagnosis is necessary.

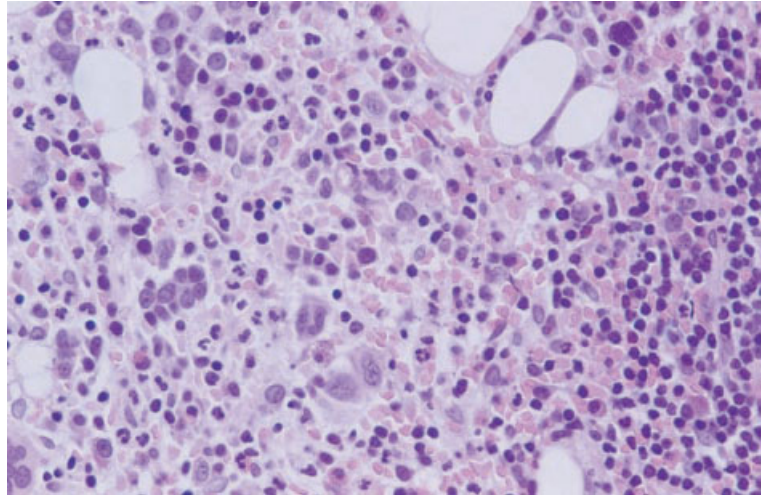


Fig. 4.43 BM trephine biopsy section from a patient with low grade T-cell lymphoma with secondary myelodysplasia; small hypolobulated megakaryocytes are apparent. Paraffin-embedded, H&E $\times 376$.

The FAB categories and other identified subtypes of MDS

Refractory anaemia

RA is characterized by ineffective erythropoiesis, with or without ineffective granulopoiesis and thrombopoiesis but, as defined by the FAB group, there are insufficient monocytes, blast cells or ring sideroblasts for the case to qualify for inclusion in other categories of MDS (see Table 4.6). RA is usually either an incidental diagnosis in the elderly or is diagnosed because of symptoms of anaemia. Many cases belonging to the FAB category of RA fall into the WHO category of 'refractory anaemia without ringed sideroblasts' but others are designated '5q-syndrome' (see below) or 'refractory cytopenia with multilineage dysplasia'.

Peripheral blood

Often morphological and numerical abnormalities are confined to the erythroid series but some patients, particularly those with secondary MDS, manifest anomalies of other lineages. A minority of patients have thrombocytosis.

Bone marrow cytology

The bone marrow is usually hypercellular as a result of erythroid hyperplasia (Fig. 4.44). A minority of

patients show marked erythroid hypoplasia, sometimes with an apparent arrest of erythropoiesis at the proerythroblast stage. Erythropoiesis usually shows dysplastic features but in some patients erythropoiesis is ineffective although dysplastic features are quite minor. Ring sideroblasts may be present but constitute no more than 15% of erythroblasts.

In RA the granulocyte series and megakaryocytes may be apparently normal or may be hyperplastic or dysplastic (see Figs 4.30 and 4.31).

Bone marrow histology

There are often no histological features of diagnostic importance in trephine biopsies of patients with RA. The marrow is usually hypercellular but hypocellular forms do occur. Erythroid hyperplasia and dyserythropoiesis are usually present and are easily seen in tissue sections (see Fig. 4.33). The granulocytic series may appear relatively normal. Dysplastic megakaryocytes are found in most cases; however, they are not universally present and, in their absence, the diagnosis of myelodysplasia may be easily overlooked if the clinical and cytological features are not taken into account.

Refractory cytopenia

A small proportion of patients with MDS are not anaemic but have refractory neutropenia or

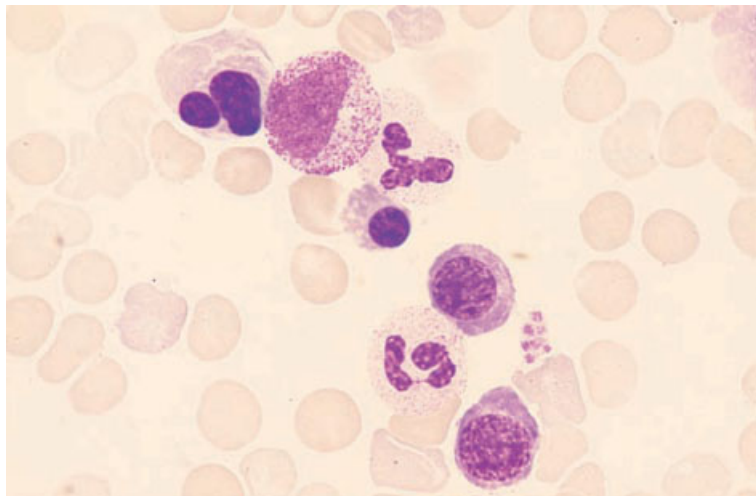


Fig. 4.44 BM aspirate, RA, showing erythroid hyperplasia and hypogranular neutrophils; note a dysplastic binucleated erythroblast. MGG $\times 940$.

thrombocytopenia. The FAB group has recommended that, if such cases lack the features of the other categories of MDS, they should be grouped with refractory anaemia and be designated refractory cytopenia.

Patients with refractory neutropenia show abnormalities predominantly of the neutrophil lineage, while patients with refractory thrombocytopenia have increased, dysplastic megakaryocytes and often dysplastic platelets.

Refractory anaemia with ring sideroblasts

RARS is also referred to as primary acquired sideroblastic anaemia. The FAB group criteria for this diagnosis are the presence of more than 15% of ring sideroblasts among bone marrow erythroblasts, with monocytes and blast cells being insufficiently increased to permit assignment to other MDS categories (see Table 4.6). In the WHO classification the majority of cases fall into the category 'refractory anaemia with ring sideroblasts' and a minority into the category 'refractory cytopenia with multilineage dysplasia'. Sideroblastic anaemia is usually either an incidental diagnosis in the elderly or is diagnosed because of symptoms of anaemia.

Peripheral blood

There is anaemia which is sometimes normocytic but more often macrocytic. The film is dimorphic, consequent on the presence of a minor population

of hypochromic and microcytic red cells. Occasional cells contain Pappenheimer bodies. There may be a small number of circulating erythroblasts, among which may be some ring sideroblasts. Abnormalities of neutrophils and platelets can occur but are uncommon. A significant minority of patients have thrombocytosis.

Bone marrow cytology

The bone marrow is usually hypercellular and shows erythroid hyperplasia. Erythropoiesis is usually normoblastic or macronormoblastic. A proportion of erythroblasts, which correspond to the ring sideroblasts, are micronormoblasts or show defective haemoglobinization or cytoplasmic vacuolation (Fig. 4.45). Other dysplastic features in red cells are uncommon. Abnormalities may occur in other lineages but they are uncommon except when the MDS is secondary.

By definition, in RARS an iron stain shows that more than 15% of erythroblasts are ring sideroblasts (see Fig. 4.32). They may be as frequent as 70 or 80% of erythroblasts and may be associated with other abnormal sideroblasts. Iron stores are commonly increased.

Bone marrow histology

Trephine biopsy is not usually very useful in the diagnosis of RARS. Bone marrow histology may be

Fig. 4.45 BM aspirate, RARS, showing five erythroblasts, two of which show defectively haemoglobinized, heavily granulated cytoplasm. MGG $\times 940$.

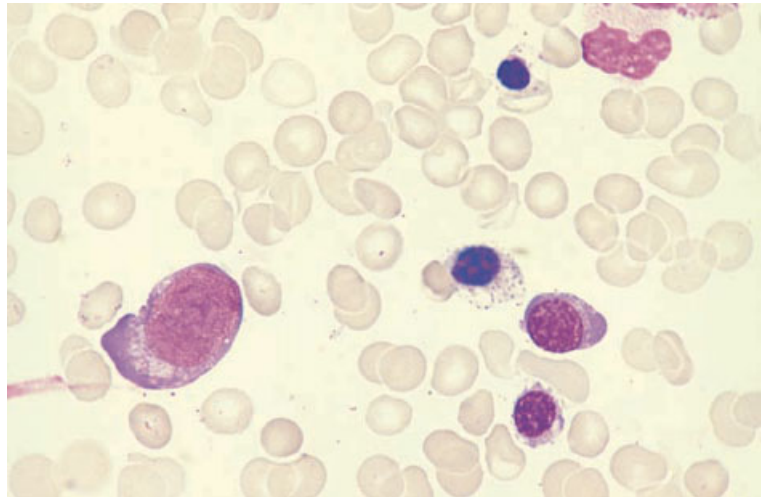
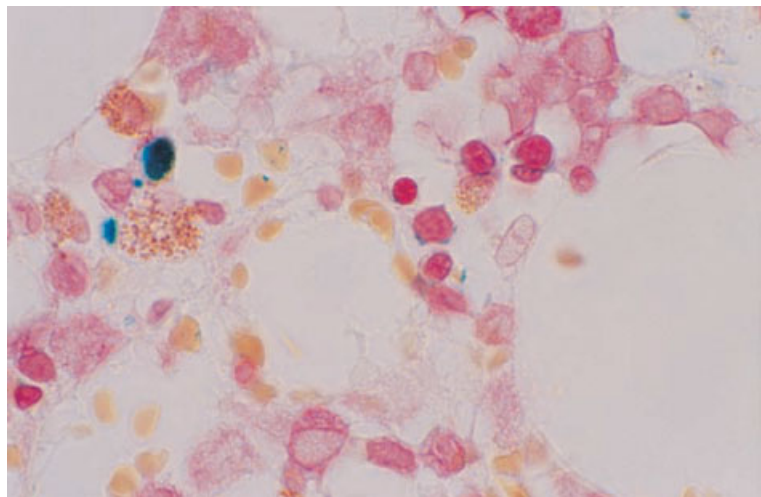


Fig. 4.46 BM clot section, RARS, showing two ring sideroblasts with blue iron-containing granules arranged around the nucleus. Paraffin-embedded, Perls' stain $\times 970$.



relatively normal with the only abnormality being erythroid hyperplasia with large, poorly formed erythroid islands. There is often an increase in stainable iron within macrophages. Ring sideroblasts can be seen in plastic-embedded sections of trephine biopsies and occasionally in paraffin-embedded marrow clot sections (Fig. 4.46); they are not visible in sections of paraffin-embedded or other decalcified trephine biopsy specimens. The granulocytic series is usually normal. Dysplastic megakaryocytes are present in a minority of cases.

Refractory anaemia with excess of blasts

RAEB as defined by the FAB group (see Table 4.6) has:

- *either* an increase of peripheral blood blasts to more than 1% but less than 5%;
- *or* an increase of bone marrow blasts to at least 5% but not more than 20%;
- *and* no Auer rods;
- *and* a monocyte count of less than $1 \times 10^9/l$ (or the case falls into the CMML category) (see page 215).

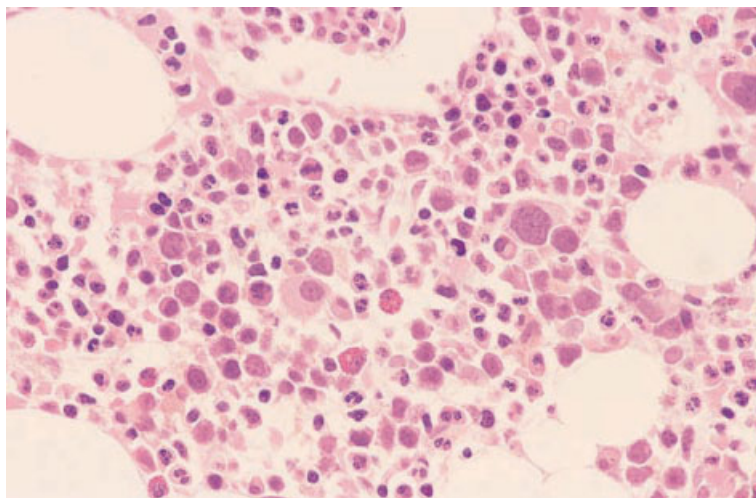


Fig. 4.47 BM trephine biopsy section, RAEB, showing dysplastic megakaryocytes including micromegakaryocytes. Plastic-embedded, H&E $\times 390$.

Diagnosis of RAEB usually follows the development of symptoms of anaemia or the occurrence of bruising, bleeding or infection. This FAB category corresponds to the WHO category 'refractory anaemia with excess blasts'.

Peripheral blood

The peripheral blood shows normocytic or macrocytic anaemia and may also show some hypochromic microcytic cells. In addition, there may be neutropenia, mild monocytosis or thrombocytopenia. Dysplastic features in neutrophils and platelets are commonly present. There may be some circulating blasts which are usually, but not necessarily, myeloblasts.

Bone marrow cytology

The bone marrow is usually hypercellular. Any or all lineages may be hyperplastic and trilineage dysplasia is common. The percentage of blasts is usually increased, although a case may qualify to be categorized as RAEB on the basis of increased peripheral blood blasts alone. Erythropoiesis may be sideroblastic but, because of the excess of blasts, the case is categorized as RAEB rather than as RARS.

An iron stain may show ring sideroblasts, other abnormal sideroblasts and increased iron stores. Either an MPO or a SBB stain should be performed

routinely both to confirm the lineage of the blasts and to exclude the presence of Auer rods, which would lead to the case being categorized as RAEB-T (see below).

Bone marrow histology

Bone marrow biopsy is not usually essential for diagnosis but can give useful supplementary information. The majority of cases have increased or normal cellularity with only a small number of cases being hypocellular. Dyserythropoiesis and megakaryocytic dysplasia are seen in almost all cases (Fig. 4.47). Blasts are increased in number but it is not uncommon for the percentage of blasts seen in the biopsy sections to be less than that observed in marrow aspirates taken at the same time [33]. ALIP is seen in most cases.

Refractory anaemia with excess of blasts in transformation

As defined by the FAB group, the diagnosis of RAEB-T requires that:

- *either* peripheral blood blasts are at least 5%;
- *or* bone marrow blasts are greater than 20% but less than 30%;
- *or* there are Auer rods in blasts, either in the bone marrow or in the peripheral blood (see Table 4.6).

In practice, most cases have more than 20% blasts

in the bone marrow whether or not they show the other features. However, occasional cases are categorized as RAEB-T on the basis of one of the other criteria alone. In the WHO classification, cases with more than 20% bone marrow blasts would be categorized as AML rather than as MDS.

Patients with RAEB-T are almost always symptomatic at diagnosis with bruising, bleeding, infection or symptoms of anaemia. Pallor, bruising, hepatomegaly and splenomegaly are common.

Peripheral blood

Most patients have anaemia, neutropenia and thrombocytopenia and show morphological abnormalities of all lineages. Some circulating blasts are usually present and they may contain Auer rods. There may be monocytosis, particularly in those patients in whom the disease represents a transformation of CMML rather than RAEB.

Bone marrow cytology

The bone marrow is usually hypercellular with trilineage myelodysplasia, an increase of blasts and sometimes Auer rods in the blasts. Sideroblastic erythropoiesis is not inconsistent with a diagnosis of RAEB-T.

Bone marrow histology

Trephine biopsy is not usually essential for diagnosis but can give useful supplementary information. In addition to trilineage dysplasia there is an increase in numbers of blasts, often with ALIP. Reticulin fibrosis has been reported to be less common than in the other subtypes [33].

The 5q- syndrome

Among patients with MDS a group of patients can be delineated who have what is designated the 5q- syndrome. This entity is a specific category in the WHO classification. Patients tend to be middle-aged or elderly women with a relatively good prognosis. Haemopoietic cells show an interstitial deletion of the long arm of chromosome 5 as a single acquired chromosomal anomaly. Such patients most often have a refractory anaemia, often macro-

cytic, with or without ring sideroblasts and also have characteristic megakaryocytes; these are more than 30 µm in diameter but have non-lobulated nuclei (see Fig. 4.31). The platelet count is usually normal or even increased. The disease usually falls into the RA category of the FAB classification but sometimes into the RARS category.

Refractory macrocytosis

Occasional patients with myelodysplasia have refractory macrocytosis but are not anaemic and lack features which would lead to their being assigned to any of the FAB categories of MDS. When erythropoiesis is clonal, they should be recognized as having MDS and can reasonably be grouped with RA. With long-term follow-up, anaemia and other features of overt MDS develop.

Refractory sideroblastic erythropoiesis

Occasional patients are seen with primary acquired sideroblastic erythropoiesis who lack anaemia and other features which would allow them to be assigned to one of the FAB categories of MDS [47]. Nevertheless, erythropoiesis is clonal and such patients should be recognized as having MDS. They can reasonably be grouped with RARS. With disease progression, anaemia occurs.

Secondary myelodysplasia

Myelodysplasia may be secondary to deliberate or accidental exposure to mutagenic agents such as cytotoxic chemotherapy, benzene and irradiation. Such cases can be categorized according to the FAB recommendations but, because they have distinctive features, it is useful to consider them separately. Secondary MDS usually occurs at a younger age than primary MDS and has a much worse prognosis. Bone marrow failure and evolution to acute leukaemia occur much earlier. Many cases of secondary MDS fall into the WHO category of 'AML and myelodysplastic syndromes, therapy-related'.

Peripheral blood

Abnormalities in the peripheral blood are usually more marked than in primary MDS. Even cases

which fall into the RA and RARS categories commonly show neutropenia, thrombocytopenia, monocytosis and evidence of trilineage dysplasia.

Bone marrow cytology

The bone marrow may be hypercellular but is often hypocellular. A poor aspirate may be obtained because of associated bone marrow fibrosis. Obvious trilineage myelodysplasia is common, even in cases which meet the criteria for RA and RARS. There are usually at least some ring sideroblasts. Hypogranular neutrophils, pseudo-Pelger–Huët neutrophils and micromegakaryocytes are also common.

Bone marrow histology

Because of the frequent difficulty experienced in obtaining a good aspirate, trephine biopsy is often important in diagnosis. The cellularity is more variable than in primary myelodysplasia and stromal injury may be prominent, with disruption of fat cells and extravasation of non-nucleated red cells into the interstitium. There is often a marked increase in reticulin and, in contrast to primary myelodysplasia, there may be collagen fibrosis. There is often a severe degree of dysplasia affecting all three lineages with numerous micromegakaryocytes.

Malignant histiocytosis

Malignant histiocytosis is a disease caused by the proliferation in tissues of a neoplastic clone of cells of monocyte/macrophage lineage; the abnormal cells show variable phagocytic activity. This disease may be regarded as the tissue counterpart of acute monocytic leukaemia. It differs from monocytic sarcoma in that the cells of the neoplastic clone are widely distributed in peripheral tissues rather than forming localized tumours. This disease is not specifically recognized by the WHO classification and would fall into the category 'histiocytic neoplasms, unclassifiable'.

It appears likely that, in the past, a significant proportion of diagnoses of malignant histiocytosis [48,49] or of histiocytic medullary reticulosis [50] (usually regarded as a form of the same disease) were actually misdiagnoses [51–55]. The majority of cases misinterpreted as malignant histiocytosis

were either reactive histiocytosis consequent on viral or other infections or reactive histiocytosis occurring as a response to large cell anaplastic lymphoma and other T-lineage lymphomas. A less common cause of confusion is a T-cell lymphoma in which the lymphoma cells are themselves phagocytic [56]. It is important that the term malignant histiocytosis be restricted to cases in which neoplastic cells are of monocyte lineage. The term histiocytic medullary reticulosis is probably best abandoned since the recent availability of immunophenotyping and other techniques has led to the recognition that, in the great majority of cases, the histiocytic proliferation and florid haemophagocytosis were secondary to a T-cell lymphoma [54,55] or a viral infection [53]. The reactive haemophagocytic syndromes are discussed further on pages 119–123.

The diagnosis of malignant histiocytosis rests on clinical, histological, cytochemical and immunophenotypic grounds. Neoplastic cells are primitive and, although phagocytosis occurs, it is not prominent [51]. Neoplastic cells can be demonstrated, by cytochemical staining or immunophenotyping, to belong to the monocyte lineage and not to the T-lymphocyte lineage whereas, in haemophagocytic syndromes consequent on a T-cell lymphoma, there is an admixture of reactive mature phagocytic histiocytes and immature neoplastic cells of lymphoid lineage [54].

Common clinical features of malignant histiocytosis are hepatomegaly, splenomegaly, lymphadenopathy, skin infiltration and systemic symptoms such as malaise, fever and weight loss.

Peripheral blood

Pancytopenia is common. Small numbers of immature cells of monocyte/macrophage lineage may be present in the blood (Fig. 4.48).

Bone marrow cytology

At the onset of disease, the bone marrow may show minimal or no infiltration by neoplastic cells. With more advanced disease there may be heavy infiltration (Fig. 4.49). The majority of neoplastic cells have the morphological features of monoblasts or, in older terminology, 'reticulum cells'. Cells are large and usually have a round nucleus with nucleoli and

Fig. 4.48 PB, malignant histiocytosis, showing anaemia, thrombocytopenia and three abnormal cells of monocyte lineage, one of which has a phagocytic vacuole. MGG $\times 940$.

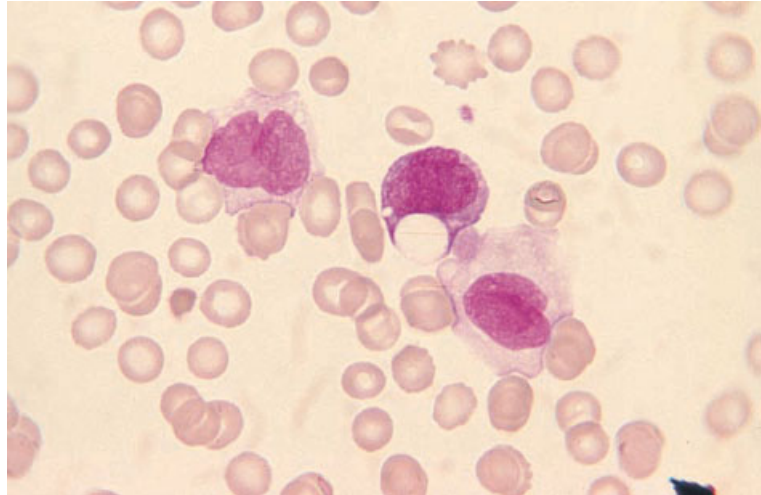
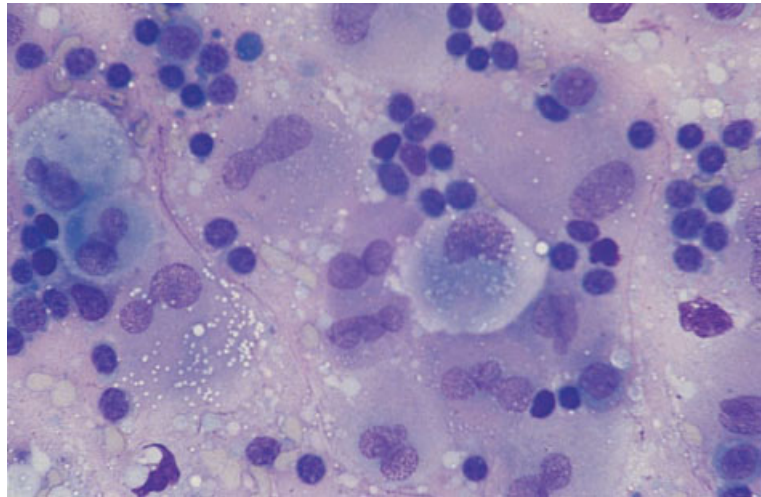


Fig. 4.49 BM aspirate, malignant histiocytosis associated with $t(9;11)(p22;q23)$. MGG $\times 376$. (By courtesy of Dr R Brunning, Minneapolis.)



a diffuse chromatin pattern. Cytoplasm is plentiful and moderately basophilic. A variable number of maturing cells with kidney-shaped nuclei and more abundant cytoplasm are also present [51]. Some cells are phagocytic and are seen to have ingested granulocytes and their precursors, erythroblasts and platelets; however, phagocytosis is much less marked than in reactive haemophagocytosis.

Bone marrow histology

Bone marrow infiltration has been reported to be more commonly detected by trephine biopsy than

by bone marrow aspiration [57]. The bone marrow may appear normal at the time of diagnosis or may show a mild focal infiltrate of neoplastic cells. There may be intrasinusoidal neoplastic cells [58]. In the later stages of the disease diffuse replacement of haemopoietic tissue commonly occurs (Fig. 4.50) [49,59,60]. The infiltrate is largely composed of immature cells with large pleomorphic nuclei which may be lobulated and contain prominent nucleoli; there are moderate amounts of basophilic cytoplasm. Mitoses are usually numerous. A variable component of more mature cells of monocytic lineage may be present.

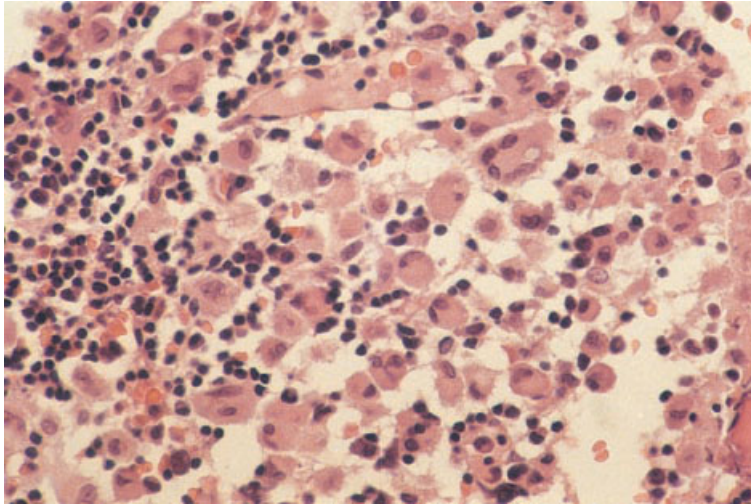


Fig. 4.50 BM trephine biopsy section, malignant histiocytosis (same case as in Fig. 4.49). Paraffin-embedded, H&E $\times 188$. (By courtesy of Dr R Brunning, Minneapolis.)

Genetics and cytogenetics

Some cases of malignant histiocytosis have been associated with translocations that are also associated with AML with monocytic differentiation, such as t(9;11)(p22;q23) [60] and t(8;16)(p11;p13).

Problems and pitfalls

The diagnosis of malignant histiocytosis is fraught with pitfalls and should be made with great circumspection. A minor degree of haemophagocytosis may be seen but marked haemophagocytosis suggests an alternative diagnosis. In children, familial or sporadic lymphohistiocytosis is likely and investigation for herpesvirus infection is indicated. In adults, reactive haemophagocytosis is often caused by mycobacterial or herpesvirus infection or by a T-cell lymphoma. Molecular analysis to demonstrate T-cell receptor gene rearrangement can be useful. Cytogenetic analysis is indicated if malignant histiocytosis appears a likely diagnosis, since it may confirm the diagnosis.

True histiocytic lymphoma

True histiocytic lymphoma initially presenting at extramedullary sites may subsequently infiltrate the bone marrow. The patterns of infiltration reported are interstitial, patchy focal and diffuse [61]. In the

WHO classification the designation 'histiocytic sarcoma' is used.

Langerhans' cell histiocytosis

Langerhans' cell histiocytosis, previously known as histiocytosis X, is a heterogeneous disease or group of diseases characterized by proliferation of Langerhans' cells [62]. Recent evidence suggests that the proliferation is clonal and neoplastic [63]. Localized and disseminated forms occur. Haematological involvement occurs in the disseminated forms of the disease, which in the past have been referred to by the eponymous terms Letterer–Siwe disease of infants and Hand–Schüller–Christian disease. Bone marrow infiltration is seen mainly in infants and children.

Peripheral blood

The peripheral blood may be normal or there may be pancytopenia as a consequence either of hypersplenism or of bone marrow infiltration. Rarely, a leukaemia of Langerhans' cells occurs.

Bone marrow cytology

The bone marrow aspirate may show Langerhans' cells together with a mixed population including eosinophils, monocytes, lipid-laden macrophages,

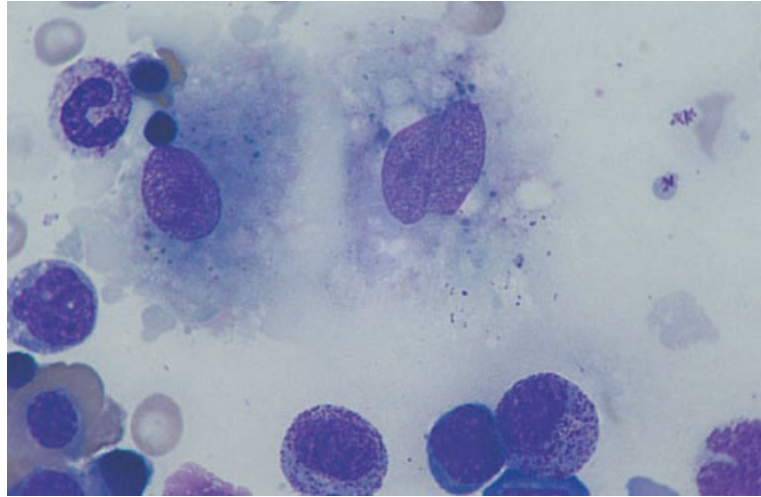


Fig. 4.51 BM aspirate in Langerhans' cell histiocytosis. MGG $\times 940$. (By courtesy of Dr R Brunning, Minneapolis.)

lymphocytes and plasma cells [64,65]. Haemophagocytosis may occur. Langerhans' cells are large and slightly irregular in shape. The nucleus is somewhat irregular and sometimes grooved with delicately clumped chromatin and inconspicuous nucleoli (Fig. 4.51). The cytoplasm is weakly basophilic with occasional azurophilic granules. Ultrastructural examination demonstrates Birbeck granules.

Cytochemistry

Langerhans' cells show tartrate-resistant acid phosphatase activity [66] and are negative for non-specific esterase.

Immunophenotyping

Langerhans' cells are positive for CD1a and HLA-DR.

Bone marrow histology

In those cases with marrow involvement, the bone marrow contains clusters or sheets of Langerhans' cells together with eosinophils, neutrophils, lymphocytes, plasma cells, monocytes, phagocytic macrophages, lipid-laden macrophages and giant cells (Fig. 4.52). Xanthomatous transformation and fibrosis may occur [64,65]. Langerhans' cells have a

characteristic appearance; the nuclei are usually convoluted or twisted and longitudinal grooves may be present.

Immunohistochemistry

Immunohistochemical staining shows Langerhans' cells to express S100 protein, although only a small proportion of cells may stain positively in some cases. Staining with the lectin, peanut agglutinin, gives a characteristic staining pattern of a cytoplasmic halo with a paranuclear dot. Langerhans' cells are positive for vimentin and CD1a. Positivity for CD1a is currently the most reliable immunophenotypic marker of Langerhans' cells; the value of new anti-TRAP monoclonal antibodies remains to be established.

Genetics and cytogenetics

A familial tendency to the development of Langerhans' cell histiocytosis has been described [67]. A clonal cytogenetic abnormality, $t(7;12)(q11.2;p13)$, has been reported in a single case of eosinophilic granuloma [68].

Problems and pitfalls

It should be noted that Langerhans' cell histiocytosis often causes focal lesions, even when widespread

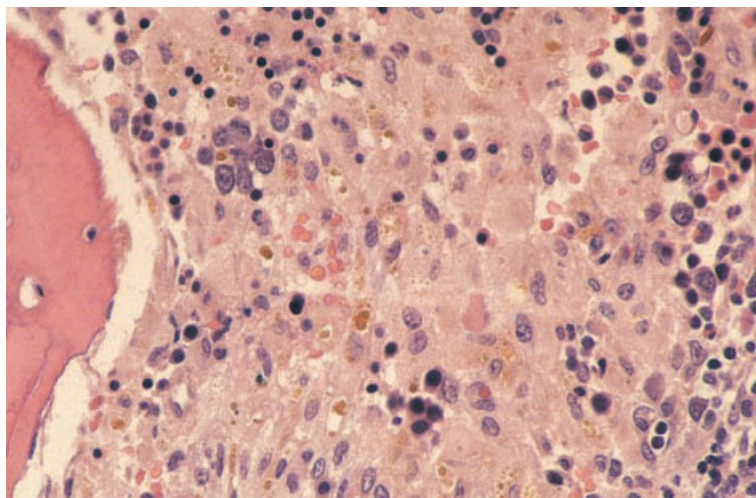


Fig. 4.52 BM trephine biopsy section in Langerhans' cell histiocytosis, showing an admixture of Langerhans' cells and normal haemopoietic cells (same case as in Fig. 4.51). Paraffin-embedded, H&E $\times 188$. (By courtesy of Dr R Brunning, Minneapolis.)

throughout the skeleton, and a targeted biopsy of a radiologically suspicious lesion may be more informative than a standard iliac crest trephine biopsy.

Langerhans' cell histiocytosis has been confused with systemic mastocytosis, hairy cell leukaemia and malignant melanoma. Careful assessment of cytological features, supplemented by immunohistochemistry, will resolve difficulties.

References

- 1 Bennett JM, Catovsky D, Daniel MT, Flandrin G, Galton DAG, Gralnick HR and Sultan C (1976) Proposals for the classification of the acute leukaemias (FAB cooperative group). *Br J Haematol*, 33, 451–458.
- 2 Bennett JM, Catovsky D, Daniel MT, Flandrin G, Galton DAG, Gralnick HR and Sultan C (1985) Proposed revised criteria for the classification of acute myeloid leukemia. *Ann Intern Med*, 103, 626–629.
- 3 Second MIC Cooperative Study Group (1988) Morphologic, immunologic and cytogenetic (MIC) working classification of acute myeloid leukaemias. *Br J Haematol*, 68, 487–494.
- 4 Bain BJ (1998) Classification of acute leukaemia: the need to incorporate cytogenetic and molecular genetic information. *J Clin Pathol*, 51, 420–423.
- 5 Harris NL, Jaffe ES, Diebold J, Flandrin G, Muller-Hermelink HK, Vardiman J *et al.* (1999) World Health Organization Classification of Neoplastic Disease of the Hematopoietic and Lymphoid Tissues: Report of the Clinical Advisory Committee Meeting—Airlie House, Virginia, November, 1997. *J Clin Oncol*, 17, 3835–3839.
- 6 Wilkins BS, Bostanci AG, Ryan MF and Jones DB (1993) Haemopoietic regrowth after chemotherapy: an immunohistochemical study of bone marrow trephine biopsy specimens. *J Clin Pathol*, 46, 915–921.
- 7 Horny H-P, Wehrmann M, Steinke B and Kaiserling E (1994) Assessment of the value of immunohistochemistry in the subtyping of acute leukemia on routinely processed bone marrow biopsy specimens with particular reference to macrophage-associated antibodies. *Hum Pathol*, 25, 810–814.
- 8 Bain BJ. *Leukaemia Diagnosis*, 2nd edn. Blackwell Science, Oxford, 1999.
- 9 Hayhoe FGJ and Quaglino D. *Haematological Cytochemistry*, 2nd edn. Churchill Livingstone, Edinburgh, 1988.
- 10 Islam A, Frisch B and Henderson ES (1989) Plastic embedded core biopsy: a complementary approach to bone marrow aspiration for diagnosing acute myeloid leukaemia. *J Clin Pathol*, 42, 300–306.
- 11 Islam A, Catovsky D, Goldman JM and Galton DAG (1985) Bone marrow biopsy changes in acute leukaemia. I: observations before chemotherapy. *Histopathology*, 9, 939–957.
- 12 Islam A, Catovsky D, Goldman J and Galton DAG (1984) Bone marrow fibre content in acute myeloid leukaemia before and after treatment. *J Clin Pathol*, 37, 1259–1263.
- 13 Hatake K, Ohtsuki T, Uwai M, Takahashi H, Izumi T, Yoshida M *et al.* (1996) Tretinoin induces bone marrow collagenous fibrosis in acute promyelocytic leukaemia: new adverse but reversible effect. *Br J Haematol*, 93, 646–649.
- 14 Lopez P and Hayme O (1992) Case report: all-*trans* retinoic acid, hyperleucocytosis and marrow infarction. *Am J Hematol*, 41, 305–306.

- 15 Manaloor EJ, Neiman RS, Heilman DK, Albitar M, Casey T, Vatuone T *et al.* (2000) Immunohistochemistry can be used to subtype acute myeloid leukemia in routinely processed bone marrow biopsy specimens: comparison with flow cytometry. *Am J Clin Pathol*, 113, 814–822.
- 16 Bloomfield CD and Brunning RD (1985) The revised French–American–British classification of acute myeloid leukemia: is new better? *Ann Intern Med*, 103, 614–616.
- 17 Hasserjian RP, Howard J, Wood A, Henry K and Bain B (2001) Acute erythroid myelosis (true erythroleukaemia): a variant of AML FAB-M6. *J Clin Pathol*, 54, 205–209.
- 18 Lorand-Metz I, Vassallo J, Aoki RY and de Souza CA (1991) Acute megakaryoblastic leukaemia: importance of bone marrow biopsy in diagnosis. *Leuk Lymphoma*, 4, 74–75.
- 19 PENCHANSKY L, Taylor SR and Krause JR (1989) Three infants with acute megakaryoblastic leukaemia simulating metastatic tumour. *Cancer*, 64, 1366–1371.
- 20 Bennett JM, Catovsky D, Daniel MT, Flandrin G, Galton DAG, Gralnick HR and Sultan C (1991) Proposal for the recognition of minimally differentiated acute myeloid leukaemia (AML-M0). *Br J Haematol*, 78, 325–329.
- 21 Stasi R and Amadori S (1999) AML-M9: a review of laboratory features and proposal of new diagnostic criteria. *Blood Cells Mol Dis*, 25, 120–129.
- 22 Needleman SW, Burns P, Dick FR and Armitage JO (1981) Hypoplastic acute leukemia. *Cancer*, 48, 1410–1414.
- 23 Howe RB, Bloomfield CD and McKenna RW (1982) Hypocellular acute leukemia. *Am J Med*, 72, 391–395.
- 24 Bain BJ. *Interactive Haematology Imagebank*. Blackwell Science, Oxford, 1999.
- 25 Bain BJ (2001) The Morphological, Immunophenotypic, Cytogenetic, Molecular Genetic (MIC-M) classification of acute leukaemia. *Exp Oncol*, in press.
- 26 Bennett JM, Catovsky D, Daniel MT, Flandrin G, Galton DAG, Gralnick HR and Sultan C (1982) Proposals for the classification of the myelodysplastic syndromes. *Br J Haematol*, 51, 189–199.
- 27 Kuriyama K, Tomonaga M, Matsuo T, Ginnai I and Ichimaru M (1986) Diagnostic significance of detecting pseudo-Pelger–Huët anomalies and micromegakaryocytes in myelodysplastic syndrome. *Br J Haematol*, 63, 665–669.
- 28 Fernández-Lago C and Romero E (1998) Myelodysplastic syndromes associated with immune thrombocytopenia. *Br J Haematol*, 102, 342–345.
- 29 Stasi R, Pagano A, Terzoli E and Amadori S (1999) Recombinant human granulocyte-macrophage colony-stimulating factor plus erythropoietin for the treatment of cytopenias in patients with myelodysplastic syndromes. *Br J Haematol*, 105, 141–148.
- 30 Thiede T, Engquist L and Billstrom R (1988) Application of megakaryocytic morphology in diagnosing 5q-syndrome. *Eur J Haematol*, 41, 434–437.
- 31 Wong KF and Chan JKC (1991) Are ‘dysplastic’ and hypogranular megakaryocytes specific markers for myelodysplastic syndrome? *Br J Haematol*, 77, 509–514.
- 32 Yoshida Y, Oguma S, Uchijino H and Maekawa T (1988) Refractory myelodysplastic syndromes with hypocellular bone marrow. *J Clin Pathol*, 41, 763–767.
- 33 Rios A, Cañizo C, Sanz MA, Vallespi T, Sanz G, Torrabadella M *et al.* (1990) Bone marrow biopsy in myelodysplastic syndromes: morphological characteristics and contribution to the study of prognostic factors. *Br J Haematol*, 75, 26–33.
- 34 Frisch B and Bartl R (1986) Bone marrow histology in myelodysplastic syndromes. *Scand J Haematol*, 36 (Suppl. 45), 21–37.
- 35 Thiele J and Fischer R (1991) Megakaryocytopoiesis in haematological disorders: diagnostic feature of bone marrow biopsies. *Virchows Arch A Pathol Anat Histopathol*, 418, 87–97.
- 36 Mangi MH and Mufti GJ (1992) Primary myelodysplastic syndromes: diagnostic and prognostic significance of immunohistochemical assessment of bone marrow biopsies. *Blood*, 79, 198–205.
- 37 Fox SB, Lorenzen J, Heryet A, Jones M, Gatter KC and Mason DY (1990) Megakaryocytes in myelodysplasia: an immunohistochemical study on bone marrow trephines. *Histopathology*, 17, 69–74.
- 38 Clark DM and Lampert IA (1990) Apoptosis is a common histopathological finding in myelodysplasia: the correlate of ineffective haematopoiesis. *Leuk Lymphoma*, 2, 415–418.
- 39 Maschek H, Georgii A, Kaloutsis V, Werner M, Bandekar K, Kressel M-G *et al.* (1992) Myelofibrosis in primary myelodysplastic syndromes: a retrospective study of 352 patients. *Eur J Haematol*, 48, 208–214.
- 40 Tricot G, de Wolf Peeters C, Hendrickx B and Verwilghen RL (1984) Bone marrow histology in myelodysplastic syndromes. *Br J Haematol*, 56, 423–430.
- 41 Delacrétaz F, Schmidt P-M, Piguet D, Bachmann F and Costa J (1987) Histopathology of myelodysplastic syndromes: the FAB classification. *Am J Clin Pathol*, 87, 180–186.
- 42 Maschek H, Gutzmer R, Choritz H and Georgii A (1994) Life expectancy in primary myelodysplastic syndromes: a prognostic score based upon histopathology from bone marrow biopsies of 569 patients. *Eur J Haematol*, 53, 280–287.
- 43 Soligo DA, Oriani A, Annaloro C, Cortelezzi A, Calori R, Pozzoli E *et al.* (1994) CD34 immunohistochemistry of bone marrow biopsies: prognostic significance in primary myelodysplastic syndromes. *Am J Hematol*, 46, 9–17.
- 44 Bazarbachi A, Haidar J, Salem Z, Solh H and Ayas M (1997) Thiamine-responsive myelodysplasia. *Blood*, 90 (Suppl. 1), 264b.

- 45 Orazi A, Albitar M, Heerema NA, Haskins S and Neiman RS (1997) Hypoplastic myelodysplastic syndromes can be distinguished from acquired aplastic anemia by CD34 and PRNA immunostaining of bone marrow biopsy specimens. *Am J Clin Pathol*, 107, 268–274.
- 46 Horny H-P, Wehrmann M, Schlicker HUH, Eichstaedt A, Clemens MR and Kaiserling E (1995) QBEND10 for the diagnosis of myelodysplastic syndromes in routinely processed bone marrow biopsy specimens. *J Clin Pathol*, 48, 291–294.
- 47 Bowen DT and Jacobs A (1989) Primary acquired sideroblastic erythropoiesis in non-anaemic and minimally anaemic subjects. *J Clin Pathol*, 42, 56–58.
- 48 Warnke RA, Kim H and Dorfman RF (1975) Malignant histiocytosis (histiocytic medullary reticulosis). I. Clinicopathological study of 29 cases. *Cancer*, 35, 215–230.
- 49 Lampert IA, Catovsky D and Bergier N (1978) Malignant histiocytosis: a clinicopathological study of 12 cases. *Br J Haematol*, 40, 65–77.
- 50 Scott RB and Robb-Smith AHT (1939) Histiocytic medullary reticulosis. *Lancet*, ii, 194–198.
- 51 Manoharan A and Catovsky D. Histiocytic medullary reticulosis revisited. In: Schmalzl F, Huhn D and Schaefer HE (eds) *Haematology and Blood Transfusion. Volume 27: Disorders of the Monocyte Macrophage System*. Springer-Verlag, Berlin, 1981.
- 52 Wilson MS, Weiss LM, Gatter KC, Mason DY, Dorfman RF and Warnke RA (1990) Malignant histiocytosis: a reassessment of cases previously reported in 1975 based on paraffin section immunophenotyping studies. *Cancer*, 66, 530–536.
- 53 Su I-J, Lin D-T, Hsieh H-C, Lee SH, Chen J, Chen RL *et al.* (1990) Fatal primary Epstein–Barr virus infection masquerading as histiocytic medullary reticulosis in young children in Taiwan. *Hematol Pathol*, 4, 189–195.
- 54 Falini B, Pileri S, de Solas I, Martelli MF, Mason DY, Delsol G *et al.* (1990) Peripheral T-cell lymphoma associated with hemophagocytic syndrome. *Blood*, 75, 434–444.
- 55 Robb-Smith AH (1990) Before our time: half a century of histiocytic medullary reticulosis: a T-cell teaser? *Histopathology*, 17, 279–293.
- 56 Kadin ME, Kamoun M and Lamberg J (1981) Erythrophagocytic T- γ lymphoma: a clinicopathological entity resembling malignant histiocytosis. *N Engl J Med*, 304, 648–653.
- 57 Sonneveld P, van Lom K, Kappers-Klunne M, Prins MER and Abels J (1990) Clinico-pathological diagnosis and treatment of malignant histiocytosis. *Br J Haematol*, 75, 511–516.
- 58 Takeshita M, Kikuchi M, Ohshima K, Nibu K, Suzumiya J, Hisano S *et al.* (1993) Bone marrow findings in malignant histiocytosis and/or malignant lymphoma with concurrent hemophagocytic syndrome. *Leuk Lymphoma*, 12, 79–89.
- 59 Ralfkiaer E, Delsol G, O'Connor NTJ, Brandtzaeg P, Brousset P, Vejlsgaard GL and Mason DY (1990) Malignant lymphomas of true histiocytic origin. A clinical, histological, immunophenotypic and genotypic study. *J Pathol*, 160, 9–17.
- 60 Brunning RD (1999) Malignant histiocytosis. *Br J Haematol*, 107, 679.
- 61 Lauritzen AF, Delsol G, Hansen NE, Horn T, Ersbøll J, Hou-Jensen K and Ralfkiaer E (1994) Histiocytic sarcomas and monoblastic leukemias: a clinical, histologic and immunophenotypical study. *Am J Clin Pathol*, 102, 45–54.
- 62 Malone M (1991) The histiocytoses of childhood. *Histopathology*, 19, 105–119.
- 63 Willman CL, Busque L, Griffith BB, Favara BE, McClain KL, Duncan MH and Gilliland DG (1994) Langerhans'-cell histiocytosis (histiocytosis X)—a clonal proliferative disease. *N Engl J Med*, 331, 154–160.
- 64 Frisch B, Lewis SM, Burkhardt R and Bartl R. *Biopsy Pathology of the Bone Marrow*. Chapman & Hall, London, 1985.
- 65 Favara BE and Jaffe R (1987) Pathology of Langerhans' cell histiocytosis. *Hematol Oncol Clin North Am*, 1, 75–97.
- 66 Mufti GJ, Flandrin G, Schaefer H-E, Sandberg AA and Kanfer EJ. *An Atlas of Malignant Haematology*. Martin Dunitz, London, 1996.
- 67 Aricò M, Nichols K, Whitlock JA, Arceci R, Haupt R, Mittler U *et al.* (1999) Familial clustering of Langerhans' cell histiocytosis. *Br J Haematol*, 107, 883–888.
- 68 Betts DR, Leibundgut KE, Feldges A, Pluss HJ and Niggli EK (1998) Cytogenetic abnormalities in Langerhans cell histiocytosis. *Br J Cancer*, 77, 552–555.

FIVE

CHRONIC MYELOPROLIFERATIVE AND MYELOPROLIFERATIVE/ MYELOYDYSPLASTIC DISORDERS

The myeloproliferative disorders (MPD) are a group of diseases which have in common that they result from proliferation of a clone of myeloid cells derived from a neoplastic precursor. Evidence suggests that, even when differentiation is predominantly to cells of a single lineage, the disorder has arisen in a multipotent myeloid stem cell or, at least in some cases, in a pluripotent stem cell capable of giving rise to cells of both myeloid and lymphoid lineages. In MPD, maturation of neoplastic cells is relatively normal and cells retain some responsiveness to normal physiological controls; for this reason, they may be regarded as relatively benign neoplasms. However, this group of conditions shows a greater or lesser propensity to evolve into a malignant neoplasm, resembling acute leukaemia, which rapidly leads to death. In the case of chronic granulocytic leukaemia (CGL), acute transformation is very frequent and occurs at a median interval of only 2–3 years. Polycythaemia rubra vera (PRV), idiopathic myelofibrosis and systemic mastocytosis undergo acute transformation less often and usually after a longer chronic phase. An acute phase is least frequent in essential thrombocythaemia (ET).

The MPD differ from the myelodysplastic syndromes (MDS) in that, early in the course of the disease, haemopoiesis is effective with overproduction of cells of at least one lineage. Dysplastic features are either absent or not prominent. However, with disease progression, haemopoiesis may become ineffective and dysplastic features may appear. Occasionally patients are seen with a condition which cannot be readily assigned to one or other category of disease because of the presence of both myeloproliferative and myelodysplastic features.

It should be noted that the correct diagnosis and classification of MPD are often more dependent on

Table 5.1 The WHO classification of the myeloproliferative and myelodysplastic/myeloproliferative diseases.

<i>Myeloproliferative diseases</i>
Chronic myelogenous leukaemia, Philadelphia chromosome positive (t(9;22)(q34;q11), BCR/ABL)
Chronic neutrophilic leukaemia
Chronic eosinophilic leukaemia/hypereosinophilic syndrome
Chronic idiopathic myelofibrosis
Polycythaemia vera
Essential thrombocythaemia
Myeloproliferative disorders, unclassifiable
<i>Myelodysplastic/myeloproliferative disorders</i>
Chronic myelomonocytic leukaemia
Atypical chronic myelogenous leukaemia
Juvenile myelomonocytic leukaemia
Other myelodysplastic/myeloproliferative disorders, unclassifiable

peripheral blood features than on bone marrow cytology or histology; consideration of cytogenetic and molecular characteristics may also be necessary.

An expert group convened by the WHO has proposed a classification of the myeloproliferative diseases and of the overlap myelodysplastic/myeloproliferative diseases which is shown in Table 5.1 [1]. We shall follow this classification although we do not accept the proposed terminology in its entirety. The important features of this classification are the recognition of a group of conditions in which there are features of both myelodysplasia and myeloproliferation and the assignment of chronic myelomonocytic leukaemia (CMML) to this group rather than to the MDS. The classification of myelodysplastic/myeloproliferative disorders in

childhood has been simplified, in accordance with the views of other expert groups. The WHO classification does not recognize systemic mastocytosis as an MPD but instead assigns it to a new group designated 'mast cell diseases'.

Myeloproliferative disorders

Chronic granulocytic leukaemia

Philadelphia-positive chronic myeloid leukaemia is a distinct, easily recognizable disease. We prefer the designation 'chronic granulocytic leukaemia', which has the advantages of brevity and clarity, to the rather cumbersome term, 'chronic myelogenous leukaemia, Philadelphia chromosome positive (t(9;22)(q34;q11)BCR/ABL)', suggested by the WHO group. CGL is an uncommon condition resulting from the neoplastic proliferation of an early haemopoietic precursor cell that can differentiate into cells of granulocyte, monocyte, erythroid, megakaryocyte and, under certain circumstances, lymphoid lineages. Approaching 95% of patients with CGL have an acquired chromosomal abnormality in the leukaemic clone consisting of a reciprocal translocation between the long arms of chromosomes 9 and 22, t(9;22)(q34;q11); the abnormal chromosome 22 is designated the Philadelphia (Ph) chromosome. As a result of this translocation, a hybrid gene is formed from the Abelson (*ABL*) oncogene, carried on the long arm of chromosome 9, and the breakpoint cluster region (*BCR*) gene on chromosome 22. The majority of patients with Ph-negative CGL, which is identical to the Ph-positive disease in all other respects, have been found to have a *BCR-ABL* fusion gene using molecular techniques, despite the absence of a 9;22 translocation [2]. This is not the case with Ph-negative atypical chronic myeloid leukaemia (aCML) (see below).

CGL is very largely a disease of adult life. The overall incidence is 1–2/100 000/year with a slow increase occurring with increasing age. The disease is more common in men than in women with a male:female ratio of about 1.5:1. Patients may present with the symptoms of anaemia, splenic pain or, rarely, leucostasis due to a very high white cell count. However, because of the insidious onset of the disease, many patients have only minor symptoms at the time of diagnosis. Occasionally,

the disease is diagnosed from a routine blood count in an asymptomatic patient.

Physical examination reveals splenomegaly, although this is not usually marked until the white cell count exceeds $100 \times 10^9/l$. Hepatomegaly is also common.

Although initially the disease pursues a chronic course, in which patients are often maintained in reasonably good health, the prognosis is very poor because of almost invariable transformation to an acute leukaemia which is refractory to treatment. Acute transformation is often preceded by an accelerated phase in which the disease becomes resistant to therapy. The median survival in CGL, in the absence of treatment, is about 2.5 years. Unless allogeneic stem cell transplantation is carried out, median survival with currently available treatments is of the order of 5 years.

Assessment of peripheral blood features is of major importance in the diagnosis of CGL; bone marrow cytological and histological features are of lesser importance.

Peripheral blood

The total white cell count is elevated, usually between 20 and $500 \times 10^9/l$. The predominant cell types in the peripheral blood are neutrophils and myelocytes (Fig. 5.1); immature granulocytic cells are also present with blasts and promyelocytes usually being less than 10–15% of cells [3]. Basophils are almost invariably increased and the absolute eosinophil count is increased in the great majority of patients; some eosinophil and basophil myelocytes are present. Granulocytes show normal maturation. A normocytic, normochromic anaemia is usual. The platelet count is usually normal or elevated, but does not often exceed $1000 \times 10^9/l$. Occasional patients have thrombocytopenia. Some giant platelets are usually present and occasional bare megakaryocyte nuclei are seen.

During successful chronic phase treatment, the peripheral blood count and film usually become almost normal, although a degree of basophilia and occasional immature granulocytes may persist. Patients presenting with or developing extensive bone marrow fibrosis have marked anisocytosis and poikilocytosis with prominent teardrop poikilocytes. The accelerated phase may be marked by increasing

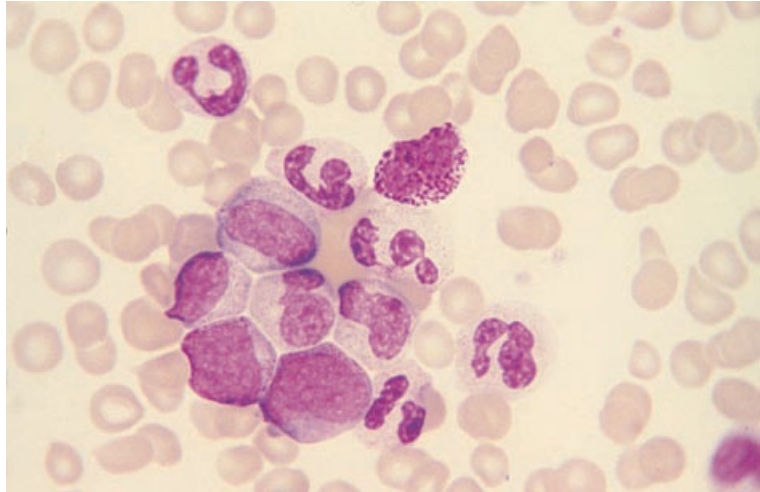


Fig. 5.1 PB, Ph-positive CGL, showing neutrophils and their precursors and one basophil. MGG ×940.

basophilia, persistent leucocytosis or the reappearance of anaemia. Acute transformation may follow an accelerated phase or the appearance of features of bone marrow fibrosis or be heralded by the appearance of dysplastic features (such as the acquired Pelger–Huët anomaly of neutrophils or the presence of circulating micromegakaryocytes) or there may be the abrupt appearance of increasing numbers of circulating blasts in a previously stable patient.

Acute transformation is myeloid in about two thirds of cases and lymphoblastic or mixed in the remainder. Myeloblasts may show neutrophil or basophil differentiation. Megakaryoblastic transformation is not uncommon. Rarely, transformation is monoblastic, eosinophilic, hypergranular promyelocytic or erythroblastic. Alternatively, there may be hybrid cells with both basophil and mast cell features. Often a single patient has blasts of diverse types, usually a mixture of megakaryoblasts and myeloblasts, but occasionally a mixture of lymphoblasts and blasts of myeloid lineage. As the number of blast cells in the blood increases, there is a gradual disappearance of mature cells and anaemia and thrombocytopenia develop. The presence of more than 20% circulating blasts is an acceptable criterion for a diagnosis of acute transformation.

The neutrophil alkaline phosphatase score can be useful in confirming a diagnosis of CGL since it is low in about 95% of cases. However, cytochemistry

is redundant when cytogenetic and molecular genetic techniques are available.

Bone marrow cytology

In the chronic phase of CGL the bone marrow is intensely hypercellular with granulocytic and often megakaryocytic hyperplasia (Fig. 5.2). The myeloid:erythroid ratio is greater than 10:1, usually of the order of 25:1 [2]. Precursors of neutrophils, eosinophils and basophils are all increased. Cellular maturation is normal. Erythropoiesis is reduced but morphologically normal. The average size and lobulation of megakaryocytes is reduced but micromegakaryocytes with one or two small round nuclei, as seen in the MDS, are not usually a feature of the chronic phase of CGL. As a consequence of the increased cell turnover, there is often an increase of macrophages and various storage cells (see below).

During the accelerated phase, the bone marrow may show increasing basophilia, some increase of blast cells or the appearance of dysplastic features. Bone marrow aspiration may become difficult or impossible because of increasing bone marrow fibrosis.

With the onset of acute transformation, the bone marrow is steadily replaced by blasts showing the usual cytological features of the lineage in question.

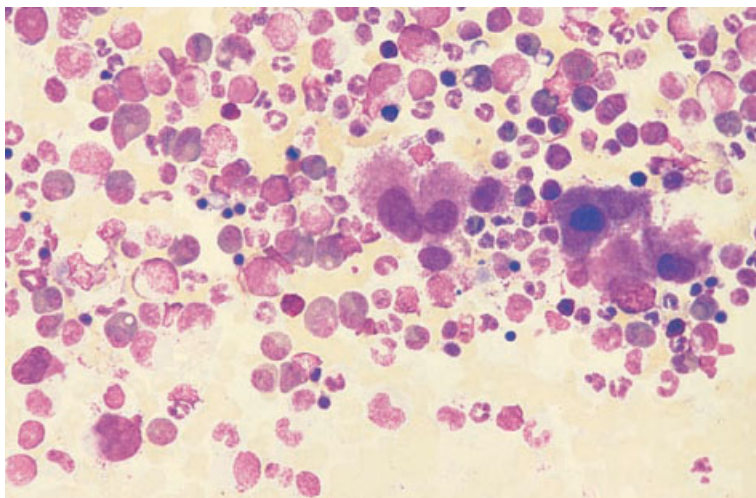


Fig. 5.2 BM aspirate, Ph-positive CGL, showing hyperplasia of all granulocytic lineages and a clump of megakaryocytes with hypolobulated nuclei. MGG $\times 377$.

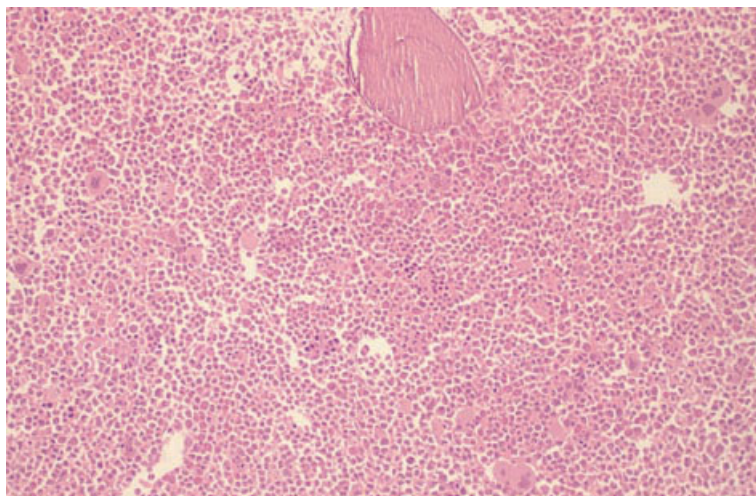


Fig. 5.3 BM trephine biopsy section, CGL, showing a packed marrow with marked granulocytic hyperplasia. Plastic-embedded, H&E $\times 97$.

Acute transformation can be diagnosed if bone marrow blasts exceed 20%.

Bone marrow histology [4–8]

The marrow is hypercellular with loss of fat cells (Figs 5.3 and 5.4). In most cases more than 95% of the marrow cavity is occupied by haemopoietic cells. There is a marked increase in granulocytic precursors with a variable degree of left shift. The normal topographic relationship of haemopoiesis is retained, with granulopoiesis occurring predominantly in the

paratrabecular, peri-arterial and pericapillary areas, although the more mature granulocytic precursors extend into the central areas of intertrabecular marrow. The increased numbers of basophils are not detected on histological sections because of dissolution of their granules during processing. Eosinophil precursors are increased in the majority of cases. A feature that may be helpful in distinguishing CGL from a leukaemoid reaction with granulocytic hyperplasia is that in CGL there is loss of fat cells from the very earliest stages of the disease; the loss of paratrabecular fat cells is marked, whereas it has

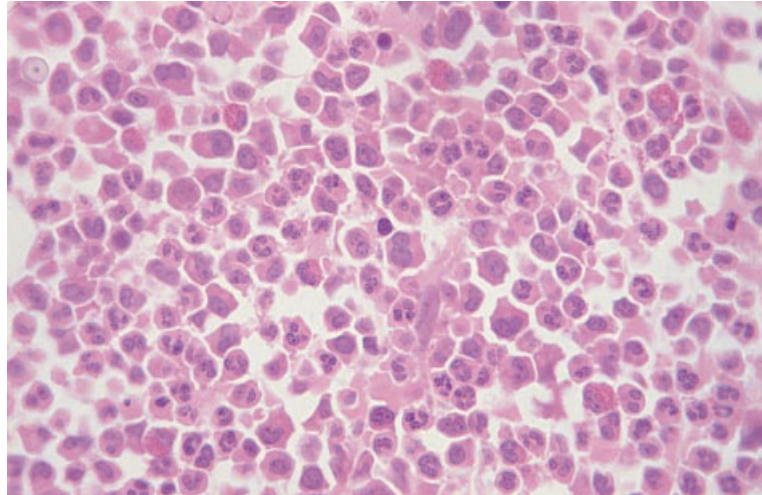


Fig. 5.4 BM trephine biopsy section, CGL, showing granulocytic hyperplasia with left shift. Plastic-embedded, H&E $\times 390$.

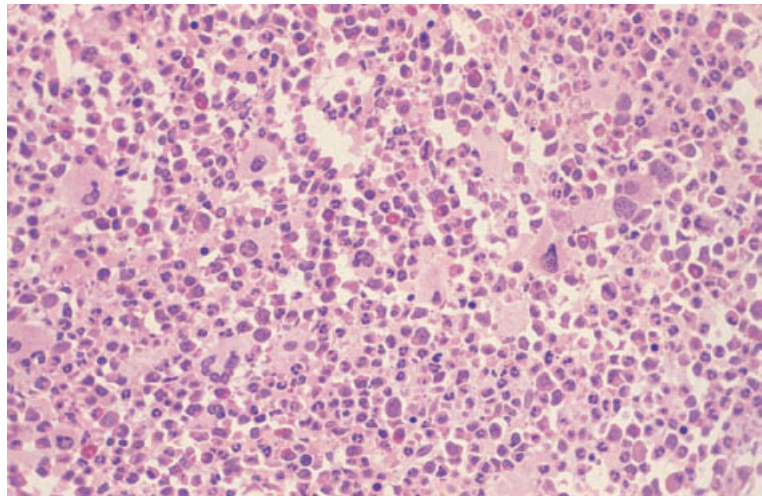


Fig. 5.5 BM trephine biopsy section, CGL with prominent megakaryocytic component, showing increased numbers of megakaryocytes with hypolobulated nuclei and granulocytic hyperplasia. Plastic-embedded, H&E $\times 195$.

been claimed that these are often preserved in a leukaemoid reaction [8].

Megakaryopoiesis and, to a lesser extent, erythropoiesis occur in the perisinusoidal areas. There may be some megakaryocytes within sinusoids and also some near bony trabeculae [9]. Megakaryocytes are usually increased in number, often forming small clusters of cells; in some cases this is a striking feature. The average size and nuclear lobe count of megakaryocytes are decreased (Figs 5.5 and 5.6). The megakaryocytic morphology is variable, with most patients having both relatively normal forms and smaller cells with small, hypolobulated nuclei.

It has been suggested that cases with marked megakaryocytic proliferation, often accompanied by fibrosis, should be distinguished from CGL and classified as chronic megakaryocytic granulocytic myelosis. However, this distinction is arbitrary and unnecessary since such cases, when they are Ph-positive, do not differ clinically in any important respect from other cases of CGL [7,10].

Increased numbers of mast cells and plasma cells are commonly seen, usually in a perivascular position. Pseudo-Gaucher cells may be seen (see Fig. 9.34); these are macrophages which contain phagocytosed glycolipids and also haemosiderin;

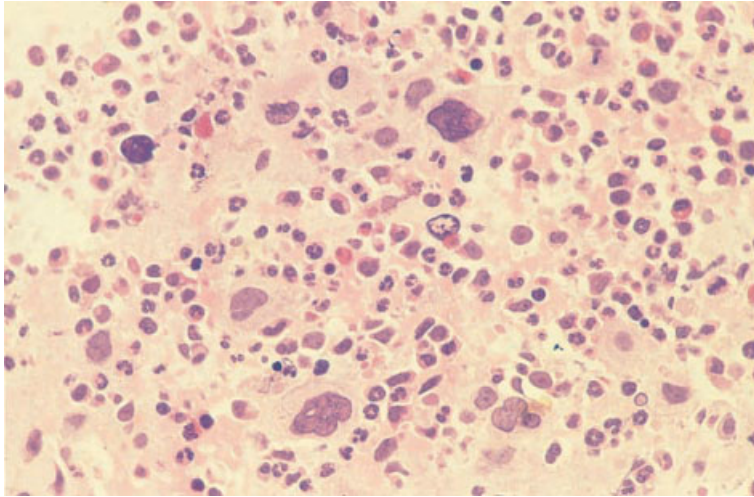


Fig. 5.6 BM trephine biopsy section, CGL with prominent megakaryocytic component, showing granulocytic hyperplasia and numerous megakaryocytes with hyperchromatic, hypolobulated nuclei. Plastic-embedded, H&E $\times 390$.

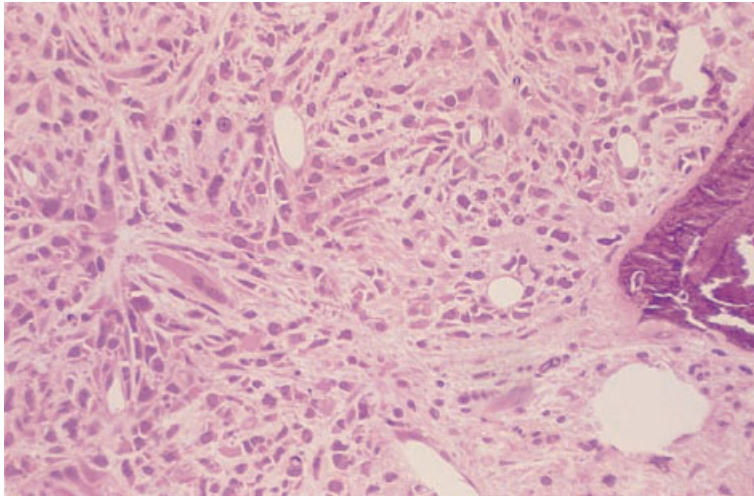


Fig. 5.7 BM trephine biopsy section, CGL with fibrosis, showing marked collagen fibrosis and 'streaming' of haemopoietic cells including numerous hypolobulated megakaryocytes. Plastic-embedded, H&E $\times 195$.

they are formed as a consequence of increased cell turnover. Sea-blue histiocytes may also be found (see page 420). Marrow necrosis is uncommon and, when present, is usually a sign of impending blast transformation.

Reticulin is usually increased and occasionally the fibrosis is severe enough to cause confusion with primary (idiopathic) myelofibrosis [11] (see page 202). Fibrosis is more common in cases with marked megakaryocytic proliferation [6] (Fig. 5.7). It may be present at the time of diagnosis although it is seen more often in the later stages of the disease.

There may be progressive reticulin deposition during therapy. This is greater during interferon therapy than during busulphan therapy [12]. During hydroxyurea therapy reticulin fibrosis may regress [13]. Heavy reticulin deposition may predict impending blast transformation. Severe fibrosis may be accompanied by osteosclerosis.

Prognostic features in chronic phase CGL include the number of megakaryocytes and the degree of reticulin and collagen fibrosis (indicative of worse prognosis) and the proportion of erythroid precursors (indicative of a better prognosis) [14].

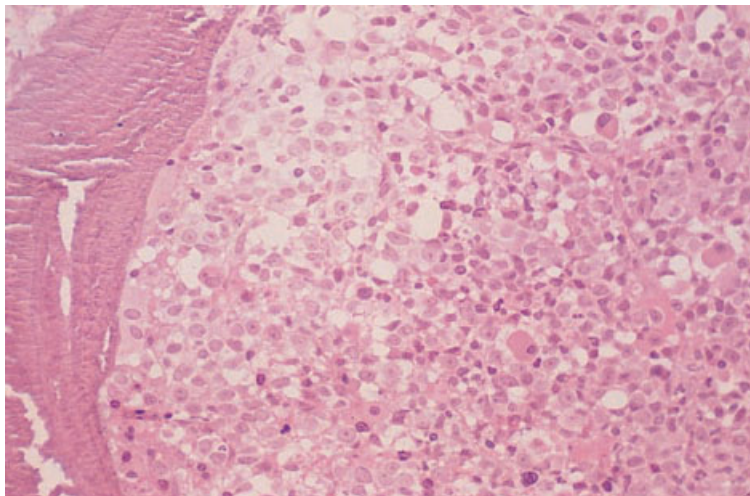


Fig. 5.8 BM trephine biopsy section, CGL in accelerated phase, showing accumulation of blasts in a broad paratrabecular band. Plastic-embedded, H&E $\times 195$.

Accumulation of immature granulocytic precursors (myeloblasts and promyelocytes) in the paratrabecular (Fig. 5.8) and perivascular regions often precedes transformation to an acute phase [15].

Blast transformation [16–19] may involve part or all of a trephine biopsy specimen. Areas of involvement contain sheets of blasts, which usually have a single prominent nucleolus and often show considerable pleomorphism. In megakaryoblastic transformation there are usually large numbers of dysplastic megakaryocytes, often with bizarre morphology, in addition to numerous megakaryoblasts. Otherwise it is often not possible to determine the lineage of blasts from H&E-stained sections. Moderate or severe myelofibrosis is seen in approximately 40% of cases of both myeloid and lymphoid transformation and is an almost universal finding in megakaryoblastic transformation. Myelofibrosis may make marrow aspiration impossible so that a biopsy is necessary to establish the diagnosis of blast transformation. Acute transformation can be diagnosed if trephine biopsy sections show extensive focal infiltration by blast cells, even if peripheral blood and bone marrow aspirate blast cells are less than 20%.

Immunohistochemistry is of limited value during the chronic phase of the disease but can be useful in the accelerated phase and in blast transformation. A monoclonal antibody directed at CD34 can be

useful in identifying blasts in accelerated phase and early transformation [20]. Immunohistochemistry can also be useful to confirm megakaryoblastic transformation and to distinguish between myeloid and lymphoid transformations.

Cytogenetics and molecular genetics

CGL is typically associated with $t(9;22)(q34;q11)$ and with formation of a *BCR-ABL* fusion gene. The *BCR-ABL* fusion gene encodes a 210-kDa protein with tyrosine kinase activity which is thought to have an important role in the pathogenesis of the disease. *BCR-ABL* fusion can also result from variant and complex translocations and from cryptic chromosomal rearrangements. The diagnosis of CGL cannot be sustained if *BCR ABL* is lacking. The diagnosis can be confirmed by conventional cytogenetics, fluorescence *in situ* hybridization or reverse transcriptase polymerase chain reaction.

A significant minority of patients with CGL have, in addition to $t(9;22)$, a fairly large deletion of chromosome 9 sequences centromeric to the *ABL* gene [21]. This has been found to correlate with a worse prognosis.

The accelerated phase and acute transformation are often associated with cytogenetic evolution. Extra cytogenetic abnormalities often include $i(17)(q)$ and further copies of the Ph chromosome.

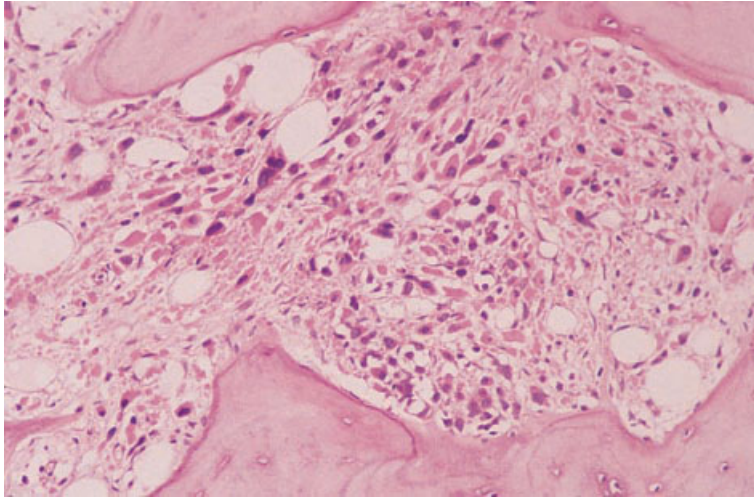


Fig. 5.9 Section of BM trephine biopsy specimen from a patient presenting in accelerated phase of CGL, showing granulocytic dysplasia, megakaryocytic hyperplasia and dysplasia and osteomyelofibrosis. The correct diagnosis was revealed by cytogenetic analysis which showed normal metaphases, a clonal population with t(9;22) as the sole abnormality and a daughter clone showing cytogenetic evolution. Paraffin-embedded, H&E $\times 188$.

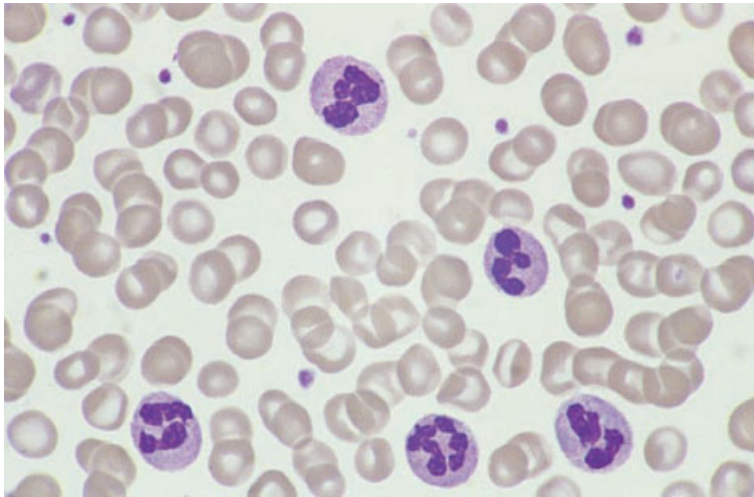


Fig. 5.10 PB film in chronic neutrophilic leukaemia, showing an increase of mature neutrophils. MGG $\times 940$.

Problems and pitfalls

The chronic phase of CGL is so characteristic that, as long as peripheral blood as well as bone marrow features are considered, misdiagnosis is unlikely. However, it is important to identify also Ph-positive cases presenting as ‘essential thrombocythaemia’ (see page 212). In patients who present already in accelerated phase (Fig. 5.9) or acute transformation, diagnosis is more difficult. Cases can be confused with aCML or with acute leukaemia. Cytogenetic and molecular genetic analysis is then of crucial importance. In an appropriate context,

the molecular abnormality is a defining feature of CGL.

Chronic neutrophilic leukaemia

Chronic neutrophilic leukaemia is a rare condition, occurring mainly in the elderly. Familial cases have been reported [22].

Peripheral blood

The peripheral blood shows an increase in mature neutrophils (Fig. 5.10) without any eosinophilia or

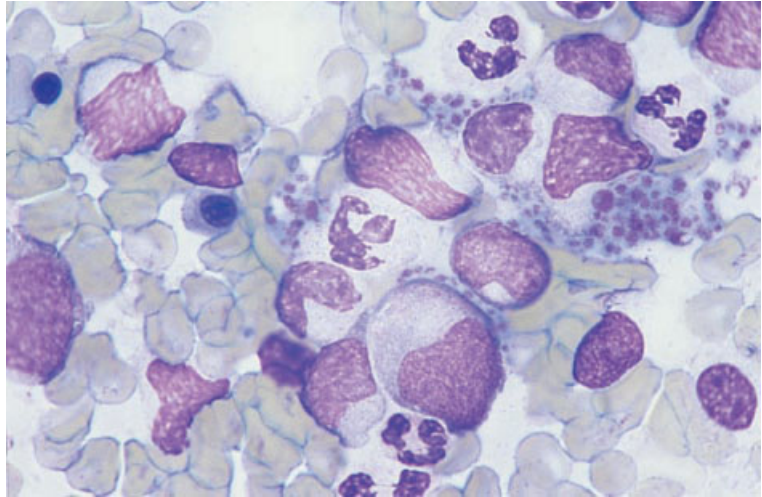


Fig. 5.11 BM aspirate in chronic neutrophilic leukaemia, showing an increase of neutrophils and precursors; neutrophils appear hypogranular and have nuclear projections. MGG $\times 940$.

basophilia and with very few neutrophil precursors. Some cases have shown heavy neutrophil granulation and others dysplastic features.

Bone marrow cytology

The bone marrow (Fig. 5.11) is hypercellular with hyperplasia of the neutrophil lineage and with no disproportionate increase in immature cells.

Bone marrow histology

The bone marrow is hypercellular with neutrophilic hyperplasia.

Cytogenetics and molecular genetics

No specific cytogenetic or molecular genetic abnormality has been recognized in association with this disease. Clonal abnormalities described have included trisomy 8, trisomy 9, del(11)(q) and del(20)(q).

Problems and pitfalls

A distinction should be drawn between chronic neutrophilic leukaemia, which is Ph-negative, and the neutrophilic variant of CGL, which is Ph chromosome and *BCR-ABL* positive, but is associated

with a p230 rather than p210 *BCR-ABL* protein. The distinction is based on cytogenetic and molecular genetic features rather than on cytology.

A neutrophilic leukaemoid reaction can occur in association with multiple myeloma (Fig. 5.12) and monoclonal gammopathy of undetermined significance [23]. It is prudent to investigate patients with apparent neutrophilic leukaemia for the presence of a paraprotein to avoid misdiagnosis of this leukaemoid reaction as neutrophilic leukaemia.

Chronic eosinophilic leukaemia

Chronic eosinophilic leukaemia is a subtype of chronic myeloid leukaemia (CML) in which differentiation is entirely or predominantly to eosinophils. The leukaemic clone can arise either from a multipotent haemopoietic stem cell or from a pluripotent lymphoid–myeloid stem cell. Eosinophilic leukaemia must be distinguished from reactive eosinophilia which is secondary to another disorder, such as allergy, a parasitic infection or a non-haemopoietic neoplasm. Clinical features of eosinophilic leukaemia may include hepatosplenomegaly and anaemia but, in addition, there may be tissue damage as a consequence of release of eosinophil granule contents. Such tissue damage often includes damage to the myocardium and endocardium with consequent heart failure.

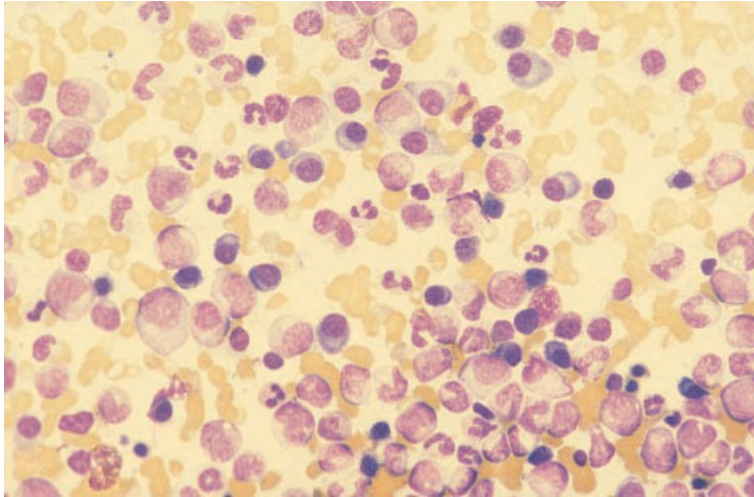


Fig. 5.12 Film of BM aspirate from a patient with a neutrophilic leukaemoid reaction to multiple myeloma, showing granulocytic hyperplasia and increased plasma cells. MGG $\times 376$. (By courtesy of Dr G Lucas, Manchester.)

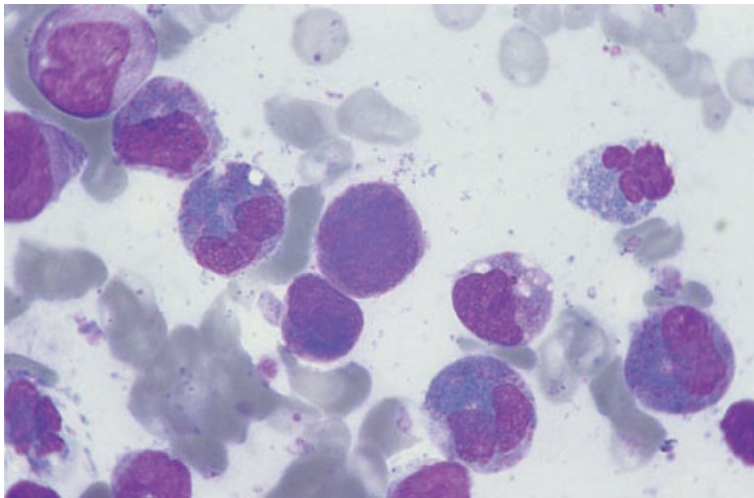


Fig. 5.13 BM aspirate, chronic eosinophilic leukaemia, showing increased eosinophils and precursors and several blast cells; some eosinophils have abnormal nuclear shapes and cytoplasmic vacuolation. MGG $\times 940$.

Peripheral blood

The blood film shows increased eosinophils and sometimes increased neutrophils or monocytes. In some patients there are circulating blast cells. The eosinophils may be cytologically normal or may show abnormalities such as degranulation, cytoplasmic vacuolation, hypolobulation or hyperlobulation.

Bone marrow cytology

The bone marrow aspirate (Fig. 5.13) shows an increase of eosinophils and their precursors. Blast cells may be increased but are less than 20%.

The eosinophil myelocytes may contain some pro-eosinophilic granules which have basophilic staining characteristics.

Bone marrow histology

The trephine biopsy shows increased eosinophils and eosinophil precursors, with or without an increase in blast cells (Fig. 5.14).

Cytogenetics and molecular genetics

A number of specific cytogenetic and molecular genetic abnormalities have been associated with

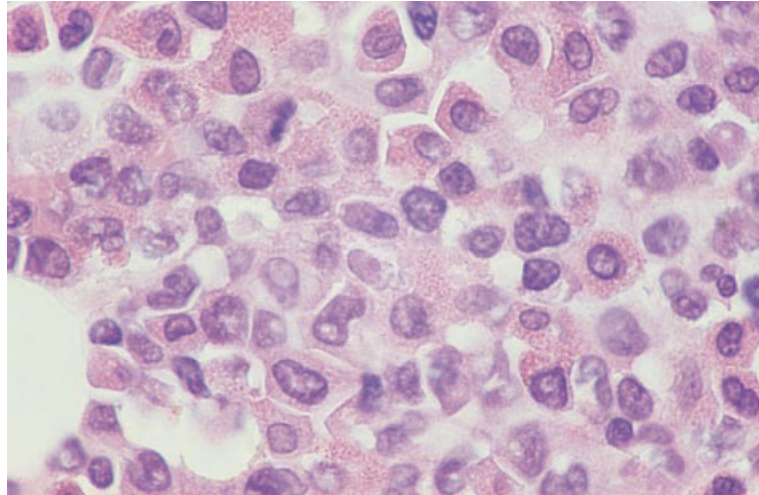


Fig. 5.14 BM trephine biopsy section, chronic eosinophilic leukaemia, showing that normal haemopoietic cells have been largely replaced by eosinophils and their precursors (same case as in Fig. 5.13). Paraffin-embedded, H&E ×940.

Table 5.2 Cytogenetic and molecular genetic abnormalities in chronic myeloid leukaemias that often or usually have an eosinophilic component (modified from [24]).

Syndrome	Cytogenetic abnormality	Molecular genetic abnormality
Chronic myelomonocytic leukaemia with eosinophilia	t(5;12)(q33;p13) t(5;10)(q33;q21)	<i>TEL-PDGFBβR</i> fusion <i>H4/D10S170-PDGFBβR</i> fusion [25]
CMML with eosinophilia/T-lineage lymphoblastic lymphoma/rarely B-lineage lymphoblastic leukaemia/lymphoma and frequent evolution to acute myeloid leukaemia	t(6;8)(q27;p12) t(8;9)(p11;q32-34) t(8;13)(p11;q12) t(8;17)(p11;q25)*	<i>FOP-FGFR1</i> fusion <i>FAN-FGFR1</i> fusion <i>ZNF198-FGFR1</i> fusion <i>FGFR1</i> rearranged [26]

* Chronic myeloid leukaemia associated with systemic mastocytosis.

chronic eosinophilic leukaemia and related conditions. Some of the best characterized syndromes with a defined oncogenic mechanism are summarized in Table 5.2 [24]. Other patients have shown other clonal but less specific abnormalities such as trisomy 8 and i(17q) [27].

Problems and pitfalls

Making a distinction between chronic eosinophilic leukaemias and the idiopathic hypereosinophilic syndrome (see page 382) is problematical. The latter diagnosis is one of exclusion, being made when there is no firm evidence of leukaemia and when no potential cause of reactive eosinophilia has been identified. Although the nature of this condition in

an individual patient is, by definition, uncertain, on prolonged follow-up some patients develop acute myeloid leukaemia (AML), thus providing strong circumstantial evidence that the initial disorder was chronic eosinophilic leukaemia with subsequent acute transformation having occurred. Others develop a clonal cytogenetic abnormality, suggesting that the disorder was clonal from the beginning with a further mutation having occurred in a clone that was initially cytogenetically normal. However, not all cases of initially unexplained hypereosinophilic syndrome are actually leukaemic. Immunophenotypic and molecular investigation has shown that some such patients have cytokine-driven hyper-eosinophilia consequent on the presence of a clone of T lymphocytes [28,29]. The initially occult

lymphoproliferative disorder subsequently becomes overt in some patients [28]. For this reason, we think it is inappropriate that cases of the idiopathic hyper-eosinophilic syndrome be assumed to have eosinophilic leukaemia. We recommend that such cases should be investigated for underlying causes of eosinophilia, such as parasitic infection, and should have cytogenetic analysis performed. When facilities permit, consideration should be given to investigation for an occult clonal proliferation of T lymphocytes. If there is no specific evidence supporting a diagnosis of leukaemia, and if no other cause of hyper-eosinophilia is found, the case should be classified as 'idiopathic'. Some such patients will subsequently be recognized, in retrospect, as having eosinophilic leukaemia. It should be noted that striking cytological abnormalities in eosinophils do not provide reliable evidence that a disorder is leukaemic in nature. They are also seen in patients with reactive eosinophilia.

Chronic idiopathic myelofibrosis

Primary or 'idiopathic' myelofibrosis is also known as myelofibrosis with myeloid metaplasia and as agnogenic myeloid metaplasia. An alternative name, which more readily encompasses the hypercellular phase of this disease, is 'chronic megakaryocytic granulocytic myelosis'. It should be noted that neither the term 'idiopathic myelofibrosis' (recommended by the WHO group) nor the term 'primary myelofibrosis' is scientifically accurate. This condition is no longer 'idiopathic', since the fibrosis is known to be a response to a myeloid neoplasm, nor is it 'primary', since the defect is in myeloid cells not in fibroblasts. Nevertheless, these terms have the advantage of relative brevity and therefore may be preferred to longer, scientifically more accurate designations. It should be noted that the term 'myelofibrosis with myeloid metaplasia' is also inaccurate since the presence of haemopoietic cells in the liver and spleen represents extramedullary haemopoiesis rather than true metaplasia.

Idiopathic myelofibrosis is a chronic MPD characterized by splenomegaly, a leuco-erythroblastic anaemia and marrow fibrosis. The incidence is 0.5–1.5/100 000/year with a median age of onset of 65 years [30]. There is extramedullary haemopoiesis, particularly in the spleen but also in the liver

and sometimes in other organs such as kidney, lymph nodes, adrenals, lung, gastro-intestinal tract, skin, dura and pleural and peritoneal cavities. The disease is due to proliferation of a clone of neoplastic cells arising from a multipotent myeloid stem cell. Proliferation of bone marrow fibroblasts with deposition of reticulin and collagen is reactive to the myeloid proliferation.

Myelofibrosis, indistinguishable from primary myelofibrosis, may also develop secondary to PRV and, less often, ET. CGL may likewise evolve into myelofibrosis or, less often, patients whose myeloid cells are Ph-positive may present with a condition which is otherwise indistinguishable from idiopathic myelofibrosis. Patients with preceding PRV, ET or CGL are classified as myelofibrosis secondary to these specific MPD, rather than as primary myelofibrosis. Similarly, patients with clinical and pathological features of myelofibrosis who are found to have an increased red cell mass or the Ph chromosome are best regarded as having variants of PRV and CGL rather than primary myelofibrosis. Primary myelofibrosis usually affects the middle-aged and elderly. It is a chronic disorder in which patients may remain relatively asymptomatic until the later stages. It is not uncommon for the diagnosis to be incidental. Except in the hypercellular phase of the disease, some degree of splenomegaly is almost invariable and splenomegaly is often very marked. Slight or moderate hepatomegaly is also common. Not surprisingly, survival is longest in those patients who are asymptomatic at the time of diagnosis. Overall, approximately 50% of patients will be alive 5 years after diagnosis. Median survival is 3–6 years from diagnosis [30]. Myelofibrosis sometimes terminates in a condition resembling CML with very striking myeloid proliferation and increasing hepatomegaly and splenomegaly. In 10–20% of cases, myelofibrosis terminates by transformation to acute leukaemia; this is usually a myeloblastic transformation but, rarely, it is lymphoblastic, suggesting that the disease may have arisen in a pluripotent rather than a multipotent stem cell. Leukaemic transformation should be suspected when there is a rapid increase in splenic size or the sudden development of anaemia or thrombocytopenia.

Acute myelofibrosis resembles chronic idiopathic myelofibrosis in that there is marrow fibrosis as a

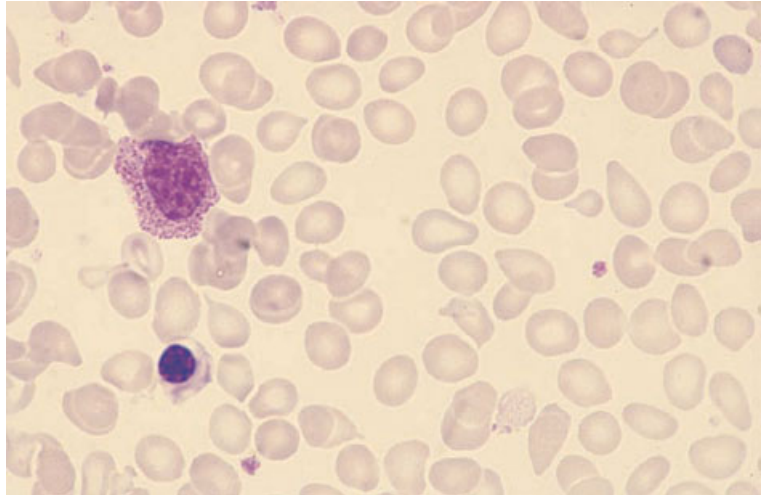


Fig. 5.15 PB, idiopathic myelofibrosis, showing anisocytosis, poikilocytosis (including teardrop poikilocytes), a myelocyte and an erythroblast. MGG $\times 940$.

consequence of proliferation of neoplastic myeloid cells. It has a rapidly progressive course characterized by severe pancytopenia with minimal or absent splenomegaly. It is best regarded as a variant of acute leukaemia (generally acute megakaryoblastic leukaemia or acute panmyelosis with myelofibrosis) (see page 156). The fibrotic marrow usually contains large numbers of megakaryoblasts, together with immature megakaryocytes; sometimes there are also myeloblasts or increased numbers of proerythroblasts. The fibrotic component may be reticulin only or reticulin and collagen.

Various diagnostic criteria for idiopathic myelofibrosis have been proposed, mainly to achieve some uniformity of diagnosis in patients entered into clinical trials. The Polycythemia Vera Study Group [31] required that the haemoglobin concentration and red cell mass not be elevated, that the Philadelphia chromosome be absent and that one third of the bone marrow be occupied by fibrous tissue. An Italian Consensus Conference did not seek to distinguish primary myelofibrosis from post-polycythaemia myelofibrosis [32] and therefore had no criteria relating to erythropoiesis. They required, as essential criteria, that there be diffuse fibrosis and that either the Philadelphia chromosome or *BCR-ABL* rearrangement be shown to be absent. Fibrosis was defined as reticulin that was visible with a $\times 100$ objective in a biopsy specimen measuring at least 3×15 mm. In addition, the patient was required to meet four minor criteria, or

three minor criteria if splenomegaly was present. The minor criteria were: (i) splenomegaly of any grade; (ii) anisopoikilocytosis with teardrop poikilocytes; (iii) circulating immature myeloid cells; (iv) circulating erythroblasts; (v) presence of clusters of megakaryoblasts and anomalous megakaryocytes in bone marrow sections; and (vi) myeloid metaplasia. These consensus criteria were estimated to have 100% specificity and 88% sensitivity. It should be noted that cases in the hypercellular phase might well be excluded by these criteria and that their use has not been validated by others.

Peripheral blood

The most characteristic peripheral blood findings of myelofibrosis are pancytopenia with a leucoerythroblastic blood film and with striking poikilocytosis including teardrop poikilocytes (Fig. 5.15). There is sometimes a mild basophil leucocytosis. Granulocytes and platelets may show some dysplastic features such as hypobolubation of neutrophil nuclei, reduced granulation of eosinophils or large or hypogranular platelets. Occasional circulating micromegakaryocytes can be seen. In the early stages of the disease, when the bone marrow is hypercellular, there is often thrombocytosis and sometimes leucocytosis rather than cytopenia. Leucoerythroblastic features and teardrop poikilocytes may also be absent [33]. With disease progression, leucopenia, neutropenia and thrombocytopenia

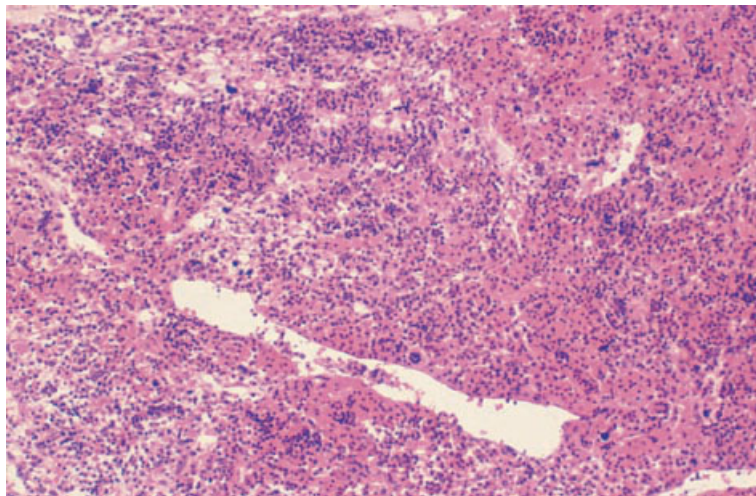


Fig. 5.16 BM trephine biopsy section, idiopathic myelofibrosis (cellular phase), showing marked hypercellularity, with an increase in cells of all three haemopoietic cell lineages, and ectatic sinusoids. Paraffin-embedded, H&E $\times 97$.

supervene and a leuco-erythroblastic blood film with prominent teardrop poikilocytes is then consistently present.

Peripheral blood features at presentation may be of prognostic significance. A worse prognosis has been associated with a haemoglobin concentration of less than 10 g/dl, 1% or more circulating blasts, more than 10% immature granulocytes and a white blood cell count (WBC) of less than 4 or more than $30 \times 10^9/l$ [34]. A study using multivariate analysis found a haemoglobin concentration of less than 10 g/dl, a WBC of $20 \times 10^9/l$ or more and a platelet count of $300 \times 10^9/l$ or less to be associated with a worse prognosis [35].

In the final phase of myelofibrosis, a progressive rise of the white cell count can be seen with a WBC up to $100\text{--}200 \times 10^9/l$ and with the appearance in the peripheral blood of increasing numbers of blasts, promyelocytes and myelocytes. Eosinophilia and basophilia may also occur in this phase and the blood film can be indistinguishable from that of CML. In other patients in whom an acute transformation occurs, there is a rapid rise in the blast count with worsening anaemia, neutropenia and thrombocytopenia.

Bone marrow cytology

As a consequence of the fibrosis, aspiration of bone marrow is often difficult in patients with myelofib-

rosis. In the early stages of the disease an aspirate is sometimes obtained and shows very hypercellular fragments with hyperplasia of all lineages; maturation is fairly normal although there may be some dysplastic features. In the later stages of the disease, there is often failure to obtain an aspirate (a 'dry tap') or attempted aspiration yields only blood (a 'blood tap'). Diagnosis then rests on the peripheral blood and trephine biopsy appearances.

Bone marrow histology

In the early stages, the marrow may be diffusely hypercellular with an increase in all haemopoietic cell lines with relatively normal maturation [33,36] (Figs 5.16 and 5.17). However, megakaryocytes often predominate and immature and dysplastic forms are usually present. The megakaryocytic morphology is extremely variable; the nuclei may be small and hypolobulated or hyperchromatic and hyperlobulated. Micromegakaryocytes and bare megakaryocyte nuclei are increased. Some megakaryocytes have bulky, lightly staining nuclei with rounded lobes. Mitotic figures are increased. Megakaryocytes may be clustered (Fig. 5.17) or sited abnormally, close to the endosteum [9] or within sinusoids. Granulocyte precursors may show an abnormal clustering centrally in the intertrabecular spaces [37]. In hypercellular marrows there is usually only a mild to moderate increase in reticulin

Fig. 5.17 BM trephine biopsy section, idiopathic myelofibrosis (cellular phase), showing a cluster of megakaryocytes with hyperlobulated nuclei. Plastic-embedded, H&E $\times 390$.

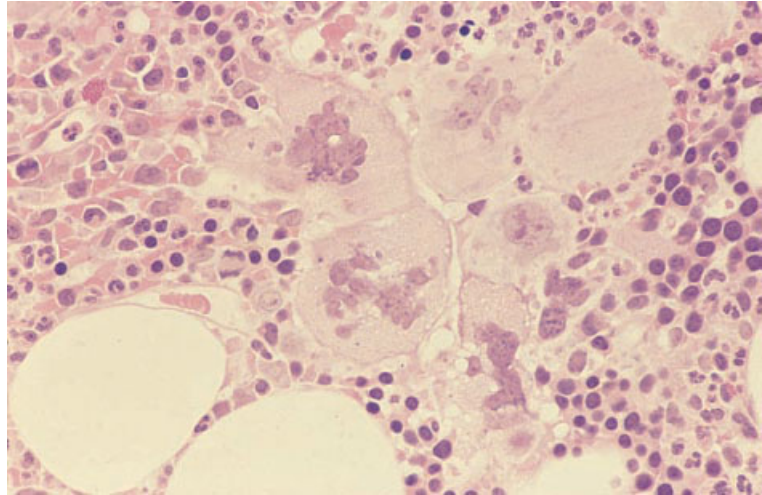
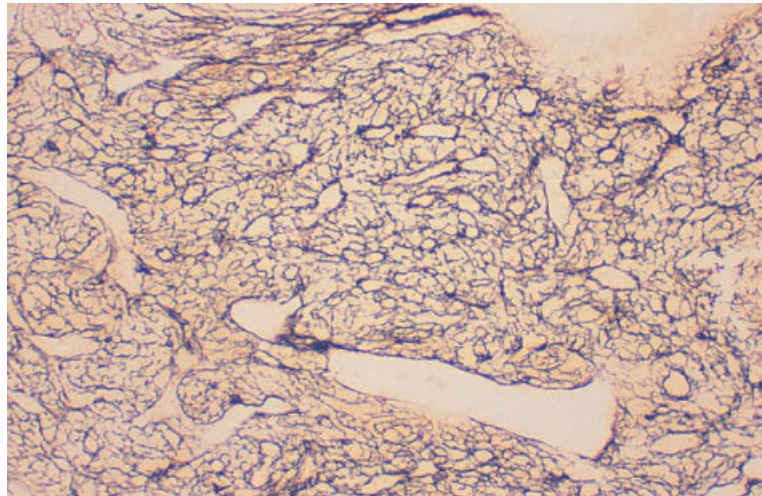


Fig. 5.18 BM trephine biopsy section, idiopathic myelofibrosis (cellular phase), showing grade 3 reticulin deposition with numerous ectatic sinusoids outlined (same case as in Fig. 5.16). Paraffin-embedded, Gordon and Sweet stain $\times 97$.



(Fig. 5.18). In some series as many as 20–30% of patients in the hypercellular phase show no reticulin fibrosis, representing the pre-fibrotic stage of idiopathic myelofibrosis [12]. Later there is a more marked increase in reticulin with coarse fibres running in parallel bundles. Streaming of haemopoietic cells may be noted when reticulin is increased (Fig. 5.19). Marrow sinusoids are increased in number and distended and contain foci of haemopoietic cells (Fig. 5.16); in the early stages this feature may be more easily detected in sections stained for reticulin. A greater degree of angiogenesis correlates with a worse prognosis [30]. The interstitium may

be oedematous and show an increase of lymphocytes, plasma cells, mast cells and macrophages. The prevalence of benign lymphoid nodules is increased. The interstitium may also contain platelets that have been released inappropriately within the marrow rather than into sinusoids.

As the degree of fibrosis increases, granulocytic and erythroid precursors in the marrow decrease and morphological abnormalities in the megakaryocytic series become more pronounced. In severely fibrotic marrows there is fibroblast proliferation and collagen deposition (Figs 5.20 and 5.21). Sinusoids may be obliterated by progressive fibrosis but

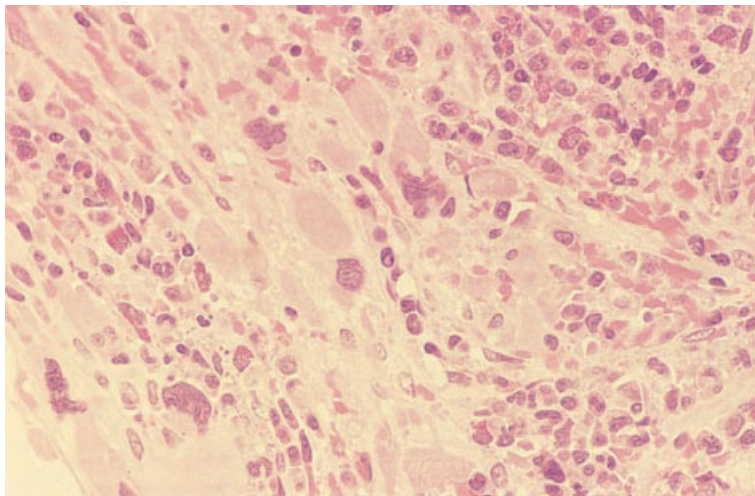


Fig. 5.19 BM trephine biopsy section, idiopathic myelofibrosis (fibrotic phase), showing 'streaming' of residual haemopoietic cells, which include numerous dysplastic megakaryocytes, and collagen fibrosis. Plastic-embedded, H&E $\times 390$.

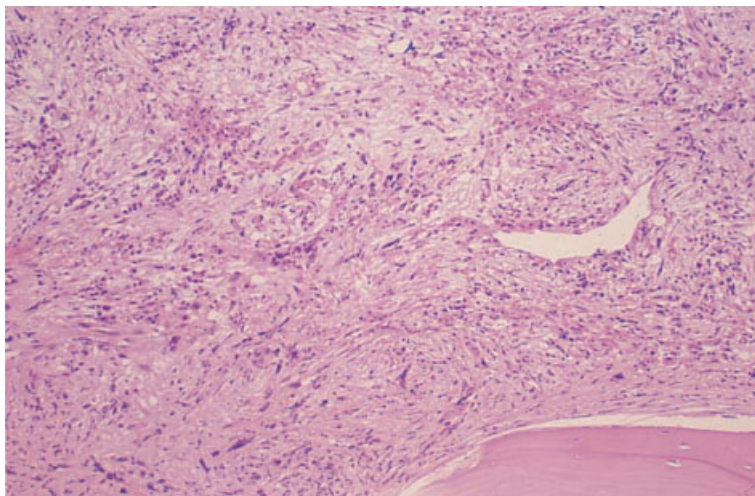


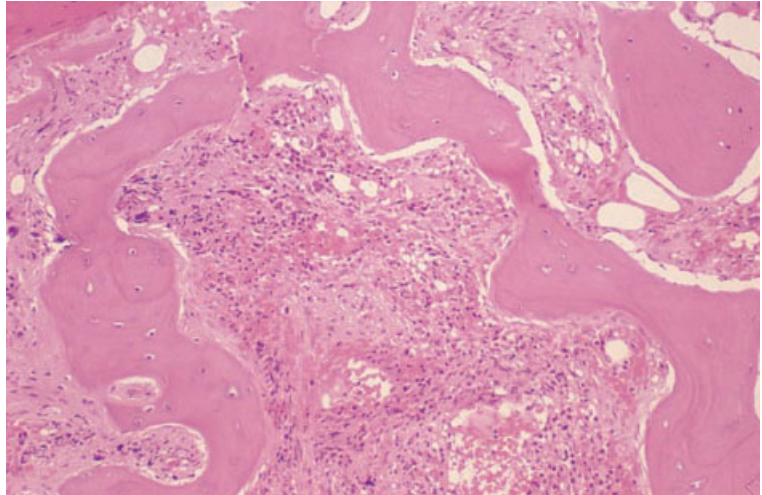
Fig. 5.20 BM trephine biopsy section, idiopathic myelofibrosis (fibrotic phase), showing marked collagen fibrosis, with reduction in all haemopoietic cell lineages. Paraffin-embedded, H&E $\times 97$.

capillaries are very numerous [38]. Fibrotic changes are often focal with marked variability within a single biopsy; one intertrabecular space may show hypercellular marrow while an adjacent one shows dense fibrosis. In severely fibrotic marrows there may also be an increase of osteoblasts with new bone formation resulting in osteosclerosis (Fig. 5.21); the thickening of bone trabeculae is often marked. Bone deposition may be both by peritrabecular osteoid deposition and by metaplastic bone formation in the marrow cavity [37]. Newly deposited bone is woven bone.

It is generally considered that myelofibrosis progresses from a hypercellular phase to a hypocellular fibrotic phase and this sequence of events may be seen on serial biopsies [36,39,40]. However, the rate of progression is very variable between patients and progressive changes have not always been observed [41]. In some patients sequential biopsies show a decrease rather than an increase in fibrosis; to what extent this is due to variation in the degree of fibrosis from one part of the bone marrow to another cannot be readily determined.

Patients who present in the hypercellular phase

Fig. 5.21 BM trephine biopsy section, osteomyelosclerosis, showing irregular thickening of bone trabeculae and marked collagen fibrosis of the intervening marrow. Paraffin-embedded, H&E $\times 97$.



of myelofibrosis have longer survivals than those who present with fully developed osteomyelosclerosis [35].

Therapy with anagrelide is associated with an increased number of megakaryocytes despite a fall in the platelet count [42]. The megakaryocytes appear left shifted suggesting that the drug interferes with megakaryocyte maturation rather than proliferation. This suggestion is supported by the observation that megakaryocyte numbers are also increased in healthy volunteers given this drug.

Amyloidosis occasionally develops in patients with myelofibrosis and amyloid deposition in the bone marrow has been observed [43].

When acute transformation supervenes in idiopathic myelofibrosis, increasing numbers of blasts are seen in biopsy sections.

Cytogenetics and molecular genetics

Clonal cytogenetic abnormalities are present in about 60% of patients. The most common are del(13)(q), del(20)(q), trisomy 8 and partial trisomy of 1q.

Problems and pitfalls

Idiopathic myelofibrosis needs to be distinguished from acute myelofibrosis, from myelofibrosis following other MPD and from myelofibrosis secondary to non-haemopoietic disorders.

Acute myelofibrosis is a clinicopathological syndrome sometimes associated with AML, either acute megakaryoblastic leukaemia or acute pancytopenia with myelofibrosis. Prominent megakaryoblastic proliferation is usual. Clinical features differ from those of idiopathic myelofibrosis in that splenomegaly is not usually present. The peripheral blood film lacks the teardrop poikilocytes and leuco-erythroblastic features that are typical of idiopathic myelofibrosis. There is usually pancytopenia and there may be circulating blast cells. Bone marrow aspiration is often impossible. Trephine biopsy sections usually show numerous megakaryocytes but, in addition, there are increased blast cells, a feature that is not seen in idiopathic myelofibrosis.

Distinction between primary myelofibrosis and that evolving out of other MPD is not possible on histological grounds alone (see Fig. 5.9). The identification of Ph-positive cases can be important in view of the generally worse prognosis. This can be achieved by molecular analysis for *BCR-ABL* performed on peripheral blood cells. Otherwise, making a distinction between idiopathic or 'primary' myelofibrosis and that following another MPD is not of clinical significance.

Making a correct diagnosis of myelofibrosis secondary to infiltration by carcinoma or lymphoma is, however, of considerable clinical significance. The blood film in patients with secondary myelofibrosis (for example, that due to bone marrow metastases)

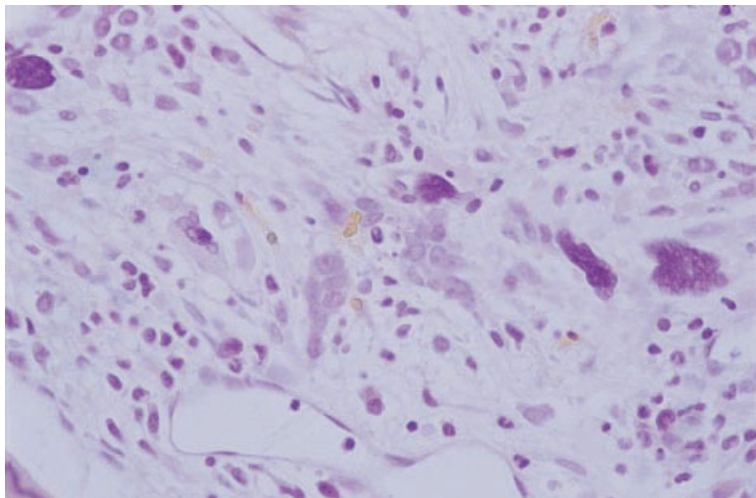


Fig. 5.22 BM trephine biopsy section. Osteomyelosclerosis with entrapped, dysplastic erythroid cells and megakaryocytes which might be mistaken for metastatic malignant cells. H&E $\times 376$.

may be virtually indistinguishable from that of idiopathic myelofibrosis, there being pancytopenia, a leuco-erythroblastic blood film and striking poikilocytosis. However, an increased basophil count, circulating micromegakaryocytes and dysplastic features do not occur. Bone marrow aspiration is usually difficult whether the patient has idiopathic or secondary myelofibrosis. However, sometimes non-haemopoietic malignant cells can be aspirated, thus providing a diagnosis. Often a trephine biopsy is necessary to make this distinction. When there is dense fibrosis it is necessary to look carefully for malignant cells embedded in the fibrous tissue. Sometimes it is difficult to distinguish metastatic carcinoma cells from small dysplastic megakaryocytes or dysplastic erythroblasts (Fig. 5.22). When necessary, immunological markers for megakaryocytes, erythroid cells or cells of epithelial origin (see Tables 2.6 and 10.1) can be used to confirm the nature of abnormal cells. Infiltration by lymphoma, particularly by Hodgkin's disease, can also lead to dense bone marrow fibrosis. Immunohistochemistry can again be useful to distinguish Reed-Sternberg cells and mononuclear Hodgkin's cells from carcinoma cells or dysplastic megakaryocytes.

Idiopathic myelofibrosis needs to be distinguished from fibrosis associated with bone disease (see pages 464–469).

The pre-fibrotic and early fibrotic stages of idiopathic myelofibrosis can be difficult to distinguish from other MPD, particularly from ET. Bone mar-

row histology is useful since, in myelofibrosis, megakaryocyte dysplasia is conspicuous whereas in ET it is not.

Polycythaemia rubra vera

Polycythaemia vera (preferred WHO terminology), also known as polycythaemia rubra vera or primary proliferative polycythaemia, is a chronic MPD in which the dominant feature is the excessive production of erythrocytes by the marrow with a consequent increase in the circulating red cell mass and the venous haematocrit. Frequently, there is also an increase in cells of other haemopoietic cell lineages, both in the marrow and in the peripheral blood, and it is likely that the neoplastic clone originates from a multipotent myeloid stem cell.

Most patients present between the ages of 40 and 70 years. Many of the symptoms are related to hyperviscosity of the blood and to the arterial or venous thromboses which occur. Symptoms include: (i) headache; (ii) a feeling of fullness of the head; (iii) dizziness; (iv) tinnitus; (v) dyspnoea; (vi) visual disturbance; (vii) Raynaud's phenomenon; (viii) claudication; and (ix) gangrene. Pruritus may occur, probably consequent on histamine secretion by basophils. Up to 70% of cases have been found to have splenomegaly and 40% hepatomegaly.

PRV must be distinguished from secondary polycythaemia which is usually a consequence of either chronic generalized tissue hypoxia (for example,

due to high altitude, chronic hypoxic pulmonary disease or cyanotic congenital heart disease) or of inappropriate erythropoietin production (usually a result of chronic renal hypoxia or ectopic production of erythropoietin by a tumour). In many patients with secondary polycythaemia the cause is readily apparent but sometimes there is diagnostic difficulty and the differential diagnosis then depends on consideration of clinical, peripheral blood and bone marrow features. Hepatomegaly and splenomegaly are not features of secondary polycythaemia.

PRV and secondary polycythaemia must also be distinguished from pseudo- or relative polycythaemia which is a consequence of a decreased plasma volume rather than an increased red cell mass.

PRV may enter a 'burnt out' or 'spent' phase in which there is initially a reduction of red cell production followed by the development of splenomegaly and bone marrow fibrosis; with disease progression, there is development of all the clinical and pathological features usually associated with idiopathic myelofibrosis. The designation 'spent phase of polycythaemia' has been suggested for the phase of the disease when there is a stable haematocrit and marked splenomegaly with minimal fibrosis, and the designation 'transitional state polycythaemia vera' when there is persisting erythrocytosis with progressive myelofibrosis [30]. A small proportion of patients, particularly those who

have been treated with alkylating agents or ^{32}P , develop AML. The incidence of acute leukaemia is much increased in those in whom myelofibrosis has developed but acute transformation can also occur without any warning signs or, occasionally, following the appearance of myelodysplastic features.

Untreated PRV had a median survival of about 1.5 years but with currently available treatment the median survival is about 12 years.

Peripheral blood

The blood count shows an elevation of the red cell count, haemoglobin concentration and haematocrit. As a consequence of the increased blood viscosity, the blood film shows a crowding together of the red cells, an appearance described as a 'packed film'. In some patients, iron stores have been exhausted and there is also microcytosis and hypochromia. The white cell count is commonly elevated due to an increase in the neutrophil count; occasionally neutrophilia is marked. Absolute basophilia is often present. Small numbers of immature granulocytes may be present. Many patients have a moderately elevated platelet count.

Bone marrow cytology

The bone marrow usually shows marked erythroid hyperplasia and often some degree of granulocytic and megakaryocytic hyperplasia (Fig. 5.23).

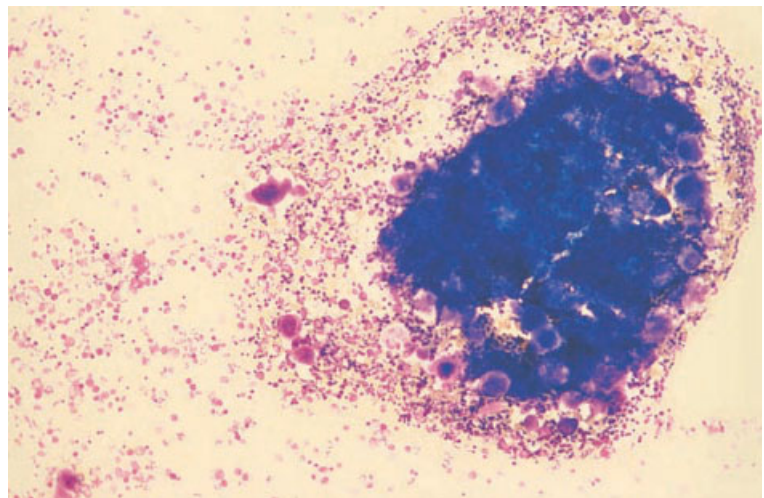


Fig. 5.23 BM aspirate, PRV, bone marrow fragment, showing marked hypercellularity attributable to erythroid, granulocytic and megakaryocyte hyperplasia. MGG $\times 94$.

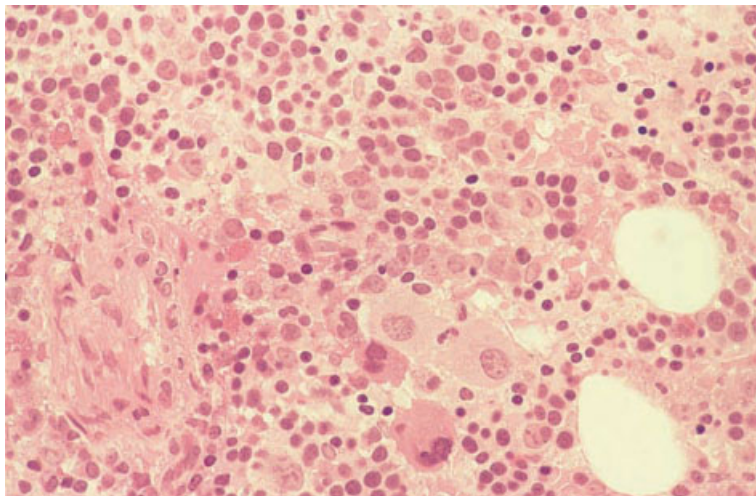


Fig. 5.24 BM trephine biopsy section, PRV, showing hypercellularity, erythroid hyperplasia and a cluster of immature megakaryocytes. Plastic-embedded, H&E $\times 390$.

Eosinophil and basophil lineages, as well as the neutrophil lineage, may be hyperplastic. The average size and nuclear lobulation of megakaryocytes are increased. Iron stores are often absent and the features of superimposed iron deficiency may be present.

Bone marrow histology [4,44–46]

There is usually marked hypercellularity, with haemopoietic cells often filling more than 90% of the marrow space. There is commonly an increase in cells of all three haemopoietic lineages. Erythropoiesis is hyperplastic but morphologically normal (Fig. 5.24). Megakaryocyte morphology is often abnormal with both large, polylobulated forms and an increased number of micromegakaryocytes being seen; the average size of megakaryocytes is considerably increased, as is their nuclear lobulation. Often there is clustering of megakaryocytes (Fig. 5.24). There is an increase in emperipolesis and in mitotic figures in megakaryocytes [9]. Granulocytic hyperplasia is of the neutrophil lineage and sometimes also the eosinophil lineage. Many cases show a mild increase in reticulin, with about 10% of patients showing a moderate or marked increase [46]. Vascular sinusoids are usually increased in number and may be dilated. Marrow iron stores are decreased or absent. Lymphoid nodules have been reported in up to 20% of patients in some series.

Up to 30% of cases of PRV develop severe marrow fibrosis which is morphologically indistinguishable from primary myelofibrosis (see page 202); this is more common in cases with marked megakaryocytic proliferation.

Cytogenetics and molecular genetics

Some patients have clonal cytogenetic abnormalities of which $\text{del}(20)(q)$ is the most characteristic.

Problems and pitfalls

The diagnosis of PRV requires demonstration of a true polycythaemia. The distinction between true and relative polycythaemia is best made by isotopic dilution studies, which are used to determine the red cell mass and plasma volume. Although these investigations may be regarded as redundant in patients with a very marked elevation of haemoglobin or with obvious clinicopathological features of PRV, they are indicated in patients with only a moderate elevation of haemoglobin since further investigation is not generally indicated in patients with only a relative polycythaemia.

PRV also needs to be distinguished from secondary polycythaemia. Peripheral blood basophilia is not seen in secondary polycythaemia and neutrophilia and thrombocytosis are unusual. In contrast to PRV, superimposed iron deficiency is uncommon

in secondary cases and trephine biopsy sections show only moderate hypercellularity. There is erythroid hyperplasia but the other haemopoietic cell lines are normal. In particular, the megakaryocytic abnormalities seen in PRV are not present, reticulin is normal and sinusoids are not increased [44,45]. Lymphoid nodules are more prevalent in PRV than in healthy subjects but may also be increased in some reactive conditions associated with secondary polycythaemia. The increase in macrophages and plasma cells that is seen in some cases of secondary polycythaemia has been said not to be a feature of PRV. Typical cases of PRV can be distinguished readily from secondary polycythaemia on histological grounds. However, not all cases can be recognized and some patients in whom a diagnosis of PRV can be made, on the basis of clinical or clinical and cytogenetic features, do not have diagnostic histopathological features [44,46].

Some patients in whom no underlying cause of secondary polycythaemia can be found do not have any clinical, haematological or histopathological features that permit a diagnosis of PRV. The appropriate diagnosis in such cases is 'idiopathic erythrocytosis'. On prolonged follow-up, some but not all of this group of patients develop features such as splenomegaly, neutrophilia or basophilia, indicating that the correct diagnosis was PRV.

Essential thrombocythaemia

ET, in common with other MPD, is a disease resulting from the clonal proliferation of a multipotent myeloid stem cell but with the predominant disease features resulting from increased platelet production. The disease is seen at all ages but is predominantly one of middle and old age. It is characterized by a marked thrombocytosis (usually $1000-4000 \times 10^9/l$) often resulting in haemorrhagic or thrombotic episodes or both. At least 20% of patients are asymptomatic and are diagnosed incidentally from routine blood counts. With the widespread use of automated blood counters, the proportion of patients in whom the diagnosis is made incidentally, before the occurrence of symptoms, is steadily increasing. About two thirds of symptomatic patients suffer venous or arterial thrombosis or symptoms attributable to small vessel obstruction, such as: (i) headache; (ii) dizziness; (iii) visual disturbance; (iv) paraesthe-

siae; and (v) peripheral vascular insufficiency. About a third of symptomatic patients have abnormal bleeding, for example, into the gastro-intestinal tract and subcutaneous tissues.

Moderate splenomegaly is seen in up to 40% of cases and hepatomegaly in up to 20% [31]. Occasional patients suffer repeated splenic infarcts, resulting in splenic atrophy and hyposplenism. Pruritus occurs in a minority of patients.

Since marked thrombocytosis can occur not only in ET but also in both PRV and CGL, the diagnosis is in part one of exclusion. Cases with an increased red cell mass are classified as PRV rather than as ET. Similarly, cases which are found to have the Ph chromosome are better regarded as a variant of CGL or, alternatively, can be designated specifically 'Ph-positive essential thrombocythaemia'; they have a different disease course from Ph-negative ET, showing a marked propensity either to develop typical CGL or to transform into acute leukaemia [31]. ET may terminate in acute leukaemia or myelofibrosis but, if Ph-positive cases are excluded, the chronic phase of the disease is usually very long. No accurate data are available on the prognosis of ET in the absence of treatment since, before the general availability of automated blood cell counters, only the more severe cases were recognized. With treatment modalities currently available, life expectancy shows little reduction from normal.

A platelet count of at least $600 \times 10^9/l$ is usually required to establish a diagnosis of ET but it has been suggested that the diagnosis can sometimes be made with a lower count [47]; such patients may have thrombotic complications, splenomegaly and typical histological features.

Peripheral blood

The blood film shows an increased number of platelets with the average platelet size being increased. There are usually some giant platelets and agranular and hypogranular platelets; platelet aggregates may also be present. Occasional bare megakaryocyte nuclei are seen. Mild leucocytosis, neutrophilia and occasional immature granulocytes may be present but the white cell count does not usually exceed $20 \times 10^9/l$. Absolute basophilia is sometimes present but the presence of more than

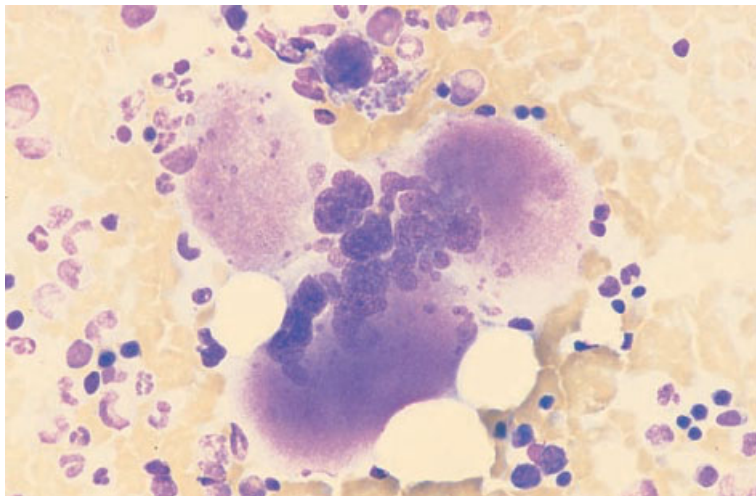


Fig. 5.25 BM aspirate, ET, showing four megakaryocytes, one of which is small while three are very large with hyperlobulated nuclei. MGG $\times 377$.

3–5% of basophils is predictive of the case being Ph positive [31,48]. In patients who have suffered splenic infarction, the usual changes of hyposplenism will be found—Howell–Jolly bodies, acanthocytes, target cells and occasional spherocytes. Patients who have suffered haemorrhagic episodes may show features of iron deficiency.

Bone marrow cytology

The bone marrow aspirate shows an increase in megakaryocytes which are generally large and well lobulated (Fig. 5.25). In some cases there is an overall increase in cellularity due to granulocytic hyperplasia.

In patients who are treated with anagrelide, a reduction in megakaryocyte size has been observed [49].

Bone marrow histology [5,9,41]

Trephine biopsy findings are extremely variable and in some cases there may be no specific diagnostic features [41]. The marrow is usually hypercellular, although this is not as marked as in the other MPD. Sometimes the bone marrow is normocellular or even hypocellular. Megakaryocytes are increased in number in all cases but the degree of hyperplasia is very variable and does not correlate closely with the platelet count. Large clusters of megakaryocytes are commonly seen (Fig. 5.26). The average size of

megakaryocytes is increased, as is the lobulation of their nuclei (Fig. 5.27); the nuclear chromatin pattern is normal, in contrast to the hyperchromatic nuclei which may be seen in primary myelofibrosis [5]. In comparison with PRV, megakaryocytes in ET are less pleomorphic and micromegakaryocytes are not increased. Some may be sited abnormally, close to the endosteum of trabeculae, and emperipolesis and mitotic figures are increased [9]. There may be mild or moderate granulocytic and erythroid hyperplasia. A mild focal increase in reticulin sometimes occurs but, if there is marked reticulin fibrosis, a diagnosis of primary myelofibrosis with thrombocytosis is more likely.

In patients with ET who are treated with anagrelide, reduction in megakaryocyte size has been noted [49].

Cytogenetics and molecular genetics

A minority of patients with ET have a clonal cytogenetic abnormality. Cases which are found to have $t(9;22)(q34;q11)$ have a worse prognosis and should be reclassified as a variant of CGL or as ‘Ph-positive essential thrombocythaemia’.

Problems and pitfalls

It is necessary to distinguish ET from reactive thrombocytosis. Making a distinction from CGL is also important but distinguishing ET from other

Fig. 5.26 BM trephine biopsy section, ET, showing mild hypercellularity with a marked increase in megakaryocytes which are forming large clusters. Plastic-embedded, H&E $\times 97$.

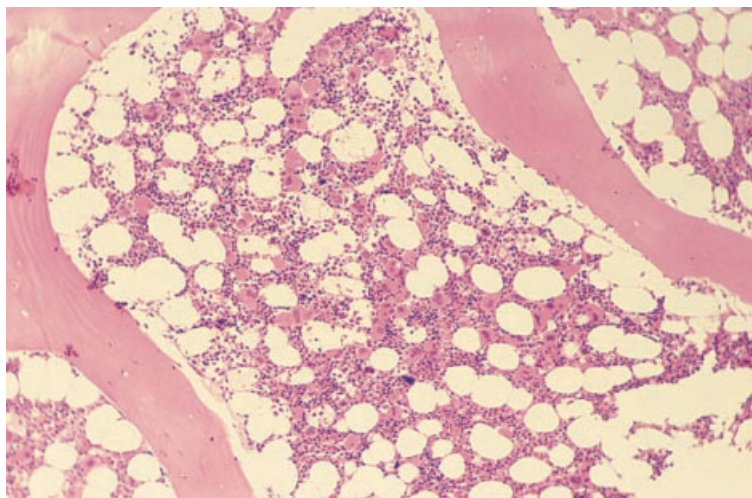
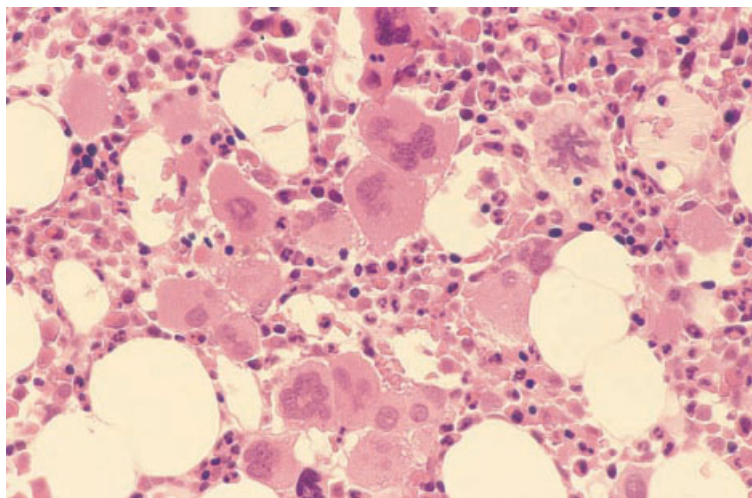


Fig. 5.27 BM trephine biopsy section, ET, showing clustering of megakaryocytes. The megakaryocytes are mainly large and hyperlobulated, although some small forms are present. Plastic-embedded, H&E $\times 390$.



MPD is of less importance since there are fewer prognostic and therapeutic implications.

Peripheral blood features can be useful in distinguishing reactive thrombocytosis from ET. In ET there are often giant platelets, some agranular platelets and occasionally circulating megakaryocyte nuclei whereas, in reactive thrombocytosis, the platelets are small and normally granulated and circulating megakaryocyte nuclei are not seen. In reactive thrombocytosis, basophilia is not seen and neutrophilia is usually absent.

In reactive thrombocytosis, the bone marrow aspirate and trephine biopsy often show an increase

in megakaryocyte number and size and an increase in emperipolesis but megakaryocytes are cytologically normal; they do not occur in large clusters or close to the endosteum [9]. The bone marrow reticulin is also normal. Bone marrow cellularity is usually increased in ET and normal in reactive thrombocytosis. However, it should be noted that, in contrast to other MPD, the bone marrow cellularity is sometimes normal or reduced in ET.

ET can be confused with other MPD, particularly with the cellular phase of myelofibrosis and with PRV complicated by iron deficiency. Peripheral blood features are not usually helpful since giant

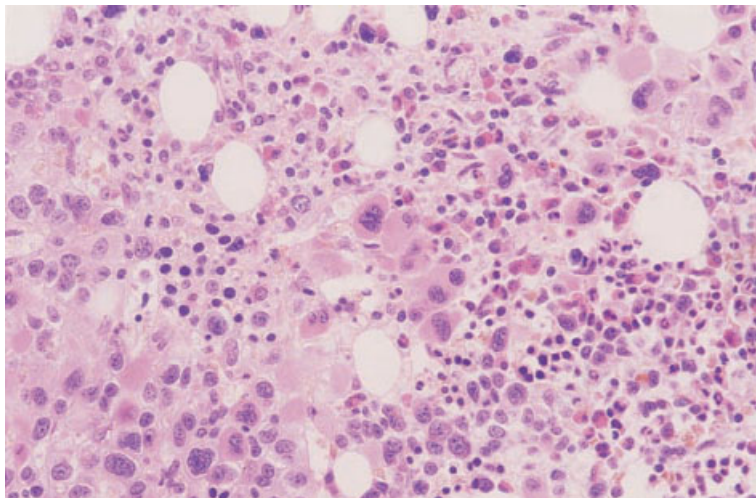


Fig. 5.28 BM trephine biopsy section in Ph-positive ET, showing marked megakaryocytic hyperplasia; the average size of megakaryocytes is reduced and there is a tendency to hypolobulation; granulocytic hyperplasia was minimal. Paraffin-embedded, H&E $\times 188$. (By courtesy of Dr R Cuthbert, Londonderry.)

platelets, agranular platelets, megakaryocyte fragments, neutrophilia and basophilia can be seen in any MPD. The bone marrow aspirate and trephine biopsy are more useful. In the cellular phase of myelofibrosis there is often quite marked megakaryocyte dysplasia whereas, in ET, the megakaryocytes are cytologically more normal. Although megakaryocytic dysplasia also tends to be more marked in PRV than in ET, making a distinction between these two conditions on histological grounds can be difficult. Some authors have considered that the lack of atypia of megakaryocytes in thrombocythaemia permits a distinction to be made [9], whereas others have suggested that, in the majority of instances, the two conditions cannot be distinguished on this basis [31]. If clinical, haematological and histopathological features are all considered, then genuine diagnostic difficulty occurs only in cases with complicating iron deficiency. Otherwise, the haemoglobin concentration and red cell mass are increased in PRV and normal in ET. A therapeutic trial of iron therapy permits the distinction to be made but is not a justifiable procedure since making a precise diagnosis does not influence therapy. In either case the clinician will seek to keep both the haemoglobin concentration and the platelet count normal.

It is desirable for cytogenetic analysis to be performed in all patients in whom a diagnosis of ET appears likely. However, if such analysis is not

performed as a routine, it should at least be performed whenever there are any features suggesting the possibility of Ph positivity. The neutrophil alkaline phosphatase has been found to be unhelpful in identifying Ph-positive cases, whereas a marked increase in the basophil count and the presence of sheets of atypical megakaryocytes (Fig. 5.28) have been found to be predictive and are an indication for cytogenetic analysis.

Occasional cases of systemic mastocytosis present with thrombocytosis as their predominant haematological manifestation. Careful examination of the trephine biopsy sections should permit their distinction from ET.

Myeloproliferative disease, unclassifiable

Occasional patients are seen who clearly have an MPD but whose disease either cannot be readily classified or, alternatively, has characteristics of two, usually distinct, MPD. This is acknowledged by the inclusion in the WHO classification of a category for unclassifiable cases. Others have already drawn attention to this group.

Pettit *et al.* [50] reported a group of patients with a condition intermediate between PRV and idiopathic myelofibrosis which they designated 'transitional myeloproliferative disorder'. In these patients the criteria for PRV were generally met but, in addition, there was moderate or marked splenomegaly, a

leuco-erythroblastic blood film, extramedullary haemopoiesis and a hypercellular marrow with increased reticulin. In the majority of patients the condition had stable characteristics for a number of years and thus did not represent a transient phase between PRV and post-polycythaemic myelofibrosis.

The Polycythaemia Vera Study Group [40] have used the designation 'undifferentiated chronic myeloproliferative disorder' for another group of patients with splenomegaly and a leuco-erythroblastic blood film without an increased red cell mass, Ph chromosome or significant marrow fibrosis.

Patients have also been described with features of both systemic mastocytosis and a variety of MPD, including CML, PRV, ET and idiopathic myelofibrosis [51] (see below). Such cases are probably best categorized as 'myeloproliferative disease, unclassifiable'.

The existence of patients with characteristics of two MPD, or with features of an MPD without specific features allowing assignment to a defined disease category, is not surprising since: (i) all MPD are the result of proliferation of a multipotent myeloid stem cell with the potential for differentiation into cells of various lineages; and (ii) reticulin and collagen deposition are a common secondary change in various subtypes of chronic MPD.

Myeloproliferative/myelodysplastic disorders

Chronic myelomonocytic leukaemia

CMML has features both of myelodysplasia and of myeloproliferation. The WHO group has recommended that this condition be assigned to a new group, designated 'myelodysplastic/myeloproliferative diseases', rather than being classified as one of the MDS. It does not support previous proposals that cases of CMML should be divided into MDS-type and MPD-type. As defined by the French–American–British (FAB) group [52], the peripheral blood monocyte count in CMML is greater than $1 \times 10^9/l$ but peripheral blood blasts are less than 5% and bone marrow blasts not greater than 20%. The WHO criteria will probably be similar. CMML needs to be distinguished from aCML with which it shares some features. It has been recommended that cases in which more than

15% of circulating white cells are granulocyte precursors should be categorized as aCML and cases with fewer as CMML [2]. Although a bone marrow examination is essential for the diagnosis of CMML, careful consideration of the peripheral blood features is equally important in the differential diagnosis. A trephine biopsy offers only supplementary information.

Clinically, CMML is characterized by features of anaemia and, often, by hepatomegaly and splenomegaly. In a minority of patients there is tissue infiltration by monocytic cells resulting in lymphadenopathy, skin infiltration and serous effusions. Diagnosis is usually either incidental or occurs when the patient develops symptoms of anaemia or when organomegaly is noted.

Peripheral blood

There is usually anaemia, most often normocytic but sometimes macrocytic or with a dimorphic blood film. There is monocytosis. The monocytes may be morphologically normal or may show atypical features such as nuclei of bizarre shapes or increased cytoplasmic basophilia or granulation. The neutrophil count is often elevated but this is not necessary for the diagnosis. The neutrophils may be morphologically normal or a varying proportion may show dysplastic features. Granulocyte precursors are infrequent, usually less than 5%. Occasional blasts may be present. The platelet count may be normal or low.

Bone marrow cytology

The bone marrow is hypercellular. There is hyperplasia of granulocyte precursors (Fig. 5.29). Hyperplasia of monocytes and their precursors is often evident but this is not always so, probably because promonocytes can be difficult to distinguish from promyelocytes and because mature monocytes leave the marrow early. The blast count in the marrow may be increased up to a level of 20%. Some patients have dysplastic erythroblasts and megakaryocytes but this is not necessarily so. Sideroblastic erythropoiesis is not inconsistent with a diagnosis of CMML.

An iron stain may show abnormal sideroblasts or increased iron stores. A myeloperoxidase (MPO) or

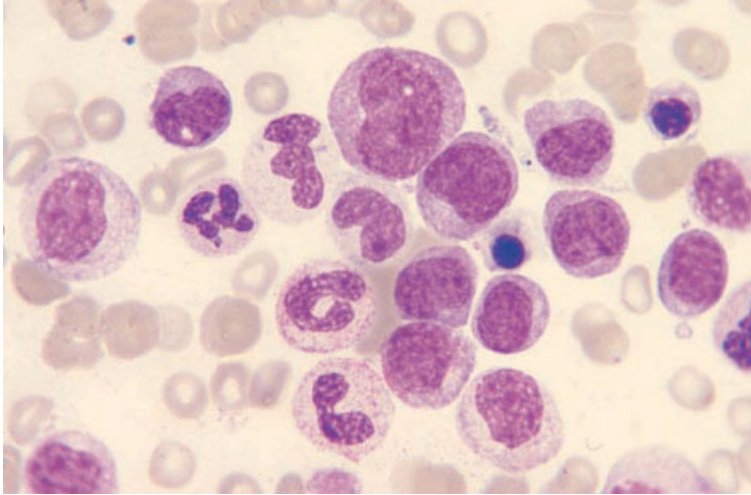


Fig. 5.29 BM aspirate, CMML, showing granulocytic hyperplasia. MGG $\times 940$.

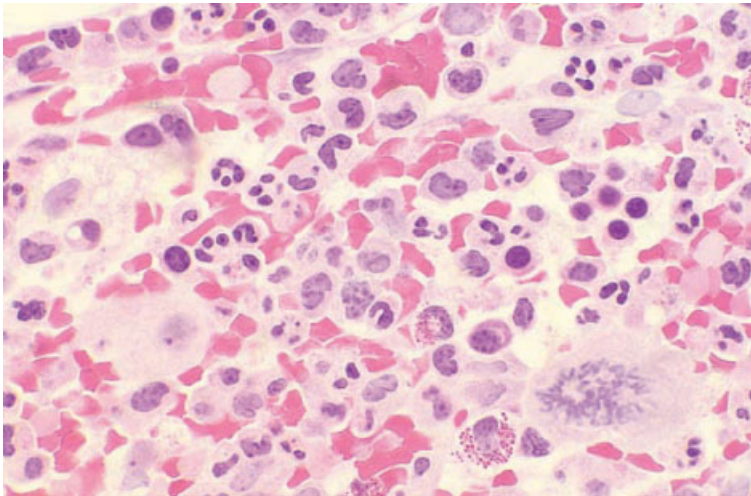


Fig. 5.30 BM trephine biopsy section in CMML, showing neutrophilic and monocytic hyperplasia, a hypolobulated megakaryocyte and a megakaryocyte in mitosis. Paraffin-embedded, H&E $\times 390$. (By courtesy of Dr D Swirsky, Leeds.)

Sudan black B (SBB) stain should be performed in all cases with an increase of blast cells, both to confirm the lineage and to exclude the presence of Auer rods. A non-specific esterase stain such as α -naphthyl acetate esterase is useful in identifying monocyte precursors.

Bone marrow histology

The diagnosis of CMML is usually established from peripheral blood and bone marrow aspirate features; trephine biopsy does not have a major role in

diagnosis. Almost all cases have a hypercellular marrow and granulocytic hyperplasia. Some also show monocytic hyperplasia (Fig. 5.30). Some, but not all, cases show erythroid and megakaryocytic dysplasia. Abnormal localization of immature precursors (see page 175) is sometimes present and there may be an absolute increase in blasts.

Atypical chronic myeloid leukaemia

aCML [2,53,54] is a rare Ph-negative condition with a higher median age of onset and a worse

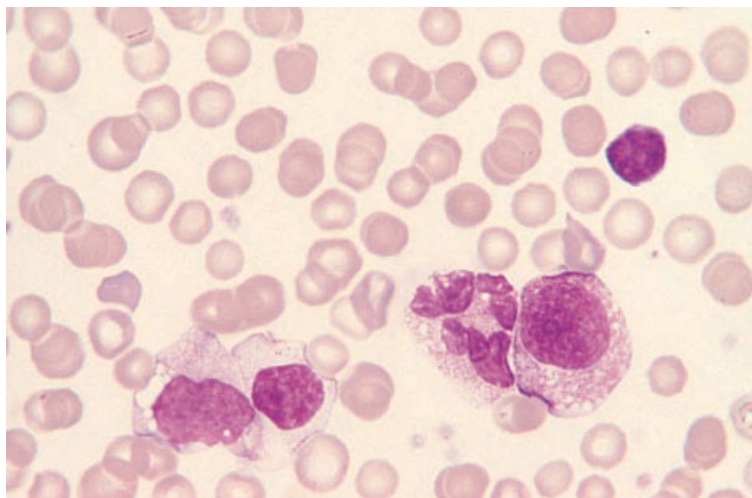


Fig. 5.31 PB, aCML (Ph-negative), showing a myelocyte, a bizarre macropolycyte, an abnormal monocyte, an unidentifiable cell and a lymphocyte. MGG $\times 940$.

prognosis than CGL. The WHO group has recommended the term 'atypical chronic myelogenous leukaemia' for this disorder. Common clinical features are anaemia and splenomegaly. The disorder appears to arise in a multipotent myeloid stem cell or possibly, since occasional lymphoblastic transformations have been observed, in a pluripotent stem cell.

Assessment of peripheral blood features is of major importance in the diagnosis of aCML. Bone marrow cytology and histology are of less importance.

Peripheral blood

The white cell count is elevated with an increase of neutrophils and their precursors (Fig. 5.31). Monocytosis is more marked than in CGL while eosinophilia and basophilia are less marked and may be absent. The white cell count at presentation is, on average, not as high as in CGL while the anaemia is more severe. The platelet count is not often elevated but is commonly reduced. Maturation of cells is less normal than in CGL and dysplastic features may be present. Distinction from CMML is largely on the basis of the sum of promyelocytes, myelocytes and metamyelocytes being 15% or higher in aCML but usually less than 5% in CMML [2].

Bone marrow cytology

The bone marrow is hypercellular. Both granulocytic and monocytic precursors are increased (Fig. 5.32), although the cellularity is not increased to the extent that is seen in CGL and the myeloid: erythroid ratio is generally less than 10:1. Blasts may be increased but do not exceed 20% (if using the WHO classification) or 30% (if using the FAB classification). Megakaryocytes are decreased in about a third of cases.

Bone marrow histology

The marrow histology in aCML may closely resemble that of CGL, particularly when examined at low power. There is marked hypercellularity with predominance of the granulocytic series. Erythroblasts are distributed as single cells or small groups throughout the marrow with well-formed erythroblastic islands being difficult to identify. Megakaryocytes may be increased in number and are sometimes morphologically abnormal. When monocytes are increased (Fig. 5.33), this is the feature that most readily distinguishes aCML from CGL. The monocytes are recognized by their irregular nuclei with a diffuse chromatin pattern and moderate amounts of cytoplasm which stains pink with H&E. aCML shows a variable degree of reticulin fibrosis and

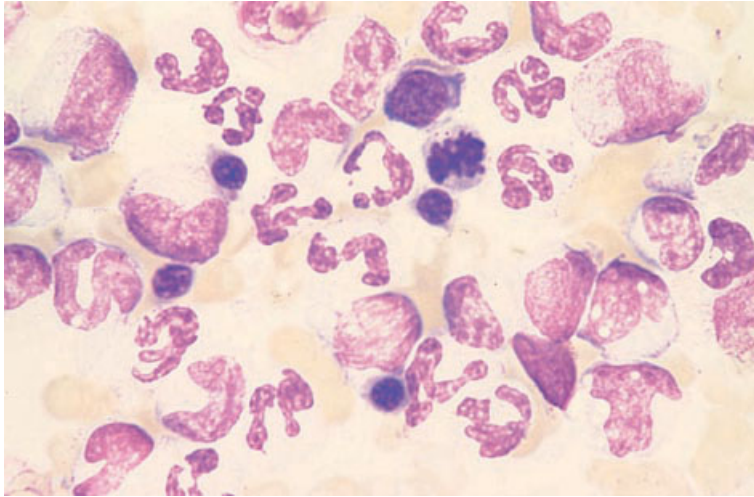


Fig. 5.32 BM aspirate, aCML (same patient as in Fig. 5.31), showing granulocytic and monocytic hyperplasia. MGG $\times 940$.

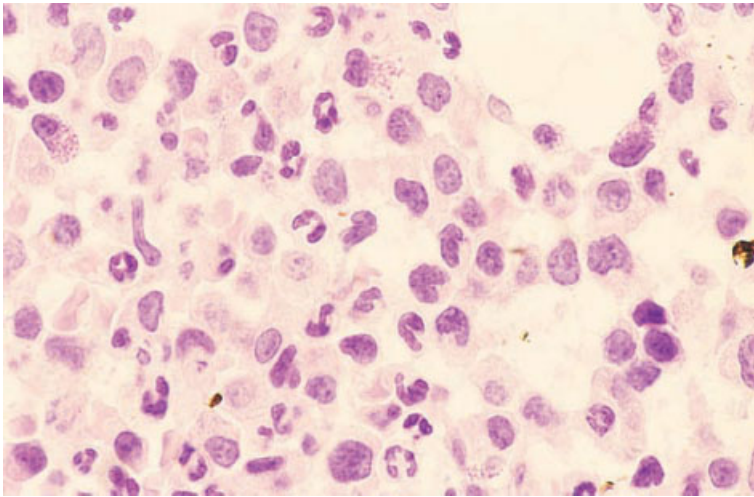


Fig. 5.33 BM trephine biopsy section, aCML, showing granulocytic hyperplasia and numerous abnormal monocytes. Paraffin-embedded, H&E $\times 970$.

collagen deposition and osteosclerosis can occur. Making the distinction between aCML and CGL is often not possible on histological grounds alone. Likewise, CMML and aCML cannot be distinguished histologically; consideration of the blood count and film is necessary.

Cytogenetics and molecular genetics

There is no specific cytogenetic or molecular genetic abnormality associated with aCML. Some cases are cytogenetically normal while others show clonal cytogenetic abnormalities such as trisomy 8.

Problems and pitfalls

Leukaemoid reactions can sometimes simulate aCML. Consideration of the clinical features permits the correct diagnosis. Cytogenetic and molecular genetic analysis may be necessary to distinguish aCML from cases of CGL presenting in accelerated phase.

Juvenile myelomonocytic leukaemia

Juvenile myelomonocytic leukaemia (JMML) is a Ph-negative condition which occurs mainly in

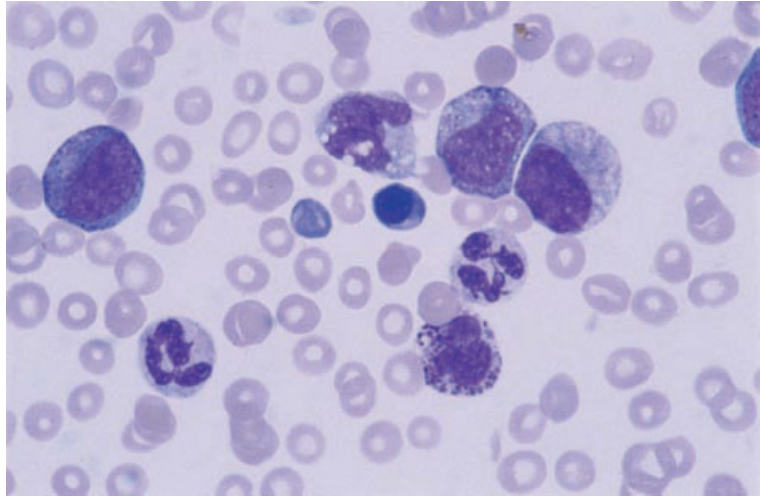


Fig. 5.34 PB, JMML, showing a monocyte, a basophil, dysplastic neutrophils, neutrophil precursors and thrombocytopenia. MGG $\times 376$.

children less than 5 years of age. This term, recommended both by the WHO group and by several international working groups on childhood MDS, encompasses not only the condition previously designated 'juvenile chronic myeloid leukaemia' but also the infantile monosomy 7 syndrome and other myelodysplastic/myeloproliferative diseases of childhood [1, 55]. There is an increased incidence in children with neurofibromatosis and in Down's syndrome. Clinical features often include anaemia, hepatomegaly, splenomegaly, lymphadenopathy and rash. Erythropoiesis may show reversion to features of fetal erythropoiesis.

Peripheral blood

The blood film (Fig. 5.34) shows neutrophilia, prominent monocytosis and sometimes immature granulocytes or nucleated red blood cells. Anaemia and thrombocytopenia are usual. In cases in which haemoglobin F is increased, a Kleihauer test shows a population of haemoglobin F-containing cells (Fig. 5.35).

Bone marrow cytology

The bone marrow shows granulocytic and sometimes monocytic hyperplasia. There may be dysplastic features (Fig. 5.36).

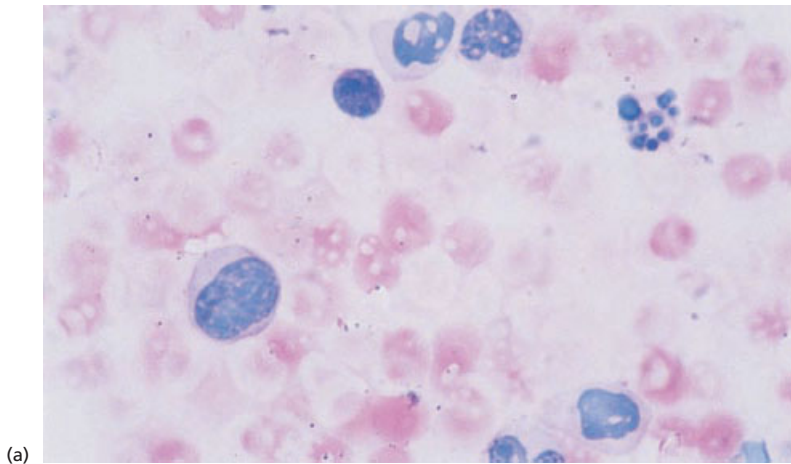
Cytogenetics and molecular genetics

Cases of JMML lack the Ph chromosome and the *BCR-ABL* fusion gene. Many cases are cytogenetically normal at presentation but develop clonal cytogenetic abnormalities during the course of the disease. Overall, 40–67% have been reported to be cytogenetically normal, 25–33% have been found to have monosomy 7, and 10–25% to have had other chromosomal abnormalities including trisomy 8 and other abnormalities of chromosome 7 [55].

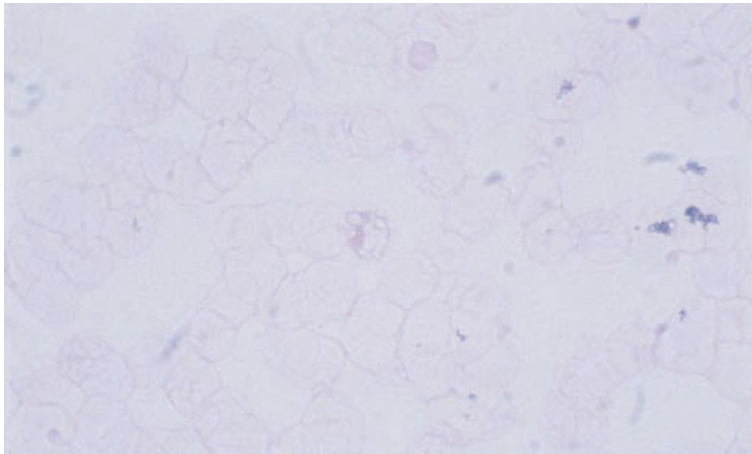
About 15% of children with JMML have clinical features of neurofibromatosis, such as café-au-lait spots. These children have a constitutional abnormality of one *NF1* gene and often an acquired deletion of the normal allele. In addition to children with clinical features of neurofibromatosis, a similar number of patients with JMML have been found to have mutations of the *NF1* gene without clinical features of the disease [55]. Mutations of the *RAS* oncogene are also common, being observed in 15–30% of patients. Since the *NF1* gene product is a negative regulator of *RAS*, the mechanism of leukaemogenesis may be related. Cases reported to date have shown either *NF1* mutation or *RAS* mutation but not both [55].

Problems and pitfalls

Leukaemoid reactions resulting from herpesvirus



(a)



(b)

Fig. 5.35 Kleihauer test on PB of patient with JMML (same case as in Fig. 5.34), showing numerous haemoglobin F-containing cells which stain pink. (a) Patient. (b) Negative control. Kleihauer tests $\times 940$.

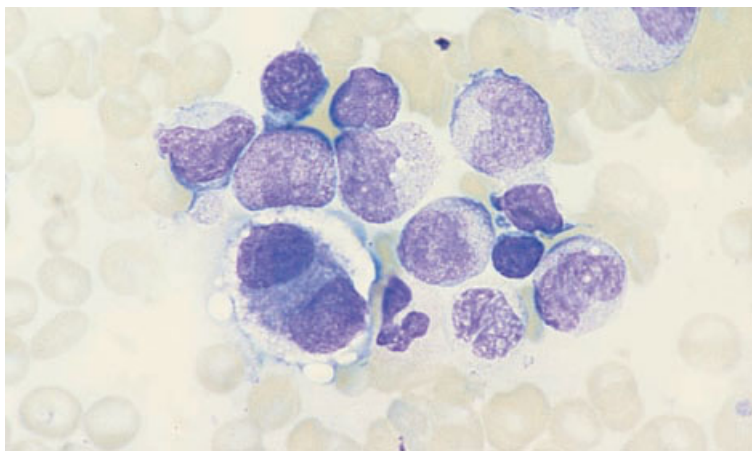


Fig. 5.36 BM aspirate, JMML, showing granulocyte precursors and a dysplastic binucleated micromegakaryocyte. MGG $\times 940$.

infections can simulate JMML; such reactions have been observed following Epstein–Barr virus infection, cytomegalovirus infection and human herpesvirus 6 infection. Reversion to features of fetal erythropoiesis, such as an increased concentration of haemoglobin F and a decreased concentration of red cell carbonic anhydrase and haemoglobin A₂, are features of JMML but not of leukaemoid reactions. Investigation of these features plus cytogenetic analysis and appropriate viral studies can be useful when there is diagnostic difficulty.

Other myelodysplastic/myeloproliferative diseases

In addition to those who conform to the three categories specific to myelodysplastic/myeloproliferative disorders of the WHO classification, there are other patients with features of both myelodysplasia and myeloproliferation [56]. For example, coexistence of sideroblastic erythropoiesis and thrombocytosis is relatively common [57]. In addition, a number of patients have been described with systemic mastocytosis and either a myelodysplastic syndrome or a myelodysplastic/myeloproliferative disease. Diagnoses have included refractory anaemia, refractory anaemia with ring sideroblasts, refractory anaemia with excess of blasts and CMML [51]. These less clearly defined disorders are appropriately assigned to the category ‘other myelodysplastic/myeloproliferative diseases, unclassified’.

Other myeloproliferative disorders

Systemic mastocytosis

Mast cell proliferation may be confined to the skin or may be generalized, the latter condition being designated systemic mastocytosis or systemic mast cell disease. Systemic mastocytosis is a rare condition characterized by neoplastic proliferation of mast cells. Mast cells are derived from a myeloid stem cell and the mast cell proliferation is often associated with hyperplasia of other myeloid lineages. It therefore seems logical to classify systemic mastocytosis as a myeloproliferative disorder and acute mast cell leukaemia as one of the acute myeloid leukaemias. It should be noted, however, that the WHO group has assigned systemic mastocytosis to a group designated ‘mast cell disease’

Table 5.3 The WHO classification of mast cell diseases.

Cutaneous mastocytosis
Systemic mast cell disease (± skin involvement)
Systemic mast cell disease with associated haematological disorder (± skin involvement)
Mast cell leukaemia/sarcoma

(Table 5.3). Mast cell leukaemia has been included in this group rather than with the other acute leukaemias [1].

Various organs may be involved in systemic mastocytosis, including the bone marrow, liver, spleen, lymph nodes and skin; the most typical skin lesions are those of urticaria pigmentosa. Patients often have symptoms related to the release of secretory products by the neoplastic mast cells; these include abdominal pain, nausea and vomiting, diarrhoea, flushing and bronchospasm [58–60]. Systemic mastocytosis may pursue either an indolent or an aggressive clinical course. The term ‘malignant mastocytosis’ is sometimes used to describe systemic mast cell disease with a rapidly progressive clinical course. Prognosis is worst in the minority of patients with overt mast cell leukaemia. Patients with an aggressive course are less likely to have skin involvement and more likely to have hepatomegaly, splenomegaly, leucocytosis, anaemia and thrombocytopenia [61,62]. Although patients can be divided into two or three groups with varying prognosis on the basis of clinical and haematological features [61,62], there is actually a continuous spectrum of disease characteristics.

Patients with systemic mastocytosis may develop myelodysplasia, all five FAB categories of MDS having been observed [63]. Systemic mastocytosis may also terminate in AML, sometimes appearing *de novo* and sometimes following a period of myelodysplasia. The leukaemia is occasionally mast cell leukaemia but more often is another category of AML. Commonest are acute myeloblastic or acute myelomonocytic leukaemia (FAB categories M1, M2 and M4) but occasional cases of erythroleukaemia or megakaryoblastic leukaemia (FAB categories M6 and M7) have also been reported [63].

Peripheral blood [60,62,64,65]

In patients with an indolent clinical course the peripheral blood is most often normal but a

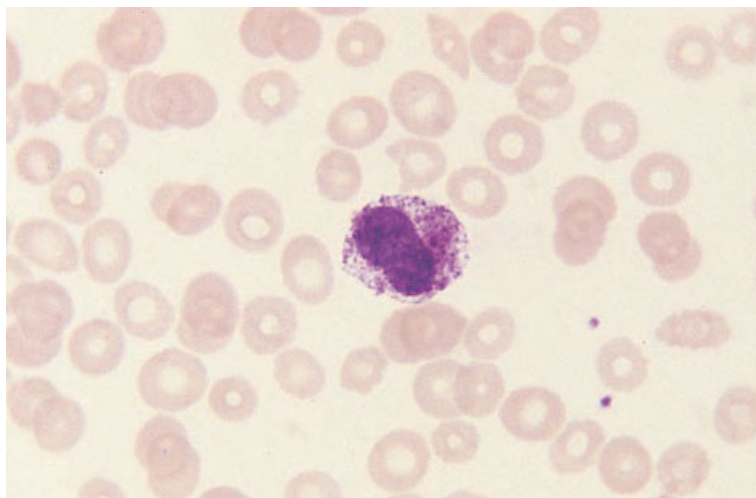


Fig. 5.37 PB, mast cell leukaemia, showing a hypogranular mast cell. MGG $\times 940$.

minority of patients show evidence of abnormal proliferation of cells of one or more myeloid lineages (neutrophilia, eosinophilia, basophilia, monocytosis, thrombocytosis). Circulating mast cells are usually not noted.

In patients who pursue an aggressive clinical course, peripheral blood evidence of an MPD is more prominent. The majority of patients have neutrophilia, many have eosinophilia, basophilia or monocytosis, and a minority have thrombocytosis. Cytopenias are also common, particularly anaemia and thrombocytopenia but sometimes leucopenia and neutropenia. Hypogranular and hypersegmented eosinophils, resembling those seen in the idiopathic hypereosinophilic syndrome, may be present [65]. In some patients the peripheral blood features cannot be distinguished from those of CML. Some patients have myelodysplastic features such as the acquired Pelger–Huët anomaly of neutrophils. Occasional patients have circulating mast cells, usually in small numbers (Fig. 5.37). In the few patients in whom mast cell leukaemia supervenes there are larger numbers of circulating mast cells, usually with atypical cytological features such as hypogranularity or nuclear lobulation (see Fig. 4.25).

Bone marrow cytology

The bone marrow aspirate is normo- or hypercellular and contains increased numbers of mast cells (Fig. 5.38). These may be under-represented in

an aspirate in comparison with a trephine biopsy because of the fibrosis provoked by mast cell proliferation. They may also remain in the fragments so that fragments as well as cell trails should be examined carefully. Clusters of mast cells may be present [64]. When mast cells are cytologically normal they are easily identifiable as oval or elongated cells with a central non-lobulated nucleus and with the cytoplasm packed with purple granules; when they are cytologically atypical they may be confused with basophils. Atypical features include nuclear lobulation (Fig. 5.39), smaller granules than normal, hypogranularity (Fig. 5.39) and a primitive chromatin pattern. In patients who pursue an indolent clinical course, the bone marrow is usually normocellular and contains a relatively small number of cytologically normal mast cells. Those patients who pursue an aggressive clinical course are more likely to show a hypercellular marrow with granulocytic hyperplasia and larger numbers of mast cells which, in some cases, are cytologically atypical. Granulocytic hyperplasia may include neutrophil, eosinophil and basophil lineages. In some cases there are myelodysplastic features such as ring sideroblasts and in some there is megakaryocytic hyperplasia. The bone marrow appearances may be confused with those of CGL if the presence of large numbers of mast cells is not appreciated.

Mast cells stain with alcian blue as well as with Romanowsky stains (such as Giemsa and May–Grünwald–Giemsa, MGG) and stain metachromat-

Fig. 5.38 BM aspirate, systemic mastocytosis, showing an intensely hypercellular fragment due mainly to granulocytic hyperplasia. MGG ×94.

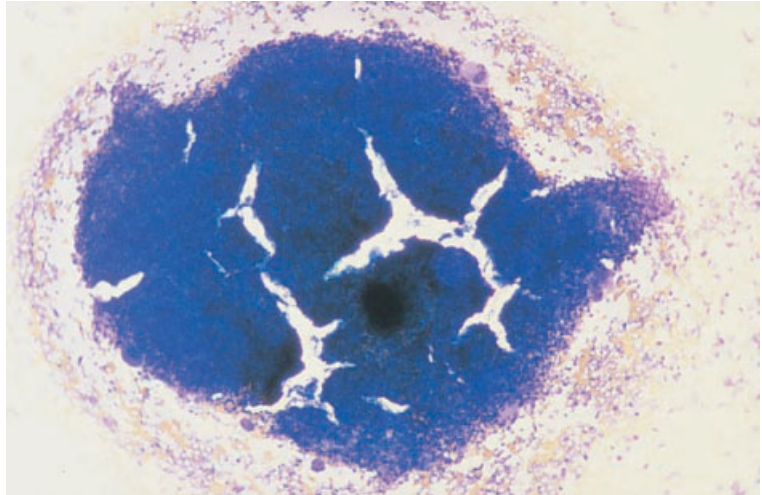
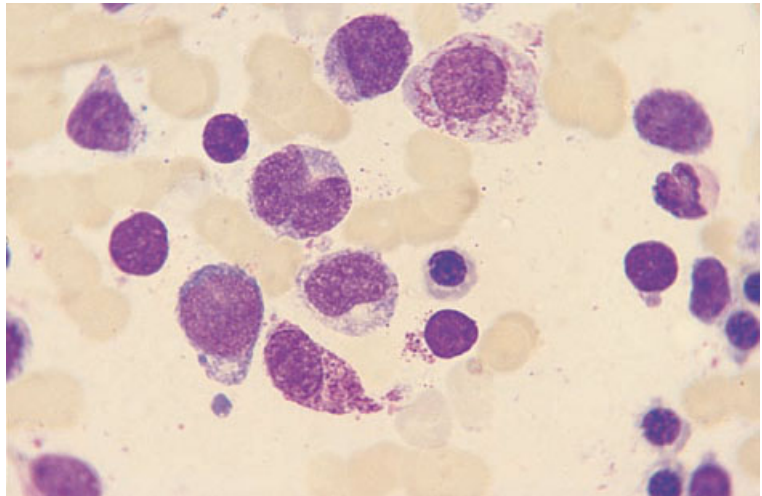


Fig. 5.39 BM aspirate, systemic mastocytosis, showing two abnormal mast cells and three cells which are probably mast cell precursors. One mast cell is hypogranular and both have a higher nucleocytoplasmic ratio than normal mast cells. MGG ×940.



ically with toluidine blue; they are MPO- and SBB-negative and periodic acid–Schiff- (PAS) and chloro-acetate esterase-positive. By immunocytochemistry or immunofluorescence, mast cells react positively with monoclonal antibodies of CD33, CD45 and CD68 clusters and with monoclonal antibodies directed against mast cell tryptase.

Bone marrow histology

The marrow biopsy histology is abnormal in the vast majority of cases [58,59,66] (Fig. 5.40). The most

common finding is focal infiltration by mast cells, often in paratrabecular and perivascular areas or as intertrabecular nodules. Perivascular lesions may be associated with prominent medial and adventitial hypertrophy and collagen fibrosis. There may be layers of mast cells encircling vessels (Fig. 5.41). Eosinophils are present in variable numbers, often concentrated at the periphery of the infiltrated areas (Figs 5.42 and 5.43). Lymphocytes, plasma cells, macrophages and fibroblasts are also frequently seen in the areas of infiltration. Occasionally, lymphocytes are aggregated either at the centre or at

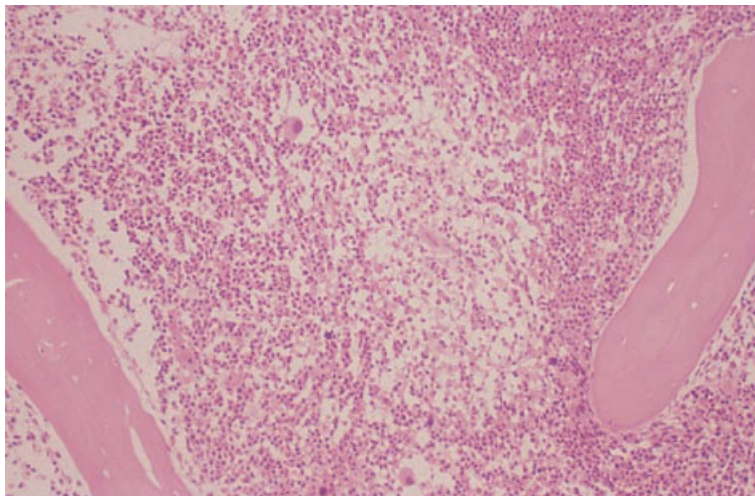


Fig. 5.40 BM trephine biopsy section, systemic mastocytosis, showing marked hypercellularity with a loose focal aggregate of mast cells (centre). Paraffin-embedded, H&E $\times 97$.

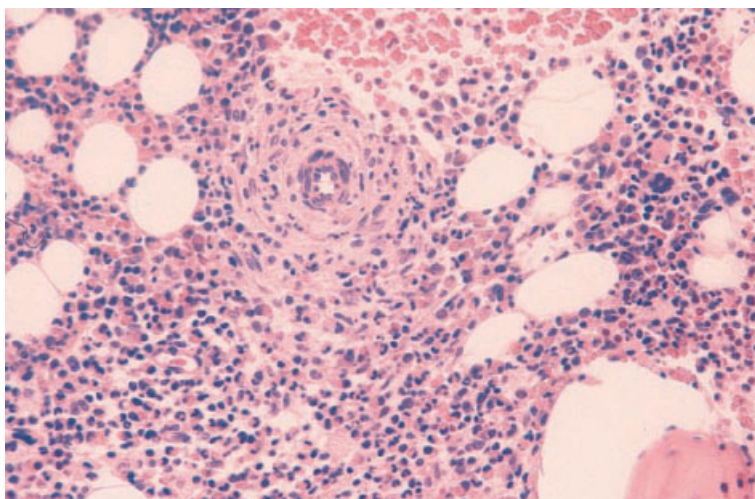


Fig. 5.41 BM trephine biopsy section, systemic mastocytosis, showing concentric mast cells encircling a vessel. Paraffin-embedded, H&E $\times 235$. (By courtesy of Dr BI Dalal, Vancouver.)

the periphery of a focal lesion [59,67]; immunocytochemical analysis has shown the lymphocytes to be a mixture of B and T cells [68]. There is usually a dense network of reticulin fibres associated with the infiltrate and, sometimes, collagen deposition. There may be osteosclerosis, osteoporosis or evidence of increased bone turnover with osteoclasts, osteoblasts and the amount of osteoid all being increased [67]; paratrabecular fibrosis, which is sometimes present, may be related to increased bone turnover.

The morphology of the mast cells is variable and this may cause difficulty in their recognition,

especially in H&E-stained sections. They may be either spindle shaped, thus resembling fibroblasts (Fig. 5.44), or have abundant pale pink cytoplasm and irregularly shaped nuclei leading to confusion with macrophages. A Giemsa stain shows purple cytoplasmic granules (see Fig. 5.43) although these are often quite scanty. With a toluidine blue stain, the granules are deep pink or purple (Fig. 5.45). Decalcification of specimens may lead to loss of metachromatic staining with toluidine blue. Zenker's and B5 fixatives may interfere with both Giemsa and toluidine blue reactivity. Mast cells have chloro-acetate esterase activity which may

Fig. 5.42 BM trephine biopsy section, systemic mastocytosis (same case as in Fig. 5.40), showing numerous abnormal mast cells—with marked variation in nuclear shape and moderate amounts of pale-staining cytoplasm—eosinophils and small numbers of lymphocytes. Paraffin-embedded, H&E $\times 970$.

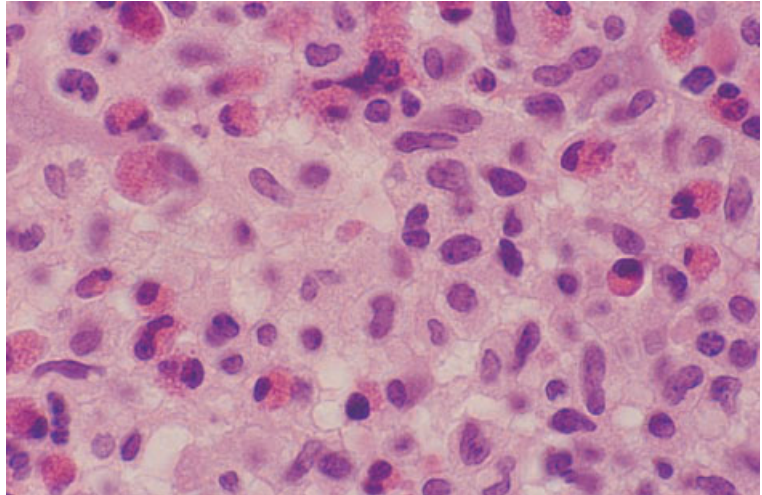
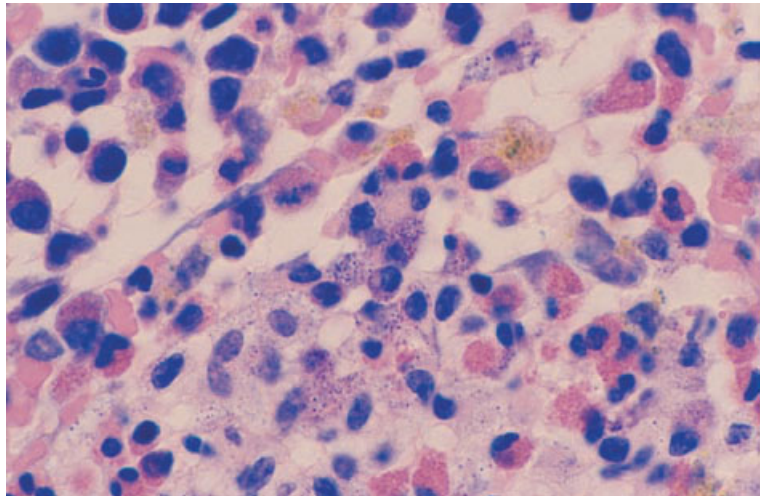


Fig. 5.43 BM trephine biopsy section, systemic mastocytosis (same case as in Fig. 5.40), showing basophilic granules in the cytoplasm of mast cells. Paraffin-embedded, Giemsa $\times 970$.



be demonstrated in both paraffin- and plastic-embedded sections using Leder's stain; however, this stain does not work well in decalcified paraffin-embedded specimens and it should be noted that neutrophil myelocytes will also stain strongly. In plastic-embedded specimens, ϵ -aminocaproate activity, which is specific for mast cells, can be demonstrated. Immunohistochemistry using monoclonal CD68 (Fig. 5.46) or anti-mast cell tryptase (Fig. 5.47) antibodies is useful. Mast cell tryptase is the preferred immunohistochemical stain since it has a high degree of specificity and sensitivity. Mast cells also express vimentin, CD45, lysozyme, S100,

α_1 -antitrypsin and α_1 -antichymotrypsin [69]. About two thirds of cases give positive reactions with a monoclonal antibody to tartrate-resistant acid phosphatase [70].

Diffuse replacement of the marrow by neoplastic mast cells occurs infrequently. In these cases the infiltrate is much more monomorphic than when lesions are focal. The mast cells are usually spindle shaped and may show nuclear atypia. There is marked reticulin fibrosis and osteosclerosis is often present. Often there are atypical mast cells in the peripheral blood allowing a diagnosis of mast cell leukaemia to be made [66].

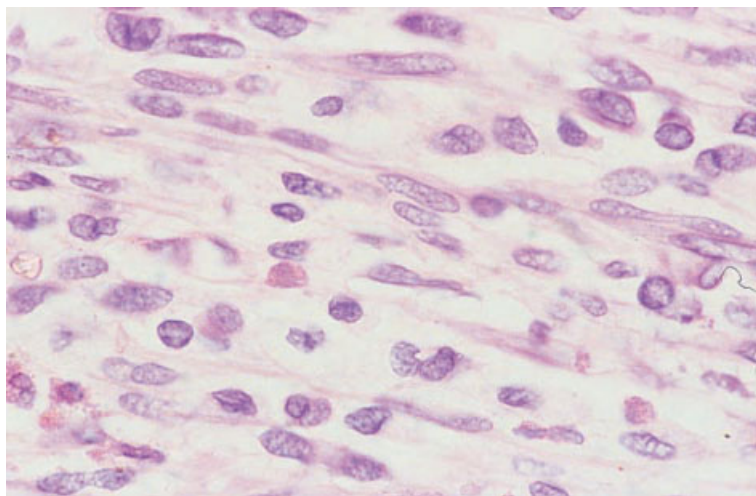


Fig. 5.44 BM trephine biopsy section, systemic mastocytosis, showing spindle-shaped mast cells. Paraffin-embedded, H&E $\times 940$. (By courtesy of Dr Wendy Erber and Dr L Matz, Perth, Western Australia.)

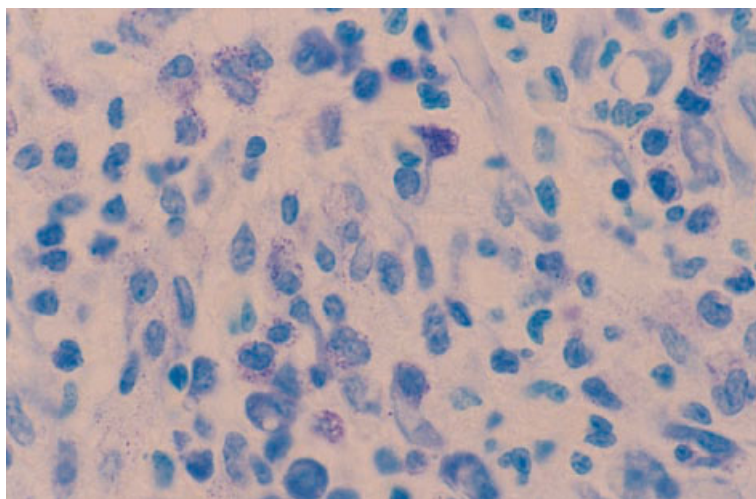


Fig. 5.45 BM trephine biopsy section, systemic mastocytosis (same case as in Fig. 5.40), showing purple metachromatic granules in the cytoplasm of mast cells. Paraffin-embedded, toluidine blue $\times 970$.

Lennert and Parwaresch [61] have used the marrow biopsy findings to divide patients into prognostic groups. They have described three main patterns of involvement: (i) type I, in which there is focal infiltration, but the intervening haemopoietic marrow is normal; (ii) type II, in which there are focal lesions and marked granulocytic hyperplasia with loss of fat spaces; and (iii) type III in which there is diffuse replacement of the haemopoietic marrow. Type I corresponds to the more benign systemic mastocytosis, type II to 'malignant mastocytosis', and type III to mast cell leukaemia. Others have also found a hypercellular bone marrow to have a poor prognostic significance [60].

Cytogenetics and molecular genetics

Clonal cytogenetic abnormalities have been demonstrated in a number of cases of systemic mastocytosis [51]. Abnormalities detected have included trisomy 8, trisomy 9, trisomy 11, del(5)(q), del(7)(q), monosomy 7 and del(20)(q).

Mutations of the stem cell factor receptor gene (*c-KIT*) have been demonstrated in a number of cases [51].

Problems and pitfalls

Many patients with systemic mastocytosis have

Fig. 5.46 BM trephine biopsy section, systemic mastocytosis (same case as in Fig. 5.44), immunohistochemistry (APAAP technique) with a CD68 McAb. Paraffin-embedded $\times 376$. (By courtesy of Dr Wendy Erber, Perth, Western Australia.)

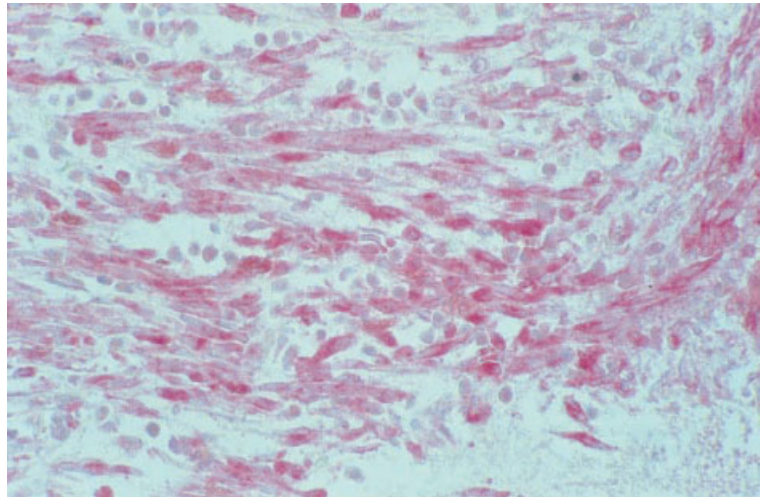
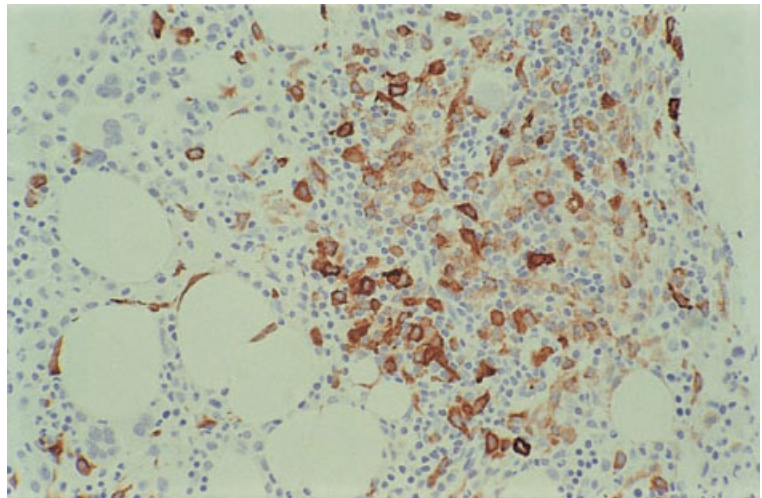


Fig. 5.47 BM trephine biopsy section, systemic mastocytosis, showing increased mast cells, some of which are spindle shaped. Paraffin-embedded, immunohistochemistry with a McAb to mast cell tryptase $\times 188$.



evidence of involvement of other myeloid lineages. In some patients, the platelet count, white cell count or haemoglobin concentration is so greatly elevated that a diagnosis of ET, CML or PRV is made. It is likely that such cases represent an MPD with differentiation to several lineages, rather than the co-existence of two separate diseases, and we therefore recommend that they be included in the WHO category, 'myeloproliferative disease, unclassifiable'. Similarly, the emergence of myelodysplasia or acute leukaemia in patients with systemic mast cell disease is likely to represent evolution of the neoplastic clone. The assignment of the former group of cases to a category designated 'other myelodysplastic/

myeloproliferative disease, unclassified' appears desirable.

Misdiagnosis of systemic mast cell disease is not uncommon, largely because the mast cells are not recognized and are misidentified as fibroblasts, macrophages or epithelioid cells. Focal marrow lesions may be misdiagnosed as granulomas, angio-immunoblastic lymphadenopathy or focal infiltrates of lymphoplasmacytic lymphoma. Confusion with idiopathic myelofibrosis has occurred; however, when marrow fibrosis occurs as a response to systemic mastocytosis, mast cells are recognizable in the fibrous tissue, allowing the distinction from other causes of myelofibrosis to be made. In patients

with a heavy mast cell infiltrate, misdiagnosis as hairy cell leukaemia is possible because of the even spacing of nuclei, a feature which is also typical of hairy cell leukaemia. The two crucial points in making a correct diagnosis are that Giemsa-stained sections are routinely examined and that the cell types in any apparent granulomas are determined. The 'pseudo-granulomas' of systemic mast cell disease commonly have eosinophils and lymphocytes associated with them and sometimes lymphoid nodules and plasma cells; the mast cells may show atypical features. Mast cells are also often associated with focal marrow infiltrates of lymphoplasmacytic lymphoma (see page 262). However, these reactive mast cells are morphologically normal and are a minority population in the areas of infiltration. In angio-immunoblastic lymphadenopathy there may be focal or diffuse infiltration by a heterogeneous population of cells that often includes plasma cells, lymphocytes and many eosinophils (see page 300). However, immunoblasts, which are not a feature of systemic mastocytosis, are present and often prominent.

By definition, cutaneous mastocytosis is confined to the skin. However, bone marrow infiltration occasionally develops in patients who initially had mast cell infiltration apparently confined to the skin. In a study of paediatric cases of cutaneous mastocytosis, 10 out of 15 trephine biopsies showed focal perivascular and peritrabecular aggregates of mast cells, eosinophils and early myeloid cells [64,71]. Similarly, of a series of 30 adults presenting with urticaria pigmentosa, there were 18 with bone marrow infiltration [72]. In addition, a clonal cytogenetic abnormality has been reported in the bone marrow of a patient with urticaria pigmentosa suggesting occult infiltration by neoplastic cells [51].

References

- Harris NL, Jaffe ES, Diebold J, Flandrin G, Muller-Hermelink HK, Vardiman J *et al.* (1999) World Health Organization classification of neoplastic diseases of the hematopoietic and lymphoid tissues: report of the Clinical Advisory Committee meeting—Airlie House, Virginia, November, 1997. *J Clin Oncol*, 17, 3835–3849.
- Shepherd PC, Ganesan TS and Galton DA (1987) Haematological classification of the chronic myeloid leukaemias. *Baillières Clin Haematol*, 1, 887–906.
- Spiers AS, Bain BJ and Turner JE (1977) The peripheral blood in chronic granulocytic leukaemia. Study of 50 untreated Philadelphia-positive cases. *Scand J Haematol*, 18, 25–38.
- Burkhardt R, Frisch B and Bartl R (1982) Bone biopsy in haematological disorders. *J Clin Pathol*, 35, 257–284.
- Burkhardt R, Bartl R, Jager K, Frisch B, Kettner G, Mahl G and Sund M (1986) Working classification of chronic myeloproliferative disorders based on histological, haematological, and clinical findings. *J Clin Pathol*, 39, 237–252.
- Lazzarino M, Morra E, Castello A, Inverardi D, Coci A, Pagnucco G *et al.* (1986) Myelofibrosis in chronic granulocytic leukaemia: clinicopathologic correlations and prognostic significance. *Br J Haematol*, 64, 227–240.
- Rozman C, Cervantes F and Feliu E (1989) Is the histological classification of chronic granulocytic leukaemia justified from the clinical point of view? *Eur J Haematol*, 42, 150–154.
- Schmid C, Frisch B, Beham A, Jager K and Kettner G (1990) Comparison of bone marrow histology in early chronic granulocytic leukemia and in leukemoid reaction. *Eur J Haematol*, 44, 154–158.
- Thiele J and Fischer R (1991) Megakaryocytopoiesis in haematological disorders: diagnostic features of bone marrow biopsies. An overview. *Virchows Arch A Pathol Anat Histopathol*, 418, 87–97.
- Knox WF, Bhavnani M, Davson J and Geary CG (1984) Histological classification of chronic granulocytic leukaemia. *Clin Lab Haematol*, 6, 171–175.
- Clough V, Geary CG, Hashmi K, Davson J and Knowlson T (1979) Myelofibrosis in chronic granulocytic leukaemia. *Br J Haematol*, 42, 515–526.
- Thiele J, Kvasnicka HM, Fischer R and Diehl V (1997) Clinicopathological impact of the interaction between megakaryocytes and myeloid stroma in chronic myeloproliferative disorders: a concise update. *Leuk Lymphoma*, 24, 463–481.
- Thiele J, Kvasnicka HM, Schmitt-Graeff A, Spohr M, Diehl V, Zancovich R *et al.* (2000) Effects of interferon and hydroxyurea therapy on bone marrow fibrosis in chronic myelogenous leukaemia: a comparative retrospective multicentric histological and clinical study. *Br J Haematol*, 108, 64–71.
- Thiele J, Kvasnicka HM, Niederle N, Kloke O, Schmidt M, Lienhard H *et al.* (1995) Clinical and histological features retain their prognostic impact under interferon therapy of CML. A pilot study. *Am J Hematol*, 50, 30–39.
- Islam A (1988) Prediction of impending blast cell transformation in chronic granulocytic leukaemia. *Histopathology*, 12, 633–639.
- Peterson LC, Bloomfield CD and Brunning RD (1976) Blast crisis as an initial or terminal manifestation of chronic myeloid leukemia. A study of 28 patients. *Am J Med*, 60, 209–220.

- 17 Islam A, Catovsky D, Goldman J and Galton DAG (1980) Histological study of chronic granulocytic leukaemia in blast transformation. *Br J Haematol*, 46, 326.
- 18 Williams WC and Weiss GB (1982) Megakaryoblastic transformation of chronic myelogenous leukemia. *Cancer*, 49, 921–926.
- 19 Muehleck SD, McKenna RW, Arthur DC, Parkin JL and Brunning RD (1984) Transformation of chronic myelogenous leukemia: clinical, morphologic, and cytogenetic features. *Am J Clin Pathol*, 82, 1–14.
- 20 Orazi A, Neiman RS, Cualing H, Heerema NA and John K (1994) CD34 immunostaining of bone marrow biopsy specimens is a reliable way to classify the phases of chronic myeloid leukemia. *Am J Clin Pathol*, 101, 426–428.
- 21 Sinclair PB, Nacheva EP, Leversha M, Telford N, Chang J, Reid A *et al.* (2000) Large deletions at the t(9;22) breakpoint are common and may identify a poor-prognosis subgroup of patients with chronic myeloid leukemia. *Blood*, 95, 738–743.
- 22 Kojima K, Yasukawa M, Hara M, Nawa Y, Kimura Y, Narumi H and Fujita S (1999) Familial occurrence of chronic neutrophilic leukaemia. *Br J Haematol*, 105, 428–430.
- 23 Standen GR, Steers FJ and Jones L (1993) Clonality of chronic neutrophilic leukaemia associated with myeloma: analysis using the X-linked probe M27 β . *J Clin Pathol*, 46, 297–298.
- 24 Bain BJ. *Interactive Haematology Imagebank*. Blackwell Science, Oxford, 1999.
- 25 Kulkarni S, Parker S, Pocock C, Cwynarski K, Goldman JM and Cross NCP (1999) Fusion of H4/D10S170 to the PDGFR β receptor in a patient with a BCR-ABL negative myeloproliferative disorder and a t(5;10)(q33;q21). *Blood*, 94 (Suppl. 1), 51a.
- 26 Sohal J, Chase A, Iqbal S, Parker S, Goldman JM and Cross NCP (1999) Two colour FISH to detect FGFR1 rearrangements in myeloproliferative disorders: identification of the t(8;17)(p11;q25) as a new cytogenetic variant. *Blood*, 94 (Suppl. 1), 180b.
- 27 Bain BJ (1996) Eosinophilic leukaemias and the idiopathic hypereosinophilic syndrome. *Br J Haematol*, 95, 2–9.
- 28 Simon HU, Plötz SG, Dummer R and Blaser K (1999) Abnormal clones of T cells producing interleukin-5 in idiopathic eosinophilia. *N Engl J Med*, 341, 1112–1120.
- 29 Bain BJ (1999) Eosinophilia—idiopathic or not? *N Engl J Med*, 341, 1141–1143.
- 30 Tefferi A (2000) Myelofibrosis with myeloid metaplasia. *N Engl J Med*, 342, 1255–1265.
- 31 Murphy S, Iland H, Rosenthal D and Laszlo J (1986) Essential thrombocythemia: an interim report from the Polycythemia Vera Study Group. *Semin Hematol*, 23, 177–182.
- 32 Barosi G, Ambrosetti A, Finelli C, Grossi A, Leoni P, Liberato NL *et al.* (1999) The Italian Consensus Conference on Diagnostic Criteria for Myelofibrosis with Myeloid Metaplasia. *Br J Haematol*, 104, 730–737.
- 33 Thiele J, Kvasnicka HM, Werden C, Zankovich R, Diehl V and Fischer R (1996) Idiopathic primary osteomyelofibrosis: a clinico-pathological study on 208 patients with special emphasis on evolution of disease features, differentiation from essential thrombocythemia and variables of prognostic impact. *Leuk Lymphoma*, 22, 303–317.
- 34 Cervantes F, Pereira A, Esteve J, Rafel M, Cobo F, Rozman C and Montserrat E (1997) Identification of ‘short-lived’ and ‘long-lived’ patients at presentation of idiopathic myelofibrosis. *Br J Haematol*, 97, 635–640.
- 35 Kvasnicka HM, Thiele J, Werden C, Zankovich R, Diehl V and Fischer R (1997) Prognostic factors in idiopathic (primary) osteomyelofibrosis. *Cancer*, 80, 708–719.
- 36 Lennert K, Nagai K and Schwarze EW (1975) Pathoanatomical features of the bone marrow. *Clin Haematol*, 4, 331–351.
- 37 Pereira A, Cervantes F, Bragues R and Rozman C (1990) Bone marrow histopathology in primary myelofibrosis, clinical and haematologic correlations and prognostic evaluation. *Eur J Haematol*, 44, 95–99.
- 38 Apaja-Sarkkinen M, Autio-Harmainen H, Alavaikko M, Risteli J and Risteli L (1986) Immunohistochemical study of basement membrane proteins and type III procollagen in myelofibrosis. *Br J Haematol*, 63, 571–580.
- 39 Lohmann TP and Beckman EN (1983) Progressive myelofibrosis in agnogenic myeloid metaplasia. *Arch Pathol Lab Med*, 107, 593–594.
- 40 Laszlo J (1975) Myeloproliferative disorders (MPD), myelofibrosis, myelosclerosis, extramedullary hematopoiesis, undifferentiated MPD, and hemorrhagic thrombocythemia. *Semin Hematol*, 12, 409–432.
- 41 Wolf BC and Neiman RS (1988) The bone marrow in myeloproliferative and dysmyelopoietic syndromes. *Hematol Oncol Clin North Am*, 2, 669–694.
- 42 Yoon SY, Li CY, Mesa RA and Tefferi A (1999) Bone marrow effects of anagrelide therapy in patients with myelofibrosis with myeloid metaplasia. *Br J Haematol*, 106, 682–688.
- 43 Ferhanoğlu B, Erzin Y, Başlar Z and Tüzüner HAN (1997) Secondary amyloidosis in the course of idiopathic myelofibrosis. *Leuk Res*, 21, 897–898.
- 44 Vykoupil KF, Thiele J, Stangel W, Krmpotic E and Georgii A (1980) Polycythemia vera. I. Histopathology, ultrastructure and cytogenetics of the bone marrow in comparison with secondary polycythemia. *Virchows Arch (A) Pathol Anat Histopathol*, 389, 307–324.
- 45 Lucie NP and Young GA (1983) Marrow cellularity in the diagnosis of polycythaemia. *J Clin Pathol*, 36, 180–183.

- 46 Ellis JT, Peterson P, Geller SA and Rappaport H (1986) Studies of the bone marrow in polycythemia vera and the evolution of myelofibrosis and secondary hematologic malignancies. *Semin Hematol*, 23, 144–155.
- 47 Lengfelder E, Hochhaus A, Kronawitter U, Höche D, Queisser W, Jahn-Eder M *et al.* (1998) Should a platelet limit of $600 \times 10^9/l$ be used as a diagnostic criterion in essential thrombocythaemia? An analysis of the natural course including early stages. *Br J Haematol*, 100, 15–23.
- 48 Stoll DB, Peterson P, Exten R, Laszlo J, Pisciotta AV, Ellis JT *et al.* (1988) Clinical presentation and natural history of patients with essential thrombocythemia and the Philadelphia chromosome. *Am J Hematol*, 27, 77–83.
- 49 Solberg LA, Tefferi A, Oles KJ, Tarach JS, Pettitt RM, Forstrom LA and Silverstein MN (1997) The effects of anagrelide on human megakaryocytopoiesis. *Br J Haematol*, 99, 174–180.
- 50 Pettitt JE, Lewis SM and Nicholas AW (1979) Transitional myeloproliferative disorder. *Br J Haematol*, 43, 167–184.
- 51 Bain BJ (1999) Systemic mastocytosis and other mast cell neoplasms. *Br J Haematol*, 106, 9–17.
- 52 Bennett JM, Catovsky D, Daniel MT, Flandrin G, Galton DA, Gralnick HR and Sultan C (1982) Proposals for the classification of the myelodysplastic syndromes. *Br J Haematol*, 51, 189–199.
- 53 Kantarjian HM, Keating MJ, Walters RS, McCredie KB, Smith TL, Talpaz M *et al.* (1986) Clinical and prognostic features of Philadelphia chromosome-negative chronic myelogenous leukemia. *Cancer*, 58, 2023–2030.
- 54 Martiat P, Michaux JL and Rodhain J (1991) Philadelphia-negative (Ph-) chronic myeloid leukemia (CML): comparison with Ph+ CML and chronic myelomonocytic leukemia. The Groupe Francais de Cytogenetique Hematologique. *Blood*, 78, 205–211.
- 55 Emanuel PD (1999) Myelodysplasia and myeloproliferative disorders in childhood: an update. *Br J Haematol*, 105, 852–863.
- 56 Bain BJ (1999) The relationship between the myelodysplastic syndromes and the myeloproliferative disorders. *Leuk Lymphoma*, 34, 443–449.
- 57 Gupta R, Abdalla SH and Bain BJ (1999) Thrombocytosis with sideroblastic erythropoiesis: a mixed myeloproliferative myelodysplastic syndrome. *Leuk Lymphoma*, 34, 615–619.
- 58 Webb TA, Li CY and Yam LT (1982) Systemic mast cell disease: a clinical and hematopathologic study of 26 cases. *Cancer*, 49, 927–938.
- 59 Brunning RD, McKenna RW, Rosai J, Parkin JL and Risdall R (1983) Systemic mastocytosis. Extracutaneous manifestations. *Am J Surg Pathol*, 7, 425–438.
- 60 Travis WD, Li CY, Bergstralh EJ, Yam LT and Swee RG (1988) Systemic mast cell disease. Analysis of 58 cases and literature review. *Medicine*, 67, 345–368. [published erratum appears in *Medicine*, 1990 (69), 34].
- 61 Lennert K and Parwaresch MR (1979) Mast cells and mast cell neoplasia: a review. *Histopathology*, 3, 349–365.
- 62 Horny HP, Ruck M, Wehrmann M and Kaiserling E (1990) Blood findings in generalized mastocytosis: evidence of frequent simultaneous occurrence of myeloproliferative disorders. *Br J Haematol*, 76, 186–193.
- 63 Travis WD, Li CY, Yam LT, Bergstralh EJ and Swee RG (1988) Significance of systemic mast cell disease with associated hematologic disorders. *Cancer*, 62, 965–972.
- 64 Parker RI (1991) Hematologic aspects of mastocytosis. I. Bone marrow pathology in adult and pediatric systemic mast cell disease. *J Invest Dermatol*, 96, 47S–51S.
- 65 Parker RI (1991) Hematologic aspects of mastocytosis. II. Management of hematologic disorders in association with systemic mast cell disease. *J Invest Dermatol*, 96, 52S–53S; discussion 53S–54S.
- 66 Horny HP, Parwaresch MR and Lennert K (1985) Bone marrow findings in systemic mastocytosis. *Hum Pathol*, 16, 808–814.
- 67 Fallon MD, Whyte MP and Teitelbaum SL (1981) Systemic mastocytosis associated with generalized osteopenia. Histopathological characterization of the skeletal lesion using undecalcified bone from two patients. *Hum Pathol*, 12, 813–820.
- 68 Horny HP and Kaiserling E (1988) Lymphoid cells and tissue mast cells of bone marrow lesions in systemic mastocytosis: a histological and immunohistological study. *Br J Haematol*, 69, 449–455.
- 69 Horny HP, Reimann O and Kaiserling E (1988) Immunoreactivity of normal and neoplastic human tissue mast cells. *Am J Clin Pathol*, 89, 335–340.
- 70 Hoyer JD, Li CY, Yam LT, Hanson CA and Kurtin PJ (1997) Immunohistochemical demonstration of acid phosphatase isoenzyme 5 (tartrate-resistant) in paraffin sections of hairy cell leukemia and other hematologic disorders. *Am J Clin Pathol*, 108, 308–315.
- 71 Kettelhut BV, Parker RI, Travis WD and Metcalfe DD (1989) Hematopathology of the bone marrow in pediatric cutaneous mastocytosis. A study of 17 patients. *Am J Clin Pathol*, 91, 558–562.
- 72 Topar G, Staudacher C, Geisen F, Gabl C, Fend F, Herold M *et al.* (1998) Urticaria pigmentosa: a clinical, hematopathologic, and serologic study of 30 adults. *Am J Clin Pathol*, 109, 279–285.

SIX

LYMPHOPROLIFERATIVE DISORDERS

In this chapter we shall discuss acute and chronic leukaemias of lymphoid lineage, Hodgkin's disease and non-Hodgkin's lymphomas (NHL). The disease entities will be classified according to the recently proposed WHO classification of lymphoid neoplasms [1], which is largely based upon the Revised European–American Lymphoma (REAL) classification, proposed by the International Lymphoma Study Group [2]. The REAL classification was an attempt to harmonize European and North American classifications. It built on the Kiel classification [3,4] but simplified some aspects and incorporated several well-recognized entities, such as mucosa-associated lymphoid tissue (MALT) lymphomas, which were not included in the Kiel classification. Where possible, we shall relate the WHO classification to other systems of lymphoma classification, in particular to the Kiel classification and the Working Formulation for Clinical Usage [5]. We shall also indicate where French–American–British (FAB) categories of leukaemia [6,7] can be related to the specific entities described by the WHO classification. The WHO and Kiel classifications are summarized and related to each other and to the Working Formulation for B-lineage and T-lineage lymphomas, respectively, in Tables 6.1 and 6.2. The WHO classification for Hodgkin's disease, which is based on the Rye classification [8], is shown in Table 6.3.

Bone marrow infiltration in lymphoproliferative disorders

Bone marrow infiltration is frequent in lymphoproliferative disorders. Such infiltration can be detected by a variety of procedures including microscopic examination of bone marrow aspirates and trephine biopsies and the use of molecular biological techniques (see Chapter 2). Assessment of cytological

details can be carried out using films of aspirates, imprints from trephine biopsy specimens or thin sections of aspirated fragments or trephine biopsy specimens. Histological features can be assessed using sections of either trephine biopsy specimens or aspirated fragments. The pattern of infiltration can only be fully assessed using sections from trephine biopsy specimens. Three major patterns can be seen, either alone or in combination [9–11] (Fig. 6.1). Such patterns are important in the differential diagnosis of lymphoproliferative disorders and can also be of prognostic significance. They are designated: (i) interstitial; (ii) focal; and (iii) diffuse.

1 Interstitial infiltration indicates the presence of individual neoplastic cells interspersed between haemopoietic and fat cells. Although there is generalized marrow involvement, there is considerable sparing of normal haemopoiesis and bone marrow architecture is not distorted.

2 Focal infiltration indicates that there are foci of neoplastic cells separated by residual haemopoietic marrow. Focal infiltration can be further categorized as paratrabecular or random. In paratrabecular infiltration the neoplastic cells are immediately adjacent to the bony trabeculae, either in the form of a band lining a trabecula or as an aggregate with a broad base abutting on a trabecula. In random infiltration the aggregates of neoplastic cells have no particular relationship to bony trabeculae. Random infiltrates can be further subdivided into nodular and patchy, the former having a well-defined round border and the latter an irregular margin. A distinction should be made between random nodules or patchy aggregates which incidentally touch the bone surface and true paratrabecular infiltration which is more broad-based.

3 Diffuse infiltration indicates extensive replacement of normal marrow elements, both haemopoietic

Table 6.1 Comparison of WHO classification with Kiel classification and Working Formulation for B-cell lymphoproliferative diseases*.

Kiel classification	WHO classification	Working Formulation
B-lymphoblastic lymphoma	Precursor B-cell lymphoblastic lymphoma/leukaemia	Lymphoblastic
B-lymphocytic, CLL; lymphoplasmacytoid lymphoma; prolymphocytic leukaemia	B-cell CLL/small lymphocytic lymphoma B-cell prolymphocytic leukaemia	Small lymphocytic, consistent with CLL; small lymphocytic, plasmacytoid
Lymphoplasmacytic lymphoma	Lymphoplasmacytic lymphoma	Small lymphocytic, plasmacytoid; diffuse, mixed small and large cell
Centrocytic lymphoma	Mantle cell lymphoma	Diffuse, small cleaved cell; diffuse, mixed small and large; diffuse large cleaved cell
Centroblastic–centrocytic lymphoma, follicular ± diffuse;	Follicular lymphoma, Grade I	Follicular: Predominantly small cleaved cell; Mixed small and large cell;
Centroblastic lymphoma, follicular	Grade II	Predominantly large cell
Centroblastic–centrocytic lymphoma, diffuse	Grade III	Diffuse, small cleaved cell; diffuse, mixed small and large cell
—	Extranodal marginal zone B-cell lymphoma of MALT type	Small lymphocytic; diffuse, small cleaved cell; diffuse, mixed small and large cell
Monocytoid lymphoma, including marginal zone lymphoma; immunocytoma	Nodal marginal zone lymphoma (± monocytoid B cells)	Small lymphocytic; diffuse, small cleaved cell; diffuse, mixed small and large cell
—	Splenic marginal zone B-cell lymphoma (± villous lymphocytes)	Small lymphocytic; diffuse, small cleaved cell
Hairy cell leukaemia	Hairy cell leukaemia	—
Plasmacytic lymphoma	Plasmacytoma/plasma cell myeloma	Extramedullary plasmacytoma
Centroblastic lymphoma	Diffuse large B-cell lymphoma	Diffuse, large cell
B-immunoblastic lymphoma		Large cell immunoblastic
B-large cell anaplastic lymphoma (Ki-1)		Diffuse, mixed large and small cell
—	Primary mediastinal large B-cell lymphoma	Diffuse, large cell; large cell immunoblastic
Burkitt's lymphoma	Burkitt's lymphoma/Burkitt cell leukaemia	Small, non-cleaved cell, Burkitt's
—	Burkitt-like lymphoma	Small, non-cleaved cell, Burkitt-like; diffuse large cell; large cell immunoblastic

* If there is more than one subtype in a category, the dominant type is indicated in bold letters.

tissue and fat, so that marrow architecture is effaced. An alternative designation is a 'packed marrow' pattern [10]; this latter term could be preferred since it is unambiguous whereas 'diffuse' could be taken to also include interstitial infiltration.

Various mixed patterns of infiltration also occur, including mixed interstitial–nodular and mixed interstitial–diffuse.

A further unusual pattern of infiltration is the presence of lymphoma cells within the marrow

Table 6.2 Comparison of WHO classification with Kiel classification and Working Formulation for T-cell and NK cell lymphoproliferative diseases*.

Kiel classification	WHO classification	Working Formulation
T-lymphoblastic lymphoma	Precursor T-lymphoblastic lymphoma/leukaemia	Lymphoblastic
T-lymphocytic lymphoma: Cleaved CLL-type PLL-type	T-cell prolymphocytic leukaemia	Small lymphocytic ; diffuse, small cell
T-lymphocytic lymphoma, CLL-type cleaved	T-cell granular lymphocytic leukaemia	Small lymphocytic ; diffuse, small cell
Small cell cerebriform lymphoma (mycosis fungoides, Sézary syndrome)	Mycosis fungoides/Sézary syndrome	Mycosis fungoides
T-zone lymphoma; lymphoepithelioid lymphoma; pleomorphic, small T-cell lymphoma; pleomorphic, medium and large T-cell lymphoma ; T-immunoblastic lymphoma	Peripheral T-cell lymphoma, not otherwise characterized	Diffuse, small cleaved cell; diffuse, mixed small and large cell ; diffuse, large cell; large cell immunoblastic
Angio-immunoblastic (AILD, LgX)	Angio-immunoblastic T-cell lymphoma	Diffuse, mixed large and small cell ; diffuse, large cell; large cell immunoblastic
—	Aggressive NK-cell leukaemia Extranodal NK/T-cell lymphoma, nasal type	Diffuse, small cleaved cell; diffuse, mixed small and large cell ; diffuse, large cell; large cell immunoblastic
—	Hepatosplenic $\gamma\delta$ T-cell lymphoma	—
—	Subcutaneous panniculitis-like T-cell lymphoma	—
—	Enteropathy-type T-cell lymphoma	Large cell immunoblastic ; diffuse, small cleaved cell; diffuse mixed small and large cell; diffuse large cell
Pleomorphic small T-cell, HTLV1+; pleomorphic medium and large T-cell HTLV1+	Adult T-cell lymphoma/leukaemia (HTLV1+)	Diffuse, small cleaved cell; diffuse, mixed large and small cell ; diffuse large cell; large cell immunoblastic
T-large cell anaplastic (Ki-1+)	Anaplastic large cell lymphoma, T/null-cell, primary systemic type	Large cell immunoblastic

* If there is more than one subtype in a category, the dominant type is indicated in bold letters.

sinusoids. In rare cases neoplastic lymphoid cells in the bone marrow are confined to the sinusoids [12,13]. Among B-lineage lymphomas, bone marrow infiltration is more common in low grade tumours than in high grade. Overall, infiltration is probably more common in B-cell lymphomas than in T-cell

[14,15] but the frequency of infiltration detected in T-cell lymphoma has varied widely in reported series (see page 285). The relative frequency of different patterns of infiltration varies between T and B lymphomas and between different histological categories but, in general, focal infiltration is

Table 6.3 The WHO classification of Hodgkin’s disease (Hodgkin’s lymphoma) [1].

Category	Specific histological characteristics
Nodular lymphocyte-predominant Hodgkin’s disease	Typical Reed–Sternberg cells are infrequent; L and H variant of Reed–Sternberg cell present; prominent proliferation of lymphocytes, histiocytes or both; nodular pattern in lymph nodes
<i>Classical Hodgkin’s disease</i>	
Nodular sclerosis	Typical Reed–Sternberg cells often very infrequent; lacunar cell variant of Reed–Sternberg cell present; collagen bands present
Lymphocyte-rich classical Hodgkin’s disease	Small numbers of typical Reed–Sternberg cells; background of small lymphocytes with infrequent plasma cells and eosinophils
Mixed cellularity	Moderately frequent Reed–Sternberg cells; variable proliferation of reactive cells; usually some disorderly fibrosis
Lymphocyte depleted	
With diffuse fibrosis	Reed–Sternberg cells frequent; extensive disorderly fibrosis; reactive cells infrequent
Reticular variant	Reed–Sternberg cells frequent and pleomorphic variant of Reed–Sternberg cell present—either may predominate; reactive cells infrequent

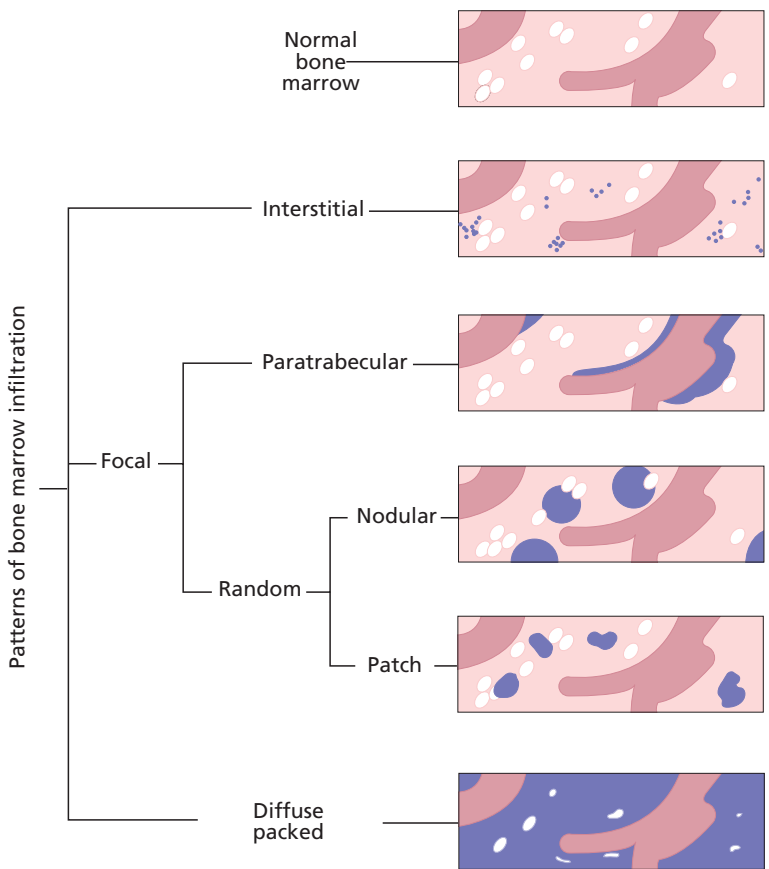


Fig. 6.1 Patterns of bone marrow infiltration observed in lymphoproliferative disorders.

more common than diffuse [16]. This is particularly so of B-cell lymphomas; diffuse infiltration is relatively more common in T-cell lymphomas than in B-cell.

Increased reticulin deposition, restricted to the area of marrow infiltration, is common in lymphoma [17]. Collagen fibrosis is less common.

Trephine biopsy is generally more successful at detecting marrow infiltration than is bone marrow aspiration; this is a consequence of the frequency of focal infiltration and of fibrosis. In a series of 93 cases, Foucar *et al.* [16] found that trephine sections and aspirate films were both positive in 79% of cases, trephine biopsy sections alone were positive in 18% and films alone were positive in 3%. Similarly, Conlan *et al.* [14] reported that in 102 cases of NHL with marrow involvement, the trephine biopsy section, marrow clot section and marrow aspirate films were positive in 94, 65 and 46% of cases, respectively; in only 6% of cases was the bone marrow aspirate positive when the trephine biopsy was negative. The rate of detection of bone marrow infiltration is increased when a larger volume of marrow is sampled; this can be achieved either by increasing the size of the trephine biopsy specimen or by performing multiple biopsies.

Immunohistochemical techniques performed on sections of paraffin-embedded tissue (see page 116) are useful in establishing or confirming the nature of lymphoid infiltrates [18]. Molecular genetic analysis using polymerase chain reaction (PCR) to detect immunoglobulin (Ig) heavy chain (*IGH*) gene rearrangements and T-cell receptor (*TCR*) gene rearrangements can be useful in confirming clonality in difficult cases. However, PCR carried out on bone marrow aspirate samples will only detect a clonal *IGH* rearrangement in approximately 57–80% of cases with unequivocal morphological evidence of marrow infiltration by B-cell lymphoma in trephine biopsy sections [19,20].

There may be discordance between the type of lymphoma seen in the marrow and that present in the lymph node or other tissues. The frequency of such discordance varies from 16 to 40% in reported series [14,21–23]. In a smaller number, varying between 6 and 21%, there is discordance as to grade of lymphoma. Discordance is most often seen in B-cell lymphomas. Although Conlan *et al.* [14] observed discordance in 25% of T-cell lymphomas,

no discordance was found in two other series of T-cell lymphomas [24,25]. One surprising and relatively common occurrence is the presence of a follicular lymphoma in the lymph node and a lymphoplasmacytic lymphoma (see page 258) in the marrow [21,23]. This may represent differentiation of tumour in the marrow site. Such a phenomenon has been reported in node-based follicular lymphomas [26].

The clinical importance of marrow involvement varies with the category of NHL. In general, in low grade lymphomas the presence of marrow involvement does not adversely affect the clinical outlook. In patients with high grade lymphoma at an extramedullary site, the presence of high grade lymphoma in the marrow is a poor prognostic sign, often predictive of central nervous system involvement [27]. The presence of low grade lymphoma in the marrow of patients with high grade lymphoma has been considered to have no adverse effect on prognosis [22]; however, there is evidence to suggest that such patients have continuing risk of late relapse of low grade lymphoma [27].

Problems and pitfalls

Lymphomatous infiltration of the marrow needs to be distinguished from infiltration by reactive lymphocytes. Consideration should be given both to the pattern of infiltration and to cytological characteristics. Interstitial infiltration can occur both in neoplastic and in reactive conditions. Paratrabecular infiltration and a 'packed marrow' (diffuse infiltration) are indicative of neoplasia. Nodular lymphomatous infiltrates have to be distinguished from reactive nodular hyperplasia (see page 116). Caution should be exercised in diagnosing lymphoma solely on the basis of the presence of nodules of small lymphocytes since there are no clear criteria at present for establishing whether infrequent small nodules are neoplastic. Reactive lymphoid nodules are usually small with well-defined margins and have a polymorphous cell population, made up predominantly of small lymphocytes with smaller numbers of immunoblasts, macrophages and plasma cells. Neoplastic nodular lymphoid infiltrates are usually larger with ill-defined margins, often extending around fat cells, and have a relatively homogeneous cellular composition. In some

cases it is not possible to make the distinction between a reactive and neoplastic process on morphological grounds alone. Immunohistochemical staining is of only limited value. Nodules composed entirely of B cells are usually neoplastic, whereas a mixed population of B and T cells may be seen in both reactive and neoplastic nodules. Although it has been suggested that immunohistochemical staining for BCL2 may be helpful in distinguishing reactive from neoplastic lymphoid aggregates [28,29], other reports do not confirm this finding [30]. In difficult cases, the use of PCR on a marrow aspirate sample to demonstrate clonal *IGH* or *TCR* gene rearrangements may be helpful [31].

Precursor B-lymphoblastic leukaemia/lymphoma (precursor B-cell acute lymphoblastic leukaemia)

The condition that has long been recognized by haematologists as acute lymphoblastic leukaemia (ALL) has been subdivided by the REAL and WHO groups according to lineage and, in addition, has been amalgamated with lymphoblastic lymphoma. The only cases of ALL not included in these two categories of precursor neoplasms are those in which cells have a mature B immunophenotype; since these show the same cytological, cytogenetic and molecular genetic features as Burkitt's lymphoma, they have rightly been amalgamated with this lymphoma (see page 281). The terminology adopted by the REAL and WHO groups is logical but somewhat cumbersome for day-to-day use. It is likely that haematologists will continue to use the designation 'acute lymphoblastic leukaemia' for those cases with a leukaemic presentation. About three quarters of these cases are of B lineage and about one quarter of T lineage.

Cases of ALL were divided by the FAB group [6] on the basis of cytological features into three categories, designated L1, L2 or L3 ALL. A more detailed classification based on morphology, immunology and cytogenetics was proposed by the MIC group [32] and subsequently the addition of molecular genetics, giving a MIC-M classification, was proposed [33]. The distinction between FAB L1 and L2 cases is now considered to be of little clinical significance. However, the FAB recognition of the Burkitt's lymphoma-related L3 category of ALL was

important, and remains so, because of the prognostic and therapeutic implications.

The majority of cases of precursor B-lymphoblastic leukaemia/lymphoma present as ALL, a disease resulting from proliferation in the bone marrow of a neoplastic clone of immature lymphoid cells with the morphological features of lymphoblasts. A minority of cases present as precursor B-lymphoblastic lymphoma. These cases are much rarer than ALL and represent only 10–15% of lymphoblastic lymphoma, the latter being more often of T lineage.

Common clinical features of ALL are bruising, pallor, bone pain, lymphadenopathy, hepatomegaly and splenomegaly. The peak incidence is in childhood but the disease occurs at all ages. Clinical features of B-lymphoblastic lymphoma are lymphadenopathy, either localized or generalized, with or without hepatomegaly and splenomegaly. Lytic bone lesions are common. B-lymphoblastic lymphoma occurs predominantly in adults, childhood lymphoblastic lymphoma being almost always of T lineage [34].

Peripheral blood

In the majority of cases of precursor B-lymphoblastic leukaemia, leukaemic lymphoblasts, similar to those in the bone marrow (see below), are present in the peripheral blood; as a consequence, the total white cell count is usually increased. Normocytic normochromic anaemia and thrombocytopenia are also common. In precursor B-lymphoblastic lymphoma the peripheral blood is usually normal; when lymphoblasts are present they are identical to those of ALL.

Bone marrow cytology

In precursor B-lymphoblastic leukaemia the bone marrow is markedly hypercellular and is heavily infiltrated by leukaemic blasts. Normal haemopoietic cells are reduced in number but are morphologically normal. The blast cells vary cytologically between cases. In the FAB category of L1 ALL (Fig. 6.2) the blasts are fairly small and relatively uniform in appearance with a round nucleus and a regular cellular outline. The nucleocytoplasmic ratio is high, the chromatin pattern is fairly homogeneous

Fig. 6.2 BM aspirate, L1 ALL, showing a uniform population of small and medium sized blasts with a high nucleocytoplasmic ratio. MGG $\times 940$.

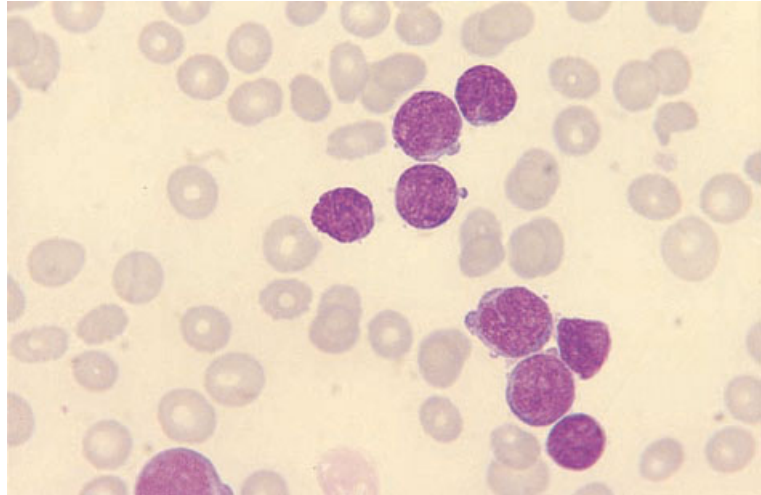
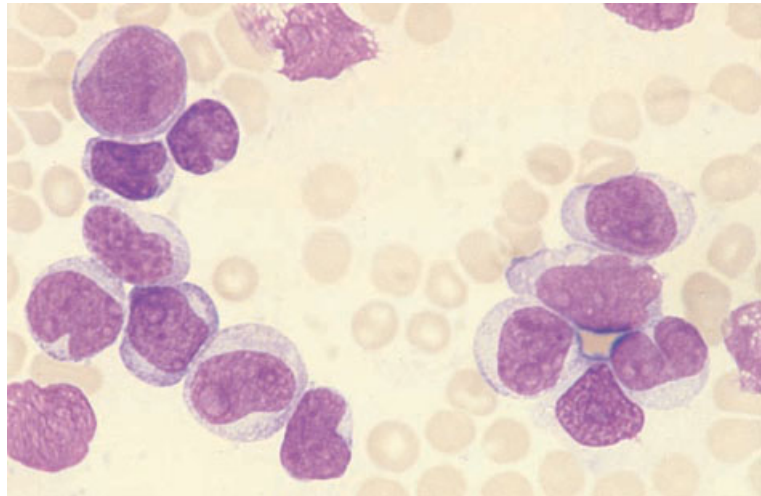


Fig. 6.3 BM aspirate, L2 ALL, showing large pleomorphic blasts. MGG $\times 940$.



and nucleoli are inconspicuous or inapparent. In L2 ALL (Fig. 6.3) the blasts are generally larger and more pleomorphic. Cytoplasm is more plentiful, the nuclei vary in shape and nucleoli may be prominent. Bone marrow necrosis may complicate ALL and, rarely, an aspirate may contain only necrotic cells.

In precursor B-lymphoblastic lymphoma the bone marrow is often normal. When there is infiltration, the cells cannot be distinguished cytologically from those of ALL. By convention, cases with fewer than 25 or 30% of bone marrow lymphoblasts are cat-

egorized as lymphoblastic lymphoma and cases with a heavier infiltration as ALL. The distinction is to some extent arbitrary since the cells are not only morphologically but also immunophenotypically indistinguishable from those of ALL.

Immunocytochemistry and flow cytometry

Cases of precursor B-lymphoblastic leukaemia/lymphoma express B-cell antigens such as CD19, CD22, CD24 and CD79a (Box 6.1). Most cases are positive for terminal deoxynucleotidyl transferase (TdT).

BOX 6.1**Precursor B-lymphoblastic leukaemia/lymphoma (precursor B-cell acute lymphoblastic leukaemia)***Flow cytometry and immunocytochemistry*

CD19+, CD22+, CD24+, CD79a+, TdT+
 Pro-B ALL—Cylg-, Smlg-, CD10-
 Common ALL—CD10+, Cylg-, Smlg-
 Pre-B ALL—CD10+, Cylg (μ)+, Smlg-

Immunohistochemistry

CD10+/-, CD20-/-, CD34+/-, CD79a+, TdT+

Cytogenetics and molecular genetics

Most cases have an abnormal karyotype

The most common abnormalities are hyperdiploidy and the translocations t(1;19)(q23;p13), t(12;21)(q12;q22) and t(9;22)(q34;q11)

Less common, but of prognostic significance, is t(4;11)(q21;q23)

Abbreviations (percentages are approximate): +>90% positive; +/->50% positive; -/+<50% positive; <10% positive; Cy, cytoplasmic; Ig, immunoglobulin; Sm, surface membrane; TdT, terminal deoxynucleotidyl transferase.

Three immunophenotypic groups are recognized which are believed to be analogous to successive stages of maturation of normal B lymphocytes. They have been defined by the European Group for the Immunological Characterization of Leukaemias (EGIL) [35] as follows:

- 1** cells of cases in the most immature group, designated pro-B ALL, express one or more of the above-mentioned B-cell antigens but do not express the common ALL antigen (CD10) or cytoplasmic or surface Ig;
- 2** the next group, which includes the majority of cases, is designated common ALL; the cells express CD10. There is no expression of cytoplasmic or surface Ig; and
- 3** in the third group, designated pre-B ALL, cells express B-lineage markers and CD10; they also express the μ chain of IgM in the cytoplasm but not surface membrane Ig.

It should be noted that the EGIL group's fourth category of mature B-ALL is classified by the WHO and REAL groups as a mature B-cell neoplasm, Burkitt's lymphoma, and not as lymphoblastic leukaemia/lymphoma.

The recognition of pro-B ALL is important since it is associated with specific cytogenetic/molecular genetic features and with a worse prognosis. However, although the cytogenetic and molecular genetic

features of common ALL differ from those of pre-B ALL, these two categories do not differ in prognosis with current therapy. The distinction is therefore not important and, for practical purposes, the amalgamation of the common and pre-B categories could be considered. The immunophenotype of precursor B-lymphoblastic lymphoma is similar to that of ALL.

Cytogenetics and molecular genetics

Up to 90% of cases of ALL have a demonstrable karyotypic abnormality, such cytogenetic abnormalities being of independent prognostic value [36] (Box 6.1). The most common abnormalities among B-lineage cases are hyperdiploidy and the translocations t(1;19)(q23;p13), t(12;21)(q12;q22) and t(9;22)(q34;q11). Less common, but of considerable prognostic significance, is t(4;11)(q21;q23).

Cases with a hyperdiploid karyotype are divided into high hyperdiploidy (greater than 50 chromosomes) and low hyperdiploidy (47–50 chromosomes). High hyperdiploidy is the most common abnormality seen in childhood ALL (25% cases) and is associated with a relatively good prognosis. Low hyperdiploidy is seen in up to 15% of cases and is associated with an intermediate prognosis. The translocation t(1;19)(q23;p13) occurs in 2–5% of

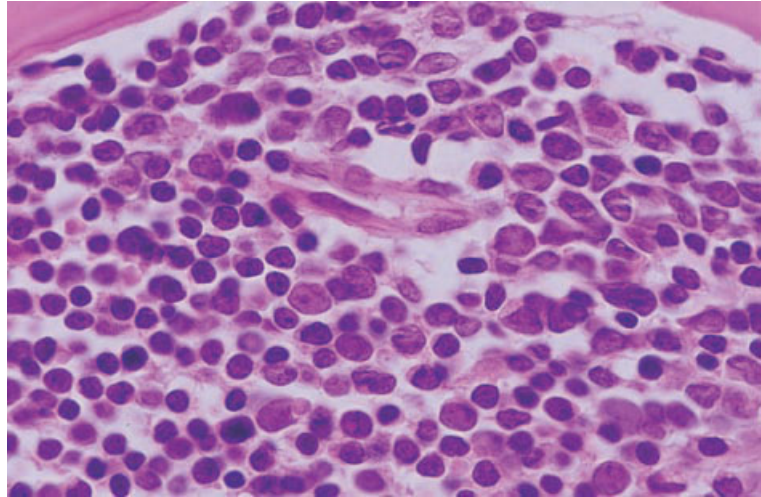


Fig. 6.4 BM trephine biopsy section, ALL, showing diffuse infiltration by predominantly small lymphoblasts. Note the high nucleocytoplasmic ratio and finely stippled chromatin pattern. Paraffin-embedded, H&E $\times 940$.

cases of childhood pre-B ALL. It was previously associated with a poor prognosis but, with modern intensive therapy, prognosis is now relatively good. The Philadelphia chromosome, formed as a result of the $t(9;22)(q34;q11)$ translocation, is seen in 2–5% of cases of childhood ALL and 15–25% of cases in adults; it is associated with a poor prognosis. $t(4;11)(q21;q23)$ is seen in less than 5% of cases of childhood ALL; it is associated with the pro-B immunophenotype and a poor prognosis. Other translocations with an 11q23 breakpoint are less common and generally indicate a poor prognosis. The $t(12;21)(q12;q22)$ rearrangement is seen in 10–30% of cases of childhood ALL. It can be associated with a pro-B, common ALL or pre-B immunophenotype and an intermediate to good prognosis. This abnormality is not usually demonstrable by conventional cytogenetic analysis.

In ALL a normal karyotype is associated with an intermediate prognosis.

Cytogenetic abnormalities can be detected by conventional cytogenetic analysis or by fluorescence *in situ* hybridization (FISH). Alternatively, the equivalent molecular genetic abnormality can be detected by DNA analysis (PCR or Southern blot) or RNA analysis (reverse transcriptase polymerase chain reaction, RT-PCR). The detection of $t(12;21)(q12;q22)$ usually requires FISH or molecular analysis to detect the *TEL-AML1* fusion gene. Other fusion products that can be detected by

molecular analysis include: (i) *BCR-ABL*, associated with $t(9;22)$; (ii) *E2A-PBX*, associated with $t(1;19)$; and (iii) *MLL-AF4*, associated with $t(4;11)$.

The cytogenetic and molecular genetic characteristics of precursor B-lymphoblastic lymphoma are believed to be similar to those of precursor B-lymphoblastic leukaemia.

Bone marrow histology

In precursor B-lymphoblastic leukaemia, the marrow is diffusely infiltrated by lymphoblasts which replace most of the haemopoietic and fat cells. The infiltrating cells vary in size but are on average about twice the diameter of red blood cells. They are characterized by a large nucleus and minimal cytoplasm (Fig. 6.4). The chromatin is finely stippled with one or two small or medium sized nucleoli. The number of mitotic figures seen is greater than in the most mature (peripheral) B-cell neoplasms but is less than is seen in Burkitt's lymphoma/L3 ALL. The number of mitoses seen in precursor B-lymphoblastic cases is less than is seen in precursor T-lymphoblastic leukaemia [37]. Bone marrow necrosis is occasionally seen. Reticulin fibrosis occurs to a varying degree in up to 57% of cases of ALL and collagen fibrosis (Fig. 6.5) in a quarter [38]. Reticulin fibrosis regresses slowly following remission of the leukaemia. Fibrosis is responsible for occasional failure to obtain an aspirate.

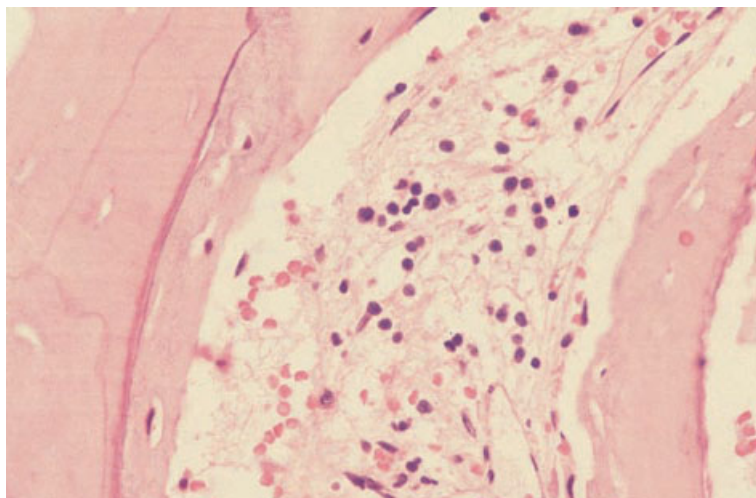


Fig. 6.5 BM trephine biopsy section in ALL, showing new bone formation and bone marrow fibrosis as a result of necrosis; there is new bone formation on the surface of a spicule of dead bone; leukaemic lymphoblasts are scattered through the fibrous tissue. Paraffin-embedded, H&E $\times 376$.

The diagnosis of ALL is usually easily made on the basis of the cytological features of neoplastic cells in bone marrow aspirates or peripheral blood films. Trephine biopsy is therefore not usually necessary. Occasionally, when there is minimal evidence of leukaemia in the peripheral blood and when bone marrow cannot be aspirated, the diagnosis is dependent on a trephine biopsy.

If bone marrow infiltration occurs during the course of precursor B-lymphoblastic lymphoma, the cytological features are similar to those of ALL but the infiltration is initially patchy with intervening areas of surviving haemopoietic tissue and fat.

Immunohistochemistry

Cells of precursor B-lymphoblastic leukaemia/lymphoma express CD79a (Box 6.1). There is variable expression of CD10, CD20 and TdT: TdT expression is more common in pro-B ALL and common ALL; cells of common ALL and pre-B ALL usually express CD10; CD20 expression is more frequent in cases with a more mature phenotype. They do not express CD1, CD3, CD4, CD5 or myeloid antigens. CD45 is expressed, expression being stronger than in myeloblasts.

Problems and pitfalls

The most important differential diagnoses of pre-

cursor B-ALL are acute myeloid leukaemia (AML) and precursor T-lineage ALL. In general, ALL blasts have a very high nucleocytoplasmic ratio and are more regular than the blasts of AML (see page 114). There are no myelodysplastic features and the primitive cells do not contain granules. Cytochemistry and histochemistry can be important in confirming a diagnosis of AML but it must be noted that negative reactions are consistent with either ALL or AML with minimal evidence of myeloid differentiation. Immunophenotyping is therefore essential for establishing a diagnosis of precursor B-lymphoblastic leukaemia/lymphoma.

It may also be necessary to distinguish precursor B-lymphoblastic lymphoma from infiltration of the marrow by mature B-cell lymphomas. The distinction from Burkitt's lymphoma is important and can be difficult. Cytological details and the high mitotic count are useful features in the recognition of Burkitt's lymphoma and, when necessary, immunohistochemistry can be employed (see page 283). In large cell lymphomas, the cells are larger and more pleomorphic than those of ALL/lymphoblastic lymphoma. In low grade lymphomas, infiltration is often focal and the nuclei show at least some degree of chromatin condensation. Mitotic figures are quite uncommon. When there is heavy infiltration, chronic lymphocytic leukaemia (CLL) can be confused with ALL, particularly if sections are too thick and cytological details are not readily assessable.

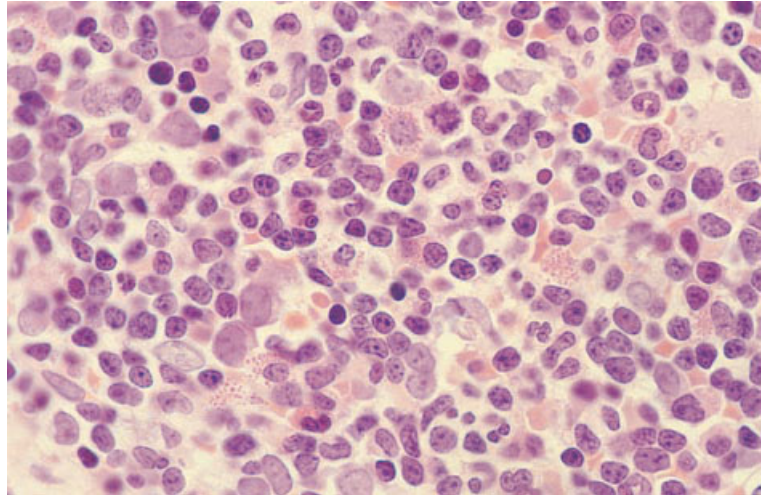


Fig. 6.6 BM trephine biopsy section from a 3-year-old child with an infection showing haematogones. Paraffin-embedded, H&E $\times 940$.

The blastoid variant of mantle cell lymphoma poses a particular problem since the chromatin pattern is diffuse and resembles ALL; immunophenotyping will allow the distinction to be made (see page 269).

A preleukaemic episode of marrow aplasia is a rare form of presentation of ALL, seen in about 2% of childhood cases and in some adults [39,40]. Trephine biopsies show a hypocellular marrow; haemopoietic cells are generally reduced but there may be some sparing of megakaryocytes. In most reported cases, increased lymphoblasts have not been detected. However, hypercellular areas with a lymphoid infiltrate have sometimes been noted, permitting a distinction from aplastic anaemia [41]. A common feature is the presence of reticulin fibrosis and increased numbers of fibroblasts [39]. Recovery of haemopoiesis occurs, usually spontaneously, and after an interval of some weeks ALL is manifest in the marrow and the peripheral blood. In the absence of an apparent increase in lymphoid cells it can be difficult to distinguish an aplastic preleukaemic phase of ALL from aplastic anaemia, although the presence of increased reticulin and fibroblasts may suggest that aplastic anaemia is not the correct diagnosis.

In making a diagnosis of *de novo* or recurrent ALL, it should be noted that increased numbers of immature lymphoid cells resembling lymphoblasts of L1 ALL are sometimes seen in children. Such cells may also be present very rarely, even in adolescents and adults who do not have ALL. The term 'haemato-

gones' has been used for these cells. The possibility of confusion with ALL is increased by the fact that they may be positive for CD34, CD10 and TdT. Such cells (Fig. 6.6) have been observed after cessation of chemotherapy for ALL, following bone marrow transplantation, during infection, in children with non-haemopoietic neoplasms, in miscellaneous benign conditions and even in healthy children (found when acting as bone marrow donors). Haematogones can be distinguished from ALL blasts by flow cytometry immunophenotyping. Haematogones tend to express TdT strongly and CD10 and CD19 weakly, whereas the reverse pattern of reactivity is seen with ALL blast cells [42].

B-lineage lymphomas and chronic leukaemias

B-cell chronic lymphocytic leukaemia/small lymphocytic lymphoma

B-cell CLL is a disease resulting from neoplastic proliferation of mature B lymphocytes which infiltrate the bone marrow and circulate in the peripheral blood. It is predominantly a disease of middle and old age. Patients diagnosed in the early stages of the disease may have no abnormal physical findings. In patients with more advanced disease, common clinical features are lymphadenopathy, hepatomegaly and splenomegaly. There is commonly an immune paresis, with impaired B- and T-cell function and

reduced concentration of Ig. Auto-immune phenomena are also common.

Various arbitrary levels of peripheral blood lymphocyte count, for example more than $5 \times 10^9/l$ or more than $10 \times 10^9/l$, have been suggested as objective criteria to establish a diagnosis of CLL. The lower count is quite adequate for diagnosis if the cells are shown to be monoclonal B lymphocytes with typical morphological and immunological features.

In the WHO classification, CLL is grouped with small lymphocytic lymphoma (see page 232). Both the Kiel and REAL classifications included CLL, with small lymphocytic lymphoma and prolymphocytic leukaemia (PLL) (see page 232), in a single category. The equivalent Working Formulation category was small lymphocytic lymphoma, consistent with CLL. It is clear, however, that PLL is a distinct entity and it is recognized as such in the WHO classification. Some cases of CLL show evidence of plasmacytoid differentiation. Although it has been suggested that this may be associated with a worse prognosis, the evidence is not conclusive and the WHO classification does not differentiate such cases from classical CLL.

Examination of the peripheral blood is essential in the diagnosis of CLL. A bone marrow aspirate is of little importance in comparison with a trephine biopsy which yields information important both for diagnosis and prognosis. Some NHL are easily confused with CLL if a trephine biopsy specimen is not examined and immunophenotyping is not employed.

In most cases CLL has a relatively indolent course

with a median survival of more than 10 years. However, in a minority of patients, the disease undergoes transformation to a more aggressive lymphoproliferative disease. The most common form of transformation is characterized by a progressive rise in the numbers of prolymphocytes in the peripheral blood and is termed prolymphocytoid transformation. Transformation to a large B-cell lymphoma, Richter's syndrome, is much less common. Transformation of CLL to Hodgkin's disease has been reported [43].

Small cell lymphocytic lymphoma is a lymphoproliferative disorder characterized by lymphadenopathy in which the histological features of involved lymph nodes are identical to those of CLL. The major differences from CLL are the absence of a leukaemic component and lower incidence of marrow infiltration. Some patients have disease clinically confined to one lymph node group. Others have generalized lymphadenopathy which may be accompanied by hepatomegaly or splenomegaly. The immunophenotype is indistinguishable from that of CLL.

Peripheral blood

The blood film shows a uniform population of mature, small lymphocytes with round nuclei, clumped chromatin, scanty cytoplasm and a regular cellular outline (Fig. 6.7). Broken cells, designated smear cells or smudge cells, are characteristic but not pathognomonic since they are occasionally seen in a variety of other conditions. With advanced

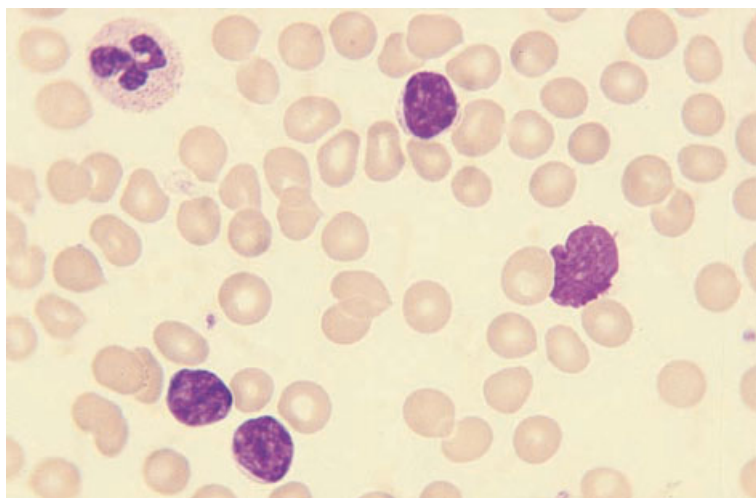


Fig. 6.7 PB film, CLL, showing a uniform population of small mature lymphocytes. One smear cell is present. MGG $\times 940$.

Fig. 6.8 PB film in CLL/mixed cell type, showing pleomorphic lymphocytes and one smear cell. MGG $\times 940$.

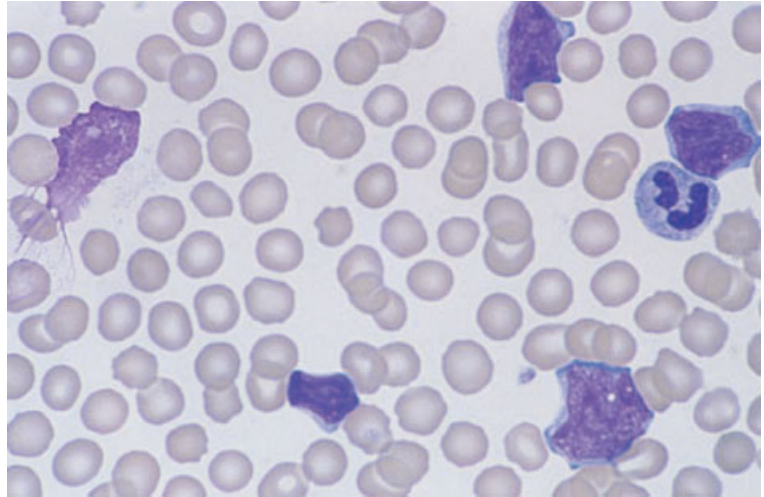
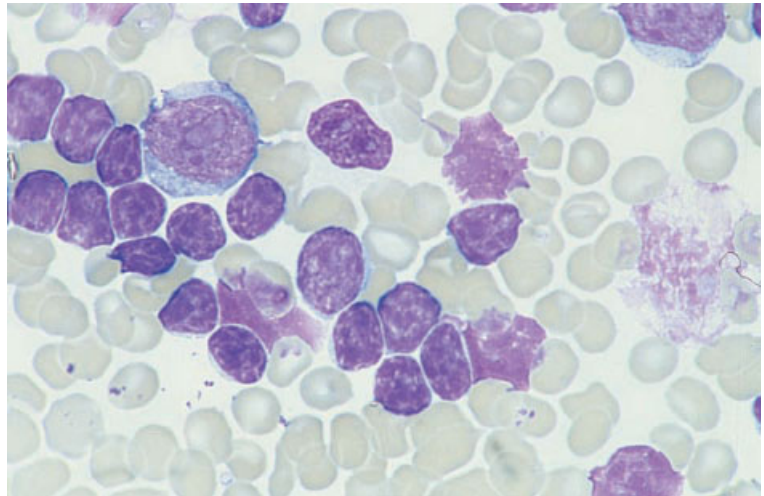


Fig. 6.9 PB film, Richter's syndrome, showing mature small lymphocytes, smear cells and a large cell with a giant nucleolus. MGG $\times 940$.



disease there is anaemia and thrombocytopenia. Auto-immune haemolytic anaemia can occur, either early or late in the course of CLL. The blood film then shows spherocytes and the direct antiglobulin test is positive. When bone marrow reserve is adequate, there is also polychromasia and the reticulocyte count is increased. Auto-immune destruction of platelets may also occur and, in patients with early disease, may be responsible for an isolated thrombocytopenia. Pure red cell aplasia is a less common complication; the peripheral blood shows morphologically normal red cells and a lack of polychromasia.

Patients with CLL may have a small proportion of cells with the morphology of prolymphocytes, i.e.

with a prominent nucleolus and more abundant cytoplasm. Cases with more than 10% prolymphocytes at presentation have been described as the mixed cell type of CLL (Fig. 6.8); in some patients the prolymphocyte count remains stable and the disease behaves like classic CLL [44]. Others have a progressively increasing prolymphocyte count and more aggressive course and probably represent prolymphocytoid transformation. When CLL undergoes transformation to large cell lymphoma, designated Richter's syndrome, transformed cells are only rarely present in the peripheral blood (Fig. 6.9) but, when present, have the same cytological features as large cell lymphoma in leukaemic phase.

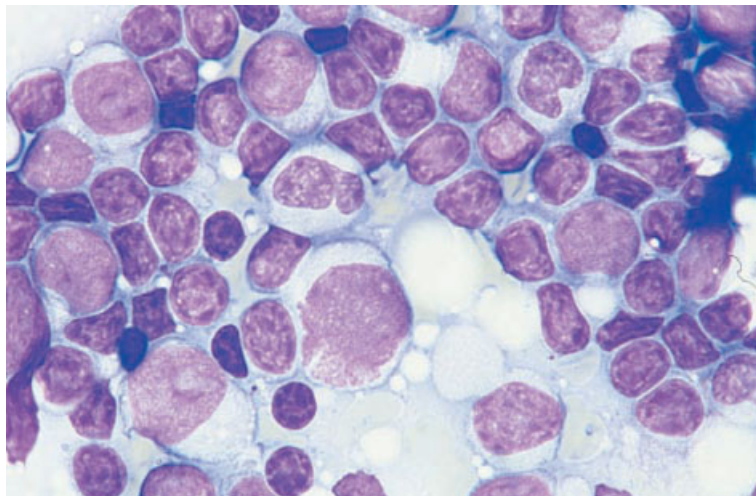


Fig. 6.10 BM aspirate, Richter's syndrome (same case as in Fig. 6.9), showing mature small lymphocytes admixed with frequent very large cells with large nucleoli. MGG $\times 940$.

In patients with small lymphocytic lymphoma, the lymphocyte count is normal at presentation and the peripheral blood film shows no specific abnormalities. A minority of patients develop lymphocytosis during the course of the illness, usually during the first few years after presentation [45].

Bone marrow cytology

The bone marrow is hypercellular and contains increased numbers of mature lymphocytes which are uniform in appearance. Normal haemopoietic cells are reduced, there being a continued fall with disease progression. Various arbitrary percentages of bone marrow lymphocytes, for example more than 30% or more than 40%, have been suggested as necessary to establish the diagnosis of CLL. A figure of 30% is quite adequate for diagnosis if a good aspirate, not diluted with peripheral blood, is obtained and if other features are typical. In one study the percentage of lymphocytes in the aspirate showed independent prognostic significance [46].

In small lymphocytic lymphoma the bone marrow is infiltrated in the majority of patients particularly, but not exclusively, those who have clinically apparent generalized disease [45,47,48]. Cytological features of the infiltrating cells are the same as those of CLL.

When CLL is complicated by auto-immune haemolytic anaemia, the bone marrow shows ery-

throid hyperplasia and, in auto-immune thrombocytopenia, there are increased megakaryocytes, at least in those patients with an adequate haemopoietic reserve. In pure red cell aplasia there is a lack of any red cell precursors beyond proerythroblasts.

When polymphocytoid transformation of CLL occurs, increasing numbers of polymphocytes are present in the bone marrow. Richter's transformation sometimes occurs in the bone marrow but more often occurs initially at an extramedullary site with bone marrow infiltration being a late event. When bone marrow infiltration occurs, the cells usually have the morphology of a pleomorphic large B-cell lymphoma, often with immunoblastic features (Fig. 6.10). Immunoblasts are large cells with deeply basophilic cytoplasm and a large nucleus with a large prominent central nucleolus.

Immunocytochemistry and flow cytometry

Cells of CLL show weak expression of monoclonal Smlg, commonly IgM with or without IgD (Box 6.2). They express pan-B markers such as CD19 and CD24. The pan-B marker CD22 is expressed in the cytoplasm but is expressed weakly, if at all, on the cell surface. CD20 is also weakly expressed. CLL cells do not usually express FMC7 or CD79b [49]. There is cell surface expression of CD5 and CD23 in the majority of cases [50]. Expression of CD5 is weaker than on normal T cells. Co-expression of

BOX 6.2**Chronic lymphocytic leukaemia***Flow cytometry and immunocytochemistry*

CD5+, CD19+, CD23+, CD24+, weak SmIg (IgM+, IgD+/-), Ig light chain type restriction
 CD10-, SmCD22-, CD79b-, FMC7-

Immunohistochemistry

CD5+, CD20+/-, CD23+/-, CD43+, CD79a+
 CD10-, cyclin D1-

Cytogenetics and molecular genetics

No specific abnormality and many cases have normal karyotype

The most common abnormalities are trisomy 12, del(13)(q12-14), del(6) and abnormalities of chromosomes 17 and 13q

Abbreviations (percentages are approximate): +>90% positive; +/->50% positive; -/+<50% positive; <10% positive; Ig, immunoglobulin; Sm, surface membrane.

CD5 and CD19 can be shown using two-colour immunofluorescence. Clonality of the CD5-positive population can be demonstrated by flow cytometric analysis of the Ig light chain type on the cell surface. A scoring system has been described using immunophenotypic data to help discriminate between CLL and other B-cell lymphoproliferative disorders [49,50]. Cases score one point for each of the following five features: (i) weak expression of SmIg; (ii) expression of CD5; (iii) expression of CD23; (iv) lack of expression of FMC7; and (v) lack of expression of CD22 (or CD79b). Most cases of CLL have a score of four or five points; a minority has a score of three points. CD38 is expressed by cells of 40–50% of cases; its expression is indicative of a worse prognosis.

Cytogenetics and molecular genetics

A normal karyotype has been reported in 40–72% of cases in different series of patients [51–53]. The most common cytogenetic abnormalities are trisomy 12, often associated with additional abnormalities, and del(13)(q12–14) (Box 6.2). Other abnormalities include del(6)(q), del(11)(q), 14q+ and abnormalities of chromosome 17. A normal karyotype, 13q deletion and most cases with an isolated trisomy 12 are associated with classical morphology and a good prognosis. Trisomy 12 with additional abnormalities, 14q+, del(6)(q) and chromosome 17 abnormalities are associated with an atypical im-

munophenotype and a worse prognosis [53]. FISH shows a much higher proportion of cases with clonal abnormalities than conventional cytogenetic analysis [54,55].

Molecular genetic analysis indicates that CLL may result from mutation in a pregerminal centre B lymphocyte (about 60% of cases) or a postgerminal centre B lymphocyte (about 40% of cases) (see page 75). Cases belonging to the former group have a worse prognosis.

Bone marrow histology

In the usual case at presentation, the vast majority of the neoplastic cells in the marrow are small lymphocytes (Fig. 6.11). These cells are slightly larger than the average normal lymphocyte. They have nuclei with coarse clumped chromatin and insignificant nucleoli; there is little cytoplasm. The nuclear outline appears somewhat irregular in sections of paraffin- and plastic-embedded specimens. In addition to the predominant small lymphocytes, there are small numbers of prolymphocytes and para-immunoblasts. The latter are medium sized cells with plentiful cytoplasm and a large nucleus with a prominent nucleolus. The cytoplasm of para-immunoblasts is less intensely basophilic than that of immunoblasts. Prolymphocytes are intermediate in size between small lymphocytes and para-immunoblasts; they have nuclei with dispersed

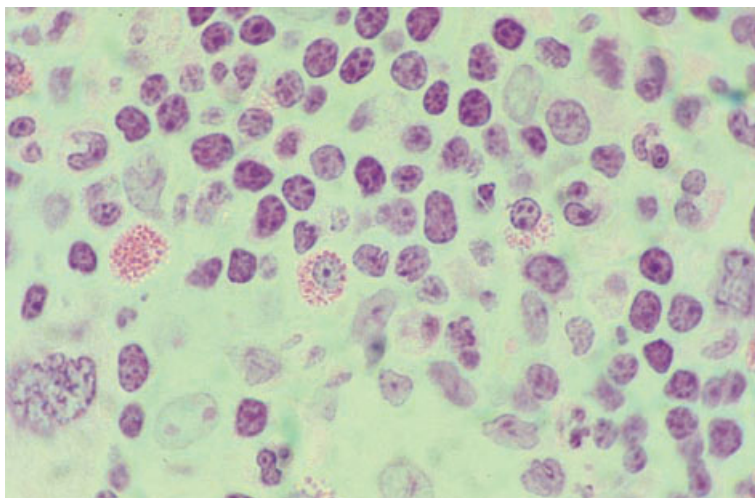


Fig. 6.11 BM trephine biopsy section, CLL, mature small lymphocytes infiltrating between residual normal haemopoietic cells. Plastic-embedded, H&E $\times 940$.

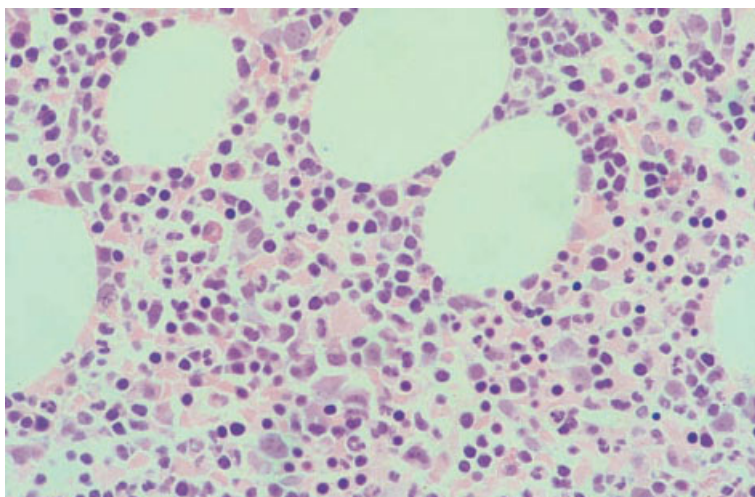


Fig. 6.12 BM trephine biopsy section, CLL, interstitial infiltration. Plastic-embedded, H&E $\times 377$.

chromatin and a nucleolus which is often large and prominent. In cases with diffuse infiltration there may be focal proliferation centres which sometimes give the infiltrate a 'pseudofollicular' pattern. The proliferation centres contain increased numbers of prolymphocytes and para-immunoblasts and are identical to those seen in lymph nodes of patients with CLL. Occasional cases of CLL have prominent non-neoplastic mast cells within and around the areas of infiltration.

Four histological patterns of marrow infiltration are seen in CLL: (i) interstitial (Figs 6.12 and 6.13); (ii) nodular (Fig. 6.14); (iii) diffuse (Fig. 6.15); and

(iv) mixed (see page 234) [9,56]. A mixed pattern represents a combination of nodular and interstitial infiltration. Paratrabecular infiltration is not seen. There is usually little if any increase in reticulin [17].

Examination of bone marrow trephine biopsy sections in CLL provides a valuable prognostic indicator which is partly independent of clinical stage. Most investigators have demonstrated a statistically significant difference between the outcome in cases with a diffuse pattern (poor prognosis) and those with non-diffuse (nodular and interstitial) patterns (good prognosis) [9,56,57]. Some workers have further found cases with a mixed pattern to have a

Fig. 6.13 BM trephine biopsy section, CLL, interstitial infiltration. Plastic-embedded, H&E $\times 940$.

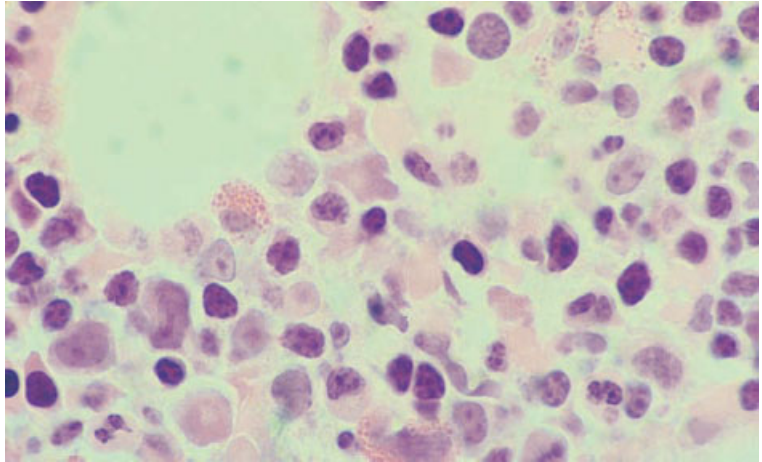


Fig. 6.14 BM trephine biopsy section, CLL, nodular infiltration. Plastic-embedded, H&E $\times 94$.

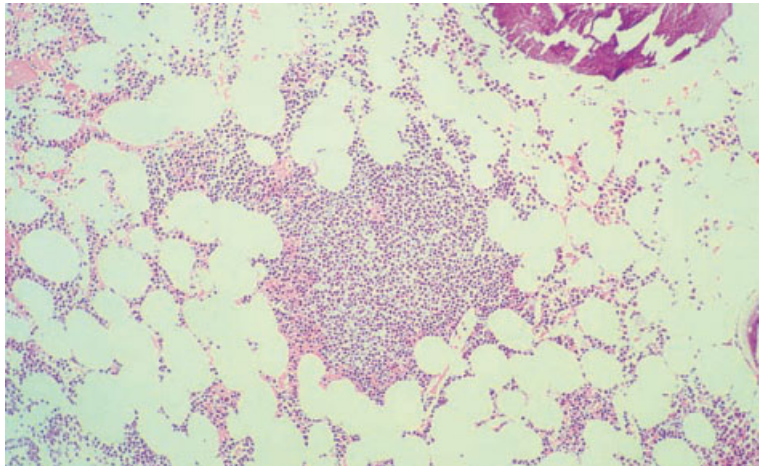
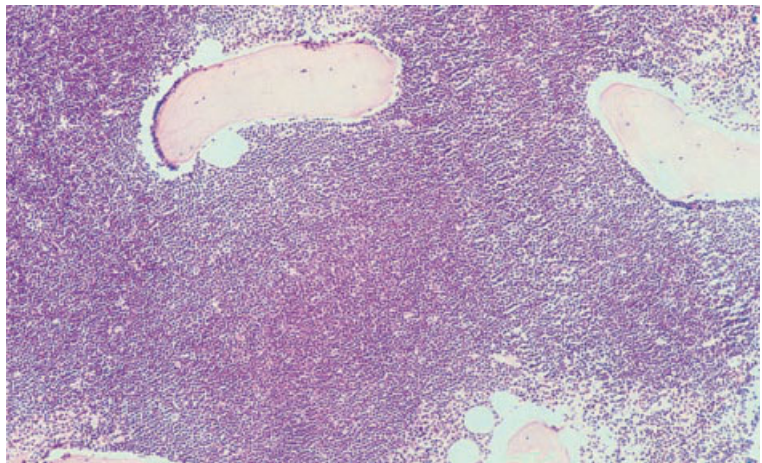


Fig. 6.15 BM trephine biopsy section, CLL, diffuse infiltration ('packed marrow' pattern). Plastic-embedded, H&E $\times 94$.



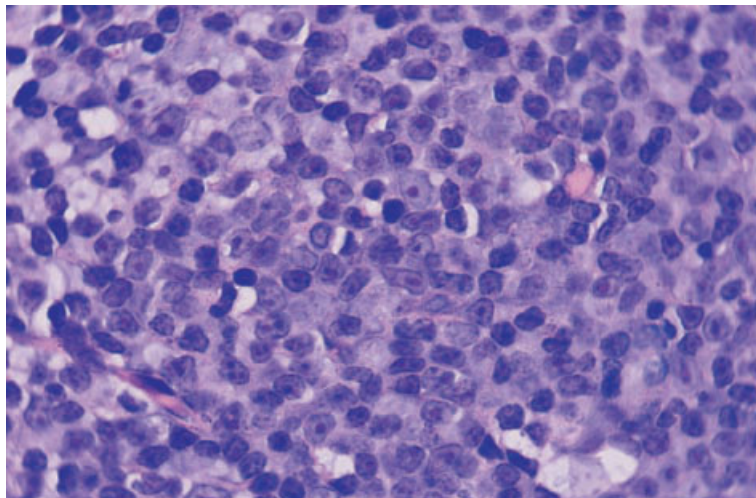


Fig. 6.16 BM trephine biopsy section, CLL, showing one immunoblast, para-immunoblasts and prolymphocytes in a proliferation centre. Paraffin-embedded, Giemsa $\times 940$.

prognosis intermediate between that of the above two groups [9]. Somewhat divergent findings were reported by Frisch and Bartl [58]; they also found the shortest survival in those with a 'packed marrow' (diffuse) pattern, but those with an interstitial pattern of infiltration had a shorter survival than those with a nodular infiltrate.

Attempts have been made, with some success, to correlate the clinical staging systems with patterns of bone marrow infiltration. In general, within a single stage, patients in whom the bone marrow is diffusely infiltrated do worse than those with non-diffuse patterns of infiltration [56,57].

The trephine biopsy is also of importance in assessing response to treatment since there may be residual lymphoid nodules when the percentage of lymphocytes in the aspirate is no longer increased [46]. This is referred to as nodular partial remission.

In prolymphocytoid transformation of CLL [44] there are increased numbers of prolymphocytes and para-immunoblasts in the marrow (Fig. 6.16). This needs to be distinguished from CLL/mixed cell type (Fig. 6.17) (see above). In Richter's syndrome [59,60] the marrow is infiltrated only in a minority of cases; the infiltrate is of immunoblasts admixed with bizarre giant cells, some of which resemble Reed–Sternberg cells (Fig. 6.18). In the majority of cases the marrow shows only the characteristic features of CLL. In rare cases of transformation to Hodgkin's disease the marrow may be involved.

The incidence of bone marrow involvement in patients with small lymphocytic lymphoma, as determined from biopsy sections, varies from 30% to 90% in reported series [16,61,62]. Various patterns of infiltration have been reported. Pangalis and Kittas [62] found a nodular pattern in all of six patients with bone marrow infiltration but others [11,16,47] have observed focal, interstitial and occasionally diffuse patterns. The cytological features of the infiltrate are similar to those seen in CLL; there are predominantly small lymphocytes with round or slightly irregular contours and occasional para-immunoblasts.

No correlation has been found between the bone marrow findings and survival in small lymphocytic lymphoma [62,63].

Immunohistochemistry

Cells of CLL express the B-cell markers CD20 and CD79a (see Box 6.2). Staining for CD20 is often weak. The markers CD5, CD23 and CD43 are usually positive and are useful in discriminating CLL from other small cell B-lymphoproliferative diseases. The expression of CD23 is weak on small CLL lymphocytes but this antigen is more strongly expressed by prolymphocytes and para-immunoblasts, highlighting the proliferation centres [64]. On occasions, only the proliferation centres stain for CD23. Staining for CD10 and cyclin D1 is negative. Staining for

Fig. 6.17 BM trephine biopsy section, CLL/mixed cell type, showing pleomorphic small and medium-sized lymphocytes. Paraffin embedded, H&E $\times 940$.

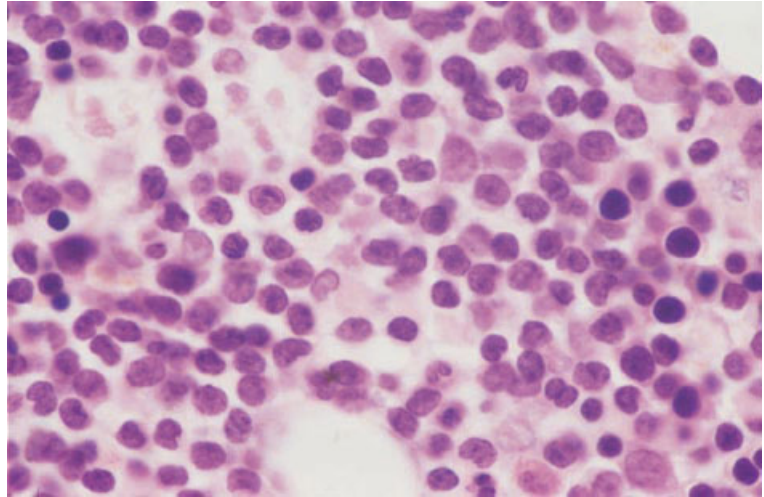
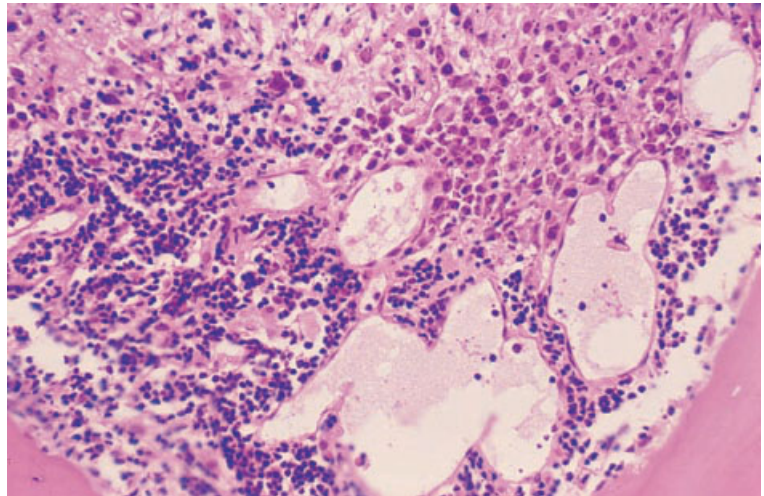


Fig. 6.18 BM trephine biopsy section, Richter's transformation of CLL: part of the section shows residual mature small lymphocytes (bottom left) and part infiltration by pleomorphic immunoblasts (top right). Paraffin-embedded, H&E $\times 390$.



Ki-67 is confined to the proliferation centres and scattered para-immunoblasts.

In large cell transformation the cells express CD79a but CD20 staining may be negative; the pleomorphic tumour cells resembling Reed–Sternberg cells often express CD30. There is little information regarding the expression of CD5 and CD23. Staining for Ki-67 shows a high proliferative fraction.

Problems and pitfalls

In its earliest stages, CLL can be diagnosed in cases with lymphocyte counts as low as $5 \times 10^9/l$, pro-

vided there is typical morphology and immunophenotype with evidence of monotypic Ig light chain expression by the CD5-positive cells on flow cytometric analysis.

Polyclonal B-cell lymphocytosis has been described in small numbers of patients, usually associated with cigarette smoking [65,66]. This condition has sometimes been confused with CLL. The lymphocytosis is usually mild and there are often morphological abnormalities including binucleation. A minority of cases have lymphadenopathy and splenomegaly. No evidence of clonality is found on immunophenotypic or molecular genetic analysis.

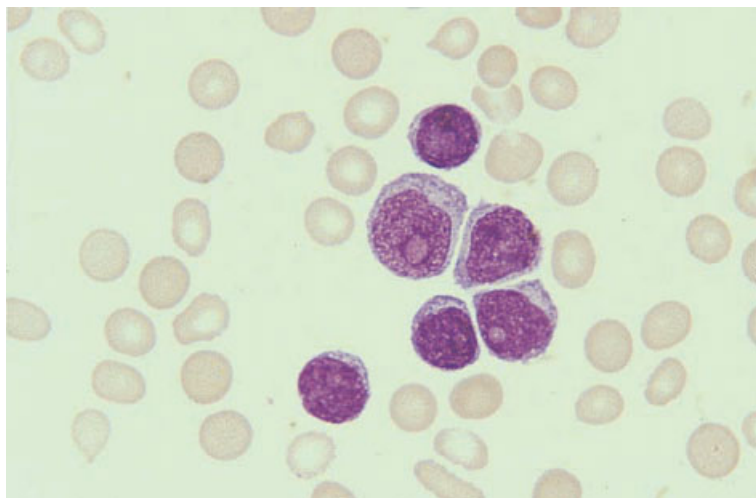


Fig. 6.19 PB film, B-PLL, showing prolymphocytes with plentiful cytoplasm and a single prominent nucleolus. MGG $\times 940$.

Lymphoproliferative disorders that may be mistaken for CLL include: (i) PLL; (ii) lymphoplasmacytic lymphoma; (iii) follicular lymphoma; (iv) mantle cell lymphoma; (v) splenic lymphoma with villous lymphocytes; (vi) T-PLL; and (vii) T-cell granular lymphocytic leukaemia. Correct diagnosis requires correlation of cytological features, immunophenotype and, in some cases, molecular genetic analysis. With careful assessment of cytological features and immunophenotype, distinction from other small B-cell lymphoproliferative disorders is usually not a problem. Cases with atypical morphological features (mixed cell type and cases undergoing prolymphocytoid transformation) may be confused with mantle cell lymphoma which also expresses CD5. In these cases, immunophenotypic and molecular genetic analysis will usually enable the distinction to be made.

The histological features in trephine biopsy sections that are helpful in differentiating CLL from other small B-cell lymphoproliferative disorders are the non-paratrabeular pattern, the presence of para-immunoblasts within the infiltrate and, in some cases, the presence of proliferation centres.

B-cell prolymphocytic leukaemia

B-cell PLL is a disease consequent on the proliferation of a clone of mature B cells with distinctive cytological characteristics. The disease is much less

common than CLL and, on average, occurs at an older age. Although PLL falls into the same category as CLL in the Kiel and REAL classifications and in the Working Formulation, it is clear that it is a distinct entity which differs clinically, cytologically, immunophenotypically and genetically from CLL. It is recognized as a separate entity in the WHO classification.

Peripheral blood examination is most important in the diagnosis of PLL; bone marrow aspiration and trephine biopsy are less important.

In PLL there is generally marked splenomegaly but only minor lymphadenopathy.

Peripheral blood

The white cell count is typically quite high, for example $50\text{--}100 \times 10^9/\text{l}$ or even higher. Anaemia and thrombocytopenia may be present. Leukaemic cells are larger and in many cases less homogeneous than those of CLL. They vary in size with the larger cells having moderately abundant, weakly basophilic cytoplasm and a round nucleus containing a prominent nucleolus (Fig. 6.19). Smaller cells tend to have a somewhat higher nucleocytoplasmic ratio and the nucleolus is less prominent.

Bone marrow cytology

The bone marrow is infiltrated by cells of similar

BOX 6.3**B-cell prolymphocytic leukaemia***Flow cytometry and immunocytochemistry*

CD19+, CD22+, CD24+, CD79a+, Smlg+ (IgM+, IgD+/-), FMC7+
CD5-, CD10-, CD23-

Immunohistochemistry

CD20+/-, CD79a+
CD5-, CD10-, CD23-, CD43-, cyclin D1-

Cytogenetics and molecular genetics

No specific cytogenetic abnormality
14q+, trisomy 3, trisomy 12, del(6)(q) and t(11;14)(q13;q32) have been reported

Abbreviations (percentages are approximate): +>90% positive; +/->50% positive; -/+<50% positive; <10% positive; Smlg, surface membrane immunoglobulin.

appearance to those in the peripheral blood. Often the morphology is less characteristic than in the blood.

Immunocytochemistry and flow cytometry

The cells of PLL show strong expression of monoclonal Smlg which is usually IgM with or without IgD. Pan-B markers are expressed; the immunophenotype differs from that of CLL in that CD5 and CD23 are not usually expressed whereas CD22 and FMC7 are commonly positive (Box 6.3).

Cytogenetics

No specific cytogenetic abnormality is described, but 14q+, trisomy 3, trisomy 12, del(6)(q) and t(11;14)(q13;q32) have been reported [67] (Box 6.3).

Bone marrow histology [68]

Recognition of prolymphocytes in tissue sections may be difficult although thin sections and techniques of plastic embedding make this easier. The cells are slightly larger than those of CLL and have round nuclei. The chromatin is in coarse clumps and there is a distinct and usually prominent nucleolus (Figs 6.20 and 6.21). The mitotic count is much lower than in large cell lymphoma, with which it may be confused. When biopsies are well fixed and preserved, it is possible to distinguish some, but not

all, cases of T-PLL from B-PLL by the presence of 'knobby' or convoluted nuclei. Some cases show increased eosinophils or plasma cells or sinusoidal dilation.

The following four patterns of marrow infiltration have been found in PLL: interstitial, interstitial-nodular, interstitial-diffuse (Fig. 6.20) and diffuse (Fig. 6.21). The commonest pattern is interstitial-nodular. The pure nodular form of infiltration which occurs in CLL is not seen in PLL. In contrast to CLL, all cases show increased reticulin.

Immunohistochemistry

Pan-B markers CD20 and CD79a are positive (Box 6.3). Staining for CD5, CD10, CD23, CD43 and cyclin D1 is usually negative.

Problems and pitfalls

PLL needs to be distinguished from CLL with mixed cell morphology (CLL/PL) and other B-cell lymphoproliferative disorders with a leukaemic component. Cytological features are more useful than histological features in making the distinction. The percentage of prolymphocytes in the peripheral blood is greater in PLL than CLL/PL, with most cases of PLL having more than 55% prolymphocytes. The immunophenotype is variable, but strong FMC7 expression will usually allow distinction from CLL.

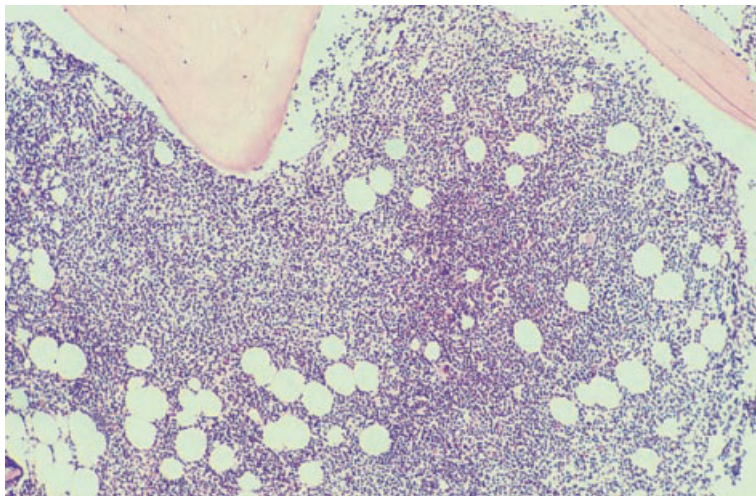


Fig. 6.20 BM trephine biopsy section, B-PLL, showing interstitial–diffuse infiltration. Plastic-embedded, H&E $\times 94$.

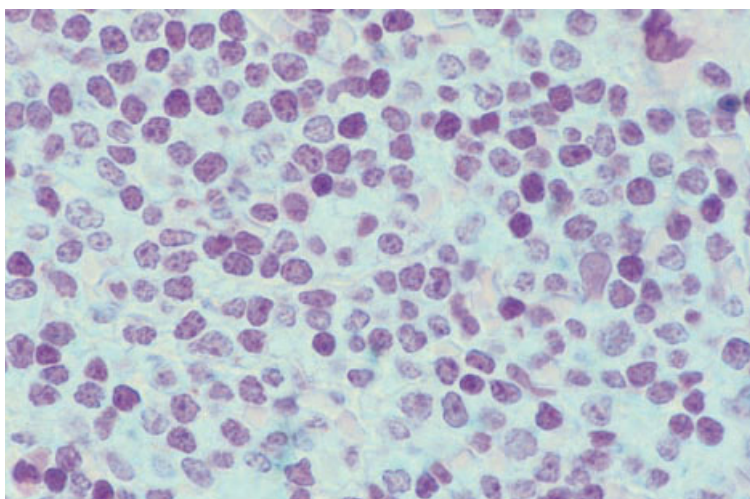


Fig. 6.21 BM trephine biopsy section, B-PLL, showing diffuse infiltration by medium sized cells, many of which have a single prominent nucleolus. Plastic-embedded, H&E $\times 940$.

It should be noted that t(11;14) is not specific for mantle cell lymphoma and may also be seen in some cases of PLL.

Distinction between B-PLL and T-PLL requires immunophenotypic analysis (see page 288).

Hairy cell leukaemia

Hairy cell leukaemia is a disease consequent on the proliferation, particularly in the spleen, of a clone of cells with distinctive morphology and the immunophenotype of late B-lineage cells. The common

clinical features are splenomegaly and signs and symptoms resulting from anaemia and neutropenia.

Hairy cells almost always have tartrate-resistant acid phosphatase (TRAP) activity in the cytoplasm; such activity is very uncommon in other lymphoproliferative disorders. Hairy cell leukaemia is not included in the Working Formulation. In the Kiel, REAL and WHO classifications it is recognized as a specific entity.

The diagnosis of hairy cell leukaemia can often be suspected from peripheral blood examination and confirmed by a bone marrow aspirate. How-

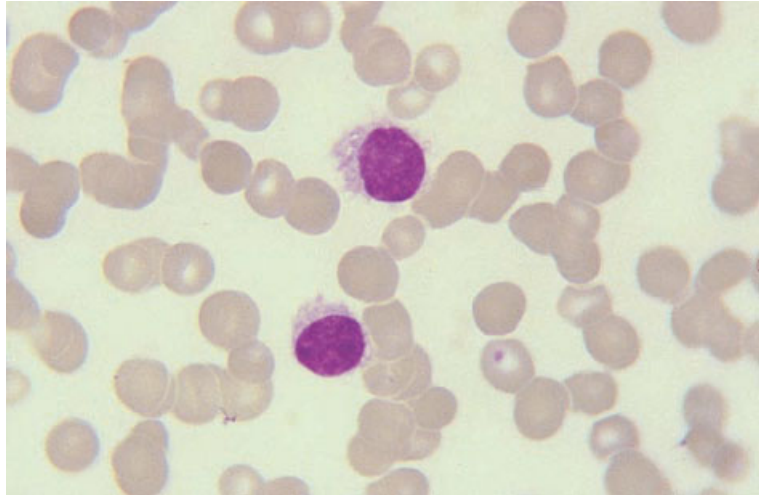


Fig. 6.22 PB film, hairy cell leukaemia, showing two hairy cells with weakly basophilic cytoplasm which has irregular hair-like projections. MGG $\times 940$.

ever, hairy cells may be infrequent in the blood and the characteristic reticulin fibrosis commonly renders aspiration difficult. Examination of trephine biopsy sections therefore plays an important role in diagnosis.

Peripheral blood

Hairy cells are usually present in the peripheral blood only in small numbers and in some cases none are detected. Pancytopenia is usual. Neutropenia and monocytopenia are particularly severe. The leukaemic cells are larger than those of CLL and have abundant weakly basophilic cytoplasm with irregular cytoplasmic margins (Fig. 6.22). The nucleus may be round, oval, kidney or dumb-bell shaped or bilobed. There is some condensation of chromatin. No nucleolus is apparent. The demonstration of TRAP activity is important in confirming the diagnosis but its value in monitoring therapy is reduced by the fact that interferon therapy causes a reduction of hairy cell TRAP activity [69].

Bone marrow cytology

The bone marrow is often difficult or impossible to aspirate. When an aspirate is obtained, the predominant cell is a hairy cell with the same morphological features as the few leukaemic cells in the peripheral blood. Aspirates are often aparticle but, when

fragments can be aspirated, mast cells are often very prominent within them.

Large cell transformation may occur in hairy cell leukaemia, particularly in abdominal lymph nodes [70]. Sometimes transformed cells are also present in the bone marrow (Fig. 6.23).

Immunocytochemistry and flow cytometry

The cells show strong SmIg expression which, in about one third of cases, is IgM with or without IgD and, in the remaining two thirds, is IgA or IgG. The pan-B markers CD19, CD20, CD22 and CD24 are usually expressed but CD5 and CD23 are usually negative (Box 6.4). There is usually expression of FMC7 and, in addition, there is expression of several markers that are otherwise uncommon in chronic leukaemias of B lineage—CD11c, CD25, CD71, CD103, HC2, the unclustered antibody DBA44 and several markers also expressed on plasma cells.

Cytogenetics and molecular genetics

No consistent cytogenetic or molecular genetic abnormality has been found.

Bone marrow histology

The degree of marrow involvement is very extensive in all but the earliest of cases [71–74]. Infiltration is

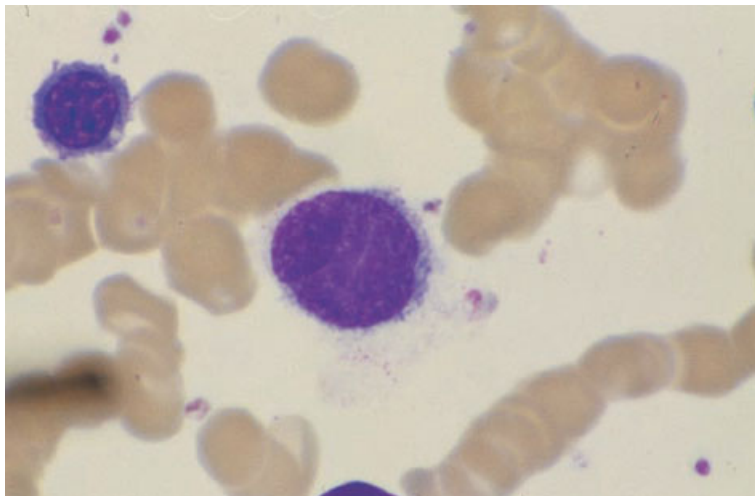


Fig. 6.23 BM film, large atypical cell in bone marrow of patient with transformation of hairy cell leukaemia. MGG $\times 940$. (By courtesy of Professor D Catovsky, London.)

BOX 6.4

Hairy cell leukaemia

Flow cytometry and immunocytochemistry

CD11c+, CD19+, CD20+, CD22+, CD24+, CD25+, CD71+, CD103+, strong Smlg, HC2+, FMC7+, DBA44+
CD5-, CD10-, CD23-

Immunohistochemistry

CD20+, CD79a+, DBA44+, TRAP+
CD5-, CD10-, CD23-, CD43-

Cytogenetics and molecular genetics

No specific abnormality

Abbreviations (percentages are approximate): +>90% positive; +/->50% positive; -/+<50% positive; <10% positive; Smlg, surface membrane immunoglobulin; TRAP, tartrate-resistant acid phosphatase.

either focal or diffuse; focal involvement is usually extensive with large confluent patches involving up to 50% of the marrow. Distinct nodules and a predilection for specific areas of the marrow are not found. A third pattern of infiltration is that of interstitial infiltration in a severely hypoplastic marrow [73,75]. Rare cases of hairy cell leukaemia occur in which no hairy cells are seen in the blood or in bone marrow biopsy sections but hairy cells are detectable in the spleen [76].

The infiltrates consist of widely spaced mononuclear cells, ranging in size from 10 to 25 μm , producing a striking appearance on low power examination

(Fig. 6.24). The relatively wide separation of the nuclei is due to a zone of abundant pale or water-clear cytoplasm and also in part, particularly in paraffin-embedded sections, to cytoplasmic retraction (Fig. 6.25); this appearance is accentuated by the underlying reticulin fibrosis which holds the cells apart. The tumour cell nuclei appear bland with pale, stippled chromatin; nucleoli are not prominent (Fig. 6.25). Nuclei vary in both size and shape and may include round, oval, indented, dumb-bell shaped and bilobed forms. The mitotic count is low. In plastic-embedded specimens the characteristic ribosome-lamellar complex can some-

Fig. 6.24 BM trephine biopsy section, hairy cell leukaemia, showing diffuse infiltration by 'hairy cells'; note the characteristic 'spaced' arrangement of the cells. Plastic-embedded, H&E $\times 188$.

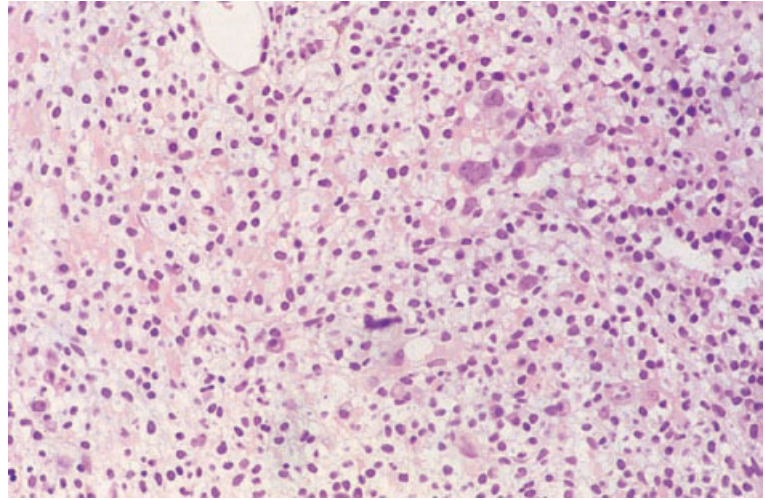
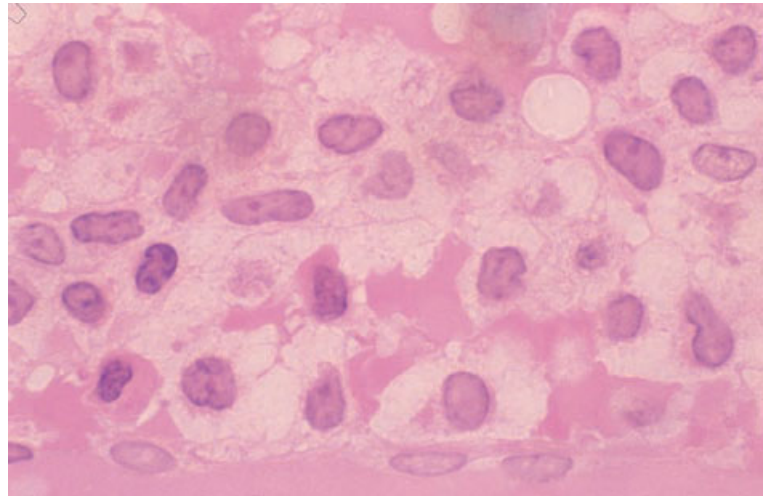


Fig. 6.25 BM trephine biopsy section, hairy cell leukaemia, showing bland nuclei of various shapes surrounded by shrunken cytoplasm with irregular margins; clear spaces surround the cells. Plastic-embedded, H&E $\times 970$.



times be identified within the cytoplasm of hairy cells and may aid in their identification [77]. In some cases there are foci of hairy cells with spindle-shaped or fusiform nuclei giving the cells a fibroblastic appearance; however, a fibrous or fusiform pattern may also be due to clusters of fibroblasts [73]. Red blood cells may be seen in infiltrated areas, either apparently extravasated or surrounded by a layer of hairy cells; this appearance resembles the red blood cell lakes seen in the spleen and liver [72,73]. Reactive plasma cells, lymphocytes and mast cells are also often apparent in areas of infiltration.

Residual haemopoiesis is observed in all but the most severely infiltrated areas. Haemopoietic elements are scattered among the infiltrating hairy cells and consist of isolated erythroid clusters and megakaryocytes; granulocyte precursors are particularly sparse [73,74].

When the marrow is hypocellular, small clusters of hairy cells and residual haemopoietic cells are identified between the fat cells.

Reticulin fibrosis occurs in the areas of marrow infiltration, producing a characteristic mesh-like pattern with fine reticulin fibres surrounding single

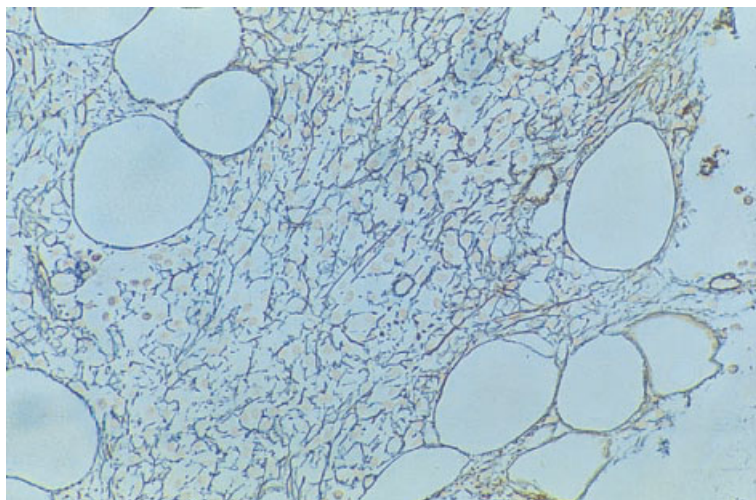


Fig. 6.26 BM trephine biopsy section, hairy cell leukaemia, showing increased reticulin. Plastic-embedded, Gomori stain $\times 188$.

cells and groups of cells (Fig. 6.26). Collagen fibrosis is not usual [17,78]. Rare patients have osteosclerosis [79,80].

Both the extent of infiltration [72,81] and cellular morphology have been found to be of prognostic importance in hairy cell leukaemia. A lesser degree of infiltration was found to be predictive of a good response to splenectomy [81] and of longer survival [72]. Nuclear form was found to be of prognostic significance, with patients whose cells had small round or ovoid nuclei having a better survival than those with cells showing intermediate sized, convoluted or large indented nuclei [72]. It has been suggested that this prognostic relevance is related more to increasing nuclear size in these three types than to nuclear shape *per se* [82]. The presence of rod-like cytoplasmic inclusions, corresponding to ribosomal-lamellar complexes, has also been found to correlate with a worse prognosis [72]. However, observations of the prognostic significance of histological features may no longer be relevant when most patients are treated with nucleoside analogues rather than by splenectomy or interferon.

When large cell transformation occurs, large atypical cells may be noted in the trephine biopsy (Fig. 6.27).

Bone marrow histology may be modified by therapy. Splenectomy corrects hypersplenism but rarely has any effect on the bone marrow tumour burden.

The two chemotherapeutic agents now most frequently employed in treatment, deoxycoformycin and α -interferon, significantly reduce infiltration. α -Interferon causes a slow but progressive decline in the number of bone marrow hairy cells over a period of several months with a response being seen in the great majority of patients [69,78,83]. This is accompanied by a slow increase in haemopoietic cells, but recovery of haemopoiesis, particularly granulopoiesis, lags behind reduction of hairy cell infiltration [78]. Despite early optimistic reports, complete clearing of hairy cells from the marrow occurs in only a small minority of patients [84]. The loss of hairy cells can continue after cessation of therapy but, in general, there is subsequently a tendency for their numbers to rise slowly [78,83]. At the end of therapy the marrow often shows reduced cellularity and occasionally it is severely hypocellular [78,83]. Deoxycoformycin is more effective than α -interferon in clearing hairy cells from the marrow, complete remission being observed in about three quarters of cases [84,85]. With clearing of hairy cells, the increased reticulin is lost progressively but, in general, loss of reticulin lags behind loss of hairy cells. Reticulin fibrosis may resolve completely when complete remission is achieved. The rare osteosclerotic lesions also resolve [79]. Immunohistochemistry is helpful in identifying residual hairy cells.

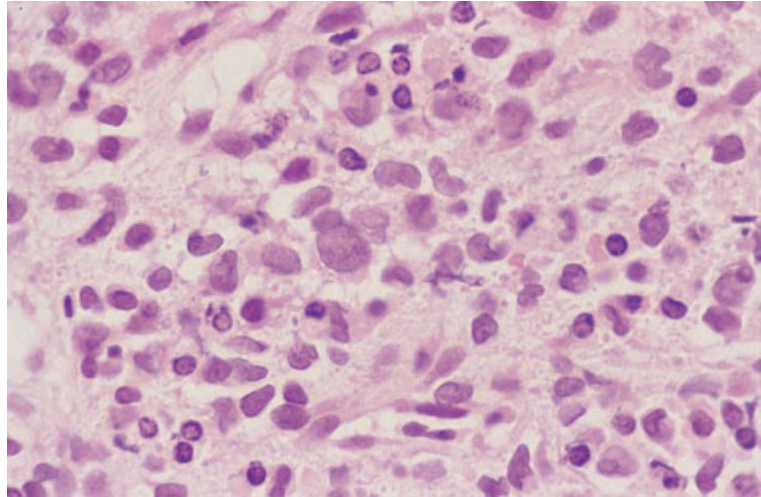


Fig. 6.27 BM trephine biopsy section, large cell transformation of hairy cell leukaemia, showing several large atypical cells. Paraffin-embedded, H&E $\times 388$. (By courtesy of Professor D Catovsky, London.)

Immunohistochemistry

Hairy cells express the B-cell antigens CD20 and CD79a [86] and the uncharacterized antigen recognized by the monoclonal antibody, DBA44 [87] (Box 6.4). When interpreting CD20-stained sections, it is important to ensure that the positive cells have the characteristic morphology of hairy cells as this antigen is expressed by most B lymphocytes. The antigen recognized by DBA44 is less often expressed on normal lymphocytes but, again, assessment of cytology is important. Monoclonal antibodies which identify TRAP also appear promising [88,89]. Staining for CD5, CD10 and CD23 is negative. There may be cytoplasmic dot-positive staining for CD68.

Problems and pitfalls

The differential diagnosis of hairy cell leukaemia includes other lymphoproliferative disorders, idiopathic myelofibrosis, systemic mastocytosis, aplastic anaemia and hypoplastic myelodysplastic syndromes (MDS). The morphological features of marrow infiltration by hairy cell leukaemia are unlike those of other lymphoproliferative disorders. In particular, the spacing of the hairy cells and the regular meshwork of reticulin are useful in making the distinction from other lymphoproliferative disorders. Co-expression of CD22 and CD11c and strong TRAP positivity are the most useful markers for hairy cell

leukaemia. Distinction between hairy cell leukaemia and systemic mastocytosis is dependent on demonstration of B-cell markers and reactivity with DBA44 in the former and demonstration of mast cells by means of a Giemsa stain or mast cell tryptase in the latter. In the past, some cases of hairy cell leukaemia were misdiagnosed as idiopathic myelofibrosis. Since the distinctive histological features of hairy cell leukaemia are now well recognized, this diagnostic problem should no longer arise. The differential diagnosis between the hypoplastic variant of hairy cell leukaemia and aplastic anaemia and hypoplastic myelodysplasia depends on recognition of the infiltrating hairy cells. In difficult cases cytochemistry and immunophenotypic analysis are invaluable.

Hairy cell variant leukaemia

A rare variant form of hairy cell leukaemia occurs which differs from hairy cell leukaemia in cytological and haematological features and in its responsiveness to various therapeutic agents [90]. The major clinical feature is splenomegaly.

Hairy cell variant falls into the Working Formulation category of low grade, lymphocytic lymphoma. The variant form of hairy cell leukaemia is not specifically identified in the Kiel, REAL and WHO classifications but, since it differs from classical hairy cell leukaemia in cytology, immunophenotype,

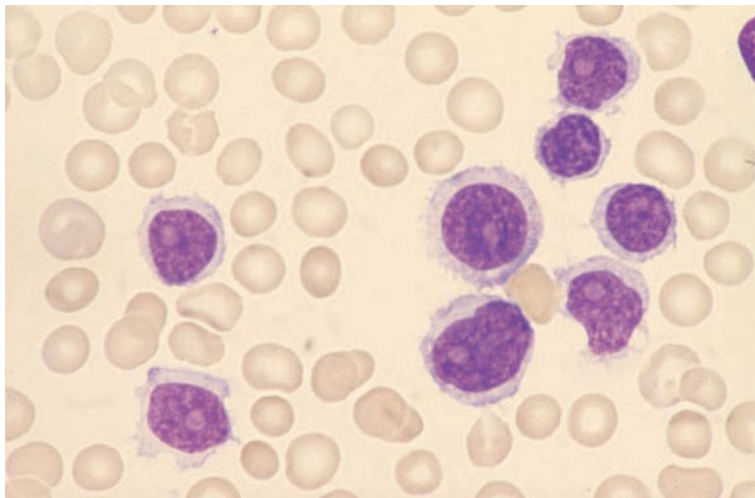


Fig. 6.28 PB film, variant form of hairy cell leukaemia: the nuclei have prominent nucleoli resembling those of prolymphocytes and the cytoplasm is weakly basophilic with hair-like projections. MGG $\times 940$.

haematological features and therapeutic responsiveness, its recognition as a discrete entity is justifiable.

Peripheral blood

Hairy cell variant differs from hairy cell leukaemia in that the white cell count is usually moderately to markedly elevated and numerous hairy cells are present in the peripheral blood. Anaemia and thrombocytopenia are each seen in about 50% of patients but pancytopenia is generally less pronounced than in hairy cell leukaemia and monocytopenia and neutropenia are not usual. The cells have somewhat more cytoplasmic basophilia than classical hairy cells but show the same irregular cytoplasmic margins. The nucleus, which shows moderate chromatin condensation, is the major distinguishing feature from hairy cell leukaemia because it contains a prominent nucleolus similar to that of PLL (Fig. 6.28). Variable numbers of binucleate cells and large cells with hyperchromatic nuclei are seen [90].

Bone marrow cytology

Bone marrow aspiration is usually easier than in hairy cell leukaemia. The aspirate contains numerous cells with the same features as those in the blood.

Immunocytochemistry and flow cytometry

The cytochemical and immunological markers of hairy cell variant differ in some respects from those of hairy cell leukaemia. Reactivity of TRAP is usually not detected. There is usually expression of CD11c, CD19, CD20, CD22, FMC7 and various plasma cell markers; CD30 is usually negative but, contrary to the typical findings in hairy cell leukaemia, CD25 and HC2 are usually negative.

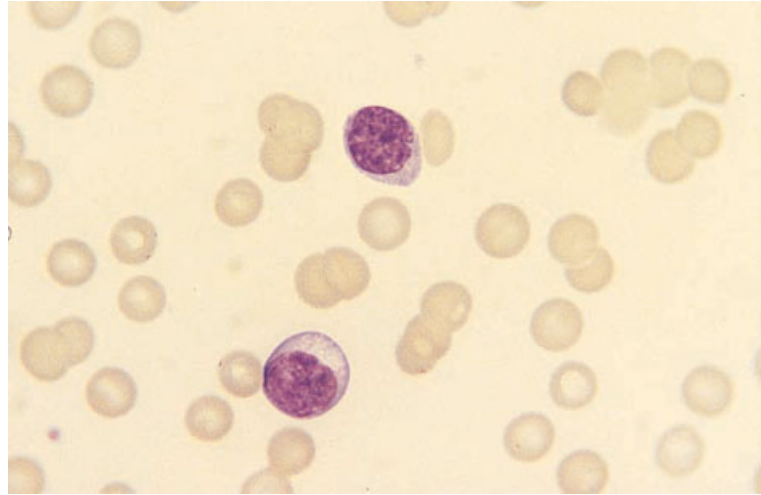
Bone marrow histology

The trephine biopsy [90] differs from that of hairy cell leukaemia. Infiltration is interstitial. Cells may be in clumps without the intercellular spaces which are characteristic of hairy cell leukaemia or there may be a mixture of clumps of cells and spaced cells. Moderately condensed chromatin and prominent nucleoli are apparent. There is only a slight to moderate increase in reticulin fibres.

Lymphoplasmacytic lymphoma

The classification of B-cell lymphoproliferative disorders showing evidence of plasma cell differentiation has been controversial and afflicted by confusing terminology. The REAL category of lymphoplasmacytoid lymphoma requires the presence of small lymphocytes, plasmacytoid lymphocytes and plasma

Fig. 6.29 PB film, lymphoplasmacytic lymphoma, showing a lymphocyte, a plasmacytoid lymphocyte, increased rouleaux formation and increased background staining. The patient had a high concentration of an IgM paraprotein and the clinical features of Waldenström's macroglobulinaemia. MGG ×940.



cells as part of the neoplastic clone. The equivalent WHO category is designated lymphoplasmacytic lymphoma. The Kiel classification included two categories: (i) lymphoplasmacytoid lymphoma, in which there were cells intermediate in appearance between lymphocytes and plasma cells; and (ii) lymphoplasmacytic in which mature plasma cells were also present. The former category is now included in the CLL/small lymphocytic lymphoma category of the REAL and WHO classifications.

Secretion of a monoclonal Ig is common; this is most often IgM but sometimes IgG, IgA, an Ig heavy chain or an Ig light chain is secreted. Clinical features are very variable. Some patients present with typical features of a lymphoma such as lymphadenopathy or splenomegaly. Others, however, present with signs and symptoms resulting from the presence of the abnormal monoclonal Ig without necessarily having any signs of lymphoma. The clinical presentations include specific syndromes such as: (i) Waldenström's macroglobulinaemia (see page 347), when there is hyperviscosity due to production of large amounts of an IgM paraprotein; (ii) cold haemagglutinin disease (CHAD), when the paraprotein is a cold agglutinin with specificity against the I, or less often the i, antigen of the erythrocyte; (iii) idiopathic or essential cryoglobulinaemia, when the paraprotein is either itself a cryoglobulin or has antibody activity against another Ig, the immune complex being a cryoglobulin; and (iv)

acquired angio-oedema due to C1 esterase inhibitor deficiency, when an immune reaction involving the paraprotein leads to consumption of C1 esterase inhibitor with a consequent susceptibility to angio-oedema. Lymphoplasmacytic lymphoma has also been described in a significant proportion of patients with mixed cryoglobulinaemia associated with hepatitis C infection [91]. These specific entities and several other rare conditions which may be associated with the histological features of lymphoplasmacytic lymphoma are dealt with in more detail in Chapter 7. Rarely, diffuse large B-cell lymphoma may supervene in lymphoplasmacytic lymphoma with an associated worsening of prognosis.

Peripheral blood

In some patients the peripheral blood film is normal. In others there are circulating plasmacytoid lymphocytes (Fig. 6.29), usually present only in small numbers. Plasmacytoid lymphocytes are slightly larger than normal lymphocytes and show various combinations of features usually associated with plasma cell differentiation, such as more abundant and more basophilic cytoplasm, an eccentric nucleus, coarse chromatin clumping or the presence of a paler-staining area adjacent to the nucleus which represents the Golgi zone. In some cases there is anaemia and increased background staining and rouleaux formation due to the presence of a para-

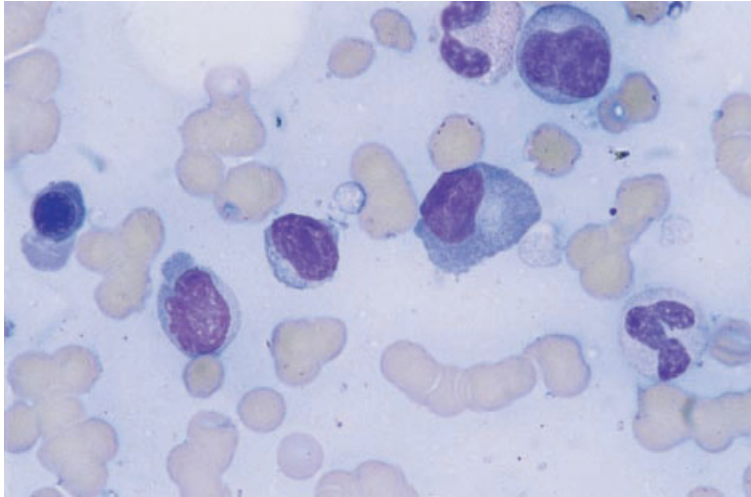


Fig. 6.30 BM aspirate, lymphoplasmacytic lymphoma. MGG $\times 940$.

BOX 6.5

Lymphoplasmacytic lymphoma

Flow cytometry and immunocytochemistry

CD19+, CD20+, CD22+, CD79a+, Cylg+, Smlg+ (usually IgM)
CD5-, CD10-, CD23-

Immunohistochemistry

CD20+, CD79a+, CD138+ (plasma cells), p63+ (antibody VS38c) (plasma cells)
CD5-, CD10-, CD23-, CD43-, cyclin D1-

Cytogenetics and molecular genetics

t(9;14)(p13;q32) frequently present

Abbreviations (percentages are approximate): +>90% positive; +/->50% positive; -/+<50% positive; <10% positive; Cy, cytoplasmic; Ig, immunoglobulin; Sm, surface membrane.

protein. Patients whose paraprotein is a cold agglutinin show red cell agglutination unless the blood specimen has been kept warm until the blood film is made. Occasionally, in patients with a cryoglobulin, globular or fibrillar deposits of the paraprotein are seen in the blood film.

Bone marrow cytology

The bone marrow aspirate may be normal or abnormal (Fig. 6.30). When present, lymphoma cells in the bone marrow vary from infrequent to numerous. They have the same cytological features as those

in the peripheral blood. Cells often contain cytoplasmic or nuclear inclusions due to Ig accumulation, but neither of these features is specific for a neoplastic proliferation; the inclusions are usually periodic acid-Schiff (PAS)-positive. There is sometimes an increase in mast cells or macrophages.

Immunocytochemistry and flow cytometry

Cells are positive with B-cell markers such as CD19, CD20, CD22 and CD79a, but are negative for CD5, CD10 and CD23 (Box 6.5). They usually express both membrane and cytoplasmic Ig, typically IgM.

Fig. 6.31 BM trephine biopsy section, lymphoplasmacytic lymphoma, showing diffuse infiltration by lymphocytes, plasmacytoid lymphocytes and occasional plasma cells; note the cytoplasmic and intranuclear inclusions. Plastic-embedded, H&E $\times 390$.

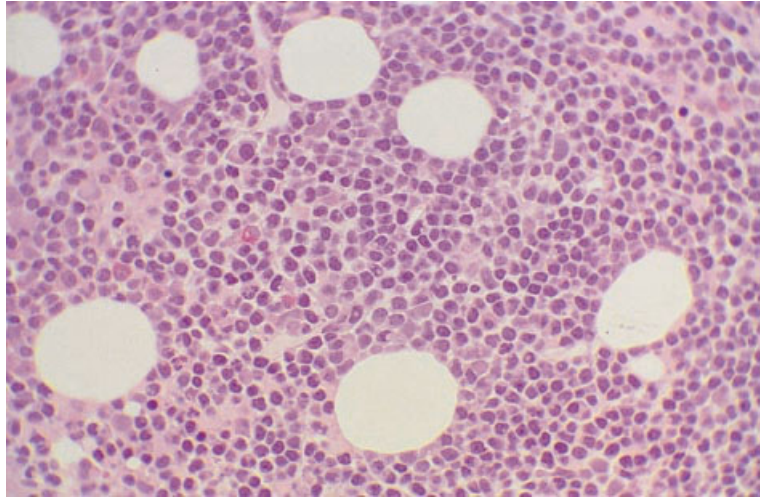
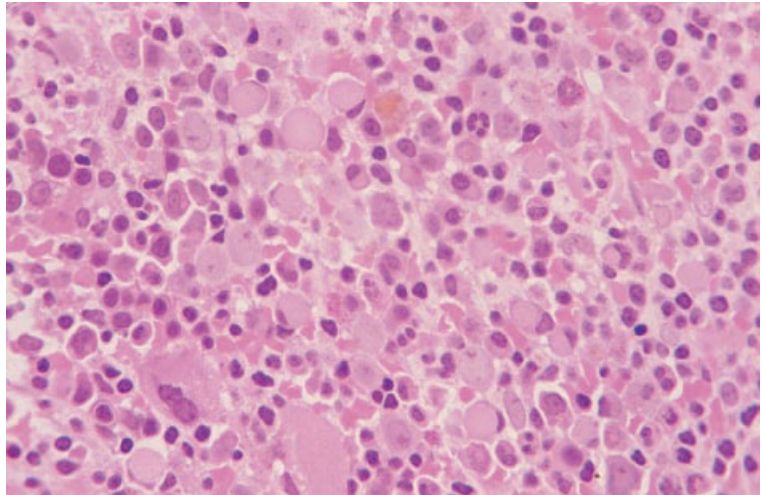


Fig. 6.32 BM trephine biopsy section, lymphoplasmacytic lymphoma, showing diffuse infiltration by lymphocytes, plasmacytoid lymphocytes and plasma cells; note the large intracytoplasmic inclusions (Russell bodies) compressing nuclei giving some cells a 'signet ring' appearance. Plastic-embedded, H&E $\times 390$.



Cytogenetics and molecular genetics

A translocation, $t(9;14)(p13;q32)$, involving the immunoglobulin heavy chain gene and *PAX5*, a paired box transcription factor gene, is a frequent finding in lymphoplasmacytic lymphoma [92,93] (Box 6.5).

Bone marrow histology

Bone marrow involvement is frequent in lymphoplasmacytic lymphoma, the reported incidence varying from 50% to more than 80% of cases

[45,48,94]. The proportion of cases with bone marrow infiltration is lower if the Kiel 'lymphoplasmacytoid lymphoma' category is excluded. The patterns of infiltration seen are interstitial, nodular, mixed (interstitial–nodular), diffuse [16,62,94] and paratrabeular [91,95]. Many of the infiltrating cells are small mature lymphocytes. Others show varying degrees of plasma cell differentiation (Figs 6.31–6.33). In addition to the usual nuclear and cytoplasmic features of plasma cells, there may be cells with intracytoplasmic or intranuclear inclusions (Russell bodies and Dutcher bodies, respectively) (Figs 6.31–6.33). Rare cases have signet ring

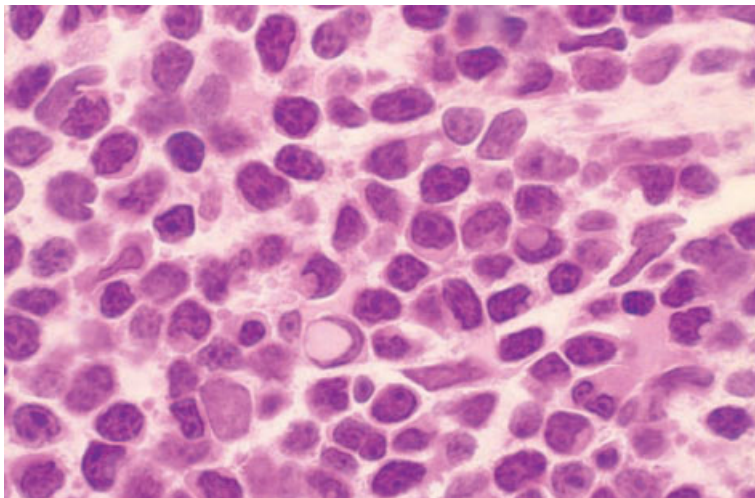


Fig. 6.33 BM trephine biopsy section, lymphoplasmacytic lymphoma, showing diffuse infiltration by lymphocytes and plasmacytoid lymphocytes; note the cytoplasmic and intranuclear inclusions. Plastic-embedded, H&E $\times 970$.

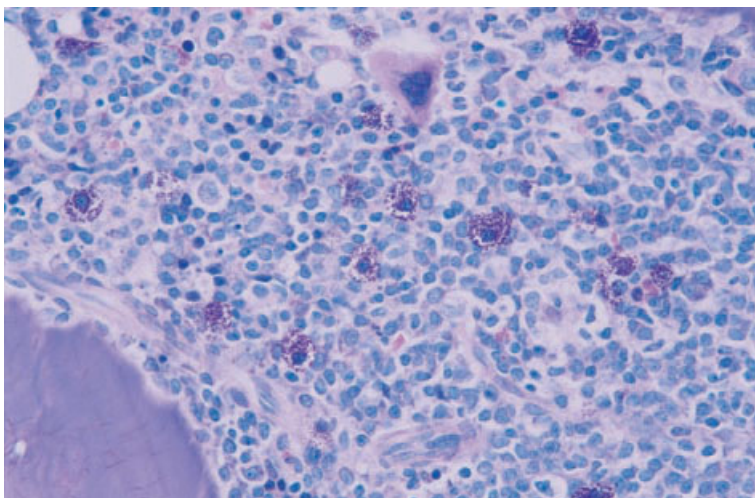


Fig. 6.34 BM trephine biopsy section, lymphoplasmacytic lymphoma, showing reactive mast cells. Plastic-embedded, Giemsa $\times 376$.

cells [96]. A small number of immunoblasts may be present. Some cases show a wide spectrum of lymphoid cells—lymphocytes, lymphoplasmacytoid cells, plasma cells and immunoblasts—and have frequent mitoses. An increase in mast cells usually accompanies neoplastic infiltration (Fig. 6.34). Reticulin fibres are frequently increased in the area of infiltration [17]. In cases with a paraprotein, bone marrow vessels may contain homogeneous PAS-positive material [97]. Paratrabeular and interstitial deposits of crystalline PAS-positive immunoglobulin may rarely be seen. Amyloid may be present in some cases.

Both the pattern of infiltration and cytological features have been found to be related to prognosis. Diffuse infiltration is associated with advanced disease and the worst prognosis [62,94]. A nodular infiltrate is associated with the best prognosis while a mixed interstitial–nodular infiltrate is intermediate [94].

Immunohistochemistry

The small lymphocytes are CD20, CD45 and CD79a positive (Box 6.5). Staining for CD5, CD10, CD23 and CD43 is usually negative. The plasma cells and

cells with plasmacytoid features express CD138, p63 (antibody VS38c) [98] and monotypic cytoplasmic immunoglobulin. Clonality may be demonstrated not only by immunohistochemistry to show κ or λ light chain restriction but also by *in situ* hybridization to show κ or λ messenger RNA; κ is more commonly expressed than λ .

Problems and pitfalls

As has been noted previously (see page 235), a proportion of patients with follicular lymphoma in lymph nodes have a bone marrow infiltrate with the histological features of lymphoplasmacytic lymphoma. Splenic marginal zone lymphoma can also have a mature plasma cell component and can resemble lymphoplasmacytic lymphoma (see page 272). Bone marrow infiltrates of CLL cells can be confused with lymphoplasmacytic lymphoma. Useful distinguishing features include the lack of proliferation centres, the presence of paratrabeular infiltration, a mature plasma cell component and a prominent mast cell infiltrate, all of which favour a diagnosis of lymphoplasmacytic lymphoma rather than CLL. Immunophenotypic analysis will resolve most diagnostic problems.

Follicular lymphoma

The terminology applied to lymphomas composed of cells considered analogous to the cells of normal lymphoid follicles has been a source of great confusion to both histopathologists and haematologists. Lymphomas of follicle centre origin usually show a follicular growth pattern in lymph nodes but some cases have a mixed follicular and diffuse pattern or are entirely diffuse. A follicular pattern in the bone marrow is rare. A specific translocation, t(14;18)(q32;q21), is associated with a high percentage of neoplasms of follicle centre origin. In the Kiel classification, cells of follicle centre origin are designated centrocytes and centroblasts. In the REAL classification they are referred to as follicle centre cells. The WHO category of follicular lymphoma and the REAL category of 'follicle centre lymphoma, follicular' are divided into grades I, II and III, which are approximately equivalent to the Working Formulation categorization of follicular lymphoma as predominantly small cell, mixed

small cell and large cell, and predominantly large cell (see Table 6.1). In the WHO classification the term 'follicle centre lymphoma, diffuse' is retained for those rare cases with a purely diffuse pattern.

Follicular lymphoma is rare in childhood and quite uncommon during adolescence. Cases occur throughout adult life. Unlike all other mature B-cell lymphomas, the incidence is similar in men and women. The most common clinical feature is lymphadenopathy, either localized or generalized. Some patients have hepatomegaly or splenomegaly. Patients with advanced disease may also have pleural effusions or ascites with neoplastic cells in the effusions. Follicular lymphoma is commonly widely disseminated (stage IV) at presentation. Transformation to diffuse large B-cell lymphoma can occur.

In the minority of patients with circulating lymphoma cells, the diagnosis of follicular lymphoma can usually be suspected from the cytological and immunophenotypic characteristics of the peripheral blood cells. In follicular lymphoma, bone marrow aspiration commonly fails to detect bone marrow involvement, as a consequence of both the focal nature of infiltration and of increased reticulin deposition in areas of infiltration. A trephine biopsy is therefore important if accurate staging is required. However, patients with stage III and stage IV disease are often treated with the same therapeutic protocols and, in such cases, bone marrow examination is not essential.

Peripheral blood

The blood count and film are often normal at presentation, even in patients with stage IV disease. When there is heavy bone marrow infiltration, the haemoglobin concentration and platelet and neutrophil counts may be reduced. A significant minority of patients have circulating neoplastic cells. These may be infrequent or may be present in very large numbers. Morphology varies between cases. In some patients, particularly those with high counts, the cells are smaller than normal lymphocytes with a very high nucleocytoplasmic ratio, condensed chromatin and narrow clefts in some nuclei (Fig. 6.35). In patients with lower counts the cells are somewhat larger. Cytological features may include scanty cytoplasm, angular shape,

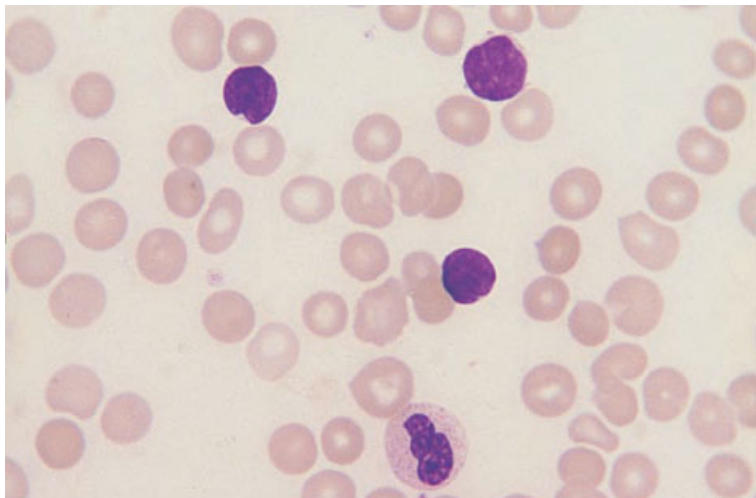


Fig. 6.35 PB film, follicular lymphoma, showing very small lymphocytes with dense, cleaved nuclei and very scanty cytoplasm. MGG $\times 940$.

homogeneous rather than clumped chromatin and narrow nuclear clefts. The lymphoma cells are more pleomorphic than those of CLL. Generally, only small lymphoid cells, corresponding to those recognized histologically as centrocytes, are present in the peripheral blood. Even cases with a large proportion of centroblasts in tissue sections usually have only centrocytes in the circulation.

Patients who do not have any peripheral blood abnormality at presentation may develop it during the course of the disease. In a minority of patients, transformation to a large B-cell lymphoma occurs and may be associated with the appearance in the blood of large cells corresponding to centroblasts. These cells are rather pleomorphic with plentiful cytoplasm, little chromatin condensation and prominent, often peripheral, nucleoli; the nuclei may be predominantly round or may be cleft.

Bone marrow cytology

The bone marrow is commonly infiltrated, even when the peripheral blood is normal. However, because bone marrow infiltration is often patchy, the bone marrow aspirate may be normal even when infiltration is detectable histologically. When the aspirate is abnormal, the cells may show the same morphological features as those in the peripheral blood but they are often less easy to recognize with certainty.

Immunocytochemistry and flow cytometry

The cells of follicular lymphoma show strong expression of SmIg and are positive for B-cell markers such as CD19, CD20, CD22, CD24 and CD79a (Box 6.6). They are CD5 negative and sometimes positive for CD38. They usually express CD10 and the antigen detected by FMC7.

Cytogenetics and molecular genetics

Most cases have a $t(14;18)(q32;q21)$ translocation resulting in dysregulation of the *BCL2* oncogene (Box 6.6). The translocation can be detected by conventional cytogenetics. Rearrangements of the *BCL2* gene can be detected by PCR, RT-PCR and FISH. A minority of cases show one of two variant translocations involving the *BCL2* gene, $t(2;18)(p12;q21)$ and $t(18;22)(q21;q11)$.

Bone marrow histology

The bone marrow is infiltrated in 25–60% of cases [16,47,48]. However, only about half of the patients with bone marrow infiltration have lymphoma cells recognizable microscopically in the peripheral blood. Infiltration is predominantly focal and very rarely diffuse. The focal lesions are overwhelmingly paratrabecular in location (Fig. 6.36) but there may be random patchy or a mixture of random and

BOX 6.6**Follicular lymphoma***Flow cytometry and immunocytochemistry*

CD10+/-, CD19+, CD20+, CD22+, CD24+, CD79a+, Smlg+
CD5-, CD23-

Immunohistochemistry

CD10+/-, CD20+, CD79a+, BCL2+

CD5-, CD23-, CD43-, cyclin D1-

There may be large numbers of reactive T cells (CD3+, CD5+) in areas of infiltration

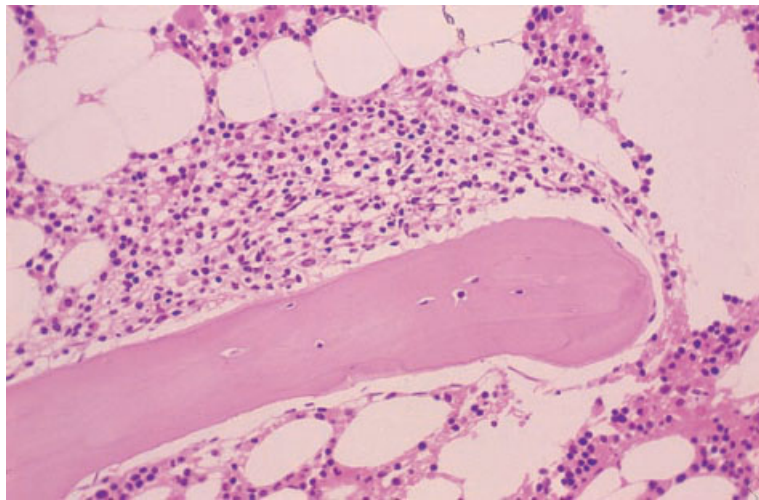
Cytogenetics and molecular genetics

Most cases have t(14;18)(q32;q21)

Smaller numbers have variant translocations—t(2;18)(p12;q21) and t(18;22)(q21;q11)

Abbreviations (percentages are approximate): +>90% positive; +/->50% positive; -/+<50% positive; <10% positive; Smlg, surface membrane immunoglobulin.

Fig. 6.36 BM trephine biopsy section, follicular lymphoma, showing a broad-based paratrabeular infiltrate of centrocytes; note normal bone marrow above and below. Paraffin-embedded, H&E $\times 195$.



paratrabeular infiltrates. When infiltration is heavy, individual focal lesions may coalesce and replace large areas of marrow; however, the paratrabeular concentration of lymphoma can usually still be appreciated. In most series of patients a follicular pattern (Fig. 6.37), resembling that in the lymph node, has been found to be quite uncommon [14,16,99–101]. Divergent findings have been reported by Bartl *et al.* [10]; they described ‘a strictly nodular pattern frequently of follicles with germinal centres’ and did not observe a paratrabeular pattern. This discrepancy may be because this group

classified lymphomas solely on the basis of morphological features in the bone marrow. It may be that some cases which others would have classified as follicular lymphoma were classified as centrocytic (mantle cell) lymphoma in this study.

The predominant lymphoma cell in the bone marrow is the small cleft lymphocyte (small follicle centre cell or centrocyte) (Figs 6.38 and 6.39). These cells appear larger than small lymphocytes with more plentiful cytoplasm and nuclei which are irregular and often angular or elongated. The nuclear chromatin is less dense and clumped than

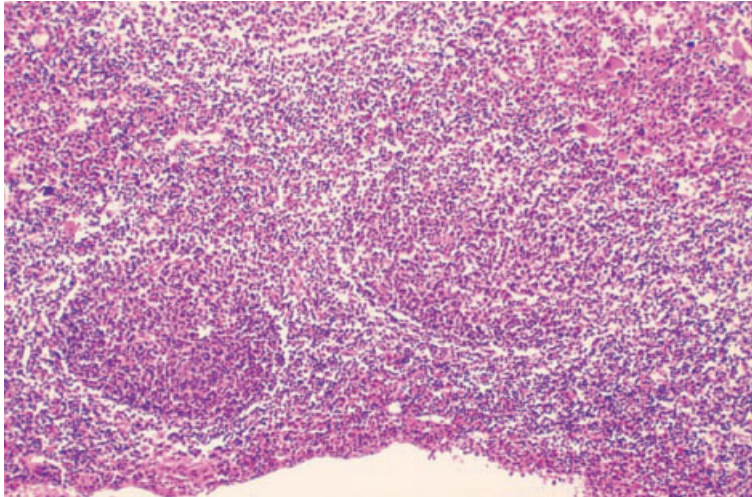


Fig. 6.37 BM trephine biopsy section, follicular lymphoma, showing diffuse infiltration with formation of follicles. Paraffin-embedded, H&E $\times 97$.

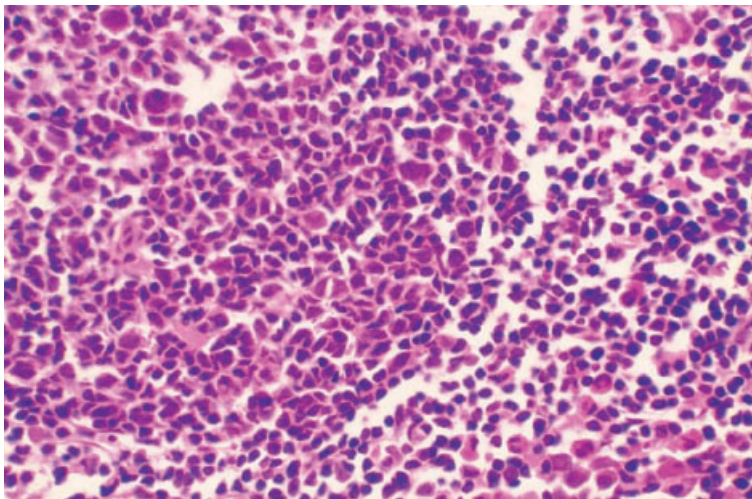


Fig. 6.38 BM trephine biopsy section, follicular lymphoma (same case as in Fig. 6.37), showing a follicle composed of centrocytes. Paraffin-embedded, H&E $\times 390$.

that of the normal small lymphocyte. The nuclear clefts may be difficult to recognize in paraffin-embedded tissue sections but can be seen in plastic-embedded sections. Smaller but variable numbers of large cells, either cleft (large centrocytes) or non-cleft (centroblasts), are present. Large centrocytes have irregular or cleft nuclei while centroblasts have round or ovoid nuclei; both cell types have a moderate amount of cytoplasm and small nucleoli abutting on the nuclear membrane. The nucleoli are more prominent in centroblasts than in large centrocytes. There may also be some large cells with large central nucleoli resembling immunoblasts. A

minority of patients have epithelioid granulomas (see Fig. 3.28) which are presumed to form as a reaction to the presence of neoplastic lymphoid cells. Reticulin fibres are significantly increased in infiltrated areas [17].

Following chemotherapy, the areas of previous infiltration may be recognized as hypocellular paratrabecular foci, containing increased reticulin, with or without recognizable neoplastic cells [101].

Immunohistochemistry

The neoplastic cells express CD10, CD20, CD79a

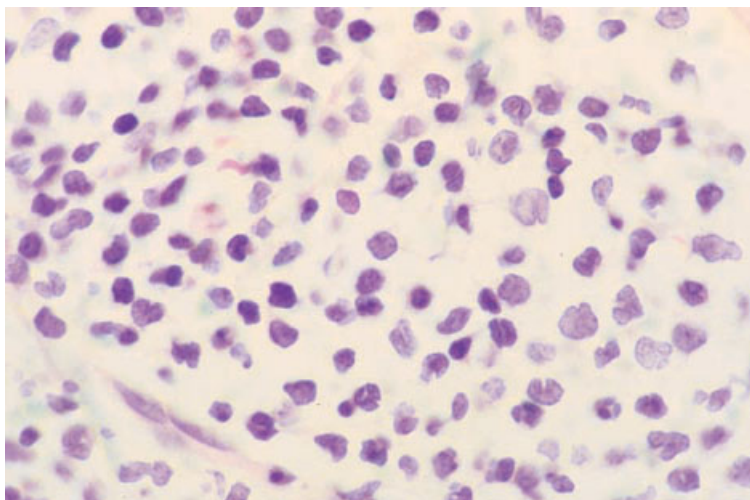


Fig. 6.39 BM trephine biopsy section, follicular lymphoma, showing an infiltrate composed predominantly of centrocytes. Plastic-embedded, H&E $\times 940$.

and BCL2 protein (Box 6.6). It should be noted that expression of BCL2 by the neoplastic cells is not useful in making the distinction from other lymphoproliferative disorders as these are often also positive. Staining for CD5, CD23, CD43 and cyclin D1 is usually negative. Interpretation is complicated by the frequent presence of a large number of reactive T cells which express CD3, CD5 and BCL2.

Problems and pitfalls

Discordant bone marrow histopathology from that seen at other sites in the same patient is not uncommon in follicular lymphoma. Occasionally, patients with follicular lymphoma have infiltration of the bone marrow by large B-cell lymphoma. Although uncommon, this is clinically important since it alters management. More commonly, patients presenting with diffuse large B-cell lymphoma at an extramedullary site are found to have low grade follicular lymphoma in the bone marrow. Discordant differentiation with bone marrow infiltrates resembling lymphoplasmacytic lymphoma (see page 258) has also been observed in patients with follicular lymphoma.

Infiltration of the marrow by follicular lymphoma can be confused with other small B-cell lymphoproliferative disorders, particularly CLL, mantle cell lymphoma and splenic marginal zone lymphoma. Paratrabecular infiltration is not seen in CLL and a

purely nodular infiltrate is very rare in follicular lymphoma. The distinction of follicular lymphoma from mantle cell lymphoma and splenic marginal zone lymphoma can be difficult on histological grounds alone and careful consideration of the morphology together with immunophenotypic and molecular genetic analysis may be required for diagnosis.

Mantle cell lymphoma

The REAL and WHO classifications identify mantle cell lymphoma as a distinct entity recognizable on the basis of morphological, clinical, immunophenotypic and molecular genetic features. The lymphoma cells are analogous to lymphocytes of the mantle zone of the lymphoid follicle [102,103]. In the Kiel classification, the term 'centrocytic lymphoma' was used for this entity whereas, in the Working Formulation, cases were included in the diffuse small cleaved cell, diffuse small and large cleaved cell and diffuse large cleaved cell categories. Mantle cell lymphoma is a disease of adult life. There is a marked male predominance. Common clinical features are generalized lymphadenopathy, splenomegaly, hepatomegaly and involvement of the gastro-intestinal tract. Histological features in the lymph node include a diffuse or vaguely nodular growth pattern and a tendency for the lymphoma cells to grow in a mantle around residual normal

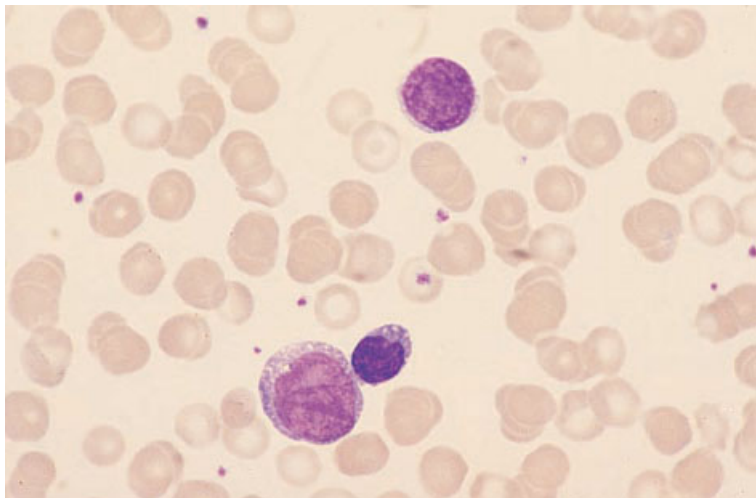


Fig. 6.40 PB film, mantle cell lymphoma, showing pleomorphic lymphocytes. MGG $\times 940$.

lymphoid follicles. Some cases of mantle cell lymphoma have a 'blastoid' morphology correlating with a worse prognosis.

Peripheral blood

In many patients the peripheral blood shows no abnormality. A leukaemic phase was reported in 20–30% of patients in two series [103,104] but, in another large series, circulating lymphoma cells could be detected in the peripheral blood in 77% of cases at some point during the course of the disease [105]. A marked elevation of the white cell count may occur but is uncommon [102,106]. In many cases the cells are larger than those of CLL, varying from small to medium or large (Fig. 6.40). They are characteristically pleomorphic; some have prominent nucleoli and some have irregular, angular or cleft nuclei [106]. In comparison with the centrocytes of follicular lymphoma, cells tend to be more pleomorphic and less angular with broader nuclear clefts and more cytoplasm. Other cases have peripheral blood lymphocytes more like those of CLL, although possibly with some cleft cells, and the diagnosis is made only from lymph node biopsy [102]. In the leukaemic phase of the blastoid variant there is a spectrum of neoplastic cells present in the peripheral blood, ranging from small lymphocytes with irregular nuclear contours to medium sized lymphoid cells with a nuclear

chromatin pattern similar to that seen in lymphoblasts [107].

Bone marrow cytology

The bone marrow is infiltrated in the majority of patients, including many who do not have lymphoma cells in the peripheral blood [103,104]. The infiltrating cells have the same morphology as those in the peripheral blood (Fig. 6.41).

Immunocytochemistry and flow cytometry

Cells show strong expression of SmIg, usually IgM and sometimes also IgD; IgG is expressed in a minority (Box 6.7). λ light chain expression is more common than κ . Cells are positive for B-cell markers CD19, CD20 and CD79a. They are usually positive for both CD5 and the antigen detected by FMC7 but do not express CD10 or CD23.

Cytogenetics and molecular genetics

A characteristic translocation, $t(11;14)(q13;q32)$, involving the *BCL1* gene is detectable in almost all cases of mantle cell lymphoma if a FISH technique is used [108] (Box 6.7). The translocation is also detectable by conventional cytogenetic analysis and RT-PCR but these are less sensitive than FISH. This translocation is not specific for mantle cell lymphoma.

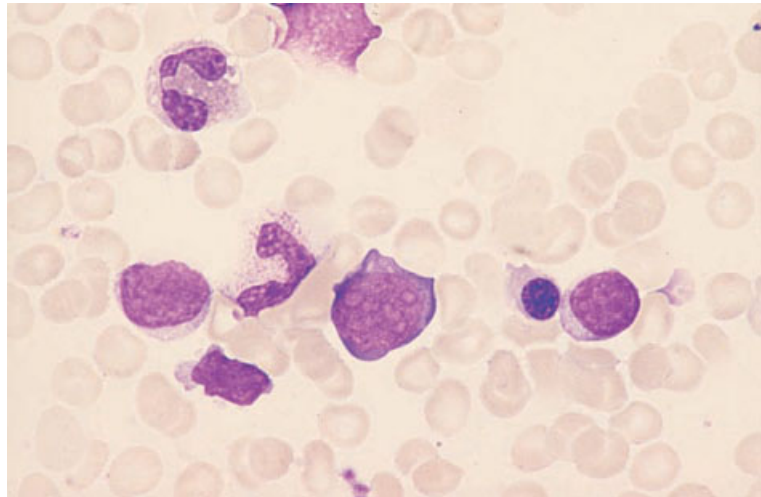


Fig. 6.41 BM aspirate, mantle cell lymphoma, showing pleomorphic lymphocytes varying from small, mature lymphocytes to large lymphoid cells with multiple nucleoli. MGG $\times 940$.

BOX 6.7

Mantle cell lymphoma

Flow cytometry and immunocytochemistry

CD5+, CD19+, CD20+, CD22+, CD79a+, Smlg+ (usually IgM, sometimes with IgD)

FMC7+/-

CD10-/+

CD23-

Immunohistochemistry

CD5+, CD20+, CD79a+, cyclin D1+

CD10-/+

CD23-

Cytogenetics and molecular genetics

The majority of cases have t(11;14)(q13;q32)

A minority have a variant translocation t(11;22)(q13;q11)

Abbreviations (percentages are approximate): +>90% positive; +/->50% positive; -/+<50% positive; <10% positive; Smlg, surface membrane immunoglobulin.

A minority of cases of mantle cell lymphoma have a variant translocation, t(11;22)(q13;q11), involving the *BCL1* gene and the λ light chain gene. The *BCL1* gene is dysregulated by its proximity to the *IGH* gene at 14q32 or the λ light chain gene at 22q11.

Bone marrow histology

Marrow involvement is frequent, being found in more than three quarters of cases [14,103,104,109].

Bone marrow infiltration may be interstitial, paratrabeular, focal non-paratrabeular or diffuse [10,106,110,111]. However, in contrast to follicular lymphoma, paratrabeular infiltration is quite uncommon [111]. The infiltrate is composed of small lymphoid cells of variable morphology, some with round nuclei and others with indented or cleft nuclei (Fig. 6.42). Some cells have small indistinct nucleoli. Centroblasts are not seen. There may be an admixture of epithelioid macrophages [106].

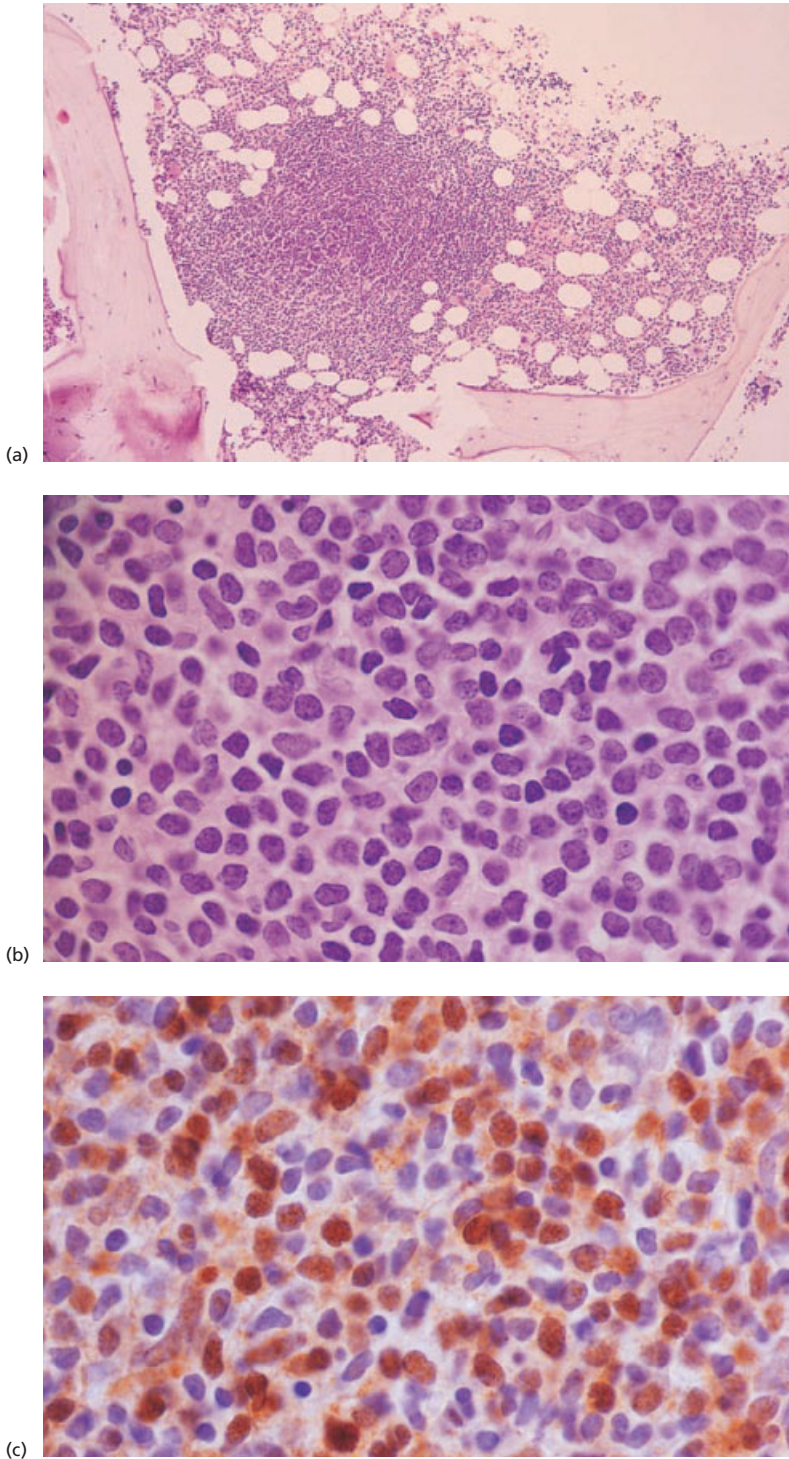


Fig. 6.42 Trephine biopsy sections, mantle cell lymphoma. Paraffin-embedded. (a) Showing a mixed interstitial and nodular infiltrate; the nodule abuts on a trabecula. H&E $\times 48$. (b) Showing very irregular small and medium sized lymphocytes with little chromatin condensation in the larger cells. H&E $\times 940$. (c) Showing nuclear staining for cyclin D1; note that not all the cells show positive staining. Immunoperoxidase $\times 940$.

Occasionally, there are naked germinal centres similar to those seen in lymph nodes in some cases [112]. Reticulin fibres are increased in infiltrated areas.

Immunohistochemistry

The cells of mantle cell lymphoma express CD5, CD20, CD79a and CD43 (Box 6.7). Nuclear staining for cyclin D1 is common, being reported in 72% of cases with bone marrow involvement in one series [113] (Fig. 6.42c). Staining for CD10 and CD23 is usually negative.

Problems and pitfalls

Mantle cell lymphoma needs to be distinguished from other small B-cell lymphoproliferative diseases, particularly mixed type CLL, PLL, follicular lymphoma and marginal zone lymphoma. Immunophenotypic analysis is essential for accurate diagnosis, with CD5 and cyclin D1 being the most useful markers. The cells of CLL also express CD5 but are negative for cyclin D1. In PLL, there is usually no expression of CD5 or cyclin D1. Follicular lymphoma usually has a paratrabeular pattern of marrow infiltration which is less common in mantle cell lymphoma. The neoplastic cells of follicular lymphoma typically express CD10 and are negative for CD5 and cyclin D1. Marginal zone lymphoma can be distinguished from mantle cell lymphoma by the lack of CD5 and cyclin D1 expression.

Extranodal marginal zone B-cell lymphoma of mucosa-associated lymphoid tissue type

The REAL classification included, under the heading of marginal zone B-cell lymphoma, two disease entities which were either excluded from or not specifically identified in earlier lymphoma classifications. They were: (i) extranodal mucosa-associated lymphoid tissue (MALT)-type lymphoma; and (ii) a provisional category of nodal marginal zone lymphoma which included monocytoid B-cell lymphoma. The WHO classification recognizes both of these disorders as distinct entities. Lymphomas of MALT type are relatively indolent neoplasms that occur at a number of extranodal sites including the gastro-intestinal tract, salivary gland, orbit, lung and skin. The most common primary site is the

stomach, where there is an association with infection by *Helicobacter pylori* [114].

Peripheral blood

Peripheral blood involvement is rare. The cells of MALT-type lymphoma are small centrocyte-like cells with irregular nuclei and scanty cytoplasm.

Immunocytochemistry and flow cytometry

Cells express SmIg and B-cell markers such as CD19, CD20, CD22 and CD79a but do not express CD5, CD23 or CD10.

Cytogenetics and molecular genetics

Trisomy 3 can be detected in 60–85% of cases using FISH [115] or comparative genomic hybridization techniques [116]. Trisomies 7 and 12 are seen less frequently [115]. Extranodal lymphomas of MALT type are commonly associated with t(11;18)(q21;q21), resulting in the formation of an *API2-MLT* fusion gene. In one study, t(11;18) was observed in 9 of 33 (27%) marginal zone lymphomas of MALT type but was not found in any cases of nodal or splenic marginal zone lymphomas [117].

Bone marrow cytology and histology

Bone marrow infiltration has generally been reported to be rare in MALT-type lymphoma. The pattern of infiltration in one case described in detail was paratrabeular and nodular with an interstitial component [118] and, in another, was paratrabeular [119]. In four personally observed cases there were large, randomly distributed nodules (Fig. 6.43).

Immunohistochemistry

The cells express CD20 and CD79a. Staining for CD5, CD10, CD23, CD43 and cyclin D1 is usually negative.

Problems and pitfalls

Marrow and peripheral blood involvement by MALT-type lymphoma is uncommon and seen only in the late stages of the disease. If the clinical features are

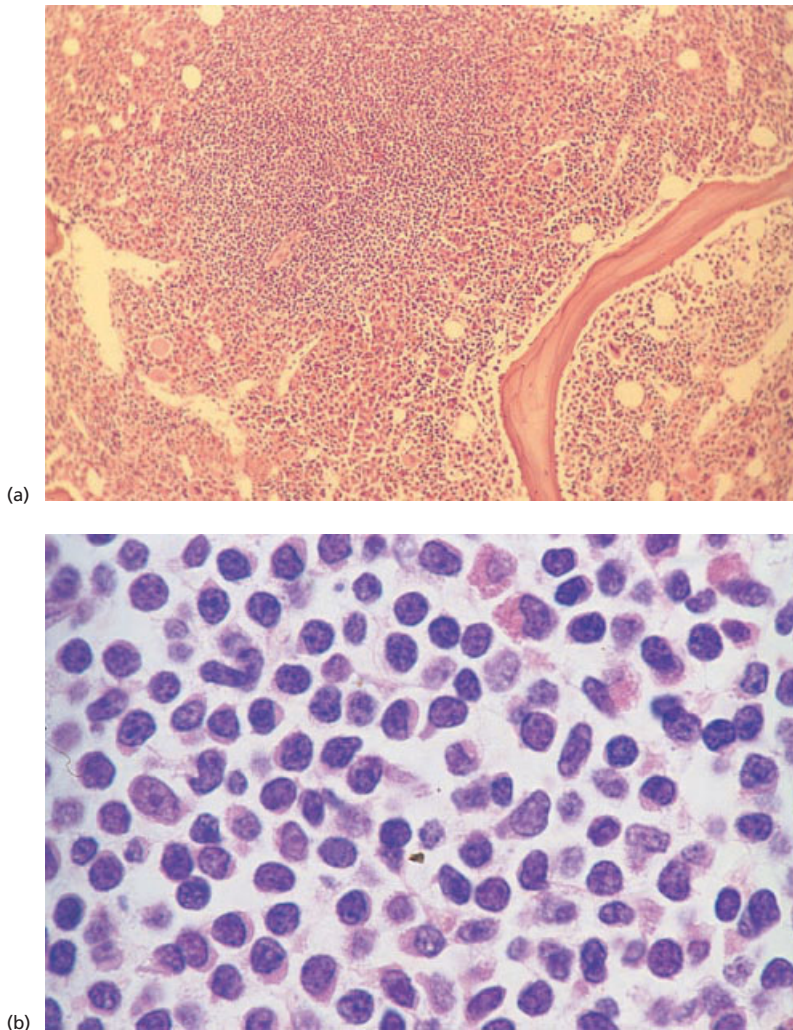


Fig. 6.43 BM trephine biopsy section in MALT lymphoma. (a) A large, ill-defined nodule. Paraffin-embedded, H&E ×97. (b) An infiltrate of small angular lymphocytes. Paraffin-embedded, H&E ×960. (By courtesy of Professor PG Isaacson, London.)

taken into account, it is unlikely to be confused with other lymphoproliferative disorders.

Splenic marginal zone lymphoma (including splenic lymphoma with villous lymphocytes)

The WHO classification recognizes splenic marginal zone lymphoma as a distinct entity. It was recognized in its own right as a provisional category in the REAL classification. Previously, only cases presenting as splenic lymphoma with villous lymphocytes (SLVL) were distinguished as being distinct from other low grade B-cell lymphomas predominantly involving the spleen [120,121]. It is an indolent

lymphoma with prominent splenomegaly and often no lymphadenopathy. The diagnosis of SLVL is usually made from peripheral blood cytology. A category of SLVL was not specifically identified in earlier lymphoma classifications but would fall into the 'lymphocytic' category of the Kiel classification and the 'small lymphocytic' category of the Working Formulation.

Peripheral blood

The white cell count ranges from normal to moderately elevated. There are pleomorphic small lymphocytes including some plasmacytoid lymphocytes

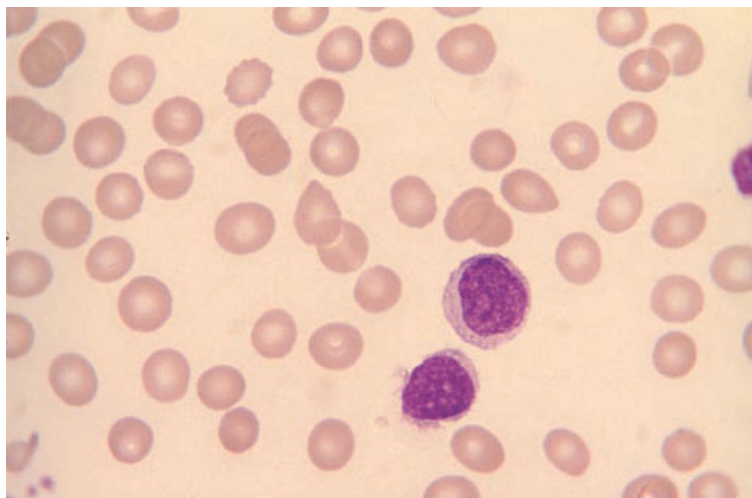


Fig. 6.44 PB film, splenic marginal zone lymphoma, showing two lymphocytes, one of which has 'villous' projections. MGG ×940.

BOX 6.8

Splenic marginal zone lymphoma

Flow cytometry and immunocytochemistry

CD19+, CD20+, CD22+, CD79a+, strong SmIg, FMC7+/-
 CD10-/-, CD11c-/-, CD25-/-
 CD5-, CD23-

Immunohistochemistry

CD20+, CD79a+
 CD10-/-, DBA44-/-
 CD5-, CD23-, cyclin D1-

Cytogenetics and molecular genetics

A minority of cases show cytogenetic abnormalities including trisomies 3, 7 and 12 and t(11;14)(q13;q32)

Abbreviations (percentages are approximate): +>90% positive; +/->50% positive; -/+<50% positive; <10% positive; SmIg, surface membrane immunoglobulin.

and 'villous' lymphocytes (Fig. 6.44). There are usually also occasional plasma cells. Villous lymphocytes are somewhat larger than CLL cells and have a round or oval nucleus with moderately condensed chromatin and, in about half of the cases, a small nucleolus; the cytoplasm is moderately basophilic with short, fine cytoplasmic projections, often at one pole of the cell.

Bone marrow cytology

The bone marrow aspirate is normal in about 50% of patients with splenic marginal zone lymphoma,

even though some such patients are found to have a nodular infiltrate on trephine biopsy [120]. The lymphoma cells are small lymphocytes, some of which show plasmacytoid differentiation.

Immunocytochemistry and flow cytometry

There is strong expression of SmIg and B-cell markers, such as CD19, CD20, CD22 and CD79a (Box 6.8). CD25 is positive in a third of cases, CD10 in a third and CD11c in half [122]. The antigen recognized by FMC7 is expressed in most cases [123].

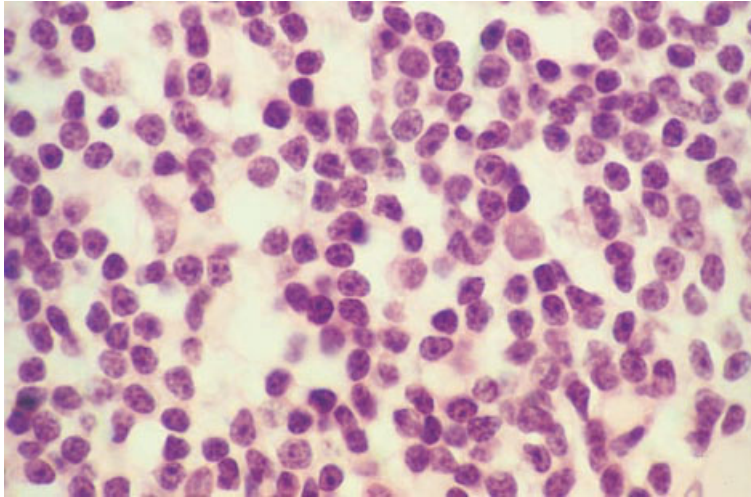


Fig. 6.45 BM trephine biopsy section, splenic marginal zone lymphoma, showing diffuse infiltration by mature small lymphocytes and occasional cells with plasmacytoid features. Plastic-embedded, H&E $\times 940$.

Cytogenetics and molecular genetics

Trisomy 3 can be demonstrated by FISH in approximately 18% of cases [115,124] (Box 6.8). Trisomies 7 and 12 are found in smaller numbers of cases. Approximately 20% of cases have $t(11;14)(q13;q32)$ [125].

Bone marrow histology

Bone marrow infiltration may be focal or diffuse (Fig. 6.45). There may be an admixture of small lymphocytes with plasma cells and plasmacytoid lymphocytes. An intrasinusoidal pattern of infiltration has been reported [126]. This pattern is not unique to splenic marginal zone lymphoma but, when it presents as the predominant pattern, it is believed to be highly suggestive of that diagnosis.

Immunohistochemistry

The neoplastic cells express the B-cell markers CD20 and CD79a. Staining for CD5, CD23 and cyclin D1 is negative. The antigen recognized by DBA44 is expressed in most cases [123]. Immunohistochemical staining for CD20 or CD79a has been found to be useful in highlighting intrasinusoidal infiltration.

Problems and pitfalls

Splenic marginal zone lymphoma needs to be distinguished from other small B-cell lymphoprolifera-

tive disorders that present with peripheral blood lymphocytosis and splenomegaly, particularly hairy cell leukaemia and CLL. The circulating cells are larger than those of CLL and have a higher nucleocytoplasmic ratio than hairy cells. Lack of CD5 and CD23 staining distinguishes splenic marginal zone lymphoma from CLL. The cells of splenic marginal zone lymphoma are usually TRAP negative, in contrast to the cells of HCL in which the TRAP reaction is positive. The pattern of marrow infiltration in trephine biopsy sections in hairy cell leukaemia is characteristic and is unlikely to be confused with splenic marginal zone lymphoma unless minimal infiltrates mimic intrasinusoidal involvement.

Nodal marginal zone B-cell lymphoma

Nodal marginal zone lymphoma (including monocytoid B-cell lymphoma) is a rare condition [127] recognized as a distinct entity in the WHO classification. It usually presents with lymphadenopathy and needs to be distinguished from nodal spread from an extranodal marginal zone lymphoma of MALT type. Bone marrow infiltration is rare.

Peripheral blood

Peripheral blood involvement is rare. The circulating neoplastic monocytoid B-cells are small to medium sized cells which may have some similarities to hairy cells. They have been described as

having homogeneous, round to reniform nuclei and relatively abundant, weakly basophilic cytoplasm which may have a few hair-like projections [128].

Immunocytochemistry and flow cytometry

The lymphoma cells express SmIg and B-cell markers such as CD19, CD20, CD22 and CD79a. There is usually no expression of CD5, CD10, CD23 or cyclin D1. There is expression of CD11c in some cases.

Cytogenetics and molecular genetics

Approximately 50% of cases have trisomy 3 [115].

Bone marrow histology

The bone marrow is rarely infiltrated in monocytoid B-cell lymphoma [128–131]. When infiltration occurs, the pattern of infiltration may be focal and predominantly paratrabeular [128] or nodular [131]. The infiltrate may consist of loose polymorphic nodules made up of monocytoid B cells, small lymphocytes with irregular nuclei and plasma cells [132].

Immunohistochemistry

The lymphoma cells express the B-cell markers CD20 and CD79a. Staining for CD5, CD10, CD23, CD43 and cyclin D1 is usually negative [133].

Problems and pitfalls

Marrow infiltration by nodal marginal zone lymphoma needs to be distinguished from other small B-cell lymphoproliferative disorders, particularly CLL, follicular lymphoma and mantle cell lymphoma. The presence of a monocytoid B-cell component and the lack of expression of CD5, CD10 and CD23 are helpful in making the distinction. Separation from splenic marginal zone lymphoma and marginal zone lymphoma of MALT type requires consideration of the clinical features and peripheral blood findings.

Diffuse large B-cell lymphoma

In the WHO and REAL classifications, diffuse large

B-cell lymphoma is considered as a single entity with various morphological variants. In the Kiel classification centroblastic lymphoma and immunoblastic lymphoma were considered to be distinct entities, with some studies showing immunoblastic lymphoma to have a worse prognosis. Since histopathologists cannot make a reliable distinction between the two categories [2], grouping them together is a pragmatic approach. The WHO classification recognizes immunoblastic lymphoma and centroblastic lymphoma as morphological subtypes of diffuse large B-cell lymphoma but does not require pathologists to specify the subtype [1]. The other morphological subtypes are T-cell/histiocyte-rich large B-cell lymphoma, lymphomatoid granulomatosis-type large B-cell lymphoma, anaplastic large B-cell lymphoma and plasmablastic lymphoma. In addition to the morphological variants, three subtypes with distinct clinicopathological features are recognized: (i) mediastinal (thymic) large B-cell lymphoma; (ii) primary effusion lymphoma; and (iii) intravascular large B-cell lymphoma. Specific features of the morphological variants are discussed below. Bone marrow infiltration is much less common in large B-cell lymphoma than in the other B-lineage lymphoproliferative diseases. Bone marrow involvement, particularly if there is a diffuse pattern of infiltration, is associated with a poor prognosis [134].

Immunocytochemistry and flow cytometry

The B-cell antigens CD19, CD20 and CD79a are expressed (Box 6.9). Expression of CD5, CD10 and CD30 is variable. There is also variable expression of oncogene products (BCL2 and BCL6) and this is of prognostic significance [135–137]. There is no expression of TdT or CD34.

Cytogenetics and molecular genetics

Typical abnormalities (Box 6.9) differ according to the specific subtype of large B-cell lymphoma. Centroblastic lymphoma may show t(14;18)(q32;q21) with *BCL2* rearrangement. The next most common groups of abnormalities are t(3;14)(q27;q32) and other translocations with a 3q27 breakpoint resulting in rearrangement of the *BCL6* gene [138]. Complex aberrant clones are common. Aneuploidy

BOX 6.9**Diffuse large B-cell lymphoma***Flow cytometry and immunocytochemistry*

CD19+, CD20+, CD79a+, Smlg+
Variable expression of CD5, CD10, CD30, BCL2 and BCL6
CD34-, TdT-

Immunohistochemistry

CD20+, CD79a+
Variable expression of CD5, CD10, CD30, BCL2 and BCL6
CD15-, CD34-, TdT-

Cytogenetics and molecular genetics

Complex abnormalities are common. Frequently seen abnormalities include t(14;18)(q32;q21), t(3;14)(q27;q32), t(1;3)(q34;q27), t(2;3)(q35;q27), t(3;12)(q27;q13), t(3;22)(q27;q11), inv(3)(q13q27) and aneuploidy with loss of Y, 6, 13, 15 and 17 and gains of X, 3, 5, 7, 12 and 18

Abbreviations (percentages are approximate): +>90% positive; +/->50% positive; -/+<50% positive; <10% positive; Smlg, surface membrane immunoglobulin; TdT, terminal deoxynucleotidyl transferase; BCL2 and BCL6 the protein products of the *BCL2* and *BCL6* oncogenes.

is a frequent finding with loss of Y, 6, 13, 15 and 17 and gains of X, 3, 5, 7, 12 and 18. Immunoblastic lymphoma is also characterized by complex aberrant clones, t(3;14)(q27;q32) and other translocations with a 3q27 breakpoint and *BCL6* rearrangement. There may also be loss of Y, 8, 10, 14 and 21 and gains of 3, 7, 12 and 18. Translocations with a 3q27 breakpoint, seen in all subtypes of diffuse large B-cell lymphoma, include t(1;3)(q34;q27), t(2;3)(q35;q27), t(3;12)(q27;q13), t(3;22)(q27;q11) and inv(3)(q13q27).

Immunohistochemistry

The tumour cells express the B-cell markers CD20 and CD79a (Box 6.9). There is variable expression of CD5, CD10, CD30, CD43, BCL2 and BCL6. Staining for Ki-67 antigen (antibody MIB-1) shows a high proliferative fraction.

Diffuse large B-cell lymphoma—morphological variant—centroblastic

Diffuse centroblastic lymphoma [1,139] is a clinically aggressive lymphoma which may occur *de novo* or may represent transformation of a follicular lymphoma.

Peripheral blood

Lymphoma cells are rarely present in the peripheral blood. When centroblastic lymphoma occurs as a transformation of follicular lymphoma, any circulating lymphoma cells are usually centrocytes. When peripheral blood dissemination of centroblasts does occur, the cells are very large and pleomorphic (Fig. 6.46). They have plentiful cytoplasm and an irregular, often lobulated nucleus containing one or more fairly prominent nucleoli.

Bone marrow cytology

Bone marrow infiltration is uncommon but is considerably more common than peripheral blood spread; in one series infiltration was detected in 15% of cases. In patients with preceding follicular lymphoma the bone marrow is sometimes infiltrated by centroblasts but more often shows only centrocytes. A significant minority of patients with apparently *de novo* centroblastic lymphoma at an extramedullary site also show infiltration of the bone marrow by centrocytes indicative of underlying follicular lymphoma [22]. The presence of low grade follicular lymphoma in the bone marrow does not have the same poor prognostic significance

Fig. 6.46 PB film, diffuse large B-cell lymphoma (variant—centroblastic lymphoma), showing large lymphoma cells with a high nucleocytoplasmic ratio, moderately basophilic vacuolated cytoplasm and medium sized nucleoli sited towards the periphery of the nucleus. MGG ×940.

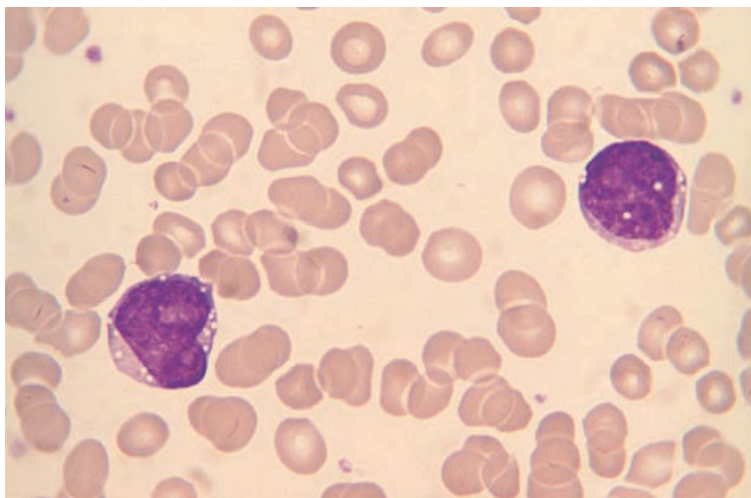
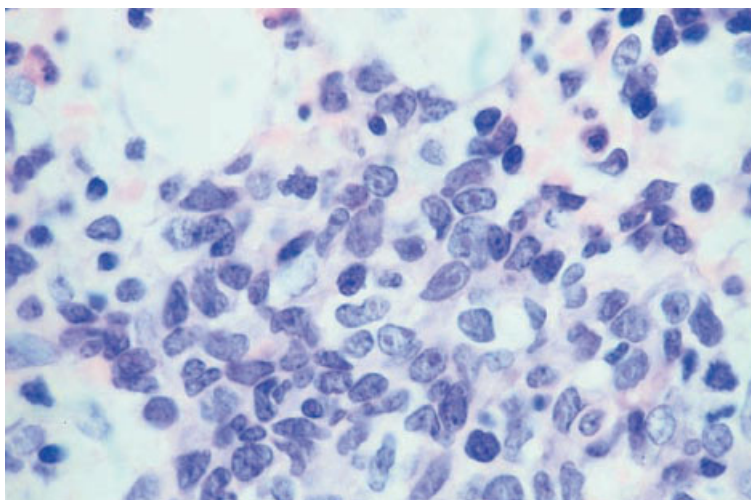


Fig. 6.47 BM trephine biopsy section, diffuse large B-cell lymphoma (variant—centroblastic lymphoma), showing infiltration by pleomorphic centroblasts and occasional immunoblasts. Plastic-embedded, H&E ×940.



as bone marrow infiltration by diffuse large B-cell lymphoma.

Bone marrow histology

Twenty to 30% of patients with centroblastic lymphoma have infiltration of the marrow [14,16]. This may be either infiltration by centroblastic lymphoma or infiltration by discordant follicular lymphoma [14,16,23]. Discordance is relatively common. Low grade lymphoma may be seen both in those with and without a previous history of low grade lymphoma. The pattern of infiltration by centroblastic lymphoma is either focal or diffuse. The

infiltrate may be composed of relatively monomorphic centroblasts or may be pleomorphic with admixed immunoblasts (Fig. 6.47), multilobulated cells and large cleft cells.

Diffuse large B-cell lymphoma— morphological variant— B-immunoblastic lymphoma

Immunoblastic lymphoma of B-cell lineage is a clinically aggressive lymphoma which may develop in previously healthy subjects or in patients with immunodeficiency. The immunodeficiency may be either congenital or consequent on infection by HIV

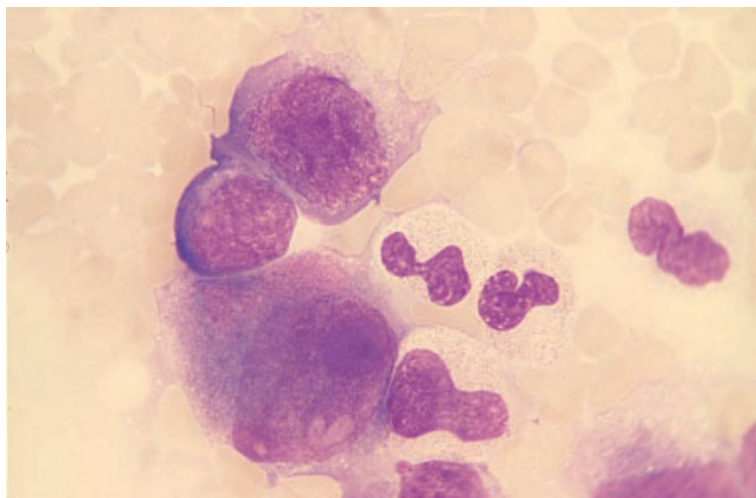


Fig. 6.48 BM aspirate, diffuse large B-cell lymphoma (variant—immunoblastic lymphoma) in a patient with AIDS, showing lymphoma cells varying from medium sized to very large; note the basophilic cytoplasm and, in the largest cell, a giant nucleolus. MGG $\times 940$.

or on immunosuppressive therapy. The Epstein-Barr virus (EBV) is implicated in the pathogenesis of many but not all cases in immunodeficient subjects. Immunoblastic lymphoma may also occur following transformation of a low grade lymphoproliferative disease such as CLL or lymphoplasmacytic lymphoma. Immunoblastic lymphoma occurs at all ages. Because of the relationship to underlying immune deficiency, this lymphoma forms a significant proportion of childhood lymphomas. Immunoblastic lymphoma of T-cell lineage also occurs (see page 310).

Peripheral blood

Neoplastic cells are rarely present in the peripheral blood. When present they are very large with plentiful, strongly basophilic cytoplasm and a large nucleus containing a prominent central nucleolus. In patients with underlying immune deficiency there may be marked lymphopenia or, in patients with AIDS, pancytopenia.

Bone marrow cytology

The bone marrow is not commonly infiltrated; in one series marrow infiltration was seen in less than a quarter of patients [48]. When lymphoma cells are present they have the same morphological features as those described above (Fig. 6.48). A significant minority of patients with immunoblastic lymphoma at an extramedullary site show low grade lymphoma

in the bone marrow, usually follicular lymphoma, but occasionally small lymphocytic lymphoma with plasmacytoid differentiation [22]; this does not have the same grave prognostic import as marrow infiltration by immunoblasts.

Bone marrow histology

The neoplastic cells of immunoblastic lymphoma are distinguished from centroblasts by virtue of their larger size, more plentiful cytoplasm and the presence of a very large, prominent and usually central nucleolus (Fig. 6.49). Some cases have marked nuclear lobulation. Binucleated and multinucleated forms may be present. Some cells may show signs of plasma cell differentiation but it is usually not possible to distinguish between T- and B-lineage immunoblasts on the basis of morphology alone [140].

The marrow is infiltrated in 15–20% of cases [14,48]. The pattern of bone marrow infiltration may be focal random, focal paratrabecular or diffuse [14,16,97]. In some patients there is marrow infiltration by discordant low grade lymphoma.

Diffuse large B-cell lymphoma—morphological variant—T-cell-rich B-cell lymphoma

Some cases of diffuse large B-cell lymphoma have admixed reactive cells, sometimes in considerable numbers. Such cases, designated T-cell-rich and

Fig. 6.49 BM trephine biopsy section, diffuse large B-cell lymphoma (variant—immunoblastic lymphoma) in a patient with AIDS (same case as in Fig. 6.48), showing diffuse infiltration by pleomorphic immunoblasts; note the prominent central nucleoli. Paraffin-embedded, H&E $\times 390$.

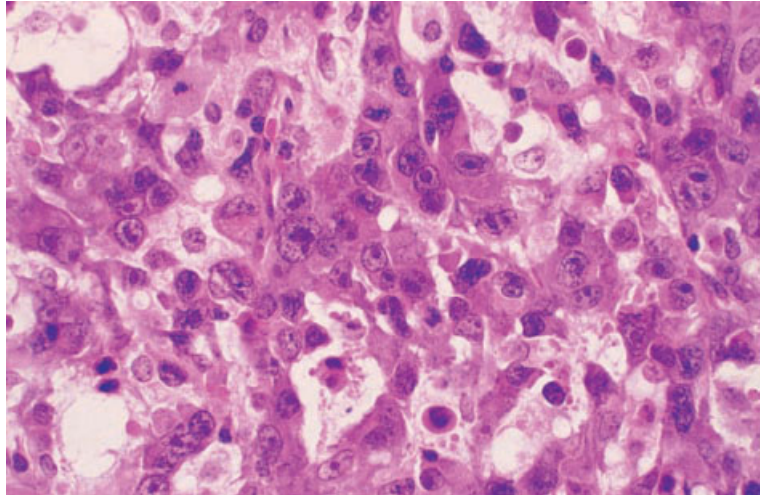
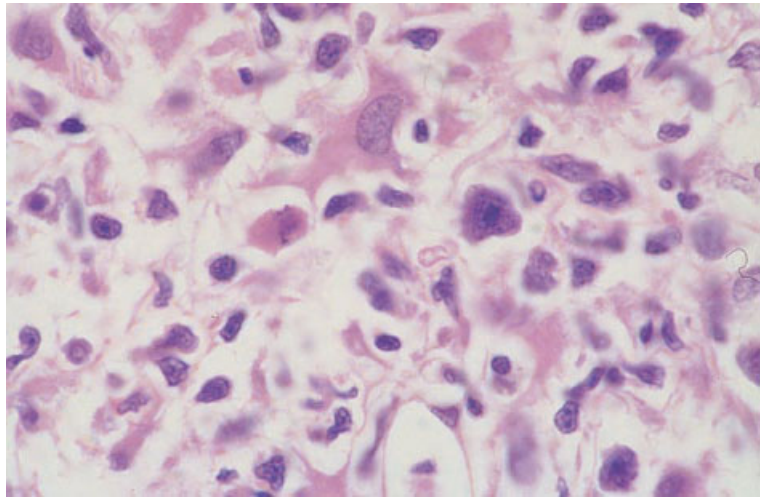


Fig. 6.50 BM trephine biopsy section, diffuse large B-cell lymphoma (variant—T-cell-rich B-cell lymphoma). Paraffin-embedded, H&E $\times 940$. (By courtesy of Dr Wendy Erber and Dr L Matz, Perth, Western Australia.)



histiocyte-rich B-cell lymphoma (Figs 6.50 and 6.51), may be confused with T-cell lymphoma or with Hodgkin's disease. One study showed a much higher incidence of bone marrow involvement than is seen in other subtypes of large B-cell lymphoma [141].

Bone marrow histology

Marrow infiltration is focal or diffuse. There are large atypical B cells with prominent nucleoli, and often with lobulated nuclei, set in a background containing large numbers of small T lymphocytes

and histiocytes. Neoplastic cells resembling Reed–Sternberg cells may be seen. The neoplastic B cells may be infrequent.

Immunohistochemistry

Immunohistochemical staining demonstrates that the large neoplastic cells are B cells (CD20 and CD79a positive). They express CD45 and are usually negative for CD30. There is no expression of CD15. The smaller reactive lymphocytes are CD3-positive T cells. The reactive macrophages are CD68 positive.

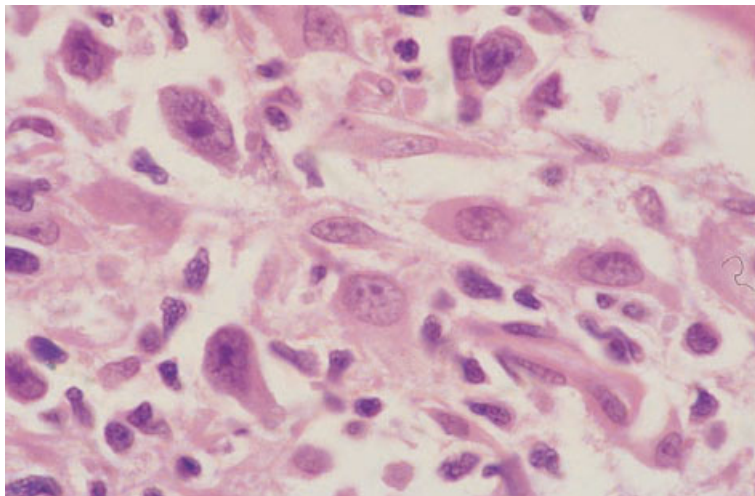


Fig. 6.51 BM trephine biopsy section, diffuse large B-cell lymphoma (variant—histiocyte-rich B-cell lymphoma). Paraffin-embedded, H&E $\times 940$. (By courtesy of Dr Wendy Erber and Dr L Matz, Perth, Western Australia.)

Diffuse large B-cell lymphoma—morphological variant—*anaplastic large cell lymphoma*

Anaplastic large cell lymphoma (ALCL) is an aggressive lymphoma which is more commonly of T than B lineage (see page 306). The REAL and WHO classifications group B-lineage ALCL in a single category with other diffuse B-cell lymphomas. Although there is the option to specify ALCL as a morphological variant of large cell B-cell lymphoma in the WHO classification, criteria for making the distinction from other cases of large cell B-cell lymphoma are not clear.

Diffuse large B-cell lymphoma—subtype—*mediastinal (thymic) B-cell lymphoma*

Mediastinal (thymic) B-cell lymphoma is a distinct subtype of large cell B-cell lymphoma which characteristically presents as bulky mediastinal disease in young women [142]. Bone marrow infiltration is seen in a very small percentage of cases, in one series only 2% [142].

Diffuse large B-cell lymphoma—subtype—*primary effusion lymphoma*

Primary effusion lymphoma is a subtype of large cell B-cell lymphoma predominantly seen in patients with AIDS. It is associated with human herpesvirus

8 and presents with pleural effusion or ascites in the absence of a tumour mass. The lymphoma usually remains localized to the body cavity in which it originated and bone marrow infiltration is not a feature [143].

Diffuse large B-cell lymphoma—subtype—*intravascular large B-cell lymphoma*

Intravascular large B-cell lymphoma is a rare subtype of large cell B-cell lymphoma characterized by a tendency for the lymphoma cells to remain confined within the lumen of blood vessels [144]. In European, but not in Asian, patients, the most common sites to be involved are the skin and central nervous system. The disease has been reported to involve a number of other organs including kidneys, liver, lungs and gastro-intestinal tract.

Bone marrow histology

Bone marrow infiltration is uncommon. In one series, 14% of cases showed bone marrow involvement [145]. When the marrow is infiltrated, large atypical lymphoma cells with multiple prominent nucleoli and moderate amounts of basophilic cytoplasm are found predominantly within sinusoids. Identification of the infiltrating cells is facilitated by immunohistochemical staining for B-cell antigens (CD20 or CD79a). The bone marrow trephine biopsy may be the initial diagnostic material (Fig. 6.52).

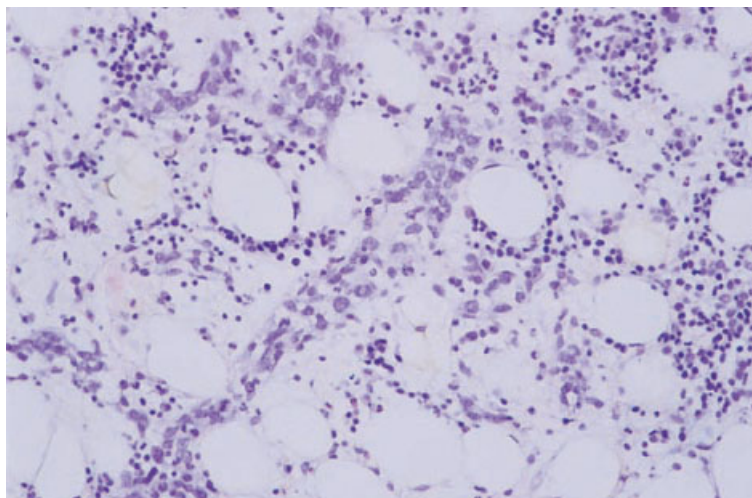


Fig. 6.52 BM trephine biopsy section, diffuse large B-cell lymphoma, subtype intravascular, showing sinusoids packed with atypical, large lymphoid cells. H&E $\times 188$.

Burkitt's lymphoma

Burkitt's lymphoma is an aggressive lymphoma, the clinical features of which differ depending on whether cases are endemic, sporadic or immunodeficiency-related. Endemic Burkitt's lymphoma occurs in tropical Africa and New Guinea and is particularly a disease of childhood; tumour formation in the jaw is usually the most prominent clinical feature. Sporadic Burkitt's lymphoma is worldwide in distribution and occurs at all ages; the commonest clinical features are abdominal tumour formation and malignant pleural or peritoneal effusions. Most cases of immunodeficiency-related Burkitt's lymphoma occur among patients with AIDS; these resemble sporadic cases but meningeal lymphoma appears to be particularly common. Burkitt's lymphoma also occurs in other immunodeficient patients, particularly following organ transplantation (see page 321). EBV is an important pathogenetic factor in endemic Burkitt's lymphoma and in a significant proportion of immunodeficiency-related cases but is much less often implicated in sporadic cases. The REAL classification recognized a particularly aggressive B-cell lymphoma with characteristics intermediate between diffuse large B-cell lymphoma and Burkitt's lymphoma, which was designated Burkitt-like lymphoma. This was equivalent to the Working Formulation category of small, non-cleaved cell, Burkitt-like lymphoma. In the WHO classification, Burkitt-like lymphoma is more

narrowly defined and is regarded as a morphological variant of Burkitt's lymphoma. Burkitt's lymphoma is common among AIDS-related lymphomas; these cases often show immunoblastic and plasmacytoid features. In the WHO classification such cases are designated Burkitt's lymphoma with plasmacytoid differentiation (AIDS-related). Burkitt-like lymphoma occurs rarely as the result of transformation from follicular lymphoma.

The FAB L3 category of ALL can be regarded as a leukaemic presentation of Burkitt's lymphoma. In the WHO and REAL classifications it is included in the Burkitt's lymphoma category.

Peripheral blood

In the majority of patients with Burkitt's lymphoma the peripheral blood shows no abnormality. Even when the bone marrow is infiltrated, circulating lymphoma cells are present in less than half of patients. Some patients whose peripheral blood is initially normal subsequently show circulating lymphoma cells with disease progression or relapse. Peripheral blood dissemination appears to be particularly common in patients with underlying AIDS. Such patients are also commonly pancytopenic, even in the absence of bone marrow infiltration. When patients present with numerous circulating neoplastic cells but no localized tumour formation, the disease is usually categorized by haematologists as L3 ALL. The cytological features of circulating

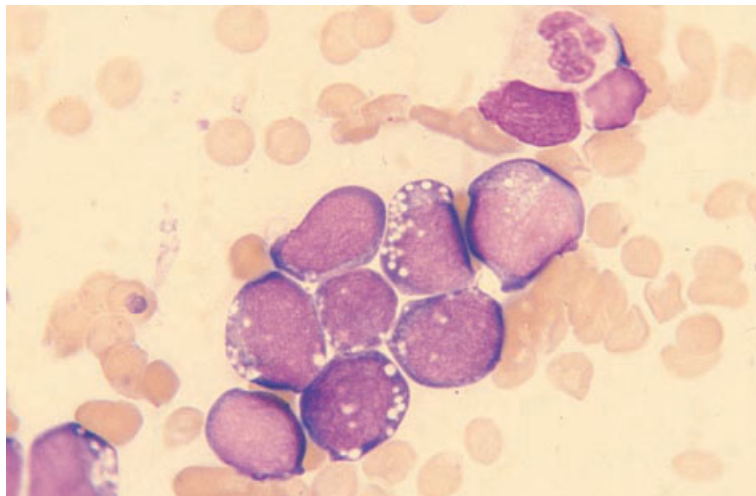


Fig. 6.53 BM aspirate, Burkitt's lymphoma presenting as L3 ALL in a patient with AIDS, showing blasts with marked cytoplasmic basophilia and heavy cytoplasmic vacuolation. MGG $\times 940$.

Burkitt's lymphoma cells and the cells of L3 ALL are identical. Specifically, they are medium sized, relatively uniform blasts with round nuclei, stippled chromatin, visible nucleoli, strongly basophilic cytoplasm and prominent cytoplasmic vacuolation.

Bone marrow cytology

The bone marrow in Burkitt's lymphoma is usually normal at presentation. The reported frequency of bone marrow infiltration has varied from 5 to 20% in different series. The frequency of infiltration appears to be similar in endemic [146,147] and in non-endemic [148–150] cases. In our experience, bone marrow infiltration is more common in AIDS-related Burkitt's lymphoma than in other cases. When bone marrow infiltration occurs, it is usually heavy and is readily detected by either an aspirate (Fig. 6.53) or a trephine biopsy. However, because of their striking cytological features, a low percentage of infiltrating cells may be detected in an aspirate when the trephine biopsy is apparently normal [151]. Some patients without infiltration of the marrow have an increase in non-neoplastic lymphocytes [149].

In patients presenting with the features of L3 ALL, heavy bone marrow infiltration is invariable.

Immunocytochemistry and flow cytometry

The tumour cells express the B-cell antigens CD19,

CD20, CD22 and CD79a and show strong SmIg expression (Box 6.10). There is usually expression of CD10 but not of CD5 or CD23.

Cytogenetics and molecular genetics

Burkitt's lymphoma is characterized by translocations involving *c-MYC* at 8q24 and the *IGH*, κ and λ genes at 14q32, 2p12 and 22q11, respectively. The oncogene *c-MYC* is brought into close proximity with one of the immunoglobulin genes as a result of any of these translocations— $t(8;14)(q24;q32)$, $t(2;8)(p12;q24)$ and $t(8;22)(q24;q11)$. Although the same three cytogenetic rearrangements are seen in all types of Burkitt's lymphoma, the precise breakpoints differ at a molecular level between sporadic and endemic cases.

Bone marrow histology

Infiltration may be interstitial, nodular or diffuse [149–151]. Cells are uniform in appearance; they are medium sized with a round or ovoid nuclear outline and a distinct, narrow rim of cytoplasm (Fig. 6.54). Cleft or folded nuclei are rare. Small nucleoli are usually present. Mitotic figures are numerous. Cytoplasmic vacuoles can sometimes be detected if specifically sought (Fig. 6.54). Tingible body macrophages, a characteristic feature in other tissues causing the so-called 'starry sky' appearance, are sometimes detected (Fig. 6.55) but are a less

BOX 6.10**Burkitt's lymphoma***Flow cytometry and immunocytochemistry*

CD10+/-, CD19+, CD20+, CD22+, CD79a+, strong Smlg+
CD5-, CD23-, TdT-

Immunohistochemistry

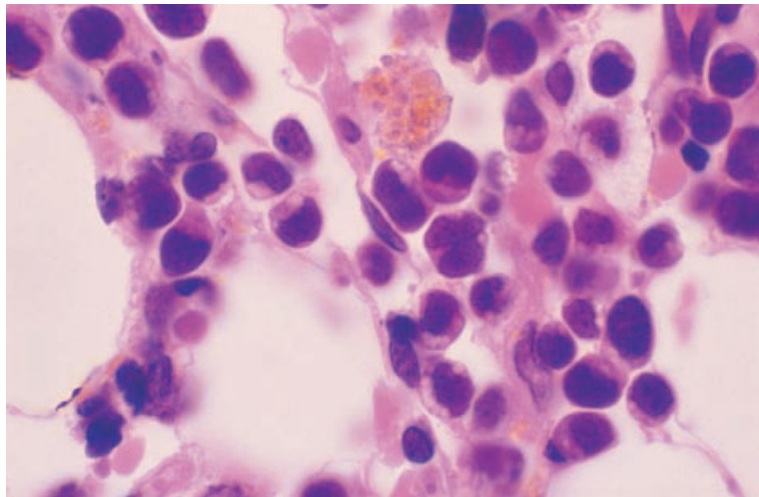
CD10+/-, CD20+, CD79a+, CD5-, CD23-, CD43-/-, TdT-
Ki-67+ (antibody MIB-1) proliferative fraction usually greater than 99%

Cytogenetics and molecular genetics

Most cases have t(8;14)(q24;q32). Smaller numbers of cases have variant translocations, t(2;8)(p12;q24) and t(8;22)(q24;q11)

Abbreviations (percentages are approximate): +>90% positive; +/->50% positive; -/+<50% positive; <10% positive; Smlg, surface membrane immunoglobulin; TdT, terminal deoxynucleotidyl transferase.

Fig. 6.54 BM trephine biopsy section, Burkitt's lymphoma in a patient with AIDS, showing diffuse infiltration by neoplastic cells; note the prominent cytoplasmic vacuoles. Paraffin-embedded, H&E $\times 970$.



consistent feature than at other sites. Bone marrow necrosis may occur both before treatment is given and to an even greater extent after chemotherapy. Increased reticulin is frequent.

In Burkitt-like lymphoma the cells are more heterogeneous and the nuclear outlines are more irregular.

Immunohistochemistry

In Burkitt's and Burkitt-like lymphoma the cells express CD20 and CD79a; expression of CD20 is often weak. There may also be expression of CD10

and CD43. Staining with Ki-67 or equivalent monoclonal antibody shows a very high proliferative fraction (usually greater than 99% of tumour cell nuclei are positive). There is no expression of TdT.

Problems and pitfalls

The diagnosis of Burkitt's and Burkitt-like lymphoma from a bone marrow aspirate is usually straightforward because of the distinctive cytological features of the neoplastic cells. More difficulty may be experienced with a trephine biopsy since cytoplasmic vacuolation may be inapparent and the 'starry sky'

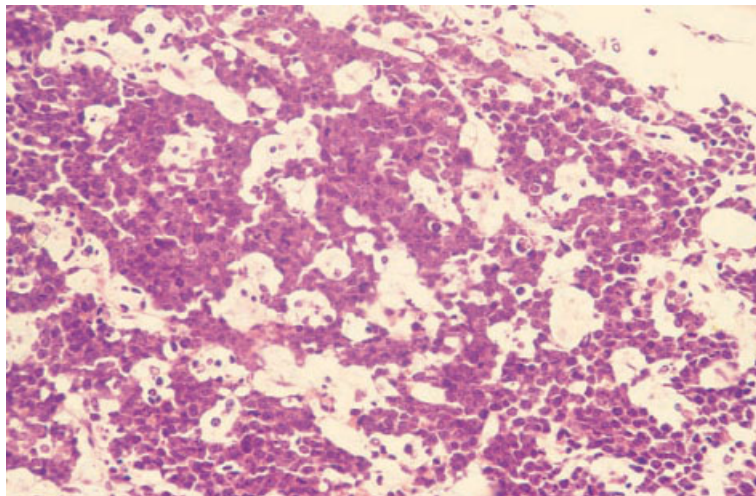


Fig. 6.55 BM trephine biopsy section, Burkitt's lymphoma in a patient with AIDS, showing a 'starry sky' appearance. Paraffin-embedded, H&E $\times 388$.

appearance, which may provide a clue to this diagnosis, is often absent. Correct assessment of cell size, the nuclear features and the frequent mitoses are of critical importance in making this diagnosis. Immunohistochemistry can be very useful in difficult cases, e.g. in making a distinction between Burkitt's lymphoma (CD5 and cyclin D1 negative and CD10 positive) and blastoid variant of mantle cell lymphoma (CD10 negative, CD5 and cyclin D1 positive). Some cases of large B-cell lymphoma can have morphological features resembling Burkitt-like lymphoma; the distinction can be aided by the very high proliferative (Ki-67-positive) fraction which is invariably present in the latter.

Lymphoproliferative disorders of T lineage and natural killer lineage

The terminology of T-lineage lymphoproliferative disorders is particularly confused, with histopathologists and haematologists often failing to recognize the same entities. It is also often difficult to harmonize different histopathological classifications. In the past, cases have sometimes been described using undefined terms and without reference to a clear system of classification. Single disease entities have been described under multiple designations and, conversely, single terms have been used to denote different diseases. The term T-chronic lymphocytic leukaemia has, for example, been used as a loose

generic term and also to indicate conditions as diverse as T-cell granular lymphocytic leukaemia and the small cell variant of PLL.

There are several further problems with the classification of T-lineage lymphomas. Firstly, it has proved difficult to devise a reproducible classification, probably as a consequence of the extreme histological diversity of T-cell lymphomas [4]. Secondly, when attempts to categorize cases histologically as low grade or high grade were made, there was no close correlation between grade assigned and prognosis. Some cases falling into low grade categories had a prognosis as poor as most high grade lymphomas. Thirdly, a single category of lymphoma may include different disease entities and, conversely, cases representing a single disease entity may fall into more than one histological category. Cases of leukaemia/lymphoma associated with the HTLV-I virus, for example, clearly constitute a clinicopathological entity but despite this they fell into more than one histological category of the Kiel classification, including at least one category of low grade lymphoma and two categories of high grade lymphoma. The converse problem occurred with the Kiel category of T-lineage, low grade, lymphocytic lymphoma which includes under the designation 'chronic lymphocytic leukaemia' both leukaemia of large granular lymphocytes (LGL leukaemia) and two other conditions, at least one of which appears to be more closely related to PLL.

Leukaemia of large granular lymphocytes clearly differs from the other T-lymphocytic lymphomas, as is recognized in the FAB [7], REAL [2] and WHO [1] classifications. We shall discuss this group of lymphomas using predominantly the definitions and terminology of the WHO group. The term 'peripheral T-cell lymphoma' also requires consideration. This designation embraces all T-lineage neoplasms with the exception of ALL and lymphoblastic lymphoma which have a prethymic or thymic phenotype [2,4]; however, the term is sometimes used in a more restricted sense with cutaneous T-cell lymphomas being excluded. The Working Formulation did not distinguish between B-cell and T-cell lymphomas. The only T-cell neoplasm that was specifically identified was mycosis fungoides; other T-cell lymphomas were aggregated with the more common B-cell lymphomas to form rather heterogeneous groups. The WHO classification uses the term mature (peripheral) T-cell lymphoma for this group.

The WHO and REAL classifications resolved some of the problems of earlier classifications of T-cell lymphoma, recognizing that not only morphology but clinical, immunophenotypic, cytogenetic and molecular genetic features are integral to the definition of specific entities [1]. Adult T-cell leukaemia/lymphoma (ATLL) is recognized as an entity. Angio-immunoblastic lymphoma and ALCL are retained. Four other categories of peripheral T-cell lymphoma which histopathologists outside the Kiel group have had some difficulty in identifying are grouped together as 'peripheral T-cell lymphoma, unspecified or not otherwise characterized'. This may well prove to be a practical approach to the classification of T-cell lymphomas. Other entities that have distinct pathological features and clinical behaviour not recognized within previous classifications are included in the WHO classification. These include hepatosplenic $\gamma\delta$ T-cell lymphoma, extranodal natural killer (NK)/T-cell lymphoma (nasal type), subcutaneous panniculitis-like T-cell lymphoma and enteropathy-type T-cell lymphoma [1].

The common patterns of bone marrow infiltration in T-cell lymphoma differ from those most characteristic of B-cell lymphomas. Infiltration is usually interstitial, random focal, nodular or diffuse. Nodular infiltration differs from that seen in

B-cell lymphomas and in reactive lymphoid hyperplasia in that the nodules often have ill-defined margins. Paratrabeular infiltration occurs [12,24] but is quite uncommon. T-cell lymphomas also differ from B-cell lymphomas in that various reactive changes are more frequent; such changes include eosinophilia, vascular proliferation, polyclonal plasma cell proliferation, macrophage proliferation, haemophagocytosis, epithelioid cell and granuloma formation, reactive follicular hyperplasia and reticulin fibrosis.

The frequency with which marrow infiltration has been reported in peripheral T-cell lymphoma has varied from 10% [152] to 80% [24]. This wide disparity may be attributable in part to the occurrence of histologically equivocal lesions which require immunophenotyping for confirmation [12], and in part to a variable mixture, in any series of patients, of different disease entities with different probabilities of bone marrow spread.

Diagnosis and classification of T-lineage lymphomas and leukaemias is not always possible on the basis of lymph node histology alone. The immunophenotype and cytological features of peripheral blood and bone marrow cells can be of critical importance in diagnosis. Histological features in a trephine biopsy section are generally of less importance than lymph node histology and peripheral blood cytology. However, in some cases, a firm diagnosis can be established from the bone marrow when other diagnostic tissue is not available [12,24]. In other patients, lesions are suggestive of NHL but are non-diagnostic unless supplemented by immunophenotypic analysis or molecular genetic demonstration of a clonal *TCR* gene rearrangement. The differential diagnosis includes Hodgkin's disease, AIDS, auto-immune diseases, malignant histiocytosis and virus-associated haemophagocytosis. Problems in the differential diagnosis of angio-immunoblastic lymphadenopathy and related conditions are discussed on page 300.

Precursor T-lymphoblastic leukaemia/lymphoma

About a quarter of cases of ALL are of T lineage. T-lineage ALL is closely related to the lymphoblastic lymphomas of the Kiel classification and the Working Formulation, the majority of which are of T

lineage. The equivalent category in the WHO and REAL classifications is precursor T-lymphoblastic lymphoma/leukaemia. Precursor T-lymphoblastic lymphoma, in which the bone marrow initially shows little or no infiltration, is less common than T-ALL. Both the leukaemic and lymphomatous forms of this disease are much more common in childhood than in adult life. About 80% of all lymphoblastic lymphomas, including the great majority of childhood lymphoblastic lymphoma, are of T lineage [34,153].

Precursor T-lymphoblastic leukaemia/lymphoma shows a male preponderance. Thymic infiltration is very common and may be associated with pleural and pericardial effusions and superior vena cava obstruction. There may also be lymphadenopathy, hepatomegaly or splenomegaly.

Peripheral blood

The peripheral blood in precursor T-ALL often shows circulating blast cells. In precursor T-lymphoblastic lymphoma, the blood is often normal but some patients have small numbers of circulating neoplastic cells. T lymphoblasts may have ALL L1 or L2 cytological features. They cannot be distinguished reliably from B lymphoblasts on cytological grounds, although cells with convoluted nuclei or hyperchromatic nuclei are sometimes noted.

Bone marrow cytology

In T-ALL the bone marrow is invariably infiltrated by lymphoblasts whereas, in precursor T-lymphoblastic lymphoma, the bone marrow is often normal, with variable infiltration by lymphoblasts in some patients. By convention, cases with more than 25% or 30% of lymphoblasts in the marrow are classified as ALL and cases with a lower percentage of lymphoblasts as lymphoblastic lymphoma. Patients with lymphoblastic lymphoma in whom the bone marrow is initially normal may later show infiltration if there is disease progression.

Immunocytochemistry and flow cytometry

T lymphoblasts express many antigens characteristic of T cells (such as CD2, CD3, CD4, CD5, CD7 and CD8) and, in addition, may show features of immaturity such as co-expression of CD4 and CD8 or expression of CD1a (Box 6.11). TdT is usually expressed and CD34 may be expressed.

Cases have been divided by the EGIL group into four immunophenotypic groups:

- 1 pro-T ALL: this has the least mature immunophenotype; the cells do not express CD2, CD5 or CD8 but may express CD7;
- 2 pre-T ALL: the cells express CD2, CD5 or CD8 but not CD1a;

BOX 6.11

Precursor T-lymphoblastic leukaemia/lymphoma

Flow cytometry and immunocytochemistry

All cases—CyCD3+, CD10^{-/+}, CD34^{+/-}, TdT+
 Pro-T ALL—CD2⁻, CD5⁻, CD8⁻, CD7^{+/-}
 Pre-T ALL—CD2+, CD5+, CD8^{+/-}, CD1a⁻
 Cortical T ALL—CD1a+, SmCD3^{+/-}
 Mature T ALL—SmCD3+, CD1a⁻

Immunohistochemistry

CD3^{+/-}, CD4^{+/-}, CD5^{+/-}, CD8^{+/-}, CD10^{-/+}, CD34^{+/-}, CD43^{+/-}, TdT+

Cytogenetics and molecular genetics

No specific abnormalities, but translocations involving the *TCR* genes, particularly the *TCR* α and δ genes at 14q11–13 and the *TCR* β gene at 7q32–36 are common. *TCR* genes may be rearranged

Abbreviations (percentages are approximate): +>90% positive; +/→50% positive; -/+<50% positive; <10% positive; Cy, cytoplasmic; Sm, surface membrane; TCR, T-cell receptor; TdT, terminal deoxynucleotidyl transferase.

3 cortical T ALL: the cells show expression of CD1a with or without surface membrane CD3; and

4 mature T ALL: the cells express surface membrane CD3 but not CD1a.

All express cytoplasmic or surface membrane CD3 and some express CD10 (although expression is weaker than in precursor B-lymphoblastic leukaemia/lymphoma).

The immunophenotypic features of precursor T-lymphoblastic lymphoma are similar to those of precursor T-lymphoblastic leukaemia; although lymphoblastic lymphoma tends to have the more mature phenotype, individual cases cannot be distinguished on this basis.

Cytogenetics and molecular genetics

Cytogenetic abnormalities are common although no specific abnormalities occur at high frequency. Many of the abnormalities are translocations involving *TCR* genes, particularly the *TCR* α and δ genes at 14q11–13 and the *TCR* β gene at 7q32–36 (Box 6.11). Many cases show monoclonal rearrangement of *TCR* genes detectable by PCR analysis.

Bone marrow histology

Bone marrow infiltration is invariable and extensive in T-ALL. In precursor T-lymphoblastic lymphoma there is marrow infiltration at diagnosis in approximately 60% of cases [16]. Infiltration is initially focal but, with disease progression, focal deposits spread and coalesce to produce a diffuse pattern of infiltration. Before the routine use of chemotherapy, bone marrow infiltration usually supervened in those who initially had a normal marrow. The cytological features of the leukaemic and lymphomatous forms of the disease are very similar [37]. Lymphoblasts are of small or medium size, slightly larger than small lymphocytes, with scanty cytoplasm and relatively large, deeply staining nuclei. Nucleoli are usually relatively small and the chromatin is finely stippled. Mitotic figures are frequent and nuclear clefting, convolution or folding can be identified in some cases. Some cases also have small, hyperchromatic nuclei [37]. A tendency to perivascular infiltration by lymphoblasts may be pronounced [97]. When marrow involvement is minimal, the lymphoblasts may be difficult to identify in trephine

biopsy sections and may more easily be detected in aspirate films.

Immunohistochemistry

Precursor T lymphoblasts express CD3 and usually CD5 and TdT (Box 6.11). They may express CD4, CD8, CD34, CD43, CD45 and CD45RO. There may also be weak expression of CD10 and some cases express CD79a, but cells do not generally express other B-cell or myeloid antigens.

Problems and pitfalls

The main differential diagnoses of precursor T-lymphoblastic leukaemia/lymphoma are precursor B-lymphoblastic leukaemia/lymphoma and AML. These differential diagnoses have been discussed on page 240.

T-prolymphocytic leukaemia

The FAB group [7] recommended that the term T-prolymphocytic leukaemia (T-PLL) be used not only for cases of low grade T-lineage lymphoma in which cells have morphological features quite similar to those of B-PLL, but also for cases with smaller cells which differ more from those of B-PLL; the Kiel group [4] preferred to classify the latter group as T-CLL. The FAB terminology is justified by the observation that, despite some variation in morphology, all of these cases have many features in common. Specifically, they share clinical and immunophenotypic profiles and characteristic cytogenetic abnormalities, namely *inv(14)(q11q32)* and trisomy 8q [7]. T-PLL falls into the Kiel category of T-lineage, low grade, lymphocytic lymphoma and the Working Formulation category of diffuse small cleaved cell lymphoma. T-PLL is a specific category in the REAL and WHO classifications [1].

T-PLL is mainly a disease of the elderly. Patients commonly present with marked splenomegaly. Other features may include lymphadenopathy, skin infiltration and serous effusions.

Peripheral blood

The white cell count is usually high. In some cases the circulating neoplastic cells are similar in size to

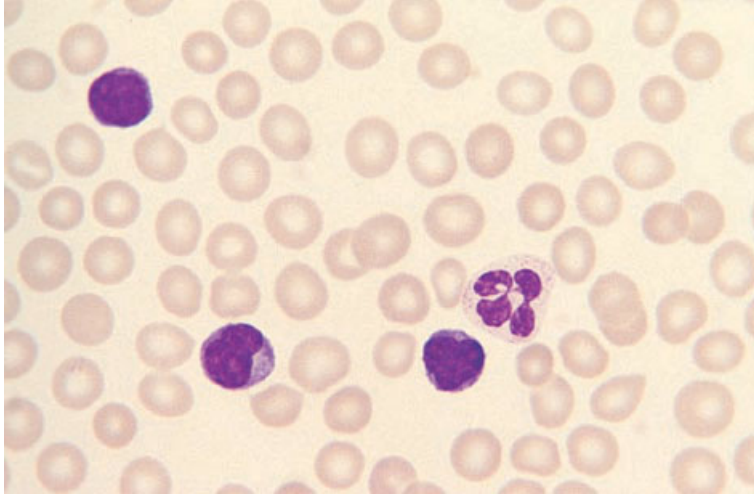


Fig. 6.56 PB film, T-PLL, showing dense irregular nuclei and, in one cell, a prominent medium sized nucleolus. MGG $\times 940$.

BOX 6.12

T-prolymphocytic leukaemia

Flow cytometry and immunocytochemistry

CD2+, CD3+, CD4+, CD5+, CD7+
CD8-, CD25-

Immunohistochemistry

CD3+, CD4+, CD5+
CD8-

Cytogenetics and molecular genetics

Most cases show either $\text{inv}(14)(q11q32)$ or $\text{t}(14;14)(q11;q32)$

Abbreviations (percentages are approximate): +>90% positive; +/->50% positive; -/+<50% positive; <10% positive.

normal small lymphocytes while in others they are considerably larger, similar in size to B-PLL cells [154]. When cells are large, there is usually relatively abundant cytoplasm and the nuclei contain a prominent central nucleolus. Some cases are cytologically indistinguishable from B-PLL cells but the majority can be distinguished. In others the cytoplasm is more basophilic and the nucleus is irregular. In cases with predominantly small cells the nucleocytoplasmic ratio is higher and the nucleolus is smaller and less prominent (Fig. 6.56); the nucleus is often irregular ('knobby') and there may also be cytoplasmic blebs.

Bone marrow cytology

The bone marrow is infiltrated by cells of the same appearance as those in the blood but the morphology is usually less well preserved.

Immunocytochemistry and flow cytometry

The leukaemic cells express the T-cell antigens CD2, CD3 and CD5 (Box 6.12). The cells are characteristically CD7 positive in contrast to most other leukaemias with a mature T-cell phenotype. In most cases, cells are CD4 positive and CD8 negative.

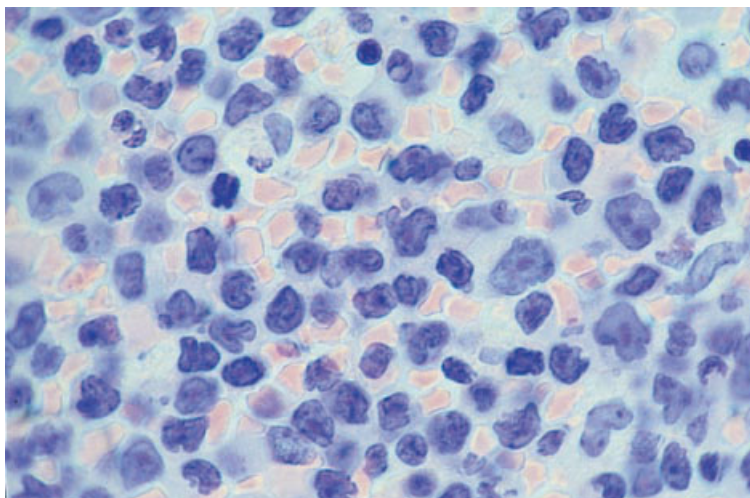


Fig. 6.57 BM trephine biopsy section, T-PLL, showing large and small prolymphocytes with prominent nucleoli, particularly in the larger cells; note highly irregular nuclei. Plastic-embedded, H&E $\times 940$.

In approximately a quarter of all cases, cells express both CD4 and CD8 [155]. Rarely, the cells are CD4 negative and CD8 positive. In most cases they are CD25 negative.

Cytogenetics and molecular genetics

Approximately 75% of cases of T-PLL show abnormalities of chromosome 14, either $inv(14)(q11q32)$ or $t(14;14)(q11;q32)$ [67] (Box 6.12); the *TCR* α chain locus is present at 14q11 and the *IGH* gene is located at 14q32. Partial trisomy or multिसomy of 8q is commonly present. Other abnormalities seen in a minority of cases are trisomy or partial trisomy of 7q and deletions of 6q.

Bone marrow histology

There may be only a modest degree of infiltration, even in those patients who have marked leucocytosis [112]. The patterns of infiltration seen are similar to those of B-PLL (see page 251). In many cases irregular nuclei and scanty cytoplasm suggest T lineage (Fig. 6.57) but some cases are indistinguishable from B-PLL. Reticulin fibrosis appears to be more common than in B-PLL [68].

Immunohistochemistry

The cells are CD3 and CD5 positive (Box 6.12). In

most cases they are CD4 positive and CD8 negative. There is no expression of B-cell markers.

Problems and pitfalls

T-PLL needs to be distinguished from B-PLL and from other leukaemias with a mature T-cell phenotype. Immunophenotypic analysis and correlation with the cytological features of the leukaemic cells will enable the distinction to be made.

T-cell granular lymphocytic leukaemia

This condition is recognized as a distinct entity in the WHO classification. The neoplastic cells are morphologically similar to normal LGL and express T-cell markers including CD3.

LGL are a normal component of the peripheral blood, with distinctive morphological features; they comprise 10–15% of peripheral blood lymphocytes [156]. Two distinct types of normal LGL are recognized on immunophenotypic analysis: (i) cytotoxic T cells expressing CD3 and CD8; and (ii) NK cells that are CD3 negative and express markers such as CD56 and CD57. A variety of names have been used for leukaemias of LGL; the FAB group [7] designated such cases T-CLL, whereas these cases fell into the Kiel category of T-lineage, low grade, lymphocytic lymphoma. The REAL classification recognized LGL leukaemias as a

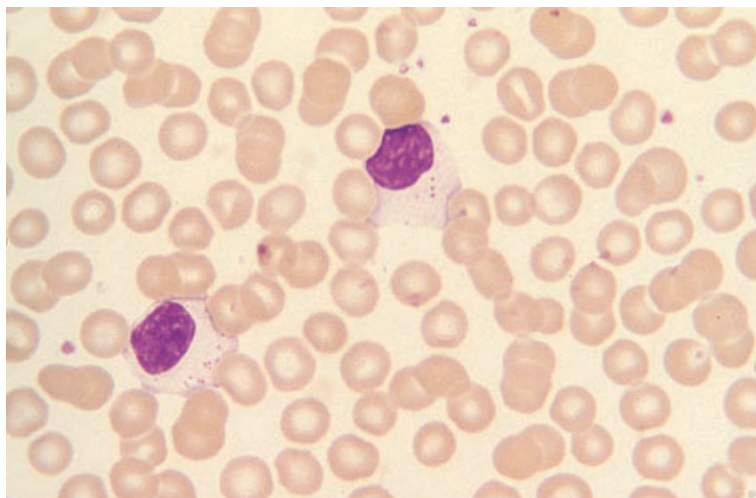


Fig. 6.58 PB film, T-cell granular lymphocytic leukaemia, showing two large granular lymphocytes. MGG $\times 940$.

separate category, subdivided into T-cell and NK-cell types.

In the vast majority of cases of LGL leukaemia, the cells are CD8 positive and have other T-cell markers, including CD3. However, there are some morphologically identical cases in which cells share some markers with NK cells but lack T-cell markers. Since the clinical features differ and the prognosis may be worse for cases with an NK-cell phenotype [157,158], the WHO classification recognizes these cases as a separate entity, aggressive NK-cell leukaemia (see page 233).

T-cell granular lymphocytic leukaemia occurs predominantly in the elderly (median age 60 years) [159]. Approximately one third of patients are asymptomatic at the time of diagnosis [160,161]. However, many patients have cytopenias (most commonly neutropenia) and may present with recurrent bacterial infections, affecting the skin, oropharynx and peri-anal region, or the symptoms of anaemia. There is a strong association with Felty's syndrome (rheumatoid arthritis with neutropenia and splenomegaly) [159]. Lymphadenopathy is uncommon, but hepatomegaly and splenomegaly are frequent findings. The disease typically has a prolonged survival with an actuarial median survival, in one series, of 166 months [160]. In a minority of patients, particularly those cases in which cells co-express CD3 and CD56, the disease has a more aggressive clinical behaviour similar to that of aggressive NK-cell leukaemia [158].

Peripheral blood

The white cell count is increased due to an increased number of LGL [162,163]. In occasional patients the total white cell count is not increased although there is an increase in the number of LGL. The neoplastic cells are morphologically very similar to normal LGL (Fig. 6.58). They have a round or oval nucleus with moderately condensed chromatin; the cytoplasm is voluminous and weakly basophilic and contains fine or coarse azurophilic granules. Smear cells are rare. Some patients have isolated neutropenia or thrombocytopenia or, less often, anaemia. These cytopenias are out of proportion to the degree of bone marrow infiltration and appear to have an immune basis. Macrocytosis is sometimes present.

Bone marrow cytology

The bone marrow shows a variable degree of infiltration by cells with the same morphology as those in the blood. In the early stages infiltration may be minimal. In patients with marked neutropenia the bone marrow usually shows immature granulocytic cells in normal numbers but mature neutrophils are lacking. Patients with thrombocytopenia usually have normal numbers of megakaryocytes. When anaemia is marked the marrow may show either a lack of maturing erythroblasts (pure red cell aplasia) or megaloblastic erythropoiesis.

BOX 6.13**T-cell granular lymphocytic leukaemia**

Flow cytometry and immunocytochemistry
 CD2+, CD3+, CD5+, CD8+, CD16+/-, CD57+/-
 CD4-, CD7-, CD56- (rare cases CD56+)

Immunohistochemistry
 CD3+, CD5+, CD8+
 CD4-, CD56- (rare cases CD56+)

Cytogenetics and molecular genetics
 No specific cytogenetic abnormality
 Monoclonal *TCR* gene rearrangements are detectable in most cases

Abbreviations (percentages are approximate): +>90% positive; +/->50% positive; -/+<50% positive; <10% positive; *TCR*, T-cell receptor.

Immunocytochemistry and flow cytometry

Neoplastic cells of T-cell granular lymphocytic leukaemia are usually positive for CD2, CD3, CD5, CD16 and CD57 and are most often negative for CD7 [159] (Box 6.13). They are usually CD8 positive and CD4 negative. The NK-cell marker, CD56, is usually negative. In rare patients, cells express both CD3 and CD56, a phenotype that is associated with a more aggressive clinical behaviour [158].

Cytogenetics and molecular genetics

No consistent cytogenetic abnormalities have been observed (Box 6.13). Monoclonal rearrangements of the *TCR* genes can be detected in most cases.

Bone marrow histology

The marrow is infiltrated in almost all cases, although the degree of marrow infiltration is usually not marked. However, the bone marrow infiltrate in T-cell granular lymphocytic leukaemia does not have distinctive features and can be confused with that of various low grade B-cell lymphoproliferative disorders. Examination of peripheral blood and bone marrow aspirate films, together with immunophenotypic analysis, is essential if the nature of the infiltrate is to be recognized.

Infiltration is usually interstitial, random focal or

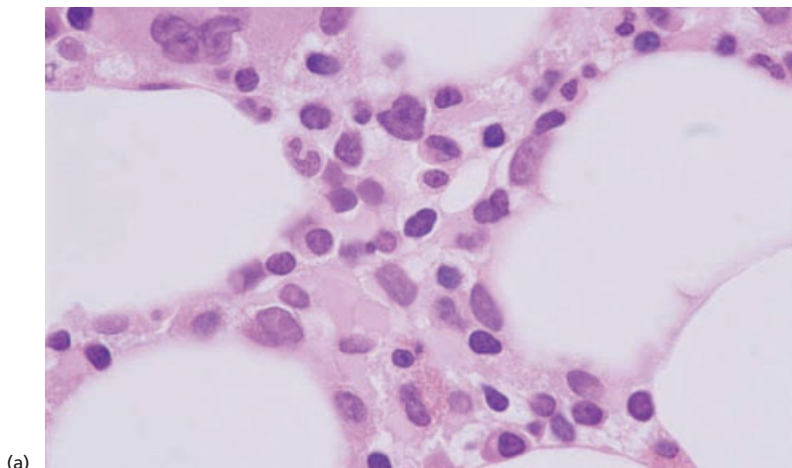
diffuse but in occasional instances has been nodular [164–166]. The infiltrates are composed of small and medium-sized lymphocytes (Fig 6.59), the nuclei of which have irregular contours, condensed nuclear chromatin and inconspicuous nucleoli [166]. There is a thin rim of cytoplasm in which granules are not visible. Some cases have plasmacytosis [166]. Neutropenic cases often show apparent maturation arrest at the myelocyte stage and increased numbers of apoptotic cells are present. Patients with thrombocytopenia usually have adequate or increased numbers of megakaryocytes although amegakaryocytic thrombocytopenia has been reported [167]. Anaemic patients often show the features of pure red cell aplasia with a reduction in mature erythroid precursors. An association with trilineage myelodysplasia has been noted in a significant minority of patients.

Immunohistochemistry

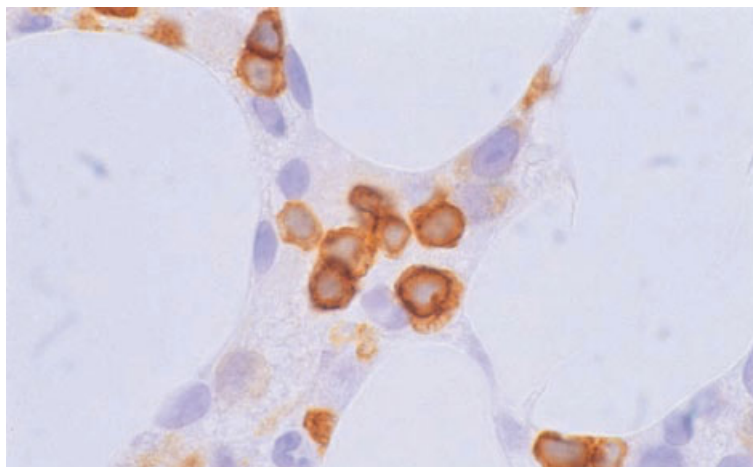
The neoplastic cells express CD3; staining for CD5 and CD56 is usually negative (Box 6.13).

Problems and pitfalls

T-cell granular lymphocytic leukaemia can be confused with other chronic lymphoid leukaemias of both B and T lineage. In most cases, the distinctive morphology of the LGL in the circulation will suggest



(a)



(b)

Fig. 6.59 BM trephine biopsy section, T-cell granular lymphocytic leukaemia. (a) Showing occasional small and medium-sized lymphocytes. Paraffin-embedded, H&E $\times 940$. (b) Infiltrating lymphoma cells are much more apparent by immunohistochemistry. Paraffin-embedded, immunoperoxidase, CD3 $\times 940$.

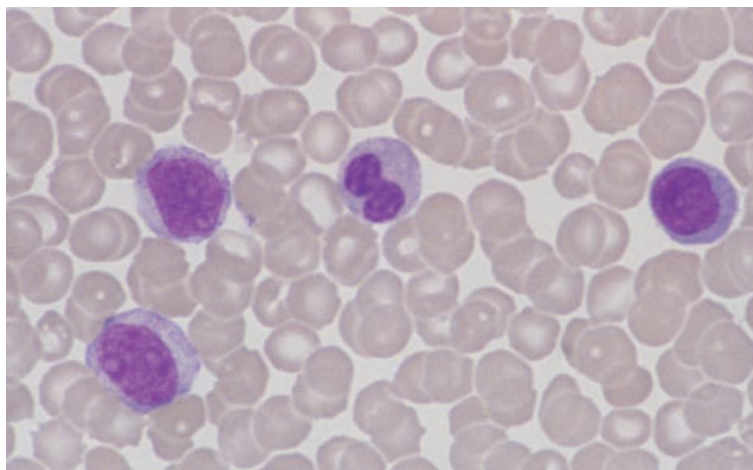
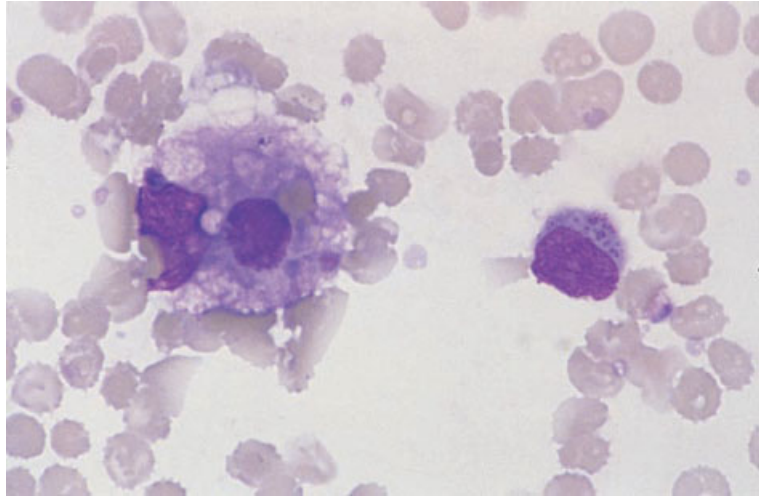


Fig. 6.60 PB film, aggressive NK-cell leukaemia/lymphoma, showing three lymphoma cells and a neutrophil. MGG $\times 940$. (By courtesy of Dr KF Wong, Hong Kong.)

Fig. 6.61 BM aspirate, aggressive NK-cell leukaemia/lymphoma (same case as in Fig. 6.60), showing one medium sized granular lymphoma cell; reactive macrophage proliferation and haemophagocytosis were prominent. MGG $\times 940$. (By courtesy of Dr KF Wong, Hong Kong.)



the diagnosis and immunophenotyping will confirm the nature of the leukaemic cells. T-cell granular lymphocytic leukaemia needs to be separated from aggressive NK-cell leukaemia (see below). It also needs to be separated from chronic NK lymphocytosis, in which there is a persistent increase of LGL with an NK immunophenotype in the peripheral blood, sometimes associated with auto-immune conditions and neutropenia [159,168]. Organomegaly is rare in chronic NK lymphocytosis and the condition does not usually progress [168].

Aggressive NK-cell leukaemia

The WHO classification identifies leukaemias in which the neoplastic cells are of NK lineage as a distinct entity. As discussed above, this condition was previously often grouped with T-cell granular lymphocytic leukaemia, but there are clear differences in immunophenotype and clinical behaviour between the two conditions. In many cases the neoplastic cells show evidence of infection with EBV [169,170]. Patients are typically younger (median age 39 years) than those with T-cell granular lymphocytic leukaemia; they often have B symptoms and hepatosplenomegaly [159]. There is no association with rheumatoid arthritis [159]. The disease has an aggressive clinical behaviour [171,172], is highly resistant to therapy and has a poor prognosis with most patients surviving less than 2 months [159,170].

Peripheral blood

The peripheral blood shows an increase in LGL with higher absolute counts than are usually seen in T-cell granular lymphocytic leukaemia. The circulating cells are similar to normal LGL, but some cells are larger with more open chromatin and distinct nucleoli [170]. There may be circulating normoblasts and myelocytes. Anaemia, thrombocytopenia and neutropenia are frequent findings [159].

Bone marrow cytology

Most cases show infiltration by cells similar to those seen in the peripheral blood [170] (Fig. 6.61). There may be evidence of haemophagocytosis.

Immunocytochemistry and flow cytometry [159,170]

The neoplastic cells are negative for CD3, CD4, TCR $\alpha\beta$ and TCR $\gamma\delta$ (Box 6.14). They usually express CD2, CD16 and CD56. There is variable expression of CD8 and CD57.

Cytogenetics and molecular genetics

Many cases show clonal cytogenetic abnormalities although no consistent pattern has been reported [159] (Box 6.14). *TCR* genes are not rearranged. In most cases, Epstein–Barr early RNA (EBER) can be detected by *in situ* hybridization [170].

BOX 6.14**Aggressive NK-cell leukaemia***Flow cytometry and immunocytochemistry*

CD2+, CD8+/-, CD16+, CD56+, CD57+/-
 CD3-, CD4-, TCR $\alpha\beta$ -, TCR $\gamma\delta$ -

Immunohistochemistry

CD56+
 CD3-, CD4-

Cytogenetics and molecular genetics

Cytogenetic abnormalities are common, but no consistent abnormality is observed
 TCR genes are not rearranged
 EBER detected by ISH in most cases

Abbreviations (percentages are approximate): +>90% positive; +/->50% positive; -/+<50% positive; <10% positive; EBER, Epstein-Barr early RNA; ISH, *in situ* hybridization; TCR, T-cell receptor.

Bone marrow histology

The degree of bone marrow infiltration is variable and may show a diffuse, interstitial or angiocentric pattern. There is a monomorphic infiltrate of medium sized cells with round nuclei and condensed chromatin [170]. Some patients show evidence of haemophagocytosis.

Immunohistochemistry

The neoplastic cells express CD56 and are negative for CD3 and CD4 (Box 6.14).

Problems and pitfalls

This condition is readily distinguished from T-cell granular lymphocytic leukaemia by immunophenotyping. More significant problems occur in distinguishing NK-cell leukaemia from chronic NK lymphocytosis which result, in no small part, from the fact that the nature of the latter condition is uncertain. There is no easy way to demonstrate clonality in NK cells since *TCR* genes are not rearranged and many cases do not have a cytogenetic abnormality. NK-cell leukaemia/lymphoma has been defined as an aggressive condition and chronic NK lymphocytosis is an indolent condition with little tendency to progress [173]. In the absence of

a usable marker of clonality it is not at present possible to determine whether a small or large proportion of cases of chronic NK lymphocytosis actually represent a chronic leukaemia. The practical solution, given our current state of knowledge, is to designate cases with a clonal cytogenetic abnormality or an aggressive clinical course as NK-cell leukaemia and use the non-committal term 'chronic NK-cell lymphocytosis' for other cases.

Extranodal NK/T-cell lymphoma, nasal type

This condition differs from aggressive NK-cell leukaemia both clinically and pathologically. Most cases are associated with EBV infection and the disease is much more common in the Far East than the rest of the world. The REAL classification referred to this entity as angiocentric T-cell lymphoma and, in the past, many cases were classified as 'lethal midline granuloma'. It is an aggressive disease that typically presents with a destructive mass in the nose or palate. Although this tumour is most common in the nasopharynx, it can present at other sites, including the skin, without nasopharyngeal involvement [170]. The primary tumours are often extensively necrotic due to infiltration of blood vessel walls by neoplastic cells. Most cases express a NK phenotype, but some have a T-cell or hybrid phenotype. The prognosis is poor [172,174].

Peripheral blood

The minority of patients who present with disseminated disease have pancytopenia. Rarely, a leukaemic phase occurs. Circulating neoplastic cells have azurophilic granules, but they have a higher nucleocytoplasmic ratio and more diffuse chromatin pattern than the cells of T-cell granular lymphocytic leukaemia [172].

Bone marrow aspirate

In a small minority of patients the bone marrow is infiltrated by medium sized cells with high nucleocytoplasmic ratio, pleomorphic nuclear morphology and azurophilic cytoplasmic granules [172].

Immunocytochemistry and flow cytometry

The neoplastic cells show variable expression of T-cell antigens. They are usually CD2 positive and often express CD5 and CD7. The cells may be CD4 or CD8 positive, but CD3 is usually negative. There is usually expression of CD56.

Cytogenetics and molecular genetics

No consistent cytogenetic abnormalities have been reported. The *TCR* and *IGH* genes show a germline pattern. Expression of EBV genes characteristic of latent infection (e.g. EBER) can usually be detected by *in situ* hybridization.

Bone marrow histology

The bone marrow may be infiltrated by pleomorphic, medium sized cells with a high nucleocytoplasmic ratio.

Mycosis fungoides/Sézary's syndrome

Mycosis fungoides and Sézary's syndrome are cutaneous T-cell lymphomas. In both conditions there is infiltration of the dermis and the epidermis by neoplastic cells. The epidermal infiltrate is focal; the intra-epidermal accumulations of lymphocytes are known as Pautrier's abscesses or micro-abscesses. Pautrier's abscesses are highly characteristic of lymphoma of small cerebriform cells but they are

not pathognomonic since they may also occur in HTLV-I-associated leukaemia/lymphoma. Sézary's syndrome is characterized by both generalized erythroderma, consequent on infiltration of the skin by lymphoma cells, and circulating neoplastic cells, which may be numerous or scanty; these features are detectable at the time of presentation. In mycosis fungoides the initial manifestation is usually the presence of patchy erythematous lesions but, subsequently, plaques, nodules and fungating tumours may form. Spread to lymph nodes occurs late in the disease. Circulating neoplastic cells are sometimes, but not always, apparent in mycosis fungoides. There is some overlap between the conditions classified, respectively, as Sézary's syndrome and mycosis fungoides and they are best regarded as different manifestations of a single disease; the circulating neoplastic cells of both are referred to as Sézary cells. Rare patients lack clinically detectable skin lesions but have circulating neoplastic cells with the cytological features of Sézary cells; this condition, which has been designated Sézary cell leukaemia, is now regarded as being more closely related to T-PLL.

Peripheral blood

The likelihood of Sézary cells being present in the peripheral blood can be related to the nature of the skin lesions. In one study, circulating neoplastic cells were not detectable in patients with localized skin plaques but were present in 9% of patients with generalized skin plaques, 27% of those with skin tumours and 90% of those with erythroderma [175]. Sézary cells vary in size from that of a normal small lymphocyte to two or three times this size. Individual patients may have predominantly small cells or predominantly large cells. Sézary cells have a high nucleocytoplasmic ratio. The chromatin is highly condensed and sometimes hyperchromatic. The nucleus is described as 'convoluted' or 'cerebriform', names indicative of the intertwined lobes resembling the convolutions of the brain (Fig. 6.62). This causes the surface of the nucleus to appear grooved. Lobes are often more readily discernible in large Sézary cells than in small forms. Nucleoli are usually inapparent but can sometimes be detected in large cells. Cytoplasm is scanty in small cells but more abundant in large cells; it is agranular and

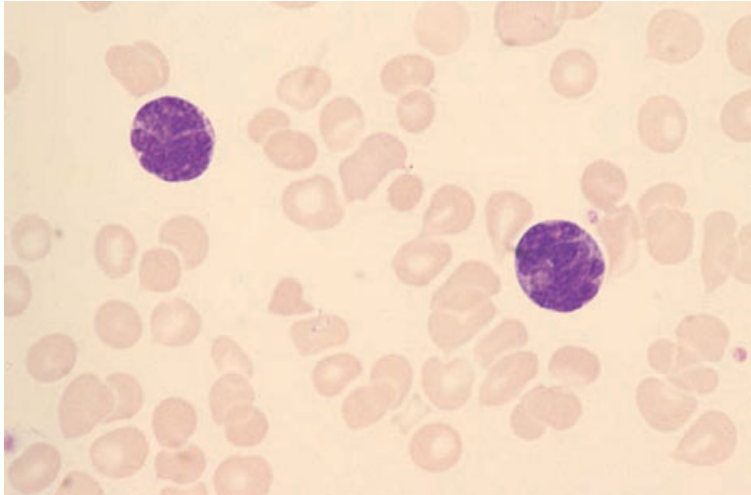


Fig. 6.62 PB film, Sézary's syndrome, showing two cells with convoluted nuclei and scanty cytoplasm. MGG ×940.

may contain a ring of vacuoles which are found to be PAS-positive. When Sézary cells are infrequent and similar in size to normal lymphocytes, they can be difficult to identify with certainty. Ultrastructural examination is very useful in those cases in which the characteristic cytological features cannot be discerned by light microscopy; demonstration of the characteristic form of the nucleus confirms the diagnosis (see Fig. 2.31).

Some patients have eosinophilia [175]. Except when disease is very advanced, anaemia and cytopenia are not usually features of Sézary's syndrome or of mycosis fungoides.

Bone marrow cytology

The bone marrow aspirate is often normal, even in a high proportion of patients with circulating neoplastic cells [175]. A variable degree of infiltration by Sézary cells can occur, particularly in the advanced stages of the disease.

Immunocytochemistry and flow cytometry

Sézary cells are usually CD4 positive, CD8 negative and express T-cell markers including CD2, CD3 and CD5 (Box 6.15); they are sometimes CD7 positive [176]. In a minority of cases, cells are CD8 positive and CD4 negative. B-cell markers are negative. Staining for CD25 is usually negative.

Cytogenetics and molecular genetics

A number of cytogenetic abnormalities have been reported and complex karyotypes are frequent (Box 6.15). Abnormalities of chromosomes 1 and 8 are common; however, no consistent or specific abnormality has been observed [177,178]. There is monoclonal rearrangement of *TCR* genes.

Bone marrow histology

In the first reported series of cases of cutaneous T-cell lymphomas bone marrow infiltration was detected in only 2–10% of patients and, even at autopsy, the detection rate was no higher than 25% [179]. However, two subsequent large series have detected infiltration in 18% [180] and 28% [181], respectively, of patients at presentation or early in the course of the disease. Infiltration is commoner in Sézary's syndrome than in mycosis fungoides [182] and shows some correlation with disease stage. However, not all patients with circulating Sézary cells have histologically detectable bone marrow infiltration [181].

Infiltrating cells are usually small and irregular in shape with convoluted and hyperchromatic nuclei (Fig. 6.63). In a minority of cases there is a population of large lymphoid cells with prominent nucleoli. Sometimes the infiltrate is pleomorphic and includes bizarre multinucleated cells. The presence

BOX 6.15**Mycosis fungoides/Sézary's syndrome***Flow cytometry and immunocytochemistry*

CD2+, CD3+, CD4+, CD5+, CD7-/+
 CD8-, CD25-

Immunohistochemistry

CD3+, CD4+, CD5+
 CD8-

Cytogenetics and molecular genetics

Cytogenetic abnormalities are common, but no consistent pattern is observed
 Monoclonal TCR gene rearrangements are detectable in most cases

Abbreviations (percentages are approximate): +>90% positive; +/->50% positive; -/+<50% positive; -<10% positive; TCR, T-cell receptor.

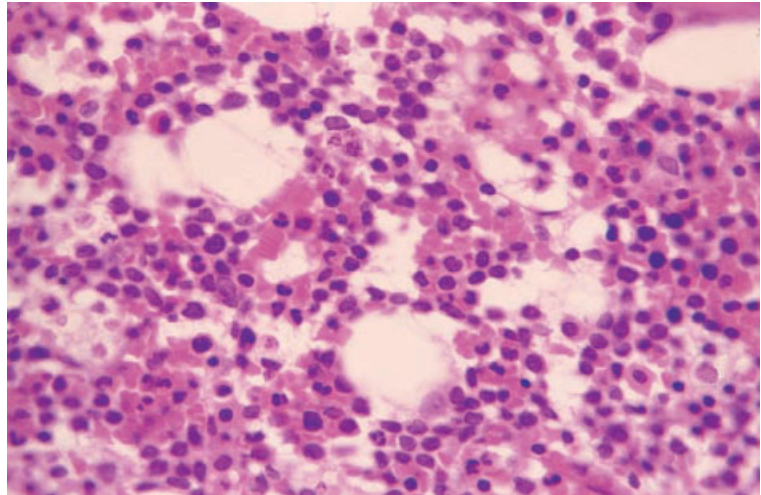


Fig. 6.63 BM trephine biopsy section, mycosis fungoides/Sézary's syndrome, showing heavy interstitial infiltration by small cerebriform cells. Paraffin-embedded, H&E $\times 390$.

of a significant proportion of transformed cells is of adverse prognostic significance [181]. Infiltrated bone marrows may also show an increase of eosinophils, macrophages or plasma cells and the presence of granulomas [181]. Reticulin is moderately increased.

When the bone marrow does not show any infiltrate of cytologically atypical cells, there may nevertheless be increased eosinophils and macrophages, granulomas and aggregates of small round lymphocytes [181]. The presence of aggregates of cytologically normal lymphocytes does not have any adverse prognostic significance.

Immunohistochemistry

The T-cell markers CD3 and CD5 are expressed (Box 6.15). Cells in most cases are CD4 positive and CD8 negative; in a minority of cases, cells are CD8 positive and CD4 negative. Rarely, staining for both CD4 and CD8 is negative. B-cell markers are negative.

Angio-immunoblastic lymphoma

The nature of the condition variously described under the names angio-immunoblastic lymphadenopathy

with dysproteinaemia (AILD), immunoblastic lymphadenopathy and lymphogranulomatosis X remains uncertain. Initially, this condition was regarded as an abnormal immune reaction but evidence subsequently emerged, derived from cytogenetic and DNA analysis, that there was an underlying clonal and probably neoplastic proliferation of T cells. It is now clear that many, if not all, cases represent a lymphoma of CD4-positive T cells. Some pathologists consider that all cases are actually lymphomas from the beginning. An alternative view is that some cases are lymphomas and other cases represent a reactive process with a propensity to lymphomatous transformation. It has been proposed that cases with demonstrable monoclonal proliferation of T cells should be classified as lymphomas and cases lacking such evidence should not. However, not all T-cell lymphomas have demonstrable rearrangement of the *TCR* genes [152]. This may be because, in some cases, the proportion of neoplastic cells is very low. Further, although there is some correlation between demonstrable gene rearrangement and cytological evidence of atypia, this correlation is not perfect [152]; there is an early difference in survival curves but they ultimately come together [152]. A final judgement as to whether all cases of AILD, or only the majority, represent lymphoma must await further evidence.

The diagnosis of angio-immunoblastic lymphoma rests on lymph node histology. Typically, there is effacement of nodal architecture with disappearance of germinal centres, a marked proliferation of venules and an infiltrate which is composed of a variable mixture of lymphocytes, plasma cells, immunoblasts, epithelioid cells and proliferating dendritic reticulum cells [4,152,183]. Many cases have extracellular PAS-positive material.

Characteristic clinical features are fever and lymphadenopathy, auto-immune haemolytic anaemia and other auto-immune phenomena, allergic reactions to drugs and hypergammaglobulinaemia.

Transformation to a more aggressive T-cell lymphoma occurs in 10–15% of patients. Some patients develop large B-cell lymphoma.

Peripheral blood

There is usually normocytic normochromic anaemia with increased rouleaux formation and an elevated

erythrocyte sedimentation rate (ESR). Occasionally the anaemia is leuco-erythroblastic. Complicating autoimmune haemolytic anaemia is common. Some patients have lymphopenia, thrombocytopenia, neutrophilia, eosinophilia or basophilia [183,184]. Plasma cells, plasmacytoid lymphocytes and atypical lymphocytes resembling those seen in viral infections or immunological reactions may be present.

Bone marrow cytology

The bone marrow aspirate may show non-specific changes such as the features of anaemia of chronic disease. There may be an infiltrate of small lymphocytes, sometimes with irregular nuclei, and of atypical lymphoid cells including immunoblasts. Inflammatory cells including eosinophils and plasma cells may be increased.

Immunocytochemistry and flow cytometry

The neoplastic cells express CD3 and other T-cell antigens CD2, CD5 and CD7 (Box 6.16). In most cases, cells express CD4 and are CD8 negative.

Cytogenetics and molecular genetics

Most cases show cytogenetic abnormalities with complex karyotypes and a high frequency of multiple cytogenetically unrelated clones [185]. The most frequent abnormalities are trisomy 3, trisomy 5 and additional copies of the X chromosome (Box 6.16). Structural abnormalities of chromosome 1, additional X chromosomes and complex aberrant clones are associated with a worse prognosis [186]. Monoclonal rearrangements of *TCR* β and γ are seen in approximately 75% of cases and monoclonal *IGH* rearrangements are present in up to 25% of cases [187]. It is possible to detect EBER by *in situ* hybridization in many cases.

Bone marrow histology

The reported incidence of bone marrow infiltration varies widely, from 10% [152] to 60% [188,189]. The lesions are usually focal (patchy or nodular), either single or multiple. Distribution is usually random but is sometimes paratrabeular [25]. Diffuse infiltration can occur. The infiltrate is composed

BOX 6.16**Angio-immunoblastic lymphoma***Flow cytometry and immunocytochemistry*

CD2+, CD3+, CD4+, CD5+, CD7+
CD8–

Immunohistochemistry

CD3+, CD4+
CD8–

Cytogenetics and molecular genetics

Cytogenetic abnormalities with complex karyotype common
The most frequent abnormalities are trisomy 3, trisomy 5 and additional copies of the X chromosome
Monoclonal *TCR* gene rearrangements are detectable in most cases

Abbreviations (percentages are approximate): +>90% positive; +/->50% positive; -/+<50% positive; <10% positive; TCR, T-cell receptor.

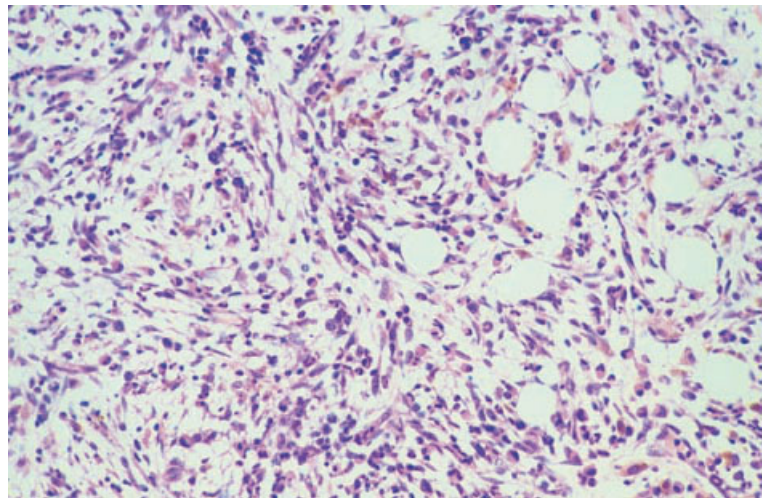


Fig. 6.64 BM trephine biopsy section, angio-immunoblastic lymphoma, showing a pleomorphic lymphoid infiltrate and irregular fibrosis. Paraffin-embedded, H&E $\times 97$.

of lymphocytes, plasma cells, immunoblasts, macrophages and sometimes eosinophils or neutrophils (Figs 6.64–6.66). The lymphocytes have somewhat irregular nuclei and may be small and medium sized, or medium sized and large. In some cases there are lymphoid cells resembling Hodgkin's cells or Reed–Sternberg cells and immunoblasts with clear cytoplasm [25]. Because of the presence of epithelioid macrophages, focal lesions may resemble granulomas [189]. Some cases have

hyperplastic capillaries which are occasionally arborizing. Reticulin is usually increased.

Although angio-immunoblastic lymphoma may sometimes be suspected on bone marrow examination, the diagnosis generally requires a lymph node biopsy. Two features which are particularly characteristic of the lymph node lesions, arborizing capillaries and PAS-positive extracellular deposits, are much less apparent and sometimes inapparent in bone marrow trephine biopsy sections.

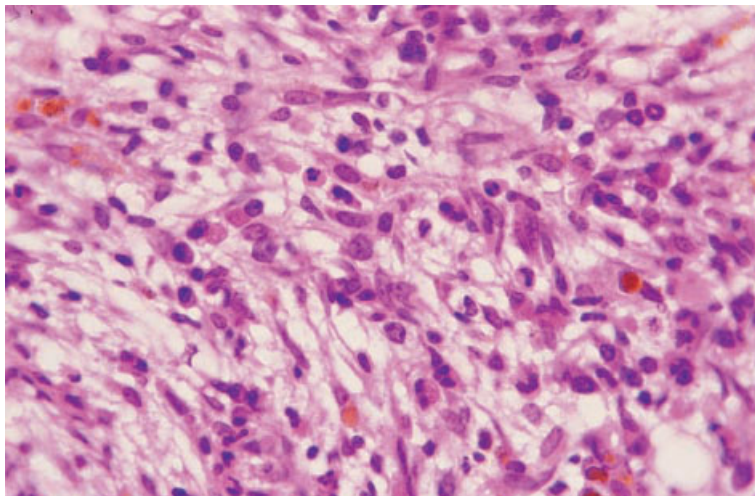


Fig. 6.65 BM trephine biopsy section, angio-immunoblastic lymphoma (same case as in Fig. 6.64), showing that the infiltrate is composed of medium sized lymphocytes admixed with fibroblasts, eosinophils, immunoblasts and plasma cells. Paraffin-embedded, H&E $\times 390$.

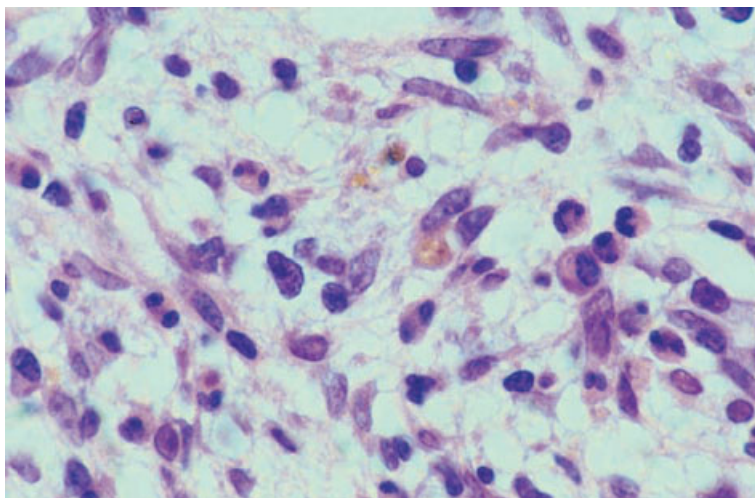


Fig. 6.66 BM trephine biopsy section, angio-immunoblastic lymphoma (same case as in Fig. 6.64), showing fibroblasts, eosinophils and medium sized lymphocytes with irregular nuclei. Paraffin-embedded, H&E $\times 970$.

Immunohistochemistry

Atypical cells in the areas of infiltration usually express CD3 (Box 6.16). In most cases, cells are CD4 positive and CD8 negative. B-cell markers (CD20 and CD79a) are negative.

Problems and pitfalls

A similar pleomorphic infiltrate can occur in the bone marrow in Hodgkin's disease and in inflammatory and auto-immune conditions. Close correlation with the clinical features, lymph node

histology and cytogenetic and molecular genetic findings is required to establish a diagnosis of angio-immunoblastic lymphoma. The lesions of systemic mastocytosis are sometimes confused with this condition if a Giemsa or toluidine blue stain or immunohistochemical staining for mast cell tryptase is not performed.

Adult T-cell leukaemia/lymphoma

ATLL is a specific entity and is recognized as such in the REAL and WHO classifications. It was not identified specifically in the Working Formulation

Table 6.4 Subclassification of ATLL [193,194].

Category	Peripheral blood lymphocytes	Tissue infiltration	Biochemistry
Smouldering ATLL	Lymphocyte count $< 4 \times 10^9/l$ and either $\geq 5\%$ abnormal lymphocytes or histological proof of lung or skin infiltration	The lungs or skin may be infiltrated but there is no infiltration of lymph nodes, liver, spleen, gastro-intestinal tract or CNS and no ascites or pleural effusion	LDH up to $1.5 \times$ the upper limit of normal No hypercalcaemia
Chronic ATLL	Lymphocyte count $> 4 \times 10^9/l$ and T lymphocytes $> 3.5 \times 10^9/l$ with morphologically abnormal cells and occasional frank ATLL cells (such as flower cells); in most cases there are $> 5\%$ abnormal lymphocytes	The lungs, skin, lymph nodes, liver or spleen may be infiltrated, but there is no infiltration of gastro-intestinal tract or CNS and no ascites or pleural effusion	LDH up to twice the upper limit of normal No hypercalcaemia
Lymphoma-type ATLL	Lymphocyte count $< 4 \times 10^9/l$ and $\leq 1\%$ abnormal lymphocytes	Histologically demonstrated lymphoma	There may be elevated LDH or hypercalcaemia
Acute ATLL		All other cases	

Modified from [194].

CNS, central nervous system; LDH, lactate dehydrogenase.

and in the Kiel classification overlapped several different categories. ATLL is a neoplasm occurring in subjects whose T cells have earlier been infected by the retrovirus HTLV-I (human T-cell lymphotropic virus I). The virus is integrated into host T cells at random sites but is integrated at a consistent site in the neoplastic clone of an individual case. The lifetime risk of leukaemia/lymphoma in patients infected by the virus has been estimated at about 1–2%. Cases of ATLL have mainly been observed in certain areas of known endemicity of the virus, specifically Japan and the West Indies, and in countries which have received immigrants from these two areas. More recently, cases have been reported from South America with a smaller number of cases being recognized in patients from Central and West Africa, the Middle East, Taiwan and other parts of the world [176,190–193]. It is likely that co-factors are necessary for the development of ATLL; these may differ in Japan and the West Indies since the disease usually has a later age of onset in Japan.

ATLL may present as a lymphoma, without bone marrow and peripheral blood involvement, or as a leukaemia/lymphoma with both tissue infiltration and peripheral blood and bone marrow involve-

ment. The majority of cases have an acute course, but chronic and smouldering forms are recognized (Table 6.4) [193,194]. Cytologically and histologically ATLL is very variable. Suchi *et al.* [4] have reported that a smouldering course is more likely in those with histologically low grade lymphoma but Jaffe *et al.* [191] did not observe any relationship between histological grade and outcome.

ATLL occurs mainly in adults but rare childhood cases have been reported, particularly from South America. Prominent clinical features in the acute form are lymphadenopathy, skin infiltration and bone lesions associated with hypercalcaemia. Some patients have splenomegaly and hepatomegaly. The prognosis of the acute form is generally poor with a median survival of less than a year.

Examination of the peripheral blood is very important in diagnosis. Bone marrow aspiration and trephine biopsy are of lesser importance.

Peripheral blood

About three quarters of patients have circulating lymphoma cells. These are distinctive [176,190], being extremely pleomorphic, varying in size,

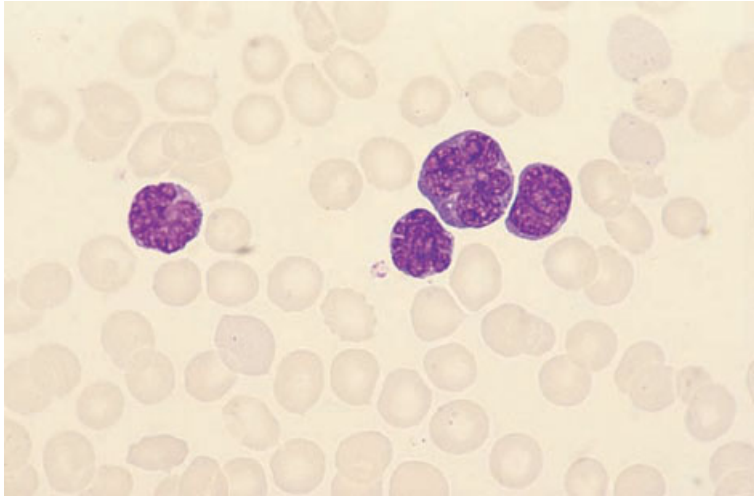


Fig. 6.67 PB film, ATLL, showing highly pleomorphic cells, the largest of which has a 'clover-leaf' or 'flower-like' lobulated nucleus containing prominent medium sized nucleoli. MGG $\times 940$.

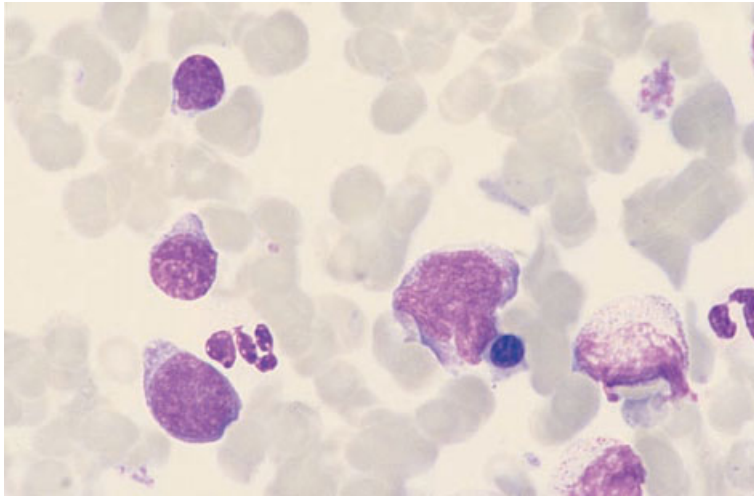


Fig. 6.68 BM aspirate, ATLL, showing an infiltrate of lymphoid cells; there is considerable variation in size; the largest cell has a lobulated nucleus. MGG $\times 940$.

shape, nucleocytoplasmic ratio and degree of chromatin condensation (Fig. 6.67). Cytoplasm varies from scanty to moderately abundant and is sometimes basophilic. Some cells have nucleoli and a primitive chromatin pattern while others, usually the majority, have condensed, sometimes hyperchromatic, chromatin. Nuclei are very variable in shape but some are deeply lobulated, resembling clover leaves or flowers. Some cerebriform cells may be present but the degree of pleomorphism usually permits the distinction from Sézary's syndrome.

Because the marrow is not usually heavily infiltrated, there may be little anaemia or thrombo-

cytopenia at presentation. Eosinophilia is not infrequent [192].

Bone marrow cytology

Patients who have leukaemia at presentation show a variable degree of bone marrow infiltration by cells similar to those described above (Fig. 6.68).

Immunocytochemistry and flow cytometry

The cells of ATLL are usually positive for CD2, CD3 and CD5 (Box 6.17). In most cases, cells lack

BOX 6.17**Adult T-cell leukaemia/lymphoma***Flow cytometry and immunocytochemistry*

CD2+, CD3+, CD4+, CD5+, CD25+
CD7-, CD8-

Immunohistochemistry

CD3+, CD4+, CD5+
CD8-

Cytogenetics and molecular genetics

Most cases have cytogenetic abnormalities. Trisomy 3, trisomy 7 and abnormalities of 6q are most common

Abbreviations (percentages are approximate): +>90% positive; +/->50% positive; -/+<50% positive; <10% positive.

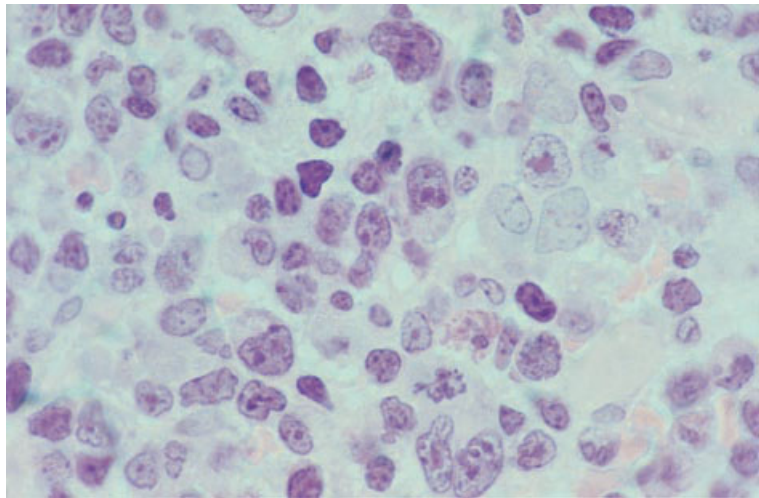


Fig. 6.69 BM trephine biopsy section, ATLL, showing diffuse infiltration by highly pleomorphic small, medium and large lymphoid cells. Plastic-embedded, H&E $\times 940$.

CD7. They are most often CD4 positive and differ from the cells of other types of mature T-cell lymphoma in that CD25 is positive in the majority of cases.

Cytogenetics and molecular genetics

Most cases have an abnormal karyotype although no consistent abnormality has been reported (Box 6.17). The most common findings are trisomy 3, trisomy 7 and abnormalities of 6q [195]. There is monoclonal rearrangement of *TCR* genes.

Bone marrow histology

The bone marrow is infiltrated in about three quarters of cases. The pattern of marrow involvement may be interstitial, random focal or diffuse. Occasionally it is paratrabecular. The degree of infiltration at presentation is often slight.

The nature of the infiltrate varies considerably between cases. Many cases show considerable variation in cell size with nuclei varying from medium size to large (Figs 6.69 and 6.70). Other cases have predominantly small cells or predominantly large

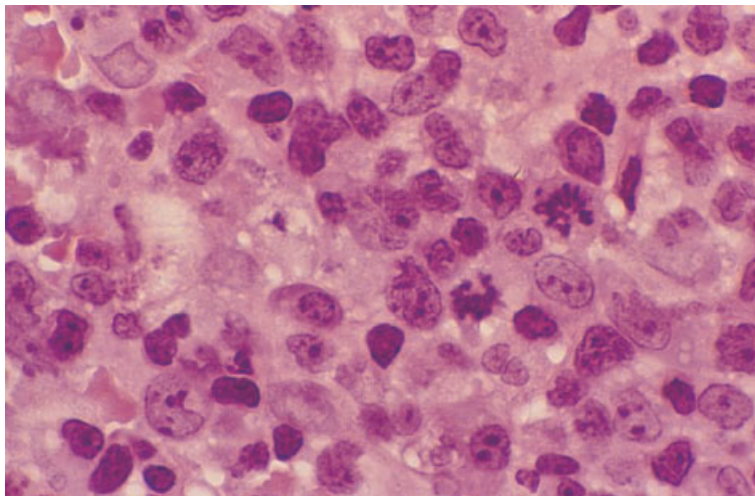


Fig. 6.70 BM trephine biopsy section, ATLL, showing diffuse infiltration by highly pleomorphic medium and large lymphoid cells. Note the high mitotic rate. Plastic-embedded, H&E $\times 970$.

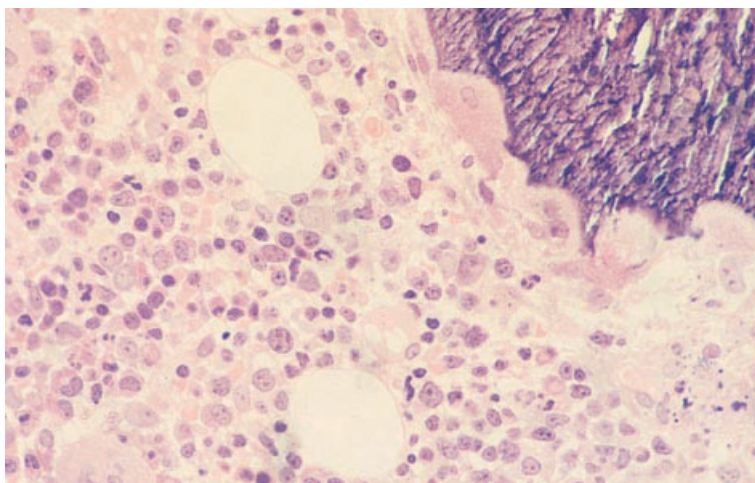


Fig. 6.71 BM trephine biopsy section, ATLL, showing heavy infiltration by pleomorphic medium and large lymphocytes; note the numerous osteoclasts in Howship's lacunae giving the bone trabecula a serrated appearance. Plastic-embedded, H&E $\times 377$.

cells. Cells are characteristically highly pleomorphic. In the larger cells, nuclei tend to be vesicular with a distinct nuclear membrane and two to five distinct nucleoli; smaller cells often show chromatin condensation. Nuclei vary in shape, being round, oval, indented, deeply lobulated or convoluted. Giant cells may be present; some of these resemble Reed–Sternberg cells while others have nuclear convolutions, coarsely aggregated chromatin and prominent nucleoli [4]. Mitotic figures are numerous (Fig. 6.70). In addition to the neoplastic cells there are often large numbers of eosinophils and plasma cells. Marrow vascularity may be increased.

A characteristic but not invariable feature of ATLL

is extensive bone resorption with large numbers of Howship's lacunae and numerous mononucleated and multinucleated osteoclasts (Fig. 6.71). There may be associated bone remodelling with a variable increase of osteoblast activity and paratrabeular fibrosis [191,196]. In some cases increased osteoclasts are apparent when there is no detectable infiltration in biopsy sections [192].

Immunohistochemistry

The neoplastic cells stain positively for the T-cell antigens CD3 and CD5 (Box 6.17). In most cases, cells are CD4 positive.

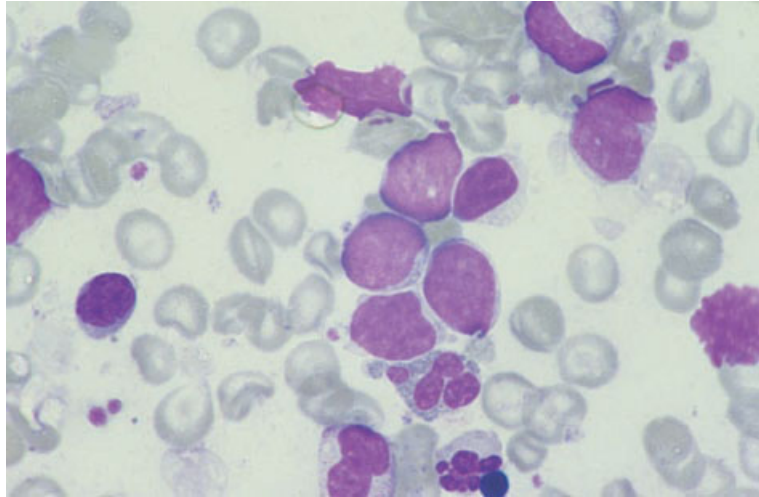


Fig. 6.72 BM aspirate, hepatosplenic $\gamma\delta$ T-cell lymphoma, showing medium sized lymphoma cells with a high nucleocytoplasmic ratio and multiple small nucleoli. MGG $\times 940$. (By courtesy of Dr Elizabeth Lombard, Cape Town.)

Problems and pitfalls

The degree of marrow infiltration may be slight and difficult to recognize by morphology alone. Immunohistochemical staining for CD3 may be helpful in identifying a subtle interstitial infiltrate of atypical cells. Even in those with a heavy infiltrate, the histological features may closely resemble other peripheral T-cell lymphomas; close attention to the cytological features in bone marrow aspirate or blood films is important in suggesting the diagnosis. The presence of increased osteoclastic activity is a useful pointer towards a diagnosis of ATLL.

Hepatosplenic $\gamma\delta$ T-cell lymphoma

This is a rare, clinically aggressive lymphoma that typically presents in young men with B symptoms, hepatosplenomegaly and cytopenia. Lymphadenopathy is not usually present [197]. The neoplastic cells express the $\gamma\delta$ form of TCR, which is normally expressed on a minor subset of peripheral blood T lymphocytes. In a small number of cases, with similar clinical and pathological features, the neoplastic cells express the $\alpha\beta$ TCR as well as, or instead of, $\gamma\delta$ TCR [198].

Peripheral blood

There is often a Coombs'-negative haemolytic

anaemia and thrombocytopenia as the result of peripheral consumption. The white cell count is usually normal.

Bone marrow cytology

The bone marrow is hypercellular with erythroid and megakaryocytic hyperplasia. The bone marrow is usually infiltrated by medium sized agranular lymphocytes, which may be in clumps [199]. The cells have moderately dispersed chromatin and moderate cytoplasmic basophilia [197] (Fig. 6.72). The infiltrate varies from scanty to moderate. There may be reactive haemophagocytosis.

Immunocytochemistry and flow cytometry

Cells in most cases express CD2, CD3 and CD7 but are negative for CD4, CD5 and CD8 (Box 6.18). In the majority of cases the cells express TCR δ chain, but not TCR β chain. In many cases, cells are positive for the NK-associated antigen, CD56 [197,200].

Cytogenetics and molecular genetics

The characteristic cytogenetic abnormalities are trisomy 8 and an isochromosome of 7q (Box 6.18). The majority of cases show a monoclonal rearrangement of the *TCR* γ chain gene, but not of the *TCR* β chain gene.

BOX 6.18**Hepatosplenic $\gamma\delta$ T-cell lymphoma***Flow cytometry and immunocytochemistry*

CD2+, CD3+, CD7+, CD56+/-, TCR $\gamma\delta$ +
 CD4-, CD5-, CD8-, TCR $\alpha\beta$ - (rarely TCR $\alpha\beta$ +)

Immunohistochemistry

CD3+, CD56+/-
 CD4-, CD5-, CD8-, TCR $\alpha\beta$ - (rarely TCR $\alpha\beta$ +)

Cytogenetics and molecular genetics

Trisomy 8 and an isochromosome of 7q are the most frequently seen abnormalities. In the majority of cases there is monoclonal rearrangement of the *TCR* γ chain gene but not the *TCR* β chain gene

Abbreviations (percentages are approximate): +>90% positive; +/->50% positive; -/+<50% positive; <10% positive; TCR, T-cell receptor.

Bone marrow histology

The bone marrow is hypercellular with erythroid and megakaryocytic hyperplasia. Marrow infiltration is present in most cases. The infiltrate may be interstitial, intrasinusoidal or both. The neoplastic cells are pleomorphic medium and large cells (Fig. 6.73).

Immunohistochemistry

The tumour cells express CD3 and, in most cases, CD56 (Box 6.18). Staining for CD4, CD5, CD8 and TCR β chain is negative. B-cell markers are not expressed.

Problems and pitfalls

The degree of infiltration may be very slight and, particularly in those cases with an exclusively intrasinusoidal pattern of infiltration, immunohistochemical staining for CD3 is important in identifying the neoplastic cells. Immunohistochemical staining for CD34 to highlight vascular endothelial cells is also useful in identifying the intrasinusoidal infiltrate.

Anaplastic large cell lymphoma

ALCL is an aggressive lymphoma which may either be of T lineage or fail to express lineage-specific

lymphoid antigens; the latter are usually designated null-cell type, although all or most are probably of T lineage [1]. The majority of cases are associated with a specific translocation, t(2;5)(p23;q35), or variant translocations involving chromosome 2, resulting in the formation of a fusion gene and expression of its product (termed ALK protein) [201,202]. The Kiel classification recognized a B-cell variant of ALCL. However, B-cell ALCL is not associated with t(2;5)(p23;q35) or the variant translocations and behaves differently from the T-cell and null-cell variants. It therefore seems preferable to consider T-cell/null-cell lymphomas and B-cell lymphomas with anaplastic cytology as separate entities. The WHO classification has a specific category designated 'anaplastic large cell lymphoma' for the T-cell and null-cell cases, and groups B-cell cases with other diffuse large cell B-lineage lymphomas [1]. In the Working Formulation ALCL falls into the large cell immunoblastic category.

ALCL has a wide age range, occurring in children, adolescents and adults. Patients commonly present with generalized lymphadenopathy, skin infiltration and systemic symptoms. A membrane antigen recognized by monoclonal antibodies of the CD30 cluster is expressed. Patients with t(2;5)(p23;q35) or variant translocations resulting in the expression of the ALK protein are predominantly young males, who usually present with stage III–IV disease. They

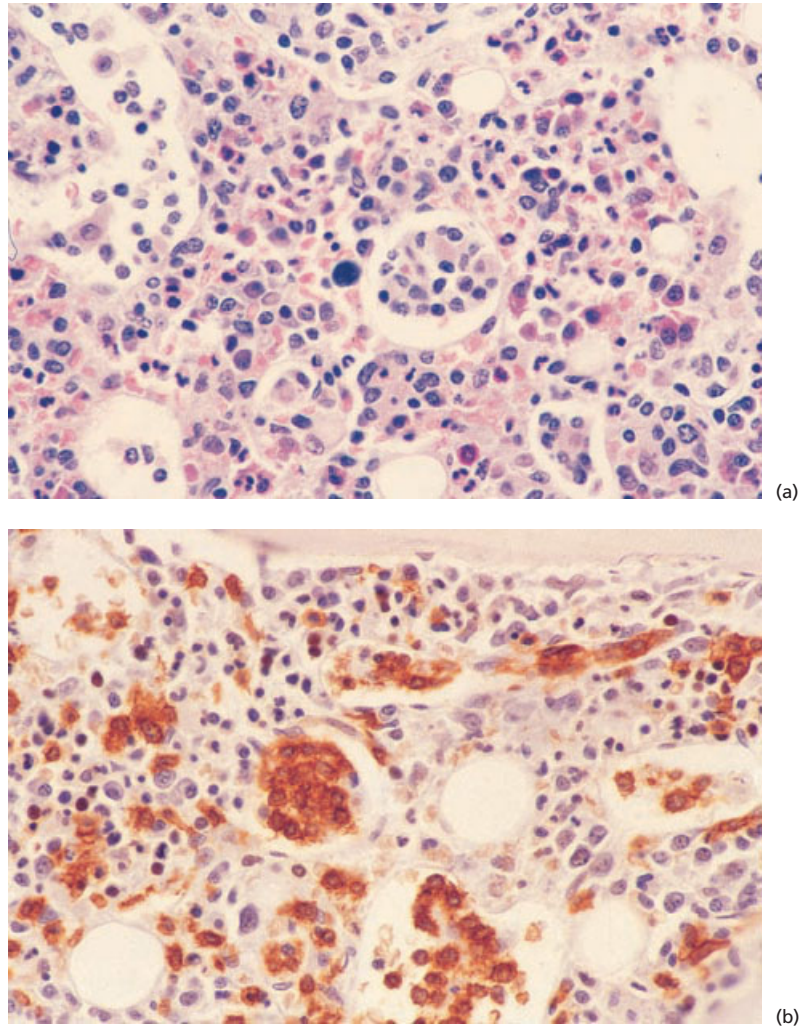


Fig. 6.73 BM trephine biopsy sections, hepatosplenic $\gamma\delta$ T-cell lymphoma (same case as in Fig. 6.72), showing intrasinusoidal and interstitial infiltrate. Paraffin-embedded: (a) H&E $\times 377$; (b) immunoperoxidase, CD45RO, $\times 377$.

have a much better prognosis following treatment than patients whose cells do not express the ALK protein; the latter may represent a different disease entity [201].

Peripheral blood

Circulation of lymphoma cells in the peripheral blood is uncommon. When it occurs the lymphoma cells are large and pleomorphic (Fig. 6.74). Pancytopenia may occur, consequent not only on bone

marrow infiltration but also on associated histiocytic proliferation and haemophagocytosis.

Bone marrow cytology

When bone marrow infiltration occurs, lymphoma cells are often infrequent (Fig. 6.75), usually less than 5% of marrow cells [203]. Neoplastic cells are large and pleomorphic, some being as large as megakaryocytes. They have weakly to strongly basophilic cytoplasm which may be finely vacuolated

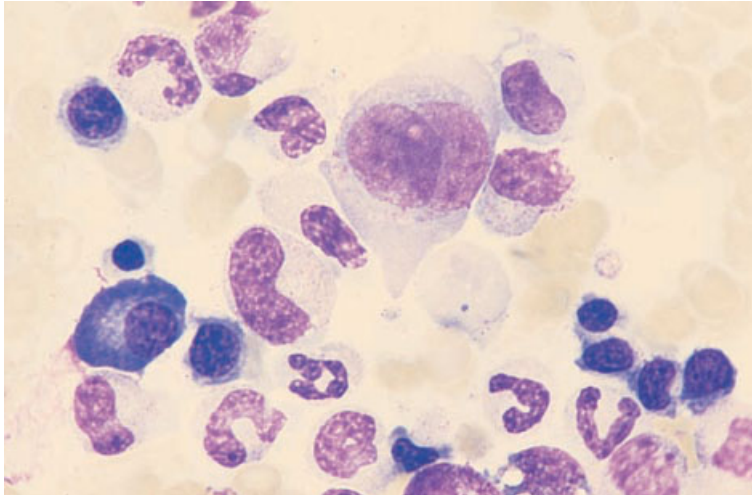


Fig. 6.74 PB film, anaplastic large cell lymphoma, showing large, pleomorphic lymphoma cells. MGG $\times 940$.

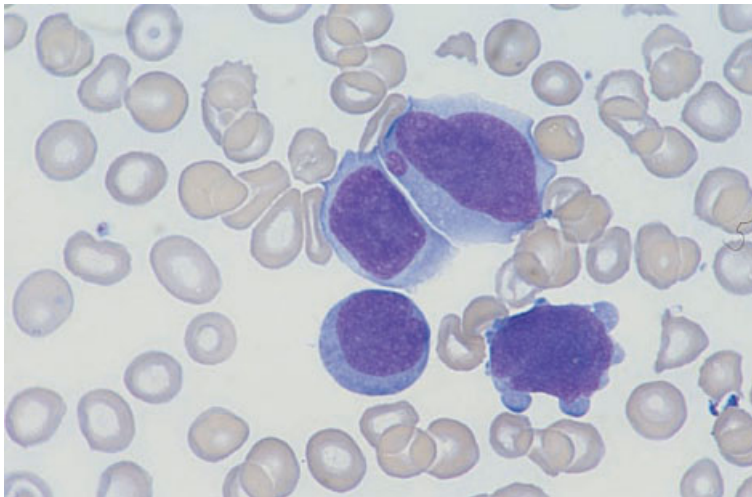


Fig. 6.75 BM aspirate, anaplastic large cell lymphoma, showing a single large binucleate lymphoma cell. MGG $\times 940$.

[203,204]; a Golgi zone may be apparent. Nuclei have irregular folds, a coarse open chromatin pattern and multiple prominent nucleoli [203]. Some cases have occasional phagocytic neoplastic cells. Associated histiocytic proliferation and haemophagocytosis are common and may overshadow a subtle lymphomatous infiltrate to the extent that a misdiagnosis of malignant histiocytosis (see page 184) is possible. Prominent haemophagocytosis may occur, even when lymphoma cells are not detectable in the bone marrow or are present

in very small numbers [203]. Histiocytes are predominantly mature.

Immunocytochemistry and flow cytometry

The tumour cells express CD30 (Box 6.19). In many cases cells also express epithelial membrane antigen (EMA), HLA-DR and activation antigens such as CD25 and CD71. There is variable expression of CD2, CD3, CD5, CD7, CD15, CD43, CD45 and CD45RO. B-cell markers are not expressed.

BOX 6.19**Anaplastic large cell lymphoma***Flow cytometry and immunocytochemistry*

CD30+

Variable expression of CD2, CD3, CD5, CD7, CD15, CD43, CD45 and CD45RO

Immunohistochemistry

CD30+, CD45+/-, ALK1+/-, EMA+/-

Variable expression of CD3, CD5, CD15, CD43 and CD45RO

Cytogenetics and molecular genetics

Most cases have t(2;5)(p23;q35). Less common abnormalities include t(2;5)(q37;q31), inv(2)(p23q35), t(2;13)(p23;q34), t(1;2)(q21;p23) and t(2;3)(p23;q21)

Abbreviations (percentages are approximate): +>90% positive; +/->50% positive; -/+<50% positive; <10% positive; ALK1, the product of the *ALK* oncogene; EMA, epithelial membrane antigen.

Cytogenetics and molecular genetics

Most cases have t(2;5)(p23;q35) with the formation of an *NPM-ALK* fusion gene (Box 6.19) detectable by conventional cytogenetic analysis or RT-PCR [205,206] (Box 6.19). Variant translocations and other rearrangements that have also been described include t(2;5)(q37;q31), inv(2)(p23q35) [207], t(2;13)(p23;q34) [208], t(1;2)(q21;p23) [209], t(2;3)(p23;q21) [209] and t(1;2)(q25;p23). In t(1;2)(q25;p23) there is formation of a *TPM-ALK* fusion gene [210].

Bone marrow histology

Bone marrow involvement has been reported in 7–30% of cases [203,204,211]. It appears to be more frequent in older patients [211]. The detection rate is significantly higher if immunohistochemistry is employed [212]. The pattern of infiltration by ALCL may be interstitial, focal (sometimes with very small clusters of lymphoma cells) or diffuse. Bone marrow infiltration is indicative of a worse prognosis [212].

Cytological features are variable. In most cases tumour cells are very pleomorphic and include multinucleated giant cells and cells with lobulated, wreath-shaped or embryo-shaped nuclei, sometimes abutting on the cell membrane [211] (Fig. 6.76). There may be cells resembling immunoblasts and

others resembling Reed–Sternberg cells. In other cases tumour cells are less pleomorphic. Lymphohistiocytic and small cell variants have been described [201]. Mitotic figures are frequent [25]. Reticulin is increased in infiltrated areas.

Immunohistochemistry

The neoplastic cells express CD30 and, in many cases, EMA is also expressed (Box 6.19). Leucocyte common antigen (CD45) is expressed in only 50% of cases. There is variable expression of CD3 and CD45RO. B-cell markers are not expressed. The ALK protein is over-expressed in cases with t(2;5)(p23;q35) and related translocations and can be detected with a monoclonal antibody, ALK1 [213]. Distribution is usually both nuclear and cytoplasmic in cases with t(2;5)(p23;q35) and restricted to the cytoplasm in those cases with variant translocations. However, occasional cases with the classical translocation show only cytoplasmic staining [202,214].

Problems and pitfalls

Immunohistochemical staining for CD30, ALK and EMA has been found to be very useful in identifying small clusters of lymphoma cells and single lymphoma cells scattered among haemopoietic cells [212]. Staining for ALK is particularly useful in this

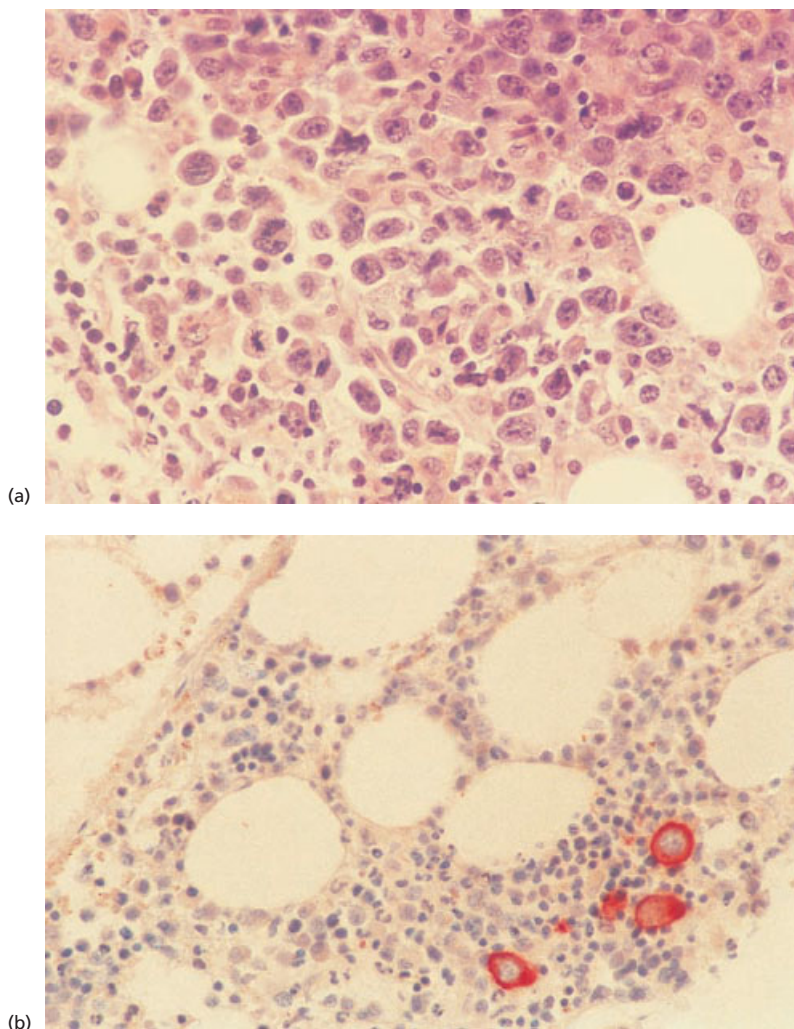


Fig. 6.76 BM trephine biopsy sections, anaplastic large cell lymphoma, showing: (a) a cohesive infiltrate of highly pleomorphic large lymphoma cells; paraffin-embedded, H&E $\times 377$; (b) an interstitial infiltrate of lymphoma cells identified by immunohistochemical staining for CD30; immunoperoxidase, anti-CD30 $\times 377$. (By courtesy of Dr S Juneja, Melbourne.)

context as it is the most specific of the markers. It should be noted that early erythroid cells may be CD30 positive; this should rarely cause any diagnostic problems as long as the cytological characteristics of such cells, compared to the pleomorphism of cells in ALCL, are remembered. The differential diagnosis of anaplastic large cell lymphoma includes Hodgkin's disease, metastatic carcinoma and amelanotic melanoma. Since ALCL is often negative for CD45 and some non-lymphoid tumours (e.g. embryonal carcinoma) are CD30 positive, the diagnosis of ALCL requires careful assessment of both

histological and immunophenotypic features. Those carcinomas which express CD30 almost invariably stain positively with anti-cytokeratin antibodies.

Peripheral T-cell lymphoma, not otherwise characterized

The Kiel classification recognized several further categories of peripheral T-cell lymphoma—T-zone lymphoma, lymphoepithelioid lymphoma, pleomorphic small T-cell lymphoma, pleomorphic medium sized T-cell lymphoma and T-

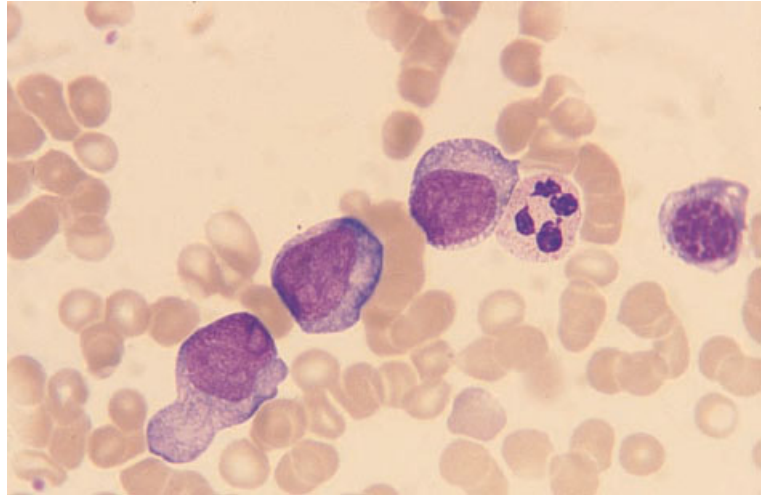


Fig. 6.77 BM aspirate, peripheral T-cell lymphoma, not otherwise categorized, showing large cells with plentiful basophilic cytoplasm and prominent nucleoli. MGG $\times 940$.

immunoblastic lymphoma. The consensus view of the REAL group was that it was not possible to make a reliable distinction between these categories and that the histological diagnosis did not predict clinical behaviour. Consequently, the REAL classification grouped these conditions together in a single category designated 'peripheral T-cell lymphomas, unspecified' [2]. The WHO classification has retained this category for peripheral T-cell lymphomas other than the specific entities described above [1] (and two other conditions that rarely involve the bone marrow, enteropathy-type T-cell lymphoma and subcutaneous panniculitic T-cell lymphoma) (see Table 6.2).

Patients usually have extensive nodal disease at the time of presentation and extranodal involvement is more common than in B-cell lymphomas. Systemic symptoms including fever are common. These lymphomas have an aggressive clinical course and, although potentially curable, they have a higher relapse rate and worse prognosis than aggressive B-cell lymphomas [215,216].

Most of the lymphomas in this category are neoplasms of mature CD4-positive cells expressing aberrant phenotypes which differ from those of normal peripheral blood T cells. Precise diagnosis usually depends on lymph node histology and immunophenotyping with bone marrow cytology and histology playing subsidiary roles. The neoplastic cells typically show marked variation in nuclear

size and shape and there are often large numbers of reactive macrophages and eosinophils. There is often vascular proliferation.

Peripheral blood

Peripheral blood involvement is rare. In a minority of cases there are circulating neoplastic cells which may be medium or large or a mixture of both. Cells are often highly pleomorphic. The nucleus may be round, oval or lobulated with either a diffuse chromatin pattern or with some chromatin condensation. One or more variably sited, prominent nucleoli are commonly present. The cytoplasm is usually moderately basophilic. There are no specific cytological features which allow T-cell lymphoma to be distinguished from lymphomas of B lineage.

Bone marrow cytology

The bone marrow aspirate may be normal or contain abnormal lymphoid cells similar to those which may be seen in the peripheral blood (Fig. 6.77).

Immunocytochemistry and flow cytometry

In most cases the cells express CD3 and CD4 and are CD8 negative [217] (Box 6.20). In a minority of cases, cells are CD8 positive or are negative for both CD4 and CD8. There is variable expression of CD2,

BOX 6.20**Peripheral T-cell lymphoma, not otherwise categorized***Flow cytometry and immunocytochemistry*

CD3+, CD4+/-, CD5+/-, CD7+/-, CD45RO+
CD8-/+

Immunohistochemistry

CD3+, CD4+/-, CD5+/-, CD43+/-, CD45RO+
CD8-/+ , CD15-, CD30-/+

Cytogenetics and molecular genetics

Cytogenetic abnormalities are common, but no consistent or specific abnormality is described. Abnormalities of chromosomes 1, 2, 3, 8 and 14 are seen most frequently
Monoclonal rearrangements of *TCR* genes are detectable in most cases

Abbreviations (percentages are approximate): +>90% positive; +/->50% positive; -/+<50% positive; <10% positive; TCR, T-cell receptor.

CD5 and CD7. B-cell markers are not usually expressed, although very rare cases of CD20-positive T-cell lymphoma have been reported [218].

Cytogenetics and molecular genetics

Cytogenetic abnormalities are common but no consistent or specific abnormality has been observed (Box 6.20). Abnormalities of chromosomes 1, 2, 3, 8 and 14 [219–222] are seen most frequently. The *TCR* genes usually show monoclonal rearrangement.

Bone marrow histology

Bone marrow involvement is present in the majority of cases in most published series [12,24,25]. Infiltration may be interstitial, focal or diffuse [12,24,25,152]. We have observed paratrabeular involvement but this is quite uncommon. The neoplastic cells are often highly pleomorphic with marked variation in size, nuclear shape, chromatin pattern and the number and size of nucleoli. Some cells may have very atypical nuclear configurations, variously described as convoluted, hyperconvoluted, cerebriform or multilobulated. There may be small lymphocytes, with round or irregular nuclei and a coarse chromatin pattern, and a variable admixture of medium sized lymphocytes or immunoblasts (Figs 6.78 and 6.79). T-immunoblasts typically have plentiful pale or clear cytoplasm. In some cases

medium sized or large cells predominate. Multinucleated cells resembling Reed–Sternberg cells may be seen. Prominent reactive changes in the bone marrow are usually present [24]. Lymphoma cells may be only a minor part of an abnormal infiltrate which may include non-neoplastic lymphocytes, plasma cells and haemophagocytic macrophages. There may be clusters of epithelioid cells (see Fig. 6.78). Stromal changes include increased vascularity, foci of haemorrhage and necrosis, and reticulin fibrosis. Reticulin is increased in the areas of neoplastic infiltration and, often to a lesser extent, in non-infiltrated areas.

Immunohistochemistry

In the majority of cases the neoplastic cells express CD3 and CD45RO (Box 6.20). Cells in many cases also express CD4, CD5 and CD43. B-cell markers are generally negative, although very rare cases of CD20-positive T-cell lymphoma have been reported [218].

Problems and pitfalls

Bone marrow infiltrates of peripheral T-cell lymphoma need to be distinguished from reactive infiltrates such as the polymorphic lymphoid aggregates seen in HIV infection (see page 126) and some auto-immune conditions [24]. Close attention to

Fig. 6.78 BM trephine biopsy section, peripheral T-cell lymphoma, not otherwise categorized (variant—Lennert's), showing a pleomorphic lymphoid infiltrate and an admixture of epithelioid macrophages. Plastic-embedded, H&E $\times 188$.

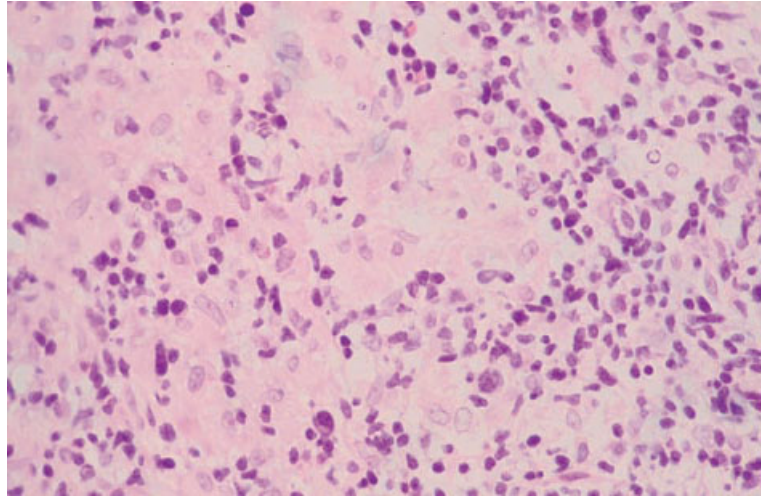
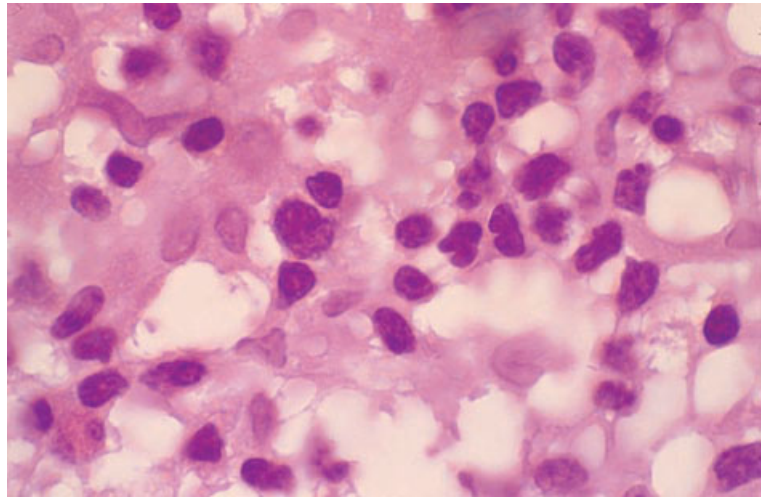


Fig. 6.79 BM trephine biopsy section, peripheral T-cell lymphoma, not otherwise categorized (variant—Lennert's) (same case as in Fig. 6.78), showing epithelioid macrophages and medium sized lymphoid cells with irregular nuclei. Plastic-embedded, H&E $\times 970$.



the clinical features, histological appearances at other sites and immunophenotypic and molecular genetic findings is required to establish the diagnosis. Hodgkin's disease and the T-cell-rich variant of large B-cell lymphoma involving the marrow can resemble peripheral T-cell lymphoma; careful assessment of the immunophenotype of the neoplastic cells will usually allow the distinction to be made. Neutrophilic and eosinophilic hyperplasia are common and dysplastic changes are sometimes noted in haemopoietic cells so that confusion with a myeloproliferative or even a myelodysplastic disorder may occur [223]. When there is a marked

reactive population of macrophages, eosinophils and fibroblasts, confusion with systemic mastocytosis can occur. Staining with Giemsa and toluidine blue plus immunohistochemical staining for mast cell tryptase will identify neoplastic mast cells in systemic mastocytosis.

Hodgkin's disease (Hodgkin's lymphoma)

The term Hodgkin's disease (Hodgkin's lymphoma) has traditionally been used to describe a group of lymphomas with common clinical and histolog-

ical features. The disease is consequent on the proliferation of neoplastic cells of lymph node origin, the vast majority of which are of B lineage. The neoplastic cells include distinctive polyploid cells designated Reed–Sternberg cells. These are giant cells which may be binucleated or multinucleated or have lobulated nuclei; they have very large inclusion-like nucleoli and abundant cytoplasm [224]. Also present are large cells of a similar appearance but with a single round nucleus and a very large nucleolus, designated mononuclear Hodgkin's cells. In addition, specific histological subtypes of Hodgkin's disease are associated with specific variant forms of Reed–Sternberg cells. The diagnosis of Hodgkin's disease requires not only the presence of characteristic neoplastic cells but also an appropriate cellular background, since cells morphologically resembling Reed–Sternberg cells may be seen in other lymphomas and in reactive conditions such as infectious mononucleosis. There is a prominent inflammatory response so that the neoplastic cells are mixed with a variable number of lymphocytes, macrophages, eosinophils, plasma cells and fibroblasts. Some histological subtypes have prominent fibrosis.

The WHO classification subdivides Hodgkin's disease into nodular lymphocyte-predominant Hodgkin's disease and classical Hodgkin's disease. The lymphocyte-predominant subtype has clear differences from classical Hodgkin's disease in both clinical behaviour and immunophenotype (see below). Classical Hodgkin's disease is further subdivided as shown in Table 6.3 [8,224]. Hodgkin's disease occurs at all ages but the sex distribution and the median age of onset differ between different histological categories.

The most common presenting feature is lymphadenopathy, most often involving cervical lymph nodes. Mediastinal lymphadenopathy is also common. Patients with advanced disease may have hepatomegaly and splenomegaly. Systemic symptoms such as fever, sweating and weight loss are common in those with advanced disease.

Occasionally, the primary diagnosis of Hodgkin's disease is made on examination of the bone marrow, particularly in HIV-positive patients and in other patients with lymphocyte-depleted Hodgkin's disease presenting with unexplained fever and pancytopenia [225]. More often, bone marrow

examination is done as part of a staging procedure in patients with a known diagnosis of Hodgkin's disease. The demonstration of infiltration usually requires a trephine biopsy. The detection rate is higher with bilateral biopsies or a single large biopsy [226]. Diagnostic cells are rarely present in films of aspirates although histological sections of aspirated fragments occasionally yield a diagnosis. Not all patients with Hodgkin's disease necessarily require investigation of the bone marrow as part of the staging procedure since a combination of clinical and laboratory features can be used as criteria to select those likely to have infiltration [227]. In one study, the results of trephine biopsy were found to influence management in less than 1% of patients [228].

Peripheral blood

The peripheral blood shows non-specific abnormalities. There may be anaemia, either normocytic normochromic or, less often, hypochromic microcytic. Rouleaux formation is often increased, as is the erythrocyte sedimentation rate. Some patients have neutrophilia, eosinophilia or thrombocytosis. Occasional patients have lymphocytosis. Lymphopenia is common, with severe lymphopenia being seen in patients with advanced disease or with unfavourable histological categories. Anaemia, leucopenia and pancytopenia are common in patients with bone marrow infiltration, but a leuco-erythroblastic blood film is relatively uncommon. The neoplastic cells of Hodgkin's disease rarely circulate in the peripheral blood but occasional instances of this phenomenon have been reported.

Bone marrow cytology

The bone marrow aspirate usually shows only reactive changes. The marrow is often hypercellular due to granulocytic (neutrophilic and eosinophilic) hyperplasia. Macrophages and plasma cells are often increased. Erythropoiesis is depressed and may show the features of the anaemia of chronic disease. Megakaryocytes are present in normal or increased numbers.

Even when the marrow is infiltrated, it is uncommon for neoplastic cells to be present in the aspirate. When Reed–Sternberg cells are present they are very striking because of their large size, paired nuclei

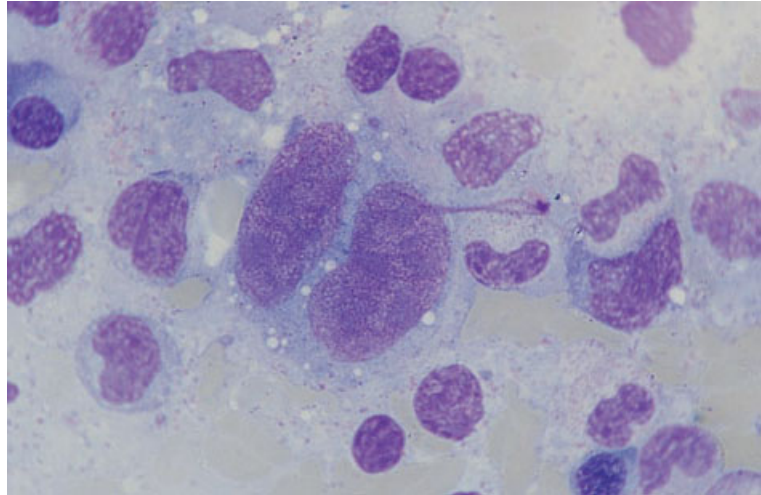


Fig. 6.80 BM aspirate, Hodgkin's disease in a patient with AIDS, showing a Reed-Sternberg cell—a binucleated giant cell with prominent inclusion-like nucleoli. MGG $\times 940$.

BOX 6.21

Classical Hodgkin's disease

Flow cytometry and immunocytochemistry
Not usually of diagnostic value

Immunohistochemistry

CD15+/-, CD30+

CD3-, CD5-, CD20-/+ , CD45-, CD45RO-, CD79a-, EMA-, ALK1-

The reactive small lymphoid population is composed largely of T cells (CD3+, CD5+)

Cytogenetics and molecular genetics

No consistent cytogenetic abnormality is described

Monoclonal *TCR* or *IGH* gene rearrangements are not generally detectable

Abbreviations (percentages are approximate): +>90% positive; +/->50% positive; -/+<50% positive; <10% positive. ALK1, the product of the *ALK* oncogene; EMA, epithelial membrane antigen; *IGH*, immunoglobulin heavy chain; *TCR*, T-cell receptor.

and large, prominent, usually centrally placed nucleoli (Fig. 6.80). With a May-Grünwald-Giemsa (MGG) stain, both these cells and any mononuclear Hodgkin's cells have moderately basophilic cytoplasm; the round, inclusion-like nucleoli stain deep blue.

Immunocytochemistry and flow cytometry

Neoplastic cells are very rarely seen in cytological preparations and flow cytometric analysis of the

blood and bone marrow (Box 6.21) is unlikely to be of value [217].

Cytogenetics and molecular genetics

There are no consistent cytogenetic abnormalities (Box 6.21). Analysis of *TCR* and *IGH* genes by PCR usually shows a polyclonal pattern. However, PCR analysis of isolated neoplastic cells often shows that they have an identical *IGH* rearrangement, indicating that they belong to a single B-cell clone.

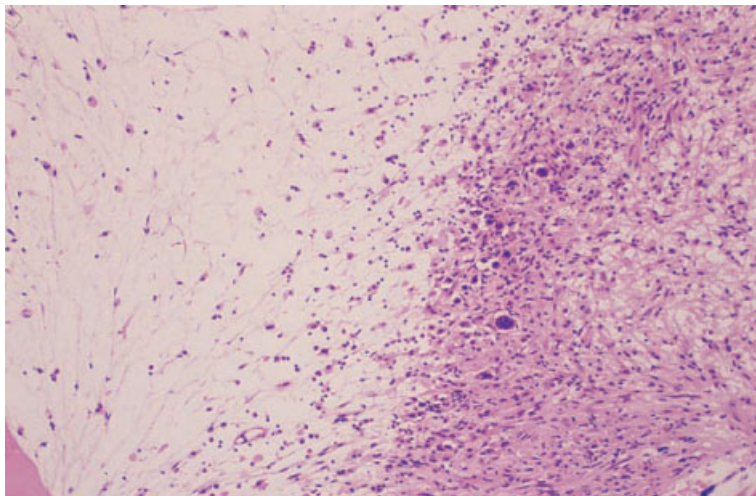


Fig. 6.81 BM trephine biopsy section, nodular sclerosing Hodgkin's disease, showing an abnormal infiltrate (right) and bone marrow hypoplasia (left). Paraffin-embedded, H&E $\times 39$.

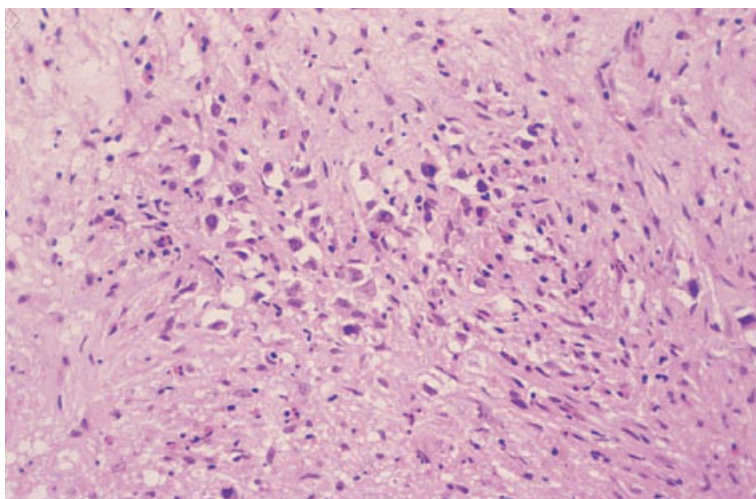


Fig. 6.82 BM trephine biopsy section, nodular sclerosing Hodgkin's disease (same case as in Fig. 6.81), showing fibrosis and a mixed infiltrate of mononuclear Hodgkin's cells, eosinophils and small lymphocytes. Paraffin-embedded, H&E $\times 195$.

Expression of *EBV* genes can be detected in up to 40% of cases of nodular sclerosing Hodgkin's disease and 30–90% of the mixed cellularity subtype, with variations in incidence in different geographic regions and age groups (see Table 6.5). *EBV* genes are not expressed in nodular lymphocyte-predominant Hodgkin's disease.

Bone marrow histology

Bone marrow infiltration is present in 5–15% of patients. Infiltration is more frequent in males, in older patients, in HIV-positive individuals, in those with unfavourable histological types and in

those with other evidence of advanced stage disease [227,229]. Infiltration is rare in lymphocyte-predominant disease and uncommon in nodular sclerosing disease, whereas in lymphocyte-depleted Hodgkin's disease it has been observed in up to 50–60% of cases [228]. In HIV-positive patients diagnosis is often made from a trephine biopsy.

With an H&E stain, Reed–Sternberg cells and mononuclear Hodgkin's cells have acidophilic or amphophilic cytoplasm, a prominent nuclear membrane and an eosinophilic inclusion-like nucleolus (Figs 6.81–6.84). The features of the various variant forms of Reed–Sternberg cells have been described in detail [224]. Criteria to establish the presence

Fig. 6.83 BM trephine biopsy section, nodular sclerosing Hodgkin's disease (same case as in Fig. 6.81), showing a Reed–Sternberg cell (left) and a mononuclear Hodgkin's cell (right). Paraffin-embedded, H&E $\times 970$.

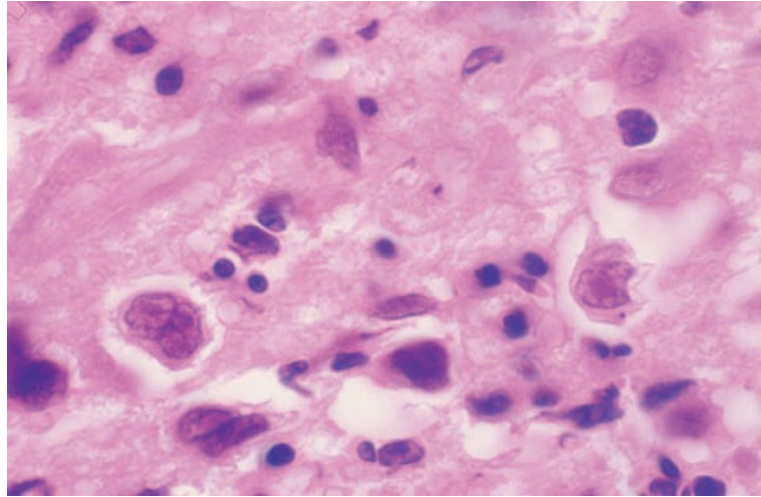
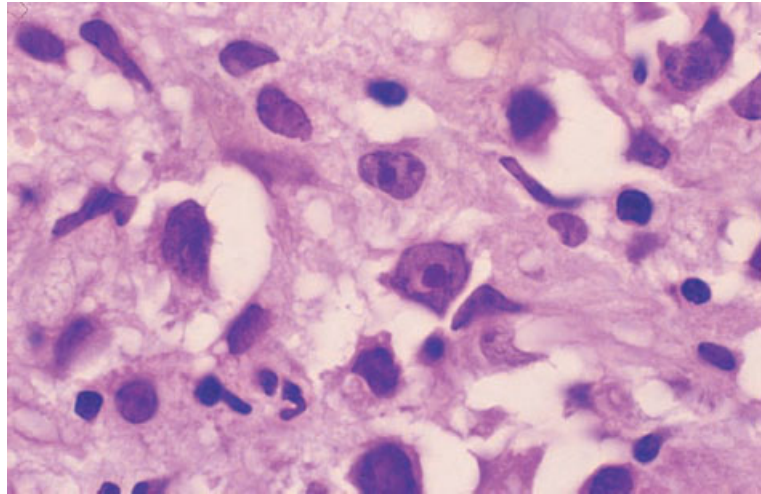


Fig. 6.84 BM trephine biopsy section, nodular sclerosing Hodgkin's disease (same case as in Fig. 6.81), showing a lacunar cell (left) and two mononuclear Hodgkin's cells (centre). Paraffin-embedded, H&E $\times 970$.



of bone marrow infiltration differ according to whether or not a tissue diagnosis of Hodgkin's disease has already been established. Recommendations were drawn up at the Ann Arbor conference in 1971 [224,230]. Primary diagnosis requires the presence of Reed–Sternberg cells (see Fig. 6.83) in an appropriate cellular background. The only exceptions to this diagnostic requirement are in the case of nodular sclerosing Hodgkin's disease and nodular lymphocyte-predominant Hodgkin's disease, in which the presence of variant forms of Reed–Sternberg cells (Fig. 6.84) in an appropriate cellular background may be considered sufficient to establish a diagnosis [231]. As previ-

ously discussed, nodular lymphocyte-predominant Hodgkin's disease is now considered to be an entity distinct from classical Hodgkin's disease, and classical Reed–Sternberg cells are not present; the neoplastic cells are large polylobulated B cells (L and H cells). If the diagnosis of classical Hodgkin's disease has already been established in another tissue and a bone marrow biopsy is being performed for the purpose of staging, the criteria for diagnosing infiltration are less stringent. In this context, the presence of mononuclear Hodgkin's cells in an appropriate cellular background is sufficient [230]; the presence of atypical 'reticulum cells' or the presence of necrosis or focal or diffuse fibrosis with

appropriate inflammatory cells is suggestive of Hodgkin's disease but not diagnostic. When suspicious features are present, the examination of serial sections is indicated.

In Hodgkin's disease the pattern of infiltration is sometimes focal but more often diffuse. Focal lesions are mainly randomly distributed although some are paratrabeular [226,232]. Focal infiltration is most common in lymphocyte-predominant and nodular sclerosing Hodgkin's disease whereas lymphocyte-depleted Hodgkin's disease is characterized by diffuse infiltration. Focal lesions tend to be highly cellular with a mixed infiltrate of small lymphocytes with variable numbers of eosinophils, plasma cells, macrophages and Reed–Sternberg cells and their variants. In Hodgkin's disease the lymphoid infiltrate does not usually show features of cellular atypia. When infiltration is diffuse, the pattern is more variable [226,232–234]. Four patterns may be recognized:

1 in the majority of patients the marrow is hypercellular with a mixed cellular infiltrate as described above;

2 in other patients the bone marrow is very hypercellular with a predominant population of Reed–Sternberg cells and variant forms; reactive cells are not numerous;

3 in a third pattern there is focal replacement of the bone marrow by dense fibrous tissue with small numbers of macrophages and lymphocytes; neoplastic cells embedded in collagen may be relatively sparse; and

4 in the fourth pattern the bone marrow is generally hypocellular with loose, sparsely cellular connective tissue through which are scattered more cellular foci containing lymphocytes, macrophages, Reed–Sternberg cells and variant forms.

Various combinations of these patterns may be seen in the same biopsy specimen or in different biopsy specimens from the same patient. In addition, amorphous eosinophilic background material may be apparent. Necrosis is occasionally detected prior to treatment [234] but is more common in treated patients. Granulomas are sometimes associated with infiltration, but also occur in the absence of bone marrow infiltration. Reticulin is increased in areas of infiltration and collagen is often present. There is sometimes osteolysis or osteosclerosis; increased bone remodelling is usual

[226]. Histological appearances in the bone marrow often differ from those in lymph nodes. Subclassification of the disease cannot be made on the basis of bone marrow histology alone. When infiltration is focal, the residual bone marrow is usually hypercellular as a consequence of granulocytic hyperplasia. Both eosinophils and neutrophils may be increased at the margin of infiltrates and diffusely in non-involved marrow. Non-infiltrated marrow may also show increased megakaryocytes and plasma cells.

The bone marrow of patients in whom infiltration is not detected may also show reactive changes. These may include: (i) increased granulopoiesis (neutrophilic and eosinophilic); (ii) increased megakaryocytes; (iii) plasmacytosis; (iv) lymphoid infiltration including formation of lymphoid aggregates; (v) increased and enlarged macrophages; (vi) haemophagocytosis; (vii) oedema; (viii) extravasation of erythrocytes; (ix) increased storage iron; and (x) the presence of sarcoid-like granulomas [226,232]; asteroid bodies may be seen in the giant cells of the granulomas. Bone marrow hypoplasia has been observed in some patients with lymphocyte-depleted Hodgkin's disease in whom infiltration was not detected [225].

Following successful treatment of Hodgkin's disease the lymphomatous infiltrate disappears and reactive changes, including fibrosis, regress. When only reticulin fibrosis is present complete regression occurs. When there has been collagen deposition some patients show complete regression and others partial.

Immunohistochemistry

Classical Reed–Sternberg cells and their mononuclear variants are usually positive for CD30; in most cases the cells are CD15 positive but negative for CD45 (Box 6.21). In a proportion of cases of classical Hodgkin's disease Reed–Sternberg cells and mononuclear variants express CD20. The neoplastic cells of lymphocyte-predominant Hodgkin's disease (L and H cells or 'popcorn cells') are CD15 and CD30 negative and CD20 and CD45 positive; reactivity of CD79a is variable but often positive. The neoplastic cells in all subtypes are almost always CD3 negative. The reactive lymphocytes are T cells expressing CD3 and CD45RO.

Table 6.5 Epstein–Barr virus-related lymphomas.

Type of lymphoma	Comment
<i>Non-Hodgkin's lymphoma</i>	
Burkitt's lymphoma	Almost all endemic cases, about a third of HIV-related cases, about 10% of sporadic cases are EBV-related
Large B-cell lymphoma	40–50% of cases in HIV-positive patients and occasional cases in individuals with normal immunity are EBV-related
Nasopharyngeal T-cell and NK-cell lymphomas	Particularly, but not only, in individuals of Chinese ethnic origin
<i>Hodgkin's disease</i>	
Classical Hodgkin's disease (nodular sclerosing and mixed cellularity subtypes)	Up to 50% of cases in developed countries, the majority of cases in the developing world and almost 100% of cases in HIV-positive patients are EBV-related. EBV association is more common in paediatric cases. EBV association is recognized in 10–50% of cases of nodular sclerosing subtype and 32–96% of cases of mixed cellularity subtype

Problems and pitfalls

Marrow infiltration by Hodgkin's disease can be confused with infiltration by peripheral T-cell lymphoma and diffuse large B-cell lymphoma (particularly the T-cell-rich B-cell variant) both of which can have neoplastic cells resembling Reed–Sternberg cells. Immunohistochemical staining will usually permit the correct diagnosis to be made. Bone marrow infiltration is very rare in nodular lymphocyte-predominant Hodgkin's disease and, if present, the diagnosis should be critically re-appraised.

A particular problem occurs in recognizing infiltration when there is a very pronounced fibroblastic response [235]. Idiopathic myelofibrosis is easily simulated since such patients often have splenomegaly, pancytopenia and radiologically demonstrable osteosclerosis. The large neoplastic cells in Hodgkin's disease can occasionally be mistaken for megakaryocytes or carcinoma cells. Megakaryocytes can be identified with monoclonal antibodies directed at platelet glycoprotein IIIa (CD61) or platelet glycoprotein Ib (CD42b). Staining for cytokeratin is useful in identifying carcinoma cells.

Post-transplant lymphoproliferative disorders and other EBV-related lymphoproliferative disease

EBV is a human herpesvirus that has the ability to

infect B lymphocytes *in vivo* and *in vitro*. *In vitro*, EBV is able to transform and immortalize B lymphocytes. Primary infection with EBV usually occurs in childhood and, in the vast majority of cases, is asymptomatic. In more prosperous countries primary infection is often delayed until adolescence or early adult life, resulting in infectious mononucleosis (see page 95).

EBV has been implicated in the pathogenesis of a number of human tumours including various types of lymphoma (Table 6.5). The EBV-related lymphomas include some cases of Burkitt's lymphoma (page 281), diffuse large B-cell lymphoma (page 275), extranodal NK/T-cell lymphoma (nasal type) (page 294) and Hodgkin's disease [236]. EBV is also strongly associated with the vast majority of cases of post-transplant lymphoproliferative disorders. Many EBV-associated lymphomas occur in immunocompromised individuals. Evidence of latent EBV infection can be detected within tumour cells using *in situ* hybridization for EBV-encoded RNA (EBER). Sometimes EBV latent proteins (LMP-1 and EBNA-2) are expressed and may be detected using immunohistochemistry.

Post-transplant lymphoproliferative disorders related to immunosuppression have been observed particularly following solid organ transplantation (renal, heart, heart/lung, thymus and liver) [237] and, to a lesser extent, following bone marrow transplantation [238]. The incidence following solid organ transplantation is related to the degree of

Table 6.6 The WHO classification of post-transplant lymphoproliferative disorders.*Early lesions*

Reactive plasmacytic hyperplasia
 Infectious mononucleosis-like

Post-transplant lymphoproliferative disorder, polymorphic

Polyclonal (rare)
 Monoclonal

Post-transplant lymphoproliferative disorder, monomorphic (classify according to lymphoma classification)

B-cell lymphomas

Diffuse large B-cell lymphoma (immunoblastic, centroblastic, anaplastic)
 Burkitt's/Burkitt-like lymphoma
 Plasma cell myeloma

T-cell lymphoma

Peripheral T-cell lymphoma, not otherwise categorized
 Other types (hepatosplenic $\gamma\delta$, T/NK)

Other types

Hodgkin's disease-like lesions (associated with methotrexate therapy)
 Plasmacytoma-like lesions

immune suppression and, in some series of patients, has been as high as 20–25%. It is highest following heart/lung and intestinal transplantation. Following bone marrow transplantation, the cumulative incidence is around 1% by 10 years with the majority of cases occurring within the first 6 months [239]. Although the incidence is low, EBV-related lymphoproliferation is responsible for more than half of the cases of malignant disease following bone marrow transplantation [238]. The incidence is greater in children because of the greater risk associated with primary EBV infection. The onset of EBV-related lymphoproliferation typically occurs 6 months or more after solid organ transplantation. A similar lymphoproliferative disorder can occur in other congenital and acquired immune deficiency states including severe combined immune deficiency, ataxia telangiectasia, Wiskott–Aldrich syndrome, adenosine deaminase deficiency, Duncan's syndrome, Chediak–Higashi syndrome, common variable immunodeficiency, HIV infection and during methotrexate or cyclosporin therapy for rheumatoid arthritis or dermatomyositis. This syndrome can result from primary infection (virus acquired from donor tissue or from blood or blood products) or from reactivation of the virus. Primary infection at the time of transplantation carries the highest risk. The proliferating virus-infected B cells

may be of donor or host origin. Following solid organ transplantation they are usually, but not always, of host origin, whereas following bone marrow transplantation they are often of donor origin [240–242].

The lymphoproliferative disorders observed range from polyclonal through oligoclonal proliferations to monoclonal lymphomas [243–246]. They have been classified by a WHO expert group, as shown in Table 6.6 [1]. Lymphoproliferative disorders observed post-transplant are often multifocal and extranodal. They often develop in the gut, central nervous system or transplanted organ, suggesting that micro-environmental factors contribute to their development. At one extreme, polyclonal proliferations may resemble severe infectious mononucleosis clinically and pathologically (with fever, pharyngitis and cervical lymphadenopathy) while, at the other extreme, are high grade, monoclonal, clinically very aggressive lymphomas.

Classification of post-transplant lymphoproliferative disorders is based on the morphology of the proliferating cell population and whether there is immunohistochemical, cytogenetic or molecular genetic evidence of monoclonality. Clonality can be demonstrated by investigation of *IGH* gene rearrangements or by showing clonality of the episomal form of EBV within the tumour cells [247].

Polymorphic post-transplant lymphoproliferative disorder is characterized by a destructive infiltrate made up of a mixed population of cells representing the full spectrum of B-cell maturation from immunoblasts to plasma cells [248]. Most cases of polymorphic post-transplant lymphoproliferative disorder show evidence of monoclonality, although a minority of cases appear to be polyclonal. Approximately half the patients have lesions in the bone marrow with variable morphology composed of aggregates of lymphoid cells and plasma cells [249] (Figs 6.85 and 6.86).

Monomorphic post-transplant lymphoproliferative disorders are usually B-cell proliferations, although a small number of T-cell lymphomas have been reported. Most cases are diffuse large B-cell lymphomas (morphological variant—immunoblastic) (see page 277) with a small number of cases showing morphological features of Burkitt's or Burkitt-like lymphoma (see page 281). In cases with bone marrow infiltration, the disease is morphologically similar to that seen in these types of lymphoma occurring in non-immunocompromised patients.

Fig. 6.85 BM aspirate from an immunosuppressed patient who developed fatal polyclonal EBV-related lymphoproliferation, showing normal myeloid cells, a plasma cell and three atypical lymphoid cells. MGG $\times 940$.

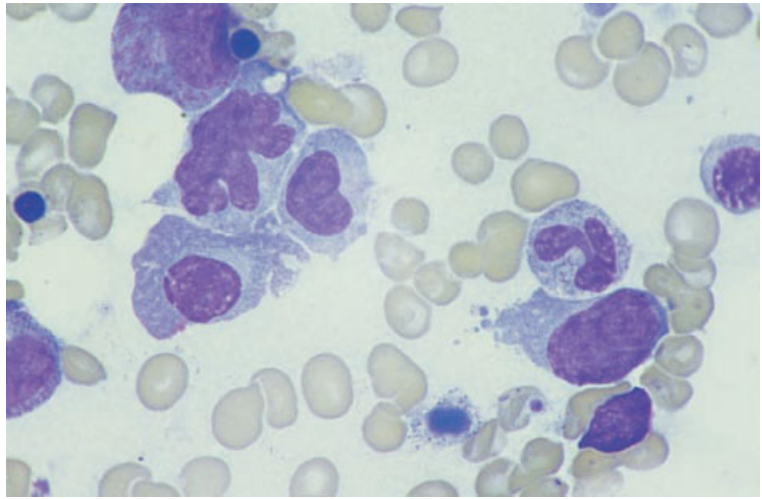
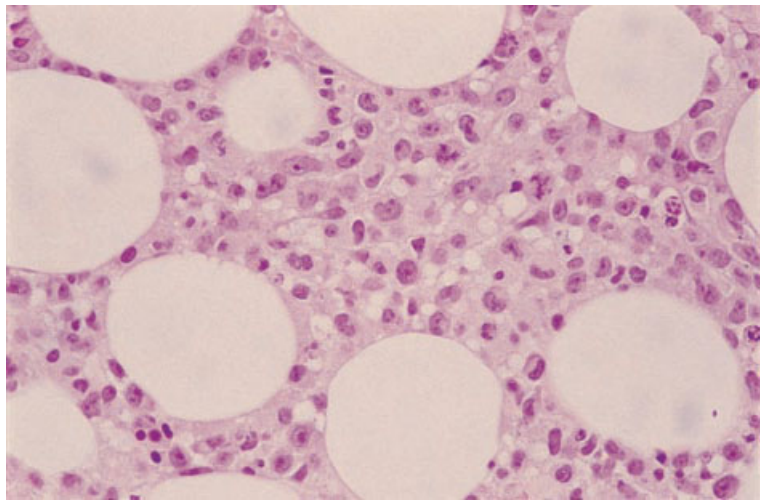


Fig. 6.86 BM trephine biopsy section, polymorphous post-transplant lymphoproliferative disorder. H&E $\times 376$.



References

- 1 Harris NL, Jaffe ES, Diebold J, Flandrin G, Muller Hermelink HK, Vardiman J *et al.* (2000) The World Health Organization classification of neoplastic diseases of the haematopoietic and lymphoid tissues: Report of the Clinical Advisory Committee Meeting, Airlie House, Virginia, November, 1997. *Histopathology*, 36, 69–86.
- 2 Harris NL, Jaffe ES, Stein H, Banks PM, Chan JK, Cleary ML *et al.* (1994) A revised European-American classification of lymphoid neoplasms: a proposal from the International Lymphoma Study Group. *Blood*, 84, 1361–1392.
- 3 Stansfeld AG, Diebold J, Noel H, Kapanci Y, Rilke F, Kelényi G *et al.* (1988) Updated Kiel classification for lymphomas [letter] [published erratum appears in *Lancet* 1988, February 13, 1 (8581), 372]. *Lancet*, 1, 292–293.
- 4 Suchi T, Lennert K, Tu LY, Kikuchi M, Sato E, Stansfeld AG and Feller AC (1987) Histopathology and immunohistochemistry of peripheral T cell lymphomas: a proposal for their classification. *J Clin Pathol*, 40, 995–1015.
- 5 The Non-Hodgkin's Lymphoma Pathologic Classification Project. (1982) National Cancer Institute sponsored study of classifications of non-Hodgkin's lymphomas: summary and description of a working formulation for clinical usage. *Cancer*, 49, 2112–2135.
- 6 Bennett JM, Catovsky D, Daniel MT, Flandrin G, Galton DA, Gralnick HR and Sultan C (1976) Proposals for the classification of the acute leukaemias. French–American–British (FAB) co-operative group. *Br J Haematol*, 33, 451–458.
- 7 Bennett JM, Catovsky D, Daniel MT, Flandrin G, Galton DA, Gralnick HR and Sultan C (1989) Proposals for the classification of chronic (mature) B and T lymphoid leukaemias. French–American–British (FAB) Cooperative Group. *J Clin Pathol*, 42, 567–584.
- 8 Lukes RJ, Craver LH, Hall TC, Rappaport H and Ruben P (1966) Report of the nomenclature committee. *Cancer Res*, 26, 1311.
- 9 Rozman C, Hernandez Nieto L, Montserrat E and Bruges R (1981) Prognostic significance of bone-marrow patterns in chronic lymphocytic leukaemia. *Br J Haematol*, 47, 529–537.
- 10 Bartl R, Frisch B, Burkhardt R, Jäger K, Pappenberger R and Hoffmann Fezer G (1984) Lymphoproliferations in the bone marrow: identification and evolution, classification and staging. *J Clin Pathol*, 37, 233–254.
- 11 McKenna RW and Hernandez JA (1988) Bone marrow in malignant lymphoma. *Hematol Oncol Clin North Am*, 2, 617–635.
- 12 Gaulard P, Kanavaros P, Farcet JP, Rocha FD, Haioun C, Divine M *et al.* (1991) Bone marrow histologic and immunohistochemical findings in peripheral T-cell lymphoma: a study of 38 cases. *Hum Pathol*, 22, 331–338.
- 13 Tateyama H, Eimoto T, Tada T, Kamiya M, Fujiyoshi Y and Kajiura S (1991) Congenital angiotropic lymphoma (intravascular lymphomatosis) of the T-cell type. *Cancer*, 67, 2131–2136.
- 14 Conlan MG, Bast M, Armitage JO and Weisenburger DD (1990) Bone marrow involvement by non-Hodgkin's lymphoma: the clinical significance of morphologic discordance between the lymph node and bone marrow. Nebraska Lymphoma Study Group. *J Clin Oncol*, 8, 1163–1172.
- 15 Thaler J, Dietze O, Denz H, Demuth R, Nachbaur D, Stauder R and Huber H (1991) Bone marrow diagnosis in lymphoproliferative disorders: comparison of results obtained from conventional histomorphology and immunohistology. *Histopathology*, 18, 495–504.
- 16 Foucar K, McKenna RW, Frizzera G and Brunning RD (1982) Bone marrow and blood involvement by lymphoma in relationship to the Lukes–Collins classification. *Cancer*, 49, 888–897.
- 17 Thiele J, Langohr J, Skorupka M and Fischer R (1990) Reticulin fibre content of bone marrow infiltrates of malignant non-Hodgkin's lymphomas (B-cell type, low malignancy)—a morphometric evaluation before and after therapy. *Virchows Arch A Pathol Anat Histopathol*, 417, 485–492.
- 18 Pezzella F, Munson PJ, Miller KD, Goldstone AH and Gatter KC (2000) The diagnosis of low-grade peripheral B-cell neoplasms in bone marrow trephines. *Br J Haematol*, 108, 369–376.
- 19 Pittaluga S, Tierens A, Doodoo YL, Delabie J and De Wolf-Peeters C (1999) How reliable is histologic examination of bone marrow trephine biopsy specimens for the staging of non-Hodgkin lymphoma? A study of hairy cell leukemia and mantle cell lymphoma involvement of the bone marrow trephine specimen by histologic, immunohistochemical, and polymerase chain reaction techniques. *Am J Clin Pathol*, 111, 179–184.
- 20 Coad JE, Olson DJ, Christensen DR, Lander TA, Chibbar R, McGlennen RC and Brunning RD (1997) Correlation of PCR-detected clonal gene rearrangements with bone marrow morphology in patients with B-lineage lymphomas. *Am J Surg Pathol*, 21, 1047–1056.
- 21 Bartl R, Hansmann ML, Frisch B and Burkhardt R (1988) Comparative histology of malignant lymphomas in lymph node and bone marrow. *Br J Haematol*, 69, 229–237.
- 22 Fisher DE, Jacobson JO, Ault KA and Harris NL (1989) Diffuse large cell lymphoma with discordant bone marrow histology. Clinical features and biological implications [published erratum appears in

- Cancer 1990, January 1, 65 (1), 64]. *Cancer*, 64, 1879–1887.
- 23 Kluin PM, van Krieken JH, Kleiverda K and Kluin-Nelemans HC (1990) Discordant morphologic characteristics of B-cell lymphomas in bone marrow and lymph node biopsies. *Am J Clin Pathol*, 94, 59–66.
 - 24 Hanson CA, Brunning RD, Gajl-Peczalska KJ, Frizzera G and McKenna RW (1986) Bone marrow manifestations of peripheral T-cell lymphoma. A study of 30 cases. *Am J Clin Pathol*, 86, 449–460.
 - 25 Caulet S, Delmer A, Audouin J, Le Tourneau A, Bernadou A, Zittoun R and Diebold J (1990) Histopathological study of bone marrow biopsies in 30 cases of T-cell lymphoma with clinical, biological and survival correlations. *Hematol Oncol*, 8, 155–168.
 - 26 Frizzera G, Anaya JS and Banks PM (1986) Neoplastic plasma cells in follicular lymphomas. Clinical and pathologic findings in six cases. *Virchows Arch A Pathol Anat Histopathol*, 409, 149–162.
 - 27 Robertson LE, Redman JR, Butler JJ, Osborne BM, Velasquez WS, McLaughlin P *et al.* (1991) Discordant bone marrow involvement in diffuse large-cell lymphoma: a distinct clinical-pathologic entity associated with a continuous risk of relapse. *J Clin Oncol*, 9, 236–242.
 - 28 Chetty R, Echezarreta G, Comley M and Gatter K (1995) Immunohistochemistry in apparently normal bone marrow trephine specimens from patients with nodal follicular lymphoma. *J Clin Pathol*, 48, 1035–1038.
 - 29 Ben-Ezra JM, King BE, Harris AC, Todd WM and Kornstein MJ (1994) Staining for Bcl-2 protein helps to distinguish benign from malignant lymphoid aggregates in bone marrow biopsies. *Mod Pathol*, 7, 560–564.
 - 30 Skálová A and Fakan F (1997) Bcl-2 protein does not help to distinguish benign from malignant lymphoid nodules in bone marrow biopsy specimens [letter; comment]. *J Clin Pathol*, 50, 87–88.
 - 31 Kröber SM, Horny HP, Greschniok A and Kaiserling E (1999) Reactive and neoplastic lymphocytes in human bone marrow: morphological, immunohistological, and molecular biological investigations on biopsy specimens. *J Clin Pathol*, 52, 521–526.
 - 32 First MIC Cooperative Study Group (1986) Morphologic, immunologic, and cytogenetic (MIC) working classification of acute lymphoblastic leukemias. Report of the workshop held in Leuven, Belgium, April 22–23, 1985. *Cancer Genet Cytogenet*, 23, 189–197.
 - 33 Bain BJ (1998) Classification of acute leukaemia: the need to incorporate cytogenetic and molecular genetic information. *J Clin Pathol*, 51, 420–423.
 - 34 Picozzi VJ Jr and Coleman CN (1990) Lymphoblastic lymphoma. *Semin Oncol*, 17, 96–103.
 - 35 Bene MC, Castoldi G, Knapp W, Ludwig WD, Matutes E, Orfao A and van't Veer MB (1995) Proposals for the immunological classification of acute leukemias. European Group for the Immunological Characterization of Leukemias (EGIL). *Leukemia*, 9, 1783–1786.
 - 36 Chessells JM, Swansbury GJ, Reeves B, Bailey CC and Richards SM (1997) Cytogenetics and prognosis in childhood lymphoblastic leukaemia: results of MRC UKALL X. Medical Research Council Working Party in Childhood Leukaemia. *Br J Haematol*, 99, 93–100.
 - 37 McKenna RW, Parkin J and Brunning RD (1979) Morphologic and ultrastructural characteristics of T-cell acute lymphoblastic leukemia. *Cancer*, 44, 1290–1297.
 - 38 Hann IM, Evans DI, Marsden HB, Jones PM and Palmer MK (1978) Bone marrow fibrosis in acute lymphoblastic leukaemia of childhood. *J Clin Pathol*, 31, 313–315.
 - 39 Breatnach F, Chessells JM and Greaves MF (1981) The aplastic presentation of childhood leukaemia: a feature of common-ALL. *Br J Haematol*, 49, 387–393.
 - 40 Dharmasena F, Littlewood T, Gordon-Smith EC, Catovsky D and Galton DA (1986) Adult acute lymphoblastic leukaemia presenting with bone marrow aplasia. *Clin Lab Haematol*, 8, 361–364.
 - 41 Reid MM and Summerfield GP (1992) Distinction between aleukaemic prodrome of childhood acute lymphoblastic leukaemia and aplastic anaemia. *J Clin Pathol*, 45, 697–700.
 - 42 Farahat N, Lens D, Zomas A, Morilla R, Matutes E and Catovsky D (1995) Quantitative flow cytometry can distinguish between normal and leukaemic B-cell precursors. *Br J Haematol*, 91, 640–646.
 - 43 Ohno T, Smir BN, Weisenburger DD, Gascoyne RD, Hinrichs SD and Chan WC (1998) Origin of the Hodgkin/Reed–Sternberg cells in chronic lymphocytic leukemia with ‘Hodgkin’s transformation’. *Blood*, 91, 1757–1761.
 - 44 Enno A, Catovsky D, O’Brien M, Cherchi M, Kumaran TO and Galton DA (1979) ‘Prolymphocytoid’ transformation of chronic lymphocytic leukaemia. *Br J Haematol*, 41, 9–18.
 - 45 Pangalis GA, Nathwani BN and Rappaport H (1977) Malignant lymphoma, well differentiated lymphocytic: its relationship with chronic lymphocytic leukemia and macroglobulinemia of Waldenström. *Cancer*, 39, 999–1010.
 - 46 Montserrat E and Rozman C (1993) Chronic lymphocytic leukaemia: prognostic factors and natural history. *Baillières Clin Haematol*, 6, 849–866.
 - 47 Dick F, Bloomfield CD and Brunning RD (1974) Incidence cytology, and histopathology of non-Hodgkin’s lymphomas in the bone marrow. *Cancer*, 33, 1382–1398.
 - 48 Mazza P, Gherlinzoni F, Kemna G, Poletti G, Zinzani PL, Verlicchi F *et al.* (1987) Clinicopathological study on non-Hodgkin’s lymphomas. *Haematologica*, 72, 351–357.

- 49 Moreau EJ, Matutes E, A'Hern RP, Morilla AM, Morilla RM, Owusu-Ankomah KA *et al.* (1997) Improvement of the chronic lymphocytic leukemia scoring system with the monoclonal antibody SN8 (CD79b). *Am J Clin Pathol*, 108, 378–382.
- 50 Matutes E, Owusu-Ankomah K, Morilla R, Garcia-Marco J, Houlihan A, Que TH and Catovsky D (1994) The immunological profile of B-cell disorders and proposal of a scoring system for the diagnosis of CLL. *Leukemia*, 8, 1640–1645.
- 51 Finn WG, Thangavelu M, Yelavarthi KK, Goolsby CL, Tallman MS, Traynor A and Peterson LC (1996) Karyotype correlates with peripheral blood morphology and immunophenotype in chronic lymphocytic leukemia. *Am J Clin Pathol*, 105, 458–467.
- 52 Matutes E, Oscier D, Garcia-Marco J, Ellis J, Copplestone A, Gillingham R *et al.* (1996) Trisomy 12 defines a group of CLL with atypical morphology: correlation between cytogenetic, clinical and laboratory features in 544 patients. *Br J Haematol*, 92, 382–388.
- 53 Geisler CH, Philip P, Christensen BE, Hou-Jensen K, Pedersen NT, Jensen OM *et al.* (1997) In B-cell chronic lymphocytic leukaemia chromosome 17 abnormalities and not trisomy 12 are the single most important cytogenetic abnormalities for the prognosis: a cytogenetic and immunophenotypic study of 480 unselected newly diagnosed patients. *Leuk Res*, 21, 1011–1023.
- 54 Gahn B, Wendenburg B, Troff C, Neef J, Grove D, Haferlach T *et al.* (1999) Analysis of progenitor cell involvement in B-CLL by simultaneous immunophenotypic and genotypic analysis at the single cell level. *Br J Haematol*, 105, 955–959.
- 55 Garcia-Marco J, Matutes E, Morilla R, Ellis J, Oscier D, Fantes J *et al.* (1994) Trisomy 12 in B-cell chronic lymphocytic leukaemia: assessment of lineage restriction by simultaneous analysis of immunophenotype and genotype in interphase cells by fluorescence in situ hybridization. *Br J Haematol*, 87, 44–50.
- 56 Rozman C, Montserrat E, Rodríguez-Fernández JM, Ayats R, Vallespi T, Parody R *et al.* (1984) Bone marrow histologic pattern—the best single prognostic parameter in chronic lymphocytic leukemia: a multivariate survival analysis of 329 cases. *Blood*, 64, 642–648.
- 57 Geisler C, Ralfkiaer E, Hansen MM, Hou-Jensen K and Larsen SO (1986) The bone marrow histological pattern has independent prognostic value in early stage chronic lymphocytic leukaemia. *Br J Haematol*, 62, 47–54.
- 58 Frisch B and Bartl R (1988) Histologic classification and staging of chronic lymphocytic leukemia. A retrospective and prospective study of 503 cases. *Acta Haematol*, 79, 140–152.
- 59 Trump DL, Mann RB, Phelps R, Roberts H and Conley CL (1980) Richter's syndrome: diffuse histiocytic lymphoma in patients with chronic lymphocytic leukemia. A report of five cases and review of the literature. *Am J Med*, 68, 539–548.
- 60 Foucar K and Rydell RE (1980) Richter's syndrome in chronic lymphocytic leukemia. *Cancer*, 46, 118–134.
- 61 Adelstein DJ, Henry MB, Bowman LS and Hines JD (1991) Diffuse well differentiated lymphocytic lymphoma: a clinical study of 22 patients. *Oncology*, 48, 48–53.
- 62 Pangalis GA and Kittas C. Bone marrow involvement in chronic lymphocytic leukemia, small lymphocytic (well differentiated) and lymphoplasmacytic (macroglobulinemia of Waldenström) non-Hodgkin's lymphomas. In: Polliack A and Catovsky D (eds) *Chronic Lymphocytic Leukaemia*. Harwood Academic Publishers, Chur, 1988.
- 63 Pangalis GA, Roussou PA, Kittas C, Mitsoulis-Mentzikoff C, Matsouka-Alexandridis P, Anagnostopoulos N *et al.* (1984) Patterns of bone marrow involvement in chronic lymphocytic leukemia and small lymphocytic (well differentiated) non-Hodgkin's lymphoma. Its clinical significance in relation to their differential diagnosis and prognosis. *Cancer*, 54, 702–708.
- 64 Lampert IA, Wotherspoon A, Van Noorden S and Hasserjian RP (1999) High expression of CD23 in the proliferation centers of chronic lymphocytic leukemia in lymph nodes and spleen. *Hum Pathol*, 30, 648–654.
- 65 Gordon DS, Jones BM, Browning SW, Spira TJ and Lawrence DN (1982) Persistent polyclonal lymphocytosis of B lymphocytes. *N Engl J Med*, 307, 232–236.
- 66 Bain B, Matutes E and Catovsky D (1998) Teaching cases from the Royal Marsden and St Mary's Hospitals. Case 14: persistent lymphocytosis in a middle aged smoker. *Leuk Lymphoma*, 28, 623–625.
- 67 Brito-Babapulle V, Pomfret M, Matutes E and Catovsky D (1987) Cytogenetic studies on polyclonal lymphocytic leukemia. II. T cell polyclonal leukemia. *Blood*, 70, 926–931.
- 68 Nieto LH, Lampert IA and Catovsky D (1989) Bone marrow histological patterns in B-cell and T-cell polyclonal leukemia. *Hematol Pathol*, 3, 79–84.
- 69 Naeim F and Jacobs AD (1985) Bone marrow changes in patients with hairy cell leukemia treated by recombinant alpha₂-interferon. *Hum Pathol*, 16, 1200–1205.
- 70 Mercieca J, Matutes E, Moskovic E, MacLennan K, Matthey F, Costello C *et al.* (1992) Massive abdominal lymphadenopathy in hairy cell leukaemia: a report of 12 cases. *Br J Haematol*, 82, 547–554.
- 71 Vykoupil KF, Thiele J and Georgii A (1976) Hairy cell leukemia. Bone marrow findings in 24 patients. *Virchows Arch A Pathol Anat Histol*, 370, 273–289.

- 72 Bartl R, Frisch B, Hill W, Burkhardt R, Sommerfeld W and Sund M (1983) Bone marrow histology in hairy cell leukemia. Identification of subtypes and their prognostic significance. *Am J Clin Pathol*, 79, 531–545.
- 73 Burke JS and Rappaport H (1984) The diagnosis and differential diagnosis of hairy cell leukemia in bone marrow and spleen. *Semin Oncol*, 11, 334–346.
- 74 Naeim F (1988) Hairy cell leukemia: characteristics of the neoplastic cells. *Hum Pathol*, 19, 375–388.
- 75 Lee WM and Beckstead JH (1982) Hairy cell leukemia with bone marrow hypoplasia. *Cancer*, 50, 2207–2210.
- 76 Bouroncle BA (1987) Unusual presentations and complications of hairy cell leukemia. *Leukemia*, 1, 288–293.
- 77 Lazzaro B, Munger R, Flick J and Moriber-Katz S (1991) Visualization of the ribosome-lamella complex in plastic-embedded biopsy specimens as an aid to diagnosis of hairy-cell leukemia. *Arch Pathol Lab Med*, 115, 1259–1262.
- 78 Flandrin G, Sigaux F, Castaigne S, Billard C, Aguet M, Boiron M *et al.* (1986) Treatment of hairy cell leukemia with recombinant alpha interferon: I. Quantitative study of bone marrow changes during the first months of treatment. *Blood*, 67, 817–820.
- 79 Verhoef GE, De Wolf-Peeters C, Zachee P and Boogaerts MA (1990) Regression of diffuse osteosclerosis in hairy cell leukaemia after treatment with interferon. *Br J Haematol*, 76, 150–151.
- 80 VanderMolen LA, Urba WJ, Longo DL, Lawrence J, Gralnick H and Steis RG (1989) Diffuse osteosclerosis in hairy cell leukemia. *Blood*, 74, 2066–2069.
- 81 Golomb HM and Vardiman JW (1983) Response to splenectomy in 65 patients with hairy cell leukemia: an evaluation of spleen weight and bone marrow involvement. *Blood*, 61, 349–352.
- 82 Katayama I (1988) Bone marrow in hairy cell leukemia. *Hematol Oncol Clin North Am*, 2, 585–602.
- 83 Ratain MJ, Golomb HM, Bardawil RG, Vardiman JW, Westbrook CA, Kaminer LS *et al.* (1987) Durability of responses to interferon alpha-2b in advanced hairy cell leukemia. *Blood*, 69, 872–877.
- 84 Doane LL, Ratain MJ and Golomb HM (1990) Hairy cell leukemia. Current management. *Hematol Oncol Clin North Am*, 4, 489–502.
- 85 Catovsky D, Golde DW and Golomb HM (1990) The third international workshop on hairy cell leukemia, Laguna Miguel, California, 19–20 October, 1989. *Br J Haematol*, 74, 378–379.
- 86 Falini B, Pileri SA, Flenghi L, Liberati M, Stein H, Gerli R *et al.* (1990) Selection of a panel of monoclonal antibodies for monitoring residual disease in peripheral blood and bone marrow of interferon-treated hairy cell leukaemia patients. *Br J Haematol*, 76, 460–468.
- 87 Hounie H, Chittal SM, al Saati T, de Mascarel A, Sabbatini E, Pileri S *et al.* (1992) Hairy cell leukemia. Diagnosis of bone marrow involvement in paraffin-embedded sections with monoclonal antibody DBA44. *Am J Clin Pathol*, 98, 26–33.
- 88 Janckila AJ, Cardwell EM, Yam LT and Li C-Y (1995) Hairy cell identification by immunohistochemistry of tartrate-resistant acid phosphatase. *Blood*, 85, 2839–2844.
- 89 Hoyer JD, Li CY, Yam LT, Hanson CA and Kurtin PJ (1997) Immunohistochemical demonstration of acid phosphatase isoenzyme 5 (tartrate-resistant) in paraffin sections of hairy cell leukemia and other hematologic disorders. *Am J Clin Pathol*, 108, 308–315.
- 90 Sainati L, Matutes E, Mulligan S, de Oliveira MP, Rani S, Lampert IA and Catovsky D (1990) A variant form of hairy cell leukemia resistant to alpha-interferon: clinical and phenotypic characteristics of 17 patients. *Blood*, 76, 157–162.
- 91 Pozzato G, Mazzaro C, Crovatto M, Modolo ML, Ceselli S, Mazzi G *et al.* (1994) Low-grade malignant lymphoma, hepatitis C virus infection, and mixed cryoglobulinemia. *Blood*, 84, 3047–3053.
- 92 Iida S, Rao PH, Nallasivam P, Hibshoosh H, Butler M, Louie DC *et al.* (1996) The t(9;14)(p13;q32) chromosomal translocation associated with lymphoplasmacytoid lymphoma involves the PAX-5 gene. *Blood*, 88, 4110–4117.
- 93 Ohno H, Ueda C and Akasaka T (2000) The t(9;14)(p13;q32) translocation in B-cell non-Hodgkin's lymphoma. *Leuk Lymphoma*, 36, 435–445.
- 94 Bartl R, Frisch B, Mahl G, Burkhardt R, Fateh-Moghadam A, Pappenberger R *et al.* (1983) Bone marrow histology in Waldenström's macroglobulinemia. Clinical relevance of subtype recognition. *Scand J Haematol*, 31, 359–375.
- 95 Brunning RD. Bone marrow. In: Rosai J (ed) *Ackerman's Surgical Pathology*, 7th edn, vol 2. Mosby, St Louis, 1989.
- 96 Molero T, De La Iglesia S, Santana C, Lemes A and Matutes E (1998) Signet-ring cells in a Waldenström's macroglobulinemia. *Leuk Lymphoma*, 32, 175–177.
- 97 Frisch B, Lewis SM, Burkhardt R and Bartl R. *Biopsy Pathology of Bone and Bone Marrow*. Chapman & Hall, London, 1985.
- 98 Banham AH, Turley H, Pulford K, Gatter K and Mason DY (1997) The plasma cell associated antigen detectable by antibody VS38 is the p63 rough endoplasmic reticulum protein. *J Clin Pathol*, 50, 485–489.
- 99 Kim H and Dorfman RF (1974) Morphological studies of 84 untreated patients subjected to laparotomy for the staging of non-Hodgkin's lymphomas. *Cancer*, 33, 657–674.
- 100 Vykoupil KF and Georgii A. Non Hodgkin's lymphomas in bone marrow: diagnosis according to the

- Kiel classification and their growth patterns and relations to survival. In: Lennert K and Hübner K (eds) *Pathology of the Bone Marrow*. Gustav Fischer Verlag, Stuttgart, 1984.
- 101 Osborne BM and Butler JJ (1989) Hypocellular paratrabecular foci of treated small cleaved cell lymphoma in bone marrow biopsies. *Am J Surg Pathol*, 13, 382–388.
 - 102 Raffeld M and Jaffe ES (1991) bcl-1, t(11;14), and mantle cell-derived lymphomas [editorial]. *Blood*, 78, 259–263.
 - 103 Jaffe ES, Bookman MA and Longo DL (1987) Lymphocytic lymphoma of intermediate differentiation—mantle zone lymphoma: a distinct subtype of B-cell lymphoma. *Hum Pathol*, 18, 877–880.
 - 104 Perry DA, Bast MA, Armitage JO and Weisenburger DD (1990) Diffuse intermediate lymphocytic lymphoma. A clinicopathologic study and comparison with small lymphocytic lymphoma and diffuse small cleaved cell lymphoma. *Cancer*, 66, 1995–2000.
 - 105 Cohen PL, Kurtin PJ, Donovan KA and Hanson CA (1998) Bone marrow and peripheral blood involvement in mantle cell lymphoma. *Br J Haematol*, 101, 302–310.
 - 106 de Oliveira MS, Jaffe ES and Catovsky D (1989) Leukaemic phase of mantle zone (intermediate) lymphoma: its characterisation in 11 cases. *J Clin Pathol*, 42, 962–972.
 - 107 Singleton TP, Anderson MM, Ross CW and Schnitzer B (1999) Leukemic phase of mantle cell lymphoma, blastoid variant. *Am J Clin Pathol*, 111, 495–500.
 - 108 Vaandrager JW, Schuurin E, Zwikstra E, de Boer CJ, Kleiverda KK, van Krieken JH *et al.* (1996) Direct visualization of dispersed 11q13 chromosomal translocations in mantle cell lymphoma by multicolor DNA fiber fluorescence in situ hybridization. *Blood*, 88, 1177–1182.
 - 109 Swerdlow SH, Habeshaw JA, Murray LJ, Dhaliwal HS, Lister TA and Stansfeld AG (1983) Centrocytic lymphoma: a distinct clinicopathologic and immunologic entity. A multiparameter study of 18 cases at diagnosis and relapse. *Am J Pathol*, 113, 181–197.
 - 110 Weisenburger DD, Kim H and Rappaport H (1982) Mantle-zone lymphoma: a follicular variant of intermediate lymphocytic lymphoma. *Cancer*, 49, 1429–1438.
 - 111 Obeso G, Sanz ER, Rivas C, Marcos B, García-Delgado R, Echezarreta G *et al.* (1994) B-cell follicular lymphomas: clinical and biological characteristics. *Leuk Lymphoma*, 16, 105–111.
 - 112 Brunning R and McKenna RW. *Tumors of the Bone Marrow*. Armed Forces Institute of Pathology, Washington, 1994.
 - 113 Vasef MA, Medeiros LJ, Koo C, McCourty A and Brynes RK (1997) Cyclin D1 immunohistochemical staining is useful in distinguishing mantle cell lymphoma from other low-grade B-cell neoplasms in bone marrow. *Am J Clin Pathol*, 108, 302–307.
 - 114 Wotherspoon AC, Doglioni C, Diss TC, Pan L, Moschini A, de Boni M and Isaacson PG (1993) Regression of primary low-grade B-cell gastric lymphoma of mucosa-associated lymphoid tissue type after eradication of *Helicobacter pylori*. *Lancet*, 342, 575–577.
 - 115 Brynes RK, Almaguer PD, Leathery KE, McCourty A, Arber DA, Medeiros LJ and Nathwani BN (1996) Numerical cytogenetic abnormalities of chromosomes 3, 7, and 12 in marginal zone B-cell lymphomas. *Mod Pathol*, 9, 995–1000.
 - 116 Dierlamm J, Rosenberg C, Stul M, Pittaluga S, Wlodarska I, Michaux L *et al.* (1997) Characteristic pattern of chromosomal gains and losses in marginal zone B cell lymphoma detected by comparative genomic hybridization. *Leukemia*, 11, 747–758.
 - 117 Rosenwald A, Ott G, Stilgenbauer S, Kalla J, Bredt M, Katzenberger T *et al.* (1999) Exclusive detection of the t(11;18)(q21;q21) in extranodal marginal zone B cell lymphomas (MZBL) of MALT type in contrast to other MZBL and extranodal large B cell lymphomas. *Am J Pathol*, 155, 1817–1821.
 - 118 Griesser H, Kaiser U, Augener W, Tiemann M and Lennert K (1990) B-cell lymphoma of the mucosa-associated lymphatic tissue (MALT) presenting with bone marrow and peripheral blood involvement. *Leuk Res*, 14, 617–622.
 - 119 Diss TC, Peng H, Wotherspoon AC, Pan L, Speight PM and Isaacson PG (1993) Brief report: a single neoplastic clone in sequential biopsy specimens from a patient with primary gastric-mucosa-associated lymphoid-tissue lymphoma and Sjogren's syndrome. *N Engl J Med*, 329, 172–175.
 - 120 Melo JV, Hegde U, Parreira A, Thompson I, Lampert IA and Catovsky D (1987) Splenic B cell lymphoma with circulating villous lymphocytes: differential diagnosis of B cell leukaemias with large spleens. *J Clin Pathol*, 40, 642–651.
 - 121 Isaacson PG, Matutes E, Burke M and Catovsky D (1994) The histopathology of splenic lymphoma with villous lymphocytes. *Blood*, 84, 3828–3834.
 - 122 Matutes E, Morilla R, Owusu-Ankomah K, Houlihan A and Catovsky D (1994) The immunophenotype of splenic lymphoma with villous lymphocytes and its relevance to the differential diagnosis with other B-cell disorders. *Blood*, 83, 1558–1562.
 - 123 Troussard X, Valensi F, Duchayne E, Garand R, Felman P, Tulliez M *et al.* (1996) Splenic lymphoma with villous lymphocytes: clinical presentation, biology and prognostic factors in a series of 100 patients. Groupe Français d'Hématologie Cellulaire (GFHC). *Br J Haematol*, 93, 731–736.
 - 124 Gruszka-Westwood AM, Matutes E, Coignet LJ, Wotherspoon A and Catovsky D (1999) The inci-

- dence of trisomy 3 in splenic lymphoma with villous lymphocytes: a study by FISH. *Br J Haematol*, 104, 600–604.
- 125 Oscier DG, Matutes E, Gardiner A, Glide S, Mould S, Brito-Babapulle V *et al.* (1993) Cytogenetic studies in splenic lymphoma with villous lymphocytes. *Br J Haematol*, 85, 487–491.
- 126 Franco V, Florena AM and Campesi G (1996) Intrasinusoidal bone marrow infiltration: a possible hallmark of splenic lymphoma. *Histopathology*, 29, 571–575.
- 127 Nathwani BN, Drachenberg MR, Hernandez AM, Levine AM and Sheibani K (1999) Nodal monocytoid B-cell lymphoma (nodal marginal-zone B-cell lymphoma). *Semin Hematol*, 36, 128–138.
- 128 Sheibani K. Monocytoid B cell lymphoma. In: Knowles DM (ed) *Neoplastic Hematopathology*. Williams & Wilkins, Baltimore, 1992.
- 129 Carbone A, Gloghini A, Pinto A, Attadia V, Zagonel V and Volpe R (1989) Monocytoid B-cell lymphoma with bone marrow and peripheral blood involvement at presentation. *Am J Clin Pathol*, 92, 228–236.
- 130 Traweek ST and Sheibani K (1990) Regarding the article entitled ‘Monocytoid B-cell lymphoma with bone marrow and peripheral blood involvement at presentation’ [letter; comment]. *Am J Clin Pathol*, 94, 117–118.
- 131 Fend F, Kraus-Huonder B, Müller-Hermelink HK and Feller AC (1993) Monocytoid B-cell lymphoma: its relationship to and possible cellular origin from marginal zone cells. *Hum Pathol*, 24, 336–339.
- 132 Henrique R, Achten R, Maes B, Verhoef G and De Wolf-Peeters C (1999) Guidelines for subtyping small B-cell lymphomas in bone marrow biopsies. *Virchows Arch*, 435, 549–558.
- 133 Kurtin PJ, Hobday KS, Ziesmer S and Caron BL (1999) Demonstration of distinct antigenic profiles of small B-cell lymphomas by paraffin section immunohistochemistry. *Am J Clin Pathol*, 112, 319–329.
- 134 Yan Y, Chan WC, Weisenburger DD, Anderson JR, Bast MA, Vose JM *et al.* (1995) Clinical and prognostic significance of bone marrow involvement in patients with diffuse aggressive B-cell lymphoma. *J Clin Oncol*, 13, 1336–1342.
- 135 Hill ME, MacLennan KA, Cunningham DC, Vaughan Hudson B, Burke M, Clarke P *et al.* (1996) Prognostic significance of BCL-2 expression and bcl-2 major breakpoint region rearrangement in diffuse large cell non-Hodgkin’s lymphoma: a British National Lymphoma Investigation Study. *Blood*, 88, 1046–1051.
- 136 Gaidano G (1996) Clinical implications of the molecular pathogenesis of non-Hodgkin’s lymphomas. *Cancer J*, 9, 187–191.
- 137 Gascoyne RD, Adomat SA, Krajewski S, Krajewska M, Horsman DE, Tolcher AW *et al.* (1997) Prognostic significance of Bcl-2 protein expression and Bcl-2 gene rearrangement in diffuse aggressive non-Hodgkin’s lymphoma. *Blood*, 90, 244–251.
- 138 Schlegelberger B, Zwingers T, Harder L, Nowotny H, Siebert R, Vesely M *et al.* (1999) Clinicopathogenetic significance of chromosomal abnormalities in patients with blastic peripheral B-cell lymphoma. Kiel-Wien-Lymphoma Study Group. *Blood*, 94, 3114–3120.
- 139 Hui PK, Feller AC and Lennert K (1988) High-grade non-Hodgkin’s lymphoma of B-cell type. I. Histopathology. *Histopathology*, 12, 127–143.
- 140 Bain B, Matutes E, Robinson D, Lampert IA, Brito-Babapulle V, Morilla R and Catovsky D (1991) Leukaemia as a manifestation of large cell lymphoma. *Br J Haematol*, 77, 301–310.
- 141 Skinnider BF, Connors JM and Gascoyne RD (1997) Bone marrow involvement in T-cell-rich B-cell lymphoma. *Am J Clin Pathol*, 108, 570–578.
- 142 Cazals-Hatem D, Lepage E, Brice P, Ferrant A, d’Agay MF, Baumelou E *et al.* (1996) Primary mediastinal large B-cell lymphoma. A clinicopathologic study of 141 cases compared with 916 nonmediastinal large B-cell lymphomas, a GELA (‘Groupe d’Etude des Lymphomes de l’Adulte’) study. *Am J Surg Pathol*, 20, 877–888.
- 143 Cesarman E and Knowles DM (1997) Kaposi’s sarcoma-associated herpesvirus: a lymphotropic human herpesvirus associated with Kaposi’s sarcoma, primary effusion lymphoma, and multicentric Castleman’s disease [published erratum appears in *Semin Diagn Pathol* 1997, May, 14 (2), 161–162.]. *Semin Diagn Pathol*, 14, 54–66.
- 144 Parrons M, Dubus P, Agape P, Rizcallah E, Marit G, de Mascarel A and Merlio JP (2000) Intrasinusoidal bone marrow infiltration revealing intravascular lymphomatosis. *Leuk Lymphoma*, 37, 219–223.
- 145 Wick MR, Mills SE, Scheithauer BW, Cooper PH, Davitz MA and Parkinson K (1986) Reassessment of malignant ‘angioendotheliomatosis’. Evidence in favor of its reclassification as ‘intravascular lymphomatosis’. *Am J Surg Pathol*, 10, 112–123.
- 146 Wright DH and Pike PA (1968) Bone marrow involvement in Burkitt’s tumour. *Br J Haematol*, 15, 409–416.
- 147 Bluming AZ, Ziegler JL and Carbone PP (1972) Bone marrow involvement in Burkitt’s lymphoma: results of a prospective study. *Br J Haematol*, 22, 369–376.
- 148 Arseneau JC, Canellos GP, Banks PM, Berard CW, Gralnick HR and DeVita VT Jr (1975) American Burkitt’s lymphoma: a clinicopathologic study of 30 cases. I. Clinical factors relating to prolonged survival. *Am J Med*, 58, 314–321.
- 149 Banks PM, Arseneau JC, Gralnick HR, Canellos GP, DeVita VT Jr and Berard CW (1975) American Burkitt’s lymphoma: a clinicopathologic study of 30

- cases. II. Pathologic correlations. *Am J Med*, 58, 322–329.
- 150 Levine AM, Pavlova Z, Pockros AW, Parker JW, Teitelbaum AH, Paganini-Hill A *et al.* (1983) Small noncleaved follicular center cell (FCC) lymphoma: Burkitt and non-Burkitt variants in the United States. I. Clinical features. *Cancer*, 52, 1073–1079.
- 151 Brunning RD, McKenna RW, Bloomfield CD, Coccia P and Gajl-Peczalska KJ (1977) Bone marrow involvement in Burkitt's lymphoma. *Cancer*, 40, 1771–1779.
- 152 Nakamura S and Suchi T (1991) A clinicopathologic study of node-based, low-grade, peripheral T-cell lymphoma. Angioimmunoblastic lymphoma, T-zone lymphoma, and lymphoepithelioid lymphoma. *Cancer*, 67, 2566–2578.
- 153 Weiss LM, Bindl JM, Picozzi VJ, Link MP and Warnke RA (1986) Lymphoblastic lymphoma: an immunophenotype study of 26 cases with comparison to T cell acute lymphoblastic leukemia. *Blood*, 67, 474–478.
- 154 Matutes E, Garcia Talavera J, O'Brien M and Catovsky D (1986) The morphological spectrum of T-prolymphocytic leukaemia. *Br J Haematol*, 64, 111–124.
- 155 Matutes E, Brito-Babapulle V, Swansbury J, Ellis J, Morilla R, Dearden C *et al.* (1991) Clinical and laboratory features of 78 cases of T-prolymphocytic leukemia. *Blood*, 78, 3269–3274.
- 156 Timonen T, Ortaldo JR and Herberman RB (1981) Characteristics of human large granular lymphocytes and relationship to natural killer and K cells. *J Exp Med*, 153, 569–582.
- 157 Loughran TP Jr (1993) Clonal diseases of large granular lymphocytes. *Blood*, 82, 1–14.
- 158 Gentile TC, Uner AH, Hutchison RE, Wright J, Ben-Ezra J, Russell EC and Loughran TP Jr (1994) CD3+, CD56+ aggressive variant of large granular lymphocyte leukemia. *Blood*, 84, 2315–2321.
- 159 Lamy T and Loughran TP Jr (1999) Current concepts: large granular lymphocyte leukemia. *Blood Rev*, 13, 230–240.
- 160 Dhodapkar MV, Li CY, Lust JA, Tefferi A and Phyliky RL (1994) Clinical spectrum of clonal proliferations of T-large granular lymphocytes: a T-cell clonopathy of undetermined significance? *Blood*, 84, 1620–1627.
- 161 Pandolfi F, Loughran TP Jr, Starkebaum G, Chisesi T, Barbui T, Chan WC *et al.* (1990) Clinical course and prognosis of the lymphoproliferative disease of granular lymphocytes. A multicenter study. *Cancer*, 65, 341–348.
- 162 Reynolds CW and Foon KA (1984) T- γ -lymphoproliferative disease and related disorders in humans and experimental animals: a review of the clinical, cellular, and functional characteristics. *Blood*, 64, 1146–1158.
- 163 Loughran TP Jr, Kadin ME, Starkebaum G, Abkowitz JL, Clark EA, Distèche C *et al.* (1985) Leukemia of large granular lymphocytes: association with clonal chromosomal abnormalities and autoimmune neutropenia, thrombocytopenia, and hemolytic anemia. *Ann Intern Med*, 102, 169–175.
- 164 Brouet JC, Sasportes M, Flandrin G, Preud'Homme JL and Seligmann M (1975) Chronic lymphocytic leukaemia of T-cell origin. Immunological and clinical evaluation in eleven patients. *Lancet*, 2, 890–893.
- 165 Palutke M, Eisenberg L, Kaplan J, Hussain M, Kithier K, Tabaczka P *et al.* (1983) Natural killer and suppressor T-cell chronic lymphocytic leukemia. *Blood*, 62, 627–634.
- 166 Agnarsson BA, Loughran TP Jr, Starkebaum G and Kadin ME (1989) The pathology of large granular lymphocyte leukemia. *Hum Pathol*, 20, 643–651.
- 167 Kouides PA and Rowe JM (1995) Large granular lymphocyte leukemia presenting with both amegakaryocytic thrombocytopenic purpura and pure red cell aplasia: clinical course and response to immunosuppressive therapy. *Am J Hematol*, 49, 232–236.
- 168 Tefferi A, Li CY, Witzig TE, Dhodapkar MV, Okuno SH and Phyliky RL (1994) Chronic natural killer cell lymphocytosis: a descriptive clinical study. *Blood*, 84, 2721–2725.
- 169 Kawa-Ha K, Ishihara S, Ninomiya T, Yumura-Yagi K, Hara J, Murayama F *et al.* (1989) CD3-negative lymphoproliferative disease of granular lymphocytes containing Epstein-Barr viral DNA. *J Clin Invest*, 84, 51–55.
- 170 Chan JK, Sin VC, Wong KF, Ng CS, Tsang WY, Chan CH *et al.* (1997) Nonnasal lymphoma expressing the natural killer cell marker CD56: a clinicopathologic study of 49 cases of an uncommon aggressive neoplasm. *Blood*, 89, 4501–4513.
- 171 Imamura N, Kusunoki Y, Kawa-Ha K, Yumura K, Hara J, Oda K *et al.* (1990) Aggressive natural killer cell leukaemia/lymphoma: report of four cases and review of the literature. Possible existence of a new clinical entity originating from the third lineage of lymphoid cells. *Br J Haematol*, 75, 49–59.
- 172 Kwong YL, Chan AC and Liang RH (1997) Natural killer cell lymphoma/leukemia: pathology and treatment. *Hematol Oncol*, 15, 71–79.
- 173 Rabbani GR, Phyliky RL and Tefferi A (1999) A long-term study of patients with chronic natural killer cell lymphocytosis. *Br J Haematol*, 106, 960–966.
- 174 Oshimi K (1996) Lymphoproliferative disorders of natural killer cells. *Int J Hematol*, 63, 279–290.
- 175 Schechter GP, Sausville EA, Fischmann AB, Soehnlen F, Eddy J, Matthews M *et al.* (1987) Evaluation of circulating malignant cells provides prognostic information in cutaneous T cell lymphoma. *Blood*, 69, 841–849.

- 176 Matutes E and Catovsky D (1991) Mature T-cell leukemias and leukemia/lymphoma syndromes: review of our experience of 175 cases. *Leuk Lymphoma*, 4, 81–91.
- 177 Karenko L, Hyytinen E, Sarna S and Ranki A (1997) Chromosomal abnormalities in cutaneous T-cell lymphoma and in its premalignant conditions as detected by G-banding and interphase cytogenetic methods. *J Invest Dermatol*, 108, 22–29.
- 178 Thangavelu M, Finn WG, Yelavarthi KK, Roenigk HH Jr, Samuelson E, Peterson L *et al.* (1997) Recurring structural chromosome abnormalities in peripheral blood lymphocytes of patients with mycosis fungoides/Sézary syndrome. *Blood*, 89, 3371–3377.
- 179 Rappaport H and Thomas LB (1974) Mycosis fungoides: the pathology of extracutaneous involvement. *Cancer*, 34, 1198–1229.
- 180 Salhany KE, Greer JP, Cousar JB and Collins RD (1989) Marrow involvement in cutaneous T-cell lymphoma. A clinicopathologic study of 60 cases. *Am J Clin Pathol*, 92, 747–754.
- 181 Graham SJ, Sharpe RW, Steinberg SM, Cotelingam JD, Sausville EA and Foss FM (1993) Prognostic implications of a bone marrow histopathologic classification system in mycosis fungoides and the Sézary syndrome. *Cancer*, 72, 726–734.
- 182 Carbone A, Tirelli U, Volpe R, Sulpharo S and Manconi R (1986) Assessment of bone marrow histology in patients with cutaneous T-cell lymphomas (CTCL) at presentation and during the follow-up [letter]. *Br J Haematol*, 62, 789–790.
- 183 Patsouris E, Noël H and Lennert K (1989) Angioimmunoblastic lymphadenopathy—type of T-cell lymphoma with a high content of epithelioid cells. Histopathology and comparison with lymphoepithelioid cell lymphoma. *Am J Surg Pathol*, 13, 262–275.
- 184 Knecht H (1989) Angioimmunoblastic lymphadenopathy: ten years' experience and state of current knowledge. *Semin Hematol*, 26, 208–215.
- 185 Schlegelberger B, Zwingers T, Hohenadel K, Hennebruns D, Schmitz N, Haferlach T *et al.* (1996) Significance of cytogenetic findings for the clinical outcome in patients with T-cell lymphoma of angioimmunoblastic lymphadenopathy type. *J Clin Oncol*, 14, 593–599.
- 186 Schlegelberger B, Zhang Y, Weber-Matthiesen K and Grote W (1994) Detection of aberrant clones in nearly all cases of angioimmunoblastic lymphadenopathy with dysproteinemia-type T-cell lymphoma by combined interphase and metaphase cytogenetics. *Blood*, 84, 2640–2648.
- 187 Smith JL, Hodges E, Quin CT, McCarthy KP and Wright DH (2000) Frequent T and B cell oligoclonal in histologically and immunophenotypically characterized angioimmunoblastic lymphadenopathy. *Am J Pathol*, 156, 661–669.
- 188 Schnaidt U, Vykoupil KF, Thiele J and Georgii A (1980) Angioimmunoblastic lymphadenopathy. Histopathology of bone marrow involvement. *Virchows Arch [Pathol Anat]*, 389, 369–380.
- 189 Ghani AM and Krause JR (1985) Bone marrow biopsy findings in angioimmunoblastic lymphadenopathy. *Br J Haematol*, 61, 203–213.
- 190 Uchiyama T, Yodoi J, Sagawa K, Takatsuki K and Uchino H (1977) Adult T-cell leukemia: clinical and hematologic features of 16 cases. *Blood*, 50, 481–492.
- 191 Jaffe ES, Blattner WA, Blayney DW, Bunn PA Jr, Cossman J, Robert-Guroff M and Gallo RC (1984) The pathologic spectrum of adult T-cell leukemia/lymphoma virus-associated lymphoid malignancies. *Am J Surg Pathol*, 8, 263–275.
- 192 Shih LY, Kuo TT, Dunn P and Liaw SJ (1991) Human T-cell lymphotropic virus type I associated adult T-cell leukaemia/lymphoma in Taiwan Chinese. *Br J Haematol*, 79, 156–161.
- 193 Shimoyama M (1991) Diagnostic criteria and classification of clinical subtypes of adult T-cell leukaemia-lymphoma. A report from the Lymphoma Study Group (1984–87). *Br J Haematol*, 79, 428–437.
- 194 Bain BJ. Morphology and classification of leukaemias. In: Whittaker JA and Holmes JA (eds) *Leukaemia and Related Disorders*. Blackwell Science, Oxford, 1998.
- 195 Fujita K, Yamasaki Y, Sawada H, Izumi Y, Fukuhara S and Uchino H (1989) Cytogenetic studies on the adult T-cell leukemia in Japan. *Leuk Res*, 13, 535–543.
- 196 Swerdlow SH, Habeshaw JA, Rohatiner AZ, Lister TA and Stansfeld AG (1984) Caribbean T-cell lymphoma/leukemia. *Cancer*, 54, 687–696.
- 197 Cooke CB, Krenacs L, Stetler-Stevenson M, Greiner TC, Raffeld M, Kingma DW *et al.* (1996) Hepatosplenic T-cell lymphoma: a distinct clinicopathologic entity of cytotoxic gamma delta T-cell origin. *Blood*, 88, 4265–4274.
- 198 Lai R, Larratt LM, Etches W, Mortimer ST, Jewell LD, Dabbagh L and Coupland RW (2000) Hepatosplenic T-cell lymphoma of alphabeta lineage in a 16-year-old boy presenting with hemolytic anemia and thrombocytopenia. *Am J Surg Pathol*, 24, 459–463.
- 199 Yao M, Tien HF, Lin MT, Su IJ, Wang CT, Chen YC *et al.* (1996) Clinical and hematological characteristics of hepatosplenic T gamma/delta lymphoma with isochromosome for long arm of chromosome 7. *Leuk Lymphoma*, 22, 495–500.
- 200 Salhany KE, Feldman M, Kahn MJ, Peritt D, Schretzenmair RD, Wilson DM *et al.* (1997) Hepatosplenic gammadelta T-cell lymphoma: ultrastructural, immunophenotypic, and functional evidence for cytotoxic T lymphocyte differentiation. *Hum Pathol*, 28, 674–685.

- 201 Falini B, Pileri S, Zinzani PL, Carbone A, Zagonel V, De Wolf-Peeters C *et al.* (1999) ALK+ lymphoma: clinico-pathological findings and outcome. *Blood*, 93, 2697–2706.
- 202 Falini B, Pulford K, Pucciarini A, Carbone A, De Wolf-Peeters C, Cordell J *et al.* (1999) Lymphomas expressing ALK fusion protein(s) other than NPM-ALK. *Blood*, 94, 3509–3515.
- 203 Wong KF, Chan JK, Ng CS, Chu YC, Lam PW and Yuen HL (1991) Anaplastic large cell Ki-1 lymphoma involving bone marrow: marrow findings and association with reactive hemophagocytosis. *Am J Hematol*, 37, 112–119.
- 204 Agnarsson BA and Kadin ME (1988) Ki-1 positive large cell lymphoma. A morphologic and immunologic study of 19 cases. *Am J Surg Pathol*, 12, 264–274.
- 205 Downing JR, Shurtleff SA, Zielenska M, Curcio-Brint AM, Behm FG, Head DR *et al.* (1995) Molecular detection of the (2;5) translocation of non-Hodgkin's lymphoma by reverse transcriptase-polymerase chain reaction. *Blood*, 85, 3416–3422.
- 206 Kadin ME and Morris SW (1998) The t(2;5) in human lymphomas. *Leuk Lymphoma*, 29, 249–256.
- 207 Wlodarska I, De Wolf-Peeters C, Falini B, Verhoef G, Morris SW, Hagemeijer A and Van den Berghe H (1998) The cryptic inv(2)(p23q35) defines a new molecular genetic subtype of ALK-positive anaplastic large-cell lymphoma. *Blood*, 92, 2688–2695.
- 208 Sainati L, Montaldi A, Stella M, Putti MC, Zanasco L and Basso G (1990) A novel variant translocation t(2;13)(p23;q34) in Ki-1 large cell anaplastic lymphoma. *Br J Haematol*, 75, 621–622.
- 209 Rosenwald A, Ott G, Pulford K, Katzenberger T, Kühl J, Kalla J *et al.* (1999) t(1;2)(q21;p23) and t(2;3)(p23;q21): two novel variant translocations of the t(2;5)(p23;q35) in anaplastic large cell lymphoma. *Blood*, 94, 362–364.
- 210 Lamant L, Dastugue N, Pulford K, Delsol G and Mariamé B (1999) A new fusion gene *TPM3-ALK* in anaplastic large cell lymphoma created by a (1;2)(q25;p23) translocation. *Blood*, 93, 3088–3095.
- 211 Chott A, Kaserer K, Augustin I, Vesely M, Heinz R, Oehlinger W *et al.* (1990) Ki-1-positive large cell lymphoma. A clinicopathologic study of 41 cases. *Am J Surg Pathol*, 14, 439–448.
- 212 Fraga M, Brousset P, Schlaifer D, Payen C, Robert A, Rubie H *et al.* (1995) Bone marrow involvement in anaplastic large cell lymphoma. Immunohistochemical detection of minimal disease and its prognostic significance. *Am J Clin Pathol*, 103, 82–89.
- 213 Pulford K, Lamant L, Morris SW, Butler LH, Wood KM, Stroud D *et al.* (1997) Detection of anaplastic lymphoma kinase (ALK) and nucleolar protein nucleophosmin (NPM)-ALK proteins in normal and neoplastic cells with the monoclonal antibody ALK1. *Blood*, 89, 1394–1404.
- 214 Benharroch D, Meguerian-Bedoyan Z, Lamant L, Amin C, Brugières L, Terrier-Lacombe MJ *et al.* (1998) ALK-positive lymphoma: a single disease with a broad spectrum of morphology. *Blood*, 91, 2076–2084.
- 215 Lopez-Guillermo A, Cid J, Salar A, Lopez A, Montalban C, Castrillo JM *et al.* (1998) Peripheral T-cell lymphomas: initial features, natural history, and prognostic factors in a series of 174 patients diagnosed according to the R.E.A.L. Classification. *Ann Oncol*, 9, 849–855.
- 216 Shimoyama M, Oyama A, Tajima K, Tobinai K, Minato K, Takenaka T *et al.* (1993) Differences in clinicopathological characteristics and major prognostic factors between B-lymphoma and peripheral T-lymphoma excluding adult T-cell leukemia/lymphoma. *Leuk Lymphoma*, 10, 335–342.
- 217 Jennings CD and Foon KA (1997) Recent advances in flow cytometry: application to the diagnosis of hematologic malignancy. *Blood*, 90, 2863–2892.
- 218 Quintanilla-Martinez L, Preffer F, Rubin D, Ferry JA and Harris NL (1994) CD20+ T-cell lymphoma. Neoplastic transformation of a normal T-cell subset. *Am J Clin Pathol*, 102, 483–489.
- 219 Inwards DJ, Habermann TM, Banks PM, Colgan JP and Dewald GW (1990) Cytogenetic findings in 21 cases of peripheral T-cell lymphoma. *Am J Hematol*, 35, 88–95.
- 220 Montaldi A, Chisesi T, Stracca-Pansa V, Celli P, Vespignani M and Stella M (1990) Recurrent chromosomal aberrations in peripheral T-cell lymphoma. *Cancer Genet Cytogenet*, 48, 39–48.
- 221 Lakkala-Paranko T, Franssila K, Lappalainen K, Leskinen R, Knuutila S, de la Chapelle A and Bloomfield CD (1987) Chromosome abnormalities in peripheral T-cell lymphoma. *Br J Haematol*, 66, 451–460.
- 222 Sanger WG, Weisenburger DD, Armitage JO and Purtilo DT (1986) Cytogenetic abnormalities in non-cutaneous peripheral T-cell lymphoma. *Cancer Genet Cytogenet*, 23, 53–59.
- 223 Auger MJ, Nash JR and Mackie MJ (1986) Marrow involvement with T cell lymphoma initially presenting as abnormal myelopoiesis. *J Clin Pathol*, 39, 134–137.
- 224 Lukes RJ (1971) Criteria for involvement of lymph node, bone marrow, spleen, and liver in Hodgkin's disease. *Cancer Res*, 31, 1755–1767.
- 225 Neiman RS, Rosen PJ and Lukes RJ (1973) Lymphocyte-depletion Hodgkin's disease. A clinicopathological entity. *N Engl J Med*, 288, 751–755.
- 226 Bartl R, Frisch B, Burkhardt R, Huhn D and Pappenberger R (1982) Assessment of bone marrow histology in Hodgkin's disease: correlation with clinical factors. *Br J Haematol*, 51, 345–360.
- 227 Ellis ME, Diehl LF, Granger E and Elson E (1989) Trephine needle bone marrow biopsy in the initial

- staging of Hodgkin disease: sensitivity and specificity of the Ann Arbor staging procedure criteria. *Am J Hematol*, 30, 115–120.
- 228 Macintyre EA, Vaughan Hudson B, Linch DC, Vaughan Hudson G and Jelliffe AM (1987) The value of staging bone marrow trephine biopsy in Hodgkin's disease. *Eur J Haematol*, 39, 66–70.
- 229 Rosenberg SA (1971) Hodgkin's disease of the bone marrow. *Cancer Res*, 31, 1733–1736.
- 230 Rappaport H, Berard CW, Butler JJ, Dorfman RF, Lukes RJ and Thomas LB (1971) Report of the Committee on Histopathological Criteria Contributing to Staging of Hodgkin's Disease. *Cancer Res*, 31, 1864–1865.
- 231 Banks PM (1990) The pathology of Hodgkin's disease. *Semin Oncol*, 17, 683–695.
- 232 O'Carroll DI, McKenna RW and Brunning RD (1976) Bone marrow manifestations of Hodgkin's disease. *Cancer*, 38, 1717–1728.
- 233 Myers CE, Chabner BA, De Vita VT and Gralnick HR (1974) Bone marrow involvement in Hodgkin's disease: pathology and response to MOPP chemotherapy. *Blood*, 44, 197–204.
- 234 Kinney MC, Greer JP, Stein RS, Collins RD and Cousar JB (1986) Lymphocyte-depletion Hodgkin's disease. Histopathologic diagnosis of marrow involvement. *Am J Surg Pathol*, 10, 219–226.
- 235 Meadows LM, Rosse WR, Moore JO, Crawford J, Laszlo J and Kaufman RE (1989) Hodgkin's disease presenting as myelofibrosis. *Cancer*, 64, 1720–1726.
- 236 Jarrett RF and MacKenzie J (1999) Epstein-Barr virus and other candidate viruses in the pathogenesis of Hodgkin's disease. *Semin Hematol*, 36, 260–269.
- 237 Cohen JI (1991) Epstein-Barr virus lymphoproliferative disease associated with acquired immunodeficiency. *Medicine (Baltimore)*, 70, 137–160.
- 238 Hopwood P and Crawford DH (2000) The role of EBV in post-transplant malignancies: a review. *J Clin Pathol*, 53, 248–254.
- 239 Curtis RE, Travis LB, Rowlings PA, Socie G, Kingma DW, Banks PM *et al.* (1999) Risk of lymphoproliferative disorders after bone marrow transplantation: a multi-institutional study. *Blood*, 94, 2208–2216.
- 240 Shapiro RS, McClain K, Frizzera G, Gajl-Peczalska KJ, Kersey JH, Blazar BR *et al.* (1988) Epstein-Barr virus associated B cell lymphoproliferative disorders following bone marrow transplantation. *Blood*, 71, 1234–1243.
- 241 Spiro IJ, Yandell DW, Li C, Saini S, Ferry J, Powelson J *et al.* (1993) Brief report: lymphoma of donor origin occurring in the porta hepatis of a transplanted liver. *N Engl J Med*, 329, 27–29.
- 242 Baumforth KR, Young LS, Flavell KJ, Constandinou C and Murray PG (1999) The Epstein-Barr virus and its association with human cancers. *Mol Pathol*, 52, 307–322.
- 243 Hanto DW, Sakamoto K, Purtilo DT, Simmons RL and Najarian JS (1981) The Epstein-Barr virus in the pathogenesis of posttransplant lymphoproliferative disorders. Clinical, pathologic, and virologic correlation. *Surgery*, 90, 204–213.
- 244 Hanto DW, Gajl-Peczalska KJ, Frizzera G, Arthur DC, Balfour HH Jr, McClain K *et al.* (1983) Epstein-Barr virus (EBV) induced polyclonal and monoclonal B-cell lymphoproliferative diseases occurring after renal transplantation. Clinical, pathologic, and virologic findings and implications for therapy. *Ann Surg*, 198, 356–369.
- 245 Craig FE, Gulley ML and Banks PM (1993) Post-transplantation lymphoproliferative disorders. *Am J Clin Pathol*, 99, 265–276.
- 246 Knowles DM, Cesarman E, Chadburn A, Frizzera G, Chen J, Rose EA and Michler RE (1995) Correlative morphologic and molecular genetic analysis demonstrates three distinct categories of posttransplantation lymphoproliferative disorders. *Blood*, 85, 552–565.
- 247 Cleary ML, Nalesnik MA, Shearer WT and Sklar J (1988) Clonal analysis of transplant-associated lymphoproliferations based on the structure of the genomic termini of the Epstein-Barr virus. *Blood*, 72, 349–352.
- 248 Harris NL, Ferry JA and Swerdlow SH (1997) Posttransplant lymphoproliferative disorders: summary of Society for Hematopathology Workshop. *Semin Diagn Pathol*, 14, 8–14.
- 249 Koeppen H, Newell K, Baunoch DA and Vardiman JW (1998) Morphologic bone marrow changes in patients with posttransplantation lymphoproliferative disorders. *Am J Surg Pathol*, 22, 208–214.

SEVEN

MULTIPLE MYELOMA AND RELATED DISORDERS

Multiple myeloma

Multiple myeloma or myelomatosis is a disease resulting from the proliferation in the bone marrow of a clone of neoplastic cells that are closely related, both morphologically and functionally, to plasma cells. In the great majority of cases, the neoplastic cells secrete a protein that is either a complete immunoglobulin (Ig) or an immunoglobulin light chain. Clinical features result either directly from the effects of the neoplastic proliferation or indirectly from effects of the protein, often designated a paraprotein, which the myeloma cells produce. The nature of this disease, in which cells of the abnormal clone are widely, randomly and diffusely distributed in the red marrow, is better reflected by the term 'myelomatosis' than by the more commonly used 'multiple myeloma'. It might be preferable if the latter term was restricted to those rare cases, more closely related to solitary myeloma (plasmacytoma), in which there are several isolated lesions but intervening bone marrow is normal. However, use of the term 'multiple myeloma' for the disease we are describing is so common that we shall retain it.

Multiple myeloma is a disease predominantly of the middle-aged and elderly. It has an incidence of 2–4/100 000/year. The disease is more common in Blacks than in Caucasians and somewhat more common in men than in women. Characteristic clinical features are anaemia, bone pain, pathological fractures, hypercalcaemia and renal failure. A minority of patients have hepatomegaly or lymphadenopathy. Splenomegaly is occasionally present. Patients with symptomatic bone lesions usually have either generalized osteoporosis or discrete osteolytic lesions but occasional patients have

osteosclerosis. The paraprotein secreted is IgG in about 60% of cases and IgA in about 20%; some patients secrete excess monoclonal light chain (Bence-Jones protein) in addition to complete Ig and, in about 15–20% of patients, only light chain is produced (Bence-Jones myeloma). A minority of patients produce an IgM, IgD or IgE paraprotein. Occasional patients have two distinct paraproteins. A small minority of patients have no paraprotein in serum or urine (non-secretory myeloma). Any paraprotein secreted will, since it arises from a single clone of cells, contain only a single light chain type, either κ or λ . Monoclonal Ig, being of high molecular weight, are usually detected only or mainly in the serum whereas, unless there is co-existing renal failure, the low molecular weight Bence-Jones protein is detected only in the urine.

Multiple myeloma can be diagnosed with reasonable certainty if two of the following three criteria are met:

- 1 more than 10% plasma cells in a bone marrow aspirate;
- 2 a paraprotein in serum or urine; and
- 3 osteolytic bone lesions or osteoporosis [1].

The probability of myeloma is high if an IgG paraprotein exceeds 30 g/l or if an IgA paraprotein exceeds 10 g/l. It is useful to distinguish 'smouldering multiple myeloma' from other cases. Smouldering multiple myeloma is an appropriate diagnosis if there are no symptoms, normal serum calcium concentration and renal function (creatinine $<170 \mu\text{mol/l}$), a relatively low paraprotein concentration (IgG paraprotein less than 70 g/l or IgA paraprotein less than 50 g/l), no bone lesions and no infections.

The median survival in multiple myeloma is 3–4

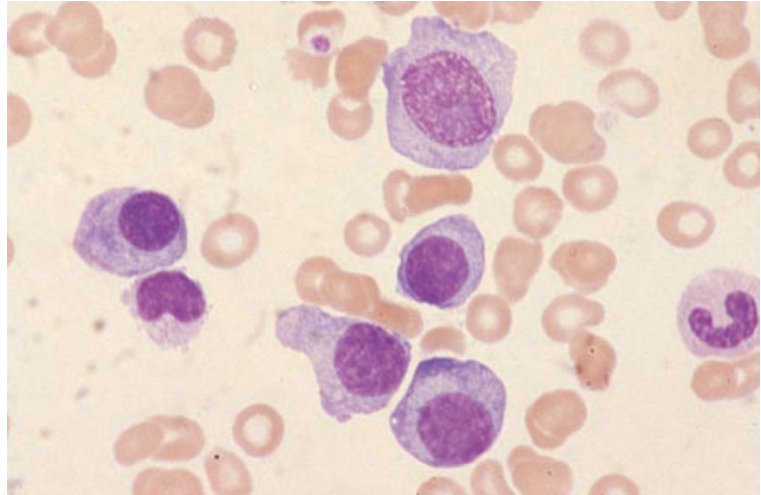


Fig. 7.1 BM aspirate, multiple myeloma, showing a range of cells from a plasmablast to mature plasma cells. MGG $\times 940$.

years. The condition usually terminates in refractory disease, sometimes with a leukaemic phase. In some cases there is transformation to immunoblastic lymphoma. A significant minority of patients (about 10% of those who survive 5–10 years after treatment) succumb to a secondary myelodysplastic syndrome or to acute myeloid leukaemia (AML); it is likely that these complications result from the administration of alkylating agents.

Peripheral blood

The great majority of patients have anaemia which is either normocytic, normochromic or, less often, macrocytic. In most patients there is increased rouleaux formation and increased background basophilic staining due to the presence of the paraprotein in the blood. These features do not occur in the minority of patients whose cells secrete only Bence-Jones protein or are non-secretory. The blood film is occasionally leuco-erythroblastic and it is often possible to find a small number of plasma cells or plasmacytoid lymphocytes. In patients with more advanced disease, there may be thrombocytopenia and neutropenia. Occasionally, there are large numbers of circulating neoplastic cells, showing mild to marked atypia, either at presentation or during the terminal phase of the disease. The designation plasma cell leukaemia is then used (see page 345). Occasional patients have a neutrophilic leukaemoid reaction.

Bone marrow cytology

The bone marrow features are very variable. Plasma cells are usually increased, often constituting between 30 and 90% of bone marrow nucleated cells. The myeloma cells may be morphologically fairly normal, showing the eccentric nucleus, clumped chromatin and Golgi zone typical of a normal plasma cell, or may be moderately or severely dysplastic. A common cytological abnormality is nucleocytoplasmic asynchrony; the cytoplasm is mature but the nucleus either has a diffuse chromatin pattern or contains a prominent nucleolus (Figs 7.1 and 7.2). Other cytological abnormalities include: (i) marked pleomorphism; (ii) increased size of cells; (iii) a high nucleocytoplasmic ratio; (iv) multinuclearity (Fig. 7.3); (v) nuclear lobulation (Fig. 7.4); (vi) phagocytosis by myeloma cells (Fig. 7.3); and (vii) the presence of mitotic figures. Occasionally, multinuclearity is extreme with up to 40 nuclei per cell [2]. Sometimes there are giant dysplastic plasma cells. Cytoplasmic abnormalities include uniform basophilia without a distinct Golgi zone, cytoplasmic eosinophilia and 'flaming' eosinophilic margins (Fig. 7.3). The cytoplasm may be voluminous or may contain crystals (Fig. 7.5), vacuoles or dilated sacs of endoplasmic reticulum (Fig. 7.6). Myeloma cells may have multiple small vacuoles containing weakly basophilic material (Fig. 7.7), the term 'Mott cell' then being used. They may have giant spherical inclusions, referred to as

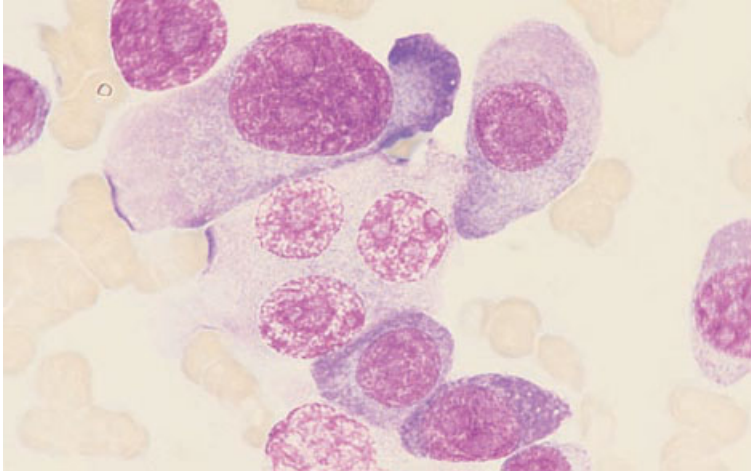


Fig. 7.2 BM aspirate, multiple myeloma, showing plasmablasts, one of which is trinucleated. MGG ×940.

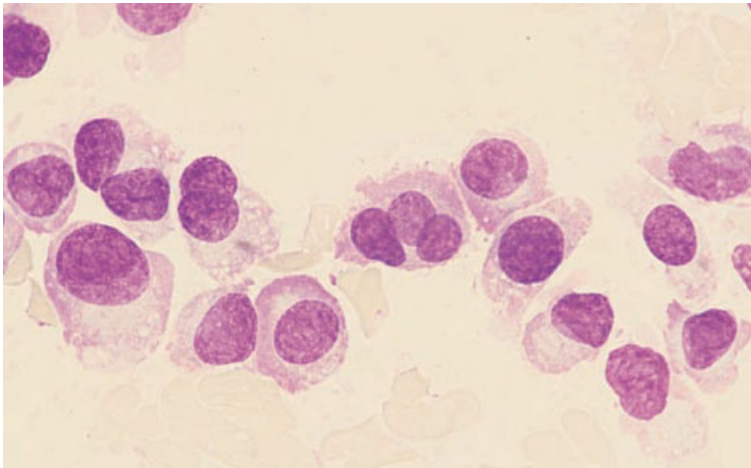


Fig. 7.3 BM aspirate, multiple myeloma, showing bi- and trinucleated myeloma cells and myeloma cells with flaming cytoplasm. MGG ×940.

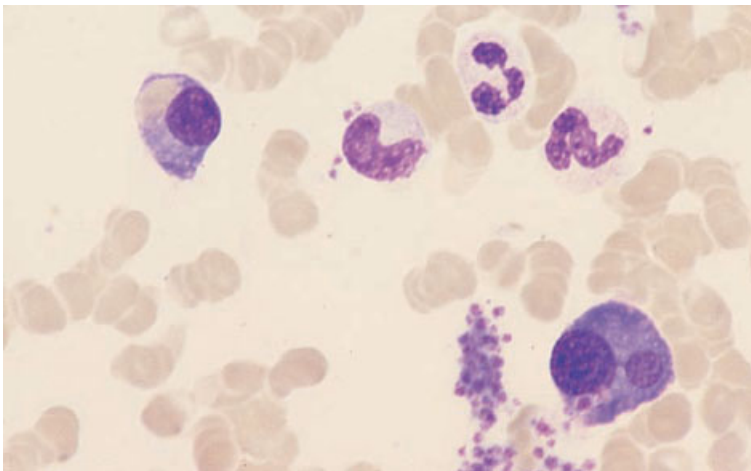


Fig. 7.4 BM aspirate, multiple myeloma, showing one myeloma cell with a bilobed nucleus and another which has ingested an erythrocyte. MGG ×940.

Fig. 7.5 BM aspirate, multiple myeloma, showing a myeloma cell containing crystals of immunoglobulin. MGG $\times 940$.

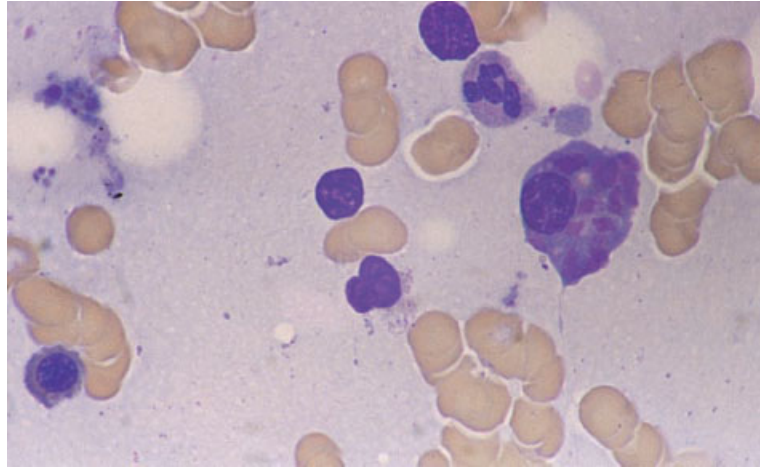


Fig. 7.6 BM aspirate, multiple myeloma, showing myeloma cells, one of which has gross distension of the endoplasmic reticulum by immunoglobulin. MGG $\times 940$.

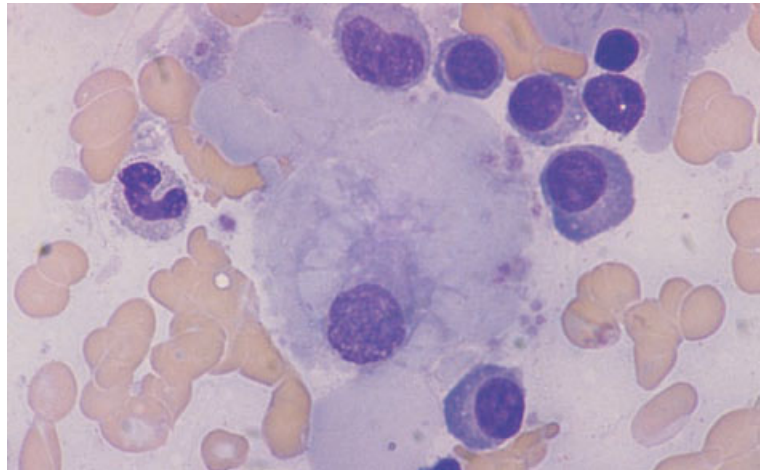
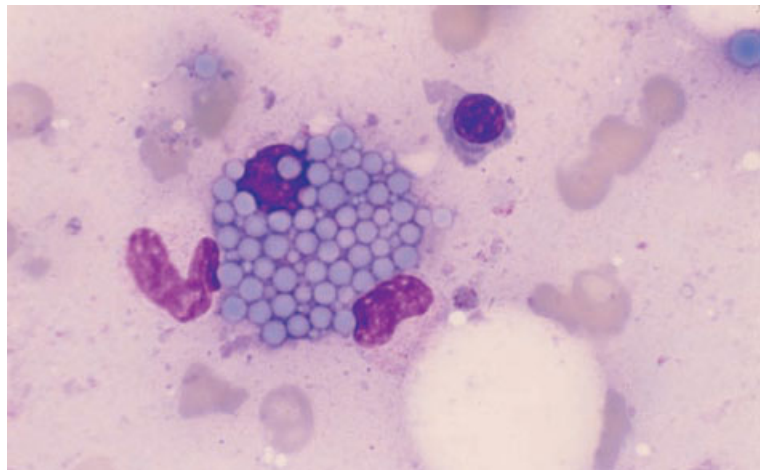


Fig. 7.7 BM aspirate, multiple myeloma, showing a Mott cell. MGG $\times 970$.



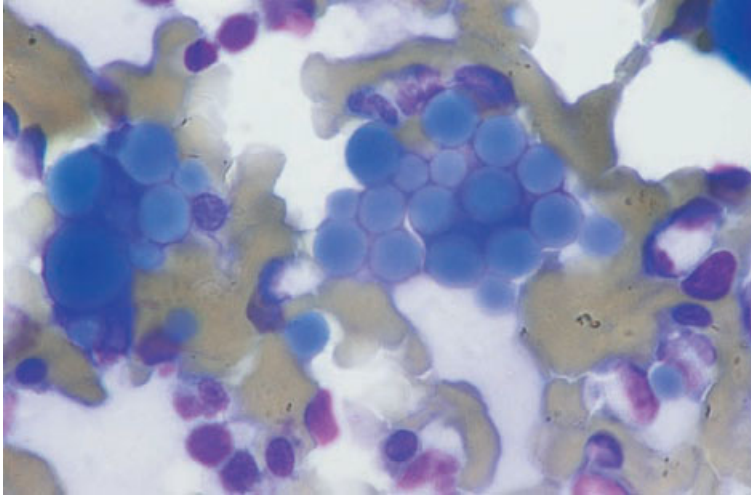


Fig. 7.8 BM aspirate, multiple myeloma, showing numerous Russell bodies. MGG $\times 940$.

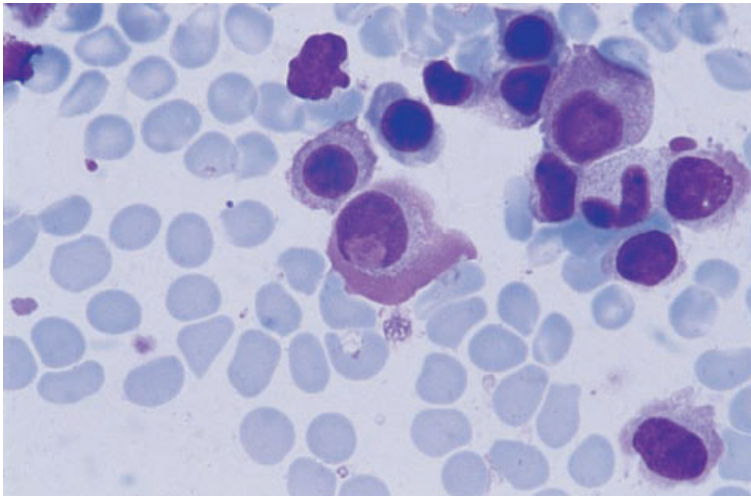


Fig. 7.9 BM aspirate, multiple myeloma, showing formation of a Dutcher body by invagination from the cytoplasm. There are also 'flame cells'. MGG $\times 940$.

Russell bodies (Fig. 7.8). Nuclear inclusions may be present (Fig. 7.9). Rarely the bone marrow aspirate contains amyloid (see Fig. 7.29).

It is not always possible to make a diagnosis of multiple myeloma on the basis of bone marrow morphology alone. Multiple myeloma characteristically affects the bone marrow in a patchy manner and an aspirate will not necessarily contain a large number of plasma cells; nor will the morphology of the myeloma cells necessarily be very abnormal. Non-diagnostic aspirates are obtained in about 5% of patients. There is no particular percentage of

plasma cells which reliably separates multiple myeloma from reactive plasmacytosis or from monoclonal gammopathy of undetermined significance (see below). It is necessary, in doubtful cases, to assess not only the bone marrow cytology and histology but also the clinical, radiological and biochemical features.

The bone marrow aspirate is of value not only in making a diagnosis of multiple myeloma but also in determining the prognosis. Both the percentage of plasma cells in the aspirate [3–5] and their degree of dysplasia [4,6–8] correlate with prognosis.

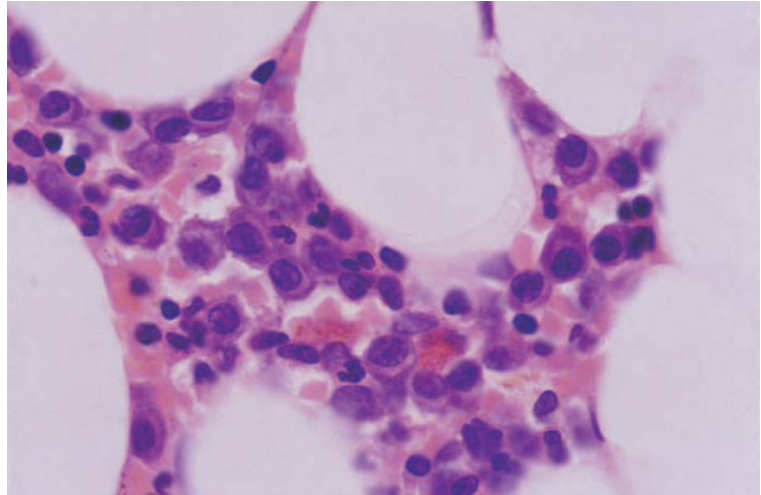


Fig. 7.10 BM trephine biopsy section, multiple myeloma, showing interstitial infiltration of the marrow by plasma cells. Paraffin-embedded, H&E $\times 940$.

Flow cytometry and immunocytochemistry

Myeloma cells give negative reactions with most B-cell markers but positive reactions are often obtained with CD79a. In addition, both normal plasma cells and myeloma cells express CD38 and CD138 and do not express CD45. Normal plasma cells usually express CD19 and not CD56, whereas myeloma cells often over-express CD56 and fail to express CD19 [9,10]. Other antigens which are not expressed in normal plasma cells but may show aberrant expression in myeloma cells include CD20, CD28 and CD117. SmIg may be expressed whereas normal plasma cells express only cytoplasmic Ig [9].

Bone marrow histology

Bone marrow biopsy can be of use both in the diagnosis of multiple myeloma and in assessing the prognosis. Non-diagnostic biopsies are obtained in 5–10% of cases, either because of early disease or because the pattern of infiltration is nodular rather than diffuse and the biopsy has included only non-infiltrated marrow [11]. In addition, increased reticulin may mean that myeloma cells are not readily aspirated. Because a larger volume of tissue is sampled than in an aspirate and since the pattern of infiltration can be ascertained, a biopsy may confirm a diagnosis of multiple myeloma when the aspirate has not done so. However, on occasions, more diagnostic information is obtained from the

aspirate than from the trephine biopsy, so the two investigations should be regarded as complementary. Three major patterns of infiltration are seen: (i) interstitial, with or without paratrabeular seams of plasma cells; (ii) nodules or broad bands; and (iii) a packed marrow [11]. When infiltration is interstitial myeloma cells are dispersed among haemopoietic and fat cells (Fig. 7.10), whereas in a 'packed marrow' (Fig. 7.11) the normal architecture of the marrow is obliterated. In reactive plasmacytosis, infiltration is interstitial and large accumulations of plasma cells are not seen. Some histopathologists have considered that plasma cells sited around capillaries are indicative of reactive plasmacytosis rather than multiple myeloma [11], but others have observed this feature also in multiple myeloma [12]. A paratrabeular pattern of infiltration (Fig. 7.12) may occur but is uncommon. Myeloma cells show varying degrees of dysplasia. In some cases myeloma cells are morphologically very similar to normal plasma cells. In others, they are very large, have nucleoli, are pleomorphic (Fig. 7.13) or are frankly blastic with a diffuse chromatin pattern and a prominent nucleolus (Fig. 7.14). Nucleocytoplasmic asynchrony is common. Dutcher bodies (Fig. 7.13), Russell bodies (Fig. 7.15), cytoplasmic crystals (Fig. 7.16) and Mott cells (Fig. 7.17) may be apparent.

Additional changes which may be associated with multiple myeloma include reduced haemopoiesis, even in the absence of heavy infiltration, increased

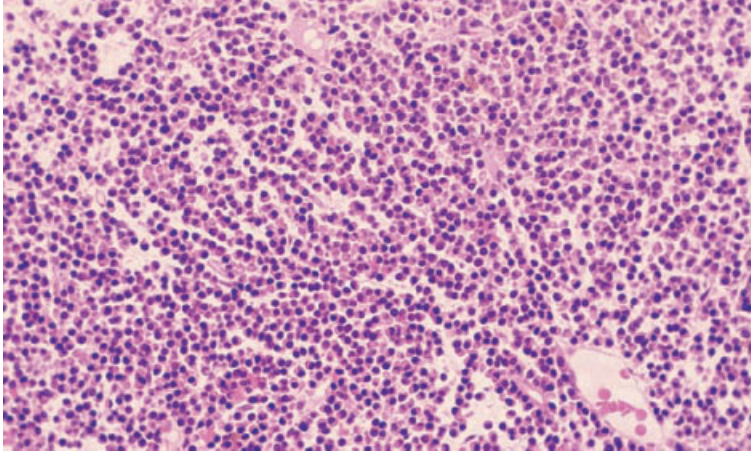


Fig. 7.11 BM trephine biopsy section, multiple myeloma, showing diffuse infiltration by plasma cells (packed marrow). Paraffin-embedded, H&E $\times 195$.

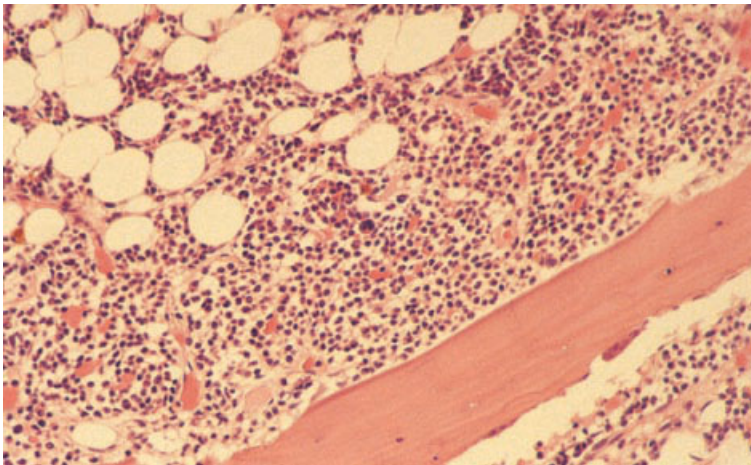


Fig. 7.12 BM trephine biopsy section, multiple myeloma, showing a paratrabecular myelomatous infiltrate. Paraffin-embedded, H&E $\times 188$.

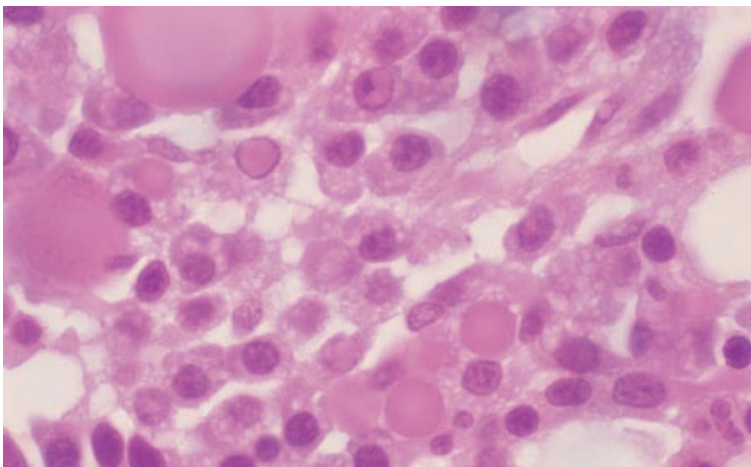


Fig. 7.13 BM trephine biopsy section, multiple myeloma, showing plasma cells with moderate nuclear pleomorphism and numerous eosinophilic intranuclear (Dutcher) and intracytoplasmic (Russell) inclusion bodies. Paraffin-embedded, H&E $\times 970$.

Fig. 7.14 BM trephine biopsy section, multiple myeloma (plasmablastic), showing plasmablasts with marked variation in nuclear size and shape and prominent central nucleoli. Plastic-embedded, H&E $\times 940$.

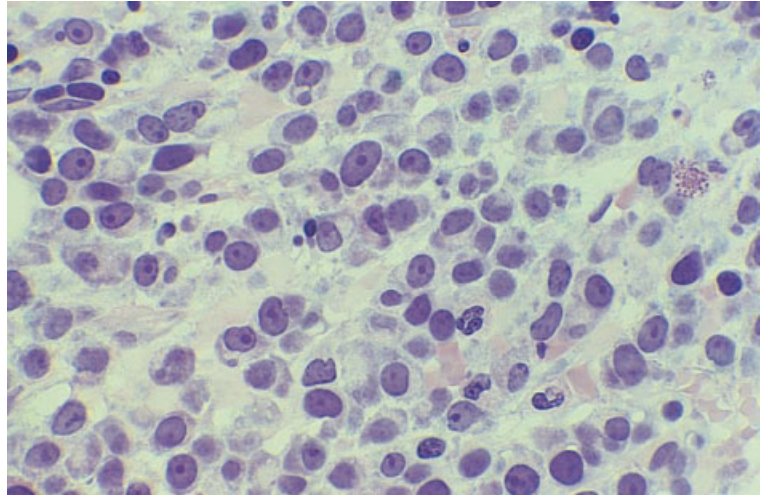
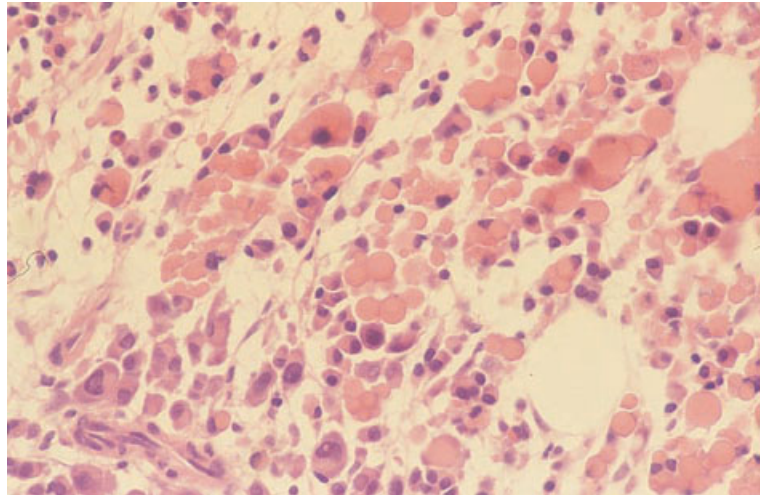


Fig. 7.15 BM trephine biopsy section, multiple myeloma, showing abundant Russell bodies. Paraffin-embedded, H&E $\times 390$.



reticulin deposition, lymphoid infiltrates and, occasionally, the presence of granulomas (see Fig. 3.29). Bone marrow vascularity is increased and is indicative of a worse prognosis [13,14]. Patients with a neutrophilic leukaemoid reaction show striking granulocytic hyperplasia. Occasionally, reticulin deposition is markedly increased and there is also collagen deposition; this appears to be particularly associated with IgD myeloma [15,16]. Collagen deposition is preferentially type II rather than type I [17], as occurs also in idiopathic myelofibrosis. If systematic evaluation is carried out, amyloid

deposition is demonstrated in the bone marrow in up to 10% of patients [18].

The bone changes usually associated with multiple myeloma are diffuse osteoporosis, with thinning of all trabeculae, and osteolytic lesions with resorption of bone by osteoclasts. In multiple myeloma there is no relationship between osteoclastic and osteoblastic activity [19]. Diffuse osteoporosis has been found to be associated with a packed marrow pattern of infiltration, while osteolytic lesions are found particularly in those with nodular infiltration [11]. Osteoclastic activity correlates with the degree

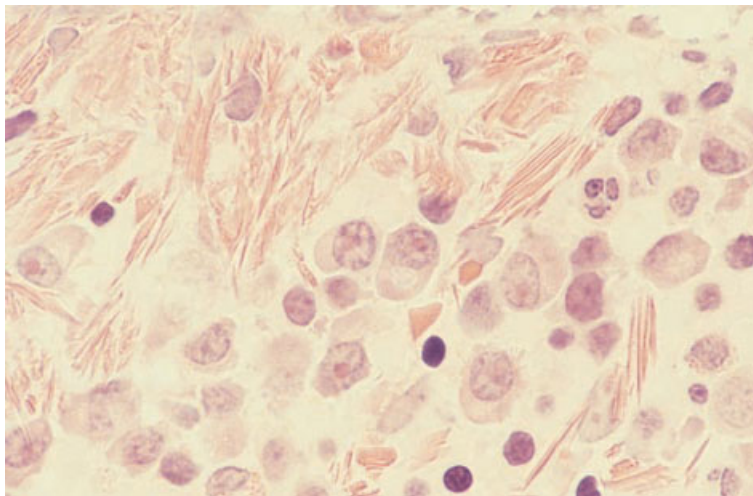


Fig. 7.16 BM trephine biopsy section, multiple myeloma, showing a striking deposition of crystals of immunoglobulin. Paraffin-embedded, H&E $\times 940$. (By courtesy of Dr P Hayes, Chatham.)

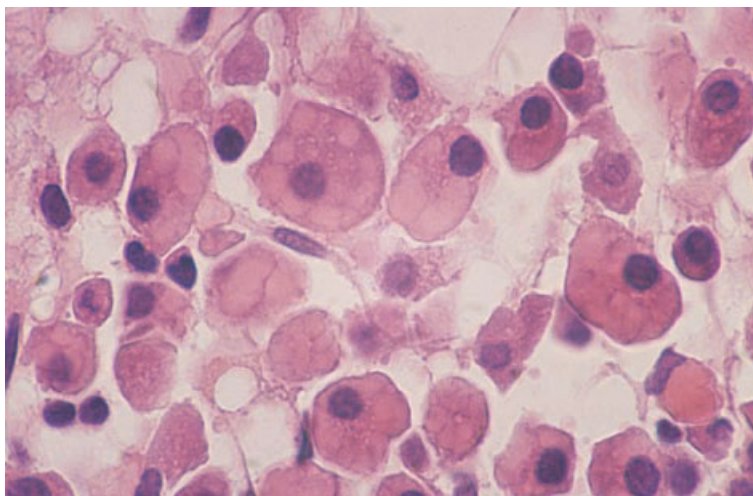


Fig. 7.17 BM trephine biopsy section, multiple myeloma, showing myeloma cells with endoplasmic reticulum distended by immunoglobulin (Mott cells). Paraffin-embedded, H&E $\times 940$.

of plasma cell infiltration. Occasional patients with multiple myeloma have osteosclerosis (Fig. 7.18).

The prognosis in myeloma can be related to: (i) the extent of plasma cell infiltration (histological stage); (ii) the pattern of infiltration; and (iii) the cytological features of the cells (histological grade) [11]. Bartl *et al.* [11] found that a nodular pattern of infiltration correlated with more aggressive disease and with a worse prognosis than was seen when the pattern of infiltration was interstitial, with or without paratrabecular seams of plasma cells; a packed marrow indicated a worse prognosis than either of

the other patterns. This has been confirmed by Pich *et al.* [20]. These two groups and a number of other investigators have been able to relate prognosis also to the degree of dysplasia of the myeloma cells [19–22]. Bartl and Frisch [19] have suggested a classification that divides myeloma into three groups: (i) low grade, in which the plasma cells are mature with minimal dysplasia; (ii) intermediate grade, in which the plasma cells are dysplastic but not frankly blastic; and (iii) high grade, comprising plasmablasts. The three grades have median survivals of 60, 32 and 10 months, respectively [7,11].

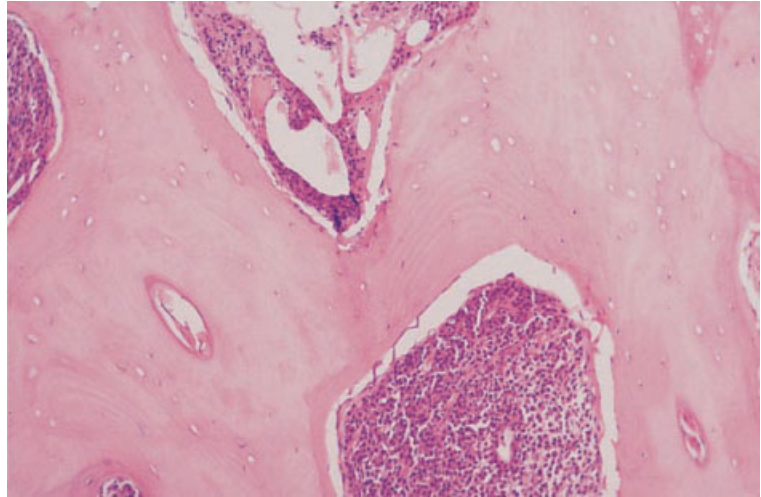


Fig. 7.18 BM trephine biopsy section in osteosclerotic multiple myeloma. Paraffin-embedded, H&E $\times 188$.

The best prognosis in multiple myeloma is found in those with ‘smouldering’ disease. Histologically, these patients have minimal interstitial infiltration by mainly mature plasma cells [19]. The minority of cases of multiple myeloma which show a high count of mitotic figures (more than one per high power field) have a shorter survival [23]. The presence of amyloid deposits in the bone marrow or elsewhere has been found not to influence prognosis in patients who are treated with intensive chemotherapy followed by autologous stem cell transplantation [18].

Response to treatment is associated with a reduction of plasma cell burden and reduced osteoclastic activity. Corticosteroid-treated patients may have aggravation of osteoporosis. Patients treated with bisphosphonates may show new bone formation with extensive osteoid seams [19].

Immunohistochemistry

Neoplastic cells in the great majority of cases of multiple myeloma express monotypic immunoglobulin, i.e. there is expression of κ or λ light chains but not both. There is usually expression of CD38 and CD138 and reactions with VS38c are positive [24–26]. Cells from cases with plasmacytic morphology, but rarely those with plasmablastic features, express the CD38 ligand CD31 [27]. Expression of CD79a is usual but, in a substantial proportion of cases, cells

fail to express this antigen. Cells in a proportion of cases express CD45 or CD20 but most do not. A variety of other antigens, including CD22, CD45RO, CD30 and non-haemopoietic antigens, such as epithelial membrane antigen (EMA) and vimentin, are sometimes expressed [28]. However, in contrast to normal plasma cells, the expression of CD30 and EMA is not at all common in multiple myeloma. Nuclear expression of cyclin D1 is observed in the majority of patients in whom $t(11;14)(q13;q32)$ is detected and in a minority of other patients [29]. Expression of CD45RO correlates with a worse prognosis [30].

Cytogenetics and molecular genetics

Because of the low proliferation rate of myeloma cells, cytogenetic analysis demonstrates a clonal abnormality in only 30–50% of cases of multiple myeloma, whereas fluorescence *in situ* hybridization (FISH) techniques demonstrate an abnormality in 80–100% of cases. No specific cytogenetic or molecular genetic abnormalities have been demonstrated but aneuploidy and chromosomal translocations involving the immunoglobulin heavy chain (*IGH*) locus at 14q32 are both common. Translocations with a 14q32 breakpoint are demonstrable by FISH in about 60% of patients [31]. They include $t(4;14)(p16;q32)$, $t(6;14)(p25;q32)$, $t(8;14)(q24;q32)$, $t(9;14)(p13;q32)$, $t(11;14)(q13;q32)$ (the

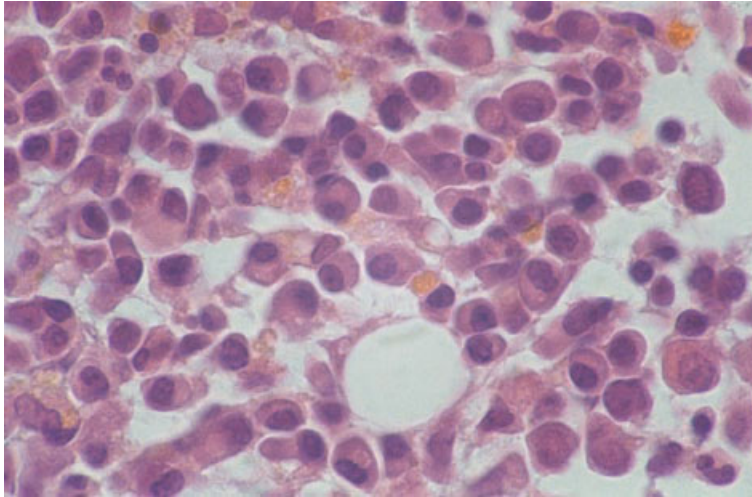


Fig. 7.19 BM trephine biopsy section, showing heavy reactive plasma cell infiltration in HIV infection. Paraffin-embedded, H&E $\times 940$.

commonest translocation demonstrated) and t(14;16)(q32;q22–23). Other translocations demonstrated have sometimes had a 22q11 breakpoint, e.g. t(8;22)(q24;q11) and t(16;22)(q23;q11). Frequently demonstrated aneuploidies include monosomy 13 and trisomies 3, 5, 6, 7, 9, 11, 15, 17 and 19 [31–34]. Common deletions are 13q14, 17p13 and 11q [35]. Hyperdiploidy is seen in more than 50% of patients with the remainder showing hypodiploidy, pseudodiploidy and near tetraploidy [34]. Deletions of 11q, 13q14 and 17p13 have been found to have a poor prognostic significance [35].

Problems and pitfalls

Problems can occur in distinguishing multiple myeloma from reactive plasmacytosis and from other lymphoproliferative disorders with plasmacytic differentiation. The diagnosis must therefore be based on correlation of clinical, biochemical, radiological, cytological and histological features.

Increased numbers of plasma cells can be seen as a reactive phenomenon in a wide range of conditions (page 116) and they can comprise more than 10% of bone marrow cells (Fig. 7.19). In assessing bone marrow aspirates, there is no cut-off point that reliably distinguishes multiple myeloma from reactive conditions. Rarely, as many as 30–50% of plasma cells are present as a reactive change. Cytological features must be assessed as well as

plasma cell number. The presence of plasmablasts and marked plasma cell dysplasia, e.g. giant forms, striking nuclear lobulation and prominent nucleoli, are strongly suggestive of multiple myeloma.

Three trephine biopsy features have been reported to be specific for multiple myeloma: (i) homogeneous nodules of plasma cells occupying at least half a high power field; (ii) monotypic plasma cell aggregates occupying the space between fat cells; and (iii) marked diffuse plasmacytosis with monotypic light chain expression [23].

Increased numbers of plasma cells are seen in monoclonal gammopathy of undetermined significance (see below) and this condition therefore needs to be distinguished from multiple myeloma [36,37]. In some cases of multiple myeloma, the neoplastic cells have the features of lymphoplasmacytoid lymphocytes rather than of plasma cells; such cases need to be distinguished from lymphoplasmacytic lymphoma.

In the rare cases of multiple myeloma which show a very marked fibroblastic response, it may be difficult to recognize distorted plasma cells (Fig. 7.20); immunohistochemistry is useful to confirm their presence.

In some patients with multiple myeloma, the neoplastic cells are so immature or atypical that they are cytologically indistinguishable from large cell lymphoma or other anaplastic tumours, including carcinoma, melanoma and AML. Plasmablastic

Fig. 7.20 BM trephine biopsy section, multiple myeloma, showing a fibroblastic reaction to myelomatous infiltration. Immunohistochemistry is useful for identifying the distorted neoplastic cells in the fibrous tissue. Paraffin-embedded, H&E $\times 376$. (By courtesy of Dr J Jip, Bolton.)

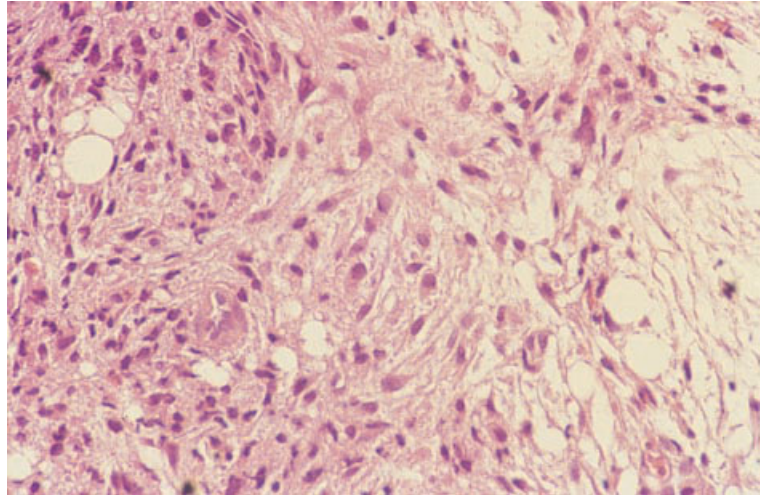
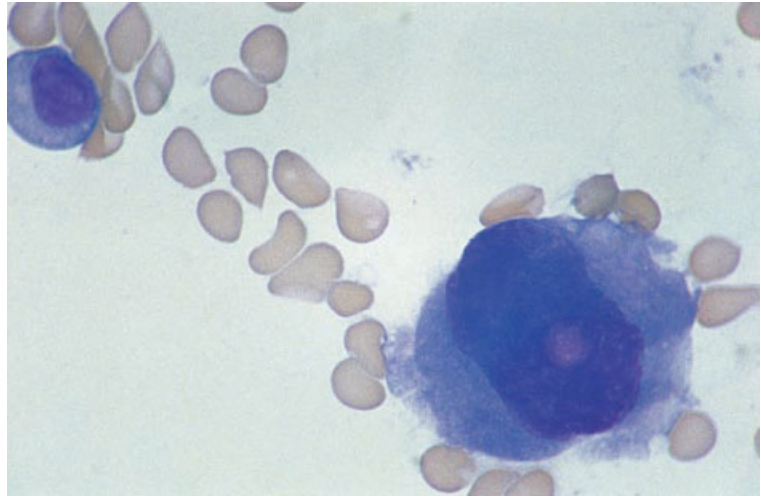


Fig. 7.21 BM aspirate, multiple myeloma, showing a giant myeloma cell which could easily be confused with a megakaryocyte; the presence of an intranuclear inclusion (a Dutcher body) is a clue to the correct diagnosis. MGG $\times 940$.



myeloma and large cell lymphoma with cells having the features of immunoblasts are particularly likely to be confused. Myeloma cells sometimes also resemble carcinoma cells in forming cohesive masses [38]. Giant, pleomorphic plasma cells may be confused with megakaryocytes (Figs 7.21 and 7.22).

A Giemsa stain can be very useful in highlighting plasma cell differentiation in an apparently anaplastic tumour but immunohistochemistry, using an appropriate panel of antibodies, is often crucial in making a correct diagnosis. Large cell lymphoma can be distinguished from multiple myeloma immunohistochemically since lymphoma cells are

usually positive for CD45, CD79a and CD20 and do not express cytoplasmic immunoglobulin. Myeloma cells are usually negative for CD45 and CD20, vary in their expression of CD79a and show strong cytoplasmic expression of monotypic immunoglobulin. AIDS-related large cell lymphomas without any apparent plasmacytic differentiation may fail to express CD20 but usually express CD45. Anaplastic large cell lymphoma (see page 306) is among the large cell lymphomas which can be confused with anaplastic multiple myeloma; both conditions are usually negative for B-cell markers and CD45 but positive for CD30 and both may express EMA.

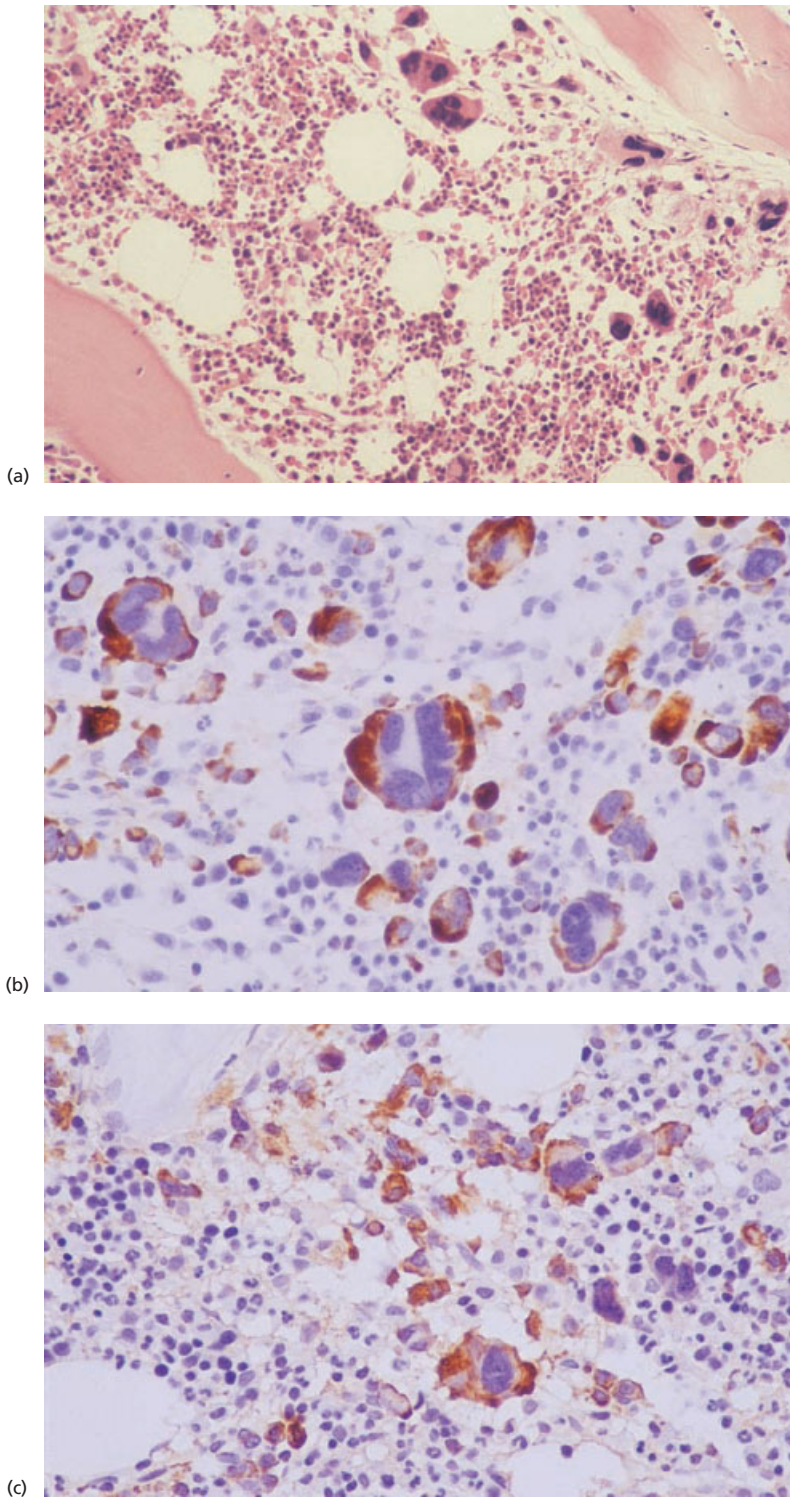
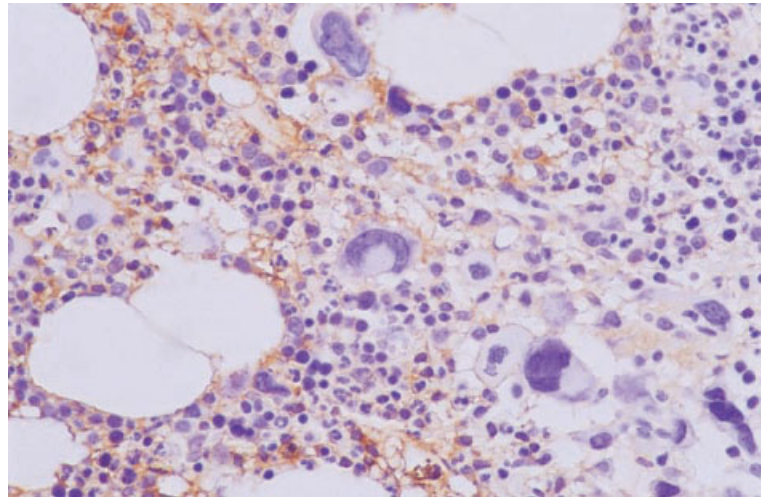


Fig. 7.22 BM trephine biopsy sections (same case as in Fig. 7.21), showing giant myeloma cells which were confused with megakaryocytes. However, the giant cells were negative for CD61, positive for a plasma cell marker and showed light chain restriction. Paraffin-embedded. (a) H&E $\times 188$. (b) Positive reaction with VS38c. Immunoperoxidase $\times 376$. (c) Positive reaction with anti-kappa. Immunoperoxidase $\times 376$.



(d)

Fig. 7.22 (d) Negative reaction with anti-lambda. Immunoperoxidase $\times 376$.

Staining for ALK1 can be useful since many cases of anaplastic large cell lymphoma are positive (see page 309). CD45RO, often used as a T-cell marker, is expressed in some cases of multiple myeloma [30].

The demonstration of light chain restriction using labelled oligonucleotide or peptide nucleic acid probes complementary to κ and λ light chain mRNA (see page 80) can be useful in distinguishing myeloma from large cell lymphoma and from other tumours. Anaplastic carcinoma cells do not express CD45 or CD20 and usually express EMA and high or low molecular weight cytokeratins. However, in this context, it should be noted that some myeloma cells also express EMA and, likewise, CD138 may be expressed by non-lymphoid tumours including some anaplastic carcinomas. It is usual practice to apply a broad panel of monoclonal antibodies in an attempt to determine the nature of anaplastic tumours. If reactions are all negative it is important to consider anaplastic myeloma and carry out immunostaining for κ and λ light chains. Immunostaining for CD138 and the antigen reactive with VS38c can also be useful in this context [25,26].

Plasma cell leukaemia

The term plasma cell leukaemia may be used to designate a *de novo* leukaemia of neoplastic plasma cells or the terminal phase of multiple myeloma when

myeloma cells are present in the peripheral blood in large numbers. Plasma cell leukaemia has been defined by the presence in the circulating blood of at least $2 \times 10^9/l$ plasma cells which also constitute at least 20% of circulating cells [39]. Patients with *de novo* or primary plasma cell leukaemia show clinical features that are common in multiple myeloma such as bone pain, lytic lesions, hypercalcaemia and renal failure, but they have a higher incidence of extramedullary lesions and, in addition, often have hepatomegaly and splenomegaly. The disease is more aggressive than multiple myeloma with a median survival of less than a year. Patients with established multiple myeloma who develop a secondary plasma cell leukaemia have advanced disease which is usually refractory to treatment. Their prognosis is likewise poor.

Peripheral blood

The blood film shows large numbers of circulating neoplastic plasma cells (Fig. 7.23), the morphology of which varies between patients from cells resembling normal plasma cells to primitive, blastic cells showing only minimal evidence of plasma cell differentiation. Anaemia is almost invariable and neutropenia and thrombocytopenia are common. Increased rouleaux formation and increased background staining are usual; in patients with plasma cell leukaemia as the terminal phase of multiple

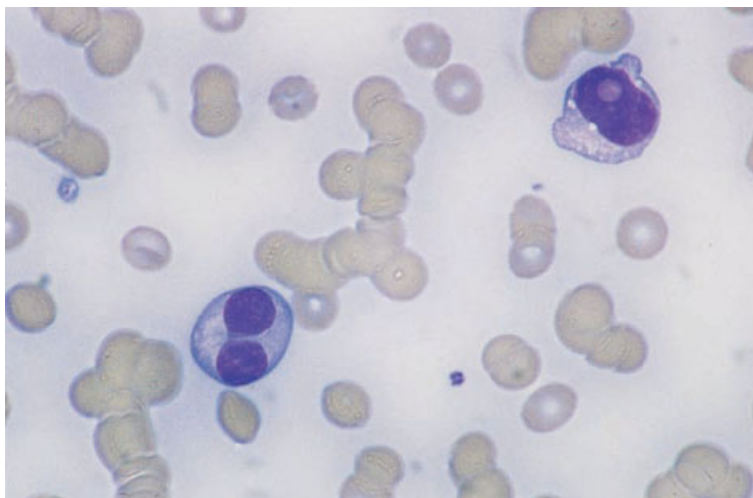


Fig. 7.23 PB film in plasma cell leukaemia, showing marked rouleaux formation and two dysplastic plasma cells, one with an intranuclear inclusion (Dutcher body). MGG $\times 940$.

myeloma these abnormalities are often striking since the paraprotein level is commonly high.

Bone marrow cytology

The bone marrow is heavily infiltrated with neoplastic cells showing the same morphological features as those in the peripheral blood. Normal haemopoietic elements are reduced.

Bone marrow histology

There is a diffuse infiltrate of plasma cells which make up the majority of cells in the marrow [40,41]. In the majority of cases, the cytological features are similar to those of multiple myeloma; in a minority of cases the cells are very immature with little morphological evidence of plasma cell differentiation.

Cytogenetics and molecular genetics

Clonal cytogenetic abnormalities are common in plasma cell leukaemia. Although no consistent association is recognized, monosomy 13 is common [32,33] and there are often chromosomal rearrangements, such as $t(11;14)(q13;q32)$, with a 14q32 breakpoint. Hypodiploidy is common whereas, in contrast to multiple myeloma, hyperdiploidy is not [32–34]. Deletion of the cancer-suppressing *RB* gene is common [32,33].

Monoclonal gammopathy of undetermined significance—benign monoclonal gammopathy

Monoclonal gammopathy of undetermined significance (MGUS) denotes a condition in which there is proliferation of a clone of plasma cells with production of a paraprotein but without the signs of disease which are characteristic of multiple myeloma and related plasma cell disorders. The paraprotein is usually an immunoglobulin (either IgG, IgA or IgM) but is occasionally a Bence-Jones protein. The paraprotein concentration is relatively low (in the case of an IgG paraprotein less than 30 g/l, in the case of an IgA or IgM paraprotein less than 20 g/l) and is usually stable. Immune paresis is not a feature. Since there are no features of disease, the diagnosis is necessarily made incidentally. Monoclonal gammopathy of uncertain significance is common. Paraproteins can be detected in about 1% of adults under the age of 70 and in about 3% of adults over this age. It is not always possible to make a distinction between multiple myeloma and MGUS on the basis of any single feature. It is necessary to assess clinical and haematological features, bone marrow cytology and bone marrow histology in order to make the distinction. A period of observation may also be necessary to establish that the concentration of the paraprotein is stable and no disease features are appearing. It should be noted that although this

condition is clinically benign, it does represent a neoplastic proliferation. If patients are followed for a prolonged period, a significant proportion eventually develop overt evidence of multiple myeloma or a related condition. In one series of patients, over a 20-year period of observation, the actuarial risk of developing multiple myeloma, Waldenström's macroglobulinaemia or primary (AL) amyloidosis was found to be approximately 30% [42]. In another small series of patients, followed for up to 31 years, seven of 11 patients developed a plasma cell neoplasm or non-Hodgkin's lymphoma (NHL) [43]. Since progression may occur, but the likelihood of this cannot be predicted currently for individual patients, the designation 'monoclonal gammopathy of undetermined significance' is preferred to 'benign monoclonal gammopathy'.

Peripheral blood

The peripheral blood film may show increased rouleaux formation but this is generally less marked than in multiple myeloma; anaemia does not occur and circulating plasma cells are not present.

Bone marrow cytology

The bone marrow may appear completely normal or there may be an increase of plasma cells. Plasma cells do not usually exceed 5% of nucleated cells but may comprise up to 10%. The plasma cells are usually morphologically fairly normal but minor dysplastic features may be noted.

Bone marrow histology

Plasma cell infiltration is usually minimal with focal accumulation around capillaries which is often indistinguishable from a reactive plasmacytosis [11].

Immunohistochemistry

Immunohistochemical staining with anti- κ and anti- λ antisera shows $\kappa:\lambda$ or $\lambda:\kappa$ ratios of greater than four in approximately 65% of cases, the majority having ratios between four and 16. In comparison, almost all cases of overt myeloma have $\kappa:\lambda$ or $\lambda:\kappa$ ratios of greater than 16, the majority being greater than 100 [44].

Cytogenetics and molecular genetics

Because the neoplastic cells make up a low proportion of bone marrow cells and have a low proliferative rate, it is uncommon for cytogenetic analysis to demonstrate any clonal abnormality in patients with MGUS. Nevertheless, FISH techniques show that translocations with a 14q32 breakpoint, such as t(4;14)(p16;q32) and t(11;14)(q13;q32), occur with a similar frequency to that seen in multiple myeloma [31]. Various aneuploidies have also been demonstrated. Monosomy 13, however, has been found to be much less common than in multiple myeloma and, when present, is likely to be predictive of disease progression [31].

Problems and pitfalls

It can be difficult to estimate $\kappa:\lambda$ ratios when plasma cells constitute less than 5% of total cells [45]. However, it should be noted that this is not an essential investigation if it is known that the patient has a paraprotein. The major purpose of the trephine biopsy in this context is to distinguish between MGUS and multiple myeloma.

Waldenström's macroglobulinaemia

The condition described by Waldenström as 'essential hyperglobulinaemia' is a disease characterized by a lymphoplasmacytic neoplasm with secretion of large amounts of an IgM paraprotein. It is a variant of lymphoplasmacytic lymphoma (see page 258) and is distinguished from other cases of this lymphoma on the basis of clinical and biochemical features rather than by cytological or histological criteria. Predominant signs and symptoms are either characteristic of a lymphoma or are caused by the hyperviscosity of blood consequent on the high concentration of IgM. Hepatomegaly, splenomegaly and lymphadenopathy are common. Clinical features resulting from the high concentration of the paraprotein include anaemia (due to a greatly increased plasma volume), impaired vision, cerebral effects, cardiac failure and a bleeding tendency. In some patients the paraprotein has characteristics of a cold agglutinin or a cryoglobulin and in others it is amyloidogenic. Peripheral neuropathy is common and the paraprotein can sometimes be shown

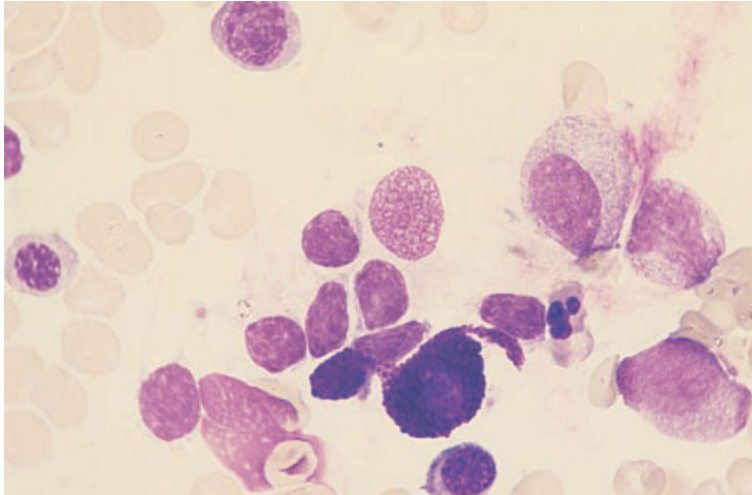


Fig. 7.24 BM aspirate, Waldenström's macroglobulinaemia, showing a mast cell and mature small lymphocytes. MGG $\times 940$.

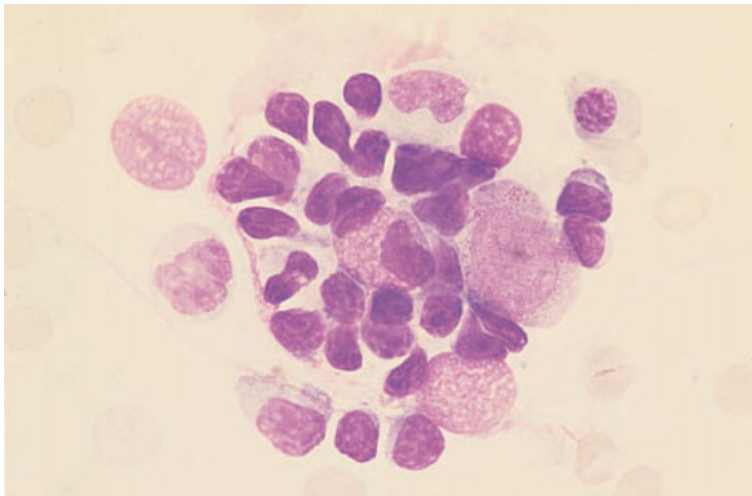


Fig. 7.25 BM aspirate, Waldenström's macroglobulinaemia (same case as in Fig. 7.24), showing mature small lymphocytes and one plasmacytoid lymphocyte clustered around a macrophage (reticulum cell). MGG $\times 940$.

to have antibody activity against neural antigens. The incidence of Waldenström's macroglobulinaemia is about a tenth that of multiple myeloma.

Peripheral blood

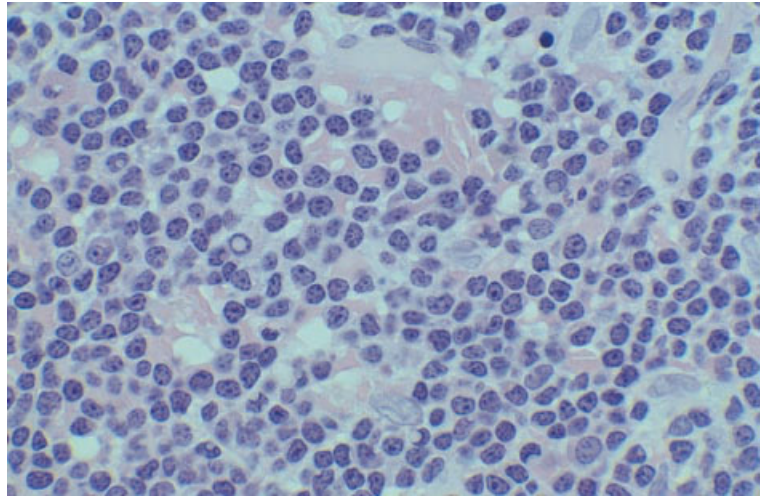
There is usually a normocytic normochromic anaemia, increased rouleaux formation and increased background staining. Some patients have thrombocytopenia. When the paraprotein has the characteristics of a cold agglutinin or of a cryoglobulin, either red cell agglutinates or a cryoglobulin precipitate may be detected in the blood film. The

lymphocyte count may be normal or elevated, with the lymphocytes usually being mature small lymphocytes showing some features of differentiation to plasma cells.

Bone marrow cytology

The bone marrow is infiltrated by neoplastic cells which most often have the morphology of small lymphocytes, with a variable proportion of cells showing some plasmacytoid features (Figs 7.24 and 7.25). Plasma cells are usually increased and, in some patients, plasmacytic differentiation is prom-

Fig. 7.26 BM trephine biopsy section, Waldenström's macroglobulinaemia, showing a diffuse infiltrate of small lymphoid cells, some of which show evidence of plasmacytoid differentiation (Dutcher bodies, 'clock-face' chromatin pattern and/or a Golgi zone). Plastic-embedded, H&E $\times 377$.



inent. Intranuclear or intracytoplasmic inclusions, which are usually periodic acid–Schiff (PAS)-positive, are sometimes present. Macrophages and mast cells (Fig. 7.25) are often increased. Lymphoplasmacytoid cells may be clustered around macrophages.

Bone marrow histology

The bone marrow histology is not uniform [46–48]. In some patients, the infiltrating cells are predominantly lymphocytes, including plasmacytoid lymphocytes whereas, in others, there is prominent plasma cell differentiation. Some patients have an interstitial infiltrate or well-circumscribed nodules of lymphoid cells but, in the majority, there is either diffuse infiltration or a mixed nodular–diffuse pattern. Paratrabecular infiltration may also occur, often accompanied by increased reticulin deposition. A variable proportion of cells show features of plasmacytic differentiation, including Russell bodies and Dutcher bodies (Fig. 7.26). Mature plasma cells are usually increased, as are macrophages, mast cells and, sometimes, eosinophils. Mast cells may be specifically associated with lymphoid infiltrates. Overall, about half of the cases show increased reticulin deposition. Trephine biopsy sections sometimes show infiltration when the bone marrow aspirate is normal. Rare observations in Waldenström's macroglobulinaemia include the deposition

of paraprotein in the bone marrow interstitium and an abnormal staining pattern caused by intrasinusoidal paraprotein (Fig. 7.27).

Immunohistochemistry

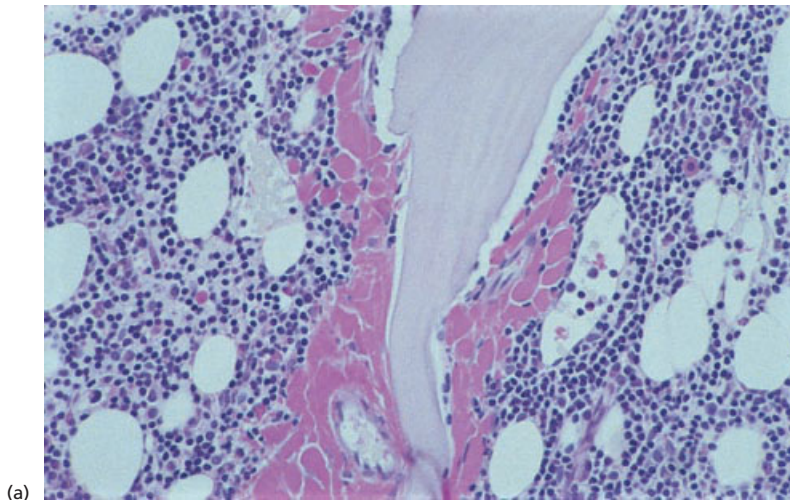
Immunohistochemical features vary between and within cases, depending on the degree of plasmacytic differentiation shown. There is usually strong expression of CD79a by most of the cells, while any neoplastic plasma cells show monotypic cytoplasmic immunoglobulin (κ or λ) and react with VS38c.

Other syndromes associated with secretion of a paraprotein

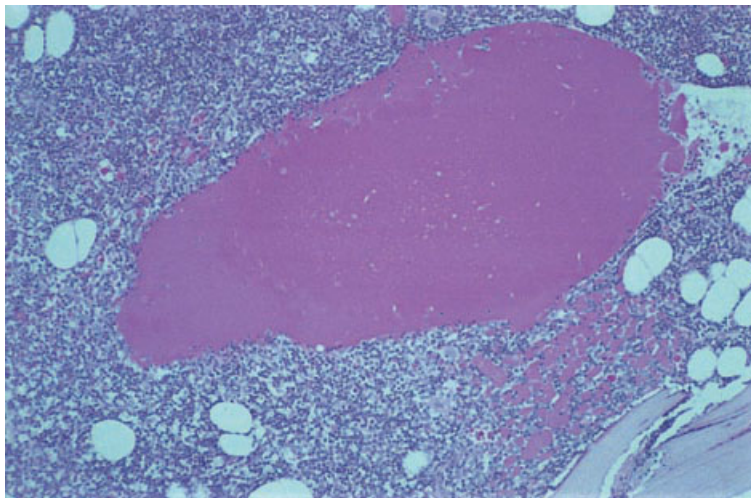
There are a number of other, relatively uncommon, syndromes associated with the secretion of a paraprotein. In some of these the features of a lymphoproliferative disorder are prominent; in others the clinical and pathological features relate to the characteristics of the paraprotein and only detailed investigation reveals the presence of an abnormal clone of plasma cells, plasmacytoid lymphocytes or lymphocytes. These conditions are summarized in Table 7.1.

Light chain-associated amyloidosis

Light chain-associated amyloidosis (AL-type of



(a)



(b)

Fig. 7.27 Paraffin-embedded BM trephine biopsy sections, Waldenström's macroglobulinaemia, showing: (a) interstitial deposition of IgM paraprotein adjacent to a trabecula, PAS stain $\times 188$; and (b) intrasinusoidal paraprotein, PAS stain $\times 94$.

Table 7.1 Monoclonal gammopathies (modified from [49]).

Multiple myeloma (including smouldering multiple myeloma)
Solitary plasmacytoma (of bone or extramedullary)
Lymphoplasmacytic lymphoma including Waldenström's macroglobulinaemia and other types of non-Hodgkin's lymphoma with a serum or urinary paraprotein
Monoclonal gammopathy of undetermined significance including idiopathic Bence-Jones proteinuria
Light chain-associated amyloidosis
Light chain or other immunoglobulin deposition disease
Adult acquired Fanconi's syndrome (renal tubular deposition and excretion of monoclonal light chain)
Essential cryoglobulinaemia (type I and type II cryoglobulinaemia)
Chronic cold haemagglutinin disease
Alpha, gamma and mu (α , γ and μ) heavy chain disease
The POEMS syndrome
Acquired angio-oedema associated with monoclonal gammopathy
Monoclonal gammopathy with peripheral neuropathy
Scleromyxoedema (mucinous deposition in the skin plus serum paraprotein)
Systemic capillary leak syndrome with paraproteinaemia
Acquired C1 inhibitor deficiency with paraproteinaemia

amyloidosis) is a disease consequent on a plasma cell disorder in which there is production of an amyloidogenic light chain [50–54]. The features of the disease are usually caused by the amyloidosis rather than by other features of the plasma cell proliferation. Heart failure and renal failure are common manifestations. In a minority of patients, light chain-associated amyloidosis is associated with overt multiple myeloma, Waldenström's macroglobulinaemia or other forms of lymphoplasmacytic lymphoma (see page 258) [53]. However, in the majority of patients, the plasma cell disorder would be classified as MGUS if it were not for the amyloidogenic characteristics of the light chains. In a small minority of patients no paraprotein is detectable in serum or urine but, in this group also, the disease results from a neoplastic proliferation of plasma cells, albeit occult. The term primary amyloidosis may be used to describe cases without evidence of multiple myeloma or other overt plasma cell neoplasm. Amyloid can be formed from either κ or λ light chains but, in the majority of patients, it is derived from λ light chains.

Peripheral blood

The peripheral blood may be normal or may show the features usually associated with multiple myeloma or lymphoplasmacytic lymphoma. Occasionally, features of hyposplenism are present, indicating that the spleen is infiltrated by amyloid and has become hypofunctional. Thrombocytosis, observed in 9% of cases in one large series, may be indicative of hyposplenism [54].

Bone marrow cytology

The bone marrow aspirate varies from normal through increased plasma cells of normal morphology to overt multiple myeloma or lymphoplasmacytic lymphoma. In a large series of patients, 40% had at least 10% bone marrow plasma cells [54]. When the bone marrow aspirate is apparently normal, κ : λ imbalance may indicate the presence of an abnormal clone of cells, even though the total number of plasma cells is not increased. Very rarely, a bone marrow aspirate from a patient with amyloidosis contains either neutrophils which have ingested amyloid [55] or extracellular amyloid deposits (Fig. 7. 28).

Bone marrow histology

Bone marrow biopsy sections may be normal or may show increased plasma cells. Sometimes, characteristic features of multiple myeloma or lymphoplasmacytic lymphoma are present. In addition, amyloid may be detected either in the walls of small blood vessels (Figs 7.29 and 7.30) or in the interstitium (Fig. 7.31). Amyloid was detected in bone marrow sections in 56% of one large series of patients [55]. In sections stained with H&E, amyloid is homogeneous and pink (Fig. 7.29a) whereas with a Giemsa stain it is blue (Fig. 7.30). It stains with Congo red (Fig. 7.29b) and, following Congo red staining, shows apple-green birefringence on examination with polarized light (Fig. 7.29c). It stains metachromatically with crystal violet and methyl violet and fluoresces after staining with thioflavine-T [56]. Light chain-associated (AL) amyloid can be distinguished from amyloid of AA type by the abolition of Congo red staining by prior treatment with potassium permanganate in the latter type [56].

Immunohistochemistry

Amyloid can be demonstrated using a monoclonal antibody that reacts with the P protein common to light chain-associated and other forms of amyloid. In the majority of cases of light chain-associated amyloid, a positive identification can be made with type-specific anti-light chain sera. Neoplastic lymphocytes and plasma cells, when present in detectable numbers, show the expected patterns of reactivity.

Cytogenetics and molecular genetics

Clonal chromosome abnormalities are common in primary amyloidosis but, because the neoplastic cells constitute a low percentage of bone marrow cells, demonstration of these abnormalities requires FISH techniques [57]. Numerical abnormalities, both monosomies and trisomies, are common as are complex cytogenetic abnormalities. The pattern of abnormal findings is similar to that observed in MGUS.

Light chain deposition disease [56,58–60]

Light chain deposition disease describes a syndrome

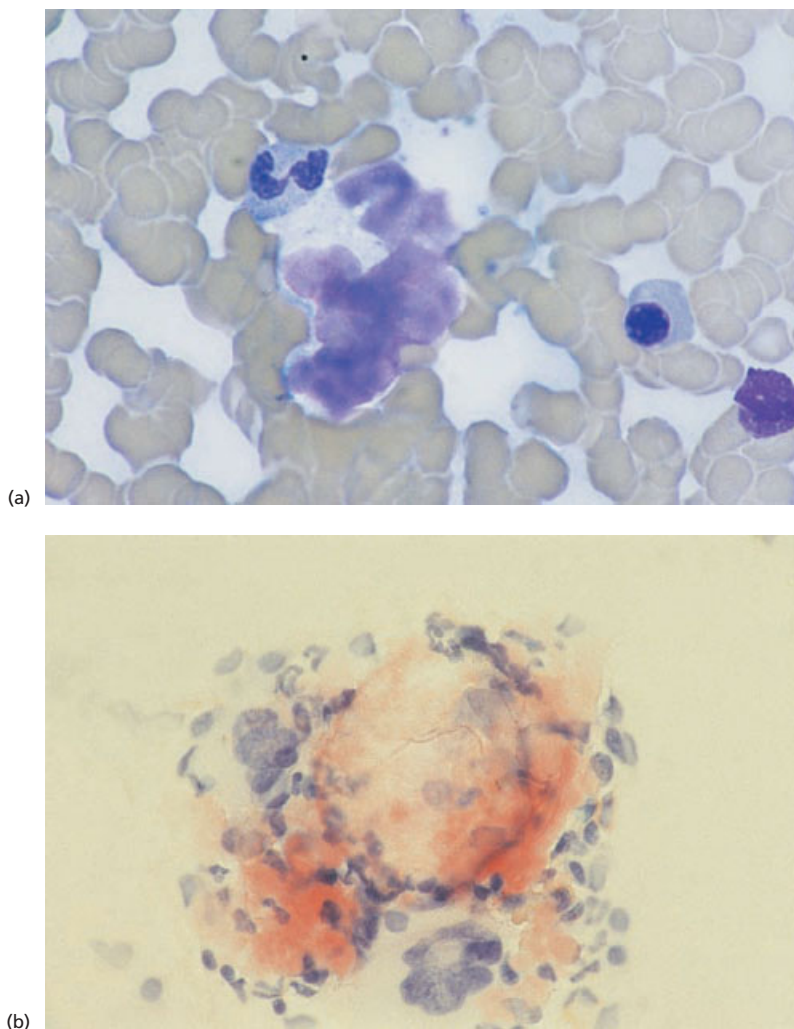
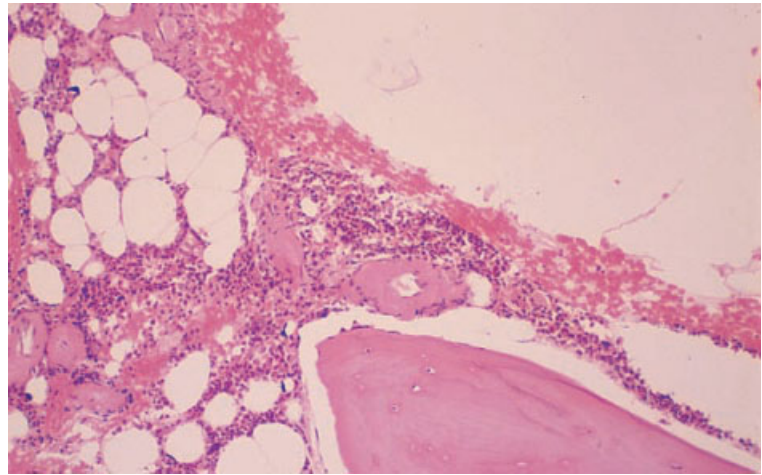


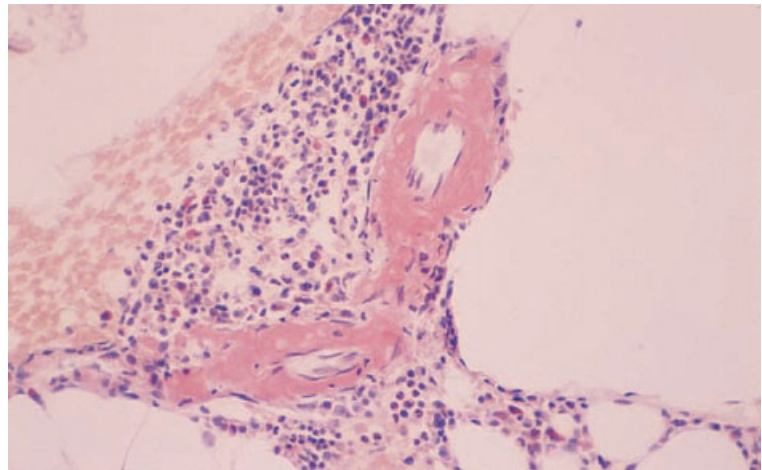
Fig. 7.28 BM aspirate, showing: (a) a deposit of amyloid, MGG $\times 940$; and (b) amyloid within a BM fragment, Congo red $\times 470$.

of organ damage consequent on the systemic deposition of free light chains. There is an associated neoplastic proliferation of plasma cells which may be occult or overt. About 70% of patients have relevant clinical features, most often of multiple myeloma but occasionally of solitary plasmacytoma, lymphoplasmacytic lymphoma or other NHL. The remaining patients either have features which would usually be interpreted as MGUS (about 15% of cases) or have no serum or urinary paraprotein detectable (also about 15% of cases) [56]. Those without a detectable paraprotein nevertheless have an occult plasma cell neoplasm, the neoplastic cells

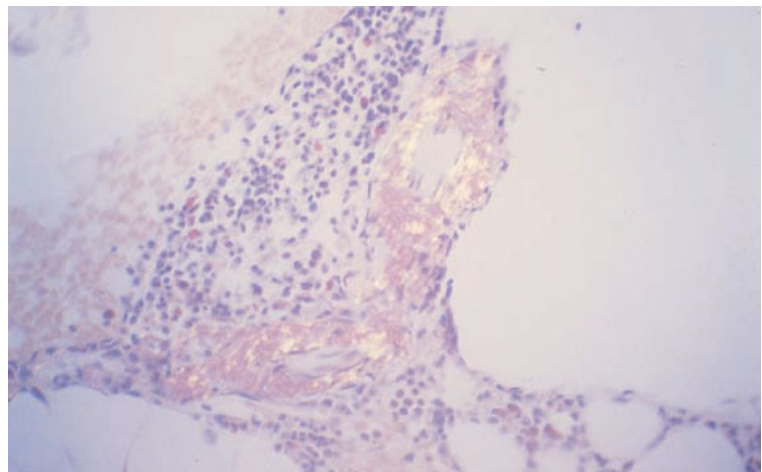
producing a light chain type which has a propensity to deposit in and damage tissues. Cases with κ light chains are over-represented relative to cases with λ light chains. In occasional patients, a similar syndrome is associated with systemic deposition of heavy chains in addition to light chains; the term 'monoclonal immunoglobulin deposition disease' has been suggested to include these cases [60,61]. The predominant organ damage is renal, with glomerular and tubular deposition causing the nephrotic syndrome, renal failure or both. Occasional patients have presented with clinical features of hepatic, cardiac or adrenal involvement.



(a)



(b)



(c)

Fig. 7.29 BM trephine biopsy sections, showing amyloid in the walls of small blood vessels. Paraffin-embedded. (a) H&E $\times 97$. (b) Congo red stain $\times 390$. (c) Congo red stain viewed under polarized light $\times 390$.

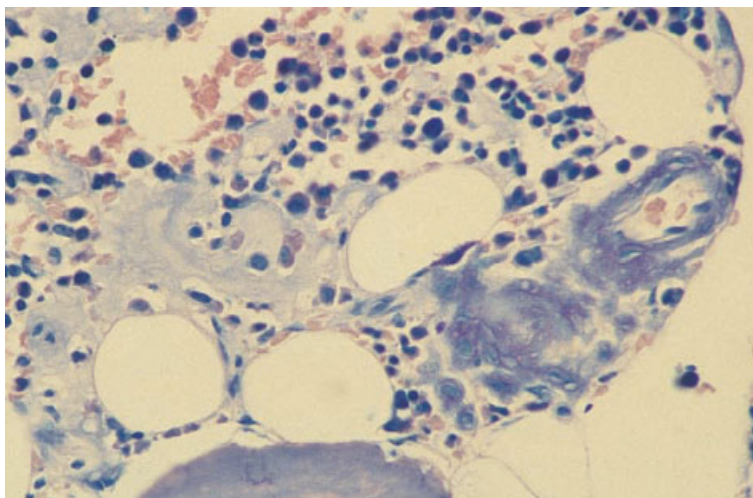


Fig. 7.30 BM trephine biopsy section, showing amyloid in the walls of small blood vessels. Paraffin-embedded, Giemsa stain $\times 376$.

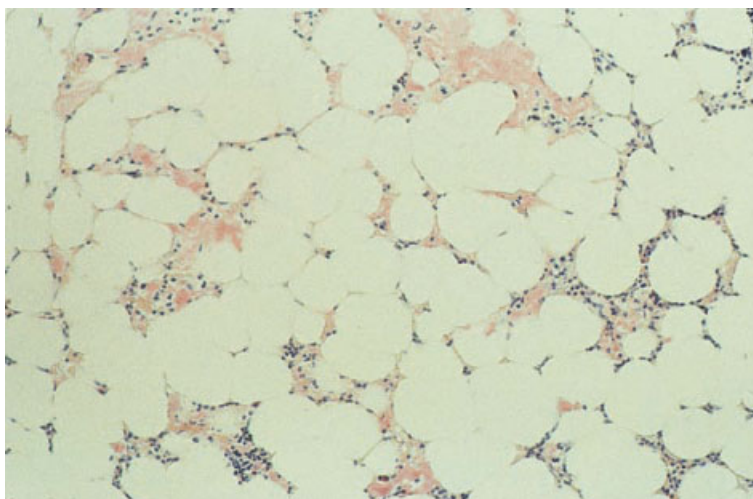


Fig. 7.31 BM trephine biopsy section, light chain-associated amyloidosis (AL type), showing deposition of amorphous eosinophilic material in the interstitium. Paraffin-embedded, H&E $\times 94$.

Peripheral blood and bone marrow

There are no specific peripheral blood findings other than those usually associated with renal failure or with multiple myeloma or other plasma cell neoplasm.

The bone marrow may appear normal or may show features usually associated with MGUS, multiple myeloma or a related condition. Some patients who initially have no evidence of multiple myeloma subsequently develop typical features of this disease. In those cases in which the bone marrow is apparently normal, it may be possible to

demonstrate a monoclonal population of plasma cells by flow cytometry. Rarely, light chains are deposited in the bone marrow, either in the interstitium or in the walls of blood vessels [56,59]. Light chain deposits are morphologically similar to amyloid deposits when stained with H&E but they do not stain with Congo red, or show birefringence with polarized light, and are negative or react weakly with thioflavine-T; they are PAS-positive and stain blue with a Giemsa or Gomori's trichrome stain. The nature of light chain deposits can be confirmed by immunohistochemistry with anti- κ or anti- λ antiserum.

Essential and other paraprotein-associated cryoglobulinaemia

A plasma cell disorder may lead to cryoglobulinaemia, either when there is secretion of a paraprotein with the characteristics of a cryoglobulin (type I cryoglobulinaemia) or when a paraprotein has antibody activity against another immunoglobulin and the immune complex formed is a cryoglobulin (type II cryoglobulinaemia); in the latter type, the paraprotein is usually IgM with antibody activity against polyclonal IgG. In about a quarter of patients, cryoglobulinaemia is a manifestation of multiple myeloma or of Waldenström's macroglobulinaemia. In the other three quarters of patients, in whom no overt neoplastic proliferation of plasma cells is present, the term 'essential cryoglobulinaemia' is appropriate; in these cases the clone of cells secreting the paraprotein is too small to produce any pathological manifestations other than those due to the characteristics of the cryoglobulin. A significant proportion of cases of type II cryoglobulinaemia are secondary to hepatitis C infection and some of these have an overt low grade NHL; these cases are not designated 'essential' cryoglobulinaemia. The clinical features of cryoglobulinaemia, e.g. purpura and peripheral cyanosis, may relate to precipitation of the immunoglobulin on chilling or, in the case of type II cryoglobulinaemia, to immune complex formation.

Peripheral blood

In the absence of overt multiple myeloma or lymphoplasmacytic lymphoma, the peripheral blood film is often normal. In a minority of patients, a cryoglobulin precipitate is present, usually as weakly basophilic globular masses, less often as crystals or a fibrillar deposit. Occasionally, cryoglobulin precipitates have been ingested by neutrophils or monocytes and are seen as globular, variably basophilic intracytoplasmic inclusions.

Bone marrow cytology and histology

The bone marrow findings are either normal or are those of multiple myeloma, a low grade NHL or MGUS.

Chronic cold haemagglutinin disease

Chronic cold haemagglutinin disease (CHAD) is a disease characterized by chronic, cold-induced haemolytic anaemia consequent on a lymphoplasmacytic neoplasm which may be either occult or overt. In patients who do not have clinical or pathological features of a lymphoma at presentation, these may evolve subsequently.

Peripheral blood

Unless it has been prepared from warmed blood, the blood film shows red cell agglutinates. If there has been a recent episode of haemolysis a few spherocytes may be present together with polychromatic macrocytes. Some patients have lymphocytosis, with the cells either having the morphology of normal mature lymphocytes or showing some plasmacytic features.

Bone marrow cytology and histology

The bone marrow appearances vary from normal to those of an overt lymphoplasmacytic lymphoma. There is usually erythroid hyperplasia.

α heavy chain disease

α heavy chain disease is a lymphoplasmacytic neoplasm, usually affecting predominantly the bowel, associated with the secretion of the heavy chain of IgA into the serum or into the bowel lumen. Some cases evolve into large cell lymphoma.

Peripheral blood and bone marrow

The peripheral blood shows no specific abnormality. The bone marrow is usually normal but may be infiltrated by plasma cells.

γ heavy chain disease

γ heavy chain disease is a lymphoplasmacytic neoplasm characterized by lymphadenopathy, hepatomegaly and splenomegaly and by the secretion of the heavy chain of IgG. Some patients have developed amyloidosis, indicating that light chain as well as heavy chain may be secreted.

Peripheral blood

Anaemia, leucopenia and thrombocytopenia are common. In about half of cases there are atypical lymphoplasmacytoid cells and some plasma cells in the peripheral blood. Some patients have eosinophilia.

Bone marrow cytology

The bone marrow is infiltrated by lymphocytes, lymphoplasmacytoid cells or plasma cells.

 μ heavy chain disease [62–65]

μ heavy chain disease is a lymphoproliferative disorder characterized by the secretion of the heavy chain of IgM. Most patients described in the published literature have had the pathological features of chronic lymphocytic leukaemia (CLL) although one recent case has been reported in association with Waldenström's macroglobulinaemia [66]. Hepatomegaly and splenomegaly are usual; abdominal lymphadenopathy is more prominent than peripheral lymphadenopathy. Light chain secretion may also occur and may give rise to amyloidosis.

Peripheral blood and bone marrow

The majority of patients show features indistinguishable from CLL.

The POEMS syndrome [67–70]

The POEMS, or 'Polyneuropathy, Organomegaly, Endocrinopathy, M-protein, Skin changes', syndrome describes a curious constellation of pathological manifestations which has been associated with multiple myeloma (particularly, but not exclusively, osteosclerotic multiple myeloma), solitary plasmacytoma and lymphoplasmacytic lymphoma. In addition, POEMS has been described in patients with bone marrow appearances which, but for the many associated pathological features, would be designated MGUS. The syndrome is rare and occurs at a younger age than is usual in multiple myeloma. The 'polyneuropathy' is both motor and sensory. The 'organomegaly' refers to hepatomegaly,

splenomegaly and lymphadenopathy. The pathological features of the enlarged lymph nodes approximate to those of the hyaline-vascular type of Castleman's disease; there is follicular hyperplasia, vascular proliferation and an interfollicular infiltrate of lymphocytes, plasma cells and immunoblasts. The 'endocrinopathy' may include primary gonadal failure, hypothyroidism, Addison's disease and diabetes mellitus. The 'monoclonal gammopathy', present in about three quarters of patients, is usually an IgG λ or IgA λ paraprotein. 'Skin' manifestations include skin thickening resembling that of scleroderma, oedema, hypertrichosis, hyperpigmentation and Raynaud's phenomenon. Other features of the syndrome include pleural effusion, ascites, papilloedema and finger clubbing.

Peripheral blood and bone marrow

There are no specific peripheral blood features. The bone marrow findings range from normal to those of overt lymphoplasmacytic lymphoma or multiple myeloma. About 60% of patients have a significant bone marrow plasmacytosis. In those with multiple myeloma, osteosclerosis is usual but some patients have osteolytic lesions.

Acquired angio-oedema associated with plasma cell neoplasia [71–73]

The majority of cases of acquired angio-oedema described have been associated with a neoplastic plasma cell proliferation or with other B-lineage neoplasms, with or without secretion of a paraprotein. Associated conditions have included multiple myeloma, lymphoplasmacytic lymphoma, splenic lymphoma with villous lymphocytes and other NHL, essential cryoglobulinaemia, MGUS and CLL. The mechanism of the acquired angio-oedema is C1 inhibitor deficiency consequent on excessive consumption; it is likely that consumption of C1 inhibitor can be due to precipitation of a cryoglobulin, to an immunological reaction involving the paraprotein or to reaction of auto-antibodies with neoplastic cells. Deficiency of C1 inhibitor may precede the development of overt lymphoproliferative disease by many years [74].

Peripheral blood and bone marrow

The peripheral blood and bone marrow findings are those usually associated with multiple myeloma, lymphoplasmacytic lymphoma or other lymphoproliferative disease. In a minority of cases the bone marrow shows only a slight increase in plasma cells or is normal.

References

- Österborg A and Mellstedt H. Clinical features and staging. In: Gahrton G and Durie BGM (eds) *Multiple Myeloma*. Arnold, London, 1996.
- Ghevaert C, Fournier M, Bernardi F, Genevieve F, Pouyol F and Zandecki M (1997) Non-secretory multiple myeloma with multinucleated giant plasma cells. *Leuk Lymphoma*, 27, 185–189.
- Merlini G, Gobbi PG and Ascari E (1989) The Merlini, Waldenström, Jayakar staging system revisited. *Eur J Haematol*, 43 (Suppl. 51), 105–110.
- Pasqualetti P, Casale R, Collacciani A, Abruzzo BP and Colantonio D (1990) Multiple myeloma: relationship between survival and cellular morphology. *Am J Hematol*, 33, 145–147.
- Finnish Leukaemia Group (1999) Long-term survival in multiple myeloma: a Finnish Leukaemia Group study. *Br J Haematol*, 105, 942–947.
- Greipp PR, Raymond NM, Kyle RA and O'Fallon WM (1985) Multiple myeloma: significance of plasmablastic morphological classification. *Blood*, 65, 305–310.
- Carter A, Hocherman I, Linn S, Cohen Y and Tatarsky I (1987) Prognostic significance of plasma cell morphology in multiple myeloma. *Cancer*, 60, 1060–1065.
- Goasguen JE, Zandecki M, Mathiot C, Scheiff JM, Bizet M, Ly-Sunnaram B *et al.* (1999) Mature plasma cells as indicator of better prognosis in multiple myeloma. New methodology for the assessment of plasma cell morphology. *Leuk Res*, 23, 1133–1140.
- Almeida J, Orfao A, Ocqueteau M, Mateo G, Corral M, Caballero MD *et al.* (1999) High-sensitive immunophenotyping and DNA ploidy studies in the investigation of minimal residual disease in multiple myeloma. *Br J Haematol*, 107, 121–131.
- Ruiz-Arguelles GJ and San Miguel JF (1994) Cell surface markers in multiple myeloma. *Mayo Clin Proc*, 96, 684–690.
- Bartl R, Frisch B, Diem H, Møndel M and Fateh-Moghadam A (1989) Bone marrow histology and serum β 2 microglobulin in multiple myeloma—a new prognostic strategy. *Eur J Haematol*, 43 (Suppl. 51), 88–98.
- Pileri S, Poggi S, Baglioni P, Montanari M, Sabattini E, Galieni P *et al.* (1989) Histology and immunohistology of bone marrow biopsy in multiple myeloma. *Eur J Haematol*, 43 (Suppl. 51), 52–59.
- Ribatti D, Vacca A, Nico B, Quondamatteo F, Ria R, Minischetti M *et al.* (1990) Bone marrow angiogenesis and mast cell density increase simultaneously with progression of human multiple myeloma. *Br J Cancer*, 79, 451–455.
- Vacca A, Ribatti D, Presta M, Minischetti M, Iurlaro M, Ria R *et al.* (1999) Bone marrow neovascularization, plasma cell angiogenic potential, and matrix metalloproteinase-2 secretion parallel progression of human multiple myeloma. *Blood*, 93, 3064–3073.
- Nakamura H, Sakamoto M, Wakasugi K and Toyama K (1991) IgD-lambda multiple myeloma associated with bone marrow fibrosis. *Rinsho Ketsueki*, 32, 395–398.
- Lam KY and Chan KW (1993) Unusual findings in a myeloma kidney: a light- and electron-microscopic study. *Nephron*, 65, 133–136.
- Abildgaard N, Bendix-Hansen K, Kristensen JE, Vejlgård T, Risteli L, Nielsen JL and Heickendorff L (1997) Bone marrow fibrosis and disease activity in multiple myeloma monitored by the aminoterminal propeptide of procollagen III in serum. *Br J Haematol*, 99, 641–648.
- Desikan KR, Dhodapkar MV, Hough A, Waldron T, Jagannath S, Siegel D *et al.* (1997) Incidence and impact of light chain associated (AL) amyloidosis on the prognosis of patients with multiple myeloma treated with autologous transplantation. *Leuk Lymphoma*, 27, 315–319.
- Bartl R and Frisch B (1995) Diagnostic morphology in multiple myeloma. *Curr Diagn Pathol*, 2, 222–235.
- Pich A, Chiusa L, Marmont F and Navone R (1997) Risk groups of myeloma patients by histologic pattern and proliferative activity. *Am J Surg Pathol*, 21, 339–347.
- Strand WR, Banks PM and Kyle RA (1984) Anaplastic plasma cell myeloma and immunoblastic lymphoma: clinical, pathologic and immunologic comparison. *Am J Med*, 76, 861–867.
- Bartl R, Frisch B, Fateh-Moghadam A, Kettner G, Jaeger K and Sommerfeld W (1986) Histologic classification and staging of multiple myeloma. *Am J Clin Pathol*, 87, 342–355.
- Sukpanichnant S, Cousar JB, Leelasiri A, Graber SE, Greer JP and Collins RD (1994) Diagnostic criteria and histologic grading in multiple myeloma: histologic and immunohistologic analysis of 176 cases with clinical correlation. *Hum Pathol*, 25, 308–318.
- Anderson KC, Bates MP, Slaughtenhaupt B, Schlossman SF and Nadler LM (1984) A monoclonal antibody with reactivity restricted to normal and neoplastic plasma cells. *J Immunol*, 132, 3172–3177.
- Dhodapkar MV, Abe E, Theus A, Lacy M, Langford JK, Barlogie B and Sanderson RD (1998) Syndecan-1 is a multifunctional regulator of myeloma pathobiology: control of tumour cell survival, growth and bone differentiation. *Blood*, 91, 2679–2688.

- 26 Turley H, Jones M, Erber W, Mayne K, de Waele M and Gatter K (1994) VS38: a new monoclonal antibody for detecting plasma cell differentiation in routine sections. *J Clin Pathol*, 47, 418–422.
- 27 Vallario A, Chilosi M, Adami F, Montagna L, Deaglio S, Malavasi F and Calgaris-Cappio F (1999) Human myeloma cells express the CD38 ligand CD31. *Br J Haematol*, 105, 441–444.
- 28 Petruich UR, Horny H-P and Kaiserling E (1992) Frequent expression of haemopoietic and non-haemopoietic antigens by neoplastic plasma cells: an immunohistochemical study using formalin-fixed, paraffin-embedded tissue. *Histopathology*, 20, 35–40.
- 29 Hoyer JD, Hanson CA, Fonseca R, Greipp PR, Dewald GW and Kurtin PJ (2000) The t(11;14) (q13;q32) translocation in multiple myeloma: a morphologic and immunohistochemical study. *Am J Clin Pathol*, 113, 831–837.
- 30 Menke DM, Horny HP, Griesser H, Atkinson EJ, Kaiserling E and Kyle RA (1998) Immunophenotypic and genotypic characterisation of multiple myelomas with adverse prognosis characterised by immunohistological expression of the T cell related antigen CD45RO (UCHL-1). *J Clin Pathol*, 51, 432–437.
- 31 Avet-Loiseau H, Li J-Y, Morineau N, Facon T, Brigaudeau C, Harousseau J-L *et al.* on behalf of the Intergroupe Francophone du Myélome (1999) Monosomy 13 is associated with the transition of monoclonal gammopathy of undetermined significance to multiple myeloma. *Blood*, 94, 2583–2589.
- 32 García-Sanz R, Orfão A, González M, Tabertero MD, Bladé J, Moro MJ *et al.* (1999) Primary plasma cell leukemia: clinical, immunophenotypic, DNA ploidy and cytogenetic characteristics. *Blood*, 93, 1032–1037.
- 33 García-Sanz R, Orfão A and San Miguel JF (1999) Primary plasma cell leukemia and multiple myeloma: one or two disease according to the methodology–response. *Blood*, 94, 3608–3609.
- 34 Smadja NV, Bastard C and Brigaudeau C (1999) Primary plasma cell leukemia and multiple myeloma: one or two disease according to the methodology. *Blood*, 94, 3607.
- 35 Konigsberg R, Zojer N, Ackermann J, Kromer E, Kittler H, Fritz E *et al.* (2000) Predictive role of interphase cytogenetics for survival of patients with multiple myeloma. *J Clin Oncol*, 18, 804–812.
- 36 Riccardi A, Ucci G, Luoni R, Castello A, Coci A, Magrini U and Ascari E (1990) Bone marrow biopsy in monoclonal gammopathies: correlations between pathological findings and clinical data. *J Clin Pathol*, 43, 469–475.
- 37 Thiry A, Delvenne P, Fontaine MA and Boniver J (1993) Comparison of bone marrow sections, smears and immunohistological staining for immunoglobulin light chains in the diagnosis of benign and malignant plasma cell proliferations. *Histopathology*, 22, 423–428.
- 38 Gatter K and Brown D. *An Illustrated Guide to Bone Marrow Diagnosis*. Blackwell Science, Oxford, 1997.
- 39 Kyle RA, Maldonado JE and Bayrd ED (1974) Plasma cell leukemia. Report on 17 cases. *Arch Intern Med*, 133, 813–818.
- 40 Kosmo MA and Gale RP (1987) Plasma cell leukemia. *Semin Hematol*, 24, 202–208.
- 41 Bernasconi G, Castelli G, Pagnucco G and Brusamolino E (1989) Plasma cell leukemia: a report on 15 patients. *Eur J Haematol*, 43 (Suppl. 51), 76–83.
- 42 Kyle RA (1989) Monoclonal gammopathy of undetermined significance and smouldering multiple myeloma. *Eur J Haematol*, 43 (Suppl. 51), 70–75.
- 43 Colls BM (1999) Monoclonal gammopathy of undetermined significance (MGUS)–31 year follow up of a community study. *Aust N Z J Med*, 29, 500–504.
- 44 Peterson LC, Brown BA, Crosson JT and Mladenovic J (1985) Application of the immunoperoxidase technique to bone marrow trephine biopsies in the classification of patients with monoclonal gammopathies. *Am J Clin Pathol*, 85, 688–693.
- 45 Menke DM, Greipp PR, Colon Otero G, Solberg LA Jr, Cockerill KJ, Hook CC and Witzig TE (1994) Bone marrow aspirate immunofluorescent and bone marrow biopsy immunoperoxidase staining of plasma cells in histologically occult plasma cell proliferative marrow disorders. *Arch Pathol Lab Med*, 118, 811–814.
- 46 Rywlin AM, Civantos F, Ortega RS and Dominguez CJ (1975) Bone marrow histology in monoclonal macroglobulinemia. *Am J Clin Pathol*, 63, 769–777.
- 47 Chalazzi G, Bettini R and Pinotti G (1979) Bone marrow patterns and survival in Waldenström's macroglobulinaemia. *Lancet*, ii, 965–966.
- 48 Pangalis GA and Kittas C. Bone marrow involvement in chronic lymphocytic leukaemia, small lymphocytic (well differentiated) and lymphoplasmacytic (macroglobulinaemia of Waldenström) non-Hodgkin's lymphoma. In: Polliack A and Catovsky D (eds) *Chronic Lymphocytic Leukemia*. Harwood Academic Publishers, Chur, 1988.
- 49 Griep PR and Lust JA. Monoclonal gammopathies of undetermined significance: their relationship to multiple myeloma. In: Gahrton G and Durie BGM (eds) *Multiple Myeloma*. Arnold, London, 1996.
- 50 Sezer O, Eucker J, Jakob C and Possinger K (2000) Diagnosis and treatment of AL amyloidosis. *Clin Nephrol*, 53, 417–423.
- 51 Perfetti V, Ubbiali P, Vignarelli MC, Diegoli M, Fasani R, Stoppini M *et al.* (1998) Evidence that amyloidogenic light chains undergo antigen-driven selection. *Blood*, 91, 2948–2954.
- 52 Perfetti V, Vignarelli MC, Anesi E, Garini P, Quaglini S, Ascari E and Merlini G (1999) The degrees of plasma cell clonality and marrow infiltration adversely influence the prognosis of AL amyloidosis patients. *Haematologica*, 84, 218–221.

- 53 Gertz MA, Kyle RA and Noel P (1993) Primary systemic amyloidosis: a rare complication of immunoglobulin M monoclonal gammopathies and Waldenström's macroglobulinemia. *J Clin Oncol*, 11, 914–920.
- 54 Kyle RA and Gertz MA (1995) Primary systemic amyloidosis: clinical and laboratory features in 474 cases. *Semin Hematol*, 32, 45–59.
- 55 Park YK, Trubowitz S and Davis S. Plasma cells in the bone marrow. In: Trubowitz S and Davis S (eds) *The Human Bone Marrow: Anatomy, Physiology and Pathophysiology*, Vol. 2. CRC Press, Boca Raton, Florida, 1982.
- 56 Feiner HD (1988) Pathology of dysproteinemia: light chain amyloidosis, non-amyloid immunoglobulin deposition disease, cryoglobulinemia syndromes and macroglobulinemia of Waldenström. *Hum Pathol*, 11, 1255–1272.
- 57 Fonseca R, Ahmann GJ, Jalal SM, Dewald GW, Larson DR, Therneau TM *et al.* (1998) Chromosomal abnormalities in systemic amyloidosis. *Br J Haematol*, 103, 704–710.
- 58 Tubbs RR, Gephardt GN, McMahon JT, Hall PM, Valenzuela R and Vidt DG (1981) Light chain nephropathy. *Am J Med*, 71, 263–269.
- 59 Silver MM, Hearn SA, Ritchie S, Slinger RP, Sholdice JA, Cordy PS and Hodsman AB (1986) Renal and systemic light chain deposits and their plasma cell origin identified by immunoelectron microscopy. *Am J Pathol*, 122, 17–27.
- 60 Gallo G, Picken M, Buxbaum J and Frangione B (1989) The spectrum of monoclonal immunoglobulin deposition disease associated with immunocytic dyscrasias. *Semin Hematol*, 26, 234–243.
- 61 Buxbaum JN, Chuba JV, Hellman GC, Solomon A and Gallo GR (1990) Monoclonal immunoglobulin deposition disease: light chain and light and heavy chain deposition diseases and their relation to light chain amyloidosis. Clinical features, immunopathology, and molecular analysis. *Ann Intern Med*, 112, 455–464.
- 62 Fermand JP, Brouet JC, Danon F and Seligmann M (1989) Gamma heavy chain 'diseases': heterogeneity of the clinicopathologic features. Report of 16 cases and review of the literature. *Medicine*, 68, 321–335.
- 63 Husby G (2000) Is there a pathogenic link between gamma heavy chain disease and chronic arthritis? *Curr Opin Rheumatol*, 12, 65–70.
- 64 Katz A, Zent R and Bargman JM (1994) IgG heavy-chain deposition disease. *Mod Pathol*, 7, 874–878.
- 65 Khamlichi AA, Aucouturier P, Preud'Homme JL and Cogne M (1995) Structure of abnormal heavy chains in human heavy-chain-deposition disease. *Eur J Biochem*, 229, 54–60.
- 66 Iwasaki T, Hamano T, Kobayashi K and Kakishita E. A case of mu-heavy chain disease: combined features of mu-chain disease and macroglobulinemia. *Int J Hematol*, 66, 359–365.
- 67 Bardwick PA, Zvaifler NJ, Gill GN, Newman D, Greenway GD and Resnick DC (1980) Plasma cell dyscrasia with polyneuropathy, organomegaly, endocrinopathy, M-protein, and skin changes: the POEMS syndrome. *Medicine*, 59, 311–322.
- 68 Moya-Mir MS, Martin-Martin F, Barbadillo R, Cuervas-Mons V, Martin-Jimenez T and Sanchez-Miro I (1980) Plasma cell dyscrasia with polyneuritis and dermato-endocrine alterations. Report of a new case outside Japan. *Postgrad Med J*, 56, 427–430.
- 69 Solomons REB and Gibbs DD (1982) Plasma cell dyscrasia with polyneuropathy, organomegaly, endocrinopathy, monoclonal gammopathy and skin changes. *J R Soc Med*, 75, 553–555.
- 70 Pareyson D, Marazzi R, Confalonieri P, Mancardi GL, Schenone A and Sghirlanzoni A (1994) The POEMS syndrome: report of six cases. *Ital J Neurol Sci*, 15, 353–358.
- 71 Bain BJ, Catovsky D and Ewan PW (1993) Acquired angioedema as the presenting feature of lymphoproliferative disorders of mature B-lymphocytes. *Cancer*, 72, 3318–3322.
- 72 Mathur R, Toghil PJ and Johnston IDA (1993) Acquired C1 inhibitor deficiency with lymphoma causing recurrent angioedema. *Postgrad Med J*, 69, 646–648.
- 73 Gordon MM, Lucic N and Porter D (2000) Acquired C1q deficiency caused by monoclonal paraproteinaemia. *Lupus*, 9, 68–71.
- 74 Qaseem T, Paterson WD, Jardine GWH, Wild G, Milford Ward A and Large DM (1991) Acquired C1-inhibitor deficiency preceding malignant lymphoma by 7 years. *J R Soc Med*, 84, 628.

EIGHT

DISORDERS OF ERYTHROPOIESIS, GRANULOPOIESIS AND THROMBOPOIESIS

In this chapter we shall discuss non-neoplastic haematological disorders, both congenital and acquired, which affect predominantly a single lineage—either erythroid, granulocytic or megakaryocytic. For a more detailed discussion of the peripheral blood features, the reader is referred to *Blood Cells: A Practical Guide* [1]. In the majority of these conditions diagnosis is based on peripheral blood and bone marrow aspirate features and on supplementary tests. In general a trephine biopsy is of little importance and is not often performed. The changes consequent on infection have been discussed in Chapter 3 and will therefore not be dealt with in this chapter.

Iron deficiency anaemia

Iron deficiency anaemia results from inadequate iron intake, increased loss of iron from the body or a combination of the two. Peripheral blood features, supplemented by biochemical assays, are often sufficient for a definitive diagnosis. In more complicated cases bone marrow aspiration permits a definitive diagnosis. Trephine biopsy is of little importance and, if iron is leached out during decalcification, histological sections can be misleading.

Useful biochemical tests in the diagnosis of iron deficiency include estimations of serum ferritin and serum iron concentration, the latter only if combined with an estimate of either transferrin concentration or serum total iron binding capacity. Serum ferritin and serum iron concentrations are reduced, whereas serum transferrin concentration and total iron binding capacity are increased. The concentration of soluble serum transferrin receptors is also increased but this test is not very specific for iron deficiency since concentration is also increased if there is increased erythropoiesis.

Peripheral blood

The peripheral blood shows initially a normocytic, normochromic anaemia and later, when the deficiency is more severe, a hypochromic, microcytic anaemia. Red cells also show anisocytosis, anisochromasia and poikilocytosis, particularly the presence of elliptocytes. Occasional patients show thrombocytosis, thrombocytopenia or the presence of occasional hypersegmented neutrophils.

Bone marrow cytology

Bone marrow cellularity is mildly increased as a result of a moderate degree of erythroid hyperplasia. Erythropoiesis is micronormoblastic with erythroblasts being smaller than normal with scanty or ragged cytoplasm or with cytoplasmic vacuolation (Fig. 8.1). There is a minor degree of dyserythropoiesis. An iron stain shows siderotic granules to be severely reduced or absent and there is a complete or virtual absence of the iron within macrophages which usually constitutes the body's iron stores (see Fig. 2.1). Since iron is irregularly distributed in the marrow, a number of bone marrow fragments must be available for the performance of an iron stain before it can be concluded that storage iron is lacking. In iron deficiency, the bone marrow sometimes shows occasional giant metamyelocytes but granulopoiesis and thrombopoiesis are otherwise usually normal. Individuals whose bone marrow lacks storage iron but in whom erythropoiesis is normal should be regarded as iron depleted rather than as iron deficient; a significant proportion of healthy women fall into this group.

Fig. 8.1 BM aspirate, iron deficiency anaemia, showing erythroblasts with poorly haemoglobinized vacuolated cytoplasm. MGG $\times 940$.

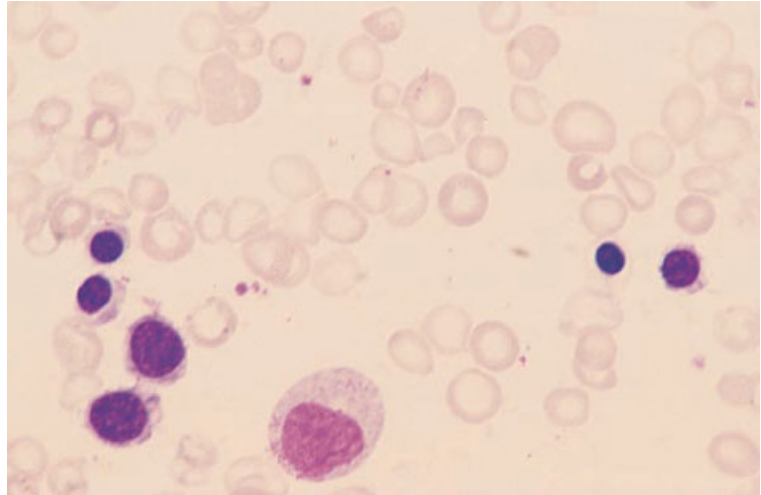
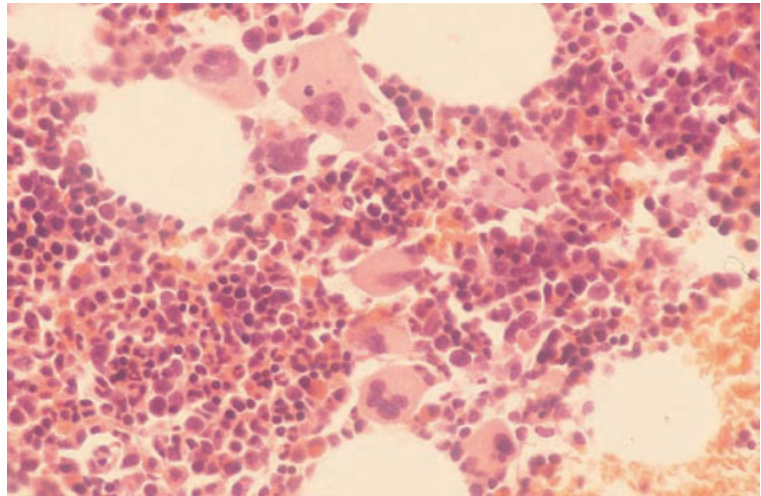


Fig. 8.2 BM trephine biopsy section, iron deficiency anaemia. Paraffin-embedded, H&E $\times 376$.



Bone marrow histology

Trephine biopsy sections show mild hypercellularity, erythroid hyperplasia and absent iron stores. Megakaryocytes are sometimes increased (Fig. 8.2).

Problems and pitfalls

An iron stain performed on a plastic-embedded, non-decalcified trephine biopsy section permits reliable assessment of iron stores. However, it should be noted that the decalcification needed for

paraffin-embedded biopsy specimens leads to leaching out of some or all of the iron. It is therefore possible to exclude a diagnosis of iron deficiency if stainable iron is present but it is not possible to state that iron stores are absent or reduced. A diagnosis of iron deficiency therefore cannot be made from a biopsy specimen that has been decalcified.

Sideroblastic anaemia

Sideroblastic anaemia as a feature of myelodysplastic syndromes (MDS)—refractory anaemia with ring

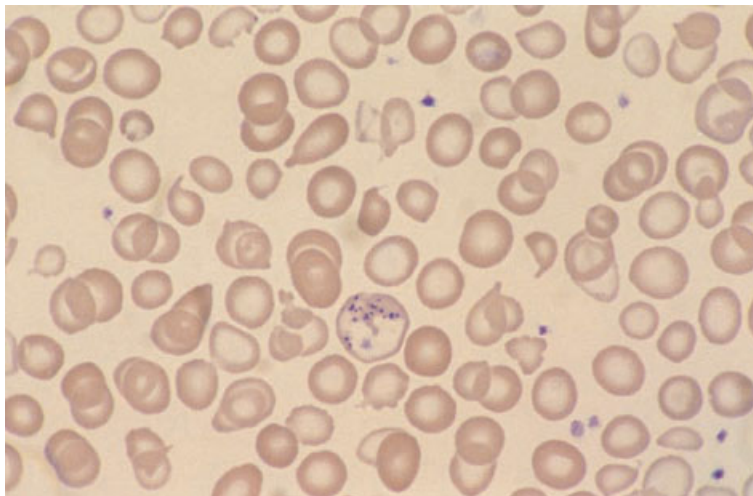


Fig. 8.3 PB film from a boy with congenital sideroblastic anaemia, showing many hypochromic and microcytic cells; there is moderate poikilocytosis and one cell containing multiple Pappenheimer bodies. MGG $\times 940$.

sideroblasts or primary acquired sideroblastic anaemia—has been discussed in Chapter 4. Sideroblastic anaemia may also be inherited or may be secondary to exogenous agents such as alcohol, chloramphenicol or certain drugs used in the treatment of tuberculosis. Congenital (inherited) sideroblastic anaemia occurs predominantly but not exclusively in males, most cases being caused by defects in synthesis of 5-amino-laevulinic acid. Other cases, in either males or females, are a feature of Pearson's syndrome (see page 407) or of thiamine-responsive megaloblastic anaemia (see page 371). Sideroblastic anaemia is most readily diagnosed from a bone marrow aspirate but diagnosis is also possible from sections of plastic-embedded trephine biopsy specimens.

Peripheral blood

Congenital and secondary sideroblastic anaemias are associated with microcytosis and hypochromia (Fig. 8.3), in contrast to the macrocytosis which is usual when sideroblastic erythropoiesis is a feature of MDS. In some patients the peripheral blood film is dimorphic with a mixture of hypochromic microcytes and normochromic normocytes. Congenital sideroblastic anaemia varies in severity from moderate to severe. Secondary sideroblastic anaemia is of mild to moderate severity. In families in which males have sideroblastic anaemia, females may show a small population of hypochromic microcytes.

Bone marrow cytology

The bone marrow shows mild hypercellularity and mild erythroid hyperplasia. A proportion of the erythroblasts show micronormoblastic maturation and defective haemoglobinization with ragged or vacuolated cytoplasm (Fig. 8.4). An iron stain shows the presence of abnormal sideroblasts including frequent ring sideroblasts (Fig. 8.5). Iron stores are usually increased. Plasma cells may contain haemosiderin (see Fig. 2.8).

Bone marrow histology

Trephine biopsy sections show some degree of erythroid hyperplasia. Increased storage iron and ring sideroblasts are detectable in plastic-embedded sections but not in sections of decalcified paraffin-embedded biopsy specimens. Plasma cells may contain haemosiderin (see Fig. 2.8). A trephine biopsy is not indicated in the investigation of suspected congenital sideroblastic anaemia but is useful if acquired sideroblastic anaemia, particularly as a feature of MDS, is suspected.

Problems and pitfalls

Making a distinction between congenital and acquired sideroblastic anaemias and between primary and secondary sideroblastic anaemias is not always possible from the peripheral blood and bone

Fig. 8.4 BM aspirate from a boy with congenital sideroblastic anaemia (same case as in Fig. 8.3), showing granulocyte precursors and five erythroblasts, one of which has a very severe defect in haemoglobinization. MGG $\times 940$.

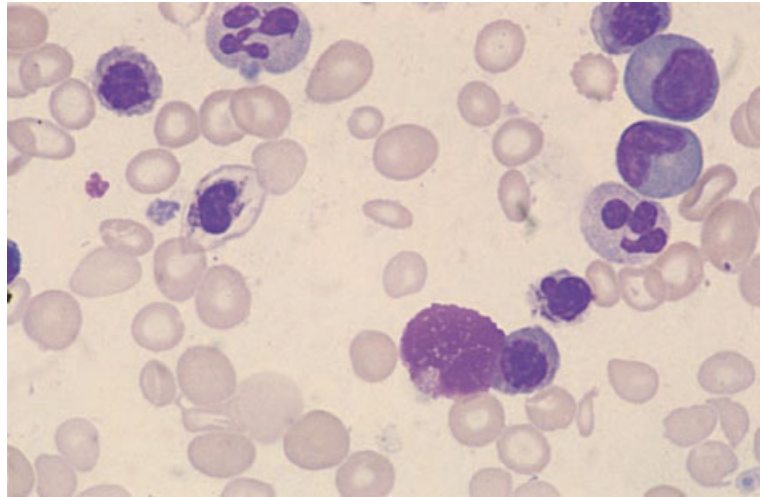
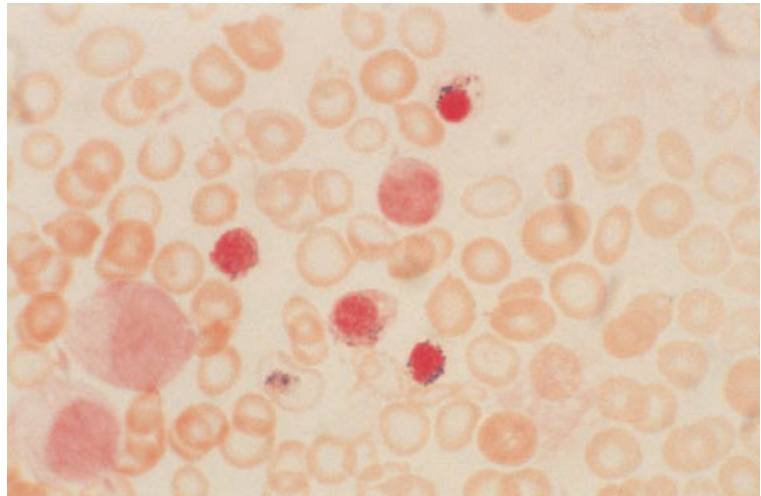


Fig. 8.5 BM aspirate from a boy with congenital sideroblastic anaemia (same case as in Fig. 8.3), showing abnormal sideroblasts, including one ring sideroblast. Perls' stain $\times 940$.



marrow features alone. In some cases a family history, drug history and supplementary tests are needed.

A diagnosis of sideroblastic anaemia cannot be made from decalcified trephine biopsy specimens.

Thalassaemia trait and thalassaemia intermedia

The various thalassaemic disorders, including thalassaemia trait, are most readily diagnosed from peripheral blood features but it is necessary for

haematologists and pathologists to be aware of the bone marrow features to avoid misdiagnosis as other conditions. Bone marrow aspiration and trephine biopsy are not of any importance in the diagnosis.

Thalassaemia trait is the term used to describe an asymptomatic condition usually consequent on dysfunction of one of the two β genes or lack of one or two of the four α genes. The term 'thalassaemia intermedia' denotes a symptomatic condition, more severe than thalassaemia trait, but in which blood transfusion is not generally necessary; the genetic basis is diverse.

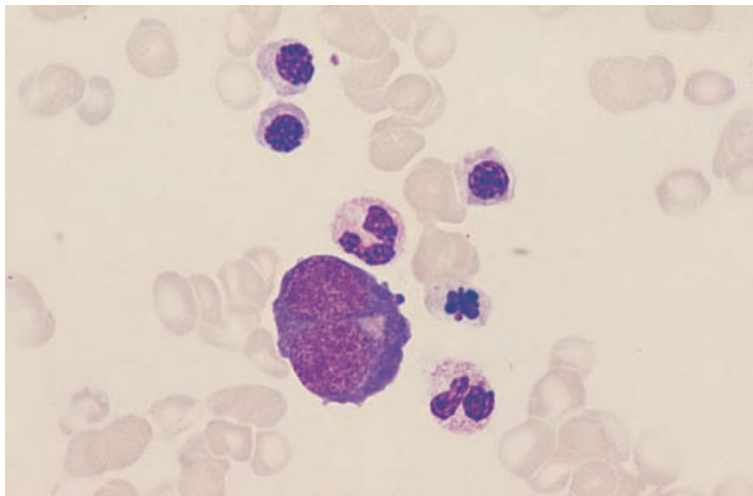


Fig. 8.6 BM aspirate, β thalassaemia trait, showing erythroid hyperplasia and dyserythropoiesis. There is a binucleated early erythroblast and the late erythroblasts are small and have irregular or lobulated nuclei. MGG $\times 940$.

Diagnosis of β thalassaemia trait is based on a typical blood count and blood film together with demonstration of an elevated percentage of haemoglobin A₂. There may or may not be an elevated percentage of haemoglobin F. The diagnosis of β thalassaemia intermedia is made on the basis of clinical and haematological features, haemoglobin electrophoresis and DNA analysis. A presumptive diagnosis of α thalassaemia trait is made when there is microcytosis that is not explained by other more readily diagnosable conditions such as iron deficiency anaemia or β thalassaemia trait. A definitive diagnosis of α thalassaemia trait requires DNA analysis, most cases being caused by deletion of one or more of the α genes.

Peripheral blood

In β thalassaemia trait, and in cases of α thalassaemia trait in which two of the four α genes are lacking, the peripheral blood shows microcytosis and sometimes a degree of hypochromia. Some, but not all, cases of β thalassaemia trait also have basophilic stippling and moderate poikilocytosis, including the presence of target cells. In cases of α thalassaemia trait in which only one of the four α genes is lacking, the haematological abnormalities are much less and the diagnosis may not be suspected. In β thalassaemia intermedia, the haematological features are intermediate between those of thalassaemia trait and thalassaemia major.

Bone marrow cytology

In thalassaemia trait, the bone marrow aspirate shows moderate erythroid hyperplasia. Erythropoiesis is micronormoblastic and there is moderate dyserythropoiesis including nuclear lobulation and nuclei of irregular shape (Fig. 8.6). An iron stain shows increased siderotic granulation and occasional ring sideroblasts. Storage iron is commonly increased. In thalassaemia intermedia, erythroid hyperplasia and dyserythropoiesis are marked and storage iron is increased.

Bone marrow histology

Trephine biopsy sections show erythroid hyperplasia and dyserythropoiesis.

Problems and pitfalls

Misdiagnosis of β thalassaemia intermedia as MDS can occur if the possibility of thalassaemia is not considered and if it is not appreciated that dysplastic features are confined to the erythroid lineage.

Thalassaemia major

Thalassaemia major indicates a transfusion-dependent thalassaemic condition, usually consequent on homozygosity or compound heterozygosity for β thalassaemia.

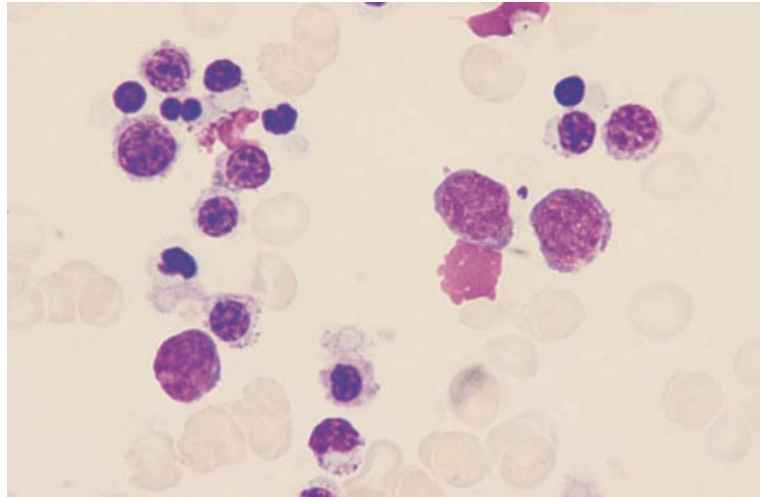


Fig. 8.7 BM aspirate, β thalassaemia major, showing erythroid hyperplasia and dyserythropoiesis. Several cells contain cytoplasmic inclusions, composed of precipitated α chains. MGG $\times 940$.

Peripheral blood

The peripheral blood shows striking hypochromia, microcytosis, anisocytosis and poikilocytosis. Basophilic stippling, Pappenheimer bodies and dysplastic circulating erythroblasts are also present. If the patient has been transfused, the blood film is dimorphic.

Bone marrow cytology

The bone marrow shows very marked erythroid hyperplasia, severe erythroid dysplasia and poor haemoglobinization (Fig. 8.7). Some erythroblasts contain cytoplasmic inclusions, seen with difficulty in MGG-stained films, which represent precipitated α chains. There is an increase in macrophages which contain degenerating erythroblasts, cellular debris and haemosiderin. In some patients the increased cell turnover leads to the formation of pseudo-Gaucher cells and sea-blue histiocytes (see pages 416 and 420). An iron stain shows numerous abnormal sideroblasts and small numbers of ring sideroblasts. Storage iron is considerably increased. Plasma cells may contain haemosiderin.

Bone marrow histology

Bone marrow sections show marked erythroid hyperplasia with disappearance of fat spaces.

Dyserythropoiesis is also very marked and iron stores are increased. Pseudo-Gaucher cells and sea-blue histiocytes may be present. Plasma cells and the endothelial cells lining sinusoids may contain haemosiderin.

Haemoglobin H disease

Haemoglobin H disease is a thalassaemic condition resulting from the lack of three of the four α genes or from a functionally similar defect. There is also a decreased red cell life span. Diagnosis rests on peripheral blood features and the results of haemoglobin electrophoresis; bone marrow examination contributes little. Haemoglobin electrophoresis shows a small percentage of haemoglobin H and haemoglobin H inclusions are seen within red cells that have been exposed to a suitable supravital dye. Occasionally, haemoglobin H disease is an acquired condition, occurring as a feature of MDS.

Peripheral blood

The peripheral blood shows marked hypochromia, microcytosis, anisocytosis and poikilocytosis. Because of the haemolytic component, there is also polychromasia and the reticulocyte count is elevated.

Bone marrow cytology

The bone marrow is hypercellular with marked ery-

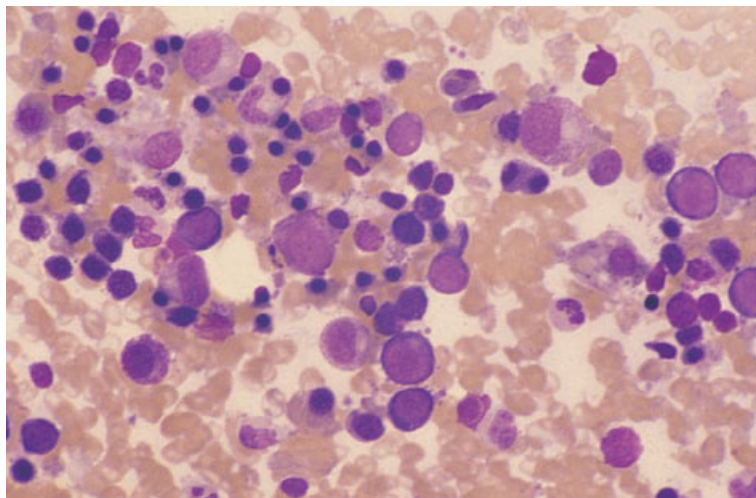


Fig. 8.8 BM aspirate, haemoglobin H disease, showing marked erythroid hyperplasia with micronormoblastic maturation. MGG $\times 376$.

throid hyperplasia, defective haemoglobinization and some dyserythropoietic features (Fig. 8.8).

Bone marrow histology

Bone marrow sections show hypercellularity due to erythroid hyperplasia.

Problems and pitfalls

It is important to distinguish acquired haemoglobin H disease from the much more common inherited condition. This is possible by examination of cells of other haemopoietic lineages.

Haemolytic anaemias

Haemolytic anaemia may be inherited or acquired. Aetiological factors, pathogenetic mechanisms and morphological features are very varied [1]. Examination of the peripheral blood is of great importance in the diagnosis but examination of the bone marrow adds little, except in detecting complicating megaloblastic anaemia or pure red cell aplasia or, occasionally, an associated lymphoma.

Peripheral blood

Haemolytic anaemias have in common polychromasia and an increased reticulocyte count. Macrocytosis is usual in those patients in whom haemolysis is chronic and severe. Other morpho-

logical features are very variable, depending on the precise nature of the condition [1].

Bone marrow cytology

The bone marrow is hypercellular as a consequence of erythroid hyperplasia (Fig. 8.9). The degree of hyperplasia reflects the extent to which the red cell life span is shortened. In some patients, fat cells are totally lost. Haemopoiesis is often macronormoblastic, i.e. the erythroblasts are increased in size but have nuclear and cytoplasmic characteristics similar to those of normoblasts. Some cases of haemolytic anaemia have quite marked dyserythropoiesis. This may occur transiently in autoimmune haemolytic anaemia [2] and has also been observed in haemolytic anaemia associated with the familial auto-immune lymphoproliferative disorder caused by *FAS* gene mutations [3]. Dyserythropoiesis is often very striking when severe haemolytic anaemia occurs in a neonate, e.g. in haemolytic disease of the newborn. A specific dyserythropoietic feature is associated with haemolytic anaemia due to haemoglobin C disease; normoblasts have irregular nuclear membranes (Fig. 8.10). Macronormoblastic erythropoiesis should be distinguished from mildly megaloblastic erythropoiesis which may occur in the haemolytic anaemias when there is complicating folic acid deficiency. When haemolysis is extravascular, bone marrow macrophages are increased and contain cellular debris. Iron stores are commonly increased,

Fig. 8.9 BM aspirate, auto-immune haemolytic anaemia, showing an erythroid island composed of erythroblasts clustered around a debris-laden macrophage. MGG $\times 940$.

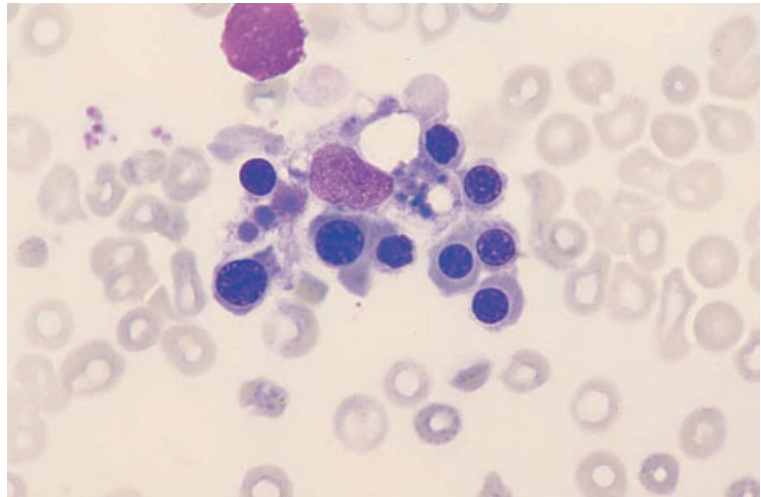
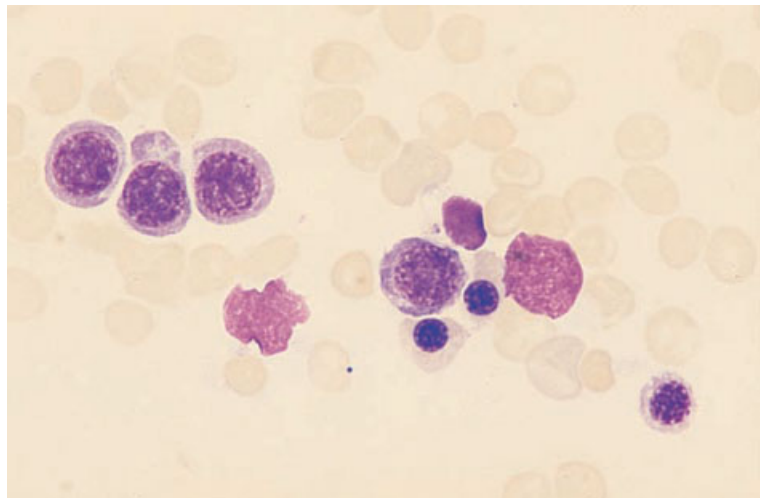


Fig. 8.10 BM aspirate, haemoglobin C disease, showing erythroid hyperplasia and an irregular nuclear outline which is characteristic of this condition. MGG $\times 940$.



except when there is severe intravascular haemolysis with consequent loss of iron from the body. Siderotic granulation is somewhat increased.

Bone marrow histology

The bone marrow is hypercellular with erythroid hyperplasia (Fig. 8.11) and a variable degree of dyserythropoiesis. The number of erythroid islands is increased and the central macrophage is large and prominent, often staining a dirty greenish colour with a Giemsa stain because of the presence of

increased haemosiderin. An iron stain confirms increased storage iron.

Problems and pitfalls

Misinterpretation of erythroid hyperplasia with a variable degree of dyserythropoiesis, which is a consequence of haemolytic anaemia, is possible if a peripheral blood film is not examined as part of the assessment of a bone marrow aspirate and trephine biopsy. This may result in a failure to consider haemolysis as a diagnostic possibility.

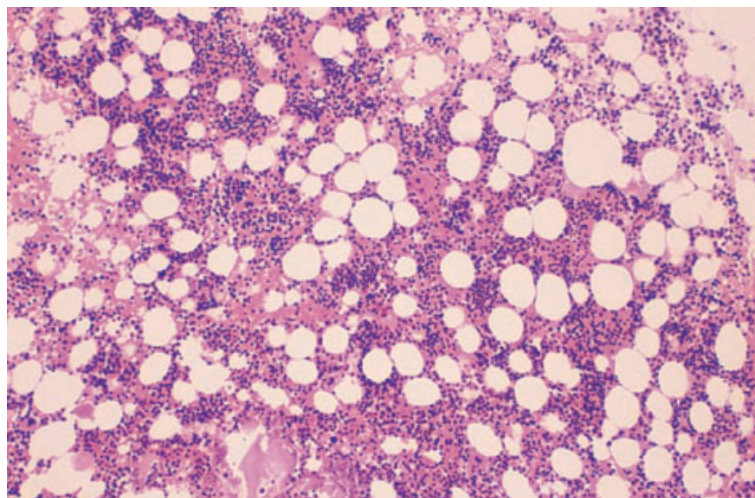


Fig. 8.11 BM trephine biopsy section, auto-immune haemolytic anaemia, showing erythroid hyperplasia. Paraffin-embedded, H&E $\times 97$.

Congenital dyserythropoietic anaemia

The congenital dyserythropoietic anaemias (CDAs) are a diverse group of inherited conditions [4,5], all of which are characterized by anaemia resulting from dysplastic and ineffective erythropoiesis. Splenomegaly and expansion of the bone marrow cavity are common. Three major types of CDA have been recognized but a considerable number of cases not conforming to these categories have also been described. Both peripheral blood and bone marrow

aspirate features are important in making the diagnosis. In type II CDA, demonstration of a positive acidified serum lysis test, using a number of normal sera to exclude false-negative results, is required for confirmation. Trephine biopsy is not important in diagnosis.

Peripheral blood

Specific morphological features vary, depending on the category of CDA (Table 8.1). All are character-

Table 8.1 Genetic, peripheral blood and bone marrow features of the congenital dyserythropoietic anaemias.

	Type I	Type II (Hempas)*	Type III
Inheritance	Autosomal recessive	Autosomal recessive	Autosomal dominant
Peripheral blood	Mild to moderate anaemia, macrocytosis, marked anisocytosis and poikilocytosis including teardrop poikilocytes, basophilic stippling	Mild to severe anaemia, normocytic red cells, moderate anisocytosis and poikilocytosis, including teardrop poikilocytes, variable anisochromasia, irregularly contracted cells, basophilic stippling	Mild anaemia, macrocytosis, marked anisocytosis and poikilocytosis, basophilic stippling
Bone marrow	Hyperplastic, megaloblastic, moderate binuclearity and internuclear chromatin bridges, nuclear budding and karyorrhexis	Hyperplastic, normoblastic, marked binuclearity and multinuclearity	Hyperplastic, megaloblastic, giant erythroblasts with single nuclei or marked multinuclearity—up to a dozen nuclei per cell, karyorrhexis

* Hereditary erythroid multinuclearity with positive acidified serum test.

Fig. 8.12 PB film, congenital dyserythropoietic anaemia, type I, showing macrocytosis, marked anisocytosis and poikilocytosis. MGG $\times 940$.

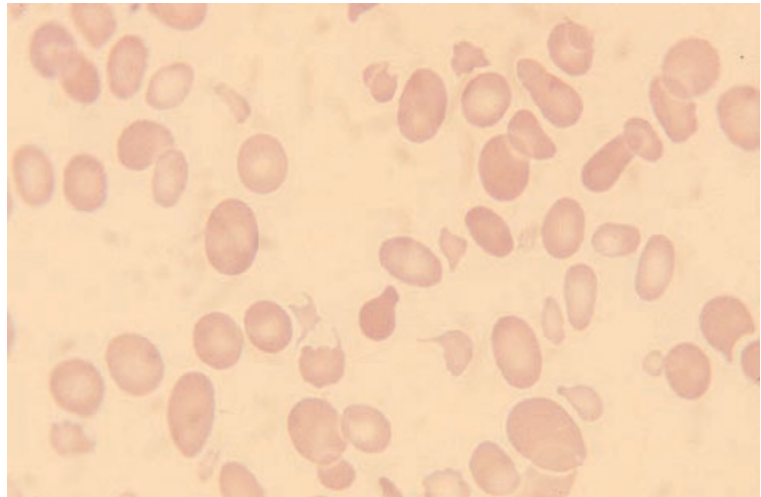
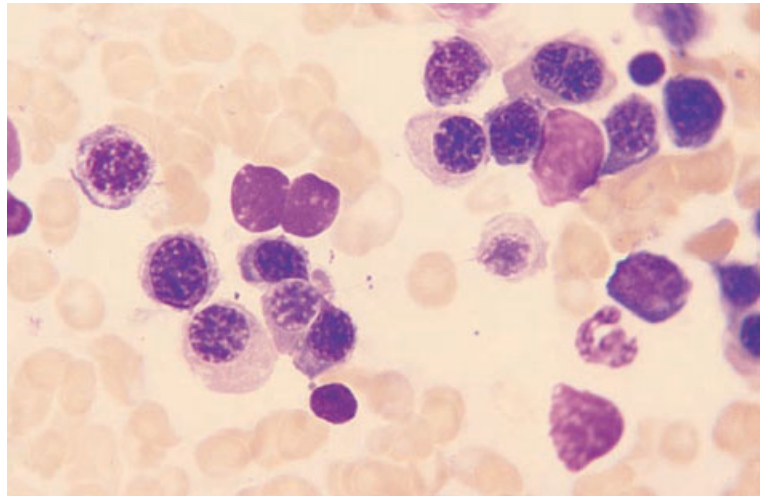


Fig. 8.13 BM aspirate, congenital dyserythropoietic anaemia, type I, showing erythroid hyperplasia and dyserythropoietic features including two pairs of erythroblasts joined by cytoplasmic and nuclear bridges, respectively. The cell (top right) with two nuclei joined together over a considerable distance is typical of this type of CDA. MGG $\times 940$.



ized by anisocytosis and by poikilocytosis (Fig. 8.12) which often includes the presence of fragments and irregularly contracted cells. Basophilic stippling is common. In all categories, the reticulocyte count is not elevated appropriately for the degree of anaemia.

Bone marrow cytology

Bone marrow features characteristic of the different categories of CDA are summarized in Table 8.1 and illustrated in Figs 8.13–8.15. In all types there is erythroid hyperplasia and dyserythropoiesis. In type II CDA the increase in cell turnover is such that

pseudo-Gaucher cells may be present. Iron stores are commonly increased. Ultrastructural examination of bone marrow cells is diagnostically useful, showing a 'Swiss cheese' appearance of the nucleus in CDA type I, a double membrane parallel to the cell membrane in CDA type II and a variety of defects in CDA type III [5].

Bone marrow histology

Examination of trephine biopsy or bone marrow clot sections confirms erythroid hyperplasia and dyserythropoiesis (Fig. 8.16).

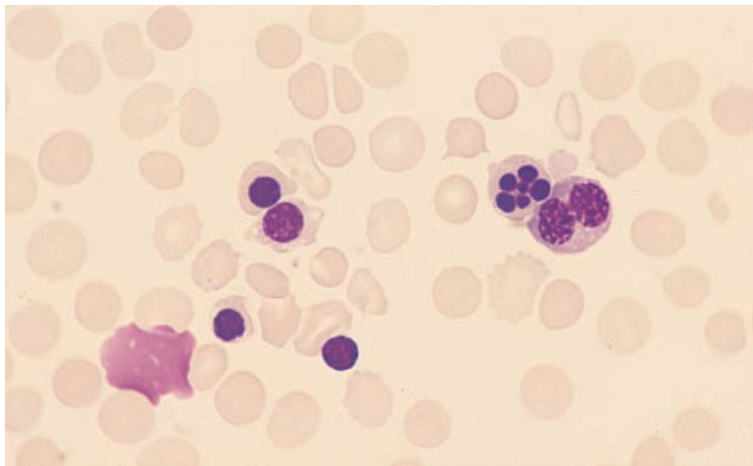


Fig. 8.14 BM aspirate, congenital dyserythropoietic anaemia, type II, showing one binucleate erythroblast and one erythroblast with a multilobulated nucleus. MGG $\times 940$.

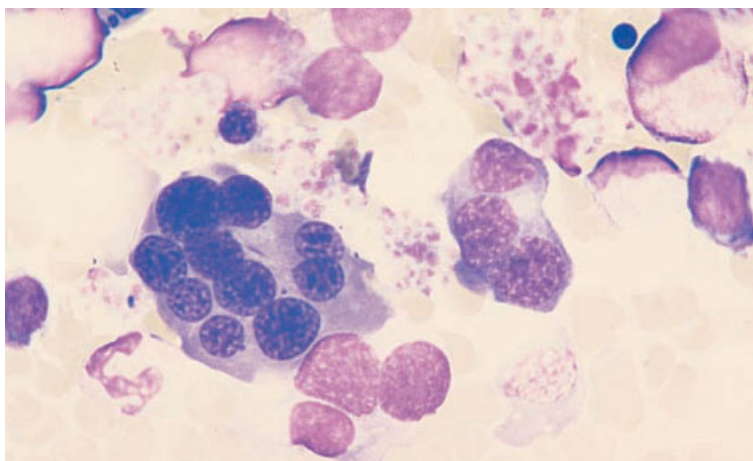


Fig. 8.15 BM aspirate, congenital dyserythropoietic anaemia, type III, showing giant, multinucleated erythroblasts. MGG $\times 940$. (By courtesy of Professor SN Wickramasinghe, London.)

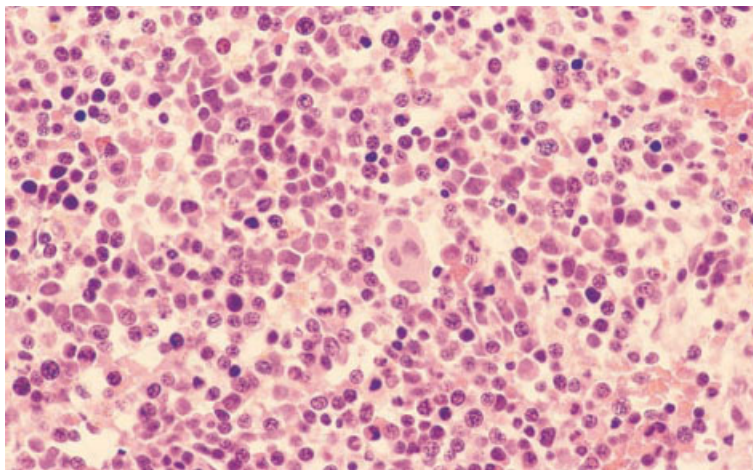


Fig. 8.16 BM clot section, congenital dyserythropoietic anaemia, type I, showing marked erythroid hyperplasia with large numbers of immature erythroid precursors and marked dyserythropoiesis. The chromatin pattern is very abnormal. Paraffin-embedded, H&E $\times 390$.

Problems and pitfalls

Some cases of CDA present quite late in life. Misdiagnosis as MDS may occur if the possibility of CDA is not considered and if due consideration is not given to the fact that the abnormalities are essentially confined to the erythroid lineage.

Megaloblastic anaemia

Megaloblastic anaemia is usually consequent on a deficiency of vitamin B₁₂ or folic acid. Less often, it is attributable to administration of a drug that interferes with DNA synthesis or, rarely, to a congenital metabolic defect. Some patients with acute myeloid leukaemia (AML) or MDS also have megaloblastic erythropoiesis. The presence of megaloblastic anaemia can usually be suspected from examination of the peripheral blood and, if features are totally typical, bone marrow aspiration is often not done. The ready availability of accurate assays for vitamin B₁₂ and folic acid has lessened the importance of bone marrow examination. However, if typical peripheral blood features of megaloblastic erythropoiesis are lacking or if atypical features are present, bone marrow aspiration should be performed. Further tests indicated in patients with megaloblastic anaemia are assays of serum vitamin B₁₂ and red cell folate followed, when appropriate, by tests for auto-antibodies and a Schilling test. If pernicious anaemia is suspected, tests for parietal cell and intrinsic factor antibodies are indicated; the former is more sensitive but less specific than the latter. If coeliac disease is suspected as a cause of malabsorption of folic acid or vitamin B₁₂, tests indicated include those for relevant auto-antibodies (antireticulin and antiendomysium antibodies), antigliadin antibodies and a small bowel biopsy.

Peripheral blood

In most cases there is a macrocytic anaemia, with oval macrocytes being particularly characteristic. The mildest cases have macrocytosis without anaemia. Some degree of anisocytosis and poikilocytosis is usual and, when anaemia is severe, there are striking morphological abnormalities including the presence of teardrop poikilocytes, fragments, basophilic stippling and occasional Howell–Jolly

bodies and circulating megaloblasts. Hypersegmented neutrophils are usually present; they are highly suggestive of megaloblastic erythropoiesis although not pathognomonic. They persist for a week or more after commencement of vitamin B₁₂ or folic acid therapy. There may also be increased numbers of macropolycytes (tetraploid neutrophils) but this feature is less strongly associated with megaloblastic erythropoiesis. In severe megaloblastic anaemia, leucopenia and thrombocytopenia also occur.

Bone marrow cytology

The bone marrow is hypercellular, often markedly so. Erythropoiesis is hyperplastic and is characterized by the presence of megaloblasts (Fig. 8.17). These are large cells with a chromatin pattern more primitive than is appropriate for the degree of maturation of the cytoplasm. Late megaloblasts may be fully haemoglobinized and lack any cytoplasmic basophilia. They may therefore be described as orthochromatic, a term which is not really appropriate in describing normal erythropoiesis, in which the most mature erythroblasts are polychromatic. Erythropoiesis is ineffective so that early erythroid cells are over-represented in comparison with mature cells; macrophages are increased and contain defective red cell precursors and cellular debris. An iron stain shows abnormally prominent siderotic granules and sometimes occasional ring sideroblasts. Storage iron is usually increased. Plasma cells may contain iron. The mitotic count is increased and examination of cells in metaphase may show that chromosomes are unusually long.

Granulopoiesis is also hyperplastic although less so than erythropoiesis. Giant metamyelocytes are usually present (Fig. 8.17). They are twice to three times the size of a normal metamyelocyte and often have nuclei of unusual shapes, e.g. E- or Z-shaped rather than U-shaped. Myelocytes and promyelocytes are also increased in size but this abnormality is less obvious and less distinctive than the abnormality of metamyelocytes. When megaloblastic features in erythroblasts are partly or largely masked by co-existing iron deficiency, the detection of giant metamyelocytes is diagnostically important.

Megakaryocytes are hypersegmented and have more finely stippled chromatin than normal megakaryocytes.

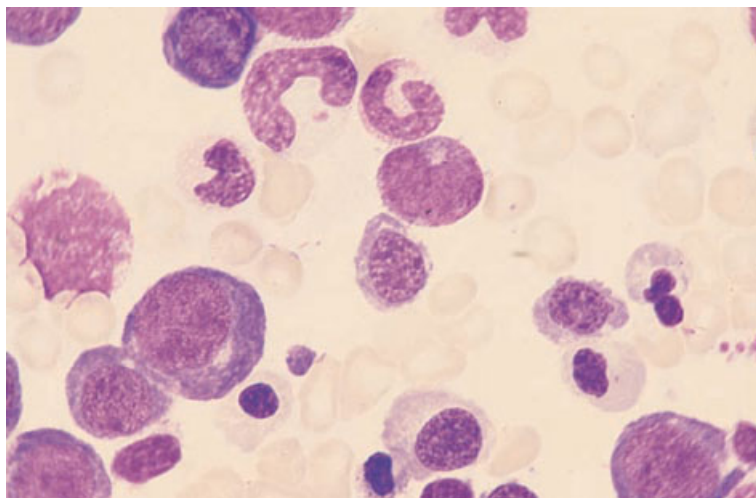


Fig. 8.17 BM aspirate, megaloblastic anaemia, showing hyperplastic megaloblastic erythropoiesis and a giant metamyelocyte. MGG $\times 940$.

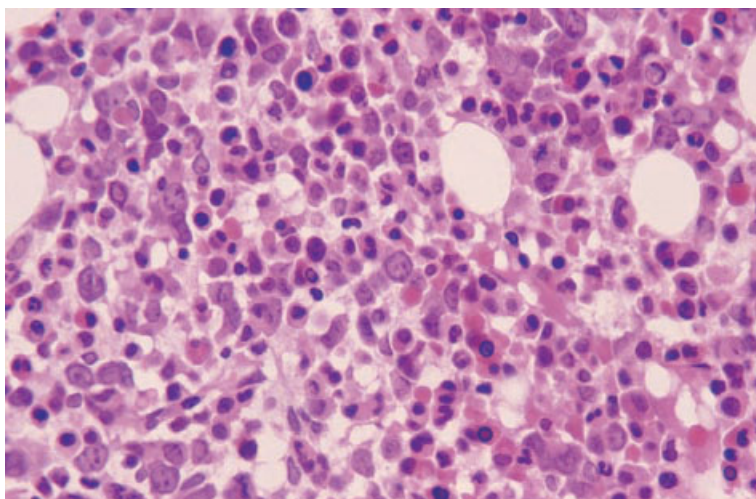


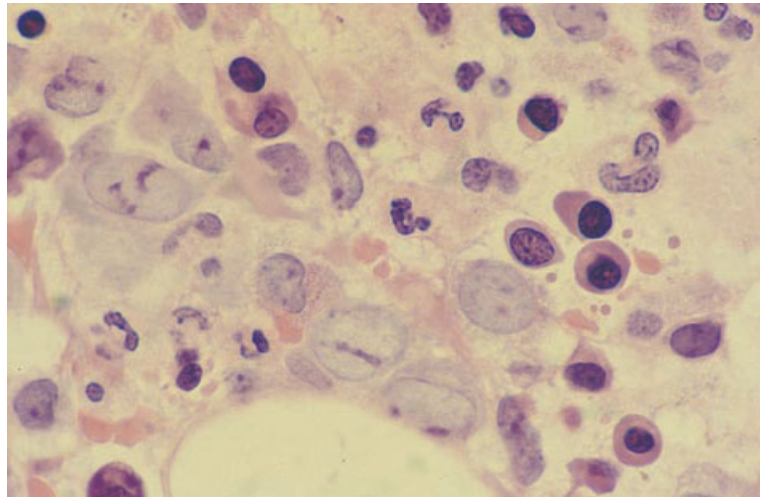
Fig. 8.18 BM trephine biopsy section, megaloblastic anaemia, showing marked erythroid hyperplasia with numerous early, intermediate and late megaloblasts. Giant metamyelocytes are also present. Paraffin-embedded, H&E $\times 390$.

Bone marrow histology

There is a variable hypercellularity with loss of fat cells. In some cases this can be so severe that it may resemble the 'packed marrow' appearance seen in acute leukaemia on examination at low power. There is erythroid hyperplasia with predominance of immature precursors (Figs 8.18 and 8.19). The early erythroid cells have large, round-to-oval nuclei with one or more basophilic nucleoli which often appear to have rather irregular margins and

often abut on the nuclear membrane (Fig. 8.19); there is usually a moderate amount of intensely basophilic cytoplasm. Small Golgi zones may be seen. The later erythroid cells show asynchrony of nuclear and cytoplasmic maturation with cells having immature nuclei but haemoglobinized cytoplasm. Granulocytic precursors are increased but may appear relatively inconspicuous in the presence of profound erythroid hyperplasia. Giant metamyelocytes are usually easily seen (Fig. 8.19). Megakaryocyte numbers may be normal or decreased.

Fig. 8.19 BM trephine biopsy section, megaloblastic anaemia, showing several early megaloblasts with prominent, often elongated nucleoli which frequently abut on the nuclear membrane. Numerous late megaloblasts are also seen. Plastic-embedded, H&E $\times 970$.



Problems and pitfalls

It is critically important that a bone marrow aspirate in severe megaloblastic anaemia is not interpreted as AML. The likelihood of these errors has probably increased in recent years as haematologists have had less experience in interpreting bone marrows from patients with straightforward megaloblastic anaemia. An appearance of 'maturation arrest' and gross dyserythropoiesis may suggest acute leukaemia but these are also features of severe megaloblastosis. Confusion with M6 AML should not occur since the bone marrow in megaloblastic anaemia does not have any increase in myeloblasts. However, confusion may occur with M6 variant AML in which the primitive cells present are all erythroid (see page 154). It is important that the diagnosis of megaloblastic anaemia is always considered in any such patient. Hypersegmented neutrophils and giant metamyelocytes should be sought since they are not a feature of AML. If there is any real doubt as to the correct diagnosis, a trial of vitamin B₁₂ and folic acid therapy should be given.

Examination of a trephine biopsy specimen is rarely useful in the diagnosis of megaloblastic anaemia but it is important for pathologists to be able to recognize the typical histological features so that misdiagnosis, particularly as acute leukaemia, does not occur. Megaloblastic change in biopsy

sections may be mistaken for acute leukaemia if the biopsy is reported without referring to the blood film and marrow aspirate findings and if the possibility of megaloblastic anaemia is not considered. Less often, there may have been failure to obtain an aspirate or the presence of immature cells in the peripheral blood in a patient with complicating infection may have given rise to the clinical suspicion of leukaemia; in these circumstances misdiagnosis of leukaemia is more likely [6].

Erythroid islands composed of early megaloblasts are also sometimes mistaken for clusters of carcinoma cells or for 'abnormal localization of immature precursors' in MDS (see Fig. 4.41). If there is any real doubt as to their nature, immunohistochemistry can be used.

Anaemia of chronic disease

The anaemia of chronic disease is characterized by a normocytic, normochromic anaemia or, when more severe, by a hypochromic, microcytic anaemia. Such anaemia is secondary to infection, inflammation or malignancy. Diagnosis is usually based on peripheral blood features and biochemical assays. Serum iron and transferrin are reduced whereas serum ferritin is normal or increased. Serum transferrin receptor concentration tends to be normal. A bone marrow aspirate is sometimes

necessary to confirm or exclude co-existing iron deficiency in a patient who has features of anaemia of chronic disease. A bone marrow biopsy does not usually give diagnostically useful information.

Peripheral blood

In addition to the possible occurrence of hypochromia and microcytosis, the peripheral blood usually shows increased rouleaux formation and sometimes increased background staining due to a reactive increase in various serum proteins. The erythrocyte sedimentation rate is increased.

Bone marrow cytology

The bone marrow is usually of normal cellularity. Erythropoiesis may show no specific abnormality or may be micronormoblastic with defective haemoglobinization. An iron stain shows storage iron to be increased, often markedly so when the condition is very chronic. Erythroblasts show reduced or absent siderotic granulation. The bone marrow often shows non-specific inflammatory changes including increased plasma cells, mast cells and macrophages.

Bone marrow histology

Sections of bone marrow trephine biopsy cores usually show normal cellularity. There may be increased lymphoid nodules, plasma cells, mast cells and macrophages. An iron stain shows increased storage iron.

Problems and pitfalls

An iron stain may be falsely negative if a trephine biopsy specimen has been decalcified, leading to a mistaken assumption that the patient has iron deficiency anaemia.

Sickle cell anaemia and other sickling disorders

Sickle cell anaemia denotes the disease resulting from homozygosity for the β^S genes and the consequent replacement of haemoglobin A by haemoglobin S. Diagnosis of sickle cell anaemia is dependent on peripheral blood features and

haemoglobin electrophoresis or an equivalent technique. Haemoglobin S comprises almost all the total haemoglobin, haemoglobin A being absent. Bone marrow aspiration is usually only indicated to detect suspected complications such as megaloblastic anaemia, pure red cell aplasia or bone marrow necrosis. Trephine biopsy is not often indicated. The clinical features consequent on sickling of red blood cells can also be found in various compound heterozygous states, such as sickle cell/haemoglobin C disease and sickle cell/ β thalassaemia trait.

Peripheral blood

The peripheral blood shows anaemia, usually with a haemoglobin concentration of 6–10 g/dl. There are variable numbers of sickle cells and, in addition, target cells and polychromasia; nucleated red blood cells may be present. After the age of 6 months, features of hyposplenism start to appear, particularly Howell–Jolly bodies and Pappenheimer bodies. The neutrophil count may be increased, particularly during episodes of sickling. The blood film in compound heterozygous states is often similar to that of sickle cell anaemia, although patients with sickle cell/haemoglobin C disease may have occasional cells containing haemoglobin C crystals and those with sickle cell/ β thalassaemia have microcytosis.

Bone marrow cytology

The bone marrow aspirate shows hypercellularity due to erythroid hyperplasia. Iron stores are often increased and sickle cells are usually present. Sometimes they are much more elongated than is usual for sickle cells in the circulating blood. When there are complicating conditions, such as megaloblastic anaemia, pure red cell aplasia or bone marrow necrosis, the appropriate morphological features are superimposed on those of the underlying disease. Bone marrow macrophages may contain occasional or numerous sickle cells (Fig. 8.20). Macrophages and various storage cells are sometimes increased (Figs 8.20 and 8.21) as a consequence of increased cell turnover and episodes of bone marrow infarction. In sickle cell/ β thalassaemia, erythropoiesis is hyperplastic and micronormoblastic (Fig. 8.22).

Fig. 8.20 BM aspirate, sickle cell anaemia, showing a foamy macrophage and a macrophage containing a sickled cell. MGG $\times 940$. (By courtesy of Professor Sally Davies, London.)

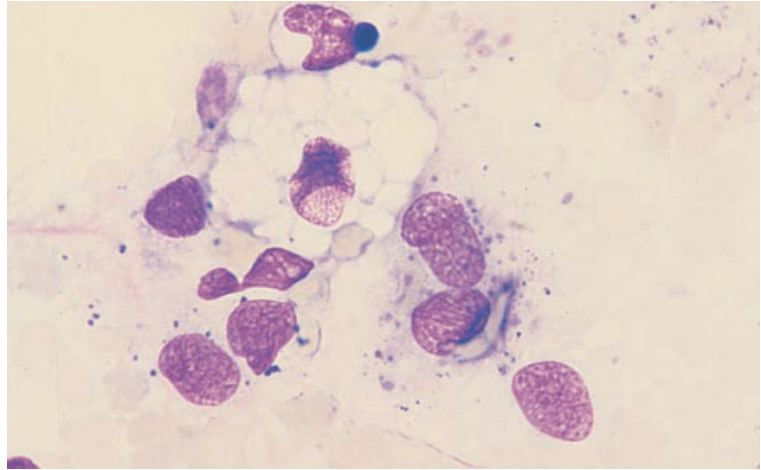


Fig. 8.21 BM aspirate, sickle cell anaemia, showing erythroid hyperplasia, a partially sickled cell and a sea-blue histiocyte. MGG $\times 940$.

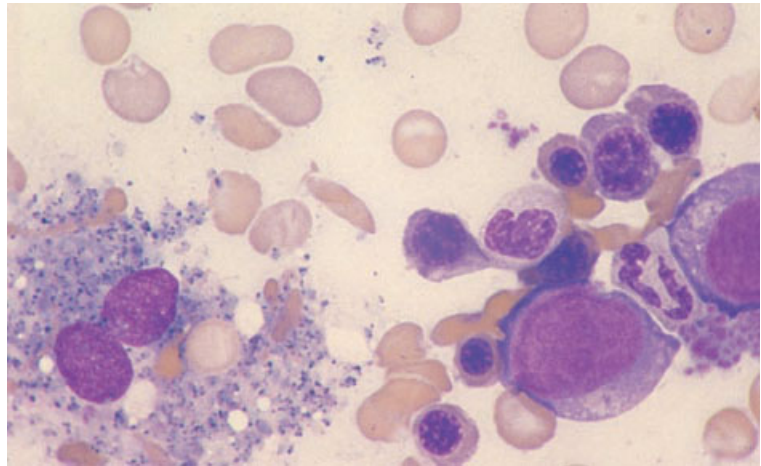
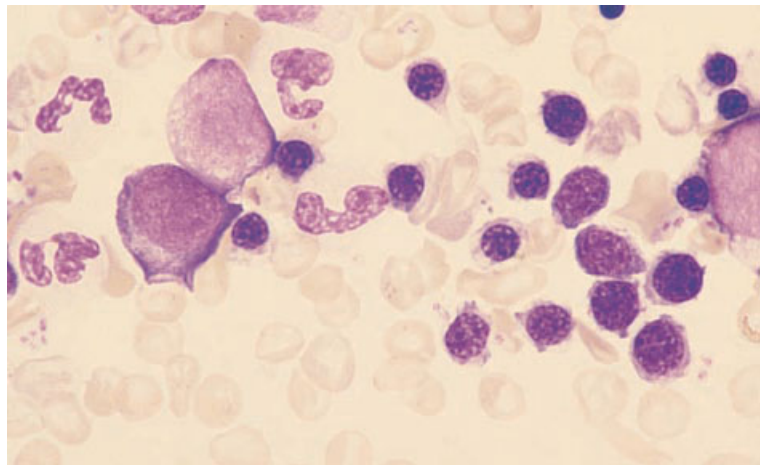


Fig. 8.22 BM aspirate, sickle cell/ β thalassaemia compound heterozygosity, showing erythroid hyperplasia and erythroblasts with scanty cytoplasm and defective haemoglobinization; several sickle cells are present. MGG $\times 940$.



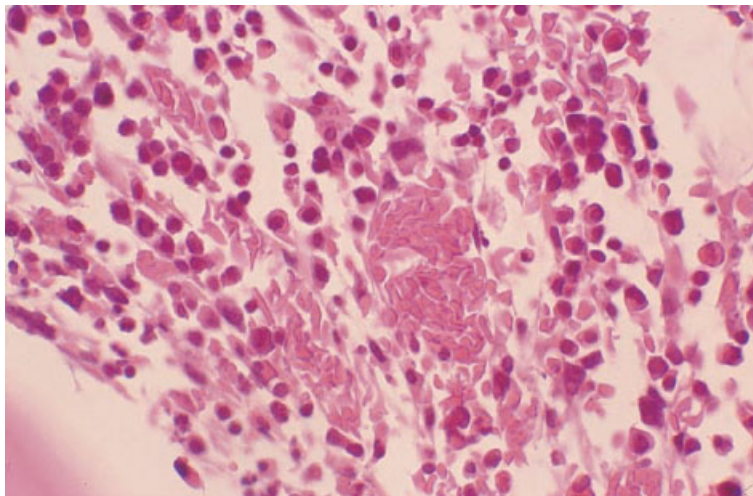


Fig. 8.23 BM trephine biopsy section, sickle cell anaemia, showing sinusoids distended by irreversibly sickled erythrocytes. Paraffin-embedded, H&E $\times 377$.

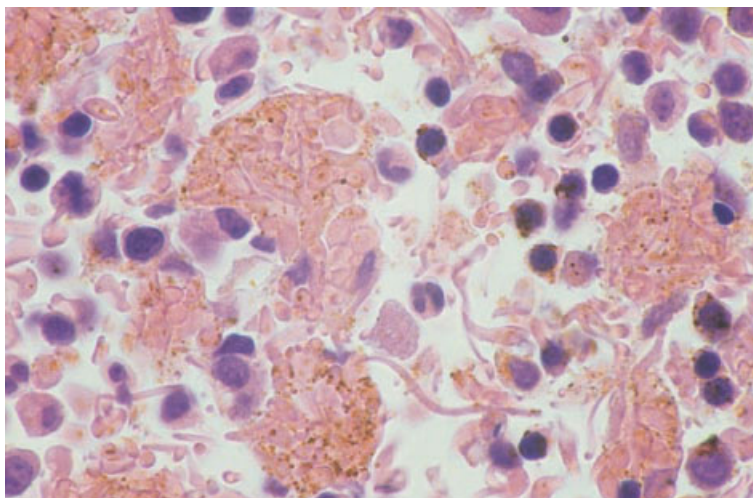


Fig. 8.24 Section of clotted BM aspirate showing macrophages stuffed with sickle cells and several extremely long sickled cells. Paraffin-embedded, H&E $\times 940$.

Bone marrow histology

Trephine biopsy sections show hypercellularity due to erythroid hyperplasia. During episodes of sickling, sickle cells may be seen within bone marrow sinusoids (Fig. 8.23). As for bone marrow aspirate films, sickle cells in bone marrow sections may be much more elongated than the typical sickle cells that are seen in blood films (Fig. 8.24). Infarcted bone and bone marrow may be present in patients who are experiencing a sickling crisis, and foamy macrophages and small fibrotic scars may mark the sites of previous bone marrow infarction.

Problems and pitfalls

It should be noted that at autopsy sickle cells may be present in histological sections of bone marrow, not only in patients with sickle cell disease but also in those with sickle cell trait.

Pure red cell aplasia (including Blackfan–Diamond syndrome)

Pure red cell aplasia has been defined as severe anaemia with the reticulocyte count being less than 1% and mature erythroblasts in a normocellular

bone marrow being less than 0.5% [7]. Pure red cell aplasia may be either constitutional or acquired and either acute or chronic. Constitutional pure red cell aplasia, also known as the Blackfan–Diamond syndrome, is a chronic condition which usually becomes manifest during the first year of life. It appears to be a trilineage disorder, consequent on an inherited stem cell defect, rather than a purely erythroid disorder. It shows some responsiveness to corticosteroids. Inheritance is usually autosomal dominant, with variable penetrance, but some cases are autosomal recessive or occur sporadically. A significant proportion of cases are due to a mutation in the gene encoding ribosomal protein S19 at 19q13 [8]. A small percentage of patients with the Blackfan–Diamond syndrome subsequently develop bone marrow aplasia [9], myelodysplasia [9] or AML. Infants, usually but not always over 1 year of age, may also suffer from acute pure red cell aplasia designated transient erythroblastopenia of childhood [10,11]; in this condition the aplasia, which is consequent on infection by human herpesvirus 6 [12], lasts only a matter of months and does not require specific treatment. In older children and adults, the most commonly recognized cause of acute aplasia is parvovirus infection; the aplasia is usually of brief duration and therefore causes symptomatic anaemia only in subjects with a pre-existing red cell defect associated with a shortened red cell life span. In adults, chronic aplasia is commonly immunological in origin and may be associated with a thymoma or with auto-immune disease. Rare cases are associated with pregnancy [13]. Pure red cell aplasia can also be a complication of T-cell granular lymphocytic leukaemia [14]; the lymphoproliferative disorder may be occult. In one series, almost 20% of cases of pure red cell aplasia were attributed to large granular lymphocyte leukaemia (LGLL) [15]. Chronic parvovirus B19 infection can also cause chronic pure red cell aplasia particularly, but not exclusively, in patients with evident causes of immune deficiency such as congenital immune deficiency, HIV infection or the prior administration of immunosuppressive drugs [16]. Cases have occurred following renal and bone marrow transplantation, following chemotherapy for solid tumours [17] and Waldenström’s macroglobulinaemia [18], and during maintenance treatment for acute lymphoblastic leukaemia (ALL).

Marked erythroid hypoplasia may also be a feature of protein-calorie deprivation (kwashiorkor), be induced by hypothermia [19], occur as part of a hypersensitivity reaction to a drug, or be the dominant feature of MDS.

Peripheral blood

The peripheral blood shows no specific abnormality. There is a complete absence of polychromatic cells and the reticulocyte count is zero or virtually zero. Associated features differ according to the cause of the red cell aplasia. Macrocytosis is usual in the Blackfan–Diamond syndrome and the red cells have some characteristics similar to those of fetal red cells; occasionally, there is mild neutropenia and the platelet count may be somewhat elevated [10]. In transient erythroblastopenia of childhood, the red cells are of normal size and lack fetal characteristics; neutropenia, which may be moderately severe, occurs in about a quarter of cases and thrombocytosis in about a third [10,11]. Since symptomatic anaemia following parvovirus-induced aplasia is largely confined to patients with an underlying red cell defect, the blood film usually shows features of an associated disease, most often hereditary spherocytosis or sickle cell anaemia. In such cases the absence of polychromasia, despite marked anaemia, is diagnostically important and should lead to a reticulocyte count being performed. Neutrophil and platelet counts are only occasionally reduced in patients with parvovirus-induced red cell aplasia. Patients with red cell aplasia associated with thymoma or with auto-immune disease sometimes also have neutropenia or thrombocytopenia. In patients with red cell aplasia as the dominant feature of MDS it is sometimes possible to detect dysplastic features in cells of other lineages.

Bone marrow cytology

Bone marrow cellularity is usually somewhat reduced. There is a striking reduction of maturing erythroid cells. Proerythroblasts are present in normal numbers and sometimes they may be increased (Fig. 8.25). Other lineages are usually normal. In Blackfan–Diamond syndrome (Fig. 8.26) there are scattered proerythroblasts and sometimes minimal evidence of maturation; haematogones and lym-

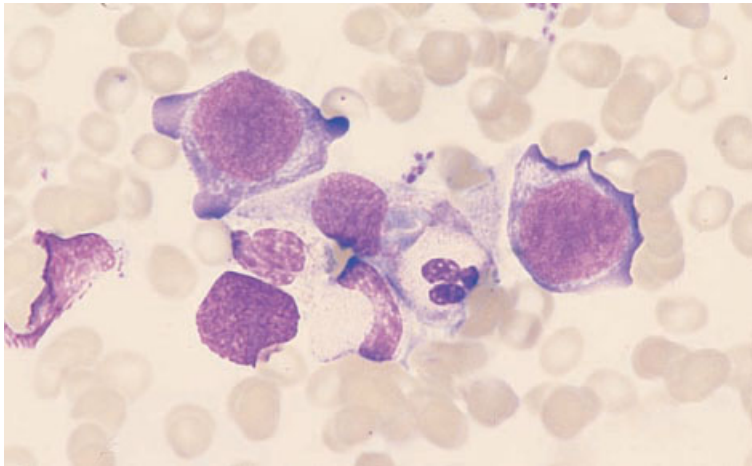


Fig. 8.25 BM aspirate, chronic idiopathic pure red cell aplasia, showing increased proerythroblasts and a lack of maturing erythroblasts. MGG $\times 940$.

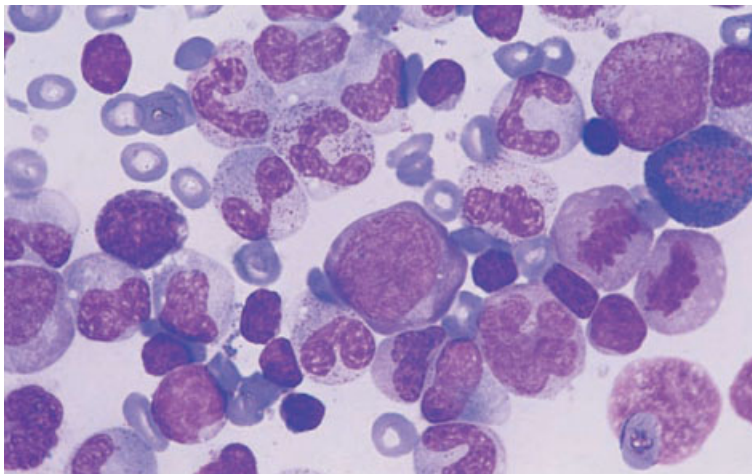


Fig. 8.26 BM aspirate, Blackfan–Diamond syndrome, showing a single intermediate erythroblast but no maturing cells. MGG $\times 940$. (By courtesy of Dr R Brunning, Minneapolis.)

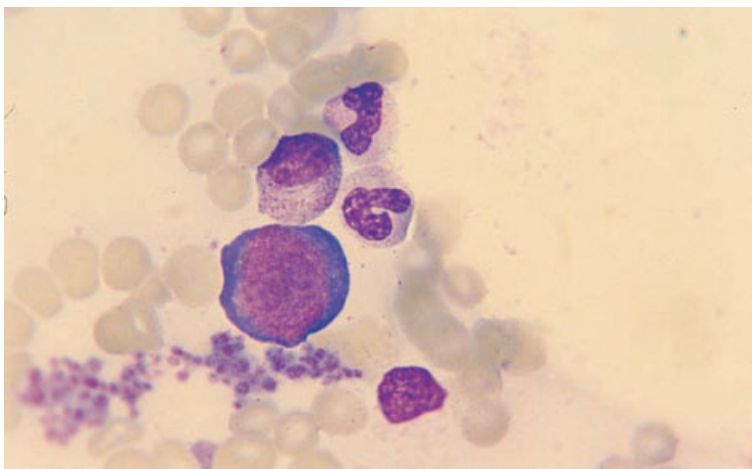


Fig. 8.27 BM aspirate, chronic pure red cell aplasia caused by parvovirus B19 infection in an HIV-positive child. MGG $\times 940$.

Fig. 8.28 BM trephine biopsy section, pure red cell aplasia, showing absence of erythroblastic islands and late erythroblasts; only occasional early and intermediate erythroblasts are present. Paraffin-embedded, H&E $\times 390$.

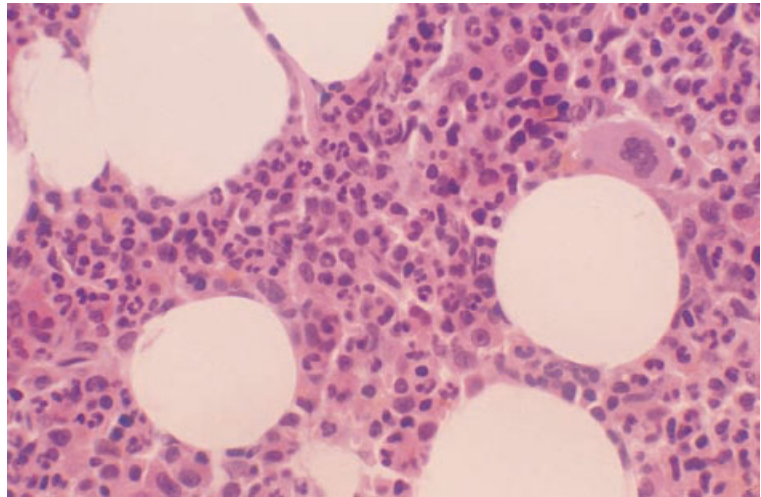
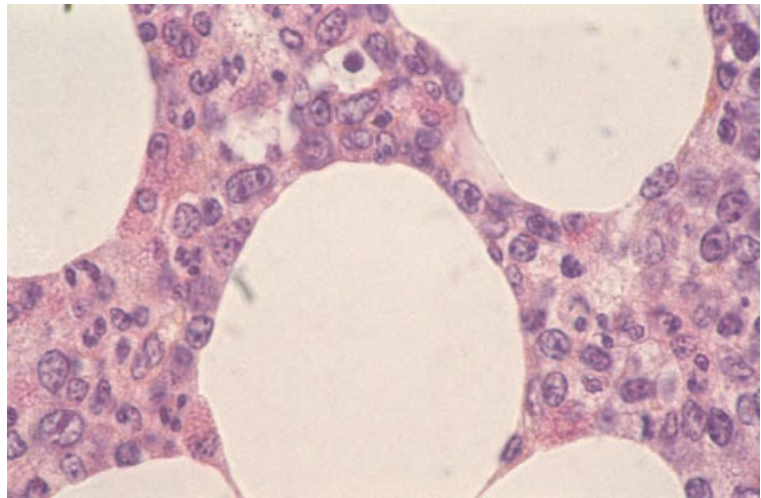


Fig. 8.29 BM trephine biopsy section, Blackfan–Diamond syndrome, showing prominent proerythroblasts and early erythroblasts but very few maturing erythroid cells (same case as in Fig. 8.26). H&E $\times 940$. (By courtesy of Dr R Brunning, Minneapolis.)



phocytes may be increased [20]. In transient erythroblastopenia of childhood, granulopoiesis may be left shifted and there may be an infiltrate of immature lymphocytes [12]. In parvovirus-induced aplasia, giant proerythroblasts with prominent nucleoli are often noted (Fig. 8.27). Iron stores are commonly increased since the iron normally in erythroid cells has been deposited in the stores.

Bone marrow histology

The overall bone marrow cellularity is somewhat reduced. There is a striking lack of erythroid islands and of maturing erythroblasts (Figs 8.28 and 8.29).

Large proerythroblasts with strongly basophilic cytoplasm are readily apparent. Occasionally, there is a striking increase in proerythroblasts (Fig. 8.30). In parvovirus infection, the giant proerythroblasts may show intranuclear eosinophilic degeneration with peripheral condensation of chromatin (Fig. 8.31). In immunocompetent patients the bone marrow is hypercellular and megakaryocytes are increased [20]. Immunohistochemistry can be used to show parvovirus antigens.

Problems and pitfalls

Since red cell aplasia may be the major manifestation

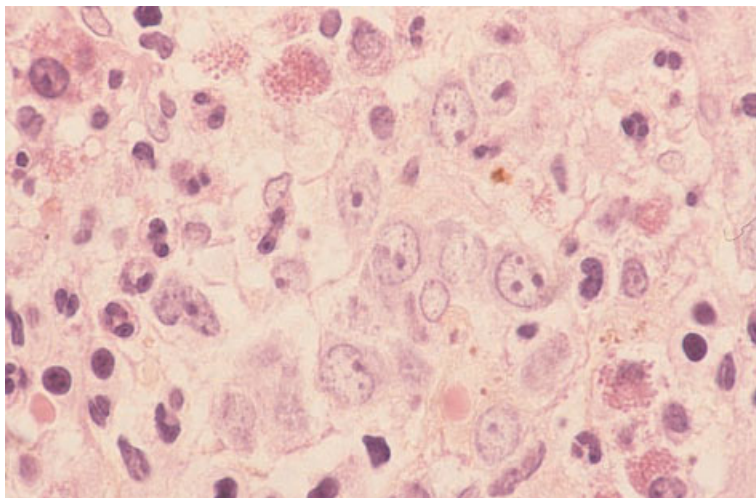


Fig. 8.30 BM trephine biopsy section, chronic pure red cell aplasia, probably auto-immune in nature, showing a striking increase of proerythroblasts. H&E $\times 940$. (By courtesy of Dr Haley, Vancouver.)

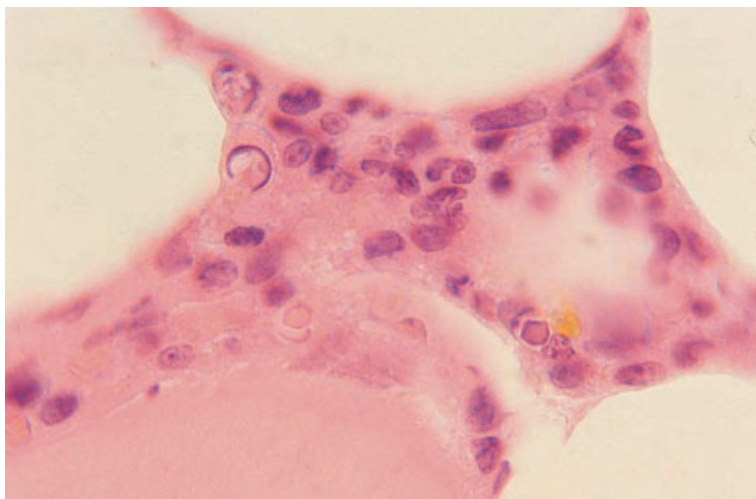


Fig. 8.31 BM trephine biopsy section in chronic parvovirus B19-induced pure red cell aplasia in an HIV-positive child (same case as in Fig. 8.27), showing several apoptotic cells and a proerythroblast with an eosinophilic intranuclear inclusion. Paraffin-embedded, H&E $\times 960$.

of MDS, it is important to examine other lineages carefully for dysplastic features.

Occasionally, patients with pure red cell aplasia show a striking increase of proerythroblasts which can cause diagnostic confusion (see Fig. 8.30).

Congenital neutropenia

Severe congenital neutropenia (Kostmann's syndrome) is a heterogeneous group of disorders with either autosomal dominant or autosomal recessive inheritance. Isolated congenital neutropenia may also be mild with a benign clinical course. Con-

genital neutropenia may be cyclical with variation over a period of 3 weeks or more from very low to normal or above normal levels. Congenital neutropenia also occurs as a feature of other congenital syndromes.

Peripheral blood

In Kostmann's syndrome, the peripheral blood shows severe neutropenia and often monocytosis, eosinophilia and the effects of chronic or recurrent infection such as anaemia and increased rouleaux formation.

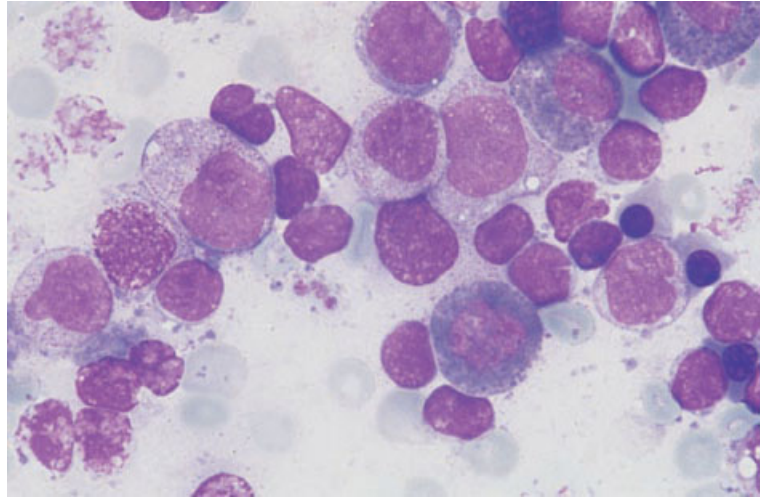


Fig. 8.32 BM aspirate in Kostmann's syndrome showing neutrophil maturation apparently arrested at the promyelocyte stage; cells of eosinophil lineage are increased. MGG $\times 940$.

Bone marrow cytology and histology

Most cases of Kostmann's syndrome show an arrest at the promyelocyte stage of differentiation (Fig. 8.32). Haematogones may be increased. Some cases show a severe reduction of all granulopoietic cells with residual cells sometimes being morphologically atypical. The latter pattern may be predictive of failure of response to granulocyte colony-stimulating factor (G-CSF) therapy [21]. An association between Kostmann's syndrome and osteoporosis has been observed [22].

In Schwachman's syndrome (congenital neutropenia with exocrine pancreatic insufficiency), the bone marrow may show apparent maturation arrest [23]. In cyclical neutropenia there is myeloid hypoplasia during the neutropenic phase but, when the neutrophil count is normal, the bone marrow appears normal. In neutropenia associated with Cohen's syndrome bone marrow examination shows left-shifted granulopoiesis [24].

Agranulocytosis

Agranulocytosis is an acute, severe, reversible lack of circulating neutrophils consequent on an idiosyncratic reaction to a drug or chemical. At least some cases result from the development of antibodies against the causative drug with destruction of neutrophils being caused by the interaction of the antibody and the drug. However, some cases may

result from abnormal metabolism of a drug so that toxic levels develop when normal doses are administered. Clinical features are due to sepsis consequent on the neutropenia.

Peripheral blood

The neutrophil count is greatly reduced, usually to less than $0.5 \times 10^9/l$. Residual neutrophils may be morphologically normal but often they show toxic changes consequent on superimposed sepsis. During recovery there is an outpouring of immature granulocytes into the peripheral blood, constituting a leukaemoid reaction.

Bone marrow cytology

The bone marrow aspirate shows a marked reduction in mature neutrophils. Sometimes myelocytes are also greatly reduced. The degree of granulocyte compartment depletion is predictive of speed of recovery; if promyelocytes and myelocytes are present, recovery usually occurs in 4–7 days, without administration of growth factors, whereas if promyelocytes and myelocytes are absent recovery takes 14 days or more [25]. In severe cases with superimposed sepsis the majority of cells of granulocytic lineage may be promyelocytes with very heavy granulation. This appearance has been confused with hypergranular promyelocytic leukaemia. Useful points allowing differentiation of the

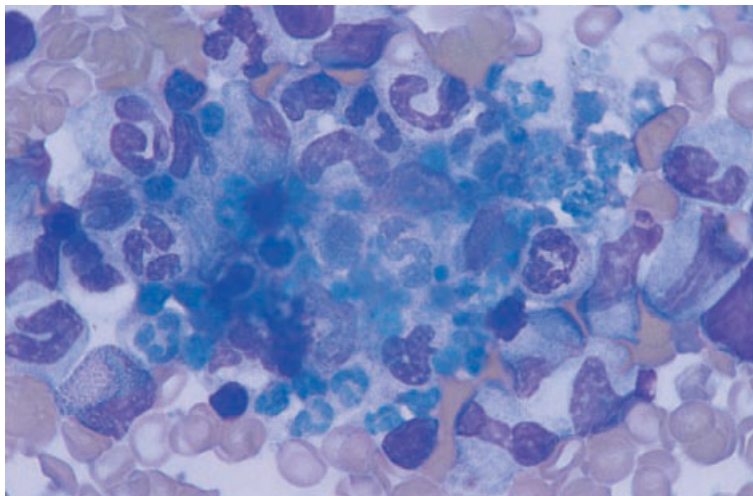


Fig. 8.33 BM aspirate in autoimmune neutropenia showing neutrophil shadows within macrophages. MGG $\times 940$.

two conditions are the prominent Golgi zone in the promyelocytes of agranulocytosis and the absence of Auer rods and giant granules.

Bone marrow histology

Bone marrow sections show a lack of mature granulocytes and, often, superimposed changes due to infection.

Auto-immune neutropenia

Auto-immune neutropenia may occur as an isolated phenomenon or be one manifestation of an auto-immune disease such as systemic lupus erythematosus. It may also occur in association with thymoma and as a complication of T-cell granular lymphocytic leukaemia (with or without associated rheumatoid arthritis). Neutropenia associated with T-cell granular lymphocytic leukaemia may be cyclical [15].

Peripheral blood

There is a reduction in neutrophils but those present are cytologically normal.

Bone marrow cytology

Granulopoiesis appears normal or hyperplastic with

a reduced proportion of mature neutrophils. An uncommon observation is phagocytosis of neutrophils by bone marrow macrophages (Fig. 8.33) [26]. In agranulocytosis associated with thymoma, the bone marrow may show either apparent arrest at the promyelocytic stage or a total absence of myelopoiesis [27].

Idiopathic hypereosinophilic syndrome

The idiopathic hypereosinophilic syndrome is a condition of unknown aetiology characterized by sustained hypereosinophilia and damage to tissues, usually including the heart and central nervous system, by eosinophil products. The clinical features are due to this tissue damage. The idiopathic hypereosinophilic syndrome has been arbitrarily defined as requiring the eosinophil count to be greater than $1.5 \times 10^9/l$ for greater than 6 months and for tissue damage to have occurred [28]. Diagnosis of the idiopathic hypereosinophilic syndrome is mainly dependent on peripheral blood and clinical features and on the exclusion of other diagnoses. A bone marrow aspirate and trephine biopsy are of importance in excluding eosinophilic leukaemia and lymphoma, the latter being an important cause of reactive eosinophilia. Some cases of idiopathic hypereosinophilic syndrome represent a myeloproliferative disorder (MPD) and subsequently transform to AML despite initially displaying no

Fig. 8.34 BM aspirate, idiopathic hypereosinophilic syndrome, showing eosinophil hyperplasia; note partial degranulation of eosinophils. MGG $\times 940$.

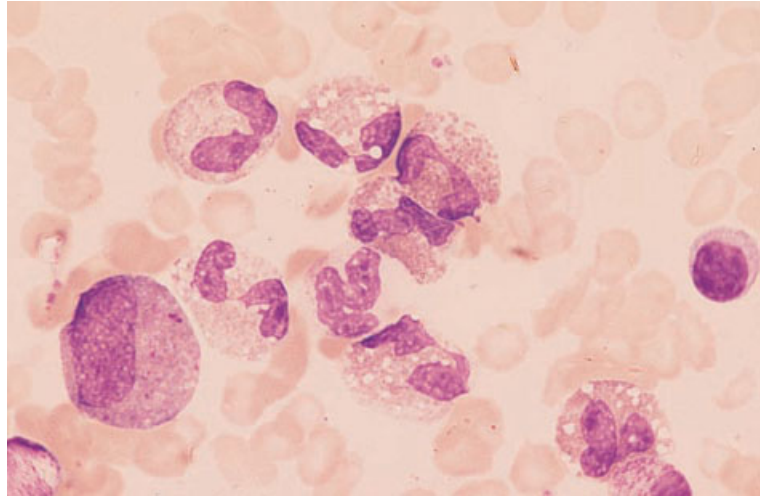
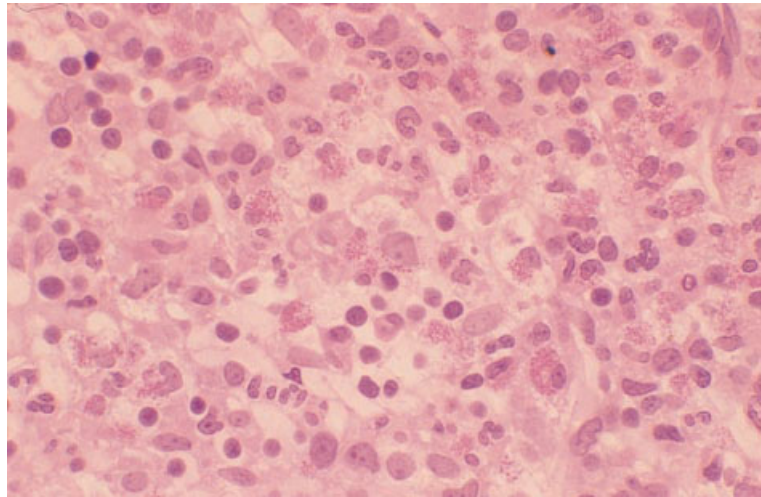


Fig. 8.35 BM trephine biopsy specimen, idiopathic hypereosinophilic syndrome, showing marked granulocytic hyperplasia and increased numbers of immature eosinophil precursors. Plastic-embedded, H&E $\times 390$.



specific evidence of the nature of the underlying disorder. Some cases of otherwise unexplained eosinophilia result from cytokine secretion by aberrant, sometimes monoclonal, T cells [29].

Peripheral blood

The eosinophil count is considerably elevated and eosinophils usually show some degree of hypogranularity and cytoplasmic vacuolation; completely agranular eosinophils are sometimes present. Eosinophil nuclei may be non-segmented or hypersegmented or occasionally ring-shaped. Neutrophils

may show heavy granulation. In contrast to eosinophilic leukaemia, there are usually only occasional if any granulocyte precursors in the peripheral blood. There may be a mild anaemia and thrombocytopenia with red cells showing anisocytosis and poikilocytosis. Nucleated red cells are sometimes present.

Bone marrow cytology

The bone marrow shows an increase of eosinophils and their precursors (Fig. 8.34). Some eosinophil myelocytes show granules with basophilic staining

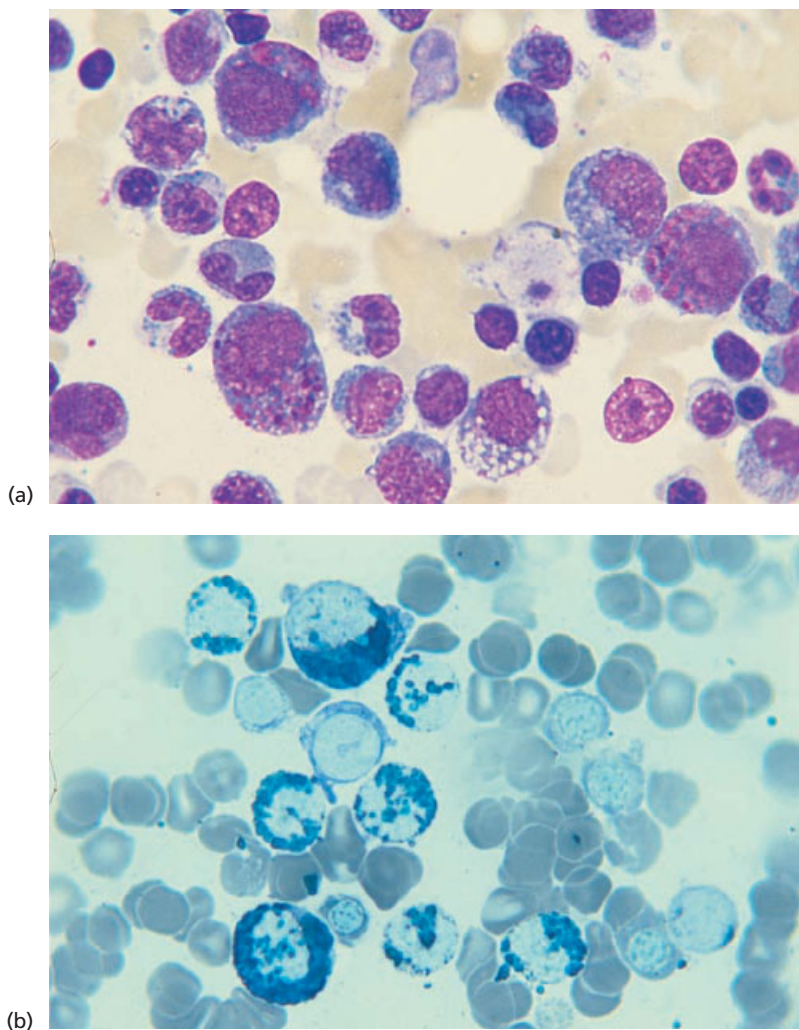


Fig. 8.36 Chediak-Higashi syndrome. (a, b) BM aspirates, showing giant granules and vacuolation of granulocyte precursors: (a) MGG; (b) Sudan black B $\times 960$.

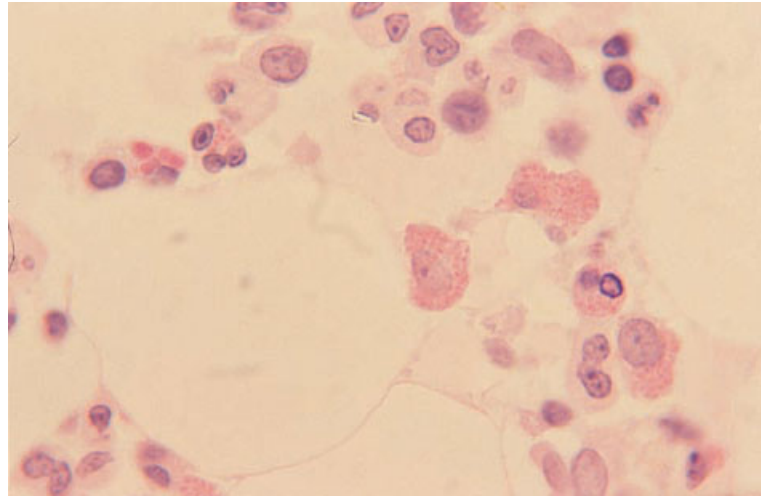
characteristics but this feature is much less striking than in AML of M4Eo type (see page 150). There is no increase in blast cells. Macrophages may contain Charcot-Leyden crystals [30].

Bone marrow histology

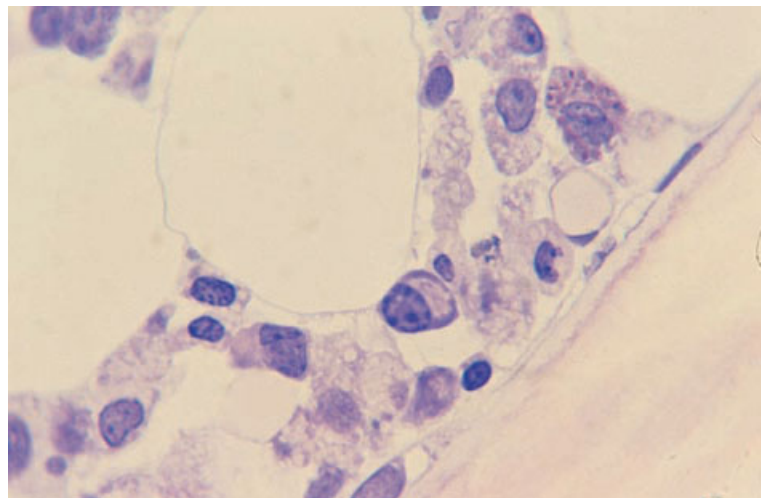
Eosinophils and their precursors are increased (Fig. 8.35). It is important to exclude marrow infiltration by lymphoma since this may be easily overlooked. However, it should be noted that benign lymphoid aggregates may be associated with the idiopathic hypereosinophilic syndrome [31].

Problems and pitfalls

The idiopathic hypereosinophilic syndrome is a diagnosis of exclusion. The bone marrow aspirate should be examined for any increase of blast cells, indicative of a diagnosis of eosinophilic leukaemia. Bone marrow aspirate films and trephine biopsy sections should be examined carefully for features of systemic mastocytosis, which occasionally presents with striking eosinophilia. Bone marrow cytogenetic analysis is indicated since demonstration of a clonal abnormality means that the condition is not 'idiopathic' but represents a chronic eosinophilic



(c)



(d)

Fig. 8.36 Chediak–Higashi syndrome. (c, d) BM trephine biopsy sections: (c) H&E stain showing giant granules; (d) Dominicini stain showing giant granules and vacuolation. Paraffin-embedded $\times 960$. (By courtesy of Dr CJ McCallum, Kirkaldy.)

leukaemia [32,33]. Immunophenotyping of peripheral blood lymphocytes is indicated and, when an aberrant population is found, T-cell receptor gene analysis can be used to identify a monoclonal T-cell proliferation. If such a clonal population is demonstrated, the eosinophilia should be regarded as secondary to a T-cell neoplasm rather than idiopathic.

Despite thorough investigation, some patients with apparently idiopathic hypereosinophilic syndrome can be recognized as having chronic eosinophilic leukaemia only in retrospect when they subsequently develop a granulocytic sarcoma or AML.

Chediak–Higashi syndrome

The Chediak–Higashi syndrome is a fatal inherited condition characterized by a defect in formation of lysosomes in multiple cell lineages. Patients suffer from albinism, neurological abnormalities and recurrent infections. Haematological abnormalities are most apparent in the granulocyte series although anaemia and thrombocytopenia also occur.

Peripheral blood

All granulocyte lineages show striking abnormalities.

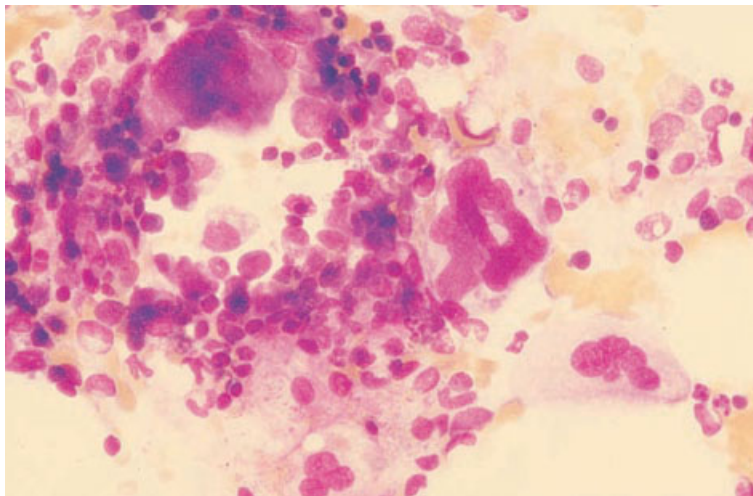


Fig. 8.37 BM aspirate, auto-immune thrombocytopenic purpura, showing five megakaryocytes of varying size and ploidy levels. MGG $\times 377$.

Granules are very large and also have abnormal staining characteristics. Lymphocytes and monocytes may also have abnormally prominent granules. With disease progression, there is development of anaemia, neutropenia and thrombocytopenia.

Bone marrow cytology

Granulocyte precursors as well as mature granulocytes show giant granules with unusual staining characteristics (Fig. 8.36a,b). Sometimes there is also vacuolation. A secondary haemophagocytic syndrome may occur; it is likely to be consequent on immune deficiency and superimposed infection.

Bone marrow histology

Giant granules may be apparent in granulocyte precursors (Fig. 8.36c,d) but, in general, detection is easier in bone marrow aspirate films. Marked haemophagocytosis may be seen during the terminal phase (see page 119).

Congenital thrombocytopenias

Congenital thrombocytopenia may be inherited or may be secondary to intra-uterine infection, mutagen exposure or platelet destruction by maternal anti-platelet antibodies.

Peripheral blood

Morphological features are dependent on which specific defect is responsible for thrombocytopenia [1]. In inherited thrombocytopenia, the platelets may be of normal size, increased in size as in Bernard–Soulier syndrome or decreased in size as in the Wiskott–Aldrich syndrome. In the grey platelet syndrome they are increased in size and lack normal azurophilic granules. In the May–Hegglin anomaly, and in several other rare inherited defects, thrombocytopenia and giant platelets are associated with weakly basophilic cytoplasmic inclusions in neutrophils. When thrombocytopenia is secondary to intra-uterine platelet destruction or damage to megakaryocytes, the platelets are usually normal in size and morphology.

Other lineages are generally normal but infants with the thrombocytopenia-absent radii (TAR) syndrome have been noted to be prone to leukaemoid reactions.

Bone marrow cytology

In inherited thrombocytopenia, megakaryocytes may be present in normal numbers, as in Bernard–Soulier syndrome, or may be severely reduced in number, as in constitutional amegakaryocytic thrombocytopenia. In the TAR syndrome megakaryocytes are greatly reduced in number and are small with

poorly lobulated nuclei; eosinophilia is common. In the Jacobsen syndrome, associated with a constitutional deletion of the long arm of chromosome 11, there are increased numbers of micromegakaryocytes [34]. In other rare syndromes characterized by familial thrombocytopenia, megakaryocyte numbers are variously increased, normal or decreased and megakaryocyte size may likewise be increased, normal or decreased [35].

When thrombocytopenia results from intrauterine damage to megakaryocytes, these cells are usually reduced in number. When platelets have been destroyed by exposure to maternal anti-platelet antibodies, megakaryocytes are present in normal or increased numbers.

Bone marrow histology

A bone marrow biopsy is not often needed in determining the cause of congenital thrombocytopenia but it can be useful in permitting an accurate assessment of megakaryocyte numbers and morphology. In the grey platelet syndrome there may be associated myelofibrosis, probably resulting from intramedullary release by megakaryocytes of granular contents capable of stimulating fibroblasts.

Acquired thrombocytopenias

Isolated acquired thrombocytopenia is commonly due to peripheral destruction of platelets, caused by anti-platelet antibodies, drug-dependent antibodies or immune complexes; the latter may attach to platelets both in auto-immune diseases and during or after viral infections, including infection by HIV. Thrombocytopenia may also be consequent on platelet consumption, as in thrombotic thrombocytopenic purpura or in disseminated intravascular coagulation. Less often, acquired thrombocytopenia results from megakaryocytic hypoplasia, such as that induced by thiazide diuretics, or a failure of megakaryocytes to produce platelets, as in some patients with MDS who present with isolated thrombocytopenia. Antibody-mediated amegakaryocytic thrombocytopenia is a rare cause [36]. Auto-immune thrombocytopenia and, rarely, amegakaryocytic thrombocytopenic purpura may be associated with LGLL [15].

Peripheral blood

When thrombocytopenia is caused by a sustained increase in the peripheral destruction or consumption of platelets, there is usually an increase in platelet size with some giant platelets being present. When thrombocytopenia is due to failure of production, as in sepsis or during chemotherapy, the platelets are small. When thrombocytopenia is consequent on MDS, platelets often show increased variation in size and hypogranular or agranular forms may be present.

Bone marrow cytology

When thrombocytopenia resulting from peripheral destruction or consumption of platelets has developed acutely, the bone marrow may show no relevant abnormality, megakaryocytes being present in normal numbers. With sustained thrombocytopenia, there is an increase in megakaryocyte numbers (Fig. 8.37) and a reduction in average size. There is often very little morphological evidence of platelet production despite the increased platelet turnover which can be demonstrated by isotopic studies.

When thrombocytopenia results from ineffective thrombopoiesis, for example in MDS, megakaryocytes may be present in normal or increased numbers and may show dysplastic features. In acquired megakaryocytic hypoplasia, for example as an adverse drug effect, megakaryocytes are usually morphologically normal although reduced in number. Antibody-mediated amegakaryocytic thrombocytopenia may be cyclical. In these cases, megakaryocyte numbers are reduced and megakaryocytes are small when the platelet count is falling. When the count is rising, they are normal or increased in number and cytologically normal [36].

Bone marrow histology

Trephine biopsy is not usually necessary in the investigation of suspected immune thrombocytopenia but is useful in confirming megakaryocytic hypoplasia and in investigating suspected myelodysplasia.

In idiopathic (auto-immune) thrombocytopenia, the bone marrow is normocellular with increased numbers of megakaryocytes (Fig. 8.38). Mean

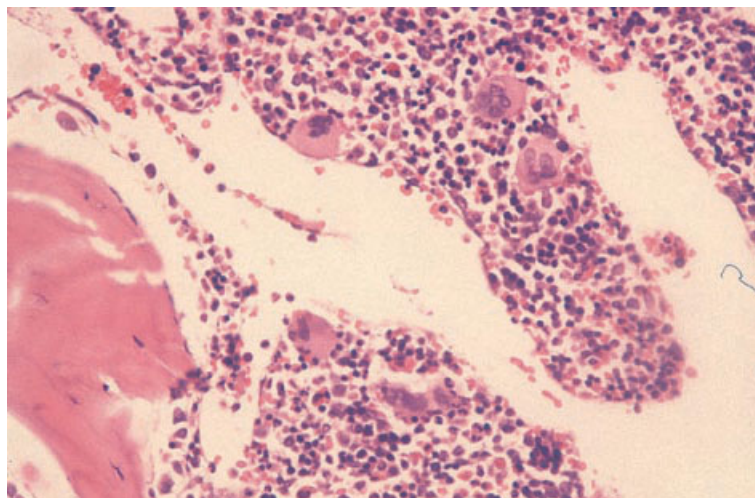


Fig. 8.38 BM trephine biopsy specimen, auto-immune thrombocytopenic purpura, showing increased megakaryocytes which are not clustered and are normally sited; two are adjacent to sinusoids. Paraffin-embedded, H&E $\times 375$. (By courtesy of Dr S Wright, London.)

megakaryocyte diameter is decreased. There is increased variation in size so that, although small megakaryocytes predominate, there are also increased numbers of giant forms. There is no abnormal localization of megakaryocytes and clusters are not usually seen [37]. In cyclical, antibody-mediated amegakaryocytic thrombocytopenia, megakaryocyte numbers are reduced when the platelet count is falling and normal when it is rising [36].

Problems and pitfalls

The differential diagnosis of isolated thrombocytopenia in children includes ALL. Leukaemia is unlikely if the haemoglobin concentration and white cell count are normal. However, a small but significant proportion of children in whom a presumptive diagnosis of auto-immune or post-viral thrombocytopenia is made turn out to have ALL. This has led to controversy as to whether a bone marrow aspirate is required in children with isolated thrombocytopenia [38]. There is concern that administration of corticosteroids without a pre-treatment bone marrow examination may lead to inadvertent suboptimal treatment of undiagnosed ALL. For this reason, UK guidelines suggest that bone marrow aspiration should be performed before corticosteroid therapy is given, whereas this is not considered essential prior to high-dose immunoglobulin therapy or if no treatment is required. USA

guidelines, however, do not regard a bone marrow examination as necessary if there are no atypical clinical or haematological features.

Familial thrombocytosis

Familial thrombocytosis has been reported in at least 17 individuals in eight families [39]. Inheritance appears to be autosomal dominant. In some, but not all, families the cause appears to be a mutation in the thrombopoietin gene. A minority of individuals have had splenomegaly.

Peripheral blood

The blood film and count show thrombocytosis as an isolated abnormality. Platelet morphology has sometimes been reported as abnormal [39].

Bone marrow cytology and histology

Megakaryocytes are increased in number and have sometimes been considered to be cytologically abnormal [39]. Bone marrow cellularity is sometimes increased.

Problems and pitfalls

Use of the term 'essential thrombocythaemia' to describe familial thrombocytosis is not recom-

mended since the condition clearly differs from the MPD that is usually intended by this term. MPD is rare in children with a significant proportion of cases of primary thrombocythaemia being found to be familial. Investigation of parents and siblings is therefore indicated when persistent unexplained thrombocytosis is found in a child or adolescent.

Reactive thrombocytosis

The platelet count may increase in response to infection, inflammation and malignant disease. In reactive thrombocytosis it is uncommon for the platelet count to exceed $1000 \times 10^9/l$.

Peripheral blood

In contrast to MPD, there is no increase in platelet size when thrombocytosis is reactive. The blood film may show other reactive changes including leucocytosis and neutrophilia but the presence of basophilia suggests MPD.

Bone marrow cytology

The bone marrow aspirate shows increased numbers of megakaryocytes of normal morphology.

Bone marrow histology

Megakaryocyte numbers are increased. The average megakaryocyte diameter is increased in comparison with normal and there is increased variation in size. There is no clustering or abnormality of distribution [37].

Problems and pitfalls

The differential diagnosis of reactive thrombocytosis includes hyposplenism and essential thrombocythaemia. Changes of hyposplenism should therefore be sought in the blood film. An increased basophil count, increased reticulin deposition in the bone marrow and clustering of megakaryocytes favour a diagnosis of essential thrombocythaemia.

References

1 Bain BJ. *Blood Cells: A Practical Guide*, 3rd edn. Blackwell Science, Oxford, 2002.

- 2 Bodnar A, Rosenthal NS and Yomtovian R (1996) Severe hemolytic anemia with marrow dyserythropoiesis. *Am J Clin Pathol*, 105, 509.
- 3 Bader-Meunier B, Rieux-Laucat F, Croisille L, Yvart J, Mielot F, Dommergues JP *et al.* (2000) Dyserythropoiesis associated with a Fas-deficient condition in childhood. *Br J Haematol*, 108, 300–304.
- 4 Wickramasinghe SNW (1997) Dyserythropoiesis and congenital dyserythropoietic anaemias. *Br J Haematol*, 98, 785–797.
- 5 Wickramasinghe SN (1998) Congenital dyserythropoietic anaemia: clinical features, haematological morphology and new biochemical data. *Blood Rev*, 12, 178–200.
- 6 Dokal IS, Cox TC and Galton DAG (1990) Vitamin B₁₂ and folate deficiency presenting as leukaemia. *BMJ*, 300, 1263–1264.
- 7 Maung ZT, Norden J, Middleton PG, Jack FR and Chandler JE (1994) Pure red cell aplasia: further evidence of a T cell clonal disorder. *Br J Haematol*, 87, 189–192.
- 8 Ramenghi U, Garelli E, Valtolina S, Campagnoli MF, Timeus F, Crescenzo N *et al.* (1999) Diamond–Blackfan anaemia in the Italian population. *Br J Haematol*, 104, 841–848.
- 9 Giri N, Kang E, Tisdale JF, Follman D, Rivera M, Schwartz GN *et al.* (2000) Clinical and laboratory evidence for a trilineage haematopoietic defect in patients with refractory Diamond-Blackfan anaemia. *Br J Haematol*, 108, 167–175.
- 10 Glader BE (1987) Diagnosis and management of red cell aplasia in children. *Hematol Oncol Clin North Am*, 1, 431–447.
- 11 Foot ABM, Potter MN, Ropner JE, Wallington TB and Oakhill A (1990) Transient erythroblastopenia of childhood with CD10, TdT, and cytoplasmic μ lymphocyte positivity in bone marrow. *J Clin Pathol*, 43, 857–859.
- 12 Penchansky L and Jordan JA (1997) Transient erythroblastopenia of childhood associated with human herpesvirus type 6, variant B. *Am J Clin Pathol*, 108, 127–132.
- 13 Fleming AF (1999) Pregnancy and aplastic anaemia. *Br J Haematol*, 105, 313–320.
- 14 Kwong YL and Wong KF (1998) Association of pure red cell aplasia with large granular lymphocyte leukaemia. *J Clin Pathol*, 51, 672–675.
- 15 Lamy T and Loughran TP (1999) Current concepts: large granular lymphocyte leukemia. *Blood Rev*, 13, 230–240.
- 16 Frickhofen N, Chen ZJ, Young NS, Cohen BJ, Heimpel H and Abkowitz JL (1994) Parvovirus B19 as a cause of acquired chronic pure red cell aplasia. *Br J Haematol*, 87, 818–824.
- 17 Shaw PJ, Eden T and Cohen BJ (1993) Parvovirus as a cause of chronic anemia in rhabdomyosarcoma. *Cancer*, 72, 945–949.

- 18 Karmochkine M, Oksenhendler E, Leruez-Ville M, Jaccard A, Morinet F and Herson S (1995) Persistent parvovirus B19 infection and pure red cell aplasia in Waldenström's macroglobulinemia: successful treatment with high dose intravenous immunoglobulin. *Am J Hematol*, 50, 227–228.
- 19 O'Brien H, Amess JAL and Mollin DL (1982) Recurrent thrombocytopenia, erythroid hypoplasia and sideroblastic anaemia associated with hypothermia. *Br J Haematol*, 51, 451–456.
- 20 Koduri PR (1998) Novel cytomorphology of the giant proerythroblasts of parvovirus B19 infection. *Am J Hematol*, 58, 95–99.
- 21 Ryan M, Will AM, Testa N, Hayworth C and Darbyshire PJ (1995) Severe congenital neutropenia unresponsive to G-CSF. *Br J Haematol*, 91, 43–45.
- 22 Simon M, Lengfelder E, Reiter S and Hehlmann R (1996) Osteoporosis in severe congenital neutropenia: inherent in the disease or a sequel of G-CSF treatment? [letter] *Am J Hematol*, 52, 127.
- 23 Van den Tweel JG (1997) Preleukaemic disorders in children: hereditary disorders and myelodysplastic syndrome. *Current Diagn Pathol*, 4, 45–50.
- 24 Kivitiie-Kallio S, Rajantie J, Juvonen E and Norio R (1997) Granulocytopenia in Cohen syndrome. *Br J Haematol*, 98, 308–311.
- 25 Patton WN (1993) Use of colony stimulating factors for the treatment of drug-induced agranulocytosis. *Br J Haematol*, 84, 182–186.
- 26 Shimizu H, Sawada K, Katano N, Sasaki K, Kawai S and Fujimoto T (1990) Intramedullary neutrophil phagocytosis by histiocytes in autoimmune neutropenia of infancy. *Acta Haematol*, 84, 201–203.
- 27 Yip D, Rasko JEJ, Lee C, Kronenberg H and O'Neill B (1996) Thymoma and agranulocytosis: two case reports and literature review. *Br J Haematol*, 95, 52–56.
- 28 Chusid MJ, Dale DC, West BC and Wolff SM (1975) The hypereosinophilic syndrome. *Medicine*, 54, 1–27.
- 29 Simon HU, Plötz SG, Dummer R and Blaser K (1999) Abnormal clones of interleukin-5-producing T cells in idiopathic eosinophilia. *N Engl J Med*, 341, 1112–1120.
- 30 Brunning RD and McKenna RW. *Atlas of Tumor Pathology*, 3rd Series, Fascicle 9, Tumors of the bone marrow. Armed Forces Institute of Pathology, Washington, 1993.
- 31 Metz J, McGrath KM, Savoia HF, Begley CG and Chetty R (1993) T cell lymphoid aggregates in bone marrow in idiopathic hypereosinophilic syndrome. *J Clin Pathol*, 46, 955–958.
- 32 Bain BJ (1996) Eosinophilic leukaemias and the idiopathic hypereosinophilic syndrome. *Br J Haematol*, 95, 2–9.
- 33 Bain BJ (1999) Eosinophilia—idiopathic or not? *N Engl J Med*, 341, 1141–1143.
- 34 Gangarossa S, Schiliró G, Mattina T, Scardilli S, Mollica F and Cavallari V (1996) Dysmegakaryopoietic thrombocytopenia in patients with distal chromosome 11q deletion. *Blood*, 87, 4915–4916.
- 35 Bellucci S (1997) Megakaryocytes and inherited thrombocytopenias. *Baillières Clin Haematol*, 10, 149–162.
- 36 Zent CS, Ratajczak J, Ratajczak MZ, Anastasi J, Hoffman PC and Gewirtz AM (1999) Relationship between megakaryocyte mass and serum thrombopoietin levels as revealed by a case of cyclic amegakaryocytic thrombocytopenic purpura. *Br J Haematol*, 105, 452–458.
- 37 Thiele J and Fischer R (1991) Megakaryocytopoiesis in haematological disorders: diagnostic features of bone marrow biopsies. *Virchows Arch (A)*, 418, 87–97.
- 38 Bolton-Maggs PHB (1998) The management of acute childhood immune thrombocytopenic purpura—a controversy revisited. *CME Bull Haematol*, 1, 79–81.
- 39 Dror Y and Blanchette VS (1999) Essential thrombocythaemia in children. *Br J Haematol*, 107, 691–698.

NINE

MISCELLANEOUS DISORDERS

Non-metastatic effects of cancer

Patients with cancer but without bone marrow metastases may show a variety of haematological abnormalities.

Peripheral blood

Anaemia is common. Red cells may be normocytic and normochromic or microcytic and hypochromic. Rouleaux formation is often increased. Some patients have neutrophil leucocytosis, eosinophilia, monocytosis or thrombocytosis.

Bone marrow cytology

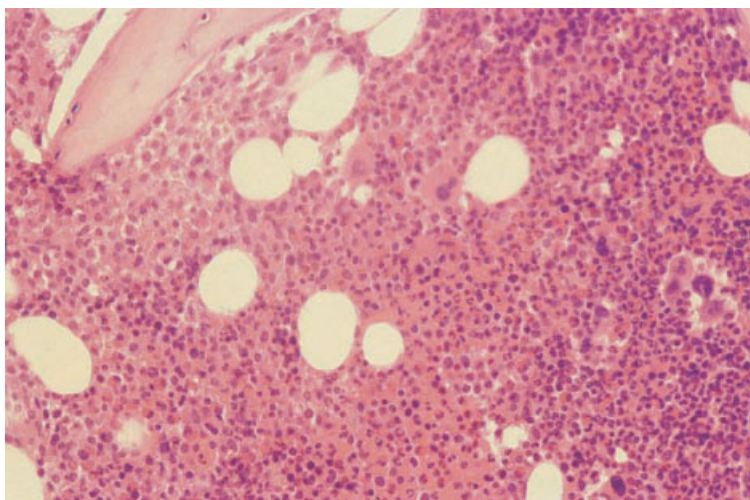
Erythropoiesis often shows the features of the anaemia of chronic disease. There may also be dyserythropoiesis. Granulopoiesis (neutrophil and/or eosinophil) may be increased and there may also be

hypogranularity or some cells showing the acquired Pelger–Huët anomaly [1]. Megakaryocytes are often increased, as are macrophages, plasma cells and sometimes mast cells. Bone marrow necrosis may occur. It has been suggested that this may be mediated by tumour necrosis factor [2].

Bone marrow histology

There may be suppression of erythropoiesis, granulocytic hyperplasia and increased megakaryocytes (Fig. 9.1). Dyserythropoiesis, abnormal localization of immature granulocytes and dysplastic megakaryocytes are sometimes noted [1]. Macrophages, plasma cells and mast cells are sometimes increased. Stromal changes can include paratrabecular fibrosis, sinusoidal congestion, oedema and bone remodelling [1]. In patients with advanced disease, there may be gelatinous transformation, which is sometimes extensive. Patients with parathyroid

Fig. 9.1 BM trephine biopsy section from a patient with cancer, showing granulocytic and megakaryocyte hyperplasia with an increase of granulocyte precursors in a paratrabecular position. The Hb was 9.7 g/dl. The white cell count and platelet count were normal. Paraffin-embedded, H&E ×280.



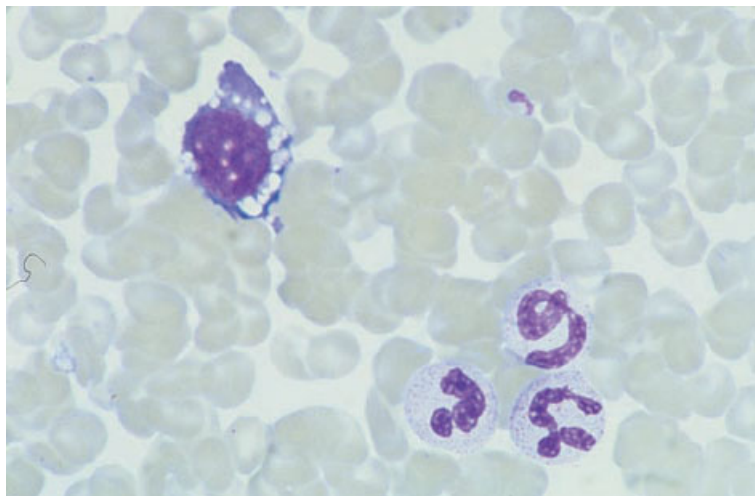


Fig. 9.2 BM aspirate from an intensive care ward patient with multi-organ failure, showing a heavily vacuolated dysplastic proerythroblast. MGG $\times 960$.

hormone-secreting tumours may show changes of hyperparathyroidism. Iron stores may be increased.

Bone marrow dysplasia with polyclonal haemopoiesis

It is important to distinguish secondary bone marrow dysplasia from the myelodysplastic syndromes (MDS). The MDS are characterized by dysplastic and ineffective clonal haemopoiesis. They are neoplastic conditions which are potentially preleukaemic. In secondary myelodysplasia, haemopoiesis is polyclonal. The condition is neither neoplastic nor preleukaemic and, if the underlying cause can be removed, it is reversible. The commonest causes of secondary bone marrow dysplasia are infections (particularly HIV infection and tuberculosis), critical illness, often with multi-organ failure [3], exposure to drugs and toxins (particularly alcohol) and auto-immune diseases (such as systemic lupus erythematosus and juvenile rheumatoid arthritis). Dyserythropoiesis, possibly with an auto-immune basis, has also been reported in the auto-immune lymphoproliferative syndrome associated with Fas deficiency [4]. Certain anti-cancer drugs have the potential to induce MDS but, in addition, many anti-cancer drugs and related agents (e.g. azathioprine, mycophenolate mofetil and zidovudine) cause reversible dysplastic changes. Dysplastic changes have been reported following liver and other solid

organ transplantation [5]. Macrocytosis and trilineage myelodysplasia have been reported in a significant minority of patients with large granular lymphocyte leukaemia (see page 290). Dyserythropoiesis is common in malaria. Anaemia with sideroblastic erythropoiesis has been observed in hypothermia [6]. The characteristic haematological effects of HIV infection (see page 123), anti-cancer and immunosuppressive chemotherapy (see page 393), excess alcohol intake (see page 399) and protein-calorie malnutrition (see page 413) are dealt with in detail elsewhere. The general features of secondary bone marrow dysplasia will be described here.

Peripheral blood

Anaemia is usual and thrombocytopenia is common. Some patients have leucopenia or pancytopenia. Red cells may show anisocytosis, macrocytosis or poikilocytosis. Neutrophils may show non-specific abnormalities such as cytoplasmic vacuolation, variable granulation, abnormalities of nuclear shape, binuclearity and detached nuclear fragments. Agranular neutrophils and the acquired Pelger–Huët anomaly are uncommon but do occur.

Bone marrow cytology

Dyserythropoiesis is common (Figs 9.2 and 9.3). Abnormalities seen include cytoplasmic bridging,

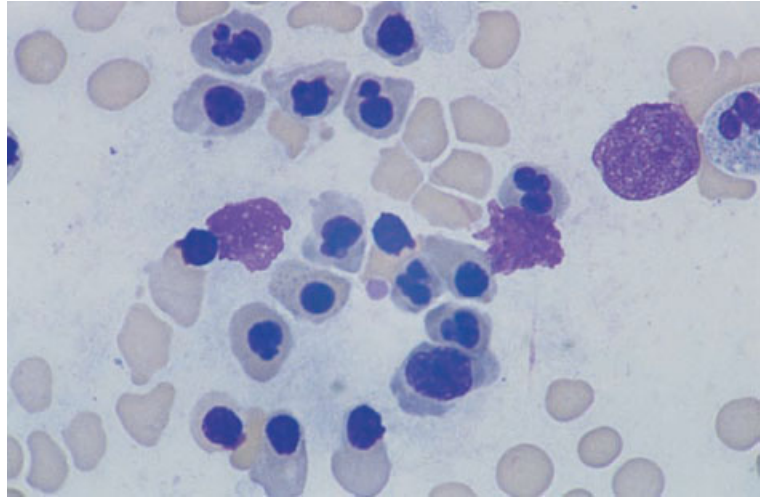


Fig. 9.3 BM aspirate from a patient with tuberculosis, showing marked dyserythropoiesis. MGG $\times 960$.

abnormal nuclear lobulation, binuclearity and vacuolation. Erythropoiesis is sometimes megaloblastic. This is particularly common in intensive care ward patients who have been exposed to nitric oxide [3]. Ring sideroblasts may be present although they are usually less frequent than in MDS. Granulopoiesis may show abnormal chromatin clumping, hypolobulation, left shift, vacuolation, hypogranularity or variable granulation and the presence of giant metamyelocytes. Erythroid and granulocyte precursors are sometimes vacuolated. Multinucleated or non-lobulated megakaryocytes may be present. In contrast to MDS, very small mononuclear or binuclear megakaryocytes are uncommon in secondary dysplasia.

Bone marrow histology

The bone marrow may be hypercellular, normocellular or hypocellular. There is often a discrepancy between a hypercellular or normocellular marrow and peripheral cytopenia. Erythropoiesis is often decreased. Reactive changes (e.g. increased macrophages with haemophagocytosis, increased lymphocytes or increased plasma cells) are often present and some patients show gelatinous transformation. Marrow architecture may be disturbed and reticulin may be increased. A marked increase in reticulin deposition may be a feature of systemic lupus erythematosus. A very rare finding in this

condition is that of lupus erythematosus (LE) cells in the bone marrow biopsy [7].

Problems and pitfalls

It is important not to over-interpret dysplastic features in the bone marrows of patients with severe illness. It is also important to distinguish dysplastic features that are a direct effect of chemotherapeutic agents from therapy-induced MDS. The former disappear on cessation of the causative agent whereas the latter do not.

The haematological effects of anti-cancer and immunosuppressive chemotherapy

The majority of anti-cancer and immunosuppressive chemotherapeutic agents are damaging to the bone marrow. Most cause hypoplasia, some cause megaloblastosis and some have other, more specific effects. The nature of the bone marrow damage depends on dose and duration of therapy. A drug may, for example, cause erythroid hyperplasia and megaloblastic erythropoiesis at a low dose and severe hypoplasia at a higher dose.

Peripheral blood

The most prominent effect of anti-cancer chemotherapy is pancytopenia. This is usual with all of the

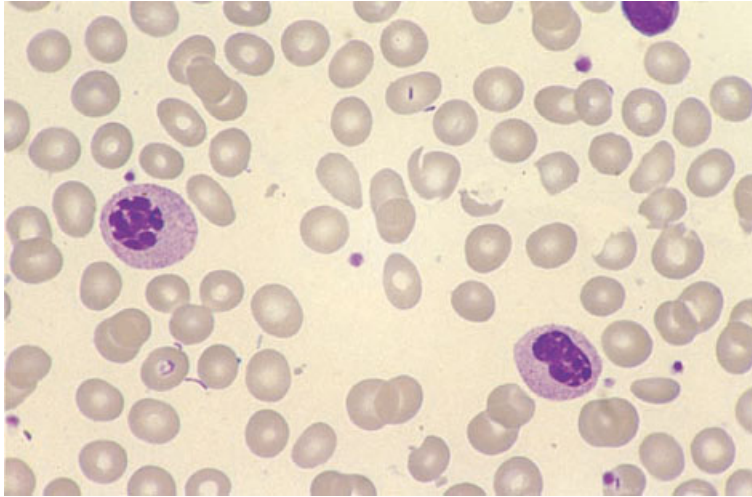


Fig. 9.4 PB film from a patient taking mycophenolate mofetil showing a reversible acquired Pelger–Huët anomaly. MGG ×940. (By courtesy of Dr Ozay Halil, London.)

commonly employed agents, the exceptions being vincristine and bleomycin. Neutropenia and thrombocytopenia are apparent well in advance of anaemia. Some degree of anisocytosis and poikilocytosis, together with basophilic stippling and Howell–Jolly bodies, occurs as a consequence of the dyserythropoiesis induced by chemotherapeutic agents. When megaloblastic change is induced, formation of Howell–Jolly bodies is more marked and macrocytosis is common. Dysplastic changes, including abnormalities of nuclear shape and nuclear inclusions within the cytoplasm, may also be apparent in neutrophils. A reversible acquired Pelger–Huët anomaly has been observed with a number of drugs including chlorambucil and mycophenolate mofetil (Fig. 9.4).

Platelets are small but do not show any specific morphological abnormality. Vincristine is unusual in occasionally causing thrombocytosis, although not when it is given in combination with other drugs which are highly toxic to the bone marrow.

Occasionally chemotherapy is followed by the development of micro-angiopathic haemolytic anaemia. This appears to be particularly a feature of therapy with mitomycin C.

Bone marrow cytology

The bone marrow aspirate shows a variable degree of hypoplasia. If bone marrow aspiration is per-

formed after an episode of severe hypoplasia, early regeneration may produce appearances misinterpreted as ‘maturation arrest’ (Fig. 9.5). Erythropoiesis is dysplastic, often strikingly so. Drugs that cause megaloblastosis include methotrexate, cyclophosphamide, daunorubicin, adriamycin, cytosine arabinoside, hydroxycarbamide (hydroxyurea), azathioprine and zidovudine. The megaloblastosis induced by anti-cancer chemotherapeutic agents, with the exception of folate antagonists, differs from that due to vitamin B₁₂ or folate deficiency in that dyserythropoiesis is very striking and hypersegmented neutrophils and giant metamyelocytes are not usually a feature. Depending on drug dose, megaloblastosis may be associated with erythroid hyperplasia (Fig. 9.6) or hypoplasia. Other drugs cause dysplastic features without megaloblastosis. Erythroid dysplasia may be striking, both with megaloblastic and with normoblastic erythropoiesis. Vincristine and other spindle poisons cause mitotic arrest in quite a high proportion of erythroblasts; this is detected if a bone marrow aspirate is performed 1–2 days after the administration of one of these drugs (Fig. 9.7). Bone marrow aspirates taken shortly after the administration of chemotherapeutic agents may show increased apoptosis and increased numbers of macrophages containing cellular debris.

When mycophenolate mofetil causes the acquired Pelger–Huët anomaly, abnormal chromatin clumping and detached nuclear fragments

Fig. 9.5 BM aspirate from a patient with severe methotrexate toxicity, showing 'maturation arrest'; two promyelocytes and one proerythroblast are seen but maturing cells are severely diminished. MGG $\times 940$.

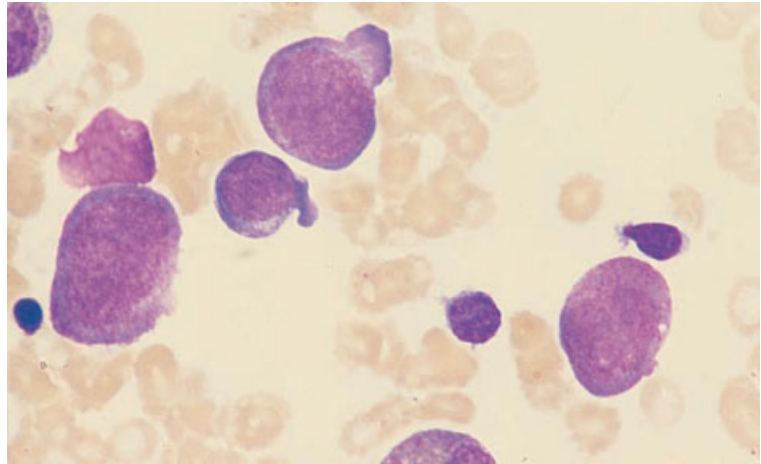


Fig. 9.6 BM aspirate from a patient taking hydroxycarbamide for psoriasis, showing erythroid hyperplasia, mild megaloblastosis and one dyserythropoietic cell. MGG $\times 940$.

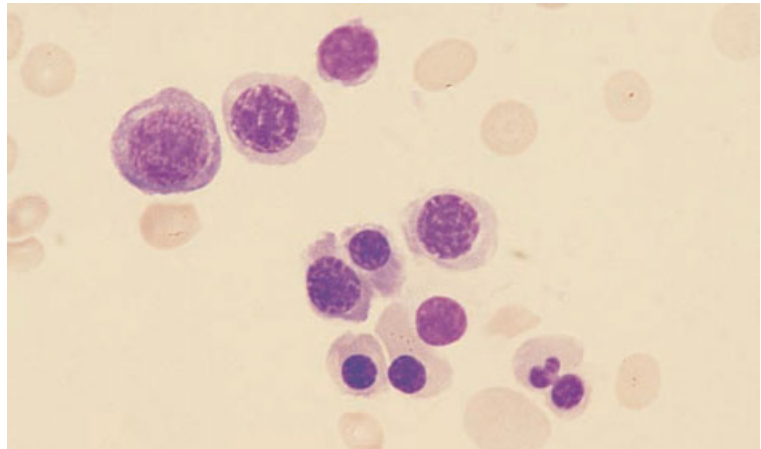
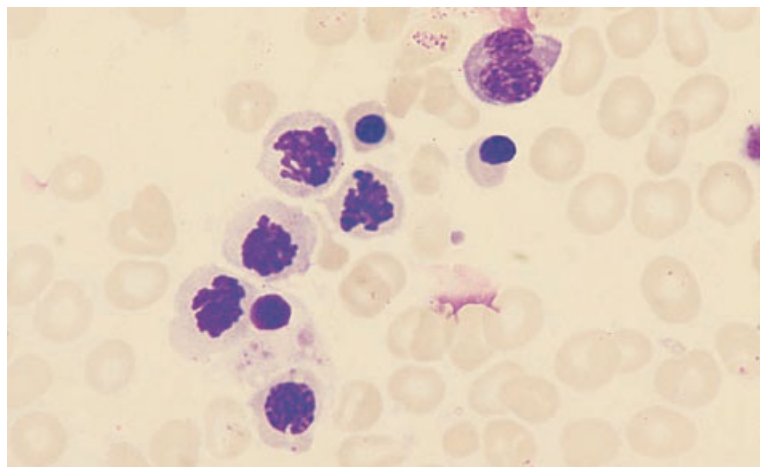


Fig. 9.7 BM aspirate, performed about 24 h after administration of vincristine, showing a binucleate erythroblast and four erythroblasts arrested in mitosis. MGG $\times 940$.



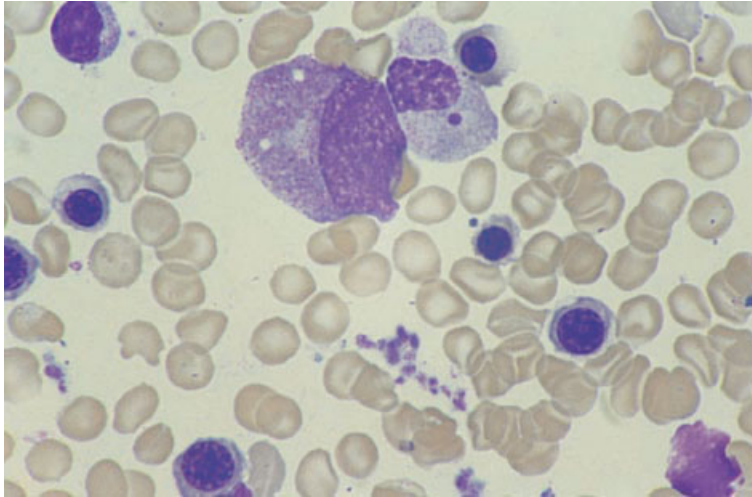


Fig. 9.8 BM aspirate from a patient taking mycophenolate mofetil, showing a myelocyte with abnormal chromatin clumping and a detached nuclear fragment (same case as in Fig. 9.4). MGG $\times 940$. (By courtesy of Dr Ozay Halil, London.)

can be seen in granulocyte precursors in the bone marrow as well as in peripheral blood cells (Fig. 9.8).

Bone marrow histology

Cells exposed to chemotherapeutic agents show apoptosis. Dead cells degenerate to granular eosinophilic debris. With intensive chemotherapy, depletion of haemopoietic cells is severe and stromal elements become prominent. There are dilated sinusoids containing red cells and fibrin [8], and sometimes residual lymphocytes and plasma cells, the latter particularly along small blood vessels. Red cells may be extravasated from dilated sinusoids. In the acute phase of bone marrow damage there may be interstitial oedema; at this stage stains for stromal mucin are negative. Subsequently, typical features of gelatinous transformation may develop.

In the majority of patients treated with intensive chemotherapy for acute leukaemia [8,9], the marrow is almost completely emptied of haemopoietic cells, particularly when therapy is of the type used in acute myeloid leukaemia (AML). Varying degrees of stromal damage occur, including stromal necrosis. Subsequently, there may be collagen deposition, increased osteoblastic activity and focal appositional or intertrabecular bone formation [8]. Prominent residual plasma cells (Fig. 9.9) are more a feature of AML than of acute lymphoblastic leukaemia (ALL) [9]. Cellular depletion persists for

3–4 weeks, to be followed by regeneration of fat cells, which are initially multivesicular, then by regeneration of haemopoietic cells. Erythroid and megakaryocytic regeneration often occurs before granulocytic regeneration but this is variable. In the early stages of regeneration, clusters of haemopoietic precursors made up of cells from a single lineage (Fig. 9.10) are often seen. Topography may be abnormal with erythroid islands adjacent to trabeculae, abnormal localization of immature precursors (ALIP) and megakaryocyte clustering. Extensive bone remodelling may be seen following intensive chemotherapy.

Problems and pitfalls

Megakaryocyte clustering and ALIP are common features during recovery from intensive chemotherapy and may persist for many months. In this context these abnormalities should not be interpreted as evidence of MDS. It is important to know if chemotherapeutic regimens include growth factors such as granulocyte colony-stimulating factor (G-CSF), since this will complicate the interpretation of increased numbers of myeloblasts and promyelocytes. Following cessation of chemotherapy, particularly in children, there may be a rebound increase in immature lymphoid cells. This should not be confused with relapse of leukaemia.

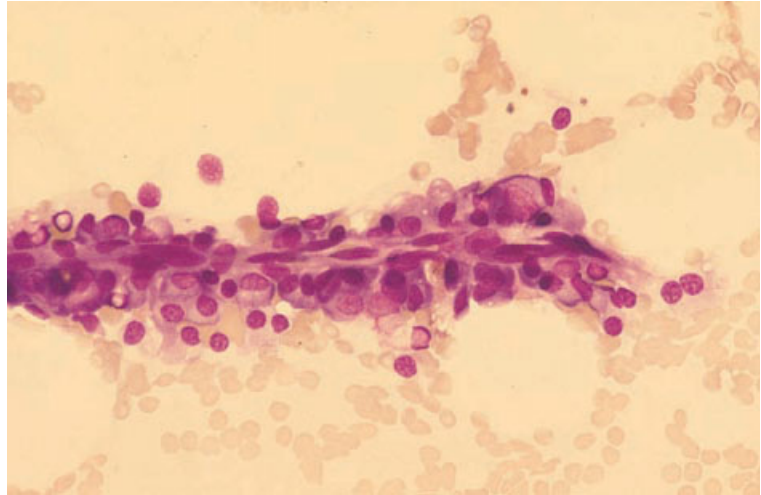


Fig. 9.9 BM aspirate, post-chemotherapy (for AML), showing plasma cells surrounding a capillary in a severely hypoplastic bone marrow. MGG $\times 377$.

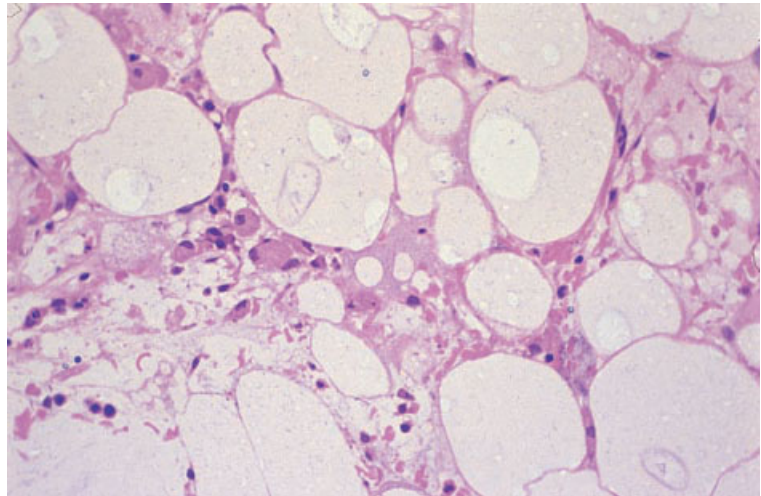


Fig. 9.10 BM trephine biopsy section, regeneration post-chemotherapy, showing decreased cellularity, oedema and a cluster of immature regenerating megakaryocytes. Plastic-embedded, H&E $\times 195$.

The haematological effects of other drugs and chemicals

Anti-cancer and related drugs have predictable haematological toxicity. Other drugs more often cause idiosyncratic reactions with an immunological mechanism such as agranulocytosis (see page 381), immune haemolytic anaemia and aplastic anaemia (see page 401). There is also a small group of other drugs with predictable toxicity. Oxidant drugs and chemicals can cause haemolytic anaemia. Chloramphenicol, as well as causing severe idiosyn-

cratic reactions, regularly causes mild bone marrow suppression with ring sideroblasts and vacuolation of erythroid and granulocyte precursors. A number of drugs including isoniazid cause sideroblastic erythropoiesis. Lead poisoning can cause basophilic stippling of erythrocytes, hypochromic microcytic anaemia, haemolytic anaemia and sideroblastic erythropoiesis. Arsenic can cause pancytopenia with dysplastic erythropoiesis including basophilic stippling and the presence of ring sideroblasts [10,11] (Fig. 9.11). Zinc toxicity can lead to copper deficiency with consequent anaemia, neutropenia

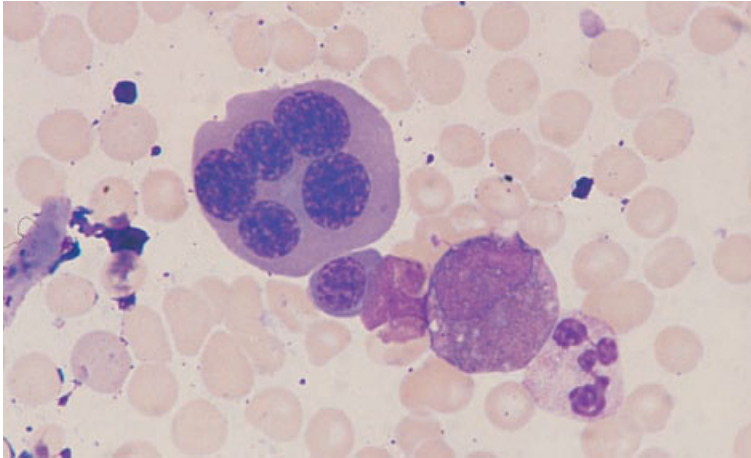
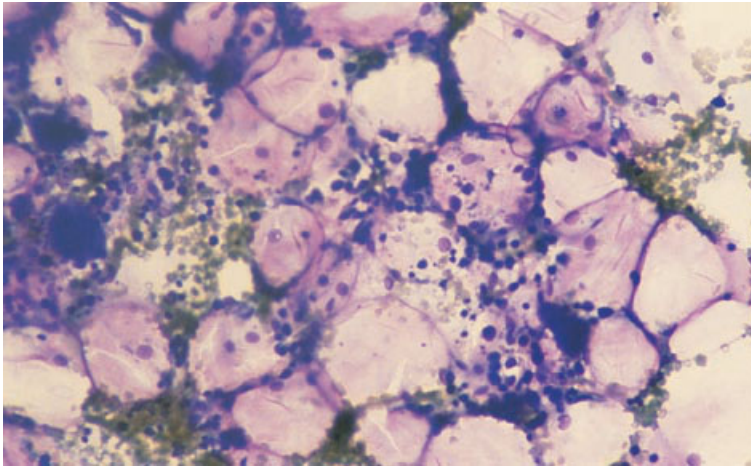
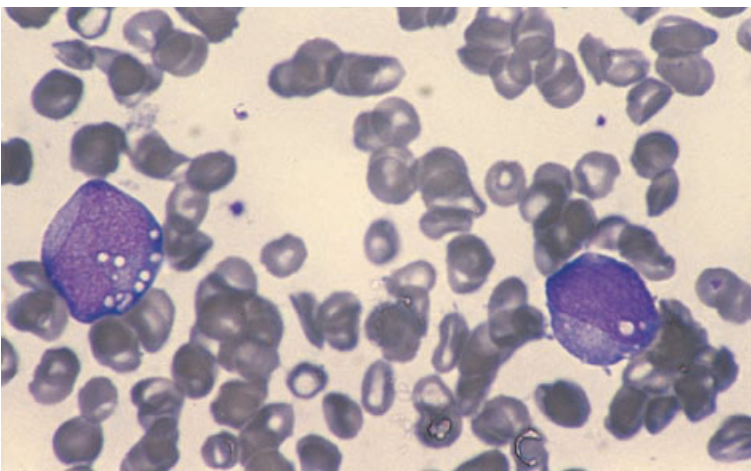


Fig. 9.11 BM aspirate, showing dyserythropoiesis induced by arsenic. MGG $\times 960$. (By courtesy of Professor A Newlands, London.)



(a)



(b)

Fig. 9.12 BM aspirate from a patient with copper deficiency caused by chelation therapy for Wilson's disease showing: (a) hypocellularity; (b) vacuolation of granulocyte precursors. MGG $\times 188$ and $\times 940$. (By courtesy of Dr A Grigg, Melbourne.)

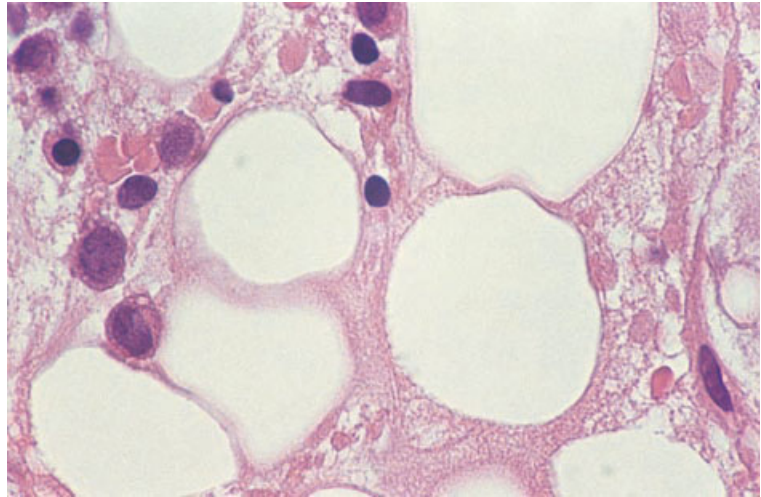


Fig. 9.13 Section of BM trephine biopsy specimen from a patient with copper deficiency caused by chelation therapy for Wilson's disease (same case as in Fig. 9.12), showing hypocellularity and vacuolation of granulocyte precursors. MGG $\times 940$. (By courtesy of Dr A Grigg, Melbourne.)

sideroblastic erythropoiesis and vacuolation of erythroid and myeloid precursors [12]. Similar features are seen with copper-depleting drugs such as penicillamine, trientine and ammonium tetrathiomolybdate used in the treatment of Wilson's disease [13] (Figs 9.12 and 9.13).

The effect of irradiation on the bone marrow

Irradiation of a significant proportion of the bone marrow causes a fall in the neutrophil and platelet counts. Extensive irradiation causes pancytopenia. Monitoring of blood counts is therefore carried out during radiotherapy.

Peripheral blood

The blood film may show neutropenia, thrombocytopenia and the features of anaemia.

Bone marrow cytology

The initial change in irradiated bone marrow is pyknosis and karyorrhexis of haemopoietic cells followed by disappearance of haemopoietic and fat cells and replacement by areas of gelatinous transformation. Subsequently, at the site of irradiation, hypoplastic marrow is found, with haemopoietic cells being replaced by fat. Extensive high-dose irradiation of the bone marrow is followed by aplastic anaemia.

Bone marrow histology

Initially, there may be necrosis of the bone marrow within the field that has received high-dose radiation. Cell loss is initially greatest adjacent to trabeculae as more mature cells are more radio-resistant. There is endothelial cell swelling, sinusoidal dilation, interstitial haemorrhage and sometimes stromal necrosis. Haemosiderin-laden macrophages appear on a background of eosinophilic debris. Subsequently, gelatinous transformation may occur. Bone necrosis may occur during the acute phase and may be followed by bone remodelling and radiation-induced osteodysplasia (Fig. 9.14). Later, there is permanent replacement of haemopoietic marrow by fat or, less often, fibrous tissue.

The haematological effects of alcohol

Excess intake of ethanol is often complicated by dietary deficiency and liver disease. However, ethanol itself has well-defined haematological toxicity.

Peripheral blood

There is a normocytic or macrocytic anaemia with red cells being normochromic. Macrocytes differ from those of megaloblastic anaemia in that they are usually round rather than oval (Fig. 9.15). Stomatocytes are common and target cells are

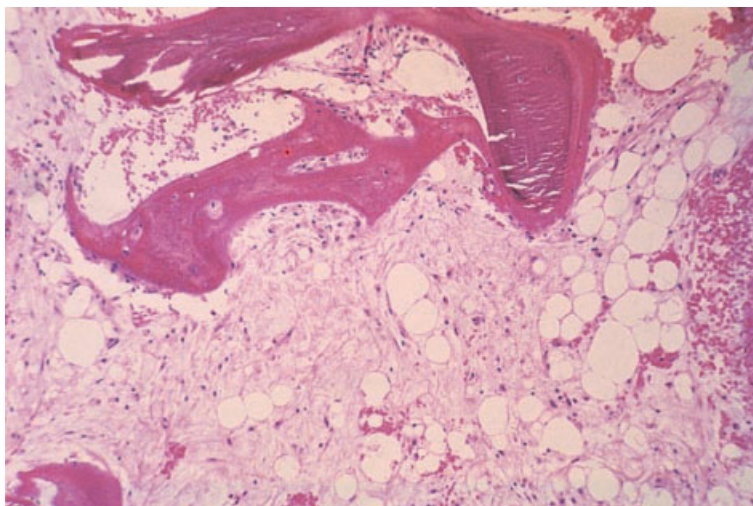


Fig. 9.14 Section of BM trephine biopsy specimen, showing stromal damage and radiation-induced osteodysplasia. H&E $\times 96$. (By courtesy of Dr Ruth Langholm, Oslo.)

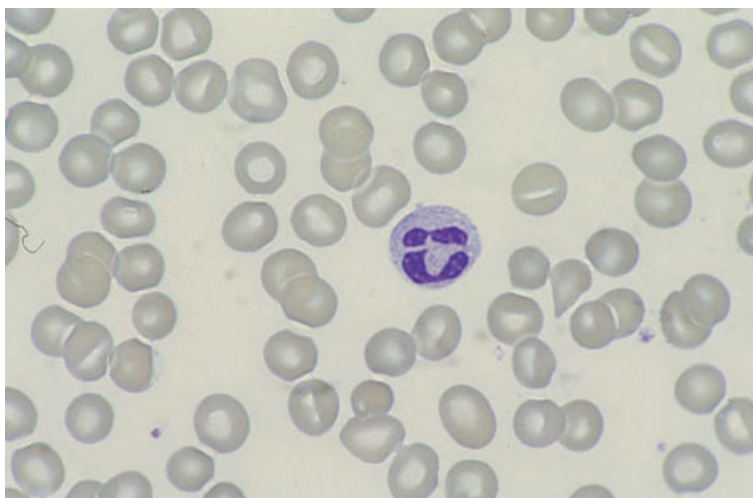

Fig. 9.15 PB film, showing macrocytosis with some stomatocytes, consequent on excess alcohol intake. MGG $\times 960$.

sometimes present. A dimorphic blood film has been reported but is not common. Heavy alcohol intake and acute alcoholic liver disease have been associated with haemolytic anaemia with hyperlipidaemia and with the blood film showing spherocytes or irregularly contracted cells; this is designated Zieve's syndrome. The neutrophil count is usually normal but the capacity of the bone marrow to mount a neutrophil response to infection is reduced and infection may lead to neutropenia. The lymphocyte count may be reduced. Thrombocytopenia is common. If alcohol intake is suddenly stopped, a rebound thrombocytosis can occur.

Bone marrow cytology

Erythropoiesis is normoblastic, macronormoblastic or mildly megaloblastic. Siderotic granules are prominent and there may be ring sideroblasts; sometimes these are numerous. There are other dyserythropoietic features such as erythroid multinuclearity. Erythroid and granulocyte precursors are sometimes vacuolated (Fig. 9.16). Iron stores may be increased; sometimes haemosiderin inclusions are present in plasma cells [14] and in endothelial cells lining sinusoids [15]. The latter phenomenon may be noted in the absence of any

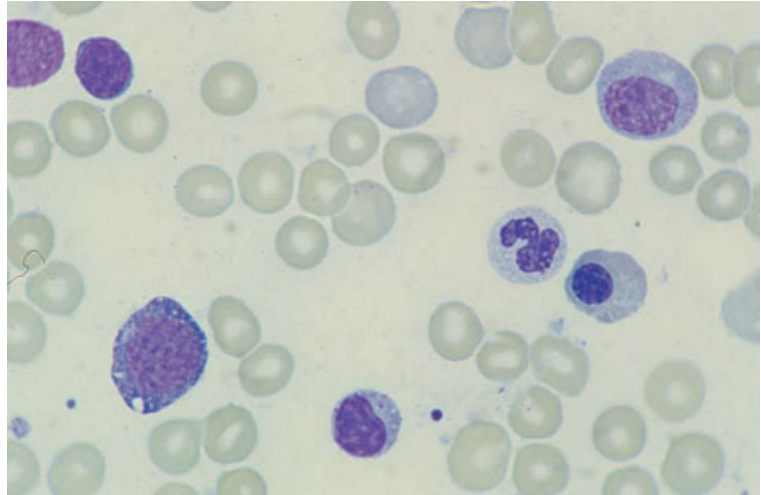


Fig. 9.16 BM aspirate, showing macronormoblastic erythropoiesis and erythroblast vacuolation caused by excess alcohol intake (same case as in Fig. 9.15). MGG $\times 960$.

increase in macrophage iron [15]. In Zieve's syndrome there may be an excess of iron-laden foamy macrophages (Fig. 9.17). Megakaryocytes are often increased [15]. Alcohol-induced reversible bone marrow hypoplasia has been reported [16].

Bone marrow histology

Trephine biopsy sections show dyserythropoiesis. There may be increased iron in macrophages and iron in plasma cells and endothelial cells.

Problems and pitfalls

It is important to be aware of the likelihood of excess alcohol intake in interpreting cytopenias and dysplastic features. Otherwise there may be a misdiagnosis of MDS.

Aplastic anaemia

Aplastic anaemia is a heterogeneous disorder characterized by pancytopenia and a hypocellular marrow without any apparent underlying neoplastic process. The name, although well established, is somewhat misleading since all haemopoietic lineages are involved. Aplastic anaemia is rare. In Europe and North America the incidence is of the order of 5–10/1 000 000/year but in various other parts of the world, for example in Asia, the disease is

considerably more common. Although some cases of aplastic anaemia result from an inherited disorder and develop in infancy or childhood, the incidence, in general, increases with age.

The commonest inherited form of aplastic anaemia is Fanconi's anaemia. This is an autosomal recessive condition in which sufferers have defective DNA repair mechanisms. The pancytopenia usually develops between the ages of 5 and 10 years. Without bone marrow transplantation many patients die from infection or bleeding but approximately 20% develop AML [17]. Other inherited disorders which may progress to aplastic anaemia include dyskeratosis congenita, the Hoyeraal–Hreidarsson syndrome (a severe variant of dyskeratosis congenita) [18], the Schwachman–Diamond syndrome and amegakaryocytic thrombocytopenia without physical defects [19]. In the Schwachman–Diamond syndrome, neutropenia often develops first; pancytopenia follows, resulting from aplastic anaemia.

Known causes of acquired aplastic anaemia include viral hepatitis, irradiation, auto-immune disease, drugs (such as chloramphenicol) and chemicals (such as benzene). Aplastic anaemia may be the initial presentation of systemic lupus erythematosus [20]. Pregnancy appears to be a rare cause of aplastic anaemia [21]. In many cases the cause is not apparent and the designation 'idiopathic aplastic anaemia' is then used.

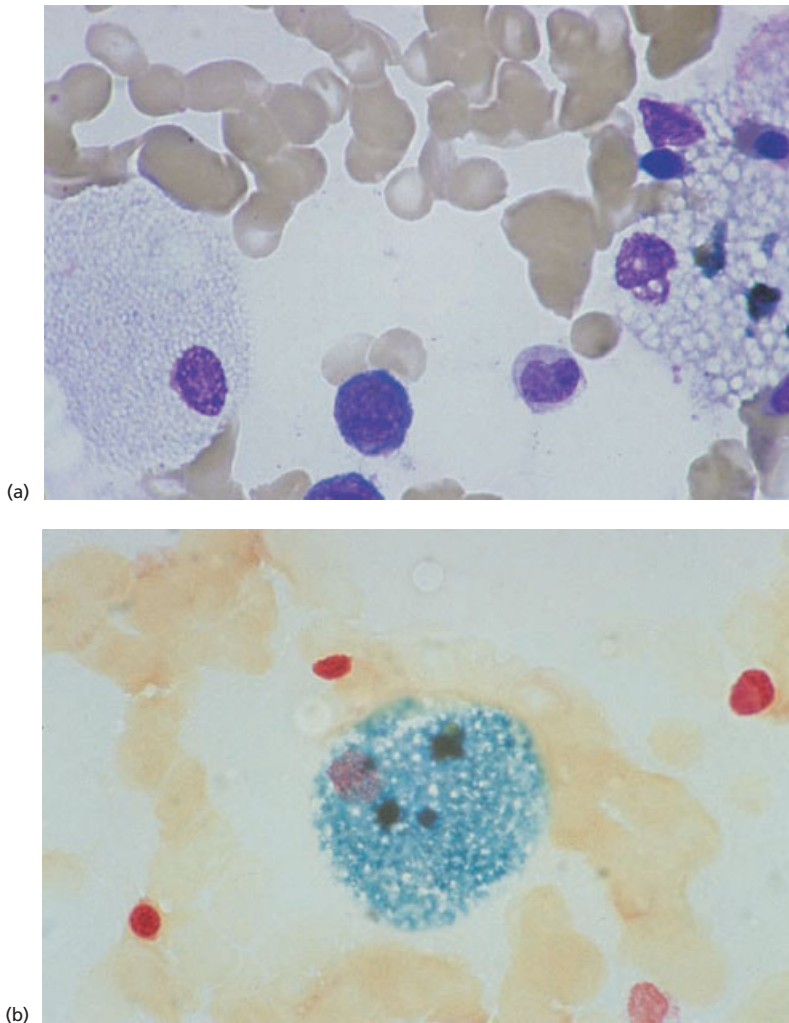


Fig. 9.17 BM aspirate from a patient with Zieve's syndrome showing: (a) foamy macrophages, MGG $\times 960$; (b) an iron-laden foamy macrophage, Perls' stain $\times 960$. (By courtesy of Dr Sue Fairhead, London.)

The diagnosis of aplastic anaemia may be suspected from peripheral blood and bone marrow aspirate findings but a trephine biopsy is essential for diagnosis. This is because of the frequent difficulty in obtaining an adequate aspirate and the variable degree of hypoplasia in different areas of the marrow. If bone marrow examination does not confirm a strong clinical suspicion of aplastic anaemia, repeat examination at another site is indicated since the bone marrow may be affected in an uneven manner.

Aplastic anaemia has been categorized on the basis of peripheral blood and bone marrow features

as severe, very severe or non-severe. Patients with severe aplastic anaemia have a platelet count less than $20 \times 10^9/l$, a granulocyte count less than $0.5 \times 10^9/l$ and bone marrow cellularity less than 25% [22]. Patients with very severe aplastic anaemia have a granulocyte count less than $0.2 \times 10^9/l$. Other cases are categorized as non-severe.

Prior to the development of stem cell transplantation and immunosuppressive therapy, the prognosis of aplastic anaemia was poor with severe cases having a median survival of less than a year. With immunosuppressive therapy (anti-lymphocyte globulin plus cyclosporin) or stem cell transplanta-

tion from a histocompatible sibling, 5-year survivals of the order of 50–70% can be anticipated. Bone marrow or other stem cell transplantation may cure aplastic anaemia whereas, following immunosuppressive therapy, defective stem cells persist giving the possibility of evolution into paroxysmal nocturnal haemoglobinuria (PNH), MDS or AML.

Peripheral blood

Severe cases are characterized by pancytopenia and a low reticulocyte count. The lymphocyte count is also low. The anaemia may be normocytic or macrocytic and poikilocytes may be present. Neutrophils often have dark red granules and high alkaline phosphatase activity, even in the absence of any apparent infection. Platelets are of normal size, in contrast to the large platelets which are common when thrombocytopenia is the result of increased platelet destruction. Macrocytosis and borderline cytopenias may persist following remission induced by immunosuppressive therapy.

Bone marrow cytology

The bone marrow may be difficult to aspirate with the result being a 'dry tap' or 'blood tap'. In the majority of patients a hypocellular aspirate is obtained with the fragments being composed largely of fat (Fig. 9.18). The cell trails are also

hypocellular. Different lineages are affected to a variable extent so that the M:E ratio may be increased, normal or decreased. Dyserythropoiesis may be seen. Ring sideroblasts are not a feature but, otherwise, the changes seen can be similar to those observed in MDS [23,24]. Dysplastic changes in granulocytes are less common and pseudo-Pelger neutrophils are not a feature. There is no disproportionate increase in immature granulocyte precursors. Megakaryocytes are often so infrequent in the aspirate that it is difficult to assess their morphology.

In a minority of patients the aspirate is normocellular or even hypercellular [23,24]. Examination of trephine biopsy specimens from such patients shows that such 'hot spots' co-exist with extensive areas of hypoplastic marrow.

The bone marrow aspirate shows at least a relative increase in lymphocytes and sometimes an absolute increase. There may also be increased numbers of plasma cells, macrophages and mast cells. Foamy macrophages are sometimes present and macrophage iron is increased.

Bone marrow histology

Trephine biopsy is crucial in the diagnosis of aplastic anaemia. The bone marrow is usually hypocellular with a marked reduction of haemopoietic cells (Figs 9.19–9.21). Myeloid cells are mainly replaced

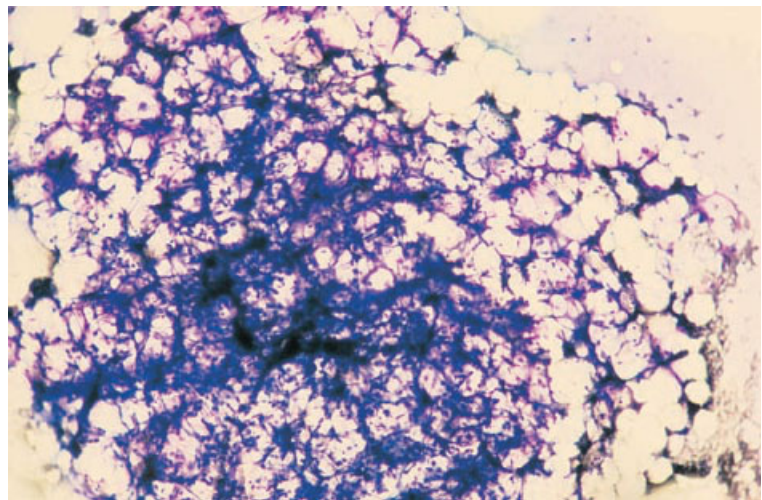


Fig. 9.18 BM aspirate, aplastic anaemia, showing a severely hypoplastic fragment. MGG $\times 94$.

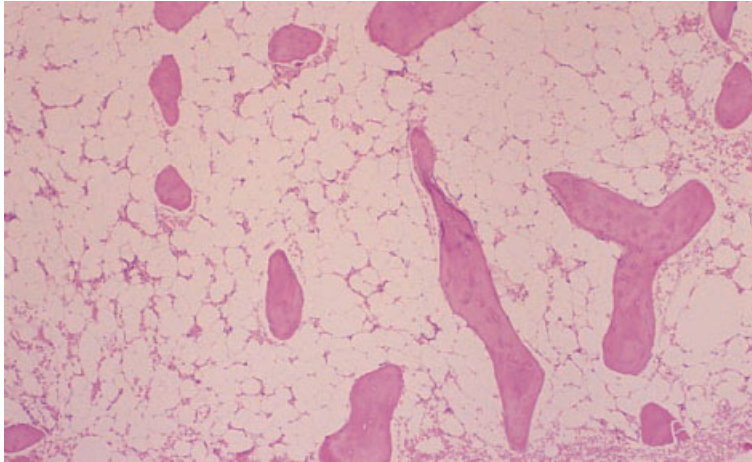


Fig. 9.19 BM trephine biopsy section, aplastic anaemia, showing marked hypocellularity. Plastic-embedded, H&E $\times 39$.

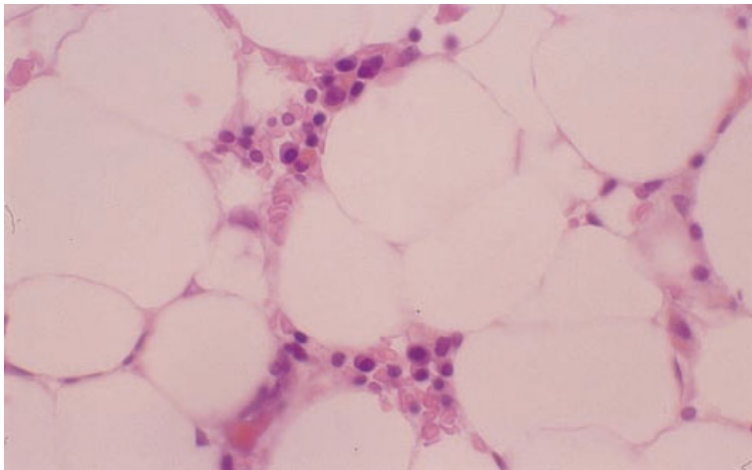


Fig. 9.20 BM trephine biopsy section, aplastic anaemia, showing a marked reduction in haemopoietic precursors; many of the remaining cells are plasma cells. Plastic-embedded, H&E $\times 390$.

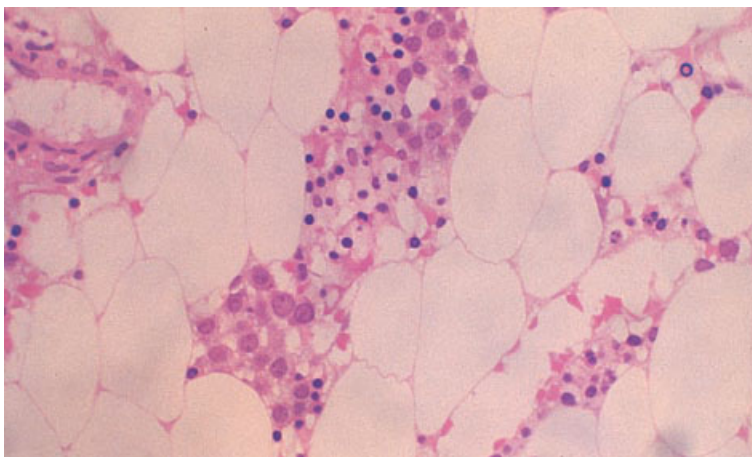


Fig. 9.21 BM trephine biopsy section, Fanconi's anaemia, showing large, poorly formed erythroblastic islands containing increased numbers of early erythroblasts. Plastic-embedded, H&E $\times 188$.

by fat but there is a variable inflammatory infiltrate composed of lymphocytes, plasma cells, macrophages, mast cells and sometimes eosinophils [25] (Fig. 9.20). Lymphocytes, which are CD3-positive and either CD4- or CD8-positive, are preferentially increased in areas of residual haemopoiesis [26]. Reactive lymphoid aggregates are also increased. Necrotic cells and cellular debris may be present. Walls of sinusoids may be disrupted and there may be oedema and haemorrhage. In some patients the inflammatory infiltrate is so heavy that the marked reduction of haemopoietic cells is not immediately apparent. Sinusoids are reduced but arterioles and capillaries are normal or increased [27]. Residual erythroid cells show dysplastic features [25]. Macrophage iron is increased. A distinctive appearance has been observed in aplastic anaemia induced by acetazolamide. In many of these patients there is depletion of haemopoietic cells leaving abnormal stroma, lymphocytes and plasma cells but without replacement by fat.

A minority of cases have some areas of normal or increased cellularity. Such cellular areas are commonly adjacent to sinusoids [27] and are composed of erythroid cells, all at the same stage of development and showing dysplastic features [24]. This finding is more common in Fanconi's anaemia (Fig. 9.21). In this condition the marrow is initially normocellular but becomes hypocellular. Megakaryocytes are often the first lineage to show reduction, followed by granulocytes and then erythroid cells.

Reticulin shows little if any increase. Various abnormalities of bone have been reported. Some studies have found osteoporosis and others increased osteoblastic and osteoclastic activity with irregular remodelling of bone [25].

When aplastic anaemia remits, for example following therapy with anti-thymocyte or anti-lymphocyte globulin, dysplastic features are very evident [28,29] and the inflammatory infiltrate often persists [29].

The presence of trilineage dysplasia and increased reticulin deposition is indicative of a worse prognosis (see below). Otherwise, there is little relationship between histological features and prognosis. Assessment of cellularity has not been found particularly useful in this regard. Prior to the development of modern treatment, an intense inflammatory infiltrate was shown to correlate with a

worse prognosis [25,30] but this was not so in three large series of patients treated either with anti-thymocyte globulin or by bone marrow transplantation [29,31].

Cytogenetics and molecular genetics

At presentation, a significant proportion of patients with acquired aplastic anaemia are found to have a clonal cytogenetic abnormality, most often trisomy 6 or 8 or anomalies of chromosomes 5 or 7. Although this is indicative of the presence of a neoplastic clone, it is not predictive of progression to MDS or AML [32]. The abnormal clone may disappear following immunosuppressive therapy [32].

Clonal cytogenetic abnormalities appearing following a response to immunosuppressive therapy are of more significance. They are often present at the time of evolution to MDS or AML. Abnormalities observed have included monosomy 6 and monosomy or deletion of chromosome 7.

The molecular genetic abnormalities underlying some types of inherited aplastic anaemia have been defined. Dyskeratosis congenita is caused by mutation or deletion of the *DKC* gene at Xq28. Fanconi's anaemia is associated with chromosomal fragility and cytogenetic analysis following exposure to clastogenic agents is diagnostically useful.

Problems and pitfalls

A diagnosis of aplastic anaemia should not be based on a bone marrow aspirate alone. A trephine biopsy is essential in order both to assess cellularity of an adequate sample of marrow and to assess the cytological features of residual cells. A trephine biopsy is particularly important in distinguishing aplastic anaemia from hypoplastic MDS and AML and from conditions in which bone marrow fibrosis leads to a hypocellular uninformative aspirate. Abnormal cells such as blast cells or hairy cells may be present in the trephine biopsy although not detectable in a hypocellular aspirate.

An adequate clinical history is important in order to avoid performing a bone marrow biopsy at the site of previous radiotherapy; the bone marrow at such sites is hypocellular and histological features may be indistinguishable from those of aplastic anaemia (Fig. 9.22). It should be noted that subcor-

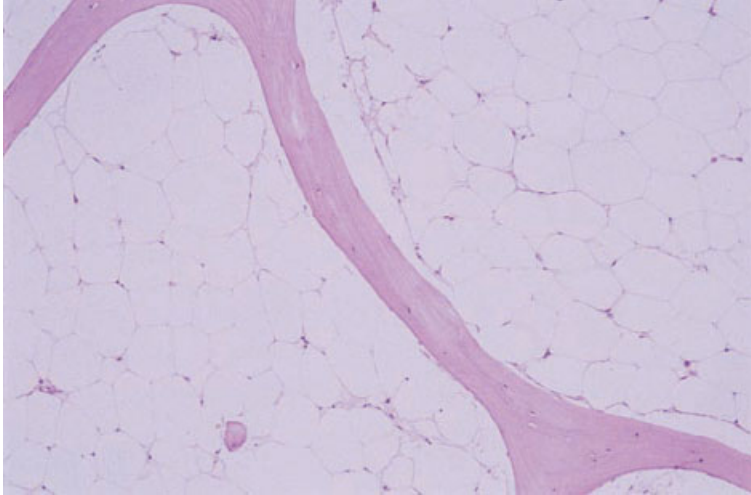


Fig. 9.22 Section of BM trephine biopsy specimen inadvertently taken from the site of previous radiotherapy, showing marked hypocellularity. H&E $\times 96$.

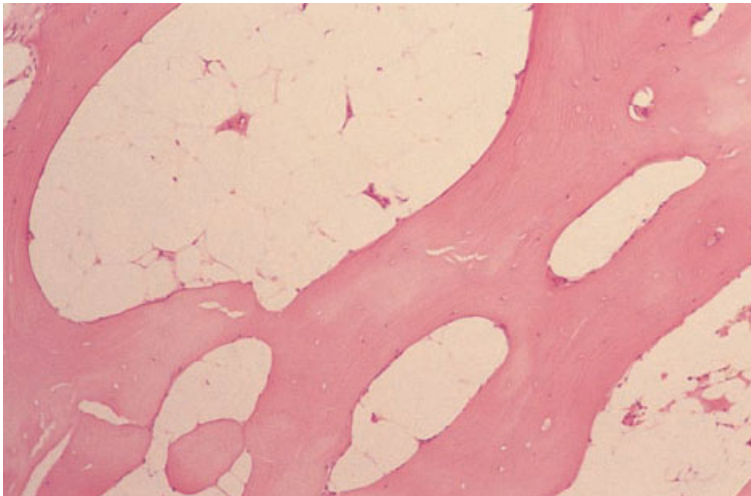


Fig. 9.23 Section of a BM trephine specimen from a patient with essential thrombocythaemia, showing very hypocellular subcortical bone marrow; elsewhere marrow was of normal cellularity with increased megakaryocytes. H&E $\times 96$.

tical bone marrow is hypocellular (Fig. 9.23) so that a diagnosis of aplastic anaemia should never be based on an inadequate biopsy composed mainly of cortical bone and subcortical bone marrow.

The relationship of aplastic anaemia to hypocellular MDS is problematical since neoplastic clones arise in some cases of aplastic anaemia and may be predictive of subsequent MDS and AML. However, it should be noted that, although the detection of a clonal cytogenetic abnormality in a hypoplastic bone marrow is indicative of the presence of a neoplastic clone, it is not necessarily predictive of disease progression. Such clones sometimes disappear

spontaneously. It may be that hypocellular MDS represents an intermediate stage of evolution of typical aplastic anaemia to MDS [19] or to AML. Aplastic anaemia can also progress through typical hypercellular MDS to AML [33]. Of the long-term survivors of aplastic anaemia, the number who develop MDS and AML may be as high as 10% [34]. In the differential diagnosis of hypoplastic MDS and aplastic anaemia the most important feature is the presence of clusters of blasts which are indicative of the former diagnosis. Other features which have been found, to some extent, to be predictive of progression to AML and which can therefore be

considered to favour a diagnosis of hypocellular MDS are: (i) trilineage atypia, particularly megakaryocyte atypia; (ii) increased numbers or clustering of megakaryocytes; and (iii) reticulin fibrosis [33]. In Fanconi's anaemia the development of trilineage dysplasia and reticulin fibrosis may herald transformation to AML.

The relationship of aplastic anaemia to PNH is discussed below.

It should be noted that, in children, apparent aplastic anaemia may represent an aplastic presentation of ALL. Spontaneous recovery of haemopoiesis occurs, to be followed within a few months by frank ALL; increased reticulin is common in pre-ALL aplasia and a proportion of patients also have prominent bone marrow lymphocytes [35]. DNA analysis has shown that leukaemic cells are present in significant numbers in the hypoplastic stage [36].

Other causes of bone marrow aplasia and hypoplasia

Reversible aplasia follows intensive cytotoxic chemotherapy. In subjects unable to mount a normal immune response to the EBV, primary infection by the virus may cause bone marrow aplasia. Hypoplasia can also be a feature of CMV infection. Other infections, including toxoplasmosis, sometimes cause bone marrow aplasia [37]. Bone marrow aplasia is also one of the features of graft-versus-host disease (GVHD) (see below).

Other causes of bone marrow hypoplasia include starvation, anorexia nervosa (Fig. 9.24), severe hypothyroidism, copper deficiency (see Fig. 9.13) and arsenic toxicity.

Pearson's syndrome and other mitochondrial cytopathies

Several congenital syndromes with mitochondrial inheritance cause anaemia and cytopenia with an onset during childhood [38]. There may be associated pancreatic dysfunction, metabolic disorder or developmental delay.

Peripheral blood

Normocytic normochromic anaemia, neutropenia and thrombocytopenia occur in variable combinations.

Bone marrow cytology

There is dyserythropoiesis with numerous ring sideroblasts and vacuolation of erythroid and granulocytic precursors (Fig. 9.25).

Other constitutional abnormalities associated with abnormal haemopoiesis

Down's syndrome may be associated, in the neonatal period, with otherwise unexplained

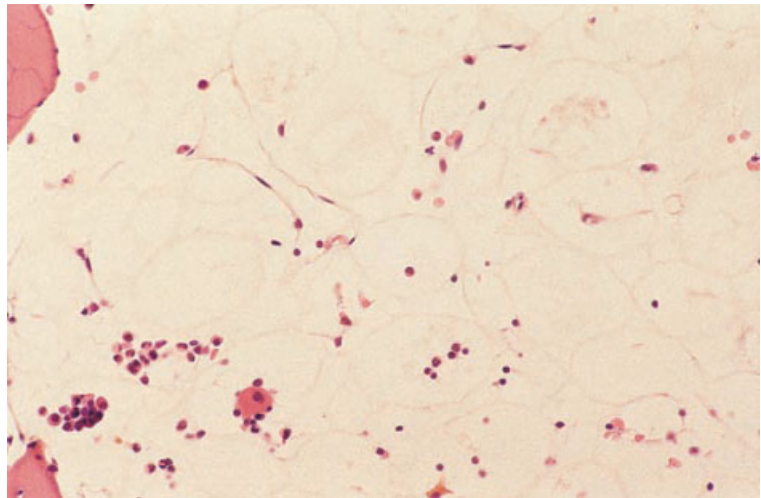


Fig. 9.24 BM trephine biopsy section in anorexia nervosa, showing marked hypocellularity. H&E $\times 192$.

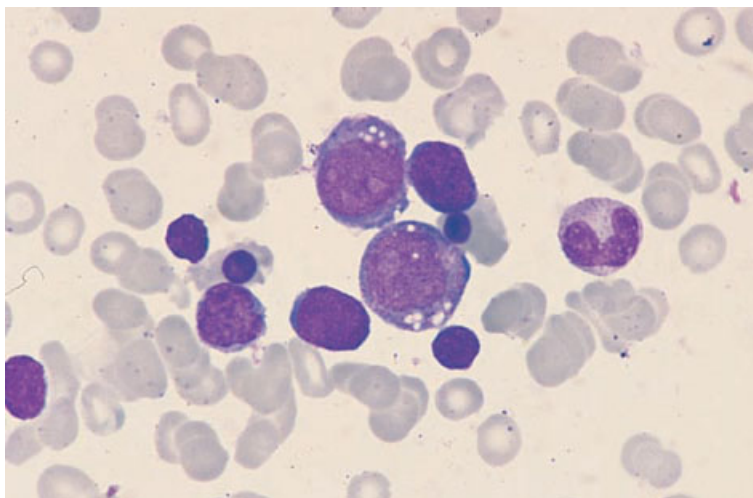


Fig. 9.25 BM aspirate from a patient with probable Pearson's syndrome, showing vacuolation of haemopoietic precursors. MGG $\times 960$. (By courtesy of Dr S Jan, Pakistan.)

polycythaemia or with transient abnormal myelopoiesis, which probably represents transient leukaemia [39]. Subsequently, there may be trilineage myelodysplasia. The incidence of AML, specifically acute megakaryoblastic leukaemia, is greatly increased.

GrisCELLI syndrome is a rare fatal disorder with abnormal pigmentation and variable cellular immune deficiency [40]. Pancytopenia is characteristic. The bone marrow may appear normal or there may be lymphohistiocytic infiltration with haemophagocytosis.

Thiamine-responsive anaemia is an autosomal recessive condition that can cause not only megaloblastic anaemia but also pancytopenia with trilineage myelodysplasia. Features include small and hypolobulated megakaryocytes, multinucleated megakaryocytes and hypolobulated neutrophils [41].

Paroxysmal nocturnal haemoglobinuria

PNH is a heterogeneous disease, the essential feature of which is abnormal complement sensitivity of red cells. PNH is a clonal disorder resulting from a somatic mutation in a multipotent myeloid stem cell. In the majority of cases, cells of the abnormal clone co-exist with normal polyclonal haemopoietic cells; in a minority the PNH clone constitutes virtually all haemopoietic tissue [42]. The causative mutation occurs in an X-linked gene, *PIG-A*, that

encodes a protein essential for the biosynthesis of glycosyl phosphatidylinositol (GPI). GPI is an important component of the red cell membrane, providing an anchor for many proteins. GPI-anchored proteins include CD55 (a complement-regulatory protein) and CD59. The defect in the red cell membrane leads, *in vitro*, to lysis of cells when serum is acidified and, *in vivo*, to intravascular haemolysis which is often nocturnal.

About a quarter of cases of PNH evolve to aplastic anaemia [19]. Conversely, 5–10% of patients with aplastic anaemia acquire a PNH clone during the course of their illness, often with associated clinical improvement [19,42]. In a small percentage of cases of PNH there is evolution to AML. The specific PNH defect of red cells leading to a positive acid lysis test has also been observed, occasionally, in patients with other clonal disorders of haemopoiesis including MDS (sideroblastic anaemia and refractory anaemia with excess of blasts) and myeloproliferative disorders (MPD) (myelofibrosis and unclassified MPD). Recovery of PNH can occur with the abnormal clone disappearing and being replaced by normal polyclonal haemopoietic cells.

The diagnosis of PNH is confirmed by an acid lysis (Ham) test or sugar-water test showing complement sensitivity of red cells. Alternatively, the diagnosis can be confirmed by flow cytometry, using monoclonal antibodies to demonstrate a deficiency of GPI-linked proteins such as CD59.

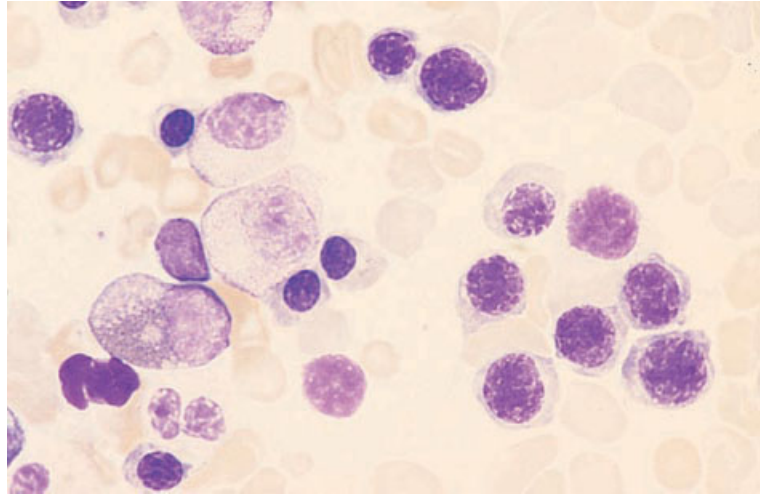


Fig. 9.26 BM aspirate, PNH, showing erythroid hyperplasia and a somewhat abnormal chromatin pattern. MGG $\times 940$.

Peripheral blood

PNH is characterized by some degree of chronic haemolysis with episodes of more severe haemolysis. Red cells do not show any morphological abnormalities other than polychromasia associated with an elevated reticulocyte count. Some patients have neutropenia, thrombocytopenia or both. Neutrophil alkaline phosphatase activity is typically low or absent.

Bone marrow cytology

The most characteristic bone marrow abnormality is hypercellularity due, at least in part, to erythroid hyperplasia (Fig. 9.26); there is often also granulocytic and megakaryocytic hyperplasia. However, in some patients the specific red cell abnormality of PNH occurs when there is bone marrow hypoplasia. Mast cells may be increased.

Bone marrow histology

Trephine biopsy sections may show erythroid hyperplasia or generalized hypoplasia.

Bone marrow and other haemopoietic stem cell transplantation

Allogeneic haemopoietic stem cells suitable for transplantation may be obtained by bone marrow

aspiration from volunteer donors. Alternatively, they may be obtained from cord blood or may be harvested from peripheral blood, following stimulation by growth factors such as G-CSF. Since stem cell transplantation necessitates prior immunosuppression, and often also ablative chemotherapy, the haematological features of bone marrow aplasia precede the signs of stem cell engraftment. Stem cell transplantation may be complicated by a variety of pathological processes [43] including sepsis, rejection and GVHD. Infection with CMV [44] and human herpesvirus 6 [45] post-transplant can cause bone marrow hypoplasia leading to pancytopenia. EBV-triggered lymphoproliferative disease (see page 319) occurs but is uncommon, in comparison with the incidence following solid organ transplantation; it occurs in about 1% of stem cell transplant recipients. Chronic parvovirus B19-induced red cell aplasia may develop as a consequence of post-transplant immune deficiency. In the early post-transplant period there is hyposplenism. Post-transplant there is also an increased incidence of auto-immune thrombocytopenic purpura (often associated with chronic GVHD), auto-immune neutropenia, auto-immune haemolytic anaemia and Evans syndrome [46]. Microangiopathic haemolytic anaemia is also observed in some patients, occurring as a result of endothelial damage caused by cyclosporin A or other agents.

Autologous stem cell transplantation may lead to some of the same pathological processes that follow

allogeneic stem cell transplantation, since there is a period of bone marrow aplasia and immune deficiency, but GVHD does not occur.

Post-transplantation, a bone marrow biopsy is generally more informative than the peripheral blood film or bone marrow aspirate.

Peripheral blood

Initially, there is a period of 2–3 weeks of severe pancytopenia, followed by a gradual rise of white cell and platelet counts as engraftment occurs. If there is failure of engraftment or if rejection occurs, there is a failure of counts to rise or a subsequent fall. Features of hyposplenism may be present. Those who develop auto-immune complications or micro-angiopathic haemolytic anaemia show the expected peripheral blood features. If patients develop EBV-triggered lymphoproliferative disease following transplantation, the peripheral blood film may be leuco-erythroblastic and show atypical immature lymphoid cells.

Bone marrow cytology

The bone marrow aspirate is initially severely hypoplastic. Subsequently, haemopoietic cells gradually reappear. Dysplastic features may be present. In the months following transplantation an appreciable increase may occur in haematogones, lymphoid cells which morphologically and immunophenotypically resemble lymphoblasts of L1 ALL [47]; with prolonged follow-up these are no longer apparent. If rejection occurs the abnormalities noted include lymphocytosis, plasmacytosis, increased macrophages and increased iron stores [43]. If chronic parvovirus infection occurs, the bone marrow aspirate shows a lack of erythroid cells beyond the proerythroblast stage. EBV-triggered lymphoproliferative disease is associated with bone marrow infiltration by highly atypical immature lymphoid cells including bizarre plasmacytoid lymphocytes. Patients with failure to engraft, particularly but not exclusively those treated with granulocyte–macrophage colony-stimulating factor (GM-CSF), may have an increase of foamy histiocytes in a hypocellular marrow [48]. When auto-immune complications occur, the expected erythroid or megakaryocytic hyperplasia may be

seen but this is dependent on adequate haemopoietic reconstitution.

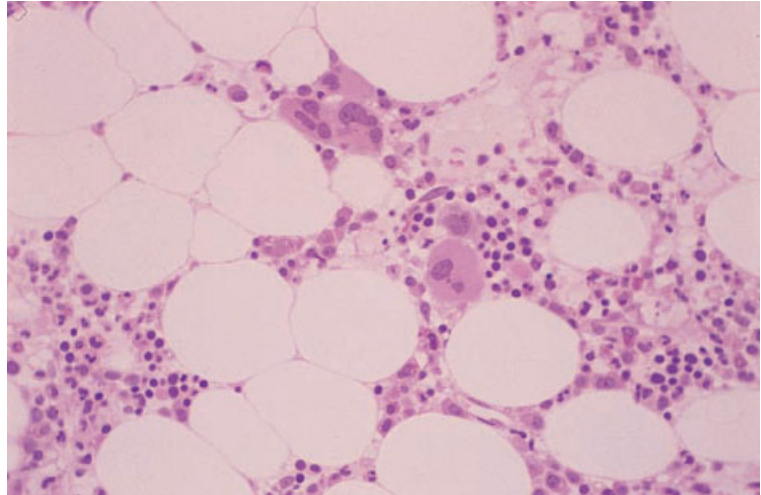
Bone marrow histology [43,49–51]

The speed of haemopoietic regeneration depends on the type of transplantation; engraftment is much more rapid after transplantation of autologous peripheral blood stem cells, least rapid after allografting from unrelated donors and intermediate with allografts from related donors. In general, during the first 2 weeks cellularity is very low. Thereafter, clusters of proliferating cells appear at a variable rate (Fig. 9.27). In the early stages of engraftment, foci of regenerating cells commonly contain cells of only one lineage and cells may be all at the same stage of development. The topography may be abnormal, with foci of granulocyte precursors present in the central intertrabecular area rather than in a paratrabecular position. Megakaryocytes are often clustered. Haemopoietic cells may be dysplastic. Often there are stromal changes such as oedema, the presence of foamy macrophages, formation of small granulomas, sinusoidal ectasia and extravasation of red cells into the interstitium; these abnormalities are probably a result of damage caused by the ablative therapy employed prior to grafting and are more marked in patients transplanted for leukaemia. There may also be lymphoid foci, sometimes with associated eosinophils. Plasma cells may be increased in patients who have had a stem cell transplant for acute leukaemia. In patients with increased reticulin or collagen, there is gradual stromal remodelling with a return to normal or near normal appearances. If rejection occurs, the trephine biopsy may show oedema and fat necrosis, in addition to the features apparent in the aspirate, which have been mentioned above. There may be small foci of lymphoblast-like cells. A hypoplastic bone marrow biopsy post-transplant may result from failure of engraftment, infection by herpesviruses or stromal damage resulting from GVHD. Selective loss of maturing red cells is seen in parvovirus B19-induced chronic pure red cell aplasia.

Problems and pitfalls

Patients who have had an autologous stem cell transplant show an increased incidence of MDS as a

Fig. 9.27 BM trephine biopsy section, showing regeneration following bone marrow transplantation; note cluster of megakaryocytes. Plastic-embedded, H&E $\times 195$.



result of damage to stem cells by preceding chemotherapy. However, the diagnosis of MDS should be made with circumspection since disturbed architecture and dysplastic features are common in the early post-transplant period. Cytogenetic and molecular genetic analysis can be useful in making the distinction.

In patients transplanted for ALL, a post-transplant excess of haematogones must be distinguished from relapse. Immunophenotyping and cytogenetic and molecular genetic analysis can be useful in making the distinction.

In patients transplanted for multiple myeloma, increased monoclonal plasma cells are often present in the first 1–2 months after transplantation. These represent residual myeloma cells rather than relapse and are not predictive of disease progression [52].

Graft-versus-host disease (including the effects of donor-lymphocyte infusion)

GVHD occurs not only in the setting of stem cell transplantation but also when viable, immunocompetent, histo-incompatible lymphocytes have been transferred to an immuno-incompetent host. This may occur *in utero*, when there is transfer of maternal lymphocytes to a fetus with severe combined immune deficiency. Following birth, it can occur following blood transfusion in congenital and certain acquired immune deficiency states. It has been

recognized in patients being treated for Hodgkin's disease and in patients with low grade lymphoproliferative disorders who have received treatment with nucleoside analogues such as fludarabine.

GVHD can also occur in immunologically normal hosts when blood for transfusion was derived from a donor who was homozygous for a human leucocyte antigen (HLA) haplotype identical to one of the host's haplotypes; the host is then unable to recognize the recipient's lymphocytes as foreign and so cannot destroy them, whereas the transfused lymphocytes are capable of recognizing and attacking host tissues. GVHD in immunologically normal hosts has most often resulted from transfusions from closely related family members.

Donor-lymphocyte transfusion, increasingly practised for post-transplant relapse of chronic granulocytic leukaemia (CGL) or other haemopoietic neoplasms, can also be complicated by GVHD.

GVHD has resulted from inadvertent transfer of donor lymphocytes following solid organ transplantation [53].

The bone marrow features of GVHD differ depending on whether bone marrow has been transplanted or not. When viable lymphocytes only have been transferred, the host's bone marrow will be among the tissues which come under immunological attack and bone marrow aplasia results. In patients who have received donor bone marrow containing viable lymphocytes, other tissues are attacked but, since the bone marrow is donor in

origin, it will not be recognized as foreign by donor lymphocytes. The haemopoietic marrow may, however, be indirectly damaged by the immunological reaction between donor cells and host cells including the bone marrow stroma.

It was previously suggested that Omenn's syndrome, a condition of infants characterized by combined immunodeficiency and signs suggestive of GVHD, may represent GVHD consequent on transplacental passage of lymphocytes [54], but this condition is now known to be an inherited disorder resulting from a mutation in one of the recombination activating genes, *RAG1* and *RAG2* [55].

Peripheral blood

In patients who have received histo-incompatible donor lymphocytes the consequent bone marrow hypoplasia is reflected in peripheral blood pancytopenia. In bone marrow transplant recipients there are no specific peripheral blood features that indicate the occurrence of GVHD but there is a delay in the appearance of signs of engraftment.

Bone marrow cytology

The bone marrow aspirate is usually hypocellular.

Bone marrow histology

When donor lymphocytes have been transferred without donor bone marrow, histological sections of trephine biopsies show aplasia. In GVHD in the setting of bone marrow transplantation, histological abnormalities include a decrease in haemopoietic cells, increased macrophages, erythrophagocytosis, oedema and perivenous lymphoid infiltrates [49].

Effects of haemopoietic growth factors and other cytokines

An increasing number of haemopoietic growth factors and other cytokines are being administered to patients. Haematological effects are often profound.

Peripheral blood

G-CSF and GM-CSF cause neutrophilia and monocytosis with a marked left shift, 'toxic' granulation,

neutrophil vacuolation and a variety of dysplastic changes in neutrophils including abnormal neutrophil lobulation and the presence of macropolyocytes. Blast cells may appear in the blood following G-CSF therapy [56]. GM-CSF causes more marked monocytosis than G-CSF and can also cause eosinophilia. In patients with MDS, the administration of G-CSF can be associated with the appearance of significant numbers of myeloblasts in the peripheral blood [57]. Neutrophilia is induced by various interleukins (IL1, IL2, IL3 and IL6) and by stem cell factor [58]. Eosinophilia is induced by IL2, IL3 and IL5. Lymphocytosis is induced by IL2, IL3, IL6, IL11 and thrombopoietin [59]. Thrombocytosis is induced by IL1, IL3, IL6 and thrombopoietin. The administration of IL2 leads to anaemia and thrombocytopenia and IL6 and IL11 [60] also cause anaemia. Erythropoietin administration raises the haemoglobin concentration and leads to erythroid hyperplasia.

Bone marrow cytology

Administration of G-CSF and GM-CSF causes a marked left shift of granulopoiesis. This is particularly prominent when these cytokines are administered to patients with suppressed bone marrow function. Myeloblasts may reach 20–40% and promyelocytes 12–60% leading to possible confusion with M2 and M3 categories of AML [61]. In haematologically normal subjects, G-CSF causes a marked increase in cellularity and an increase of all cells of neutrophil lineage [62]; the greatest increase is in promyelocytes and myelocytes. Morphological alterations include increased granularity, particularly of early cells, and an increased prevalence of ring neutrophils [62]. GM-CSF can cause a marked increase in macrophage numbers and its administration has been associated with development of a haemophagocytic syndrome [63]. The administration of IL5 causes an increase in bone marrow eosinophils. Stem cell factor causes some increase in cellularity with increased promyelocytes and, in some cases, increased basophils and mast cells [58]. Administration of thrombopoietin (in the form of pegylated recombinant human thrombopoietin) leads to increased numbers of megakaryocytes of increased size and nuclear lobularity [59].

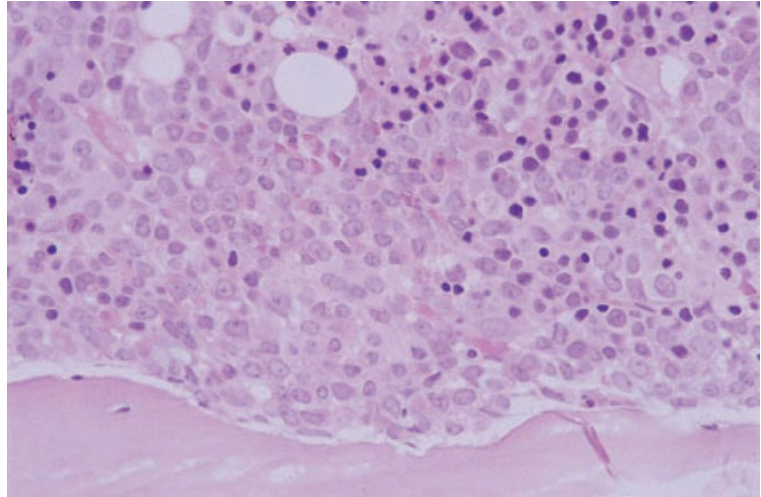


Fig. 9.28 BM trephine biopsy specimen from a patient receiving G-CSF, showing an expanded paratrabecular seam of neutrophil precursors. H&E $\times 384$.

Bone marrow histology

The bone marrow following administration of G-CSF and GM-CSF may be hypocellular, normocellular or hypercellular, depending on the underlying disease and prior therapy. There is granulocytic hyperplasia, left-shifted granulopoiesis and expansion of the paratrabecular zone of neutrophil precursors (Fig. 9.28). There may be aggregates of granulocyte precursors [61] resembling ALIP seen in MDS. Administration of thrombopoietin increases megakaryocyte numbers, size and nuclear lobularity [59] and leads to megakaryocyte clustering with increased reticulin deposition (Fig. 9.29).

Problems and pitfalls

When blast cells appear in the peripheral blood in response to G-CSF therapy, there are usually other granulocyte precursors present and maturing cells show 'toxic' changes such as heavy granulation. These blast cells also show some immunophenotypic differences from leukaemic myeloblasts [56]. They express CD34 but not terminal deoxynucleotidyl transferase, co-express CD19, and express CD13 and CD33 weakly [56].

In patients receiving G-CSF following induction therapy for AML, an increased blast cell percentage may be misinterpreted as persisting leukaemia [64]. G-CSF can also increase the blast cell percentage in MDS so that AML is simulated [57,65].

An adequate clinical history should prevent ALIP resulting from G-CSF therapy leading to a misdiagnosis of MDS and, similarly, should prevent the changes induced by thrombopoietin from being misinterpreted as an MPD.

Protein-calorie malnutrition and calorie deficiency

Peripheral blood

Protein-calorie malnutrition (kwashiorkor or marasmus) is not usually associated with deficiency of specific haematinics such as iron, vitamin B₁₂ or folate but, nevertheless, anaemia occurs. Red cells are normocytic and normochromic. The white cell and platelet counts may also be reduced. Severely reduced calorie intake, as in anorexia nervosa, is associated with mild anaemia, lymphopenia, neutropenia and thrombocytopenia; the blood film may show small numbers of acanthocytes.

Bone marrow cytology

The bone marrow in protein-calorie malnutrition usually shows reduced cellularity with normoblastic but dyserythropoietic haemopoiesis (Fig. 9.30). Giant metamyelocytes (Fig. 9.31) are common, even in the majority of cases which have normoblastic erythropoiesis. There is vacuolation of erythroid and granulocyte precursors.

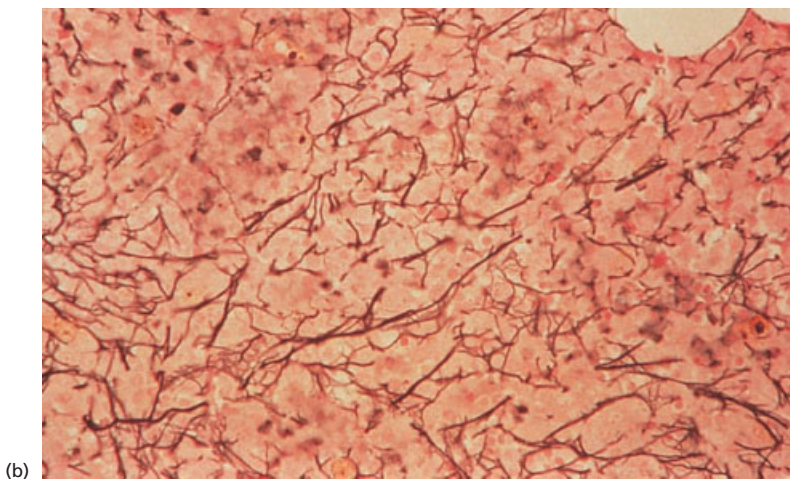
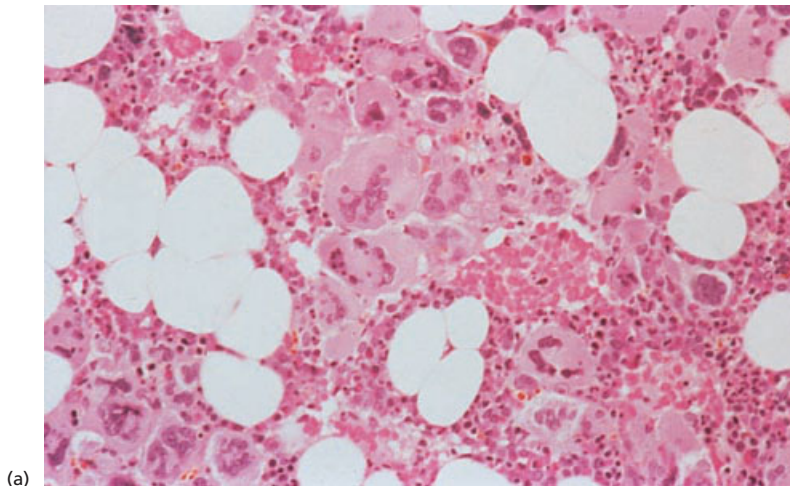


Fig. 9.29 BM trephine biopsy specimen from a patient receiving thrombopoietin, showing: (a) a marked increase in megakaryocytes which are pleomorphic and forming clusters; (b) increased reticulin deposition; both abnormalities reversed on cessation of therapy. H&E and reticulin stain $\times 192$.

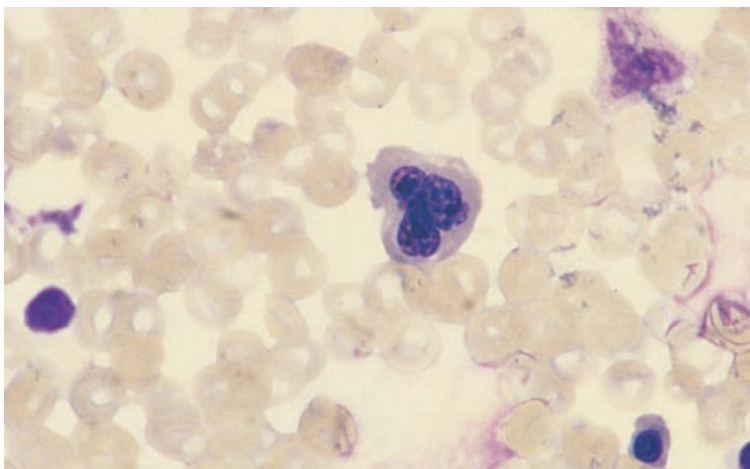


Fig. 9.30 Bone marrow aspirate, showing dyserythropoiesis in protein-calorie malnutrition. MGG $\times 960$. (By courtesy of Professor SN Wickramasinghe, London.)

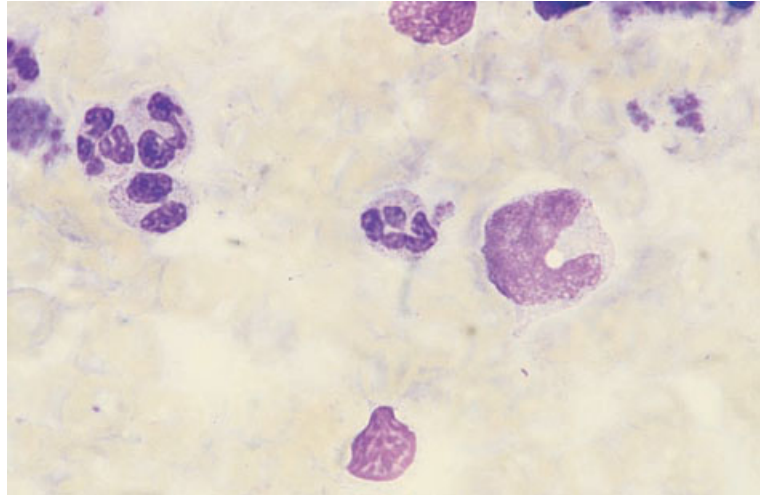


Fig. 9.31 Bone marrow aspirate, showing a giant metamyelocyte in a patient with protein-calorie malnutrition. MGG $\times 960$. (By courtesy of Professor SN Wickramasinghe, London.)

Dysmegakaryopoiesis is uncommon. Iron stores are normal or increased. There may be abnormal sideroblasts including ring sideroblasts. In anorexia nervosa, the bone marrow is hypocellular and may show gelatinous transformation.

Storage diseases and storage cells in the bone marrow [66–70]

In various inherited diseases the deficiency of an enzyme leads to accumulation of a metabolite in body cells, often in macrophages. The morphologically abnormal bone marrow macrophages, containing an excess of the relevant metabolite, are referred to as storage cells. Storage cells may also result from an abnormal load of a metabolite such that the enzymes of normal cells are unable to cope. Both bone marrow aspiration and trephine biopsy are useful in the detection of storage diseases. Peripheral blood cells may show related abnormalities [66,71].

Gaucher's disease

Gaucher's disease (hereditary glucosyl ceramide lipidosis) is an inherited condition in which glucocerebrosides accumulate in macrophages including those in the liver, spleen and bone marrow. Although Gaucher's disease can be diagnosed readily by bone marrow aspiration and by trephine biopsy, it has been pointed out that this is unnecessary

when assays for the relevant enzyme, β -glucocerebrosidase, are available [72]. Gaucher's disease can be transferred to graft recipients by bone marrow transplantation [73].

Peripheral blood

There are usually no specific peripheral blood features although very occasionally Gaucher cells may be seen in the peripheral blood, particularly after splenectomy. Pancytopenia develops slowly, as a consequence of hypersplenism. The monocytes of patients with Gaucher's disease are positive for tartrate-resistant acid phosphatase (TRAP) activity, whereas normal monocytes are not [70].

Bone marrow cytology

Gaucher cells are large, round or oval cells with a small, usually eccentric nucleus and voluminous weakly basophilic cytoplasm with a wrinkled, fibrillar or 'onion-skin' pattern (Fig. 9.32). The cells stain with Sudan black B (SBB) and periodic acid-Schiff (PAS). They are non-specific esterase- and TRAP-positive and may be positive for iron, particularly in older children and adults. Patients with Gaucher's disease may also have an increase in foamy macrophages and in cells which resemble typical Gaucher cells but also contain more strongly basophilic granules.

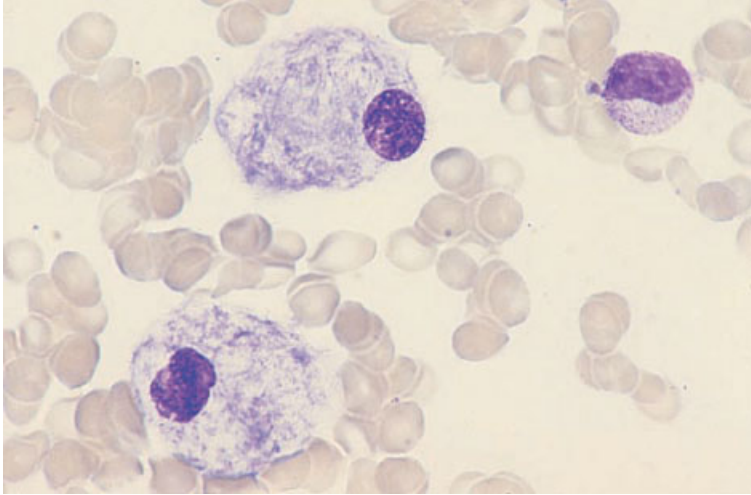


Fig. 9.32 BM aspirate, Gaucher's disease, showing two Gaucher cells. MGG $\times 377$.

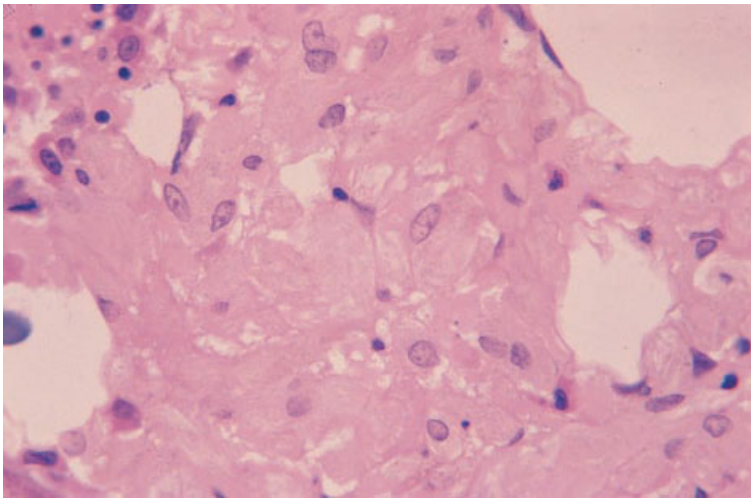


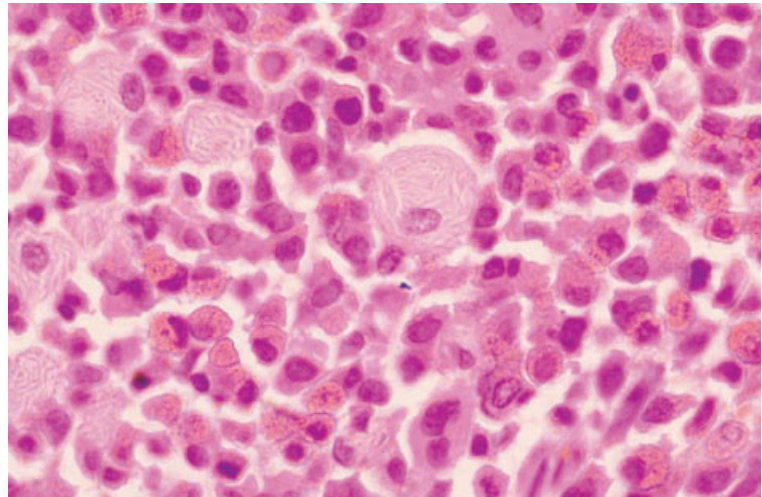
Fig. 9.33 BM trephine biopsy section, Gaucher's disease, showing a sheet of large macrophages with characteristic 'watered silk' texture to their cytoplasm. Plastic-embedded, H&E $\times 390$.

Bone marrow histology

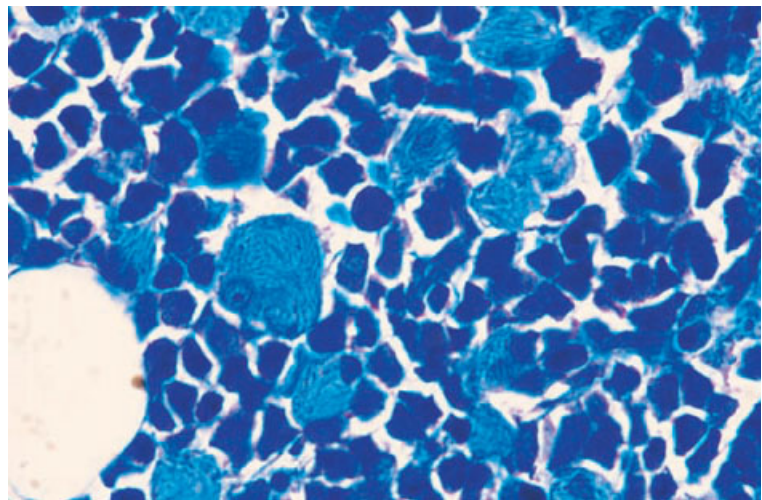
Gaucher cells may be isolated or appear in clumps or sheets, sometimes replacing large areas of the marrow (Fig. 9.33). The cells have abundant pale-staining cytoplasm with a texture that has been likened to watered silk or crumpled tissue paper. The fibrillar pattern is accentuated by PAS staining. There may be an increase in reticulin and collagen deposition [70]. In advanced disease, osteolytic lesions occur [74]. Gaucher cells are strongly positive with an immunohistochemical stain for TRAP [74].

Pseudo-Gaucher cells

Cells resembling Gaucher cells, but not identical to them on ultrastructural examination [67], are seen in the bone marrow in a variety of haematological conditions [68,69] in which they result from an abnormal load of glucocerebroside presented to macrophages. They are seen in chronic granulocytic leukaemia (Fig. 9.34), acute leukaemia, occasional cases of MDS [75], thalassaemia major and congenital dyserythropoietic anaemia (particularly type II). They have also been recognized in occasional



(a)



(b)

Fig. 9.34 BM trephine biopsy section in CGL, showing pseudo-Gaucher cells: (a) H&E; (b) Giemsa stain. Paraffin-embedded $\times 960$.

patients with Hodgkin's disease, non-Hodgkin's lymphoma and a variety of other conditions [68,76]. They have been reported as a consequence of repeated platelet transfusions [77].

Problems and pitfalls

If there is any difficulty distinguishing pseudo-Gaucher cells from Gaucher cells, it is possible to assay β -glucosidase in peripheral blood leucocytes.

Cells resembling Gaucher cells have been seen in multiple myeloma and in lymphoplasmacytic lymphoma but the macrophages in these cases may

contain material derived from immunoglobulin rather than glucocerebroside [76]. Cells considered to resemble Gaucher cells have also been reported in the bone marrow of a patient with atypical mycobacterial infection complicating AIDS [78]; in this case it appears that the abnormal morphology was consequent on large numbers of mycobacteria packing the macrophage cytoplasm rather than on storage of a breakdown product. Similar appearances have been reported in an immunosuppressed patient who had received a renal transplant [79]. The distinction is easily made with a stain for acid-fast bacilli.

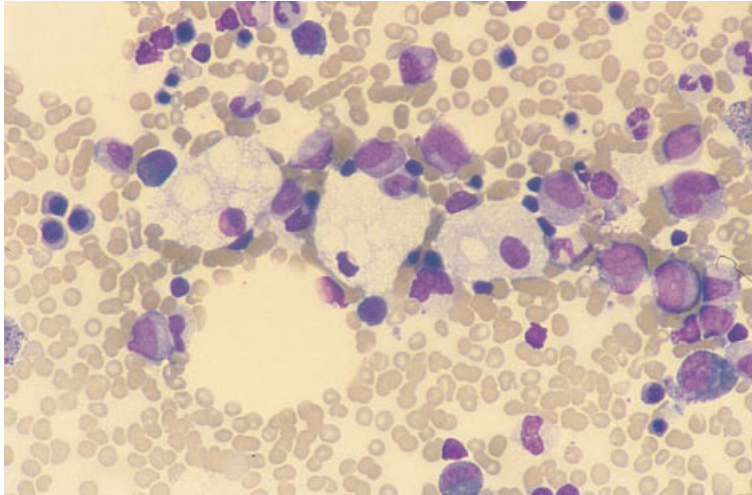


Fig. 9.35 BM aspirate, Niemann–Pick disease, showing foamy macrophages. MGG $\times 375$. (By courtesy of Dr SG Davis, Birmingham.)

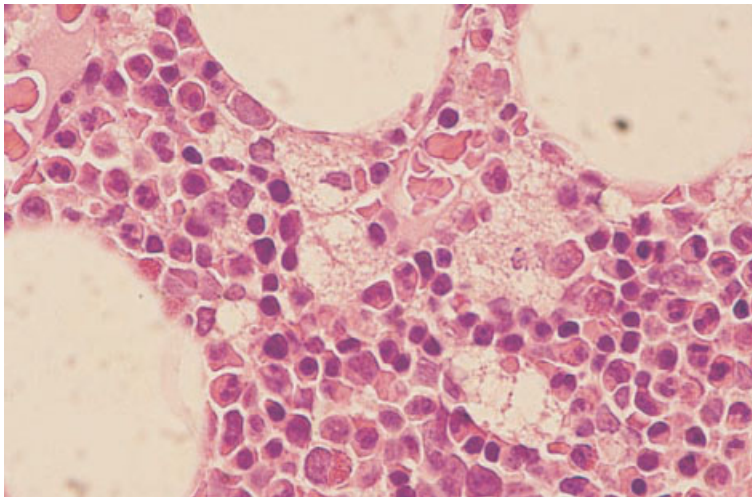


Fig. 9.36 BM trephine biopsy section in Niemann–Pick disease, showing foamy macrophages. Paraffin-embedded, H&E $\times 960$.

Niemann–Pick disease

Niemann–Pick disease is an inherited condition (sphingomyelin lipidosis) caused by reduced sphingomyelinase activity (type I), or a related ill-defined defect of cholesterol esterification (type II). It is characterized by the presence of foamy lipid-containing macrophages in the bone marrow and other tissues.

Peripheral blood

Lipid-containing monocytes and lymphocytes may be present in the peripheral blood. Anaemia and

various cytopenias may occur as a consequence of hypersplenism.

Bone marrow cytology

The foamy macrophages of Niemann–Pick disease are large cells (exceeding 50 μm in diameter) with a nucleus which is usually central. They stain pale blue with Romanowsky stains (Fig. 9.35) and variably with PAS and lipid stains. There are also increased numbers of sea-blue histiocytes (see below), possibly reflecting slow conversion of sphingomyelin to ceroid [68].

Fig. 9.37 BM trephine biopsy section in Wolman's disease, showing foamy macrophages. Paraffin-embedded, H&E $\times 960$.

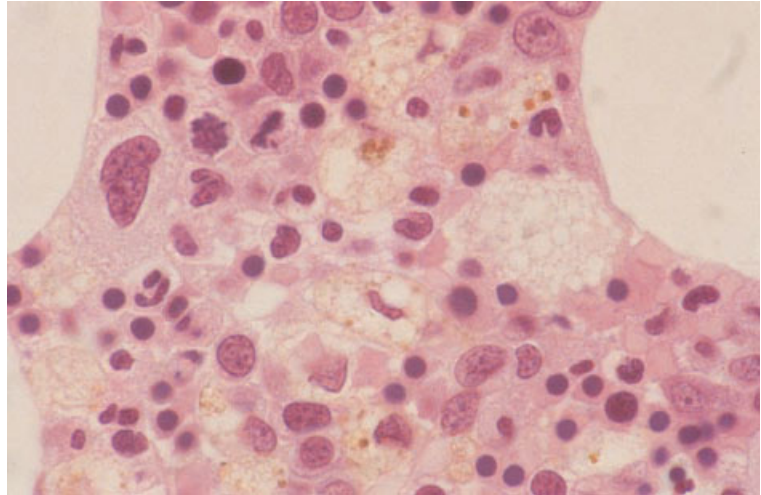
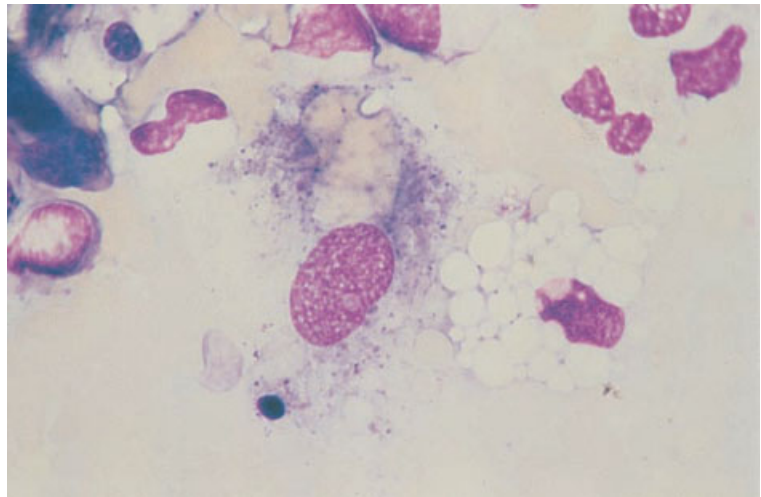


Fig. 9.38 BM aspirate, sickle cell anaemia, showing a foamy macrophage and a sea-blue histiocyte containing a clump of red cells. MGG $\times 940$.



Bone marrow histology

Foamy macrophages may appear yellow–green when stained with Giemsa and are light brown or pink in H&E-stained sections (Fig. 9.36); they are PAS-positive and may be positive for iron [70].

Other causes of foamy macrophages [69]

Other metabolic defects which can lead to the presence of increased numbers of foamy macrophages in the bone marrow include hypercholesterolaemia

(e.g. Zieve's syndrome—see Fig. 9.17), hyperchylomicronaemia, Wolman's disease (Fig. 9.37), late-onset cholesteryl ester storage disease, Fabry's disease, neuronal lipofuchsinosis (Batten's disease) and Tangier disease. In Fabry's disease the storage cells have small globular inclusions which appear weakly basophilic with Romanowsky stains and lightly eosinophilic with H&E; they are PAS-negative and SBB-positive [80].

Foamy cells are also increased as a result of damage to fat cells (Fig. 9.38) including trauma, fat necrosis, bone marrow infarction, infection, pancreatitis and

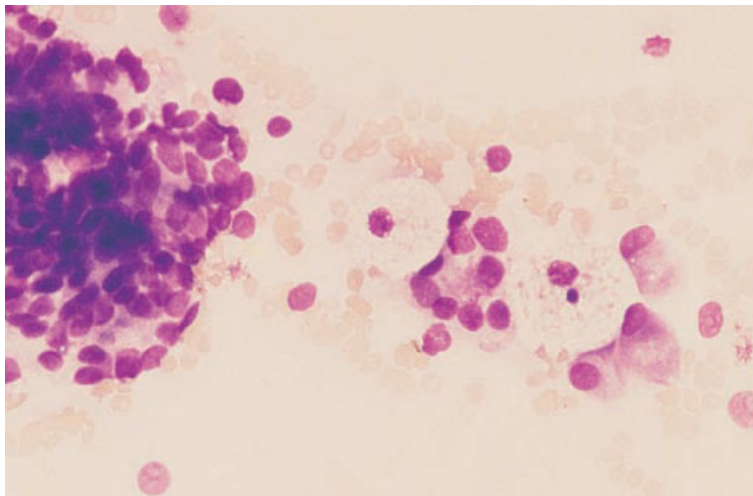


Fig. 9.39 BM aspirate, carcinoma of prostate, showing a clump of carcinoma cells, dispersed carcinoma cells, two osteoblasts and two foamy macrophages. MGG $\times 377$.

recent performance of a bone marrow biopsy at the same site [81]. Acquired diseases which have been associated with an increase of foamy macrophages include Langerhans cell histiocytosis (Hand–Schüller–Christian disease, Letterer–Siwe disease and eosinophilic granuloma), bone marrow metastases (Fig. 9.39), sickle cell disease (see Fig. 9.38) and a variety of other conditions [68]. Foamy cells have been noted in subjects who have, in the past, received polyvinyl pyrrolidone as a plasma expander; they contain amorphous grey–blue material and are PAS-, mucicarmine- and Congo red-positive [82–84]. In trephine biopsy sections, reticulin is increased [84]. Occasionally, the foamy cell infiltration is so heavy that bone marrow failure occurs [84]. Foamy ceroid-containing macrophages (see below) are seen in patients receiving prolonged intravenous nutrition with lipid emulsions [85].

Macrophages containing cholesterol crystals

Bone marrow macrophages may contain cholesterol crystals in various hyperlipidaemic conditions, both congenital and acquired. Such conditions include alpha-lipoprotein deficiency, hyperbeta-lipoproteinaemia, poorly controlled diabetes mellitus and hypothyroidism [86]. The cholesterol crystals are soluble and thus give rise to unstained needle-like clefts within the macrophages.

Sea-blue histiocytosis

The terms ‘sea-blue histiocytosis’ [87] and ‘ceroid lipofuchsinosis’ [88] encompass an inherited group of conditions characterized by the presence of ‘sea-blue histiocytes’—distinctive macrophages containing ceroid or lipofuchsin—in the bone marrow, liver, spleen and other organs. The designation of the disease derives from the staining characteristics of the storage cells with Romanowsky stains. In unstained films, ceroid is brown. The inherited conditions causing increased numbers of sea-blue histiocytes include the Hermansky–Pudlak syndrome (oculocutaneous albinism with a bleeding diathesis).

Bone marrow cytology

Sea-blue histiocytes stain blue or blue–green with Romanowsky stains. They are SBB-, PAS- and oil-red- λ -positive, and are sometimes positive for iron. With ultraviolet illumination they exhibit yellow–green autofluorescence.

Bone marrow histology

Sea-blue histiocytes are brownish-yellow in H&E-stained sections and blue with a Giemsa stain. They are PAS-positive and may be positive for iron. Their cytoplasmic contents are acid-fast and exhibit autofluorescence.

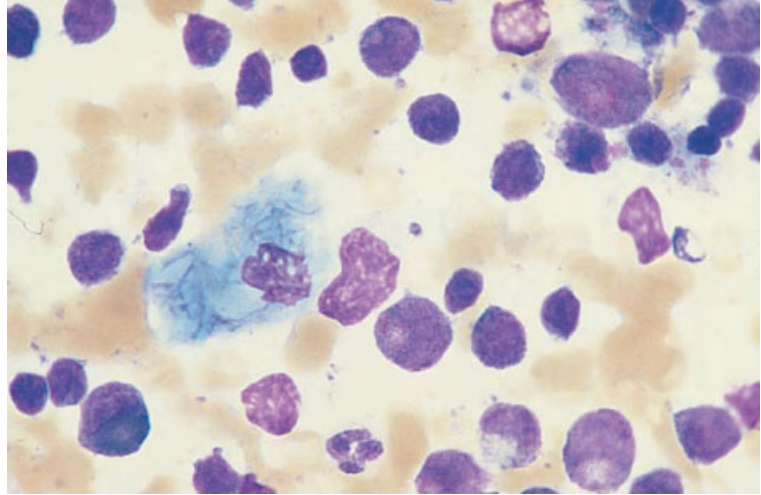


Fig. 9.40 BM aspirate from a patient with AML, showing a sea-blue histiocyte. MGG $\times 960$.

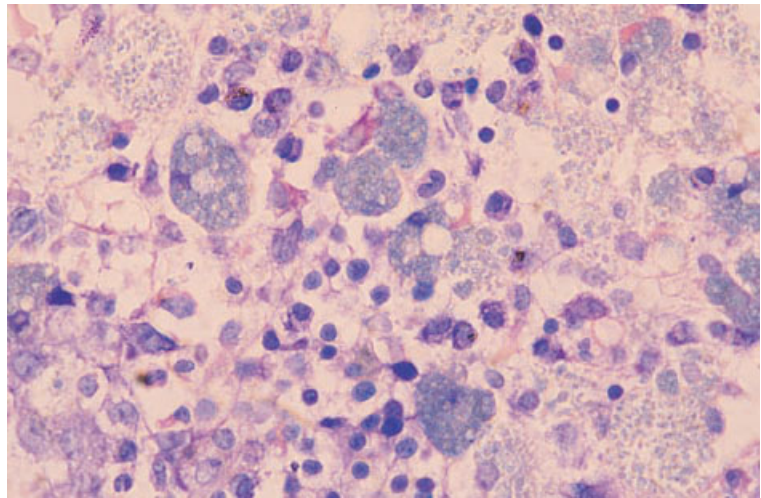


Fig. 9.41 BM trephine biopsy section from a patient with MDS, showing sea-blue histiocytes. Paraffin-embedded, Giemsa stain $\times 360$.

Other causes of sea-blue histiocytes

Increased numbers of sea-blue histiocytes are seen in the bone marrow in a great variety of conditions [87] including many of the same disorders in which pseudo-Gaucher cells are present or foamy macrophages are increased (Figs 9.38, 9.40 and 9.41). Most of these conditions are characterized by increased turnover of bone marrow cells. Less often there is an exogenous cause, as in prolonged intravenous nutrition with fat emulsions [85].

Cystinosis

Peripheral blood

There are no specific abnormalities in the peripheral blood.

Bone marrow cytology

Bone marrow histiocytes are packed with almost colourless, refractile crystals of various shapes. They

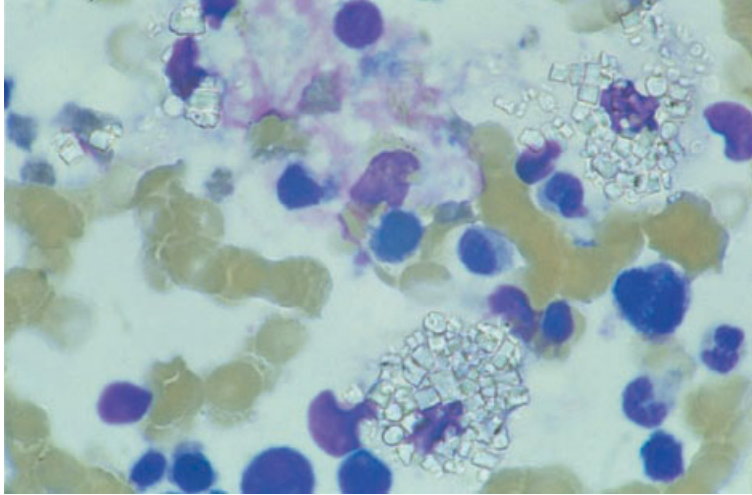


Fig. 9.42 BM aspirate from a patient with cystinosis, showing two macrophages containing colourless cystine crystals. MGG $\times 960$. (By courtesy of Dr J Yin, Manchester.)

are best seen under polarized light when they are birefringent but are also readily apparent with normal illumination (Fig. 9.42). Bone marrow aspiration has sometimes confirmed a provisional diagnosis of cystinosis when other diagnostic measures were negative [89].

Bone marrow histology

Crystals dissolve out of histological sections leaving a negative image.

Hyperoxaluria [90–92]

Hyperoxaluria or oxalosis is a metabolic disorder in which oxalate is deposited in various tissues including the bone, bone marrow, liver, spleen and kidneys. Renal deposition leads to renal failure. The introduction of haemodialysis has prolonged life in these patients and has permitted advanced bone marrow lesions to become apparent.

Peripheral blood

There is anaemia as a consequence of renal failure. Hypersplenism also contributes to anaemia and may cause pancytopenia. Deposition of oxalate in the bone marrow further aggravates anaemia and

other cytopenias and causes a leuco-erythroblastic blood film.

Bone marrow biopsy

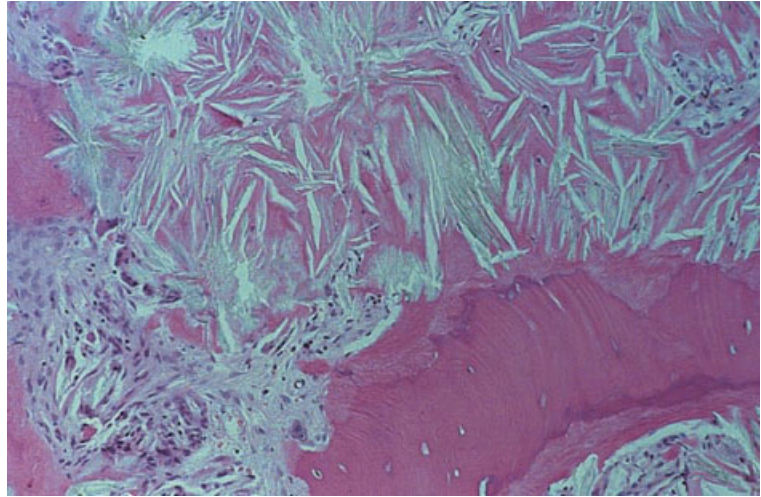
Central areas of intertrabecular bone marrow are extensively replaced by needle-like crystals arranged in a radial pattern (Fig. 9.43). There are variable numbers of epithelioid cells and multinucleated cells, including foreign body giant cells, present at the periphery of the crystalline deposits and engulfing crystals. The surrounding paratrabecular bone marrow shows mild fibrosis.

Mucopolysaccharidoses

The mucopolysaccharidoses are inherited diseases characterized by the storage of various mucopolysaccharides [66]. They are consequent on a deficiency of one of the lysosomal enzymes needed to degrade mucopolysaccharide.

Peripheral blood

Peripheral blood neutrophils may show the Alder–Reilly anomaly [66,71]. Lymphocytes may either be vacuolated or contain abnormal granules which stain metachromatically with toluidine blue.



(a)



(b)

Fig. 9.43 BM trephine biopsy sections in oxalosis: (a) H&E; (b) with polarized light. (By courtesy of Dr MJ Walter and Dr CV Dang, Johns Hopkins University School of Medicine, Baltimore.)

Bone marrow cytology

Bone marrow granulocytes may contain inclusions similar to those observed in the peripheral blood. Similar inclusions have been observed in plasma cells. Bone marrow macrophages also contain abnormal metachromatic granules (Fig. 9.44) [66].

Bone marrow histology

In histological preparations, macrophages appear foamy since mucopolysaccharides are water-

soluble. Abnormal histiocytes may be scattered between haemopoietic cells or in small clusters.

Deposition of foreign substances

Foreign substances may be deposited in the bone marrow, principally in bone marrow macrophages. Such substances may be apparent in bone marrow aspirates and in trephine biopsy sections. There are not usually any associated peripheral blood abnormalities.

In anthracosis there is widespread deposition of

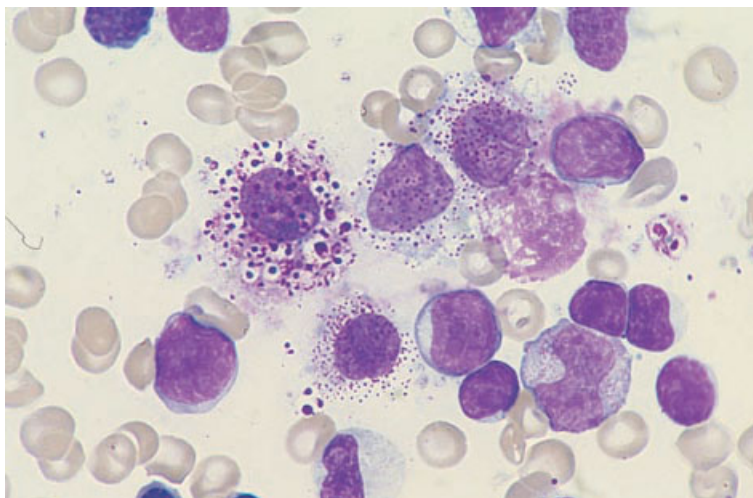


Fig. 9.44 BM aspirate, San Filippo syndrome, showing cells containing abnormal granules. MGG $\times 940$. (By courtesy of Dr R Brunning, Minneapolis.)

anthracotic pigment in body macrophages including those of the bone marrow. Large aggregates of dense black particles are apparent [93]. Silica and anthracotic pigment are often co-deposited. Silica crystals are detected by their birefringence. There may be consequent granuloma formation.

Occasional patients are still seen who have, in the past, been exposed to Thorotrast (thorium dioxide) as a radiographic medium. Thorotrast within macrophages appears as a pale grey refractile material (see Fig. 10.28). Bone marrow abnormalities associated with the presence of Thorotrast include hypoplasia, hyperplasia, fibrosis and the development of MDS, acute leukaemia and haemangioendothelioma [94]. The peripheral blood film may be bizarre because of the combined effects of bone marrow fibrosis and Thorotrast-induced splenic atrophy.

Vascular and intravascular lesions [69,95]

The bone marrow vasculature may be altered as a consequence of bone marrow diseases but, in addition, the blood vessels within the marrow, particularly arterioles and capillaries, may be involved in a variety of generalized diseases. The peripheral blood film may show related abnormalities but in general the bone marrow aspirate does not give relevant information and a trephine biopsy is necessary to show the lesion.

Peripheral blood

The peripheral blood shows red cell fragments in patients with thrombotic thrombocytopenic purpura or with micro-angiopathic haemolytic anaemia as a consequence of disseminated malignancy. Eosinophilia may be a feature of some types of vasculitis and also of cholesterol embolism which may involve the marrow as well as other tissues. Leucocytosis and an elevated erythrocyte sedimentation rate have also been associated with cholesterol embolism. The peripheral blood film may show pancytopenia and leuco-erythroblastic features in patients with bone marrow necrosis as a consequence of vascular occlusion.

Bone marrow cytology

There are no specific abnormalities in the bone marrow aspirate in patients with vascular lesions.

Bone marrow histology

In patients with generalized atherosclerosis the bone marrow arterioles may show atherosclerotic changes. Embolism of atheromatous material to bone marrow vessels may occur; the embolus may be acellular or composed of hyaline material or cholesterol crystals (Fig. 9.45) [96,97]. Bone marrow

Fig. 9.45 Trepine biopsy section showing a cholesterol embolus; cholesterol crystals are seen as negative images. Paraffin-embedded, H&E $\times 192$.

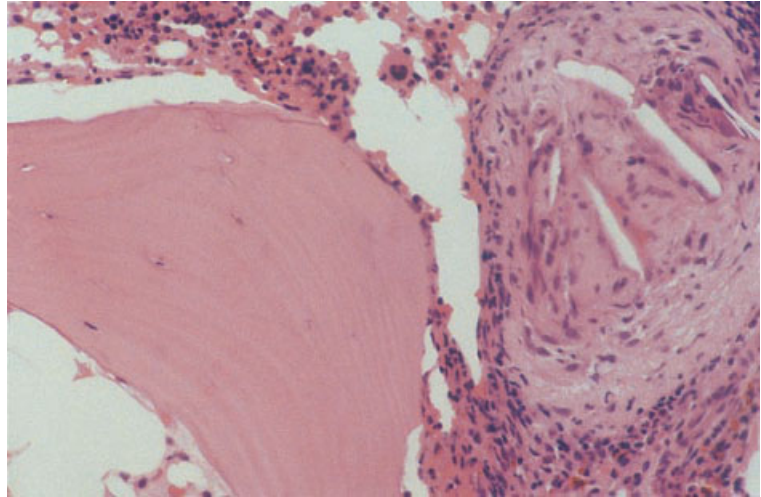
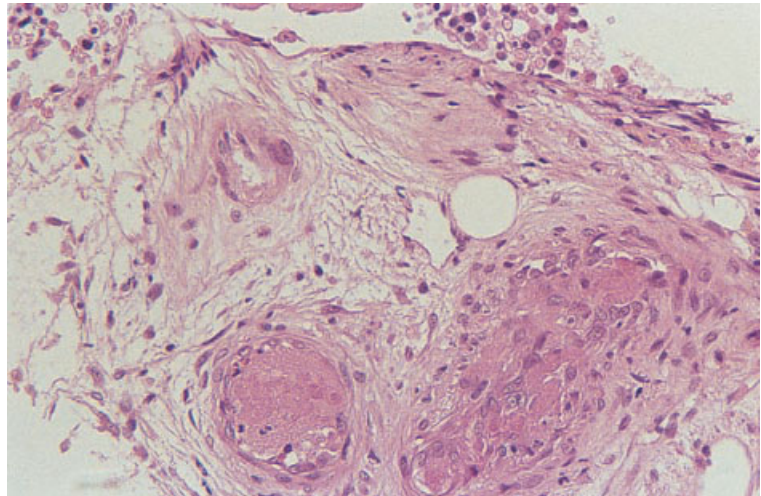


Fig. 9.46 Trepine biopsy section from a patient with an anti-cardiolipin antibody showing thrombi in bone marrow vessels. Paraffin-embedded, H&E $\times 192$.



emboli are present at autopsy in about 10% of patients with generalized cholesterol embolism [96]. Vessels are partly or totally occluded by this material and by the granulomatous tissue which develops as a reaction to it. Any cholesterol crystals appear as empty clefts. There may be foreign body giant cells in addition to proliferating histiocytes, together with fibrosis and new bone formation simulating bone marrow metastases [98]. Vasculitic lesions are seen in polyarteritis nodosa, with fibrinoid necrosis being a feature. In patients with hypersensitivity reactions to drugs, a granulomatous vasculitis may occur. Patients with vasculitis may

show granulocytic hyperplasia with both neutrophils and eosinophils being increased. Intravascular and subendothelial hyaline deposits may be seen in bone marrow capillaries in thrombotic thrombocytopenic purpura. In patients with microangiopathic haemolytic anaemia as a consequence of disseminated carcinoma, the bone marrow capillaries, like other capillaries, may contain tumour thrombi. Thrombi may also be seen in patients with thrombophilia, e.g. in patients with anti-cardiolipin antibodies (Fig. 9.46). In patients with sickle cell disease, sickle cells are usually present in sinusoids. During sickling crises there may also be thrombotic

lesions and associated areas of bone marrow necrosis. Sickle cells may also be present in autopsy specimens from patients with sickle cell trait; their presence does not have any particular significance. Thrombi may also be noted in vessels in other patients with bone marrow necrosis. In amyloidosis, there may be deposition of amyloid in bone marrow vessels (see Fig. 7.29). Abnormal vessels encircled by mast cells may be seen in systemic mastocytosis (see Fig. 5.41).

References

- Castello A, Coci A and Magrini U (1992) Para-neoplastic marrow alterations in patients with cancer. *Haematologica*, 77, 392–397.
- Knupp C, Pekala PH and Cornelius P (1988) Extensive bone marrow necrosis in patients with cancer and tumor necrosis factor in plasma. *Am J Hematol*, 29, 215–221.
- Amos RJ, Deane M, Ferguson G, Jeffries G, Hinds CJ and Amess JAL (1990) Observations of the haemopoietic response to critical illness. *J Clin Pathol*, 43, 850–856.
- Bader-Meunier B, Rieux-Laucat F, Croisille L, Yvart J, Mielot F, Dommergues JP *et al.* (2000) Dyserythropoiesis associated with a Fas-deficient condition in childhood. *Br J Haematol*, 108, 300–304.
- Clatch RJ, Krigman HR, Peters MG and Zutter MM (1994) Dysplastic haemopoiesis following orthoptic liver transplantation: comparison with similar changes in HIV infection and primary myelodysplasia. *Br J Haematol*, 88, 685–692.
- O'Brien H, Amess JAL and Mollin DL (1982) Recurrent thrombocytopenia, erythroid hypoplasia and sideroblastic anaemia associated with hypothermia. *Br J Haematol*, 51, 451–456.
- Schleicher E. *Bone Marrow Morphology and Mechanics of Biopsy*. Charles C Thomas, Springfield, 1973.
- Wittels B (1980) Bone marrow biopsy changes following chemotherapy for acute leukemia. *Am J Surg Pathol*, 4, 135–142.
- Brody JP, Krause JR and Penchansky L (1985) Bone marrow response to chemotherapy in acute lymphocytic and acute non-lymphocytic leukaemia. *Scand J Haematol*, 35, 240–245.
- Resuke WN, Anderson C, Pastuszak WT, Conway SR and Firshein SI (1991) Arsenic intoxication presenting as a myelodysplastic syndrome. *Am J Hematol*, 36, 291–293.
- Pye A, Kelsey SM, House IM and Newland AC (1992) Severe dyserythropoiesis and autoimmune thrombocytopenia associated with ingestion of kelp supplements. *Lancet*, 339, 1540.
- Phatak PD, Janas J-AS, Kouides PA, Sham RL and Marder VJ (1997) Unusual anemias. *Am J Hematol*, 54, 249–252.
- Karunajeewa H, Wall A, Metz J and Grigg A (1998) Cytopenias secondary to copper depletion complicating ammonium tetrathiomolybdate therapy for Wilson's disease. *Aust NZ J Med*, 28, 215–216.
- Michot F and Gut J (1987) Alcohol-induced bone marrow damage. A bone marrow study in alcohol dependent individuals. *Acta Haematol*, 78, 252–257.
- Wulfhekel U and Düllmann J (1999) Storage of iron in bone marrow plasma cells: ultrastructural characterization, mobilization, and diagnostic significance. *Acta Haematol*, 101, 7–15.
- Ballard HS (1980) Alcohol-associated pancytopenia with hypocellular bone marrow. *Am J Clin Pathol*, 73, 830–834.
- Gordon-Smith EC and Rutherford T (1989) Fanconi's anaemia—constitutional, familial aplastic anaemia. *Baillières Clin Haematol*, 2, 139–152.
- Knight S, Heiss N, Vuillamy T, Aalfs C, McMahon C, Jones A *et al.* (1999) Hoyeraal–Hreidarsson syndrome of progressive pancytopenia, immunodeficiency, growth retardation, and cerebellar hypoplasia is due to mutations in the dyskeratosis congenita gene. *Br J Haematol*, 105 (Suppl. 1), 66.
- Marsh JCW and Geary CG (1991) Is aplastic anaemia a pre-leukaemic disorder? *Br J Haematol*, 77, 447–452.
- Chute JP, Hofmeister K, Cotelingam J, Davis TA, Frame JN and Jamieson T (1996) Aplastic anaemia as the sole presentation of systemic lupus erythematosus. *Am J Haematol*, 51, 237–239.
- Fleming AF (1999) Pregnancy and aplastic anaemia. *Br J Haematol*, 105, 313–320.
- Camitta BM and Thomas ED (1978) Severe aplastic anaemia: a prospective study of the effect of androgens on haematological recovery and survival. *Clin Haematol*, 7, 587–595.
- Frisch B and Lewis SM (1974) The bone marrow in aplastic anaemia: diagnostic and prognostic features. *J Clin Pathol*, 27, 231–241.
- Kansu E and Erslev AJ (1976) Aplastic anaemia with 'hot pockets'. *Scand J Haematol*, 17, 326–334.
- te Velde J and Haak HL (1977) Aplastic anaemia: histological investigation of methacrylate embedded bone marrow biopsy specimens: correlation with survival after conventional treatment in 15 adult patients. *Br J Haematol*, 35, 61–69.
- Melenhorst JJ, van Krieken JHM, Dreef E, Landegent JE, Willemze R and Fibbe WE (1997) T cells selectively infiltrate bone marrow areas with residual haemopoiesis of patients with acquired aplastic anaemia. *Br J Haematol*, 99, 517–519.
- Burkhardt R, Frisch B and Bartl B (1982) Bone biopsy in haematological disorders. *J Clin Pathol*, 35, 257–284.

- 28 Tichelli A, Gratwohl A, Würsh A, Nissen C and Speck B (1988) Late haematological complications in severe aplastic anaemia. *Br J Haematol*, 69, 413–418.
- 29 de Planque MM, Van Krieken JHJM, Kluin-Nelemans HC, Colla LPJM, van der Burgh F, Brand A and Kluin PM (1989) Bone marrow histopathology of patients with severe aplastic anaemia before treatment and at follow-up. *Br J Haematol*, 72, 439–444.
- 30 Heimpel H (2000) Aplastic anemia before bone marrow transplantation and antilymphocyte globulin. *Acta Haematol*, 103, 11–15.
- 31 Sale GE, Rajantie J, Doney K, Appelbaum FR, Storb R and Thomas ED (1987) Does histologic grading of inflammation in bone marrow predict the response of aplastic anaemia patients to antithymocyte globulin therapy? *Br J Haematol*, 67, 261–266.
- 32 Geary CG, Harrison CJ, Philpott NJ, Hows JM, Gordon-Smith EC and Marsh JC (1999) Abnormal cytogenetic clones in patients with aplastic anaemia: response to immunosuppressive therapy. *Br J Haematol*, 104, 271–274.
- 33 Fohlmeister I, Fischer R, Mödder B, Rister M and Schaefer H-E (1985) Aplastic anaemia and the hypocellular myelodysplastic syndrome: histomorphological, diagnostic, and prognostic features. *J Clin Pathol*, 38, 1218–1224.
- 34 de Planque MM, Kluin-Nelemans HC, Van Krieken HJM, Kluin PM, Brand A, Beverstock GC *et al.* (1988) Evolution of acquired severe aplastic anaemia to myelodysplasia and subsequent leukaemia. *Br J Haematol*, 70, 55–62.
- 35 Reid MM and Summerfield GP (1992) Distinction between aleukaemic prodrome of childhood acute lymphoblastic leukaemia and aplastic anaemia. *J Clin Pathol*, 45, 697–700.
- 36 Morley AA, Brisco MJ, Rice M, Snell L, Peng L-M, Hughes E *et al.* (1997) Leukaemia presenting as marrow hypoplasia: molecular detection of the leukaemic clone. *Br J Haematol*, 98, 940–944.
- 37 Beyan C, Ural AU, Çetin T, Omay SB, Doğançlı L and Yalçın A (1997) Uncommon cause of severe pancytopenia: toxoplasmosis. *Am J Hematol*, 55, 164.
- 38 Pearson HA, Lobel JS, Kocoshis SA, Naiman JL, Windmiller J, Lammi A *et al.* (1979) A new syndrome of refractory sideroblastic anemia with vacuolation of bone marrow precursors and exocrine pancreatic dysfunction. *J Pediatr*, 95, 976–984.
- 39 Bain BJ (1994) Transient leukaemia in newborn infants with Down's syndrome. *Leuk Res*, 18, 723–724.
- 40 Çetin M, Hicsönmez G and Göğüs S (1998) Myelodysplastic syndrome associated with the Griscelli syndrome. *Leuk Res*, 22, 859–862.
- 41 Bazarbachi A, Muakkit S, Ayas M, Taher A, Salem Z, Solh H and Haidar JH (1998) Thiamine-responsive myelodysplasia. *Br J Haematol*, 102, 1098–1100.
- 42 Rotoli B and Luzzatto L (1989) Paroxysmal nocturnal haemoglobinuria. *Semin Haematol*, 26, 201–207.
- 43 Sale GE and Buckner CD (1988) Pathology of bone marrow in transplant recipients. *Hematol Oncol Clin North Am*, 2, 735–756.
- 44 Bilgrami S, Almeida GD, Quinn JJ, Tuck D, Bergstrom S, Dainiak N *et al.* (1994) Pancytopenia in allogeneic marrow transplant recipients: role of cytomegalovirus. *Br J Haematol*, 87, 357–362.
- 45 Carrigan DR and Knox KK (1994) Human herpesvirus 6 (HHV-6) isolation from bone marrow: HHV-6-associated bone marrow suppression in bone marrow transplant patients. *Blood*, 84, 3307–3310.
- 46 Rocha V, Devergie A, Socié G, Ribaud P, Espérou H, Parquet N and Gluckman E (1998) Unusual complications after bone marrow transplantation for dyskeratosis congenita. *Br J Haematol*, 103, 243–248.
- 47 Kobayashi SD, Seki K, Suwa N, Koama C, Yamamoto T, Aiba K *et al.* (1991) The transient appearance of small blastoid cells in the marrow after bone marrow transplantation. *Am J Clin Pathol*, 96, 191–195.
- 48 Rosenthal NS and Fahri DC (1994) Failure to engraft after bone marrow transplantation: bone marrow morphologic findings. *Am J Clin Pathol*, 102, 821–824.
- 49 Müller-Hermelink HK and Sale GE. Pathological findings in human bone marrow transplantation. In: Lennert K and Hübner K (eds) *Pathology of the Bone Marrow*. Gustav Fischer Verlag, Stuttgart, 1984.
- 50 van den Berg H, Kluin PM, Zwaan FE and Vossen JM (1989) Histopathology of bone marrow reconstitution after bone marrow transplantation. *Histopathology*, 15, 363–375.
- 51 van den Berg H, Kluin PM and Vossen JM (1990) Early reconstitution of haematopoiesis after allogeneic bone marrow transplantation: a prospective histopathologic study of bone marrow biopsy specimens. *J Clin Pathol*, 43, 335–369.
- 52 Maia DM, Kell DL, Goates J and Warnke RA (1997) The significance of light chain-restricted bone marrow plasma cells after peripheral blood stem cell transplantation for multiple myeloma. *Am J Clin Pathol*, 107, 643–652.
- 53 Au MY and Kwong YL (1999) Haemophagocytosis in the peripheral blood. *Br J Haematol*, 105, 321.
- 54 Jouan H, Deïst F Le and Nezelof C (1987) Omenn's syndrome—pathologic arguments in favour of a graft versus host pathogenesis: a report of nine cases. *Hum Pathol*, 18, 1011–1108.
- 55 Wada T, Takei K, Kudo M, Shimura S, Kasahara Y, Koizumi S *et al.* (2000) Characterization of immune function and analysis of RAG gene mutations in Omenn syndrome and related disorders. *Clin Exp Immunol*, 119, 148–155.
- 56 Aslund SL, Miller ML and Kalacyio ME (1999) Immunophenotypic characterization of granulocyte colony-stimulating factor-induced blast cells in peripheral blood. *Am J Clin Pathol*, 112, 558.

- 57 Meyerson HJ, Farhi DC and Rosenthal NC (1998) Transient increase in blasts mimicking acute leukemia and progressing to myelodysplasia in patients receiving growth factor. *Am J Clin Pathol*, 109, 675–681.
- 58 Orazi A, Gordon MS, John K, Sledge G, Neiman RS and Hoffman R (1995) *In vivo* effects of recombinant human stem cell factor treatment: a morphologic and immunohistochemical study of bone marrow biopsies. *Am J Clin Pathol*, 103, 177–184.
- 59 Rasko JEJ, Basser RL, Boyd J, Mansfield R, O'Malley CJ, Hussein S *et al.* (1997) Multilineage mobilization of peripheral blood progenitor cells in humans following administration of PEG-rHu MGDF. *Br J Haematol*, 97, 871–880.
- 60 Du X and Williams DA (1997) Interleukin-11: review of molecular, cell biology, and clinical use. *Blood*, 89, 3897–3905.
- 61 Harris AC, Todd WM, Hackney MH and Ben-Ezra J (1994) Bone marrow changes associated with recombinant granulocyte-macrophage and granulocyte colony-stimulating factors. *Arch Pathol Lab Med*, 118, 624–629.
- 62 Tegg EM, Tuck DM, Lowenthal RM and Marsden KA (1999) The effect of G-CSF on the composition of human bone marrow. *Clin Lab Haematol*, 21, 265–270.
- 63 Urabe AU (1994) Colony stimulating factor and macrophage proliferation. *Am J Clin Pathol*, 101, 116.
- 64 Kaddar A, Edinger M, Wirth K, Schaefer HE, Lubbert M and Lindemann A (1997) Increased numbers of bone marrow blasts in acute myeloid leukaemia patients treated with G-CSF after chemotherapy. *Br J Haematol*, 98, 492–493.
- 65 Cummings GH (1998) The effect of growth factor therapy on blast percentages. *Am J Clin Pathol*, 111, 709.
- 66 Brunning RD (1970) Morphological alterations in nucleated blood and marrow cells in genetic disorders. *Hum Pathol*, 1, 99–124.
- 67 Hayhoe FGT, Flemans RJ and Cowling DC (1979) Acquired lipidosis of marrow macrophages. *J Clin Pathol*, 32, 420–428.
- 68 Savage RA (1984) Specific and not-so-specific histiocytes in bone marrow. *Lab Med*, 15, 467–471.
- 69 Bain BJ and Wickramasinghe SNW. Pathology of the bone marrow: general considerations. In: Wickramasinghe SNW (ed) and Symmers W St C (series ed) *Systemic Pathology, Volume 2: Blood and Bone Marrow*, 3rd edn. Churchill Livingstone, Edinburgh, 1986.
- 70 Lee RE (1988) Histiocytic diseases of the bone marrow. *Hematol Oncol Clin North Am*, 2, 657–667.
- 71 Bain BJ. *Blood Cells: A Practical Guide*, 3rd edn. Blackwell Science, Oxford, 2002.
- 72 Beutler E and Saven A (1990) Misuse of marrow examination in the diagnosis of Gaucher's disease. *Blood*, 76, 646–648.
- 73 Beutler E (1988) Gaucher disease. *Blood Rev*, 2, 59–70.
- 74 Hoyer JD, Li C-Y, Yam LT, Hanson CA and Kurtin PJ (1997) Immunohistochemical demonstration of acid phosphatase isoenzyme 5 (tartrate-resistant) in paraffin sections of hairy cell leukemia and other hematologic disorders. *Am J Clin Pathol*, 108, 308–315.
- 75 Stewart AJ and Jones RDG (1999) Pseudo-Gaucher cells in myelodysplasia. *J Clin Pathol*, 52, 917–918.
- 76 Papadimitriou JC, Chakravarthy A and Heyman MR (1988) Pseudo-Gaucher cells preceding the appearance of immunoblastic lymphoma. *Am J Clin Pathol*, 90, 454–458.
- 77 Yamauchi K and Shimamura K (1995) Mild thrombocytopenia induced by phagocytosis of marrow pseudo-Gaucher cells in a patient with chronic myelogenous leukaemia. *Eur J Haematol*, 54, 55–56.
- 78 Solis OG, Belmonte AH, Ramaswamy G and Tchertkoff V (1986) Pseudogaucher cells in *Mycobacterium avium intracellulare* infections in acquired immune deficiency syndrome (AIDS). *Am J Clin Pathol*, 85, 233–235.
- 79 Agiris A, Maun N and Berliner N (1999) *Mycobacterium avium* complex inclusions mimicking Gaucher's cells. *N Engl J Med*, 340, 1372.
- 80 Brunning RD. Bone marrow. In: Rosai J (ed) *Ackerman's Surgical Pathology*, 7th edn, vol 2. Mosby, St Louis, 1989.
- 81 Wong KF and Chan JKC (1989) Foamy histiocytes in repeat marrow aspirates. *Pathology*, 21, 153–154.
- 82 Hyun BH, Gulati GL and Ashton JK. *Color Atlas of Clinical Hematology*. Igaku-Shoin, New York, 1986.
- 83 Kuo TT and Hsueh S (1984) Mucicarmophilic histiocytosis in polyvinylpyrrolidone (PVP) storage disease simulating signet ring carcinoma. *Am J Surg Pathol*, 8, 419–428.
- 84 Dunn P, Kuo T, Shi L-Y, Wang P-N, Sun C-F and Chang MJW (1998) Bone marrow failure and myelofibrosis in a case of PVP storage disease. *Am J Hematol*, 57, 6–71.
- 85 Bigorne C, Le Torneau A, Messing B, Rio B, Giraud V, Molina T *et al.* (1996) Sea-blue histiocyte syndrome in bone marrow secondary to total parenteral nutrition including fat-emulsion sources: a clinicopathologic study of seven cases. *Br J Haematol*, 95, 258–262.
- 86 Frisch B, Lewis SM, Burkhardt R and Bartl R. *Biopsy Pathology of the Bone Marrow*. Chapman & Hall, London, 1985.
- 87 Varela-Duran J, Roholt PC and Ratliff NB (1980) Sea-blue histiocyte syndrome: a secondary degenerative process of macrophages? *Arch Pathol Lab Med*, 104, 30–34.
- 88 Armstrong D, Gadoth N and Harvey J (1985) Sea-blue histiocytes in canine ceroid-lipofuscinosis. *Blood Cells*, 11, 151–155.
- 89 Varan A and Tuncer AM (1991) The importance of the bone marrow examination in cystinosis. *Pediatr Hematol Oncol*, 8, 373–374.

- 90 Mathews M, Stauffer M, Cameron EC, Maloney N and Sherrard DJ (1979) Bone biopsy to diagnose hyperoxaluria in patients with renal failure. *Ann Intern Med*, 90, 777–779.
- 91 Hricik DE and Hussain R (1984) Pancytopenia and hepatosplenomegaly in oxalosis. *Arch Intern Med*, 184, 167–168.
- 92 Walter MJ and Dang CV (1998) Pancytopenia secondary to oxalosis in a 23-year-old woman. *Blood*, 91, 4394.
- 93 Miller D (1959) Observations in a case of probable bone marrow anthracosis. *Blood*, 14, 1350–1353.
- 94 Jennings RC and Priestley SE (1978) Haemangioendothelioma (Kupffer cell angiosarcoma), myelofibrosis, splenic atrophy, and myeloma paraproteinaemia after parenteral Thorotrast administration. *J Clin Pathol*, 31, 1125–1132.
- 95 Rywlin AM. *Histopathology of the Bone Marrow*. Little Brown, Boston, 1976.
- 96 Pierce JR, Wren MV and Cousar JB (1978) Cholesterol embolism: diagnosis antemortem by bone marrow biopsy. *Ann Intern Med*, 89, 937–938.
- 97 Retan JW and Miller RE (1966) Microembolic complications of atherosclerosis. *Arch Intern Med*, 118, 534–543.
- 98 Muretto P, Carnevali A and Ansini AL (1991) Cholesterol embolism of bone marrow clinically masquerading as systemic or metastatic tumor. *Haematologica*, 76, 248–250.

METASTATIC TUMOURS

The bone marrow is one of the more common organs to be involved by tumours that metastasize via the bloodstream. In adults the tumours most often seen are carcinomas of the prostate gland, breast and lung, although any tumour that gives rise to blood-borne metastases may infiltrate the marrow [1,2]. In children neuroblastoma, rhabdomyosarcoma, Ewing's sarcoma, other primitive neuro-ectodermal tumours (PNET) and retinoblastoma account for the majority of metastases [3,4]. Bone marrow metastases from squamous cell carcinoma, other than that of the lung, and from soft tissue tumours of adults are uncommon [1]. Intracranial tumours rarely metastasize outside the cranial vault. Of those cases reported with bone marrow involvement, glioblastoma multiforme has been the most frequent [5]; examples of metastatic medulloblastoma [6] and oligodendroglioma [7] have also been recorded.

Infiltration of the marrow may be suspected on the basis of: (i) bone pain; (ii) pathological fractures, lytic lesions or sclerotic lesions demonstrated radiologically; (iii) unexplained 'hot spots' on isotopic bone scans; (iv) hypercalcaemia or elevated serum alkaline phosphatase activity; or (v) unexplained haematological abnormalities. The haematological abnormality most suggestive of marrow infiltration, though not specific for it, is leuco-erythroblastic anaemia (see below). Metastases are also demonstrated occasionally when bone marrow examination is carried out for staging purposes in the absence of any features suggestive of bone marrow infiltration. Overall, the presence of leuco-erythroblastic anaemia is a relatively insensitive indication of infiltration since it is observed in less than half of patients in whom bone marrow metastases can be demonstrated by biopsy [8–10]. Aspirates and trephine biopsies are occasionally positive even

when skeletal radiology and isotopic bone scans [8,11] are normal.

Considering the small volume of tissue sampled, both bone marrow aspiration and trephine biopsy are relatively sensitive techniques for detecting bone marrow infiltration by metastatic tumours. In two autopsy studies which simulated biopsy procedures, it was estimated that, when osseous metastases were present, a bone marrow aspirate would give positive results in 28% of cases [12] and a single trephine biopsy in 35–45% [13]. Trephine biopsy is more sensitive than bone marrow aspiration and sensitivity is increased by performing bilateral biopsies or by obtaining a single large biopsy. The sensitivity of aspiration is increased if large numbers of films are examined and if a clot section is also examined. It is common for tumour cells to be detectable in trephine biopsy sections when none are demonstrable in films of an aspirate [8,14]. Overall, about three quarters of metastases detected by a trephine biopsy are also detected by simultaneous bone marrow aspirate. Discrepancy between biopsy and aspirate findings usually results from a desmoplastic stromal reaction to the tumour which renders neoplastic cells more difficult to aspirate than residual haemopoietic cells. It is also, to some degree, a consequence of the different volumes of tissue sampled. Because of its greater sensitivity, trephine biopsy should always be performed when metastatic malignancy is suspected. However, tumour cells are seen occasionally in aspirate films when trephine biopsy sections appear normal [2,8,14] and the two procedures should therefore be regarded as complementary.

Increasingly, bone marrow aspiration and trephine biopsy are being performed as staging procedures at the time of diagnosis in a number of solid tumours, principally neuroblastoma in children and

carcinomas of the breast and lung in adults. Such investigations are indicated when there is a significant probability of bone marrow metastases and when knowledge of their presence would affect the choice of primary treatment. Biopsy may be indicated, for example, when radical surgery or radiotherapy with curative intent is to be undertaken or when intensive chemotherapy with autologous bone marrow transplantation is being considered.

It can be important to suggest the likely primary site of metastatic lesions detected in the bone marrow. This is particularly so in the case of adenocarcinoma since, although many such tumours are relatively resistant to therapy, those originating in the breast and prostate gland may respond to hormonal therapy. Identification of metastatic thyroid carcinoma is likewise important although, in practice, this tumour is rarely found unexpectedly in bone marrow biopsy samples since malignant thyroid tumours generally manifest themselves clearly at their primary site. Investigation for an unknown primary tumour is therefore rarely necessary in this context and radio-isotope imaging is the preferred staging technique for known thyroid malignancies.

The main areas of difficulty in the diagnosis of metastatic tumour in bone marrow are:

- 1** distinguishing metastatic tumour cells from tumours of haemopoietic cells—for example, marrow involvement by high grade non-Hodgkin's lymphoma (NHL) or M7 AML (WHO categories of acute megakaryocytic leukaemia and acute panmyelosis with myelofibrosis);
- 2** determining the site of origin of metastatic tumour when the primary is unknown;
- 3** detecting small foci of metastatic tumour in biopsies performed as part of tumour staging; and
- 4** identifying scanty metastatic malignant cells in severely sclerotic deposits.

Immunohistochemistry is very useful in the identification of metastatic tumours in the bone marrow (Table 10.1).

Peripheral blood

Normocytic normochromic anaemia is commonly present when there is infiltration of the bone marrow by malignant cells; other cytopenias are less common. In a third to a half of patients with bone marrow infiltration there are nucleated red

cells and neutrophil precursors in the blood—designated leuco-erythroblastic anaemia when the patient is also anaemic. The presence of a leuco-erythroblastic anaemia correlates with the degree of reactive bone marrow fibrosis rather than with the extent of malignant infiltration [9]; it is most commonly seen in association with carcinoma of the breast, stomach, prostate gland and lung. Sometimes bone marrow infiltration is identified in the absence of anaemia or any other abnormality in the peripheral blood.

Significant numbers of circulating malignant cells are rare but may occur in the small cell tumours of childhood, particularly neuroblastoma, rhabdomyosarcoma and medulloblastoma. Circulating neoplastic cells may also be seen in adult patients with carcinoma but this is a very rare occurrence.

Patients with metastatic malignant cells in the bone marrow may show peripheral blood abnormalities which are caused by the underlying malignant disease but are not directly due to bone marrow infiltration. Such abnormalities can include: (i) iron deficiency anaemia; (ii) the anaemia of chronic disease; (iii) micro-angiopathic haemolytic anaemia; (iv) neutrophilia; (v) eosinophilia; (vi) thrombocytopenia; (vii) thrombocytosis; and (viii) increased rouleaux formation.

Bone marrow cytology

When bone marrow infiltration has led to reactive myelofibrosis, attempts at aspiration may result in a 'dry tap' or a 'blood tap', or a small amount of marrow containing haemopoietic cells, tumour cells or both may be aspirated with difficulty. When there is an associated increase in bone turnover, the aspirate may contain a mixture of tumour cells, osteoblasts and osteoclasts (Fig. 10.1). Sometimes the aspirate is wholly or partly necrotic and this observation should lead to the suspicion of malignant infiltration. When a satisfactory aspirate is obtained, it may contain large numbers of tumour cells mixed with a variable number of residual haemopoietic cells, or tumour cells may be scanty and found only after a prolonged search. Examination of the tail and edges of the film and examination of many films are important if scanty tumour cells are to be detected. The detection of scattered neoplastic cells in films of bone marrow aspirates is enhanced by the use of

Table 10.1 Antigens expressed by non-haemopoietic cells, useful for demonstration of metastatic tumours by immunohistochemistry in fixed, decalcified bone marrow trephine biopsy specimens.

Antigen	Antibody	Specificity	Comments
Low molecular weight cytokeratins	CAM5.2, AE1, MNF116	Epithelial cells (cytoplasmic expression)	Cells in occasional cases of anaplastic large cell lymphoma are also positive
High molecular weight cytokeratins	AE3	Epithelial cells (cytoplasmic expression)	Cells in occasional cases of anaplastic large cell lymphoma are also positive
Epithelial membrane antigen	E29	Epithelial cells (membrane expression)	Anaplastic large cell lymphomas and non-neoplastic plasma cells are also positive
Carcino-embryonic antigen (epitopes include CD66)	Polyclonal antisera and 85A12	Epithelial cells (membrane expression, often apical or periluminal distribution)	Metamyelocytes and mature neutrophils are also positive
Prostate-specific antigen	ER-PR8, PSA 28/A4	Prostatic epithelial cells (cytoplasmic expression)	
Prostatic acid phosphatase	PASE/4LJ	Prostatic epithelial cells (preferential apical/periluminal distribution)	
Thyroglobulin	DAK-Tg6 1D4	Thyroid epithelial cells (cytoplasmic expression)	
Calcitonin	Polyclonal antisera and CAL-3-F5	Thyroid medullary C-cells (cytoplasmic expression)	
Oestrogen receptor	1D5	Oestrogen-sensitive cells, including those of breast, ovary and endometrium (nuclear expression)	Of limited diagnostic value in metastases from an unknown primary source but may assist in prognostication in breast carcinoma
Progesterone receptor	1A6	Oestrogen-sensitive cells, including those of breast, ovary and endometrium (nuclear expression)	Of limited diagnostic value in metastases from an unknown primary source but may assist in prognostication in breast carcinoma
P53	D07	Tumours of diverse origins with excessive wild-type P53 or mutant P53 (nuclear expression)	Of limited diagnostic value in metastases from an unknown primary source but may assist in prognostication in breast carcinoma
S100 protein	Polyclonal antisera	Malignant melanoma (nuclear and cytoplasmic expression)	Perineurial cells, a subset of macrophages, cells of Langerhans cell histiocytosis and 20% of breast cancers are positive
Melanosome matrix protein gp100-cl	HMB-45	Malignant melanoma (cytoplasmic expression)	Varying proportions of cells are negative in many tumours
Melanoma-associated MART-1 gene product	Melan A	Malignant melanoma (cytoplasmic expression)	
Protein gene product 9.5 (PGP9.5)—ubiquitin related	Polyclonal antisera	Neuro-ectodermal tumours (especially neuroblastoma) and small cell carcinomas from lung and other sources (nuclear and cytoplasmic staining)	Newly produced reticulins, chondrocytes and late granulocyte precursors may be positive
Uncharacterized	NB84	Primitive neuro-ectodermal tumours, especially neuroblastoma (cytoplasmic expression)	Extensive background nuclear staining occurs with some fixation protocols Endothelial cells and some adult malignant epithelial tumours may also be positive
Uncharacterized	NeuN	Primitive neuro-ectodermal tumours, especially neuroblastoma (cytoplasmic expression)	

Table 10.1 (*cont'd*)

Antigen	Antibody	Specificity	Comments
CD99 (MIC2)	12E7, HO36-1.1	Primitive neuro-ectodermal tumours, especially Ewing's sarcoma (membrane expression)	Some normal T lymphocytes and cells in many cases of ALL are also positive
Desmin	D33	Rhabdomyosarcoma (cytoplasmic expression)	
MyoD1	5.8A	Rhabdomyosarcoma (nuclear expression)	Cytoplasmic staining is found in most neuroblastomas and occasional cases of Ewing's sarcoma/PNET. Consistent good performance with the currently available McAb is difficult to achieve in fixed tissue
Myogenin	F5D	Rhabdomyosarcoma (nuclear expression)	
Myoglobin	MG-1 and polyclonal antisera	Rhabdomyosarcoma (cytoplasmic expression)	
von Willebrand factor (previously known as Factor VIII-related antigen)	F8/86 and polyclonal antisera	Endothelium and tumours of endothelial origin (cytoplasmic expression)	Megakaryocytes are also positive
CD34	QEnd10	Endothelium and tumours of endothelial origin (cytoplasmic expression)	Some non-endothelial spindle cell tumours, normal and neoplastic early haemopoietic cells are also positive
CD31	JC70a	Endothelium and tumours of endothelial origin (cytoplasmic expression)	Macrophages, monocytes, megakaryocytes and plasma cells are also positive
a-L-fucosyl residues, including those expressed on blood group H core glycoprotein	<i>Ulex europaeus</i> agglutinin-1 (the lectin is used as an antibody equivalent)	Endothelium and tumours of endothelial origin (cytoplasmic expression)	Megakaryocytes, erythroid cells and some epithelial cell types are also positive

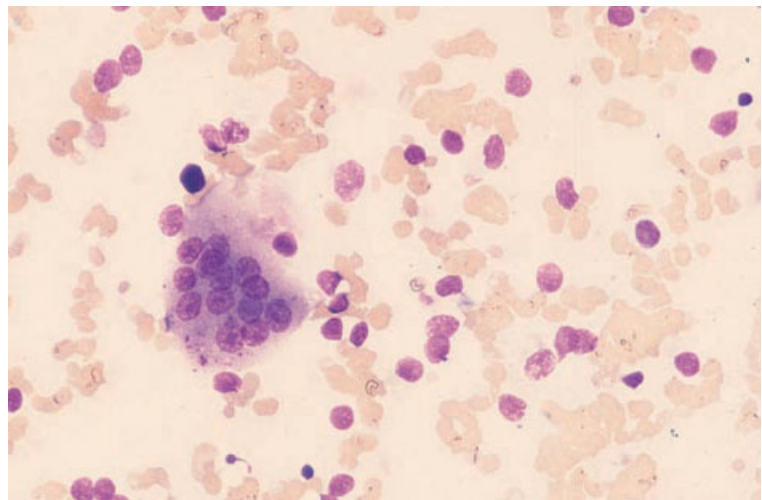


Fig. 10.1 BM aspirate, carcinoma of prostate, showing carcinoma cells and an osteoclast. MGG $\times 377$.

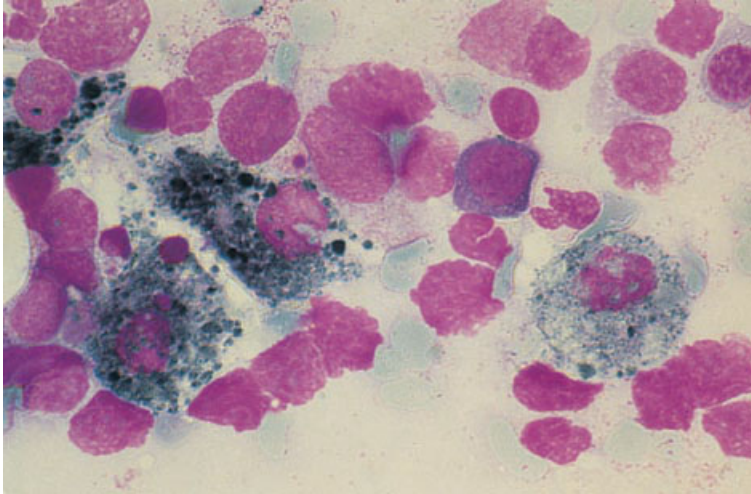


Fig. 10.2 BM aspirate, malignant melanoma, showing melanoma cells containing melanin. MGG $\times 940$. (By courtesy of Dr J Luckit, London.)

appropriate monoclonal antibodies such as those reactive with cytokeratins, carcino-embryonic antigen, human milk-fat globulin and epithelial membrane antigen (EMA) [15,16]. Positive reactions with such antibodies allow single neoplastic cells to be identified with more confidence.

Malignant cells are usually considerably larger than any haemopoietic cells other than megakaryocytes. However, in the small cell tumours of childhood, malignant cells may be similar in size to blast cells and acute leukaemia then enters into the differential diagnosis. Malignant cells are commonly cohesive and therefore occur as tight clumps with or without dispersed cells. Sometimes only irregularly distributed, dispersed cells are present. Neoplastic cells are usually pleomorphic with regard to size, shape and nuclear characteristics. Cell outlines may be indistinct or cells may appear smudged. Some cells may be multinucleated. The nuclei are often hyperchromatic and may contain nucleoli. Mitotic figures may be numerous. Carcinoma cells usually have moderately abundant cytoplasm which shows a variable degree of basophilia and may contain vacuoles; they are sometimes phagocytic. In the small cell tumours of childhood, cytoplasm may be scanty, thus increasing the resemblance to leukaemic blast cells, and sometimes, because of their marked fragility, the cells are represented only by single or clustered bare nuclei. It should also be noted that neuroblastoma cells are positive for α -naphthyl acetate esterase activity [17]. However,

they do not resemble cells of the monocyte lineage cytologically and they lack α -naphthyl butyrate esterase activity.

It is not usually possible to predict the tissue of origin from the cytological features of neoplastic cells in films of bone marrow aspirates. In view of this, it is important also to examine histological sections of marrow particles, particularly if a trephine biopsy has not been performed. Sections may show features, such as gland formation, which are helpful in suggesting the tissue of origin. In a small percentage of cases, cytological features in aspirate films may suggest the tissue of origin. Melanoma cells may be recognized by the presence of pigment (Fig. 10.2), the nature of which can be confirmed by specific stains (see below). Such stains may be positive even when no pigment is detected in routinely stained films but otherwise the cells of amelanotic melanoma cannot be distinguished from other neoplastic cells. Melanin may also be present in macrophages. Clear cell carcinomas are distinctive and suggest a renal primary; the cells have a relatively small nucleus and abundant, very weakly basophilic cytoplasm (Fig. 10.3). Cells of metastatic carcinoid tumour also have a relatively small nucleus and moderately abundant cytoplasm (Fig. 10.4). In children, neuroblastoma (Fig. 10.5) may sometimes be identified by the presence of extracellular blue-grey fibrillar material or by the presence of cells with irregular 'tails'; rosettes of tumour cells are distinctive and are found in up to two thirds of

Fig. 10.3 BM aspirate, carcinoma of kidney, showing 'clear cells' with voluminous pale cytoplasm. MGG $\times 377$. (By courtesy of Dr D Gill, Brisbane.)

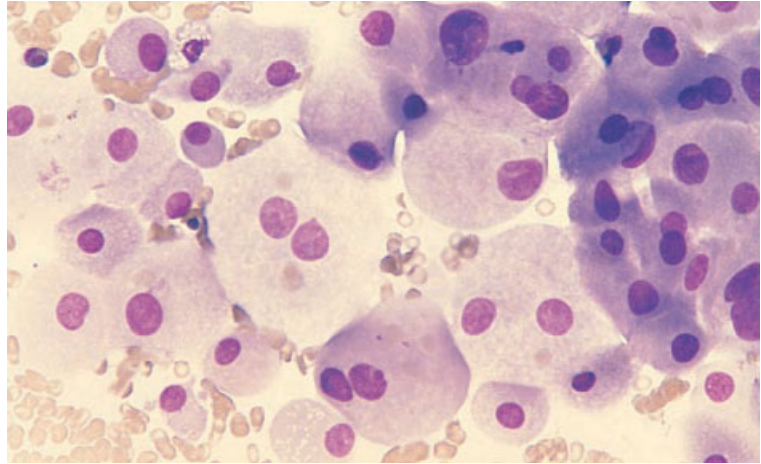


Fig. 10.4 BM aspirate, carcinoid tumour, showing cells with relatively small nuclei and a variable amount of cytoplasm. MGG $\times 377$.

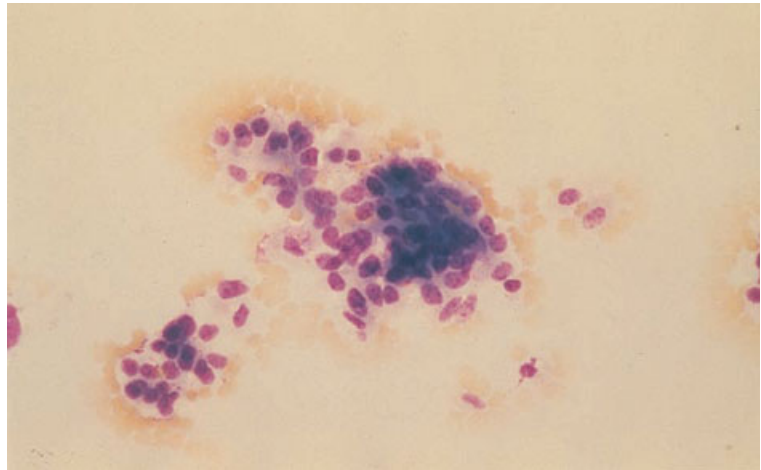
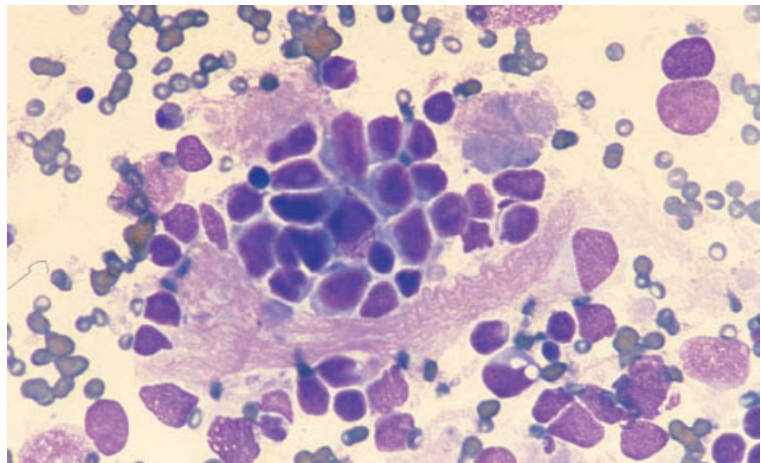


Fig. 10.5 BM aspirate, neuroblastoma, showing neoplastic cells which are relatively small and have a high nucleocytoplasmic ratio and a diffuse chromatin pattern. Neurofibrillary bundles are apparent. MGG $\times 376$.



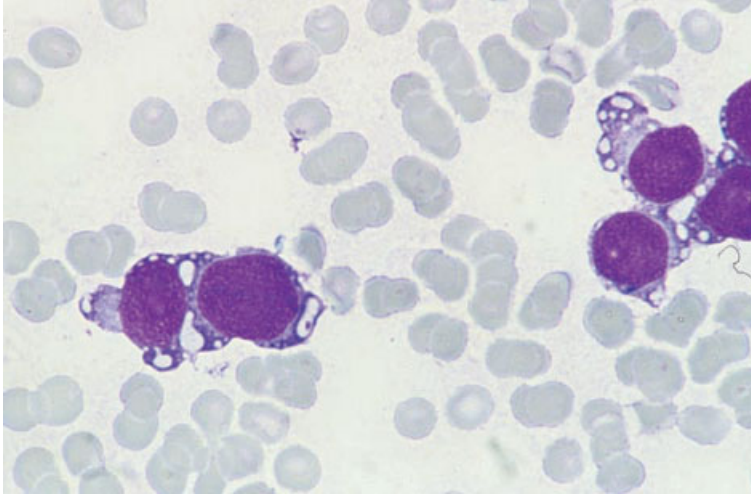


Fig. 10.6 BM aspirate, rhabdomyosarcoma, showing coalescing vacuoles. MGG $\times 940$.

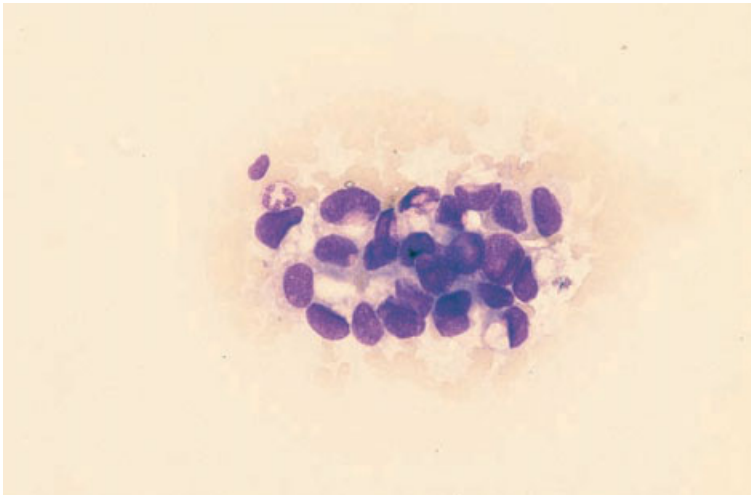


Fig. 10.7 BM aspirate, carcinoma of breast, showing adenocarcinoma cells with secretory globules. MGG $\times 377$.

patients [18]. Rosettes are uncommon in other small cell tumours of childhood but small numbers may be seen in Ewing's sarcoma [18] and other PNET. In metastatic rhabdomyosarcoma there may be multinucleated giant cells or spindle-shaped binucleated rhabdomyoblasts [4]. The cytoplasm is often vacuolated and large vacuoles may coalesce to form lakes [19] (Fig. 10.6). Such cells are periodic acid–Schiff (PAS)-positive. In some cases, some of the tumour cells are phagocytic. Less specific changes, such as foamy or vacuolated cytoplasm or displacement of nuclei by cytoplasmic mucin, may

be noted in metastatic adenocarcinoma originating from various primary sites (Fig. 10.7). In squamous cell carcinoma, metastatic tumour cells have sometimes been noted, with Romanowsky stains, to have a reddish cytoplasmic margin; the cytoplasm adjacent to the nucleus is more basophilic [20]. In small cell carcinoma of the lung, the neoplastic cells are usually smaller than those of most carcinomas but are nevertheless still larger than haemopoietic blasts. They have scanty, weakly basophilic cytoplasm and nuclei with coarse chromatin and inconspicuous nucleoli. The nuclei may appear to be bare

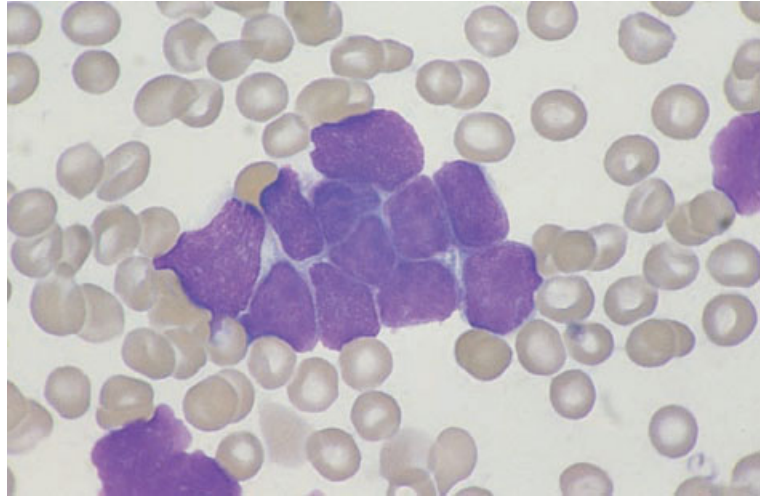


Fig. 10.8 BM aspirate, small cell carcinoma of lung, showing carcinoma cells with scanty cytoplasm and 'moulding' of cells by adjacent cells. MGG $\times 940$.

and 'moulded' by the nuclei of adjacent tumour cells (Fig. 10.8).

Non-haemopoietic neoplastic cells in a bone marrow aspirate must be distinguished from lymphoma cells, blast cells of acute leukaemia and the neoplastic cells of Langerhans cell histiocytosis or systemic mastocytosis. Other cells which are sometimes confused with malignant cells include: (i) osteoblasts; (ii) osteoclasts; (iii) stromal fibroblasts; (iv) endothelial cells; (v) atypical megakaryocytes; and (vi) crushed erythroblasts.

When the bone marrow is infiltrated by malignant cells there may be associated reactive changes including increased plasma cells or mast cells, granulocytic or megakaryocytic hyperplasia, increased macrophages and increased storage iron. Gelatinous degeneration is rare but may be seen in severely cachectic patients.

Immunocytochemistry

Immunocytochemistry can be useful both to confirm the presence of carcinoma cells in a bone marrow aspirate and to detect infrequent cells (Fig. 10.9). A number of studies have been undertaken to assess the value and reliability of immunocytochemistry for epithelial antigens as a means of assessing the extent of bone marrow involvement by metastatic carcinoma (see page 455).

Cytogenetics and molecular genetics

Cytogenetic analysis may be useful in suggesting the non-haemopoietic nature of malignant cells infiltrating bone marrow and in confirming the specific diagnosis in small cell tumours of childhood. For example, $t(2;13)(q35;q14)$ can be demonstrated in many cases of rhabdomyosarcoma [21] and the variant translocation, $t(1;13)(p36;q14)$ [22], in a minority. In neuroblastoma, +7 and 17q+ are typical, the latter often resulting from an unbalanced translocation with chromosome 1 in which 1p is lost [23]. Ewing's sarcoma and other PNET may be associated with $t(11;22)(q24;q12)$; examples of Ewing's sarcoma have also been found with $t(7;22)(p22;q12)$ and $t(21;22)(q22;q12)$. Recurrent cytogenetic abnormalities have also been reported in several types of adult sarcomas but we have not yet seen examples of these involving bone marrow.

Molecular genetic analysis in Ewing's sarcoma shows rearrangement of the *EWS* gene at 22q12. In alveolar rhabdomyosarcoma, the *PAX3* and *PAX7* genes at 2q25 and 1p36, respectively, are rearranged resulting in formation of *PAX3-FKHR* and *PAX7-FKHR* fusion genes [22]. Neuroblastoma may be associated with *N-MYC* oncogene amplification; when present, such amplification is associated with an adverse prognosis.

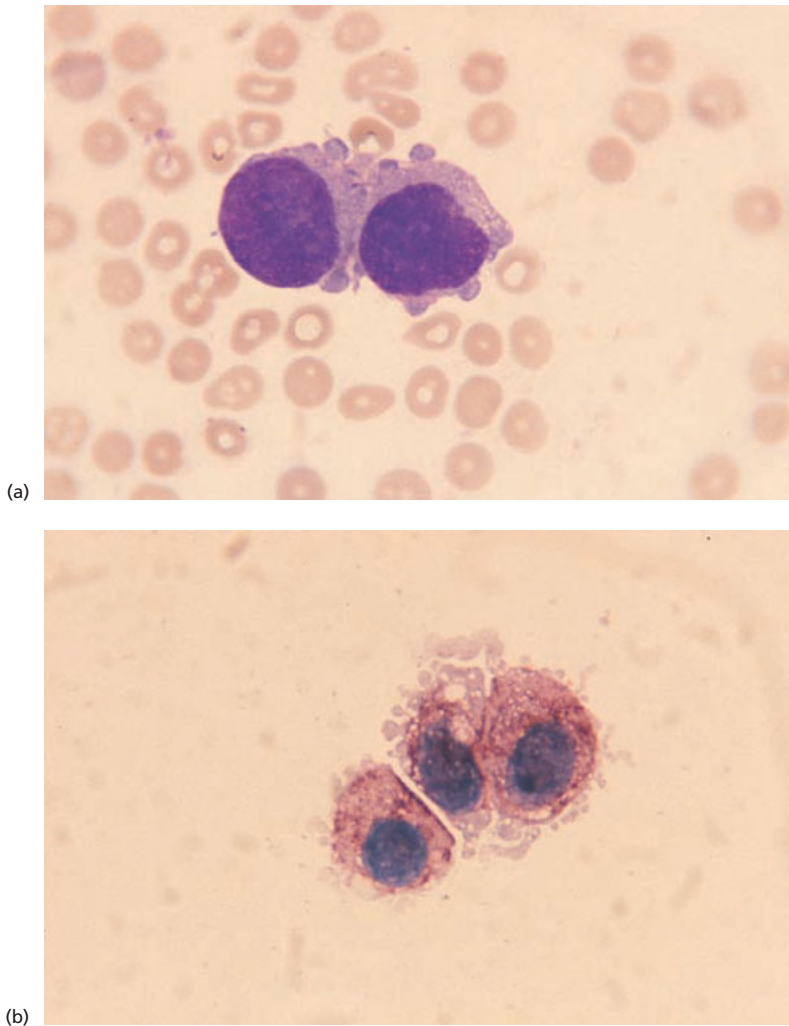


Fig. 10.9 BM aspirate, metastatic carcinoma of breast. (a) MGG $\times 940$. (b) Immunoperoxidase with anti-cytokeratin antibody $\times 940$.

Bone marrow histology

Marrow infiltration by metastatic tumour may be focal or diffuse. Reticulin and collagen fibrosis are commonly present. Marked fibrosis is most frequent in carcinomas of the breast and prostate gland but is also found relatively commonly in metastases from cancers of the stomach and lung [9,24,25]. The proportion of tumour cells to stroma is variable and, in cases with severe myelofibrosis, there may be associated osteosclerosis (Figs 10.10 and 10.11). Failure to recognize tumour cells within the fibrous stroma can result in a mistaken diagnosis of idiopathic myelofibrosis. The degree of

differentiation of metastatic tumour is very variable and it is often impossible to be certain of the site of the primary tumour on purely morphological grounds. Frequently, metastases are undifferentiated and the differential diagnosis includes poorly differentiated carcinoma, high grade NHL and malignant melanoma (Figs 10.12–10.14); immunohistochemistry is invaluable (see below) [26]. In undifferentiated or poorly differentiated carcinomas it is not usually possible to determine the site of origin of the tumour. In tumours showing differentiation it may be possible to determine the type of carcinoma and suggest the likely site of origin—for example, in metastatic squamous carcinoma, lung is the most

Fig. 10.10 BM trephine biopsy section, carcinoma of the breast, showing osteosclerosis and replacement of the marrow by dense fibrous tissue containing tumour cells. Paraffin-embedded, H&E $\times 39$.

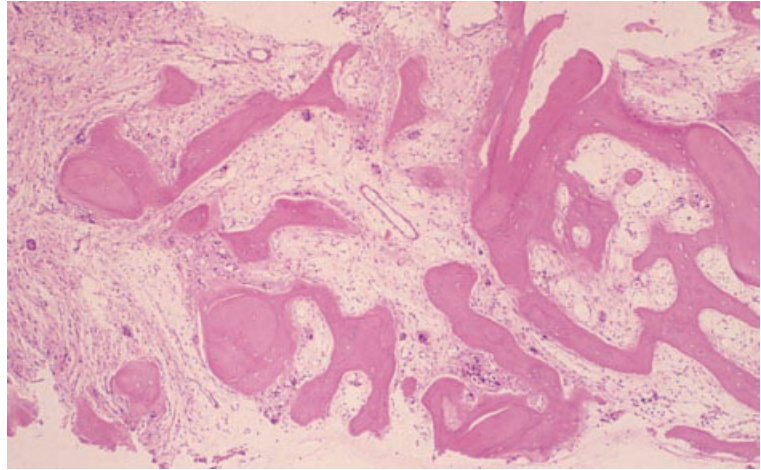


Fig. 10.11 BM trephine biopsy section, carcinoma of the breast (same case as in Fig. 10.10), showing a group of tumour cells with hyperchromatic nuclei and vacuolated cytoplasm. Paraffin-embedded, H&E $\times 390$.

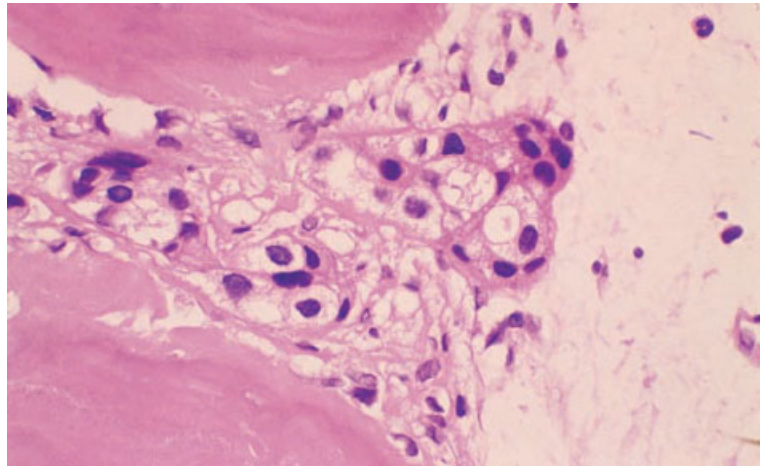
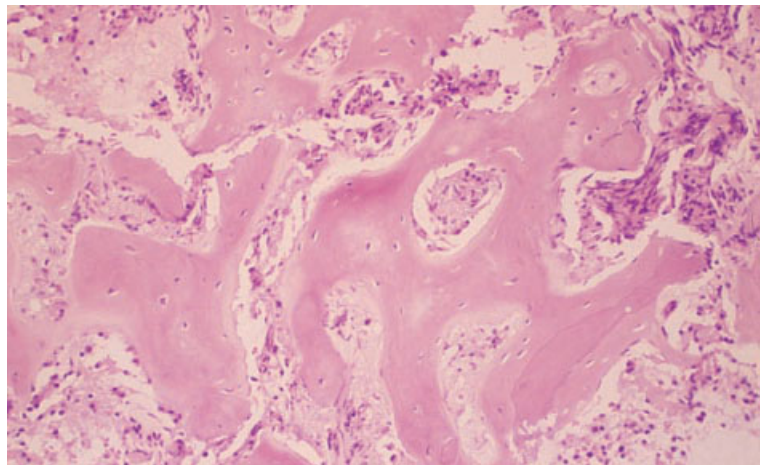


Fig. 10.12 BM trephine biopsy section, poorly differentiated prostatic carcinoma, showing osteosclerosis and replacement of the marrow by dense fibrous tissue containing tumour cells. Paraffin-embedded, H&E $\times 97$.



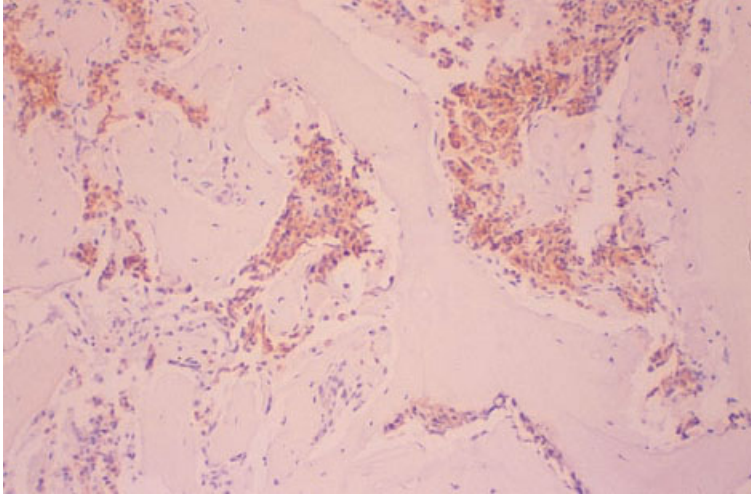


Fig. 10.13 BM trephine biopsy section, poorly differentiated prostatic carcinoma, showing expression of cytokeratin by tumour cells (same case as in Fig. 10.12). Paraffin-embedded, peroxidase–antiperoxidase, anti-cytokeratin monoclonal antibody $\times 97$.

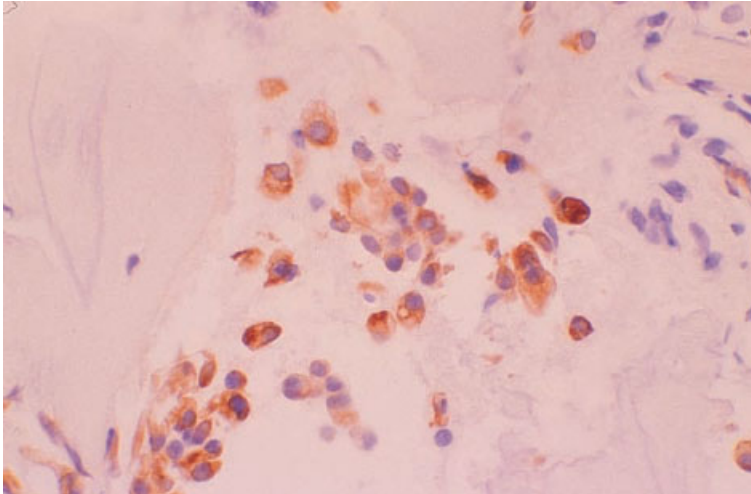


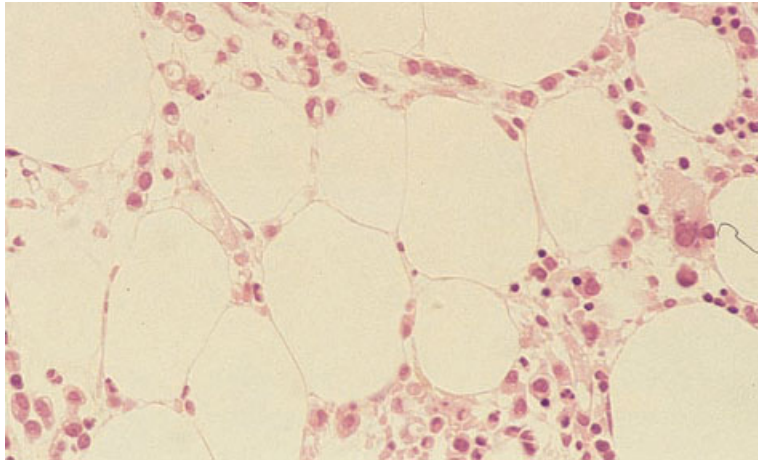
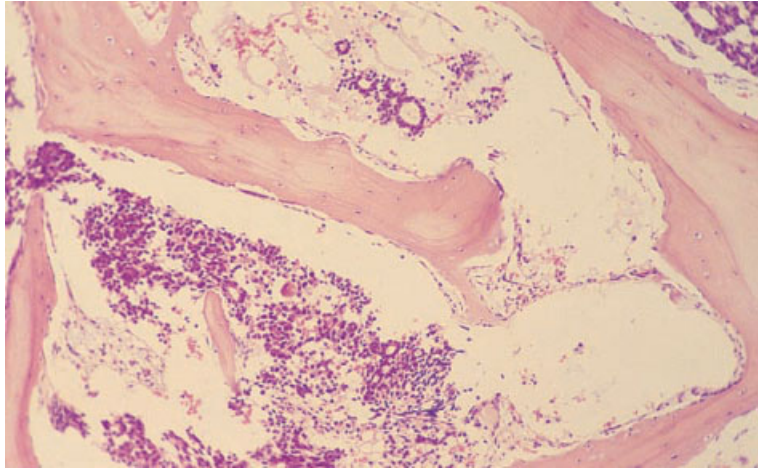
Fig. 10.14 BM trephine biopsy section (as for Fig. 10.13), $\times 390$.

likely primary site. Squamous differentiation is recognized by the formation of keratin and the presence of intercellular bridges. A mixed pattern of differentiation, with squamous cell carcinoma, small cell carcinoma and adenocarcinoma in any combination, is highly suggestive of origin from the lung.

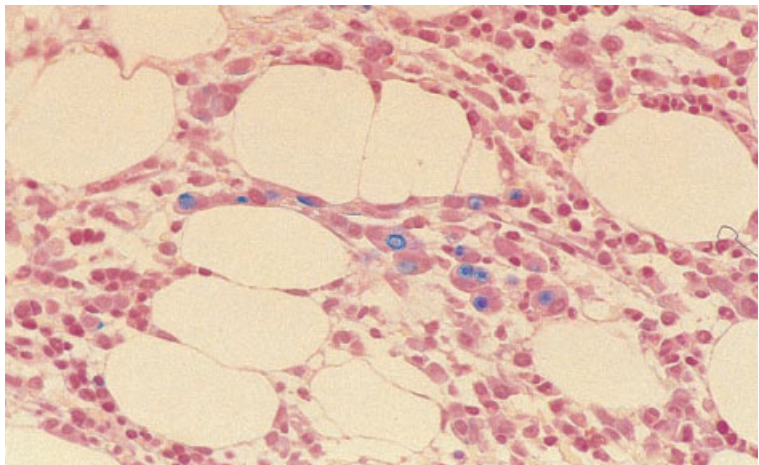
Metastatic adenocarcinoma (Fig. 10.15) can be diagnosed on the basis of the formation of glands, the presence of signet ring cells and/or the presence of mucin (best detected using a combined diastase-treated PAS–alcian blue stain). A mucin stain facilitates the detection of small numbers of carcinoma

cells which may be difficult to detect when they are present as an interstitial infiltrate (Fig. 10.16). Some adenocarcinomas produce large amounts of extracellular mucin, also detectable with a mucin stain (Fig. 10.17). It should be noted that, very rarely, signet ring cells occur in lymphomas [27]. Metastatic adenocarcinoma may arise from primary tumours in the gastro-intestinal tract, breast, prostate gland, ovary, endometrium, pancreas and many other sites. The two primary sites whose identification is most important because of their sensitivity to hormonal therapy are breast and

Fig. 10.15 BM trephine biopsy section, well-differentiated prostatic carcinoma, showing a tumour composed of small, well-defined glandular structures. Plastic-embedded, H&E $\times 97$.



(a)



(b)

Fig. 10.16 BM trephine biopsy sections, adenocarcinoma, showing interstitial infiltrate. (a) H&E $\times 370$. (b) Alcian blue stain $\times 370$. (By courtesy of Dr S Wright, London.)

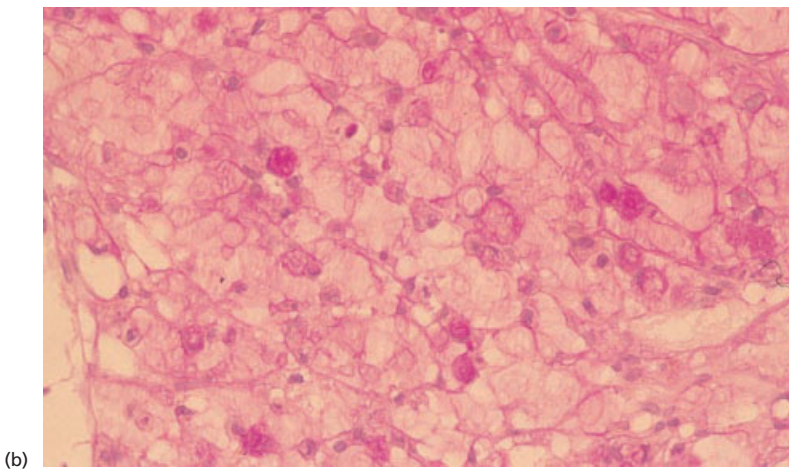
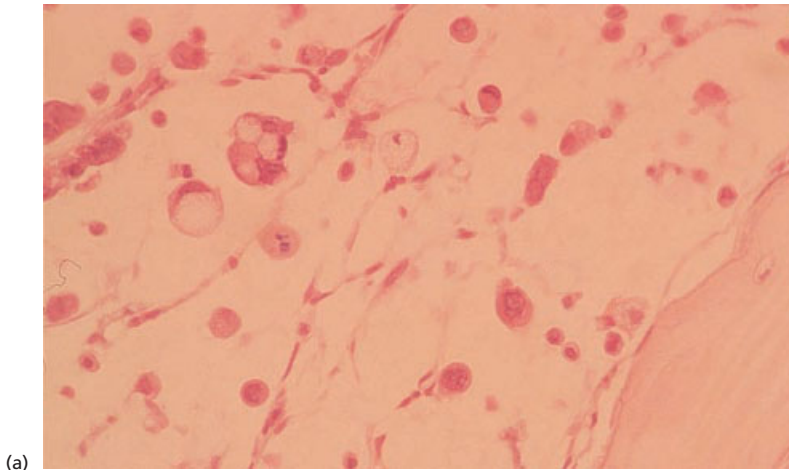


Fig. 10.17 BM trephine biopsy sections, adenocarcinoma, showing intracellular mucin and abundant extracellular mucin. (a) H&E $\times 370$. (b) PAS stain $\times 370$.

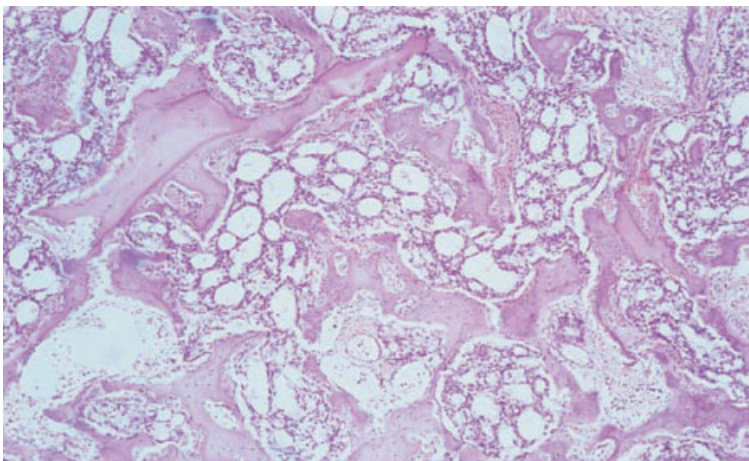


Fig. 10.18 BM trephine biopsy section, prostatic adenocarcinoma, showing microglandular pattern with extensive new bone formation. Paraffin-embedded, H&E $\times 188$.

Fig. 10.19 BM trephine biopsy section, macroglandular pattern of prostatic adenocarcinoma. Paraffin-embedded, H&E $\times 188$.

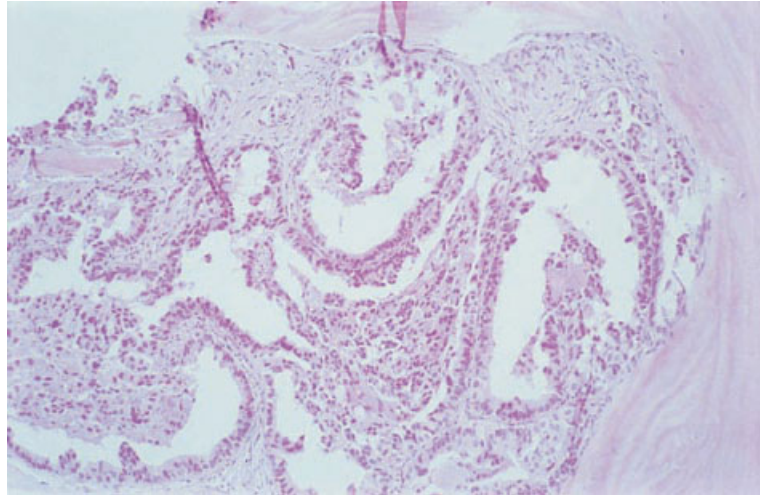
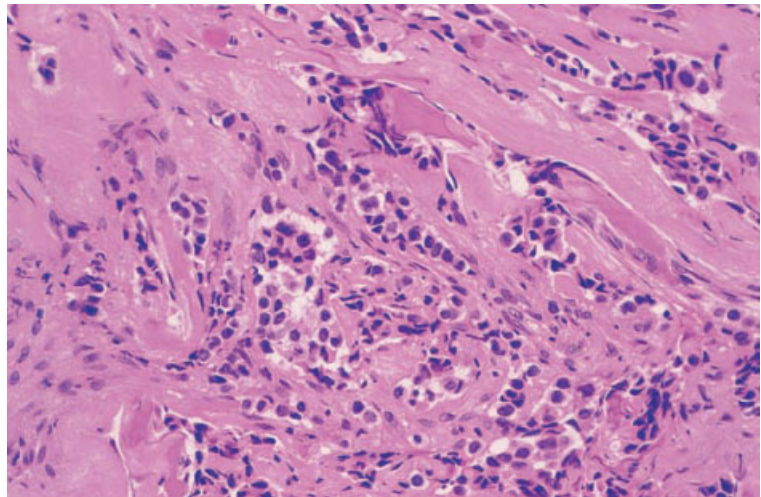


Fig. 10.20 BM trephine biopsy section, carcinoma of the breast, showing tumour cells with hyperchromatic nuclei arranged in cords and strands in a dense fibrous (desmoplastic) stroma. Paraffin-embedded, H&E $\times 390$.



prostate gland. Prostatic origin is suggested by a cribriform, microglandular pattern associated with fibrosis and new bone formation (Fig. 10.18). Occasionally, a macroglandular pattern is present (Fig. 10.19), also usually accompanied by fibrosis and neo-osteogenesis. Identification of breast carcinoma is usually based on its morphological resemblance to primary breast cancer, including duct formation and, particularly in lobular carcinoma, the presence of cell columns forming 'Indian file' patterns (Fig. 10.20). Intracytoplasmic lumina are sometimes visible within individual breast carcinoma cells and these can be highlighted by com-

bined alcian blue–PAS staining (Fig. 10.21). Most, but not all, bone marrow metastases from breast cancer are associated with fibrosis and new bone formation. Immunohistochemical staining is not usually helpful in confirming the primary site of suspected metastatic breast carcinoma. Because metastatic lobular carcinoma of the breast can produce an interstitial infiltrate with little cellular reaction, its detection can be difficult. Routine use of immunohistochemistry when a biopsy is carried out for staging purposes has therefore been advised [28]. Adenocarcinoma composed predominantly of ribbons or villous formations of columnar epithelium

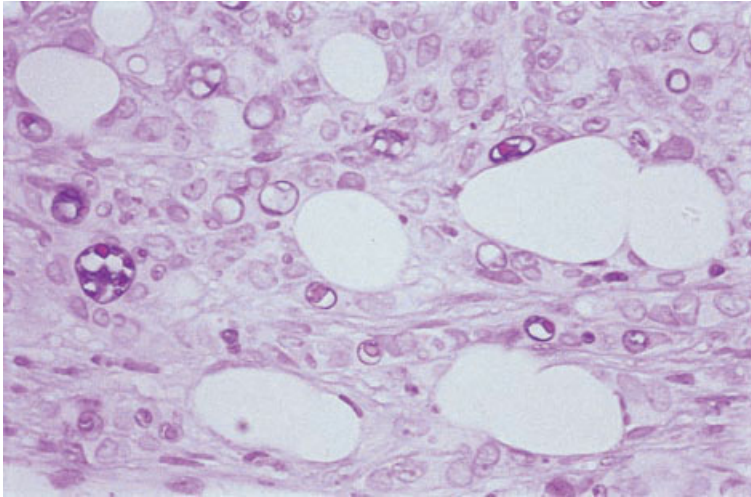


Fig. 10.21 BM trephine biopsy section, lobular carcinoma of breast, showing intracytoplasmic lumen formation. Alcian blue-positive material is present at the periphery of what appears to be a cytoplasmic vacuole and PAS-positive material is present within the centre. Electron microscopy has shown that these structures in lobular breast carcinoma represent true lumina, formed within individual cells, rather than simple secretory vacuoles. Paraffin-embedded, combined alcian blue–PAS stain $\times 960$.

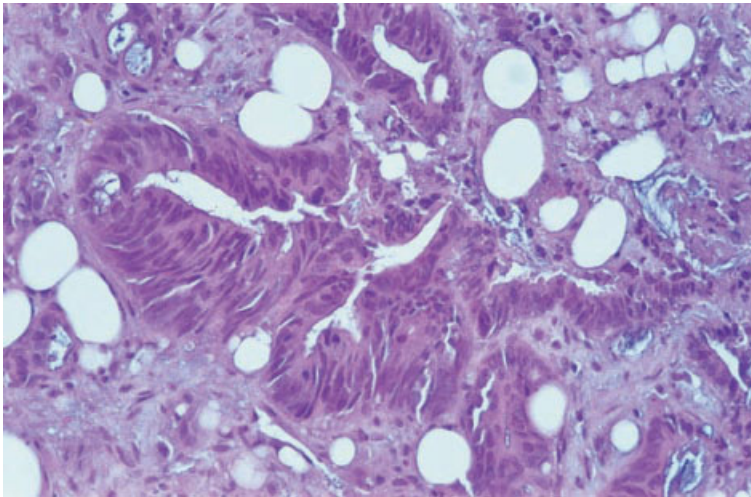


Fig. 10.22 BM trephine biopsy section, metastatic adenocarcinoma from a colonic primary tumour, showing a glandular and villous pattern. Paraffin-embedded, H&E $\times 376$.

with intracellular mucin (goblet cells) is usually of large bowel origin (Fig. 10.22). Clear cell carcinomas have large amounts of pale cytoplasm due to the presence of abundant glycogen or lipid; mucin stains are negative. Likely primary sites of metastatic clear cell carcinoma include kidney, ovary and lung. In rare cases when metastatic follicular carcinoma of the thyroid gland is present, it may be suspected on morphological grounds if follicles containing colloid are seen.

Metastatic small cell carcinoma of the lung commonly involves the bone marrow (see below). The

cells are usually small with intensely hyperchromatic, round or oval nuclei and scant cytoplasm (Fig. 10.23). Necrosis is common and there is often smearing of nuclei which can render interpretation difficult. Morphological variants of small cell carcinoma also occur, in which the cells are slightly larger and have either a fusiform or polygonal shape. The principal differential diagnosis of metastatic small cell carcinoma is that of NHL. Metastases from other tumours with neuroendocrine differentiation, such as malignant carcinoid tumours, may also occasionally spread to bone

Fig. 10.23 BM trephine biopsy section, small cell carcinoma of the bronchus, showing a sheet of small cells with hyperchromatic ovoid nuclei and scanty cytoplasm; in places there is nuclear 'moulding'. Plastic-embedded, H&E $\times 390$.

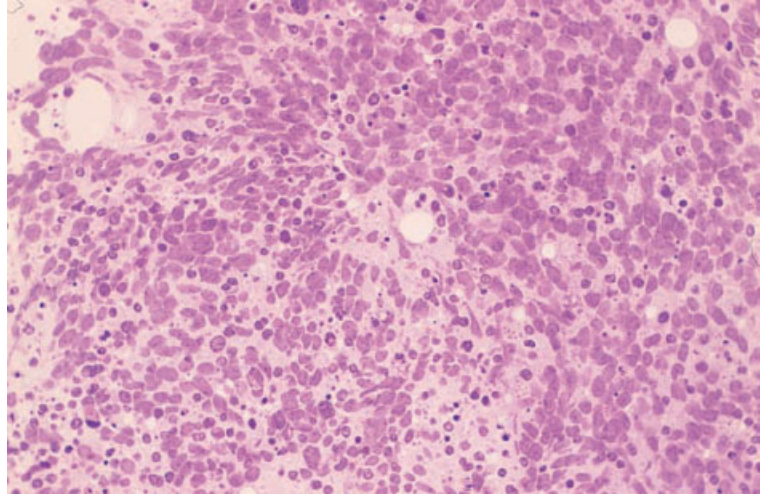
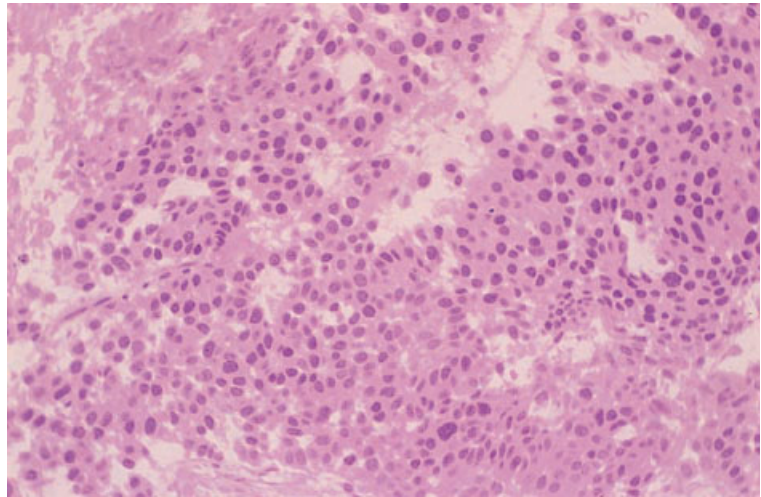


Fig. 10.24 BM trephine biopsy section, carcinoid tumour (unknown primary site), showing relatively uniform cells with ovoid hyperchromatic nuclei and eosinophilic cytoplasm; in some areas the cells are arranged in trabeculae. Plastic-embedded, H&E $\times 390$.



marrow; these may have distinctive morphology, with nests and ribbons of monomorphic cells having nuclei with dense, evenly distributed chromatin (Fig. 10.24).

Malignant melanoma is found in the bone marrow in approximately 5% of patients with disseminated disease [29]. If melanin is present in the tumour cells (Fig. 10.25) or associated macrophages, the diagnosis is relatively easy although, if the patient is not already known to have melanoma, the nature of any pigment present should be confirmed by either a Masson-Fontana or

a Schmorl stain for melanin. However, not infrequently, metastatic malignant melanoma is amelanotic (Fig. 10.26) and immunohistochemistry should then be considered for confirmation. Malignant melanoma should be suspected if metastatic tumour is composed of polygonal or spindle cells with prominent nucleoli.

The differential diagnosis of metastatic spindle cell tumour within the marrow includes carcinoma showing spindle cell differentiation, malignant melanoma and various sarcomas. Sarcomas rarely metastasize to the marrow and, when they do, the

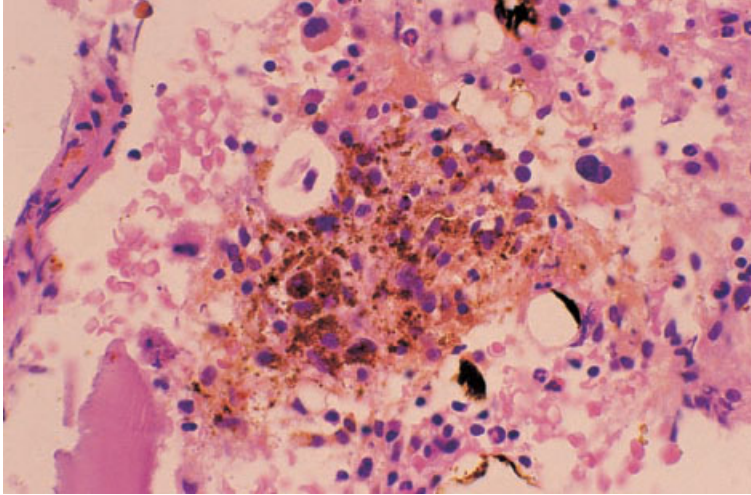


Fig. 10.25 BM trephine biopsy section, malignant melanoma, showing a focal tumour infiltrate composed of cells containing large amounts of melanin; the tumour cells have hyperchromatic nuclei, and some have prominent nucleoli. (It should be noted that it is unusual to see large amounts of melanin in metastatic malignant melanoma.) Paraffin-embedded, H&E $\times 390$.

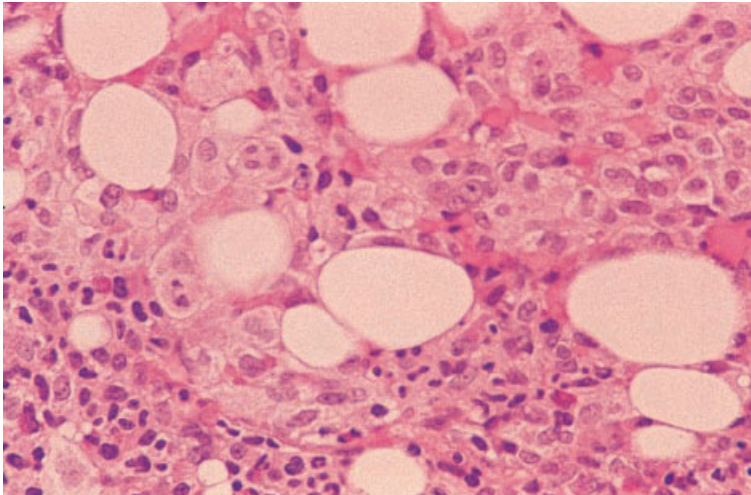
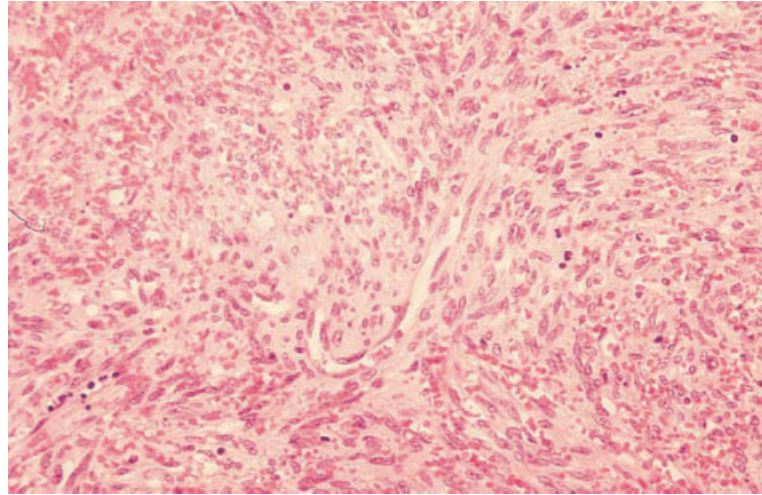


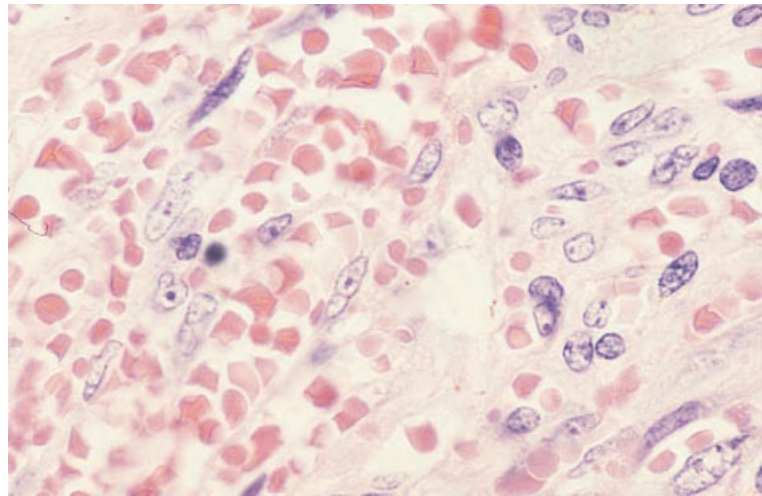
Fig. 10.26 BM trephine biopsy section, amelanotic melanoma, composed of fairly bland epithelioid cells. Immunohistochemistry was required to confirm the true nature of this tumour; cells expressed S100 protein and the antigen recognized by HMB-45. Paraffin-embedded, H&E $\times 376$.

primary tumour is usually readily apparent. Occasionally, Kaposi's sarcoma and other angiosarcomas may present in the bone marrow or may be sampled when bone marrow is investigated for reasons other than staging in patients (e.g. individuals with AIDS) who have known primary tumours elsewhere. Bone marrow involvement by Kaposi's sarcoma is rare but has been observed both in AIDS [30] and in occasional HIV-negative patients [31]. Genomic sequences of the human herpesvirus 8 (HHV8) have been demonstrated in many cases of Kaposi's sarcoma and this virus is believed to be

involved in the pathogenesis of the neoplasm [32]. The bone marrow may be extensively replaced by abnormal tissue composed of slit-like vascular channels lined by spindle-shaped endothelial cells (Fig. 10.27). Large, plump nuclei of neoplastic endothelial cells protrude into the abnormal vascular channels, some of which are engorged with erythrocytes. Haemosiderin-laden macrophages are increased. Angiosarcomas, including Kaposi's sarcoma, show widely varying degrees of vascular differentiation and may form reticular or solid spindle cell areas (Fig. 10.28). Immunohistochemistry to



(a)



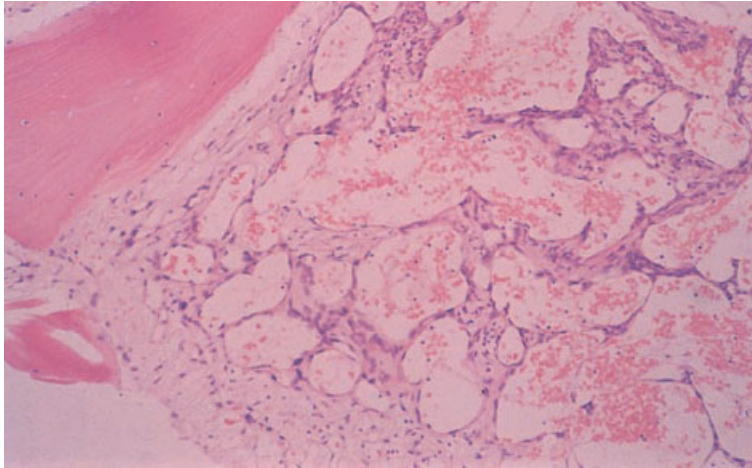
(b)

Fig. 10.27 BM trephine biopsy sections, showing Kaposi's sarcoma in a patient who did not have AIDS. Paraffin-embedded, H&E. (a) $\times 240$. (b) $\times 960$. (By courtesy of Dr RM Conran and Dr VB Reddy, Aurora, Colorado.)

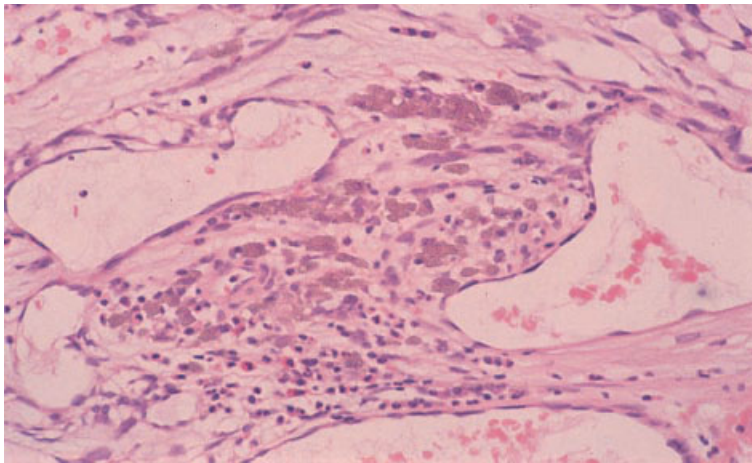
demonstrate expression of endothelial antigens may be helpful in cases lacking obvious vessel formation. However, it should be noted that one case of Kaposi's sarcoma has been reported which lacked expression of von Willebrand factor although there was positive staining with *Ulex europaeus* lectin [31].

Many of the malignant tumours that occur in childhood are composed of small cells with relatively uniform round nuclei. The differential diagnosis of bone marrow infiltration by such cells in a child includes NHL (usually lymphoblastic or Burkitt's lymphoma), metastatic neuroblastoma, rhabdomyosarcoma, Ewing's sarcoma, other PNET

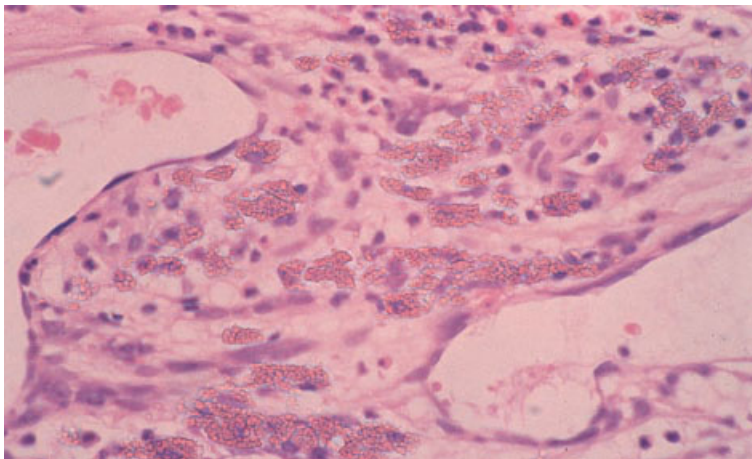
and retinoblastoma. In order to make a specific diagnosis, the clinical features, morphological findings and histochemical and immunohistochemical staining characteristics all need to be considered. The marrow findings in lymphoblastic and Burkitt's lymphoma are described on pages 239 and 282; both express CD45 and B-cell immunophenotypic markers. Neuroblastoma is the most common malignant solid tumour in children and often metastasizes to the bone marrow. The majority of cases occur in children under 4 years of age. The neoplastic cells are slightly larger than small lymphocytes with regular, round hyperchromatic nuclei



(a)



(b)



(c)

Fig. 10.28 BM trephine biopsy sections, metastatic Thorotrast-induced angiosarcoma, showing refractile Thorotrast. Paraffin-embedded, H&E: (a) $\times 97$; (b) $\times 390$; (c) $\times 960$.

Fig. 10.29 BM trephine biopsy section, neuroblastoma, showing extensive, diffuse infiltration by small cells with scanty cytoplasm. Paraffin-embedded, H&E $\times 376$.

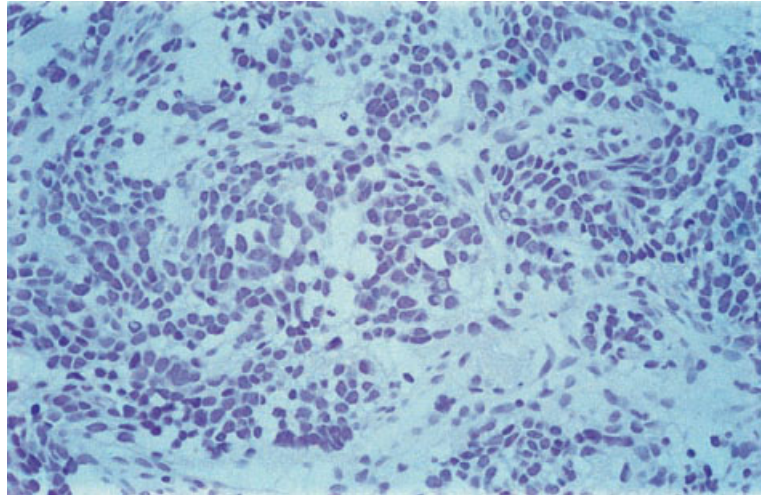
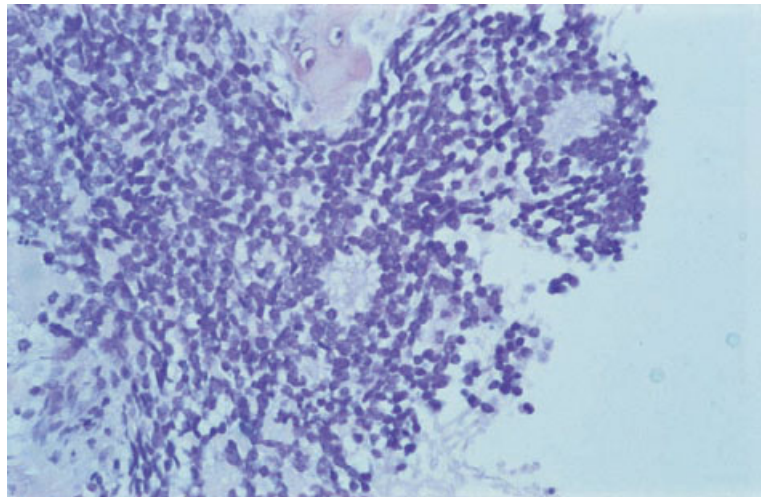


Fig. 10.30 BM trephine biopsy section, neuroblastoma, with rosette formation. Note the collections of pink material around which neuroblastoma cells are clustered. Paraffin-embedded, H&E $\times 376$.



and little cytoplasm [33] (Fig. 10.29). Rosettes are present in a minority of cases, consisting of tumour cells arranged around central fibrillary material which is pink in H&E-stained sections (Fig. 10.30). The cells of neuroblastoma may show focal PAS positivity but this is usually less marked than that seen in rhabdomyosarcoma and Ewing's sarcoma. In all of these neoplasms, PAS positivity is difficult to detect in fixed tissue sections; it should be sought by staining of aspirate films, as described above.

In one series, rhabdomyosarcoma was found to have metastasized to the bone marrow in 16%

of cases [1]. Several histological variants are recognized:

- 1** embryonal, which may be further subdivided into myxoid, spindle cell or round cell patterns [34], with the round cell subtype being represented most commonly in bone marrow metastases;
- 2** alveolar, characterized by a pattern of irregular spaces lined by tumour cells [35]; and
- 3** pleomorphic, which is very rare and not usually seen in children.

In any of these subtypes there may be a few multinucleated rhabdoid cells with peripheral nuclei. A

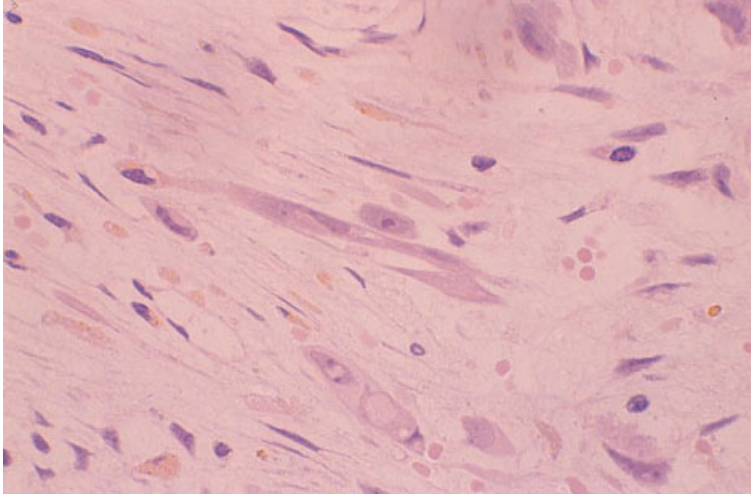


Fig. 10.31 BM trephine biopsy section, rhabdomyosarcoma, showing elongated cells with plentiful eosinophilic cytoplasm (rhabdomyoblasts). Plastic-embedded, H&E $\times 390$.

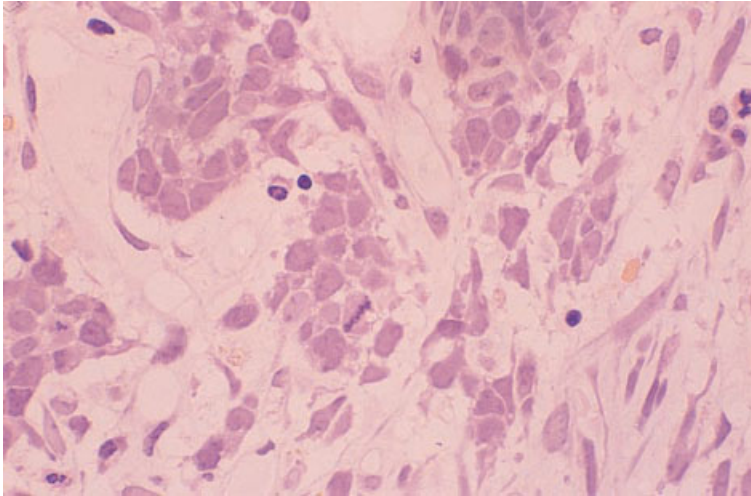


Fig. 10.32 BM trephine biopsy section, Ewing's sarcoma, showing irregular groups of cells in a fibrous stroma; the cells have ovoid nuclei with indistinct nucleoli and scanty cytoplasm. Plastic-embedded, H&E $\times 390$.

pseudo-alveolar pattern may be produced by cells adhering to the margins of vascular channels [19]. Erythrophagocytosis may be seen [36]. Diagnosis depends on the recognition of skeletal muscle differentiation. Rhabdomyoblasts may be oval, spindle, tadpole or strap-shaped. They have abundant pink granular cytoplasm which may show cross-striations (Fig. 10.31). The number of rhabdomyoblasts present is highly variable; in many patients the majority of cells are undifferentiated round or spindle cells. Ewing's sarcoma and related PNET are malignant tumours that may arise in bone or soft tissue. Most patients are in the second decade of life

and approximately 35% of cases develop bone marrow metastases [1]. The tumour cells are approximately twice the size of small lymphocytes and have round to oval vesicular nuclei (Fig. 10.32). They may show PAS-positive cytoplasmic staining for glycogen, either finely dispersed or forming large blocks of positively stained material (Fig. 10.33). Haemophagocytosis by malignant cells has been reported in rhabdomyosarcoma but is not a specific feature; it also occurs rarely in other neoplasms, including small cell carcinoma, medulloblastoma, breast carcinoma and haemangio-endothelioma [37,38].

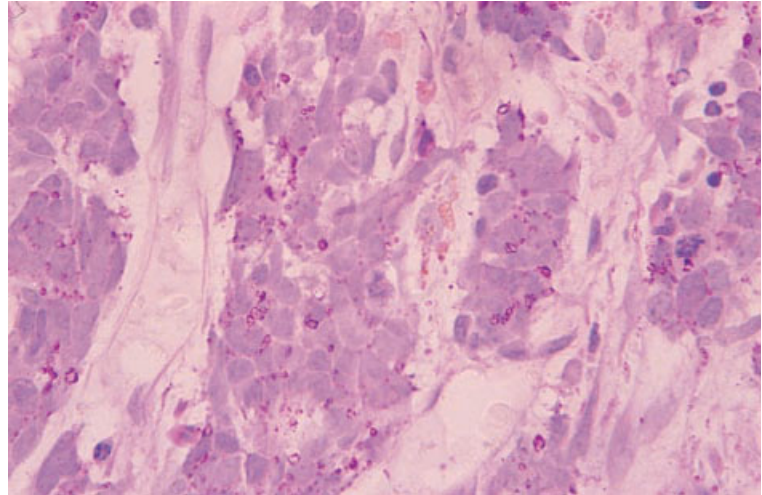


Fig. 10.33 BM trephine biopsy section, Ewing's sarcoma, showing large granules of glycogen in the cytoplasm. Plastic-embedded, PAS $\times 390$.

Immunohistochemistry

In bone marrow trephine biopsies containing metastatic poorly differentiated tumours, immunohistochemistry with a small panel of antibodies is useful to demonstrate lymphoid antigens (CD45, CD20 and CD3), epithelial markers (cytokeratins and EMA) and melanoma-associated antigens (S100 protein and the antigens recognized by antibodies HMB-45 and Melan A) [15,26,39,40].

The prostatic origin of a metastatic adenocarcinoma may be confirmed by immunohistochemical staining with antibodies that react with prostate-specific antigen [41]. Since these antibodies may also react with some colonic tumours [42], the use of parallel immunostaining for prostate-specific acid phosphatase is recommended. Use of both antibodies considerably improves sensitivity and specificity in confirming the prostatic origin of metastatic cancer. Unfortunately, there are no antigens with equivalent tissue specificity for breast carcinoma. Of the markers available, α -lactalbumin (which is expressed in most primary breast cancers) has been claimed to be relatively specific [43] but is not widely used. Nuclear expression of oestrogen and progesterone receptors may be demonstrated immunohistochemically (Fig. 10.34) but these antigens are also expressed in a variety of other adenocarcinomas, particularly those arising in the uterus or ovary. It should be noted that human milk-fat globulin,

despite its name, is another antigen that is expressed by many adenocarcinomas and has no specificity for those of breast origin. Immunohistochemical staining for thyroglobulin is useful in confirming the thyroid origin of metastatic tumour cells.

Small cell carcinoma reacts positively with antibodies directed against protein gene product 9.5 (PGP9.5), an antigen expressed by neuroectodermal cells, but it should be noted that polyclonal anti-PGP9.5 antisera cross-react with some lymphomas [44]. Small cell carcinomas also often express various sizes of cytokeratin filaments that can be detected by their distinctive intracytoplasmic dot-like or perinuclear ring patterns of immunohistochemical staining. Other tumours showing neuroendocrine differentiation, such as carcinoid tumours and medullary carcinoma of the thyroid gland, may metastasize to the bone marrow; immunohistochemical staining for chromogranin or for PGP9.5 identifies neuro-endocrine differentiation in these tumours [45,46]. In addition, medullary carcinomas of the thyroid may express calcitonin.

In cases of metastatic melanoma, immunohistochemical staining for S100 protein is usually positive [26]. Newer antibodies such as HMB-45 and Melan A also react well with metastatic malignant melanoma in bone marrow trephine biopsy sections. Spindle cell carcinomas and melanomas express cytokeratins and S100 protein (or other melanoma-associated antigens), respectively. Use

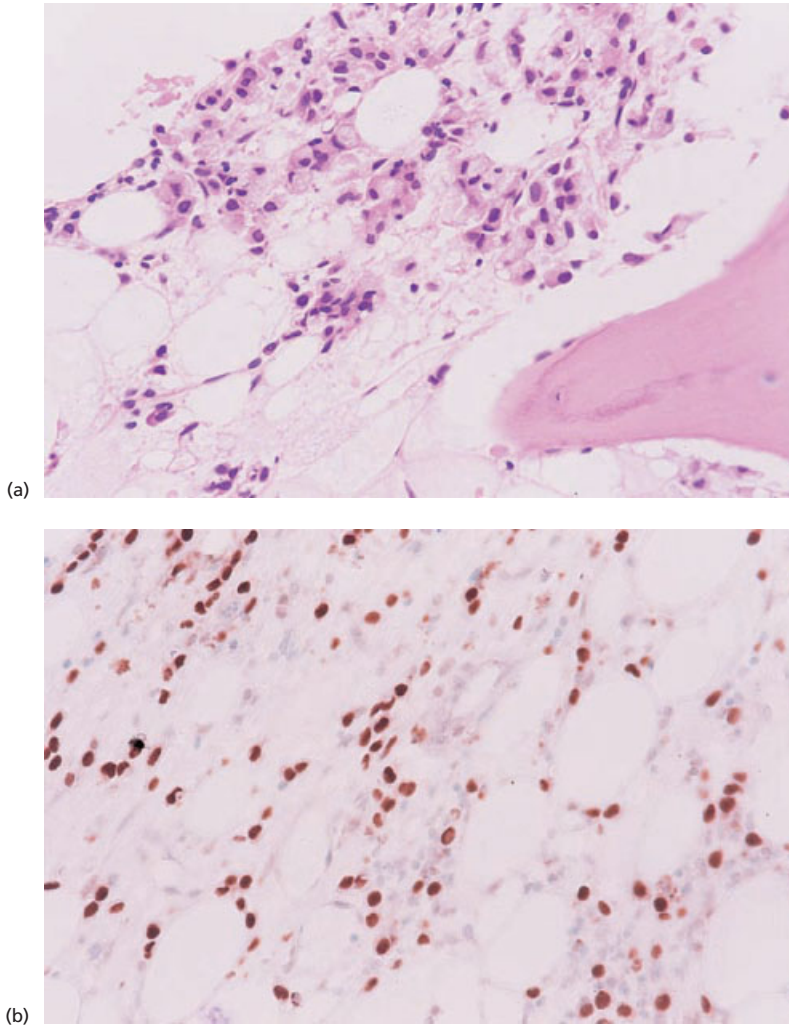


Fig. 10.34 BM trephine biopsy sections, interstitial infiltration by oestrogen receptor-positive breast carcinoma. (a) H&E; (b) immunostained to show nuclear expression of oestrogen receptors. Paraffin embedded, $\times 390$.

of vimentin to distinguish such spindle cell tumours from true sarcomas is unreliable, since many non-sarcomatous tumours with spindle cell morphology express vimentin; apart from variants of angiosarcoma, however, metastatic sarcomas are exceptionally rarely seen in bone marrow biopsies. In difficult cases of angiosarcoma or Kaposi's sarcoma, the endothelial origin of malignant cells can be demonstrated by immunohistochemical staining for von Willebrand factor, CD31 and CD34. The *Ulex europaeus* lectin can also be used to stain endothelium.

Neuroblastoma cells usually express neurone-specific enolase and PGP9.5; less consistently, chromogranin (Fig. 10.35) and the antigens detected by

antibodies NB84 and NeuN are expressed. In rhabdomyosarcomas, immunohistochemical staining for desmin, myogenin and MyoD is usually positive [47] although staining for myoglobin, which is said to be more specific, is variable [34]. Ewing's sarcomas with $t(11;22)(q24;q12)$ express the MIC2 gene product, CD99 [48,49], but so do some ALL.

The role of bone marrow examination in the staging of solid tumours

Examination of the bone marrow by aspiration and trephine biopsy is an established part of the staging of neuroblastoma in children in most large centres.

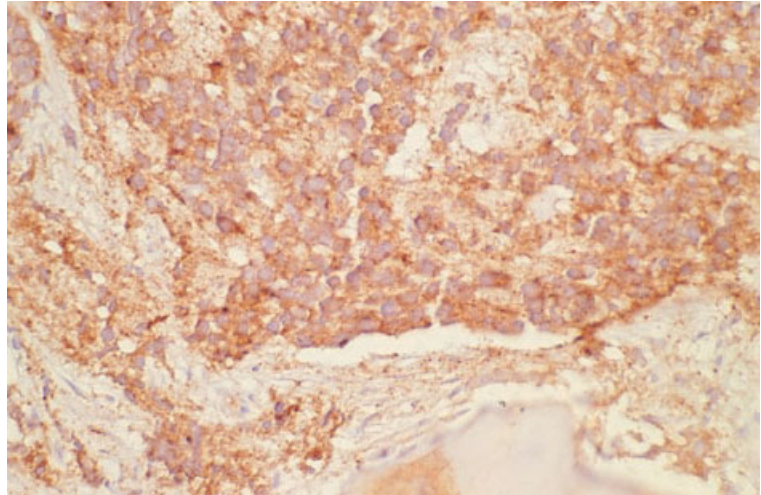


Fig. 10.35 Bone marrow trephine biopsy section, neuroblastoma. Immunoperoxidase for chromogranin $\times 390$. (By courtesy of Professor D Evans, London.)

The bone marrow biopsy is positive at the time of initial diagnosis in approximately half of all patients, most of whom have evidence of metastatic spread at other sites [50]. Discordance between marrow aspirate and trephine biopsy findings is common. In one reported series, the trephine biopsy alone was positive in 20% of cases whereas neoplastic cells were seen in the aspirate films when trephine biopsy sections appeared normal in 7%. Taking bilateral bone marrow aspirates and trephine biopsies from the iliac crests increases the sensitivity of the staging procedure by approximately 10%. Particularly careful examination of aspirate films and trephine biopsy sections is necessary because infiltration is often extremely focal [51,52]. In cases in which the marrow appearances are suspicious but not diagnostic of infiltration, immunocytochemical staining of aspirate films using antibodies reactive with neuro-ectodermal antigens (UJ13A and UJ127.11) may be of value in confirming marrow involvement [53,54]. Immunohistochemical staining of paraffin-embedded sections of trephine biopsies for neurone-specific enolase has not been found to increase the sensitivity of marrow biopsy as a means of detecting tumour cells [46]. Detection of PGP9.5 expression is considerably more reliable and should be performed in all cases; its use permits demonstration of tiny clusters and even single cells in patients with minimal bone marrow involvement (Fig. 10.36).

The additional utility of immunohistochemical staining with newer antibodies, such as NB84 [55,56] and NeuN [57], has yet to be established. Assessment of marrow infiltration by neuroblastoma is more difficult in patients who have been treated with chemotherapy; it is essential that trephine biopsies are of adequate size and quality [58–60]. It has been suggested that the appearances in post-treatment marrow trephine biopsy sections should be divided into four grades:

- 1 grade 1, normal (or hypocellular) marrow;
- 2 grade 2, marrow with reticulin fibrosis as the only abnormality;
- 3 grade 3, distorted architecture with collagen fibrosis; and
- 4 grade 4, marrow with obvious tumour cells, with or without other abnormalities [33].

Grades 2–4 were all considered by Reid and Hamilton [33] to be compatible with continued bone marrow involvement by tumour, even when individual neoplastic cells could not be identified with certainty. It remains unclear whether this is really true for grades 2 and 3 [61] and whether the different grades correlate with differences in clinical outcome. An important additional feature to recognize in follow-up bone marrow samples obtained during treatment of neuroblastoma is differentiation of the primitive small cells to produce large, ganglion-like cells and areas of pink, fibrillary tissue resembling neuropil (Fig. 10.37). Ganglion-like

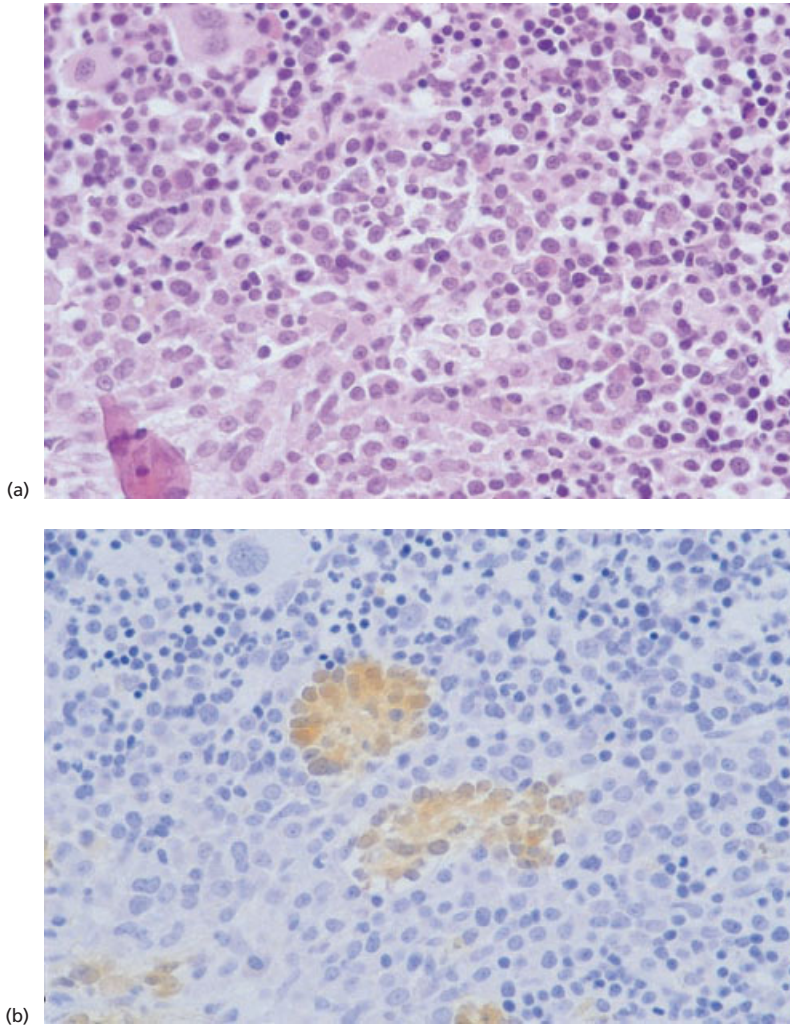


Fig. 10.36 BM trephine biopsy sections, minimal infiltration by neuroblastoma shown using (a) H&E and (b) immunohistochemistry for PGP9.5. Paraffin-embedded, $\times 376$.

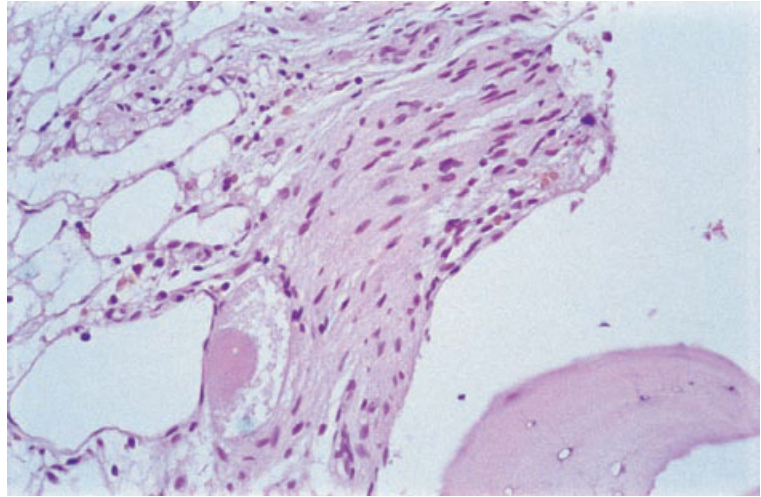
cells may show superficial resemblance to megakaryocytes and the neuropil-like tissue requires differentiation from fibrous tissue. Immunostaining for PGP9.5 is positive in both components of differentiated neuroblastoma tissue and is very helpful in confirming their true nature.

In adults, examination of the bone marrow is not a routine staging procedure for most solid tumours and, although it has been advocated for small cell lung carcinoma and breast cancer, it is by no means practised universally, even for these tumours. In small cell carcinoma of the lung, bone marrow trephine biopsy is positive in 25–30% of cases [10,62,63]; the aspirate is only slightly less sensitive for detecting marrow involvement. It has been

suggested that bone marrow examination is indicated in patients with small cell lung carcinoma in order to identify patients who may be suitable for attempted curative therapy [64]. However, some studies have shown no difference in survival between patients with and without marrow involvement [10,64], and the value of routine bone marrow examination has therefore been questioned [10]. Imaging techniques such as magnetic resonance imaging have been proposed as more sensitive alternative staging procedures [65].

Several studies have evaluated the use of marrow aspiration and trephine biopsy in the staging of breast cancer. Detection of subclinical metastatic disease may be useful in identifying patients with

Fig. 10.37 BM trephine biopsy section, post-treatment follow-up for neuroblastoma. Cellular 'fibrous' tissue remains and the cytoplasm of at least one large ganglion-like cell can be seen. Paraffin-embedded, H&E $\times 376$.



apparently localized disease who might benefit from adjuvant chemotherapy. Bone marrow biopsy is positive in 25–55% of patients with positive radio-isotope bone imaging, but only 4–10% of patients with negative radio-isotopic imaging have tumours detected by bone marrow biopsy [8,66]. In one reported series, 23% of all breast cancer patients had positive bone marrow biopsies at the time of first recurrence [66]. In an attempt to increase the sensitivity of bone marrow examination as a staging procedure, some studies have used immunocytochemical staining to identify micrometastases that would not be detected by conventional techniques. The method used has involved aspirating bone marrow from multiple (up to eight) sites under general anaesthesia at the time of initial surgery, pooling the material and preparing several films. Tumour cells are then detected by immunostaining with antibodies reactive with EMA [67,68], cytokeratins [69] or a cocktail of antibodies recognizing these antigens [70]. Using this approach, micrometastases have been found in 27–35% of cases at the time of diagnosis and correlation has been shown between their presence and the size of the primary tumour [67,68]. The presence of bone marrow micrometastases is a predictor of early relapse in bone. Despite these findings, application of immunocytochemistry to detect micrometastases in bone marrow aspirates performed for staging of breast cancer has not yet become standard practice. A similar approach has been suggested for:

(i) detection of oral, oesophageal and gastric cancers [71–74]; (ii) pancreatic cancer [75,76]; (iii) non-small cell lung cancer [77]; (iv) urological cancers [78]; and (v) malignant melanoma [79]. Use of reverse transcriptase polymerase chain reaction (RT-PCR) directed at carcino-embryonic antigen mRNA to detect occult involvement of aspirated bone marrow by carcinomas arising from breast or colon [80,81], and directed at cytokeratin mRNA in cases of breast cancer [82], has also proved successful in initial studies. The clinical value of detecting occult bone marrow micrometastases in such tumours by these techniques remains unproven [83]. In all cases, including breast carcinoma detection, technical problems with the immunocytochemical approach, including false-positive results due to skin contamination or non-specific haemopoietic cell reactivity, limit its applicability in routine practice [84,85].

Problems and pitfalls

Normal components of bone marrow may be mistaken for malignant non-haemopoietic cells in aspirate films and biopsy sections. These include megakaryocytes, crushed erythroid cells, osteoblasts (Fig. 10.38), osteoclasts, stromal macrophages, endothelium and fibroblasts. Awareness of the appearances of stromal components in aspirate films is particularly important in avoiding confusion with malignant cells.

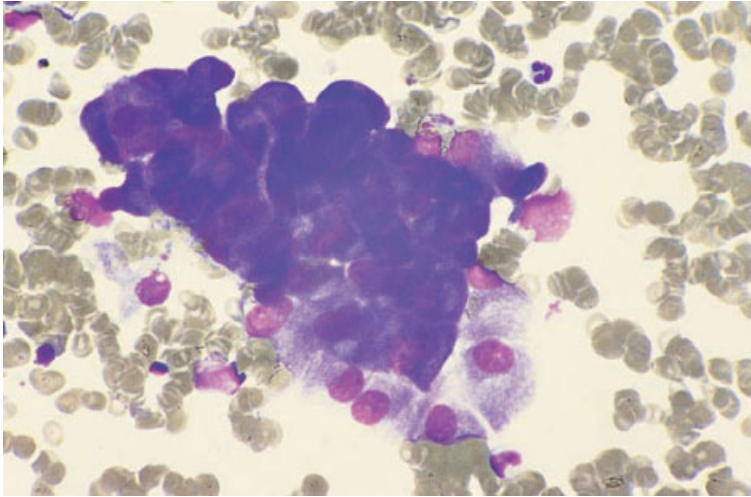


Fig. 10.38 BM aspirate, showing a cluster of osteoblasts mimicking carcinoma cells. MGG $\times 970$.

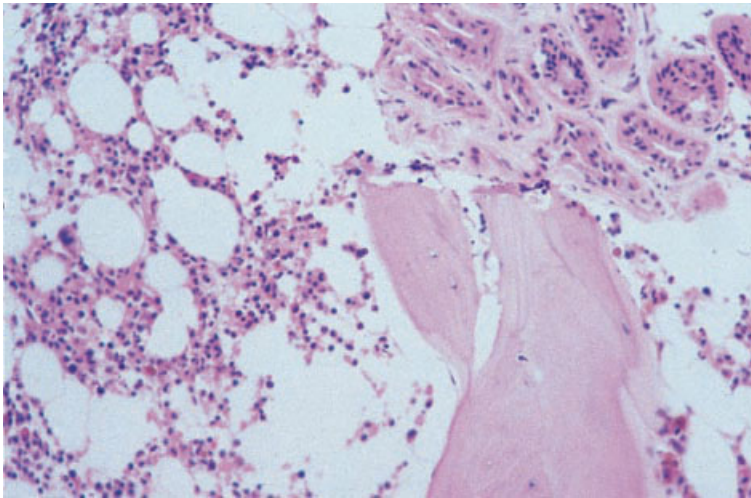


Fig. 10.39 BM trephine biopsy section, sweat gland interposition mimicking adenocarcinoma. Paraffin-embedded, H&E $\times 376$.

Artefactual inclusions of extraneous tissue in trephine biopsy specimens (e.g. skin, sweat glands, hair follicles or skeletal muscle) may mimic malignant non-haemopoietic cells (Fig. 10.39 and see also Figs 1.64, 1.66 and 1.67). Care should be taken to avoid such inclusions by making a small skin incision prior to insertion of the biopsy needle and using disposable needles to ensure a sharp cutting edge. Carry-over from other specimens into the paraffin block during tissue processing should be avoided by good laboratory practice with regard to preparation of small or friable biopsy specimens; such specimens should be wrapped in tissue paper or sponge, or placed in a wire mesh insert, before

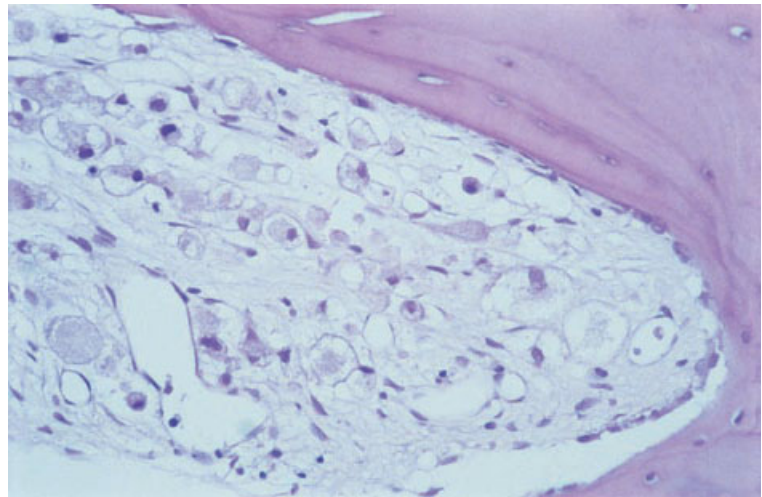
processing. If carry-over is suspected, it can be confirmed by molecular analysis of major histocompatibility antigen genes to demonstrate the different patient origins of separate tissue fragments in a single wax-embedded block [86]. However, formic acid decalcification limits the quality of DNA obtainable from trephine biopsy samples and this approach may therefore be unsuccessful in specimens decalcified in this way. Extraneous tissue may also appear to be present in histological sections due to contamination by a 'floater' from another tissue block as sections are cut, floated on a water-bath and picked up on individual glass slides (see Fig. 1.70). Good laboratory practice will ensure that

fragments of previous sections are not allowed to contaminate the water-bath between cases. If such contamination is suspected, examination of the complete set of stained trephine biopsy sections should show that other sections are free of extraneous material. If doubt persists, new sections cut from the trephine biopsy specimen will be free of contamination.

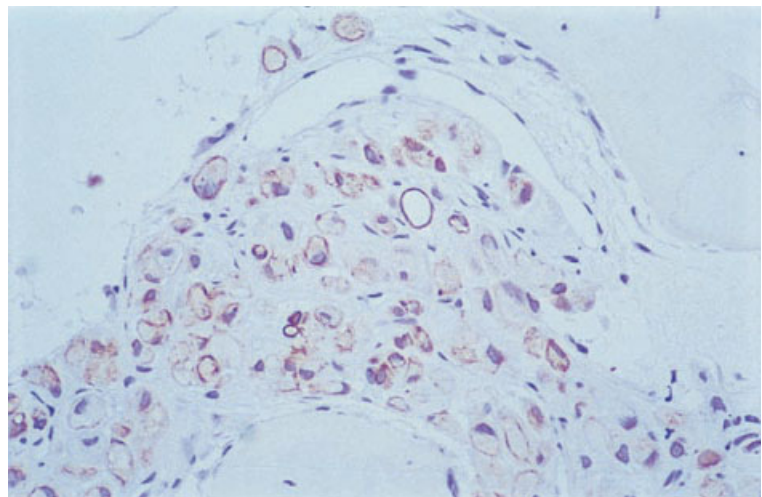
Other pathological components in trephine biopsy samples may occasionally be mistaken for malignant non-haemopoietic cells. These include macrophages (present singly or within granulomas), lymphoid cells in some types of NHL, Reed–Sternberg cells in Hodgkin’s disease, neoplastic mast cells in systemic mastocytosis and the cells of

Langerhans cell histiocytosis. Immunohistochemistry will establish the nature of each of these types of cell. Macrophages are best demonstrated by the CD68 antibody PGM1 and lymphoid cells by their expression of CD3 (T cells) or CD20 (B cells). Reed–Sternberg cells express CD30, mast cell tryptase can be demonstrated with the monoclonal antibody AA1 and cells in Langerhans cell histiocytosis express CD1a.

Malignant cells may be confused with normal bone marrow constituents or with haemopoietic malignancies. Examples include undifferentiated carcinomas that may infiltrate bone marrow without any stromal reaction, clear cell carcinoma, signet ring carcinoma (Fig. 10.40), malignant



(a)



(b)

Fig. 10.40 BM trephine biopsy section, signet ring carcinoma of unknown primary origin. (a) In H&E-stained sections, malignant cells are indistinct and resemble macrophages. (b) Immunostaining for low molecular weight cytokeratins confirms their epithelial nature. Paraffin-embedded, both $\times 376$.

melanoma and the small cell solid tumours of childhood. Deposits of metastatic carcinoma eliciting a fibrotic response may also be confused with myelofibrosis, Hodgkin's disease or NHL. Among the NHL, those of T-cell lineage are most likely to produce significant stromal fibrosis. Immunohistochemistry will assist in making a correct diagnosis. Expression of low and high molecular weight cytokeratins is present in almost all carcinomas, S100 protein in melanomas and CD45 (plus CD3 or CD20) in T- or B-cell lymphomas, respectively. Neoplastic plasma cells frequently lack CD45 and CD20 expression but their nature can be confirmed by p63 expression (detected using monoclonal antibody VS38c) in the absence of expression of cytokeratins; CD79a is expressed in many cases, but not all, and a negative result can therefore be misleading. The diagnosis of most solid small cell tumours of childhood can be confirmed on the basis of expression of PGP9.5 (neuroblastoma), CD99 (Ewing's sarcoma) or desmin (rhabdomyosarcoma).

Detection of malignant non-haemopoietic cells in necrotic deposits can be very difficult. Reticulin staining may demonstrate a preserved pattern of nested cells or gland formation despite loss of cellular detail. Immunohistochemistry is often unhelpful in necrotic tissue and can be misleading due to non-specific false-positive results, as well as loss of antigen expression by dead or dying cells [87].

References

- Anner RM and Drewinko B (1977) Frequency and significance of bone marrow involvement by metastatic solid tumours. *Cancer*, 39, 1337–1344.
- Singh G, Krause JR and Breitfeld V (1977) Bone marrow examination for metastatic tumour. *Cancer*, 40, 2317–2321.
- Finkelstein JZ, Ekert H, Isaacs H and Higgins G (1970) Bone marrow metastases in children with solid tumours. *Am J Dis Child*, 119, 49–52.
- Delta BG and Pinkel D (1964) Bone marrow aspiration in children with malignant tumours. *J Paediatr*, 64, 542–546.
- Kleinschmidt-Demasters BK (1997) Bone marrow metastases from glioblastoma multiforme: the role of dural invasion. *Hum Pathol*, 27, 197–201.
- Hoffmann M, Henrich D, Dingeldein G and Uppenkamp M (1999) Medulloblastoma with osteoblastic metastasis and bone marrow fibrosis. *Bone Marrow Transplant*, 23, 631.
- Dawson TP (1997) Pancytopenia from a disseminated anaplastic oligodendroglioma. *Neuropathol Appl Neurobiol*, 23, 516–520.
- Ingle JN, Tormey DC and Tan HK (1978) The bone marrow examination in breast cancer. *Cancer*, 41, 670–674.
- Rubins JR (1983) The role of myelofibrosis in malignant myelosclerosis. *Cancer*, 51, 308–311.
- Tritz DB, Doll DC, Ringenberg S, Anderson S, Madsen R, Perry MC and Yarbrow JW (1989) Bone marrow involvement in small cell lung cancer. *Cancer*, 63, 763–766.
- Becker FO and Schwartz TB (1973) Normal fluoride 18 bone scans in metastatic bone disease. *JAMA*, 225, 628–629.
- Suprun H and Rywlin AM (1976) Metastatic carcinoma in histologic sections of aspirated bone marrow: a comparative autopsy study. *South Med J*, 69, 438–439.
- Lang W, Stauch G, Soudah B and Georgii A. The effectiveness of bone marrow punctures for staging carcinomas of the breast and lung. In: Lennert K and Hübner (eds) *Pathology of the Bone Marrow*. Gustav Fischer Verlag, Stuttgart, 1984.
- Savage RA, Hoffman GC and Shaker K (1978) Diagnostic problems involved in detection of metastatic neoplasms by bone-marrow aspirate compared with needle biopsy. *Am J Clin Pathol*, 70, 623–627.
- Gatter KC, Abdulaziz Z, Beverley P, Corvalan JRF, Ford C, Lane EB *et al.* (1982) Use of monoclonal antibodies for the histopathological diagnosis of human malignancy. *J Clin Pathol*, 35, 1253–1267.
- Athanasou NA, Quinn J, Heryet A, Woods CG and McGee JO'D (1987) The effect of decalcification on cellular antigens. *J Clin Pathol*, 40, 874–878.
- Mufti GJ, Flandrin G, Schaefer H-E, Sandberg AA and Kanfer EJ. *An Atlas of Malignant Haematology: Cytology, Histology and Cytogenetics*. Martin Dunitz, London, 1996.
- Smith SR and Reid MM (1994) Neuroblastoma rosettes in aspirated bone marrow. *Br J Haematol*, 88, 445–447.
- Reid MM, Saunders PWG, Bown N, Bradford CR, Maung ZT, Craft AW and Malcolm AJ (1992) Alveolar rhabdomyosarcoma infiltrating bone marrow at presentation: the value to diagnosis of bone marrow trephine biopsy specimens. *J Clin Pathol*, 45, 759–762.
- Jonsson LL and Rundles RW (1951) Tumour metastases in bone marrow. *Blood*, 6, 16–25.
- Stindl R, Fiegl M, Regele H, Gisslinger H, Breitenseher MJ and Fonatsch C (1998) Alveolar rhabdomyosarcoma in a 68-year-old patient identified by cytogenetic analysis of bone marrow. *Cancer Genet Cytogenet*, 107, 43–47.
- Anderson J, Gordon A, Pritchard-Jones K and Shipley J (1999) Genes, chromosomes, and rhabdomyosarcoma. *Genes Chromosomes Cancer*, 26, 275–285.

- 23 Bown N, Cotterill S, Lastowska M, O'Neill S, Pearson AD, Plantaz D *et al.* (1999) Gain of chromosome arm 17q and adverse outcome in patients with neuroblastoma. *N Engl J Med*, 340, 1954–1961.
- 24 Kiely JM and Silverstein MN (1969) Metastatic carcinoma simulating agnogenic myeloid metaplasia. *Cancer*, 24, 1041–1044.
- 25 Spector JI and Levine PH (1973) Carcinomatous bone marrow invasion simulating acute myelofibrosis. *Am J Med Sci*, 266, 145–148.
- 26 Gatter KC, Ralfkiaer E, Skinner J, Brown D, Heryet A, Pulford KAF *et al.* (1985) An immunohistochemical study of malignant melanoma and its differential diagnosis from other malignant tumours. *J Clin Pathol*, 38, 1353–1357.
- 27 Talbot DC, Davies JH, MacLennan KA and Smith IE (1994) Signet-ring lymphoma of bone marrow. *J Clin Pathol*, 47, 184–186.
- 28 Bitter MA, Fiorito D, Corkill ME, Huffer WE, Stemmer SM, Shpall EJ *et al.* (1994) Bone marrow involvement by lobular carcinoma of the breast cannot be identified reliably by routine histological examination alone. *Hum Pathol*, 25, 781–788.
- 29 Savage RA, Lucas PV and Hoffman GC (1978) Melanoma in marrow aspirates (letter). *Am J Clin Pathol*, 79, 268–269.
- 30 Karcher DS and Frost DR (1991) The bone marrow in human immunodeficiency virus (HIV)-related disease: morphology and clinical correlation. *Am J Clin Pathol*, 95, 63–71.
- 31 Conran RM, Granger E and Reddy VB (1986) Kaposi's sarcoma of the bone marrow. *Arch Pathol Lab Med*, 110, 1083–1085.
- 32 Moore PS and Chang Y (1995) Detection of herpesvirus-like DNA sequences in Kaposi's sarcoma in patients with and without HIV infection. *N Engl J Med*, 332, 1181–1185.
- 33 Reid MM and Hamilton PJ (1988) Histology of neuroblastoma involving bone marrow: the problem of detecting residual tumour after initiation of chemotherapy. *Br J Haematol*, 69, 487–490.
- 34 Variend S (1985) Small cell tumours in childhood: a review. *J Pathol*, 145, 1–27.
- 35 Enzinger FM and Shiraki M (1969) Alveolar rhabdomyosarcoma; an analysis of 110 cases. *Cancer*, 24, 18–31.
- 36 Reid MM (1999) Erythrophagocytosis by rhabdomyosarcoma. *Br J Haematol*, 106, 835–836.
- 37 Tsoi W-C and Feng C-S (1997) Hemophagocytosis by rhabdomyosarcoma cells in bone marrow. *Am J Hematol*, 54, 340–341.
- 38 Kounami S, Douno S, Takayama J and Ohira M (1998) Haemophagocytic ability of rhabdomyosarcoma cells. *Acta Haematologica*, 100, 160–161.
- 39 Bacchi CE, Bonetti F, Pea M, Martignoni G and Gown A (1996) HMB-45—A review. *Appl Immunohistochem*, 4, 73–85.
- 40 Orchard GE (1998) Melan A (MART-1): a new monoclonal antibody for malignant melanoma diagnosis. *Br J Biomed Sci*, 55, 8–9.
- 41 Nadji M, Tabei SZ, Castro A, Chu TM, Murphy GP, Wang MC and Morales AR (1984) Prostate specific antigen. An immunohistologic marker for prostatic neoplasms. *Cancer*, 48, 1229–1239.
- 42 Wilbur DC, Krenzer K and Bonfiglio TA (1987) Prostatic specific antigen staining in carcinomas of non-prostatic origin. *Am J Clin Pathol*, 88, 530.
- 43 Lee AK, Lellis RA, Rosen PP, Herbert-Stanton T, Tallberg K, Garcia C and Wolfe HJ (1984) Alpha-lactalbumin as an immunohistochemical marker for breast carcinomas. *Am J Surg Pathol*, 8, 93–100.
- 44 Langlois NEL, King G, Herriot R and Thompson WD (1995) An evaluation of the staining of lymphomas and normal tissues by the rabbit polyclonal antibody to protein gene product 9.5 following non-enzymatic retrieval of antigen. *J Pathol*, 175, 433–439.
- 45 Lloyd RV, Cano M, Rosa P, Hille A and Huttner WB (1988) Distribution of chromogranin A and secretogranin I (chromogranin B) in neuroendocrine cells and tumour. *Am J Pathol*, 130, 296–304.
- 46 Reid MM, Wallis JP, McGuckin AG, Pearson ADJ and Malcolm AJ (1991) Routine histological compared with immunohistological examination of bone marrow trephine biopsy specimens in disseminated neuroblastoma. *J Clin Pathol*, 44, 483–486.
- 47 Wang NP, Marx J, McNutt MA, Rutledge JC and Gown AM (1995) Expression of myogenic regulatory proteins (myogenin and myoD1) in small blue round cell tumors of childhood. *Am J Pathol*, 147, 1799–1810.
- 48 Fellingner EJ, Garin-Chesa P, Triche TJ, Huvos AG and Rettig WJ (1991) Immunohistochemical analysis of Ewing's sarcoma cell surface antigen p30/32^{MIC2}. *Am J Pathol*, 139, 317–325.
- 49 Lazda EJ and Berry PJ (1998) Bone marrow metastasis in Ewing's sarcoma and peripheral primitive neuroectodermal tumor: An immunohistochemical study. *Pediatr Dev Pathol*, 1, 2–30.
- 50 Franklin IM and Pritchard J (1983) Detection of bone marrow invasion by neuroblastoma is improved by sampling at two sites with aspirates and biopsies. *J Clin Pathol*, 36, 1215–1218.
- 51 Reid MM (1994) Detection of bone marrow infiltration by neuroblastoma in clinical practice: how far have we come? *Eur J Cancer A Gen Top*, 30, 134–135.
- 52 Cheung NKV, Heller G, Kushner BH, Liu CY and Cheung IY (1997) Detection of metastatic neuroblastoma in bone marrow: when is routine marrow histology insensitive? *J Clin Oncol*, 15, 2807–2817.
- 53 Rogers DW, Treleavan JG, Kemshead JT and Pritchard J (1989) Monoclonal antibodies for detecting bone marrow invasion by neuroblastoma. *J Clin Pathol*, 42, 422–426.
- 54 Carey PJ, Thomas L, Buckle G and Reid MM (1990)

- Immunocytochemical examination of bone marrow in disseminated neuroblastoma. *J Clin Pathol*, 43, 9–12.
- 55 Thomas JO, Nijjar J, Turley H, Micklem K and Gatter KC (1991) NB84: a new monoclonal antibody for the recognition of neuroblastoma in routinely processed material. *J Pathol*, 163, 69–75.
 - 56 Miettinen M, Chatten J, Paetau A and Stevenson A (1998) Monoclonal antibody NB84 in the differential diagnosis of neuroblastoma and other small round cell tumors. *Am J Surg Pathol*, 22, 327–332.
 - 57 Wolf HK, Buslei R, Schmidt-Kastner R, Schmidt-Kastner PK, Pietsch T, Wiestler OD and Blühmke I (1996) NeuN: a useful neuronal marker for diagnostic histopathology. *J Histochem Cytochem*, 44, 1167–1171.
 - 58 Reid MM and Roald B (1996) Adequacy of bone marrow trephine biopsy specimens in children. *J Clin Pathol*, 49, 226–229.
 - 59 Reid MM and Roald B (1996) Central review of bone marrow biopsy specimens from patients with neuroblastoma. *J Clin Pathol*, 49, 691–692.
 - 60 Reid MM and Roald B (1999) Deterioration in performance in obtaining bone marrow trephine biopsy cores from children. *J Clin Pathol*, 52, 851–852.
 - 61 Turner GE and Reid MM (1993) What is marrow fibrosis after treatment of neuroblastoma? *J Clin Pathol*, 46, 61–63.
 - 62 Lawrence JB, Eleff M, Behm FG and Johnston CL (1984) Bone marrow examination in small cell carcinoma of the lung. *Cancer*, 53, 2188–2190.
 - 63 Levitan N, Byrne RE, Bromer RH, Faling J, Caslowitz P, Pattern DH and Hong WK (1985) The value of the bone scan and bone marrow biopsy in staging small cell lung cancer. *Cancer*, 56, 652–654.
 - 64 Kelly BW, Morris JF, Harwood BP and Bruya TE (1984) Methods and prognostic value of bone marrow examination in small cell carcinoma of the lung. *Cancer*, 53, 99–102.
 - 65 Imamura F, Kuriyama K, Seto T, Hasegawa Y, Nakayama T, Nakamura S and Horai T (2000) Detection of bone marrow metastases of small cell lung cancer with magnetic resonance imaging: early diagnosis before destruction of osseous structure and implications for staging. *Lung Cancer*, 27, 189–197.
 - 66 Landys K (1982) Prognostic value of bone marrow biopsy in breast cancer. *Cancer*, 49, 513–518.
 - 67 Mansi JL, Berger U, Easton D, McDonnell T, Redding WH, Gazet J-C *et al.* (1987) Micrometastases in bone marrow in patients with breast cancer: evaluation as an early predictor of bone metastases. *BMJ*, 295, 1093–1096.
 - 68 Berger U, Bettelheim R, Mansi JL, Easton D, Coombes RC and Neville AM (1988) The relationship between micrometastases in the bone marrow, histopathologic features of the primary tumor in breast cancer and prognosis. *Am J Clin Pathol*, 90, 1–6.
 - 69 Braun S, Pantel K, Müller P, Janni W, Hepp F, Kantenich CRM *et al.* (2000) Cytokeratin-positive cells in the bone marrow and survival of patients with stage I, II or III breast cancer. *N Engl J Med*, 342, 525–533.
 - 70 Untch M, Harbeck N and Eiemann W (1988) Micrometastases in bone marrow in patients with breast cancer. *BMJ*, 296, 290.
 - 71 Mathew BS, Jayasree K, Madhavan J, Nair MK and Rajan B (1997) Skeletal metastases and bone marrow infiltration from squamous cell carcinoma of the buccal mucosa. *Oral Oncol*, 33, 454–455.
 - 72 Thorban S, Roder JD, Nekarda H, Funk A, Pantel K and Siewert JR (1996) Disseminated epithelial tumor cells in bone marrow of patients with esophageal cancer: detection and prognostic significance. *World J Surgery*, 20, 567–573.
 - 73 Heiss MM, Allgayer H, Gruetzner KU, Babic R, Jauch KW and Schildberg FW (1997) Clinical value of extended biologic staging by bone marrow micrometastases and tumor-associated proteases in gastric cancer. *Ann Surg*, 226, 736–744.
 - 74 Maehara Y, Hasuda S, Abe T, Oki E, Kakeji Y, Ohno S and Sugimachi K (1998) Tumor angiogenesis and micrometastasis in bone marrow of patients with early gastric cancer. *Clin Cancer Research*, 4, 2129–2134.
 - 75 Thorban S, Roder JD and Siewert JR (1999) Detection of micrometastasis in bone marrow of pancreatic cancer patients. *Ann Oncol*, 10, 111–113.
 - 76 Roder JD, Thorban S, Pantel K and Siewert JR (2000) Micrometastases in bone marrow: prognostic indicators for pancreatic cancer. *World J Surgery*, 23, 888–891.
 - 77 Pantel K, Izbicki J, Passlick B, Angstwuhan M, Häussinger K, Thetter O and Reithmüller G (1996) Frequency and prognostic significance of isolated tumour cells in bone marrow of patients with non-small cell lung cancer without overt metastasis. *Lancet*, 347, 649–653.
 - 78 Schwaibold H, Wenck S, Huland E and Huland H (1997) Immunocytologic staining of cytokeratin in bone marrow aspirates to detect micrometastatic cells fails in patients with metastatic urologic carcinoma. *Int J Oncol*, 11, 1197–1201.
 - 79 Thybusch-Bernhardt A, Klomp HJ, Maas T, Kremer B and Juhl H (1999) Immunocytological detection of isolated tumour cells in the bone marrow of malignant melanoma patients: a new method for the detection of minimal residual disease. *Eur J Surg Oncol*, 25, 498–502.
 - 80 Castells A, Boix L, Bessa X, Gargallo L and Pique JM (1998) Detection of colonic cells in peripheral blood of colorectal cancer patients by means of reverse transcriptase and polymerase chain reaction. *Br J Cancer*, 78, 1368–1372.
 - 81 Zhong XY, Kaul S, Thompson J, Eichler A and Bastert G (1998) Evaluation of the reverse transcriptase/polymerase chain reaction for carcinoembryonic antigen

- for the detection of breast cancer dissemination in bone marrow and peripheral blood. *J Cancer Res Clin Oncol*, 125, 669–674.
- 82 Vannucchi AM, Bosi A, Glinz S, Pacini P, Linari S, Saccardi R *et al.* (1998) Evaluation of breast tumour cell contamination in the bone marrow and leukapheresis collections by RT-PCR for cytokeratin-19 mRNA. *Br J Haematol*, 103, 610–617.
- 83 Funke I and Schraut W (1998) Meta-analyses of studies on bone marrow micrometastases: an independent prognostic impact remains to be substantiated. *J Clin Oncol*, 16, 557–566.
- 84 Lagrange M, Ferrero JM, Lagrange JL, Machiavello JC, Monticelli J, Bayle C *et al.* (1997) Non-specifically labelled cells that simulate bone marrow metastases in patients with non-metastatic breast cancer. *J Clin Pathol*, 50, 206–211.
- 85 Borgen E, Beiske K, Trachsel S, Nesland JM, Kvalheim G, Herstad TK *et al.* (1998) Immunocytochemical detection of isolated epithelial cells in bone marrow: non-specific staining and contribution by plasma cells directly reactive to alkaline phosphatase. *J Pathol*, 185, 427–434.
- 86 Bateman AC, Leung ST, Howell WM, Roche WR, Jones DB and Theaker JM (1994) Detection of specimen contamination in routine histopathology by HLA class II typing using the polymerase chain reaction and sequence specific oligonucleotide probing. *J Pathol*, 173, 243–248.
- 87 Judkins AR, Montone KT, LiVolsi VA and van de Rijn M (1998) Sensitivity and specificity of antibodies on necrotic tumor tissue. *Am J Clin Pathol*, 110, 641–646.

DISEASES OF BONE

Trephine biopsies, particularly transcortical biopsies, are useful in assessing bone pathology. Diseases of bone are also not infrequently encountered when examining bone marrow trephine biopsies taken for the investigation of haematological disease. The normal structure of bone is described in Chapter 1 (pages 1–3). Before discussing the more important diseases of bone that can be diagnosed by trephine biopsy, it is necessary to consider briefly some aspects of normal bone physiology [1]. Advances in the understanding of the molecular processes involved in normal bone turnover also provide new clues to the pathogenesis of bone disease [2].

Bone is in a constant state of turnover in adult life, by a process of remodelling during which resorption and formation are balanced in order to maintain the total skeletal mass [1]. Microscopic portions of the trabecular and cortical bone surface are resorbed by osteoclasts which form small resorption bays (Howship's lacunae). Bone formation starts soon after resorption ceases, with the deposition of unmineralized matrix (osteoid) in layers (lamellae) by osteoblasts. After a time lag of 10–15 days (the osteoid maturation time), the osteoid becomes mineralized along an advancing front (the mineralization front), starting at the base of the previous resorption bay (the cement line) [3].

For the study of metabolic bone disease, undecalcified sections of bone are essential. Osteoid seams, i.e. layers of non-calcified bone on the surface of trabeculae, are a feature of normal bone. In H&E-stained sections they appear paler and pinker than calcified bone but they can be recognized more easily in sections stained for calcium with alizarin red or von Kossa's silver stain. The mineralization front appears as a metachromatic granular line in toluidine blue-stained sections.

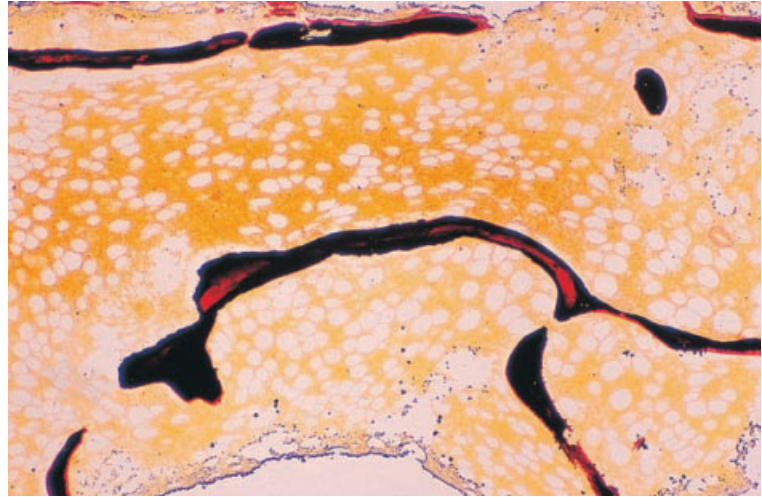
Morphometry of bone

Morphometric methods are commonly used in the diagnosis of diseases of bone. These may be divided into static and dynamic measurements. Static measurements include: (i) the proportion of trabecular surface which is resting, resorbing or covered by osteoid (by a perimeter intersect technique); (ii) the thickness of osteoid seams; and (iii) the proportion of the section occupied by mineralized bone, osteoid, woven bone, lamellar bone or fibrous tissue (by a point-counting technique or by computerized image analysis). Dynamic studies may be performed using a tetracycline labelling method. When a single dose of tetracycline is administered, it becomes incorporated at the mineralization front; this can be visualized as a single line in undecalcified sections examined under ultraviolet light. By giving two doses of tetracycline at a known interval and measuring the distance between the two lines of incorporation, it is possible to measure the mean rate of mineralization.

Osteoporosis

Osteoporosis is defined as a decreased amount of bone per unit volume. There is no decrease in the external dimensions of the bone, which is histologically normal, but there is a reduction in the amount of trabecular bone per unit volume of cancellous bone and there may also be thinning of the cortex (Fig. 11.1). Fragility of the bone may lead to spicules being fractured during the biopsy procedure [4]. Histomorphometry shows that approximately 60% of patients have reduced numbers of osteoblasts [5]. The disorder is common in the elderly, in whom it causes considerable morbidity as a result of increased susceptibility to fractures. Osteoporosis is

Fig. 11.1 BM trephine biopsy section, osteoporosis, showing a decrease in the total amount of bone with thinning of trabeculae. Paraffin-embedded (non-decalcified), Tripp and MacKay stain $\times 39$.



more common in women and its frequency increases progressively after the menopause; severe osteoporosis has also been reported in men [6] and in children [7]. The cause is not known but genetic factors have been implicated [8]. The mechanism is thought to be increased osteoclastic resorption in conjunction with a reduced rate of bone formation [9]. In a minority of cases, osteoporosis is secondary to other diseases such as Cushing's syndrome, thyrotoxicosis, hypopituitarism, malnutrition, malabsorption and chronic heparin or corticosteroid administration. Diffuse osteoporosis is also sometimes associated with multiple myeloma, aplastic anaemia, chronic granulocytic leukaemia, systemic mastocytosis and polycythaemia rubra vera. Localized osteoporosis can occur following immobilization of a limb.

Plain radiographs of the vertebral column are usually only abnormal in advanced disease and are an unreliable means of diagnosing osteoporosis. An assessment of the severity of osteoporosis can be made using biopsies from the iliac crest [10]. The trabeculae are thinned and are reduced to slender strands, often with complete transection, but they are otherwise normal and there is no increase in the width of osteoid seams. Rather, osteoid seams and the number of osteoblasts tend to be reduced. Accurate assessment of the severity of osteoporosis requires the use of static morphometric measurements. Iliac trabecular bone normally occupies

approximately 23% (SD $\pm 3\%$) of the measured area in adults under 50 years of age, but this falls to 16% (SD $\pm 6\%$) in elderly individuals [11]. When the amount of trabecular bone falls below 11% (SD $\pm 3\%$), vertebral fractures tend to occur [3].

Recently, reliable non-invasive techniques for the measurement of bone mass at the sites most prone to fracture have become available; these include dual proton absorptiometry, quantitative computerized tomography (CT) and dual-energy X-ray absorptiometry [12]. It seems likely that these techniques will render iliac crest biopsy unnecessary for the diagnosis of osteoporosis.

The peripheral blood is normal in osteoporosis; the bone marrow is essentially normal, although increased numbers of mast cells have been reported [13]. There may, however, be an appearance of hypocellularity since the loss of bone leads to an increased percentage of the marrow cavity being occupied by fat cells.

Osteomalacia

Osteomalacia literally means softening of the bones. It is a consequence of failure of mineralization of bone matrix, resulting in abnormally wide osteoid seams around the bone trabeculae (Fig. 11.2). Numerous causes of osteomalacia have been described but the majority of cases result from deficiency of vitamin D due, in turn, to: (i) reduced

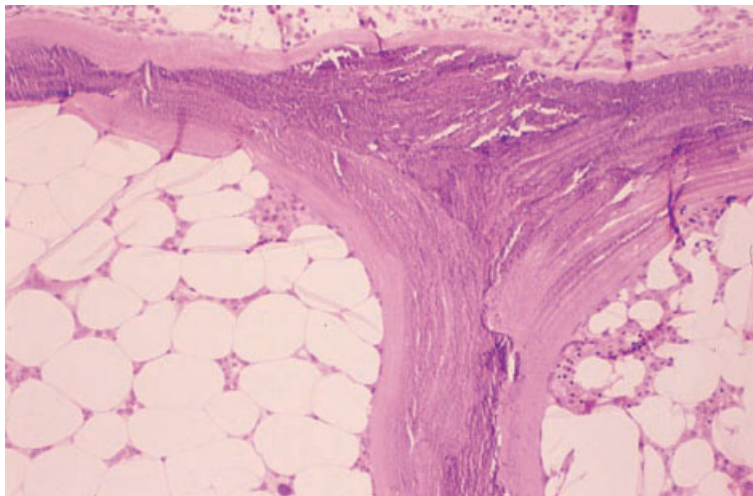


Fig. 11.2 BM trephine biopsy section, osteomalacia, showing wide osteoid seams on the surface of the bone trabecula. Plastic-embedded, H&E $\times 97$.

intake; (ii) inadequate exposure to sunlight; or (iii) abnormalities of absorption or metabolism of the vitamin (as in renal disease). Rarely, osteomalacia is caused by a hereditary end-organ resistance to vitamin D and its metabolites. In adults, severe osteomalacia predisposes to fractures. In children, in whom the epiphyses have not yet closed, the clinical picture is that of rickets, with its characteristic skeletal deformities.

In normal adults, approximately 0.5% of the whole bone area (that is, bone plus marrow) is made up of osteoid, which covers 13% (SD $\pm 7\%$) of the trabecular bone surface. A mineralization front is seen in more than 60% of the surface osteoid. Under polarized light, normal osteoid seams are seen to be composed of between one and four lamellae [3]. In osteomalacia there is an increase in both total osteoid and the area of trabecular surface covered by osteoid; the osteoid seams are greater than five lamellae in thickness and the mineralization front is decreased. Double tetracycline labelling shows a reduction in the mineralization rate (normal mean value 0.7 μm per day). The bone marrow is usually normal.

The peripheral blood and bone marrow aspirate are usually normal in osteomalacia. However, children with severe vitamin D deficiency have been reported to develop a hypocellular bone marrow with fibrosis, thrombocytopenia and a leuco-erythroblastic anaemia associated with extramedullary erythropoiesis [14].

Hyperparathyroidism

Skeletal changes occur in both primary and secondary hyperparathyroidism [15–18]. The extent of these changes depends on the severity and duration of the underlying disease. Primary hyperparathyroidism is usually the result of a parathyroid adenoma; primary hyperplasia is a less common cause. Very rarely, there is an underlying parathyroid carcinoma. Secondary hyperparathyroidism is usually a consequence of renal disease; less commonly the underlying cause is intestinal malabsorption and rare cases have been reported following gastric bypass surgery for treatment of severe obesity [19]. In one reported case, high levels of secretion of parathyroid hormone-related protein, by cells of an HTLV-I-positive adult T-cell leukaemia, produced bone disease indistinguishable from osteitis fibrosa cystica [20]. Parathyroid hormone and related molecules increase osteoclast generation and function, resulting in increased bone resorption; more recently, parathyroid hormone has also been shown to increase bone formation [21].

Skeletal changes in hyperparathyroidism follow a predictable sequence. The earliest change is the presence of excess osteoid seams around the bone trabeculae, an appearance that closely resembles osteomalacia. Later, osteoclasts are activated and there is increased bone resorption. Howship's lacunae and osteoclasts are prominent and there is fibrosis of the paratrabecular marrow (Fig. 11.3).

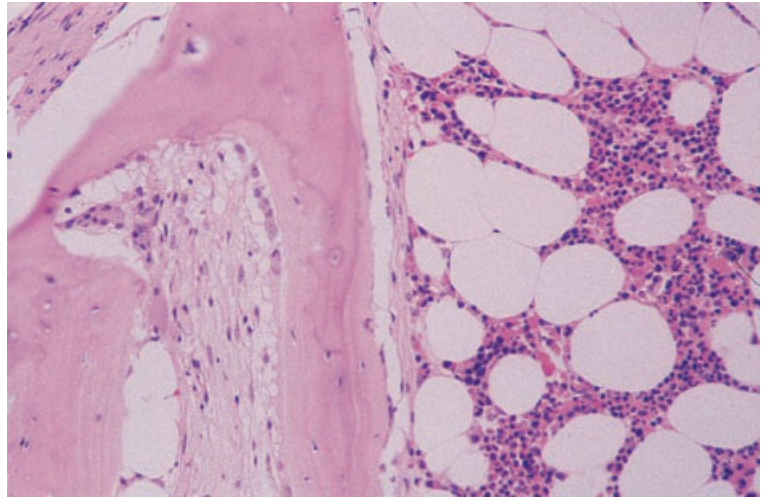


Fig. 11.3 BM trephine biopsy section, primary hyperparathyroidism, showing paratrabeular fibrosis. Paraffin-embedded, H&E $\times 188$.

This appearance is known as osteitis fibrosa. The Howship's lacunae may be filled by large osteoclasts and, as the lacunae enlarge, trabeculae may be transected. Fibrosis increases and fibrous tissue eventually fills some intertrabecular spaces completely. There is a moderate increase in the vascularity of the marrow. At this stage, macroscopic cysts may be visible. Haemosiderin-laden macrophages are frequently seen within the fibrous tissue, resulting from microhaemorrhages; foreign body-type giant cells may also be present. This final stage is sometimes referred to as osteitis fibrosa cystica.

Only a minority of patients with hyperparathyroidism have significant bone disease and, with earlier diagnosis and treatment, severe manifestations (osteitis fibrosa cystica) are rarely seen nowadays. The features are important to remember, however, since bone marrow biopsy is occasionally performed to investigate either hypercalcaemia or radiographic lesions suspicious of metastatic carcinoma in patients with unsuspected severe hyperparathyroidism [22–24].

There are no specific peripheral blood or bone marrow aspirate abnormalities associated with primary hyperparathyroidism although mild anaemia may occur [25].

Renal osteodystrophy

The majority of patients with chronic renal failure have some abnormality of bone structure [17,18].

The manifestations are complex [26] and include combinations of bone disease due to secondary hyperparathyroidism (80–90% of cases), osteomalacia (20–40% of cases) and osteosclerosis (around 30% of cases) [3,27]. The most severe changes are seen in those patients with chronic renal failure who are maintained on dialysis. There is marked geographical variation in the nature of renal osteodystrophy, with hyperparathyroid bone disease predominating in the United States and osteomalacia in the United Kingdom. In adults, the symptoms are rarely severe. Secondary hyperparathyroidism in renal failure is consequent on hypocalcaemia which is, in turn, caused by a combination of reduced hydroxylation of vitamin D and phosphate retention by the kidney [28]. The major cause of renal osteomalacia is the toxic action of aluminium derived from dialysate; geographical variations in the incidence are related to the concentration of aluminium in water used for dialysis [28,29]. The use of de-ionized water for dialysis has resulted in a fall in the incidence of renal osteomalacia in some centres [3].

The histological changes are identical to those previously described in hyperparathyroidism (osteitis fibrosa), often combined with those of osteomalacia (Fig. 11.4). Bone trabeculae may have tunnels excavated within them by osteoclasts (Fig. 11.5) but the most severe changes of osteitis fibrosa cystica are seen only rarely. Osteosclerosis, due to increased formation of woven bone, may be widespread

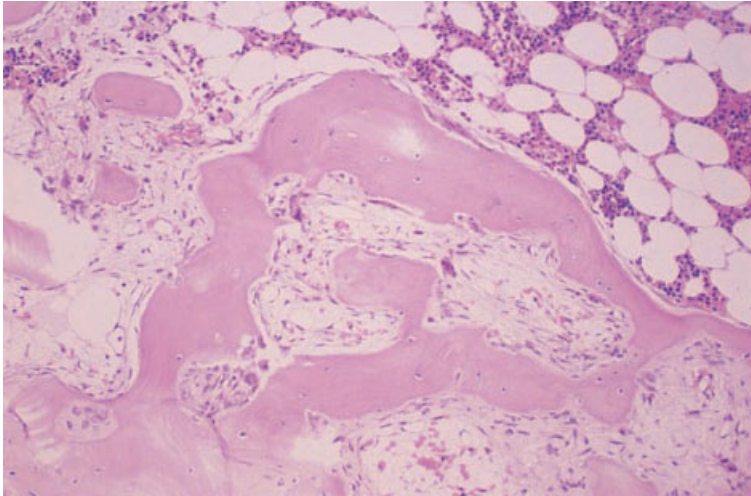


Fig. 11.4 BM trephine biopsy section, renal osteodystrophy, showing irregular bone trabeculae with prominent resorption bays (Howship's lacunae) and replacement of haemopoietic marrow by fibrous tissue. Paraffin-embedded, H&E $\times 97$.

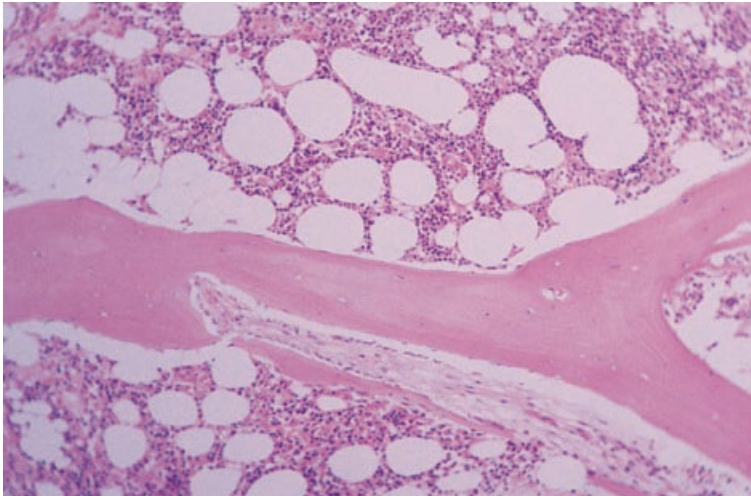


Fig. 11.5 BM trephine biopsy section, renal osteodystrophy, showing prominent tunnelling into a trabecula by fibrous tissue. Paraffin-embedded, H&E $\times 97$.

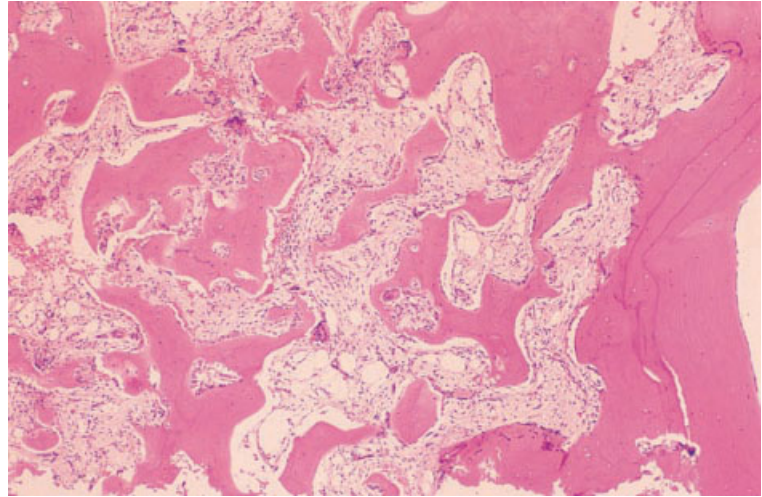
throughout the skeleton. With advanced renal osteodystrophy, the bone marrow may be hypocellular and extensively fibrosed with proliferation of vessels, particularly arterioles. Patients with renal osteodystrophy have been noted to have mononuclear cells within the haemopoietic marrow which are positive for tartrate-resistant acid phosphatase; these cells are probably osteoclast precursors [30,31].

There may also be abnormal deposition of aluminium or iron. Aluminium deposition occurs at the junction between osteoid and mineralized bone.

It is detected as a red/purple line in an Irwin stain using an undecalcified biopsy [32] and provides evidence of exposure to an excessive aluminium concentration in the dialysate. Aluminium may also be detected inside bone marrow cells, possibly macrophages [33]. In dialysis patients who are iron-overloaded, iron may also be deposited at the mineralization front [34]; iron deposition may be aetiologically related to osteomalacia.

Renal osteodystrophy may contribute to the anaemia of chronic renal failure and may also cause leucopenia or thrombocytopenia [35]. There are no

Fig. 11.6 BM trephine biopsy section, Paget's disease of bone, showing thickening of bone trabeculae, numerous resorption bays (Howship's lacunae) containing large osteoclasts and replacement of marrow by vascular connective tissue. Paraffin-embedded, H&E $\times 39$.



specific associated morphological abnormalities in the peripheral blood or bone marrow aspirate although a 'dry tap' may occur. Response to erythropoietin therapy is worse in those patients who have more severe secondary hyperparathyroidism [36] and iron overload [37].

Paget's disease of bone

Paget's disease of bone is a disease of unknown aetiology, characterized by increased osteoclastic resorption of bone followed by unco-ordinated formation of disordered reactive bone. Infection by a virus of the paramyxovirus group (including measles virus, respiratory syncytial virus and canine distemper virus) has been investigated extensively as a possible cause but the findings have been inconclusive [38,39]. In one series of patients, molecular genetic analysis has failed to find evidence of paramyxovirus RNA sequences in tissue from pagetic bone [40]. Paget's disease of bone occurs with familial clustering in some instances [39,41] and genetic linkage to chromosome 18q21–22 has been established in some, but not all, families [41–43]. Occupational exposure to lead has also been proposed as a possible contributory factor in development of the disease [44,45]. Paget's disease is uncommon before the age of 40 years and becomes progressively more common with increas-

ing age. In approximately 15% of cases, the disease is confined to a single bone (monostotic). In the majority of cases, several bones are involved, most commonly the vertebral column, pelvis, femur, skull and sacrum. The clinical features are pain, due to microfractures, and neurological symptoms consequent on damage to nerves as they pass through the foramina of the skull and vertebrae. Rarely, there is high-output cardiac failure as a result of the highly vascular lesions acting as arteriovenous shunts. The development of osteosarcoma is an uncommon, but well-established, complication of Paget's disease.

In the initial stages of the disease, increased bone resorption is the dominant feature. Trabeculae have a scalloped appearance due to increased numbers of resorption bays containing very large osteoclasts with numerous nuclei (Fig. 11.6). The increased resorption of bone is followed by deposition of disordered woven bone. Osteoblasts are increased. At this stage, the marrow cavity is partly occupied by loose connective tissue; there is increased vascularity with arterioles and capillaries being particularly increased. Eventually, new bone formation becomes the dominant feature and lamellar bone is laid down causing thickening of the bone trabeculae. However, the lamellar bone is laid down in an unco-ordinated and haphazard fashion. The irregular cement lines, which appear more basophilic

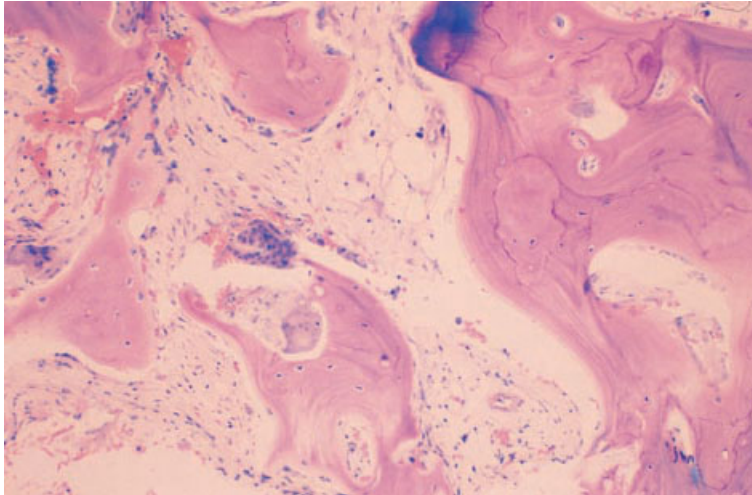


Fig. 11.7 BM trephine biopsy section, Paget's disease of bone (same case as in Fig. 11.6), showing thickening of bone trabeculae with a typical mosaic pattern of cement lines and large osteoclasts. Paraffin-embedded, Giemsa $\times 97$.

than the surrounding bone, form a characteristic mosaic or tessellated ('tile-like') pattern that is a hallmark of Paget's disease (Fig. 11.7). Each of the cement lines represents a surface where bone resorption has been followed by bone deposition. The trabeculae eventually become massively thickened and encroach upon the marrow cavity.

Severe Paget's disease may have an associated mild anaemia. The bone marrow aspirate does not show any specific abnormality but increased osteoblasts and osteoclasts are sometimes seen.

It should be noted that prolonged bleeding, consequent on the greatly increased vascularity, has been reported following trephine biopsy in a patient with Paget's disease [46].

Osteosclerosis

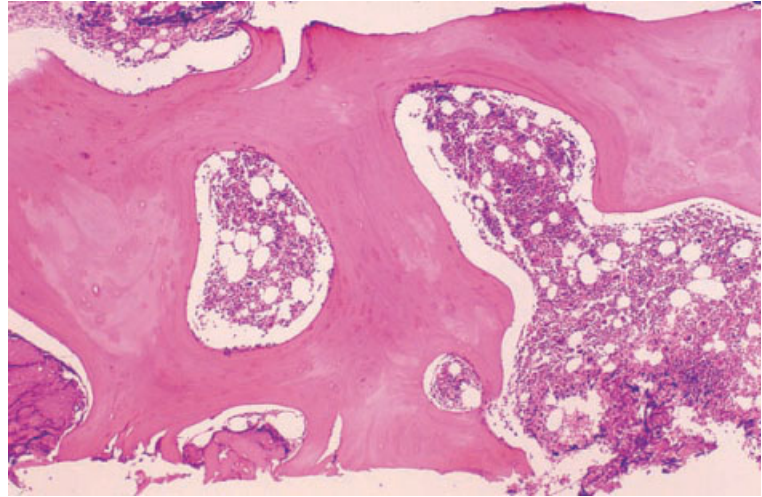
Osteosclerosis is the term used to describe a group of conditions in which there is an increase in the amount of bone per unit volume, usually resulting from increased bone formation. Osteosclerosis is most often seen in conjunction with severe bone marrow fibrosis, either in a myeloproliferative disorder or in metastatic carcinoma. It has been reported in patients with systemic mastocytosis [47] although the more usual finding in this disease is diffuse osteoporosis. Osteosclerosis occasionally occurs in multiple myeloma but osteolytic lesions

are much more characteristic. It is also associated with plasma cell neoplasia in the polyneuropathy, organomegaly, endocrinopathy, M-protein, skin changes (POEMS) syndrome (see page 356) and has been reported in patients with hairy cell leukaemia, in whom it has regressed or stabilized with treatment of the underlying lymphoproliferative disease [48,49]. Osteosclerosis may occur without primary bone marrow disease in the congenital condition designated osteopetrosis (see below) and also, rarely, in adults in the absence of any associated disease (Fig. 11.8). The cause of isolated osteosclerosis in adults is unknown; some reported cases have suggested an association with intravenous drug abuse [50].

In the myeloproliferative disorders (see Fig. 5.21), the term osteomyelosclerosis [51,52] is sometimes used. The new bone may be either bone formed on the endosteal surface of trabeculae, leading to marked trabecular thickening or, less commonly, irregular spicules of metaplastic woven bone within the fibrous tissue. The strands of woven bone may form an irregular network in the intertrabecular spaces and, in severe cases, the medullary cavity is almost completely obliterated. Some conversion of woven bone to mature bone occurs.

Metastases from various types of carcinoma may cause dense bone marrow fibrosis and osteosclerosis but these changes are most commonly associated

Fig. 11.8 BM trephine biopsy section, idiopathic osteosclerosis, showing marked thickening of bone trabeculae by mature lamellar bone. The intervening marrow is normal. Paraffin-embedded, H&E $\times 39$.



with carcinomas of the breast and prostate (see Figs 10.10 and 10.12, page 439). When osteosclerosis is due to metastatic carcinoma, malignant cells can be detected within the fibrous tissue. The bone changes do not differ from those associated with the myeloproliferative diseases.

In idiopathic osteosclerosis, the bone trabeculae are increased in thickness by mature lamellar bone.

Peripheral blood and bone marrow changes in osteomyelosclerosis are those of the underlying disease. In osteosclerosis associated with metastatic carcinoma, a leuco-erythroblastic anaemia is usual and there is sometimes also thrombocytopenia or leucopenia; bone marrow aspiration may be impossible or the aspirate may contain tumour cells or increased osteoblasts and osteoclasts. In idiopathic osteosclerosis, the peripheral blood and the bone marrow aspirate are normal.

The bone may be so hard in osteosclerosis that penetration is impossible or needles bend or break. Open biopsy may then be necessary for diagnosis.

Thyroid disease [53,54]

Thyrotoxicosis has been found to be associated with osteoporosis, an increased percentage of osteoid and a marked increase in osteoclasts. Hypothyroidism is associated with osteosclerosis, normal or decreased osteoid percentage and reduced osteoclasts.

Bone necrosis and repair

Conditions causing bone marrow necrosis (see page 128) also cause necrosis of trabecular bone in many instances. In the acute phase, necrotic bone is recognized by the absence of osteocytes from lacunae. It should be noted that occasional lacunae may appear empty in normal bone if the plane of section does not pass through an osteocyte nucleus.

Repair occurs by appositional new bone formation. Woven bone is deposited on the surface of the dead lamellar bone (Fig. 11.9). This is followed by the normal processes of bone remodelling in which the woven bone is replaced by lamellar bone.

Osteopetrosis (Albers-Schoenberg disease)

Osteopetrosis, also known as marble bone disease or Albers-Schoenberg disease, is a hereditary metabolic disease consequent on a defect in osteoclast function [55,56]. Osteoclasts may be increased (Fig. 11.10), decreased (Fig. 11.11) or present in normal numbers but are always qualitatively abnormal [57,58]. The result is osteosclerosis with gradual obliteration of the marrow cavity by both bony encroachment and associated fibrosis. Although the bone density is increased, the bone is more fragile than normal. Osteopetrosis occurs in an autosomal recessive form, which manifests itself

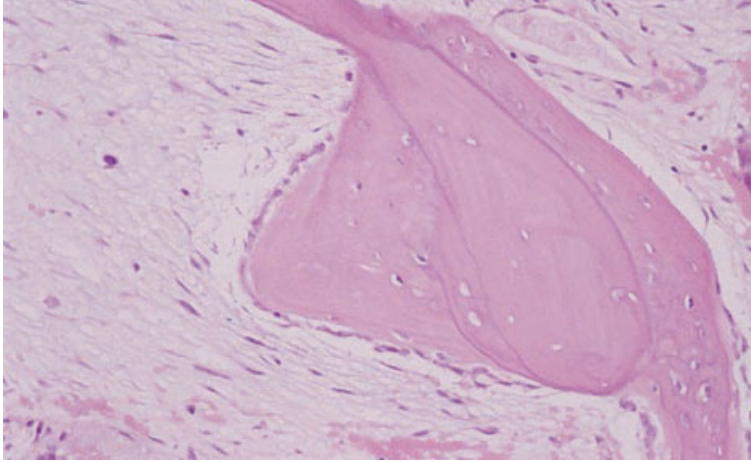


Fig. 11.9 BM trephine biopsy section. Newly deposited woven bone on the surface of a necrotic trabecula. Paraffin-embedded, H&E $\times 188$.

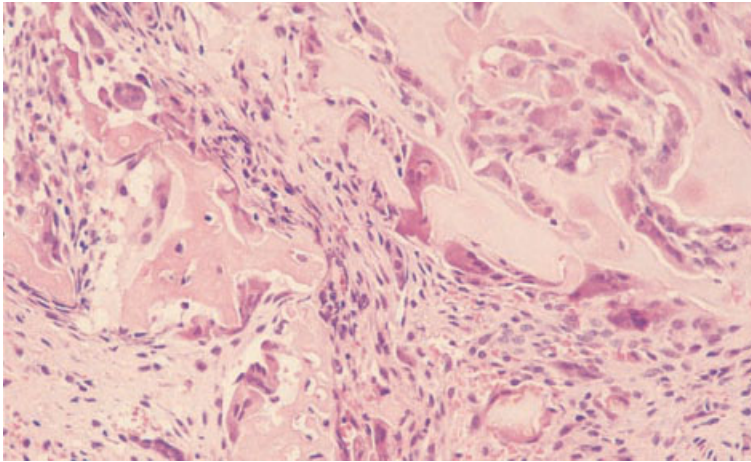


Fig. 11.10 BM trephine biopsy section from a child with osteopetrosis, showing marked increase in osteoclast numbers and bone marrow fibrosis. H&E $\times 188$. (By courtesy of Adrienne Flanagan, London.)

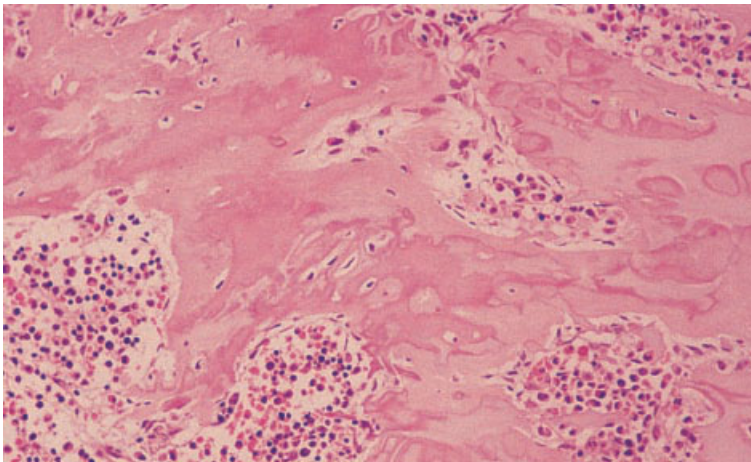


Fig. 11.11 BM trephine biopsy section from a child with osteopetrosis, showing abnormal bone structure and no detectable osteoclasts. H&E $\times 188$. (By courtesy of Adrienne Flanagan, London.)

either *in utero* or during infancy, and as an autosomal dominant form in adults. The autosomal recessive form is a severe disease with symptoms of marrow failure due to obliteration of the marrow cavity; the autosomal dominant form has much milder clinical manifestations with an increased predisposition to fractures. Histologically, the trabeculae appear thickened due to increased amounts of mature lamellar bone and osteoclasts are prominent in some cases [57]. Masses of irregularly mineralized osteoid surrounding unresorbed cartilaginous cores have also been described [59].

In the severe infantile form of osteopetrosis there is increasingly severe leuco-erythroblastic anaemia and thrombocytopenia associated with extramedullary haemopoiesis. Occasionally, the white cell count is increased and immature granulocytes are present in the blood [60]. In the milder adult form of the disease there is only a minor degree of anaemia.

Osteogenesis imperfecta

Osteogenesis imperfecta comprises a group of related hereditary diseases due to abnormalities in the synthesis of type I collagen [61,62]. Several different biochemical defects have been identified, all of which are associated with increased fragility of the skeleton and a tendency to fractures. Other manifestations include blue sclerae, laxity of joints and abnormalities of dentition. The most severe variant (type II) has an autosomal recessive inheritance and is fatal in the perinatal period. Several other variants have been described that are compatible with survival into adult life; these usually have an autosomal dominant pattern of inheritance. Histologically, thinning of the cortex and trabeculae is seen [7]. In some cases there is loss of the normal lamellar structure of the bone [63].

The peripheral blood and bone marrow aspirate findings are normal.

Problems and pitfalls

Damage caused by torsion or crushing of the trephine biopsy core may generate fragments of bone that mimic Paget's disease or bone necrosis. The artefactual changes are usually limited to the inner end of the biopsy core and trabecular bone in areas with well-preserved architecture will be normal.

Incomplete decalcification may lead to basophilic staining of bone with H&E, particularly affecting central areas within trabeculae, which may suggest abnormal bone growth. If sections are examined from several levels through the biopsy specimen, it is usually clear that the incomplete decalcification is more extensive towards the centre of the core. When the sections are studied carefully, a normal pattern of lamellae and lacunae can be seen, even in partly calcified areas. If poor decalcification causes difficulty with cutting or staining of sections, surface decalcification of the wax block can be used but the routine laboratory protocol for decalcification should also be reviewed.

Trabeculae of bone may become detached from trephine biopsy sections during staining (see Fig. 1.62, page 44) and, in particular, during proteolysis or wet-heat exposure for antigen retrieval in immunohistochemical techniques. The spaces remaining may mimic dilated sinusoids but careful attention to their contours and comparison of their position relative to any preserved trabeculae usually makes their true nature obvious.

Regenerating bone post-chemotherapy may mimic hyperparathyroid bone disease or renal osteodystrophy but does not show the tunnelling of trabeculae by fibrous tissue that is such a prominent feature of the latter conditions.

Newly made woven bone has large lacunae and the resident osteocytes may not all be apparent in a particular section. The bone may therefore appear to lack osteocytes and may be mistaken for necrotic bone. However, only a few lacunae, at most, will appear acellular and the lack of lamellar structure (confirmed, if necessary, with a reticulin or trichrome stain) will confirm that woven bone is present.

The irregular bone of severe Paget's disease may mimic osteomyelosclerosis due to idiopathic myelofibrosis or metastatic malignancy. The diagnosis of Paget's disease is confirmed by the presence of giant osteoclasts and the distinctive tessellated pattern of irregular bony plates with scalloped edges that make up individual trabeculae.

Reactivities of some monoclonal antibodies with normal bone components should not be mistaken for reactions with abnormal cells (see Tables 2.6 and 2.7): VS38c and (less consistently) CD30 react with osteoblasts, while antibodies of the CD68 cluster

react with osteoclasts, the latter being of macrophage origin.

References

- Raisz LG (1999) Physiology and pathophysiology of bone remodeling. *Clin Chem*, 45, 1353–1358.
- Boyce BF, Hughes DE, Wright KR, Xing L and Dai A (1999) Recent advances in bone biology provide insight into the pathogenesis of bone diseases. *Lab Invest*, 79, 83–94.
- Ellis HA. Metabolic bone disease. In: Anthony PP and Macsween RNM (eds) *Recent Advances in Histopathology*, 11. Churchill Livingstone, Edinburgh, 1981.
- Gatter K and Brown D. *An Illustrated Guide to Bone Marrow Diagnosis*. Blackwell Science, Oxford, 1994.
- Byers RJ, Denton J, Hoyland JA and Freemont AJ (1997) Differential patterns of osteoblast dysfunction in trabecular bone in patients with established osteoporosis. *J Clin Pathol*, 50, 760–764.
- Kelepouris N, Harper KD, Gannon F, Kaplan FS and Haddad JG (1995) Severe osteoporosis in men. *Ann Intern Med*, 123, 452–460.
- Rauch F, Travers R, Norman ME, Taylor A, Parfitt AM and Glorieux FH (2000) Deficient bone formation in idiopathic juvenile osteoporosis: a histomorphometric study of cancellous iliac bone. *J Bone Miner Res*, 15, 957–963.
- Zmuda JM, Cauley JA and Ferrell RE (1999) Recent progress in understanding the genetic susceptibility to osteoporosis. *Genet Epidemiol*, 16, 356–367.
- Raisz LG (1988) Local and systemic factors in the pathogenesis of osteoporosis. *N Engl J Med*, 318, 818–828.
- Beck JS and Nordin BEC (1960) Histological assessment of osteoporosis by iliac crest biopsy. *J Pathol Bacteriol*, 80, 391–397.
- Ellis HA and Peart KM (1972) Quantitative observations on mineralised and non-mineralised bone in the iliac crest. *J Clin Pathol*, 25, 277–286.
- Fogelman I and Blake G. How to measure osteoporosis. In: Smith R (ed) *Osteoporosis*. Royal College of Physicians, London, 1990.
- Frame B and Nixon RK (1968) Bone marrow mast cells in osteoporosis of aging. *N Engl J Med*, 279, 626–630.
- Yetgin S and Ozsoylu S (1982) Myeloid metaplasia in vitamin D deficiency rickets. *Scand J Haematol*, 28, 180–185.
- Broadus AE (1989) Primary hyperparathyroidism. *J Urol*, 141, 723–730.
- Parisien M, Silverberg SJ, Shane E, Dempster DW and Bilezikian JP (1990) Bone disease in primary hyperparathyroidism. *Endocrinol Metab Clin North Am*, 19, 19–34.
- Dabbagh S (1998) Renal osteodystrophy. *Curr Opin Pediatr*, 10, 190–196.
- DeVita MV, Rasenas LL, Bansal M, Gleim GW, Zabetakis PM, Gardenswartz MH and Michelis MF (1992) Assessment of renal osteodystrophy in hemodialysis patients. *Medicine*, 71, 284–290.
- Shaker JL, Norton AJ, Woods MF, Fallon MD and Findling JW (1991) Secondary hyperparathyroidism and osteopenia in women following gastric exclusion surgery for obesity. *Osteoporos Int*, 1, 177–181.
- Yamaguchi T, Hirano T, Kumagai K, Tsurumoto T, Shindo H, Majima R and Arima N (1999) Osteitis fibrosa cystica generalisata with adult T-cell leukaemia: a case report. *Br J Haematol*, 107, 892–894.
- Finkelstein JS, Klibanski A, Schaefer EH, Hornstein MD, Schiff I and Neer RM (1994) Parathyroid hormone for the prevention of bone loss induced by estrogen deficiency. *N Engl J Med*, 331, 1618–1623.
- Bassler T, Wong ET and Brynes RK (1993) Osteitis fibrosa cystica simulating metastatic tumor. An almost-forgotten relationship. *Am J Clin Pathol*, 100, 697–700.
- Joyce JM, Idea RJ, Grossman SJ, Liss RG and Lyons JB (1994) Multiple brown tumors in unsuspected primary hyperparathyroidism mimicking metastatic disease on radiograph and bone scan. *Clin Nucl Med*, 19, 630–635.
- Pai M, Park CH, Kim BS, Chung YS and Park HB (1997) Multiple brown tumors in parathyroid carcinoma mimicking metastatic bone disease. *Clin Nucl Med*, 22, 691–694.
- Zingraff J, Druke T, Marie P, Man NK, Jungers P and Border P (1978) Anaemia and secondary hyperparathyroidism. *Arch Intern Med*, 138, 1650–1652.
- Llach F (1991) Renal bone disease. *Transplant Proc*, 23, 1818–1822.
- Teitelbaum SL (1984) Renal osteodystrophy. *Hum Pathol*, 15, 306–323.
- Lee DB, Goodman WG and Coburn JW (1988) Renal osteodystrophy: some new questions on an old disorder. *Am J Kidney Dis*, 11, 365–376.
- Iwamoto N, Ono T, Yamazaki S, Fukuda T, Kondo M, Yamamoto N *et al.* (1986) Clinical features of aluminum-associated bone disease in long-term hemodialysis patients. *Nephron*, 42, 204–209.
- Kaye M and Henderson J (1988) Nature of mononuclear cells positive for acid phosphatase activity in bone marrow of patients with renal osteodystrophy. *J Clin Pathol*, 41, 277–279.
- Hoyer JD, Li CY, Yam LT, Hanson CA and Kurtin PJ (1997) Immunohistochemical demonstration of acid phosphatase isoenzyme 5 (tartrate-resistant) in paraffin sections of hairy cell leukemia and other hematologic disorders. *Am J Clin Pathol*, 108, 308–315.
- McClure J, Fazzalari NL, Fassett RG and Pugsley DG (1983) Bone histoquantitative findings and histochemical staining reactions for aluminium in chronic renal failure patients treated with haemodialysis fluids

- containing high and low concentrations of aluminium. *J Clin Pathol*, 36, 1281–1287.
- 33 Kaye M (1983) Bone marrow aluminium storage in renal failure. *J Clin Pathol*, 36, 1288–1291.
- 34 Pierides AM and Myli MP (1984) Iron and aluminium osteomalacia in haemodialysis patients. *N Engl J Med*, 310, 323.
- 35 Weinberg SG, Lubin A, Weiner SN, Deorus MP, Ghose MK and Kopelman SN (1977) Myelofibrosis in renal osteodystrophy. *Am J Med*, 63, 755–776.
- 36 Rao DS, Shih M-S and Mohini R (1993) Effect of serum parathyroid hormone and bone marrow fibrosis on the response to erythropoietin in uremia. *N Engl J Med*, 328, 171–175.
- 37 El Reshaid K, Johnny KV, Hakim A, Kamel H, Sebata A, Hourani H and Kanyike FB (1994) Erythropoietin treatment in haemodialysis patients with iron overload. *Acta Haematol*, 91, 130–135.
- 38 Singer FR (1999) Update on the viral etiology of Paget's disease of bone. *J Bone Miner Res*, 14 (Suppl. 2), 29–33.
- 39 Gallacher SJ (1993) Paget's disease of bone. *Curr Opin Rheumatol*, 5, 351–356.
- 40 Ralston SH, Digiiovine FS, Gallacher SJ, Boyle IT and Duff GW (1991) Failure to detect paramyxovirus sequences in Paget's disease of bone using the polymerase chain reaction. *J Bone Miner Res*, 6, 1243–1248.
- 41 Hocking L, Slee F, Haslam SI, Cundy T, Nicholson G, van Hul W and Ralston SH (2000) Familial Paget's disease of bone: patterns of inheritance and frequency of linkage to chromosome 18q. *Bone*, 26, 577–580.
- 42 Haslam SI and Ralston SH (1998) The genetics of Paget's disease of bone. *Curr Opin Orthop*, 9, 17–20.
- 43 Haslam SI, van Hul W, Morales-Piga A, Balemans W, San Millan JL, Nakatsuka K *et al.* (1998) Paget's disease of bone: evidence for a susceptibility locus on chromosome 18q and for genetic heterogeneity. *J Bone Miner Res*, 13, 911–917.
- 44 Spencer H, O'Sullivan V and Sontag SJ (1994) Occupational exposure to lead: preliminary observations in Paget's disease of bone in women and in family members of affected patients. *J Trace Elem Exp Med*, 7, 53–58.
- 45 Spencer H, O'Sullivan V and Sontag SJ (1995) Exposure to lead, a potentially hazardous toxin: Paget's disease of bone. *J Trace Elem Exp Med*, 8, 163–171.
- 46 Ben-Chetrit E, Flusser D and Assaf Y (1984) Severe bleeding complicating percutaneous bone marrow biopsy. *Arch Intern Med*, 144, 2284.
- 47 de Gennes C, Kuntz D and de Vernejoul MC (1992) Bone mastocytosis: a report of nine cases with a bone histomorphometric study. *Clin Orthop Relat Res*, 279, 281–291.
- 48 VanderMolen LA, Urba WJ, Longo DL, Lawrence J, Gralnick H and Steis RG (1989) Diffuse osteosclerosis in hairy cell leukemia. *Blood*, 74, 2066–2069.
- 49 Verhoef GEG, De Wolf Peeters C, Zachee P and Boogaerts MA (1990) Regression of diffuse osteosclerosis in hairy cell leukemia after treatment with interferon. *Br J Haematol*, 76, 150–151.
- 50 Whyte MP, Teitelbaum SL and Reinus WR (1996) Doubling skeletal mass during adult life: the syndrome of diffuse osteosclerosis after intravenous drug abuse. *J Bone Miner Res*, 11, 554–558.
- 51 Burkhardt R, Frisch B and Bartl R (1982) Bone biopsy in haematological disorders. *J Clin Pathol*, 35, 257–284.
- 52 Thiele J, Hoepfner B, Zankovich R and Fischer R (1989) Histomorphometry of bone marrow biopsies in primary osteomyelofibrosis/-sclerosis (agnogenic myeloid metaplasia)—correlations between clinical and morphological features. *Virchows Arch A Pathol Anat Histopathol*, 415, 191–202.
- 53 Bordier P, Miravet L, Matrajt H, Hioco D and Ryckewaert A (1967) Bone changes in adult patients with abnormal thyroid function with special reference to ⁴⁵Ca kinetics and quantitative histology. *Proc Roy Soc Med*, 60, 1132–1134.
- 54 Abu E and Compston J (1998) The impact of thyroid hormones on bone. *Curr Opin Endocrinol Diabetes*, 5, 282–287.
- 55 Singer FR and Chang SS (1992) Osteopetrosis. *Semin Nephrol*, 12, 191–199.
- 56 Shankar L, Gerritsen EJA and Key LL Jr (1997) Osteopetrosis: pathogenesis and rationale for the use of interferon-gamma-1b. *BioDrugs*, 7, 23–29.
- 57 Helfrich MH, Aronson DC, Everts V, Mieremet RHP, Gerritsen EJA, Eckhardt PG *et al.* (1991) Morphologic features of bone in human osteopetrosis. *Bone*, 12, 411–419.
- 58 Flanagan AM, Sarma U, Steward CG, Vellodi A and Horton MA (2000) Study of the nonresorptive phenotype of osteoclast-like cells from patients with malignant osteopetrosis: a new approach to investigating pathogenesis. *J Bone Miner Res*, 15, 352–360.
- 59 Strauchen JA. *Diagnostic Histopathology of the Bone Marrow*. Oxford University Press, Oxford, 1996.
- 60 Toren A, Meyer JJ, Mandel M, Sohiby G, Kende G and Bassat I (1993) Malignant osteopetrosis manifesting as juvenile chronic myeloid leukemia. *Pediatr Hematol Oncol*, 10, 187–189.
- 61 Cole WG (1988) Osteogenesis imperfecta. *Baillieres Clin Endocrinol Metab*, 2, 243–265.
- 62 Cole WG (1993) Etiology and pathogenesis of heritable connective tissue diseases. *J Pediatr Orthop*, 13, 392–403.
- 63 Falvo KA and Bullough PG (1973) Osteogenesis imperfecta: a histometric analysis. *J Bone Joint Surg*, 55A, 275–286.

APPENDIX

Many readers of the previous editions of this book have given helpful comments that have been incorporated into this edition. One of the most common requests has been for methods used for processing and staining of bone marrow biopsies. This Appendix gives details of various methods, including the stains most commonly used for bone marrow trephine biopsy sections in the laboratories in which the authors work. We find these give good results. However, it cannot be stressed too strongly that the key to obtaining high quality sections and stains is close co-operation between pathologists and laboratory scientists. A more detailed discussion of the various techniques described may be found in the references at the end of this Appendix.

Technical methods applicable to trephine biopsy specimens

Fixation

Adequate fixation of a trephine biopsy core is essential if one is to prepare sections that preserve the fine cytological detail needed for interpretation of haematological disorders. In most laboratories, 10% neutral buffered formol-saline is used as a general purpose fixative for all specimens and this gives satisfactory results with bone marrow trephine biopsies. It is important to ensure that the formol-saline is not left for long periods at high temperature before being used because formic acid and formalin pigment may be produced. Use of stale fixative is one of the more common causes of poor quality sections. Trephine biopsy cores should be fixed in formol-saline for a minimum of 18 h but fixation for longer periods does not affect subsequent processing or morphology and is desirable for large samples.

Other fixatives, such as Bouin's fixative and the mercury-based fixatives, Zenker's and B5, are also used with trephine biopsy specimens. These fixatives give excellent preservation of cytological detail but are less practical in laboratories processing a wide range of tissues, in which the majority of other specimens will be fixed in formol-saline. The reactivity of antibodies used for immunohistochemical staining may also be affected by the choice of fixative and Zenker's fixative can destroy chloroacetate esterase activity. If Zenker's fixative is used, the biopsy core should be fixed for a minimum of 4 h but longer periods of fixation are perfectly acceptable. Fixation in Bouin's fixative should be for 4–12 h. If B5 fixative is used, the duration of fixation is more critical—4 h is optimal; if fixation lasts for more than 6 h, hardening of the tissue can make it difficult to cut sections. Recently, an alternative fixative has been adopted for trephine biopsy specimens in one of our laboratories, with excellent results and no impairment of tinctorial or immunohistochemical staining. This fixative is a combined aceto-zinc formalin solution; conditions for its use are essentially identical to those employed with standard formol-saline.

Decalcification

The method of decalcification used depends on how the biopsy is to be processed. If the biopsy is to be embedded in plastic, it may not be necessary to use any decalcification at all, although better results are often obtained by decalcifying the specimen using the chelating agent ethylene diamine tetra-acetic acid (EDTA).

If the biopsy is to be embedded in paraffin wax, decalcification using EDTA, formic or acetic acid is required, as described in Chapter 1. Decalcification

using inorganic acids, such as hydrochloric or nitric acid, should be avoided as this affects morphological preservation adversely and impairs metachromatic staining of sections, e.g. with Giemsa or toluidine blue. Decalcification using EDTA may require longer incubation than methods using organic acids; speed may be increased by agitation and/or warming to 37°C. Decalcification of paraffin-embedded biopsy specimens using formic or acetic acid destroys chloro-acetate esterase activity but use of EDTA preserves this. Both acid and chelation methods remove variable amounts of iron from the tissue, rendering assessment of iron stores unreliable in decalcified specimens.

Whichever method is preferred locally, it is essential to achieve good fixation before exposure of the tissue to any decalcifying agent. The use of proprietary combined decalcifying fixative solutions should be avoided unless absolutely necessary to obtain rapid haematoxylin and eosin (H&E)-stained sections in an exceptionally urgent situation. If they must be used, it must be recognized that many other staining techniques will be unsuccessful although reticulin is generally well preserved.

Processing

Paraffin-embedding

One of the major advantages of this technique is that it can be used in virtually any diagnostic histopathology department using the automated processors used routinely for other histopathology specimens. The cytological detail is not as good as that seen in high quality plastic-embedded sections but, with care, excellent results can be obtained. The key to obtaining good results is co-operation between the pathologist interpreting the biopsy and the laboratory staff processing the sample, ensuring that careful attention is paid to the various steps involved in preparing histological sections. If sections are unsatisfactory, in most cases the problem lies in the fixation, decalcification, cutting or staining rather than in the processing itself.

Sections should be cut at no more than 3–4 µm thickness. If a focal lesion is suspected clinically, sections should be cut at multiple levels. H&E staining and a stain for reticulin (Gomori or Gordon and Sweet's stains) are usually performed on all speci-

mens. We also perform a Romanowsky stain (Giemsa or one of its variants) on all specimens. Although many pathologists do not use this routinely, it can be helpful in the identification of early erythroid precursors, plasma cells and mast cells and in distinguishing neutrophil and eosinophil granules. Almost all of the stains used routinely with other paraffin-embedded tissues may be employed with trephine biopsy specimens but, as mentioned previously, most enzyme histochemistry is unsuccessful because of irreversible denaturation of the enzymes during decalcification and processing. One exception is acid phosphatase activity which is sometimes retained. When hairy cell leukaemia is suspected, demonstration of tartrate-resistant acid phosphatase (TRAP) activity may be useful, although the recent introduction of monoclonal antibodies for the immunohistochemical detection of this enzyme in fixed tissues may offer a simpler technical alternative for many laboratories.

Plastic (resin)-embedding

Glycol methacrylate and methyl methacrylate are the most commonly used resins for embedding trephine biopsies. Both allow sections to be cut without decalcification, with preservation of excellent cellular detail and without the shrinkage artefacts that are prominent in most decalcified specimens. Resin-embedding allows staining by many enzyme histochemical techniques. All of the routine stains used with paraffin-embedded sections can be employed with resin sections although many require some modification of the method to optimize results. Because resins continue to polymerize over long periods of time, antigen retrieval techniques for immunohistochemistry need to be modified for older specimens. In general, progressively longer proteolysis or wet-heat exposure is needed as the resin becomes more highly polymerized.

Methods

Fixation, decalcification and paraffin-embedding

1 The trephine biopsy core should be expelled from the needle and placed directly into fixative solution. If touch preparations are needed, the core should be

transferred into fixative as quickly as possible after they have been prepared.

2 Leave the biopsy to fix in 10% neutral-buffered (pH 7.6) formol-saline for 24 h.

3 Decalcify overnight in 5% formic acid or 5% EDTA solution. Large cores may require up to 48 h, particularly if EDTA is used.

4 Wash in 70% alcohol.

5 Place back into formol-saline until required for processing.

6 Process routinely in an automated tissue processor with other histological samples.

7 Embed specimen in paraffin wax. Use of a high melting point (hard) wax, if feasible within the laboratory routine, may assist section cutting.

8 Cut sections at no more than 3–4 µm.

Aceto-zinc fixative method

Fixative solution

- Zinc chloride—12.5 g
- Formaldehyde (concentrated)—150 ml
- Distilled water—1000 ml
- Glacial acetic acid—7.5 ml

This can be prepared in advance and aliquotted into universal containers with appropriate hazard labelling. It is used in an identical manner to formol-saline, following the schedule described above.

Aceto-zinc fixative solution has a weak decalcifying action but the presence of zinc ions seems to stabilize nucleic acids and provides protection against the adverse effects on morphological preservation seen with some proprietary combined fixative-decalcifier solutions. Trephine biopsy cores still require further decalcification with organic acid or EDTA after fixation in aceto-zinc.

Resin-embedding (glycol methacrylate)

Materials

1 Monomer.

- 2-hydroxyl ethyl methacrylate—80 ml
- 2-butoxyethanol—8 ml
- benzoyl peroxidase—1 g

2 Activator.

- Polyethylene glycol 400—15 parts
- N-N*-dimethylaniline—1 part

3 Embedding mixture.

- Monomer—42 ml
- Activator—0.1 ml

Procedure

1 70% alcohol—two changes of 15 min each.

2 95% alcohol—two changes of 15 min each.

3 Absolute alcohol—two changes of 15 min each.

4 Glycol methacrylate monomer for 2 h.

5 Glycol methacrylate monomer second change—leave overnight.

6 Embed in embedding mixture and leave for several hours to polymerize.

Histochemical staining for paraffin-embedded sections

Haematoxylin and eosin

Solutions

1 Eosin 1% aqueous solution.

- Eosin—10 g
- Distilled water—1 litre

2 Harris's haematoxylin solution.

- Haematoxylin—5 g
- Ethyl alcohol—50 ml
- Ammonium or potassium alum—100 g
- Distilled water—1 litre
- Mercuric oxide red—2.5 g

Dissolve the alum in the distilled water, over heat, stirring frequently. Dissolve the haematoxylin in the alcohol and add to the alum solution. Bring to the boil while stirring. Remove from the heat and add the mercuric oxide. Mix and allow to cool. Filter into a glass stain bottle and the solution is ready for use. It is advisable to filter the solution at regular intervals of a few days, to avoid precipitates developing, and to prepare fresh solution on a weekly or fortnightly basis, depending on frequency of use.

3 Scott's tap water.

- Sodium hydrogen carbonate—3.5 g
- Magnesium sulphate—20 g
- Distilled water—1 litre

4 Acid alcohol.

- 0.5% hydrochloric acid in 70% alcohol

Procedure

Many laboratories use automated staining machines for bulk staining histological sections with H&E. Bone marrow biopsy sections stained in this way can give perfectly acceptable results. However, some laboratories prefer manual staining as this allows the timing of individual steps to be optimized for marrow sections.

- 1 De-wax sections with two changes of xylene.
- 2 Rehydrate sections using two changes of absolute alcohol, followed by 95% alcohol and wash briefly in running tap water.
- 3 Stain with haematoxylin solution for up to 5 min.
- 4 Wash in running tap water.
- 5 Differentiate in acid alcohol for approximately 5 s.
- 6 Wash in running tap water.
- 7 'Blue' in Scott's tap water for a few seconds.
- 8 Wash in running tap water.
- 9 Stain with eosin for approximately 5 min.
- 10 Wash in running tap water.
- 11 Dehydrate, clear and mount sections.

Giemsa

Solutions

- 1 1% aqueous acetic acid.
- 2 10% solution of Giemsa stain, freshly prepared in distilled water.

Procedure

- 1 De-wax sections with two changes of xylene.
- 2 Rehydrate sections with two changes of absolute alcohol, 95% alcohol and wash in running water.
- 3 Stain sections with Giemsa solution for 20 min.
- 4 Rinse in distilled water.
- 5 Dip sections quickly into 1% acetic acid.
- 6 Wash with distilled water.
- 7 Check the staining microscopically and if required restain.
- 8 Dehydrate, clear and mount sections.

Gordon and Sweet's technique for reticulin staining

Solutions

- 1 Acidified potassium permanganate solution.

- 0.5% aqueous potassium permanganate—95 ml
- 3% sulphuric acid—5 ml
- 2 2% aqueous oxalic acid.
- 3 5% aqueous ferric ammonium sulphate (iron alum).
- 4 5% aqueous sodium thiosulphate.
- 5 0.1% aqueous gold chloride.
- 6 Nuclear fast red.

0.1 g nuclear fast red in 100 ml 5% aluminium sulphate

7 Ammoniacal silver solution.

To 5 ml of 10% silver nitrate add concentrated ammonia drop by drop, mixing continuously, until the formed precipitate just redissolves. Add 5 ml of 3% sodium hydroxide, mix, and a black precipitate will form. Add concentrated ammonia, as described previously, until the precipitate just redissolves. Make the solution up to 50 ml with distilled water.

Procedure

- 1 De-wax sections with two changes of xylene.
- 2 Rehydrate sections with two changes of absolute alcohol, 95% alcohol and wash in distilled water.
- 3 Treat with potassium permanganate solution for 5 min.
- 4 Rinse in distilled water.
- 5 Bleach sections in 2% oxalic acid solution for 1 min.
- 6 Wash well in distilled water.
- 7 Treat sections with iron alum for 20 min.
- 8 Wash well in several changes of distilled water.
- 9 Treat with ammoniacal silver solution for approximately 10 s.
- 10 Wash well in distilled water.
- 11 Treat with 10% formalin for 1–2 min.
- 12 Wash well in distilled water.
- 13 Tone in gold chloride solution for up to 1 min.
- 14 Wash well in distilled water.
- 15 Treat with sodium thiosulphate solution for 2 min.
- 16 Wash well in distilled water.
- 17 Stain nuclei with nuclear fast red for 2–3 min.
- 18 Wash in distilled water.
- 19 Dehydrate, clear and mount sections.

Results

Reticulin fibres—black.

Collagen—yellow—brown (if sections are untuned; black, if toned).

Nuclei—red.

Note

Microscopic examination of sections at stage 10 is important since the staining can vary from section to section. If the fibres are not adequately stained, steps 7–10 can be repeated if the sections have not been toned. If non-specific silver deposition is a persistent problem, which appears to be the case in some laboratories, toning will give a cleaner result at the expense of losing differentiation between reticulin and collagen. Since alternative stains for collagen can be employed in individual cases when needed, this approach can be greatly preferable to everyday poor quality reticulin staining.

Periodic acid–Schiff stain

Solutions

- 1 1% solution of periodic acid in distilled water.
- 2 Schiff's reagent.
Pararosaniline C.I.—1 g
Distilled water—200 ml
Potassium metabisulphite—2 g
Concentrated hydrochloric acid—2 ml
Activated charcoal—2 g

Boil the distilled water, remove from the heat and add the pararosaniline. Allow to cool to 50°C and add the potassium metabisulphite. Mix and allow to cool to room temperature. Add the hydrochloric acid and activated charcoal, mix and leave overnight. Filter. The resulting liquid will be clear or straw-coloured. Store in a dark container at 4°C.

Procedure

- 1 De-wax sections with two changes of xylene.
- 2 Rehydrate sections with two changes of absolute alcohol, 95% alcohol and wash in distilled water.
- 3 Treat sections with periodic acid solution for 5 min.
- 4 Wash well in distilled water.
- 5 Treat with Schiff's reagent for 15 min.
- 6 Wash sections in running tap water for 10 min.

7 Counterstain the nuclei lightly with Mayer's haematoxylin (approximately 60 s).

8 Wash in tap water to 'blue' the haematoxylin (10 min).

9 Dehydrate, clear and mount sections.

Results

Periodic acid–Schiff (PAS)-positive material (neutral mucins and glycogen)—magenta.

Nuclei—pale blue.

Note

In histological sections of bone marrow, the following can be generally expected to be PAS-positive: (i) granulocytes (neutrophil series); (ii) megakaryocytes; and (iii) Russell bodies (in plasma cells).

Pre-treatment with diastase (see below) removes glycogen from the sections. Following diastase treatment neutrophils and megakaryocytes are no longer PAS-positive. The lack of neutrophil staining makes screening a section for small PAS-positive fungi such as *Histoplasma* much easier, and we generally prefer pre-treatment with diastase when using PAS to demonstrate such organisms.

Perls' reaction for iron

Solutions

- 1 Nuclear fast red.
0.1 g nuclear fast red in 100 ml 5% aluminium sulphate
- 2 Incubating solution.
Potassium ferrocyanide 2%—25 ml
Hydrochloric acid 2%—25 ml

Procedure

- 1 De-wax sections with two changes of xylene.
- 2 Rehydrate sections with two changes of absolute alcohol, 95% alcohol and wash in distilled water.
- 3 Treat sections with incubating solution for 30 min.
- 4 Wash well with several changes of distilled water.
- 5 Counterstain nuclei with nuclear fast red for 2 min.
- 6 Dehydrate, clear and mount sections.

Results

Ferric iron salts—blue.

Nuclei—red.

Note

Decalcification, whether by acid or EDTA, results in variable loss of stainable iron from tissue sections.

Histochemical staining for resin-embedded sections

Haematoxylin and eosin

Solutions

Mayer's Haem-alum.

Haematoxylin—1 g

Distilled water—1 litre

Ammonium or potassium alum—50 g

Sodium iodate—0.2 g

Citric acid—1 g

Chloral hydrate—50 g

Dissolve the alum, haematoxylin and sodium iodate in the distilled water by standing overnight at room temperature. Add the chloral hydrate and citric acid, mix and boil for 5 min. Mix and allow to cool. Filter into a glass stain bottle and the solution is ready for use.

All other solutions are prepared as described in the method for paraffin-embedded sections.

Procedure

- 1 Stain with Mayer's Haem-alum for up to 5 min.
- 2 Wash in running tap water.
- 3 Differentiate in acid alcohol for approximately 5 s.
- 4 Wash in running tap water.
- 5 'Blue' in Scott's tap water for a few seconds.
- 6 Wash in running tap water.
- 7 Stain with eosin for approximately 5 min.
- 8 Wash in running tap water.
- 9 Dehydrate, clear and mount sections.

Reticulin stain

Solutions

1 Silver solution.

10% silver nitrate—20 ml

10% potassium hydroxide—4 ml

Concentrated ammonia

Mix the silver nitrate and potassium hydroxide solutions together and a brown flocculant precipitate will appear. Add concentrated ammonia drop by drop until the precipitate disappears. Add silver nitrate solution drop by drop until the solution just discolours to a pale yellow-brown colour. Add six drops of ammonia. Filter into a Coplin jar. Add approximately 25 ml of distilled water.

2 1% aqueous potassium permanganate.

3 1% aqueous oxalic acid.

4 4% aqueous ferric ammonium sulphate (iron alum).

5 5% aqueous sodium thiosulphate.

6 Nuclear fast red.

0.1 g nuclear fast red in 100 ml 5% aluminium sulphate

Procedure

- 1 Treat sections with potassium permanganate solution for 10 min.
- 2 Rinse in distilled water.
- 3 Bleach sections in 1% oxalic acid solution for 1 min.
- 4 Wash well in distilled water.
- 5 Treat sections with iron alum for 10 min.
- 6 Wash well in several changes of distilled water.
- 7 Treat with silver solution for approximately 10 min.
- 8 Wash well in distilled water.
- 9 Treat with 10% formalin for 1–2 min.
- 10 Wash well in distilled water.
- 11 Treat with sodium thiosulphate solution for 2 min.
- 12 Wash well in distilled water.
- 13 Stain nuclei with nuclear fast red for 2–3 min.
- 14 Wash in distilled water.
- 15 Dehydrate, clear and mount sections.

Giemsa staining

We have found great difficulty in obtaining satisfactory Giemsa staining of resin-embedded sections. However, prior microwaving of the section produces excellent results.

Solutions

- 1 Staining solution.
Giemsa stain—1 ml
Phosphate buffer—2 ml
Distilled water—47 ml

2 Phosphate buffer.

To 20 ml of 0.1 M sodium hydrogen orthophosphate add 0.1 M disodium orthophosphate drop by drop until the pH reaches 5.1. **The buffer should be freshly prepared.**

Procedure

- 1 Place slides in water then transfer to Giemsa staining solution and microwave at 500 watts for 45 s. **Do not boil.**
- 2 Remove slide container from microwave and place in a preheated oven at 55°C for 15 min.
- 3 Rinse slides briefly in a solution of four drops of acetic acid in 100 ml of distilled water.
- 4 Rinse slides in clean absolute alcohol.
- 5 Clear and mount sections.

Immunohistochemical staining of paraffin-embedded sections (which have been fixed in 10% neutral buffered formol saline)***Streptavidin-biotin-peroxidase method*****Solutions**

- 1 Antibody diluent.
0.01 M phosphate-buffered saline (PBS) or Tris-buffered saline (TBS) pH 7.4–7.6, prepared with ultra-pure or distilled water. If necessary, this may be modified by the addition of 0.1% bovine serum albumin and 0.1% sodium azide to reduce background staining. However, peroxidase-linked reagents should be diluted in PBS/TBS which does not contain azide, since azide inhibits peroxidase activity.

2 Peroxidase development solution (freshly made immediately before use).

0.05% diaminobenzidine tetrachloride (DAB) in PBS with 0.1% (w/v) hydrogen peroxide. (Note: DAB is a possible carcinogen; for convenience and to minimize handling, it can be purchased ready-prepared with peroxidase in stabilized solution or tablet form.)

Procedure

1 Mount paraffin-embedded sections on slides pre-coated with poly L-lysine or other adhesive. If wet-heat pre-treatment is to be used, silanized slides are recommended. Negatively charged glass slides may also be used but do not provide reliable adhesion with wet-heat antigen retrieval techniques.

2 De-wax paraffin-embedded sections in xylene and rehydrate through graded alcohols.

3 Block endogenous peroxidase activity by incubation at room temperature, in a humidified staining tray, with two changes of freshly prepared 0.3% (w/v) H₂O₂ in methanol, for 15 min each. It is important to make up fresh peroxidase-blocking solution immediately before each incubation, as H₂O₂ activity is lost rapidly.

4 Pre-treat sections (antigen retrieval) with protease or wet-heat, as required for the antigen under investigation*. Proteolysis may be conducted at 37°C with freshly prepared trypsin solution (in PBS/TBS, pH 7.6, with added CaCl₂) or, more conveniently, at room temperature using a commercially prepared solution of Pronase (Dako, Ely, U.K.). Wet-heat methods generally employ a microwave oven at medium setting for approximately 25 min or a pressure cooker brought to full pressure for approximately 2 min; citrate solution at pH 6.0 or EDTA solution at pH 8.0 are used, depending on the particular antigen of interest. Precise conditions need to be established in each laboratory. It is important to note that decalcified bone marrow trephine biopsy sections, in general, require less intensive antigen retrieval than sections from non-decalcified tissues; it is usually most convenient to modify the various techniques by shortening the exposure time of sections.

5 Block possible non-specific background staining with 10% bovine serum albumin in PBS/TBS or non-immune serum from the species that is to pro-

vide the second antiserum (e.g. normal goat serum if the second antiserum is raised in a goat). Non-immune serum is usually diluted 1 in 20 (5%) in the standard antibody diluent. Sections should be incubated with blocking solution, in the humidified staining tray, at room temperature for 10–20 min.

6 Drain off the blocking serum solution but do not wash the sections. Apply the primary monoclonal antibody or polyclonal antiserum* at its optimal dilution (determined by prior titration) and incubate sections in the humidified staining tray for a predetermined standard time. The latter may vary from 30 min to overnight (e.g. 2 h at room temperature or overnight at 4°C).* Polyclonal antibodies are generally effective with relatively short incubations at room temperature; many monoclonal antibodies, when used with manual immunostaining techniques, require overnight incubation. Overnight incubation should always be carried out at refrigerator temperature (4°C) to minimize non-specific background staining. Protocols for automated immunostaining equipment often permit considerably shorter incubations with primary antibodies.

7 Allow sections to re-warm to room temperature, if necessary, and then rinse in three changes of PBS/TBS (5 min each). Remove excess buffer but keep the sections moist.

8 Dilute the appropriate second layer (biotinylated) antiserum in the antibody diluent. The second layer antiserum is chosen according to the species from which the primary antibody is derived, e.g. biotinylated goat anti-mouse Ig (when the primary antibody is a murine monoclonal antibody) or swine anti-rabbit Ig (when the primary antibody is a polyclonal rabbit antiserum).

9 Apply the diluted second layer antiserum to the sections and incubate at room temperature in a humidified staining tray for a period which is normally between 30 min and 1 h.* At this time, prepare streptavidin–biotin solution as described below in step 11, so that complexes have at least 30 min to form.

10 Rinse the sections in three changes of PBS/TBS (5 min each).

11 Add solutions of streptavidin and biotinylated peroxidase together in PBS/TBS at predetermined concentrations and leave the prepared solution to stand at room temperature for 30 min for complexes to form. Apply this solution to the sections for a

standard time (30 min to 1 h) in the humidified staining tray. New third layer reagents are now available that potentially offer even greater sensitivity than streptavidin–biotin complexes. Although these are not yet used routinely by most laboratories, tyramide catalysed biotinylation and mirror-image immune complex techniques may be of considerable value for demonstration of antigens expressed at very low concentrations by cells of interest.

12 Rinse sections in three changes of PBS/TBS (5 min each).

13 Develop the final coloured product by incubation of sections with the peroxidase development solution for 10 min at room temperature. The end-product of the reaction is an insoluble, dark brown precipitate.

14 Rinse sections in running tap water. Counterstain lightly with haematoxylin (30 s to 1 min) and allow to 'blue' in running tap water (5–10 min).

15 Dehydrate, clear and mount.

* Precise details of the use and duration of heat or protease pre-treatment, and of the appropriate antibody dilutions and duration for which they are applied, are not given in the above general method since these are variable. For example, there is considerable variation in the optimal dilution between antibodies supplied by different manufacturers and even between different batches of one antibody from a single source. We recommend that the manufacturer's directions be consulted but that, for any new batch of antibody, the optimal conditions are determined before diagnostic use. Empirically, it has been found that pre-treatment by either protease digestion or heating of sections may expose antigenic sites and permit immunohistochemical staining. The choice of pre-treatment method, the duration of exposure needed and the antigens requiring this treatment must be determined by experiment. Useful sources of additional reference are given in the list below. However, there is continuing rapid expansion in the range of antibodies available for immunohistochemistry and no published work in this field can be fully comprehensive. Current product catalogues from major commercial suppliers generally provide substantial technical guidance concerning techniques for use of their antibodies for immunohistochemistry in fixed tissue sections.

Acknowledgements

The aceto-zinc fixation method was kindly provided by Dr Robert Hasserjian, Department of Histopathology, Hammersmith Hospital, London.

Further reading

Bancroft JD, Cook HC and Turner DR. *Manual of Histological Techniques and Their Diagnostic Application*. Churchill Livingstone, Edinburgh, 1994.

- Brunning RD. Bone marrow specimen processing. In: Knowles DW (ed) *Neoplastic Haematopathology*. Williams & Wilkins, Baltimore, 1992.
- Erber WN, Willis JI and Hoffman GJ (1997) An enhanced immunocytochemical method for staining bone marrow trephine sections. *J Clin Pathol*, 50, 389–393.
- Leong AS-Y, Cooper K and Leong FJW-M. *Manual of Diagnostic Antibodies for Immunohistology*. Greenwich Medical Media, London, 1999.
- Li C-Y and Yam LT. Cytochemical, histochemical and immunohistochemical analysis of the bone marrow. In: Knowles DW (ed) *Neoplastic Haematopathology*. Williams & Wilkins, Baltimore, 1992.
- Mangham DC and Isaacson PG (1999) A novel immunohistochemical detection system using mirror image complementary antibodies (MICA). *Histopathology*, 35, 129–133.
- Mengel M, Werner M and von Wasielewski R (1999) Concentration dependent and adverse effects in immunohistochemistry using the tyramine amplification technique. *Histochem J*, 31, 195–200.
- Polak JM and van Norden S (eds) *Immunocytochemistry: Modern Methods and Applications*, 2nd edn. John Wright & Sons Ltd, Bristol, 1986.
- Sabattini E, Bisgaard K, Ascani S, Poggi S, Piccioli M, Ceccarelli C *et al.* (1998) The EnVision++ system: a new immunohistochemical method for diagnostics and research. Critical comparison with the APAAP, ChemMate, CSA, LABC, and SABC techniques. *J Clin Pathol*, 51, 506–511.
- Toda Y, Kono K, Abiru H, Kokuryo K, Endo M, Yaegashi H and Fukumoto M (1999) Application of tyramide signal amplification system to immunohistochemistry: a potent method to localize antigens that are not detectable by ordinary method. *Pathol Int*, 49, 479–483.

INDEX

Page numbers in *italics* refer to figures; those in **bold** refer to tables or boxes.

- ABL* oncogene 192
abnormal localization of immature precursors (ALIP) 173, 175, 182, 373, 413
ABO blood group H glycoprotein **67**
acetazolamide 405
acetic acid 474–5
aceto-zinc formalin solution 474, 476
 fixation method 476
actinomycosis 99
acute basophilic leukaemia 161–2
acute eosinophilic leukaemia 160–1, 162
acute erythroleukaemia (M6 AML) **142**, 154–6
 immunohistochemistry 71
 variant 154
 vs megaloblastic anaemia 166, 373
acute leukaemia
 cytochemical stains 53
 cytogenetic analysis 74, 75
 immunophenotyping 62, **63**
 pseudo-Gaucher cells 416
 reticulin fibrosis 132
 see also specific types
acute lymphoblastic leukaemia (ALL)
 aplastic presentation 241, 407
 classification 236
 common 238
 cortical T 287
 histiocytosis in 118–19
 L1 236–7
 L2 236, 237
 L3 236, 239, 281–2
 mature B-cell *see* Burkitt's lymphoma
 mature T 287
 molecular genetic analysis 85
 post-treatment flow cytometry 62
 pre-B 238
 precursor B-cell 236–41
 precursor T-cell 285–7
 pre-T 286
 pro-B 238
 pro-T 286
 stem cell transplantation 411
 vs AML 143, 159, 166
 vs other causes of thrombocytopenia 388
acute mast cell leukaemia 162–3, 221, 222, 225
acute megakaryoblastic leukaemia (M7 AML) **142**, 156–8
 acute myelofibrosis 143, 157, 158
 diagnostic problems 166–7
acute monoblastic leukaemia (M5a AML) **142**, 152–3, 154
 vs large cell non-Hodgkin's lymphoma 168
acute monocytic leukaemia (M5b AML) 119, **142**, 152–3, 154
acute monocytic/monoblastic leukaemia (M5 AML) 152–3
acute myeloblastic leukaemia (M1 and M2 AML) **142**, 144–7, 166
 basophilic (M2Baso) 161
 eosinophilic (M2Eo) 160
acute myelofibrosis *see* myelofibrosis, acute
acute myeloid leukaemia (AML) 141–68
 acute myelofibrosis 203
 aplastic anaemia evolving to 401, 405, 406, 407
 chemotherapy 396, 397
 clinical features 143
 cytochemistry 164
 cytogenetic analysis 74, 166
 de novo-type 166
 in Down's syndrome 157, 158, 408
 electron microscopy 86
 essential thrombocythaemia transforming to 211
 FAB classification 141, **142**
 G-CSF therapy 413
 granulomas 113
 hypoplastic 163–4, 165, 167–8, 177–8
 idiopathic hypereosinophilic syndrome and 382–3
immunocytochemistry and flow cytometry 164–5
immunohistochemistry 165–6
M0 **142**, 158–9, 166
M1 and M2 *see* acute myeloblastic leukaemia
M3 *see* acute promyelocytic leukaemia
M4 *see* acute myelomonocytic leukaemia
M5a *see* acute monoblastic leukaemia
M5b *see* acute monocytic leukaemia
M6 *see* acute erythroleukaemia
M7 *see* acute megakaryoblastic leukaemia
megaloblastic erythropoiesis 371
MIC classification 141, 166
MIC-M classification 141, 166, **167**
 with minimal evidence of myeloid differentiation (M0) **142**, 158–9, 166
molecular genetic techniques 83, 166
multiple myeloma following 333
myelofibrosis transformation to 202
 polycythaemia rubra transforming to 209
 problems and pitfalls 143, 166–8
 reticulin fibrosis 132
 systemic mastocytosis transforming to 221
 vs leukaemoid reactions 94
 vs myelodysplastic syndromes 169
 vs precursor B-ALL 240
 WHO classification 141–2, **143**
acute myelomonocytic leukaemia (M4 AML) **142**, 149–51
 basophilic (M4Baso) 149, 151, 161
 eosinophilic (M4Eo) 149, 150, 151, 160
acute panmyelosis with myelofibrosis 159–60, 166–7

- acute promyelocytic leukaemia 62, **142**, 147–9
hypergranular (M3 AML) **142**, 147–9
hypogranular (M3 variant AML) **142**, 147, 148, 149
- adenocarcinoma, metastatic 431, 436, 440–4, 451
- adenovirus infections 95, 96
- adriamycin 394
- adult T-cell leukaemia/lymphoma (ATLL) 285, 300–5, 464
acute **301**
chronic **301**
lymphoma-type **301**
smouldering **301**
- adventitial cells 5
- Afpipia felis* infection 127
- age
marrow cellular composition and **33**, **34–5**
marrow cellularity and **9**, **10**
- aggressive natural killer (NK)-cell leukaemia 290, 292, 293–4
- agranulocytosis 382, 397
- AIDS *see* HIV infection/AIDS
- Albers–Schoenberg disease (osteopetrosis) 468, 469–71
- alcian blue **59**
- alcohol intake, excess 117, 399–401
- Alder–Reilly anomaly 422
- ALIP *see* abnormal localization of immature precursors
- alkaline phosphatase
endogenous 65, 73
neutrophil 193
- alkaline phosphatase–anti-alkaline phosphatase detection system 73
- ALK protein **70**, 306–7, 309–10, 345
- alkylating agents 209, 333
- ALL *see* acute lymphoblastic leukaemia
- all-*trans* retinoic acid (ATRA) 148–9
- alpha-1-antitrypsin **66**
- α-heavy chain disease 355
- alpha-lipoprotein deficiency 420
- aluminium deposition 465, 466
- ε-aminocaproate 53, 225
- 5-amino-laevulinic acid synthesis 362
- AML *see* acute myeloid leukaemia
- AML1-ETO* fusion gene 147
- ammonium tetrathiomolybdate 399
- amplification, oncogene 78
- amyloidosis 426
AA-type 351
in idiopathic myelofibrosis 207
light-chain–associated (AL-type) 349–51, 352, 353–4
in lymphoplasmacytic lymphoma 262, 351
in multiple myeloma 336, 339, 341, 351
- primary 351
- anaemia
aplastic *see* aplastic anaemia
of chronic disease 373–4
in chronic infections 91
of chronic renal failure 466–7
congenital dyserythropoietic *see* congenital dyserythropoietic anaemia
Fanconi's 401, 404, 405, 407
haemolytic *see* haemolytic anaemia
iron deficiency 360–1
leuco-erythroblastic 430, 431
megaloblastic *see* megaloblastic anaemia
pernicious 371
in reactive plasmacytosis 116
refractory *see* refractory anaemia
sickle cell *see* sickle cell anaemia
sideroblastic 180, 361–3
in T-cell granular lymphocytic leukaemia 290, 291
thiamine-responsive 177, 362, 408
- anagrelide 207, 212
- anaplastic large cell lymphoma (ALCL)
B-cell 280, 306
null-cell type 306
T-cell 306–10
vs multiple myeloma 342–5
- anaplastic lymphoma-associated kinase *see* ALK protein
- angiocentric T-cell lymphoma 294
- angio-immunoblastic lymphadenopathy 116, 228
with dysproteinaemia (AILD) 297–8
- angio-immunoblastic lymphoma 297–300
- angiomatosis
bacillary 127
epithelioid 127
- angio-oedema, acquired 259, 356–7
- angiosarcoma 446–7, 448, 452
- anisocytosis 369, 371
- anorexia nervosa 130, 407, 413, 415
- anthracosis 423–4
- antibodies
in AML **165**
cross-reactivity between cell types 70–3
flow cytometry and immunocytochemistry 63–4
immunohistochemistry **66–7**, **68–70**
monoclonal *see* monoclonal antibodies
non-specific binding 65, 73
polyclonal 60
- anti-cancer chemotherapy 392, 393–6, 397, 407
- anti-cardiolipin antibodies 425
- anti-lymphocyte globulin 402–3, 405
- anti-phospholipid antibodies 127
- anti-thymocyte globulin 405
- aplasia, bone marrow 407
- aplastic anaemia 397, 401–7
acquired causes 401
bone marrow cytology 403
bone marrow histology 403–5
cytogenetics and molecular genetics 405
differential diagnosis 167–8, 178
idiopathic 401
inherited causes 401
paroxysmal nocturnal haemoglobinuria 408
peripheral blood 403
problems and pitfalls 241, 257, 405–7
radiation-induced 399
- arsenic toxicity 397, 398, 407
- artefacts 38–48
cytology 38–40
histology 40–8
mimicking bone disease 471
mimicking metastatic tumours 456
shrinkage 15–16, 41–3
- arterial thromboses 208, 211
- arteries 4
- arterioles 4
- Aspergillus (fumigatus)* 99, 103
- aspirates, bone marrow
artefacts 38–40
cellular composition 32–3
cytochemical stains 51–4
examination 35–6
flow cytometry 60, 61–2
guidelines and audit 38
immunocytochemistry 62
interpretation 34–8
reporting 36
routine stains 51
special diagnostic techniques 51–89
- aspiration biopsy 5–6
complications 6, 7
in lymphoproliferative disorders 231, 235
metastatic tumours 430–1
at site of trephine biopsy 47–8
vs trephine biopsy 7
- atherosclerosis, generalized 424–5
- ATLL *see* adult T-cell leukaemia/lymphoma
- audit, bone marrow examination 38
- Auer rods
detection 53
in M2 AML 144, 145

- in M3 AML 147
- in M4 AML 141, 150
- in M6 AML 155
- in myelodysplastic syndromes 168, 170, 173, 182, 183
- auto-immune disease
 - aplastic anaemia 401
 - bone marrow dysplasia 392
 - neutropenia 382
 - pure red cell aplasia 377
 - in stem cell transplantation 409, 410
- auto-immune lymphoproliferative disorder, with Fas deficiency 366, 392
- autopsy specimens 7
- avidin–biotin detection system 65, 73
- azathioprine 392, 394
- B5 solution 474
- babesiosis 103
- bacillary angiomatosis 127
- bacterial infection 90–4
 - bone marrow cytology 92
 - bone marrow histology 93–4
 - haemophagocytic syndromes 92, 93, 120
 - peripheral blood 90–2
 - problems and pitfalls 94
- band forms (band cells) 17
- normal counts **34–5, 36–7**
- basophilic leukaemia, acute 161–2
- basophils
 - normal counts **34–5, 36–7**
 - precursors 17, 18–19
- Batten's disease 419
- B-cell lymphocytosis, polyclonal 116, 249
- B-cell lymphoproliferative diseases 241–84
 - bone marrow infiltration 233–5
 - classification **232**
 - post-transplant **320, 321**
- B cells *see* B lymphocytes
- BCL1* gene 268, 269
 - in diffuse large B-cell lymphoma 275
 - in follicular lymphoma 264, 267
- BCL2* protein **69, 236**
 - detection problems 72, 73–4
- BCL6* gene 275
- BCL6* protein 275, 276
- BCR-ABL* fusion gene 83, 192, 197
- Bence-Jones protein 332, 346
- benign monoclonal gammopathy (monoclonal gammopathy of undetermined significance) 342, 346–7
- benzene 401
- Bernard–Soulier syndrome 386
- biopsy, bone marrow
 - open 7
 - scar of previous 40, 48, 49
 - at site of previous 47–8
 - at site of previous radiotherapy 40, 405, 406
 - for tumour staging 430–1, 452–5
 - see also* aspiration biopsy; trephine biopsy
- biotin, endogenous 65, 73
- Birbeck granules 86, 187
- bisphosphonates 341
- Blackfan–Diamond syndrome 377, 378, 379
- blasts
 - in M0 AML 158–9
 - in myelodysplastic syndromes 170
- bleeding tendency 143
- bleomycin 394
- blood supply, bone marrow 4–5
- 'blood tap' 204, 403, 431
- blood transfusion 411
- blood viscosity, increased 208, 209
- B lymphocytes 30
 - determination of clonality 75, 82–3, 85–6
 - EBV immortalization 319
 - immunohistochemistry **68–70, 72**
 - large polylobated (L and H cells) 317, 318
- bone 1–3
 - cancellous (trabecular) 1
 - compact 1
 - cortical 1
 - diseases 462–73
 - formation, new 128–30, 442, 443, 467
 - see also* osteosclerosis
 - lamellar 1, 2, 3
 - lesions
 - in aplastic anaemia 405
 - in multiple myeloma 332, 339–40
 - mass, measurement 463
 - medullary 1
 - morphometry 462
 - necrosis 128, 399, 469, 470
 - problems and pitfalls 471
 - remodelling 2, 318, 462
 - repair 469
 - resorption, in ATLL 304
 - woven 1, 2, 3
 - newly deposited 469, 470, 471
- bone marrow
 - blood supply 4–5
 - cellular composition 5, 32–4, **34–5, 36–7**
 - cellularity 7–10
 - distribution of haemopoietic 1
 - examination 5–7
 - normal 1–50
 - organization 1–5
- bone marrow transplantation 409–11
 - histiocytosis 118
 - lymphoid aggregates 116
 - short-term culture for 86–8
- Borrelia* infections 91
- Bouin's solution 59–60, 474
- bovine serum albumin 73
- breast carcinoma 430, 431
 - bone marrow histology 438, 439, 440–4
 - immunohistochemistry 451
 - osteosclerosis 469
 - staging 431, 454–5
- brucellosis 91, 92, 109
- Burkitt-like lymphoma 281, 283–4, 321
- Burkitt's lymphoma 281–4
 - AIDS-related 124, 127, 281, 282, 283, 284
 - classification 236, 238, 281
 - EBV-related **319**
 - endemic 281
 - leukaemic (L3 ALL) 236, 239, 281–2
 - post-transplant 321
 - sporadic 281
 - vs precursor B-lymphoblastic lymphoma 240
- burst-forming unit, erythroid (BFU-E) 87–8
- busulphan 196
- Cl esterase inhibitor deficiency 259, 356
- cachexia 130
- calcitonin **432, 451**
- calgranulin (calprotectin) **67, 143**
- calorie deficiency 413–15
- calprotectin **67, 143**
- cancer
 - bone marrow biopsy for staging 430–1, 452–5
 - metastatic *see* metastatic tumours
 - non-metastatic effects 391–2
 - see also* carcinoma; *specific types*
- Candida albicans* 99, **101**
- capillaries 4–5
- carcino-embryonic antigen **432, 455**
- carcinoid tumours 434, 435, 444–5, 451
- carcinoma 430
 - myelofibrosis secondary to 207–8, 438, 439
 - vs Hodgkin's disease 319
 - vs multiple myeloma 342–3, 345
 - vs myelodysplastic syndromes 177
 - see also* metastatic tumours; *specific types*
- cartilage 3, 4
 - extraneous 43, 44
- Castleman's disease 114, 127

- cat scratch disease, disseminated 127
- CD (cluster of differentiation)
antigens 60
- CD1a **67**, 187
- CD2 **69**
- CD3 **64**, **69**, 72
- CD4 **69**, 72
in angio-immunoblastic lymphoma 298
detection problems 73
in peripheral T-cell lymphoma 311
in prolymphocytic leukaemia 288–9
- CD5 **69**
in CLL 244–5, 248
detection problems 72, 73
in mantle cell lymphoma 271
- CD8 **69**, 288–9, 290
- CD10 **68**
in ALL 238, 240, 241
in follicular lymphoma 264
- CD14 **66**
- CD15 **66**, **70**, 318
- CD19 241, 245, 275
- CD20 **68**, 72, 240
in CLL 244, 248, 249
in diffuse large B-cell lymphoma 275, 276
in hairy cell leukaemia 257
- CD22 244
- CD23 **68**, 248
- CD30 **70**, 72
in anaplastic large cell lymphoma 309, 310
in Hodgkin's disease 318
- CD31 **433**, 452
- CD34 **66**, 73, 175–6, **433**, 452
- CD38 **68**, 337, 341
- CD42b **67**
- CD43 **69**, 72, 248
- CD45 **66**, **68**, 72, 240, 309
- CD45RA **68**, 72
- CD45RO **69**, 72, 341, 345
- CD55 408
- CD56 **69**, 337
- CD57 **69**
- CD59 408
- CD61 **67**, 71
- CD66e **66**
- CD68 **66**, 225, 227
- CD79a **64**, **68**, 72, 240, 458
in CLL 248, 249
in diffuse large B-cell lymphoma 275, 276
in hairy cell leukaemia 257
in multiple myeloma 337, 341
in Waldenström's macroglobulinaemia 349
- CD79b 64
- CD99 **433**, 452, 458
- CD117 **67**
- CD138 **68**, 337, 341, 345
- CD163 **66**
- CDw75 **68**
- cell counts, differential 33, 35
- cells
extraneous non-haemopoietic 39, 40
haemopoietic *see* haemopoietic cells
- cellular composition, bone marrow 5, 32–4, **34–5**, **36–7**
- cellularity, bone marrow 7–10
age-related changes 9, 10
assessment methods 8–9
variability 9–10
- central arteries 4
- central venous sinusoid 5
- centroblastic lymphoma, diffuse 275, 276–7
- centroblasts 263, 264, 266, 276
- centrocytes 263, 264, 265–6, 267
- centrocytic lymphoma *see* mantle cell lymphoma
- centromeric probes 76, 77, 78
- cerebriform cells 295, 302
- ceroid lipofuchsinosis 420
- CGL *see* chronic granulocytic leukaemia
- Charcot–Leyden crystals 160, 161, 384
- Chédiak–Higashi syndrome 123, 384, 385–6
- chemicals, haematological toxicity 397–9, 401
- chemotherapy
anti-cancer 392, 393–6, 397, 407
bone regeneration after 471
immunosuppressive 393–6
- children
aspiration biopsy 6
bone appearances 3, 4
cellular composition of marrow 33, 34, **34–5**
haematogones 31
metastatic tumours 430, 431, 434, 447–50
- chlorambucil 394
- chloramphenicol 397, 401
- chloro-acetate esterase stain (Leder's stain) 53, **59**, 60
in AML 145, 153, 155
- decalcification and 6–7, 60
- mast cells 26
- neutrophil haemopoiesis 19
- in systemic mastocytosis 224–5
- cholesterol
crystals 420, 425
embolism 424–5
- cholesteryl ester storage disease 419
- chromogranin 451, 452, 453
- chromosomal abnormalities, detection 74–5, 76–8
- chromosome paints, whole 76, 78, 81
- chromosome rearrangements, detection 76–7, 78, 81
- chronic disease, anaemia of 373–4
- chronic eosinophilic leukaemia 160, 199–202, 383, 384–5
- chronic granulocytic leukaemia (CGL) 192–8
accelerated phase 192, 197, 198
acute transformation 191, 192, 193–4
bone marrow cytology 193–4
bone marrow histology 194–7
cytogenetics and molecular genetics 197
myelofibrosis 196, 197, 202
neutrophilic variant 199
peripheral blood 192–3
problems and pitfalls 198, 212–13
pseudo-Gaucher cells 195–6, 416, 417
vs atypical CML 217, 218
vs systemic mastocytosis 222
- chronic lymphocytic leukaemia (CLL) 241–50
bone marrow cytology 244
bone marrow histology 245–8
classification 242
cytogenetics and molecular genetics 245
immunocytochemistry and flow cytometry 244–5
immunohistochemistry 73, **245**, 248–9
mixed cell type 243, 246–8, 249, 251, 271
molecular genetic analysis 75
μ-heavy chain disease 356
nodular partial remission 248
peripheral blood 242–4
problems and pitfalls 240, 249–50, 263, 267, 274
prognostic indicators 246–8
prolymphocytoid transformation 242, 243, 244, 248
Richter's (large cell) transformation 242, 243, 244, 248, 249
T cell 284, 289
- chronic megakaryocytic granulocytic myelosis 195, 202
- chronic myeloid leukaemia (CML) with eosinophilic component 199, **201**
juvenile (juvenile myelomonocytic leukaemia) 218–21
Ph-negative atypical (aCML) 192, 215, 216–18
Ph-positive 192
vs systemic mastocytosis 222

- chronic myelomonocytic leukaemia (CMML) 215–16
 classification **169**, 191, 215
 with eosinophilic component **201**
 vs atypical CML 215, 218
 vs leukaemoid reactions 94
- chronic natural killer (NK) lymphocytosis 113, 293, 294
- chronic neutrophilic leukaemia 198–9
- clear cell carcinoma 434, 435, 444
- CLL *see* chronic lymphocytic leukaemia
- clonality, determination of 75, 82–3, 85–6, 235
- Clostridium welchii* infections 91
- cluster of differentiation (CD) antigens 60
- CML *see* chronic myeloid leukaemia
- coccidioidomycosis 99
- coeliac disease 130, 371
- cold haemagglutinin disease (CHAD) 259, 260, 355
- collagen
 fibrosis 131, 133–4
 in ALL 239, 240
 in idiopathic myelofibrosis 205, 206, 207
 in metastatic carcinoma 438
 in multiple myeloma 339
- grading 54–6
 problems and pitfalls 59
 stains 57–9, 133
- colonic carcinoma 444, 455
- colony-forming units
 erythroid (CFU-E) 88
 granulocyte/monocyte (CFU-GM) 87
 megakaryocyte (CFU-Meg) 88
 mixed (CFU-mix) 87
- comparative genomic hybridization (CGH) 84
- congenital dyserythropoietic anaemia (CDA) 86, 368–71, 416
 type I **368**, 369, 370
 type II (Hempas) **368**, 369, 370
 type III **368**, 369, 370
- Congo red stain **59**, 351, 353
- connective tissue 3–5
- copper deficiency 177, 397–9, 407
- core biopsy *see* trephine biopsy
- corticosteroid therapy 463
- Coxiella burnetii* 94
- Coxsackie virus infections 96
- critical illness 392, 393
- cryoglobulinaemia
 idiopathic/essential 259, 355
 mixed 96, 259
 paraprotein-associated 355
 type I 355
 type II 355
- Cryptococcus neoformans* 99, 100, **101**, 110–12
- crystals
 cholesterol 420, 425
 cystine 421–2
 glove powder 39, 40
 immunoglobulin 333, 335, 337, 340
 oxalate 422, 423
 silica 424
- culture, bone marrow 86–8
 in fungal infections 102
 long-term 88
 for micro-organisms 88, 92
 short-term 86–8
- Cushing's syndrome 463
- cutaneous T-cell lymphoma 295–7
- cyclin D1 **69**
 detection problems 73
 in mantle cell lymphoma 270, 271
 in multiple myeloma 341
- cyclophosphamide 394
- cyclosporin (A) 402–3, 409
- cystinosis 421–2
- cyto-centrifuge preparations 62, 79
- cytochemical stains 51–4, 59
- cytogenetic analysis 6, 74–5
- cytokeratins **432**, 438, 440, 451, 455, 458
- cytokines 412–13
- cytomegalovirus (CMV) infections 97, 98, **98**
 bone marrow aplasia 407
 granulomas 110
 peripheral blood 95, 96
 in transplant recipients 409
- cytosine arabinoside 394
- cytotoxic T cells 289
- daunorubicin 394
- DBA44 257, 274
- deafness, sensorineural 177
- decalcification 6–7, 474–5
 histochemical staining and 6–7, 60
 immunohistochemistry and 65, 73
 incomplete 471
 iron staining and 54, 56, 361
 methods 475–6
 polymerase chain reaction and 82
- deletions, chromosomal 78
- deoxycoformycin 256
- desmin **433**, 452, 458
- diabetes mellitus 177, 420
- dialysis, chronic 465, 466
- diffuse large B-cell lymphoma 259, 275–80
 anaplastic variant 280
 centroblastic variant 275, 276–7
 cytogenetics and molecular genetics 275–6
 EBV-related 278, **319**
- immunoblastic variant 275, 276, 277–8, 279
- immunocytochemistry and flow cytometry 275, 276
- immunohistochemistry 72, 276
- intravascular variant 280, 281
- mediastinal (thymic) variant 280
- post-transplant 321
- primary effusion variant 280
- T-cell/histiocyte-rich 278–9, 280, 313
 vs Burkitt's lymphoma 284
 vs follicular lymphoma 267
 vs Hodgkin's disease 319
- disseminated intravascular coagulation 387
- DNA
 degradation 83
 quantification 64
 sequencing 84
 synthesis-inhibiting drugs 177
- Döhle bodies 90
- donor-lymphocyte infusion 411–12
- double esterase stain 151
- Down's syndrome (trisomy 21) 157, 158, 219, 407–8
- drugs
 haematological effects 392, 393–9, 401
 hypersensitivity reactions 114, 118, 377, 425
 'dry tap' 6, 204, 403, 431
- Dutcher bodies 117
 in lymphoplasmacytic lymphoma 261
 in multiple myeloma 336, 337, 338
 in Waldenström's macroglobulinaemia 349
- dyserythropoiesis
 chemotherapy-associated 394
 differential diagnosis 176–7
 in haemolytic anaemia 366
 in HIV infection/AIDS 125
 with polyclonal haemopoiesis 392–3
- dyserythropoietic anaemia, congenital *see* congenital dyserythropoietic anaemia
- dyskeratosis congenita 401, 405
- dysplasia, bone marrow
 secondary 182–3, 392–3
see also myelodysplastic syndromes
- EBV *see* Epstein–Barr virus
- EDTA (ethylene diamine tetra-acetic acid) 6, 474, 475
- ehrlichiosis 94, 95
 canine granulocytic 91
 human granulocytic 92
 human monocytic 91, 92
- elastase, neutrophil **66**, 70
- electron microscopy 86, 87

- EMA *see* epithelial membrane antigen
- embolism, cholesterol 424–5
- emperipolosis 22, 23, 24, 25
- endocarditis, bacterial 92
- endochondrial ossification 3, 4
- endogenous enzymes 65, 73
- endoplasmic reticulum, dilated 333, 335, 340
- endothelial cells 5, 39
- enzymes, endogenous 65, 73
- eosinophil count
- in idiopathic hypereosinophilic syndrome 382, 383
 - normal **34–5, 36–7**
- eosinophilia
- differential diagnosis 384–5
 - reactive 199
- eosinophilic fibrohistiocytic lesions 118
- eosinophilic granuloma 420
- eosinophilic leukaemia
- acute 160–1, 162
 - chronic 160, 199–202, 383, 384–5
- eosinophil major basic protein **67**
- eosinophils
- in acute eosinophilic leukaemia 160, 161, 162
 - in M4 AML 150
 - precursors 17, 18
 - in systemic mastocytosis 223, 225
- epithelial cells 39, 40
- epithelial membrane antigen (EMA) **70, 432**
- in anaplastic large cell lymphoma 309
 - in breast carcinoma 455
 - in multiple myeloma 341, 345
- Epstein–Barr early RNA (EBER) 80, 293, 298, 319
- Epstein–Barr virus (EBV) 319
- bone marrow aplasia 407
 - bone marrow histology 97, **98**
 - DNA amplification 82–3
 - haemophagocytosis 122
 - infection *see* infectious mononucleosis
- latent proteins (LMP-1 and EBNA-2) 319
- related lymphoproliferative disorders 96, 319–21
 - aggressive NK-cell leukaemia 293
 - classification **319**
 - diffuse large B-cell lymphoma 278, **319**
 - extranodal NK/T-cell lymphoma, nasal type 294, 295
 - Hodgkin's disease 315–16, **319**
 - post-transplant 319–20, 409, 410
- erythroblastic islands 12–14, 15, 16
- absence 379
 - in myelodysplastic syndromes 173
- erythroblasts 11–12
- early 12, 13, 14–15
 - identification 15–16
 - intermediate 12, 13
 - iron content 51–3
 - late 12, 13
 - in M6 AML 155, 156
 - orthochromatic 12, 371
 - polychromatophilic 12
 - shrinkage artefacts 15–16, 41–3
- erythrocytosis, idiopathic 211
- erythroderma, generalized 295
- erythroid burst-forming unit (BFU-E) assay 87–8
- erythroid cells
- in AML 154, 155–6
 - examination 38
 - identification 15–16
 - in infants 33, 34
 - normal counts **34–5, 36–7**
 - see also* myeloid:erythroid (M:E) ratio
- erythroid colony-forming unit (CFU-E) 88
- erythroid hyperplasia 210
- in congenital dyserythropoietic anaemia **368, 370**
 - in haemolytic anaemia 366, 367, 368
- erythroleukaemia, acute *see* acute erythroleukaemia
- erythrophagocytosis 119
- erythropoiesis 11–16
- cytology 11–12
 - disorders of 360–80
 - histology 12–16
- erythropoietin 87, 412, 467
- Escherichia coli* infections 91
- essential thrombocythaemia *see* thrombocythaemia, essential
- ethanol (alcohol) intake, excess 117, 399–401
- ethylene diamine tetra-acetic acid (EDTA) 6, 474, 475
- Evans syndrome 409
- Ewing's sarcoma
- bone marrow cytology 436, 437
 - bone marrow histology 447, 450, 451
 - immunohistochemistry 452
- EWS* gene 437
- extraneous cells 39, 40
- extraneous tissue 43–7, 456–7
- extranodal marginal zone B-cell lymphoma of MALT-type 271–2
- extranodal natural killer (NK)/T-cell lymphoma, nasal type 294–5
- Fabry's disease 419
- factor VIII-related antigen (von Willebrand factor) **67, 433, 452**
- faggot cells 147, 148
- familial haemophagocytic lymphohistiocytosis 119, 120, 121, 122, 123–4
- Fanconi's anaemia 401, 404, 405, 407
- Fas deficiency, auto-immune lymphoproliferative disorder with 366, 392
- fat cells 4, 29–30
- atrophy 130–1
 - in chronic granulocytic leukaemia 194–5
 - cytology 29, 31
 - damage to 419–20
 - histology 30
- fat content, marrow 5
- Felty's syndrome 290
- ferritin, serum 360, 373
- fibrinoid necrosis 425
- fibroblasts, in idiopathic myelofibrosis 205
- fibrosis, bone marrow 131–4
- bone marrow cytology 133
 - bone marrow histology 133–4
 - causes **132**
 - grading **57, 133**
 - nomenclature 59, 133
 - peripheral blood 133
 - problems and pitfalls 134
 - see also* collagen, fibrosis; myelofibrosis; reticulin, fibrosis
- filariasis 103, 104, 105
- films, wedge-spread 33, 35–6
- FISH *see* fluorescence *in situ* hybridization
- 5q- syndrome 171, 183
- fixation
- artefacts 39, 41, 42
 - histochemical staining and 59–60
 - immunohistochemistry and 73
 - methods 475–6
 - trephine biopsy specimens 474
- flaming cells 116, 333, 334, 336
- flow cytometry 60–2, 64
- antibodies 63–4
 - gating techniques 62–3
 - problems and pitfalls 61–2
 - vs immunocytochemistry 62–3
- fludarabine 411
- fluorescence *in situ* hybridization (FISH) 76–81
- double fusion (D-FISH) 77, 78
 - problems and pitfalls 80–1
 - triple colour 77, 79
- fluorescent immunophenotyping and interphase cytogenetics (FICTION) 78

- FMC7 251–2, 253, 264, 273
 focal lesions, detection of 10
 folic acid deficiency 177, 371, 394
 follicle centre cells 263
 small *see* centrocytes
 follicular lymphoma 263–7
 bone marrow cytology 264
 bone marrow histology 264–6
 cytogenetics and molecular genetics 83, 264, **265**
 diffuse 263
 granulomas 113, 266
 immunocytochemistry and flow cytometry 264, **265**
 immunohistochemistry **265**, 266–7
 large cell transformation 264, 276
 peripheral blood 263–4
 problems and pitfalls 263, 267, 271
 foreign body-type giant cells 107
 foreign substances, deposition of 423–4
 formalin
 fixation 60, 83
 pigment 41, 42
 formic acid 474–5
 formol-saline, neutral buffered 474
 fractures, healing 48
 frozen sections 6
 a-L-fucosyl residues **433**
 fungal infections 99–103
 bone marrow cytology 99–101
 bone marrow histology 101–2
 granulomas 110–12
 peripheral blood 99
 problems and pitfalls 102–3
 vs protozoal pathogens **101**
 fusion genes
 detection 86
 in normal people 84
 $\gamma\delta$ T-cell lymphoma, hepatosplenic 305, 307
 γ -heavy chain disease 355–6
 gastric cancer 431, 438, 455
 Gaucher cells 415, 416
 see also pseudo-Gaucher cells
 Gaucher's disease 415–16
 G-CSF 409, 412, 413
 gelatinous transformation 125, 130–1
 gender differences, chronic granulocytic leukaemia 192
 giant cells 107
 foreign body type 107
 Langhans' 107, 108, 109
 Giemsa stain 15, 26, 51, 60
 amyloid 351, 354
 in multiple myeloma 343
 techniques 477, 480
 glioblastoma multiforme 430
 glove powder crystals 39, 40
 glycogen 450, 451
 glycol methacrylate 7, 475, 476
 glycophorin A **67**
 glycophorin C **67**, 71
 glycosyl phosphatidylinositol (GPI) 408
 GM-CSF *see*
 granulocyte–macrophage colony-stimulating factor
 goblet cells 444
 Gomori's reticulin stain 57, 58, 133
 Gordon and Sweet stain 58, 477–8
 gouty tophus 43, 47
 graft-versus-host disease (GVHD) 407, 409, 411–12
 granulocyte colony-stimulating factor (G-CSF) 409, 412, 413
 granulocyte–macrophage colony-stimulating factor (GM-CSF)
 bone marrow culture 87
 therapy 118, 396, 410, 412–13
 granulocyte/monocyte colony-forming unit (CFU-GM) assay 87
 granulocytes
 examination 38
 in infections 92, 93
 left shift 90, 93
 polymorphonuclear 17, 19
 granulomas 107–14
 aetiology **107**
 bone marrow cytology 108
 bone marrow histology 108–14
 doughnut-type 109–10
 eosinophilic 420
 epithelioid 109, 112
 in follicular lymphoma 113, 266
 in HIV infection/AIDS 107, 125–7
 in Hodgkin's disease 110, 112–13, 318
 lethal midline 294
 lipid 108–9
 in multiple myeloma 112, 113, 339
 in mycobacterial infections 93, 108, 109, 110–11
 in parasitic diseases 105–6, 112
 peripheral blood 107
 in rickettsial infections 94
 in viral infections 97, 110
 granulopoiesis 11, 16–19
 cytology 16–17
 histology 18–19
 in megaloblastic anaemia 371
 grape cells 116
 grey platelet syndrome 386, 387
 Griscelli syndrome 408
 Grocott's methenamine silver stain (GMS) **59**, 107
 growth factors, haemopoietic 396, 412–13
 guidelines, bone marrow examination 38
 haematogones 31, 62, 241
 haematoxylin and eosin (H&E) stain 51, 475
 techniques 476–7, 479
 haemoglobin A **67**
 haemoglobin C disease 366, 367
 haemoglobin F 219, 220, 221, 364
 haemoglobin H disease 169, 365–6
 haemoglobinuria
 paroxysmal cold 96
 paroxysmal nocturnal 408–9
 haemolytic anaemia 366–7
 auto-immune 366, 367, 368, 409
 in angio-immunoblastic lymphoma 298
 in CLL 243, 244
 drug-induced 397
 in bone marrow transplantation 409, 410
 cold-induced 355
 in infections 91, 96, 97
 micro-angiopathic 394, 409, 410, 424, 425
 haemophagocytic
 lymphohistiocytosis, familial 119, 120, 121, 122, 123–4
 haemophagocytic syndromes 119–24
 in anaplastic large cell lymphoma 308
 in bacterial infections 92, 93, 120
 in Chediak–Higashi syndrome 123, 386
 conditions associated with **120**
 in HIV infection/AIDS 119, 121, 123, 124
 in malaria 105
 in malignant histiocytosis 119, 122–3, 185, 186
 in metastatic malignancy 450
 in viral infections 96, 97, 99, 120
 haemopoiesis
 distribution 1
 extramedullary 202
 in hairy cell leukaemia 255
 ineffective 141, 191
 haemopoietic cells 5, 11–27
 streaming 205, 206
 haemopoietic progenitor cells,
 assessment of numbers 86–8
 haemorrhage, complicating biopsy 7
 haemosiderin 14
 in plasma cells 53, 54, 56, 117, 362
 staining 51–3, 54–6
 haemozoin 105
 hair follicles, extraneous 43, 45

- hairy cell leukaemia 252–7
 bone marrow cytology 253
 bone marrow histology 253–6, 475
 granulomas 113
 immunocytochemistry and flow cytometry 253, 254
 immunohistochemistry 254, 257
 large cell transformation 253, 254, 256, 257
 osteosclerosis 468
 peripheral blood 253
 problems and pitfalls 228, 257, 274
 reticulin fibrosis 132, 255–6
 hairy cell variant leukaemia 257–8
 Hand–Schüller–Christian disease 186, 420
 α -heavy chain disease 355
 γ -heavy chain disease 355–6
 μ -heavy chain disease 356
 heavy chains, immunoglobulin **68**, 80
 genes *see IGH* genes
 helminth infections 103
 heparin, chronic use 463
 hepatitis, viral 96, 401
 hepatitis A 95
 hepatitis B 97
 hepatitis C 96, 97–9, 259, 355
 hepatomegaly 143, 202, 211
 hepatosplenic $\gamma\delta$ T-cell lymphoma 305, 307
 Hermansky–Pudlak syndrome 420
 herpes simplex infections **98**
 herpesvirus infections 97, 219–21
 histiocyte-rich B-cell lymphoma 279, 280
 histiocytes 20
 cystine crystals 421–2
 sea-blue 196, 365, 418, 420–1
 see also macrophages
 histiocytic lymphoma, true 186
 histiocytic medullary reticulosis 184
 histiocytosis 118–24, 184
 haemophagocytic syndromes 119–24
 Langerhans' cell 86, 186–8, 420, 457
 malignant *see* malignant histiocytosis
 sea-blue 420
 X 186
 histochemical stains 54–60, 476–80
 histological sections 6
 histoplasmosis (*Histoplasma capsulatum*) 99, 102–3
 granulomas 110
 histological features 101, **101**
 HIV infection/AIDS 124–7
 biopsy methods 7
 bone marrow cytology 124
 bone marrow histology 125–7
 Burkitt's lymphoma *see* Burkitt's lymphoma, AIDS-related
 diffuse large B-cell lymphoma 277–8, 279, 280
 flow cytometry 64
 fungal infections 99, 100, 101, 102, 103
 gelatinous transformation 125, 130
 granuloma formation 107, 125–7
 haemophagocytic syndromes 119, 121, 123, 124
 Hodgkin's disease 125, 127, 316
 Kaposi's sarcoma 128, 446
 mycobacterial infections 110–11, 124, 127, 417
 peripheral blood 95, 96, 124
 polymorphous lymphoid aggregates 116, 125, 126
 reactive plasmacytosis 342
 reticulin fibrosis 132
 Hodgkin's cells, mononuclear 314, 315, 316, 317–18
 Hodgkin's disease 313–19
 in AIDS/HIV infection 125, 127, 316
 bone marrow cytology 314–15
 bone marrow histology 316–18
 classical 314
 CLL transformation to 242
 cytogenetics and molecular genetics 315–16
 EBV-related 315–16, **319**
 graft-versus-host disease 411
 granulomas 110, 112–13, 318
 immunocytochemistry and flow cytometry 315
 immunohistochemistry **315**, 318
 lymphocyte-depleted 318
 mixed cellularity 315–16
 myelofibrosis secondary to 208
 nodular lymphocyte-predominant 314, 316, 317, 318
 nodular sclerosing 315–16, 317, 318
 peripheral blood 314
 problems and pitfalls 300, 313, 319
 pseudo-Gaucher cells 417
 WHO classification **234**, 314
 Howell–Jolly bodies 374, 394
 Howship's lacunae 2, 29, 30, 462
 in hyperparathyroidism 464–5
 in renal osteodystrophy 466
 Hoyeraal–Hreidarsson syndrome 401
 HTLV-I 284, 301
 proviral DNA 81
 human herpesvirus 6 (HHV6) 97, 377, 409
 human herpesvirus 8 (HHV8) 127, 280, 446
 human immunodeficiency virus infection *see* HIV infection/AIDS
 human serum 73
 human T-cell lymphotropic virus I *see* HTLV-I
 hydrochloric acid 475
 hydroxyurea (hydroxycarbamide) 196, 394, 395
 hyperbetalipoproteinaemia 420
 hypercholesterolaemia 419
 hyperchylomicronaemia 419
 hyperdiploidy 238, 342
 hypereosinophilic syndrome, idiopathic 201–2, 382–5
 hyperoxaluria (oxalosis) 422, 423
 hyperparathyroidism 464–5
 primary 134, 464
 secondary 464, 465
 hyperplasia, bone marrow 10
 hypochromia 362
 hypopituitarism 463
 hypoplasia, bone marrow 10, 393, 407
 see also aplastic anaemia
 hypoplastic acute myeloid leukaemia (AML) 163–4, 165, 167–8, 177–8
 hypoplastic myelodysplastic syndromes (MDS) 167–8, 178, 257, 406–7
 hyposplenism
 in bone marrow transplantation 410
 in essential thrombocythaemia 211, 212
 in sickle cell anaemia 374
 vs reactive thrombocytosis 389
 hypothermia 377, 392
 hypothyroidism 130, 407, 420, 469

IGH genes
 clonal rearrangements
 detection 85, 235
 in lymphoma 282, 315
 somatic hypermutation 75, 85
 iliac crest
 aspiration biopsy 5–6
 marrow cellularity 9, 10
 trephine biopsy 6
 immunoblastic lymphadenopathy 298
 immunoblastic lymphoma 275, 276, 277–8, 279
 multiple myeloma transformation to 333
 immunoblasts 244, 278, 279, 312
 immunocompromised patients
 Burkitt's lymphoma 281
 cytomegalovirus infection 96

- diffuse large B-cell lymphoma 277–8
- EBV-related lymphoproliferative disorders 319–21
- fungal infections 99, 101, 110
- parvovirus B19 infections 377
- immunocytochemistry 62
- antibodies 63–4
- problems and pitfalls 62
- vs flow cytometry 62–3
- immunodeficiency, congenital 116
- immunofluorescence flow cytometry *see* flow cytometry
- immunoglobulin
- affinity maturation 75
- crystals 333, 335, 337, 340
- heavy chains *see* heavy chains, immunoglobulin
- light chains *see* light chains, immunoglobulin
- monoclonal *see* monoclonal immunoglobulins
- surface membrane *see* surface membrane immunoglobulin
- immunohistochemistry 38, 64–74
- antigens and antibodies **66–7**, **68–70**
- interpretation 73–4
- in lymphoproliferative disorders 235
- non-specific staining 65
- problems and pitfalls 70–4
- techniques 480–1
- immunophenotyping 6, 60–74
- immunosuppressive therapy 393–6, 402–3, 405
- infections 90–107
- bone marrow aplasia 407
- bone marrow dysplasia 392
- opportunistic, in HIV infection/AIDS 125–7
- infectious mononucleosis 97, 319
- granulomas 110, 112
- peripheral blood 95, 96
- in situ* hybridization (ISH) 76–81
- intensive care patients 393
- interferon therapy 196, 253, 256
- interleukins 412
- intracranial tumours, metastatic 430
- intravascular large B-cell lymphoma 280, 281
- intravascular lesions 424–6
- intravenous drug abuse 468
- intravenous nutrition, with lipid emulsions 420
- inv(16)(p13q22) 149, 150, 151
- inversions, chromosome 78, 79
- iron
- deficiency 210–11, 214
- deficiency anaemia 360–1
- deposition in bone 466
- laden macrophages 401, 402
- overload 117
- serum 360, 373
- stain
- in myelodysplastic syndromes 168, 171, 180
- in thalassaemia 364
- see also* Perls' stain
- stores
- assessment 35–6, 51–3, 54–6
- deficient 360, 361
- in excess alcohol intake 400–1
- grading 51, **52**
- in megaloblastic anaemia 371
- problems and pitfalls 53, 56
- in sideroblastic anaemia 362
- irradiation *see* radiation therapy
- isochromosomes 78, 79
- isoniazid 397
- Jacobsen syndrome 387
- juvenile myelomonocytic leukaemia (JMML) 218–21
- Kaposi's sarcoma 127, 446–7, 452
- karyogram 74
- karyotype 74
- keratin 440
- Ki67 antigen **70**, 249
- in Burkitt's lymphoma 283
- in diffuse large B-cell lymphoma 276
- kinetoplast 106
- c-KIT* mutations 226
- Kleihauer test 219, 220
- knife
- blunt 43
- transfer of foreign tissue 43–7
- kwashiorkor 377, 413–15
- alpha-lactalbumin 451
- Langerhans' cell histiocytosis 86, 186–8, 420, 457
- Langerhans' cells 186–7, 188
- Langhans' giant cells 107, 108, 109
- large B-cell lymphoma
- diffuse *see* diffuse large B-cell lymphoma
- follicular lymphoma
- transformation to 264, 287
- hairly cell leukaemia
- transformation to 253, 254, 256, 257
- large bowel carcinoma 444
- large cell lymphoma
- CLL transformation to *see* Richter's syndrome
- vs M5a AML 168
- vs multiple myeloma 342–5
- see also* large B-cell lymphoma
- large granular lymphocyte (LGL) leukaemia 284–5, 289–93
- bone marrow cytology 290
- bone marrow dysplasia 392
- bone marrow histology 291, 292
- cytogenetics and molecular genetics 291
- immunocytochemistry and flow cytometry 291
- immunohistochemistry 291
- peripheral blood 290
- problems and pitfalls 291–3
- pure red cell aplasia 290, 377
- thrombocytopenia 290, 291, 387
- lateral cutaneous nerve of thigh 7
- lead poisoning 397
- Leder's stain *see* chloro-acetate esterase stain
- leishmaniasis (*Leishmania donovani*) **101**, 103, 104
- granulomas 105–6, 112
- leprosy (*Mycobacterium leprae*) 92, 94, 109
- lethal midline granuloma 294
- Letterer-Siwe disease 186, 420
- leuco-erythroblastic anaemia 430, 431
- leuco-erythroblastosis 91, 203, 204
- leukaemia
- bone marrow necrosis 128
- molecular genetic techniques 84–6
- see also* acute leukaemia; *specific types of leukaemia*
- leukaemoid reactions 93, 94
- neutrophilic 199, 200
- vs atypical CML 218
- vs chronic granulocytic leukaemia 194–5
- vs juvenile myelomonocytic leukaemia 219–21
- levamisole 73
- L and H cells 317, 318
- light chain-associated amyloidosis 349–51, 352, 353–4
- light chain deposition disease 351–4
- light chains, immunoglobulin **68**, 80
- in multiple myeloma 332, 341, 345
- lipid granulomas 108–9
- long-term culture-initiating cell (LTC-IC) assay 88
- lung carcinoma 430, 438–40
- small cell 436–7, 444, 445, 451, 454
- staging 431
- lupus erythematosus, systemic 382, 393, 401
- lupus erythematosus (LE) cells 393
- lymphadenopathy 143, 242, 314
- angio-immunoblastic *see* angio-immunoblastic lymphadenopathy
- immunoblastic 298

- lymph nodes
 in angio-immunoblastic lymphoma 298, 299
 discordant, in lymphoma 235
- lymphoblasts
 in ALL 236–7, 239
 in precursor T-lymphoblastic leukaemia/lymphoma 286, 287
- lymphocytes 30–1
 atypical, in viral infections 95–6, 97, 99, 124
 in CLL 242, 244
 cytology 30–1
 donor 411–12
 histology 31
 large granular (LGL) 289, 290, 291–3
 in mantle cell lymphoma 268, 270
 normal counts **34–5, 36–7**
 plasmacytoid 259–60, 261, 262, 333
 small 245, 246
 small cleft 263, 264, 265–6, 267
 in splenic marginal zone lymphoma 272–3
 in systemic mastocytosis 223–4
 villous 273
see also B lymphocytes;
 T lymphocytes
- lympho-epithelioid lymphoma 310–11
- lymphogranulomatosis X 298
- lymphohistiocytosis, familial
 haemophagocytic 119, 120, 121, 122, 123–4
- lymphoid aggregates, reactive (benign) 114–16
 in HIV infection/AIDS 116, 125, 126
 in myelodysplastic syndromes 178
- lymphoid cells 11
 examination 38
 immunohistochemistry **68–70**, 72–3
 vs malignant non-haemopoietic cells 457
- lymphoid follicles 31
- lymphoid hyperplasia, polymorphous 114–16, 312
- lymphoid nodules, reactive 235–6
- lymphoma
 in AIDS 124, 127
 bone marrow necrosis 128, 129
 classification 231, **232, 233**
 discordant 235
 haemophagocytosis 119, 122
 molecular genetics 75, 84–6, 235
 myelofibrosis secondary to 207–8
see also Hodgkin's disease; non-Hodgkin's lymphoma; *specific types*
- lymphoplasmacytic lymphoma 258–63, 347
 amyloid deposition 262, 351
 bone marrow cytology 260
 bone marrow histology 261–2
 cytogenetics and molecular genetics **260**, 261
 Gaucher-like cells 417
 immunocytochemistry and flow cytometry 260–1
 immunohistochemistry **260**, 262–3
 peripheral blood 259–60
 POEMS syndrome 356
 problems and pitfalls 228, 263, 267, 342
- lymphopoiesis 30–2
- lymphoproliferative disorders 231–331
 antibodies for immunophenotyping **64**
 bone marrow infiltration patterns 231–6
 diffuse 231–2
 focal 231
 interstitial 231
 mixed 232
 nodular and patchy 231
 paratrabeular 231
 problems and pitfalls 235–6
 random 231
 classification 231, **232, 233**
 cytochemistry 54
 EBV-related *see* Epstein–Barr virus (EBV), -related
 lymphoproliferative disorders
 familial auto-immune, with Fas deficiency 366, 392
 molecular genetics 75, 84–6, 235
 post-transplant 319–21, 409
- lysozyme **66**
- macrocytosis
 alcohol-induced 399, 400
 refractory 183
- macrophages 4, 19, 20
 cholesterol crystals within 420
 deposits of foreign substances 423–4
 in erythroblastic islands 11–12, 14
 examination 38
 foamy 109, 111, 418, 419–20
 fungi within 99, 101
 granuloma formation 107
 increased numbers *see* histiocytosis
 iron-laden 401, 402
Leishmania donovani within 104, 106
 in mycobacterial infections 94
 network of dendritic 20, 21
 sickle cells within 374, 375, 376
 in storage diseases 415
- tingible body 282–3
 vs malignant non-haemopoietic cells 457
see also monocytes
- macropolycytes 371
- major basic protein, eosinophil **67**
- malabsorption 463
- malaria 103, 104, 105, 392
- malignant histiocytosis 184–6
 differential diagnosis 99, 122–3, 186, 308
 haemophagocytosis 119, 122–3, 185, 186
- malnutrition 463
 protein-calorie 377, 413–15
- MALT-type lymphoma 271–2
- mantle cell lymphoma 267–71
 blastoid variant 268, 284
 cytogenetics and molecular genetics 74, 83, 268–9
 differential diagnosis 241, 250, 267, 271
 immunohistochemistry 73, **269**, 271
- marasmus 413
- marble bone disease (osteopetrosis) 468, 469–71
- marginal zone (B-cell) lymphoma 271
 extranodal MALT-type 271–2
 nodal 271, 274–5
 splenic 263, 267, 272–4
- Martius Scarlet Blue stain 57, **59**, 133
- mast cell diseases
 systemic *see* mastocytosis, systemic
 WHO classification **221**
- mast cell leukaemia, acute 162–3, 221, 222, 225
- mast cells 25–7, 117–19
 cytology 25–6
 histology 26–7
 increased numbers 117–19, 222
 in lymphoplasmacytic lymphoma 262
 in systemic mastocytosis 222–3, 224, 225
- mast cell tryptase **67**, 73, 162, 225, 457
- mastocytosis
 cutaneous 221, 228
 malignant 221
 systemic 118, 221–8
 acute transformation 191, 221
 bone marrow cytology 222–3
 bone marrow histology 223–6
 classification 192, **221**
 cytogenetics and molecular genetics 226
 and myelodysplastic/
 myeloproliferative disease 221

- osteosclerosis 224, 225, 468
 peripheral blood 214, 221–2
 problems and pitfalls 226–8
 prognostic groups 226
 vascular lesions 426
 vs angio-immunoblastic lymphoma 300
 vs hairy cell leukaemia 228, 257
 vs idiopathic hypereosinophilic syndrome 384
- 'maturation arrest' 94, 394, 395
- mature (peripheral) T cell lymphoma 285
- May–Grünwald–Giemsa (MGG) stain 31, 51, 145, 315
- May–Hegglin anomaly 386
- MDS *see* myelodysplastic syndromes
- measles 96
- mediastinal (thymic) B-cell lymphoma 280
- medulloblastoma 431
- megakaryoblasts 157–8
- megakaryocyte colony-forming unit (CFU-Meg) 88
- megakaryocytes 20–2
 artefacts 43
 assessment of numbers 21–2, 24–5
 bare nuclei 21, 22, 23–4
 'budding' 21
 in CGL 193, 194, 195, 196
 clusters 24, 125, 396
 emperipolesis 22, 23, 24, 25
 in essential thrombocythaemia 212
 examination 38
 in familial thrombocytosis 388
 hypoplasia 387
 in idiopathic myelofibrosis 204, 205, 207
 in infections 93
 in megaloblastic anaemia 371
 in myelodysplastic syndromes 171, 173–4, 175
 in polycythaemia rubra vera 210
 precursors 20
 stages of maturation 20–1
 in thrombocytopenia 387, 388
 vs Hodgkin's cells 319
 vs myeloma cells 343, 344
- megakaryocytic granulocytic myelosis, chronic 195, 202
- megakaryopoiesis 20–5
 cytology 20–2
 histology 23–5
- megaloblastic anaemia 371–3
 thiamine-responsive 362
 vs M6 AML 166, 373
- megaloblastic erythropoiesis 177, 371, 394, 395
- melanin 434, 445, 446
- melanoma 455
 amelanotic 445, 446
 associated antigens 432, 451
 bone marrow cytology 434
 bone marrow histology 445, 446
 immunohistochemistry 451, 458
- men, cellular composition of marrow 33, 36–7
- messenger RNA (mRNA)
in situ hybridization 80
 in RT-PCR 83
- metamyelocytes 17, 19
 giant 124, 371, 372
 normal counts 34–5, 36–7
- metaphase spreads 74
- metastatic tumours 420, 430–61
 bone marrow biopsy for detection 452–5
 bone marrow cytology 431–7
 bone marrow histology 438–50
 cytogenetics and molecular genetics 437
 immunocytochemistry 437
 immunohistochemistry 432–3, 451–2
 osteosclerosis 438, 439, 468–9
 peripheral blood 431
 problems and pitfalls 455–8
see also carcinoma; *specific tumours*
- methanolic hydrogen peroxide 73
- methotrexate 394, 395
- methyl methacrylate 7, 475
- micro-abscesses 295
- Micrococcus lysodeikticus* suspension 153
- microfilariae 103, 104, 105
- micromegakaryocytes
 in myelodysplastic syndromes 170, 171, 174, 175
 in polycythaemia rubra vera 210
- micro-organisms, bone marrow
 culture for 88, 92
- microsporidiosis 106
- milk-fat globulin, human 451
- minimal residual disease, detection of 83, 84
- mitochondrial cytopathies 177, 407
- mitomycin C 394
- mixed colony-forming unit (CFU-mix) 87
- MLL* gene 151, 153
- molecular genetic analysis 75–86
 in lymphoproliferative disorders 75, 84–6, 235
- monoblasts 19
 in AML 149, 151, 152–3, 154
 in malignant histiocytosis 184–5
- monoclonal antibodies 60
 in AML 165
 reactions with bone components 471
- monoclonal gammopathies 350
- monoclonal gammopathy of undetermined significance (MGUS) 342, 346–7
- monoclonal immunoglobulin deposition disease 352
- monoclonal immunoglobulins
 in lymphoplasmacytic lymphoma 259
 in monoclonal gammopathy of undetermined significance 346, 347
 in multiple myeloma 332, 341, 345
see also paraproteins
- monocytes 19, 20
 in AML 152, 153
 in atypical chronic myeloid leukaemia 217, 218
 in chronic myelomonocytic leukaemia 215
 normal counts 34–5, 36–7
see also macrophages
- monocytic sarcoma 184
- monocytoid B-cell lymphoma 274–5
- monocytopenia 19–20
 cytology 19–20
 histology 20
- mononuclear cells, atypical 95, 96
- monosomies, detection 76, 77, 81
- monosomy 7 syndrome, infantile 219
- morphometry, bone 462
- morular cells 116
- Mott cells 116, 118
 in multiple myeloma 333, 335, 337, 340
- MPD *see* myeloproliferative disorders
- MPO *see* myeloperoxidase
- mRNA *see* messenger RNA
- mucin 440, 442, 444
- mucopolysaccharidoses 422–3, 424
- mucosa-associated lymphoid tissue (MALT) lymphoma 271–2
- μ -heavy chain disease 356
- multiple myeloma 332–45
 amyloid deposition 336, 339, 341, 351
 bone marrow cytology 333–6
 bone marrow histology 337–41
 cryoglobulinaemia 355
 cytogenetics and molecular genetics 341–2
 diagnostic criteria 332
 Gaucher-like cells 417
 granulomas 112, 113, 339
 immunocytochemistry and flow cytometry 337
 immunohistochemistry 341
 neutrophilic leukaemoid reaction 199, 200
 non-secretory 332
 osteosclerosis 340, 341, 468

- multiple myeloma (*cont.*)
 peripheral blood 333
 POEMS syndrome 356
 problems and pitfalls 342–5, 347
 prognostic grading 340–1
 reticulin fibrosis 132, 339
 smouldering 332, 341
 stem cell transplantation 411
 transformation to immunoblastic lymphoma 333
- multiple organ failure 392
- muramidase (lysozyme) **66**
- muscle, extraneous 43, 45
- c-MYC gene 282
- mycobacterial infections 93–4
 granulomas 93, 108, 109, 110–11
 in HIV infection/AIDS 110–11, 124, 127, 417
- Mycobacterium avium intracellulare*, disseminated 109, 110–11
- Mycobacterium leprae* infection (leprosy) 92, 94, 109
- mycophenolate mofetil 392, 394–6
- mycoplasma infections 91
- mycosis fungoides 295–7
- myeloblasts 16, 17, 18
 in AML 144, 145, 149
 in M6 AML 155, 156
 normal counts **34–5, 36–7**
- myelocytes 16–17, 18–19
 normal counts **34–5, 36–7**
- myelodysplasia, secondary 183–4, 392–3
- myelodysplastic/myeloproliferative disorders 191, 215–21
 other 221
 of childhood 219
 unclassified 221, 227
 WHO classification 191–2
- myelodysplastic syndromes (MDS) 141, 168–88
 bone marrow cytology 171
 bone marrow histology 172–5
 clinical features 168
 cytochemistry 53, 171–2
 cytogenetics and molecular genetics 75, 176
 FAB classification 168, **169**
 G-CSF therapy 412
 haemoglobin H disease 169, 365
 hypoplastic, differential diagnosis 167–8, 178, 257, 406–7
 identified subtypes 179–88
 immunocytochemistry and flow cytometry 175
 immunohistochemistry 70, 71, 175–6
 M6 AML and 155
 megaloblastic erythropoiesis 371
 multiple myeloma transformation to 333
 peripheral blood 169–71
 post-transplant 410–11
 problems and pitfalls 176–8
 pseudo-Gaucher cells 416
 pure red cell aplasia 377, 380
 reticulin fibrosis 132, 174, 183
 sea-blue histiocytes 421
 systemic mastocytosis
 transforming to 221
 thrombocytopenia 178, 387
 vs congenital dyserythropoietic anaemia 371
 vs myeloproliferative disorders 191
 vs secondary myelodysplasia 392
 vs thalassaemia 364
 WHO classification 168–9
- myelofibrosis
 acute 202–3, 207
 in M7 AML 143, 157, 158
 acute panmyelosis with 159–60, 166–7
 in CGL 196, 197, 202
 chronic idiopathic 191, 202–8
 acute transformation 202, 207
 bone marrow cytology 204
 bone marrow histology 204–7
 cytogenetics and molecular genetics 207
 peripheral blood 203–4
 problems and pitfalls 166–7, 207–8, 213–14
 vs hairy cell leukaemia 257
 vs Hodgkin's disease 319
 vs systemic mastocytosis 227
- focal **132**
 generalized **132**
 with myeloid metaplasia 202
 nomenclature 59, 133
 primary 133, 202
 secondary
 to carcinoma 207–8, 438, 439
 to lymphoma 207–8
 to other MPD 202, 207, 210, 211
 vs metastatic tumours 458
see also fibrosis, bone marrow
- myeloid:erythroid (M:E) ratio 33, 34
 in CGL 193
 normal values **34–5, 36–7**
- myeloid cells 11, 33
 immunohistochemistry **66–7, 72**
- myeloid metaplasia
 agnogenic 202
 myelofibrosis with 202
- myelomatosis *see* multiple myeloma
- myeloperoxidase (MPO) 53, 64, **66**
 in AML 145, 151, 153, 155, 164
 in myelodysplastic syndromes 168, 172
 sensitivity 166
- myeloproliferative disorders (MPD) 191, 192–215
 idiopathic hypereosinophilic syndrome and 201–2, 382–3
 myelofibrosis secondary to 132, 134, 202, 207
 osteosclerosis 468
 other 221–8
 'transitional' 214–15
 unclassifiable 214–15, 227
 'undifferentiated chronic' 215
 vs idiopathic myelofibrosis 208
 WHO classification 191–2
- myelosclerosis 59
- MyoD1 antigen **433, 452**
- myogenin **433, 452**
- myoglobin **433, 452**
- naphthol AS-D chloroacetate esterase *see* chloro-acetate esterase
- α -naphthyl acetate esterase 53
 in AML 155, 157–8, 164
 in neuroblastoma 434
- α -naphthyl butyrate esterase 53, 157–8
- nasal type extranodal natural killer (NK)/T-cell lymphoma 294–5
- nasopharyngeal T-cell and NK-cell lymphomas **319**
- natural killer (NK)-cell leukaemia, aggressive 290, 292, 293–4
- natural killer (NK) cell lymphoproliferative diseases **233, 284–313**
- natural killer (NK) cells 289
 immunohistochemistry **68–70**
- natural killer (NK) lymphocytosis, chronic 113, 293, 294
- natural killer (NK)/T-cell lymphoma, extranodal, nasal type 294–5
- necrosis
 bone 128, 399, 469, 470
 bone marrow 127–30
 causes **128**
 in metastatic tumours 458
 radiation-induced 399
 vascular lesions 426
- needle biopsy *see* trephine biopsy
- neonates
 aspiration biopsy 5, 6
 cellular composition of marrow 33, **34**
 marrow cellularity 9
 neuroblastoma 431, 434–6, 437
 bone marrow histology 447–9
 immunohistochemistry 435, 452, 453
 staging 430–1, 452–4, 455
- neurofibromatosis 219
- neuronal lipofuchsinosis 419
- neurone-specific enolase 452, 453

- neutropenia 90
 auto-immune 382, 409
 refractory 180
 in T-cell granular lymphocytic leukaemia 290, 291, 382
- neutrophilia, in infections 90, 91
- neutrophilic leukaemia, chronic 198–9
- neutrophils
 in chronic myelomonocytic leukaemia 215
 hypersegmented 371
 left shift 90
 in myelodysplastic syndromes 169–70
 normal counts **34–5**, **36–7**
 precursors 17, 18–19
 toxic changes 90, 92, 94
- Nf1* gene 219
- NHL *see* non-Hodgkin's lymphoma
- Niemann–Pick disease 418
- nitric acid 475
- nitric oxide 393
- N-MYC* gene 437
- nodal marginal zone B-cell lymphoma 271, 274–5
- non-Hodgkin's lymphoma (NHL)
 bone marrow infiltration 235
 granulomas 112–13
 in HIV infection/AIDS 127
 pseudo-Gaucher cells 417
 vs metastatic tumours 458
 vs myelodysplastic syndromes 178
see also specific types
- non-specific antibody binding 65, 73
- non-specific esterases 53
 in AML 153, 164
 in myelodysplastic syndromes 171
- normoblast 11
- northern blot analysis 84
- NPM-ALK* fusion gene 309
- nutrient artery 4
- oesophageal cancer 455
- oestrogen receptor **432**, 451
- Omenn's syndrome 412
- opportunistic infections, in HIV infection/AIDS 125–7
- oral cancer 455
- osteitis fibrosa 464, 465
 cystica 465
- osteoblasts 1, 2, 27–9, 462
 cytology 27–8
 histology 28–9, 30
 vs carcinoma cells 456
- osteoclasts 1, 2, 27–9, 462
 in ATLL 304
 cytology 27–8
 histology 28–9
 in hyperparathyroidism 464
 in osteopetrosis 469, 470
 in Paget's disease 467, 468
- osteocytes 1, 2, 28, 29
- osteodysplasia, radiation-induced 399, 400
- osteogenesis imperfecta 471
- osteoid 2, 462, 464
 in hyperparathyroidism 464
 seams 462, 464
- osteolytic lesions, in multiple myeloma 332, 339–40
- osteomalacia 463–4
- osteomyelosclerosis 207, 468
- osteopetrosis 468, 469–71
- osteoporosis 462–3
 in multiple myeloma 332, 339–40, 341
 in systemic mastocytosis 224
- osteoprogenitor cells 2
- osteosarcoma 467
- osteosclerosis 7, 468–9
 in bone marrow fibrosis 131
 idiopathic 468, 469
 in idiopathic myelofibrosis 206
 in metastatic carcinoma 438, 439, 468–9
 in multiple myeloma 340, 341, 468
 in renal osteodystrophy 465–6
 in systemic mastocytosis 224, 225, 468
- oxalosis 422, 423
- p53 protein 62, **432**
- 'packed marrow' (diffuse infiltration) 231–2
 in megaloblastic anaemia 372
 in multiple myeloma 337, 338, 340
- Paget's disease of bone 134, 467–8, 471
- pancreatic cancer 455
- pancreatitis 419–20
- pancytopenia
 in AML 143
 chemotherapy-induced 393–4
- Pappenheimer bodies 169, 180, 374
- paraffin-embedded sections 6–7, 475–6
 artefacts 41–3
 decalcification 474–5
 histochemical staining 476–9
 immunohistochemical staining 480–1
 iron staining 56
- para-immunoblasts 245–6, 248
- paramyxoviruses 467
- paraproteins
 cryoglobulin 355
 in lymphoplasmacytic lymphoma 259, 262
 in monoclonal gammopathy of undetermined significance 346
 in multiple myeloma 332
- other syndromes associated with 349–57
- in Waldenström's macroglobulinaemia 347, 349, 350
- parasitic diseases 103–7
- parathyroid hormone-related protein 464
- parathyroid hormone-secreting tumours 391–2, 464
- paratyphoid 90
- 'paroxysmal' cold haemoglobinuria 96
- paroxysmal nocturnal haemoglobinuria 408–9
- parvovirus (B19) infections 96, 97
 bone marrow histology 97, **98**
 pure red cell aplasia 377
 bone marrow cytology 97, 378, 379
 bone marrow histology 97, 379, 380
 post-transplant 409, 410
- Pautrier's abscesses 295
- PAX3* and *PAX7* genes 437
- PCR *see* polymerase chain reaction
- peanut agglutinin 187
- Pearson's syndrome 362, 407, 408
- Pelger–Huët anomaly, acquired 170, 173, 394
- penicillamine 399
- Penicillium marneffei* 99, 100, **101**, 103
- periodic acid-Schiff (PAS) 53, **59**
- peripheral T-cell lymphoma 285
 not otherwise characterized 285, 310–13
 unspecified 285, 311
 vs Hodgkin's disease 313, 319
- Perls' stain 14, 478–9
 aspirates 51–3, 54, 56
 trephine biopsy sections 54–6
- pernicious anaemia 371
- peroxidase, endogenous 65, 73
- phagocytic reticulum cells 4
- phenytoin therapy 116
- Philadelphia (Ph) chromosome (t(9;22)(q34;q11))
 in ALL 239
 in chronic granulocytic leukaemia 192, 197
 -positive essential thrombocythaemia 211, 212, 214
- phosphorus-32 (³²P) 209
- PIG-A* gene 408
- plasmablasts 334, 339, 342
- plasma cell leukaemia 333, 345–6
de novo or primary 345
 secondary to multiple myeloma 345
- plasma cell neoplasia
 acquired angio-oedema with 259, 356–7
 in AIDS 127

- plasma cells 31–2
 around capillaries 337
 cytological abnormalities 116–17
 cytology 31
 haemosiderin in 53, 54, 56, 117, 362
 histology 32
 immunohistochemistry 71
 in light chain-associated amyloidosis 351
 in light chain deposition disease 352
 in lymphoplasmacytic lymphoma 261
 in monoclonal gammopathy of undetermined significance 346
 in multiple myeloma 332, 333, 336, 342
 normal counts **34–5, 36–7**
 in plasma cell leukaemia 345, 346
 vs metastatic tumours 458
 vs osteoblasts 27
 in Waldenström's macroglobulinaemia 348–9
- plasmacytic satellitism 93, 117
- plasmacytoid lymphocytes 259–60, 261, 262, 333
- plasmacytoma, solitary 356
- plasmacytosis
 in infections 93
 reactive 116–17, 337, 342
- plastic (resin)-embedded sections 7, 475
 decalcification 474
 histochemical staining 479–80
 iron stain 54
 methodology 476
- platelets
 formation 21, 23
 in myelodysplastic syndromes 171
- pleomorphic medium-sized T-cell lymphoma 310–11
- pleomorphic small T-cell lymphoma 310–11
- ploidy, megakaryocytes 20
- PML protein 62
- Pneumocystis carinii* 105, 107
- pneumothorax 7
- POEMS syndrome 356, 468
- poikilocytes, teardrop 203, 204
- poikilocytosis 203, 369, 371
- polyarteritis nodosa 425
- polyclonal antibodies 60
- polyclonal B-cell lymphocytosis 116, 249
- polycythaemia
 primary proliferative *see*
 polycythaemia rubra vera
 pseudo- or relative 209, 210
 secondary 208–9, 210–11
- polycythaemia rubra vera (PRV)
 191, 208–11
 acute transformation 209
 bone marrow cultures 88
 'burnt out' or 'spent phase' 209
 myelofibrosis secondary to 202, 203, 210
 problems and pitfalls 210–11, 213–14
 'transitional state' 209
- polymerase chain reaction (PCR) 75, 81–3
 detection of clonality 85–6
 detection of fusion genes 86
 genomic or DNA-PCR 82
in situ 82
 long and accurate (LA-PCR) **84**
 long-range **84**
 in lymphoproliferative disorders 235, 236
 modifications 83, **84**
 multiplex 83, **84**
 nested **84**
 problems and pitfalls 83
 real-time (RQ-PCR) 83, **84**
 reverse transcriptase *see* reverse transcriptase polymerase chain reaction
- polymorphonuclear granulocyte 17, 19
- polymorphous lymphoid hyperplasia 114–16, 312
- polyvinyl pyrrolidone 420
- popcorn (L and H) cells 317, 318
- post-transplant lymphoproliferative disorders 319–21, 409
 classification **320**
 monomorphic **320**, 321
 polymorphic 321
- precursor B-lymphoblastic leukaemia/lymphoma 236–41
 bone marrow cytology 236–7
 bone marrow histology 239–40
 cytogenetics and molecular genetics 238–9
 immunocytochemistry and flow cytometry 237–8
 immunohistochemistry **238**, 240
 peripheral blood 236
 problems and pitfalls 240–1
see also acute lymphoblastic leukaemia
- precursor T-lymphoblastic leukaemia/lymphoma 285–7
- pregnancy 401
- primary effusion lymphoma 280
- primitive neuro-ectodermal tumours (PNET) 436, 437, 447, 450
- probes 76
 centromeric 76, 77, 78
- processing
 artefacts 41–3
 trephine biopsies 6–7, 475–6
- pro-eosinophilic granules 17
- proerythroblasts 12, 13
 in pure red cell aplasia 377, 378, 379, 380
 vs myeloblasts 16
- progenitor cells, haemopoietic, assessment of numbers 86–8
- progesterone receptor **432**, 451
- prolymphocytes
 in B-cell prolymphocytic leukaemia 251
 in CLL 243, 244, 245–6, 248
- prolymphocytic leukaemia (PLL)
 B-cell (B-PLL) 250–2, 271, 288
 classification 242, 250
 T-cell (T-PLL) 252, 287–9
- promonocytes 19
- promyelocytes 16, 17, 18
 in acute promyelocytic leukaemia 147, 148
 normal counts **34–5, 36–7**
- prostate carcinoma 430, 431, 433, 438
 bone marrow histology 439, 440, 441, 442, 443
 immunohistochemistry 451
 osteosclerosis 469
- prostate-specific antigen **432**, 451
- prostatic acid phosphatase **432**, 451
- protein-calorie malnutrition 377, 413–15
- protein gene product 9.5 (PGP.9.5) **432**, 451, 452, 454, 458
- proteins, non-specific antibody binding 73
- protozoal pathogens, vs fungal infections **101**
- Prussian blue stain *see* Perls' stain
- pseudo-Gaucher cells 416–17
 in CGL 195–6, 416, 417
 in congenital dyserythropoietic anaemia 369
 in thalassaemia 365
- pseudo-Pelger-Huët anomaly 170, 173, 394
- pseudophagocytosis (emperipolesis) 22, 23, 24, 25
- pure red cell aplasia *see* red cell aplasia, pure
- Q fever 94, 109–10
- 5'-RACE (rapid amplification of cDNA ends) **84**
- radiation therapy (irradiation) 399, 400, 401
 biopsy at site of previous 40, 405, 406
- RAS mutations 219

- reactive lymphoid aggregates 114–16
- reactive nodular hyperplasia 235–6
- red cell agglutination 260
- red cell aplasia, pure 376–80
- in CLL 243, 244
 - constitutional (Blackfan–Diamond syndrome) 377, 378, 379
 - in parvovirus infections *see* parvovirus (B19) infections, pure red cell aplasia
 - in T-cell granular lymphocytic leukaemia 290, 377
- red marrow 1
- Reed–Sternberg cells 314–15, 316–17, 318
- cells resembling 248, 249, 279
 - variant forms 317
 - vs malignant non-haemopoietic cells 457
- refractory anaemia (RA) **169**, 179
- with excess of blasts (RAEB) **169**, 181–2
 - with excess of blasts in transformation (RAEB-T) **169**, 182–3
 - with ringed sideroblasts (RARS) **169**, 172, 177, 180–1
- refractory cytopenia **169**, 179–80
- relapsing fever 91
- renal failure, chronic 130, 464, 465
- anaemia of 466–7
- renal osteodystrophy 134, 465–7
- resin-embedded sections *see* plastic (resin)-embedded sections
- restriction endonucleases 81
- reticulin 5
- fibrosis 59, 131–4
 - in ALL 239
 - in CGL 196
 - in hairy cell leukaemia 132, 255–6
 - in HIV infection/AIDS 125, 126
 - in Hodgkin's disease 318
 - in idiopathic myelofibrosis 204–5
 - immunophenotyping 61, 65
 - in lymphoma 235
 - in metastatic carcinoma 438
 - in multiple myeloma 132, 339
 - in myelodysplastic syndromes 132, 174, 183
 - in polycythaemia rubra vera 210
 - in systemic mastocytosis 225
 - grading 54–6
 - problems and pitfalls 59
 - stains 38, 51, 57–9, 475
 - techniques 477–8, 479
- reticulocytes 12
- reticulum (reticular) cells 4, 184–5
- atypical 317–18
- retinoblastoma 430, 447
- all-*trans* retinoic acid (ATRA) 148–9
- reverse transcriptase-polymerase chain reaction (RT-PCR) 82, 83
- detection of fusion genes 86
 - modifications **83**, **84**
 - problems and pitfalls 83–4
- rhabdomyosarcoma 431, 436, 437
- bone marrow histology 447, 449–50
 - immunohistochemistry 452
- rheumatoid arthritis 115, 116, 290, 293
- Richter's syndrome (large cell transformation) 242, 243, 244, 248, 249
- ricketts 464
- rickettsial infections 92, 94
- ring sideroblasts 52, 54, 171–2
- in excess alcohol intake 400
 - in refractory anaemia 179
 - in refractory anaemia with ringed sideroblasts 172, 180, 181
 - refractory anaemia with *see* refractory anaemia (RA), with ringed sideroblasts
 - in secondary myelodysplasia 393
 - in sideroblastic anaemia 362, 363
- Rochalimaea* infection 127
- Rocky Mountain spotted fever 94
- Romanowsky stain 51, 475
- rosettes, tumour cell 434–6, 449
- rough endoplasmic reticulum-associated antigen **68**
- rubella 96
- Russell bodies 116, 117
- in lymphoplasmacytic lymphoma 261
 - in multiple myeloma 336, 337, 338, 339
 - in Waldenström's macroglobulinaemia 349
- S100 protein 187, **432**, 451
- San Filippo syndrome 424
- sarcoidosis 113–14
- sarcoma 445–7, 452
- scars, previous biopsy 40, 48, 49
- Schwachman–Diamond syndrome 401
- sea-blue histiocytes 196, 365, 418, 420–1
- sea-blue histiocytosis 420
- sections, trephine biopsy *see* trephine biopsy, sections
- serous (gelatinous) degeneration (atrophy) 125, 130–1
- severe combined immunodeficiency 411
- Sézary cell leukaemia 295
- Sézary cells 86, **87**, 295, 296
- Sézary's syndrome 295–7
- Shigella infections 91
- shrinkage artefact 15–16, 41–3
- α -sialoglycoprotein **67**
- β -sialoglycoprotein **67**
- sickle cell anaemia 374–6, 425–6
- foamy macrophages 419, 420
 - peripheral blood 374, 377
- sickle cell/ β thalassaemia 374, 375
- sickle cell/haemoglobin C disease 374
- sickle cells 374, 375, 376, 425–6
- sideroblastic anaemia 361–3
- congenital (inherited) 362, 363
 - primary acquired 180
 - secondary 362
- sideroblastic erythropoiesis 169, 171
- drug-induced 397
 - refractory 183
 - and thrombocytosis 221
- sideroblasts 52, 53
- abnormal 52, 54–6, 171–2, 362, 363
 - ring *see* ring sideroblasts
- signet ring carcinoma 457–8
- signet ring cells 261–2, 440
- silica crystals 424
- silver-impregnation technique 57
- sinusoids 5
- in bone marrow fibrosis 133
 - in idiopathic myelofibrosis 204, 205–6
 - megakaryocytes and 23
 - in polycythaemia rubra vera 210
- skin
- extraneous 43, 44, 456
 - mastocytosis 221, 228
- small cell carcinoma of lung 436–7, 444, 445, 451, 454
- small cell tumours of childhood 431, 434, 447–50, 458
- small lymphocytic lymphoma 241–50
- bone marrow cytology 244
 - bone marrow histology 248
 - classification 242
 - peripheral blood 244
 - see also* chronic lymphocytic leukaemia
- smear cells 242, 243
- smudge (smear) cells 242, 243
- sodium azide 73
- soft tissue tumours 430
- Southern blot analysis 75, 81, 82
- detection of clonality 85–6
- spectral karyotyping (SKY) 78–9
- spectrin **67**
- spherocytosis, hereditary 377
- spindle cell tumours 445–7, 451–2
- splenic lymphoma with villous lymphocytes (SLVL) 272–4

- splenic marginal zone lymphoma 263, 267, 272–4
- splenomegaly 143, 202, 211
- squamous cell carcinoma 430, 436, 438–40
- squashed bone marrow fragments 33, 36
- staging, solid tumour 430–1, 452–5
- staining techniques
cytochemical 51–4, 59
histochemical 54–60
routine 51
- ‘starry sky’ appearance 282–4
- starvation 407, 413–15
- stem cell factor 412
- stem cells
long-term culture 88
myeloid 11
- stem cell transplantation 402–3, 409–11
allogeneic 409
autologous 409–11
flow cytometry 64
rejection 409, 410
short-term culture for 86–8
- sternum
aspiration biopsy 5
marrow cellularity 9, 10
- stomach cancer 431, 438, 455
- stomatocytes 399–400
- storage cells 415–24
- storage diseases 415–24
- streptavidin–biotin detection system 65, 73
- streptavidin–biotin–peroxidase method 480–1
- stroma, bone marrow 3–4, 38
- Sudan black B (SBB) 53
in AML 145, 151, 153, 155
in myelodysplastic syndromes 168, 172
- surface membrane immunoglobulin (SmIg) 62
in B-cell lymphoproliferative disorders 244, 251, 253, 264, 268
in multiple myeloma 337
- sweat glands 43, 45, 46, 456
- syndecan (CD138) 68, 337, 341, 345
- synovium 43, 46
- systemic lupus erythematosus 382, 393, 401
- t(1;19)(q23;p13) 238–9
- t(1;22)(p13;q13) 158
- t(2;5)(p23;q35) 306, 309
- t(6;9)(p23;q34)
M1 and M2 AML 144, 145, 147
M4 AML 149, 151
- t(8;16)(p11;p13) 153
- t(8;21)(q22;q22) 144, 145, 146–7
- t(9;22)(q34;q11) *see* Philadelphia chromosome
- t(11;14)(q13;q32) 268
- t(11;18)(q21;q21) 271
- t(11;22)(q13;q11) 269
- t(12;21)(q12;q22) 239
- t(14;18)(q32;q21) 263, 264
- t(15;17)(q22;q21) 149
- t(16;16)(p13;q22) 149, 150, 151
- tachyzoites 106
- Tangier disease 419
- target cells 399–400
- tartrate-resistant acid phosphatase (TRAP) 54, 68
in Gaucher’s disease 415, 416
in hairy cell leukaemia 252, 253, 257, 475
in Langerhans’ cell histiocytosis 187
osteoclasts 29
- T-cell granular lymphocytic leukaemia 289–93, 294
neutropenia 290, 291, 382
pure red cell aplasia 290, 377
see also large granular lymphocyte (LGL) leukaemia
- T-cell/histiocyte-rich B-cell lymphoma 278–9, 280, 313
- T-cell lymphoproliferative diseases 284–313
bone marrow infiltration 233–5, 285
classification 233, 284–5
differential diagnosis 184, 285
post-transplant 320, 321
- T-cell receptor (TCR)
β chain 69
γδ 305
genes *see* TCR genes
- T cells *see* T lymphocytes
- T-chronic lymphocytic leukaemia 284
- TCR genes
clonal rearrangements
in angio-immunoblastic lymphoma 298
detection 85, 235
in hepatosplenic γδ T-cell lymphoma 305
in precursor T-lymphoblastic leukaemia/lymphoma 287
in T-cell granular lymphocytic leukaemia 291
somatic hypermutation 75, 85
- terminal deoxynucleotidyl transferase (TdT) 68, 237, 240, 241
- tetracycline labelling 462, 464
- thalassaemia
intermedia 363–4
major 364–5, 416
trait 363–4
- thesaurocytes 116
- thiamine-responsive anaemia 177, 362, 408
- thiazide diuretics 387
- Thorotrast (thorium dioxide) 424, 448
- thrombi 425, 426
- thrombocythaemia, essential (ET) 191, 211–14
bone marrow cultures 88
myelofibrosis 202, 211
Ph-positive 211, 212, 214
vs CGL 198
vs familial thrombocytosis 388–9
vs idiopathic myelofibrosis 208
vs reactive thrombocytosis 389
- thrombocytopenia
acquired 387–8
amegakaryocytic
antibody-mediated 387, 388
constitutional 386, 401
auto-immune 387–8
in CLL 243, 244
congenital 386–7
in HIV infection 124
inherited 386–7
in myelodysplastic syndromes 178, 387
secondary to intra-uterine damage 386, 387
in T-cell granular lymphocytic leukaemia 290, 291
in viral infections 96, 97
- thrombocytopenia-absent radii (TAR) syndrome 386–7
- thrombocytopenic purpura
auto-immune 386, 409
thrombotic 387, 424, 425
- thrombocytosis
in essential thrombocythaemia 211
familial 388–9
reactive 212–13, 389
and sideroblastic erythropoiesis 221
in systemic mastocytosis 214
- thrombophilia 425
- thrombopoiesis 20–5
cytology 20–2
disorders of 386–9
histology 23–5
- thrombopoietin 412, 413, 414
- thromboses 208, 211
- thymic (mediastinal) B-cell lymphoma 280
- thymoma 116, 377, 382
- thyroglobulin 432, 451
- thyroid carcinoma 431, 444, 451
- thyroid disease 469
see also hypothyroidism
- thyrotoxicosis 463, 469
- tibia, aspiration biopsy 5, 6

- T-immunoblastic lymphoma 310–11
tissue, extraneous 43–7, 456–7
T lymphocytes 30, 31
 determination of clonality 75,
 82–3, 85–6
 immunohistochemistry **68–70**,
 72
toluidine blue 53, **59**
 in AML 145, 151, 162
 in systemic mastocytosis 224, 226
topoisomerase-II-interactive drugs
 166
torsion artefact 41, 42
touch preparation 6
Toxoplasma gondii (toxoplasmosis)
 101, 103
 bone marrow aplasia 407
 bone marrow cytology 105
 granulomas 106, 112
 in HIV infection/AIDS 125–7
trabeculae, bony 1, 3
 artefacts 43, 44, 471
transferrin, serum 360, 373
transient erythroblastopenia of
 childhood 377, 379
translocations
 detection 76–7, 78, 81, 86
 see also specific translocations
transplantation
 bone marrow dysplasia after 392
 see also bone marrow trans-
 plantation; post-transplant
 lymphoproliferative disorders;
 stem cell transplantation
TRAP *see* tartrate-resistant acid
 phosphatase
trephine biopsy 5, 6–7
 aspiration biopsy at site of 47–8
 in bone disease 462
 complications 7
 in lymphoproliferative disorders
 231, 235
metastatic tumours 430–1
scars of previous 48, 49
sections
 artefacts 40–8
 in bone pathology 462
 cellular composition 334
 decalcification *see* decalcification
 examination 37–8
 fixation 474
 guidelines and audit 38
 histochemical stains 54–60
 immunohistochemistry 64–74
 interpretation 34–8
 methods 475–81
 molecular genetic techniques
 79–80, 82
 processing 6–7, 475–6
 reporting 38
 routine stains 51
 special diagnostic techniques
 51–89
 technical methods 474–5
 vs aspiration biopsy 7
trichrome stain 57
trientine 399
trisomies, detection 76, 77, 81
trisomy 21 (Down's syndrome) 157,
 158, 219, 407–8
trypanosomes 103, 104
tryptase, mast cell *see* mast cell
 tryptase
tuberculosis 91–2, 94
 granulomas 108, 109
 haemophagocytosis 121, 122
tularaemia 90
tumour necrosis factor 127, 391
typhoid fever 90, 92, 109
T-zone lymphoma 310–11

Ulex europaeus agglutinin-1 **433**, 452
ultrastructural examination 86, 87
unclustered antigen **68**
urological cancer 455
urticaria pigmentosa 221, 228
vascular lesions 424–6
vasculitis 424, 425
venous thromboses 208, 211
vertebrae, marrow cellularity 9
vimentin 187, 452
vincristine 394, 395
viral infections 95–9
 granulomas 97, 110
 haemophagocytic syndromes 96,
 97, 99, 120
 molecular genetic techniques 75,
 80, 96
vitamin B₁₂ deficiency 177, 371,
 394
vitamin D deficiency 463–4
von Willebrand factor **67**, **433**, 452
Waldenström's macroglobulinaemia
 259, 347–9, 350, 351
 cryoglobulinaemia 355
 μ-heavy chain disease 356
western blot analysis 84
Whipple's disease 92
white cell counts 143, 192, 204
whooping cough 91
Wilson's disease 398, 399
Wiskott–Aldrich syndrome 386
Wolman's disease 419
women, cellular composition of
 marrow 33, **36–7**
Wright–Giemsa stain 51
yellow marrow 1, 5
Zenker's solution 59–60, 474
zidovudine 124, 125, 177, 392, 394
Ziehl–Neelsen stain (ZN) **59**
Zieve's syndrome 400, 401, 402, 419
zinc toxicity 397–9