

Julia Harfin · Somchai Satravaha
Kurt Faltin Jr. *Editors*

Clinical Cases in Early Orthodontic Treatment

An Atlas of When,
How and Why to Treat

 Springer

Clinical Cases in Early Orthodontic Treatment

Julia Harfin • Somchai Satravaha • Kurt Faltin Jr
Editors

Clinical Cases in Early Orthodontic Treatment

An Atlas of When, How and Why to Treat

 Springer

Editors

Julia Harfin
Department of Orthodontics
Maimonides University
Buenos Aires
Argentina

Kurt Faltin Jr
Department of Orthodontics
University Paulista – UNIP
São Paulo
São Paulo
Brazil

Somchai Satrahava
Department of Orthodontics
Faculty of Dentistry
Mahidol University
Bangkok
Thailand

ISBN 978-3-319-46250-9 ISBN 978-3-319-46251-6 (eBook)
DOI 10.1007/978-3-319-46251-6

Library of Congress Control Number: 2017937778

© Springer International Publishing Switzerland 2017

This work is subject to copyright. All rights are reserved by the Publisher, whether the whole or part of the material is concerned, specifically the rights of translation, reprinting, reuse of illustrations, recitation, broadcasting, reproduction on microfilms or in any other physical way, and transmission or information storage and retrieval, electronic adaptation, computer software, or by similar or dissimilar methodology now known or hereafter developed.

The use of general descriptive names, registered names, trademarks, service marks, etc. in this publication does not imply, even in the absence of a specific statement, that such names are exempt from the relevant protective laws and regulations and therefore free for general use.

The publisher, the authors and the editors are safe to assume that the advice and information in this book are believed to be true and accurate at the date of publication. Neither the publisher nor the authors or the editors give a warranty, express or implied, with respect to the material contained herein or for any errors or omissions that may have been made. The publisher remains neutral with regard to jurisdictional claims in published maps and institutional affiliations.

Printed on acid-free paper

This Springer imprint is published by Springer Nature
The registered company is Springer International Publishing AG
The registered company address is: Gewerbestrasse 11, 6330 Cham, Switzerland

Contents

1 Introduction	1
Julia Harfin	
2 The Importance of the Speech Therapist During the Interceptive Orthodontics and Myofunctional Therapy	19
Lic Ana Delia Vassallo	
3 Early Treatment of Open Bite Problems	37
Julia Harfin	
4 Early Treatment of Periodontal Problems in Children	67
Julia Harfin	
5 Orthodontic Treatment of Atypically Rotated Central Incisor	81
Maria Florencia Mana	
6 Impacted Central Incisors: Different Options of Treatment	91
Julia Harfin	
7 The Treatment of Class II, Division 1 Malocclusion in Stages	105
Kurt Faltin Jr	
8 Early Treatment of Class III Malocclusions	135
Somchai Satrahava	
9 Correction of the Transverse Problems	215
Julia Harfin	
10 How to Normalize the Position of the Maxillary Molar in Early and Late Mixed Dentition	231
Jose Cortes Bedon	
11 Assymetries	243
Julia Harfin	
12 Temporomandibular Disorders in Children	271
Elsa Pérez Ruiz	
13 Nonsyndromic Oral Cleft Interdisciplinary Treatment	299
Ricardo D. Bennun	
14 Controversies Concerning Early Treatment	327
Julia Harfin and Kurt Faltin Jr	
Index	347

Julia Harfin

This atlas was written taking into consideration the most common problems that are frequently encountered in young children.

Interceptive treatment is intervening in the developing dentition to allow it to achieve the best occlusion possible or to make subsequent treatment as simple and short as possible (DiBiase 2002).

There is no doubt that early treatment can be justified if it provides additional benefits to the patient.

The question of when, how, and why is answered in depth in all the clinical cases contained in this atlas. The goal is to focus on functional and skeletal rather than dental correction.

Knowing the diagnosis criteria and which type of cases should be treated early, will permit the clinician to offer the most efficient solution for each individual patient. In general the first phase of treatment in the early mixed dentition has to be followed by a second phase in the permanent dentition.

When and how much growth will occur is unpredictable in some patients, but the direction of growth can be managed (Sureh). However, it is important for the clinician to be able to diagnose and intercept certain developing problems through early treatment.

Many other cases should be supervised, but not treated until the permanent teeth are in place. We must base our decision on a correct diagnosis taking into account that the correction of functional and skeletal imbalances is fundamental before the eruption of all the permanent teeth.

One of the most important advantages to begin the treatment early is to take advantage that in early mixed dentition, the skeletal growth pattern can be modified to a certain point. Other doctors with different protocols suggest that the treatment has to begin after the eruption of the second molars (Behrents 2006). At this time growth modification will be limited.

Specific indications for early treatment include class II or class III malocclusion, with maxillary midface deficiency anterior and posterior crossbite (unilateral and bilateral), midline discrepancies due to early loss of deciduous teeth with a midline shift, severe anterior open bite, severe deep bite with palatal impingement, finger-sucking habits, crowding resulting in ectopic positioning of permanent teeth, etc. (Dugoni 1998).

But not all the circumstances are black or white; each patient is unique.

For example, the most appropriate timing for the treatment of class II malocclusion is controversial (Cozzani et al. 2013). Some clinicians advocate starting a first phase in mixed or temporary dentition, but others prefer to wait until the second molars were erupted.

Also, the timing of treatment interventions can be influenced by the severity of the malocclusion, the age, and maturity of the patient at the time the treatment begins.

It is important to emphasize that different types of brackets and wires were used by the authors to treat the patients since there isn't a single type of bracket or wire that performs a correct diagnosis in each clinical case, until now.

The role of the orthodontist is to manage the problem in the most efficient way for a better diagnosis. It is fully recognized that some malocclusions are best treated early for biological, functional, and social reasons.

Different alternatives for each malocclusion will be described step by step in each chapter.

It is evident that to design an efficient treatment plan, the clinician must understand the growth and development process very clearly.

It is well known that the difference in the response of patients with the same orthodontic treatment is the result of variability in the direction and rate of craniofacial growth.

It is impossible to decide the best time to begin the treatment based solely on the chronological age since the majority of the malocclusions that have to be treated during mixed dentition are the result of multiple factors.

J. Harfin
Department of Orthodontics, Maimonides University,
Buenos Aires, Argentina
e-mail: harfinjulia@gmail.com

In general mixed dentition is the best time to start treatment when the correction of habits with or without anterior or lateral transverse crossbite is indicated.

A panoramic radiograph is mandatory at age 8–10 years to confirm the presence or absence of agenesias, supernumerary teeth, cysts, mesiodens, etc.

The last chapter Controversies analyzes the most common ones in depth.

The following examples show the importance of the timing of treatment according to the initial pathology, the direction of growth, and the normalization of the functional problems such as nasal breathing and tongue posture at rest or during swallowing.

Although they were skeletal and dental class III at the beginning of the treatment with a similar biotype, the results that were achieved in the long term were completely different.

The parents of this 6-year-old patient asked for a second opinion about the best time to begin his treatment. They were very interested in having him treated very early and avoid the orthognathic procedure that was suggested. The front photographs confirmed a significant negative overjet and overbite that was present in the anterior region (Fig. 1.1a, b).

From the etiological point of view, it is important to consider that his two older sisters had class I molar and canine, but two of his seven cousins were class III and were treated with orthognathic surgery.

The dental front and lateral photographs showed that the lower incisors were in contact with the upper labial gingival tissues, and, until then and for unknown reasons, he only ate soft meals.

The lateral radiograph confirmed the negative anterior position of the front teeth. Ricketts analysis demonstrated normal convexity with a retruded upper lip and everted lower lip. An increased facial axis was present (95°), along with a short lower anterior height (41°) (Fig. 1.2a, b).

The real question is when would be the best treatment time to begin the correction of this Class III malocclusion? Is it advisable to begin now or to wait until 11–12 or 18 years of age?

There is no doubt that the normalization of the anterior negative crossbite should take place as early as possible since it will help achieve a normal development of the maxilla and to improve the soft tissue profile.

These were the results after 26 months with a functional appliance (Fig. 1.3a, b). Overjet and overbite were improved and midlines were almost normal. The objectives of phase I of treatment were accomplished. It was important to improve the anterior position of the tongue.

However, the most important question is if the treatment results will remain stable over the long term.

These were the photos 9 years after treatment. The results were maintained or even improved even though some gingival

retractions were seen in the upper canine area (Fig. 1.4a, b). Fortunately, in this particular clinical case, a second phase of treatment was not necessary.

The comparison between the smile photos at the beginning and 9 years after treatment was the best proof that the results were maintained throughout his whole childhood and adolescence (Fig. 1.5a, b).

As a conclusion, it is possible to affirm that the treatment of very young class III patients with a significant anterior deep overbite is more reliable than when the class III is in combination with a significant open bite, as it is observed in the second patient.

The next case is very different from the first. It was clear proof that although that early treatment is essential, the type of growth and direction of growth also determine what the result will be. She was only 4 years, 9 months of age. Her dental history showed that her parents were skeletal class III but not her young sister.

The front photographs showed an important dentoalveolar class III with a significant open bite in the anterior region and crossbite in the lateral areas.

As a consequence of the lower and anterior position of the tongue, significant diastemas were present in the lower arch (Fig. 1.6a, b). The normalization of the position of the tongue is one of the most difficult issues and requires a lot of time and effort for the patients and their parents.

Although Ricketts analysis was developed for 9-year-old patients, the lateral radiograph confirmed that the patient had a dental and skeletal open bite – class III with braquifacial biotype. This combination has the poorest long-term prognosis.

It is very important to take into account that patients with class III and open bite are harder to treat than those with class III and deep bite. The normalization of the tongue posture at rest and in function is mandatory to avoid relapse (Fig. 1.7a, b).

The real question is until when it is possible to redirect growth in these class III patients and how to know, at an early age, how the mandible will develop.

Evaluation of the overall treatment and posttreatment changes confirm that overcorrection in this first phase of treatment is recommendable (Baccetti and Franchi 2006).

These are the results after 3 years of treatment with a rapid maxillary expander in conjunction with a face mask. Although most of the treatment objectives were achieved, it would have been better to finish this first phase of treatment with more overjet and overbite, but the patient and her parents decided to conclude this phase for personal reasons. No speech therapy treatment was recorded.

At the end of this first phase, the posterior crossbite was not totally corrected, and midlines were not coincident. The change of color of the right upper central incisor was the result of trauma produced while riding her bicycle (Fig. 1.8a, b).

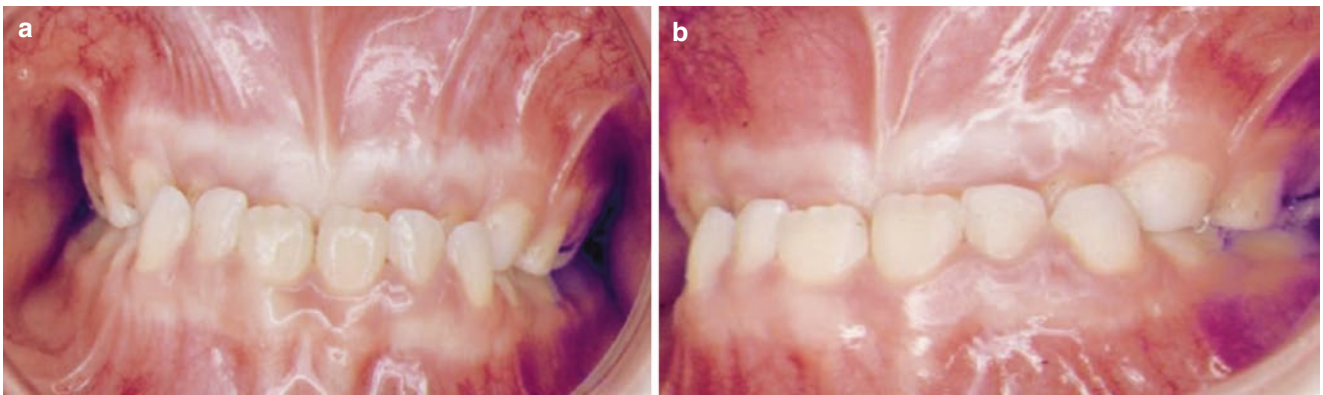


Fig. 1.1 (a, b) Frontal and lateral pretreatment photographs. A significant negative overbite was present

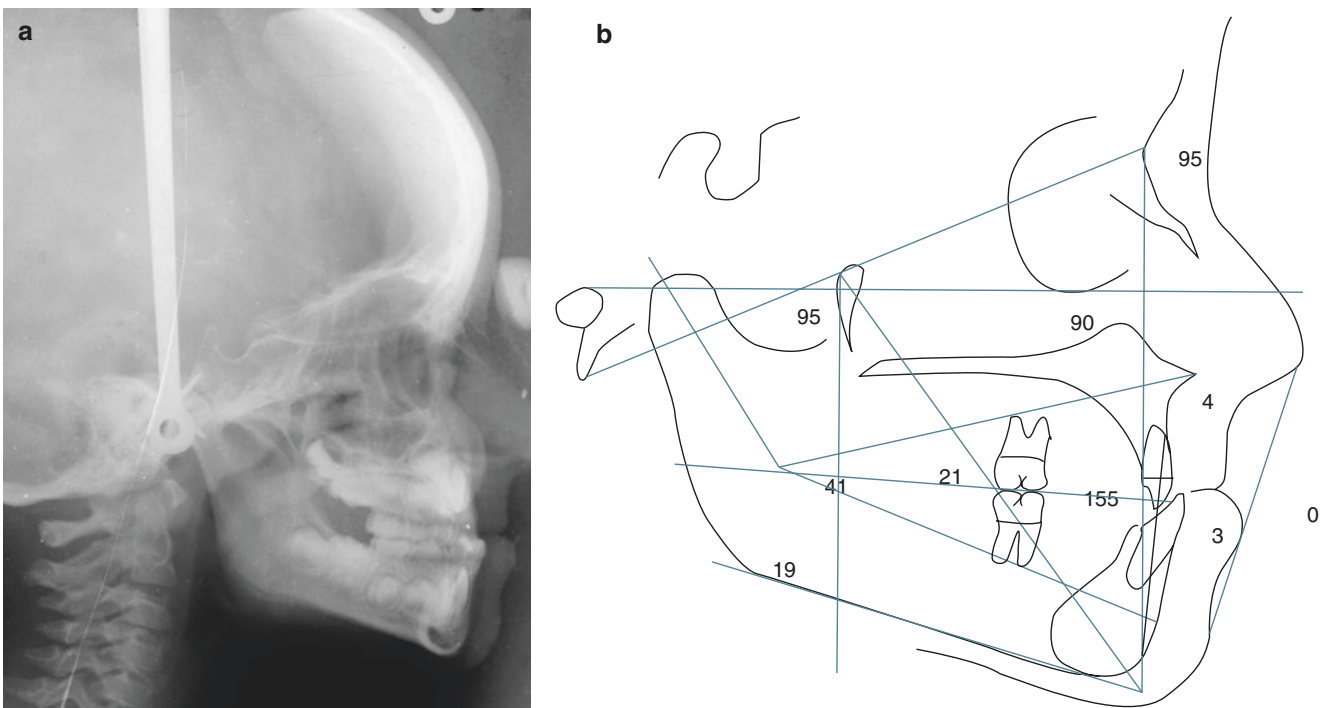


Fig. 1.2 (a, b) Pretreatment lateral radiograph and Ricketts analysis

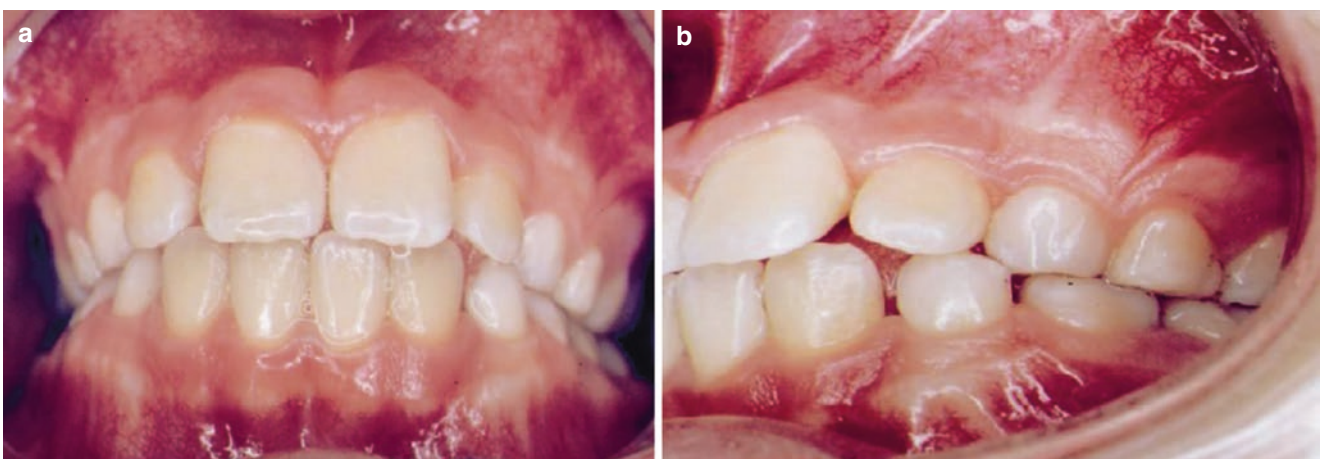


Fig. 1.3 (a, b) Frontal and lateral posttreatment photographs at the end of phase I of treatment

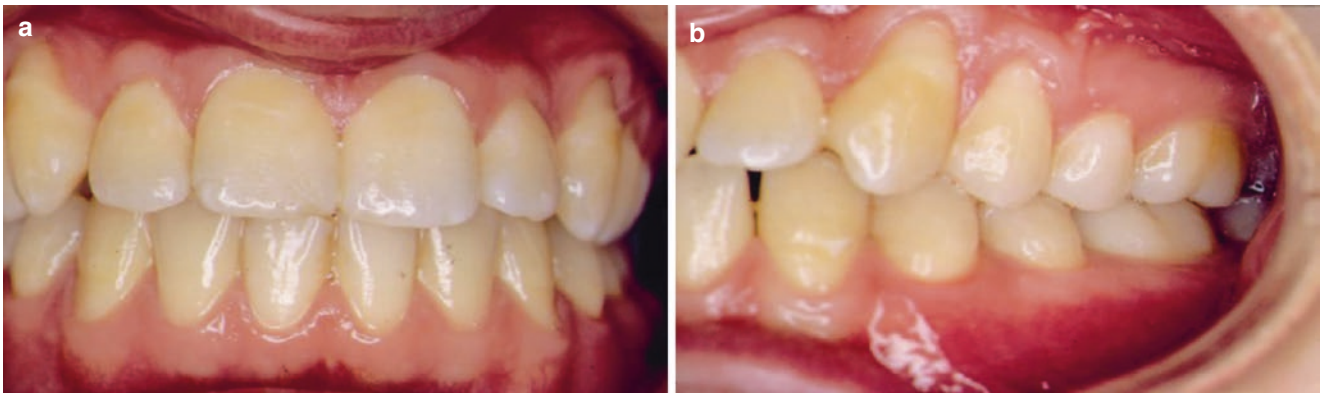


Fig. 1.4 (a, b) Control 9 years after treatment. The results were maintained. Overjet, overbite, and midlines were improved



Fig. 1.5 (a, b) Comparison of the smile photographs pre and 9 years after treatment

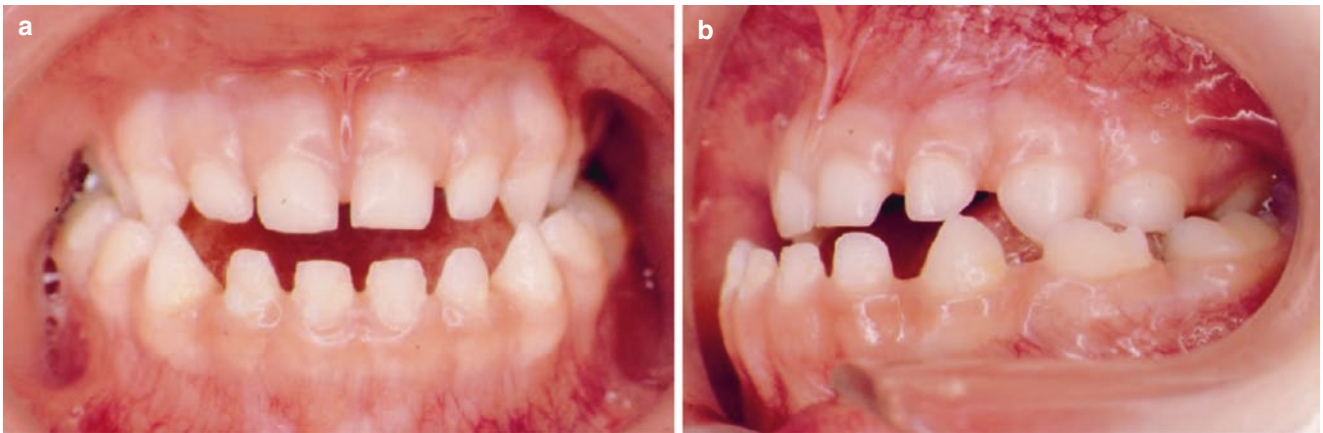


Fig. 1.6 (a, b) Frontal and lateral pretreatment photographs. A significant skeletal and dental class III with a considerable open bite was present in this 4-year, 9-month girl

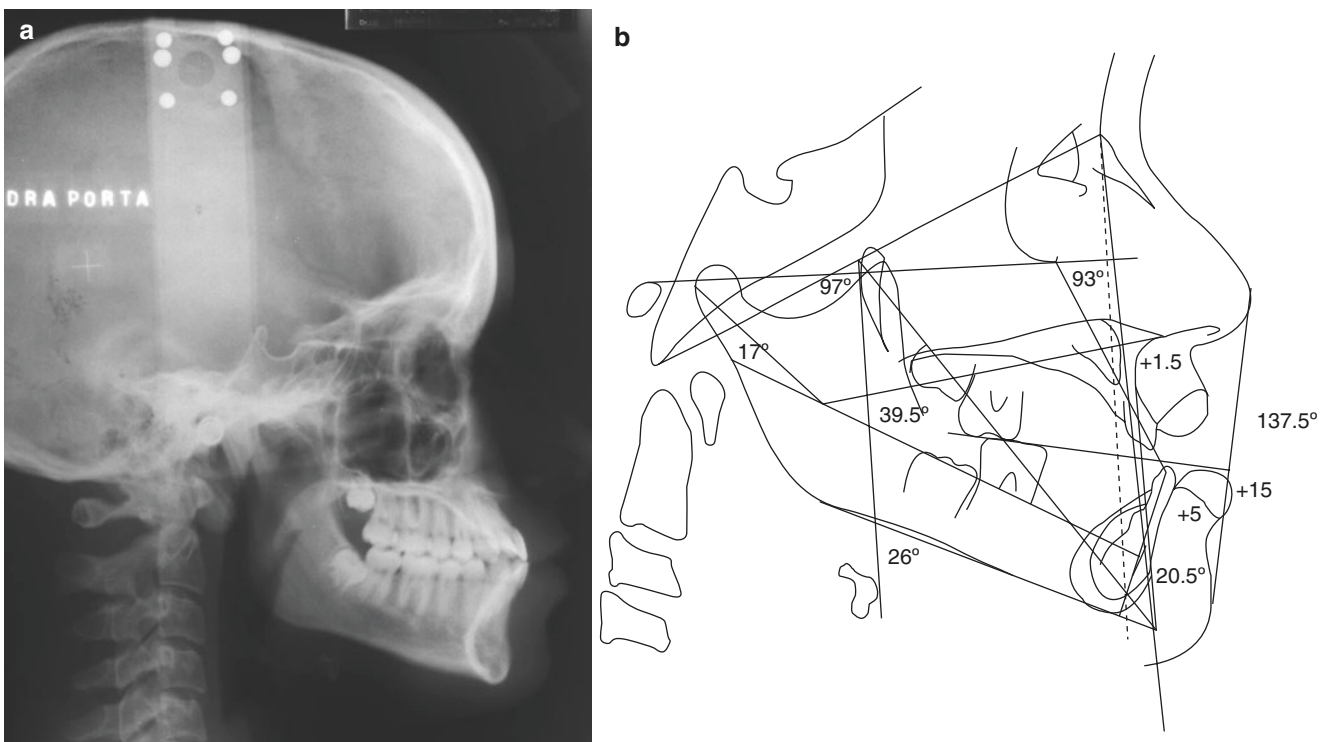


Fig. 1.7 (a, b) Lateral radiograph and Ricketts analysis at the beginning of the treatment. Class III with a significant open bite was confirmed

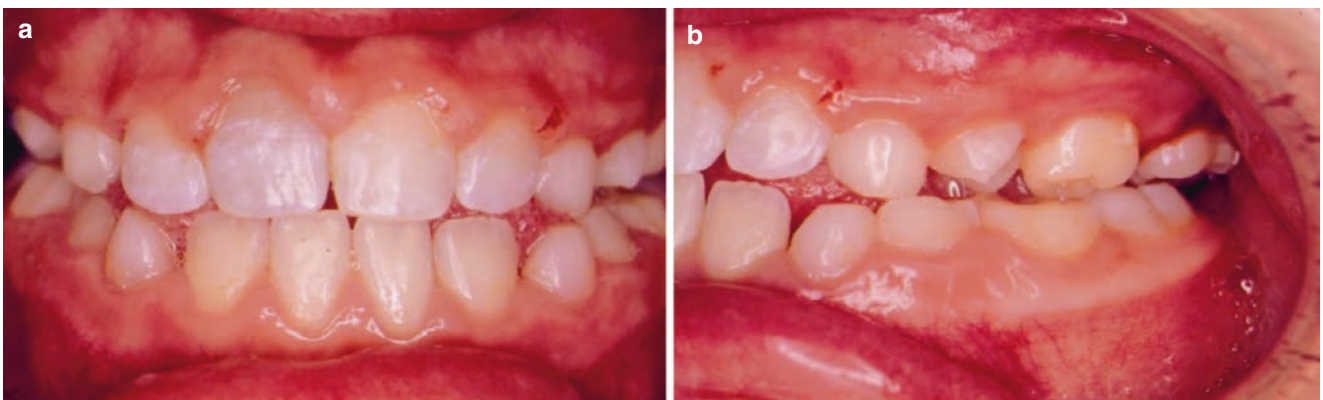


Fig. 1.8 (a, b) Frontal and lateral photos at the end of this phase of treatment. Not all the objectives for phase 1 were completed

The lateral radiograph at the end of the first phase of treatment confirmed the clinical results (Fig. 1.9a, b).

The patient returned after 5 years without any previous follow-up. The parents admitted that due to some personal problems, they neglected her treatment. She also discontin-

ued the treatment with the speech therapist and never used the retainers. The results were totally unexpected.

The clinical photos clearly showed that the open bite in conjunction with class III molar and canine worsened more than expected (Fig. 1.10a, b).

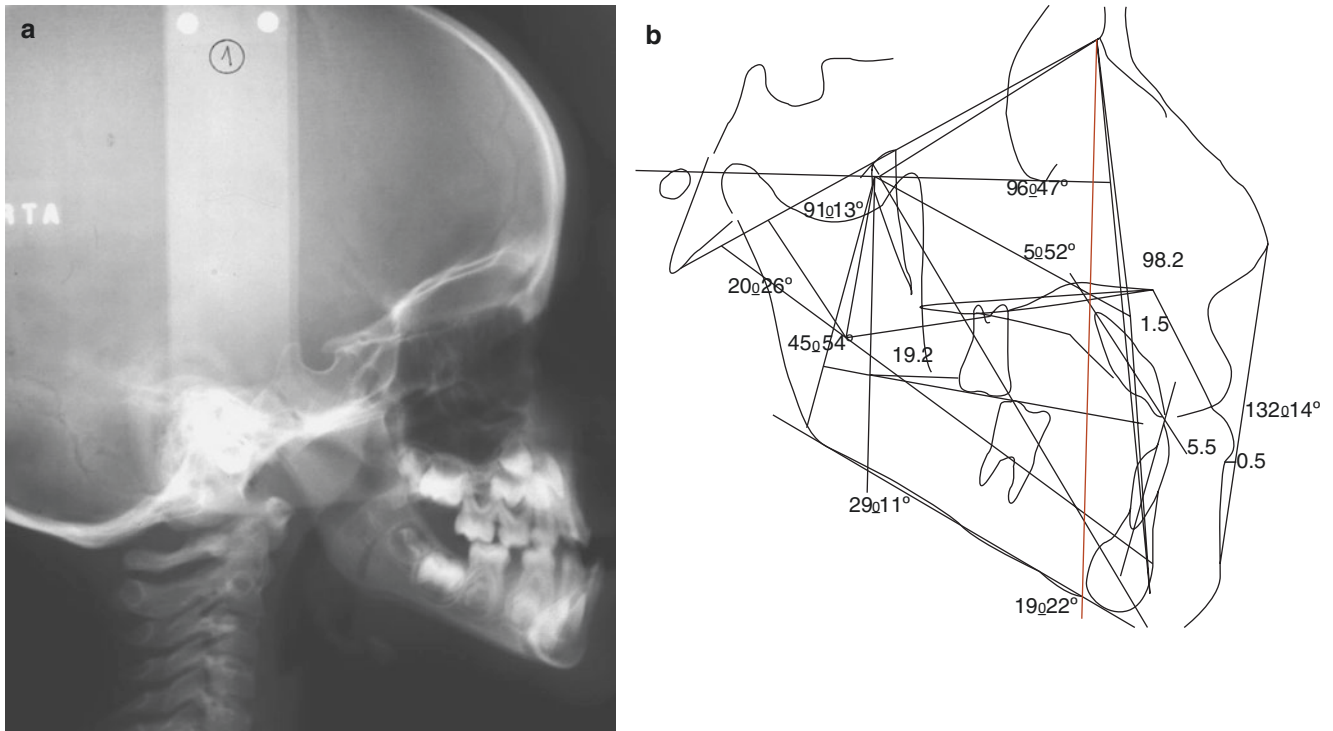


Fig. 1.9 (a, b) Lateral radiographs and Ricketts cephalogram at the end of phase I of treatment. Most of the objectives were fulfilled

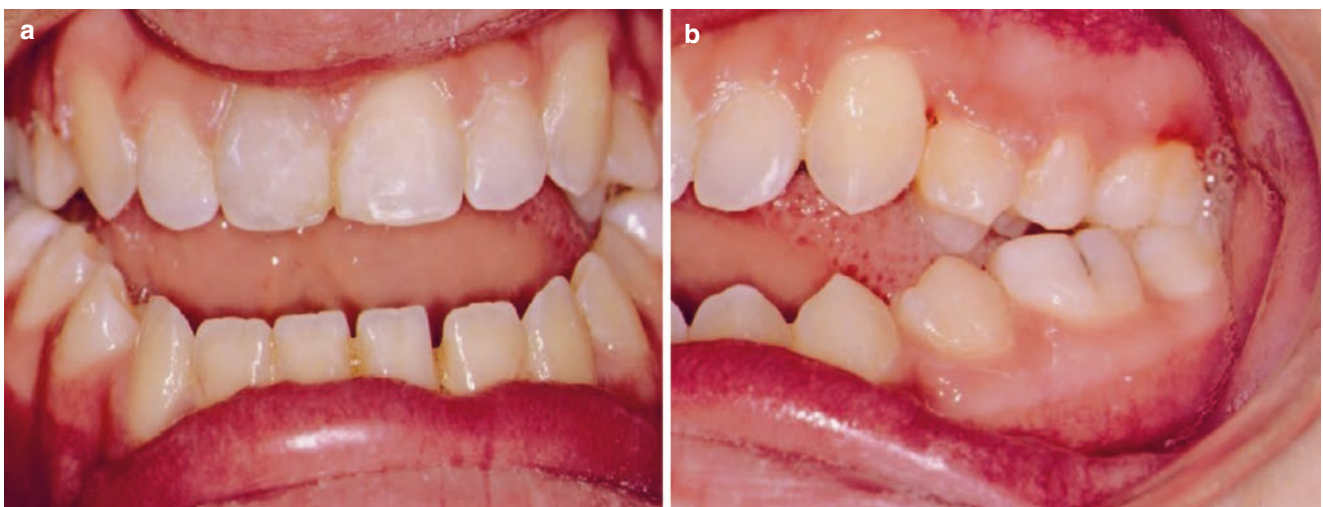


Fig. 1.10 (a, b) Frontal and lateral photographs 5 years without follow-up. The results were worse than expected

The cephalometric radiograph and Ricketts analysis confirmed the skeletal open bite – class III. The treatment plan at that time had to include an orthognathic surgical procedure when the patient was almost 20 years old (Fig. 1.11a, b).

These two clinical cases clearly demonstrated the importance of the normalization of the function and that the possibility to redirect growth is one of the major goals in this phase of treatment.

The difference in the response of patients with a similar orthodontic treatment protocol is the result of variability in the direction and rate of craniofacial growth as it was demonstrated with these two young class III patients.

Integrated diagnosis is the basis that will allow us to determine the best treatment plan while considering the direction and quantity of growth.

It is important to take into consideration that maintaining the results for a long term depends on a number of factors: facial biotype, direction of growth, heredity, control of habits, etc.

The early treatment of the following patient was mandatory not only because of his profile but also due to the position and protrusion of the upper incisors.

The objectives of the first phase of treatment included the normalization of the position and inclination of the upper incisors to prevent any type of dental or dentoalveolar fracture as a consequence of an accident at home or at school. At the same time, the improvement of the position of the lower lip was necessary (Franchi).

The consultation with the otorhinolaryngologist was also mandatory because it was necessary for the patient to be able to breathe without any problems in order to reeducate the position of the lips and the tongue.

The real question is what the best orthodontic treatment approach for this specific patient with prominent upper front teeth is. The answer can vary from the beginning at that time or waiting until all the permanent teeth erupt.

Since one of the treatment objectives was to avoid the fracture of the anterior upper incisors, there is no doubt that the treatment had to begin at that moment.

A consultation with the otorhinolaryngologist was fundamental since the patient had to learn how to start breathing through his nose.

Before selecting the best treatment plan for this patient, it was necessary to determine which type of class II he had.

Without knowing the etiology, it is very difficult to determine the correct, individualized treatment plan.

It is well known that functional matrix facilitates the lower third development in the three directions; thus, in early mixed dentition, the normalization of habits is fundamental to facilitate tooth eruption in normal position.

To complete the diagnosis protocol, the patient was sent to his pediatrician because he snored loudly at night. He had a convex profile with a closed nasolabial angle in conjunction with difficulties to close his mouth. Also, he had some respiratory problems along with thumb-sucking and lower lip interposition (Fig. 1.12a, b).

In order to determine the best and most efficient treatment protocol, it is necessary to consider if it is only an anteroposterior problem or if it is combined with a transversal one. In this situation, it is highly recommendable to treat the transversal discrepancy first (Subtelny 2000). Also, it is advisable to restrain the forward displacement of the maxillary dentition and its alveolar process and at the same time allow the normal development of the mandible.

As a consequence of all the functional problems, the mandibular dentition was retro-positioned with retroinclined mandibular incisors and total lack of space for the lower left canine (Fig. 1.13a, b).

The panoramic radiograph confirmed the normal path of eruption of the other permanent teeth. The lateral radiograph showed the important frontal displacement of the upper incisors. He had a meso-facial biotype with a convexity of 9 mm.

The interincisal angle was 135° and his facial axis 85° (Fig. 1.14a, b).

The evidence suggests that providing early orthodontic treatment for children with prominent upper front teeth is more effective in reducing the incidence of incisal trauma than providing one course of orthodontic treatment when the child is in his adolescence (Thiruvengkatachari et al. 2014).

A myofunctional appliance (Trainer) was suggested in order to normalize nasal breathing and the position of the oral muscles.

The mother and the patient were very enthusiastic about the treatment since other doctor suggested to wait until 18 years of age and then correct the malocclusion with the help of an orthognathic procedure.

The patient was controlled by the orthodontist every 2 months, but he went to the speech therapist twice a week during the first year and then only once a week.

It is advisable that the patient use the appliance 2 h during the day and all night.

These are the results after 3 years of treatment with a functional appliance that helped to normalize function and as a consequence redirected the position of the erupting teeth (Fig. 1.15a, b).

The patient continued using the appliance every night with a 3-month control. No brackets were bonded until that moment of the treatment, and the mother confirmed that the snoring disappeared.

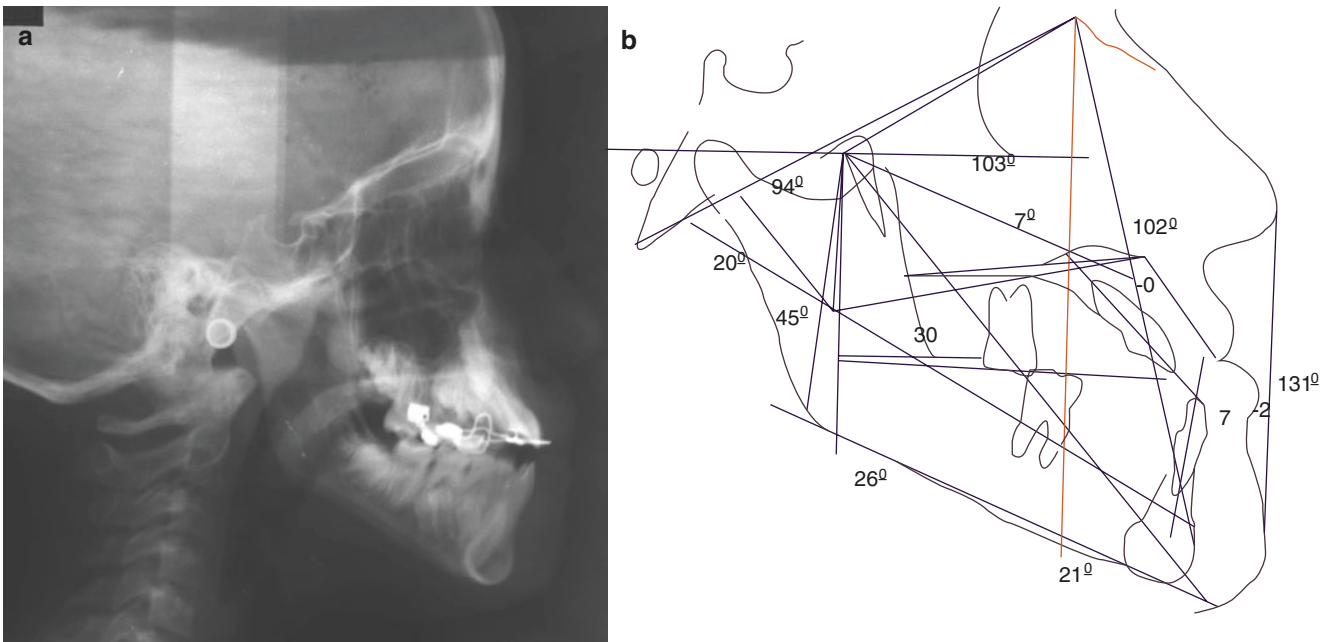


Fig. 1.11 (a, b) Lateral radiographs and Ricketts analysis 5 years later. The results clearly showed the adverse direction of growth

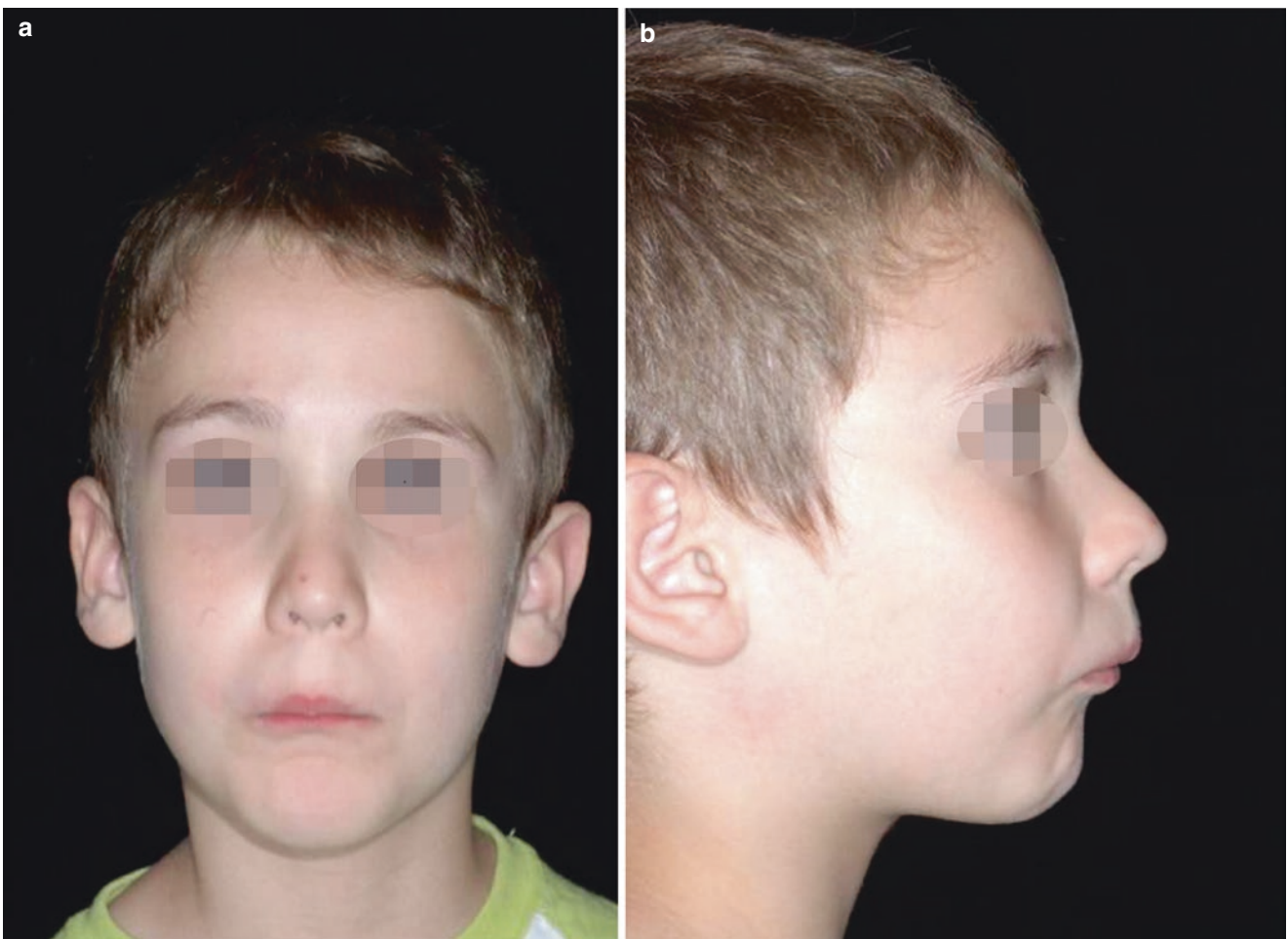

Fig. 1.12 (a, b) Frontal and lateral facial pretreatment photographs. Difficulties in closing his mouth were clearly visible

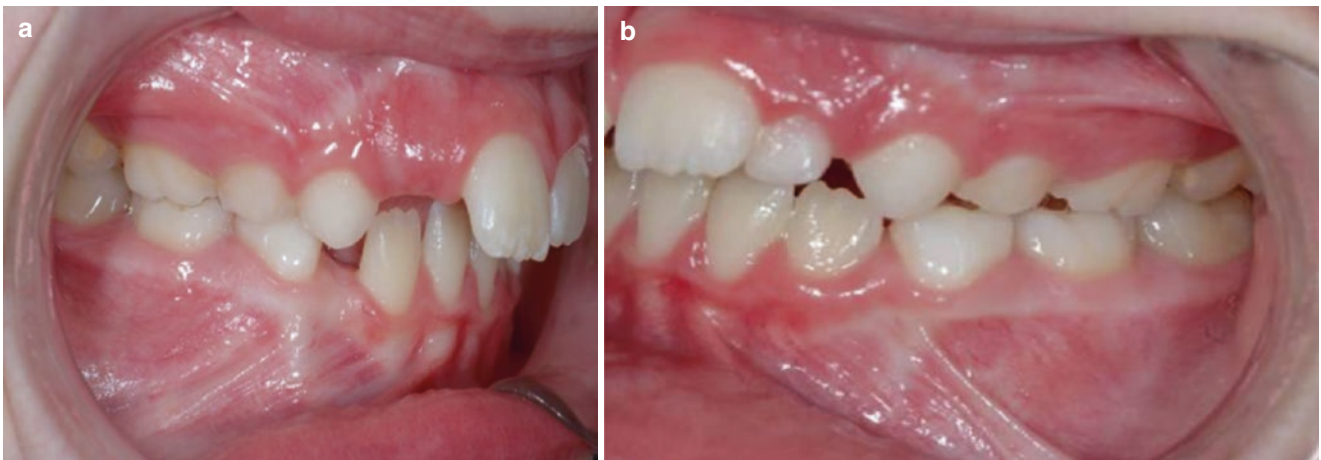


Fig. 1.13 (a, b) Pretreatment of the right and left sides. Total lack of space for the left lower canine was confirmed along with the retroinclination of the lower incisors

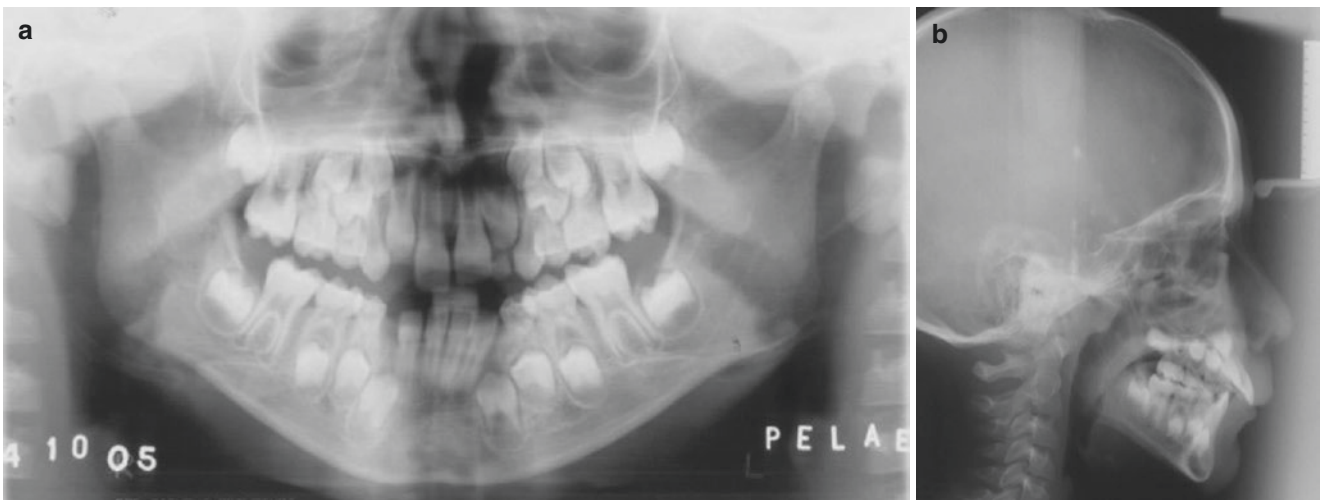

Fig. 1.14 (a, b) Pretreatment panoramic and lateral radiograph. The anterior position of the upper incisors was confirmed

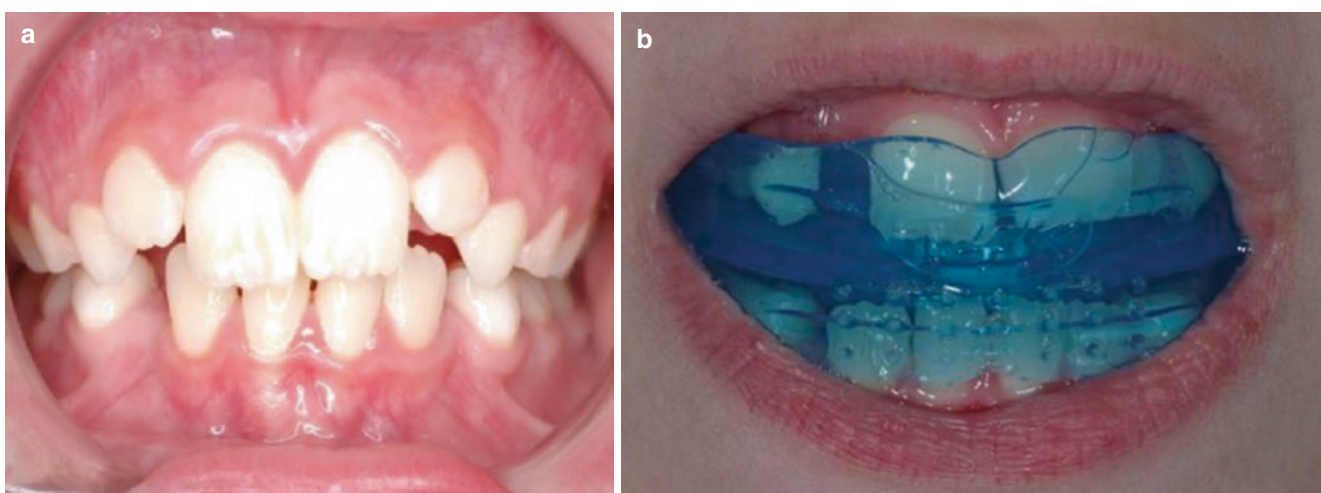


Fig. 1.15 (a, b) Frontal view with and without the appliance in place after 3 years of treatment

His profile improved more than expected. No brackets were used during all the second phase of treatment.

Since he can breathe normally, his behavior improved not only at school but also at home with her brothers too (Fig. 1.16a, b). There was an important improvement in his profile and in his dental anterior position.

A control 6 months later confirmed that the results were maintained. The incisors are normally positioned with good overjet and overbite. The gingival line and the occlusal plane were parallel (Fig. 1.17a, b).

The lateral views confirmed that the lower canines erupted normally although they didn't have sufficient space at the beginning of the treatment (Fig. 1.18a, b).

The normalization of the upper and lower arch was the result of the new function of the oral muscles. Now they were rounded with space for all the permanent teeth (Fig. 1.19a, b).

In order to maintain the results and to control the position of the tongue and the width of the upper and lower arches, a new, more rigid (second-phase) Trainer was recommended (Fig. 1.20a, b).

After analyzing this type of patient, the conclusions would be that the early transitional dentition period seems to be the best time to correct these functional alterations in a very controlled and efficient manner.

The final photographs clearly demonstrated the normalization not only of the frontal teeth but also of the soft tissues. At that point, he could close his mouth without any muscle tension, and the nasolabial angle was within normal ranges (Fig. 1.21a, b).

Front and occlusal photographs 1 year after treatment. All the teeth erupted in normal position. Class I canine and molar

were achieved and maintained with perfect alignment. The patient had good oral hygiene during the whole treatment (Fig. 1.22a, b).

The comparison between the two profile photographs is the best demonstration of the results that were achieved when the function is recover. No extractions were performed in the upper arch (Fig. 1.23a, b). The change in the nasolabial angle was better than expected as a consequence of the normalization of the stomatognathic system.

This clinical case strongly supports the benefits of the protocol that include 2- or 3-phase treatment. An early and accurate diagnosis is the most important issue, no matter the number of phases that the patient requires to achieve the best result in a more conservative manner with fewer orthognathic procedures.

Another malocclusion that has to be treated very early is the anterior deep bite since the musculature plays an important role before, during, and after treatment during the long retention period. The early treatment protocol to correct the anterior deep bite can be divided in three big groups: intrusion of the anterior teeth, extrusion of the posterior ones, or a combination of both.

To design the best treatment plan, a careful analysis of the smile at rest and during function is fundamental. The position of the upper incisors during the smile determines if the upper incisors have to be intruded or not.

The next patient is a clear example. She was 9 years, 6 months of age. Her mother, a well-known odontopediatric, was very disappointed since her daughter never used any removable functional appliances in order to correct the considerable anterior deep bite.

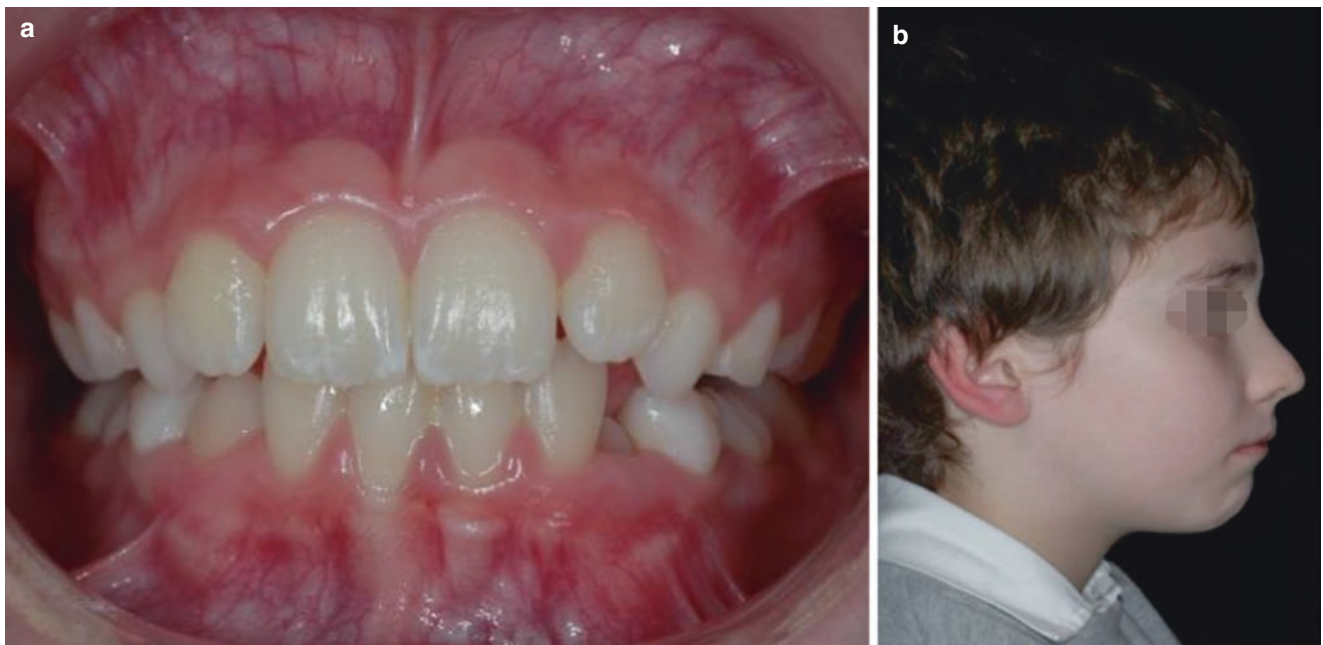

Fig. 1.16 (a, b) Frontal and profile photograph at this moment of the treatment. The normalization of the anterior occlusion and the position of the lips were remarkable

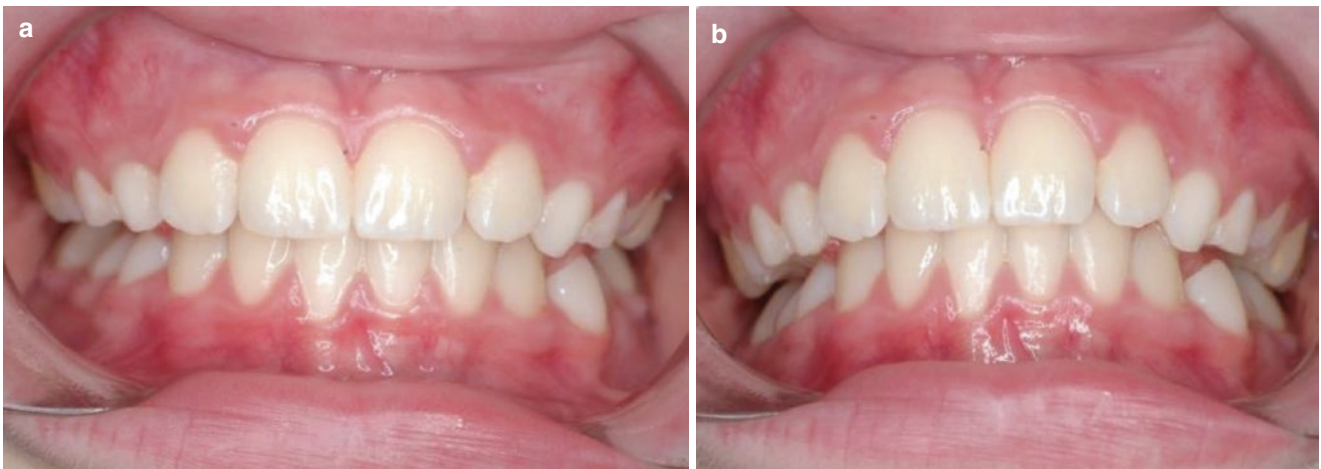


Fig. 1.17 (a, b) Control 6 months after treatment. Midlines, overjet, and overbite were pretty normal

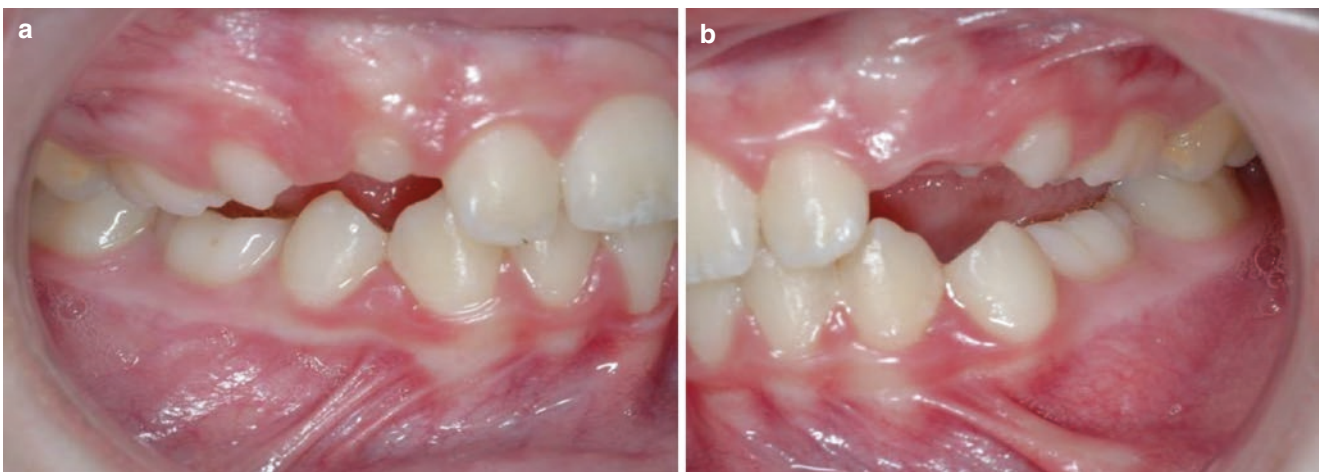


Fig. 1.18 (a, b) Right and left lateral views. Class I molar was maintained, and at this moment, the right and left canine had enough space to erupt

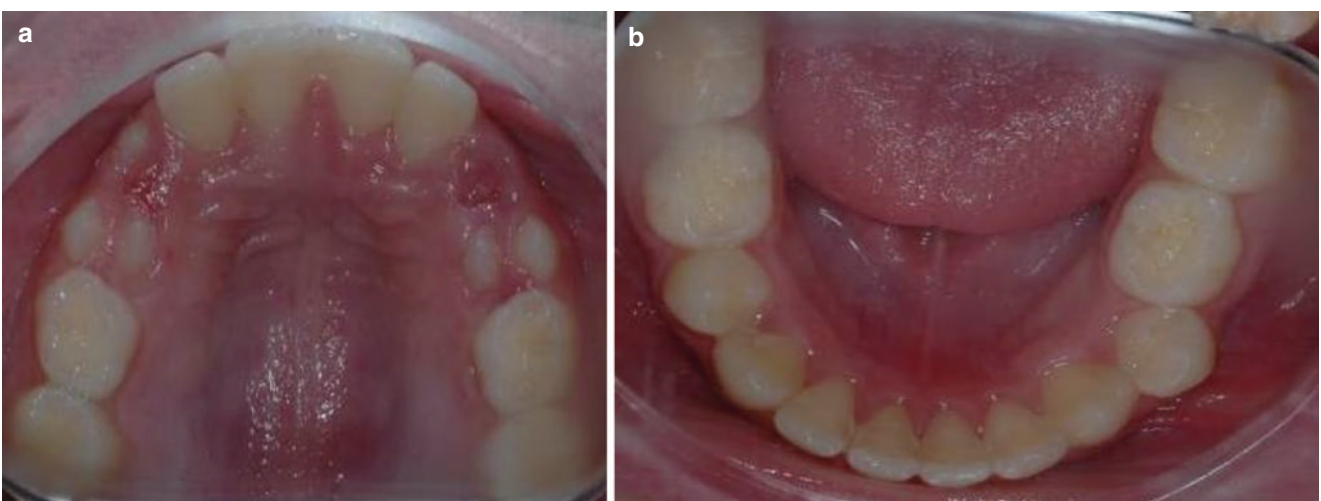


Fig. 1.19 (a, b) Upper and lower arch at this moment of the treatment. They had normal transverse and anteroposterior dimension

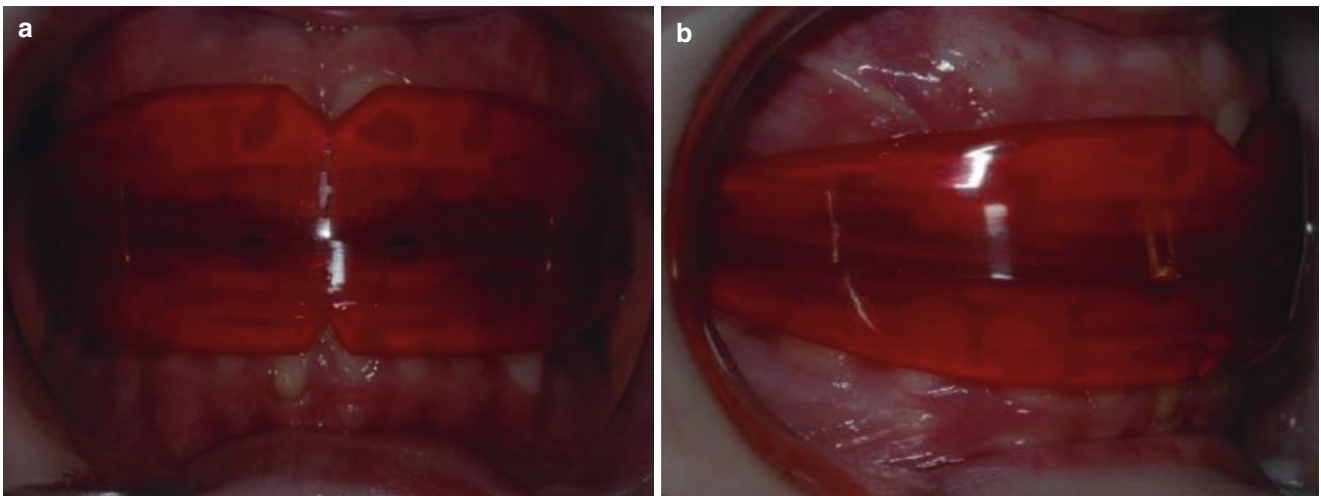


Fig. 1.20 (a, b) Second-phase Trainer was recommended in order to maintain the excellent results that were achieved

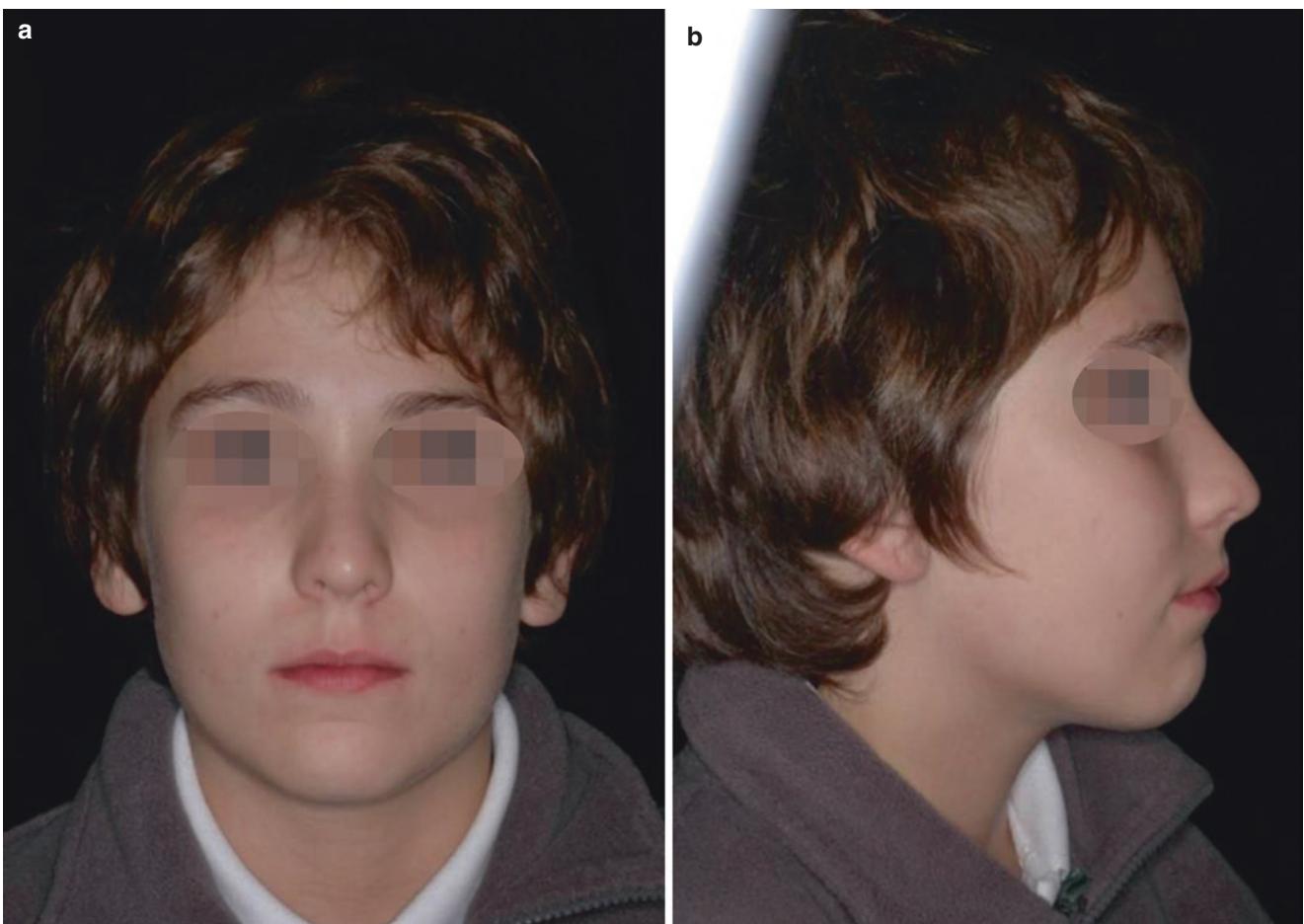

Fig. 1.21 (a, b) Posttreatment front and profile photographs. The lips closed without any muscular tension, and the nasolabial angle was totally normal

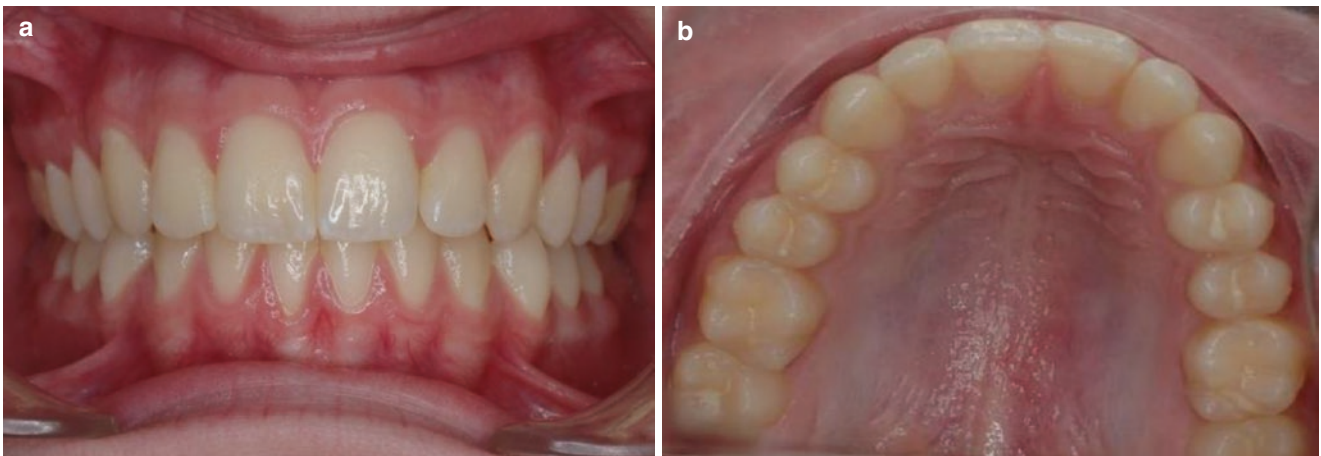


Fig. 1.22 (a, b) Frontal and occlusal view 1 year after treatment. The results improved with good oral hygiene. Midlines, overjet, and overbite were maintained

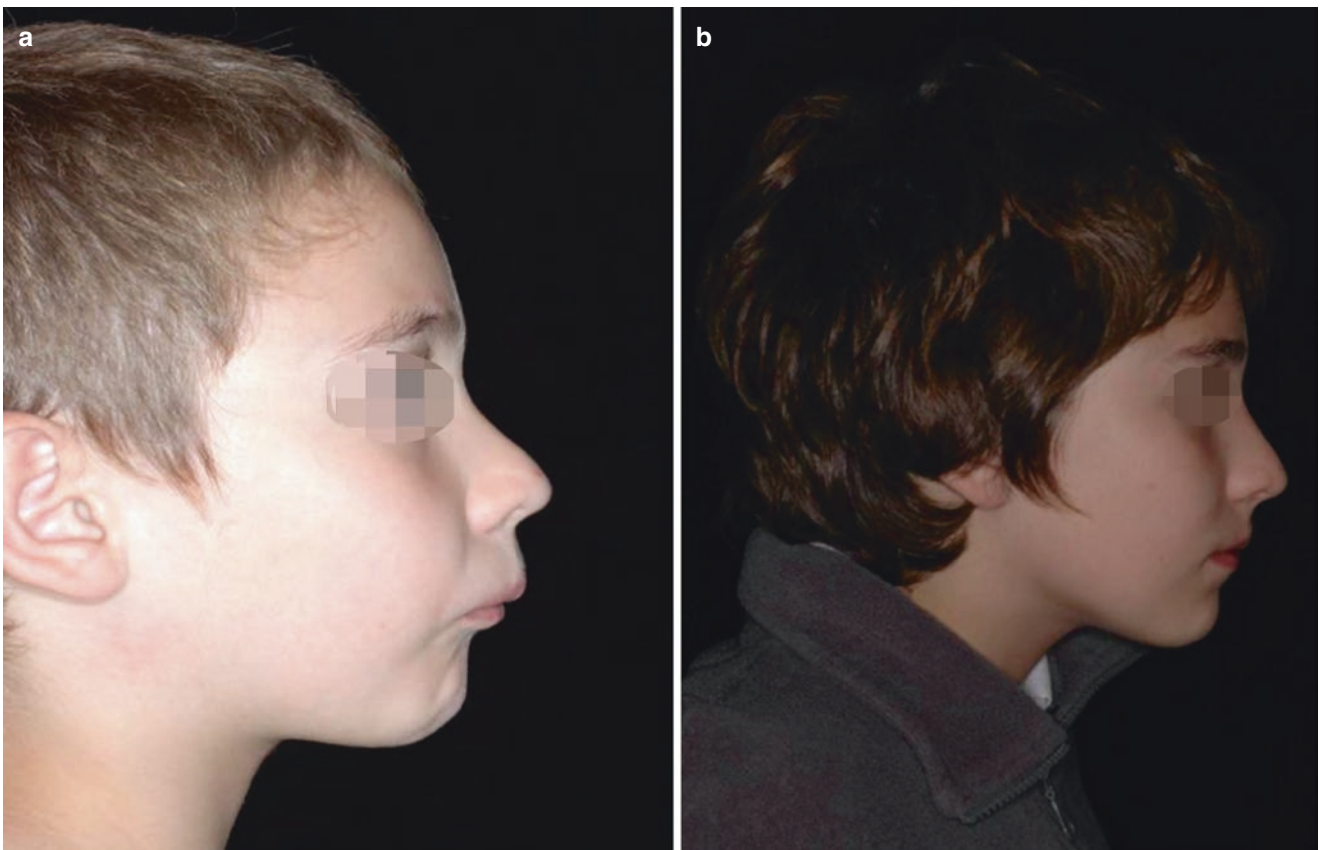

Fig. 1.23 (a, b) Comparison pre- and posttreatment profiles. A significant improvement in the soft tissues was achieved and maintained

The front photograph confirmed an overbite of 100% in the central incisor region that was confirmed in the lateral radiograph. Dental midlines were coincident and the upper lateral left incisor was more extruded than the right one. The lower anterior height was clearly diminished (41°) (Fig. 1.24a, b).

The lateral views confirmed the significant overbite and the retroclination of the upper incisors. The first upper and lower molars were not fully erupted (Fig. 1.25a, b). The occlusal plane wasn't parallel to the gingival line.

Taking into consideration that in this specific patient the first priority was the normalization of the anterior vertical dimension, four lingual brackets were bonded on the palatal surface of the central and lateral incisors along with a coaxial arch. An indirect method with an individualized setup was fully recommended to bond the brackets correctly. No bands or tubes were placed on the molars to allow their physiological eruption and achieve a normal overbite (Fig. 1.26a, b).

As a consequence an expected lateral open bite was present in the posterior region (Fig. 1.27a, b). Bearing in mind that when the molars erupt slowly, they erupt with bone, no other appliance was used in this phase.

A follow-up 4 months later showed a significant improvement of the anterior overbite only with this fixed appliance. The lower incisors were clearly visible (Fig. 1.28a, b).

The extrusion on the right and left region was remarkable. Since this extrusion was performed very slowly, the muscles accompanied it and consequently relapse would be not expected (Fig. 1.29a, b).

The comparison pre- and posttreatment (6 months) confirmed that the treatment plan that was suggested was efficient. Phase 1 was very important since the adaptation of the musculature system is very predictable. It is possible that a second phase of treatment would be necessary when all the permanent teeth erupted. Although a significant posterior extrusion was performed, the midlines were stable (Fig. 1.30a, b).

The key was that the patient uses this "fixed functional appliance" 24 h a day, and in this way, the whole stomatologic system would adapt to the new vertical dimension, and a normal functional occlusion would be achieved. The retention plan has to include a functional appliance until all the permanent teeth were erupted to maintain the achieved results.

There is no doubt regarding all the benefits of the early orthodontic treatment, no matter if more than one phase of treatment (Bowman 1998) is necessary.

The focus has to be placed on the treatment response since each patient is unique.

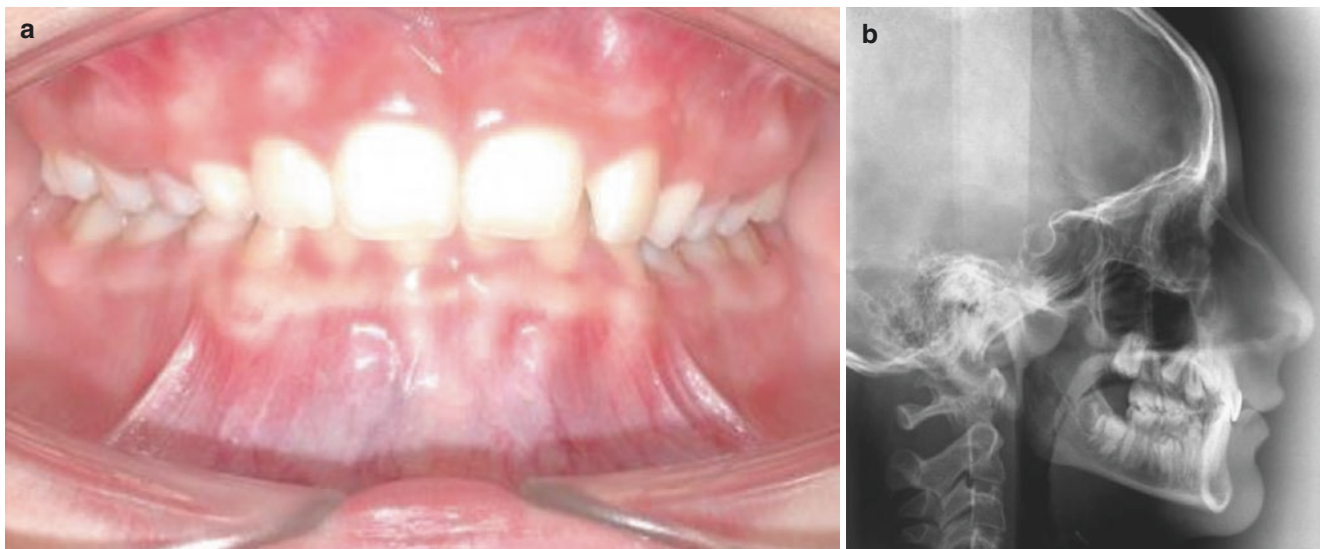


Fig. 1.24 (a, b) Frontal view and lateral radiograph of this important overbite

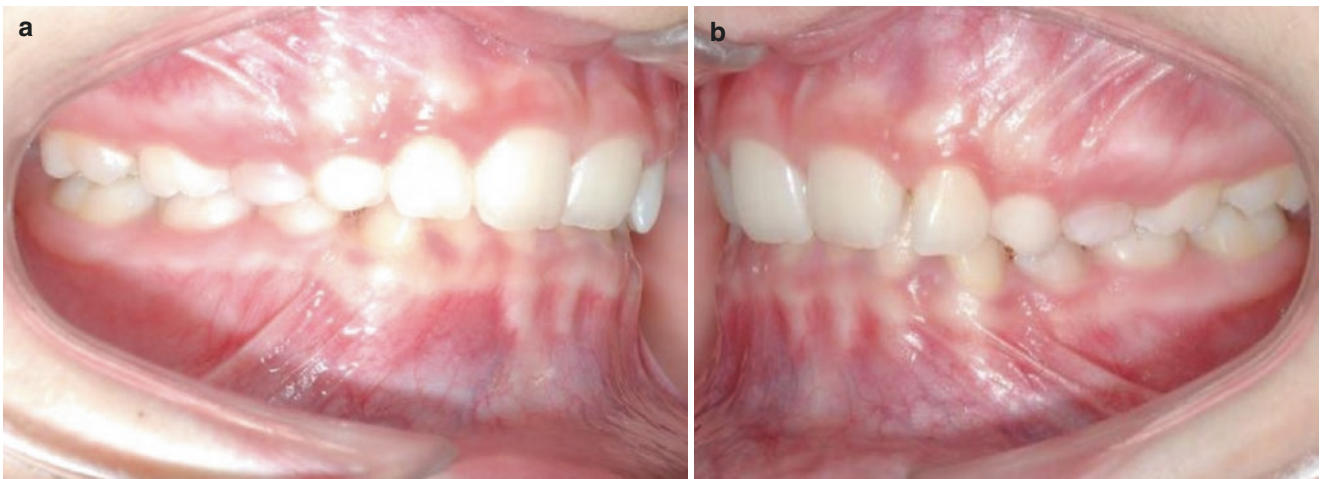

Fig. 1.25 (a, b) Class I right and left molar and canine were observed. The anterior overbite was almost 100%, and the retroinclination of the upper incisors was confirmed

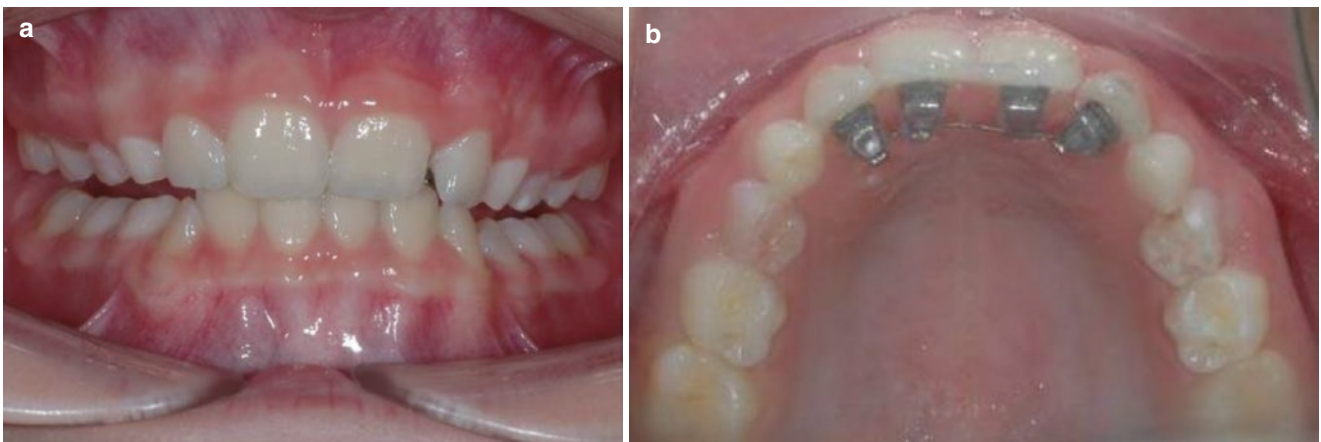


Fig. 1.26 (a, b) Lingual brackets were bonded on the palatal surface of the upper incisors with a partial coaxial arch

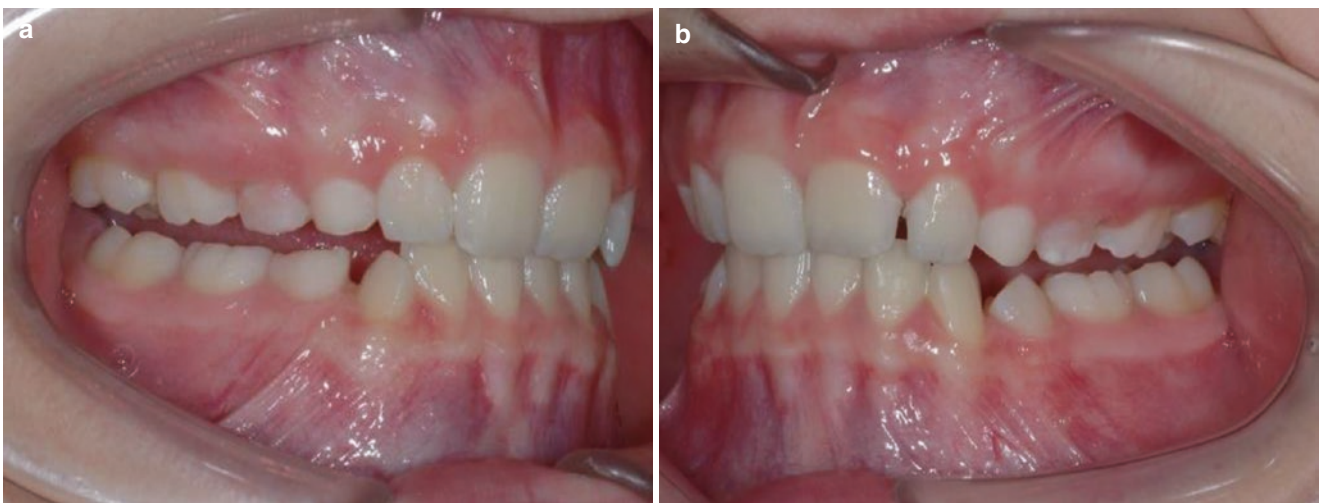


Fig. 1.27 (a, b) Lateral views after the indirect placement of the lingual brackets with an expected transitional lateral open bite

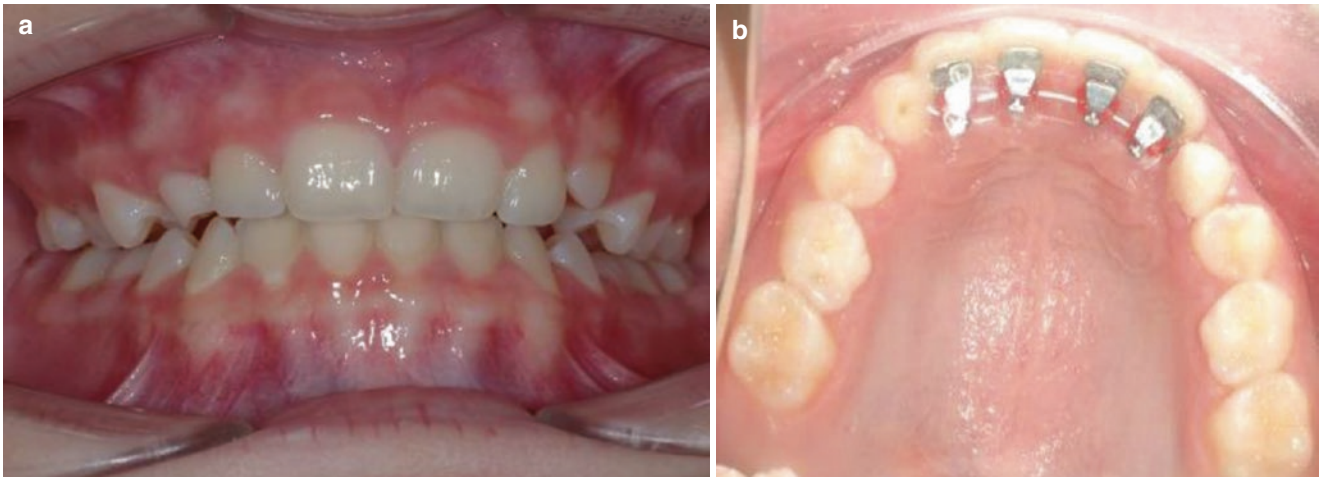


Fig. 1.28 (a, b) Frontal and occlusal photos after 4 months of treatment

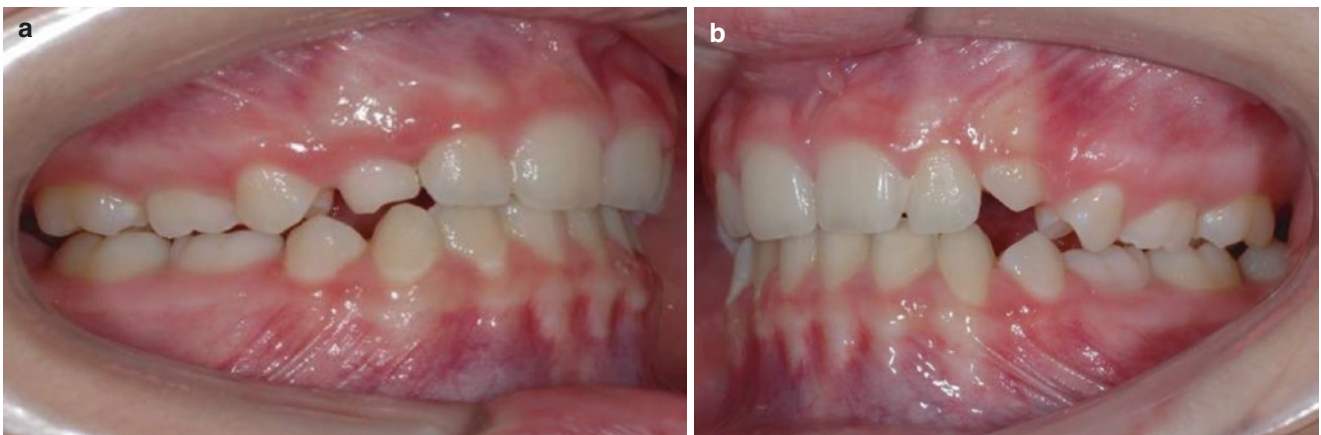


Fig. 1.29 (a, b) The extrusion in the temporary and first permanent molar region was important

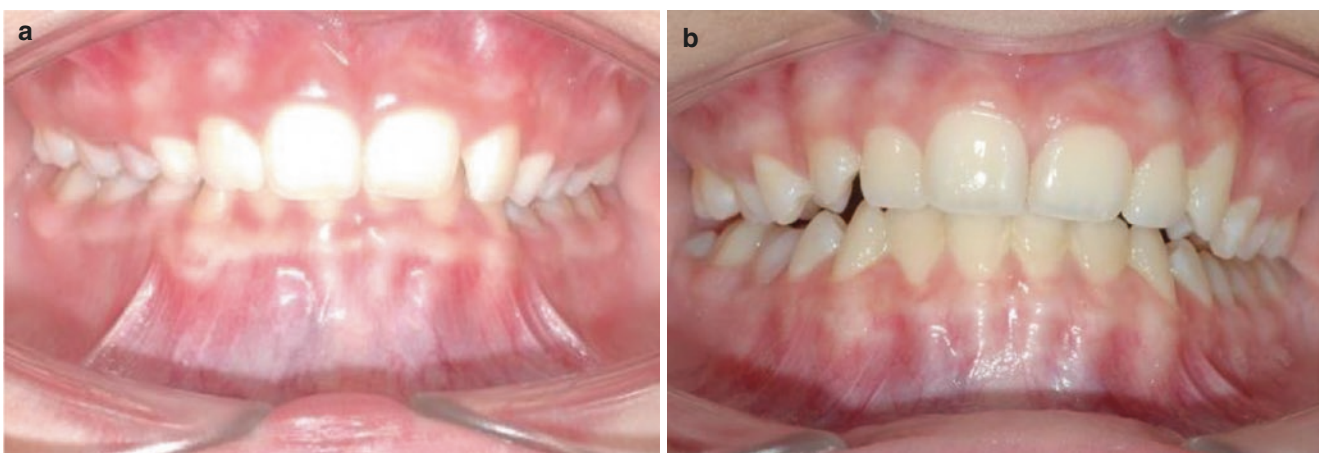

Fig. 1.30 (a, b) Comparison pre and after 6 months of treatment with a fixed appliance that acts as a functional appliance

Conclusions

One of the benefits of the early orthodontic treatment is the improvement of the self-esteem of the patients since personal interactions at school are very significant at this age. It is important to emphasize that different types of brackets and wires were used since there is no intelligent bracket that performs a correct diagnosis in each patient, until now.

The early normalization of the neuromuscular behavior is more important than simply the position of some teeth and as a result early treatment has a real advantage to avoid adverse effects.

The role of the orthodontist is to manage in the most efficient way for a better diagnosis, prognosis, treatment, and retention plan.

It was totally demonstrated that there is not one appliance that fits all the patients even with a similar age and malocclusion. In general the treatment plan was divided into one, two, or more phases: the first phase has to be undertaken only on the primary teeth or early mixed dentition to correct habits and alleviate functional problems before the second or third phase of treatment with fixed appliances in the permanent dentition. The key question is diagnosis, timing, and efficacy of treatment.

The selection of the best therapy has to be based on available evidence.

It is important to remember that early treatment phase cannot avoid a second phase of treatment but does reduce its length and complications.

Bibliography

- Baccetti T, Franchi L. The long term perspective on orthopedic treatment of Class III malocclusion. In: *Early Orthodontic Treatment: is the benefit worth the burden*. Thirty-third Annual Moyers Symposium, Ann Harbor; 2006.
- Behrents R. The decision of when to intervene: the nature of the question in terms of faith, passion and evidence. In: *Early Orthodontic Treatment: is the benefit worth the burden*. Thirty-third Annual Moyers Symposium, Ann Harbor; 2006.
- Bowman SS. One stage vs two stages treatment: are two really necessary? *Am J Orthod Dentofacial Orthop*. 1998;113:111–6.
- Cozzani M, Mazzota L, Cozzani P. Early interceptive treatment in the primary dentition. A case report. *J Orthod*. 2013;40:345–51.
- DiBiase A. The timing of orthodontic treatment. *Dent Update*. 2002;29:434–41.
- Dugoni S. Comprehensive mixed dentition treatment. *Am J Orthod Dentofacial Orthop*. 1998;113:75–84.
- Dugoni S, Aubert M, Baumrind S. Differential diagnosis and treatment planning for early mixed dentition malocclusions. *Am J Orthod Dentofacial Orthop*. 2006;129(4 Suppl 1):S80–1.
- Franchi L, Baccetti T, Giuntini V, Masuccu C, Vangelistia C, De Fraia E. Outcomes of two-phase orthodontic treatment of deepbite malocclusions. *Angle Orthod* 2011;81:945–52.
- Jang JC, Fields H, Vig KWL, Beck M. Controversies in the timing of orthodontic treatment. *Semin Orthod*. 2005;11:112–8.
- Subtelny JD. *Early orthodontic treatment*. Chicago: Quintessence Publishing Co; 2000.
- Suresh M, Ratnaditya A, Kattimanis VS, Karpe S. One phase versus two phase treatment in mixed dentition: a critical review. *J Int Oral Health*. 2015;7:144–7.
- Thiruvengkatachari B, Harrison JE, Worthington HV, O'Brien KD. Early orthodontic treatment reduced incisal trauma in children with class II malocclusions. *Evid Based Dent*. 2014;15:18–20.

The Importance of the Speech Therapist During the Interceptive Orthodontics and Myofunctional Therapy

2

Lic Ana Delia Vassallo

The orofacial region is a common area of different specialties. It was denominated stomatognathic system for a long while. After detailed analysis of the complex number of tissues and organs and after considering the totality of the anatomical and functional elements, researchers have reached the conclusion that the name stomatognathic system is insufficient. That's why currently, with wider and more modern criteria, it is now called cranial-cervical orofacial system (Moyano).

This system is a heterogeneous group of tissues and organs. Anatomical or functional alterations have the capacity to compensate or adapt and lead the child, youth, or adult to live in an unhealthy imbalance. The morphology of a subject is the result of the activity of the different muscular groups which throughout growth give shape to the skeleton. Our field of interest, orofacial, is included (Soulet 1989). After all, orofacial shapes are generated by osteogenesis which is produced by minimal pressure exerted by surrounding tissues. This is due to the fact that orofacial bones have intramembranous ossification. Its growth and development are associated with the force of soft tissues along with genetic and environmental characteristics.

Not all bone structures have the same consistency. The quality is related to the osseous biography of the patients. It is important to recognize the prenatal antecedents, the quality of food consumed by the mother during pregnancy, whether the gestation was normal or had problems, and what type of medication was taken (Moyano).

Functions carried out by the cranial-cervical orofacial system:

- Swallowing (sucking)
- Respiration/breathing
- Chewing

These are vital functions that are well defined and reciprocal among them.

Functions in relation to communication:

- Speaking/language
- Expressive mimic

2.1 Functions of the Cranial-Cervical-Orofacial System

2.1.1 Swallowing

Swallowing is a complex biological function; it is meant to transfer saliva, solids (previously chewed), liquids, and other substances safely from the mouth to the stomach. It is the beginning of the digestive process which prepares and conduces food so that it is later absorbed in the gastrointestinal tract. The purpose of these physiological habits is to produce energy which is needed for growth, development, and maturity of the child. It also provides adults with energy for their daily activities.

2.1.2 Evolution of Swallowing

2.1.2.1 Swallowing in the Fetus

It is a biological and physiological process that is programmed genetically. This function begins inside the womb; the fetus swallows amniotic liquid and this contributes to the regulation of the volume of the liquid between mother and fetus (Moyano). The motor activity is made evident through the reflex of opening the mouth, the stimulation of the lip, and the proximity of the hand to the mouth, all of which show neurological maturity. Once the reflex of sucking appears, sucking and swallowing are associated and continue until birth. Its efficiency is of utmost importance for the

L.A.D. Vassallo
Assistant Professor, Department of Orthodontics, Maimonides
University, Buenos Aires, Argentina
e-mail: anavassallo@yahoo.com.ar

newborn baby's feeding. This activity reflects where all the motor nuclei of the brain stem participate.

2.1.2.2 Swallowing in Newborn and Nursing Babies

Sucking while nursing is a consequence of the stimulation of the upper lip or the mucosa of the premaxilla. Its efficacy is paramount since suction ensures swallowing because they are inseparable. At this stage, swallowing is still a mere reflex, from the mouth to the stomach. It is solely something that occurs as a consequence of the relationship the anatomical structures have.

The tongue is large in relation to the tissue that surrounds it; it is in an anterior position and rests on the gingival mamelons, stimulating the development of future teeth (Juri).

Nursing develops and consolidates the function of swallowing. It is extremely important for the harmonious development of the structures since propulsive movements of the mandible are produced along with neuromuscular orofacial activity that collaborates in the development of shape. Nursing is extremely important for the development of the child, not only because of the components in the milk but also because it consolidates the bond between the mother and child which ensures the psycho-affective development of the child. Health in this case does not only refer to physical well-being but also psychological. Many believe the origin of well-being begins when nursing.

2.1.2.3 Swallowing in Children

When teeth begin to erupt, the behavior is modified and new occlusal contacts begin to appear; new habits such as lateralization of food in the mouth in order to chew begin to develop. These changes start progressively as of age 3, when all primary teeth are present. The orbicular shape of the lips meant to close firmly is no longer needed. Also, the tongue rests on the palate; there is molar contact and there is a change in the pattern of swallowing, from the anterior region

to the posterior region. This stage of transition is consolidated thanks to the growth of the anatomical structures involved as well as to the maturation of the central nervous system.

If interposition of the tongue when swallowing or at rest is still present between ages 3 and 5, it will affect the primary teeth, even more so the permanent teeth. As a consequence, harmonious dental-maxillary growth will be affected.

2.1.2.4 Functional or Mature Swallowing

It is the fine neuromuscular coordination that contributes to a balanced morphogenesis of the maxillary-mandibular arches, in concordance to growth, to the development of muscular anatomical structures, and to the level of maturity of the central nervous system.

What characterizes it are the following:

- Contact of both lips, without muscular contraction.
- Dental occlusion.
- The tip of the tongue lies on the (lingual incisor-anterior) retro-incisive area.
- The back of the tongue rests against the palate.
- The base descends at an angle of 45°.

Functional swallowing is intimately associated with nasal breathing. Any pathology that obstructs the airway will cause alterations in chewing and as a consequence, in the behavior of the tongue when swallowing (Moyano).

2.1.3 Stages or Phases of Functional Swallowing

Though, here, functional swallowing has been divided into four stages, it is important to keep in mind that swallowing is a succession of motions that occur quickly and that are interconnected (Gardiner).

2.1.3.1 Oral Preparative Stage

In this stage solid food is processed, semisolid food is tasted, and liquids are displaced. It is completely conscious. How long this lasts depends on personality, emotions, size and consistency of food, secretion of saliva, and dental occlusion. Also, it is voluntary, so ingestion can be interrupted in case food is too hot, tastes bad, or contains odd particles (Segovia).

This is when pleasure is felt upon tasting food which is very associated with the sense of smell. The soft palate is in contact with the base of the tongue, the food stays in the mouth while chewing, and simultaneously breathing through the nostrils takes place. This enhances the ability to capture scents and aromas which make the experience more enjoyable. Sight also collaborates in this.

It begins with grip, cut, and transfer of the solid food toward the premolars and molars to be ground, crushed, and salivated. Mastication or chewing adequately prepares food to be swallowed (Fig. 2.1). This food processing stage requires muscular integrity that enables complex movements as well as adequate dental occlusion.

Adequate bilateral mastication which is multidirectional, alternate, stimulates the support structures that contribute to the development of the maxilla, the mandible, and the stability of the occlusion and oral hygiene (Moyano).

Once food has been crushed and ground, aided by saliva, the food is moved to the back of the tongue in order to be pushed back and thus, the second stage begins.

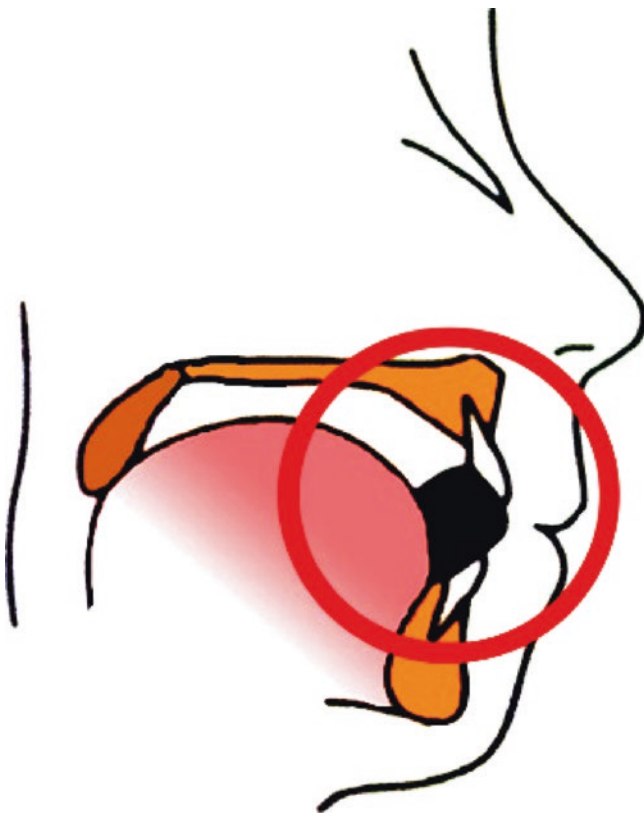


Fig. 2.1 Oral preparative stage

2.1.3.2 Exclusively Oral Stage or Transfer

Once food has been prepared and positioned on the back of the tongue, transfer of the food begins thanks to peristaltic motion that moves food to an anteroposterior position to push it toward the oropharynx (Fig. 2.2). The tongue is of vital importance at this stage. The tip rests against the lingual surface of the incisors; the back is in contact with the soft palate, exerting pressure against the midpalatal suture. At this point, negative intraoral pressure is produced which favors the descent of the palate and multi-directional expansion. There is dental occlusion. The lips and muscles are not in contact; the soft palate is elevated to come into contact with the pharynx.

Both stages (oral preparative and transfer) are conscious and voluntary and affect proper dentoalveolar growth and development.

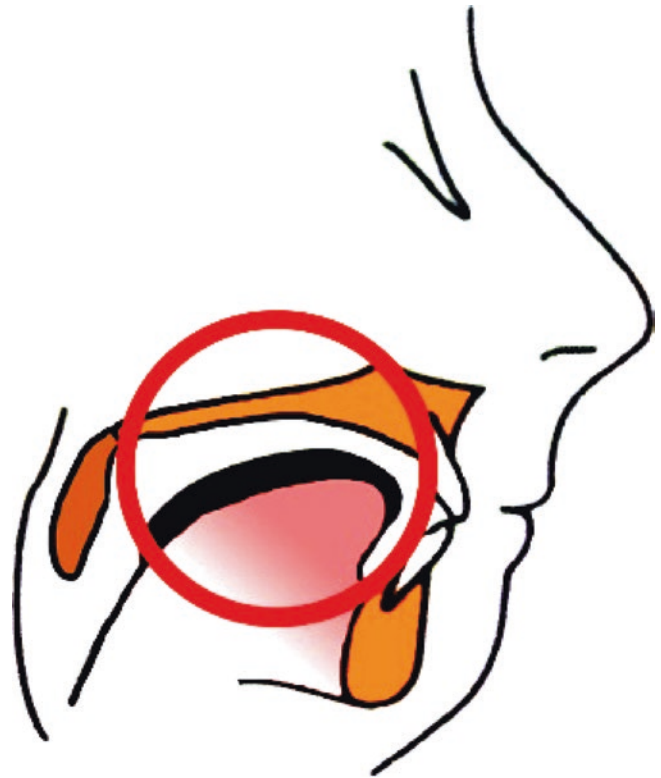

Fig. 2.2 Exclusively oral stage or transfer

2.1.3.3 Pharyngeal Stage

When the food reaches the oropharyngeal isthmus, the swallowing reflex is initiated. This includes (Fig. 2.3) elevation and retraction of the soft palate; in order to contact the posterior and lateral soft pharynx, the isthmus faucium closes. Elevation and closing of the larynx to stop food from moving into the airway and relaxation of the superior esophageal valve is necessary.

This stage is crucial to stop the bolus from being regurgitated by the nose, returning to the mouth, or moving into the airway.

The sequence of motions during this pharyngeal phase pushes the bolus back and the intraoral pressure increases. This takes seconds and it is conscious and involuntary. At this point, respiratory apnea is produced (Segovia).

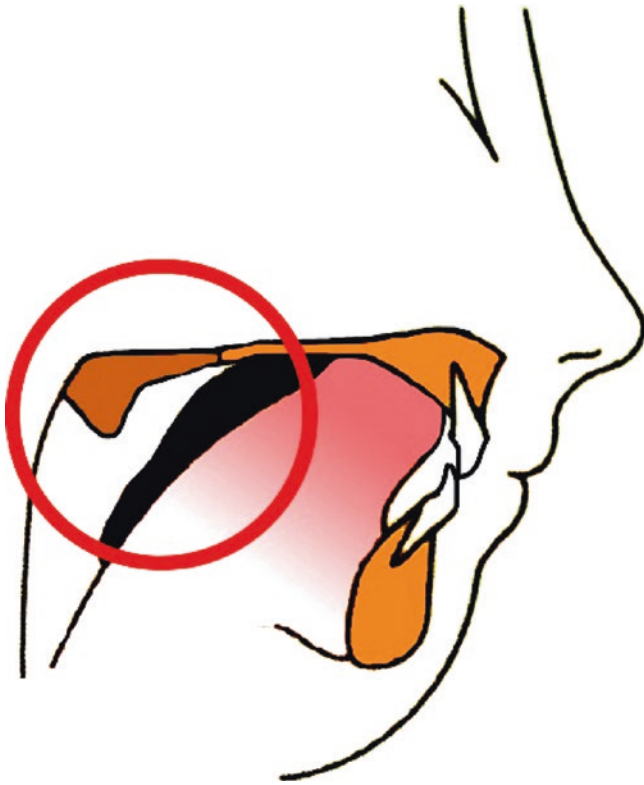


Fig. 2.3 Pharyngeal stage

2.1.3.4 Esophageal Stage

This stage starts when food moves through the superior esophageal sphincter and ends when it moves into the inferior esophageal sphincter (Fig. 2.4).

This is unconscious and involuntary. It takes 8–20 s.

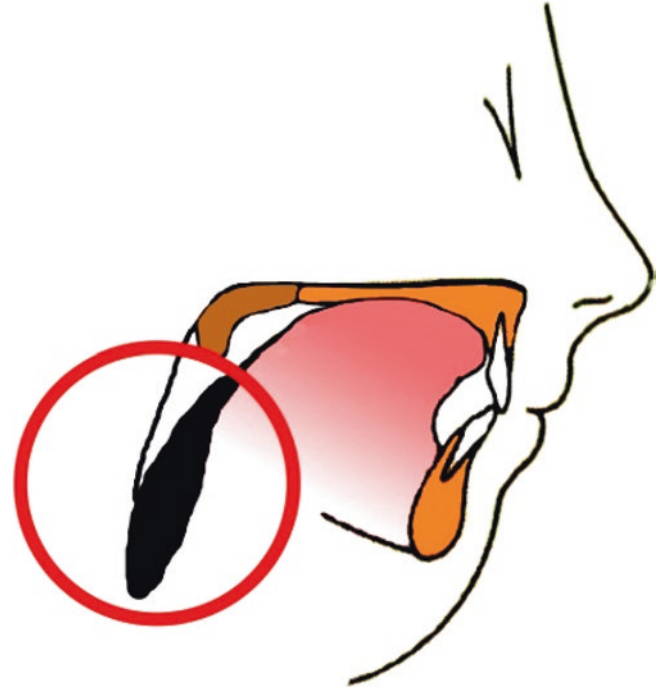


Fig. 2.4 Esophageal stage

2.1.3.5 Dysfunctional Swallowing or Tongue Thrusting

It is the malposition of the tongue, at rest and while swallowing. This dysfunction of the tongue affects the growth and development of the mouth. When it isn't treated and continues, it is considered among the most common etiological factors that produce maxillofacial disharmony. It can also worsen and produce malocclusion, bearing in mind that proper function is not possible if the shape is not adequate. One way or another, dysfunction of the tongue must be taken into account and treated.

High position of the tongue (anterior open bite) (Fig. 2.5a–d).

In general this malposition of the tongue exerts pressure on the premaxilla, causing an open bite. Another situation is

dysfunctional swallowing and low tongue thrust as a consequence of hypertrophied tonsils (Fig. 2.6a–d).

Other patients have a combination of dysfunctional swallowing or low tongue thrust with predisposition (Fig. 2.7a–d).

Other patients have dysfunctional swallowing with lip interposition (Fig. 2.8a–d).

It is an orofacial neuromuscular imbalance that is characterized by constant lip interposition while swallowing at rest, while pronouncing bilabial P B M, and during mimic. This interposition is harmful for harmonious maxillofacial growth and development. Many call it the lip trap. This dysfunction of the lip is sometimes accompanied by tongue thrust, thus affecting the dental-maxillary relation even more.

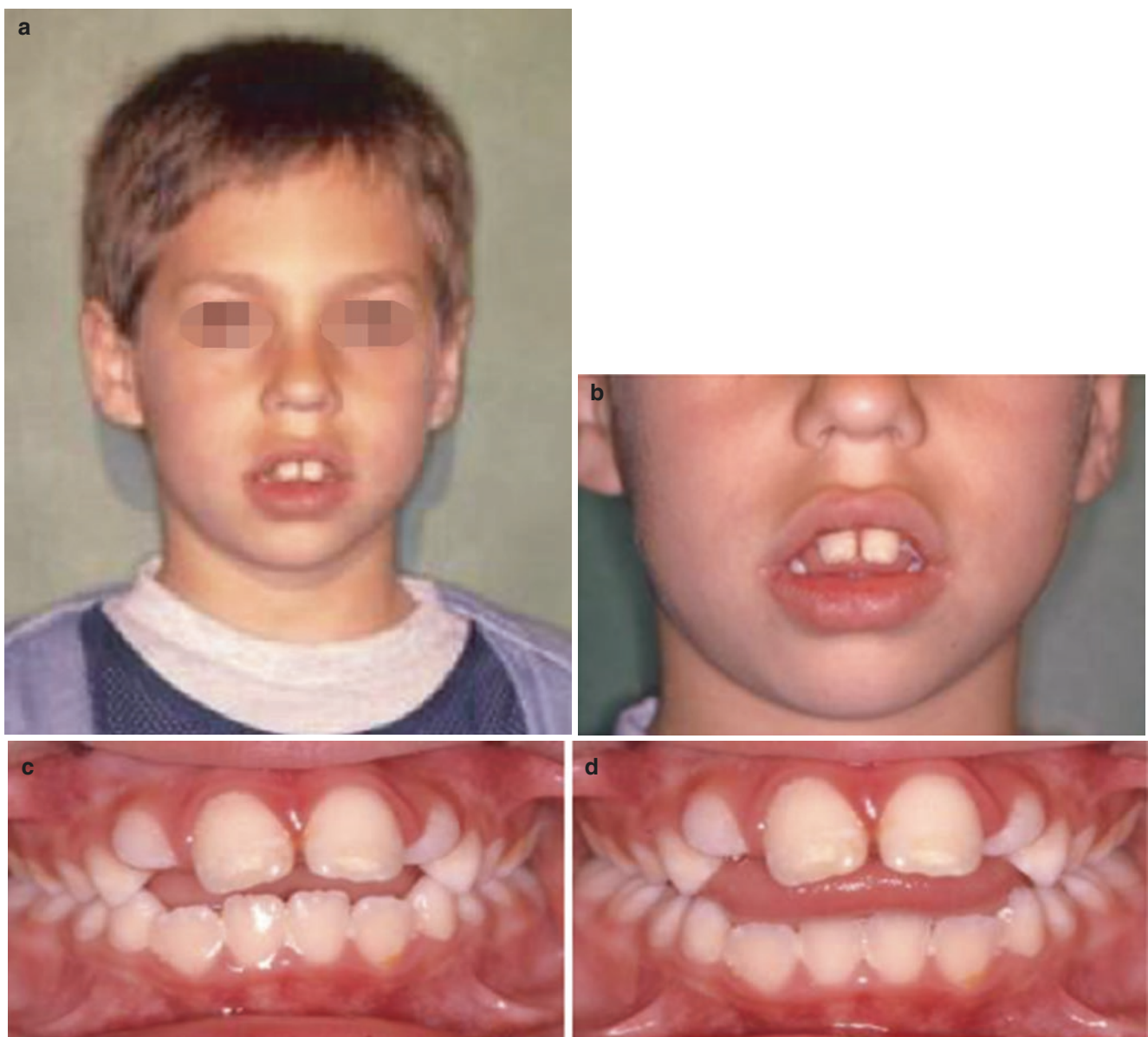

Fig. 2.5 (a) High position of the tongue. (b) Poor tongue position at rest. (c) Anterior open bite. (d) Dysfunctional swallowing

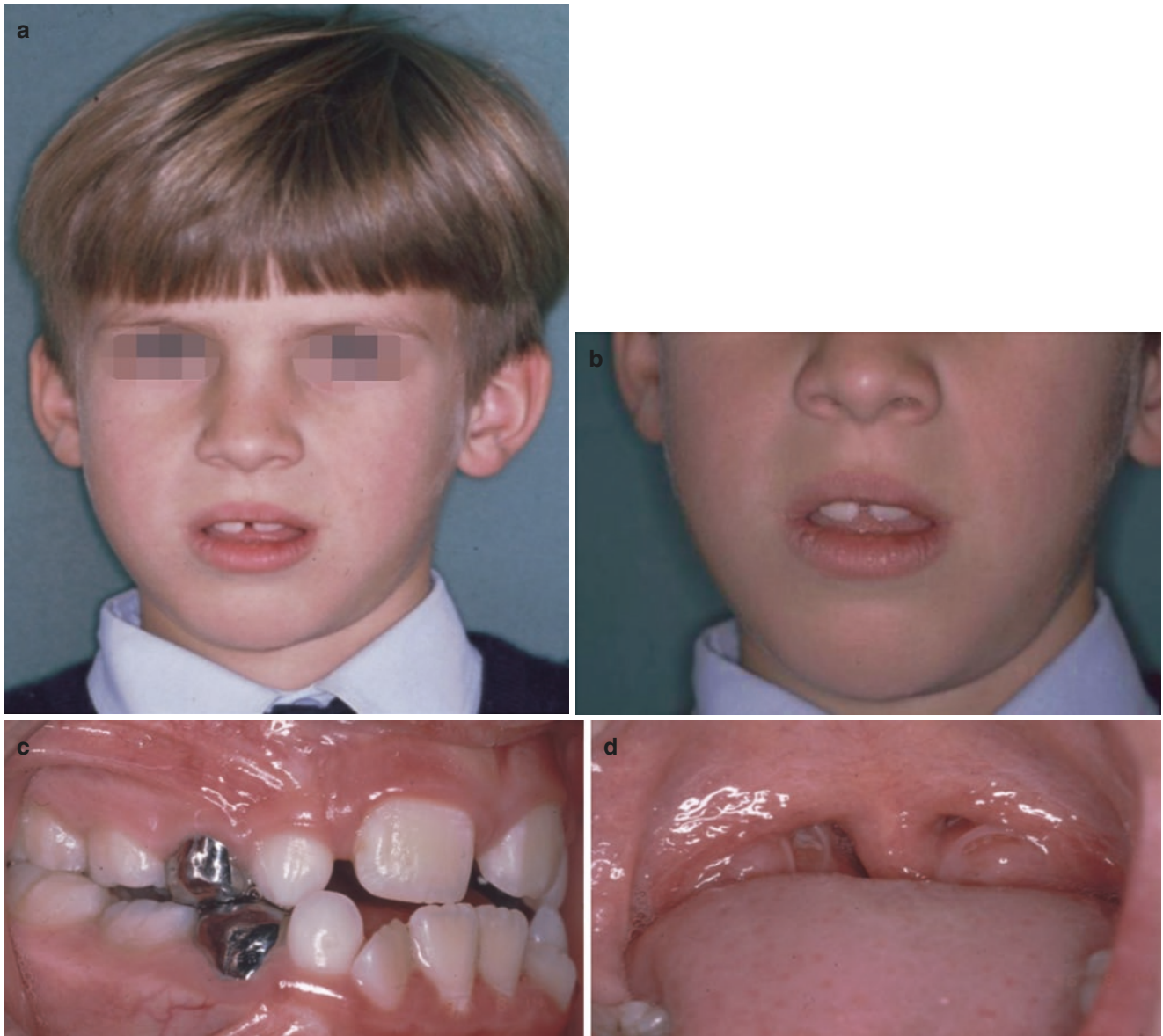


Fig. 2.6 (a) Poor facial muscle balance. (b) Low tongue thrust. (c) Occlusion caused by low tongue thrust. (d) Hypertrophied tonsils

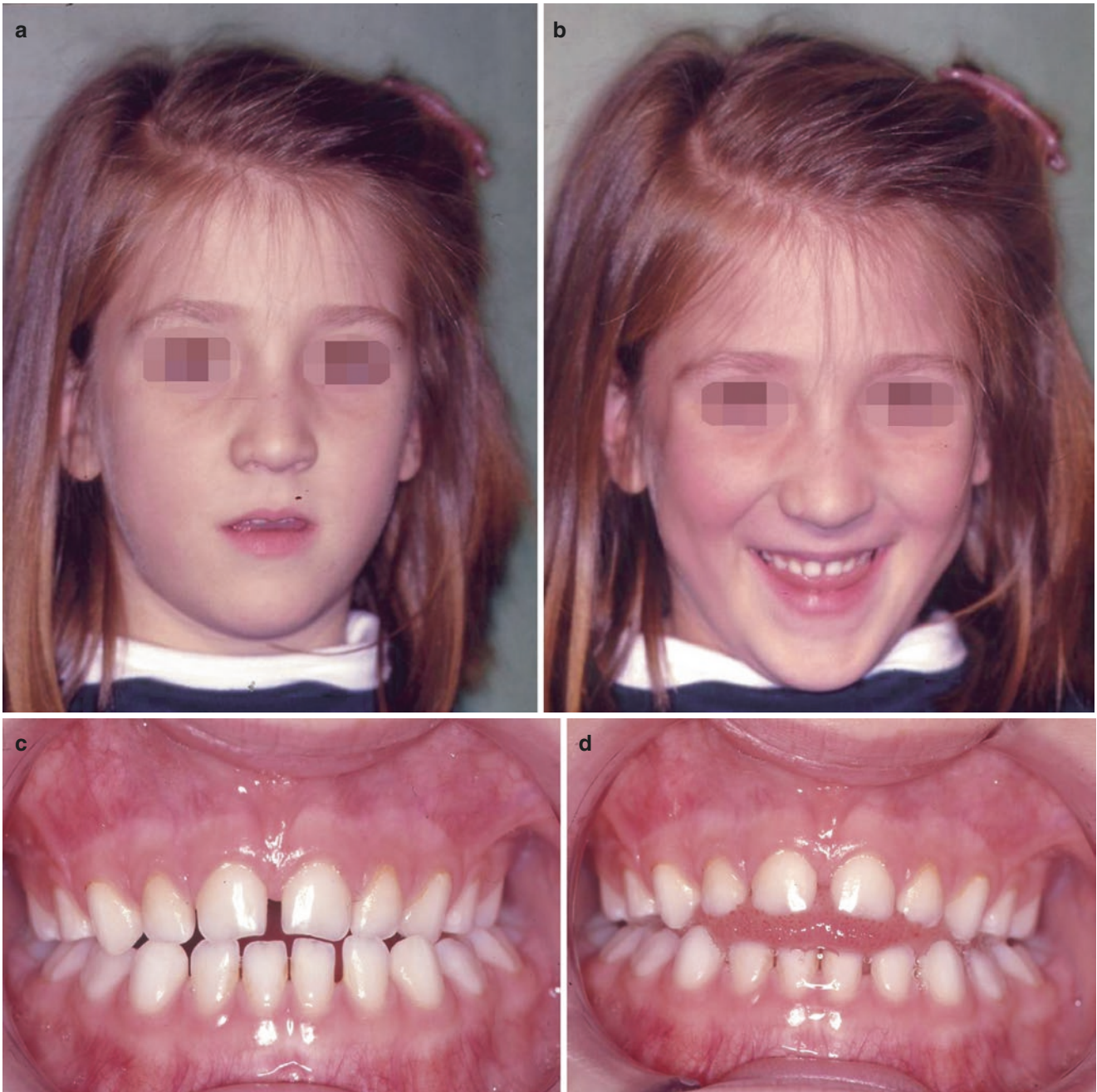


Fig. 2.7 (a) Usual position at rest. (b) Lingual dysfunction during smile. (c) Altered tooth relationship. (d) Dysfunctional swallowing with tongue thrust

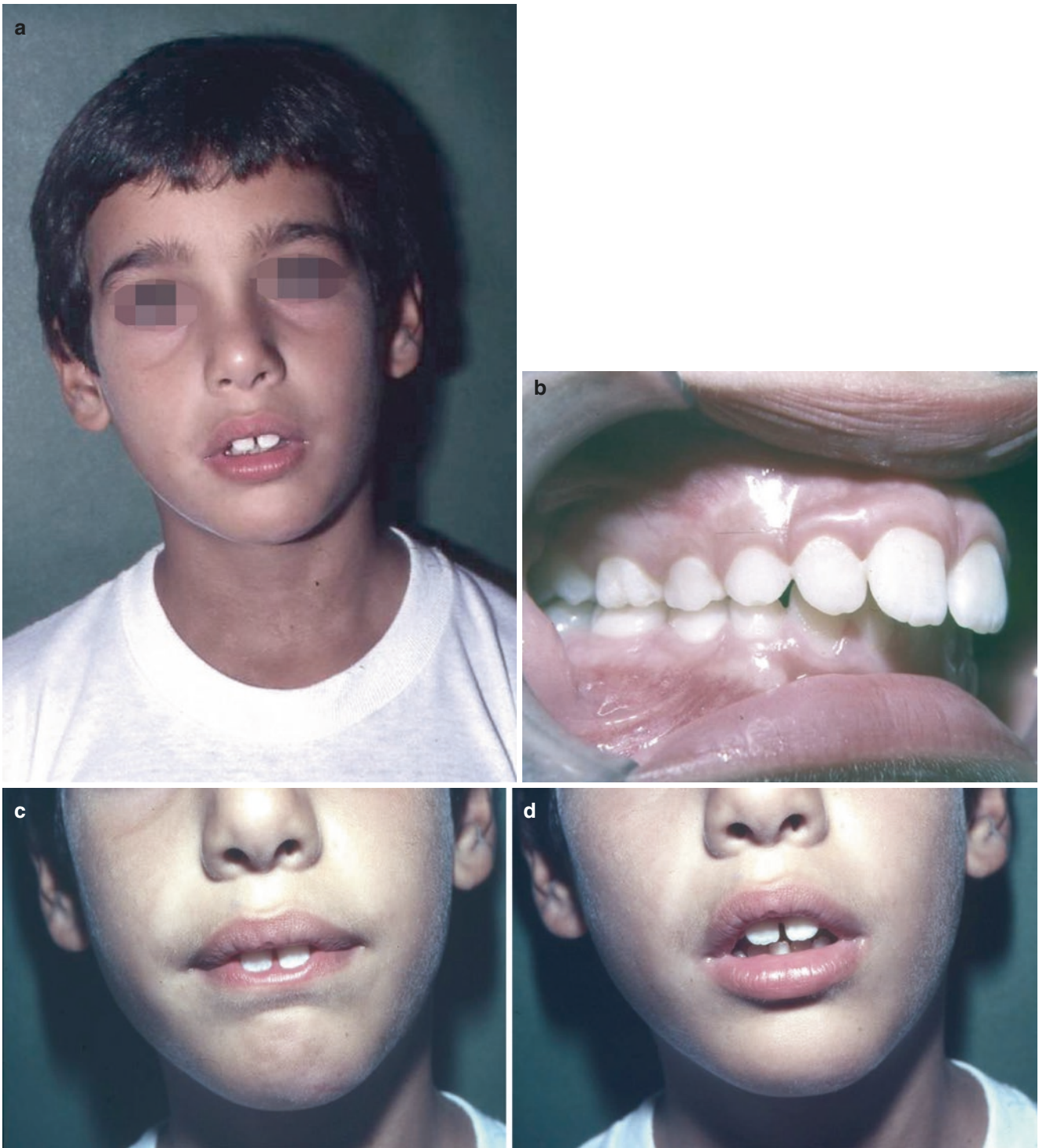

Fig. 2.8 (a) Usual position at rest. (b) Occlusion altered by labial interposition. (c) Labial interposition in swallowing. (d) Labial incompetent in the rest position

2.1.3.6 Etiology of Dysfunctional Swallowing

- A. Digital sucking. If this habit continues after 2 1/2–3 years of age, it is considered pathological and disrupts the dental-maxillary harmony. It is also considered a triggering factor of orofacial muscular imbalance which in turn causes open anterior open bite (Melsen et al. 1979, 1987) (Fig. 2.9a, b).
- B. Habit of tongue sucking. The upper incisors bite the back of the tongue during the day and night, stimulating the displacement of the lower maxillary which causes the open bite. This habit causes great deformity and has a psychological component which must be given priority during dental treatment and myofunctional therapy (Fig. 2.10a–d).
- C. Use of feeding bottle (Fig. 2.11). Prolonged use of feeding bottles alters the swallowing pattern. When it continues beyond 3 years of age, the dysfunctional behavior of the tongue affects the dental relation.
- D. Another significant issue is the persistent use of pacifiers (Fig. 2.12). When it is used beyond 3 years of age, it is no longer physiological and becomes pathological, thus generating alterations in the growth and development of the mouth and position of the teeth.
- E. The presence of hypertrophied tonsils can cause functional problems. Since they are swollen, they predispose the displacement of the tongue in a posterior-anterior direction, generating protrusion of the tongue while swallowing (Fig. 2.13).

Hypertrophied adenoids cause difficulties in nasal breathing, and this modifies the position of the tongue at rest. Also, swallowing becomes dysfunctional.

In addition, dysfunctional swallowing can be caused by emotional immaturity because of emotional lip movements and difficulty adapting.

- F. The short tongue frenum limits the mobility of the tongue which can't make contact with the palate, altering its behavior during swallowing and talking (Fig. 2.14).
- G. When the premature loss of the incisors is present, the tip of the tongue can't rest against the retro-incisive papillae while swallowing. It pushes forth due to the absence of teeth and a dental and functional open bite will be the result.
- H. Blocked noses. Whether this occurs because of a deviated septum or other causes, it affects muscular balance, altering dental-alveolar development and causing dysfunctional swallowing (Fig. 2.15a, b).
- I. Sucking two fingers. This habit is considered pathological and disrupts the dental-maxillary harmony. As a result, the patient will have hypercontraction of the mental muscles or dysfunctional swallowing with lip thrust and altered teeth relationship as a consequence (Fig. 2.16a–d).

The causes mentioned affect malleable alveolar edges that are being calcified. This distortive pressure produces changes in facial and dental development of the child. The altered forces against dental arches, teeth, and soft tissues produce dental and functional disturbances in the stomatognathic system.

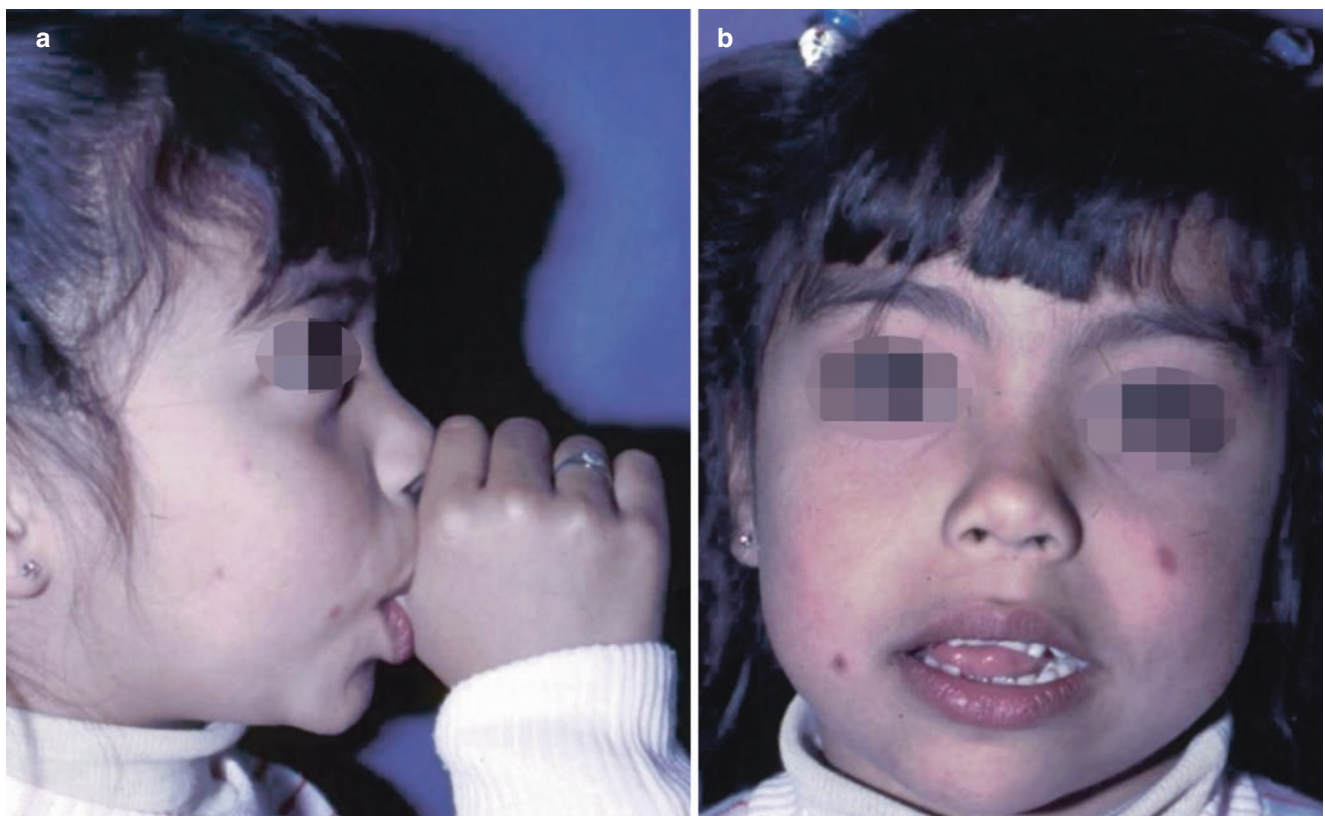

Fig. 2.9 (a) Young child with digital sucking. (b) Oral facial muscle imbalance with open bite

Fig. 2.10 (a) Tongue thrust into rest. (b) Anterior position of the mandible. (c) Lingual overflow in rest position. (d) Open bite by habit of tongue sucking

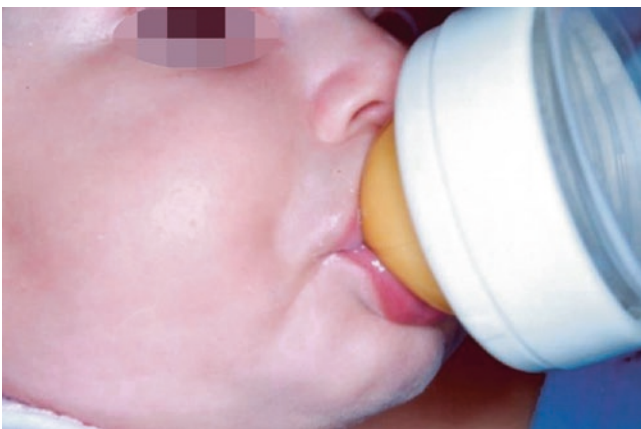
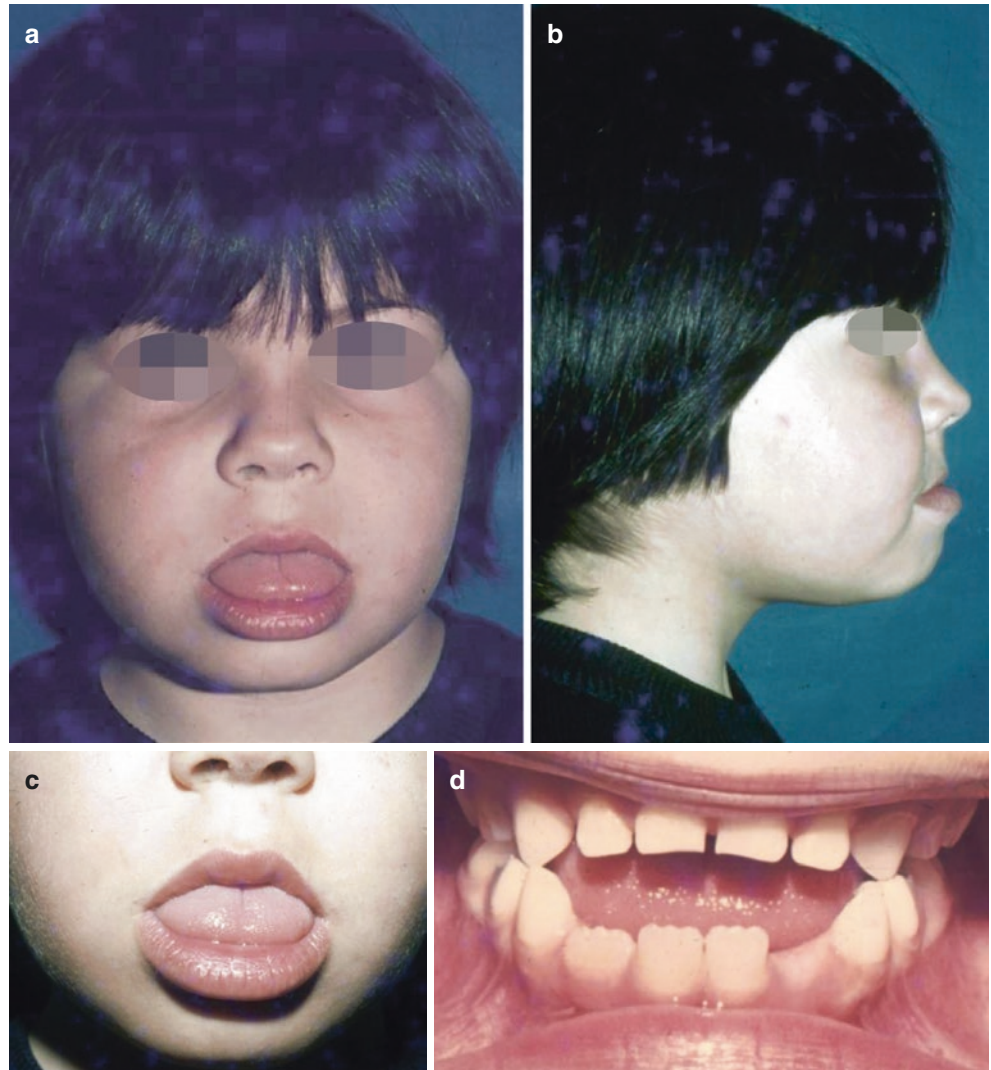
Fig. 2.11 Prolonged use of feeding bottle

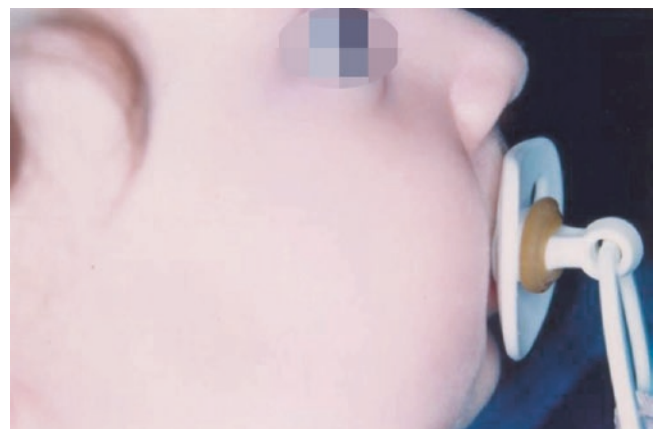

Fig. 2.12 Prolonged uses of pacifiers

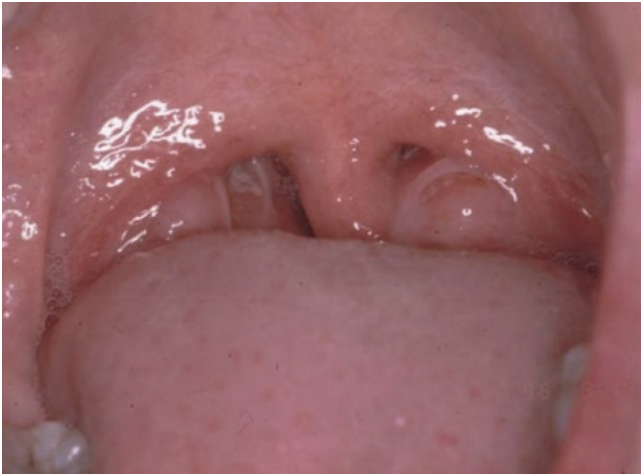

Fig. 2.13 Presence of hypertrophied tonsils

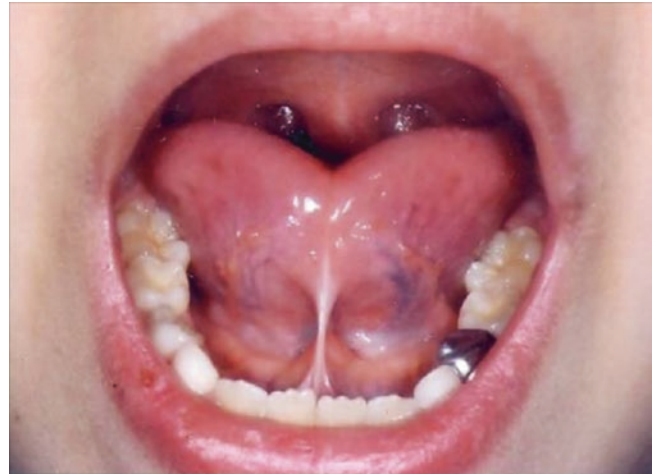
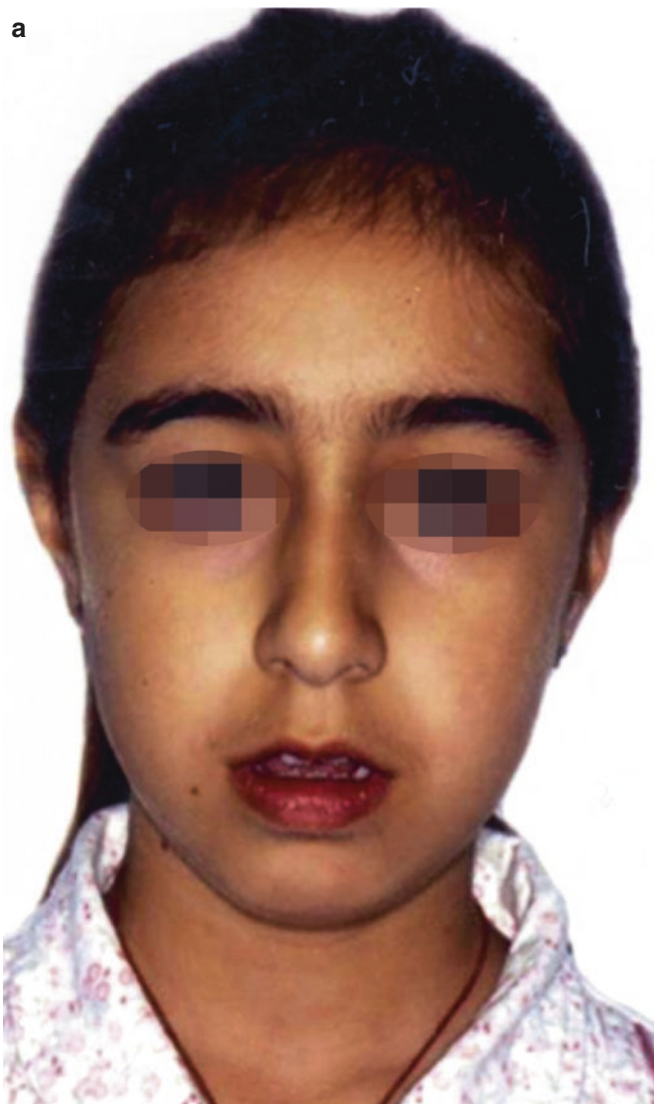
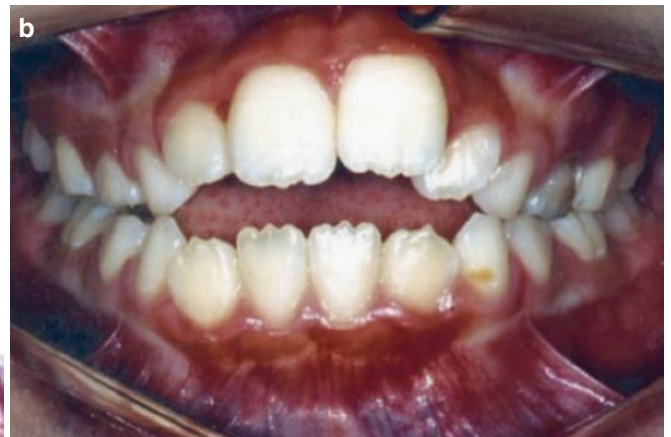Fig. 2.14 Short tongue frenum



a



b

Fig. 2.15 (a) Facial appearance caused by mouth breathing. (b) Open bite as a consequence of a dysfunctional swallowing

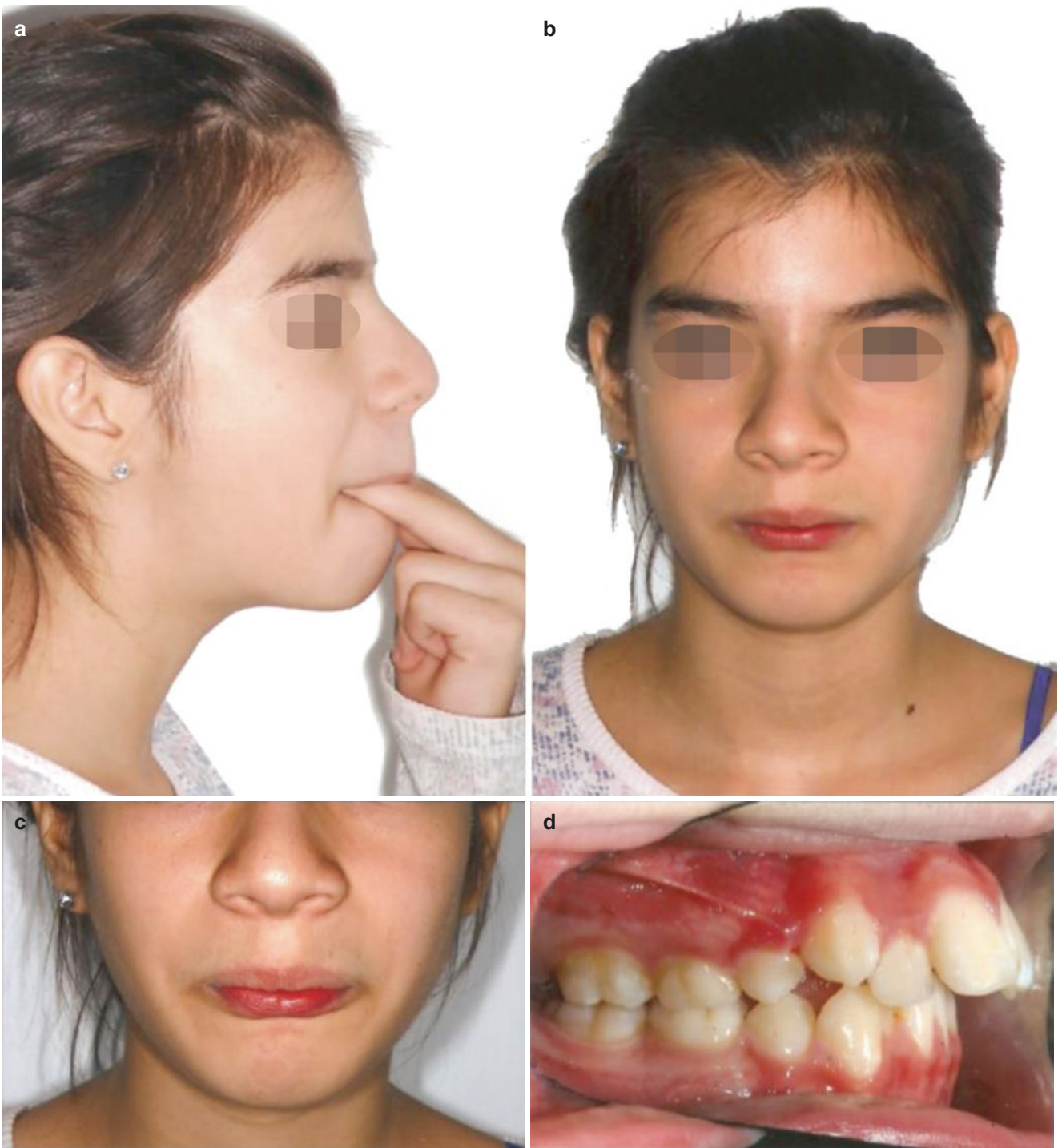

Fig. 2.16 (a) Girl sucking two fingers. (b) Hypercontraction of the mental muscles. (c) Dysfunctional swallowing with lip thrust. (d) Altered tooth relationship

2.1.4 Functions of the Respiratory System

Respiration is a chemical and biological mechanism that ensures an abundant supply of oxygen for the cells, eliminating carbon dioxide and controlling ventilation. The newborn baby activates the respiratory system when they begin to breathe through the nose.

The mechanical motion of air passing through the nostrils activates nerve endings found there, which generate responses. Some of the most important are the control of the movement of the thorax, ventilation, tridimensional development of nostrils, the base of the upper maxilla, and the size of the sinuses as well as many other stimuli that are vital for the body.

Nasal breathing leads to the liberation of energy needed for growth, development, and maturation of the child and youth and also provides the energy adults need for both intellectual and physical activities (Juri).

As air passes through the nostrils, it is conditioned. Since it is humidified and warmed, it is sterilized.

The motion of inhaling and exhaling through the nose is a morphogenetic condition produced by tension and distension in the area of the facial bone sutures and mouth. Since these bones have intramembranous ossification and are joined by sutures, they respond to functional stimuli. Air, especially when exhaled, is one of these stimuli. The maxilla is responsible for transversal growth of the face. Along with sinuses, they contribute to the development of the top middle third of the face. This area is similar to a honeycomb, with many small cells through which exhaled warm air enters, generating pressure that causes the distention, its development, and even its migration.

This is why air is considered to be responsible for the shape of the face. Its presence contributes to the harmonious growth and development of the face (Moyano).

The air that is exhaled exerts pressure toward the base of the nostrils. Since the tongue rests upon the palate, each time swallowing takes place, it presses against the hard palate,

generating negative intraoral pressure that contributes to the descent of the palate. Since the lips are closed, it causes the upper lip to traction the anterior nasal spine, contributing to the advancement and descent of the maxilla (Moyano).

2.1.5 Repercussions of Mouth Breathing

It is important to discard diseases in organs present in the respiratory system above all, those in the upper respiratory tract. Referral to an ear, nose, and throat specialist is recommended (Fig. 2.17a–c).

Mouth breathing with lip thrust during rest and swallowing causes the protrusion of the upper maxilla and the extrusion of the lower incisors. In concordance with a pale face, sad eyes and dark circles (Sabaschi) were clearly observed.

In addition mouth breathing produces dry lips in conjunction with hypertrophied gums that bleed very easily (Figs. 2.18a–d).

Since mouth breathing alters the whole cranio-orofacial system, an altered posture is observed in almost all the patients with a tendency toward thoracic kyphosis and protrusive shoulder blades (Hanson and Barrett 1988; Hanson and Mason 2003) (Fig. 2.19a, b).

The collaboration with the physiotherapist is so important in correcting posture in order to achieve normal growth in these children.

Myofunctional therapy is a specialty within speech therapy that was designed to correct the functional alterations in breathing, swallowing, chewing, and language to achieve a muscular factorial balance which affect the dental arches.

Myofunctional therapy is a discipline that collaborates in orthodontics.

This specialist is familiarized with the orthodontic terms which allows them to work in an interdisciplinary team to attend different aspects of the dysfunctions present in patients without forgetting the biological, social, and psychological aspects.

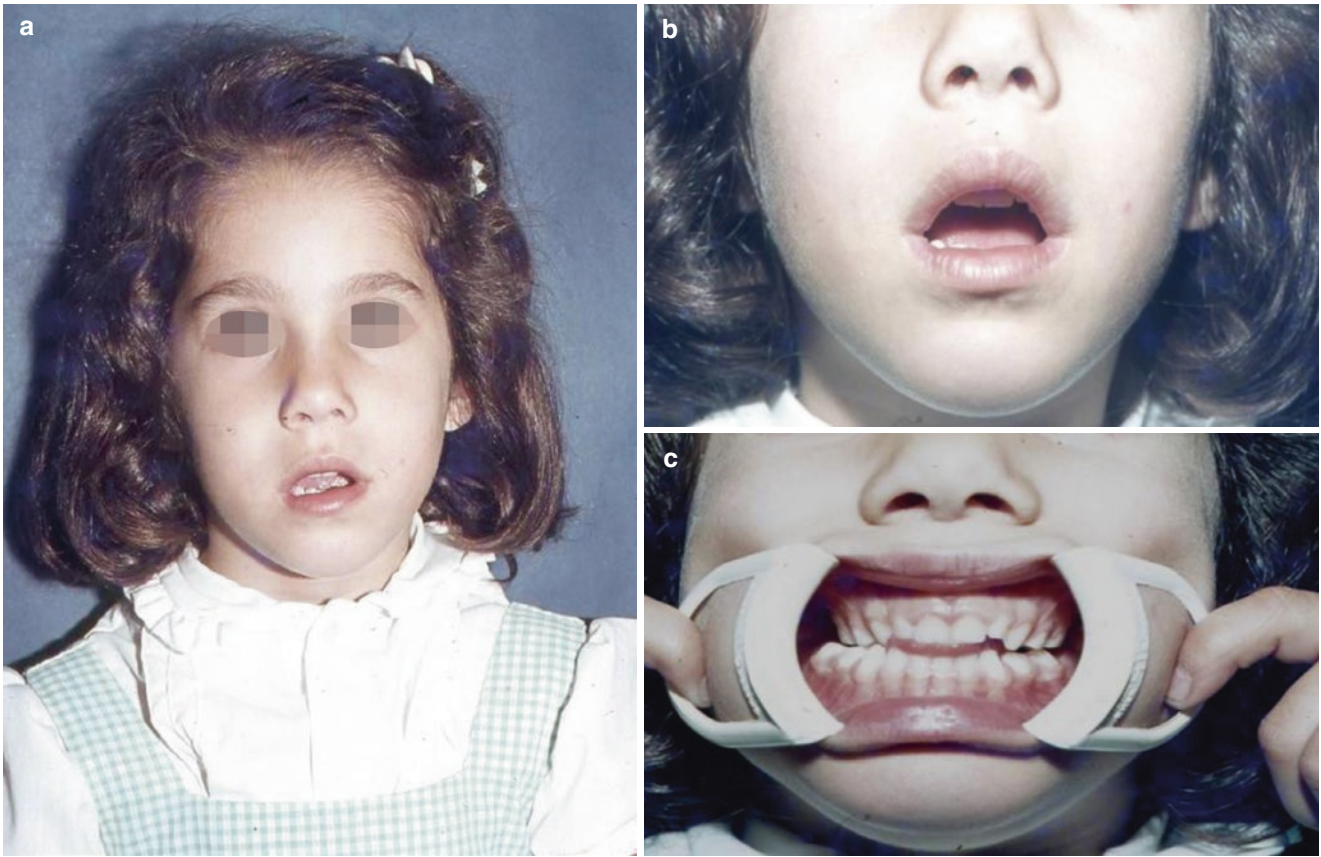

Fig. 2.17 (a) Poor facial appearance due to mouth breathing. (b) The tongue is on the base of the mouth. (c) Dentoalveolar crossbite

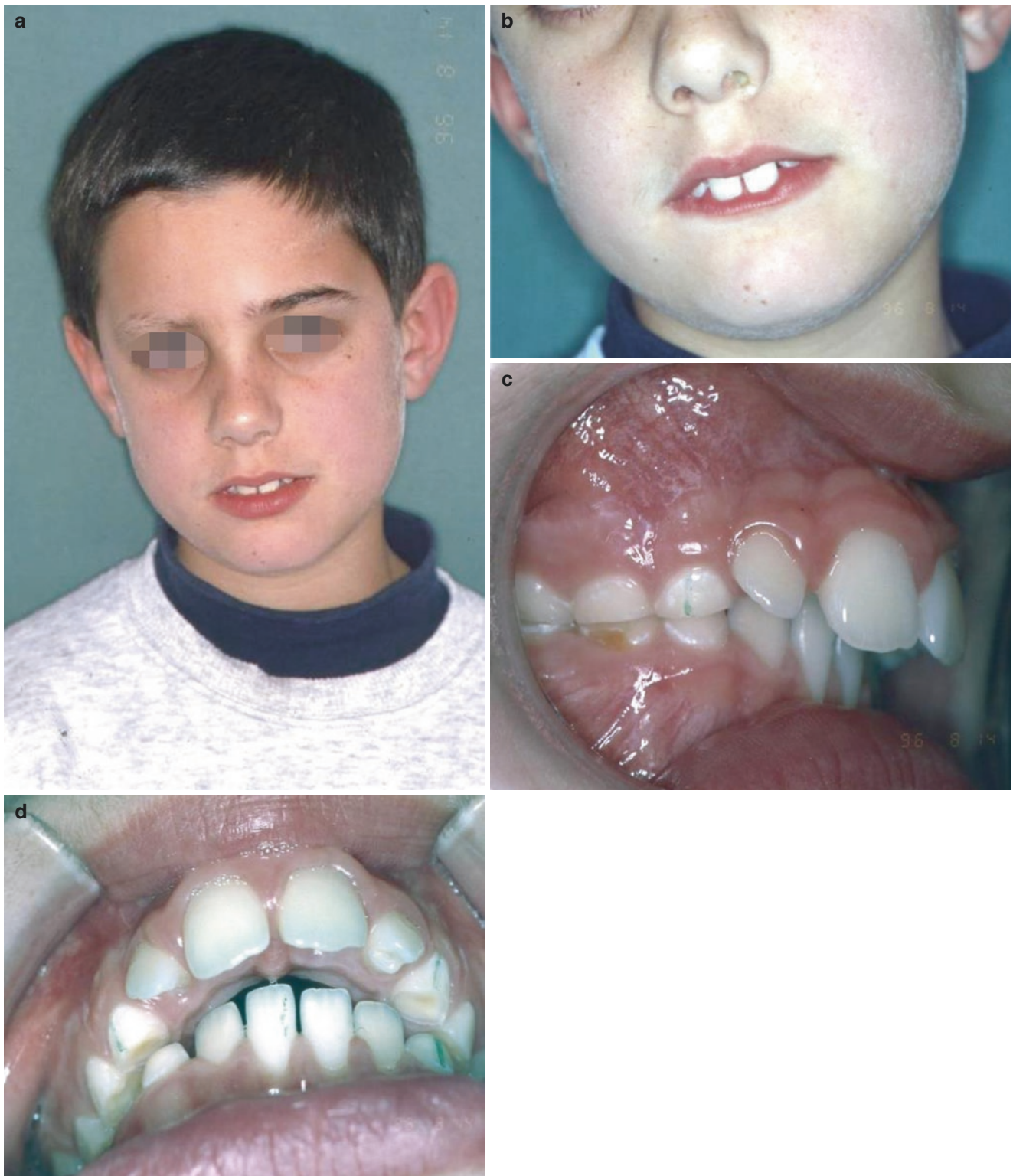

Fig. 2.18 (a) Lip incompetence. (b) Labial interposition at rest and swallowing. (c) Protrusion of the upper maxilla. (d) Extrusion of the lower incisors

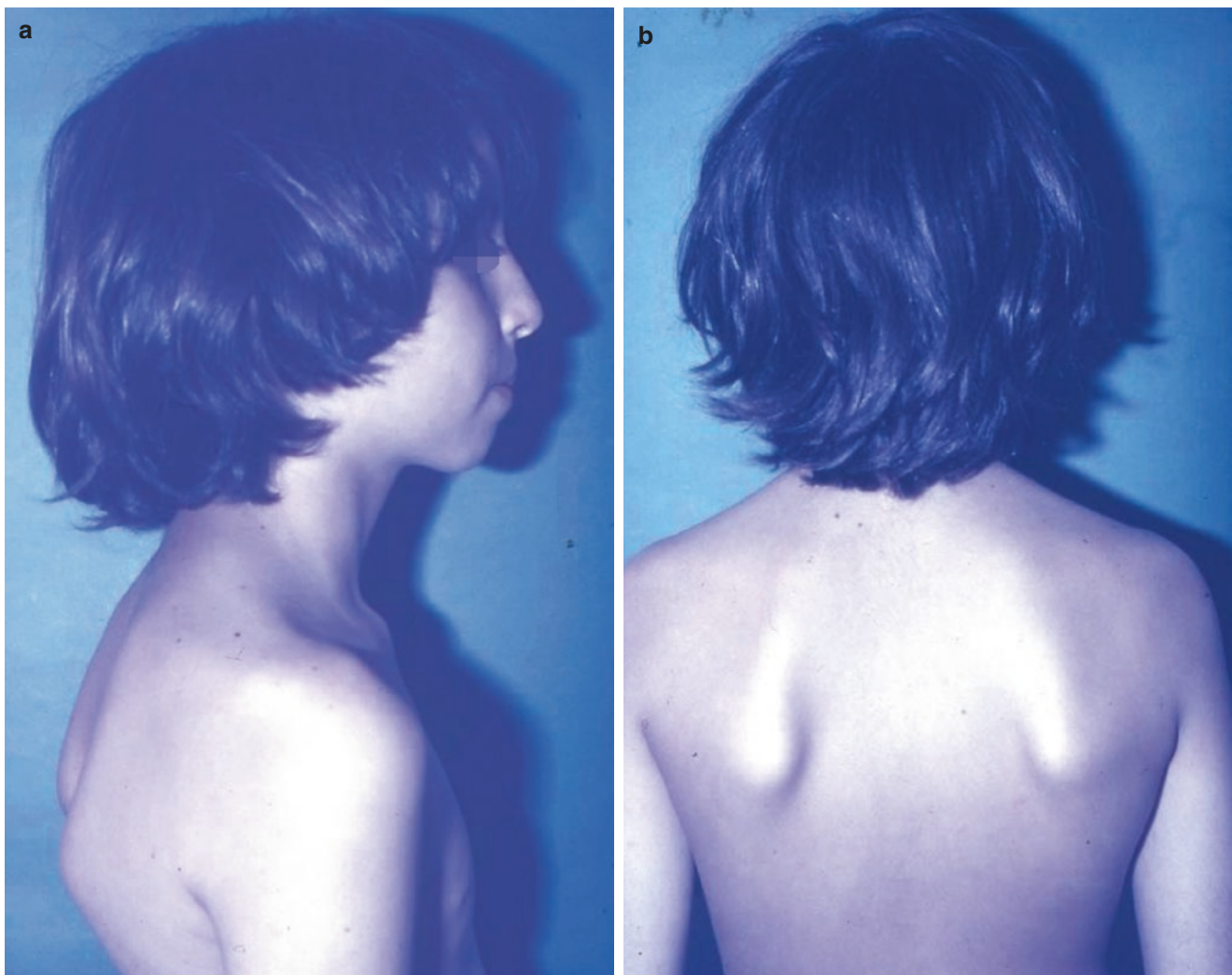

Fig. 2.19 (a) Tendency toward thoracic kyphosis. (b) Protrusive shoulder blades

Conclusions

The orofacial shape is caused by minimal pressure exerted by soft surrounding tissues. The stimuli generated by functions such as nasal breathing, functional swallowing, and efficient chewing collaborate in optimal bone growth and development.

When functional or anatomical alterations are present, the cranial-cervical orofacial system has the capacity to compensate and adapt to certain cases with deformities of the structures, thus producing an increase or decrease of bone growth.

The upper maxillary is responsible for the transversal growth of the face. It contains the bones that compose the intramembranous ossification that are responsible for these functions.

A myofunctional therapist is a speech therapist that has a specialization and can evaluate, forecast, and correct these functional alterations, and consequently the muscular orofacial pressure interdisciplinary teams are neces-

sary to achieve treatment goals in the most efficient way possible. The ear, nose, and throat specialist will attend to and solve problems related to the high respiratory tract. The physiotherapist can participate in correcting posture in order to achieve harmony, flexibility, and the adequate muscle tone (Zickefoose and Zickefoose 2000).

The psychologist can provide counseling in cases where habits are a consequence of emotional distress.

When other disciplines are considered, the objective of orthodontics goes beyond mere dental relation:

1. Making accurate etiological diagnosis, prognosis, and treatment plan is essential.
2. Interdisciplinary teamwork.
3. Choose order and priorities of professional team members that are going to intervene and make sure criteria for treatment are uniform.
4. Reinstate form and function with harmony and balance.

5. Integrate the family of the patient to ensure treatment objectives.

6. Keep in mind that the main objective is the patient's well-being.

The importance of an early treatment to re-establish a normal growth with integrated team members cannot be denied.

Bibliography

Garliner D. Myofunctional therapy in dental practice. Florida Ed: Institute for myofunctional therapy; 1973. p. 21–149.

Garliner D. Swallow right or else. Florida Ed: Institute for myofunctional therapy. Coral Gables; 1979.

Hanson M, Barrett R. Fundamentals of orofacial myology. Springfield: Charles C. Thomas Publisher; 1988.

Hanson ML, Mason RM. Orofacial myology. International perspectives. Springfield: Charles C. Thomas Publisher; 2003.

Melsen B, Stensgeaard K, Pedersen J. Sucking habits and their influence on swallowing pattern and prevalence of malocclusion. *Eur J Orthod.* 1979;1:271–80.

Melsen B, Attina L, Santuari M, Attina A. Relationship between swallowing pattern, mode of respiration, and development of malocclusion. *Angle Orthod.* 1987;57:113–20.

Moyano H, Ronconi T. Importancia de la interrelación entre Deglución-Respiración- Postura en niños. Talleres gráficos de imprenta Acosta Hnos, SH. Ciudad de Santa Fé- República Argentina; 2002.

Sabashi K, Washino K, Saitoh I, Yamasaki Y, Kawabata A, Mukai Y, Kitai N. Nasal obstruction causes a decrease in lip-closing force. *Angle Orthod.* 2011;81:705–53.

Soulet A. Éducation neuro-musculaire des fonctions oro-faciales. *Rev Orthop Dento Faciale.* 1989;23:135–75.

Zickefoose W, Zickefoose J. Orofacial myofunctional therapy. A manual for complex cases. Sacramento: OMT Materials; 2000.

Julia Harfin

The normalization of functional disturbances is one of the main objectives that need to be achieved during early orthodontic treatment.

There is a close relationship between anterior open bite in young patients and abnormal habits that are some of the main etiological factors of malocclusion.

The most common habits are thumb-sucking, lip/nail biting, tongue thrusting, and mouth breathing mode.

Normally, all of these habits could cause interferences with the circumoral musculature and tongue pressure balance, and as a consequence, they develop unaltered maxillary and mandibular arch forms.

Of course, the duration, frequency, and intensity of these habits play an important role, not only in the diagnosis and treatment plan but also during the whole retention phase.

Since there isn't only one reason for digital sucking or the prolonged use of pacifiers, there isn't only one treatment for all of them. It is important to control the habit after 2 years of age. In some patients, the help of a psychologist is valuable.

Digital sucking is responsible for causing significant changes in the maxilla and in the mandible during the growth period.

In general, the maxilla becomes narrow and V shaped, the mandible tends to be retrognathic, and, as a consequence, a significant open bite is developed with proclined upper incisors and retruded lower incisors.

Due to the excessive proclination of the upper incisors, lips become incompetent and the tongue is placed between the upper and lower incisors during the swallowing process, worsening it.

Also, there is a significant link between the respiration mode, the direction of the facial growth, and the development of the malocclusions (posterior cross bite and anterior open bite), due to abnormal contraction of the cheek muscles.

Hypertrophic lymphoid tissues and nasal obstruction in combination with large adenoids and tonsils are the most common cause of nasal obstruction and mouth breathing as they push the tongue forward due to pain and decrease in the amount of posterior space for the tongue.

This atypical swallowing pattern and the anterior posture of the tongue at rest prevent the eruption of the incisors and increase the anterior open bite with lower lip interposition every time the patient swallows.

In general, these young patients are sent to the speech therapist in order to improve the pronunciation of certain words, but it is important to remember that the anterior open bite is the consequence, not the cause.

Also, orofacial and speech dysfunction could be combined with problems at the TMJ that could worsen in the future.

In addition to TMJ problems, episodes of sleep apnea could be added. The child could stop breathing several times during the night (20–40 times per hour of sleep). As a consequence, he or she would feel daytime sleepiness, headaches, fatigue, obesity, changes in personality, lack of attention at school in the morning, etc.

Since sleep apnea is a progressive disorder, the consultation with the specialist is very important from the first day in order to perform a multi- and interdisciplinary treatment plan and avoid relapse (Pascualy et al.).

It is important to remember that sleepwalking in young children and enuresis are commonly related to open bite problems.

The real question is who, when, why, and how to treat.

The higher the percentage of environmental factors in relation to the genetic ones, the better the prognosis. Among the deleterious habits, the prolonged use of pacifiers, mouth breathing, or thumb-sucking are determinants. In some patients, the help of a psychologist is fundamental to control the habits.

Unfortunately, there isn't only one type of appliance to treat all these patients. The appliance selection has to be related to the etiology, age of the patient, seriousness of the

J. Harfin
Department of Orthodontics, Maimonides University,
Buenos Aires, Argentina
e-mail: harfinjulia@gmail.com

problem, etc. The orthodontist is responsible for the appropriate selection.

The decision of whether to use a removable, fixed appliance or a combination of both is related to the etiology and the skeletal maturity in order to maximize the effectiveness of the orthodontic treatment.

The normalization of the vertical dimension is extremely challenging for the orthodontist to control, especially in high-angle patients with mouth breathing.

If problems leading to an open bite could be identified and treated early, it might be possible to minimize or even eliminate an undesirable pattern of growth.

According to the structures affected, anterior open bite can be divided into three main categories: dental, dentoalveolar, and skeletal.

Dental and dentoalveolar open bites develop as a result of prolonged mechanical blockage of the normal vertical development of anterior teeth and alveolar process (Torres et al. 2012).

The skeletal form, in turn, is characterized by a significant vertical skeletal discrepancy, with features such as counterclockwise rotation of the palatine process, increased lower anterior facial height and gonial angle, short mandibular ramus, and increased posterior dentoalveolar height in both mandible and maxilla.

3.1 Diagnosis

Medical and dental analysis

Patients' chief complaint

Evaluation of growth

Functional analysis

Photographic and radiologic evaluation

Vertical facial pattern

Unfavorable growth pattern

The treatment goals should include the removal of the etiological and environmental factors to permit the normalization of the anterior growth development.

Until now, no consensus has been reached to determine the best time to initiate the orthopedic/orthodontic treatment. Nonetheless, it is totally accepted that the earlier the correction of the open bite begins, the better the results will be. Also, early treatment helps avoid relapse.

Myofunctional therapy is the best option to normalize mouth breathing.

Control and reduction of the extrusion of the molars are fundamental to allow a counterclockwise rotation of the mandible to maintain the results.

Failure to control bad habits may be the most important reason of relapse.

The role of the otolaryngologist to improve and normalize nasal breathing during the diagnosis process and speech pathology is of prime importance.

In general, anterior open bite in temporary or early mixed dentition is associated with digital sucking habit and tongue anterior interposition.

Its correction is very important since otherwise the problem could worsen and turn into a skeletal alteration.

The size and length of the lips are also important to maintain a proper lip seal during day and night. Also, it is necessary to normalize the position and function of the tongue.

Normally, children who breathe through their mouth have a narrow maxillary arch, protrusive incisors, Class II occlusion, convex facial profile, bags under the eyes, an open mouth posture, and narrow nostrils.

The importance of the multidisciplinary treatment cannot be denied.

Treatment strategies are in close relationship with etiology, facial biotype, age of the patient, and clinical experiences.

The management of the tongue thrust and mouth breathing involves the interception of the habit. First of all, the doctor has to determine that the patient can use his/her nose to breathe normally.

It is important to remember that mouth breathing is abnormal and can affect the whole stomatognathic system, body posture, etc., and not only the position of the teeth.

As soon as this problem is corrected, fewer consequences appear.

Different appliances could be used according to the age of the patient and his/her medical history, in order to establish a new neuromuscular pattern.

According to the etiology and the importance of the problem, removable, fixed, or a combination of both types of appliances can be used.

The orthodontist has the final decision.

The following examples will describe each option in detail.

This 6-year, 8-month-old patient is sent to the office by her family dentist in search of a second opinion regarding her anterior open bite.

An adenoidectomy was performed 4 months earlier. Nonetheless, mouth breathing and tongue thrusting continued. It was difficult for her to close and maintain the lips sealed. She used a pacifier until 4 years of age (Fig. 3.1a, b).

Her profile was convex, and the nasolabial angle was reduced.

Even though she was only 6 years and 8 months of age, she had a double chin.

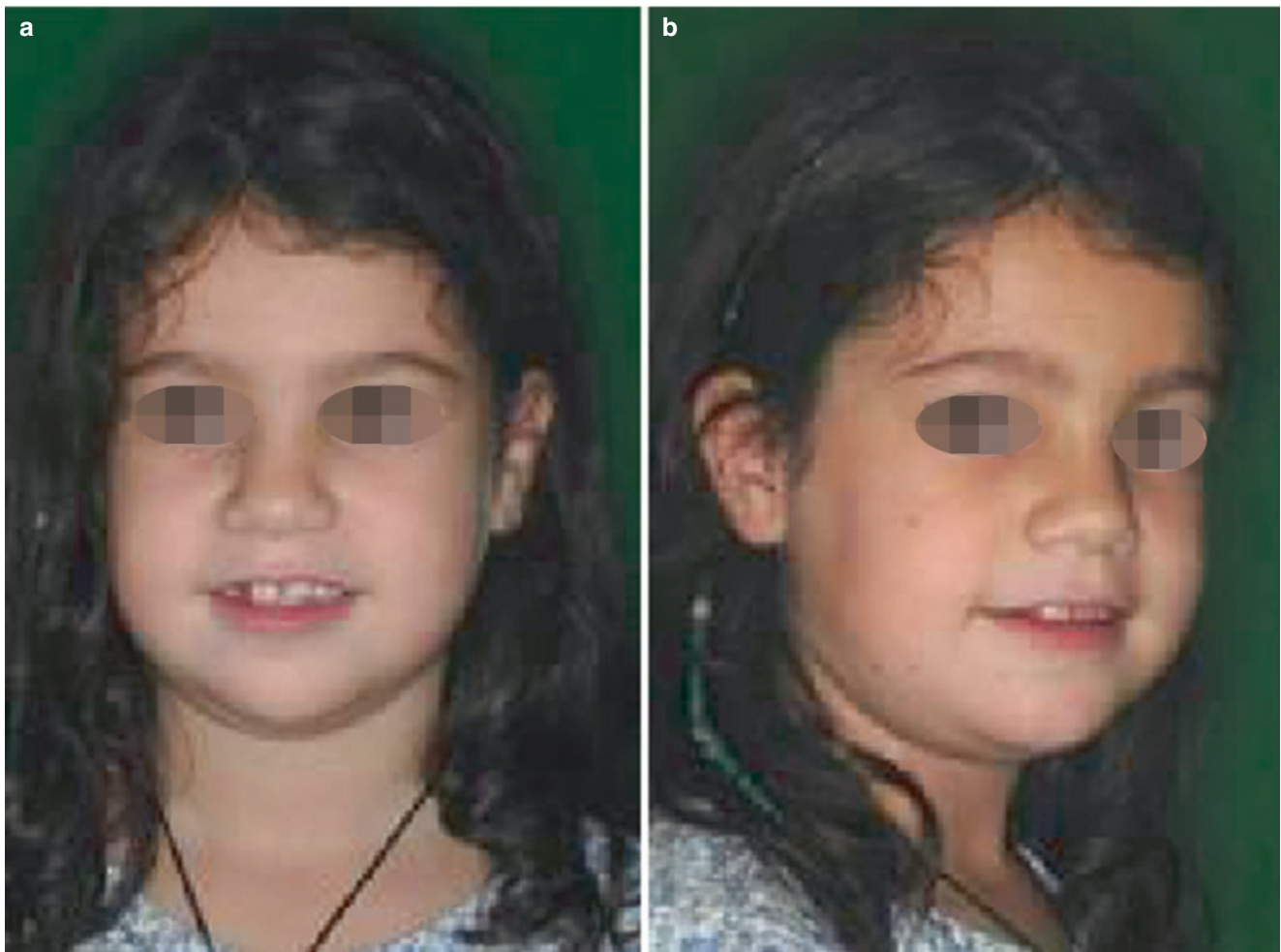

Fig. 3.1 (a, b) Pretreatment photographs of a 6-year, 8-month-old girl with problems to keep her lips closed

Hyperactivity of the musculature of the lips in combination with tongue thrust with abnormal tongue posture during speech was observed during the clinical examination.

The front photograph showed a significant open bite in the anterior region in combination with a midline deviation. Only the central upper and lower incisors were erupting at that time (Fig. 3.2a, b).

No posterior cross bite was present. All day and night, the tongue was placed between the upper and lower incisors which were why they could not erupt normally. Due to the presence of large cavities, some stainless steel crowns were placed on the temporary molars (Fig. 3.3a, b).

The treatment objective (Phase I) was to normalize overbite and overjet, maintain Class I molar, control tongue thrust, improve the activity of the lips, and enhance her profile.

To achieve this objective, the use of a functional appliance is decided on. Of all the possible choices, a prefabricated functional appliance also known as Trainer System TM

(Myofunctional Research Co. Australia) was chosen. It is fabricated with a special type of polyurethane and helps the correction and normalization of the muscular dysfunction.

The appliance is especially designed to stimulate anterior and lateral muscles and help to achieve normal nasal breathing. Since the material is soft, no major problems of adaptation are present (Fig. 3.4a, b).

It is recommendable that at the beginning, this appliance be used few hours during the day (2–3 h) and then all night (Fig. 3.5a, b).

After 9 months, a significant improvement of the maxilomandibular relationship was clearly observed. The anterior open bite was totally closed, and midlines were almost normalized (Fig. 3.6a, b).

The transverse development observed in some patients could be due to the buccal shields of the trainer that stimulates the lateral muscles using the same principles that Frankel regulator does.

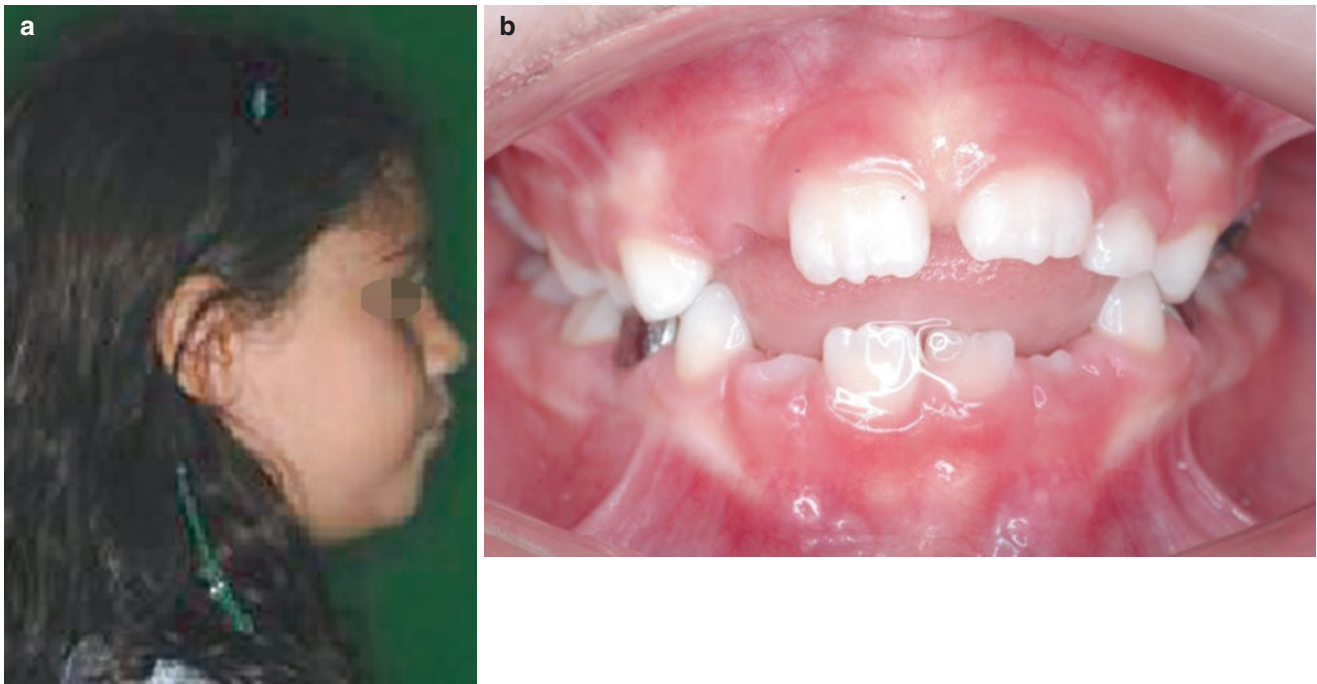


Fig. 3.2 (a, b) A significant convex profile along with a significant anterior open bite was present

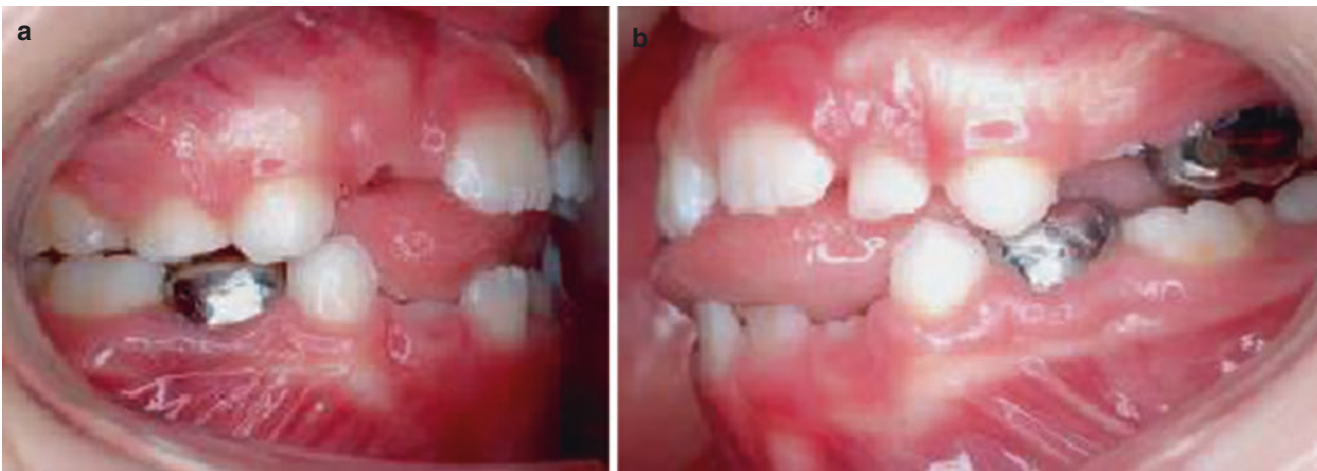

Fig. 3.3 (a, b) Pretreatment right and left side. The upper temporary second molar had been extracted 6 months earlier



Fig. 3.4 (a, b) In order to achieve nasal breathing, a pre-orthodontic trainer was recommended. In general, it needs to be used 2–3 h during the day and all night

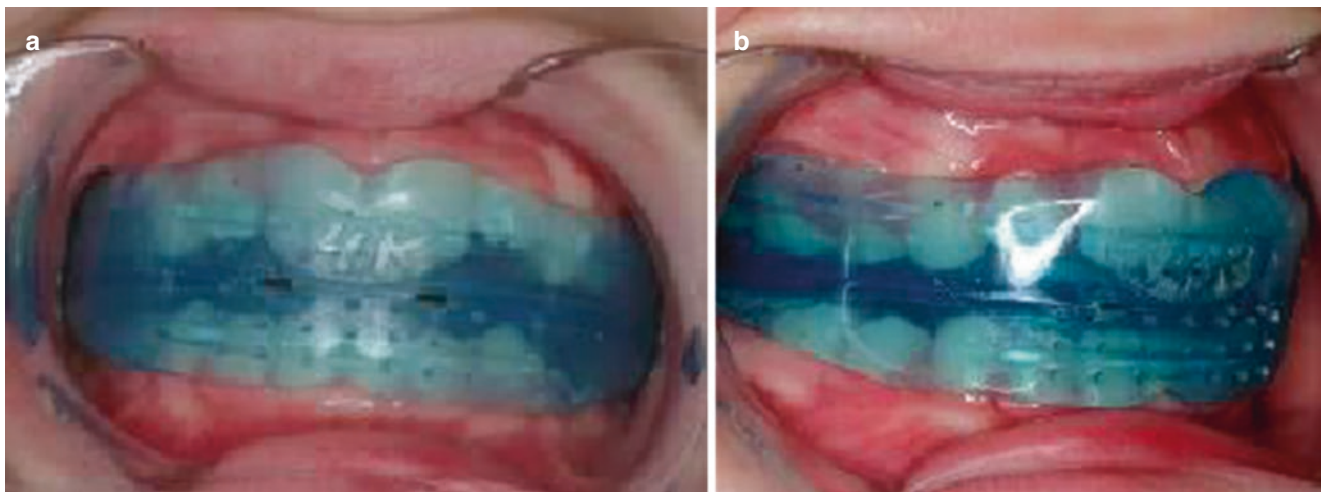


Fig. 3.5 (a, b) Frontal and lateral views with the trainer appliance in place

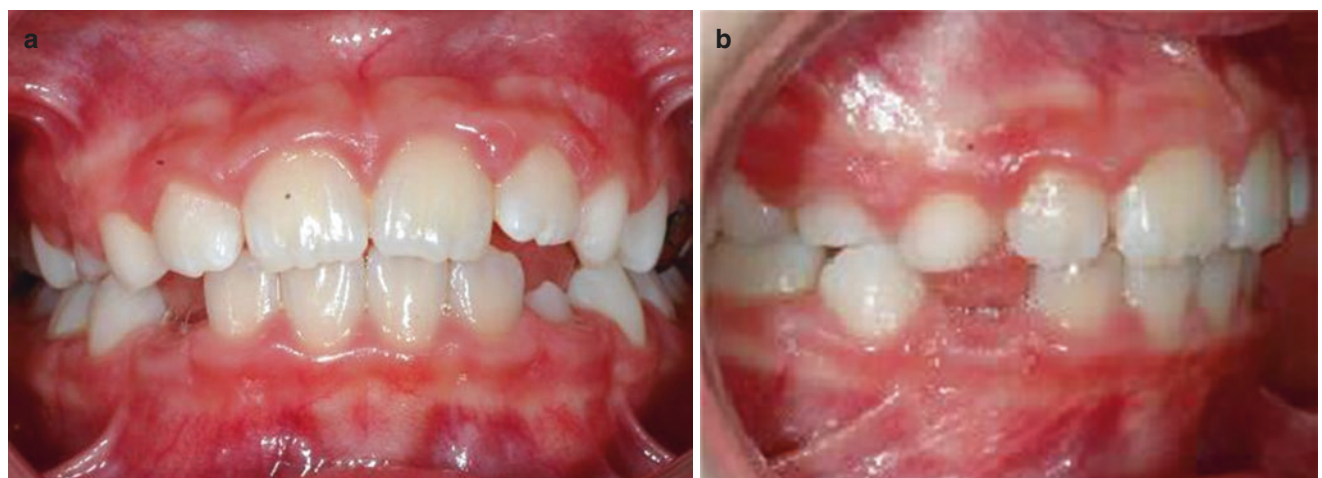


Fig. 3.6 (a, b) All the first phase treatment objectives were achieved after 9 months in treatment

The treatment goals were totally achieved without the use of any other appliance.

Upon analyzing the front and lateral photographs, a significant improvement in the lower third of the face was achieved. The patient could close her lips without tension, and the tongue was located in its right position not only at rest but in active position too (Fig. 3.7a, b).

These were the results 18 months later. Class I canine was achieved and Class I molar was maintained. Overjet and overbite were normalized and midlines were normal. Oral hygiene was fairly good (Fig. 3.8a, b).

The profile and smile lateral photographs confirmed the results. The lips were relaxed and the double chin was absent. A 6-month follow-up was highly recommended (Fig. 3.9a, b).

It is advisable that open bites be treated as early as possible and in this way reinstate normal oral and breathing functions to reduce the possibility of relapse.

The type of trainer (T4K) is a valid alternative to treat these open bite patients at an early age. It also helps to

improve dental arch development during the early and late mixed dentition, and most importantly, this appliance helps normalize bad habits.

Also, other types of functional appliances can be used according to the orthodontist's preferences. As always, correct diagnosis is more important than the type of the appliance used.

The comparison between the pre- and posttreatment front dental photographs showed evidence of the normalization of the anterior open bite and the parallelism between the occlusal and gingival planes.

No brackets were required to achieve the expected results.

Ideally an overcorrection of the overjet and overbite is highly recommended (Fig. 3.10a, b).

A 6-month control was recommended until all the second molars erupted.

Upon analyzing the lower third of the face and the nasolabial angle, a significant improvement was confirmed. Moreover, the lips were more relaxed and the double chin was normalized (Fig. 3.11a, b).

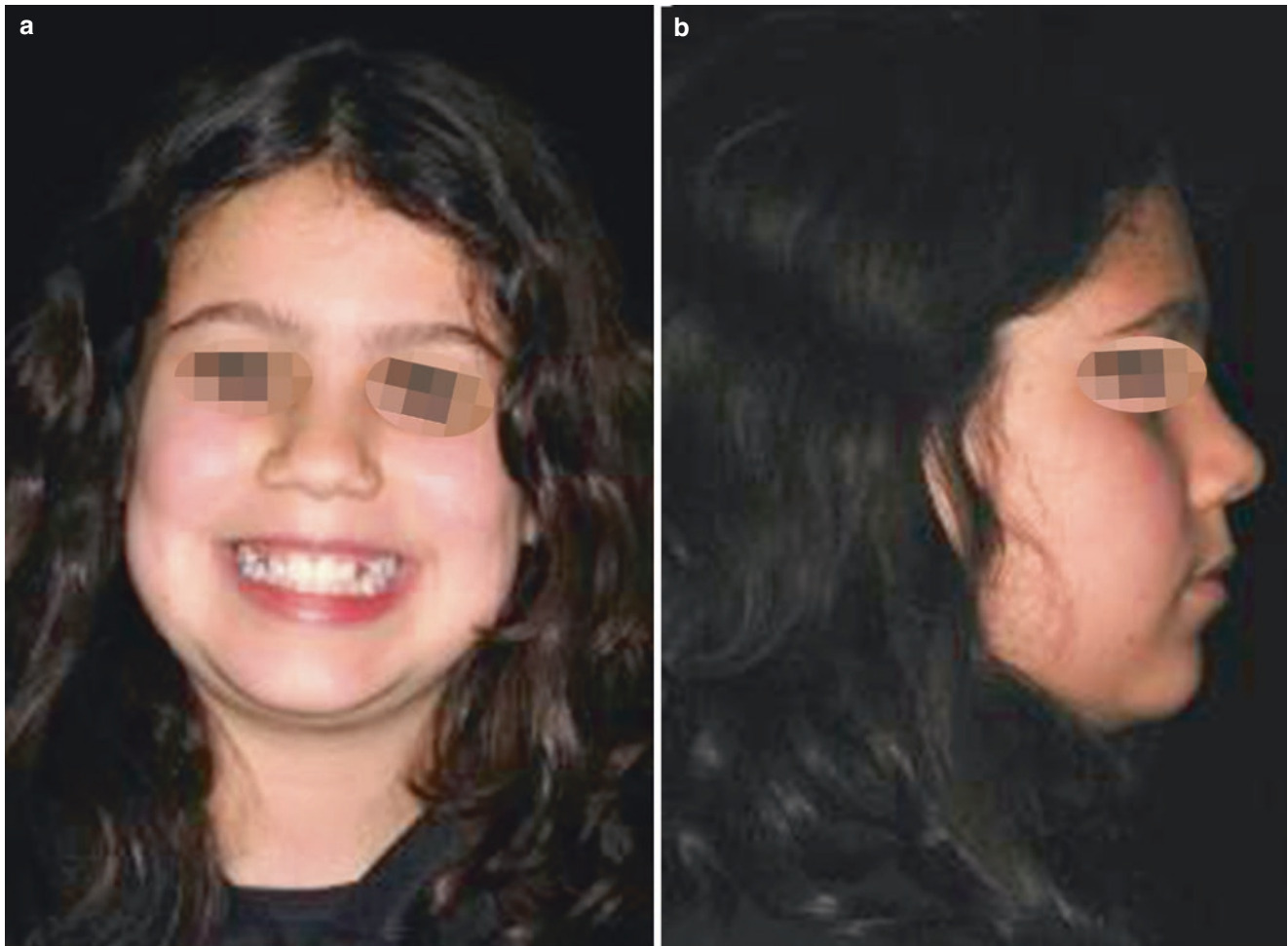

Fig. 3.7 (a, b) Significant improvement in the lower third of the face was achieved

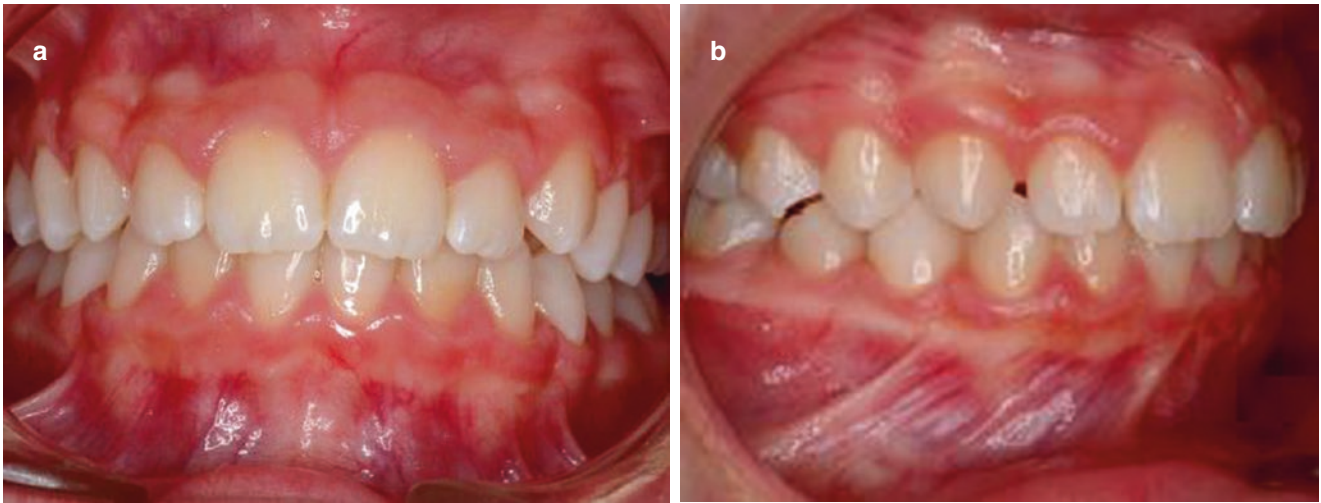


Fig. 3.8 (a, b) Results 18 months later. Overjet and overbite were within normal ranges

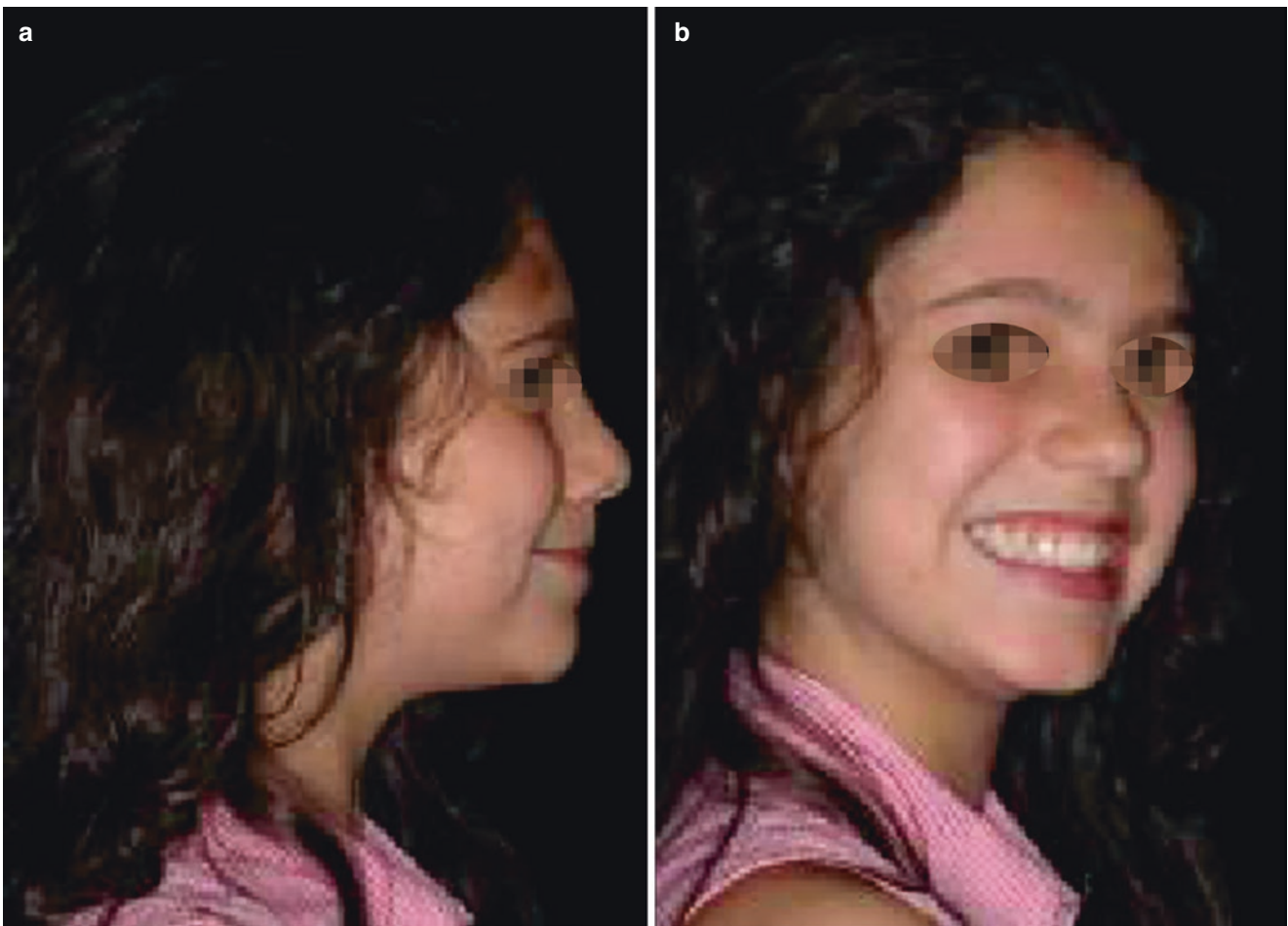


Fig. 3.9 (a, b) Follow-up 18 months later

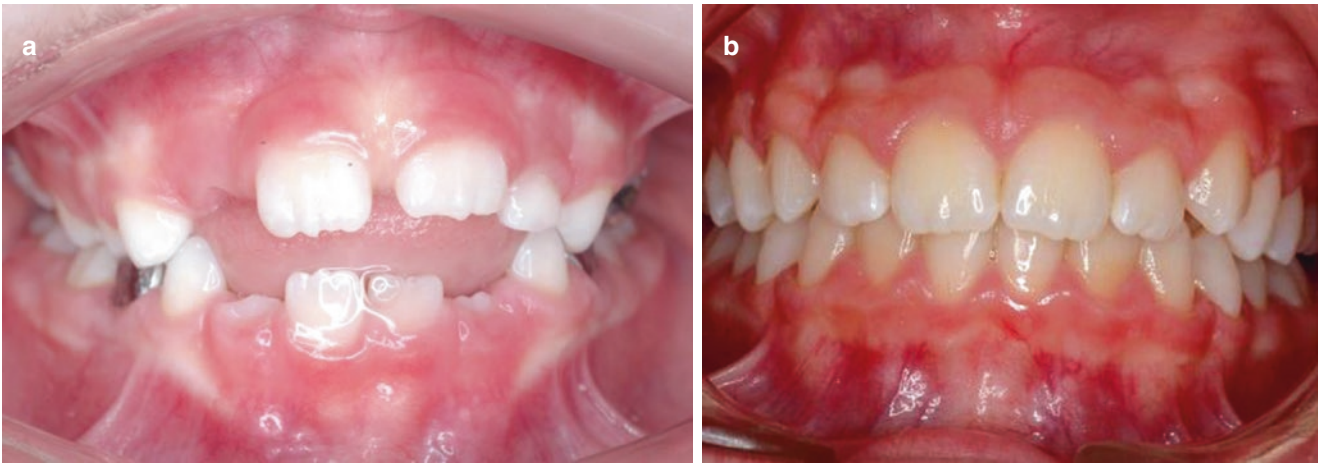


Fig. 3.10 (a, b) The comparison between the pre- and posttreatment front dental photographs showed normalization of the anterior open bite

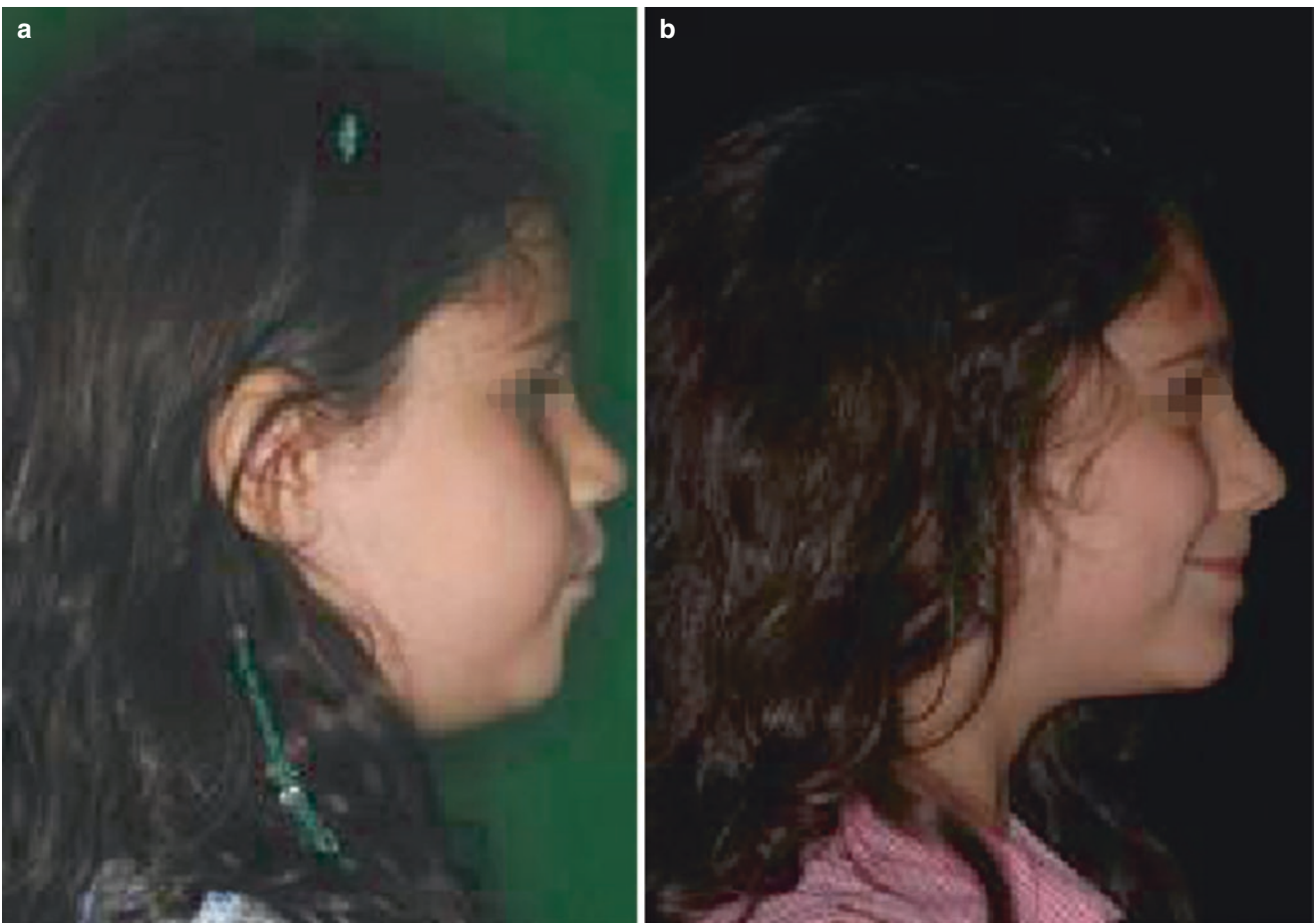

Fig. 3.11 (a, b) Comparison pre- and 18-month posttreatment

Further studies should be conducted to analyze if the use of this treatment protocol would have a skeletal effect in patients with anterior open bite.

In general, patients with anterior open bite have a high-angle facial pattern and also have discrepancies in the anteroposterior and transverse dimensions. The retention protocol has to include a strict control of the position and function of the tongue.

This 9-year, 2-month-old patient was sent by her family dentist due to her significant midline deviation and slight Class III tendency.

Her profile was straight with a normal nasolabial angle. She snored loudly at night, very often (Fig. 3.12a, b).

The dental front photograph clearly showed the anterior open bite and the important deviation of the

midlines (3 mm). She had a V-shaped maxilla (Fig. 3.13a, b).

The right second temporary molars had a Class III tendency, and there was a significant lateral cross bite on the left side that was maintained in central relation.

No TMJ symptoms were present until then, but she preferred to eat only soft food.

Her dental hygiene was fairly good and no cavities were present (Fig. 3.14a, b).

The panoramic Rx confirmed that no agenesis or supernumerary teeth were present, and the lateral radiograph showed normal development according to her age. The anterior open bite was clearly visible (Fig. 3.15a, b).

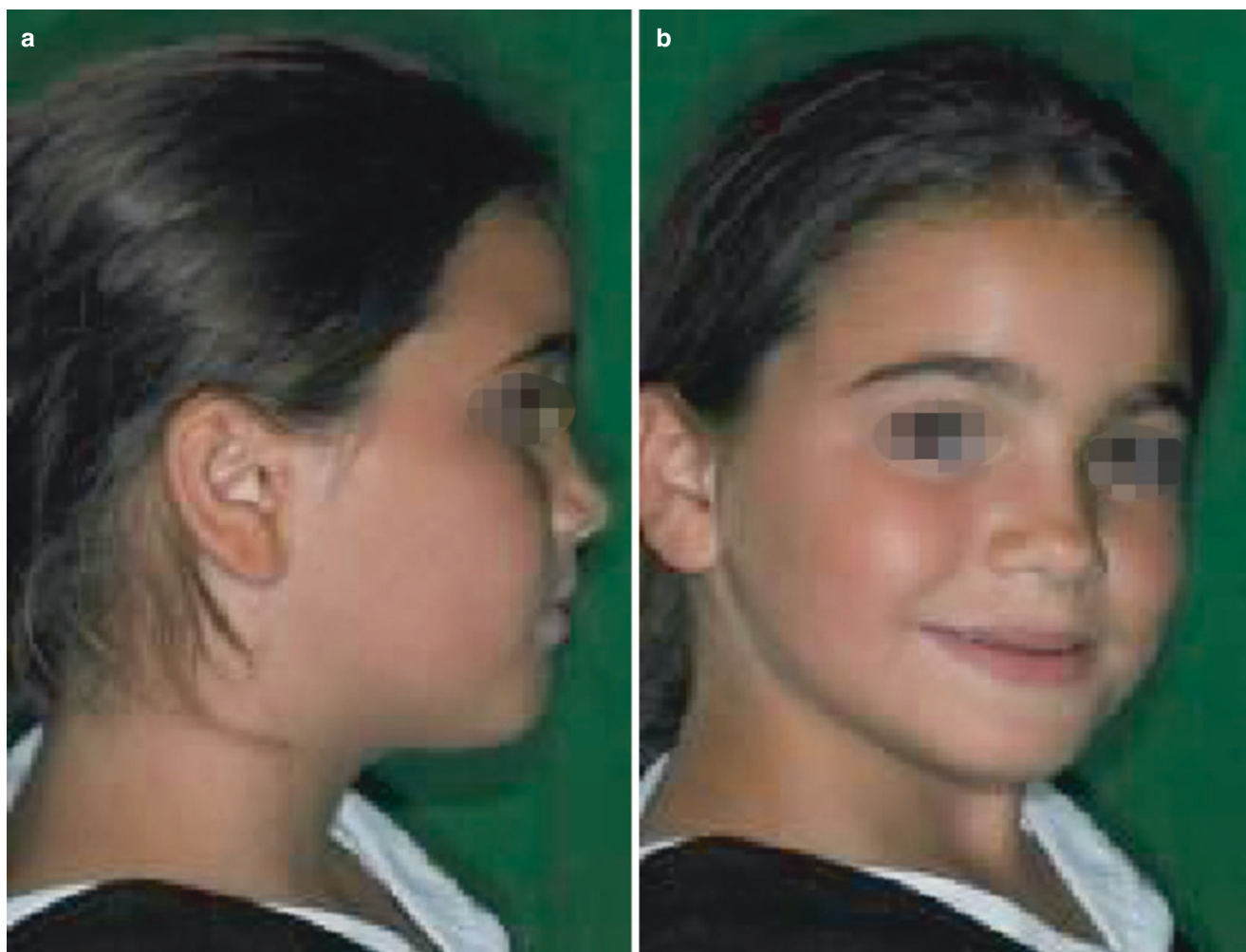

Fig. 3.12 (a, b) Profile and smile photographs at the beginning of treatment

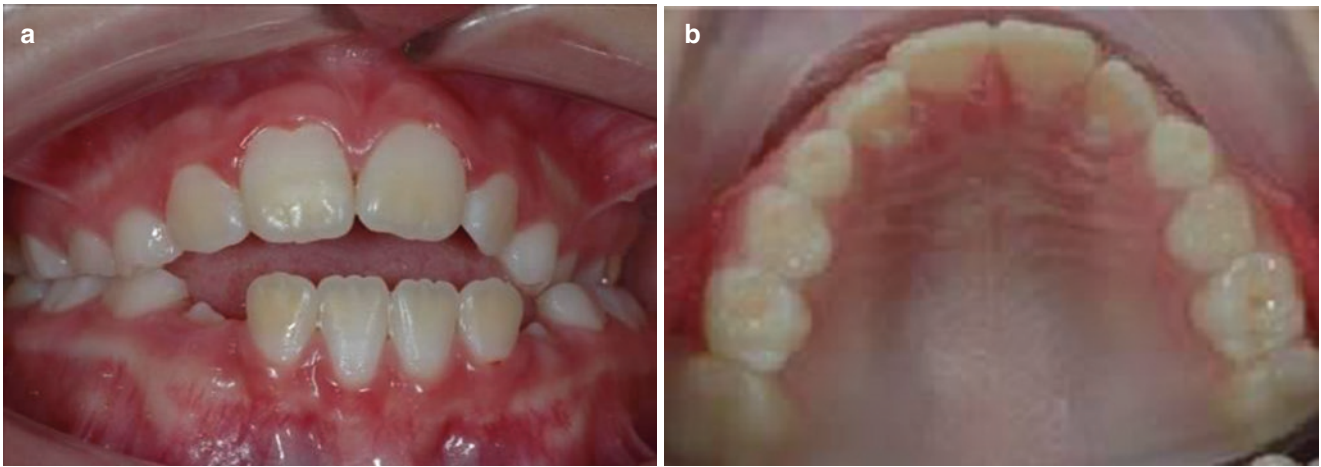


Fig. 3.13 (a, b) Frontal and occlusal pretreatment photographs with a noncoincident midline

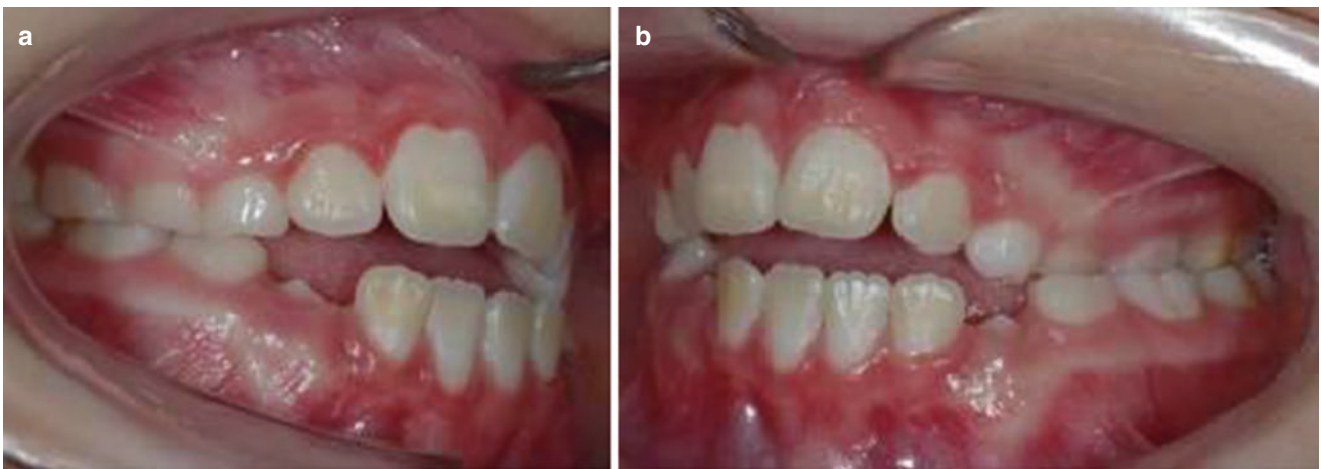

Fig. 3.14 (a, b) Initial lateral views. Lateral cross bite was present at the left side and a Class III tendency on the right side

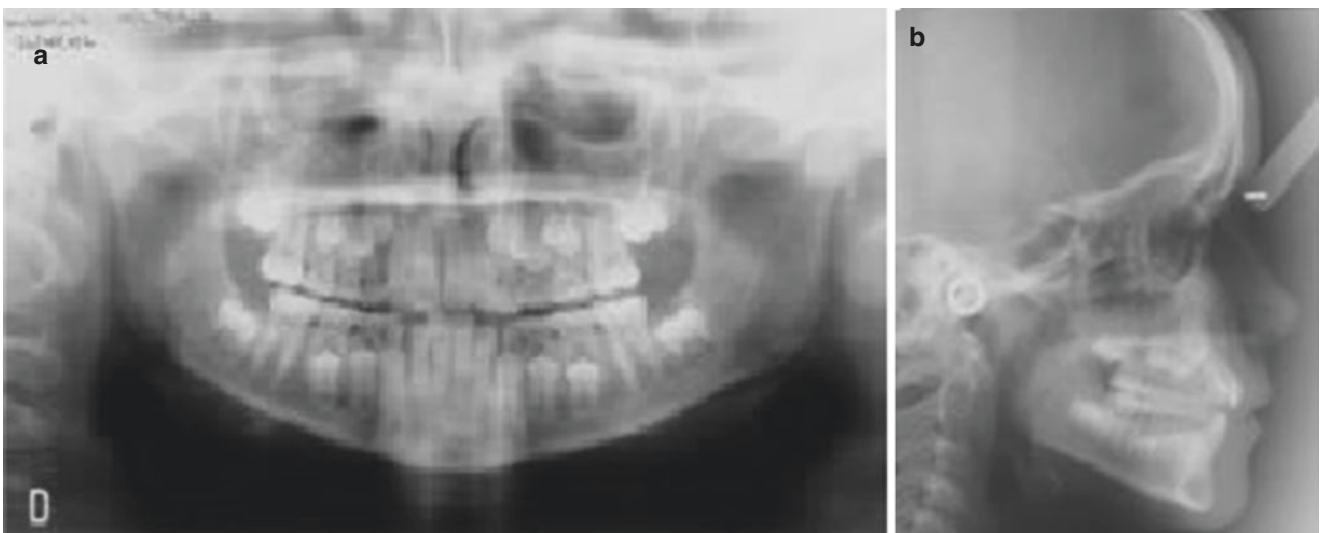


Fig. 3.15 Pretreatment panoramic and lateral radiographs

The treatment objectives were:

1. Align and level the arches.
2. Normalize transverse dimension.
3. Normalize overjet and overbite.
4. Achieve Class I molar and canine.
5. Control tongue thrust.
6. Long-term stability.

To achieve these objectives, the following treatment plan was designed:

Phase I

1. Rapid maxillary expansion to normalize the transverse problems
2. Speech therapy treatment to control tongue thrust

Phase II

If necessary, esthetic brackets, 0.22" slot in order to normalize dental positions, will be used.

To correct the transverse deficiency, a modified hyrax appliance was suggested. The protocol of activation was twice a day. The lateral arms were bonded with composite to the temporary molars to improve stability. After 2 weeks, the inter-incisal diastema between the central incisors confirmed that the central suture was open (Fig. 3.16a, b).

The correction of maxillary constriction is very often a target for treatment in open bite patients (McNamara and Brudon 1993).

As usual, 1 month later, the diastema closed on its own, and a monthly follow-up was suggested. The anterior open bite was totally normalized with the help of a speech therapist. Midlines were almost corrected.

In these cases, it is highly recommendable that RME appliance be maintained in place a minimum of 6 months to prevent relapse (Fig. 3.17a, b).

At the end of the first phase of treatment, all the objectives were achieved. The overjet and overbite were normalized as well as the position of the first molars. A removable retainer used during the night was recommended to maintain the

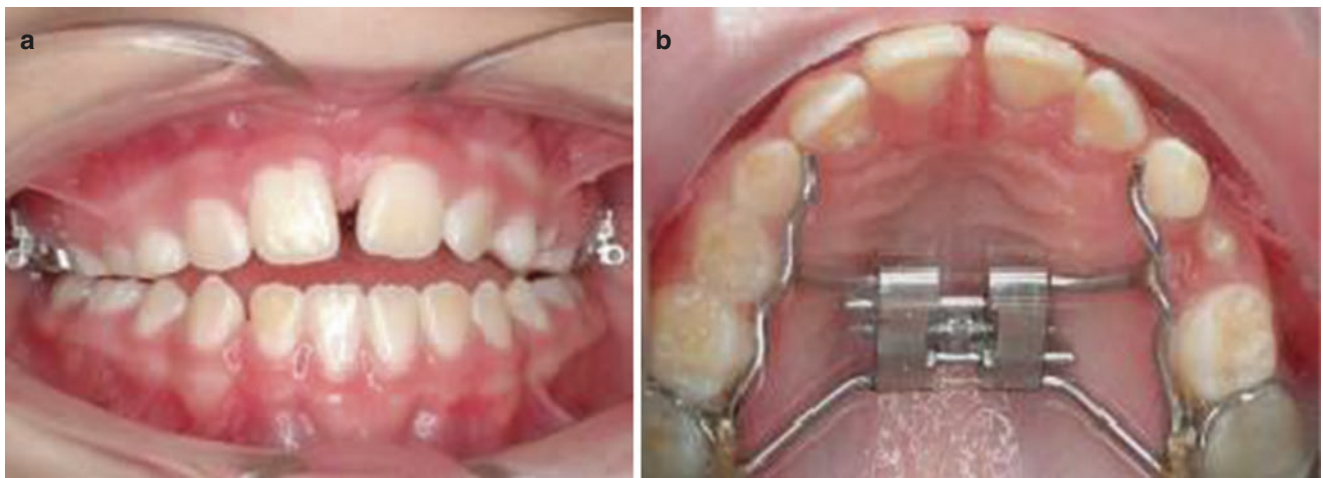


Fig. 3.16 (a, b) Frontal and occlusal view with RME appliance in place

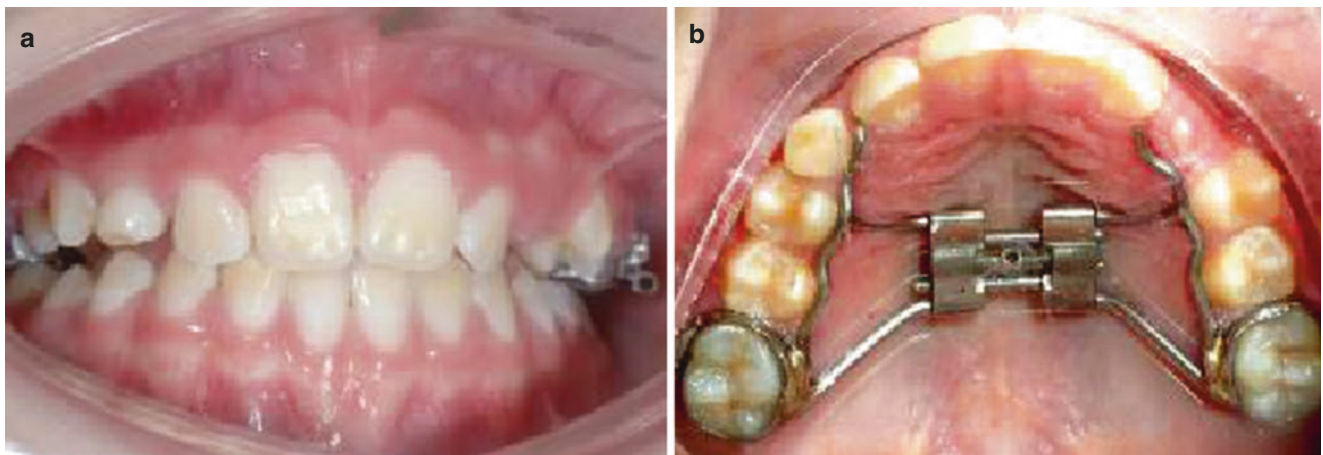


Fig. 3.17 (a, b) Six months later. The RME acted as a retention appliance. Midlines were coincident

correction of the transverse dimension, until the second molars and upper canines erupted (Fig. 3.18a, b).

The lateral and smile posttreatment photographs confirmed the results that were achieved. The lips closed smoothly without tension and the nasolabial angle was normal (Fig. 3.19a, b).

Twenty months later, the patient returned to the office seeking improvement of the position of the canines. To achieve

these results, esthetic bracket slot 0.022" were bonded in conjunction with a 0.016" SS wire (Fig. 3.20a, b)

A nickel-titanium open-coil spring, slightly activated, was placed on the left side to improve the position of the first upper left bicuspid (Fig. 3.21a, b).

Seven months later, upper esthetic brackets were removed and the tongue thrusting habit was totally corrected (Fig. 3.22a, b).

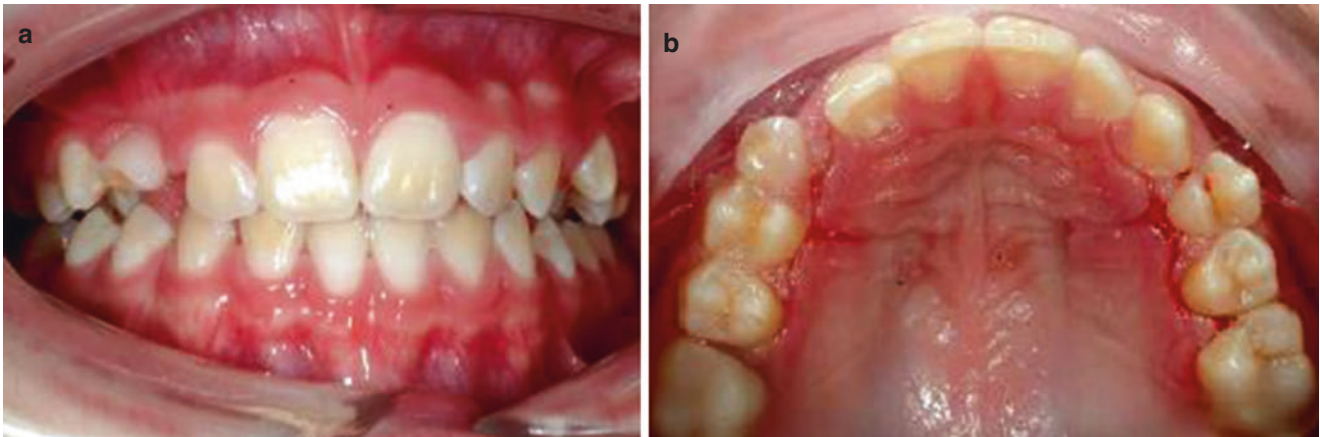


Fig. 3.18 (a, b) At the end of the first phase of treatment, all the objectives were achieved

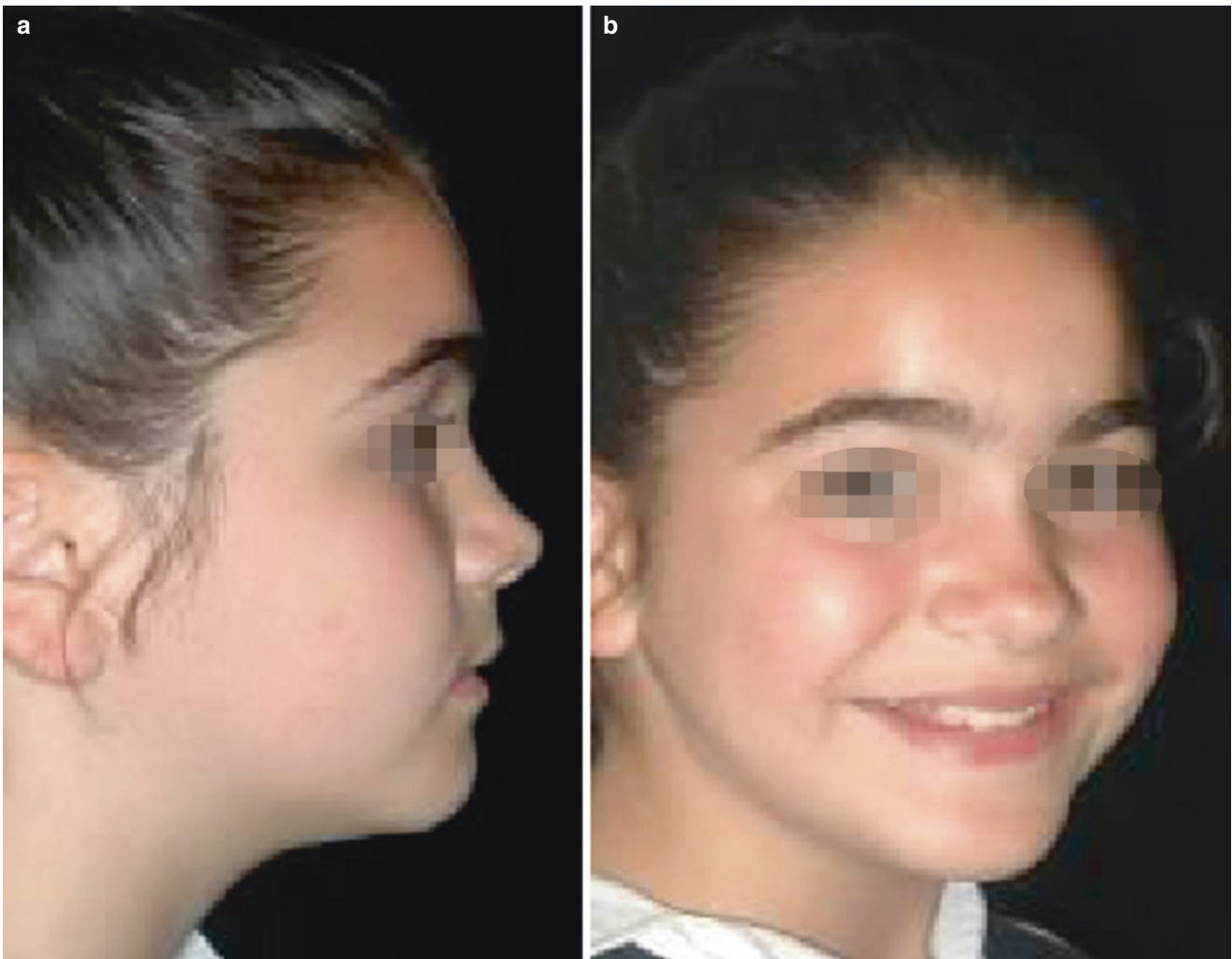

Fig. 3.19 (a, b) Profile and smile at the end of the Phase I

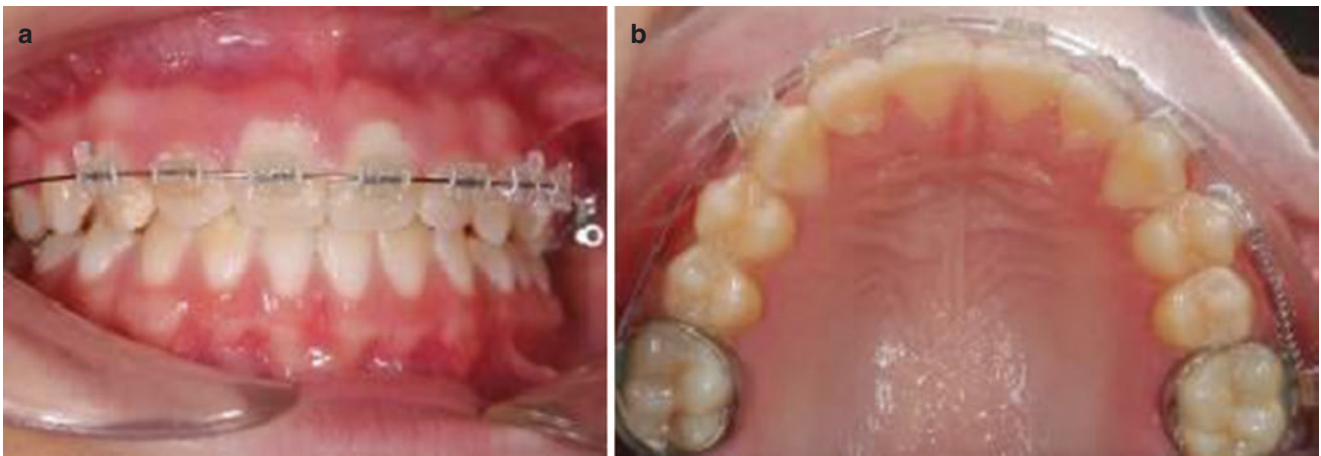


Fig. 3.20 (a, b) Esthetic preprogrammed brackets were bonded on the upper arch at the beginning of the second phase of treatment

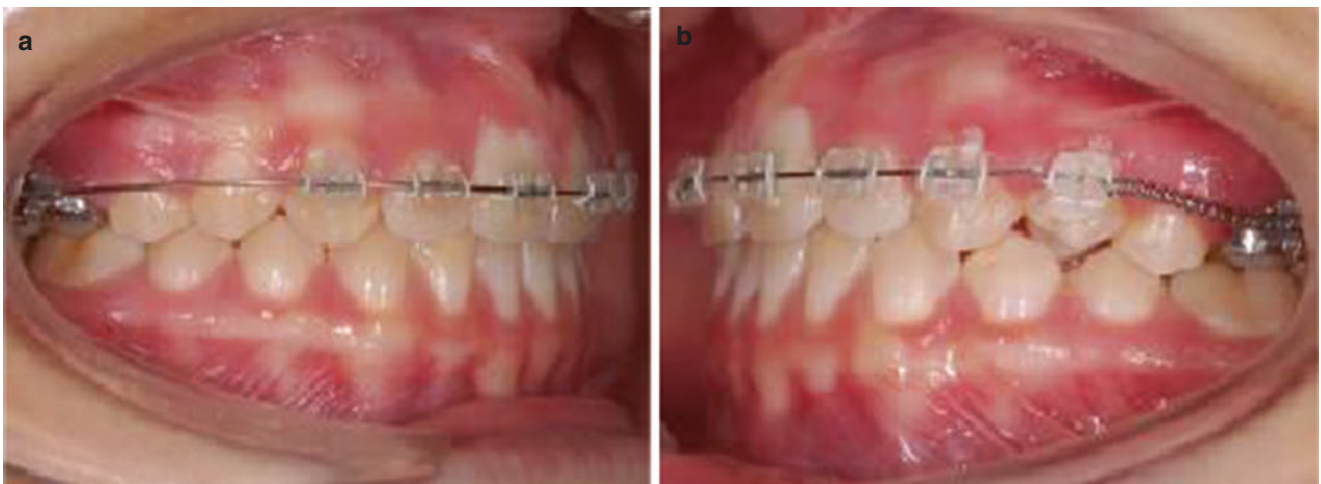


Fig. 3.21 (a, b) Lateral views with a Ni-Ti open-coil spring on the left side

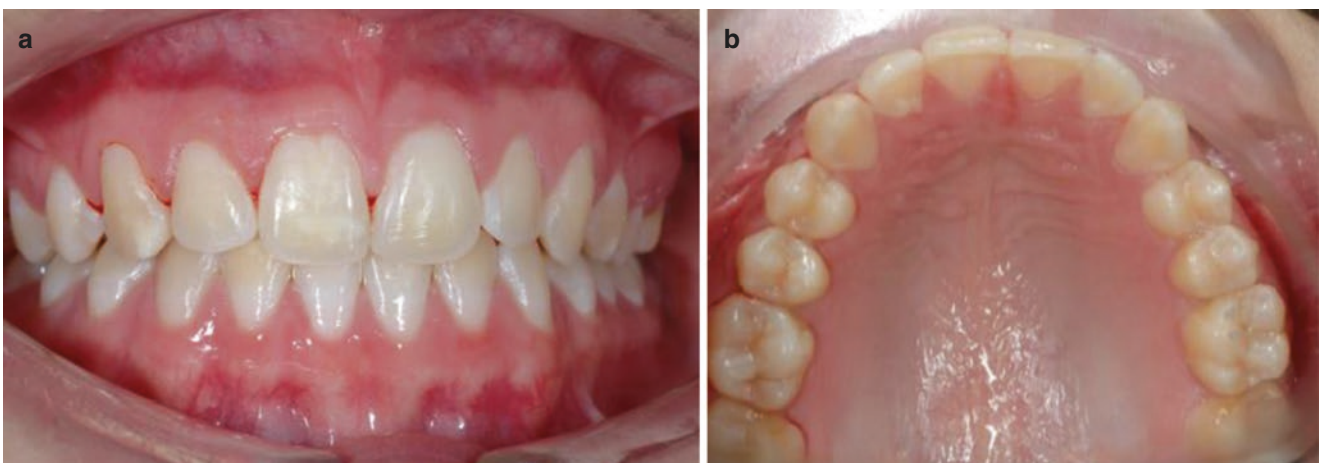


Fig. 3.22 (a, b) Frontal and occlusal view at the end of the treatment

Front photographs at the end of the second phase treatment. The face was symmetrical with balanced proportions and normal exposure of the maxillary teeth. The smile and tongue positions were totally normalized (Fig. 3.23a, b).

The lateral photographs confirmed the results. The patient was able to close her lips gently in concordance with a nice and pleasant profile and a passive lip seal (Fig. 3.24a, b).

The comparison pre- and posttreatment dental front photographs confirmed that the treatment objectives were totally achieved.

Dental midlines were corrected and overjet and overbite were normalized.

The gingival and occlusal plane were parallel and the oral hygiene was fairly good (Fig. 3.25a, b).

The importance of the normalization of the functional problems is clearly demonstrated when the following patient is analyzed.

She was 7 years, 3 months of age and was sent to the office by her pediatric doctor due to her loud night snoring that disturbed not only her sister but also her parents' sleep.

She had a convex profile, difficulty to achieve lips closure, and a double chin that are typical in all mouth breathers in conjunction with a larger lower third face and the presence of circles under their eyes.

Frequently, she had colds with fever and was medicated with corticoids and antibiotics.

It is important to remember that abnormal tongue posture is associated with enlarged adenoids and tonsils in addition to sucking habits and tongue thrust (Fig. 3.26a, b).

The front dental photographs clearly confirmed the anterior position of the tongue at rest and an important open bite of 7 mm at the incisor region (Fig. 3.27a, b). A significant cross bite was present in the right side.

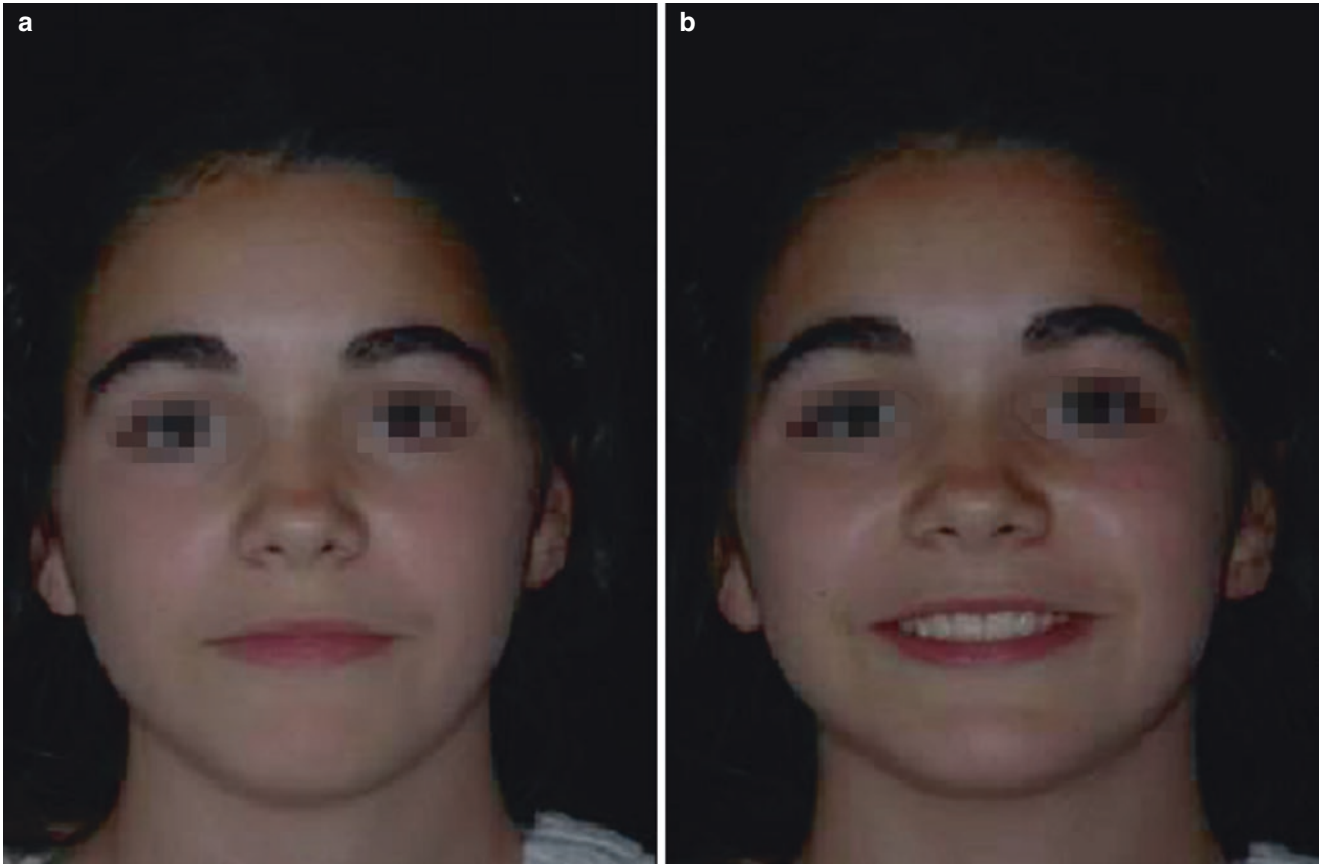

Fig. 3.23 (a, b) Frontal and smile photographs at the end of the second phase of treatment

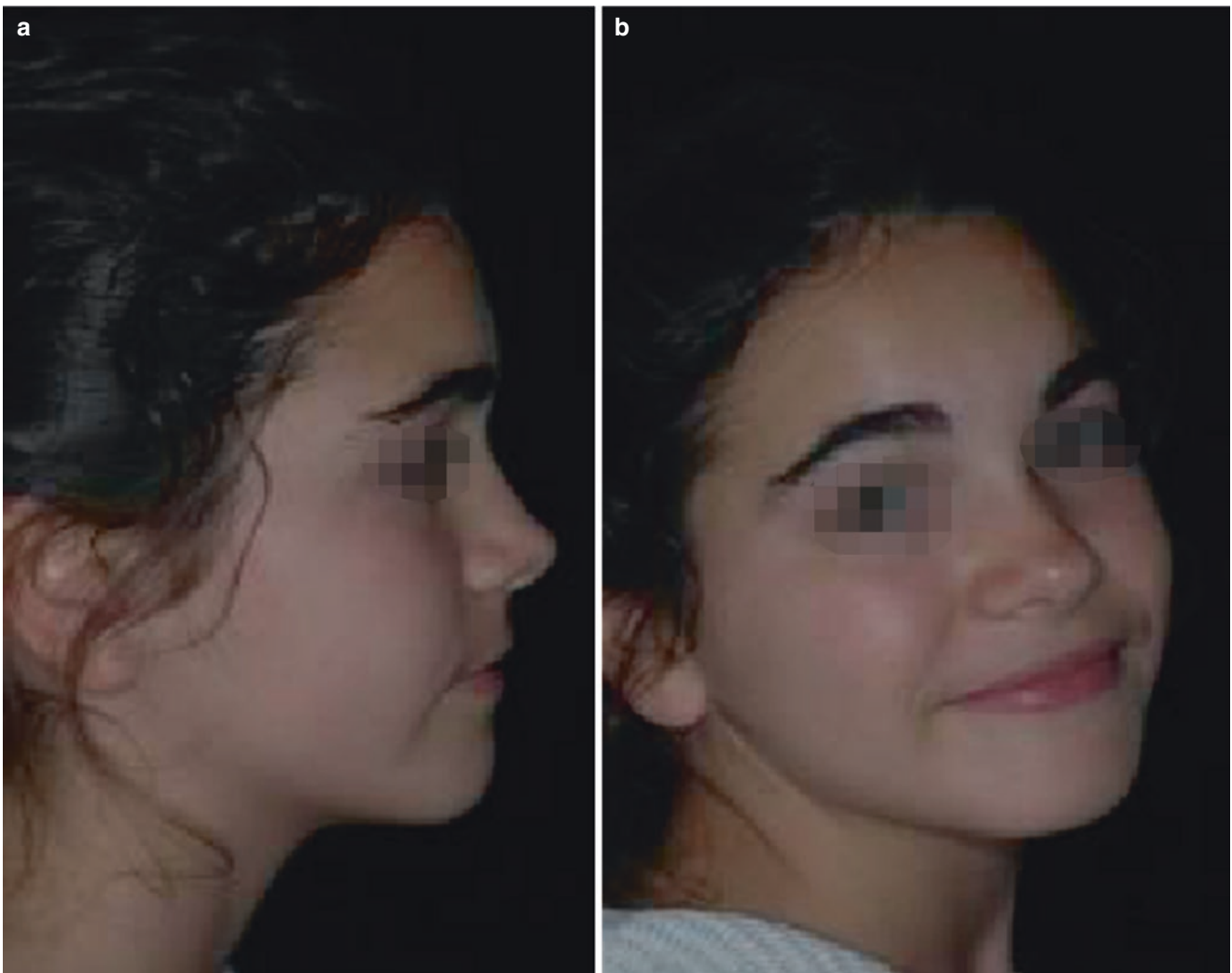


Fig. 3.24 (a, b) Lateral photos at the end of treatment

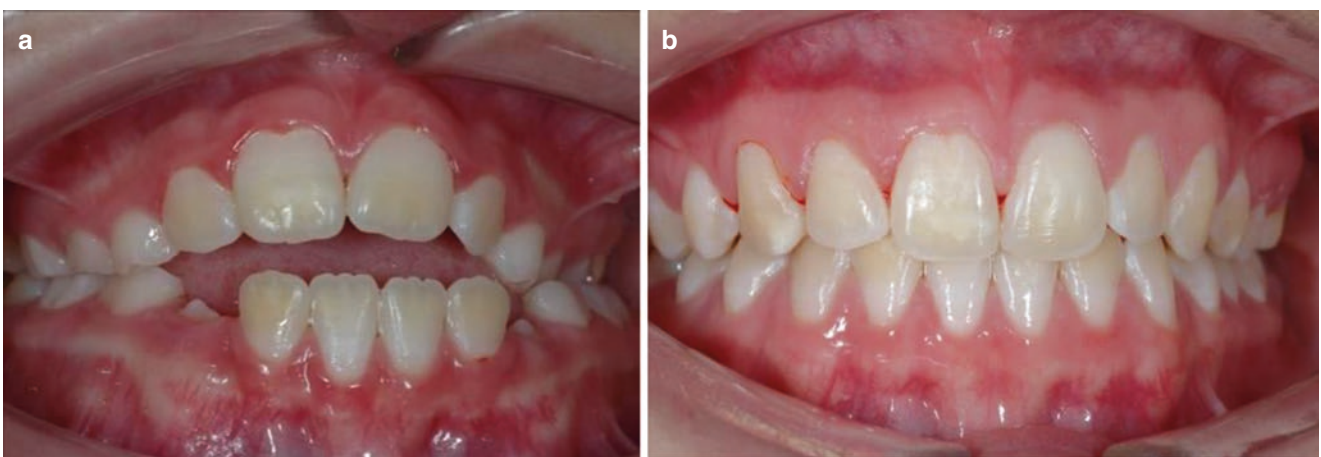


Fig. 3.25 (a, b) Comparison pre- and posttreatment frontal dental occlusion. Midlines were totally corrected, and overjet and overbite were within normal ranges

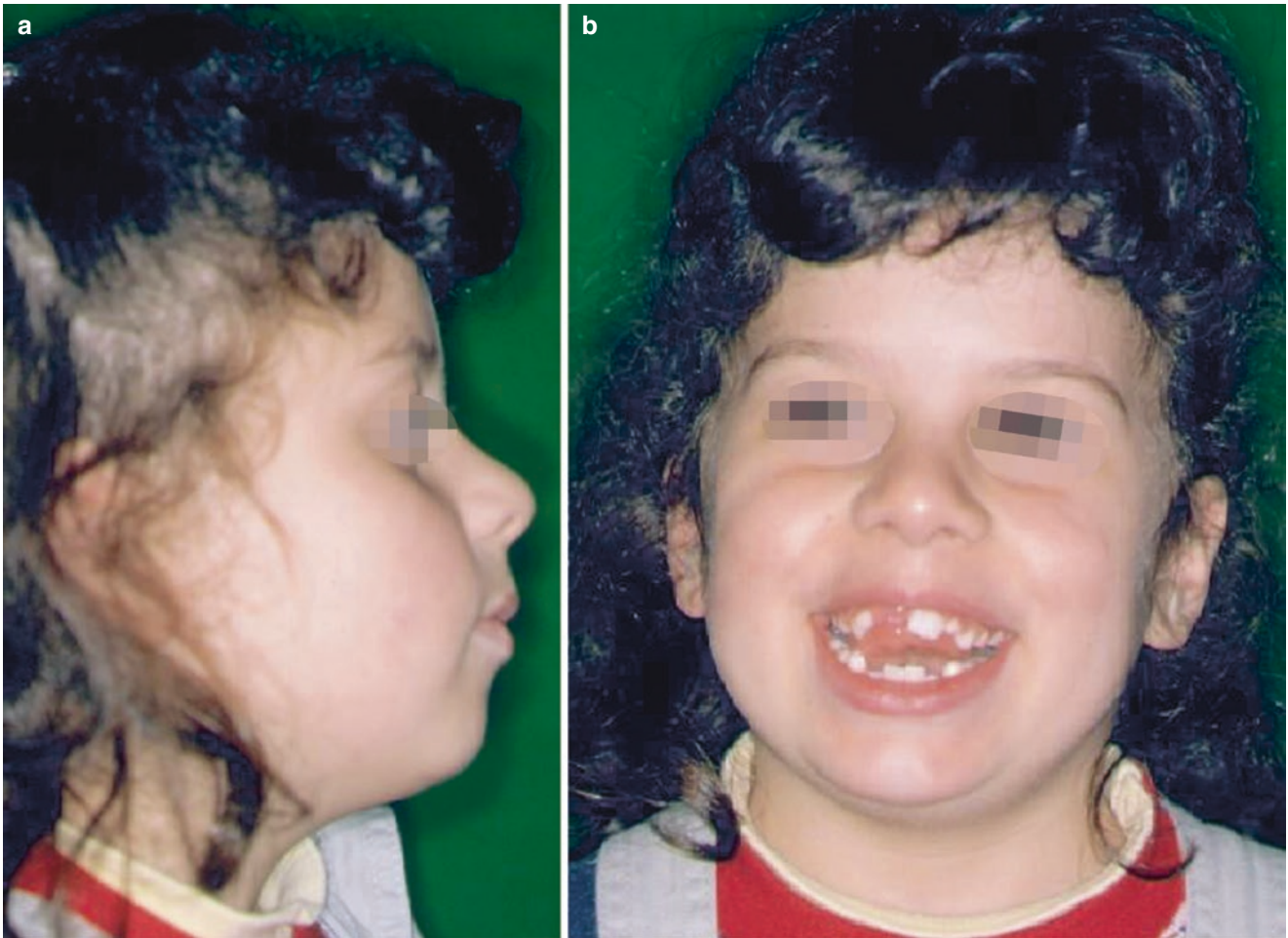

Fig. 3.26 (a, b) Pretreatment profile and smile photographs. The double chin was noticeable

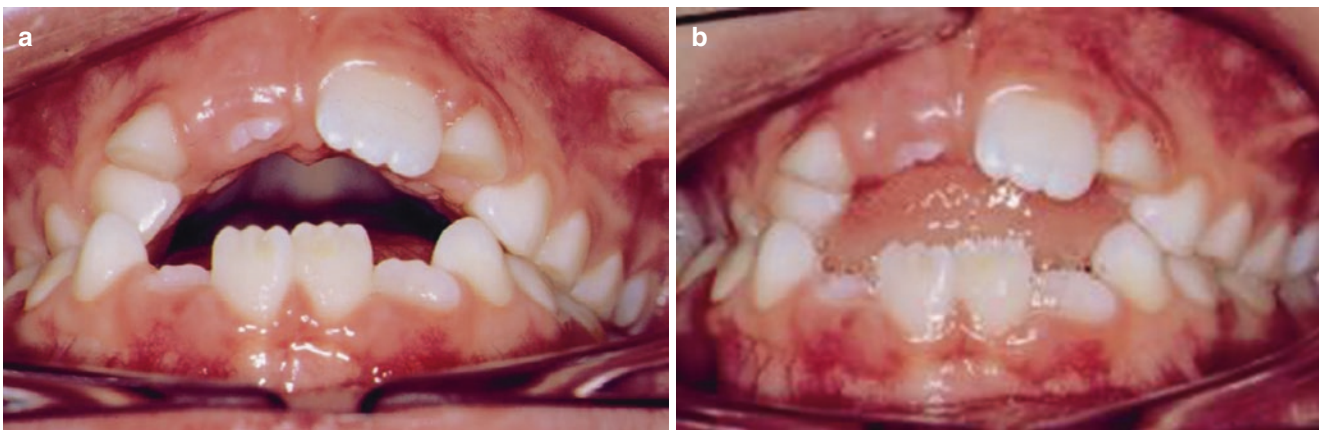


Fig. 3.27 (a, b) A significant open bite was present along with an anterior tongue thrust

The lateral views showed Class II molar on the right side and Class I molar on the left side. The temporary right canine, first and second molars, as well as the permanent first molar were in cross bite occlusion.

The oral hygiene was good and no cavities were observed (Fig. 3.28a, b).

The panoramic radiograph confirmed that all the permanent teeth were present in different stages of development in accordance to her age. The open bite was confirmed on the lateral radiograph, and it was clearly visible that the respiratory airway was obstructed (Fig. 3.29a, b).

After the consultation with the pediatrician, the following treatment plan was decided:

1. Normalize the mouth breathing pattern.
2. Improve the position of the tongue at rest.
3. Normalize the position of the right canine and molars.
4. Achieve normal overjet and overbite.
5. Long-term stability.

In order to correct the transverse problem, a fixed bonded rapid maxillary expander was suggested. The design included bands on the right and left temporary second molars to protect the permanent first molars.

The activation was a quarter twice a day for 2 weeks (Fig. 3.30a, b).

At the same time, she was sent to the speech therapist to normalize the position of the tongue and in this way help close the anterior open bite.

After 2 weeks, the expansion was completed. It is highly recommendable that the expander be maintained in place for a minimum of 6 months to have better control over relapse (Fig. 3.31a, b).

The speech therapist had to continue working with the patient until the overjet and overbite were normalized.

A follow-up 2 months later confirmed the improvement achieved. The inter-incisal diastema was closing normally, and the position of the central incisors was normalized (Fig. 3.32a, b).

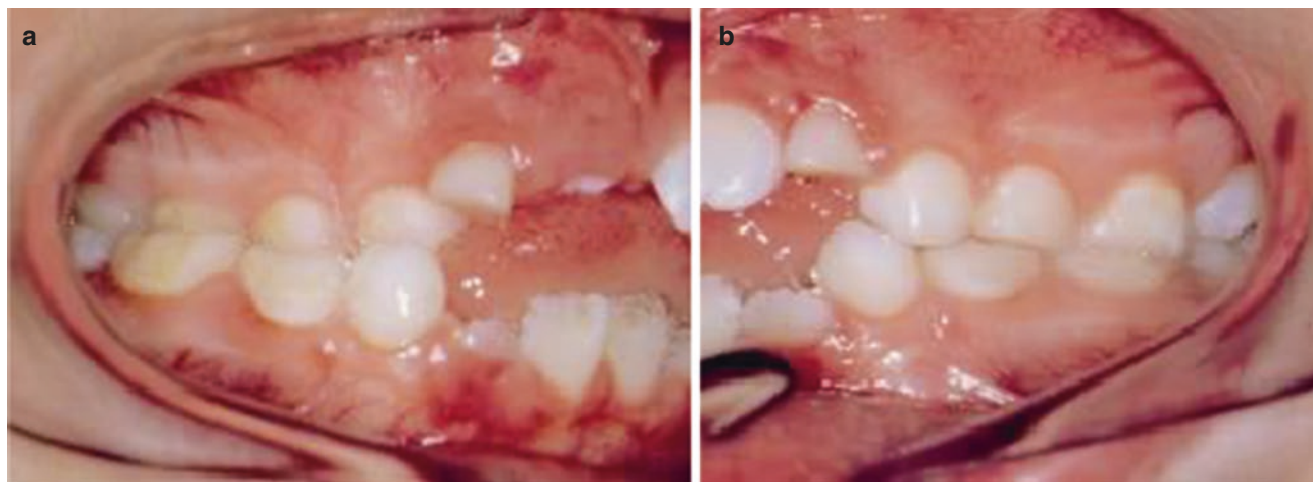


Fig. 3.28 (a, b) Lateral views at the beginning of the treatment with a significant cross bite on the right side

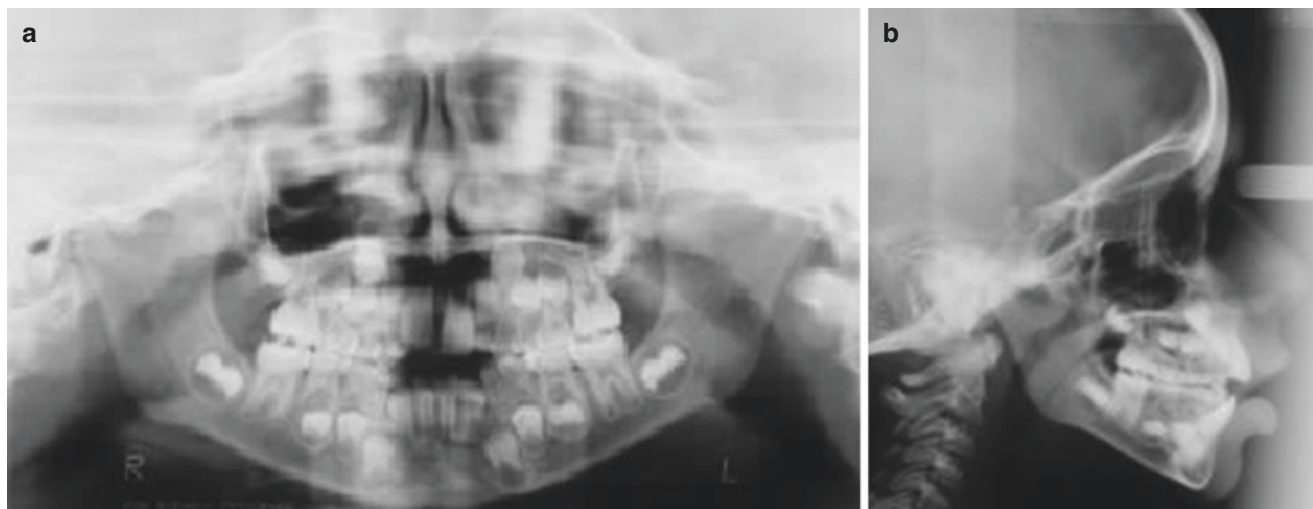


Fig. 3.29 (a, b) Pretreatment panoramic and lateral radiograph. The respiratory airway was obstructed

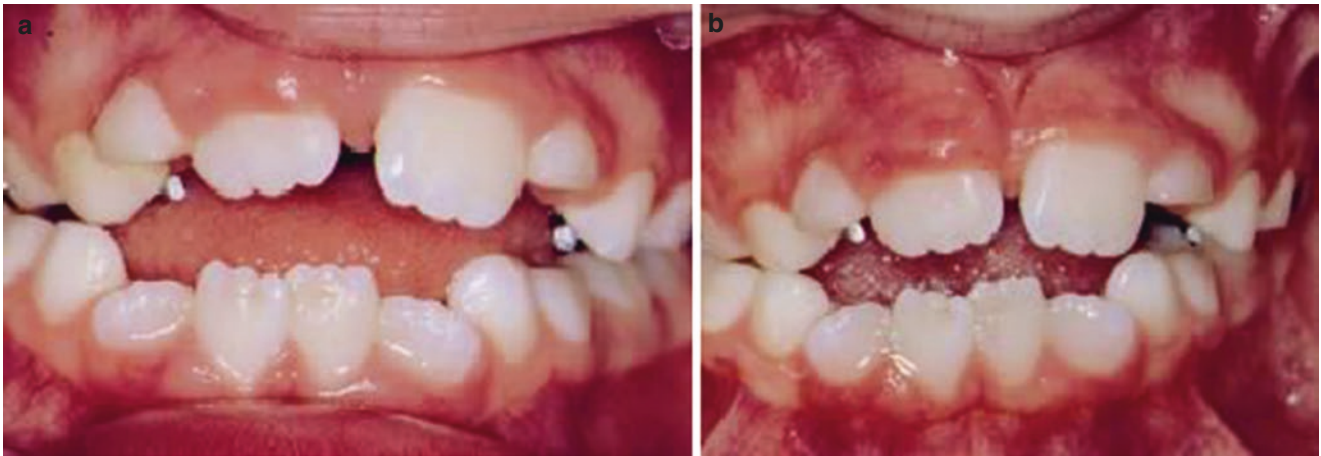


Fig. 3.30 (a, b) Frontal photographs with the rapid maxillary expansion in place

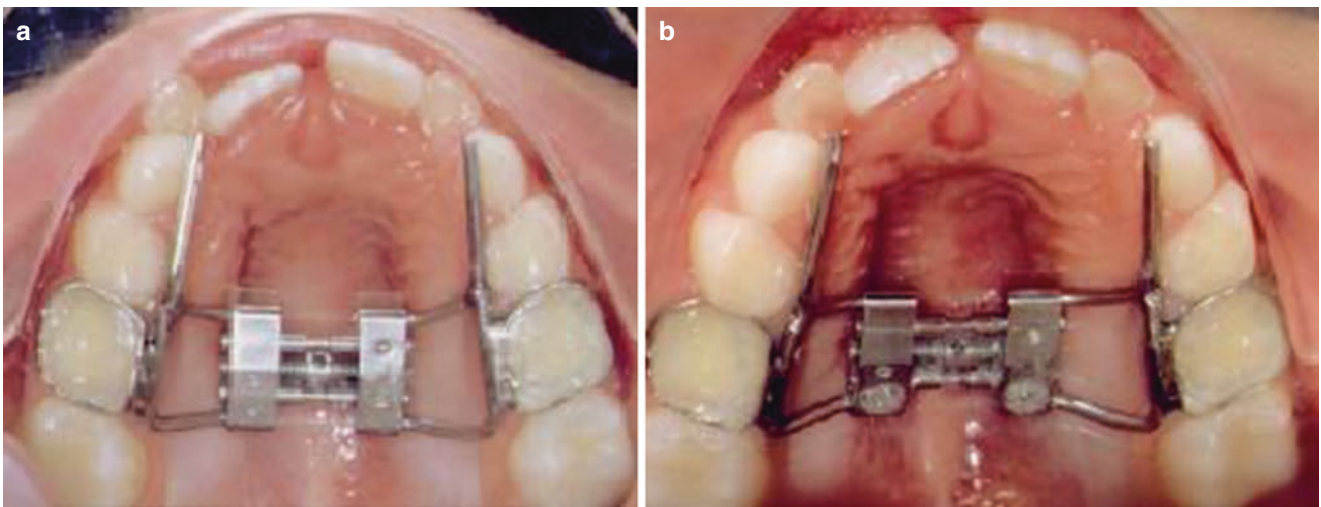


Fig. 3.31 (a, b) Occlusal view with the maxillary expander after total activation in place

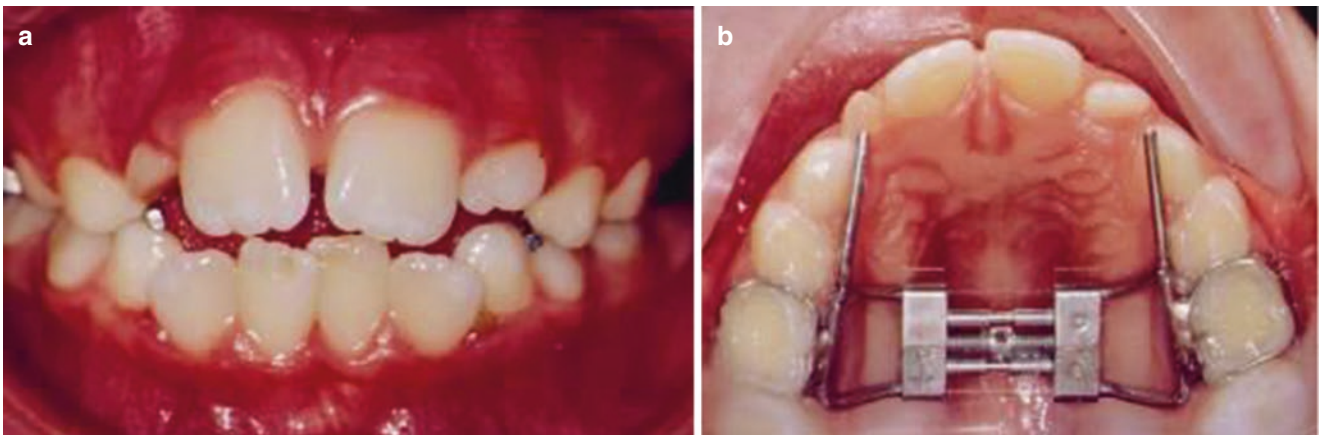


Fig. 3.32 (a, b) Follow-up 2 months later

Different types of RME can be used, but it is preferable to use those without acrylic plates not only on the palatal tissues but also on the occlusal surfaces of the molars.

The protocol of activation is determined by the orthodontist, but twice a day is usually sufficient.

The patient was gone for 2 years and she returned without the RME.

The anterior occlusion was edge to edge, and a slight open bite was still present. Cuspid and bicuspid had almost erupted (Fig. 3.33a, b).

The lateral photographs showed slight lateral open bite in the lateral incisor and canine region, and tongue interposition was still present in this area (Fig. 3.34a, b).

After a long conversation with the parents and the patient, they accepted a second phase of treatment with fixed appliances in order to improve her dental occlusion and prevent any type of relapse of the anterior open bite (Fig. 3.35a, b).

New panoramic and lateral radiographs showed normal eruption of the cuspid and bicuspid with no evidence of root resorption.

According to Ricketts, she had a dolichofacial pattern with some protrusive incisors and a moderately increased lower anterior facial height and gonial angle (Fig. 3.36a, b).

Esthetic preprogrammed 0.022" slot brackets were bonded on the upper and lower teeth with SS 0.016" wires to align and level the arches. No extraction of bicuspid was planned at that time.

Midlines are almost coincident (Fig. 3.37a, b).

No brackets were bonded on the second lower temporary molars. However, manual stripping was performed on the mesial side in order to achieve Class I canine on the left and right side (Fig. 3.38a, b).

The upper and lower arches showed great improvement. The lower second right and left temporary molars were still in place (Fig. 3.39a, b). The dentoalveolar changes were significant with a greater improvement in the incisor position and inclination. The vertical control was very important in order to avoid an increase of the lower facial height, during the growth period.

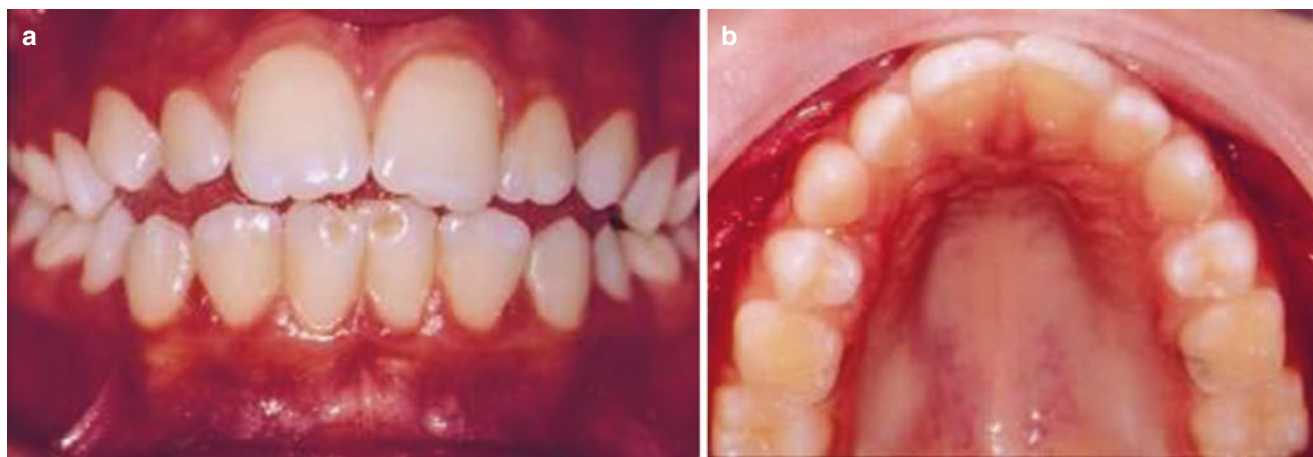


Fig. 3.33 (a, b) Frontal and occlusal photographs 2 years later without follow-up

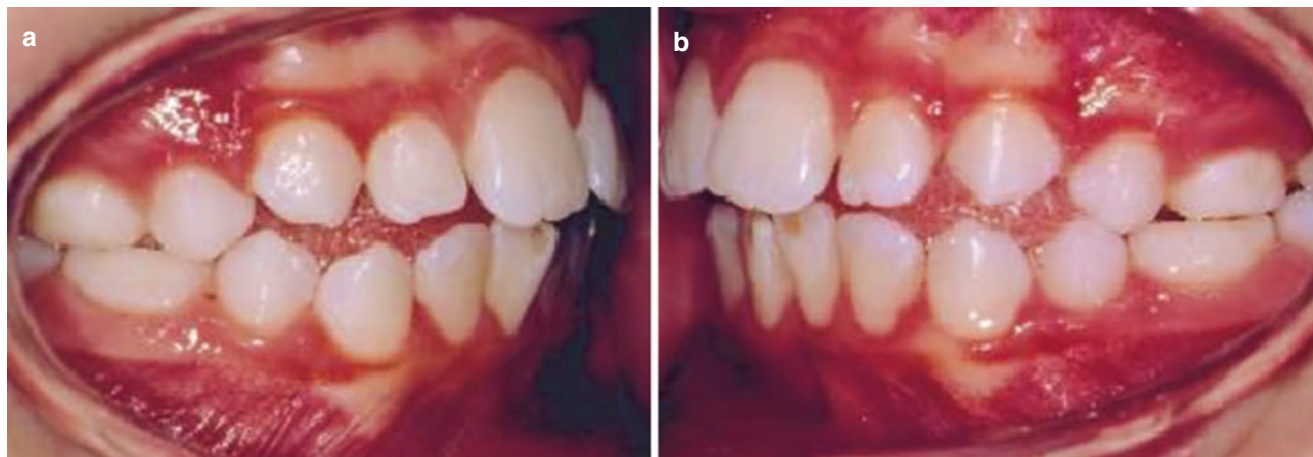


Fig. 3.34 (a, b) Open bite in the lateral areas was still present

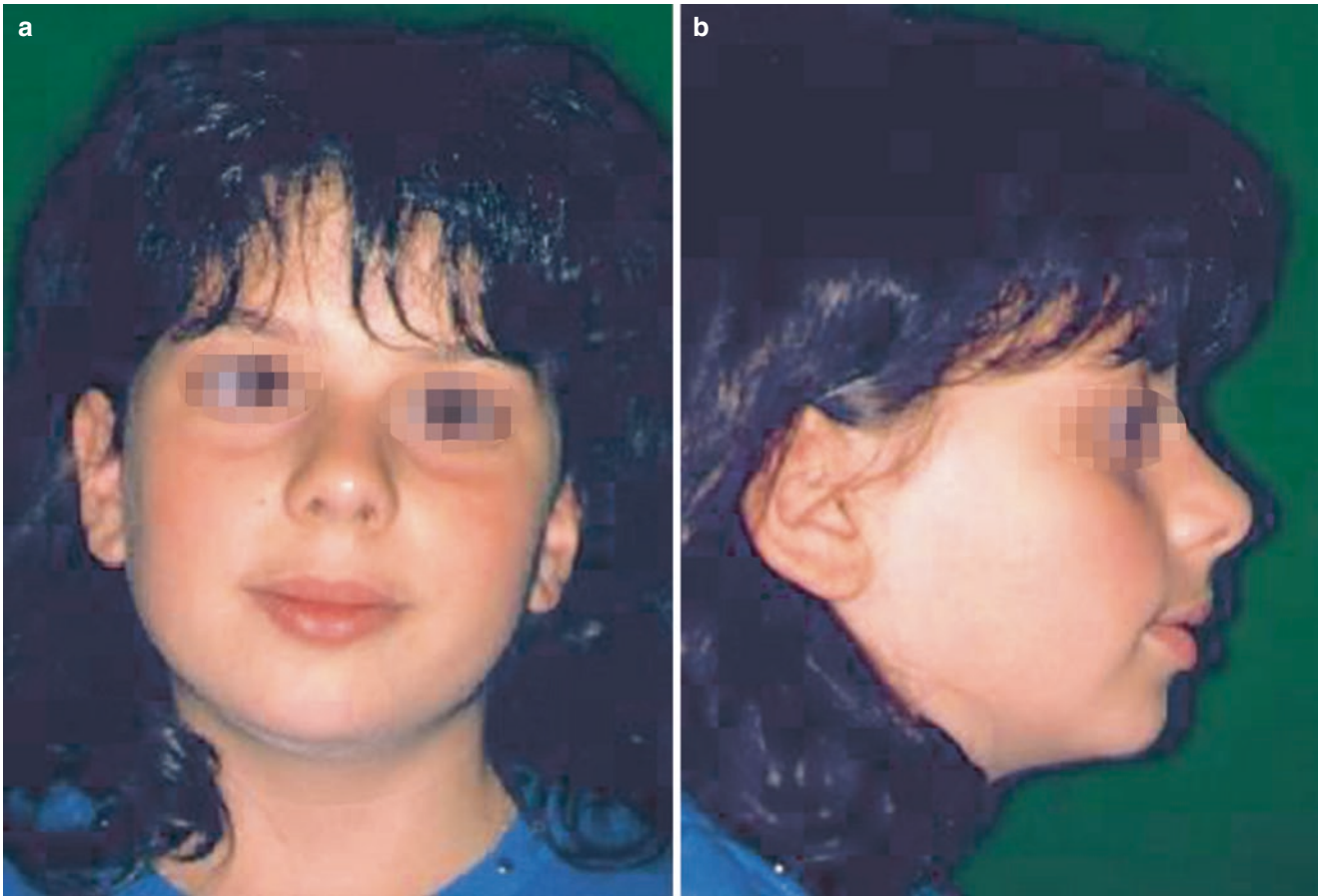

Fig. 3.35 (a, b) Frontal and profile before second phase of treatment

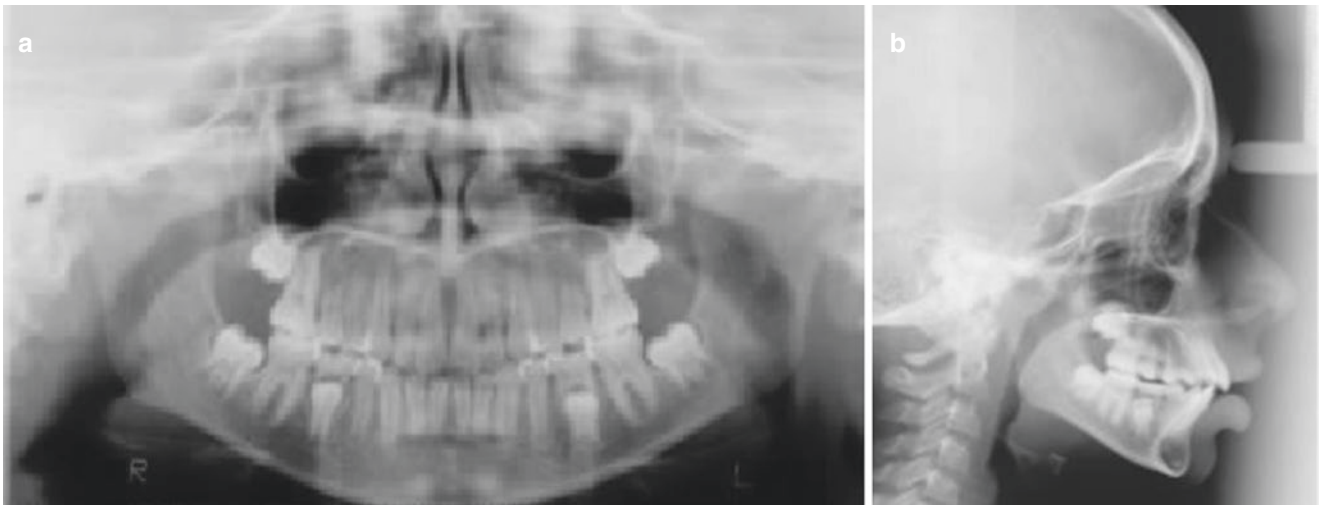


Fig. 3.36 (a, b) Panoramic and lateral radiograph before second phase treatment

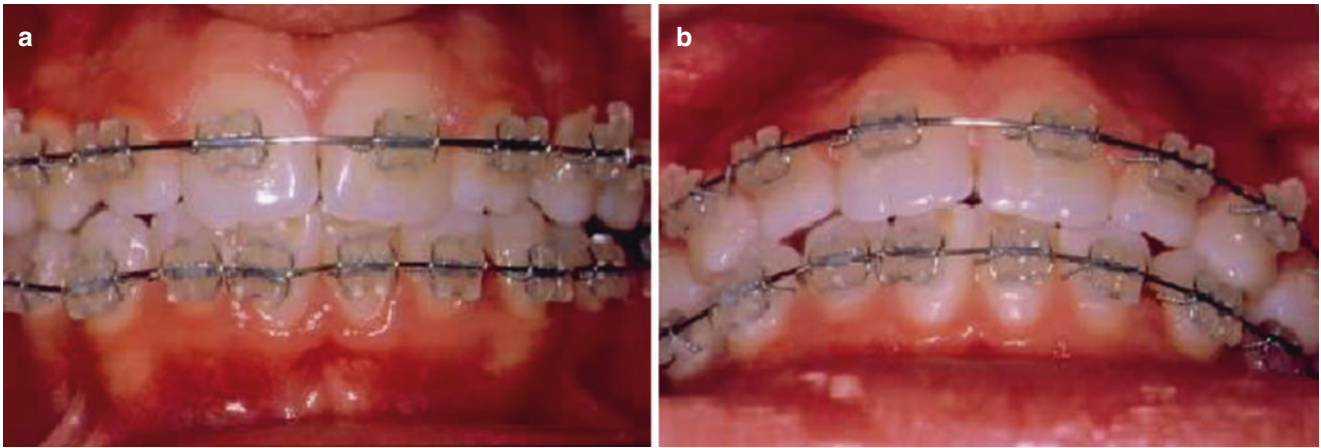


Fig. 3.37 (a, b) Esthetic 0.022" slot preprogrammed brackets were bonded on the upper and lower arches

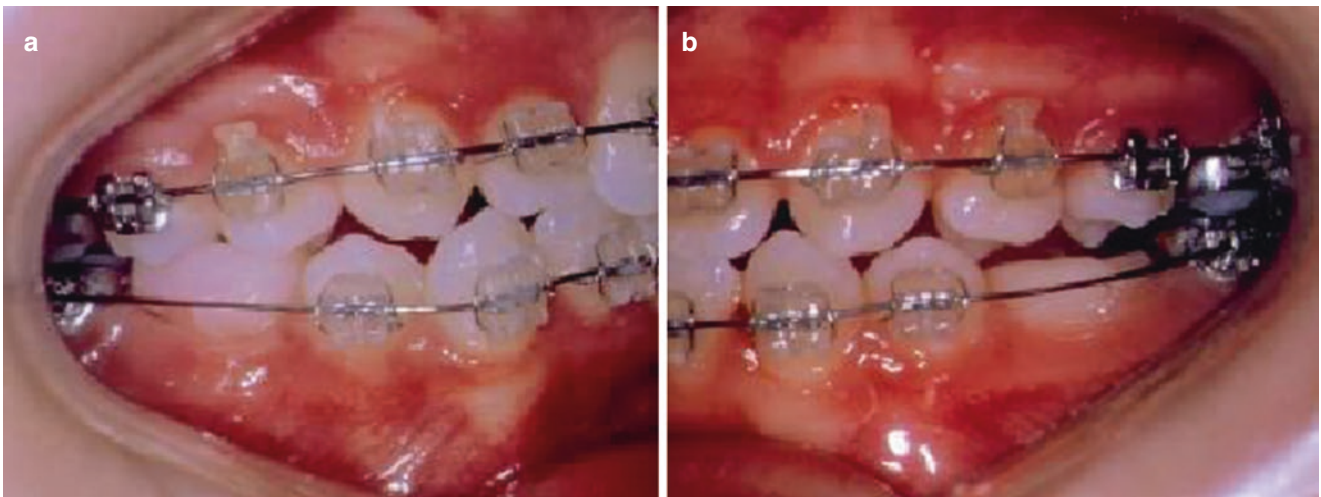


Fig. 3.38 (a, b) Lateral views. No brackets were bonded on the temporary molars

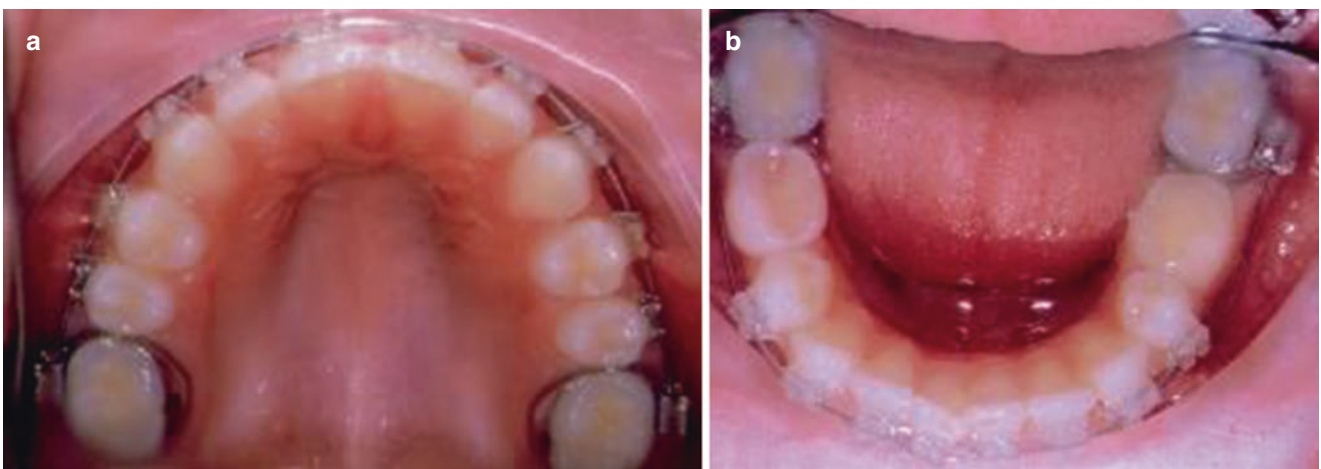


Fig. 3.39 (a, b) A significant improvement on the upper and lower arches was visible

These were the results 2 months after debonding. Midlines were coincident. Overbite and overjet were almost normal and the oral hygiene was fairly good (Fig. 3.40a, b).

Right and left Class I canine and molar were obtained with good interdigitation in the bicuspid area. The gingival line and the occlusal plane were parallel (Fig. 3.41a, b).

A fixed retention wire was bonded on the upper and lower arches to maintain the position of the incisors. Long-

term retention as well as a removable appliance were recommended to control the function of the tongue (Fig. 3.42a, b).

The final photographs after the orthodontic treatment showed a significant improvement in the lower third of the face. She could close the lips without tension and there wasn't a gingival smile. The dental midline was coincident with the facial one (Fig. 3.43a, b).

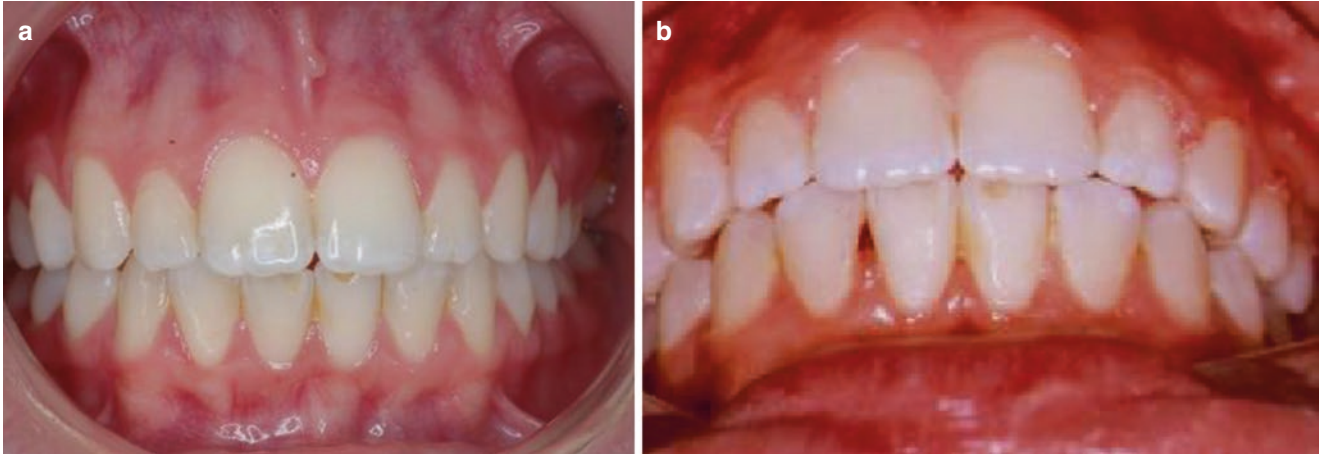


Fig. 3.40 (a, b) Frontal photographs 2 months after debonding. Midlines were coincident

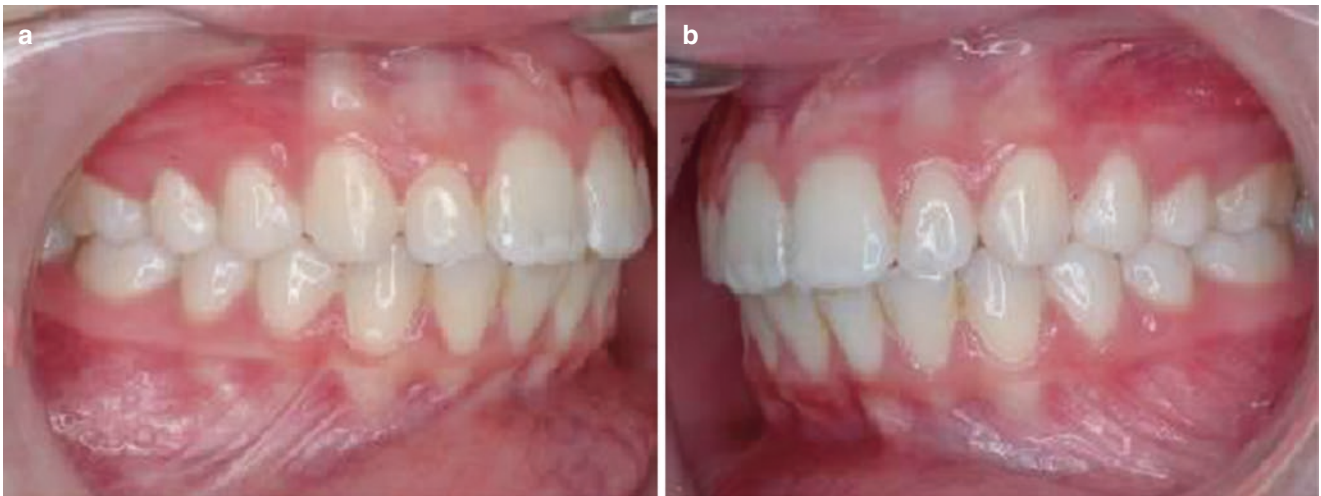


Fig. 3.41 (a, b) Lateral views 2 months after debonding with Class I canine and molar

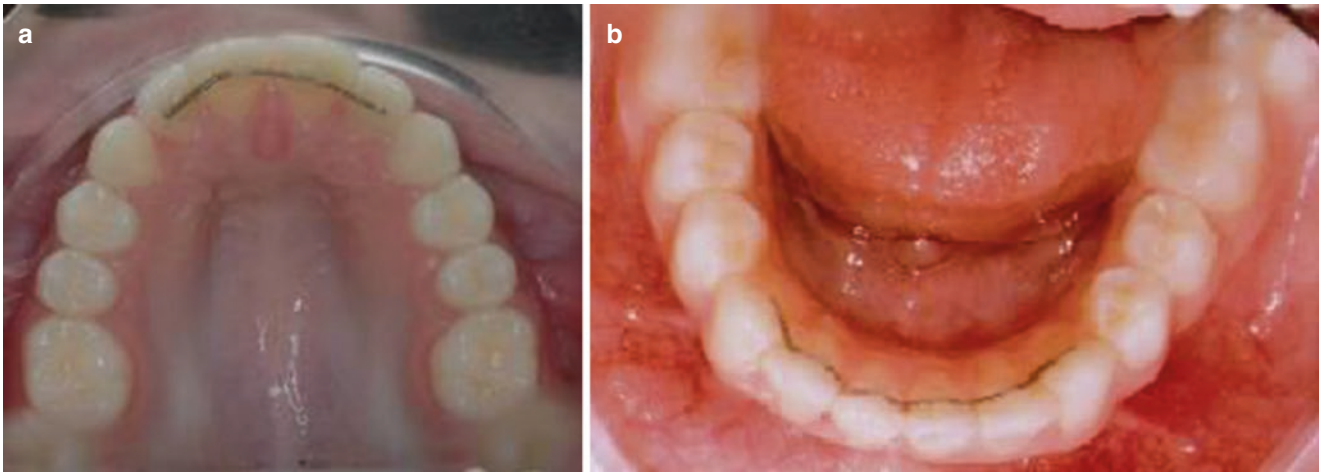


Fig. 3.42 (a, b) Upper and lower fixed retention wires were recommended for a long period of time

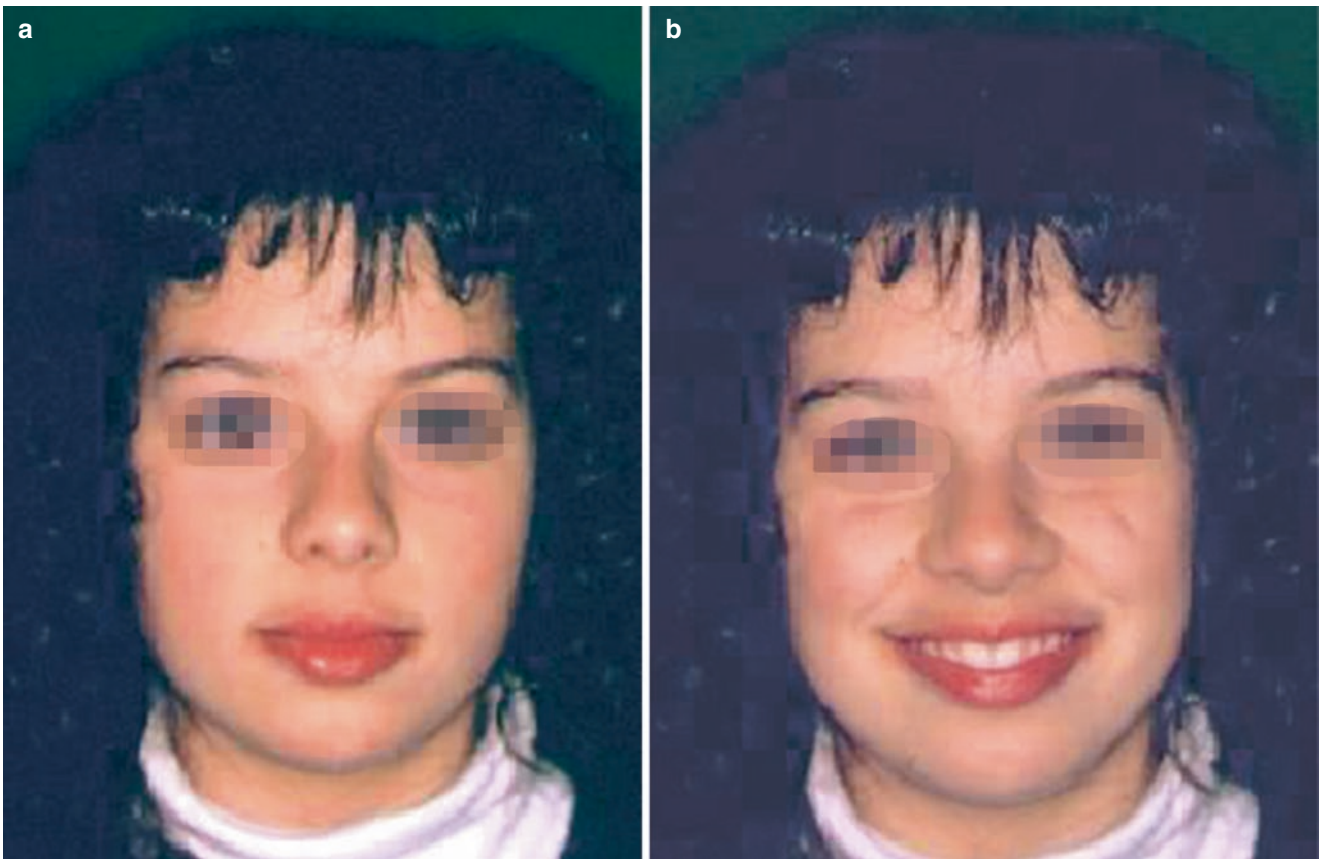


Fig. 3.43 (a, b) Final photographs at the end of the second phase of treatment

The profile photographs clearly showed a muscle equilibrium. The profile was still straight and the nasolabial angle was normal (Fig. 3.44a, b).

The patient returned 3 years later for follow-up of her retention wires.

Her smile was better than ever and the oral muscles were completely relaxed. In the end, she had a symmetrical face with balanced proportions (Fig. 3.45a, b).

The nasolabial angle was more open even though no extractions were performed in the upper arch nor in the mandible. A nice and broad smile was achieved (Fig. 3.46a, b).

When analyzing the front photographs 3 years later, a slight relapse in the anterior region was observed. With this in mind, it was advisable to finish the case with a bigger overbite in order to avoid relapse (Fig. 3.47a, b).

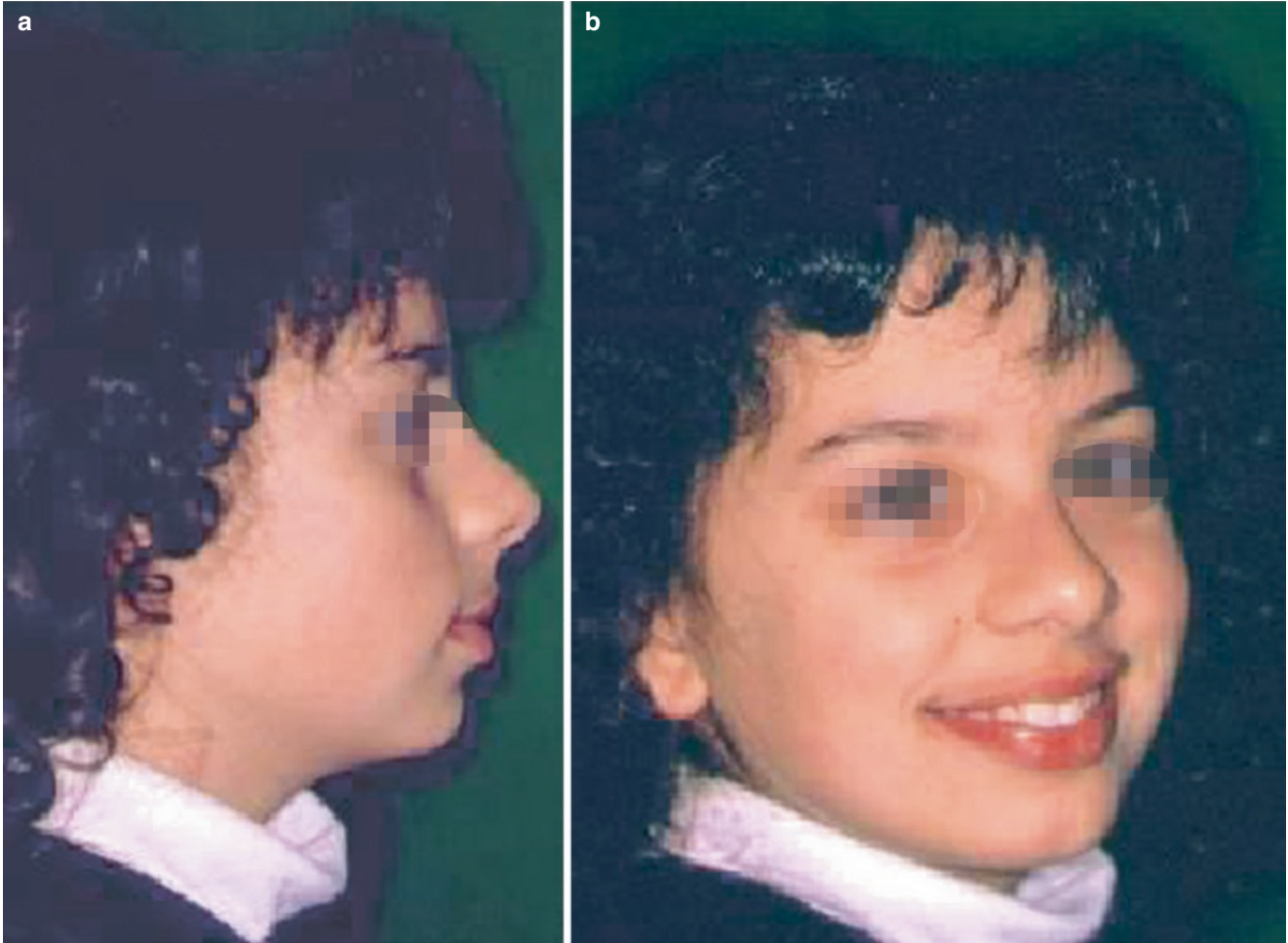

Fig. 3.44 (a, b) Final profile and smile photographs

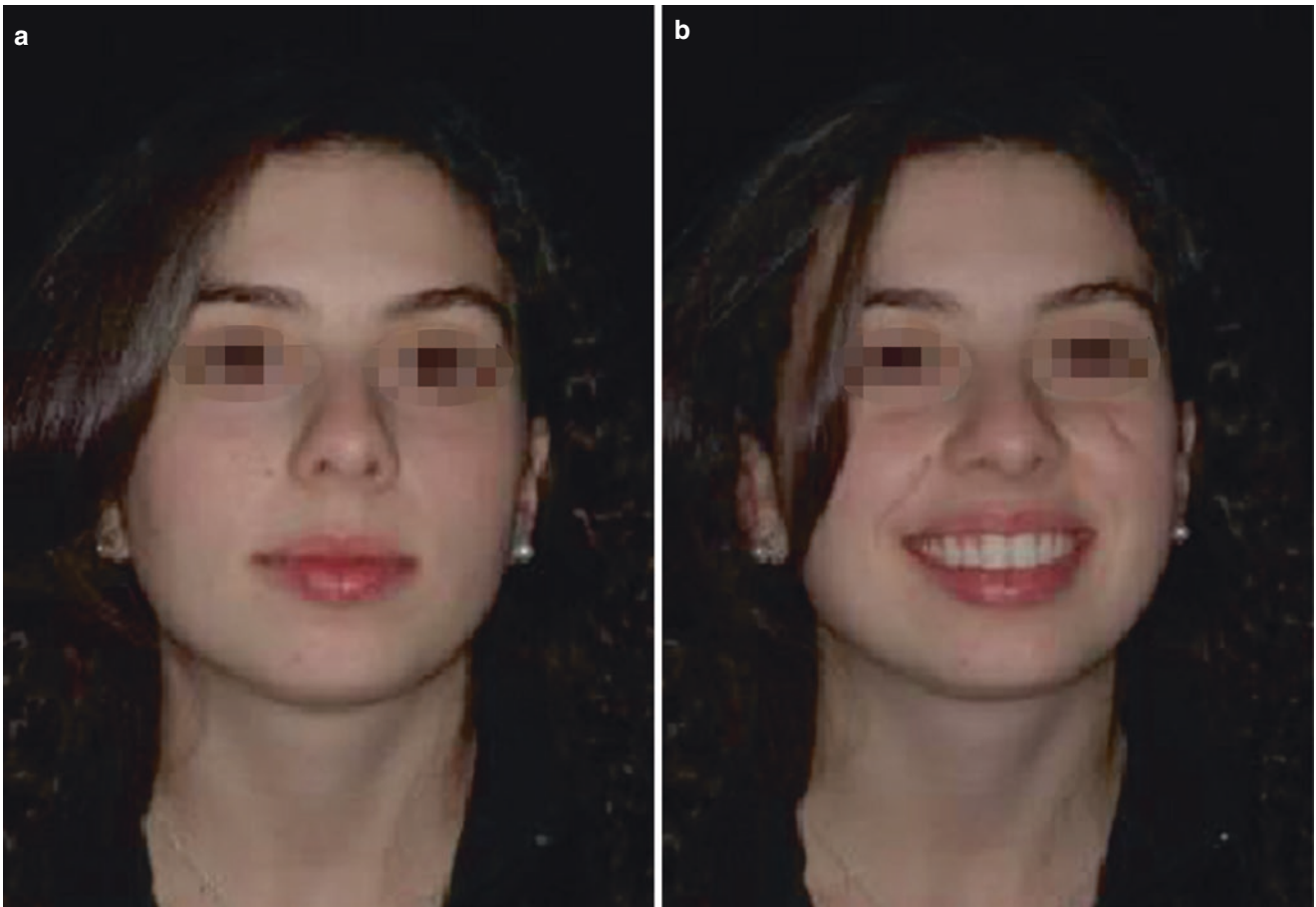


Fig. 3.45 (a, b) A follow-up 3 years later



Fig. 3.46 (a, b) Profile and lateral smile 3 years later. The upper lip was slightly more retruded

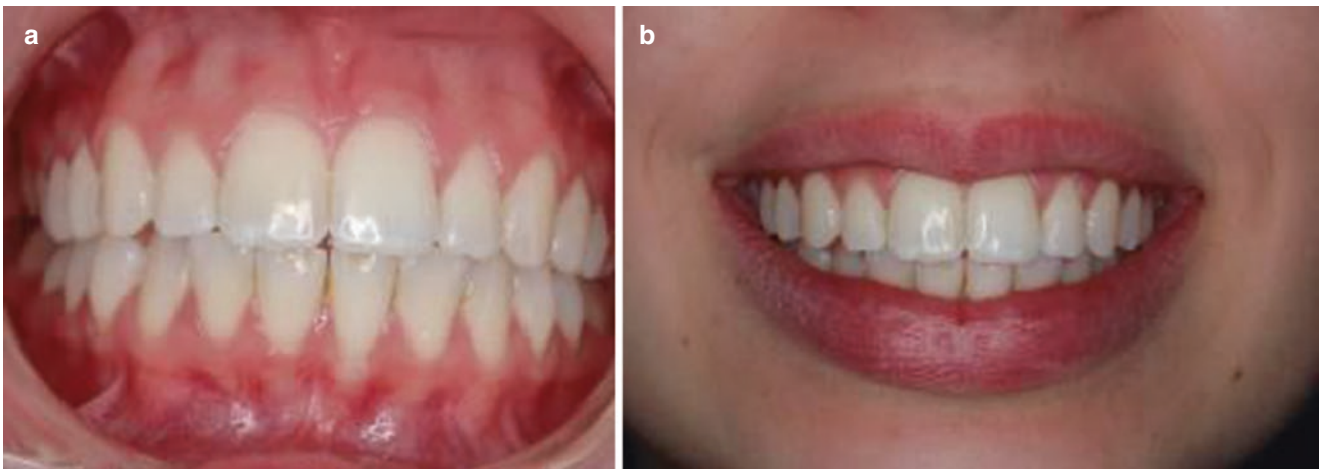


Fig. 3.47 (a, b) Slight relapse in the anterior region was present

Class I canine and molar were maintained. A 6-month follow-up was highly advisable in order to maintain or improve the results that were achieved (Fig. 3.48a, b).

The observation of the pre- and postfrontal dental photographs showed that the treatment objectives were achieved. The gingival line and the occlusal plane were parallel, and the hygiene was very good.

This confirmed that to obtain an efficient therapeutic result, correct diagnosis and treatment timing are very important (Fig. 3.49a, b).

The comparison of the pre- and postfrontal photographs clearly demonstrated how the soft tissues were improved as a consequence of the correction of the bad habits. Now, the patient closes her lips normally.

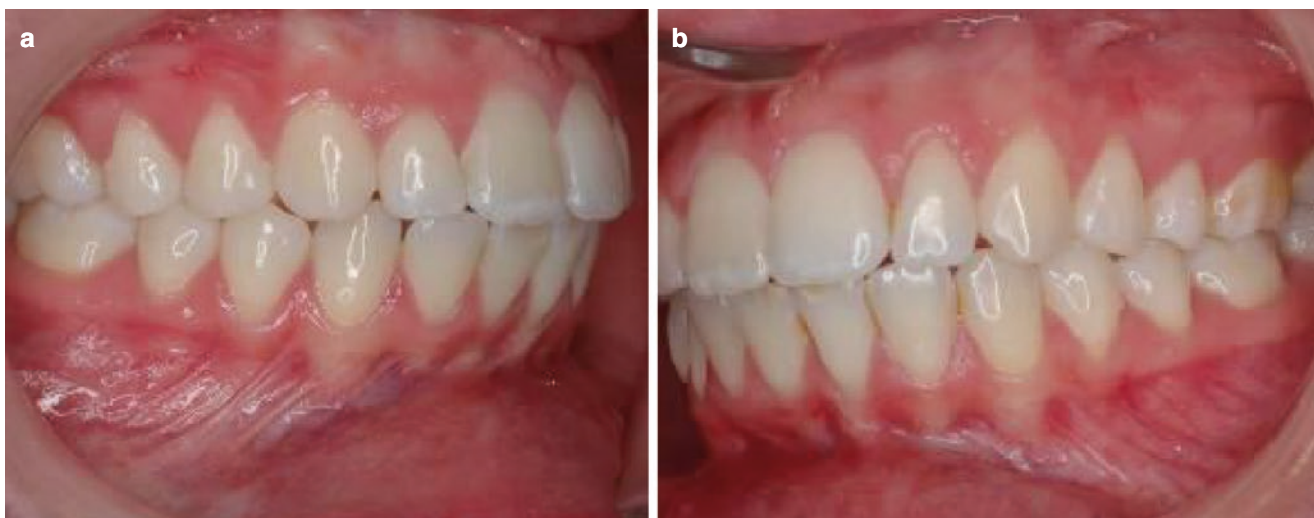


Fig. 3.48 (a, b) Class I canine and molar was maintained

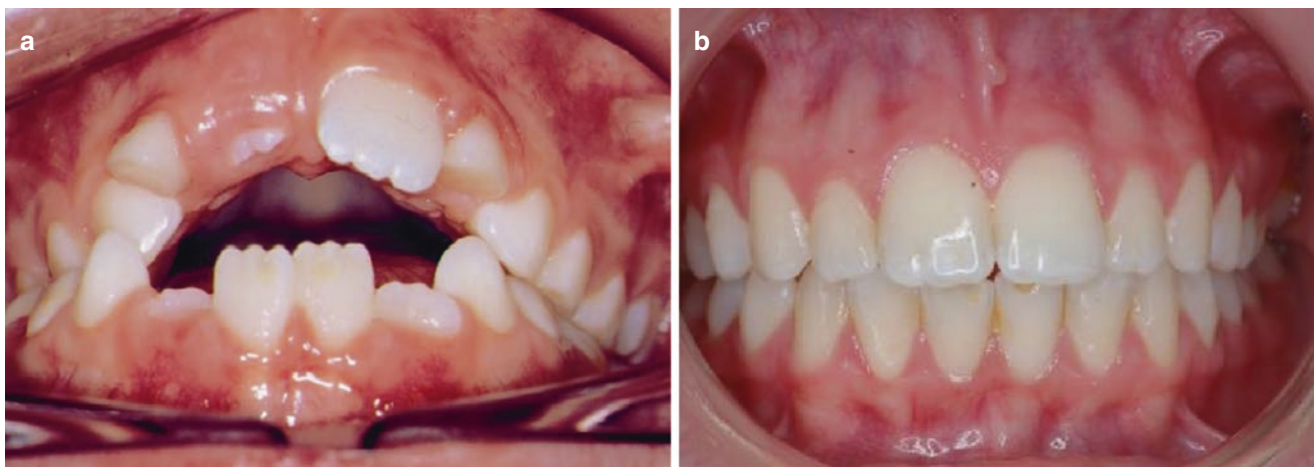


Fig. 3.49 (a, b) Comparison pre- and posttreatment frontal occlusion

The importance of tongue posture and tongue function cannot be denied (Fig. 3.50a, b).

The results were similar from the lateral side. She had a straight profile and closed her mouth in a normal way with reduction of the lip protrusion and decreased mentalis strain.

The nasolabial angle was less protrusive even though no bicuspid extractions were performed.

There was a significant improvement in vertical skeletal and dentoalveolar relationships due to the elimination of the tongue thrust and mouth breathing. This patient confirms the theory that early treatment in conjunction with the normalization of the functional habits prevents asymmetric alveolar bone growth that affects the permanent dentition (Fig. 3.51a, b).

The present clinical case clearly demonstrates that if proper diagnosis is obtained and orthodontic biomechanics are well designed, stable results can be achieved in a patient with severe anterior open bite.

The post-retention stability of open bite treatment is a controversial topic in orthodontics. Relapse is unpredictable.

The etiology could be tongue thrust because of its size or posture, respiratory problems, sucking habits, condylar resorption, direction of growth, etc.

Habit elimination is mandatory to prevent open bite relapse. How can relapse be prevented? Better diagnosis and an individualized treatment and retention plan.

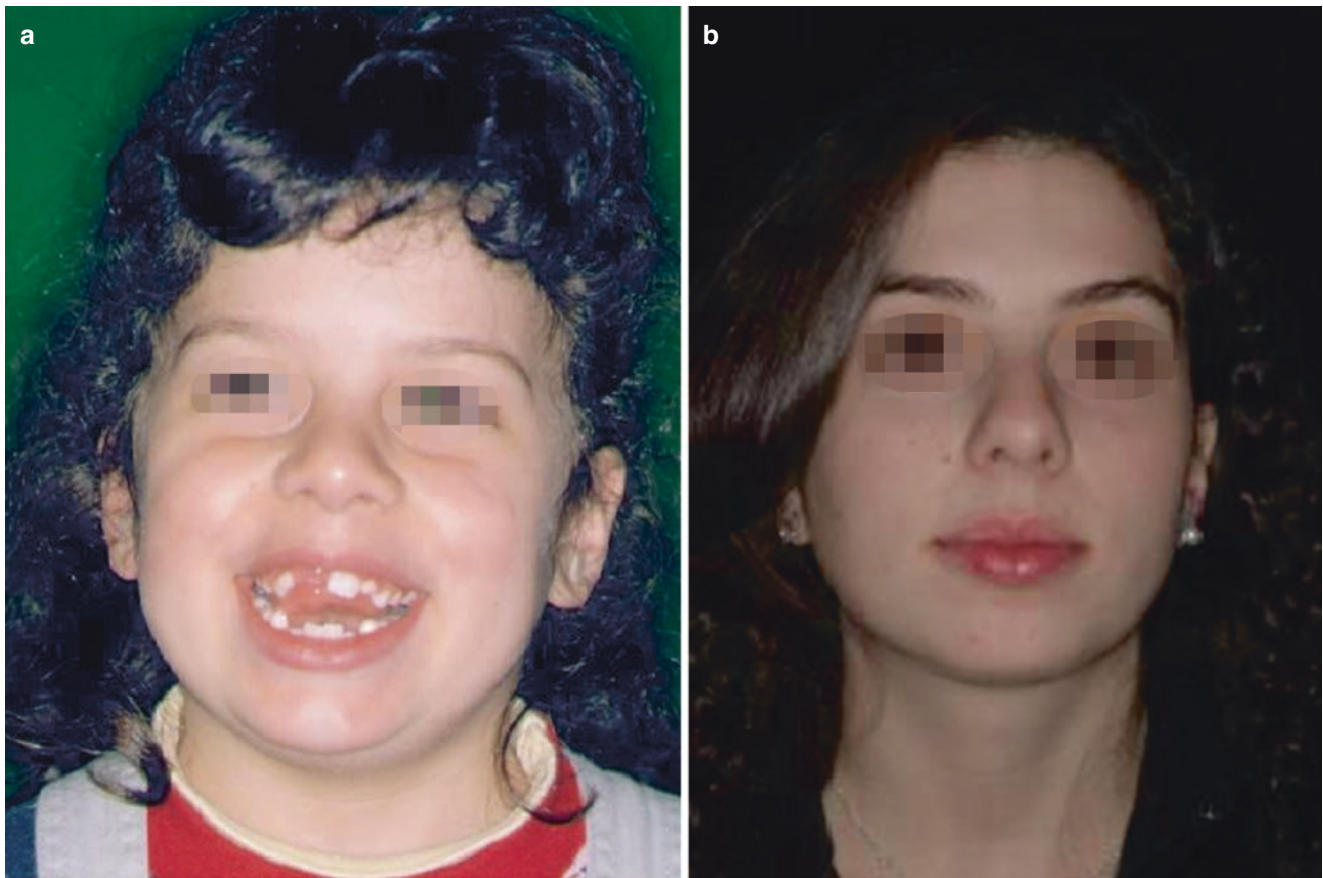


Fig. 3.50 (a, b) Frontal photos pre- and posttreatment

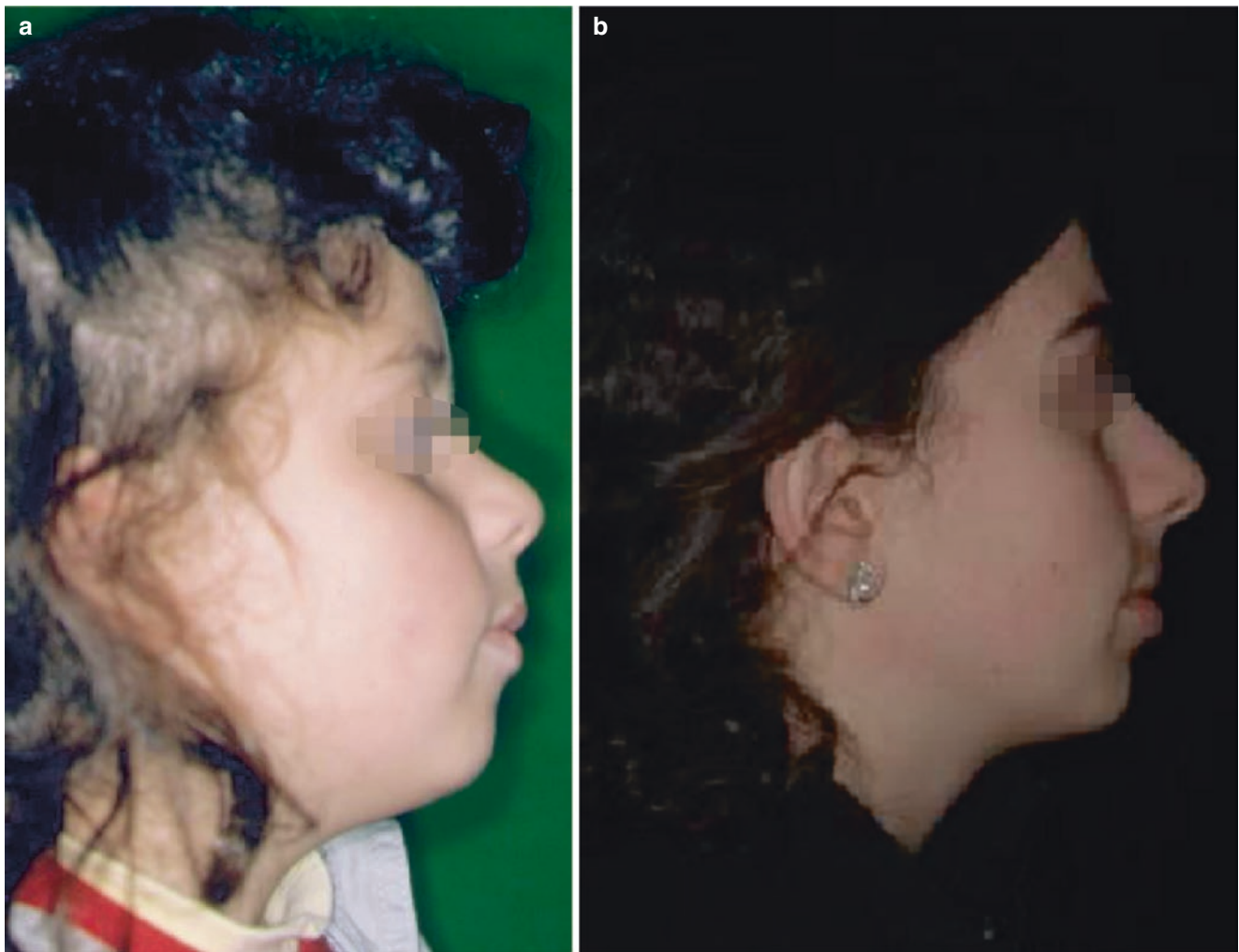

Fig. 3.51 (a, b) Changes in the profile and nasolabial angle were remarkable

Conclusions

Ideally, open bite patients should be treated as early as possible.

Unfortunately, there is no specific bracket or arch wire to help the normalization of the position of the tongue.

These three patients were treated with different appliances since the etiologic reasons at the beginning were different: the first one used a pacifier until 4 years of age and had an adenoidectomy, the second one had a persistent tongue thrusting habit until 9 years of age, and the third one was a combination of both.

The young patient has to understand that the appliance will help him or her to control the habit. The positive role of the parents to accompany the process was essential.

From a clinical point of view, early treatment with removable or fixed appliances is more effective and reduces the length of treatment in the permanent dentition with less surgical procedures and more stability.

It is well known that environmental and neuromuscular influences may alter the position of the teeth and the direction of the maxilla and mandibular growth.

It is important to determine the presence or absence of naso- or oropharyngeal obstructions that can alter the position of the tongue and the mandibular posture.

Dentofacial changes associated with mouth breathing and its relation with some types of malocclusions that involve the presence of long face syndrome are well recognized (Linder-Aronson and Woodside 2000).

The role of the otolaryngologist and speech therapist is unquestionable in the diagnosis and treatment procedures.

There is strong evidence that the earlier the open bite malocclusion is corrected, the better the prognosis will be, and of course, habit elimination is mandatory to prevent open bite relapse.

Ideally, the treatment has to begin when the children are 4–6 years old as most of the functional and dentofacial problems begin at this age, and also there is a reduction in the risk of trauma of the upper front teeth.

The prevention of the apnea problems is more important than the correction of the snoring. Remember that snoring in children in conjunction with poor concentration at school and behavioral problems are the most typical signs of sleep apnea episodes in children.

Relapse is unpredictable since the etiology could be multifactorial (condylar resorption, respiratory problems, continuous tongue thrust, direction of growth, habits, etc.).

It is well known that the stability after retention of the open bite treatment is a controversial issue for the orthodontists.

The effectiveness and efficiency of an early orthopedic/orthodontic treatment, based on a correct, individualized, and exhaustive diagnosis, are undeniable.

Long-term control is fundamental to confirm the achieved results (Huang 2002).

The normalization of the anterior open bite is imperative taking into account the health problems that can occur later on.

Unfortunately, there isn't a specific bracket or wire to treat all these patients nor to help in the normalization of the tongue position.

The parents and the young patients have to be aware that the earlier the correction of the dysfunctional habits begins, the better and more effective the results will be.

A complete multi- and interdisciplinary early treatment plan is the key to correct the anterior open bite and the functional disturbances associated with it.

Bibliography

- Cozza P, Baccetti T, Franchi L, Mucedero M, Polimeni A. Sucking habits and facial hyperdivergency as risk factors of anterior openbite in the mixed dentition. *Am J Orthod Dentofacial Orthop.* 2005a;128:517–9.
- Cozza P, Mucedero M, Baccetti T, Franchi L. Early orthodontic treatment of skeletal openbite malocclusion: a systematic review. *Angle Orthod.* 2005b;75:707–13.
- Cozza P, Baccetti T, Lorenzo F, Mucedero M. Comparison of 2 early treatment protocols for open -bite malocclusions. *Am J Orthod Dentofacial Orthop.* 2007;132:743–7.
- English JD. Early treatment of skeletal openbite malocclusions. *Am J Orthod Dentofacial Orthop.* 2002;121:563–5.
- Huang GJ, Justus R, Kennedy DB, Kokich VG. Stability of anterior openbite treated with crib therapy. *Angle Orthod.* 1990;60:17–24.
- Huang GJ. Long-term stability of anterior open-bite therapy: a review. *Semin Orthod.* 2002;8:162–72.
- Linder-Aronson S, Woodside D. Excess face height malocclusion. Etiology, diagnosis and treatment. Chicago: Quintessence Books; 2000. p. 67–71.
- McNamara Jr JA, Brudon WL. Orthodontic and orthopedic treatment in the mixed dentition. Ann Arbor: Needham Press; 1993. p. 20–1.
- Ngan P, Fields HW. Open-bite : a review of etiology and management. *Pediatr Dent.* 1997;19:91–8.
- Pascualy R, Warren Soest S. Snoring and sleep apnea. USA: Raven Press; 1951.
- Ramirez-Yañez G, Sidlauskas A, Junior E, Fluter J. Dimensional changes in dental arches after treatment with a prefabricated functional appliance. *J Clin Pediatr Dent.* 2007;31:279–83.
- Ramirez-Yañez G, Paulo F. Early treatment of a Class II, division 2 malocclusion with the Trainer for Kids (T4 K) : a case report. *J Clin Pediatr Dent.* 2008;32:325–30.
- Silva Filho OG, Gomes Goncalves RJ, Maia FA. Sucking habits: clinical management in dentistry. *J Clin Pediatr Dent.* 1991;15:137–56.
- Torres FC, Rodriguez de Almeida R, Rodriguez d Almeida Pedrin R, Pedrin F, Paranhos RL. Dentoalveolar comparative study between removable and fixed cribs, associated to chincup, in anterior open bite treatment. *J Appl Oral Sci.* 2012;20:531–7.
- Urzal V, Braga AC, Ferreira AP. Oral habits as risk factors for anterior openbite in the deciduous and mixed dentition -cross sectional study. *Eur J Pediatric Dent.* 2013;14:299–302.

Julia Harfin

Patients with a nice and attractive smile, white teeth and normal gingivo-periodontal tissues are the gold standard for all orthodontists.

To obtain this goal, a complete and profound understanding of the histology and physiology of the periodontal tissues is fundamental. It is essential to be aware of its pathology, especially in young patients.

The periodontium is a complex tissue that includes the gingiva and the gingival attachment to the tooth, the cementum, periodontal ligament, and alveolar bone.

It is important to take into account that these tissues are in constant changes during the growth period and its maintenance in health is crucial before, during, and after all the orthodontic movements.

Clinical observation demonstrates that teeth in lingual position have wider bands of keratinized and attached gingiva than teeth in facial position. Labial displacement of the central lower incisors during eruption is more predisposed to having localized gingival recession and loss of periodontal attachment in concordance to an uneven gingival line.

A complete and exhaustive diagnosis is fundamental in every patient.

It is well known that gingivitis is a gingival inflammation without loss of connective tissue attachment (Armitage 1995). Although it is a reversible process, it could be easily transformed into periodontitis with apical migration of the junctional epithelium and loss of the connective tissue and alveolar bone.

The presence of gingivitis and local recessions in the lower anterior region is a challenging condition. In general it is more prevalent in older patients than in children and frequently observed more in mandibular than in maxillary teeth. It also has a close relationship with alveolar bone

dehiscences. Almost 80% of the mandibular incisors with recession are positioned labially (Andlin-Sobocki et al. 1991).

It can affect negatively the smile and may cause pain and hypersensitivity on the affected teeth.

The prevalence of this recession ranges from 4 to 8% in children between 7 and 12 years old (Seehra et al. 2009). The etiology is multifactorial, but ectopic tooth eruption may play an important role in conjunction with localized gingivitis in this zone. Patients with thin periodontal biotype are more prone to this problem than those with thick periodontal biotype. The central mandibular incisors are the teeth with highest prevalence as the lateral incisors tend to erupt more lingually (Vasconcelos et al. 2012).

It is important to establish the difference between true and pseudo-recession. True recession is an exposure of cementum with apical migration of the junctional epithelium (Song 2013).

The predisposing factors include excessive labial position of the lower incisors, minor width of the attached gingiva, gingiva trauma, and poor oral hygiene. On the contrary lingually positioned incisors have more keratinized gingival width and reduced crown length.

Crowding is an important factor that can accelerate this process, and the association with occlusal trauma can lead to an important gingival recession (Fig. 4.1a, b). In these circumstances, this recession never improves by itself; on the contrary, it worsens year after year and can lead to the loss of the tooth.

Careful oral hygiene plays an important role in the maintenance of the results, and it has to be reinforced all the time by giving patient leaflets as well as verbal instructions.

A close relationship between the orthodontist and the periodontist is crucial in order to minimize and control the lower incisor recession.

It was demonstrated that the normalization of the position of the upper and lower incisors can improve and/or normalize the position and height of the gingivo-periodontal tissues (Seehra et al. 2009).

J. Harfin
Department of Orthodontics, Maimonides University,
Buenos Aires, Argentina
e-mail: harfinjulia@gmail.com

When it is necessary, the surgical treatment choice is a free gingival graft, and the recommendation is that this graft is to be placed after the orthodontic treatment when the position of the lower incisors is normalized. In some adult patients and in certain circumstances, a previous free gingival graft is suggested, but it is not recommendable in young patients since some normalization is achieved when the position of the teeth is corrected.

A long junctional epithelium attachment is the most common result.

Predisponent factors are the prominent anterior position of the lower incisors and the minor width of the gingival attachment. The position of the localized lower anterior recession in conjunction with a plaque-induced gingival inflammation due to the malposition of the incisors acts as determining factor in these patients (Parfit and Mjör 1964).

It is important to take into account that dental hygiene plays an important role in the maintenance and improvement of the gingivo-periodontal status.

Long-term observations of early correction of this condition demonstrate that the normalization of the anterior crossbite is maintained all lifelong. Some patients will need a second phase of treatment but others will not. There is no doubt that these problems should be treated as early as possible to avoid more complex problems.

The following two patients will clearly demonstrate these concepts.

The first patient is a boy who was 8 years old with a severe localized gingival recession in conjunction with anterior crossbite in the incisor region (Fig. 4.2a, b). His mother's chief complain was the position of the central upper incisors. No relevant medical history was present.

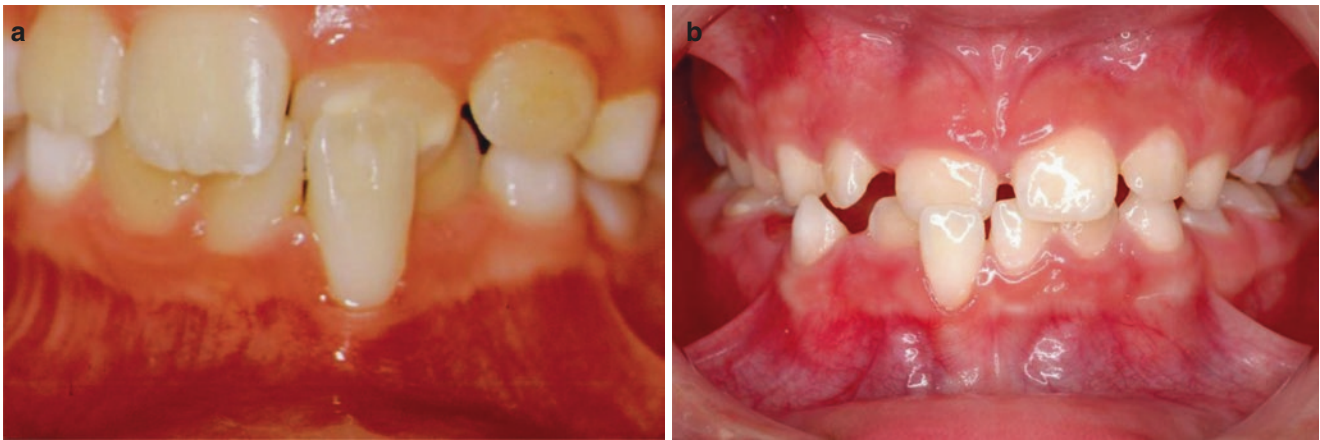


Fig. 4.1 Examples of gingival recession in labially positioned lower incisors during early mixed dentition with less width of attached gingiva

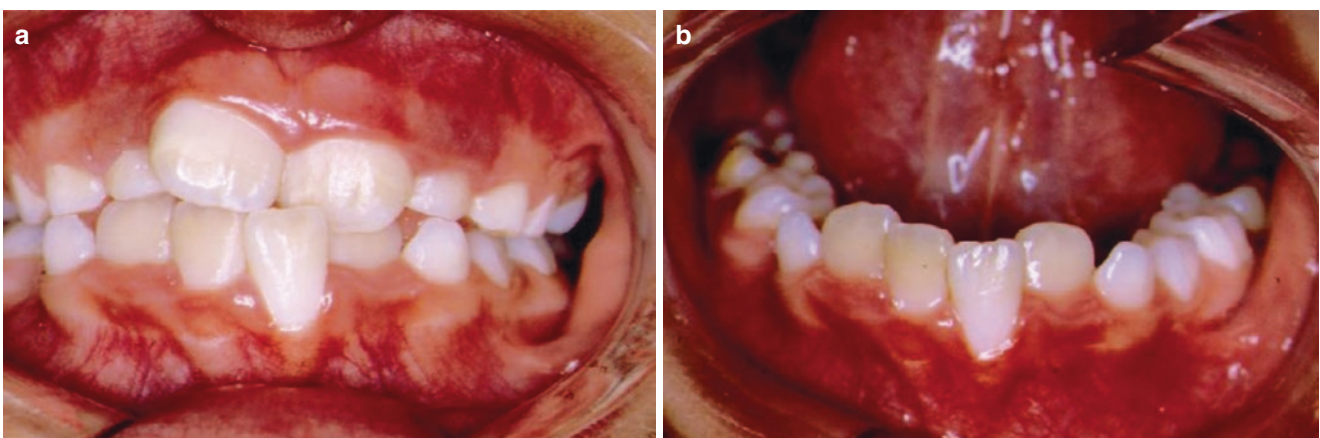


Fig. 4.2 Significant lower anterior gingival recession in an 8-year-old boy along with an upper and lower mild crowding

He also had 5 mm of crowding at the lower arch and an uneven upper and lower gingival line.

The lateral photographs confirmed the anterior position of the lower central incisor with a significant loss of periodontal attachment and the absence of the right first temporary molar that was extracted due an important caries (Fig. 4.3a, b). The oral hygiene was fairly good. Right and left Class I molar was present although the right one was in crossbite position.

After analyzing the models, rx, and photos, the following treatment objectives for the first phase of treatment were:

1. Align and level de arches
2. Maintain Class I molar
3. Achieve Class I canine
4. Improve gingival conditions at the lower anterior region
5. Normalize overjet and overbite
6. Long-term stability

In order to achieve these objectives, a utility arch (0.016" × 0.016" Elgiloy wire) was placed with preprogramed brackets 0.022" slot. No brackets were bonded on the lower arch during this phase of treatment (Fig. 4.4a, b).

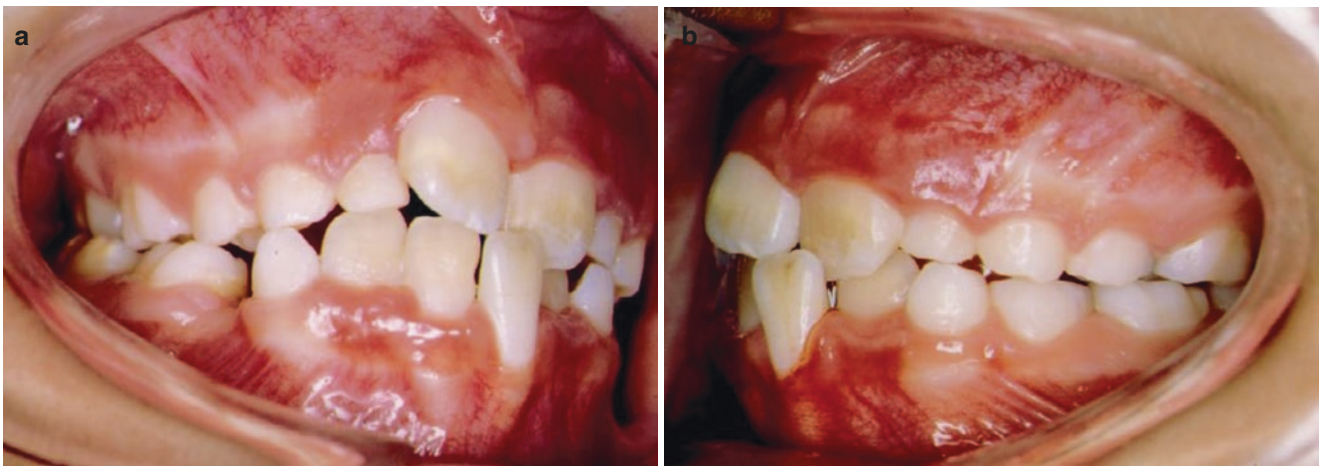


Fig. 4.3 Pretreatment lateral views. The anterior position of the right central incisor and the periodontal attachment loss were confirmed

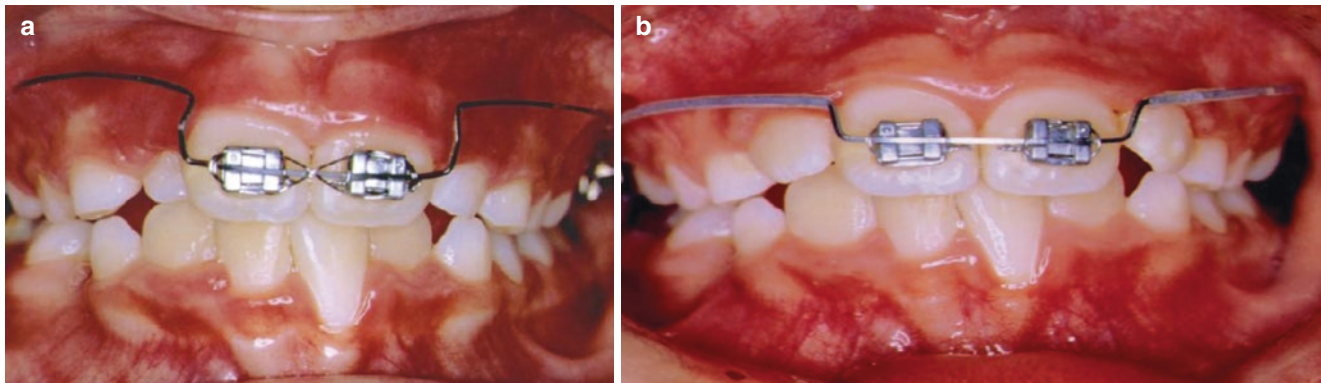


Fig. 4.4 Brackets were placed on the central upper incisors with a utility arch (0.016" × 0.016" Elgiloy wire) to normalize overjet and overbite

Seven months later, the position of the central and lateral upper incisors was normalized. An exhaustive dental plaque control was recommended with special emphasis at the lower anterior region, in order to improve gingival condition. No brackets were bonded on the lower arch until that point (Fig. 4.5a, b).

The lateral photographs confirmed the actual status. A fixed lower inner arch (SS 0,036") with two mesial loops was placed

to maintain the anteroposterior position of the first lower molars and to avoid the mesialization of the right first molar. An SS 0.016" \times 0.022" was placed on the upper arch to control the inclination and torque of the upper incisors (Fig. 4.6a, b).

No brackets were bonded on the lower teeth since the normal eruption of the cuspids and bicuspid was expected. For work-related reasons, his parents moved abroad for approximately 24 months.

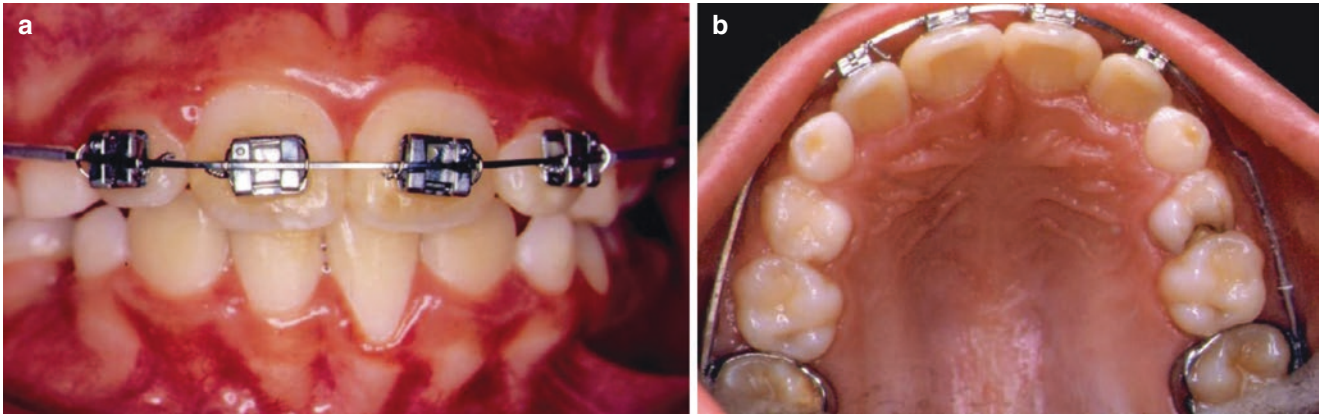


Fig. 4.5 After 7 months in treatment the position of the upper incisors was normalized with a 0.016" SS archwire

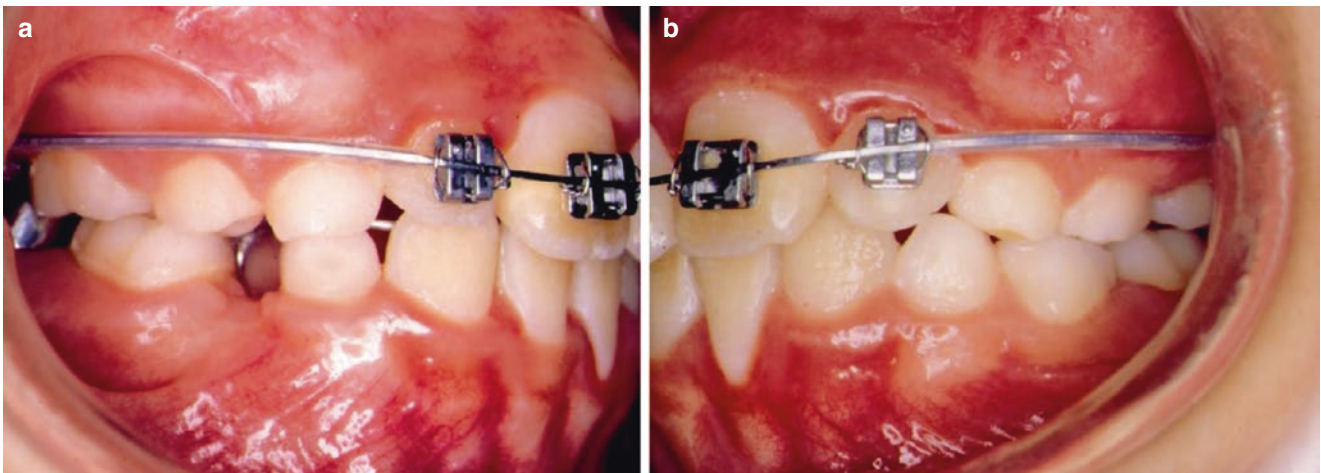


Fig. 4.6 Lateral views with a lower inner arch to maintain the anteroposterior position of the lower molars

Two years after debonding, the position and inclination of the upper and lower incisors were almost normal. Midlines were coincident, the occlusal plane was parallel to the gingival plane, and overjet and overbite were normalized. The recovery of the gingiva in the lower central incisor

area was noticeable. No type of gingival graft was necessary (Fig. 4.7a, b).

The lateral photographs confirmed that Class I molar and canine were achieved with acceptable overjet and overbite not only in the front region but also in the lateral areas (Fig. 4.8a, b).

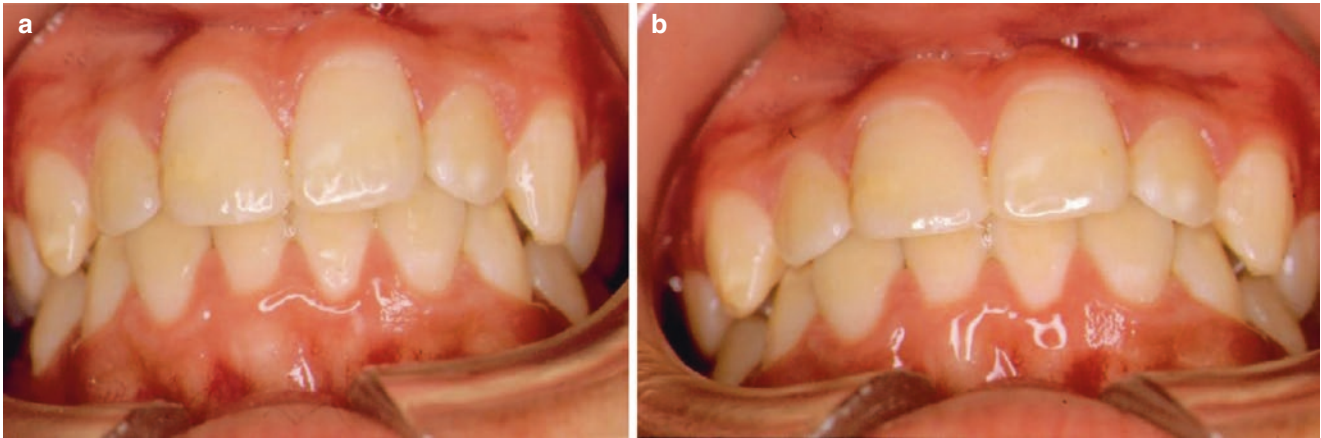


Fig. 4.7 2 years after the end of the treatment, the results were maintained or even improved. Midlines were coincident and overjet and overbite were within normal ranges

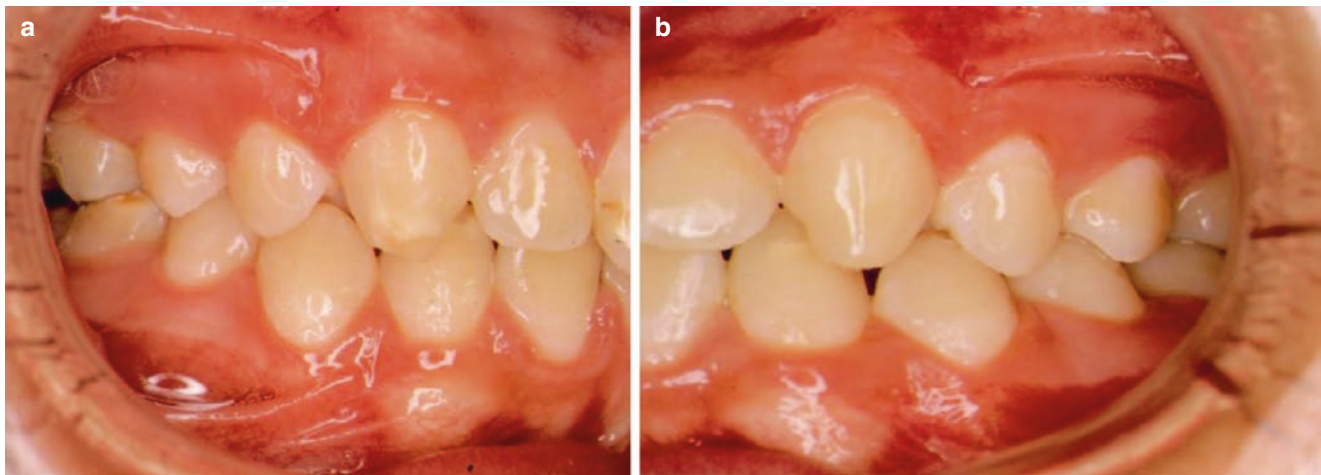


Fig. 4.8 Lateral views at the end of the treatment Class I canine and molar was achieved

The occlusal views confirmed the results that were obtained. A fixed retention wire was bonded on each tooth in the lower arch to prevent any kind of relapse, even though no brackets had been bonded on them. A long-term follow-up was recommended every 6 months (Fig. 4.9a, b).

The patient returned for follow-up of the retention wire after 4 years and 9 months. The results were maintained or even improved. The gingival margin was still normal (Fig. 4.10a, b).

The lateral views confirmed that Class I canine and molar was maintained with normal overjet and overbite (Fig. 4.11a, b).

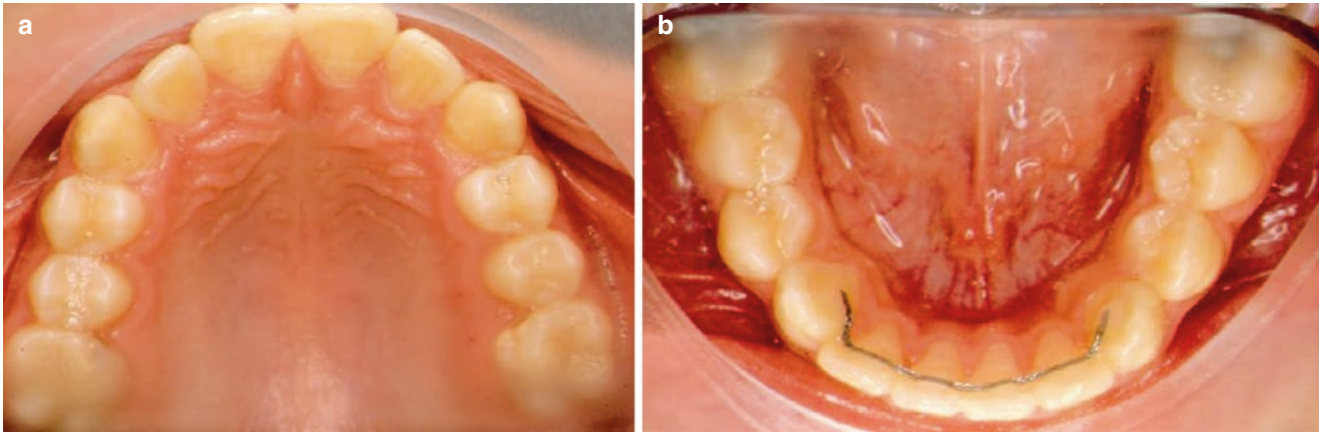


Fig. 4.9 Upper and lower occlusal views 2 years after the end of the treatment

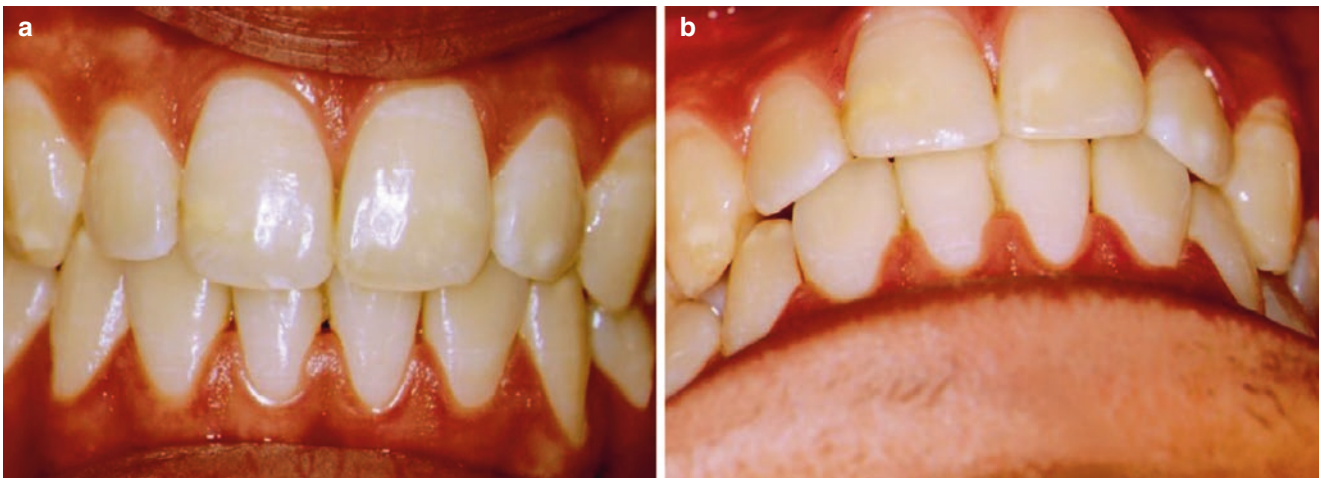


Fig. 4.10 A follow-up 4 years and 9 months later. The results were maintained and the gingival tissues were totally normalized

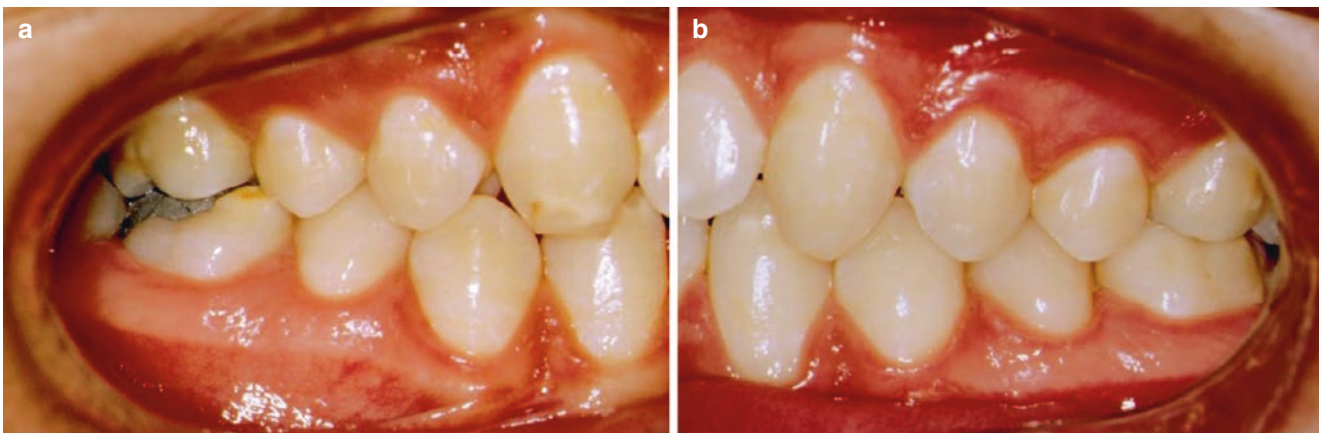


Fig. 4.11 Right and left side occlusion after 4 years and 9 months of active orthodontic treatment

The comparison of the pre- and posttreatment front photographs clearly demonstrates the huge improvement not only of the left central lower incisor gingival position but also of the occlusion plane. Bone recession at the central lower incisor was self-corrected, and no further periodontal treatment was required. The gingival status of the upper and lower incisors is totally normal (Fig. 4.12a, b).

The next case is yet another good example of why it is important to begin treatment early. The second patient was a 9-year and 8-month-old girl who was sent to the office by her pediatric dentist who wanted a second opinion regarding the best time to begin the correction of the palatal position of the upper right central incisor. Her mother was confused by the completely different opinions she received. Some of them recommended waiting for the eruption of the second molars,

another suggested the extraction of the left central lower incisor to improve occlusion, another that the only way was the use of micro-implants, and so on (Fig. 4.13a, b).

In order to lower her mother's anxiety, some similar clinical cases were shown to her and her daughter in order to explain different alternatives of treatment. It was very important that the parents understand the importance of the early correction of the position of the incisors to prevent more dental and periodontal complications in the future.

It is essential that patients and their parents be fully aware that excellent oral hygiene is fundamental to achieve and maintain normal gingivo-periodontal tissues.

It is important to highlight that this patient had diastemas in the upper teeth due a positive discrepancy with an uneven gingival line (Fig. 4.13a, b).

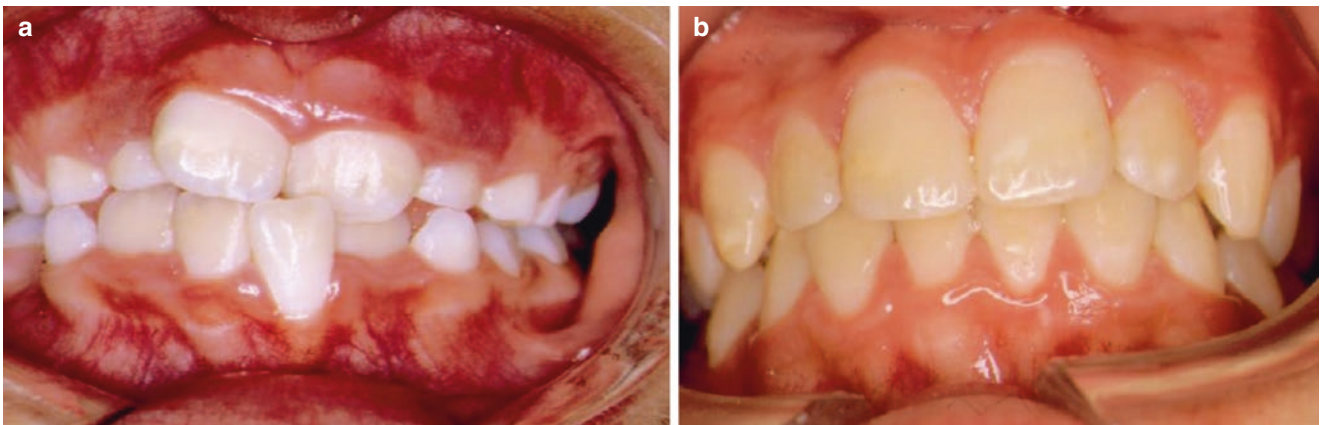


Fig. 4.12 Comparison pre- and posttreatment. Upper and lower midlines and gingival margins are totally normal

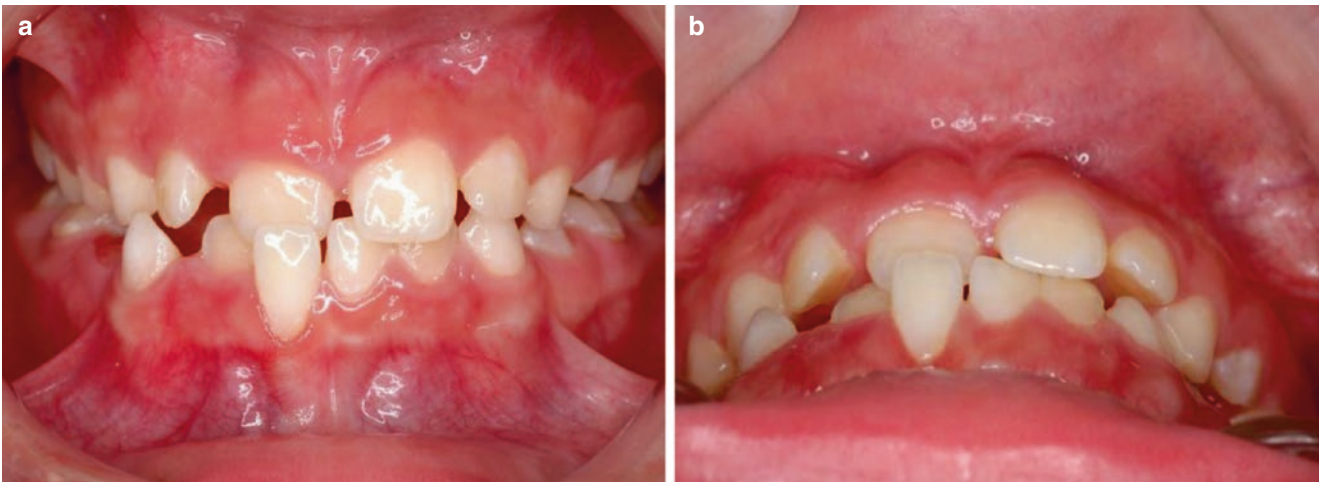


Fig. 4.13 Pretreatment front photographs. The labial position of the central left lower incisor is clearly observed

The lateral views confirmed Class I canine and molar and the excessive proclination of the left central lower incisor. Although she was a very young girl, some loss of periodontal attachment was seen in this area. The upper left central incisor was palatinized and extruded (Fig. 4.14a, b).

The occlusal photographs showed a positive discrepancy of 2.5 mm in the upper arch and +2 mm in the mandible (Fig. 4.15a, b). Oral hygiene was fairly good and no cavities were seen.

After analyzing the models, rx, and photos, the following treatment objectives for the first phase of treatment were:

1. Normalize the position of the right upper and lower central incisor
2. Align and level the arches
3. Maintain Class I canine and molar
4. Improve gingivo-periodontal condition
5. Long-term stability

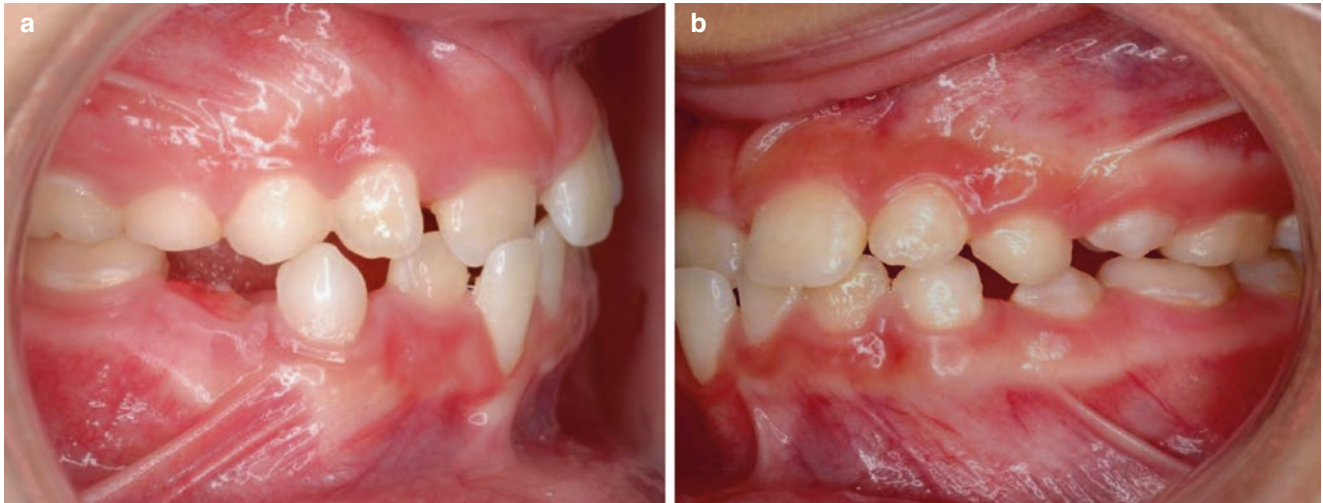


Fig. 4.14 Class I molar along with an excessive labial position of the central left lower incisor was present

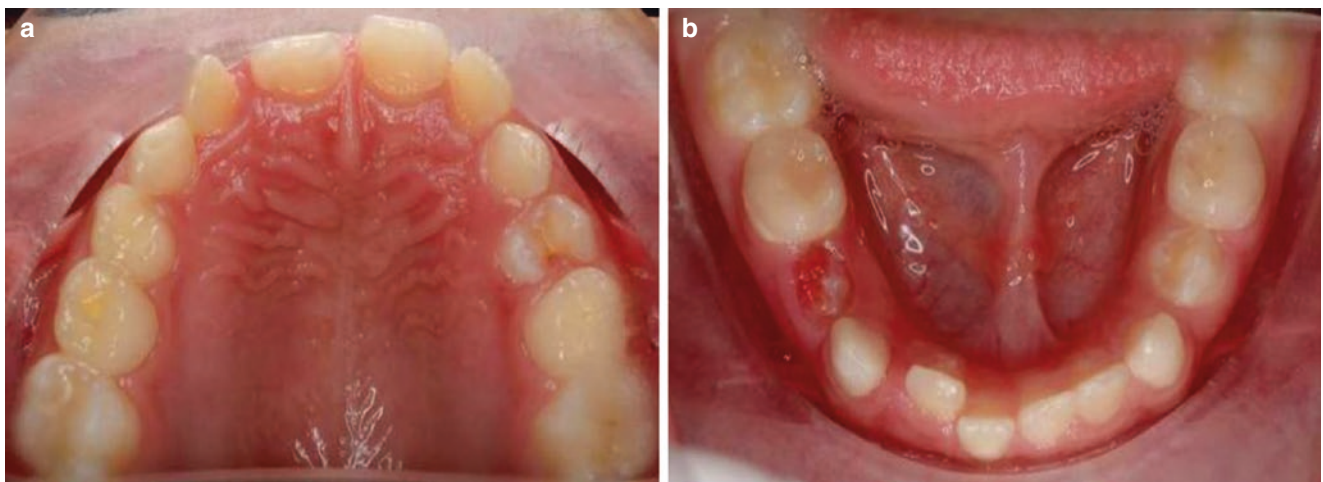


Fig. 4.15 Pretreatment upper and lower arches. The malposition of the lower left central incisor was confirmed

In order to achieve these treatment objectives, 0.022" esthetic preprogrammed brackets were bonded on the upper incisors in conjunction with an SS 0.014" wire and bands on the upper first molars (Fig. 4.16a, b).

The lateral views confirmed the results that were achieved after 5 months of treatment.

Temporary right and left molars maintained their normal position (Fig. 4.17a, b). Oral hygiene was checked regularly.

A figure-of-eight ligature was placed between the central incisors to close the anterior diastema. Overjet and overbite were almost normal and bicuspid were erupting normally (Fig. 4.18a, b).

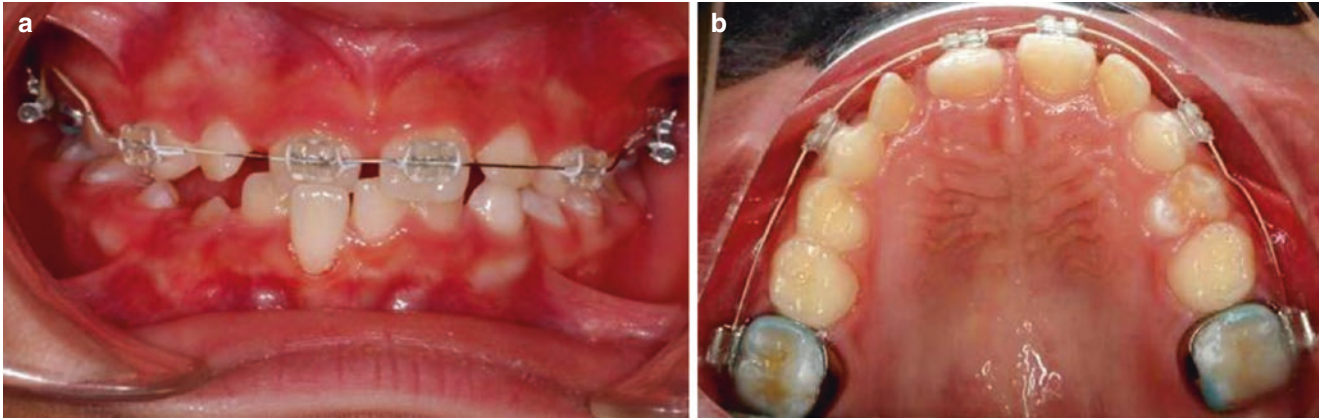


Fig. 4.16 Esthetic preprogrammed brackets with a 0.016" SS wire at the beginning of the treatment

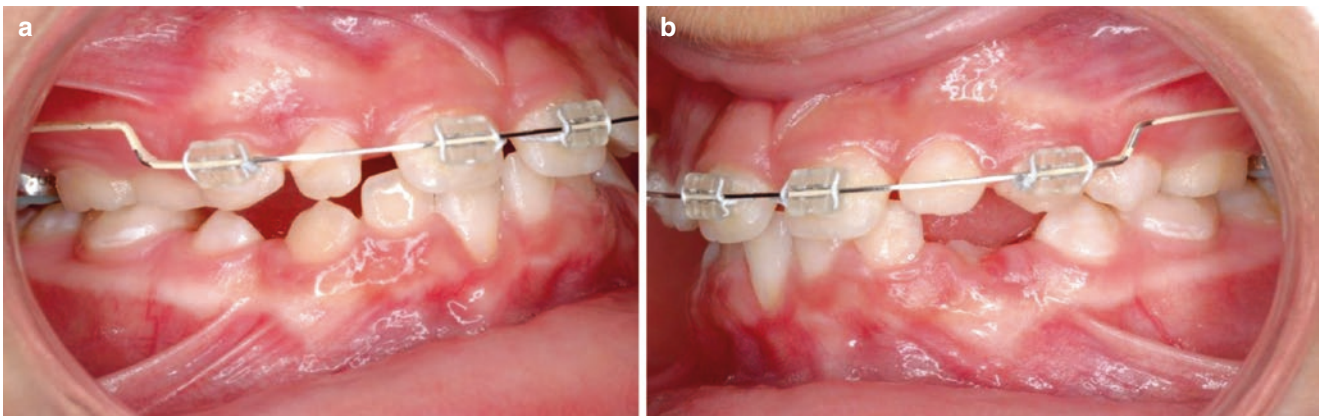


Fig. 4.17 Lateral photographs with a 0.016" SS arch in place

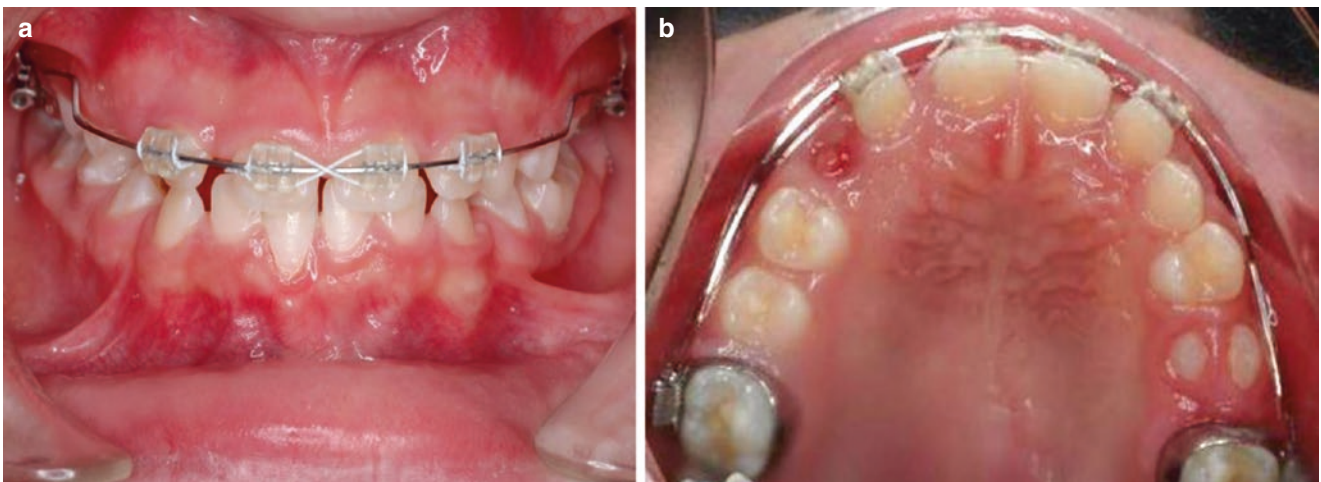


Fig. 4.18 A figure-of-eight ligature was placed between the central incisors to close the anterior diastema

When all the bicuspid and the right canine erupted, a 0.018" SS archwire was used to complete alignment and leveling of the upper arch with an open coil spring to obtain sufficient space for the left canine. A NiTi 0.014" wire as a double arch was suggested to level the canine without alterations of the adjacent teeth (Fig. 4.19a, b).

Esthetic brackets 0.022" slot were also bonded on the lower arch, and a 0.016" SS archwire was placed to correct anterior crowding in the anterior region and rotations in the bicuspid area (Fig. 4.20a, b).

These were the results at the end of the active orthodontic treatment. Midlines were coincident and the gingival line

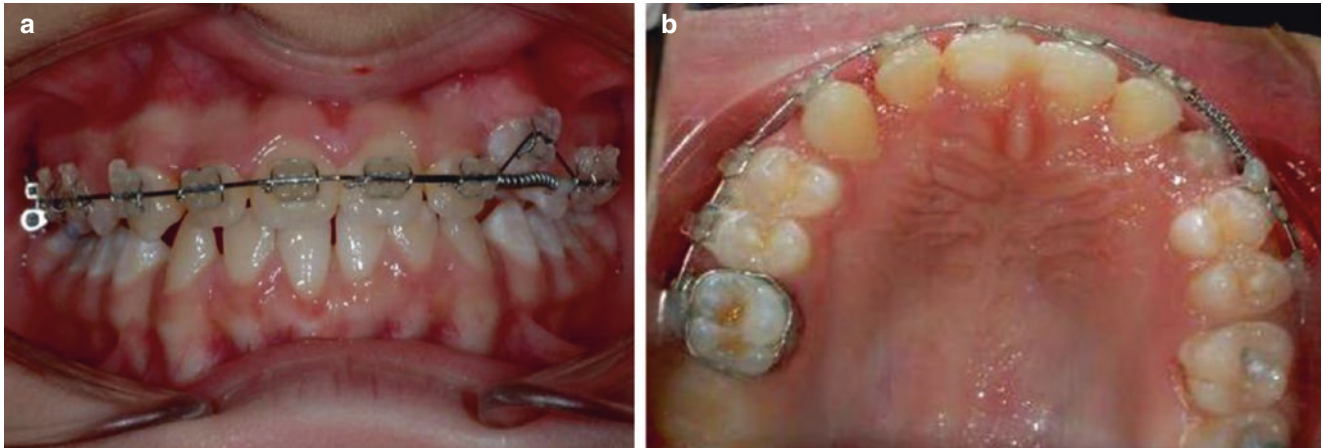


Fig. 4.19 Front and occlusal photos with an open coil spring and a NiTi 0.014" as a double arch

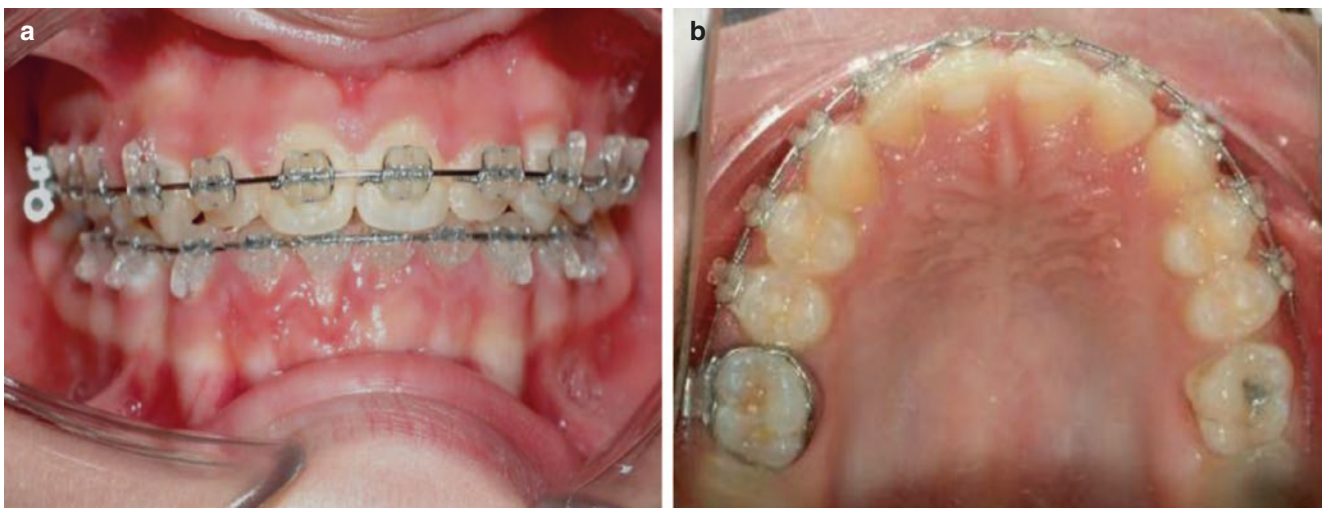


Fig. 4.20 Front and occlusal photographs at this stage of the treatment. The upper left canine was totally erupted

and occlusal plane were parallel. Overjet and overbite were within the normal parameters (Fig. 4.21a, b).

A follow-up 18 months later showed that the results were maintained. Overjet and overbite in the upper and lower central and lateral incisor region were almost normal. The oral hygiene was much better (Fig. 4.22a, b).

The lateral photographs confirmed that Class I canine and molar was maintained. The position of the incisors as well as the gingival recession at the left lower central incisor was improved (Fig. 4.23a, b).

The improvement in the position and inclination of the upper and lower incisors was noticeable. A long-term

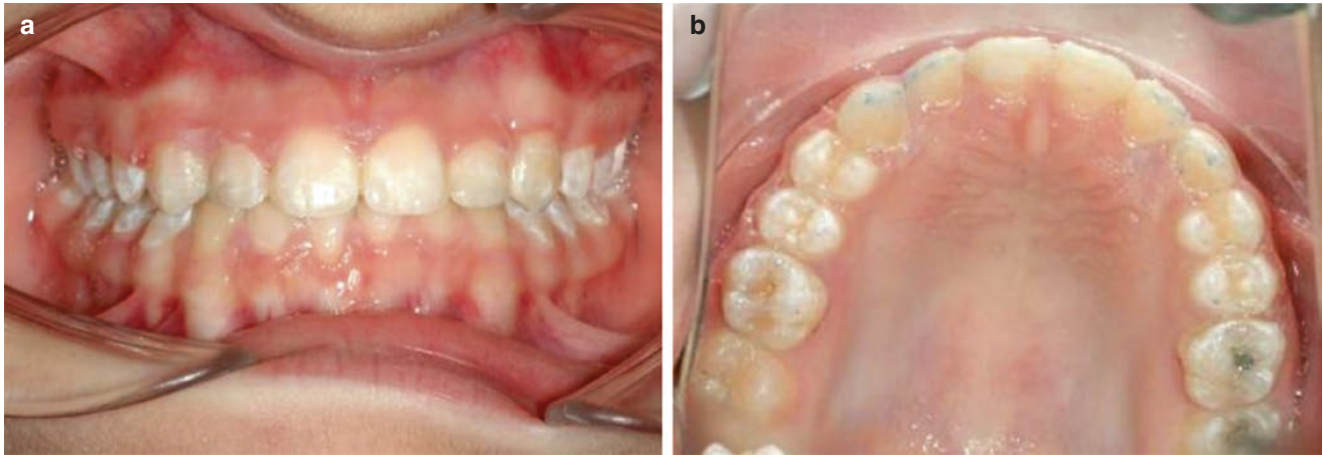


Fig. 4.21 End of the active orthodontic treatment. All the treatment objectives were fulfilled

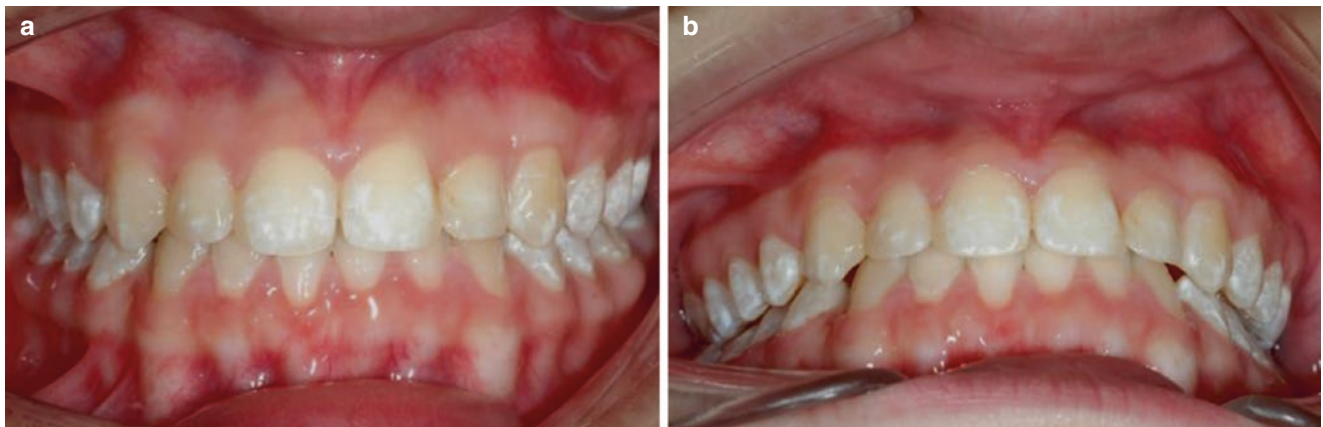


Fig. 4.22 18-month follow-up. The results were maintained and the lower gingival margin continued normal

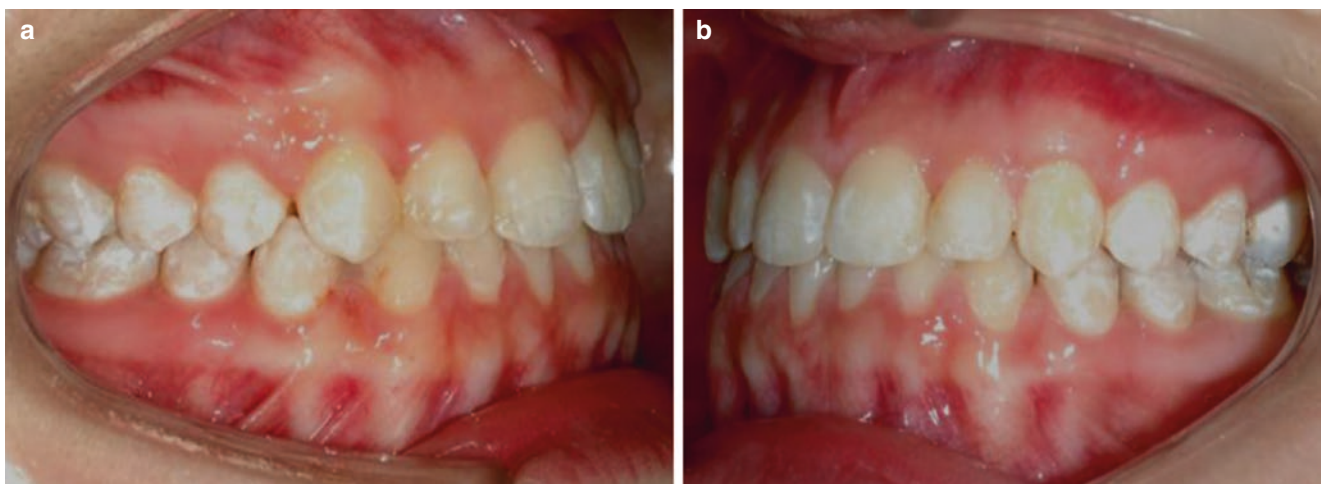


Fig. 4.23 Right and left occlusion 18 months after ending the active treatment. Class I molar and canine was maintained

fixed retention wire on the lower arch was advisable (Fig. 4.24a, b).

The comparison between the pre- and posttreatment with front photographs clearly showed the enhancement of the occlusion in the anterior region. All the treatment objectives were achieved, and the normalization of the gingivo-periodontal tissues was noticeable (Fig. 4.25a, b).

Similar results were achieved in this 9-year-old patient that had the same problem.

The comparison between the pre- and 5 years post-treatment frontal photos was the best example after using

the same treatment protocol without the aid of any surgical procedures. The malposition of the anterior teeth was normalized, and the interincisal papillae were totally recovered. Dental occlusion was significantly improved, and the gold standard was achieved only through the use of orthodontic movements. No signs of relapse were seen in a 5-year follow-up, and the gingival and periodontal tissues were completely normalized (Fig. 4.26a, b).

The normalization of the gingival tissues was remarkable.

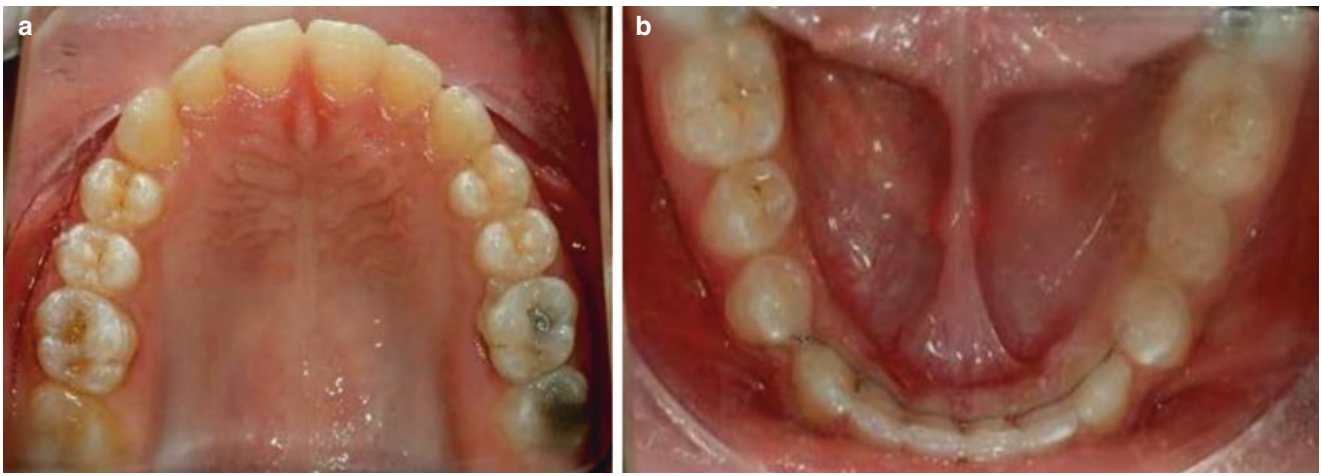


Fig. 4.24 A long-time fixed retention on the arch was recommended

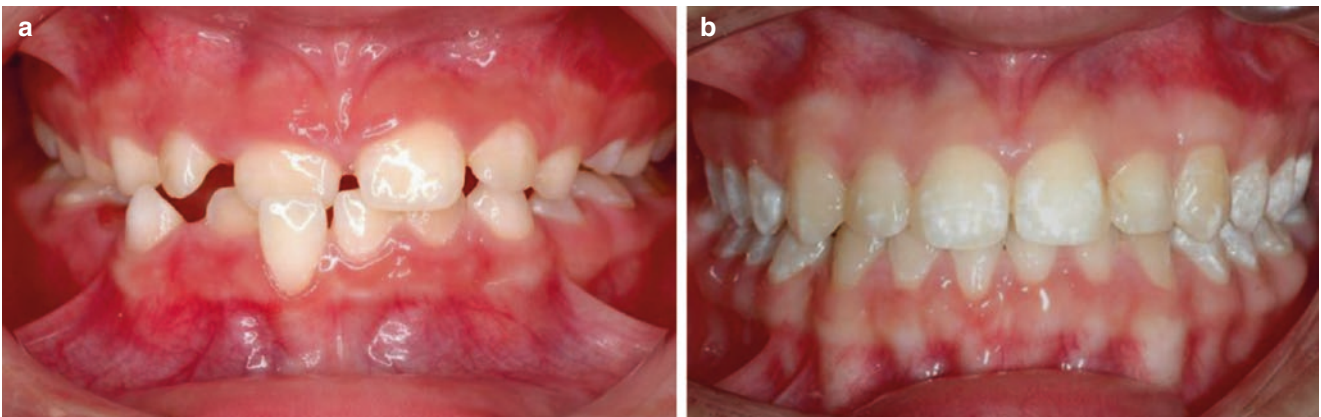


Fig. 4.25 Comparison of pre- and posttreatment front photographs. The improvement of the position of the central incisors and the gingival tissues was clearly visible

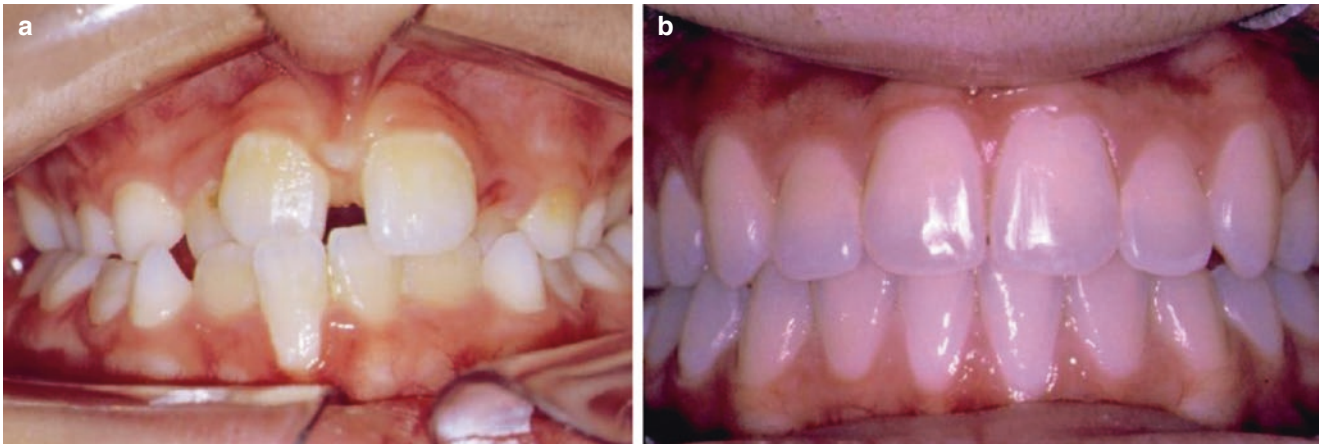


Fig. 4.26 Comparison pre-treatment and 5 years posttreatment frontal photos using a similar protocol

Conclusions

It is well accepted that proclined incisors have a higher incidence of severe labial gingival recession when compared to less proclined ones.

The results showed that significant alterations in the widths of the keratinized and attached gingiva took place when the teeth changed positions in facial or lingual directions (Bimstein and Eidelman 1988).

The clinical cases that were presented in this chapter demonstrated that excellent results can be achieved using fixed orthodontic appliances at early age and in this way reverse the recession process. No reparative surgical procedures are necessary before the orthodontic treatment since the total recovery of the gingival tissues is clearly visible.

It is advisable to normalize the proclination of the lower incisors as soon as possible since the improvement in their position helps the normalization of the gingival tissues.

A multi- and interdisciplinary treatment is the only way to achieve optimal results for long time. There is no doubt that the gold standard is to keep the gingiva as healthy as possible during and after the orthodontic treatment.

Strict plaque control is important to maintain and improve the results that are achieved as gingivo-periodontal inflammation is a very important detrimental factor that causes irreversible loss of periodontal attachment.

Special attention should be given to the zone of attached gingiva and its relationship with the proclination of the lower incisors since it could be an etiologic factor in the development of mucogingival recessions in this area.

There is no doubt about treatment efficiency (result vs treatment time), and the long-term results confirm this approach.

Bibliography

- Ainamo J, Paloheimo L, Nordblad A, Murtomaa H. Gingival recession in school children at 7, 12 and 17 years of age in Espoo, Finland. *Community Dent Oral Epidemiol.* 1986;14:283–6.
- Albandar JM, Rams TE. Risk factors for periodontitis in children and young persons. *Periodontol 2000.* 2001;29:207–22.
- Andlin-Sobocki A, Marcusson A, Persson M. 3-year observations on gingival recession in mandibular incisors in children. *J Clin Periodontol.* 1991;18:155–9.
- Armitage GC. Clinical evaluation of periodontal diseases. *Periodontol 2000.* 1995;7:39–53.
- Bimstein E, Eidelman E. Morphological changes in the attached and keratinized gingiva and gingival sulcus in the mixed dentition period. A 5-year longitudinal study. *J Clin Periodontol.* 1988;5:175–9.
- Kassab MM, Cohen RE. The etiology and prevalence of gingival recession. *JADA.* 2003;134:220–5.
- Ngan PW, Burch JG, Wei SH. Graft and ungrafted labial gingival recession in pediatric orthodontic patients: effects of retraction and inflammation. *Quintessence Int.* 1991;22:103–11.
- Parfitt GJ, Mjör IA. A clinical evaluation of local gingival recession in children. *J Dent Child.* 1964;31:257–62.
- Renkema AM, Fudales PS, Renkema A, Bronhorst E, Katsaros C. Gingival recessions and the change of inclination of mandibular incisors during orthodontic treatment. *Eur J Orthod.* 2013;35:249–55.
- Seehra J, Fleming P, DiBiase AT. Orthodontic treatment of localized gingival recession associated with traumatic anterior crossbite. *Aust Orthod J.* 2009;25:76–81.
- Song HJ. Periodontal considerations for children. *Dent Clin N Am.* 2013;57:17–37.
- Vasconcelos G, Kjellsen K, Preus H, Vandevska-Radunovic V, Hansen BF. Prevalence and severity of vestibular recession in mandibular incisors after orthodontic treatment. *Angle Orthod.* 2012; 82:42–7.

Maria Florencia Mana

The aim of this chapter is to describe all the causes that affect the normal eruption of maxillary central incisors.

Parents and children are worried since the position of the upper incisors affects not only the esthetic of the smile but also the function. There is no doubt that it has to be corrected as soon as possible. Early correction is always more reliable and produces less relapse.

Tooth rotations are described as any displacement of at least 20° or more (60°, 90°, even 180°) of the tooth with respect to its longitudinal axis (Parisay and Boskabady 2014).

The prevalence of tooth rotations is 2.1–5.1% (Parisay and Boskabady 2014).

There are numerous variables that influence occlusal development and tooth alignment. It was demonstrated that 40% of upper central incisors erupt rotated at least 25°, and 90% of the rotations were observed in the first 2 years of eruption (Jahanbin et al. 2010).

To make a correct diagnosis, it is very important to know what predisposing factors are producing that malocclusion. Different causes that produce a tooth rotation will be mentioned below.

Rotations are divided in two groups based on etiologic factors, rotations produced before tooth eruption and after tooth eruption.

Preeruptive rotations are caused in most cases by injuries or traumas in the premaxilla during childhood. This factor can cause a displacement and changes in alignment of the tooth germ. The presence of any kind of pathology such as a cyst, a tumor, an odontoma, or a supernumerary tooth can interfere in the eruption (Kim et al. 1961; Suresh et al. 2015).

On the other hand, the main cause that produces dental rotation after eruption is related to available space; rotations most often occur in a dental arch with crowding but can also appear in cases with space excess (Kim; Baccetti 1998). Another major cause is the path of tooth eruption; an improper way may interfere with tooth alignment. Finally certain habits, performed by the patient, such as interposing objects or biting nails, can produce dental rotations.

It is important to know when the ideal timing to treat any kind of malocclusion is. The American Orthodontic Association recommends that all kids should visit an orthodontist at the age of 7 for early diagnosis and in this way prevent major difficulties and best control during the growth period.

It is considered ideal to start the first phase of treatment during early mixed dentition, more specifically when the upper central incisors start to erupt (Suresh et al. 2015).

This early intervention will decrease the need of a complex treatment later, avoiding in some cases tooth extraction.

It has been proven that the best time to treat upper central incisor rotation is when it is diagnosed, specifically when incisors start erupting.

Rotated upper central incisor treatment can be done in many ways. The two most common options are using fixed or removable appliances.

After evaluating different alternatives, it was proven that the best one is through fixed appliances. The advantage of this method is that treatment effectiveness will not depend on patient behavior. This system works 24 h a day, so it will decrease treatment time, with more controlled results making it ideal for children as it will be demonstrated.

A series of cases will be described to diagnose this kind of malocclusion and to identify what the best treatment plan is.

The following patient was 7 years old in her first visit. The upper right central incisor was rotated, and an anterior crossbite was present (Fig. 5.1a, b).

M.F. Mana, DDS
Department of Orthodontics, Maimonides University,
Buenos Aires, Argentina
e-mail: florenciamana@gmail.com

Lack of space in the upper dental arch could cause tooth rotation of upper right central incisor and upper left lateral incisor as it was observed. There was atresia of the maxilla in the anterior area that increases the anterior crowding. After careful clinical observation, x-ray examination, and cast study, the use of a fixed appliance was chosen to treat this patient.

Metal preprogrammed brackets (0.022" slot) were placed to start with the alignment and create the necessary space for the right central and upper left lateral incisor. To control anchorage, bands on the temporary upper secondary molars were bonded. A 0.016" NiTi archwire was used with NiTi open coil springs that were mildly activated to gain space and correct the anterior crossbite (Fig. 5.2a, b).

Two months later, the space was achieved for the right central incisor, and a bracket was bonded to start alignment. A NiTi 0.014" arch with mild activated NiTi coil spring was placed to help the development of the upper arch (Fig. 5.3a, b).

After 4 months, the improvement was clearly evident. Overjet and overbite were almost normal. After the alignment was almost completed, the interincisal diastema was closed with a stainless steel ligature along with a SS 0.18" arch and a mild elastomeric chain (Fig. 5.4a, b). A 4 weeks' appointment control was suggested.

After 20 months, the first phase of treatment was finished. The occlusal views confirmed the results that were obtained. No fixed retention wire was bonded until now. A Hawley retainer was given to the patient for a long-term period. Follow-up was recommended every 6 months (Fig. 5.5a, b).

All the treatment objectives were fulfilled in a short period of time (20 months). The parents and the patient recognized the benefits of the early treatment and are aware that a second phase of treatment would be possible. The efficacy of this protocol is interesting to take into account since it reduced the complications if an only phase of treatment during the permanent dentition was decided.

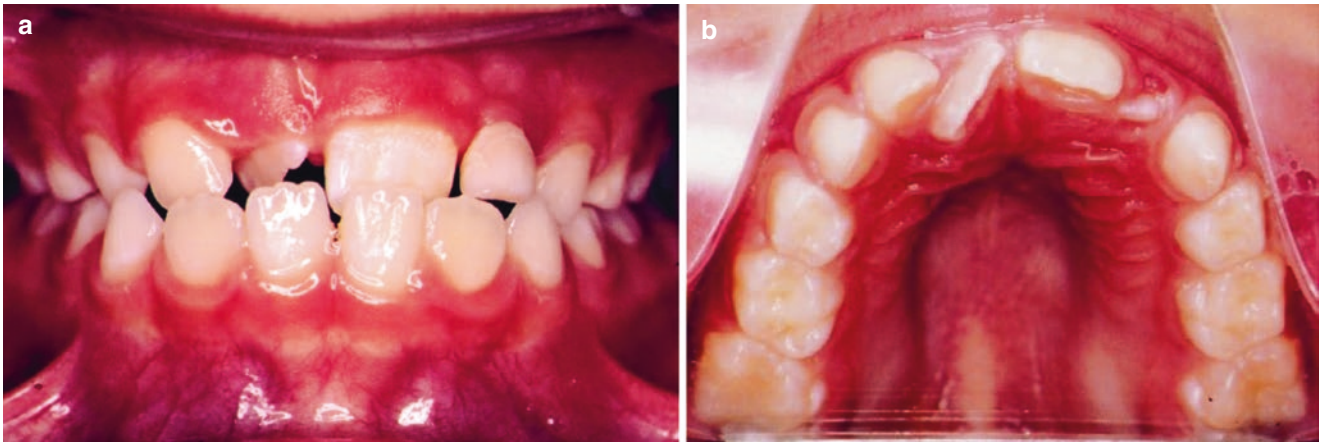


Fig. 5.1 (a) Pretreatment photographs frontal view of upper right central incisor rotated. (b) Occlusal pretreatment view of the arch

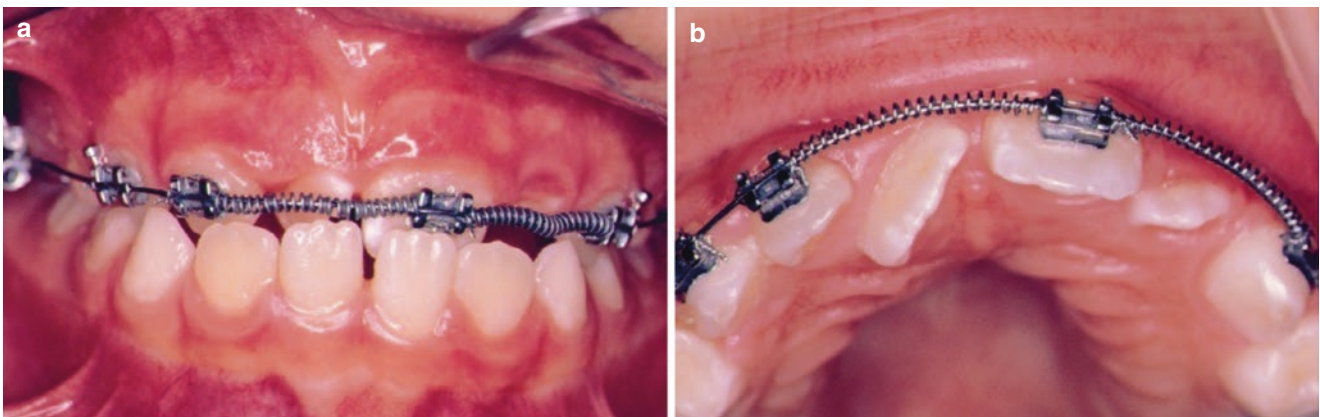


Fig. 5.2 (a, b) Frontal and occlusal view with fixed appliances in place (slot 0.022") along with an active open coil spring to recover the anterior space and correct crossbite

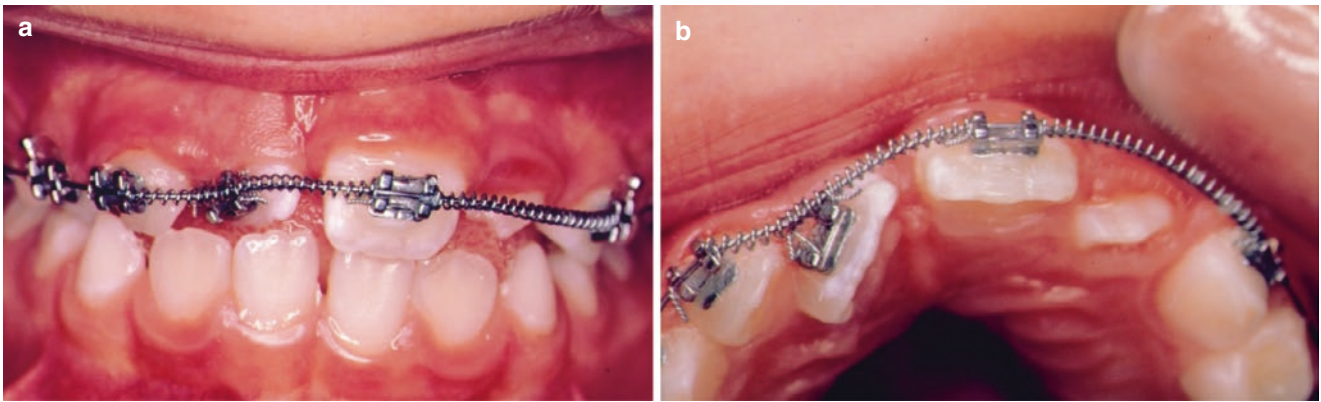


Fig. 5.3 (a, b) After the space for the central incisor was recovered, a bracket was bonded to begin the correction of its malposition

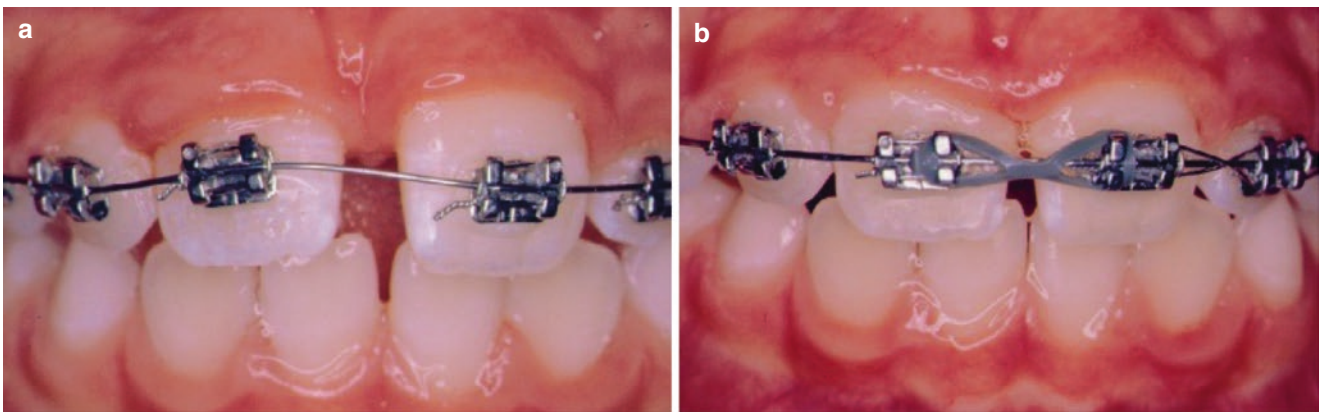


Fig. 5.4 (a) Four months after bonding, upper central incisor was almost aligned. (b) The diastema was closed and midlines were coincident

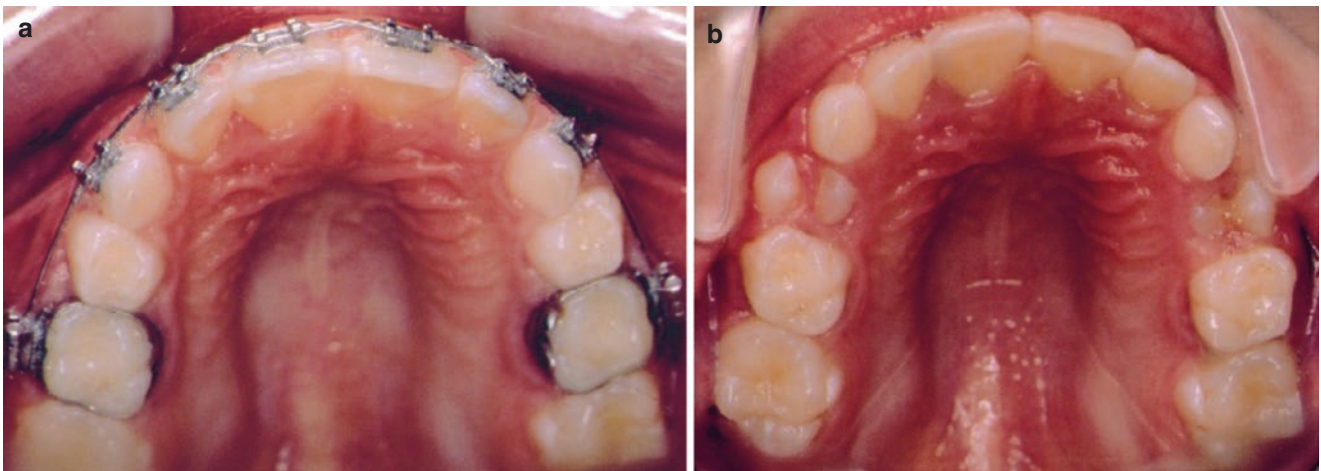


Fig. 5.5 (a) Occlusal view before debonding. (b) Posttreatment view 20 months later, after debonding

The following case is a 9-year-old girl, with a 90° rotation of the upper left central incisor. In the picture below, sufficient space can be observed compared to the tooth size (Fig. 5.6a, b).

After analyzing x-rays, a supernumerary tooth was observed between the upper central incisors. Before orthodontic treatment started, the patient was sent to a dental surgeon to perform the supernumerary tooth extraction (Fig. 5.7a).

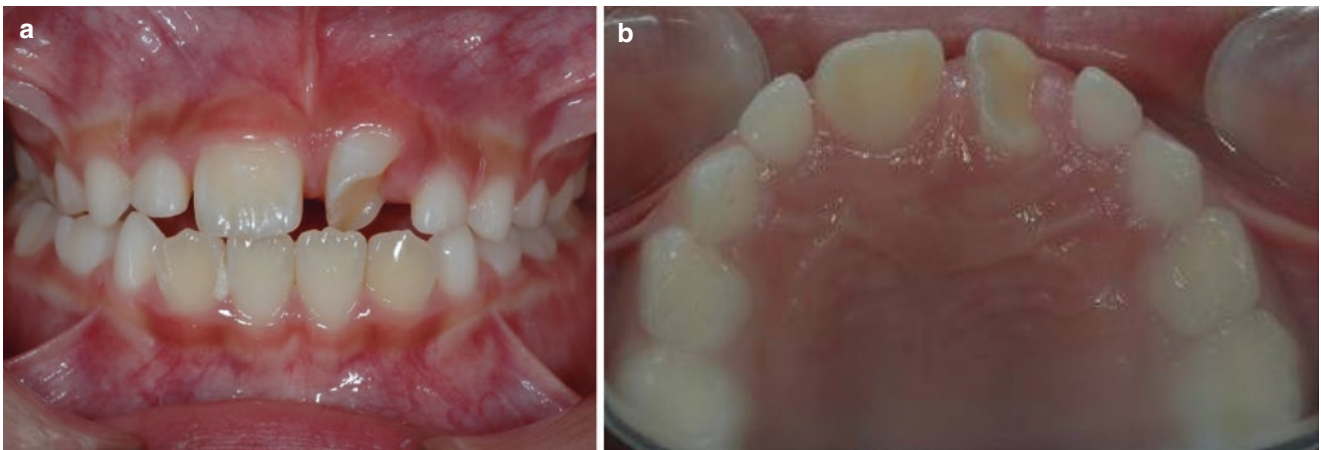


Fig. 5.6 (a, b) Pretreatment frontal and occlusal views. Upper left central incisor was rotated 90°

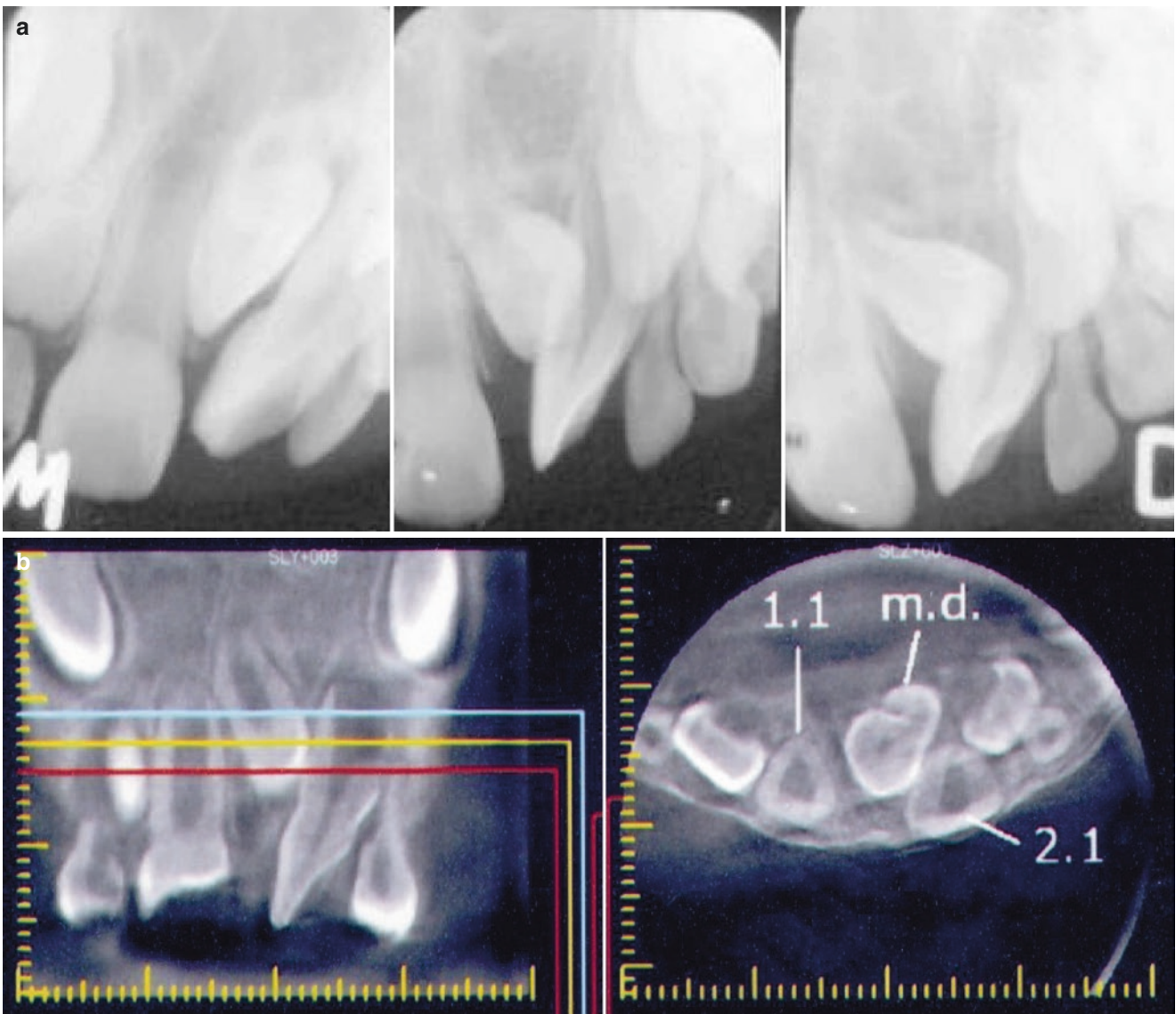


Fig. 5.7 (a) Periapical radiographs indicated the presence of a mesiodens. (b) Digital tomography confirmed the presence of a mesiodens between the central incisors

Brackets were bonded on both upper central incisors and upper temporary left canine along with two bands on temporary second molars with a 0.014" stainless steel arch. The bracket was bonded on the distal face of the incisor to start derotation (Fig. 5.8a, b).

After few months, the position of the tooth started to normalize, so the bracket was rebonded near the FA point (Fig. 5.9a, b).

Two months later, the brackets had to be rebonded again, and a SS rectangular wire (Fig. 5.10a, b) was placed to achieve the correct inclination and torque along with another NiTi coil spring to improve overjet and overbite.

Seven months later, the position of the central left upper incisor was normalized. Orthodontic treatment continued until the alignment was completed. To avoid the possibility of relapse, and decrease the possibility of a second treatment, a fixed retainer 0.017" coaxial arch wire was bonded (Fig. 5.11a, b). Follow-up was recommended every 6 months.

The patient returned 9 months after debonding with the retainer that had broken (Fig. 5.12a, b). Frontal and occlusal photographs confirmed that the results were maintained. The

position and inclination of the upper central incisor was the same. A new retention wire was suggested.

The next patient was 7 years old at the moment the picture was taken. It was a patient with mixed dentition and a 90° rotation of the upper right central incisor. The treatment was planned to begin as soon as possible to regularize tooth position and create space to the upper lateral incisors to erupt (Fig. 5.13a, b).

No supernumerary teeth or agenesis was observed in the panoramic radiograph (Fig. 5.14).

After a careful analysis, fixed appliances were chosen to treat this case. Two preprogrammed 0.022" brackets were bonded on the central incisors and right and left molar bands to start with the alignment of both central incisors with a 0.014" NiTi arch (Fig. 5.15a, b).

Four months later, the position of the right central incisor was almost normal, but the right upper lateral incisor erupted labially in consequence of the lack of space.

It is evident how both central incisors were aligned and the interincisal diastema was closed in 7 months. A labial bend was made in the arch to let the lateral incisor erupt (Fig. 5.16a, b). The individualized labial arch bend can be observed in frontal view with a figure of eight to close the

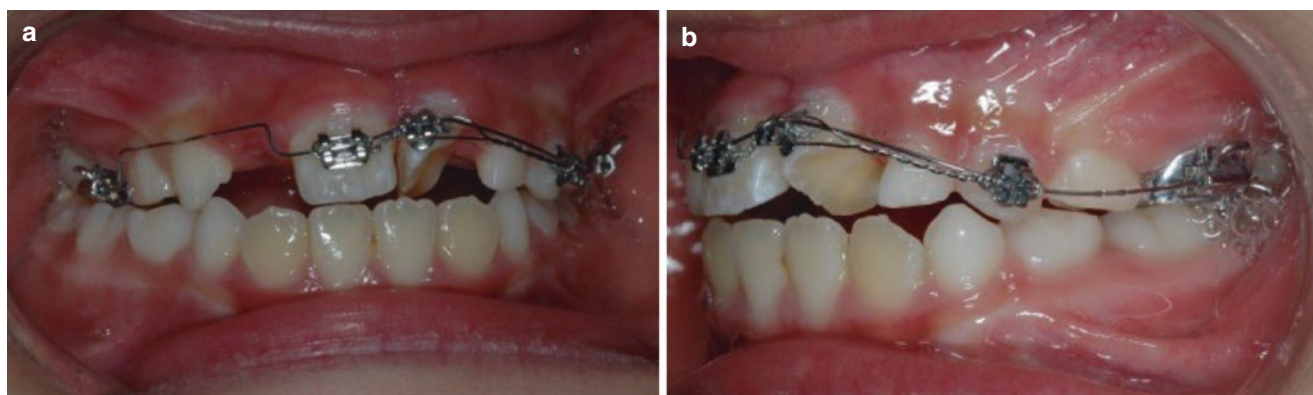


Fig. 5.8 (a, b) Frontal and lateral view of the left central incisor with a bracket bonded on distal face of the left central incisor

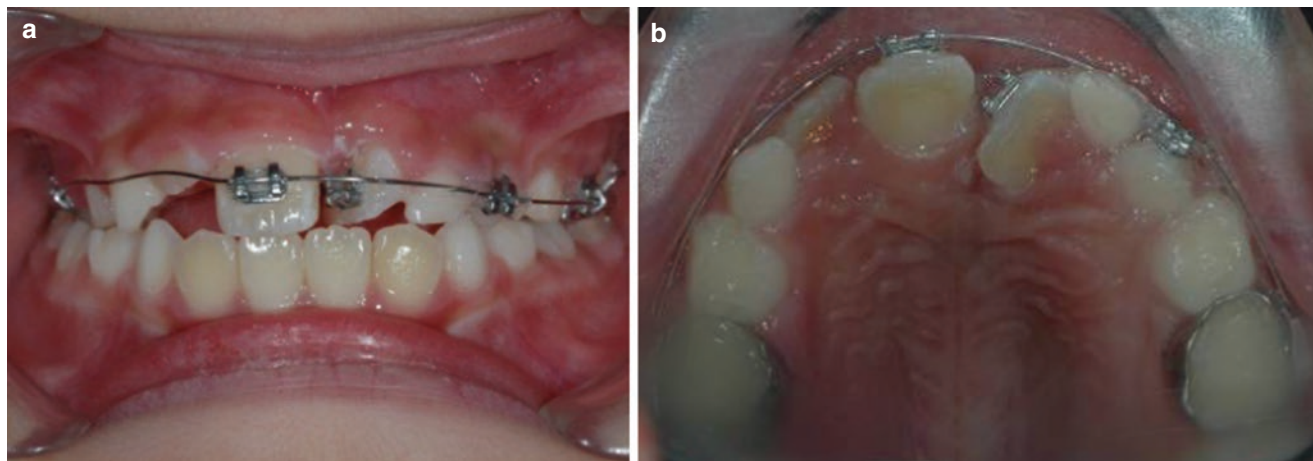


Fig. 5.9 (a, b) The bracket on the upper left central incisor was rebonded near the FA point

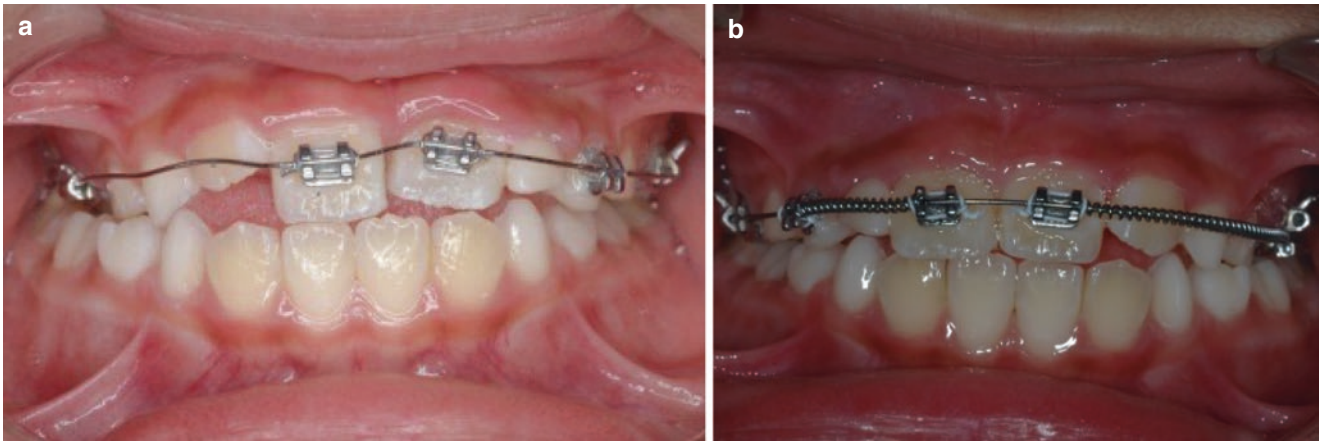


Fig. 5.10 (a, b) Bracket was rebonded to complete alignment and leveling with a bilateral NiTi coil spring to normalize overjet and overbite

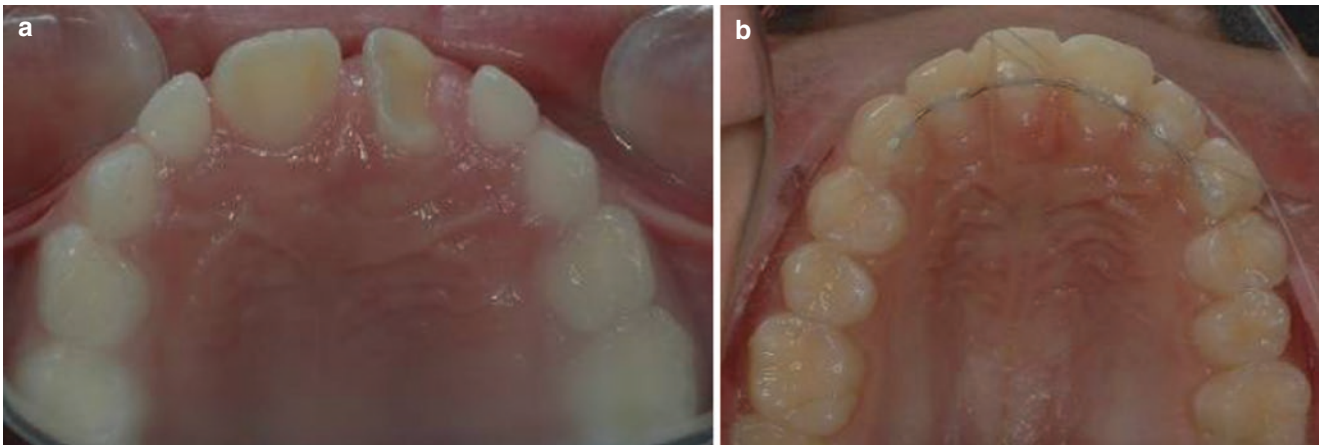


Fig. 5.11 (a, b) Comparison of the occlusal upper arch pre- and posttreatment. The normalization of the left upper central incisor was maintained

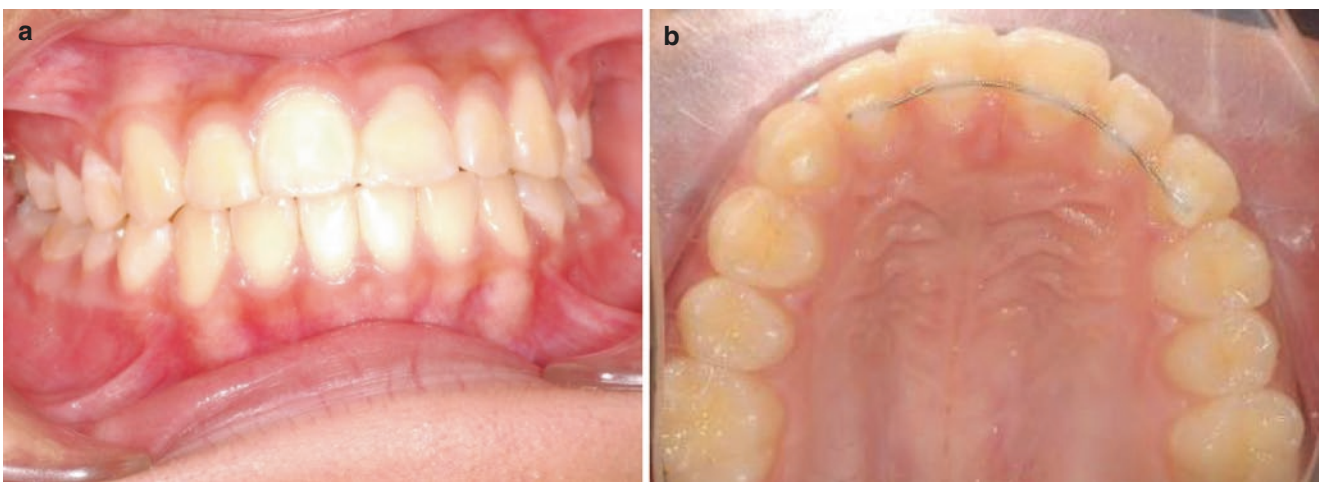


Fig. 5.12 (a, b) A control 9 months after debonding with retention wire broken. It can be observed that the position of the incisor is still correct

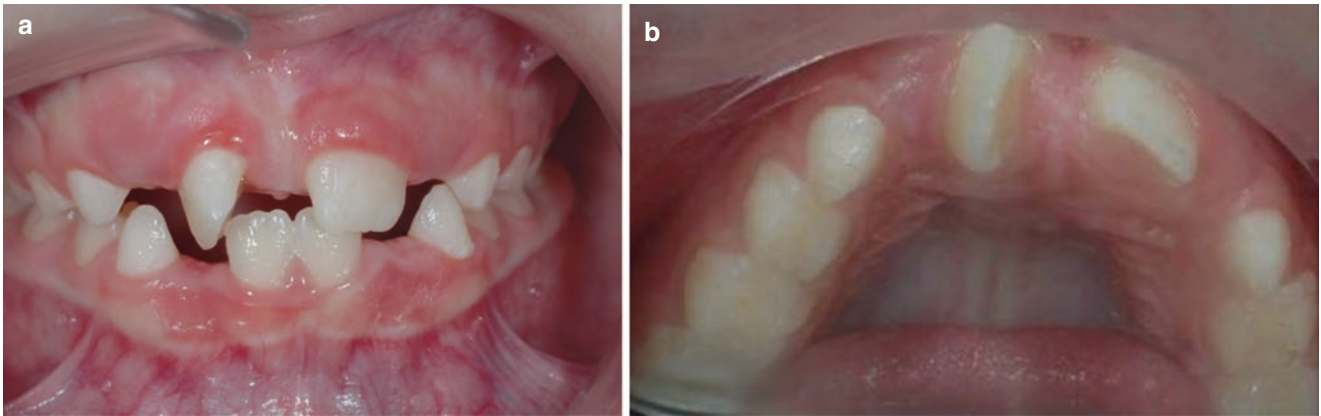


Fig. 5.13 (a, b) Pretreatment frontal and occlusal view. The malposition of the right central incisor was clearly visible and the lack of available space to let the lateral incisor erupt

Fig. 5.14 Panoramic radiograph, no supernumeraries or agenesis was observed

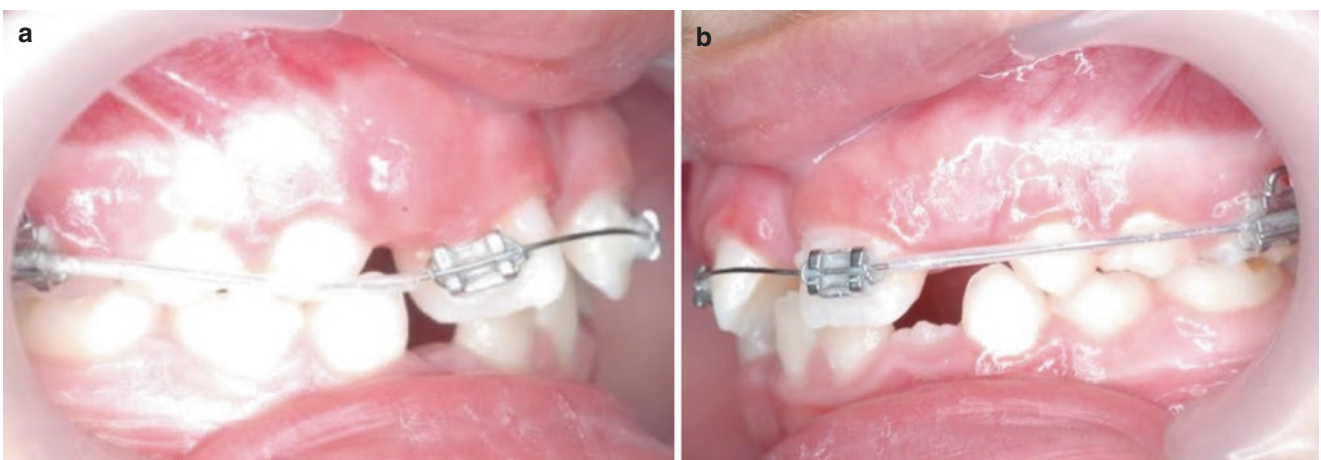
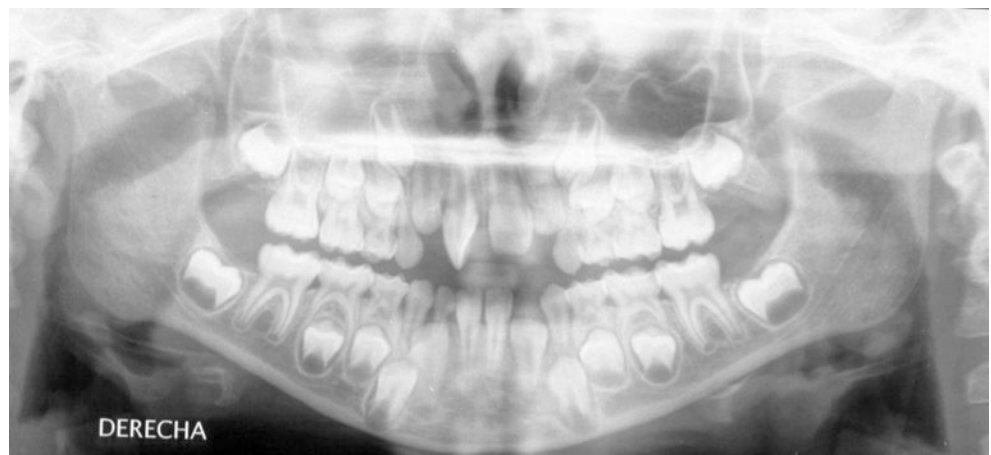

Fig. 5.15 (a, b) Fixed appliances were bonded with a 0.014" NiTi arch and plastic spaghetti to prevent mucosal lesions

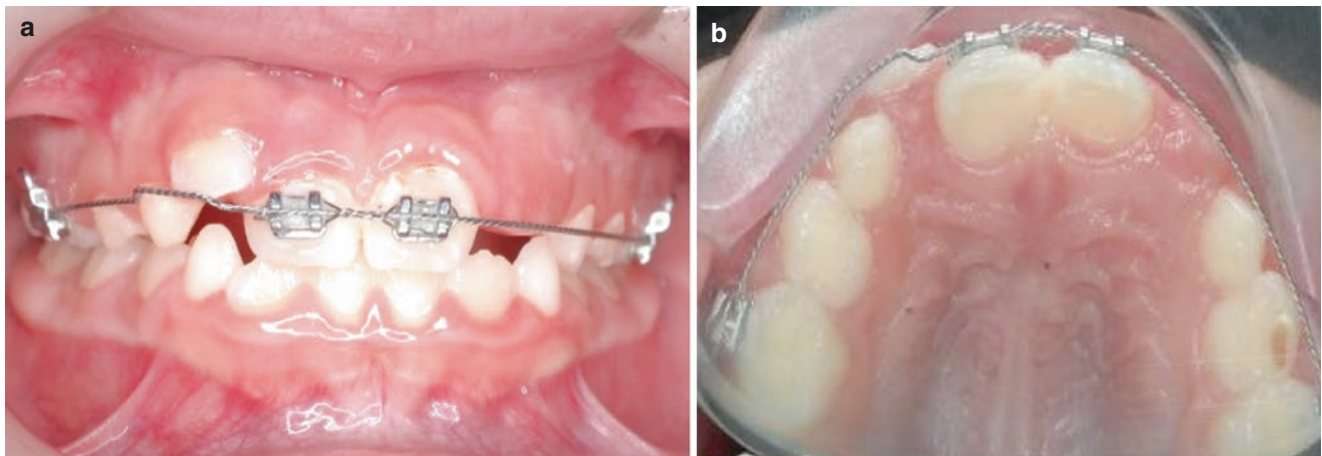


Fig. 5.16 (a, b) Frontal and occlusal view after closing the inter-incisal diastema with an individualized bend to allow the normal eruption of the upper right lateral incisor

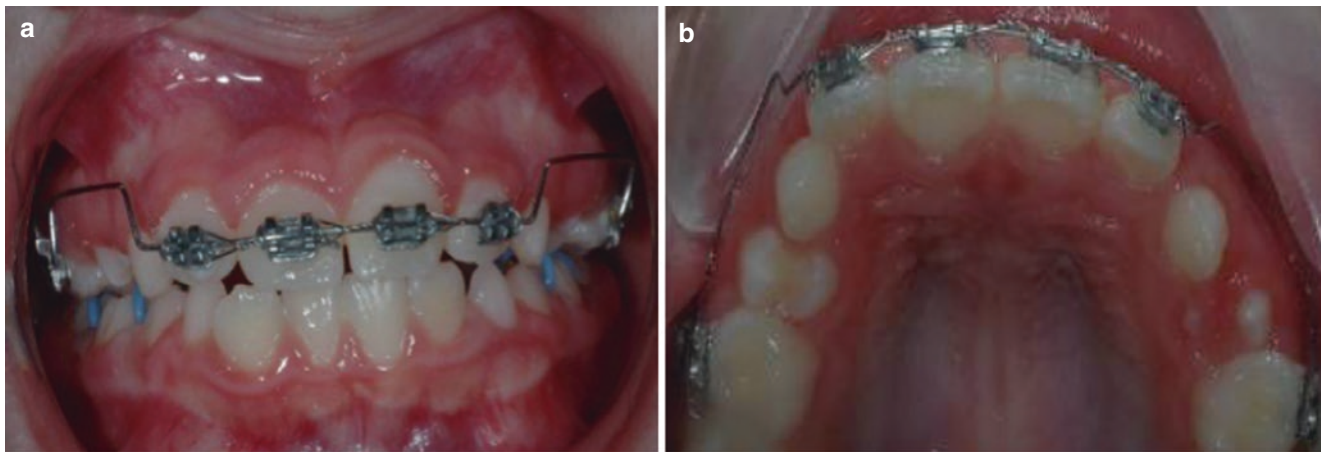


Fig. 5.17 (a, b) A utility arch (Elgiloy 0.016" × 0.016") was placed to normalize overjet and overbite

diastema. The occlusal view confirmed the labial bend to let the lateral right incisor erupt in its normal position.

After the right and left lateral incisor erupted, brackets were bonded along with a utility arch (Elgiloy 0.016" × 0.016") (Fig. 5.17a, b).

Eighteen months later, the brackets were debonded. The comparison between pre- and posttreatment confirmed the results that were achieved. A Hawley retainer was given to this patient, and long-term follow-up was recommended every 6 months (Fig. 5.18a, b).

Patient returned 53 months later, final results were maintained and even improved. All the cuspids and bicuspid were erupted in their normal position without any orthodontic treatment (Fig. 5.19a, b).

The relapse of orthodontically rotated teeth is one of the biggest concerns. It was demonstrated that upper central incisors have a high tendency to relapse once the treatment is

finished. Recurrence of rotations is higher in cases treated with rapid movements.

It was proven that the main cause of this relapse is because of the contraction produced by periodontal fibers and supra-crestal structures that were displaced by orthodontics. Early correction of tooth rotation will produce a new bunch of fibers in the apical zone that will prevent the relapse after treatment (Reitan 1959).

The most popular types of retentions are fixed, Hawley, and vacuum retainers. In interceptive orthodontics some retainers, such as vacuum, are not recommended because it can alter normal tooth eruption.

It has been proven that fixed retainers are reliable to avoid tooth relapse; they keep tooth position, but it will depend on patient cooperation. One of the fears of fixed retainers is the accumulation of plaque; however, it was proven that in most of the cases it doesn't produce periodontal problems or tooth decay.

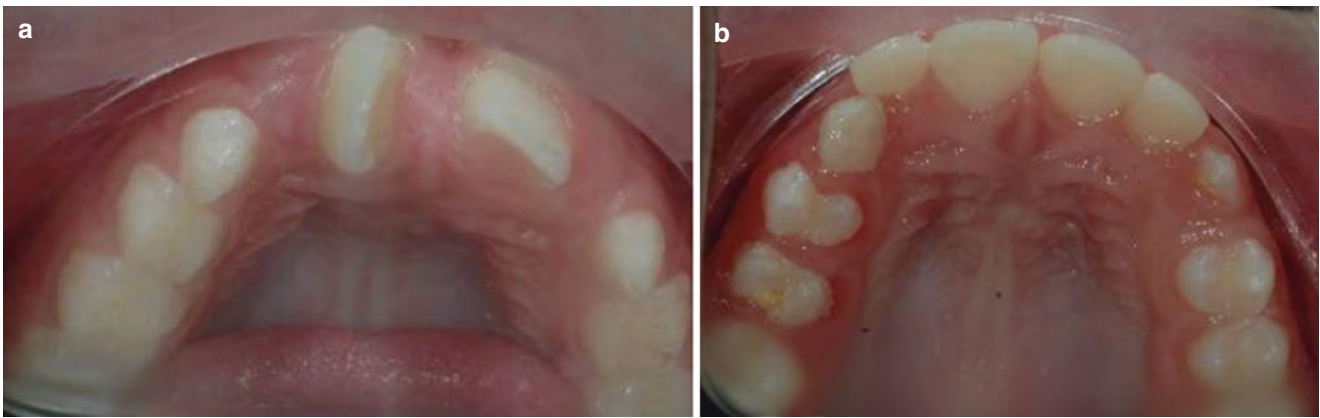


Fig. 5.18 (a, b) Comparison occlusal view pre- and posttreatment

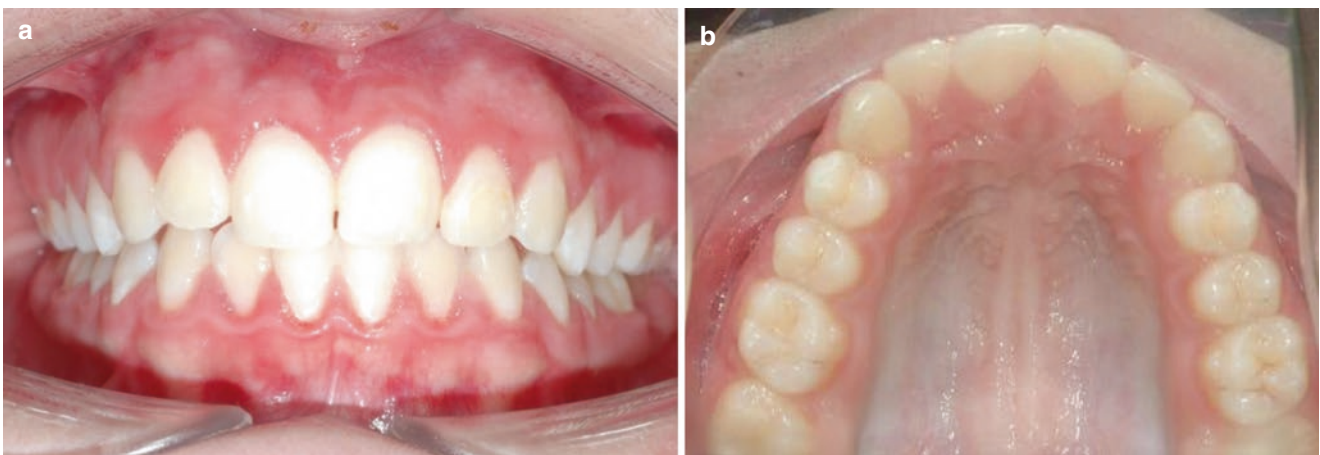


Fig. 5.19 (a, b) Posttreatment control 53 months after debonding

The predisposing factors to failure of fixed retainers are quality and width of the wire, composite type used, clinical management of adherence, and occlusal trauma produced in the arch (Schneider and Sabine 2011).

Conclusions

The most challenging and difficult task in our profession is to recognize the patient's problem and have the knowledge to perform a correct diagnosis of a specific pathology knowing when the ideal timing to treat each malocclusion is.

After analyzing this chapter and studying each case in profound, it was demonstrated that rotation of central maxillary incisor should be treated in the exact moment it is diagnosed. As it was mentioned, early treatment will decrease relapse and prevent future inconveniences. The relation cost/benefit is important in the moment to decide the best mechanotherapy for each patient.

There are many protocols to achieve the same result. The use of fixed appliances was decided bearing in mind

the importance to reduce the first phase of treatment and make it more comfortable and controlled for the patient.

It is considered very significant to decrease the time of a first phase of treatment to achieve the best results with the least cost possible.

Bibliography

- Baccetti T. *Tooth rotation* associated with aplasia of non adjacent teeth. *Angle Orthod.* 1998;68:471–4.
- Jahanbin A, Baghahi B, Parisay I. Correction of a severely rotated maxillary central incisor with the whip device. *Saudi Dent J.* 2010;22:41–4.
- Kim YH, Shiere FR, Fogels HR. Pre-eruptive factors of tooth rotation and axial inclination. *J Dent Res.* 1961;40:548–57.
- Parisay I, Boskabady M. Treatment of severe rotations of maxillary central incisors with whip appliance: report of three cases. *Dent Res J (Isfahan).* 2014;11(1):133–9.
- Reitan K. Tissue rearrangement during retention of orthodontically rotated teeth. *Angle Orthod.* 1959;29(2):105–13.

- Schneider E, Sabine R. Upper bonded retainers. *Angle Orthod.* 2011;81(6):1050–6.
- Sanin C, Hixon EH. Axial rotations of maxillary permanent incisors. *Angle Orthod.* 1968;38(4):269–83.
- Suresh M, Ratnaditya A, Kattimani VS, Karpe S. One phase versus two phase treatment in mixed dentition: a critical review. *J Int Oral Health.* 2015;7(8):144–7.
- Swanson WD, Riedel RA, D'Anna JA. Post-retention study: incidence and stability of rotated teeth in humans. *Angle Orthod.* 1975;45:198–203.
- Tsung-Ju H, Pinskaya Y, Roberts E. Assessment of orthodontic treatment outcomes: early treatment versus late treatment. *Angle Orthod.* 2009;75(2):162–17.
- Vermeulen FM, Aartman IH, Kuitert R, Zentner A. The reliability of assessing rotation of teeth on photographed study casts. *Angle Orthod.* 2012;82:1033–9.

Julia Harfin

According to the literature about impacted central incisors, the prevalence is less than 1% (Machado et al. 2015); however, for the patient, it is quite disturbing from an esthetic and functional point of view.

Normally, the upper incisors erupt between 6 and 10 years of age. However, when a lateral incisor erupts before the central incisor, impaction of the central incisor could be a result (Kuroi 2002).

Tooth impaction may result as a consequence of different conditions such as mesiodens, supernumerary teeth, ectopic position of the tooth bud, odontoma, cysts, local tumor, scar tissue, lack of space ankylosis of the primary teeth, trauma on the deciduous incisors, loss of or inadequate space, delayed resorption of the primary roots, etc.

Trauma in primary dentition, especially traumatic incisor intrusion, may result in the crown or root dilaceration of the developing permanent incisors (Uematsu et al. 2003) (Fig. 6.1a, b) as was shown in the following radiographs. The consequence will depend on the stage of development of the root at the moment of the trauma. The angulation between the crown and the root will determine the prognosis of the result. In general, pulp vitality is preserved but in some cases necrosis is the consequence.

Traumatic intrusion is a dental injury that involves the upper anterior teeth and is often associated with a comminution or fracture of the alveolar bone (Turley et al. 1984).

Some accidents during early childhood can have consequences due to the proximity to the temporary incisor roots on the permanent teeth.

An early diagnosis is very important for the clinician, for the parents, and, above all, for the patient.

If the contralateral incisor erupts 6–8 months earlier, a panoramic radiograph is mandatory. Some patients require

complementary studies such as a periapical and occlusal radiograph and a cone beam CT to accurately define the position of the incisor and its relation with the roots of the adjacent teeth.

A careful treatment plan is required in order to obtain a reasonable result. It is important to take into consideration the angle between the crown axis and the root.

Sometimes, one of the major problems is the recovery of the space for the incisor, in conjunction with the elimination of functional interferences that can alter the path of the eruption.

In general, the prognosis is the result of several factors such as etiology, quantity of bone, root length and shape, dilaceration of the crown, etc. Treatment timing plays an important role.

Different orthodontic techniques can be used, and in some cases, spontaneous eruption can be observed when the space is recovered (Becker 2002), but in other patients, orthodontic traction may be required.

In 28–60% of the cases, mesiodens and odontomas cause incisor impaction (Suri et al. 2004; Batra et al. 2004). Their extraction is necessary before initiating the extrusion process. If an impacted incisor is associated with a cyst, a conservative approach is preferred in order to prevent the loss of the incisor. When the preservation of the tooth is desired in a young patient where the lesion is isolated, marsupialization is the treatment of choice.

When the intrusion is severe, ankylosis of the tooth could be the result. Orthodontic treatment to move the tooth to its correct position was not possible, until now. Also, the result of trying this is the undesirable movement of the adjacent tooth.

It is very difficult to determine the duration of the treatment since it depends on a lot of circumstances such as residual eruption potential, localization of the impacted tooth, bone density, surgical procedures, root dilaceration, missed appointments, etc. The higher the position of an impacted incisor, the longer the duration of the orthodontic treatment (Tanaka et al. 2001).

J. Harfin
Department of Orthodontics, Maimonides University,
Buenos Aires, Argentina
e-mail: harfinjulia@gmail.com

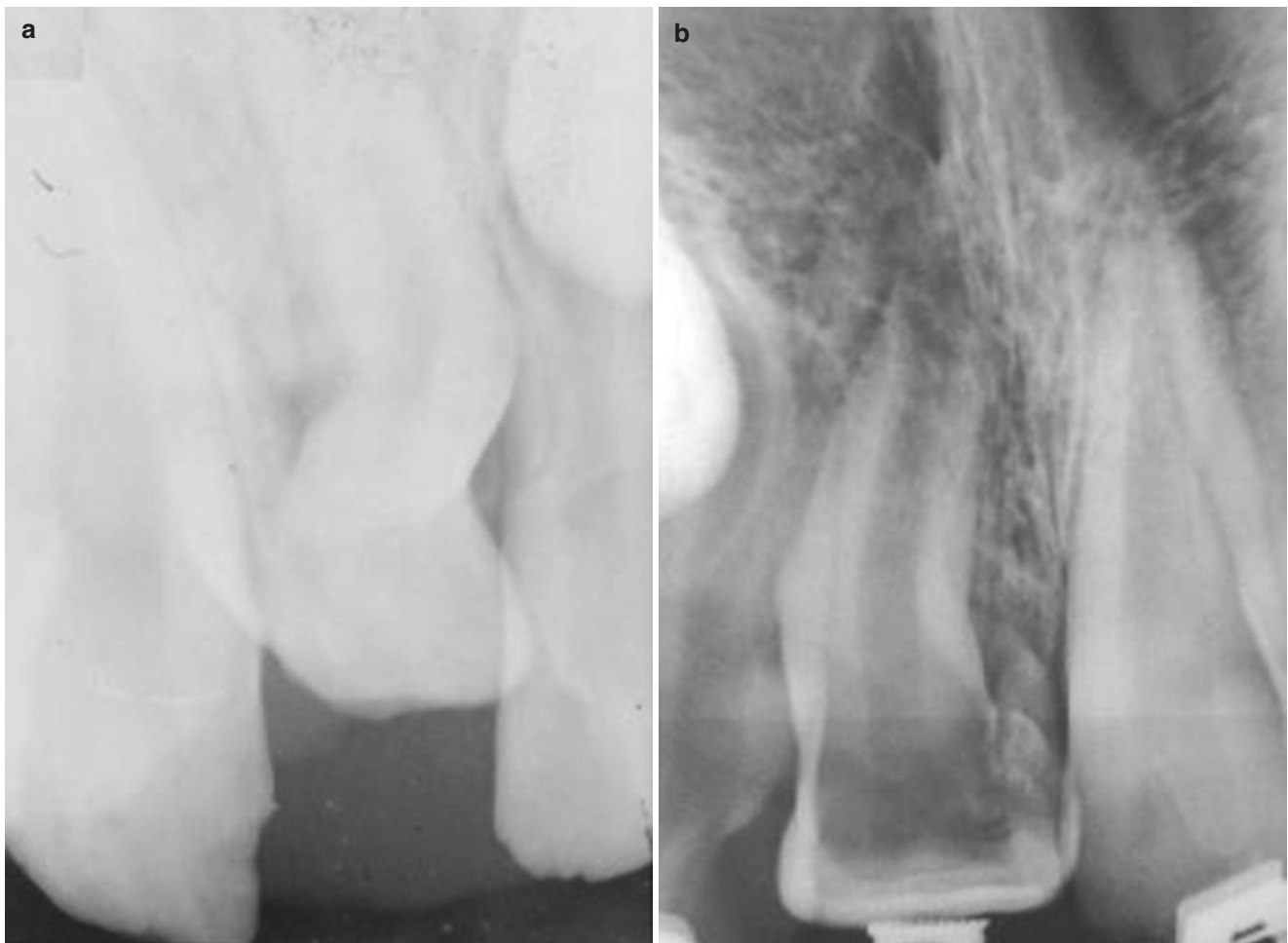


Fig. 6.1 (a, b) Root and crown dilaceration after primary incisors trauma

The treatment plan includes three steps: presurgical orthodontics, exposure and bonding, and postsurgical orthodontics.

During the surgical procedure, at least 1/2 or 2/3 of the crown has to be uncovered.

Gingivectomy would be the most conservative procedure when a normal attached gingiva is present but when its width is compromised, an apically positioned flap is required (open eruption) (Vermette et al. 1995).

However, for some patients, a close eruption technique would be the best option. During this procedure the attached gingiva is raised, and after placement of a button or a bracket on the impacted incisor, it is fully replaced to its original position. Studies have shown less recession, better bone support, and superior periodontal parameters with the closed-eruption method (Becker 2002).

The patient has to be aware that some problems can appear during the surgical-orthodontic treatment, such as some root canal obliteration, devitalization of the tooth, or ankylosis (Chaushu et al. 2003).

Unfortunately, there isn't a single and specific bracket available to treat all of these patients. Nonetheless, a controlled and light force is highly recommendable to erupt the tooth with bone and normal gingivo-periodontal tissues. In addition, controlled oral hygiene is fundamental for this purpose.

The following patients are clear examples of some of these circumstances. The parents of this 9-year-old patient asked for a second opinion regarding the right upper central incisor that hadn't erupted. The family dentist told them that they had to wait until the patient was 12 years old, but they were worried about waiting so long.

The left central incisor erupted 20 months earlier without any inconvenience, and now a mild crown mesial inclination was present without enough room for the right intruded incisor (Fig. 6.2a, b). The occlusal view confirmed that there was no room for the right incisor and the buccal-palatal width was diminished.

Lateral views showed Class I right and left canine and molar with a normal path of eruption. The mesio-inclination

of the left upper central incisor was clearly evident. There was a significant overbite in the left central incisor region. The oral hygiene was good (Fig. 6.3a, b).

According to the studies by Becker and Chaushu, the first phase of treatment is to achieve sufficient mesiodistal space to have room for the intruded incisor. Esthetic brackets 0.022" were bonded on the upper laterals and the left central incisor along with an esthetic Ni-Ti 0.014" archwire. In order to have better anchorage, brackets were also placed on the temporary canines (Fig. 6.4a).

The periapical Rx showed the position and inclination of the right central incisor and an open coil spring to recover the right central incisor space (Fig. 6.4b).

After 5 months of treatment, the space was achieved and midlines were normalized. A 0.016" × 0.016" Elgiloy archwire was placed and a control radiograph was taken (Fig. 6.5a, b).

Since the intruded incisor didn't erupt by itself, the patient was sent to the oral surgeon to perform a closed surgical procedure and bond a bracket at the same time. However, the surgeon decided to perform an open procedure. When the patient returned 3 weeks later, an esthetic bracket was bonded on the labial surface of central incisor along with a ligature to the main arch. The occlusal photographs confirmed that the space was recovered and the biomechanics that were used (Fig. 6.6a, b).

Taking into account that it is very important to maintain healthy gingivo-periodontal tissues, a controlled extrusion force was applied. A second Ni-Ti 0.012" archwire was placed between the upper canines. An 8-week activation period was recommended (Frank) (Fig. 6.7a, b).

Four months later, the incisor was extruded very slowly. When analyzing the front photograph, a ligature-of-eight was placed on the left side to correct the midline to the left.

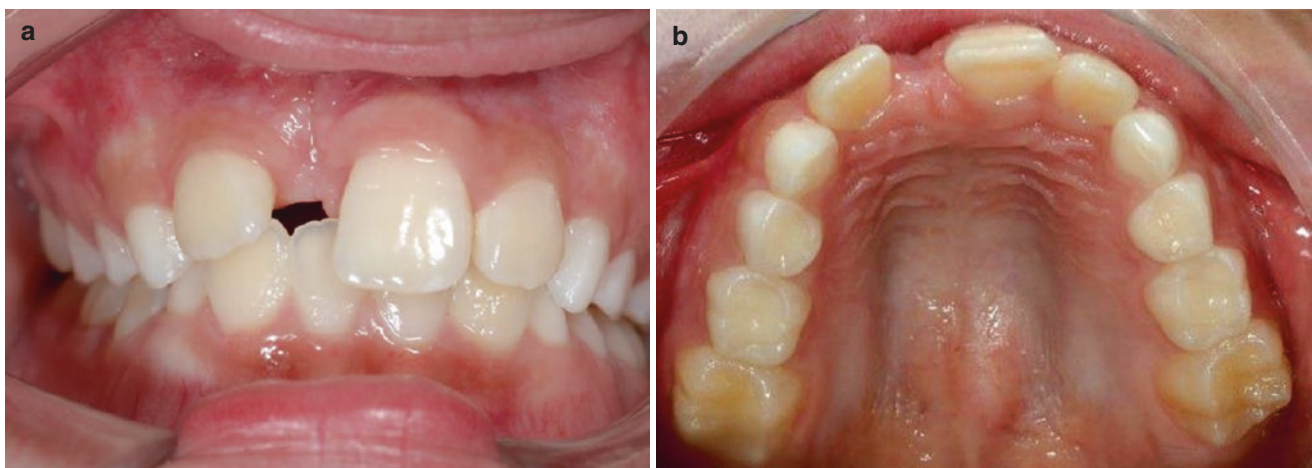


Fig. 6.2 (a, b) Impaction of the right maxillary central incisor caused by trauma on the primary incisor

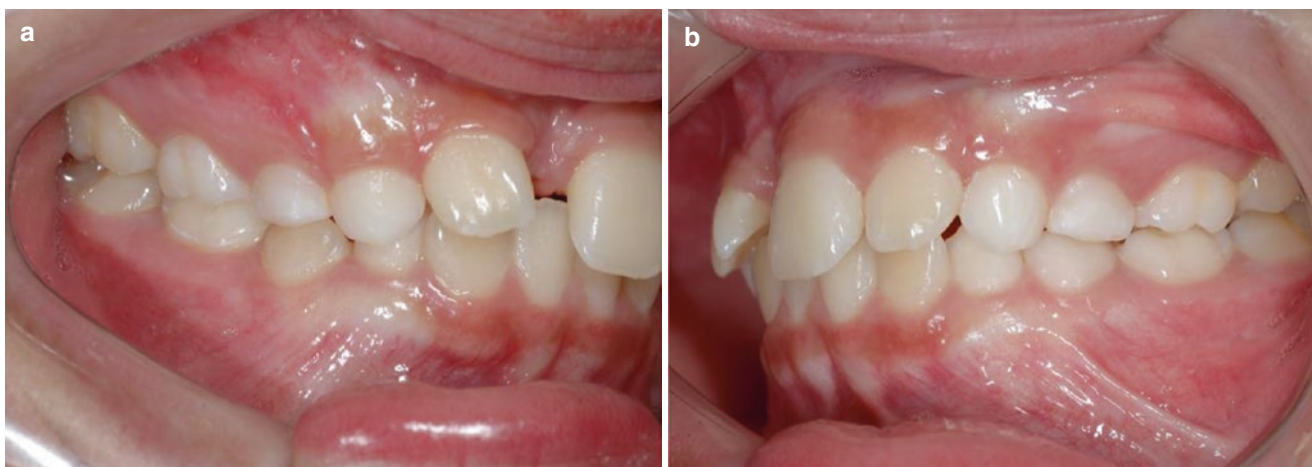


Fig. 6.3 (a, b) Pretreatment lateral view Class I molar was observed along with lack of space for the eruption of the right central incisor

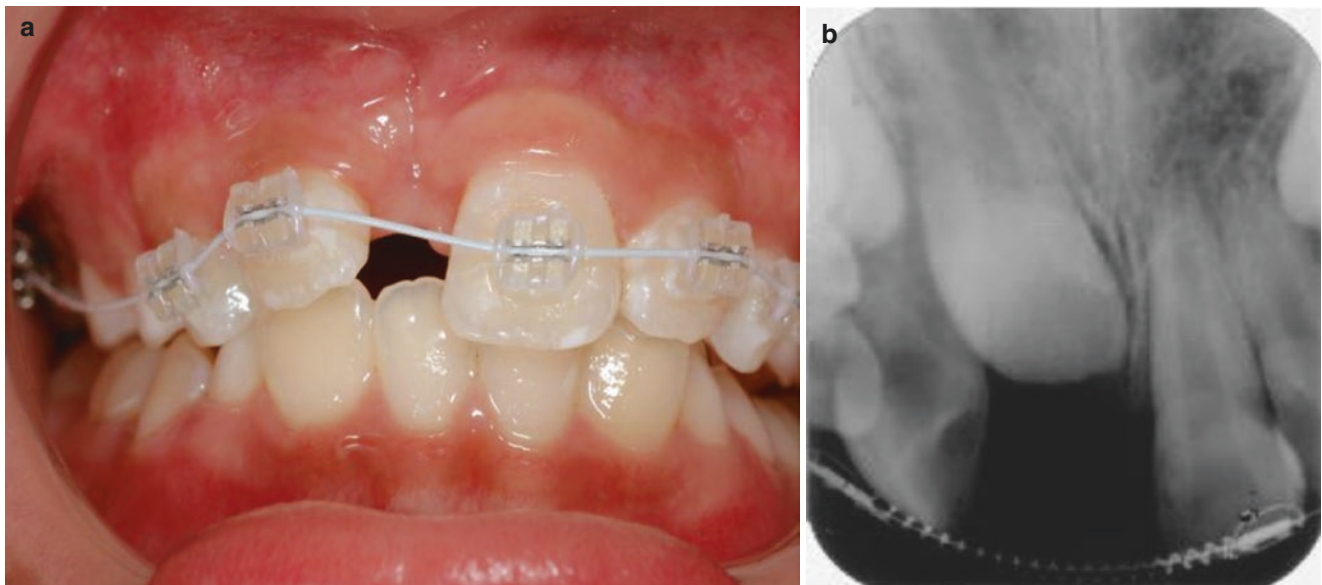


Fig. 6.4 (a, b) Esthetics brackets were bonded on the upper anterior teeth. Rx showed the impacted right central incisor and the coil spring to recover the space

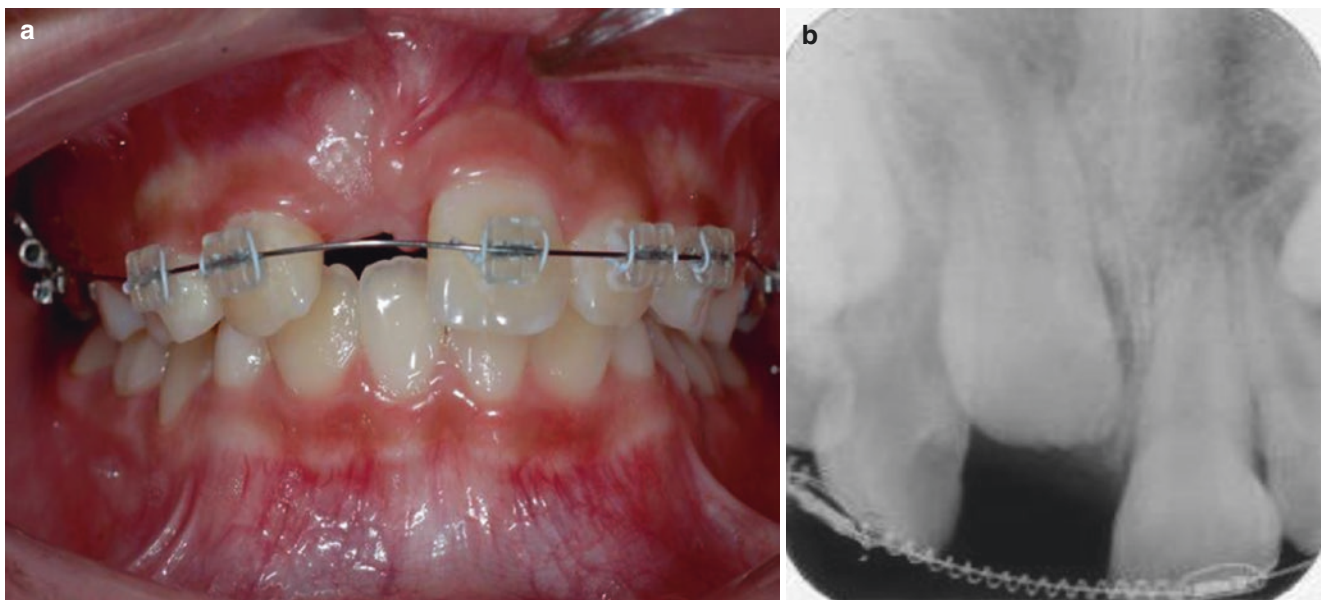


Fig. 6.5 (a, b) Front photograph and periapical Rx after 5 months in treatment

Also, the bracket on the right central incisor had to be repositioned to improve its alignment (Fig. 6.8a, b).

To control leveling and alignment, a 0,018" SS archwire was placed. No brackets were bonded on the bicuspids until that point (Fig. 6.9a, b). A slight difference was still present on the gingival margin of the incisors along with a mild inflammation on the right side. The interincisal diastema had to be closed very smoothly to achieve complete closure with a normal dental papillae.

These were the results after 23 months of treatment. All the treatment objectives were completed: the upper right

central incisor and midlines were corrected (Fig. 6.10a, b). No important root resorption was seen and the upper right central incisor pulp was still vital. Since there was a slight difference in the gingival height, no further mucogingival surgery was recommended.

A fixed retainer wire was recommended for a long period of time, in conjunction with a night vacuum maxillary retainer.

Bilateral Class I canine and molar relationship with normal overjet and overbite were achieved. Gingivo-periodontal tissues were almost normal (Fig. 6.11a, b).

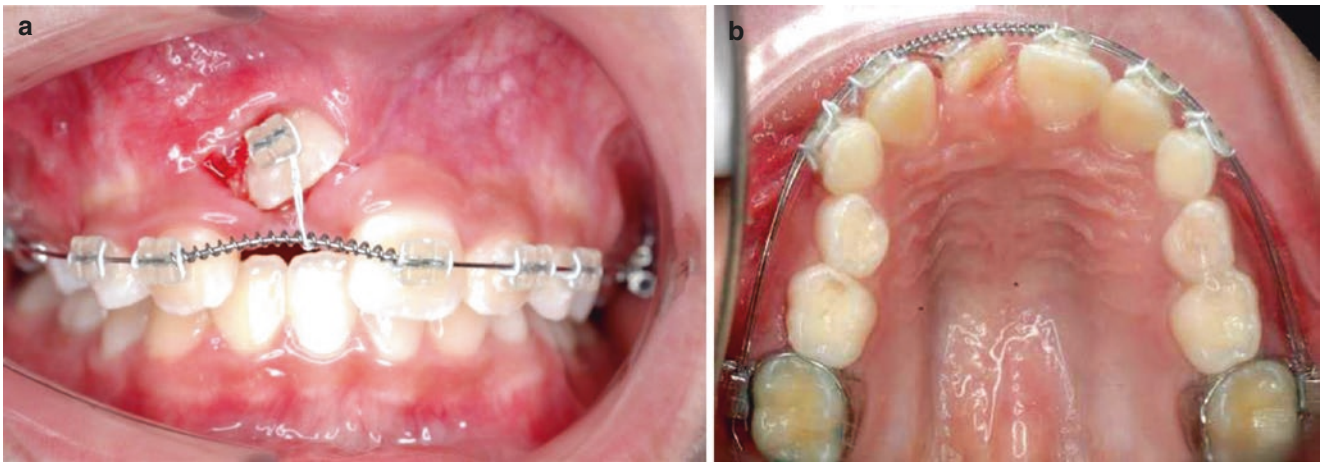


Fig. 6.6 (a, b) Front and occlusal photograph 1 month after the surgical incisor exposure

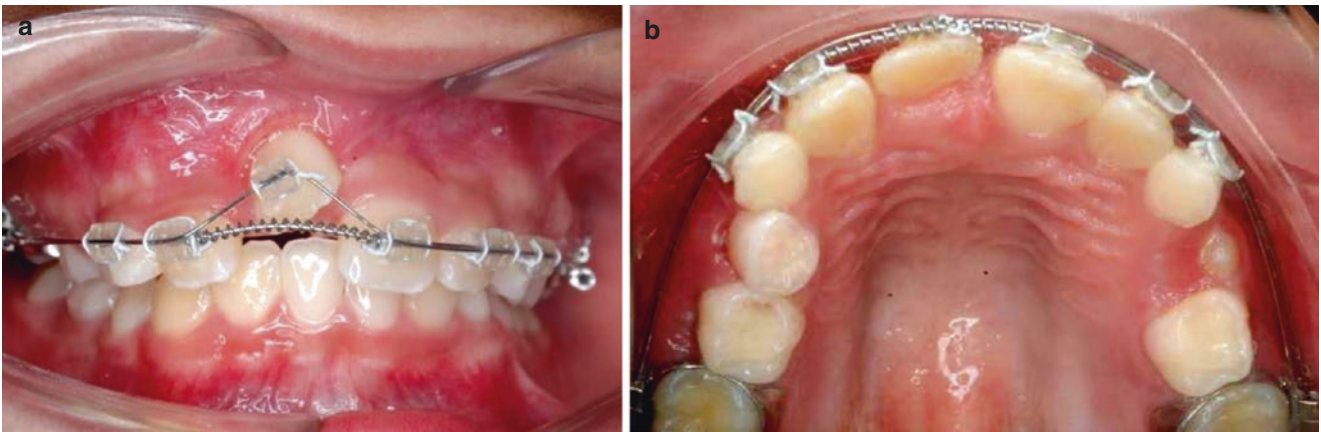


Fig. 6.7 (a, b) A second arch (Ni-Ti 0.012") was placed to control eruption with very low forces

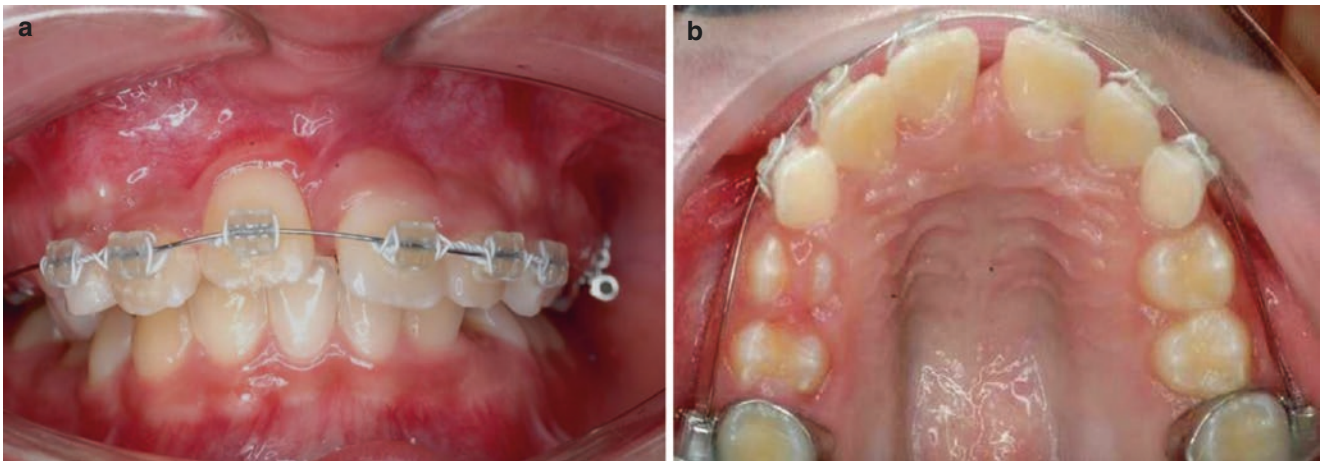


Fig. 6.8 (a, b) Front and occlusal photographs 4 months after the open flap surgery

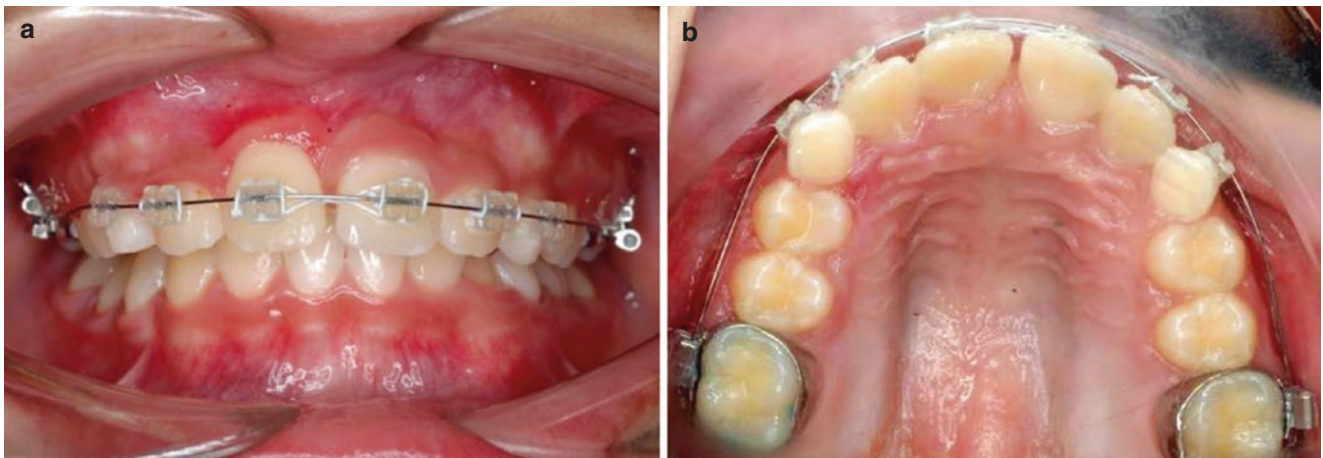


Fig. 6.9 (a, b) Front and occlusal photographs at the end of the Phase I treatment

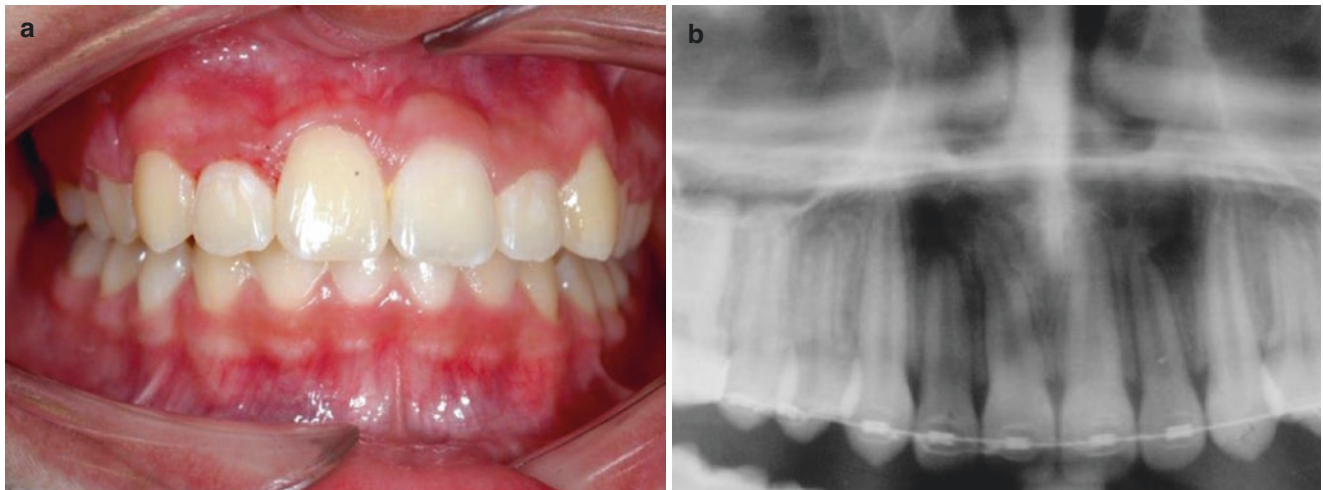


Fig. 6.10 (a, b) Final records after 23 months of treatment. Upper and lower midline was almost normal and no significant root resorption was seen

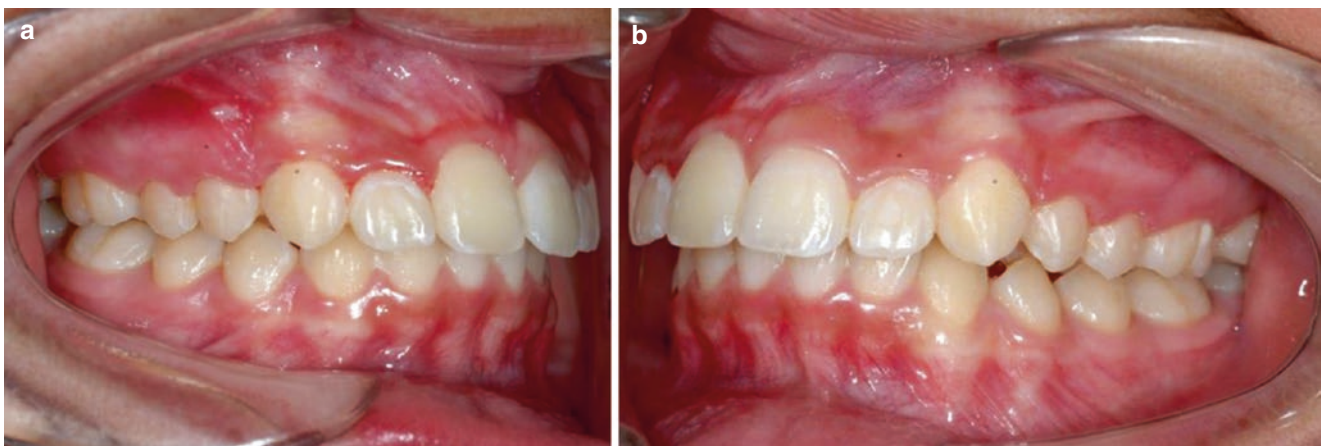


Fig. 6.11 (a, b) Lateral views at the end of the treatment. Class I molar was maintained

The patient returned after 30 months for a control of the retainer. The results were almost maintained although the fixed retention wire was lost 1 year earlier.

The gingival tissues were normal, and a subtle relapse could be observed on the right upper central incisor (Fig. 6.12a, b).

A comparison between the pre- and post radiographs confirmed the results that were achieved. No important root resorption was visible (Fig. 6.13a, b).

Delayed eruption has to be monitored very closely to avoid major inconveniences that can produce impaction or ankylosis of the incisor and can have direct effects on the development of the occlusion.

The next case provides a visible example. A 10 years and 10 months old girl was sent for a second opinion since her upper central right incisor was absent. She was in good health and no history of supernumerary teeth, mesiodens, or

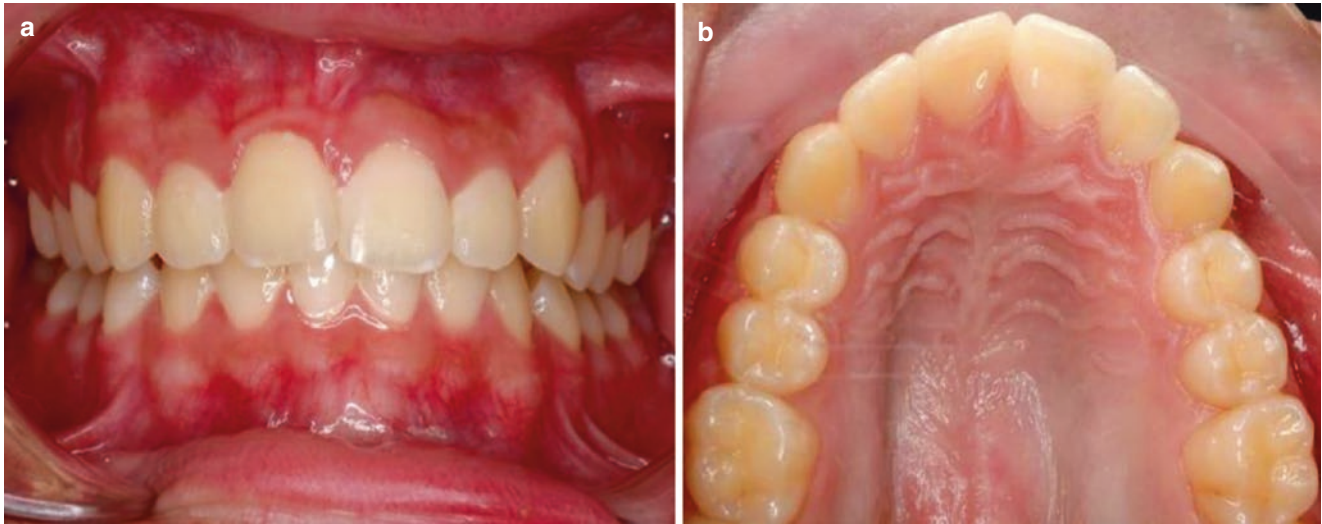


Fig. 6.12 (a, b) A control 12 months later. The results were almost maintained

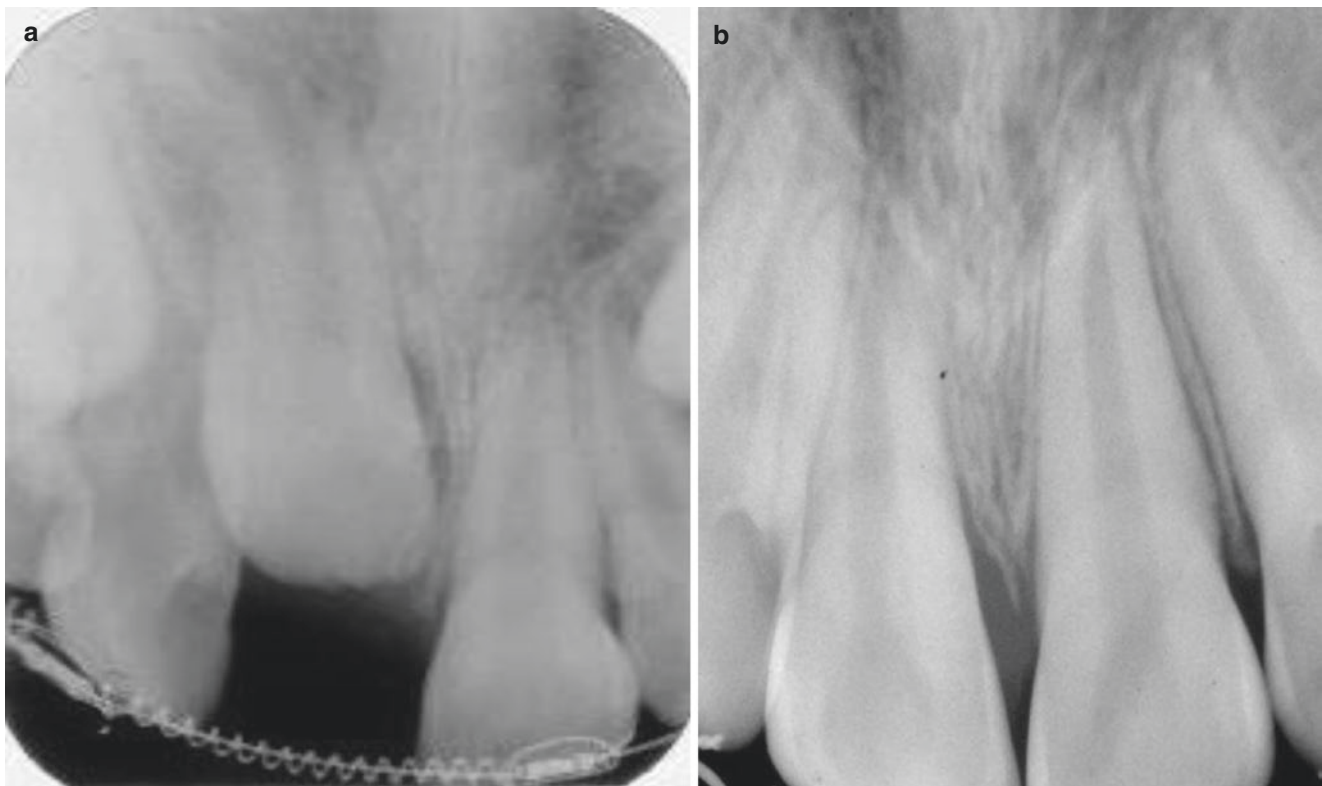


Fig. 6.13 (a, b) Pre- and post periapical radiographs. No root resorption was visible

odontoma was present. Although, she had a history of dental trauma when she was 4 years old, and she had the habit of nail biting from the age of 5.

The etiology of the impacted incisor was mainly due to trauma. The periapical radiograph showed the impacted incisor with a short and rounded root (Fig. 6.14a, b).

Upon analyzing the lateral views, the patient had a skeletal Class I malocclusion with a balanced facial pattern. Although she was almost 11 years old, all the canines and bicuspids had erupted. Intraoral examination revealed Class I molar relationship with an overbite of 2 mm and an overjet of 1.5 mm. A mild diastema distal the right and left lateral incisors was present (Fig. 6.15a, b).

The surgeon decided on an open flap and the bracket was bonded 2 weeks after the surgery. Ideally, bonding has to take place during the surgical procedure, but if for any reason it is not possible, a wide exposure must be performed and a surgical pack may need to be placed, in order to prevent the closure of the wound. It is important to prevent damage to the cementum-enamel junction (Becker 2002). An open coil spring was placed to open the space and at the same time to hold a metallic ligature. The extrusion has to be performed very slowly to protect the rounded root and to obtain normal gingivo-periodontal tissues. Due to the high position of the tooth, it was very difficult for the patient to maintain good oral hygiene in this zone (Fig. 6.16a, b).

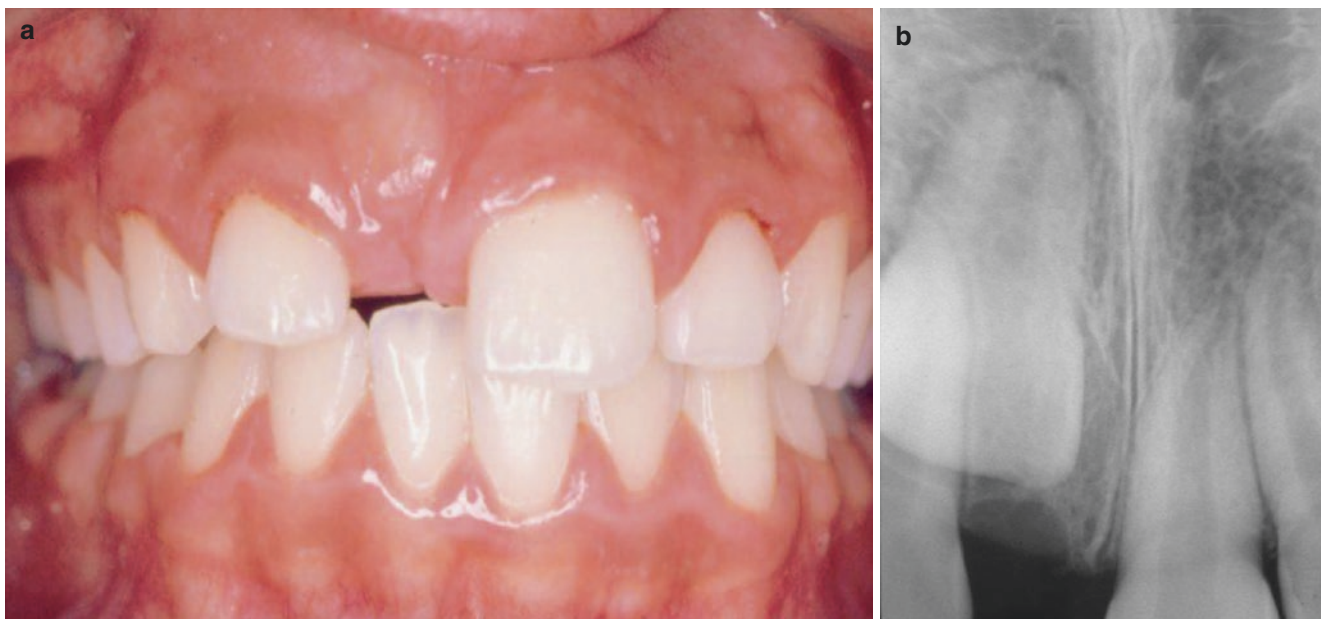


Fig. 6.14 (a, b) Front photograph and Rx showing the right impacted incisor with a rounded and short root

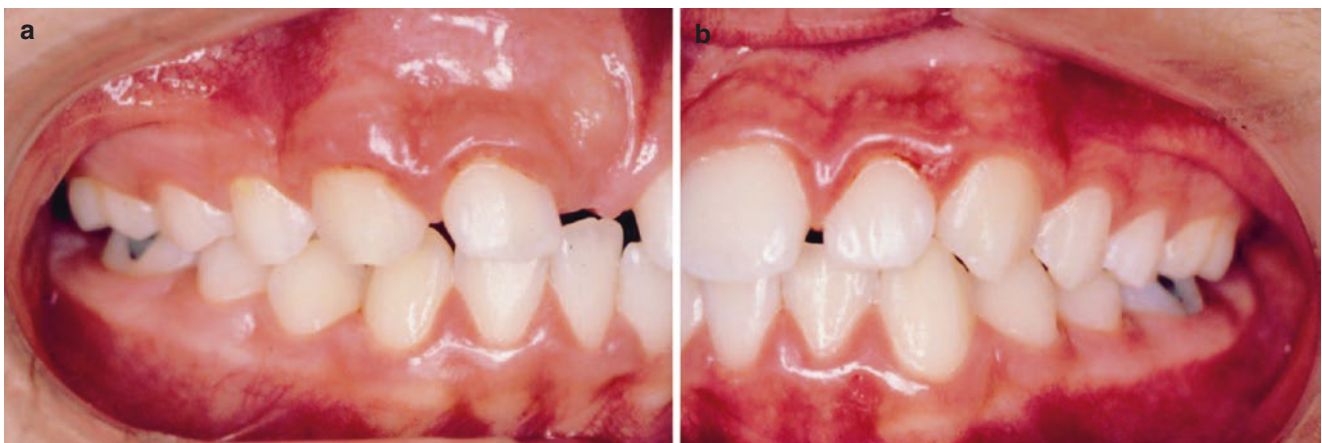


Fig. 6.15 (a, b) Lateral views at the beginning of the treatment. Class I molar and cuspid was present

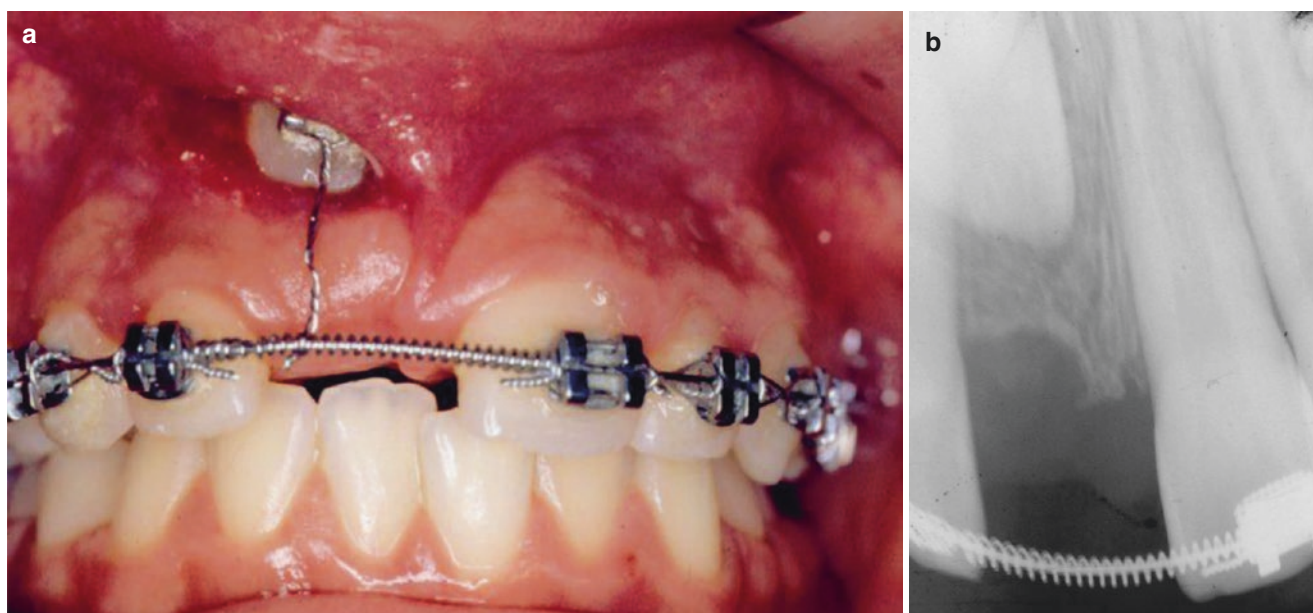


Fig. 6.16 (a, b) Front photograph and Rx 2 weeks after the open flap surgery

After 7 months, the incisor erupted but in a rotated position. A 0.016" × 0.016" TMA archwire with some bends was placed in order to normalize the position of the right incisor. The periapical radiograph confirmed that the extrusion was performed with no more root resorption (Fig. 6.17a, b).

The following photographs showed the results of orthodontic treatment. A slight recession was present on the gingival margin of the upper central right incisor. Overjet and overbite were almost normal and at the end of the treatment, midlines were coincident (Fig. 6.18a, b).

The comparison between the pre- and post frontal photographs demonstrated that the results that were obtained were excellent. All the treatment objectives were achieved: extrusion of the impacted central right incisor, normalized overjet and overbite, and an occlusal plane parallel to the gingival plane (Fig. 6.19a, b). It is very interesting to see how the interincisal papillae were totally recovered with normal color and shape.

Also, the periodontal status of the exposed incisor after orthodontic treatment showed a normal gingival contour. No further mucogingival surgery was recommended.

The following case was a 12-year-old patient and the most challenging in reference to impacted incisors. He was worried about his smile. The temporary upper right central incisor had fallen 6 months earlier, and the permanent incisor hadn't erupted. The panoramic radiograph confirmed the distal inclination of the crown and the lack of space. Some mild crowding in the lower arch was also present (Fig. 6.20a, b).

Preprogrammed brackets were bonded on the upper arch along with a Ni-Ti Cu 0.016" broad arch in order to begin the alignment and to obtain sufficient space for the impacted

incisor. The surgeon decided on an open flap, and the bracket was placed on the right central incisor in the same procedure. No bracket was bonded on the upper right lateral incisor to protect it. A wire ligature between the right central incisor and the left canine was placed to improve its position. An activation was recommended every 3 weeks (Fig. 6.21a, b).

These are the results after 6 and 9 months in treatment. A 0.014" Ni-Ti archwire was ligated, and light forces were used with the intention of extruding the incisor with bone and not through it (Fig. 6.22a). There were significant results after 3 months (Fig. 6.22b).

When the upper right central incisor reached the occlusal plane, a bracket was bonded on the upper right lateral incisor along with an open coil spring to recover enough space for the central and lateral incisor (Fig. 6.23a) A 0.016" SS archwire was placed to finish the leveling and alignment of the upper arch. At the same time, brackets were bonded on the lower teeth to correct the mild lower anterior crowding (Fig. 6.23b).

Six months later the lower anterior crowding was normalized as well as midlines (Fig. 6.24a). Since the patient decided to continue his studies abroad, two fixed retention wires were bonded between the canines (Fig. 6.24b). Oral hygiene needed improvement.

Although the patient was 12 years old at the beginning of the treatment, the normalization of the position of the upper right central incisor was clearly demonstrated when the pre- and posttreatment radiographs were compared. No major root resorption was observed but a slight mesio-inclination of the root of the upper right lateral incisor was present (Fig. 6.25a, b).

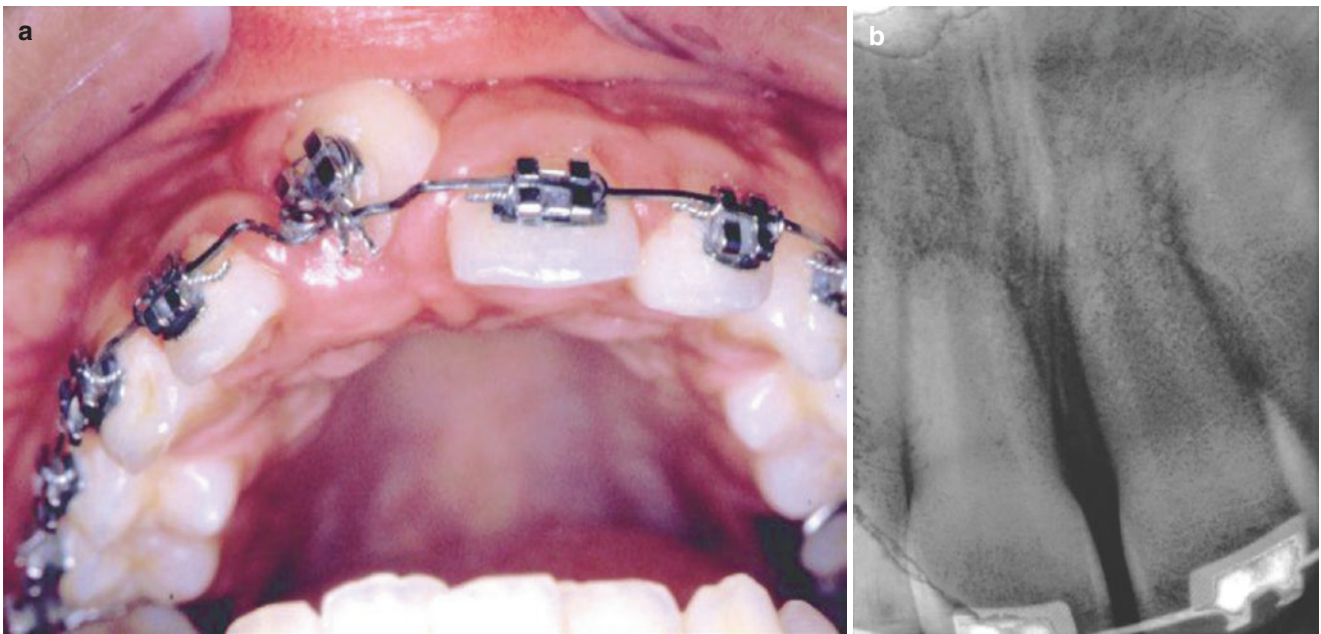


Fig. 6.17 (a, b) 7 months in treatment. No more root resorption was present

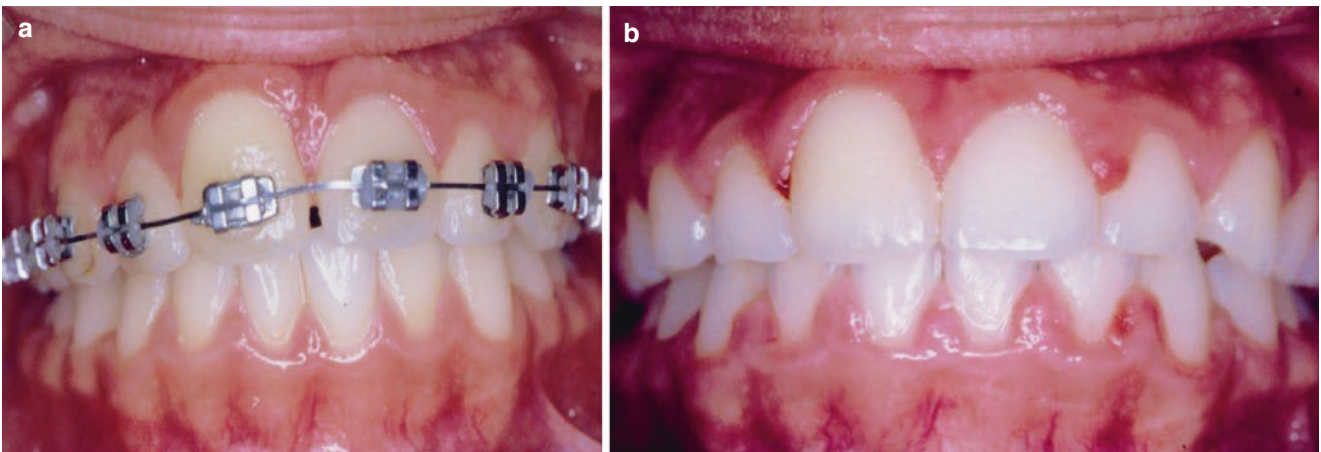


Fig. 6.18 (a, b) Front photographs with the last archwire and at the end of the treatment

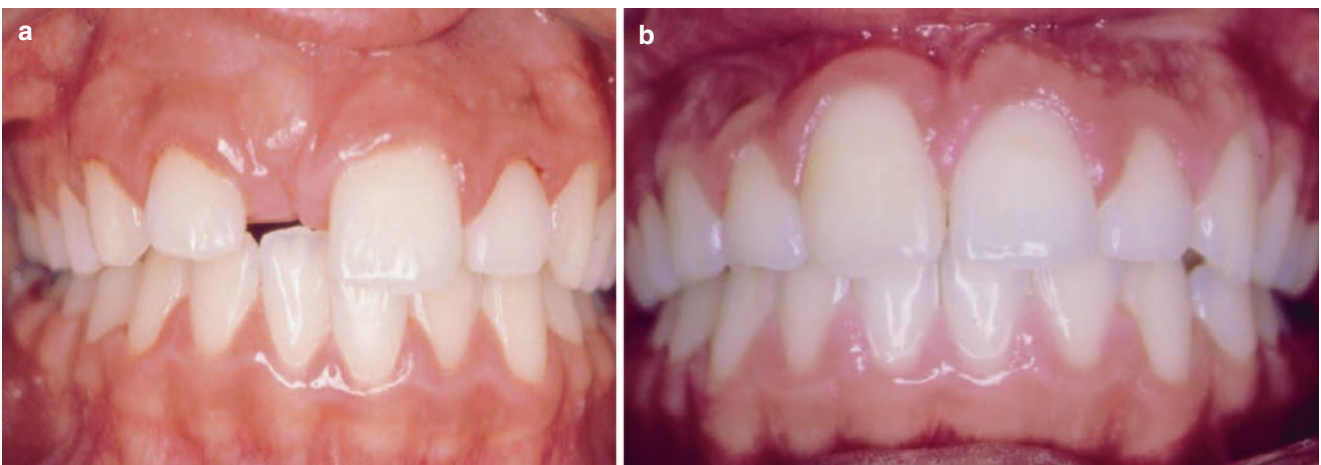

Fig. 6.19 (a, b) Comparison pre- and posttreatment. The gingival line is almost normal

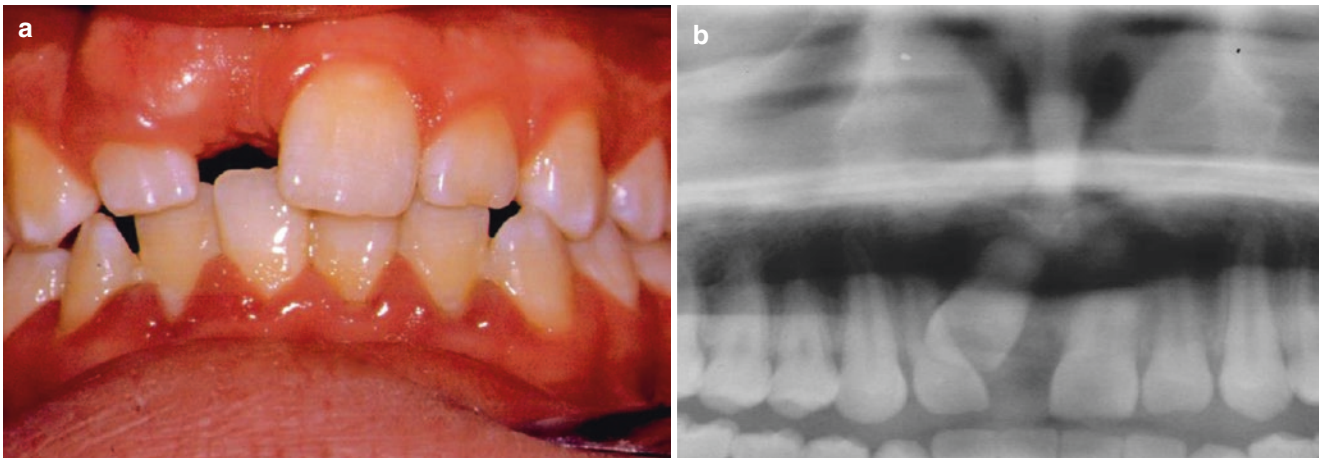


Fig. 6.20 (a, b) Pretreatment frontal photograph and panoramic radiograph. An important disto-inclination of the right central impacted incisor is visible

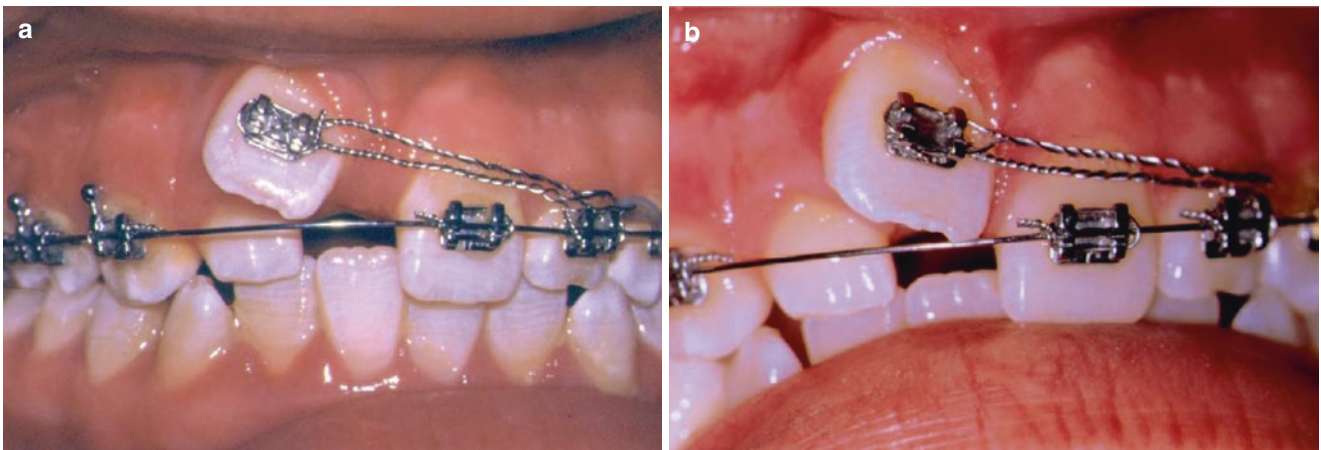


Fig. 6.21 (a, b) A control 2 and 6 weeks postsurgery. Very low forces was recommended to move the incisor with bone

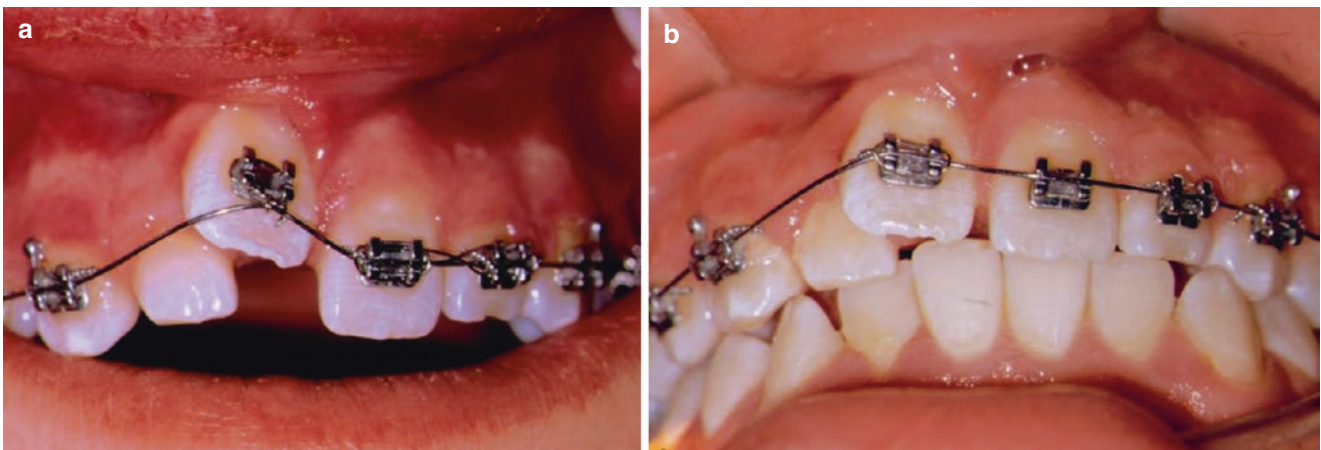


Fig. 6.22 (a, b) A Ni-Ti 0.014" was placed to extrude the incisor very slowly with bone

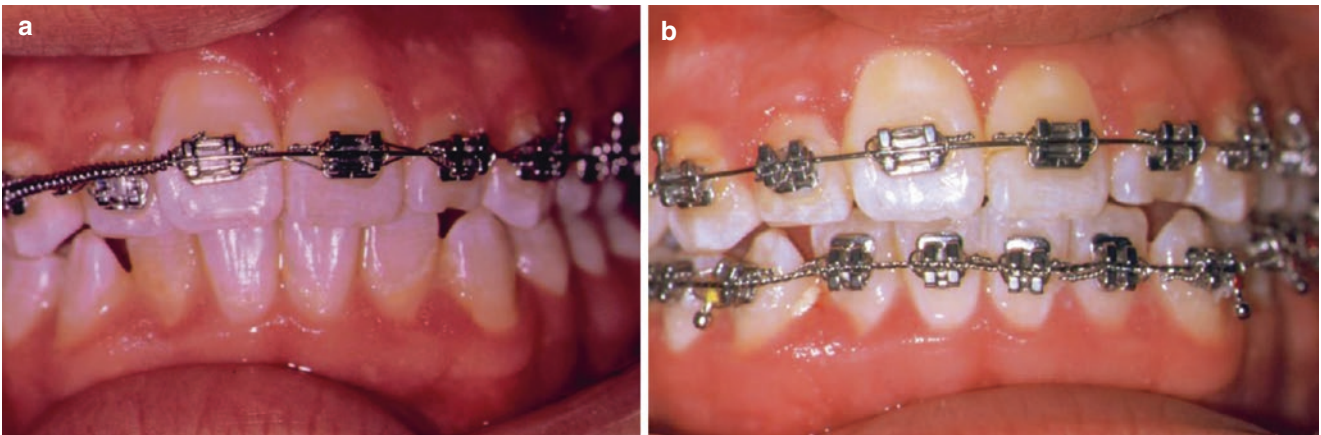


Fig. 6.23 (a, b) A bracket was bonded on the upper right lateral incisor when enough space was achieved with brackets on the lower arch to correct the mild crowding that was present

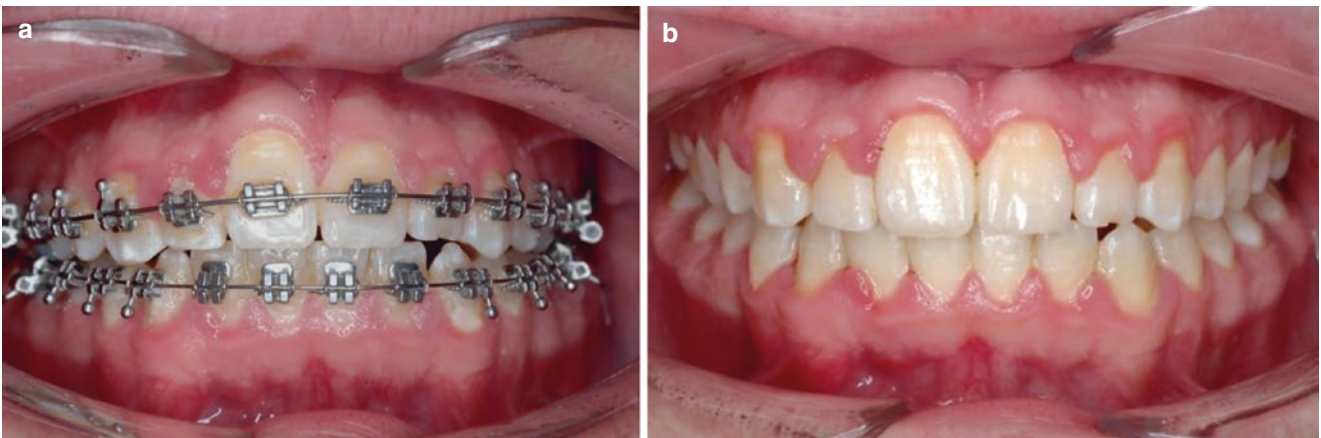


Fig. 6.24 (a, b) Front photographs before and after debonding. Oral hygiene had to be improved

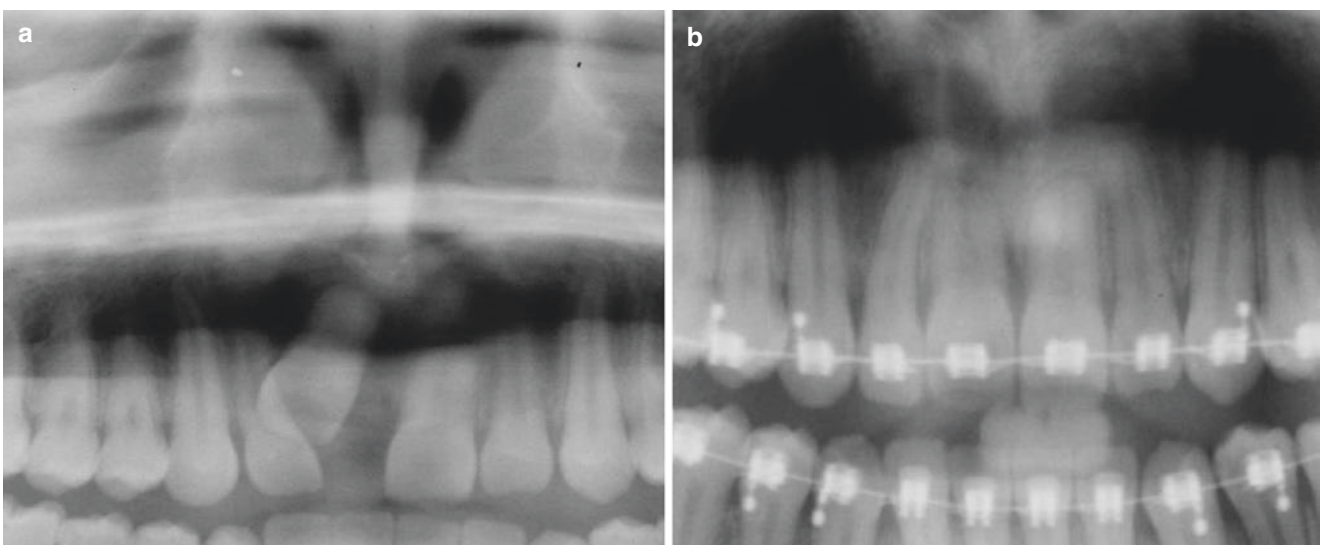


Fig. 6.25 (a, b) Comparison of pre- and post panoramic radiographs. No more root resorption was present

Conclusions

Early diagnosis is critical for the success of the treatment.

Each clinical case must be treated with an individualized treatment plan in order to achieve the best functional and esthetic result.

Light and controlled extrusive forces are the most recommendable to bring the tooth down to the occlusal plane.

A careful soft tissue management is necessary to achieve a successful long-term esthetic outcome. The incisor has to be extruded with a normal quantity of attached gingiva, and the maintenance of excellent oral hygiene is crucial to obtain a normal interincisal papillae.

It is important to take into consideration that the preservation of the vitality of the tooth during the surgical and orthodontic procedure is mandatory.

The duration of the surgical-orthodontic treatment of an impacted maxillary incisor varies widely since the etiology could be different as well as the position and inclination of the impacted incisor.

Unfortunately, there are no specific brackets or wires available to treat these patients. The most important issue to take into consideration is to apply light and continuous forces during the whole active treatment. It is highly recommendable that the last arch be maintained at a minimum of 6 months before the finishing process begins.

A long-term fixed retention wire is also recommended in all the clinical cases.

Bibliography

- Batra P, Duggal R, Kharbanda OP, Parkash H. Orthodontic treatment of impacted anterior teeth due to odontomas: a report of two cases. *J Clin Pediatr Dent.* 2004;28(4):289–94.
- Becker A, Brin I, Ben-Bassat Y, Zilberman Y, Chaushu S. Closed-eruption surgical technique for impacted maxillary incisors: a post-orthodontic periodontal evaluation. *Am J Orthod Dentofacial Orthop.* 2002;122:9–14.
- Becker A. Early treatment for impacted maxillary incisors. *Am J Orthod Dentofacial Orthop.* 2002;121(6):586–7.
- Chaushu S, Brin I, Ben-Bassat Y, Zilberman Y, Becker A. Periodontal status following surgical-orthodontic alignment of impacted central incisors with an open-eruption technique. *Eur J Orthod.* 2003;25:579–84.
- Crawford LD. Impacted maxillary central incisor in mixed dentition treatment. *Am J Orthod Dentofacial Orthop.* 1997;112(1):1–7.
- Foley J. Surgical removal of supernumerary teeth and the fate of incisor eruption. *Eur J Paediatr Dent.* 2004;5:35–40.
- Frank CA, Long M. Periodontal concerns associated with the orthodontic treatment of impacted teeth. *Am J Orthod Dentofacial Orthop.* 2002;121(6):639–49.
- Kuroe K, Tomonari H, Soejima K, Maeda A. Surgical repositioning of a developing maxillary permanent central incisor in a horizontal position: spontaneous eruption and root formation. *Eur J Orthod.* 2006;28:206–9.
- Kurokawa J. Early treatment of tooth-eruption disturbances. *Am J Orthod Dentofacial Orthop.* 2002;121(6):588–91.
- Lin YT. Treatment of an impacted dilacerated maxillary central incisor. *Am J Orthod Dentofacial Orthop.* 1999;115:406–9.
- Machado AW, Maia LGM, Vianna AP, Júnior G. Orthodontic traction of impacted upper central incisors related to mesiodens. *RGO, Rev Gaúch Odontol, Porto Alegre.* 2015;63(1):75–80.
- Pinho T, Neves M, Alves C. Impacted maxillary central incisor: surgical exposure and orthodontic treatment. *Am J Orthod Dentofacial Orthop.* 2011;140:256–65.
- Suri L, Gagari E, Vastardis H. Delayed tooth eruption: pathogenesis, diagnosis, and treatment. A literature review. *Am J Orthod Dentofacial Orthop.* 2004;126(4):432–45.
- Tanaka E, Watanabe M, Nagaoka K, Yamaguchi K, Tanne K. Orthodontic traction of an impacted maxillary central incisor. *J Clin Orthod.* 2001;35(6):375–8.
- Turley P, Joiner M, Hellstrom S. The effect of orthodontic extrusion on traumatically intruded teeth. *Am J Orthod Dentofacial Orthop.* 1984;85:47–56.
- Uematsu S, Uematsu T, Furusawa K, Deguchi T, Kurihara S. Orthodontic treatment of an impacted dilacerated maxillary central incisor combined with surgical exposure and apicoectomy. *Angle Orthod.* 2003;74:132–6.
- Valladares Neto J, Pinho Costa S, Estrela C. Orthodontic-surgical-endodontic management of unerupted maxillary central incisor with distoangular root dilaceration. *J Endod.* 2010;36:755–9.
- Vermette ME, Kokich VG, Kennedy DB. Uncovering labially impacted teeth: apically positioned flap and closed-eruption techniques. *Angle Orthod.* 1995;65:23–33.
- Zilberman Y, Fuks A, Ben Bassat Y, Brin I, Lustmann J. Effect of trauma to primary incisors on root development of on their permanent successors. *Pediatr Dent.* 1986;8:289–93.

Kurt Faltin Jr

Class II malocclusion has high clinical prevalence, about 45%. It is accepted that Class II is acquired during the growth and development stages by general dysfunction of the neuromuscular dysfunction. There are several methods we can adopt. The treatment design and protocol must be used in the clinic by a therapy that really solves the problem. The treatment of each stage will produce: facial harmony, correct implantation of the teeth and function. Our long clinical activity gave us the right way to treat our more than 4000 patients.

The diagnosis carried out in three aspects:

1. Functional analyses
2. Orthopedic analyses
3. Orthodontic analyses

The diagnosis and the growth stages of the patient (Analyses of Cervical Vertebral Maturation – Baccetti and Franchi) are the most important aspects to be considered for the organization of an efficient treatment planning.

Another very important aspect is the evaluation of the maxillary transverse deficiency, which is the first part of the treatment planning, respecting orthopedic priorities.

In regard of orthopedic treatment plan, there are four important aspects to determine:

1. Class II with mandibular retrognathism
2. Class II with maxillary prognatism
3. Class II with fault in mandible and maxilla
4. Class II caused by orthodontic disharmonies

Subjects with mandibular retrognathism should be treated with functional orthopedic appliances that promote mandibular advancement such as Balters Bionator, Franckel Functional Regulator, Clark Twin Block, and Sanders Double Plate.

Subjects with maxillary prognatism should be treated with extraoral traction.

Subjects with fault in mandible and maxilla should be treated first with extraoral traction and completed with functional orthopedics.

In regard to the decision earlier or later treatment, it is definable that close to the pubertal peak, we expected that there is a significant increase of mandibular growth.

On the other hand, if the mandibular retrognathism is accentuated, it is necessary to treat the case immediately (mixed dentition) to achieve good orthopedic result.

The last part is the fixed orthodontic treatment resulting to the normal balanced occlusion.

Keep in mind: treat at the right place and right time!

Retain treatment for 6–12 months with orthopedic and orthodontic appliances is required.

A clinical observation should be executed until the second molars are erupted in normal occlusion.

For sure, our goal is the entire balanced stomatognathic neuromuscular system.

The purpose of this chapter is to reinforce the individualized diagnosis and the corresponding treatment protocol indicated for each individual patient as it is demonstrated by the examples presented.

** There is not a unique treatment protocol to be used for all Class II patients.*

The treatment of Class II Division I malocclusion is a multifactorial event whose factories should be analyzed by an individualized diagnostic protocol and the decision-making established. It has high clinical prevalence, about 40%. This anomaly is considered be acquired during the growth and development stages by general dysfunction of the neuromuscular epigenetic factors (Enlow 1968; Moyers 1988; Korkhaus 1930).

- The orthopedic diagnosis shows the prevalent of 80% of mandible retrognathism and 20% of maxillary prognatism. The treatment protocol for both categories must be totally different (McNamara 1984).

K. Faltin Jr
Universidade Paulista – UNIP, São Paulo, Brazil
e-mail: kurt@faltin.odo.br

First of all, we must have very clear the priorities of the neuro-functional, orthopedic, and orthodontic aspects that are individually determined by accurate diagnosis protocols (Ricketts 1960; Schwarz 1961; Björk 1955).

7.1 The Mandibular Retrognathism Treatment

The most important priority, as the first stage to be considered, is the maxillary transverse deficiency. It's absolutely necessary that the maxilla and upper dental arch be prepared to receive mandible in facial harmony, providing a normal Class I occlusion (Faltin et al. 2003).

The Balters Bionator is a totally functional appliance; there is no active component (*Balters W*).

It is composed by only three parts are (Fig. 7.1a, b):

1. The acrylic body (green color) which reproduced the new mandibular posture obtained at the construction bite. The amount of forward and vertical alteration might not be larger than 5 mm when necessary advancement must be realized step by step.

The body controls the vertical eruption of the teeth and the occlusal plane and supports the other two parts.

2. The lingual arch, made with 1.2 mm stainless steel a constant excitation for normal tongue posture. Never it is activated!

3. The vestibular arch, 0,9 mm with two functions: in the posterior part avoiding the interposition of soft tissues as buccinator complex (buccinator arch). The same arch in the frontal part, from canine to canine region, is adapted as a trainer for leap seal, again a functional trainer, labial arch. The new mandibular posture, the enhance in volume and in shape, the new lingual function, the normal functional behavior conduct to functional adaptation, and total correction of form and function were achieved (Fig. 7.1c-e).

The first example represents a case with a pronounced mandible retrognathic posture without dental arches discrepancies. The treatment protocol was Balters Bionator to normalize facial harmony in anterior and vertical directions (*Balters W*).

Patient 1: M.S., 9y. 3 m. At the beginning of treatment (Fig. 7.2a-e).

During 3y. 2 m. The patient used three Balters Bionators, with no use of any other fixed appliance.

In the follow-up, after finishing treatment, patient used the last Bionator full days during 6 months and nighttime for another 6 months. The results are observed at Fig. 7.3a-e).

Figure 7.4a, b illustrates a lateral cephalometric study before and after the treatment.

The long-term evaluation after 7 years (Fig. 7.5a-e) was performed and demonstrates the stability even a better situation after orthopedic mandible Class II treatment.

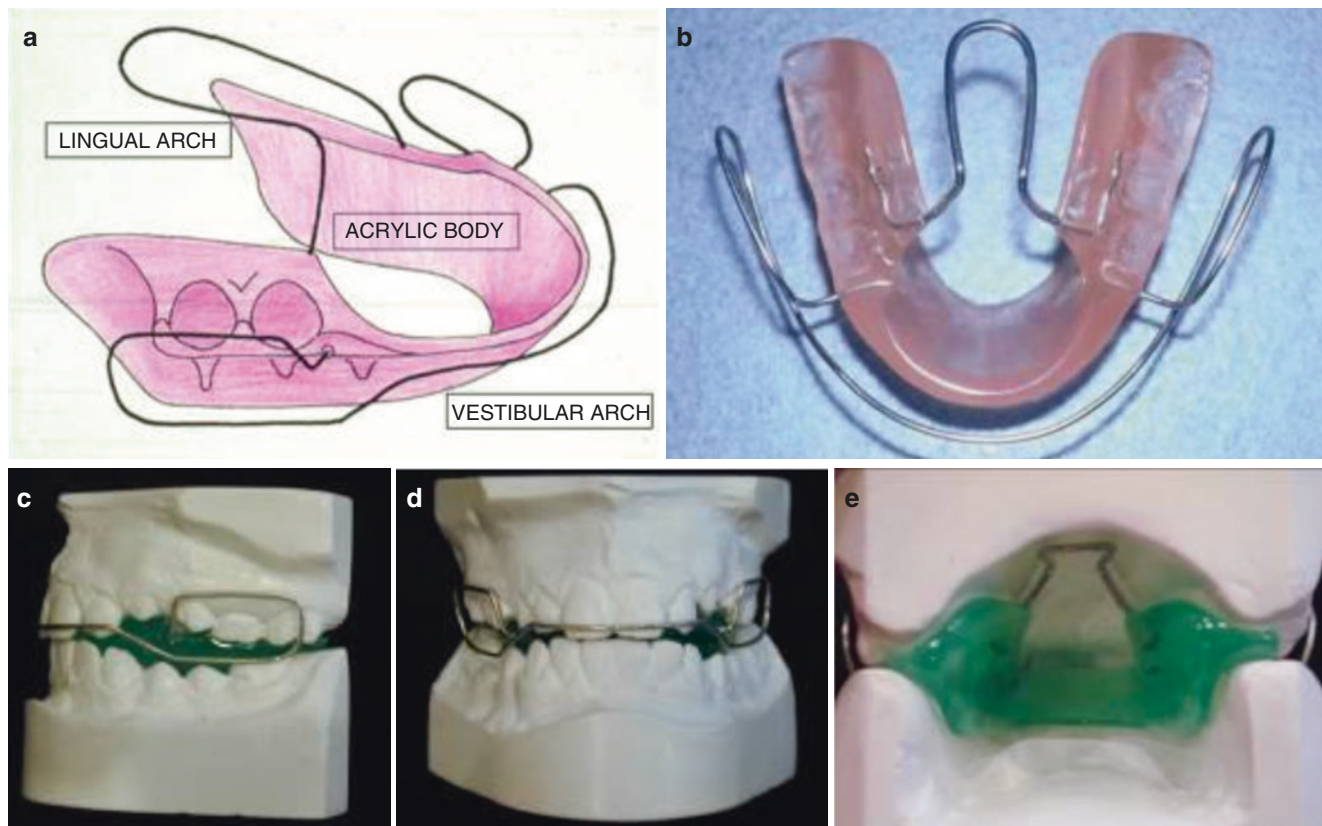


Fig. 7.1 Balters Bionator appliance

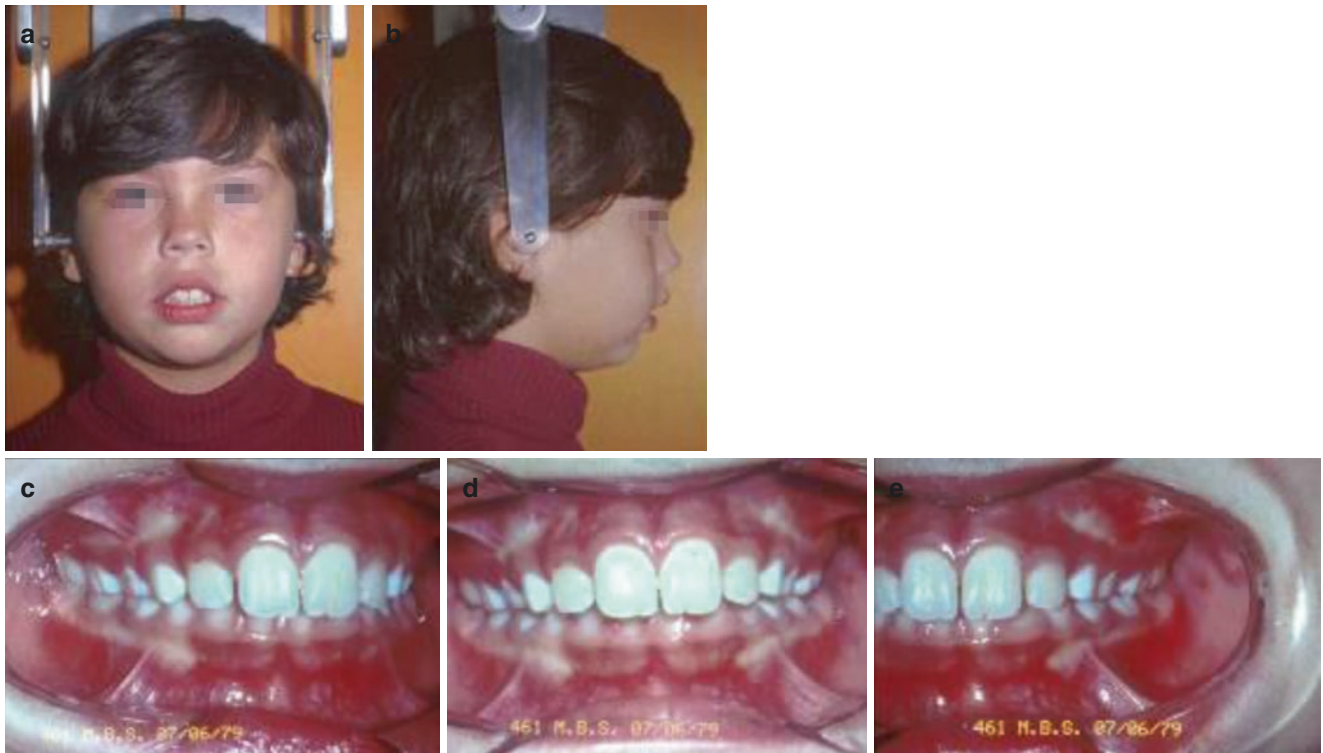

Fig. 7.2 Pre treatment frontal and lateral photographs. A convex profile is clearly observed

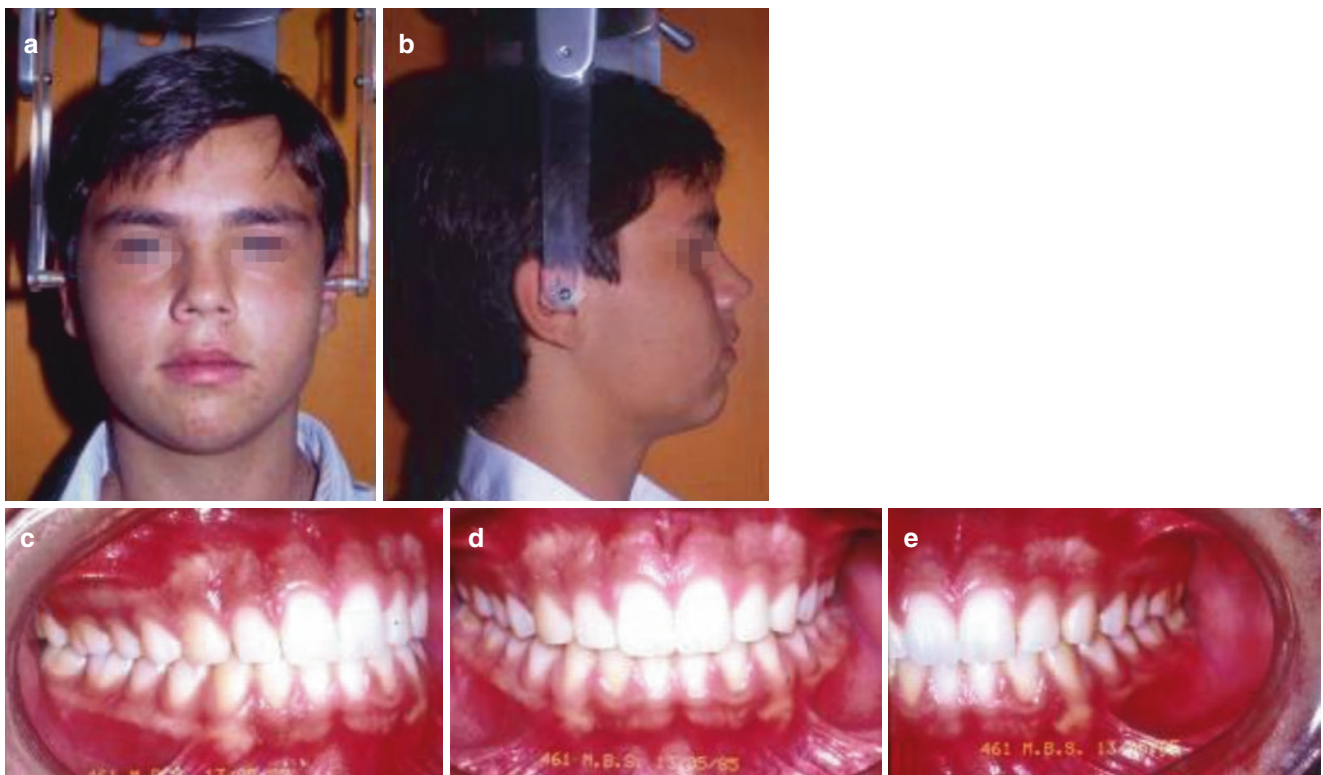


Fig. 7.3 Post treatment frontal and lateral photographs. Overbite is totally corrected and midlines are coincident

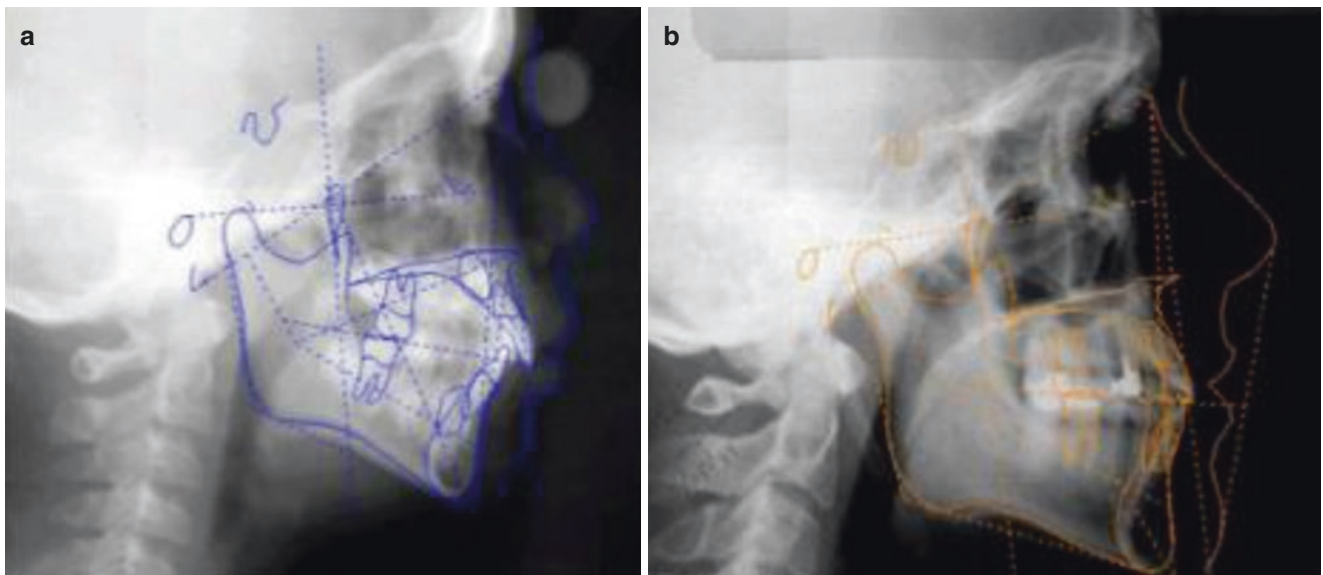


Fig. 7.4 Comparison pre and post treatment lateral cephalograms

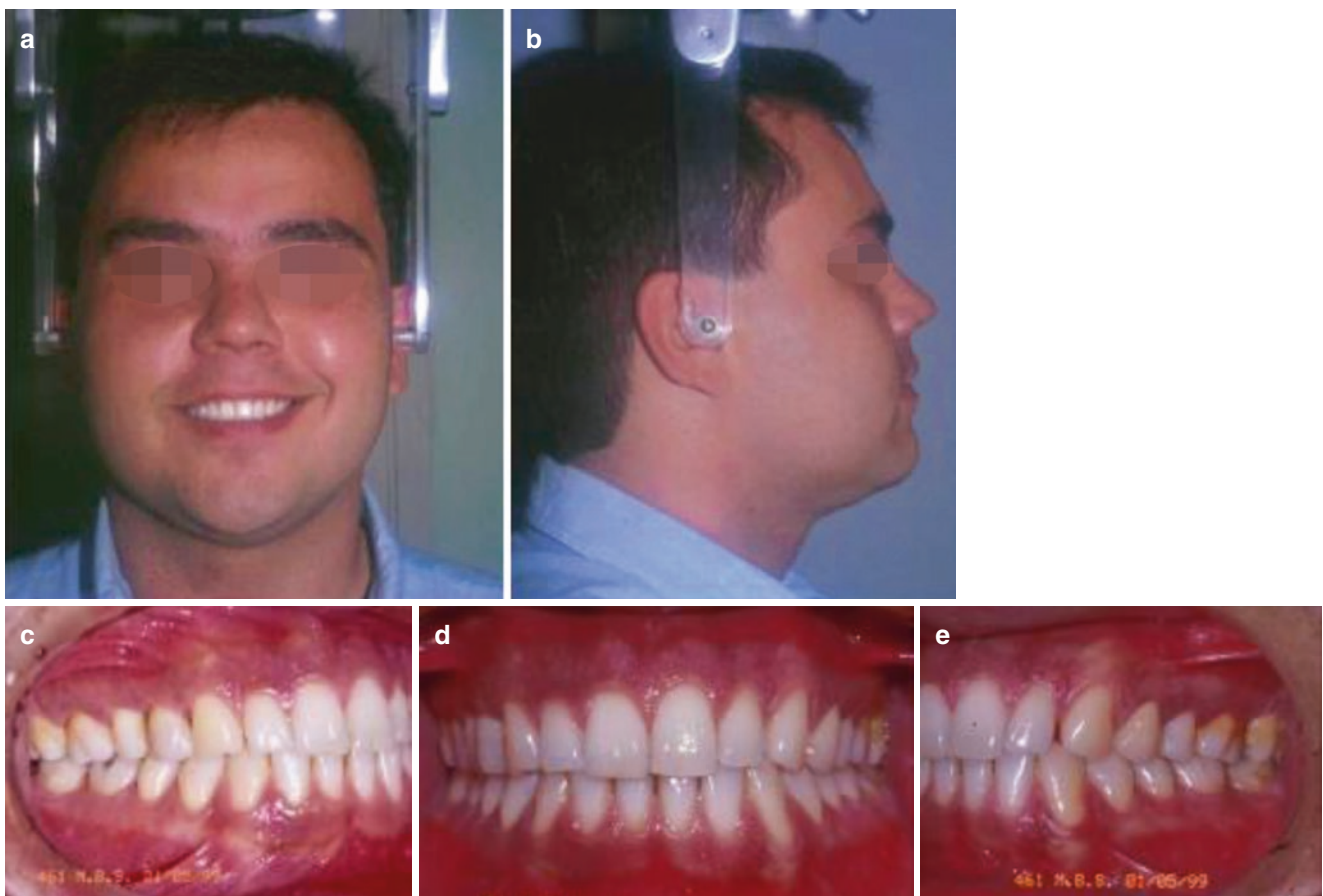

Fig. 7.5 7 years follow up. The results are maintained

It is to be convinced that the functional orthopedic intervention normalizing development factors and correcting neurophysiologic impute, through the central neuron system, promotes a very balanced and stable development and excellent result (Petrovic and Stutzmann 1977).

Frankel functional regulator – RF2 – is another orthopedic appliance that is used in the treatment of Class II Division I malocclusion with mandible retrognathism, in *growing* pre-pubertal period (Fig. 7.6a–c) (Frankel 1989, 2000).

Frankel appliances are located in the “vestibules orals” posturing the mandible, maintaining away the perioral capsule pressure and stimulating the whole respiratory system.

Patient 2: P.H.L., 8y At the beginning of treatment, (Fig. 7.7a–e) is similar compared with the first patient, but this case has some orthodontic problems: crowding, upper arch protruded teeth, narrow maxilla arch, deep vertical bite, and dysfunctions.

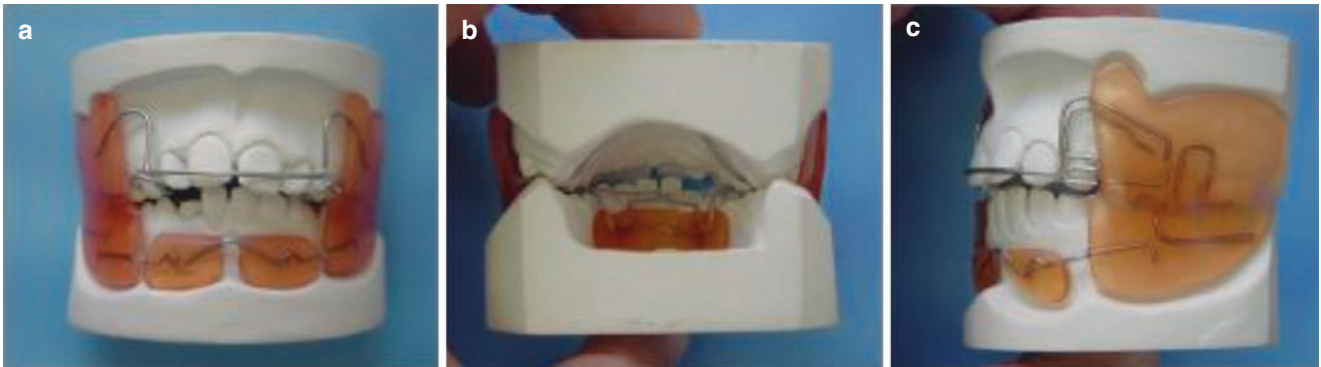

Fig. 7.6 Frankel functional regulator (RF2)

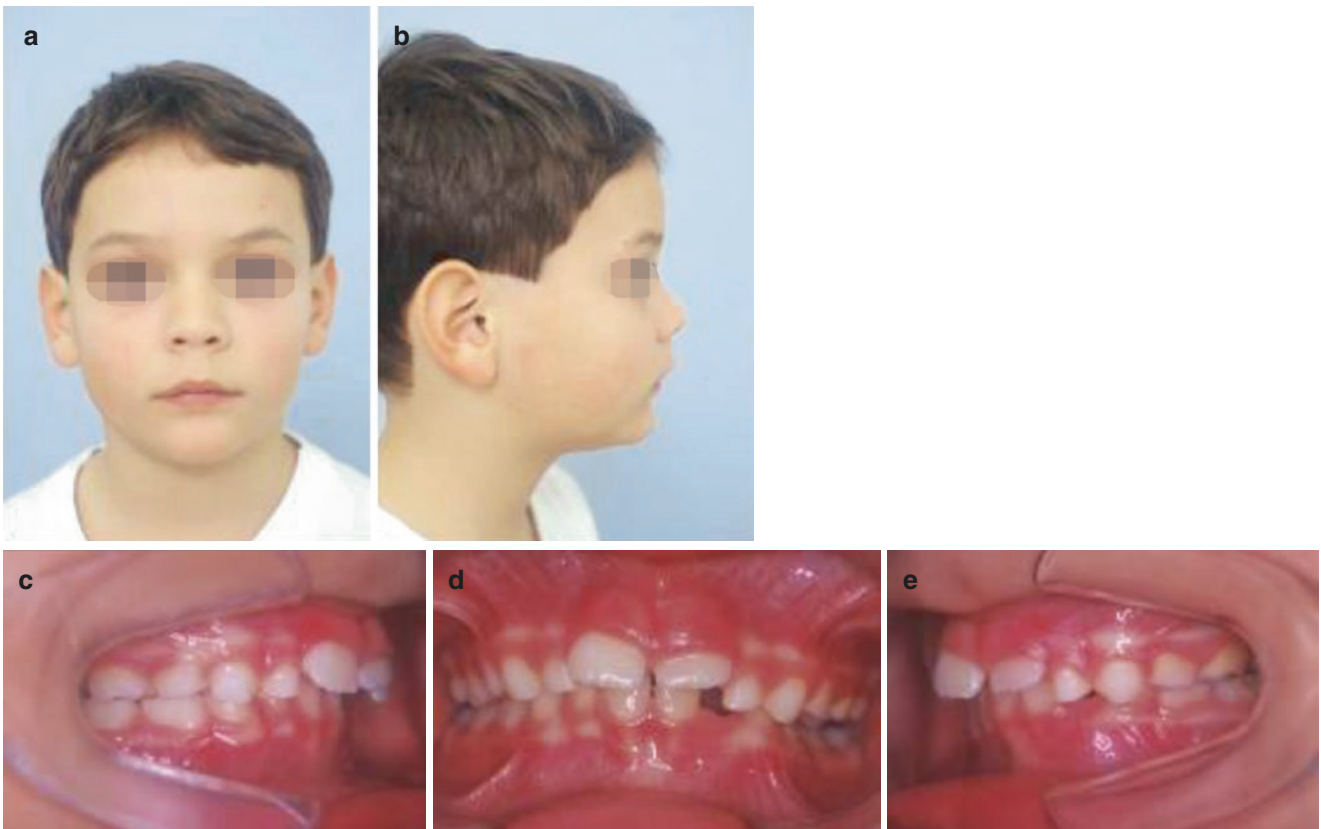


Fig. 7.7 Pre treatment frontal and dental facial and dental photos in a Class II 8 year old patient

The patient used three FR2 over 5 years of treatment, progress situation at 12y. 7 m (Fig. 7.8a–e).

Figure 7.9a–e shows the stability posttreatment over 2 years with no retention.

Figure 7.10a, b illustrates a lateral cephalometric study before and after the treatment and the excellent quality of mandibular development.

We must consider that only few patients are treated exclusively with Balters Bionator, Frankel functional regulator, or other functional therapies. Both therapies are similar and considered the only totally functional jaw orthopedic devices (Bishara and Ziara 1989).

The great majority of Class II Division 1 is patients with retrognathic mandible, transverse discrepancy of the maxilla, upper incisors protrusion, lower dental crowding, total Class II distal occlusion, and general dysfunctions. They need to be prepared before being submitted to a functional orthopedic treatment like the Bionator therapy.

R.M.E is the first recommended intervention. The Schwarz Plate or Ricketts lower utility arch may be indicated (McNamara 1985).

The next step of treatment will be the functional orthopedic stage with Balters Bionator, respecting all aspects from the construction bite to the adjustment in patient's mouth, instruction, and treatment control.

Unfortunately, a small percentage of cases can be treated only using Bionators.

After total analysis of the various, complementary examinations and appropriate analysis, the diagnosis will demonstrate upper transverse discrepancy in comparison with lower one, a deep bite, or an open bite, dental crowding, and respiratory dysfunction (Van der Linden 1986).

The patient must be prepared before being submitted to functional therapy like Balters Bionator.

Patient 3: J.D.S., 9y. 3 m At the beginning of treatment (Fig. 7.11).

Figure 7.12 shows the sequence before Balters Bionator used.

Sequence of the first stage: rapid maxillary expansion and simultaneously lower utility arc indicated to correct the lower incisors implantation. This phase took 8 months.

The second stage related with the facial harmony started immediately and was treated by an appropriated protocol in vertical, latero-lateral, and anterior-posterior directions. In this stage, the patient used a modified Balters Bionator.

Balters Bionator was installed without removing the Lower Utility Arch in place. The use of Balters Bionator during 1 year and after the treatment was finished with fixed

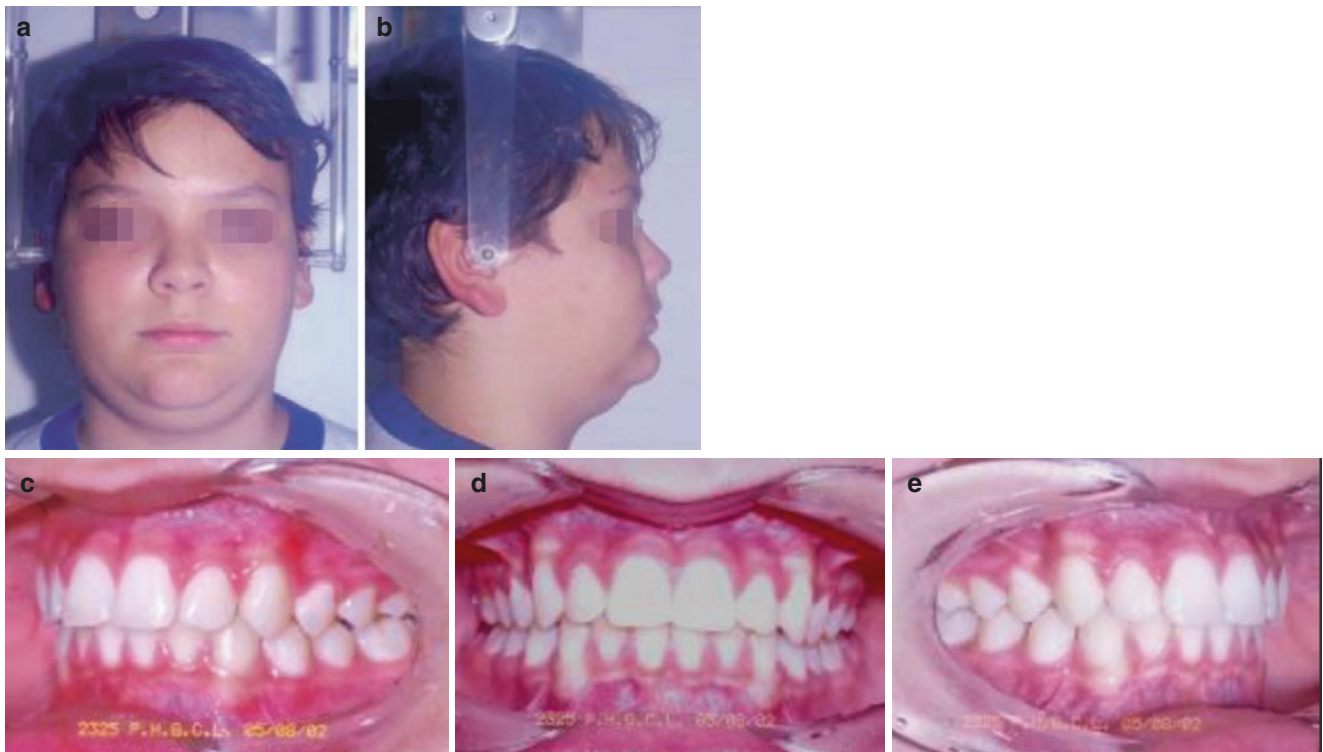

Fig. 7.8 Post treatment facial and dental photos : Class II is normalized as well as overjet and overbite

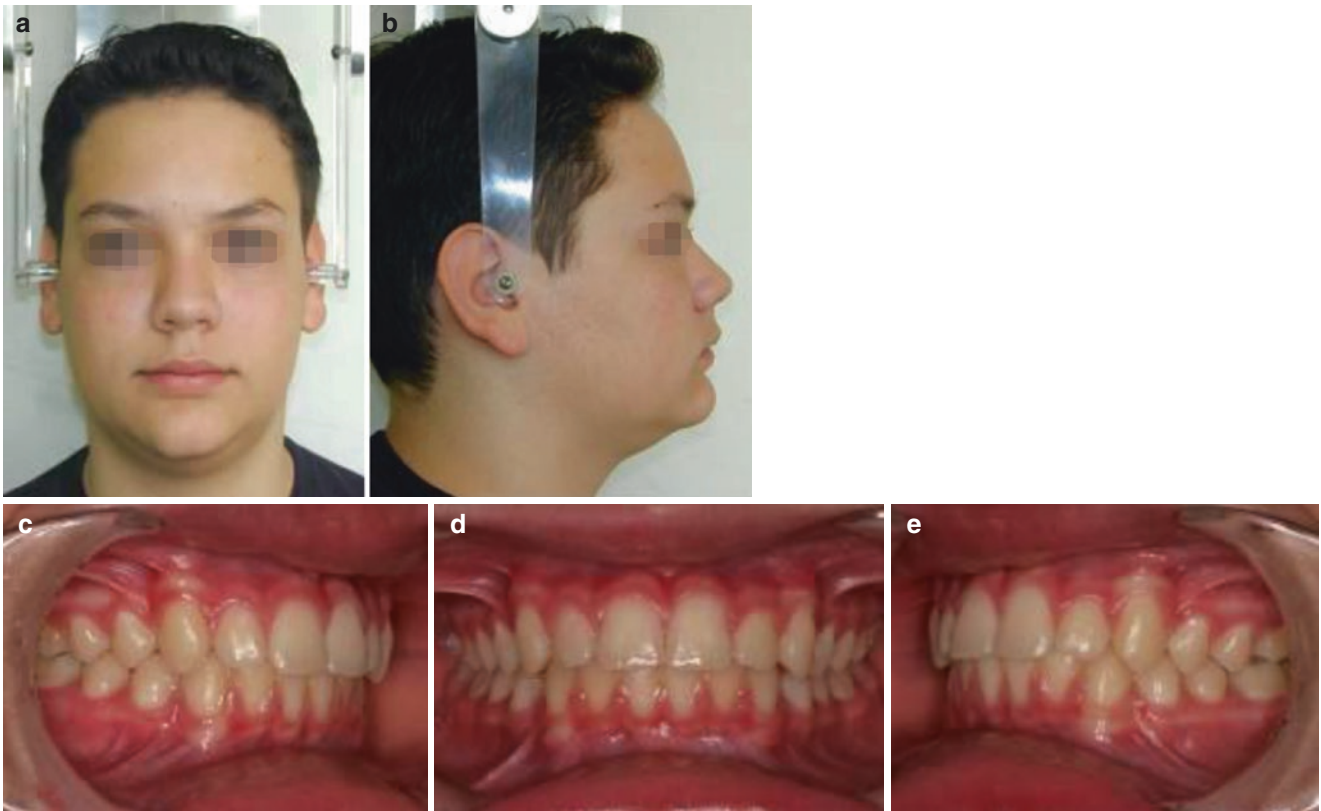


Fig. 7.9 2 years follow up with no retention

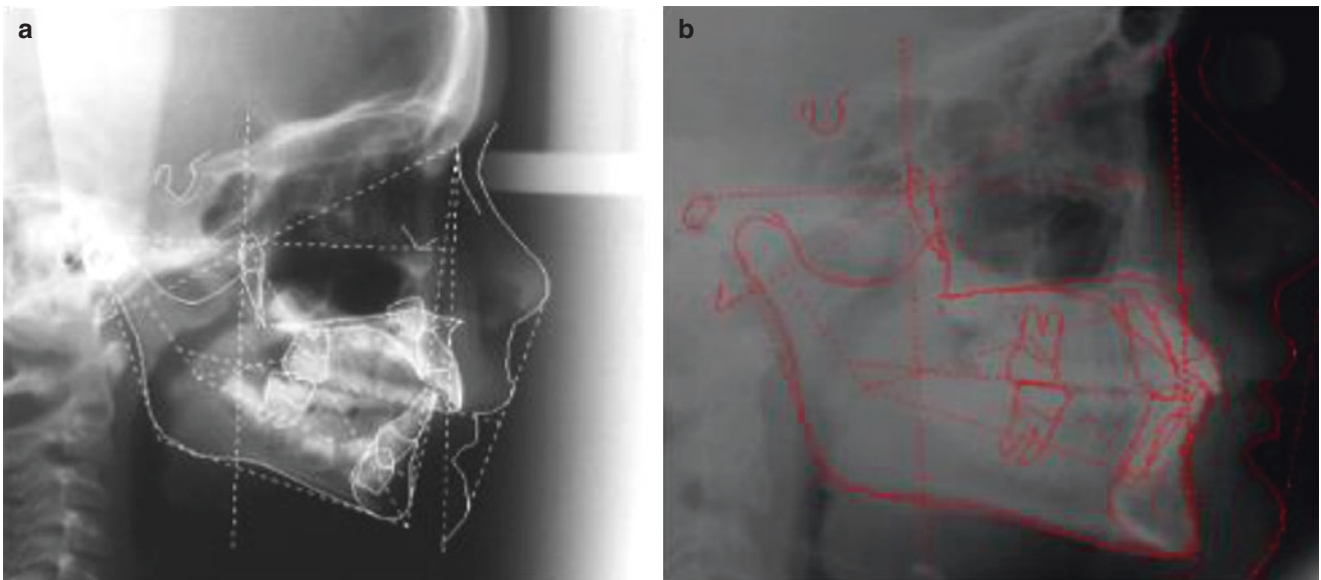


Fig. 7.10 Pre and post lateral radiographs

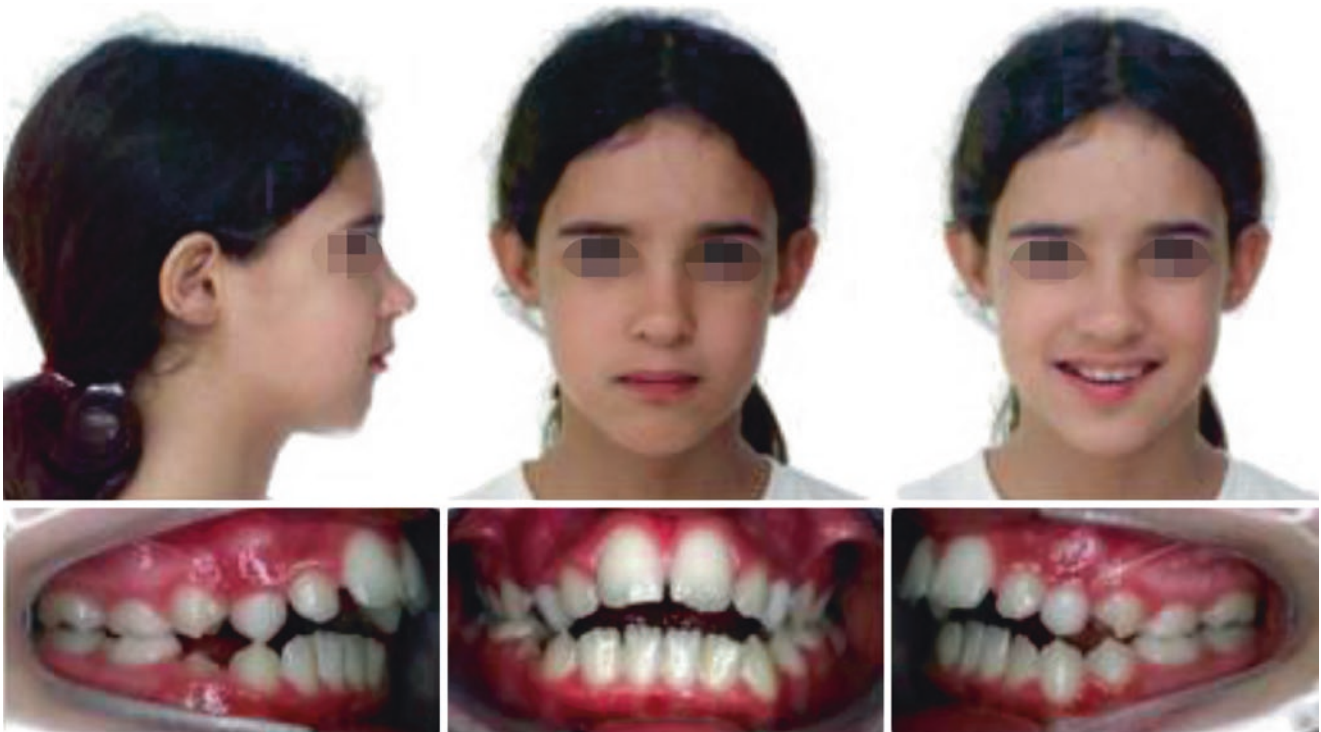

Fig. 7.11 Initial records

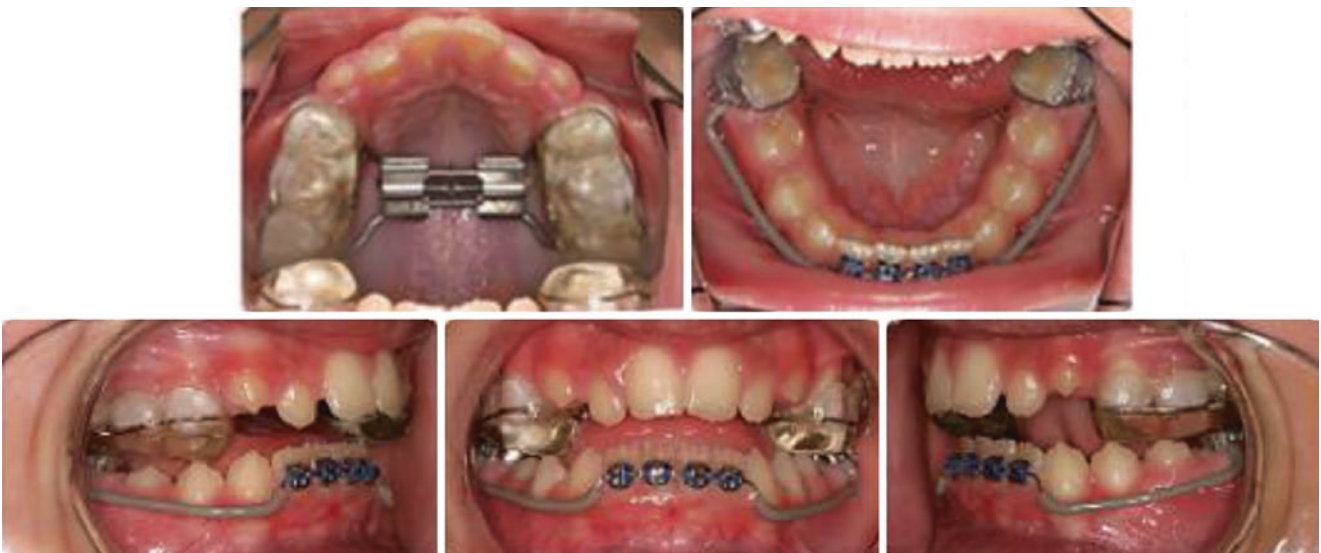

Fig. 7.12 RME appliance in place

total appliance to correct teeth alignment and implantation and finally achieve functional normal occlusion.

The retention was upper plate and lower lingual fixed (Fig. 7.13 shows the final case and Fig. 7.14 shows the lateral cephalometric image). Excellent facial result. Facial dimensions are according to Fibonacci's divine proportion.

In cases like this, orthopedic and orthodontic treatment must be started very soon in order to be able to correct facial harmony, normal occlusion, and neuromuscular behavior.

Sander, G., 1995, developed a new appliance – Bite Jumping Appliance – SII. It consists of two plates, remov-

able appliances with expansion screws and the upper one with a metallic guide that contacts the lower plate in the anterior region (Fig. 7.15a–c). Each time the patient closes the teeth, he or she advances the mandible and makes gymnastic with muscles induced by contacts on the front part as explained (Sander and Wichelhaus 1995) (Fig. 120).

At the same time, the SII appliance is a mandible protractor with transverse expansion of the maxilla and uprighting of molar posterior teeth. The advantage of SII treatment is the possibility to enlarge the maxilla, correct deep bite, open space for dental orthodontic treatment, and advance mandible at the same time. In these simultaneous cases, it is recommended to use

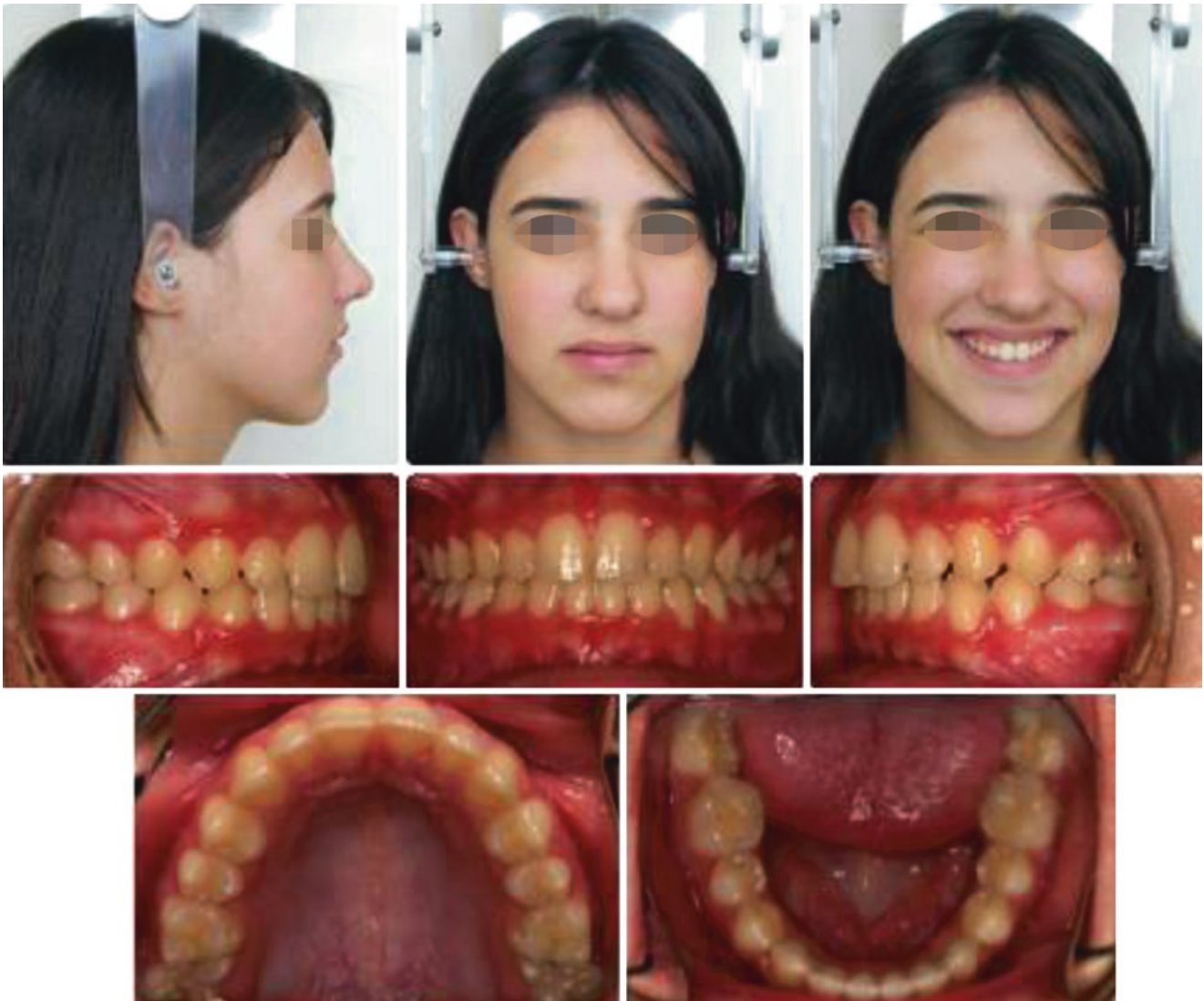

Fig. 7.13 Front, profile and final dental results

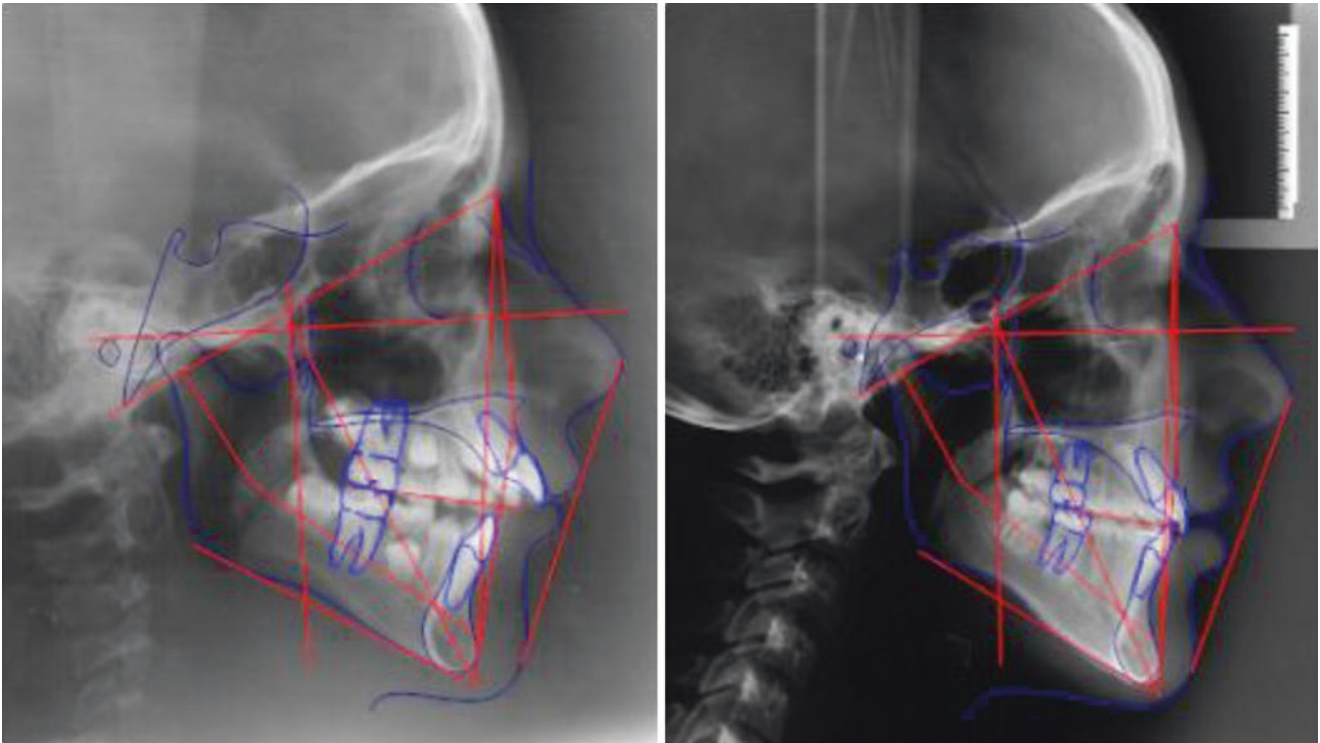


Fig. 7.14 Lateral cephalometric study before and 5 years after



Fig. 7.15 Upper and lower SII appliance in place

Sander jumping the bite (SII). Sander's SII and Clark's Twin Block have a similar action.

Patient 4: R.L.B.H., 12y At the beginning of treatment (Fig. 7.16a–e). The first stage of treatment that lasted 1 year and 6 months shows the evolution and complete treatment with SII (Sander 2001) (Fig. 7.17).

Next stage with fixed appliance including retention took 15 months and present very stable results. Figure 7.18a–e presents the end of treatment.

The long-term evaluation confirms a very stable result (Fig. 7.19a–e).

Cases of patients with pronounced Class II Division 1 with severe retrognathic mandible, upper protrusion, deep bite, and dysfunctions but without lower crowding must be treated immediately, even in the deciduous dentition. The biological reason is that the development of the dental facial complex under such reverse epigenetic factors will get worse with time (Korhaus 1940) (Fig 7.20).

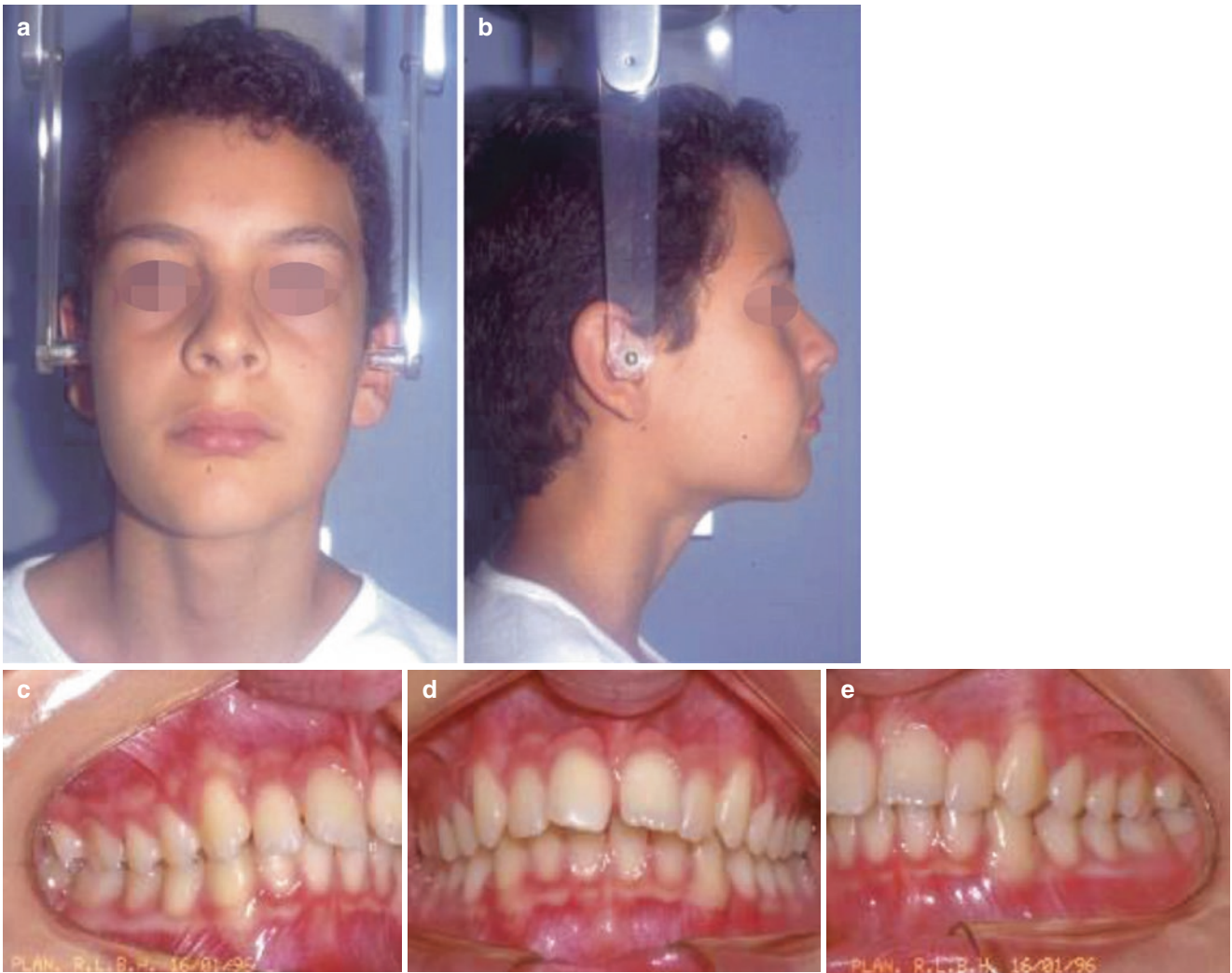

Fig. 7.16 Pre treatment records of a 12 year patient with Class II molar and canine

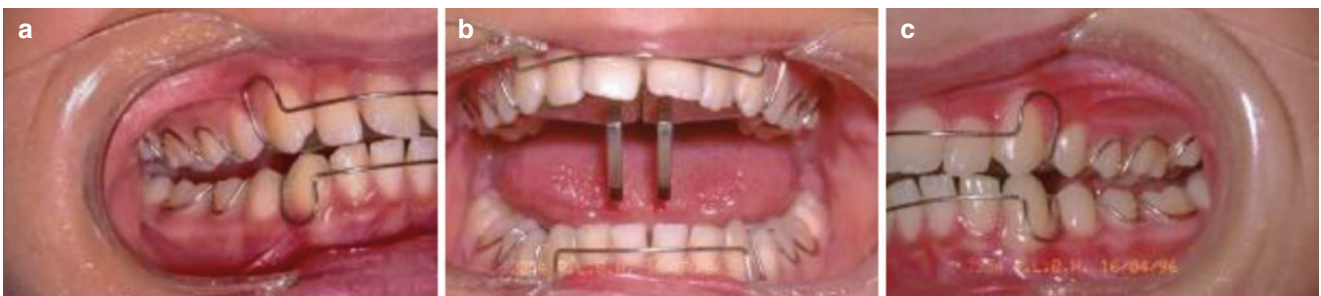

Fig. 7.17 SII appliance in place after 18 months of treatment

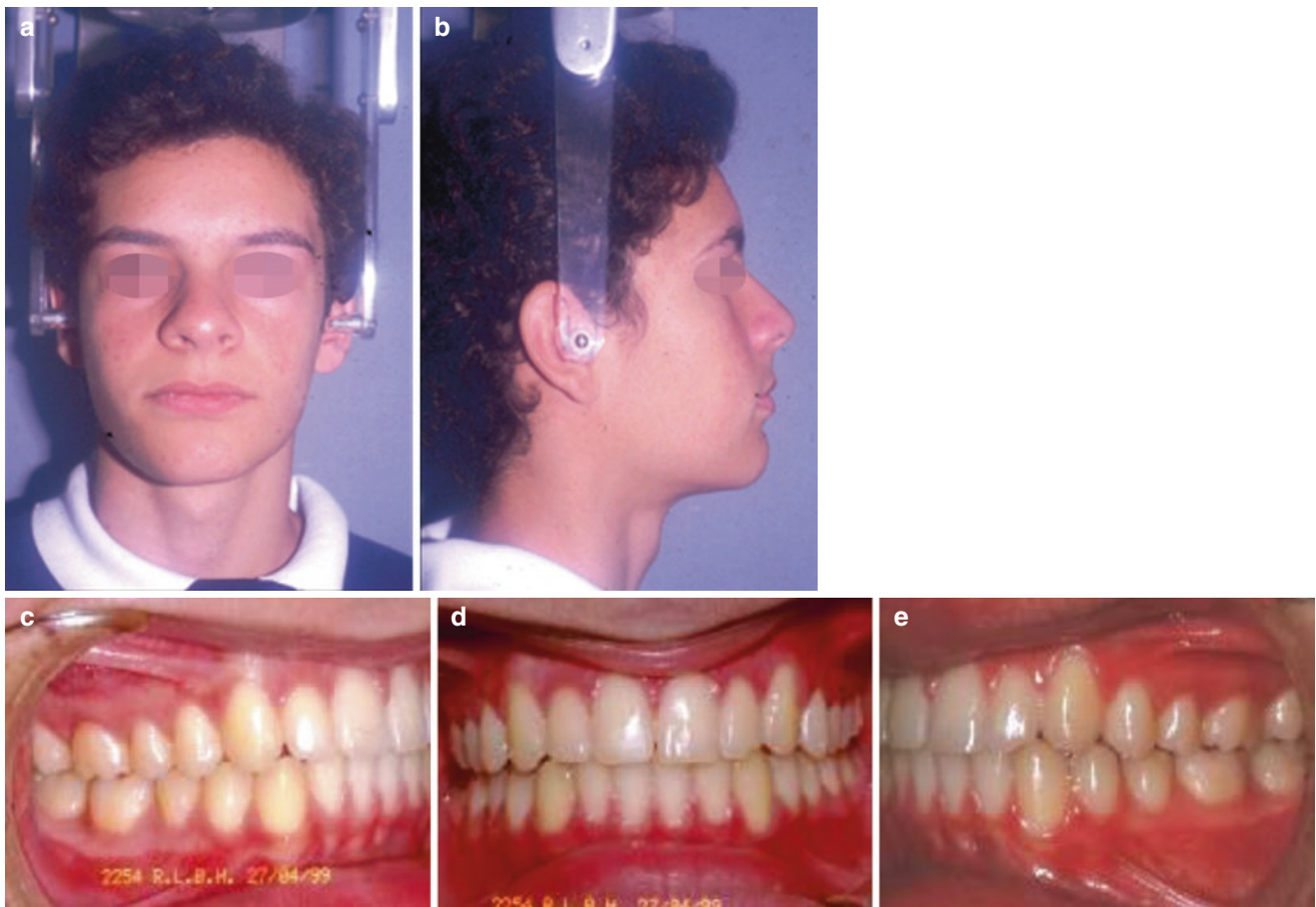

Fig. 7.18 Post treatment facial and dental photographs

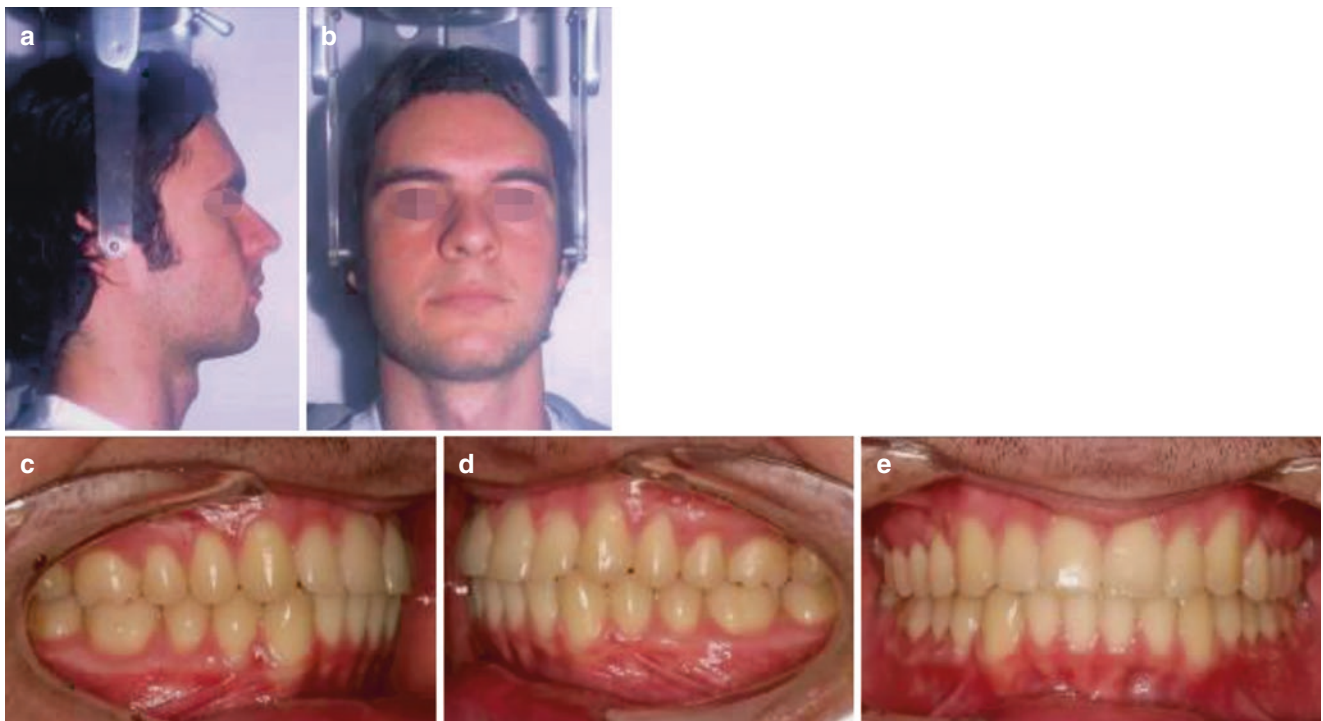


Fig. 7.19 Final results

Patient 5: L.M., 4y. 6 m At the beginning of treatment. The treatment will take a long time using the Balters Bionator during the first stage and Sanders' double plates (SII) during second stage (Figs. 7.21, 7.22, 7.23, and 7.24).

All priorities could be normalized, facial orthopedic harmony, balanced occlusion, and balanced neuromuscular function. That is the real stimulation for normal functional adaptation including form, size, and shape of the masticator system (Faltin et al. 2003; Malta et al. 2010).

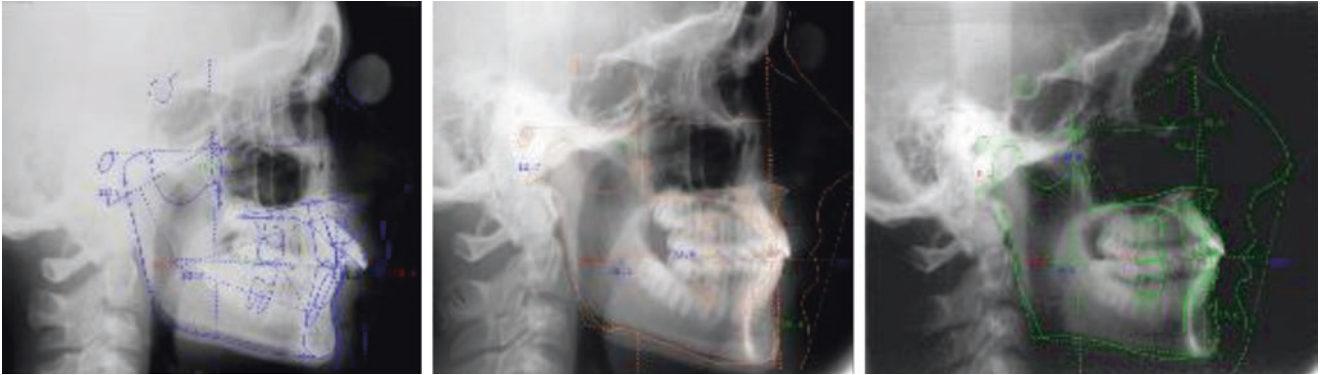


Fig. 7.20 Lateral cephalometric measurements: before, during and after treatment

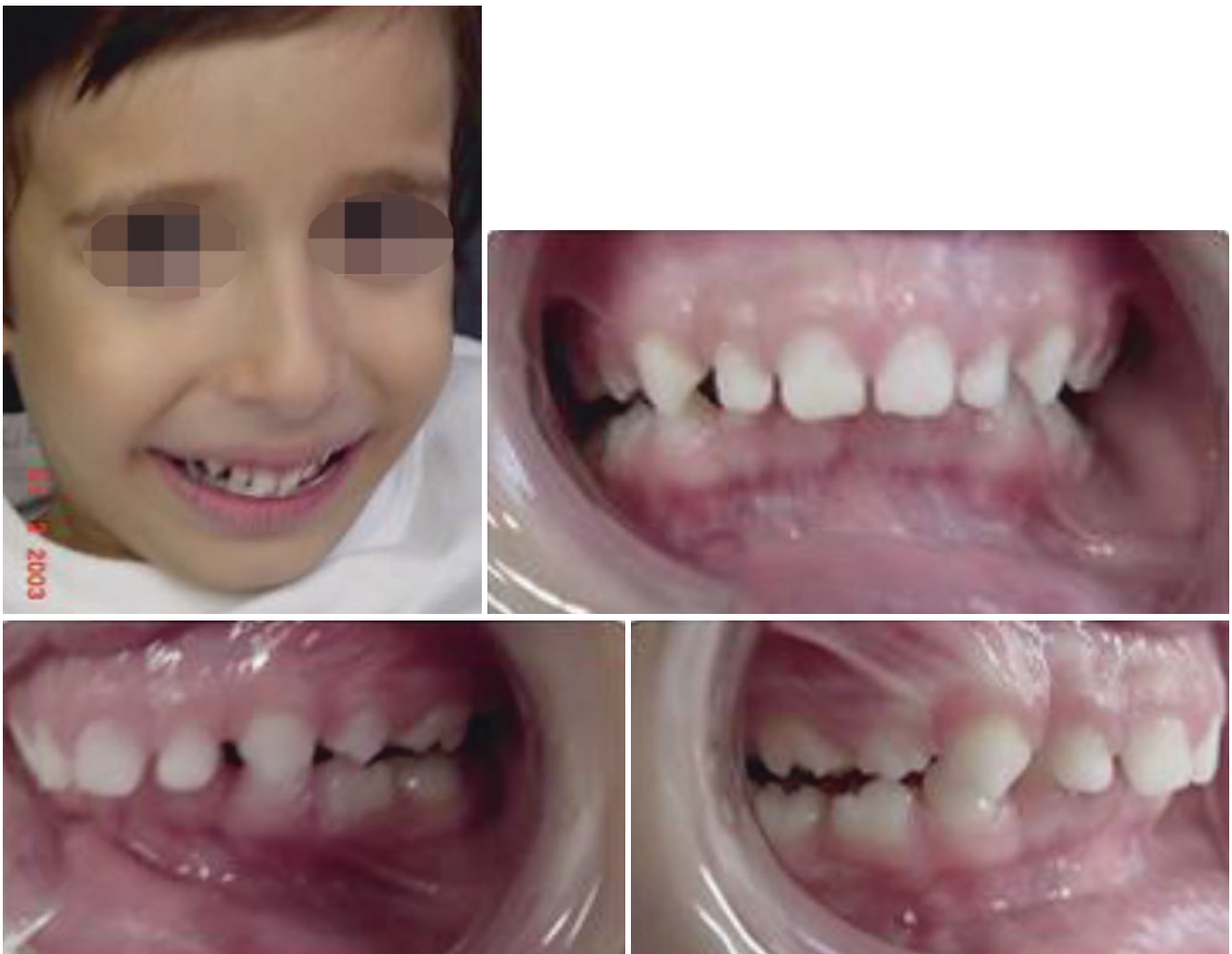

Fig. 7.21 Pre treatment photographs of a 4-year, 6-month old boy

The advanced of SII treatment is the possibility to wide maxilla, correct deep bite, open space for dental orthodontic treatment, and advance mandible.

The patient used upper expansion removable plate with super elastic screws, SII, and Bionator from November 2001 to March 2005 (Fig. 7.22).

From June 2010 to June 2013, the second stage was treated with fixed appliance and retention (Fig. 7.23). These excellent results could only be obtained when the treatment starts at a very young age.

The SII in treatment of Class II Division I with mandible retrognathism is indicated when the patient is in the prepu-

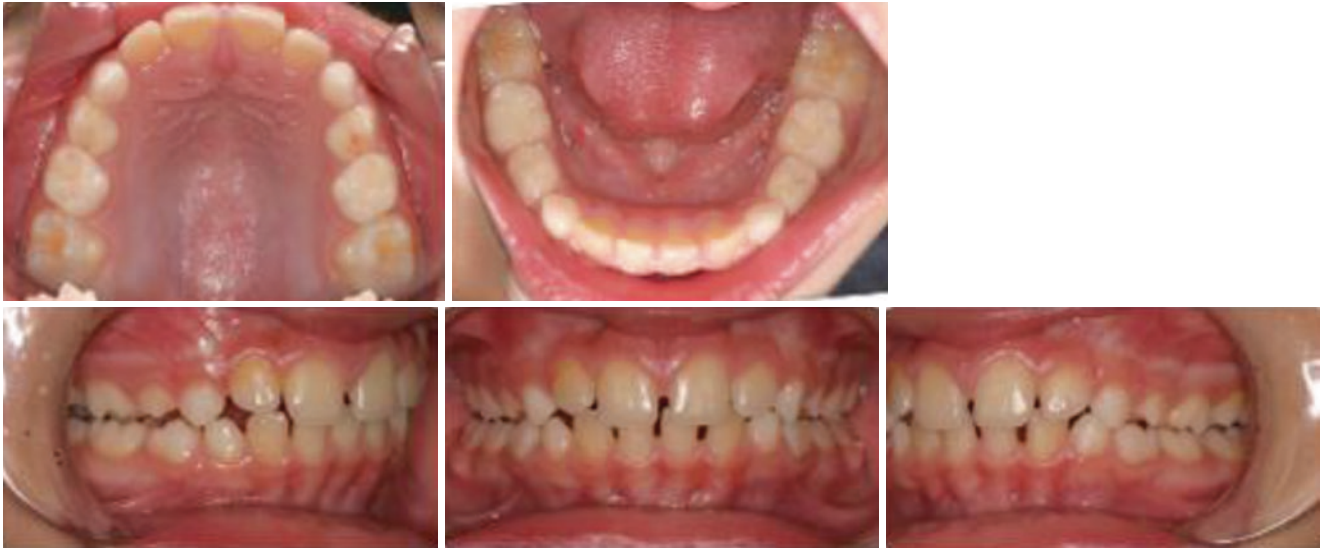

Fig. 7.22 After using SII appliance and Bionator for Nov 2001 to March 2005

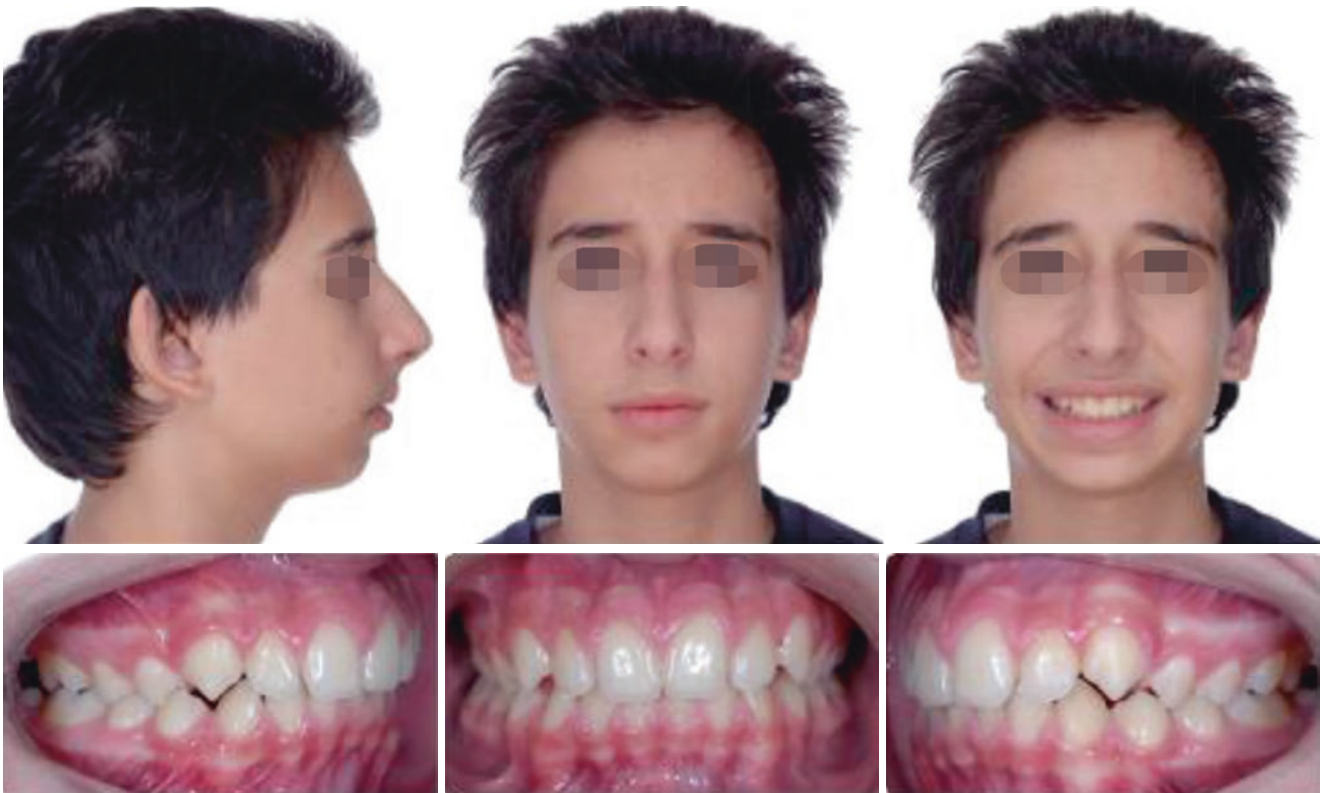

Fig. 7.23 Final results

bertal stages of cervical vertebral maturation up to IV or V, as proposed by *Franchi e Baccetti*, with maxillary transverse deficiency and dental crowding.

In special situations of facial development, it is necessary to focus first on facial aesthetics.

Patient 6: K.B., 10y At the beginning of treatment (Fig. 7.25). The patient was treated in a unique stage. The priority was to achieve first the facial harmony because of the poor vertical dimensions. In sequence she was treated with bio-mechanics fixed therapy.

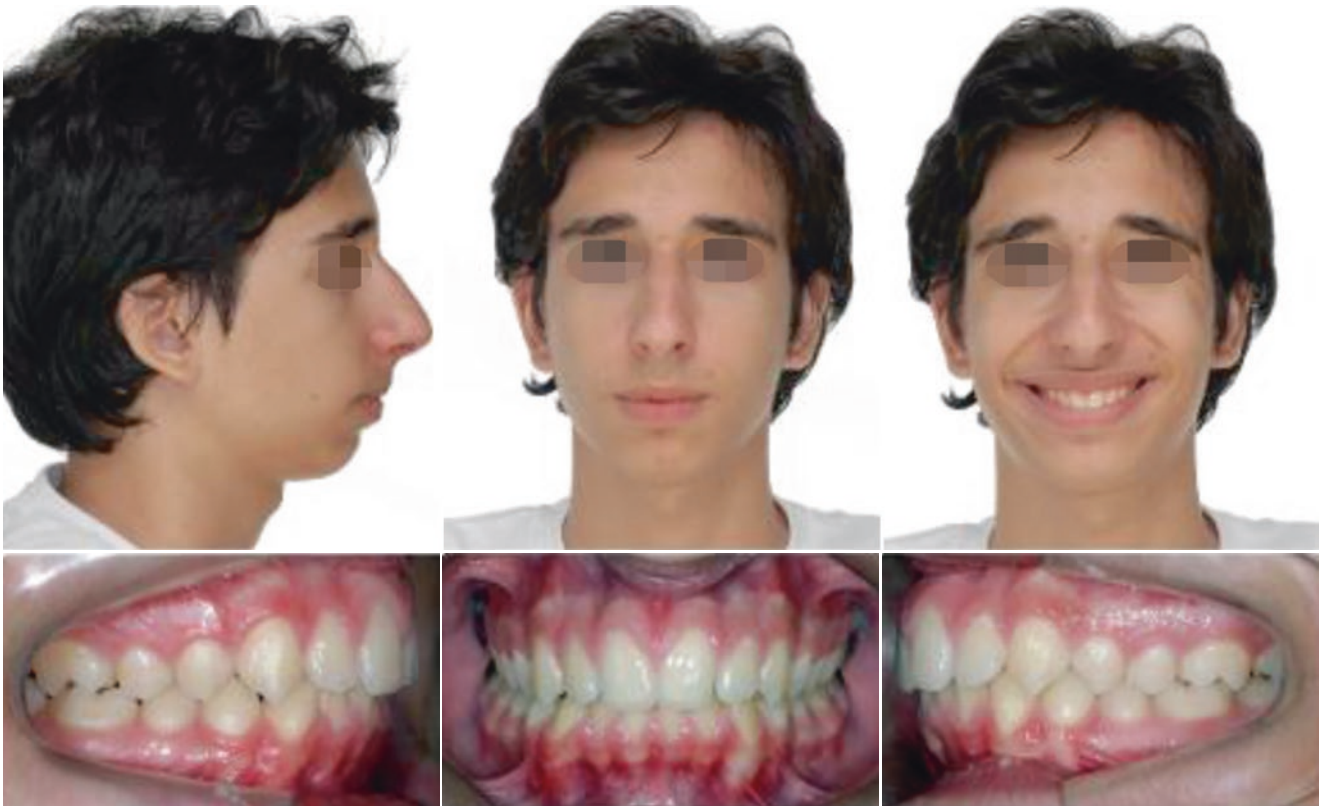

Fig. 7.24 After long-term treatment

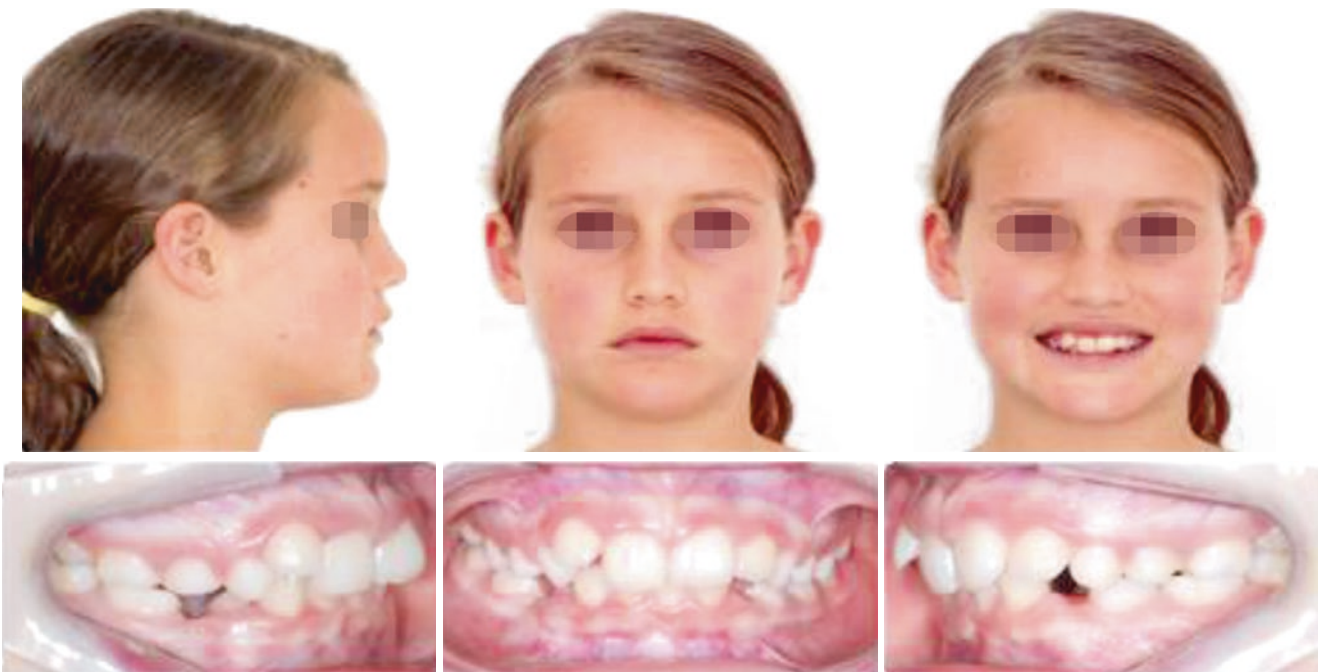

Fig. 7.25 Pre treatment photos of a 10 year old Class II patient

7.1.1 The treatment sequence:

Balters Bionator result (Fig. 7.26) than fixed appliance and quadric helix (Fig. 7.27) and the end of treatment (Fig. 7.28). Figure 7.29 is lateral cephalometric study: before and immediately after and a long term (Balters 1964a,b).

In this case, because of the advanced stage of development, we decided to treat first the facial harmony with Balters Bionator philosophy than fix appliance according to Ricketts' philosophy.

Patient 7: F.A., 10y.2 m At the beginning of treatment. Another typical case of mandible retrognathism (Figs. 7.30a–c and 7.31a–c).

Figure 7.32 shows the occlusion with and without the Balters Bionator when the class I was achieved. The patient used five Balters Bionator during 2 years and 3 months and completed the treatment using fixed appliance.

Figure 7.33 presents the end of the treatment and the total treatment time was 4y. 3 m.

Figure 7.34 shows the stability of the treatment in long-term observation 6 years after retention.

Figure 7.35 shows the lateral Rx where it is possible to observe very clear the development of the face and recognize the mandible growth.

Figure 7.36a, b are images from CBCT, before and after the treatment, demonstrating the functional adaptation on TMJs, relocating the condyles in glenoid cavities.

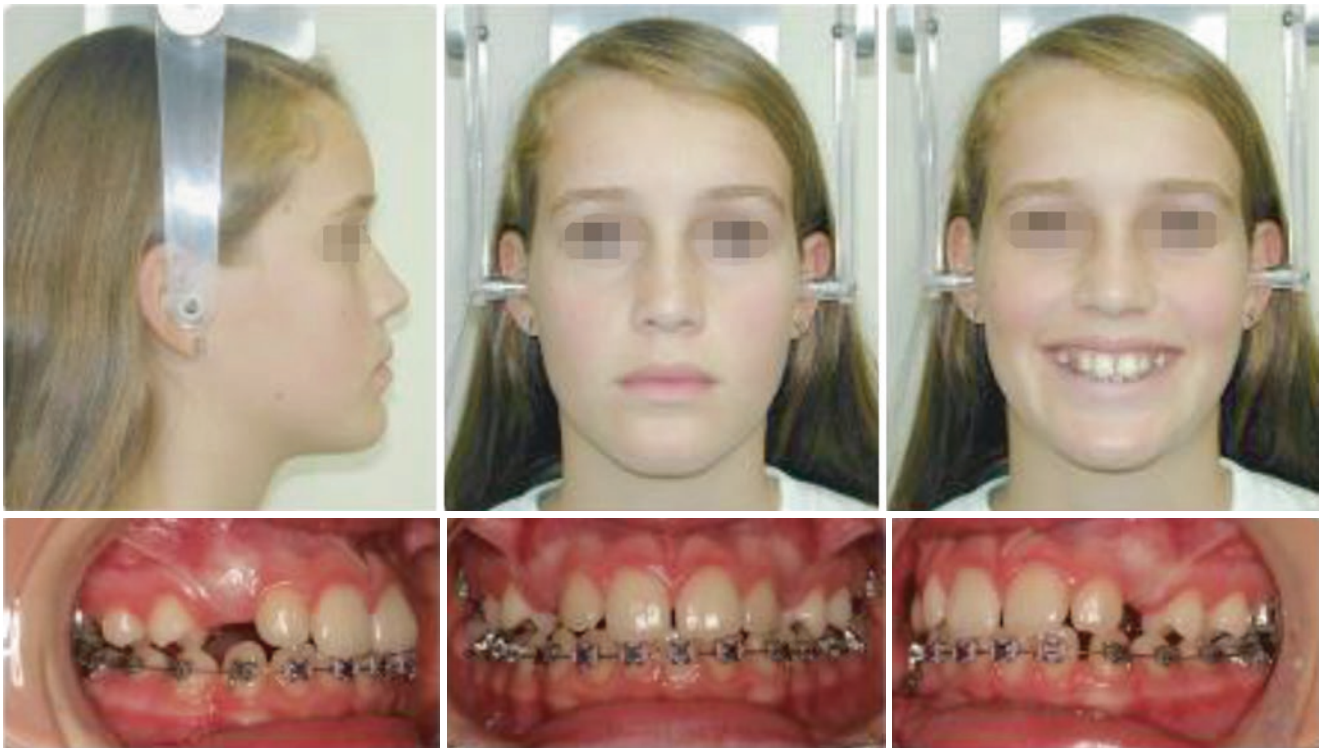


Fig. 7.26 1 yera in treatment with fixed appliances

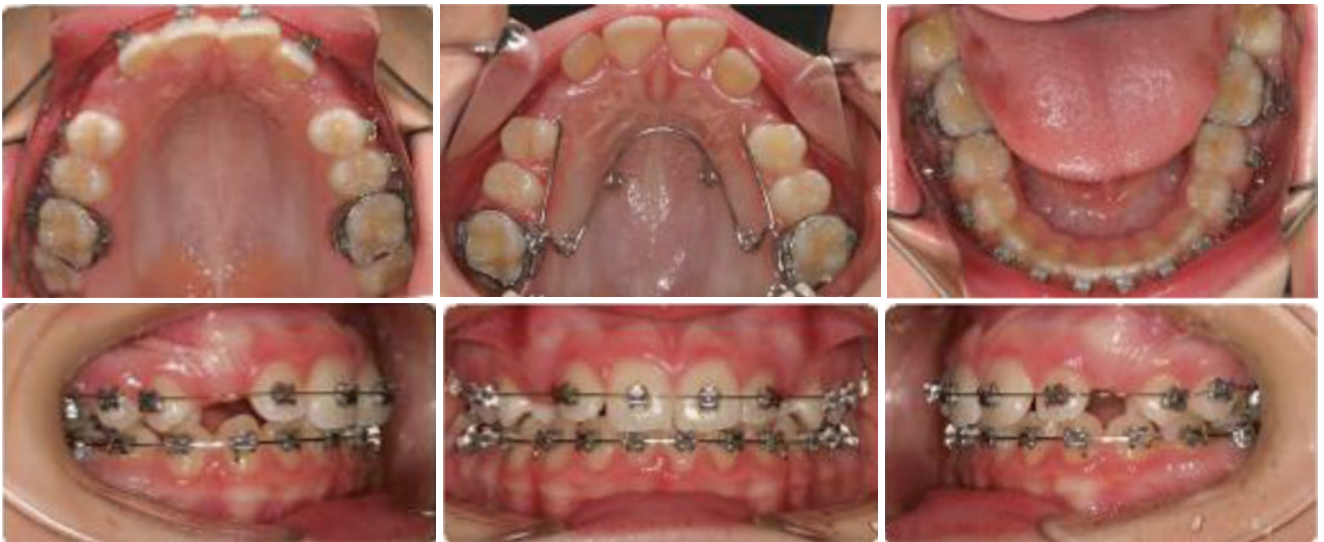

Fig. 7.27 Dental upper and lower photos with brackets in place along with an upper quad-helix

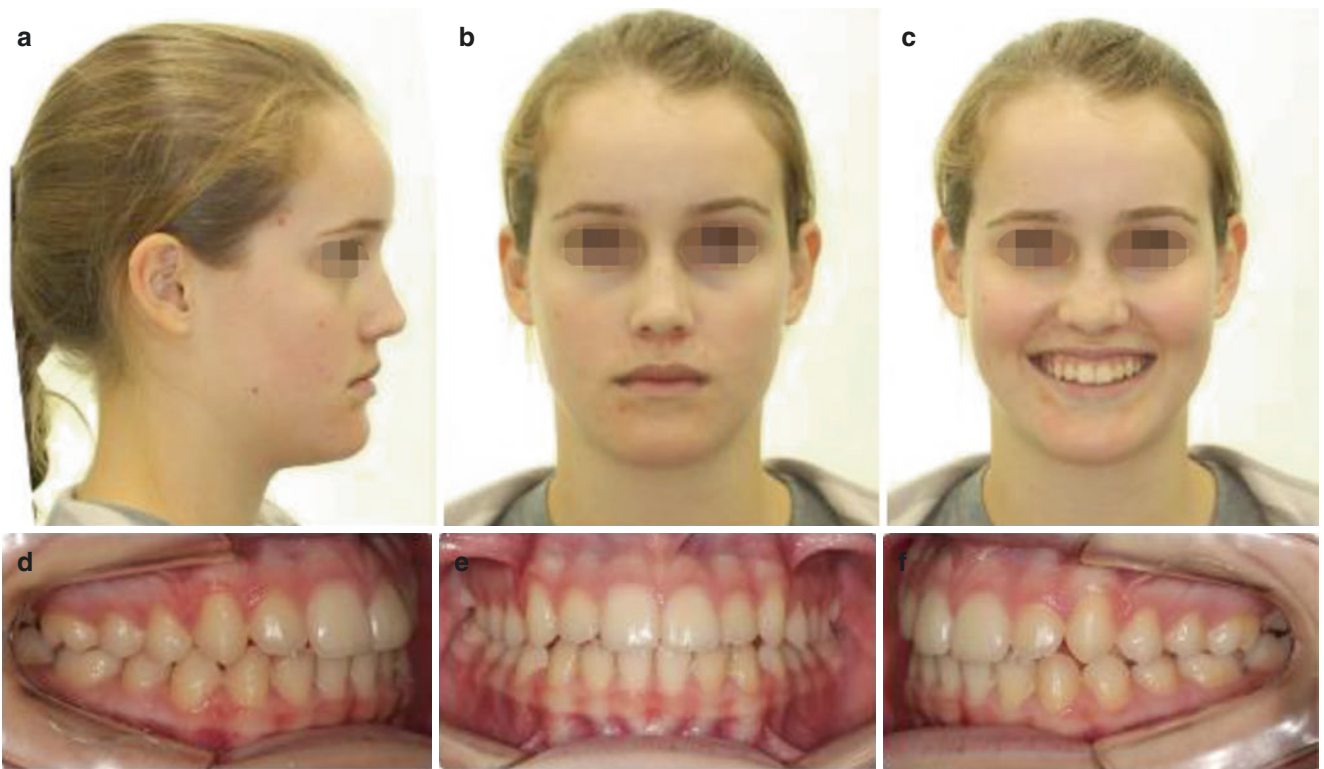


Fig. 7.28 Facial and dental post-treatment photos

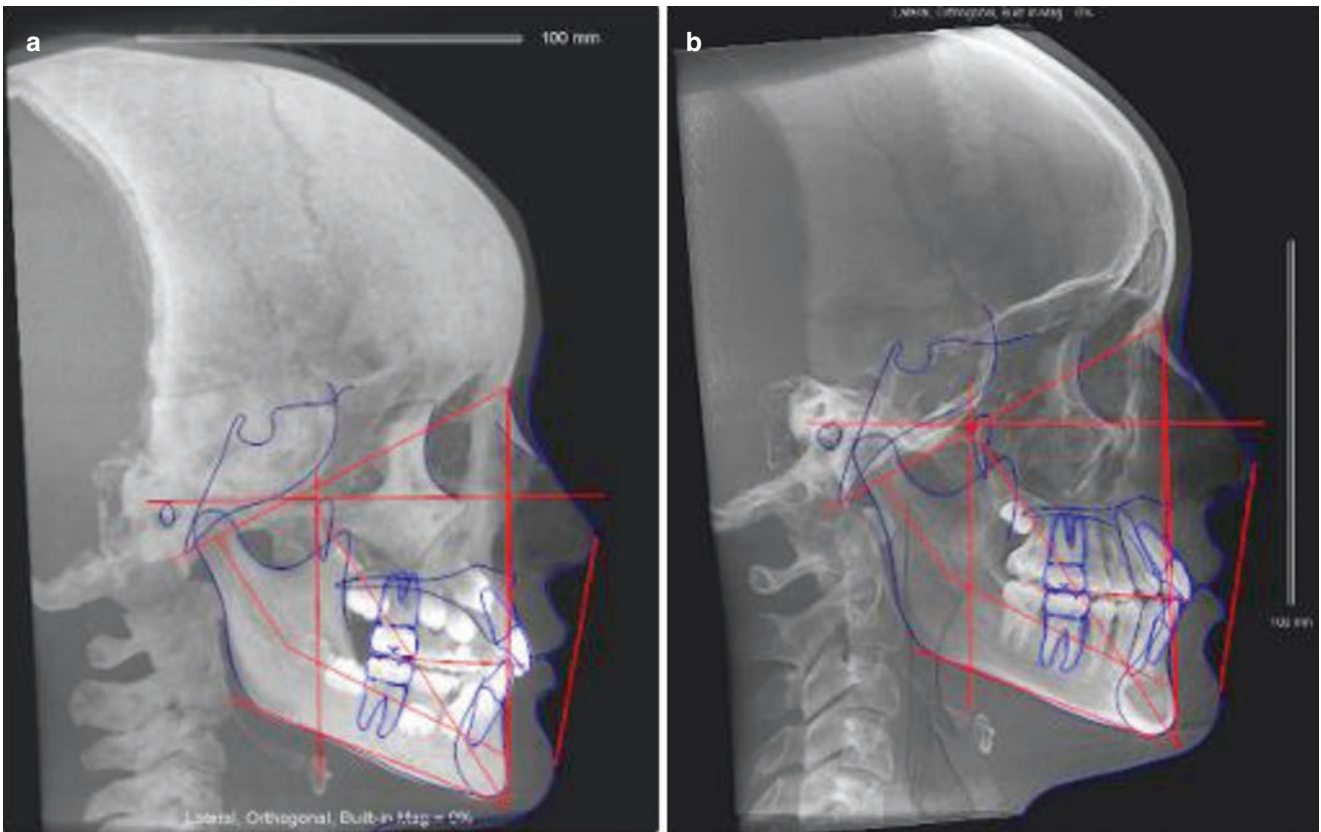


Fig. 7.29 Comparison pre and post lateral radiographs

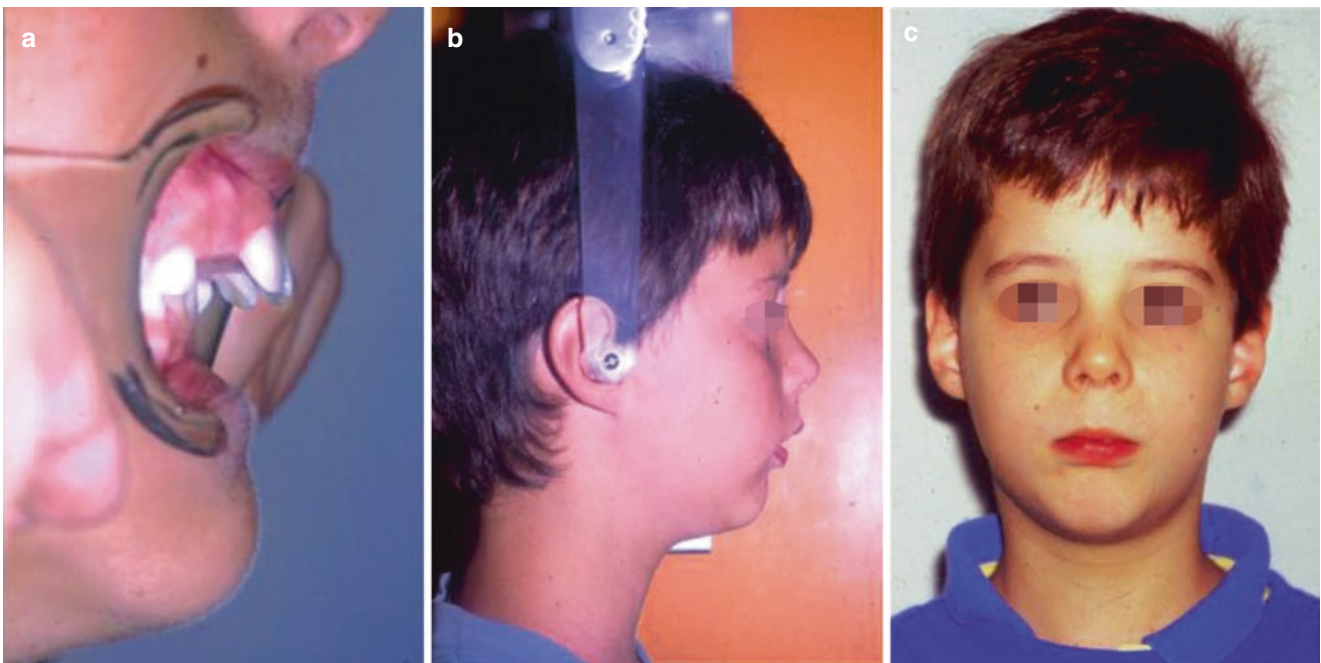


Fig. 7.30 A 10 year 2 month boy with an important retrognathic mandible at the beginning of the treatment

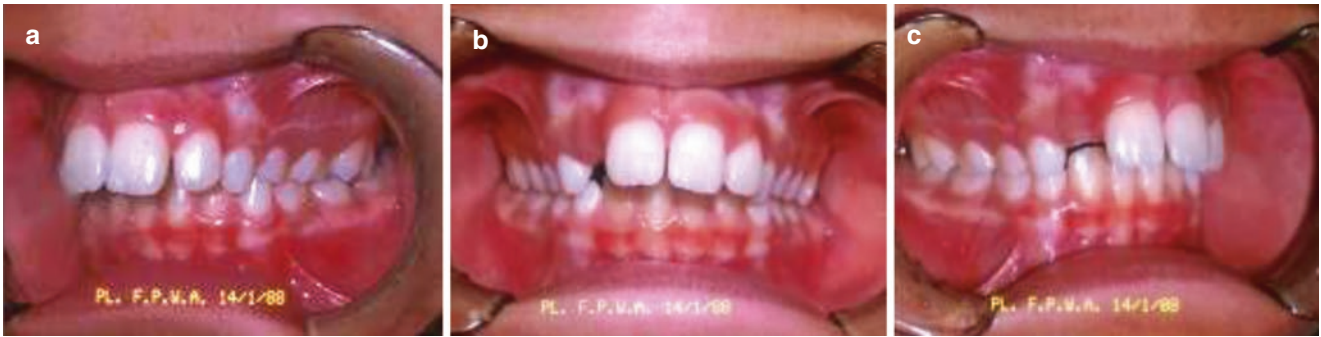

Fig. 7.31 Pre treatment dental occlusion Midlines are not coincident and a significant overbite is present

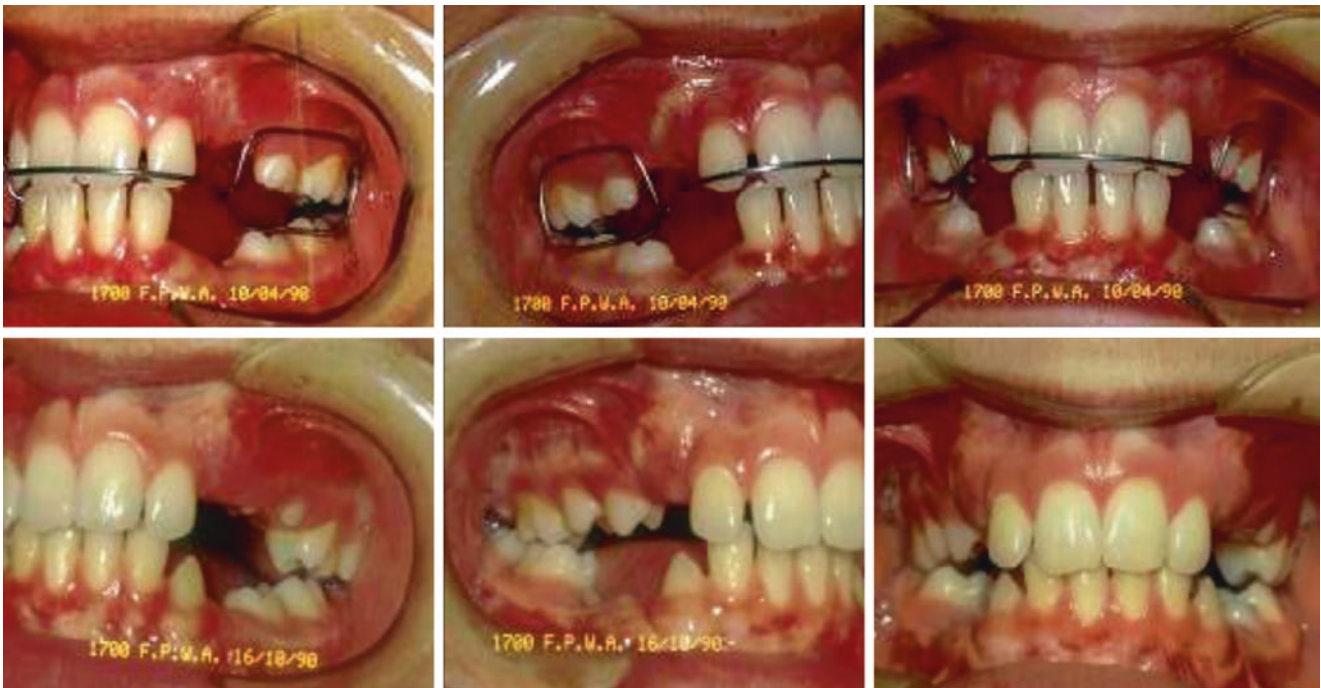


Fig. 7.32 Occlusion with and without Balters Bionator appliance

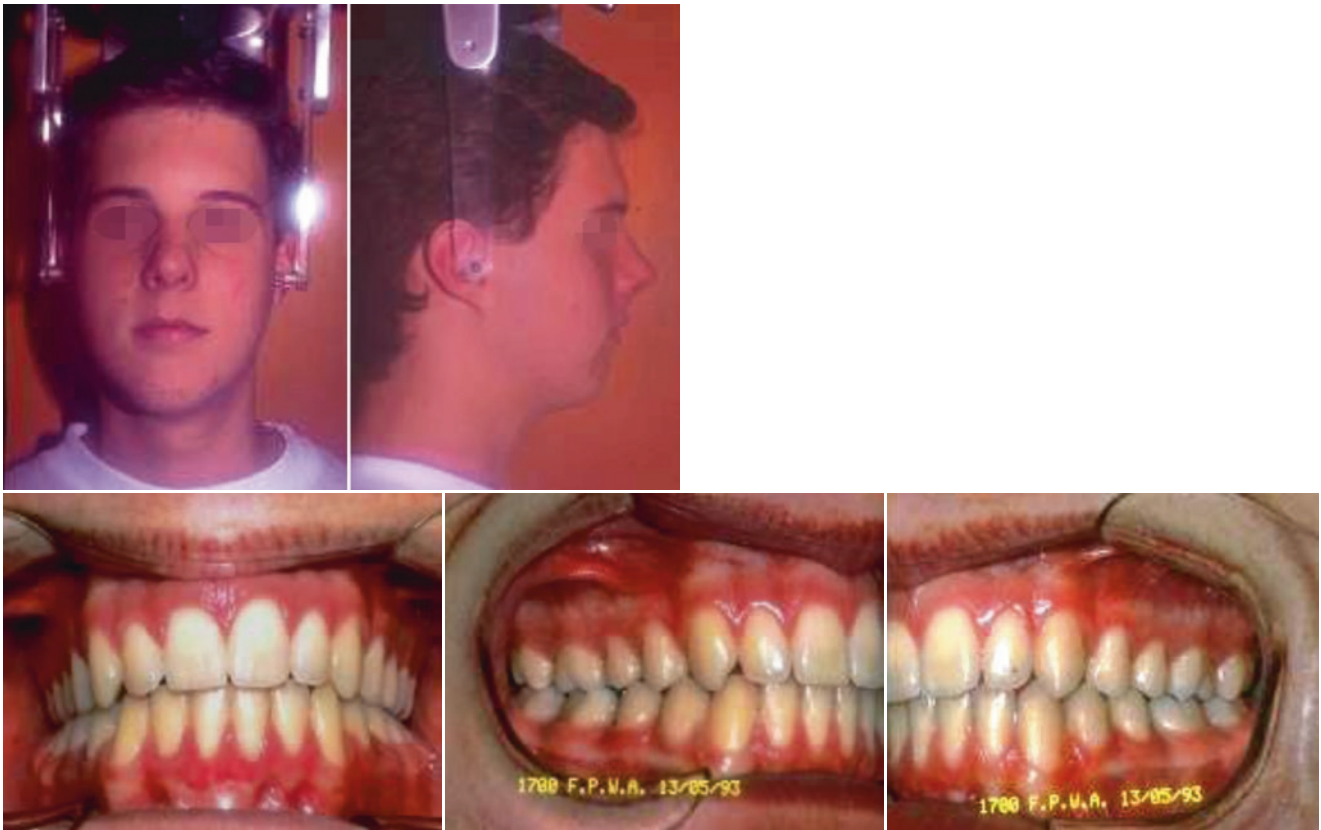

Fig. 7.33 Facial and dental photographs at the end of the treatment

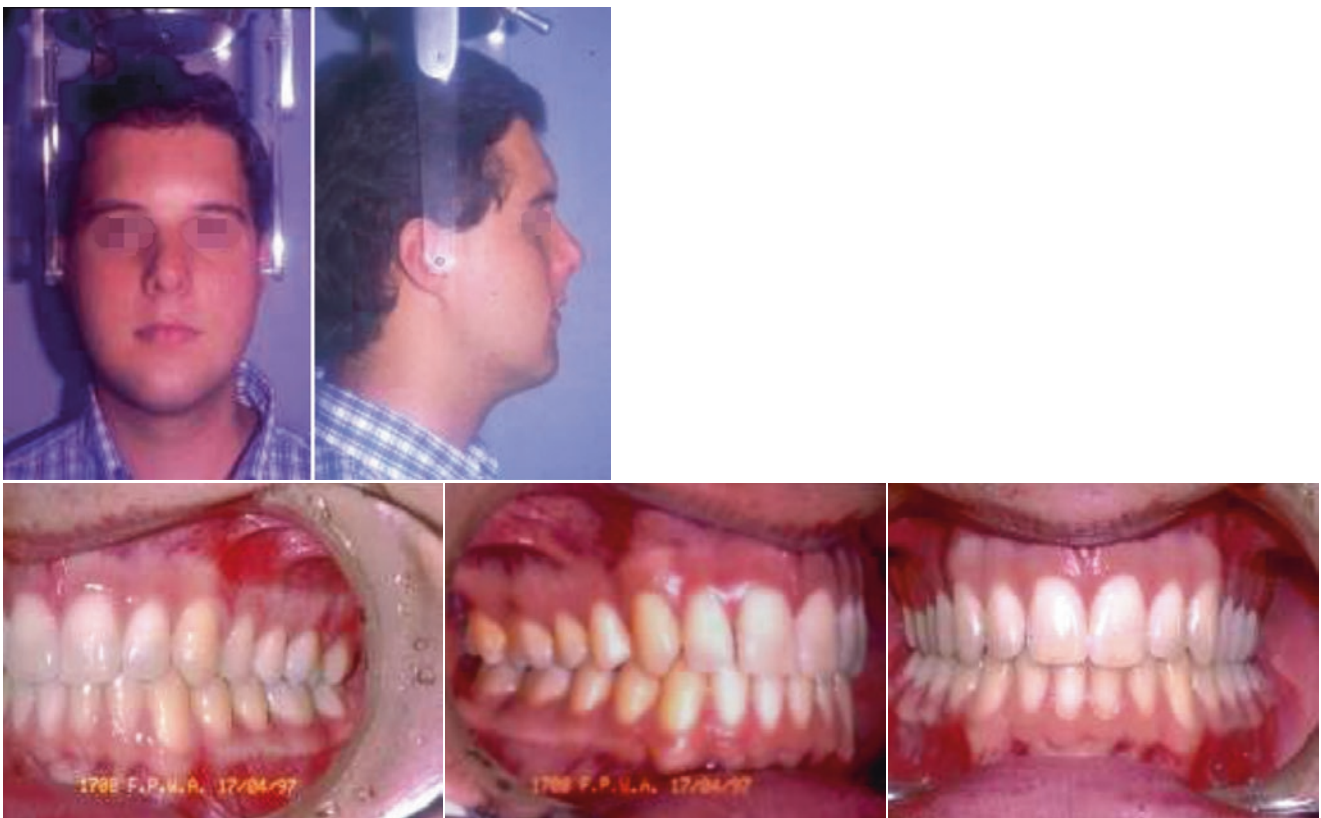

Fig. 7.34 Follow up 6 years after the end of the treatment

Fig. 7.35 Pre, Post and follow-up lateral radiographs

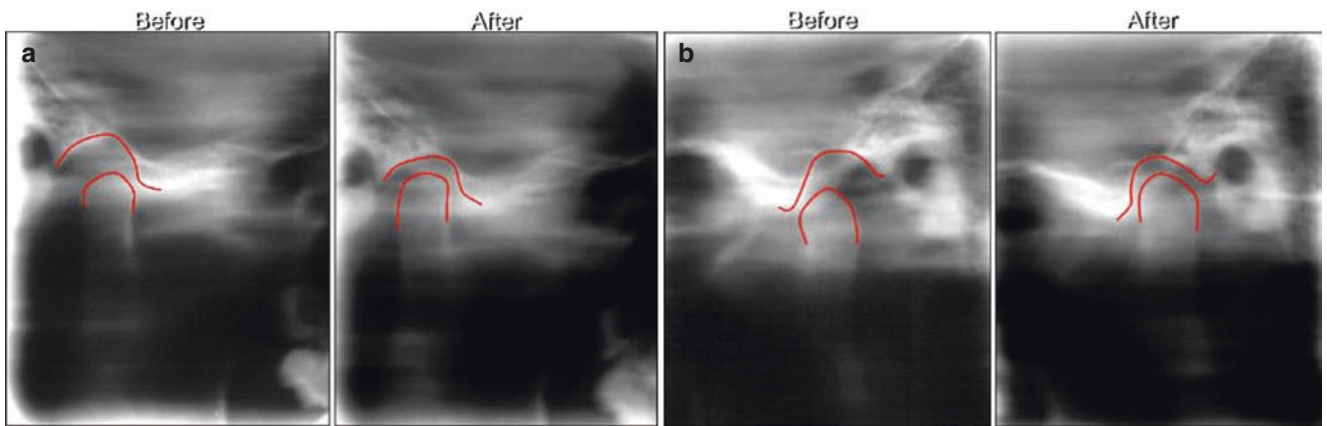
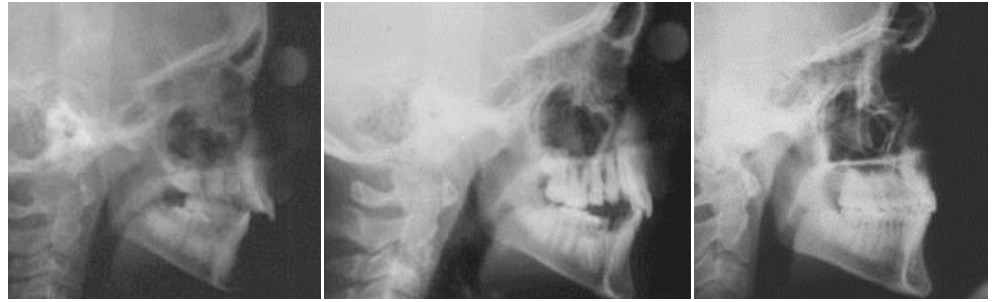

Fig. 7.36 (a) Right condyle. (b) Left condyle

7.2 The Maxillary Prognathism Treatment

When Class II Division I is characterized as maxillary protrusion, the treatment protocol indicated is extraoral traction, developed by G. Sander (Fig. 7.37). This special extraoral traction appliance has constant cervical force of 4–5 newtons. The appliance needs to be used for 18 h per day.

When the individual diagnosis shows a narrow transverse midface and the RME is priority number one, start treatment with maxillary expansion is primordial.

The traction is always cervical. If the patient has a horizontal growth tendency, it is necessary to associate with an upper anterior bite plate. If the patient has a vertical growth tendency, it is indicated a lower posterior bite plate.

After the orthopedic correction, the treatment is finalized with biomechanics fixed appliances and finally retention.

Patient 8: S.C.W., 11y The beginning of treatment (Figs. 7.38a, b and 7.39a–c).

The first stage of treatment was maxillary expansion with upper removable expansion plate; treatment time is 8 m (Fig. 7.40).

The total treatment took 2 years and 11 months (Fig. 7.41).

Lateral cephalometric evaluation (Fig. 7.42) before, during, and long-term control shows total stable situation.

Patient 9: C.P., 9y 10 m The beginning of treatment (Fig. 7.43). This case illustrates a combined treatment of extraoral appliance and Balters Bionator.

The sequence was:

1. Maxilla transverse correction
2. Balters Bionator therapy during 2y and 10 m (Fig. 7.44).
3. Extraoral appliance (1 year) and another (13 months) total fixed appliance (Fig. 7.45) shows the case at the end of the treatment.
4. Long-term control (Fig. 7.46).
5. Lateral cephalometric images before and after the treatment (Fig. 7.47).

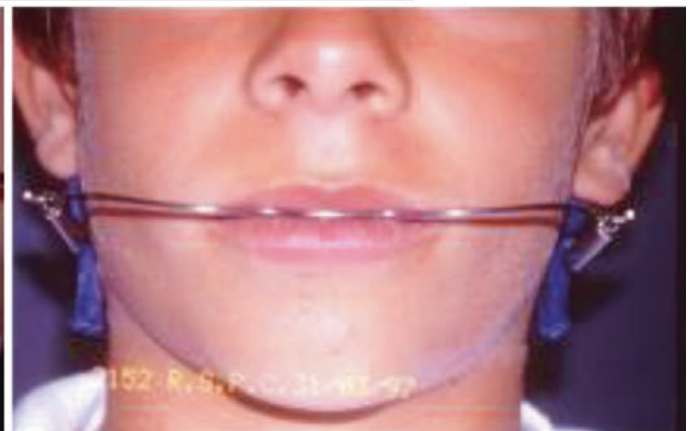
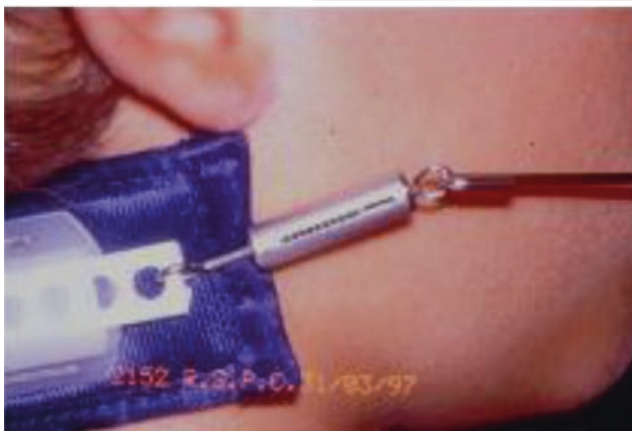
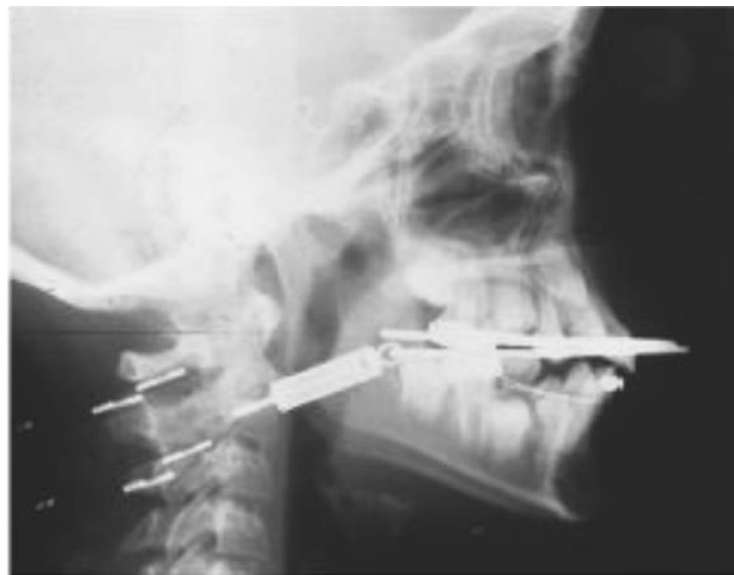Fig. 7.37 Lateral radiographs and Sander's extraoral traction appliance in place

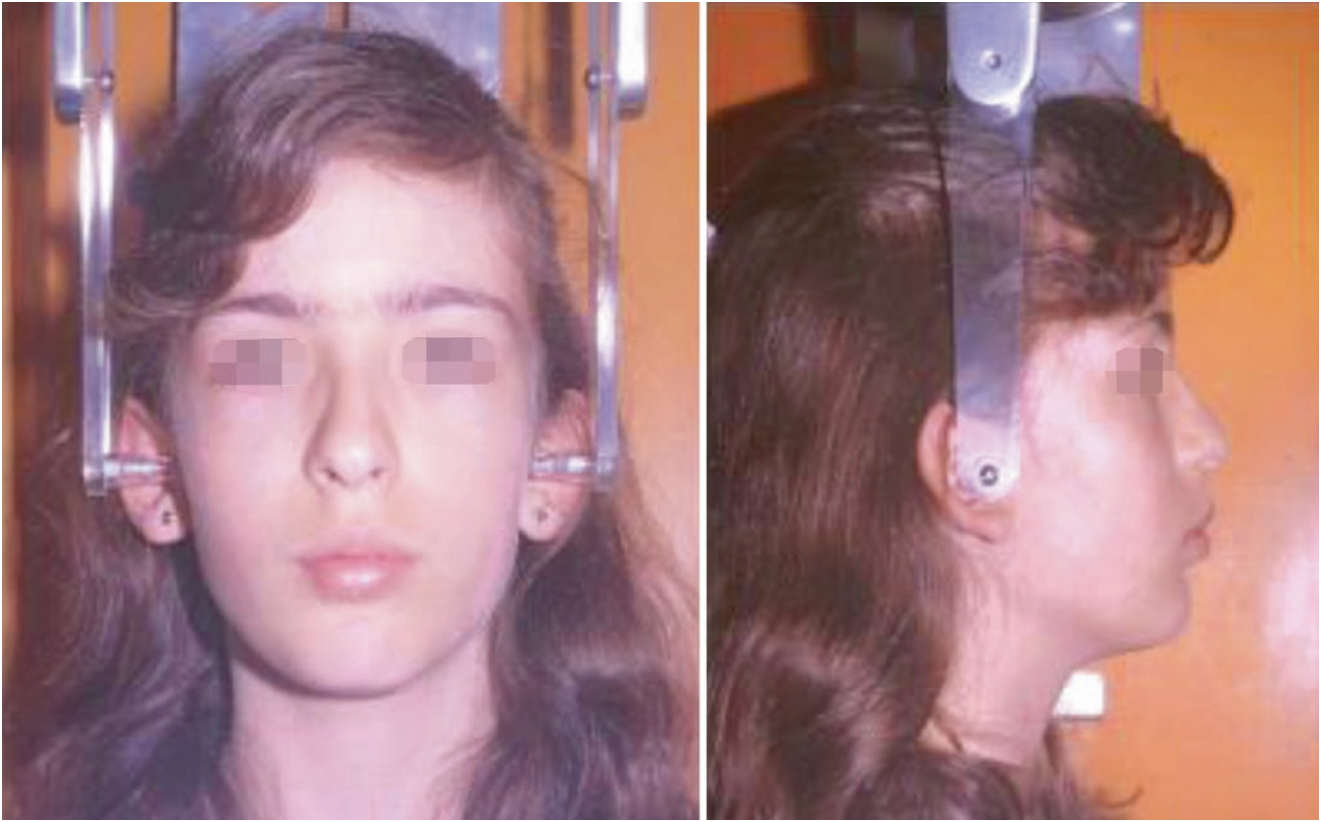


Fig. 7.38 Facial photos before treatment

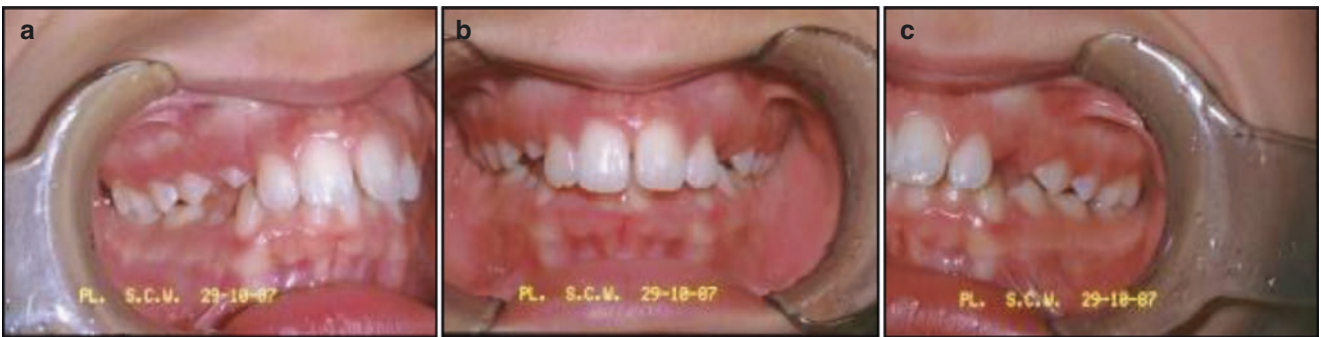

Fig. 7.39 Pre treatment frontal and lateral dental photographs along with an important overbite

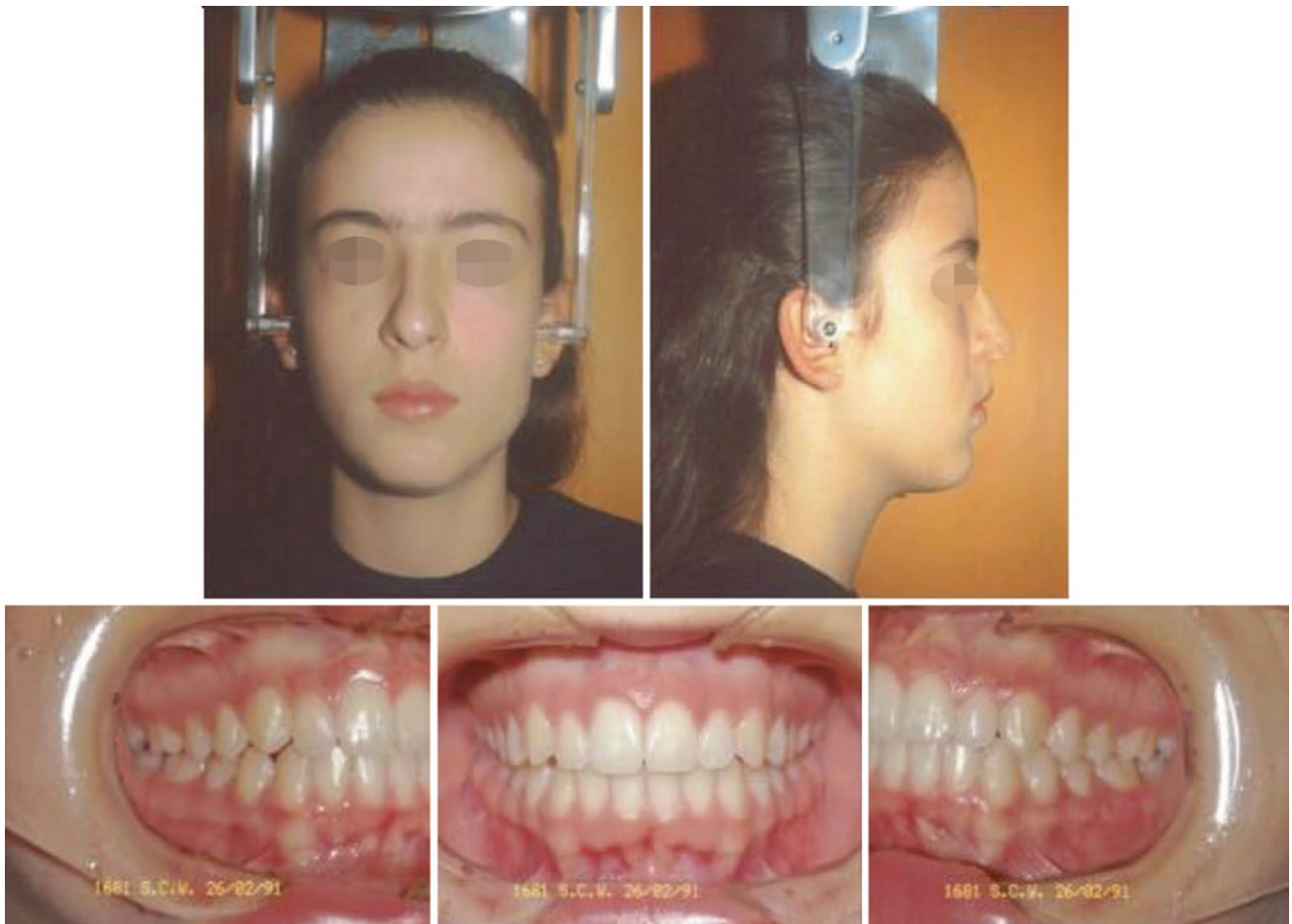


Fig. 7.40 A significant improvement were observed after 8 months in treatment with an upper removable appliance

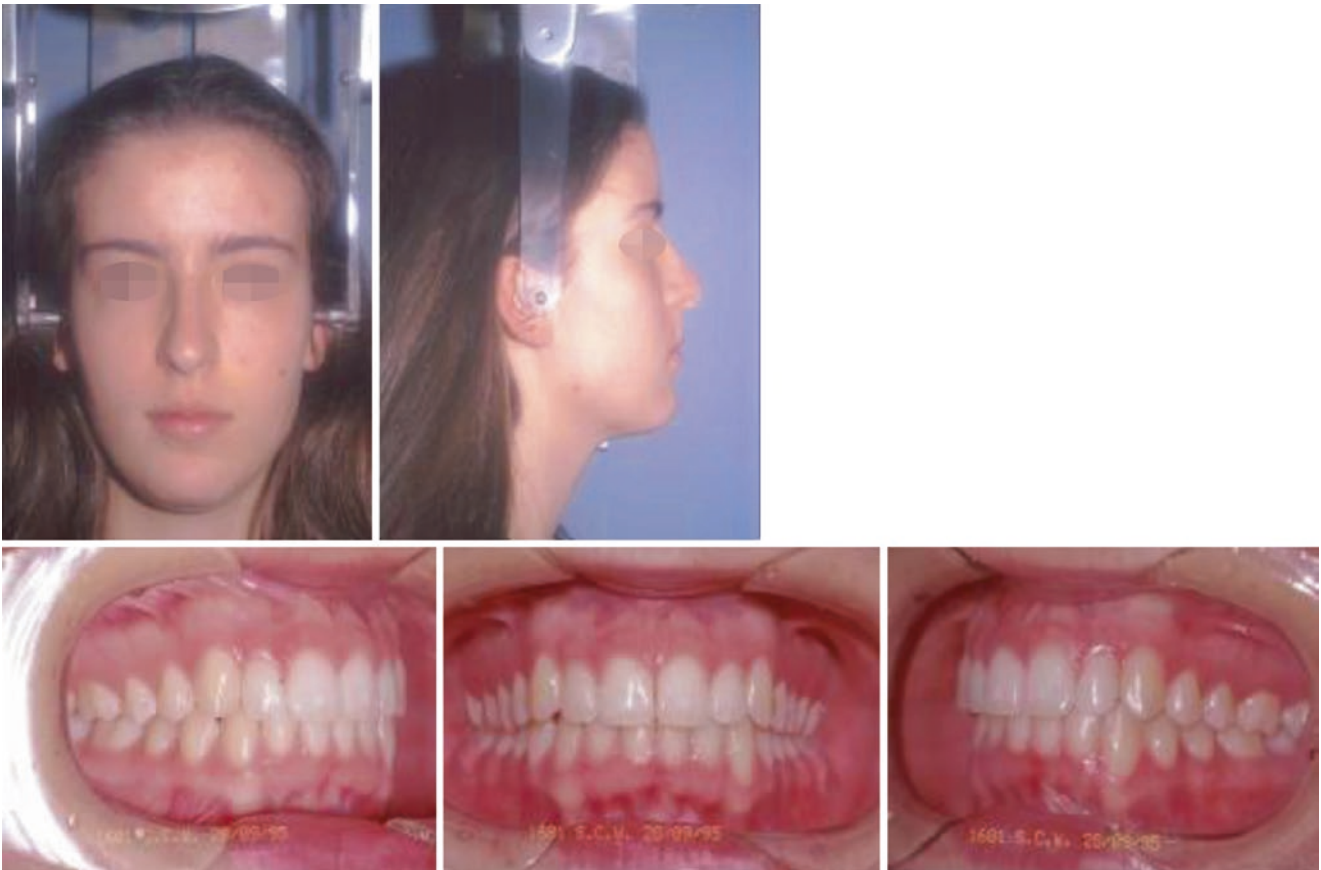

Fig. 7.41 Final photographs after 2 years in treatment 11 months

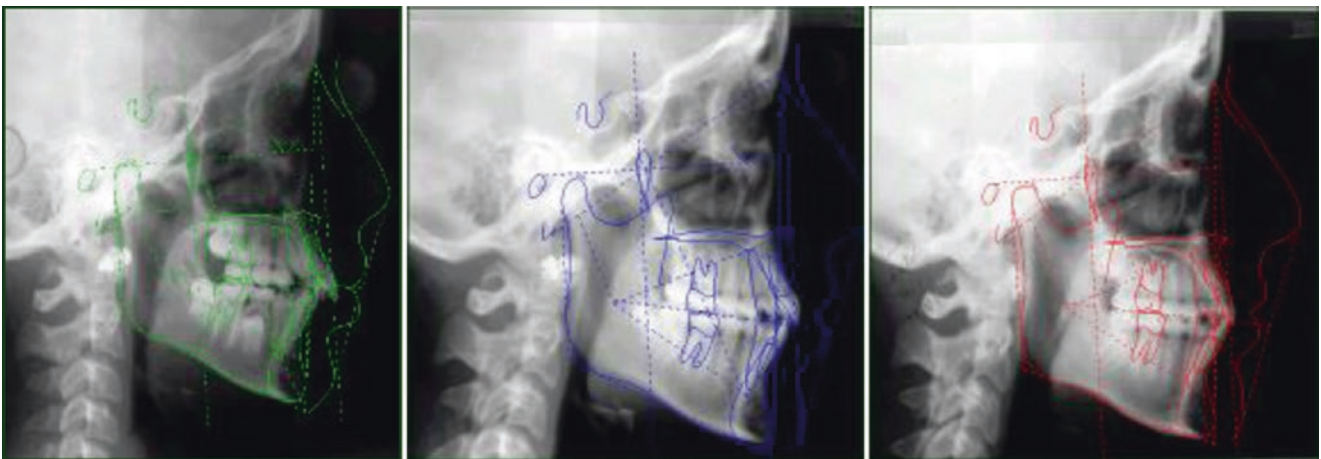


Fig. 7.42 Lateral cephalograms evaluation before, during and after treatment

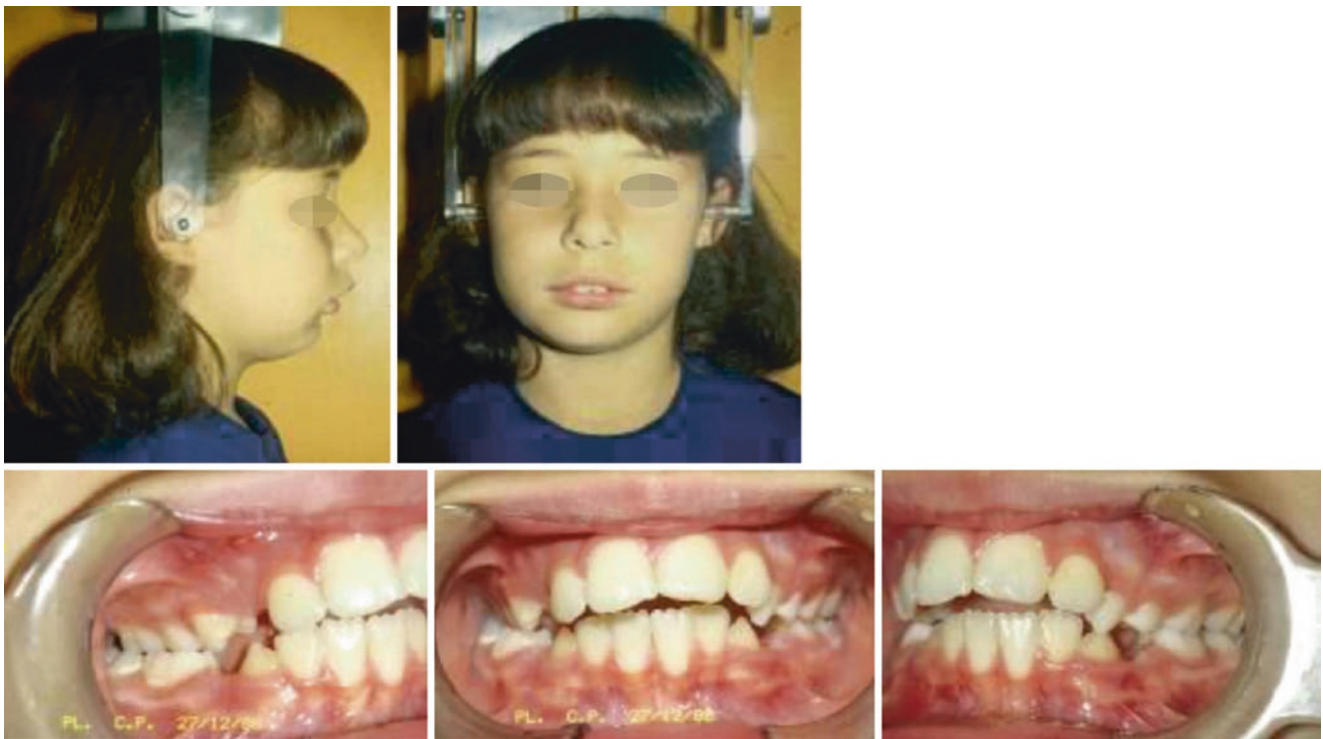

Fig. 7.43 A 10 year 10 months old patient

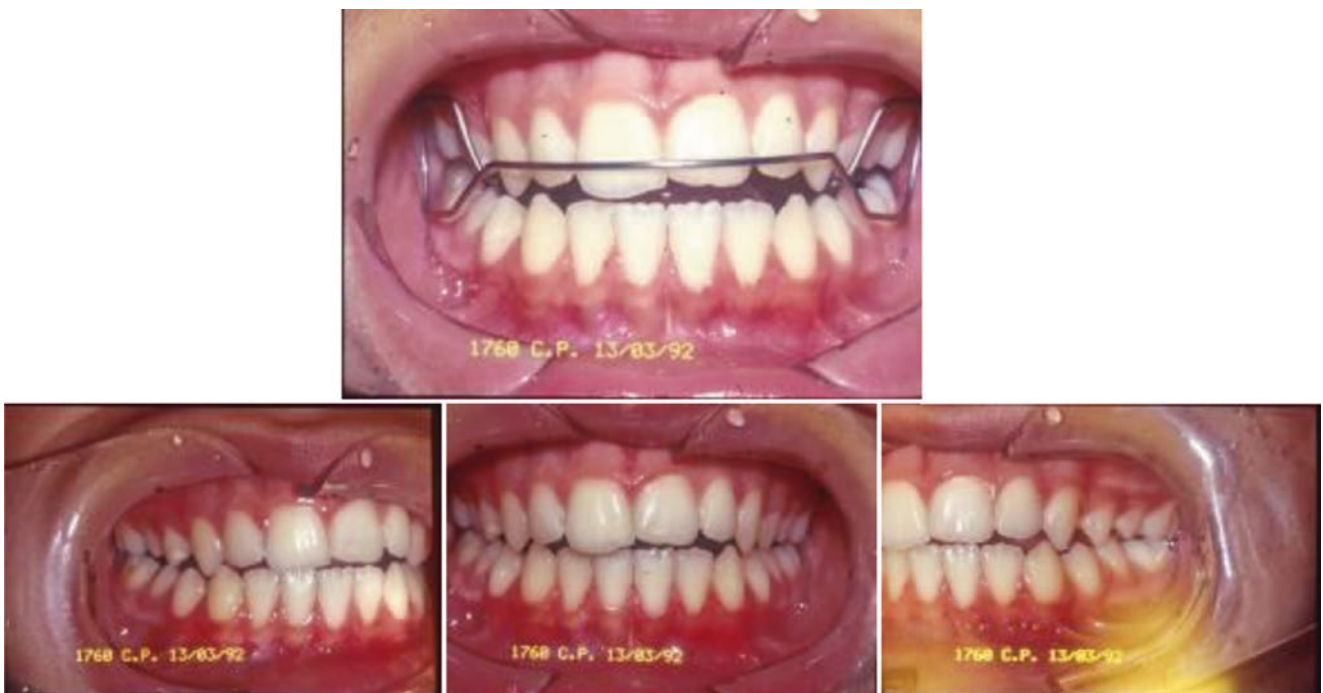

Fig. 7.44 Results after a Balters Bionator therapy during 2 years

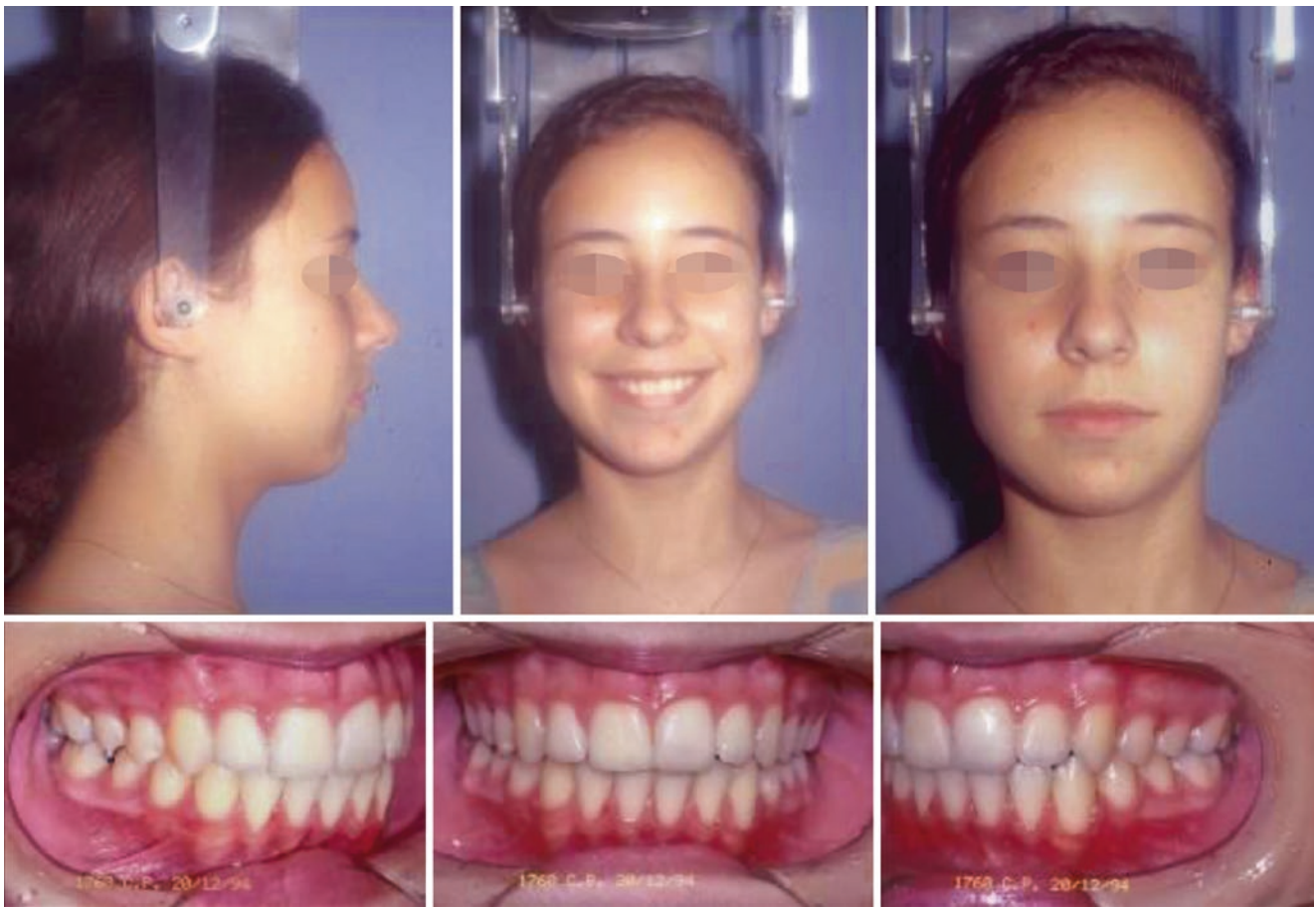

Fig. 7.45 1 year after Extraoral appliance and 13 months with fixed appliances

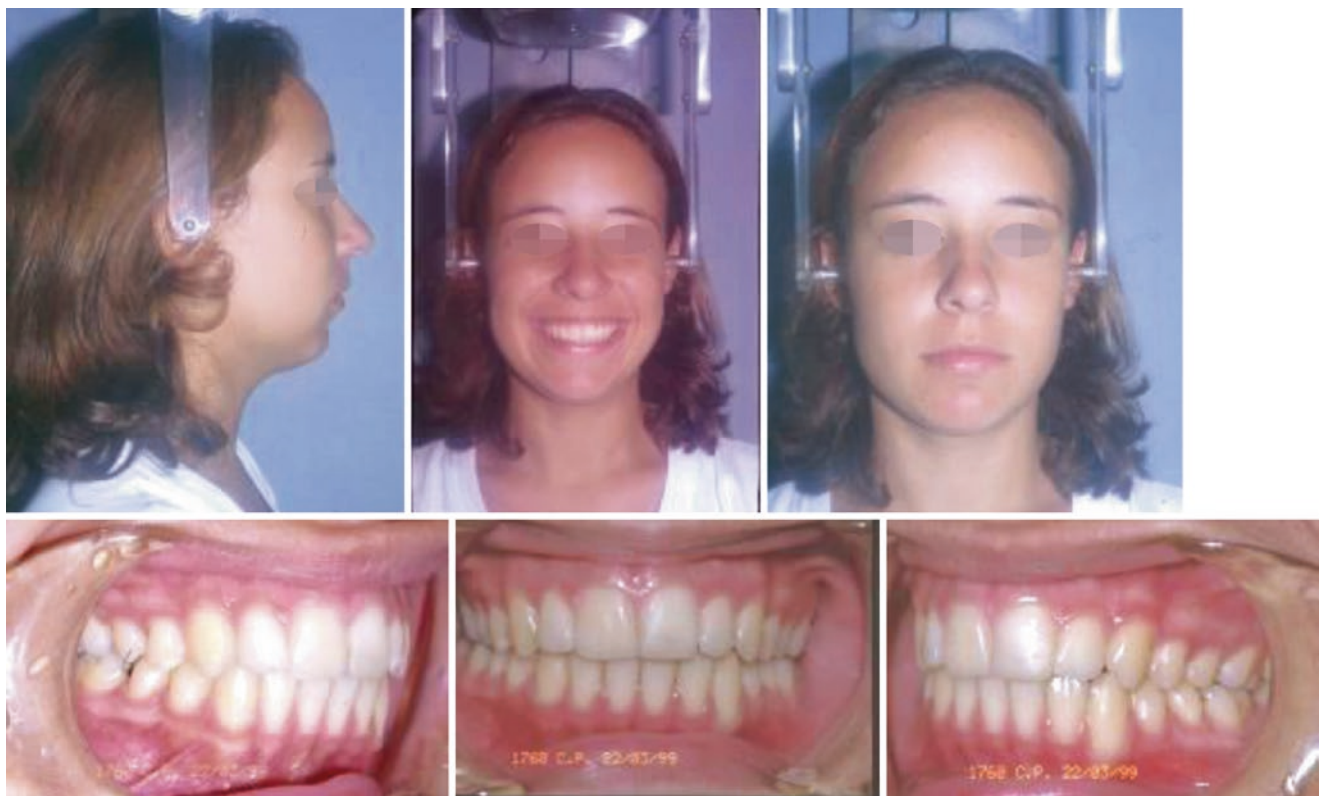

Fig. 7.46 Long term follow up . The results were maintained

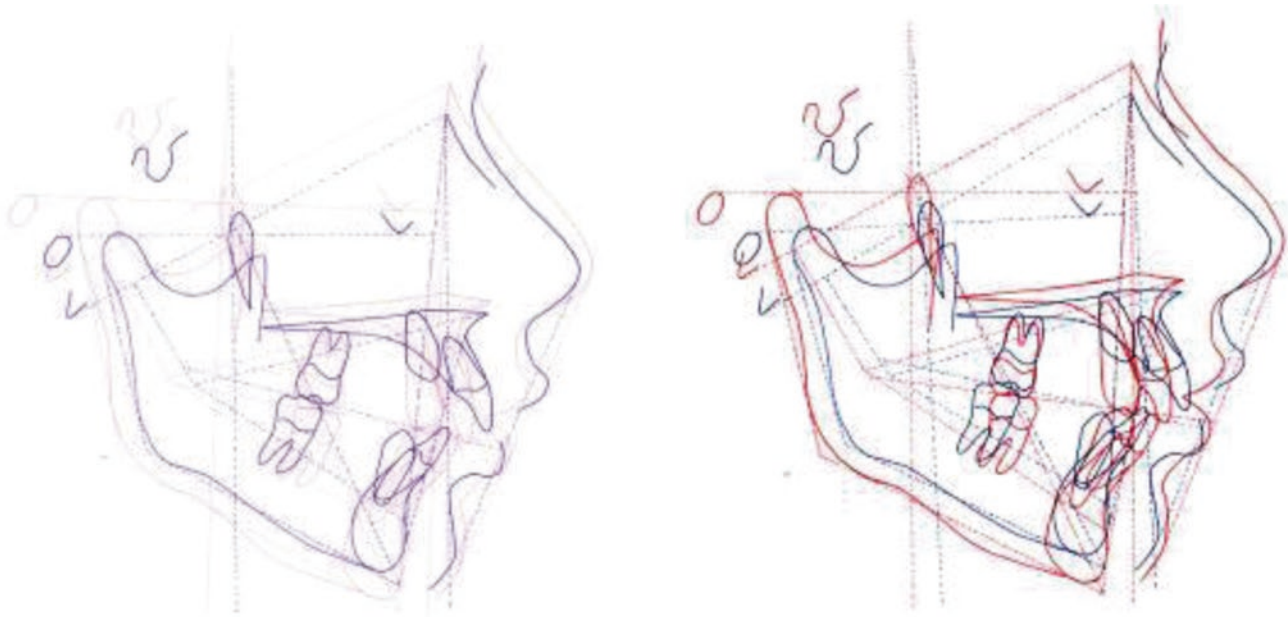


Fig. 7.47 Final photos. Pre treatment cephalogram and superposition pre and post treatment

Conclusion

According to the knowledge of the biological process involved in the dental masticatory system, the use of methods to individualize diagnosis and to create and correspond treatment planning, using the most efficient and appropriate therapeutic appliances, we certainly achieve facial harmony, normal occlusion, and neurophysiological that provides a homodynamic activity.

The future tendency of science philosophy of our professional activity encourages us to recognize that facial orthopedics is the first priority before orthodontics every time. The neuromuscular balance gives the long-term stability and the maintenance of the normal occlusion.

We must be prepared to understand the permanent evolution of our profession especially respecting the basic principles.

Our profession has the characteristic of permanent evolution. We are blessed with new basic, biological knowledge conducting us to be the first *facial orthopedist* than *orthodontists* guided by *physiological neuromuscular activities!*

References

- Balters W. Die Technik und Übung der allgemeinen und speziellen Bionator- Therapie. Quintessenz 1964a; Heft 5.77,IV.
- Balters W. Extrait de technique du Bionator. Rev Franc Odontostomat. 1964b;11:191–212.
- Bishara SE, Ziara RR. Functional appliances: a review. Am J Orthod Dentofacial Orthop. 1989;95:250–8.
- Björk A. Cranial base development: a follow-up x-ray study of the individual variation in growth occurring between the ages of 12 and 20 years and its relation to brain case and face development. Am J Orthod Oral Surg. 1955;41:106–24.
- Björk A. Prediction of mandibular growth rotation. Am J Orthod Oral Surg. 1969;55:585–99.
- Enlow DH. The human face. New York: Hoeber Medical Div., Harper and Row; 1968.
- Fränkel R. Orofacial orthopedics with function regulator. Berlin: Karger GmbH; 1989.
- Fränkel R, Fränkel C. Clinical Implications of Roux's concept in orofacial orthopedics. J Orofac Orthop. 2001;1:1–21.
- Faltin Jr K, Faltin RM, Baccetti T, Franchi L, Ghiozzi B, Mc Namara Jr JA. Long-term effectiveness and treatment timing for bionator therapy. Angle Orthod. 2003;73:221–30.
- Korkhaus G. Antropologic and odontologic studies of twins. Am J Orthod Oral Surg. 1930;16:640–7.
- Korkhaus G, La Escuela Odontológica Alemana. Editorial Labor. Génesis de las anomalías de la oclusión y de las deformaciones de los maxilares 1940.
- Malta LA, Baccetti T, Franchi L, Faltin Jr K, Mcnamara JA. Long-term dentoskeletal effects and facial profile changes induced by Bionator therapy. Angle Orthod. 2010;80(1):10–7.
- Mc Namara Jr JA. A method of cephalometric evaluation. Am J Orthod Dentofacial Orthop. 1984;86:449–69.
- Mc Namara Jr JA, Brookstein FL, Shaughnessy TG. Skeletal and dental changes following function regulator therapy on Class II patients. Am J Orthod. 1985;88:91–110.
- Moyers RE. On the nature of orthodontics. Ann Arbor. Published by The University of Southern California School of Dentistry and Center for Human Growth and Development The University of Michigan; 1985.
- Moyers RE. Handbook of orthodontics. Chicago: Year Book Medical Publishers; 1988.
- Petrovic A, Stutzmann J. Further investigations of the functioning of the “comparator” of the servosystem (respective positions of the upper and lower dental arches) in the control of the condylar

- cartilage growth rate and of the lengthening of the mandible. The biology of occlusal development, Ann Arbor, 1977 Monograph No. 7: 255–91.
- Ricketts RM. The influence of orthodontic treatment on facial growth and development. *Angle Orthod.* 1960;30:103.
- Sander FG. Functional processes when wearing the SII appliance during the day. *J Orofac Orthop.* 2001;62(4):264–74.
- Sander FG, Wichelhaus A. Skeletal and dental changes during the use of the bite jumping plate. A cephalometric comparison with an untreated Class II group. *Fortschr Kieferorthop.* 1995;56:127–39.
- Schwarz AM. *Lehrgang der Gebissregelung.* Band I, 3 Aufl., Urban u. Schwarzenberg, Wien- Innsbruck, 1961.
- Van der Linden FPGM. *Facial growth and facial orthopedics.* Chicago: Quintessence, Inc.; 1986.

Somchai Satrahava

Class III malocclusions are considered among the most difficult malocclusions to be treated. If it is possible to intercept early, severity of the malocclusions will be reduced. To treat early, careful considerations must be taken such as treatment possibility and limitation in certain cases. Complexities of Class III malocclusions involve their etiologies which can be hereditary (Figs. 8.1, 8.2, 8.3, and 8.4) or environmental in origin (Figs. 8.5, 8.6, 8.7, 8.8, and 8.9) or both.

Skeletal Class III malocclusions become more severe if the etiologies are from hereditary combined with environmental origins.

According to Rakosi, Class III malocclusions can be cephalometrically categorized into five types:

1. Dentoalveolar Class III malocclusion (Fig. 8.10)
2. Skeletal Class III malocclusion with fault in the maxilla (Fig. 8.11)
3. Skeletal Class III malocclusion with fault in the mandible (Fig. 8.12)
4. Skeletal Class III malocclusion with combination of 2 and 3 (Fig. 8.13)
5. Skeletal Class III malocclusion with pseudo-forced bite (Figs. 8.14 and 8.15)

In many cases, Class III malocclusions are both skeletal and dental (Rakosi 1985), (Graber et al. 1997), (Rakosi and Graber 2010).

S. Satrahava
Department of Orthodontics, Mahidol University,
Bangkok, Thailand
e-mail: samsunshine5@yahoo.com

Fig. 8.1 A 9-year-old girl with concave facial profile

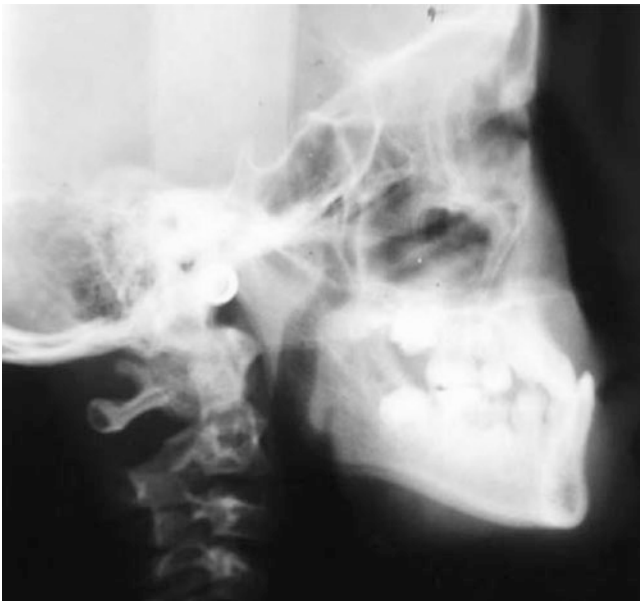
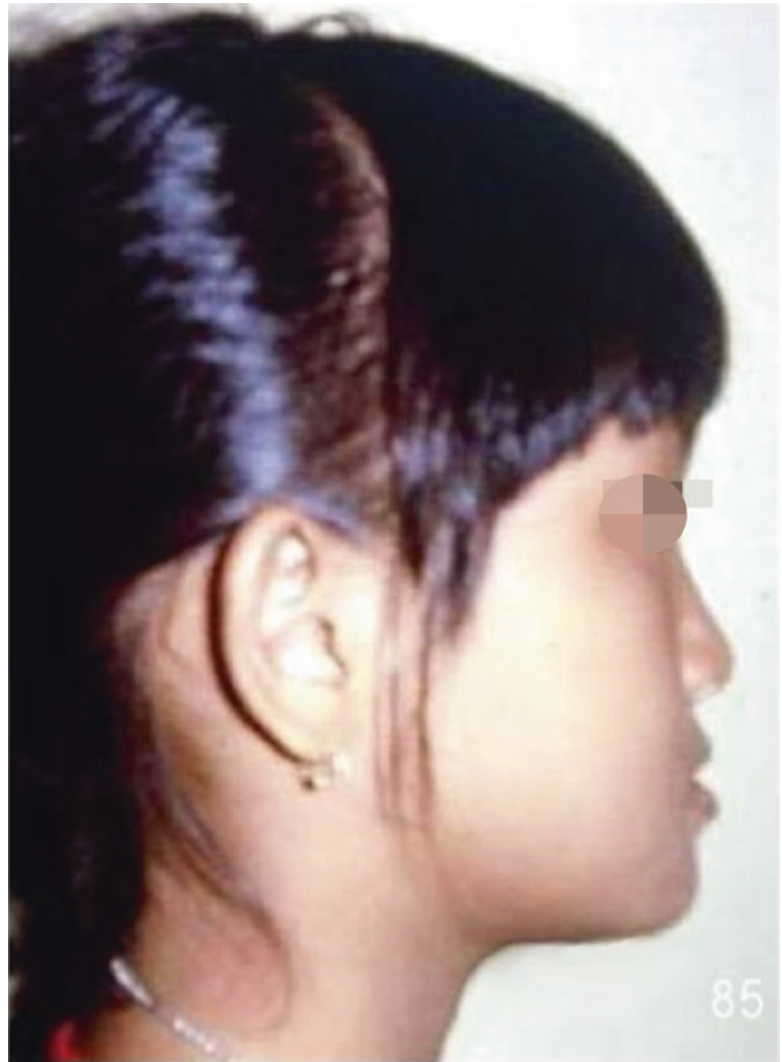
Fig. 8.2 Her cephalometric head film showed skeletal Class III malocclusion

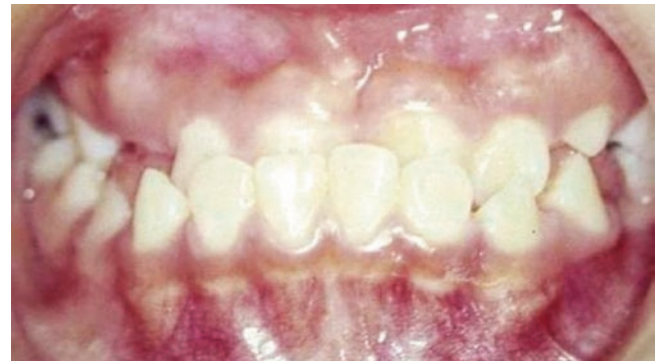

Fig. 8.3 She had a deep anterior cross bite

Fig. 8.4 A photograph of her taken with her father showed both of them had concave facial profiles, clinically her father also had an anterior cross bite, which obviously indicates hereditary cause for the daughter's malocclusion

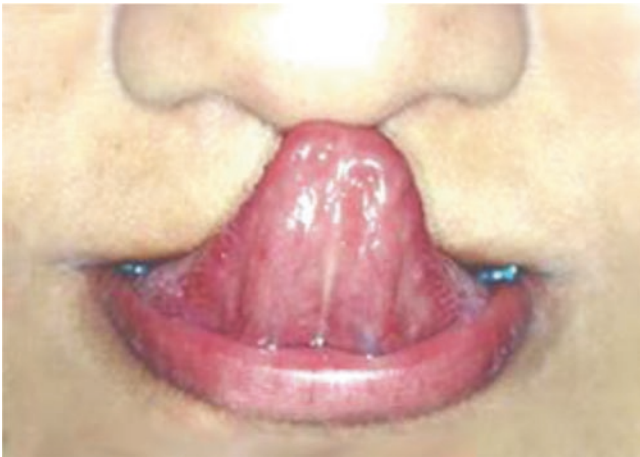

Fig. 8.5 Oral habit as seen here can cause anterior cross bite because the mandible was dragged forward to a more anterior position to the maxilla when this patient tried to touch the tip of her nose with her tongue. Anterior portion of her maxilla was compressed by the force from the tongue, which could cause anterior cross bite and could develop into skeletal Class III malocclusion if not intercepted

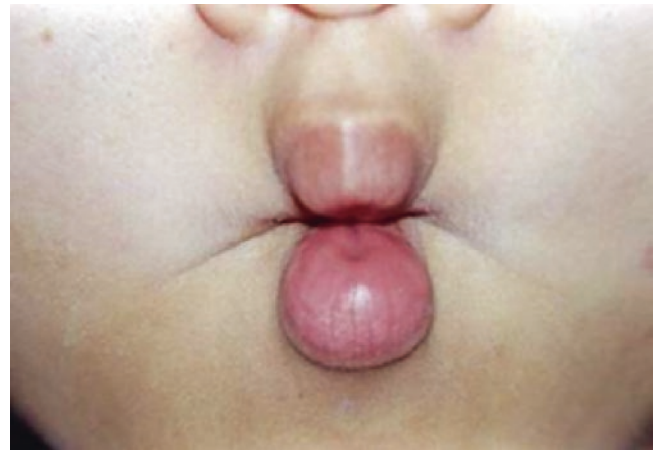


Fig. 8.6 An additional habit of making a ribbon with the lips as seen here can cause narrow upper and lower arches

Fig. 8.7 Two intraoral pictures of the same patient in Figs. 8.5 and 8.6 showed anterior cross bite with large negative overjet and bilateral posterior cross bites. Narrow upper and lower arches with linguoversion of posterior teeth in both arches were caused by her abnormal oral habits

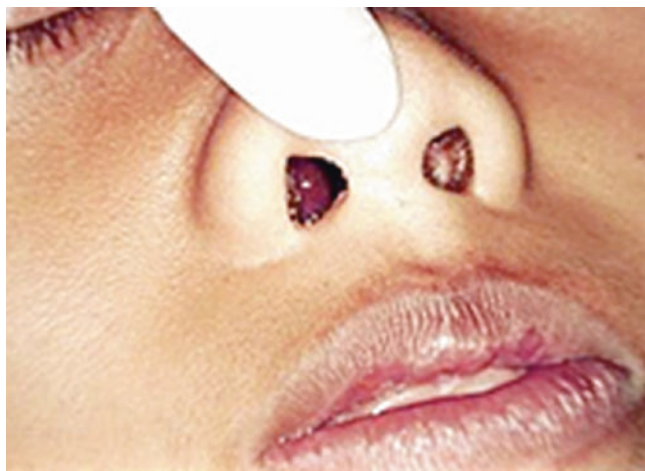
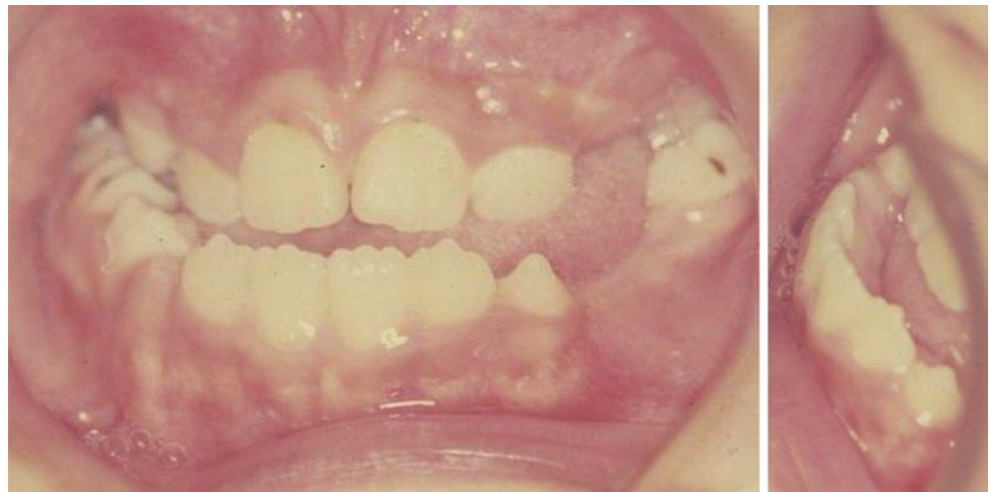
Fig. 8.8 Polyp seen in the right nostril can obstruct the patient's upper airway and cause mouth breathing

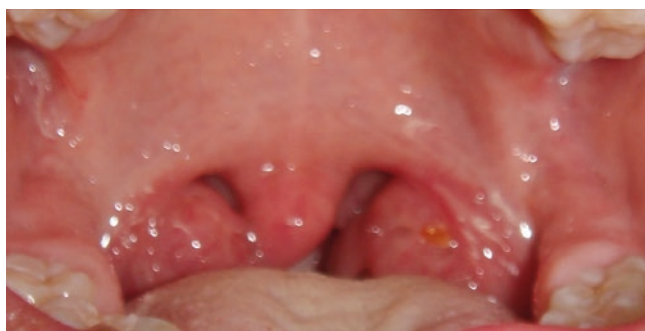

Fig. 8.9 Large tonsils can obstruct the patient's upper airway and cause mouth breathing and low tongue position. Force from flat tongue position can cause lower anterior teeth to flare out labially

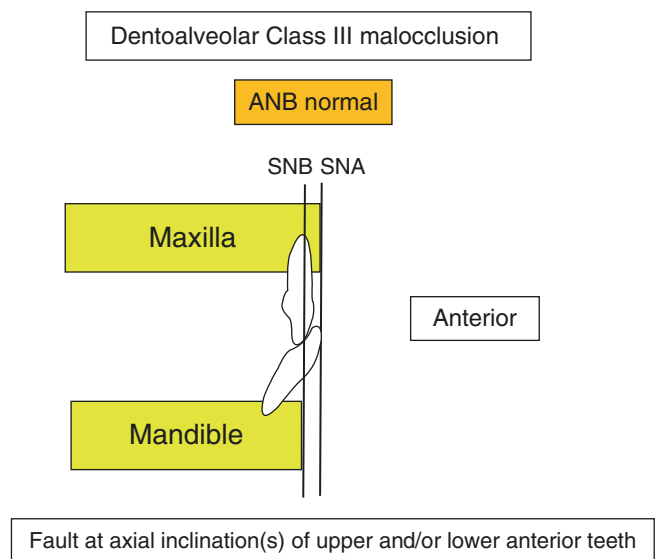


Fig. 8.10 Dentoalveolar Class III malocclusion with fault at axial inclination(s) of upper and/or lower anterior teeth

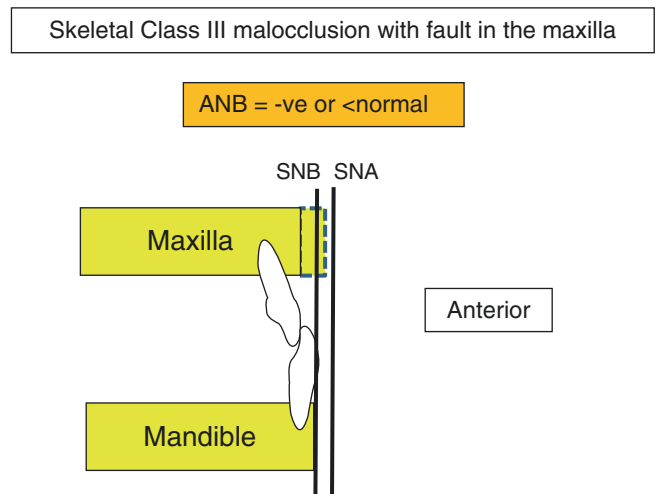


Fig. 8.11 Skeletal Class III malocclusion with fault in the maxilla; the maxilla is underdeveloped, while the mandible is normal

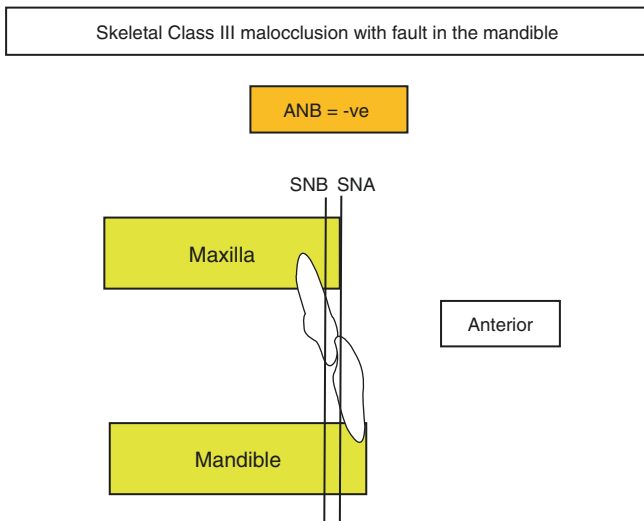


Fig. 8.12 Skeletal Class III malocclusion with fault in the mandible; the mandible is overdeveloped, while the maxilla is normal

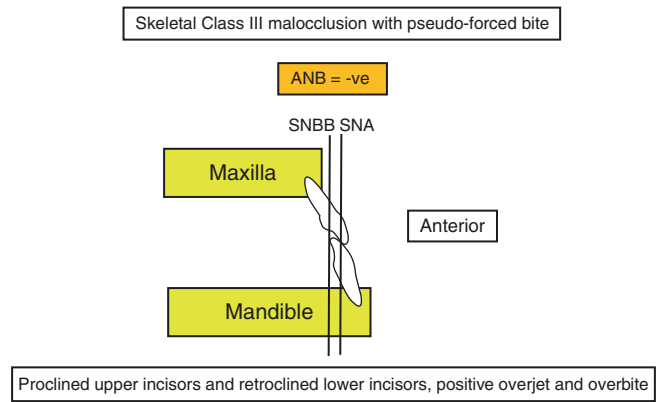


Fig. 8.14 Skeletal Class III with pseudo-forced bite, proclination of the upper anterior teeth and retroinclination of the lower anterior teeth compensate skeletal discrepancy resulting in positive overjet and positive overbite

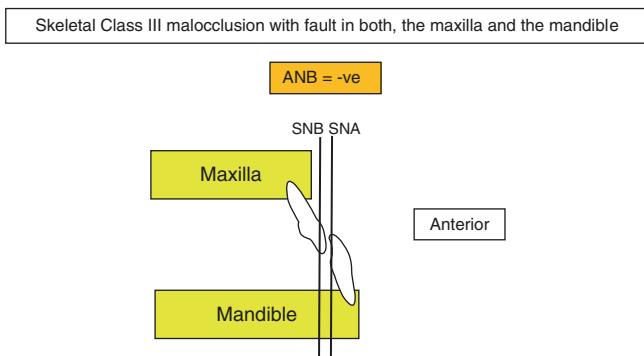


Fig. 8.13 Skeletal Class III malocclusion with fault in both the maxilla and the mandible. The maxilla is underdeveloped, while the mandible is overdeveloped

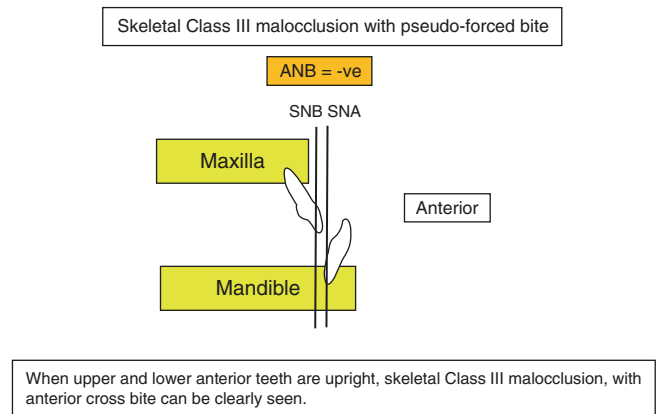


Fig. 8.15 When both the upper and lower anterior teeth in Fig. 8.14 are upright, severe skeletal Class III malocclusion is revealed

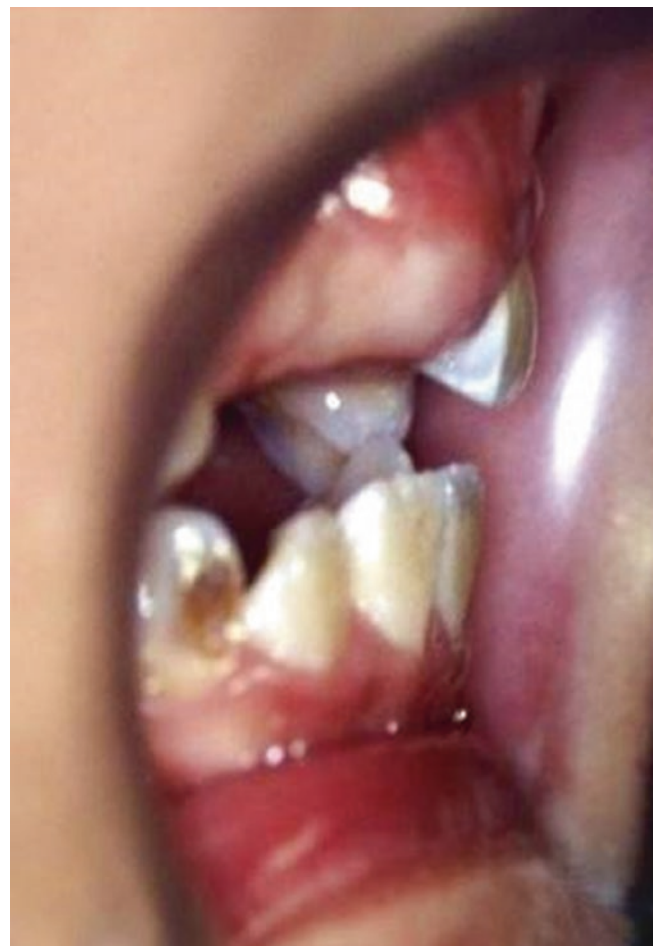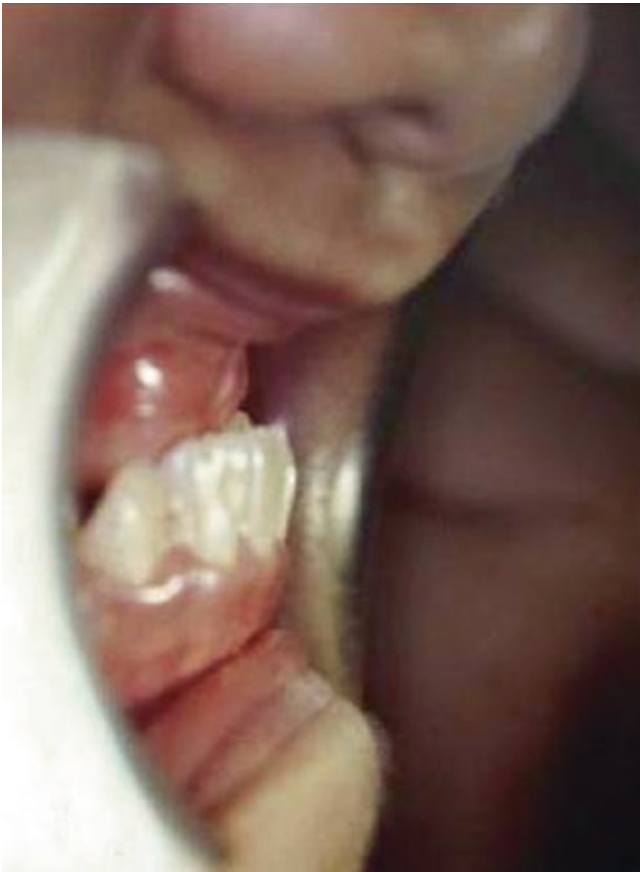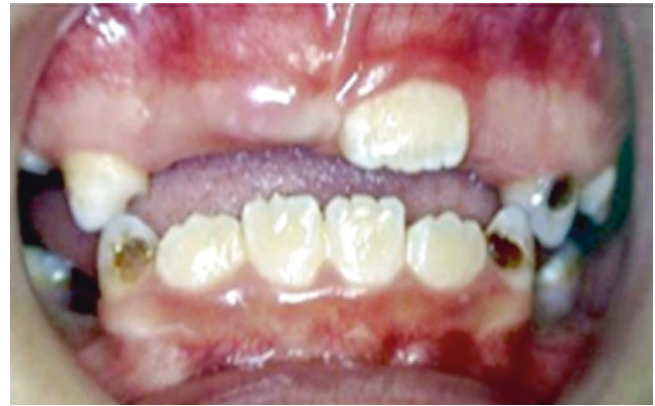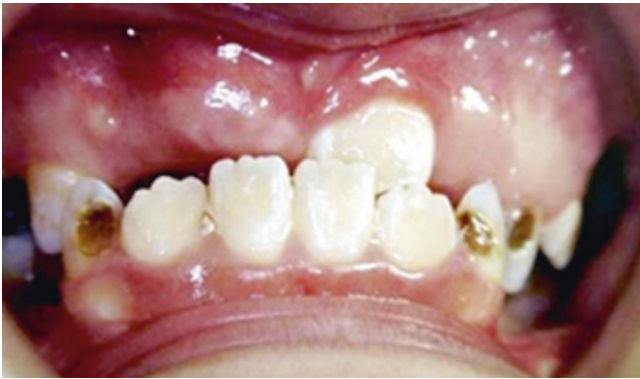8.1 Functional Class III Malocclusion

Function analysis can help in differential diagnosis of Class III malocclusions to specify whether the malocclusion is of hereditary or environmental or from both origins as stomatognathic system is dynamic not static. The temporomandibular joints are the most used joints in the whole human body. Therefore, movement of the mandible and joint function must be examined (Figs. 8.16–8.19).

Rakosi mentioned that mandibular movement plays important clue to the prognosis of skeletal Class III malocclusions when treated with his Class III activator, when the

mandible is pushed backward to a new desired posterior position. He suggested that the mandible normally closes in a rotating manner into initial tooth contact and then slides either forward or backward into maximum tooth contact. The case where the mandible closes with rotation and slides forward has better prognosis than that of a rotation with a slide backward.

In addition, from doing functional analyses on the patients, it can be concluded that patients with skeletal Class III malocclusions have incompetent lips and low tongue position with anterior thrust and have visceral or infantile swallowing pattern. The characteristic of the



Figs. 8.16 and 8.17 Intraoral pictures of a patient at maximum tooth contact or CO showed anterior cross bite

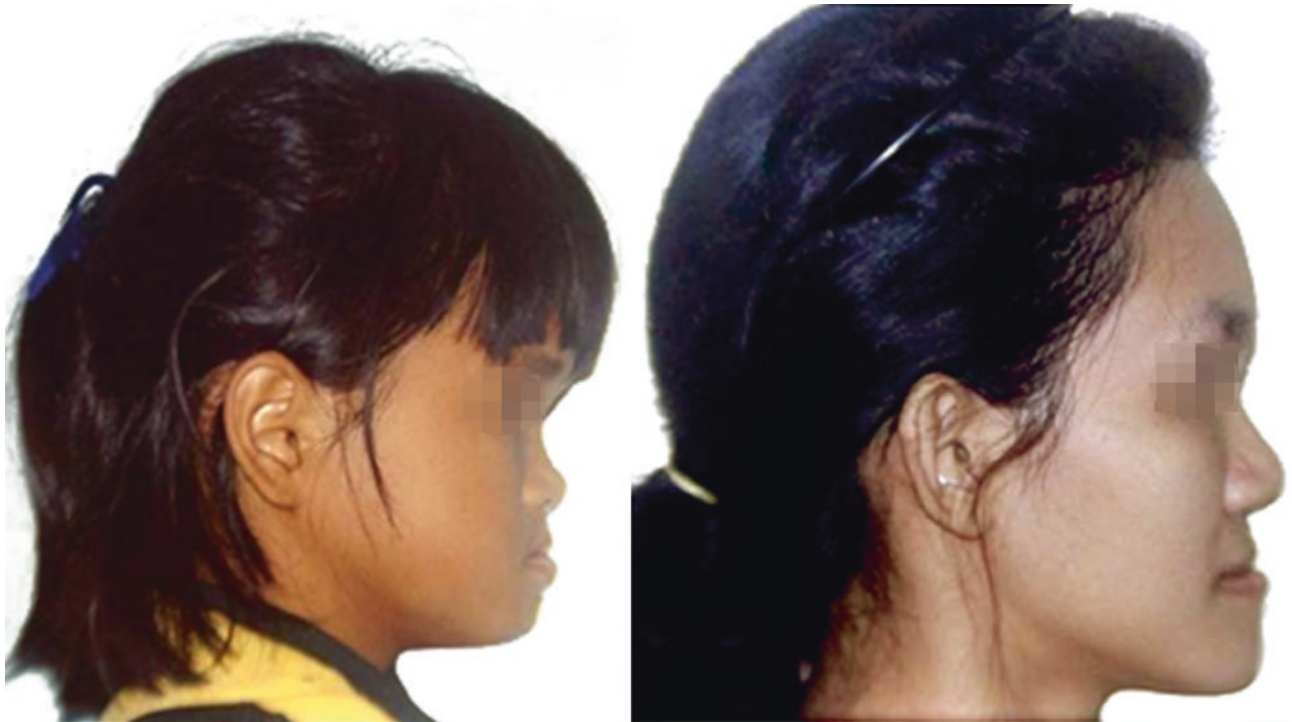Figs. 8.18 and 8.19 Intraoral pictures of the same patient at physiologic rest position; no anterior cross bite was presented

tongue and lips and their functions contribute to more severity of the malocclusions and instability of treatment outcomes (Graber 1963), (Rakosi 1985), (Graber et al. 1997), (Rakosi and Graber 2010).

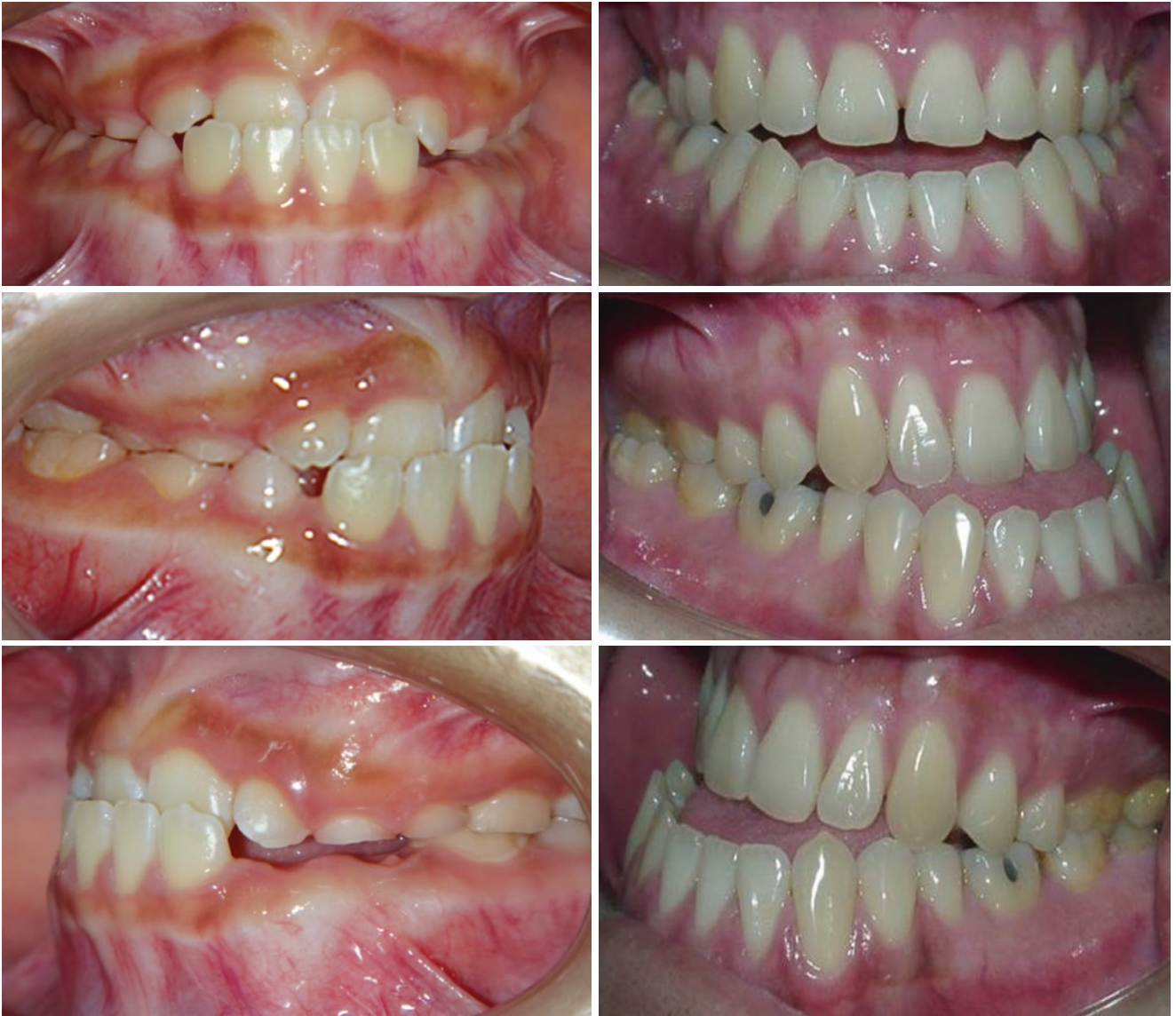8.2 Reasons for Early Treatment

If not treated, severity of the malocclusions will increase which can cause function problems and has psychological impact on the patients (Figs. 8.20–8.29).

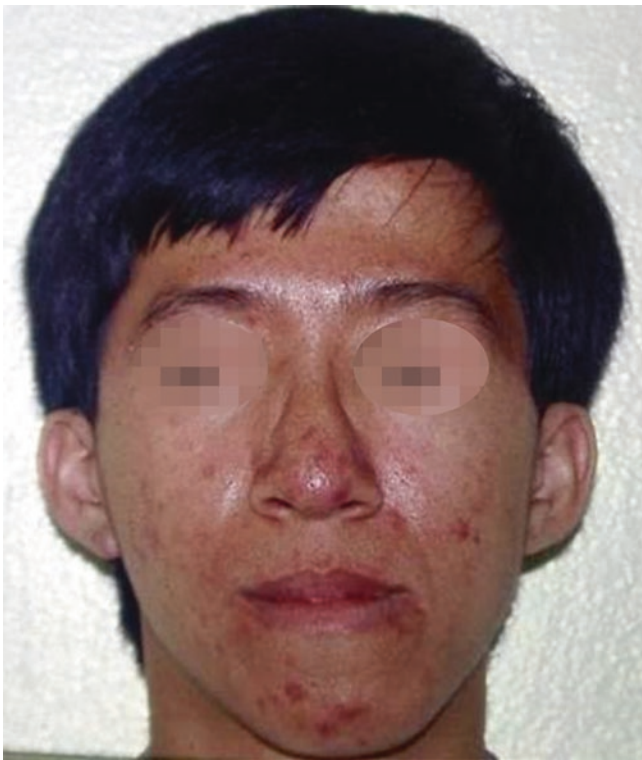There has been a controversy in early treatment of Class III malocclusions, especially whether growth can be modified. There are natural growth and induced growth which cannot be measured separately. The author believes that the treatment outcomes are the most crucial for the decision whether to treat early or not. If the treatment outcomes can reduce severity of malocclusions and are satisfactory to both patients and orthodontists, then the interception is worth doing.



Figs. 8.20 and 8.21 If not treated early, the girl on Fig. 8.20 might grow up to become a woman on Fig. 8.21. This certainly has psychological impact on the patient, especially, being teased for having a nonaesthetic concave facial profile



Figs. 8.22, 8.23, 8.24, 8.25, 8.26, and 8.27 Severity of the malocclusion could increase tremendously if not treated



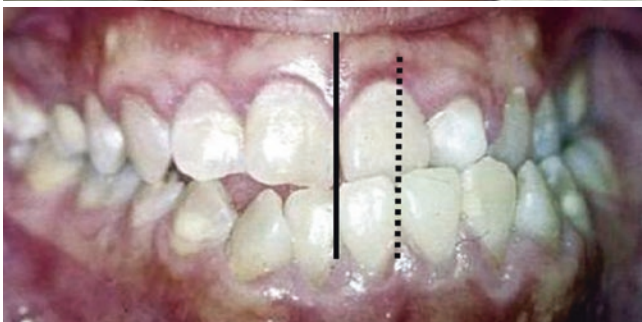8.2.1 To Treat Early: When Is the Right Time?

Once we decide to treat the cases, we must begin with the end in mind knowing the goals and how the finished cases should be.

Treatment objectives should be the same as all orthodontic treatments which are to achieve good function, acceptable esthetics, and good stability. The treatment should be at the right place, at the right time, and with proper appliances.

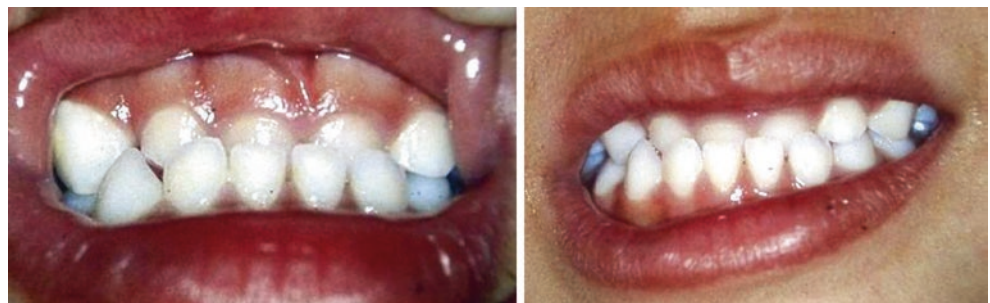8.2.2 In Deciduous Dentition

It is rather early to treat Class III malocclusions during this stage as Class III malocclusions are rather complex. The treatment might take a very long time, and patients can get burnt out. Most cases are to be under growth and development observation (Figs. 8.30, 8.31, 8.32, 8.33, 8.34, and 8.35), and many of the anterior cross bite cases were corrected through eruption of the permanent upper and lower anterior teeth.

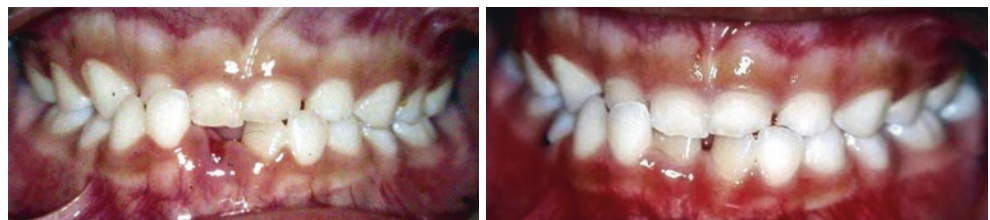


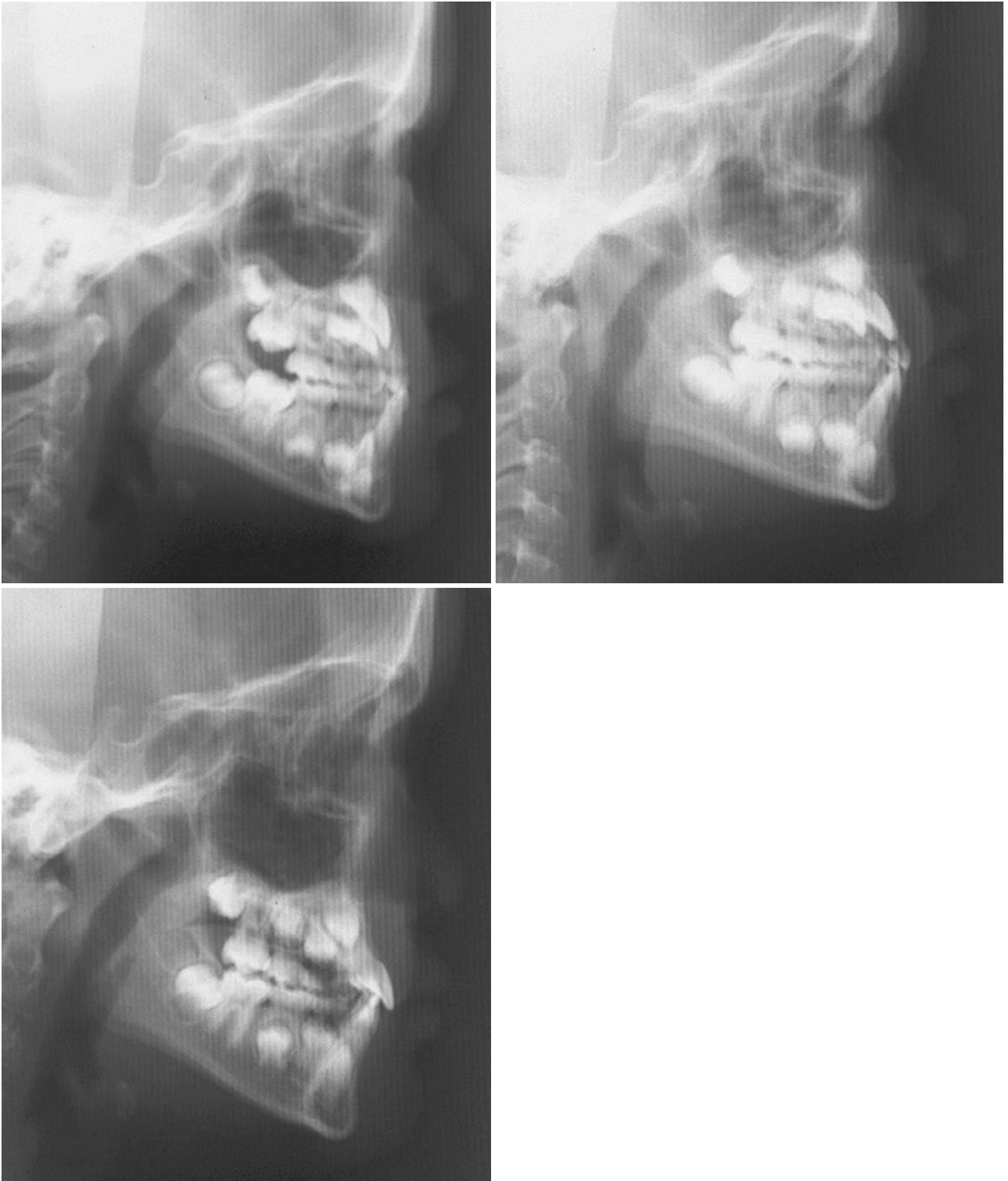
Figs. 8.28 and 8.29 An untreated male patient who showed a facial asymmetry in a permanent dentition illustrated anterior cross bite and unilateral posterior cross bite on the left side (Chebib and Chamma 1981), (Joondeph 2001), (Pirttiniemi 1994), (Ross 2001)

Fig. 8.30 Anterior cross bite in the deciduous dentition



Figs. 8.31 and 8.32 Tooth #31 and #41 erupted lingually to tooth #61 and #51; cross bite was self-eliminated





Figs. 8.33, 8.34, and 8.35 Cephalometric head films of the patient in Figs. 8.30, 8.31, and 8.32 at age 6, 7, and 8, respectively, showed path of eruptions of the upper and lower anterior teeth. Anterior cross bite was self-corrected through eruption of the upper and lower anterior teeth

8.3 Early Treatment of Dentoalveolar Class III (Figs. 8.36–8.65)

8.3.1 In Early Mixed Dentition

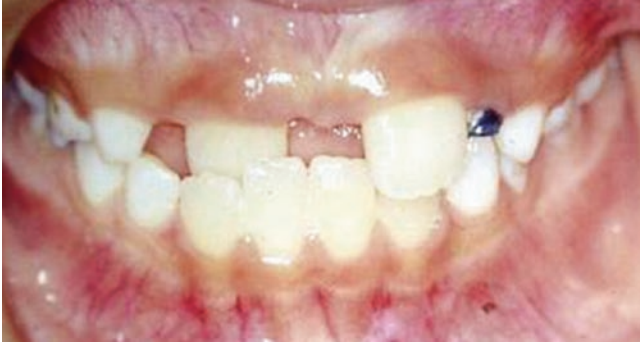

Fig. 8.36 An intraoral picture of an 8-year-old girl in an early mixed dentition; #11 was in cross bite with #41 and #42. A treatment to correct the cross bite was needed. If not treated, growth of the maxilla at #11 would be inhibited

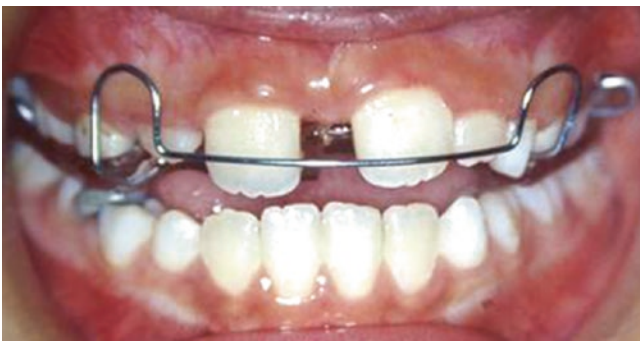

Fig. 8.37 An upper plate with posterior raised bite and a protrusion spring were used to correct the cross bite

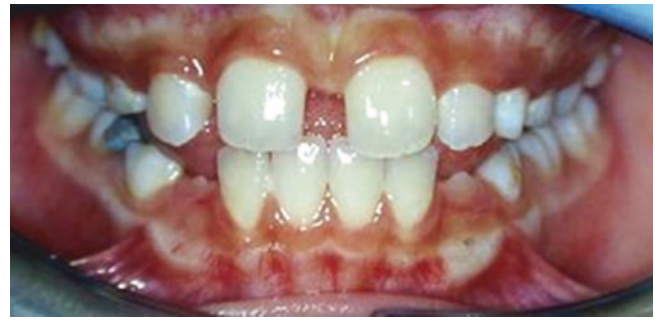

Fig. 8.38 The cross bite was corrected. Upper permanent lateral incisors erupted more into the oral cavity, while the lower canines started to erupt

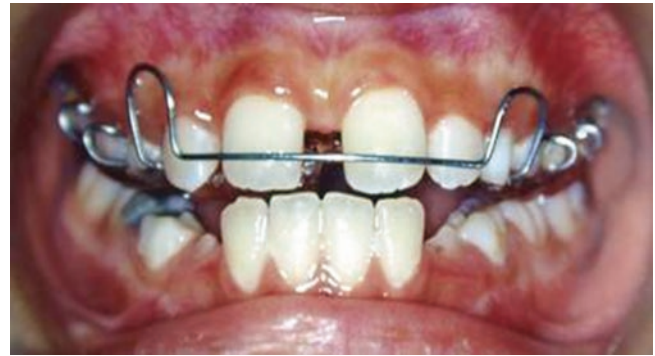

Fig. 8.39 Diastema media was seen here

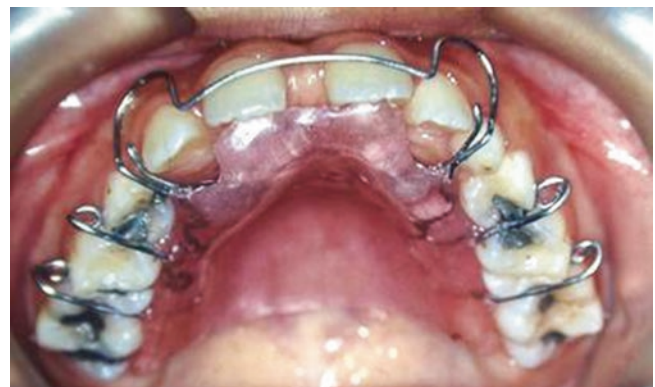

Fig. 8.40 An upper plate with two finger springs were used to close the spaces in the upper anterior region. No raised bite needed here

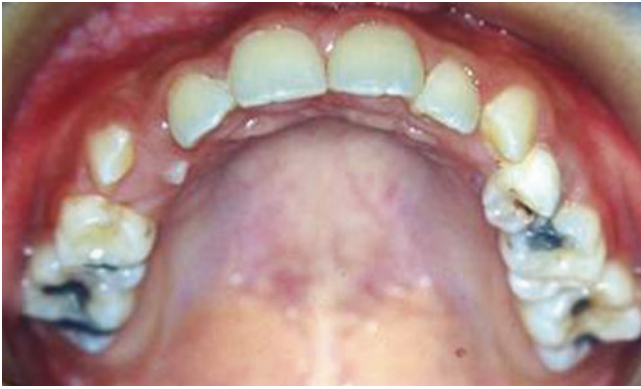
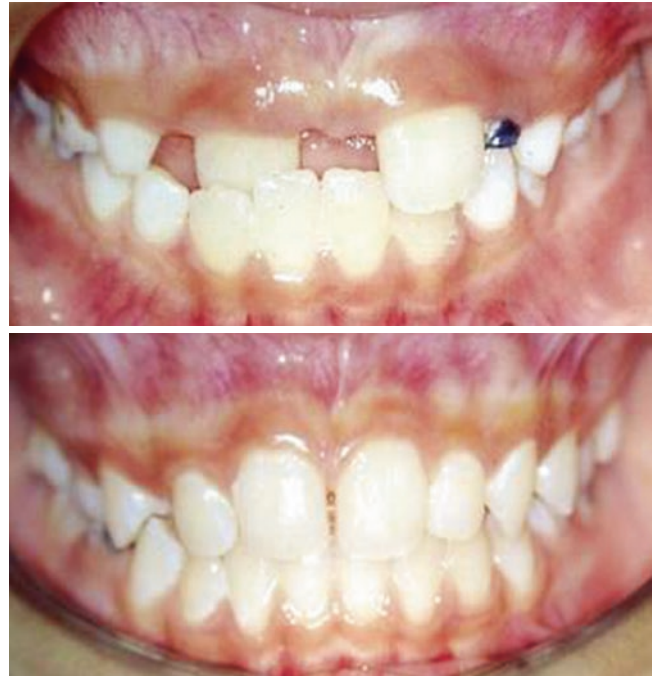
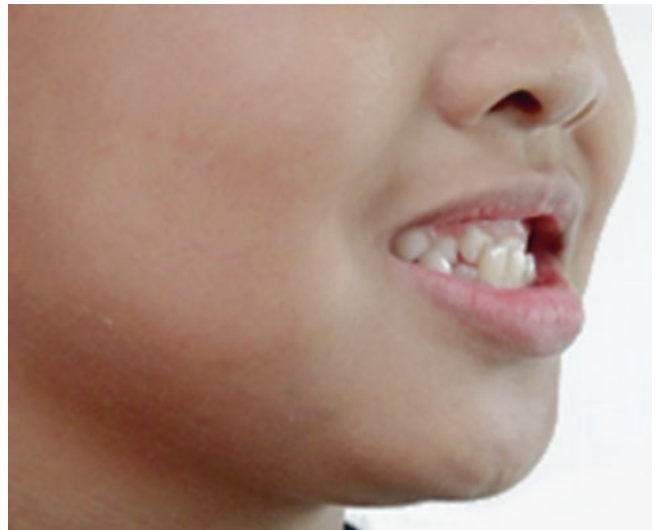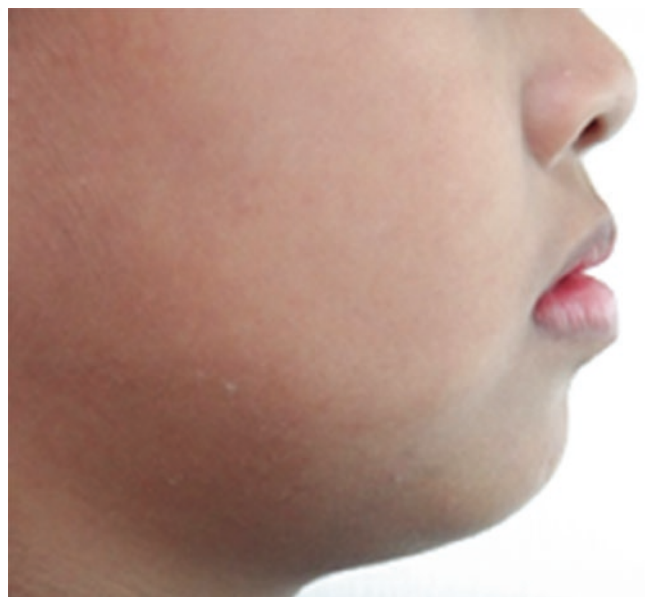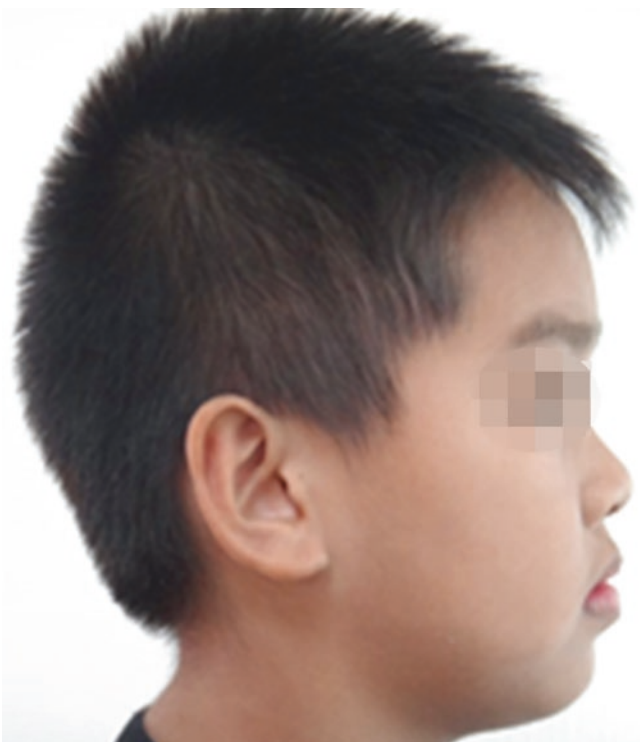Fig. 8.41 Spaces were closed



Figs. 8.42 and 8.43 Comparison between before the treatment and sometime after correction of the cross bite and spaces closing in the upper anterior region



Figs. 8.44 and 8.45 An 8-year-old boy with dentoalveolar Class III malocclusion; he showed lower anterior teeth when smiling



Figs. 8.46 and 8.47 He had normal facial profile

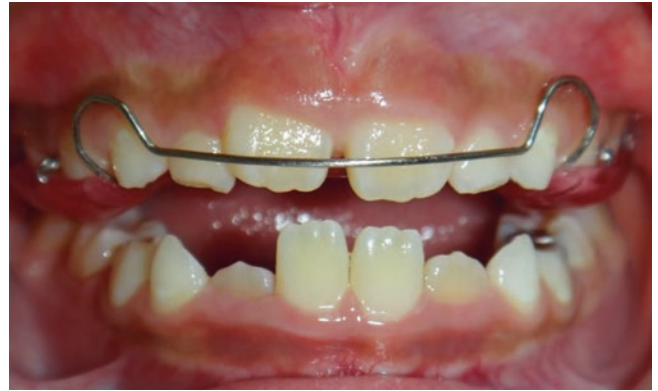
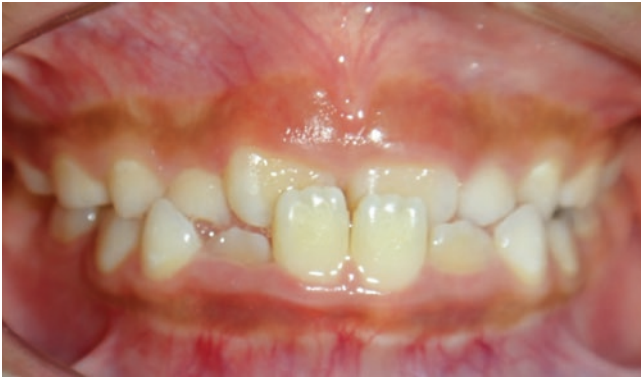
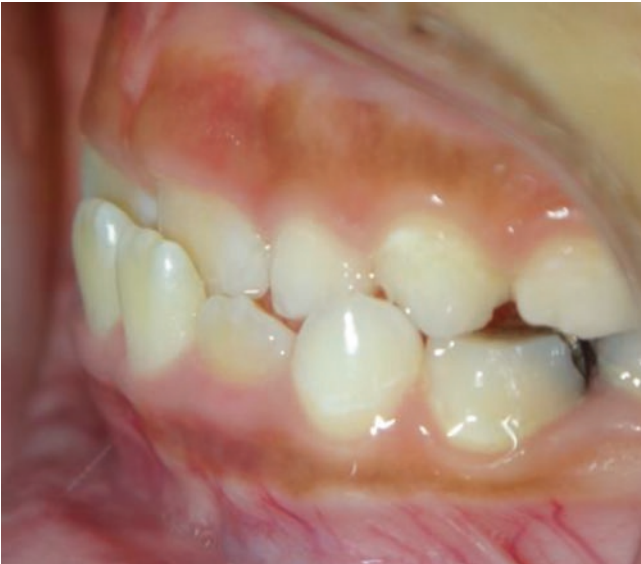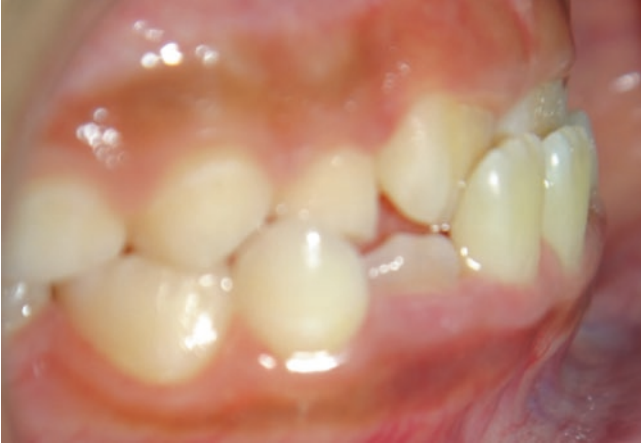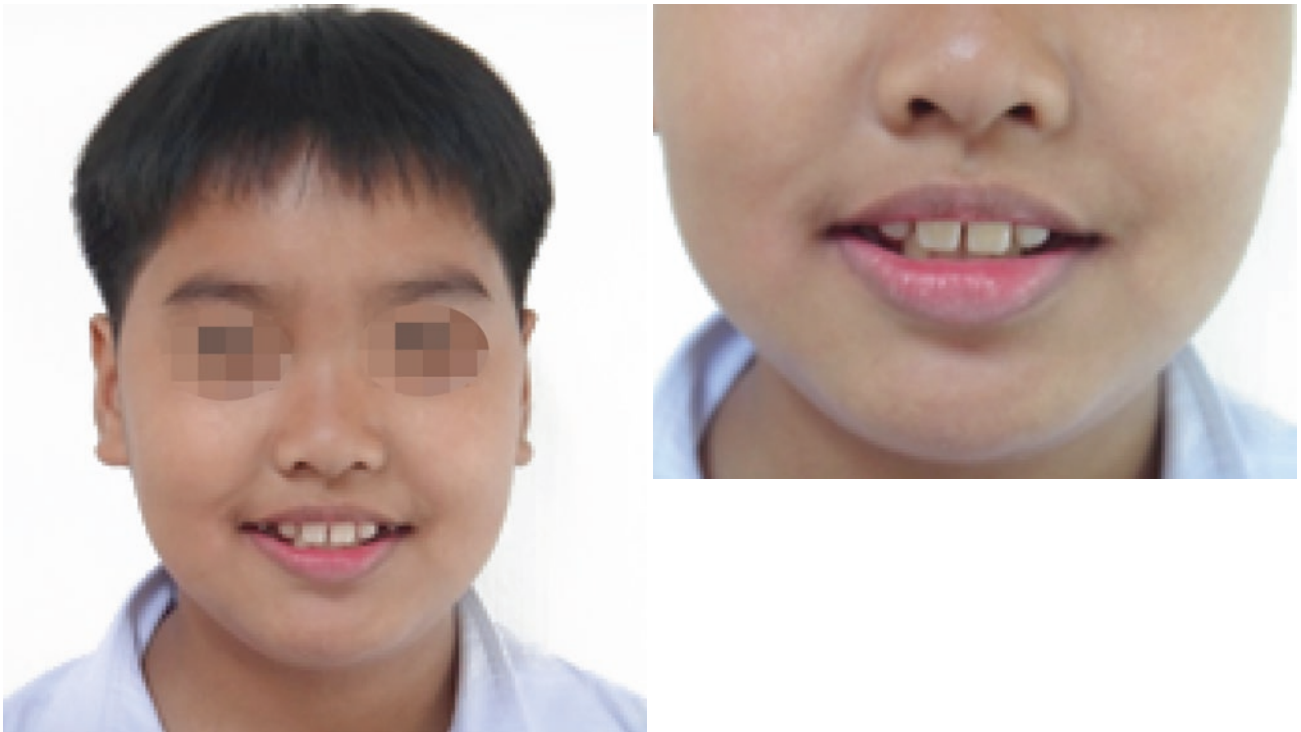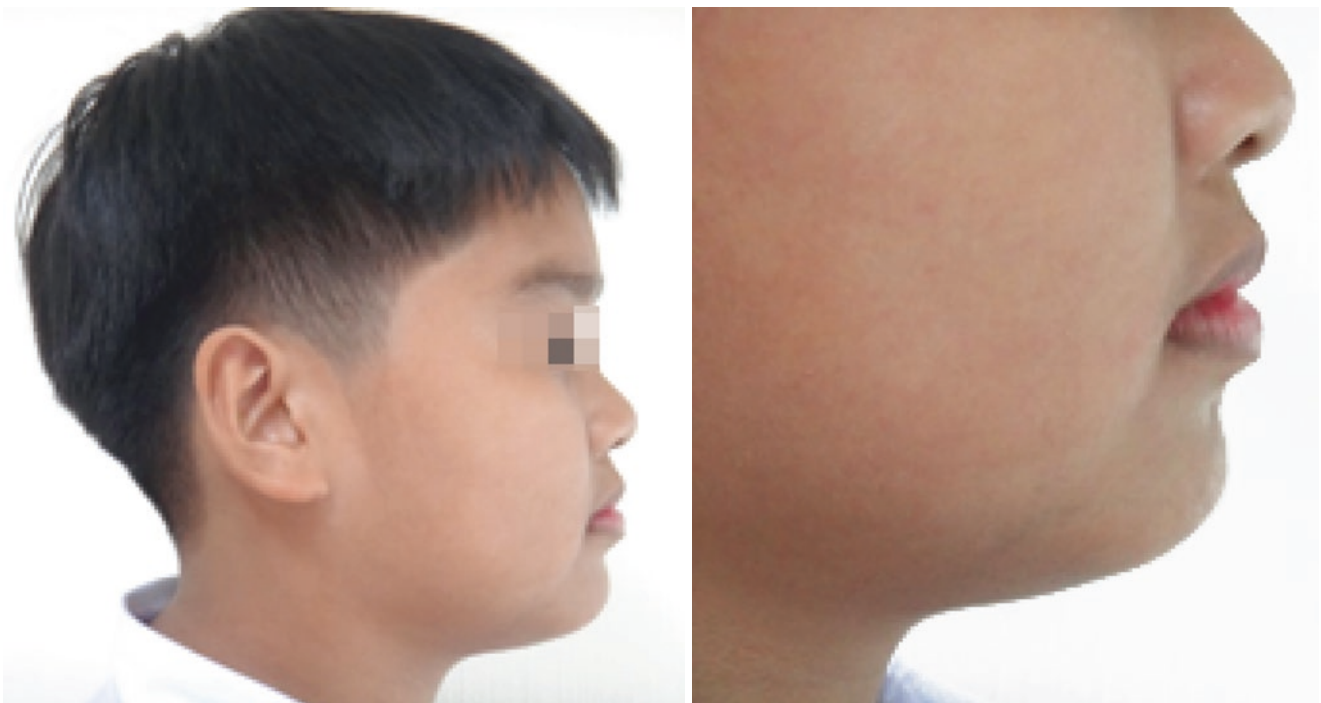Fig. 8.51 Anterior cross bite was corrected by using an upper plate with protrusion screw to protrude the upper permanent anterior teeth



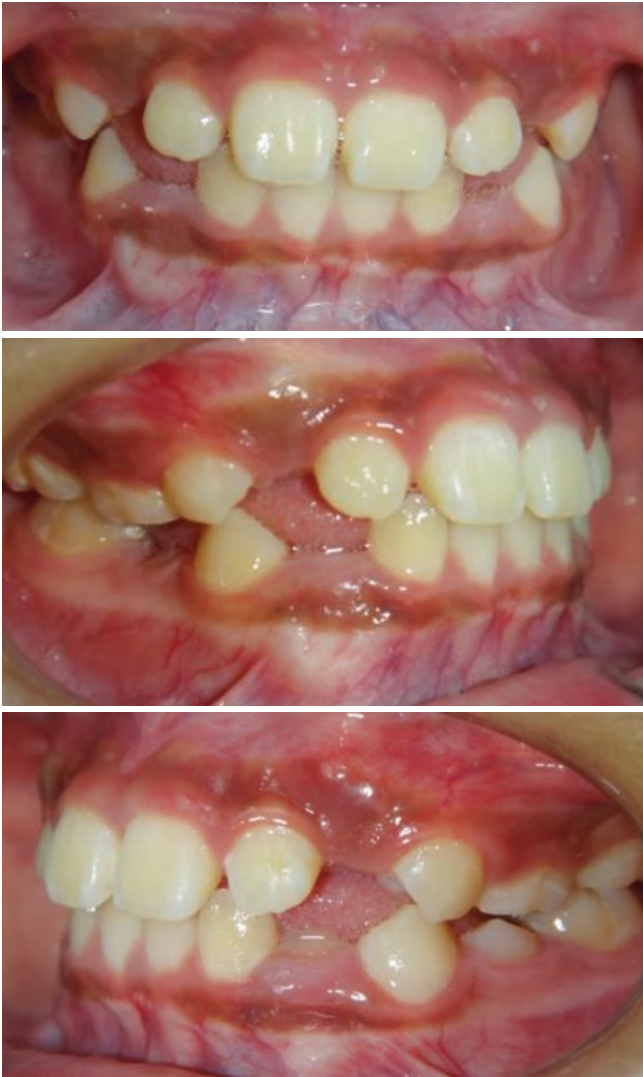Figs. 8.48, 8.49, and 8.50 Anterior cross bite was presented



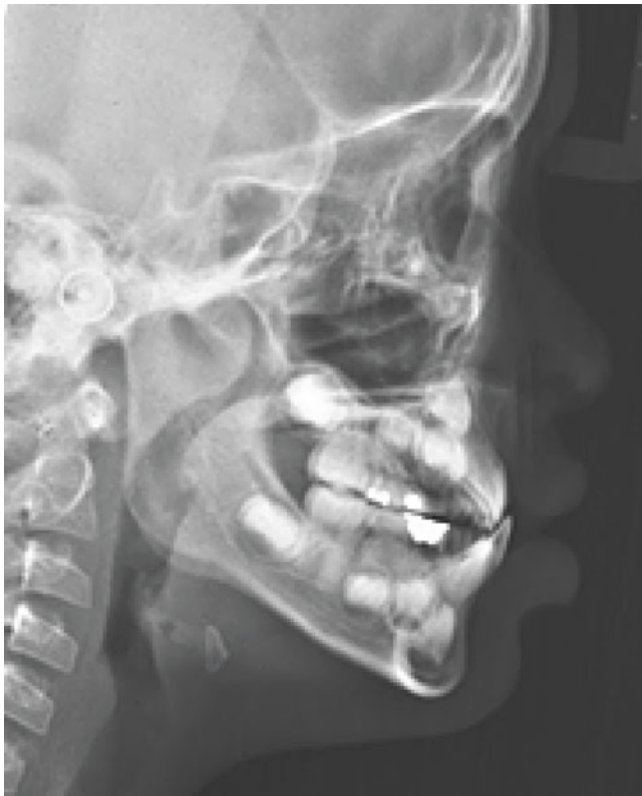
Figs. 8.52 and 8.53 After correction of the anterior cross bite, the patient showed upper anterior teeth when smiling which is esthetically more pleasant than before the treatment



Figs. 8.54 and 8.55 His profiles remained acceptable

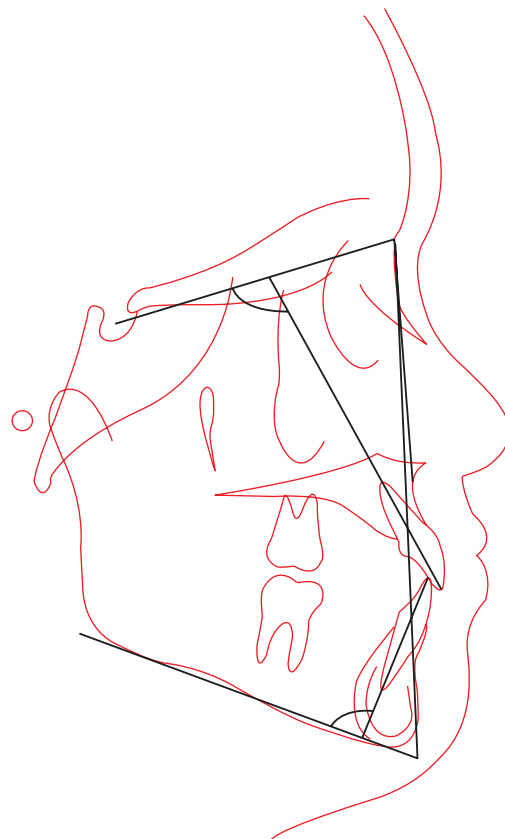
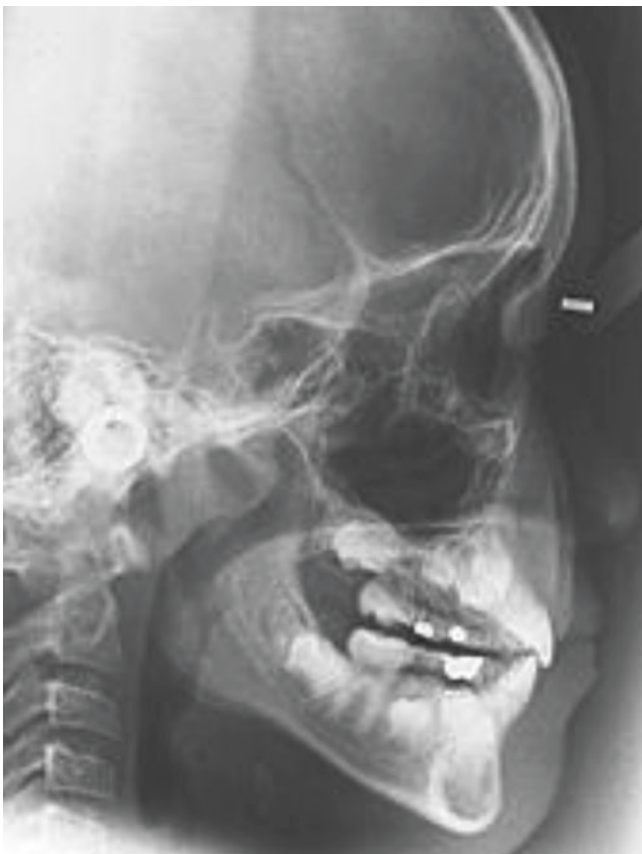

Figs. 8.56, 8.57, and 8.58 Intraoral pictures, 2 years after the beginning of the treatment



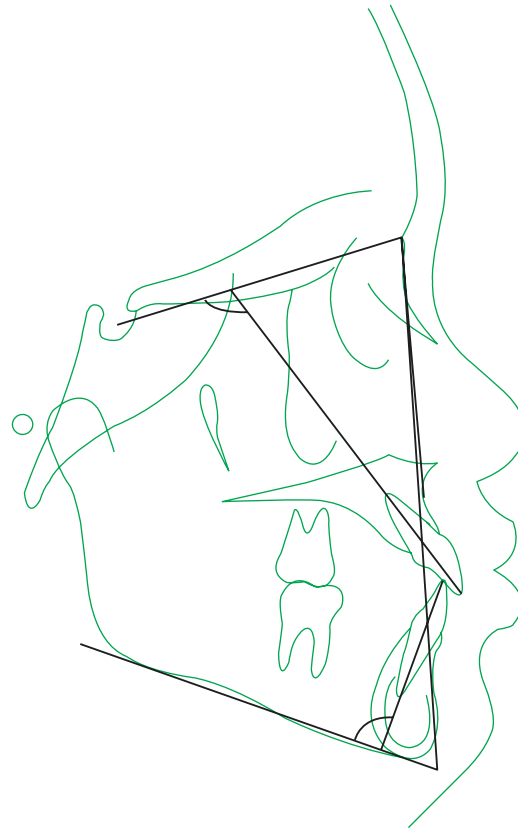
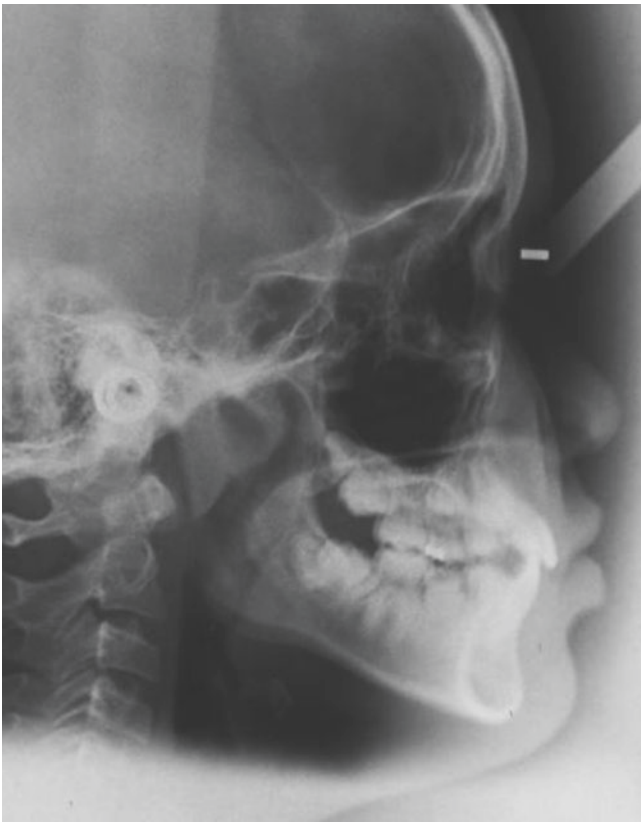SNA	77
SNB	75
ANB	2
U1 - SN	95
L1 - MP	93

Figs. 8.59 and 8.60 Cephalometric X-ray of the patient in Fig. 8.44, 8.45, 8.46, 8.47, 8.48, 8.49, and 8.50, and the tracing showed that he has a +2 ANB before the treatment which indicated no fault in both the maxilla and the mandible. The cause for the anterior cross bite was from inclination of the upper and lower anterior teeth



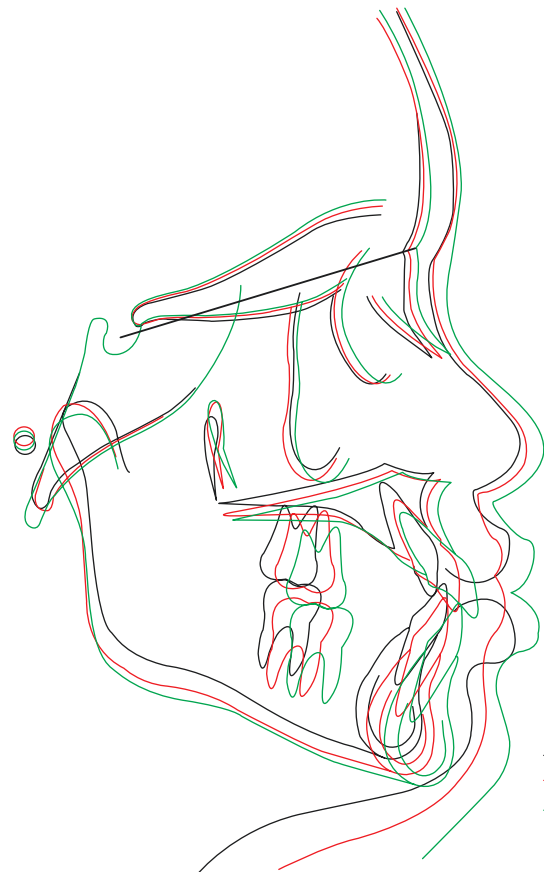
SNA	77
SNB	75
ANB	2
U1 - SN	99
L1 - MP	94

Figs. 8.61 and 8.62 Cephalometric X-ray of the same patient and the tracing after correction of the anterior cross bite



SNA	77
SNB	76
ANB	1
U1 - SN	108
L1 - MP	94

Figs. 8.63 and 8.64 2 years after the anterior cross bite was corrected



—	T0
—	T1
—	T2

Fig. 8.65 Superimposition of the tracings at the three timelines, before treatment (T0), after correction of the anterior cross bite (T1), and 2 years after the treatment began (T2)

8.4 Treatment of Skeletal Class III Malocclusions

8.4.1 The Use of Face Mask or Face Mask Combined with Rapid Palatal Expansion (Figs. 8.66–8.84)

Many authors suggested the use of face mask or RPE (rapid palatal expansion) or face mask combined with RPE to enhance growth of the maxilla or together with the attempt to control growth of the mandible. Temporary anchorage device (TAD) has also been used to protract the

maxilla. Beccetti and McNamara 2004), (Cha 2003), (Gallagher et al. 1998), (Ghiz et al. 2005), (Gu et al. 2000), (Hass 1980), (Kajiyama et al. 2000), (Keles et al. 2002), (Liou 2005), (McNamara 2000), (Mermingo et al. 1990), (Ngan 2002), (Ngan et al. 2015), (Pangrazio-Kulbersh et al. 1998), (Saadia and Torres 2000), (Satravaha 1987), (Turley 2002), (Yüksel et al. 2001).

The author prefers to use RPE not too early as it is easier to work with the patient, and it was mentioned in many researches that the results of doing RPE early or late have no significant difference.

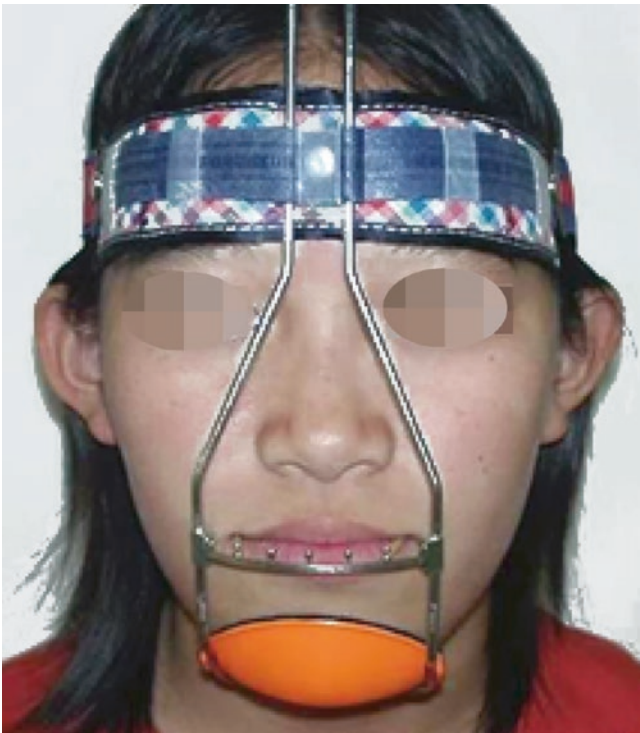
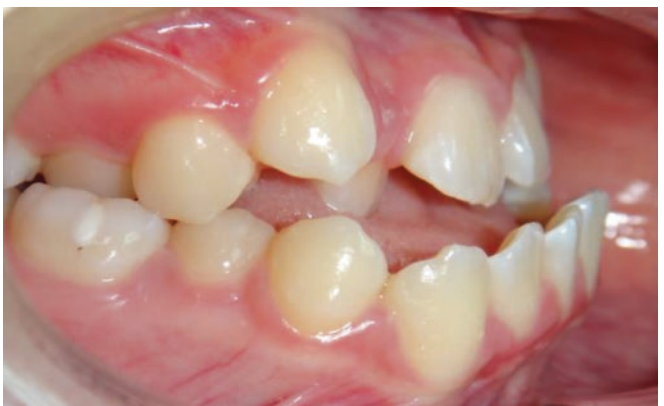
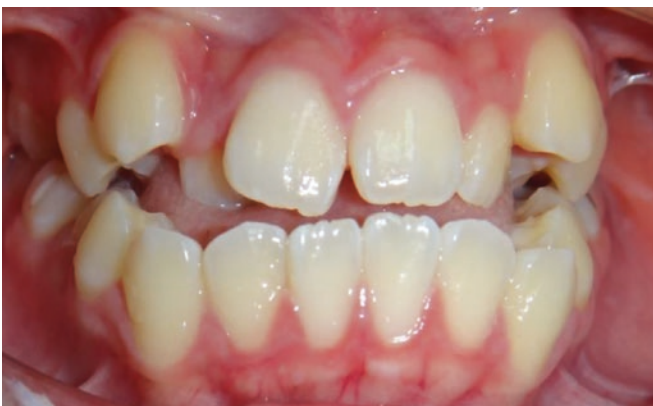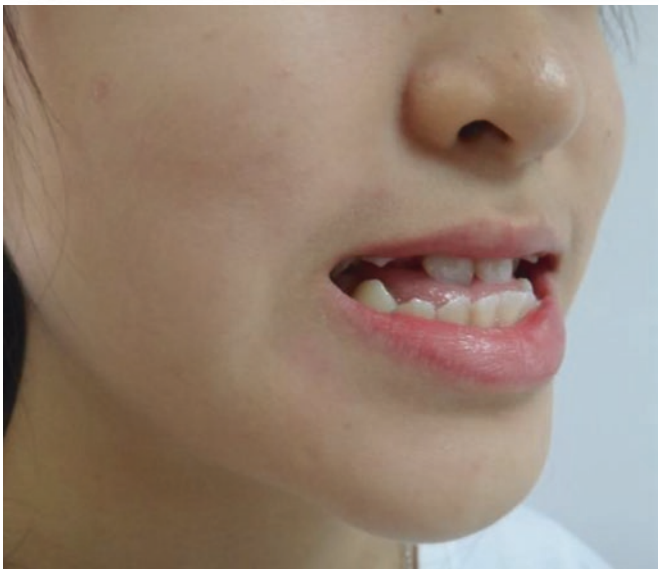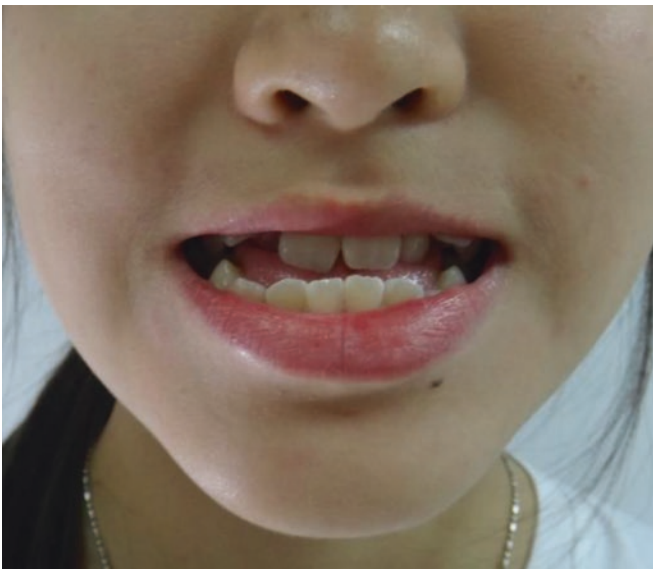Fig. 8.66 Face mask to protract the maxilla and to inhibit growth of the mandible



Figs. 8.67, 8.68, 8.69, 8.70, 8.71, and 8.72 Extra- and intraoral pictures of a 14-year-old girl, with a concave facial profile; she had a Class III malocclusion with large negative overjet and severe crowding in the upper arch. She had a large tongue with low tongue position, and the bite was slightly opened. When smiling, a large anterior cross bite appeared, and she showed more of the lower anterior teeth than the upper anterior teeth

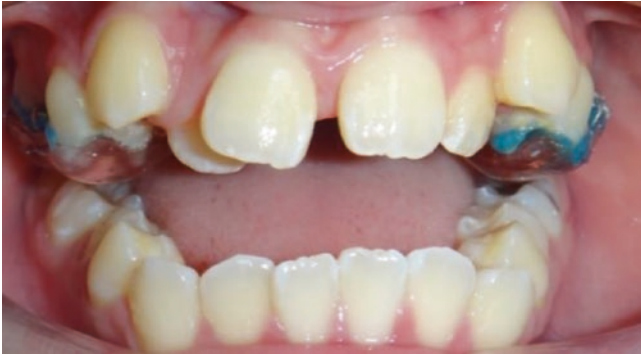

Fig. 8.73 RPE was used to expand the upper arch transversally and to bring the maxilla forward

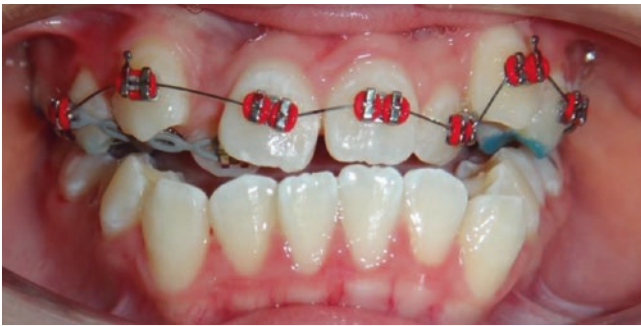

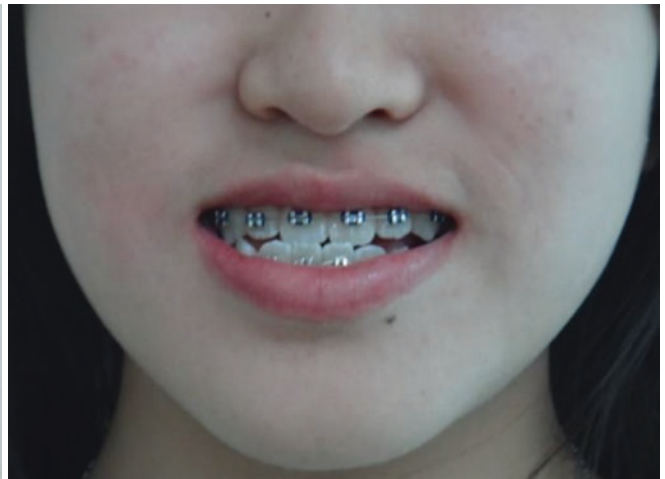
Fig. 8.74 After removal of RPE, fixed appliances were used to correct upper arch crowding

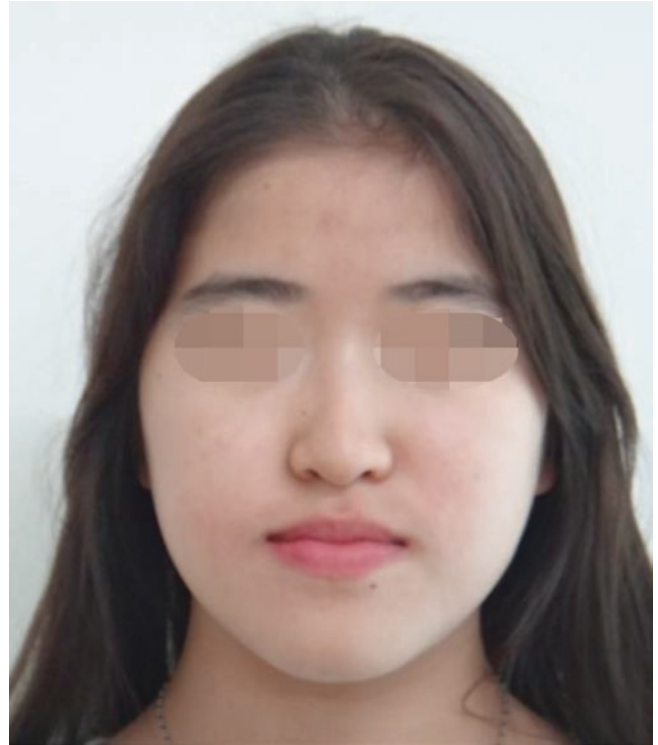

Fig. 8.75 Extraoral picture of the same girl in Fig. 8.67 after the use of RPE. Her long delichocephalic face became more pleasing resulting from transverse expansion of the maxilla

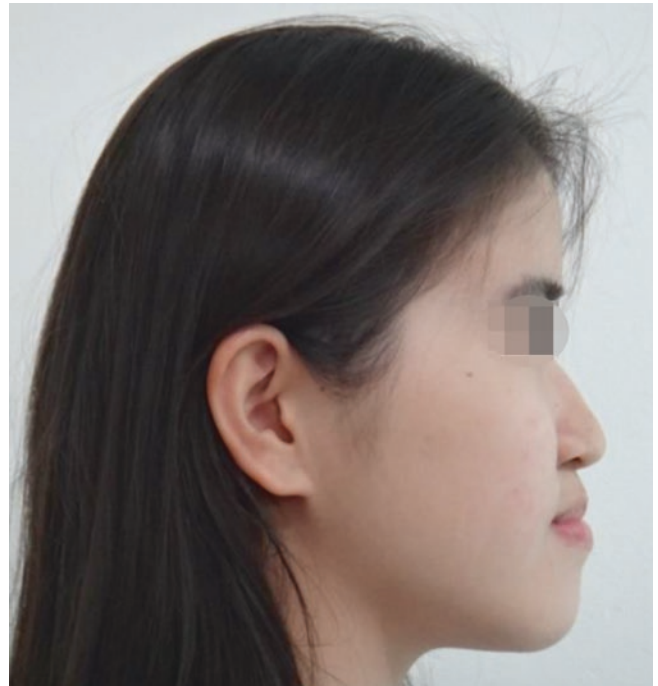

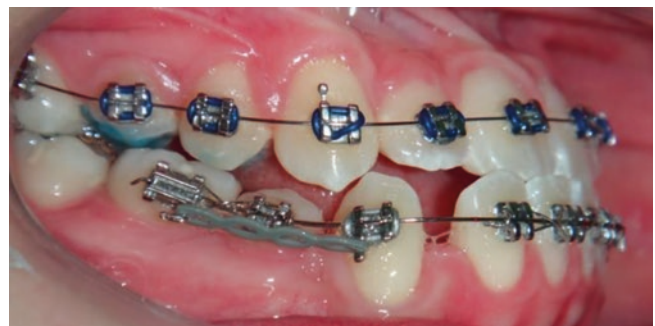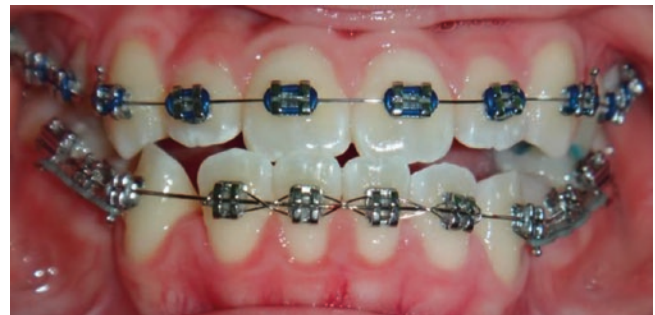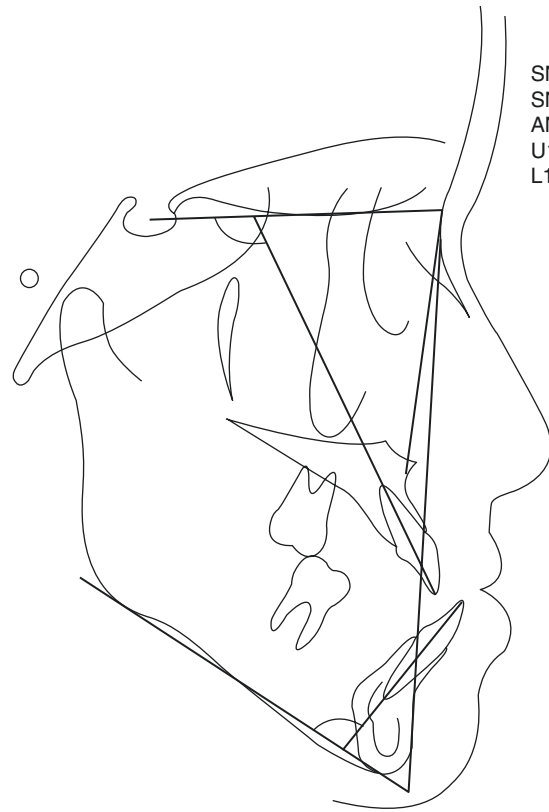
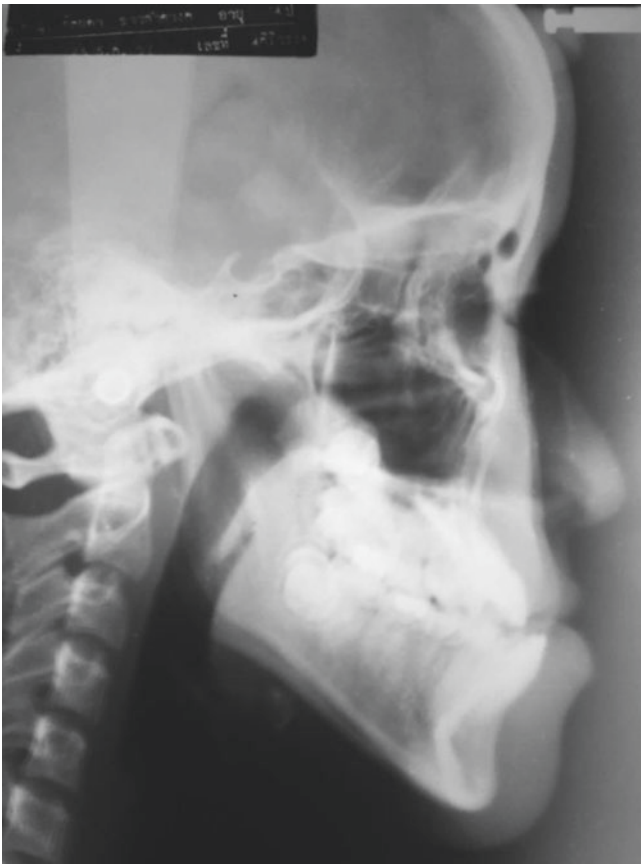Fig. 8.76 Lateral profile of the same girl in Fig. 8.68 after the use of RPE. Her midface became noticeably less concave



Figs. 8.77 and 8.78 After removal of the RPE, orthodontic fixed appliances were used during the second phase of treatment; her facial appearance and lateral profile were esthetically improved

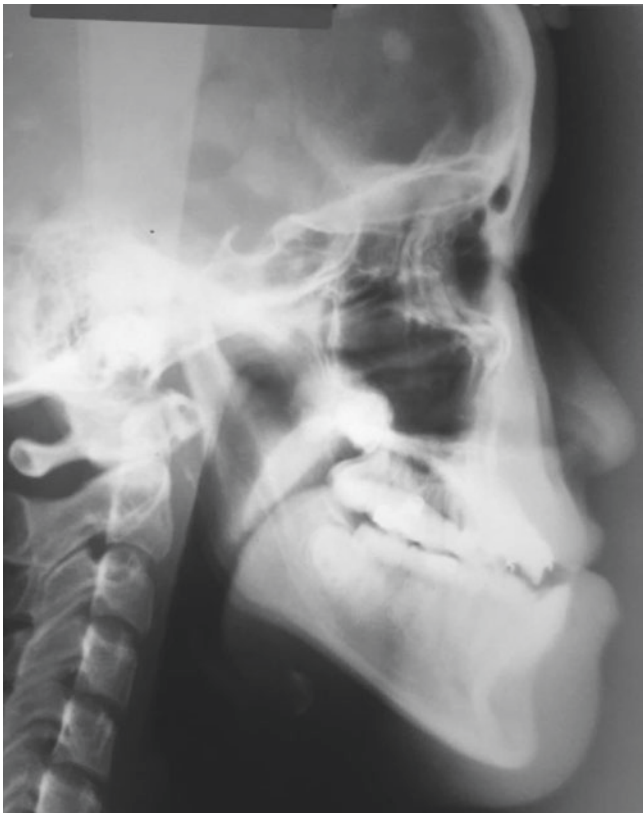


Figs. 8.79 and 8.80 Severe crowding in the upper anterior region was corrected; teeth #34 and #44 were extracted in order to move lower canines backward and later lower anterior teeth to achieve positive overbite and positive overjet



SNA	81
SNB	85
ANB	-4
U1 - SN	115
L1 - MP	95

Figs. 8.81 and 8.82 Cephalometric and tracing of the same girl before an RPE was used to expand the upper arch, and her SNA angle was 81°



SNA	82
SNB	86
ANB	-4
U1 - SN	111
L1 - MP	90

Figs. 8.83 and 8.84 After RPE was used, SNA increased from 81° to 82°

8.4.2 The Use of Chincap (Chincup) (Fig. 8.85)

A chincap has been used to modify growth of the mandible and the maxilla, and many studies on the effectiveness of its use have been done by many authors. Hideo Mitani stated on his article, "Early application of Chincap therapy to skeletal Class III malocclusion," that chincap works sufficiently on the first 2 years of the treatment but needs long retention time as the condylar cartilage might gradually become accustomed to the chincap force, allowing bone formation to return to the initial level even under compressive force, and if the chincap therapy is stopped before facial growth is complete, the decreased pressure appears to stimulate and accelerate condylar growth, and some recovery growth might take place. He also added that the improper use of the chincap can cause temporomandibular disorders and that the chincap should be used and monitored carefully. (Deguchi et al. 1999), (Deguchi et al. 2002), (Graber 1977), (Ishikawa et al. 1988), (Ko et al. 2004), (Mitani 2002), (Sugawara et al. 1990), (Wendell et al. 1985).

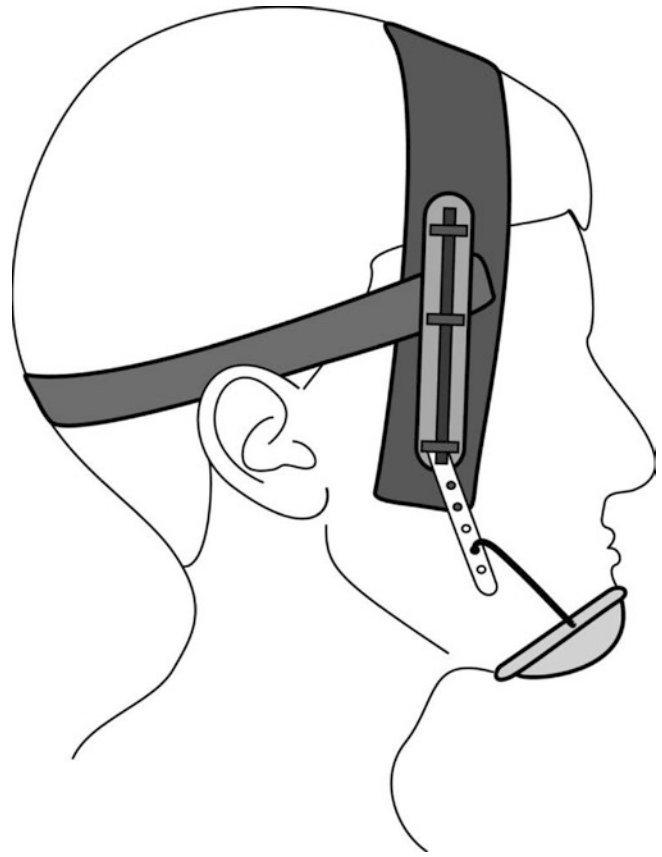


Fig. 8.85 Chincap

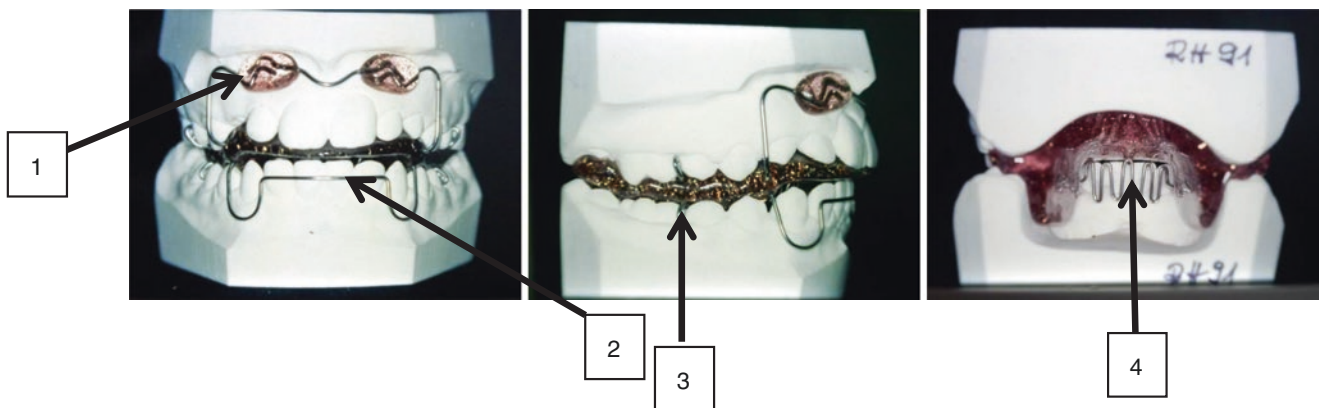
8.4.3 The Use of Functional Appliances

Functional appliances such as Fränkel's FR-3, Bimler's bionator, etc. have been used to treat skeletal Class III malocclusions. (Fränkel and Fränkel 1989), (Graber et al. 1997), (Levin et al. 2008), (Rakosi 1985), (Rakosi and Graber 2010), (Satravaha 1993), (Satravaha and Taweeseedt 1996a), (Satravaha and Taweeseedt 1996b), (Satravaha and Taweeseedt 1999).

8.4.4 The Use of Class III Activator (Figs. 8.86–8.90)

The author recommends Class III activator of Thomas Rakosi (Rakosi 1985), (Satravaha 1993), (Graber et al. 1997), (Rakosi and Graber 2010) to be used in early stage of treatment of skeletal Class III malocclusion; the objectives of using this appliance are:

1. To achieve a more posterior position of the mandible
2. To protract the maxilla
3. To get positive overjet
4. To get positive overbite



Figs. 8.86, 8.87, and 8.88 Class III activator

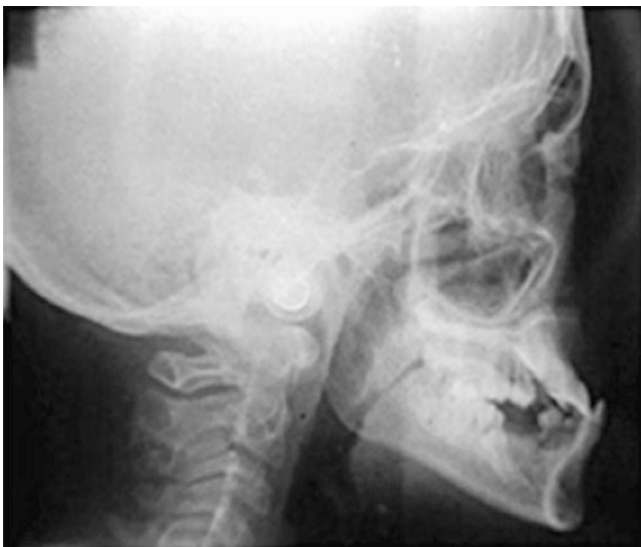

Fig. 8.89 Cephalogram taken before using Class III activator

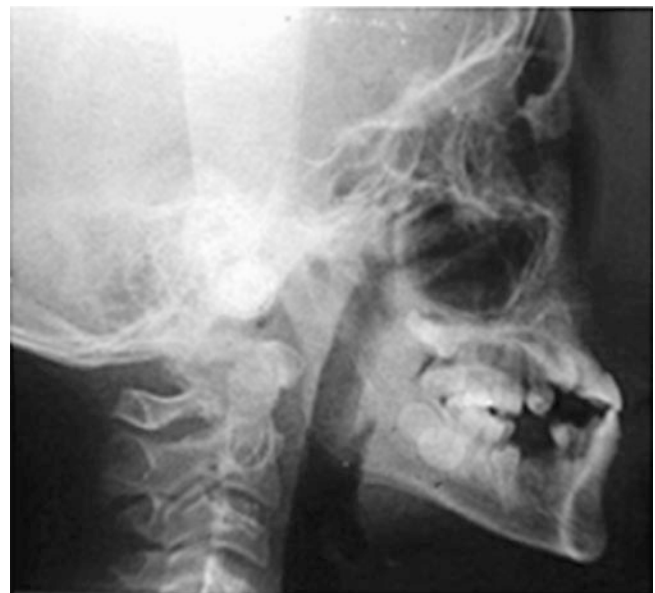

Fig. 8.90 Cephalogram of the same patient in Fig. 8.89 showed positive overjet and positive overbite after the use of Class III activator, and it can be clearly seen here that the mandible of this patient was pushed backward into a new position

Class III activator of Thomas Rakosi is a bimaxillary appliance, composed of acrylic part and wire components. The components and their functions are:

1. Upper labial pads to stimulate bone formation or enhance growth of the maxilla.
2. Lower labial bow, to stabilize the appliance; the author recommends not having any force from the lower labial bow on the lower anterior teeth. Its distance to the labial surfaces of the lower anterior teeth should be about 2 mm.
3. Stop loops located mesial to all the 6-year molars, to stabilize the appliance.
4. Tongue guard, to prevent force from a flat and low tongue position, which exert force upon and flare out the lower anterior teeth.

Fig. 8.91 A construction bite

8.5 Construction of Class III Activator (Figs. 8.91–8.97)

A construction bite must be registered to designate a new position of the mandible which is more posterior to its original position. Construction bite must be done on the patient. Its thickness varies according to growth pattern of the patient but must be thicker than the freeway space of that patient as activator functions thru natural force of the muscles. (Rakosi 1985), (Graber et al. 1997), (Rakosi and Graber 2010), (Witt and Gehrke 1981).

In horizontal growth pattern patients, the mandible can be pushed backward in a more distance than that of the patients with vertical growth pattern. Patients with horizontal growth pattern, therefore, have more favorable prognosis than those of vertical growth pattern when using Class III activator for correction of sagittal discrepancy.

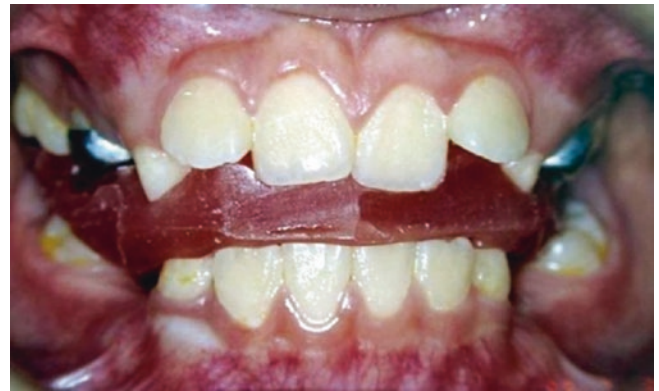
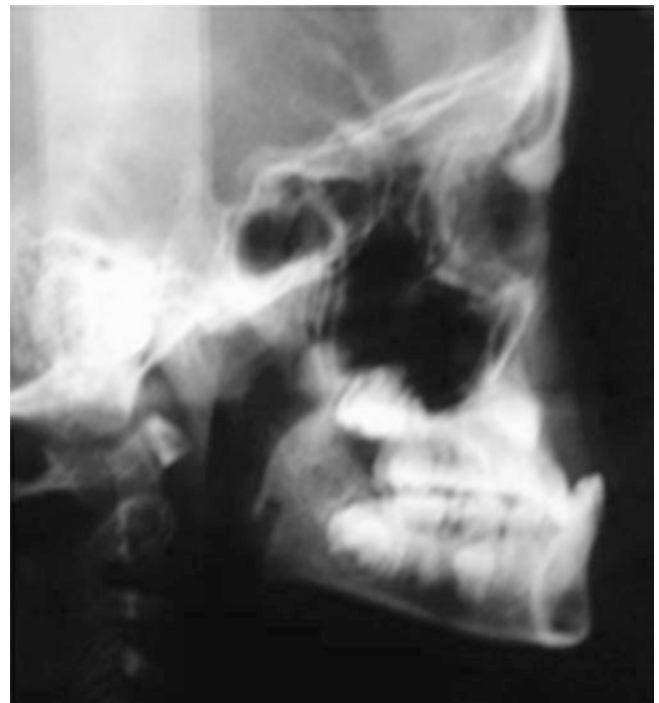
Fig. 8.92 A cephalogram of a horizontal growth pattern patient



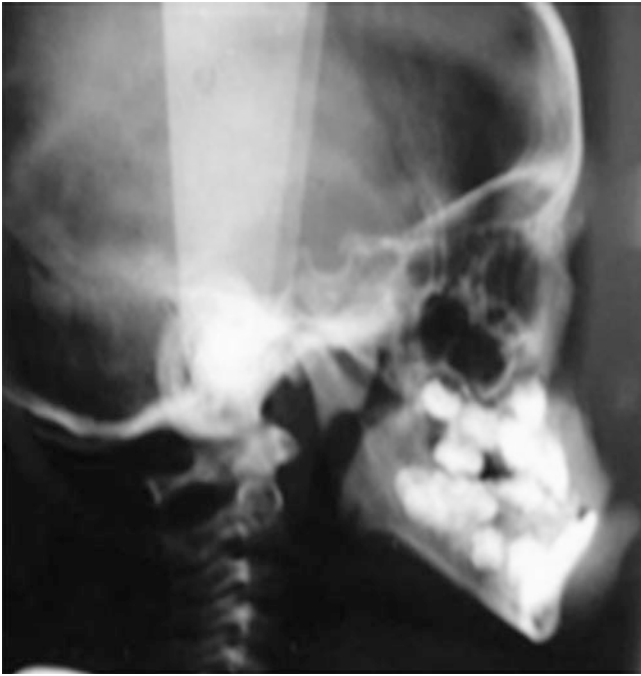

Fig. 8.93 A cephalogram of a vertical growth pattern patient



Figs. 8.94 and 8.95 Fig. 8.94 showed lateral profile of a 9-year-old girl without a construction bite in the mouth and Fig. 8.95 The same girl with construction bite in the mouth. Her lower face height increased

while having construction bite in the mouth, resulting in better proportion of the face and improving in esthetics

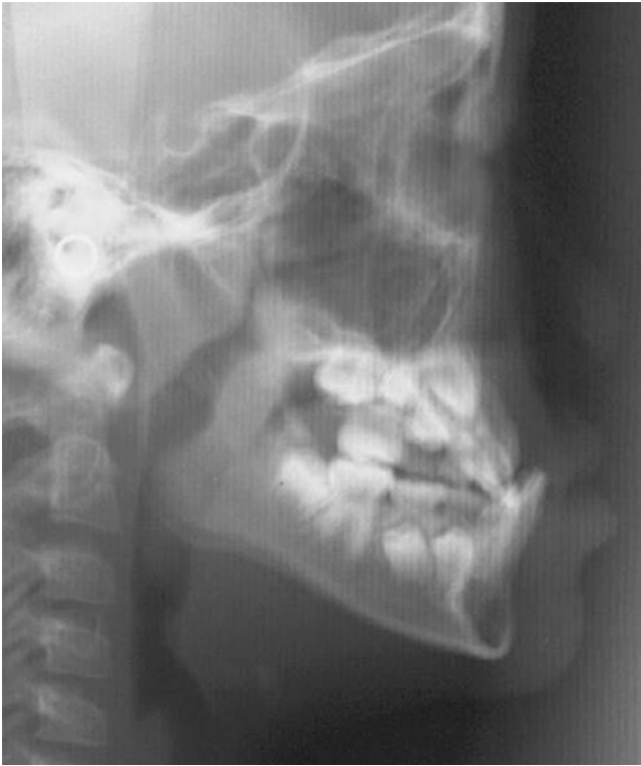

Fig. 8.96 A cephalometric X-ray of a patient at occlusion

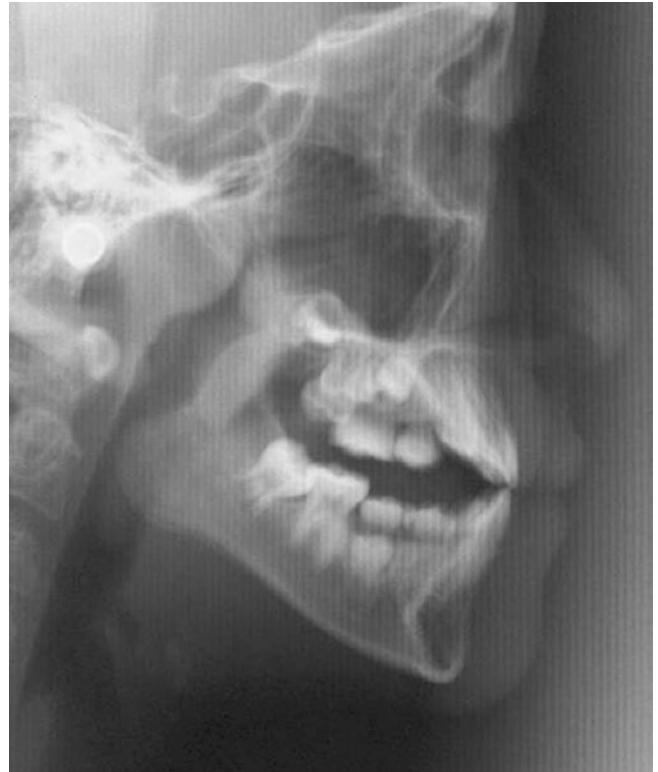

Fig. 8.97 A cephalometric X-ray of the same patient with a construction bite; note that the construction bite brought the mandible backward into a more posterior position. Lower facial height of the patient increased and resulted in a better facial proportion and esthetics

8.6 Checklist When Registering Construction Bite

1. The patients with the construction bites in the mouth must be able to close their lips without muscle strain.
2. The patients' mandibular and facial midlines must coincide. Skeletal midline shift should be corrected through construction bite registration.
3. As there will be permanent changes in facial appearances of the patients, patients' and parental approvals are needed.

8.7 Patient's Instruction at Insertion of Class III Activator (Figs. 8.98 and 8.99)

1. Inform the patients and their parents that Class III activator is a bimaxillary appliance, which loosely fits in the patients' mouth.

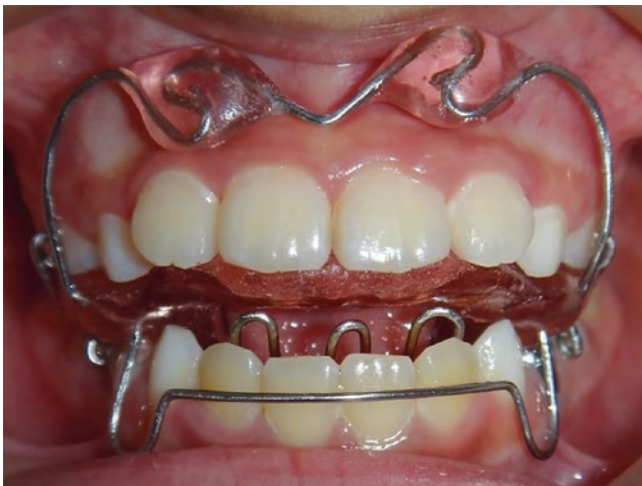

Fig. 8.98 Class III activator in situ

2. The patients should wear the appliances at least 12 hours a day and mostly at night due to secretion of growth hormone. (Funatsu et al. 2006).
3. The patients can wear the activators during doing their homework; they can talk while having the appliances in the mouths.
4. After the insertion, the patients should be able to put the appliances on and take them off by themselves. At the first night, when waking up in the morning, the patients should check whether the appliances are still in the mouth. If not, they should wear the appliances more during the daytime.

The patients with large adenoid/tonsils or mouth breathers will have difficulties in holding the appliances in the mouths during sleep. This problem should be eliminated before using Class III activator.

5. The average time for the use of Class III activator is approximately 1 year

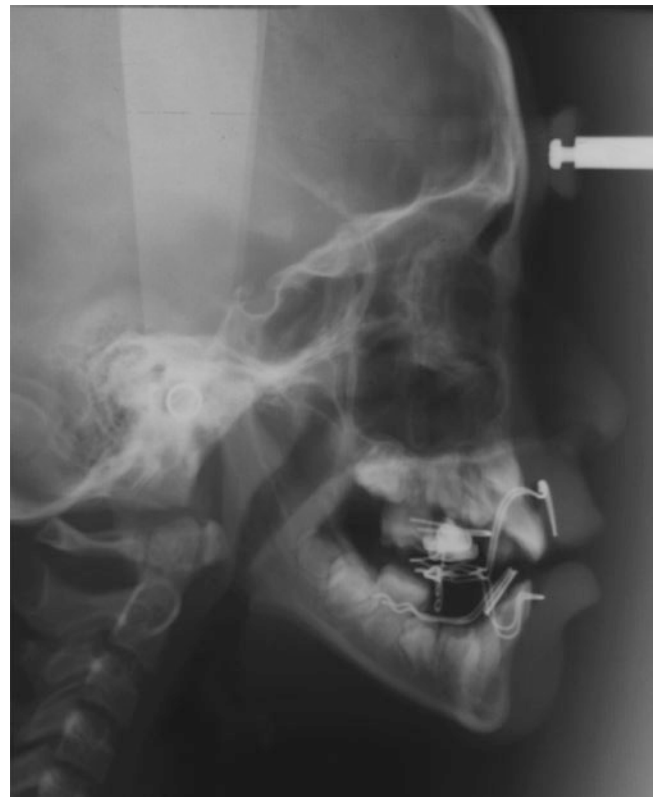


Fig. 8.99 Cephalogram of a patient with Class III activator

8.8 Patient's Appointment

The patients should come for appliance adjustment every 4 weeks.

8.9 Appliance Adjustment

Objectives:

1. To achieve positive overbite
2. To achieve positive overjet
3. To control tooth eruption
4. To get good intercuspitation

Appliance activation is done by: (Fig. 8.100)

1. Adding self-curing acrylic on the appliance at the area lingually to lingual surfaces of the upper anterior teeth, to protrude the upper anterior teeth.
2. Activating upper labial pads to produce periosteal pull to enhance growth of the maxilla.
3. Leveling curve of Spee by trimming of the acrylic and controlling tooth eruption.
4. Keeping the lower labial bow negative as the lower anterior teeth trend to tip more lingually when using Class III activator, which might result from contraction of perioral muscle during visceral swallowing and from tongue guard. Tongue guard prevents opposite force from the tongue from acting upon the lower anterior teeth.

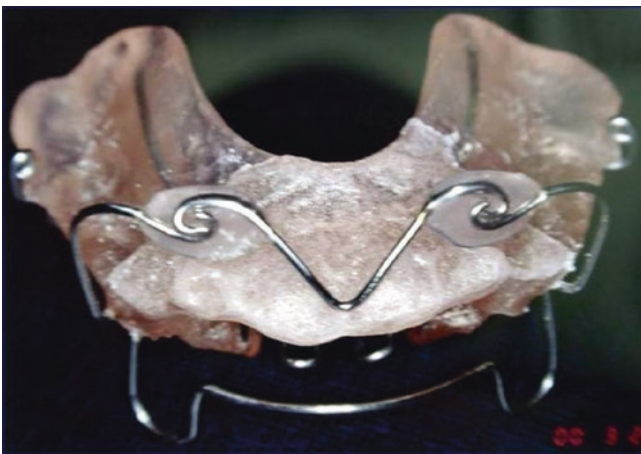
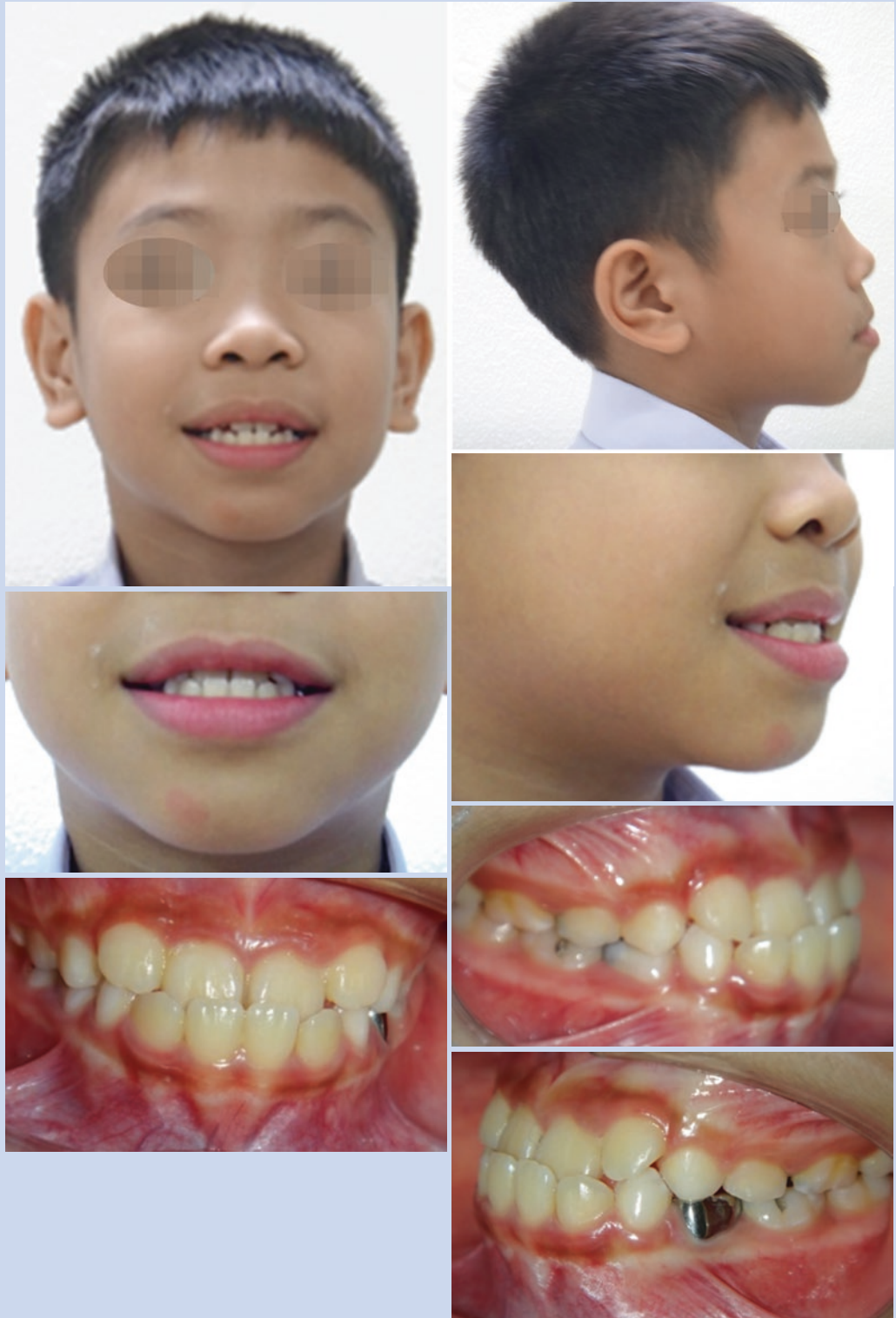
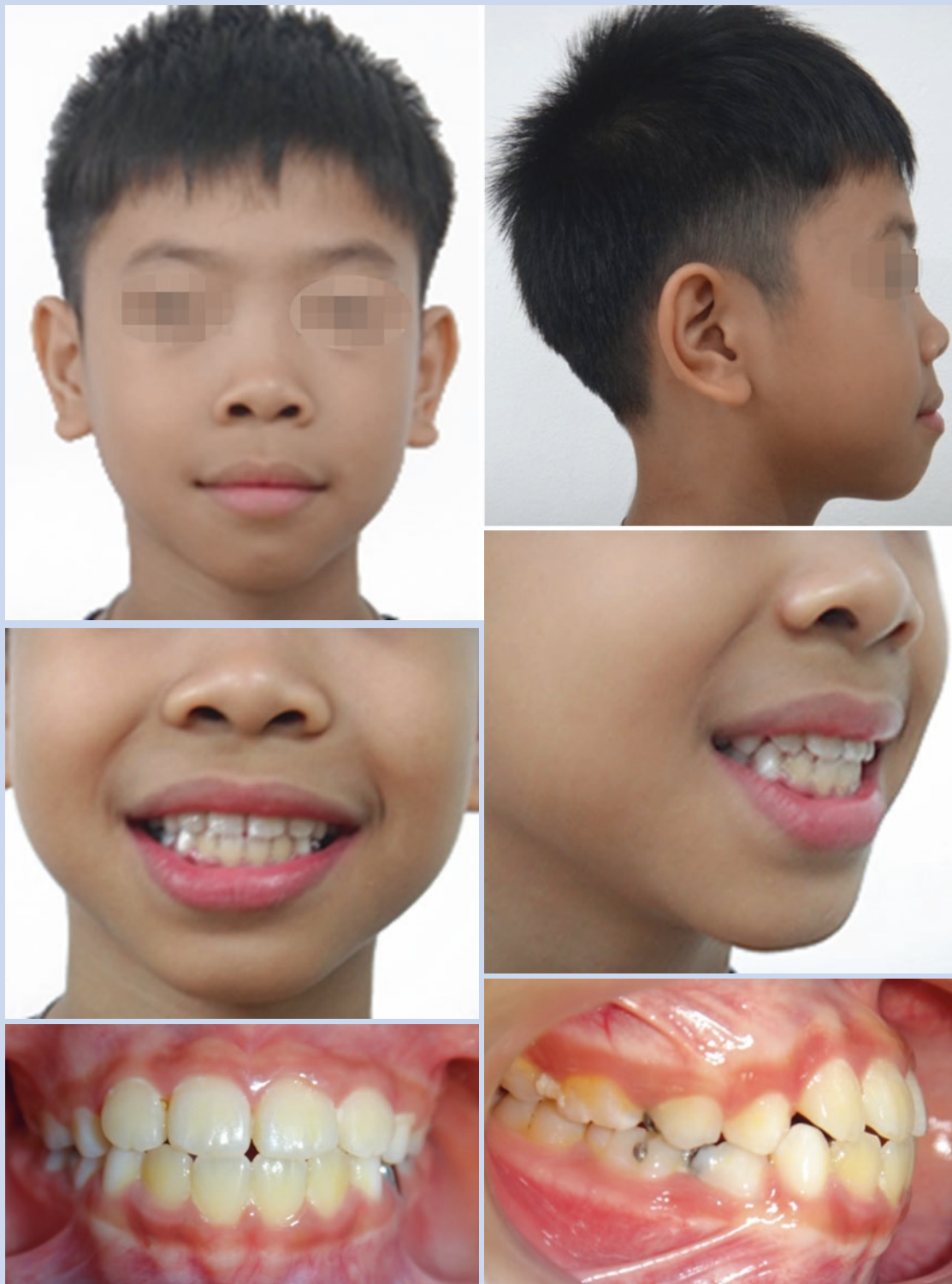Fig. 8.100 Self-curing acrylic was added to protrude the upper anterior teeth at every appointment in order to achieve positive overjet and overbite

8.10 Example of Cases Treated with Class III Activator (Figs. 8.101–8.278)

Case #1 (Figs. 8.101–8.121)

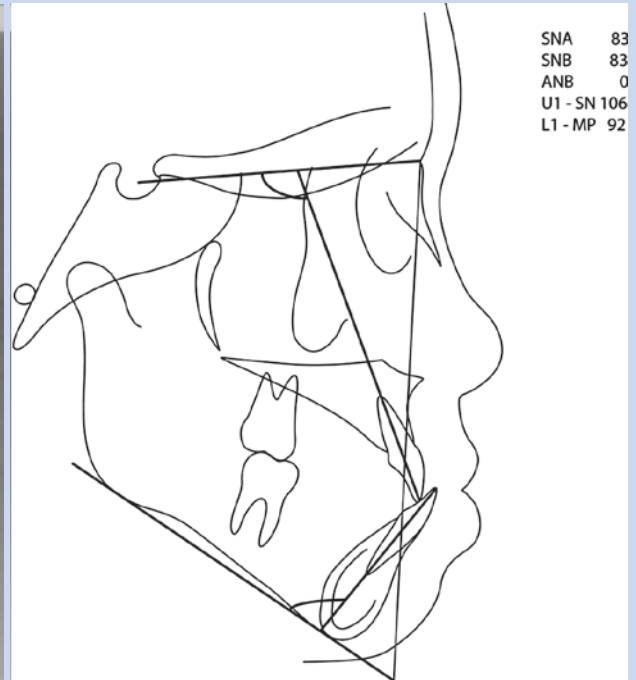
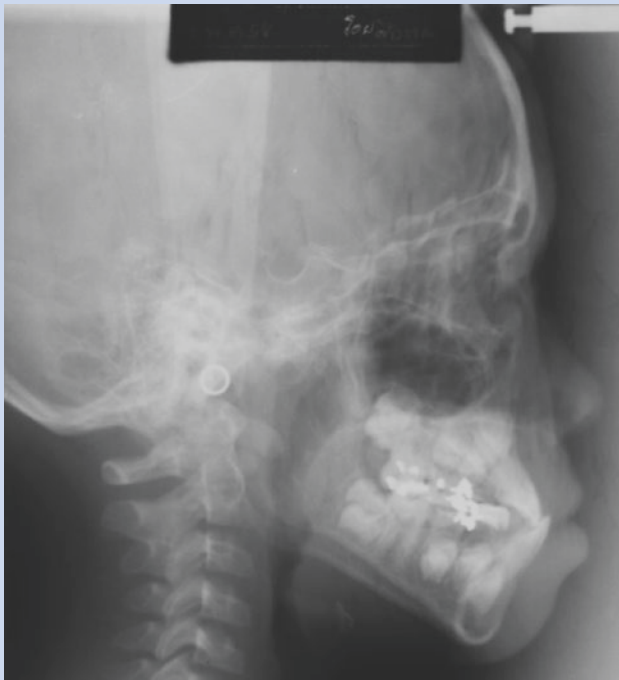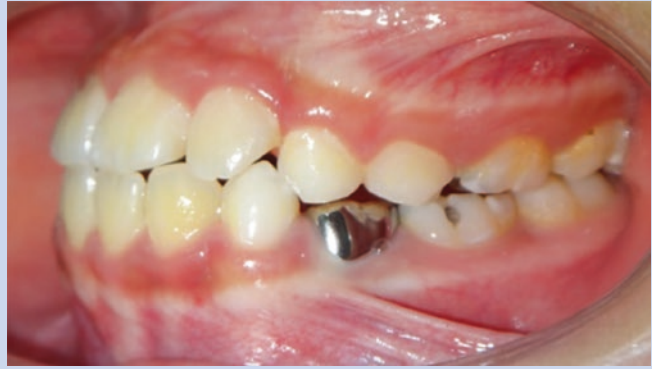Figs. 8.101, 8.102, 8.103, 8.104, 8.105, 8.106, and 8.107 Extra- and intraoral pictures of a 9-year-old boy showed protrusive profile, Class III molar, canine relationships, and anterior cross bite. He showed more lower teeth when smiling



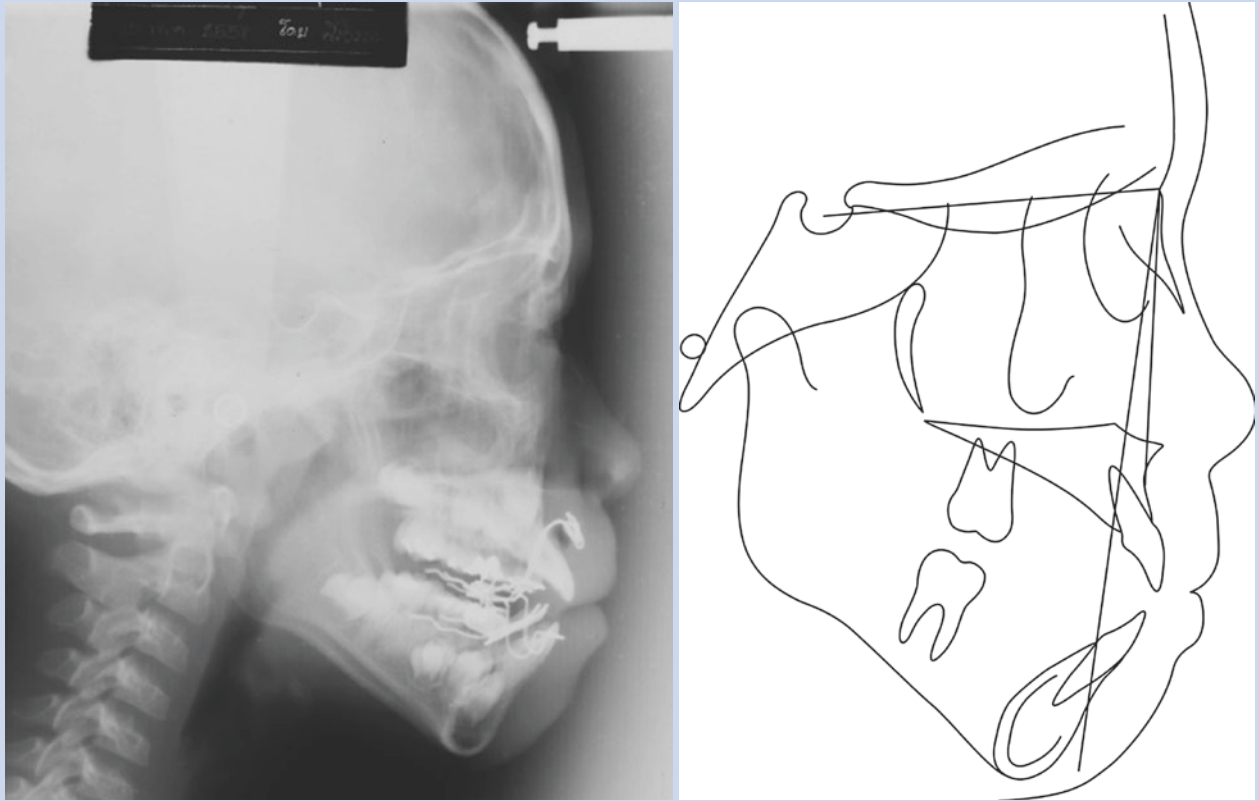


Figs. 8.108, 8.109, 8.110, 8.111, 8.112, 8.113, and 8.114 Extra- and intraoral pictures of the same boy after being treated with class III activator; his facial profile improved. He showed more upper teeth when smiling than before the treatment which is esthetically improved. Anterior cross bite was corrected. Class I molar and canine relationships were achieved

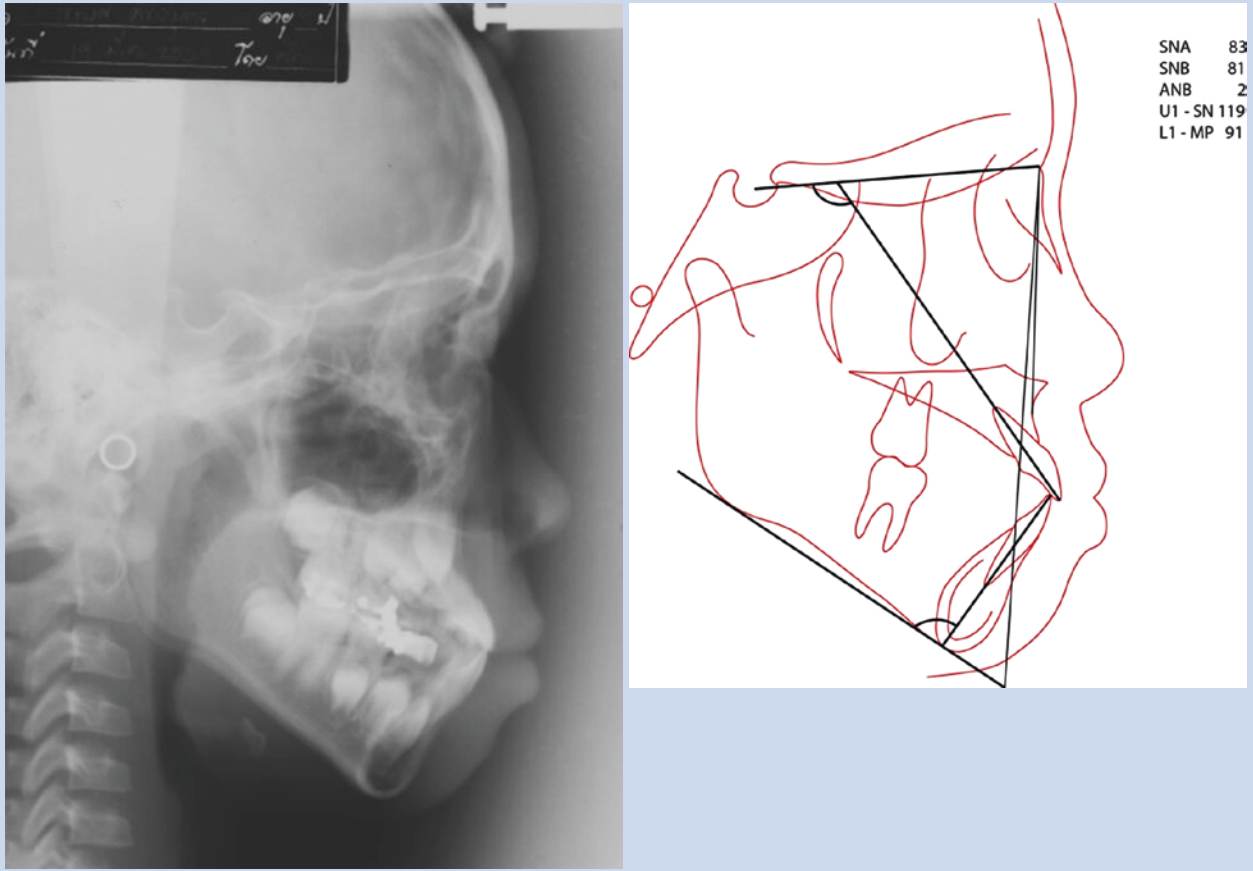
Figs. 8.108, 8.109, 8.110, 8.111, 8.112, 8.113, and 8.114 (continued)



Figs. 8.115 and 8.116 Cephalogram and tracing before the treatment. ANB angle was 0°

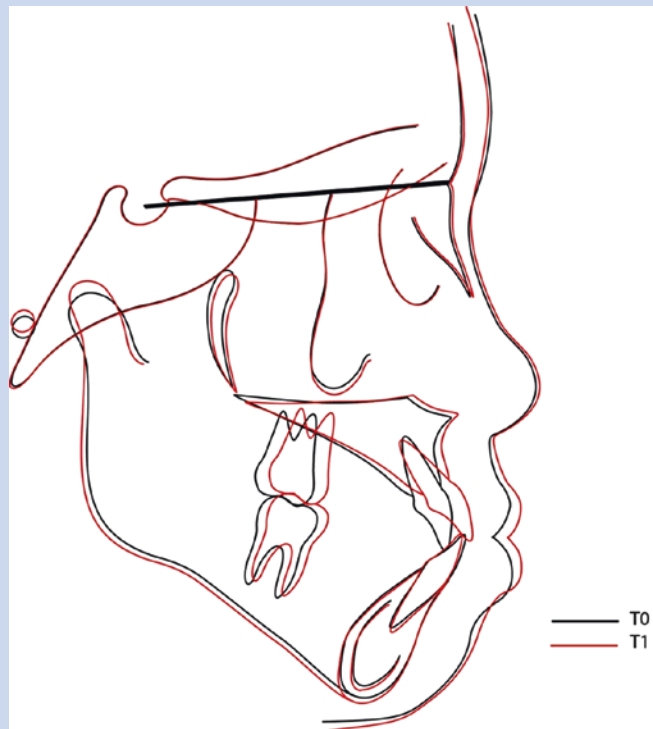

Figs. 8.117 and 8.118 Cephalogram and tracing with Class III activator in situ, showing that the mandible was brought to a more posterior position than its original position

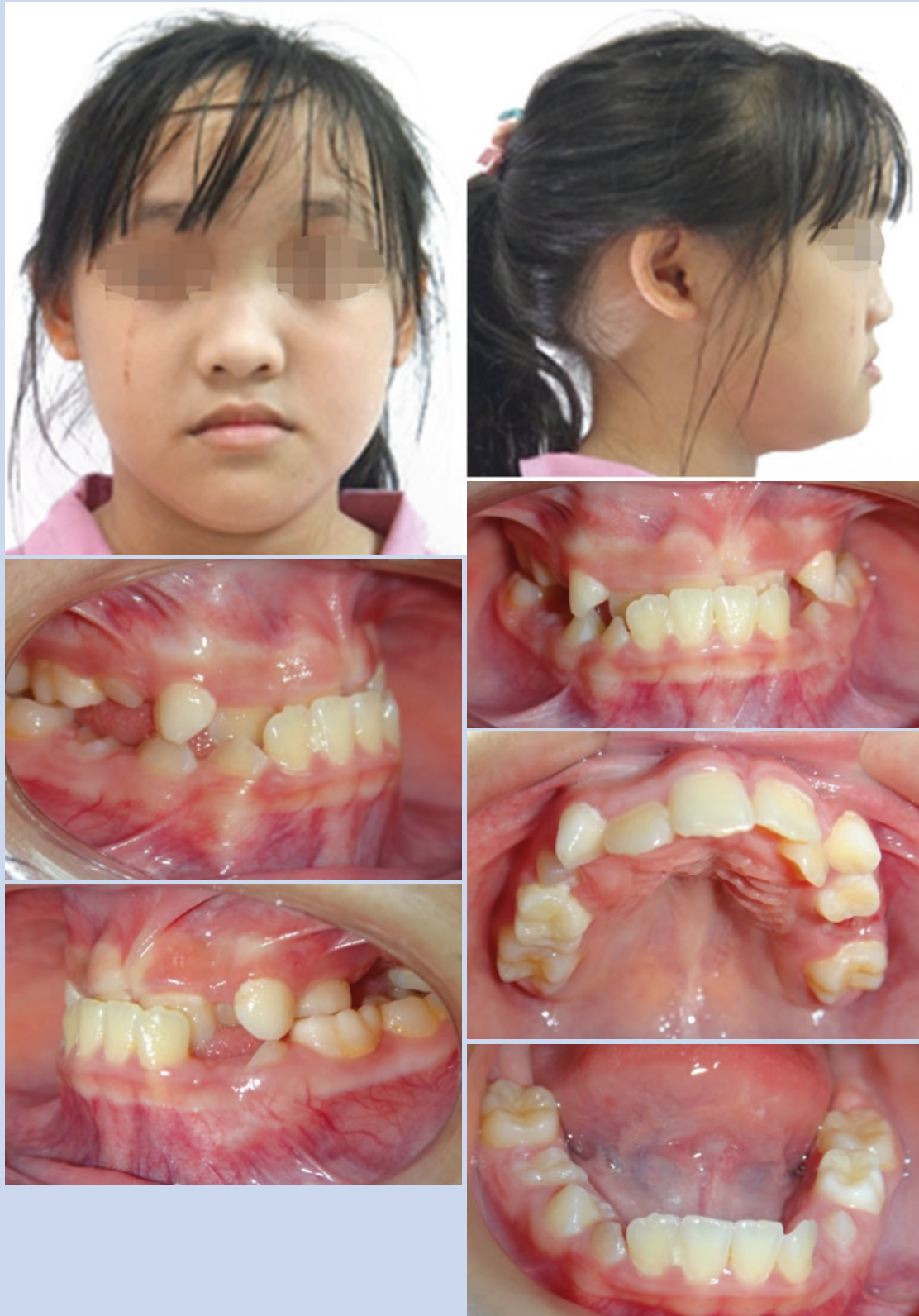

Figs. 8.119 and 8.120 Cephalogram and tracing after positive overjet and positive overbite were achieved; ANB angle increased from 0° to 2°

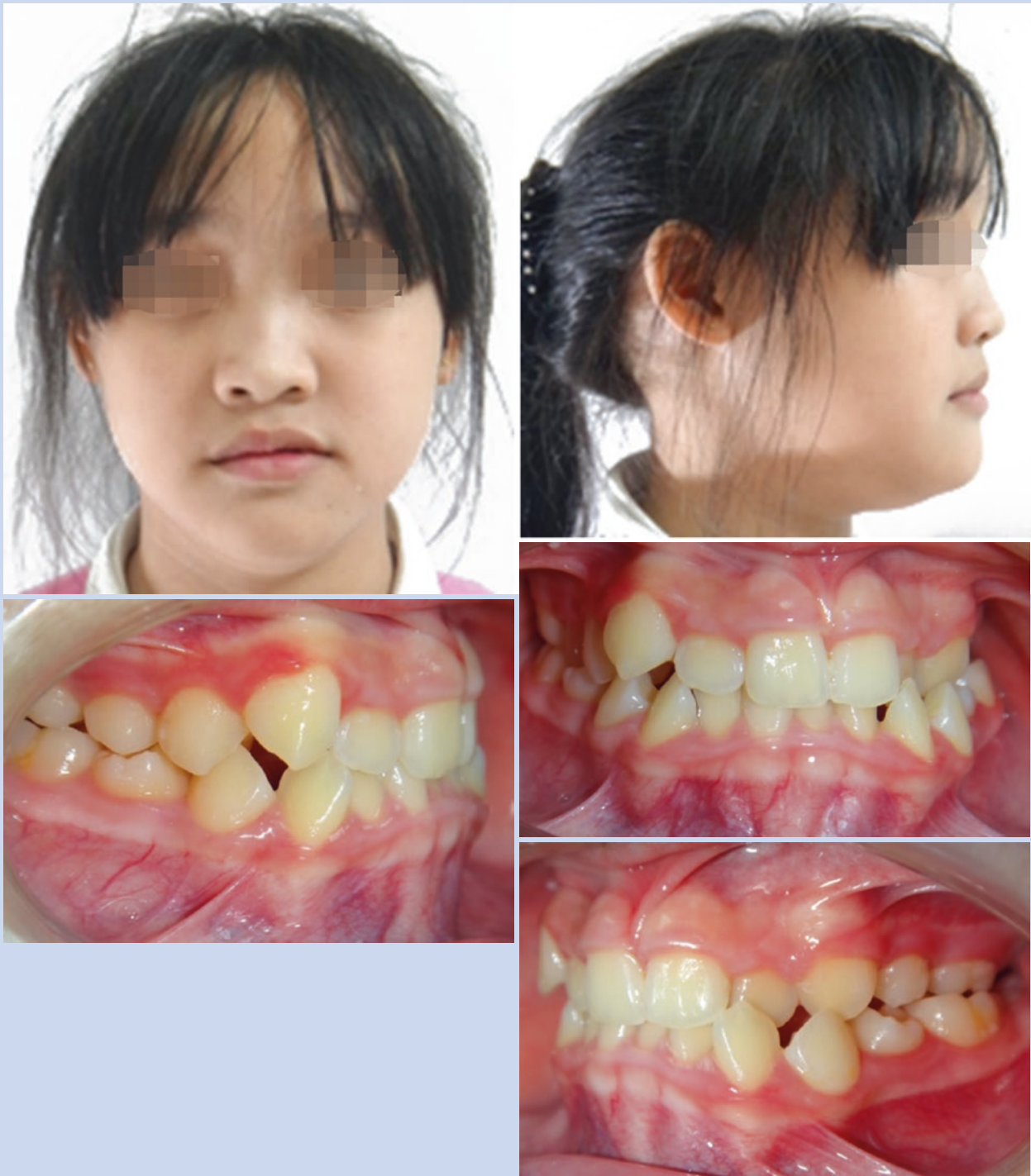Fig. 8.121 Superimposition of cephalometric tracings before the treatment (T0) and after positive overjet and positive overbite was achieved (T1)



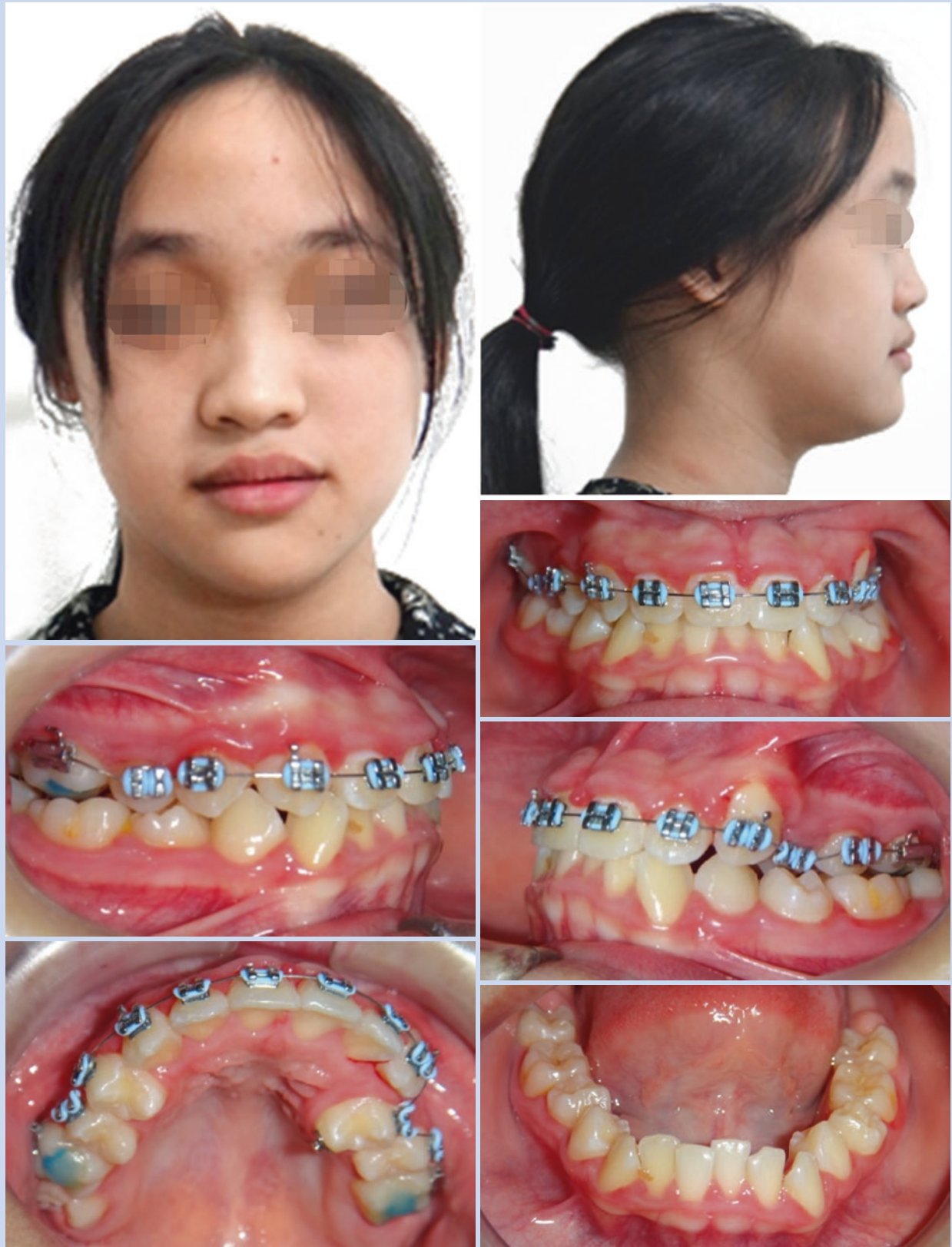Case #2 (Figs.8.122–8.149)



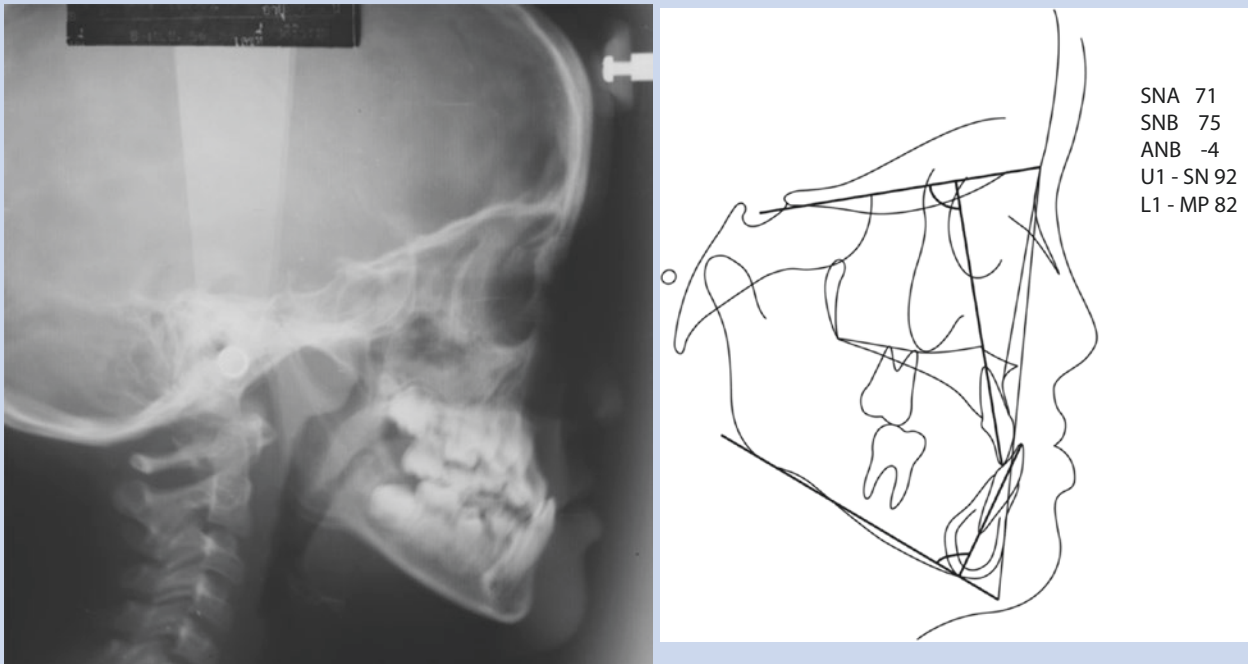
Figs. 8.122, 8.123, 8.124, 8.125, 8.126, 8.127, and 8.128 Extra- and intraoral pictures of a 9-year-old girl. She had concave facial profile. Intraoral pictures showed deep anterior cross bite with severe crowding in the upper arch



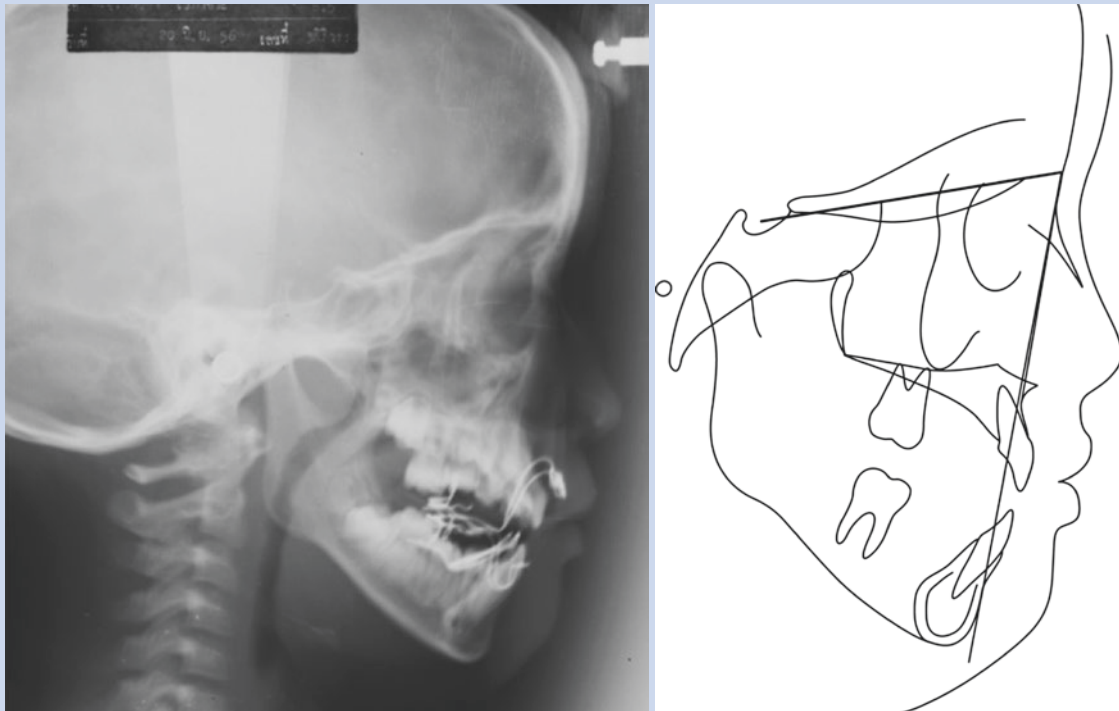
Figs. 8.129, 8.130, 8.131, 8.132, and 8.133 Extra- and intraoral pictures of the patient after Class III activator treatment. Her facial appearance was esthetically improved. Anterior cross bite was partially corrected



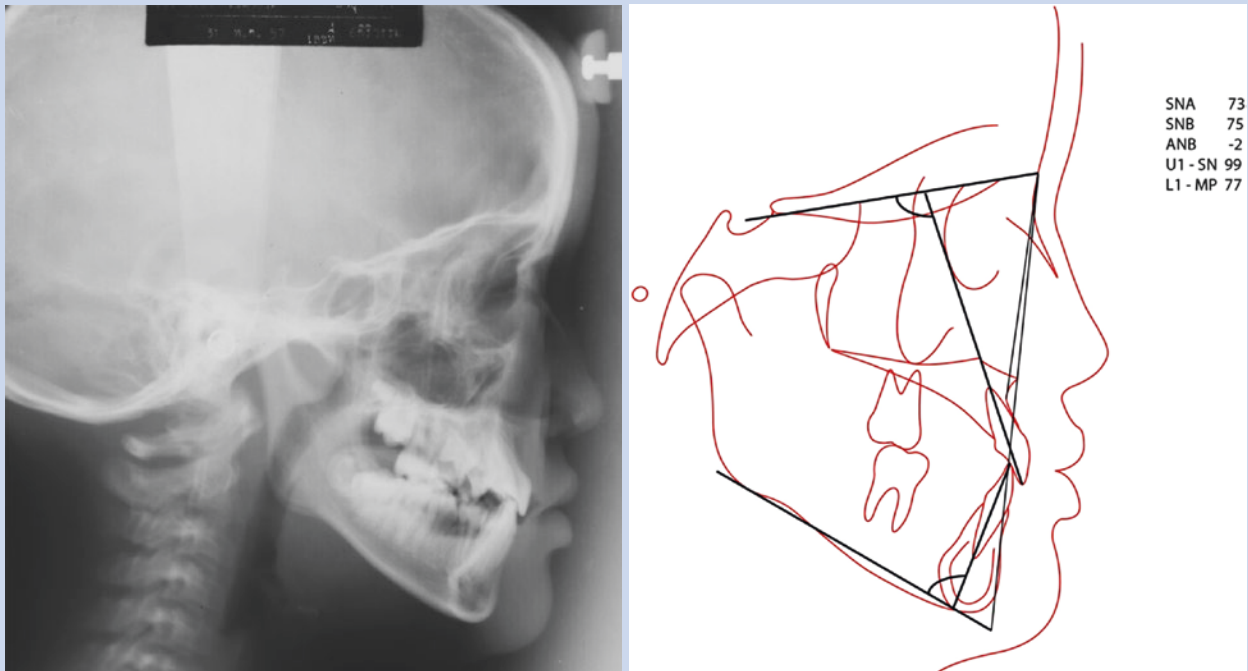
Figs. 8.134, 8.135, 8.136, 8.137, 8.138, 8.139, and 8.140 Extra- and intraoral pictures of the same girl during the second phase of the treatment with fixed appliances to correct the persisted anterior cross bite and crowding of the upper arch. Lower arch will later be treated as well with the fixed appliances. Her facial profile was tremendously improved



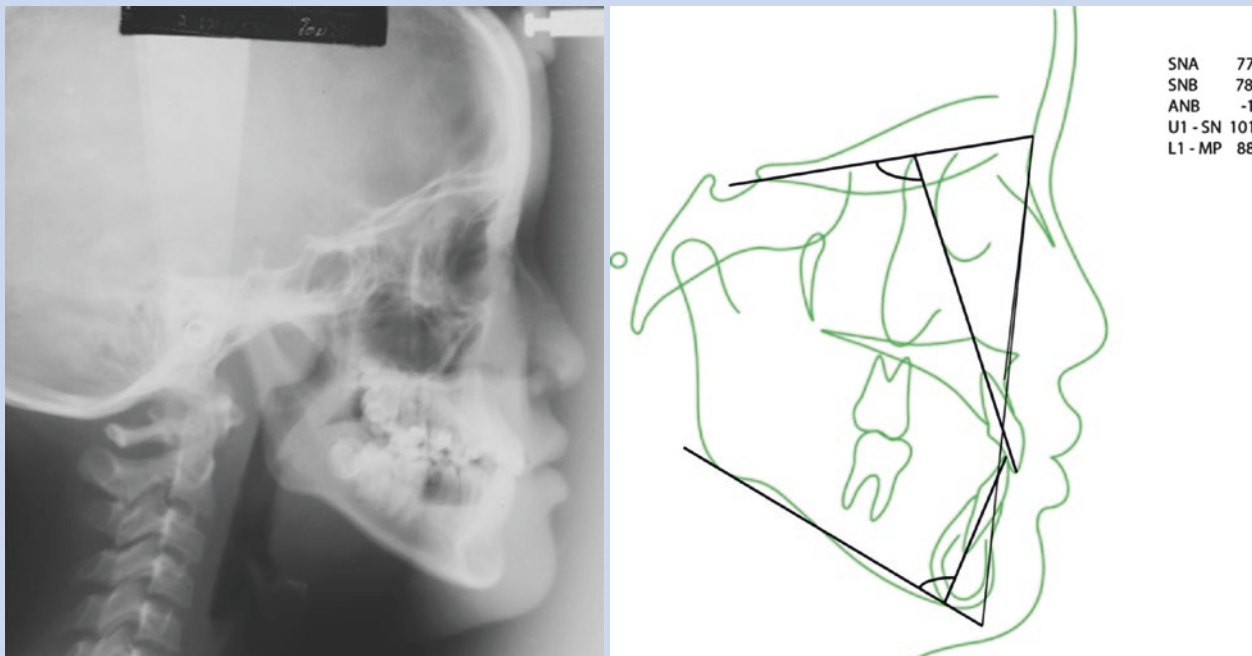
Figs. 8.141 and 8.142 Cephalogram and tracing before the treatment; she had an ANB of -4°



Figs. 8.143 and 8.144 A cephalogram and a tracing with Class III activator showed that the mandible was brought backward into a new position

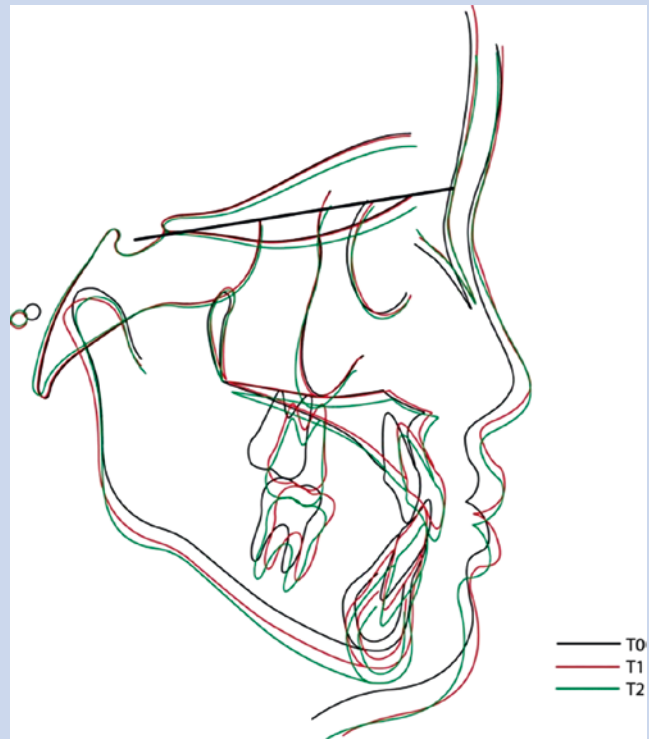


Figs. 8.145 and 8.146 Cephalogram and tracing after positive overjet and overbite were achieved



Figs. 8.147 and 8.148 Cephalogram and tracing 1 year after positive overjet and overbite were achieved. Sagittal relationship between the maxilla and the mandible was improved. ANB angle was increased from -2° to -1°

Fig. 8.149 Superimposition of tracings of different timelines, before treatment (T0), after achieving positive overjet and positive overbite (T1), and 1 year afterward (T2)



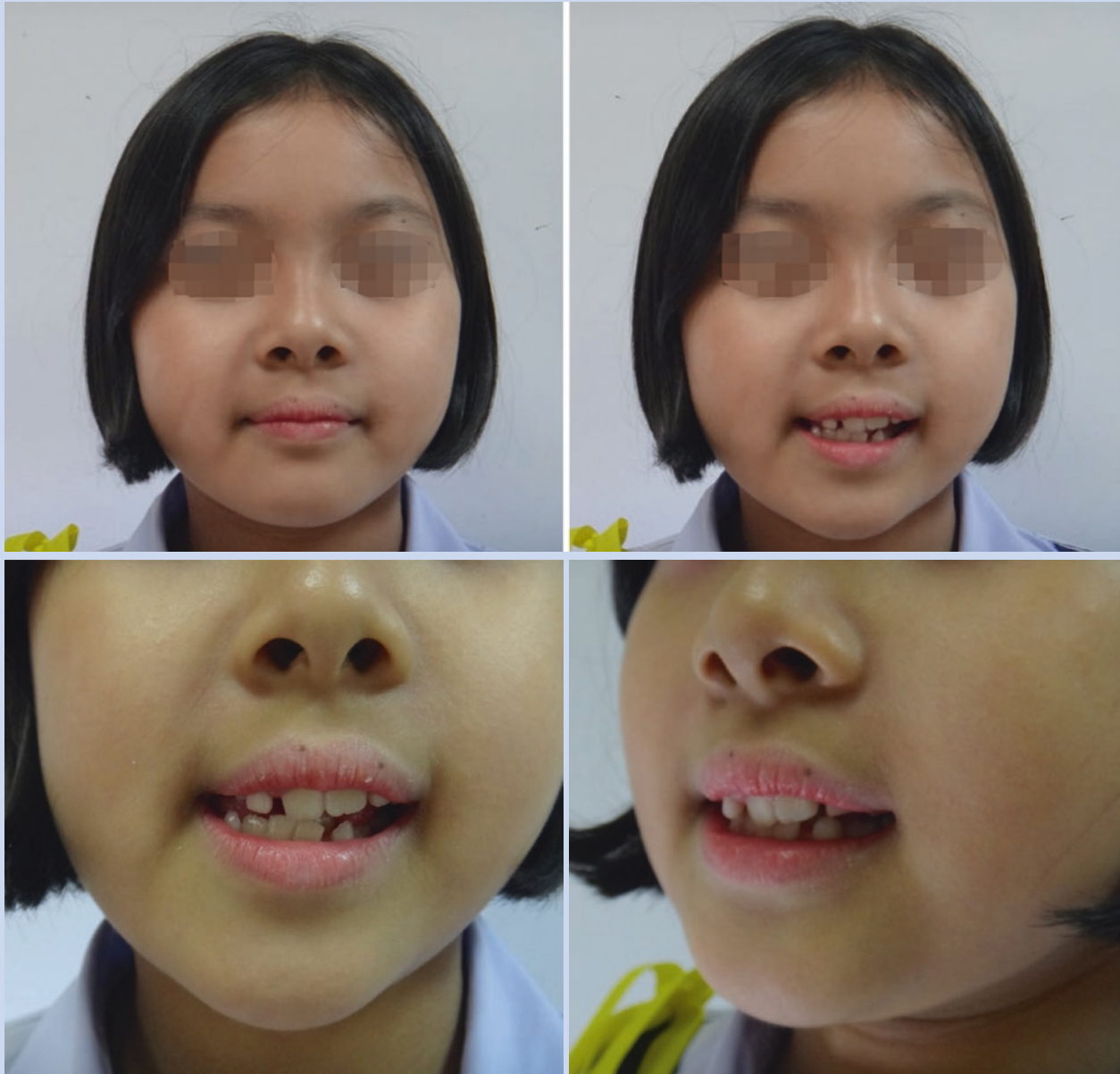8.11 Treatment of Class III Malocclusion with Pseudo-Forced Bite (Figs. 8.150–8.191)

In many cases of skeletal Class III malocclusion with pseudo-forced bite, the skeletal discrepancies are very severe;

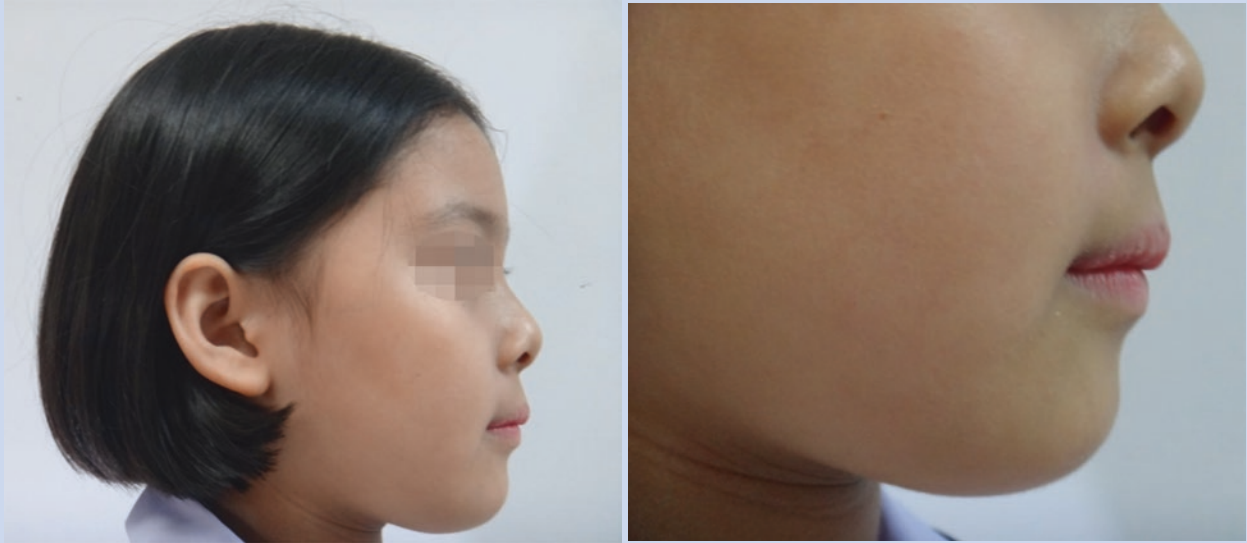orthognathic surgery might be required in later age when mandibular growth ceases.

In some cases when we treat early enough, interceptive attempt could be made to reduce severity of the malocclusion.

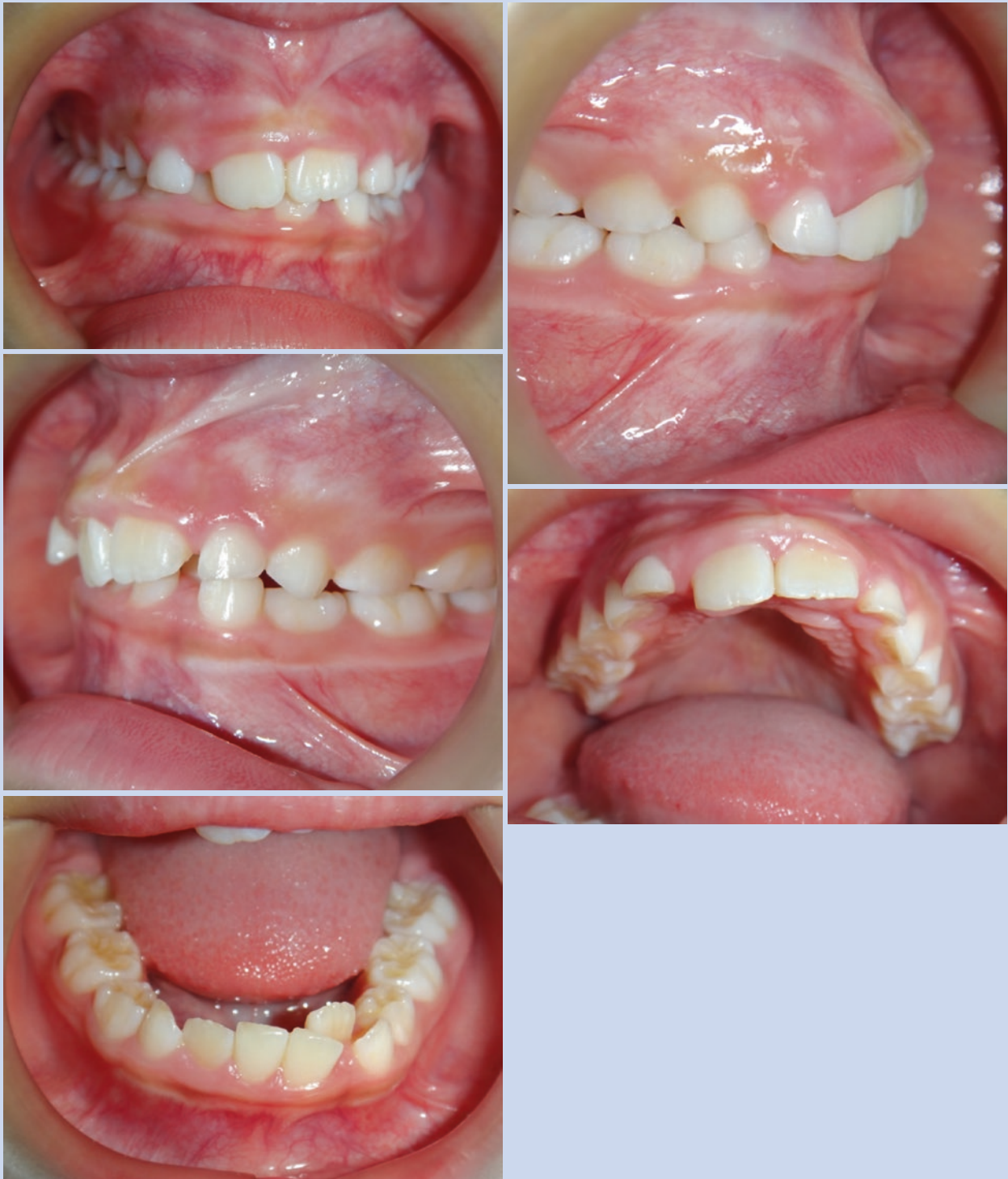Case #3



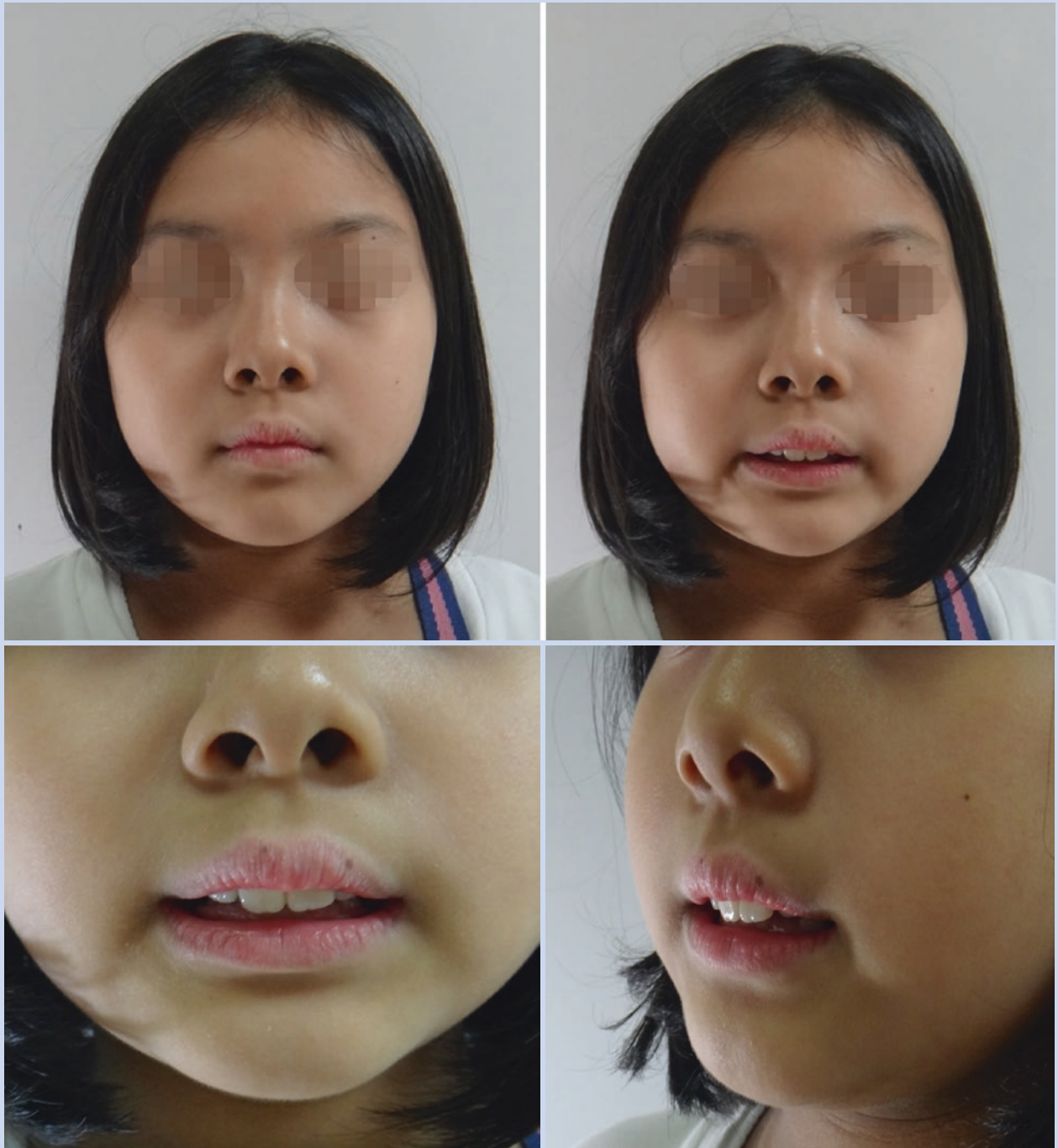Figs. 8.150, 8.151, 8.152, and 8.153 Extraoral pictures of a 7-year-old girl showed facial asymmetry when smiling, her chin deviated to the right side



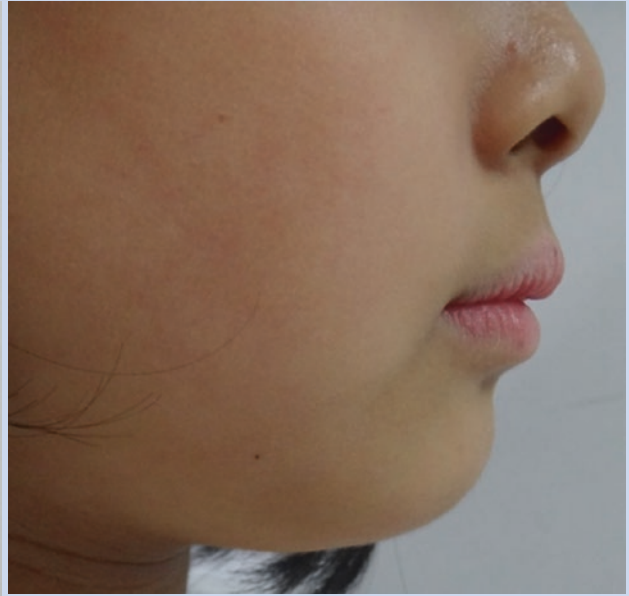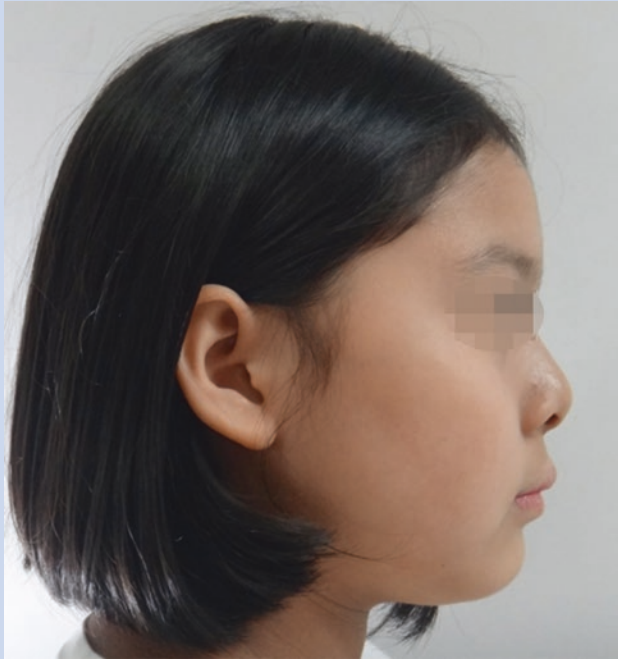Figs. 8.154 and 8.155 Her lateral profile showed a large body of the mandible and prominent chin. Her mandible was obviously too large for her age



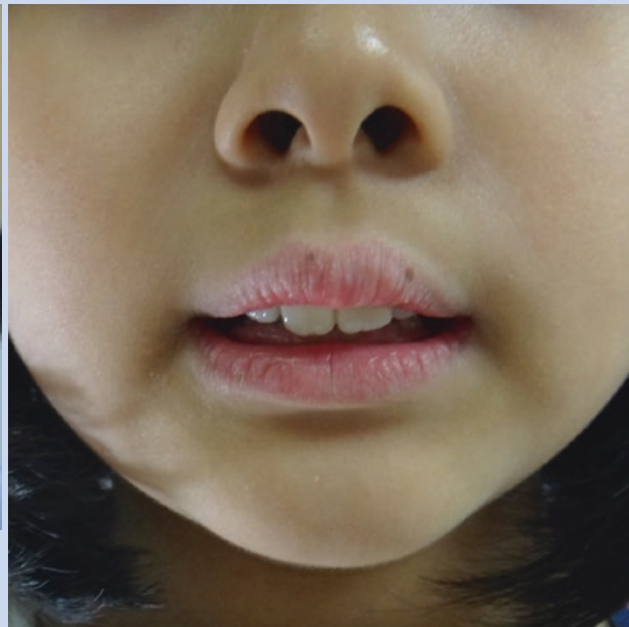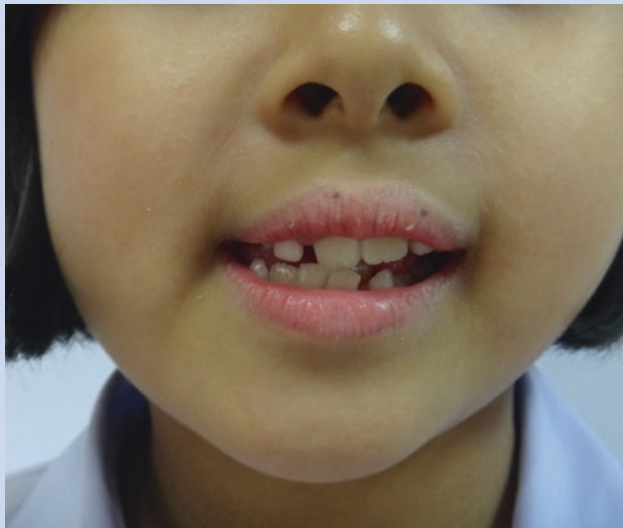Figs. 8.156, 8.157, 8.158, 8.159, and 8.160 Intraoral pictures showed moderate crowding of the lower anterior teeth, tooth #32 erupted lingual to tooth #73, positive overjet and overbite, resulting from retroclined lower anterior teeth. No cross bite presented



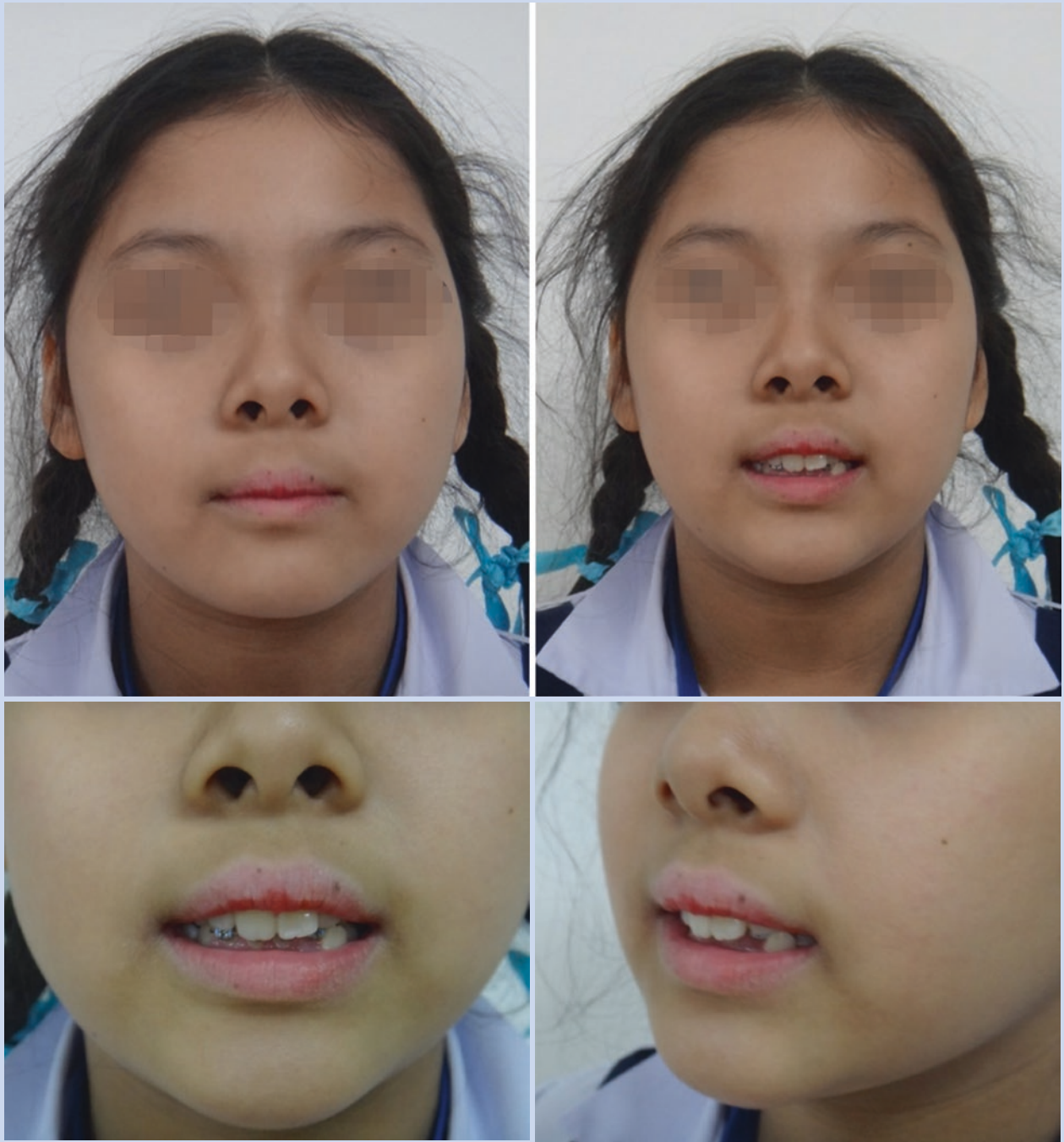Figs. 8.161, 8.162, 8.163, and 8.164 After the use of Class III activator, the mandibular midline was brought to coincide with the facial midline and the facial asymmetry was eliminated



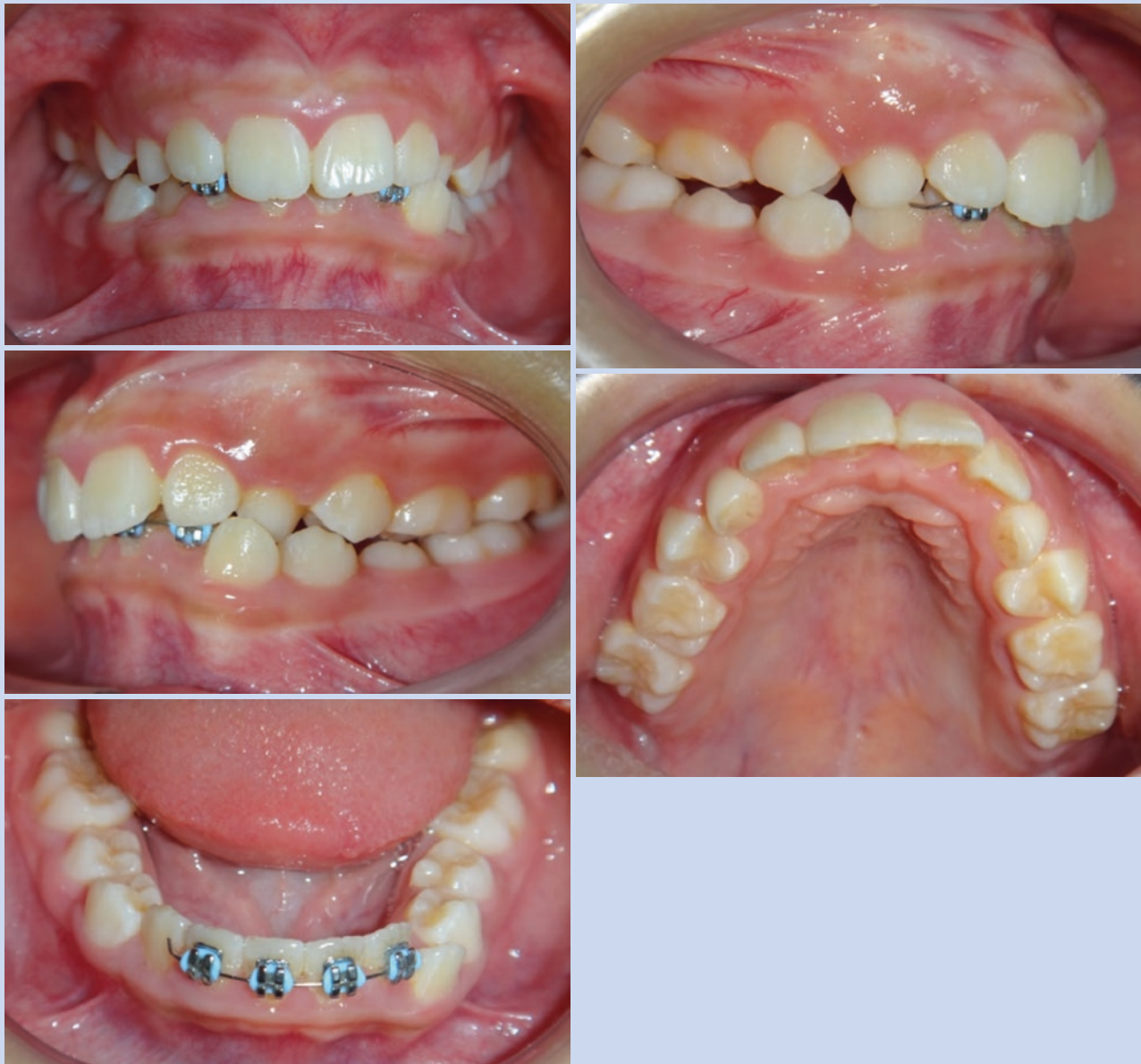Figs. 8.165 and 8.166 Lateral profile was esthetically improved after the use of Class III activator; the mandible and the chin appeared to be in good proportion to the maxilla



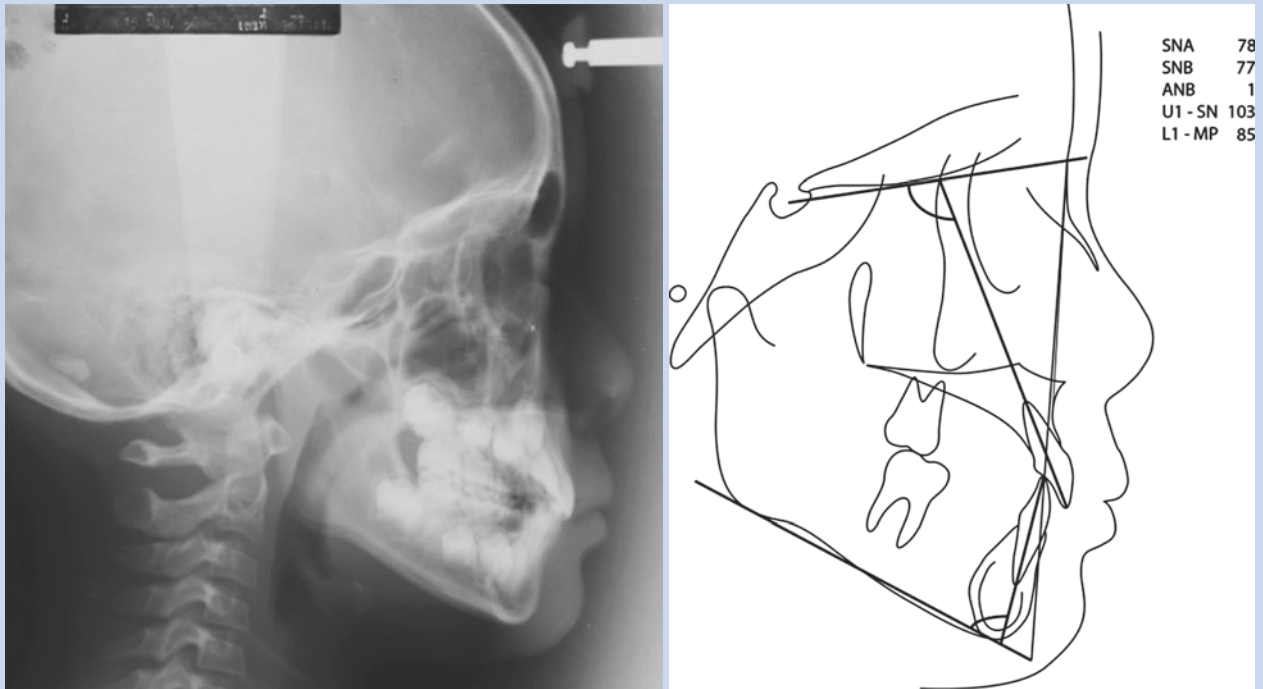
Figs. 8.167 and 8.168 Comparison of her smiles before the treatment and after the midline correction using Class III activator



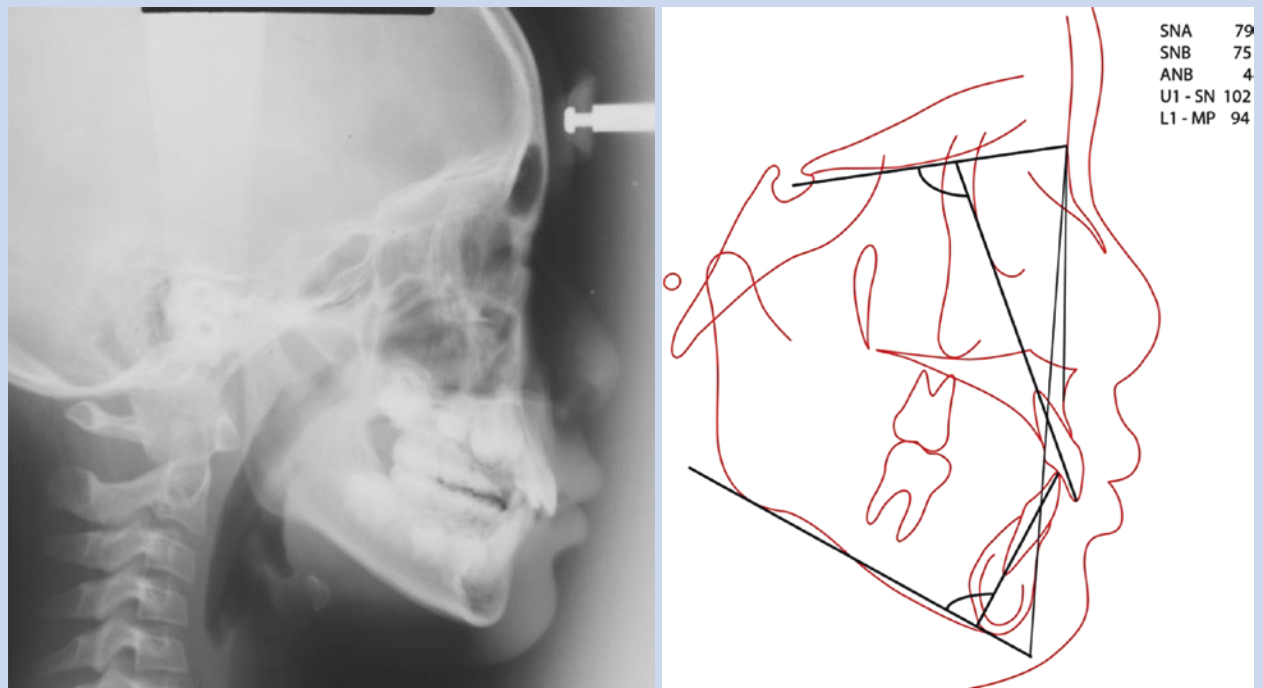
Figs. 8.169, 8.170, 8.171, and 8.172 She maintained a facial symmetry 2 years after the treatment. The treatment result was stable



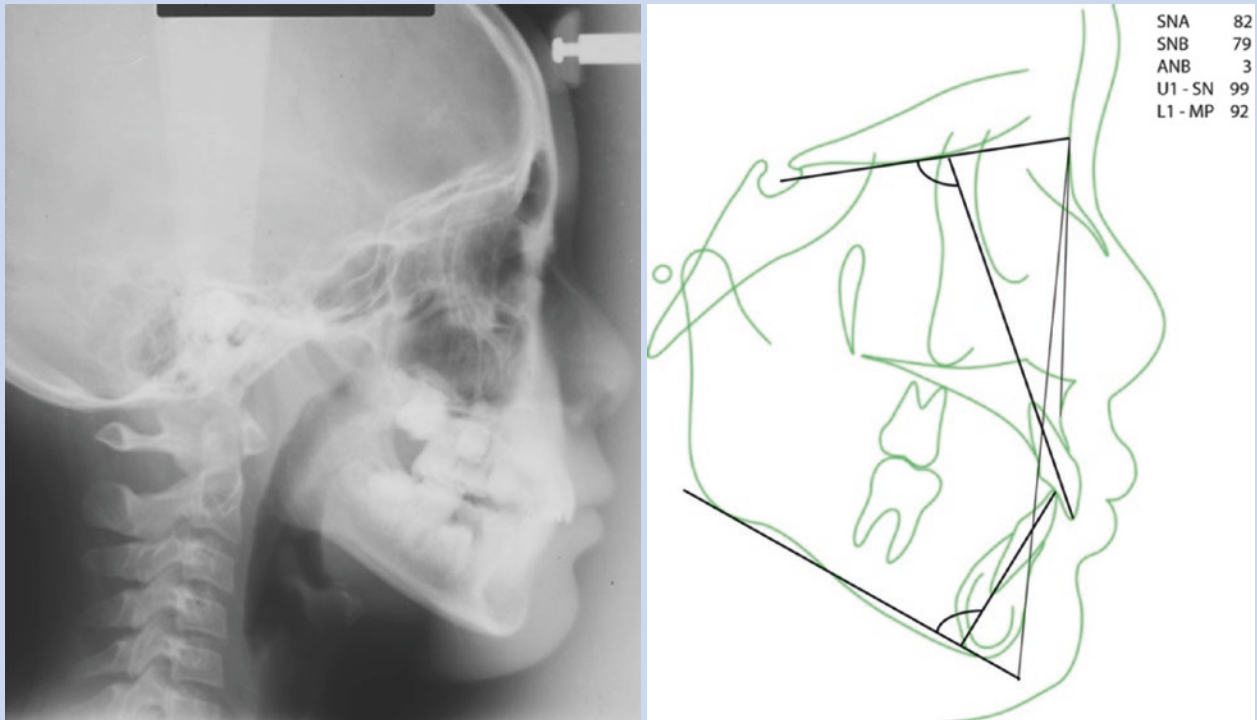
Figs. 8.173, 8.174, 8.175, 8.176, and 8.177 Intraoral pictures showed cross bite at #63, #73, and #34; lower anterior teeth were aligned by the use of partial-fixed appliances



Figs. 8.178 and 8.179 A cephalogram and a tracing before the treatment showed the ANB angle of $+1^\circ$, positive overjet, and positive overbite thru retrocline of lower anterior teeth, which fell into category skeletal Class III malocclusion with pseudo-forced bite



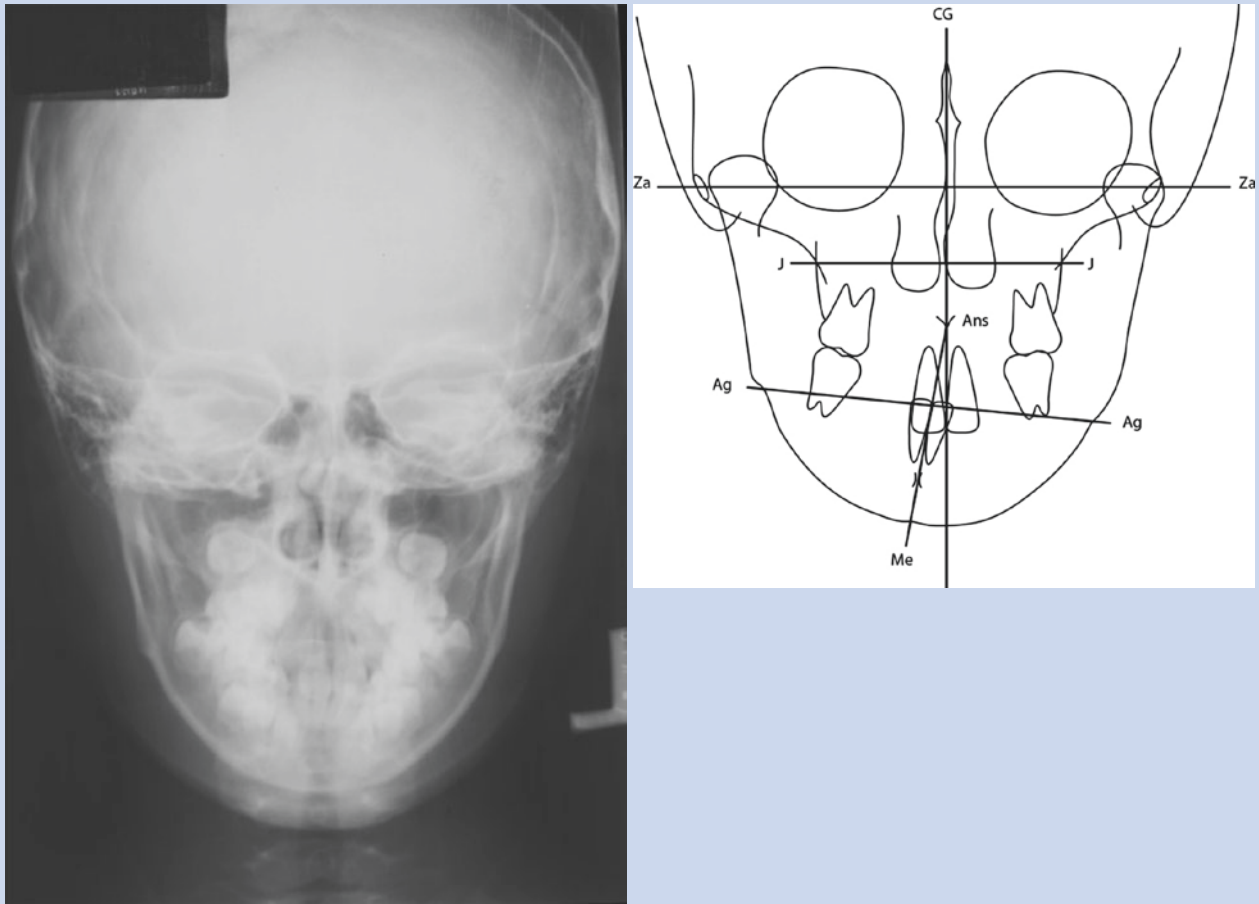
Figs. 8.180 and 8.181 The mandible was pushed backward into a more posterior position thru the use of Class III activator; ANB angle became bigger changing from $+1^\circ$ to $+4^\circ$



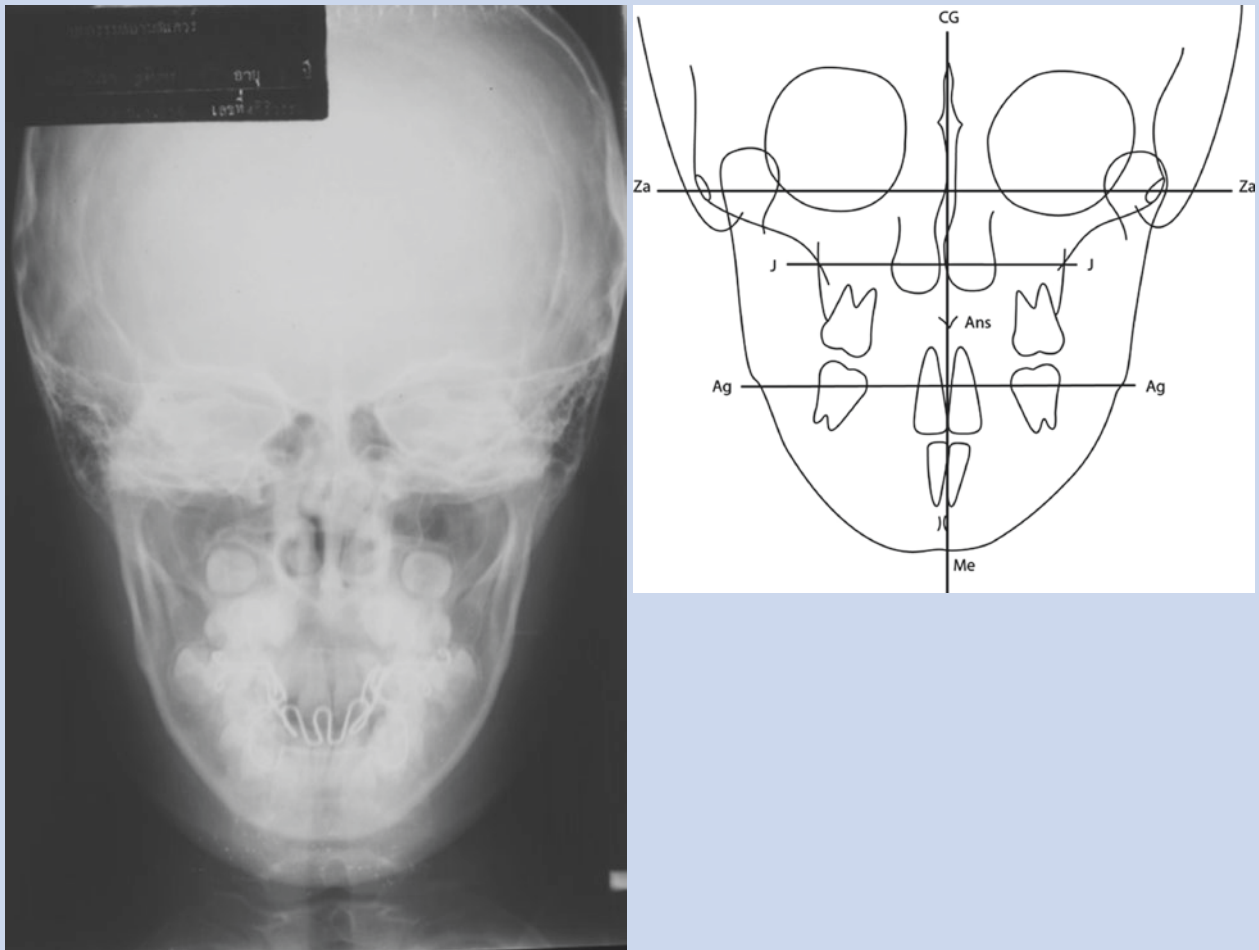
Figs. 8.182 and 8.183 A cephalogram and a tracing 2 years after the treatment with Class III activator and before beginning of partial-fixed appliances to align the crowded lower incisors. The mandible continued to grow fast as the ANB angle decreased from $+4^\circ$ to $+3^\circ$

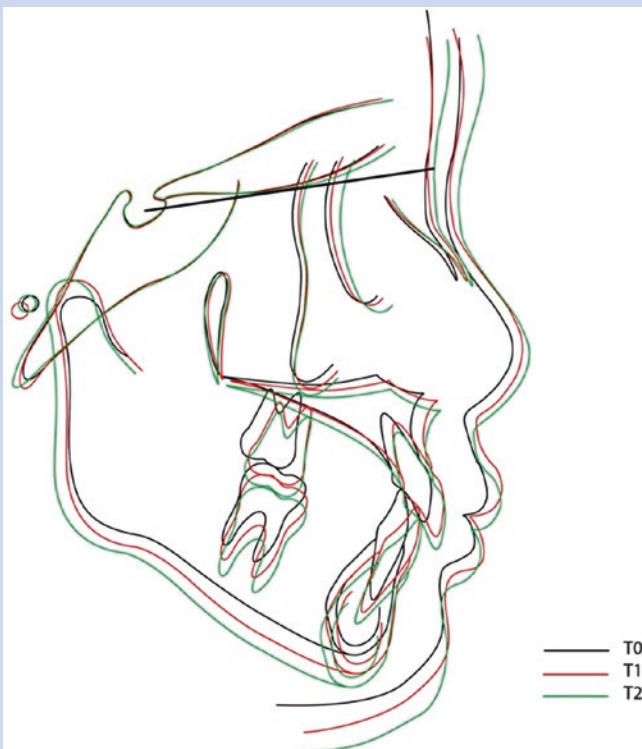

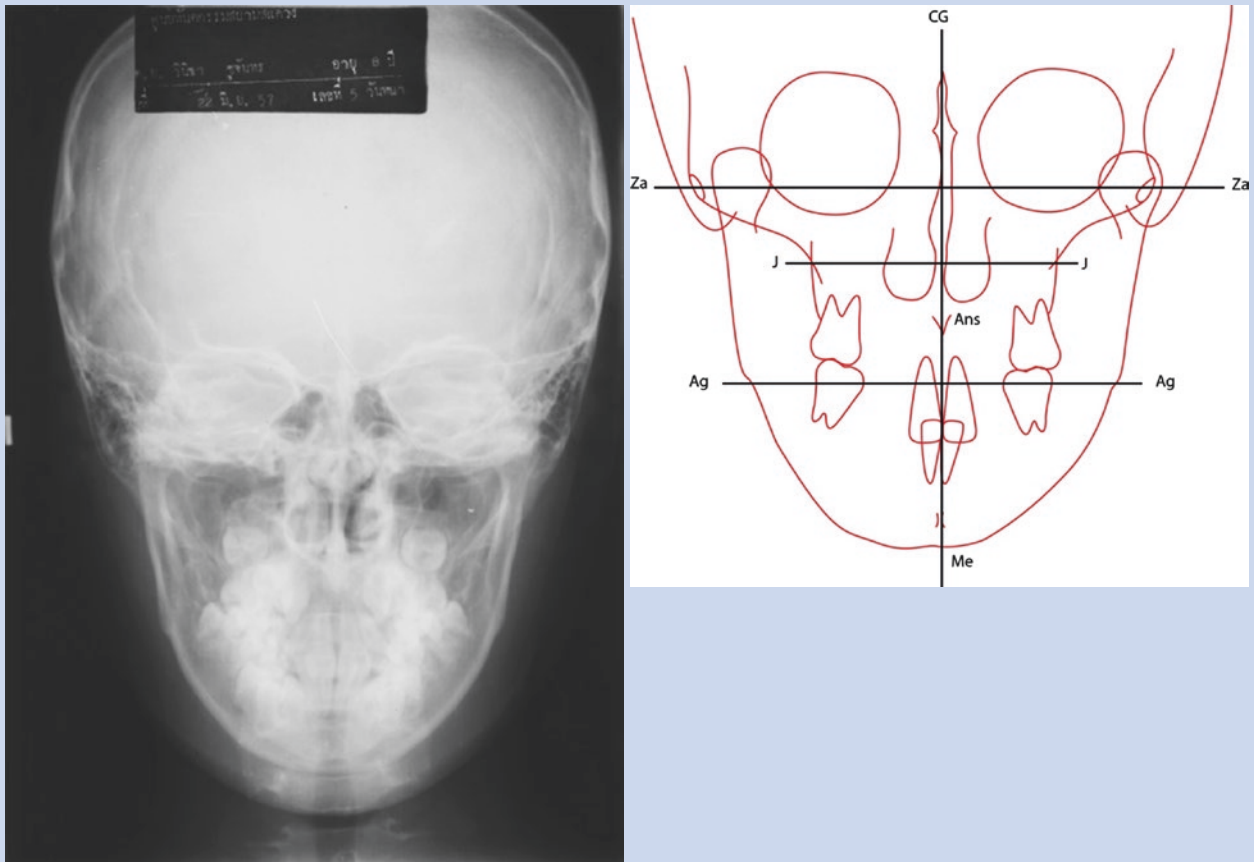
Fig. 8.184 Superimposition of cephalometric tracing at the three time-lines, before treatment (T0), 1 year after Class III activator treatment (T1), and 2 years after the treatment began (T2)



Figs. 8.185 and 8.186 Posteroanterior cephalometric X-ray (PA) and tracing of the patient before the treatment showed obvious facial asymmetry with the mandibular midline shifted to the right side of the patient (Letzer and Kronman 1967)



Figs. 8.187 and 8.188 A PA head film and a tracing of the patient with Class III activator in situ showed the shifted mandibular midline was brought to a position which coincides with the facial midline. No facial asymmetry presented



Figs. 8.189 and 8.190 A PA head films of the patient and a tracing after the use of Class III activator to correct facial asymmetry, where the mandibular midline coincides with the facial midline

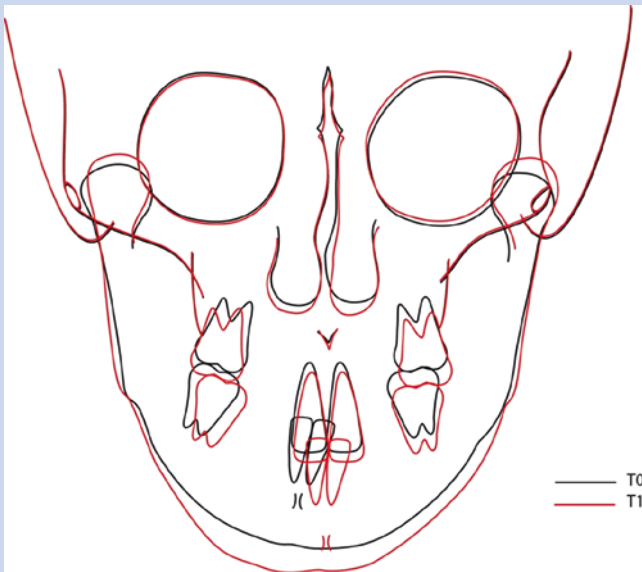
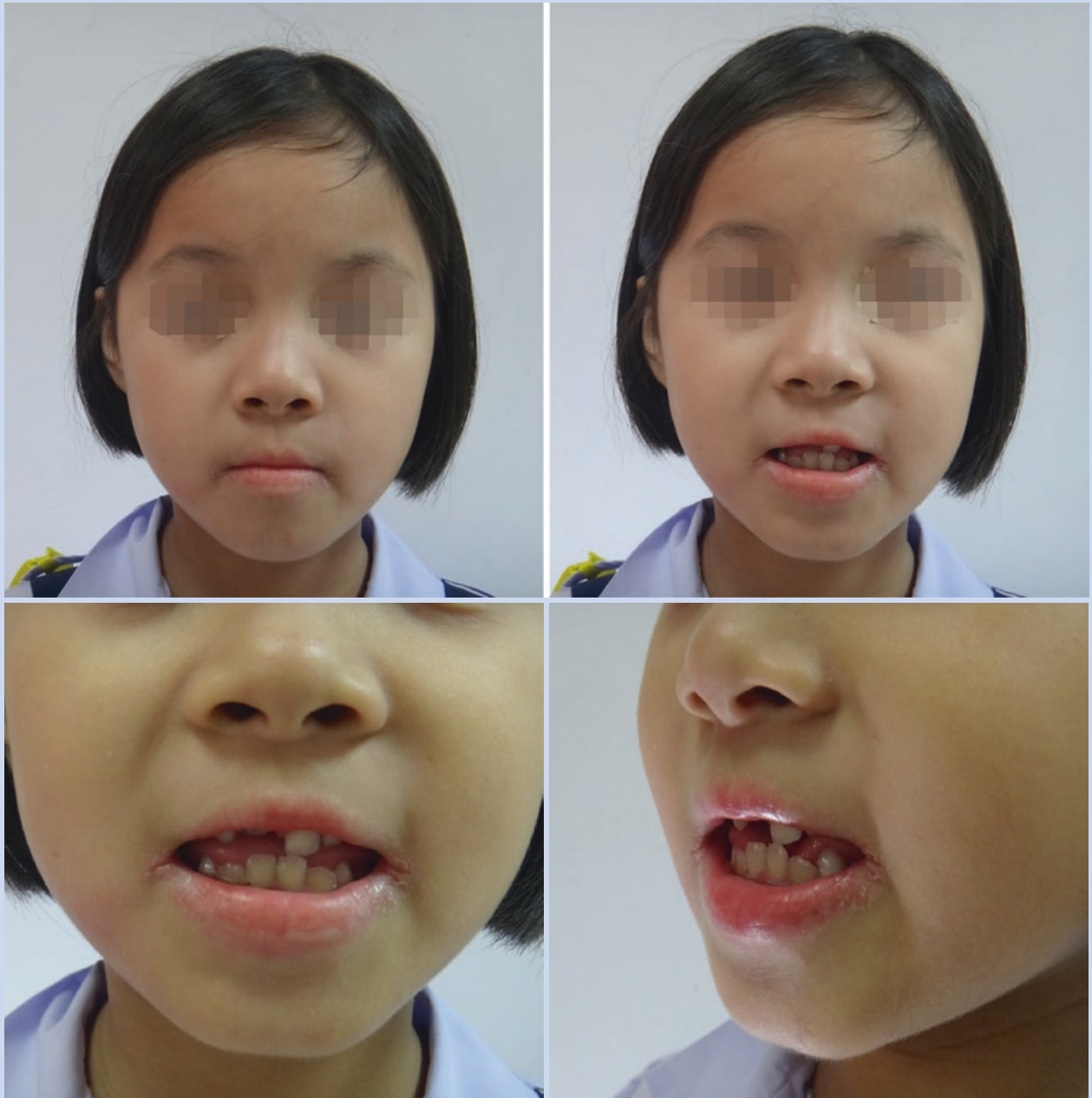

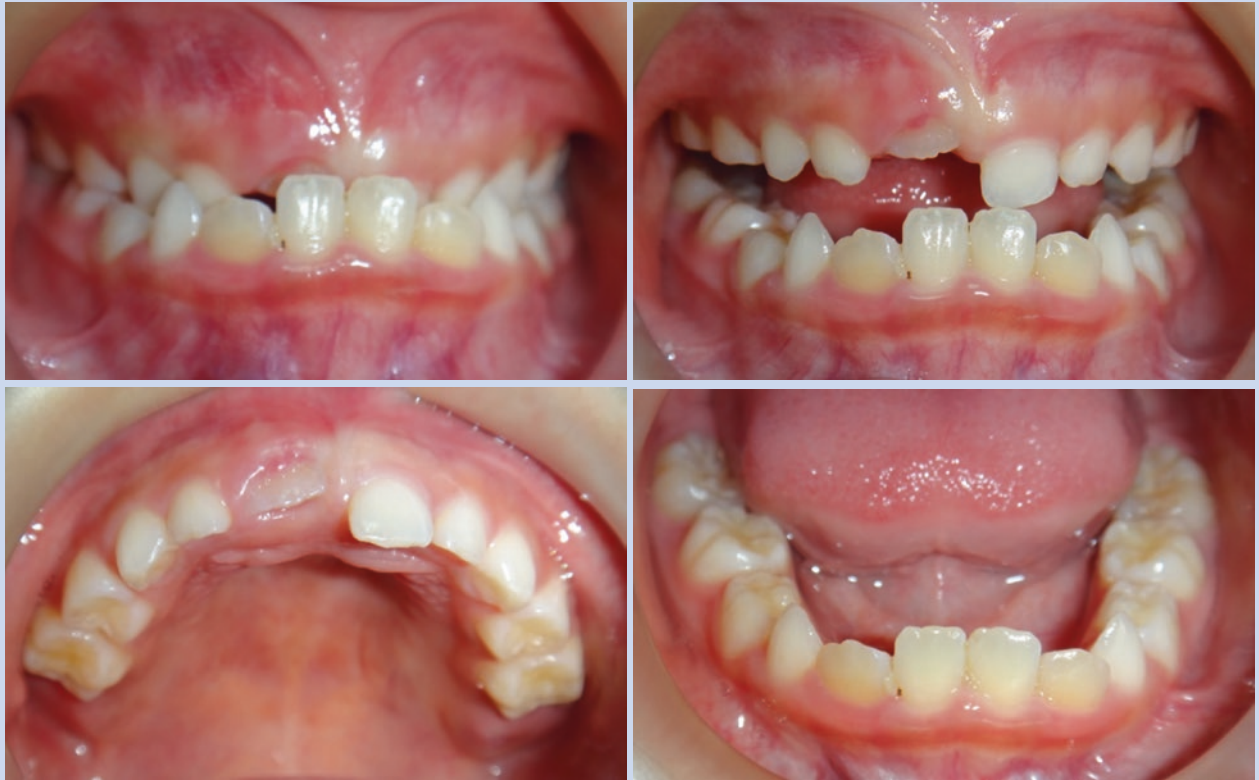Fig. 8.191 Superimposition of the PA head films of the patient before the treatment (T0) and after correction of facial asymmetry with the use of Class III activator (T1)

8.12 Class III Activator Can Be Used for Treatment of Functional Class III Malocclusion When the Patient Can Do an Edge-to-Edge Bite
(Figs. 8.192–8.211)

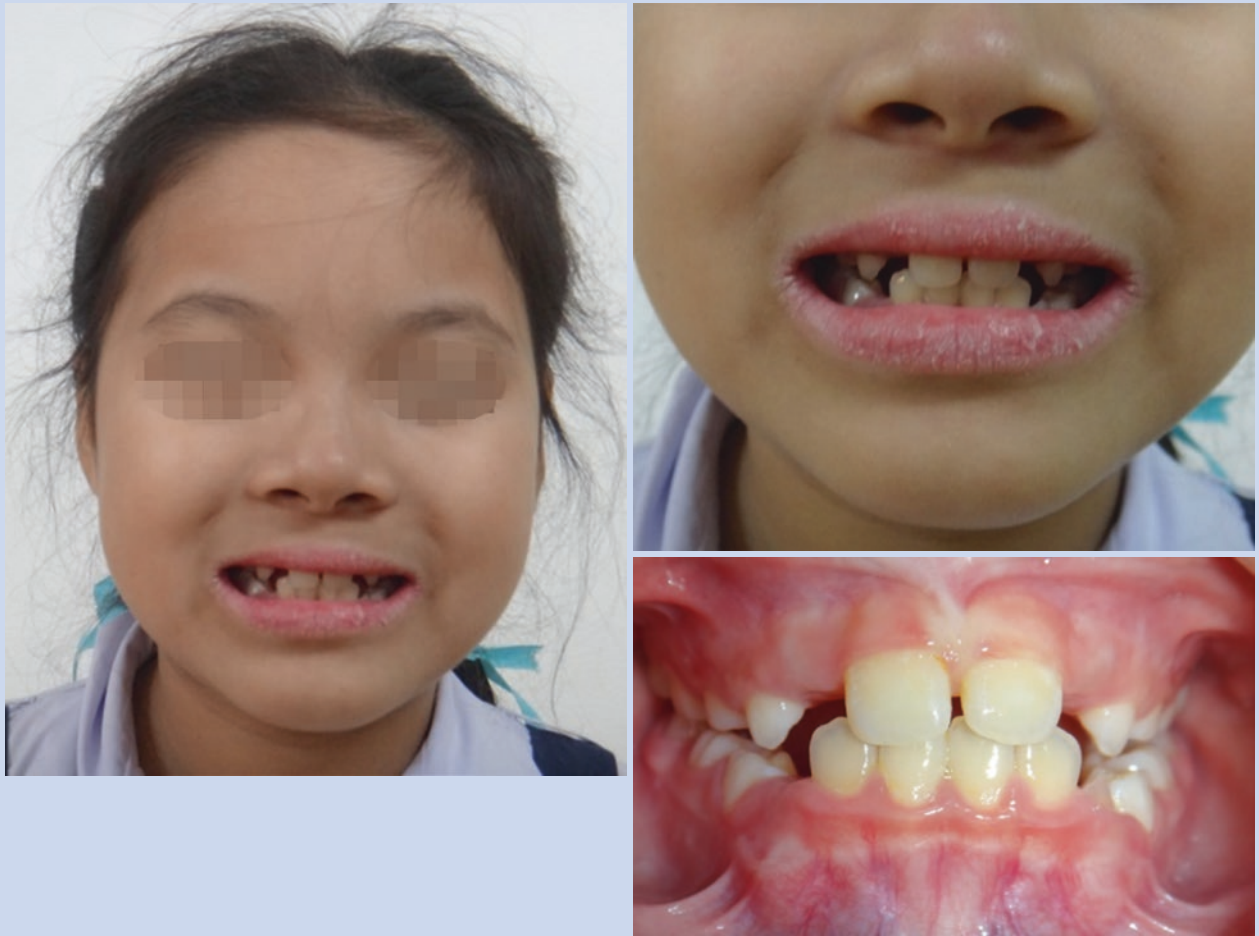Case #4



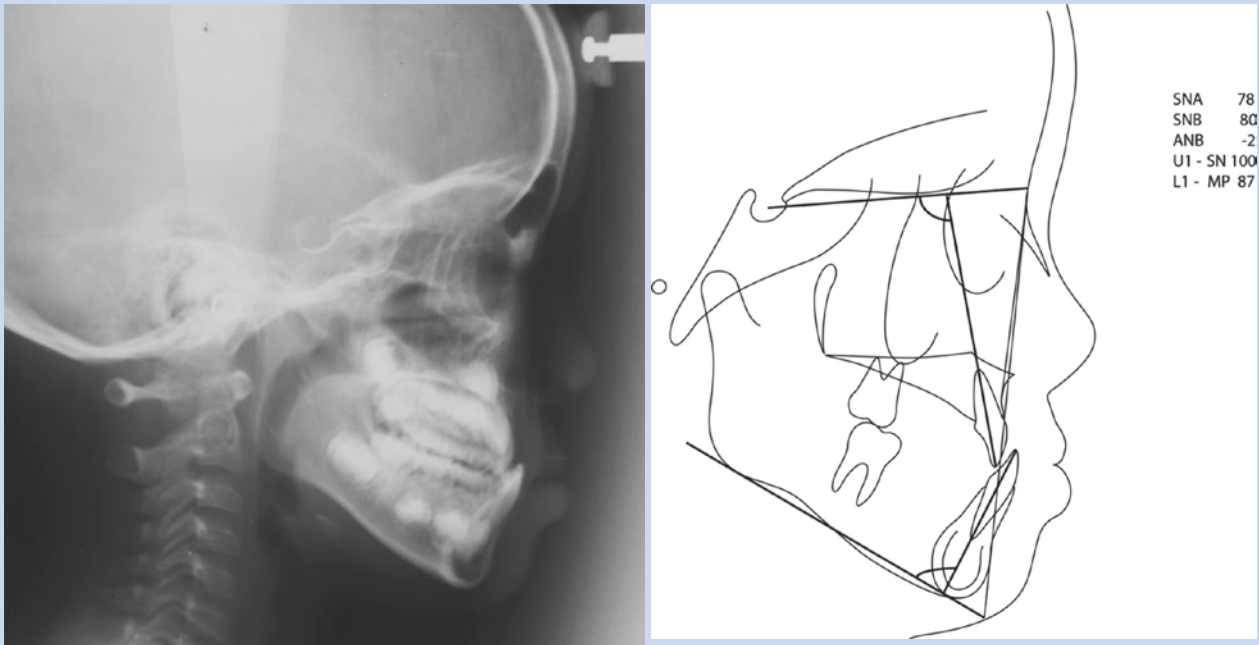
Figs. 8.192, 8.193, 8.194, and 8.195 Extraoral pictures of a 7-year-old girl at physiologic rest position and when smiling; she showed both upper and lower anterior teeth



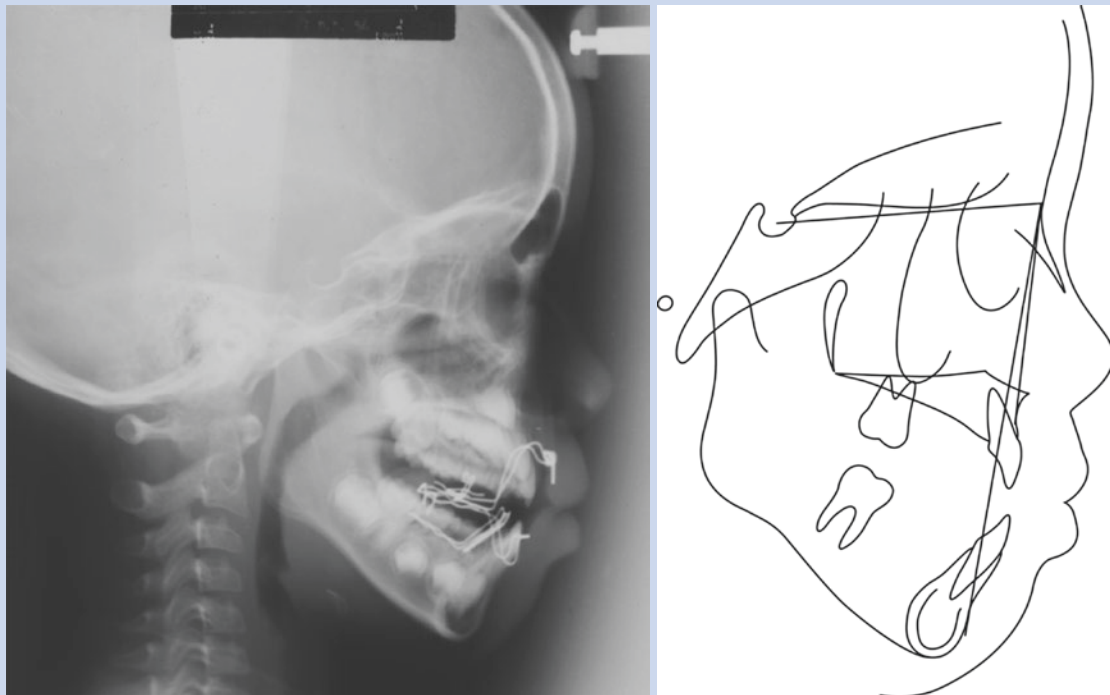
Figs. 8.196, 8.197, 8.198, and 8.199 Her intraoral pictures showed a very early stage of mixed dentition with a complete blockout of the upper anterior deciduous teeth. Tooth #11 was erupting; the patient was able to bite edge to edge



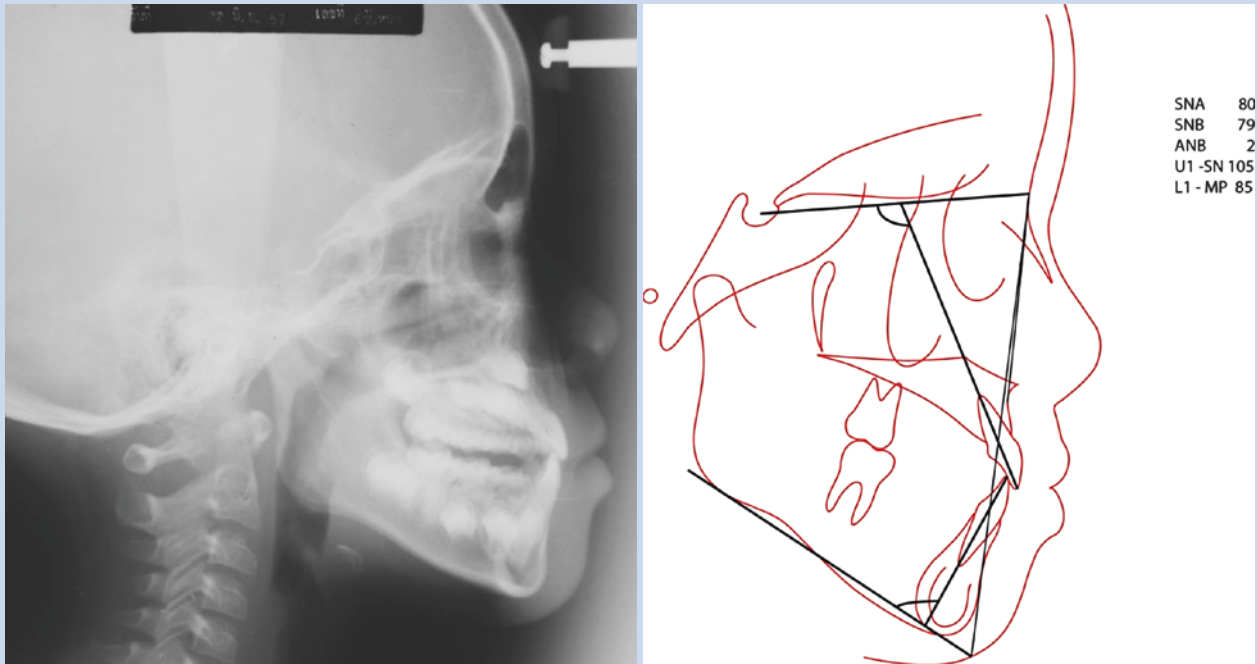
Figs. 8.200, 8.201, and 8.202 After using Class III activator, the mandible was pushed into a more posterior position; path of eruption of #11 and #21 was guided, and positive overjet and positive overbite were achieved



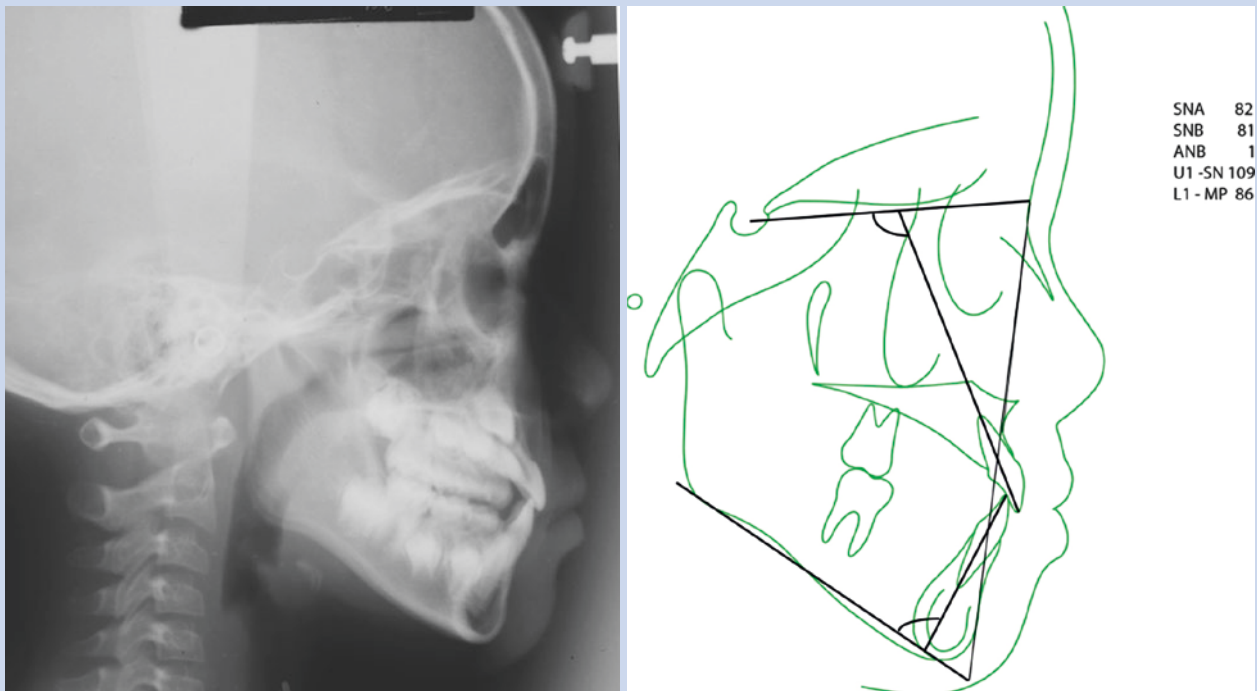
Figs. 8.203 and 8.204 A cephalogram and tracing before the treatment showed anterior cross bite and the ANB angle of -2° . Both upper and lower anterior teeth were both retroclined



Figs. 8.205 and 8.206 A cephalogram and a tracing with Class III activator in situ showed that the mandible was brought backward into a new position



Figs. 8.207 and 8.208 A cephalogram and a tracing during the treatment with Class III activator; the ANB angle increased from -2° to $+2^\circ$, and increase in inclination angle of the upper anterior teeth from 100° to 105° and positive overjet and positive overbite were achieved



Figs. 8.209 and 8.210 A cephalogram and a tracing during the treatment with Class III activator after positive overjet and positive overbite were achieved by guided path of eruption of teeth #11 and #21. The mandible continued to grow fast as the ANB angle decreased from $+2^\circ$ to $+1^\circ$

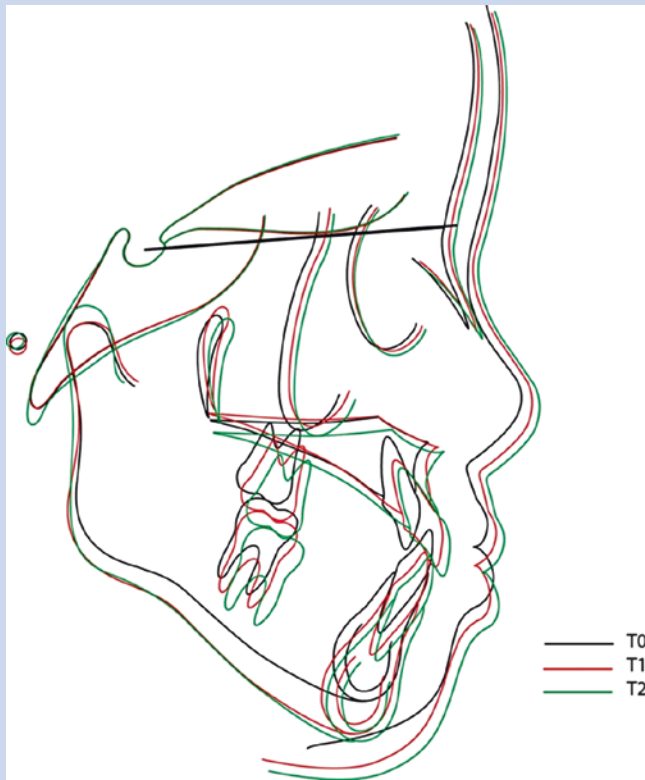


Fig. 8.211 Superimposition of the three timelines, before treatment (T0), after positive overjet and positive overbite was achieved (T1), and after they were secured by occlusion of posterior teeth (T2)

8.13 Stability of the Skeletal and Dental Changes After Treatment with Class III Activator (Figs. 8.212–8.278)

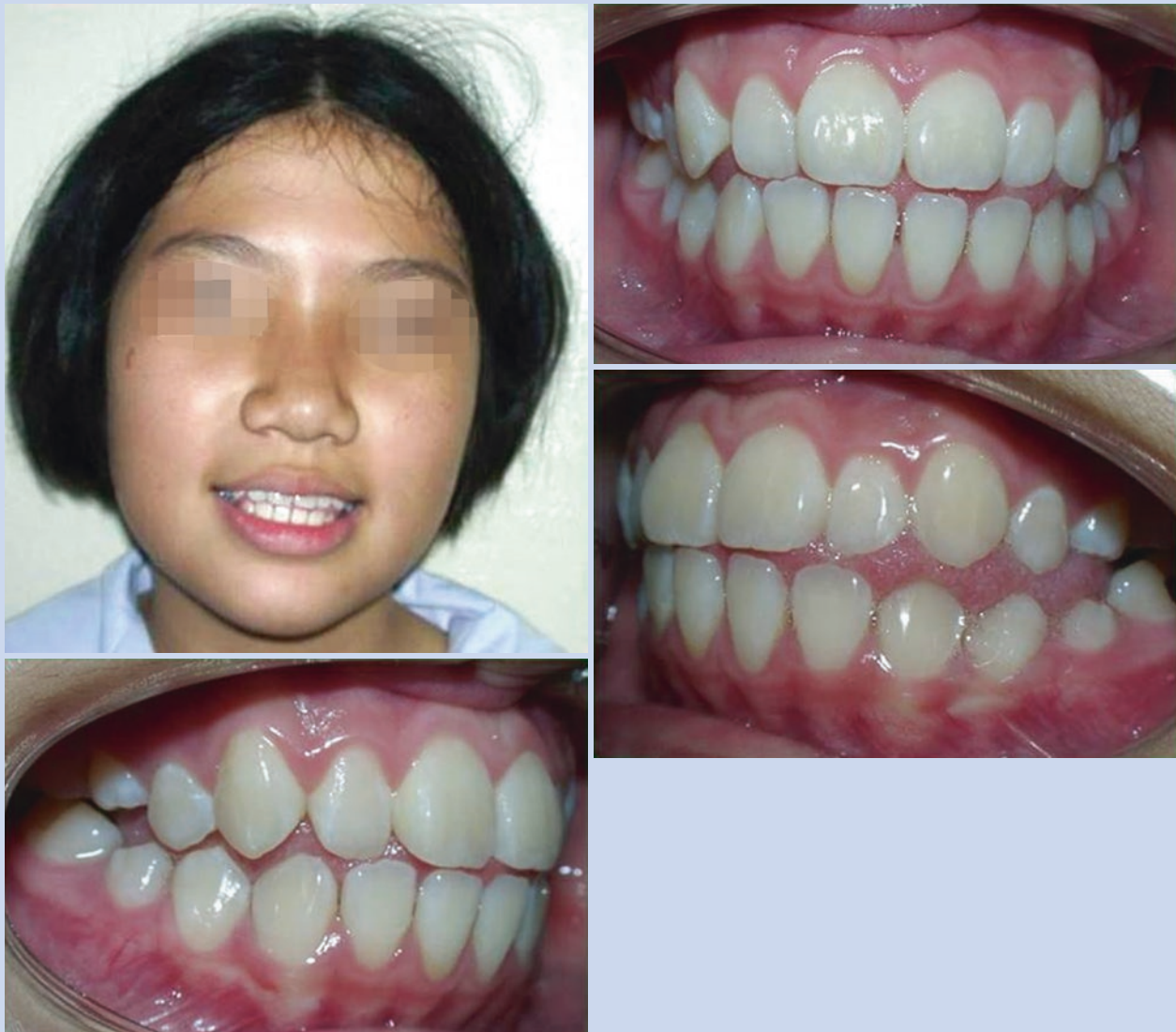Class III activator causes changes in both skeletal and dental. Clinical research on stability of skeletal changes after activator treatment of patients with Class III malocclusions was done by Satrahava and Taweeseedt. They found significant skeletal effects with improvement of skeletal profiles, and these changes remained. (Satrahava and Taweeseedt 1996a),

(Satrahava and Taweeseedt 1996b), (Satrahava and Taweeseedt 1999).

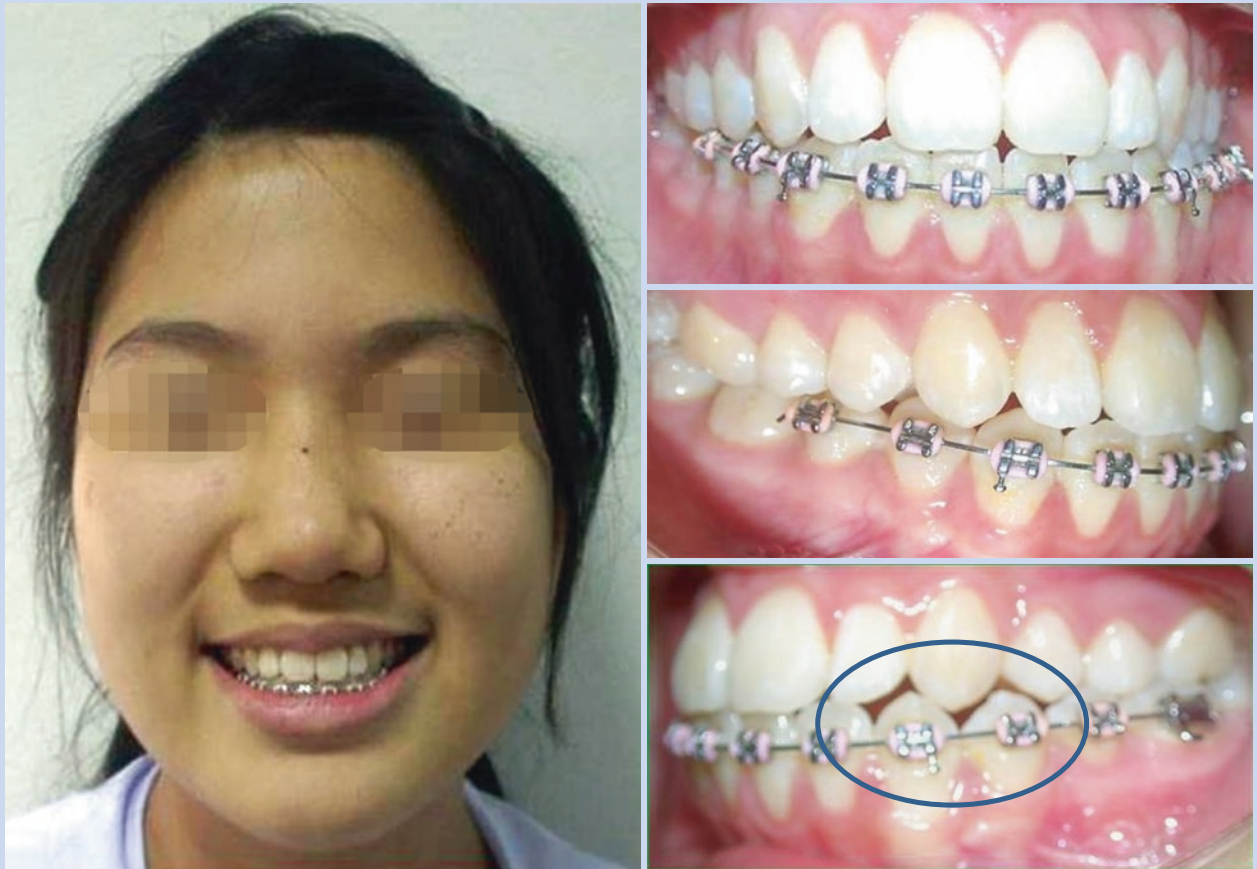8.14 Cause of Dental Instability

As previously mentioned, patients with Class III malocclusions mostly have large tongue and/or lower tongue position and visceral swallowing pattern. Force from the tongue plays a major role in the cause of dental instability (Figs. 8.212–8.224).

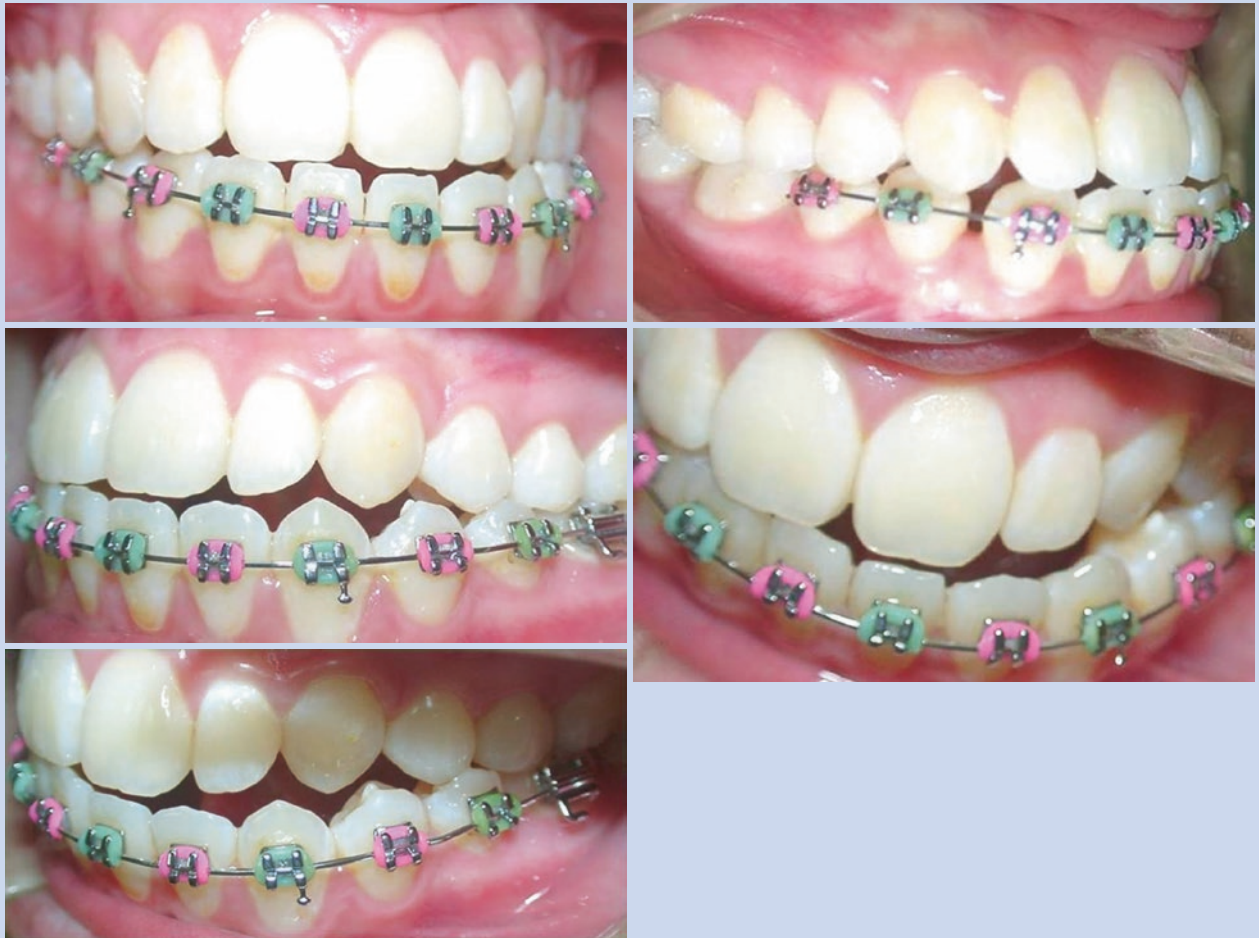Case #5



Figs. 8.212, 8.213, 8.214, and 8.215 Extra- and intraoral pictures of a 12-year-old girl after using Class III activator, large tongue thrusting anteriorly and laterally. Her tongue and both upper and lower anterior teeth could be seen when smiling



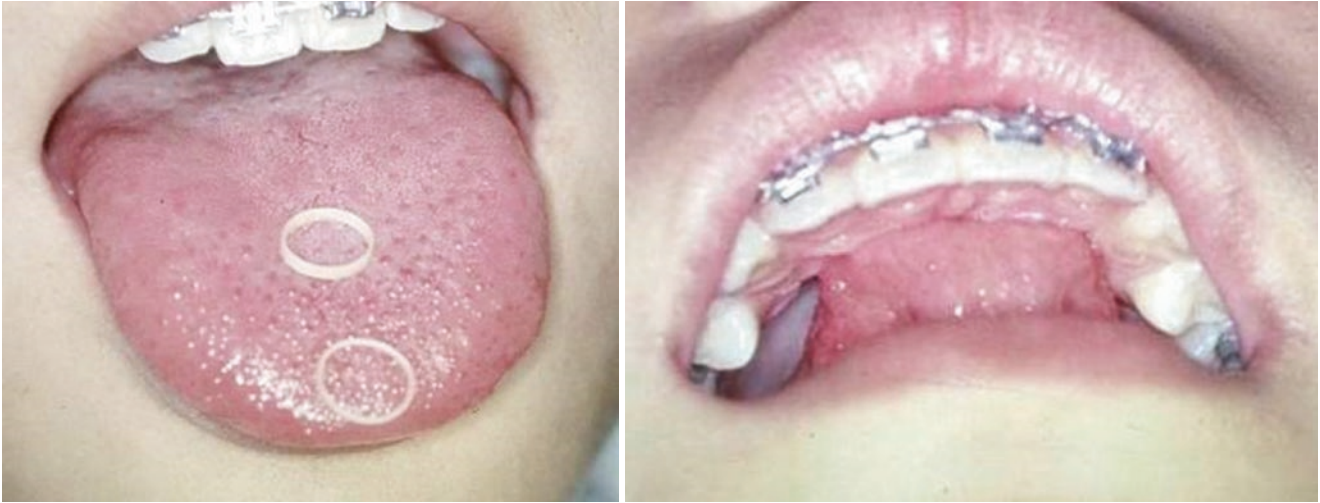Figs. 8.216, 8.217, 8.218, and 8.219 The upper brackets were debonded, despite persistent tongue thrusting at the area in the *circle* in Fig. 8.219. The father of the patient and the patient were informed about the risk of having dental relapse



Figs. 8.220, 8.221, 8.222, 8.223, and 8.224 A few months after, as a result from large tongue and tongue thrusting cross bite, open bite and space can be seen in the intraoral pictures

The author routinely recommends myofunctional exercises according to Daniel Garliner for all Class III malocclusion patients and uses in addition Pearlen plate as upper retainer as a reminder and for tongue exercise (Figs. 8.225–8.227). (Garliner 1981), (Satravaha 1990), (Satravaha and Taweeseedt 2002).

Stability of both skeletal and dental could be achieved after Class III activator treatment combined with myofunctional exercises.



Figs. 8.225 and 8.226 Rubber ring is used in myofunctional exercises

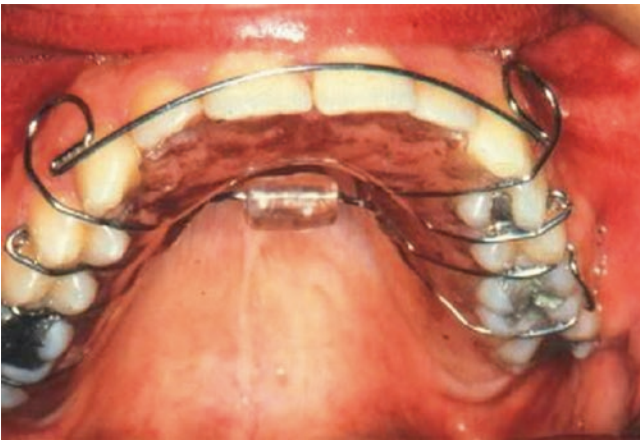
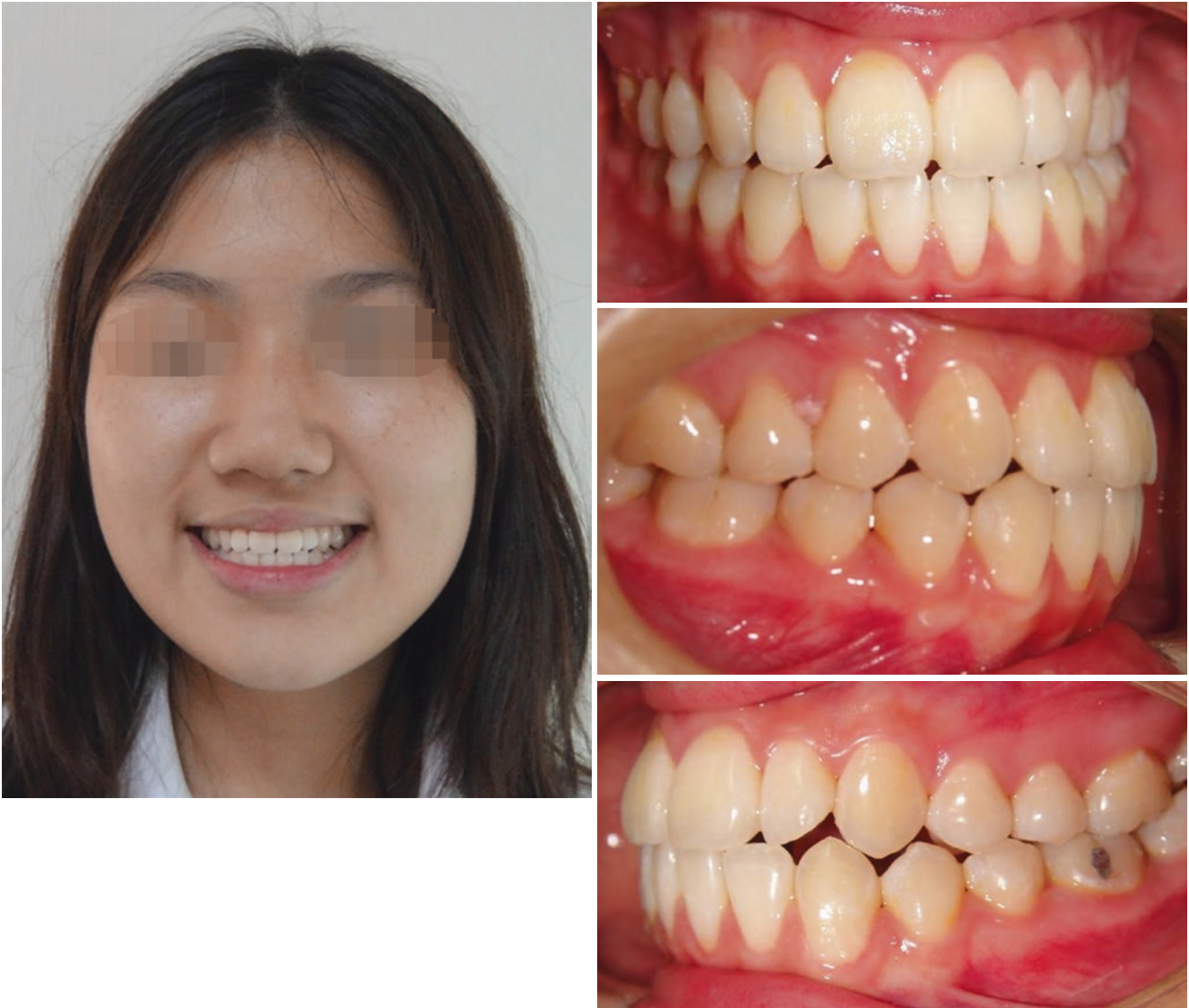
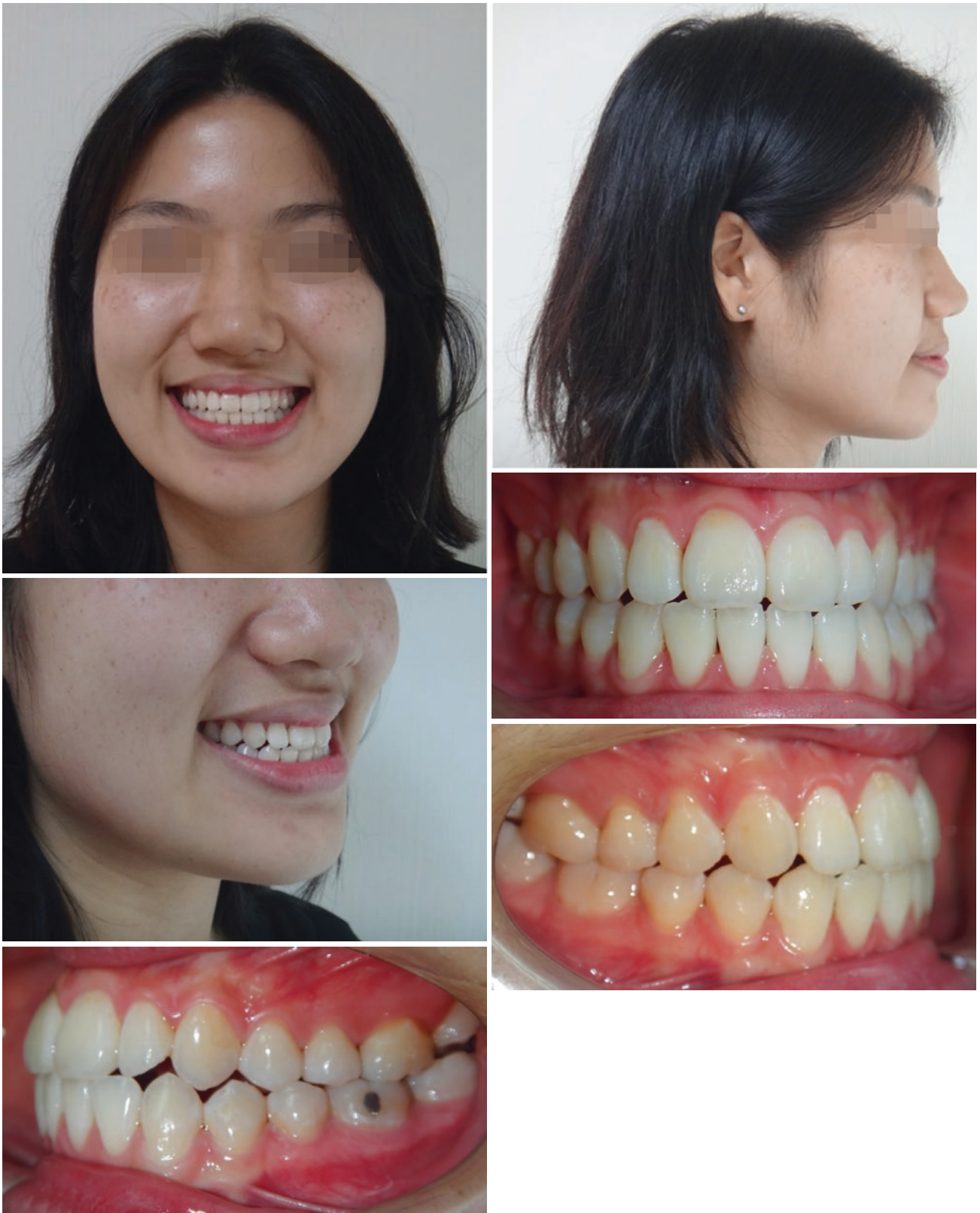
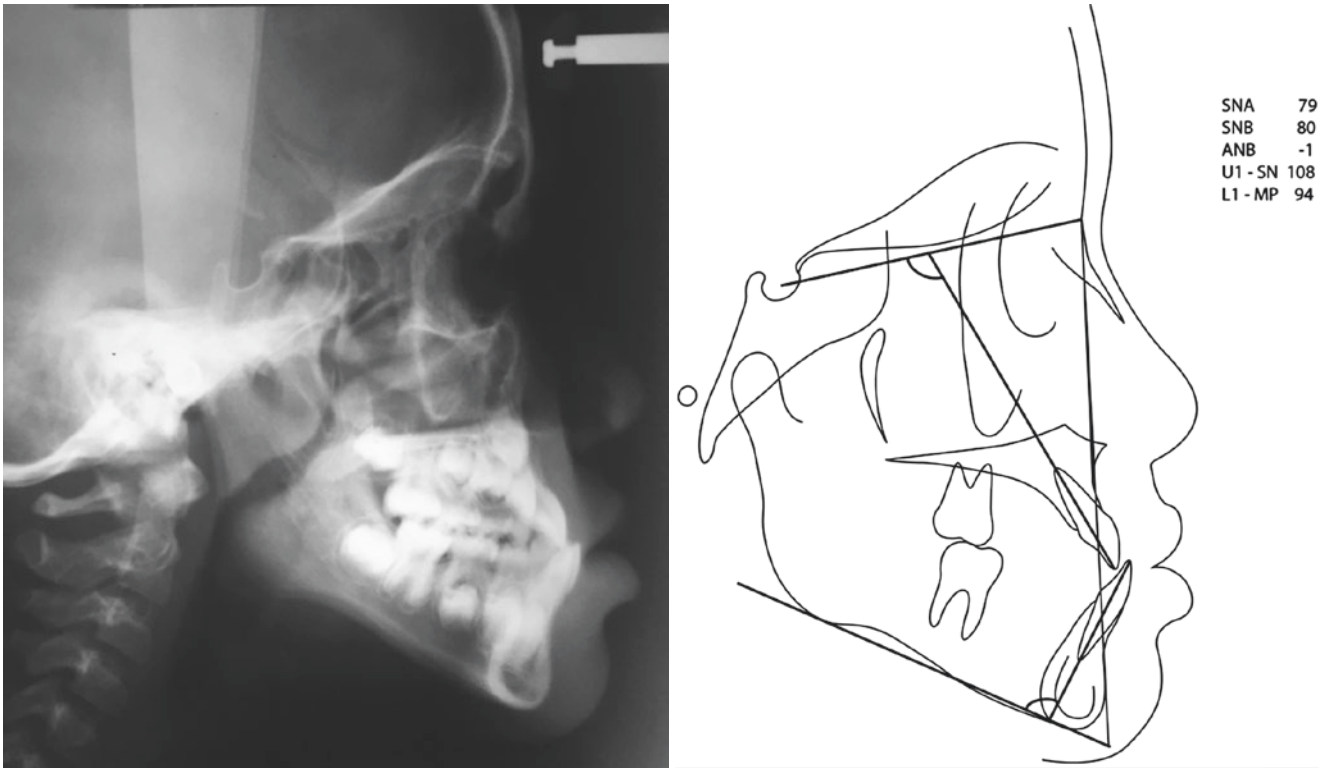
Fig. 8.227 Pearlen plate



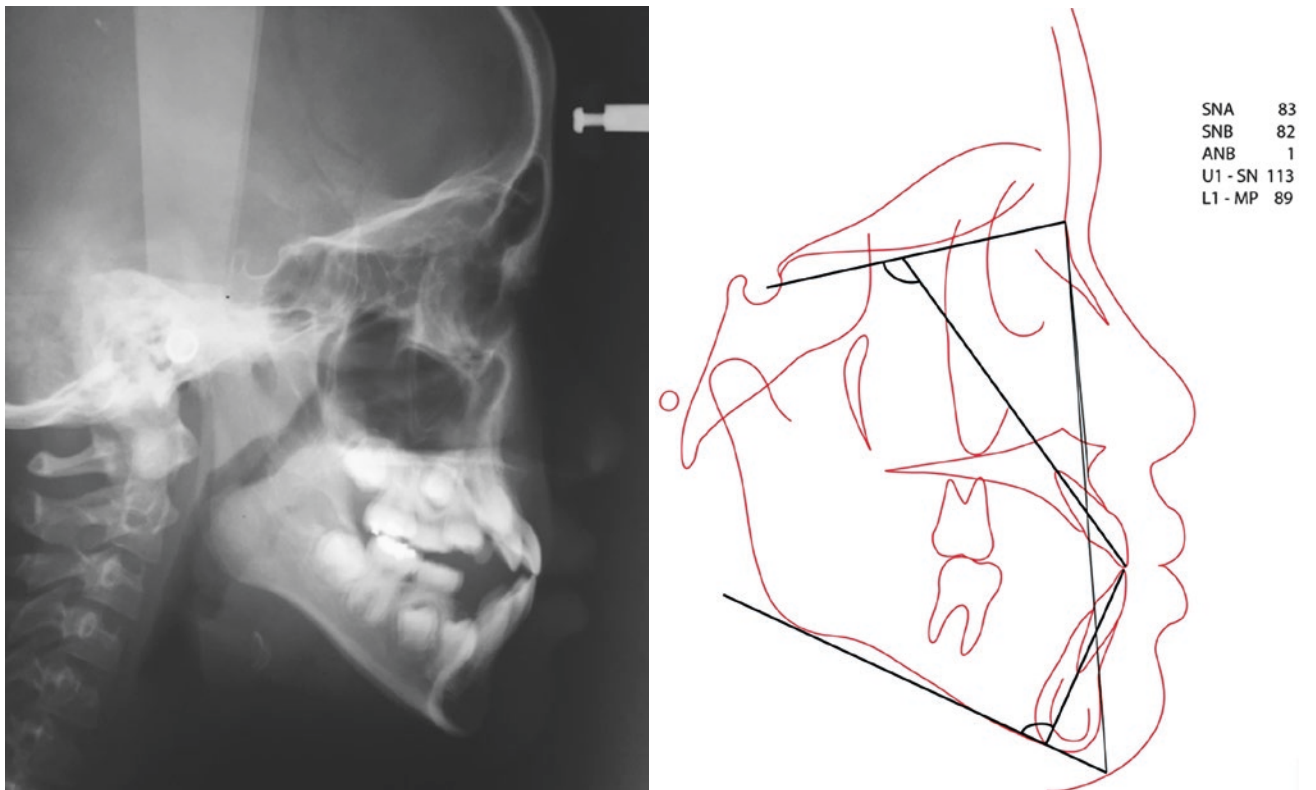
Figs. 8.228, 8.229, 8.230, and 8.231 Extra- and intraoral pictures at the time of debonding all fixed appliances; the occlusion was improved but the risk of having relapse was still present. Tendency of having open bites at the #13, #43, #44, #23, #24, #33, and #34 can be seen in Figs. 8.230 and 8.231. Pearlen plate was used as upper retainer to help as a reminder and for tongue training



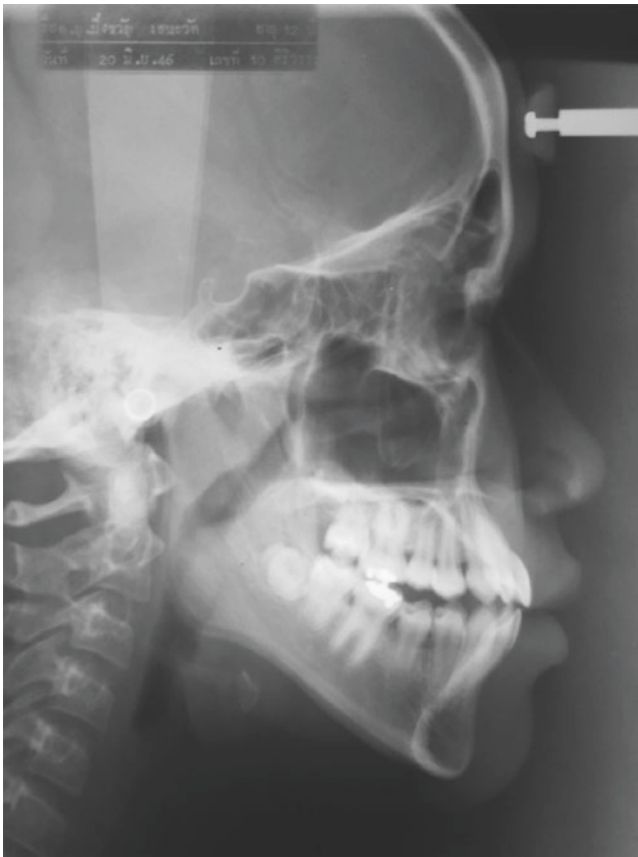
Figs. 8.232, 8.233, 8.234, 8.235, 8.236, and 8.237 Extra- and intraoral pictures at recall, 3 years and 1 month after debonding all the fixed appliances; the patient carried on with myofunctional exercises, and the treatment outcomes remained stable



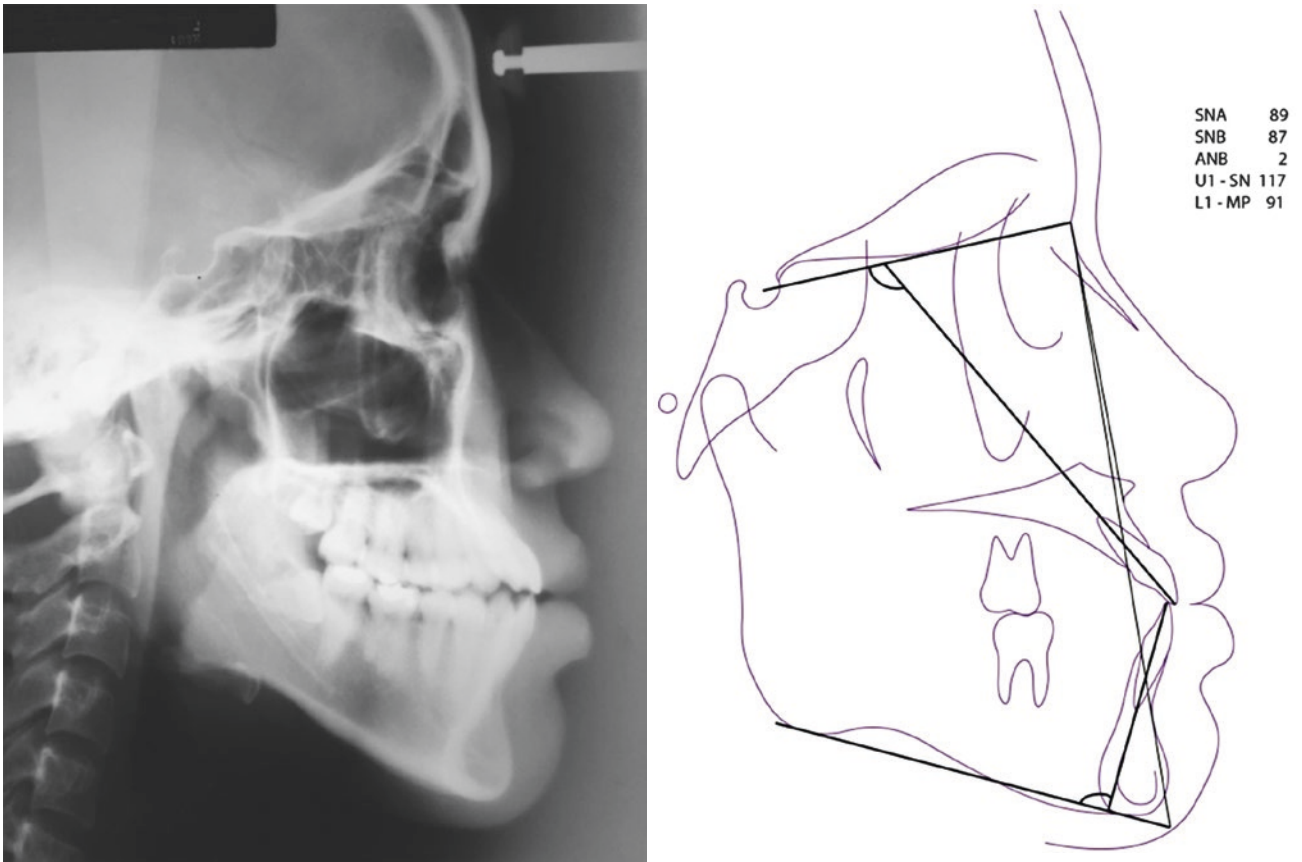
Figs. 8.238 and 8.239 Cephalometric head film and tracing at beginning of the treatment; ANB angle was -1°



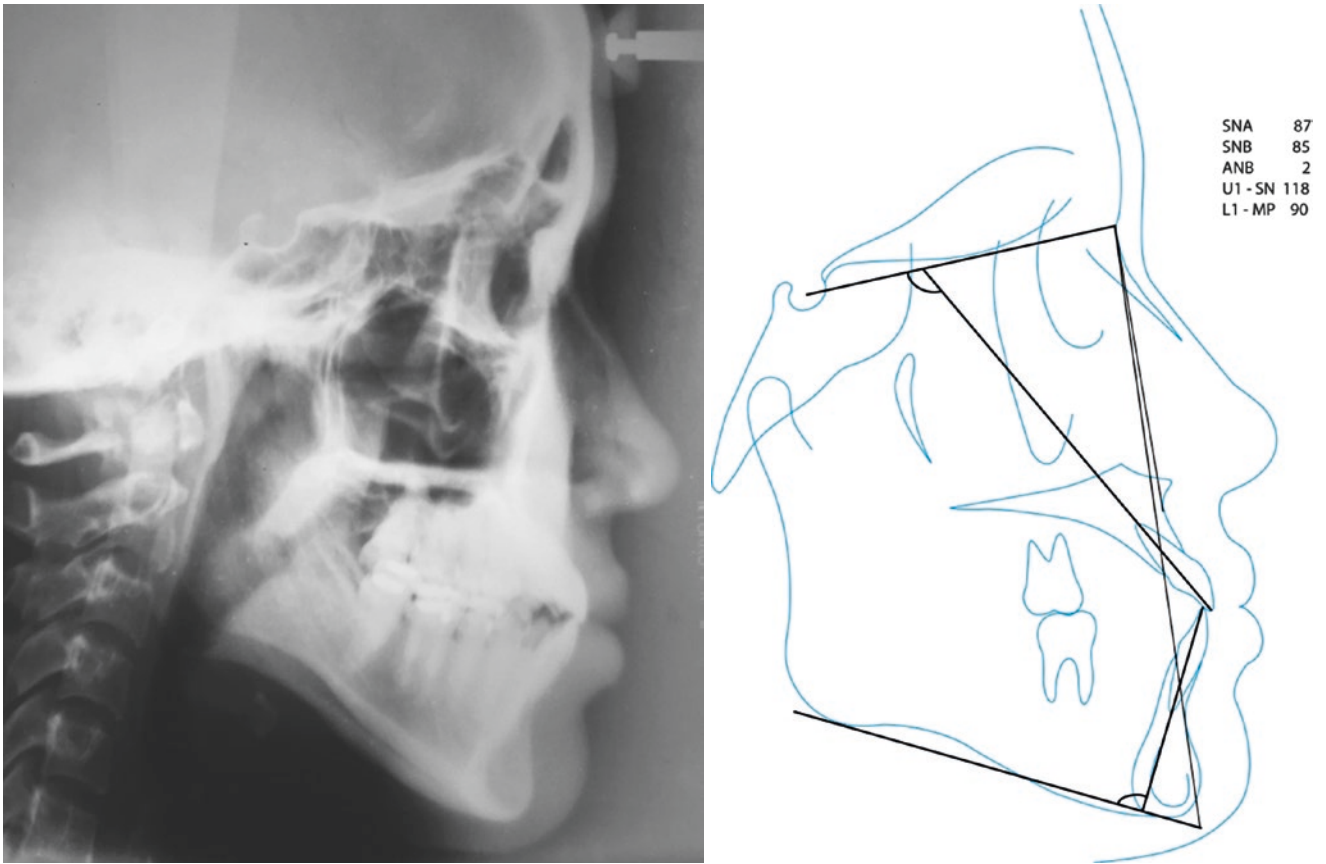
Figs. 8.240 and 8.241 Cephalometric head film and tracing after the use of Class III activator; ANB angle increased from -1° to $+1^{\circ}$. The upper anterior teeth were more proclined, and U1-SN increased from 108° to 113° , while lower anterior teeth were more retroclined. L1-MP decreased from 94° to 89°



Figs. 8.242 and 8.243 Cephalometric head film and tracing before the use of fixed appliances in the second phase of treatment; ANB angle was 2°. The upper anterior teeth remained stable, while the lower anterior teeth became more proclined; L1-MP increased from 89° to 95°



Figs. 8.244 and 8.245 Cephalometric head film and tracing at the end of fixed appliances; ANB angle was 2°; the upper anterior teeth U1-SN became more proclined from 113° to 117°, while the lower anterior teeth were more retroclined. L1-MP reduced from 95° to 91°



Figs. 8.246 and 8.247 Cephalometric head film and tracing 3 years and 1 month after the end of the treatment; ANB angle and the upper and lower anterior teeth remained stable

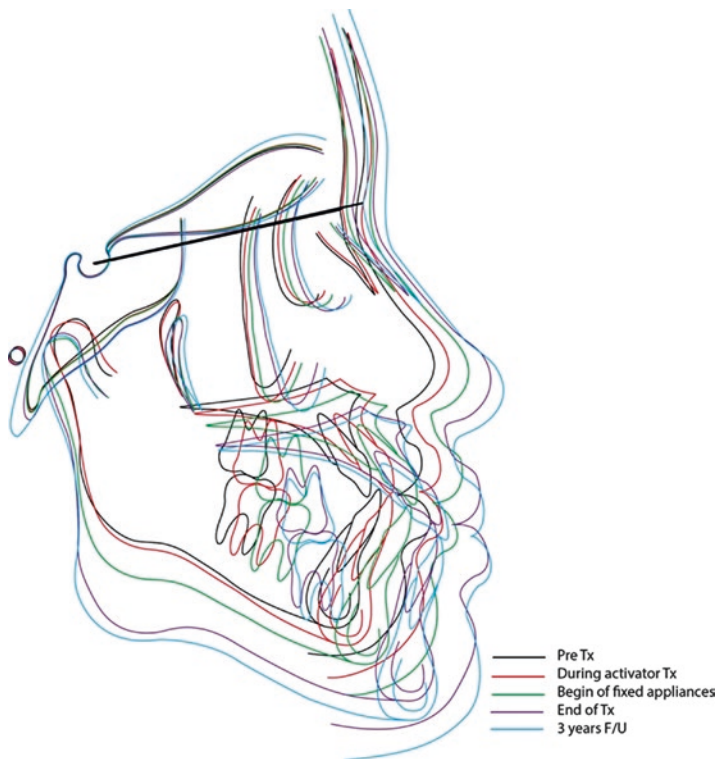
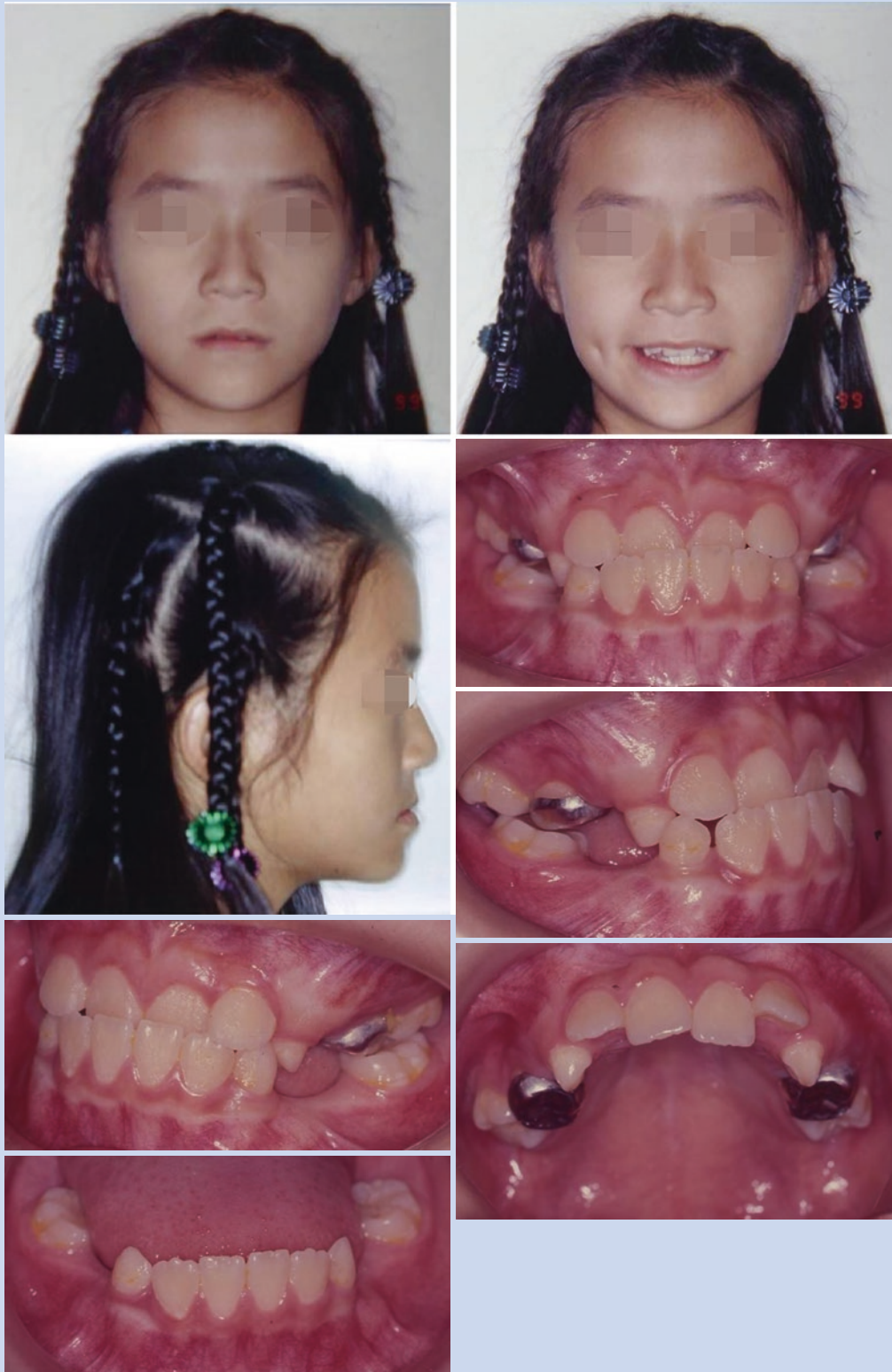
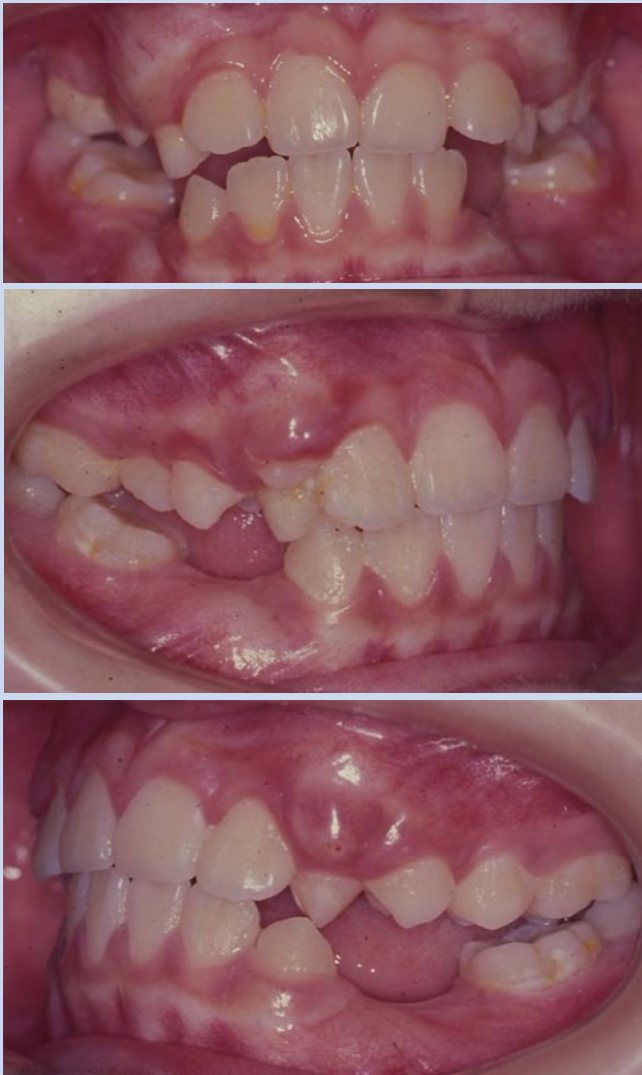
Fig. 8.248 Superimposition at different timelines

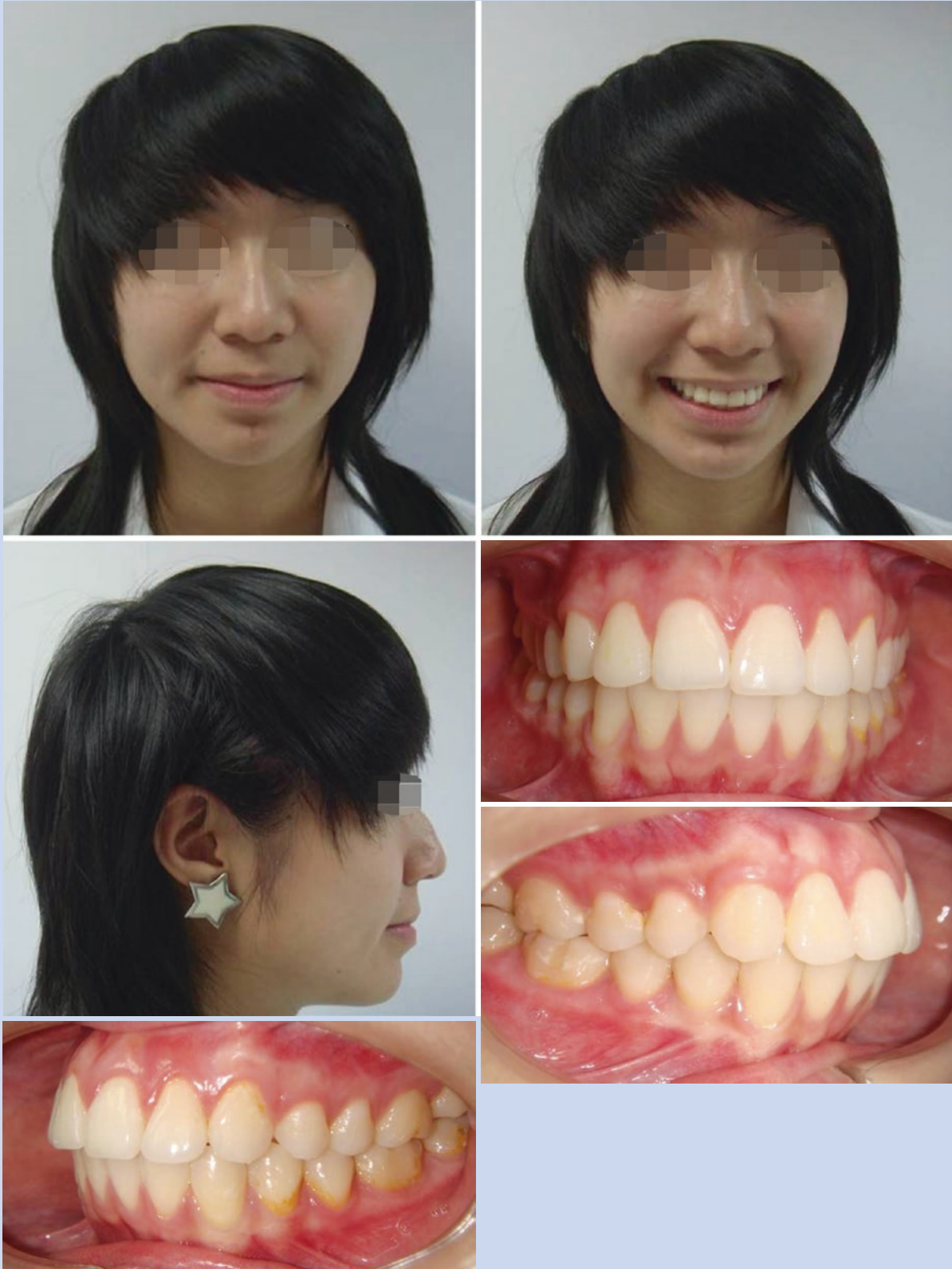Case #6 (Figs. 8.249–8.278)



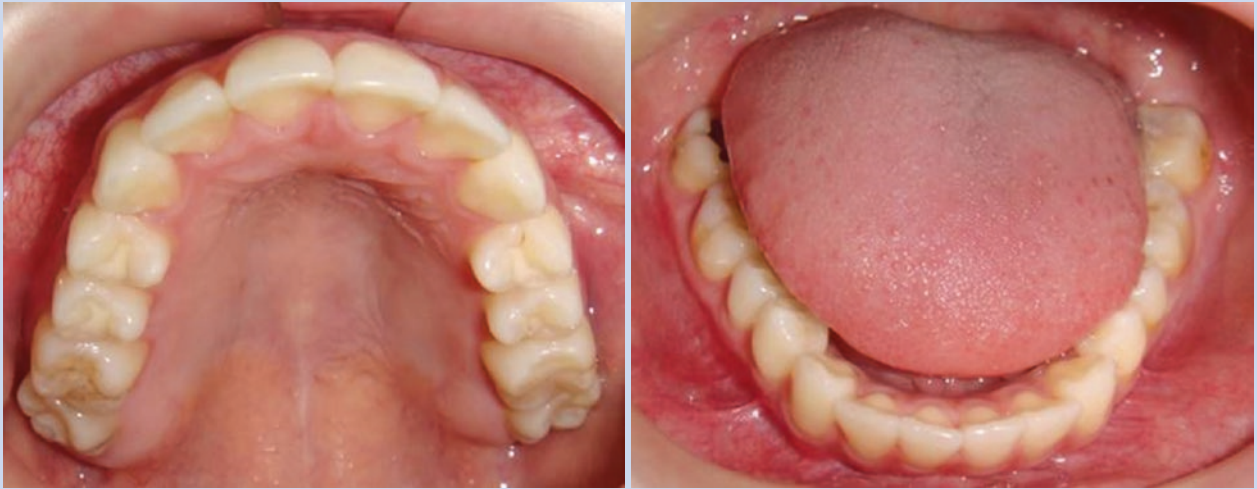
Figs. 8.249, 8.250, 8.251, 8.252, 8.253, 8.254, 8.255, and 8.256 Extraoral pictures of a 9-year-old girl showed a concave facial profile; intraoral pictures showed that teeth #11, #21, #42, #41, #31, and #32 were in cross bite, teeth #12 and #22 were proclined, and she had Class III molar relationships



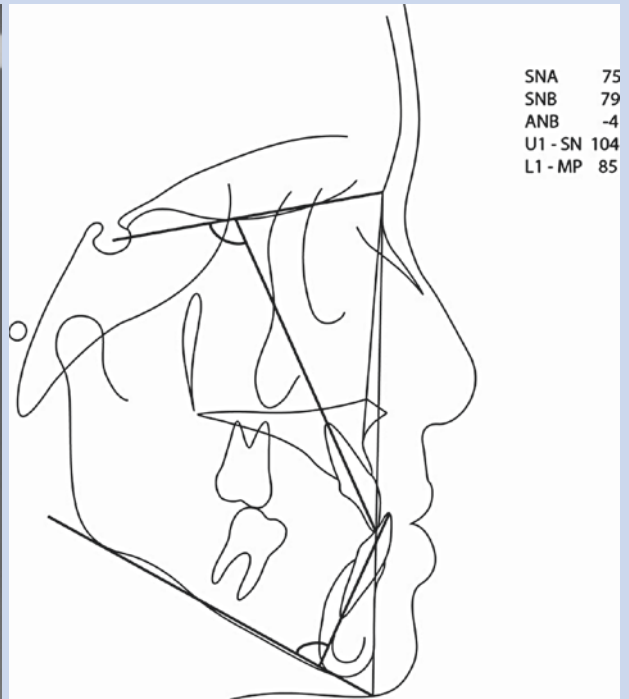
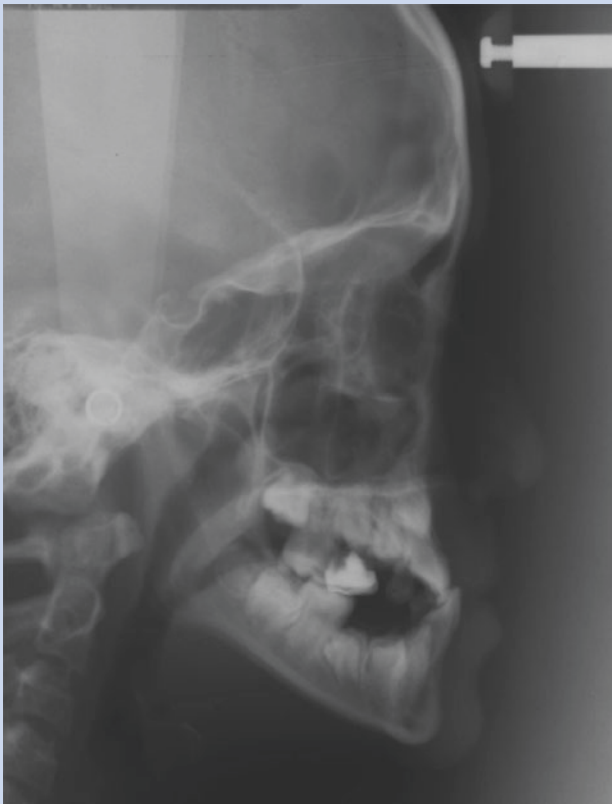Figs. 8.257, 8.258, and 8.259 Pictures showed positive overjet and positive overbite during Class III activator treatment



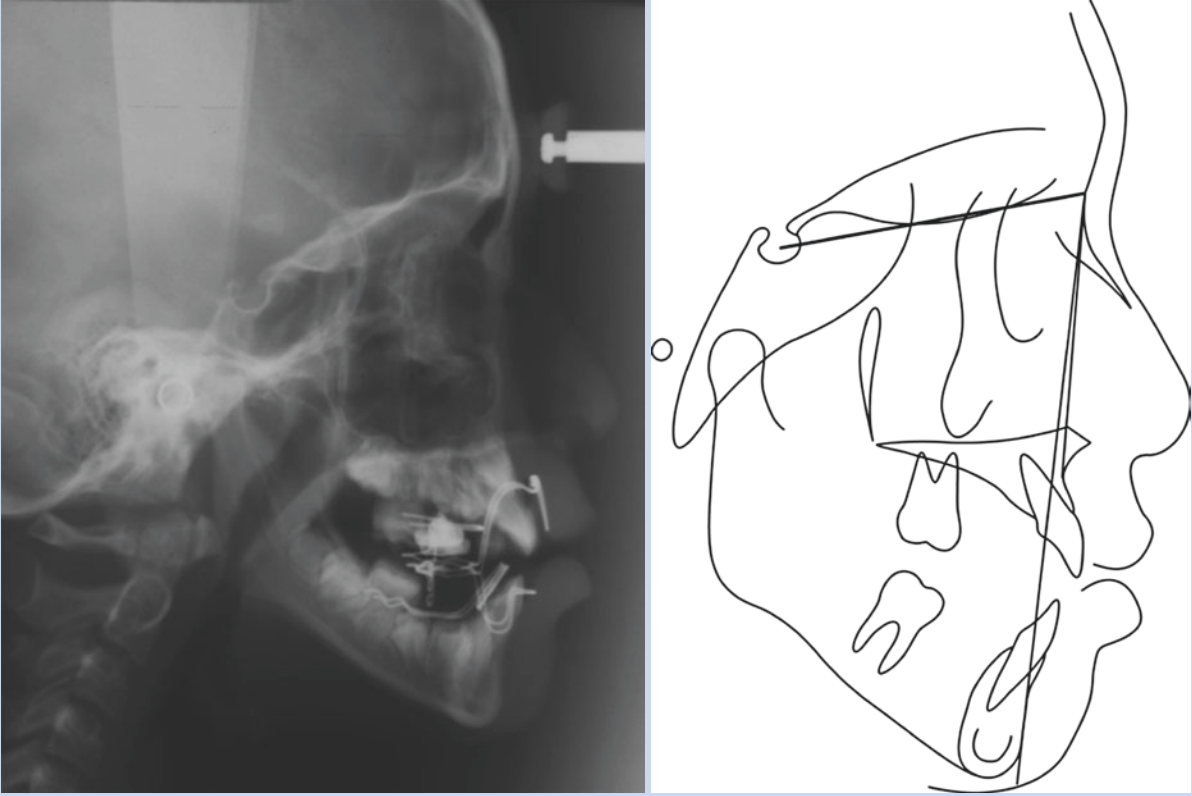
Figs. 8.260, 8.261, 8.262, 8.263, 8.264, 8.265, 8.266, and 8.267 Extra- and intraoral pictures at recall, 5 years after the end of second phase of treatment with fixed appliances, showed good stability of the treatment outcomes. The patient had large tongue, but she was well aware of the relapse risk, and she continued with myofunctional exercises



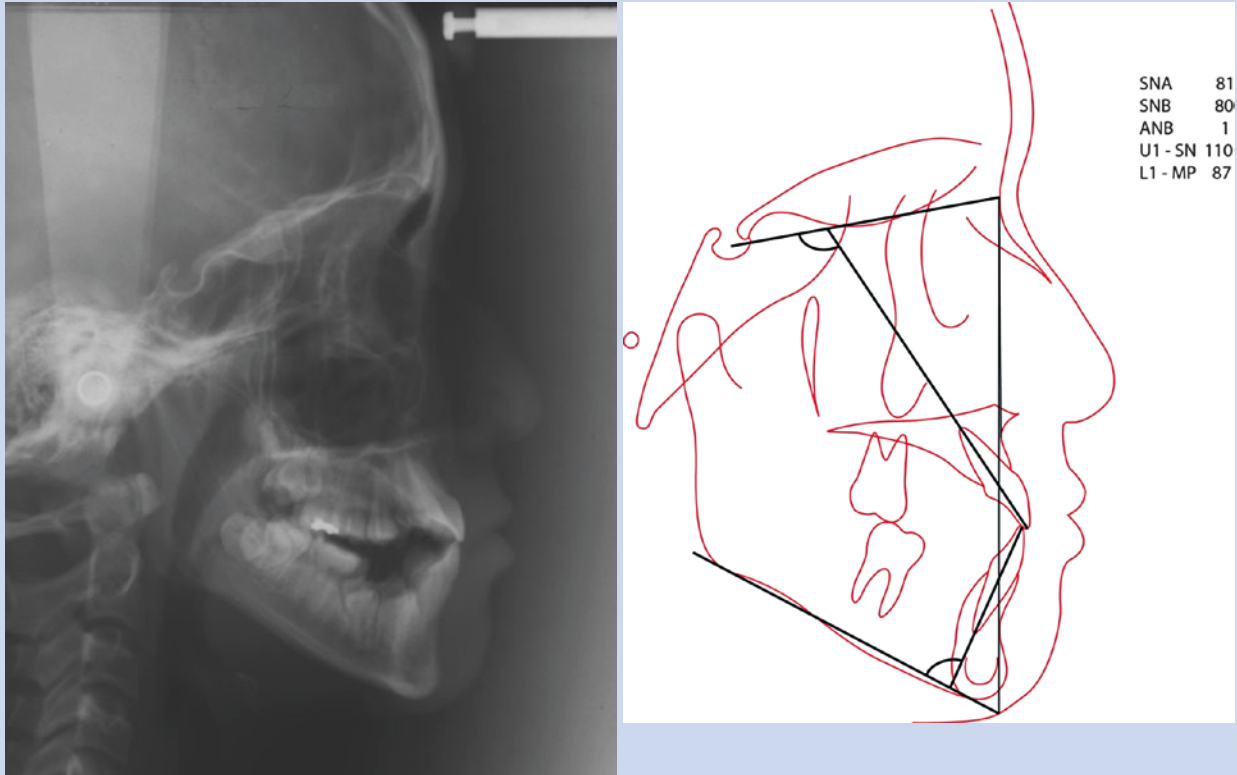
Figs. 8.260, 8.261, 8.262, 8.263, 8.264, 8.265, 8.266, and 8.267 (continued)



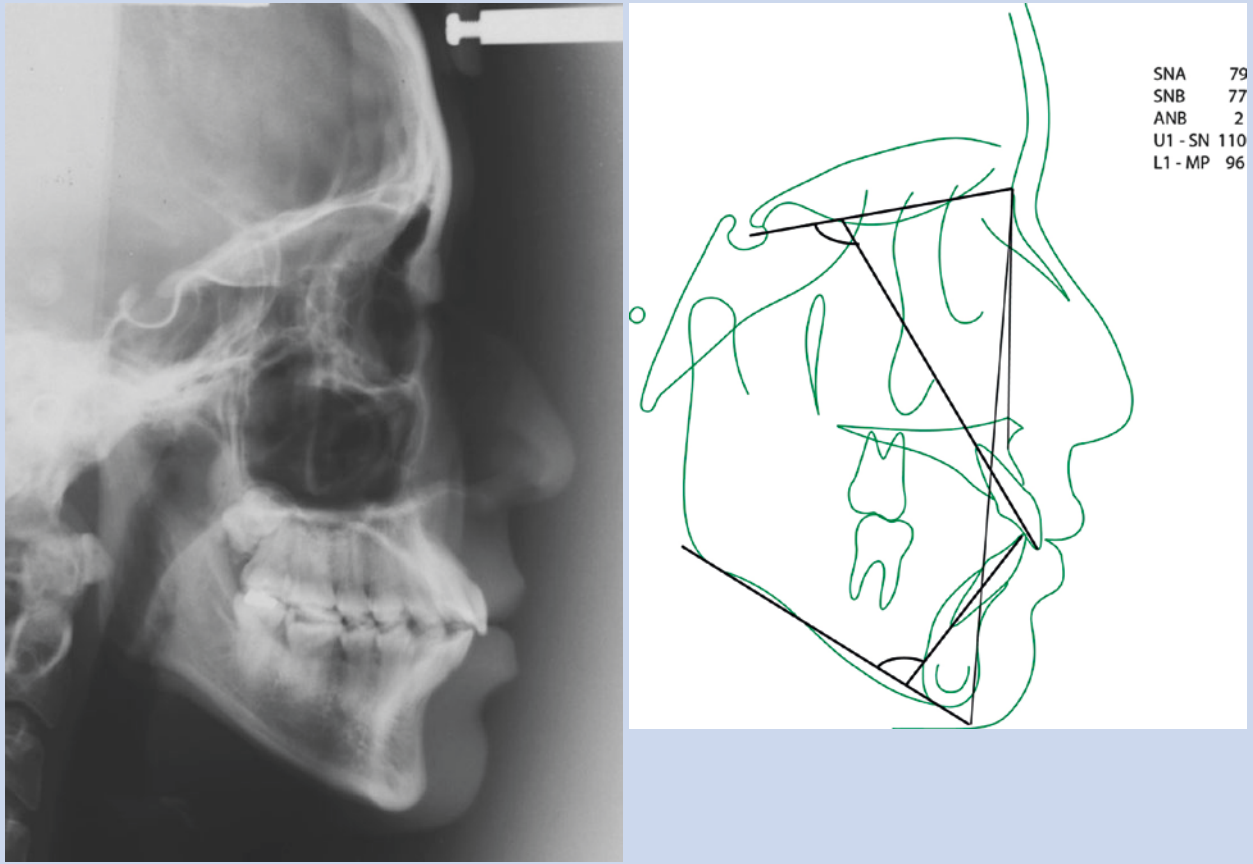
Figs. 8.268 and 8.269 Cephalometric head film and tracing at beginning of the treatment; ANB angle was -4°



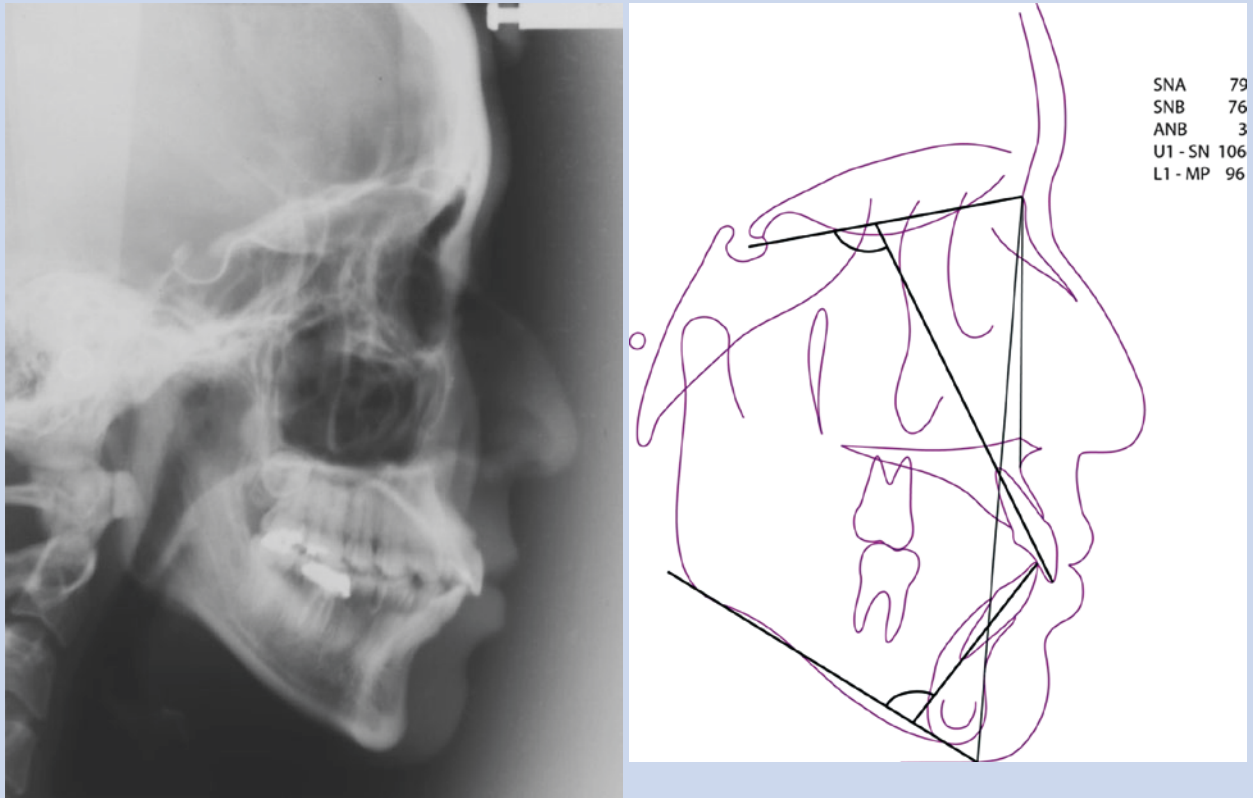
Figs. 8.270 and 8.271 A cephalogram and a tracing with Class III activator in situ



Figs. 8.272 and 8.273 A cephalogram and a tracing during the treatment with Class III activator; the ANB angle increased from -4° to $+1^{\circ}$, and there was increase in inclination angle of the upper anterior teeth from 104° to 110° and lower anterior teeth from 85° to 87° . Positive overjet and positive overbite were achieved



Figs. 8.274 and 8.275 Cephalometric head film at the end of the treatment; ANB angle was 2°



Figs. 8.276 and 8.277 Cephalometric head film and tracing 9 years after the end of the treatment; the treatment results in both skeletal and dental were stable

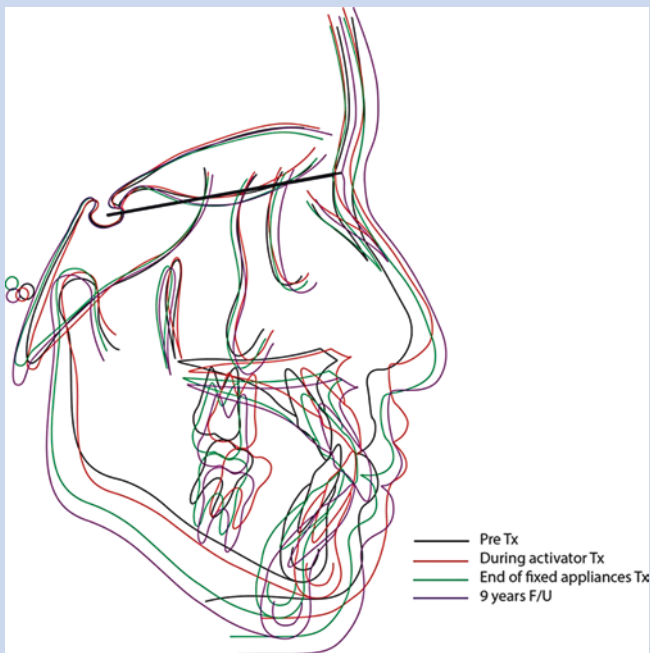


Fig. 8.278 Superimposition of cephalometric tracings at different timelines

Conclusion

As mentioned before, Class III malocclusions are one of the most difficult malocclusions to be treated. Anyhow, early Class III treatment could be done successfully when proper diagnosis and proper treatment plan are carefully carried out, and the treatments are done following the concept of treating at the right place, at the right time, and with the right appliances. The purposes of early treatment can be causative treatment, in the case of dentoalveolar Class III malocclusion. In case of skeletal Class III malocclusions, growth modification can be done with awareness of limitation in severe cases where orthognathic surgery is required in the later stage.

Most skeletal Class III malocclusions exhibit discrepancies in all dimensions, in the sagittal, transversal, and vertical dimension. Therefore, second phase of treatment is required in many cases. Anyhow, early treatment of Class III malocclusions, when carefully done, helps reduce severity of the malocclusions, thus preventing major surgery. Therefore, it can be concluded that Class III activator may be a viable mode for initial stage of Class III treatment in conjunction with fixed or removable therapy.

References

- Baccetti T, Franchi L, McNamara Jr JM. Cephalometric variables predicting the long-term success or failure of combined rapid maxillary expansion and facial mask therapy. *Am J Orthod Dentofacial Orthop.* 2004;126:16–22.
- Cha KS. Skeletal changes of maxillary protraction in patients exhibiting skeletal Class III malocclusion: a comparison of three skeletal maturation groups. *Angle Orthod.* 2003;73:26–35.
- Chebib FS, Chamma AM. Indices of craniofacial asymmetry. *Angle Orthod.* 1981;51:214–26.
- Deguchi T, Kuroda T, Hunt NP, Graber TM. Long-term application of chincup force alters the morphology of the dolichofacial Class III mandible. *Am J Orthod Dentofacial Orthop.* 1999;116:610–5.
- Deguchi T, Kuroda T, Minochima Y, Graber TM. Craniofacial features of patients with Class III abnormalities: growth-related changes and effects of short-term and long-term chincup therapy. *Am J Orthod Dentofacial Orthop.* 2002;121:84–92.
- Fränkel R, Fränkel C. Orofacial orthopedics with the function regulator. Basel/München/Paris/London/New York/Tokyo/Sydney: Karger; 1989.
- Funatsu M, Sato K, Mitani H. Effect of growth hormone on craniofacial growth. *Angle Orthod.* 2006;76(6):970–6. doi:10.2319/011905-17.
- Gallagher RW, Miranda F, Buschnang PH. Maxillary protraction: treatment and posttreatment effects. *Am J Orthod Dentofacial Orthop.* 1998;113:612–9.
- Garliner D. Myofunctional therapy. 1981 ISBN 75-14781.
- Ghiz MA, Ngan P, Gunel E. Cephalometric variables to predict future success of early orthopedic Class III treatment. *Am J Orthod Dentofacial Orthop.* 2005;127:301–6.
- Graber TM. The “three M’s” muscles, malformation, and malocclusion. *Am J Orthod.* 1963;49(6):418–50.
- Graber LW. Chincup therapy for mandibular prognathism. *Am J Orthod.* 1977;72:23–41.
- Graber T, Rakosi T, Petrovic A. Dentofacial orthopedics with functional appliances. 2nd ed. St. Louis: Mosby; 1997.
- Gu Y, Rabie AB, Hägg U. Treatment effects of simple fixed appliance and reverse headgear in correction of anterior crossbites. *Am J Orthod Dentofacial Orthop.* 2000;117:691–9.
- Hass AJ. Long-term posttreatment evaluation of rapid palatal expansion. *Angle Orthod.* 1980;50(3):189–217.
- Ishikawa H, Nakamura S, Kim C, Iwasaki H, Satoh Y, Yoshida S. Individual growth in Class III malocclusions and its relationship to the chin cap effects. *Am J Orthod Dentofacial Orthop.* 1988;114:337–46.
- Joondeph DR. Mysteries of asymmetries. *Am J Orthod Dentofacial Orthop.* 2001;117:577–9.
- Kajiyama K, Murakami T, Suzuki A. Evaluation of the modified maxillary protractor applied to Class III malocclusion with retruded maxilla in early mixed dentition. *Am J Orthod Dentofacial Orthop.* 2000;118:549–59.
- Keles A, Cetinkaya Tokmak E, Erverdi N, Nanda R. Effect of verifying the force direction on maxillary orthopedic protraction. *Angle Orthod.* 2002;72:387–96.
- Ko YL, Baek SH, Mah J, Yang WS. Determinants of successful chincup therapy in skeletal Class III malocclusion. *Am J Orthod Dentofacial Orthop.* 2004;126:33–41.
- Letzer G, Kronman J. A posteroanterior cephalometric evaluation of craniofacial asymmetry. *Angle Orthod.* 1967;37:205–11.
- Levin AS, McNamara JA, Franchi L, Beccetti T, Fränkel C. Short-term and long-term treatment outcomes with the FR-3 appliance of Fränkel. *Am J Orthod Dentofacial Orthop.* 2008;134:513–24.
- Liou JWE. Tooth borne orthopedic maxillary protraction in Class III patients. *JCO.* 2005;39:68–75.
- McNamara JA. Maxillary transverse deficiency. *Am J Orthod Dentofacial Orthop.* 2000;117:567–70.
- Mermingos J, Full CA, Anderson G. Protraction of the maxillofacial complex. *Am J Orthod Dentofacial Orthop.* 1990;98:47–55.
- Mitani H. Early application of chincup therapy to skeletal Class III malocclusion, presented at the International Symposium on Early Orthodontic Treatment, February 8–10, 2002; Phoenix, Ariz. *Am J Orthod Dentofacial Orthop.* 2002;121:584–5.
- Ngan P. Biomechanics of maxillary expansion and protraction in Class III patients, presented at the International Symposium on Early Orthodontic Treatment, February 8–10, 2002; Phoenix, Ariz. *Am J Orthod Dentofacial Orthop.* 2002;121:582–3.
- Ngan P, Wilmes B, Drescher D, Martin C, Weaver B, Gunel E. Comparison of two maxillary protraction protocols: tooth-borne versus bone-anchored protraction facemask treatment. *Prog Orthod.* 2015;16:26. doi:10.1186/s40510-015-0096-7.
- Pangrazio-Kulbersh V, Berger J, Kersten G. Effects of protraction mechanics on the midface. *Am J Orthod Dentofacial Orthop.* 1998;114:484–91.
- Pirttiniemi PM. Association of mandibular and facial asymmetry—a review. *Am J Orthod Dentofacial Orthop.* 1994;106:191–200.
- Rakosi T. Funktionelle Therapie in der Kieferorthopädie. München Wien; Hanser; 1985.
- Rakosi T, Graber T. Orthodontic and dentofacial orthopedic treatment. Stuttgart/New York: Thieme; 2010.
- Ross B. Commentary: the orthodontist and complex craniofacial anomalies. *Am J Orthod Dentofacial Orthop.* 2001;119:92–4.
- Saadia M, Torres E. Sagittal changes after maxillary protraction with expansion in Class III patients in the primary, mixed, and late mixed dentitions: a longitudinal retrospective study. *Am J Orthod Dentofacial Orthop.* 2000;117:669–80.
- Satrahava S. Rapid maxillary expansion in an adult patient with/in spite of torus palatinus. *Prakt Kieferorthop.* 1987;1:97–100.
- Satrahava S. Combined therapy with appliances and myofunctional exercises in an adult with periodontal involvement. *Prakt Kieferorthop.* 1990;4:49–52.

- Satravaha S. Frühbehandlung bei Progeniefällen in Thailand. *Prakt Kieferorthop.* 1993;7:23–30.
- Satravaha S, Taweeseedt N. Skeletal and dental changes following activator therapy on Class III patients. *Mahidol Dent J.* 1996a;16:31–39.
- Satravaha S, Taweeseedt N. Changes in maxillary and mandibular body lengths following Class III activator therapy. *Mahidol Dent J* 1996b;16:40–47.
- Satravaha S, Taweeseedt N. Stability of skeletal changes after activator treatment of patients with Class III malocclusions. *Am J Orthod Dentofacial Orthop.* 1999;116:196–206.
- Satravaha S, Taweeseedt N. Nonsurgical orthodontic treatment of anterior open-bite in adult: a case report. *J Tha A O.* 2002;1:25–31.
- Sugawara J, Asano T, Endo N, Mitani H. Long-term effects of chin cap therapy on skeletal profile in mandibular prognathism. *Am J Orthod Dentofacial Orthop.* 1990;98:127–33.
- Turley PK. Commentary: managing the developing Class III malocclusion with palatal expansion and facemask therapy. *Am J Orthod Dentofacial Orthop.* 2002;122:349–52.
- Wendell PD, Ravinda N, Sakamoto T, Nakamura S. The effect of chin cup therapy on the mandible: a longitudinal study. *Am J Orthod Dentofacial Orthop.* 1985;87:265–74.
- Witt E, Gehrke ME. *Leitfaden der kieferorthopädischen Technik.* Berlin/Chicago/Rio de Janeiro und Tokio: Quintessenz Verlags-GmbH; 1981.
- Yüksel S, Ücem TT, Keykubat A. Early and late facemask therapy. *Eur J Orthod.* 2001;23:559–68.

Julia Harfin

Normalization of the upper arch has always been one of the most important issues in the treatment of young children with constricted maxillary arch or with uni- or bilateral crossbite.

The etiology is multifactorial and the functional problems play an important role. The environmental factors are determinant not only in the beginning but also in the maintenance of the malocclusion. It can be present in class I, II, or III patients with or without crowding.

It is acknowledged worldwide that transverse problems have to be normalized in temporary or early mixed dentition to allow a normal eruption of the bicuspid and cuspids.

It is well accepted that the younger the patient, the easier it is to achieve excellent results with fewer chances of relapse. The most appropriate timing for treatment appears to be before the eruption of the permanent lateral incisors.

The recovery of the normal maxillary width not only allows the gaining of space in the lateral areas but also gives the tongue more space to function in the correct position and maintain the results until adulthood.

After the treatment not only is the normalization of the arch perimeter achieved but in most of the cases the patients recover normal nose breathing (day and night) and stop snoring.

Moreover, limited information is available about the long-term stability of the changes of the airway produced by RME (Mc Namara). Some studies have shown that maxillary constriction has a very close relationship with apnea in children, and this is an important issue to take into account.

Treatment planning includes palatal expansion that can be carried out by different appliances depending on whether the objective is to obtain a skeletal or dentoalveolar expansion.

Dentoalveolar expansion produces dental expansion without any skeletal change and in general a removable appliance is used. This type of appliance is able to tip the teeth buccally but is not able to open the midpalatal suture (Fig. 9.1a, b).

When the diagnosis indicates that a skeletal expansion is recommendable, it has to be performed by a fixed appliance, and the result is the movement of the maxillary shelves away from each other (Fig. 9.2a, b) The pre- and post-occlusal radiographs after 2 weeks of activation of a rapid palatal expander showed the expansion that was produced in the midpalatal suture very clearly.

Dr. Emerson Angell (Angell 1860) was one of the first to splint the midpalatal suture and described the use of a screw to achieve maxillary expansion in 1860. However, it was Dr. Andrew Haas who presented the RME as a routine clinical procedure to treat the narrow maxilla (Haas 1961, 1965, 1980, 1997).

It is highly recommendable that this procedure be initiated prior the ossification of the midpalatal suture. There is an individual variation among all the patients, but it is recognized that in general girls complete their growth period between 12 and 14 years of age and boys a little later (14–17 years old).

This procedure is always used in order to increase maxillary arch perimeter, correct uni- or bilateral crossbite, improve anterior crossbite, and in some cases improve airway flow.

According to the diagnosis and treatment plan, all the appliances have a similar design with bands on the first molars or metallic crowns on the first and second temporary molars. Different designs were described by different authors (bonded or cemented), but all of them include a central expansion screw.

The activation protocol involves the generation of orthopedic forces that could split the midpalatal suture. The screw has to be activated 1, 2, or 3 times a day (one quarter turn) according to the individualized treatment objectives. No pain and little discomfort could be present during the first days.

J. Harfin
Department of Orthodontics, Maimonides University,
Buenos Aires, Argentina
e-mail: harfinjulia@gmail.com

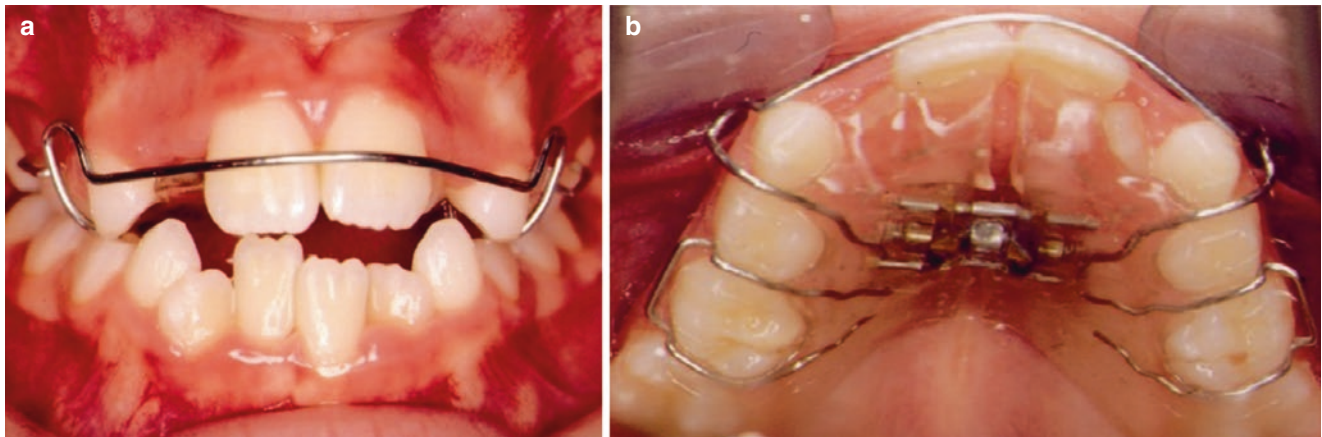


Fig. 9.1 (a, b) Example of a removable appliance to correct a slight transverse problem

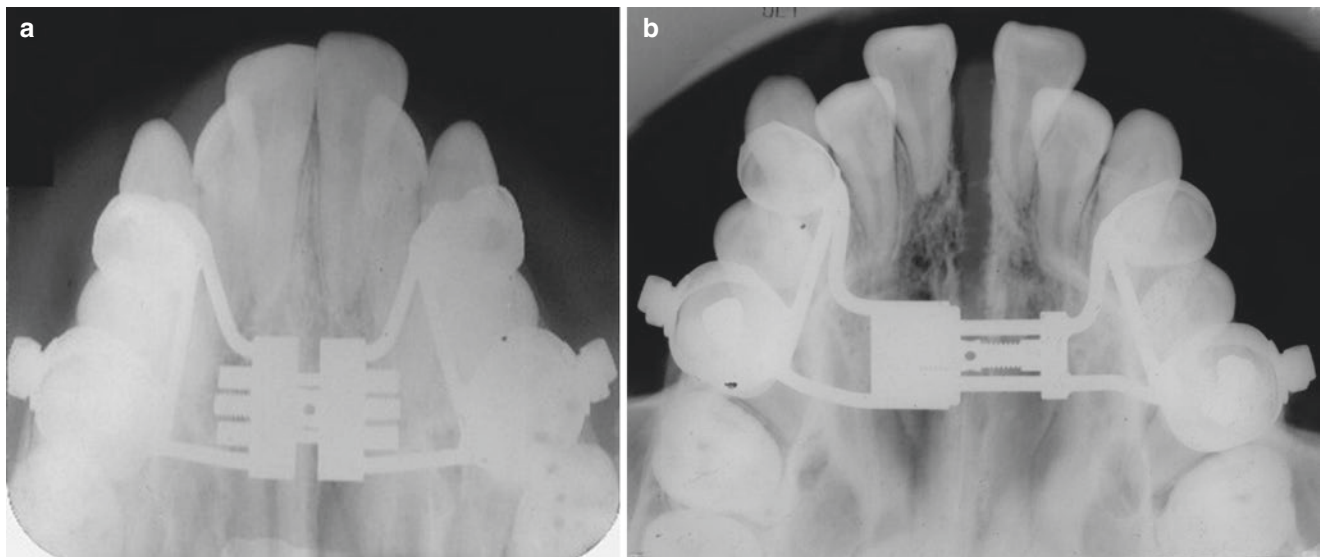


Fig. 9.2 (a, b) Pre and post-occlusal radiographs after the use of a rapid maxillary expander for 2 weeks

The parents and the patients have to be instructed on the maintenance of the appliance, and strict oral hygiene is necessary. Very few difficulties in speech and mastication could be present during the first 3–4 days.

It is advisable to give the patient an instruction sheet listing the schedule of activation and all the cares to take into account during the whole procedure. The parents' help is invaluable.

Normally the suture will open between 6 and 10 days.

An important interincisal diastema is always present when the midpalatal suture is set apart and then closes spontaneously after in 2–3 weeks due to the action of the supra-crestal fibers. The patient has to be controlled once a week to monitor the treatment during the expansion phase.

The lack of space in the anterior region is also an indication for using RME during the early mixed dentition period

(Rosa et al. 2012). This procedure does not require any patient cooperation and allows the increase of the perimeter of the upper arch.

In general, raising of the bite is not necessary in meso-, braqui-, or dolichofacial patients. The results are very predictable in a relatively short period of time.

Different types of RME can be used (Fig. 9.3a, b).

The following patients are a clear example of the results that can be achieved using this protocol.

The first one is an 8-year-old patient that was sent to the office by the family dentist due to a lack of space for the eruption of the upper lateral incisors. The mother was worried about the central interincisal diastema. Mild constriction of the upper arch was present at the beginning of the treatment (Fig. 9.4a, b).

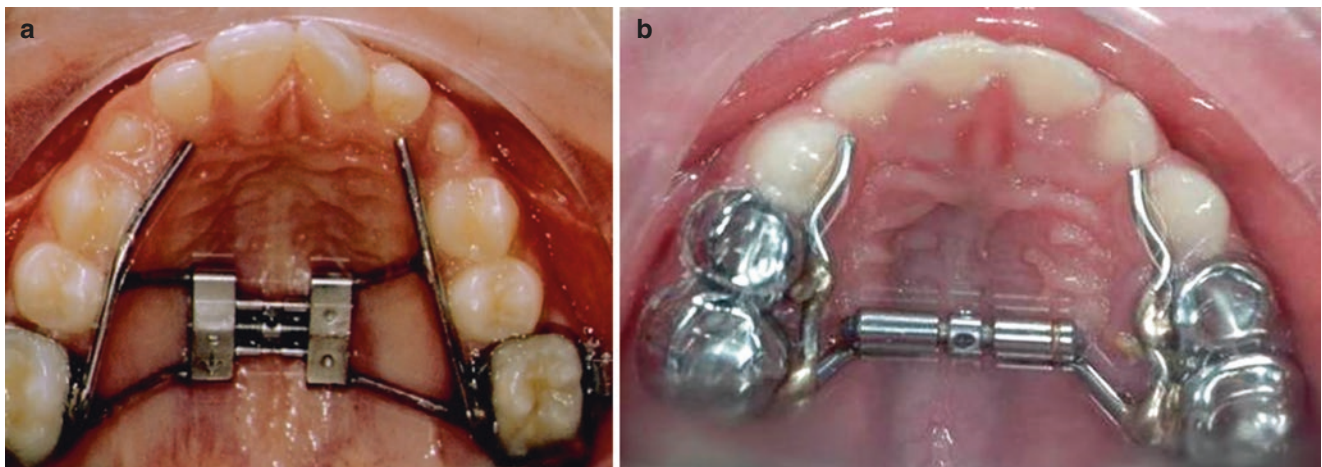


Fig. 9.3 (a, b) Different types of RME can be used with the same protocol of activation

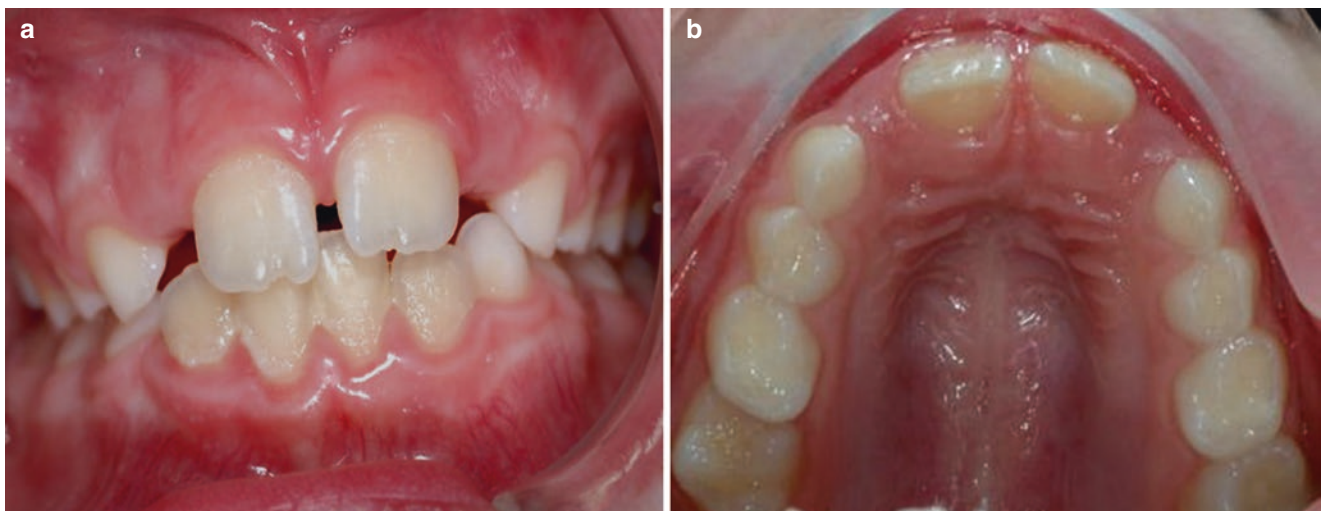


Fig. 9.4 (a, b) Pretreatment intraoral photographs. The lack of space for the upper lateral incisors was evident

To increase the transversal width of the upper arch, a standard rapid maxillary expander was bonded with bands on the second temporary upper molars in order to protect the first molars and avoid eventual decalcifications or cavities. A distal extension wire was welded to the screw toward the right and left first molars and a mesial one until the temporary canines (Fig. 9.5a). The screw was activated twice a day (once in the morning and again after dinner). The results were achieved in 2 weeks and as always the interincisal diastema became wider (Fig. 9.5b).

As was expected 3 weeks later, the diastema was almost closed, and the upper lateral incisors began to erupt. The expander's screw was fixed with composite. In these cases, it is highly recommendable that the same appliance be used as a fixed retainer for a period of 6 months, at least (Fig. 9.6a, b).

For personal reasons the patient returned 3 years later, and no other orthodontic treatment had been performed

in that time. The upper lateral incisors erupted and the interincisal diastema was closed. The occlusal photograph showed that the bicuspid erupted in their right position and the width of the upper arch was maintained (Fig. 9.7a, b).

This patient is a clear example of the importance of the normalization of the arch perimeter in the early mixed dentition.

In cases where the extraction of bicuspid is necessary, it is important that they be postponed until the rapid maxillary expansion process is concluded.

In general, a retention period of 6 months with the appliance in place is recommendable in order to control any type of relapse and permit a complete reorganization of the suture and all the surrounding tissues. This time is also important to allow the adaptation of the facial muscles to the new transverse dimension of the maxillary arch.

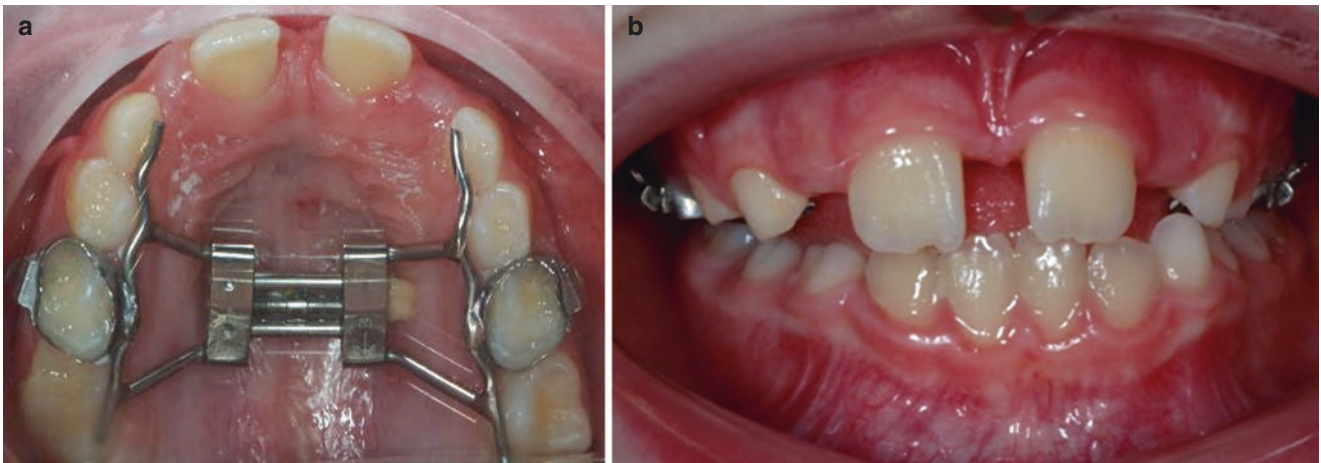


Fig. 9.5 (a, b) Results after 14 days of activation. A wider diastema was clearly visible

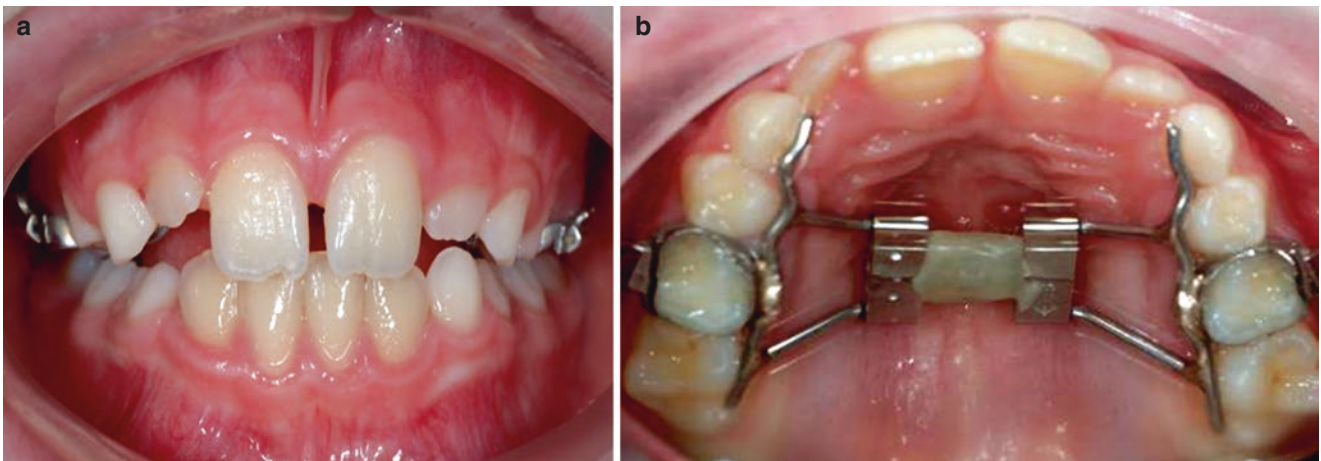


Fig. 9.6 (a, b) After 3 weeks the diastema was almost closed. The expander screw was fixed with composite

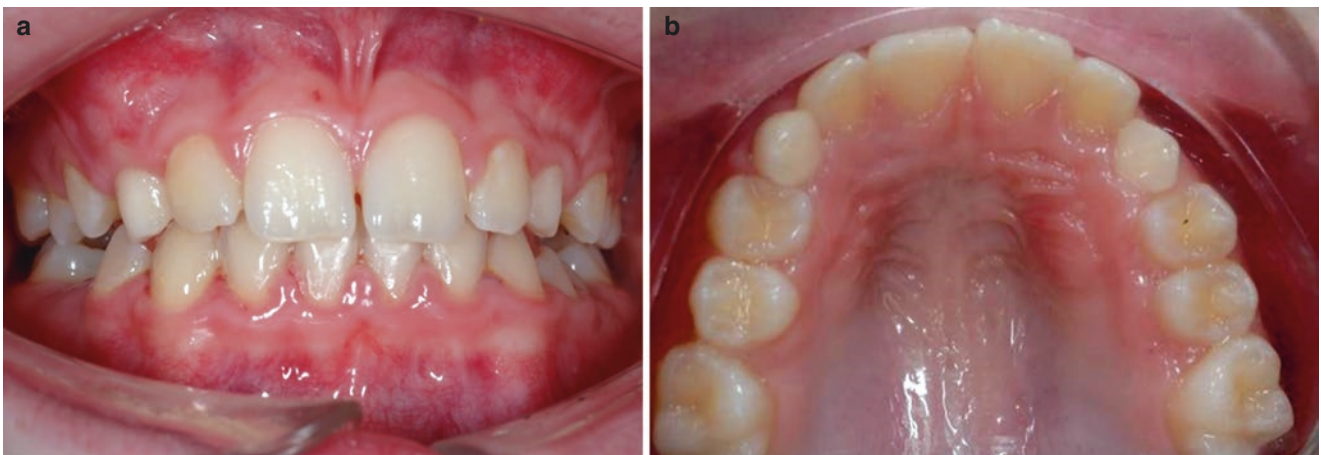


Fig. 9.7 (a, b) Results 3 years later without any orthodontic treatment. All the treatment objectives were achieved

Otherwise, relapse will be the consequence. It is important to keep in mind that muscles play an important role in maintaining the results achieved in the transverse dimension.

In general, when the RME appliance is placed on the temporary molars, a slight normalization of the position of the incisors is achieved as a result of the anterior expansion of the upper arch perimeter in the early mixed dentition.

There is no doubt about the effectiveness of the RME when it is cemented on the temporary molars with a wire welded to the palatal surfaces of the first permanent molars. In general expansion is achieved in the first permanent molar area too (Mutinelli et al. 2008) (Fig. 9.8).

The efficacy of this appliance is well acknowledged by all the orthodontists. The relationship between the arch perimeter and arch expansion was very well studied by Adkins and co-workers. They concluded as an average 0,7 mm of arch perimeter is increased after 1 mm of transpalatal width enlargement, but these proportions could vary according to the age and patient facial biotype.

The next 8-year-old patient was sent to the office by her mother, a pediatric pulmonologist, that was worried about the triangular shape of the her maxillary arch (Fig. 9.9a). The child was a mouth breather until 6 years of age, and after a 1-year treatment with a speech therapist, she was able to correct this habit. To normalize the shape of the upper arch and at the same time make sufficient space for the upper incisors, a RME was placed with bands on the first molars and extension wires bonded to the temporary canines. The activation protocol was two turns a day. The interincisal diastema was visible after the first week of treatment (Fig. 9.9b).

Eight months later, metal preprogrammed brackets (0.022") were bonded on the rotated upper incisors and temporary canines to correct their position with a SS 0,016" archwire for a 6-month period (Fig. 9.10a). Excellent results were achieved 7 months later. The cuspids and bicusps erupted in the correct position without any additional appliance. The arch width was maintained and a removable retention was placed (Fig. 9.10b).

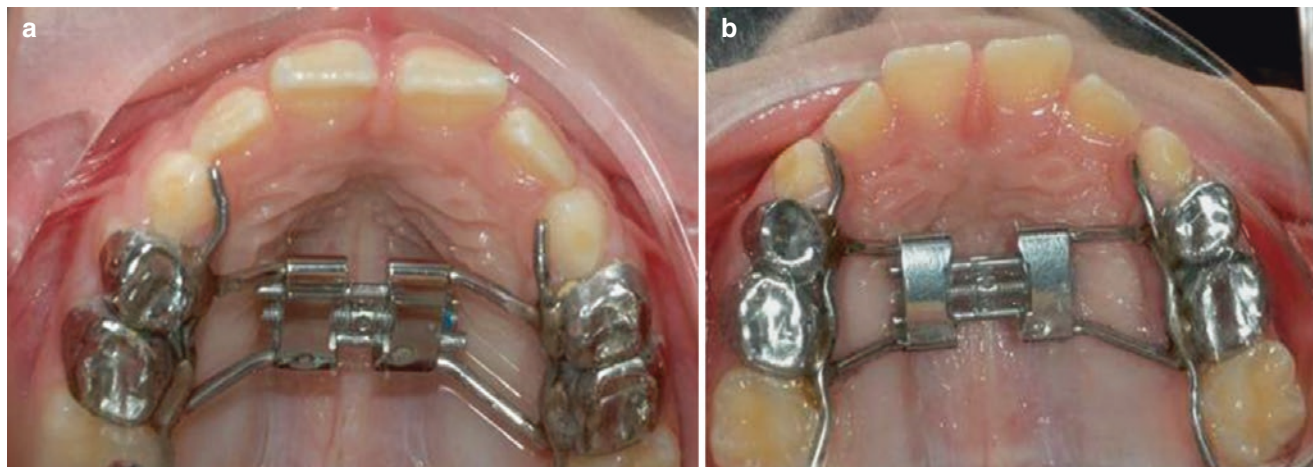


Fig. 9.8 (a, b) An example of a RME bonded on the temporary molars. The use of crowns on the temporary molars is advisable for better retention

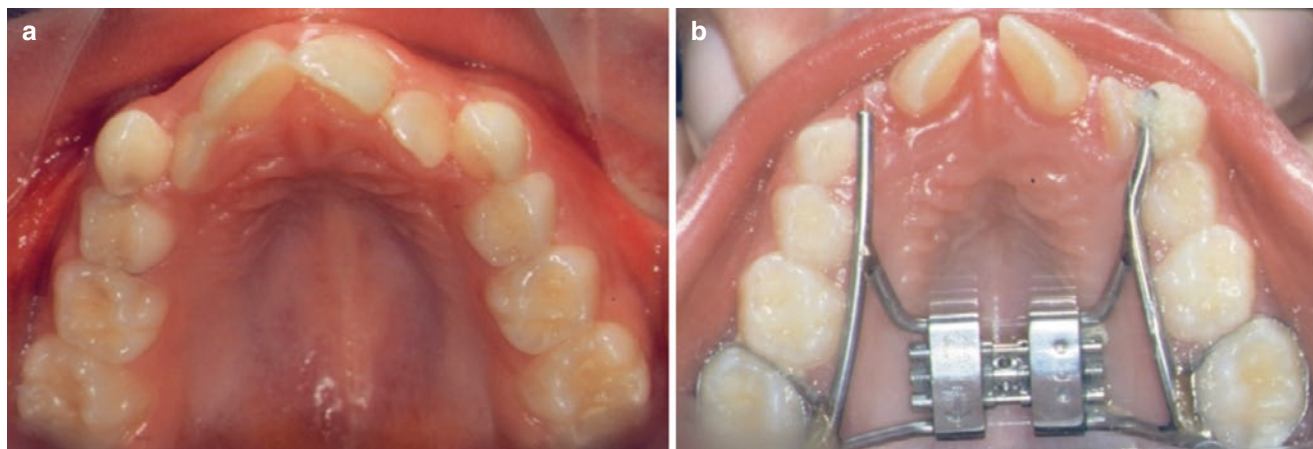


Fig. 9.9 (a, b) Pretreatment occlusal photograph and 1 week after the activation of a RME

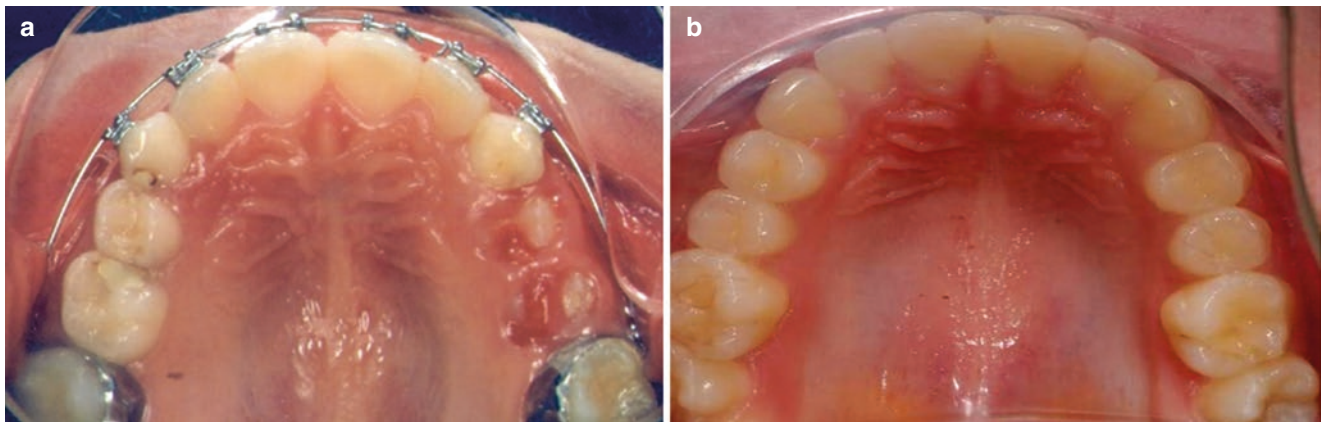


Fig. 9.10 (a, b) Occlusal photographs during second phase of treatment and at the end of the active procedure

The comparison between the pre- and posttreatment smile clearly showed its improvement. This is one of the best protocols to obtain a broad smile in a very controlled procedure (Fig. 9.11a, b).

The lateral smile photographs confirmed how the thickness of the upper lip changed. Since the facial biotype plays an important role in the maintenance of the results, it is important to determine an individualized treatment plan. A 6-month follow-up was recommended until the second molars are fully erupted (Fig. 9.12a, b).

Silva and co-workers describe that after RME, the maxilla is displaced downward and backward. Meanwhile, Hass showed that the result is a slight bite opening and a forward displacement of point A. It is very difficult to compare all these studies.

The retention protocol could change according to various circumstances and includes a removable palatal plate such as a Hawley or Schwartz appliance or functional appliances like Trainers. There is no specific period of time for all patients, but a minimum of 12 months is required in order to give the reorganization of the soft and hard tissues enough time to avoid relapse.

The following case is another interesting example of correction of transverse problems. The following patient was 7 years, 6 months of age in the first consultation. He was the youngest of four children, three of them with class III molar and canine.

No important medical history was present.

She had difficulties with the pronunciation of some consonants due to the absence of the upper incisors in conjunction with the anterior position of the tongue (Fig. 9.13a, b).

Upon analyzing the lateral views, a slight compression in the temporary canine and molar region was present. The right canines were in crossbite position (Fig. 9.14a, b).

The panoramic radiograph showed that there were no agenesis nor supernumerary teeth (Fig. 9.15a), and the lateral radiograph confirmed that the patient would have a

meso-facial growth. The lips were closed without tension with a normal nasolabial angle (Fig. 9.15b).

The treatment objectives were:

1. Normalize the transverse dimension.
2. Normalize overjet and overbite.
3. Maintain class I canine and molar.
4. Long-term stability.

To fulfill the treatment objectives, a two-phase treatment was suggested. During the 1st phase, a Haas expander was placed with metallic bands on the second temporary molars and extension wires bonded on the temporary canines. An activation twice a day was recommended along with a weekly control. This protocol has been demonstrated to be efficient at this age (Fig. 9.16a, b). No brackets were placed on the lower arch to correct the anterior crowding during this phase of treatment.

One of the disadvantages of the RME is that in some clinical cases the anterior open bite can be increased when the molars are crossed to the labial position (Fig. 9.17a). To monitor the position of the tongue, a removable functional appliance (Trainers) was used to enhance tongue position and nasal breathing. Its use was recommended 3–4-h during the day and all night (Fig. 9.17b).

A follow-up 3 months later showed the improvement in the position of the upper incisors, while the RME was still in place as a retention appliance. No molar tipping was observed (Fig. 9.18a, b). The patient had to continue using the Trainer to control the position of the tongue.

One year later the patient was ready for the second phase of treatment. The open bite was totally closed. Esthetic brackets (0,022" slot) with an esthetic 0,016" SS archwire were placed in the upper and lower arches. To recover the space for the upper canines, an open coil spring was placed on the right and left side with more activation on the left quarter to correct midlines (Fig. 9.19a, b).

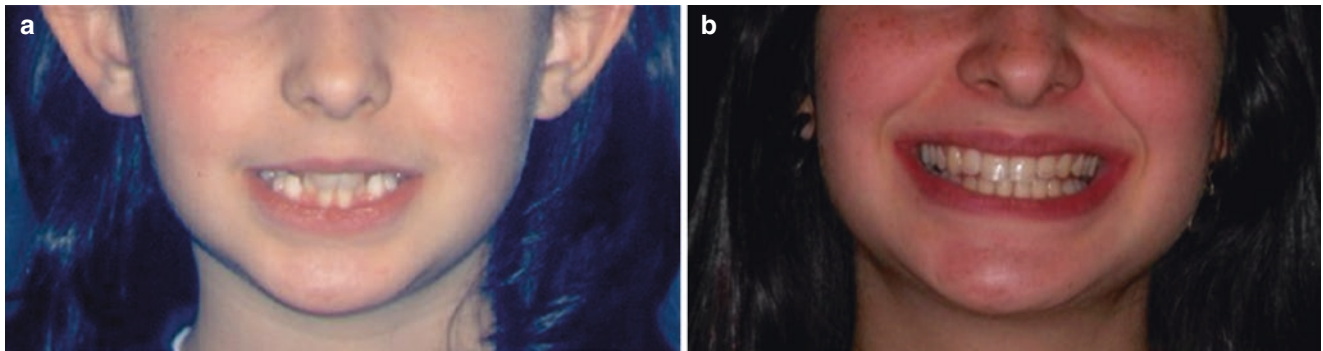


Fig. 9.11 (a, b) Comparison pre- and posttreatment frontal smile. A significant improvement was achieved

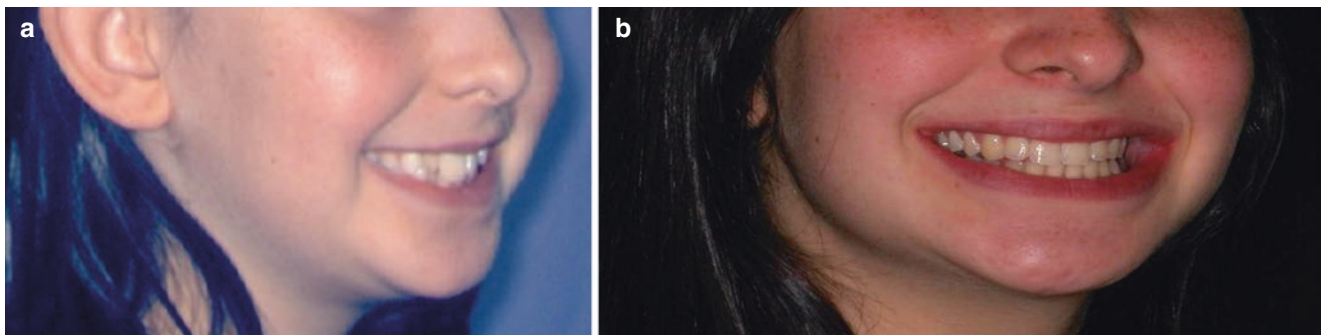


Fig. 9.12 (a, b) The improvement in the thickness of the upper lip in concordance with a broadened smile was more than satisfactory

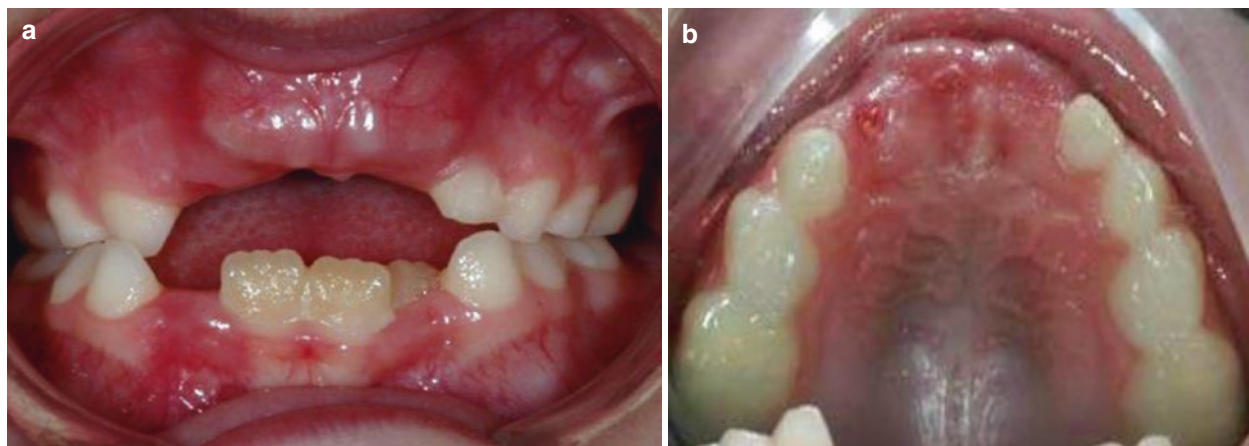


Fig. 9.13 (a, b) Pretreatment frontal and occlusal photographs of a 7-year, 6-month-old patient

Since there was enough room for the eruption of the canine on the right side, but not on the left side, additional activation of the left open coil spring was necessary. To correct anterior crowding, the same type of brackets were bonded on the lower arch with bands on the temporary second molars along with a 0,014" NI-Ti wire (Fig. 9.20a, b).

A follow-up 3 months later showed a considerable improvement. Overjet and overbite were almost normal. The oral hygiene was fairly good (Fig. 9.21a, b).

Although the patient was 11 years old, the upper canines began to erupt before the second bicuspid. To improve anterior torque, the upper coil springs along with a 0,016" × 0,022" SS esthetic archwire were maintained until the eruption of all the bicuspid. A 0.018" Ni-ti lower archwire with an open coil spring was placed on the left side to gain space for the left canine and first bicuspid (Fig. 9.22a, b).

The evaluation of the upper and lower arch confirmed that all the first bicuspid erupted and no crowding was present.

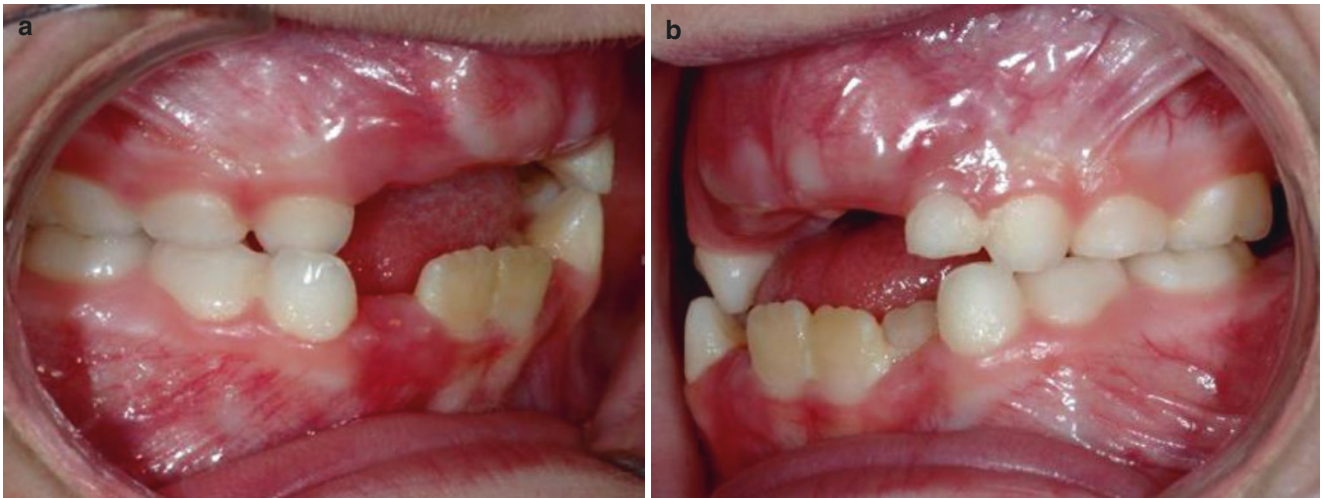


Fig. 9.14 (a, b) Lateral views at the beginning of the treatment. A crossbite relationship was present on the right side

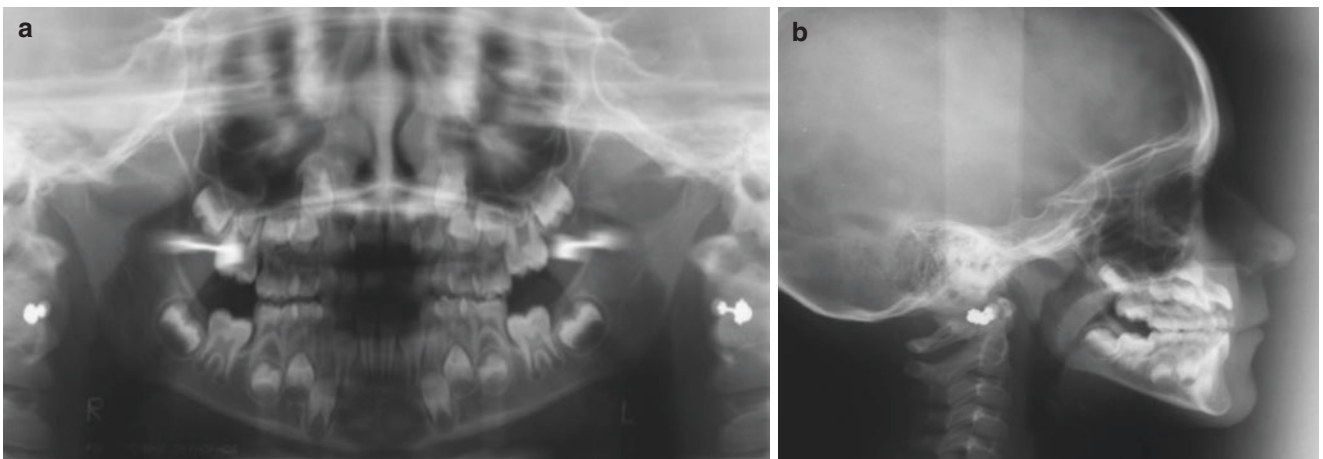


Fig. 9.15 (a, b) Pretreatment panoramic and lateral radiograph

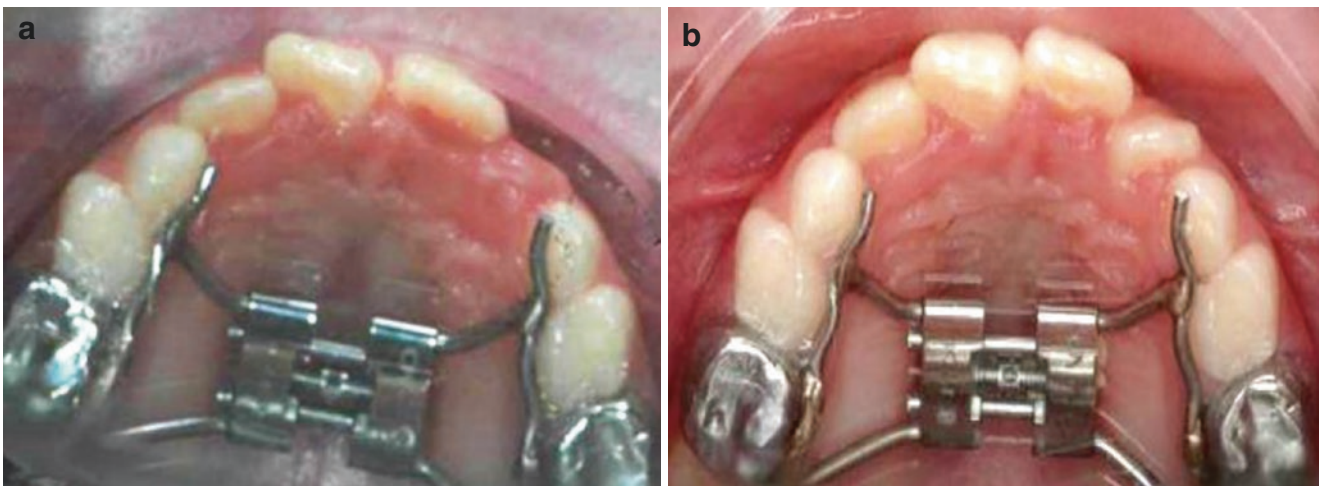


Fig. 9.16 (a, b) 1st phase of treatment. RME in place with bands on the temporary upper second molars

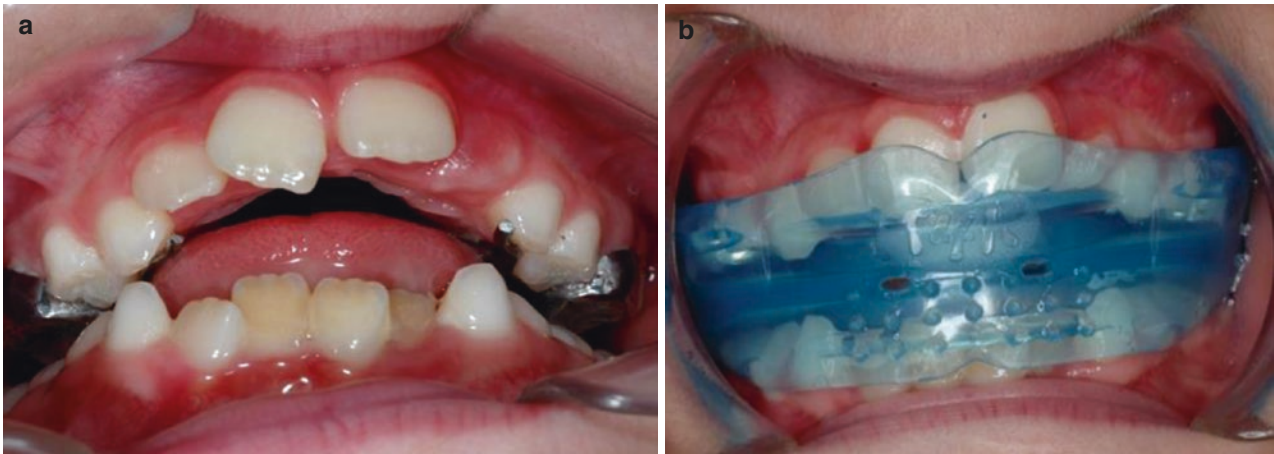


Fig. 9.17 (a, b) The use of a removable functional appliance to normalize nasal breathing and tongue position is highly advisable (Trainer Myofunctional Research)

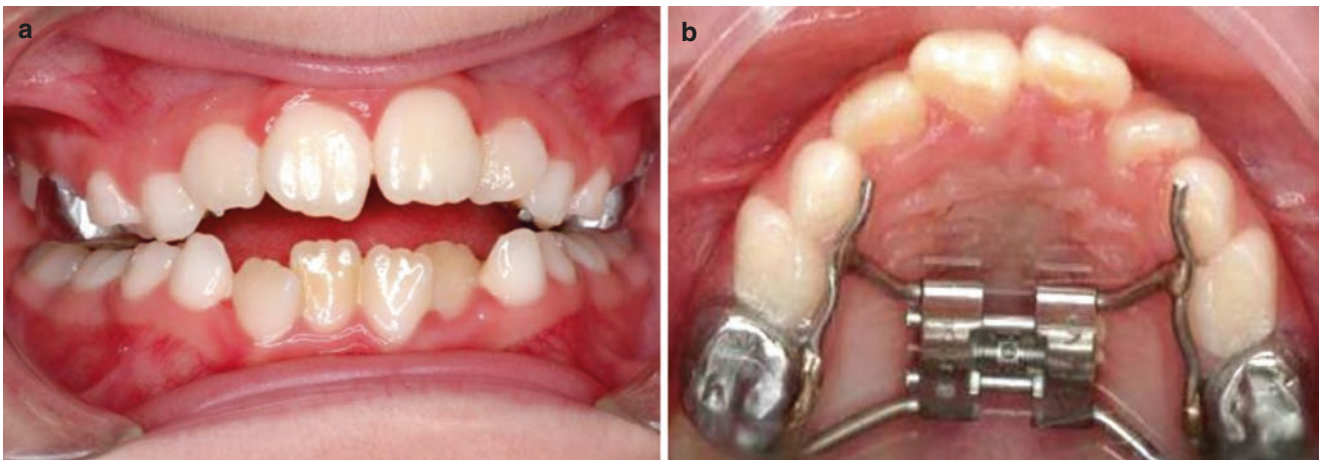


Fig. 9.18 (a, b) Follow-up 3 months later with the RME in place as a retention device in conjunction with the use of the Trainer to normalize the position of the tongue

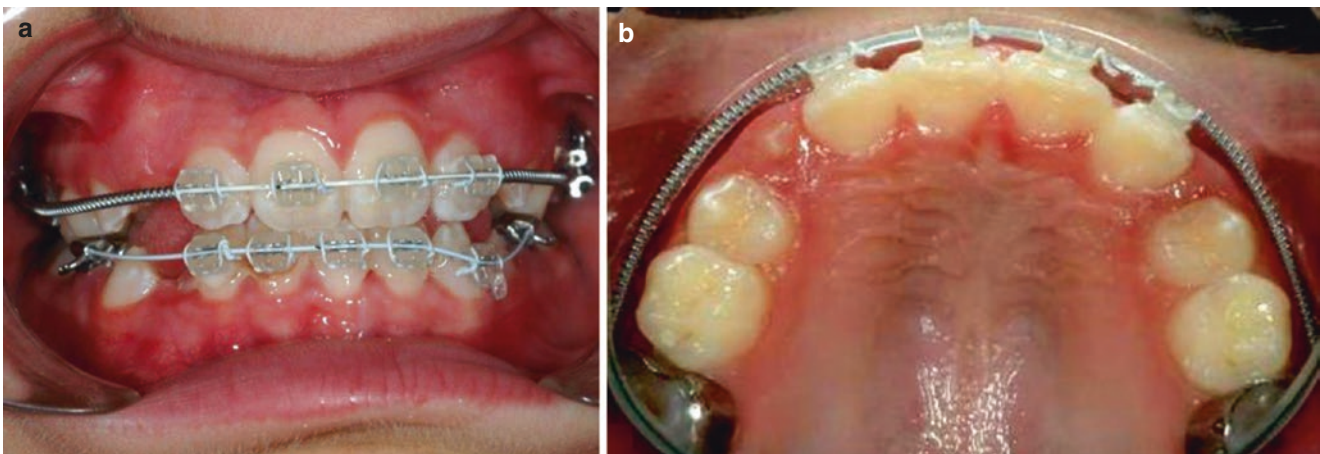


Fig. 9.19 (a, b) At the beginning of the 2nd phase of treatment upper and lower 0.022" esthetic brackets were bonded. An activated coil spring on the left side was placed to achieve the space for the left canine

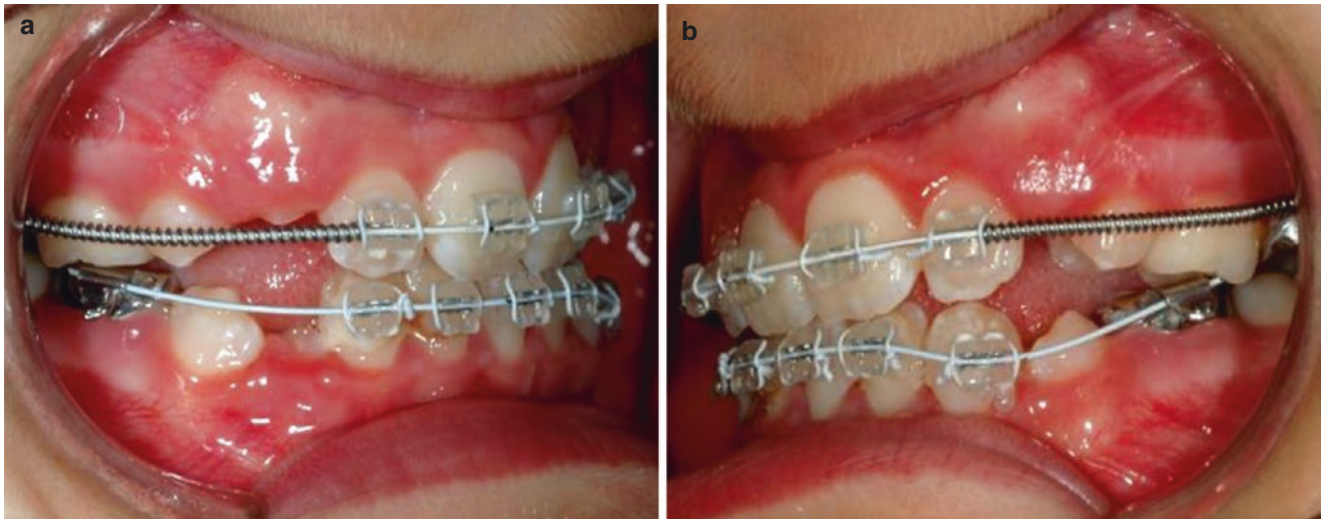


Fig. 9.20 (a, b) Right and left side at this stage of the treatment. A coil spring was placed on the left side and activated more

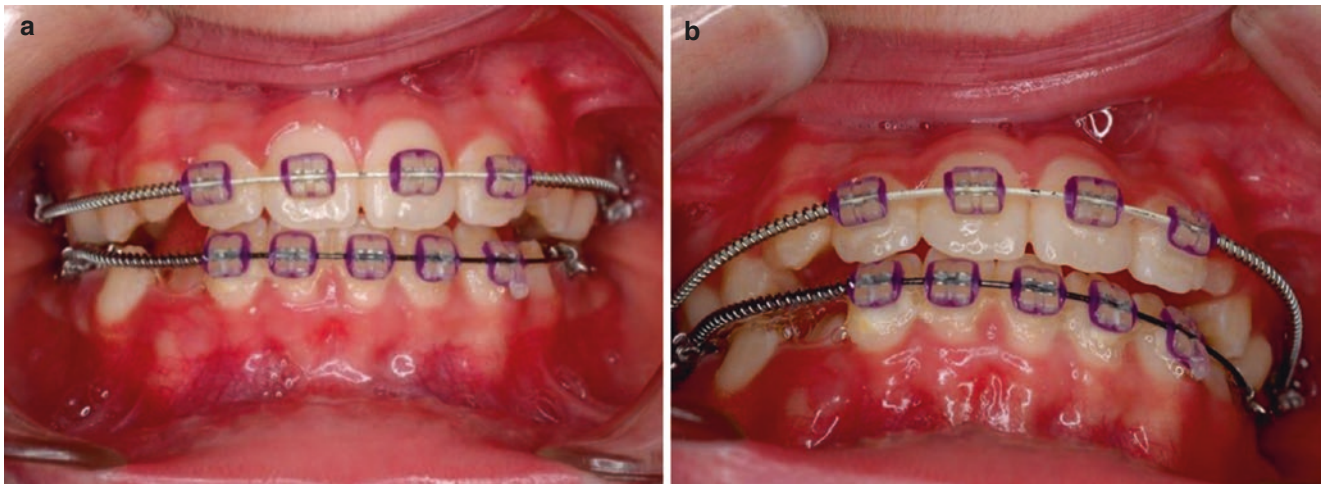


Fig. 9.21 (a, b) Follow-up 3 months later. The anterior lower crowding was almost corrected

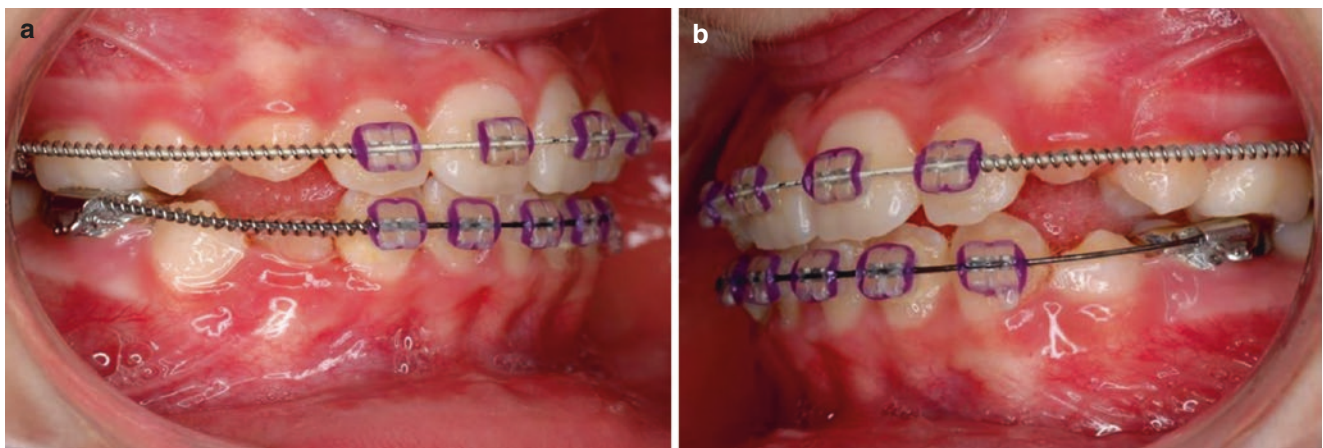


Fig. 9.22 (a, b) Lateral views at this stage of treatment. Right and left upper canines began their eruption path before the second bicuspids

Lower bands were still in place on the temporary second molars (Fig. 9.23a, b).

The final front photographs reveal that all the objectives were fulfilled: midlines were almost coincident, gingival line was parallel to the occlusal plane, and overjet and overbite were within the normal values (Fig. 9.24a, b).

The lateral views corroborated that all the treatment objectives of the 2nd phase of treatment were achieved. The normalization of the occlusal plane as well as the gingival line was achieved with class I canine and molar (Fig. 9.25a, b).

The retention plan included upper and lower fixed retention wires at least until the third molars erupted (Fig. 9.26a, b).

The final radiographs confirmed the parallelism of the roots. Also, the second and third upper and lower molars were erupting normally (Fig. 9.27a, b).

The comparison of the front photographs pre- and post-treatment showed the significant improvement that was achieved during the two-phase orthodontic treatment (Fig. 9.28a, b).

Similar results were observed from the occlusal point of view. A fixed retention wire was bonded from the right to the left canine to maintain the position of the upper anterior teeth (Fig. 9.29a, b).

A follow-up 30 months after the finalization of the active treatment showed that there was a little relapse in the anterior region, regarding overjet and overbite. A consultation with the speech therapist was recommended to improve the position of the tongue and certain swallowing habits in order to maintain the results in the vertical dimension (Fig. 9.30a, b).

Similar conclusions were observed after analyzing the right and left side. Class I canine and molar was perfectly

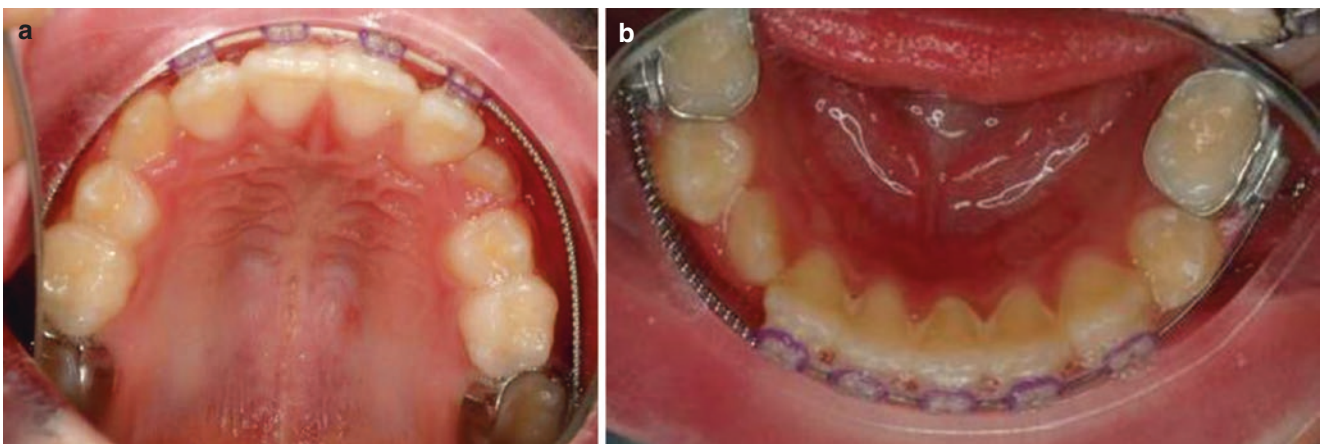


Fig. 9.23 (a, b) Upper and lower occlusal photographs. The second upper and lower temporary molars are still in place

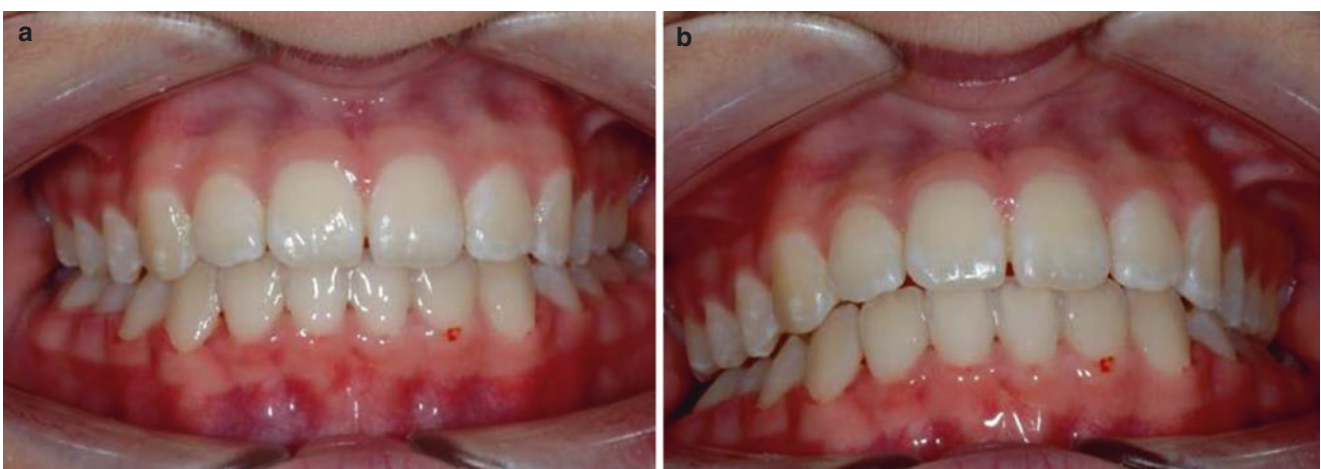


Fig. 9.24 (a, b) Frontal photographs at the end of the orthodontic active treatment. Midlines were almost coincident with overjet and overbite within normal ranges

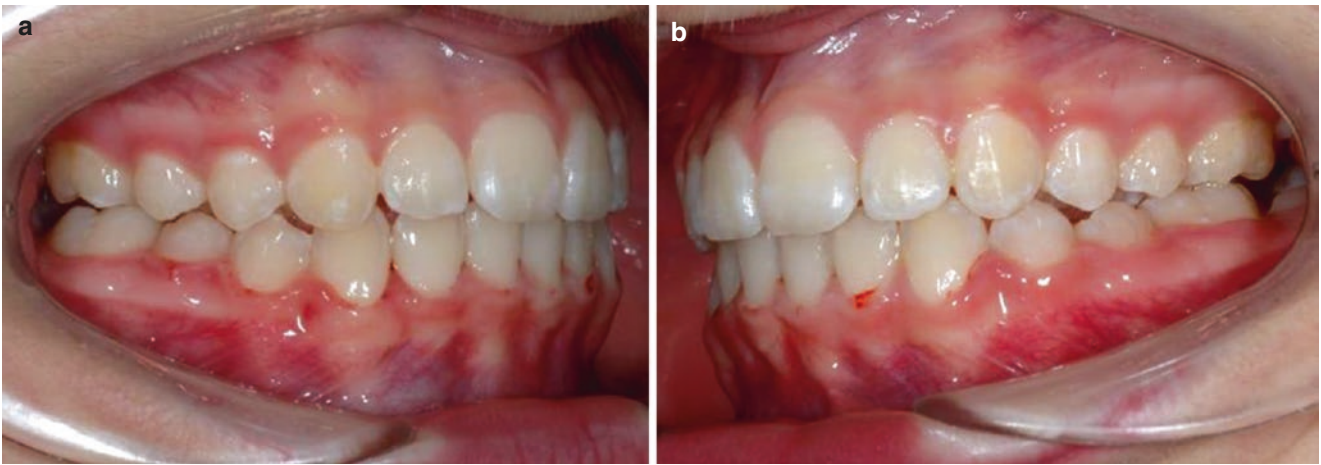


Fig. 9.25 (a, b) Lateral views at the end of the 2nd Phase of treatment

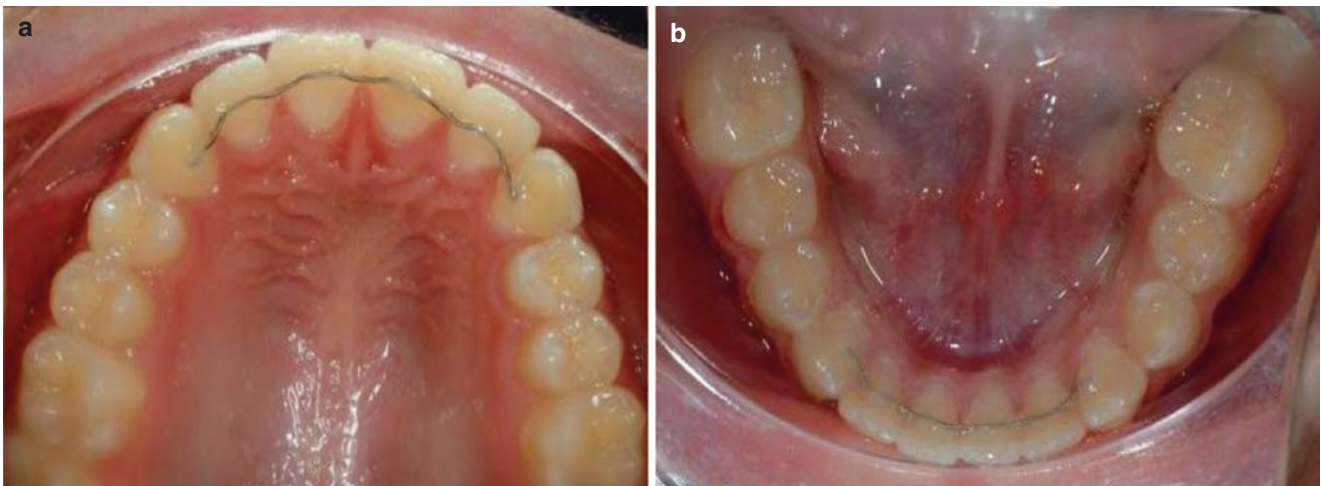


Fig. 9.26 (a, b) Upper and lower occlusal views with the retention wires bonded between upper and lower right and left canines

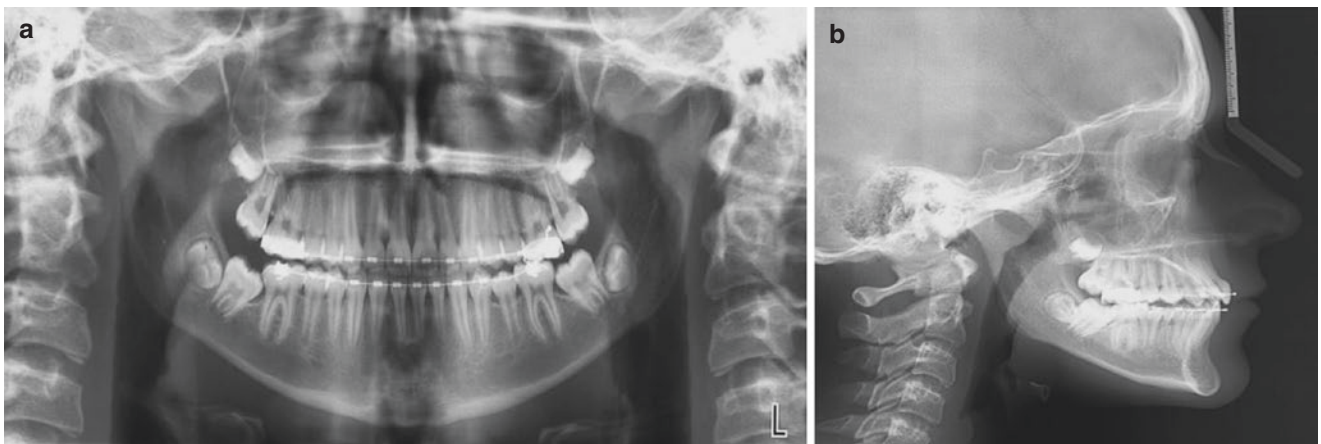


Fig. 9.27 (a, b) Panoramic and lateral radiograph at the end of the treatment

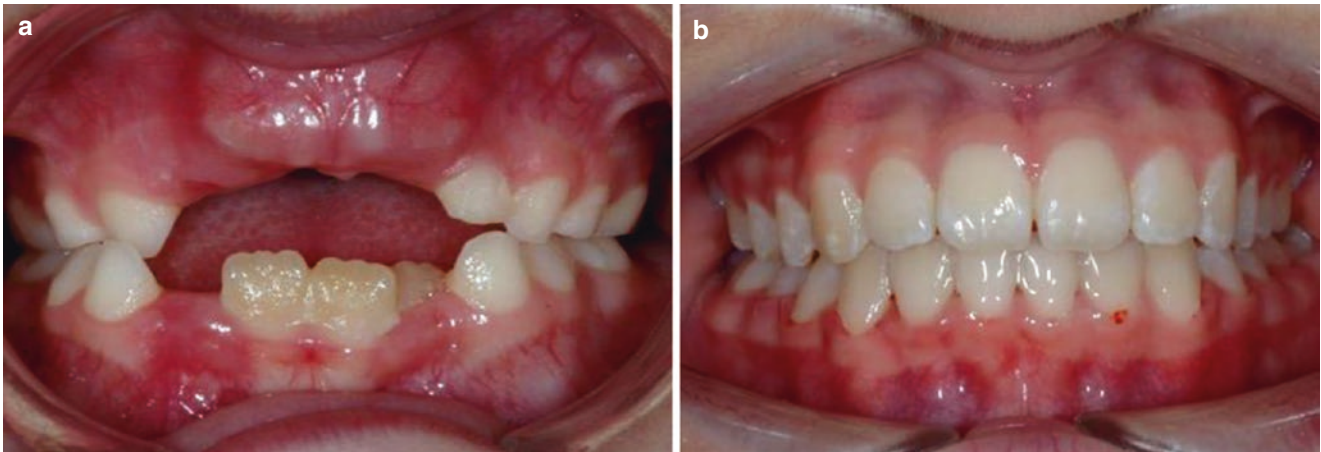


Fig. 9.28 (a, b) Comparison of the front photographs pre- and posttreatment. The improvement was noticeable. Overjet and overbite were normal. Occlusal and gingival lines were parallel

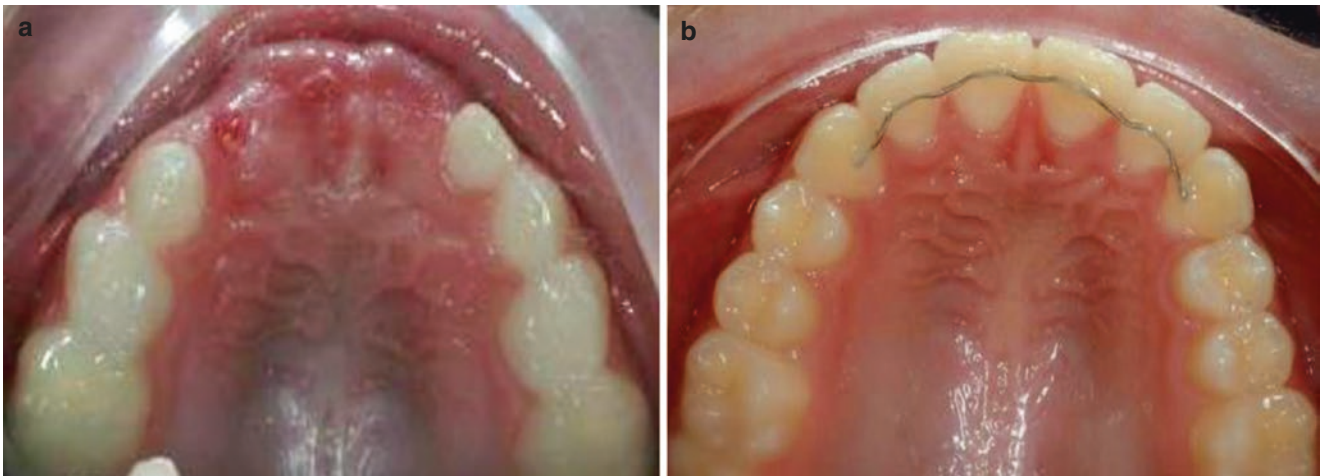


Fig. 9.29 (a, b) A significant change in the upper arch was evident. The final photograph showed the retention wire bonded between the canines

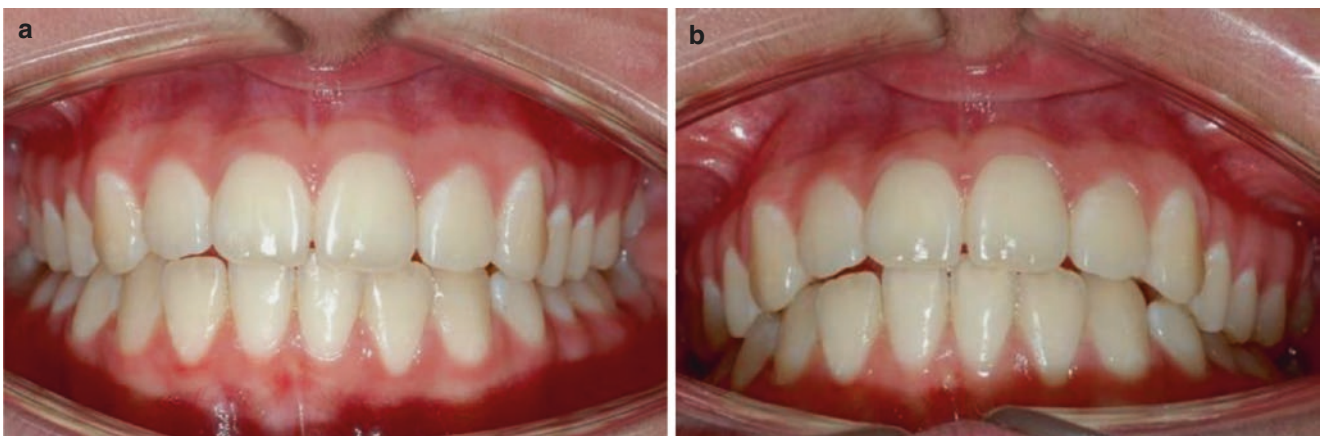


Fig. 9.30 (a, b) A slight relapse was visible in the anterior region during the 30-month follow-up. It was important that the patient continues to go to the speech therapist to control the anterior position of the tongue

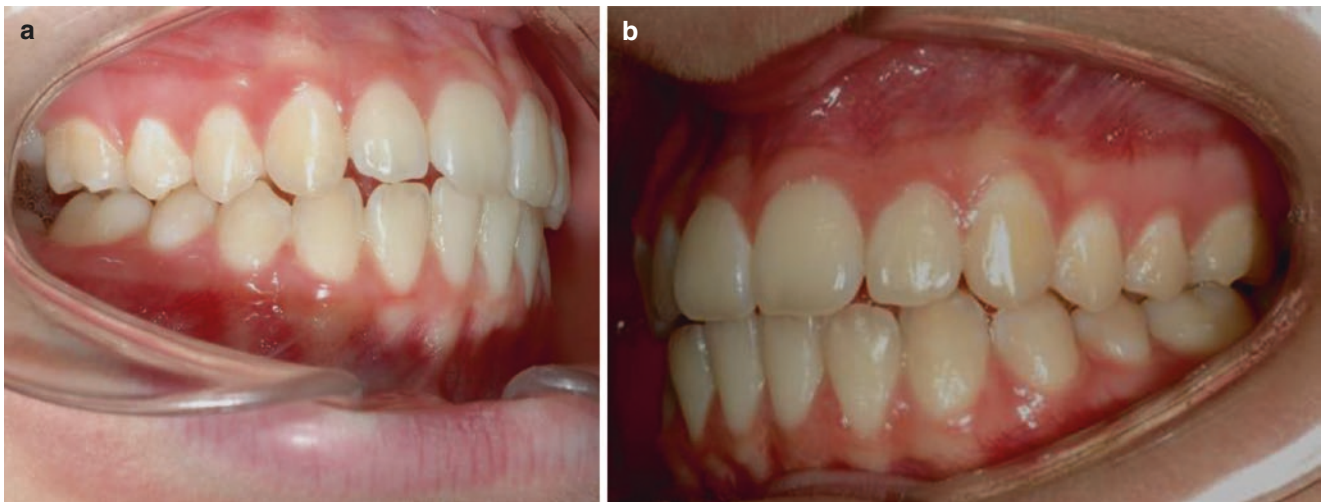


Fig. 9.31 (a, b) Lateral views confirmed a slight relapse in the anterior region

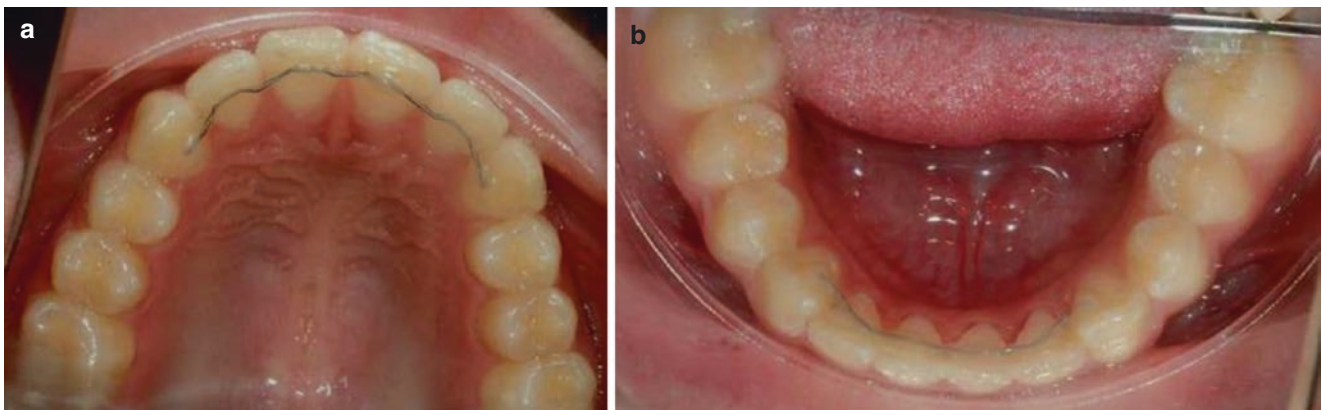


Fig. 9.32 (a, b) Occlusal photographs 30 months later with the retention wires in place

maintained, but slight changes were observed in the anterior region (Fig. 9.31a, b).

Fixed retention wires were placed and the upper and lower dental arch forms were maintained (Fig. 9.32a, b). The treatment objectives were fulfilled with a very conservative and efficient protocol.

To conclude, the best time to normalize the transverse width of the maxilla is during late primary or early mixed dentition. This procedure provides better and more stable results.

Conclusions

Rapid maxillary expansion performed in temporary or mixed dentition did not produce undesirable root resorption or side effects on the periodontal bone tissues (Garib et al. 2014) when the appliance was bonded on deciduous molars. Also, it protects the first permanent molars from undesirable side effects.

The use of a RME appliance is a procedure that was used to split the midpalatal suture and widen the dental arches. Its action has a more skeletal effect with less dental tipping than the removable ones.

Ideally it has to be used prior to the ossification of the midpalatal suture and long-term results are confirmed. Of course there is variability in the amount of changes according to the age, facial biotype, and etiology of the problem.

The protocol of activation has to be determined by the orthodontist, but during the early or late mixed dentition, two turns a day is the most commonly used.

Since there is a considerable correlation between the transverse, anteroposterior, and vertical discrepancies, the early normalization of the transverse dimension discrepancy is very important. It was widely demonstrated that maxillary arch constriction produces insufficient maxillary arch width causing anterior crowding and lack of the space for the canines (Bahreman 2013).

Rapid maxillary expansion is useful in correcting posterior crossbites, increasing arch length, facilitating class II and III correction, improving space for canine eruption, improving nasal breathing, and broadening the smile (McNamara and Brudon 2001; McNamara 2002; McNamara et al. 2015).

Different types of RME can be used, but to avoid caries or enamel decalcifications, it is preferable to use those without acrylic plates not only on the palatal tissues but also cemented on the occlusal surfaces of the molars.

This protocol creates optimal conditions for the normal growth of the craniofacial skeleton and helps to develop a normal stomatognathic system.

In general, no significant secondary effects were observed in patients in either gender.

Bibliography

- Adkins MD, Nanda RS, Cuurrier GF. Arch perimeter changes on rapid palatal expansion. *Am J Orthod Dentofacial Orthop.* 1990;97:194–9.
- Angell EC. Treatment of irregularities of the permanent or adult teeth. *Dent Cosmos.* 1860;1:540–4.
- Bahreman A. Early – age orthodontic treatment. Hanover Park: Quintessence Books; 2013.
- Da Silva Filho OG, Boas MC, Capelloza FL. Rapid maxillary expansion in the primary and mixed dentition: a cephalometric evaluation. *Am J Orthod Dentofacial Orthop.* 1991;100:171–9.
- Garib DG, Ockle Menezes MH, da Silva FG, Bittencourt Dutra dos Santos P. Immediate periodontal bone plate changes induced by rapid maxillary expansion in the early mixed dentition: CT findings. *Dental Press J Orthod.* 2014;19:36–43.
- Haas A. Palatal expansion. Just the beginning of dentofacial orthopedics. *Am J Orthod Dentofacial Orthop.* 1997;112:219–55.
- Hass A. Rapid expansion of the maxillary dental arch and the nasal cavity by opening the mid palatal suture. *Angle Orthod.* 1961; 31:73–90.
- Hass A. Treatment of the maxillary deficiency by opening the mid palatal suture. *Angle Orthod.* 1965;65:200–17.
- Hass A. Long term posttreatment evaluation of rapid palatal expansion. *Angle Orthod.* 1980;50:189–217.
- Lima Filho RM, de Oliveira Ruella AC. Long term maxillary changes in patients with skeletal Class II malocclusion treated with slow and rapid palatal expansion. *Am J Orthod Dentofacial Orthop.* 2008;134:383–8.
- McNamara Jr JA. Early intervention in the transverse dimension. Is it worth the effort? *Am J Orthod Dentofacial Orthop.* 2002;121(6): 572–4.
- McNamara JA Jr, Brudon WL. Orthodontic and dentofacial orthopedics. Ann Arbor: Needham Press; 2001.
- McNamara Jr JA, Lione R, Franchi L, Angelier F, Cevidanes L, Darendeliler A, Cozza P. The role of rapid maxillary expansion in the promotion of oral and general health. *Prog Orthod.* 2015; 16:33.
- Mutinelli S, Cozzani M, Manfredi M, Bee M, Siciliani G. Dental arch changes following rapid maxillary expansion. *Eur J Orthod.* 2008;30:469–76.
- Rosa M, Lucchi P, Mariani L, Captiogli A. Spontaneous correction of anterior crossbite by RME anchored on deciduous teeth in the early mixed dentition. *Eur J Paediatr Dent.* 2012;13:176–80.

How to Normalize the Position of the Maxillary Molar in Early and Late Mixed Dentition

10

Jose Cortes Bedon

It is well known that the anterior-posterior position of the upper first molar is crucial to achieve stable long term results.

The aim of this chapter is to describe the most reliable appliances to normalize the anteroposterior and transversal position of the first molar.

It is important to know the real etiology of the problem and in this way determine if it is the result of a dental or skeletal malocclusion or both.

The deviation path of eruption could be related to pre-eruptive disturbances like asymmetrical root resorption of the deciduous molars, pathological involvement of the deciduous root, cysts, or early extraction of the temporary molars.

Also, it could be combined with class I, II, or III facial biotypes.

The most common dental problems include ectopic molar eruption due to caries or premature extraction of the temporary molars. These situations are the easiest to normalize.

A panoramic radiograph is essential to determine if the mesialization affects only the crown or the whole molar. Figure 10.1a is a clear example of the mesio-inclination of the left upper molar, and observing Fig. 10.1b, the molar was totally mesialized.

In many cases, skeletal sagittal problems are present along with vertical malocclusions (deep bite or open bite malocclusion).

Facial biotype as well as the direction of growth plays an important role in class II patients when deciding the best biomechanics for each one.

Unfortunately, there isn't a single appliance that is adequate for all the patients alike, and excellent results can be achieved with any removable, fixed appliances or a combination both.

The final decision depends on the severity of the problem, the orthodontist, and the collaboration of the parents and the patient.

It is well accepted that the sooner the problem is detected, the easier it is to treat the problem.

To illustrate these concepts, three different alternatives will be described. The first patient is a clear example on how to solve this problem in a very easy and conservative way. When the panoramic radiograph was analyzed, the mesio-inclination of the left first upper molar as well as the inclusion of the second temporary molar was observed (Fig. 10.2).

For that reason, the transition between mixed and permanent dentition is critical when treating the mesial rotation or mesial inclination of the first maxillary molar to place it in its normal position.

As was demonstrated before, it isn't always necessary to bond brackets on all the teeth. A partial treatment to normalize the molar position is recommendable.

Brackets were bonded on the temporary canine and temporary upper first molar, along with a band on the first permanent left molar (Fig. 10.3a). To distalize and derotate the first molar, a SS 0.016" wire with an open close spring was placed (Fig. 10.3b).

A Rx follow-up 5 months later showed how the position of the molar was normalized (Fig. 10.4a). The upper left second molar continued its normal path of eruption. When the first upper bicuspid erupted, a bracket was bonded to maintain the space that was achieved (Fig. 10.4b).

The comparison between the pre and after 5 months in treatment clearly demonstrated the normalization of the first upper left molar and the recovery of the space for the second bicuspid (Fig. 10.5a, b) with a very simple and efficient protocol.

According to the diagnosis, a class II molar relationship is the result of the

mesialization of the upper molar with or without a skeletal problem, the retroposition of the mandible, or the combination of both.

J.C. Bedon

Department of Orthodontics, Maimonides University,
Buenos Aires, Argentina
e-mail: cortes2cortes@hotmail.com

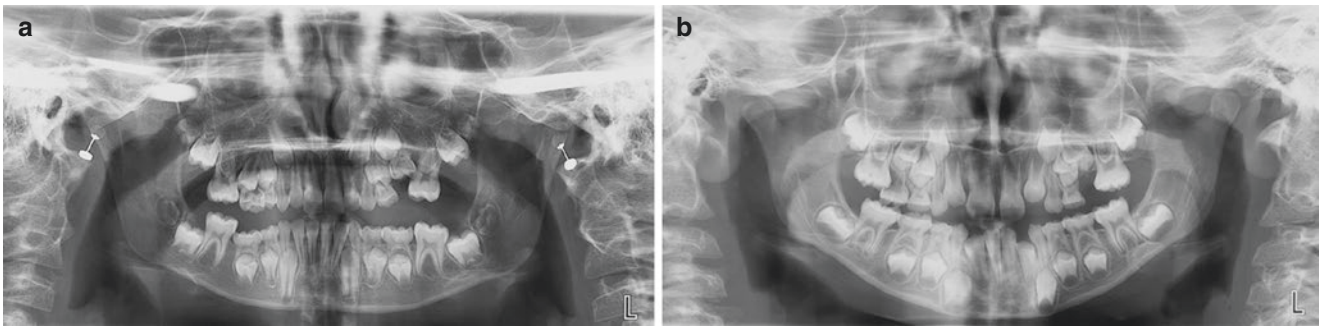


Fig. 10.1 (a, b) Panoramic radiographs with different types of molar mesialization and inclination

Fig. 10.2 A significant mesio-inclination of the left upper first molar and the inclusion of the second temporary was present

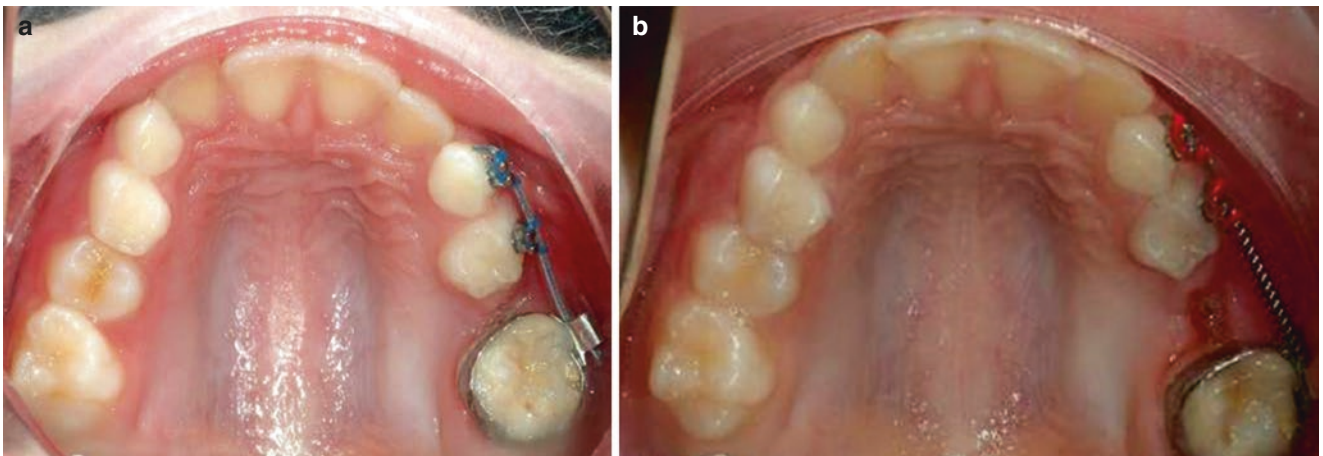
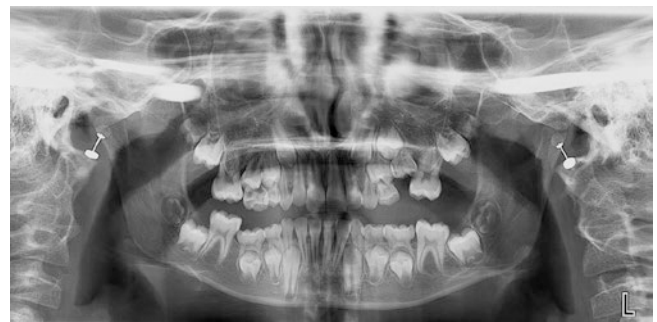

Fig. 10.3 (a, b) Brackets were placed on the canine and temporary molar, with a and on the first molar and an open close spring to normalize its position

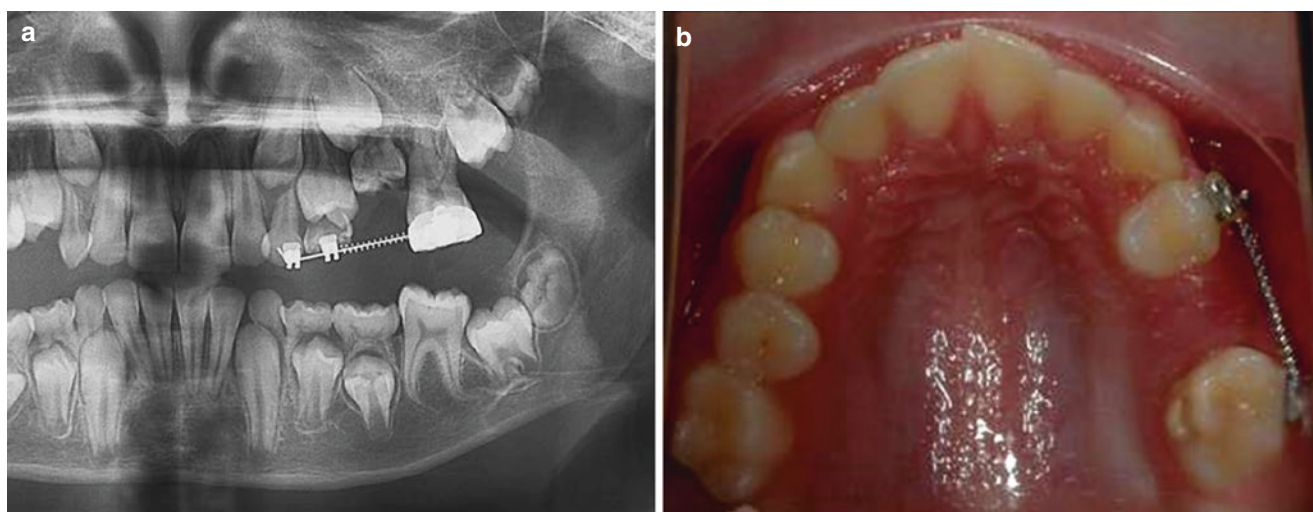


Fig. 10.4 (a, b) Panoramic radiograph after 5 months in treatment and occlusal photograph after the eruption of the first upper left bicuspid

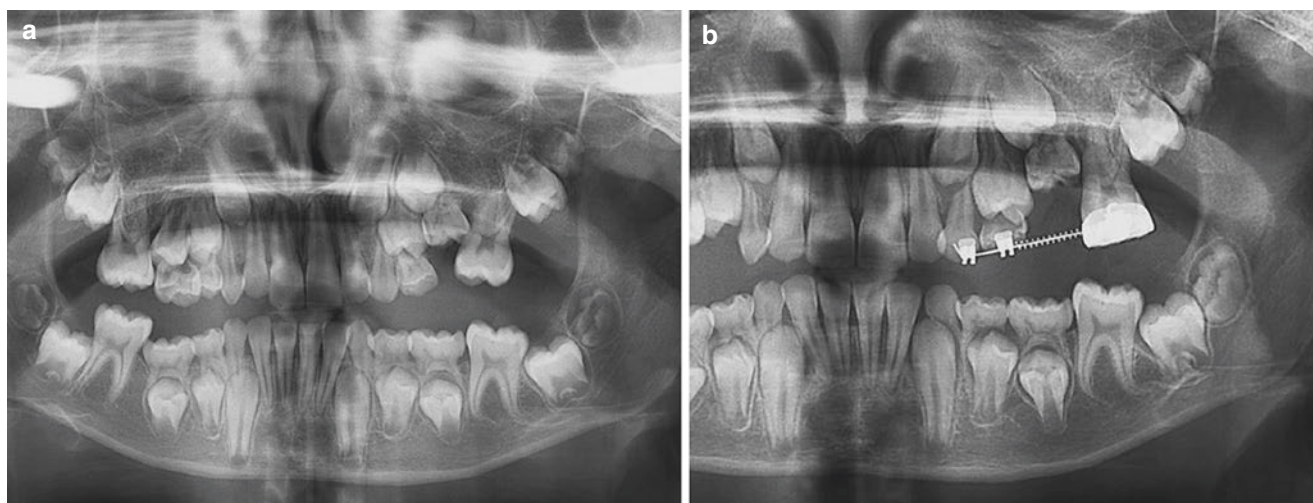


Fig. 10.5 (a, b) The comparison between the pre and after 5 months of active orthodontic treatment demonstrated the efficient results that were achieved

Regarding biomechanics, it is important to upright the molar first. To achieve this goal, the buccal tube has to be bonded parallel to the occlusal plane or slightly more mesio-inclined. After the molar is uprighted, it is easier to distalize it to the normal position.

To normalize the anteroposterior position of the first molar, an open coil spring, a headgear, or a pendulum is suggested.

The use of a cervical headgear is widely accepted. The following patient is a clear example of how this type of biomechanics is used. She was 11 years old when her first orthodontic consultation took place.

After careful diagnosis, the use of a cervical headgear was recommended to normalize the position of the first molar

(Fig. 10.6a, b). A significant protrusion of the incisors was visible.

Upon analyzing the lateral and occlusal photos, the mesialization and mesio-rotation of the right first molar was clearly visible. The patient had a meso-facial pattern, and her oral hygiene was fairly good.

Taking into account that the patient collaborated greatly and in order to normalize the inclination and mesio-rotation of the first molar, the use of a cervical headgear was indicated. It was recommended that the patient use it 12–14 h a day (Fig. 10.7a, b).

These were the results 14 months later. No brackets were bonded in the maxillary nor in the mandibular arch. Class I molar and canine were achieved (Fig. 10.8a, b).

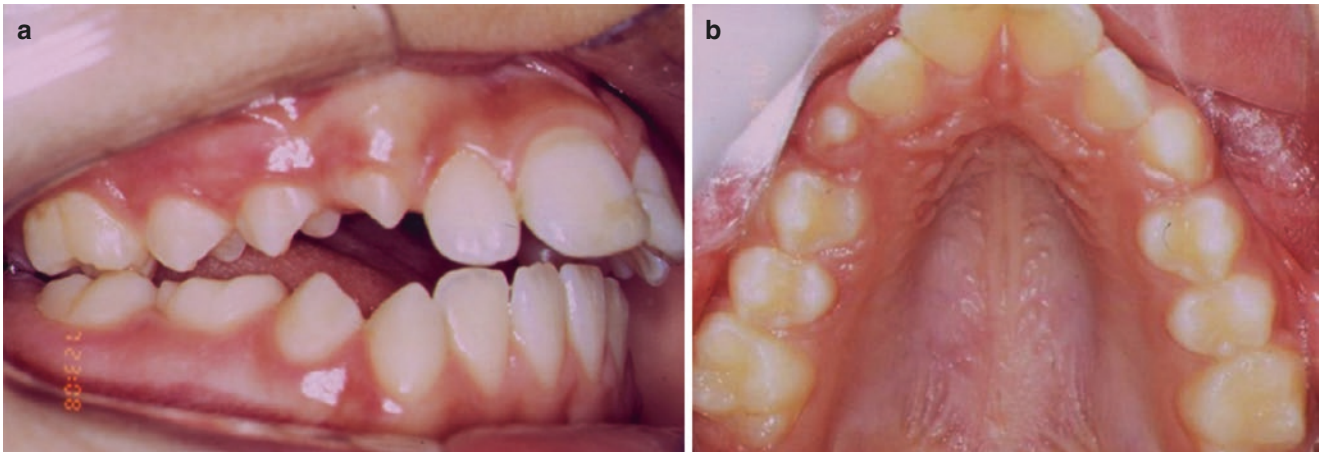


Fig. 10.6 (a, b) Pretreatment lateral and occlusal photographs. The mesio-inclination and mesio-rotation of the molar were noticeable with a mild compression in the bicuspid area

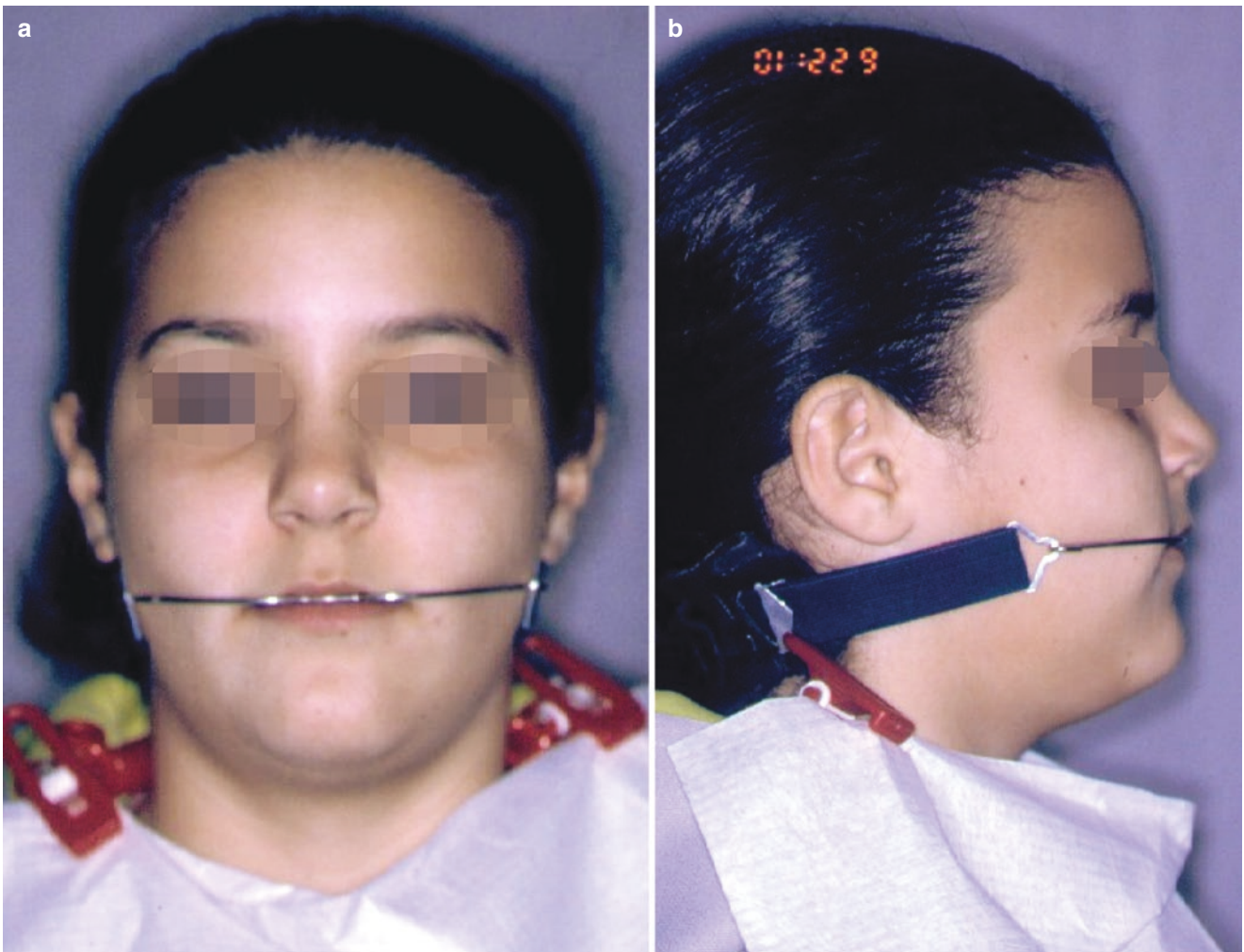

Fig. 10.7 (a, b) Frontal and lateral views with the cervical headgear in place

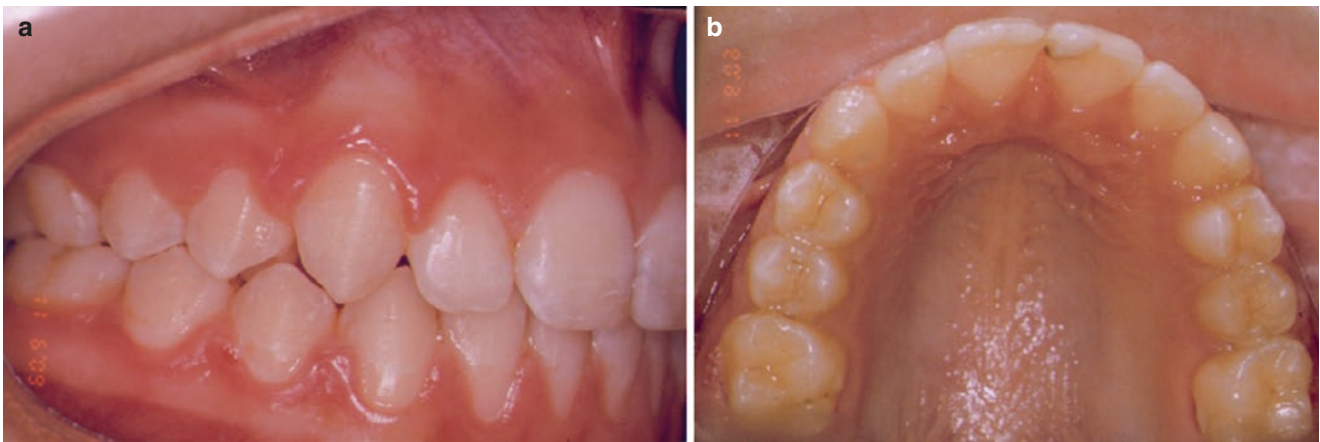


Fig. 10.8 (a, b) Lateral and occlusal photographs after 14 months in treatment. The normalization of the position of the first molar was evident

A follow-up of 2 years after finishing the treatment showed that class I molar relationship was maintained with normal overjet and overbite. (Fig. 10.9a, b). The efficacy of the cervical headgear when it is used correctly is unquestionable.

The 2-year posttreatment photographs confirmed that the facial biotype was maintained. The lips were relaxed and closed without tension (Fig. 10.10a, b).

In other patients, the use of a non-compliance appliance is highly recommended to normalize the first molar position (Hilgers 1993).

Among them the pendulum appliance is effective for the normalization of the sagittal position of the upper molars and the establishment of a class I molar relationship in a short period of time. However, strict control is needed to monitor collateral effects (Fuziy et al. 2006).

During the first phase, the normalization of the position of the first molar is the goal that needs to be achieved, and during the second phase, final orthodontic movements are required to complete the treatment.

It is advisable to control the distal inclination of the molars carefully to avoid excessive tipping. Overcorrection is recommended because slight relapse could be expected. The best time to begin the normalization of the position of the first molars is as soon as possible in order to recover the space for the eruption of the bicuspid and canine.

The appliance includes an acrylic palatal button with or without a central screw.

It is recommendable for the posterior springs to be removable and made of 0.032" TMA wire (Fig. 10.11a, b). To maintain the appliance in place, two SS wires are bonded to the occlusal surfaces of the first and second bicuspid.

This design allows adjustments to be made very easily and directly in the mouth.

The following photos showed the first day the pendulum was bonded in a 9-year, 9-month-old patient. Class II molar

was confirmed. A utility arch was placed on the lower arch to level the occlusal plane (Fig. 10.12a, b).

These were the improvements after 3 months in treatment with only an initial intraoral activation of 45° in the posterior springs (Fig. 10.13a, b).

The distalization of the molar was clearly observed.

When the first molars are overcorrected, it is advisable to cut the SS wires that are bonded on the second temporary molars.

The occlusal and left lateral photos confirmed that the upper second bicuspid erupted distally. The lateral view showed the improvement of the position of the upper right and left first molars and second bicuspid (Fig. 10.14a, b).

A bracket and a palatal button were bonded on the second bicuspid to complete their distalization (Fig. 10.15a, b).

A three-dimensional control of the molars is mandatory to diminish unwanted inclination.

Another important issue is how to maintain the molar in the new position until the bicuspid and canines complete their eruption process. An extended Nance button with a transpalatal bar has to be bonded the same day the pendulum is removed (Fig. 10.16a, b).

To continue the orthodontic treatment, esthetic pre-programmed brackets 0.022" were bonded on the upper arch. Meanwhile, metallic brackets were placed in the lower arch to complete phase II treatment (Fig. 10.17a, b).

These were the results 7 months later. The total time of treatment was 25 months.

Class I molar and canine were achieved with a non-compliance appliance.

To maintain the results, anterior upper and lower fixed retention wires were bonded for long period of time (Fig. 10.18a, b).

A follow-up 3 years later showed that the results were maintained with class I molar and canine and overjet and overbite within the normal limits. Gingival line and occlusal plane were parallel (Fig. 10.19a, b).

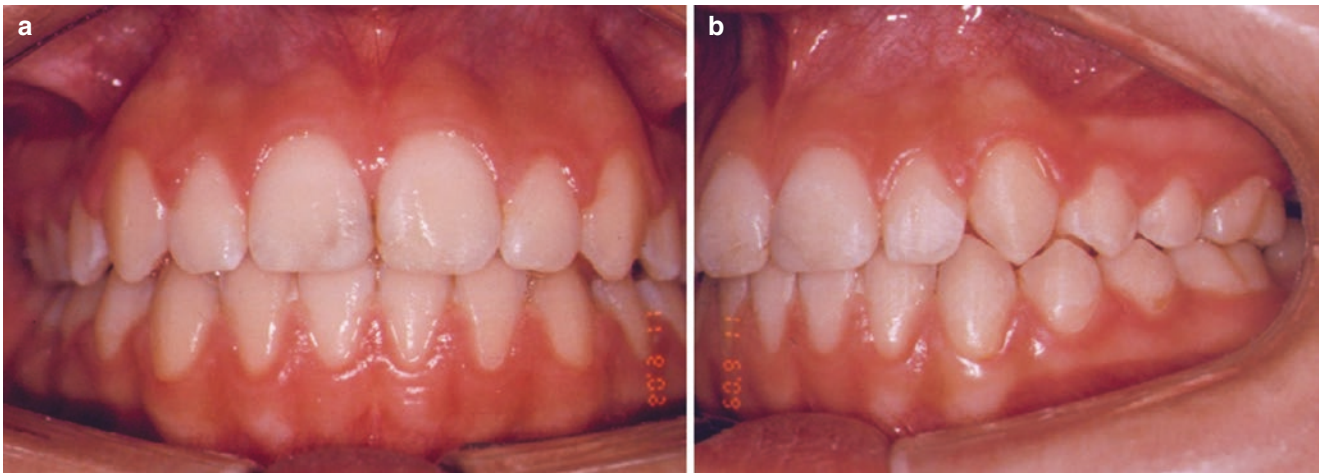


Fig. 10.9 (a, b) Follow-up 2 years later class I molar was maintained with normal overjet and overbite

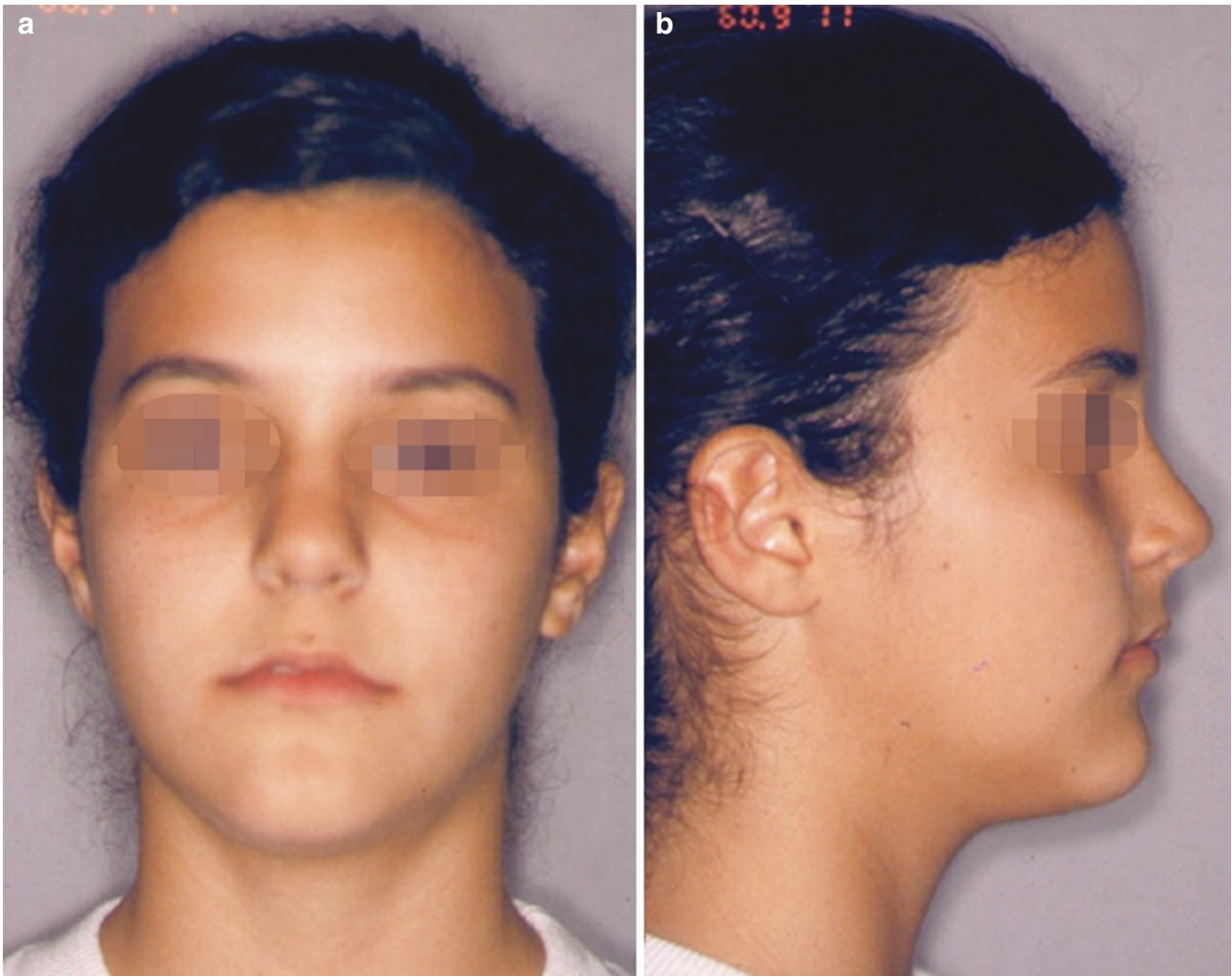

Fig. 10.10 (a, b) Frontal and profile photographs of a 2-year follow-up

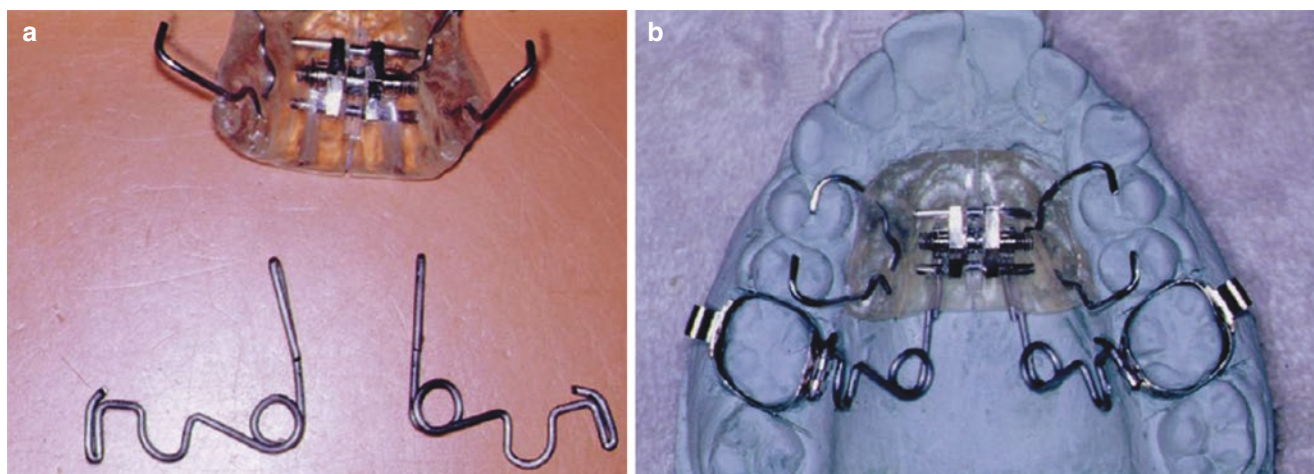


Fig. 10.11 (a, b) Parts of the pendulum appliance. Removable 0.032" TMA posterior springs with SS wires bonded on the bicuspids were designed

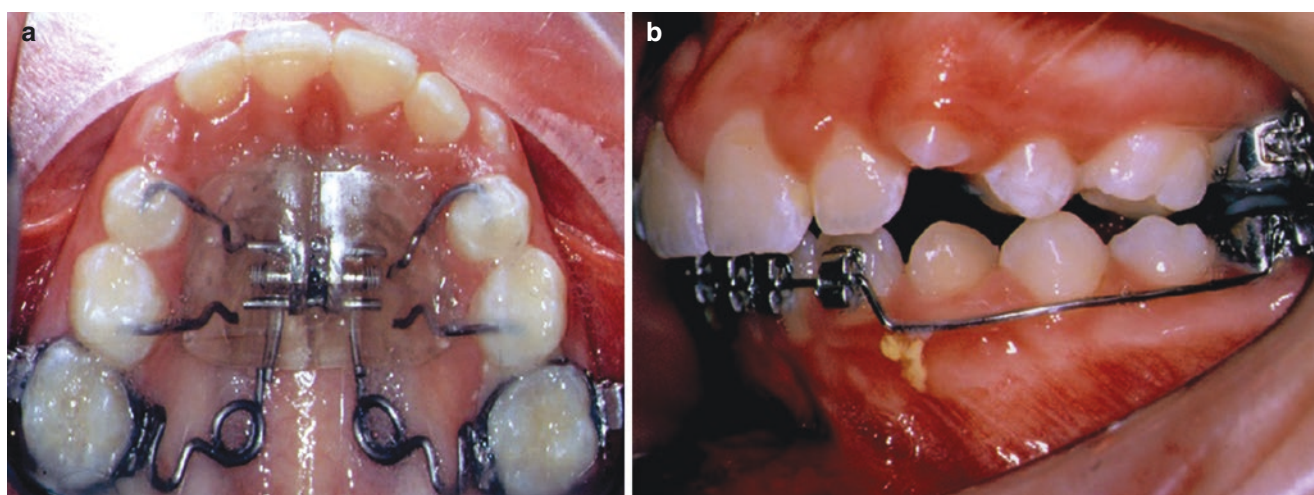


Fig. 10.12 (a, b) Occlusal and lateral view at the beginning of the treatment

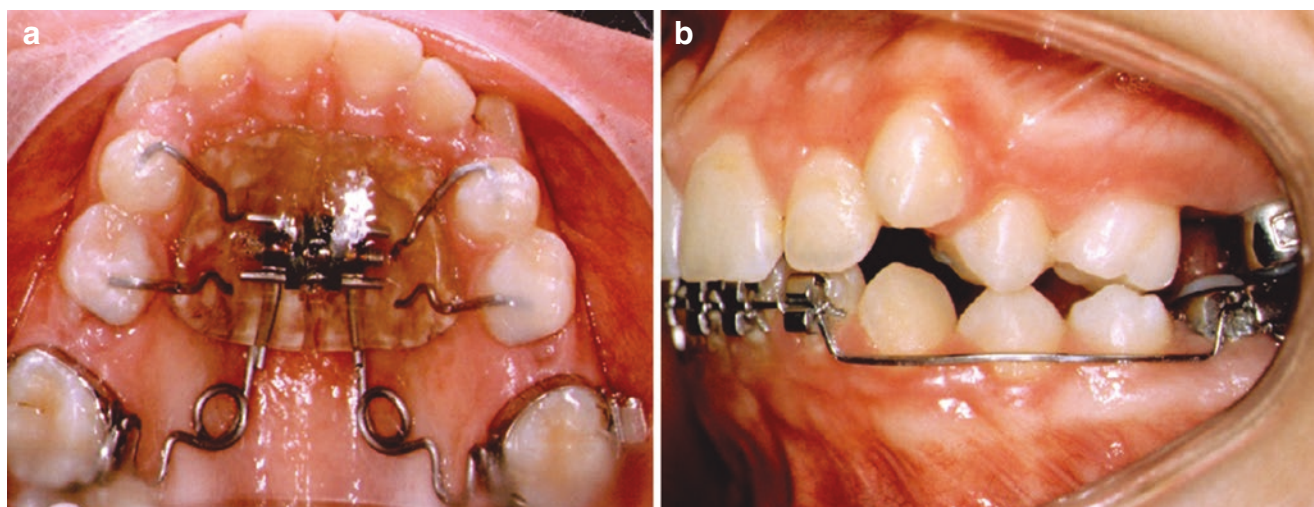


Fig. 10.13 (a, b) Three months later, nearly 3 mm of distalization of the first molars was observed with only an initial 45° activation in the posterior springs

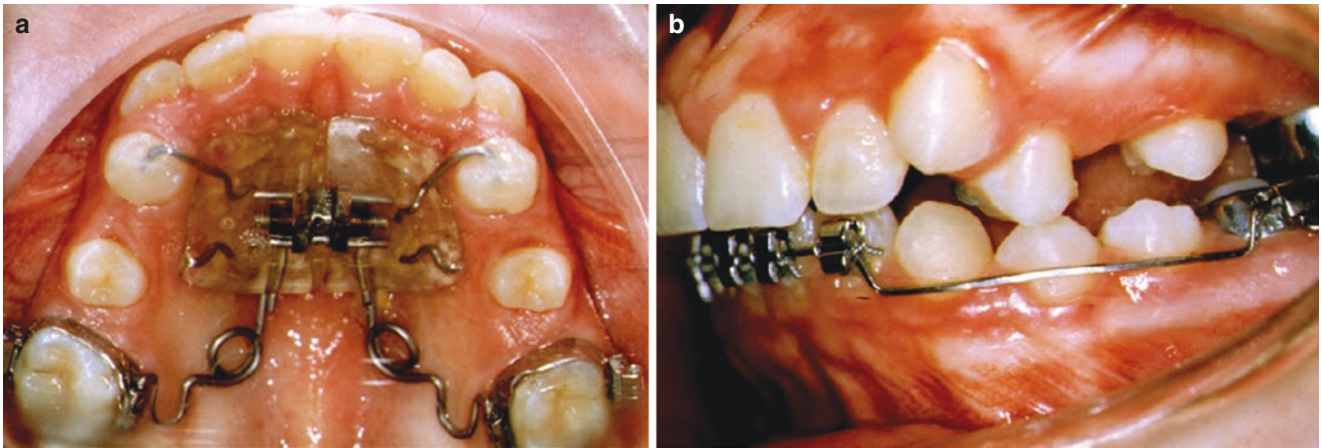


Fig. 10.14 (a, b) Occlusal and lateral view after 6 months in treatment. The second bicuspids erupted distally

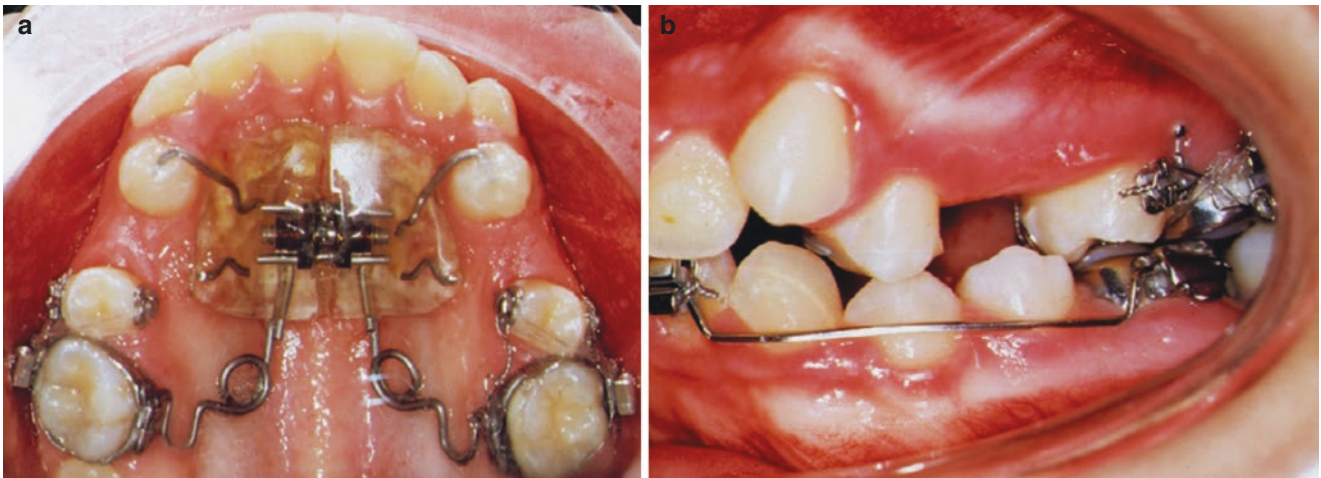


Fig. 10.15 (a, b) The second bicuspids were totally distalized

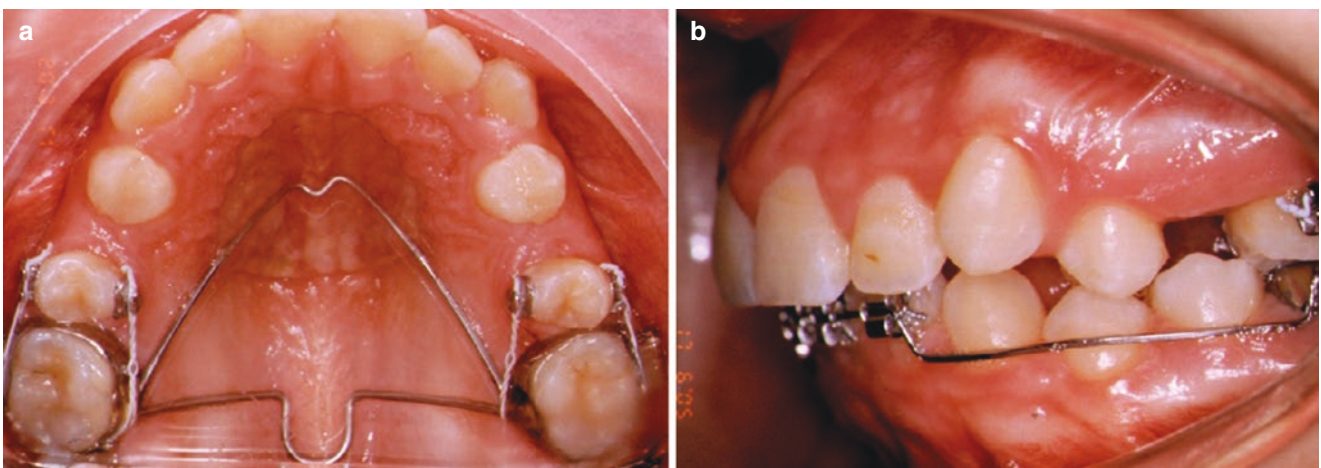


Fig. 10.16 (a, b) A Nance button with a transpalatal bar was bonded to maintain the new position of the upper right and left first molars

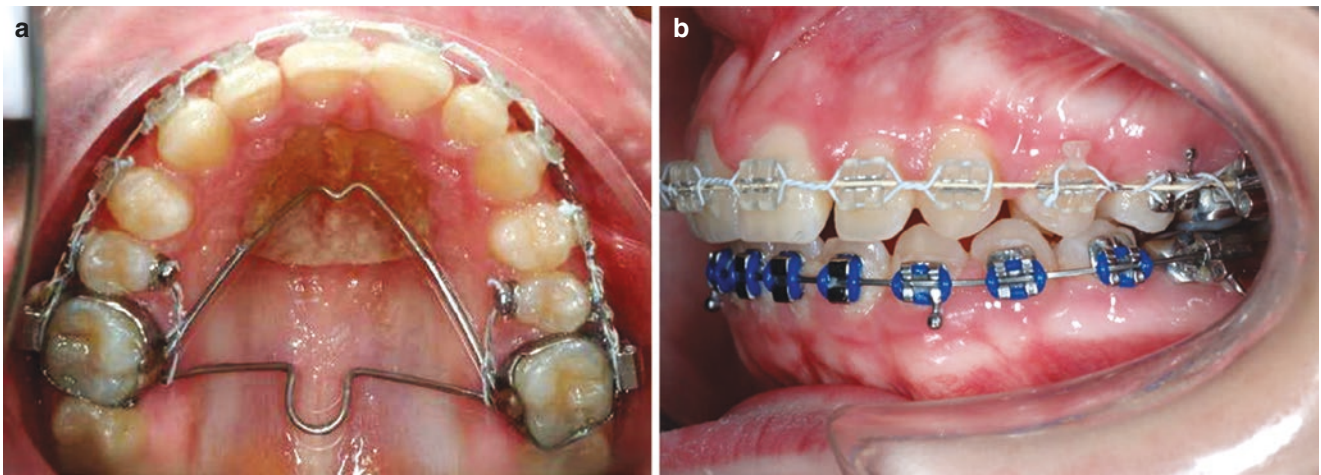


Fig. 10.17 (a, b) Occlusal and left lateral view at the end of phase II treatment

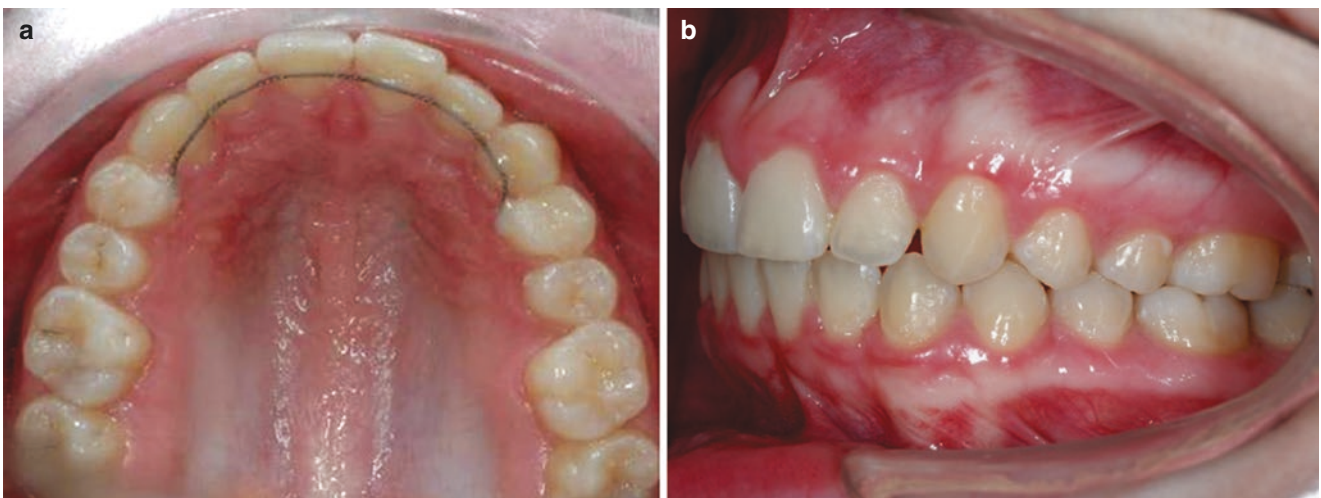


Fig. 10.18 (a, b) Final results at the end of the active orthodontic treatment class I canine and molar were normalized

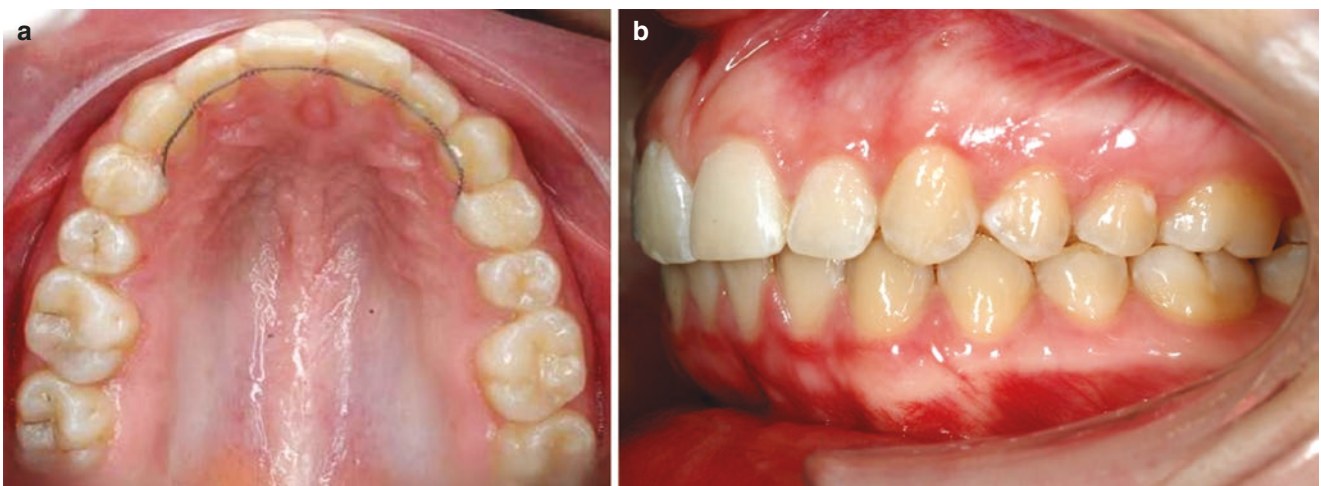


Fig. 10.19 (a, b) Follow-up 3 years later. All the results were maintained with normal overjet and overbite

When the pre- and posttreatment results using a non-compliance appliance were compared, the normalization of the position of the canine first molar was evident (Fig. 10.20a, b).

The normalization of the position of the upper first molars was clearly visible when pre- and posttreatment panoramic radiographs were compared.

As was shown in the last clinical case, the pendulum is a very effective non-compliance appliance to normalize the position of the molars in late mixed dentition (Bussik and McNamara 2000). Similar results can be achieved with other biomechanics, but the importance of the pendulum appliance is that it doesn't require the compliance of the patient.

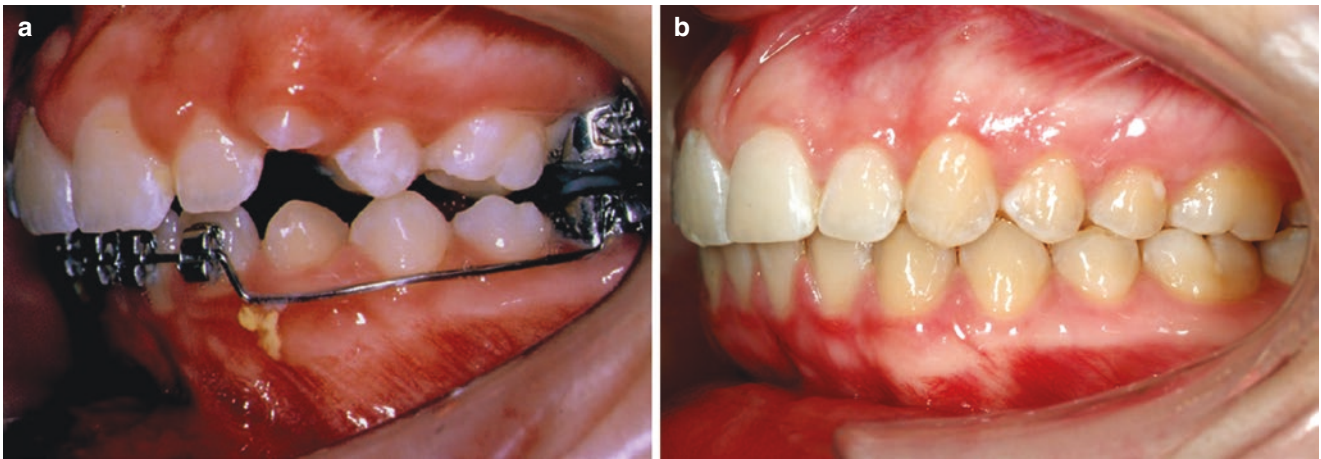


Fig. 10.20 (a, b) Comparison of pre- and 3-year posttreatment

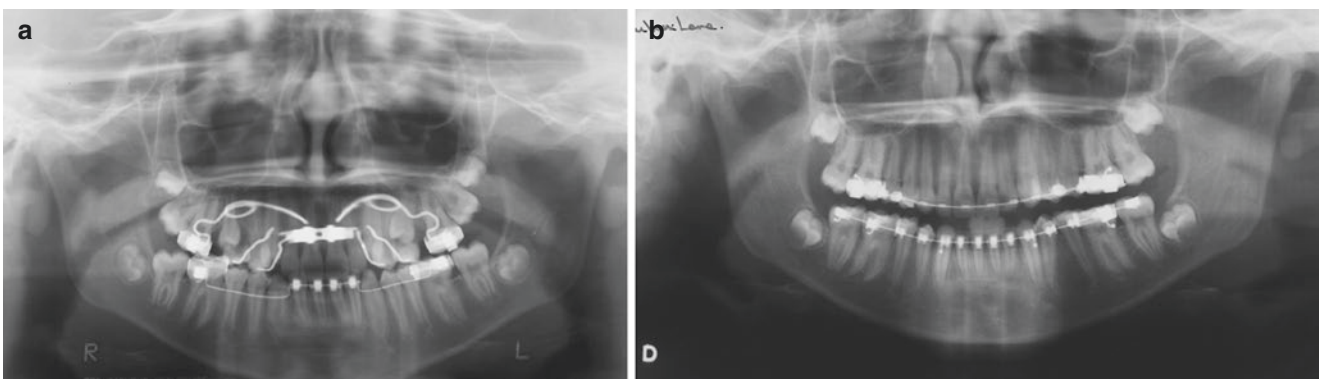


Fig. 10.21 (a, b) The upper second molars were erupted in their normal position

Conclusions

The recovery of the first molar position and inclination is a real challenge and represents the gold standard at the end of the orthodontic treatment, especially when the patients are in the late mixed or early permanent dentition.

Correct diagnosis and timing are key for successful and stable results.

Unfortunately, there isn't a single bracket or a type of wire that can achieve class I molar, but a detailed plan is necessary to reach the treatment objectives.

Each patient must be evaluated individually as well as his or her treatment protocol to achieve the best results.

It is important to take into consideration that if class I molar is achieved during phase I of treatment, the second

phase will be easier and excellent results will be obtained in a less time.

Bibliography

- Bussick TJ, McNamara JA. Dentoalveolar and skeletal changes associated with the pendulum appliance. *AJODO*. 2000;117:333–43.
- Fuziy A, Rodriguez de Almeida R, Janson G, Angelieri F, Pinzan A. Sagittal, vertical and transverse changes consequent to maxillary molar distalization with the pendulum appliance. *AJODO*. 2006;130:502–10.
- Hilgers JJ. The pendulum appliance. An updated. *Clin Impressions*. 1993;1:5–7.
- Hilgers JJ, Bennet RK. The pendulum appliance Part II maintaining the gain. *Clin Impressions*. 1994;3:5–9.

Julia Harfin

Symmetry of the face is one of the most important goals in orthodontic treatment.

The smile involves not only the teeth but also the soft tissues around them. This is very important during the diagnosis process and treatment planning procedures since patients view themselves from the frontal perspective and no coincidence of midlines is very evident.

Treatment strategies include growth modification and occlusal guidance. They have to be applied in growing children during primary or mixed dentition to minimize dentoalveolar and skeletal disharmonies that can affect normal growth.

Facial symmetry means balance throughout all the structures of the face. There is a very thin line to determine when asymmetry really begins.

A thorough diagnosis is the basis for success. A detailed medical and dental history along with radiographs and functional studies that help to determine the real reason of the asymmetry are important.

The digital panoramic radiograph is very useful to determine bone and dental discrepancies between the right and left structures. A midsagittal reference plan is also useful to determine not only the quantity but also the place of the discrepancies.

Normally there are differences between the right and left side of the face. Unfortunately there is not a critical number or measurement that can delimit it and is often determined “by the clinician’s sense of balance and the patient’s perception of the imbalance” (Bishara 2001).

Asymmetries can be classified in dental, skeletal, functional, or a combination of all of them. Soft tissues play an important role since they can make asymmetries more evident or, contrary to this, hide them (Fig. 11.1a, b). It is

important to remember that abnormal muscle function often results in skeletal and dental deviations, and the younger the patient, the easier the normalization becomes.

Etiology could be multifactorial. The genetic factors involve craniofacial syndromes as cleft palate, hemifacial microsomies, craniocleidynostosis, ankylosis, facial clefts, etc., as was shown in the following photographs (Fig. 11.2a, b).

The following patient had an important left deviation due to a fibrous ankylosis of the same side. She also showed a limited mouth opening, only 29 mm instead of 40 mm, as the norm indicates. Unilateral condyle ankylosis affects normal growth at one side in conjunction with a facial asymmetry due to deficient growth on the affected side (Fig. 11.3a, b).

Significant differences were seen when skeletal or dental asymmetries were analyzed. Skeletal asymmetries may involve the maxilla, the mandible, or both and can be accompanied with muscular or functional imbalances (McNamara 2002). Dental asymmetries can be caused by proximal caries, loss of temporary molars, agenecias, discrepancies in the mesiodistal size of the anterior teeth, compression of the upper arch with molars in crossbite position, etc.

Both types of asymmetries can cause uni- or bilateral posterior dental or skeletal crossbite. Posterior crossbite is one of the most prevalent malocclusions in the primary and early mixed dentition and is reported to occur in 8–22% of the cases (Kutin and Hawes 1969 and Egermark Eriksson et al. 1990). The functional factors most frequently found are premature contacts that deviate the path of occlusion when the patient closes in central occlusion.

Diagnosis is the most important stage to determine the correct treatment plan. In general some patients in early mixed dentition have a shifted midline in addition to a unilateral crossbite when they bite in central occlusion. However, when the patient is in central relation, the occlusion changes completely: midlines coincide and the crossbite is bilateral (Fig. 11.4a, b).

These functional deviations may be caused by a narrow maxilla or an upper or lower tooth in a malposition that

J. Harfin
 Department of Orthodontics, Maimonides University,
 Buenos Aires, Argentina
 e-mail: harfinjulia@gmail.com

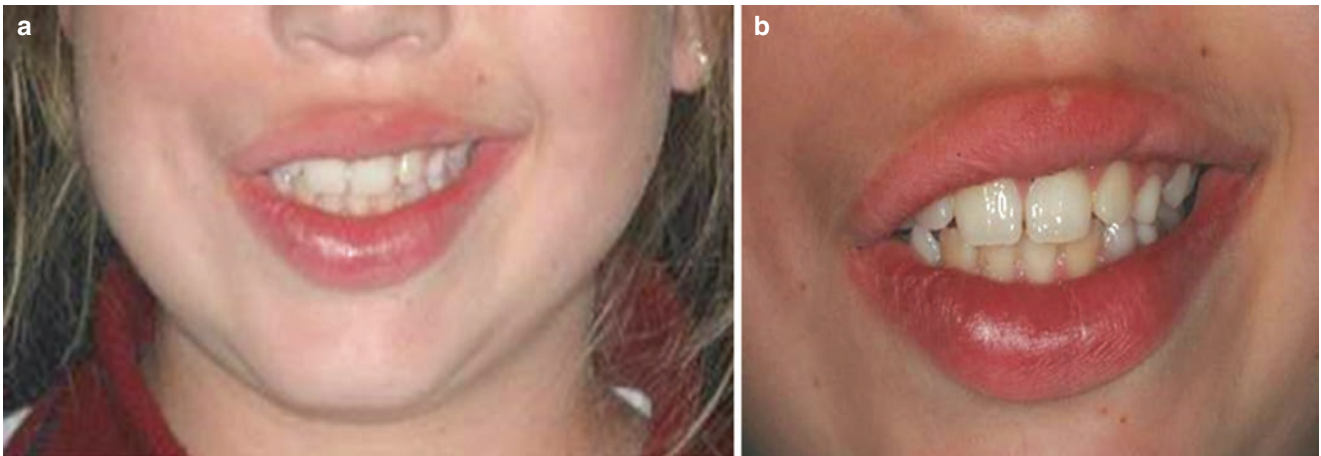


Fig. 11.1 (a, b) Patient with an asymmetric smile due to temporary paralysis after a car accident and fracture of the left ramus

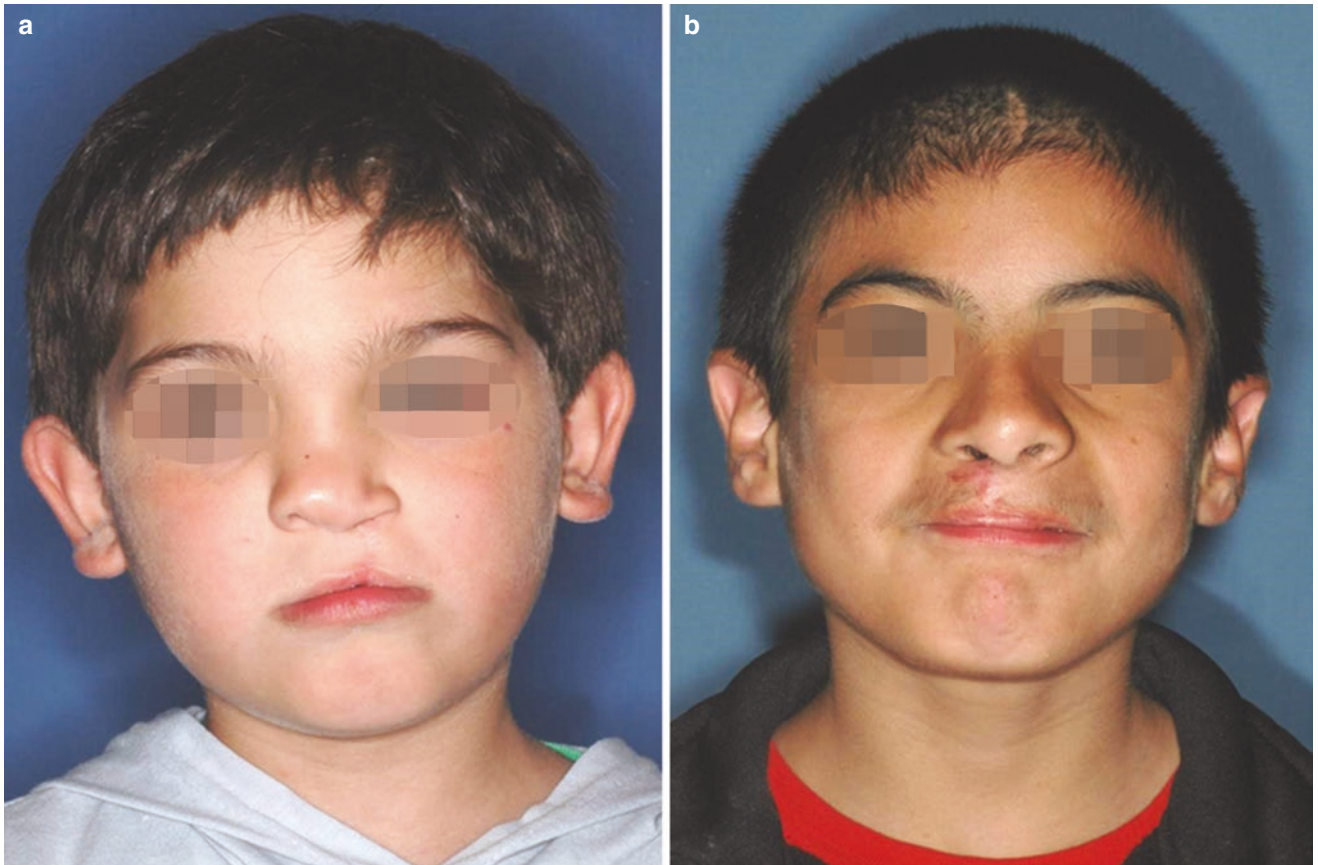

Fig. 11.2 (a, b) Cleft lip and palate patients. The facial asymmetry in the middle and lower third of the face is evident

produces an abnormal initial tooth contact and a midline deviation in centric occlusion as a consequence.

Treatment mechanics are chosen in correlation with a correct diagnosis and treatment plan. Some clinical cases need asymmetric mechanics, while with others, surgery is the best option.

The following patient clearly demonstrates this.

This 8-year and 6-month-old patient was sent to the office by her family dentist to correct the posterior right crossbite. No TMJ problems were present until this moment (Fig. 11.5a, b).

These crossbites develop early and are not self-correcting. Some of the suggested etiologic factors in crossbite

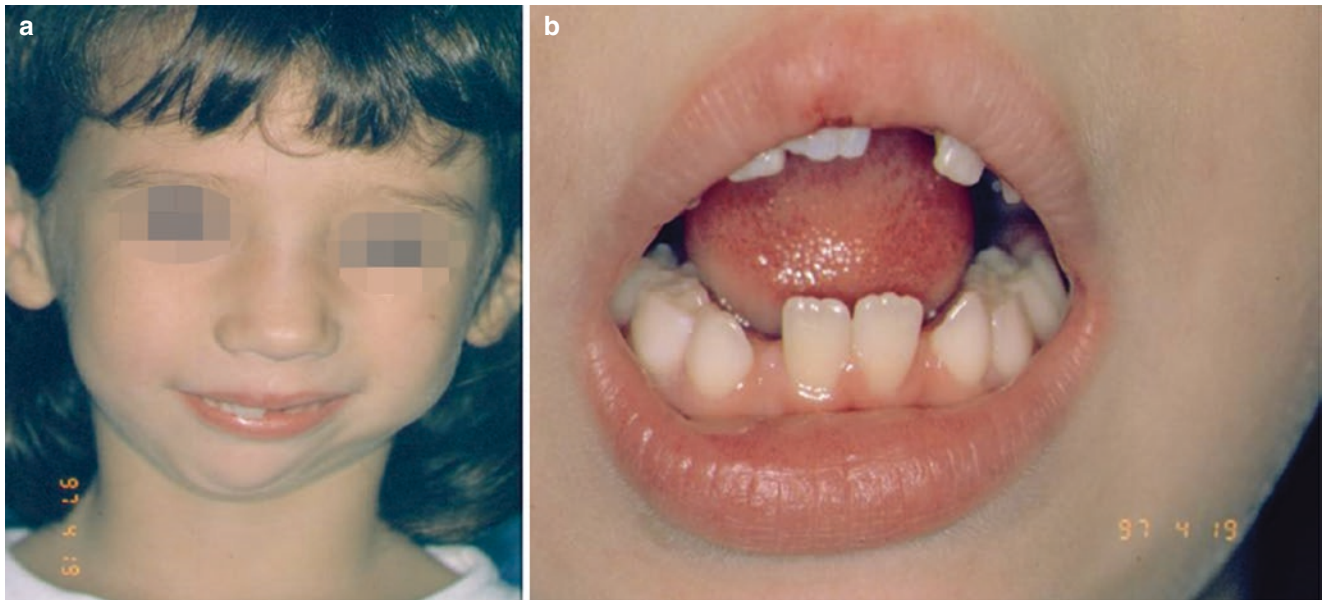


Fig. 11.3 (a, b) Facial asymmetry due to condyle ankylosis

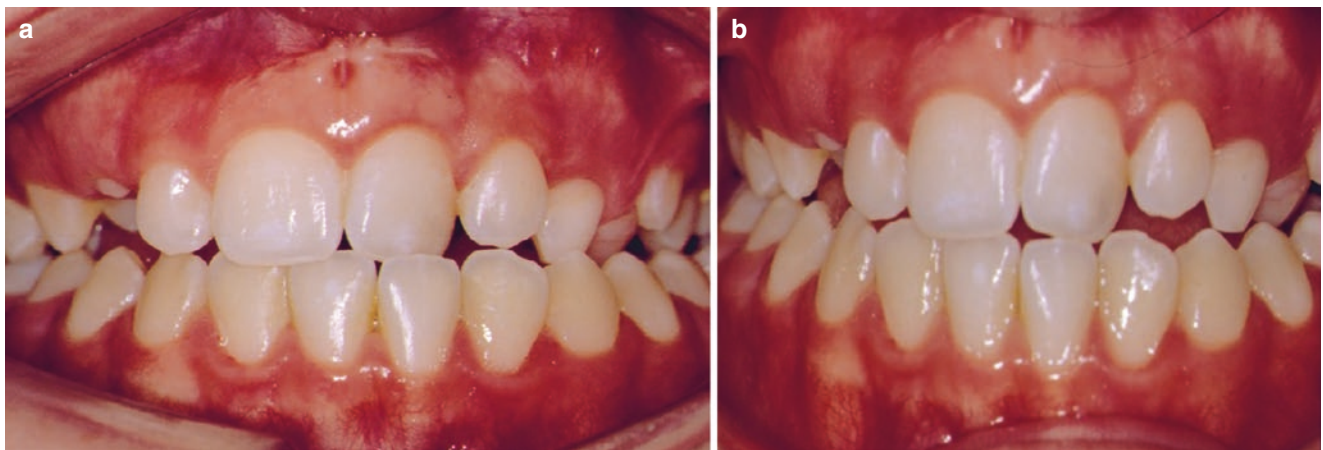


Fig. 11.4 (a, b) Patient with a functional deviation. The centric occlusion and centric relation occlusion are quite different. Midlines are coincident in centric relation

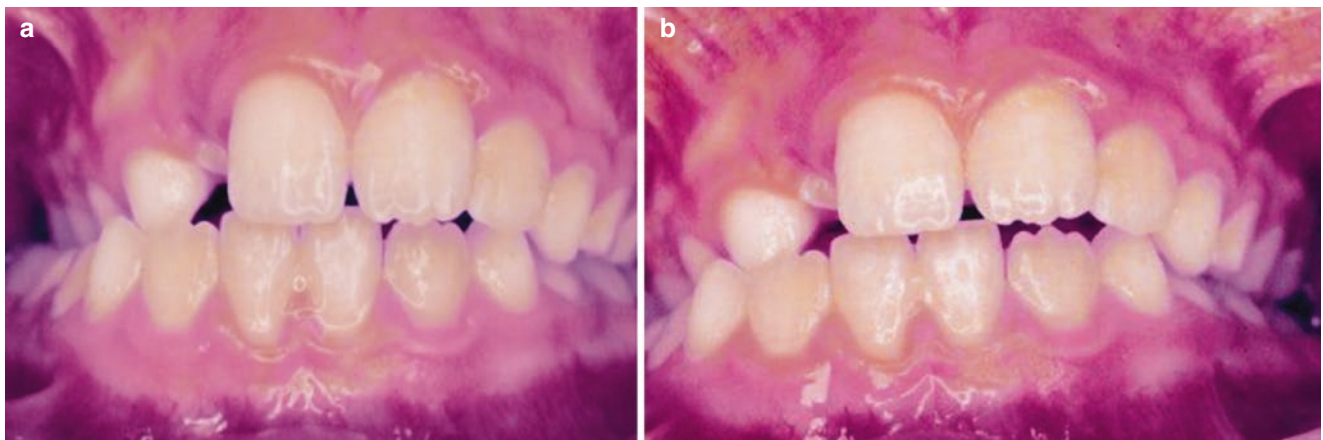


Fig. 11.5 (a, b) Front dental photographs in central occlusion (a) and in central relation (b)

include prolonged retention of deciduous teeth, crowding, premature loss of the deciduous teeth, arch deficiencies, etc.

The first issue is to attain a correct diagnosis to identify the real problem. When the lateral crossbite is accomplished with a midline deviation, a diagnosis in centric relation is mandatory to determine if the patient has a skeletal asymmetry or if it is a posterior crossbite with a functional shift.

The treatment and retention plan would be completely different in each case.

The lateral photos showed that the first and second temporary molars as well as the permanent first molar were in a complete crossbite position on the right side and “normal” occlusion on the left side with fairly good oral hygiene (Fig. 11.6a, b).

However, when the patient was in centric relation, the occlusion changed dramatically. Now midlines were coincident, and an anterior and lateral open bite was present. The sole contact point was between the left upper and lower temporary canines (Fig. 11.7a, b).

The treatment plan was grinding the cuspids of the left upper and lower canines until centric occlusion and centric relation were coincident.

In general, unilateral posterior crossbite is due to an asymmetric mandibular shift from OC to RC. The mandible is usually symmetric but markedly positioned asymmetrical. However, if this position were not correct, a skeletal asymmetry would be the result (Fig. 11.8a, b).

The midline was typically deviated to the crossbite side, and the patient had Class III on one side and Class II on the other, but in centric relation midlines were coincident.

Due to the fact that neuromuscular guidance of the mandible is generated by the central nervous system, as soon as it is diagnosed, it helps prevent the asymmetrical positioning and growth of the condyles.

It was demonstrated that children with posterior crossbite can have reduced bite force and asymmetrical muscle function where the anterior temporalis is more active and the masseter less active on the crossbite side. Moreover, there is a significant association between crossbite and TMJ problems (da Silva Andrade et al. 2008).

The patient returned when she was 14 years old without having had any other orthodontic treatment. Midlines were centered, and the occlusion was almost normal but with a reduced overjet and overbite. A second phase of orthodontic treatment was suggested, but the patient refused it (Fig. 11.9a, b).

After analyzing right and left dental photographs, normal Class I canine and molar relationship was confirmed without any other orthodontic treatment (Fig. 11.10a, b).

The comparison between the pre- and postfrontal photographs clearly demonstrated that the treatment objectives were achieved with a very simple and conservative protocol (Fig. 11.11a, b).

As always, diagnosis is the most important tool to identify these asymmetries and to differentiate between the dental, dentoalveolar, or skeletal cause (Burstone 1998).

Also, an overall evaluation of the skeletal and facial pattern of the patient is necessary to complete the final treatment and retention plan.

Early normalization is very important because it is very difficult to achieve spontaneous correction, and posterior crossbite could be transferred from primary to permanent dentition, with long-term effects on the growth and development of the stomatognathic system.

The condyles on the crossbite side are positioned relatively more superiorly and posteriorly in the glenoid fossa than those on the noncrossbite side, and this position has a great influence on the development of the mandible.

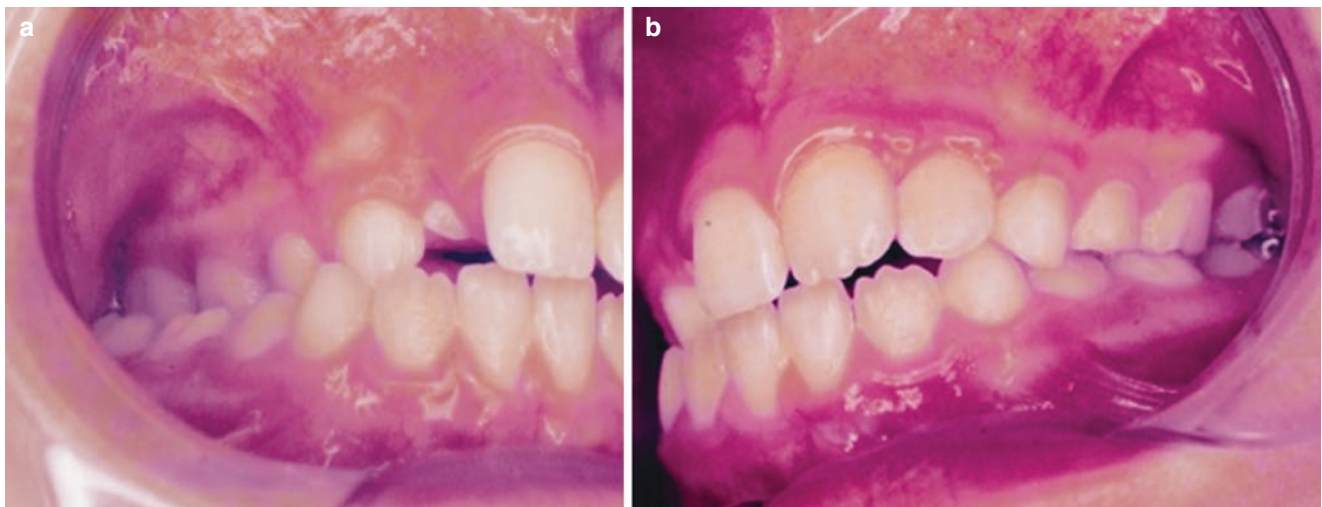


Fig. 11.6 (a, b) Lateral views in the first appointment. The right side showed a crossbite occlusion; meanwhile a normal one could be seen on the left side

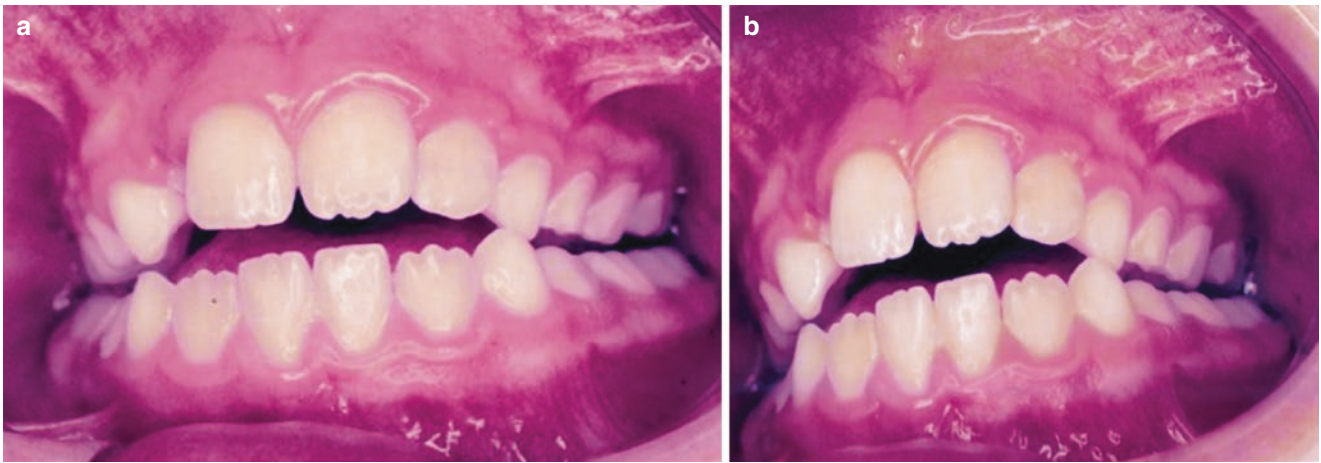


Fig. 11.7 (a, b) Occlusion in centric relation. There was only one contact point in the left canines

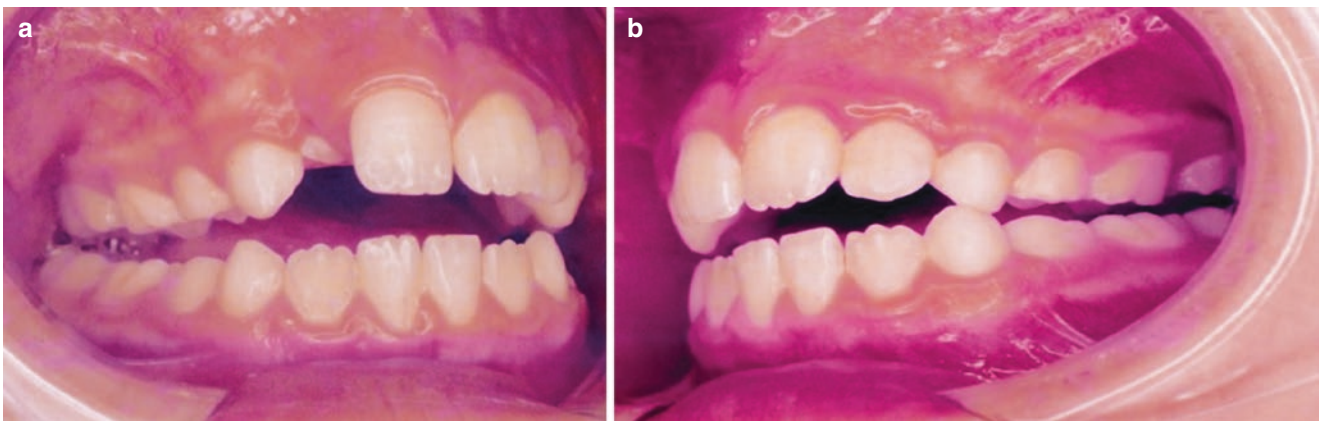


Fig. 11.8 (a, b) Lateral photos in central relation. A significant open bite was present along with a premature contact at the canine region

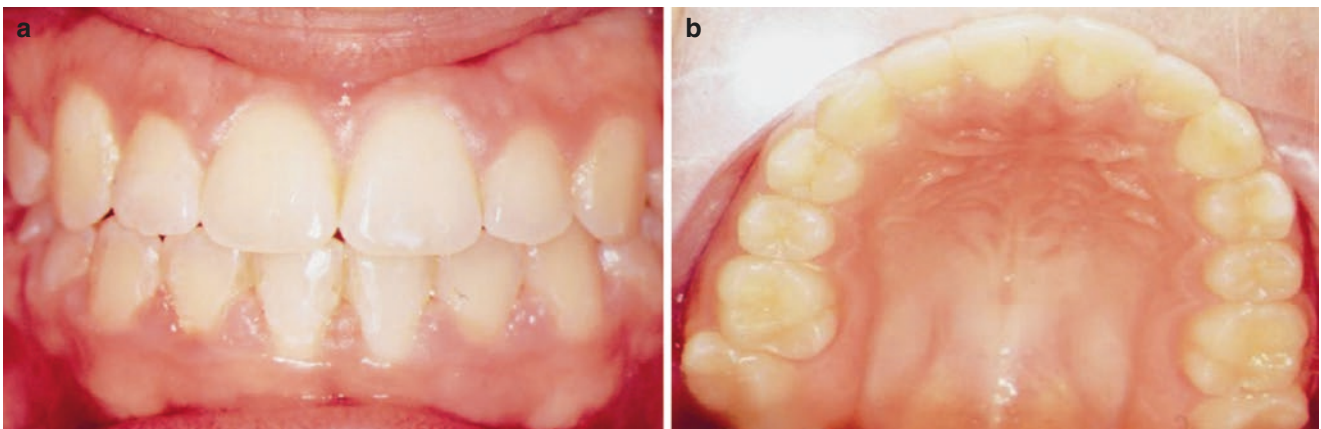


Fig. 11.9 (a, b) 5 years later without any orthodontic treatment. Midlines were coincident with reduced overjet and overbite

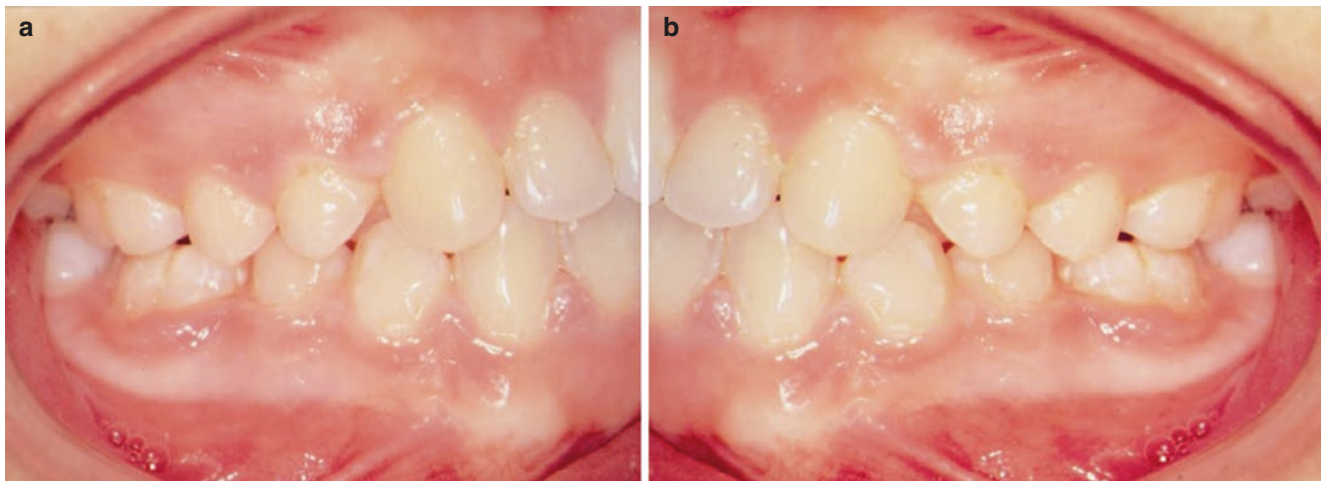


Fig. 11.10 (a, b) Lateral occlusion at 14 years of age. Class I molar and canine was present. No brackets or other removable appliance was used

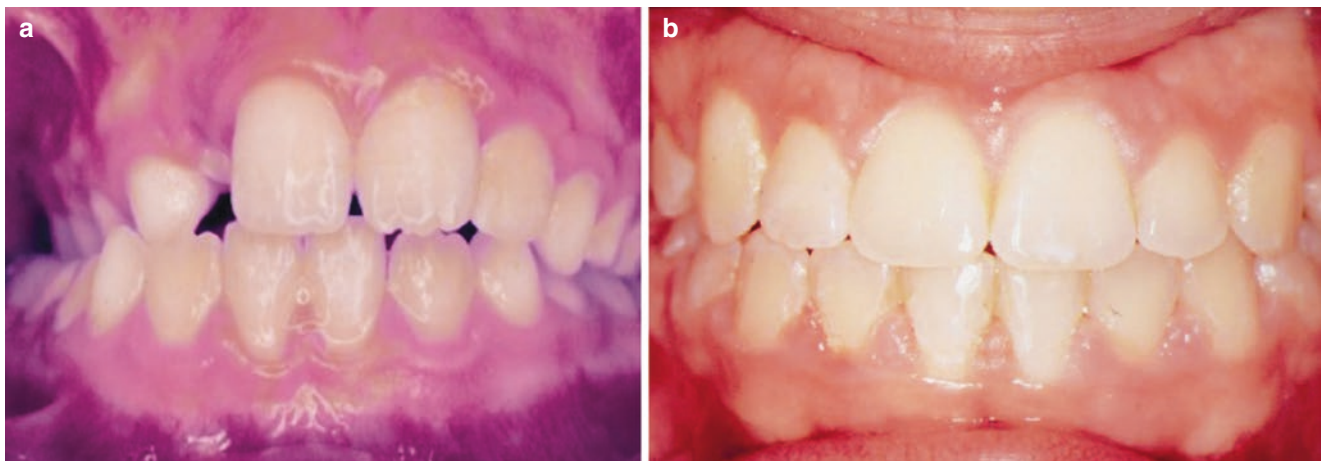


Fig. 11.11 (a, b) Pre- and posttreatment frontal photographs without any active orthodontic treatment

The following patient is a clear example of this pattern. An 11-year and 8-month-old boy was sent to the orthodontic department for a second opinion due to a significant asymmetry in the lower third of the face. He lived 850 Km from the city. The chin accompanied the deviation to the right, and apparently the left side of the mandible was longer than the right side.

Although he was almost 12 years old, nearly all the teeth had erupted.

The first diagnosis was to wait until he was 20–22 years old and correct the problem through an orthognathic surgery procedure.

As always, the first step is to identify the problems in order to determine the cause or causes of the asymmetry and in this way decide the most realistic treatment plan for this patient at this age (Fig. 11.12a, b).

A close clinical examination in concordance with some radiographs is required in order to make a reliable diagnosis. Ideally some radiographs have to be taken in central relation

to determine the exact position of the mandible. Also, it is necessary to know the percentage of dental and skeletal influence in the anterior or posterior crossbites.

Analyzing the dental front photograph in centric occlusion, a significant midline deviation was observed (Fig. 11.13a), but when the patient was in centric relation (Fig. 11.13b), midlines coincided, and a large anterior and lateral open bite was present.

When the lateral photographs were observed in central occlusion, Class II canine and Class I molar on the right side were present. Meanwhile, on the left side Class III canine and Class I molar were seen (Fig. 11.14a, b).

But in centric relation a significant lateral open bite was present, and because of this, the treatment plan would be completely different. It is important to observe the mesiodistal axial inclination of the posterior teeth before brackets are bonded (Burstone 1998). The normalization of the axial inclination of the anterior and posterior teeth has to be obtained during the first phase of treatment (Fig. 11.15a, b).

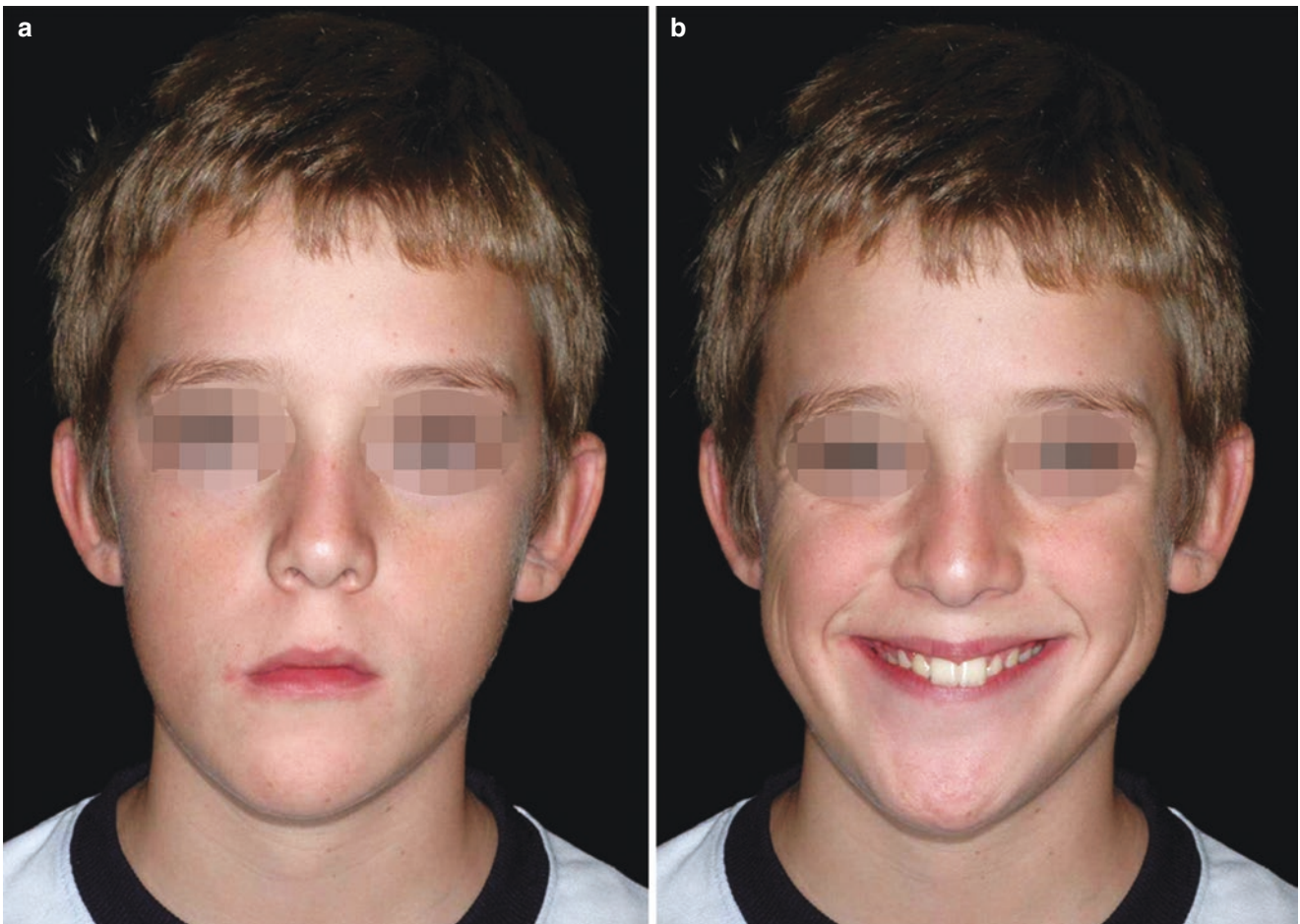

Fig. 11.12 (a, b) Pretreatment front photographs. The asymmetry is visible with the chin deviated to the right

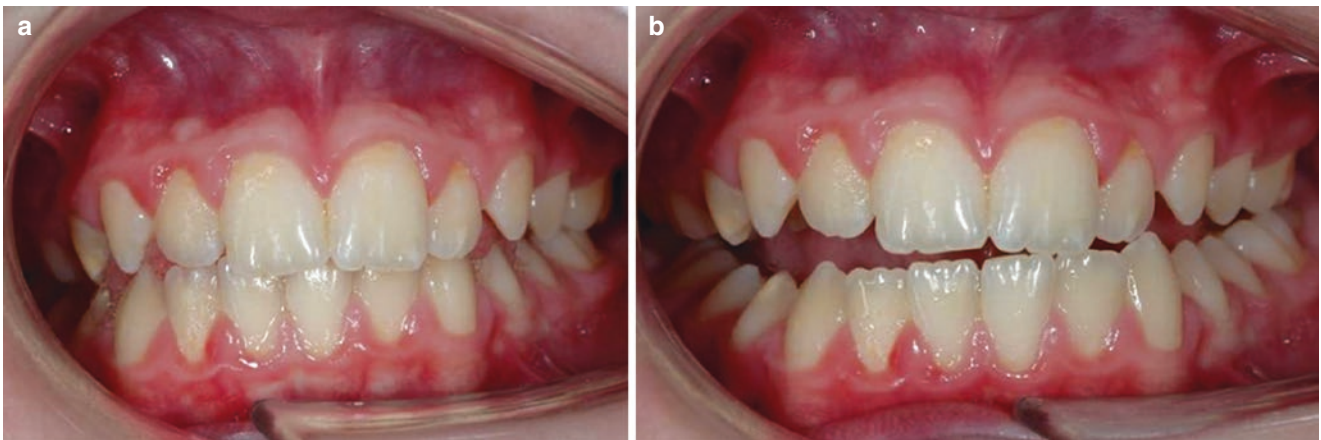


Fig. 11.13 (a, b) Significant difference between central occlusion and central relation. In central relation the midlines were almost coincident

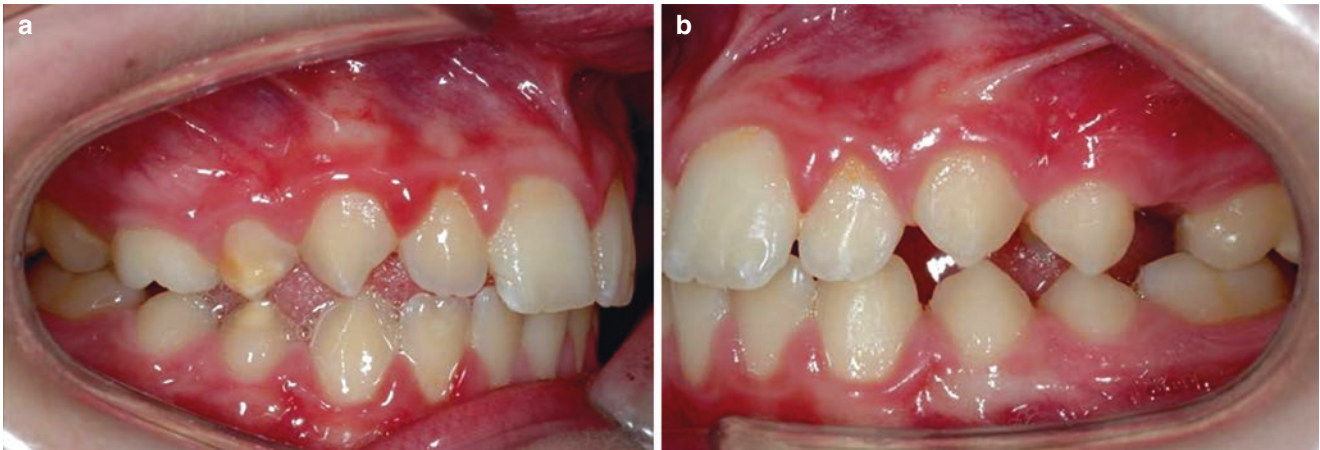


Fig. 11.14 (a, b) Lateral views at centric occlusion Class II canine on the right side and Class III canine on the left side were observed

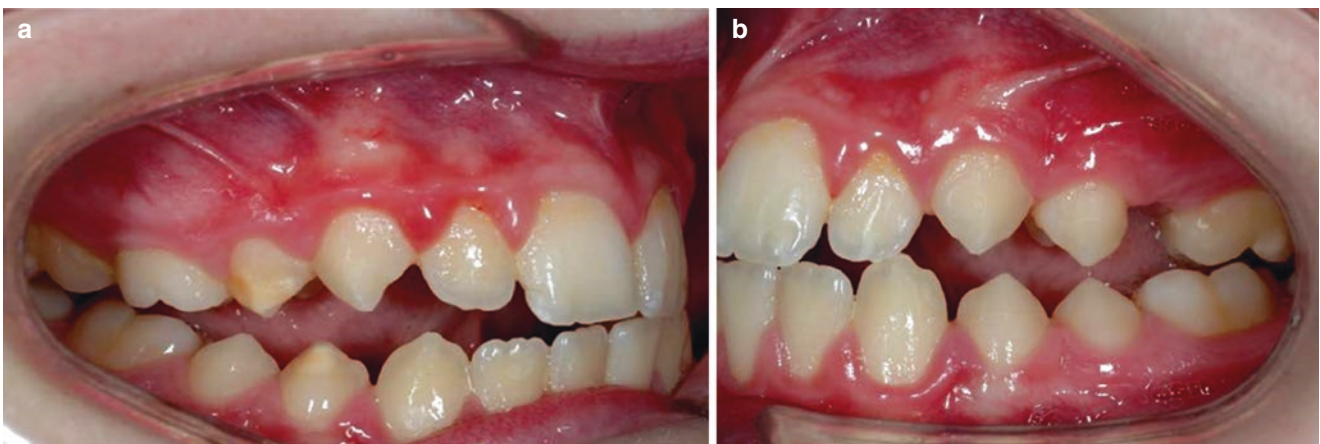

Fig. 11.15 (a, b) Lateral views at centric relation. A significant right and left open bite was present

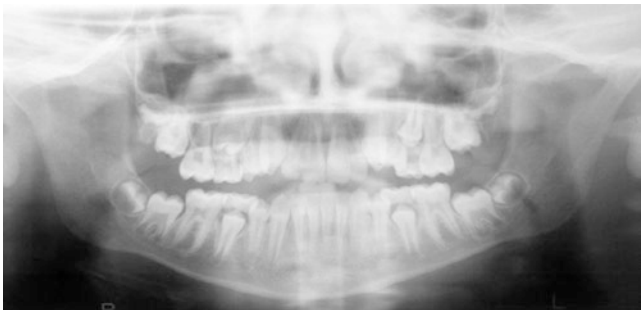

Fig. 11.16 The panoramic radiograph clearly showed the asymmetry between the right and left side at the condyle and ramus area

Radiographs are very useful to confirm the clinical findings. The most commonly used radiograph is the panoramic that shows the potential differences in size and shape of the condyles, as well as the ramus and corpus of the mandible (Fig. 11.16).

Patients with unilateral posterior crossbite had more asymmetric condyles than symmetrical patients. In addition,

condylar, ramus, and condylar-plus-ramal heights on the crossbite side were smaller than those on the noncrossbite side (Kilic et al. 2008).

The lateral and frontal radiographs confirm the asymmetry in centric occlusion (Fig. 11.17a, b). In this patient the deviation of the mandible to the right is very evident. Another radiograph in centric relation would have been helpful to confirm these findings.

It was demonstrated that the adaptation of the neuromusculature to the acquired mandibular position can cause asymmetric mandibular growth, facial disharmony, and several functional changes in the masticatory muscles and TMA as was seen in the following patient (Fig. 11.18a, b).

There was a large difference between the two photos only in 3 years without treatment. In order to determine the best treatment plan, it is mandatory to know if the asymmetry is stable or progressive and distinguish the real etiology of the problem before the treatment plan is defined.

An individualized and profound diagnosis is mandatory to determine the real causes of such asymmetry. Without a

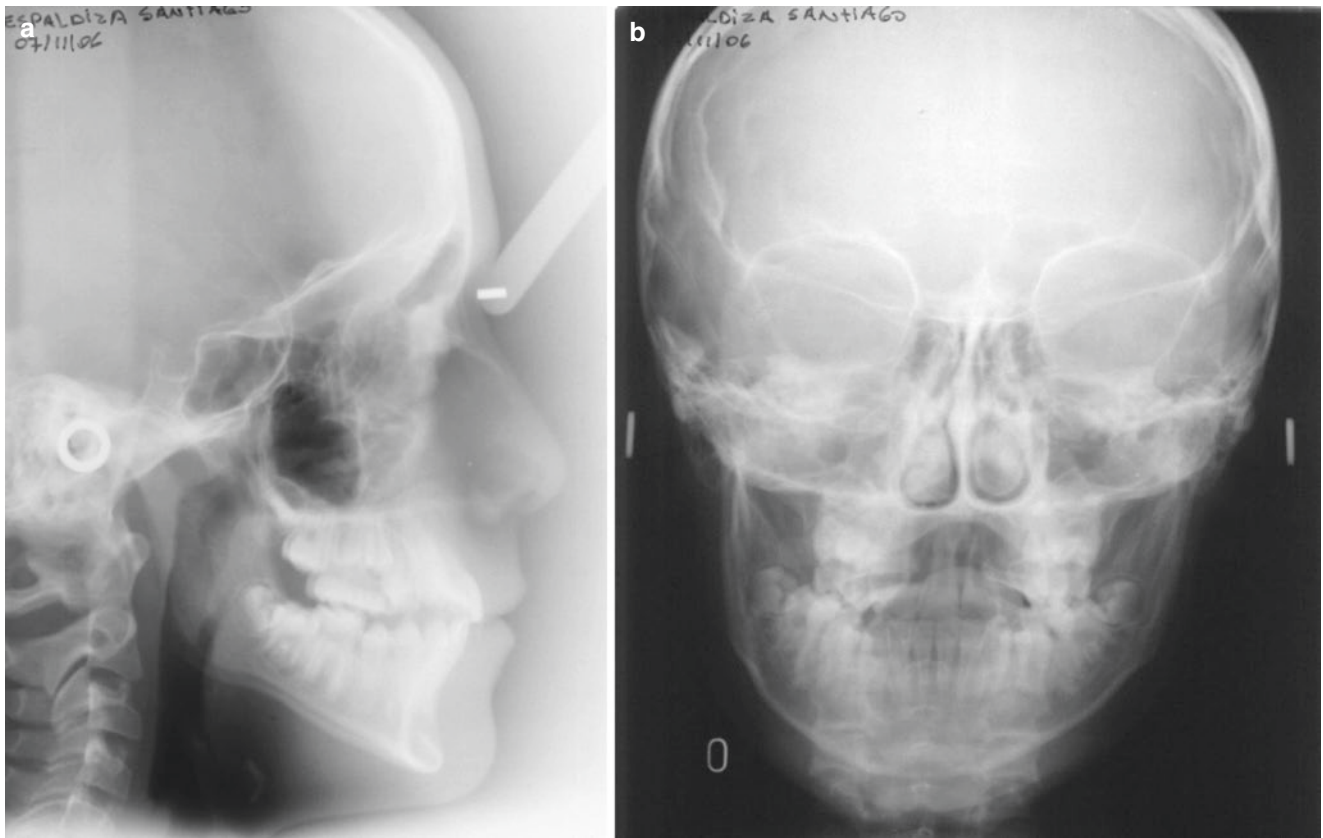


Fig. 11.17 (a, b) Lateral and front radiographs where the asymmetry is clearly evident

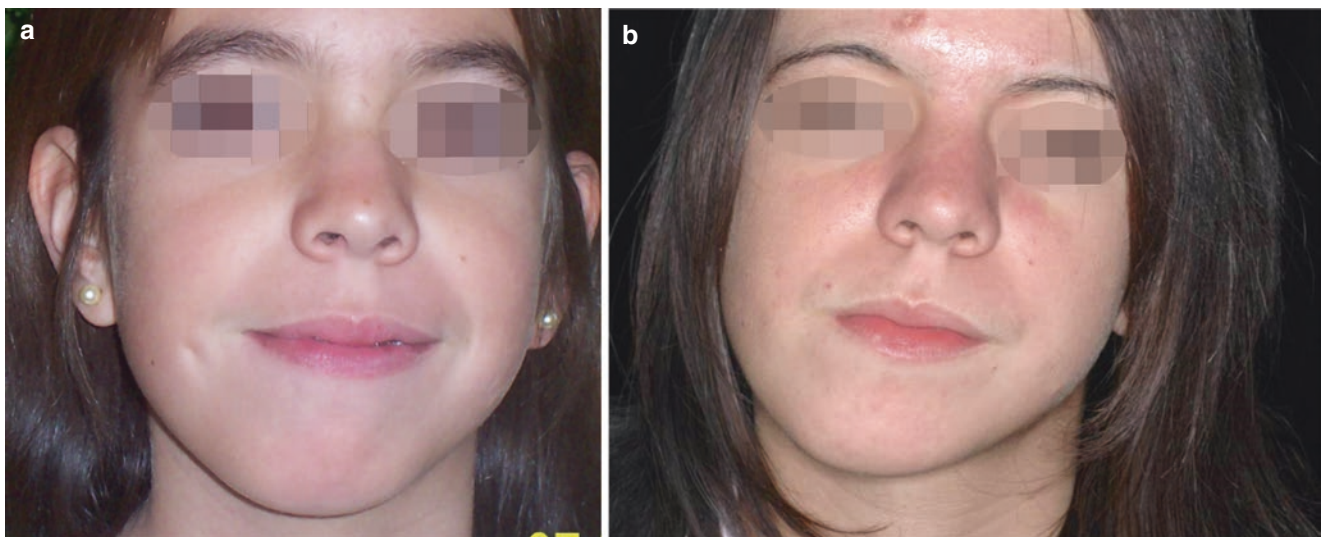

Fig. 11.18 (a, b) Front photographs with a 3-year difference without any kind of treatment

real and comprehensive diagnosis, it is not possible to achieve the treatment goals.

Studies have shown that crossbites, especially when associated with a lateral shift, play an important role in cranio-

mandibular disorders. Since posterior crossbite generally causes dual bite with a lateral mandibular shift, an asymmetrical condylar movement pattern can develop (Schmid et al. 1991).

Changes in condylar movement might induce asymmetrical mandibular growth.

Schmid et al. indicated that morphological asymmetry in growing children is the result of mandibular displacement consequent to occlusal alterations.

Positional asymmetries might have immediate morphological influence in the mandibular growth.

These characteristics were shown in the following patient that was sent to the orthodontic department for a second opinion since her doctor at that time realized that she had a lateral deviation to the left when she opened her mouth. The asymmetry was barely noticeable when the mouth was closed. The left side was little more rounded than the right side (Fig. 11.19a, b).

Her medical record provided insight as to why this happened. When she was 2 years old she had fallen from a high place and fractured her condyle. No surgical intervention nor other treatment was offered at that time.

She was able to open her mouth normally (40 mm). Also, no dysfunction (clicking, popping) or pain was present in the TMJ at that time. To decide on a correct diagnosis, it is important to determine the anatomic level of the fracture. No previous radiographs were available.

The front dental photographs showed a very slight dental deviation and a compression in the upper arch. A premature contact between the upper and lower incisors was visible in conjunction with an edge to edge occlusion and anterior open bite (Fig. 11.20a, b).

Class I molar was present along with crossbite position of the right and left temporary molars (Fig. 11.21a, b). The premature contact between the upper and lower central incisors was clearly visible.

The panoramic radiograph confirmed the fracture on the neck of the condyle. In addition, there was a significant difference between the right and left ramus and coronoid process. The eruption of the permanent teeth seemed to be normal according to her age (Fig. 11.22a).

The lateral radiograph confirmed the mandibular asymmetry and showed a double image in the lower and distal border of the mandible (Fig. 11.22b).

The patient returned 1 year later with the same pathology: a significant deviation to the left side when the mouth was opening without any pain or clicking. The TMJ specialist described an anteromedial discal displacement and mild musculature atrophy on that side (Fig. 11.23a, b).

The front dental photographs at this stage showed that the midlines were almost coincident with a significant open bite on the right side. The tongue was interposed between the maxilla and the mandible at rest and in function. Oral hygiene was fairly good (Fig. 11.24a, b).

It is well known that form and function are intimately related. With this in mind, a functional appliance was designed in order to improve musculature function.

Clinical observations have shown large adaptive changes in condyle fractures that can cause functional disturbances and alterations during the growth period. For this reason, it is

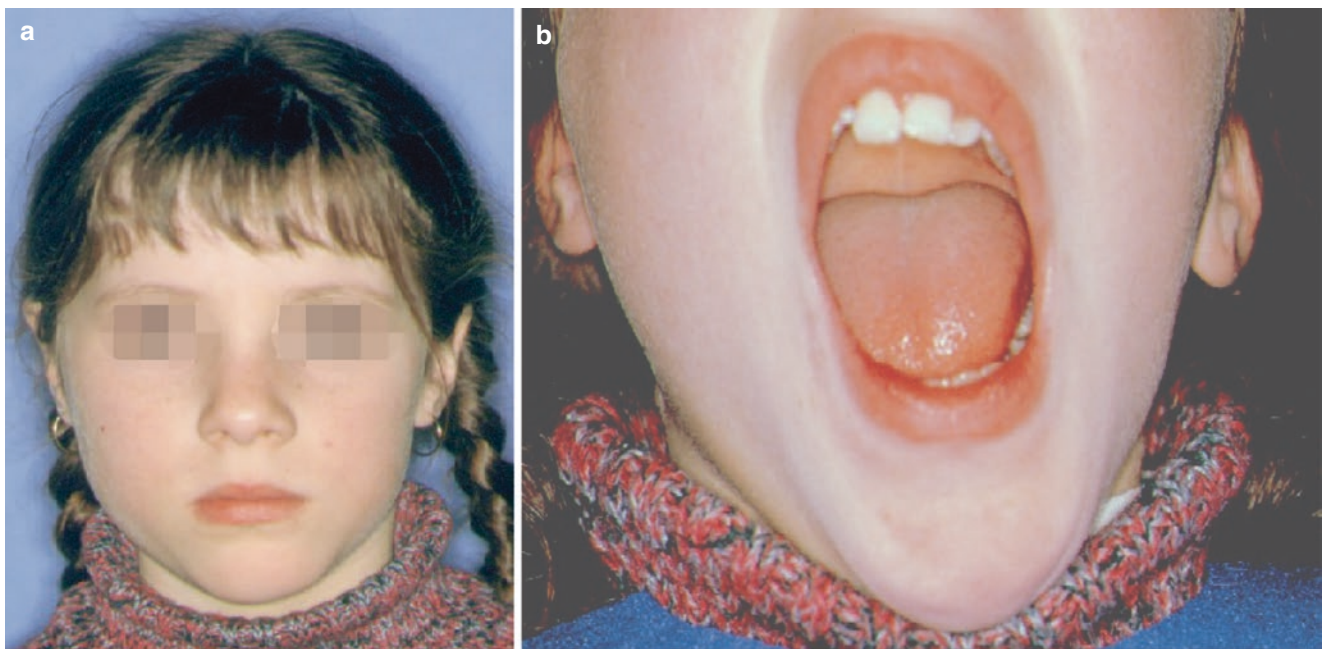

Fig. 11.19 (a, b) The asymmetry was clearly confirmed when the patient opened her mouth although she could open it 40 mm, which is average

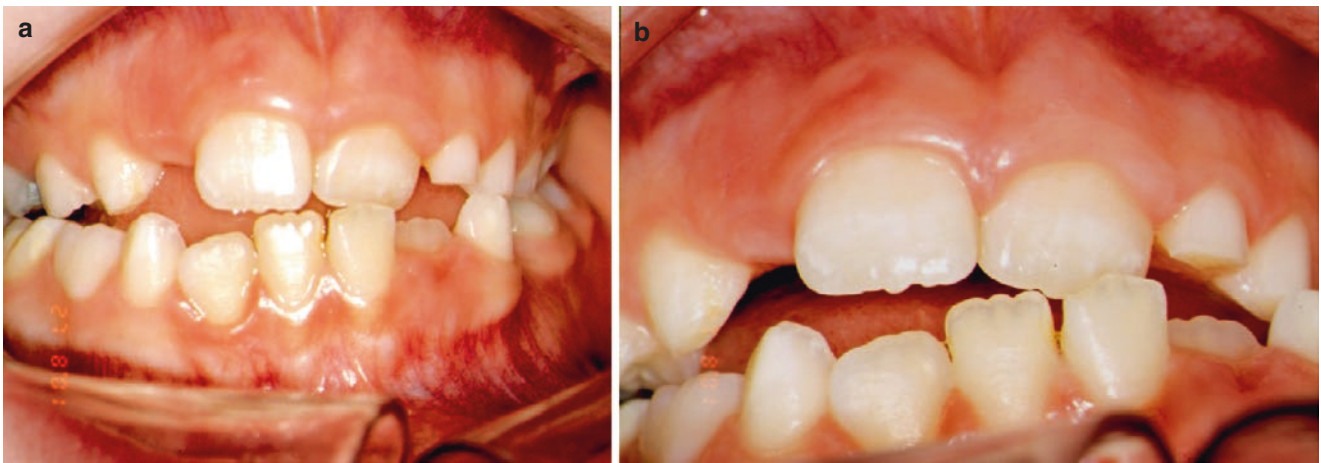


Fig. 11.20 (a, b) Pretreatment frontal dental photographs. A premature contact was clearly seen between the upper and lower central incisors with non-coincident midlines

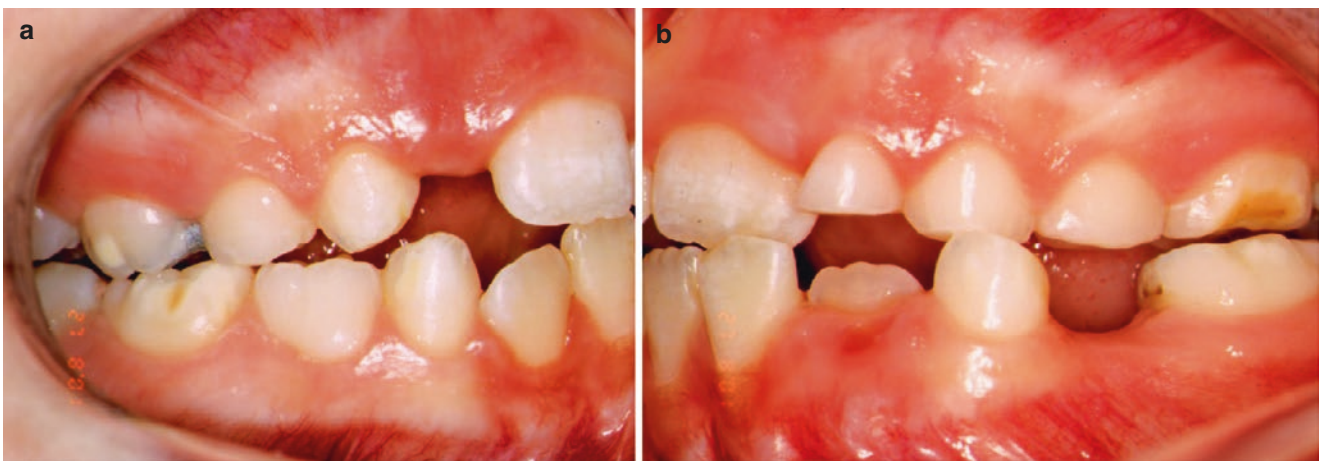


Fig. 11.21 (a, b) The compression of the upper arch was noticeable

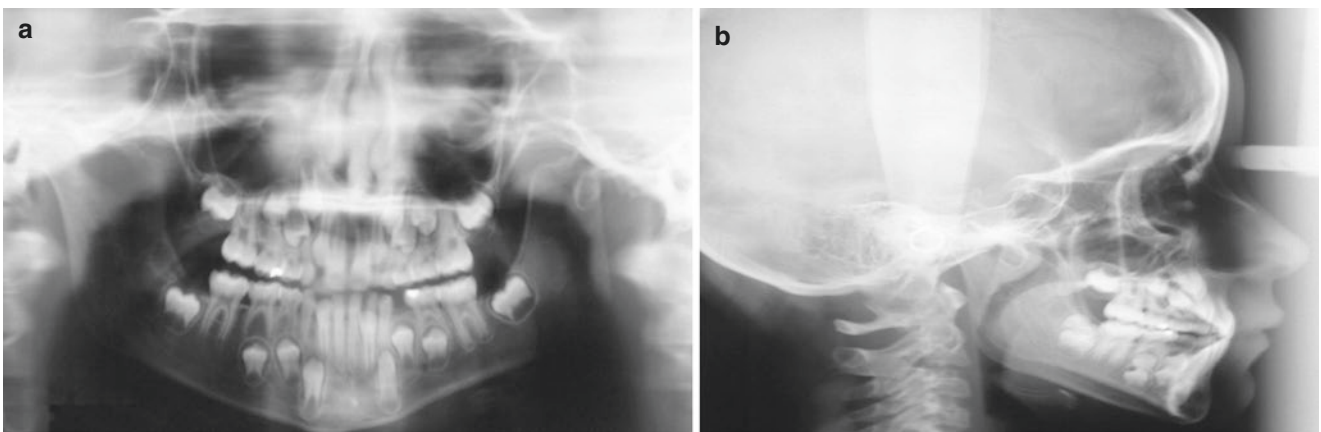


Fig. 11.22 (a, b) Pretreatment panoramic and lateral radiographs. The fracture of the condyle and a significant mandibular asymmetry were confirmed

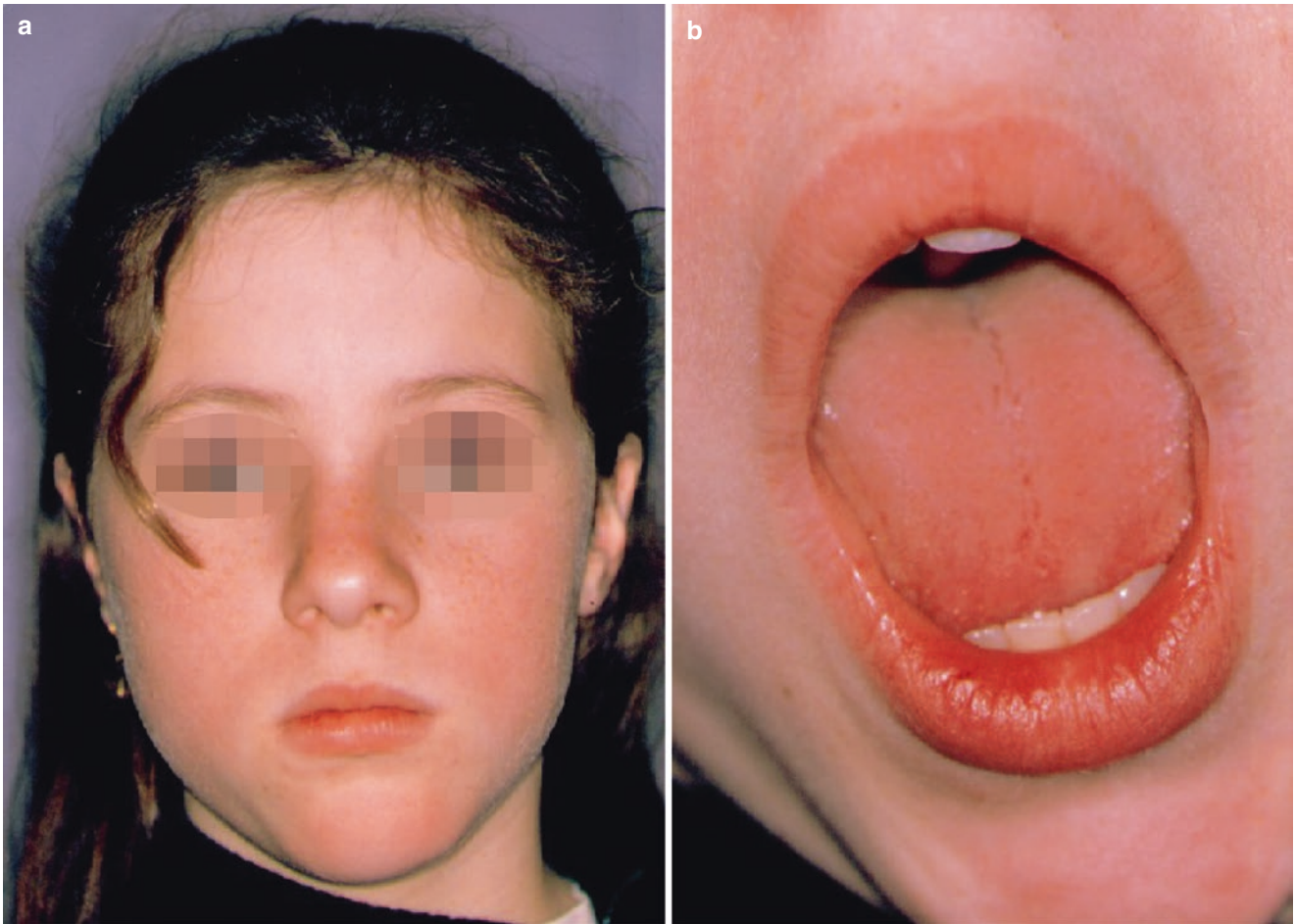

Fig. 11.23 (a, b) The significant deviation to the left side when the mouth was opening remained. No pain or clicking was present

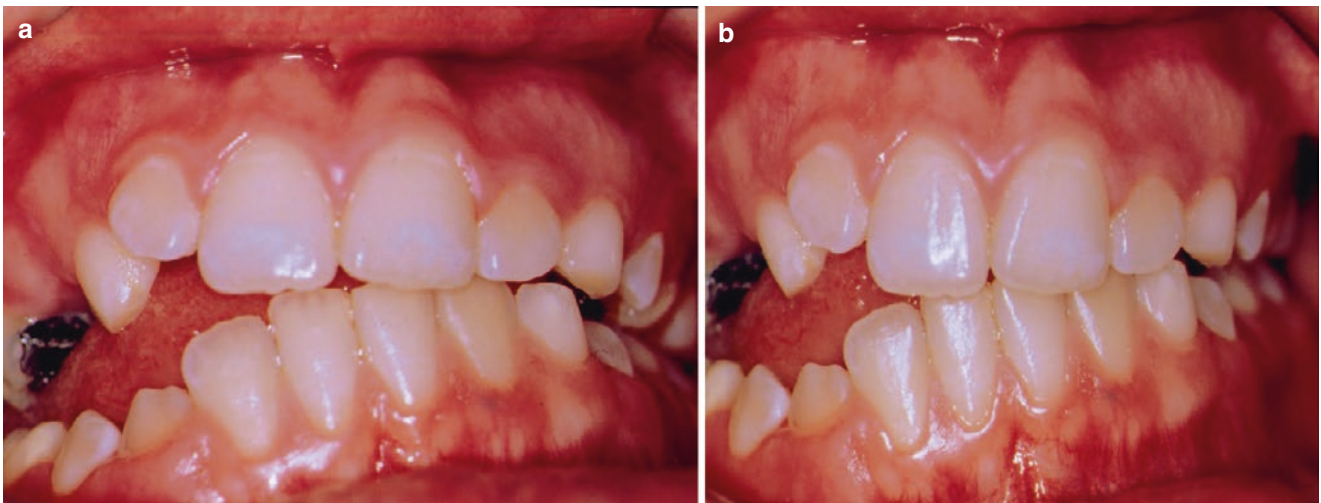


Fig. 11.24 (a, b) Frontal photographs one year later without treatment. Midlines are almost coincident but a significant right open bite was present

important to treat the patient as soon as it is diagnosed (Tavares and Aligayer 2012). A conservative orthodontic treatment was recommended with an Andresen-Haulp activator that was controlled every 6–8 weeks.

The patient cooperated very well by using it almost all day (Fig. 11.25a, b).

Upon detailed analysis of the following rx, an improvement of the shape of the left condyle was observed with a satisfactory remodeling of the condylar fracture region. The second left lower molar continued its eruption path (Fig. 11.26a, b).

In order to correct the lateral open bite, metallic preprogrammed brackets (0.022" slot) with bands on the first molars were bonded on the upper arch with a 0.016" Ni–Ti–Cu archwire. Slow and controlled forces were recommendable to extrude the right side with bone and not through it. The help of the speech therapist was essential to normalize tongue function and position (Fig. 11.27a, b).

The lateral views corroborate the beginning of the alignment of the upper arch (Fig. 11.28a, b). A 6-week control is advisable. No brackets were bonded on the canines until that point.

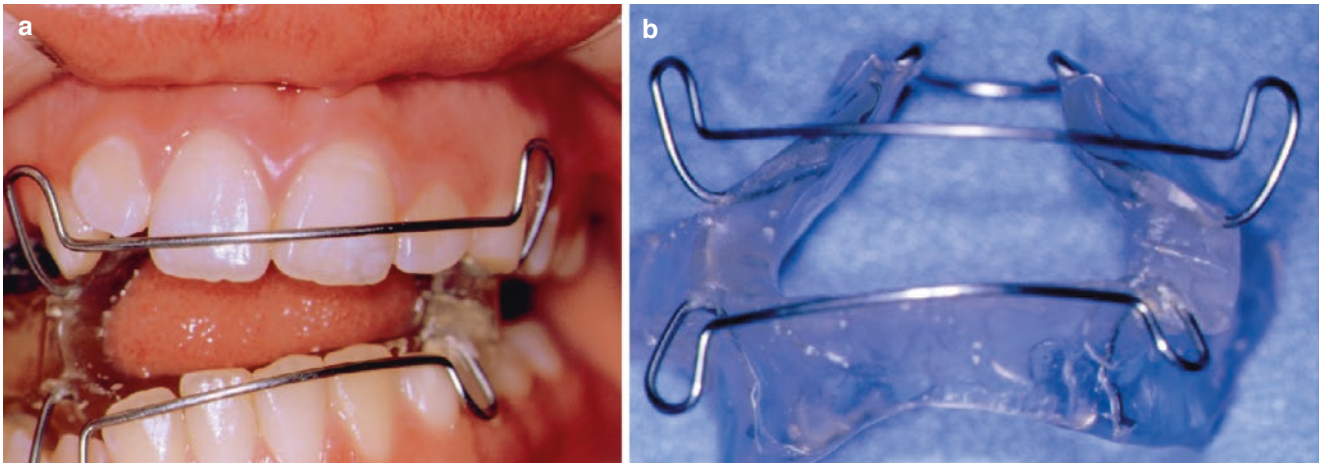


Fig. 11.25 (a, b) An Andresen-Haulp activator was recommended that was controlled every 6–8 weeks

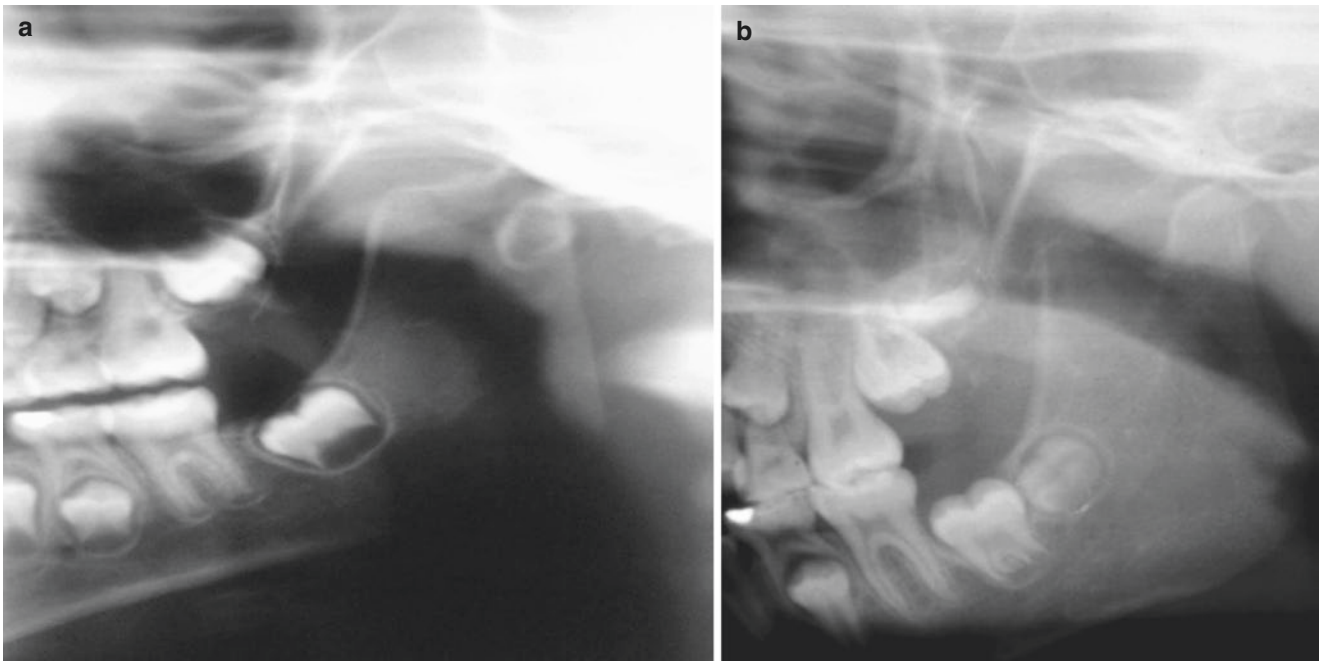


Fig. 11.26 (a, b) A significant remodeling in the condylar area was visible

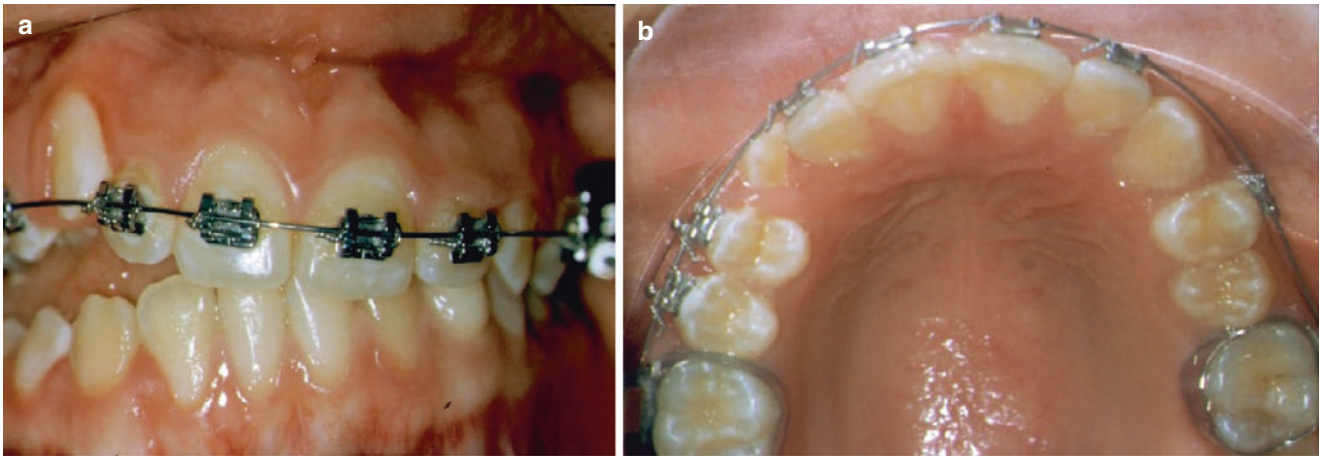


Fig. 11.27 (a, b) A Ni-Ti-Cu 0.016" archwire was placed to begin alignment and leveling in the upper arch with preprogrammed 0.022" brackets

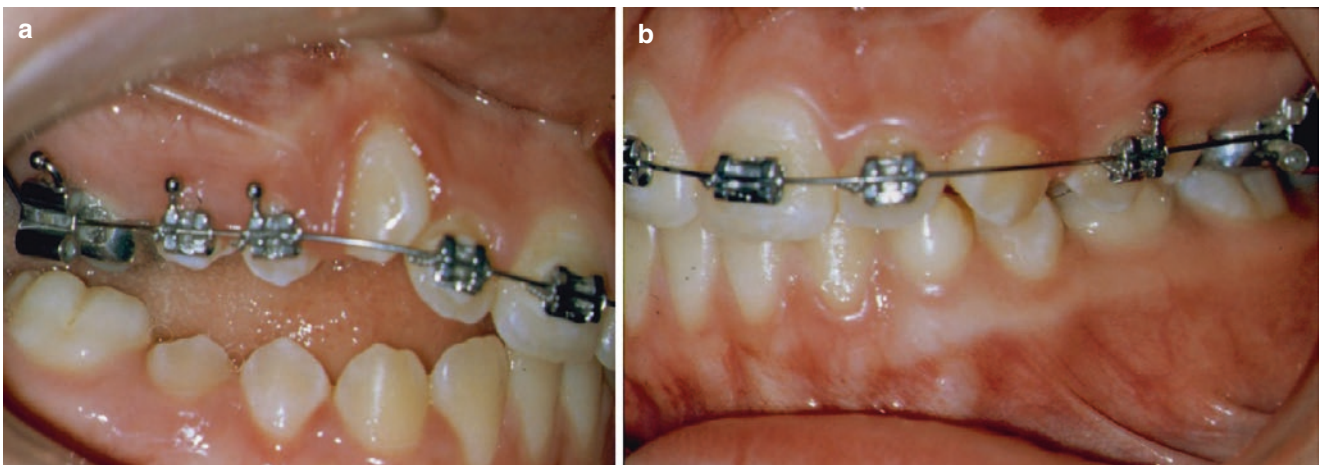


Fig. 11.28 (a, b) Lateral views at the beginning of the treatment with a Ni-Ti-Cu 0.016" in place

When the alignment and leveling of the arches were completed, a rectangular wire SS 0.016" \times 0.022" was placed on the upper arch, and a 0.017" \times 0.025" turbo wire was ligated in the lower arch (Fig. 11.29a, b).

The use of triangular elastics (1/8 heavy) was important to normalize the occlusal plane and helps to maintain the correct position of the tongue. Ideally elastics have to be used 22–23 h a day. When the expected results were achieved, reinforcement was recommended during the night for 4–6 months (Fig. 11.30a, b).

At the end of the orthodontic treatment, excellent functional and esthetic results were achieved. Midlines were coincident and the gingival line and the occlusal plane were parallel. Overjet and overbite were within normal range (Fig. 11.31a, b).

Intraoral examination revealed Class I canine and molar on the right and left side. Overjet and overbite were within the normal ranges, and there was no pain or clicking in the

TMJ (Fig. 11.32a, b). It was important to continue the treatment with the speech therapist to control the position of the tongue at rest and in function in order to avoid any type of relapse.

At the end of the treatment, facial proportions were improved and natural lip closure too (Fig. 11.33a, b).

The radiographs at the end of the treatment demonstrated the results that were obtained. No disturbances of dental development were seen. All the teeth were well aligned, and there was an evident improvement in the condyle zone. On the lateral radiograph, a considerable asymmetry was confirmed in the mandibular region in the inferior and posterior border of the mandible (Fig. 11.34a, b).

The comparison between the pre- and posttreatment frontal photographs showed that facial asymmetry seemed to be enhanced. A conservative treatment approach for unilateral condyle fracture using a functional appliance during the growth period can lead to the restoration of the fracture area

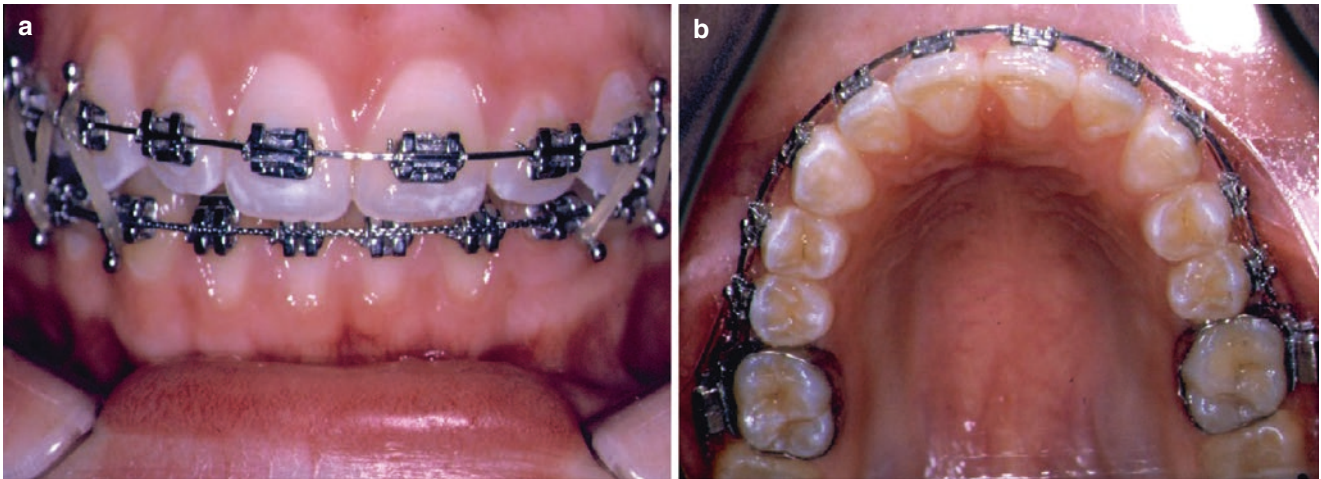


Fig. 11.29 (a, b) To achieve better torque control, rectangular wires were placed in the upper and lower arches

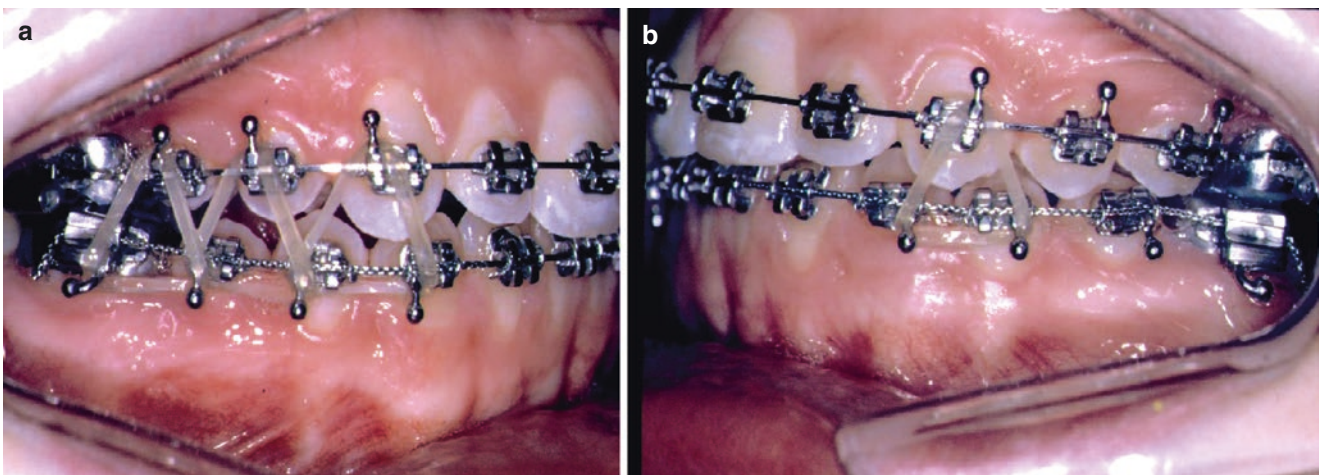


Fig. 11.30 (a, b) Triangular elastics were recommended to improve lateral occlusion (1/8 heavy)

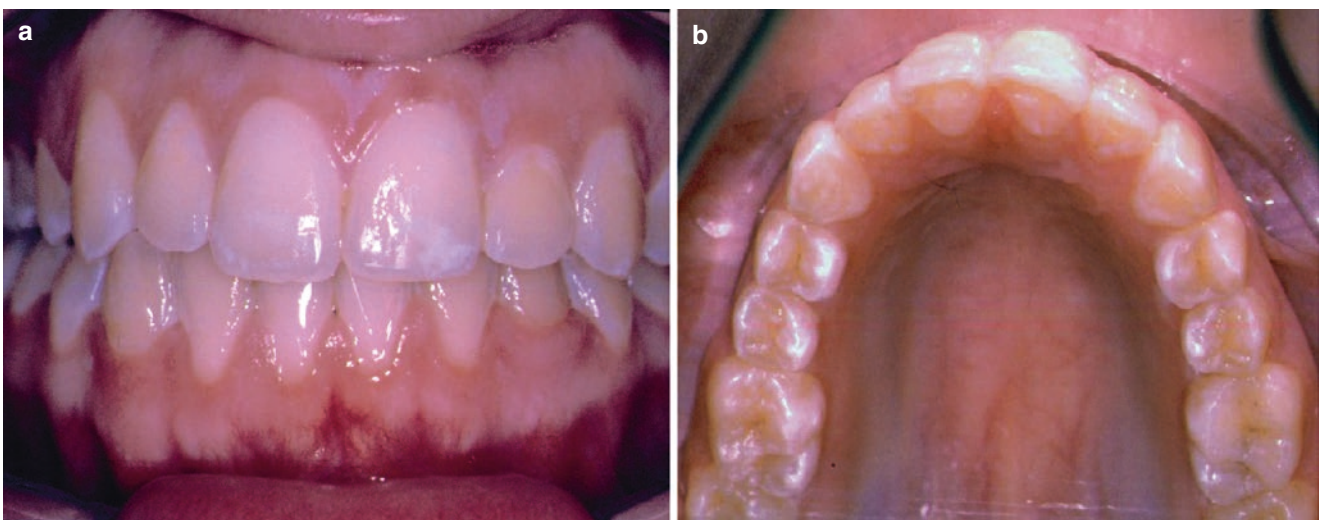


Fig. 11.31 (a, b) Frontal and occlusal view at the end of the active orthodontic treatment. Midlines, overjet, and overbite were normalized

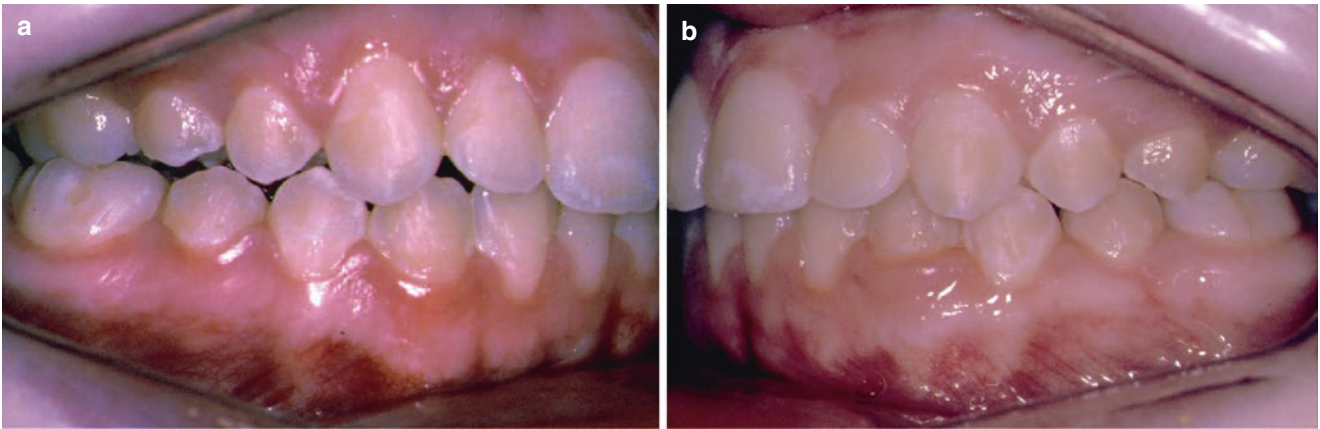


Fig. 11.32 (a, b) Lateral views at the end of the active orthodontic treatment

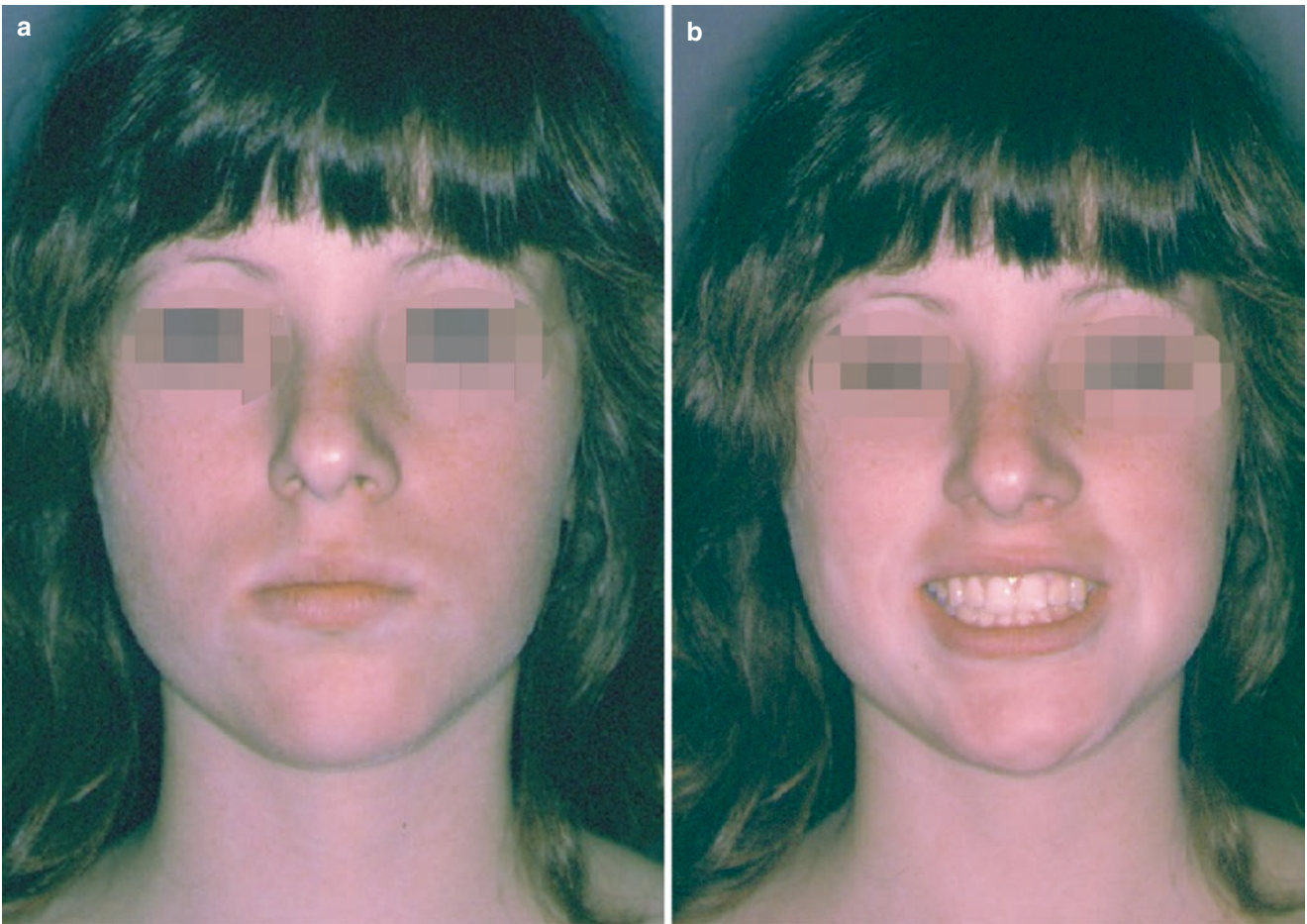

Fig. 11.33 (a, b) Frontal and smile photos at the end of orthodontic treatment

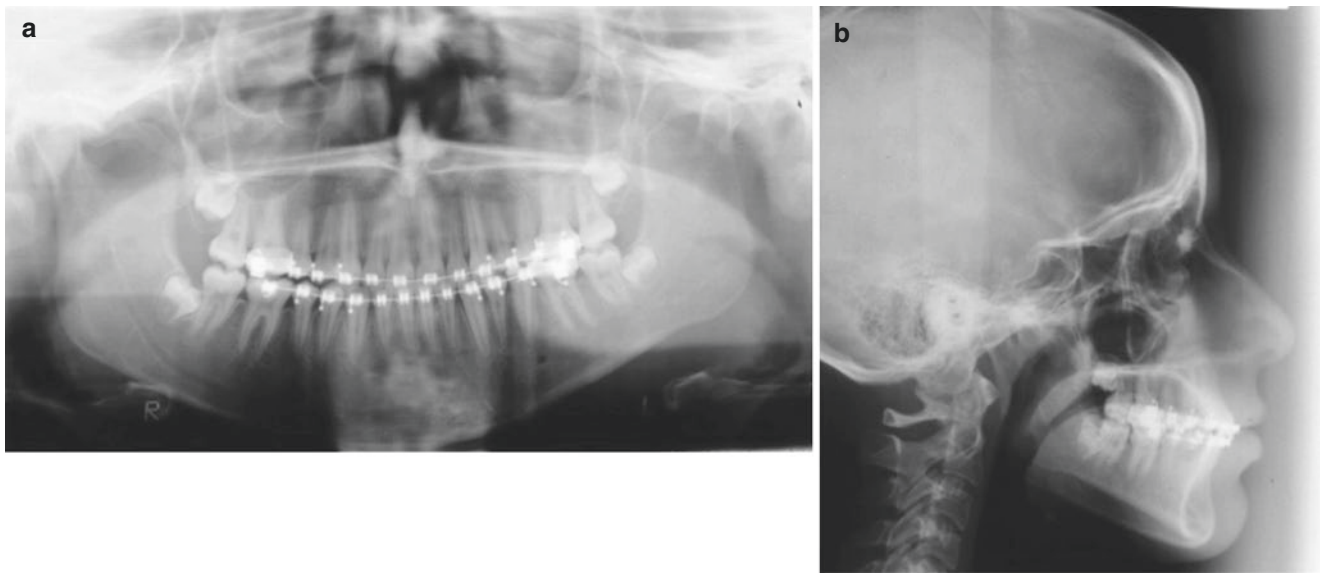


Fig. 11.34 (a, b) Panoramic and lateral radiograph at the end of the treatment. All the measurements were within the normal ranges

with the reestablishment of the function (Chatzistaurov and Basdra 2007) (Fig. 11.35a, b).

The comparison among pre-, middle, and final radiographs confirmed that the improvement in the condylar region was better than expected at the beginning of the treatment (Fig. 11.36a–c). Long-term control with functional appliances was necessary to maintain or even improve the excellent results that were achieved.

It is very interesting to highlight that the remodeling of the condylar fracture was highly satisfactory. In addition, improvement of the occlusion was also obtained.

Similar results were desired in the following 7-year and 6-month-old patient that was sent to the orthodontic department due to a great latero-deviation while opening the mouth. The chin was shifted toward the right side, and TMJ evaluation did not show pain or clicking during function (Fig. 11.37a, b). Facial asymmetry was visible in the middle and lower third of the face.

The mother did not remember when this problem began, but the teacher at school was worried about this situation.

Lips were incompetent and a day and night mouth breathing habit was present. No other important issues were present in the medical history.

The front dental photographs showed that a considerable midline deviation in conjunction with a significant overbite was present. Gingival margins were uneven (Fig. 11.38a, b).

Class I canine and molar was present on the right side; meanwhile on the left side, Class II molar with a normal eruption process was seen (Fig. 11.39a, b).

Upper and lower dental arches showed an ovoid shape with very slight crowding. No cavities or gingivo-periodontal problems were observed. Upper and lower second temporary molars were still present (Fig. 11.40a, b).

Unfortunately no radiographs were taken at this time. The mother consulted a traumatologist who recommended some physical exercises, twice a week.

The patient returned 14 months later without any orthodontic or orthopedic treatment, and as was expected, no big changes were observed (Fig. 11.41a, b). Clinically the midline shift when opening remained.

The most important treatment objective was the reestablishment of the normal skeletal and muscle growth.

A functional appliance was suggested to improve patient's problems, bearing in mind that oral physiologic functions such as mastication, swallowing, or speech are highly coordinated with neuromuscular function.

An individualized double activator was specially designed for her (Fig. 11.42a, b). It was highly recommended that the patient use the appliance 20–22 h a day.

Ideally, this appliance should be used nearly 20 h a day, but the cooperation of the patient was very insufficient. The arguments were difficulties in speech and swallowing, and she was supported by her parents. After 10 months, the decision to perform an orthodontic treatment was accepted by the parents and the patient. Intraoral photos at the beginning of the orthodontic treatment. Midlines were not coincident and a considerable overbite was still present (Fig. 11.43a, b).

The lateral photographs confirmed Class I canine and molar on the right side and Class II canine and molar on the left side. All the permanent teeth had erupted (Fig. 11.44a, b).

The panoramic radiograph confirmed the normal eruption of the permanent teeth; no agenesis or supernumerary teeth were present. Also, no root resorption was observed (Fig. 11.45).

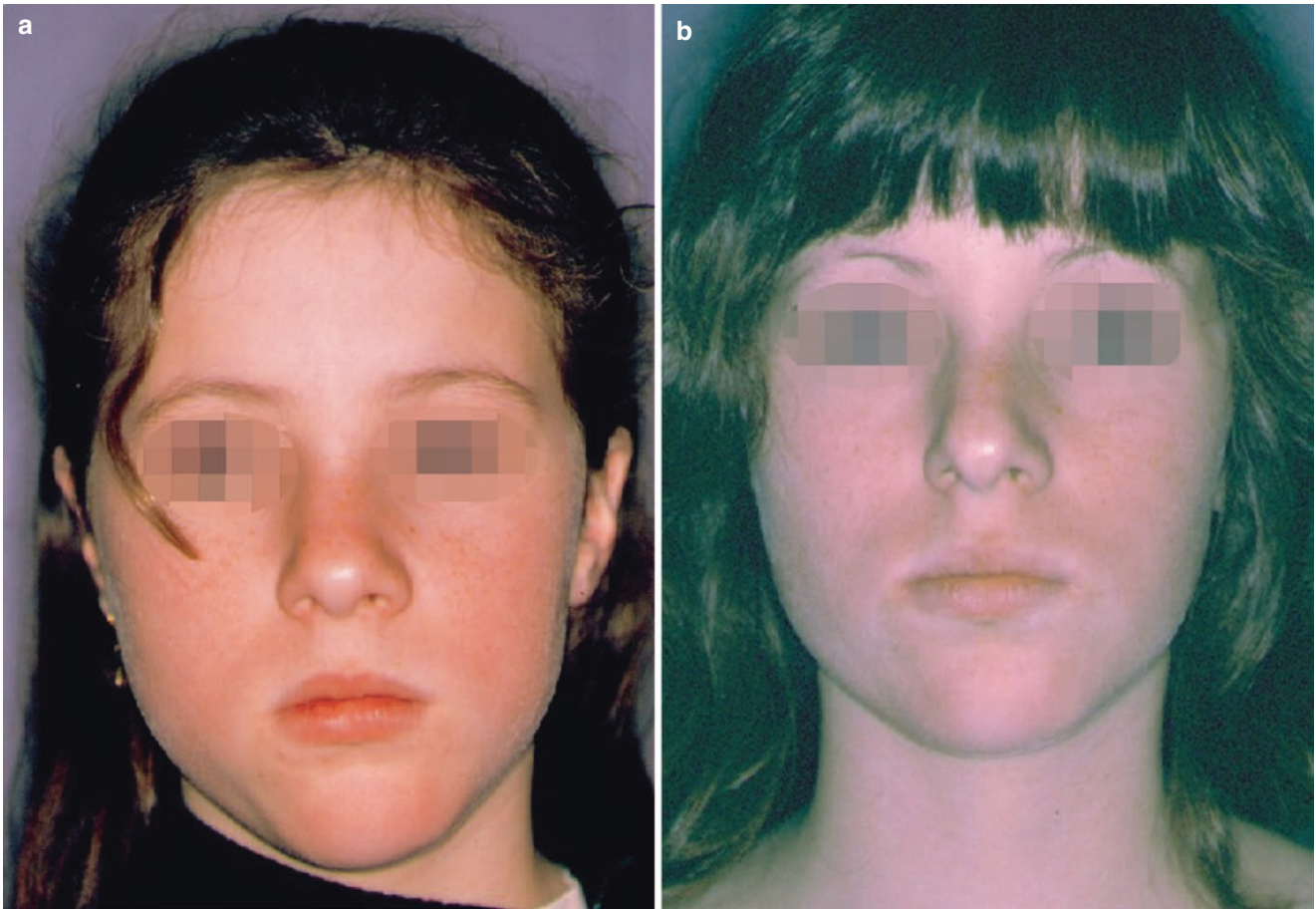

Fig. 11.35 (a, b) Comparison between pre- and postfrontal photographs

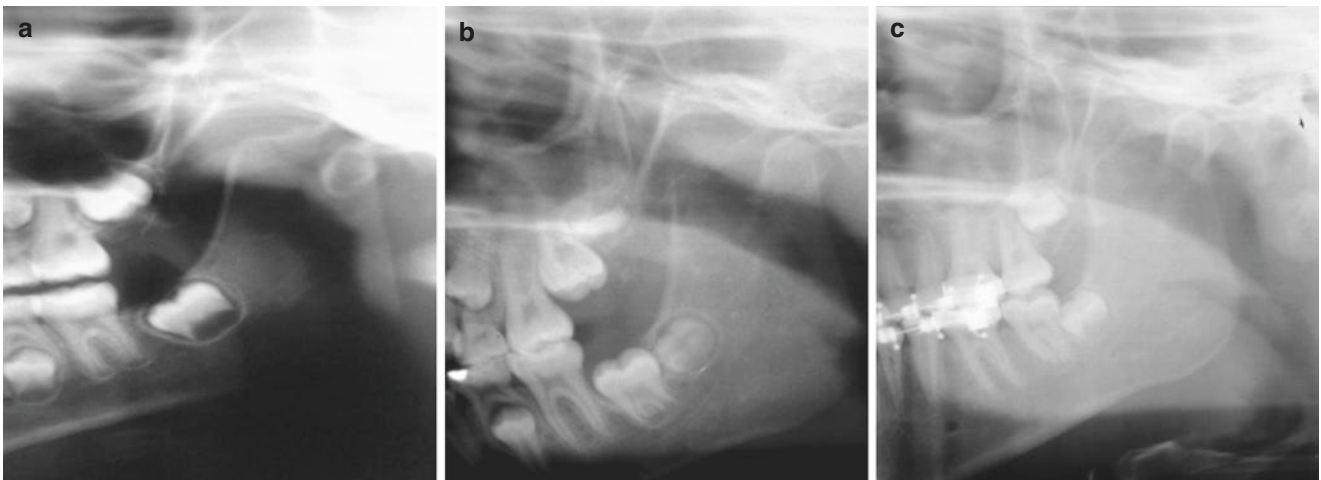


Fig. 11.36 (a–c) Comparison of the pre-, middle, and posttreatment radiographs at the condyle area. The results were better than expected at the beginning

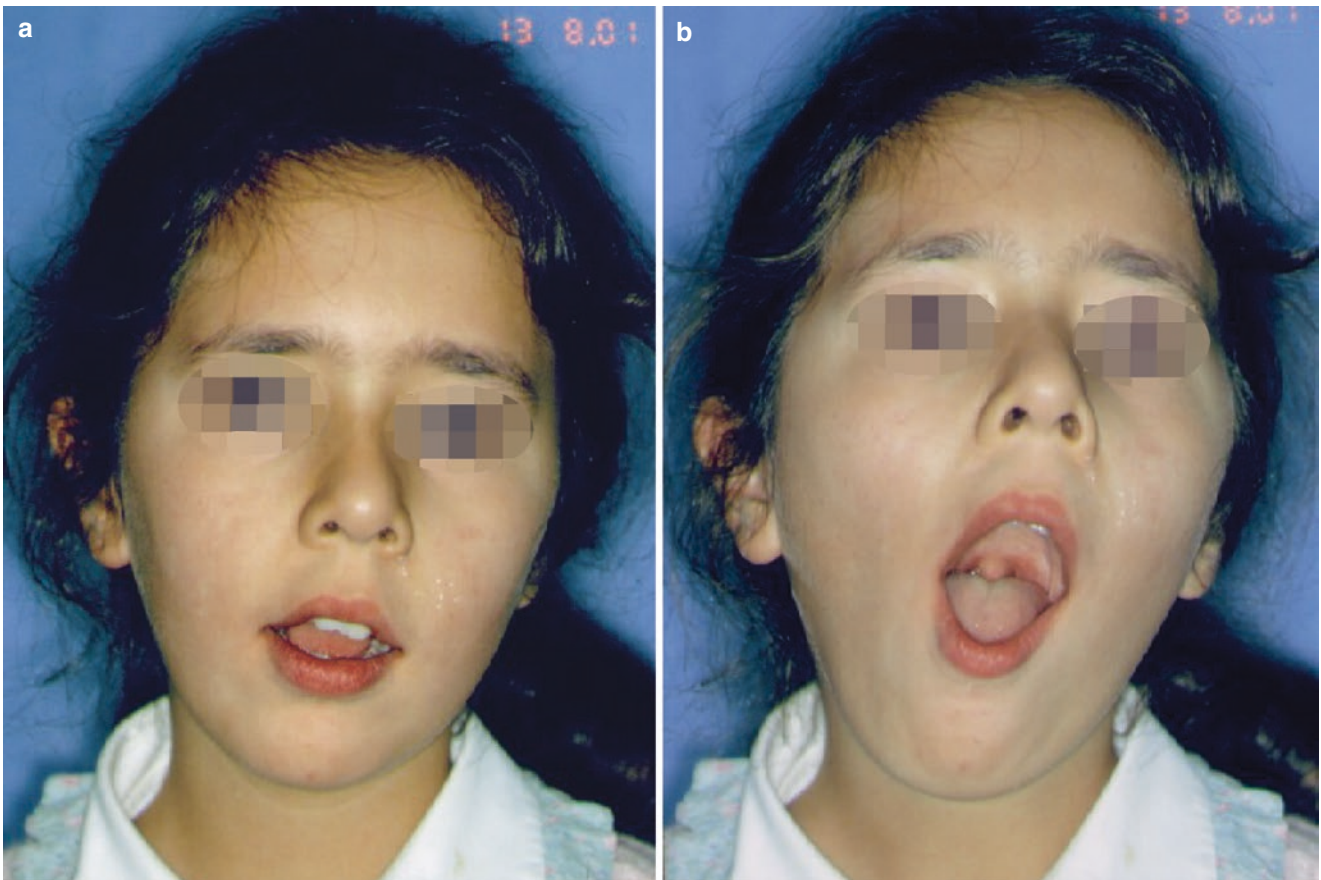

Fig. 11.37 (a, b) Important latero-deviation at rest and when opening the mouth was observed in the pretreatment photos. Day and night mouth breathing was present

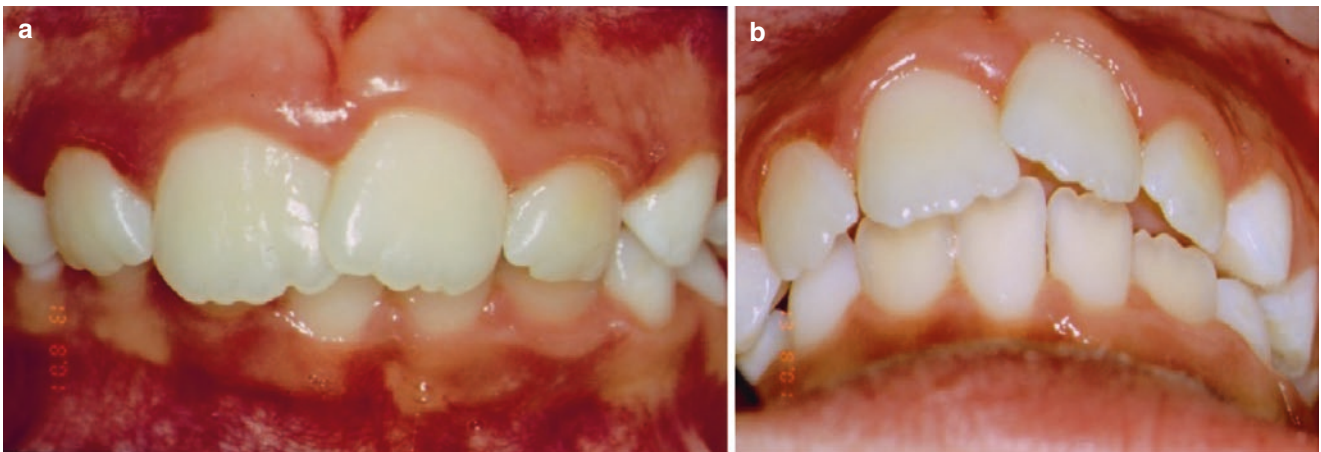


Fig. 11.38 (a, b) Pretreatment frontal and overbite photos. An important overbite was present along with the overlapping of the upper central incisors

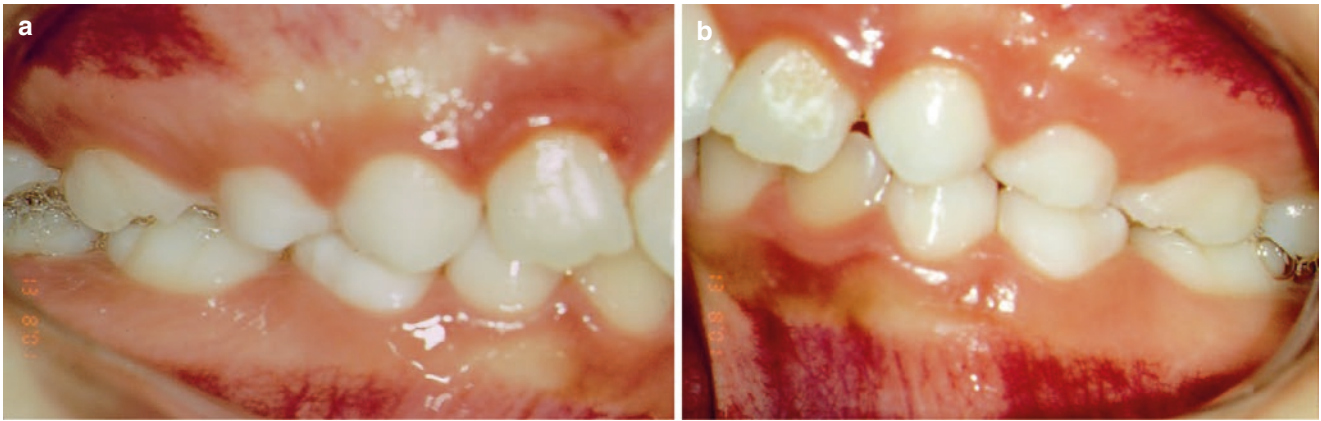


Fig. 11.39 (a, b) Lateral views at the beginning of the treatment. A significant overbite was present in the anterior and canine region

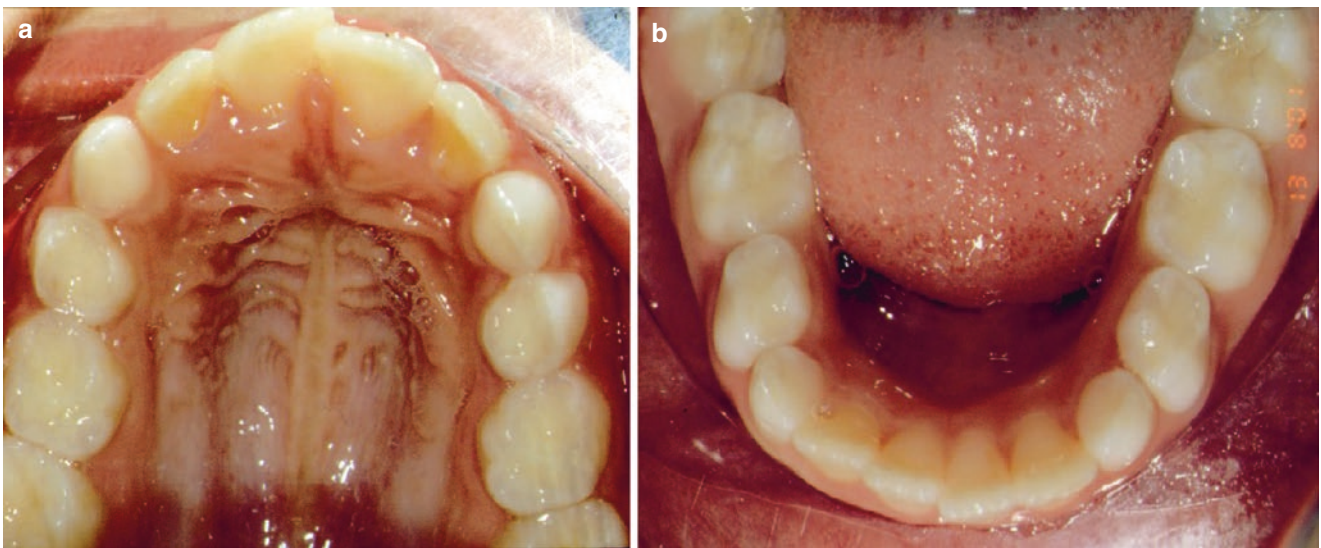


Fig. 11.40 (a, b) Upper and lower dental arches. Upper and lower second temporary molars were present

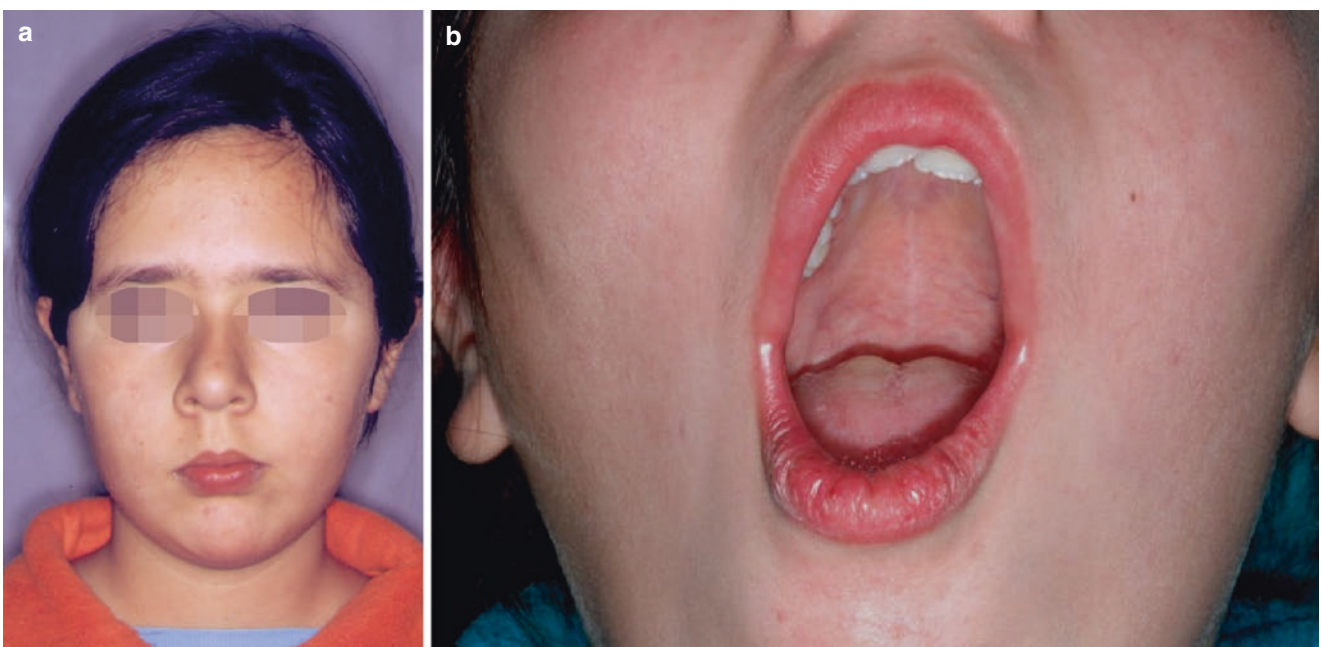


Fig. 11.41 (a, b) Frontal photographs 14 months later without any orthopedic/orthodontic treatment

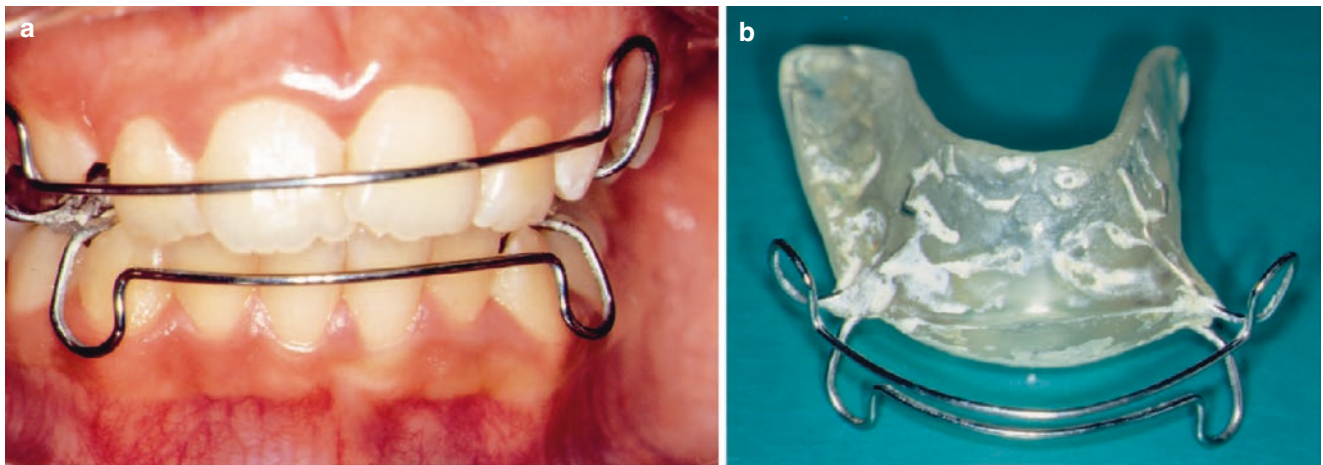


Fig. 11.42 (a, b) An individualized activator was designed to improve muscle activity

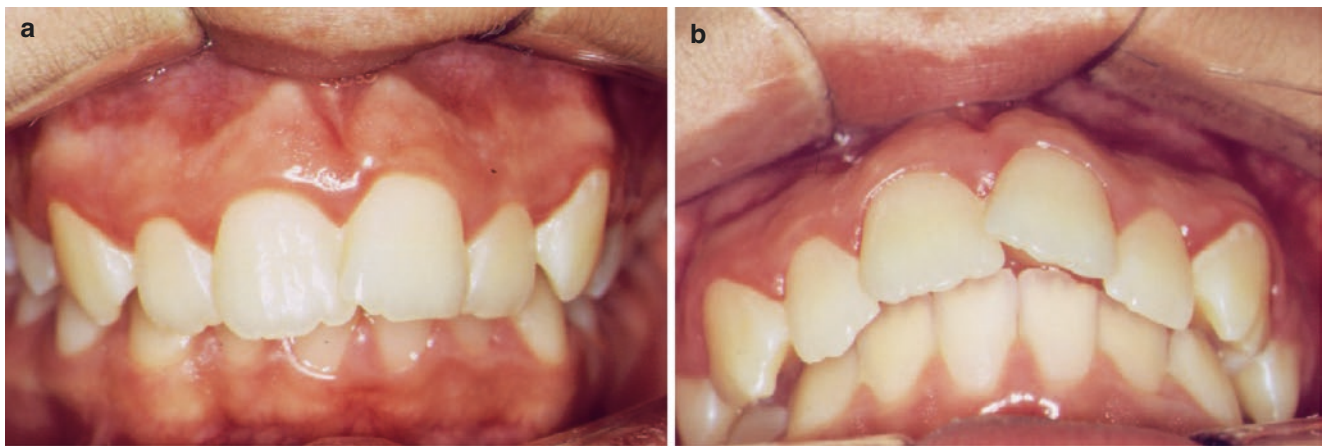


Fig. 11.43 (a, b) Frontal photographs before the beginning of the orthodontic treatment

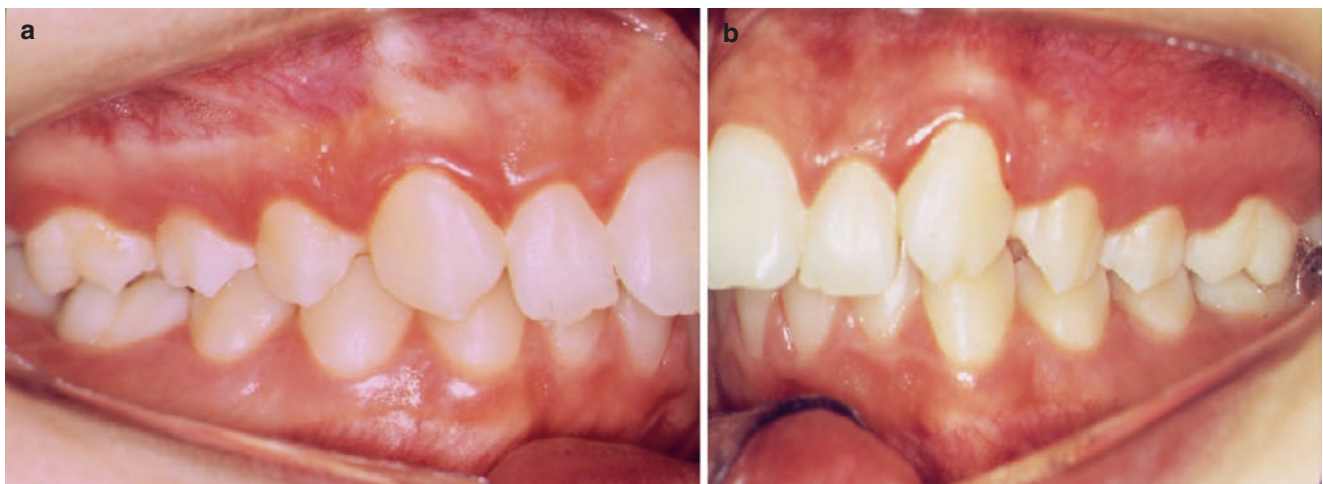


Fig. 11.44 (a, b) Right and left occlusion before orthodontic treatment

Fig. 11.45 Panoramic radiograph pre-orthodontic treatment

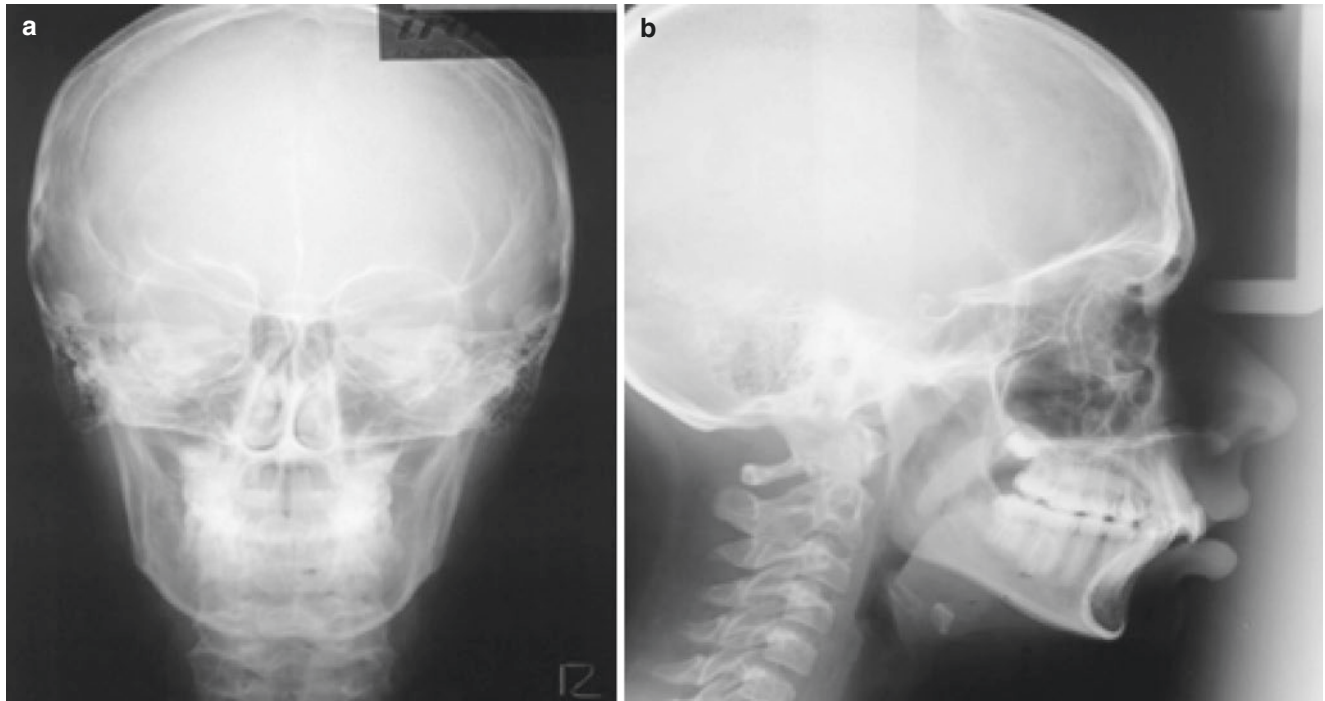
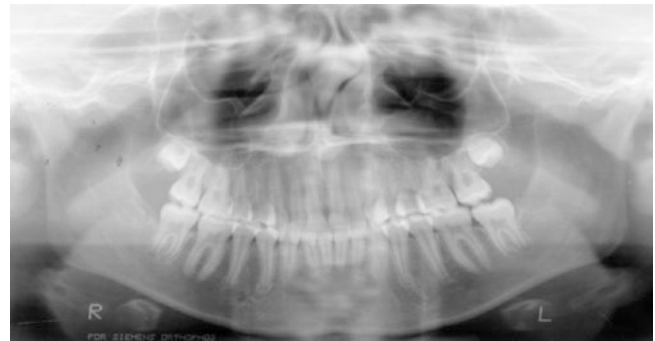

Fig. 11.46 (a, b) Pretreatment frontal and lateral radiographs. The asymmetry and the protrusion of the upper incisors were evident

The asymmetry was clearly confirmed in the frontal radiograph where the differences between the right and left side were evident. The lateral radiograph confirmed that the patient had a mesofacial biotype with a significant protrusion of the upper incisors ($+11^\circ$) and a diminished interincisal angle (112°). The lower facial height was normal (47°) (Fig. 11.46a, b).

Since in this patient the asymmetry was a combination of skeletal, muscular, and soft tissue discrepancies, an individualized treatment protocol had to be designed in order to achieve the best results. Metallic preprogrammed brackets slot 0.022" were bonded with SS 0.016" archwires to align and level the arches (Fig. 11.47a, b).

Class II elastics were suggested to improve lateral occlusion. Overjet and overbite were in a normal range and midlines were still non-coincident.

According to the clinical and radiographic diagnosis, it was very difficult to achieve Class I molar and canine on the left side due the presence of a skeletal asymmetry (Fig. 11.48 a, b).

The upper and lower occlusal arches were well rounded, and all the rotations were corrected. In general, it is advisable that the last archwire be maintained in place for at least 5–6 months to obtain mature bone around the new position of the teeth (Fig. 11.49a, b).

Photographs at the end of the treatment showed that all the objectives were fulfilled in a 2-year and 6-month orthodontic treatment. Midlines were coincident as well as overjet and overbite within the normal ranges. Occlusal plane and gingival lines were parallel (Fig. 11.50a, b).

Perfect Class I canine and molar were achieved on the right side and as expected Class II on the left side. Good oral hygiene was maintained (Fig. 11.51a, b).

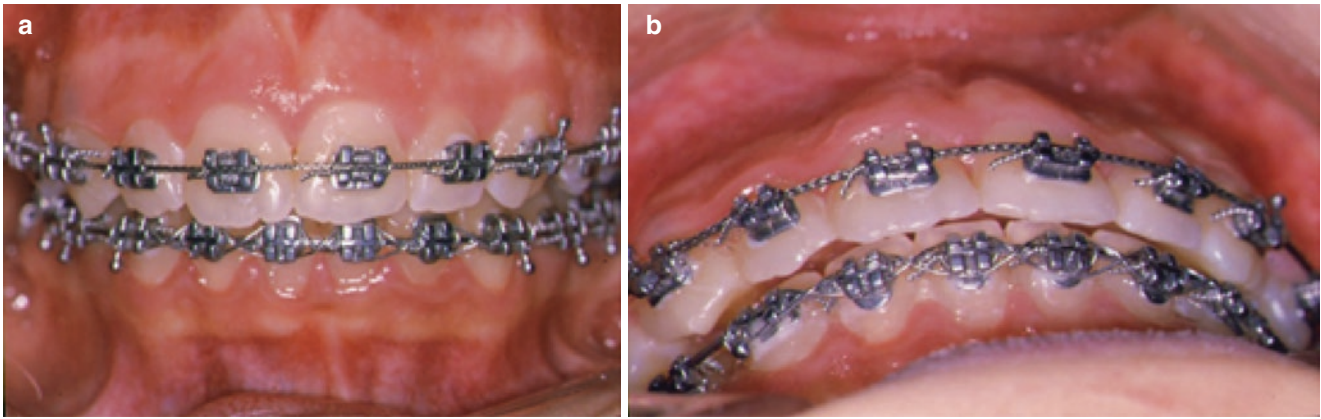


Fig. 11.47 (a, b) Frontal view after 20 months in active orthodontic treatment with preprogramed 0.022" metal brackets. Gingival line was parallel to the occlusal plane

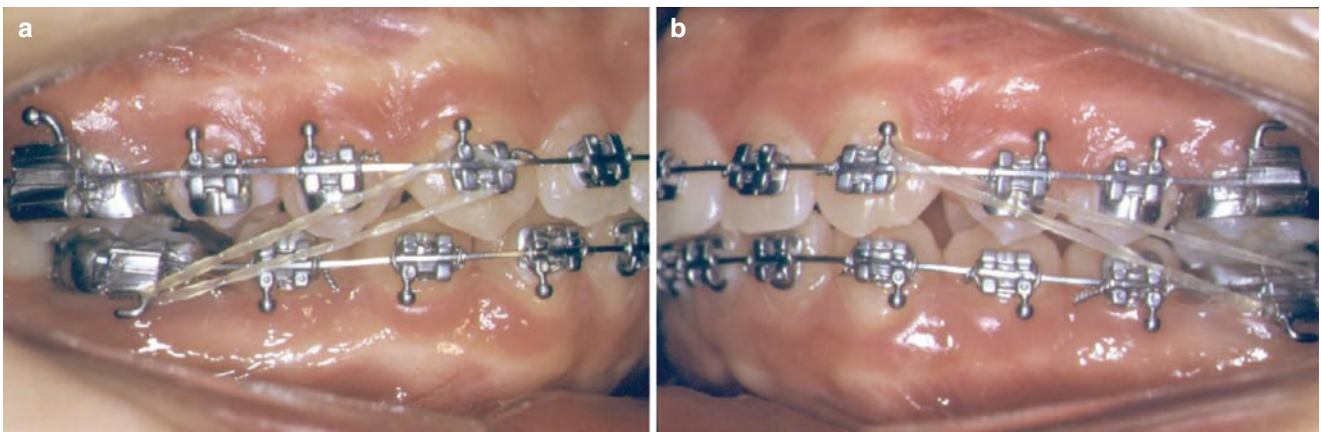


Fig. 11.48 (a, b) Class I elastics were recommended 20 h a day to improve occlusion

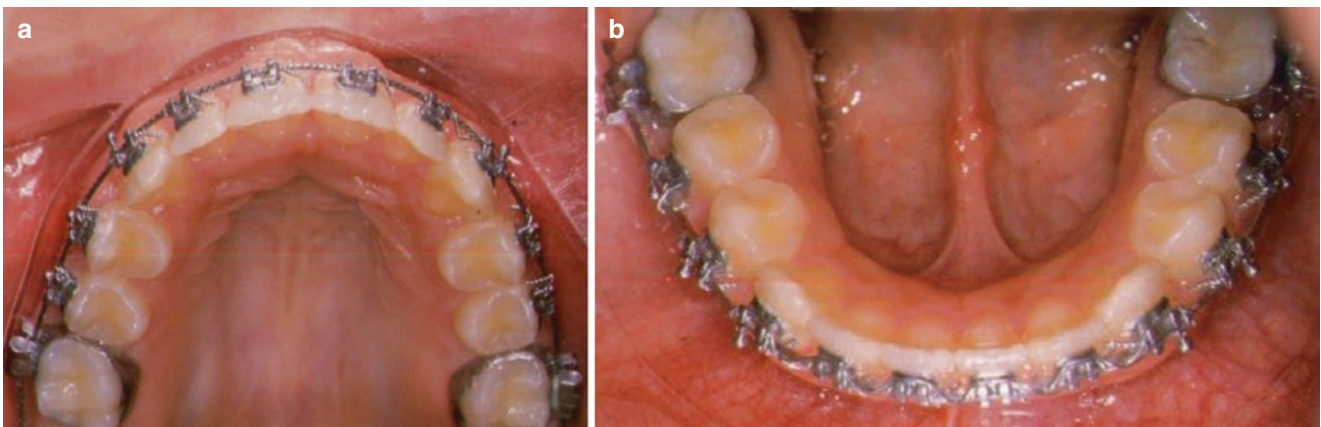


Fig. 11.49 (a, b) Upper and lower arches before the end of the orthodontic treatment

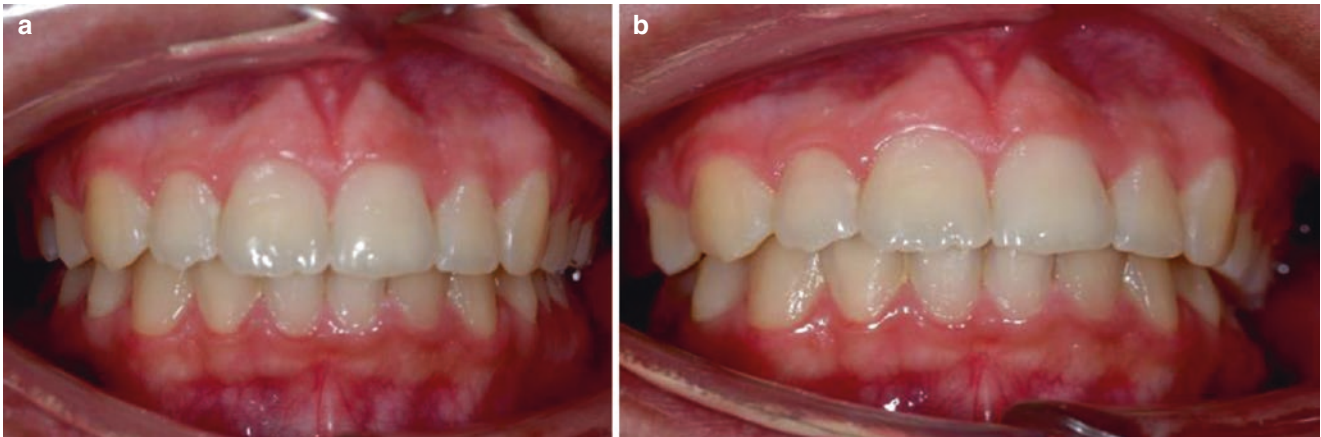

Fig. 11.50 (a, b) Posttreatment frontal photographs. All the objectives were fulfilled with no extractions

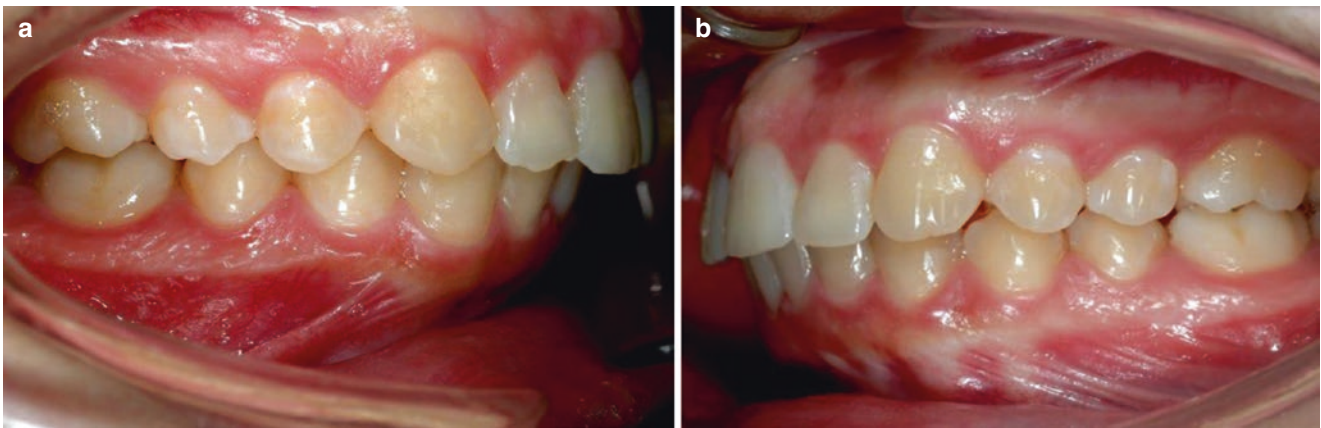


Fig. 11.51 (a, b) Lateral views at the end of the orthodontic treatment

Upper- and lower-fixed retention wire were bonded in order to maintain the position of the upper and lower incisors. To maintain the results that were achieved, another functional appliance similar to one made by Trainers was recommended for a long period (4–5 years) since the normalization of the musculature activity takes several years (Fig. 11.52a, b).

Subtle soft tissue facial asymmetry can be observed at the end of the active orthodontic treatment (Fig. 11.53a, b). A functional appliance was recommended as a retainer for a long period of time.

After a careful analysis of the panoramic radiograph, a good parallelism of the roots without resorption was observed. The second molars had completely erupted, and the third molars were in their normal process of eruption (Fig. 11.54a). The lateral radiograph confirmed the substantial improvement in the profile (Fig. 11.54b).

The comparison between the pre- and posttreatment photographs clearly showed that the treatment objectives were reached. Although some asymmetry was observed, it was less visible (Fig. 11.55a, b). No TMJ pain or dysfunction was present.

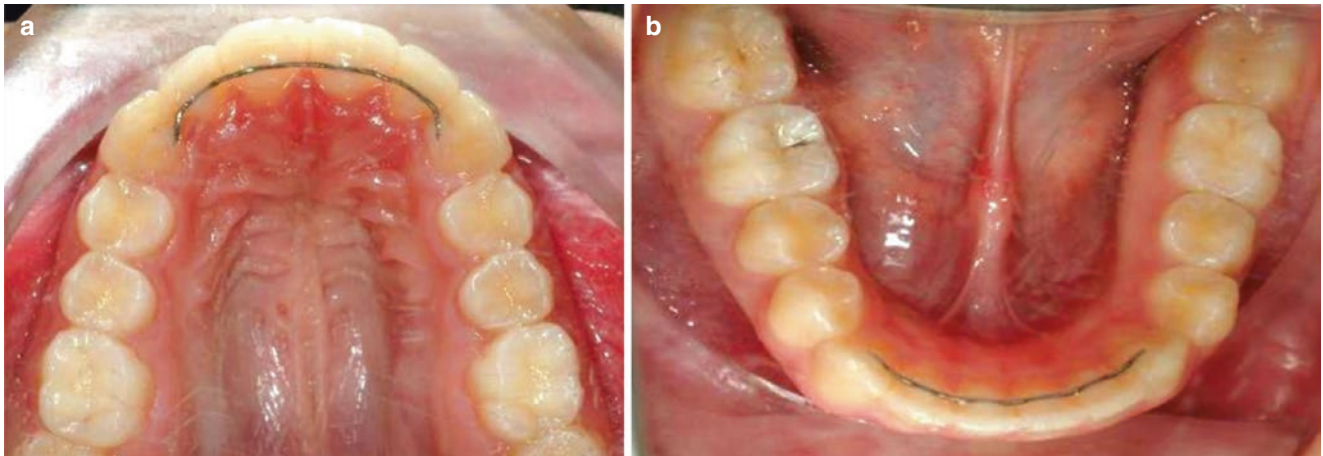


Fig. 11.52 (a, b) Upper and lower fixed retainers were bonded on the anterior teeth along with a functional appliance to maintain the results

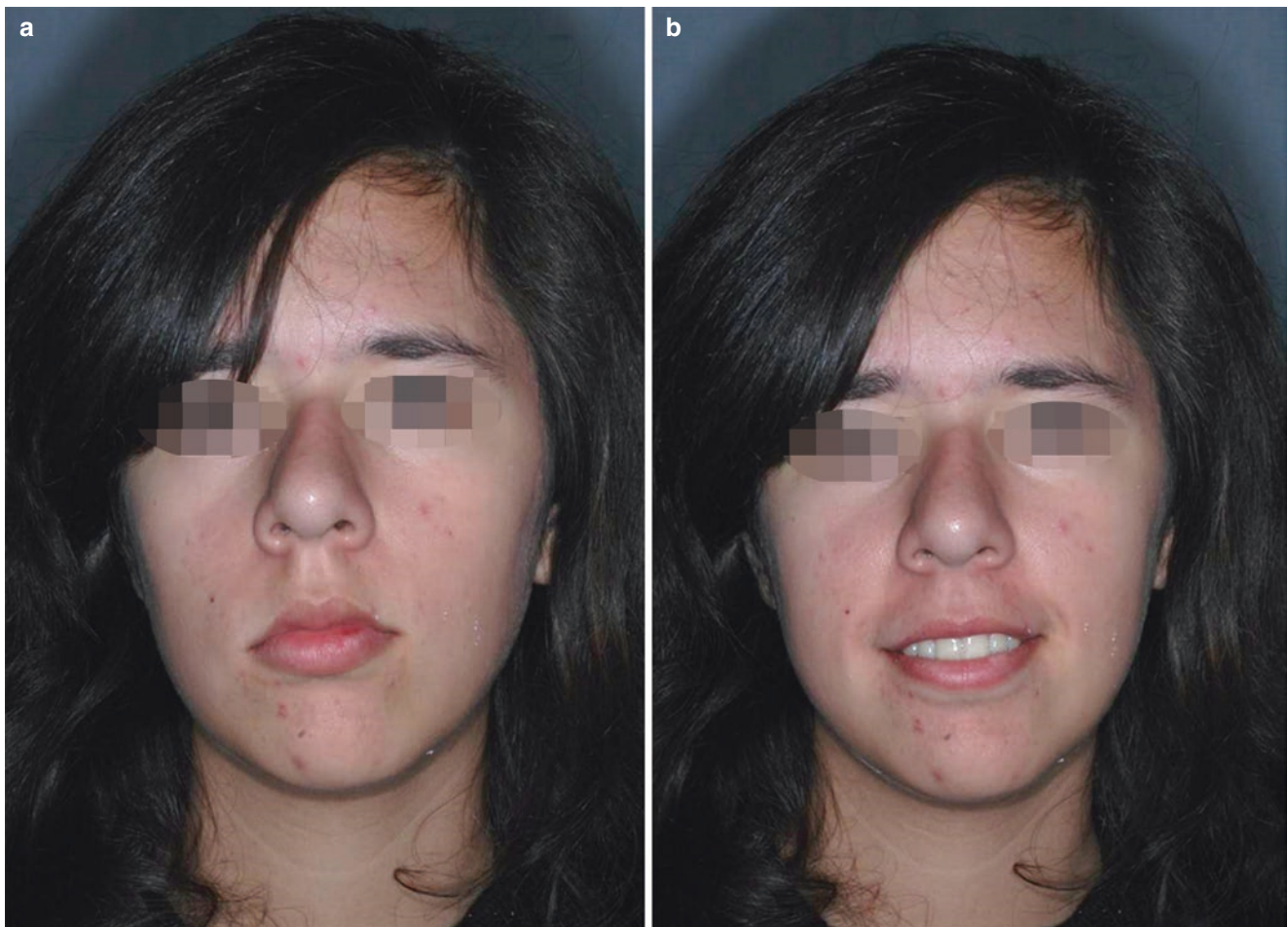

Fig. 11.53 (a, b) Frontal and smile photos at the end of the treatment . The asymmetry is less noticeable

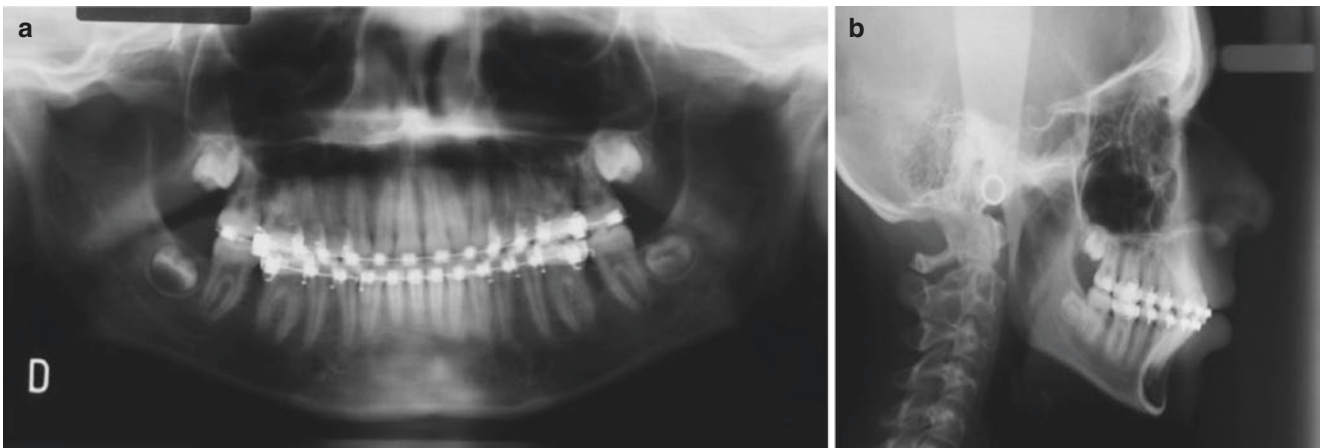


Fig. 11.54 (a, b) Panoramic and lateral radiograph at the end of the active orthodontic treatment

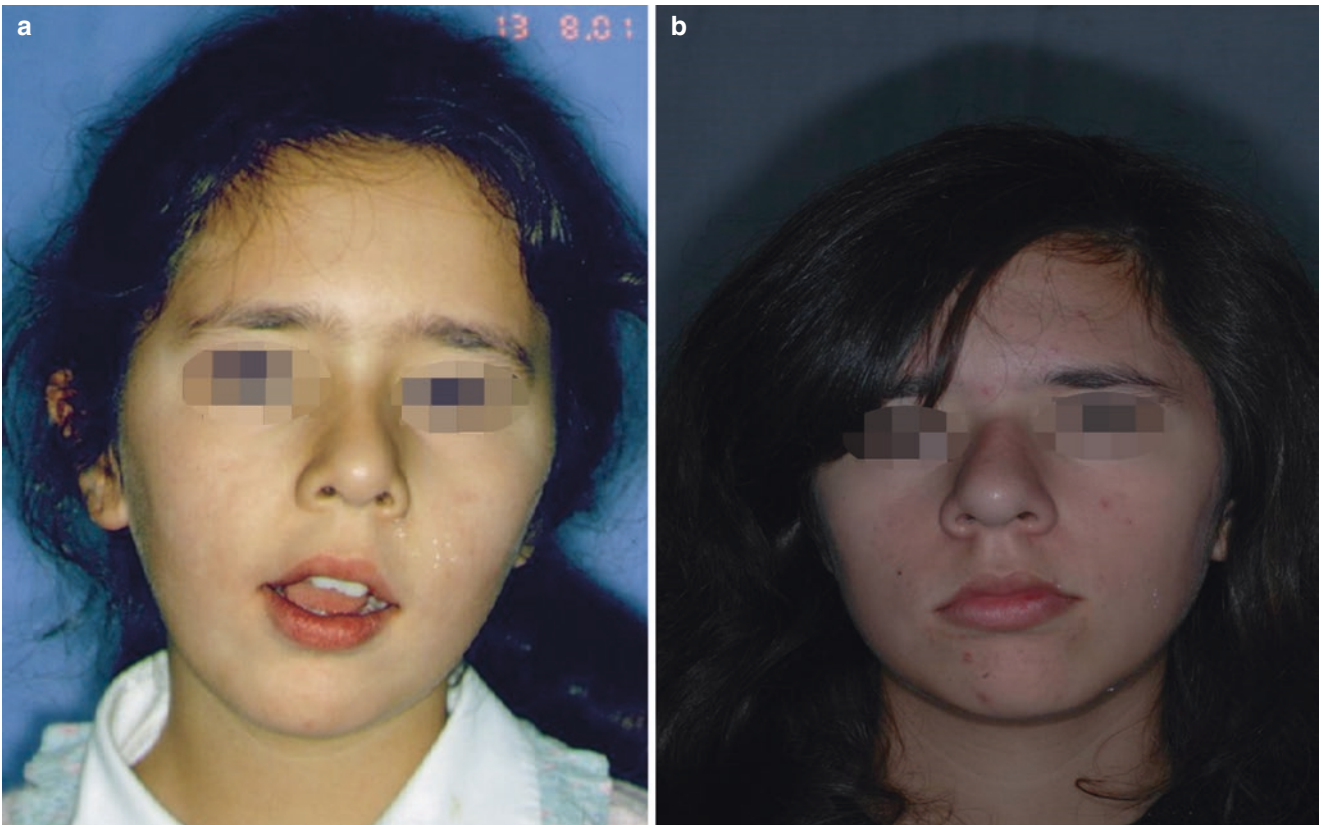

Fig. 11.55 (a, b) Frontal photographs pre- and postorthodontic treatment. A substantial esthetic and functional improvement was achieved

Conclusions

One of the biggest challenges for the orthodontist is the treatment of dentoalveolar and skeletal asymmetries.

It is crucial to determine the real factors that cause the asymmetry and in this way to define the best treatment and long-term retention plan.

The treatment of asymmetries in early mixed dentition requires a detailed study of all the records that are available (radiographs, cast models, tomographs, photographs, etc.) to determine the location, the extent, and the causes that produce these results (Thilander et al. 1984).

For accurate diagnosis, all the frontal, transverse, and lateral asymmetries have to be diagnosed in centric relation.

A panoramic radiograph is useful to survey dental and bone structures of the maxilla and the mandible and to determine the presence of gross pathologic condition or the shape of the mandibular ramus and condyles on the both sides.

Clinical observations have shown large adaptive changes in fractured condyles than can cause functional disturbances and alterations in dentofacial growth.

The retention plan has to be individualized for each patient and be determined at the same time as the treatment plan. A long-term retention plan with functional appliances is always recommendable in all the patients.

Unfortunately there is no particular bracket or wire that can solve all of the different types of asymmetries that could be present in all patients.

Further studies should be conducted to analyze whether the use of this treatment protocol for a longer period time

would have a significant skeletal effect in growing patients with asymmetries.

Bibliography

- Bishara SE. Textbook of orthodontics. Philadelphia, London, New York, St Louis, Sydney, Toronto: WB Saunders Company; 2001. p. 532–545.
- Burstone C. Diagnosis and treatment planning of patients with asymmetries. *Semin Orthod.* 1998;4:153–64.
- Chatzistauro E, Basdra E. Conservative treatment of isolated condylar fractures in growing patients. *WJO.* 2007;8:241–8.
- Da Silva Andrade A, Hauber Gameiro G, DeRossi M, Duarte Gavião MB. Posterior crossbite and functional changes. *Angle Orthod.* 2008;79:380–6.
- Egermark-Eriksson I, Carlsson GE, Magnusson T, Thilander B. A longitudinal study on malocclusion in relation to signs and symptoms of cranio-mandibular disorders in children and adolescents. *Eur J Orthod.* 1990;12:399–407.
- Kilic N, Kiki A, Oktay H. Condylar asymmetry in unilateral posterior crossbite patients. *AmJ Orthod Dentofacial Orthop.* 2008;133:382–7.
- Kutin G, Hawes RR. Posterior cross-bites in the deciduous and mixed dentitions. *Am J Orthod.* 1969;56:491–504.
- McNamara JA. Early intervention in the transverse dimension: is it worth the effort? *Am J Orthod Dentofacial Orthop.* 2002;12:572–4.
- Schmid W, Mongini F, Felisio A. A computer-based assessment of structural and displacement asymmetries of the mandible. *Am J Orthod Dentofacial Orthop.* 1991;100:19–34.
- Tavares CA, Aligayer S. Conservative orthodontic treatment for a patient with a unilateral condylar fracture. *AJODO.* 2012;141:e75–84.
- Thilander B, Wahlund S, Lennartsson B. The effect of early interceptive treatment in children with posterior crossbite. *Eur J Orthod.* 1984;6:25–34.

Elsa Pérez Ruiz

Temporomandibular disorders (TMD) is a collective term for a group of musculoskeletal conditions which include the muscles of mastication, the temporomandibular joint (TMJ) and associated structures.

In a recent update, the American Academy of Orofacial Pain (AAOP 2013) divided TMD in two broad categories: masticatory muscle disorders and TMJ disorders.

Masticatory muscle disorders include muscle pain limited to the orofacial region, muscle pain due to systemic/central diseases, dyskinesia, dystonia and other muscle disorders (contracture, hypertrophy, neoplasia).

TMJ disorders include joint pain, joint disorders (disc displacement with and without reduction), hypomobility (ankylosis, adhesions), hypermobility (luxation) and joint diseases (juvenile osteoarthritis, systemic arthritis, neoplasia, condylar and sub-condylar fractures).

The reported prevalence of TMJ disorders in children varies widely in the scientific literature (Thilander et al. 2002). In many areas the paediatric dental literature is insufficient, and it is tempting to extrapolate information from adult studies. Some conditions in children are similar to those in adults, but differences do exist, especially in the area of craniofacial growth, so when the treatment is planned for the growing child, these differences must be considered.

There are a significant number of epidemiologic studies in children and young adolescents (Carlsson et al. 2002). These studies give insight to the prevalence of signs and symptoms of TMJ disorders which reveal that they are quite common in the young population, but only a few children complain of such a problem. However severe and moderate signs and symptoms are not frequent, and only a few need

treatment. Further results of these studies are as follows: there is a high prevalence of signs and symptoms that increase with age, and also there is a greater need for treatment in girls than boys.

The TMJ is comprised of three major components: the mandibular condyle, the temporal fossa and the associated connective tissue, including the articular disc. The first evidence of development of the TMJ in humans is seen 8 weeks after conception. During the first decade of life, the mandibular condyle becomes less vascularized, and most of the morphological changes are completed.

During the second decade there is continued but progressive growth. The shape of the mandibular condyle may change during growth between 12 and 16 years of age (Dibbets and Van der Weele 1992). From adolescence to adulthood, the condyle changes to a form that is greater in width than in length. Although there is a full active growth in the first two decades, after that it merely undergoes adaptive remodelling changes throughout life.

Disturbance of such growth (Isberg 2001) can occur as a consequence of TMJ pathology but can also be induced by nonfunctional masticatory muscle activity and changes in the joint function.

Temporomandibular dysfunction in growing individuals can be associated with reduced mandibular growth and also with reactive hyperplasia growth of the condyle and coronoid process and the gonial region.

TMDs have multiple aetiological factors. The TMJ and masticatory system is complex and requires a thorough understanding of anatomy and physiology of the structural, vascular and neurological components in order to manage TMD (Greene 2001).

E. Pérez Ruiz
Department of Orthodontics, Maimonides University,
Buenos Aires, Argentina
e-mail: elsaperezruiz@yahoo.com.ar

There is no scientific documentation to predict which patient will or will not develop TMD neither to prevent such a problem. But there are risk factors or initiating factors and sustaining factors that contribute to the development of TMD. Furthermore, we must consider systemic and psychosocial factors that may reduce the adaptive capacity of the masticatory system and contribute also to TMD. Aetiological factors are:

- Macro trauma: Orofacial injuries such as trauma to the chin during childhood are a common occurrence because of falling; chin trauma has been reported to be a factor in the development of TMD in paediatric patients (Fischer et al. 2006). Other factors such as motor vehicle accidents, sports, physical abuse, forceful intubation and unilateral or bilateral intracapsular or sub-condylar fractures are the most common mandibular fractures in children.
- Micro trauma: from parafunctional habits. Bruxism clenching (Huynh and Guileminault 2009), hyperextension and other habitual behaviours are known to contribute to the development of TMD by joint overloading that leads to cartilage breakdown as well as synovial fluid alterations and other changes within the joint.
- Anatomical factors: skeletal and occlusal. There is a relative low association of occlusal factors and the development of TMD. Current literature does not support that the development of TMD is caused or improved by orthodontic treatment (Henrikson and Nilner 2003), regardless of whether premolars were extracted prior to treatment. While most children may be able to compensate disorders without occlusal problems, in others the masticatory system failed to adapt, which leads to a greater risk of dysfunction. There are malocclusions that were found to be associated with TMD:
 - Skeletal anterior open bite
 - Overjet greater than 6–8 mm
 - Class III malocclusion
 - Posterior crossbite
 Craniocervical posture is suggested to be associated with occlusion and dysfunction of TMJ. Steep articular eminence of the temporal bone:
- Psychosocial factors include emotional stress.
- Systemic factors include connective tissue diseases such as rheumatoid arthritis, lupus erythematosus, juvenile idiopathic arthritis and psoriasis arthritis; others can be joint hypermobility, genetic susceptibility and hormonal fluctuations.

Proper diagnosis is the key to successful treatment. All comprehensive dental examinations should include a screening evaluation of the TMJ and surrounding area. Diagnosis is a combination of historical information, clinical examinations and TMJ imaging. The patients must have a history of facial pain combined with physical find-

ings and supplemented by radiographic or imaging data when indicated (Okeson 2013).

A screening history as part of the health history may include a preliminary questionnaire. Clinical and physical assessment may include manual palpation of the muscles and TMJ to evaluate tenderness of intraoral and extraoral jaw muscles, neck muscles and TMJ. Evaluation of mandibular movements including assessment of mandibular range of motion is measured using a millimetre ruler (maximum opening, maximum opening with pain, maximum lateral excursion, maximum protrusive excursion) and drawing of mandibular opening pattern like deviation (when the opening pathway is altered but it returns to a normal midline relationship at maximum opening) or deflection (when the opening pathway is shifted to one side, and at maximum opening is deflected). Determination of TMJ sounds by auscultation with stethoscope is done during opening and closing mandibular movement (click, pop or crepitation). Radiographs (panoramic, lateral transcranial view, etc.) or imaging (TMJ tomography, MRI, scintigraphy) are used to examine for TMJ pathology. Psychosocial factors related to temporomandibular symptoms should also be considered like mood disorders, anxiety disorders, migraine headaches, tension headaches and emotional factors, among others.

On the other hand, differential diagnosis of the pain perceived but not originating in the TMJ is important. Certain medical conditions are reported occasionally as TMD: trigeminal neuralgia, central nervous system lesions, odontogenic pain, sinus pain, otologic pain, development abnormalities, neoplasia, parotid diseases, vascular diseases, myofascial pain, cervical muscle dysfunction and Eagle's syndrome, among others, that can cause symptoms similar to TMD: otitis media, allergies, airway congestion, rheumatoid arthritis, etc. (Loos and Aaron 1989).

Generally the prognosis of the TMD is good. Most of the patients improve very much their signs and symptoms naturally; so the goal of treatment should be to accompany natural process, decrease the pain, improve the healing and repair and restore the function.

TMJ disorders in children can be managed effectively by relatively simple conservatives and reversible therapies. The reversible therapies may include:

- Patient educations (relaxation training, awareness of clenching and bruxing habits if present).
- Physical therapy: jaw exercises or TENS, ultrasound, iontophoresis, massage, thermotherapy, coolant therapy (Medlicott and Harris 2006).
- Behavioural therapy (avoiding excessive chewing of hard foods or gums, decreasing stress, anxiety and/or depression).
- Prescription medication (non-steroidal anti-inflammatory drugs, anxiolytic agents, muscle relaxers).
- Occlusal splints: the goal is to provide orthopaedic stability to the TMJ (Wahlund et al. 2003). These alter the

patient occlusion temporarily and may be used to decrease parafunctional activity. The stabilization type of splint is balanced so that all the teeth are in occlusion, when the patient is in closed position and the jaw is in a musculo-skeletal position.

Irreversible therapies can include:

- Occlusal adjustment: altering permanently the occlusion or mandibular position by selective grinding or full-mouth restorative dentistry.
- Orthodontics: mandibular reposition devices are designed to alter the growth or the permanent reposition of the mandible (headgear) (Rey et al. 2008). There is a little evidence that orthodontic treatment can prevent or relieve TMD.
- Botulinum toxin A injections: this modality has not been approved for use in children.
- Surgery: open, when absolutely indicated. Closed, especially in intracapsular condyle fractures.

For children and young adolescents with signs and symptoms of TMD, reversible therapies should be considered, but irreversible therapies should be avoided. Referral to a medical specialist may be indicated when primary headaches, otitis media, allergies, abnormal posture, airway congestion, rheumatoid arthritis, connective tissue disease, physical disorders or other medical conditions are suspected.

After extensive review and discussions of a large number of incredibly diverse treatments of TMD that have been proposed over the years (Stohler, Zarb), we conclude that patient safety should be the top criterion for selection of appropriate therapies, and we, as clinicians, must choose low-tech and high-prudence treatment approaches that work for many patients. The objective can be summarized quite simply as reducing pain, inflammation and psychologic effects, while increasing muscle strength, range of motion and bite comfort.

As indicated above, the appropriate treatment for condylar fractures range from doing nothing in children whose only problem is that the mandible can force back into a strained retruded position, to functional appliance therapy in elementary school years, mandibular advance in teen ages and surgical relief of ankylosis in young children. The same criterion should hold in OA juvenile where treatment is palliative in order to encourage the patient to relieve pain, among other objectives. Selected case reports illustrate these treatment possibilities

12.1 Condylar Fracture

TMJ fractures must be focused not only as a cause of direct damage to osseous structures but also of future disturbances of dentofacial development. Treatment is aimed at restoring normal joint function, occlusion and symmetry. The effect

will be more accurated if the disturbance occurs early in life, during childhood when growth activity is greater and mandibular shape and size have not completed yet.

It was thought that fracture of the condyle produced a growth deficit in proportion to the age at time of the injury; the younger the child, the greater the potential growth problem. It seems clear now that this is incorrect for two reasons: (1) frequently regeneration of the condyle is complete in young patients, with no residual deficit following fracture, and (2) better regeneration occurs in actively growing patients under the age of 12 (Proffit et al. 1980).

Compensatory growth was defined as more growth on the fractured than on the non-fractured side, in which the deficit caused by the fracture is not necessarily overcome (Lund 1974).

When growth deficit does occur following condyle injury, there are two possible causes: (1) a loss of the stimulus to normal growth (2) or secondary to mechanical restrictions created by scarring and loss of motion. For many years, the cartilage at the mandibular condyle was viewed as having primary growth potential, but in recent years, many investigators have shown that the condyle and the cartilage apparently grow in most instances in response to other growth, rather than serving as a primary growth centre (McNamara 1975).

Following a clean fracture, the external pterygoid muscle often retracts the condylar segment out of the fossa. If occlusion is restored and normal function continues, the articulating surface will regenerate and remodel (even to the extent of a new fibrocartilage layer), and the position of the mandible will be maintained.

But as in the management of any wound, restoration of function with less harm to the patient should be the primary focus and thus is also true with fractured mandibular condyles.

The management of fractured mandibular condyles remains in discussion. New diagnostic technologies and an improved understanding of the process connected to facial growth have led to a more conservative approach in managing TMJ trauma. Surgical intervention (Hall 1994) for condylar fractures on young children appears to worsen rather than improve the tendency towards growth disturbances. Closed reduction (Walker 1994) combined with physiotherapy is the advocated treatment.

Adequately restored function of the jaw after fracture of the condyle consists of five determinable features: (1) pain-free and mouth opening with an interincisal distance beyond 40 mm, (2) good jaw movement in all excursions, (3) pre-injury occlusion of the teeth, (4) stable temporomandibular joint and (5) good facial and jaw symmetry.

Successfully managed fractures of the mandibular condyle in children heal and restore themselves by remodelling of the bone to reasonable anatomic morphology and function. The manner of non-surgical management requires close supervision and attention by the therapist and compliance by the patient.

Case 1: Treatment of Unilateral Condyle Fracture

The patient was a 9-and-half-year-old girl. She came at the TMJ Dysfunction Department at a university, about 1 month after a car accident (Figs. 12.1a, b and 12.2).

She had unilateral fracture on the right condyle and had pain in the temporomandibular joint region. She could not open her mouth as well as before the accident and showed typical deviation of the mandible to the right (Fig. 12.3a, b).

The tomography showed an intracapsular fracture on the right condyle with internal displacement (Figs. 12.4 and 12.5). There are no alterations on the glenoid fossae neither on the soft tissues.

Joints are dependent on movement for well-being; this occurs by allowing immediate or early use of the jaw. Orthodontic bands are placed on both sides (right and left) for accommodation of maxillo-mandibular elastics to hold the teeth correctly in occlusion at night (Figs. 12.6 and 12.7a–c). The elastics are removed each morning upon waking up, and the patient is allowed full daytime use of the jaw with no dietary restrictions. Chewing brings energy and loading through the mandible to the fractured condyle being remodelled to the needs of function. This situation is controlled and observed closely for a minimum period of 3 months and at 3-month intervals during the next 12 months.

The patient is supervised and assisted in regaining mouth opening beyond an interincisal gape of 40 mm as quickly as possible, no longer than 10–14-day period after the start of physiotherapy. We control and provide immediate assistance if the occlusion begins to drift or the incisal opening begins to decrease. Jaw symmetry and occlusion are thus maintained during rehabilitation.

The soft tissues heal concomitantly with the condyle during jaw movement. If jaw movement is not maintained at its fuller range, the soft tissues heal (and scar) to whatever that range might be.

A simple technique to increase the interincisal opening and with which patient compliance is high is to use progressively stack tongue blades together and have the patient insert them between the incisal edges of the anterior teeth (Fig. 12.8a, b). A stack of 24 tongue blades placed between the teeth will produce an opening of 40 mm at the incisal edges, a minimum goal in rehabilitation. The stacked tongue blade regimen is hard to impose in this time of high technology (TheraBite), but is very effective in children.

Most patients will initially tolerate 17–18 tongue blades stacked together, and it is not very difficult to proceed to 24 blades or more within 5- to 10-day period, and the patient keeps them available to use 4 or 5 times daily during the 3-month period of rehabilitation.

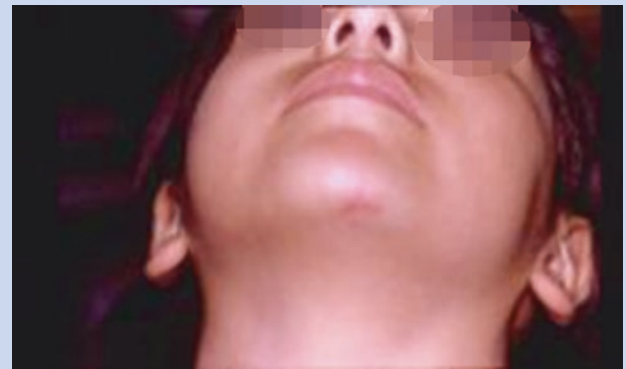

Fig. 12.2 Visible chin scar

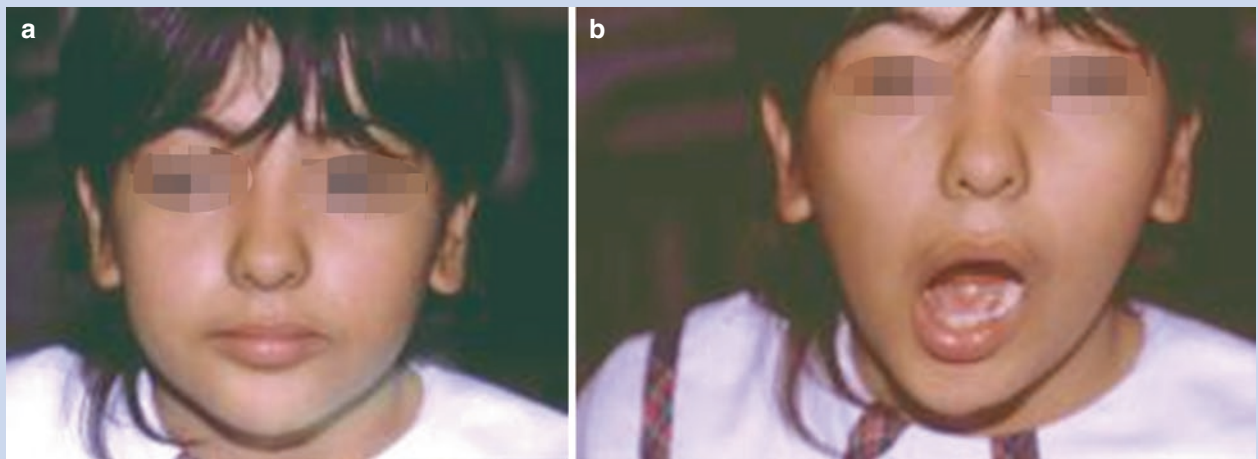

Fig. 12.1 (a) Initial pictures - Face view. (b) Initial pictures - Face with mouth open

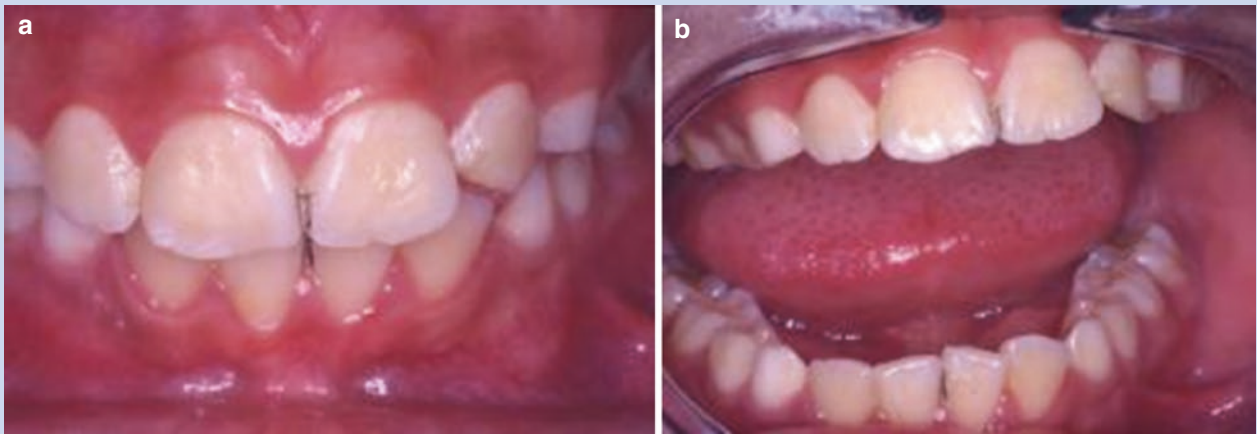

Fig. 12.3 (a) Mouth relationship (closed). (b) Mouth relationship (open)

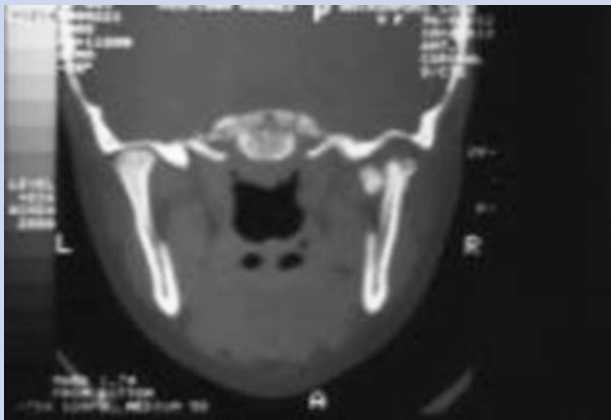

Fig. 12.4 Tomography: Intracapsular fracture on the right condyle

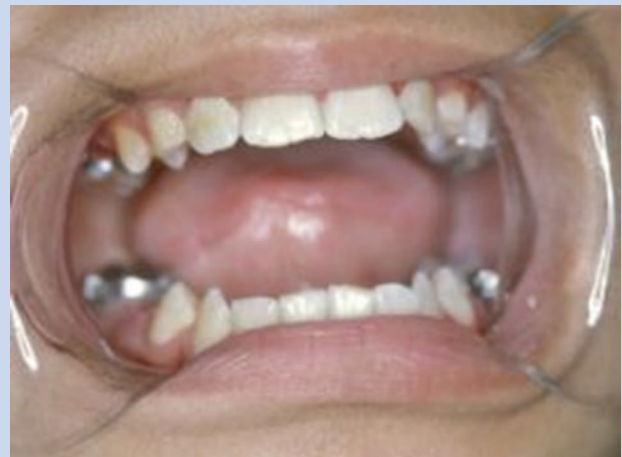

Fig. 12.6 Orthodontic band in upper and lower first molar

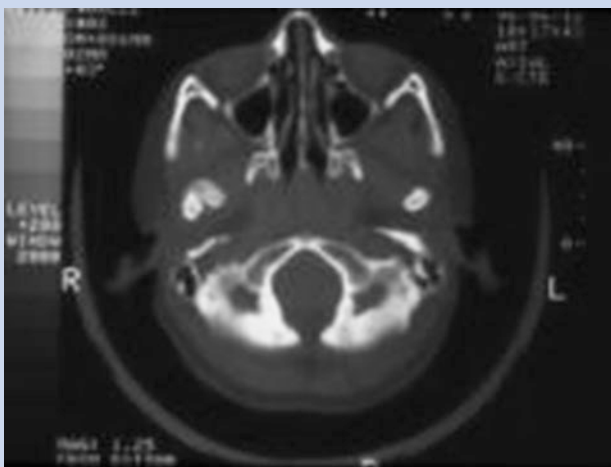


Fig. 12.5 Tomography: Axial view

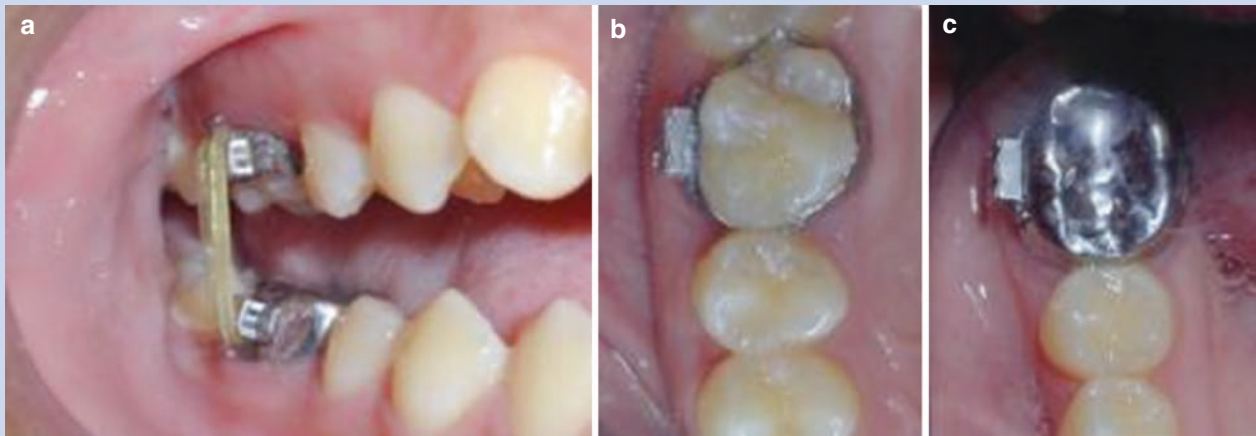


Fig. 12.7 (a) Maxillo-mandibular elastics in place. (b) Upper molar band. (c) Lower molar band

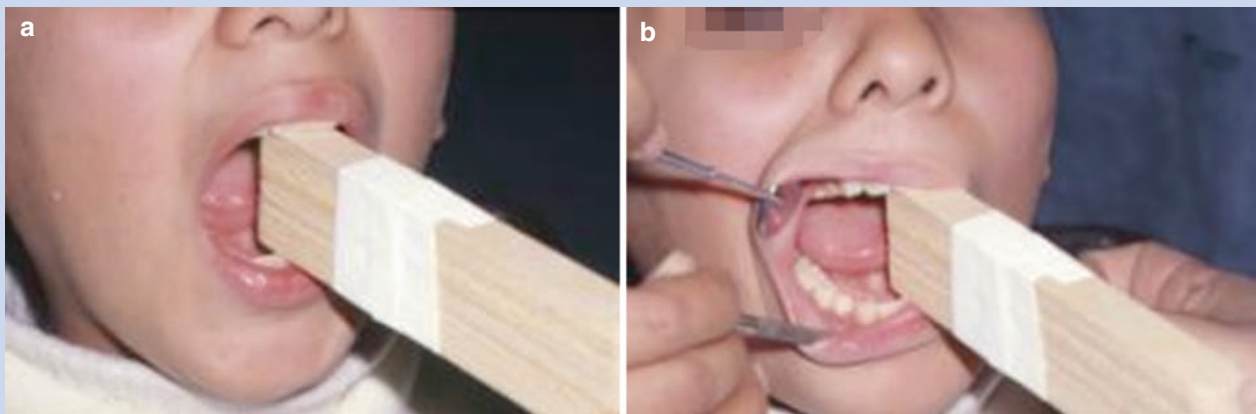


Fig. 12.8 (a) Tongue blades in place. (b) Tongue blades, lateral view

Fifteen days after treatment started, the patient maintains normal but still reduced mouth opening, and mandibular deviation to the right side as well. (Fig. 12.9a, b). Meanwhile the occlusion keeps normal relationship (Fig. 12.10).

After two months the patient almost reached the horizontal plane when closing her mouth (Fig. 12.11), and also the mouth opening became more straight (Fig. 12.12). There was a rehabilitation improvement as a result of persistent exercising.

The most cooperative and willing patients proceed up to 30 tongue blades taped together, which will produce a

mouth opening beyond 45 mm at the incisal edges of the anterior teeth.

During multiple times of the day when the jaw opening exercise is done, the patient is also required to move the jaw from side to side actively or passively with assistance if needed and in protrusion to maintain or restore these very important excursive movements.

Two years after, the CT images of the TMJ area show the condylar head growing and in good position (Fig. 12.13).

After two years and ten months, we can see the good relationship in the maxillar – mandibular occlusion both

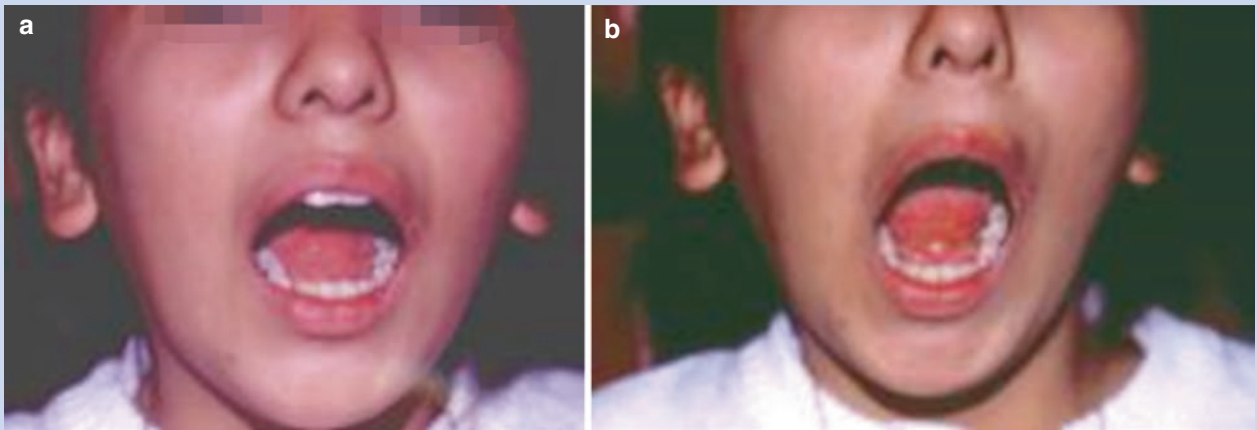


Fig. 12.9 (a) After fifteen days of use. Normal opening. (b) Idem. Maximum opening

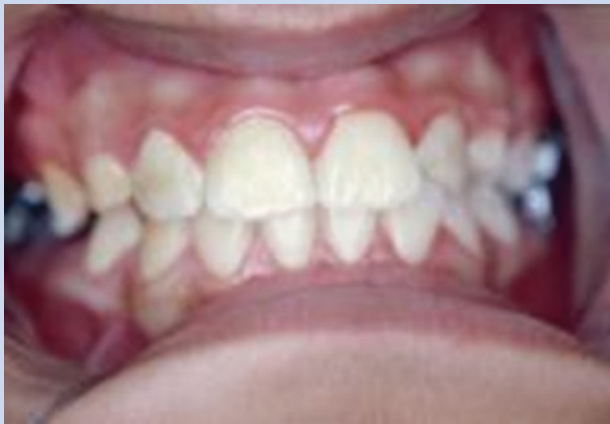

Fig. 12.10 Mouth relationship

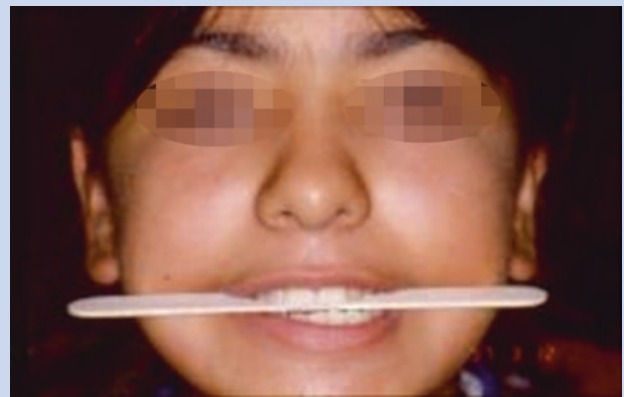

Fig. 12.11 Two months of treatment. Occlusal plane

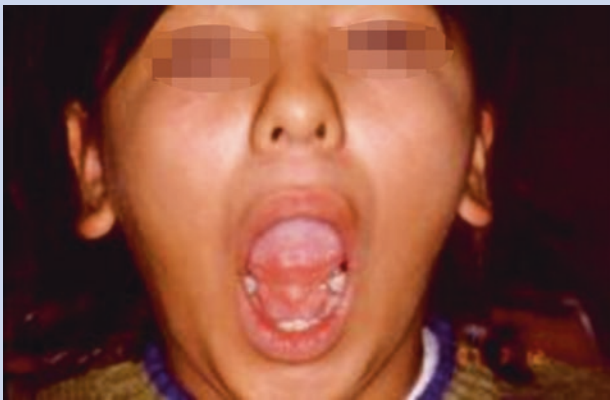


Fig. 12.12 Two months of treatment. Maximum opening

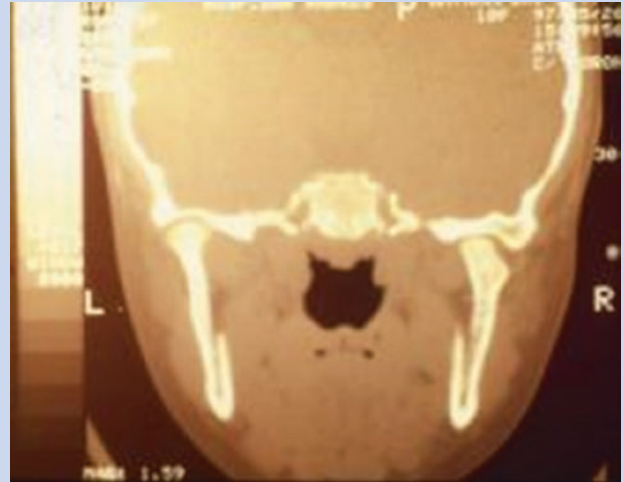

Fig. 12.13 Tomography after twenty four months of treatment

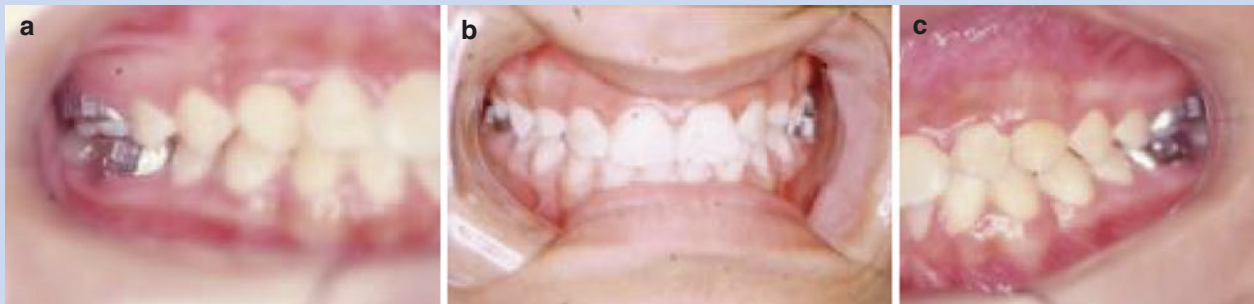

Fig. 12.14 (a) After thirty four months of treatment. Mouth relationship, right side. (b) Idem. Anterior relationship. (c) Idem. Left side relationship

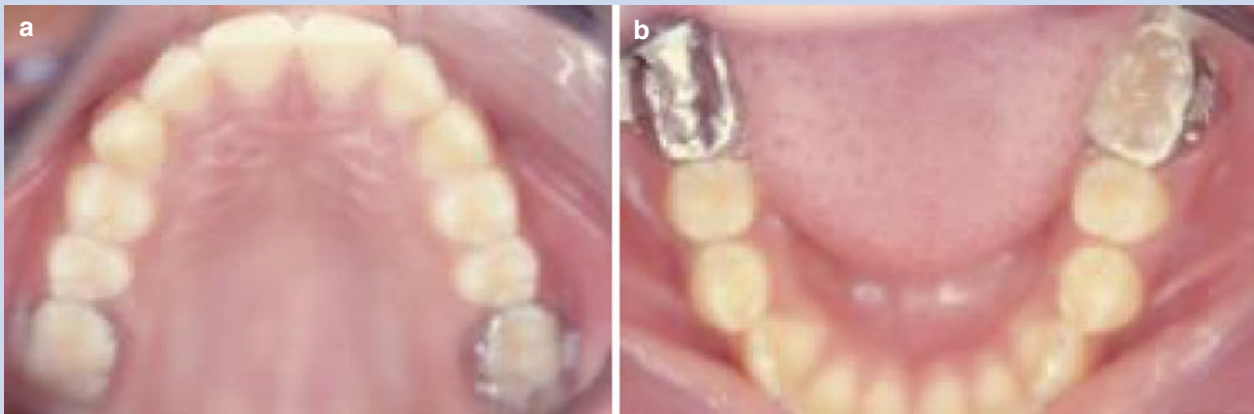

Fig. 12.15 (a) Idem. Upper occlusal view. (b) Idem. Lower occlusal view

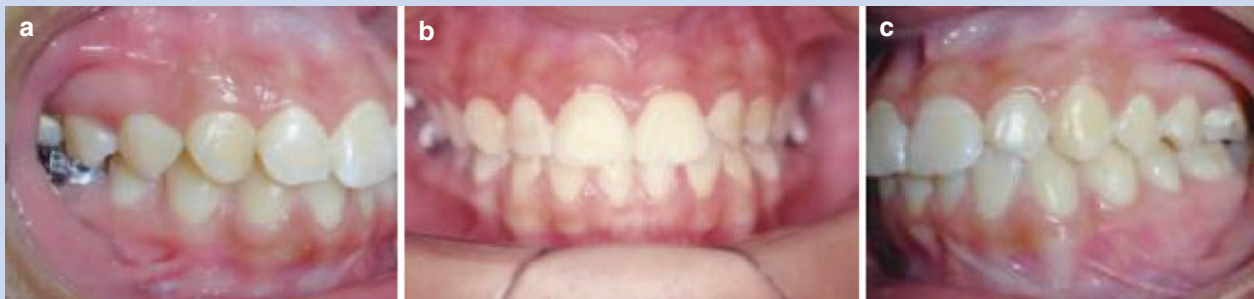

Fig. 12.16 (a) After seven years and four months. Right side relationship. (b) Idem. Front view. (c) Idem. Left side

from the frontal view (Fig. 12.14a, b, c) and also, from the occlusal view (Fig. 12.15a, b).

Non-surgical management of fractured mandibular condyles means restoring movement of the jaw on fractured condyle as quickly as possible and maintaining the jaw and occlusion intermittently in their correct position while jaw motion is strictly supervised and healing is slowly occurring.

After 7 years and 4 months of follow up, the patient holds a good maxillo-mandibular relationship (Fig. 12.16 a, b, c). Clinically, the maximum opening is wide and straight. When measured, it is 48-mm wide (Figs. 12.17 and 12.18). Additionally, a frontal X-Ray shows that the condylar head on the right side has grown satisfactorily as to maintain symmetry respect to the middle line (Figs. 12.19 and 12.20); no further problems, neither pain or TMJ disorders

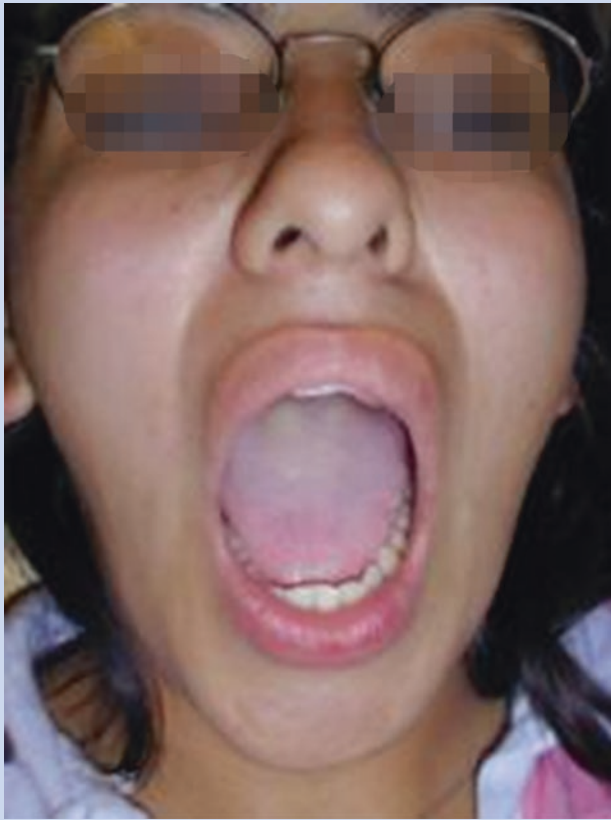


Fig. 12.17 Idem. Maximum opening

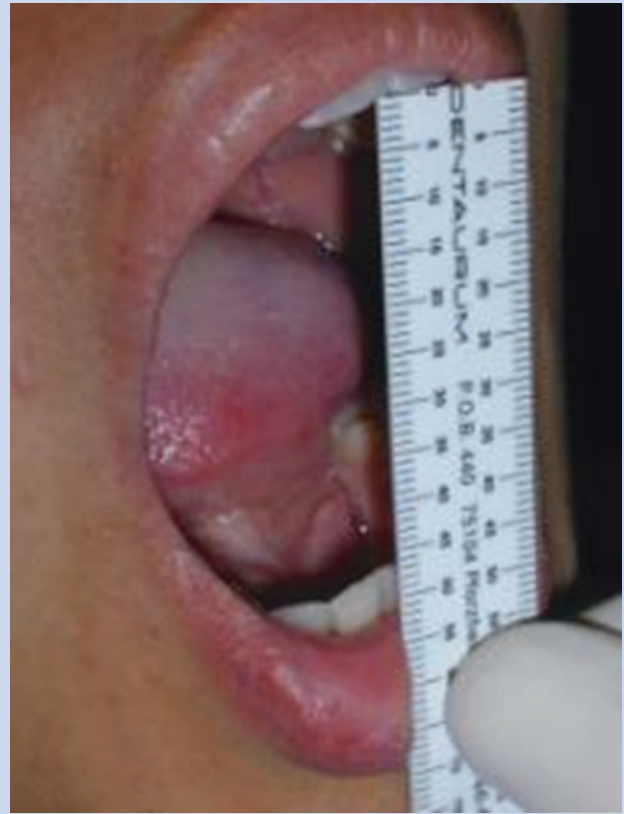

Fig. 12.18 Idem. Maximum opening: 48 mm

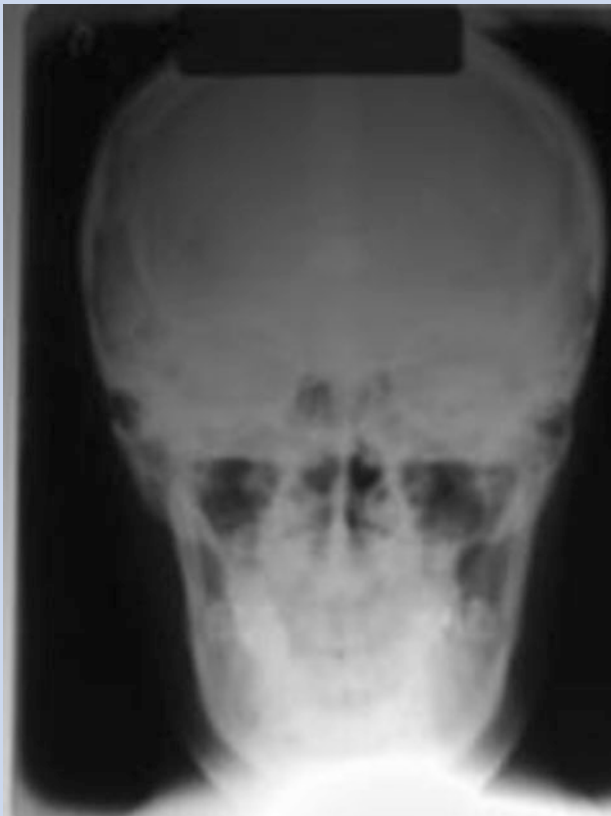


Fig. 12.19 Idem. Frontal X-Ray

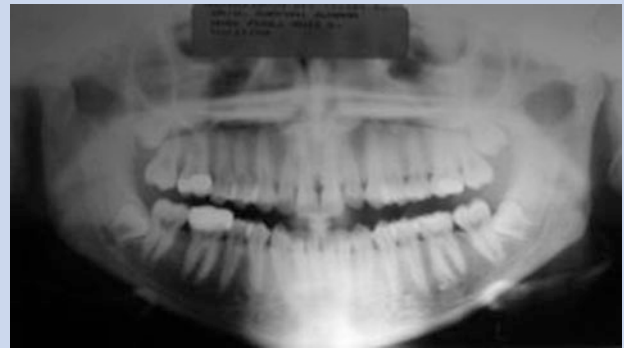

Fig. 12.20 Idem. Panoramic X-Ray

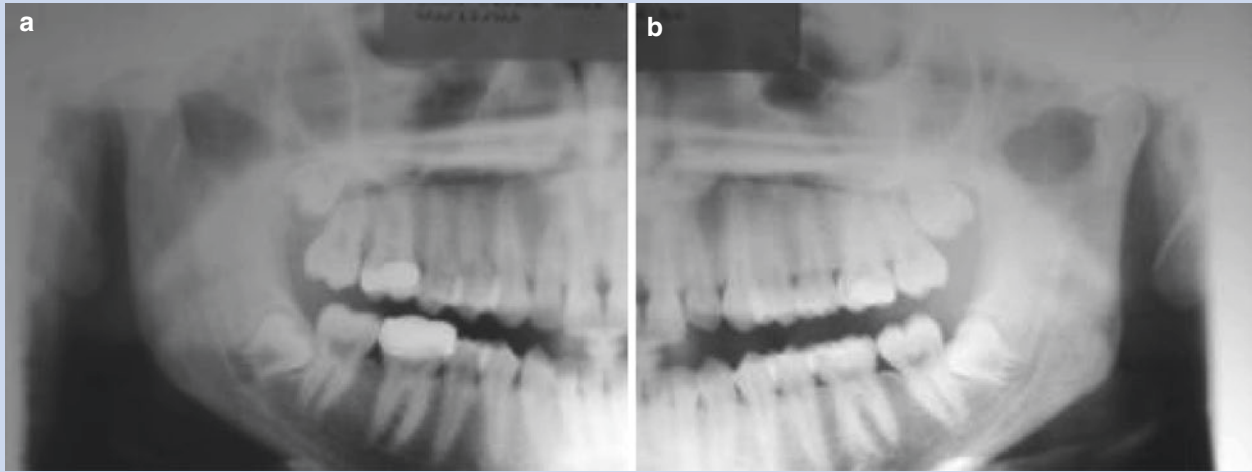


Fig. 12.21 (a) Panoramic X-Ray, right side. (b) Panoramic X-Ray, left side

were registered at this time. The panoramic X-Ray (Fig. 12.21a, b) also shows the good position of the right condyle.

There are reasons for open surgery of fractured mandibular condyles that are beyond the scope of this discussion. However, as long as there are ways to control jaw position via the occlusion or splints, non-surgical management of the problem has proven to be a predictable and reliable way to handle these fractures.

When analyzed by age groups, the fractures in children 10 years or younger were judged to be intracapsular; children represent a special category when younger than age 12. The condylar neck tends to be shorter, and many fractures are thus high neck with only the con-

dyle fractured free from the mandible. Considering their healing capabilities (e.g. regeneration of a new condylar head) (Hovinga et al. 1999), the technical difficulty of reducing and fixing a condylar head displaced medial to the coronoid notch and the amount of soft tissue dissection required, open reduction in children younger than 12 should logically be performed infrequently.

Children between 12 and 18 years old still benefit from their growth potential following close reduction, but have fractures similar to adults (i.e. more low necks/ramus due to the mandibular reaching adult shape). Thus open reduction with rigid fixation and immediate function is a strong option in this age range.

12.2 Ankylosis

Although TMJ ankylosis is one of the most common pathologies affecting the facial skeleton, it is also the most overlooked and under-managed problem in children. Ankylosis leads to reduced mandibular opening, from partial reduction to complete restriction.

Ankylosis in growing children affects the growth and development of the jaws and occlusion.

It can be defined as “inability to open the mouth due to either a fibrous or bony union between the head of the condyle and the glenoid fossae” (Shashikiran et al. 2005).

Ankylosis is most commonly associated with trauma, local or systemic infection or systemic disease. The onset of incidence frequently believed to be before the age of 10.

Clinical features of TMJ ankylosis in childhood are:

- Restricted mouth opening and its associated results including poor oral hygiene and rampant caries
- Facial asymmetry
- Mandibular macrognathia and bird face deformity
- Class II malocclusion with posterior crossbite/anterior open bite

TMJ ankylosis occurring in childhood can impair mandibular growth and function, which may later produce severe facial asymmetry and mandibular retrusion. Early diagnosis of TMJ ankylosis is important, and early surgical intervention is an accepted mode of treatment (Chidzonga 1999). Surgery is indicated to restore mandibular opening. Early and aggressive postoperative opening of the mandible is necessary to maintain good opening.

The treatment of TMJ ankylosis faces a significant challenge because of technical difficulty and a high incidence of recurrence.

Recurrence is a major problem that occurs after the release of TMJ ankylosis.

At present the surgical procedures most frequently used for treatment of ankylosis are:

1. Gap arthroplasty, in which a joint space is recreated either at the side of the pre-existing space or below it; in this case no substance is interposed between the recreated bony surfaces.
2. Interpositional arthroplasty, which also recreates a joint space but, in addition, an autogenous temporalis muscle flap or alloplastic material, is introduced into the gap (Brusati et al. 1990).

Case 2

A 3-year-old child reported with the complaint of inability to open his mouth wide, deflexion of the mandible to the left and facial asymmetry (Figs. 12.22 and 12.23). When he was examined, his mouth opening was as little as 10 mm, and there was a deviation of the mandible to the left side; he also was showing signs of retrognathism and bird face deformity.

His mother did not remember a trauma as the cause of the problem. History revealed that at the moment of his birth, his mother had a local infection; as a consequence the child developed suppurative otitis media towards the joint, which was resolved in due course of time.

Panoramic X-ray evaluation (Figs. 12.24 and 12.25) and tomography (Figs. 12.26 and 12.27) revealed deformity of condylar head and blot out of the joint space and also antegonial notching of the left mandibular ramus and a shortened ramus in comparison to the right ramus.

Extra-articular ankylosis usually involves the coronoid process (coronoid hyperplasia); the image shows the elongated coronoid process (Figs. 12.28, 12.29, 12.30, 12.31 and 12.32) also in tomography (Figs. 12.33, 12.34 and 12.35).

Based on all these findings, a diagnosis of TMJ ankylosis secondary to post-delivery infection was confirmed and the surgery was recommended.

Furthermore, the use of functional appliances (Figs. 12.36, 12.37 and 12.38) is also recommended before and after the surgery because they allow the mandible to be properly positioned to the maxilla while stimulating continuous functional movements (Kirk and Farrar 1993).

After complete evaluation he was derived for surgery consisting of unilateral arthroplasty with interposing temporalis muscle graft under general anaesthesia. The use of the appliance after offers comfort while haematomas are resolving and tissues are recovering. Furthermore, it provides stimulation to the muscles and favours the removal of metabolites resulting from the muscle spasms and help the mandible to keep its normal position.

Early stimulation and control of muscular activity is an important key in treatment; the mobilization of tissues within and around the joint frees restraints of fibrotic capsule components, and the lateral eminences increase disc mobility, reducing load concentrations. In this way we improve condylar remodelling, favour restoration of a proper function of the masticatory system and prevent mechanical restrictions originated by scarring and loss of motion.

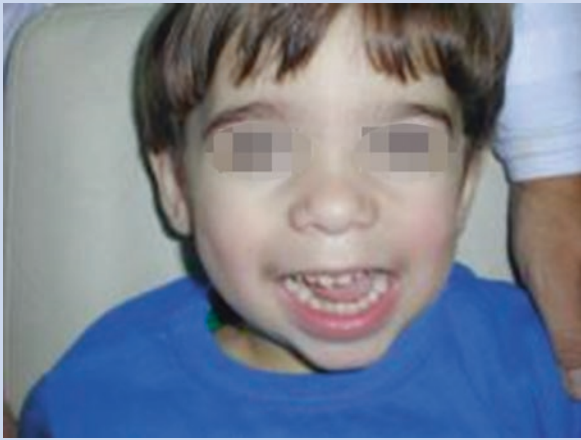

Fig. 12.22 Initial picture. Face

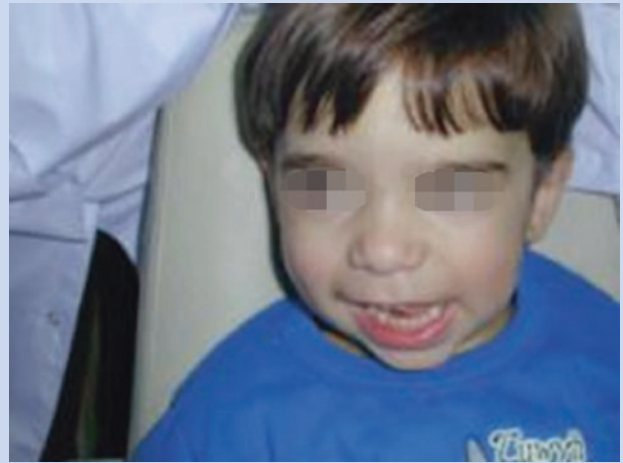

Fig. 12.23 Initial picture showing deviation

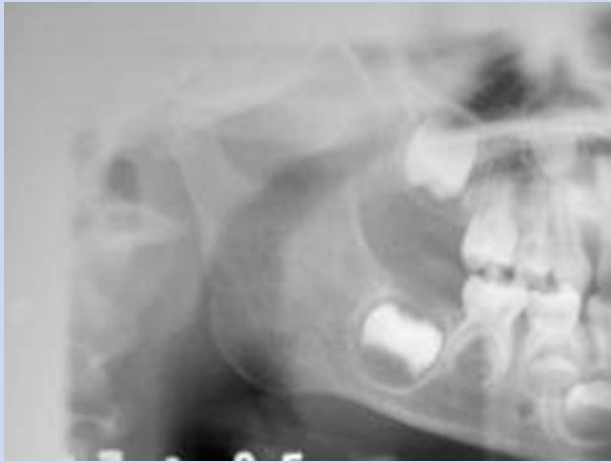

Fig. 12.24 Initial panoramic X-Ray. Right side

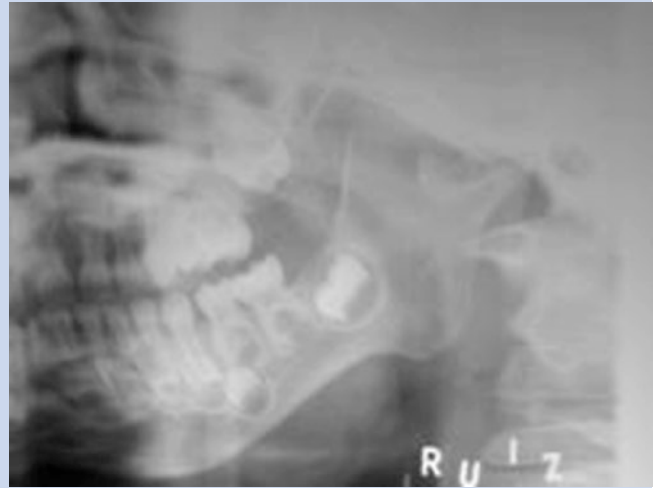

Fig. 12.25 Idem. Left side

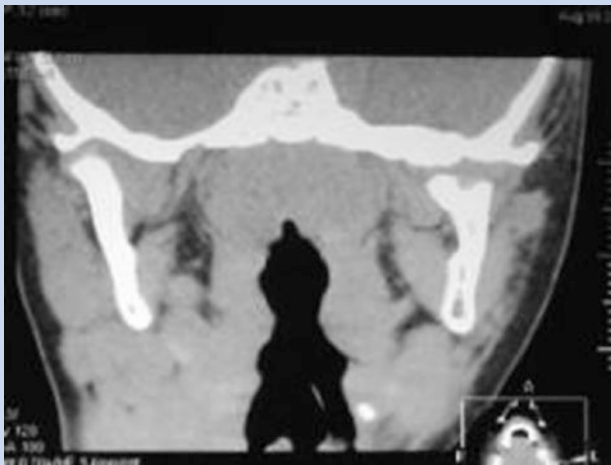

Fig. 12.26 Initial tomography

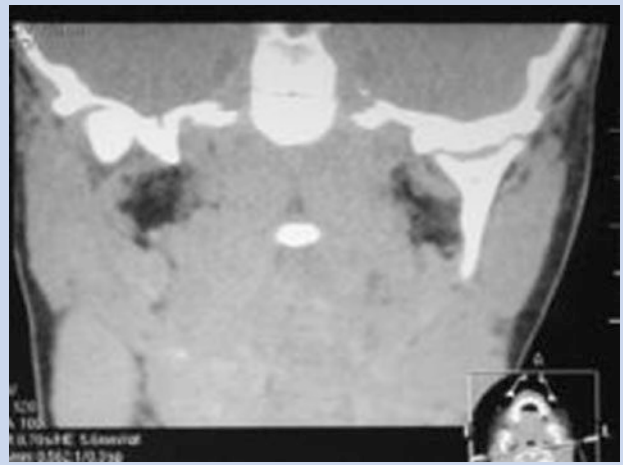


Fig. 12.27 Initial tomography, other view

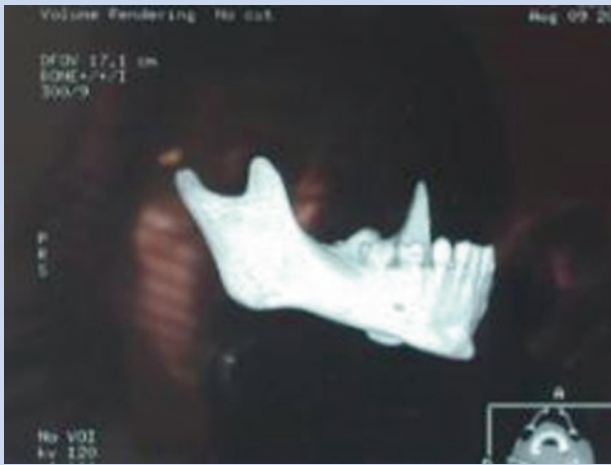

Fig. 12.28 3-D reconstruction from tomography. Right side

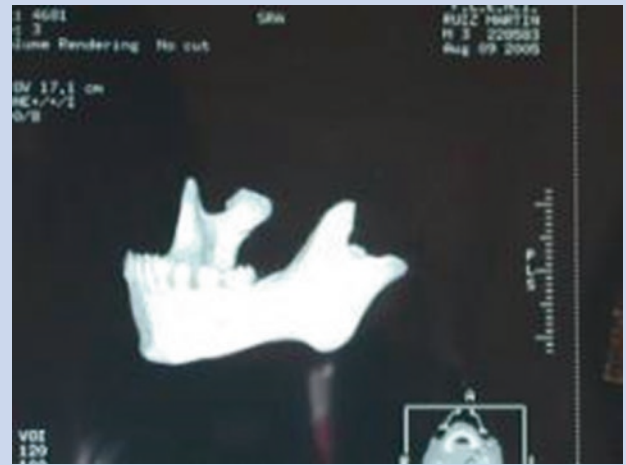

Fig. 12.29 Idem. Left side with coronal hyperplasia

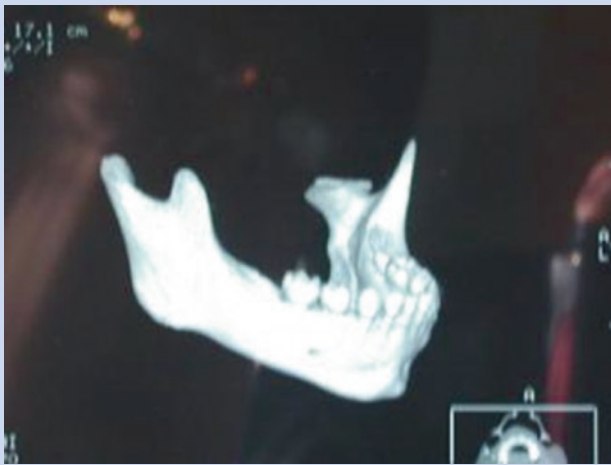

Fig. 12.30 Idem. Coronal hyperplasia from the right view

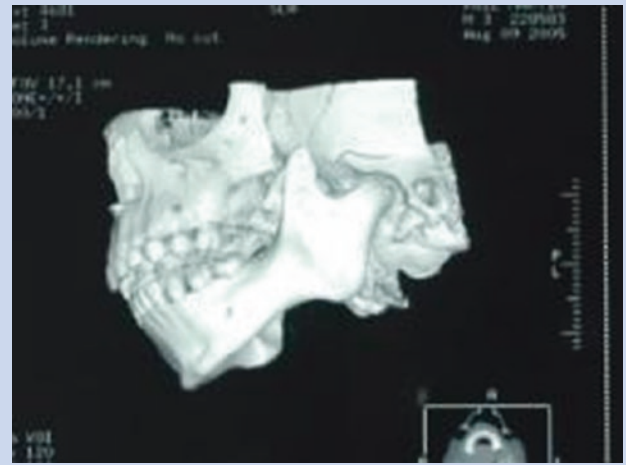


Fig. 12.31 Idem. Right side

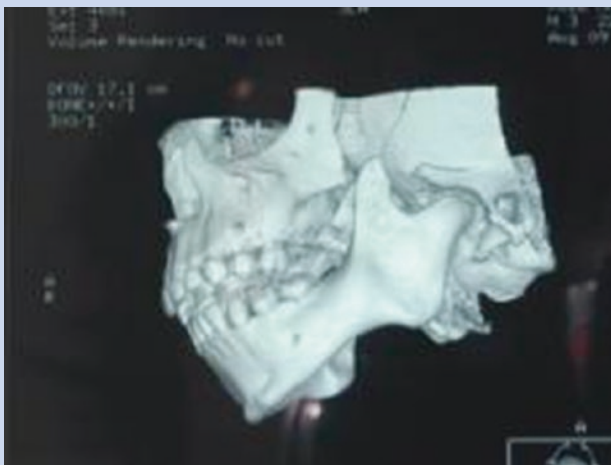

Fig. 12.32 Idem. Right side, other view

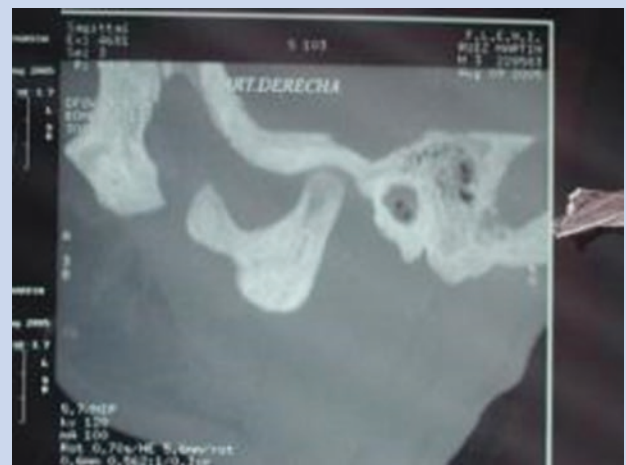

Fig. 12.33 Tomography. Right side

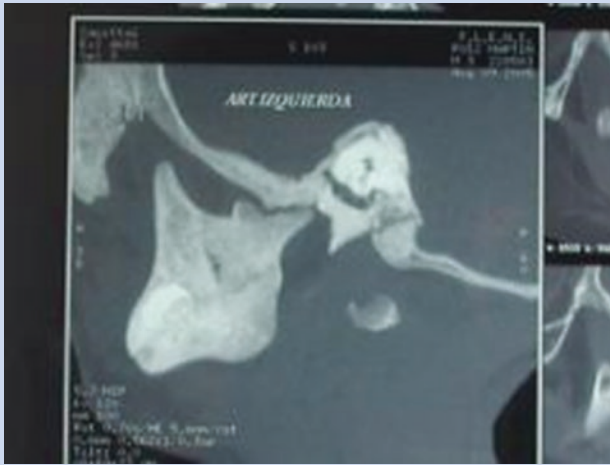


Fig. 12.34 Tomography. Left side

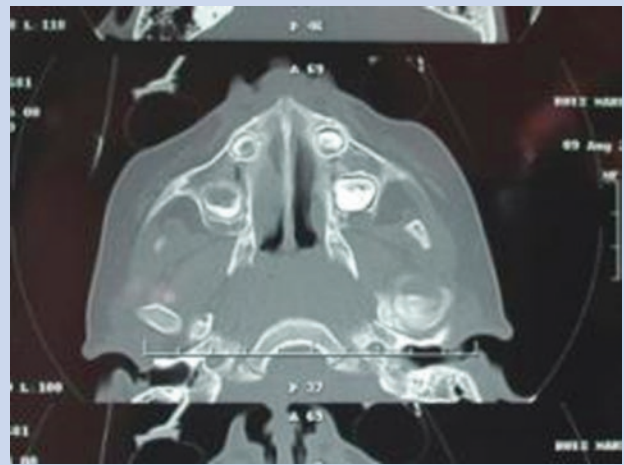


Fig. 12.35 Tomography. Axial view

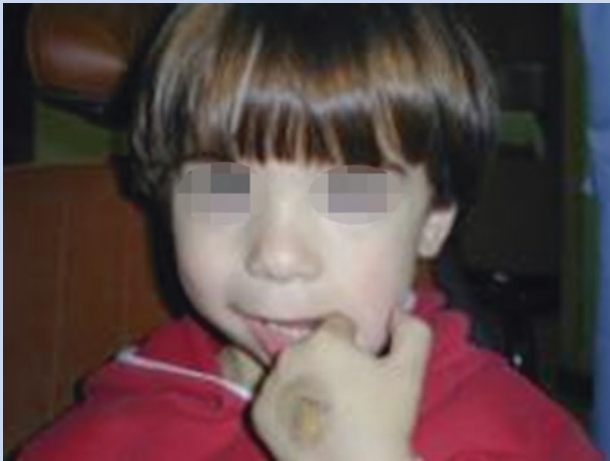

Fig. 12.36 Face before surgery

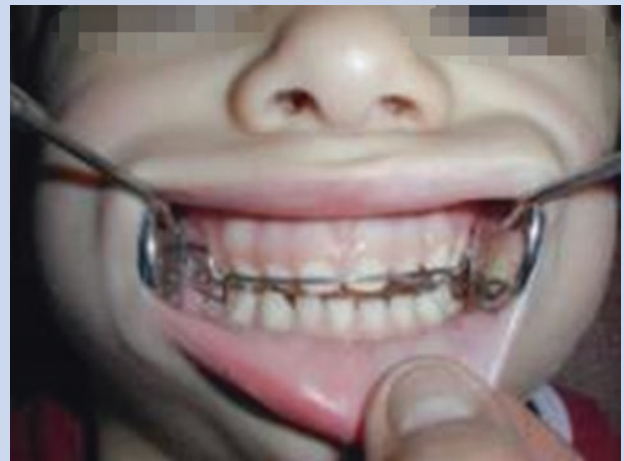

Fig. 12.37 Functional appliance in place

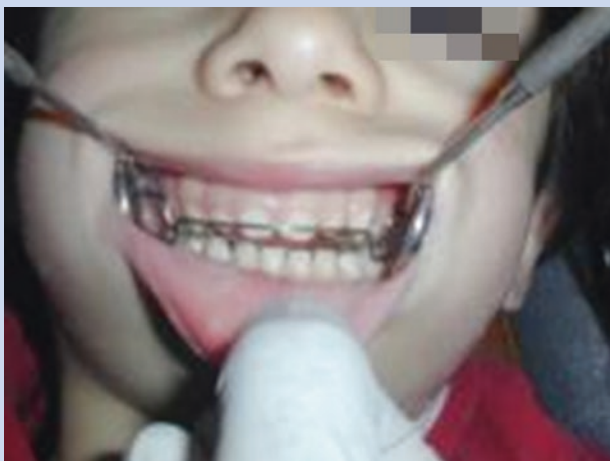

Fig. 12.38 Bionator. Lateral view

In my experience, results with functional appliance therapy are more effective than those obtained with traditional physiotherapeutic exercises which are more difficult to perform for children. Such treatment is indicated not only during healing but also during the following years (at least 2) when bone regeneration and compensatory growth are to occur. In this case both the child and his parents were provided comprehensive psychological assistance before, during and after the surgical intervention. The parents were similarly motivated and encouraged to prepare their child for surgery.

After surgery, the panoramic X-Ray (Fig. 12.39) shows that compared to the right side (Fig. 12.40), the left TMJ area is still with deficient condylar growing (Fig. 12.41). The CT images (coronal view) of the TMJ areas after surgery show the left condylar head separated from the bone (Fig. 12.42) but also shows an early healing process (Fig. 12.43).

He was monitored clinically after the beginning of the functional treatment and routinely monitored for the following years to evaluate symptoms, masticatory functions and facial development.

The patient was controlled for about 7 months clinically and through Tomography (Figs. 12.44, 12.45 and 12.46). Physiotherapy was very important at this moment; exercises consist of opening and closing the mouth with clothespins from both sides (Fig. 12.47). Parental support at this time is fundamental.

Six months after surgery, the face symmetry (Fig. 12.48) and mouth opening (Fig. 12.49) are already significantly improved. Through physiotherapy further improvement may be achieved and also relapse may be avoided.

Failing to do jaw opening exercises is the main cause of relapse. Sometimes the surgery has to be done again for the second time. In such case the observed factor for recurrence was deficient resection of the anterior and midline extension of the ankylotic mass and also deficient postoperative physical therapy; this therapy must be continuous until the raw bone surface has cicatrized. Careful surgical technique and further meticulous attention to long-term physiotherapy are both essential to the achievement of satisfactory results.

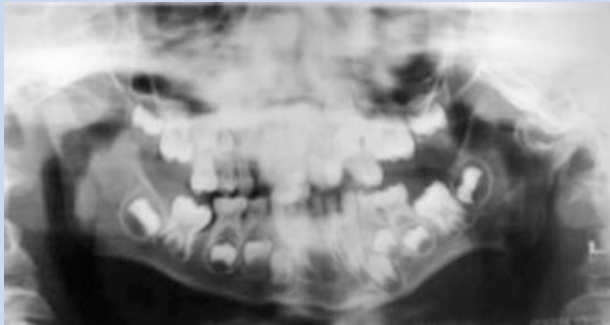


Fig. 12.39 Panoramic X-Ray after surgery

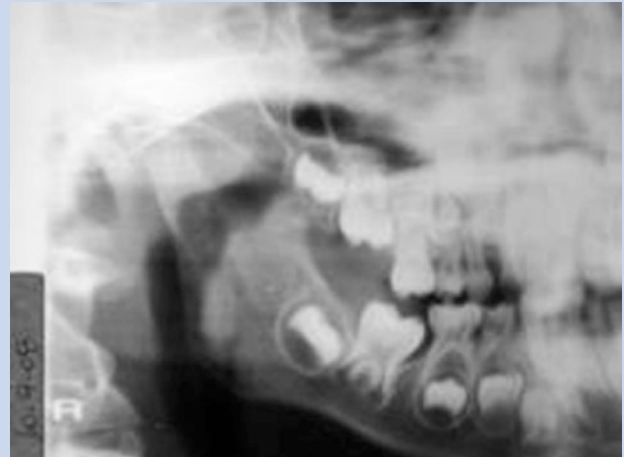

Fig. 12.40 Idem. Right side

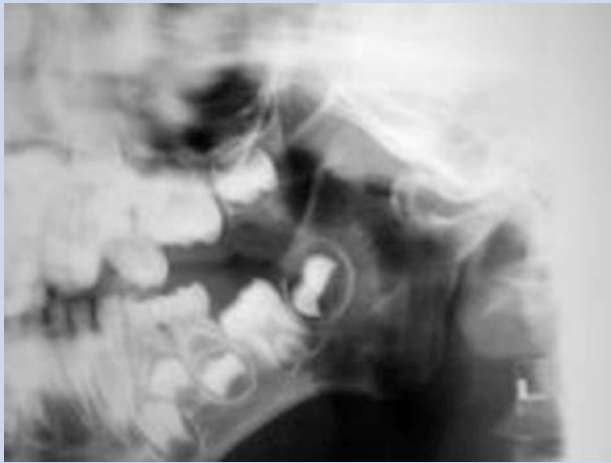


Fig. 12.41 Idem. Left side

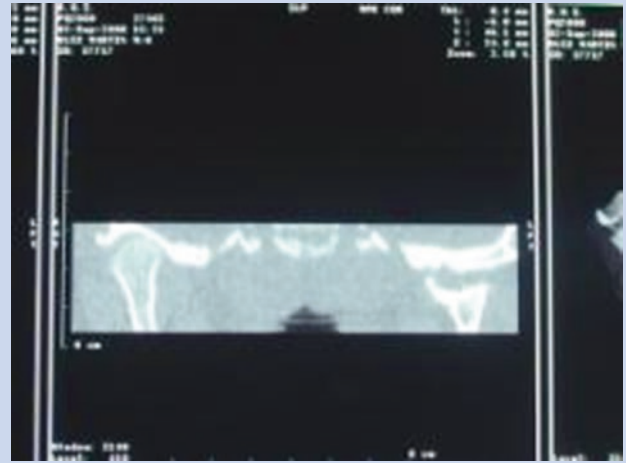

Fig. 12.42 Tomography after surgery. Frontal view

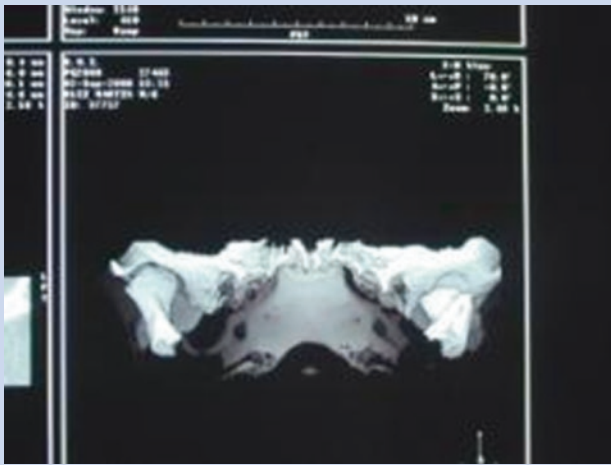

Fig. 12.43 Idem. Frontal view

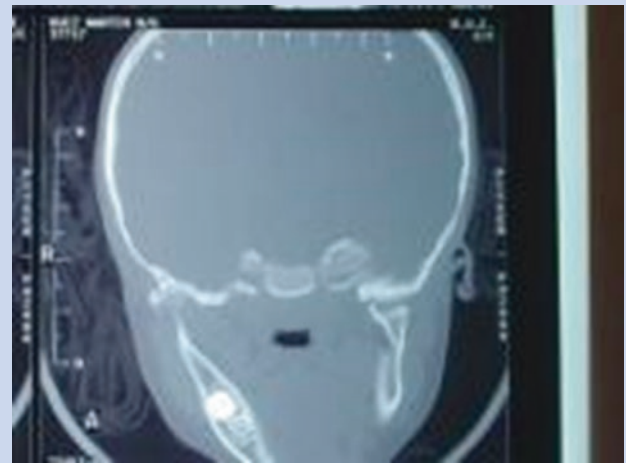


Fig. 12.44 Sequential Tomography. 1

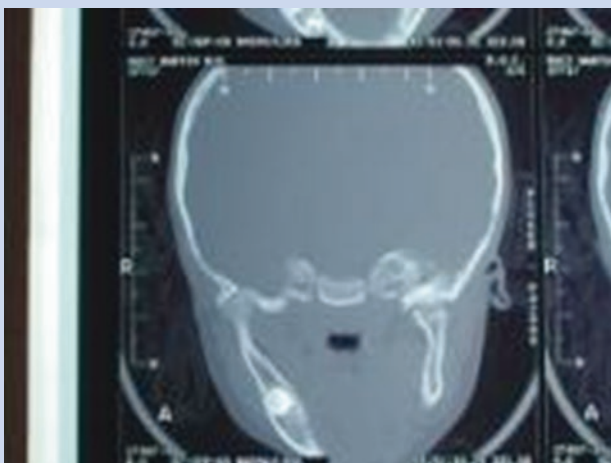


Fig. 12.45 Sequential Tomography. 2

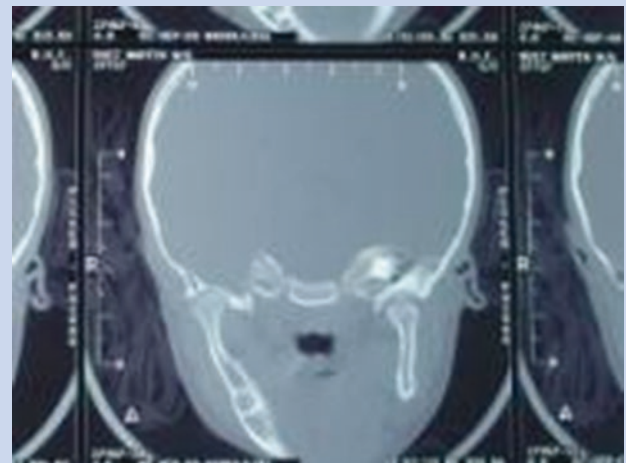


Fig. 12.46 Sequential Tomography. 3

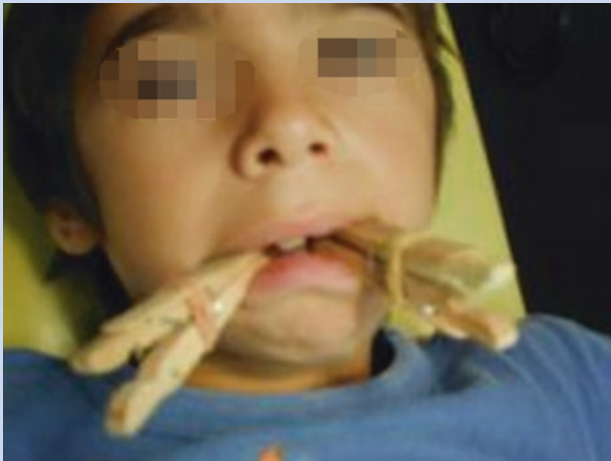

Fig. 12.47 Physiotherapy after surgery: exercise with clothespins

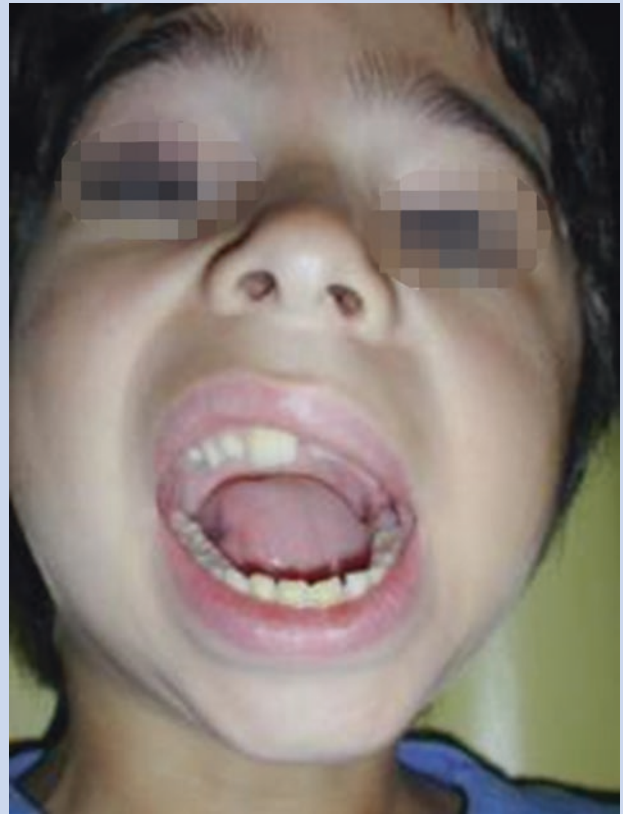


Fig. 12.49 Following up: six months after surgery. Mouth maximum opening

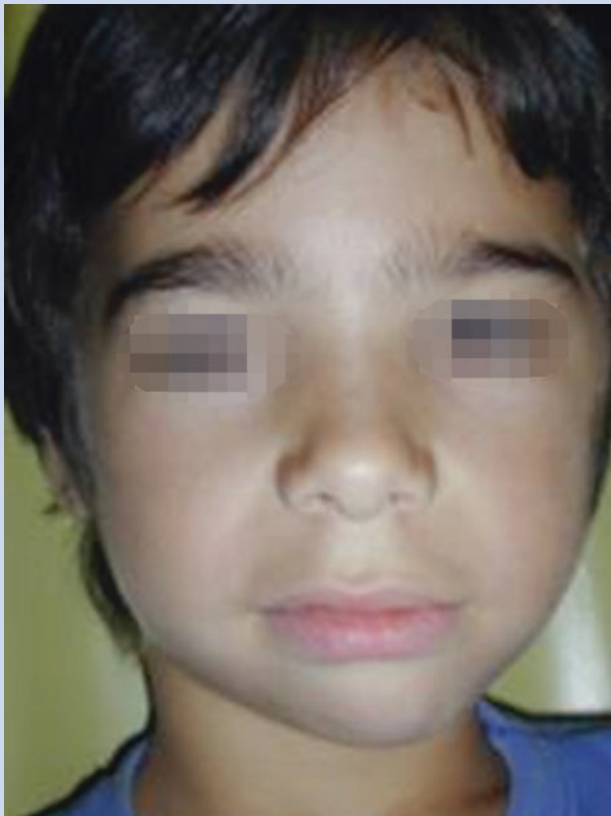

Fig. 12.48 Following up: six months after surgery

12.3 Osteoarthrosis/Osteoarthritis

Osteoarthrosis (OA) is a chronic degenerative disease of the movable joints. The osteoarthritis term is the secondary inflammatory component of these disorders (Isberg 2001).

The disease is a joint failure that results from an imbalance between the mechanical stresses and catabolic processes acting on the joint and the ability of the tissue to withstand and repair those injuries. It has been regarded progressive once it has become symptomatic, but the concept of reversibility has been supported (Bland 1983).

There are two forms of OA: primary arthrosis that is of unknown aetiology and is mostly seen in elderly individuals and secondary OA that is secondary to another process, such as trauma, internal derangement or inflammatory disease which is much more common in the TMJ than the primary and also occurs in children, teenagers and adolescents.

Head and neck injuries may have short- and long-term sequelae, including some affecting the face and jaw region and involving the TMJ. This would include impact injuries such as trauma to the chin. A common occurrence in childhood because of falling, chin trauma, is reported to be a factor in the development of TMD in paediatric patients 12–14 years old.

Mandibular injuries in infancy and early childhood are not rare, but the clinical manifestations are likely to be neglected in comparison to the most conspicuous lacerations of the skin overlying the chin. The damaging effect that such injuries have on the mandibular condyle regarding growth arrest and distortions of mandibular form becomes increas-

ingly apparent as time goes by and contributes significantly to the progressive facial asymmetry that is observed later.

Symptoms of TMD such as TMJ dysfunction, headache and neck pain following injuries have been documented in young adolescents. During the acute phase, the patient demonstrates severe tenderness upon palpation over the TMJ and the preauricular region. Because pain is the most troublesome symptom of TMD and is the overwhelming reason, people seek care; we examine the association of previous head and neck injury with the presence of TMD pain.

OA is a group of disorders with chronic synovitis as common denominator and with the onset before the age of 16 years.

Previous studies in children with condylar involvement affected with OA have reported and altered craniofacial structure like smaller dimensions of the condyle, obtuse gonial angle and gonial notching, among others.

Clinically it is characterized by a complex set of signs and symptoms including pain, limitation of joint movement and joint sounds. It is considered to be a disease of the articular cartilage that causes with time condyle erosion and finally development of osteophyte.

Crepitus still remains in some cases many years after the patient is free of pain and when good movements of the jaw have been established with adequate function.

Treatment is palliative to encourage the patient to relieve pain, to preserve function and to prevent or minimize deformity. It includes medical therapy, physiotherapy, orthopaedic splint to unload the joint and occasionally surgery. It is hoped that treatment will shorten the course of the illness or make it more tolerable.

Case 3

A 12-year-old girl with anterior open bite developing during adolescence (Figs. 12.50 and 12.51) was in the middle of orthodontic treatment and had complained of pain very frequently when she opened and closed her mouth, and also the opening was diminished to less than 30 mm (Figs. 12.52 and 12.53).

She had a history of clicking that disappears at the onset of a sudden limitation of mouth opening. Her facial profile was concave and no asymmetry was observed.

Clinical examination and X-ray (Figs. 12.54, 12.55 and 12.56), with RMI evaluation (Figs. 12.57, 12.58, 12.59, 12.60, 12.61 and 12.62), confirm the diagnosis of bilateral internal derangement (non-reducing disc displacement), with morphological changes on both condyles: bilateral juvenile osteoarthritis, secondary to trauma.

The late stage of disc displacement is characterized by the development of degenerative changes involving the bony joint components. They initially remodel which are seen as a flattening of the surfaces, having intact soft tissue

covering. When the physiological adaptation is surpassed, tissue breakdown begins, implying the start of the development of osteoarthritis.

It was decided to stop the orthodontic treatment and used an occlusal splint (Figs. 12.63a, b, and 12.64) all the time (except for eating and chewing) for several months, following controls.

TMJ pain and difficulty in mouth opening gradually decreased (Fig. 12.65) and finally disappeared 6 or 7 months after her first visit (Fig. 12.66a–c).

A relationship between TMJ degeneration and facial deformity has been noted through MRI. This case showed a sudden occurrence of a negative overbite during adolescence, due to a rotated mandible with TMJ OA and a labial inclination of the upper incisors. In this case, a balance of growth in maxilla and mandible may have kept edge to edge bite. After time of controls, orthodontic treatment can be continued very carefully. However, habits and lifestyle, which load condyle, have to be in control always.



Fig. 12.50 Initial picture of the face

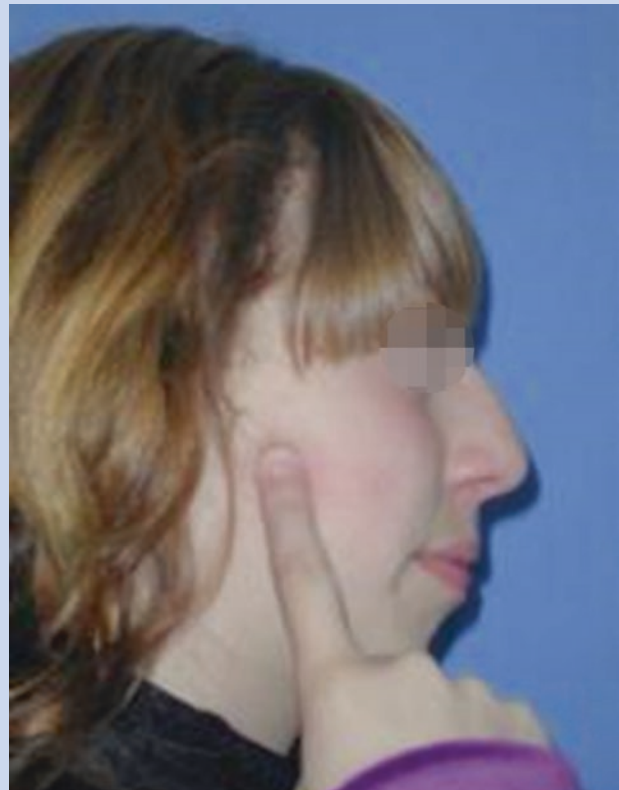

Fig. 12.51 Lateral side: pain location

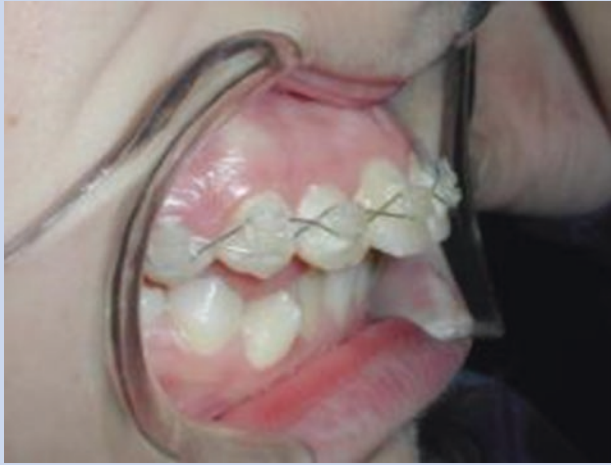

Fig. 12.52 Maxillo-mandibular relationship. Lateral side

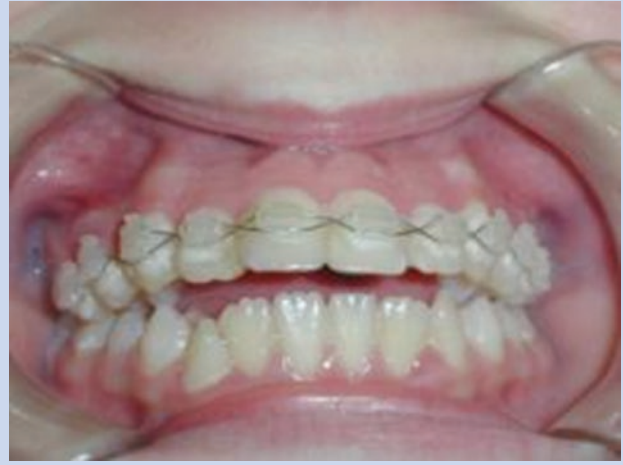

Fig. 12.53 Idem. Anterior bite

Fig. 12.54 Panoramic X-Ray

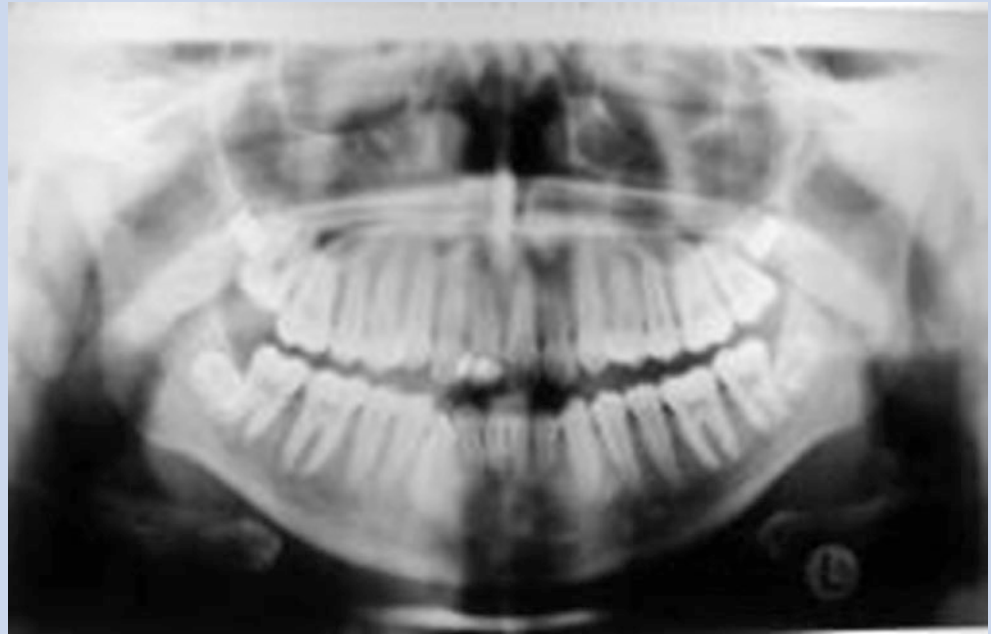

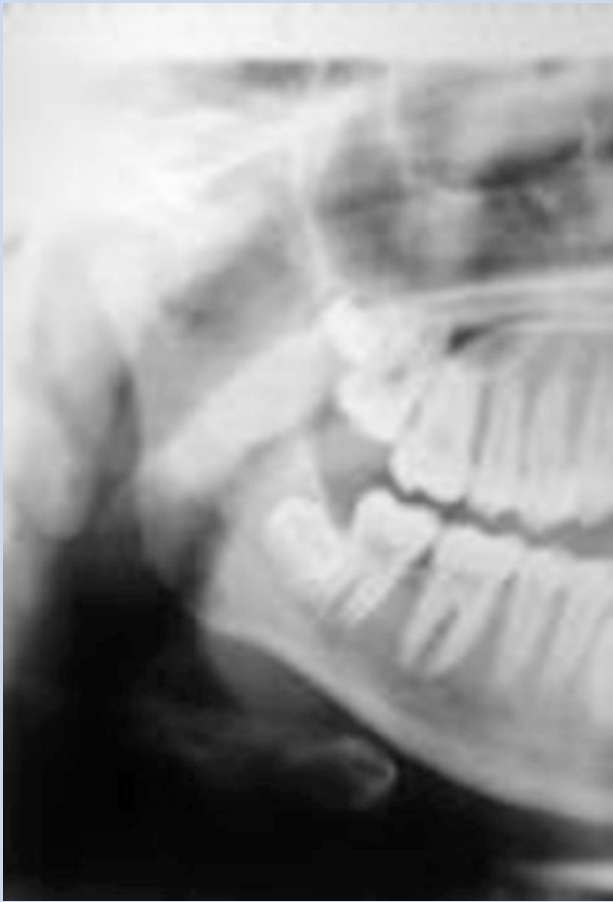


Fig. 12.55 Idem. Lateral right side

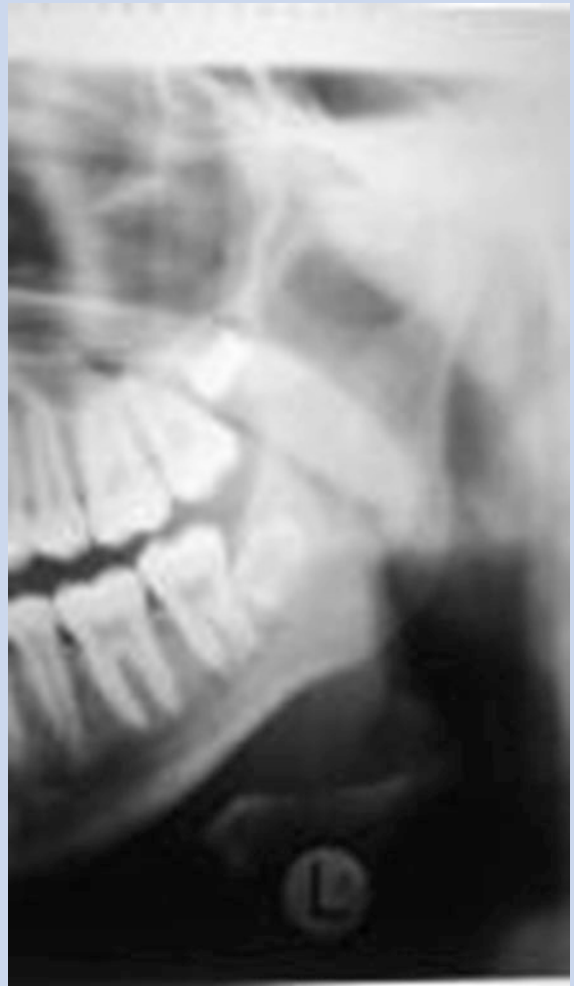

Fig. 12.56 Idem. Lateral left side

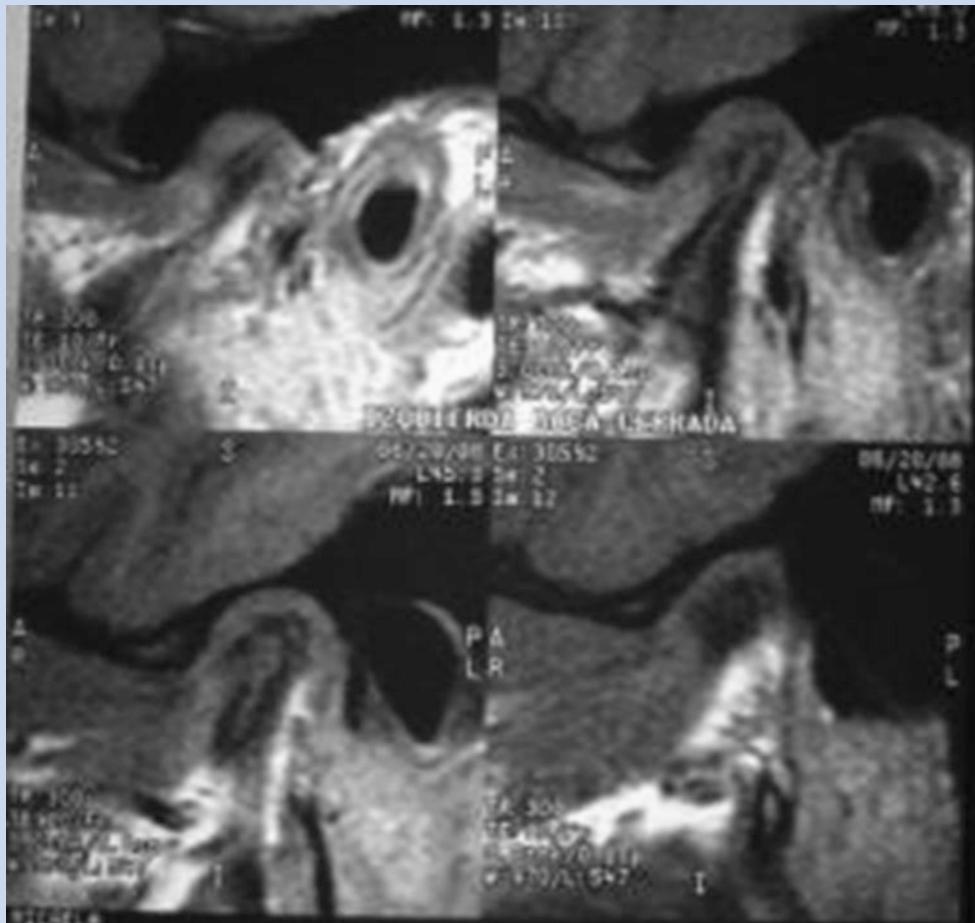


Fig. 12.57 MRI image of the left TMJ. Patient mouth closed

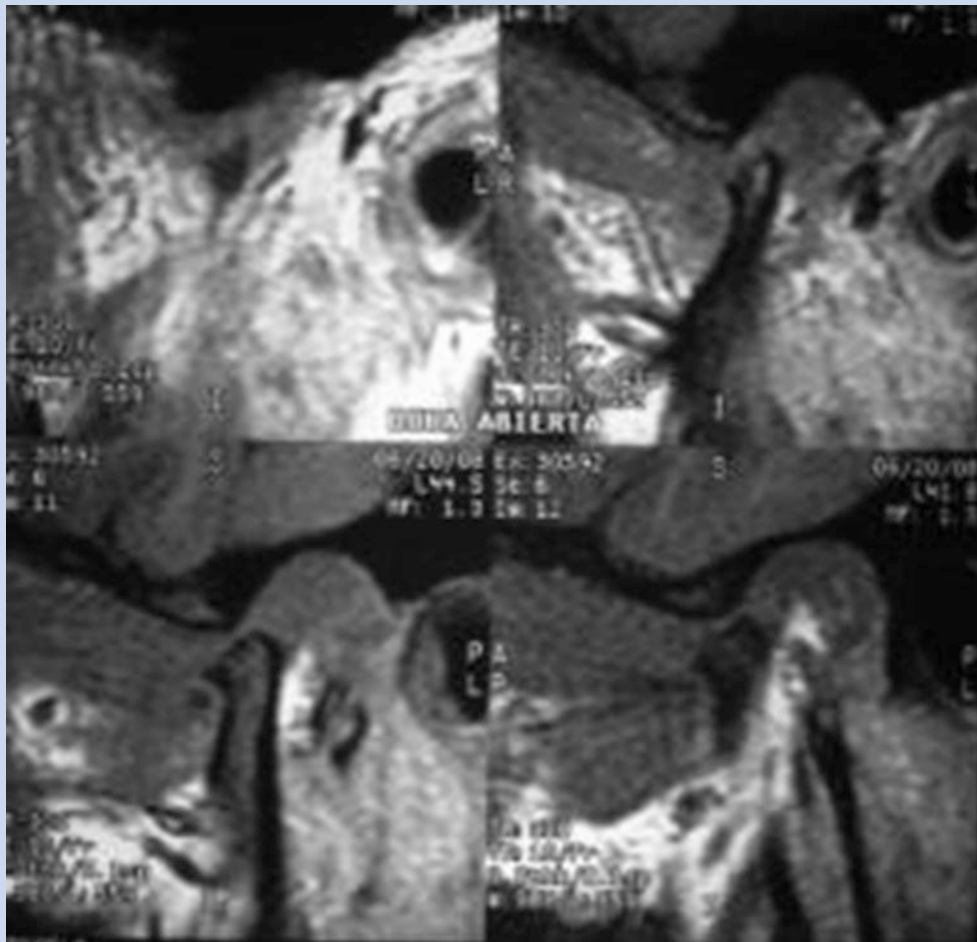


Fig. 12.58 Idem. Patient mouth open

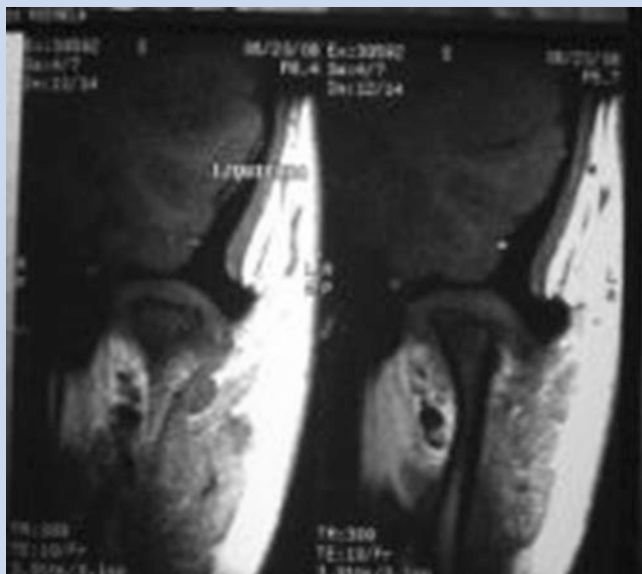


Fig. 12.59 MRI coronal view. Left side

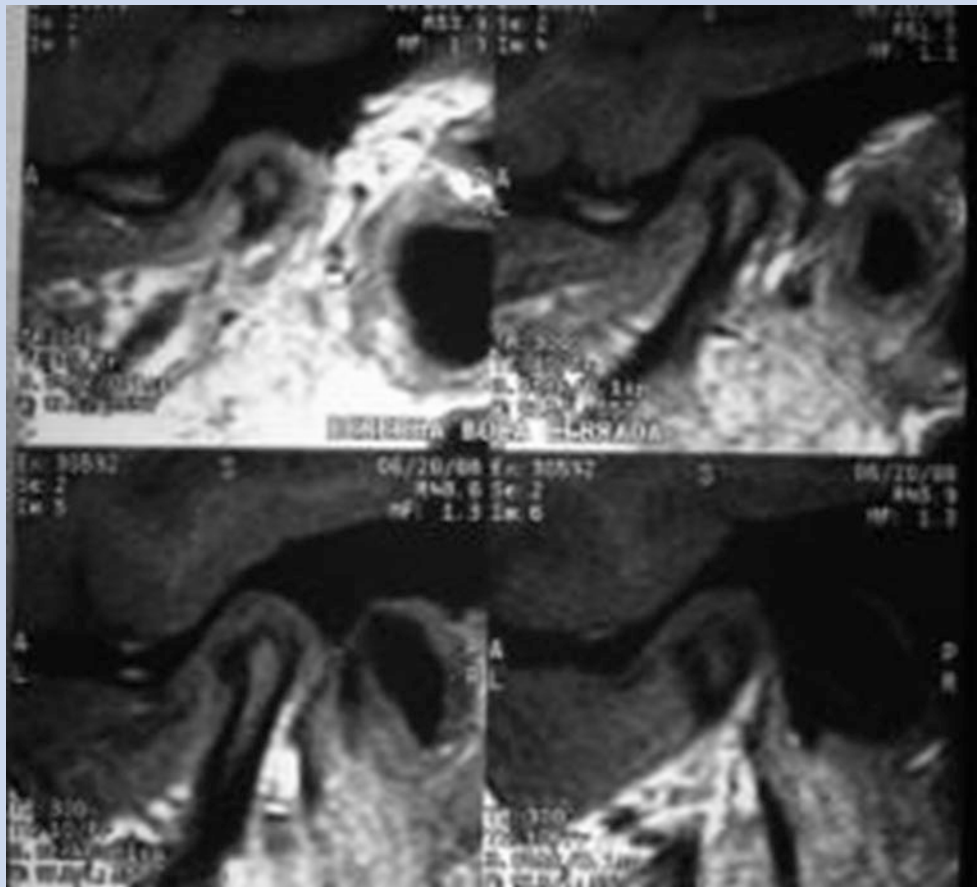


Fig. 12.60 MRI image of the right TMJ. Patient mouth closed

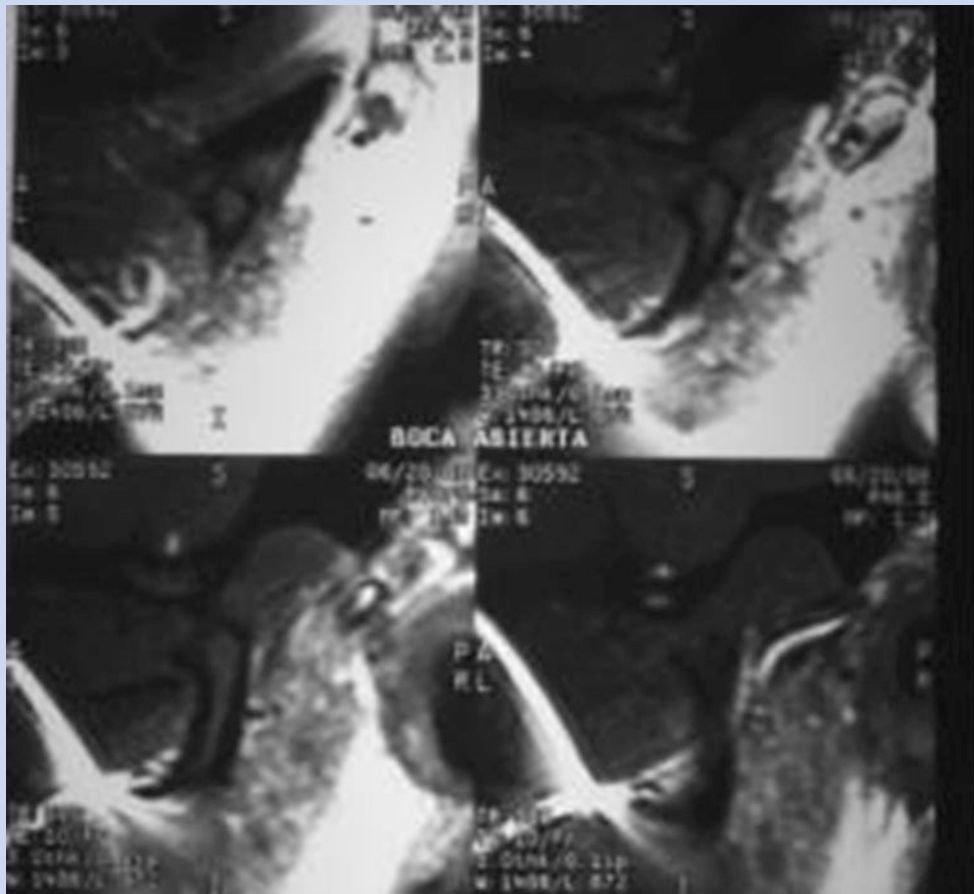


Fig. 12.61 Idem. Patient mouth open

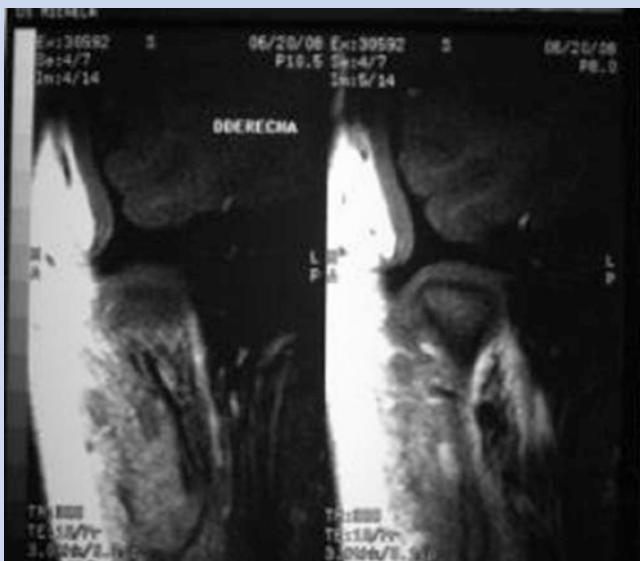


Fig. 12.62 MRI coronal view. Right side

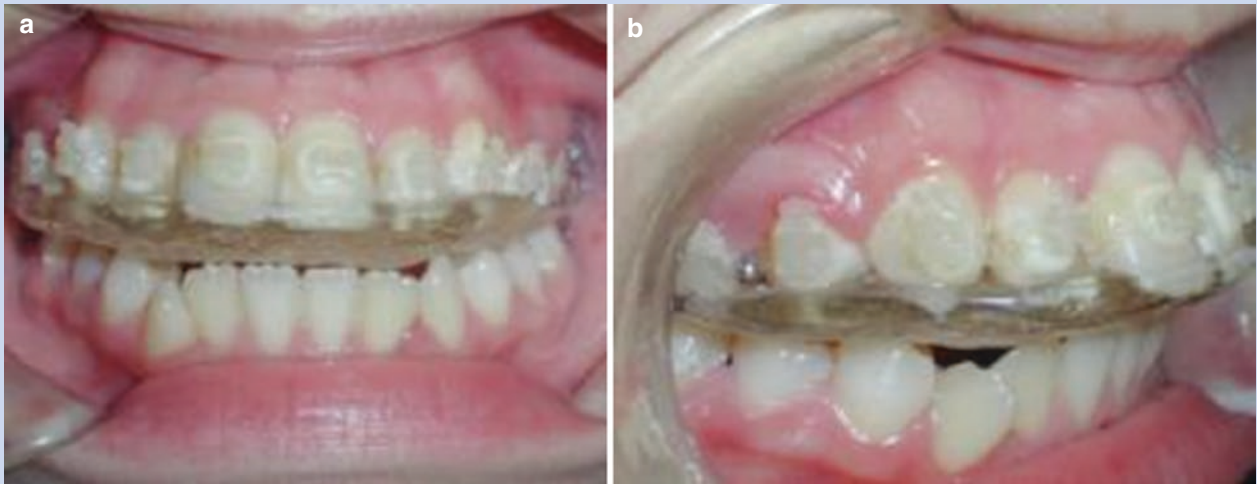

Fig. 12.63 (a) Occlusal Splint in the patient mouth. (b) Occlusal Splint. Lateral view

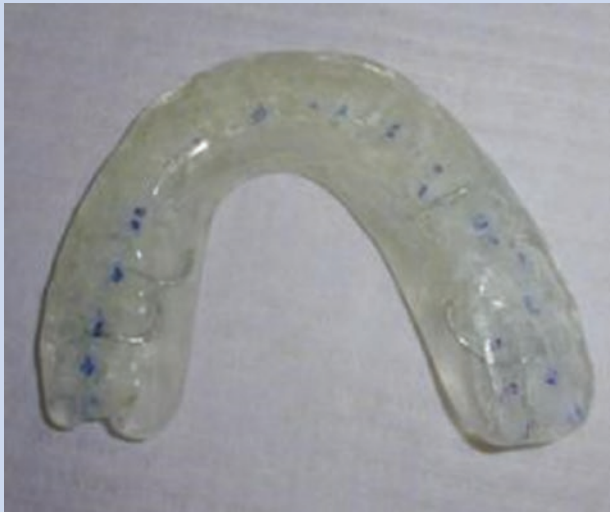

Fig. 12.64 Idem. Control

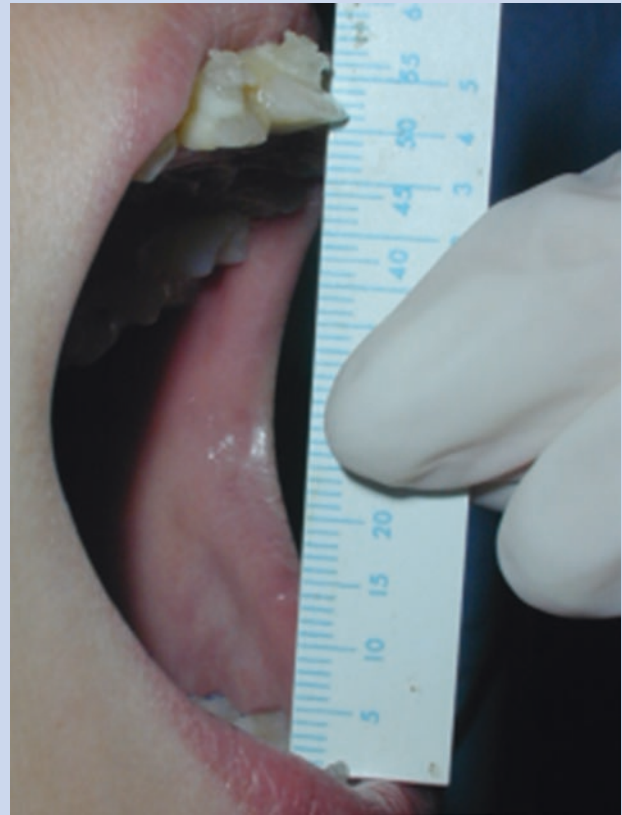

Fig. 12.65 Opening recuperation after 7 months of treatment

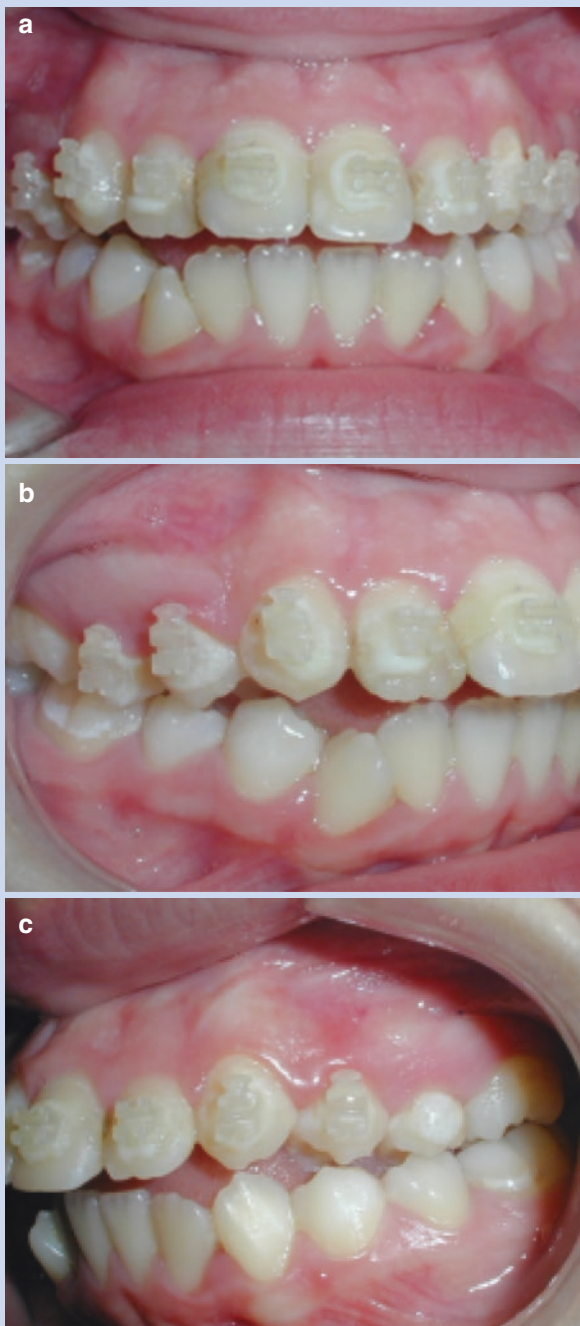


Fig. 12.66 (a) Final maxillo-mandibular relationship. Front view. (b) Final maxillo-mandibular relationship. Right side. (c) Final maxillo-mandibular relationship. Left side

Conclusion

Acute orofacial injuries in children are often confined to the anterior teeth and lips, but also there are other associated injuries such as closed head injuries, soft tissue lacerations and fractured jaws. Although the mandibular condyle is one of the most common sites of injury of the facial skeleton, it is also the most overlooked and less diagnosed site of trauma in the head and neck region.

Injuries to the mandibular condyle in growing children may affect growth and development of the jaws and the occlusion with adverse sequelae that are more difficult to treat at a later stage in the patient. Therefore, children who present acute dental injuries should always be examined for the possibility of concomitant condylar injuries.

Early diagnosis and subsequent close monitoring through regular follow-up can reduce the probability of severe long-term mandibular growth and functional disturbances.

All dental practitioner should be fully aware of the implications of condylar injuries in growing children.

References

- American Academy of Orofacial Pain. In: de Leeuw R, Klasser GD, editors. Orofacial pain: guidelines for assessment, diagnosis, and management. 5th ed. Chicago: Quintessence Publishing; 2013. p. 127–86.
- Bland JH. The reversibility of osteoarthritis: a review. *Am J Med.* 1983;74:16–26.
- Brusati R, Raffaini M, Sesenna E, Bozzetti A. The temporalis muscle flap in temporomandibular joint surgery. *J Craniomaxillofac Surg.* 1990;18:352–8.
- Carlsson GE, Egermark I, Magnusson T. Predictors of signs and symptoms of temporomandibular disorders: a 20-year follow up study from childhood to adulthood. *Acta Odontol Scand.* 2002;60(3):180–5.
- Chidzonga MM. Temporomandibular joint ankylosis. Review of thirty two cases. *Br J Oral Maxillofac Surg.* 1999;37:123–6.
- Dibbets JM, Van der Weele LT. Prevalence of structural bony change in the mandibular condyle. *J Craniomandib Disord.* 1992;6(4): 254–9.
- Fischer DJ, Mueller BA, Critchlow CW, LeResche L. The association of temporomandibular disorder pain with history of head and neck injury in adolescents. *J Orofac Pain.* 2006;20(3):191–8.
- Greene CS. The etiology of temporomandibular disorders: implications for treatment. *J Orofac Pain.* 2001;15(2):93–105.
- Hall MB. Condylar fractures: surgical management. *J Oral Maxillofac Surg.* 1994;52:1189–92.

- Henrikson T, Nilner M. Temporomandibular disorders, occlusion and orthodontic treatment. *J Orthod.* 2003;30(2):129–37. discussion 127.
- Hovinga J, Boering G, Stegenga B. Long term results of nonsurgical management of condylar fractures in children. *Int J Oral Maxillofac Surg.* 1999;28:429–40.
- Huynh N, Guilleminault C. Sleep bruxism in children. In: Lavigne GJ, Cistulli PA, Smith MT, editors. *Sleep medicine for dentists. A practical overview.* Chicago: Quintessence Publ. Co, Inc; 2009. p. 125–31.
- Isberg A. Temporomandibular joint dysfunction. A practitioner's guide. Isis Medical Media Ltd, British Library Cataloguing. 2001.
- Kirk WS, Farrar JH. Early surgical correction of unilateral TMJ ankylosis and improvement in mandibular symmetry with use of an orthodontic functional appliance. A case report. *J Craniomandibular Pract.* 1993;11(4):308–11.
- Loos PJ, Aaron GA. Standards for management of the pediatric patient with acute pain in the temporomandibular joint or muscles of mastication. *Pediatric Dent.* 1989;11(4):331.
- Lund K. Mandibular growth and remodelling processes after mandibular fractures. *Acta Odontol Scand.* 1974;32(Supp 64):3–117.
- McNamara JA, editor. *Determinants of mandibular form and growth.* Ann Arbor. Center for Human Growth and Development, University of Michigan. 1975.
- Medlicott MS, Harris SR. A systematic review of the effectiveness of exercise, manual therapy, electrotherapy, relaxation training and biofeedback in the management of temporomandibular disorder. *Phys Ther.* 2006;86(7):955–73.
- Okeson J. Etiology of functional disturbances in the masticatory system. In: *Management of temporomandibular disorders and occlusion.* 7th ed. St. Louis: Elsevier Mosby Inc; 2013. p. 102–69.
- Proffit WR, Vig KWL, Turvey TA. Early fracture of the mandibular condyles: frequently an unsuspected cause of growth disturbances. *AJO-DO.* 1980;78(1):1–24.
- Rey D, Oberti G, Baccetti T. Evaluation of temporomandibular disorders in Class III patients treated with mandibular cervical headgear and fixed appliances. *Am J Orthod Dentofacial Orthop.* 2008;133(3):379–81.
- Shashikiran ND, Reddy SV, Patil R, Yavagal C. Management of temporomandibular joint ankylosis in growing children. *J Indian Soc Pedod Prev Dent.* 2005;23(1):35–7.
- Thilander B, Rubio G, Pena L, Mayorga C. Prevalence of temporomandibular dysfunction and its association with malocclusion in children and adolescents. An epidemiologic study related to specific stages of dental development. *Angle Orthod.* 2002;72(2):146–54.
- Wahlund K, List T, Larsson B. Treatment of temporomandibular disorders among adolescents. A comparison between occlusal appliance, relaxation training, and brief information. *Acta Odontol Scand.* 2003;61(4):203–11.
- Walker R. Condylar Fractures: Nonsurgical management. *J Oral Maxillofac Surg.* 1994;52:1185–8.

Ricardo D. Bennun

13.1 Introduction

The goal of this chapter is to provide parameters to care children with oral clefts, in an interdisciplinary range of expertise during primary dentition.

Early evaluation of a child born with cleft lip and palate is imperative and should begin perinatally. In fact, interdisciplinary treatment starts during pregnancy with prenatal detection of the malformation.

Proper timing interventions are critical, and coordinated care is necessary because of the complexity of the medical, surgical, psychosocial, and social factors.

Early management may lead to better results (e.g., fewer operations, shorter rehabilitation, and lower social and economic costs).

The continuity of care in a team setting is essential because outcomes are measured throughout the child's growth and development (Campbell et al. 2010; Paiva et al. 2014).

To be considered successful, a protocol treatment must be completed until the age of 6 years, to allow the child to start with normal school education.

13.2 Key Treatment by Age (Bennun and Harfin's Protocol)

Prenatal Diagnosis

- Parent's consultation with the team coordinator
- Family handling and understanding of diagnosis and treatment needs
- Indication of main interventions

Supporting Delivery

- Avoid baby separation from parents, oral tube utilization, and prolonged unnecessarily hospital stay.

Orofacial Dysmorphology

- Participate in the diagnosis and collection of pertinent records.
- Distinguish between syndromic and nonsyndromic.

Oral Health

- Oral examination.
- Dentist should collect an impression to build the oral plate.
- Early presurgical treatment.

Psychosocial Support

- Address barriers to medical and healthcare with family.
- Monitor parent-child issues.
- Referral to parent support groups.

Suction

- Assess feeding and swallowing with interdisciplinary team.

Speech and Language Support

- Counsel parents on early stimulation development.
- Assessment of early vocal output and communicative behavior.

General Pediatric Health

- Pediatric care provider screening and presurgical evaluation

R.D. Bennun, MD, MS, PhD
Post Graduate Program In Pediatric Plastic & Craniofacial Surgery,
National University of Buenos Aires, Maimonides University,
Association PIEL, Buenos Aires, Argentina
e-mail: ricardobennun@gmail.com

ENT Health

- Physical assessment of oral and pharyngeal structures
- Middle ear status diagnosis

Surgical Reconstruction

- Lip and nose primary reconstruction from 2 to 6 months

Anesthesiology

- In order to maximize success and minimize risk, the airway skills of an experienced pediatric anesthesiologist are required during the surgical procedures.
- The use of local and regional anesthesia with epinephrine as a complement is useful in reducing bleeding, pain, and general anesthesia dose, and to allow ambulatory care surgeries.

Oral Health

- Nasal component removing and oral plate adaptation
- Caries prevention anticipatory guidance

ENT Health

- Follow-up for patients with recurrent infections, hearing loss, Eustachian tube dysfunction, myringotomy tube indication

General Pediatric Health

- Pediatric care provider screening and presurgical evaluation

Surgical Reconstruction

- Complete cleft palate closure from 8 to 14 months
- Same-step myringotomy and tube insertion

Complete Diagnostic Assessment (2 Years)

- Address barriers to medicine and healthcare within family.
- Speech and language development.
- Facial growth and development.
- Scars and esthetic evaluation

Complete Sequels Detection (4–6 Years)

- Annual pediatric care provider screening.
- Monitor dental development and malocclusion.
- Assess Eustachian tube dysfunction, recurrent infections, sleep apnea, and airway issues.
- Monitor school achievement, screen for precursors of learning disability, and assess emotional and behavioral functioning.
- Evaluation of language comprehension and competence and phonologic and phonetic development.

Complete Sequels Treatment (6–12 Years)

- After permanent teeth eruption orthodontics treatment must be implemented.
- The interdisciplinary team must be ready to solve any dysfunctional condition.

13.3 Prenatal Diagnosis Importance

Routine ultrasound tests using a 3.5 MHz scanner performed at the end of the first trimester or beginning of the second have demonstrated that oral clefts can be easily identified during the 21st week. Nevertheless, face and palate structures could be identified from week 15 by using a 6.5 MHz intravaginal scanner (Bäumler et al. 2011; Maarse et al. 2011; Dong Wook et al. 2015).

Prenatal diagnosis of orofacial cleft gives the parents the possibility to prepare themselves in an emotional and practical way. A frank discussion with the specialist of the strategies can help them having an enjoyed pregnancy

finalization. Knowing the diagnosis before delivery also allows the cleft team to discuss plans about feeding issues, baby/mother relationship, early hospital discharge, etc. This would make delivery much less traumatic, especially for the parents and the extended family (Jones 2002; Manganaro et al. 2011; Wang et al. 2011; Martinez-Ten et al. 2012).

Our team offers information manual for the future parents when they visit for first counseling. Information manual should contain the concerns of parents-to-be, including longitudinal management of clefts and contact numbers (Moss 2001; Nusbaum et al. 2008; Grollemund et al. 2012; Ribeiro Soares and Alonso 2012) (Fig. 13.1).

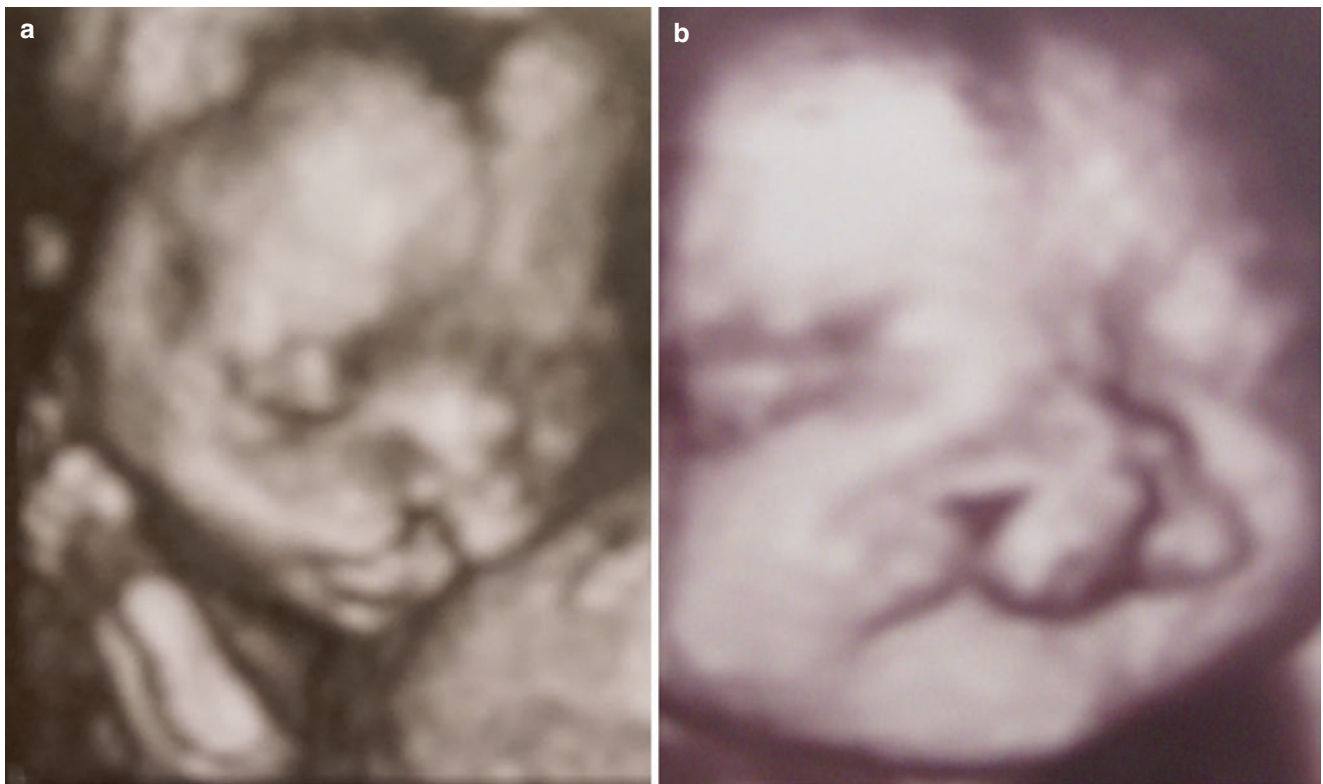


Fig. 13.1 (a, b) Ultrasound views of a unilateral and bilateral cleft lip disruption

13.4 The Deformity Process

In a normal baby with intact lips and palate, the muscles of the lip, cheek, and pharynx use their usual sphincter-like action against the developing maxillary and mandibular arches. The compressive external muscular forces neutralize the expansive forces of the tongue. The neonatal arch form changes as these forces modify with growth and maturation; yet the opposing muscles always maintain a precise and dynamic balance with each other. When this muscular balance is upset, the arch form and teeth relationship is altered (Shi and Losee 2015).

A cleft of the lip and palate is the result of the fusion failure of lip elements and palatal segments, within the first 8 weeks of fetal life.

The loss of muscular continuity of the orbicularis oris-buccinator-superior constrictor ring in complete unilateral and bilateral clefts changes the normal muscular force diagram.

Because clefts differ in their location and magnitude, lip and palate clefts can vary in the degree of geometric distortion, as well as in the size and shape of the cleft palatal segments. The muscular forces that act on the bony platform of the palate and pharynx begin very early in intrauterine life; therefore, the palatal and facial configuration at birth has been formed over the major portion of the infant's existence prior to birth (Tse 2012).

The cleft lip and palate deformities are complex, with the involvement of not only the palate and lip but also the nose. The shape of the nose is affected in all three planes of space (Fig. 13.2).

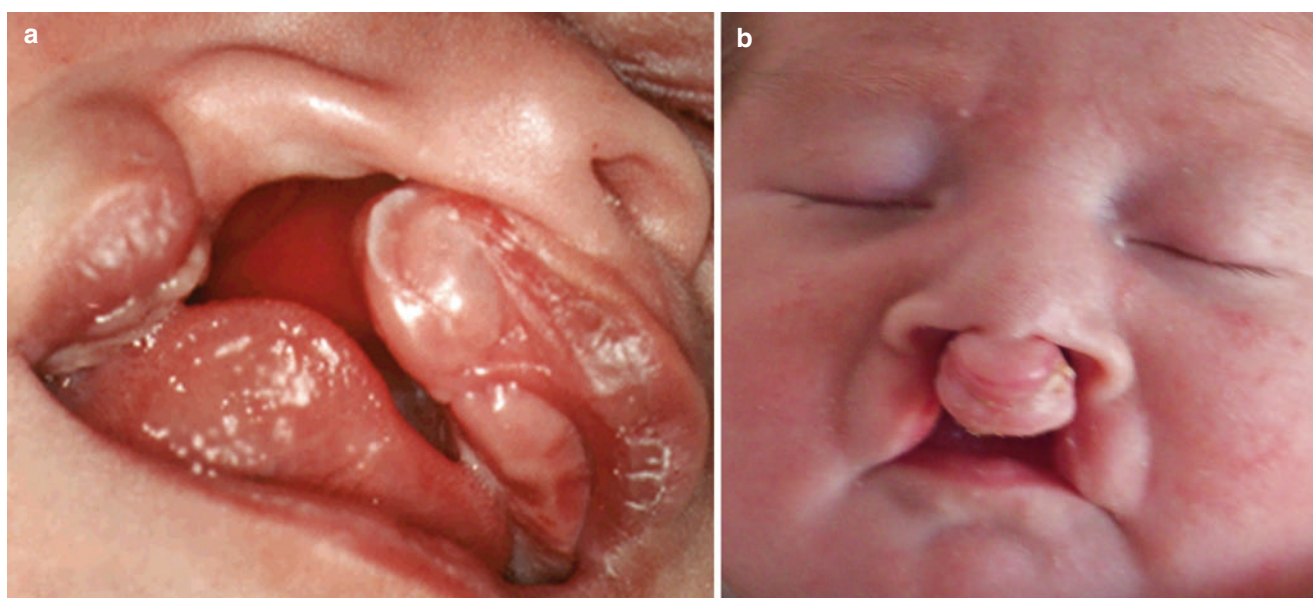


Fig. 13.2 (a, b) Unilateral complete cleft tongue interposition helping to increase distortion and bilateral complete cleft showing premaxilla protrusion with columella shortening

13.5 Presurgical Infant Orthopedic Indication

13.5.1 Background

The concept of presurgical maxillary orthopedics describes the use of serial appliances to approximate the alveolar cleft segment (McNeil 1950). Many changes have taken place in appliance design, from McNeil's concept to the actual concept of dynamic nasoalveolar remodeling (Hotz and Gnoinski 1976; Murthy et al. 2013).

The appliances can be classified as:

- Active or passive
- Presurgical or postsurgical
- Intraoral or extraoral

Active appliances move alveolar cleft segments in a predetermined manner with controlled forces, whereas passive appliances deliver no force but act as a fulcrum upon which forces created by surgical lip closure contour and mold the alveolar segments in a predictable fashion (Berkowitz 1977).

Clefting is due to disturbance of embryogenesis, and the proper closure of all involved structures should be achieved as soon as possible to favor normal growth of the face (Millard 1986).

Several approaches have been used in order to reduce nasal asymmetry and the alveolar gap early in life using surgery alone or in conjunction with other approaches.

In treatment of the cleft lip nasal deformity, correction of the nose continues to be the greatest challenge. In patients with unilateral cleft lip/palate, the nasolabial defect influences the physical appearance of the child and also facial growth and development because of ventilatory insufficiency (Talmant 2006). Hence, it is recommended to perform nasal remodeling prior to primary lip repair.

Auricular cartilage can be remodeled with permanent results if treatment is started within 6 weeks of life (Matsuo et al. 1984). During this period, there are high levels of maternal estrogen in fetal circulation which generates an increased hyaluronic acid (HA) in blood. The HA modifies cartilage, ligament, and connective tissue elasticity by breaking down the intercellular matrix (Hardingham and Muir 1972; Kenny et al. 1973).

Levels of estrogen start dropping at 6 weeks of age. It is based on this principle that the concept of nasoalveolar remodeling works (Shetty et al. 2012).

Repair of early gestation fetal skin occurs in the absence of acute inflammation, and without excessive fibroblast infiltration, and massive collagen deposition.

The healed wound resembles normal skin and, hence, reflects a regenerative-like process (West and Kumar 1989; Thomas et al. 1998).

Fetal skin repair occurs in the presence of abundant HA throughout the repair process (weeks), whereas in adults, skin repair HA levels peak at 2–4 days and then fall rapidly. The results demonstrate that HA affects the cellular and matrix events in fetal healing and suggest that HA plays an important role in the process of fetal regeneration (Adzick et al. 1985; Chen et al. 1989; Adzick and Lorenz 1994).

It is also suggested that nasoalveolar remodeling stimulates immature nasal chondroblasts, producing an interstitial expansion that is associated with an improvement in the nasal morphology (Hamrick 1999).

The use of presurgical rigid nasal stents in newborns with unilateral or bilateral cleft lip and palate was initiated, as early as 1987, with the unique aims to prevent alar cartilage disruption memory fixation. This protocol, utilized in a group of 80 patients, was introduced by Dogliotti et al. (1991).

A six-year follow-up of the same patients was published (Bennun et al. 1999, 2001). The original idea was popularized as the nasoalveolar molding (NAM) technique (Grayson et al. 1999) and adopted by other groups (Shetty et al. 2012) (Fig. 13.3).

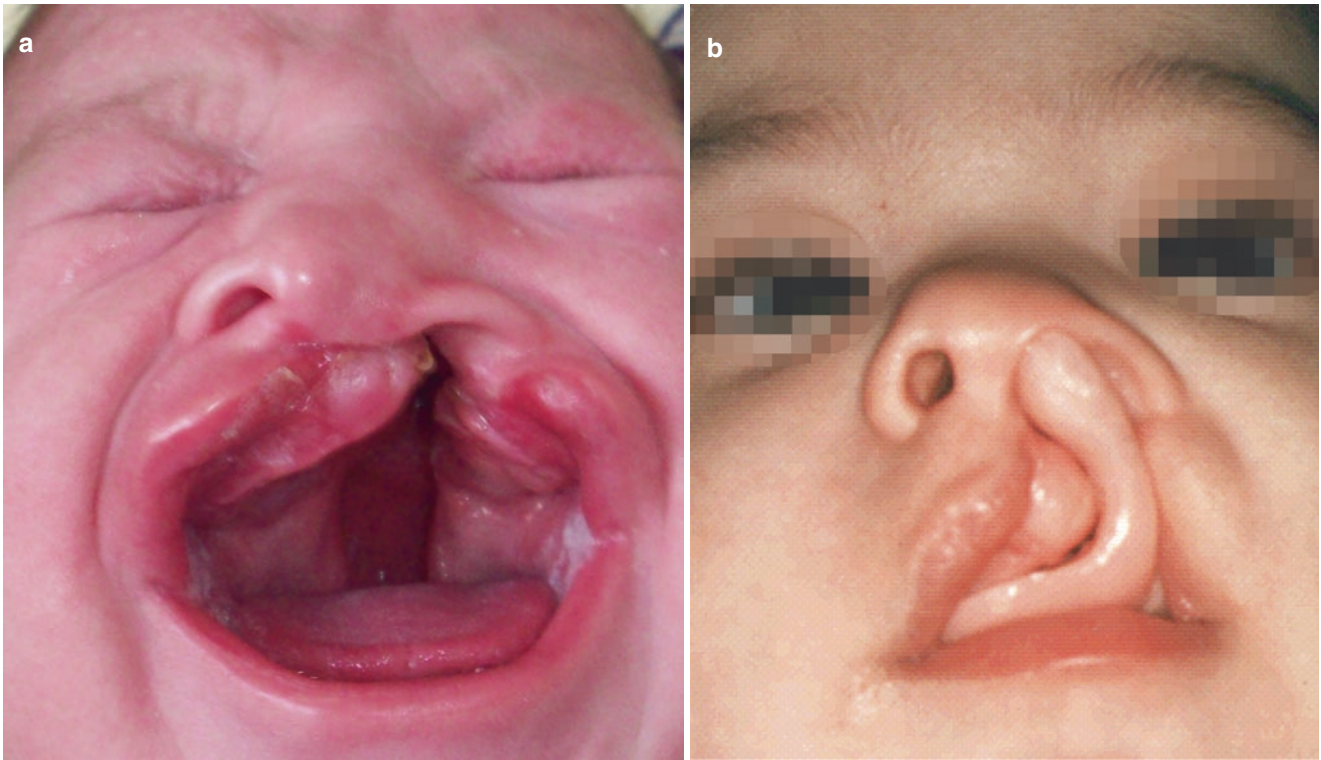


Fig. 13.3 (a, b) Initial view of the nasal deformity showing the collapsed alar cartilage. The nasal component added to the labial vestibular flange of the perfectly adapted conventional intraoral plate helping to rapidly modify nasal distortion

13.6 Dynamic Presurgical Nasoalveolar Remodeling (DPNR) Technique

A fundamental principle of reparative medicine, which governs our efforts to regenerate differentiated tissue, is to organize the reparative circumstances to recapitulate selected aspects of embryonic developmental sequence, including attempts to mimic the embryonic microenvironment in which tissue initiation, formation, and expansion take place (Caplan 2002).

Tissue engineering ought not to focus on whether or not to utilize in vivo remodeling approaches, but rather on how to best induce the most desirable remodeling (Greisler 2002).

DPNR represents a unique form of clinical tissue engineering.

Using easily controlled mechanical conditions, a pediatric orthopedist is able to guide the position/formation of new tissues and their spatial orientation. This happens without application of any growth factor or other controlling agents.

The principle behind this procedure is the use of the force generated during suction and swallowing. This force can be

transmitted by means of a nasal dynamic component to produce remodeling effects on the nasal structures and also in the lip function by stimulating labial muscle contraction.

This newly designed intraoral appliance consists of two elements:

- (1) A perfectly adapted conventional acrylic intraoral plate
- (2) A dynamic nasal bumper attached to the vestibular flange of the intraoral plate (Bennun et al. 2002; Bennun and Figueroa 2006)

Alignment of the alveolar segments and repositioning of the nasal structures create a foundation upon which excellent results of primary cleft lip and nasal repair are dependent (Bennun and Langsam 2009).

The purpose of this segment is to illustrate the step-by-step process of the dynamic nasoalveolar remodeling technique in order to obtain alveolar ridge and lip and nose tissue repositioning in presurgical treatment of clefts patients (Fig. 13.4).

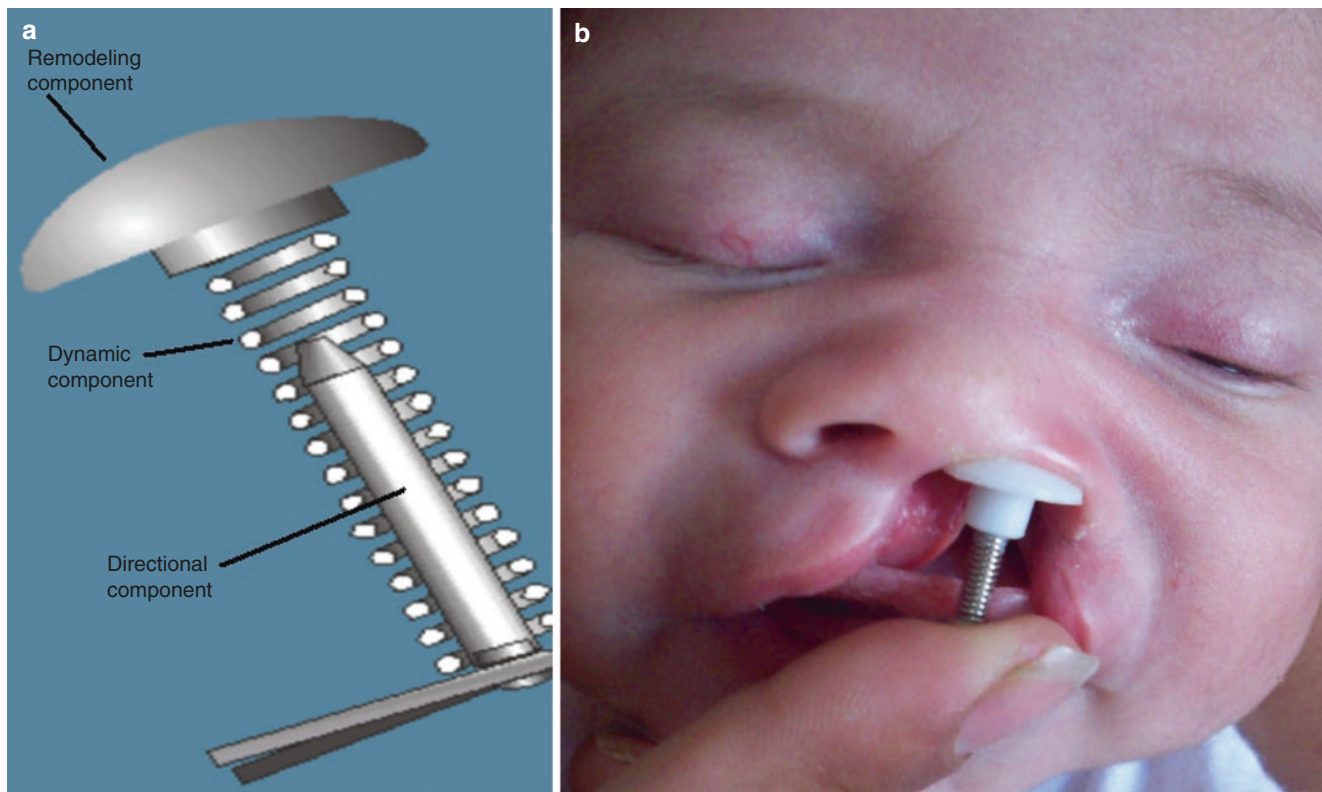


Fig. 13.4 (a, b) The dynamic nasal stent illustration. The *directional component* allows the specialist to rapidly modify the force of impact in any direction. The *dynamic component* regulates the force of the impact

and reduces rebound. The silicone remodeling component avoid soft tissues lesion. The nasal component added to the palatal plate is in the right position and ready to start treatment

13.7 Step-by-Step Procedure Description

The treatment must be initiated placing a palatal plate as a way to close oronasal communication, to avoid lingual interposition, and to help guide the alveolar segments. Utilizing an elastic mask, we can also produce facial muscular traction in an intend to approximate the alveolar cleft segments.

The nasal stent is initially placed at the external border of the alar nose. The aim is to obtain muscle and mucosa relaxation, to produce the internal nasal bridge elimination, preventing the alar collapse.

In a second step, the odonto-pediatrician centralizes the nasal component to ameliorate the alar cartilage breaking

down. If this modification is achieved during the first month, tissue distortion can be eliminated from the cartilage memory.

In posterior visits, the expert will follow with the centralization of the nasal device, to achieve a longer collumellar side by pushing up and repositioning the crus medialis.

Once all these improvements are accomplished, the directional component must be substituted by a longer one, with the aim of obtaining the nasal tip projection. In that way, the nasal device also could help to produce labial muscle traction and a subsidiary vertical high increasing of the lip in both sides of the cleft (Bennun and Langsam 2015) (Figs. 13.5, 13.6, 13.7, 13.8, 13.9, 13.10, 13.11, 13.12, and 13.13).

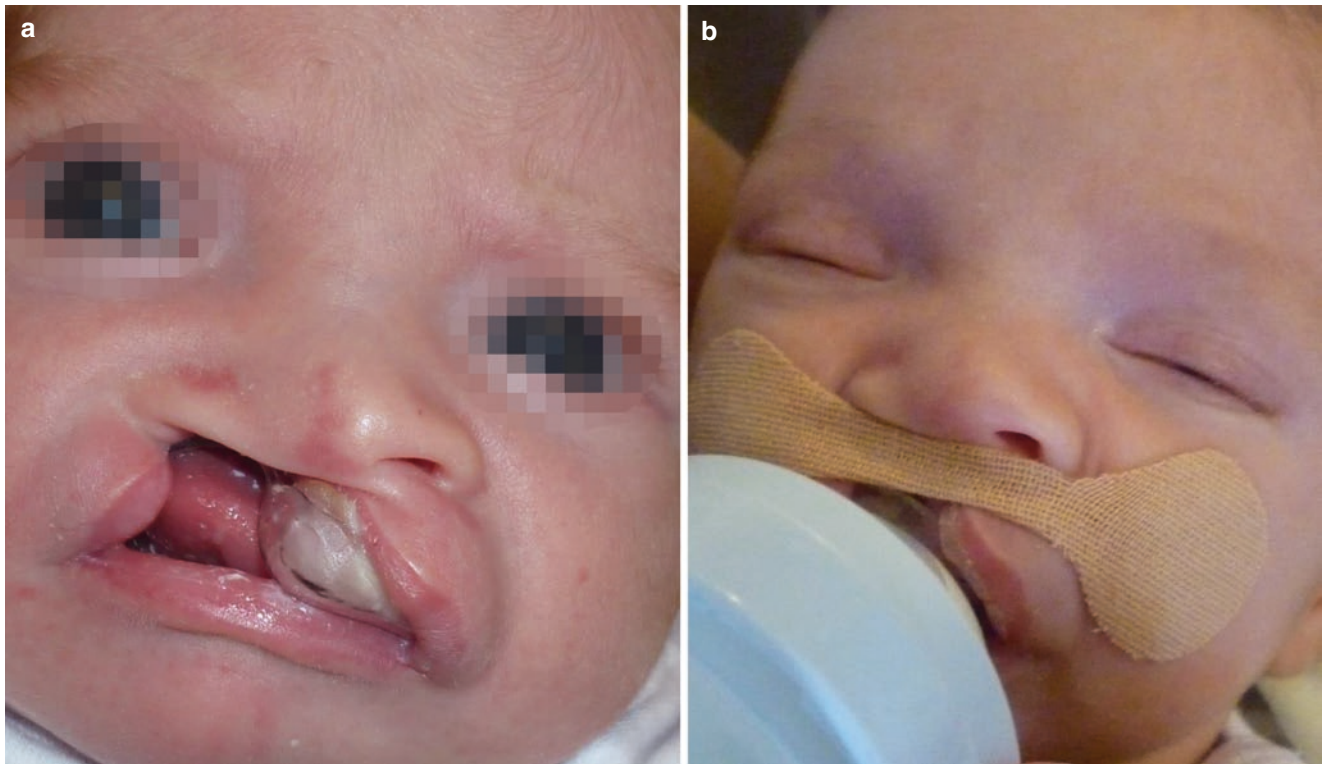

Fig. 13.5 (a, b) The oral plate is in place and the elastic facial mask has been installed. The baby has normally started suctioning

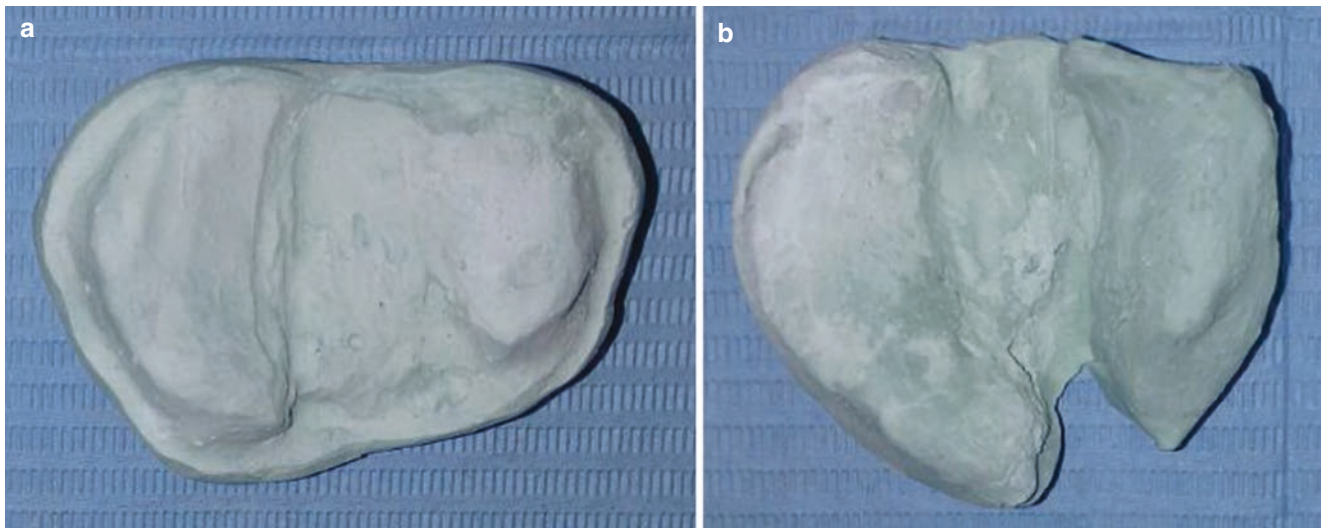


Fig. 13.6 (a, b) Bone impression view illustrating the important initial alveolar gap. One week later, after using elastic traction, showing bone narrowing

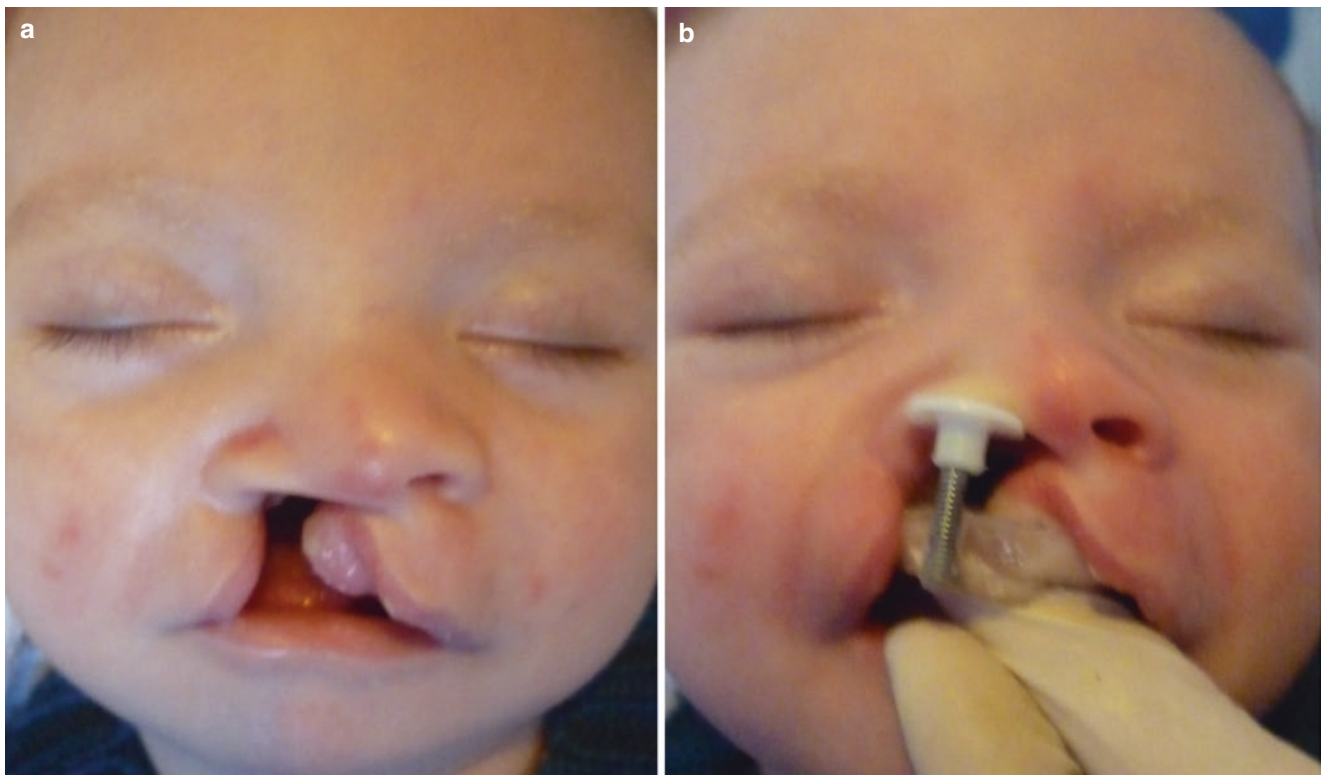

Fig. 13.7 (a, b) Nasal tissues are gradually remodeled correcting their alterations and preventing memory cartilage fixation

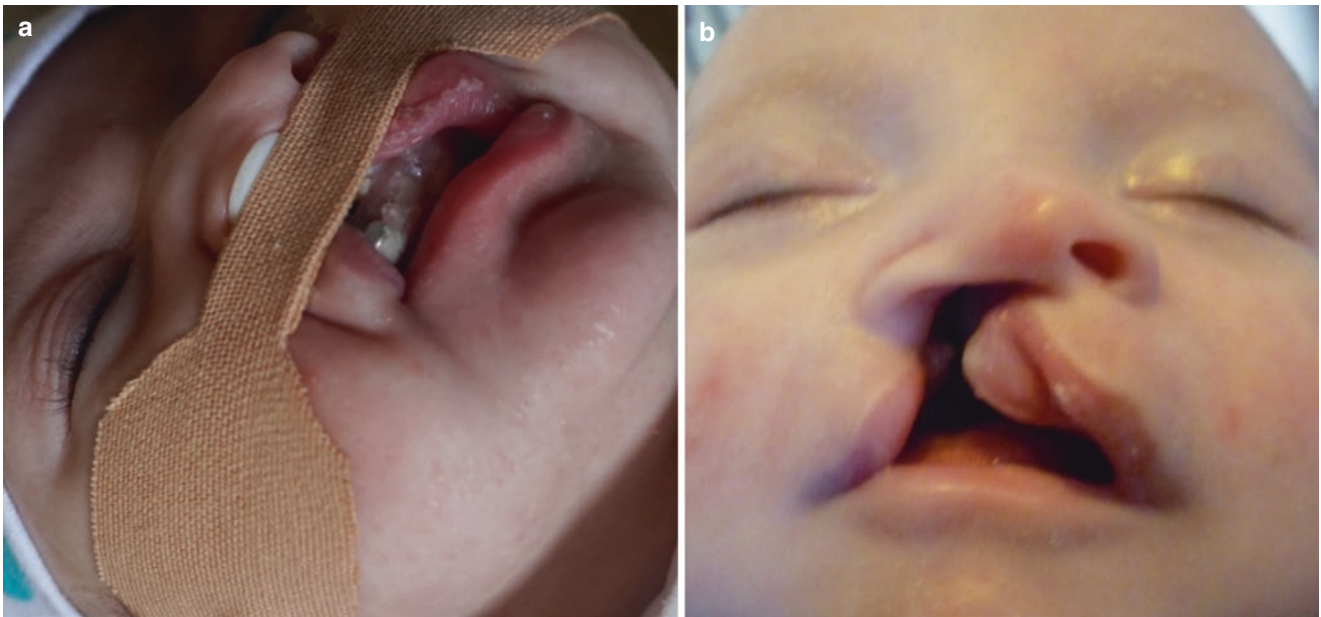

Fig. 13.8 (a, b) DPNR technique acts by producing relaxation of the nasal transverse muscle. Soft tissues remodeling and repositioning helps to eliminate the intranasal bridge

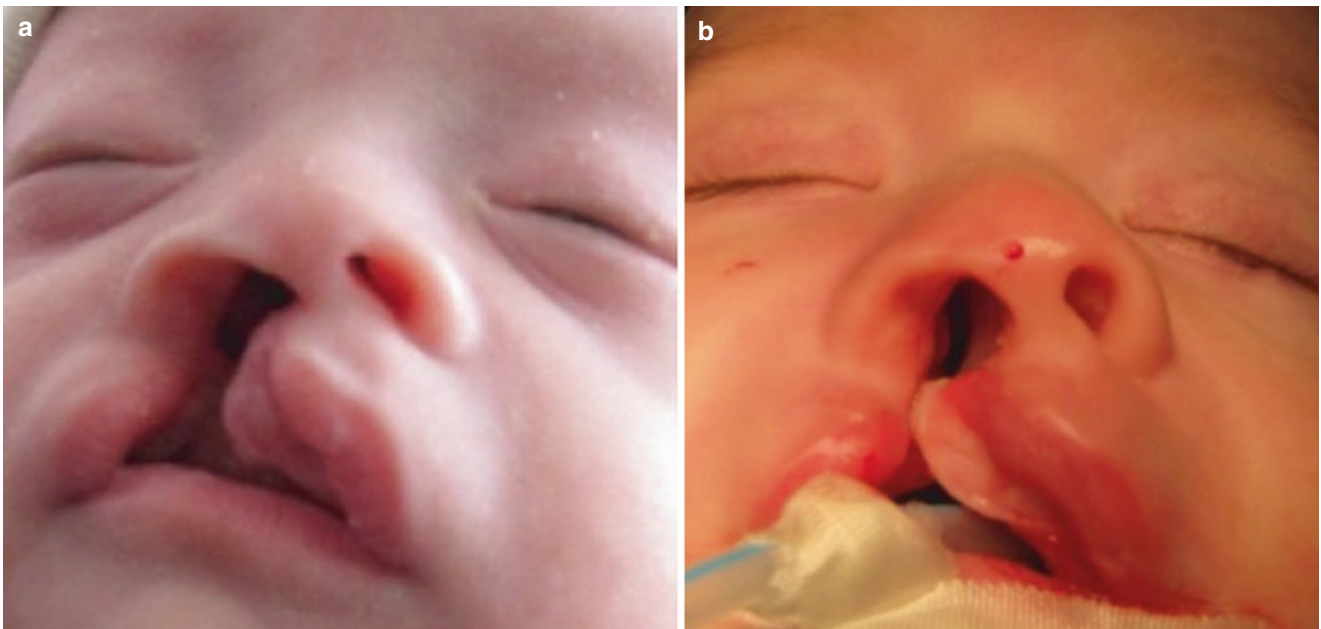

Fig. 13.9 (a, b) Substantial modifications in all tissues distortion can be observed after 1 month of treatment. Lip and nose remodeling process has finalized, and the baby is ready to be reconstructed. The advantages of this procedure may be considered not only from soft tissue perspective but also from bone perspective

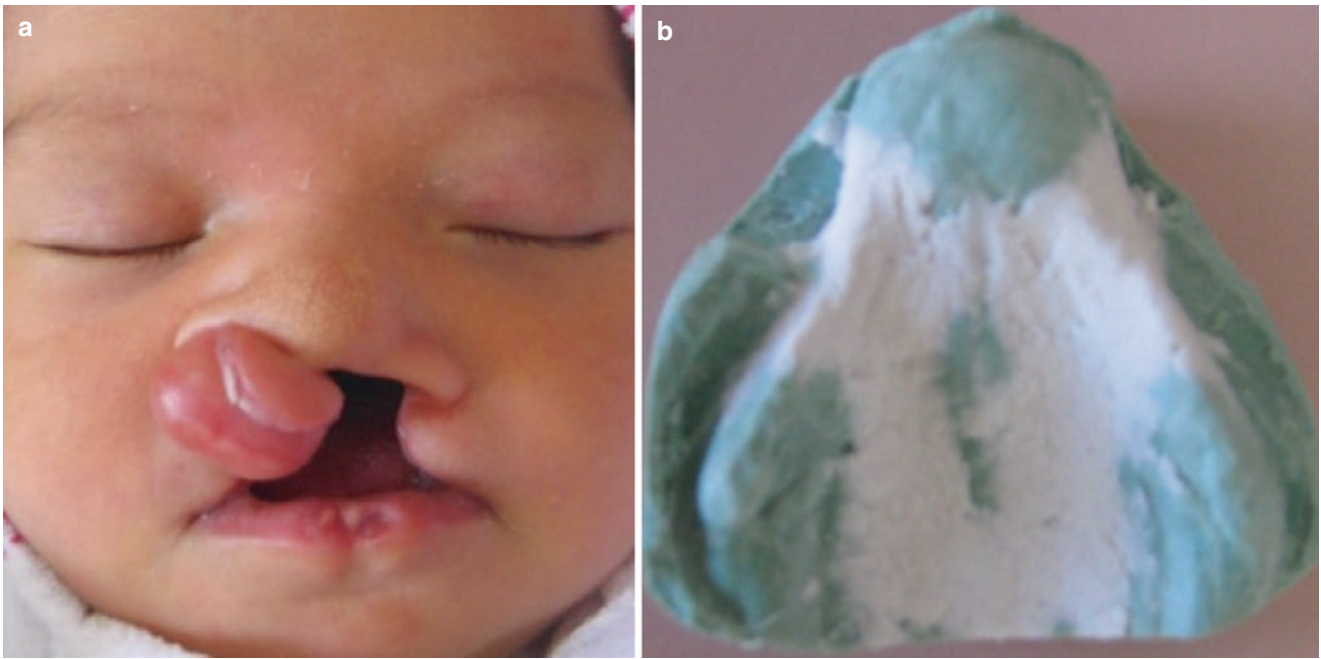


Fig. 13.10 (a, b) Bilateral complete case, with a severe rotated and protruded premaxilla. Initial bone impression with an instantly premaxilla correction and centralization

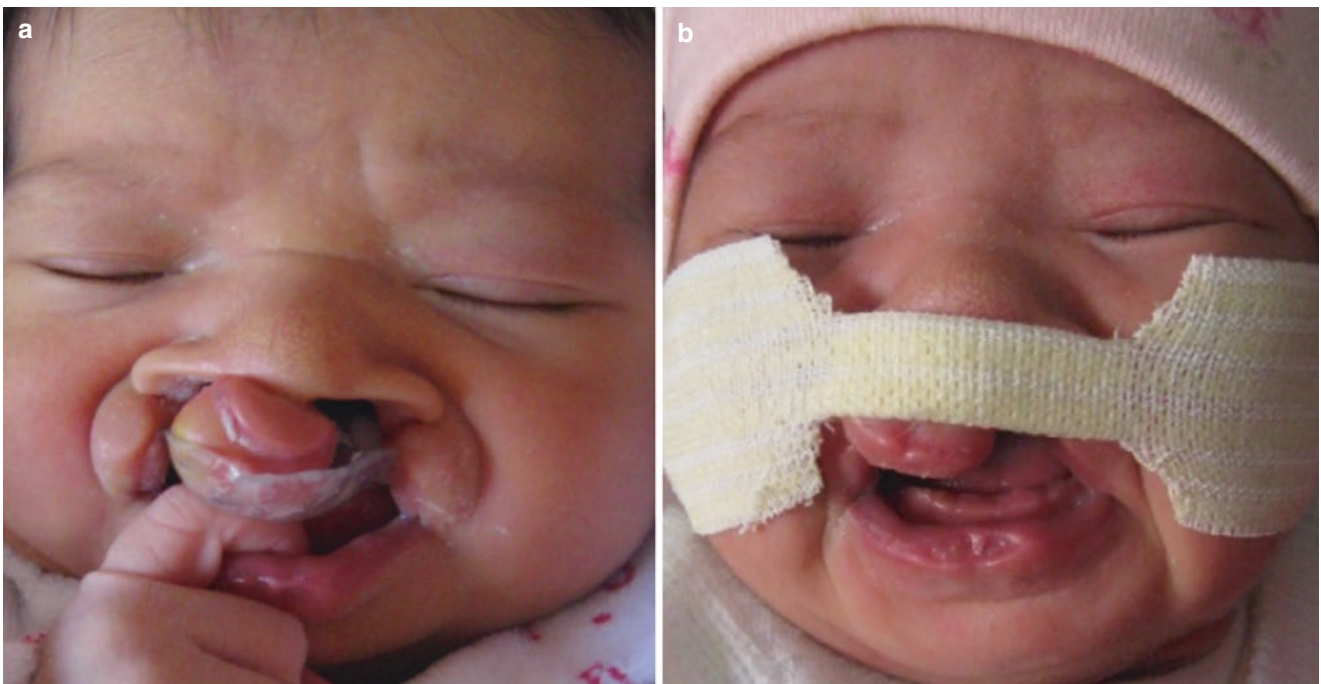

Fig. 13.11 (a, b) Premaxilla centralization view. Muscular facial traction is initiated with the aim to approximate both lateral segments to the premaxilla

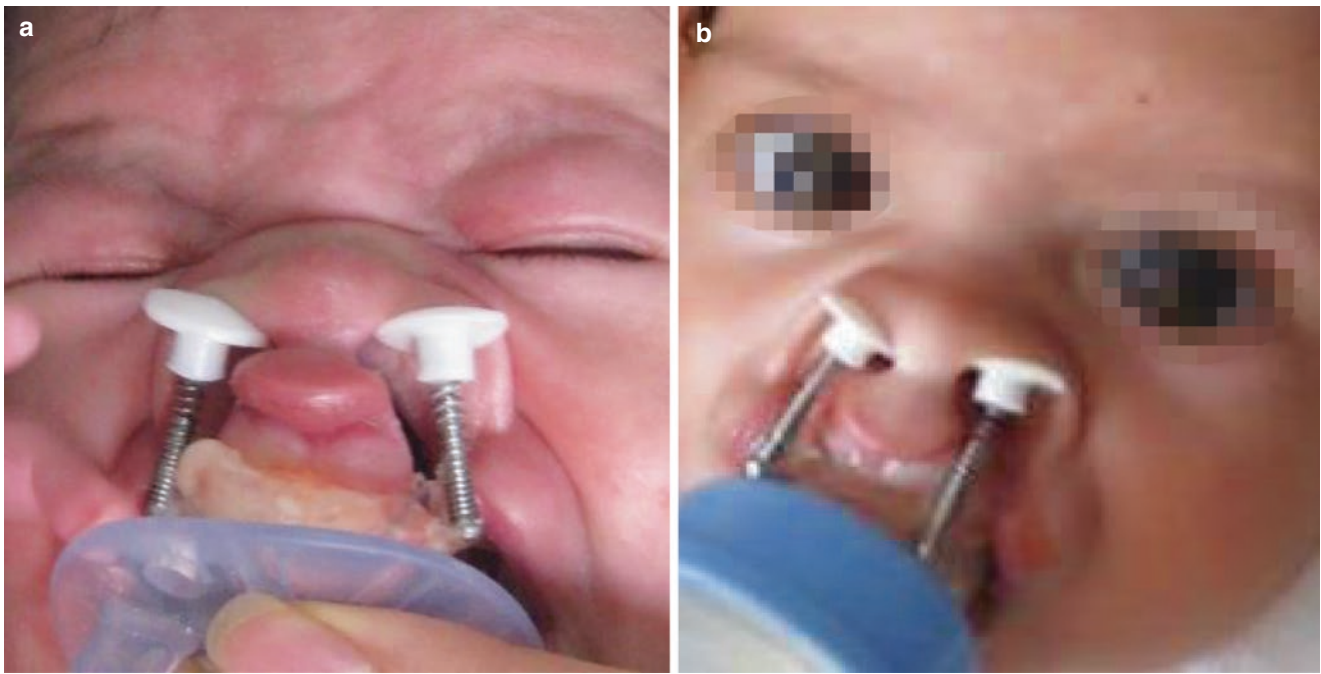


Fig. 13.12 (a, b) The principle of DPNR technique is to employ suctioning and swallowing to create a controlled, discontinuous, and directional force to be applied or transmitted to the nasolabial structures

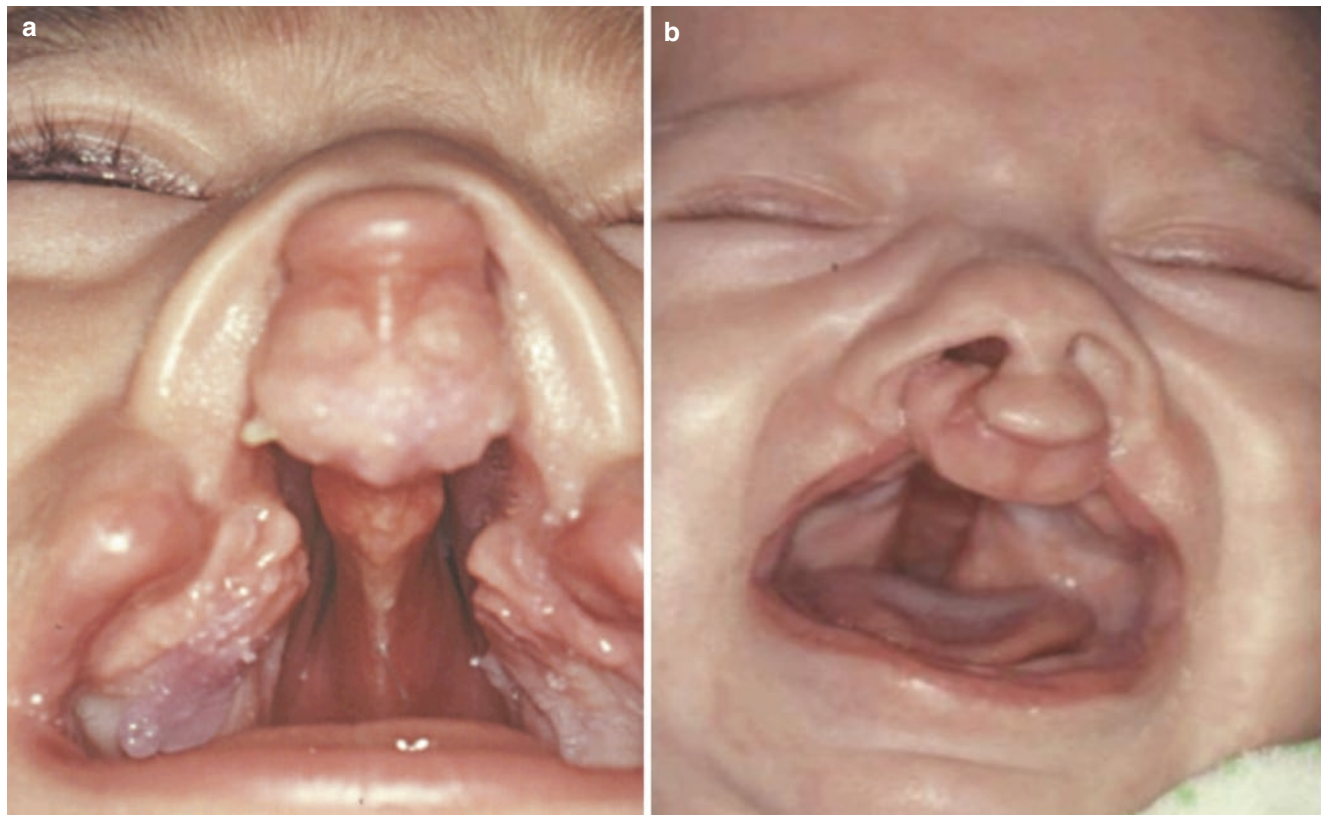


Fig. 13.13 (a, b) Bilateral complete case initial view. The same patient treated by presurgical dynamic remodeling, and ready for the reconstructive procedure. Our strategy is to presurgically reconstruct the new

columella and nasal tip by remodeling adjacent skin and mucosa, and anatomically repositioning the alar cartilages, to make surgical correction less aggressive

13.8 Pediatric Anesthesia Considerations

Induction anesthesia was safely performed by inhalation with gradually increasing doses of halothane or sevoflurane. Intravenous access was secured after an adequate depth anesthesia was achieved. Endotracheal intubation was performed under deep volatile anesthesia. The hydration protocol included 13 ml/kg/hour with 0.85% NaCl physiological solution. A neuromuscular blocking agent was used to relax muscles: atracurium besylate at doses between 0 and 0.4 mg/kg, fentanyl citrate 1–3 ug/kg, and nalbuphine hydrochloride 30 ug/kg.

Regional anesthesia of both the face and palate were performed using superficial safe techniques by slowly infiltrating small volumes of local anesthetic with epinephrine to obtain a good and persistent neurosensory block.

At the end of the surgical procedure, we stop administering anesthetics and proceed with ventilatory recovery, administering antagonists (atropine-neostigmine in doses of 10 and 30 ug/kg respectively). Extubation is performed in forced inspiration, and the patient is transferred to the post-

anesthesia care unit, where the baby recovers with its parents.

Surgical intervention time was between 49 ± 13 minutes for unilateral cleft lips and cleft palate repair, compared to 75 ± 28 minutes for bilateral cleft lip, and 68 ± 31 for revisions (Moggi et al. 2015).

Facial and palatal regional anesthesia is the key in general anesthesia to let the use of fewer central nervous system depressant drugs, allowing for a faster recovery and facilitating the possibility of moving these procedures to outpatient surgeries (Bingham 2012).

Ambulatory surgery is increasing worldwide, reducing hospital stays, lessening family separation, lowering costs in health insurance, and thus in the long run providing the desired results (Maestre 2000).

Understanding the physiopathology of these malformations facilitates the reduction of risks in nutrition. These maneuvers lead to the implementation of better policies in healthcare (Kundra et al. 2009; Paine et al. 2014) (Fig. 13.14).

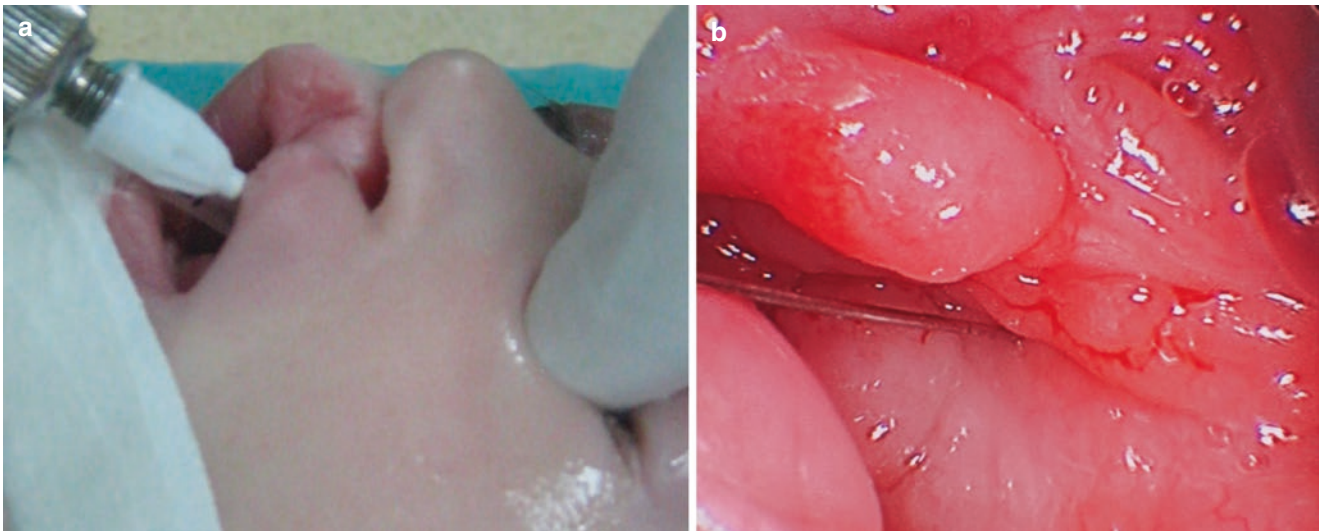

Fig. 13.14 (a, b) Regional anesthesia procedure in cleft lip/palate reconstruction

13.9 Unilateral Cleft Lip and Nose Repair

Since Millard (1958) introduced his rotation advancement technique, stability and predictability have been much easier to achieve.

To provide consistent results that not only repair the congenital defects but also achieve symmetry and esthetic balance, proper education, training, and a constant flow of patients are necessary (Gillies and Millard 1957).

These combined procedures are generally performed at 3 months of age (Laberge 2007).

The size of the airway is drastically changed after lip closure and nostril reshaping, and there is more resistance to breathing. In these young babies, airway monitoring and specialized nurses are essential in the immediate post-op.

Fortunately, if the baby is awake and without pain, the adapting process is very short, and the patient can initiate breast or bottle feeding after 30 min.

We believe that dynamic presurgical nasoalveolar remodeling with primary reconstruction of the lip and nose, in one setting, is the best option for children presenting with a unilateral cleft lip and palate (Bennun and Genecov 2015). Primary bone graft and alveolar gap closure, in the area of dental germs, do not seem to be necessary. A conservative high gingivoperioplasty, with muscular nasal floor reconstruction, to prevent oronasal fistula is recommended. Fewer revisions mean less scarring and more predictable results. The first team definitely has the best chance of a good result (Figs. 13.15, 13.16, 13.17, 13.18, and 13.19).

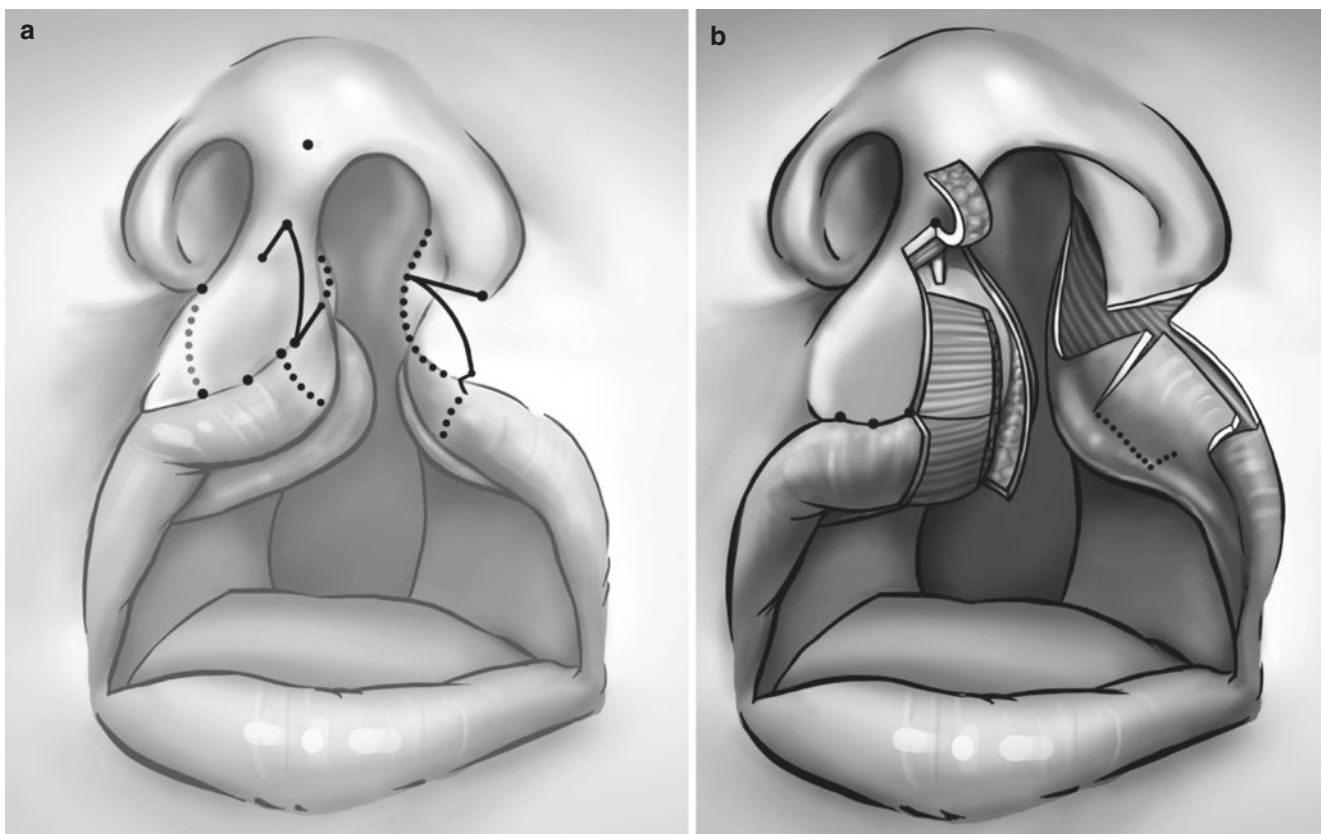


Fig. 13.15 (a, b) Unilateral complete cleft lip repair. The rotation/advancement procedure illustration. By plane dissection view

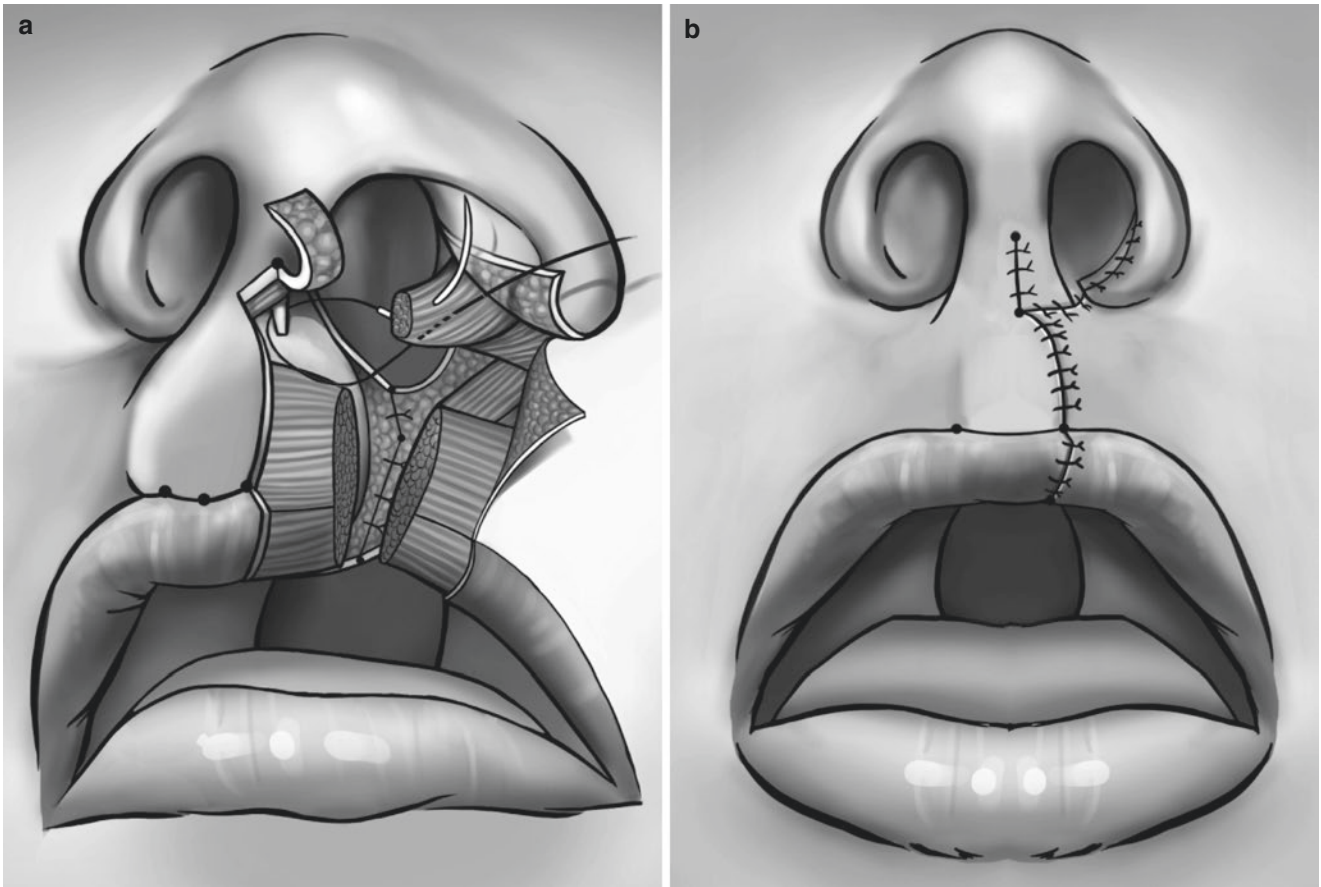


Fig. 13.16 (a, b) Three-plane reconstruction, showing the oral mucosal plane totally closed and the nasal and labial muscles ready to be approximated. Final result scar view

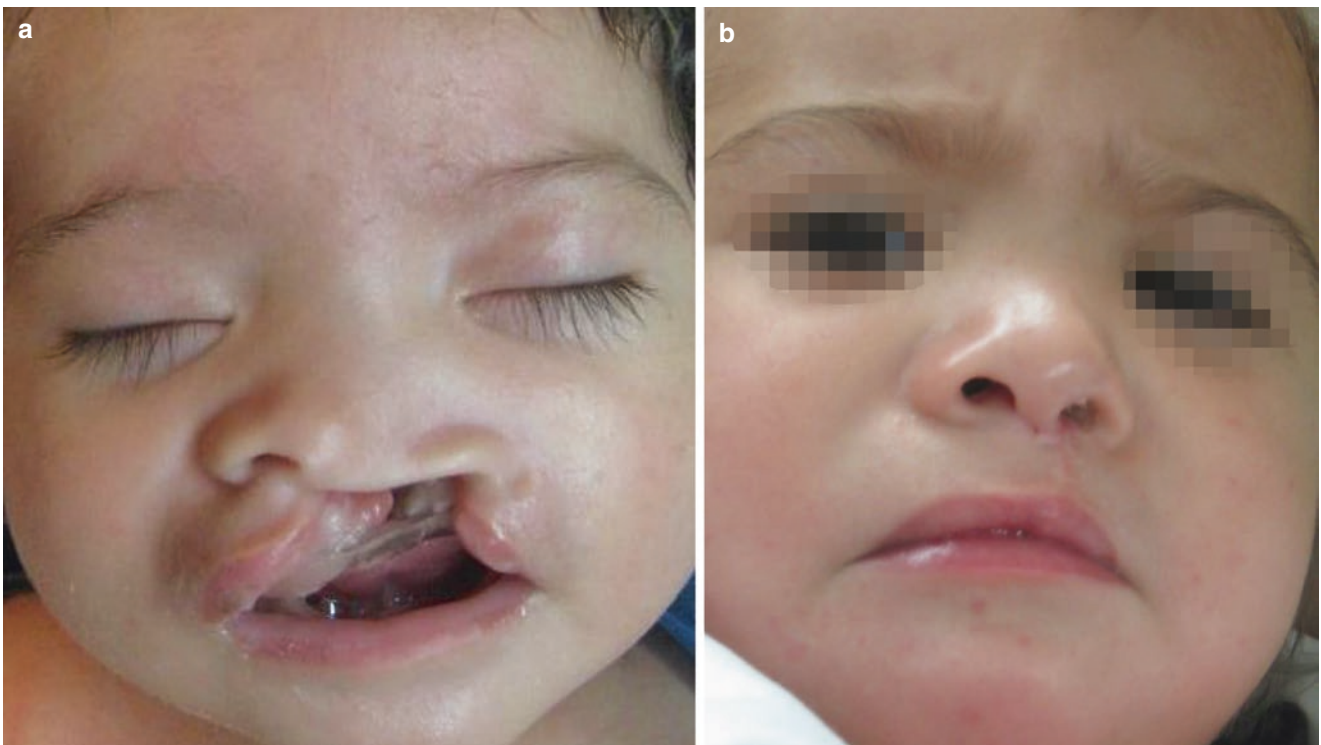

Fig. 13.17 (a, b) Unilateral complete case, without nasal remodeling, presurgical view. Six-month post-op result

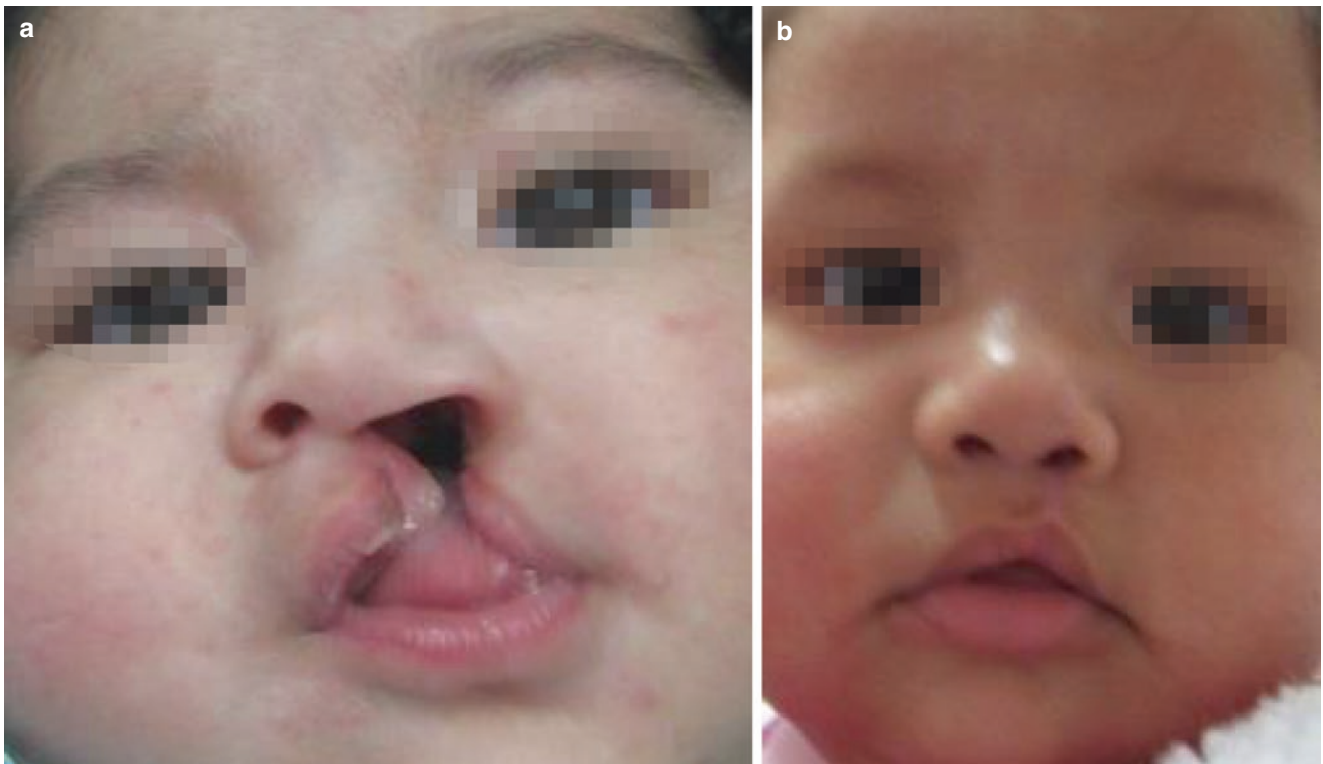


Fig. 13.18 (a, b) Unilateral complete case, with presurgical nasoalveolar remodeling, presurgical view. Six-month post-op result

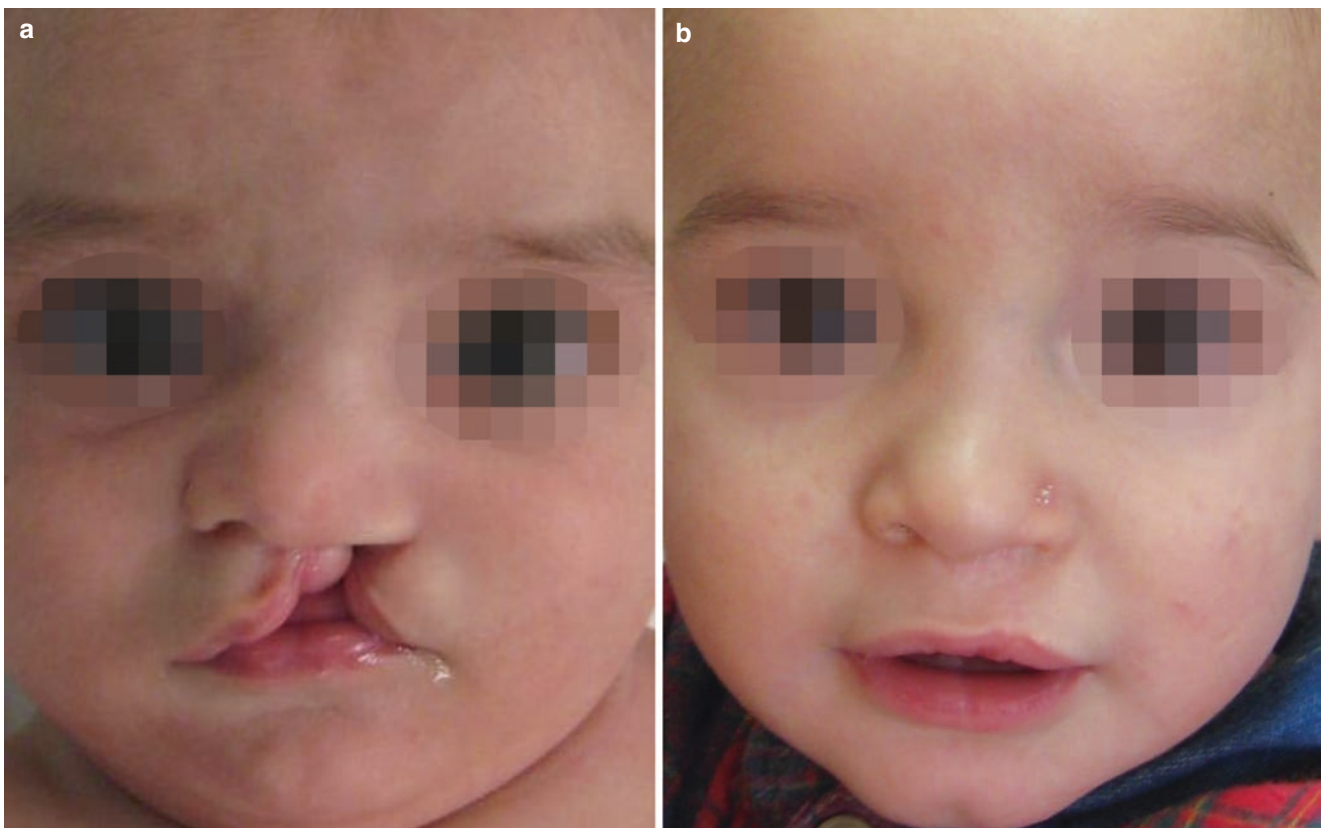


Fig. 13.19 (a, b) Unilateral complete case presurgical view. One-year post-op result

13.10 Bilateral Cleft Lip and Nose Repair

The deformity is characterized by a protruding maxilla, prolabium lacking muscle fibers with a blunted white roll, vertically long lateral lip elements widely spaced due to discontinuity of the orbicularis oris, short columella, flattened nose, and abnormally positioned alar cartilages. A single-stage bilateral cleft lip and nose repair to correct the deformity and allow for proper growth is believed to be better for future appearance and function.

This concept is based on two major advances in the surgical management of bilateral cleft lip over the past quarter century.

First is the understanding of the need for preoperative remodeling of the cleft maxillary segments and nasal/labial tissues.

Second is the recognition of the principles of bilateral labial repair, especially the significance of simultaneous correction of the nasal deformity (Mulliken 2009).

A one-stage procedure to reconstruct complete and incomplete bilateral cleft lip and nose deformities is presented. Emphasis was made on closure of the lip muscles, correction of the nostril floor, correction of the alveolar cleft, as well as reconstruction of the nose through an intranasal approach (Bennun and Sandor 2015) (Figs. 13.20, 13.21, 13.22, 13.23, and 13.24).

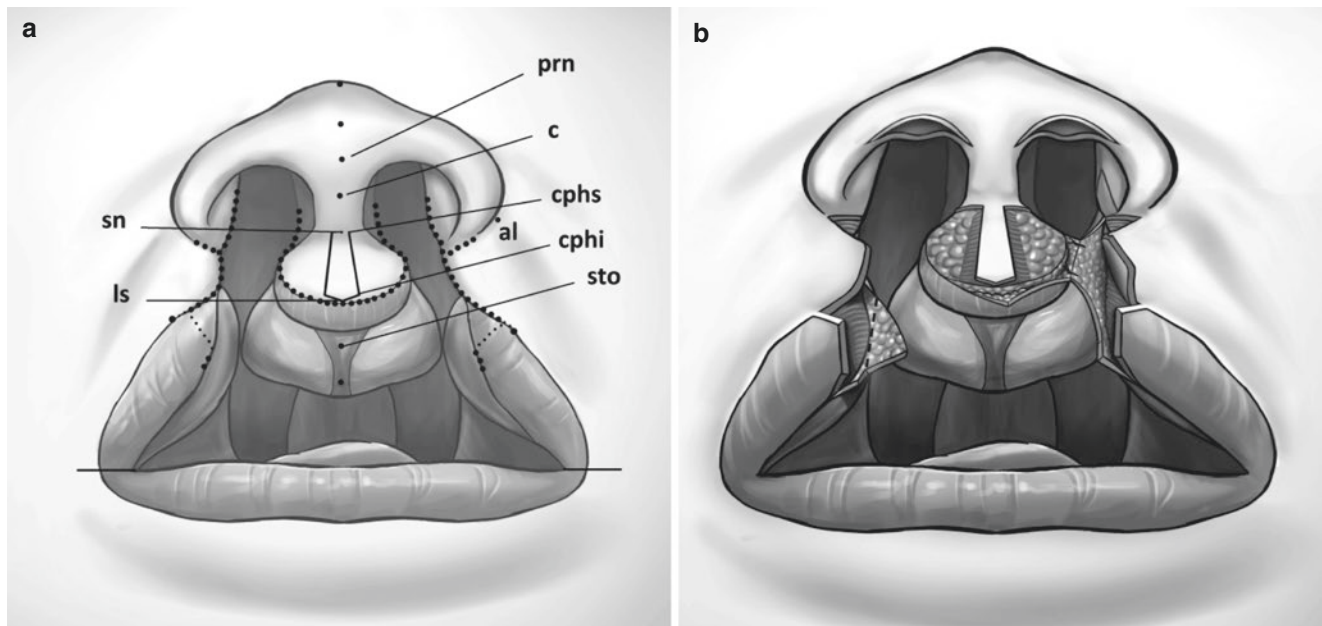


Fig. 13.20 (a, b) Mulliken-type variant illustration. Principal morphological parameters have been marked. Three-plane dissection view

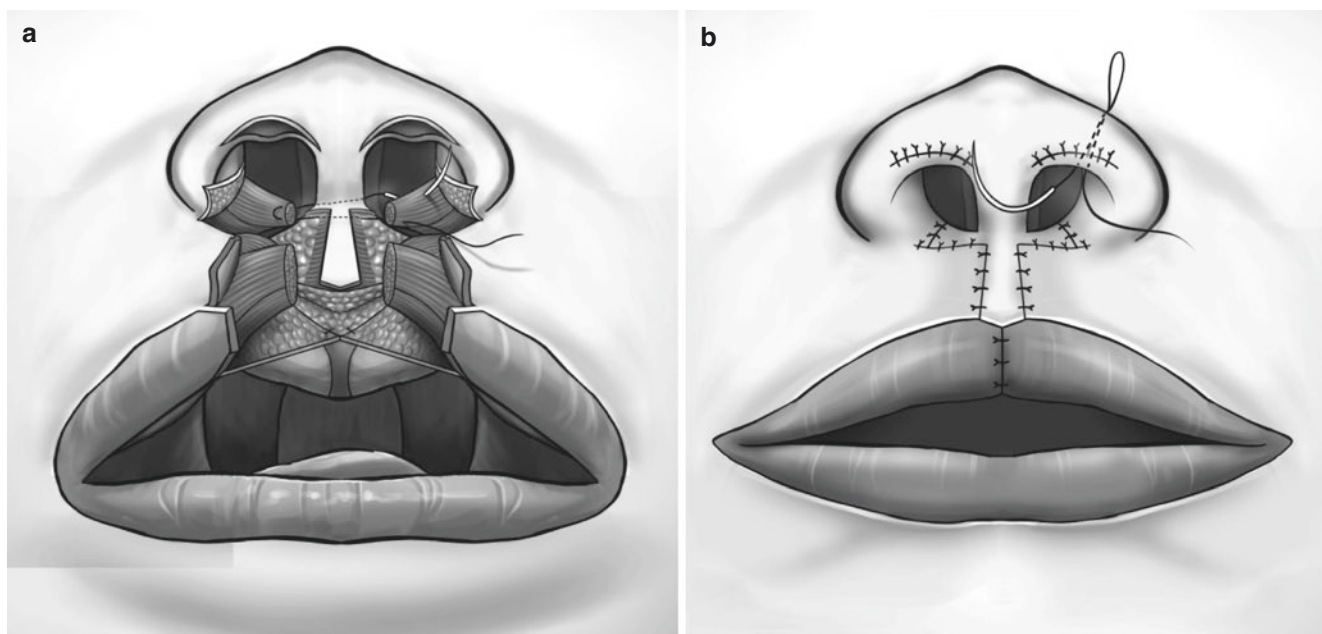


Fig. 13.21 (a, b) By plane reconstruction view. Oral mucosa has been closed in both sides. Nasal and lip muscles are ready to be approximated. Final result scar view

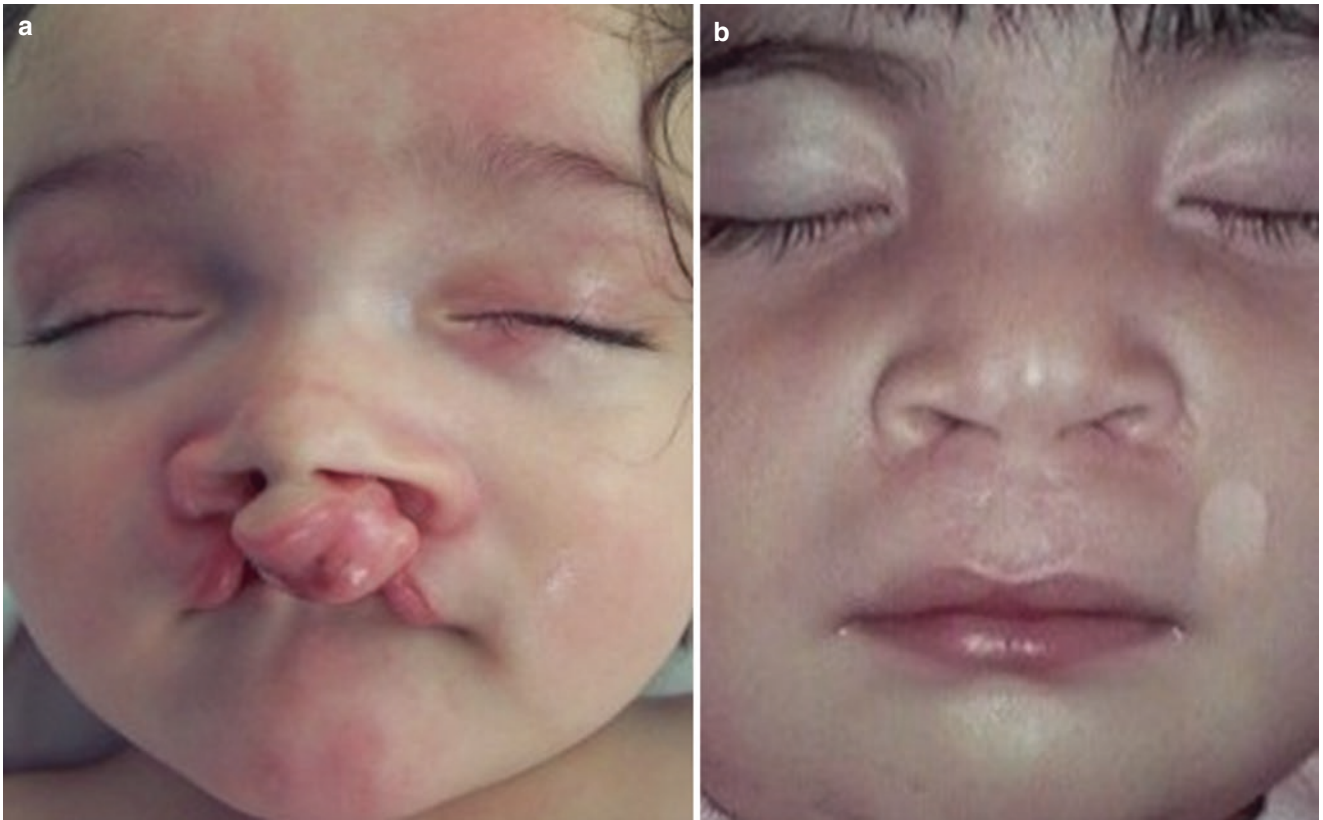

Fig. 13.22 (a, b) Bilateral complete presurgical view. One-year post-op frontal view. A normal prolabial conformation can be observed

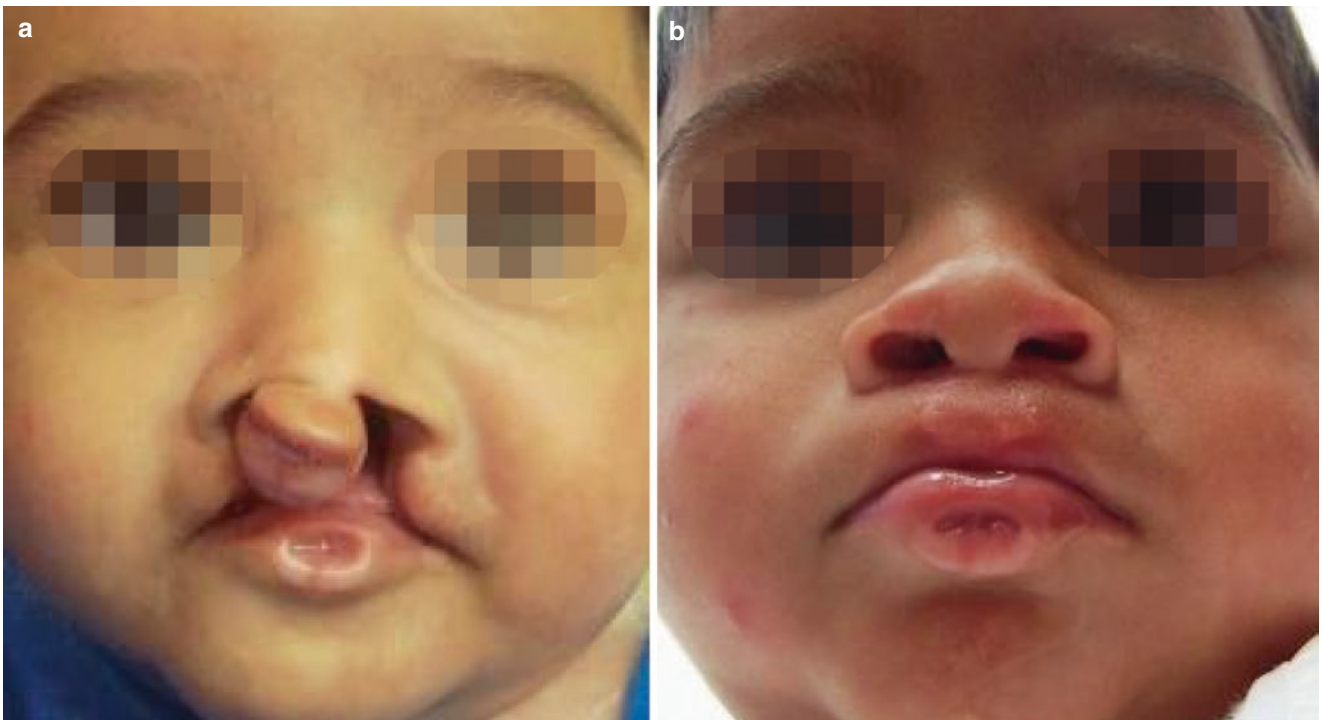


Fig. 13.23 (a, b) Bilateral complete presurgical view. One-year post-op inferior view. A natural nose conformation and symmetry can be observed

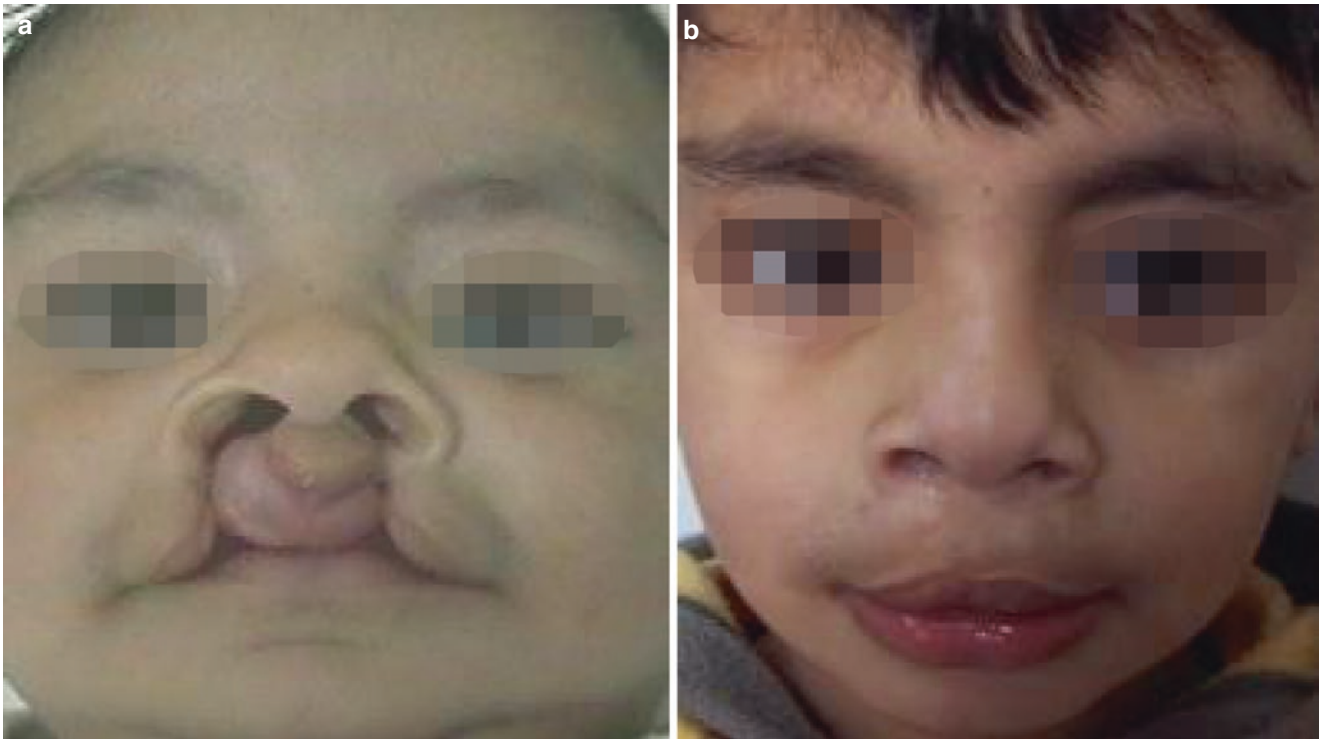

Fig. 13.24 (a, b) Bilateral case presurgical view. Four-year follow-up view

13.11 One-Stage Complete Cleft Palate Repair

Basically there are three groups of palate repair techniques.

One is for hard palate repair, the second for soft palate repair, and the third based on the surgical schedule.

Hard palate repair techniques are Veau–Wardill–Kilner V-Y, von Langenbeck, two-flap, alveolar extension variant, vomer flap, raw area free palatoplasty, and so on.

The soft palate techniques are intravelar veloplasty, double-opposing Z-plasty, radical muscle dissection, primary pharyngeal flap, and so on. And the protocol-based techniques are Schweckendiek's, Malek's, whole in one, modified schedule with palatoplasty before lip repair, and so on.

Today, the majority accept 8–14 months as the optimum age for palate closure. Ideally, the development of babbling

should be considered as an indicator of the best time to reconstruct the palate.

Conventional methods of cleft lip repair deprive the anterior (buccolingual) alveolar mucoperiosteum of blood supply from the facial–internal maxillary arcade. Six months later, at palatoplasty, lingual incisions permanently isolate the lingual mucoperiosteum from its blood supply: the greater palatine artery. The osteogenic alveolar mucoperiosteum is thus converted from a richly supplied boundary zone between the two angiosomes into an isolated tissue dependent on osseous ackflow.

Cleft-sided growth disturbance is considered from this perspective. Subperiosteal techniques that preserve the blood supply to this tissue are considered in a sequential plan of cleft management (Carstens 1999; Rossell-Perry et al. 2015) (Figs. 13.25, 13.26, 13.27, 13.28, 13.29, and 13.30).

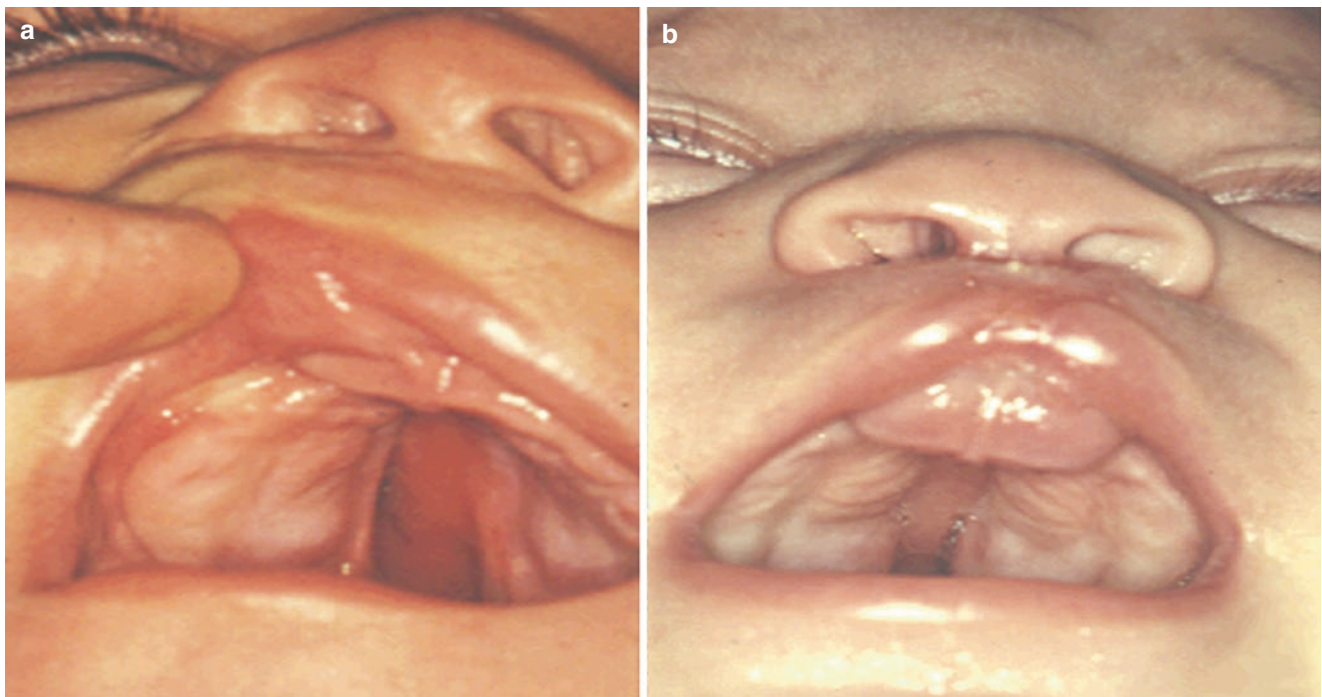


Fig. 13.25 (a, b) A correct dental arch alignment at the moment of total palate closure is essential to perform a proper procedure

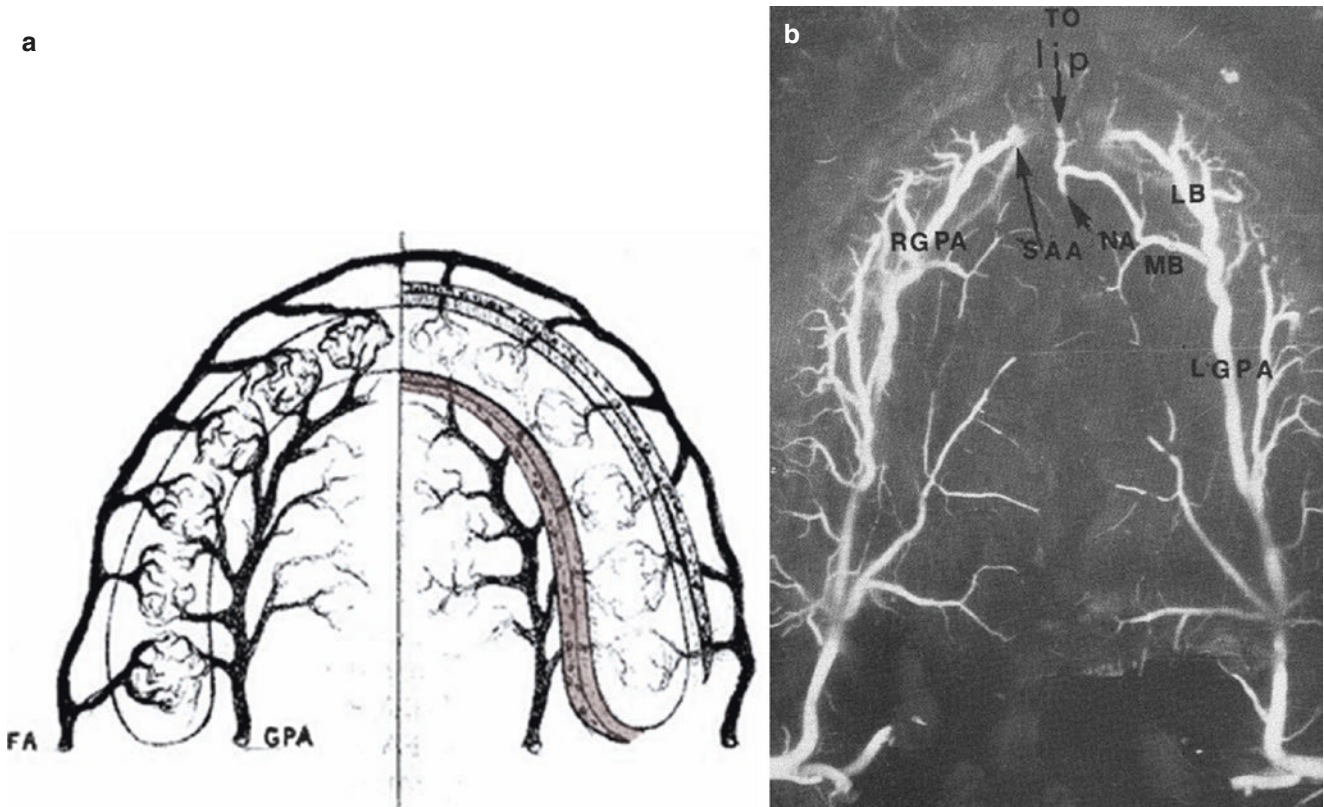


Fig. 13.26 (a, b) Anatomical concepts and irrigation preservation are transcendental to prevent complications and sequels

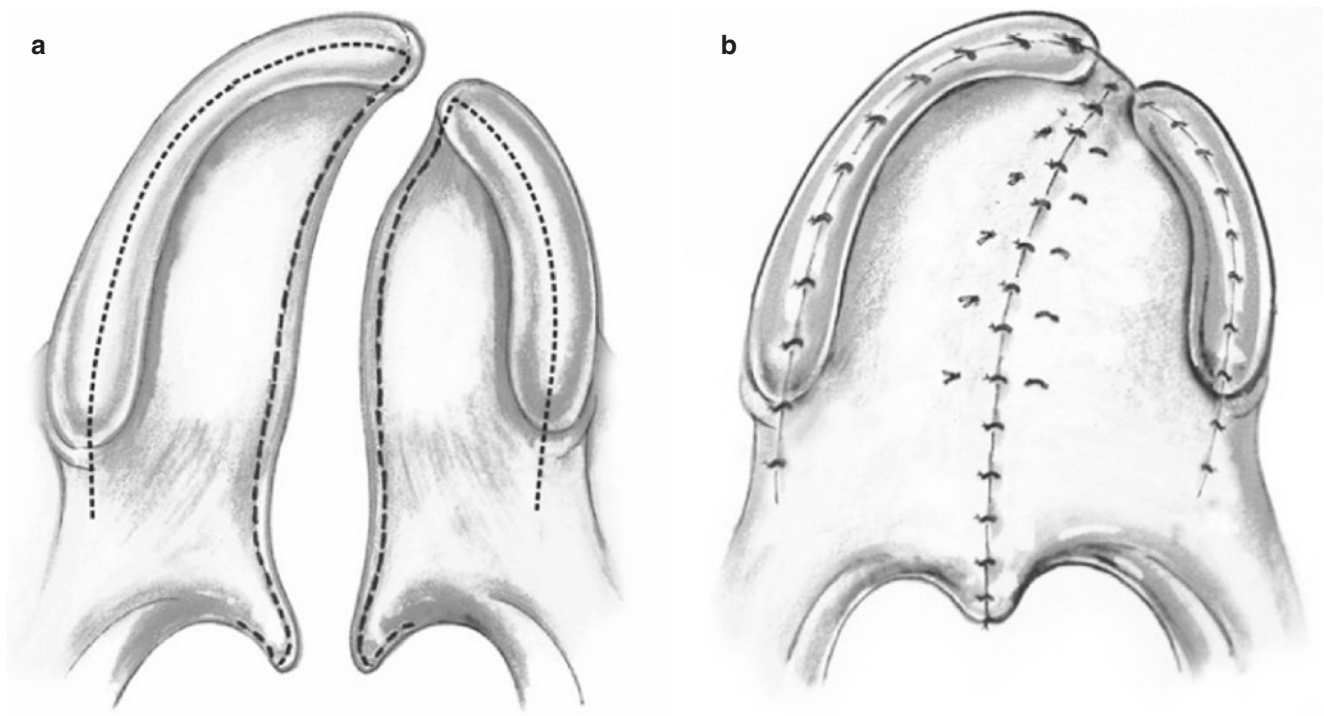


Fig. 13.27 (a, b) Carstens variant illustration. The alveolar expanded palatal incisions can be observed. Bigger flaps make the total closure easier and help surgeons to prevent sequels

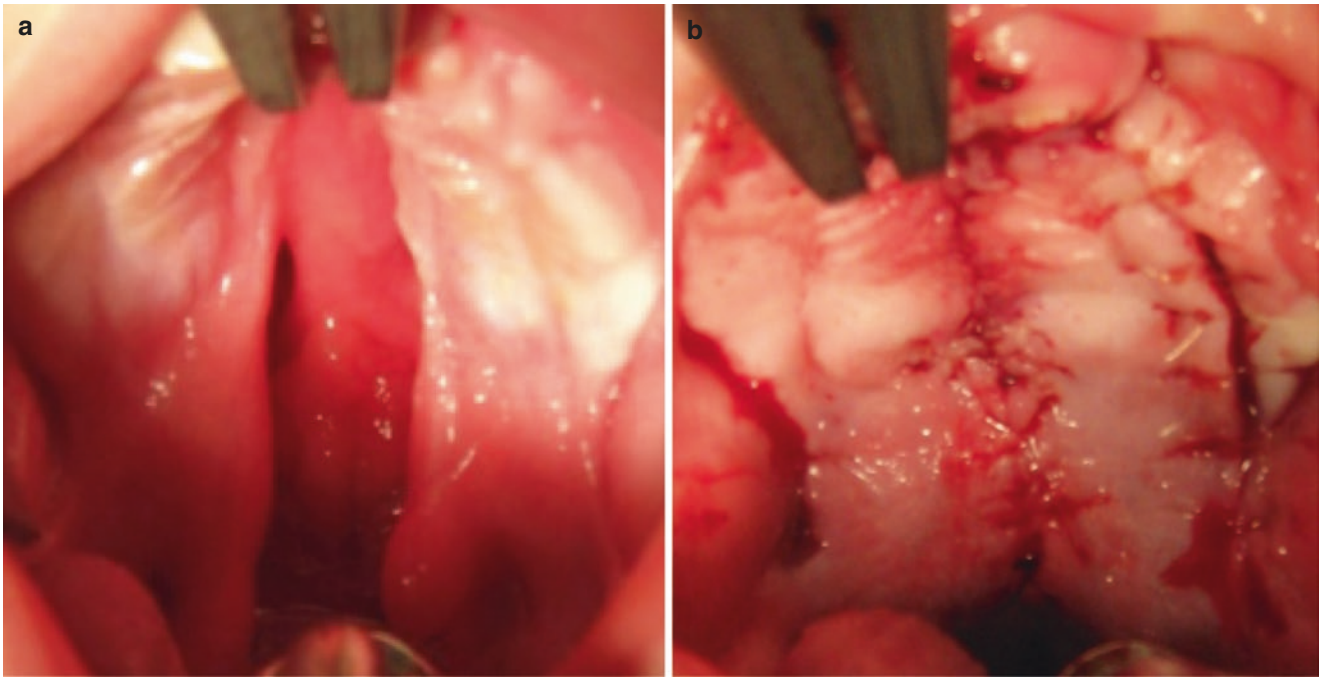


Fig. 13.28 (a, b) Unilateral complete case presurgical view. Immediate post-op view. Primary and secondary palates have been totally closed in a one-step procedure

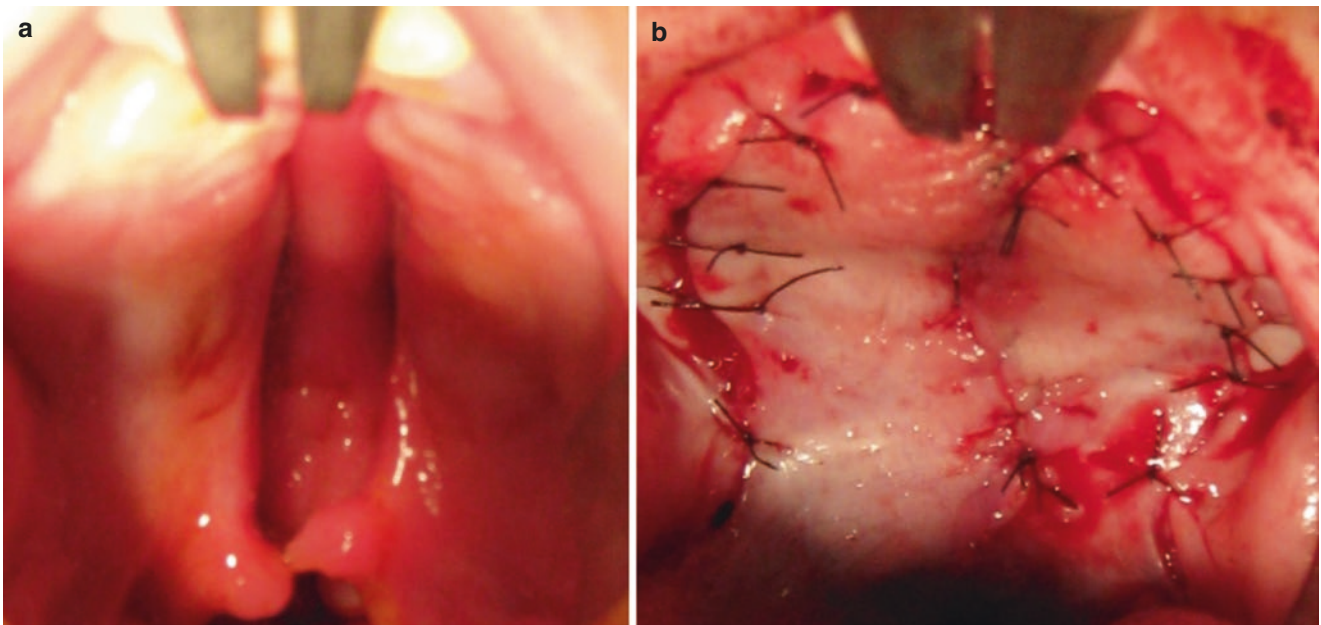


Fig. 13.29 (a, b) Bilateral complete case presurgical view. A total palate closure has been achieved in a one-step procedure. A two-plane muscular reconstruction has been performed

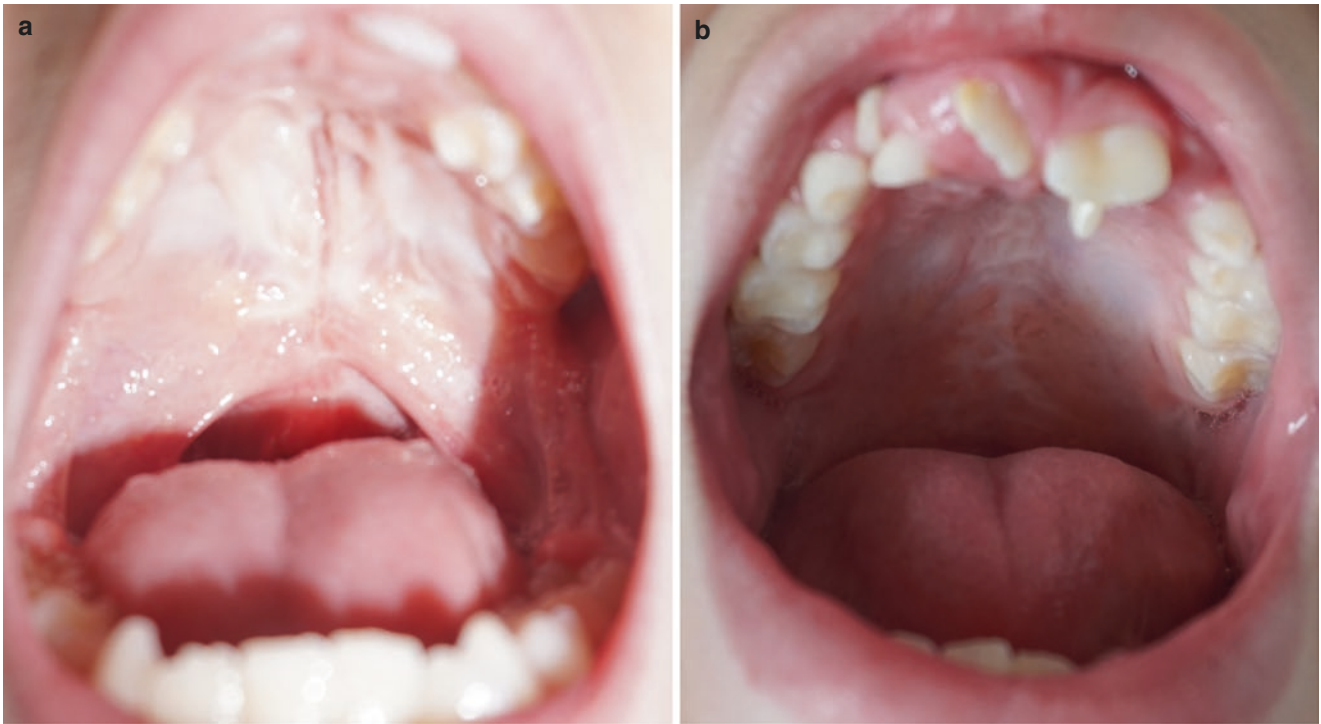

Fig. 13.30 (a, b) Unilateral and bilateral 7-year follow-ups. No anterior fistula, no transversal retraction, and a good velar elongation can be observed

13.12 Discussion

Some types of surgery performed on the tip of the nose, such as secondary rhinoplasty on cleft lip and palate (CLP) patients, may have an uncertain end result due to difficulty in maintaining the surgically created status constant over time.

Experience has shown that application of a dynamic nasal splint has contributed efficiently in maintaining the surgical results by opposing healing contraction (Cenzi and Guarda 1996).

Based on a literature review, nasal molding seems to be more beneficial and effective with better long-term results (Matsuo et al. 1991; Singh et al. 2005).

Hence, it can be concluded that not only the interdisciplinary approach but also a thorough knowledge of the changing concepts of nasoalveolar molding and timing of initiation is essential to improve results (Matsuo et al. 1989; Abbott and Meara 2012).

Considering the physiopathology of the nasolabial deformity, it is clear how important early prevention of unfavorable factors is. Taking into consideration wound healing concepts, we can conclude that premature treating of tissues “without memory” allows avoidance of alar cartilage deformity fixing.

The DPNR technique does not rely on the relatively static force exerted by an orthopedic plate held in place by means of tape or adhesives.

Introduced changes make it more comfortable to keep the oral plate in the mouth longer without being expelled, and also it means the use of tape or adhesives is not necessary.

A new, well-adapted nasal component allows better remodeling effects, reducing the time and frequency of visits and avoiding tissue lesions.

The device can be employed in any child and in any type of cleft, and a completed successful treatment results in fewer economic and social costs than any other described procedure.

The possibility of easily modifying the device size and impact direction allows step-by-step treatment of all the components of nasal distortion, reproducing the described distortion process in an opposing manner.

The possibility of achieving a well-conformed and repositioned alar cartilage with more relaxed nose and labial tissues lets the normal airway passage through this nose allowing normal facial growths and development.

Also it avoids aggressive surgical dissection and diminishing scars, preventing sequels.

A reduced number of surgical procedures and the shortening of treatments contribute to reduced social and monetary expenses and facilitate normal social insertion of the child at school age (Figs. 13.31, 13.32, 13.33, 13.34, and 13.35).

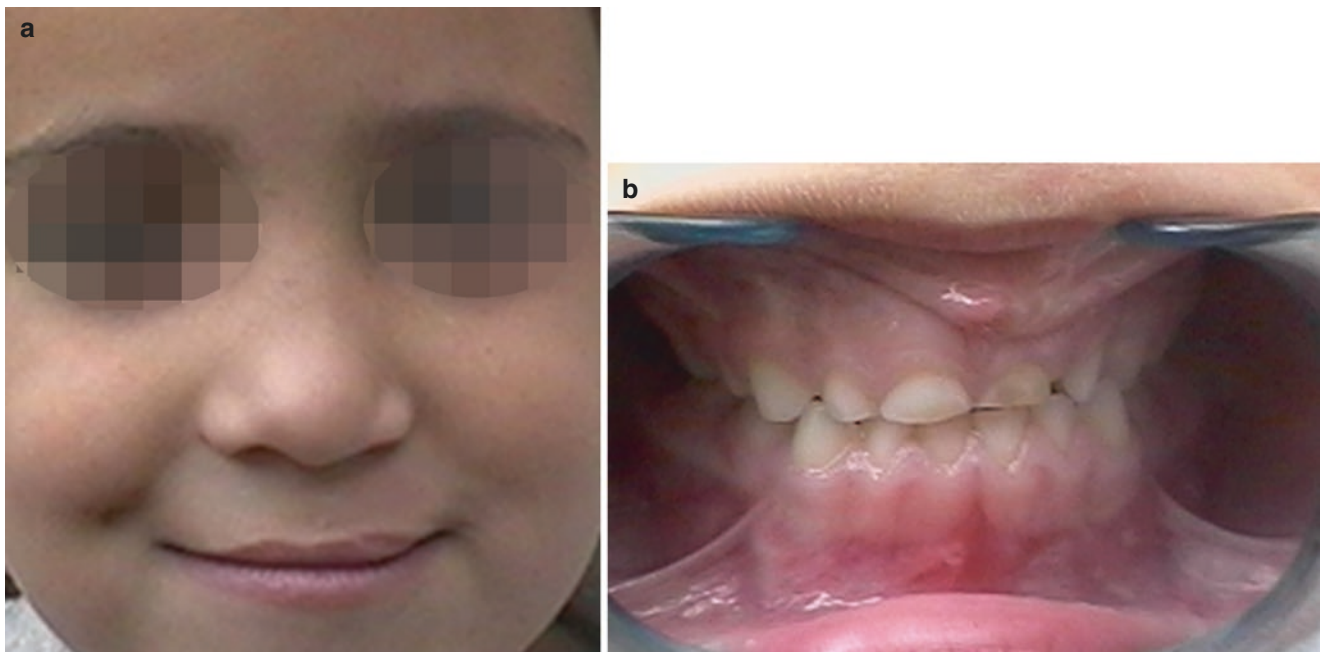


Fig. 13.31 (a, b) Five-year follow-up in a unilateral incomplete case. Frontal and oral views

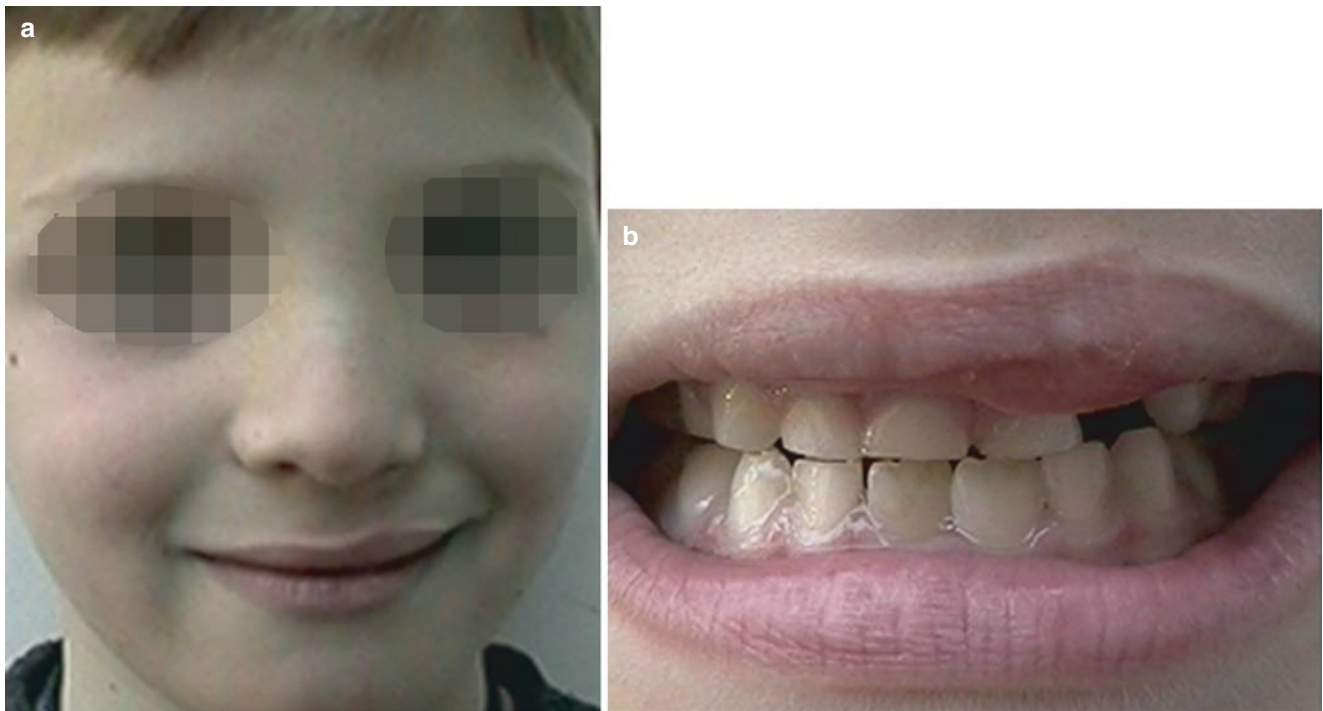


Fig. 13.32 (a, b) Seven-year follow-up in a unilateral complete case. Frontal and oral views

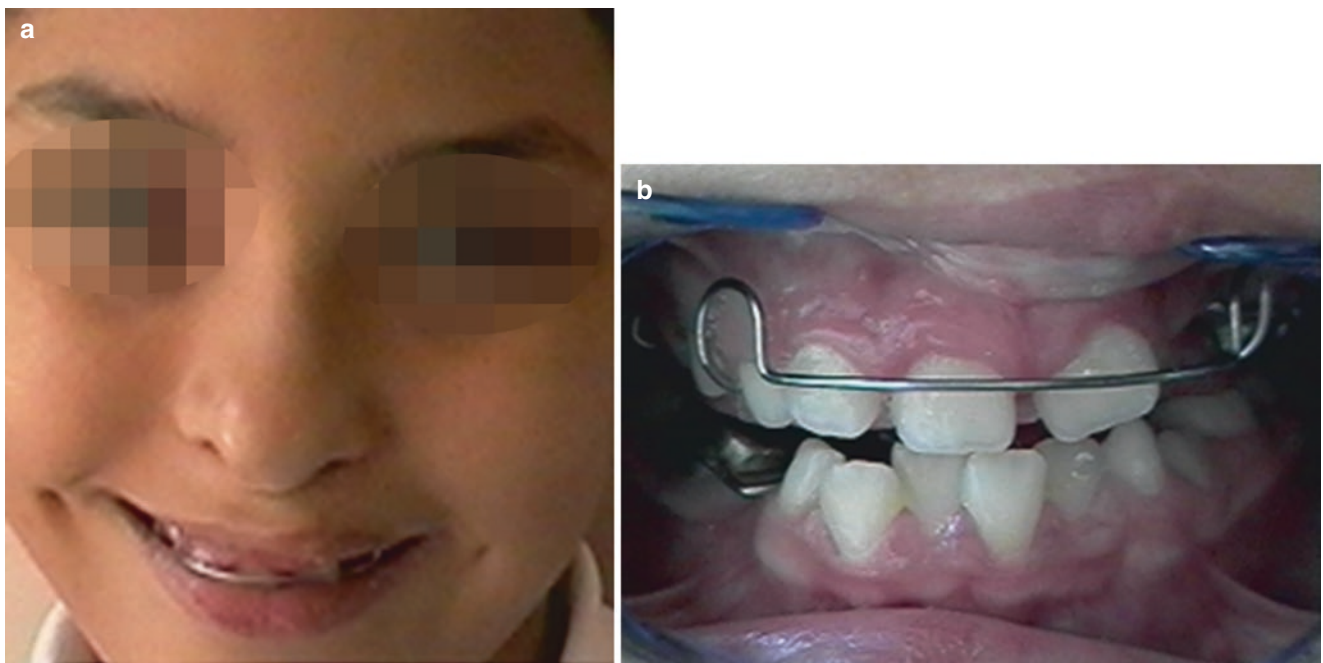

Fig. 13.33 (a, b) Eight-year follow-up in a unilateral complete case. Frontal and oral views

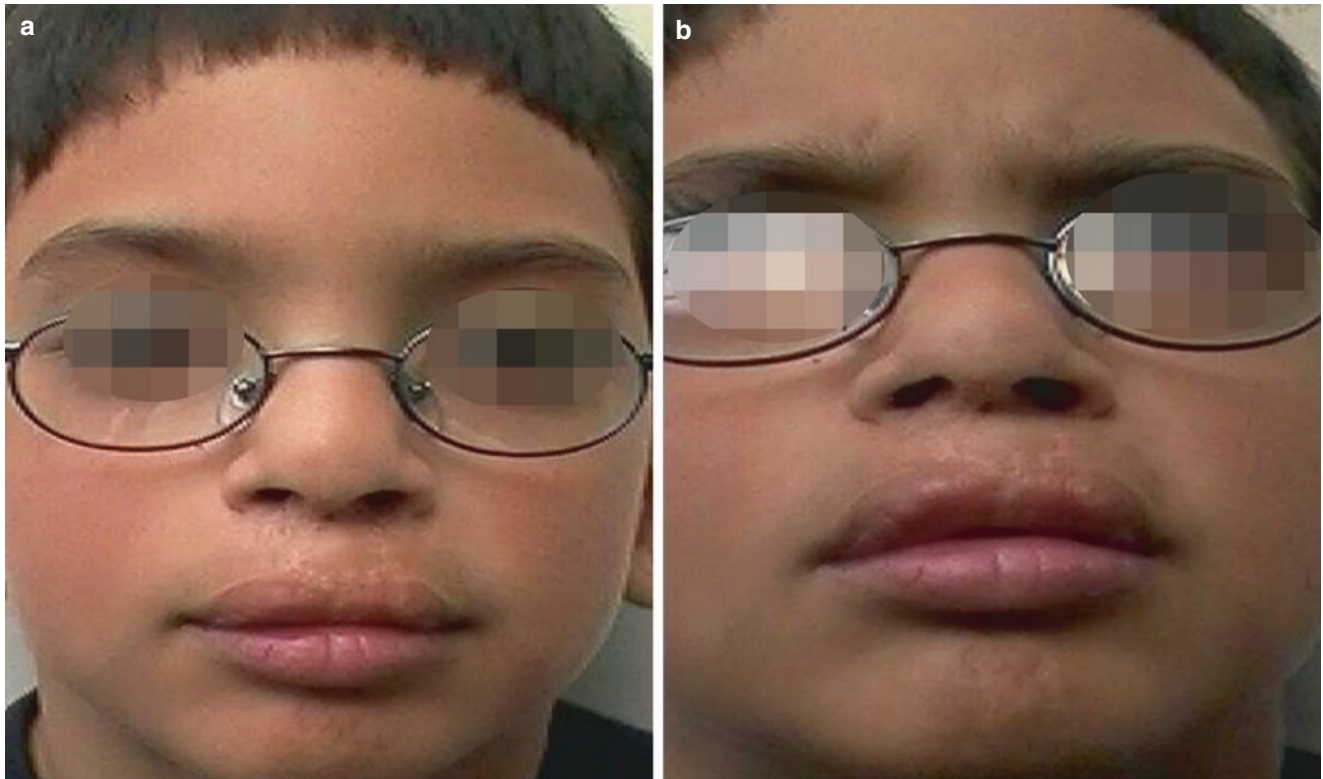

Fig. 13.34 (a, b) Seven-year follow-up in a bilateral complete case. Frontal and inferior views

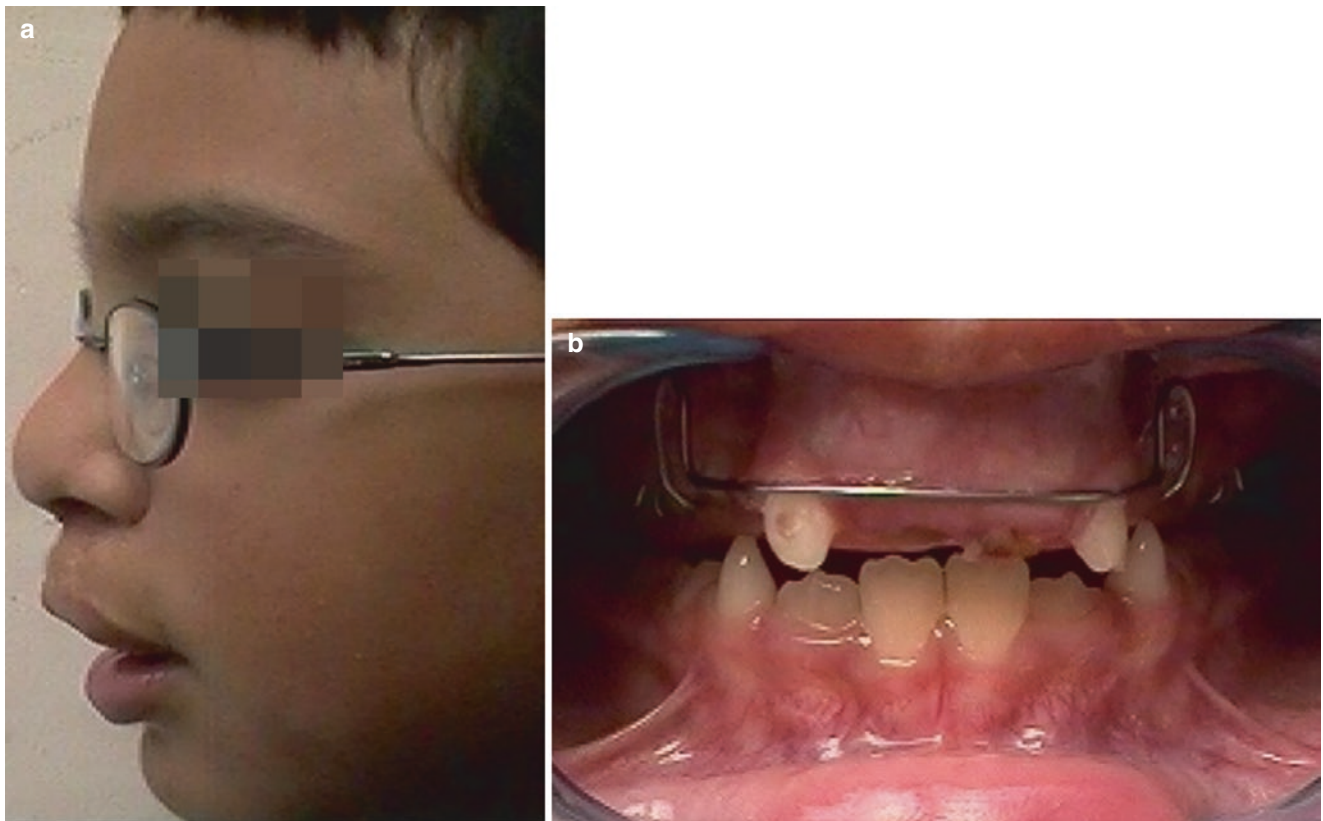

Fig. 13.35 (a, b) Seven-year follow-up in a bilateral complete case. Lateral and oral views

Conclusions

Cleft lip and palate patients present multiple dysfunctional alterations.

Interdisciplinary treatment starts during pregnancy with prenatal diagnosis.

Right after delivery, the use of an oral plate is necessary to close the open palate.

At present, presurgical treatment is an indication to improve tissue distortion and respiratory dysfunction.

An early and correctly implemented method will be beneficial to reduce surgical aggression, to decrease the number of procedures, and to prevent sequels.

In unilateral and bilateral cases, primary lip and nose reconstruction is performed between three and six months old and complete palate closure is planned from 8 to 14 months old and so on.

Interdisciplinary follow-up is essential to avoid facial growth and development alterations, hearing and speech dysfunctions, and poor esthetic results.

Orthodontic will be the final step of this treatment to guarantee an excellent occlusion.

References

- Abbott MM, Meara JG. Naso alveolar molding in cleft care. Is it efficacious? *Plast Reconstr Surg.* 2012;30(3):659–66.
- Adzick NS, Lorenz HP. Cells, matrix, growth factors, and the surgeon. The biology of scarless fetal wound repair. *Ann Surg.* 1994;220:10–8.
- Adzick N, Harrison M, Glick P. Comparison of fetal, newborn and adult wound healing by histologic, enzyme-histochemical and hydroxyproline determination. *J Pediatr Surg.* 1985;20:315.
- Bäumler M, Faure JM, Bigorre M, Bäumler-Patris C, Boulout P, Demattei C, Captier G. Accuracy of prenatal three-dimensional ultrasound in the diagnosis of cleft hard palate when cleft lip is present. *Ultrasound Obstet Gynecol.* 2011;38(4):440–4.
- Bennun RD, Perandones C, Sepliarsky VA, et al. Non-surgical correction of nasal deformity in unilateral complete cleft lip: a 6 years follow-up. *Plast Reconstr Surg.* 1999;3:616–30.
- Bennun RD, Perandones C, Sepliarsky VA, et al. Non-surgical correction of nasal deformity in unilateral complete cleft lip: a 6 years follow-up. In: *Year Book Plast Reconstr and Aesthetic Surg.* vol. 1. St. Louis: Mosby; 2001. p. 16–7.
- Bennun RD, Zaszczynski S, Celnik R. Remodelacion naso-labial prequirúrgica en fisura labio alveolo palatina: Nuevo diseño del componente nasal. *Rev Arg Ortodon.* 2002;66:16–21.
- Bennun RD, Figueroa AA. Dynamic presurgical naso alveolar remodeling in patients with unilateral and bilateral cleft lip and palate: modification to the original technique. *Cleft Palate Craniofac J.* 2006;43:639–48.
- Bennun RD, Langsam AC. Long term results after using Dynamic Presurgical Nasoalveolar Remodeling technique in patients with unilateral and bilateral cleft lips and palates. *J Craniofac Surg.* 2009;20(1):670–4.
- Bennun RD, Langsam AC. Dynamic Presurgical nasoalveolar remodeling in unilateral and bilateral complete cleft :the DPNR technique. Chapter 6:65–78. In: *Cleft Lip and Palate Management: a comprehensive Atlas.* Hoboken: Wiley Blackwell Ed; 2015.
- Bennun RD, Genecov D. Unilateral cleft lip and nose repair. Chapter 9:113–141. In: *Cleft Lip and Palate Management: a comprehensive Atlas.* Hoboken: Wiley Blackwell Ed; 2015.
- Bennun RD, Sandor GKB. Bilateral cleft lip and nose repair. Chapter 10:143–162. In: *Cleft Lip and Palate Management: a comprehensive Atlas.* Hoboken: Wiley Blackwell Ed; 2015.
- Berkowitz S. Cleft lip and palate research: an updated state of the art. Section III: orofacial growth and dentistry: a state of the art report on neonatal maxillary orthopedics. *Cleft Palate J.* 1977;14:288–301.
- Bingham AE, Fu R, Horn JL, Abrahams MS. Continuous nerve block: a systematic review and meta-analysis of randomized controlled trials. *Reg Anesth Pain Med.* 2012;37(6):583–94.
- Campbell A, Costello BJ, Ruiz RL. Cleft lip and palate surgery: an update of clinical outcomes for primary repair. *Oral Maxillofac Surg Clin North Am.* 2010;22(1):43–58.
- Caplan AI. In vivo Remodeling. *Ann N Y Acad Sci.* 2002;961:307–8.
- Carstens MH. Sequencial cleft management with the sliding sulcus technique and alveolar extension palatoplasty. *J Craniofac Surg.* 1999;10(6):503–18.
- Centi R, Guarda LA. A dynamic nostril splint in the surgery of the nasal tip: technical innovation. *J Cranio Maxillofac Surg.* 1996;24(2):88–91.
- Chen WY, Grant ME, Schor AM, et al. Differences between adult and fetal fibroblasts in the regulation hyaluronate synthesis: correlation with migratory activity. *J Cell Sci.* 1989;94:577.
- Dogliotti PL, Bennun RD, Lozoviz E, et al. /tratamiento no quirúrgico de la deformidad nasal en el paciente fisurado. *Rev Ateneo Argent Odontol.* 1991;27:31–5.
- Dong Wook K, Seung-Won C, Hwi-Dong J, Young-Soo J. Prenatal ultrasonographic diagnosis of cleft lip with or without cleft palate: pitfalls and considerations. *Maxillofac Plast Reconstr Surg.* 2015;37(1):24.
- Grayson BH, Santiago P, Brecht L, et al. Presurgical naso-alveolar molding in patients with cleft lip and palate. *Cleft Palate Craniofac J.* 1999;36:486–98.
- Greisler HP. Regulated in Vivo remodeling. *Ann N Y Acad Sci.* 2002;961:309–11.
- Grollemund B, Guedeny A, Vazquez MP, et al. Relational development in children with cleft lip and palate: influence of the waiting period prior to the first surgical intervention and parental psychological perceptions of the abnormality. *BMC Pediatr.* 2012;12:65.
- Hamrick MW. A chondral modeling theory revisited. *J Theor Biol.* 1999;201(3):201–8.
- Hardingham TE, Muir H. The specific interaction of hyaluronic acid with cartilage proteoglycans. *Biochim Biophys Acta.* 1972;279:401–5.
- Hozt M, Gnoinski W. Comprehensive care of cleft lip and palate children at Zurich University: a preliminary report. *Am J Orthod.* 1976;70:481–504.
- Jones MC. Prenatal diagnosis of cleft lip and palate: detection rates, accuracy of ultrasonography, associated anomalies, and strategies for counseling. *Cleft Palate Craniofac J.* 2002;39:169–73.
- Kenny FM, Angsusingha M, Chen PK, et al. Unconjugated estrogens in the perinatal period. *Pediatr Res.* 1973;10:976–81.
- Kundra P, Supraja N, Agrawal K, Ravishankar M. Flexible laryngeal mask airway for cleft palate surgery in children: a randomized clinical trial on efficacy and safety. *Cleft Palate Craniofac J.* 2009;46:368–73.
- Laberge LC. Unilateral cleft lip and palate: Simultaneous early repair of the nose, anterior palate and lip. *Can J Plast Surg.* 2007;15(1):13–8.
- de Ladeira RS, Alonso N. Protocols in cleft lip and palate treatment: systematic review. *Plast Surg Int.* 2012;2012:1–9.
- Maarse W, Pistorius LR, Van Eeten WK, Breugem CC, Kon M, Van den Boogaard MJ, Mink van Der Molen AB. Prenatal ultrasound

- screening for orofacial clefts. *Ultrasound Obstet Gynecol.* 2011;38(4):434–9.
- Maestre JM. Control de calidad en cirugía mayor ambulatoria. *Rev Esp Anestesiol Reanim.* 2000;47:99–100.
- Manganaro L, Tomei A, Fierro F, Di Maurizio M, Sollazzo P, Sergi ME, Vinci V, Bernardo S, Irimia D, Cascone P, Marini M. Fetal MRI as a complement to US in the evaluation of cleft lip and palate. *Radiol Med.* 2011;116(7):1134–48.
- Martinez-Ten P, Adiego B, Illescas T, Bermejo C, Wong AE, Sepulveda W. First-trimester diagnosis of cleft lip and palate using three-dimensional ultrasound. *Ultrasound Obstet Gynecol.* 2012;40(1):40–6.
- Matsuo K, Hirose T, Tomono T. Nonsurgical correction of congenital auricular deformities in early neonatal period. *Plast Reconstr Surg.* 1984;73:38–50.
- Matsuo K, Hirose T, Otagiri T, et al. Repair of cleft lip with non surgical of nasal deformity in the early neonatal period. *Plast Reconstr Surg.* 1989;83(1):25–31.
- Matsuo K, Hirose T, Otagiri T, et al. Preoperative non surgical over correction of cleft lip nasal deformity. *Br J Plast Surg.* 1991;44(1):5–11.
- McNeil CK. Orthodontic procedures in the treatment of congenital cleft palate. *Dent Rec.* 1950;70:126–32.
- Millard Jr DR. A redical rotation in single harelip. *Am J Surg.* 1958;95:318–22.
- Millard Jr DR. *Pincipalization of Plastic Surgery.* Boston: Little Brown; 1986.
- Moggi L, Ponce D, Bevilacqua M. Pediatric anesthesia considerations. Chap 7:79–81. In: *Cleft Lip and Palate management: a comprehensive atlas.* Hoboken: Wiley Blackwell Ed; 2015.
- Moss A. Controversies in cleft lip and palate management. *Ultrasound Obstet Gynecol.* 2001;18:420–1.
- Mulliken JB. Repair of bilateral cleft lip and its variants. *Indian J Plast Surg.* 2009;42(Suppl):S79–90.
- Murthy PS, Deshmukh S, Bhagyalakshmi A, et al. Pre surgical nasoalveolar molding: changing paradigms in early cleft lip and palate rehabilitation. *J Int Oral Health.* 2013;5(2):76–86.
- Nusbaum R, Grubs RE, Losee JE, Weidman C, Ford MD, Marazita ML. A qualitative description of receiving a diagnosis of clefting in the prenatal or postnatal period. *J Genet Couns.* 2008;17:336–50.
- Paine KM, Tahiri Y, Wes A, et al. Patient risk factors for ambulatory cleft lip repair: an outcome and cost analysis. *Plast Reconstr Surg.* 2014;134:275e–82e.
- Paiva TS, Andre M, Paiva WS, et al. Aesthetic evaluation of the nasolabial region in children with unilateral cleft lip and palate comparing expert versus nonexperience health professionals. *Biomed Res Int.* 2014;2014:460106.
- Rossell-Perry P, Cotrinal-Rabanal O, Caceres-Nano E. One-flap palatoplasty: a cohort study to evaluate a technique for unilateral cleft palate repair. *Plast Reconstr Surg Glob Open.* 2015;3(4):e373.
- Shi B, Losee JE. The impact of cleft lip and palate repair on maxillofacial growth. *Int J Oral Sci.* 2015;7(1):14–7.
- Singh GD, Levy-Bercowski D, Santiago PE. Three-dimentional nasal changes following nasoalveolar molding in patients with unilateral cleft lip and palate; Geometric morphometrics. *Cleft Palate Craniofac J.* 2005;42(4):403–9.
- Tse R. Unilateral cleft lip: principles and practice of surgical management. *Semin Plast Surg.* 2012;26(4):145–15.
- Talmant JC. Evolution of the functional repair concept for cleft lip and palate Patients. *Indian J Plast Surg.* 2006;39(2):197–209.
- Thomas BL, Krummel TM, Melany M, et al. Collagen synthesis and type expression by fetal fibroblasts in vitro. *Surg Forum.* 1998;39:642–4.
- Shetty V, Vyas HJ, Sharma SM, et al. A Comparison of results using nasoalveolar molding in cleft infants treated within 1 month of life versus those treated after this period: development of new protocol. *Int J Oral Maxillofac Surg.* 2012;41(1):28–36.
- Wang G, Shan R, Zhao L, Zhu X, Zhang X. Fetal cleft lip with and without cleft palate: comparison between MR imaging and US for prenatal diagnosis. *Eur J Radiol.* 2011;79(3):437–42.
- West DC, Kumar S. The effect of hyaluronate and its oligosaccharides on endothelial cell proliferation and monolayer integrity. *Exp Cell Res.* 1989;183:179–96.

Julia Harfin and Kurt Faltin Jr

Why are controversies in early treatment a continuous topic in all worldwide meetings after more than 100 years? Will it be solved in the next 10 years?

The first question to answer would be: Is it really an efficient and effective method of treatment? Yes, it is, respecting the biological sequence of priorities established through a complete diagnosis.

Unfortunately, there is not only one answer; since every patient is unique, their malocclusion is the result of the deviation of skeletal, dental, and neurophysiological problems along with different direction and amount of growth.

An individualized diagnosis is the criteria of decision on which type of cases should be treated by the clinician to offer the best option for each individual patient.

Since a considerable amount of growth occurs during the transitional period, it is a real advantage to begin the skeletal correction during this period and to avoid the problem to worsen, especially when craniofacial dysfunctions are present.

It is important to emphasize that the early treatment stage does not avoid a second phase of treatment but surely reduces its length and complications.

Therefore, many of the incipient malocclusions could be prevented since they are affected by environmental factors. The interaction between the perioral musculature and orofacial structures determines the future occlusion.

The need to control oral habits, such as mouth breathing, tongue thrust swallowing, and finger or lip interposition during rest or function, plays an important role. The cooperation between the patient and the parents in combination with the speech therapist is fundamental when the treatment plan has

to be determined. Unfortunately there isn't a single appliance that can suit all patients alike. Nonetheless, different approaches of treatment are available depending on etiological factors.

What are the risks, costs, and benefits of early orthodontic treatment?

The answer for this question is a correct diagnosis and a profound knowledge of craniofacial and dental development.

It is important to remember that some malocclusions are best treated early for biological, functional, and social reasons.

The normalization of the function and the possibility to redirect growth is the best option.

One of the most common controversies in the early mixed dentition is how, when, and why to treat patients in one, two, three, or more phases.

The problem in orthodontics is to move the teeth in harmony with the face and keep them stable after treatment (Horn 2005). The transition between mixed to permanent dentition is an important period in orthodontic decision-making.

This stage is the most important because it is the unique opportunity to use the prepubertal growth spurt.

There are no doubts about the early correction of anterior or posterior crossbite in order to prevent further and more complicated malocclusions. The normalization of the position and inclination of the incisors and molars have a close relationship with the direction of growth of the maxilla and mandible, no matter the type of appliance that is used.

Numerous papers confirmed this approach (Mandal et al. 2010; Sugawara et al. 1990), although others suggested waiting until the post-peak of growth to solve all the problems in only one stage. More extractions or orthognathic procedures would be the answer.

Before deciding on the final treatment plan, it is important to determine the etiology, severity, and nature of the problem. It is important to know how long the child has had this habit, when the habit takes place (day, night, or all day), and the willingness of the child to correct it.

J. Harfin (✉)

Department of Orthodontics, Maimonides University,
Buenos Aires, Argentina
e-mail: harfinjulia@gmail.com

K. Faltin Jr

Universidade Paulista UNIP,
São Paulo, Brazil

The following examples show the importance of beginning the treatment as soon as possible and in this way to reduce further inconveniences and in some cases avoid extractions and/or orthognathic surgery, no matter the severity of the initial Class II or III problem.

The next clinical case is a clear example of the importance of a two-stage treatment.

She was 8 years and 9 months old and was sent to the office for a second opinion regarding the best moment to begin the correction of her occlusion. She had recurring colds in concordance with episodes of high fever and asthma attacks. The odontopediatrician recommended that the best time to begin orthodontic treatment was when the second molars had erupted, and with this protocol, only one phase would be needed. An early consultation with the maxillofacial surgeon was also recommended.

The facial photographs showed a convex profile with a short upper lip and the impossibility to close her mouth at rest position. The lower lip was behind the upper incisors. The nasolabial angle was acute and the mandible was totally retruded. An early consultation with the otorhinolaryngologist is strongly advisable, since oral respiration and nasal obstruction are common findings among orthodontic patients. An abnormal respiratory function can affect craniofacial growth and produce or enhance malocclusions.

Early intervention is mandatory to reduce the risk of fracture of the upper incisors and from the psychological aspect too (Fig. 14.1a, b).

The upper and lower incisors had fully erupted, and some diastemas were present in the upper arch. The interincisal upper papillae were absent (Fig. 14.2a, b), and oral hygiene was fairly good. The lower lateral incisors were lingually positioned in the lower arch.

The lateral photographs confirmed a significant overjet (8 mm), that is, an important risk factor in the fracture of maxillary incisors at school or at home (Fig. 14.3a, b). A considerable overbite was also present. The lower incisors were in contact with the palatal tissues.

The pretreatment occlusal photographs showed rounded arcades with diastemas in the upper arch and slight crowding in the lower arch. No caries or periodontal problems were present (Fig. 14.4a, b).

The panoramic radiograph demonstrated normal sequence of eruption of the permanent teeth according to her age. No agenesis or supernumerary teeth were present (Fig. 14.5a). The lateral radiograph clearly showed the considerable pro-

trusion of the upper incisors in concordance with the protrusion of the upper lip (Fig. 14.5b).

Taking into account that functional problems had to be normalized first, the following treatment plan was designed: (a) normalization of the position of the first molar since it is easier before the eruption of the second and (b) correction of the habits as soon as possible to facilitate tooth eruption in a normal position and allow the normal development of the mandible.

Habits are needed to be corrected as early as possible to reestablish the normality in the maxilla and mandibular direction of growth, as well as reduce the length of the second phase of treatment.

Among all the factors that had to be considered, the most significant were determining the best treatment plan and the enhancement of the profile with facial balance and long-term stability.

It is well known that the normalization of the position of the first molar is easier before the eruption of the second molar. To achieve this objective, a pendulum was bonded along with esthetic brackets on the central incisors to close the interincisal diastema that was one of her parents' concerns. An 8-week activation period was suggested (Fig. 14.6a, b).

After the distalization of the second temporary molars, brackets were bonded on the upper lateral incisors with a SS 0.016" archwire to normalize their position and inclination (Fig. 14.7a, b).

In order to maintain the anteroposterior position of the upper first molars, a Nance button was recommended. Upper and lower utility arches (Elgiloy 0.016" × 0.016") were placed to normalize overjet and overbite. All the anterior diastemas were closed and the position and inclination of the upper incisors improved (Fig. 14.8a, b).

After the eruption of the bicuspid, two lingual brackets were bonded on the palatal surfaces of the upper central incisors along with a SS 0.018" archwire with two vertical loops distal to the upper lateral incisors to improve the pretreatment overjet and overbite (Fig. 14.9a, b).

Lateral views with the same arch in place, Class I molar and canine were achieved. To maintain Class I canine and molar, ligature of eight was used between the cuspids and first molars (Fig. 14.10a, b).

The results after the active orthodontic treatment confirmed the normalization of the overjet and overbite. All the diastemas were closed and midlines were coincident.

The gingival line and occlusal plane were parallel (Fig. 14.11a, b).

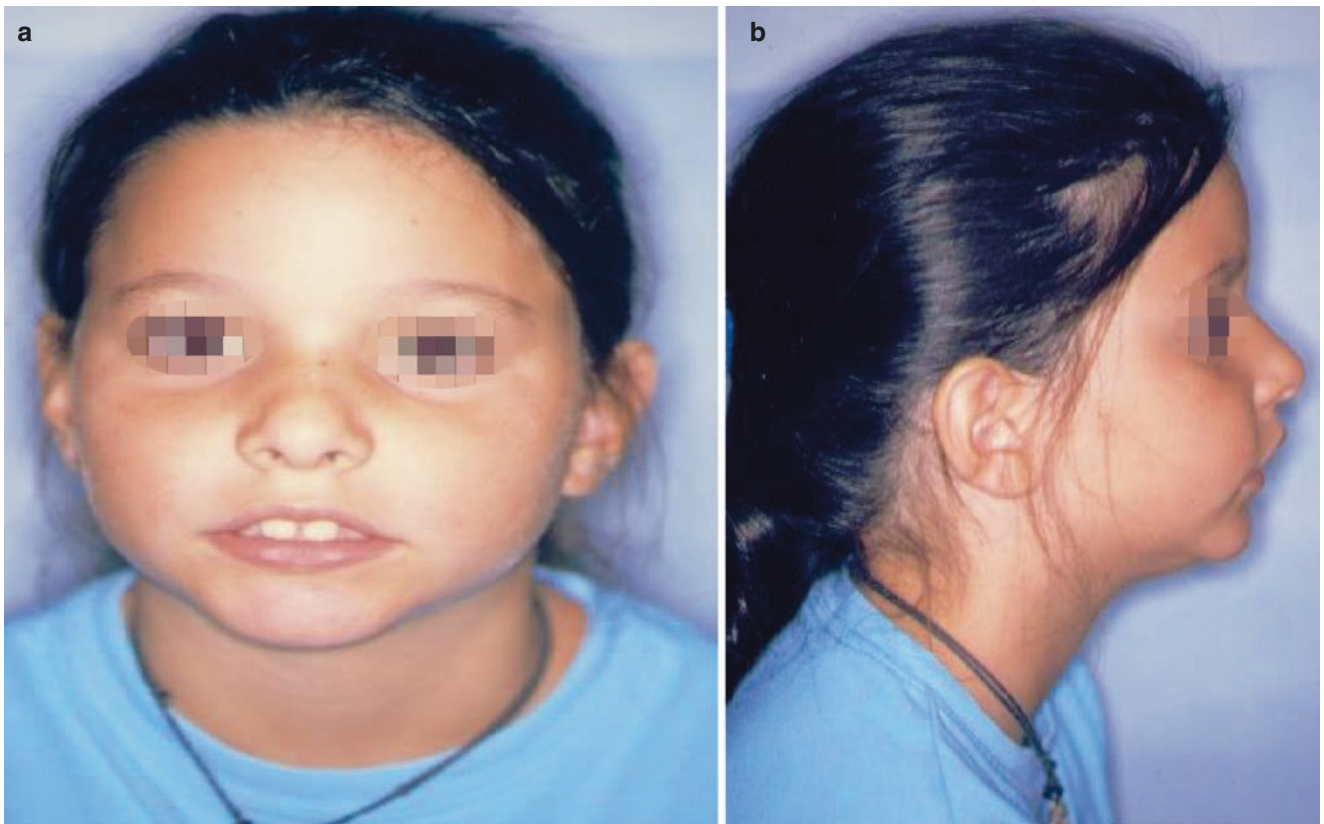

Fig. 14.1 (a, b) Pretreatment frontal and profile photographs. A significant convex profile with a short upper lip was confirmed in concordance with the position of the lower lip behind the upper incisors

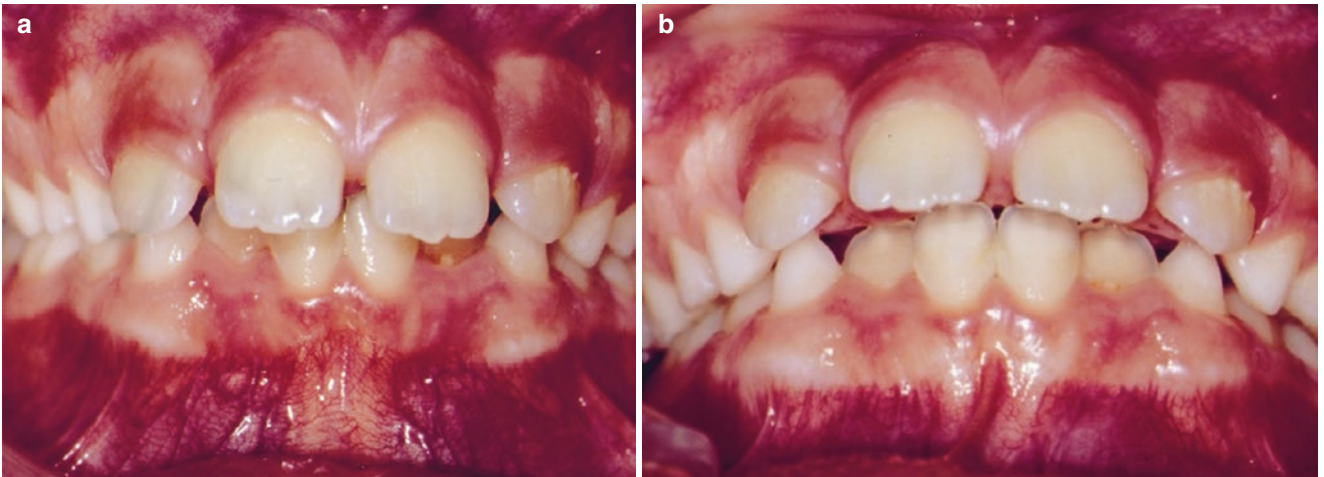


Fig. 14.2 (a, b) Frontal photographs at the beginning of the treatment. An upper interincisal diastema was present

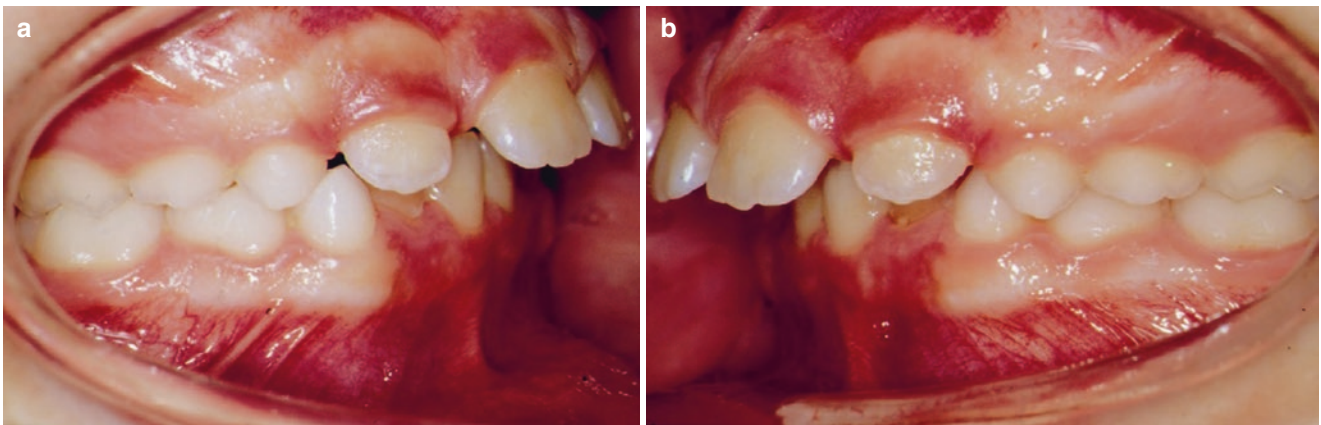


Fig. 14.3 (a, b) Significant overjet and overbite were confirmed along with Class I molar and a significant overbite with retroposition of the lower incisors

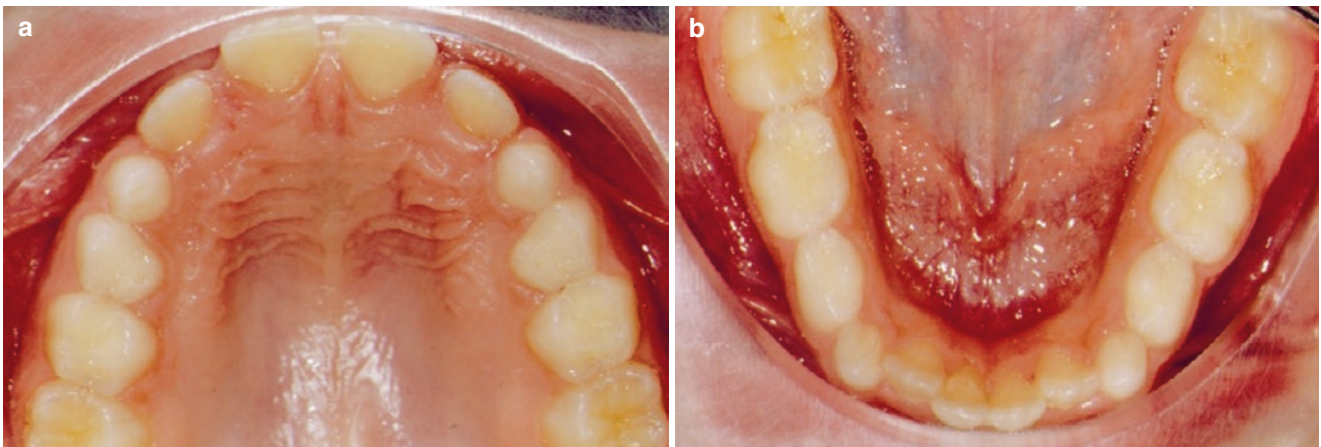


Fig. 14.4 (a, b) Upper and lower pretreatment rounded arches

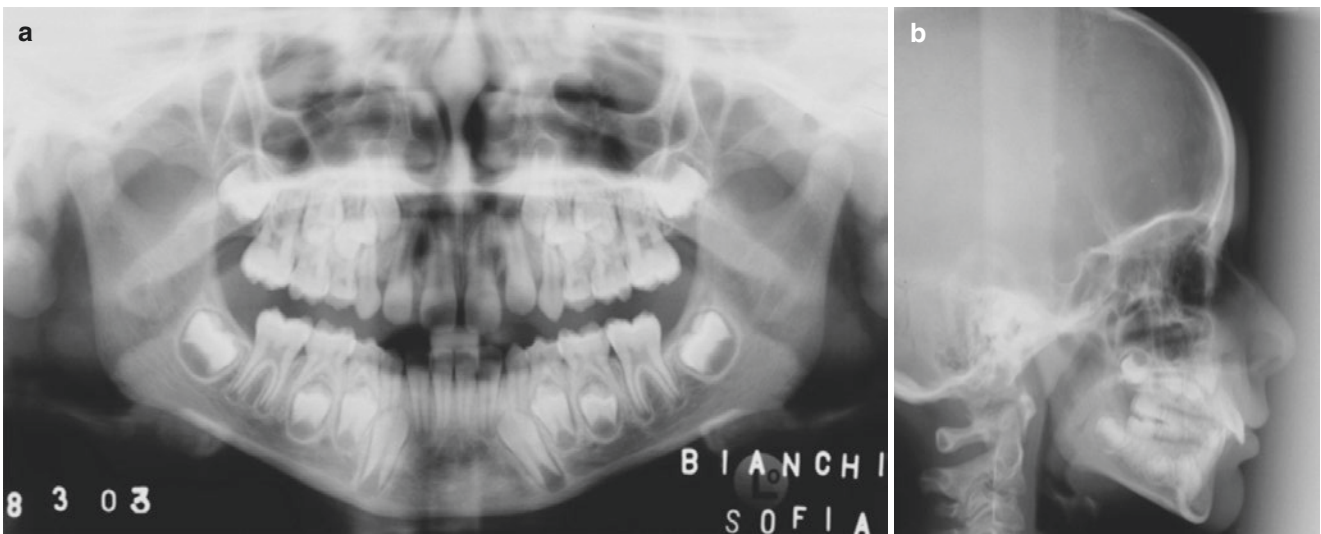


Fig. 14.5 (a, b) Pretreatment panoramic and lateral radiograph. The protrusion of the upper incisors was confirmed as well as the significant overbite

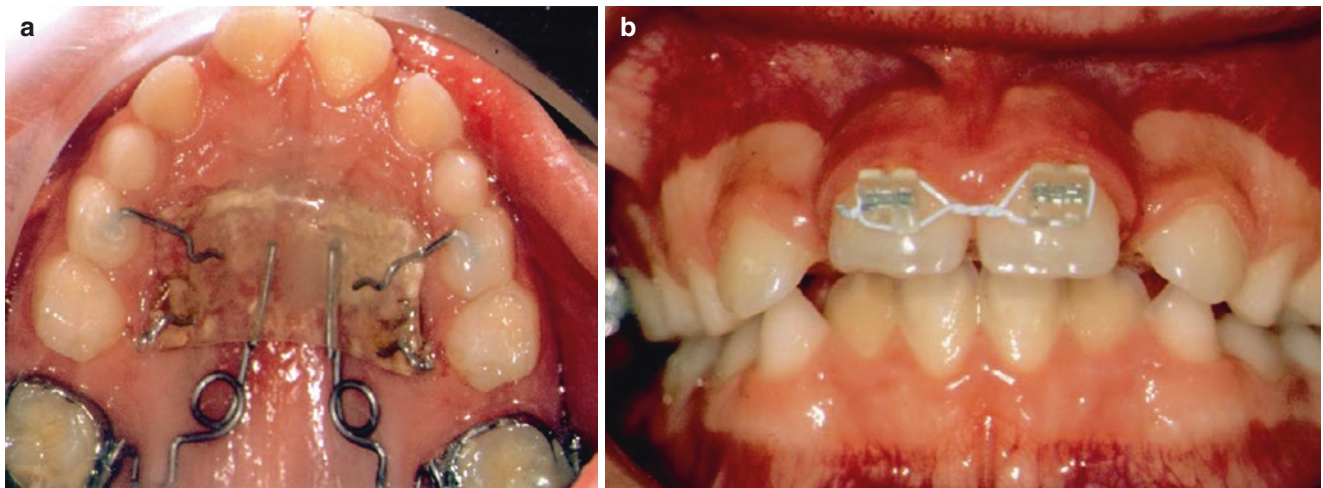


Fig. 14.6 (a, b) A pendulum was bonded to normalize the position of the first molars in conjunction with esthetic brackets on the central incisors to close the interincisal diastema

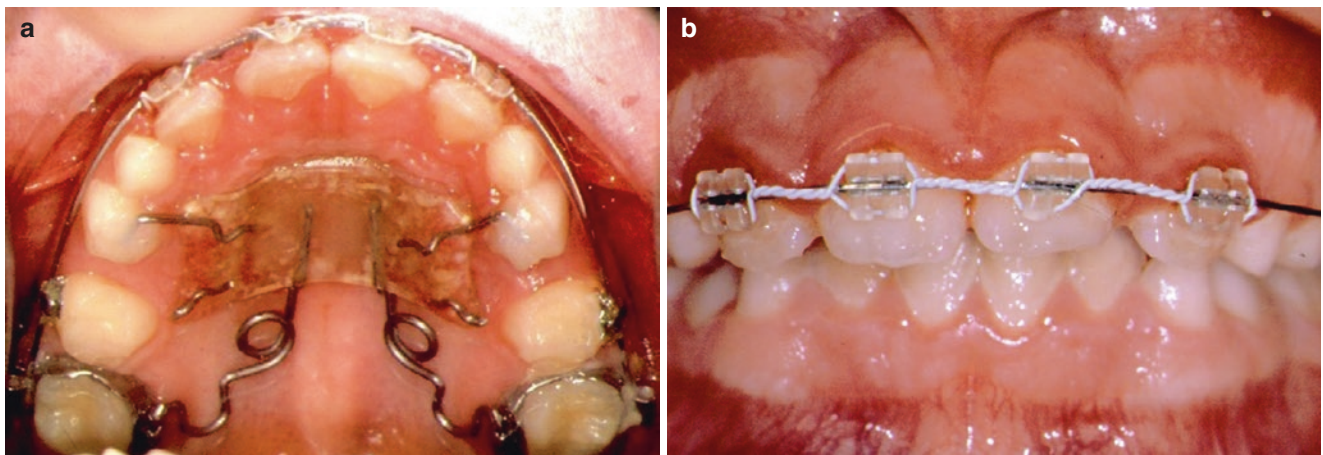


Fig. 14.7 (a, b) The second temporary molars were completely distalized, and the anterior diastemas were closed with a ligature of eight on a 0.016" SS archwire

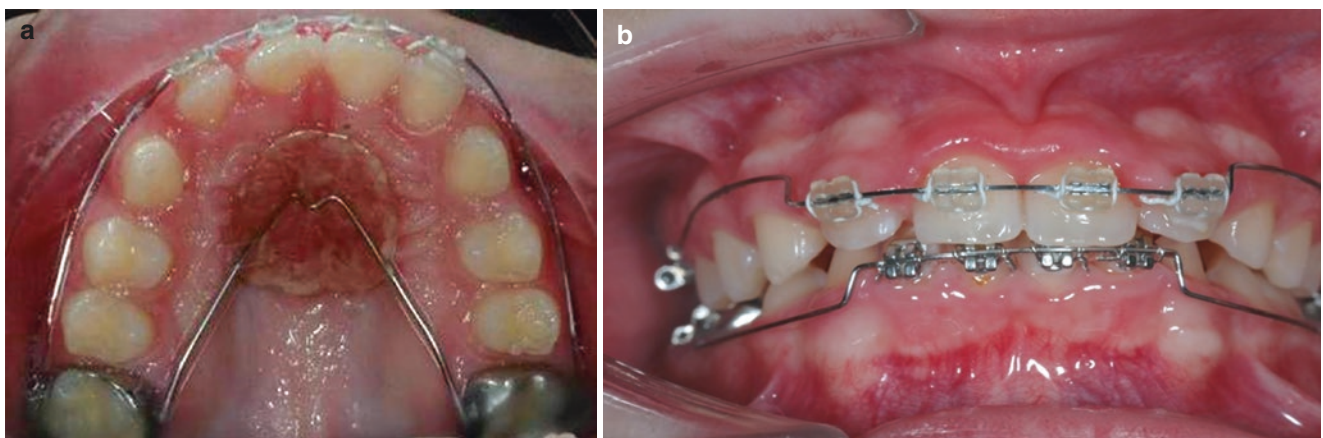


Fig. 14.8 (a, b) A Nance button in place to maintain the new position of the right and left first molars with an upper and lower utility arches to help the normalization of the overjet and overbite

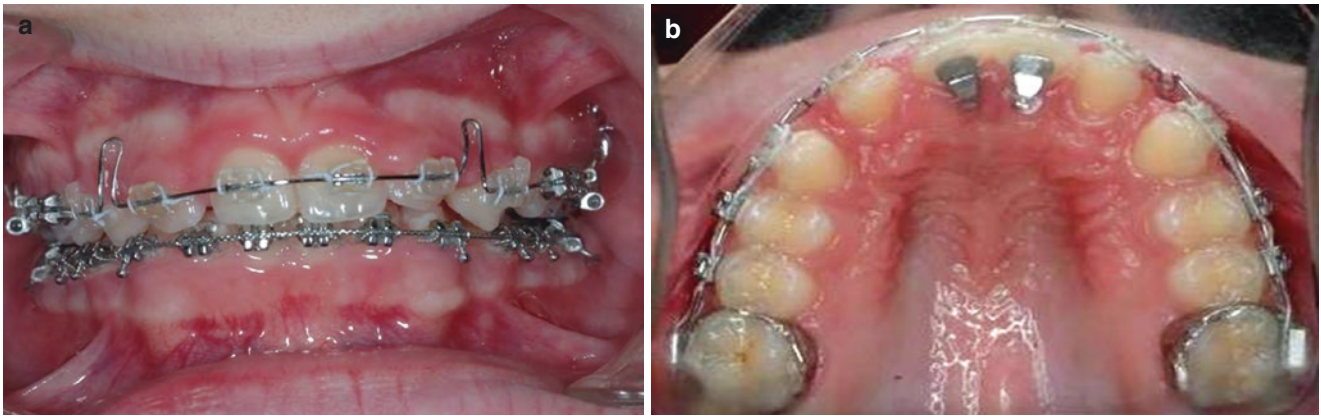


Fig. 14.9 (a, b) A SS 0.018" archwire with two vertical loops were placed to achieve normal overjet and overbite after the eruption of the bicuspids. Also, two lingual brackets were bonded on the palatal surfaces of the central incisors

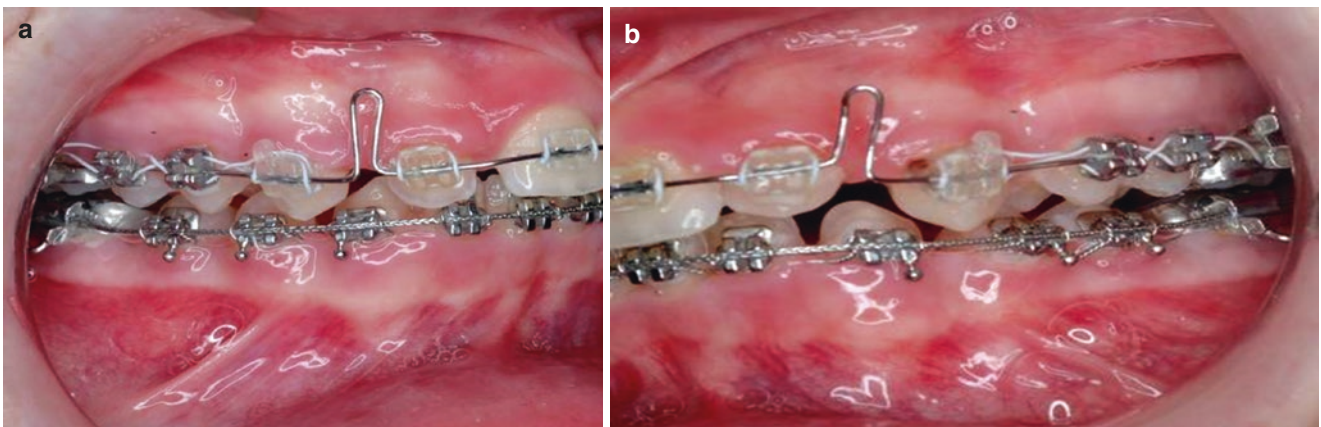


Fig. 14.10 (a, b) Right and left side with the double-loop arch in place. Class I canine and molar were maintained

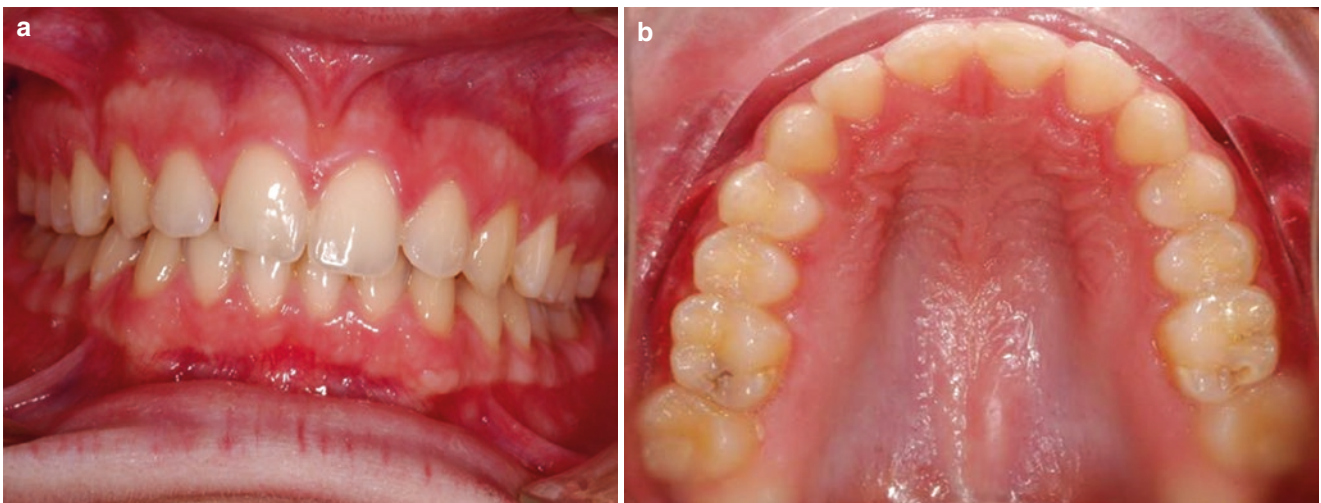


Fig. 14.11 (a, b) Final frontal and occlusal photographs. All the treatment objectives were fulfilled; midlines were almost coincident

Class I canine and molar were achieved with normal occlusion in the bicuspid area. The patient maintained good oral hygiene during the whole treatment (Fig. 14.12a, b).

Final frontal and lateral photographs 2 years after treatment. The patient was able to close her lips without any mus-

cular strain. She had a straight profile with a normal nasolabial angle; as a consequence she became a nose breather (Fig. 14.13a, b).

The comparison of the photographs pre- and posttreatment clearly demonstrates the importance of the early treatment with better patient and parent compliance. The improvement

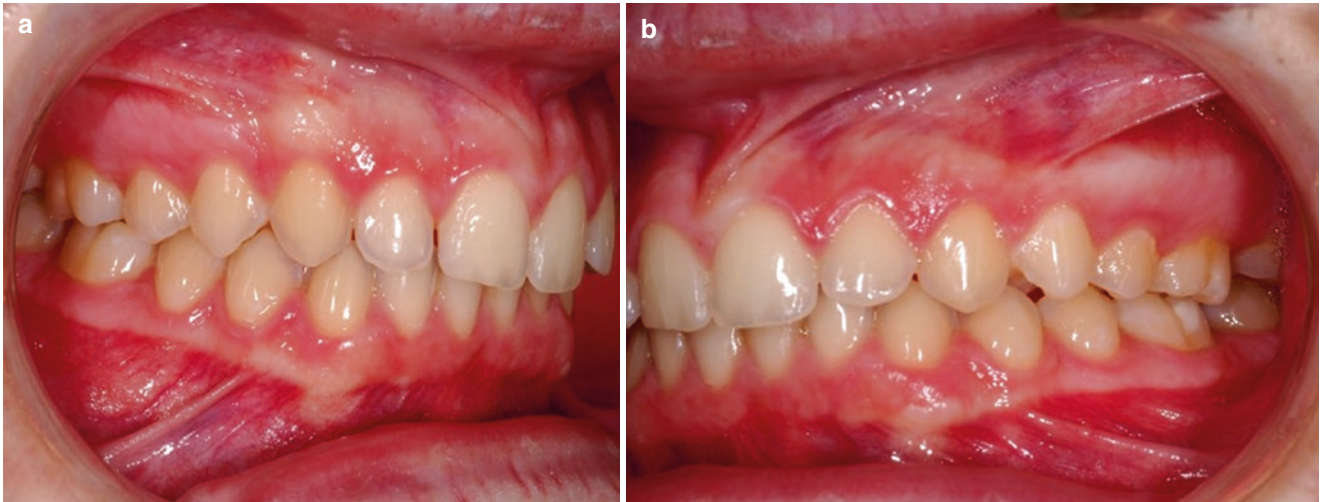


Fig. 14.12 (a, b) Right and left Class I molar and canine at the end of the active treatment

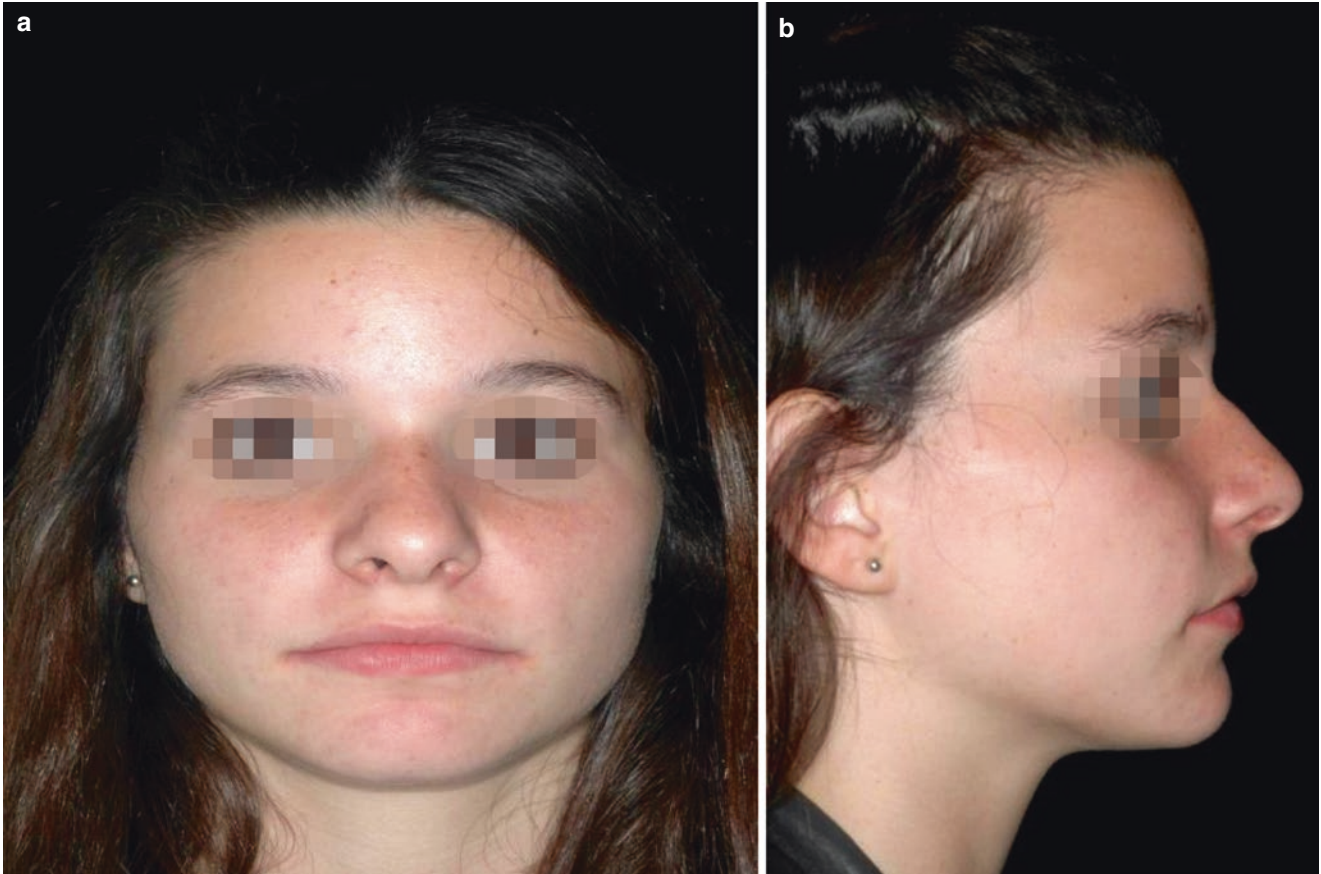


Fig. 14.13 (a, b) Frontal and profile photographs 2 years after treatment. The patient was able to close her lips without any strain

of the lower third of the face was remarkable (Fig. 14.14a, b). All the treatment objectives were fulfilled.

The same results were observed when the profile photographs were compared. Since the orofacial functions were normalized, the change in the position and length of the upper lip was remarkable (Fig. 14.15a, b).

The pre- and post-lateral radiographs confirmed the theory that when function is normalized, the soft and hard tissues will develop in the normal direction. Since the radiographs were taken in different institutes, it was impossible to compare the tracings of the two cephalograms (Fig. 14.16a, b).

It is highly recommendable to correct deepbite malocclusion early on because the unfavorable consequences of an untreated deepbite include an increase in lower anterior crowding, maxillary dental flaring, and associated periodontal breakdown (Franchi et al. 2011). In this patient, the normalization of the deepbite and the correction of lower anterior crowding are noticeable (Fig. 14.17a, b).

Follow-up 2 years later confirmed that the results that were achieved were maintained. As it is expected, the profile was slightly straighter, and she could easily close her mouth. Not only was there a significant improvement in function but also in facial esthetics (Fig. 14.18a, b).

Twenty-four months later, the front and lateral dental photographs confirmed that all the treatment objectives were fulfilled: the overjet and overbite were normalized as well as the frontal and lateral occlusion (Fig. 14.19a, b).

One of the main objectives in early treatment is the correction of abnormal oral habits since oral function and the growth and development of the face are closely interrelated (Bahreman 2013). It has been shown that many deformities caused by muscle dysfunction during primary and mixed dentition are not self-corrected and become worse during the permanent dentition.

It is important to remember that the early elimination of the bad habits is one of the most significant treatment objectives to achieve during this stage.

Finger and lip sucking habits have to be corrected as soon as possible. Their persistence beyond 4 years of age is considered a chronic non-nutritive habit and needs to be corrected before it causes negative impact on dental occlusion and facial esthetics (Bahreman 2013).

The following patient is a clear example regarding this protocol. She was an 8-year and 3-month-old girl that was sent to the office looking for an appliance to protect her upper incisors since they had been chipped in a bicycle-related accident. No significant medical history was present until that point.

One of the most important things to consider was the interposition of the lower lip behind the upper incisors along with a convex profile. Also, she was a mouth breather with a short upper lip and a slight facial asymmetry (Fig. 14.20a, b). It is well known that mouth breathing can have an adverse effect on the maxillary structure and its relation with the

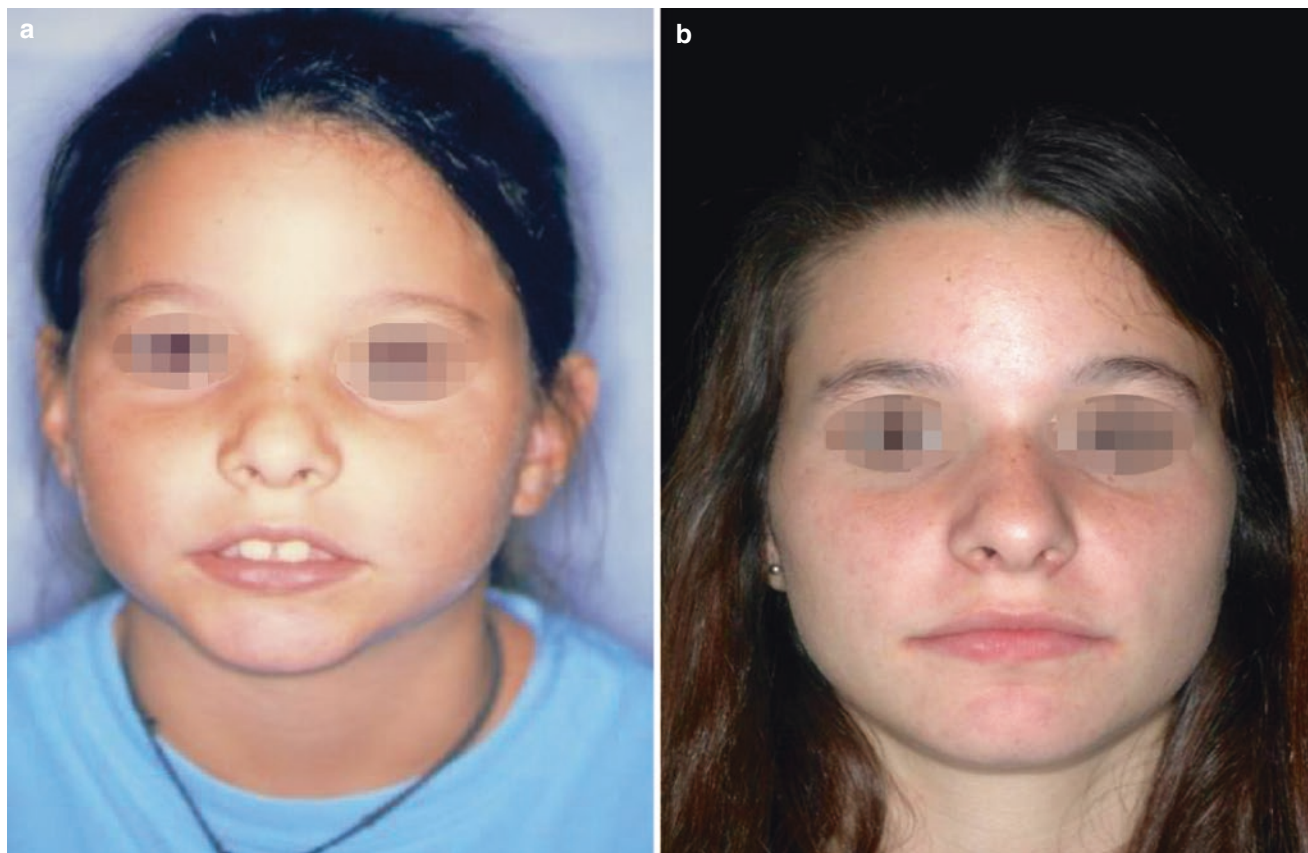


Fig. 14.14 (a, b) Comparison of frontal photographs pre- and posttreatment. The normalization of the lip seal was significant as well as the musculature in the lower third of the face

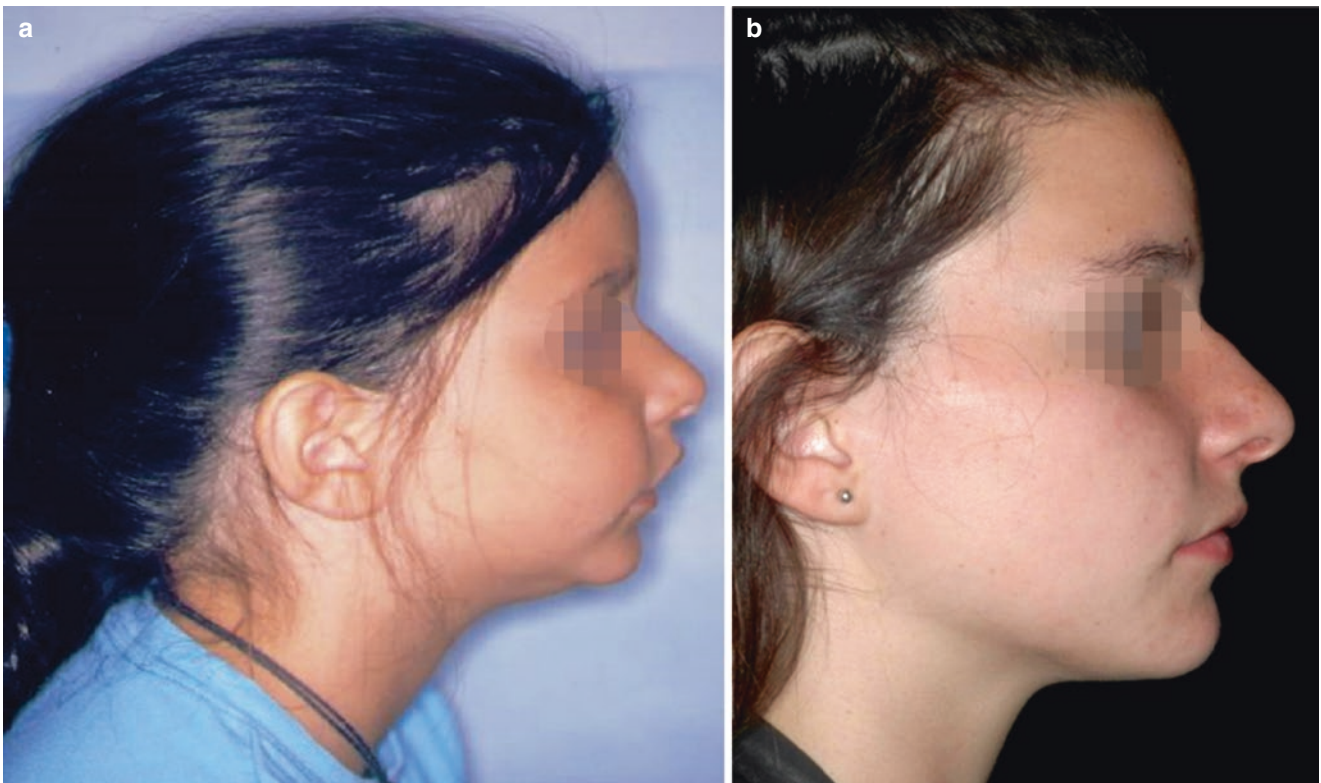

Fig. 14.15 (a, b) Pre- and posttreatment profile photographs. There was considerable improvement in the middle and lower third of the face

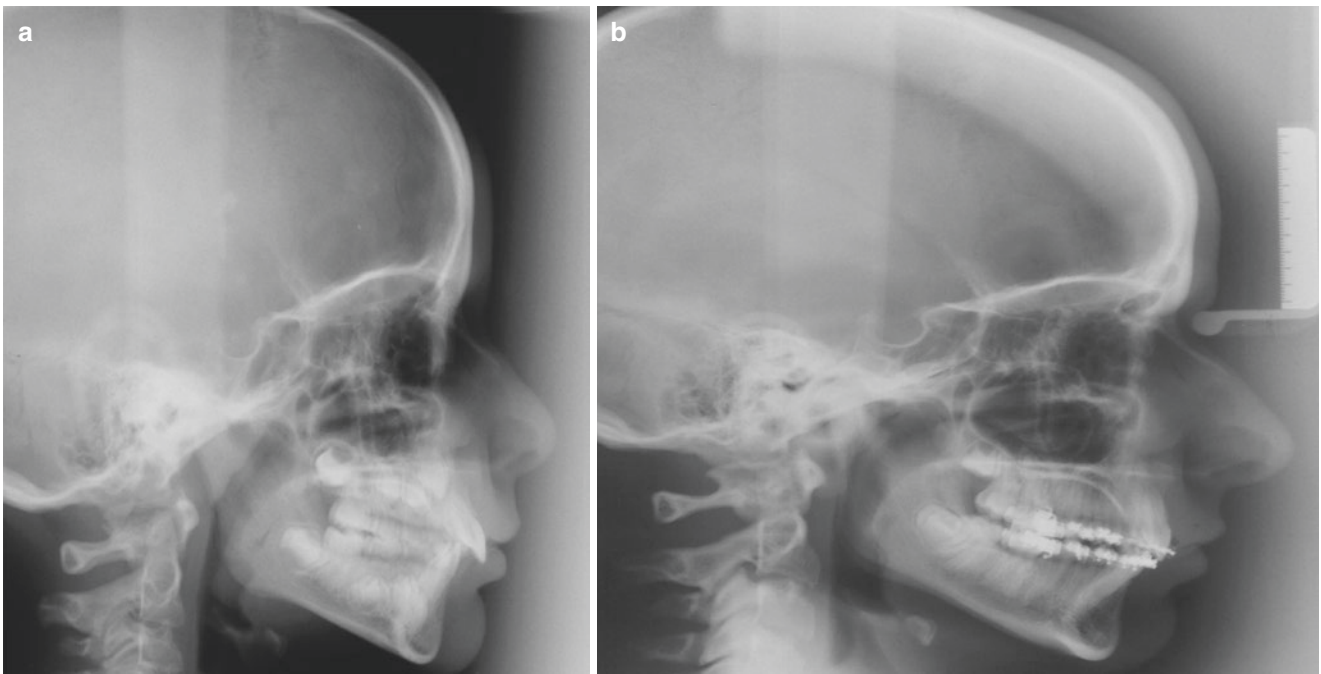


Fig. 14.16 (a, b) Pre- and posttreatment lateral radiographs. The changes in the anterior occlusion and in the profile were evident

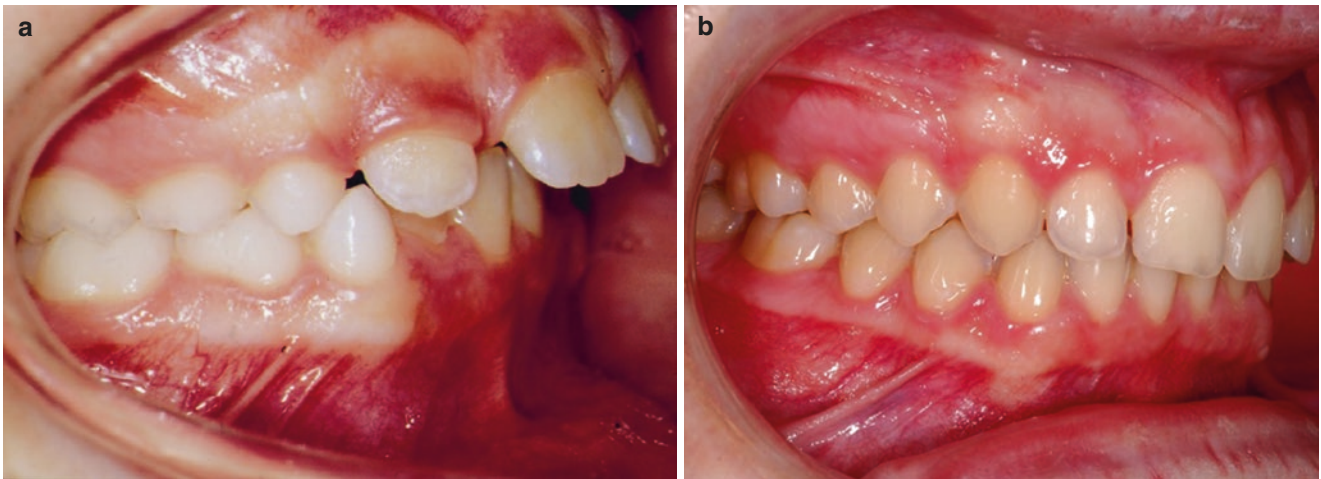


Fig. 14.17 (a, b) Class I molar and canine were maintained, and overjet and overbite were clearly normalized

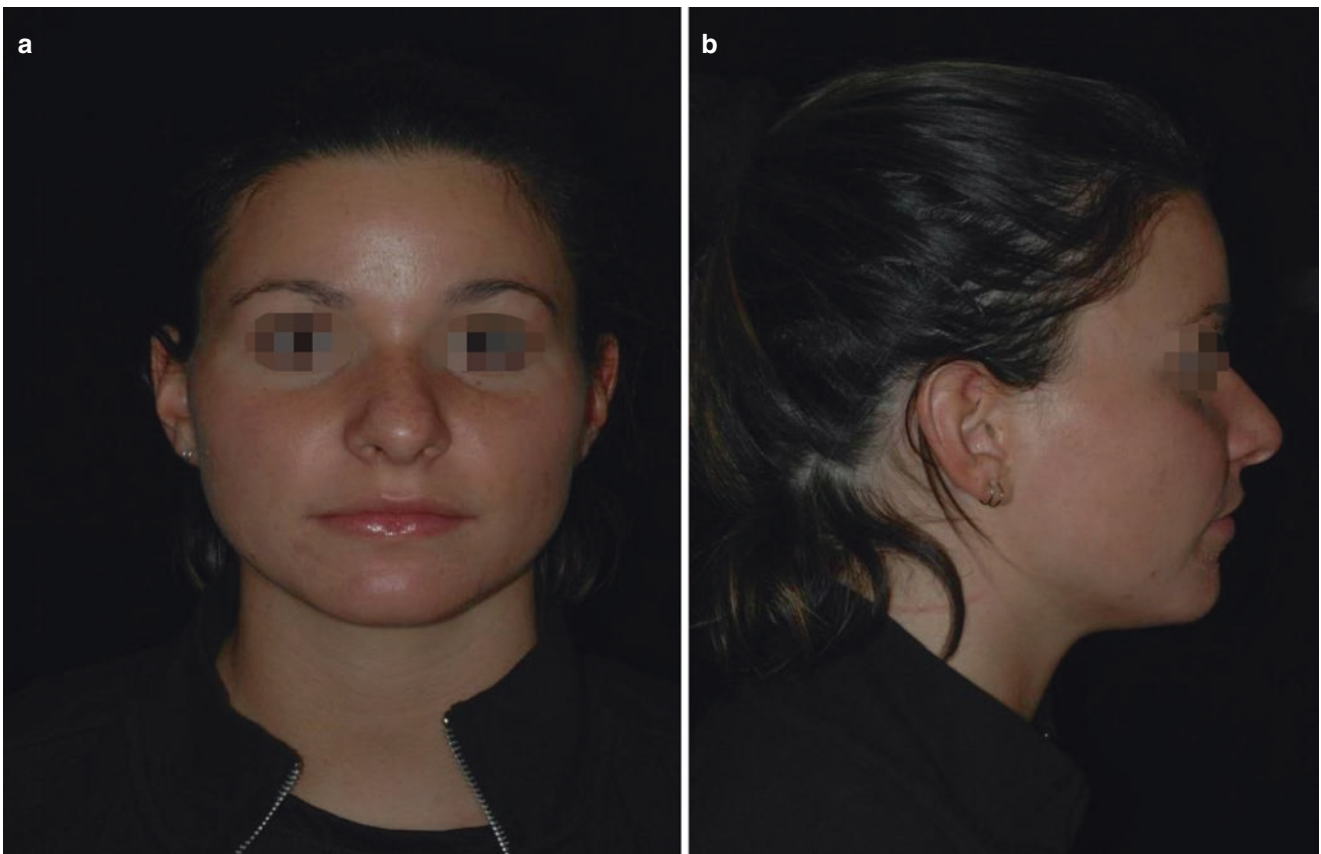


Fig. 14.18 (a, b) Results 2 years after treatment. The patient easily closed her mouth, and the lip seal was totally relaxed

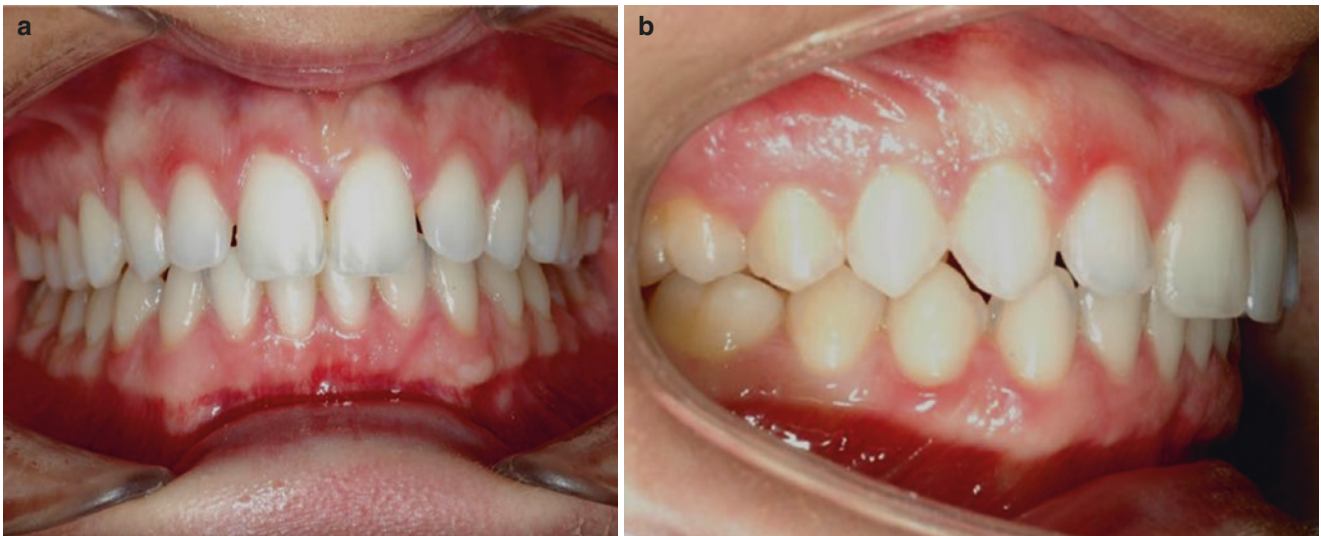

Fig. 14.19 (a, b) Follow-up after 24 months corroborated that all treatment objectives were maintained

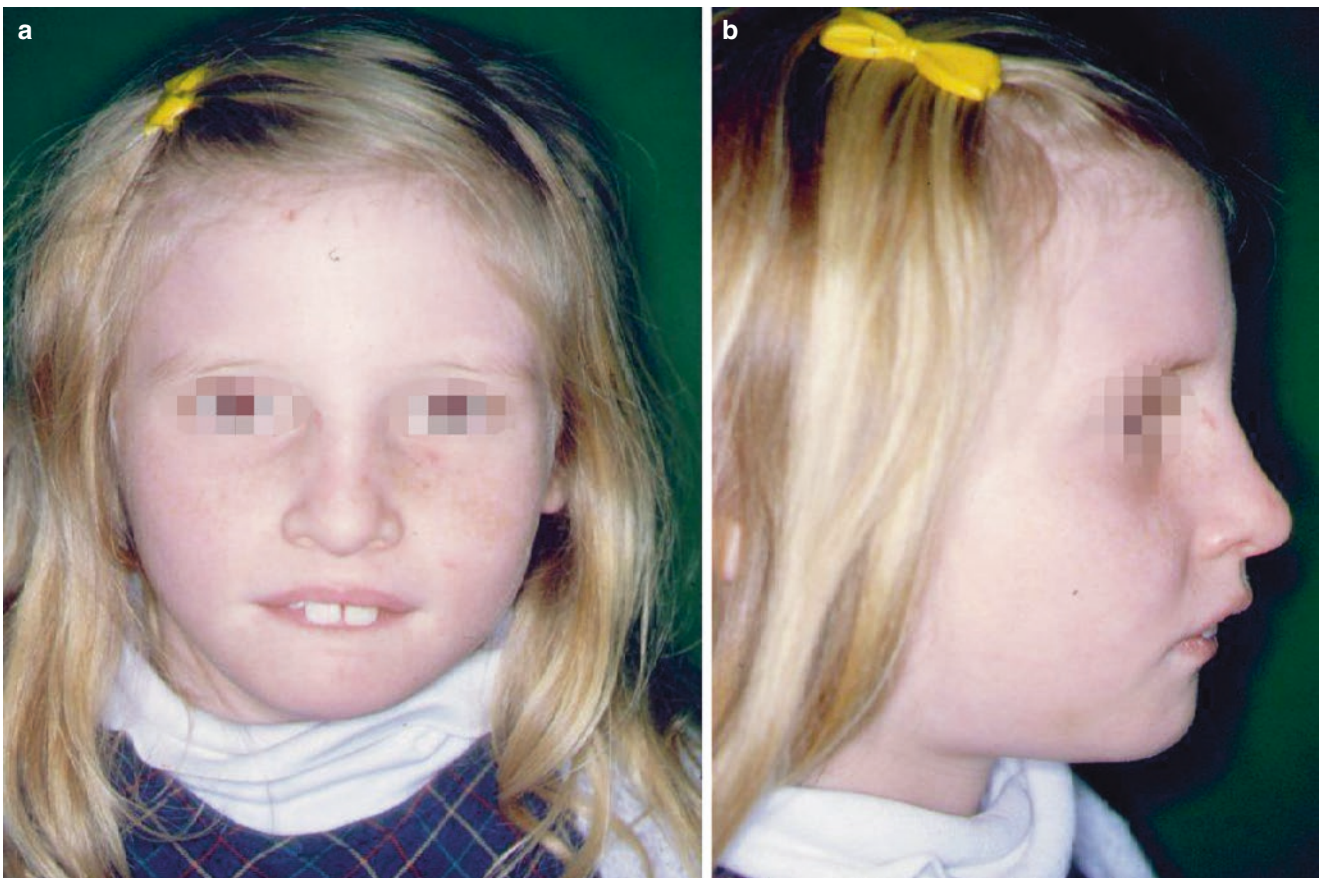

Fig. 14.20 (a, b) Pretreatment front and profile photographs. Mouth breathing and the interposition of the lower lip behind the upper incisors were visible

position of the mandible. Also the reduction of the protrusion of maxillary incisors reduces the chance of incisor trauma. Dry lips and dark circles under the eyes are also visible.

The treatment plan is determined taking into consideration the correction of the bad habits, improvement in oral function, and facial esthetics.

The front dental photographs confirmed a considerable overbite and proclination in the central incisor region and the extrusion of the lower incisors. Midlines were not coincident (Fig. 14.21a, b). Excessive anterior overlap of incisors is a common malocclusion that is difficult to solve and causes delays in treatment as well as skeletal problems.

Upon observing the periapical radiograph, the transposition of the lower lateral incisor and temporary right canine was confirmed. The extraction of the temporary right lower canine was suggested to normalize the position of the lower right lateral incisor (Fig. 14.22a, b).

To improve the position of the partially transposed right lateral incisor, a Ni-Ti open coil spring was used with bands on the temporary second molars, and preprogrammed brackets were placed on the lower incisors (Fig. 14.23a). An upper quad helix was placed to normalize the upper arch size and the position of the upper left lateral incisor, with a monthly activation (Fig. 14.23b).

Six months later, preprogrammed 0.022" brackets were used along with upper and lower utility arches (Elgiloy 0.016" × 0.016") to correct the incisor protrusion and excessive overbite (Fig. 14.24a, b).

These were the results 9 months later. Class I canine and molar were achieved and overjet and overbite were normalized. Midlines were coincident, and occlusal plane and gingival lines were parallel (Fig. 14.25a, b). Also, oral hygiene is improved.

The posttreatment facial photographs clearly showed how the soft tissues accompanied the positive upper and lower dental changes. The patient could close her lips properly and her profile was straight (Fig. 14.26a, b). The advantage of early treatment is to enable the normal eruption of the upper and lower canines and bicuspid in order to minimize the dentoalveolar discrepancies that can affect normal growth and development. No extraction was needed to achieve Class I molar and canine with a normal overjet and overbite.

There were no major changes in follow-up 3 years later. Overjet and overbite were maintained stable as well as Class I canine and molar (Fig. 14.27a, b). Gingival line and occlusal plane maintained their parallelism, and excellent oral hygiene was present.

The facial photographs accompanied the normal growth according to her age and facial biotype (Fig. 14.28a, b).

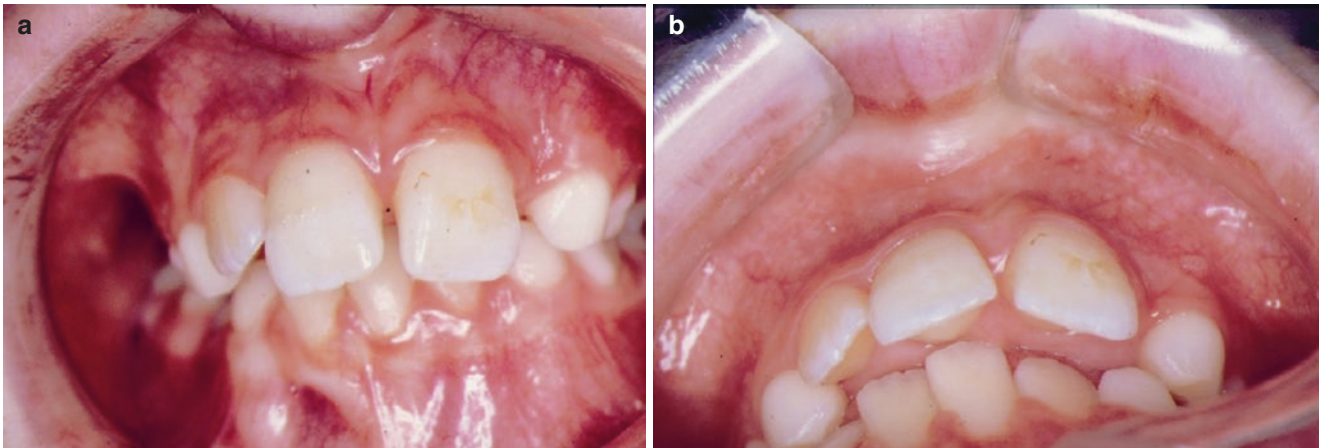


Fig. 14.21 (a, b) A considerable overbite and overjet was confirmed in the central incisor region with no coincident midlines

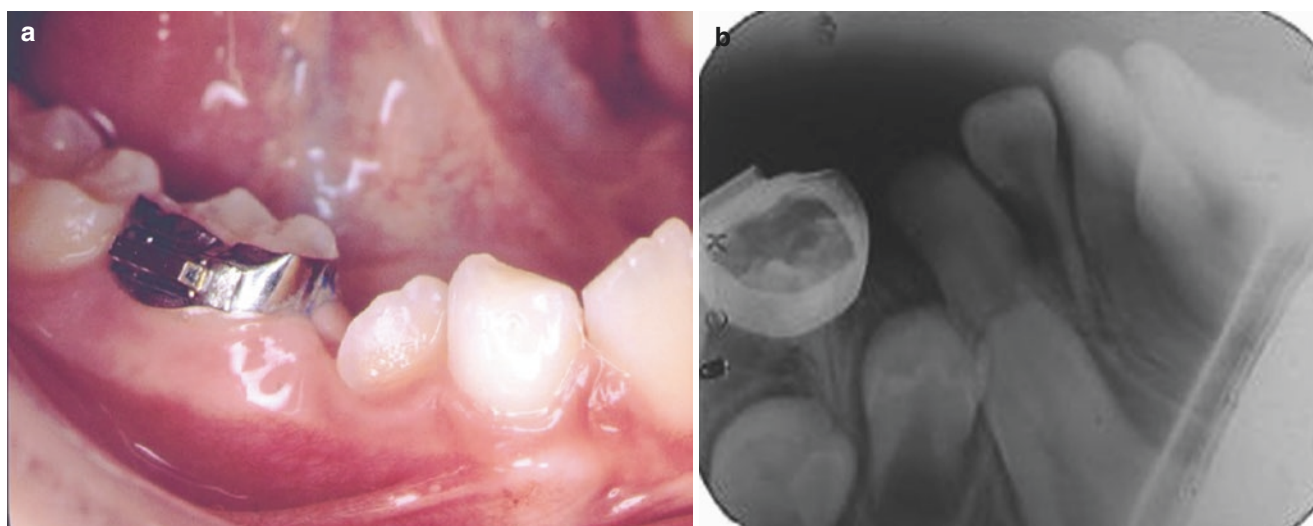


Fig. 14.22 (a, b) The transposition of the right lateral and right canine is clearly visible

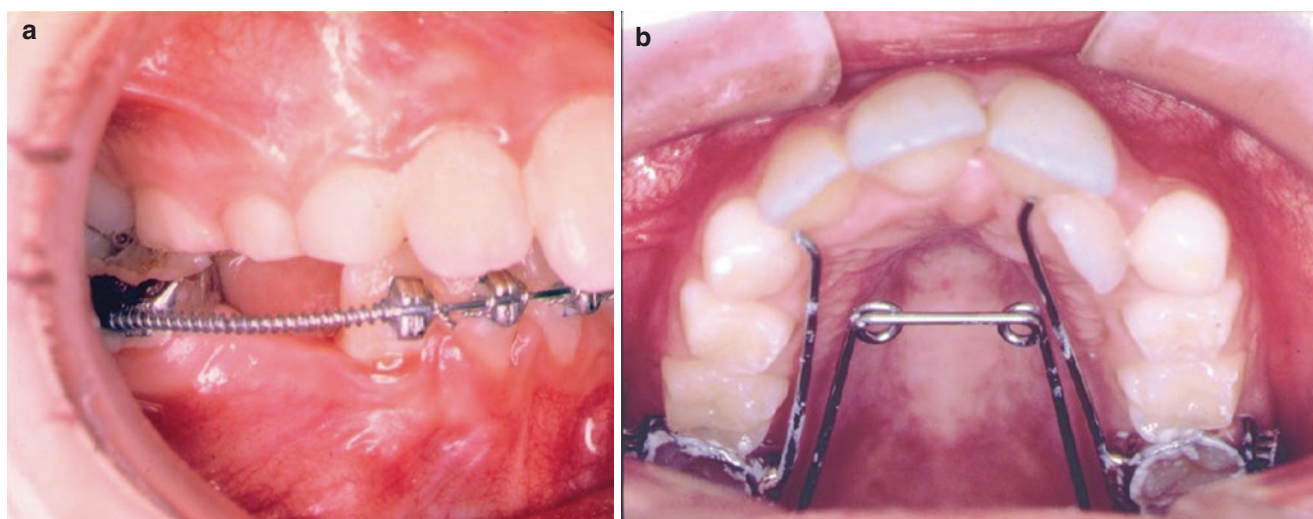


Fig. 14.23 (a, b) In order to mesialize the crown of the lateral right lower incisor, an open coil spring was placed on the lower right side in conjunction with an upper quad helix to improve the position of the upper left lateral incisor

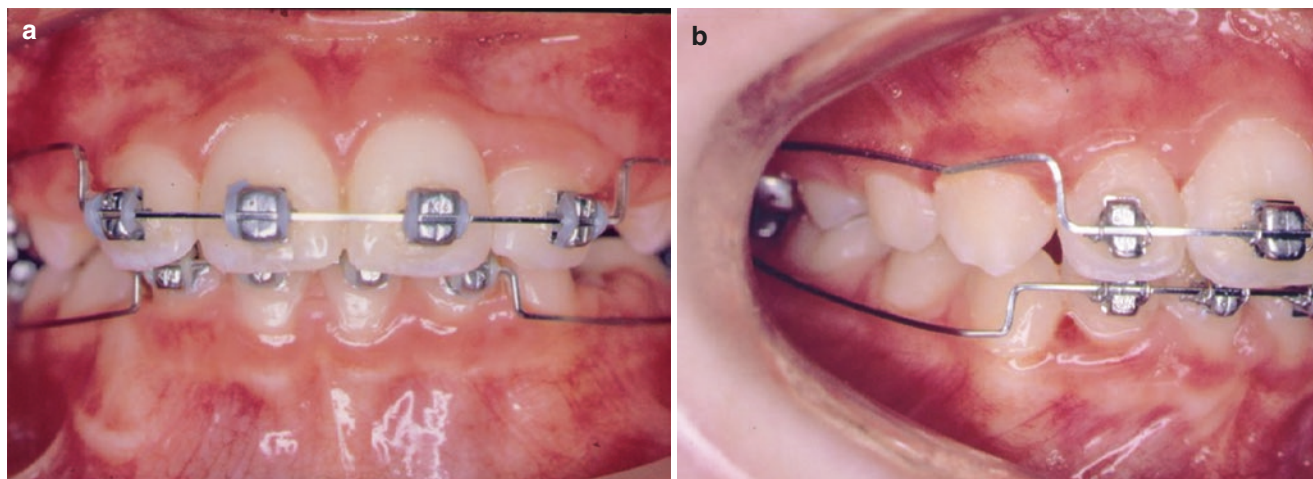


Fig. 14.24 (a, b) Upper and lower utility arches (0.016" × 0.016" Elgiloy wire) to normalize anterior overjet and overbite

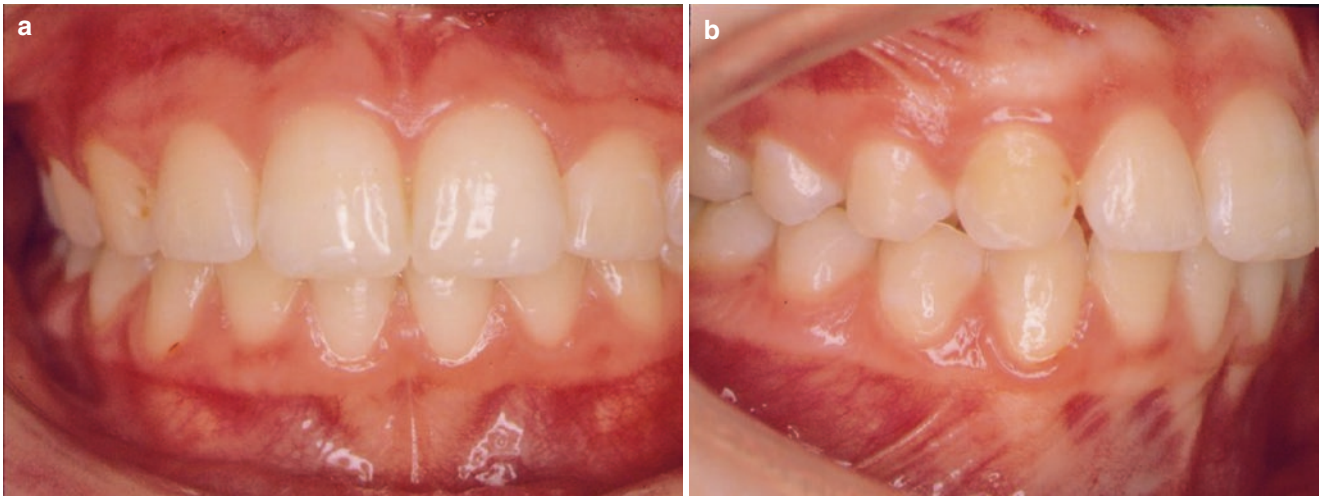


Fig. 14.25 (a, b) Results at the end of the active orthodontic treatment. All the treatment objectives were achieved including the parallelism of the occlusal plane

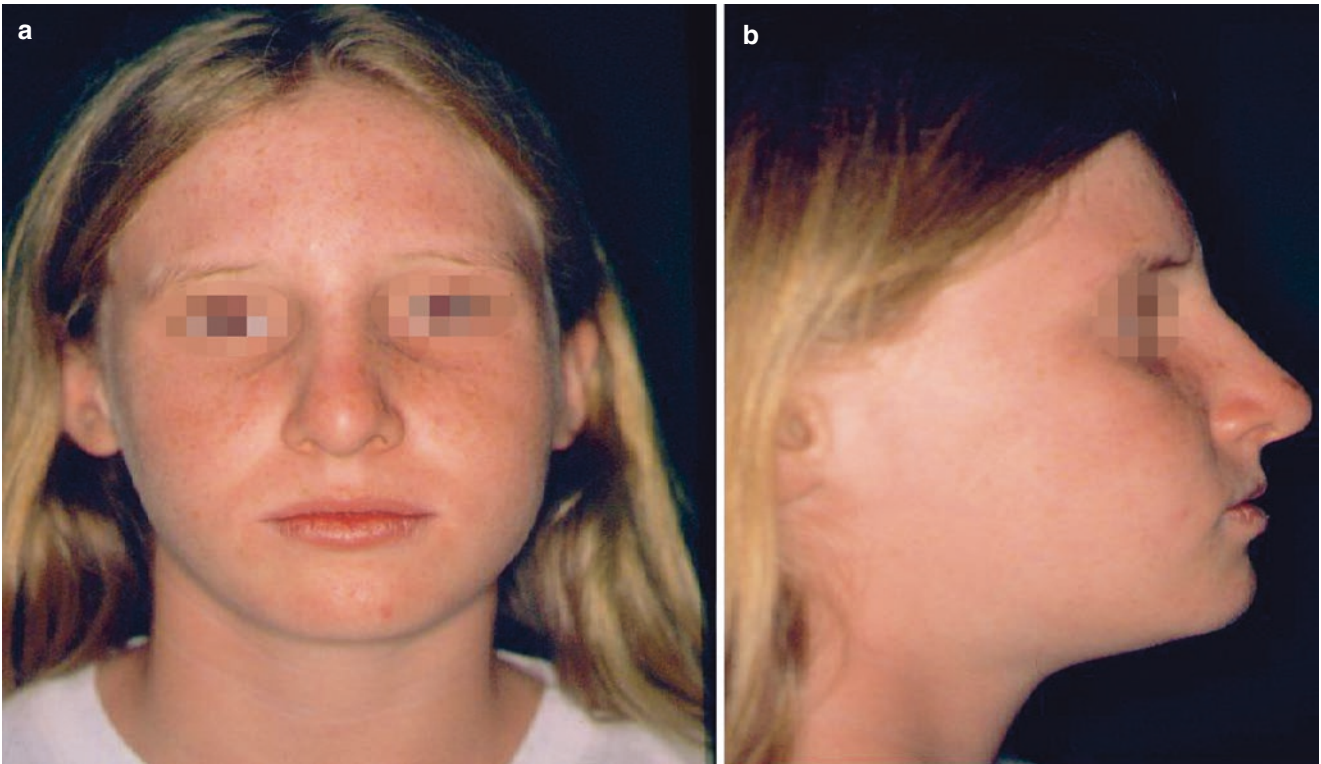


Fig. 14.26 (a, b) Frontal and profile photographs at the end of the active orthodontic treatment. The patient could close her lips without any tension

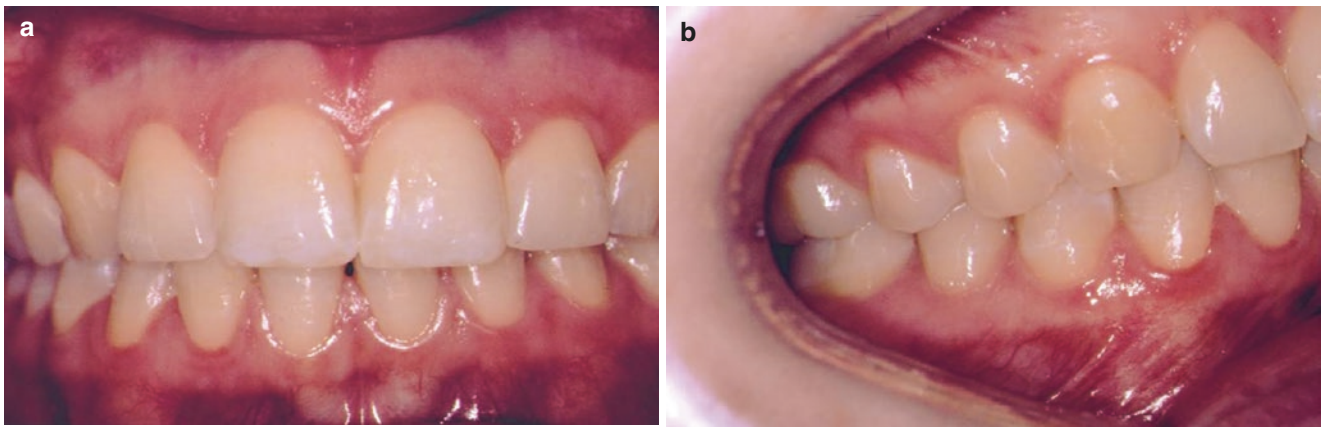


Fig. 14.27 (a, b) Frontal and right lateral photographs during a follow-up 3 years later

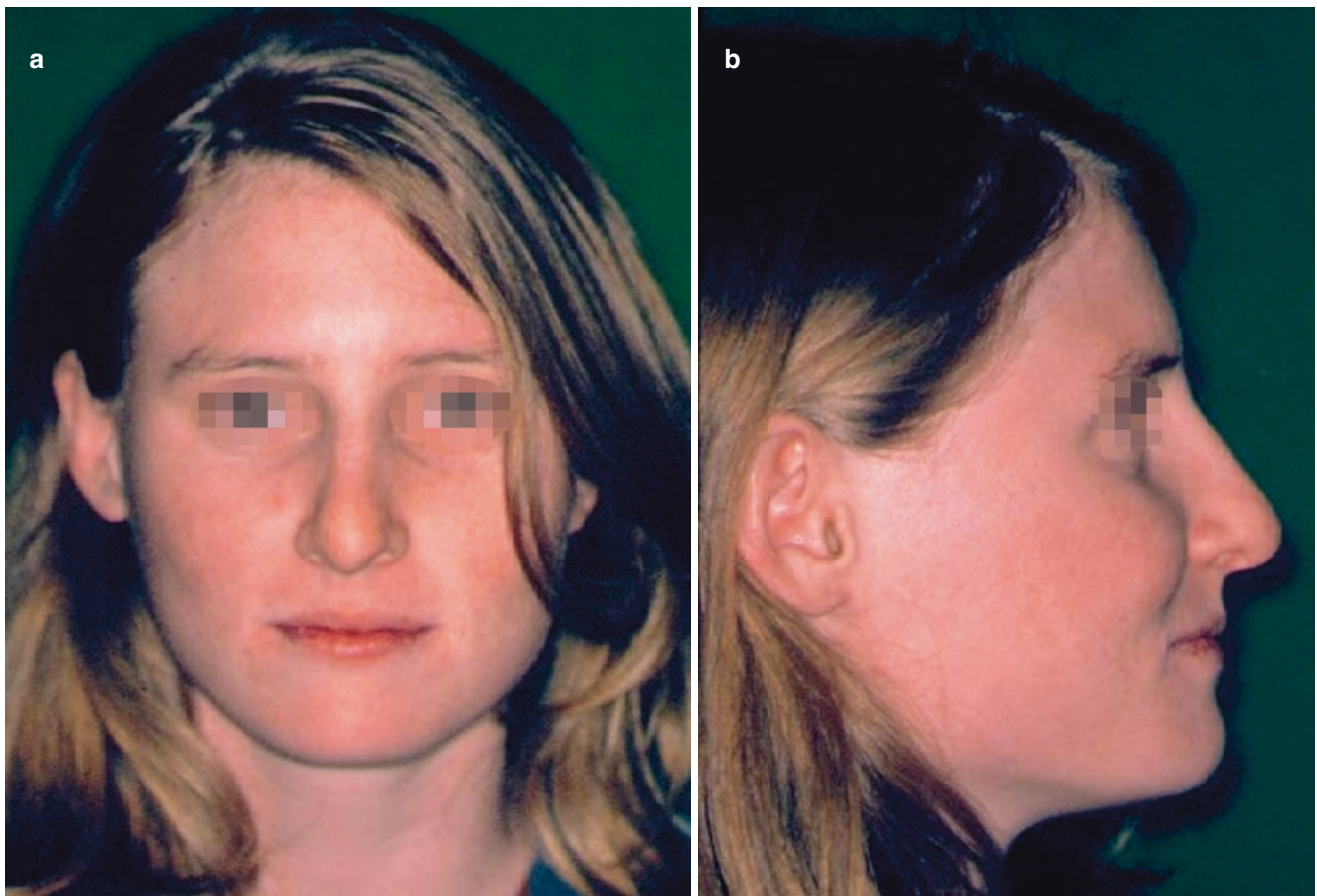


Fig. 14.28 (a, b) Facial photographs 3 years later confirming normal maxillary and mandibular development

The comparison between the profiles pre- and posttreatment demonstrated the significant reduction of the lip protrusion and decrease of the mentalis strain. Another benefit of early orthodontic intervention in these patients is improved self-esteem (Fig. 14.29a, b).

These results clearly demonstrated that excellent long-term results were achieved when orthodontic treatment was provided to patients who were 6–9 years old and had prominent front teeth. The best time for early intervention is during the early mixed dentition.

The Ricketts's cephalogram superimposition demonstrated the differences pre- and posttreatment (Fig. 14.30a).

Anterior crowding is another malocclusion that has to be treated in mixed dentition, especially when it is present in the lower arch. One of the primary reasons could be a negative discrepancy between primary and permanent teeth which could be the result of different morphologic and etiological factors.

The space deficiency can be divided in slight, mild, or severe, and it is the result of the tooth size-arch size discrepancy. One of the most common situations is when a tempo-

rary canine falls out as a consequence of the distal eruption of the lateral incisor. The lower incisors erupt without apparent crowding, but as a result the midline is shifted to this side.

The controversy is when the best time to begin the treatment is to avoid major problems such as the mesialization of the posterior teeth in combination with the distalization of the anterior with the consequent loss of space for the permanent canines and bicuspid.

A guided eruption protocol would be the best option according to the individual facial biotype and quantity of growth. The soft tissue analysis plays an important role too.

The decision is always based on what is best for the patient with efficient mechanotherapy and long-term stable results. Also a thorough knowledge of tooth formation and development is vital for timing interceptive procedures (Graber 2001).

It is recommendable that every child has an orthodontic appointment at 7 years of age to perform a diagnostic assessment of a potential malocclusion.

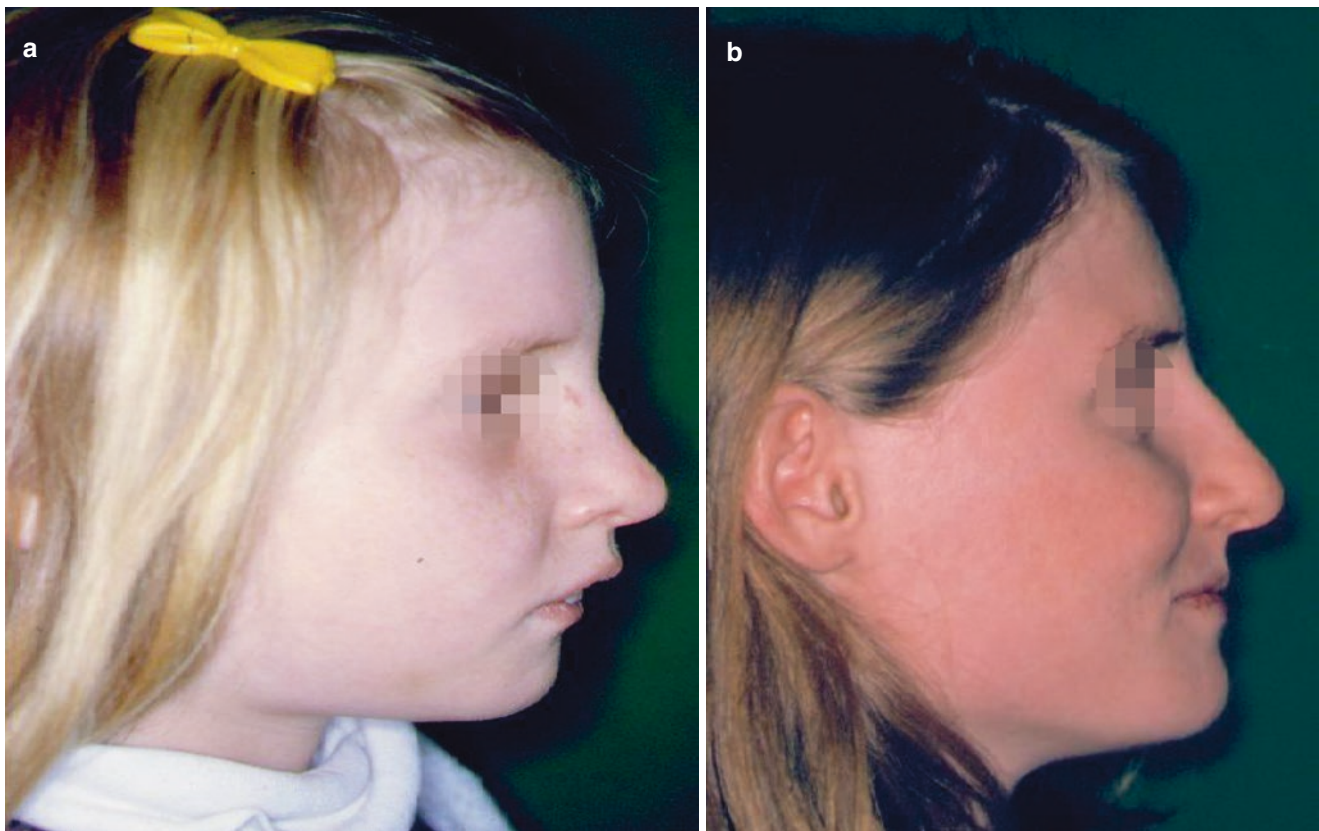

Fig. 14.29 (a, b) Significant changes were achieved in the dentoskeletal and soft tissues. The results were better than expected. No upper extractions were needed to improve the profile

As soon as the lack of space is detected, it is important to determine which would be the best treatment option for the patient.

The next patient is a clear example of this protocol.

He was sent to the orthodontic office with an order to have the left temporary canine extracted to have the central midlines coincide. Lack of space for the eruption of the right lower canine was clearly observed in the panoramic radiograph (Fig. 14.31) along with a significant overbite.

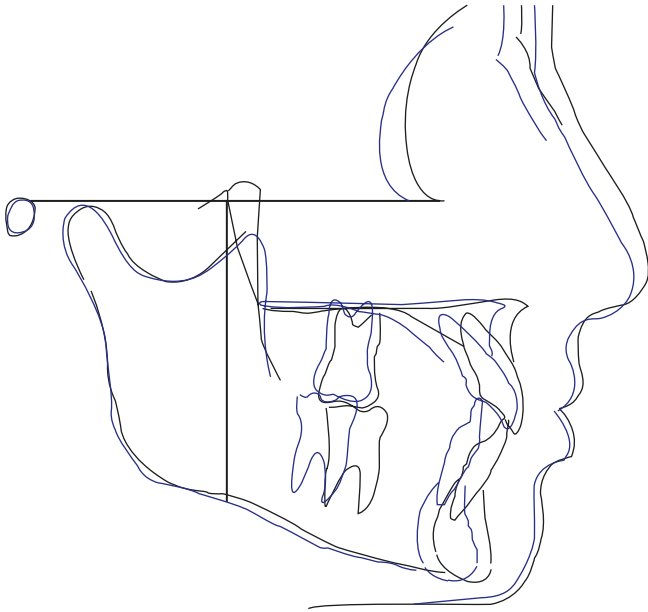


Fig. 14.30 Pre- and post-Ricketts superimposition where the changes were clearly visible

A careful study of the leeway space (differential between the primary and permanent teeth in the lateral region) was performed.

The right lateral and lower occlusal photographs showed Class I molar on the right side with the midline displacement of the permanent mandibular incisors to the right (Fig. 14.32a, b).

In order to recover the necessary space for the lower right canine and bicuspids, sequential stripping of the temporary

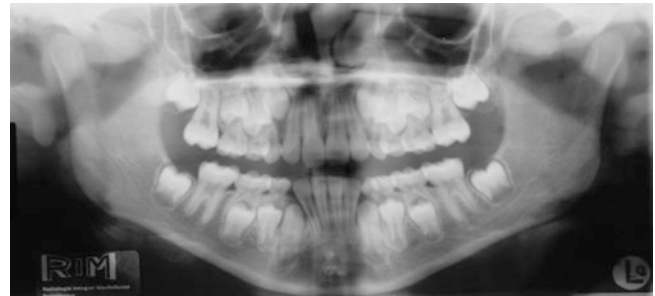


Fig. 14.31 Pretreatment panoramic radiograph. The lack of space for the eruption of the lower right canine was confirmed

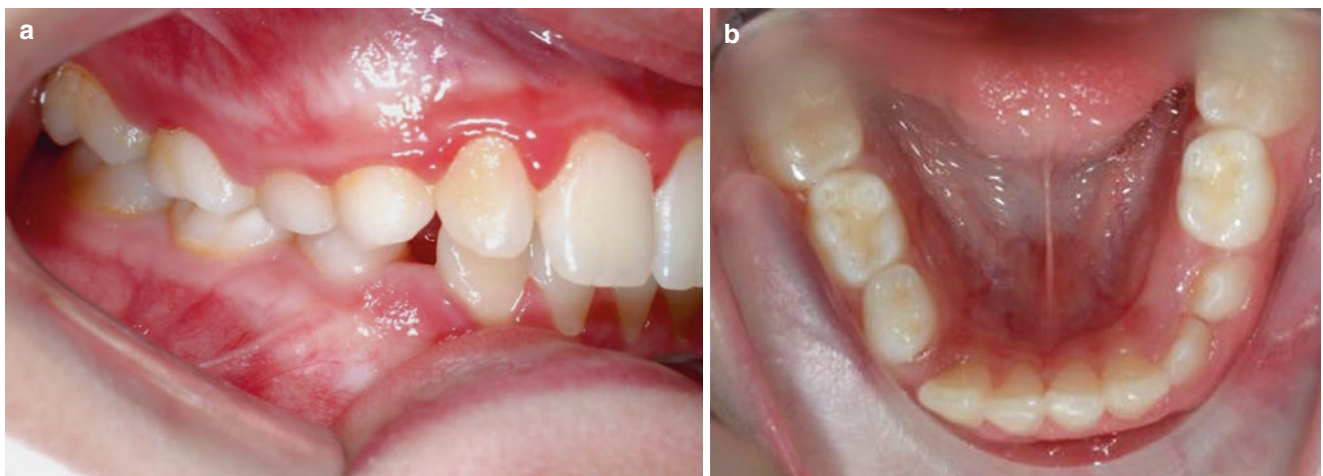


Fig. 14.32 (a, b) Pretreatment lateral and lower occlusal photographs. The lack of space for the eruption of the right lower canine was evident

molars helped control the leeway space. The second temporary molars were banded to protect the permanent first molars (Fig. 14.33a).

Three months later the right canine and first bicuspid began their path of eruption (Fig. 14.33b). A SS 0.016" arch-wire was placed to maintain the lower arch length.

There are several approaches to improve or maintain the lower arch length and, as a consequence, to avoid future permanent extractions. The following protocol was chosen since it is considered to be the most conservative one in this particular patient.

To normalize the discrepancy between the temporary and permanent bicuspid and canine, a 0.016" \times 0.016" SS arch-wire with active Ni-Ti coil springs was placed on the right and left side (Fig 14.34a, b). A 6-week activation was highly recommended.

Six months later, all the lower cuspids and bicuspid erupted, and bands were placed on the permanent first molars in conjunction with brackets on the canines to normalize their position (Fig. 14.35a, b).

Class I molar and canine were achieved 6 months later. Overjet and overbite were within normal parameters. No brackets were bonded on the upper arch during the whole treatment (Fig. 14.36a, b). It is advisable to place a fixed

retainer wire between right and left lower canines and maintain it in place for a long term in order to avoid anterior crowding relapse.

The comparison between the pre- and posttreatment panoramic radiographs clearly demonstrated the results that were obtained. All the space for the right canine was recovered and midlines normalized (Fig. 14.37a, b).

Treatment planning is the result of a profound diagnosis for each particular patient.

Some crowding can be corrected with occlusal guidance and space supervision.

The real question is how to identify the problem and manage the different situations to obtain the best result in a more effective way.

The preservation of the e-space to maintain or even improve the length of the lower arch and guide the eruption of the cuspids and bicuspid is more than essential.

The protocol has to be individualized for each patient according to the facial biotype and amount of skeletal and dental discrepancy in concordance with facial esthetics. The early mixed dentition period plays an important role in the first phase of treatment since major changes occur during this period. There are no doubts about the importance of the normalization of the direction of growth during this phase of treatment.

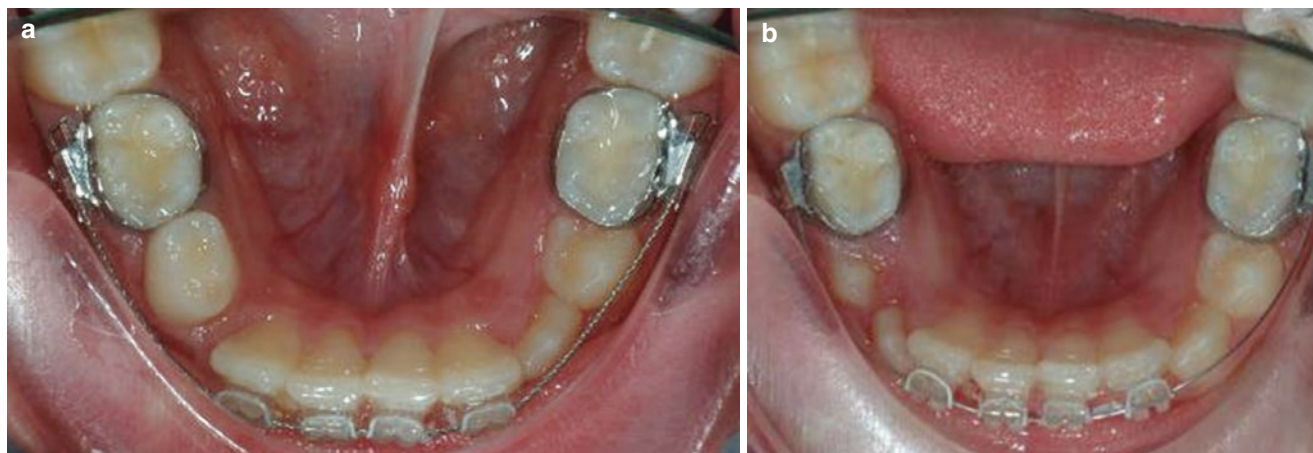


Fig. 14.33 (a, b) Comparison between two stages of treatment. Bands on the secondary temporary molars were placed to maintain the lower initial arch length. Right canine and first bicuspid during their eruption path

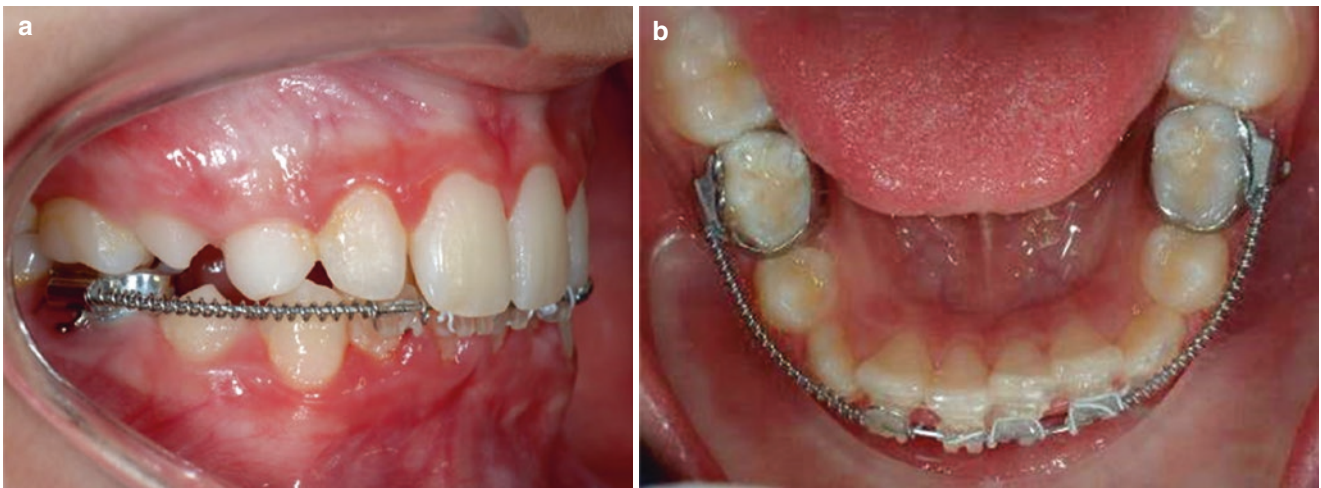


Fig. 14.34 (a, b) A SS 0.016" × 0.016" SS archwire with right and left Ni-Ti coil spring activated every 6 weeks to maintain lower arch length was placed

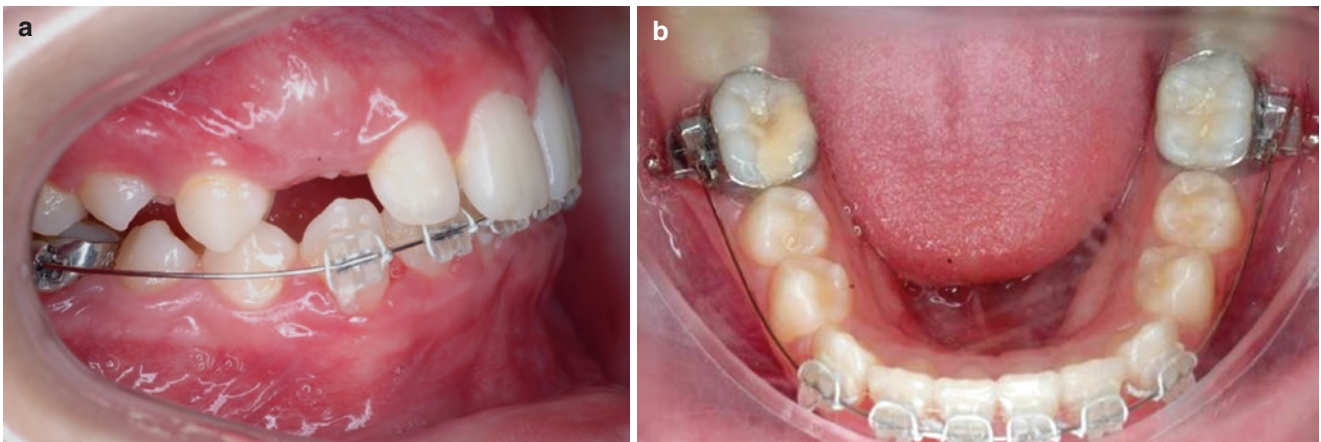


Fig. 14.35 (a, b) Esthetic brackets were bonded on the right and left canine to normalize their position

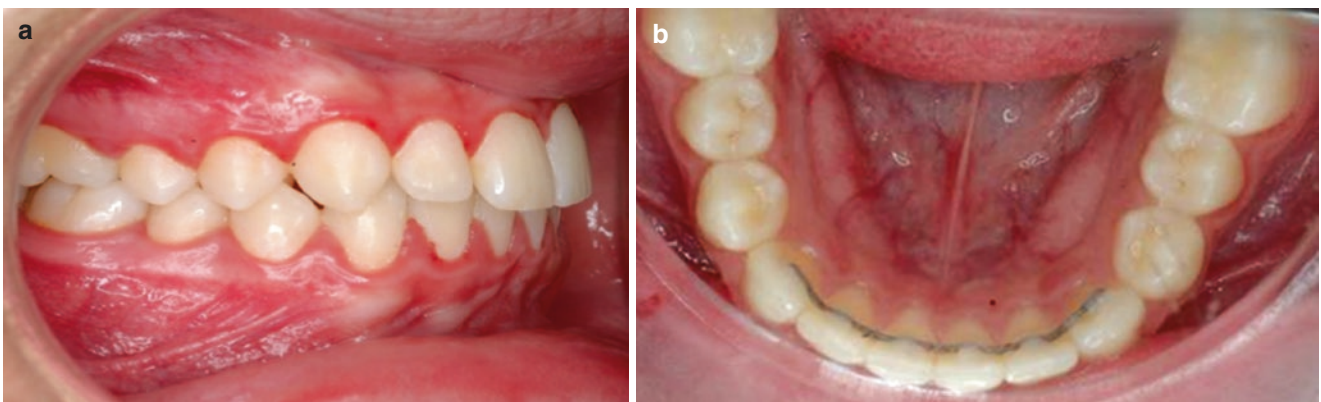


Fig. 14.36 (a, b) Lateral and lower occlusal photographs at the end of the treatment Class I molar and canine with normal overjet and overbite were achieved

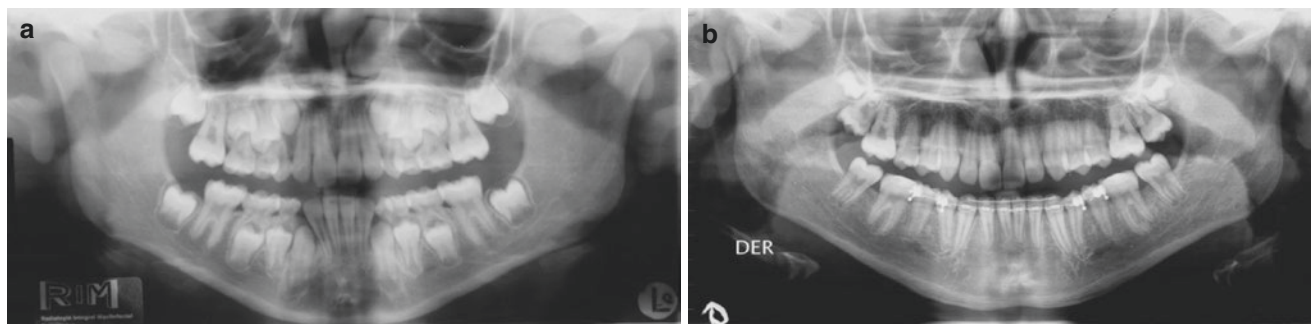


Fig. 14.37 (a, b) Pre- and posttreatment panoramic radiographs. All the treatment objectives were fulfilled

Conclusions

It is widely accepted that early treatment does not avoid a second phase of treatment. However, it reduces its length and complications.

The timing of treatment interventions was influenced by the severity of the malocclusion and the age and maturation of the patient at the time they started the treatment (Jang et al. 2005).

Although some support the idea that all treatment goals can be accomplished in only one phase of treatment, it was demonstrated by the authors that in some clinical cases, early intervention may reduce treatment time and the need for complex orthodontic treatment that includes permanent tooth extraction or orthognathic surgery.

Unfortunately, there is no single bracket that produces more growth than others, and it is confirmed that early treatment is the best option to improve some malocclusions from a functional and esthetic point of view.

Orthodontist needs to understand that the timing to initiate orthodontic treatment is different according to the type of malocclusion and in this way maximize the effectiveness of the long-term results (Di Biase 2002).

There are no “recipes” that can be used for all patients alike, since the answer is an individualized treatment plan no matter the type of appliance that is chosen by the orthodontist.

More consensus among clinicians about one- or two-stage treatment is necessary, but it is important to remember that the answer is a correct diagnosis.

It is important that over the past three decades, parents are more involved and more interested in early treatment, especially when they were orthodontic patients. The family dentist has a substantial role during this challenging phase.

The keys to success in early treatment include a correct diagnosis, comprehensive treatment planning, and contin-

ued active supervision until the eruption of the permanent dentition (Dugoni et al. 1995).

The more dentition is monitored, the better long-term results can be achieved.

Bibliography

- Bahreman A Early age orthodontic treatment. Quintessence: Bahreman Quintessence Publishing Co. Chicago/Berlin/Tokyo/London/Paris/Milan/Barcelona. 2013.
- Di Biase A. The timing of orthodontic treatment. *Dent Update*. 2002;29:434–41.
- Dugoni S, Lee J, Varela J, Dugoni A. Early mixed dentition treatment : post-retention evaluation of stability and relapse. *Angle Orthod*. 1995;65:311–20.
- Franchi L, Baccetti T, Giuntini V, Masucci C, Vangelisti A, Defraia E. Outcomes of two-phase orthodontic treatment of deepbite malocclusions. *Angle Orthod*. 2011;81:945–52.
- Gianelli A. One-phase vs two -phase treatment. *Am J Orthod Dentofacial Orthop*. 1995;108:556–9.
- Graber T. Mixed dentition guidance of occlusion. Serial extraction procedures in Bishara Samir Textbook of Orthodontics WB Saunders Company; Graber Mosby St Louis/Philadelphia/London/Sydney/Toronto. 2001;257–89.
- Horn A, Thiers-Jegou I. Class II deep bite faces One phase or two-phase treatment ? *World J Orthod*. 2005;2:171–9.
- Jang JC, Fields HW, Vig KW, Beck FM. Controversies in the timing of Orthodontic Treatment. *Semin Orthod*. 2005;11(3):108–11.
- King GJ, McGorray SP, Wheeler TT, Dolce C, Taylor M. Comparison of peer assessment ratings (PAR) from 1-phase and 2-phase treatment protocols for Class II malocclusions. *Am J Orthod Dentofacial Orthop*. 2003;123(5):489–96.
- Littlewood S, Nute S, Stivaros N, McDowall R, et al. Is early Class III protraction facemask treatment effective? A multicentre, randomized, controlled trial: 15-month follow-up. *J Orthod*. 2010;37:149–61.
- Mandall N, DiBiase A, Littlewood S, Nute S, Stivaros N, McDowall R, et al. Is early Class III protraction facemask treatment effective? A multicentre, randomized, controlled trial: 15-month follow-up. *J Orthod*. 2010;37:149–61.
- Sugawara J, Asano T, Endo N, Mitani H. Long-term effects of chincape therapy on skeletal profile in mandibular prognathism. *Am J Orthod Dentofacial Orthop*. 1990;98:127–33.

Index

A

- Adenoid, 37
 - enlarged, 50
 - hypertrophied, 27
- Adenoidectomy, 38, 65
- Alar cartilage, 303, 304, 306, 315
 - deformity fixing, 322
 - repositioning, 310, 322
- Alveolar cleft segments, 303, 306
- Alveolar gap, 303, 307, 312
- Ankylosis, 281–287
- Archwire, 100
 - Elgiloy, 93
 - nickel-titanium (Ni-Ti), 82, 93, 95, 99, 101
 - SS, 70, 76, 94, 328, 331, 332, 344, 345
 - TMA, 99
- Assymetry
 - anterior and posterior teeth, 248, 250
 - centric relation, 248
 - class I canine and molar, 246, 248, 252, 253, 259, 262–264, 266
 - classification, 243
 - class II elastics, 264
 - clinical observations, 252, 255
 - condylar movement, 252
 - condyle anquilosis, 243, 245
 - crossbite, 251
 - dental, 243
 - diagnosis, 243, 250
 - digital panoramic radiograph, 243
 - early normalization, 246
 - facial proportions, 256, 258
 - facial symmetry, 243
 - front dental photograph, 248, 249, 252–254
 - functional appliance, 259
 - functional deviations, 243, 246
 - genetic factors, 243, 244
 - individualized double activator, 259, 263
 - intraoral examination, 256, 258
 - lateral photographs, 248, 250
 - lateral radiograph, 252, 253, 256, 259, 264, 266, 268
 - mandible, 246, 247
 - masticatory muscles, 250, 251
 - midlines, 246, 259, 263
 - Ni–Ti–Cu 0.016” archwire, 255, 256
 - occlusal plane and gingival lines, 264, 266
 - orthodontic treatment, 256, 257
 - panoramic radiograph, 252, 253, 256, 259, 264, 266, 268
 - posterior crossbite, 243, 246
 - pre-and postorthodontic treatment, 266, 268
 - pre-and posttreatment, 246, 248
 - realistic treatment, 248, 249

- remodeling of condylar fracture, 255
 - skeletal, 243
 - soft tissues, 243, 244, 266, 267
 - treatment strategy, 243
 - triangular elastics, 256
 - upper and lower arches, 256, 257, 259, 262, 264, 265
 - upper-and lower-fixed retention wire, 266, 267
- Auricular cartilage, 303

B

- Balters Bionator appliance, 105, 106, 110, 117, 120, 126
- Bennun protocol, 299–300
- Bilateral cleft lip and nose repair, 315–317
- Bilateral mastication, 21
- Bite jumping appliance, 113
- Blocked noses, 27
- Bottle, feeding, 27, 28, 312
- Breathing
 - mouth, 29, 31, 32, 37, 38, 64, 65, 327, 334, 337
 - nasal, 2, 7, 20, 27, 31, 34, 38, 39, 41

C

- Canine, 11, 15, 48, 76, 98, 339, 343, 344
 - class I, 2, 10, 42, 55, 58, 63, 71, 72, 74, 77, 92, 94, 328, 330, 332, 333, 336, 338, 344, 345
 - class III, 6
 - lower, 7, 9, 10, 338, 343, 344
 - temporary, 93, 341, 343
 - upper, 2, 48, 93
- Carstens variant illustration, 319
- Cartilage. *See also* Alar cartilage
 - auricular, 303
 - fixation, 307
- Central incisor, 332, 338
 - with bracket bond, 85
 - debonding, 83
 - eruption of right, 93
 - impaction, 91–103
 - lower, 67
 - malposition of lower left, 74
 - malposition of right, 87
 - mesiodens between, 84
 - normalization of the left upper, 86
 - rebonding, 85
 - treatment of atypically rotated, 81–89
- Cephalogram
 - anterior occlusion changes, 335
 - maxillary prognathism treatment, 126, 132
 - Ricketts, 6, 342, 343

- Cervical headgear, 233, 234
- Children
 swallowing in, 20
 TMD, 271–297
- Chincap (chincup), 158
- Class III activator
 changes after, 194
 construction of, 160–162
 insertion, patient's instruction, 163
 Thomas Rakosi, 159–160
 treatment, 165–175, 188–193
 use, 159–160
- Class III malocclusions
 appliance adjustment, 164
 checklist, 163
 class III activator (*see* Class III activator)
 construction bite, 160–162
 in deciduous dentition, 143–144
 dental instability, 194–211
 early treatment reasons, 141–152
 edge-to-edge bite, 188–193
 function analysis, 140–141
 patient's appointment, 164
 with pseudo-forced bite, 176–187
 treatment, 153–160
 types, 135–139
- Class I molar, 10, 11, 15, 39, 42, 53, 58, 63, 69, 71, 72, 74, 77, 93, 94, 96, 98, 233, 235, 236, 239, 328, 330, 332, 333, 336, 338, 343–345
- Clefting, 303
- Cleft lip and nose repair
 bilateral, 315–317
 unilateral, 312–314
- Cleft lip and palate (CLP)
 reconstruction, 311
 secondary rhinoplasty on, 322
 unilateral, 302
- Cleft lip disruption, 301
- Cleft palate repair, 311
 one-stage complete, 318–321
- CLP. *See* Cleft lip and palate (CLP)
- Condylar fracture, 273–280
- Contralateral incisor, 91
- Cranial-cervical orofacial system functions, 19
 respiration/breathing, 31, 32
 swallowing, 19–30
- Cross bite, 1, 2, 39, 50, 53, 68, 69, 81, 82, 327
 dentoalveolar, 32
 lateral, 45, 46
- Crowding, 67
 anterior, 76, 82, 221, 224, 334, 342, 344
 mild, 68, 99, 102
- D**
- Deciduous dentition, 143–144
- Dental asymmetry, 243
- Dental instability, cause of, 194–211
- Dental occlusion, 21, 51, 55, 78, 334
- Dentoalveolar Class III malocclusion, 135, 138
- Dentoalveolar crossbite, 32
- Dentoalveolar open bite, 38
- Diastema, 2, 47, 53, 73, 75, 83, 85, 328
 interincisal, 82, 88, 94, 219, 328, 329, 331
 mild, 98
- Digital sucking, 27, 37, 38
- Dynamic presurgical nasoalveolar remodeling (DPNR) technique, 305, 308, 310, 322
- Dysfunctional swallowing, 23–26
 etiology of, 27
 with lip thrust, 30
 open bite as consequence of, 29
- E**
- Elgiloy archwire, 93
- Emotional immaturity, 27
- Emotional lip movements, 27
- Esophageal stage, swallowing, 22
- Esthetic brackets, 47–49, 55, 57, 75, 76, 93, 94, 328, 331, 345
- Exclusively oral stage, swallowing, 21
- Exhaustive dental plaque control, 70
- F**
- Facial muscle balance, 24
- Facial symmetry, 243
- Feeding bottle, 27, 28, 312
- Fetal skin repair, 303
- Fetus, swallowing in, 19–20
- Figure-of-eight ligature, 75
- Fingers, sucking, 27, 30
- Fixed functional appliance, 14, 16
- Fixed retention wires, 58, 59, 72, 78, 82, 97, 99
- Frankel functional regulator, 109, 110
- Free gingival graft, 68
- Functional swallowing, 20
 esophageal stage, 22
 oral preparative stage, 21
 pharyngeal stage, 22
- G**
- Gingiva, 67, 68, 71, 92, 103
 grafts, 68
 lines, 264, 266
 margin, 72, 73, 77, 94, 99
 recession, 67, 68, 77, 79
 tissues, 2, 72, 78, 79, 97
- Gingivectomy, 92
- Gingivitis, 67
- Gingivoperioplasty, 312
- H**
- Harfin's protocol, 299–300
- Hydration protocol, 311
- Hyperactivity, of musculature of lips, 39
- Hypercontraction, of mental muscles, 27, 30
- I**
- Incisor
 central (*see* Central incisor)
 contralateral, 91
 lateral, 91
 lower (*see* Lower incisor)
 maxillary, 89, 103, 328, 338
 mandibular, 7, 67, 343
 upper (*see* Upper incisor)
- Interincisal diastema, 82, 88, 94, 219, 328, 329, 331
- K**
- Kyphosis, thoracic, 31, 34

- L**
- Labial incompetent position, 26
 - Labial interposition
 - occlusion altered by, 26
 - at rest, 33
 - in swallowing, 26, 33
 - Lateral incisor, 91
 - Lesions, 91
 - mucosal, 87
 - Lingual brackets, 14, 15, 328, 332
 - Lingual dysfunction, during smile, 25
 - Lingual overflow, rest position, 28
 - Lip
 - hyperactivity of musculature of, 39
 - incompetence, 33
 - movement, emotional, 27
 - Lip seal, 38, 50, 334, 336
 - Lip thrust
 - dysfunctional swallowing with, 27, 30
 - mouth breathing with, 31
 - Lower incisor, 73, 339
 - extrusion of, 33
 - retroinclination of, 9
 - retroposition of, 330
 - Lymphoid tissue, hypertrophic, 37
- M**
- Macro trauma, 272
 - Malocclusions, 1, 10, 65, 81, 98, 105, 109, 327, 328, 334, 338, 344.
 - See also* Class III malocclusions
 - Mandible
 - anterior position, 28
 - assymetry, 246, 247
 - counterclockwise rotation of, 38
 - development, 7, 341
 - incisors, 7, 67, 343
 - movements of, 20
 - position, 328, 338
 - Mandibular retrognathism treatment, 106–125
 - Mastication, 21
 - muscle disorders and, 271
 - Maxilla, 31, 37
 - centralization, 309
 - development, 120, 328, 341
 - expansion, 47, 54, 110, 126
 - incisors, 89, 103, 328, 338
 - mandibular arches, 20
 - orthopedics, 303
 - upper, protrusion of, 33
 - Maxillary molar
 - anteroposterior position, 233
 - biomechanics, 233
 - brackets, 231, 232
 - cervical headgear, 233, 234
 - class I molar, 233, 235, 236, 239
 - deviation path, 231
 - distal inclination, 235
 - facial biotype, 231
 - gingival line and occlusal plane, 235, 239
 - lateral view, 235, 238
 - Nance button, 235, 238
 - normalization of position, 240
 - orthodontic treatment, 235, 239
 - palatal button, 235, 238
 - panoramic radiograph, 231, 232
 - pendulum appliance, 235
 - posterior springs, 235, 237
 - treatment, 231, 233
 - utility arch, 235, 237
 - Maxillary prognathism treatment, 126–132
 - Mental muscles, hypercontraction of, 30
 - Mesiodens, 84, 91
 - Metal preprogrammed brackets, 82
 - Micro trauma, 272
 - Midline, 1, 2, 4, 11, 13, 39, 51, 99
 - assymetry, 246
 - coincident, 47, 58, 71, 76, 83, 328, 332, 338, 343
 - noncoincident, 46
 - upper and lower, 73, 94, 96
 - Mixed dentition, 145–152
 - Molar, 16, 331
 - class I, 10, 11, 15, 39, 42, 53, 58, 63, 69, 71, 72, 74, 77, 93, 94, 96, 98, 233, 235, 236, 239, 328, 330, 332, 333, 336, 338, 343–345
 - class II, 53
 - class III, 6
 - lower, 70
 - temporary, 39, 40, 45, 47, 55, 57, 69, 328, 331, 344
 - Mouth breathing, 29, 31, 32, 37, 38, 64, 65, 327, 334, 337
 - Mucosal lesions, 87
 - Mulliken-type variant illustration, 315
 - Muscular facial traction, 306, 309
 - Myofunctional appliance, 7
 - Myofunctional therapist, 34
 - Myofunctional therapy, 31, 38
- N**
- Nance button, 235, 238, 328, 331
 - Nasal breathing, 2, 7, 20, 27, 31, 34, 38, 39, 41
 - Nasal deformity, 303, 304, 315
 - Nasal obstruction, 37, 328
 - Nasal stent, 303, 305, 306
 - Nasal tissues, 307
 - Nasoalveolar molding (NAM) technique, 303
 - Nasoalveolar remodeling, 303, 305, 312, 314
 - Nasolabial structures, 310
 - Neuromuscular behavior, 17
 - Neuromuscular blocking agent, 311
 - Newborn baby, swallowing in, 20
 - Nickel-titanium (Ni-Ti)
 - archwire, 82, 93, 95, 99, 101
 - coil spring, 48, 49, 338, 344, 345
 - Nonsyndromic oral cleft interdisciplinary treatment
 - bilateral cleft lip and nose repair, 315–317
 - deformity process, 302
 - discussion, 322–324
 - DPNR technique, 305, 308, 310, 322
 - one-stage complete cleft palate repair, 318–321
 - pediatric anesthesia considerations, 311
 - prenatal diagnosis, 301
 - presurgical infant orthopedic indication, 303
 - step-by-step procedure, 306–310
 - treatment by age (Bennun and Harfin's Protocol), 299–300
 - unilateral cleft lip and nose repair, 312–314
 - Nose, blocked, 27
 - Nose repair
 - bilateral cleft lip and, 315–317
 - unilateral cleft lip and, 312–314
 - Nursing baby, swallowing function, 20

- O**
- Occlusal plane, 10, 50, 58, 63, 71, 99, 103, 106, 264, 266, 328, 338, 340
 - Occlusal trauma, 67, 89
 - Occlusion, 21, 55, 78, 105, 106, 120, 132, 327, 328, 334
 - changes in anterior, 335
 - labial interposition alteration, 26
 - by low tongue thrust, 24
 - normalization of anterior, 10
 - pre-and posttreatment frontal, 51, 63
 - right and left side, 72, 77
 - Open bite, 38
 - as consequence of dysfunctional swallowing, 29
 - dentoalveolar, 38
 - diagnosis, 38–65
 - by habit of tongue sucking, 28
 - in lateral areas, 55
 - problems, 37–38, 40–66
 - Open flap surgery, 95, 99
 - Oral facial muscle imbalance, 27
 - Oral hygiene, 13, 42, 50, 53, 58, 67, 69, 73–75, 77, 92, 93, 98, 102, 103, 216, 221, 252, 254, 333, 338
 - Oral preparative stage, swallowing, 21
 - Orofacial cleft, prenatal diagnosis of, 301
 - Orofacial shape, 19, 34
 - Orthodontically rotated teeth, 88
 - Osteoarthritis/osteoarthritis (OA), 288–297
 - Osteogenesis, 19
 - Overbite, 4, 11, 13, 14, 43, 51, 69, 71, 88, 221, 224, 225, 227, 235, 236, 239, 247, 256, 257
 - Overjet, 4, 11, 13, 43, 51, 69, 71, 88, 221, 224, 225, 227, 235, 236, 239, 247, 256, 257
- P**
- Pacifiers, 27, 28, 37
 - Pendulum, 328, 331
 - Periodontium, 67
 - Pharyngeal stage, swallowing, 22
 - Predisponent factors, 68
 - Prefabricated functional appliance, 39
 - Protrusive shoulder blades, 31, 34
- R**
- Rapid palatal expansion (RME)
 - activation protocol, 219
 - appliance, 47, 55, 110, 112, 126, 219
 - different types, 216, 217
 - disadvantages, 220, 223
 - occlusal photograph, 219
 - retention appliance, 220, 223
 - temporary molars, 219
 - Respiratory system function, 31
 - RF2 orthopedic appliance, 109
 - Ricketts
 - analysis, 2, 3, 5, 7, 8
 - cephalogram, 6, 342, 343
- S**
- Sanders' double plates (SII) appliance, 113, 114, 117–119
 - Schwarz plate, 110
 - Short tongue frenum, 27, 29
 - SII appliance. *See* Sanders' double plates (SII) appliance
 - Skeletal asymmetry, 243
 - Skeletal Class I malocclusion, 98
 - Skeletal Class III malocclusion
 - with fault in mandible, 135, 139
 - with fault in maxilla, 135, 138, 139
 - functional appliances, 159
 - with pseudo-forced bite, 135, 139, 176–187
 - treatment, 153–160
 - Sleep apnea, 37, 66
 - Soft palate technique, 318
 - Speech therapist, 34, 37, 63, 65, 327
 - SS archwire, 70, 76, 99, 328, 331, 332, 344, 345
 - Stimuli, 31, 34
 - Strict plaque control, 79
 - Sucking, 20
 - digital, 27, 37, 38
 - fingers, 27, 30
 - tongue, 27, 28
 - Swallowing, 19, 37
 - in children, 20
 - dysfunctional, 23–30
 - esophageal stage, 22
 - exclusively oral stage/transfer, 21
 - in fetus, 19–20
 - functional, 20
 - labial interposition, 26, 33
 - in newborn and nursing babies, 20
 - oral preparative stage, 21
 - pharyngeal stage, 22
- T**
- Temporary molars, 39, 45, 47, 55, 57, 69, 328, 331, 344
 - Temporomandibular disorders (TMD)
 - aetiological factors, 271–272
 - ankylosis, 281–287
 - category, 271
 - clinical and physical assessment, 272
 - condylar fracture, 273–280
 - diagnosis, 272
 - epidemiologic studies, 271
 - irreversible therapy, 273
 - masticatory muscle disorders, 271
 - osteoarthritis/osteoarthritis, 288–297
 - prognosis, 272
 - radiographs, 272
 - reversible therapy, 272–273
 - TMJ disorders, 271
 - Temporomandibular joint (TMJ), 37, 271
 - Thoracic kyphosis, 31, 34
 - TMA archwire, 99
 - Tongue frenum, short, 27, 29
 - Tongue sucking, 27, 28
 - Tongue thrust, 23–26, 38, 39, 48, 50, 52, 64
 - Tonsils, 37, 50
 - hypertrophied, 23, 24, 27, 29
 - Trainer System TM appliance, 39, 41
 - Transverse problems
 - activation protocol, 215
 - anterior crowding, 221, 224
 - canine and bicuspid, 221, 224
 - crossbite position, 220, 222
 - dentoalveolar expansion, 215, 216
 - diastema, 217, 218
 - distal extension wire, 217, 218
 - esthetic brackets, 220, 223
 - etiology, 215

facial biotype, 220, 221
fixed retention wires, 225, 227, 228
front photographs pre-and posttreatment, 225, 227
limited information, 215
lower bands, 225
metal preprogrammed brackets, 219, 220
oral hygiene, 221, 224
orthodontic treatment, 217, 218
ossification of, midpalatal suture, 215
panoramic and lateral radiograph, 220, 222, 225, 226
position of upper incisors, 219, 223
pre-and post-occlusal radiographs, 215, 216
pre-and posttreatment frontal smile, 220, 221
pretreatment intraoral photographs, 216, 217
removable functional appliance, 219, 223
retention plan, 225, 226
retention protocol, 219
RME, 216, 217, 219
2nd phase of treatment, 225, 226
slight relapse, 225, 227–228
smile photographs, 219, 220

tongue, anterior position of, 220, 221
treatment, 219–220, 223–228
upper arch, significant change in, 225, 227
Trauma, 66, 81, 98
 incisal, 7
 macro, 272
 micro, 272
 occlusal, 67, 89
 in primary dentition, 91–93
Traumatic intrusion, 91

U

Unilateral cleft lip and nose repair, 312–314
Upper incisor, 7, 9, 10, 14, 15, 27, 68–70, 75, 80, 91, 328, 334, 337
 excessive proclination of, 37
 position of, 219, 223
 protrusion of, 330
 retroinclination of, 15
 risk of fracture of, 329